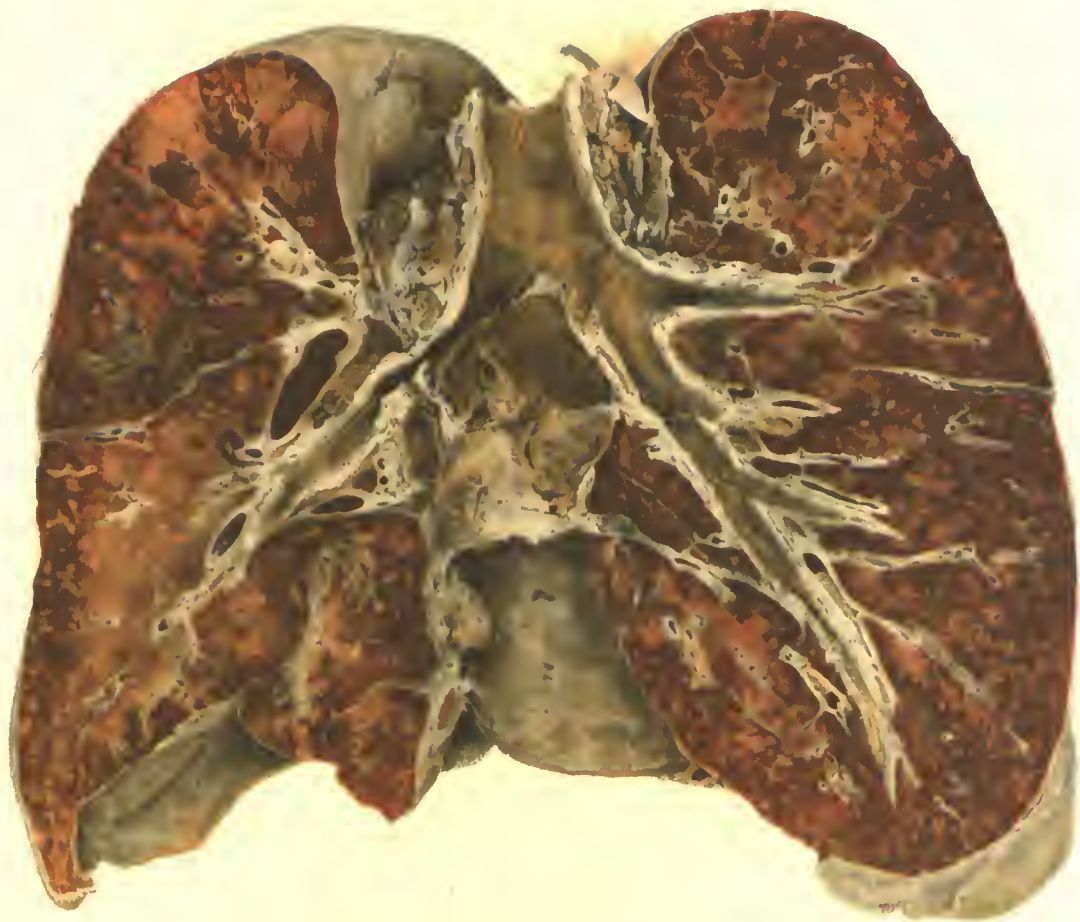



PNEUMONIA FOLLOWING INFLUENZA
Accession 2704, Army Medical Museum
(Colored photograph)

UH
S 224.4 m

The
MEDICAL DEPARTMENT
OF THE UNITED STATES ARMY
IN THE WORLD WAR

REFERENCE ONLY

VOLUME XII

PATHOLOGY OF THE ACUTE RESPIRATORY
DISEASES, AND OF GAS GANGRENE
FOLLOWING WAR WOUNDS

PREPARED UNDER THE DIRECTION OF
MAJ. GEN. M. W. IRELAND
The Surgeon General

BY

MAJ. GEORGE R. CALLENDER, M. C.

AND

MAJ. JAMES F. COUPAL, M. C.

ACC#
783



REFERENCE ONLY.

WASHINGTON : U. S. GOVERNMENT PRINTING OFFICE : 1929

OTIS HISTORICAL ARCHIVES
ARMED FORCES MEDICAL MUSEUM, AFIP

ADDITIONAL COPIES
OF THIS PUBLICATION MAY BE PROCURED FROM
THE SUPERINTENDENT OF DOCUMENTS
U. S. GOVERNMENT PRINTING OFFICE
WASHINGTON, D. C.
AT
\$3 60 PER COPY

LETTER OF TRANSMISSION

I have the honor to submit herewith Volume XII of the history of the MEDICAL DEPARTMENT OF THE UNITED STATES ARMY IN THE WORLD WAR. The volume submitted is entitled "PATHOLOGY OF THE ACUTE RESPIRATORY DISEASES, AND OF GAS GANGRENE FOLLOWING WAR WOUNDS."

M. W. IRELAND,
Major General, the Surgeon General.

The SECRETARY OF WAR.

Lient. Col. FRANK W. WEED, M. C., *Editor in Chief*.
LOY McAFEE, A. M., M. D., *Assistant Editor in Chief*.

EDITORIAL BOARD ^a

Col. BAILEY K. ASHFORD, M. C.
Col. FRANK BILLINGS, M. C.
Col. THOMAS R. BOGGS, M. C.
Col. GEORGE E. BREWER, M. C.
Col. W. P. CHAMBERLAIN, M. C.
Col. C. F. CRAIG, M. C.
Col. HAVEN EMERSON, M. C.
Brig. Gen. JOHN M. T. FINNEY, M. D.
Col. J. H. FORD, M. C.
Lient. Col. FIELDING H. GARRISON, M. C.
Col. H. L. GILCHRIST, M. C.
Brig. Gen. JEFFERSON R. KEAN, M. D.
Lient. Col. A. G. LOVE, M. C.
Col. CHARLES LYNCH, M. C.
Col. JAMES F. MCKERNON, M. C.
Col. S. J. MORRIS, M. C.
Col. R. T. OLIVER, D. C.
Col. CHARLES R. REYNOLDS, M. C.
Lient. Col. G. E. DE SCHWEINITZ, M. C.
Col. J. F. SILER, M. C.
Brig. Gen. W. S. THAYER, M. D.
Col. A. D. TUTTLE, M. C.
Col. WILLIAM H. WELCH, M. C.
Col. E. P. WOLFE, M. C.
Lient. Col. CASEY A. WOOD, M. C.
Col. HANS ZINSSER, M. C.

^a The highest rank held during the World War has been used in the case of each officer.

PREFACE

The contents of this volume comprise two sections, the one, devoted to the pathology of acute respiratory diseases; the other, to the pathology of gas gangrene following war wounds. These two subjects were chosen as the most important conditions of the war from the standpoint of pathology.

The first section is divided into a brief description of critical nature of the whole subject; the pathology of acute respiratory diseases at those camps on which sufficient data were available to give a good general picture of these diseases; an illustrated description based on the articles used in describing the pathology in the various camps and in the American Expeditionary Forces and on the specimens and protocols of necropsies in the collections of the Army Medical Museum; and a brief résumé of the bacteriology.

That part of the first chapter, which concerns the acute respiratory diseases in the various camps, is based on articles published in current medical journals during or soon after the war. Medical officers were encouraged to prepare articles, for immediate publication, on the diseases affecting the Army, with a view of assisting in solving the perplexing problems in connection with these diseases, particularly influenza. Most of this material was forwarded to the publishers by the Surgeon General, with the avowed intention of making use of it later in compiling the medical and surgical history of the World War.

It was also the policy of the Medical Department to send specimens, resulting from necropsies, to the Army Medical Museum where personnel was available properly to preserve and file such material for the purpose of future study. Similar action was taken in the American Expeditionary Forces, which resulted in sending to the United States a large number of specimens illustrating wounds of war, largely amputated limbs, as well as numerous specimens from necropsies on acute respiratory and other diseases.

No general reference list on the acute respiratory diseases is included herein. The literature reviewed is listed in the catalogue of the Army Medical Library under the titles influenza and pneumonia. Most of the important articles for this section were written by medical officers and were based on their experience in the service of the Army of the United States. Acknowledgment is here made to all of these officers for their splendid contributions to our knowledge of the acute respiratory diseases not only in these writings but also in the specimens and protocols which they have added to the collections of the Army Medical Museum. Though only a few of the articles written by medical officers appear as references herein every one on the subject of the acute respiratory diseases has been of value in some way in the preparation of this volume.

The second section is based on personal experience, the protocols and specimens of the Army Medical Museum collection, articles written by medical officers of the Army, and the literature.

The discussion of the organisms is based largely on unpublished articles prepared by Maj. A. P. Hitchens, M. C., and Benjamin Jablons, M. C. These articles reviewed in abstract the entire subject of the bacterial etiology of gas gangrene and were invaluable. Capts. T. H. Sweetser, M. C., and R. T. Petit, M. C., made valuable studies on the incidence of gas gangrene and on the relation of the bacteria to the clinical course and outcome of infected wounds. These are included in the text.

The technique used in the preparation of the pathological tissues for study and in their photography is included in the appendix, in order that results similar to those recorded herein may be obtained by others if desired. It was prepared largely by Capt. R. W. French, Infantry. Grateful acknowledgment is made to the following persons for their assistance in the technical work of pathology and photography: Maj. Theodore Bitterman, S. C., Capt. R. W. French, Inf., and Roy M. Reeve, F. E. Prior, Garnet Jex, L. W. Ambrogi, Walter Parker and Edward V. McCarten.

TABLE OF CONTENTS

	Page
PREFACE.....	v
SECTION I.—PATHOLOGY OF THE ACUTE RESPIRATORY DISEASES. By Maj. GEORGE R. CALLENDER, M. C.	
INTRODUCTION.....	1
CHAPTER I. In camps in the United States.....	7
II. In the American Expeditionary Forces.....	187
III. Pathological anatomy.....	196
IV. Lesions in organs outside the respiratory tract.....	388
V. Bacteriology.....	399
SECTION II.—PATHOLOGY OF GAS GANGRENE FOLLOWING WAR WOUNDS. By Maj. JAMES F. COUPAL, M. C.	
APPENDIX.....	571
INDEX.....	579

LIST OF CHARTS

Chart	
I. The incidence and fatality of the acute respiratory diseases at Camp Beauregard.....	12
II. The incidence and fatality of the acute respiratory diseases at Camp Bowie.....	22
III. The incidence and fatality of the acute respiratory diseases at Camp Cody.....	32
IV. The incidence and fatality of the acute respiratory diseases at Camp Custer.....	38
V. The incidence and fatality of the acute respiratory diseases at Camp Devens.....	43
VI. The incidence and fatality of the acute respiratory diseases at Camp Dix.....	55
VII. The incidence and fatality of the acute respiratory diseases at Camp Dodge.....	63
VIII. The incidence and fatality of the acute respiratory diseases at Camp Fremont.....	76
IX. The incidence and fatality of the acute respiratory diseases at Camp Grant.....	82
X. The incidence and fatality of the acute respiratory diseases at Camp Lewis.....	99
XI. The incidence and fatality of the acute respiratory diseases at Camp MacArthur.....	108
XII. The incidence and fatality of the acute respiratory diseases at Camp Pike.....	125
XIII. The incidence and fatality of the acute respiratory diseases at Camp Sherman.....	138
XIV. The incidence and fatality of the acute respiratory diseases at Camp Taylor.....	145

LIST OF PLATES

Plate	Facing page
Pneumonia following influenza.....	Frontispiece
I. Diffuse, hemorrhagic pneumonia; <i>Streptococcus hemolyticus</i> infection following influenza.....	208
II. Generalized streptococcus lymphangitis secondary to confluent, lobular pneumonia following influenza.....	208
III. Hemorrhagic edema with beginning leucocytic infiltration.....	236
IV. Hemorrhagic edema, acute bronchiectasis, beginning purulent consolidation.....	236
V. Perivascular proliferation.....	242
VI. Two ruptures in an atrial wall.....	242
VII. Peribronchiolar, hemorrhagic consolidations.....	244
VIII. Organizing pneumonic process.....	258
IX. Organization of exudate in influenzal pneumonia.....	266

Plate	Facing page
X. Organization following influenzal pneumonia.....	268
XI. Bronchopneumonia. Spreading or confluent consolidation.....	284
XII. Peribronchial and perivascular lymphangitis.....	354
XIII. Zenker's degeneration, rectus abdominis muscle.....	388
XIV. Zenker's degeneration.....	388
XV. Debrided wound of the right thigh.....	422
XVI. Vertical section of the amputated thigh.....	422
XVII. Gas gangrene of the calf muscles.....	468
XVIII. Edema within muscle envelopes and between muscle bundles.....	510
XIX. Cross section of muscle taken from an area of toxic edema near the wound tract.....	510
XX. Typical brick-red discoloration of the calf muscles due to gas gangrene.....	530
XXI. Muscle fibers from an area of putrefactive gangrene.....	530
XXII. Comminution of bone; putrefactive infection of the marrow.....	556
XXIII. Showing the typical color of the bronzing in avirulent gas gangrene.....	562
XXIV. Putrefactive gangrene. Cross section of leg shown in Plate XXIII.....	562

LIST OF FIGURES

Figure	Page
1. Postinfluenzal pneumonia.....	199
2. Dilated small vessel in a lung in the congestive stage of lobar pneumonia.....	200
3. Alveolus in the early stage of red hepatization.....	202
4. Stage of late red hepatization stained for reticulum.....	203
5. Alveolus of early gray hepatization.....	204
6. Lung in gray hepatization.....	205
7. Postinfluenzal pneumonia.....	206
8. Postinfluenzal pneumonia.....	207
9. Subdural abscess following suppurative frontal sinusitis after influenza.....	211
10. Hemorrhagic, necrotic inflammation of the lining of the trachea.....	213
11. Cellular reaction in a bronchial lymph node in pneumonia following influenza.....	214
12. Pneumonia following influenza. Diffuse, hemorrhagic inflammation of the lungs.....	215
13. Postinfluenzal pneumonia.....	217
14. Early changes in bronchiolar epithelium.....	218
15. Degeneration of bronchial mucosa.....	219
16. Gram-negative bacilli along bronchiolar epithelium.....	221
17. Wall of bronchiole. Epithelium being raised and separated by serous exudate beneath.....	222
18. Lobular pneumonia.....	223
19. Lobular pneumonia.....	224
20. Minute Gram-negative bacteria in bronchiolar mucosa.....	225
21. Minute Gram-negative bacteria, free and in phagocytes.....	226
22. Ductus alveolaris showing streptococci and minute Gram-negative bacteria.....	227
23. Minute Gram-negative bacteria and streptococci in the exudate along the epithelium of the beginning of a ductus alveolaris.....	228
24. Gram-negative bacteria and a few streptococci along the wall of a ductus alveolaris.....	229
25. Bronchiole infiltrated with leucocytes, Gram-negative bacteria and streptococci.....	230
26. Seropurulent exudate in a bronchiole.....	231
27. Longitudinal section of a bronchiole containing purulent exudate.....	232
28. Bronchiole showing purulent inflammation.....	233
29. Bronchiole showing purulent exudate.....	234
30. Serous exudate in a ductus alveolaris.....	236
31. Cross section of an atrium containing air and hemorrhagic exudate.....	237

Figure	Page
32. Early exudate in a diffuse inflammation of the lungs.....	238
33. Early exudate in a confluent, lobular pneumonia.....	239
34. Proliferated adventitia.....	241
35. Early hemorrhagic lesion.....	242
36. Degenerated wall of atrium.....	243
37. Peribronchiolar consolidation, surrounded by zones of hemorrhage.....	245
38. Gram-negative bacillary forms in the alveolar wall.....	246
39. Minute Gram-negative bacteria in the alveoli.....	247
40. Minute Gram-negative bacteria in alveolar wall.....	248
41. Peribronchiolar lesions in pneumonia following influenza.....	249
42. Pneumonia following influenza.....	250
43. A bronchiole showing absence of columnar cells at either side.....	251
44. Ductus alveolaris surrounded by purulent exudate.....	252
45. Peribronchiolar pneumonia.....	253
46. Consolidation about a ductus alveolaris.....	254
47. Infiltration of alveolar wall by mononuclear leucocytes.....	255
48. Section of the trachea showing complete loss of the columnar cells.....	256
49. Section of trachea showing practically complete loss of columnar cells, with marked proliferation of the basal layer.....	257
50. Bronchus showing purulent exudate and air in the lumen.....	258
51. Proliferation of alveolar epithelium.....	259
52. Proliferation of basal layer appearing as a stratified, squamous type of epithelium.....	260
53. Alveoli and atria filled with masses of epithelium.....	261
54. Exudate in an atrium in an early stage of the process of organization.....	262
55. Types of cells in organization.....	263
56. Early stage of organization of exudate in an alveolus.....	264
57. Early stage of organization of the exudate in a pulmonary atrium.....	265
58. Early organization of the exudate in a pulmonary atrium.....	266
59. Organization of exudate in influenzal pneumonia.....	267
60. Organization following influenzal pneumonia.....	268
61. Organization complete in an alveolus.....	269
62. Collagenous fibers extending to the group of mononuclear cells.....	270
63. Practically complete organization of a group of alveoli.....	271
64. Newly formed capillaries about a small blood vessel.....	272
65. Increase in the number of capillaries in alveolar walls.....	273
66. Alveolar walls showing new formation of connective tissue.....	274
67. Organization extending from an ulcerated area in a bronchiole.....	275
68. Granulation tissue in the wall of a bronchiole.....	276
69. New fibrous tissue encroaching on the lumen of a bronchiole.....	277
70. Late stage of interstitial reaction about bronchioles.....	278
71. Purulent bronchiolitis with bronchiectasis following influenza.....	281
72. Purulent bronchitis with marked dilatation and bronchiectasis.....	282
73. Acute, ulcerative bronchitis and bronchiectasis.....	283
74. Bronchiectasis.....	284
75. Pneumonic consolidation spreading out about the bronchi.....	285
76. Experimental bronchopneumonia in a monkey.....	286
77. Experimental bronchopneumonia in a monkey.....	287
78. Acute bronchitis.....	288
79. Bronchus showing an acute inflammatory reaction.....	289
80. Purulent bronchiolitis with ulceration.....	290
81. Purulent bronchitis.....	291
82. Purulent bronchitis and bronchiectasis.....	292
83. Bronchitis and bronchiectasis.....	293
84. Bronchiole involved in an inflammatory reaction.....	294
85. Postinfluenzal pneumonia.....	296
86. Bronchopneumonia spreading out about bronchi and blood vessels.....	298

Figure	Page
87. Wall of bronchiole containing numerous pneumococcus forms.....	299
88. Alveolar walls containing numerous pneumococcus forms.....	300
89. Walls of alveoli and exudate containing pneumococcus forms.....	301
90. Early stage of reaction in the alveoli.....	302
91. Section of wall of the main bronchus showing desquamation of epithelium.....	305
92. Section of wall of bronchus showing the lumen of a duct plugged with serofibrinous exudate.....	306
93. Section of wall of bronchus showing fibrinous exudate.....	307
94. Blood vessels and alveoli in a case of pneumococcus Type II infection.....	308
95. Peribronchiolar consolidations.....	309
96. Postinfluenzal pneumonia.....	310
97. Postinfluenzal pneumonia.....	311
98. Lobular, pneumonic consolidation.....	312
99. Pneumonia following influenza.....	313
100. Postinfluenzal pneumonia.....	314
101. Lobular pneumonia.....	315
102. Section of a bronchial wall in a streptococcus bronchitis.....	317
103. Wall of main bronchus in a case of streptococcus bronchitis and bronchopneumonia.....	318
104. Bronchus showing the extension of inflammation between the cartilages.....	319
105. Bronchus containing serous exudate.....	320
106. Streptococci in lymph spaces.....	321
107. Streptococcus forms beneath the bronchial mucosa.....	322
108. Serofibrinous exudate in an early stage of a lobular pneumonia caused by hemolytic streptococci.....	323
109. Early stage of consolidation in a lobular pneumonia.....	324
110. Purulent exudate in a lobular pneumonia.....	325
111. Early stage of streptococcus, lobular pneumonia.....	326
112. Hyaline membrane in a group of atria and alveoli.....	327
113. Hemorrhagic inflammation of alveolar walls.....	328
114. Confluent, lobular pneumonia.....	329
115. Alveolus with serious exudate containing streptococci.....	330
116. Streptococci in lymph spaces in alveolar walls.....	331
117. Postinfluenzal pneumonia.....	332
118. Postinfluenzal pneumonia.....	333
119. Postinfluenzal pneumonia.....	334
120. Confluent, lobular pneumonia.....	335
121. Confluent, lobular pneumonia with central necrosis.....	336
122. Confluent, lobular pneumonia with extensive central necrosis.....	337
123. Necrotic confluent lobar pneumonia.....	338
124. Streptococcus, lobular pneumonia showing beginning abscess formation.....	339
125. Abscess formation in the center of a lobule of streptococcus, lobular pneumonia.....	340
126. Lobule going on to abscess formation.....	342
127. Pneumonia due to hemolytic streptococci, showing abscess formation.....	343
128. New capillaries in granulation tissue projecting into an abscess caused by streptococci.....	344
129. Purulent bronchitis.....	347
130. Exudate in a bronchiole.....	348
131. Bronchus showing almost complete desquamation of columnar cells and proliferation of the basal layer.....	349
132. Small bronchus showing proliferation of basal layers.....	350
133. Lungs, heart, pericardium, pleura and mediastinal tissues of a case of empyema, pericarditis and mediastinitis.....	351
134. Bronchus in an area of lobular pneumonia from which <i>Streptococcus hemolyticus</i> was cultivated.....	353
135. Oblique section of a bronchus in an area of lobular pneumonia.....	354

Figure	Page
136. Oblique section of a bronchus (next to that shown in Figure 134), showing increases in vessels in submueosa.....	355
137. Peribronchial lymphangitis.....	356
138. Perivascular lymphangitis about a small pulmonary vein.....	357
139. Interlobular lymphangitis in a lobular pneumonia due to hemolytic streptococci.....	359
140. Lymphatics of an interlobular septum filled with fibrinopurulent exudate.....	360
141. <i>Streptococcus hemolyticus</i> pneumonia.....	361
142. Phlegmonous inflammation of interlobular septa.....	362
143. Purulent lymphangitis in an interlobular septum.....	363
144. Fibrinopurulent pleuritis with subpleural lymphangitis.....	364
145. Abscesses in interlobular septa arising in thrombosed lymphatics.....	365
146. Interlobar empyema.....	366
147. Pneumonia following measles.....	367
148. Pneumonia following influenza complicated by empyema.....	369
149. Purulent phlebitis of a pulmonary vein.....	370
150. Dilated capillary in the mediastinal tissues.....	371
151. Pneumonia following measles with fibrinopurulent pleuritis.....	372
152. Late streptococcus lymphangitis following influenzal, lobular pneumonia.....	373
153. Organization in an interlobular septum.....	374
154. Advanced fibrosis in an interlobular septum.....	375
155. Organizing process in interlobular septa.....	376
156. Staphylococcus pneumonia. Abscesses arising in the bronchioles.....	381
157. Staphylococcus pneumonia. Multiple abscesses in bronchi.....	382
158. Multiple abscesses arising in bronchi, due to staphylococcus.....	383
159. Confluent, lobular pneumonia with groups of staphylococcus abscesses.....	384
160. Purulent staphylococcus bronchiolitis.....	385
161. Purulent staphylococcus bronchiolitis.....	386
162. Zenker's degeneration of reetus abdominis musele in a case of influenza and pneumonia.....	389
163. Zenker's degeneration in the reetus abdominis muscle in a case of pneumonia following influenza.....	390
164. Zenker's degeneration in the rectus abdominis musele.....	391
165. Zenker's degeneration in the reetus abdominis muscle.....	392
166. Hemorrhagic adrenalitis.....	395
167. Hemorrhagic adrenalitis.....	396
168. Rupture of the long saphenous vein, probably produced by shell fragment, through hydraulic transmission of its foree.....	418
169. Vein filled with large bacteria of putrefactive type.....	420
170. Vertical midsection through the thigh.....	422
171. Section of gangrenous musele.....	423
172. A gaseous area in musele.....	424
173. Gangrenous area in musele.....	425
174. Gram-positive round-ended rods between muscle fibers.....	426
175. Cross section of a nerve which shows a spiral rupture.....	427
176. Medium sized vein which shows numerous Gram-positive rods in the muscularis and in the lymphatics.....	428
177. Longitudinal section of a musele near the debrided wound.....	429
178. Spiral rupture of musele caused by gases within the musele faseia.....	430
179. Accumulations of gas between muscle bundles and within muscle fibers.....	431
180. Connective tissue and fat which shows gas and edema and digestion of fat cells.....	432
181. Left knee with a debrided wound.....	435
182. Midsection of the knee in Figure 181, showing gas formation.....	436
183. Medium sized artery with marked shredding of the adventitia and hemorrhage into the subcutaneous tissues.....	437
184. Medium sized vein and artery, branches of the vessels shown in Figure 183.....	438

Figure	Page
185. Area of advanced emphysematous gangrene.....	439
186. Muscle fibers with two-thirds of their diameter occupied by gas bubbles....	440
187. Gas infiltration of one muscle fiber.....	441
188. Gas gangrene change in muscle infiltrated with large cocco-bacilli.....	442
189. Thigh amputated at the level of a fracture in the middle third of the femur....	443
190. Vertical section of the limb in Figure 189, showing putrefactive gangrene.....	444
191. Midsection of the amputated limb shown in Figure 189, with accumulation of large gas bubbles.....	445
192. X ray of limb showing gas bubbles.....	446
193. Section from the gangrenous area.....	447
194. Section from the emphysematous area.....	448
195. Section from the putrefactive, gangrenous process.....	449
196. Anterior surface of the right thigh with a debrided, high-explosive wound, and midsection of the limb.....	450
197. X ray of the thigh showing gas in the muscle.....	451
198. Two muscles, one of which shows rupture of fibers in gas gangrene.....	452
199. Area of advanced emphysematous gangrene.....	453
200. Gangrenous area close to the wound tract.....	454
201. Muscle fiber with numerous fine bubbles.....	455
202. Two isolated muscle fibers which have been split by gas.....	456
203. Area of comparatively pure emphysematous gangrene.....	457
204. Cross section of the leg showing surgical free dissection of muscles.....	458
205. Muscles invaded by gas.....	459
206. Infiltration of muscle fibers by gas.....	460
207. Section from the gangrenous muscles.....	461
208. Ground-glass appearance of muscle fibers.....	462
209. Muscle fibers in the putrefactive gangrenous process.....	463
210. Left arm with a debrided bullet wound.....	464
211. Large gas bubble between fibers of an isolated muscle bundle.....	465
212. Section of muscle in an area of gas gangrene.....	466
213. Section from the brachial nerve showing edema and gas and numerous round- ended Gram-positive rods between fibers.....	467
214. Section of fascia and fat from the area of putrefactive gangrene over the biceps muscle.....	468
215. High explosive shell wound caused by contact explosion.....	469
216. Opposite side of thigh shown in Figure 215.....	470
217. Fractured tibia and fibula and gas gangrene of the calf muscles.....	371
218. Shredding and thrombosis of the popliteal vessels with beginning putrefactive gas gangrene.....	472
219. Putrefactive change in the clot around the upper end of the fractured tibia.....	473
220. Destruction of muscle fibers and surrounding fascias.....	474
221. Bubbles of gas within the fibers and small collections of gas around them.....	475
222. Deeper portion of the wound which contained bacteria.....	476
223. Gas within a ruptured muscle fiber.....	477
224. Variation in the way muscle fibers retain the basic dye.....	478
225. Separation of myomeres.....	479
226. Putrefactive infection of superficial hemorrhages of right thigh following several small wounds due to high-explosive shell fragments.....	480
227. Debrided, high-explosive wound with projecting muscle masses.....	481
228. Putrefactive infection around the wound tract.....	482
229. High explosive wound of the middle of the biceps.....	483
230. Section of the wound showing fragments of bone, dirt, and foreign bodies.....	484
231. Rupture of a muscle fiber.....	485
232. Splitting of fibers due to direct trauma.....	486
233. Muscle fiber completely honeycombed with fine bubbles.....	487
234. End of a muscle fiber showing large rod-shaped organism with an end spore....	488

TABLE OF CONTENTS

XIII

Figure	Page
235. Area of hemorrhage around the wound tract.....	489
236. Debrided wound below the external malleolus and putrefactive gangrene.....	490
237. Putrefactive gangrene of the os calcis.....	491
238. Gas bubbles within muscle fibers.....	492
239. Emphysematous gangrene in the interosseus muscles.....	493
240. Swollen muscle fibers showing gas and a marked variation in their staining reaction.....	494
241. Section nearer the wound tract.....	495
242. Section through putrefactive gangrenous area.....	496
243. Vertical section of left leg injured by high-explosive shell fragments.....	497
244. Wound tract with a surrounding putrefactive gangrene.....	498
245. X ray showing numerous foreign bodies and emphysematous gangrene.....	499
246. Section from the gangrenous, emphysematous gastrocnemius.....	500
247. Accumulation of gas between muscle bundles.....	501
248. Putrefactive gangrenous process.....	502
249. A lymphatic distended with gas and lined by masses of bacteria.....	503
250. Chemical changes of the muscle fibers as indicated by retention of the basic dye.....	504
251. Thrombosis of the femoral artery and vein and gas gangrene of muscle.....	505
252. Secondary infection of the bone marrow, extensive gas gangrene.....	506
253. Shredding of the adventitia of artery, with gas gangrene of the muscular coat.....	507
254. Muscle fibers from the putrefactive area.....	508
255. Large gas bubbles in muscle bundles.....	509
256. Debrided wound of arm.....	511
257. Injury to the musculospiral nerve.....	512
258. Beginning putrefactive gangrene around the humerus.....	513
259. Edematous muscle around the fractured humerus.....	514
260. Edema along the fascial planes.....	515
261. Edema of muscle fibers and muscle bundles and gas within muscle fibers.....	516
262. Edema within muscle envelopes and between muscle bundles.....	517
263. Edema, swelling and loss of markings in muscle fibers.....	518
264. Biceps muscle which shows reaction of the muscle fibers to the basic dye.....	519
265. Early regeneration of muscle fibers.....	520
266. Emphysematous gangrene around the fracture of the humerus.....	521
267. Gangrene due to failure of the blood supply.....	522
268. Cross section of the forearm showing emphysematous gangrene.....	523
269. X ray showing accumulations of gas around the fracture.....	524
270. Loss of normal markings of muscle fibers; accumulation of gas and hemoglobin detritus.....	525
271. Leucocytic exudate in the debrided wound.....	526
272. Intense basic staining of parts of muscle fibers.....	527
273. Debrided high-explosive shell wound of thigh. Toxic, edematous gangrene.....	528
274. Gas gangrene of muscles, and edema.....	529
275. X ray showing gas gangrene, comminution of the fracture and a piece of high-explosive shell.....	530
276. Muscles of the calf above the fragment showing gas gangrene.....	531
277. Comminuted fracture of tibia with mixed putrefactive and edematous gangrene.....	532
278. A fragment of bone surrounded by putrefactive gangrene.....	533
279. Shredding of the coats of a medium-sized vein.....	534
280. Muscle fibers from the gaseous area of gangrene.....	535
281. Muscle fibers in the putrefactive area of gangrene.....	536
282. Muscle fibers from an area of putrefactive change in gas gangrene.....	537
283. Muscle fibers from a contaminated area near the wound tract.....	538
284. Popliteal and thigh muscles affected by a putrefactive gangrene.....	539
285. X ray of the leg showing gas bubbles in the muscles.....	540
286. Muscle fibers from the putrefactive area.....	541
287. Section from the gaseous area of the calf muscle showing foreign bodies.....	542

Figure	Page
288. Left leg with high-explosive wound.....	543
289. Debrided wound exposing fractured ends of the tibia and fibula.....	544
290. Clot in the marrow of the tibia undergoing a putrefactive process.....	545
291. X ray showing fracture of both bones, and foreign bodies.....	546
292. Section from the putrefactive area around the larger blood vessels, showing missile tract which scores the margin of the posterior tibial artery.....	547
293. Missile tract showing a tear through the adventitia and media of the artery....	548
294. Beginning chemical change in the muscle fiber.....	549
295. External surface of an amputated left thigh showing machine gun bullet wound..	551
296. Putrefactive change along the wound tract.....	552
297. Muscle from the putrefactive area.....	553
298. Liquefaction of muscle fiber.....	553
299. Gram-positive bacilli between muscle fibers from an area of putrefactive gangrene.....	554
300. Cross section of a small nerve showing accumulation of gas.....	554
301. Rupture of muscle fibers, in close relation to the wound tract, probably caused by the trauma of the missile.....	555
302. Muscle fiber separated by gas and exudate.....	556
303. Necrotic muscle fibers in the gaseous area.....	557
304. A cross section of a medium-sized artery showing marked shredding and swelling of the adventitia.....	558
305. Clot in tissue near the vessel shown in Figure 304.....	559
306. Field of hemorrhage in the gangrenous area.....	560
307. A small vessel in the putrefactive area.....	561
308. Showing four cross sections of leg shown in Plate XXI.....	562
309. An area of putrefactive gangrene of the muscles with beginning gas gangrene....	563
310. Field from the putrefactive gangrenous area with a beginning gaseous process..	564
311. A typical picture in putrefactive gangrene.....	565
312. Putrefactive gangrene of muscle with considerable gaseous change.....	566

SECTION I

PATHOLOGY OF THE ACUTE RESPIRATORY DISEASES

INTRODUCTION

Hospital Surgeon, James Mann, introduced his report of the influenza epidemic of 1815-16, with the following significant paragraph:¹

We find diseases at the present day, described under new names, which are calculated to seduce the young practitioner, from a correct and established practice. It is true, that improvements have been made in the science of medicine; but it requires a discriminating mind, and an extensive knowledge of ancient as well as modern authors, so to apply these improvements, as to be able to meet diseases, in all the varying shapes, which they assume in the routine of years.

Few physicians in active practice in 1917 were practising at the time of the pandemic of 1889-92. Perhaps fewer still were familiar with the history of acute epidemic respiratory diseases and the admirable clinical and pathological descriptions which were recorded in medical literature in the nineteenth century. It is thus not surprising that the high morbidity, and more especially the high mortality, of acute respiratory diseases which occurred during the World War caused doubts to arise as to the identity of the diseases, and led to differences in opinion as to the proper nomenclature of the pathologic processes. Nevertheless, though the morbidity possibly was higher in 1918 than has been reported for any previous pandemic of this disease, the influence of increase in world population and the greater facility of transportation must be considered.

In the pandemic of 1918 it appeared that, for the first time, the medical profession was prepared to settle the bacteriology of influenza. That it did not do so was to some extent caused by the fact that the entire profession was engaged in the care of the sick. Some groups of medical men were able to investigate the bacteriology of the cases in an intensive manner, but an insufficient number were able to do so; furthermore, there was no opportunity to develop a standard technique for such investigations. While it is probable that the etiologic agent responsible for influenza has been reported and described, there is not sufficient evidence in the form of agreement among workers or verification of bacteriological results to determine that agent beyond doubt. Furthermore, no explanation of the varied bacteriological results that satisfies even the majority of the medical profession has been made.

The influenza bacillus of Pfeiffer still has the greatest claim for consideration as the etiologic agent of epidemic and pandemic influenza. In its favor are its increased prevalence just preceding and in the early part of the influenza epidemics and pandemic; its decrease in prevalence during the latter portion and after the pandemic;² its presence in culture in the early mild and also fulminant cases; the finding of organisms morphologically and tinctorially identical in tissues from which influenza bacilli were not recovered by cultural methods and the fact that it produces a true toxin, thus accounting for generalized symptoms in the probable absence of general dissemination of the bacteria throughout the body.

Against the etiologic relationship of this organism to influenza is the failure to find a common strain as shown by serological and immunological reactions, though this is discounted by the fact that there are numerous hemophilic bacteria of similar cultural and staining characteristics frequently found in other conditions, the organism thus apparently being a member of a large group, to be compared with Group IV pneumococci. The failure of many bacteriologists to find the organism in appreciable numbers of cases is in part explained by the demonstration that streptococci and pneumococci growing in the same culture inhibit the growth of the influenza bacillus, also that fresh or unchanged blood inhibits the growth, while blood heated, as in the so-called chocolate plates, favors it. The infrequency of influenza bacilli in blood cultures can be explained at least partly by this inhibitory influence of unchanged blood and also by the fact that in histologic sections the organism is rarely found except on the surface of tissues, apparently having little power to penetrate them. It extends rapidly along air passages, however, producing lesions on the surface and there can generate easily the toxic products which give rise to the general symptoms. A review of published reports of bacteriological investigations does not justify us in saying, on the evidence presented, that the organism was not present even though the cultures were negative.

The fact that suspensions of killed bacteria apparently show no protective influence presents no argument, pro or con, since the method of preparation may have been of such character as to destroy their immunity-producing action; moreover, we are familiar with many organisms, killed suspensions of which do not protect against infection. Failure to produce the disease by inoculation is not a very strong point against the etiologic significance of the organism, for, with the widespread dissemination of the disease and the occurrence of mild cases, the presence of immunity or lack of susceptibility can not be ruled out. Certain experiments, particularly those of Cecil and Steffan,³ indicate that, given a virulent strain with which to inoculate, characteristic symptoms can be produced in susceptible persons. The difficulty of determining the pathogenicity of the organism used and the possibility of bacterial variation must be considered in this connection.

No other organism, isolated from the pandemic, appears to deserve much consideration as an etiologic factor of influenza. *Bacterium pneumosintes*⁴ was isolated from cases after the peak of the pandemic had passed and its status can not be determined until the occurrence of another similar outbreak of the disease.

While it is not appropriate here to discuss the history of acute respiratory disease, certain lessons are taught by the experience of the armies of the United States in previous wars which should be reviewed in connection with the consideration of such diseases during the World War.

WAR OF 1812¹

During the winter of 1812-13, there was a high incidence of acute respiratory disease among the troops stationed on the northern frontier. Measles was epidemic among the troops from September to December, 1812. As the epidemic continued the symptoms increased in severity and pneumonic complications became more frequent. Beginning in October, 1812, acute respiratory disease independent of measles assumed epidemic proportions and replaced the diarrheas, dysenteries and "intermittents" (malaria) of the summer. It was noted that the morbidity and mortality was greater among troops from south of the Delaware River. Morbidity and mortality were less in the next winter for the Army as a whole, as it consisted for the most part of seasoned troops, yet it was noted that troops joining at that time were as severely affected as were the men mobilized the preceding year.

The clinical features and the pathological anatomy of the cases were identical with those of the epidemics of the fall of 1917 and the spring of 1918; the pathology of which, as is now realized, is not to be differentiated from that of the influenza pandemic of the fall of 1918.

This influenzal disease attacked the troops of 1812 throughout the various Army stations but showed varied clinical pictures in different stations. A catarrhal affection was universal among the men at all stations at the time of the epidemic.

In many of the early cases death occurred within one to four days of the onset of severe symptoms and appeared to be from suffocation rather than from that group of symptoms usually associated with pneumonia. The labored respirations were not from pain but from a sense of suffocation. Mann considered that the lung, by reason of engorgement of the bronchi, excluded air from the smaller ramifications and thus was "incapable of absorbing or transmitting through its membrane the vital principle of the atmospheric air." The lungs were filled with blood, were dense and heavy and frequently sank in water. Empyema was apparently frequent in cases surviving sufficiently long. The clinical picture varied as did the pathology not only as between stations but also at the same station. Repeated removal of small amounts of blood was found an efficacious method of treatment. The explanation of the efficacy of bleeding is somewhat obscure but it is noteworthy that during the last pandemic the blood was found to be concentrated and the removal of small amounts of blood and forcing fluids appeared to be an efficacious treatment in the early stages of the disease.⁵

Acute respiratory diseases were not as prevalent in the winter season of 1813-14 but in the fall of 1815-16, epidemic influenza spread over the eastern United States and Brazil.⁶

Mann described the clinical course and pathology of this epidemic in the civil population of Sharon, Mass., in considerable detail and stated that they were identical with that seen in the troops of the northern frontier during the two preceding seasons.^a

CIVIL WAR (1861-1865)

Acute respiratory diseases were an important cause of morbidity and mortality throughout the entire period of the Civil War.⁷

There was no such epidemic as the one of the fall of 1918 in the World War, but there were excessive seasonal variations in the respiratory disease rates with a curve for "catarrh" in the winter of 1862, resembling that for the influenza epidemic of 1918. The percentage of fatal cases of pneumonia for the five years 1861 to 1866, inclusive, was 24.08 for white troops, and during the last three years it was 32.44 for colored troops. The rates were higher during the first year, decreasing rather slowly in the white troops and more rapidly in the colored. In the Confederate troops the acute diseases of the respiratory tract are represented as being of more serious import than among the Federal troops. In one hospital 37.18 per cent of the cases of pneumonia and pleurisy proved fatal. A comparison table shows an annual death rate per thousand for pneumonia of the Confederate armies as 20.6 and of the Union troops 7.8. The influence of measles in epidemic form was recognized as a predisposing factor to a marked increase in the bronchitis and pneumonia rate accompanied by an increase in mortality.

The diseases recorded were catarrh, epidemic catarrh, acute and chronic bronchitis, pneumonia, and acute diseases of the upper respiratory tract. After 1862, catarrh disappears from the record, practically the entire rate of which in subsequent reports appears to have been included in that for acute bronchitis. Many cases of "epidemic catarrh" were reported but there was no spread of this condition as a general epidemic. The increased incidencies were local in character and occurred independently in different camps throughout the course of the war. New levies and organizations new to field service appeared to be most liable to this condition.

Acute bronchitis had a low death rate. Many of the deaths, however, followed attacks of measles. The pathological findings reported in the fatal cases were in part those of intense bronchitis, while a few showed the pathological

^a At Sharon, the *peripneumonia notha* made its first attack, with symptoms of uncommon coldness and torpor, which pervaded the whole system, without those strong rigors observed in pleurisy, and intermittent fever; the heat of the body at the same time, to the touch, much below the standard of health. * * * There was a remarkable pale pink coloured suffusion over the whole face, distinct from the usual febrile blush in the cheeks; the appearance was similar to the sudden flush colour, produced by sitting before a fire, after having been exposed to cold. This appearance was most conspicuous on persons having fair and light complexions. This was accompanied with a bloated countenance, which gave to the spare and pale-faced patient, additional beauty to the general features. This rouge-like appearance, was less conspicuous on the body, than the face. It is to be noticed, that during the cold stage, the patients suffered from pain throughout the muscles of the body, in one case similar to rheumatism. In four or five instances, this epidemic made its assault upon the head; which bleeding immediately relieved; upon enquiry, I found there was here no complaint whatever within the chest. It was then prognosticated, that in 24 hours, more or less disease would exhibit itself on the lungs. This prediction, which was presumed upon former experience, on the northern frontiers, was fulfilled in every instance where made; while the pneumonic symptoms which followed, were not eventually less severe, than in those cases, where the first symptoms of disease showed themselves, within the breast. The appearances were engorgements, congestions, and inflammations, even where there was previous to death no increase of heat. The bronchiæ were charged with a mixture of blood, and mucus. Where the disease had been of some duration, adhesions of the lungs to the circumjacent parts were noticed. The spongy mixture of this viscus was lost; while it assumed in some measure, the solid and compact state of the liver. It was sometimes covered with a yellowish, glutinous, extravasated fluid, which adhered with some force to its surface.

lesions of a hemorrhagic pneumonitis without definite foci of consolidation, a pathology with which we became familiar during the epidemics of 1918. Some cases described clinically as bronchitis were found at necropsy to have a lobular pneumonia which was considered to have supervened on the attack of bronchitis.

"Chronic bronchitis" gave rise to a moderate discharge rate for disability and to a certain number of deaths. It appeared to follow "acute bronchitis" and to represent those cases not infrequently observed during the last war of the failure of the bronchopneumonia to clear up, or to those cases of bronchiectasis following influenza which have given rise to some degree of invalidism among the veterans. The necropsy reports are not sufficiently definite to enable one to judge of the pathologic condition present.

Under "pneumonia" it is stated that many diseases were of more frequent occurrence than pneumonia, but only diarrhea and dysentery and the continued fevers furnished a larger death list. It was shown, however, in the discussion of the points of interest connected with these grave camp diseases, that pneumonia was present, and caused or hastened the fatal issue in 21.6 per cent of the deaths from diarrhea and dysentery and in 68.3 per cent of those attributed to the continued fevers; the mortality from measles also resulted largely from inflammatory processes in the lungs.

Under the title of pneumonia are described many cases of the various forms including the unfavorable terminations of abscess of the lung, gangrene, unresolved pneumonia and bronchiectasis. Some of these cases the physical signs of which indicated a persistence of consolidation were termed "chronic pneumonia" or "chronic interstitial pneumonia."

Acute hemorrhagic pneumonitis does not appear as such under the heading pneumonia but under that of fatal acute bronchitis, and it is quite clear that the pathological entity is that seen during the epidemic of September and October, 1918, in the United States, and in a lesser number of cases in the high respiratory incidence of the spring of the same year.

The high fatality in cases in which the pleura and pericardium were involved is noted in the general discussion. Practically every type of lesion seen during the World War is described in these protocols of the necropsies of the Civil War. Under secondary pneumonia are included a large proportion of those pulmonary inflammations which appeared at the time to be entirely secondary, in fact the descriptions of the clinical course indicate the presence of an acute respiratory infection without severe embarrassment of respiration and no physical signs of pneumonia preceding the increased symptoms due to consolidation. The clinical descriptions of these cases correspond with those recorded during both the spring and fall epidemics of 1918. The clinicians and pathologists of that time considered that a primary bronchitis was followed by a distinct and separate disease, namely, pneumonia, and believed that the first made the patient more susceptible to the second rather than that they were definite manifestations of the same disease either in character or extent.

Under pleurisy are recorded numerous fatal cases in most of which there was general involvement of the chest cavity. The records showed that no definite differentiation was made between mild pleuritic involvement and frank empyema.

MEXICAN BORDER MOBILIZATION (1915-16)

During the mobilization on the Mexican border of 1915-16, an epidemic of about 400 cases of pneumonia occurred among 40,000 troops with a 20 per cent case fatality. The epidemiological and bacteriological characteristics of this outbreak were described by Nichols.⁸ Pneumococci and streptococci were cultivated from the sputum. Type determinations showed pneumococcus Type I in 56 per cent, Type II in 22 per cent, Type III in 2 per cent and Group IV in 20 per cent. Many of the troops were from Northern States where Type I was prevalent in the pneumonia of the camps in 1917. In view of our experience during 1917 and 1918, it is probable that an acute respiratory infection preceded the pneumonia. Had this not been so, a greater proportion of the pneumonic lesions should have been caused by a single type of organism, though in the present state of our knowledge, bacterial variation must be considered. The lack of all pathologic description prevents us from making a definite decision as to the character of the pulmonary inflammation which was recorded as lobar on the basis of clinical observation. Direct evidence of tent, company and regimental contagion was obtained. In reporting the epidemic Nichols made the following prophecy which was overlooked in the rush of war preparation taking place at the time of publication: "Epidemic lobar pneumonia is to be expected in large camps in the winter months."

REFERENCES

- (1) Mann, James: Medical Sketches of the Campaigns of 1812, 13, 14. Dedham, 1816, p. 306.
- (2) Zinsser, Hans: The Etiology and Epidemiology of Influenza. *Medicine*, Baltimore, Vol. 1, No. 2, 1922, 213-309.
- (3) Cecil, R. L., and Steffan, G. I.: Acute Respiratory Infection in Man Following Inoculation With Purulent Bacillus Influenzae. *Journal of Infectious Diseases*, Chicago, 1921, xxviii, 201-225.
- (4) Olitsky, P. K., and Gales, F. L.: Experimental Studies of the Nasopharyngeal Secretions from Influenza Patients. *Journal of Experimental Medicine*, Baltimore, 1921, xxxiii, 125, 361, 375, and 713; *ibid.*, 1921, xxxiv, 1; *ibid.*, 1922, xxxv, 1, 553 and 813; 1922, xxxvi, 685.
- (5) Underhill, F. P., and Ringer, M.: Blood-concentration Changes in Influenza, with Suggestions for Treatment. *Journal of the American Medical Association*, Chicago, 1920, lxxv, 1531.
- (6) Hirsch, August: Handbook of Geographical and Historical Pathology. *The New Sydenham Society*, London, 1883, i, 12, 17, 23.
- (7) Medical and Surgical History of the War of the Rebellion. Part 3, Medical, 719.
- (8) Nichols, Henry J., Maj., M. C.: The Lobar Pneumonia Problem in the Army From the Viewpoint of the Recent Differentiation of Types of Pneumococci. *The Military Surgeon*, Washington, D. C., 1917, xli, 149-161.

CHAPTER I

IN CAMPS IN THE UNITED STATES

Measles in epidemic form made its appearance in our newly mobilized troops in the fall of 1917 and as the epidemic progressed the incidence of pneumonia as a complication increased just as it has in former wars. In most of the camps, in addition to measles, there was a high incidence of acute respiratory disease independent of measles, which assumed epidemic proportions and was accompanied by a large number of cases of pneumonia. At first the pneumonia corresponded with that seen in civil life, and this was particularly true in the northern camps. Mortality increased, however, in cases following the acute respiratory diseases and following measles, and it became evident that organisms of unusual virulence were present. Pneumococci of the fixed types showed their highest prevalence during the earlier weeks, becoming less frequent as the epidemic wave progressed, pneumococcus Group IV and streptococci replacing them in incidence in cultures. In certain camps where case fatality was high, bacteriological investigations revealed that hemolytic streptococci were present in a majority of the severe cases. Lobar pneumonia was seen in the early weeks of this outbreak of acute respiratory disease, but in typical form became much less frequent, being succeeded by lobular pneumonia, bronchopneumonia or bronchiolar consolidations accompanying severe bronchitis. In pulmonary inflammations associated with hemolytic streptococci empyema was frequent, and many of the lungs showed a phlegmon of the interstitial, peribronchial and perivascular tissues. This epidemic condition waned about the beginning of 1918.

During the fall of 1917 the receipt of fresh troops was followed by a sharp increase in acute respiratory diseases, not only in the recent arrivals, but also among troops which already had passed through the acute respiratory epidemic. In the spring of 1918 in the majority of camps there was another epidemic wave of acute respiratory diseases, and this occurred whether or not any considerable number of new recruits had been received. At first the epidemic resembled that of the previous fall, and in the majority of camps continued to its termination without marked variation. In certain camps, however, there was a sharp rise in case fatality which, so far as can be ascertained from bacteriological examination, was due to hemolytic streptococci. Where there was found a relatively small proportion of these organisms in cultures of the sputum and lung, there was a relatively low case fatality rate. In a few camps where these organisms were prevalent, in the spring of 1918, the case fatality rate exceeded that recorded during the pandemic influenza of the following fall. In these instances the pandemic was not accompanied by a high incidence of hemolytic streptococci, but by nonhemolytic streptococci and pneumococci, a large proportion of the latter being Group IV.

The morbidity of the three periods of high incidence of acute respiratory diseases of the World War varied, but the clinical description of the cases, the

pathology of the lesions and the bacteriology of the pneumonic processes were similar. Such variations as occurred in the bacteriology of pneumonia account for the differences in the case fatality rates.

The acute respiratory diseases of the three periods appeared in three waves of influenza, the second having greater morbidity and mortality than the first, the third or pandemic one by far the greatest. The pandemic occurred at about the peak of the greatest mobilization in history of men into military units, a mobilization unavoidably accompanied by an interchange of the flora of the respiratory tract between the peoples of all great land divisions of the world, except South America.

It is difficult to imagine a greater opportunity for enhancement of virulence by rapid passage from man to man of the organisms causing influenza, and of those producing secondary infections. Increase in virulence by this means must be considered as a factor of great importance in the production of the high morbidity and mortality.

The pathological anatomy of the pulmonary lesions was characterized by its variety, but no new or hitherto undiscovered lesions were seen. The prevalence of but one type of lesion in the lungs of a single case was rare. Typical lobar pneumonia was infrequent, and when present was usually caused by pneumococcus Type I, occasionally Type II, and rarely by Group IV.

Bronchopneumonia, that is, pneumonic consolidation spreading out from the bronchial tree, was frequent, though rarely the only process present. This type of distribution resulted from extension of the inflammation from the bronchial lumen out into the parenchyma, largely by direct continuity. In some cases the inflammation spread to the walls of neighboring bronchi, enveloped them and, extending still farther, involved the surrounding parenchyma before it penetrated the bronchial wall. A similar gross picture was produced by extension outward from a lymphangitis or phlegmon of peribronchial lymphatics resulting from the drainage of pneumonic areas in pulmonary tissue not always supplied with air passages by that bronchus.

The most frequent type of pneumonic consolidation was the lobular which occurred in isolated lobules in lungs, the major portion of which was affected by other types of distribution, and took the form of confluent or grouped lobular consolidations varying in extent from small areas to an entire lobe. In a lung where a large proportion of a lobe was involved, it was distinguished from lobar pneumonia by the lack of uniform hepatization, by variations in the character of the consolidation in different and often adjacent lobules, by its apparent extension by continuity at the periphery, and by its tendency to destroy pulmonary tissue. This resulted in necrosis, the formation of abscesses and gangrene. This type of distribution was the one usually present in lungs showing interstitial lymphangitis or phlegmon, caused by hemolytic streptococci.

Acute bronchitis accompanied by small consolidations about respiratory bronchioles, and involving their terminal atria, air sacs, and alveoli, was found occasionally in the fall of 1917, more frequently in the spring of 1918, and almost constantly in some part of the lungs of the cases of the epidemic period of the fall of 1918. So far as can be judged by the examination of histologic sections, backed by a considerable amount of bacteriological evidence, this type of lesion

was associated with influenza bacilli, often in pure cultures, both in this country and abroad. In discrete lesions, the exudate was purulent, though the individual nodules frequently were surrounded by zones of hemorrhage. In some of the fulminant cases the nodules were definitely hemorrhagic and resembled small infarcts on gross examination, but in the microscopic sections these were seen to be peribronchiolar consolidations rather than hemorrhages about blocked vessels. This hemorrhagic type of lesion occurred in patients who died within the first 24 hours of the onset of pulmonary symptoms. None of the cases occurring in the troops in the United States died within 24 hours of the onset of respiratory symptoms, so far as can be learned from the necropsy records, though many died within 24 hours of the onset of symptoms indicating pulmonary involvement. The more rapid the fatal outcome after the onset of serious pulmonary symptoms, the more universal was the involvement of the lungs.

In the early part of the pandemic wave of the fall of 1918, and occasionally during the epidemic of the spring of that year, cases occurred, the lungs of which showed a uniform lax consolidation. The lungs would sink in water, and were hemorrhagic, extremely moist, and dripped blood and frothy serum. Subsequent fixation in formaldehyde solution usually revealed areas of early consolidation and zones of clotted hemorrhagic infiltration. In such cases it appeared microscopically as though practically every alveolus in the lung was uniformly and simultaneously involved with a serous inflammation completely filling the lung with fluid which was accompanied by varying amounts of hemorrhage. In these cases death probably was from suffocation rather than the toxic effects of the etiologic agents. Such cases were responsible for the feeling that the old classification of pneumonia by distribution of the lesions was inappropriate, and that the name acute pneumonitis was more applicable. In such cases bacteriologists found influenza bacilli, and in the collections of the Army Medical Museum every case examined of this type in which the tissues were well fixed, showed small Gram-negative bacilli, though all of this type came from cases dying during the pandemic of the fall of 1918. Lesions of this character involving lobes or parts of lobes were seen frequently in cases of less fulminant character, and represented extensions of the process shortly preceding the death of the individual. All variations in the confluence of the process were seen, from the isolated foci, which resembled conglomerate tubercles, to uniform generalized pneumonitis.

In some instances hemolytic streptococci invaded the lung and produced a fatal issue within the first few days. On gross examination these lungs showed more hemorrhage than when the influenza bacillus alone was present, but the most striking difference was seen in the microscopical examination which revealed as the characteristic picture a leucocytic infiltration of the alveolar walls. In some cases this infiltration was predominantly lymphocytic, but usually polymorphonuclear cells equaled or exceeded the lymphocytes.

Mononuclear leucocytes were seen in lungs of the diffuse pneumonitis type from which influenza bacilli were cultivated, but the principal changes in the alveolar walls of such cases were edema, greater or lesser desquamation of the epithelium and, in many instances, the formation of the so-called hyaline

membrane. This membrane was formed by a secondary exudation of more viscid character along the alveolar wall subsequent to the casting off of the epithelium of the alveoli and atria. It was rarely seen along walls still covered with epithelium.

The picture at necropsy, except for the variation in distribution, depended to a very large extent on the length of the time the patient lived following the onset of the pulmonary complications. The earliest deaths were due to diffuse inflammations. Later came the various types of distribution of the consolidation, streptococcic lymphangitis occurring sometimes apparently simultaneously with the consolidation, or, where this lymphangitis occurred in lobar consolidations, it usually manifested itself during the stage of gray hepatization. Interstitial lymphangitis and phlegmon were secondary to streptococcic inflammation of the alveoli and bronchi and formed a prominent part of the picture in most of the cases caused by streptococci. Unlike the pneumococcus, the hemolytic streptococcus spreads through the lymph spaces of the alveolar walls rather than along air passages, irritating the lymphatic channels which drain the regions invaded by it, so that they take part in the inflammation. The lymph channels become blocked by the clotting of the fibrinopurulent exudate and in them abscesses are formed. It is also possible that when lymphatic channels at the hilus are blocked by such a process the lymphatic circulation may extend outward into the lung by collaterals as yet uninvolved; but this method was not frequent. The lymphangitis usually was secondary to the inflammation of the air passages and alveoli.

Necrosis and the extension of peribronchiolar lesions to complete involvement of the lobules required that the patient live a longer time. With increased length of life hemorrhagic features disappeared. The lesions were first purulent, and later there occurred necrosis, which formed so prominent a feature in cases dying after two or three weeks of illness. Abscesses formed slowly except in pneumonic lesions due to staphylococci in which the rapid lytic action of this organism gave rise to definite abscessed lesions about the bronchioles in cases dying within a week of the onset of pneumonic symptoms.

Numerous complicating or associated lesions of the various types of pulmonary inflammation have been described. Certain of them appeared with such frequency or were of such nature as to excite considerable interest. Acute emphysema, giving rise to blebs beneath the pleural surface, air in the interstitial tissues of the lung, in the mediastinum, along vessels, and in the subcutaneous tissues, was a spectacular condition. Escaping as the result of degeneration and rupture of the alveolar and atrial walls, possibly also through ruptures of acute bronchiectases of the bronchioles, it made its way along interstitial tissues, perivascular and peribronchial structures, and eventually appeared in the subcutaneous regions. Occurring as it did when the medical profession was interested in wounds infected with the Welch bacillus, it caused considerable concern but was of little clinical importance. Much more important was the extension of the inflammatory process to the pleura, usually after considerable portions of the lung had been involved, but occasionally directly from the mediastinum without much, if any, pulmonary involvement other than an

acute bronchitis. The organisms responsible in most instances were hemolytic streptococci.

Empyema is adequately described in another volume so its discussion in this is limited solely to tracing its relationship to the other pathology of the respiratory tract.

The involvement of the peritoneum, of the meninges, and of the joints, other than from direct extension from other processes, was probably due to the virulence of the invading organism, and though infrequent, occasionally occurred in every camp. Organisms isolated from these lesions were occasionally streptococci, more frequently pneumococcus Type II, occasionally Group IV. In several camps pneumococcus Type II showed a virulence exceeding that of all other organisms.

Atelectatic areas in the lung were caused by the blocking of the small bronchi by the primary inflammatory processes, also as a result of abscess formation which encroached upon the lumens of bronchioles.

Thickening of the epithelium of the air passages by a proliferation of the basal cells after the columnar layer had been desquamated was seen even in the earliest cases, and was particularly noticeable in those from which influenzal bacilli were cultivated. The result of this proliferative change resembled stratified squamous epithelium and sometimes extended out from the bronchi into the alveoli, particularly those alveoli situated along the walls of the respiratory bronchioles. Some part of the respiratory epithelium in every case showed this change in varying degree, but it was absent in the trachea and bronchi of cases in which streptococcus infection apparently occurred early, where usually the surface epithelium and sometimes the hyaline basement layer was destroyed.

CAMP BEAUREGARD, LA.^a

The diagnosis "influenza" was used throughout the history of this camp. There was a definite epidemic outbreak during the months of March and April of 1918, although the most marked incidence was in September and October, 1918. Measles was a serious factor at this camp and was responsible for a considerable number of deaths, showing a sharp increase at the time of the original mobilization, and just before and just after the influenza epidemic, although, due to a decrease in personnel, the high rates of November and December, 1918, do not represent very many cases.

The exact character of the pneumonia preceding the epidemic of influenza is not indicated in the history of the camp or in reports on the subject. It is probable that a certain number of the cases of primary pneumonia, as in other camps, were secondary to a preceding acute respiratory infection. There is no indication from available records that empyema was a particularly serious complication in this camp, and the high percentage of cases diagnosed lobar pneumonia strongly suggests a preponderance of the fixed types of pneumococci both in the fall of 1917 and the spring of 1918.^b

^a Source of information, except as otherwise indicated: Medical reports to the Surgeon General, 1917, 1918, and 1919.

^b The following statements of fact are based, in the main, on: A Review of the Epidemic of Influenza at the Base Hospital, Camp Beauregard, La., with Special Reference to Symptoms and Sequelæ, by Donald J. Frick, *American Journal of the Medical Sciences*, Philadelphia, 1919, clviii, 68-80.

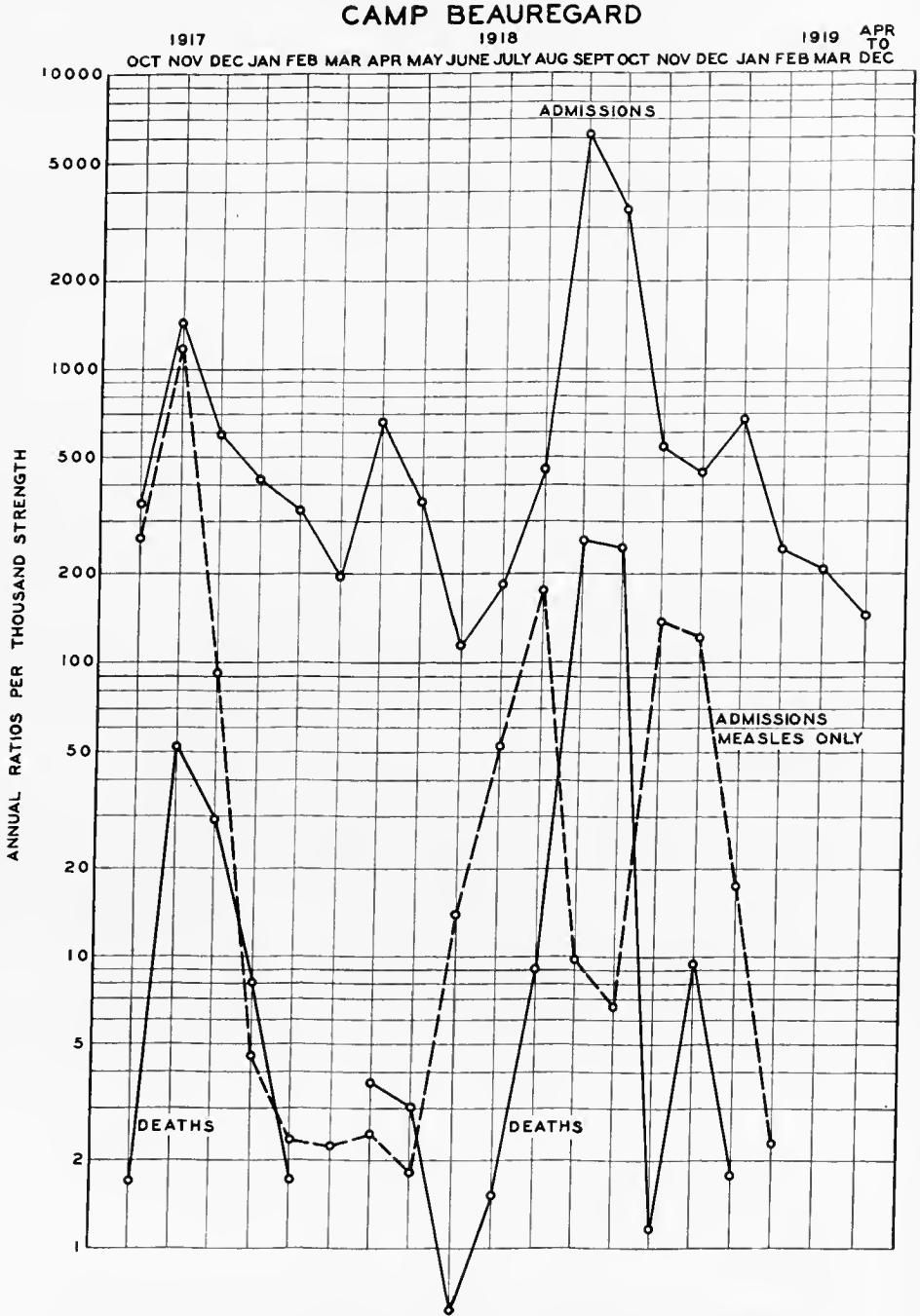


CHART I.—The incidence and fatality of the acute respiratory diseases at Camp Beauregard

The symptoms were of exceeding variety as to severity and kind. Most of the cases had severe backache, headache, a racking cough, flushed face, injected eyes, and, as a rule, pulse between 80 and 100, with a temperature from 101° to 104° F. Most of them were dull and apathetic, went to sleep in the ambulance, slept on the litter while they were being carried into the hospital, and had to be aroused to answer questions. They roused up only to cough, take medicine or nourishment. All looked prostrated and sick. All slept 12 hours, some 16 to 24 hours. The fever and prostration in the mild cases lasted 48 hours; the patients then began to get up and sit on the edge of the beds. They were all weak and some fainted in trying to get out of bed. The more severe cases had fever for three or four days. Practically all cases that had fever longer than this proved to have bronchopneumonia. Many had vomiting; some became tender over the abdomen, imitating an intra-abdominal condition.

There was a leucopenia in practically all cases and no rise of leucocytes with the advent of pneumonia.

Besides the ordinary symptoms, a striking feature in the early stages of these cases was the bleeding from some portion of the body; 15 per cent suffered from epistaxis. Everywhere one went one saw men with bleeding or packed noses. Fifty cases of subconjunctival hemorrhage were counted. Twelve had a true hemoptysis, bright red blood with no admixture of mucus. Six cases vomited blood. One case died from loss of blood from this cause. Among the nurses, menstruation began in about 80 per cent 2 or 3 days after going to bed. Three cases had intestinal hemorrhage. Most of the bleeding came early, with the exception of three cases of hemoptysis, which came after bronchopneumonia had begun.

Twelve to 15 per cent of all cases had herpes either of the lips, tongue, nose, or mouth, the eruption being exceedingly extensive in some cases.

Pneumonia developed secondarily to the influenza in 1,342 cases, and the complications given below must be regarded as complications of this disease, in most cases, rather than of influenza.

Jaundice of a mild or severe degree developed in 112 cases of bronchopneumonia. In those recovering, the jaundice disappeared very rapidly, in some cases clearing up entirely in seven or eight days. The liver in all cases seen was enlarged, so it was believed to be a true cholangitis.

Otitis media was reported in 41 cases. Fortunately the otologists were on duty day and night and did immediate paracentesis on all bulging drums. No mastoid operations were necessary.

Infectious psychoses were seen in 18 cases, the patients exhibiting all grades of aberration from simple transient hallucinations to maniacal frenzy which needed mechanical restraint for 12 to 24 hours.

Two cases developed an hysterical aphonia (which cleared up in three and eight days respectively).

Five cases of pneumococcus meningitis were diagnosed clinically and proved positive by lumbar puncture; six to eight cases were punctured that had some signs of meningitis; these all showed a clear fluid under pressure, no increase in cells and no bacteria.

Eleven cases of epidemic cerebrospinal meningitis were diagnosed and isolated during the epidemic; three cases developed after the patients were convalescing from pneumonia and had been in the hospital from three to four weeks.

Empyema cases appeared at the end of the epidemic. Twenty-nine were reported, 3 cases showed hemolytic streptococcus, 20 cases pneumococci, 7 cases no organism found.

The most interesting complication on account of its usual rarity was interstitial emphysema, of which there were 10 cases. The only reason that can be given for the great number of these cases is the violence of the cough and the degenerative changes brought about in the disease. All of these cases had influenza, followed by bronchopneumonia, the subcutaneous emphysema coming from 6 to 10 days after the beginning of the disease. The air was first felt in all cases in a collar about the neck and then gradually spread over the back, chest, and arms to the hands as far as the knuckles and down the thighs to the middle. A rupture of the bronchus at the root of the lung seemed to be the only explanation.

Two cases after violent coughing developed a pneumothorax, the heart being pushed to the right as far as the midline on that side. One case proved to be a pyopneumothorax.

No reason could be given for the frequency of hemorrhages, but it was felt that there must have been some definite change in the constituents of the blood, although no estimation was made of the coagulation and bleeding time, nor were the platelets counted.

Death came rapidly and could be prognosticated practically from the moment the man entered the hospital.

Autopsy protocols of some of the most interesting cases are given below.

AUTOPSY PROTOCOL, No. 1

(Autopsy No. 6)

E. V., Sergt., Co. E, 5th Infantry. Time of death: 2 a. m., September 28, 1918. Time of autopsy: 9 a. m., September 28, 1918. Admitted: September 26, 1918.

Clinical diagnosis.—Lobar pneumonia, right lower.

Anatomical diagnosis.—(1) Acute catarrhal bronchitis; (2) diffuse bronchopneumonia of both lower lobes; (3) acute hemorrhagic pleuritis of right lung; (4) acute splenic tumor; (5) cloudy swelling of liver, kidneys, and myocardium.

External examination.—The body is that of a well-developed, white male, about 71 inches long, weighing about 185 pounds. Strong rigor is present, and there is marked lividity of the posterior surface of the body and of the left side of the face. There are no external marks of injury or of identification.

Internal examination.—A thin layer of subcutaneous fat is present. The peritoneal cavity is free of adhesions and of fluid. The pericardial cavity contains a slight excess of fluid which is partly clotted. The left pleural cavity is normal. The right contains a slight excess of fluid, which is faintly clouded and slightly blood-tinged.

Lungs.—The pleural surface of the left is smooth and glistening. The lower lobe, although it contains air, feels heavier and less eripitant than normal. On section the lower lobe is congested, and the cut surface, from which frothy fluid escapes, is very finely granular, the appearance suggesting the consolidation of innumerable groups of small numbers of alveoli, these being separated by small groups of air-containing alveoli. The upper left lobe is eripitant and pale pink in color. The pleura of the lateral surface of the right lung is finely granular and hemorrhagic, but its surface contains fibrin. The lower lobe is con-

gested, and like the lower left lobe is heavier and less crepitant than normal. On section it is somewhat more deeply congested than the lower left lobe, but has the same very finely granular appearance. The upper and middle left lobes appear normal. The bronchi of both lungs are deeply congested, but contain no exudate.

Heart.—The right side is distended with blood. All the valves and the root of the aorta are normal. The heart muscle is pale and cloudy.

Spleen.—The spleen is enlarged to about three times the normal and feels rather soft. The outer surface is smooth and is dark bluish red in color. On section the tissue is dark red and much blood escapes from the surface.

Liver.—Normal externally. On section the tissue is cloudy. Gall-bladder and ducts are normal.

Kidneys.—Each is slightly increased in size. On section the cortex is swollen and cloudy and the glomeruli stand out as minute, slightly congested points.

Adrenals, pancreas, gastrointestinal tract, bladder, and prostate.—Negative.

Bacteriology.—Cultures from the heart's blood and from the fluid of the right pleura show no growth. Smears from the lower lobes of the lungs show Gram-negative small bacilli and Gram-positive diplococci. Cultures from the lung yield *B. influenzae* and a Gram-positive, bile insoluble, nonhemolytic streptococcus.

AUTOPSY PROTOCOL, No. 2

F. W. T., Pvt., Co. E., Dev. Bn. Admitted: September 29, 1918. Died: 9 a. m., October 4, 1918. Autopsy: 10 a. m., October 4, 1918.

Clinical diagnosis.—Lobar pneumonia.

Anatomical diagnosis.—(1) Lobar pneumonia of the right lower lobe (red hepatization); (2) pseudolobar pneumonia of the left lower lobe; (3) bronchopneumonia of both upper lobes and of the right middle lobe; (4) acute catarrhal bronchitis of both lungs; (5) acute fibrinopurulent pleuritis of right lung; (6) acute splenic tumor; (7) cloudy swelling of liver, myocardium, and kidneys.

External examination.—The body is that of a slenderly built white male, about 70 inches tall, weighing about 146 pounds. The body is still warm and rigor is absent. The neck and face are cyanotic. On the inner surface of the left knee is a large old scar of a burn.

Internal examination.—Peritoneal, pericardial, and left pleural cavity are normal. A thin layer of yellow exudate is present over the lower outer half of the right upper lobe and between the lobes.

Lungs.—The lower lobe of the left lung is occupied by irregularly shaped confluent patches of dark red, airless tissue, which is congested and granular on section. A smaller wedge-shaped area is present at the lower border of the right upper lobe. The right lower lobe is completely consolidated and on section the tissue is dark red and granular and contains much blood. A few small patches of consolidation are present in the right upper and middle lobes. The bronchi of both lungs are congested and contain no exudate.

Heart.—Negative except for cloudy swelling of the muscles.

Spleen.—The spleen is increased to twice the normal size. On section the tissue is dark red and soft.

Liver.—Cloudy.

Kidneys.—The cortex is swollen and cloudy.

Adrenals, pancreas, gastrointestinal tract, bladder, and prostate.—Negative.

Bacteriology.—Smears from the right upper and lower lobes and from the pleural exudate contain many Gram-positive diplococci. Cultures from these situations contain pneumococci. Culture from the spleen is negative. The heart's blood culture is contaminated by a large Gram-negative bacillus, but contains Gram-positive diplococci, which prove to be Type IV pneumococci in the peritoneal exudate of a mouse injected with the culture.

AUTOPSY PROTOCOL, No. 3

R. F., Pvt., Co. H, 5th Infantry. Admitted: September 26, 1918. Died: 12.50 p. m., October 10, 1918. Autopsy: 3.30 p. m., October 10, 1918.

Clinical diagnosis.—Influenza. Bronchopneumonia of the left lower lobe. Interstitial emphysema bilateral.

Anatomical diagnosis.—Interstitial emphysema bilateral. (1) Pseudolobar pneumonia of both lower lobes; (2) bronchopneumonia of both upper lobes and of the right middle lobe; (3) interstitial emphysema of the mediastinum and of the subcutaneous tissue of the face, neck, thorax, and arms.

External examination.—The body is that of a sparely built white male about 66 inches tall, weighing about 130 pounds. Rigor and lividity are not present. The skin of the right side of the face and of the entire neck appears swollen, and on pressure it has a crepitant crackling feel. The same crepitant sensation is elicited upon pressure of the skin of the chest anteriorly as far down as the nipple line, literally on both sides of the chest to a slightly lower level and about halfway down on both arms. The skin of the crepitant regions is not discolored.

Internal examination.—The peritoneal cavity is normal. When the sternum is removed the tissues of the mediastinum are found filled with air, which occurs in the form of bubbles of varying size held in the loose tissues. The loose tissues of the root of the neck show a similar condition. The pericardial cavity is normal. Both pleural cavities are free of fluid and of adhesions. The lungs are not collapsed and no air is present in the pleural cavities.

Lungs.—The two lungs are removed *in toto*, together with the trachea. Bubbles of air are present beneath the pleura of the left lung; these bubbles follow the lines of the interlobular septa. The pleura of each lower lobe posteriorly and laterally is granular and cloudy, but no macroscopic fibrin is present. All the loose tissue about the roots of the lungs contain bubbles of air. The lungs feel heavy, the lower lobes being enlarged and dark red in color. Areas of consolidation are present in both upper lobes, and about half of the right middle lobe is solid. Although the lower lobes are almost completely consolidated, small areas of air-containing tissues are present at the margins and in several places beneath the pleura. When the lungs are immersed in water and inflated by a tube placed in the trachea a steady stream of air bubbles escape from the tissue at the bifurcation of the trachea, the air apparently coming from the left bronchus anteriorly at the level of the bifurcation. On opening the trachea a small tear is found in the mucosa of the anterior wall of the left bronchus in the region from which the air was seen to escape. On section of the lungs both lower lobes are dark red and granular. Scattered about in the dark red tissue are numerous more opaque gray areas two or three lobules in size; these areas appear to have a peribronchial distribution. The right middle and both upper lobes contain areas of consolidation, of varying size, which are grayish red in color and rather soft and friable. The bronchi contain no exudate and their mucosa is not reddened.

Spleen.—The spleen is moderately enlarged, firm, and dark red. The remaining organs were not examined further.

Bacteriology.—Smears and cultures from the right lower lobe show nothing. Cultures from the spleen and heart's blood remain sterile. Smears from the left lower lobe show a few Gram-positive diplococci; the cultures show numerous Gram-negative small bacilli and Gram-positive cocci in pairs and chains. The latter type are Type III pneumococcus.

AUTOPSY PROTOCOL, No. 4

W. McC., Pvt. Co. A., M. P. Died: 5.15 a. m., October 20, 1918. Autopsy: 11 a. m., October 20, 1918.

Clinical diagnosis.—Pneumothorax.

Anatomical diagnosis.—Pneumothorax (left); suppurative pneumonia of the left lung; bronchopneumonia in the right.

Histological section of the tissue of the right lung, left lung, and spleen.

External examination.—The body is that of a well-developed male, weight about 165 pounds, 6 feet in height. Rigor mortis is present. The skin is clear and there are no deformities or marks; the appearance of his face indicates some emaciation.

Internal examination.—An incision is made from the suprasternal notch to the pubes. The subcutaneous tissue is in good shape.

Lungs.—The left lung has completely collapsed. It is nodular, grayish in color which is due to a fibrinous exudate, but there are no adhesions and a little fluid containing pus in the pleural cavity. On section pus flows freely from every nodule. The lung is full of abscesses

ranging from the size of a hen's egg to minute abscesses. The bronchi are filled with pus. The right lung has a consolidation in the lower posterior portion of the upper lobe involving the upper posterior third of the lower lobe. The rest of the lung feels as though it is in fairly good shape, with plenty of air in it. On section there is pus in the consolidated portions and also some little pus in the bronchi. The air cells in the seemingly good portions of the lung contain in various areas a little frothy fluid but there are no evidences of inflammation. There are no adhesions except the adjacent consolidated portion. There is little fluid in the right pleural cavity.

Heart.—The heart is negative.

The *liver, pancreas, intestines, and peritoneum* are all negative.

Spleen.—The spleen has an infarct about the size of a 50-cent piece on the upper anterior third. On section it seems inflamed and is somewhat enlarged.

Kidney.—The right kidney is large, red, and seems swollen, and the capsule peels off easily, but on section it is negative. The left kidney seems identical with the right. The appendix is negative.

The bacteriology and pathology of the epidemic were given special consideration.^c

On the first day of the epidemic it was decided to select two widely separated wards and to make nose and throat cultures on every patient. Half of the cultures were taken on whole blood-agar plates and half on laked blood-agar plates. One plate was used to a patient, the nasal swab being smeared over one half and the throat swab over the other half. On the same day specimens of sputum from patients with productive coughs were examined microscopically and washed portions injected intraperitoneally into mice. Next, six patients who had the highest temperatures were selected as subjects for blood cultures, 10 c. c. of blood being inoculated into 150 c. c. of plain meat-infusion broth.

The examination of the nose and throat cultures the following day showed that the vast majority of the plates contained countless numbers of small colonies transparent to transmitted light, and of such minute size that often the aid of a hand lens was required for identification. Smears from these colonies showed large numbers of small Gram-negative bacilli having in general the morphology and staining characteristics of the *B. influenzae*, but showing considerable pleomorphism. Colonies were fished and subcultures made and the same organism obtained in pure culture. The organism proved to be a very delicate one, and even when subcultured daily on blood medium soon died out. It was observed that while large numbers of colonies were obtained from both nose and throat, the greater numbers were found in the throat cultures. In one ward 35 patients were cultured and everyone showed positive cultures as described above. Three of the plates also showed hemolytic streptococcus colonies. Unfortunately the cultures from the other ward were not reported on exactly, as part of this record was lost. However, the findings were practically identical. The influenza colonies grew to much larger size when in the vicinity of staphylococcus colonies. In the second ward there were found five hemolytic streptococcus carriers.

The direct microscopic examination of the specimens of sputum showed both small Gram-negative bacilli and Gram-positive diplococci, the latter

^c The following statements of fact are based, in the main, on: Bacteriological Observations of the Epidemic of Influenza at Camp Beauregard, La., by J. E. McClelland. *American Journal of the Medical Sciences*, Philadelphia, 1919, clviii, 80-87.

predominating. From the peritoneal exudate and the heart's blood of the inoculated mice both *B. influenza* and Group IV pneumococci were obtained.

All the six blood cultures taken on the first day of the epidemic remained sterile, nor was it possible subsequently to identify *B. influenza* in any of the blood cultures.

It was then decided to make throat cultures of the entire hospital, as far as practicable, with the idea of determining how many patients would show typical influenza colonies, and also in order to locate the hemolytic streptococcus carriers, that they might be isolated from the other patients. From September 25 to October 3, throat cultures were made on 1,919 patients. Of these 1,749, or 91.1 per cent, were positive for influenza, 80 were positive for hemolytic streptococcus, 39 showed both influenza and hemolytic streptococcus and 90 were negative. The total number of hemolytic streptococcus carriers then was 109, or 5.7 per cent of the entire number cultured.

As soon as the cases of pneumonia developed the attempt was made to make microscopic and bacteriological examinations on as many of the sputa as possible. While many of the direct smears showed numerous Gram-negative bacilli, the predominating organisms were Gram-positive diplococci having the morphology of pneumococci. Type determinations for pneumococci were made on 723 cases, using the Avery method. The results of type determinations were Type I, 1.1 per cent; Type II, 8.4 per cent; Type III, 11.6 per cent; Group IV, 78.9 per cent.

From a consideration of the relative incidence of the various types in normal carriers it would seem reasonable to suppose that many of the patients developed a pneumonia that was really an autoinfection from the organisms already present in their own upper passages. Undoubtedly the added influenza infection played a very important rôle either in reducing the patients' general or local resistance to secondary infection, or in some way enhancing the invasiveness of those organisms which were shown to be the most important etiological factors in the complicating pneumonias. At any rate the combined infection was much more virulent and fatal than a pure infection would have been. Moreover, the character of the pneumonia, as given below in the summary of the autopsies, was quite different anatomically, and much more extensive in its distribution than the typical lobar type we are accustomed to associate with pneumococcus pneumonitis.

It was thought important to make blood cultures in as many of the pneumonia cases as time and equipment would permit, in order to check up on the sputum examinations and to determine accurately the true etiology of the pneumonias. The technique was simply to inoculate 10 to 15 c. c. of blood into 100 to 150 c. c. of plain meat-infusion broth. Plates were not made as a routine but only in specially selected cases. In all 129 blood cultures were made on 111 different patients, 54 of these patients, or 48.7 per cent, had one or more positive cultures, while 57, or 51.3 per cent, had negative cultures. In other words, practically one-half of the patients had a septicemia associated with their pneumonia.

The bacteriology of the blood cultures showed Type I, 5 cases, with 2 deaths; Type II, 7 cases, with 7 deaths; Type II (A), 7 cases, with 6 deaths;

Type III, 12 cases, with 12 deaths; Group IV, 19 cases, with 17 deaths; hemolytic streptococcus, 3 cases, with 3 deaths; nonhemolytic streptococcus, 1 case with 1 death; total of 54 cases with 48 deaths, or 88.8 per cent mortality. Two of the 5 Type I cases with septicemia received large doses of specific serum and recovered.

Only two of the pneumonia cases developed meningitis as a complication. Both showed a Group IV pneumococcus in the spinal fluids and in the blood cultures. One of these patients had such a severe septicemia that it was impossible even to approximate the number of colonies in the plates. Probably in both cases the meningitis was of hematogenous origin. Both patients died soon after the appearance of the meningitis. No cases of influenzal meningitis were encountered.

There were 29 cases in which thoracentesis revealed the presence of fluid in the pleural cavity. Again, the high percentage of Type III pneumococcus infections was remarkable. The number of sterile effusions (seven) seemed rather large, but corresponded with previous experience that the elaboration of a sterile pleural effusion was not uncommon following pneumonia. Cases of this type got along very well with simple aspiration and practically never required more radical surgical interference. The large number of empyema cases that showed pneumococci in the smears and cultures again indicated that organism as the true etiological factor in the majority of cases of postinfluenzal pneumonia. The influenza bacillus was not found in any of the cultures made from the pleural fluids.

The type of organism found in the 29 cases of empyema was Type I, 4; Type III, 6; Group IV, 7; undetermined type, 2; hemolytic streptococcus, 3; sterile effusions, 7.

During the early part of the epidemic 12 autopsies were performed. In eight of the cases there was found a very extensive bronchopneumonia, most marked in the lower lobes, but, as a rule, involving portions of all five lobes. The process was usually so extensive in the lower lobes that the pathology was described as pseudolobar pneumonia. In seven of these eight cases both *B. influenzae* and pneumococci were demonstrated in smears or cultures from the lung tissue, showing that these patients were suffering from a double infection. Seven of the eight cultures from the heart's blood were positive. Two yielded a Type II pneumococcus, two a Type III pneumococcus, and three a Group IV pneumococcus, and in one of the Group IV cases a pure culture of pneumococcus was also obtained from the spleen. In none of these eight cases was there any pericarditis, endocarditis, or peritonitis. The amount of pleuritis was small considering the extensiveness of the pneumonias, and none had any collection of fluid in either pleural cavity.

The remaining four autopsies differed essentially from the foregoing and merit separate descriptions. One case showed bronchopneumonia of the left upper lobe, atelectasis of the right lung with a fibrinopurulent pleuritis with effusion (1,000 c. c.) and fibrinopurulent pericarditis with effusion (250 c. c.). Cultures from the affected portions of lung, from the empyema fluid, from the pericardial fluid, and from the heart's blood all yielded pure cultures of hemolytic

streptococcus. This was evidently identical with the hemolytic streptococcus pneumonias which were so prevalent in some of the camps in the past winter, especially following measles.

Another case proved to be a typical lobar pneumonia involving the right upper and lower lobes with a marked fibrinopurulent pleuritis. Smears and cultures from the affected lung showed many pneumococci but no *B. influenzae*. The spleen culture yielded pneumococci in pure culture and a Type IIA pneumococcus was obtained from the heart's blood. This case was evidently a straight uncomplicated lobar pneumonia.

The third case was also a typical lobar pneumonia involving the right upper and middle lobes, with a marked fibrinopurulent pleuritis. In addition, however, there was an acute purulent bronchitis of both lungs. Smears from the right lung showed many Gram-positive diplococci, but the smears from the bronchial exudate of the left lung showed also many Gram-negative bacilli. Cultures from the heart's blood gave a pure culture of Type I pneumococcus. This patient had then both a pneumococcus pneumonia and an influenzal bronchitis.

The fourth case showed a diffuse bronchopneumonia of both lower lobes, an acute hemorrhagic pleuritis of the right lung, with a slight amount of cloudy, blood-tinged fluid in the right pleural cavity. Cultures from the heart's blood and from the pleural fluid remained sterile. Smears from both lower lobes showed many Gram-negative bacilli and many Gram-positive diplococci. The lung cultures yielded a Gram-positive, bile insoluble, nonhemolytic streptococcus. This patient evidently had a combined influenza and streptococcus infection.

The postinfluenzal pneumonia may be due to a secondary invasion by any of the ordinary organisms producing pneumonia, but they are apparently more severe, more extensive, and often rapidly fatal. The severity of the secondary infection seems to be augmented by the coexistent influenzal infection. The majority of the pneumonias here were due to a secondary invasion by pneumococci, all types contributing, but Type III and Group IV standing out more conspicuously than Types I and II. The streptococcus, both hemolytic and nonhemolytic varieties, were responsible for a small percentage of the pneumonias. So far as could be determined none of the pneumonias were due to the *B. influenzae* alone, nor was it possible to recover the *B. influenzae* from any of the blood cultures or pathological fluids or exudates.

The pathology and bacteriology of the influenza epidemic at this camp suggest a primary acute infection with the bacillus of Pfeiffer, followed by a high incidence of pneumonia, practically all of which was of the bronchopneumonic variety. The predominant organisms in the latter disease were pneumococci, with a relatively low incidence of the fixed types except Type III, which showed a distinctly higher incidence than in most camps. *Streptococcus hemolyticus* was relatively rare as a secondary infecting agent. The type of the reaction in the lung appears to have been lobular in the peripheral portions of many of the lungs with confluent spreading pneumonic areas along the bronchial tree, together with lobar or pseudo-lobar types characterized by incomplete consolidation of whole lobes appearing with relative frequency.

Here, as in other camps, the high incidence indicated in the statistics as primary pneumonia did not confuse the observers, who were quite aware of the preceding acute respiratory infection. It is noteworthy that in this camp, as in some others, the acute respiratory outbreak in the spring of 1918 appeared to have no relation to the reception of new increments of troops into the camp and suggests an increase in the virulence of organisms already present, although with the constant movement in and out of the camp one can not exclude a virulent organism being carried to it from without and setting up an epidemic condition even in a stabilized and seasoned personnel.

The influenza pandemic occurred shortly after the receipt of a considerable number of unseasoned men, these forming a large proportion of the total personnel of the camp. This undoubtedly accounts in part for the high incidence as shown in Chart I. It is to be noted that the death rate in October was practically the same as in September, yet the morbidity had decreased. In other words, the case fatality rate increased in the latter part of the epidemic.

CAMP BOWIE, TEX.^d

The chart of incidence and fatality of the acute respiratory diseases at Camp Bowie shows four peaks at which times a mortality above the average for the camp occurred. The first three were due to definite epidemic increases, the last to a high incidence in a smaller personnel present during the demobilization period, representing relatively few cases.

The material considered in the presentation of the respiratory diseases at this camp consists of 261 necropsy protocols of cases dying of pneumonia, and a study of 2,344 cases of pneumonia and the various complications at the base hospital.^e The cases may be grouped into three periods.

Period 1, from the opening of the base hospital, September 24, 1917, to January 1, 1918: During this period occurred an epidemic of measles, with a large incidence of pneumonia, followed by numerous serious complications and a high death rate.

Period 2, from January 1, to September 27, 1918: The first three and a half months of this period continued to show a high incidence of pneumonia, though the number and severity of the complications were not as great as in period 1. From April 15 to September 27 was a comparatively quiet period.

Period 3, from September 28, 1918, to January 1, 1919: This period included a very high incidence of influenza and a high percentage of pneumonia. In contrast to the pneumonia of 1917, there were comparatively few complications, and these were of a less virulent type.

During period 1 there were 3,624 cases of measles. In addition to the measles there was a widespread infection of the upper respiratory tract throughout the camp. There were 973 cases of pneumonia, and in only 363 of these could there be obtained a history of measles within a month preceding the development of the pneumonia. During the epidemic there may have been in camp a

^d Sources of information, except as otherwise indicated: (1) Necropsy protocols, Camp Bowie. On file, Army Medical Museum, Washington, D. C. (2) Reports of sick and wounded, 1917 and 1918. On file, Surgeon General's Office.

^e The following statements of fact are based, in the main, on: Pneumonia and Some of Its Complications at Camp Bowie, by James C. Greenway, Carl Boettiger, and Howard S. Colwell. *Archives of Internal Medicine*, Chicago, 1919, xxiv, No. 1, 1-34.

CAMP BOWIE

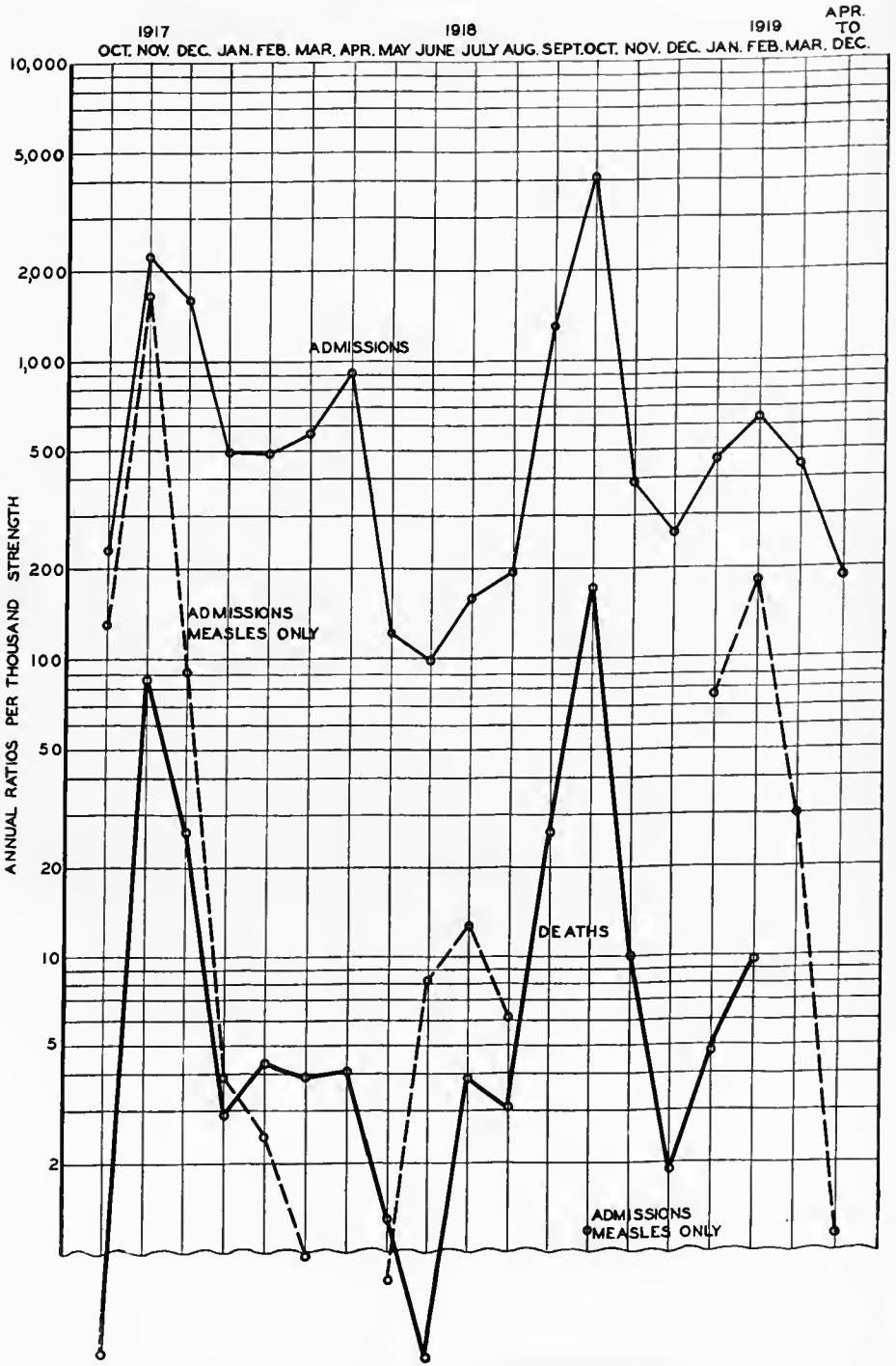


CHART II.—The incidence and fatality of the acute respiratory diseases at Camp Bowie

number of cases of abortive measles, unrecognized at the time, in which pneumonia developed later.

There were 237 deaths among these pneumonia cases, a mortality of 24.4 per cent. In 17 per cent of the pneumonia cases empyema developed, with a mortality of 32.5 per cent.

The peak was not reached until two weeks after the beginning of the measles epidemic, a much longer time than in the case of the influenza epidemic. There was then a diminution in the number of cases, but following the arrival of 6,000 draft troops, a second peak, almost as great, occurred two weeks after the first. There was a steady decline for 10 days thereafter, when the admissions gradually ceased.

The pneumonia curve did not follow that of measles so closely as in the later influenza epidemic. The first pneumonia peak followed the first measles peak by 10 days; six days after the second measles peak there was a rise in the number of cases of pneumonia.

The bacteriology during the period December 6 to 15, 1917, showed, in the sputum examination of 62 cases, pneumococci, Type I, 22; Type II, atypical, 9; Type III, 2, and Group IV, 29. Of the 17 cases in which fluids were examined during this period the hemolytic streptococcus was found in 13, pneumococcus Type II, atypical, in 2, *Streptococcus viridans* in 2. Lung cultures in 30 cases showed the hemolytic streptococcus in 18. In the period of December 15 to 31, 1917, sputum culture in pneumonia cases of which there were 33 examined, showed pneumococcus, Type I, 9; Type II, 7; Type III, 1; Group IV, 13; pneumococcus Group IV and hemolytic streptococcus, 2; hemolytic streptococcus alone, 1.

This group of examinations differs considerably from those obtained by the Empyema Commission from the questionnaires, charts, and data sent in to them, as it clearly indicates a decided preponderance of the *Streptococcus hemolyticus* during the fall period.

The first cases coming to necropsy in November, 1917, showed the well known typical lesions of acute lobar pneumonia. Of the first 8 cases 2 showed pleural effusions, 1 serofibrinous, and the other purulent.

As measles became more prevalent, and as both the incidence and mortality of pneumonia rose, the picture changed. More lobes were involved. Instead of feeling uniformly firm and airless, the affected tissue felt nodular, or "shotty," and distinct crepitation could be elicited between the firm nodules. Fibrinous deposits over the pleural surface were more constant and more extensive. On section, the cut surface of lung presented a mottled appearance, usually a dark, bluish-red background, with many small slightly elevated grayish-red areas, each presenting the opening of a bronchiole, at or near its center. In many cases these areas were confluent. The interlobular septums were distinctly visible, dividing the lobe into a number of irregularly shaped areas. Abscess formation, especially multiple small abscesses, was occasionally found.

Effusions into the pleural cavity became increasingly frequent, and were usually purulent. Adhesions between the visceral and parietal pleura occurred, often dividing the pleural cavity into two or more distinct compartments. Perhaps the most frequent site of such adhesion was between the anterior

edge of the lung and the costal margin, the inner surface of the sternum or pericardial sac. Here, elongated pockets were formed, at times divided by transverse bands into two, which contained thick greenish pus and masses of fibrin. Adhesions between the lobes with formation of interlobular abscesses were also found.

The pericardium was involved in many cases. In some instances only the external surface showed a fibrin deposit of varying thickness with organization, and adhesion to sternum, ribs, and left lung. In other instances, the inner surface was dull, covered with a rough fibrin deposit, and the sac contained a large amount of serofibrinous or purulent fluid, in which hemolytic streptococci were found.

The microscopic picture in these cases was that described as interstitial pneumonia. (See Camp Dodge, p. 62.)

The pathologic anatomy of the early cases in this period is that of lobar or fibrinous consolidations affecting whole lobes or large parts of lobes, with occasional bronchopneumonic lesions in other lobes. The bacteriology showed pneumococcus Types I and II in about 50 per cent of such cases. The streptococci were responsible for the interstitial changes which accompanied some of the lobar consolidations, causing thickening of the septa and giving rise to pleural exudates. There were also peribronchial consolidations such as are found usually in infections with the influenza bacillus. As the epidemic progressed the pathologic anatomy, though still showing some of the lobar types, was preponderantly bronchopneumonic in character. Lesions spreading out from the bronchial tree, and confluent lobular consolidations were seen, together with interstitial lymphangitis and abscess formation. Pneumococcus Types I and II decreased to 33 per cent with an increase in streptococci and Group IV pneumococci. Empyema increased also, as did the case fatality. The latter was 3.68 per cent in November, at the height of the epidemic curve. By far the greater part of the pneumonias and empyemas followed measles; there being in November 127 deaths from pneumonia following measles and 45 deaths from primary pneumonia. It is probable that influenza in epidemic proportions preceded many if not most of the cases of primary pneumonia and may well have been a coincident infection with measles in many cases. The case fatality for measles was 4.01 per cent, while that for the cases of measles-pneumonia was 39.18 per cent.

During period 2, January and February, 1918, there was a large incidence of pneumonia, the clinical variety showing a greater percentage of lobar pneumonias and differing very little from the variety seen in civil life. Type I pneumonia constituted 26.5 per cent of the whole number. Between March 15 and April 15, 1918, 117 cases of pneumonia were admitted to the hospital, 10 of these (8.5 per cent) showing *Streptococcus hemolyticus* in the sputum. The Type I cases dropped to 13.6 per cent and Group IV pneumococcus showed 69.2 per cent.

Between March 26 and April 13, 349 cases of an acute respiratory infection were admitted. These were not called influenza because of lack of bacteriologic support for such a diagnosis. Clinically, they closely resembled the condition subsequently called influenza, although this diagnosis is questionable.

During the latter half of June, 1918, a large number of recruits in the detention camp developed severe bronchitis. Sputum from 20 of the more severe cases was submitted to the laboratory for examination. In addition, nasopharyngeal cultures were made from 60 contacts with these cases and from 60 men, chosen at random, throughout the camp.

The sputum in each case was washed three times in saline and emulsified in broth, then planted in dextrose-blood-broth. After six to eight hours' incubation, human blood-agar plates were streaked from these cultures and were studied after 12 to 18 hours' incubation, and again after 48 hours' incubation. Pneumococcus colonies were fished into dextrose-blood-broth, and pure cultures were submitted to the test for bile solubility and agglutination with type serums. Colonies showing a wide area of hemolysis and having morphologic characteristics were considered hemolytic streptococcus.

In obtaining nasopharyngeal cultures, the nasopharynx was swabbed as for meningococcus carrier detection. Swabs were placed immediately into plain broth tubes, and from these, human blood-agar plates were streaked and incubated for 24 to 36 hours. Plates then were studied for types of colonies. Organisms such as staphylococci and *Micrococcus catarrhalis* were not recorded.

The result of this examination showed hemolytic streptococci in 100 per cent of the 20 cases of more severe type, in 3 of which there were also pneumococcus Type I, and in 15, pneumococcus Group IV. Of the 60 nasopharyngeal cultures, 3 showed hemolytic streptococcus, 7 pneumococcus type undetermined, 8 pneumococcus and hemolytic streptococcus, and 20 neither pneumococci nor streptococci, other organisms than these not being recorded.

During the remainder of period 2, especially after the 36th Division left in July, there were only 43 cases of pneumonia with 2 deaths. Nine of the 43 showed the hemolytic streptococcus predominating in the sputum, and 2 were a mixed infection of hemolytic streptococcus and Group IV pneumococcus.

Of the 538 pneumonia patients, only 48 gave a history of an antecedent infection within a month.

The total mortality for this period was 7.4 per cent, there being 40 fatalities among the 538 cases. Fifty-two patients (9.7 per cent) developed empyema and provided 37.5 per cent of the total deaths.

It is significant that in all the lobar pneumonia cases pneumococci were found in the sputum, and 10 of the 18 fatal cases reacted to specific type serums I and II. Hemolytic streptococci were still an important factor, and in three of nine purulent pleurisies this organism was present in addition to the pneumococcus. During the month of April there occurred four cases of interstitial bronchopneumonia caused by the hemolytic streptococcus. These cases occurred at the time of the small epidemic of acute respiratory infection previously described.

Of 25 post-mortem examinations made during this period, lobar pneumonia was found in 19 cases; bronchopneumonia, of the interstitial type, was found in 6 cases. The incidence of purulent pleurisy was high (50 per cent). This may be explained by the fact that five of the six bronchopneumonia cases showed this complication, and hemolytic streptococci were found as complicating organisms in one-third of the cases following pneumococcus infection.

After the epidemic wave of October, 1917, to January, 1918, the fixed type pneumococci again preponderated in the pneumonias until March-April, when the streptococcus hemolyticus invasion increased and the type of pneumonia present, lobar, in considerable proportions at first, became almost wholly of the bronchopneumonic, lobular, and interstitial varieties. A definite influenza outbreak occurred in April and, though the streptococcus appears to have been prevalent, the case fatality was only 0.45 per cent of the total respiratory disease. Recruits arriving at the camp picked up the prevailing infection with the streptococcus and other organisms. The bacteriological examinations in June showed the flora present in the interepidemic period and preceding the wave of the pandemic.

The development of the epidemic, period 3, on September 17, began with the admission of cases of a not uncommon type of upper respiratory tract infection, numbering about five daily, before the semblance of an epidemic was evident. On September 26, 24 cases of influenza were admitted to hospital. During the epidemic, which continued to November 15, 1918, 3,876 cases of this infection were admitted to hospital; 634 cases were held in the observation wards of the detention camp.

Study of the blood counts in uncomplicated influenza showed that during the first five weeks, representing the period of highest incidence, the largest number of counts was below 10,000; the polynuclear percentage was below 70, and the lymphocyte percentage was over 25. As the severity of the epidemic declined, the total white counts were higher, and the polynuclear percentages were correspondingly increased. The same transition was apparent in the pneumonia following influenza, although the percentage of high counts was greater than in the uncomplicated cases. Leucopenia (counts under 5,000) was not a common finding, though absence of leucocytosis was the rule.

This change in the blood findings was synchronous with a somewhat changed clinical picture. The epidemic reached its peak in numbers in seven days, and at the end of the second week the severity of the infection was decreasing, as shown by a less profound prostration, diminished general malaise, less frequent and milder toxic erythema, and more rapid convalescence.

The first peak of the influenza preceded that of the pneumonia by five days. The second peak, occurring three weeks later, coincident with the arrival of the first increment of drafted troops from Missouri, preceded the second peak of the pneumonia by seven days. There were received at the detention camp during the course of the epidemic 4,108 drafted white men and 2,360 drafted colored men.

Among the white men, 252 per 1,000 men who were exposed developed the infection, 114 per 1,000 developed pneumonia. Not every pneumonia patient gave a history of an antecedent influenza infection. Among the 795 cases of pneumonia, a history of influenza within the preceding month was obtained in 728.

No deaths were attributable to uncomplicated influenza. The total deaths in the 833 cases of pneumonia, numbered 156, a mortality of 18.7 per cent. Thirty-six men (4.3 per cent) developed empyema and furnished 11.5 per cent of the total deaths.

In spite of the higher morbidity rate for influenza and pneumonia among colored troops, the mortality percentage (17.1 per cent) among them was somewhat less than that of the white troops (20.8 per cent).

It would appear at first that the highest mortality was reached quickly after the onset of the epidemic, the virulence of the infection decreasing thereafter and the mortality diminishing from 21.2 and 19.1 per cent to 12 and 9.1 per cent, respectively, for semimonthly periods. That this may have been partly true is evidenced by the fact that the patients admitted after the first two weeks did not appear to be so severely ill. That the virulence of the infecting organisms persisted is shown by the incidence and mortality of pneumonia among the Missouri drafted men, who arrived three weeks after the peak of the epidemic was reached. These men arrived in camp from October 22 to October 25. They were overtaken by influenza October 23 to 31 and developed pneumonia October 28 to November 4. Among them there developed 199 cases of pneumonia with 39 deaths, a mortality (19.6 per cent) almost equal to that occurring at the height of the epidemic. The lower total mortality for the first half of November was due to the inclusion of 91 scattered cases occurring among troops that had been in camp longer. Among these cases there were only 11 deaths, a mortality of 12 per cent.

On September 25, 1918, routine nasopharyngeal swabs were made in all cases admitted with the diagnosis of influenza. In all, 75 cases were examined satisfactorily.

Swabs were made as for meningococcus carrier detection. These were streaked first on human blood-agar plates, and afterwards immersed in glucose-blood-broth. The latter cultures were incubated about six hours and human blood-agar plates then were streaked from them.

The identification of streptococci and pneumococci was in accordance with "Standard Method for U. S. Army," except that press of other work prevented identification of types of pneumococci. Plates were incubated for 18 to 24 hours. Influenza bacilli when found in quantity were present in characteristic growth in this time. The nasopharyngeal cultures showed hemolytic streptococci preponderating in 45 per cent of the cultures, pneumococci, undetermined, in 35 per cent, influenza bacilli present in 9 per cent, nonhemolytic streptococcus colonies predominating in 10 per cent. Fixed type or Group IV pneumococci predominated throughout the epidemic, with a sharply rising incidence of streptococcus toward the latter part, followed by a decline and a sharp rise in Group IV incidence. The bacteriology of the lobar pneumonia by lung cultures and of the bronchopneumonia showed a preponderance of pneumococci, type undetermined, and Group IV, 2 cases of Type I, 2 cases of Type III in 68 examinations, while the hemolytic streptococcus was found alone in 2 and associated in 12. The influenza bacillus was found in 16 per cent of the cases of bronchopneumonia and 25 per cent of the cases of lobar pneumonia. The streptococcus predominated in the pneumonias of interstitial type, being found alone in 10 of 33 cases and in 64 per cent of all cases, while the influenza bacillus was present in 2, or 9 per cent of the cases. Empyema was most frequent in the interstitial type as compared with the other two types. The bacteriology of the heart's blood at necropsy showed pneumococci, type undetermined, in 19, Group IV in

17, Type I in 1, Type II in 2, Type III in 1, hemolytic streptococcus in 11, and nonhemolytic streptococcus in 11; total cases examined numbered 81, in 19 of which there were no growths.

Three distinct types of cases were found: (1) lobar pneumonia; (2) bronchopneumonia of interstitial type; and (3) bronchopneumonia of a lobular or confluent type.

In cases of the third type, the lungs were large, moderately firm, all more or less nodular. Frequently, by careful palpation, crepitating areas could be felt, even in a lobe which was apparently completely consolidated. The pleural covering was usually smooth and transparent, many cases showing scattered small areas of subpleural hemorrhage. Fine fibrinous deposits were found in some cases very early in the course of the pneumonia. In cases which showed emphysema of the mediastinal tissues there was usually an emphysema just beneath the pleura which extended mainly along the interlobular septa.

Section of the lung was followed by the outpouring of a large amount of dark, bloody fluid. The cut surface was dark, bluish-red, mottled with lighter areas, which varied in color from a deep brownish-red to a light grayish-red, or grayish-yellow, and varied in size from one or two centimeters in diameter up. It was very common to find areas of different color and consistency in the same lobe. In the lower lobes these areas were largest and most confluent, so that at times it was difficult to say whether or not the consolidation was homogeneous. In such cases, however, the upper lobes always showed distinct patchy consolidation.

The characteristic features of the microscopic pictures were the intense edema and congestion of all interstitial tissues, the marked predominance of bloody exudate in the alveoli in most cases, and the irregular distribution of the lesion, not strictly peribronchial nor diffuse, but showing areas at different stages of development in the same section.

Empyema as a complication occurred in 249 (10.6 per cent) of the 2,344 cases of pneumonia. This incidence was a steadily decreasing one for the three periods: 16.5, 9.5, and 4.3 per cent, respectively. Period 1 furnished 41.5 per cent of the total pneumonias, and 64.6 per cent of the total cases of empyema, whereas period 3 furnished 35.5 per cent of the total pneumonias, and only 14.4 per cent of the total empyemas.

Metastatic abscess, single or multiple, occurred in 17 cases of pneumonia. Of these 17 cases, 4 accompanied empyema; 5 came to necropsy, 3 not being diagnosed before death. One of these undiagnosed cases was a small abscess in the first intercostal muscle; a second case was a perirenal abscess. The most interesting cases of this group were five cases in which a painless tumor was noted just above the symphysis pubis, not red and not tender to pressure. The first of these cases was not recognized until there appeared a rounded tumefaction exactly in the midline, extending about 2 inches above the symphysis pubis. The tumor was thought to be a distended bladder, but on catheterization a very small amount of urine was obtained; 100 c. c. of salt solution was introduced into the bladder, and the same amount was withdrawn. The tumor was still present. The possibility of a diverticulum of the bladder was considered. There was no increase in temperature, and no muscular

rigidity. During the next six days there was a slight, but constant, increase in the size of the tumor, the patient meanwhile voiding a normal amount of urine. On the sixth day fluctuation was obtained. An incision was made and about 150 c. c. of thick pus was found between the right rectus muscle and its posterior sheath. Culture showed a pneumococcus, type undetermined. The other cases presented practically the same picture, except that in three the tumor was slightly asymmetrical.

Generalized subcutaneous emphysema, as a complication of pneumonia, occurred in 8 cases, 7 white men and 1 colored man; 3 of these patients recovered.

The onset of the emphysema appeared to be definitely associated with an unusually severe paroxysm of coughing in one case. Hoarseness and increased dyspnea were the only symptoms apparently referable to this complication.

The tissues of the neck, posteriorly especially, but also in the supraclavicular region, were involved in all the 8 cases; the interseapular region was involved in 4; the axillæ and pectoral region in 3; the face in 3; the flanks and thighs in 1.

The three patients who recovered had a prolonged convalescence. Each one had a persistent hoarseness. Laryngeal examination showed only an acute laryngitis, which disappeared slowly. One patient has since been found to have pulmonary tuberculosis.

Anaerobic ante-mortem blood cultures were sterile in two cases; in the third case they showed pneumococcus, type undetermined.

Of the post-mortem cases all showed emphysema of the mediastinal connective tissue, in addition to the evident subcutaneous emphysema noted during life. Petechial subpleural hemorrhages were evident in two cases. Free air beneath the visceral pleura, especially along the interlobular spaces and lung fissures, was seen in two cases. One case showed confluent patches of consolidation having undergone softening and produced abscess cavities. Microscopically small areas of hemorrhage were frequent in these cases as in other pneumonia cases of the same period.

In addition there were 10 cases of emphysema of mediastinal tissue diagnosed only at necropsy.

Cultures of the mediastinal tissue showing marked emphysema in 8 cases, which gave no growths in 3; pneumococcus Group IV in 3; streptococcus, non-hemolytic, in 1; streptococcus, hemolytic, in 1. In each case the organism present was found also in the blood culture.

Certain cases, especially of lobar pneumonia, offered no difficulty in diagnosis. In the secondary pneumonias, those following measles in 1917, and especially those following influenza in 1918, it was the rule rather than the exception for the signs to be so irregular as to offer the greatest difficulty in diagnosis, not only as to the evidence of consolidation, but especially as to the clinical variety. The sputums from these cases practically all showed streptococcus, pneumococcus Group IV, or a mixed infection.

Considerable difficulty was experienced in making correct diagnoses as to the type of pneumonia. In October and November, 1917, 50 per cent of the cases of bronchopneumonia were wrongly diagnosed as lobar, 45 per cent were wrongly diagnosed in September and October, 1918. Even post mortem the

differentiation was frequently puzzling and the data as reported on the sick and wounded records are stated to be distinctly unreliable.

A study of the protocols shows that most of the lungs were affected by a mixture of types of pneumonia not all of which appeared to be of the same duration. Early symptoms therefore were the result of one lesion which may or may not have preponderated throughout the clinical course and at the necropsy.

Positive blood cultures in this camp, as in others, indicated an unfavorable prognosis. The mortality by type of organism in the pneumonia cases showed, for Type I, 4.9 per cent; Type II, 20.6 per cent; Type III, 13.3 per cent; Group IV, 10.4 per cent; Group IV and hemolytic streptococcus, 24 per cent; nonhemolytic streptococcus, 100 per cent; hemolytic streptococcus alone, 13.3 per cent. Mortality of all types of organisms was distinctly increased during the influenza epidemic, with the exception of Type III which showed an apparent decrease.

Experience at this hospital showed that to limit the investigation of sputum to a determination of the type of pneumococcus present, does not always give a reliable guide as to the nature of the existing infection.

Three waves of influenza or influenza like disease occurred at this camp during the World War. The variations in the proportions of the types of lesions in the lung governed the varying physical signs and clinical course in those affected and were dependent on the type of organism causing the disease. Those of the personnel who had passed through an epidemic showed a decreased incidence to influenza or influenza like disease and to the complicating pneumonias and also a lower case fatality rate than did the unseasoned recruits. Lobar consolidations appear to have been caused by pneumococci with a large proportion of the fixed Types I and II. Streptococcus not only produced characteristic lesions alone but also infected lungs already the seat of pneumococcus lesions, producing interstitial lesions and empyemas. The bronchopneumonias—lobular, interstitial, and spreading confluent types—were associated with pneumococcus Group IV and streptococcus, hemolytic and nonhemolytic, the latter producing most of the interstitial pneumonic reactions.

While the bacteriological examinations at this camp were excellent it is doubtful if the total incidence of *B. influenzae* was determined. The fact that the respiratory lesions spread downward along the air passages as stated by the clinicians and as indicated in the necropsy descriptions strongly suggests an infection with this organism. The frequency of multiple infections with different bacteria is well brought out in the necropsy protocols at the Army Medical Museum and in the study made by the hospital staff.

Chart II indicates that an increased mortality from respiratory disease occurred just preceding the influenzal waves of the spring and fall of 1918. The case fatality rate for all respiratory diseases was practically the same for the epidemic of 1917 and the pandemic incidence at this camp in 1918, 3.68 per cent in November, 1917, and 3.86 per cent in October, 1918. How much these figures would be changed had all of the light cases been recorded can not be determined. With the higher incidence of October, 1918, it might well reduce the figure for that month.

CAMP CODY, N. MEX.^f

The epidemic of respiratory diseases at Camp Cody in the fall of 1917, aside from measles, was due to influenza and common respiratory diseases. During the beginning of this outbreak, or in the month of November, the case fatality rate for all respiratory diseases was 0.95 per cent. With the continuation of the epidemic, the streptococcus appeared in considerable numbers and the case fatality rate increased to 1.71 per cent in December. The deaths during these two months were charged very largely to the primary pneumonias, of which lobar pneumonia exceeded, so far as can be judged from the records of sick and wounded. The few autopsy protocols and specimens available from this camp do not include any for this period, but the records of the Empyema Commission indicate a considerable incidence of streptococci. These organisms may have been secondary invaders of cases primarily affected by pneumonia of lobar type, but it is much more probable that the pneumonic lesions were of the usual type seen in other camps in the majority of which the typical fibrinous consolidation of croupous pneumonia was rarely seen. Influenza cases increased in March, 1918, without increase in case fatality, as is indicated by Chart III. The sharp rise in June followed the receipt of between four and five thousand men, and the streptococcus again was prevalent at this time, the case fatality rate being 1.95 per cent for this month. The case fatality dropped in July to 0.46 per cent, but rose sharply in August to 3.73 per cent preceding any apparent clinical evidence of the beginning of an epidemic. In September the case fatality rate dropped to 2.83 per cent, there being the same number of deaths in September as in August, namely 6, while the incidence increased from 161 cases in August to 212 in September, apparently the beginning of the influenza pandemic. The case fatality jumped to 6 per cent in October and increased to 12.75 per cent in November, with approximately a third as many cases occurring as in the previous month. The streptococcus had a large part in producing this increase in the case fatality rate.^g

On September 24, 1918, there was admitted to one of the general medical wards of the base hospital at Camp Cody, a soldier who had just come from Camp Dix, N. J., with prisoners. He gave a history of having been sick for three days, on the train, with headache, rhinitis, general aching, soreness in the chest, and cough. In addition, he presented a well-marked pharyngitis. Within 24 hours from admission, certain unusual features were present. The pulse was slow in proportion to the high temperature. The respiratory rate was greater than physical signs warranted, and the leucocyte count was 4,800. Repeated physical examinations on that day finally revealed a few crepitant râles near the angle of the right scapula. In the afternoon of this second day, cyanosis of the finger tips became noticeable, and an ashy color of the face appeared. The condition in the lung spread rapidly to the left lower lobe posteriorly, and on October 1 the man died. This was the introduction of this camp to the acute respiratory disease which was then prevalent in the northern and eastern camps.

^f Sources of information, except as otherwise indicated: (1) Medical reports to the Surgeon General, 1917, 1918, and 1919. (2) Empyema records, on file, Surgeon General's Office. (3) Necropsy protocols, on file, Army Medical Museum.

^g The following statements of fact are based, in the main, on: *The Epidemic of Respiratory Infection at Camp Cody, N. Mex.*, by Frederick H. Lamb and Edward B. Brannin. *Journal of the American Medical Association*, Chicago, 1919, lxxii, No. 15, 1056-62.

CAMP CODY

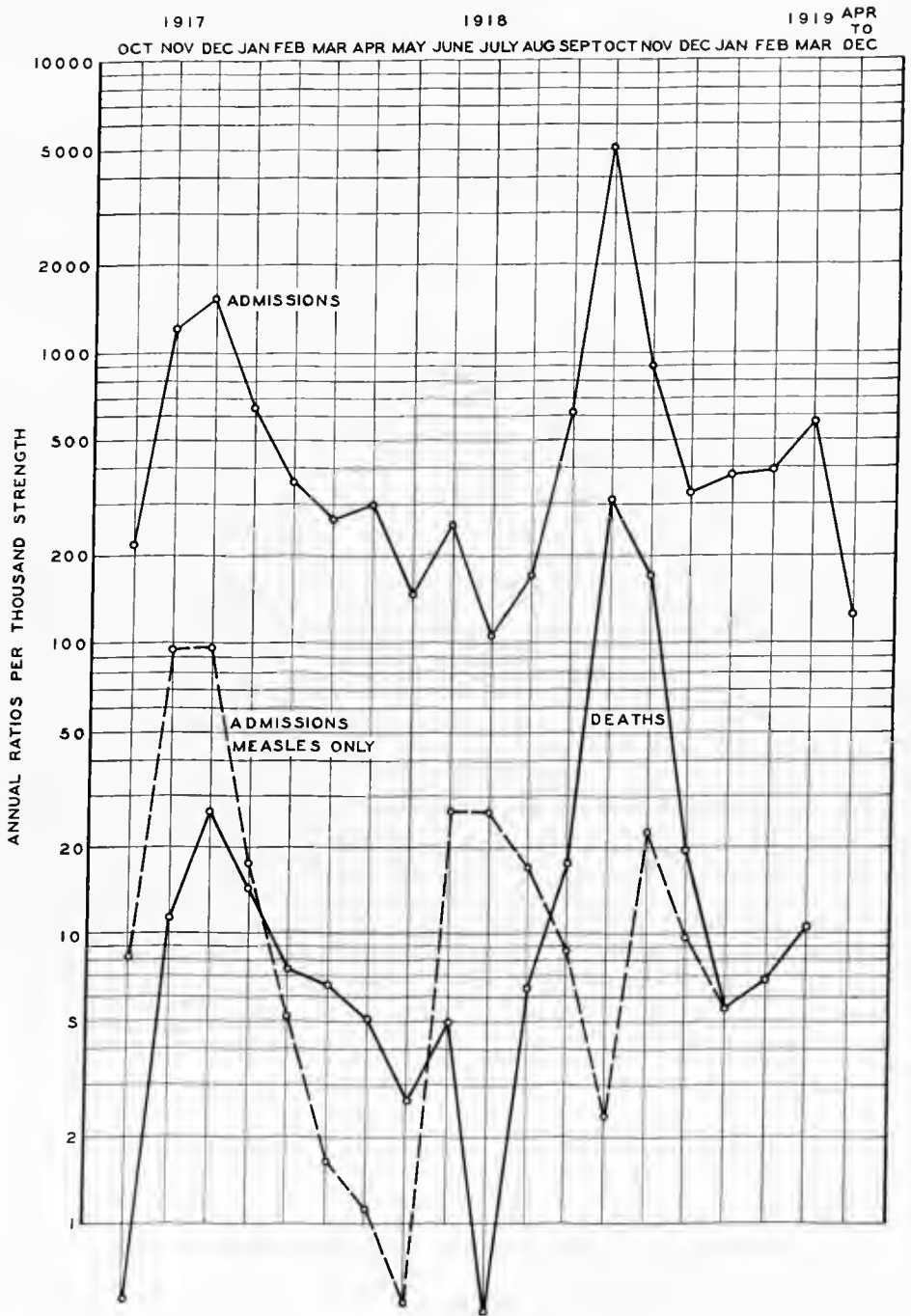


CHART III.—The incidence and fatality of the acute respiratory diseases at Camp Cody

The epidemic here may be said to have begun, October 1, 1918, with the admission of nine cases which were diagnosed influenza, and, from the standpoint of this study, it closed, December 1, 1918.

Laboratory investigations were made during the first 10 days of the epidemic in 80 typical cases of influenza. At the time of examination, none of these patients presented any physical signs of pneumonia or other complication. Nasopharyngeal and sputum cultures, blood cultures, blood counts, and urine examinations were made in practically all of these cases.

Assuming that droplet infection was the most important factor in the dissemination of the disease, the bacteria of the nasopharynx and sputum were studied in detail. Nasopharyngeal swabs, obtained by means of West tubes, and specimens of sputum collected in sterile Petri dishes, were inoculated into blood agar and serum boullion. Considerable pains were taken to identify colonies by subcultures in differentiating media. In order to gain some idea of the virulence of the organisms, 58 white mice were given intraperitoneal injections of sputum.

It was found that there were five predominating pathogenic organisms: Pneumococcus, *B. influenzae*, *M. catarrhalis*, staphylococcus and streptococcus, both hemolytic and nonhemolytic. Intraperitoneal inoculations of the pneumococcus, staphylococcus and both forms of streptococci were fatal to white mice. Injections of cultures of *B. influenzae* and *M. catarrhalis* produced only toxic symptoms in the mouse.

In 80 cases investigated, the organisms recovered from both the throat and sputum cultures showed pneumococcus present in 90 per cent; *B. influenzae* in 46 per cent; *M. catarrhalis* in 84 per cent; hemolytic streptococcus in 14 per cent; nonhemolytic streptococcus in 26 per cent, and staphylococcus in 20 per cent. Colonies of both *B. influenzae* and pneumococcus were found in 41 per cent of the plates. A few plates showed colonies of all these organisms. In many cases it was difficult to tell which was the predominating organisms, and such a classification was given up as being unsatisfactory. Of the 58 white mice that received intraperitoneal injections in 1 c. c. doses of ground sputum, 9, or 18 per cent, died. From seven of these the pneumococcus alone was recovered in the heart blood; from two, the pneumococcus and *B. influenzae* were recovered. The foregoing bacteriologic observations indicated that *B. influenzae* was not the specific organism.

Fifty-four blood cultures were made in this series of 80 cases, all of which remained sterile.

The average of 80 leucocyte counts was 6,780. In 54 cases, or 67 per cent, the count was less than 8,000. The highest count of the series was 22,600, and the lowest 3,300. The differential count was not remarkable.

Sixteen specimens of urine, or 20 per cent out of 78, showed a trace of albumin. Two cases showed considerably more than a trace, with a few granular and hyaline casts.

In connection with the experimental work, it is interesting to note that very soon after the epidemic of influenza reached this camp, laboratory guinea pigs, housed in a small building beside the laboratory, began to die. At first it was thought to be the result of food poisoning, but a necropsy on a dead pig revealed

unmistakable signs of pneumonia. The mucosæ of the trachea and bronchi were deeply injected and covered with a glairy, serofibrinous exudate. Cultures and smears from this exudate and pieces of lung tissue revealed pneumococci in large numbers, a few streptococci and small Gram-negative bacilli, identical in every way with *B. influenzae*. These observations were confirmed in subsequent necropsies. The guinea pigs were sick from two to four days before death. During this time, the sick animal, trembling from chills, with hair ruffled, sat huddled up in a corner of the pen, moving about only to eat. This it would do until shortly before death. The respirations were rapid and wheezing; the characteristic shrill whistle became scarcely audible. The animal was apparently in a stupor which gradually deepened until death supervened. Altogether, it presented the picture of a profound intoxication. Just before death the animal would fall on one side, rise a time or two, then make a few feeble efforts to do so again. Within 15 or 30 minutes it would die after several rather weak, clonic, convulsive movements.

All of the pigs in a batch of 30 died within three weeks. Fifty more were received from El Paso, Tex., just about this time, four of which were dead on arrival. The others were apparently healthy. These were placed in a different room of the animal house, which had not been in use for several months. It was thoroughly cleaned and supplied with fresh hay, which was changed daily. A heater was placed in the house, and every effort was made to keep this new batch clean and healthful. No deaths occurred for about two weeks. One morning one pig was found dead, and within three weeks all of this second group had died just as the first had done. Segregating the sick animals did not save the others.

Pneumonia occurred in 624 Army cases. In type, with few exceptions, it was of a lobular variety. Clinically it was considered a hemorrhagic atypical bronchopneumonia. The massive consolidations were thought to be the result of the confluency of contagious inflamed areas.

Blood cultures in 248 cases of influenza-pneumonia showed 4 positive results; hemolytic streptococcus in 1 case and pneumococcus in 3, of which 1 was Type II, 1, Type II atypical, and 1, Group IV. These findings contrast with those of the blood cultures made in the spring and summer preceding, where 26 per cent of 92 and 18 per cent of 180 cases were positive. Typing of the sputa with white mice and Avery's blood broth was made in about 50 per cent. Typing did not have the satisfactory results recorded during the year previous to the pandemic period. The organisms found were pneumococcus Type I, 2.6 per cent, Type II, 2.01 per cent, Type II, atypical, 6.89 per cent, Type III, 4.02 per cent, Group IV, 46.55 per cent. In the examination of 91 cases hemolytic streptococcus was found 37 times and nonhemolytic streptococcus 54 times. The organism recorded was considered to predominate in the cultures, other organisms also being present.

The comparative incidence of the five most frequently found organisms in the pneumonia cases were pneumococcus in 89.1 per cent, streptococcus in 63.3 per cent, *B. influenzae* in 23 per cent, *M. catarrhalis* in 6 per cent, and staphylococcus in 8.6 per cent.

Taken as a whole, the patients who died were, if anything, somewhat better nourished and more robust than the average individual. The rapidity with which death took place precluded much external change. Post-mortem lividity usually was marked; the finger nails and mucosæ were very cyanotic. In about one-half of the cases a foamy, blood-stained liquid ran from the nose and mouth when the head was lowered.

In all except one of the 16 cases examined at necropsy, the post-mortem picture was strikingly uniform. This exceptional case presented all the characteristics of a true, dry, lobar pneumonia.

The mucosæ of the trachea and bronchi were intensely red, slightly edematous, and covered with a red, mucopurulent exudate. In many instances the smaller bronchi were filled with a red foam. The peribronchial lymph nodes were twice or thrice normal size, very red, soft, and the cut surface granular.

No changes were noted in the mediastinal space.

The pathologic changes in the lungs were certainly not those one is accustomed to see in the ordinary lobar pneumonia, nor were they typical of bronchopneumonia. In fact, the terminal hypostatic pneumonia, sometimes seen in the aged, compares more nearly, in gross characteristics, than does either of the other types.

In the 15 cases designated as atypical, hemorrhagic bronchopneumonia, the pneumonic process was bilateral. In nine cases it was of nearly equal extent on the two sides; in six it was decidedly more pronounced on one side than on the other. In three cases there were extensive, dense, pleural adhesions; in four, there were recent, friable adhesions; in eight, the lungs were free. In two cases, there were 500 c. c. and 700 c. c. quantities, respectively, of a dark red, serosanguineous exudate. Both parietal and visceral pleuræ were deeply injected. The lungs were voluminous and heavy. As a rule the posterior half or three-fourths of the lung was a dark, purplish red, the remaining anterior portion, gray or pink. That this appearance was due to the filling of the posterior portion with dark red blood could be clearly demonstrated by an anteroposterior section. The posterior portion felt uniformly firm, yet somewhat resilient. The anterior part, especially of the middle and upper lobes, was elastic, soft, and air containing; here sometimes a discrete, irregular, consolidated area could be felt.

On section, a profuse bloody exudate welled from the cut surface of the consolidated portion. With slight pressure, 300 c. c. of this liquid could be drained from a single longitudinal section. That the firmest portions of the lung contained air could be demonstrated by the presence of numerous air bubbles in the exudate. Small sections from the more dense areas would barely sink in water; other sections floated. After the surface of a section had been squeezed and washed, the polygonal boundaries of the lobules could be plainly seen. A section through the anterior, air containing portion, which was rather sharply demarcated from the posterior consolidated portion, revealed a comparatively dry cut surface. Twelve out of 30 lungs presented peribronchial areas of consolidation from 1 to 4 cm. in diameter, in this air containing portion. The cut surfaces of these isolated areas bulged slightly, and were

dark gray but not hemorrhagic. A mucopurulent exudate could be expressed from the bronchioles involved. These areas were typically those of bronchopneumonia. The marked hemorrhagic, edematous element was entirely lacking in this upper and anterior half of the lung; in fact, the gravitation of the blood and exudate to the posterior of the lung was striking.

Gross changes in the heart or pericardium were not encountered. No evidences of dilatation on either side were found; the muscle was firm; the ventricles, usually contracted, contained a small amount of dark, semiclotting blood. The "chicken-fat" clots, often observed in pneumonia and slow deaths, were not found. Only the changes usually resulting from the toxemia of a severe infection were noted in the other viscera. No marked evidences of nephritis were found. The average weight of the spleen was 240 gm. It was usually of firm consistency; the cut surface moist and purplish red. A small amount of red, gruel-like pulp could be scraped from the surface. The bone marrow was pale, and quite noticeably dry, an observation in keeping with the leucopenia.

Bacteriologic cultures were made from the lungs and the heart's blood in 14 cases.

Of the complications, the most frequent was that of pleuritis with exudate. In the group of fatal cases, a serofibrinous effusion of sufficient quantity to merit attention was recorded in 20 instances. Seven of these became purulent. In the nonfatal group it was more common, and resulted in 30 empyemas. The bacteriology of the fluids examined showed the streptococcus to be present alone in 36 per cent, the pneumococcus alone in 36 per cent, the streptococcus and pneumococcus associated in 20 per cent, and the staphylococcus in 8 per cent. A striking feature was the frequency with which the accumulation, probably beginning in a fissure, would press the lobes apart, giving a V-shaped area of fluid as seen with the roentgen ray, with the point of the V at the hilum of the lung and the open part at the chest wall. Physical examination in these cases naturally showed an area of compressed lung both above and below the fluid.

Otitis media was infrequent, although next in incidence, to the pleurisy. Phlebitis of the left leg occurred in three instances. Furunculosis and a tendency to small abscess formation were noted in a few cases. One case of cerebral thrombosis was recorded. Pulmonary edema, as a terminal condition, often was seen. Pericarditis was not found, and but one instance of acute endocarditis was observed. Meningitis with pneumococci in the fluid was recorded seven times.

Relapses or recurrences were unusual. Remissions in the severity of the process with subsequent intensification of symptoms, as early involved lung areas improved and new areas became infected, were seldom observed. Two cases of subcutaneous emphysema were recorded; both patients recovered. Spontaneous pneumothorax occurred in two instances. The picture of mild neurocirculatory asthenia was seen many times in convalescents. Reactivated, chronic tuberculosis was an unusual finding in spite of the fact that many patients had never had their induction examination. Very few mental or nervous sequelæ were observed. It was not unusual to find, long after recovery, the per-

sistence of the physical signs of fluid in the bases, in patients in whom repeated aspiration had failed to establish its presence. This was thought to be due more often to a fibrinous pleural exudate than to an unresolved pneumonic process. Crepitant and subcrepitant râles in the bases were found in some instances to persist for a period of four or five weeks from the onset of normal temperature.

This camp showed the usual mobilization epidemic of measles and acute respiratory diseases, with the medical officers frequently calling acute respiratory affections "influenza." There was no apparent epidemic in the spring. Although the rise in June may possibly be considered such, it is more likely an increase due to a considerable number of raw troops being received, and was accompanied by the sharp rise in measles. The only bacteriological data available for the cases of the fall and spring are those of the Empyema Commission which, as previously noted, show that there was a very definite high incidence of streptococcus. The indications are that the pneumonias were less hemorrhagic in character in the fall of 1917 than in October and November of 1918. During the influenza epidemic, the presence of the streptococcus was an important factor in the pulmonary lesions. In the month of October the ratio per 1,000 for empyema was over 3, the rate for December, 1917, being 1.7, and in January, 1918, 1.2. The nonhemolytic streptococcus apparently predominated over the hemolytic during the influenza period.

There are 12 protocols with specimens from 7 cases from the influenza epidemic at Camp Cody in the accessions of the Army Medical Museum. The organisms described bacteriologically can be found in the sections, and in addition in well-fixed specimens minute Gram-negative bacteria are abundant along the walls of the smaller air passages and in the infundibula, particularly in the hemorrhagic lesions and in the periphery of the lung. Pathology at this camp differs in no way from that of several other camps where the streptococcus predominated, giving a high proportion of interstitial and hemorrhagic types of pneumonia, though all of the ordinary types are represented. The camp peculiarity is the lack of a wave of epidemic influenza in the spring months, while no camp shows better than this one the increased case fatality during the latter part of the influenza pandemic.

CAMP CUSTER, MICH. ^A

Coincident with mobilization at Camp Custer, acute respiratory diseases occurred in epidemic proportions, with a case fatality rate for all respiratory diseases of 0.32 per cent in December, 1917, rising to 1.15 per cent in January, 1918. In addition to measles, influenza was diagnosed in the cases during this period, though the deaths therefrom were attributed, in the official statistics, largely to primary pneumonia. The presence of the streptococcus among respiratory cases became more noticeable during the month of January, contributing to the increase in the case fatality rate. Following the recession of all respiratory diseases in February, there was a sharp rise extending over March and April, the principal increase being due to cases of influenza. The total case fatality rate for respiratory diseases was 1.67 per cent in March and 2 per

^A Source of information, except as otherwise indicated: Medical reports to the Surgeon General, 1917, 1918, and 1919.

CAMP CUSTER

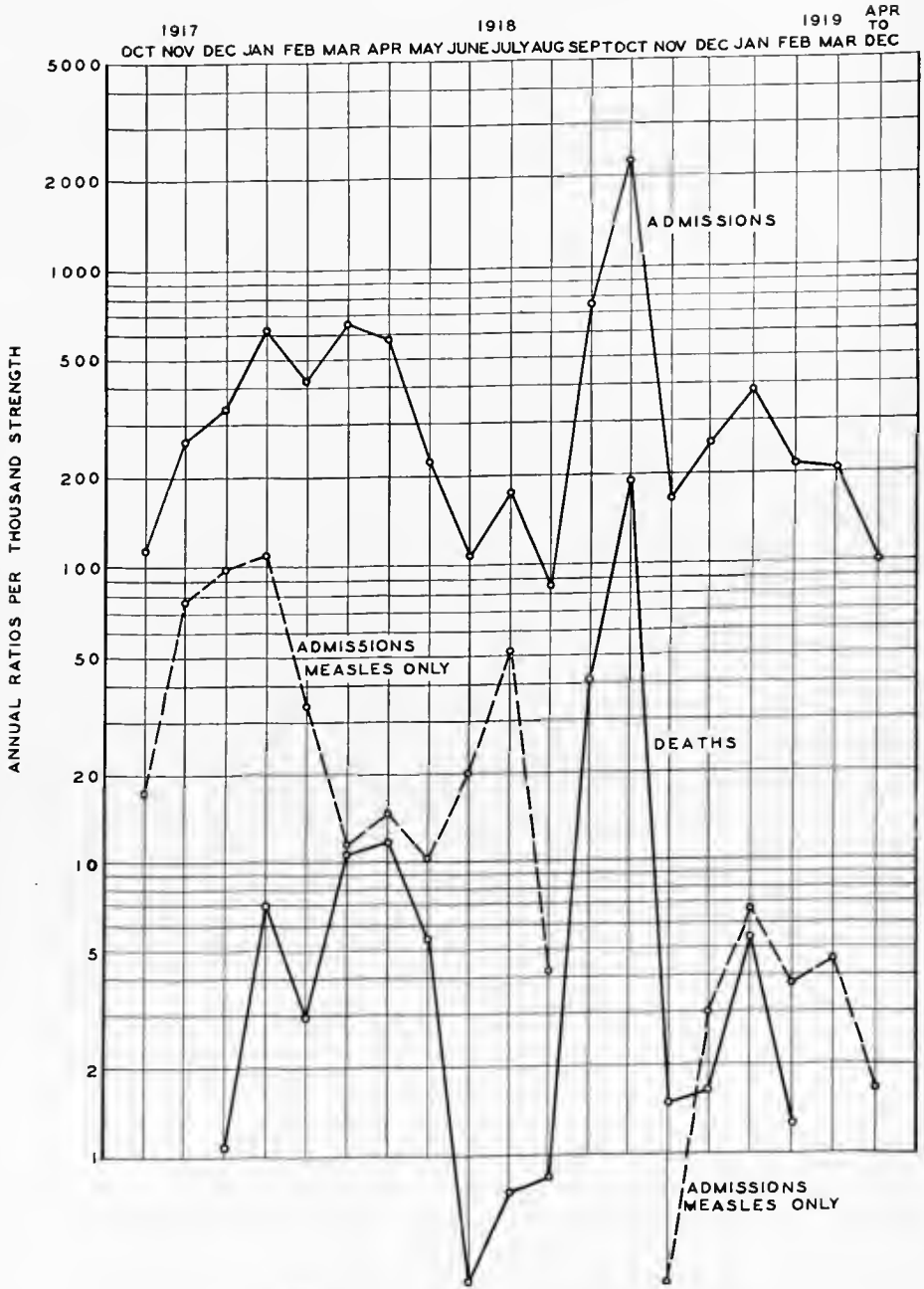


CHART IV.—The incidence and fatality of the acute respiratory diseases at Camp Custer

cent in April. During these two months the streptococcus was commonly present, as is shown by the records of the Empyema Commission. This wave of respiratory diseases was definitely influenzal in nature, though the deaths were attributed to or diagnosed as primary pneumonia. Here, as in other camps, while the cases may have been admitted with influenza or acute respiratory disease, the diagnosis was frequently changed to pneumonia and the deaths were so recorded.

Prior to the influenza epidemic, and in anticipation of its occurrence, the personnel of the camp made a study of the prevalent mouth flora of 357 healthy individuals.⁴ Smears and cultures on plain and blood-agar plates were made from the nose and nasopharynx. The usual mouth organisms were recovered. Seventy-five per cent of the cultures showed hemolytic streptococcus; in only five cases (a little more than 1 per cent) was the influenza bacillus identified.

After the epidemic had begun, cultures were made from the throat in 366 cases, which showed no physical signs of pneumonia, plain blood-agar plates being used. The organisms found were hemolytic streptococci, 34 per cent; nonhemolytic streptococci, 33 per cent; pneumococci, 12 per cent; influenza bacilli, 8 per cent. One hundred and forty blood cultures made on these patients remained sterile. Blood counts showed leucopenia as the most impressive feature, 70 per cent of the counts being below 8,000. Twenty per cent of the urinalyses showed albumin, in the majority of cases in small amount; casts occurred in 4.7 per cent.

In the cases with pneumonia the hemolytic streptococcus was the most common organism found in the blood, but only 2 per cent of 510 blood cultures in cases of pneumonia showed organisms, whereas in the previous winter, 20 per cent of the streptococcus pneumonias were positive. There appeared to be an increase in the number of positive cultures during the latter part of the epidemic.

Typing the sputum was found much less satisfactory than had been the experience during the year preceding, and the reactions with immune sera were less clear-cut. The organisms isolated from the sputum of pneumonia patients showed 25.8 per cent pneumococci, 20 per cent of these being due to Group IV. Streptococci were found in 60.9 per cent of the cases, 43.9 per cent nonhemolytic, 17 per cent hemolytic. The influenza bacillus was found in 5.2 per cent. In only eight cases it was the organism found alone.

In the blood counts 67.8 per cent showed 8,000 or fewer leucocytes per cubic millimeter. Albumin was present in the urine of 40 per cent of these cases, and casts were found in 22 per cent of the urines examined.

The incidence of organisms as found at necropsy in the lungs of pneumonia patients (280 cases) were Type I, 8; Type II, 34; Type III, 18; Group IV, 18; streptococcus, hemolytic, 76; nonhemolytic, 66; influenza bacillus, 8. The incidence of organisms as found at necropsy in the heart's blood of pneumonia patients (280 cases) were Type I, 6; Type II, 33; Type III, 16; Group IV, 22; streptococcus, hemolytic, 62; nonhemolytic, 48; influenza bacillus, 3.

⁴ The following statements of fact are based on: A Recent Epidemic of Acute Respiratory Infection at Camp Custer, Mich., by Wyndham B. Blanton and Ernest E. Irons. *Journal of the American Medical Association*, Chicago, 1918, lxxi, No. 24, 1988.

Without exception the deaths from this respiratory epidemic were due to secondary pneumonia. In no instance did a case come to necropsy in which death occurred from influenzal infection alone. The bodies were those of well nourished young men, the termination having been reached too quickly for gross external changes. Many of the bodies showed a moderate degree of corpulence. Associated chronic lesions occurred in sufficient number to warrant the belief that in a fair proportion of fatal cases the patients were seriously handicapped beforehand in the battle with the infection.

For the most part there was a striking similarity in the appearance of the respiratory organs in the 123 cases of bronchopneumonia coming to necropsy. The mucous membrane of the trachea and bronchi appeared intensely red, swollen, and covered with a mucopurulent exudate. The bronchial glands were enlarged, soft, and reddened on section. In the majority of cases the lungs were voluminous and heavy. As a general rule the posterior lobes varied from the remaining lobes, and presented a surface, dark purplish red, sometimes smooth, sometimes roughened and dull from collections of fibrin. They felt firm throughout, and only occasionally could areas of greater density be made out.

The remaining lobes showed a greater proportion of air-containing tissue. They usually presented pale, nonresilient emphysematous patches interspersed with dark red, firm, and slightly depressed areas, which were to be felt as irregular consolidations extending to various depths into the lung substance. Section of the lung throughout the lower lobes usually displayed an exceedingly moist cut surface, the slightest pressure forcing to the surface quantities of blood-tinged fluid. Sometimes this existed to such a degree as to obscure the underlying process. Again, the confluence of separate patches of consolidation was sometimes so complete as to be confusing, but careful study usually made evident the bronchial distribution of the process. As a general occurrence, however, patchy areas of consolidation clustered about the bronchi were easily made out. Mucopurulent plugs filled the bronchi and bronchioles. Section of the remaining lobes showed a much drier lesion. Here islands of dark red, often hemorrhagic, consolidated lung showed against a paler background of nonelastic emphysematous pulmonary tissue.

Only one case of lobar pneumonia occurred. This was caused by a Type I pneumococcus. It appeared during the first days of the epidemic, and its occurrence was undoubtedly fortuitous. Four cases showed the changes of an interstitial bronchopneumonia. Here the white, thickened, pus-filled bronchioles surrounded by hemorrhagic, edematous or indurated areas of consolidation presented a very distinctive picture, entirely different from the great majority of the pneumonia processes seen.

Microscopically, various pulmonary changes were found, but nothing was encountered beyond what one is accustomed to expect in bronchopneumonia. The accumulations of inflammatory cells either were patchy or so massed as to present, in a limited number of sections, an appearance indistinguishable from lobar pneumonia. The exudate was either very dense or thin; in either case edema and congestion were marked, thus greatly compromising the remaining lung tissue. As a rule, polymorphonuclear leucocytes greatly predominated in the exudate. In other sections, however, the presence of many mononuclear

wandering cells and epithelial cells were noted. Often great quantities of erythrocytes were massed together in the air cells, sometimes presenting a very striking picture, especially when contiguous to the other air cells stuffed with the inflammatory exudate. Fibrin was not a prominent part of the exudate except in one case. In a few cases, wide stretches of exudate appeared, from which all remains of alveolar walls had disappeared. In several such cases, focal areas of disintegration were in process, evidenced by poorly stained, fused masses of cellular débris in which many remains of destroyed nuclei appeared. The terminal bronchioles usually contained the same type of exudate described in the alveoli. The mucous membrane was often separated off, and tangled fragments appeared free in the exudate. Smears of the lungs usually showed enormous numbers of Gram-positive diplococci. It was rare to find organisms arranged in chains. Microscopic study of the remaining organs did not lead to any noteworthy disclosures. Eighty of the 123 cases of pneumonia examined post-mortem showed an associated pleurisy; 34 were described as serofibrinous, 25 as serofibrinopurulent, and 21 as fibrinous.

Strange as it may seem, no difference was to be made out in the nature of the process caused by the streptococcus, pneumococcus, or influenza bacillus. It was not difficult to distinguish Type III pneumococcus by the sticky exudate and the greater tendency toward confluence, but no matter what the infecting organism, each appeared to produce the same type of pulmonary lesion with equal facility.

There were no particularly constant extrapulmonary complications. Nine cases showed hemolytic jaundice, the majority of these appearing late in the epidemic. Four cases showed a massive interstitial emphysema, probably beginning in the multiple rupture of the emphysematous alveoli at the pulmonary hila. Four cases of pneumococcus meningitis developed in the course of the disease, only two of which came to necropsy. There were relatively few splenic tumors; a firm, congested organ not a great deal larger than normal was the rule. Acute changes in other parenchymatous organs were inconspicuous. Marked acute nephritis occurred only three times. Rupture of the rectus muscles was found in four instances. The bone marrow of the femur in all cases studied appeared, to gross examination, pale and unreactive.

There was a noticeable and instructive change in the course and manifestations of the disease in the last days of the epidemic. The leucopenia disappeared in large measure; 20 of 35 leucocyte counts averaged 20,000 cells per cubic millimeter. A far higher percentage of blood cultures showed positive results. Of the total of 11 positive findings, 7 were obtained in the last 80 cultures made. At necropsy the following synchronous changes were revealed: Older processess in the chest, more fibrin and pus in the pleural cavities, and collapsed lungs showing various stages of resolution and extension of the bronchopneumonia.

The important complications in 123 cases of bronchopneumonia as disclosed at necropsy were 74 cases of infection of the pleura (serofibrinous, 34; serofibrinopurulent, 20; fibrinous, 20); lung abscess, 5; interstitial emphysema, 4; pneumococcus meningitis, 2; acute serofibrinous pericarditis, 3; rupture of the rectus muscle, 3.

The average leucocyte count in the cases of streptococcus pneumonia of the winter of 1917-18 was 17,000, and positive blood cultures were obtained in 20 per cent of the cases. The duration of the pneumonia cases in the 1918 epidemic to the time of death was noticeably shorter than among cases in the previous winter. There is possible significance in the fact that the few cases of pneumonia of the 1918 epidemic that presented a picture at necropsy most like those of the winter of 1917-18 were those which had a period of longest illness, in this respect also corresponding to the cases of pneumonia which occurred during the winter of 1917-18.

From this study of the bacteriology of the deaths of January and the spring of 1918 it appears that the streptococcus played a very important rôle at this time. The high death rate and case fatality rate of September and October, 1918, were apparently accompanied by a preponderance of streptococcus in the cultures, with an usually large proportion of the nonhemolytic variety. Type II pneumococcus also appears to have had a rather high incidence. The pathology indicates that the fulminant cases of short duration were affected with a hemorrhagic more or less generalized lesion with areas of spreading bronchopneumonia. Only four cases of the typical interstitial reaction are reported and occasionally cases of the lobular variety were seen. In the four cases available for study from the influenza epidemic, all showed hemorrhagic lung, the types of lesion varying in different portions of these organs. Confluent bronchopneumonia spreading out from the bronchial tree is found in all, although lobular consolidations, interlobular lymphangitis and focal areas of hemorrhages and necrosis can be found in certain portions of the lungs in each one of the cases. In two cases, in which the tissues are well fixed, Gram-negative minute bacteria are found along the air passages, but not in the tissues. These are always accompanied by Gram-positive cocci of varying morphology.

In this camp the streptococcus was predominant throughout the entire period of the war, with an unusually large number of the nonhemolytic variety, which here, as in other camps, were found in the cases of confluent bronchopneumonia as well as occasionally in cases of the interstitial variety.

The case fatality rate for all respiratory diseases was 5.38 per cent in September, 1918, rising to 8.34 per cent in October; the influence of the streptococcus increased as the epidemic progressed and it was responsible for the increased case fatality rate during the latter part of the epidemic.

CAMP DEVENS, MASS.†

Chart V indicates that, whereas the incidence of acute respiratory diseases at this camp, shortly after mobilization, was high, the mortality was relatively low, the case fatality rate for the month of December, 1917, being 0.21 per cent, and for January, 1918, 0.8 per cent. There was a sharp rise in the case fatality rate in March, the rate being 1.07 per cent, and increasing to 1.97 per cent in the month of April. This increase in deaths is ascribed to primary

† Source of information, except as otherwise indicated: Medical reports to the Surgeon General, 1917, 1918, and 1919.

CAMP DEVENS

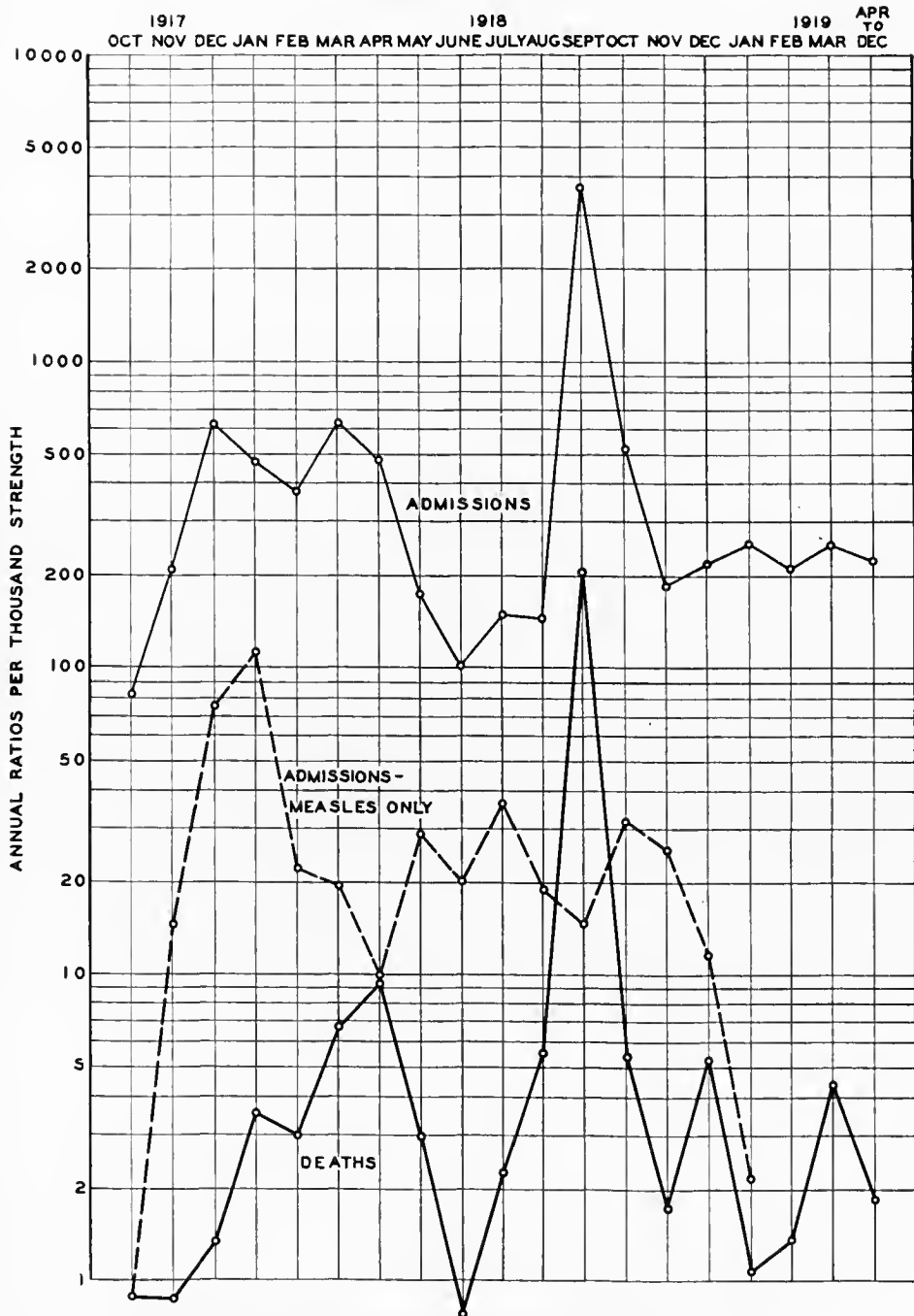


CHART V.—The incidence and fatality of the acute respiratory diseases at Camp Devens

pneumonia. The character of the cases, as shown in the histories and in the protocols of necropsies, makes it quite probable that an influenzal wave occurred at this time.

In this camp, as in several others, a rise in the total case fatality rate of all respiratory diseases preceded the wave of influenza. The case fatality rate was 0.61 per cent in June, 1918, rising to 1.48 per cent in July, and to 3.83 per cent in August, while the definite wave of the pandemic is not recorded as having started until September. In September the case fatality rate reached 5.48 per cent, with 13,733 cases of acute respiratory disease recorded. The rate dropped sharply in October to 1.04 per cent. Most of the fatal cases during the influenza epidemic were admitted for pneumonia, and the deaths are recorded in the month of September as 281 from influenza among the white personnel, while in the same personnel 48 were ascribed to primary bronchopneumonia and 340 to primary lobar pneumonia. With very few exceptions all of these cases were secondary to attacks of clinical influenza.

During the period from September 27, 1917, to May 31, 1918, there were 485 admissions to the base hospital with a primary diagnosis of pneumonia.^k The average strength of command for this period was 29,613. The 485 cases is an annual morbidity rate per 1,000 of 14.3; 64 died, or a case fatality rate of 13; there were 77 cases of empyema, with 34 deaths, or an empyema case fatality rate of 44. The frequency of empyema in pneumonia was 16 per cent.

Negroes began to arrive at this camp in number in April and were gradually increased until August when approximately 4,000 men of this race were at the camp. Those affected during the period under consideration showed 39 times as much pneumonia as did whites, while the mortality was 16 per cent as against 12 per cent of the whites. Pneumonia was lobar in 94 per cent of the Negroes and 74 per cent of the whites. Lobar and bronchopneumonia in the Negroes and bronchopneumonia in the whites showed a mortality of 15 to 18 per cent, while lobar pneumonia in the whites showed only 9 per cent. Empyema was one-third as frequent in the Negroes as in the whites, the Negroes apparently dying too early in the disease to develop empyema. Their mortality with empyema, however, was 89 per cent as against 38 per cent among the whites.

The incidence of pneumonia decreased in proportion to the length of service, but the mortality was lower in the unseasoned men. Lobar pneumonia was four times as frequent as bronchopneumonia during this period. One must consider, however, that in a considerable proportion of these lobar pneumonia cases this diagnosis was made during the increase of the spring and that a relatively small proportion of them were autopsied. It is stated that the acute minor upper respiratory infections were disregarded because unsatisfactory histories were obtained. The diagnosis of pneumonia was made frequently by the X ray in the absence of definite physical signs. Enlarged hearts in pneumonia were also demonstrated satisfactorily by this method.

In the typing of the organisms increased proficiency in the use of technical methods resulted in a marked decrease in the undetermined types, and suggests

^k The following statements of fact are based on: Pneumonia and Empyema, by Horace Gray. *Boston Medical and Surgical Journal*, 1919, clxxx, 265, 305, 330, 351, 388, 422, 448, and 475.

that the bacteriological determinations for the whole series had only a relative value. In the first 100 cases of pneumonia 43 per cent were reported as unknown types; in the second 100, 56 per cent; in the third 100, 66 per cent; the fourth 100, 38 per cent; and in the last 85 cases, only 14 per cent. Unsatisfactory specimens were responsible for a considerable number of the "undetermined" of the earlier findings.

Pathologically speaking, the three main kinds of pneumonia seen in the hospital at Camp Devens were lobar, broncho, and empyema without prior pneumonic consolidation. Lobar pneumonia was nearly four times as frequent as bronchopneumonia. Measles-pneumonia was by no means always bronchopneumonia, but in 24 per cent of the cases it was lobar; of these 10 cases clinically lobar, three were proven at autopsy to be lobar, not confluent-lobular. Of all the cases of lobar pneumonia, 16 per cent got empyema, as did practically the same, 15 per cent, of the cases of bronchopneumonia.

The death rate for lobar-pneumonia-empyema, however, was less than half that for bronchopneumonia-empyema.

Etiologically speaking, the three main kinds of pneumonia in this camp were primary, postmeasles, and postether. The primary made up 88 per cent of the 845 cases, while only 8 per cent were consequent on measles. Empyema developed in measles-pneumonia more than twice as often as in primary pneumonia.

From the viewpoint of mortality, the highest among the pneumonias was postmeasles, 32 per cent; among the primary, only 12 per cent died; among the postether pneumonias 1 died, or 6 per cent. Among the empyemas, the measles-pneumonia-empyemas, furthermore, had more than twice the death rate of the primary pneumonia-empyemas.

While it is clear that pneumonia here was essentially a primary disease, there were included under that heading some cases which by more refined interpretations might be called secondary, rather than associated. Among these acute minor upper respiratory infections (rhinitis, pharyngitis, tonsillitis, laryngitis, even sinusitis) were disregarded, because: (1) Accurate data as to their presence had not been consistently recorded; nor, indeed, is it likely that satisfactory histories could be obtained here. (2) Further, even where present, these complaints can not be considered primary causes of pneumonia, for they have been extraordinarily frequent in healthy men. The tuberculosis examining boards found high percentages of the examinees with these symptoms but with scant signs.

The etiology of the 77 empyemas was primary pneumonia in 88 per cent as against measles-pneumonia in 8 per cent. When it is recalled that primary pneumonia, in this series, was 10 times as common as measles-pneumonia, it is realized that one must consider rather the converse of the first sentence of this paragraph, namely, the fraction of the primary pneumonias to develop empyema (15 per cent), compared with the fraction of the measles-pneumonias (34 per cent) to do so. From this it is seen that the prognosis for measles-pneumonia is unfavorable.

The cases of primary pneumonia (427) made up 88 per cent of the series (485 cases). Their mortality was strikingly low, only 12 per cent. They de-

veloped empyema only half as frequently as did the cases of postmeasles-pneumonia, and when they did get empyema, the mortality was only half that for measles-pneumonia-empyema.

Of the first 100 cases of pneumonia, 24 were due to measles, presumably because of much greater frequency of measles during that period. The largest figure in any of the four succeeding periods was 9 per cent.

Measles cases developed pneumonia twice as often during the second period as during any other; in the second period, 20 per cent of the measles cases got pneumonia, while the maximum in any other period was 12 per cent. However, during the first period there were nine and one-half times as many measles cases, this greatly reducing the element of chance. This applies to the third period in which measles did not occur as an etiological factor in a single instance.

Measles-pneumonia cases developed empyema twice as often during the first period as during any other.

In the 485 cases, the distribution of the pneumococcus was as follows, the organisms being isolated from the sputum: Type I, 34 cases with 4 deaths, and 2 empyemas with 1 death; Type II, 54 cases with 7 deaths, among which there were 2 empyemas with 1 death; Type III, 38 cases with 5 deaths, 2 empyemas with 1 death; Group IV, 80 cases with 5 deaths, in which group there were 5 empyemas with 2 deaths; type undetermined, 7 cases with 5 deaths. This gives a pneumonia mortality for this group of 12 per cent, and there was empyema incidence of only 10 per cent with a mortality of 52 per cent. Cultures in which the streptococcus was found with the pneumococcus occurred in 14 cases with 5 deaths, a mortality of 36 per cent, 13 of the cases having empyema with a mortality of 4, or 31 per cent. Streptococcus without pneumococcus occurred in 43 cases with 21 deaths, a mortality of 49 per cent; 41 empyemas with 19 deaths, a mortality of 46 per cent.

The organism in pneumonia was most often unknown (in 44 per cent), then pneumococcus alone, i. e., without streptococcus (in 44 per cent), then streptococcus alone (in 9 per cent), lastly, a mixture of streptococcus and pneumococcus (in 3 per cent).

The mortality of pneumonia was greatest when the organism was streptococcus alone, 49 per cent; then from mixed streptococcus and pneumococcus, 36 per cent; then from pneumococcus alone, 12 per cent; and least when the organism was unknown, only 6 per cent.

The most frequent organism in empyema was streptococcus alone, occurring in 53 per cent of the 77 cases. Next came pneumococcus alone, 27 per cent; mixed streptococcus and pneumococcus in 17 per cent, and finally unknown organisms in the remaining 3 per cent.

The mortality of empyemas differed from that of the pneumonias in general by being highest from the pneumococcus alone, 52 per cent. Next in fatality came streptococcus, 46 per cent; and mixed, 31 per cent. This is in striking contrast to the figures obtained by an earlier analysis of the empyemas during the first six months, 53 out of 241 pneumonias. Among these empyemas the mortality was exactly reversed, i. e., highest with mixed pneumococci and streptococci, 66 per cent; then with streptococci alone, 49 per cent died, while with pneumococci alone, only 38 per cent. The explanation is that the first series,

the white men, did not die so readily unless the streptococcus was superimposed upon the pneumococcus, while the Negroes later died with the pneumococcus alone.

The improvement in the number of cases typed is striking, toward the latter part of the period reviewed. The percentage of cases whose bacteriology was "undetermined" in the first 100 cases of pneumonia was 43; in the second 100, 56; third, 66; fourth, 38; and in the last 85 cases of the series, only 14. This satisfactory diminution in the number of untyped pneumonias was largely due to the growth of a general appreciation of: (1) The importance of coughed lung sputa, not hawk-up throat mucus; (2) the surprisingly large number of pneumonias from which such satisfactory specimens were obtainable only after insistence on an early morning coughing spell; (3) the kind of sputum likely to prove serviceable for typing, not easy to describe, but thin rather than thick.

The bacteriology in the 148 cases of pneumonia in Negroes compared with that of the 337 in whites showed that the organism was streptococcus and pneumococcus in 1.4 per cent of the Negroes and in 3.6 per cent of the whites; streptococcus alone in 1.4 per cent of the Negroes and in 12.2 per cent of the whites; pneumococcus alone in 66.1 per cent of the Negroes and 34.1 per cent of the whites, the balance being undetermined. The typing of the pneumococcus alone in the 148 Negroes showed Type I, 16 cases, with 3 deaths; Type II, 33 cases, with 6 deaths, Type III, 20 cases, with 2 deaths; Group IV, 26 cases, with 1 death, the balance being undetermined. In the 337 whites, pneumococcus alone, was found: Type I, 18 cases, with 1 death; Type II, 21 cases, with 1 death; Type III, 18 cases, with 3 deaths; Group IV, 54 cases, with 4 deaths. In 97 whites in whom pneumonia occurred at the same time as in the 148 Negroes, pneumococcus alone was found; Type I, 9 cases, with 1 death; Type II, 10 cases, with no deaths; Type III, 11 cases with 2 deaths, Group IV, 11 cases, with 2 deaths, the balance being undetermined.

It was felt that the bacteriological determinations could not be compared satisfactorily with the types of pneumonia present in the cases. This is undoubtedly true, as the only satisfactory cases from the standpoint of pathology would be those examined post mortem, and in some of these cases the bacteriology was either lacking or inadequate for the purpose. Streptococcus was definitely more prevalent among the whites.

The complications noted were renal in 55 per cent of the 485 cases, empyema in 27 per cent, pericarditis in 3 per cent, otitis media in 2 per cent, while pulmonary abscess, jaundice, and relapse were present in 1 per cent. Thirty-three per cent of the cases of pneumonia showed albumin; 14 per cent more had casts without blood, and another 8 per cent had red blood corpuscles. Thus less than half the cases escaped kidney involvement as demonstrated by examination of the urine.

Purulent peritonitis was found in one case in which there was empyema in the left pleura. Pleural effusions with negative cultures not diagnosed as tuberculosis were present in appreciable numbers. One patient developed empyema on the side opposite the pneumonic consolidation, with pneumococcus in the culture, while two cases of empyema developed without preceding consolidation having been demonstrated. Though it may be considered probable

that pneumonic consolidation of some kind existed in these cases, it was entirely within the realm of possibility that infection spread from the involved mediastinal lymphatics directly to the pleura without causing pneumonic consolidations in the lung. In one case an effusion occurred a week before consolidation was demonstrated.

The failure to demonstrate pneumonia at autopsy, even though it had been clinically present during the course of the illness, though infrequent, did occur and was reported from many camps and towns of the United States as well as abroad. Five cases of this variety were reported at Camp Devens, but the deaths occurred in such stage of the disease that the presence of pneumonia at some time during the course of the illness can not be ruled out. Three of the cases had relatively marked empyemic involvement.

It was frequently impossible to diagnose definite pneumonic consolidation on the basis of physical signs. A large proportion of the cases were diagnosed lobar pneumonia but all types of bronchopneumonia are described, while the autopsy protocols indicate that in a high percentage of cases in which diagnosis of lobar pneumonia was made, there was really mixed pneumonia, with varying reactions in different lobes of the lung, though massive consolidations were frequent. With the high incidence of the fixed types of pneumococci it is to be expected that the lobar consolidations would be found frequently at least in some of the lobes and this was evidently true, yet it was relatively rare that clear-cut lobar pneumonia, without other consolidation in the lung, was described. The classification of such cases is based on the predominance of one type of lesion and in that sense only does true lobar pneumonia predominate, as indicated by the necropsy protocols.

The bacteriology of the influenza epidemic at this camp was carefully studied.¹

In addition to sputum typing, smears were examined and careful cultures were made using, for a while, blood on agar plates, and later, 10 per cent defibrinated blood agar plates. Symbiotic action of staphylococcus and *B. subtilis* was used in some instances to enhance the growth of the influenza bacillus.

The presence of *B. influenzae* in the smear alone was considered inconclusive and its location in pure culture was considered necessary. From the sputum, *B. influenzae* was cultivated 104 times, 12 times in pure culture and 92 times in association with other organisms. In the 92 cases there were 5 Type I; 2 Type II; 1 Type II atypical; 5 Type III; 52 Group IV; not typed, 25. Cultures of the pleural fluid showed pneumococcus Type I, 11, Type II (subgroup), 5; Type III, 2; Group IV, 7; *Streptococcus hemolyticus*, 3; *B. influenzae* (pure) 2; *B. influenzae* and *Streptococcus hemolyticus*, 2; *B. influenzae* and pneumococcus, 4; no growth (serous), 8. *B. influenzae* was not isolated from the blood cultures. The organisms found in the blood culture were pneumococcus, Type I, 10; Type II, 7; Type III, 1; Group IV, 9; *Streptococcus hemolyticus*, 1. The high incidence of pneumococcus Type I and II is noteworthy. Cultures at autopsy in 37 cases showed *B. influenzae* predominating in 14; *B.*

¹ The following statements of fact are based on: A Bacteriologic Study of the Influenza Epidemic at Camp Devens, Mass., by Lesley H. Spooner, Joseph M. Scott, and Elmer H. Heath, jr. *Journal of the American Medical Association* Chicago, 1919, lxxii, No. 3, 155-159.

influenzæ and pneumococcus, 4; *B. influenza* and *Streptococcus hemolyticus*, 3; *B. influenza* and *Staphylococcus aureus*, 1; *B. influenza*, *Streptococcus viridans* and pneumococcus, 1; *Streptococcus hemolyticus*, 1; pneumococcus, 6; negative, 7.

B. influenza occurred alone or with other organisms in 23, or 62 per cent, of 37 cases. In addition, *B. influenza* was recovered from the frontal sinus in 4 cases; from the sphenoidal sinus in 4, and from the middle ears in 2.

Although the *B. influenza* was present in frequency enough to warrant the statement that it was the most important etiologic factor of this epidemic, yet considerable importance must be placed on the secondary invaders, the pneumococcus, and in this hospital rarely the *Streptococcus hemolyticus*, which were found in such a large percentage of cases examined, both during life and post mortem.

Agglutination reactions of cultures of *B. influenza* were made with patients' serum at various periods after the onset of the disease.

From these studies it seems reasonable to suppose that the prime factor in this epidemic was *B. influenza* since it was found in such a large proportion of specimens of sputum when the latter was derived from the lower air passages and was properly examined; since the organism was recovered from lungs post mortem in 62 per cent of the cases carefully studied, and in pure culture from at least one lobe in 50 per cent of the same series; and since the blood of patients convalescent from the disease showed a rising agglutinating power not only to their own organism, but also to heterologous cultures.

The direct smear method was of value in indicating what might be expected in culture. The most striking fact in regard to such preparations lies in the great frequency of intracellular *B. influenza*. The absolute necessity of immediate necropsies, if the influenza bacillus is to be cultured before overgrown by other organisms, was convincingly demonstrated.

Interesting studies were made of the pathology of the fatal cases of influenza in the pandemic.^m Two types of lungs were noted as strikingly characteristic findings in this disease. The first was encountered in cases in which death occurred within a few days after the onset of pulmonary signs. These cases yielded lungs which were partially collapsed, dark red, lax, but meaty in consistency. The pleural surfaces were often partly covered with a dusky red mottling, due to small extravasations of blood beneath the serous coat. In some cases there was a thin layer of dusky red fibrinous exudate upon the pleural surfaces, particularly over the posterior borders. On section these lungs were dark red and wet. They were dripping wet, and the fluid from some portions was a blood-tinged serous liquid and from others dark red and bloody. On close inspection the cut surfaces usually were found to be thickly sprinkled with air vesicles of considerable size. The lung tissue as a whole, after the liquid had drained from it, was brownish-red in color, and somewhat translucent and friable. The mucosa of the bronchi was usually very dark red in color, and the bronchial lymph nodes were enlarged and deep red in color.

The other type of lung, which was found in patients that had lived for 10 days or more after the onset of the disease, while showing traces of the type of

^m The following statements of fact are based on: Comments on the Pathology and Bacteriology of Fatal Influenza Cases as Observed at Camp Devens, Mass., by S. Burt Wolbach. *Johns Hopkins Hospital Bulletin*, Baltimore, 1919, xxx, 104-109.

lesion just described, was characterized by a very extensive bronchitis, with bronchopneumonia, discrete or confluent, and peribronchitis. Such lungs were more voluminous than the preceding, but they did not fill the chest cavity post mortem. They were nodular, and the pleural surfaces occasionally showed a striking tracery, due to the injection of the subpleural lymphatics. Portions of the surfaces of the lungs, in some instances, were covered with a thin layer of fibrinous exudate. On section, the most prominent feature was the extensive injection of the bronchi, particularly the smaller ones, with a fibrino-purulent exudate. The injection of the bronchi at times was so extensive and uniform as to produce geometrical patterns, which were very striking when the condition was accompanied, as it usually was, by a marked infiltration of the interlobular septa. A casual inspection sufficed to show that the smaller bronchi were distended, usually markedly dilated, and in cases of two weeks' duration spherical and cylindrical bronchiectases were very common. The condition, in fact, was one of panbronchitis; peribronchitis with extensive infiltration of the interlobular septa; and organization in alveoli and bronchioles.

In the first type of cases, in which emphasis was laid on the gross appearance of the lungs, *B. influenza* was the only organism which could be cultivated, and these distinctive conditions were unhesitatingly associated with that organism. In the lungs showing other types of solidification, other organisms were responsible for the exudation characterizing the pneumonias. The hemolytic streptococcus, the staphylococcus, and the pneumococcus, each produced its distinctive picture, the last often that of lobar pneumonia.

While the bacteriological evidence, based upon the assumption that *B. influenza* is the cause of influenza, was very good in support of the stand that there was a distinctive lung lesion in these influenza pneumonias, the histological study afforded very definite proof. Early in this study of the Camp Devens cases, the fact was recognized that a striking type of reaction was present, a condition of acute alveolar emphysema with the deposit of a hyaline fibrinous material on the alveolar walls. The intervening alveoli were compressed and filled with exudate, which in the early cases was largely serous or bloody, containing but little fibrin. It was this acute alveolar emphysema, with the serous and hemorrhagic exudate, that gave the characteristic gross appearance to the lungs in the early stage of the disease. In order to determine how common this lesion was all of the General Hospital No. 10, Boston, autopsies on influenza cases were studied, and it was found to be constant. It might be masked by a pneumococcus or streptococcus exudation or by extensive hemorrhage, but its presence could always be determined by the finding of the hyaline fibrin outlining greatly distended air spaces in the lungs. It was the one distinctive feature in the pathology of influenza pneumonias, and its constant occurrence was indicative of the entity of the initial lung infection. The interpretation of this lesion was not easy. The hyaline fibrin, because of its prominence and the juxtaposition of cellular exudate, often simulated the outlines of alveoli. As a matter of fact it outlined cavities filled with air which might or might not completely fill groups of alveoli. Although alveolar walls in contact with this fibrin might be necrotic, tissue elements played no part in its formation. A similar hyaline fibrin was found in two cases of emphy-

sema of the mediastinum where the mediastinal areolar tissues were infected by pneumococcus, secondary to pneumococcus pericarditis. The physical characteristics of this fibrin were determined by its contact with air, and an important factor was probably the mechanical compression of strands of fibrin by air. What is the source of the exudation in the alveoli in these early pneumonias? The exudation might be present in alveoli with intact walls, or walls showing very slight reaction, mainly evidenced by activity of the respiratory epithelium. In all cases severe lesions were found in the finest bronchioles and in the alveolar ducts. The latter showed an exudation composed mainly of polymorphonuclear leucocytes and small quantities of fibrin. The walls were filled with leucocytes, and often were necrotic in places. The intralobular bronchioles showed severe lesions of the mucosa, and often it was possible to demonstrate the source of hemorrhages from capillaries. The obvious explanation, and indeed the only possible one from the material studied, is that the major injury was to the bronchial system, and mainly in the finest bronchioles and alveolar ducts. To secure the degree of emphysema present it was necessary to assume a valve action of the exudate in the bronchi. The character of the hyaline fibrin deposit around air vesicles upon the alveolar walls suggested a pouring of exudation into the alveoli from the bronchioles and alveolar ducts, at a time when air was able to pass. Thus the patient was virtually blowing bubbles in his own lungs, into a medium of exudation relatively poor in fibrin.

The mechanism of interstitial emphysema formation was easily seen, where the greatly distended alveoli were in contact with the pleura of interlobular septa. In these locations it was possible to demonstrate rupture of the alveolar walls and the direct continuity of fibrinous strands, partially filling clefts dissected by the air from alveoli to plueral or interlobular connective tissue. A series of gross sections and microscopic sections from lungs with interstitial emphysema showed that the air found the easiest route of exit from the lung in the connective tissue surrounding blood vessels. It dissected along blood vessels to the hylus of the lung and from there along the great vessels and bronchi into the mediastinum, over the pericardium into the anterior mediastinum, and upwards along the trachea into the tissues of the neck, whence it escaped into the subcutaneous tissues. This subcutaneous emphysema might appear very early. The earliest case was seven days from the first symptom, which meant, of course, a shorter duration of the lung involvement. The majority of the cases were noted on or after the tenth day from the initial symptoms of the disease.

It must be borne in mind, in considering the pathology of these lungs, that the lesions were not uniformly distributed, and therefore very extensive injury in portions of one or several lobes was compatible with life for a considerable period of time. The bronchial lesions apparently progressed, and might extend throughout the whole of one or both lungs, producing the anatomical picture of the more chronic cases, that of a panbronchitis with bronchiectases and peribronchitis. During this period of extension in bronchi, a number of things might happen to the portions of the lungs first involved. They might become

secondarily infected with pneumococcus or streptococcus, or the Gram-negative diplococcus, called by English workers, "*Diplococcus mucosus*." In rare instances staphylococcus and Friedlander's bacillus were encountered. The fate of the tissue depended on the nature of the infecting organism; as, for example, fibrinous exudation with the pneumococcus and abscess formation with the staphylococcus. In a number of instances these portions of the lungs, severely damaged at the onset, did not become secondarily infected; at least, these lungs showed only the influenza bacillus at the autopsy, and had undergone extensive organization resulting in cicatrices of large sizes. If one take a series of lungs which have shown only the influenza bacillus in cultures and in sections, one may still have all the stages described, exclusive of those with secondary infection, and accordingly it must be concluded that the reaction to the influenza bacillus is less intense in the later stages of lung involvement than in the earlier. This was shown best in comparing two lungs from the same case, where in one lung, usually the right, there was found the severe damage of the early lesion with bronchiectasis and peribronchitis, and in the other lung a much less intense bronchial reaction, with much less marked peribronchitis, or none at all. The involvement of the pleura in lungs infected solely with influenza bacillus was very slight. There were hemorrhages into the pleura and perhaps a thin layer of fibrin upon the surface. The amount of fluid in the pleural cavities was always small, though blood-tinged. Empyema was found in cases secondarily infected with the streptococcus or pneumococcus. The involvement of the pleura sometimes results from the extension of the inflammatory process along the interlobular septa and lymphatics, or, as was more commonly the case, from bronchiectatic cavities situated close to the pleural surface.

Gangrene of the lung was noted in one of the Camp Devens series in a case showing very extensive bronchiectases, with bronchiectatic abscesses. Extensive necrosis of the lung was observed in a number of cases in this same series and at General Hospital No. 10 necrosis due to organisms other than the influenza bacillus.

Organization in the pure *B. influenzae* cases was a common end result. The organization of the exudate began early, certainly before the tenth day of the disease, and a prominent factor in bringing about this result was believed to be the plugging of the bronchi with exudation. In patients who had survived three weeks or more there were very complicated gross appearances, due to extensive cicatrization of large portions of the lung. The contraction of the interlobular septa, due to the avascular organization of exudate, caused marked distortion of the lobules of the lung, and peculiar lines of retraction on the pleural surfaces.

While it is not the purpose here to include the whole pathology of influenza, a few interesting features in other organs are worthy of emphasis. Eight of the Camp Devens series showed waxy degeneration of the rectus muscles, and subsequent experience at General Hospital No. 10 indicates that it was probably overlooked in some of the earlier post-mortem examinations made at Camp Devens. A number of these cases showed rupture and extensive hemorrhage into the rectus muscle. This lesion was noted in other muscles; for instance,

the transversalis, the internal and external oblique muscles, the latissimus dorsi, the pectoralis major and the intercostal muscles. The testes occasionally showed minute petechiæ, but on the whole no striking gross change was observed. Microscopically very striking changes were encountered in nearly every case, namely, the cessation of activity in the seminiferous tubules; actual degenerative changes frequently were noted, and in late cases beginning fibrous tissue replacement of the degenerated tubules. This lesion of the testis seemed to be wholly a toxic one, as there was very little cellular reaction. It was difficult to understand why such severe toxic lesions of the muscle and testes should occur, in the absence of effects attributable to toxins in other organs. For instance, the reaction of the spleen was very slight, the heart muscle rarely showed any gross or microscopic lesion, and in general seemed to escape entirely the toxic effect of the disease. Lesions of the adrenal, when extensive, such as hemorrhage, could be attributed to secondary infection, usually the hemolytic streptococcus. Minor acute lesions constantly were found in the cortex in influenza cases, but these lesions were similar to those found in many infectious diseases—the disappearance of lipoid content, and focal necrosis with mononuclear phagocytic cell reaction. The head was opened in 20 of these cases. Infection of the middle ears was found in 13, infection of the sphenoidal sinus in 20, frontal sinus in 7, and of the ethmoidal cells in 8 cases. Three cases showed punctuate hemorrhages in the cerebral cortex.

From the foregoing studies it is seen that the early pneumonias of this camp following measles, primary, and during the apparent influenza rise in the spring, were characterized by a relatively large number of cases which bacteriological examination indicated were due to infection with the fixed types of pneumococci, with a high mortality from both pneumococcus and streptococcus infections. The type of reaction in the lungs was either lobar or confluent bronchopneumonia, with a relatively small number of the suppurative variety, in which *Streptococcus hemolyticus* was most frequently found. The relatively few cases in the influenza epidemic of September, 1918, suggest *B. influenzae* as the causative organism of the primary infection. At least, it was the earliest and most frequent of all bacteria discovered.

Necropsy protocols for 229 cases of pneumonia, with 19 specimens, were received at the Army Medical Museum from this camp. As previously stated, the type of the pneumonic consolidation showed a large percentage of fibrinous consolidation, usually, however, accompanied by other types of consolidation in other portions of the lung. Lobar types were apparently much less frequent during the influenza epidemic. The picture given above of the lesions accompanying infection by the influenza bacillus is recorded in the protocols as having been present in most if not all of the cases during the epidemic period though frequently masked by other types of lesion. The bacteriological picture as shown by stains of the fixed tissue is rarely satisfactory unless autopsy followed death within a relatively few hours. Throughout the duration of this camp *Streptococcus hemolyticus* did not play an important part. The fixed types of pneumococci appear to have been largely responsible for the secondary pneumonias.

CAMP DIX, N. J.*

Measles and common respiratory diseases assumed epidemic proportions shortly after mobilization began in September, 1917. Relatively few deaths occurred and the case fatality rate was low, as is indicated in Chart VI. Influenza was diagnosed in considerable numbers throughout the fall of 1917. The sharp rise in respiratory diseases, with peak in March, 1918, was due to an epidemic of influenza, over 1,100 cases being so diagnosed in that month. The case fatality rate, however, was low. The deaths were ascribed to primary pneumonia for the most part, the preliminary respiratory infection not being considered as a diagnosis, as is true of most of the other camps. In a general way the pneumonic lesions in the spring of 1918, appear to have been, in large part, bronchopneumonia, and the streptococcus does not appear to have been very frequent, though it was observed, particularly in the empyema cases. The low case fatality rate suggests that the organisms were not particularly virulent during this period.

Thorough clinical and laboratory studies were made during the influenza epidemic at Camp Dix, which began September 15, and ended October 6, 1918.^o During the 22 days of the epidemic, 6,500 patients were cared for. Approximately 6,000 of these men had influenza; 800 deaths were due to the epidemic.

The usual history was one of gradual onset with prodromes for four or five days prior to admission, consisting of headache, malaise, backache, myalgia, fever and chills or chilly sensations, and marked prostration. There was a history of anorexia, and of aggravation of symptoms, after drill or exercise. Occasionally the onset was sudden, sharp, and severe. A low temperature in a severe case was an unfavorable sign. The blood count usually showed leucopenia. The urine contained albumin and casts. The patients looked very ill, but often did not feel so. Few complained of sore throat or the early sticking pains in the chest, aggravated by coughing, so commonly observed in beginning pneumonia.

One-third of the cases presented frank signs of pneumonia. Every patient who had fever, prostration, rapid pulse, increased respirations, cough, and bloody sputum was at once put down as a pneumonia suspect, which diagnosis could usually be confirmed later by physical signs and roentgen examination.

Frequently no physical signs of pneumonia were apparent on the initial examination. A day or two later, bronchopneumonia was discovered, the lobules subsequently tending to become confluent. This condition sometimes gave the physical signs of a lobar pneumonia, but the real condition was repeatedly demonstrated at necropsy. The roentgen ray was an invaluable aid in the diagnosis of such cases.

The outstanding feature of the disease was the extreme toxemia noted in the serious cases. Almost from the first inspection the outcome of each case could be predicted. There was a sharp line of demarcation between the serious and mild cases. In the former many patients developed cyanosis early in the disease and died promptly, after periods varying from a few hours to three days after admission.

* Source of information, except as otherwise indicated: Medical reports to the Surgeon General, 1917, 1918, and 1919.

^o The following statements of fact are based, in the main, on: The Influenza Epidemic at Camp Dix, N. J., by Martin J. Synnott and Elbert Clark. *Journal of the American Medical Association*, Chicago, 1918, lxxi, No. 22, 1816-21.

CAMP DIX

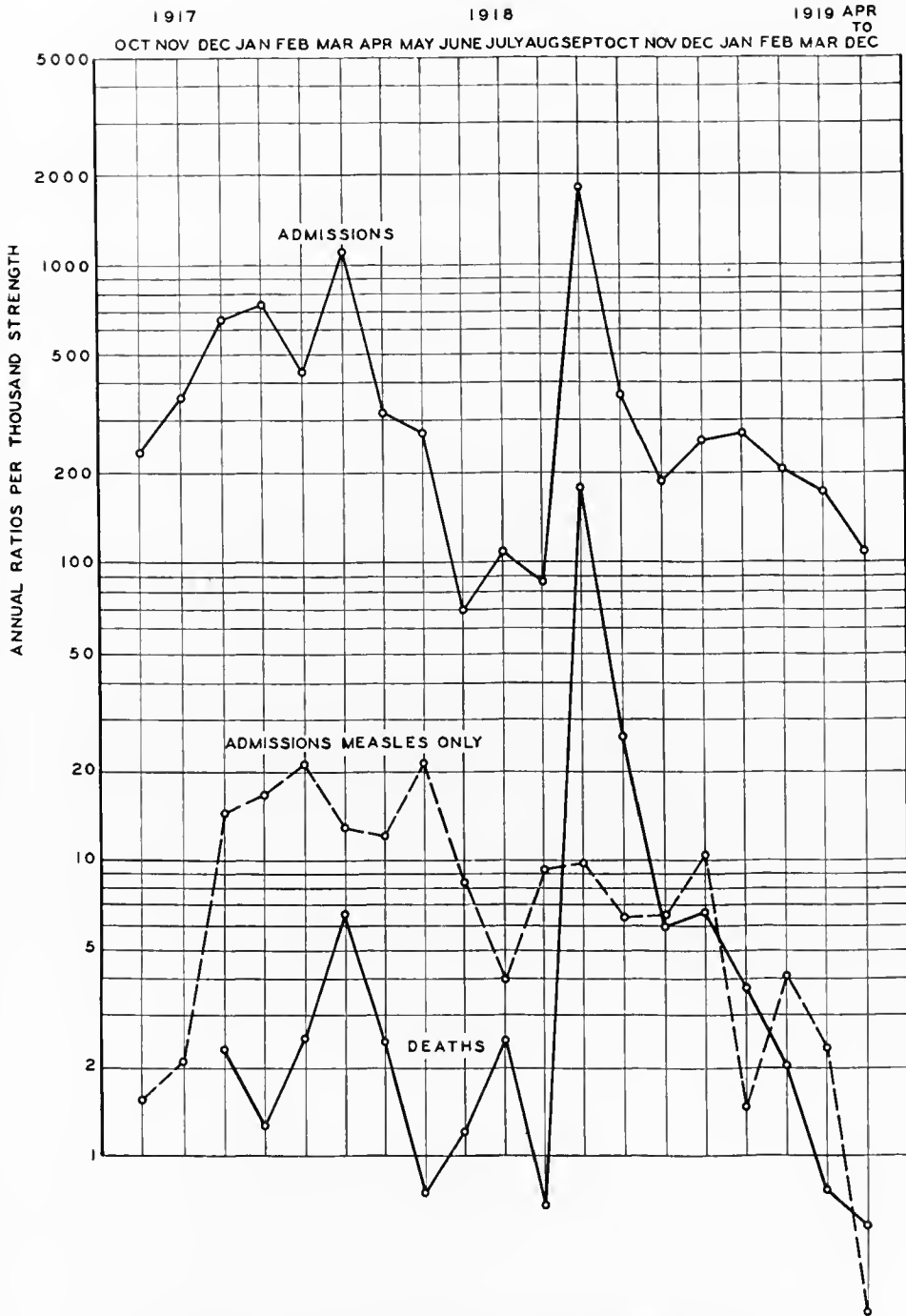


CHART VI.—The incidence and fatality of the acute respiratory diseases at Camp Dix

The cyanosis appeared early and was progressive. It was a fairly constant and characteristic symptom in the severe cases. This intense cyanosis was a striking phenomenon. The lips, ears, nose, cheeks, tongue, conjunctivæ, fingers, and sometimes the entire body, partook of a dusky, leaden hue. Frequently this cyanosis was apparent before there were any demonstrable physical signs of pneumonia. The cause could not be ascertained, a few spectroscopic readings failing to show absorption bands of methemoglobin. As necropsy revealed marked so-called compensatory emphysema in these cases, and as cyanosis is a common accompaniment of emphysema, possibly this was in some way accountable for the condition. Otherwise a purely mechanical conception of the mode of production of the cyanosis seems untenable. Lividity, occurring early in the disease, proved to be an ill omen.

Very often this cyanosis came on suddenly in patients who had been doing well. It was not due to cardiac dilatation. The pulse was often slow, full and regular in such cases, and remained so, with a rate under 100, almost until death.

The disparity between temperature and pulse was striking. Patients with temperature between 104° and 106° F., not infrequently had a pulse rate below 80. This was regarded as a strong point in differential diagnosis between these influenzal pneumonias and those of pure pneumococcal origin.

There was noted in many instances a distinct tendency to relapse. In several mild cases, after a day or two of nearly normal temperature, exacerbations occurred and the infection changed to the severe, toxic type.

Herpes labialis was relatively infrequent, but became more common as the disease advanced. It was seemingly of little help in prognosis, as many with herpes died, contrary to the teachings of the older clinicians.

The sputum showed varying characteristics. It was mucoid, mucopurulent, blood streaked, frothy and bloody, or bloody as in infarct. In one it was thin, brown, without froth, and homogeneous (prune juice variety). At times it was rusty but lacking tenaciousness and of the consistency of typically pneumonic sputum; it was odorless. In one case the patient coughed up a large quantity of homogeneous, thick, purulent, greenish sputum at one time. Necropsy in this instance revealed multiple bronchopleural fistulas leading to an encapsulated empyema on the right side.

Flushing of the face was common. An early generalized erythema resembling that of scarlatina, most noticeable on the chest and back, was often observed. Miliaria (subamina) was common later in the disease, especially in lethal cases in which sweating was frequent and excessive.

The throat was usually infected, but not painful; the tonsils were not swollen as a rule; there was marked conjunctival congestion at the outset of the disease. The tongue was variable; usually coated, moist in mild cases, dry, cracked and occasionally bleeding in severe cases. Sordes appeared frequently on the teeth.

Hoarseness was frequent, due either to the trauma of coughing or to superficial laryngeal ulceration or edema, as demonstrated at necropsy.

The mental condition either was apathetic or there was an active delirium. In moribund patients, motor and psychic restlessness was remarkable. In

some cases the typical typhoid state existed; stupor, low muttering delirium, subsultus tendinum, carphology, incontinence of urine and feces.

In one case necropsy revealed the presence of bilateral abscess in the lower rectus (Zenker's hyaline degeneration).

There were fewer cases of empyema in this epidemic than might be expected, owing to the extreme toxicity of the disease, with the result that death occurred early. Most of the cases examined post mortem showed lesions in the pleura which undoubtedly would have resulted in empyema had the patients lived longer.

One of the most striking of the complications was hemorrhage from the mucous membranes, especially from the nose, stomach, and intestine. Frequently, pneumonia patients would have hemoptysis like the hemorrhage of tuberculosis. Bleeding from the ears, and petechial hemorrhages in the skin also occurred. Purpura was seen rather frequently. Other complications were phlebitis, thrombosis, or embolism of peripheral arteries (with gangrene of the foot in two cases), toxic erythema, vomiting, diarrhea, conjunctivitis, convulsions, purulent peritonitis, inflammation of the accessory sinuses and of the middle ear, and pericardial effusion. A pronounced jaundice, not obstructive, as the stools were not acholic, and probably of infectious origin, was noted in many of the severe cases. Retention of urine was not uncommon.

In several instances the infection produced a pronounced hemolytic effect, with rapidly progressive anemia. In one instance, that of a medical officer, the red corpuscle count was reduced to 1,600,000 with 50 per cent hemoglobin on the fifth day of the disease.

The pathology of the cases of influenzal pneumonia coming to necropsy at Camp Dix presented very diverse pictures. In the cases seen at necropsy the lesions were confined for the most part to the chest cavity. This was especially true of the cases which ran a rapidly fatal course. In the latter, the greater part of the visible pathologic changes consisted of very much congested and hemorrhagic, water-logged lungs.

A notable feature of the cases in which death occurred early in the disease was the extreme water-logged appearance of the lungs—lungs that were almost, if not completely filled with a watery, bloody and frothy fluid, with petechial and large hemorrhagic areas in the pleura. The right lung in one case weighed nearly $4\frac{1}{2}$ pounds and was devoid of air except for a small area at the apex of the upper lobe and small areas here and there along the anterior margin. The latter areas appeared to contain air under pressure. The remainder of the lung was tightly filled with fluid, was soft at all points, and did not contain any nodules or firmly consolidated areas. When the lung was held up, large quantities of fluid ran out. A slice cut from the lung lost about half its weight in fluid squeezed out by pressure with the hand. From this lung there was grown a nonhemolytic streptococcus and the influenza bacillus. Pronounced inflammation of the trachea and bronchi was noted in all cases in which death occurred early in the disease.

While only one case of well-marked empyema came to necropsy several showed evidence of beginning empyema.

The heart showed nothing beyond dilatation of the right ventricle in the more acute cases. Early pericarditis was seen in cases of longer duration. The spleen as a rule showed no evident change. The liver weighed on the average approximately 2,000 gm. and was congested and often yellowish. The kidneys showed a markedly congested and yellowish cortex. The intestinal tract showed in the majority of cases, only slight congestion, and petechial hemorrhages in the gastric mucosa.

Blood examination in more than 700 cases revealed in most instances an absence of leucocytosis in the more severe cases and during the acute stage of those running a more favorable course. The average was about 5,000 white cells per cubic millimeter during the acute stage. The lowest recorded was 1,200.

The lymphocytes experienced a relative percentage increase. The red corpuscle count, as a rule showed no decrease and frequently a high count during the acute stage. After two or three weeks in the hospital the picture changed in most of the serious cases. The red corpuscle count decreased sometimes to 1,600,000 and a leucocytosis developed, ranging from 12,000 to 30,000 white cells, with polymorphonuclear leucocytes running as high as 95 per cent. The hemoglobin varied directly with the red corpuscle count.

The urine in practically all seriously ill patients showed a liberal amount of albumin with frequent casts.

A large variety of organisms was encountered in cultures and smears from the lung substance, from the bronchial mucous membrane and from the sputum. Streptococci and pneumococci were most frequently found. The influenza bacillus (Pfeiffer's) was encountered in sputum, bronchi and lungs, but no particular effort was made to study it or to determine its frequency. It was encountered, however, in the majority of cases when looked for. It was recovered from the lung substance, from the bronchi, from the trachea and from the sputum, but in none of the large series (over 300) of blood cultures.

It is worthy of note that *Bacillus influenzae* in no single instances was the sole invading organism. It occurred, as stated, in the sputum and in secretions taken directly from the trachea and bronchi and from the lung, but it never was in pure culture. It was always associated with one or more pathogenic organisms. It was found associated with *Micrococcus catarrhalis*, with the pneumococcus of various types, with *Streptococcus hemolyticus* or *viridans*, with pneumococci and streptococci, and in one or more of these combinations, plus various other undetermined organisms. Of the latter class there were observed spirilla, Gram-negative cocci and bacilli and frequently a pleomorphic Gram-positive coccus. It would thus appear that, whatever rôle *Bacillus influenzae* played in this epidemic, it did not invade the blood, and in all probability was not solely responsible for the fatal termination.

The sputum in more than 500 cases was examined as to organisms and subjected to test for pneumococcus type by the white mouse necropsy method. The organisms mentioned above were recovered, namely, pneumococci of various types, *Streptococcus viridans* and *hemolyticus*, *Micrococcus catarrhalis* *Bacillus influenzae*, a Gram-positive pleomorphic coccus, and Gram-negative bacilli and cocci in the associations already noted. During the early phase of

the epidemic when the pneumococcus was encountered it failed, as a rule, to give any type reaction by either the precipitin or the agglutinin test. Later, Type III and to a less extent Type II pneumococci became more and more frequent.

Three hundred and fifty urines and 120 spinal fluids from seriously ill patients were subjected to the precipitin test. The results were comparable to those from the sputum examination; Types III and II became more frequent during the later phase of the epidemic.

It would thus appear that neither pathologically nor bacteriologically was this a definite disease. At necropsy there were found a variety of conditions and a multiplicity of organisms in the various cases. The epidemic, however, showed phases, the later of which tended to resemble the bronchopneumonia of streptococcus and pneumococcus origin.

From this study it is seen that, so far as bacteriology is concerned, the lesions for the cases dying early appear to have been caused by the influenza bacillus. Infection with this organism was followed by secondary infection with other organisms, most frequently pneumococci. Pneumococcus, Types II and III, apparently increased towards the latter part of the epidemic. These organisms, in several camps, were found more frequently as the case fatality rate increased. The case fatality rate, in September, 1918, the peak of the pandemic, was 9.65 per cent, a relatively high case fatality rate, which, in the absence of any indication of a prevalence of *Streptococcus hemolyticus*, must be attributed, at least in part, to members of the pneumococcus group.

The cases, referred to above, in which subcutaneous emphysema was noted, were made the subject of special study.²

Twelve cases showing peculiar accumulation of gas in the fascial tissues were studied as closely as the exigencies of a crowded service would permit. Three of the cases recovered. A total of 20 was reported.

Gas first made its appearance in the subcutaneous tissue at the base of the neck anteriorly and laterally and over the upper portion of the chest from the clavicle to about the third rib. While this was the usual location two cases showed a more extensive distribution of gas. In one case gas was found also in the subcutaneous tissue of the cheeks, eyelids, mesial aspect of the entire right arm and in small areas over the sides of the chest and abdomen and in the flanks.

During life the patients showed a slight ballooning of the skin over the affected areas. These areas were distinctly crepitant, the gas disappearing from the immediate region of the palpating finger on pressure. A notable feature was that the skin over the ballooned area felt cold to the touch while the neighboring tissues were feverish. There was no perceptible change in color of the tissues in the affected areas.

The patients with this accumulation of gas showed no related subjective symptoms, and no symptoms of an intercurrent infection. There was no discoloration of the affected areas. No edema, no congestion and no induration or other signs of infection were observed. It was not associated with any other

² The following statements of fact are based, in the main, on: Influenza-pneumonia Cases Showing Gas in Fascial Tissues, by Elbert Clark and Martin J. Synnott. *American Journal of the Medical Sciences*, Philadelphia, 1919, clvii, 219-221.

especially characteristic symptoms or physical signs. The accumulation of gas apparently did not affect the course of the disease. It appeared to be an inert gas in the tissue spaces. The affected tissues gave a crackling sound on pressure with the stethoscope. In one case there were recorded, over the precordium, râles very similar to sounds elicited with moderate pressure of stethoscope over emphysematous cutaneous tissue. At autopsy the mediastinal connective tissue was distended with gas in this case.

Three of the cases came to necropsy. The pathological findings were not those of cases dead of infection with *Bacillus aerogenes capsulatus*, nor in fact did the lesions present the characteristics of an infection.

In the three subjects which came to necropsy the distribution of the gas likewise varied in extent. In the most pronounced case the gas was distributed in the subcutaneous fascia as follows: Over the upper anterior portion of the chest as far laterally as the axilla, continuing upward over the front of the neck and laterally as far as the anterior border of the trapezius muscle, over the parotid region, over both cheek areas and eyelids. Similarly it could be felt in the vascular sheaths of the right axillary, brachial and radial arteries as far as the base of the thumb. Within the chest the fascia of the anterior and posterior mediastinum appeared as a reticular tissue distended with gas and bearing more or less fatty tissue. Gas was found also beneath the pleura at the hilum of the lung and in the smaller septa of the lung. In the last-named situation small gas vesicles were seen especially frequently at the edges of the small septa passing inward from these. In no case was gas observed within the muscle sheaths, and the muscles were firm and normal in appearance.

On section the superficial gas-containing fascia of the neck appeared distinctly whitish. The blood vessels appeared to contain less blood than those elsewhere. There was no discoloration, no fluid, no infiltration or other signs of pathological change. There was no particular odor to the affected tissue and neither the liver nor any other internal organ gave any evidence of gas accumulation.

Small bits of the gas-containing fascia were removed for inoculation on various solid and liquid media. These were incubated both aerobically and anaerobically. In no case was a growth obtained. No bacteria were found in the smears made directly from the excised and crushed gas-containing tissue.

It is evident that air from the lung reached the pleura along the vessels and interlobular tissues and followed the adventitia to the mediastinum. From the latter location it appears to have been distributed along the vessels to the subcutaneous tissues.

A special board for investigating pneumonia was sent to Camp Dix during the influenza pandemic. The following is a description of one of the cases. It is typical of cases of infection with the influenza bacillus which were not primarily fatal, yet apparently were not followed by infection with other organisms.⁴

The pleural cavities contained no fluid, but the pleural surfaces were adherent or covered with a thin layer of fibrin. The bronchi were pale, and exuded a thick, sticky, yellow pus. The lungs were pale, and rather distended with air,

⁴ Pathological Anatomy of Pneumonia Associated with Influenza, by W. G. MacCallum. *Johns Hopkins Hospital Reports*, Baltimore, 1921, xx, 149-249.

but throughout their substance could be felt many shotlike nodules and firm areas of rather larger size. On section the whole cut surface was pale and rather dry, and there projected everywhere firm, yellow nodules with smooth, dense, shiny surface of larger area or similar grayish yellow, firm tissue. In the center of many of the nodules could be seen the lumen of a bronchiole exuding a tiny droplet of pus.

The bronchi, trachea, and larynx were pale, but covered with a sticky mucopurulent exudate. This exudate, whether from the bronchioles in the lung or from the trachea, was rich in influenza bacilli. In two cases these were in pure culture, as shown by bacteriological methods and by the staining of the bacteria in sections of the lung. In several other cases the bacillus of Pfeiffer was the predominant organism, although there were other bacteria in small numbers in the lungs.

In every case studied at Camp Dix the influenza bacillus was found either in the lungs or in the upper respiratory tract or nasal sinuses.

Microscopically, the changes in such a lung reminded one at once of those in the interstitial bronchopneumonia caused in the former epidemic by the hemolytic streptococcus, and it is indeed an interstitial bronchopneumonia.

The bronchiolar walls were greatly thickened by infiltration of mononuclear cells and by an enormous new formation of connective tissue. Leucocytes were strewn abundantly through these walls also, and extended into the walls of the adjacent alveoli.

The bronchi were filled with an exudate of polymorphonuclear leucocytes, many of which were loaded with influenza bacilli, while numerous bacilli were free in the fluid. The adjacent alveoli contained leucocytes, with some fibrin and epithelial cells, but no conspicuous hemorrhage. Instead, the exudate was rapidly undergoing organization, and the strands of connective tissue added to the density of the nodule. The alveolar walls were very greatly thickened, partly by the leucocytic infiltration referred to above, partly by the inwandering of mononuclear cells and the new formation of connective tissue. The walls of blood vessels, the interlobular septa and the pleura all were moderately thickened in the same way. The change differed from that produced by the streptococcus in several ways. The influenza bacilli were restricted to the bronchi, and did not appear in the alveoli, the lymphatics were quite inconspicuous, and were not found distended with thrombi laden with bacteria, and the pleura was not infected as in the streptococcal pneumonia. The absence of great pleural effusions of fluid made these cases very different from those caused by the streptococcus. Organization of the exudate was a far more striking feature in the pneumonia caused by the influenza bacillus than in the streptococcal form.

In the collection at the Army Medical Museum the influenza pandemic at Camp Dix is represented by 48 necropsy protocols of cases dead of pneumonia, in 9 of which gross and microscopic specimens were included. The studies by Clark and Synnott, and MacCallum, and the material available at the Army Medical Museum, indicate that during the pandemic the pneumonias, as a whole, resembled those in other camps in which the streptococcus hemolyticus was not an important factor. The pneumococcal lesions of the early part of the

pandemic were massive infiltrations without definite consolidation, or with relatively lax consolidations not typically lobar in their character or distribution. Excellent cultural methods, which included taking material from many parts of the respiratory tract, resulted in the isolation of the influenza bacillus in a large proportion of the cases, together with the predominant organisms of the secondary infections. The pneumococci appeared to have had considerable virulence at this camp, particularly during the latter part of the epidemic, and it is significant that at this time there was noted an increase in Type II and Type III. Pneumococcus Types II and III which have shown, as a whole, a high mortality, gave rise to the high case fatality rates.

CAMP DODGE, IOWA *

Camp Dodge was a National Army cantonment and received its first increment of troops between September 1 and 15, 1917. Promptly upon opening the camp, measles, together with other acute respiratory diseases, made its appearance in epidemic proportions, as is indicated by Chart VII. A peak of incidence is shown in December at which time the case fatality rate for all respiratory diseases was 0.7 per cent. Two hundred and sixty-five cases were diagnosed influenza in this month, though the deaths were attributed, for the most part, to primary pneumonia. The increase shown in the chart, with apex of incidence in March, 1918, followed an increase in personnel, but there was a marked change in the character of the pneumonias in anatomical type and in the variety of organisms which preponderated in the cultures. The case fatality rate for all respiratory diseases which had been below 1 per cent rose to 2.63 per cent in the month of March and increased sharply during the latter part of this epidemic wave, the rate for all respiratory diseases for the month of April being 3.84 per cent. The increased incidence of streptococcus in the cultures with resultant change in the type of pneumonia is responsible for this increased death rate. This epidemic was followed by a decrease in the incidence and fatality of all respiratory diseases, with the exception of the incidence of measles, which remained relatively high.

The case fatality rate increased from 0.64 per cent in July, to 3.85 per cent in August, preceding the occurrence of the pandemic of influenza. Definite influenza cases appeared in considerable numbers in September, when the case fatality rate increased to 5.40 per cent and reached its peak for the war at this camp in October, when it was 6.28 per cent. It dropped to 1.61 per cent in November and thereafter continued to decline.

The clinical course of the pneumonias and the pathology found therein during the fall months of 1917 and up to the epidemic of March, 1918, were not considered remarkable by the medical personnel of the camp. The majority of the cases of this period were clinically lobar pneumonia although, with few exceptions, the lesions found at necropsy were not typical croupous or lobar pneumonia. The acute fulminant cases which were seen in the spring of 1918 and more frequently in the fall epidemic were rarely present.

* Source of information, except as otherwise indicated: (1) Medical reports to the Surgeon General, 1917, 1918, and 1919; (2) Necropsy records, on file, Army Medical Museum, Washington, D. C.

CAMP DODGE

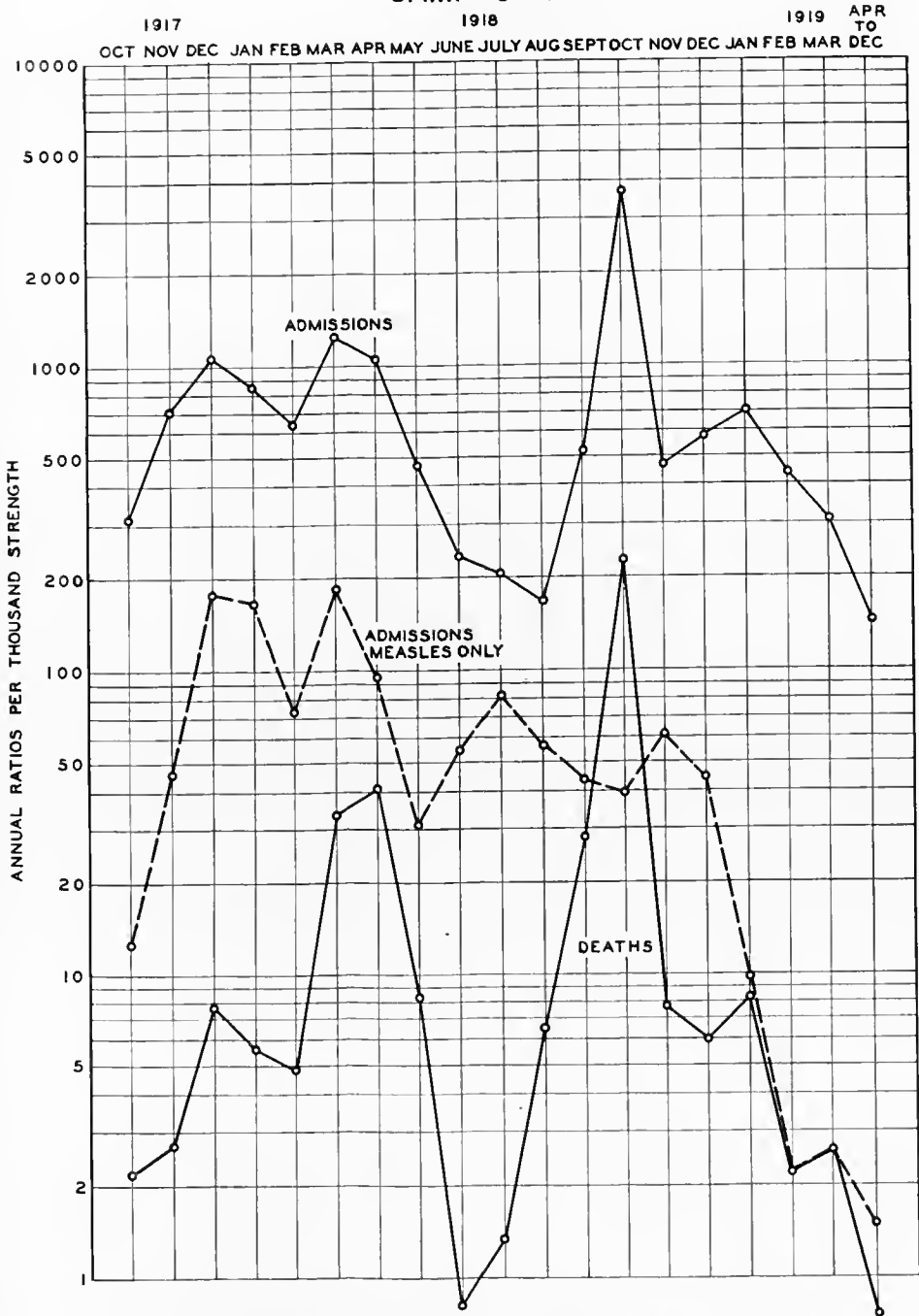


CHART VII.—The incidence and fatality of the acute respiratory diseases at Camp Dodge

From September 20, 1917, until May 10, 1918, 675 patients whose cases were diagnosed as lobar pneumonia, were admitted to the base hospital. ⁸

The ordinary clinical lobar pneumonia, due to the pneumococcus, prevailed until about March 20; then, abruptly the streptococcus type predominated, with a very great increase in the incidence of the disease. From September 20 until March 20, which marks the period of ordinary lobar pneumonia, 276 cases were treated.

A very mild type of pneumonia prevailed during the early autumn, with a mortality in the first 100 cases of 7 per cent. The onset was usually severe and evidence of intense toxemia prevailed, but the course of the disease was short. In the first 88 cases terminating by crisis, the duration in 7 was 2 days; in 11, 3 days; in 13, 4 days; in 13, 5 days; in 18, 6 days; in 9, 7 days; in 10, 8 days; in 2, 9 days; and in 5, 10 days or more. In this series of 276 cases, empyema was present in 31, or 11.2 per cent. Even in these early cases, however, there was a marked tendency to multiple pus foci and the mortality from empyema was high. In those of this series where the type of pneumococcus was determined, Type I was found in 22.8 per cent; Type II, typical and atypical combined, 46.8 per cent; Type III, 7.6 per cent, and Group IV, 22.8 per cent.

The lobar pneumonia, presented the usual symptomatology. The only point of interest was the gradually increasing virulence, as manifested by the mortality from October 1, 1917, to January 1, 1918, and the gradually increasing frequency of empyema. In October this complication appeared in 2.3 per cent of cases; in November, 2.2 per cent; in December, 17.3 per cent, reaching its maximum in January with 27.9 per cent. Empyema was further characterized by loculated pus pockets, which accounted for the high mortality.

No necropsy material from this period is available for study.

As indicated in Chart VII, there was a moderate increase in respiratory disease during March and April, which gradually declined to its low point in August. The death rate shows a marked increase in March, continuing through April. Mild respiratory affections not requiring hospitalization, and therefore not appearing on the records of admissions, were very frequent.

The epidemic of streptococcus pneumonia appeared suddenly between March 18 and 20, continued with great severity for six weeks, then gradually became less intense, still continuing, however, May 10 at the rate of four or five cases daily. The virulence of the epidemic, however, became less marked after the first three weeks, although the number of new cases remained high.

Evidence of severe intoxication appeared very early; empyema became very frequent and developed extremely early, two patients entering the hospital with pleural exudate who had been drilling the previous day. While the involvement in the lung maintained a lobar type, clinical evidence of complete consolidation was far from constant. Dullness with suppressed breathing and subcrepitan râles, but inconstant or localized bronchial breathing, were the usual findings; rusty sputum, provided there was expectoration, was the rule. Early roentgenoscopy showed that the infiltration was lobar in character. The devel-

⁸ The following statements of fact are based, in the main, on: (1) Epidemic of Streptococcus Pneumonia and Empyema at Camp Dodge, Iowa, by Joseph L. Miller and Frank B. Lusk. *Journal of the American Medical Association*, Chicago, 1918, lvi, No. 9, 702-704. (2) Pneumonia and Empyema at Camp Dodge, Iowa, by Joseph L. Miller; in Contributions to Medical and Biological Research, 1919, Vol. II, 1134-1137.

opment of an exudate was often exceedingly difficult to determine by the ordinary physical findings, aided by the roentgen ray, and it became necessary to resort to frequent exploratory aspirations. Often these were repeated several times before the fluid could be located. Early this exudate was only moderately turbid, contained numerous polynuclear leucocytes, and showed on smear short chain streptococci. Gradually the fluid became definitely purulent.

The bacteriologic findings in 95 of these exudates showed pure streptococci in 88, all being hemolytic. Pneumococci combined with streptococci were found in three; two of Type II and one of Type I. Pneumococci without streptococci, but often combined with other bacteria, were found in four cases; one of Type I, two of Type II and one of Group IV.

In 596 cases of both types, the first involvement occurred in the lower left lobe in 253; lower right, 252; upper right, 45; upper left, 23; middle, 12; entire right lung, 5; entire left lung, 1; and in both lungs, 5.

Complication with pus formation was very frequent. While empyema developed in 11 per cent of the cases of pneumonia previous to the epidemic, it appeared in 34.8 per cent during the epidemic. One case of suppurative peritonitis was found in the 276 cases of pneumonia preceding the epidemic and five cases in the first 364 streptococcus cases. In three of these it was associated with suppurative pericarditis and in all cases with empyema. It was interesting that four of these cases developed within a few days of each other. Suppurative pericarditis was found in 15 of the 142 cases of empyema, or 10.5 per cent. It was found only in association with empyema, and in only one case was it found in a colored soldier. Rectus abscess, which was more or less frequent in similar epidemics in other camps, was not present in the first 364 cases, but one abscess developed in a more recent case. The colored soldiers developed empyema in 20 per cent of the pneumonia cases and the white soldiers in 45 per cent. The empyema mortality was 44 per cent in the colored and 64.8 per cent in the white soldiers. This lessened tendency to empyema and suppurative pericarditis in the colored troops was striking. The deaths from uncomplicated streptococcus pneumonia in the colored was 19.97 per cent, and 10.7 per cent in the white.

The mortality in 142 cases of streptococcus empyema was 60.4 per cent. This is considerably higher than the average in other camps. There is no apparent explanation of this unusually high mortality, as the method of treatment was similar to that carried out elsewhere. It is true that in only a moderate percentage of these cases, death was due not to empyema itself, but rather to severe infection, the majority of the patients dying with merely a turbid fluid, the time being too short for it to become thick and creamy.

The cases of streptococcus empyema may be divided into three groups: (1) Those who die early, no matter what form of treatment is instituted, from acute toxemia; (2) those with multiple pus foci, difficult to detect, because of the inability to locate and drain all foci; these all die, and (3) those who usually recover, either from early operation or aspiration followed by operation; here are included those with moderate toxemia and those with localized pus accessible to drainage.

The mortality in 364 streptococcus pneumonias was 32.5 per cent as compared with a mortality of 11 per cent in the previous pneumococcus type.

Arthritis as a complication appeared in only six cases. Suppurative otitis media was quite common. Erysipelas developed as a complication in seven cases. These were facial except in one case, where it developed at the site of the exploratory puncture.

The pathology of this acute outbreak presented certain interesting aspects.¹

The organism found in the great majority of the cases was the streptococcus hemolyticus. It produced its initial infection in the oral cavity in the form of pharyngitis. Sometimes it gave rise to tonsillitis, rarely of the follicular type; often an exudative membranous inflammation extended over the tonsils, the uvula, and the pharynx. In this was found practically a pure culture of this organism. There was produced, then, first of all, a pharyngitis, which was likely to last for weeks, the patient then becoming a true carrier. If he had good resistance, the process stopped at this stage, and this was usually the case. However, the infection might extend to the accessory sinuses of the nose, it might enter the frontal sinus, it might produce otitis media, and, in some cases, a streptococic meningitis. The route which the organism usually took, in a susceptible individual, was downward through the pharynx to the trachea, and into the bronchioles. Sometimes it produced only an ordinary catarrhal inflammation, but very frequently the infection was more severe than that, so that there developed a hemorrhagic tracheitis and laryngitis, with necrosis, at times, of the bronchi and of the arytenoid and thyroid cartilages. The process might stop, however, before extending into the bronchioles and the person entirely recover. Or it might go on, producing a bronchiolitis, which often was suppurative, with extension of the process into the lung substance.

The infection, then, apparently extended out through the bronchial walls. These became attacked and infiltrated with lymphocytes, following which the infection spread peripherally into the lung substance, so that a number of nodules simulating, to some extent at least, tubercles, developed in the lung. These usually spread, attaining a size as great as 1 centimeter in diameter. The lungs were studded with these nodules. The infection extended through the lymphatics to a great extent. The nodules then became confluent in some cases, producing clinical lobar pneumonia, which was not a true lobar pneumonia, but bronchial pneumonia, in which most of the lung substance between the nodules had become involved. The area involved, as a rule, was not so firm and did not contain the plugs of fibrin which one sees in the ordinary pneumonia due to the pneumococcus. In other cases these nodules occurred in patches, a true lobular pneumonia which is also due to the streptococcus. In some other cases the streptococcus infection followed a true pneumococcus pneumonia.

The empyemata formed were often very peculiar, differing greatly from empyemata usually seen. The fluid rarely filled the entire pleural cavity, but at times a large amount was present. Sometimes the fluid was thin and but slightly cloudy due to the presence of but few leucocytes. The most striking feature was the marked tendency toward encapsulation, often forming a number

¹ The following discussion is based on: The Pathology of Streptococcus Infection of the Lungs, by D. J. Glomset, *Journal Iowa State Medical Society*, Clinton, 1919, ix, No. 4, 143-145.

of pockets. These were made by the deposits of fibrin. In many cases the deposits on the parietal pleura were over a centimeter thick. This fibrin sealed off the fluid-seeping areas, forming encapsulating empyemas, which were found in the most unlooked-for places. Occasionally there was found an apical empyema, encapsulated so as to cover half of the upper lobe. Again, there were found various pockets, some smaller, some larger, under the sternum, in the mediastinum, and especially between the lobes, and more particularly between the lower lobe and the diaphragm.

The next complication in order of frequency was pericarditis, of which there were many varieties, from cases in which only a few floccules of fibrin were present with a slight increase of the fluid, to cases in which the sac was distended with a thick, greenish pus.

In several cases the mediastinum was absolutely filled with purulent material. Sometimes localized pockets of pus were found between the esophagus and the trachea, and in two cases at least death was due to pressure on the heart.

The next most frequent complication was an inflammation of the peritoneum. This occurred in 10 cases. The peritonitis was generalized and not so much fibrin seemed to be formed there as in the thorax.

The high incidence of fatal pneumonia at this camp caused the Surgeon General to send specially qualified medical officers to Camp Dodge to study the condition. As a result of the studies there and at other camps, attention of the medical profession was directed to the condition described as "interstitial pneumonia" and attributed to the streptococcus hemolyticus, which was found practically constantly.^u

Usually a few days after the onset of measles, or a few days after convalescence from that disease, the patient had pain in the chest, sore throat, cough, a chill, high fever, and general malaise. The physical signs were indefinite, but there was usually some vague dullness over the chest and râles were scattered widely throughout both lungs, especially at the bases and behind. The patient became dyspneic, the respiration being especially labored in inspiration, cyanosis of a curious livid type appeared, and there was a great deal of nervous excitability and apprehension. The dyspnea produced extreme discomfort and the most violent inspiratory efforts were made, bringing into play all the necessary muscles; this made sleep impossible. The eyes were bright and shining, the mind most alert and filled with dread.

After a few days, dullness or flatness over the thorax became apparent and an exploratory aspiration revealed the presence of turbid fluid in the pleural cavity. The accumulation of this took place with extreme rapidity, and when removed it was replaced in a surprisingly short time.

Delirium was not uncommon, and death often occurred after 10 days or 2 weeks of such illness, although in some cases the whole course of the disease from the onset of the bronchial symptoms to death was only four or six days. Hoarseness or complete aphonia was especially characteristic of the cases which developed most rapidly and intensely after measles, but it sometimes occurred in those who had not had that disease.

^u The Pathology of the Streptococcal Pneumonias of the Army Camps, by W. G. MacCallum; in *Medical Clinics of North America*, Philadelphia, September, 1918, 379-391.

At autopsy in the cases in which death occurred a few days after the onset of the disease the pleural cavities often were found to contain no excess of fluid and their surfaces were smooth and glistening. In the great majority of the cases, however, there was present a considerable amount of exudate in at least one pleural cavity, sometimes in both. The pleural surfaces were sprinkled with small petechial hemorrhages, especially over the back of the lung, and covered with a thin rough exudate of fibrin. In such instances the fluid was thin and watery, turbid and brown or greenish brown, with a granular sediment easily stirred up from the bottom and many floating shreds or flakes of fibrin. It was swarming with the streptococci in chains usually unmixed with any other organism. In cases which ran a longer course the fibrin on the surface was thick, yellow, and shaggy. There were often to be found adhesions between the lobes, between the lung and the costal pleura or diaphragm, or in such an arrangement as to enclose separately a space between the mesial surface of the lung, the pericardium, and the diaphragm.

There the fluid exudate was distinctly purulent in character and either opaque greenish yellow or brownish gray with a slight bloodstaining. The disposition of the adhesions often allowed of the encapsulation of pockets of this pus between the lobes or elsewhere, especially often in the situation above described between the lung and the pericardium. Incision into the surface of the lung showed that the pleura itself had become greatly thickened by being converted into a layer of granulation tissue which tended to organize and replace the fibrinous exudate. The rapidity with which this organization occurred was surprising. When the pleura had been evacuated by operation the character of the exudate and the thick layer of granulation tissue upon the surface was unchanged, unless secondary infection had occurred, when the pus might become exceedingly foul.

The effect of this great accumulation of exudate in the pleura, which might amount to 1 or 2 liters or more, was to cause the extensive collapse of the lung, which appeared as a blue pasty mass of tissue plastered against the mediastinal tissue. This was not the only cause of collapse, however, since obstruction of the bronchi played a part, and it frequently appeared in parts of the opposite lung even when there was no exudate in that pleural cavity.

The lung, in general, was flabby, but there might be felt throughout its substance nodules or larger areas of consolidation. The bronchi exuded a thick brownish purulent exudate, and the bronchial glands were enlarged and soft. One section of the lung itself presented in different cases a very great variety of appearances. In some there was the anatomic complex of interstitial bronchopneumonia, in others, lobular pneumonia, and it must be remembered that these were very frequently combined.

In the early stages of interstitial bronchopneumonia there was already a patchy atelectasis of the lung, the bronchi were filled even to their smallest branches with opaque yellow pus and were surrounded by a halo of hemorrhage. Otherwise the lung substance was air-containing in part and in part edematous. In all cases microscopic examination showed the bronchioles filled with polymorphonuclear leucocytes, and streptococci often in tangled masses ranged along

the wall. The lymphoid tissue in the bronchial wall was slightly swollen through an increase in the number of its lymphoid cells. The adjacent alveoli were filled with blood and contained a few leucocytes.

Somewhat older cases showed on section numerous firm projecting nodules throughout the lung, which on close inspection were found to be cross-sections of bronchioles with surrounding consolidation. If the bronchioles happened to be cut longitudinally, these condensations of the tissue appeared not as nodules, but as very thick-walled tubes further surrounded by a mantle of consolidated lung tissue. The area to which such a bronchus, obstructed as it was with a mass of purulent exudate, should supply air was collapsed completely. The consolidation was scarcely in this area, but rather in the alveoli adjacent to the bronchus. These, too, were sometimes surrounded by hemorrhage, but usually that was only in the freshest cases. Viewed on cross section the tiny bronchiole, with its thickened wall and surrounding area of consolidation, projected like a tubercle from the cut surface. Indeed, it is probable that when these were fairly small and uniform they were often mistaken for miliary tubercles. As they increased in size they became more and more nearly confluent, and the intervening tissue showed a viscid edema which drove out its original content of air. In time, quite extensive areas showed a patchy, irregular consolidation through the coalescence of such peribronchial areas.

Microscopically the bronchial wall was still found to be the part most intensely affected; the streptococci were present in the purulent exudate in about the same numbers. Much of the epithelium was found to be desquamated and in some cases of most intense infection the whole lining of the bronchus was necrotic and coagulated, and appeared as a diphtheritic pseudomembrane. The wall of the bronchus was greatly thickened and densely infiltrated with mononuclear cells of the type of lymphoid cells, with some larger forms. It is probable that much of this represented a hyperplasia of the lymphoid tissue normally found scattered in the wall and condensed at the angles of division. This was especially indicated by the peculiar course of the blood vessels in this cellular tissue, which was that of the blood vessels of the lymph nodes. But much of the thickening of the wall was due to actual new formation of connective tissue cells, to edema and hyperemia, and to a true infiltration of wandering mononuclear cells. It assumed the appearance in many cases of a richly vascular granulation tissue in which the new blood vessels were radially arranged, and in which, in the case of larger branches, remnants of mucous glands were to be found. The infiltration with mononuclear cells extended to the walls of the adjacent alveoli, which were thereby much thickened. These alveoli contained a dense exudate which was no longer composed of blood, but of desquamated epithelial cells, mononuclear cells, and solid plugs of fibrin. Further out the fibrin was replaced by fluid which appeared to be especially thick and viscid. No streptococci were discoverable in the substance of the bronchial wall or alveolar walls, or even in the exudate in the alveoli. They were present, however, in abundance in the lymphatic canals in the bronchial walls, and there they were entangled in a thrombus mass which included also many mononuclear cells. Such lymphatics extended in this thrombosed condition throughout the lung and communicated, on the one hand, with the sinuses of the lymph-

nodes at the hilum of the lung, on the other, with the network of lymphatics in the pleura. It was thought that it was through them that infection extended from the bronchi to the pleura. This was against the natural current of the lymph, but the organisms extended by growth along the obstructed lymphatic canals.

The blood vessels were not thrombosed or otherwise altered except that their adventitious tissue was densely infiltrated with cells. This, again, might have been partly due to hyperplasia of the normal lymphoid tissue, especially since such infiltration after extending outward from the bronchial walls faded away in the alveolar walls until one approached blood vessels or interlobular septa, when it increased again.

The interlobular septa were greatly widened and most conspicuous on the cut surface of the lung. This was due, first, to their infiltration with fluid cells and fibrin, which later became replaced by connective tissue, and second, to the presence in their course of lymphatic canals which were thrombosed and distended with opaque yellowish white material. Such thrombosed lymphatics stood out on the cut surface of the lung running to the pleural network as huge opaque beaded strands sometimes large enough to be mistaken for bronchi.

Finally the organization of the exudate in the alveoli and in the bronchi and its replacement by strands and columns of connective tissue ultimately clothed in alveolar epithelium, formed a striking feature of the late stages of this process. The thrombosed lymphatics were similarly converted into solid vascularized cords of fibrous tissue, which indicated the need for a most extensive new formation of lymphatics if absorption from the pleura was to be resumed. Then, as described above, the pleura itself became a thick red velvety layer of granulation tissue through the organization of the overlying fibrin.

The restricted distribution of the streptococci was most interesting. They were found in the bronchi, in the lymphatics, and in the pleural exudate, where they were limited practically to the surface layer of the fibrin and the fluid. The whole process indicated their inability to invade the tissue proper, and showed that the body was offering a strong resistance and erecting massive barricades against their entrance.

All this was quite different in the second form of the pneumonic process, designated "lobular pneumonia." In these lungs patches of consolidation were found associated with wide zones of hemorrhage, but in no such regular relation to the bronchioles as has just been described. These patches might be terminal, occupying the area supplied by a bronchiole, or they might be confluent and large enough to occupy one or several lobules; sometimes they had the granular appearance of the cut surface of a lobular pneumonia, but more often they were elevated, dry, dull and opaque, and thickly surrounded by dense hemorrhage. There was no especial thickening or prominence of the bronchi. The interlobular septa were not necessarily prominent and often the pleura was but little thickened. The lymph channels, however, were thrombosed and very large and conspicuous in many cases. Microscopically there was no remarkable change in the bronchi except that they were full of purulent exudate and blood, but all the alveoli in the area were packed tightly with leucocytes in a network of fibrin, and among these leucocytes and often enclosed within them were

great quantities of streptococci uniformly scattered throughout the alveolar contents, a condition totally at variance with that found in the interstitial bronchopneumonia. The alveolar capillaries were sometimes occluded by hyaline fibrinous thrombi. Whole areas of such consolidated and intensely infected lung became necrotic, and it was especially about such patches that extensive hemorrhage occurred. In these necrotic patches the streptococci grew out into long chains which formed a dense tangle.

Small areas of such exudation into the alveoli with abundant streptococci were quite often found in the most intense and acutely developed lesions of interstitial bronchopneumonia constituting a combination of the two lesions. The explanation of the existence of two such distinct types of reaction to the invasion of the streptococcus is not entirely easy. It seems very similar to the condition in tuberculous infection of the lung. In one case there may be a few tubercle bacilli setting up the formation of tubercles, tuberculous invasion of the lymph channels, interstitial induration, etc., while in another case, or later or earlier in the same case, there is a sudden exudation into a whole area of pulmonary tissue, and the production of a gelatinous and caseous tuberculous pneumonia with great numbers of bacilli and rapid destruction of the tissue. It must be due to a remarkable difference in the power of resistance to invasion on the part of the tissues. It has been suggested that this sudden invasion of the tissue by bacteria which were formerly held within bounds is due to a sensitization of the tissue by the previous infection. Possibly the same explanation might hold in this case, although the whole process occupied a very short time. At any rate, that seems to be another way of expressing the idea that resistance in one case is strong, in the other almost absent.

In the cases of lobular pneumonia great areas of necrotic tissue often became coagulated, opaque, and yellow, and appeared as abscesses which might occupy a large part of a lobe. This was not limited to the obvious cases of lobular pneumonia, but sometimes occurred in those in which interstitial changes were prominent. The liquefaction of this material and its discharge through a bronchus left a ragged cavity which might in some instances, through forming a communication with the pleura, set up a fistulous connection between the pleura and a bronchus.

To summarize, it may be said that an extensive epidemic of pulmonary disease resulted from widespread infection with a hemolytic streptococcus which invaded most readily upon the bases of a predisposing attack of measles. This produced inflammatory and ulcerative changes in pharynx and larynx and, extending to the bronchioles, set up a bronchopneumonia which, in persons of poor resistance, might take the form of a lobular pneumonia with extensive spread of the organisms and rapid necrosis, or in those with better powers of resistance it might produce a purulent bronchitis with great thickening of the bronchial walls and consolidation of the adjacent pulmonary tissue, infection of the lymphatics, and thence of the pleura. Induration of the framework of the lung and organization of the exudate tended to limit the process. In both types pleurisy with abundant effusion was very common.

Uncomplicated influenza was diagnosed in a large number of instances at this camp prior to the pandemic, with a peak of 939 cases in the month of March,

common respiratory diseases for this month being 1213. The diagnosis of influenza was made in 136 cases in July, 28 in August, 573 in September, 6,480 in October, 1917.

During the week preceding the sudden appearance of the epidemic of September 28, 1918, three distinct outbreaks of an infectious nature occurred in widely separated sections of the base hospital at Camp Dodge.* Pharyngeal cultures from these cases showed *Streptococcus hemolyticus* and *Bacillus influenzae* present in unusually large numbers. Admissions to hospital during this period increased moderately in number, and an unmistakable but not alarming number of acute nasorespiratory disturbances, not unlike similar clinical conditions of the preceding month, gave warning of impending trouble.

September 29, 1918, laboratory workers detailed to the admitting office, cultured and made white blood counts on 152 cases. It was found that the *Bacillus influenzae* was present in 66 per cent, *Streptococcus hemolyticus* in 45 per cent, and the *M. catarrhalis* in 71 per cent of the cultures, and that the average white cell count was 9,300.

Further observation of these cases revealed that 890 white blood counts ranged as follows per day: First day, 9,300; second day, 8,000; third day, 8,200; fourth day, 6,000; fifth day, 7,200; sixth day, 7,700; seventh day 8,200; eighth day, 8,200.

Between October 3 and October 11, 53 complete autopsies were performed. The following data were compiled from the records on the first 53 cases of epidemic pneumonia autopsied.

A purplish mottling of face, neck, and dependent portions was present in nearly all cases dying within two weeks of onset. The gross pathological lung lesions divided the findings into three classes or types of pneumonia: The broncho-interstitial type, which showed small interstitial hemorrhagic areas about moderately thickened bronchi of varying size, standing out prominently from the sectioned surface and exuding dark red blood. The lobular type, in which hemorrhagic areas of infiltration of varying sizes, without noticeable bronchial thickening, were encountered. Both types were not unlike the conditions found and described by MacCallum during the pneumonia epidemic of May, 1918 (q. v. supra). Several cases were found having in one lobe lesions characteristic of the broncho-interstitial type, while the adjoining lobe revealed a picture of the lobular form. To this condition the term mixed or broncho-lobular pneumonia was given. This nomenclature, while describing accurately many of the lung lesions grossly should not be relied upon too implicitly, as further histological study may place a much larger number of cases in the mixed or broncholobular class.

The number and percentages of the various types of pneumonia and empyema found at autopsy in 53 cases were as follows: Broncho-interstitial, 23; lobular, 18; mixed, 10; lobar, 2. The empyemas, 22 in number, were bilateral in 7, right in 5, left in 10. In 19 cases, infected serosanguineous pleuritis was present with lobular pneumonia in 12, broncho-interstitial in 4, mixed in 3.

* The following statements of fact are based in the main on: Laboratory Report on Epidemic Pneumonia, Camp Dodge, Iowa, by William G. Dwinnell. *American Journal of the Medical Sciences*, Philadelphia, 1919, cviii, n. s., 216-232.

Of the 31 cases dying without empyema, 29 died within 2 weeks of onset of the first symptoms, the average duration being 7 days; the extremes were 3 to 13 days. The 2 dying later than 14 days died at 15 and 44 days, respectively, from the date of onset.

Because of the uncertainty attending the onset of the pneumonia the duration of the disease in all cases was figured from date of onset of first symptoms of illness.

The important complications in 53 cases were acute adrenalitis 28, mediastinitis 19, pericarditis 9, peritonitis 6, necrosis of the lung 4.

The *Streptococcus hemolyticus* was recovered in 80.7 per cent of the cases from the lung, the pleural cavity, or the heart's blood, and from the last source in 52 per cent of the cultures. The *Bacillus influenzae* was recovered in five cases, or 9.6 per cent of the cultures, and was found in three cases in both the lungs and pleural cavities, in the heart's blood once, and in the peritoneal cavity once. The *Bacillus influenzae* was found associated with the *Streptococcus hemolyticus* four times and the *Staphylococcus aureus* once. A non-hemolytic streptococcus was recovered five times and the *Staphylococcus aureus* twice.

The low incidence of *Bacillus influenzae* found was undoubtedly due to poor technique in handling the cultures. The large number of positive cultures obtained from the 69 cases of the second series may be ascribed to excision of lung tissue and direct smearing of freshly-made human blood-agar plates adapted to influenza work at a reaction of 0.2 acid of phenolphthalein and containing two drops of blood to 200 c. c. of glucose agar, meat infusion. This medium gave more positive cultures than the laked rabbit blood previously used.

The cultures reported as *Bacillus influenzae* did not grow as typical dewdrop colonies as described by Pfeiffer and others. The colonies were less definitely outlined, slightly granular in the center, suggesting a faint opaquish color. There was no growth on plain agar. The bacilli varied in size from a coccobacillus to a rod of slightly larger than the typical Pfeiffer bacillus in the original culture. Mannite, sucrose and lactose were not fermented. One cubic centimeter of moderately heavy emulsion was not lethal to either mice or guinea pigs.

No post-mortem work was done between October 11 and 23; 69 necropsies were made between October 23 and December 1, 1918. The necropsy findings were as follows: Pneumonia, broncho-interstitial, 26; lobular, 27; mixed, 14; lobar, 2. Empyema, bilateral, 21; right, 19; left, 8. Serosanguineous pleuritis was bilateral in no case, right in 2, left in 1.

Of the 21 cases dying without empyema, 11 died within 2 weeks from the onset of the first symptoms, the average duration being 7 days, the extremes being 1 to 12 days; the 10 dying later than 14 days averaged 24 days; extremes, 15 to 54 days. Eleven of the 48 empyema cases lived an average of 11 days, extremes 5 to 14 days. The remaining 37 cases averaged 32 days; extremes, 17 to 72 days.

The important complications that occurred in the 59 cases were: Acute adrenalitis, 45; pericarditis, 20; mediastinitis, 19; necrosis of lung, 17; pleural pockets of pus, 17; peritonitis, 6; interlobular pockets of pus, 11.

The bacteriology in the 69 cases was as follows: Hemolytic streptococcus, 41; *Bacillus influenzae*, 34; nonhemolytic streptococcus, 17; Type I pneumococcus, 1; Type II pneumococcus, 2; Type III pneumococcus, 4; Group IV pneumococcus, 1.

Mediastinitis occurred 38 times in 122 cases. It was associated 32 times with empyema. Three cases, showing general subcutaneous emphysema of the face and neck to Poupart's ligaments, were associated with mediastinitis. Pericarditis occurred 29 times, in 15 of which mediastinitis was present, and in 22 of which empyema was present. There were 12 cases of peritonitis, 9 of which were with empyema, 1 with lung abscess, and 2 were associated with operative procedures. Only two of the four cases of lobar pneumonia showed no other type in the lungs.

The predominant organism in this camp during the entire period of its existence was the hemolytic streptococcus. Lobar pneumonia due to the fixed types of pneumococci occurred in considerable numbers during the fall of 1917 and the following winter and spring. In the influenza period the access of the streptococcus to the injured lung resulted in fewer instances of the hemorrhagic type of pulmonary inflammation discoverable at necropsy.

From the reports cited above, it is seen that, with the exception of the period of greatest intensity of the influenza pandemic, when the exigencies of the situation prevented it, the pathology of the respiratory diseases at this camp were unusually well studied and reported. It appears, however, that, as occurred in most camps, no line could be drawn between the pathology of clinical influenza and of the secondary infections which followed or occurred practically simultaneously. It is not at all certain, for instance, that some of the lesions attributed to the streptococcus, in which that organism was scarce or absent from considerable areas microscopically, were in fact due to that organism. It is quite possible that such lesions as the acute reaction about terminal bronchioles and the hemorrhagic lesions occupying more or less the whole of lobules were due to the bacillus of Pfeiffer or to the cause of influenza. Cultural work during the spring of 1918 and even early in the pandemic period was admittedly inadequate to show the incidence of *B. influenzae* even in the material cultured.

Streptococci of the hemolytic variety appear to have been responsible for the high case fatality of all respiratory diseases, and were associated with practically all types of pulmonary lesion, including lobar pneumonia, though in many cases it was evident that the invasion by these organisms was secondary not only to the virus of measles or influenza but also to pneumococcal lesions, the majority of which followed measles or influenza.

The respiratory diseases of this camp are represented in the collections of the Army Medical Museum by 232 protocols of necropsies and 59 lung specimens with some of the other tissues from the necropsies. Suitable stains demonstrate numerous Gram-negative, minute coccobacilli in many of the well fixed tissues from cases in which no such organism was isolated in culture, and organisms of the pneumococcus type, as well as streptococci are found in the pulmonary parenchyma from cases in which only streptococci were isolated in culture.

Study of the histopathology of this camp yields convincing evidence that bacteriologic methods considered of the highest grade at the time were not to be depended on to reveal all the organisms present in the pulmonary inflammations of this period.

Study of the cases diagnosed interstitial pneumonia reveals the fact that in the majority of instances the perivascular lymphatics are as much involved as the peribronchial, and in some instances the oldest or farthest advanced process is along the vessels rather than the bronchi. This is strong evidence that the streptococcal invasion is a spreading lymphangitis in such cases, with abscess formation and secondary invasion of the bronchial lumen. The pneumonic areas in these cases are of two types: First, that extending a varying distance into the lung from the purulent lymphatics, and second, nodular areas, representing the parenchyma supplied by a smaller bronchiole, which resemble and may well be pneumonias of the inhalation type resulting from the rupture of abscesses or dilated lymphatics into the bronchial lumen, just as happens in tuberculosis, to which MacCallum called attention as having points of resemblance in the varying types of tissue reaction and bacterial content of the lesions.

CAMP FREMONT, CALIF.^w

Mobilization at this camp did not start until the first of the year 1918, and as the first increments were seasoned troops, respiratory diseases in epidemic proportions did not occur until late. The epidemic rise, with peak in April, was due to influenza and common respiratory diseases, the case fatality being low. Case fatality for all respiratory diseases increased prior to the onset of the influenza epidemic.^z

The expected storm of the prevailing pandemic infection broke suddenly on the 8th Division, at this camp, October 8, 1918, and during the next 6 weeks 2,418 patients suffering from respiratory diseases were admitted to the base hospital. In addition, many soldiers having more or less mild infections were cared for in the various camp infirmaries in order to avoid overcrowding in the base hospital. Altogether there were, at a conservative estimate, 3,000 cases.

Pneumonia was diagnosed in 408 cases, an incidence of nearly 14 per cent. We know now, however, that there were many cases of pneumonia that were diagnosed as bronchitis, and that the true incidence of pneumonia was greater than that indicated.

Of the 408 patients with pneumonia diagnosed, 147 died, a mortality of 36 per cent for the pneumonia series and about 5 per cent for the epidemic. No deaths occurred without a complication of either lobar pneumonia or bronchopneumonia.

Epistaxis was a common feature throughout. At first it was looked on as merely an incidental occurrence, as in typhoid fever, and not as possessing special significance. Instances of epistaxis multiplied, however, and often blood was seen to gush from a patient's nose and mouth. When pneumonia appeared, the pa-

^w Source of information, except as otherwise indicated: Medical reports to the Surgeon General, 1917, 1918, and 1919.

^z The following statements of fact are based, in the main, on: Pandemic "Influenza" and Secondary Pneumonia at Camp Fremont, Calif., by Walter V. Brem, George E. Bolling, and Ervin J. Casper. *Journal of the American Medical Association*, Chicago, 1918, lxxi, No. 26, 2138-44.

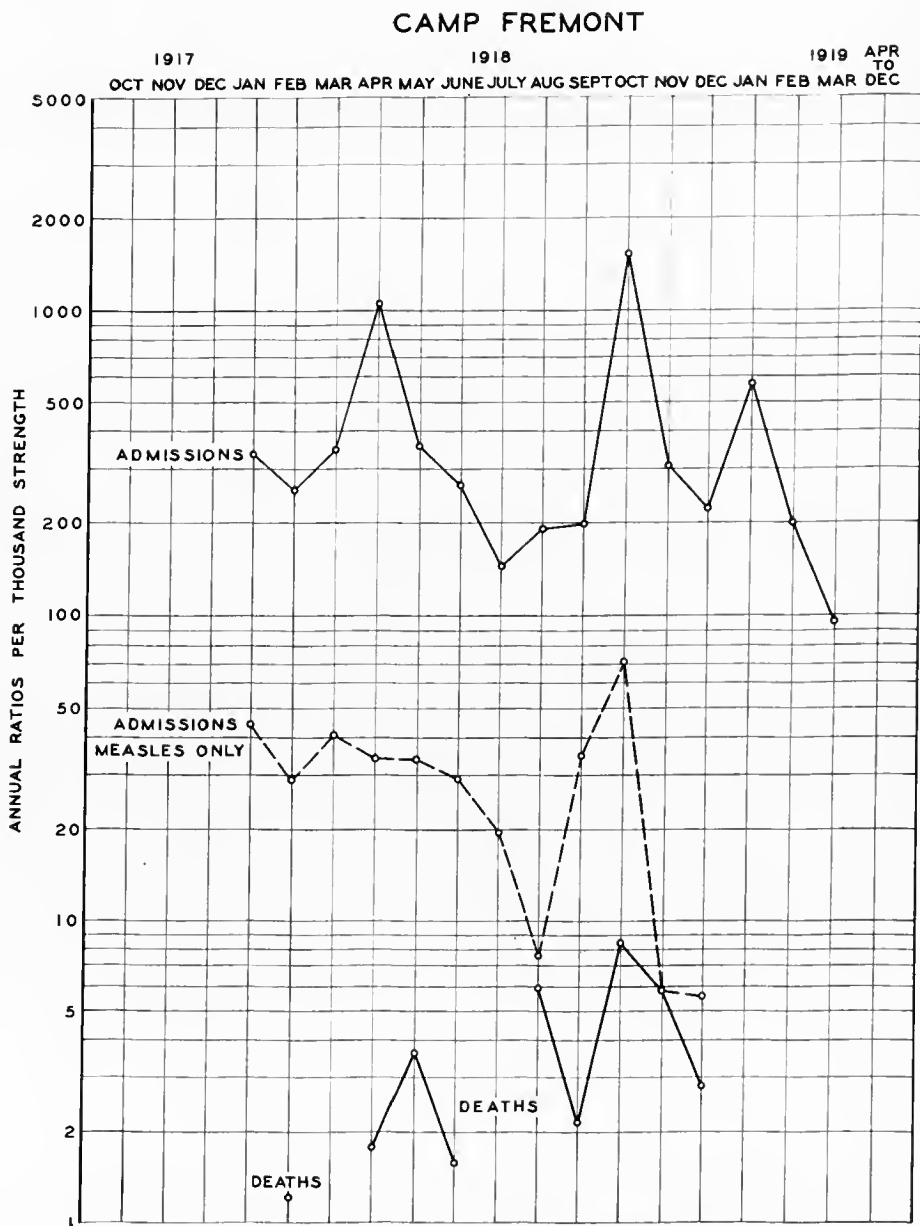


CHART VIII.—The incidence and fatality of the acute respiratory diseases at Camp Fremont

tients often spat quantities of almost pure blood. Female patients, of whom there were altogether about 100, had a hemorrhagic vaginal discharge, which at first was thought to be coincident menstruation, but later was interpreted as hemorrhage from the uterine mucosa. Finally, the extraordinary hemorrhagic picture seen at necropsy, together with the constant leucopenia in the initial stages, completed the evidence that led to the belief that an important feature of the disease was some kind of blood dyscrasia, which was of grave significance and suggestive of purpura hemorrhagica. In a few patients, large purpuric areas developed in the skin.

It was believed that this condition was due to a depressant influence exerted by the initial infection on the bone marrow, and that it was closely related to the next extraordinary feature of the disease.

In the influenzal stage, leucopenia was practically always found, and at first it appeared to be a feature also of the pneumonic stage. Indeed, one saw many full-blown cases of apparently lobar pneumonia with a leucocyte count of less than 5,000; there were five cases with a count of 3,000 or less. Smears from the lungs of some of the fatal cases showed innumerable diplococci with the large pneumococcus type of capsule, and the cultures were positive for pneumococci.

But other pneumonia patients with early leucopenia recovered, and when subsequent counts were made, it was found that in each case there was a gradual rise to from 10,000 to 24,000 leucocytes.

The conviction gradually developed, therefore, that the influence of the initial infection was a depressant one on the bone marrow resulting in leucopenia, while, on the contrary, the pneumonic infection tended to stimulate, as usual, the production of leucocytes, which gradually increased in number in the blood stream as the depressant influence waned.

Two characteristic types of pneumonia were differentiated. The first, and most common type, was that which, when well developed, gave the physical signs of lobar pneumonia. The onset usually occurred when defervescence of the symptoms of the initial infection was almost or quite complete, about the third or fourth day. It was ushered in frequently by a chill, a sharp rise of temperature, a localized explosive shower of fine râles usually about the angle of the scapula and more frequently on the left side, and bloody sputum, amounting often to marked hemoptysis. A few roentgenographic examinations at this stage showed shadows indicating that already consolidation was beginning. Occasionally the milder of these cases cleared up quickly without further signs of pneumonia developing, but most of them proceeded to a stage of definite signs of consolidation of one or more lobes.

The temperature curve was irregular, frequently not rising as high as from the initial infection, and usually ending by lysis, the mean duration of the pneumonia fever being about seven days. The pulse rate was slow in proportion to the fever, and the blood pressure was low, the systolic pressure frequently being 100, and the diastolic pressure from 40 to 50. The pulse pressure was good, and there were no signs of cardiac insufficiency except in the fatal cases after the onset of respiratory insufficiency and shortly before the end. The danger never appeared to arise from the effect of the infection on the cardiovascular mechanism.

The respiratory rate, likewise, was slow in proportion to the fever until the toxemia became marked, when the respirations became accelerated and the respiratory abdominal excursions limited. The chief toxic effect of the infection seemed to be exerted on the respiratory mechanism, failure of which, due to excessive toxemia and to the mechanical effect of extensive consolidations and hemorrhagic edema of the lungs, caused the death of patients.

It was not known whether this type was a true lobar pneumonia or a massive bronchopneumonia due to the fusion of small areas, but it was believed that it was a lobar pneumonia with the pathologic picture modified by the hemorrhagic exudate and the paucity of leucocytes.

The lungs at necropsy showed massive, air-free consolidations without any definite lobular pattern; no pus could be expressed from the bronchi; the bronchial mucosa did not show a purulent exudate or any special inflammatory thickening or change other than marked congestion, and there was practically no fibrin in the exudate. These findings were in marked contrast to the true bronchopneumonia type.

The second type was that of true bronchopneumonia. The onset was not clearly defined, the course being continuous with that of the initial infection; the temperature curve was irregular; the sputum was not bloody, but purulent (nummular); physical signs of diffuse bronchitis were usually present. Fatal cases sometimes showed a low or even normal temperature with cyanosis and marked "air hunger." The patient belonging to this group had a normal temperature, good pulse, no sputum, and no râles in the chest. The percussion note over the lungs was hyperresonant, the breath sounds distant and scarcely audible; there was marked dyspnea and cyanosis. The diagnosis was not suspected until necropsy disclosed the real condition. The bronchi were full of pus; and little nodules, bronchopneumonic consolidations, were scattered uniformly throughout the lungs. Death appeared to be due to actual asphyxiation.

Five patients with this type of pneumonia developed a puzzling subcutaneous emphysema, which, in the most marked case, extended from the forehead to Poupart's ligament in front and the buttocks behind. The post-mortem examination demonstrated in two cases that emphysematous air cells at the root of the right lung had ruptured into the loose mediastinal tissues, and that the air had progressed upward to the neck, and infiltrated the subcutaneous tissues. Cultures from the subcutaneous tissue for anaerobic organisms were negative.

The clinical features of this type, and also the pathologic features, to be described, indicated that it was due to a direct extension of the inflammation down the bronchial mucosa. *B. influenza* was found in cultures from the pus droplets of the small consolidated areas in the three cases carefully studied bacteriologically at necropsy—twice in pure culture, one with *M. catarrhalis*.

The leucocyte counts in this group were few. In two fatal cases there were 7,600 and 6,000 leucocytes, respectively. In the second case the count rose to 16,400 before death. *B. influenza* was present in pure culture in the lungs in both cases.

The relative percentages of the two types of pneumonia could not be estimated, for they were differentiated but late in the epidemic, and the clinical records did not enable one to separate them. It is certain, however, that the first type was far more common, but the second type was by no means infrequent.

Deaths were always due to pneumonia. In 30 post-mortem examinations, lobar pneumonia was diagnosed 25 times, bronchopneumonia, 5 times. The two types presented striking differences at the post-mortem examination.

In the lobar pneumonia type, frothy, bloody serum poured from the nose and mouth when the body was moved or the head lowered. On section of the skin, dark blood oozed from the cut vessels. The pleural cavities always contained a quantity of serosanguineous fluid, but the pleuræ did not show the fibrinopurulent exudate commonly found in lobar pneumonia. The lungs were extensively involved, there being practically always large areas of consolidation in several lobes; hemorrhages under the pleuræ were frequently seen; the lungs were dark red and irregularly mottled, very moist and bloody, the cut surface smooth and velvety; the consolidated areas contained no air and no pus could be expressed from the bronchi. The early condition was that of acute hemorrhagic edema. The peribronchial lymphatic glands were very large, dark red, congested, soft and friable. The heart muscle was dark red, relaxed and flabby, offering a strong contrast to the firm, contracted left ventricle nearly always present post mortem in bodies of patients dying from lobar pneumonia; the heart's blood was fluid and dark, there being only small, flimsy, post-mortem clots and no "chicken fat" clots. The abdominal viscera showed marked congestion, the glomeruli of the kidneys standing out distinctly. Microscopically, the alveoli of the lungs were full of red blood corpuscles in the portions recently involved; in the older portions polymorphonuclear leucocytes became more or less prominent in the exudate; no fibrin was seen; the bronchi were not plugged with pus; the blood vessels were engorged.

In the bronchopneumonia type the tissues of the bodies were dry; there was no "frothing at the mouth;" no blood oozed from small cut vessels; the pleural cavities contained no fluid, but there were patchy areas of fibrinopurulent exudate with recent, easily separated plural adhesions. The lungs were very pale and extremely voluminous, and did not collapse when the chest was opened. Emphysematous bullous-like areas beneath and elevating the pleuræ were common; these had transparent bubble-thin walls and were divided into numerous compartments by the walls of the dilated air cells. Pus streamed from the trachea when the lungs were removed. Small areas, from 2 to 5 mm. in diameter, of consolidated tissue were scattered uniformly throughout the lungs, and these little areas felt like disseminated conglomerate tubercles. On section, the lungs were dry, the solid areas were gray and granular in appearance, and a drop of pus could be expressed from the center of each. In one case, about half of the right upper lobe was consolidated; it had a mottled gray, granular appearance, and there were numerous points where droplets of pus could be expressed, the large area of consolidation being evidently formed by the confluence of smaller areas of bronchopneumonia. The peribronchial lymphatic glands were very large, the cut surface gray and granulated. They were soft and friable. The heart showed nothing remarkable, nor did the abdominal viscera. In one case the spleen was quite large and the malpighian bodies stood out distinctly, and the liver and kidneys showed cloudy swelling. In two necropsies the mediastinal and subcutaneous tissues showed marked emphysema due to the rupture of dilated thin walled air cells on the anterior surface of the

root of the right lung into the loose mediastinal tissue. Microscopically, the consolidated areas of the lungs showed a bronchiole full of pus cells and the surrounding alveoli packed with pus cells and desquamated epithelium, and there was considerable fibrin formation. The air cells of the adjacent uninvolved lung were dilated and the walls were thin; the vessels were not engorged.

Cultures from the nasopharynx were made from every patient admitted to two of the wards; 148 patients were examined, and *B. influenzae* was isolated from 37 patients, or 25 per cent. Ten of these patients, or 27 per cent, developed pneumonia.

Similar cultures from the nasopharynx were made in 537 cases. These were usually selected severe cases of respiratory infections.

The results were as follows: *B. influenzae*, usually associated with other organisms in 259 cases, or 46 per cent; pneumococci in 149 cases, or 28 per cent; streptococci, all kinds, in 160 cases, or 30 per cent; staphylococci, all kinds, in 64 cases, or 12 per cent; and *M. catarrhalis* in 62 cases, or 11.5 per cent. Cultures from the nasopharynx and sputum of 158 pneumonia cases showed *B. influenzae* in association with other organisms 58 cases, or 38 per cent; pneumococci in 64 cases, or 40.5 per cent; streptococci in 46 cases, or 29 per cent; staphylococci in 21 cases, or 13 per cent, and *M. catarrhalis* in 11 cases, or 7 per cent.

In three cases of the bronchopneumonia type, smears from the pus droplets expressed from the small consolidated areas in the lungs showed innumerable small Gram-negative bacilli, and *B. influenzae* was cultivated, twice in pure culture and once with *M. catarrhalis*. Cultures from the heart's blood were negative in all three cases.

Pneumococci from all cultures were typed 38 times.

For cultures of *B. influenzae* during the first part of the epidemic, the surface of ordinary blood-agar plates was inoculated. Later the blood-agar was heated to 70° C. for 15 minutes, poured in plates, and the surface inoculated. The latter method proved much more effectual for the isolation of *B. influenzae*.

Cultures from the lungs in 20 lobar pneumonia cases showed influenza and streptococcus viridans in 1, influenza and pneumococci in 2, pneumococci alone in 9, pneumococci and *Streptococcus hemolyticus* in 1, *Streptococcus viridans* alone in 1, and staphylococcus alone in 1. Cultures from the heart's blood in post-mortem cultures in 20 cases of lobar pneumonia showed influenza and *Streptococcus viridans* 1, influenza and pneumococcus 2, pneumococci alone 7, pneumococci and *Streptococcus hemolyticus* 1, *Streptococcus hemolyticus* alone 1, *Streptococcus viridans* alone 1, staphylococcus alone 4. Thirty-eight cultures from pneumonia cases were typed with the result as follows: Pneumococcus Type II, 3; Type IIA, 1; Group IV, 34.

The results of the bacteriologic examinations were disappointing and their value small in proportion to the amount of work entailed.

B. influenzae was a common organism during the epidemic, and was the one encountered most frequently in the group of selected severe respiratory infections. It was less frequently found than the pneumococcus in the series of 148 consecutive cases, and it was isolated only three times in the post-mortem cultures from the lungs and three times from the heart's blood in 20 lobar

pneumonia cases, twice with the pneumococcus and once with *Streptococcus viridans*. It was present, however, in cultures from the lungs in all of three fatal cases of bronchopneumonia, twice in pure culture and once with *M. catarrhalis*.

Measles in this camp was not accompanied by an appreciable incidence of pneumonia and by practically no fatality. The influenza epidemic of the spring of 1918 was accompanied by considerable pneumonia, with a sharp rise in the mortality. The influenza epidemic in October, while accompanied by a distinctly higher fatality rate than in the spring, was not as serious as in many camps. The types of lesion appear to have been similar to those generally present with the exception that there was no evidence of the presence of interstitial pneumonia with its high empyema incidence caused by the streptococcus. *Streptococcus hemolyticus* was found much less frequently than in most of the camps, pneumococcus Group IV being distinctly the predominant organism according to cultural findings. Cultural work was not sufficiently extensive to offer much of value on the subject of the epidemic etiology. The types of pneumonia found corresponded with the types found in other camps where the same or similar bacterial distribution occurred.

An increase in respiratory-disease fatality preceded the epidemic wave of influenza in this camp by a considerable period. Whether this indicates an increasing virulence of organisms causing these infections it is impossible to determine. In many camps it preceded the epidemic wave by a very short time, usually a matter of days or weeks. Its wide separation in this camp suggests that it has no particular relationship to the increase in virulence of organisms causing the pandemic.

CAMP GRANT, ILL.^v

Data, other than the reports of sick and wounded, are not available to determine the types of serious infection of the respiratory tract prior to the influenza pandemic of the fall of 1918. These reports show a relatively low case fatality at the peak of incidence in January, 1918; 0.6 per cent of the total respiratory disease incidence. The deaths were attributed to primary lobar pneumonia, and Group IV pneumococci preponderated in the cultures from the cases. During February, 1918, the incidence of inflammatory respiratory diseases declined, but the case fatality rose sharply to nearly double that of January, or 1.10 per cent. The occurrence of the streptococcus among the cases increased at this time, as did empyema.

In April, there was a sharp increase in the case fatality rate to 3.73 per cent, at which time streptococci were abundant in the cultures and empyema was more frequent. Since the camp personnel had been practically constant for four months, this increase in the case fatality rate suggested an increase in the virulence of the infecting organisms. No available data reveal information about the influenza bacillus prior to the pandemic of the fall of 1918. The incidence and type of the acute respiratory infection suggest an influenzal wave both in the fall of 1917 and in April of 1918, particularly in the latter month.

^v Source of information, except as otherwise indicated: Medical reports to the Surgeon General, 1917, 1918, and 1919.

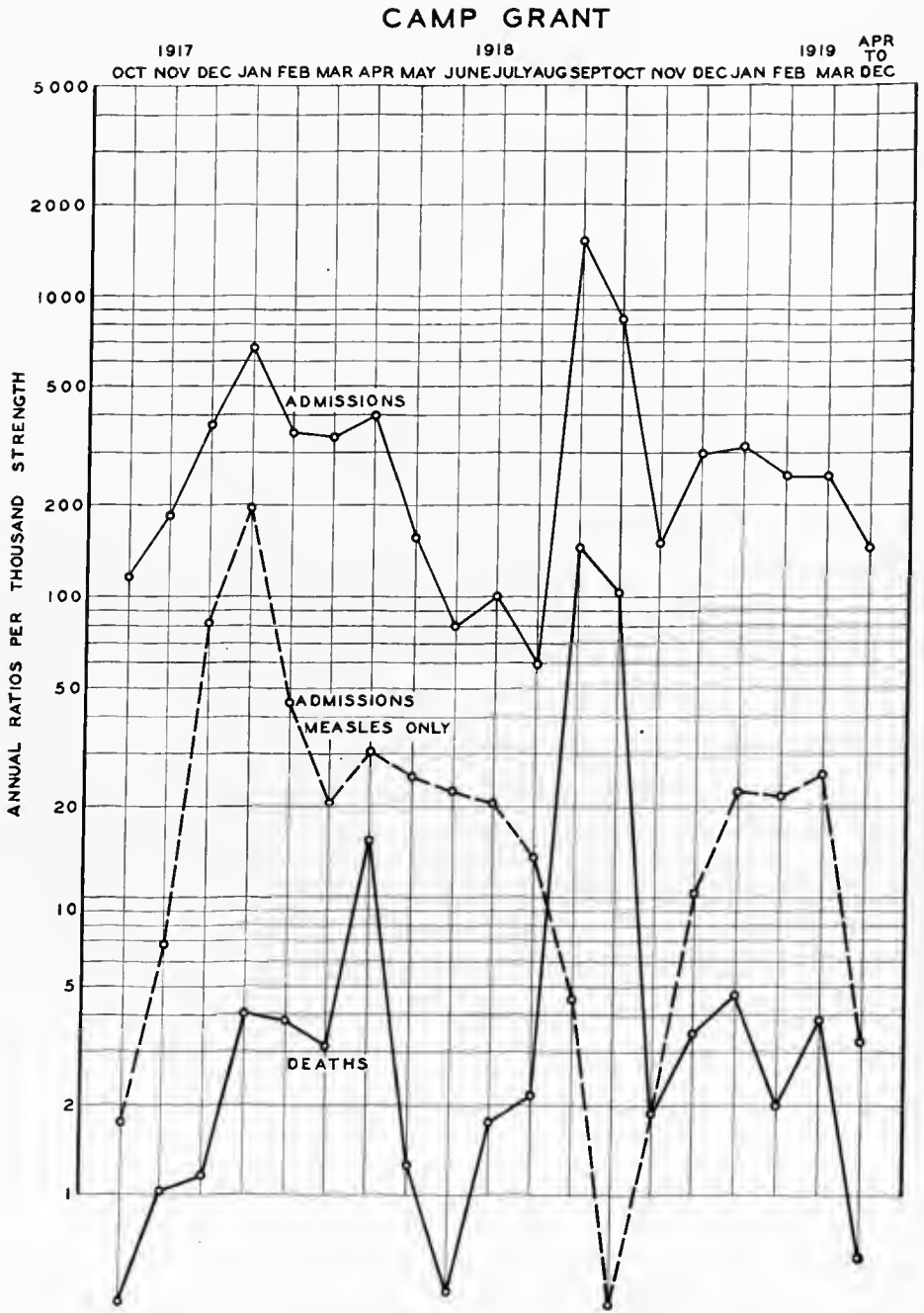


CHART IX.—The incidence and fatality of the acute respiratory diseases at Camp Grant

The following discussion concerns the pandemic of the fall of 1918.²

An epidemic of unusual virulence swept with great rapidity through several organizations in Camp Grant between September 21, and October 18, 1918 (approximately). During this time 9,037 patients were admitted to the base hospital, representing about one-fourth the strength of the camp, and of them 26 per cent developed pneumonia. About 11 per cent of the total admissions, or 43 per cent of the total pneumonia patients died.

From the throat cultures of the early admissions pneumococci were recovered with remarkable constancy; influenza bacilli were found exceptionally. Post-mortem examination of patients dying during the epidemic demonstrated regularly a massive bronchopneumonia. In cultures of the diseased lungs, heart blood, exudates, fluids, and other diseased foci of the body, pneumococci were the predominating organisms. Blood cultures of 90 patients in the hospital with pneumonia of the epidemic disease were positive in 50 per cent, pneumococci being the only organisms recovered. Pneumococci in pure cultures were recovered from infected sinuses of the head, the middle ear, conjunctival and empyenic exudates. Inoculation of animals with pneumococci isolated during the epidemic demonstrated a high virulence of these organisms. Control throat cultures made of prisoners in the camp escaping the epidemic disease contained practically no pathogenic organisms.

Of 21 positive blood cultures during life, 14 were Type II, 1 Type I, and 6 Group IV. Of 16 post-mortem, positive blood cultures 10 were Type II, and 6 Group IV. Of 13 cultures from the lung, post-mortem, 8 were Type II and 5 Group IV.

During the epidemic 198 post-mortem examinations were made.

A decided cyanosis of the face, neck, and extremities was observed frequently, and commonly there was a distinct yellow tinge to the skin and conjunctivæ. Dryness of the skeletal muscles was usual. The parietal pleura commonly was hyperemic and glistening, or slightly dull, with loss of the normal smoothness, and covered by a scanty layer of fibrin. Turbid brown fluid, from a few to 300 c. c., was contained in each pleural cavity when the inflammation had penetrated into these serous spaces. Changes in the pericardial sac consisted largely in an increase in the amount of yellow fluid normally contained. A true serofibrinous or suppurative pericarditis was not seen until late in the epidemic, and acute changes in the heart valves were not observed in any post-mortem examination. The myocardium, and all the parenchymatous organs as well, presented a moderate or severe grade of cloudy swelling, with commonly disseminated areas of acute fatty changes. Subserous, petechial hemorrhages were common.

The parabronchial lymph glands constantly were enlarged, very soft, sometimes with small areas of necrosis. The lining of the trachea and of the main bronchi was intensely hyperemic, and on the mucous membranes there was a thin milky gray, brown, or sanguineous fluid, sometimes frothy. In the deeper

² The following statements of fact are based, in the main, on studies by Edwin F. Hirsch and Marion McKinney: Epidemic of Broncho-pneumonia at Camp Grant, Ill. *Journal American Medical Association*, Chicago, 1918, lxxi, 1735. An Epidemic of Pneumococcus Broncho-pneumonia. *Journal of Infectious Diseases*, Chicago, 1919, xxiv, 594, and xxv, 394, respectively.

portions of the respiratory tree the bronchioles were lined by an intensely red mucous membrane covered by a relatively thin, gray, exudate. The consolidation of the lungs was extensive. When removed from the chest the lungs appeared voluminous, dark red or cyanotic, with no, or very little, exudate on the pleural surface, these membranes commonly being quite smooth and glistening. Underneath the pleura there were hemorrhages into the lung tissue from one to several centimeters in extent, as a rule, in addition to nodular consolidations which sometimes were so extensive as to form large confluent areas of firm tissue. Such extensive consolidation usually occurred in patients who had survived several days, those in whom the lungs were extremely hemorrhagic dying relatively early in the disease. Several of the lobes were involved. From the surfaces of the lung tissue large quantities of blood and bloody fluid escaped, and there were firm areas of red tissue slightly granular and moist, with edematous and hemorrhagic lung tissue between. As the epidemic progressed gray nodular consolidations often confluent were noted. On the cut surface the tissue was distinctly granular and moist, with a brown or brownish-red exudate.

The yellow of the adrenal cortices was moderately diminished, or entirely absent, and in one case there were several small subcapsular hemorrhages in each organ. As a rule, the spleen was increased in size from one-half to twice the normal, and the substance of the organ was soft and dark red. The biliary and mesenteric lymph nodes constantly were increased in size, the former much more so relatively than the latter, the substance moderately firm and red. Changes in the common bile duct, the portal vein, the splenic, and the upper portion of the superior mesenteric veins were not seen.

The liver was enlarged, its capsule tense, and the tissue beneath mottled with disseminated areas of acute fatty changes and passive hyperemia. Focal necrosis was not recognized grossly. In the lining of the stomach there were multiple petechial hemorrhages.

In a limited number of cases in which the brain was examined there was found a moderate hyperemia of the pia-arachnoid, with dryness of the cerebral cortex. The spinal fluid of such patients usually without meningeal manifestations, commonly was turbid. In a limited number of examinations collection of a mucopurulent exudate was found in the sinuses of the face and middle ears.

As the epidemic progressed, complications commonly following pneumonia were found post mortem, including serofibrinous pleuritis, empyema of the chest, acute serofibrinous pericarditis, acute suppurative pericarditis, and peritonitis. The character of the lung changes varied, too, in the later stages, and it was in the last few days of the epidemic that gray consolidations of the lungs were noted, and in a few of these extensive softening of the lung tissue. In some, lung changes grossly corresponded with descriptions of acute suppurative interstitial pneumonia. Mention should be made of cases in which the lung changes were comparatively insignificant, but in which disease of some of the bony spaces of the head occurred and subsequently or coincidentally infection of the leptomeninges. In these the greatest interest centers in the bacteriologic examinations which are discussed later.

Following the decline of the epidemic, deaths occurred in the hospital fairly often with diseases primarily pulmonary, the lung changes of which differed from those observed during the epidemic. Usually such deaths followed an illness in the hospital of more than one week. In the lungs of those dying within the first or second week there were red or reddish-brown nodular peribronchial consolidations irregularly scattered throughout one or more lobes. The bronchioles contained a white viscid exudate, the lining membrane being hyperemic and swollen. As this process became moderately advanced, the lungs contained many soft, yellow, peribronchial areas of necrotic tissue from 1-3 mm. in diameter, contrasting sharply with the red, air-containing or compressed lung tissue. Removal of the exudate from these areas exposed shallow crater-like peribronchial excavations in the tissue, without a definite limiting membrane, being covered by a yellow shaggy exudate. The tissue beneath the exudate was hyperemic or hemorrhagic. Lungs in which this peribronchial destruction of tissue was general were riddled by many abscesses of relatively small dimension without a definite limiting membrane. Such lobes sometimes were just masses of necrotic tissue held together by the supporting framework. Other lungs not as extensively diseased contained several or many scattered peribronchial abscesses of relatively small dimension having a thin pyogenic membrane.

Clinically, the patients with extensive destruction of the lung tissue expectorated great quantities of yellow exudate and liquefied necrotic tissue, a phenomenon regarded by some as the emptying of an empyema through an eroded bronchus. The post-mortem examination demonstrated clearly that the yellow expectoration came from the lung itself and not from the pleural cavity.

This acute suppurative interstitial pneumonia, however, was not the pneumonia that characterized the epidemic proper.

Microscopic examination of tissue from various places in diseased lungs disclosed irregularly distributed and developed inflammatory changes. In the alveolar spaces over small or wide areas corresponding with the gross changes, were red corpuscles in large numbers, and leucocytes in the ratio usually in the circulating blood. Such areas were distributed irregularly. Other alveolar spaces either in areas of hemorrhage or elsewhere contained endothelial cells in addition to the leucocytes, the number of endothelial cells increasing apparently with the progress of the lung lesion. Delicate strands of fibrin were present in such alveolar spaces, and also polymorphonuclear leucocytes, which gradually approached and exceeded the endothelial cells in number. In later stages the alveolar spaces contained numerous polynuclear leucocytes, slightly less numerous endothelial cells, fewer red corpuscles, strands and masses of fibrin, cellular detritus, and amorphous particles of coagulated material.

In large confluent areas of consolidation the alveolar spaces regularly contained polynuclear leucocytes, endothelial cells, red corpuscles, and granular protein material as mentioned.

The bronchioles invariably contained many polynuclear leucocytes, endothelial cells, red corpuscles, fibrin, and other products of an acute inflammatory reaction.

The post influenza respiratory diseases also were investigated. Starting in December, 1918, and continuing into March, 1919, 455 throat cultures of

patients admitted for influenza were studied on plain blood agar according to the methods used in the earlier studies. The results of study of throat cultures of influenza patients showed Gram-positive, lancet-shaped diplococci, sometimes in chains, growing in green colonies on plain blood agar in 71.87 per cent; hemolytic streptococci in 21.98 per cent; nonhemolytic streptococci in 9.01 per cent; *B. influenzae* in 19.58 per cent; and *Micrococcus catarrhalis* in 72.31 per cent.

Of the Gram-positive, lancet-shaped diplococci, 169 pure cultures were isolated and studied more carefully; 19 were soluble in bile and fermented inulin, 43 were soluble in bile only, 45 fermented inulin only, and 32 gave no reaction with either of these tests.

The anatomic changes observed after death, when the epidemic had subsided, were chiefly such as complicate or follow pneumonia. Empyema was the commonest, usually in patients in whom the purulent exudate in the chest had been drained. Acute suppurative pneumonia with multiple peribronchial abscesses without definite limiting membranes was fairly common. The amount of destruction in such lungs varied widely, in some practically all the respiratory tissue of a lobe or a lung having been destroyed. Hemolytic streptococci were recovered from the exudate of such lungs with great regularity. It is possible that all of these acute suppurative pneumonias were essentially such from the beginning, but there is reason for believing that some of them were superimposed on a primary pneumonia without suppuration, because the examination of sections from earlier stages of such lungs showed necrosis in the alveolar walls or ductuli alveolares, this necrosis being but a small part of a much larger consolidation with changes like those in pneumococcus infection. In addition acute suppurative leptomeningitis and acute thrombo-ulcerative endocarditis were observed a few times.

Much different were the results in deaths from respiratory infections that in no way could be considered a complication of the epidemic disease. This group contains the largest number. Here the lungs were mottled by many, comparatively small, dark red areas, the increased firmness being due largely to the escape of blood into the substance. Large amounts of bloody fluid escaped from the cut surfaces, and the pleural cavities contained from 100 to 500 c. c. of thin reddish-brown fluid. Hemolytic streptococci were recovered in pure culture from the lungs and heart blood. In other cases the lungs contained irregular, nodular consolidations several centimeters in dimension, representing an older stage, and culturally yielding a similar bacterial flora. These nodules did not resemble in close detail the consolidations observed during the height of the epidemic in that the surfaces of the latter at the same stage of development were more coarsely granular without the yellow focal areas of necrosis, and the fluid expressed from the tissues was more viscid and grayish-brown rather than the reddish-brown of hemolytic streptococcus infection. The early acute hemolytic streptococcus pneumonia is also quite distinctive from the pneumonia of the epidemic.

During the five months in which these observations were made, there were only three cases in which the typical lobar pneumonia was approached. All of these were noted after March 15, 1919. Consolidations of entire or

nearly entire lobes were observed, but these were confluent bronchopneumonia rather than lobar pneumonia. That lobar pneumonia should be submerged during the epidemic and for months after is of great interest. There seems to have been some fundamental change in the reaction of the host toward the infecting agent, some difference in the activity of the invading organism, or change in the interaction of both.

Cultures of tissues and fluids taken post mortem afford valuable information in acute infectious diseases of the variety of pathogenic bacteria present, and correlate the lesions with the organism concerned. The methods used during the epidemic were continued, with slight modification, in this study. As a rule, the cultures were obtained within six hours after death, and usually were controlled by direct smears made at the same time, stained later by Gram's method and dilute aqueous fuchsin.

During the period when complications of pneumonia were observed post mortem, and again later in a number of acute respiratory infections, hemolytic streptococci were recovered in mixed and pure cultures. With the ascendance of hemolytic streptococci in cultures, pneumococci became less frequent, although there were a few examinations during the first three months in which the lung changes and results of cultures corresponded well with those of the epidemic. In all the cultures from various places, influenza bacilli were found only occasionally with other organisms, never in pure culture. Pure cultures of *Staphylococcus albus* were recovered from diseased lung tissues, body fluids, and the spleen in two examinations.

The lung culture results are briefly as follows for 49 of the 89 cases studied in which death probably had resulted from an acute respiratory disease after the epidemic or from lung complications of the epidemic disease: Hemolytic streptococci in 30; pneumococci in 20; *Staphylococcus albus* in 11; *B. influenzae* in 8; nonhemolytic streptococci in 2.

These results may be misleading in that each of the various organisms listed as being present were not regarded in every instance as being the predominant organism. Of the remaining 40 examinations, 31 presented no immediate reason for culture of the lung, 3 others were not tabulated because of an active tuberculosis, while in the remaining 7 an acute suppurative leptomeningitis was demonstrated, the spinal fluid of 4 containing pneumococci, and of 3 hemolytic streptococci.

Heart-blood cultures of the 89 necropsies gave the following results: Hemolytic streptococcus, pure, 26; pneumococcus, pure, 18; *Staphylococcus albus*, pure, 2; negative, 16; not cultured, 27.

These results indicate that, with the decline of the epidemic and subsequently, hemolytic streptococci became important as invaders of tissues already diseased and frequently provoked disease in tissues not the site of a preceding change.

The post-mortem bacteriologic studies demonstrated the presence of hemolytic streptococci, pneumococci and staphylococci in diseased fluids and tissues.

The fixed types of pneumococci, particularly Type II, were extremely important in this camp. Group IV apparently had a relatively high incidence during the early months, with an increase in streptococcus during the epidemic or increased incidence of acute respiratory disease in the month of April, in a

personnel which had been practically constant since September, 1917. Pneumococcus Type II was an extremely important infecting agent and evidently of very high virulence during the influenza epidemic. The incidence of streptococcus increased during the influenza epidemic. It continued important throughout the postepidemic period. While the influenza bacillus was found in some numbers, it is doubtful if the total incidence was revealed. Descriptions of many of the cases are quite typical of the changes in the lung produced by this organism when not accompanied by others. There was evidence, however, of other organisms in such lungs in each necropsy. Pneumococcus Type II may be extremely virulent and occasionally produces a completely hemorrhagic lung with rapid death without appreciable consolidation other than inflammatory edema; in fact death, with septicemia without more than slight localization in the lungs, has been reported. At the Army Medical Museum there are on file several protocols of Type II infection which were essentially cases of septicemia, with little evidence of localization other than an acute bronchitis of hemorrhagic type.

It is noteworthy that, in spite of the marked increase of camp personnel during August and September, 1918, there was no corresponding rise in the measles rate. Measles practically disappeared in several camps during the influenza epidemic period, but rarely did this happen when, coincidentally with the onset of the epidemic, considerable numbers of unseasoned troops were received. The possibility that the virus of influenza can act unfavorably on that of measles is suggested by such an occurrence as is portrayed in the history of Camp Grant.

There are 73 necropsy protocols of cases dying of acute respiratory disease at this camp in the collections of the Army Medical Museum, 37 of which are accompanied by gross and microscopical specimens of lungs and other organs.

Organisms morphologically and tinctorially identical with *B. influenzae* are found along the smaller air passages in well fixed material of cases dying within the first 7 to 10 days. Other organisms, Gram-positive cocci, are present, however, in all cases. There are several cases from which pneumococcus Type II was isolated, but these show definite pneumonic lesions bronchopneumonic in character, with considerable diffuse hemorrhage, a true hemorrhagic inflammation.

CAMP GREENE, N. C.^{aa}

The acute respiratory diseases following mobilization at this camp, aside from the high incidence of measles, were due to influenza and common respiratory diseases. Five hundred and sixty-five cases were diagnosed influenza in the month of December, 1917. The deaths for December were 24 from complications of measles and 20 from primary pneumonias, the latter undoubtedly representing the terminations of unfavorable character in the influenza outbreak. Another outbreak of respiratory diseases, during a time when measles was dropping in incidence rate, occurred with a peak in April, the majority of the deaths being charged to primary lobar pneumonia. Here, as in other camps, patients were admitted for pneumonic complications, the preliminary respir-

^{aa} Source of information, except as otherwise indicated: Medical reports to the Surgeon General, 1917, 1918, and 1919.

atory attack having occurred before their entrance into hospital and therefore not appearing as an admission diagnosis.

Cases of pneumonia began to appear as soon as the base hospital was opened in September, 1917, but were comparatively few until about the middle of December.^{bb} With the onset of the cold weather, however, they increased until, by the end of April, 1918, when the cases ceased to come in, there had been admitted 427 cases of lobar pneumonia.

Of the 427 cases, there were 34 of lobar pneumonia which appeared as a complication of measles. The other 393 were primarily cases of lobar pneumonia sent in from their respective commands or from the regimental infirmaries.

The cases as they appeared from September to the end of January did not differ from those one sees in young people in municipal hospitals. During December the cases began to show a tendency to involve more than one lobe. During February they seemed to assume a somewhat different character and were more severe. Besides the multiple lobe involvement, the patients were usually pale, showed no herpes labialis, had an increased pulse rate out of proportion to the ordinary cases, and in general they seemed to be in a more or less typhoid state.

In practically all cases there was obtained a history of cold in the head or chest or exposure to cold from a few days to a week before the onset of the disease.

More than half the cases gave a history of onset with a chill and pain in the side. Localization of the pain is important and in a good many cases the area of pain was watched for signs of consolidation which appeared a few days later.

A good many cases did not begin with a chill, but had pain in the side with cough and expectoration. Of these cases there were first the very mild ones, and, second, some of those appearing during February with more of a typhoid state.

In a considerable number of cases the onset began with symptoms of meningeal irritation. The patients complained of headache, were stuporous, had stiff neck and a Kernig sign. These cases were usually sent in with the diagnosis of meningitis and the necessity of confirming or disproving this promptly led to the tapping of the spinal canal. The spinal fluid obtained, however, was clear, showed no cell increase, but was under plus pressure. Usually the meningeal symptoms improved with the puncture, but at times they persisted for more than 24 hours. None of the patients showed at this stage any signs in the chest, but in a few it was possible, after making them cough repeatedly, to obtain rusty sputum, making spinal puncture unnecessary.

Quite a number were first admitted to the surgical service with a diagnosis of appendicitis.

The dullness in pneumonia was usually moderate. Rarely was there complete flatness and the dullness usually stopped half an inch or so short of the vertebral column, never reaching the median line; while the cases of fluid were

^{bb} The following statements of fact are based, in the main, on: Pneumonia at Camp Greene: A Few Considerations from a Clinical Standpoint, by Herman Elwyn, *Southern Medical Journal*, Birmingham, 1918, xi, No. 12, 780-785.

nearly always flat on percussion over the vertebral column and the dullness usually crossed to the other side.

There were all kinds of variations, in the course of the disease, from the very mildest cases, lasting not more than three days, to the most severe.

As soon as pneumonia cases began to appear in the hospital, pneumococcus type determination was requested from the laboratory. This was ascertained by injecting the washed sputum into the peritoneal cavity of a mouse. The mouse was killed in 8 to 12 hours, and an emulsion of the organisms, obtained from the peritoneal fluid of the mouse, was tested for agglutination with standard sera of the various types.

Of the complications the most important was empyema. Besides the empyemas complicating lobar pneumonia, a great number of empyemas complicated the purulent bronchitis following measles, and there were some empyemas secondary to other infections. Up to March 1 the following were observed: (1) Empyemas following bronchopneumonia and lobar pneumonia after measles; total cases, 14; deaths, 10; mortality, 71.4 per cent. (2) Empyema after measles without pneumonia; total cases, 29; deaths, 18; mortality, 62 per cent. (3) Empyemas without measles or pneumonia; total cases, 14; deaths, 4; mortality, 28.5 per cent. (4) Among the 393 cases of primary lobar pneumonia there were 45 cases of empyema, a percentage of 11.4. Of these cases 21 died; that is, 46.6 per cent of the 45 cases.

As there was a good deal of similarity among these various empyemas, it is well to consider them together. Clinically they presented themselves in three varieties.

In the first class were the empyemas following early cases of pneumonia. They were usually of a mild degree. They did not show very marked prostration. The pus was thick and creamy and showed in the aspirated diagnostic sample either no organisms or mixed pneumococci and streptococci.

In the second class were the cases of empyema in which the clinical picture was not so mild. Among these were cases which developed during or following the course of pneumonia or measles or were admitted as such. They were of various grades of severity. They presented on aspiration a brownish or milky-white, purulent, rather thin fluid, containing in a thin smear of the noncentrifuged specimen a moderate number of short-chain streptococci, which the laboratory classified as either hemolytic or viridans. Often the fluid was so clear that it was repeatedly aspirated before the case was sent to the surgical service. But in every case where clear fluid showed the presence of organisms, and where it was hoped that operation could be avoided, the fluid eventually became purulent and drainage had to be resorted to.

In the third class are included the very severe cases. These often appeared after the pneumonia had subsided; they appeared also in the course of measles, bronchitis, and in a few cases secondary to a tonsillitis, or without any apparent cause. They presented a clinical picture totally unlike any other cases of empyema.

The onset was with a sudden sharp pain in the side or in the abdomen. The most striking cases were those after measles in which normal convalescence had seemed established and the patients were up and about the wards with

normal temperature. The face assumed a grayish color, was pinched and anxious, the pupils were moderately dilated. The temperature rose promptly to 103° or 104° F. The pulse was rapid, usually about 140° to 160°. Breathing was shallow and rapid and the breath sounds on the affected side were diminished or absent. The prostration was extreme. Within four to six hours after the onset, fluid could be obtained on aspiration over the base of the lung. The fluid increased rapidly and in 12 to 18 hours could be percussed above the angle of the scapula. Dyspnea and prostration were present; pulse rate increased to a marked degree; the pupils became completely dilated; the patient sweated profusely; and death often resulted within 24 to 48 hours.

The fluid was thin, of a brownish color, cloudy and contained in a thin smear a great number of short-chain streptococci, and practically amounted to a pure concentrated culture of streptococci. The greatest mortality was among these cases, many of which were entirely too sick for a rib resection, so that repeated aspiration was resorted to. A few cases received antistreptococcus serum intravenously, but without benefit. Most cases were operated upon and quite a few recovered.

From the data available it is difficult to determine the acutal type of pathology found in the lungs in the cases of the fall of 1917 and early months of 1918. Available data indicate that the pneumonias were rarely the characteristic fibrinous or croupous lobar pneumonia. Many lobes usually were involved, the picture varying in different parts of the same lung and in different lungs. Empyema was an extremely important complication and for the most part appeared to be due to one of the members of the streptococcus group. The last group of cases was quite typical of empyema following the breaking down of streptococcus lesions after the decline of acute inflammatory reaction in the lung, or of cases of interstitial pneumonia in which suppuration occurred late.

Empyema was the most serious condition with which the personnel had to deal. A special problem occurred in cases in which the pus had become encapsulated, either before or after rib resection. Of these encapsulations the most difficult to detect were collections of pus between the heart and the lung, which were practically inaccessible to diagnostic puncture. In other cases the pus was localized over an upper lobe anteriorly or had burrowed underneath the great vessels.

There were several cases of bilateral empyema. One patient, who was operated upon on both sides, recovered.

Among the 427 lobar pneumonias there were 8 cases of pericarditis. Among these were three cases of dry pericarditis that recovered. The rest were hemorrhagic or purulent, all containing short-chain streptococci. There was one case with acute endocarditis.

There were five cases of peritonitis. All died. The organism obtained from the peritoneal cavity upon autopsy was a streptococcus and not a pneumococcus. Clinically the cases were characterized by the absence or lack of prominence of abdominal pain. The symptoms which called attention to the peritoneal involvement were distention, stoppage of all bowel movement and of flatus, followed by persistent vomiting. In cases of distention not due to peritoneal inflammation, so frequently occurring in lobar pneumonia, there

was no vomiting. The autopsy in these cases revealed a thin, purulent fluid in the peritoneal and pleural cavities. Thin smears showed the presence of organisms.

In three cases pneumococcal meningitis complicated lobar pneumonia. The meningitis appeared relatively late in the course of the pneumonia, and was characterized by irregular pupils, stiff neck, a Kernig sign, and a stuporous and restless condition. The pneumococcus was recovered from the spinal fluid. In one case antipneumococcus serum was injected into the spinal canal, but without any benefit. All three cases died.

There were two cases of pneumonia occurring two months or more after recovery from empyema. Both came to autopsy, thus giving an opportunity to view the end result of a cured empyema. It was not at all encouraging. The pleura was markedly thickened, densely adherent, and it was astonishing to see to what an extent the lung had shrunk.

Two cases were complicated during their convalescence by abscess of the abdominal wall. This was drained in each case and a pneumococcus was obtained from the pus.

Two cases were followed by suppurative parotitis, which necessitated drainage.

One case of pneumonia, which was complicated by one of the fulminating empyemas and which died within 24 hours after the onset of the empyema, showed several areas of gangrene in the lung.

Of special interest were the cases of recurrent pneumonia. The following three are examples:

Hospital case No. 4818, age 25, was admitted January 14, 1918, with lobar pneumonia of the left lower lobe. Temperature became normal on January 15 and remained normal until January 31. On the 1st of February he had a rise in temperature with consolidation of the right lower lobe, and on February 6 consolidation of the right upper lobe. Temperature became normal on February 15. February 18 he developed consolidation of the left upper lobe. This last consolidation was followed March 6 by signs of an abscess in the left upper lobe. Elastic tissue was found in the sputum. He died on March 14. No autopsy.

Hospital case No. 6295 and 7406, age 20, had a chill on February 5, 1918, followed by fever and pain in the left side. Admitted February 7 with lobar pneumonia of the left upper lobe. Crisis on the 9th. Uneventful recovery. February 26, returned to duty in good condition. The same night he had a chill followed by fever and was readmitted to the hospital the next day, February 27, with signs of consolidation of the left lower lobe and part of the left upper lobe. Temperature became normal on March 4 and remained normal. Discharged to convalescent camp on March 24.

Hospital case No. 6702, age 19, was admitted February 13 with acute bronchitis. February 17 he developed signs of consolidation of the left lower lobe. Temperature dropped to 100° F. on February 19 and continued irregularly between 99° and 100° until March 1, while the left lower lobe was gradually cleaning up. On March 2 he had a sudden rise of temperature to 104°, with signs of consolidation of the left upper lobe anteriorly. Temperature became normal on March 8, with the left upper lobe beginning to clear up. On March 10 he had a rise of temperature to 105° F., and the next day signs of consolidation of the right upper lobe. Crisis occurred on the fourteenth day. Temperature was subnormal and in a few days became normal. Returned to duty.

There were 34 cases of lobar pneumonia following measles. Of these, 17 died, that is, 50 per cent. Contrast with these figures the mortality among the other cases of lobar pneumonia. Of the 394 cases, 68 died, that is, 17.2

per cent. Of the 34 cases mentioned above, 11 had empyema, 4 among which recovered. Here the problem was somewhat different. The course of events was as follows: The patient was admitted for measles and developed during the course the ordinary mild bronchitis accompanying measles. This gradually increased in severity, and after a time became purulent, involving every bronchus and bronchiole in both lungs. This was followed by consolidation of one or more lobes. Empyema complicated the pneumonia or occurred without the pneumonia.

The difficulty in these cases was the purulent bronchitis. The patients coughed up pure pus for days and weeks. They became intensely dyspneic, cyanotic, and exhausted from the coughing. The absorption of toxic products from the bronchi must have been enormous and certainly must have contributed to the severity of the disease. When consolidation of a lobe supervened, this still increased the dyspnea and cyanosis and of course added to the severity.

On the autopsy table the lungs showed besides the consolidation, which was of the lobar type, all bronchi and bronchioles filled with a thick yellow pus, which could be squeezed out under the slightest pressure.

From this study it was learned that it is practically impossible to recognize clinically whether these cases of purulent bronchitis are accompanied by bronchopneumonia or not. Two cases of purulent bronchitis that died the same day had shown identical clinical pictures and had both been diagnosed bronchopneumonia. At autopsy one showed areas of bronchopneumonia in both lungs with the purulent bronchitis. The other showed the purulent bronchitis with not even the slightest trace of bronchopneumonia.

During the influenza epidemic the mortality was due almost entirely to pneumonia and was so recorded by the medical personnel of this camp. One hundred and forty-one autopsies were done on cases dying during the influenza epidemic. Of these pneumonias 72 per cent were diagnosed as of the lobar type.⁶⁶

The fact that clinically there seemed to be a sharp distinction between the simple cases without pneumonia and those resulting in pneumonia inclined the clinician to favor the view that the epidemic was one of a definite disease of which pneumonia was a distinct though prevalent complication.

Clinically, the disease was one of sudden onset with symptoms seeming to show a severe initial general intoxication with little evidence of local source. The negro soldiers who were the first and most numerous attacked at this camp would frequently lie down wherever they happened to be when taken with the disease, having to be carried to the infirmary or hospital; headache and general pain in the lower lumbar or sacral regions were the almost general early complaints.

Cough usually developed gradually on the second or third day. Coryza and lachrymation were infrequently noticed by the patient but in most cases objectively slight snuffling and slight conjunctival congestion were present. Expistaxis was frequent in early cases. A few patients had hematemesis or small intestinal hemorrhages. Many white patients on admission, showed

⁶⁶ The following statements of fact are based, in the main, on: Influenza-pneumonia at Camp Greene, N. C., by Claude P. Brown and Francis W. Palfrey. *New York Medical Journal*, 1919, cx, 316-321; 368-372.

slight cyanosis of lips and ears. Somnolence was a conspicuous feature, almost all patients would apparently go to sleep as soon as they were put to bed, complaining of headache, if aroused, but otherwise lying perfectly quiet for long periods. No skin rashes were observed, although from two to three weeks after onset there was a general fine desquamation similar to that of measles, conspicuous especially on the skin of Negroes. The throat was often slightly reddened but never to such a degree as to suggest the throat as an important seat of infection. Examination of heart and lungs in the stage of onset was uniformly negative. The spleen was not found enlarged, nor was there any abnormality of the abdomen, except in cases with vomiting in which there was often more or less vague abdominal tenderness, usually more marked in the upper portion. There was no general glandular enlargement which was not explicable by other existing causes. The urinary secretion was diminished as usual in acute febrile diseases, the urine concentrated and slightly albuminous. The white count was inconstant, as will be discussed under laboratory findings, together with blood cultures, sputa, and other bacteriological studies. The incubation period in one group of cases which could be traced to a probable source was five days.

In clinical course the first day was marked by fever, general pain and prostration without other features. On the second and third days cough developed but at first without râles in the chest. On the third or fourth day in the milder cases the temperature was lower or normal and convalescence began. In a certain proportion of patients an apparent relapse occurred after one or two days, and in some patients several of these relapses occurred.

The increased respiratory rate of beginning pneumonia was often of quite sudden appearance and in conspicuous contrast to the slow quiet breathing in uncomplicated cases. Thus while signs of consolidation were not infrequently found in patients with normal rate of respiration, all patients with rates approaching 30 a minute were examined with special care. Rusty or bloody viscid sputum was taken as evidence of pneumonia for purposes of isolation and treatment without waiting for signs of consolidation which regularly appeared later.

The evolution of the symptoms and signs of pneumonia showed certain variations from those commonly observed in primary lobar pneumonia. Pleural pain, while present in certain patients, was relatively infrequent. Dyspnea while sometimes extreme was in many cases slight. The sputum, while typically rusty in many cases, in many others was light green and less tenacious. Whereas in primary lobar pneumonia it is exceptional to hear râles before bronchial breathing and then only a fine explosion of very fine crepitations at the end of inspiration, in these patients it was the rule to hear rather coarse crackling râles with somewhat diminished breath sounds for a day or more before bronchial breathing appeared. Dullness was often marked in the area of these râles while bronchial breathing was still absent. (Certain patients that died while this combination of coarse râles, dullness, and diminished breathing was present showed in the corresponding portion of the lungs dark red areas of consolidation of somewhat flabby jellylike consistency.) In practically all serious cases the signs of consolidation were extensive and in a great majority of the fatal cases this process was bilateral.

Whereas in other hospitals bronchopneumonia predominated, in this hospital, with the exception of the variations noted above, the clinical course of the great majority of cases was typical of lobar pneumonia. With few exceptions the local physical signs of consolidation were distinct; few cases came to autopsy without local consolidation in part or in whole correctly predicted, and in the relatively few cases which proved to be bronchopneumonia the absence of clinical signs of consolidation had been noted as unusual. These cases of pneumonia tended to rather long course with successive appearance of new areas on consolidation. Their favorable termination was more often by rapid lysis than by sharp crisis.

A tendency to delayed resolution was marked in a distinct proportion of cases, the physical signs and X-ray picture of consolidation persisting for one or more months. Exploratory punctures proved negative. The dullness and bronchial breathing would then gradually disappear but coarse crepitant râles would continue in the area for another long period after which complete return to normal was apparent.

Serous pleural effusions of sufficient volume to be of clinical importance were occasionally found but were not numerous. Pericarditis was infrequent and pericardial effusions few. Empyema occurred in two classes, the early and the late. The first comprised turbid bacteria containing fluids appearing while acute pneumonic symptoms still dominated the clinical picture. Many of these cases were fatal, but it was believed that death, in these cases, was to be attributed to pneumonia rather than to empyema, the symptoms being pneumonic, and at autopsy the lungs being extensively involved in red or early gray hepatization. Experience with empyema in the previous year (1917) had led to the conviction that operation in the presence of an active pneumonia only aggravated an already severe condition and often accelerated a fatal outcome. When fluids even if becoming purulent and rich in bacteria were found, therefore, where it was believed that active pneumonia was still present, particularly if it involved the opposite side, it was the practice to depend upon aspiration only, deferring surgical drainage until a more favorable opportunity. The second class of cases comprised empyemas first developing after the pneumonia had run its course. In most of these the pus was encapsulated in rather small accumulations of relatively low toxicity. Some of these encapsulated areas gave one the impression of the fluid having accumulated within areas walled off by fibrous bands of adhesions which were due to an old pleurisy. Pneumothorax occurred in 12 patients. In eight which came to autopsy all but one had no tuberculosis or other lesion which could be found to account for the escape of air. Since acute emphysema with air vesicles of more or less prominence was not an uncommon finding in other cases it is probable that these collapsed lungs had previously contained such vesicles, the rupture of one of which had produced the pneumothorax. In all cases entrance of external air from aspiration was excluded. Wounding of the lung by exploratory puncture was not regarded as probable in any; in most no exploratory puncture had been made. In three of these patients pyopneumothorax developed. In two the pneumothorax was bilateral.

A group of cases of considerable interest, studied by the radiologist, presented X-ray evidence apparently conclusive of lung abscess, tending to quite rapid spontaneous recovery by an absorption. From two of these, sterile nonodoriferous thin green pus was aspirated. None had profuse expectoration or foul breath. Local physical signs were slight or absent. All showed progressive disappearance of the lesion, became free of symptoms, and returned to duty. There were five cases of suppurative parotitis. In twelve cases of tuberculosis the disease may have been activated by influenza.

As to the etiology of the epidemic, bacteriological data failed to establish the influenza bacillus of Pfeiffer as the infecting organism. The following studies of cases were made in the acute stage of influenzal symptoms, usually in the first 24 hours. In cultures from throat swabs, plated on defibrinated blood agar from 88 cases, *Bacillus influenzae* was present in 18, but never predominating and in most cases but few colonies, while the pneumococcus, streptococcus, and the usual respiratory organisms were present in large numbers. In the cultures from these 88 cases the organisms observed and the number of cases were as follows: Pneumococcus, 20; hemolytic streptococcus, 19; non-hemolytic streptococcus, 28; streptococcus viridans, 45; micrococcus catarrhalis (group), 70; staphylococcus, 8; *Bacillus influenzae*, 8.

Smears from the throat stained by Gram's method in 109 cases showed influenza-like organisms 63 times. The organisms observed (morphologically) occurred in the following number of cases: *Bacillus influenzae*, 63; pneumococcus 59; streptococcus, 35; Gram-negative bacillus (not influenza), 19; staphylococcus, 35; Vincent's bacillus and spirillum, 6; diphtheroids, 10.

Blood cultures were made in 101 cases; all proved negative. The blood counts taken within 24 hours after the first symptoms were no indication of impending pneumonia.

As efforts to recover *Bacillus influenzae* resulted in few of them being found in pure culture or even predominating from sputum and throat swabs, further effort was made to recover them by animal inoculation. Sterile cotton swabs were passed up and back of the uvula, then with a downward stroke the swab was rubbed over the nasopharynx and pharynx, and was then withdrawn. This swab was shaken in about one c. c. of sterile bouillon which was then injected into mice, intraperitoneally. This was done in 12 cases; 6 of the 12 mice did not die; from the 6 mice that died cultures made from both the heart blood and peritoneum, all proved negative for influenza bacilli.

There were 403 white blood counts taken, practically all from pneumonia patients during the period in which type determinations were made. These varied within such wide limits that they were of little significance except that those showing high blood counts were considered as showing great resistance. Two hundred and ninety-one blood cultures were taken; 19 of these were positive for pneumococcus.

Following the great wave of the epidemic, sporadic cases of the disease continued to occur and patients with pneumonia continued to be admitted, many of whom undoubtedly were preceded by mild unrecognized influenza. There were 4,789 cases of influenza and 688 cases of pneumonia up to February 28, 1919, with 295 deaths.

In the period of the epidemic proper there were 4,595 cases of influenza, resulting in 626 cases of pneumonia. There occurred among these 45 cases of otitis media, specimens of which were sent to the laboratory. Pneumococcus was present in 20 cases.

Deaths occurring September, 1918, to February 23, 1919, numbered 308, of which 141 came to necropsy. It is to be noted that 72.34 per cent were due to lobar pneumonia. Lobar pneumonia, 102 cases; bronchopneumonia, 12 cases; miscellaneous (influenza was the primary cause for admission in 14 of these cases, and 13 deaths from other causes), 27 cases. The 167 cases on which necropsy was not performed were diagnosed almost entirely as lobar pneumonia, and in practically all in which necropsy was not performed it was dispensed with under stress of the epidemic because of the fact that the clinical signs were considered sufficiently clear to render it unnecessary.

Of the 141 autopsies, in 102 cases the lungs showed the pathology of lobar pneumonia.

At the Army Medical Museum the pathology of the respiratory disease at this camp is represented by 33 cases of pneumonia, 27 of which occurred during the influenza epidemic. Microscopical sections are available of the 27 cases and gross specimens of 11 of these. From a study of the reports quoted, the protocols, and the specimens, it is evident that in a large number of instances the cases called lobar pneumonia were not the typical fibrinous or croupous pneumonia, but irregularly spreading consolidations involving many lobes, with a predominance of the type more generally called confluent bronchopneumonia. Areas of typical hepatization, however, were unusually frequent, particularly during the influenza epidemic, and may possibly be accounted for by a relatively high incidence, as shown in the bacteriological examinations, of the fixed types of pneumococci. The specimens available for study show every type of pneumonic consolidation described during the epidemic; some of these are obviously lobular or confluent bronchopneumonias which were diagnosed as lobar pneumonia in the descriptive data accompanying these specimens.

The bacteriology by culture is indicated in the material quoted. Gram-negative minute bacteria were present in sections of the well fixed material, particularly in cases predominantly of hemorrhagic type. Of the 27 cases in the influenza epidemic only 7 show in the descriptions accompanying them that a definite hepatization was present. In one of the seven cases, a typical consolidation of the lobar croupous type was present. In the remaining six, hepatized areas and bronchopneumonias of various types were described. In the influenza epidemic of the spring of 1918 streptococci were evidently an extremely important factor in the production of empyema and mortality, while during the influenza epidemic of the fall of 1918, these organisms were not predominant, empyema was rare (2 cases), and a large proportion of the fatalities appeared to be due to the fixed types of pneumococci, particularly Type II.

The recording of cases of empyema without pneumonia is exceedingly interesting and suggests involvement of the pleura from infected mediastinal lymphatics, without extension of the process to the pulmonary parenchyma. The

sharp rise in respiratory diseases in the month of April, 1918, with a constant or decreasing personnel speaks for an increase of the virulence of the organisms not dependent upon an influx of new susceptible material.

CAMP LEWIS, WASH.⁴⁴

The character of the respiratory diseases at this camp is of considerable interest not only because of their relatively low incidence but because of the very low case fatality of the group as a whole. The increase in respiratory diseases of the mobilization period showed a case fatality of 0.3 per cent in November, 1917, dropping to 0.06 per cent the following month. This is contrary to the experience in other camps, the majority of which showed an increase in the case fatality rate as the epidemic continued. An increase in case fatality in February, 1918, when it was 0.56 per cent, preceded the increased incidence or epidemic peak in March, when, however, the case fatality dropped to 0.19 per cent.

Aside from this minor rise there was no spring epidemic, as seen in so many of the camps, but there was a sharp increase in case fatality to 1.67 in June, when 14 cases died from pneumonia, diagnosed as primary. This increase in case fatality appears to have occurred too long before the pandemic rise of September and October, 1918, to have any relation to it.

No written data or necropsy protocols are available for study from this camp for the period preceding the pandemic.

A thorough study of influenza and bronchopneumonia at this camp was made by the pneumonia unit.⁴⁵

In making this study, the records of 407 cases of influenza, and the records and necropsy findings of 152 fatal cases of bronchopneumonia were critically reviewed. They were fortunate in having necropsy reports in practically every fatal case.

The symptoms of influenza in the epidemic of the fall of 1918 were exactly similar to the symptoms of previous influenza epidemics. The onset, as a general rule, was attended with malaise, headache, chills or chilliness, diffused body pains, aching muscles and joints, and more or less severe prostration. The temperature and symptoms were out of all proportion to the physical findings; in fact, in the majority of cases (61.7 per cent) the physical examination was entirely negative.

During the epidemic at this camp, there were 7,088 cases of influenza, not including 1,126 cases showing definite signs of bronchopneumonia on admission. Of these 7,088 cases, 2,730 showed signs of bronchitis during the course of the disease, and bronchopneumonia developed in 858, an incidence of 38.3 per cent for bronchitis and 12.1 per cent for bronchopneumonia. Considering the cases diagnosed on admission as bronchopneumonia, secondary to influenza, the incidence of bronchopneumonia was 24.2 per cent.

The course of the simple influenza was very short. In most instances the temperature, which on admission ranged from 100° to 104° F., returned to nor-

⁴⁴ Source of information, except as otherwise indicated: Medical reports to the Surgeon General, 1917, 1918, and 1919.

⁴⁵ The following statements of fact are based, in the main, on: Influenza and Broncho-pneumonia at Camp Lewis, by William J. Kerr, Hugh K. Berkeley, and T. Homer Coffin. *New York Medical Journal*, 1919, ex. No. 4, 133-140; 184-187.

CAMP LEWIS

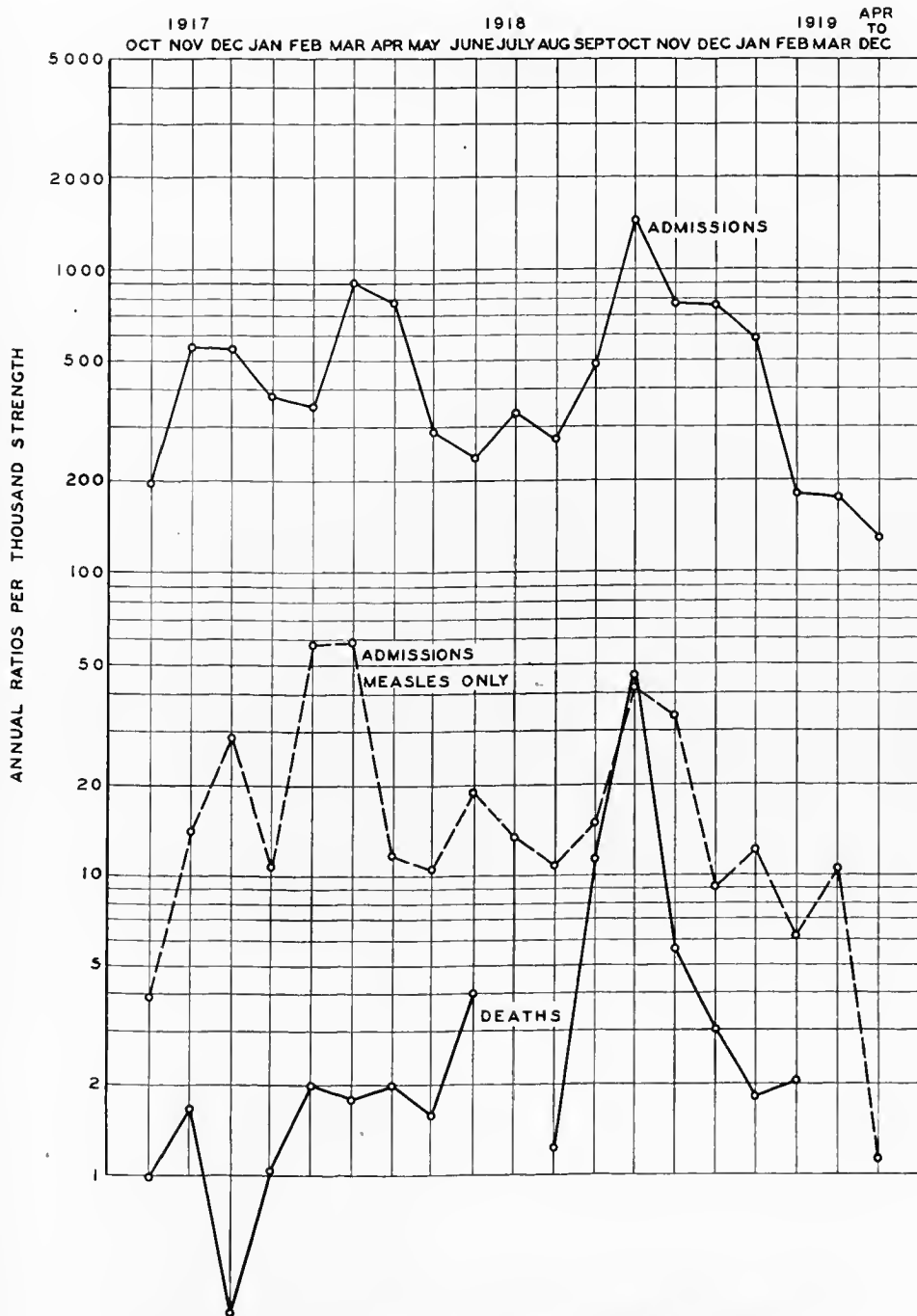


CHART X.—The incidence and fatality of the acute respiratory diseases at Camp Lewis
42706—29—8

mal in from 48 to 72 hours. Persistence of a fever over a longer period of time was almost invariably indicative of a complication or an extension of the process to the lungs. With the return of the temperature to normal all symptoms disappeared, and although general weakness persisted for a week or more, the majority of the men were able to return to their organizations in from 7 to 10 days after admission to the hospital. Cases showing bronchitis ran a very similar course to those of simple influenza. The range and duration of the temperature were practically the same in either type of case. The signs of bronchitis usually persisted for a few days after the temperature had returned to normal. The cough frequently persisted for two or three weeks.

The presence of a leucopenia was noted early in the epidemic and was found to be a constant characteristic. Even with a relatively high temperature, the blood count, in the majority of cases, was found to be well under 10,000 cells to the cubic millimeter. Leucopenia did not always obtain when complications arose or when pneumonia developed. The leucopenia may be a possible factor in the frequent occurrence of complications, being indicative of a diminished resistance on the part of the individual.

Epistaxis was a not infrequent occurrence in influenza, though usually not severe, and in no instance was it found necessary to apply special therapeutic measures for its control. It was observed that cases of influenza and also of bronchopneumonia with epistaxis, ran rather a somewhat milder course than those in which epistaxis did not occur.

Hemoptysis was noted in only two instances. Both occurred in patients with influenzal bronchopneumonia, who presented extensive emphysema of the lungs. It was believed that the hemoptysis bore a definite relation to interstitial emphysema of the lungs where dissection of air along the blood vessels toward the hilus of the lung took place.

Tonsillitis, pharyngitis, laryngitis, and tracheitis were of such common occurrence among our cases as to be considered rather as integral parts of the disease than as complications. The same was believed to be true of bronchitis and even bronchopneumonia, that they were not true complications but a progressive extension of the initial process to the bronchioles or to the lung tissue, either because of a lowered resistance of the subject or because of an increased virulence of the invading organism or organisms; that the disease, influenza, in this epidemic, had a selective action on the respiratory tract, and that the development of a simple pharyngitis in some cases and bronchopneumonia in others was merely a clinical variation in degree of one and the same process.

Acute suppurative otitis media, as a complication, was not infrequent. The subjective symptoms of otitic involvement were usually very slight. Purulent discharge from the ear was occasionally the first indication. In a few cases the otitis media was of the nonsuppurative type, the symptoms then being in the ear, and a slight degree of deafness. The nonsuppurative otitis usually cleared up after a few days. The suppurative type, in most cases, cleared on treatment, but in a few cases progressed to mastoiditis requiring surgical procedures.

The mastoid cells were opened at necropsy in 20 cases where no evidence of involvement was exhibited during life. Five of these patients showed acute

changes in one mastoid, and changes on both sides were noted in three patients. Cultures were positive in two of these cases, in one pneumococcus Group IV being obtained, and in the other the hemolytic type of streptococcus.

Involvement of the accessory sinuses was noted in several instances, the frontal sinuses being the ones most frequently involved.

Sputum cultures and studies were made whenever possible in the bronchopneumonia patients, and in a large number of the influenza patients. During the epidemic 1,948 specimens were submitted to the laboratory for examination. Of this total 542 were found unsatisfactory because of difficulty in obtaining a specimen from the lungs. The findings in the 1,406 satisfactory specimens follow:

	Sep- tember	October	Novem- ber	Decem- ber	Total	Per- centage
Specimens studied.....	218	684	306	198	1,406	-----
Pneumococcus total.....	166	684	306	198	1,354	96.37
Type I.....	20	20	1	0	41	2.91
Type II.....	1	4	0	2	7	0.49
Subgroup II.....	30	7	2	3	42	2.99
Type III.....	0	0	1	3	4	0.28
Group IV.....	115	653	302	190	1,260	89.61
Pneumococcus alone.....	60	79	69	41	249	17.70
Type I.....	8	0	0	0	8	0.56
Type II.....	0	1	0	0	1	0.07
Subgroup II.....	16	1	0	1	18	1.28
Group IV.....	36	77	69	40	222	15.70
Pneumonia with streptococcus.....	103	527	233	114	977	69.48
<i>Streptococcus hemolyticus</i>	1	0	0	0	1	0.07
<i>Streptococcus anhemolyticus</i>	88	0	233	112	433	30.80
<i>Streptococcus viridans</i>	13	537	0	2	542	38.55
<i>Streptococcus mucosus</i>	1	0	0	0	1	0.07
Pneumococcus with <i>Bacillus influenzae</i>	5	210	20	8	243	17.28
Type I.....	0	0	0	0	0	-----
Type II.....	0	0	0	0	0	-----
Subgroup II.....	0	0	0	0	0	-----
Type III.....	0	0	0	0	0	-----
Group IV.....	5	210	20	8	243	17.28

The above tabulation shows an interesting change in the predominance of bacterial species and varieties. The proportion of cases in which fixed types of pneumococci were present dropped sharply in October, and late in this month pneumococcus Type II (atypical) and Group IV increased. During the same period streptococci were more abundant, as were influenza bacilli. The case fatality was 2.25 per cent in September, 1918, rising to 3 per cent in October, but receded sharply to 0.7 per cent in November, when it might have been expected to rise because of the increased prevalence of nonhemolytic streptococci, the hemolytic streptococcus being found only once in September and not again during the epidemic. Three per cent is a low case fatality for this period as judged by the rates of other camps.

It was considered very significant that the *Bacillus influenzae* was found in only 243 of the 1,406 specimens, an incidence of but 17.2 per cent, and that when present it was associated always with the Type IV pneumococcus. From this it seemed evident that the only part Pfeiffer's bacillus played in the epidemic at this camp was that of a secondary invader.

Although many patients admitted to the hospital during the epidemic evidently had bronchopneumonia at the first examination, it was not believed that any of the cases could be considered as primary. On the contrary, all of the bronchopneumonia cases were considered secondary and, as stated above, all cases of pneumonia seen during the epidemic were merely those which, through lowered resistance or because infected with a more virulent organism, progressed to a point of actual parenchymal involvement of lung tissue. In accordance with this view there is no sharp dividing line between a severe bronchitis, bronchiolitis, and a mild bronchopneumonia. With the methods of examination at hand it was impossible to determine when one stage of the process left off and the other began. It is inconceivable that a severe bronchitis or bronchiolitis can exist without some associated parenchymal involvement.

The clinical and physical signs of the pneumonia seen in this epidemic were atypical. The usual signs of pneumonia, as seen in young adults, were conspicuously absent. Even men showing a definite bronchopneumonia on admission had reported on sick call only because they had a bad cold or felt weak. Interrogation, however, revealed the fact that they had been feeling poorly for several days with the same train of symptoms as given in the influenza cases.

Whether bronchopneumonia was present on entry into this hospital, or developed after admission, the clinical signs were identical. The face was flushed, a dry and unproductive cough was present, and, although very uncomfortable, the majority of these patients did not appear seriously ill until the process in the lungs had become quite extensive. The respiratory rate was moderately increased, usually to 24 or 30 a minute. Unusual for pneumonia but very characteristic of the cases seen in this epidemic was the fact that, although the respiratory rate was increased, dyspnea or orthopnea was never present. Patients critically ill and having a respiratory rate of 40 to 50 a minute seemed quite as comfortable in the supine as in the reclining position.

The pulse rate was relatively slow, practically never faster than would correspond to the rise in temperature. The quality remained good throughout the course of the disease except in those cases going to a fatal issue. In fatal cases it often became weak, thready, and irregular some 24 hours prior to death. In other patients in whom death seemed imminent there was a full bounding pulse. This observation, together with the recognized frequency of right heart dilatation and the fact that, on the average, patients having epistaxis did well, led, in a few instances, to the performance of venesection. Four to eight ounces of blood were removed at one bleeding. Although, as a rule, this did not alter the progress of the disease, there were some cases in which it was felt that this procedure alone prevented a fatal issue.

The temperature, in the milder cases, seldom exceeded 103° F., and returned to normal in from three to five days. In many fatal cases the fever did not exceed 101° F. The return of the temperature to normal was almost invariably by lysis, covering a period of from two to four days. In isolated instances there was noted a drop by crisis, similar in every respect to that seen in ordinary lobar pneumonia.

Cyanosis was a very constant observation in cases of bronchopneumonia. This varied between the wide limits of a marked flushing of the face to the heliotrope and the dusky gray types.

The word atypical, as used in the description, applies only if the cases were considered pneumonia from the start of the symptoms of illness, as the characteristic of bronchopneumonia as a whole is its varied rather than typical symptomatology. In the early stages the fluid accumulation with little tissue response was in accord with the clinical signs above described, an asthenic state which was followed by signs of pneumonic consolidation if the patient survived a sufficient time for such changes to take place.

The physical signs in the cases of bronchopneumonia were probably the most varied of any of the unusual characteristics of the epidemic. The diagnosis of bronchopneumonia was often very difficult. Cases showing a relatively small lung involvement occasionally went to a fatal issue, while other patients showing a tremendous involvement recovered.

From the early and rather indistinct signs the course of the disease changed rapidly. In a large majority of the patients the disease progressed no further and went on to a prompt and uninterrupted recovery. The remainder showed a rapid extension of the process, marked dullness, with markedly increased or markedly decreased breath sounds frequently appearing but a few hours after the first indefinite signs were noted.

In 152 cases analyzed it was found that the incidence of absolute accuracy of lobes involved was but 20.38 per cent. The diagnosis of pneumonia was made in all but one of the fatal cases, and the diagnosis was pathologically confirmed in all cases, except in the few instances where post-mortem examinations were not made. The one fatal case which was not recognized as pneumonia occurred in a soldier who walked to the hospital at 11 a. m., became suddenly comatose at 5 p. m., and died at 8.30 p. m., with no positive diagnosis made. Necropsy revealed a bronchopneumonia of both lower lobes with a markedly dilated right heart. This makes an error of but 0.6 per cent in the recognition of the presence of pneumonia when the distribution of the process is not considered.

The physical signs were occasionally those of a lobar consolidation, with marked dullness, increased fremitus, and bronchial breathing. Early in the epidemic a few errors were made at this hospital because of these signs, and lobar pneumonia was diagnosed in cases which, at necropsy, revealed the true condition to be a lobar consolidation produced by the coalescence of lobular involvement. In the 152 cases coming to necropsy lobar pneumonia was anatomically diagnosed but six times.

In three of these cases there seemed to be no good reason to doubt this diagnosis, but in the other three instances bronchopneumonia was present also, leading one to suspect that these possibly were cases of coalescent bronchopneumonia, though in the gross specimen it was not obvious. Granting, however, these were cases of true lobar pneumonia, the incidence was still less than 4 per cent as judged by 152 necropsies.

Inasmuch as lobar and bronchopneumonia, pathologically, differ from each other macroscopically rather than microscopically, the macroscopic signs upon which the differentiation between lobar pneumonia and bronchopneumonia

was based are given. The cases of bronchopneumonia showing small isolated areas of consolidation offered no special difficulty in recognition. The areas of consolidation, on cut section, stood out from the remainder of the lung tissue, were different in color, firm on palpation, and sank in water. On palpation of the lung, prior to section, they were easily felt as firm masses surrounded by soft lung tissue. When, however, large numbers of these areas coalesced, the problem of differentiating the coalescent mass from lobar consolidation was often somewhat difficult. Palpation prior to section in these cases frequently, though not always, revealed irregularities in the consolidation. This irregularity, if present, was due to variations in the stages of consolidation of the lobules, some being merely in the stage of congestion while others were in the stage of red or grey hepatization. On cut section the surface was not the even, smooth surface of lobar consolidation. It was found, on close examination, to have slightly raised areas scattered about with distinct variations in color corresponding to the stage of the involvement. Invariably, by careful dissection, small areas of air containing lung tissue could be found and dissected out as evidenced by floating the sections in water.

On microscopic examination sections taken across the interlobular septa usually showed a variation in the reactions in the two lobules quite as characteristic as the gross appearance.

In the majority of the cases of bronchopneumonia, the process was not limited to a single lobe, but usually involved two or more lobes.

In the fatal cases analyzed 51.8 per cent of the patients died on or before the eighth day after admission to the hospital and only 11.8 per cent lived longer than 15 days.

Blood counts were made in 71 of the 152 fatal cases. The leucopenia, so characteristic in simple influenza cases, was found frequently to pertain still when the cases had gone on to a bronchopneumonia, though usually not to so marked a degree. In most instances the white count was found to increase as the pneumonia developed, e. g., 2,320 to 11,160 per cubic millimeter. The highest white count encountered among the fatal cases was 28,800. The average white count was 10,023.

Tonsillitis, pharyngitis, laryngitis, and tracheitis occurred as complications in bronchopneumonia in the same proportion as in straight influenza. Aphonia, however, was a more frequent finding during or after the acute stage of pneumonia than was experienced in simple influenza. This aphonia was due to ulceration, inflammation, and edema of the vocal cords. Otitis media occurred in bronchopneumonia in occasional instances. Sinusitis occasionally occurred in bronchopneumonia, but was never severe and never required surgical procedures. Other complications, however, occurred which were experienced only in cases of bronchopneumonia.

Pericarditis occurred as a complication in a number of instances. Clinical recognition of fluid in the pericardium was found rather difficult, and suspected cases always were fluoroscoped or radiographed for confirmation. A few cases, unsuspected clinically, were found on routine roentgenological examination. Purulent pericarditis was encountered clinically in but one instance.

Empyema, considering the number of cases of bronchopneumonia, was rather uncommon. Lung abscess occurred as a complication in but two cases. Subcutaneous emphysema, pneumothorax, and interstitial emphysema were unusual complications encountered in some of the cases of bronchopneumonia.

Delirium, both mild and severe, was very common in the cases of bronchopneumonia.

Prolonged uterine hemorrhage occurred so constantly among the female patients that it required special mention.

The mildness and relative infrequency of serious complications indicate a low virulence of the secondarily invading organisms and are in conformity with the relatively low total case fatality rate of 3 per cent in October, the month of the peak of the pandemic.

In the cultures on 152 cases pneumococcus Type I was found three times in sputum and twice at necropsy; Subgroup II, six times in sputum and twice at necropsy; Group IV, 61 times in sputum and 53 times at necropsy; pneumococcus, type undetermined, four times at necropsy; nonhemolytic streptococcus, 44 times in sputum and 44 times at necropsy; hemolytic streptococcus, once in sputum and nine times at necropsy; streptococcus viridans, 4 times in sputum and 18 times in necropsy; streptococcus mucosus, once at autopsy only; *Bacillus influenzae*, 15 times in the sputum and 9 times at necropsy.

During the epidemic 1,196 blood cultures were taken of which 1,170 were negative and 26 positive (2.25 per cent). The organisms found in the positive cases were: Pneumococcus type undetermined, 19, Group IV. 1; streptococcus, type undetermined, 3; nonhemolytic, 1; hemolytic, 1; viridans, 1.

The infrequency of streptococcus in the blood cultures is in conformity with the low case fatality and is, in part, explanatory of it.

The urinary findings in the fatal cases were as follows: Specimens examined, 48; casts present, 2; albumin present, 7; casts and albumin present in 13. From this it would seem that some renal changes occurred in approximately 33 per cent of the cases.

The gross pathological features of the fatal cases of influenzal bronchopneumonia were no less unusual or interesting than the clinical.

In the 152 cases coming to necropsy, emphysematous areas in the lung tissue were found in 47. These areas varied in size from that of a markedly distended alveolus to a large emphysematous excavation formed by the rupture of numerous adjacent alveoli. Frequently, leading off from these emphysematous excavations, there were air streaks appearing as shiny, glasslike tubes. In their course they definitely followed the blood vessels running to the hilus. In five of these patients generalized emphysema developed.

The rectus muscles were found ruptured on one or both sides in five cases. This rupture, when present, was associated with surrounding extravasation of blood and was always below the umbilicus. Several additional cases showed definite hemorrhage into the rectus muscles without rupture. In most instances it seemed that coughing was intimately associated with the rupture of the muscles; however, owing to the fact that the muscle tissue in each instance was pale and extremely friable, it is evident that the cough was but a secondary contributing factor, and that the primary factor was a degenerative process in the muscle tissue itself.

The pathological picture of the lungs, in the cases of bronchopneumonia, has been briefly mentioned. In most instances the anatomical picture was well marked and characteristic for bronchopneumonia. Scattered areas of involvement usually were encountered in several lobes. They appeared, on cut section, as irregular, raised, firm areas of varying color, corresponding to the stage of the process. Usually several stages of infection were found in each case. In many instances several lobular areas of consolidation had become coalescent, forming a large area, not markedly dissimilar to lobar pneumonia. Careful palpation usually revealed variations in density, and dissection showed marked variations in specific gravity. In this way it was possible definitely to show that all but six of the cases were bronchopneumonia. Three specimens, on section, showed a definite greenish tinge over the areas of consolidation, and culture revealed the presence of *Streptococcus viridans* in each of these instances. The lungs were described as edematous or congested in 105 cases. An excess of bloody, purulent and frothy fluid came away with the knife, on scraping. The lung tissue was described as friable in but five instances. Hemorrhagic areas resembling infarcts were noted in 13 cases. Small abscesses or pus pockets were described in 15 cases, being under the sternum in 1 case, interlobar in 1 case, in the lung tissue in 8 cases, and multiple in 5 cases.

The peribronchial lymph nodes were enlarged definitely in 104 cases, being noted more frequently on the right side. They were softer than normal in 15 cases. The bronchi contained an exudate in 54 instances, frothy in 11 cases, purulent in 22, bloody in 2, and taking the form of mucous or fibrinous casts in 19. The outer surface of the lungs, usually at the bases, showed exudate in 31 cases, purulent in 5 cases and fibrinous in 26. The pleural cavity contained abnormal fluid in 99 cases. In 64 the fluid was serous, serofibrinous, flocculent or bloody, and in 35 cases was seropurulent, fibrinopurulent, or purulent. The abnormal fluid was usually small in amount. In several cases the area of lung involvement seemed too slight to be considered the cause of death.

Pathological changes in cardiac muscle were extremely frequent. The most common evidence of muscular changes was the presence of dilatation of the right heart. Dilated right heart (thin, pale, and flabby walls, and enlargement of the tricuspid ring) was found at necropsy in 100 cases, 66.4 per cent. Dilatation of the left heart was much less frequent, being found in but 12 instances. Definite myocarditis was recognized anatomically in six cases. Pericarditis, although recognized clinically in but two cases, was encountered at necropsy in 10 instances. Usually the pericarditis seemed due to direct extension from an adjacent septic pleurisy. Hemorrhages into the pericardium were encountered four times. Acute endocarditis was a very rare complication, being found but three times.

The most frequent changes encountered in the liver were enlargement, 43 cases, and congestion, 67. Fatty degeneration was present in 15 instances, cloudy swelling in 18, infarct in 1, and acute hepatitis in 2 instances. An abscess was found in the liver in one instance. Jaundice was noted in 12 fatal cases.

The spleen was enlarged in 90 cases, being markedly enlarged in 26. In 62 cases it was described as soft or friable, and was classified as acute splenitis in 35 cases. Hemorrhagic areas were noted in five cases, and definite infarcts were found in two.

The kidneys presented the usual features associated with acute infections. A large majority presented cloudy swelling, enlargement and congestion. Four cases showed hemorrhage into the kidney substance. Thirteen cases were classified as acute and four as chronic nephritis.

The adrenals were classified as normal in practically all cases. Three cases showed enlargement, and in two cases the adrenals were hemorrhagic.

The respiratory diseases at this camp throughout its duration and including the pandemic period had a relatively low case fatality rate. This low rate appears to have been due to the relatively low virulence of the secondarily infecting organisms.

Pneumococcus Group IV predominated and that group apparently had a large proportion of relatively avirulent organisms. Streptococci of the non-hemolytic variety appear to have been prevalent with *Streptococcus hemolyticus* practically absent. No other factor appears to explain this low case fatality. The types of pneumonia were the same as at other camps except that the interstitial variety is not described, neither do there appear to have been many deaths in the early stages before definite consolidation was present, unless in cases where, as stated by the investigators referred to, there "was a seemingly insufficient amount of pathological changes in the lung to account for death."

There are 27 protocols of necropsies on cases dying of acute respiratory disease but no lung specimens from this camp in the collections at the Army Medical Museum.

CAMP MACARTHUR, TEX.¹⁷

Acute respiratory diseases at this camp show an epidemic incidence beginning in November, 1917, there being at first, however, relatively little pneumonia and few fatalities. The epidemic reached its peak in January, 1918, accompanied by a relatively high fatality rate, the deaths being ascribed very largely to primary pneumonia. While measles, in January, 1918, showed the highest rate for the period of the war, there was also an epidemic rise of influenza in this month, 199 cases of this disease being diagnosed. Influenza and common respiratory diseases were responsible for the peak in April during which the case fatality, as is indicated by Chart XI was very low.

The data concerning the period from the opening of the camp to the influenza pandemic are insufficient to make possible an explanation of the difference in case fatality in the two periods of high incidence.¹⁸ Empyema appears to have been more frequent in the second series and fixed type pneumococci were also more prevalent.

¹⁷ Source of information, except as otherwise indicated: Medical reports to the Surgeon General, 1917, 1918, and 1919.

¹⁸ The following statements of fact are based, in the main, on: (1) Lobar Pneumonia at a Base Hospital, by Leon S. Medalia and Nathan S. Schiff, *Journal of the American Medical Association*, 1918, lxxi, No. 22, 1821-1822. (2) Influenza Epidemic at Camp MacArthur: Etiology, Bacteriology, Pathology, and Specific Therapy, by Leon S. Medalia. *Boston Medical and Surgical Journal*, 1919, clxxx, No. 12, 323-330.

CAMP MacARTHUR

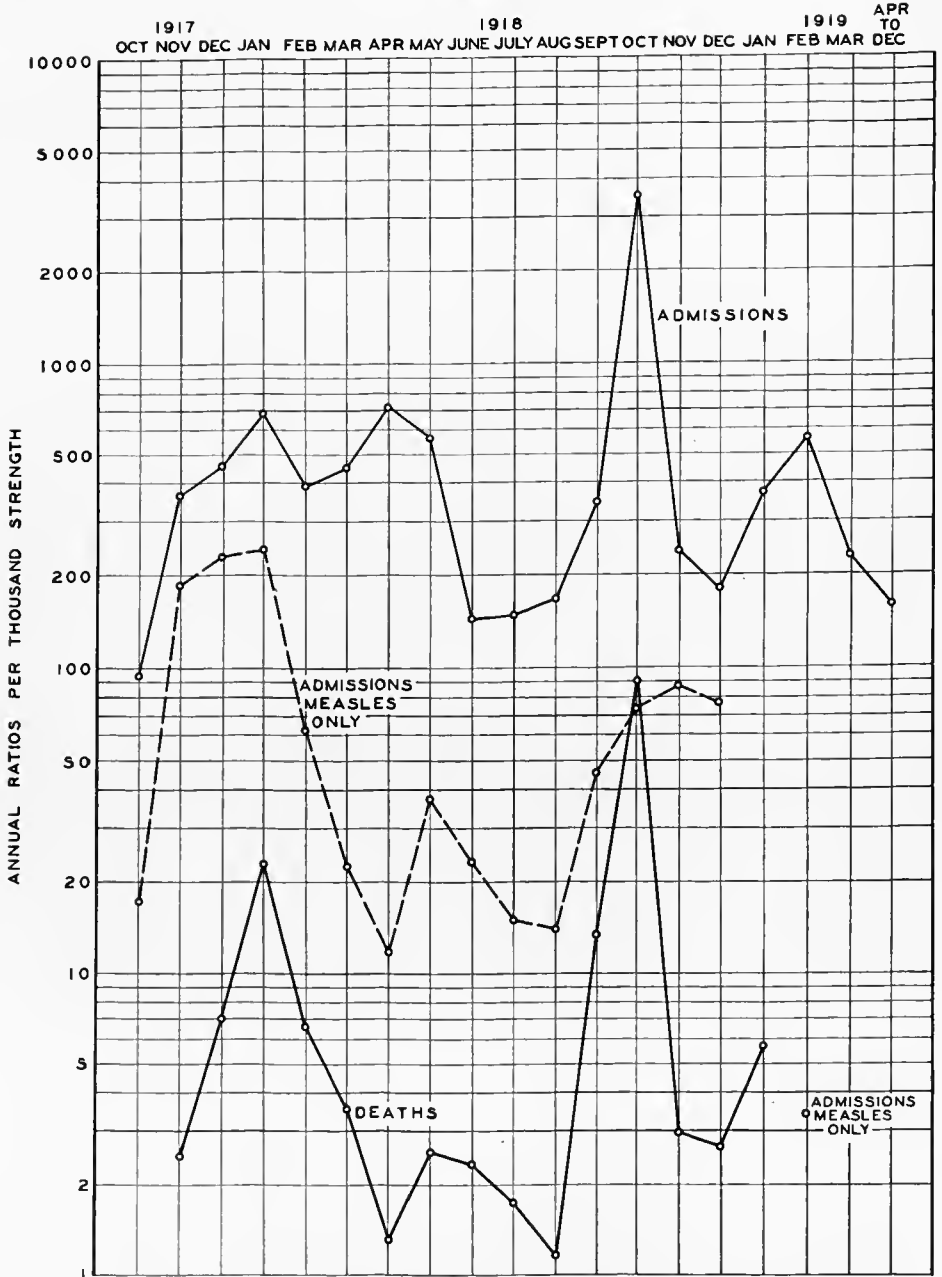


CHART XI.—The incidence and fatality of the acute respiratory diseases at Camp MacArthur

An examination of the sputum of the very first case that appeared in this camp demonstrated the abundance of *B. influenzae* in the sputum and the ease with which it could be found in direct smears. Sputum smears were made, dried, fixed, and stained by a weak solution of carbol fuchsin (carbol fuchsin, 1; water 4, parts). The influenza bacilli were found in clumps varying in size. These clumps were very abundant in the vast majority of the cases that were positive. The clumps when stained by Gram's method of staining were found to consist of Gram-negative ovoid, very small bacilli agreeing in every respect with the classical description of the Pfeiffer bacillus, mixed with numerous Gram-positive cocci and diplococci.

The ease with which the influenza bacillus was demonstrated in the direct smears of the sputum suggested the possibility, in the beginning, of controlling the spread of the disease by isolating tent mates of each case as it appeared; to have these contacts sent to the laboratory, have their sputum examined, and, if found positive to isolate and treat them as carriers, while the negative contacts were to be released—in short, to handle them similarly to the handling of the diphtheria contacts.

This was carried out in 7 squads, from 5 to 8 men each, a total of 44 men, 38 of whom were found negative and 6 positive. It was soon realized, however, that the contagiousness and the spread of this infection was so rapid that the procedure became impracticable and had to be abandoned. The examination of the sputum, however, was made the basis of diagnosis of influenza in all cases that were sent to the base hospital as influenza "suspects."

Sputum examinations of 2,279 influenza "suspects" showed 76.8 per cent positive for influenza bacilli. Cases with negative laboratory findings were discharged when that was found possible clinically. The practicability of sputum smears as an aid in diagnosis was amply demonstrated in this series of examinations.

The sputums were studied also for the presence of associated organisms, more especially the pneumococci and streptococci, and for the presence of pus cells. Thus in 1,613 sputums that were found positive to *B. influenzae*, 861, or 53.3 per cent, showed the presence of the pneumococci; 148, or 9 per cent, streptococci. Out of the 552 sputums negative to *B. influenzae*, 296, or 53.6 per cent, showed the presence of pneumococci; 26, or 4.7 per cent, streptococci. The large number of pneumococci in both the positive and negative influenza sputums suggest the ever-presence of this organism generally, and explains the reason for the finding of this organism in practically all the bronchopneumonia cases complicating the influenza. The low percentage of positive findings of the streptococcus, in both those that were positive to *B. influenzae* and those that were negative, explain the lack of finding this organism in the bronchopneumonia cases. It also demonstrates the comparative freedom from this organism generally of the troops in this camp during this epidemic.

Cultures were obtained in a number of cases, that showed positive sputums early in the disease, from the posterior nares and tonsils. These were also found culturally positive to *B. influenzae*.

It would seem fair to conclude from the foregoing that the sputum and mucous membranes of the upper respiratory tract contained *B. influenzae* in

abundance. The sputum droplets in speaking, coughing, and sneezing were probably the largest, if not the only, means of conveyance of these organisms from individual to individual and the most important etiologic factor.

By far the most important problem, from a mortality standpoint, to be dealt with was the accompanying bronchopneumonia.

The type determination was made in 445 cases of this type of pneumonia with the following results: Type I, 1 case; Type IIa, 15 cases; Type II, 8 cases; Type III, 5 cases; Group IV, 378 cases; undetermined (bile insoluble), 38 cases. The other organisms, beside the pneumococcus, noted in direct smears in 405 sputums on which the type determination was done, were *B. influenza*, 54 per cent; streptococcus, 15 per cent. The associated organisms found in the same sputums culturally were *B. influenza*, 10.6 per cent; streptococcus, 15.2 per cent; staphylococcus and *B. mucosus capsulatus*, 20 per cent each. The small percentage of positive findings of *B. influenza* in the sputum culturally as compared to the direct smears was due in part to the hardships encountered in cultivating this organism in culture media used in routine for the type determination. The findings were characteristic of the bacteriology of the sputum in this disease. The very large percentage (86 per cent) of Group IV in these bronchopneumonia cases well illustrates the difference between secondary pneumonias and primary, such as lobar.

Blood cultures were taken in 233 cases. The usual technique was followed. Both agar plates and broth cultures were obtained in each case. The plates were made with 2 to 3 c. c. of blood to the plate while 10 c. c. were used for the broth cultures. Among the 34 positive cultures were 31 pneumococci; 20 of these pneumococci were type undetermined (being bile insoluble), and 1 of the 20 also showed *B. influenza*, 7 showed Group IV, and 4 Type IIa. Five of the seven with Group IV died. Four of the 20 pneumococcus type undetermined died. (One that showed *B. influenza* mixed with pneumococci died.) None of those that showed the staphylococcus died. The large number of pneumococci found to be bile insoluble in this series suggests that not all the pneumococci are bile soluble.

B. influenza was found in the blood cultures during life in two cases. In one case, *B. influenza* was found in pure culture, while in another it was mixed with pneumococcus. In both these cases the broth cultures were the only ones in which the organisms were found, not in the plates.

The mortality of the 198 cases with negative cultures was 16 per cent, while of the 34 positive it was 23 per cent. In 12 of the positive cultures growth was present in broth only, none in the plates. The negative cultures were kept under observation for 5 days, and quite a number showed growth only after the third or fourth days.

Since the blood cultures were taken at all stages of the disease, but always before convalescence had set in, the findings under these circumstances could therefore be considered characteristic of this disease even though the cultures were not repeated excepting in a few of the cases.

During this epidemic 61 consecutive autopsies were performed on influenza-pneumonia cases, beginning with the first case that died of this disease on October 3, 1918.

Cultures were taken at time of autopsy from the heart, spleen, both pleural cavities, both lungs, and from the brain in case of meningitis. Culture media used consisted of Loeffler's blood serum, glucose agar, and blood agar. Direct smears were also made from the pleural cavities and from both lungs. The bacteriological findings in direct smears of these necropsies were as follows: Of 58 cases examined of right and left lungs, *B. influenzae* was found in 79 per cent of each. The pneumococcus was found in 97 per cent and 93 per cent, respectively, while the streptococcus was found in 12 per cent and 9 per cent, respectively.

Direct smears of the right and left pleuræ in 50 cases were examined; *B. influenzae* was found in 62 per cent and 56 per cent, respectively; the pneumococcus in 78 per cent and 68 per cent, respectively; the streptococcus in 2 per cent and 4 per cent, respectively. In two cases of meningitis complicating the bronchopneumonia, *B. influenzae* was found in both cases, 100 per cent. One was mixed with pneumococcus.

The cultural findings in 65 influenza-pneumonia necropsies (61 consecutive and 4 additional), 3 of which were complicated with meningitis, were as follows: Among those in which the right and left lungs were cultured, 83 per cent each showed *B. influenzae*; the pneumococcus was found in 78 per cent and 85 per cent, respectively; the hemolytic streptococcus in 6 per cent and 5 per cent, respectively. Of 62 cases in which the right and left pleuræ were cultured, *B. influenzae* was found in 81 per cent and 76 per cent, respectively, the pneumococcus in 77 per cent and 74 per cent, respectively, while the hemolytic streptococcus was found in 5 per cent each.

The high percentage (56 per cent) of positive findings of *B. influenzae* in the heart cultures, the spleen (56 per cent), and brain (66 per cent), as well as in the lungs and pleural cavities is worthy of note, in view of the difference of opinion concerning the presence of the Pfeiffer bacillus in this pandemic. The low percentage of the streptococcus hemolyticus in these bronchopneumonia cases as compared with the bronchopneumonia following measles, during the preceding year, which were practically all due to the hemolytic streptococcus, is another noteworthy point.

The pneumococcus which was found in 57 of the 61 necropsies conformed to the following types: Type I, 3.5 per cent; Type IIa, 10.5 per cent; Type II, 5.5 per cent; Group IV, 63.2 per cent; undetermined, 19.3 per cent. The *B. influenzae* and the pneumococcus both in direct smears and in cultures were in some cases difficult to find, and required considerable search, due to poor preparations and scanty growth. The Loeffler's blood serum with its abundant water of condensation was found to be the best culture medium for the *B. influenzae* and the pneumococcus. The carrying along of body exudates onto the surface of the culture media was probably responsible to a great extent for the results obtained on this ordinary culture medium, since this same culture medium proved unsatisfactory for subcultures.

Tissues for histological specimens were obtained from all the autopsies. Paraffin sections were made from the lungs and spleen, stained by 1 to 20 carbol fuchsin for *B. influenzae* and by Gram-Weigert stain for the pneumococcus and associated Gram-positive organisms.

Sections from the lungs stained by Gram-Weigert and carbol fuchsin were examined in 64 cases (61 consecutive necropsies and 3 additional); 88 per cent were found positive to *B. influenzae* and 68 per cent positive to the pneumococcus. Sections from spleen were examined in 45 cases; 69 per cent were found positive to *B. influenzae* and 42 per cent positive to pneumococcus. The streptococcus was found only in 3 cases out of the 64—all in the lungs, none in the spleen. The staphylococcus was found in 8 per cent of the lung cases; none in the spleen.

In a number of the cases it required considerable search to find organisms in the tissue; especially was this true of *B. influenzae*.

Thus the tissues as well as the cultures of the necropsy cases showed the presence of *B. influenzae* and the pneumococcus as the predominating organism responsible for the disease.

The majority of the 61 consecutive cases of influenza-pneumonia that came to necropsy were in the hospital from three to seven days only, the disease lasting longer than seven days being the exception rather than the rule.

The types of pneumonia found in the 61 consecutive necropsies were 56, or 92 per cent, bronchopneumonia, and only 5 cases, or 8 per cent, were lobar, 4 bilateral and 1 unilateral. In over 75 per cent of the cases, empyema or a bloody-sero-fibrino-purulent pleurisy was present—52 per cent bilateral and 24 per cent unilateral (right 13 per cent, left 11 per cent); 24 per cent had no fluid.

The lung tissue in the majority of the cases was extensively involved, ballooned out, but not friable, having a dense tissue feel, as if filled with fluid exudate to its maximum capacity rather than with fibrin or cellular elements. The surface of the consolidated areas was of a dark red to a dark bluish red, and in the majority of the cases covered with a thin fibrinous exudate. In no case did it show the matlike appearance of the post-measles bronchopneumonia cases that obtained at this camp during the winter of 1917-18. The picture was that of a markedly congested organ. The consolidation was only rarely nodular or shotlike in feel, excepting in those lobes which showed beginning of the process; even here the unaffected parts would be crepitant or edematous, as the case may be, with a confluent patch posteriorly or centrally located.

There was only one case where the lungs presented the appearance of miliary tuberculosis; and another where the lungs were pinkish gray in color with shotlike nodules throughout and immediately under the pleural surface, giving the latter a granular appearance.

The outstanding feature of the pathological anatomy was the marked congestion. On cut section, dark fluid blood would escape from the consolidated areas as if under pressure. The surface of the cut section presented dark reddish gray areas with hemorrhagic or congested areas intervening. Distinct lobular consolidations could not be made out. In a few cases pin-point grayish purulent droplets would escape on pressure, but those were the exception. The case that did show shotlike feel presented on section a granular surface—grayish red raised areas, with lung tissues depressed and fairly dry in appearance. The lack of purulent exudate was the outstanding

feature which suggested a study of the leucocytosis in this condition to be referred to later.

The mucous lining of the bronchi and tracheæ was bright red and inflamed but not markedly swollen. In a number of cases dark fluid blood, at times frothy, would escape from the nostrils and mouth on slight pressure of thorax while handling the body.

Histologically, the early cases, those showing nodular consolidations, presented a characteristic picture of terminal bronchiolitis, conforming in all respects to the textbook description of the same. Fibrin formation was found to be the exception. In the majority of the cases that showed the confluent type of involvement, vast areas of alveoli could be seen filled with a granular appearing coagulable substance, containing loose cellular elements of red and white cells—the so-called catarrhal pneumonia was the rule. Large hemorrhagic areas of alveoli filled with red corpuscles were seen in the lung tissues of a number of cases. Areas suggesting infarcts were also encountered. The case that showed an abundance of leucocytic exudation was the exception rather than the rule.

The other organs in the 61 consecutive necropsies showed little pathologic changes. Not a single case of pericarditis or endocarditis was met with. The liver, as a rule, was congested and occasionally a case would show typical nutmeg liver, probably due to other causes rather than the bronchopneumonia. The kidneys showed congestion and only in a rare instance were there parenchymatous changes. The spleen, too, did not show more than congestion, and fluid blood would escape on section. The same was true of the stomach and intestines; very little change, if any.

It was evident from the necropsy findings of these 61 consecutive cases that the disease, as it appeared in this camp, was primarily an upper respiratory infection due to *B. influenzae* and pneumococcus. The rapidity with which death occurred was probably responsible for the lack of pathologic changes in any of the other organs. This contention was well borne out by later necropsies on cases that were sick from four to seven weeks in which complications such as otitis media and meningitis occurred; pericarditis and thick purulent empyemas also were found. In these cases the other organs too showed parenchymatous changes concomitant with the duration of the disease.

In order to account for the lack of purulent changes in the pathologic picture of the lungs in these bronchopneumonia cases, a study was made on 224 cases with reference to the leucocyte and differential counts. The fact that from 72 per cent to 75 per cent of the cases showed a leucocyte count below 15,000 fairly well explains the pathologic picture. The differential counts showed that 71 per cent of the cases receiving serum had a neutrophile count between 60 per cent and 80 per cent, while in those not receiving serum only 56 per cent had a neutrophile count between 60 per cent and 80 per cent. The differential count showed nothing unusual otherwise.

The technique used at this camp was such as to obtain the highest possible incidence of *B. influenzae*; though it is possible that the characteristic morphological and tinctorial picture in the smears was depended upon to too great an extent. It is confirmed, however, by the high percentage of positive results in

the histopathology of the lungs, 88 per cent, which exceeded the percentage found by either smear of the sputum or culture of the exudates and tissues.

Protocols and specimens from 82 cases illustrate the pathology of this camp in the collections in the Army Medical Museum. Practically every type of pulmonary lesion described is illustrated in this material, though there are no cases showing the advanced stages of universal involvement of the lungs with interstitial, suppurative pneumonia. In these tissues, as in those of other camps, the well fixed material shows minute Gram-negative organisms, morphologically influenza bacilli, while the material not well fixed and that from some cases of longer duration, are less apt to contain such organisms.

CAMP MERRITT, N. J.

This camp was an embarkation and debarkation camp, and records from which a graph could be made are not available. Troops passed through the camp from practically all the others in the United States, so that the distribution of types of respiratory affection was somewhat more varied than usually seen in any one camp with a more constant population.

The pneumonia and empyema of the period preceding the influenza epidemic of the fall of 1918 was studied in the bacteriological laboratory of the base hospital.⁴⁸

Every effort was made to have the laboratory study as complete as is possible. By hospital orders sputum from every patient, as soon as diagnosed clinically as having pneumonia, was sent to the laboratory and then without special request the white blood cells were counted on the first and tenth days of the disease. Every fluid withdrawn from the chest was sent to the laboratory for examination and again without request the white blood cells were determined on that day, the first, second, third and tenth days after operation. Throat cultures were taken on all patients admitted to the measles wards. All cultures obtained were studied and a number of patients with measles, pneumonia, and empyema received repeated injections of autogenous vaccine made from their respective cultures.

The type of pneumonia and empyema prevailing at this hospital probably represented the types found at the various camps, as troops were sent there from practically all of the camps. The material for pathological study was derived from a very small number of necropsies performed at the base hospital.

While there were many predisposing or contributing factors, the chief exciting causes appear to have been pneumococci and hemolytic streptococci. Other organisms were present, such as nonhemolytic streptococcus, influenza bacillus, and a Gram-negative bacillus. This study was concerned chiefly with the *Diplococcus pneumoniae* and the *Streptococcus haemolyticus*, for it was believed that the former produces most of the acute lobar pneumonias, such as are seen in civil life, and the latter a special variety of "bronchopneumonia," sometimes called interstitial bronchopneumonia. A few cases also were found at

⁴⁸ The following statements of fact are based, in the main, on: Pneumonia and Empyema in the Late Winter of 1917-1918, by Edwin Henry Schorer, F. D. Clark, Raymond Sanderson, John D. Dickson, and Frank M. Huntoon. *Medical Record*, New York, 1919, xev, No. 17, 673-680.

necropsy where a combination of the two types of the disease occurred with a mixed infection of pneumococcus and streptococcus. It is more than likely that one or the other of the diseases was primary, producing its type, followed later by a secondary infection and subsequently developing another variety.

The lobular type of the disease, from a pathological standpoint, divided itself into three groups of cases: (1) Those with a marked bronchitis and bronchiolitis with very little consolidation. Microscopic examination showed the alveolar passages and a few contiguous air cells filled with the products of inflammation. This is sometimes called capillary bronchitis. (2) This was by far the most common and presented a disseminated bronchopneumonia. There were scattered areas of peribronchial hepatization with patches of collapse of lung tissues. Much of the lobe was still crepitant. When this type was produced by an overwhelming infection with a virulent organism there was more marked interstitial change, with hemorrhagic foci scattered throughout the lung. This has been called "interstitial bronchopneumonia," a term seemingly better expressing the more salient features of the lesion. (3) The pseudolobar form. Here the greatest part of the lobe was consolidated, though not uniformly. There were intervening areas or strands of congested lung tissue between the hepatized lobules.

The microscopical picture in lobular pneumonia was quite different from that of lobar pneumonia. The exudate was less fibrinous and not, as a rule, hemorrhagic. It consisted of mucus, leucocytes, and swollen epithelium. The walls of the bronchi were swollen and presented marked round-cell infiltration. The avenue of infection was bronchiogenic, the inflammation began in the tubes and worked downward and outward, the continuous and contiguous alveoli next to the bronchi was densely filled.

Macroscopically, in the frequently occurring interstitial or organizing bronchopneumonia the lung presented in the early stages a smooth and glistening pleural surface. It was also found to contain considerable air while at the same time might be noted the beginning formation of patches of atelectasis. Small nodular masses might be felt throughout the lungs. On section the surface was studded with gray peribronchial nodules which protruded. These nodules were surrounded by a red or grayish halo, and were many times mistaken for miliary tubercles. On close inspection the lumen of the bronchiole might be seen as a crater-like opening or it might be filled with an opaque material. The exudate in this stage was like that in the earlier stage, showing very little fibrin, but with detached and disintegrated bronchial epithelium. The walls were hyperemic and much thickened, due to the process of infiltration. Large numbers of mononuclear cells seemed to replace many leucocytes that were found in the earlier stage of the disease. The exudate in the contiguous and continuous alveoli appeared less hemorrhagic. The interlobular septa were markedly thickened and stood out very prominently as grayish yellow lines. Empyema was present in all the cases of bronchopneumonia that came to autopsy. In all these cases the *Streptococcus hemolyticus* was demonstrated. In the early stages the exudate was thin, turbid, and greenish in color, containing shreds of fibrin, and a thin fibrinous coating covered the lungs' surface. This

in the early cases could be easily wiped off, but later by reason of organization it became very adherent. In many of the cases there was a very large amount of fluid accumulated, between both the parietal and visceral pleuræ, and between the lobes of the lungs themselves, giving rise to what at times appeared as lung abscesses.

From February 22, 1918, to May 15, 1918, there were made 219 examinations of sputum for type of pneumococcus and the presence of hemolytic and nonhemolytic streptococci. At times other organisms, especially *B. influenza*, were noted on the records, but inasmuch as the other organisms found were not noted carefully, reports on these are excluded from this study.

On the clinical records the 219 specimens of sputum examined were classified as being from the following types: Lobar pneumonia, 151 cases; bronchopneumonia, 28 cases; combined lobar and bronchopneumonia, 2 cases; not pneumonia, 38 cases. This leaves 181 cases of clinical pneumonia to be considered.

Of these 181 cases the following organisms were found: Pneumococcus Type I alone, 8; pneumococcus Type I and hemolytic streptococcus, 17; pneumococcus Type I and nonhemolytic streptococcus, 6; pneumococcus Type II alone, 4; pneumococcus Type II and hemolytic streptococcus, 6; pneumococcus Type II and nonhemolytic streptococcus, 5; pneumococcus Type III alone, 6; pneumococcus Type III and hemolytic streptococcus, 9; pneumococcus Type III and nonhemolytic streptococcus, 3; pneumococcus Group IV alone, 7; pneumococcus Group IV and hemolytic streptococcus, 19; pneumococcus Group IV and nonhemolytic streptococcus, 11; hemolytic streptococcus alone, 43; nonhemolytic streptococcus alone, 24; neither pneumococci nor streptococci, 13.

Empyema was the most frequent and important complication of pneumonia. As indicated above, purulent fluid was found free and encapsulated between the parietal and visceral pleuræ, between the lobes, in the pericardium, the peritoneum, the mediastinum, and between the layers of fascia.

During the time covered by the investigation 81 cases of empyema occurred. These were recognized from the examination of the exudate obtained at the aspiration, the operation, or at the autopsy. Operations were done on seven patients, the fluids of which were not sent to the laboratory.

Sterile chest fluids were sent in from 25 patients. Cultures obtained were studied from the fluids of 66 patients. From 56, or 84.8 per cent of these fluids, hemolytic streptococci alone were obtained, pneumococci Type I were obtained 3 times, Type II 2 times, Group IV 4 times, and Group IV and hemolytic streptococci together 1 time. The disposition and results obtained as far as the cases in which the laboratory played a part were as follows: Hemolytic streptococcus, 56 cases with 27 deaths; streptococcus not studied, 7 cases with 7 deaths; pneumococcus Type I, 3 cases with 1 death; pneumococcus Type II, 2 cases with 1 death; pneumococcus Group IV, 4 cases with 3 deaths; pneumococcus and hemolytic streptococcus, 1 case with 1 death.

The empyema complicating type pneumococcus pneumonia was more frequently caused by hemolytic streptococci than by pneumococci. In four cases the empyema was caused by type pneumococci when no pneumococci were found in the sputum. Of 22 cases of pneumonia in the sputum of which no

pneumococci but hemolytic streptococci were found, three had empyema caused by type pneumococci. In all but four of the empyemas complicating pneumonia, in the sputum of which hemolytic streptococci alone or together with type pneumococci were found, the empyema was caused by hemolytic streptococci. Of the chest fluids obtained from cases of hemolytic streptococcus pneumonia seven, or nearly one-third, were sterile.

Type pneumococcus pneumonia was complicated by fluid in 35.5 per cent of the cases; hemolytic streptococcus pneumonia in 37.2 per cent of the cases; hemolytic streptococcus and type pneumococcus pneumonia in 26.8 per cent of the cases; nonhemolytic streptococcus pneumonia in 16.6 per cent of the cases and mixed nonhemolytic streptococcus and type pneumococcus pneumonia in 13.8 per cent of the cases. Twenty-five of the pleural fluids were sterile; 28 per cent of these complicated hemolytic streptococcus pneumonia.

It was the usual custom in the hospitals in the port of embarkation, Hoboken N. J., to send to the laboratory of the base hospital at Camp Merritt, patients diagnosed clinically as having pneumonia. The laboratory then made a white blood count on that day and again on the tenth day. While there was marked variation in the initial leucocyte counts, generally in the actual cases of pneumonia the white cell count varied from 8,000 to 25,000. After 10 days in uncomplicated cases the leucocyte count was usually down to 10,000 or less. In a few cases there was no increase in the leucocyte count on the first days of the disease; these terminated unfavorably.

All fluids withdrawn from the chest were sent to the laboratory and white blood counts were made on the first, second, third, and tenth days following. In all of the empyemas there was an increase in leucocyte count. The 10-day count on the pneumonias was of value in detecting some of the empyemas, and after operation if the leucocyte count did not go down, or if it again came up on the third or tenth days, some foci had not been located and drained or new ones were being formed. The leucocyte counts were not constant for the various pneumococcus and streptococcus types in either pneumonia or empyema.

From the above details it appears that most of the pneumonias at this camp were secondary, although a few cases, as indicated by the laboratory study quoted, and by the protocols from the camp, with reason might be termed primary lobular pneumonia. At any of the periods of high incidence of pneumonia it was noted that as such incidence was prolonged, streptococcus increased in the cultures both ante mortem and post mortem. With soldiers coming to the camp from various sources in the United States it is quite reasonable that streptococci of more or less virulence should be practically constantly present.

The relatively large number of empyemas appeared to follow all of the different types of pneumonia, but more frequently the interstitial type. The streptococcus was the most important etiological agent in their production.

During the pandemic of influenza, September to November, 1918, observations as to the nature and general character of the disease and of the epidemic were made at United States Base Hospital, Camp Merritt, N. J.⁴⁴ These obser-

⁴⁴ The following statements of fact are based, in the main, on: *The Epidemic of Influenza at Camp Merritt, N. J.*, by Francis M. Rackemann and Samuel Brock. *Archives of Internal Medicine*, Chicago, 1919, xxiii, No. 5, 582-602.

vations were made with respect to (a) the clinical and pathologic picture of influenza and bronchopneumonia; (b) the importance of secondary invaders in the latter part of the epidemic, and (c) the change in character of the latter part of the epidemic consequent on the activity of these secondary invaders.

From September 19 to November 6, 1918, 4,979 cases of influenza were treated at this hospital. Of these 4,979 cases, 1,015, or 20.4 per cent, developed bronchopneumonia, and of these latter 31 per cent died—a mortality for all the admissions of 6.3 per cent.

The clinical picture of uncomplicated influenza in the early stages was very striking. The more important points on which the diagnosis was made were: The extreme and characteristic prostration; the history of very sudden onset—from health to prostration without warning often in a few hours; the general complaint of headache, with generalized muscular pains through the trunk and limbs; the high fever and the essentially negative physical examination.

A few of the early typical cases (perhaps 10 or 15 per cent) presented a very faint pinkish macular eruption on the face, neck, and anterior chest which often simulated the early eruption of measles, but which usually cleared up in about 18 hours. The pharynx was usually red, at times showing small punctate hemorrhagic spots, but no enanthemata or true Koplik spots were ever seen. Epistaxis was frequent, often severe. The lungs showed in a small proportion of cases a few râles at the bases, but this was by no means a characteristic finding.

The clinical course was rapid. In the majority of these cases the temperature fell to normal, usually subnormal, within four days, leaving the patient still prostrated and weak. The pulse was not rapid; at the height of the disease it was full and showed a tendency to diastolic murmurs. Immediately after the fall in temperature the bradycardia was striking; observations of as low as 50 beats per minute being not infrequent.

Blood cultures on hormone gelatin broth (10 c. c. of blood in 100 c. c. of medium) were sterile in each of the nine cases studied.

Throat cultures planted on Loeffler's blood serum gave a mixture of organisms in each of 30 cases. Similar throat cultures from the same patients streaked on defibrinated blood infusion agar plates showed nonhemolytic streptococci in 17 cases, in 2 of which they were associated with pneumococci, and in 3 others with Gram-negative influenzalike bacilli. In four cases Gram-positive diplococci predominated, and two showed only staphylococci.

Postnasal cultures were streaked on laked blood hormone agar plates and showed a mixture of organisms in 17, a predominance of Gram-negative influenzalike bacilli in 5, while in 2 there was no growth.

Total leucocytes were counted on the first day of admission in 10 cases, and averaged 9,200 cells per cubic millimeter. On the fourth day, in the same patients, they averaged 8,500, at which time none of these patients had developed pneumonia. A study of the sputum was anticipated, but these patients in the early stage of the disease did not raise suitable sputum, in spite of the fact that coughing was often a definite symptom.

Quite as typical in its clinical unity as influenza proper was the serious manifestation of this infection spoken of as "bronchopneumonia." After the

first symptom of influenza, the average time of onset of this manifestation was 4.03 days in a series of 726 recovered cases, and 5.7 in a series of 47 fatal cases.

In the bronchopneumonia cases, the temperature maintained itself or even rose higher, the pulse became rapid, and the respiratory rate, which had been between 20 and 24, now ascended, reaching anywhere from 28 to 50 per minute; cyanosis became quite noticeable, cough more severe, and physical examination of the lungs revealed a most constant finding, namely, one or more collections of small moist râles, patchy in distribution, usually located at the bases posteriorly. At this stage, dullness to percussion and the characteristic high-pitched bronchial expiration were usually lacking. On the contrary, there was frequently a diminution or even a suppression of breath sounds in the area affected. Experience soon taught us that in the following 24 or 48 hours signs of consolidation would appear in an area so affected. The heart, pericardium, and abdomen proved uniformly negative.

The clinical picture now became characteristic. The patient was severely prostrated and apathetic: cyanosis of lips, cheeks, and finger tips, with dyspnea, was impressive, the severe cough produced a glairy mucous sputum containing a small amount of purulent material; it had not the viscid tenacity of the sputum seen in lobar pneumococcus pneumonia. Blood in the sputum was a frequent finding; it ranged from a mere streaking to a considerable amount, and was reddish or dark reddish in color, and had not the orange rusty tint seen in lobar pneumonia. Occasionally considerable amounts were expectorated, giving evidence of the hemorrhagic extravasation going on in the pulmonary tissues. Epistaxis, often seen in the earlier stages of the disease, now became quite marked, occasionally even alarming. Headache and chest pain require mention; the latter a more or less constant substernal pain, apparently due to the intense acute tracheobronchitis, the former a continuation of the pain of the milder stage, and probably due to cerebral congestion.

In from 12 to 72 hours, as the patient became more acutely ill, the cyanosis deepened and dyspnea became more marked. Symptoms of the profound intoxication now dominated the picture: abdominal distention; urinary retention; sordes on lips and teeth, and dry, parched, heavily coated tongue with foul breath appeared. Symptoms referable to the central nervous system were seen at times, as twitching of the muscles of the fingers, forearms, and face. In this connection the delirium which appeared in all of the fatal, and in a good many of the recovery cases, deserves mention. It took on the form either of an active, even maniacal occupational delirium, or more usually the low mumbling type described by the old writers as being associated with the asthenic fevers. Nausea and vomiting occasionally were seen. Jaundice was a rare symptom, probably depending on an increase in the viscosity of the bile and, therefore, obstructive in origin.

The temperature, pulse, and respiration curves differed in the fatal and recovery patients. The fatal cases had a short course; in a series of 39 such cases the duration of the pulmonary involvement averaged only 4.7 days. The temperature curve seldom assumed the sustained plateau so common in lobar pneumococcus pneumonia, but was rather of an irregular, remittent type, ranging from 99° to 105° or even to 107° F.

The pulse rate was usually considerably slower in these primary cases than would ordinarily be expected in a lobar pneumonia of similar severity. However, a stepladder rise in the pulse rate was of serious prognostic import, the continuance of this rise for over three days almost invariably indicating a fatal outcome. Irregularity of the pulse was seldom seen.

Of greater value than either the temperature or the pulse was the respiratory rate, which was always raised. Here, again, a climb in the rate, sometimes precipitous, usually more gradual, presaged death.

The systolic blood pressure was normal in the acute stage of the disease, the diastolic was at times often as low as 55. With the drop in temperature the systolic pressure also declined, the diastolic pressure remaining low. These relatively low pressures were then maintained for several days, during the period of subnormal temperature and slow pulse, when they slowly recovered. No other marked or consistent observations were made on blood pressure, nor were essentially different observations made in the fatal and recovered cases. Readings within 24 hours of death were made in several instances at a time when the pulse was very rapid, but no additional fall was seen. From these observations it may be deduced that in this disease vasomotor tone is depressed, but that the heart's strength remains good to the end.

Total leucocyte counts were made in many cases, but no consistent findings were observed except that in the cases of primary influenzal bronchopneumonia the average count was low (5,000 to 15,000 cells per cubic millimeter). The presence of the hemolytic streptococcus tended to increase this average count but slightly, although the individual counts varied from 5,000 to 30,000 or even higher. Several cases were observed with counts below 2,000 cells, all of which were fatal.

In a small series of these bronchopneumonia cases the coagulation time of the blood was determined and found normal. The urine showed, as a rule, a trace of albumin with granular and hyaline casts. Red blood cells were found frequently. No other evidences of renal insufficiency were noted.

In the patients who recovered, the following interesting facts stood forth. In a series of 25 such patients, 16, or 64 per cent, had a temperature fall by "crisis"; that is, a drop from 102° to 105° F. to normal in 48 hours or less, whereas 9, or 36 per cent, had a defervescence by lysis. In these crisis cases a decline occurred usually on the third day of the pulmonary involvement; in the lysis cases, usually on the fourth day, in which group an average of 5.5 days then elapsed before the normal base line was reached.

Complications and sequelæ of influenzal bronchopneumonia in a series of 705 cases included otitis media, acute, 28 cases; tonsillitis, acute follicular, 15; relapse, 12; laryngitis, acute, 8; abscess, subcutaneous; parotitis, 7; phlebitis, acute, 5; sinusitis, frontal, acute, 3; emphysema, subcutaneous, 3; epistaxis, very severe, 2.

"Unresolved pneumonias" were somewhat frequent. Of 635 convalescent patients, 121, or 19 per cent, showed râles with occasionally slight dullness and harsh breathing over the site of the original lung involvement, persisting for two weeks after the fall in temperature.

Toward the end of the third week of the epidemic, as seen at this hospital, surprising changes took place. Reports from the laboratory, as noted above, showed an ever-increasing proportion of the hemolytic streptococcus in the sputum. In the early days of the epidemic it was difficult to obtain satisfactory specimens of sputum for study; the cough in the pure "influenza-bronchopneumonia" is usually unproductive of any definite purulent or mucopurulent plugs of sputum, so that washing the sputum was practically impossible, and results could be obtained only by streaking the crude material on blood agar plates.

The hemolytic streptococcus was at first present in inconsiderable numbers, but in the third and fourth weeks its curve closely approximated the curve of the total examinations. The influenza bacillus at first outnumbered the hemolytic streptococcus, but in the third week its curve fell below the curve of the latter organism and remained below throughout the epidemic.

Curiously enough, it was recognized that the streptococcus patients seemed to "do better" or at least as well as did the other patients, and, further, that the death rate in proportion to the daily admissions seemed to fall markedly. Of the patients who entered the ward in the first five-day period, 65 per cent died, while at the end of the epidemic, none of the patients admitted in the last three five-day periods died. Furthermore, the individual ward was losing its homogeneous appearance. The clinical course of the individual patient was no longer true to the type described.

The sudden and remarkable change in the clinical picture, in laboratory findings, and in necropsies is to be explained by the invasion of secondary organisms and the construction of a new pathology.

Beside showing the hemolytic streptococcus in such numbers, the sputum became more profuse and purulent.

The most striking change, however, was that whereas in the influenzal type of bronchopneumonia already described, pleural effusions were never encountered, they now became comparatively common complications. Pericarditis was also noted.

EMPHYEMA

By empyema here is meant the pleuritic effusion complicating bronchopneumonia, regardless of gross appearance or of bacterial flora. The bacteriology of 50 such fluids coming to the laboratory of the hospital from October 1 to November 9, 1918, was studied.

The bacteriological examination of 50 pleural fluids showed the following organisms: Hemolytic streptococcus, 52 per cent; sterile, 2 per cent; pneumococcus, Type I, 6 per cent; Group IV, 16 per cent; nonhemolytic streptococcus, 4 per cent.

In the study of etiology, a comparison of the bacteriology of chest fluid with the sputum in the same patient is important. Of 27 instances in which organisms were determined in both fluid and sputum, 17, or 63 per cent, showed the same organisms, while 10, or 37 per cent, showed different organisms.

At the necropsy table an explanation was sought as to why the classical auscultatory signs of fluid were so often lacking. The answer to the question is believed to be that whereas, in the typical pleural effusions of tuberculosis

or lobar pneumonia, the lung is pushed up toward the hilus by the fluid, here the tendency toward sacculation is so strong that the lung very frequently is adherent over larger or smaller areas of the parietal chest wall, and it is believed that lung tissue, so adherent and compressed by the surrounding fluid, makes an admirable conducting medium for the passage of breath and voice sounds.

The various and peculiar sacculations of the fluid at the base, between the lobes, between the pleura and pericardium, in the anterior mediastinum, etc., represent a later stage of this process of sacculation and render the localization of such fluid extremely difficult. The encapsulation of these fluids was often beautifully shown by the roentgen ray, and was found by it to be more frequent than free fluid in large amounts.

NECROPSY FINDINGS

Necropsy findings in the different periods of this influenza epidemic varied considerably. Capillary damage, with resulting hemorrhages, represented the keynote of the pathology and explained not only the wet, bloody, soggy lung seen at necropsy, but also the bleeding from nose, bowels, or kidneys which occurred clinically.

In this acute disease, the upper respiratory tract was acutely inflamed, the mucosa throughout being injected, swollen, succulent, with hemorrhages in places. The bronchial lymph glands were enlarged, and on cut section appeared injected and hemorrhagic.

Pleural effusions, except for a small amount of sanguineous fluid in a few cases, were never found, and although the visceral pleura frequently lost its glossy sheen, fibrin in any considerable amounts was absent. The lungs were the site of the most important lesions: the involved lobes, especially the lower, presented a deep blue-red appearance, and seemed bulky; while on palpation they were heavy and soggy, without, however, the solidity of pneumococcus hepatization. On section, the involved area was almost blue-black and literally dripped a frothy, bloody fluid in large amounts, in marked contrast to the "dryness" of lobar consolidation. No fibrin plugs came away with the knife. Areas of hemorrhagic infarction were fairly frequent. The anterior borders of the lungs were almost invariably emphysematous and uninvolved. A few cases showed some interstitial emphysema in the lung tissue, which led to a generalized subcutaneous emphysema in the three cases already mentioned. Pneumothorax was found once.

In the less severe cases, only parts of lobes were involved and they appeared like the areas of marked congestion seen in hypostatic pneumonia. In the slighter involvements, patches of engorged or congested lung tissue were noted.

In these early acute cases the absence of pus deserves repeated emphasis. The pericardium was normal, the heart occasionally revealed a right-sided dilatation, which, however, was rarely marked. The endocardium was normal, as was also the aorta.

The stomach and intestines occasionally revealed small areas of capillary hemorrhage in the mucosa. While the gall-bladder was normal, the viscosity of the bile therein was markedly increased in a few cases to the consistency of thin paste. It was believed that the flow of such bile can be retarded to the

extent of producing an obstructive jaundice. Mere mention may be made of toxic degeneration in the liver, and the congestion of kidneys, spleen, and brain.

The alveoli and bronchioles contained an exudate composed mainly of red blood cells and serum; polymorphonuclear leucocytes with desquamated epithelial cells occurred to a lesser extent. Fibrin was not found.

In the areas of advanced disease, the structure of the alveolus was lost: large numbers of erythrocytes and a large amount of serum with a moderate number of leucocytes "packed" the alveoli and smaller bronchi. The capillaries were engorged and stood out. The bronchial walls were edematous.

In less-advanced stages, the same cellular elements in the same proportion were found in lesser numbers and were at times grouped about the bronchi.

The heart muscle showed but slight granular degeneration. The kidneys showed considerable albuminous degeneration of the tubular epithelium, with granular debris in the lumina. The glomeruli were frequently congested.

The liver showed varying degrees of granular degeneration, the spleen, of congestion.

With the advent of the secondary invaders, the pathology changed. Pus formation and the resemblance to post-measles bronchopneumonia were noted. The mucous membrane of the upper respiratory tract was bathed in a mucopurulent exudate, beneath which the mucous membrane was acutely inflamed. Edema of the glottis and ulceration of the vocal chords were seen.

The pleura in these cases showed the most important and most striking lesions. Larger or smaller areas of the visceral and parietal pleura were very often coated with a heavy, shaggy coat of fibrin, which by adhesions to the contiguous lung tended to form the pockets of pus which were so common. These encapsulated empyemas not infrequently were multiple, in the positions already noted. It is of interest that often different pockets contained fluids of different color and consistency, ranging from a cloudy-amber to a greenish-yellow pus, and frequently showing shreds of fibrin.

The lungs revealed a condition of bronchopneumonia which can be divided into states: First, beginning bronchopneumonia, where small reddened nodular areas stood forth on cut section, their center being a small bronchus which exuded pus, between which fairly normal crepitant lung was found; second, these same nodular areas became larger, grayish in color, and on pressure exuded considerable yellow pus from both bronchi and lung tissue; third, the spread and confluence of these areas produced a large area of consolidation—pseudolobar bronchopneumonia; and fourth, larger or smaller areas underwent necrosis with abscess formation, the affected tissue becoming soft, mushy, and losing its distinctive markings. Atelectasis and septic infarction need only be mentioned: the former common, the latter occasional.

The pericardium revealed not infrequently an acute serofibrinous inflammation: an acute vegetative endocarditis was seen but once; otherwise the heart and aorta were consistently "negative." The spleen in these areas was often enlarged, its pulp quite degenerated, mushy, and necrotic.

The other viscera revealed no pathologic changes.

In contrast to the hemorrhagic exudate of the former picture, the alveoli and bronchi in these cases of secondary bronchopneumonia contained an exudate of polymorphonuclear leucocytes and serum, whereas red blood cells were

insignificant. The bronchial walls were edematous, infiltrated with polymorphonuclear leucocytes; their epithelium was frequently desquamated. While in less advanced areas polymorphonuclear cells were grouped about the bronchi, later this distinction was lost. In some of the specimens the number of large mononuclear (epithelioid) cells was quite astonishing; these cells equaling, if not outnumbering, the polymorphonuclear leucocytes.

While actual giant cells were rarely seen in such specimens, a distinct tendency toward their formation was not infrequently noted.

Whether the presence of these large mononuclear cells was a part of cellular resolution indicative of a strong phagocytic process is problematical; however, the presence of a good many pigment-bearing cells in certain areas led toward the belief that these mononuclear cells were capable of considerable phagocytic activity.

In certain cases edema was considerable.

A comparison of the bacteriology of the lungs between the first 15 and the last 30 of 45 autopsies gave the following results: Hemolytic streptococcus in 26.4 per cent of the first and 63.7 per cent of the last; influenza bacillus in 72.6 per cent of the first and 57.2 per cent of the last; pneumococcus in 59.5 per cent of the first and 34.3 per cent of the last; nonhemolytic streptococcus in 6.6 per cent of the first and 9.9 per cent of the last.

In the more advanced areas cells in various stages of degeneration, indicating necrosis, were found.

The kidneys and liver showed extensive acute granular degeneration; the spleen, cellular necrosis with dilatation of the lymph spaces (producing the large mushy spleen).

Between the acutely engorged hemorrhagic lung of the pure influenza-bronchopneumonia, on the one hand, and this more advanced, less acute process associated with pus formation on the other, were all stages of transformation and all combinations. In fact, in many of the cases a mixed type of lung infection was found. The invasion by the secondary organisms was in no sense invariably productive of a pure type. This was thought to account for the discrepancy found on bacteriologic examinations of sputum and chest fluids. In measles, on the other hand, the invaders were almost invariably the hemolytic streptococcus, and as a consequence a purer pathologic type of interstitial or lobular pneumonia was produced and the complicating empyema was naturally almost invariably due to the hemolytic streptococcus.

The effect of a marked increase in a number of streptococci is clearly portrayed. The fact that many of the streptococcus cases presented because the patients lived longer and gave opportunity for such infection was not appreciated.

CAMP PIKE, ARK.ⁱⁱ

At this camp, the total case fatality rate for all respiratory diseases was as high during the epidemic incidence of the fall and early winter of 1917 as it was during the influenza pandemic of the fall of 1918. The measles cases of the fall of 1917 were accompanied by a high incidence of secondary pneumonia, with a high case fatality rate for pneumonia.

ⁱⁱ Source of information, except as otherwise indicated: Medical reports to the Surgeon General, 1917, 1918, and 1919.

Observations were made on 1,100 cases of pneumonia during the period from September, 1917, to April 27, 1918.^{kk}

From the opening of the base hospital at Camp Pike, Ark., in September, 1917, to April 27, 1918, there were admitted to the medical wards 1,285 pneumonia patients; 857 of these had lobar pneumonia and 428 had bronchopneumonia.

The majority of the cases in September and October, 69 in number, were of the lobar pneumonia type, commonly seen in civil practice. During the month of September there were no deaths from either bronchopneumonia or lobar pneumonia, and during the month of October also there were no deaths from bronchopneumonia; but there were 6 deaths, with a 10 per cent mortality, from lobar pneumonia. The cases observed in September and October were typical of the lobar pneumonia described in textbooks. There were the sudden onset with chill, high temperature, rusty sputum, and well marked areas of consolidation. The cases of bronchopneumonia did not differ in any marked way and were essentially the same as those seen in civil practice.

In November there were 170 cases of lobar pneumonia and 75 of bronchopneumonia; in December there were 225 of lobar pneumonia and 139 of bronchopneumonia. The mortality of these two months of the lobar pneumonia cases was, respectively, 32 and 29 per cent, and of bronchopneumonia, 4 and 29 per cent. In January the mortality of lobar pneumonia was 29 per cent and of bronchopneumonia 53 per cent. The percentages of deaths gradually declined, and up to April 27, 1918, the total percentage of deaths in lobar pneumonia was 28. The total percentage of mortality in bronchopneumonia was 26, and from both bronchopneumonia and lobar pneumonia up to April 27, 1918, it was 26.07 per cent.

The difference in the mortality in the later months compared with that of the first two months was possibly due to several factors: First, the large number of cases of bronchopneumonia that followed measles. Up to March 22, 1918, 33 per cent of all pneumonias were those that followed measles. There were in the hospital up to the middle of April, 1918, 3,100 cases of measles. Second, in the wards in which there were many patients with respiratory diseases, the streptococci undoubtedly gained in virulence by their passage through the human host. Third, because of the large number of patients in a ward who were infected with streptococci, it must undoubtedly follow that the patients in that ward received a larger number of organisms than they otherwise would.

Many of the cases of bronchopneumonia began with the most trivial subjective symptoms and with practically no objective signs. These men were sent to the hospital because they had been coughing for a few days and had had a rise of temperature, with a rather severe headache in the majority of cases. Many of these patients, on their entrance to the hospital, said they were not feeling ill and should not have been taken from their duty.

The physical signs were trivial and slight. In the majority of cases a few fine, moist râles were heard, usually at the back and near the angle of the scapula,

^{kk} The following statements of fact are based, in the main, on: *Pneumonia at a Base Hospital*, by Arthur A. Small. *Journal of the American Medical Association*, Chicago, 1918, lxxi, No. 9, 700-702.

on one or both sides. On percussion this area showed a slight amount of dulness. These were often the only physical signs present, and there were no subjective complaints of any kind, except a slight cough that was nonproductive. Examination made of the same patient from 12 to 24 hours afterward often showed a disappearance of these objective signs. The same patient examined in another 12 to 24 hours showed in the same area well-marked consolidation, with an increased number of moist râles and often bronchovesicular or tubular breathing. The fever usually was not high, rarely going above 103° F. The pulse was not very rapid and did not become so during the course of the disease.

The large majority of these patients presented no respiratory distress of any kind. There was practically no dyspnea until dissolution approached.

Cyanosis was very rare, and was seen in only about 2 per cent of the fatal cases.

At first there was no expectoration; it gradually became more free, but always was moderate in amount. In practically all cases, the sputum was mucopurulent, though at times it was streaked with blood. At times the amount of blood in the sputum was so extensive that it might easily have been mistaken for hemoptysis due to tuberculosis of the lung, but on post-mortem examination, tuberculosis was proved not to exist. In none of the bronchopneumonia cases was the sputum rusty in color, nor did it have the gummy consistency seen in lobar pneumonia.

In contradistinction to this mild type of bronchopneumonia, there was seen a most malignant and fulminating type, which is illustrated by the following case:

Pvt. M., who was drilling in the afternoon, complained of feeling slightly ill. He entered the hospital at 7 o'clock that evening and died next morning at 6. On examination, he presented practically no signs of pneumonia, except a few moist râles which were distributed over both lungs and not confined or isolated to any particular part of the lung. He did, however, show the following signs of meningitis: Headache, depression, hyperesthesia and stiff neck. There was no rash, no Kernig sign, no Babinski reflex, no Oppenheim sign and no Gordon reflex. The diagnosis of bronchopneumonia was not made before death on account of the trivial findings. The post-mortem examination disclosed a small number of bronchopneumonia patches in the left lung and in the lower lobe of the right lung. There were no signs of meningitis. There was an acute and well-marked lymphadenitis of the bronchial lymph nodes. There was a cloudy swelling of the liver and kidney and an acute splenitis.

There were many cases in which there were signs of bronchopneumonia only in one lung, and some cases in which there was a bronchopneumonia in one lung and a lobar pneumonia in the other lung.

Empyema occurred in 9 per cent of the total number of pneumonia cases. It was a most difficult matter to detect the presence of fluid, and because of this difficulty, exploratory puncture was made in every case in which the physical or constitutional signs indicated fluid or pus. There was a standing order in the pneumonia wards that roentgenoscopy be performed in all cases of pneumonia in which there was the slightest suspicion of fluid, and in every case of pneumonia at the expiration of 14 days.

In some cases it was impossible to detect the formation of pus. This was especially true when an isolated abscess cavity was formed by adhesions between the pericardium and the visceral and parietal layers of the pleura near the median

line. In other cases the pus was contained in a fibrinous exudate, which acted not unlike a sponge, and confined the pus and limited its border as definitely as if it were surrounded by a cofferdam.

At times, the formation of pus was so slow that its presence was almost impossible to discover, for in many of these cases it simply plastered itself over the surface of the lung in a layer that was about one-half inch thick, so that the signs of the consolidated lung beneath it were transmitted through this layer, and there were no signs of the presence of fluid. In one case fluid had developed in a unique position. It developed and entirely covered the top of the right lung, fitting over it and displacing it down to the third rib in front and the fourth rib behind, capping it as an extinguisher does a candle. The upper lobe was pushed downward, forward, and inward and accounted for the increased tympany, which was found on percussion over and to the right of the sternum. The fluid was held in this peculiar and elevated position because of the dense adhesions, which existed in the whole of the pleural cavity below it. The formation of this fluid was extremely rapid, for over the area occupied by the fluid and 24 hours before death, there were all the signs of a consolidated lung with well defined tubular breathing. The breath sounds gradually became fainter and a tympany developed near the right margin of the sternum from the third rib downward. These were the only signs that were found, and their significance was misinterpreted. On the other hand, there were cases in which empyema developed with a tremendous rapidity.

In 48 per cent of the cases in which the sputum examinations were made, pneumonia was due to the pneumococcus, of which 21 per cent were Type I, 34 per cent Type II, and 45 per cent Group IV. Streptococci were found in 46 per cent of the total number of cases. Of these, 46 per cent were nonhemolytic and 54 per cent were hemolytic.

In ward 1, 23 blood cultures were taken from patients in whom the clinical diagnosis was pneumonia. The blood cultures were taken as soon after admission as possible. The time of cultures relative to that of the prodromal symptoms ranged from three to seven days. Of the 23 cases examined, 6 gave blood cultures showing the *Streptococcus hemolyticus*. In none of these positive cases was the diagnosis of empyema made at the time or prior to the taking of the blood culture. In one case a blood culture was reported positive; but neither clinical examination, the exploratory needle nor the roentgen ray revealed the presence of fluid in the pleural cavity. A few days later, however, the exploratory needle revealed fluid which contained the same streptococcus as was secured from the blood. Three patients with positive streptococcus findings in the blood developed empyema. Two of the cases developed in the pleural cavity, the fluid containing the *Streptococcus hemolyticus*. In all of these cases the blood culture was taken not later than seven days after the onset of the disease, and in none of them was the patient in a serious or moribund condition when the culture was taken.

Jaundice was not infrequent and, in the Negroes suffering from pneumonia, it occurred in 10 per cent of the cases. About 5 per cent of all pneumonia patients had fibrinous pericarditis. There were three cases of purulent pericarditis.

Pneumothorax occurred five times, on one occasion accompanied by pus in the pleural cavity, but this was complicated with chronic tuberculosis.

Otitis media occurred frequently, and in many cases was followed or accompanied by mastoiditis. Strange as it may seem, mastoiditis occurred and was found, post mortem, without having given any objective or subjective signs during life.

This study indicates a very high incidence of pneumonia with a considerable number of the more severe varieties and with a rather high case fatality rate. *Streptococcus hemolyticus* was an important factor during this period.

A study of the bacteriology of patients admitted during February and March, 1918, gives further information on the bacteriology of this period which, as indicated in Chart XII, did not have an excessive case fatality rate.¹¹

Pneumococcus pneumonia presented but little out of the ordinary. Of the Type II cases several were complicated by severe jaundice. All were in colored persons, some of whom were known to have syphilis and one multiple gummas of the liver. The pneumococcus cases formed 48 per cent of the 60 cases studied. Of these, 21 per cent were Type I, 34 per cent Type II, and 45 per cent Group IV. Only one Type III case was seen in the hospital.

In 46 per cent of the cases, streptococci were the predominating organisms; of these, 46 per cent were nonhemolytic. These organisms formed colonies similar to the hemolytic streptococci, but had no effect on blood, neither hemolysis nor green formation being observed. The organisms were like the hemolytic streptococci as to morphology, but had more tendency to diplococcus formation, and the chains formed were short. Growth in both was flocculent and collected in the bottom of the broth. In the cases coming to necropsy the pneumonia in which this type of organisms was found resembled the ordinary pneumococcus lobar pneumonia. This type of streptococcus was found in the sputum in two cases diagnosed as influenza, and in the pus from a gangrenous appendix, in greatly predominating numbers.

Fifty-four per cent of the streptococci found were hemolytic. The lesions found at necropsy in these cases were of two kinds: 1. A pneumonia similar to lobar pneumonia due to pneumococci, but with a tendency to pus formation. In many cases this was not more marked than that sometimes observed in the pneumococcus cases in others. Abscesses with areas of necrosis varied in extent, sometimes amounting to gangrene of large portions of the lung. 2. Bronchopneumonia in which the lungs were studded with hard, shotlike nodules, which were extremely hard to the palpating fingers. Cut sections of such lung showed areas up to 1 cm. in diameter which were dark red and completely consolidated. This form was most commonly observed following measles. The areas in some instances coalesced to form areas, in cases amounting to a lobe. In 25 of a series of 30 cases of mastoiditis, streptococci indistinguishable from these were isolated. The remaining five were Group IV pneumococcus infections.

¹¹ The following statements of fact, except as otherwise indicated, are based on: A Bacteriologic Study of the Pneumonia Occurring at Camp Pike, Ark., by George F. Dick. *Journal of the American Medical Association*, Chicago, 1918, lxx, No. 21, 1529-30.

Both the types of streptococci were more frequently complicated by empyema than were the pneumococcus cases. In the hemolytic cases in two instances there was peritonitis.

Leptothrix organisms predominated on the plates in 6 per cent of the cases. These were very minute colonies, barely visible to the naked eye, but extremely numerous. There was no effect on blood. The organisms were Gram-negative, and varied in length from organisms resembling influenza bacilli to long, slightly wavy organisms extending half way across the field. It was not possible to cultivate these organisms beyond one or two subcultures, and their importance was undetermined.

The series is interesting on account of the high percentage of streptococcus infections, particularly those due to nonhemolytic organisms, which were found also associated with cases diagnosed as influenza and in the pus from appendicitis.

A board of medical officers, detailed for the investigation of respiratory diseases, centered their activities at Camp Pike during the pandemic, concerning which they made extensive studies.^{mm}

The existence of an epidemic of influenza at Camp Pike was recognized when 214 cases of influenza were admitted to the base hospital, September 23, 1918. The epidemic was foreshadowed by a steady increase in the number of admissions to the base hospital diagnosed as acute bronchitis. This increase began about September 1, and on September 18 there were 50 admissions with this diagnosis.

Beginning September 23, the number of cases showed a sudden and alarming increase. September 27, there were 1,037 new cases, and the number continued in the neighborhood of 1,000 a day until October 3, when the final decline began. During the period from September 20 to October 19, there were 11,899 cases of influenza.

During the two months, September and October, there occurred 12,393 cases of influenza and 1,499 cases of pneumonia. Only two patients died with a diagnosis of uncomplicated influenza (not confirmed by necropsy), while of the patients with pneumonia, 466 died. Of the patients with influenza, therefore, 12.1 per cent developed pneumonia, and the mortality for the epidemic as a whole was 3.8 per cent of those attacked by influenza.

Between September 30 and October 14 there were 972 cases of influenza in the camp, with 107 cases of pneumonia.

The incidence of pneumonia in cases of influenza was much higher among the Negroes than among the whites. Of 10,296 white patients with influenza, 12.7 per cent developed pneumonia, while among 1,429 Negroes with influenza, 283, or 19.8 per cent, developed pneumonia. The rate of fatality from pneumonia was slightly higher in white men than in Negroes. Of 1,216 white pneumonia patients, 386, or 31.7 per cent, died, while of 283 Negro pneumonia patients, 80, or 28.2 per cent, died.

^{mm} The following statements of fact are based, in the main, on: Pneumonia Following Influenza (at Camp Pike, Ark.), by Eugene L. Opie, Allen W. Freeman, Francis G. Blake, James C. Small, and Thomas M. Rivers. *Journal of the American Medical Association*, Chicago, 1919, lxxii, No. 8, 556-565.

The influenza was characterized by sudden onset with chilliness and sharp elevation of temperature, often from 103° to 105° F. There was extreme prostration, severe backache, suffusion of the face, and injection of the conjunctivæ. Coryza, pharyngitis and tracheitis with a harrassing cough were almost invariable; epistaxis and slight hemoptysis, were frequent. In the majority of cases the temperature subsided after from two to five days, usually rather abruptly. About one-third of the patients developed purulent bronchitis.

Search was made for *Bacillus influenzae* in a group of 23 patients from 1 to 6 days after the onset of the disease. From each patient a culture on blood agar (5 per cent horse's blood in meat, infusion agar) was made (*a*) from the nose, (*b*) from the throat, and (*c*) from sputum; and (*d*) sputum was injected into the peritoneal cavity of a white mouse.

Multiple cultures demonstrated in some instances in almost pure culture the presence of *B. influenzae* in all of the cases of early influenza. Passage of sputum through the white mouse proved the most effective means of demonstrating the organism; cultures from the sputum or throat were nearly as effective. There was some difficulty in demonstrating the organism in consequence of the minute size of colonies, which might be wholly overlooked by those not familiar with its cultural characters, in the presence of other organisms; for example, in the zone of hemolysis of the hemolytic streptococci the colonies became conspicuous.

In the 23 cases *B. influenzae* was found in the nose 5 times, in the throat 13 times, in the sputum culture 14 times, and in the sputum passed through the mouse, 18 times.

A considerable number of those attacked by influenza developed bronchitis. Of 103 influenza patients kept under observation, 36 had purulent bronchitis. The sputum was profusely mucopurulent and sometimes streaked with blood. The sputum on direct smear or on culture almost invariably showed *B. influenzae*, often in great numbers.

In attempting to establish the relation of *B. influenzae* to influenza and its complications, it was borne in mind that at Camp Funston, *B. influenzae* was found in the mouths of 35.1 per cent of all healthy men examined and was present, in the absence of an epidemic of influenza, in the sputum of a very large proportion of those suffering with bronchitis. Observations at Camp Pike showed that the organism was invariably present in the upper respiratory passages of patients with influenza.

Pneumonia occurred in 12.1 per cent of all influenza patients in this camp, and all pneumonia patients were treated in the base hospital. Among 103 influenza patients selected for observation from the onset of influenza, 4 developed clinical evidence of bronchopneumonia and 3 of lobar pneumonia.

Description of the clinical features of pneumonia following influenza is facilitated by division of the cases into three groups. It should be borne in mind, however, that the picture was a complex one and that correct clinical interpretation was not always possible, since many cases did not conform sharply to any one type. These groups are: (1) Bronchopneumonia, (2) lobar pneumonia, and (3) lobar pneumonia with purulent bronchitis.

In the first group, bronchopneumonia usually developed gradually as a sequence to influenza in which purulent bronchitis occurred, one condition passing into the next without sharp demarcation. In the second group apparent recovery from influenza occurred, as evidenced by fall of temperature to normal. After from one to three days of normal temperature, typical lobar pneumonia with characteristic rusty sputum developed suddenly. In the third group, lobar pneumonia developed in cases of influenza that were complicated by purulent bronchitis. Such cases occasionally presented the picture of both lobar pneumonia and bronchopneumonia in the same individual.

Bacteriologic study disclosed that all these types of pneumonia were of pneumococcus origin in most instances. As described in greater detail below, some were further complicated by a superimposed *Streptococcus hemolyticus* infection.

The bacteriology of the sputum early in the disease was studied by inoculation of white mice and by direct cultures. The occurrence of pneumococci, *B. influenzae* and *Streptococcus hemolyticus* in 69 cases of lobar pneumonia was as follows: Pneumococcus Type I, 9 times (once with Group IV), or 13.1 per cent; Type II, 3 times, or 4.3 per cent; Type II atypical, 15 times, or 21.7 per cent; Type III, 5 times (once with Group IV), or 7.3 per cent; Group IV (alone), 37 times, or 53.6 per cent.

Streptococcus hemolyticus was found three times, or 4.3 per cent, in all three instances associated with pneumococcus Group IV.

B. influenzae was found 43 times, or 62.2 per cent, always associated with pneumococcus (Type I, 6 times; Type II, once; Type II atypical, 10 times; Type III, twice, and Group IV, 24 times).

Pneumococcus Types I and II, which have a predominant part in the production of the pneumonia of civil life, were present in a relatively small proportion of cases, whereas Type II atypical and Type III and Group IV were found with 82.6 per cent of cases.

The bacteriology of the sputum in 43 cases of bronchopneumonia was as follows: Pneumococcus Type I, none; Type II, once, or 2.3 per cent; Type II atypical, 3 times, or 7 per cent; Type III, 3 times, or 7 per cent; Group IV, 30 times, or 69.8 per cent.

Streptococcus hemolyticus was found 6 times, or 14 per cent; twice with pneumococcus Group IV and 4 times with no pneumococci.

B. influenzae was found 38 times, or 88.4 per cent, associated with pneumococci 33 times (Type II, once; Type II atypical, 3 times; Type III, 3 times; Group IV, 26 times); with *Streptococcus hemolyticus* 3 times, and alone twice.

Here again pneumococcus Group IV was found predominant, being present in more than two-thirds of the cases. *Streptococcus hemolyticus* unassociated with pneumococci was found in 9.3 per cent of these cases. *B. influenzae* unaccompanied by pneumococci or hemolytic streptococci was present in two cases; but in view of observations made at necropsy, it is doubtful if this organism alone was responsible for pneumonic consolidation of the lungs.

The characters of the group of pneumonias that occurred in association with the present outbreak of influenza may be defined by the pulmonary lesions found at necropsy, described in relation to the associated bacteria.

Two hundred necropsies were performed during the outbreak of pneumonia, of which there are here analyzed 79 cases which, occurring with few exceptions in sequence at the height of the outbreak, were subjected to careful bacteriologic study. Cultures were made from the heart's blood, from the lung and from a bronchus. When the hemolytic streptococcus was found in the lung it was usually demonstrable in the blood. The number of instances in which *B. influenzae* was obtained in cultures would have been diminished more than half if cultures from the mucosa of the bronchi had not been made.

Necropsies showed the presence of purulent bronchitis in a large proportion of those who died with pneumonia during the course of this epidemic of influenza. When edema of the lungs was present, the content of the small bronchi was not usually purulent, though the mucosa might be intensely injected. *B. influenzae* could be grown with few exceptions from the mucopurulent material scraped with a platinum loop from the main branches. In 27 of 30 instances of purulent bronchitis from which cultures were made at necropsy, *B. influenzae* was found.

When purulent bronchitis was found, the lungs were very voluminous and preserved the shape and size of the thoracic cavity after removal; they showed little tendency to collapse, even when shut. Most of the affected lungs, being from men who came from rural districts, were pale pink and almost wholly free from coal pigment. After section a small droplet of mucopurulent fluid marked the site of each bronchus or bronchiole and doubtless explained the failure of the lung to collapse. The cyanosis of the patients with the disease was doubtless referable in part at least to the same change. The mucosa of the bronchi was intensely injected. Further evidence of severe injury to the bronchi was the frequent occurrence of a zone of hemorrhage about the smaller bronchi, particularly in the lower lobes. At times this zone of hemorrhage gave place to an encircling zone of pneumonia consolidation. Further evidence of profound injury to the bronchial wall was the dilatation of the small bronchi. Bronchiectasis was most conspicuous in the basal part of the lower lobes, and was usually more advanced on the left side than on the right. Small bronchi with no cartilage in their wall may reach a diameter of 0.5 cm. More advanced bronchiectasis was found in several necropsies performed late in the outbreak.

Among 79 necropsies, selected from the 200 performed, because they were in sequence and accompanied by careful bacteriologic study, there were 36 instances of lobar pneumonia, 19 instances of bronchopneumonia, 1 instance of associated lobar pneumonia and bronchopneumonia, and 23 instances of pneumonia with suppuration of lung tissue.

A group of 36 cases of lobar pneumonia, taken at necropsy in sequence and studied bacteriologically, gave further knowledge of the bacteriology of the disease as it occurred here. The results of this study were as follows: Pneumococcus Type I, 3 times; Type II, none; Type II atypical, 5 times; Type III, 6 times; Group IV, 19 times; total, 33, or 91.7 per cent. *Streptococcus hemolyticus* with pneumococci, 10 times; with no pneumococci, 3 times; total, 13, or 36.1 per cent. *B. influenzae* 31 times, or 86.1 per cent.

B. influenzae was present with few exceptions. Of pneumococci, which are frequently found in the mouths of healthy men, Type II atypical and Type III and Group IV were predominant, Group IV occurring in more than half of all cases, whereas Type I was found only three times in the present series, and Type II in no typical instance of lobar pneumonia. Hemolytic streptococci were found in approximately one-third of the cases of lobar pneumonia that were unassociated with gross evidence of suppuration. When the hemolytic streptococcus was unassociated with the pneumococcus it is probable that the latter had disappeared from that part of the lung from which the culture was taken.

The following two varieties of bronchopneumonia were observed repeatedly; however, they did not include all of the instances of bronchopneumonia that occurred: (a) Confluent consolidation of large parts of lobes; patches of consolidation, accurately limited to the secondary lobules of the lungs. The larger patches of consolidation were sharply limited by lobule boundaries so that the consolidated tissue on the cut section projected conspicuously above the air-containing lung substance. Even within the large consolidated areas, which were blackish red, red or grayish red and finely granular, the lobules were well defined; but there was no thickening of the interstitial tissue. Two instances of pneumonia due to pneumococcus Type II were of this character. In three other cases the lesion was caused by pneumococcus Group IV. (b) This confluent lobular consolidation was not the predominant variety, and disseminated nodules or patches of reddish, gray or yellow consolidation were more commonly seen.

The bacteriology of 19 cases of bronchopneumonia was as follows: Pneumococcus Type I, none; Type II, twice; Type II atypical, none; Type III, none; Group IV, 10 times; total, 12, or 70.6 per cent. *Streptococcus hemolyticus* with pneumococci, 7 times; with no pneumococci, 5 times; total, 12, or 70.6 per cent. *B. influenzae*, 17 times, or 89.4 per cent.

Pneumococci doubtless had a predominant part in the production of the disease, and hemolytic streptococci acted as secondary invaders. Nevertheless it is possible that hemolytic streptococci in the presence of influenza may independently invade the lung and produce bronchopneumonia without suppuration.

Suppuration had occurred in more than one-fourth of the cases examined post mortem. Three varieties of suppurative lesion were found:

(a) Localized abscess formation within a patch of pneumonic consolidation. A patch of consolidation about one abscess was occasionally the only evidence of pneumonia, but more frequently there were multiple patches of bronchopneumonia. The abscess or abscesses were usually situated immediately below the pleura, often separated from the cavity by remains of the membrane no thicker than tissue paper, and the cavity was the site of purulent pleurisy with effusion varying from several hundred up to 1,700 c. c. In all but 1 of 11 cases of abscess with bronchopneumonia, hemolytic streptococci were found both in the blood of the heart and in the affected lung. In the one exceptional case, pneumococcus Type IV was obtained from the blood; no growth was obtained on the plate inoculated from the lung, and hemolytic streptococci with *B.*

influenzæ were found in the bronchus. *B. influenza* was found in the bronchi (6) or in the lung (2) in all but 3 cases of these 11 cases. There can be no doubt that the suppurative process due to hemolytic streptococci was in some instances superimposed on pneumonia caused by pneumococci. In one instance, associated pneumococcus Type II was present in blood, lungs and bronchus; in one instance, pneumococcus Group IV was present in blood and bronchus. Of less significance was the demonstration of associated pneumococci, Type II atypical or Group IV, in the bronchi or lungs (three instances).

(b) Pneumonia with suppuration of the interstitial tissue. In association with bronchopneumonia (three times), with typical lobar pneumonia (twice) or with all defined patches of consolidation (three times), probably best classified as bronchopneumonia, suppuration of the interstitial tissue of the lung occurred eight times among the cases with completed bacteriologic examination. The interstitial septums appeared as conspicuous yellow lines from which purulent fluid might be scraped. The septums usually were swollen to a thickness of about 1 or 2 mm., but wide lines of suppuration 0.5 cm., across were seen. Edematous swelling of the septums outside of the consolidated tissue not infrequently was found. These suppurating septums extended up to the pleura, and the overlying lymphatics were often widely distended with fluid. Purulent pleurisy, usually with copious effusion up to 1,900 c. c., was found. In seven of these eight cases, hemolytic streptococci were found both in the heart's blood and in the affected lung. In one instance of lobar pneumonia with interstitial suppuration, pneumococcus Group IV with no hemolytic streptococci was found in the heart's blood and lungs. By unfortunate error, no culture from the affected lung was recorded. The relation of the lesion to associated infection with pneumococci is important. Pneumococcus Type II was found in one instance associated with hemolytic streptococci in the heart's blood, lung and bronchus. In one instance, pneumococcus Type II atypical with *B. influenza* was found in the sputum during life unassociated with hemolytic streptococci whereas three days later pneumococci were not demonstrable in the lungs or bronchi, and hemolytic streptococci were found in blood, lungs and bronchus. In another case, pneumococcus Group IV and hemolytic streptococci were found in the sputum during life, whereas after death five days later pneumococci had apparently disappeared and hemolytic streptococci were found in the blood and the bronchus, with *B. influenza* in the latter situation.

(c) Multiple abscesses clustered about bronchi. In four instances in the group of cases under consideration, suppuration occurred within bronchopneumonic patches clustered about a medium sized bronchus. These abscess cavities in communication with the bronchus were several millimeters up to 0.5 cm., in diameter, and were surrounded by gray, consolidated tissue. The patch of consolidation studded with abscesses might be scarcely more than 5 cm. across, but a much larger area might be involved. There was no empyema or pleural effusion in these cases.

The bacteriology of the four cases cited was as follows:

Necropsy 280.—Hemolytic streptococci were found in the heart's blood, in consolidated lung tissue and in the bronchus. In the bronchus were found *B. influenza* and a few staphylococci. Culture from the abscess was contaminated.

Necropsy 322.—The blood was sterile. *Staphylococcus aureus* was obtained from consolidated lung; *Staphylococcus aureus* and pneumococcus Type III were obtained from the abscess.

Necropsy 329.—The blood was sterile. *Staphylococcus aureus* and pneumococcus Group IV were obtained from the abscess; *B. influenzae*, *Staphylococcus aureus* and pneumococcus Group IV from the bronchus.

Necropsy 333.—The blood contained pneumococcus Type II atypical; *Staphylococcus aureus* and pneumococcus Type II atypical were obtained from the lung on the opposite side; *Staphylococcus aureus*, *B. influenzae* and a few hemolytic streptococci from the bronchus.

The foregoing observations indicate that *Staphylococcus aureus* may be engrafted on a pneumococcus pneumonia and cause suppuration in clustered foci, unaccompanied by empyema.

Hemolytic streptococci introduced into ward 1 containing patients suffering with pneumonia due, as experience showed, to pneumococci, produced an epidemic of secondary infection with streptococci. Routine necropsies with bacteriologic examination of the blood and lungs of every patient that died with pneumonia furnished a certain means of recognizing the occurrence of ward infection with hemolytic streptococci. These necropsies, with the accompanying bacteriologic studies, gave the first conclusive evidence that the pneumonia in this hospital following influenza was subject to secondary invasion with hemolytic streptococci.

Infection with pneumococcus Type II occurred in two patients apparently recovering from other types of infection, in one instance caused by pneumococcus Type II atypical, and in another by Group IV. In both instances pneumococcus Type II apparently was acquired from a third patient occupying an adjacent bed.

There were two instances in which, after one type of organism, namely, pneumococcus Group IV, was found in the sputum by inoculation of white mice and subsequent identification of the pneumococcus, a different type was demonstrated in the blood or lung at necropsy.

Pneumonia of one type does not establish any trustworthy immunity from other types of pneumococci. Patients with one type of pneumococci, notably in the examples cited of Type II, may infect with fatal result patients suffering with or recovering from other types of pneumonic infection. In the absence of streptococcus pneumonia it is essential to maintain in a pneumonia ward precautions that will prevent transmission of infection from one patient to another.

The studies at Camp Pike show that the primary lesion of the respiratory tract in this epidemic was descending bronchitis and bronchiolitis, which, according to the cultural results, was considered due to *Bacillus influenzae*. Lesions in addition to that pathology were produced by pneumococci and streptococci or both, and consisted of all the varieties of bronchopneumonia described, with a smaller proportion of the typical croupous lobar pneumonia. Among other things of pathological importance, the study shows that the deaths which occurred in the early days of the disease from an interstitial type of reaction of acute nature, usually accompanied by areas of hemorrhage, were due apparently to the *Streptococcus hemolyticus*. The *Streptococcus hemolyticus* is a relatively common secondary invader in any type of pneumonic condition,

and is to be suspected in any lung where abscesses are found and where empyema results. Any one of the following organisms—pneumococcus, streptococcus, and Friedlander bacillus—may invade a lung already the site of an infection by any of the others. Increase of virulence as well as invasiveness of the streptococcus, is clearly shown in the studies made at Camp Pike.

CAMP SHERMAN, OHIO ⁷⁷

The curve for respiratory diseases rates at this camp, as shown in Chart XIII, rises gradually. The case fatality rate for all respiratory diseases reached a high point in January, 1918, at 1.1 per cent, dropping during February to 0.5 per cent and increasing sharply in the month of March, 1918, to 1.16 per cent. At this time the pneumonias appeared to be somewhat more severe and streptococci were found in a greater number in cultures. From then on relatively low rates prevailed until August, when the case fatality rate rose from 1 per cent in July to 2 per cent in August. In September the influenza pandemic struck the camp and the case fatality rate rose sharply to 11.25 per cent and was maintained at about this figure (11.05 per cent) in October. These high case fatality rates at this camp, which was visited by approximately the same varieties of pneumonia as seen in other camps, can be explained by the fact that considerable numbers of patients were treated at the regimental infirmaries and did not reach the hospital, therefore these cases did not appear on the permanent sick and wounded records. Over 3,000 cases were treated in the regimental infirmaries during the month of October. If these were included, the case fatality rate was only about 7.75 per cent, a rate quite close to that seen in many other camps throughout the United States.

There are no data concerning the pneumonias preceding the pandemic of influenza, with the exception of the sick and wounded report made to the Surgeon General.

The respiratory lesions of the pandemic of influenza were carefully studied by members of the base hospital staff.⁷⁸

The camp medical personnel realized that cases of coryza and bronchitis were increasing during the early part of September but did not consider the clinical picture sufficiently definite to justify a diagnosis of influenza. This uncertainty was definitely terminated by the sudden occurrence, about September 24, of large numbers of cases exhibiting the characteristics of clinical influenza.

At this time the population of the camp was 33,044. Of this number, 24,513 were white, and 8,531 were colored. Two-thirds of these cases occurred in a group of 15,493 recent arrivals, comprising less than one-half of the camp's population.

In addition to the cases admitted to the base hospital, other cases of influenza to the extent of 3,361 were reported from the various camp organizations. The addition of this number to those admitted to the base hospital afforded a total of 10,979 as the number of individuals affected in this epidemic.

⁷⁷ Source of information, except as otherwise indicated: Medical reports to the Surgeon General, 1917, 1918, and 1919.

⁷⁸ The following statements of fact are based, in the main, on: The Epidemic of Influenza at Camp Sherman, Ohio, by Alfred Friedlander, Carey P. McCord, Frank J. Sladen, and George W. Wheeler. *Journal of the American Medical Association*, 1918, lxxi, No. 20, 1653-56.

The following accrued statistics are of significance in relation to the extent of the epidemic: Of the camp's population (33,044), 33.22 per cent were affected, and 23.05 per cent were admitted to the hospital; 18.22 per cent of those affected developed pulmonary edema or pneumonia, and the total mortality or case fatality of the total number affected was 7.66 per cent, while the mortality among those developing pulmonary edema or pneumonia was 42 per cent. The mortality of the total population of the camp was 2.55 per cent.

During all stages of the epidemic, examinations were made to establish the identity of the responsible organism. This organism was sought in materials obtained from: (1) Smears and cultures from sputum of influenza patients; (2) cultures from swabbings of throat and nasopharynx of influenza patients and immediate contacts; (3) cultures from sputum of patients after development of pneumonia; (4) blood cultures from patients after development of pneumonia; (5) post-mortem cultures from heart's blood, lung exudate, pleural fluid, pericardial fluid, spleen and kidneys.

Smears and cultures of sputum of influenza patients uniformly exhibited the pneumococcus as the predominating organism. On typing, these pneumococci conformed to the following groups: Group IV, 80 per cent; Type III, 18 per cent; Type IIa, 2 per cent. One culture containing the pneumococcus as the predominating organism presented two colonies of Pfeiffer's organism. Certain immediate contacts with influenza patients were examined bacteriologically at a time when free from any manifestations of disease. Seventy-six per cent exhibited pneumococci. Such of these as were typed were uniformly Group IV.

Cultures from swabbings of the throat and nasopharynx of influenza patients exhibited pneumococci in 54 per cent and hemolytic streptococci in 4 per cent of all examined. In none of these cases were influenza bacilli demonstrated.

On the detection of a complicating pneumonia, cultures were again made of the sputum. Regularly the pneumococcus was demonstrated with 80 per cent characteristic of Group IV. Cultural conditions were suitable for the propagation of *Bacillus influenzae*, but in no instance was it detected.

Blood cultures were obtained from 100 patients after the recognition of a complicating pneumonia. In 6 per cent of these cultures, growths were obtained. All were identified as pneumococcus Group IV. No other organisms have been detected in blood cultures, the remaining 94 per cent being sterile.

Cultures obtained at necropsy from various thoracic and abdominal tissues and fluids indicated the presence of the pneumococcus as the dominating organism in 53.3 per cent of the bodies examined post-mortem, while in 46.7 per cent *Streptococcus hemolyticus* was the outstanding organism. The pneumococcus on being typed was classified as 75 per cent Group IV and 25 per cent Type III. In only one instance were both pneumococci and hemolytic streptococci encountered in large numbers in the same case. In this instance Group IV pneumococci and hemolytic streptococci were demonstrated in all cultures taken, heart's blood, lung exudate, pleural fluid, pericardial fluid, spleen and kidney. In conjunction with the Group IV pneumococcus isolated from the lung exudate

of one body, numerous colonies of the *Bacillus influenzae* (Pfeiffer) were detected.

The persistent absence of influenza bacilli in the diverse materials examined militated against attributing this epidemic to the Pfeiffer organism. Cultural conditions favorable to the growth of influenza bacilli were maintained. However, within the period covered by this study, this organism was exhibited in only two individuals. More consistently did the cultures yield growths of the pneumococcus, to the end that significance is to be attached to the pneumococcus-streptococcus group of organisms as a dynamic factor in this epidemic. It was not maintained that the pneumococcus was the specific agent causing the epidemic, as prior to the epidemic a high percentage of this camp's population harbored Group IV pneumococci. The nature of the clinical manifestations and the process evidenced at necropsy strongly bore out the contention that some member of the pneumococcus group had rapidly been distributed among the individuals of the camp, with activities of a character and severity not previously observed in this camp.

The clinical manifestations observed necessitated a grouping into two form types. As already intimated, this epidemic was introduced by an atypical clinical picture characterized by mildness (Type I). The rapid spread gave a serious aspect to this simple catarrhal infection of the respiratory tract. The clinical features were fever, coryza, conjunctivitis, dry hacking cough, little or no leucocytosis, and no noteworthy chest findings.

This type of infection was noted first among patients already in the hospital. It probably occurred also in the camp, as within a few days increasing numbers of such admissions required special provisions for their separate care.

The absence of prostration and aches and pains led some to regard the diagnosis of influenza as unwarranted. Gradually, however, the type changed, and within five days there was a full realization that an epidemic of influenza was in force. The transition seemed rapid, once it started, and the momentum the epidemic acquired was appalling. This second type (Type II), recognized as true influenza, was characterized by sharper onset, chills, and quicker and higher rise of temperature, frequent epistaxis, distressing aches and pains, increasing prostration, red, glazed pharynx without tonsillitis, and an increase in the subjective manifestations of bronchitis, but still without noteworthy physical findings in the chest. Some cases of gastroenteritis and a few of the so-called nervous form of influenza were observed.

At once two types of more seriously ill patients demanded attention. In the one (Type III), respiratory distress was marked, with meager signs in the lungs. At the most, suppressed breath sounds with fine râles in the lower axillary spaces were found. There was no local change in expansion, vocal fremitus, percussion, or transmission of whispered or spoken voice sounds. Such signs did not necessarily progress to pneumonic consolidation. The other severely ill type, at this stage (Type IV), was the outstanding clinical feature of the epidemic. This formed a distinct clinical picture not emphasized in any published reports. During the height of the epidemic, many patients exhibited on admission a strikingly intense cyanosis, especially noticeable in the lips. This was not the dusky pallid blueness to which one is accustomed in a failing pneu-

monia, but rather the deep blueness characteristic of methemoglobinemia. These patients had high fever, intense air hunger, complete exhaustion, and prostration. They were semicomatose or in a low, muttering delirium. The lungs contained diffuse bubbling râles, increasing rapidly in number and extent, in addition to subcrepitant râles. The course was rapid to death in 24 or 48 hours. The patient was practically a drowning man. The picture resembled an acutely progressive pulmonary edema. With the increasing moisture in the lungs, however, there was no sign of myocardial insufficiency or dilatation. The pulse was fair in volume and tension. Cardiac outlines were unchanged. There were neither enlargement of the liver, nor serous effusions or edema in other portions of the body.

These clinical observations were supported by the necropsy findings in these cases.

At necropsy, those dead of the condition designated clinically as an acute inflammatory pulmonary edema presented lungs having one or more lobes dark red or bluish gray, firm and rounded, with no tendency to collapse. The pleural surface was smooth and glistening, not thickened, without exudate. The lung tissue pitted deeply on pressure. The process was essentially massive and confluent. There was no evidence of a lobular distribution. Section through an involved lobe revealed an extreme grade of congestion and edema. Immediately on section there was a free outflow of thin, dark red fluid from the cut surface. From 150 to 200 c. c. of this fluid were measured from a single section across the lung in the different cases. The cut surface was somewhat rough but not granular; there was no evidence of fibrinous exudation. Stained films of this thin fluid showed large numbers of red cells, very few leucocytes and epithelial cells, and many Gram-positive cocci in pairs and short chains. The appearance of the bronchi was the same as that described below. The pericardium was normal throughout. The pericardial cavity contained from 25 to 30 c. c. of clear, straw-colored fluid. No portion of the heart evidenced any enlargement. The myocardium presented normal color and consistency.

These cases occurred frequently during the first three days and persisted to a less degree throughout. They diminished as bronchopneumonia increased.

The condition was suggestive of that occurring after exposure to chlorine gas. In many, the serous fluid almost poured from mouth and nostrils on change of position, or bubbled out in the distressing efforts to breathe. The man struggled against asphyxia with all the accessory muscles of respiration. Some of the patients retained consciousness for a remarkable period, suffering intensely. In a word, it was as if the irritation in the respiratory tract was so caustic as to produce an immediate reaction, serous in character. It was essentially an acute inflammatory pulmonary edema.

The complication naturally to be anticipated in an epidemic of the respiratory type of influenza was pneumonia. By October 2, the cases of pneumonia were so numerous as to occupy the entire bed capacity of the hospital. Arrangements were then in force to admit influenza patients to an improvised annex and only pneumonia patients to the hospital. Shortly thereafter the available hospital beds were filled, and it was necessary to place 383 pneumonia patients

in a special section of the annex. Secondly, the epidemic resolved itself into a pneumonia rather than an influenza problem.

A careful estimation of the circumstances would lead one to expect a secondary bronchopneumonia of virulent character, in an already acutely prostrated individual. This was the picture: The early cases in particular showed leucocyte counts, low fever, and rapid pulse and respirations. The asthenia incident to influenza was so profound as to greatly diminish the resistance to the pneumonia.

A striking feature at this stage was the absence of physical signs to localize the particular area of involvement. A peculiar tympany with crepitant râles and distant bronchovesicular breath sounds was frequently all that was found. This was explained at necropsy by finding the pneumonic exudate in lobular distribution mainly about the hilum of the lung and progressively diminishing toward apex and base.

In the cases enduring longer than the average, as well as later in the epidemic, impairment of percussion was found more frequently, in varying superficial areas. With this were bronchial breathing and the other signs indicative of outspoken superficial consolidation. In many of these cases the consolidation was lobar in distribution, often distinguishable with difficulty from acute lobar pneumonia. In some a clearing by crisis occurred. However, as noted below, the pathology of the fatal cases of this type was distinctly different from that of acute lobar pneumonia.

Many of these patients lay in muttering delirium which persisted after the temperature was normal. This could be explained by the asthenia, although there were several instances of serous meningitis. Only once did secondary pneumococcal meningitis complicate the picture. Acute hemorrhagic nephritis was a frequent clinical observation.

Five cases developed subcutaneous emphysema without demonstrable pneumothorax. This was distributed over chest wall, neck, and face, although in one case it involved the abdominal wall, scrotum, and lower extremities.

Acute fibrinous pleurisy, even pleural pain, was not observed, except in a few instances in the latter days of the epidemic. One case of empyema appeared.

The more hopeful cases frequently were characterized by small patches of consolidation which completely cleared, often in from 10 to 12 hours. This was one of the striking features of the epidemic.

Other than pneumonia, complications of influenza were slight. Profuse epistaxis without nasal ulceration was very frequent at onset, and later acute catarrhal otitis media was common, but fortunately always cleared without perforation of the drum. Hemorrhages into the middle ear and a few instances of acute sinusitis occurred.

In the necropsies of patients who died of pneumonia the lesions noted in the lungs were those of a confluent bronchopneumonia involving one or more lobes. In the average case more than 50 per cent of the lung tissue was involved and frequently as much as 90 per cent. The order of frequency of lobe involvement in this confluent pneumonia was right lower, left lower, right upper, left upper, right middle. In addition to this massive confluent

process, there were patches affecting only a few lobules scattered throughout the remainder of the lungs, which resembled the ordinary type of bronchopneumonia.

The lobe affected with the confluent pneumonia was rounded, tense, and firm, with no tendency to collapse; it pitted on pressure and did not crepitate. The affected lobe, when placed in water, invariably sank. The pleura was smooth and glistening; a few presented a beginning fibrinous exudate. The color of the involved lung in some was a deep red, in others a deep bluish-gray, giving the lung a cyanotic appearance. Lobular outlines were indistinct or wholly obliterated. At rare intervals in a confluent involvement isolated lobules were unaffected.

On sectioning the lung there occurred an immediate exudation of dark bloody fluid. In patients characterized clinically as having pulmonary edema, this exudation was profuse to the extent of the spontaneous outflow of from 150 to 200 c. c. of this thin, dark red fluid. The consistency of the lung tissue was that of soft muscle and not friable. On scraping the surface with a knife only a thin bloody exudate was expressed; no air bubbles or fibrinous plugs. The scraped surface was dull and somewhat rough, but not granular. The color was a deep red, showing in places small areas from 4 to 5 mm. in diameter which were firm in consistency, almost black, and slightly raised above the surrounding tissue. These were noted more frequently adjacent to the smaller bronchi. The blood vessels of the affected lobe were dilated and contained dark fluid blood.

In the discrete lobular type of involvement, the affected lobules were distinctly raised above the surrounding lung tissue and were rather firm and resistant to the touch. The color, consistency, and appearance on cut section were similar to those of the confluent lesion described above, excepting that the amount of fluid exudate was much less. These discrete areas were more numerous near the hilum of the lung and diminished in number and size toward the apex and base.

The portions of the lungs not affected by the pneumonic process showed varying degrees of congestion and edema. At times the amount of congestion was surprisingly small, even in portions of the lung that were contiguous to the involved areas.

The bronchi contained thin, frothy, blood-tinged fluid, no mucus, no purulent material. The mucous membrane of the trachea and larger bronchi was swollen, causing distinct narrowing of the lumen. The color was pink, deep red, or purplish, the small blood vessels showing intense injection. The smaller bronchi were dilated, the walls thin, and the swelling and infection of vessels not so prominent as in the larger tubes.

Most cases showed a complete absence of pleural involvement, no excess of fluid, and no adhesions. In one case the right pleural cavity was filled with thin pus, from which a pure culture of pneumococcus was obtained.

The pericardium presented no indication of involvement. The pericardial cavity contained from 16 to 60 c.c. of clear straw-colored fluid at times slightly greenish. The heart usually presented trivial enlargement on the right side; the right auricle was distended with blood; the right ventricle presented moder-

ate dilatation; the myocardium was red or brownish-red, bled easily and was usually of firm consistency. On occasion the right ventricular wall was moderately thin and flabby. The valves and cavities of the heart presented no characteristic findings.

The liver and spleen presented varying degrees of congestion, but were without other significant findings. The kidneys in a number of necropsies exhibited a beginning acute hemorrhagic nephritis.

There are 144 protocols of necropsies performed on cases dying of acute respiratory disease at Camp Sherman. Twenty-five of these are illustrated by specimens of lungs as well as other tissue. A great deal of the material has excellent fixation, autopsies being done relatively shortly after demise. In several of the cases especially studied, which showed relatively early lesions, minute Gram-negative bacteria were found along the smaller air passages. While it is realized that this morphological and tinctorial resemblance to Pfeiffer's organism does not constitute an absolute diagnosis, it is strongly suggestive that all the bacteria which were present in this epidemic were not discovered as a result of the cultural methods used. It was demonstrated in other camps as the result of particularly careful methods that cultures must be made from the bronchial tree soon after death if one is to show the total incidence of *B. influenza* in the lungs. The fact that media are satisfactory to the growth of the organisms does not make certain that the material planted on the media contains it as it may have had a prominent part in the production of the pathological lesions without being present in the particular area cultured.

CAMP TAYLOR, KY.^{pp}

Measles occurred in epidemic form immediately on the mobilization at this camp in September, 1917. It was accompanied by bronchial pneumonia in a considerable number of cases. Influenza, which was present with the measles, increased in December, and this increase was accompanied by an increase in the case fatality rate, ascribed in the records to primary pneumonia but actually due to pneumonia secondary to influenza, and other respiratory diseases. The sharp rise in acute respiratory diseases in March and April, 1918, was due to influenza and measles, over 50 per cent of the deaths being due to pneumonia following measles. The pandemic of influenza occurred over the months of September, October, and November, 1918, the peak being in October. The case fatality rate for the pandemic was 6.04 per cent in September, and 6.12 per cent in October, dropping sharply to 1.26 per cent in November. This drop is of considerable interest, for in many of the camps a rise in case fatality rate took place during the latter part of the pandemic period. The sharp rise in the case fatality rate in the month of December, 1918, to 3.07 appears to have been due to the streptococcus and the staphylococcus acting as secondary invaders during a wave of influenza.

A careful study was made of pneumonia and empyema as they occurred in the winter of 1917-18.^{qq}

^{pp} Source of information, except as otherwise indicated: Medical reports to the Surgeon General, 1917, 1918, and 1919.

^{qq} The following statements of fact are based, in the main, on: Pneumonia and Empyema at Camp Zachary Taylor, Ky., by Walter W. Hamburger and Lawrence H. Mayers. *Journal of the American Medical Association*, Chicago, 1918, 1xx, No. 13, 915-918.

CAMP TAYLOR

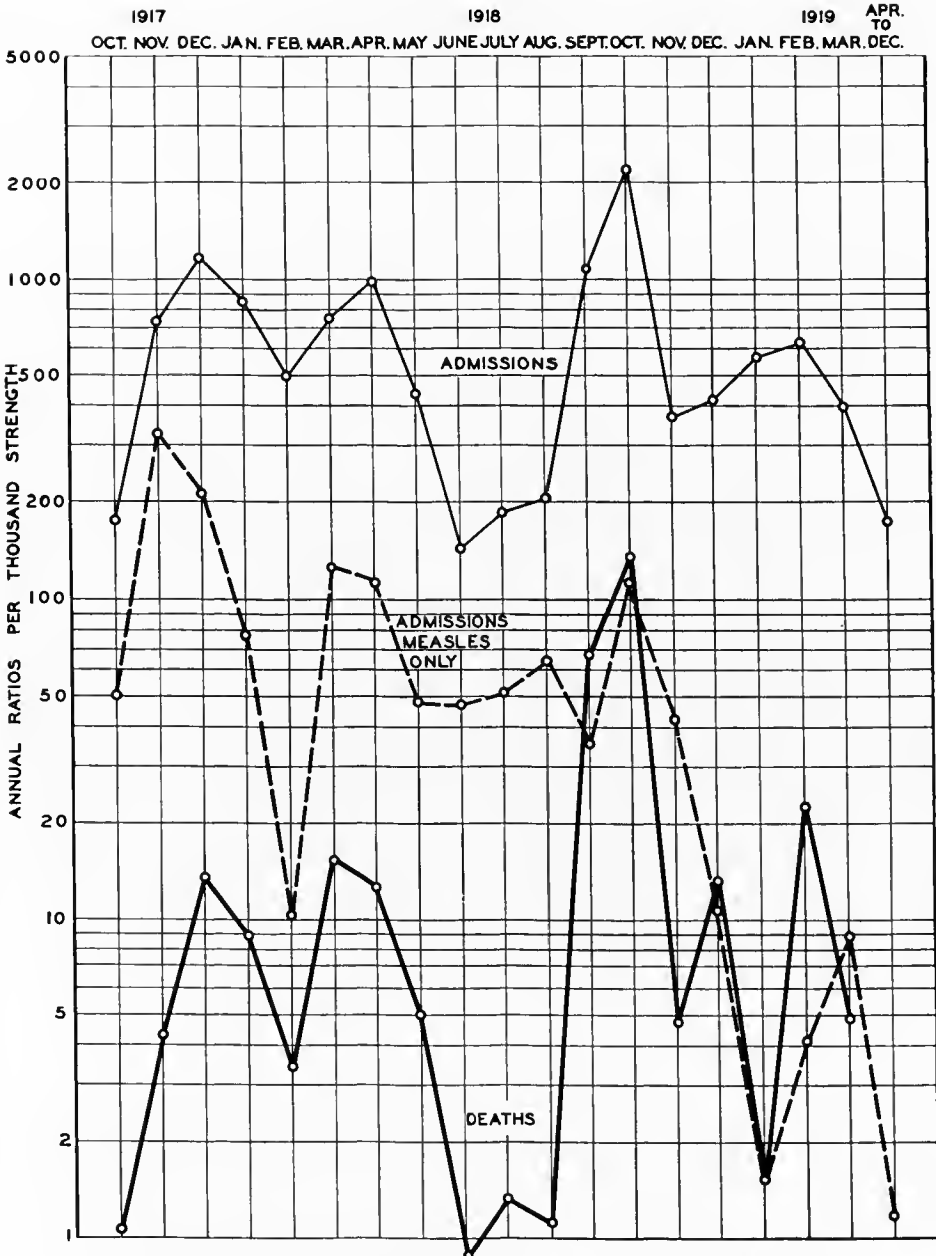


CHART XIV.—The incidence and fatality of the acute respiratory diseases at Camp Taylor

There were admitted to the medical service 374 pneumonia patients, 176 with the lobar and 98 with the bronchopneumonia type.

The early cases, in September and October, about 30 in number, apparently conformed to the usual picture of lobar pneumonia, with sudden onset, chill, temperature, rusty sputum, localized areas of consolidation, etc. Although type determinations of sputum could not be made, because of inadequate laboratory facilities in the early days of the hospital, these pneumonias undoubtedly belonged to the more benign type of organisms (Group IV), as only one death occurred in the series. This patient, who apparently had a mild case, developed a severe pneumococcic meningitis three days after a typical crisis, and died within 24 hours. The first case definitely diagnosed bronchopneumonia occurred, October 22, 10 days after the first measles admission. From then on the number of cases of pneumonia following measles increased rapidly, paralleling closely the measles admissions, latterly decreasing *pari passu*. In contrast to the early benign lobar pneumonias, these bronchopneumonias following measles were most severe and fulminant. Developing usually during the third or fourth day of the rash, the pneumonic process was ushered in by an increase in temperature, respiratory rate, patchy areas of dullness, roughened bronchovesicular breathing, moist bubbling râles and, of particular interest, marked dyspnea and dusky cyanosis of the face. The latter two symptoms, interpreted as evidences of air hunger, increasing in severity with the progress of the pneumonitis, were most distressing and difficult to relieve. With fair degree of accuracy, one often could pick out the incipient pneumonias by noting the degree of cyanosis and blueness of the face, and by the same token could estimate the patient's chances of recovery.

Of a total of 102 cases of pneumonia following measles developing up to January 17, 1918, 87 developed during the soldiers' stay in the hospital, while only 15 were readmitted after discharge to quarters. In other words, the majority developed while in the hospital wards as close sequelæ to the primary disease.

At necropsy, the lungs of these patients contained scattered, small or large areas of bronchopneumonic consolidation, with often multiple peribronchial abscesses from which thick greenish-gray pus could be expressed. Hemorrhagic and purulent tracheitis, bronchitis, bronchiolitis and bronchiectasis were usually present, while a markedly dilated right auricle served as evidence of ante-mortem cardiac failure.

About December 1, 1918, the fulminant atypical lobar pneumonias, later proved to be streptococcal in origin, began to appear and continued well past the middle of January. From the standpoint of the prodromes, these cases divided themselves into two classes: First, those starting insidiously with "sore throat," "cough," "grip," for a few days, progressing gradually until frank signs of consolidation could be elicited, and second, cases starting abruptly, severely, with sudden overwhelming prostration and collapse, profoundly toxic, progressing rapidly to death within three or four days, with symptoms so profound and acute as to suggest a general sepsis. These cases were most distressing. Because of the speed of development of the disease, and the evident urgency of the soldier's distress, little could be done to stay the progress of the disease.

In both of these groups of cases, empyema developed in an extremely high percentage, 86 cases in 274 pneumonias, an incidence of 31.4 per cent. In the four-week period from December 17, 1917, to January, 1918, the empyema "epidemic" reached its height. Of 109 pneumonias, 52 developed pus in the pleural cavity, an incidence of almost 50 per cent. This rise in the empyema cases, reaching its height Christmas week (15 out of 18 lobar pneumonias developing empyemas), was in marked contrast to the week of January 15 (of 26 pneumonias, only 4 empyemas). These variations in the empyema curve were quite separate and distinct from the pneumonic curve per se, and were probably due to the virulence (selective action?) of the invading organisms (hemolytic streptococci).

This series of 86 empyemas differed in several striking respects from the metapneumonic and parapneumonic empyemas usually seen. Many patients came into the receiving ward from the regiments with chests full of pus. In other cases, within an hour or two of admission to the wards, quantities of pus could readily be demonstrated. In both, a history of illness not to exceed 24 hours often was obtained. The extremely rapid development of the empyemas, often well within 24 hours, was demonstrated repeatedly by fluoroscopic and roentgenographic examination.

Clinically, the severe prostration, with flushed cheeks, hollow bright eyes, short grunting dyspnea, deep boring chest pain, and asymmetric chest excursion were most prominent. Later this severe pleural pain was relieved somewhat, owing probably to the separation of the inflamed surfaces by the developing exudate.

Many cases, diagnosed clinically massive lobar pneumonia, showed at necropsy widespread atelectasis, with the lung compressed to half its normal size, but with little or no evidence of pneumonic consolidation. In these cases, purulent pericarditis frequently was associated, the pericardium containing a pint or more of thick, creamy pus.

Hemolytic streptococci were found in pure culture in a majority of the empyema fluids, 52 out of 93 examined, the remaining containing pneumococci or mixed organisms, or remaining sterile. The preponderance of streptococci was emphasized further by their presence in blood culture, pericardial pus, lung smears, and the heart's blood in these cases. Similar organisms were found widely distributed in various types of disease coming into the hospital at this time—almost universally in tonsil and throat smears, mastoid, middle ear and antrum pus, joints, abscesses, etc. The laboratory findings, together with complete absence of lung involvement in many instances, and the sudden overwhelming prostration and profound toxemia, with death in a few days, suggest that these so-called pneumonias were, in fact, true cases of streptococcal sepsis, with early localization in pleura and pericardium.

Another study was reported of a series of 233 cases occurring from January 3 to April 20, 1918, including infections of the lung and pleura only.^{rr} In the group were 98 cases of lobar pneumonia, 59 of pneumonia complicated with

^{rr} The following statements of fact are based, in the main, on: Report on a Series of Cases with Acute Infection of Lung and Pleura at Camp Taylor, by P. J. McDonnell. *Interstate Medical Journal*, St. Louis, 1918, xxv, 837-849.

empyema, 27 of pleuritis with empyema, 24 of bronchopneumonia,⁴ and 25 of pleurisy, none of which was of the measles-pneumonia group.

Previous to December, 1917, the cases were nearly all straight pneumonias. In December, a peculiar empyema began to complicate the usual type. At the time when the study of this series of cases was started one had to deal with the lobar type, with its complicating empyema, and a few cases of pleuritis with empyema. In addition to this, the medical service of the base hospital was burdened with measles-pneumonia and empyema group. At the middle of March and continuing through April the type of pleuritis with empyema predominated. These were called "primary empyema" cases because no consolidation was found in the lung at autopsy or by physical signs. The onset was an intense pleuritis, which rapidly threw out a serous exudate. The effusion was nearly always massive and required frequent aspirations. In every instance the isolated organism was the hemolytic streptococcus.

There were periods when the streptococcus infections seemed far more virulent than at others. There were two large epidemics of measles-pneumonia, and at the end of both the patients were not so ill and the mortality was not so great as the beginning. After the early part of May this was noticeable also in the other types of pneumonia and empyema, as there were very few deaths.

The following figures show the distribution of lesions, empyema, and pleurisy in the 233 cases: Lobar pneumonia, 98 cases, with 10 deaths; lobar pneumonia with empyema, 59 cases, with 16 deaths; primary empyema, 27 cases, with 8 deaths; bronchopneumonia, 24 cases, with 2 deaths; pleurisy, 25 cases with no deaths; a total mortality rate of 15.4 per cent.

In this group of 233 cases there were 98 cases of lobar pneumonia uncomplicated by empyema. Of this number 10 died, giving a mortality of slightly over 10 per cent. Many of the cases had mixed infection, as both the pneumococcus were obtained from the sputum. Furthermore, a streptococcus empyema often developed upon a typed lobar pneumonia. In a large number streptococcus alone was isolated from the sputum.

The onset and course in the lobar group was very atypical. Instead of sudden pain in the side and chill, the patient would give a history of a slow onset with a cold or grippe infection. Usually he performed his duties until his strength gave away. With most of them the temperature dropped by lysis and the rusty sputum was absent. No doubt many of these cases had a pseudo-lobar consolidation with a large area of infiltration. To separate this form from the true lobar type was difficult in all cases and impossible in the many that developed fluid early.

Of the 157 cases, from only 19 was the Type I pneumococcus obtained. These, as a rule, were very sick and the serum was used in all but a very few instances. Among the 19 there were 4 deaths, giving a mortality of 21 per cent. Every one of the four, however, had a severe complication and three had apparently recovered from the pneumococcus infection.

The total number of cases of lobar pneumonia in the group was 157. Of these 59, or 39.5 per cent, developed empyema, a higher percentage than found in the measles-pneumonia cases. Of the 59 cases of empyema 16, or

27 per cent, died. The mortality of the entire pneumonia group, including all complications, was 16.6 per cent.

In the series of 59 cases of empyema complicating pneumonia, 50 were of the hemolytic streptococcus type, 7 of the pneumococcus type, and in 2 the organism was undetermined. All the deaths took place among the streptococcus infections. In the pneumococcus group not a single death occurred, although every case showed a severe toxemia. From the streptococcus cases these seven differed remarkably in one respect, namely, in the amount of fluid that formed. This was greatly decreased. The fluid formed slowly and seldom was it necessary to aspirate oftener than once a week. No case totaled over 500 c. c. in all its aspirations, an ordinary amount for one tapping in a streptococcus case.

In this series there were 27 cases of pleuritis with empyema, of which 8 died. All were completely prostrated and many recovered that seemingly had no chance. All had a most intense pleuritis, of which they continually complained. They presented a typical picture, with flushed face, rapid and shallow breathing, and signs of great suffering. Nearly all were what was termed "rapid fillers," and required almost daily aspirations at the beginning. Several entered with a chest full of fluid and giving a history of only a few days' illness. In this respect they differed markedly from the lobar cases, where a history of preceding infection was usually obtained. Nearly all of the 27 cases came in at the end of March and the first three weeks of April. Many had pericarditis and two a purulent peritonitis, thus showing the severity with which the patient was attacked. In every instance the hemolytic streptococcus was obtained from the pleuritic effusion.

This type of case was called primary empyema, because no signs of lung consolidations were found previous to the pleuritis and effusion. Inside of a day or two the loud leathery friction rub would be replaced by the signs of fluid. In none of these cases were there present the typical tubular breathing and increased fremitus as with consolidation. Any that showed the slightest pneumonic signs were not placed in this group. Quite a number started off with a pleurisy, then showed signs of consolidation, and later fluid. These undoubtedly developed the empyema from the beginning pleurisy and not primarily from the lung infection. These, however, were not placed in this group. During this period there were numerous cases of plain pleurisy. They usually went to normal in a few days, while the infected ones went on to pus formation. It was impossible to predict which would develop pus. A few had large serous effusions in which no organism was found, and these cleared up nicely.

The autopsies performed on these cases showed no consolidation. Usually small patches of bronchopneumonia were present, but this condition was in all likelihood secondary to the pleurisy. The mortality in the 27 cases was 30 per cent.

Of straight pleurisy, uncomplicated, there were 25 cases, without a death. The group was interesting in two respects. In the first instance nearly all occurred at the same period when the primary empyema cases developed in such numbers. And secondly in the first few days of the illness it was most

difficult to differentiate the two types. It was impossible to forecast which would develop pus or which would clear up with the ordinary symptoms of pleurisy. Seemingly it was a matter of degree of infection or ability to combat it. After a few days all symptoms would disappear wherever fluid did not form. In some, however, the physical signs would remain much longer. Many of these could easily be mistaken for a pneumonia with a small patch of consolidation, as with impairment present the breath sounds were markedly accentuated over a certain area. Typical tubular breathing would persist in some cases for a week with the patient feeling perfectly well. This was a most disconcerting physical sign and one apt to be given the wrong interpretation. Apparently it occurred only when there was present a very thin layer of serum. The X ray would demonstrate a light shadow and usually a few cubic centimeters could be aspirated with a small needle. All had to be carefully observed as in several instances a flare-up occurred and empyema developed. Three of the cases had large serous effusions, which cleared up after aspirating. This group, occurring in large numbers at one certain period, with many developing a purulent effusion, offered a most interesting study from a diagnostic and prognostic standpoint.

The average high leucocyte count was: Simple pleurisy, 13,100; bronchopneumonia, 16,200; lobar pneumonia, 20,400; primary empyema, 27,000; pneumonia empyema, 27,500.

The leucocyte count in the entire series of 233 cases ran about as might be expected, being highest in the most toxic group. The lowest count was in the pleurisy group, and the highest in the empyema group. Nothing new was learned. Where daily counts were made, the change in the condition of the patient usually was reflected by the leucocytosis.

Of the 157 cases of pneumonia, in 90 the right lung was affected, in 56 the left, and in 11 both lungs. Of this number 59, or 37.5 per cent, developed empyema, 29 in the right pleura and 29 in the left. This shows a marked proportionate preponderance of the infection for the left pleural cavity. This same tendency was apparent in the cases of pleuritis with empyema, where 17 of a total of 29 occurred in the left pleura. This is probably a coincidence, and doubtless no significance can be attached to it.

Pericarditis occurred in about 8 per cent. In only three cases was there a well-developed effusion and one of these died following a thoracotomy. In the other two the fluid disappeared without leaving any bad effects. This complication was always a serious sign because the cases were the very sickest. Delirium was constantly present at the start. In nearly all the rub disappeared as soon as the acute symptoms subsided, and in none of this series was pus demonstrated in the pericardium. The rub in most of the patients was heard at the start, but with several it was not noticed until the pleuritic effusion began. With the primary empyema cases pericardial pain was often the first symptom, and in auscultation both pericardial and friction rubs were heard. The complication was far more frequent in left than in right side empyema.

Otitis media was the most frequent complication, occurring in about 10 per cent. It was not usually of serious omen, but often produced a sudden rise in the temperature. It was present at all stages of the disease. Only two developed mastoiditis, one being double.

Deep jaundice was present in five cases. These comprised a most toxic group, as the severity of the infection was manifested by three deaths.

Three developed a purulent peritonitis, all of whom died. At the same time all had a hemolytic streptococcus empyema.

One patient developed an ileus overnight. He had a very painful pleuritis and pericarditis, and had just been transferred from the cardiac ward. Inside of six hours there was a complete obstruction which could not be relieved by the usual measures. He was then transferred to surgery and the abdomen was explored. No pus was found. He died three hours after laparotomy. The sudden onset overnight and the complete paralysis of the bowel were striking features.

Abscess of the lung occurred in two patients. One, who had also a streptococcus empyema, died. Several cases developed body abscesses, usually on the back. Most of these occurred in the empyema group, and were largely due to the infection being carried back by the aspirating needle.

Four of the patients had a well-marked meningeal irritability, but in all of them the spinal fluid was negative. The meningismus usually cleared in about three days.

There were two cases of slow resolution. Both presented marked impairment, with distant tubular breathing and râles. The X ray showed shadows to correspond.

Pyopneumothorax complicated two cases. In the group of 86 empyemas no case had pus in both pleural sacs.

During the winter 1917-18, necropsies were performed in 62 cases at Camp Zachary Taylor, Ky.⁸⁸ The patients were soldiers, with one exception white, native born, physically and mentally sound, in the third decade of life, most of them country bred and from the Central States. This uniformity of type permitted comparative study.

In the fall of 1917, the etiologic agent was the pneumococcus with its customary results. Measles appeared late in October, causing the first death, November 7, from what is considered a typical measles pneumonia, with a catarrhal or purulent bronchitis. On the advent of the streptococcus infection, causing the first death, December 13, the pathologic picture changed, the bronchitis being now hemorrhagic, the pneumonia patchy and hemorrhagic, while the causative organism began to show a predilection for serous surfaces.

Causes of death as determined by necropsy in this series were: Bronchopneumonia, 27; lobar pneumonia, 8; empyema, primary, 6; pericarditis, primary, 1; the rest being meningitis and noninfectious diseases.

Bronchopneumonia was the lesion most frequently found, 35 of the 52 cases presenting this change; in 27 it was looked on as a primary cause of death.

To study more closely the effect of the various etiologic agents on the disease picture, all cases of bronchopneumonia were grouped into four classes: (A) Following measles; the *Streptococcus hemolyticus* isolated; 3 cases. (B)

⁸⁸ The following statements of fact are based, in the main, on: Post-mortem Findings in Measles, Bronchopneumonia, and Other Acute Infections, by Baldwin Lucke. *Journal of the American Medical Association*, Chicago, 1918, lxx, No. 26, 2006-2011.

Following measles; the *Streptococcus hemolyticus* not isolated; 13 cases. (C)
Not following measles; the *Streptococcus hemolyticus* isolated; 10 cases. (D)
Not following measles; the *Streptococcus hemolyticus* not isolated; 9 cases.

The bronchopneumonia, then, was preceded by measles in 16 instances, and not preceded by measles in 19 cases. The streptococcus was isolated in 13 cases, and not isolated in 22 cases. In the latter group the pneumococcus was frequently found. In a small number of cases, no bacteriologic studies were made.

Four anatomic types of bronchopneumonia were observed. These were found with such regularity that they were classified as Types Ia, Ib, II, and III. The first two types were found mainly in bronchopneumonia following measles; the last two in hemolytic streptococcic infection.

In Type Ia the lungs were large, expanded, and very heavy. The weight of each lung ranged from 600 to 1,100 gm., the combined weight often approaching 1,500 gm. The pleural surface might be smooth and glistening, but more often was dulled and overlaid with fibrin exudate. The general surface of the lung was mottled, dusky gray-red with a distinct bluish tint. Small, ill-defined areas of elevation and depression often were seen. On palpation, innumerable small, firm areas were felt throughout all the lobes. The lungs may be said to have had a "shotlike" feel. The intervening lung tissue was boggy. The cut surface was pale bloody-red; light pressure caused the outpouring of a large amount of moderately blood-stained, frothy serum. Scattered over the entire cut surface were numberless rounded, light gray-red, definitely raised, firm areas, appearing very much like large, gray miliary tubercles. They usually distinctly surrounded a small bronchial branch, and measured from 3 to 5 mm. in diameter. About one-half to one-third of the entire tissue was taken up by these consolidations.

The bronchial branches stood out distinctly; from many, a thick, yellow purulent fluid exuded. The bronchial mucosa was swollen and somewhat reddened. In some instances the bronchial tubules were dilated, forming small and rather smooth-walled cylindric or globular bronchiectases. The peribronchial lymph nodes were swollen, juicy, and dark grayish red. Their cut surface was very moist and had a mottled appearance.

Type Ib was a later stage of the preceding process. All the various anatomic changes were more accentuated. The pleura generally was covered with soft yellow exudate. The organ was markedly distended and the combined weight of the lungs approximated 2 kg. The surface of the lung lacked definite rounded contour, showing many smaller and larger elevations, blue, reddish brown or purplish in appearance, fading gradually. Subpleural punctate hemorrhages occasionally were encountered. The nodules palpated were larger than in the preceding type, but were of approximately uniform size. No large consolidated patches were felt. The anterior edges of the lung and the upper lobes might be inflated. The cut surface was moderately bloody. The general color was grayish red; innumerable well outlined, slightly but definitely raised areas of a yellowish, grayish red or dark reddish brown surrounded the bronchial tubes. These consolidations varied from about 5 mm. to 1 cm. in diameter. The grayish areas were quite firm, while the yellowish patches were

more or less softened. The bronchi showed the same general changes as in the preceding type.

The principal features of Types Ia and Ib, then, were marked edema, the discrete character of the consolidations, their distinct peribronchial situation and their occurrence in all lobes. They varied in color, size, and consistency, being small, firm, and light gray in the earliest stages and then becoming larger, grayish red, dark red, and finally yellow and softer in appearance and consistency. The aggregate total of these areas would equal from one-third to two-thirds of the entire pulmonary substance, depending on the stage. A purulent bronchitis accompanied the lesions. The marked edema and the very small size of the consolidations often obscured the clinical picture of bronchopneumonia.

In Type II the pleura usually showed inflammation; empyema was often present and the lung was slightly or not at all enlarged. On palpation, various sized areas of resistance were noted. On section, the lung tissue was not nearly so moist as in Types Ia and Ib. The areas of consolidation were several centimeters in diameter, of irregular contour, slightly or indefinitely raised and not visibly peribronchial. They varied in color from dark red to grayish yellow and often showed a surrounding hemorrhagic zone. Usually the lesions were confined to one or two lobes. The bronchial branches were not unduly distinct and almost always showed a deep red hemorrhagic mucosa and exuded a sanguineous or sanguinopurulent fluid. The peribronchial lymph nodes were large and more reddish than in Types Ia and Ib. This type of bronchopneumonia resembled the ordinary kind seen in the necropsy room excepting the great frequency with which empyema occurred and the hemorrhagic character of the bronchitis.

Type III was confluent bronchopneumonia or pseudolobar lobular pneumonia. A large part of a lobe was consolidated. The cut surface was moist and finely granular; the granularity being less distinct than that of lobar pneumonia. The lobes showed several distinctly different processes. While the general color was brownish red, there were areas more yellowish and others more grayish or reddish; but all faded into one another, so that the end picture appeared at first glance more homogeneous than heterogeneous. The pseudolobar pneumonia, therefore, was made up of a number of units placed so closely together that they gave the appearance of a single large consolidated patch.

Nine of the 16 cases of bronchopneumonia following measles were of Type Ia or Ib. The spleen was slightly enlarged, being about one and one-half to twice its normal size and averaging 225 gm. in weight. The capsule was smooth and transparent, the outside cover being bluish red. The organ was somewhat less firm than normal, the cut surface dull red, the trabeculae of usual size, the splenic follicles were prominent, a light yellowish gray, and about twice their normal size. The splenic pulp showed no gross changes. The splenic picture, therefore, was one usually termed "acute follicular splenitis."

In five cases not showing Type I bronchopneumonia, complications were present which may have influenced the character of the lung lesions. In two instances a streptococcic infection was superimposed. In others epidemic

meningitis, lobar pneumonia, and erysipelas coexisted. As to the development of the bronchopneumonia after the onset of measles and as to its duration no uniformity existed. The kidneys, in a majority of cases, showed various grades of acute parenchymatous nephritis.

One of the dominant symptoms of measles is bronchitis appearing early and often persisting. The cause of this bronchitis is not known, but it is reasonable to suppose that it is due to the virus of measles. In the epidemic under consideration, hemolytic streptococci appeared in the throat in a large percentage of the cases of measles, general medical cases as well as apparently normal cases. The great invasive power and virulence of the streptococcus found in this epidemic was demonstrated at necropsy by the extensive involvement of all the principal organs. It was most likely that they would thrive readily in an already pathologic field, that is, the inflamed bronchial tubes of measles. In the early post-mortems, before the epidemic of streptococcus had appeared, a definite type of measles-bronchopneumonia was found, here termed Type Ia and Type Ib. From a study of the necropsies, it was believed that these were true measles-bronchopneumonia, caused by the virus of measles. Since, however, a number of organisms, as pneumococci and streptococci, occurred almost constantly in the throat, secondary invasion would take place in the bronchial system and one or another organism would be found in the bronchial branches and pulmonary lesions. If these organisms possessed marked virulence and invasive powers, and if they intruded early in the disease, the anatomic picture would be determined by the invading bacteria, and the possible influence of the measles virus might be obscured. In fact, the lesions established would be a true streptococcic or pneumococcic bronchopneumonia. If, on the other hand, the invading organisms entered the system late in the disease, were few in number, or did not possess marked virulence and invasive powers, they would influence the pathologic process slightly or not at all, and a true measles-bronchopneumonia would be produced. This explanation readily fitted the anatomic findings. Because of certain technical accidents, the microscopic sections were largely unfit for study; for this reason, only the gross anatomic picture is given.

The majority of cases of streptococcic bronchopneumonia were of Type II. The bronchi showed hemorrhagic inflammation. Empyema occurred frequently. The spleen presented the picture of an acute splenitis often with hemorrhages, or a distinct hemorrhagic condition; it was slightly enlarged, having a smooth capsule of a slaty color or dark red. The consistency was flaccid, the cut surface pale grayish brown and often containing irregular dark red hemorrhagic areas; the follicles and trabeculæ were indistinct.

Otitis media, mastoiditis, and other complications were frequently present. The mastoiditis was characterized by reddish-black discolorization of the bone, which was so necrotic that it could be easily cut with a knife. Subserous hemorrhages, usually small and of pin-point size, were frequently encountered on the pleural, pericardial, renal, cerebral, and hepatic surfaces. Similar hemorrhages were found in the mucosa of the renal pelvis, the stomach, and the intestine. In a general way, organic changes were more widespread and of greater severity in the streptococcic infections.

Cases of bronchopneumonia not following measles and not streptococcic occurred usually as a complication of some other disease. The lung picture was classified as Type II, but the bronchial and visceral changes were less pronounced.

The eight cases of lobar pneumonia resembled, in every way, those usually encountered. In three, coexisting bronchopneumonia was found, in all of which the pneumococcus was isolated. One pneumonic lung presented an interesting picture. The entire right lung was consolidated; the upper and middle lobe had a grayish-red cut surface, granular in appearance, from which pneumococcus cultures were made. The lower lobe possessed a distinctly more reddish appearance, and from this part hemolytic streptococci were isolated. It may be that the streptococcic and pneumococcic inflammation coexisted, or, what is more likely, the streptococcus process was superadded to the pneumococcic involvement.

The necropsies during the winter of 1917-18 showed an unusually high percentage of empyema, this condition being present in 21 of 52 cases. (The term "empyema" is here used to include serofibrinous pleurisy).

Clinically, a "cold" or "sore throat" frequently preceded the empyema by a few days; then, after exertion, or without discoverable cause, the following syndrome was noted: A chill, which was described as severe and sometimes lasting for an hour, followed by a cough, pain in the side, fever and dyspnea. This clinical history, with the finding of dullness in the side often led to the diagnosis of lobar pneumonia. The roentgen ray and clinical studies showed that the empyema was of unusually rapid occurrence, often developing over night.

Only five cases of measles were complicated by empyema; in 10 instances "sore throat" or a "cold" preceded the disease. The organisms found were: Hemolytic streptococcus, 14; pneumococcus, 5; no growth, and undetermined, one each. In all cases the fluid obtained at necropsy was distinctly turbid, in most cases frankly purulent. It usually was a thick, yellow, and creamy liquid, in which large clumps of fibrin floated. Occasionally a greenish tint was found, and, in the streptococcic cases, a brownish, light coffee color. The quantity varied from 100 to 2,500 c. c.; this variation was due, in part, to previous aspiration or operation. In 9 instances the right, in 8 the left, in 4 both pleural cavities were affected. In the latter, various developmental stages could be observed; the empyema was walled off or pocketed by a tough, fibrinous adhesion between the lung and the lateral chest wall. Interlobar empyema was found only once. Sometimes only one, sometimes several pus pockets were present; a certain amount of free basal empyema usually existed. These cases were of considerable clinical interest since drainage proved difficult and occasionally a large pocket was not reached, while another was perfectly emptied. In all cases of empyema, the pleural surface was almost completely enveloped by a thick coat of yellow, soft exudate averaging from 3 to 10 mm. in thickness, and binding the lung lightly to the chest wall here and there. If the exudative process had existed for some time, organization occurred. The pleural surface then was grayish, and had a somewhat scaly, dry appearance. The exudate was much tougher and adhesion firmer; in the latter cases empyema pockets

were found. This would seem to indicate that, other conditions permitting, early operations offered the best chance for complete drainage. The changes in the lung were usually those of bronchopneumonia; lobar pneumonia was found in only one case. The lung on the infected side showed compression varying in degree with the quantity of fluid present. In several instances the lung was no larger than a fist, having then a dry fleshy appearance and a tough meat feel. The cut surface was dark red, airless and dry, the bronchial branches standing out prominently because of the loss of separating tissues. More often than atelectasis of the entire lung, compression of only one lobe was found; this had the same appearance as described above. The uninvolved side showed compensatory inflation, the organ being widely distended and hypercrepitant.

In six cases no inflammatory changes were present in the lungs, and the empyema had to be looked on as primary. The lung tissue was carefully examined in these cases; and while it is conceivable that the existing atelectasis obscured the inflammatory changes, careful study failed to reveal any. Five of these primary empyemas were streptococcal in origin. In the other, no organism was isolated.

Ten instances of acute pericarditis were discovered, with one exception, in the serofibrinous or purulent stage. One case was preceded by measles, another by "rheumatism." The hemolytic streptococcus was isolated six, the pneumococcus four times (twice Type II, once Type I, once type not determined). Lobar pneumonia existed in one of the cases, bronchopneumonia in six, and in three instances the lung did not show any inflammatory processes. In all but one patient the pericardial inflammation was associated with empyema. In one case the pericarditis was looked on as primary, since no inflammatory processes in other organs were found present. In this case hydrothorax and ascites of undetermined origin were found.

The heart, in the majority of cases of bronchopneumonia and lobar pneumonia, showed right-sided dilatation and cloudy swelling. The aorta, in an unusual percentage of instances, presented atheroma. In 42 cases detailed notes concerning the state of the aorta were made. In 30 of these aortic atheroma was present in the form of elevated yellow patches or streaks. They were situated mostly in the ascending arch, and to a less extent in the abdominal aorta and other portions of the arch. The thoracic aorta was almost always normal. The atheromatous lesions numbered from a very few to several dozen. They were subintimally located, and varied in consistency from hyaline firmness to definite softening. The coronaries showed distinct involvement in a considerable number of cases. Since the common causes of aortic disease, syphilis and other chronic infections, were not to be elicited in the history or necropsy findings, one was forced to consider the possibility that this infection was the cause of the intimal changes, which speculation pointed out that close observation should be made of aortas in these young men coming to necropsy from acute infections. Since the patients were only in the third decade of life, the presence of aortic change is of interest.

The liver usually showed cloudy swelling. The gastrointestinal tract presented no noteworthy changes.

Pneumococcal meningitis occurred in one instance and was associated with bronchopneumonia. The anatomic picture was similar to that of meningococcal meningitis.

In three cases of streptococcal meningitis, purulent otitis and mastoiditis was the atrium of the infection. Parts of the mastoid and petrous bone were bluish black and necrotic. The mastoid cells and internal ear contained greenish pus. The pia-arachnoidal vessels showed greater infection than in meningococcal meningitis. The exudate had a greenish tint, and was more abundant. Punctate subpial hemorrhages were present. Thrombosis of the right lateral sinus was seen once. The ventricles were overdistended in one instance, and in all cases contained semipurulent fluid. The ependyma was moderately reddened. The visceral changes were more pronounced than those of meningococcal meningitis. Parenchymatous nephritis was the principal lesion noted.

One case of bronchopneumonia was complicated with a marked hemorrhagic encephalitis. Clinically the patient developed delirium two days after the onset of the bronchopneumonia, and the neck became stiff. Lumbar puncture yielded clear spinal fluid containing a considerable number of polymorphonuclear cells.

The brain showed extensive subpial hemorrhagic extravasations, particularly over the frontal and superior parietal areas. The large veins were greatly congested. In the cut surfaces an unusual number of bleeding points were present. The cortex of the superior portion of the right frontal lobe contained an area of punctate hemorrhages about 2.5 cm. in diameter. In the cortex of the left parietal region a similar hemorrhagic area was found. The ventricles were normal in size and contained a slightly blood-tinged fluid. The ependyma was normal in size. The internal ear and mastoid cells showed no evidences of inflammation. In microscopic sections, extensive subpial hemorrhages were seen. The vessels in the cortex were greatly distended, and in many instances packed with polymorphonuclear leucocytes; at many points hemorrhagic extravasations were present in the cortex.

The pathologic anatomy and bacteriology of influenza during the epidemic of the fall of 1918 at Camp Zachary Taylor and Camp Knox, Ky., were reported from the cantonment laboratory, base hospital, Camp Taylor.⁴⁴

Necropsies, with routine bacteriologic cultures, were performed throughout the entire epidemic, so that a fairly definite picture of its various stages could be formed. The investigation was limited to 126 definitely proven fatal cases of influenza. These were selected from a considerably larger number by ruling out all patients who clinically gave evidence of preexisting disease, such as tuberculosis, measles, etc., or where such evidence was found at the necropsies. Thus the morbid changes encountered may be looked on as primarily representing the end results of the virus of influenza and its commensals.

The pandemic manifested itself here (Camp Taylor) first September 22, 1918, reaching an apex comparable to the first on October 5, and terminated about November 15, after which time only a small number of cases occurred.

⁴⁴ The following statements of fact are based, in the main, on: *Pathologic Anatomy and Bacteriology of Influenza*, by Baldwin Lucke, Toynbee Wight, and Edwin Kime. *Archives of Internal Medicine*, Chicago, 1919, xxiv, 154-237.

The first death due to influenza occurred September 28. The death curve gradually rose, reaching its highest point (70 cases) October 5, and then gradually declined.

The average aggregate population of this camp and of Camp Knox (30 miles distant) during the influenza epidemic was 58,000. Of these, 5,500 were Negroes. A considerable discrepancy in the morbidity and mortality rate was observed between the two races. The number of cases of influenza per 1,000 population was 231 for the whites and 70 for the Negroes. The number of deaths per 1,000 population was 16 for the whites and 7 for the Negroes, but the number of deaths per 100 cases of influenza was 6.8 for the whites and 10.2 for the Negroes. It showed, then, that while the incidence of influenza was considerably less among the colored soldiers, the mortality among those that contracted the disease was considerably higher.

There are three possible explanations for this discrepancy: Exposure to infection, immunity, and anatomic differences. Exposure may be dismissed since practically all men were exposed equally. Immunity does not seem to have played any part here, since once the disease was contracted the mortality among the colored race was higher. It was observed in Camp Taylor throughout the years 1917 and 1918 that various acute respiratory infections, such as catarrh of the nasal sinuses, were relatively uncommon among the colored soldiers, and the explanation seemed to be that the rarely obstructed air passages of the Negro afforded a good defense against lodgment of microorganisms. This would hold true, of course, only for the individuals with more pronounced African features, disappearing with increased admixture of white blood.

The duration of diseases was as follows: 8 patients, or 6.7 per cent, died within the first 5 days; average duration, 4.3 days; 49 patients, or 40.8 per cent, died within 6 to 10 days; average duration, 8.2 days; 31 patients, or 25.8 per cent, died between 11 and 15 days; average duration, 12.8 days; 13 patients, or 10.8 per cent, died between 16 and 20 days; average duration, 17.5 days; 19 patients, or 15.8 per cent, died after 20 days; average duration 25.3 days. In one case the duration of the disease was not obtainable. The average duration for the entire series was 14 days. In 5 cases the disease exceeded 40 days in duration. These, however, were typical influenza patients and may be looked on as having suffered from the chronic form of this disease.

ACUTE INFLUENZA

The following statements, apply to the 121 cases of acute influenza.

The relation of the duration of the disease to the period of epidemic was estimated. For this purpose the entire epidemic was divided into five periods, generally of 10 days each, except the last, which comprised the more scattered forms occurring in November and December. Of the 42 cases necropsied during the first 10 days after the first death of influenza had occurred, the average duration of the disease was 10 days. In the second period, it rose to 13.6 days, in the third to 16.6, in the fourth to 16.7 days. In the fifth period it dropped to 13.1 days. This last period, as stated, comprises the time when the disease had lost more or less of its epidemic character. The difference in the duration of disease as the epidemic progressed is doubtless due to the fact that the most

susceptible patients succumbed first, and that the least susceptible resisted a longer period. The duration of disease during the fifth period is more difficult to explain, but it may have been due to the incoming of nonexposed troops, or to fewer precautions taken by individuals because of the belief that the epidemic was over. Later it will be shown that the bacterial findings of this period approximated those of the earlier stages of the epidemic. It should also be remarked that at this time there occurred a particularly severe outbreak of the disease in the neighboring town of Louisville.

PATHOLOGIC ANATOMY

The necropsies were performed under ideal conditions, usually within a few hours, only rarely later than 12 hours after death. The tissues were preserved in Zenker's fluid, occasionally in liquor formaldehyde. Fresh material sometimes was used for the study of cloudy swelling. Tissues sectioned were heart, lungs, peribronchial lymph nodes, suprarenal, kidney, liver, and brain. As occasion demanded, sections were taken from skin, subcutaneous tissues, muscles, aorta, and vessels in general, thoracic duct, extra-pulmonary bronchi, semilunar ganglia, ureter, prostate, bladder, testes, tongue, tonsils, intestines, pancreas, mesenteric lymph nodes, pituitary gland, and spinal cord.

The description of the structures will be given in the order in which they usually were examined here at the necropsy (modified Zenker-Letulle method).

External appearance.—The average age was 25.21 years; the average weight 76 kg., the average height 174 cm. No great variations from these figures occurred. Emaciation was observed only in the more protracted cases. The post-mortem lividity was generally most extensive. The face as well as almost the entire body was of a dusky color, sometimes even purplish black. In about two-thirds of the cases a bloody, sometimes frothy discharge exuded from the nostrils and from the mouth. There was no marked variation from the standard of cadaveric rigidity, but there seemed to be a tendency for it to be somewhat delayed. The superficial glands were never found palpably enlarged. Edema, although always looked for, was never present, and this should be emphasized in view of considerable kidney changes to be described below. The joints never were enlarged, nor was any arthritic condition demonstrated at necropsy, although it sometimes was seen clinically.

The chest was frequently considerably expanded, often unequally. This was due, no doubt, to the marked compensatory inflation of the lung and the pleuritic effusions. Scaphoid abdomen, which was probably coincidental, did not occur here, excepting in isolated cases.

Skin.—Miliaria was very frequent and due to the profuse sweating (grippe sudorale). In this series two cutaneous lesions occurred in a large number of cases. In about 29 per cent of the patients there were multiple petechial hemorrhages in the form of minute, dusky, blue-black areas, varying in diameter from 1 to 3 mm., and being most frequently met with in the axilla and over the scapula, although occasionally seen elsewhere. Because of the intense post-mortem lividity they were recognized with difficulty. Microscopically, small hemorrhages (up to the size of a low power microscopic field), were seen in the papillary layer of the skin, a papillary projection being often entirely flooded with

red cells and only occasionally were these hemorrhages seen in the deeper layers. These extremely superficial hemorrhages may be looked on as resembling the purpura hemorrhagica of influenza.

The other skin lesions occurred in the form of small, discrete, slightly raised, red papules or vesicles with slightly turbid but rarely frankly purulent contents, in about 60 per cent of this series. This condition was almost entirely confined to the sternal region. Microscopically, the sebaceous glands were hugely dilated and heavily infiltrated with polymorphonuclear cells; frequently they were destroyed entirely and replaced by a necrotic mass of a small abscess. Besides the polymorphonuclear cells, small, round cells, with occasional plasma cells, could be seen. The sweat glands seldom were involved. This condition did not seem to resemble acne nor the several forms of erythema multiforme described in relation to influenza. It was regarded as a toxic necrosis of the sebaceous gland, produced, perhaps by endothelial proliferation of its vessels, and analogous to the toxic aenitis of tuberculosis. Its characteristic site, over the sternal region, rendered it unlikely that it was a simple acne.

In about 19 per cent of our series jaundice was present. This was never very marked, and amounted to little more than a tingeing of the sclera and skin. In the majority of cases it appeared late in the epidemic.

Subcutaneous tissues.—In most of the cases the tissue was grossly somewhat more moist and congested than normal. Microscopically, nothing further was noted. In three necropsies, and in another not included here, a generalized subcutaneous emphysema was present. In Camp Taylor, including all the clinical cases, it occurred nine times, the incidence, therefore, being 0.07 per cent. It was always most pronounced over the upper anterior chest, the neck, and the lower part of the face, but in several cases it was distributed over the entire body; in one instance the left side of the scrotum was hugely ballooned. The subcutaneous tissue appeared as if innumerable air bubbles were scattered throughout. There were found neither gross nor microscopic changes in the various organs which differed in any way from those of the rest of this series, with the exception that acute ulcerative bronchiectasis was noted more frequently here. It was believed that the air escaping through the eroded bronchial wall was forced into the loose peribronchial areolar tissue, and thence by line of least resistance gained the mediastinum and the subcutaneous tissue.

Muscles.—In three instances considerable portions of the recti were of smooth, light reddish-brown color, and had a peculiar, translucent appearance; in several more cases, about 10 similar but smaller areas could be seen. This condition was confined to the abdominal muscles. Microscopically, typical Zenker's coagulation necrosis was met with. This sometimes was present in only isolated fibers, but, in the three cases mentioned, extended over large areas. In one instance a marked acute myositis, with areas of necrosis and peripheral regeneration, was seen. Here dense masses of fibrin penetrated between the muscle fibers and into the structureless necrotic mass. Large numbers of round cells, polymorphonuclear cells and aggregations of muscle nuclei, in bundles and rows, were seen, especially at the periphery of the necrosed area. Abscesses occurred in only one of this series, and in another instance among the cases of chronic influenza, although in the surgical wards, six abscesses of the rectus

muscle were treated as complications of influenza. Rupture of the rectus muscle and hemorrhagic exudations did not occur in this series, although it was found in noninfluenzal infections. The two most pronounced instances of coagulation necrosis were present in conjunction with subcutaneous emphysema; this, however, is probably coincidental.

General internal inspection.—Usually the liver and the lower pole of the spleen extended well beyond the costal margins, due not only to a general increase in the size of these organs, but also to accumulations of pleural fluid, pressing them downward.

Peritoneum.—Peritonitis occurred in none of the acute, and three times in the chronic cases, associated, in every instance, with pleuritis, and undoubtedly secondary to the pleural complication. The rarity of this condition was in striking contrast to the frequency with which it occurred during the measles-streptococcic epidemic of 1917.

The blood vascular system.—Grossly, there was an extreme congestion of practically all the structure of the body, the cut surface generally being excessively bloody. This was especially noticeable in the heart, kidneys, liver, and brain. Microscopically, congestion and hemorrhages constituted ever recurrent findings. The capillary endothelium was frequently considerably proliferated, and the lumen of even good sized arterioles and venules was occluded with smooth, homogeneous, hyaline thrombi, or densely packed conglutination thrombi, consisting of degenerating red cells. The occlusion of the capillaries occasioned hyperemia of the neighboring parts, inflammations and exudations, and the deposition of pathogenic organisms which found in the thrombotic tissue a favorable medium.

Throughout the tissues one frequently saw shadow erythrocytes, denoting considerable blood destruction. The relative scarcity of polymorphonuclear leucocytes in the various tissues showing pathologic changes was striking, and gave the impression that a myeloid intoxication existed here. Leucopenia occurred practically in all clinical cases, and was looked on as one of the most important diagnostic aids. Generally the leucopenia persisted throughout the disease, but sometime a slight leucocytosis occurred toward the end. In the case where leucocytosis was present throughout, the pneumonic complications were of the croupous lobar type, or an associated purulent meningitis existed.

Aorta, thoracic duct and vena cava.—Definite subintimal changes, commonly looked on as the earliest manifestation of arteriosclerosis, were found in 98 of a total of 120 cases in which a note was made on the condition of the aorta. The changes appeared as opaque, pale yellowish, or light orange yellow, narrow firm streaks and corrugated ridges, generally occurring longitudinally on the posterior wall. The term "willow-tree branches," which has been applied to this condition, aptly describes it. Only exceptionally were hyaline plaques found. The elasticity was never impaired, as tested in instances by a stretching apparatus. Generally, the entire length of the vessels presented these changes, but sometimes they seemed more marked in the ascending arch than in the abdominal aorta. Microscopically, the endothelium was not affected. The more superficial layers of the intima were generally somewhat loosely arranged. The deepest layer was fibrous and swollen. At what appeared to be a later stage the swell-

ing was more pronounced. Very large cells with a ragged, granular, vacuolated, distintegrating autoplasm were seen. Their nuclei were variable in their staining affinities and were often entirely absent.

Small, ragged-walled cavities, bounded by the muscular wall and the most superficial layer of the intima were met with commonly. These, no doubt, were sometimes due to the dropping out of the degenerated cells during the process of sectioning, but were likewise the product of fatty and granular degeneration. A few scattered, small round cells were found, but no definite infiltration.

The only other condition worthy of note was a diffuse hemoglobin tinting of the aorta and other great vessels. This occurred in many instances, even at necropsies performed within a few hours after death, and was probably a manifestation of rapid blood destruction. The vena cava and the other large vessels presented no gross alterations.

The thoracic duct, in every instance, was of normal diameter, thin walled, with a slightly pink mucosa. Neither gross nor microscopic changes were noted.

Pericardium.—Pericarditis was met with seven times; twice serofibrinous, on three occasions fibrinous, once fibrinopurulent, and once frankly purulent. Microscopically, the usual fibrinopolynuclear exudate was found. In each instance an associated pleuritis was probably the starting point of the inflammation. In approximately 20 per cent of the series the pericardial fluid amounted to 50 or 60 c. c.; this, however, was most likely mechanical in origin, due to the pressure on the great veins by pleural exudate. Punctate, hemorrhagic extravasations were often seen over both the visceral and parietal pericardium, and in a majority of cases definite hyperemia was present.

Heart.—The weight of the heart was estimated in detail in 66 cases. In 30 per cent of these it was below 300 gms., and in 10 per cent it weighed 400 gm. with an average of 429 gms. On the whole, the heart weight appeared increased, due probably more to congestion and edema than to actual hypertrophy. In 115 cases of the series the right heart presented more or less dilatation, and in a number of instances the left side was likewise relaxed. In 89 cases an associated cloudy swelling was diagnosed grossly. In the majority of instances, then, parenchymatous changes were encountered, analogous to those seen in other acute infections.

The heart muscle was usually flaccid, sometimes excessively so. The cut surface practically was always opaque, grayish red, with fine lines due to capillary congestion. The characteristic tigroid markings of fatty degeneration were never seen. Microscopic examinations were conducted on both fresh and fixed preparations. As a rule, a granularity obscuring striations and clearing on the addition of acetic acid was found. In the stained preparation these changes were less clear, but here also one would frequently see haziness or disappearance of the cross striations, and very frequently, small vacuolization. Here and there the nuclei were pale and irregularly stained; many being swollen, oval, granular, and fragmented. All these changes are similar to those seen in diphtheria and typhoid fever. In the interstitial tissue, occasionally, a few wandering cells, or a granular débris, were found. The intermuscular spaces were sometimes broad and contained a precipitated, granular mass, probably edematous in origin. The capillaries were often distended to an extreme degree;

but very rarely small hemorrhages were seen. Conglutination and hyaline thrombi, spoken of above, were often seen, but not with the same frequency as in some of the other organs.

The endocardium, in a few instances, presented subendothelial, petechial hemorrhages of slight extent. The valve leaflets were involved only once, where acute vegetations were seen on the mitral valve.

Respiratory system.—The mucosa of the nares, especially in the cases early in the epidemic, was somewhat swollen, deep red and frequently exuded blood. No microscopic sections were made.

Accessory nasal sinuses.—In 65 cases the accessory nasal sinuses were examined. In eight of them no gross alterations were present. Generally, the mucosa was reddened, thickened, loose, and the cavity contained a purulent or seropurulent material. Frequently this was heavily blood-stained, varying in consistency from a thin, watery, sanguineous exudate to a heavy creamy, yellow, thick pus. The sphenoid sinus was involved 51 times, the ethmoid sinus 43 times, the frontal sinus 17 times, and the mastoid cells, on one or both sides, 14 times. Necrosis of the bone was never present, in marked contradistinction to the frequent and pronounced bone necrosis seen here during the measles outbreak of 1917–1918, even though at that time the accessory nasal sinuses were on the whole not so frequently affected as during the present pandemic.

Peribronchial lymph nodes.—In 115 cases congestion and edema of the peribronchial lymph nodes were grossly noted. In 11 cases no microscopic changes were demonstrable. The glands often attained remarkable proportions, and it was not uncommon to see a mass the size of a walnut. Such excessive enlargement was present in 32 instances. The external appearance was generally a light reddish gray, occasionally a dark pinkish red. The consistency varied from mushy softness to flaccidity. The cut surface was practically always very moist, dripping blood-stained fluid. The degree of congestion varied, but the majority of cases were definitely congested, and, in some, tiny hemorrhages visible to the naked eye occurred. Microscopically, the lymph sinuses were widely distended and often packed with very large mononuclear, pale staining, phagocytic cells, containing bacteria and cell remnants. Other sinuses showed a granular débris with delicate threads of fibrin, and, in some, dense accumulations of red cells were intermingled with the other constituents. Many cells resembled the phagocytic epithelial cells of the lung exudate. A number of camera lucida drawings of these cells made from both sources were compared and it seemed very probable that they belonged to the same group of elements. The lymphoid tissue was generally loosely arranged, sometimes intermingled with a fine precipitate and occasionally fibrin. An active proliferation, as indicated by great numbers of large cells of the lymphoid type, appeared to be going on. Plasma cells occurred in considerable numbers in cases where the disease had persisted for some time.

The vessels throughout the glands were enormously congested, and now and then hemorrhagic foci were encountered. Almost in every instance some of the vessels contained smooth hyaline or conglutination, and in a few cases,

fibrin thrombi. The vascular endothelium was considerably swollen, the nuclei being often very large and the cytoplasm protruding into the lumen of the vessel. On the whole, bacterial phagocytosis in the lymph node was rare. The perivascular spaces were packed with cells similar to those described, the relative absence of polynuclear elements being striking. In fact, these latter occurred only when the adjacent lung surface was covered with fibrinocellular exudate. Now and then eosinophiles, in inconspicuous numbers, were encountered. Occasionally the reticular fibrous tissue was actively proliferating, and large numbers of loosely arranged young connective tissue cells could be seen throughout the section. This subacute productive lymphadenitis occurred mainly in cases of some duration and appears to indicate the end-result of the process.

Larynx.—The mucosa of the larynx was definitely reddened and somewhat swollen in only about one-third of the cases. Occasionally the glottis and surrounding structures were edematous, but ulcerations were never encountered. In a general way, the laryngeal mucosa was never as much involved as that of the lower trachea or of the bronchi.

Trachea and bronchi.—The mucosa of the trachea and principal bronchi was generally markedly reddened, cloudy and swollen, at other times it was of a paler red color and overlaid with mucopurulent or purulent secretions. The changes may be summarized as follows: The tracheitis and bronchitis were hemorrhagic in character 63 times, catarrhal 31 times, purulent 23 times, while in 9 cases no gross alterations were noted. Hemorrhagic types were chiefly met in the more acute cases, the catarrhal and purulent forms occurring usually at later stages. Fibrinous exudates now and then covered a part of the tracheal or bronchial walls, but there were no distinct macroscopic ulcerations. The contents of the tubes consisted usually of large amounts of frothy, blood-stained material in the hemorrhagic types, while in the catarrhal and purulent forms great quantities of mucopus, or thick yellow, purulent fluid were found.

The alterations, with respect to distribution of bronchial inflammation, were usually not uniform. Thus, the bronchi leading to diseased parts were usually more affected than those supplying healthy lung tissue. On the other hand, occasionally there were seen bronchial tubes intensely inflamed, while no marked changes in the surrounding lung tissue existed. The small bronchial branches presented generally the same changes as the larger tubes. Microscopically, most pronounced alterations were observed. Of these, desquamative bronchiolitis was the most frequent, the mucosa here being almost entirely destroyed. Ulcerative bronchiolitis was also very common. Sometimes the entire bronchial wall was eroded and replaced by a densely necrotic mass containing strands of fibrin and polymorphonuclear cells in various stages of degeneration. In the less affected bronchioles, and in the larger bronchial branches, extreme congestion and submucous hemorrhages were very general. Thrombi of various natures, but usually hyaline, were common. The endothelium was often actively proliferated. Infiltration of the bronchial walls with polynuclear cells was frequent. The mucous glands usually presented mucoid degeneration. Bronchiectasis was relatively uncommon. Large ulcerations occurred in four instances only. This was referred to above in connection with subcutaneous emphysema.

Pleuræ.—Early cases presented far less pleural involvement than those occurring later in the epidemic. In each instance an associated pneumonitis was present. Primary pleuritis was never observed.

The pleura was involved on one or both sides in 90 cases. The exudate was sanguineous in 12, fibrinous in 27, serofibrinous in 19, serofibrinopurulent in 23, and frankly purulent in 9 instances. The left pleura was somewhat more frequently involved than the right. The exudate was generally thin and apparently low in fibrin content. In the early part of the epidemic the sero-sanguineous types occurred most frequently, the fluid being definitely blood-tinged. Under fibrinous pleuritis are included all degrees of fibrinous exudation. Generally, only a small, fine, grayish, patchy deposit, often not more than a roughening of the pleura, was present. In the serofibrinous exudates small clumps of fibrin were floating in a relatively clear or only slightly turbid fluid. By serofibrinopurulent exudates are understood those fluids which were most definitely turbid. The purulent exudates were of the usual type. Analysis as to the amount of fluid could be made in 71 instances. The figures given apply to the fluid in either cavity. Thus, if both the right and left cavities contained a varying amount they were considered separately. Fluid was less than 100 c. c. in 10, between 100 and 500 c. c. in 38, between 500 and 1,000 c. c. in 15, between 1,000 and 2,000 c. c. in 7, and over 2,000 c. c. in 1 instance; the greatest number, therefore, containing less than 500 c. c.

Analysis in reference to the duration of the disease and period of the epidemic reveals the fact that the purulent and more pronouncedly fibrinous fluids occurred at a later stage of the disease or epidemic. Petechial hemorrhages were observed frequently, varying in extent, sometimes involving considerable areas and being in 50 per cent associated with a pleuritis. Cytologically, the pleural exudate consisted chiefly of large mononuclear cells, with considerable numbers of polynuclear elements. Phagocytosis of bacteria was common. Microscopically, the pleura presented the usual changes encountered in exudative inflammations. The subserous vessels were generally hyperemic and frequently contained hyaline or conglutination thrombi.

Lungs.—The anatomic alterations of the lungs were usually the most pronounced and most striking.

The duration of the pneumonitis was estimated from the day that lung involvement was first observed to day of death. Such an estimation is only accurate in a relative way, but certain interesting features were brought out thereby. Eight of the 109 cases developed pneumonia within the first 5 days of the disease, and 43 more within the first 10 days, so that about half of the entire series presented lung involvement relatively early in the attack. The other half showed definite pneumonitis considerably later, 15 cases developing it after the disease had persisted for 20 days. Once the pneumonitis was established it proved fatal within a relatively short time. Thus, in 45 instances, the duration was 3.68 days, in 37 it was 8.02 days, while in only 3 cases did the pneumonic process persist over 20 days, giving an average of 26 days. Pneumonitis occurred in 124 instances, in 2 cases none was present. In both of these a rapidly fatal epidemic meningitis occurred.

Usually the involvement was extensive, in 98 cases 3 or more lobes presented areas of consolidation. Both lungs were involved in 116 cases, the right lung alone in 3, the left alone in 5 instances.

The weights of the lungs were estimated in 65 instances. In only a small per cent relatively was the weight of either lung below 500 gm. In 67 per cent of the cases the left lung averaged 717 gm.; in 55 per cent the right lung averaged 761 gm., in 17 per cent the left lung averaged 1,328 gm., and in 36 per cent the right lung averaged 1,343 gm. The lungs, therefore, were considerably heavier than in the average case of bronchopneumonia, especially that of the aged.

The cut surface of the lung was generally very moist and excessively bloody, especially in the cases dying after a relatively short duration of disease. From the inflated anterior edges large amounts of lightly and heavily blood-tinged, frothy serum could be expressed. In the posterior two-thirds larger and smaller areas of consolidation were present. These varied in color, size, and consistency, resulting in a number of distinct pictures, often within the same lobe. Generally, the consolidated areas were indistinctly outlined and gradually faded into the surrounding hyperemic lung tissue. A marked tendency to become confluent was noted, and pseudolobar involvement occurred very commonly.

The texture was as diverse as the other features; smooth and velvety consolidations, bordering on coarsely and finely granular neighboring areas. These granular consolidations resembled in every way the cut surface of a croupous pneumonia, except for their lobular character. The consistency ranged from definite necrotic softening to total firmness, and the color varied through all shades of red and gray. Only exceptionally were the consolidated areas definitely peribronchial. Now and then the interlobar septa were thickened and indurated areas were present. Atelectasis, due to obstruction of bronchial branches, was common, sometimes involving considerable areas. In a general way, the consolidations according to their extent, might be classified as patchy and confluent or pseudolobar. There was but slight difference in the distribution of these two types in the various lobes of the lung; that the upper lobes were somewhat less confluent than the lower lobes, and that the middle lobes were the least affected.

Microscopically, as wide a variation was seen as in the gross appearance. The exudates had, however, sufficiently distinctive character to allow the division into three main groups. In the first, the exudate was chiefly catarrhal, consisting of large, desquamated, epithelial cells. In the second group the same features obtained, with the addition of a heavy fibrin network. In the third group, the exudate was mainly purulent, with the addition of fibrin. All three types often existed in the same lung. Commonly, even the same microscopic section presented all three of them, so the great variation of the exudate might be taken as one of the main characteristic features of influenzal pneumonitis. This is readily explained if it is remembered that one or more organisms invade these tissues, and that each class of bacteria may set up distinctive inflammatory processes in adjoining or closely placed together alveoli. In addition to the cellular character of the exudates, there was usually a heavy admixture of red blood cells with large amounts of precipitated serum. It is very difficult to estimate the incidence of the three groups of exudates, since

they so commonly occurred together. By taking several sections from each lung and noting the predominant character of the exudate, the following group might be made: Catarrhal bronchopneumonia, 34 per cent; fibrinocatarrhal bronchopneumonia, 39 per cent; fibrinopurulent bronchopneumonia, 27 per cent.

Such grouping, however, is only highly approximate and represents but the predominating character of the exudate in the majority of the sections examined. Fibrin, in varying amounts, could practically always be found in some sections, and in over two-thirds of the cases it was prominent. The exudate of the more catarrhal types generally presented pronounced swelling of the lining epithelium, and not infrequently groups of alveoli were lined with huge cuboidal cells, giving the appearance of tubules and resembling the condition of the fetal lung. Such changes, as is well known, are often seen after indurative bronchopneumonia processes, but only rarely is this extreme proliferation encountered in an acute pneumonitis. In some sections the condition was so uniform as to make one consider the possibility of a reversion to fetal types, an anaplasia produced by excessive stimulation of the lung epithelium. It is doubtful whether such anaplastic changes ever occur in acute inflammations, and the statement here is merely an analogy.

In sections where definite fibrosis was present—usually in cases where the pulmonary infection had persisted for a relatively considerable time—such proliferation of the lining membrane was likewise frequently encountered. Occasionally the alveolar membrane was intact, but more generally a part, at least, was desquamated, and these huge cells were lying free in the air sacs.

All stages of cellular degeneration could be observed, the most noteworthy being vacuolization with shrinkage of the nucleus. Phagocytosis was often seen; the phagocytized structures being most often red blood cells, polymorphonuclear leucocytes and cellular débris. Bacterial phagocytosis was relatively infrequent in the large cells, but quite common in polymorphonuclear leucocytes. Sometimes the epithelial cells were fused together, forming huge, syncytial masses, apparently consisting of from three to five fused cells and measuring up to 60 microns in diameter. These giant structures frequently contained inclusions of red cells and leucocytes, and were probably degenerative in character. Besides the lining cells the exudate consisted chiefly of precipitated serum and red corpuscles, polymorphonuclear elements being uncommon. Definite hemorrhages were frequent and often involved large areas. The alveolar capillaries were hugely distended and often contained hyaline conglutination thrombi. Generally, the walls were well preserved and cellular infiltration was rare. The perivascular and peribronchial spaces contained cells of the same type as those described.

This catarrhal type of pneumonitis predominated early in the epidemic and throughout the epidemic in patients dying after a relatively short illness, and it was believed that the changes enumerated were more directly due to the virus of influenza than to the associated bacteria; in fact, that the pronounced epithelial proliferation and the marked hyperemia constitute the essential early lesions of true influenza.

The second type of pneumonitis was fibrinocatarrhal in character, and differed from the preceding not only in the addition of large amount of fibrin, but also in cellular reaction. Catarrhal cells were still present in relatively large numbers and presented the general characters mentioned above, excepting that more intense degenerative changes were seen. The fibrin occurred in the form of dense networks, consisting sometimes of fine, sometimes coarse, strands, and it was generally more pronounced at the periphery of the air cells. Polymorphonuclear cells were present in greater numbers than in the preceding forms. Red blood cells were abundant, but generally not so excessive as in the preceding type. The alveolar walls were frequently ruptured and infiltrated with mononuclear and polymorphonuclear leucocytes, and often showed a fibrin network. This type was looked on as an intermediate stage in the disease process.

The third group was fibrinopurulent or purulent in character, the exudate containing relatively few epithelial cells, while polymorphonuclear leucocytes were abundant. Fibrin was present in varying amounts. The alveolar contents were rarely hemorrhagic, though sometimes a few red cells were seen. Serum was seldom as pronounced as in the earlier stages. Typical plasma cells were frequently observed in considerable numbers in the exudate as well as in the lymphatics and alveolar walls. These last often showed widespread destruction, and large areas of necrosis were often seen.

Fibrosis was not infrequent. The bronchial walls were often entirely destroyed and abscesses were many times encountered. This was considered the end of influenzal pneumonitis. It occurred at a later period in the epidemic when the duration of the illness was considerably longer than in the earlier part of the epidemic, and when the pneumonic processes had persisted for some time. It is the second and third type of influenzal pneumonitis which is probably produced by the commensals of the virus of influenza.

An attempt was made to correlate the anatomic findings with the bacteriologic results, and to classify the types of pneumonitis encountered according to the bacteria present. As will be seen in the bacteriologic part of this discussion, the microorganisms which were most often isolated were: *B. influenzae*, hemolytic and nonhemolytic streptococci, pneumococcus of various types, *M. catarrhalis* and staphylococcus. These were usually present in various combinations. Indeed, it was not uncommon to find most or all of them in cultures from the different lobes of the same lung. It was exceedingly difficult therefore to attribute this or that anatomic change to any special bacterial type. The fact that all of these bacteria must be looked on as commensals, or as secondary or tertiary invaders of the pathologic tissue prepared by the virus of influenza, make separation on an etiologic basis generally quite impossible.

It was the custom at Camp Taylor to take cultures from all lobes of the lungs, as well as from the principal organs. In only two instances were pure cultures of the influenza bacillus isolated; once the staphylococcus, once *M. catarrhalis*, five times the nonhemolytic streptococcus and somewhat more frequently the pneumococcus, and hemolytic streptococcus were found in an unmixed form in the lungs and elsewhere. If to this be added the difficulty

in isolating this or that bacterium there is introduced an added source of error; nevertheless, in the patients where pure cultures of one type were obtained, a correlative study was undertaken.

It has been stated that it was not uncommon to find several distinct types of exudates within the same lung, and even within the same microscopic section, and it was not surprising, therefore, to obtain the same results when comparison of the anatomic and bacteriologic studies was undertaken. Thus, for instance, in the two cases where *B. influenzae* occurred in pure culture, the exudate was fibrinocatarrhal in the majority of sections of one case, and purulent, with relatively small amount of fibrin, in the other. The same condition was present in the staphylococcus and *M. catarrhalis* cases, while in the pneumococcus and hemolytic and nonhemolytic streptococcus cases the results were even more confusing. Thus, in 19 cases where the hemolytic streptococcus predominated, the lung exudate in the majority of the sections was catarrhal 8 times, fibrinocatarrhal 5 times, fibrinopurulent 4 times, purulent with areas of necrosis twice. The nonhemolytic streptococcus and the pneumococcus cases showed a similar discrepancy. It is not feasible, therefore, to divide the pneumonitis of influenza on bacteriologic basis excepting in a general way, and this can be done by considering the mixtures of bacteria that predominated at the various stages of the epidemic and in the different periods of the disease, remembering always that one deals with a definite morbid process, more or less modified by commensal or invading organisms.

Spleen.—In 10 of 68 cases the spleen weighed less than 150 gm., in 31 it weighed between 150 and 249 gm., with an average of 195 gm. In 25 it weighed between 250 gm. and 449 gm. with an average of 321 gm. In 2 cases it weighed more than 450 gm. with an average of 590 gm. It would seem, then, that in more than 80 per cent of the cases the spleens were definitely enlarged, and in almost one-third of the total number they were considerably increased in size. Definite diminution never occurred, the spleen in no instance weighing less than 100 gm.

The capsule was generally tense, the external color reddish brown to purplish red, consistency slightly flaccid, occasionally much softened. The cut surface was usually uneven, moist, and often very bloody. The trabeculae could not rarely be recognized distinctly. The follicles were plainly visible or somewhat prominent in 57 instances and indistinct or entirely obscured in 69 instances. The pulp was usually softened, and in about 20 per cent of the cases it was definitely mushy. The duration of the disease process, the period of the epidemic, the size of the spleen and its follicular or diffuse character did not appear to exhibit any constant relation. Microscopically, the commonest change consisted in the excessive blood contents; often large areas flooded with red cells, constituting undoubted hemorrhages, many of these cells being shadow rings. An endothelial hyperplasia of the vessels and sinuses was usually present and often pronounced. Oftentimes desquamated endothelial cells were found free in the venules and arterioles, occasionally obstructing their lumen; hyalin and conglutination thrombi were likewise present. Widespread necrosis of the reticulum commonly occurred, partly due, probably, to the hemorrhages and partly to toxic action. Now and then the arterial

walls presented a smooth, homogeneous staining, evidencing toxic hyaline degeneration. Elsewhere definite hyperplasia was present, manifesting itself by greatly increased numbers of large mononuclear splenic cells. Polymorphonuclear cells were rarely met with, and then only in small numbers. The malpighian bodies were generally loosely arranged, with many large, pale, staining, germinal lymphocytes. Within the follicles one frequently encountered eosin staining, smooth, hyaline areas, occasionally of considerable size. On minute inspection these areas seemed to be composed of huge, partly fused, indefinite staining, degenerating cells.

Semilunar ganglia.—These structures in practically every instance were slightly swollen and occasionally of a faint pink color. There was no appreciable change in the consistency. The cut surface was usually moist, often decidedly pinkish, and a number of bleeding points were always seen. Microscopically, the ganglion cells were swollen, devoid of definite outline, with a granular cytoplasm which stained poorly and did not show Nissl granules. The nuclear changes varied from loss of nuclear outline to poor or excessive staining, granularity, and often total disappearance of the nucleus. The nucleoli, as a rule, remained, but occasionally they likewise disappeared. Extreme changes consisted in loss of the entire cell. The above-enumerated alterations usually affected only isolated cells or groups of cells, for in other parts of the section the structures were normal. The condition was comparable to the ganglionic changes in the cerebral cortex and seems to point to the widespread toxic effects of the virus. The vascular changes were similar to those described in other organs, such as definite hemorrhages, and practically always, marked congestions. Occasionally, the perivascular lymphatics were dilated and packed with large and small round cells. The interstitial substance was often loosely arranged.

Suprarenals.—In three instances frank hemorrhages were present in the suprarenal substance, enlarging the organ to about twice its normal size. In 20 cases the suprarenals showed no gross changes. In the remaining 103 cases there was slight increase in size and definite congestion. In these latter cases the outside color was pinkish-brown, and the cut surface decidedly bloody. The outer zone of the cortex was generally narrow and pale grayish-yellow, rarely presenting the deep orange yellow tint so frequently seen in the suprarenal cortex. The intermediate zone was a deep reddish brown and exuded blood, while the medulla varied from a reddish-gray to a deep red. Microscopically, extreme congestion and frequent small hemorrhages were found, involving the medulla and intermediate zone. The cells of the cortex appeared slightly swollen and usually devoid of their lipid granules. This lipid exhaustion was observed almost constantly. Other cells appeared in the state of acute cloudy swelling, with indefinite cell outlines and poorly staining nucleus. The interstitial substance was usually arranged loosely and was definitely edematous. Focal necrosis, with small round cell infiltrations, was occasionally observed. In a number of the gland cells, especially of the cortex, numerous deep blue staining, coarse granules were encountered. Very occasionally diffuse infiltration with polymorphonuclear cells, pointing to an acute inflammatory suprarenalitis, was seen.

Kidneys.—The details of the weights and measurements were tabulated for 50 pairs of kidneys. In 10 per cent both kidneys weighed less than 150 gm. each. In 86, or 88 per cent, the weight of each organ averaged 202 and 207 gm., respectively. In 4, or 2 per cent, respectively, each organ weighed 210 gm. Both kidneys were of the same weight in 7 per cent, the left was heavier than the right in 54 per cent, and the right kidney heavier than the left in 39 per cent of the cases. The measurements corresponded to the size. This means that in 90 per cent of the examinations the kidneys were somewhat increased in size or weight. In every instance parenchymatous changes, usually of mild degree, but often quite severe, were observed. It was not possible, grossly, and frequently impossible minutely, to decide whether the condition present should be looked on as an early parenchymatous nephritis, or as a transitory cloudy swelling. Definite nephritis was present in about 10 per cent of the cases, but generally the organs were flaccid, with an easily stripping capsule, leaving a smooth, grayish red, often mottled, surface, on which the stellate veins often stood out prominently. The cut surface, as a rule, was moist and bloody. The cortex was usually moderately increased in width, the cut edges gaping slightly, and, in a number of cases, considerably. The glomerular markings were sometimes washed out, but at other times very definite, and, in a considerable number of instances, the glomeruli and cortical striations were prominent. The corticomedullary junction, as a rule, was very indefinite. The medullary junction was usually very indefinite. The medullary striations varied, but, as a rule, were distinct. The pelvic mucosa usually presented injection, and in about 30 per cent of the cases submucous, petechial hemorrhages were encountered.

Microscopically, the kidney picture was quite uniform, varying only in degree. The interstitial substance was moderately edematous, the glomeruli were large, the capsule of Bowman was not thickened. The capsular epithelium was swollen and proliferated in about 20 per cent of the cases. Multiple layers of capsular epithelium were met with in a few instances. The capsular space, in 50 per cent of the cases, contained a granular, eosin staining precipitate. The tufts were large because of vascular congestion. The endothelium was swollen, with large nuclei, but there was no evident active multiplication. Frequently, hyaline and conglutination thrombi were seen. The tubular epithelium was generally swollen, the cell outlines poor, the cell borders ragged, and the lumen filled with granular débris. Often vacuolization was observed. The nuclear changes ranged from poor staining reactions to total absence. In one instance, a large part of the kidney appeared necrotic. Small microbial abscesses were present in only one instance. In every case the convoluted tubules were more affected than the straight tubules. The degeneration and necrosis of the epithelium was rarely uniformly distributed, sometimes entire tubules, or groups of tubules, were attacked, with apparently normal epithelium in close proximity.

The kidney changes observed here and elsewhere during the epidemic seem to be of the nature of a parenchymatous degeneration, with edema, rather than of a productive nephritis, although this too occurred several times.

Ureter and bladder.—The ureter, in its upper fourth, frequently showed submucous, hemorrhagic extravasations, similar to those observed in the renal

pelvis. The rest of the mucosa was occasionally moderately injected. The urinary bladder was similarly affected, showing injection, and commonly submucous, petechial hemorrhages.

Prostate.—No gross or microscopic changes were observed, with the exception of slight congestion. The prostatic acini presented no noteworthy alterations.

Seminal vesicles, spermatic cords, and testicles.—The seminal vesicles were generally filled with a viscid, sometimes slightly turbid fluid. The spermatic cords presented no gross changes. The testicles very frequently possessed a moist, definitely bloody, cut surface and were of softened consistency. The cells, microscopically, were commonly swollen and ragged; cessation of spermatogenesis was frequently seen.

Tongue.—The tongue was often reddened, but no characteristic changes, as in typhoid fever or scarlet fever, were observed. The mucosa of the mouth and posterior pharynx was likewise often reddened. Microscopically, the lymphoid tissue was frequently very prominent. The youthful age of the patients made it unlikely that a pathologic change was being dealt with, although the lymph tissue generally in the body was proliferated above the normal state for the age of these patients.

Tonsils and thyroid.—An acute tonsillitis was occasionally encountered, but it is probably coincidental. The thyroid was now and then somewhat enlarged, but presented no noteworthy microscopic changes.

Pharynx, esophagus, and stomach.—The mucosa was frequently dusky. The lymph follicles, in the lower part of the esophagus, were usually prominent. In the stomach there was found almost constantly extensive submucous, petechial, hemorrhagic extravasations, not confined to the dependent parts, and probably not post-mortem in origin, since they were found in bodies necropsied within an hour or so after death. The condition is comparable to the hemorrhagic extravasation noted beneath mucous and serous surfaces and in the skin. The stomach contents, which were generally fluid, often had a light brown or reddish-brown tint, due, probably, to slight leaking of the extravasated areas. No other gross or microscopic changes occurred.

Liver.—The details of the weight and size of the liver were estimated in 61 instances. In 7 per cent the liver weighed less than 1,500 gm.; in 47 per cent the weight averaged 1,829 gm.; in 46 per cent the weight averaged 2,254 gm. The consistency was generally flaccid, occasionally definitely soft. The lower edge was, as a rule, rounded, the capsule smooth and translucent and the subcapsular lobulation generally indefinite but sometimes prominent. The cut surface was generally slightly but considerably bloody. The lobulation appeared washed out. The translucency of the tissue, in the majority of instances, was dull, gray and often parboiled. In about one-third of the cases the centers of the lobules were large and deeply congested. Frequently, especially near the periphery of the organ, pale, yellowish fatty areas were seen. In a number of cases lobulation appeared usually distinct, the centers being very large and dull brownish-red or yellowish-red, with a narrow, grayish-brown peripheral zone. Very exceptionally the surface possessed a fatty sheen; evidences of biliary pigmentation were never observed grossly.

Microscopically, the principal change was albuminous degeneration, the cells being large, with cloudy cytoplasm, the nucleus presenting various degenerative changes. Inconspicuous biliary pigmentation was common but not prominent. A few areas of fatty infiltration were frequently seen, but this was never excessive. Fatty degeneration was rare, but hydropic degeneration was common. In fully 50 per cent of the cases areas of focal necrosis were present. In 11 per cent these were pronounced and large, and, in one instance, a marked acute yellow atrophy was present. The areas of focal necrosis, in the majority of instances, were relatively small, involving only groups of a few liver cells, but all degrees were present with an extreme condition in one case where practically no normal liver cells occurred. The necrotic tissue consisted of structureless, eosin staining cells, intermingled with free nuclei, lymphocytic elements and moderate numbers of plasma cells with relatively few polynuclear elements. In the cases of acute yellow atrophy all but the periphery of the lobules was destroyed, the peripheral cells being swollen and multivacuolated and presenting pronounced nuclear changes. The Kupfer cells throughout the liver, but especially in the necrotic areas, possessed swollen, oval nuclei and large amounts of cytoplasm. Red cells were present in moderate numbers. The gross appearance of the liver gave little evidence of the excessive microscopic changes. It was softened, of reddish-brown color, the cut surface presenting very large, reddish-brown lobular centers with a pale periphery.

Frequently, the liver cells contained fine, blue-staining granules. Searching with the oil immersion lens, one occasionally saw small groups of micrococci in the sinusoids, and it seems that these granules were similar to those described by Adami in his subinfection theory as being the final stages of bacterial destruction. The same doubtless holds true of the blue granules described above in connection with the suprarenals. Sometimes this condition could be studied exceptionally well, especially when only small numbers of microorganisms were present in the sinusoids, for here all stages of bacterial lysis could be observed in the adjoining liver cells. The periportal connective tissue was rarely proliferated, but occasionally a lymphocytic or leucocytic infiltration of unimportant degree was observed. The number of biliary ducts was never increased, but in extensive necrosis there was a swelling, without multiplication of the component cells. The vascular changes were similar to those described elsewhere, and frequently consisted of intense congestion and hyaline or conglutination thrombosis.

Pancreas.—The gross changes were slight and consisted in flaccidity and dusky gray appearance, and the cut surface was often moderately bloody. Microscopically, the vascular changes were of the usual type. The cells of the acini were frequently swollen, with poor staining or faulty staining nuclei. The ductal cells presented similar changes, and occasionally were desquamated. The most important alterations were noted in the islands. These were indefinitely outlined; their cells had a washed out appearance, and were poorly differentiated from one another. They were increased in size, often fragmented, and usually presented pronounced nuclear changes or absence of nucleus. This is a similar toxic degeneration to that observed in the liver, spleen and elsewhere.

Mesenteric lymph nodes.—The lymph nodes were moderately swollen, but never were larger than a bean. Their cut surface was slightly moist and had a grayish-pink appearance. Frequently, they were definitely reddened. Microscopically, there was a slight sinus catarrh, slight lymphoid proliferation, and a moderate edema, the changes being comparable to those in the peribronchial lymph nodes, although always of a much less degree.

Intestines.—Practically always, larger or smaller areas of the mucosa were definitely congested and frequently submucous hemorrhages were seen. The mucosa was commonly swollen, gray and turbid, and, in the duodenum, much bile stained. In the majority of instances, the lymphoid tissue was definitely hyperplastic, this condition being especially pronounced in the ileum. Of 97 cases, where notes as to the lymphoid status were made, the solitary follicles and Peyer's patches were markedly hyperplastic in 40, the hyperplasia being slight, or not present in the remaining 57 instances. In the pronounced cases the follicles were swollen to the size of two or three millimeters, and usually were surrounded by a definite hemorrhagic zone, giving the mucosa a coarsely granular appearance. The Peyer's patches were well raised above the surface and of a grayish-brown color. Occasional central liquefaction necrosis of the follicles was encountered, resulting in the formation of vesicular structures with turbid contents. Microscopically, congestion and submucous hemorrhages were the rule. The lymphoid tissue was actively hyperplastic, presenting many large lymphoid cells and some endothelial elements.

Nervous system.—The brain and its membranes were examined in 85 cases, and next to the diseases of the respiratory apparatus, the changes in the nervous system seem to be the most frequent and important complications in influenza.

Dura mater.—Congestion, generally of a mild degree, was found in 29 instances. In one case a marked internal hemorrhagic pachymeningitis occurred in conjunction with a purulent meningococcal meningitis. The entire inner surface of the dura was coated with a thick layer of firmly clotted blood, averaging from 2 to 5 mm., which adhered but slightly to the pia-arachnoid, but was firmly affixed to the dura.

Pia-arachnoid.—Fibrinopurulent leptomeningitis was found thirteen times, serolymphatic meningitis with congestion seventeen times, and in the remaining 55 cases edema and congestion of more or less pronounced degree. The origin of the purulent meningitis was meningococcal in seven cases, pneumococcal in four, and streptococcal in two instances. The constantly present congestion and edema doubtless created a focus of lessened resistance, explaining the frequency of meningeal complications. The frankly purulent inflammations generally occurred late in the disease, but some developed within a few days after the onset of the influenza. They differed anatomically in no way from the usual lesions of this type. The other meningeal infections which we have here termed serolymphatic appear to be the direct result of the virus of influenza. In all of these cases the membranes were soft, watery, and considerably congested.

The subarachnoid fluid, especially in the large cisterns, was definitely turbid. In the sulci and surrounding the larger vessels, there was a cloudy, turbid, grayish-yellow exudate. This was most frequently observed over the temporal and parietal regions, and was slight or absent over the base of the

brain. Microscopically, two types were recognized. In the first the pia-arachnoid was loosely arranged and distended with fluids, the vessels were densely filled. Isolated red blood cells and small round lymphatic cells were scattered throughout the tissue with occasional large endothelial cells. In the second type the pia-arachnoid was densely infiltrated with small round, many large, deep-staining mononuclear, some pale-staining endothelial together with plasma cells. Polymorphonuclear leucocytes were rarely encountered, and then in small numbers; fibrin was absent, or at most present only in small traces. This type of meningitis was characterized, then, by the lymphocytic type of the cellular exudate and the scarcity or absence of polymorphonuclear cells and fibrin, together with pronounced hyperemia, edema, and occasional hemorrhages.

Brain.—The weight of the brain was tabulated for 46 cases. In 39 per cent it averaged 1,300 gm., in 50 per cent 1,452 gm.; in 11 per cent 1,739 gm. The weight, therefore, was increased from 100 to 200 gm. in about half of the patients. Consistency was somewhat more flaccid. The ventricles were generally of normal size, or only slightly distended. Slight cloudiness of the ventricular fluid often was observed, even in the cases not associated with purulent meningitis. The ependyma presented no noteworthy alteration. The pineal gland was grossly normal, or at the most, somewhat softened. No microscopic studies of them are included in this series. The cut surface of the brain in practically every instance, presented an excessive number of bleeding points. They were most pronounced in the white matter of the hemispheres, but occasionally the corpus thalamus was especially involved. The cerebral cortex was less affected and the pons, cerebellum, medulla, and spinal cord presented these changes in considerably less degree. These bleeding, points appeared usually as closely placed, punctate, minute, hemorrhagic areas.

Microscopically, intense congestion of the vessels and numerous minute hemorrhagic foci were encountered. Their distribution corresponded to the grossly hyperemic areas. The hemorrhages never exceeded, in size, the diameter of a low-power microscopic field and were generally only of about half this size. The vascular endothelium was frequently swollen and hyaline and conglutination thrombi were often met. The perivascular spaces were frequently large and contained precipitated, edematous fluid. Occasionally only was a perivascular cellular infiltration noted. The ganglion cells presented most pronounced changes. Sometimes only isolated, sometimes large groups of cells, were affected. They were generally swollen and without definite cell outline. Commonly, a small, clear, edematous zone surrounded the cells. The cytoplasm was devoid of Nissl granules and the nuclei were frequently entirely absent or showed a loss of outline. In short, all stages of cell degeneration were present, ranging from acute cloudy swelling to chromatolysis and total disappearance. In no instance, however, was invasion and phagocytosis of ganglion cells observed. The glia matrix was generally arranged loosely. The cell degenerations enumerated did not appear to attack constantly any special part of the brain, and the sections of spinal cords examined were too few to formulate an opinion.

Pituitary gland.—This gland was examined only a few times. In each instance it was somewhat swollen, pinkish in color, the cut surface being moist.

definitely bloody, and reddened. Microscopically, the tubular acini were markedly distended with a colloid material, the lining cells flattened; sometimes throughout the section coarse strands of fibrin were present. The vessels were much dilated and small hemorrhages frequently were seen. Unfortunately, the posterior lobe never was included in the sections. These unusual findings are explained readily by the great frequency of purulent nasal sinus involvement and by the frequent association of suppurative meningitis.

Ear.—Suppurative otitis media was present in only four instances. This stands in marked contrast to the frequency with which it occurred during a coexisting epidemic of measles where it was present in 9 of 25 necropsied patients.

Eye.—Hyperemia and inflammation of the conjunctiva very frequently were found and would probably indicate the generalized vascular engorgement rather than a localized condition. No microscopic sections of the eyes were made.

CHRONIC INFLUENZA

While influenza, as a rule, runs an acute course, it may become protracted over a considerable period. Any case of influenza which extends over a period of four weeks or more, generally with remittent or intermittent fever, and various lung symptoms, may be looked on as typical of the chronic form of this disease. Clinically such a condition often resembled typhoid fever, malaria, tuberculosis, or low-grade septicemia.

Five patients of the series of 126 presented this condition. The duration of the disease varied from 44 to 88 days, with an average of 60 days. Judging from the clinical records, each patient suffered with an initial typical attack of influenza, which was followed, sooner or later, by signs of pneumonic consolidation and accompanied throughout by a fluctuating fever curve. The pneumonitis seemed to persist, but shifted from place to place, constantly involving new areas, while the older pneumonic patches persisted or sometimes cleared up.

PATHOLOGICAL ANATOMY

All these cases came to necropsy during the last period of the epidemic, or rather after the bulk of the epidemic had subsided. They showed certain anatomic differences which justify their separate discussion.

There was emaciation in each instance, two showed slight icterus, none the intense cyanosis and lividity so commonly seen in the acute cases. The cut surface of the subcutaneous tissues and muscles was never so bloody and moist as in the acute disease. In one instance a large abscess in the rectus muscle was present. Acute purulent peritonitis occurred thrice, which is in marked contrast to its absence in the acute cases of the series. The changes in the aorta and other vessels were similar but more profound.

Pericardium and heart.—Purulent pericarditis, associated with a purulent inflammation of the other serous membranes, was present once. In the rest no noteworthy changes were found. There was particularly an absence of subserous, hemorrhagic extravasations and of hyperemia.

The heart varied in weight from 205 to 425 gm., with an average of 310 gm. The right heart was constantly dilated, and in one instance both chambers

were markedly dilated. The muscle was always very flaccid, light grayish-red and turbid.

Microscopically, there was shown marked swelling and vacuolization of hydropic character, and while the vessels were not congested, usually they contained hyaline thrombi, which were more pronounced in the chronic than in the acute cases. Endothelial hyperplasia varied in degree in the chronic form, and no definite comparative picture could be formed.

Respiratory tract.—The peribronchial lymph nodes were always greatly swollen, soft and edematous, but only slightly congested. Microscopic section presented edema, sinus catarrh, slight connective tissue proliferation, and, in two instances, an acute purulent adenitis, with the presence of large numbers of polymorphonuclear leucocytes and small areas of necrosis. The vessels showed no other changes than those mentioned above.

The trachea and bronchi possessed a relatively pale mucosa which was covered in every instance with mucopus; in the smaller branches a thick, creamy, yellow pus was present. Microscopically, well marked erosion of the wall, and the presence of enormous numbers of polymorphonuclear cells characterized the picture. Bronchiectasis never occurred, although commonly seen in chronic influenza.

The pleuræ, in each instance, were adherent in places by relatively firm, fibrous bands and by more recent fibrinous exudate. This seemed to have persisted for some time, since it was generally rather tough. The pneumonic process, according to the records, varied in duration from 27 to 74 days with an average of 44.1 days. The lungs were never so voluminous as in the acute type, and in no instance exceeded the volume usually seen in a chronic bronchopneumonia, the left lung averaging 440, the right 480 gm. in weight. Slaty blue, sometimes depressed, firm areas could be felt, especially on the posterior border in either lung. The cut surface was only slightly bloody, and in every instance the interpulmonary septa were prominent and there were larger and smaller areas of fleshy appearance and consistency. Soft, grayish-brown foci, finely and coarsely granular, apparently recent consolidations, and smooth, velvety, firm areas could be seen, but in general the extent of pulmonary involvement was less than in the acute cases.

Microscopically, certain characteristic features were always present; namely, areas of atelectasis, sometimes of considerable extent; areas of young connective tissue overgrowth (carnification) and areas of necrosis and abscess formation. All stages of pneumonic involvement could be observed in the sections from these lungs. In every instance small, bronchopneumonic patches, with fibrinocatarrhal exudate of recent origin, were found. Generally, however, the exudate consisted of polymorphonuclear leucocytes, with little or no fibrin; the alveolar walls were infiltrated in places with such cells, and were frequently destroyed, resulting in abscesses which often reached considerable dimensions. The perivascular and peribronchial tissues were often definitely fibrous. In one instance a pronounced hyperplasia of epithelium, similar to that described in acute cases, was encountered.

Spleen.—The spleen varied in weight from 105 to 260 gm., with an average of 185 gm.; on the whole, the organ was therefore smaller than in the acute

cases. The capsule was generally wrinkled; the color of the organ was a reddish-gray; the consistency was always flaccid, but never soft or mushy. The cut surface was only slightly bloody; trabeculae could generally be seen, but were not thickened. In one case the follicles were prominent, in the others indistinct.

Microscopically, there was a distinct hyperplasia of endothelial cells throughout the organ; in two instances large numbers of polymorphonuclear leucocytes were present. Fibrosis of the reticulum was noted twice. Definite toxic hyaline degeneration of the arterial walls was noted in another case. Areas of hemorrhage were seen twice.

Suprarenals and semilunar ganglia.—Slight congestion and edema were observed. In one instance there was infiltration of the adrenal with polymorphonuclear leucocytes, otherwise the changes were similar to those previously described.

Comparative incidence of bacterial flora in one or more organs of 120 necropsies of influenza, and 101 other acute diseases occurring during the influenza epidemic

	Heart's blood				All organs			
	Influenza (107)		All other diseases (101)		Influenza (120)		All other diseases (101)	
	Num-ber	Per-cent	Num-ber	Per-cent	Num-ber	Per-cent	Num-ber	Per-cent
<i>B. influenzae</i>	30	28.0	4	3.9	74	61.6	22	21.7
Hemolytic streptococcus.....	32	29.9	32	31.6	41	34.1	51	50.4
Nonhemolytic streptococcus.....	31	28.9	10	9.9	56	46.6	18	17.8
Pneumococci (typed).....	24	22.4	5	4.9	43	35.8	11	10.8
Pneumococci (untyped).....	6	5.6	5	4.9	25	20.8	12	11.8
<i>M. catarrhalis</i>	3	2.8	1	0.9	35	29.1	11	1.1
Meningococcus.....	0	0.0	0	0.0	2	1.6	4	3.9
<i>M. tetragenus</i>	0	0.0	1	0.9	6	5.0	2	1.9
Staphylococcus.....	2	1.8	5	4.0	18	15.0	30	29.7
Diphtheroids.....	0	0.0	0	0.0	6	5.0	0	0.0

Kidneys.—Twice the kidneys were below average weight, and three times increased in size and weight, the average for the series being 193 gm. for the left and 190 gm. for the right kidney. In two cases the capsule was slightly adherent, tearing the parenchyma on stripping. The consistency in every instance was flaccid; the cut surface was pale, swollen, and reddish-gray, with poor differentiation of cortex and medulla. Cortical and medullary markings had a washed-out appearance. Hemorrhagic exudates in the renal pelvis were never observed.

Microscopically, there was a slight edema and congestion present in all, but no connective tissue overgrowth. The glomerular and tubular changes were similar to those described, differing only in greater degree of severity. In one instance polymorphonuclear leucocytes in large numbers were present in the glomerular capillaries; in another case the capsular epithelium was slightly proliferated. The tubular epithelium was considerably more degenerated than in the acute cases; many tubules were lined with entirely necrotic cells.

Liver.—Two cases were below the average in weight (1,330 gm.) the other three averaged 2,270 gm. The consistency was flaccid in each instance, the lower border well rounded. The color was generally grayish-brown. The cut

surface was slightly bloody. Lobulation was indistinct, but sometimes the centers of the lobules were large and deep red.

Microscopically, the two small livers presented marked degeneration of cells, areas of focal necrosis and a diffuse infiltration of polymorphonuclear cells which latter was somewhat more marked in the periportal tissue. In the other organs varying degrees of cloudy swelling were observed.

Meninges and brain.—The dura mater presented no changes. The pia-arachnoid was twice slightly edematous, and in one case of the three examined the vessels were considerably congested. Much opacity was present in this case, and over the superior surface of the cerebellum there was a small amount of grayish-yellow exudate. This patient had shown symptoms of spinal meningitis for about one month, but repeated lumbar punctures failed to bring out the causative organism.

Microscopically, there was a round cell infiltration with few leucocytes and some fibrin. The brain weight in the 3 cases averaged 1,480 gm. Only once did the cut surface show the marked congestion and petechial hemorrhage described above, while in the other two no gross changes were noted. Microscopically, there were degenerative changes in the ganglion cells similar to those already described; hemorrhages never were found.

BACTERIOLOGY

From the inception of the epidemic at Camp Taylor it was the routine to take cultures from the principal tissues at each necropsy—heart's blood, pericardium, right and left pleuræ, right and left lungs (all lobes), spleen, bronchial exudate, nasal accessory sinuses, subarachnoid space and ventricles, and elsewhere as occasion demanded.

Besides cultures, routine smears were made to act as a check on cultural findings.

The reports, both pathologic and bacteriologic, of this pandemic, as shown in the literature, revealed such an appalling divergency in conclusions, such diversity in reading results and in the means employed to get those results, that the findings in the study at Camp Taylor were analyzed in comparison with those from cases not to be considered as due in any degree to the prevailing epidemic, in order to see if there were not some underlying principles governing what appeared to be a disordered mélange in the organisms found.

In this series the bile solubility test was regarded as final; a diplococcus or diplostreptococcus, whether capsulated or not, whether lanceolate or not, if bile insoluble was regarded as streptococcus, either hemolytic or nonhemolytic according to a predetermined estimate of hemolysing ability. Frequently there were encountered pneumococci agglutinating with two or more of our type antisera; these were properly regarded as Group IV.

The gradations between hemolytic and nonhemolytic streptococci are so fine and indistinct that it was necessary to adopt a standard of differentiation and arbitrarily choose the ability of an 18 hours' broth culture to produce hemolysis with equal parts of a 5 per cent sheep suspension in the water-bath at 37.5° C. for two hours. The amount of the hemolysis, whether complete

or not, was not considered. Some strains would give complete hemolysis in half an hour or less, while others would not cause complete hemolysis in the two hours, but an evident hemolysis, however slight, at the end of the time period was sufficient to enable one to make a differentiation. All tests were run with two saline controls. The hemolytic streptococci were again subdivided in a number of instances by the Holman sugar standard (*Manual of Medical Research*, 1916, xxxiv, 377). By this means was determined the curious fact that *S. pyogenes*, which had so abounded at Camp Taylor in 1917-1918 (reported: *Journal of Infectious Diseases*, 1919, May 25; *Journal of the American Medical Association*, 1918, lxx, 775) was not represented among those found in the epidemic of autumn, 1918, its place being taken by hemolytic streptococcus No. 2. Double tests with fresh sugars were taken and corroborated these findings. Fifty strains of streptococcus were examined with the following results:

Hemolytic streptococcus:	Per cent	Nonhemolytic streptococcus:	Per cent
No. 2.....	70.3	Equinus.....	45.5
No. 1.....	3.7	Ignavius.....	22.7
No. 3.....	7.4	No. 2.....	11.3
Equinus.....	11.2	Mitior.....	11.3
Infrequens.....	7.4	Salivarius.....	11.3

This hemolytic streptococcus No. 2 was very frequently Gram-negative, not taking the Gram stain after repeated cultivation. It was recovered at one time or another from practically every organ or tissue, and on two occasions from the spinal fluid.

By the *B. influenzae* is meant a minute organism, Gram-negative, pleomorphic, hemophilic, which would not grow at room temperature, or only very slightly, and was generally killed by ice-box temperature. As a medium, rabbits' blood glycerin agar was used for a time, the growth appearing as multitudinous dewdrop colonies in from 20 to 48 hours. With the Washington formula the colonies were much larger, ringed and diverse in size and contour, giving a false impression of contamination. More latterly Avery's oleate medium (*Journal of the American Medical Association*, 1918, lxxi, 2051) was used with very gratifying results. Agglutination experiments of cultures against serum from recovered cases were doubtful or unsuccessful, except in two instances where the following results were obtained after incubation at 55° C. for 18 hours followed by 12 hours in the ice box:

1:2	1:10	1:20	1:40	1:80
++	++	++	++	±

Under the head of *Micrococcus catarrhalis* were included all members of this group, hardly any attempt at sugar or other differentiation having been made in the time at our disposal. Latterly, though, a prevalent diplococcus was found, both in sputum and at necropsy, the colonies resembling the *Micrococcus catarrhalis*, but morphologically showing slight differences. Since it fermented dextrose, saccharose and lactose the possibility of its being *Micrococcus crassus* was considered.

In the preceding table a comparison is made of the bacterial findings from 120 influenzal cases with those from 101 necropsies from other causes. These deaths all occurred during the period under consideration and should give a fair line, if such is to be obtained, on the leading bacterial factors in the epidemics seen at Camp Zachary Taylor. Four organisms especially predominated in the influenza cases; these were *B. influenzae*, a nonhemolytic streptococcus, pneumococcus of the various types, and *M. catarrhalis*.

The presence of the Pfeiffer bacillus in the heart's blood of 3.9 per cent of the noninfluenza cases is to be explained by the fact that there was a concurrent epidemic of measles, and these cases in a high percentage carried an organism indistinguishable from the *B. influenzae*, judging from a series of nasopharyngeal swabbings. The hemolytic streptococcus was not found in so high a percentage as in the noninfluenzal cases, and it was only at the latter end of the epidemic, and in those cases which were protracted, that it was met with to any considerable extent; so that it was looked on as a tertiary invader, in view of the fact that it had been endemic in this camp for 18 months.

The outstanding prominence of the *B. influenzae* is very noteworthy, and when the difficulty of its isolation and the fact that in the long continued cases it seemed to have died out or been replaced by the secondary or tertiary invaders, it is evident that these figures represent only the minimum number of times it was present during some period of the disease. In only two of the series was there a pure infection with this organism, and these were very early in the epidemic. Early also were eight cases of mixed infection with *B. influenzae* and a nonhemolytic streptococcus, and three of *B. influenzae* and pneumococcus; eight cases scattered throughout the epidemic of pure nonhemolytic streptococcus. Midway was one of pure *M. catarrhalis*; 10 cases mostly at the very end of pure hemolytic streptococcus, and 8 cases in this last period of mixed hemolytic streptococcus and staphylococcus. Nonhemolytic streptococcus and pneumococcus were found about three times as often in the influenza as in the noninfluenza cases. *M. catarrhalis* was very prominent in the latter part of the middle of the epidemic.

One very interesting organism encountered was a small biflagellated protozoon, measuring from 5 to 8 microns, and without undulating membrane, tentatively assigned to the Prowazekia. This was discovered in three cases close together toward the middle of the epidemic. In one instance it was recovered from the heart's blood; in another from the sphenoid sinus, and in the third from the left lung.

The following table gives the incidence and distribution of the bacteria according to the period of the epidemic. This table points out forcibly (a) the gradual lowering in the incidence rate of *B. influenzae*, nonhemolytic streptococcus, and pneumococcus; (b) the sudden rise into prominence in the third period of the *M. catarrhalis*, and (c) the remarkable manner in which the hemolytic streptococcus and the staphylococcus came to the fore in the last period. The latter especially had been practically nonexistent, so far as the necropsy cultures showed during the first three periods. The sudden recurrence of *B. influenzae* in the fourth period will be discussed later.

Incidence and distribution of bacteria, according to period of epidemic (in per cent)

Period.....	Organs															
	Heart's blood				Pleurae, right 41, left 43				Lungs, right 116, left 117				Bronchial exudate			
	1	2	3	4	1	2	3	4	1	2	3	4	1	2	3	4
Number of examinations...	41	30	16	33	45	21	7	11	82	60	32	59	16	22	9	4
<i>B. influenzae</i>	48.7	3.3	6.2	24.2	20.0	19.0	0	0	54.8	25.0	37.5	3.3	50.0	36.3	66.6	0
Hemolytic streptococcus.....	21.9	10.0	6.2	54.4	26.6	9.5	14.2	54.5	26.8	15.0	6.2	54.2	18.7	18.1	0	50.0
Nonhemolytic streptococcus.....	26.8	50.0	18.7	6.0	22.2	42.8	85.7	9.0	45.1	45.0	37.5	15.2	3.7	45.4	22.2	0
<i>Pneumococcus</i> , total.....	21.7	26.4	37.4	18.0	24.2	52.2	42.7	9.0	41.7	49.7	46.7	19.9	24.9	58.7	55.5	0
Type I.....	2.4	3.3	0	3.0	0	9.5	0	0	4.8	6.6	0	3.3	0	9.0	0	0
Type II.....	4.8	6.6	0	3.0	2.2	0	14.2	0	3.6	5.0	6.2	6.7	0	4.5	0	0
Type IIa.....	4.8	6.6	0	0	6.6	9.5	0	9.0	3.6	6.6	3.1	0	6.2	9.0	11.1	0
Type III.....	0	0	6.2	3.0	0	0	0	0	1.2	1.6	6.2	3.3	0	0	11.1	0
Type IV.....	2.4	6.6	25.0	6.0	6.6	19.0	28.5	0	3.6	18.3	25.0	5.0	12.5	27.2	22.2	0
Untyped.....	7.3	3.3	6.2	3.0	8.8	14.2	0	0	16.9	11.6	6.2	1.6	6.2	9.0	11.1	0
<i>M. catarrhalis</i>	0	0	18.7	0	4.4	0	14.2	0	18.1	6.6	34.3	6.7	6.2	4.5	55.5	50.0
<i>Meningococcus</i>	0	0	6.2	0	0	0	0	0	0	0	0	0	0	0	0	0
<i>M. tetragenus</i>	0	0	0	0	2.2	0	0	0	2.4	0	0	0	0	4.5	0	0
Diphtheroids.....	4.8	0	6.2	0	0	0	0	0	0	3.3	0	6.7	0	9.0	11.1	25.0
<i>Staphylococcus</i>	0	0	0	12.1	0	0	0	18.1	2.4	0	0	27.1	0	0	0	25.0

Period.....	Organs															
	Spleen				Subarachnoid and brain ventricles				Accessory nasal si- nuses and mastoid cells				Other structures *			
	1	2	3	4	1	2	3	4	1	2	3	4	1	2	3	4
Number of examinations...	37	28	14	31	16	26	17	9	24	42	15	18	26	15	4	8
<i>B. influenzae</i>	48.3	10.7	25.0	0	6.2	11.5	17.6	0	33.3	30.9	46.6	0	34.6	13.3	50.0	0
Hemolytic streptococcus.....	10.7	10.7	0	22.8	0	3.8	5.8	44.4	4.1	9.5	6.6	38.8	3.8	6.6	50.0	62.5
Nonhemolytic streptococcus.....	19.1	32.1	21.4	5.4	31.2	30.7	5.8	11.1	45.8	40.4	20.0	11.1	19.2	6.6	25.0	0
<i>Pneumococcus</i> , total.....	10.8	28.3	7.1	16.0	6.2	38.2	35.0	22.2	24.8	49.7	59.8	27.6	3.8	39.8	50.0	12.5
Type I.....	0	7.1	0	3.2	0	0	0	0	0	2.3	0	5.5	0	6.6	0	0
Type II.....	2.7	7.1	0	0	0	11.5	5.8	0	0	7.1	0	11.1	0	6.6	0	0
Type IIa.....	2.7	3.5	0	3.2	0	7.6	5.8	0	12.4	4.7	6.6	0	0	18.3	25.0	0
Type III.....	0	0	0	3.2	0	0	5.8	22.2	0	0	6.6	5.5	0	0	0	0
Type IV.....	2.7	7.1	7.1	6.4	0	11.5	17.6	0	4.1	21.4	26.6	5.5	0	0	25.0	12.5
Untyped.....	2.7	3.5	0	0	6.2	7.6	0	0	8.3	14.2	20.0	0	3.8	13.3	0	0
<i>M. catarrhalis</i>	2.7	0	25.0	3.2	0	0	5.8	0	0	2.3	20.0	5.5	7.6	6.6	25.0	0
<i>Meningococcus</i>	0	0	0	0	0	0	11.7	0	0	0	13.3	0	0	0	0	0
<i>M. tetragenus</i>	0	0	0	0	0	0	0	0	0	0	6.6	0	0	0	0	0
Diphtheroids.....	0	7.1	0	0	0	0	0	0	0	0	0	0	0	0	0	0
<i>Staphylococcus</i>	0	0	0	16.3	0	0	0	22.2	0	0	0	11.1	0	0	0	12.5

* By "other structures" are meant liver, peritoneum, gall-bladder, skin, enteric follicles, or whatever tissue seemed to be worthy of examination outside of those adopted as routine.

The following table shows the incidence of the bacteria in the various organs. In this table is given in brackets the actual number of times each organism was found, also the resulting percentage per number of examinations made. Here again it is seen that the trinity, *B. influenzae*, nonhemolytic streptococcus and pneumococcus were the predominating findings in all the tissues examined. The high percentage of hemolytic streptococcus was due in most part to the very considerable frequency with which it appeared in the fourth period, as above pointed out. Group IV, as elsewhere, was the principal pneumococcus found, followed by considerably less than half that number of Types IIa and II,

which were almost equal in point of frequency. In this table the figures for the heart's blood are based on the total number of cultures taken, and not excluding the hopelessly contaminated, 13 in number. If these last be taken into account, a slight increase in all the percentages would have to be recorded.

It is in line with the pathologic picture revealed at necropsy that the findings for the subarachnoid and brain ventricles were so frequently positive.

Incidence of bacteria in the various organs

	Organs							
	Heart's blood		Pleuræ right 41, left 43		Lungs, right, 116, left, 117,		Bronchial exudate	
	(120)	(84)	(233)	(51)				
Number of organs examined.....								
		<i>Per cent</i>		<i>Per cent</i>		<i>Per cent</i>		<i>Per cent</i>
B. influenzae.....	(30)	25.0	(13)	15.4	(74)	31.7	(22)	43.1
Hemolytic streptococcus.....	(31)	25.8	(21)	25.0	(65)	27.8	(9)	17.6
Nonhemolytic streptococcus.....	(31)	25.8	(26)	30.9	(85)	36.4	(18)	35.2
Pneumococcus:								
Type I.....	(3)	2.5	(2)	2.3	(10)	4.2	(2)	3.9
Type II.....	(5)	4.1	(2)	2.3	(12)	5.1	(1)	1.9
Type IIa.....	(4)	3.3	(6)	7.1	(8)	3.4	(4)	7.8
Type III.....	(2)	1.6	(0)	0	(6)	2.5	(1)	1.9
Type IV.....	(9)	7.5	(9)	10.7	(25)	10.7	(10)	19.6
Untyped.....	(6)	5.0	(7)	8.3	(24)	10.3	(4)	7.8
M. catarrhalis.....	(3)	2.5	(3)	3.5	(34)	14.5	(9)	17.6
Meningococcus.....	(1)	0.8	(0)	0	(0)	0	(0)	0
Diphtheroids.....	(3)	2.5	(0)	0	(6)	2.5	(4)	7.8
Staphylococcus.....	(4)	3.3	(2)	3.3	(18)	7.5	(1)	1.9
M. tetragenus.....	(0)	0	(1)	1.1	(2)	.8	(1)	1.9
Total number organisms found.....	(132)		(92)		(369)		(86)	

	Organs								
	Spleen		Subarachnoid and brain ventricles		Accessory nasal sinuses and mas- toid cells		Other structures		Total
	(110)	(68)	(99)	(53)	(818)				
Number of organs examined.....									
		<i>Per cent</i>		<i>Per cent</i>		<i>Per cent</i>		<i>Per cent</i>	
B. influenzae.....	(25)	22.7	(7)	10.2	(28)	28.8	(13)	24.5	(212)
Hemolytic streptococcus.....	(14)	12.7	(6)	8.7	(13)	13.1	(9)	16.9	(168)
Nonhemolytic streptococcus.....	(21)	19.0	(15)	22.0	(33)	33.3	(7)	13.2	(236)
Pneumococcus:									
Type I.....	(3)	2.7	(0)	0	(2)	2.0	(1)	1.8	(23)
Type II.....	(3)	2.7	(4)	5.8	(5)	5.0	(1)	1.8	(33)
Type IIa.....	(3)	2.7	(3)	4.3	(6)	6.0	(3)	5.6	(37)
Type III.....	(1)	0.9	(3)	4.3	(2)	2.0	(0)	0	(15)
Type IV.....	(6)	5.5	(6)	8.7	(15)	15.1	(2)	3.7	(82)
Untyped.....	(2)	1.8	(3)	4.3	(11)	11.1	(3)	5.6	(60)
M. catarrhalis.....	(6)	5.5	(1)	1.4	(5)	5.0	(4)	7.5	(65)
Meningococcus.....	(0)	0	(2)	2.9	(2)	2.0	(0)	0	(5)
Diphtheroids.....	(2)	1.8	(0)	0	(0)	0	(0)	0	(15)
Staphylococcus.....	(5)	4.5	(2)	2.9	(2)	2.0	(1)	1.8	(35)
M. tetragenus.....	(0)	0	(0)	0	(1)	1.0	(0)	0	(5)
Total number organisms found.....	(91)		(52)		(125)		(44)		(991)

The following table divides the findings according to a different method; that is, according to the time the disease lasted before a fatal termination. Detailed figures have already been given in showing the relation of duration of disease to period of epidemic. Naturally, those that endured the longest came to necropsy in the later periods; so that there must necessarily be some

similarity between this and the preceding table. But this table shows most foreibly the gradual disappearance of the *B. influenzae* in the longest enduring cases and the encroachment of the hemolytic streptococcus in the same. The relative infrequency of the hemolytic streptococcus in the bronchial exudate as compared with its appearance in the lungs may be due to the fact that so many more lung examinations were made, especially as toward the end of the epidemic examination of the bronchial exudate was discontinued, and at this time the hemolytic streptococcus flourished most vigorously.

Distribution and incidence of bacteria present according to duration of disease (in per cent)

	Organs															
	Heart's blood				Pleurae, right 45, left 45				Lungs, right 177, left 117				Bronchial exudate			
	1 to 5	6 to 10	11 to 15	16 to 40	1 to 5	6 to 10	11 to 15	16 to 40	1 to 5	6 to 10	11 to 15	16 to 40	1 to 5	6 to 10	11 to 15	16 to 40
Number examined.....	8	49	24	26	10	48	17	15	16	98	60	60	3	34	16	10
<i>B. influenzae</i>	25.0	36.7	29.1	11.5	10.0	18.7	29.4	0	25.0	45.9	23.3	18.3	33.3	26.4	56.2	30.0
Hemolytic streptococcus.....	0	28.5	3.7	34.6	0	31.2	29.4	26.6	0	32.6	26.6	30.0	0	11.7	18.7	0
Nonhem. streptococcus.....	25.0	30.6	29.1	26.9	10.0	25.0	35.2	46.6	56.2	36.7	35.0	25.0	33.3	14.6	50.0	40.0
Pneumococcus:																
Type I.....	0	0	1.2	0	0	2.0	5.8	0	12.5	1.0	8.3	0	0	2.9	0	0
Type II.....	0	4.0	8.3	3.8	0	2.0	5.8	0	0	6.1	6.6	3.3	0	0	6.2	0
Type IIa.....	12.5	4.0	4.1	0	10.0	8.3	5.8	0	12.5	3.0	5.0	0	33.3	2.9	12.5	0
Type III.....	0	2.0	0	3.8	0	0	0	0	0	5.1	0	3.3	0	0	0	10.0
Type IV.....	12.5	4.0	8.3	19.2	10.0	2.0	11.7	13.3	12.5	5.1	8.3	21.6	33.3	2.9	12.5	40.0
Untyped.....	12.5	6.1	0	7.6	30.0	6.2	11.7	0	18.7	18.3	5.0	5.0	0	11.7	18.7	30.0
Total.....	37.5	20.1	21.9	34.4	50.0	20.5	40.8	13.3	56.2	38.6	33.2	33.2	66.6	20.4	49.9	80.0
<i>M. catarrhalis</i>	0	0	4.1	7.6	20.0	0	5.8	0	37.5	11.2	6.6	15.0	33.3	5.8	18.7	20.0
<i>Meningococcus</i>	0	0	0	0	0	0	0	0	0	0	0	0	0	0	0	0
<i>M. tetragenus</i>	0	0	0	0	10.0	0	0	0	0	2.0	0	0	0	0	6.2	0
Diphtheroids.....	0	0	4.1	3.8	0	0	0	0	0	1.0	5.0	3.3	0	2.9	12.5	10.0
Staphylococcus.....	0	0	4.1	3.8	0	0	0	0	12.5	8.1	3.3	11.6	0	0	0	10.0
	Organs															
	Spleen				Subarachnoid and brain ventricles				Accessory nasal sinuses and mastoid cells				Other structures			
Duration of disease (in days).....	1 to 5	6 to 10	11 to 15	16 to 40	1 to 5	6 to 10	11 to 15	16 to 40	1 to 5	6 to 10	11 to 15	16 to 40	1 to 5	6 to 10	11 to 15	16 to 40
Number examined.....	2	47	28	31	4	23	25	20	4	32	30	47	2	11	6	20
<i>B. influenzae</i>	100.0	34.0	17.5	6.4	0	8.6	8.0	10.0	25.0	18.7	46.6	14.9	50.0	27.2	66.6	5.0
Hemolytic streptococcus.....	0	19.1	17.5	9.6	0	13.0	4.0	15.0	0	15.6	16.6	6.3	0	9.0	16.6	30.0
Nonhem. streptococcus.....	50.0	17.0	21.4	16.1	25.0	29.0	24.0	25.0	75.0	3.4	36.6	14.9	0	27.2	33.3	5.0
Pneumococcus:																
Type I.....	0	2.1	7.1	0	0	0	8.0	0	0	0	3.3	0	0	0	0	0
Type II.....	0	0	0	0	0	0	12.0	0	0	0	6.6	4.2	0	0	33.3	0
Type IIa.....	0	2.1	3.5	3.2	25.0	0	12.0	0	25.0	9.3	6.6	0	0	0	33.3	0
Type III.....	0	2.1	0	0	0	8.6	0	5.0	0	3.1	0	2.1	0	0	0	5.0
Type IV.....	50.0	4.2	3.5	3.2	0	4.3	0	15.0	0	9.3	23.3	10.6	0	0	0	0
Untyped.....	0	6.3	0	0	0	4.3	4.0	0	0	9.3	9.9	4.2	50.0	9.0	16.6	0
Total.....	50.0	16.8	14.1	6.4	25.0	17.2	36.0	20.0	25.0	31.0	49.7	21.1	50.0	9.0	83.2	5.0
<i>M. catarrhalis</i>	0	2.1	0	16.1	0	0	4.0	10.0	0	6.2	0	6.3	50.0	9.0	16.6	5.0
<i>Meningococcus</i>	0	0	0	0	0	0	8.0	0	0	0	0	0	0	0	0	0
<i>M. tetragenus</i>	0	0	0	0	0	0	5.0	0	0	0	0	0	0	0	16.6	0
Diphtheroids.....	0	4.2	0	3.2	0	0	0	5.0	0	0	0	0	0	9.0	0	0
Staphylococcus.....	50.0	2.1	0	3.2	0	4.3	0	0	0	3.1	0	4.2	0	0	0	5.0

Early in October, 1918, the sputum of 129 influenza patients was examined, as shown in the following table. It will be seen that in the early days the hemolytic streptococcus was not very prominent, showing in 5 per cent, whereas the trinity of *B. influenza*, nonhemolytic streptococcus and pneumococcus, and of those typed, Group IV constituted 76.9 per cent, were very much the most prominent organisms. One hundred and fifty other sputums sent to the laboratory routinely during October and November showed *B. influenza* in 9.4 per cent, and hemolytic streptococcus in 33 per cent, indicating how much oftener hemolytic streptococcus was generally found than in the actual influenza cases.

Sputum examination from influenza patients during October, 1918 ^a

[Total examinations, 729 organisms]

	Number	Per cent
<i>B. influenza</i>	315	43.2
Hemolytic streptococcus.....	39	5.3
Nonhemolytic streptococcus.....	309	42.3
Pneumococcus:		
Type I.....	7	^b 13.4
Type II.....	2	^b 3.8
Type III.....	3	^b 5.7
Group IV.....	40	^b 76.9
Unsuitable for typing.....	447	61.3
Total.....	499	68.4
Staphylococcus.....	191	26.2
<i>M. catarrhalis</i>	99	13.5
<i>M. tetragenus</i>	5	0.7

^a In the great majority of instances these sputums were unsuitable for type determination, being thin and unwashable. Also they were taken in such quantities and in so brief a time that with the force at our command we could only select the best specimens which showed as nearly as possible pure culture.

^b Of those typed.

In the very first 10 days of the epidemic (from September 21 to October 1) swabbings from the throats of 250 influenza cases were taken. (See following table.) It is remarkable how closely the findings simulate those of the sputum from the same class of patients taken during the ensuing 10 days or so. Here again the hemolytic streptococcus was found in only 5 per cent, while nonhemolytic streptococcus, *M. catarrhalis* and *B. influenza* together with pneumococcus and staphylococcus in lesser degree were the most prominent. In other words, the organisms which were considered most responsible were most evident even in the initial swabbings before the epidemic had broken in its full fury.

Incidence of organisms in throats of 250 cases of influenza

[First 10 days of epidemic, from Sept. 21 to Oct. 1]

	Number	Per cent		Number	Per cent
<i>B. influenza</i>	45	18.0	<i>M. catarrhalis</i>	82	32.8
Hemolytic streptococcus.....	13	5.2	Staphylococcus.....	43	17.2
Nonhemolytic streptococcus.....	76	30.4	Pneumococcus.....	44	17.6

It is interesting to note from the records that in two months—January and February—following the epidemic, 178 sputum examinations were made with the following findings:

	Per cent		Per cent	
Pneumococcus.....	71.9	}	<i>Bacillus influenzae</i>	6.7
Hemolytic streptococcus.....	33.4		Staphylococcus.....	45.5
Nonhemolytic streptococcus.....	30.8		<i>Micrococcus catarrhalis</i>	58.9

One hundred and sixteen pneumococci were typed as follows:

	Cases		Cases	
Type I.....	1	}	Type III.....	3
Type II.....	4		Group IV.....	108
Type IIa.....	0		Untyped.....	12

Thirty-three necropsies for the same period showed:

	Heart's blood (number of cases)	Lungs (number of cases)	Spleen (number of cases)	Pleural cavities (number of cases)
Pneumococcus.....	2	3	0	1
Hemolytic streptococcus.....	17	22	12	9
Nonhemolytic streptococcus.....	5	5	0	0
<i>B. influenzae</i>	1	1	0	0
Staphylococcus.....	2	4	0	1
<i>Micrococcus catarrhalis</i>	1	3	1	1

These last are very interesting as showing the extraordinary predominance of hemolytic streptococcus to the exclusion of the main factors during the epidemic. As regards the overwhelming preponderance of Group IV pneumococcus in these more recent sputum examinations, it should be remembered first, the liability to salivary contamination, and second, in the wave of enthusiasm for type determination of pneumococcus one unconsciously subscribed to the premise that it alone, when present, was responsible for the pathologic condition, often overlooking entirely the more dangerous cohabitant. It is worthy of note, too, how the *B. influenzae* almost disappeared from both necropsy and sputum findings. These latter statistics contained a very few cases of undoubted influenza, so the presence of bacillus of Pfeiffer in small percentages was agreeably accounted for.

In every one of the five cases which lasted 40 days or more, hemolytic streptococcus was the offending organism. In four cases it was recovered from the heart's blood. In one it was associated with *M. catarrhalis* in the left lung. But with this exception they were all five pure hemolytic streptococcus infections. This bears out the contention that hemolytic streptococcus was a tertiary invader, and by its luxuriant growth supplanted the original organisms.

From the foregoing studies of acute respiratory diseases as they occurred at Camp Taylor it is seen that the streptococcus, which played so important a part prior to the pandemic, had little effect during the latter period until its close, when it presumably was a factor in the production of a secondary rise in case fatality in the month of December, 1918. Practically every variety of pneumonic lesion is described and is attributed, in so far as possible, to the type of organisms with which it was most frequently associated. Lesions of organs other than those of respiration, while possibly in part due to the virus or organism causing clinical influenza, were undoubtedly in large part the result of the secondary or tertiary infections. This has particular reference to such lesions as focal necroses in the spleen and lymph nodes, degeneration of parenchymatous organs and possibly the purpuric eruptions.

CHAPTER II

IN THE AMERICAN EXPEDITIONARY FORCES ^a

In the spring of 1918 reports appeared of an epidemic disease in various parts of southern France, Italy, and Spain. By midsummer this disease had spread widely throughout Europe, and in the autumn had involved South Africa and America. Were it not for the epidemiologic evidence it would have been difficult to characterize the disease as a clinical entity.

In the majority of cases, the onset of the disease was sudden, particularly in the warmer season. Epistaxis was an early manifestation in a considerable proportion of cases. In some outbreaks, particularly those in the fall months, a slight sore throat or a feeling of cold in the head, and in some instances a distinctly localized burning sensation in the nasopharynx was noticed 12 to 24 hours before the fever became evident. The first symptoms, although in most instances severe enough to fix the moment of onset in the patient's mind, were, so mild as a rule, that soldiers did not report sick unless especially ordered to do so. The morale of the average soldier was such that he hesitated to go to sick call, regarding it as a confession of weakness or perhaps an indication that he desired to shirk. While this attitude is, in general, to be commended, and was undoubtedly encouraged by medical officers, it was a distinct source of danger in the presence of the epidemic.

Prostration was marked in some cases and a few men fainted while awaiting examination at sick call, and many of those performing physical labor found it impossible to continue. The pharyngeal mucous membrane was slightly reddened and rather dry; the nose was remarkably clear and unobstructed; the conjunctivæ were injected. The patient complained of headache, pain in the back, weakness, pain and tenderness in the eyeballs, and sometimes of a burning in the nasopharynx or a slight sore throat. Leucocytosis was usually absent in uncomplicated cases, but appeared along with the bronchopneumonia. Leucopenia was observed early in the disease.

In a series of 125 cases, coryza was noticed by half the patients, but a dark red, dry mucous membrane was found in 90 out of 100 cases. Sore throat was complained of by 37 per cent, a dry red pharynx with swollen lymphoid tissue on the lateral wall was present in 80 per cent. Epistaxis occurred in 35 per cent. The eyes were injected, perhaps somewhat more so than in most fevers. The neck was somewhat stiff in 12 per cent., but this stiffness was never marked. Herpes was observed in 17 per cent. Careful examination failed to reveal any distinctive rash. Among the 125 cases definite signs of bronchopneumonia on admission were present in 40 per cent. There were a few cases of catarrhal otitis media, usually with considerable pain for a few hours, but without enough exudate to bulge the drum. This series may be regarded as fairly typical of the disease as it occurred in France about October 1, 1918. The respiratory symp-

^a Based on: The Influenza Epidemic of 1918 in the American Expeditionary Forces in France and England. By Maj. Ward J. MacNeal, M. C., commanding officer, Central Medical Department Laboratory, Dijon. *Archives of Internal Medicine*, Chicago, 1919, xxiii, No. 6, 657.

toms were less well marked in the cases seen in the early months, May, June, and July, and in them cough, otitis media and signs of bronchopneumonia were rare.

Course and outcome.—In the early months, May, June, and July, rest in bed and a purgative were followed by subsidence of the fever and amelioration of all symptoms in 24 to 72 hours, and prompt recovery without further manifestations, except slight weakness and depression. Complications were so rare as to be considered nonexistent and the relatively few cases of pneumonia observed were subsequently regarded as instances of mistaken initial diagnosis. In the later months, from about the beginning of September, the disease was perhaps less sudden in onset, but the course was distinctly more malignant and a complicating fatal bronchopneumonia became alarmingly frequent; so frequent, indeed, as to suggest a new epidemic of an entirely different disease.

In the more severe cases, distinct evidence of tracheobronchitis and bronchopneumonia appeared, sometimes within the first 48 hours, but usually at the end of the third or fourth day. In many instances the temperature fell nearly or quite to normal on the third day, only to rise again along with the gradual appearance of physical signs of extension of the inflammation in the finer bronchi and alveoli of the lungs. This complication was observed particularly in patients who failed to go to bed promptly at the onset of the disease, in those who got out of bed before they should, and in those patients who were transported during the febrile period. Pleural effusion occurred in some cases; empyema occurred rarely. Unconsciousness for some hours before death, with considerable extension of the thoracic dullness in the last 48 hours, were commonly observed in the fatal cases. When the patient recovered, the fever fell by lysis after 6 to 12 days.

The death rate in patients with pneumonia was high, varying from 5 to 100 per cent. The bulk of these deaths resulted from the bronchopneumonia of the influenza epidemic. In the series of 125 cases there were 18 deaths, or 14.4 per cent of the cases of influenza. Inasmuch as 40 per cent of these patients showed bronchopneumonia on admission, the maximum death rate of the pneumonia cases was 18 in 50, or 36.0 per cent. Doubtless many others in the series also developed pneumonia in the hospital, so that the death rate for the pneumonia in the series may be placed at 14.4 per cent as a minimum and 36 per cent as a maximum.

Another series of cases evidently originated on the transports during voyage from the United States. In this series there were 4 cases of lobar pneumonia, 1 of them primary and 3 secondary to influenza, with 1 death; 156 cases of bronchopneumonia, of which 1 was primary, 148 cases secondary to influenza, and 7 secondary to bronchitis, with 52 deaths. Pleural fluid was found in 13 cases. It was clear in nine cases and turbid in four cases. Bloody sputum was observed in 118 cases. Twenty-two cases of pneumonia developed in the wards, 20 from influenza and 1 from bronchitis. There were 268 cases of influenza at the same time, of which 246 were respiratory; 1 was nervous; 9 were gastrointestinal; and 12 were febrile. Ear complications and sinus involvement were uncommon. Bacteriologic examinations showed the presence of the influenza

bacillus and of pneumococci in almost every case. Hemolytic streptococci were not found. The death rate in the pneumonia was 32 per cent.

Without regard to the bacteriologic findings or questions of etiology the disease is certainly properly designated as influenza on the basis of its epidemic and clinical characters alone.

PATHOLOGIC ANATOMY

In the early months of the epidemic the disease was so benign in character that deaths which did occur were invariably ascribed to other cause. After August 15, 1918, deaths became much more frequent and the records of necropsy in this disease were very numerous. From the clinical evidence it appeared that the bulk of the necropsy records were based on complicated cases. The pathology of these later cases is discussed first.

The respiratory organs.—The larynx, trachea, and larger bronchi showed swelling, edema, injection and infiltration of the mucous membrane, which was covered by frothy mucopurulent, often blood-stained exudate. The smaller bronchi and bronchioles also were involved in the same process and some of them were plugged with mucus. As a rule, all lobes of both lungs were involved; both lungs were large, dark, heavy, and firm. On section, the cut surfaces were very moist, dripping a bloody, frothy fluid; the color was somewhat variegated, often showing a few firmer grayish patches of older consolidation centrally located. Invariably the lower lobes were more severely involved. The whole process in the lungs might be designated as an example of a massive, pseudolobar form of bronchopneumonia of a very malignant type. Considerable variation in the appearance of the lungs occurred even in the same series. Some prosectors were able to distinguish a type showing more or less fibrinous pneumonia and a type in which this was not present and to foretell from the gross appearance the bacteriologic demonstration of pneumococci in the former. In some instances gross evidence of hemolysis indicated the presence of hemolytic streptococci which was subsequently confirmed.

Necropsies on individuals dying of influenza pneumonia revealed the following characteristics: (1) Frequency of an associated hemorrhagic tracheo-bronchitis; (2) extensive though irregular involvement of multiple lobes in massive areas of lobular pneumonia consolidation; (3) frequent existence of a much older focus of central pneumonia near the hilus of one or both lower lobes; (4) evidence of an explosive-like spread of the pneumonic process from this central focus to large areas of the adjacent lung parenchyma within the last day or few days before death; (5) relative infrequency of suppuration, empyema being found only in two cases.

Serous cavities.—In many instances the pleural surfaces were fairly normal or only slightly dulled in luster; in others, a slight increase in clear fluid, with or without a tinge of hemoglobin, was noted; in from 5 to 30 per cent, varying in different series, a large pleural effusion was present, usually serous, but sometimes serofibrinous or purulent; in 10 to 20 per cent a plastic fibrinous exudate existed on the pleural surfaces. In short, the conditions within the pleural cavities were exceedingly diverse. Pericardial effusion and pericarditis were observed in a few instances. When large volumes of fluid were found in the chest, the changes in the lungs were less advanced and less extensive than usual.

Subcutaneous emphysema.—This was observed in comparatively few cases in several different outbreaks. It began in the supraclavicular region or over the anterior chest wall, and became more or less generalized over the surface of the body. It did not appear to affect the outcome of the case. A post-mortem study of several such cases failed to reveal bacteria in the majority of the cases. Mechanical obstruction of small bronchi by plugs of mucopus and subsequent solution of continuity in the structure of the lung is the probable explanation of its pathogenesis.

Rectus abdominis.—In a very few instances lesions of the rectus muscles were found. In some cases a necrosis resembling Zenker's necrosis, in others hemorrhages into the muscle were present.

Cranial sinuses.—The first wave of the epidemic in May and June did not have any recognized cases of sinus or aural complications, and as there were few if any deaths from influenza at this time no opportunity presented itself to prove the absence of sinus involvement by necropsy. Clinical evidence of such involvement was entirely lacking. In the latter phases of the epidemic, sinus and aural complications occasionally were encountered.

Other organs.—The changes in other organs were those of acute toxemia, manifested particularly in the kidneys, liver, and spleen. Icterus, apparently of hemolytic origin, was observed in a few instances.

PATHOLOGY OF PARTICULAR CASES

In some instances clinical histories permit a determination of the exact duration of the disease before death occurred. Significant features of a few necropsies on such cases follow:

Necropsy 1: Patient had a slight cold on Saturday, October 5, but took dinner with friends on that date. He was admitted to the hospital at 6 p. m. on October 7 in a dying condition; died October 8 at 8.30 a. m. Duration of illness was therefore about 60 hours. Pleural cavities contain a few cubic centimeters of cloudy fluid. There are no adhesions. Both lungs are of the size of full inspiration. There is practically no exudate on either pleural surface. The upper two thirds of the upper lobe, the apex of the middle lobe and scattered patches throughout the lower lobe of the right lung contain solid bluish-red areas, which have ill-defined margins. On section these areas are dark red in color and comparatively airless, the surfaces being bathed with a very large amount of bloody fluid. The remaining portions of the lungs are heavy with congestion and edema, except for a few areas anteriorly, which are dilated and feathery. The bronchi of both lungs are deep red in color, bathed with abundant blood-stained frothy mucus and covered with a thin, closely adherent, grayish-yellow, fibrinous pseudomembrane. The peribronchial lymph nodes are not markedly swollen. The sinuses at the base of the skull show some thickening of the mucosa and a small amount of mucoïd fluid in the left sphenoid and left frontal. Smears and cultures from the lungs show streptococci and Gram-negative bacilli. Smears from the frontal sinus show staphylococci Gram-negative bacilli and a short Gram-positive bacillus; cultures from the same place show staphylococci.

Necropsy 2: Patient was admitted to hospital October 16, 1918, with a diagnosis of acute influenza; temperature, 103° F.; pulse, 116; respiration, 24. October 17, the temperature rose to 104° F.; pulse, 104; respiration, 30. The temperature remained above 104° F.; at times reaching 105° F.; respirations increased to 50, but the pulse rate did not rise above 104 until the day of his death, when it reached 120. Death occurred October 20, 1918, at 11.30 p. m., four days after admission.

The pleural cavities each contain about 10 c. c. of clear serum. The parietal pleura is speckled thinly with petechial hemorrhages on both sides, and small tags of fibrin hang from it. The areolar tissues of the anterior mediastinum are moderately infiltrated with glistening, gelatinous material. The posterior and apical portions of the right pleural cavity are obliterated by very firm fibrous adhesions. The apical and posterior surfaces of the right lung are covered with fibrous tags and the pleura is thickened and rough. At the apex of the right upper lobe the pleura is puckered and thickened, and on section the thickened pleura at this point measures 4 mm.; it is whitish in color, very dense and resistant and fibrous in character. Beneath this, the cut surface of the apical portion of the right upper lobe is made up of irregular grayish-yellow areas, all coalescing, and separated here and there by fibrous strands. The middle and lower lobes are large, heavy, and dark; their pleural surface has the appearance of pavement, the lines being formed by distended lymph channels. The cut surface is very dark, moist, and compact; the lobes are entirely consolidated, but the consolidation is peculiar in that it is made up of coalescing patches of bronchopneumonia massed together. From the atypical appearance one is led to think of a mixed infection. The left lung is in the same condition, except the anterior portion of the upper lobe, the cut surface of which is markedly hyperemic and has, scattered in it, some dark red patches similar in appearance but much larger than the patches ordinarily seen in typical bronchopneumonia. The mucosa of the trachea and bronchi is very hyperemic and bathed in an abundance of thin, frothy fluid. The tracheobronchial lymph nodes are moderately enlarged, unusually moist and slightly bloody. The tissues of the posterior mediastinum are slightly infiltrated with glistening jelly-like material.

Necropsy 3: Patient entered hospital September 12, 1918, having been in France one week. He had been sick since landing and had been riding in a baggage car for several days. He died September 12 at 11.50 p. m. The necropsy was performed at 3.25 p. m., September 13. The mediastinum is well covered with fat, the right visceral pleura hemorrhagic and injected and covered with fibrinous deposits. The pericardial cavity contains about 70 c. c. of a straw-colored fluid. The left lung weighs 1 pound 12½ ounces and shows irregular consolidated areas. The right lung weighs 2 pounds 12½ ounces. The left lung floats in water; on section it shows irregular consolidated areas from which frothy mucus exudes. The lobular type is more evident to the sense of touch than of sight. The entire right lung floats in water as do portions from the most nearly consolidated portions. Bronchi are red and inflamed. Cultures from the brain and from the heart blood are negative; cultures from the right lung show *B. influenzae* and *Streptococcus viridans*.

Necropsy 4: Patient entered hospital October 8, 1918, from a newly arrived transport. He died at 4 a. m. October 15. Necropsy was performed at 9.30 a. m., October 15. Pericardial cavity contains about 10 c. c. of a clear yellow fluid. There are numerous hemorrhages on the left side of the pericardium. The right lung is adherent posteriorly and the right pleural cavity contains about 300 c. c. of a cloudy yellow fluid. The lower half of the pleura is covered with a thick layer of yellow fibrinous exudate. The left pleura is slightly adherent at the base posteriorly and is also covered with fibrinous exudate. The right lung has four lobes, the fourth being a very small one at the apex. This is firm and on section is gray and consolidated throughout. The main upper lobe is collapsed and contains some nodules. Its surface is dull, granular, and varying in color from light pink to bluish-red. Centrally located there is a nodule of gray consolidation the size of a hen's egg. Around the periphery the lung is well aerated and for the most part of a light pink color. The cut bronchi exude thick yellow pus. The middle lobe is well aerated, light pink in color and shows a few hemorrhagic areas. Pus exudes from the cut bronchi in this lobe also. The lower lobe is a gray consolidated mass of friable tissue and on pressure exudes thick pus. In the left lung the upper, middle, and anterior portions of the lower lobe are aerated. Surfaces of the upper and middle lobes are of a dark red color; on palpation small nodules are felt throughout. The posterior half of the lower lobe is consolidated and nodules may be felt. The larger nodules in the upper lobe are gray and exude pus everywhere when squeezed. For the most part, the tissue is spongy, light pink to deep red and quite friable. At the periphery and at the base there is a dark red consolidation from which a considerable amount of pus exudes. Bacteriology: *B. influenzae*, pneumococcus, and a Gram-positive bacillus.

These four abbreviated protocols are fairly typical examples of the records of many hundreds of cases coming to necropsy in September, October, and November, 1928, and indicate the diversity of picture observed within the thorax. These differences appear to have depended essentially on the rapidity with which the patient succumbed. The fulminant cases showed a picture of malignant coalescing bronchopneumonia which rapidly involved almost all the pulmonary tissue. The more chronic cases showed distinct foci of older gray consolidation; usually multiple with recent more extensive, even general, spread of the pneumonic process.

BACTERIOLOGY

The bacteriologic examinations made during life on sputum or material from the pharynx showed various organisms, usually mixed together. The interest in many instances centered on the Pfeiffer's bacillus and reports in regard to it showed the very widest variations. Cultures made on blood-agar or on hemoglobin-agar revealed, in the large majority of cases, pneumococci, streptococci, influenza bacilli, staphylococci and Gram-negative cocci. Blood cultures taken during life were usually negative, but in a moderate proportion of the cases showed pneumococci or streptococci. Fluids obtained by puncture from the pleural cavity or from the lung tissue showed the same organisms and at times the influenza bacillus. In certain localities enormous numbers of Gram-negative cocci, identified as meningococci, were found in the sputum during life and in the lungs at necropsy in a certain number of cases. Attempts to detect a filterable virus have been reported, but experiments of this kind were not carried out in the American Expeditionary Forces.

At necropsy, also, the bacteriologic findings were variable and usually showed a mixture of various species of microbes. Influenza bacilli, pneumococci of various types, hemolytic and nonhemolytic streptococci occurred most frequently in the infiltrated lungs. Post-mortem blood cultures showed *B. influenzae* in a few instances, pneumococci and streptococci in a considerable number of cases. Cultures taken from the cut surface of the lung at necropsy in one series of necropsies during September, 1918, showed influenza bacilli in 40 per cent of the cases, hemolytic streptococci in 30 per cent, and pneumococci in 40 per cent, Group IV, Type I, Type II, and Type III in order of frequency. In many cases, two or more of these organisms were isolated from the same tissue. More significant, perhaps, were those necropsies in which a more thorough bacteriologic survey of the respiratory tree was carried out by culturing in turn the mucous membranes of the trachea, large and small bronchi, and alveolar tissue. In fulminant cases, large numbers of influenza bacilli were found, especially in the trachea and bronchi, sometimes apparently in pure culture. In most instances, however, the mucous membrane of the respiratory tract showed a mixture of organisms; in the trachea, influenza bacilli, streptococci, staphylococci, pneumococci, Gram-negative cocci and occasionally larger Gram-negative bacilli; farther down, influenza bacilli, pneumococci, and streptococci; still lower, influenza bacilli, and one species of the cocci, and finally in the consolidated alveolar tissue, the pneumococcus or the streptococcus alone, as a rule, but sometimes mixed together or even associated with the influenza bacillus in this tissue.

These findings suggest that the disease was essentially due to an invasion of the respiratory tract by influenza bacilli, followed by and associated with other pharyngeal organisms, and that the fatal outcome, in most instances, was brought particularly by these secondary invaders, in some instances streptococci, in others pneumococci.

The reports from some hospitals indicate that the important secondary infections were due to pneumococci, but in those instances in which type determination was carried out, the strains usually fell into three or four type groups, a considerable proportion of them belonging to Group IV. In other hospitals streptococci were found to be the important secondary invaders. The explanation of these results is not entirely clear. It is possible that the distinction between pneumococcus and streptococcus was not always accurately made, and that there was a tendency in one place to call all these organisms pneumococci and in another to call them streptococci. These reports suggest, however, that the secondary invaders may have spread from patient to patient, possibly within the hospital wards. In certain series of necropsies, where considerable attention was devoted to the identification of the cocci in the lungs, these invaders were found to be quite variable, even in bodies coming from the same hospital ward, indicating that their specific nature depended on the type of organisms which happened to be present in the upper respiratory tract of the man at the time of his illness, rather than on contagion.

The identity of the summer epidemic with the disease prevailing after September 1 may be called into question, particularly because of the benign character of the earlier outbreaks and the high death rate observed later. In the later months bronchitis and bronchopneumonia were very common, while such involvement was extremely rare in the summer. In favor of the essential identity may be mentioned the similar epidemic character of the outbreaks, the clinical resemblance between the milder autumn cases and those of the summer, the rather clear evidence indicating a gradual increase in malignancy and the similar bacteriologic findings during life. Most convincing, perhaps, was the similar epidemic character, which alone almost suffices to prove the essential unity of causation for the disease in the two seasons. Medical officers who observed the disease in both seasons were inclined to the view that the primary disease was essentially the same, with the secondary complication of bronchopneumonia in the colder weather. The unfavorable influence of cold and exposure is universally recognized in relation to this disease.

In its epidemiologic, clinical, bacteriologic, and pathologic features, the disease is everywhere recognized as being identical with influenza as it was observed in the pandemic of 1889-90. The bacterial findings are those of influenza. In the American Expeditionary Forces, the bacillus of Pfeiffer was demonstrated in a very large percentage of the cases properly examined; in several series it was demonstrated in every case. The other bacteria isolated; namely, streptococci, pneumococci, Gram-negative cocci, although undoubtedly the cause of death in many cases, can be excluded from consideration as the primary cause of the epidemic disease, because of the inconstancy with which any one specific type was encountered. The possible causative relation of the bacillus of Pfeiffer can not be similarly excluded. On the other hand, the causative rela-

tionship of this organism can not be accepted as proven. During this epidemic, as during previous epidemics of influenza, a considerable proportion of throats of persons not suffering from the disease were found to harbor this organism, or organisms indistinguishable from it by the methods employed.

In a series of 35 selected cases of epidemic influenza without signs of bronchopneumonia, cultures of swabs from the nasopharynx showed streptococcus in 57 per cent, pneumococcus in 74 per cent, and influenza bacillus in 46 per cent. In a second group of 15 cases diagnosed clinically as bronchopneumonia, cultures of the sputum revealed hemolytic streptococcus in 33 per cent, pneumococcus in 87 per cent, and influenza bacillus in 87 per cent. Only one of these patients died and in his case pneumococcus and hemolytic streptococcus were present in the lung at necropsy. In four cases the sputum was inoculated into mice and pneumococcus of Group IV and the influenza bacillus were recovered from the animal's peritoneum and heart blood. In a third group of 22 meningitis contacts, nasopharyngeal cultures showed influenza bacilli in 48 per cent.

One report under date of September 5, 1918, contained the records of nasopharyngeal cultures from 106 cases of influenza, of which 46.2 per cent showed the influenza bacillus and 20.7 per cent showed streptococci. In a series of 12 normal individuals, direct contacts of these cases, the influenza bacillus was found in 41.6 per cent and the streptococcus in 25 per cent. A series of 42 normal individuals, not contacts, examined in the same way, showed influenza bacillus in 7 per cent, and streptococcus in 10 per cent.

The essential similarity in the anatomic changes observed in the later epidemic and in these earlier cases warrants the quotation of the important parts of a few of the protocols of early cases.

Necropsy 5: The patient enlisted August 12, 1917. He had had a cold for the past few weeks but was not admitted to hospital until October 24, 1917, with symptoms of prostration, dyspnea, fever, cough and marked evidence of general sepsis. Pneumococcus (Group IV) was isolated from the sputum by mouse inoculation. The man died October 26 at 11.55 p. m. At the necropsy the left lung was found expanded to full inspiration; the surfaces were smooth, at the inner anterior margin of the upper lobe were several firm areas, the largest about the size of a walnut, grayish to bluish in color, with distinct puckering of the surrounding pleural surfaces. A few similar areas were located at the outer posterior margin of the lower lobe. Scattered throughout the pulp were smaller foci of increased consistence. Remaining portions of the lung were light, feathery, particularly the lingula. On section the firm areas had moist grayish surfaces and were comparatively airless. From the cut bronchioles purulent fluid escaped on pressure. The bronchial mucosa was bathed by a mucopurulent frothy liquid and was distinctly reddened and swollen. Peribronchial lymph nodes were markedly swollen, soft and red. There was no evidence of tuberculosis. The larynx and trachea showed the mucosa congested, especially near the bifurcation of the trachea, and covered by a frothy, mucopurulent exudate; the lymph nodes at the bifurcation were very greatly swollen, reddened and friable. The middle ears and mastoids were normal; the sphenoidal air cells were full of thick, yellow fluid and the mucosa was swollen and congested. The posterior ethmoidal cells contained some thin yellowish fluid, while the anterior cells were apparently free; the mucosa in both groups was distinctly thickened. Bacteriologic examination showed *B. influenzae* and Gram-positive diplococci in sphenoidal sinus, in the lungs and in the liver.

Necropsy 6: The patient was admitted to hospital February 7, 1918, complaining of severe cold, with cough, which began three days before; also pains in his joints and sore throat. February 13 a fine papular eruption appeared, especially over the chest and abdomen. At this time his temperature was 102° F., pulse and respiration rapid. Harsh râles were

heard at the base of the right lung and fine moist râles in the lower lobe of the left lung. Death occurred February 13, 1918, 11.35 p. m. Necropsy, February 14, at 9.30 a. m.: The pleural cavities were free from abnormal fluid; the left visceral and parietal pleura were bound together by fresh fibrinous adhesions, uniformly distributed over the lower lobe. The right pleural cavity presented numerous firm fibrous adhesions over the surface of the middle and lower lobes, especially at the base. The left lung was rather voluminous; the upper lobe was grayish in color and air-containing; the lower lobe was of darker hue, mottled with reddish-purple. The pleura here and there was covered with a yellowish, shaggy, friable exudate. Beneath these areas and also scattered in the deeper areas of the lung tissue were rather firm airless areas. The bronchial mucous membrane was intensely swollen and covered with mucopurulent secretion; this condition was seen likewise in the bronchioles. The pulmonary vessels showed no thrombi; the bronchial lymph nodes were swollen and friable. On section there were found, scattered throughout the lower lobe, corresponding for the most part with the bronchioles, areas varying in size from a pea to a walnut. In color they varied from gray to purple; were firm and quite friable. The lung tissue in the immediate neighborhood showed intense congestion. In the right lung, the upper lobe was grayish in color and air-containing; the middle and lower lobes were voluminous, dark red in color. The pleura was rough and showed numerous fibrous tags. In all other respects it resembled the left lung. The tracheal mucosa was intensely swollen and covered with an abundant mucopurulent exudate. The middle ears were normal; the mucosa of the posterior and anterior ethmoids was slightly swollen and moist; no purulent exudate was present; the frontal sinuses were normal. Bacteriologic examination of the ethmoidal sinuses by both smear and culture was negative.

Necropsy 7: The patient was admitted to hospital March 13, 1918, having had a cough since March 6. On admission, he had severe headache, shortness of breath, pain in the right side, with temperature of 102.4° F., pulse 120, dullness over both lower lobes and moist râles everywhere. Pneumococcus, Type II, was isolated from the sputum. Death occurred March 20, 1918, at 3 a. m. Necropsy at 9 a. m. same date: Pleural surfaces were everywhere smooth and there was no abnormal fluid. In the lower lobes of both lungs, there were numerous small, grayish, consolidated areas, corresponding with the terminal bronchioles, which were considerably swollen. The lung tissue everywhere was intensely congested and of a deep red color. The lymph nodes at the bifurcation were swollen, soft, and red. Culture from the heart was sterile; cultures from the lung showed pneumococci and influenza bacilli.

Necropsy 8: The patient was admitted to hospital April 5, 1918, with a diagnosis of measles. April 8, he developed signs of diffuse bronchitis, with marked dyspnea and cyanosis; the white blood cells numbered 8,400; the sputum showed chiefly *B. influenza*. Death occurred April 13, 1918, at 1.30 p. m. Necropsy April 13, at 4 p. m.: The pleural cavities were free, without exudate or adhesions; the fluid was not increased. The right lung weighed 660 grams. Externally all three lobes were irregularly mottled, with raised grayish margins and depressed dark brownish centers. On section the same characteristic mottling was seen throughout all lobes. Interspersed between the grayish aerated tissue, from which a bloody froth exuded, were dark red firm areas of consolidation, the latter being found especially near the hilum. The bronchi were filled with a greenish purulent material. The left lung weighed 630 grams, and was identical in appearance with the right. Bacteriologic examination of pus from the right and left bronchi showed pure culture of *B. influenza*.

The records of these necropsies indicate very clearly the prevalence of influenzal bronchopneumonia.

CHAPTER III

PATHOLOGICAL ANATOMY

In order to portray the pathology of the respiratory diseases of the World War it is necessary to classify the lesions and to define the meaning of certain descriptive terms so that misunderstanding may be minimized. While it is impossible in the present state of our knowledge to separate the lesions according to the organisms producing them, certain conditions found in the respiratory tract appear to have been associated with some organisms more frequently than with others. Bacteria, therefore, must be considered, and it is convenient to describe a type of pathological change as most characteristically produced, in so far as careful and painstaking bacteriological research of the period of this war has divulged, by one organism. For instance, interstitial pneumonia, as described by MacCullum,¹ is the result of infection of the lung with a hemolytic streptococcus, although there were found numerous changes of interstitial type in lungs from which this organism was not isolated by methods which ordinarily showed its presence, other organisms, as *Streptococcus viridans* or Group IV pneumococci, apparently acting as the etiologic agents.

By force of circumstances we are unable to portray the acute respiratory lesions which did not prove fatal. While undoubtedly persons in the early stages of acute respiratory disease died from other causes, no observations have been found on the pathology of the respiratory tract in such cases. Certain assumptions are based on the condition of tissues at death which seem to indicate the sequence of events leading up to the final condition. Furthermore, it is manifest that the complete sequence can be surmised only from the study of lesions observed at varying periods after the onset of clinical symptoms. Here variations in judgment are bound to occur as the variables are numerous, including, as these do, the virulence of the organism, its numbers, the resistance of the host both physically and chemically, and those accidents which, on the one hand, favor the patient, on the other, assure a fatal outcome of the disease. Examples are the penetration of a pulmonary vein by an abscess and superimposed infections with additional species of organisms. The previous experience of those who made the examinations and of those who interpreted them is also responsible for variations not only by reason of the amount of this experience but also its character. The endeavor is therefore made to delineate a picture which will be clear and interpretable in the light of both present and future knowledge.

The specimens which form the basis of the illustrations were selected from the collections of the Army Medical Museum and were obtained in the necropsies of over 600 cases at various Army stations during and immediately following the World War. The fatal respiratory lesions were considered primary by those writing the protocols in a relatively small proportion of the cases. The majority were considered secondary to clinical influenza, measles, or other acute respiratory infections, either not definitely diagnosed or diagnosed as acute pharyngitis,

bronchitis, tonsillitis, or rhinitis. The indefinite diagnoses, acute pharyngitis, bronchitis, tonsillitis, and rhinitis were found rarely in the material sent to the Army Medical Museum, as most of the specimens were collected during waves of acute respiratory disease of epidemic proportions.

The pathology of measles independent of its serious complications will not be described, as the material studied offers no possibility of clearly differentiating it from the secondary infections responsible, in large part at least, for death. A few observers were of the opinion that the virus or etiologic organism causing measles produced a characteristic picture in the lungs.² A similar picture was described as probably due to the influenza bacillus and indeed a similar organism was present in cases complicating or following measles. Since, clinically, both measles and influenza were prevalent at the same time it is quite possible that patients with measles were affected also by influenza. It is impossible, in the light of present knowledge, to determine where the lesions due to the cause of influenza left off and those of secondary invaders began, but in certain instances the sequence of events leading to death occurred so rapidly as to make the process clinically and anatomically a disease entity. It is quite possible, however, that the secondary invader produced its lesions synchronously with those of the primary, the latter acting either to increase the virulence of the secondary or to depress the resistance of the host.

In the larger waves of acute respiratory disease in the spring and fall of 1918, and in the fall of 1917, an acute infection with measles or influenza-like disease was followed by varying numbers of some type of pneumonia. In a few of the measles cases pneumonia occurred after discharge from hospital, but in most instances this disease was manifest during hospitalization and while measles was present. The onset of the pneumonia was sometimes simultaneous with that of measles but more often followed the drop in temperature at the stage of full eruption.

In the cases diagnosed clinically as influenza, there was also a lack of uniformity in the time of onset of pneumonic symptoms. The fulminant cases appeared to have serious pulmonary involvement from the start, while others, though showing the prostration and other symptoms of the clinical disease, did not have definite pulmonary signs for a varying time afterwards.

Cases which were fulminant from the start were the ones in which culture showed *B. influenzae* most often, and in which this organism was found most frequently alone in the culture from the lungs. Such cases occurred, according to available data, rarely in the fall of 1917, more frequently in the spring epidemics of 1918, and most often during the pandemic of the early fall of 1918. The same anatomical picture varying in the extent of the process in the lungs and in the stage of the lesion was found in some part of the pulmonary parenchyma in most of the lungs of the pandemic wave and in many of those from the spring epidemic. The material available is too scanty to enable one to judge of its frequency in the fall of 1917, but it did occur. Lesions in which other organisms, pneumococci, streptococci and staphylococci appeared to be responsible varied in time of appearance of clinical symptoms, in extent of tissue involved, and in severity. Some of them (pneumococcus Type II at Camp Grant) invaded early in the course of the pandemic infection and some fulminant

cases appeared to be attributable to these organisms alone, though this was the exception.

The lesions in the lung at necropsies, whether such cases were recorded as primary or secondary, were characterized by their extreme variety not only in different cases but also in the same case. It was frequently difficult to decide which type of pneumonic process predominated in the lungs of a single case, and the more carefully these organs were sectioned, the more difficult the decision. For example, a lower lobe might show a large part uniformly consolidated by a fibrinous exudate of the character usually seen in lobar pneumonia, the peripheral portions lax and studded with small peribronchiolar consolidations, in the lower lobe on the other side a pneumonic consolidation surrounding and spreading out from the bronchus nearest the vertebræ, in the balance a scattering or confluent lobular consolidation, while the upper lobes contained scattered lobular and peribronchiolar consolidations and striæ of interstitial lymphangitis about bronchi and in interlobular septa.

The age of the lesions as judged by the gross and microscopic appearances, also varied and often to extreme degrees, so that it was evident to the pathologists that in most of the fatal cases at least there had been several periods of advance, or the infection, originating in one part of the lungs, had spread to another and then another part, or else other organisms than those causing the initial process had gained entrance and, in turn, had produced pulmonary inflammation. The organisms recovered were often of different species and varieties, which accounts in large part for the varied bacteriological findings at necropsy and probably also the changes which occurred in the bacterial flora as determined by culture of the discharges from the respiratory tract during life. In fact, the varied bacterial flora, with the differences in the media required for their growth, made it extremely difficult to ascertain the bacterial cause or causes of the pneumonic lesions. The epidemic proportions in which these diseases appeared made it physically impossible for the laboratories to carry out sufficiently extensive cultural work to determine the organisms concerned with any degree of certainty, though at most camps the predominant ones in the etiology of the secondary pneumonia undoubtedly were recognized.

It was difficult in many instances to determine the boundaries of the pathological anatomical processes, yet certain distinct types or distributions did occur as the only ones in a given lobe or lung, or were so separated from others as to render differentiation possible and to enable the pathologist to determine the organisms they contained as shown by smear, culture, and microscopical section of the tissue. In the illustrated description which follows, the lesions are considered according to anatomical type and are preceded by definitions descriptive of these types.

LOBAR PNEUMONIA

Typical lobar pneumonia was present in all camps and was particularly noted during the fall and winter of 1917-18. Its exact incidence can not be determined, since the clinical diagnosis, lobar pneumonia, frequently was proven incorrect at necropsy. The morbidity, as judged by a study of the reports in the literature from the Army camps and the protocols at the Army Medical

Museum, was not high, and the case fatality rate was low. The condition followed measles and acute epidemic respiratory disease but was not nearly as frequent as other types, and if found, usually was associated with other varieties of pneumonia in lobes of the lung not affected by the lobar process. In order to separate the anatomical types of pneumonia one from the other, a rather narrow interpretation has been made of the anatomical characteristics used as

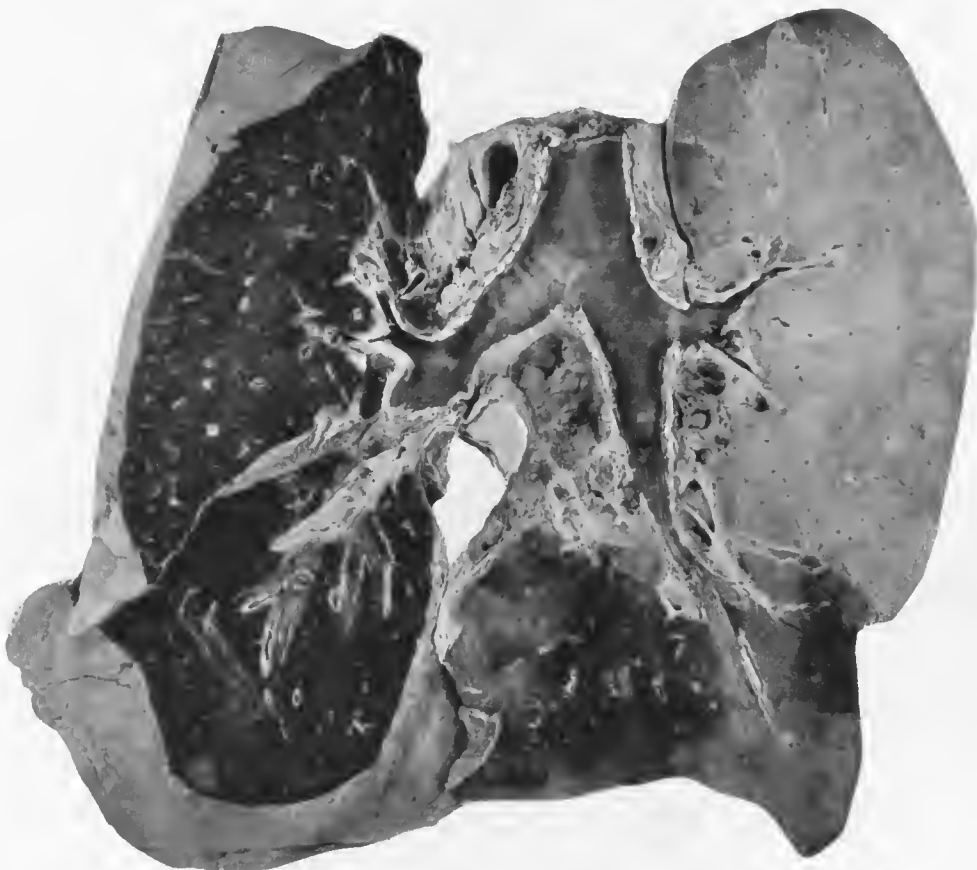


FIG. 1.—Postinfluenzal pneumonia. Typical lobar pneumonia in the right upper lobe at the stage of gray hepatization. Confluent bronchopneumonia in the right lower lobe surrounding two of the larger bronchi. In the vertebral portion of the right lower lobe are seen numerous peribronchiolar foci of consolidation with confluent lobular pneumonia. Acute hemorrhagic bronchitis of both lungs, congestion of the left upper lobe, peribronchial consolidations in the left lower lobe. Just beneath the bifurcation of the trachea there is an abscess involving the lymph nodes of the mediastinum. Pneumococcus Group IV was isolated from the sputum and lung. Sections of tissue show streptococci in the abscess of the interlobular septum in the right upper lobe and Gram-negative bacilli in the peribronchiolar consolidations. Accession number 2711, Army Medical Museum. Negative number 30583

criteria of the diagnosis, lobar pneumonia. The pathologic anatomy of the condition has been described in detail so that it may be easily differentiated from the other pneumonia types.

Lobar pneumonia is an inflammation of the lung characterized by the uniform consolidation of a whole lobe or practically all of a lobe. (Fig. 1.) Three stages are presented in this type.

In the first, or congestive stage, the lung is heavy but compressible, there is little or no crepitation, it is moist, red in color, drips blood on section and the markings are visible. It is not firmly consolidated but collapses slightly if at

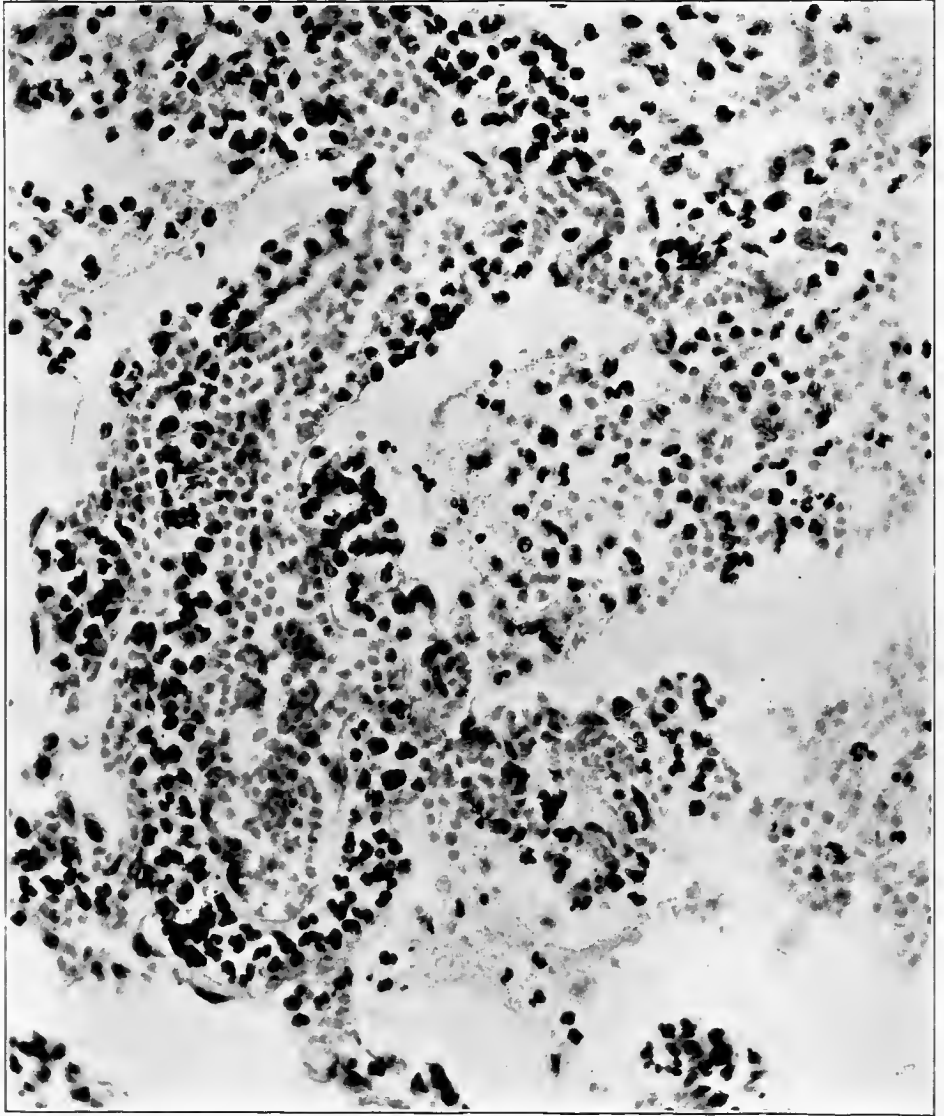


FIG. 2.—Dilated small vessel in a lung in the congestive stage of lobar pneumonia. Capillary vessels are engorged and there is an escape of red blood corpuscles, serum, a small amount of fibrin, and fairly numerous leucocytes into the alveoli adjacent to the small vessel. The lymphatics surrounding the vessel are distended with leucocytes, which infiltrate the alveolar walls. Accession number 22728, Army Medical Museum. Negative number 41224. Hematoxylin and eosin stain; $\times 400$

all. The vessels are engorged with blood which distends the alveolar capillaries, increasing the thickness of the alveolar walls. The alveolar walls are also thickened by edema, the epithelium is more or less desquamated, and the

alveoli contain serum, red blood corpuscles in varying numbers, and a few leucocytes. Strands of fibrin form early but do not dominate the picture at this stage. (Fig. 2).

In the second or red hepatization stage, the lung is firmly consolidated. It fills the pleural cavity and usually shows the rib markings. It is friable and dark purplish red in color. On section the surface is dry, a dull dark-red in color. Plugs of firm exudate can be expressed with the knife edge. The markings are obscured but bronchi of medium and large size are distinct and do not project above the surface. The degree of completeness of the consolidation is common to practically all of the tissue involved though the process is usually slightly more advanced about the larger bronchial and vascular trunks near the hilus. The larger vessels are filled with blood but the smaller vessels and alveolar capillaries are compressed to a greater or lesser degree by the exudate which now fills the alveoli, compressing the walls. The exudate usually contains many leucocytes and a dense fibrin mesh has formed, producing a clot of the entire exudate mass. Red corpuscles retain their stain and vessels still contain an excess of blood. (Figs. 3 and 4.)

In the third or gray hepatization stage, the lobe affected is large, does not collapse, is firm and usually shows rib markings. The color is lighter than in the second stage and may be yellowish gray. It is friable to a greater extent usually than in the preceding stage. On section the cut surface is plane, dull and dry. It is usually somewhat mottled a reddish-gray to yellowish-gray. Firm plugs may be expressed by the knife edge. Because of the lighter color the bronchial walls do not stand out distinctly. The process is uniform for practically all of the tissue affected except that it is slightly more advanced near the hilus where, in the lungs typical of this stage, some liquefaction of the exudate may have occurred. The alveoli are distended with exudate composed of a dense mass of leucocytes in a meshwork of fibrin. Red blood corpuscles do not stain well and the alveolar walls are compressed to such a degree that it is difficult to see them or to make out the capillaries. In the later stages the exudate becomes necrotic and autolyzed as solution takes place and this is accompanied by a filling of the capillaries with blood. (Figs. 5 and 6.) This stage passes over gradually into that of resolution which is somewhat less uniform as the resumption of the full blood and lymphatic circulation is irregular. Lesions corresponding to the description of the three stages but not involving practically all of a lobe are not designated as lobar. Neither are lesions of the same type in lobules which show varying stages in the process even when the greater part of a lobe was thus consolidated.

BRONCHOPNEUMONIA

Bronchopneumonia is a pneumonic consolidation spreading outward from the bronchi a varying distance into the surrounding alveoli, the oldest process being in the vicinity of the bronchus situated in the approximate center of the lesion. Macroscopically, a lung so affected is irregularly consolidated; usually both lungs are affected. On section, the consolidations surround the bronchi extending irregularly out into the parenchyma. When two or more neighboring or adjacent bronchi are affected the lesions may coalesce to form

one large pneumonic mass, the lines of division into separate components being difficult to determine macroscopically, though microscopically variations in the

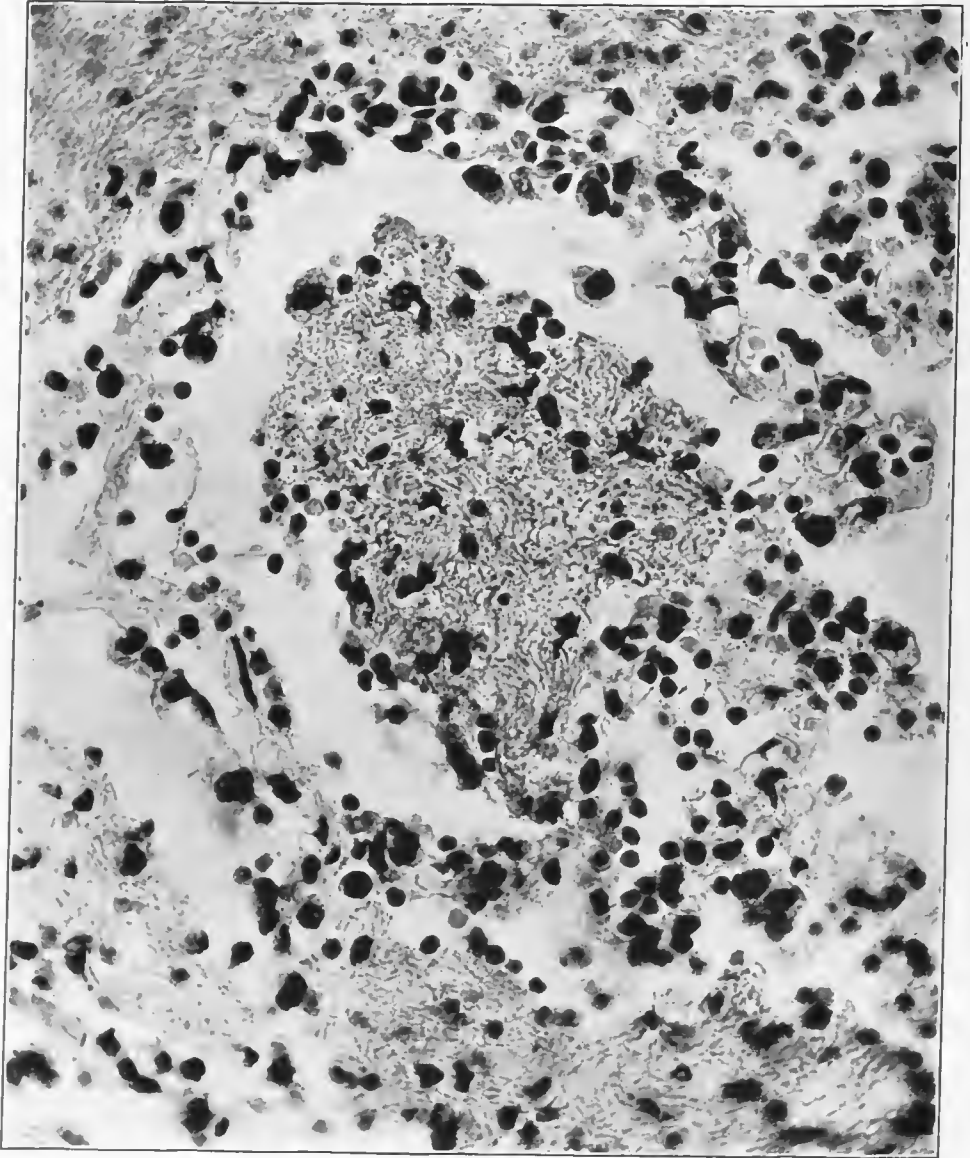


FIG. 3.—Alveolus in the early stage of red hepatization, showing capillary engorgement, nearly complete desquamation of the epithelium, and an alveolar exudate in which fibrin is abundant. Swollen epithelial cells are seen along the alveolar wall and free in the serum-filled space between the fibrinous mass and the alveolar wall. Accession number 22728, Army Medical Museum. Negative number 41217. Hematoxylin and eosin stain; $\times 600$

stage of the process in different areas can usually be made out. The character of lesion varies widely and may show the same stages as the lobar type but is more irregular, the oldest lesions being near the bronchi. Hemorrhagic areas

are frequent and may predominate or constitute practically the entire gross picture. As a rule, there is less fibrin formation and the distribution is irregular

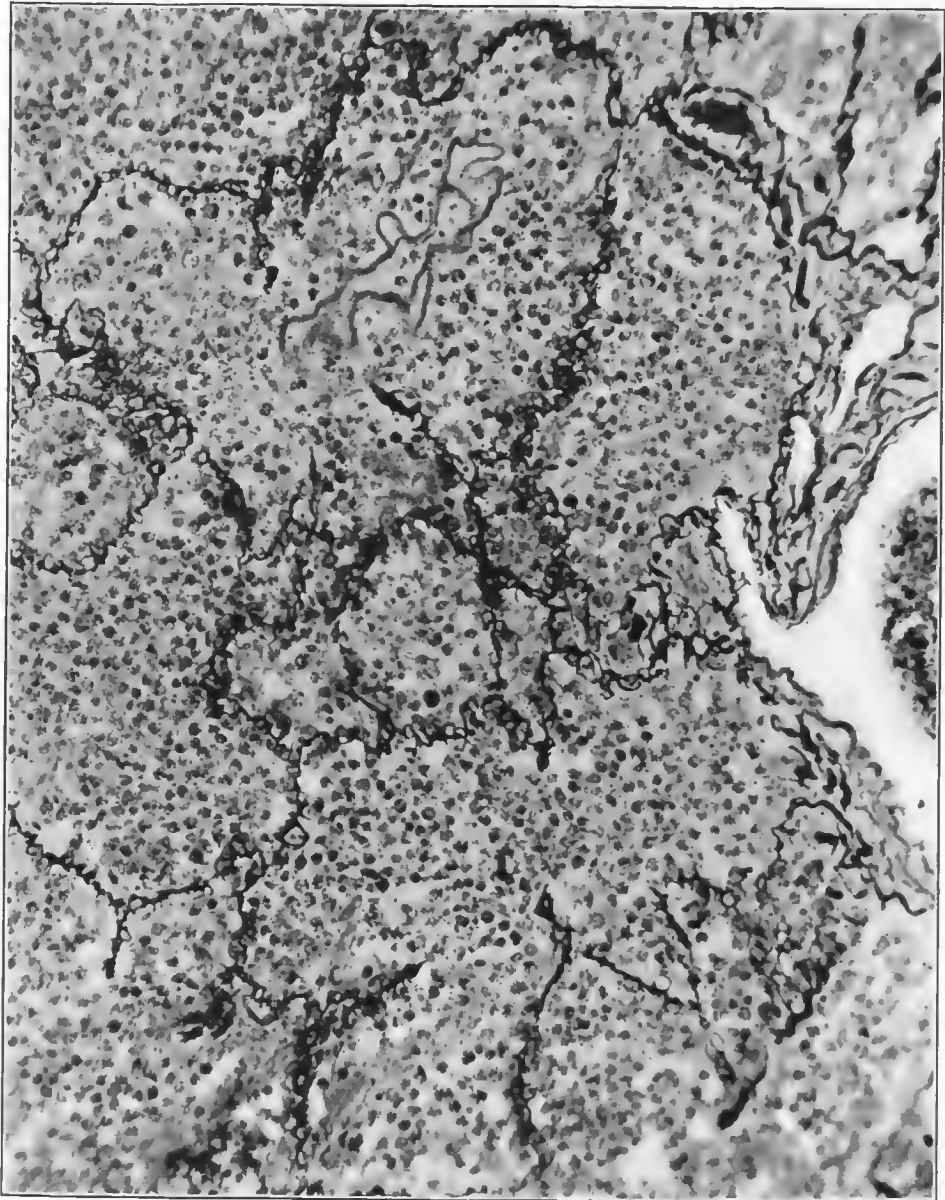


FIG. 4.—Stage of late red hepatization stained for reticulum and showing the dilated capillaries in the alveolar walls. Accession number 3115, Army Medical Museum. Negative number 45561. Reticulum stain; $\times 250$

Sections of small areas frequently show a wide variation in the character of the exudate between neighboring alveoli. (Fig. 7.)

There are two types of pneumonia which answer the description above. In one the bronchi are the site of a severe inflammation usually purulent in

character. The epithelium is largely desquamated, the wall densely infiltrated with exudate, often predominantly purulent and sometimes the wall is necrotic. The process appears to have extended through the bronchial wall to the surrounding alveoli. In the second, the bronchial mucosa is little affected in the earlier stages. The peribronchial and perivascular tissues are densely infil-

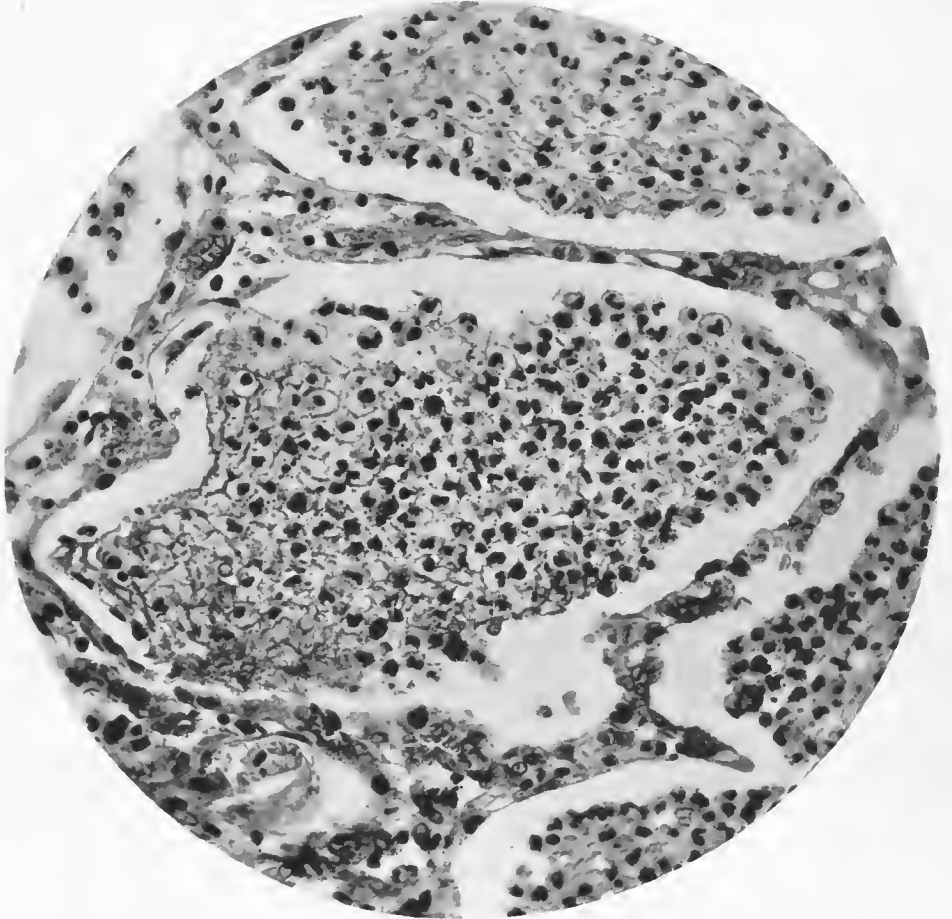


FIG. 5.—Alveolus of early gray hepatization. The exudate has contracted as the result of fixation. Alveolar walls are compressed, some capillaries still being filled with red blood corpuscles. Some of the epithelium is still adherent to the alveolar wall. Accession number 22728, Army Medical Museum. Negative number 41223. Hematoxylin and eosin stain: $\times 400$

trated with exudate, usually purulent, but the leucocytes are often predominantly lymphocytic and the inflammation appears to have extended primarily as a lymphangitis along the peribronchial and perivascular lymphatics and then extended out into the surrounding alveoli. In the later stages the inflammation extends through the bronchial wall to the mucosa which is thus secondarily affected.

LOBULAR PNEUMONIA

Groups of lobules, occasionally single isolated lobules, are affected. Approximation of groups may cause most of a lobe to be involved. Grossly there

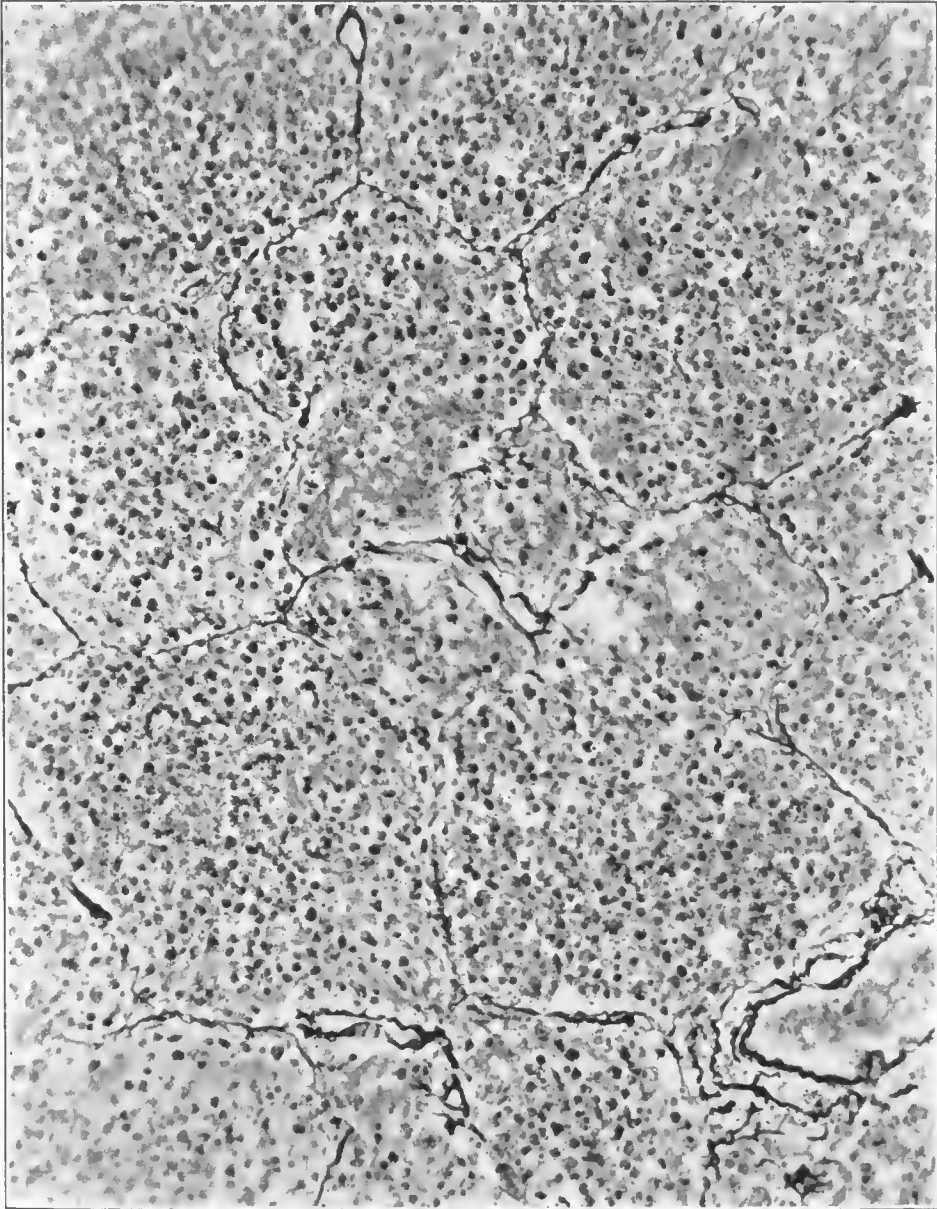


FIG. 6.—Lung in gray hepatization, showing compression of the alveolar walls and capillaries. Accession number 3115, Army Medical Museum. Negative number 45562. Reticulum stain; $\times 250$

are scattered nodular areas of varying size throughout one, usually many lobes. Where these nodules reach the pleural surface as in those of the periphery of the pulmonary parenchyma, the outlines of the lobules can be made out as a

mosaic-like pattern on the pleural surface. The individual lobule is usually uniformly consolidated though the lesions microscopically appear more advanced near the bronchiole of the lobule. The nodules vary in firmness and in

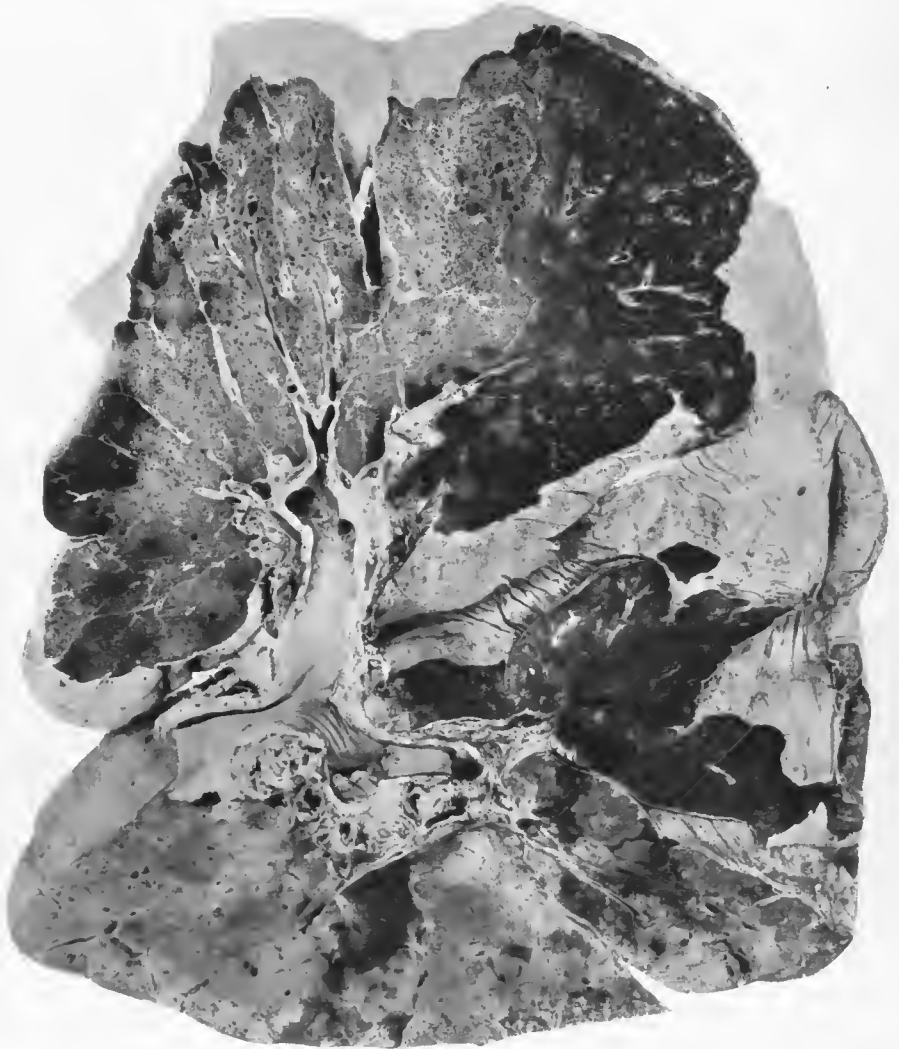


FIG. 7.—Postinfluenzal pneumonia. Spreading bronchopneumonia of left upper lobe and upper portion of left lower lobe. Peribronchiolar foci in base of left lower lobe. Confluent lobular pneumonia of right upper and middle lobes. Peribronchiolar foci in right lower lobe. Pneumococcus, Group IV, in sputum. Streptococci and bacillus of Friedländer in cultures from the bronchi. Accession number 1433, Army Medical Museum. Negative number 30649

friability. Hepatization as seen in the lobar type is occasionally found in affected lobules and groups of lobules, but is rarely found at the same stage in many lobules of the same group. More often the consolidation is less dense and the tissue is more resilient. This type of lesion is usually found accompanied by other types. (Fig. 8.)

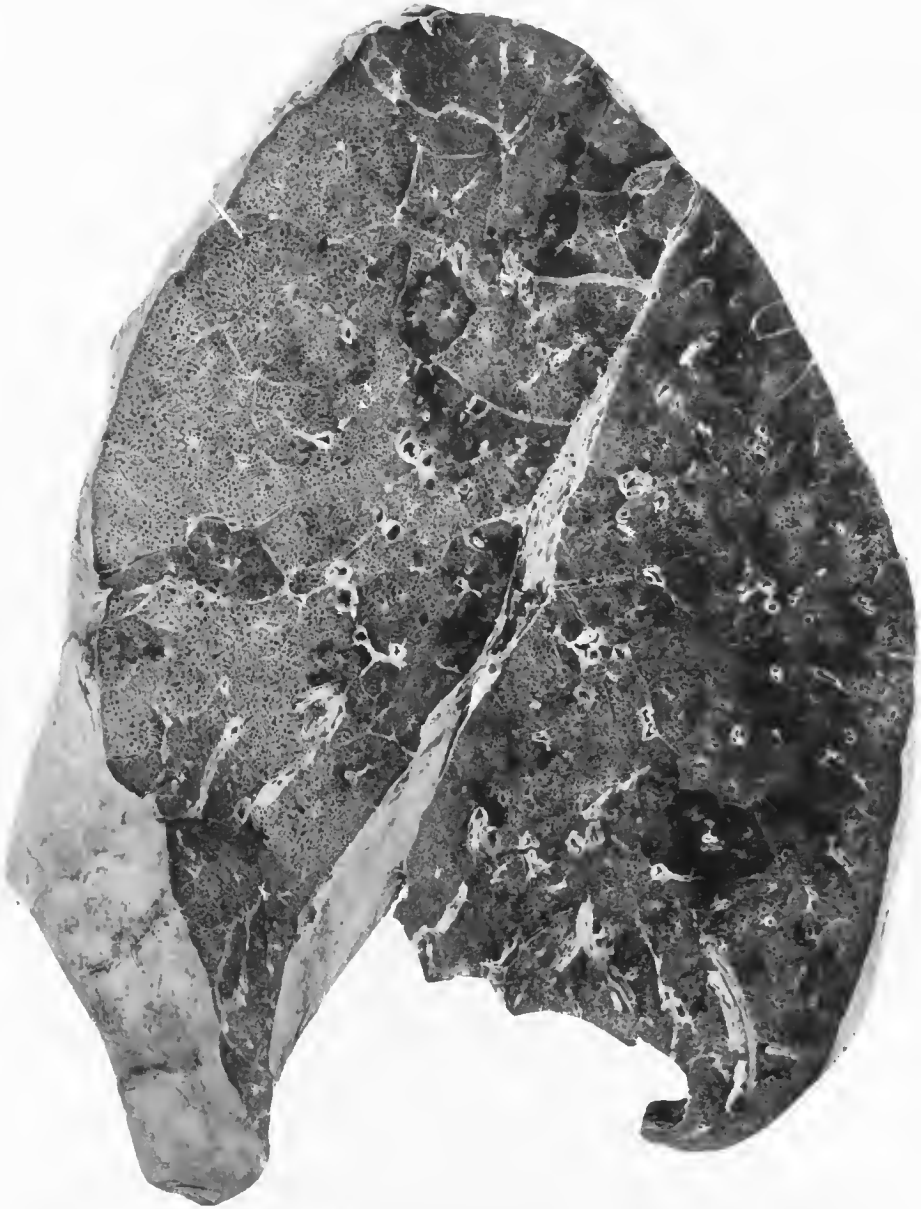


FIG. 8.—Postinfluenzal pneumonia. Generalized confluent lobular pneumonia. *Streptococcus hemolyticus* was cultivated from the lung at necropsy. The pneumonia was accompanied by an acute hemorrhagic tracheitis, bronchitis and an acute mediastinitis. The histological picture was one of marked leucocytic infiltration of the walls of the bronchioles, atri, sacculi, and alveoli, and an alveolar exudate composed of serum, little fibrin, and moderately numerous leucocytes, of which lymphocytes constituted about one-half. Lymphatics were distended with a similar exudate in which streptococci were abundant. There were relatively few organisms in the alveoli. Considerable areas of tissue were filled with extravasated blood. Accession number 3097, Army Medical Museum. Negative number 30666

INTERSTITIAL PNEUMONIA

A reaction, the greatest intensity of which is in the supporting tissue of the lung, has been recognized for some time as a part of the process in some cases of bronchopneumonia. Such a reaction is seen in the lungs of pneumonic plague, where it constitutes a prominent part of the picture. It is never the only type of reaction but lungs have been seen in pneumonic plague, and were described in the influenza of 1918, in which reactions other than interstitial inflammation and its accompanying alveolar edema were not evident on macroscopical examination, though microscopical sections showed at least the early stages of consolidation.

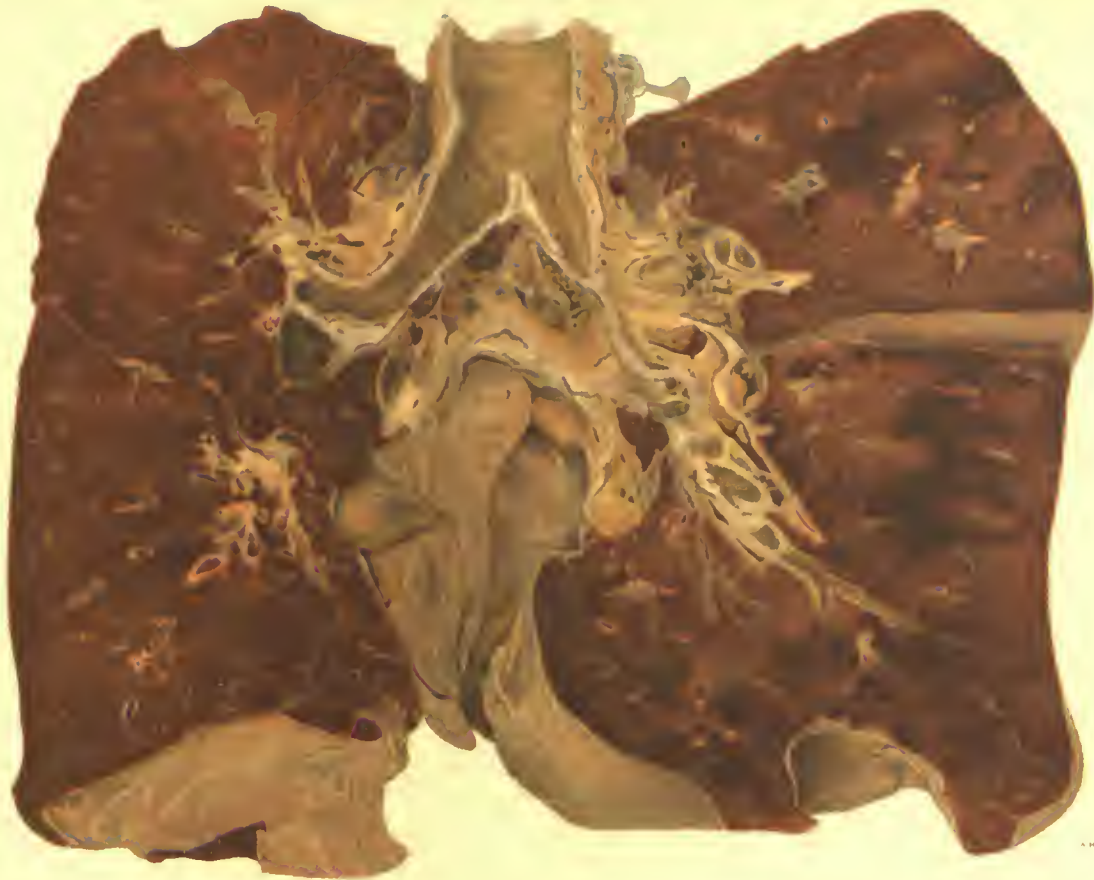
The more acute stage was seen in cases dying in the first two to four days of illness. Grossly the lung resembled that of the acute fulminant type of reaction seen in the influenza pandemic but were more hemorrhagic, that is areas of frank hemorrhage were usual. (Plate I.)

Macroscopically such a lung is heavy and boggy. Though it does not collapse, crepitation is not easily elicited. On section the lung drips blood, and bloody serum which appears dull and brownish. The bronchi stand out, filled with hemorrhagic exudate, the walls are thickened and often surrounded by hemorrhagic zones, while areas of frank hemorrhage already clotted are frequent. Histologically the peribronchial and perivascular tissues, aside from edema and hemorrhage, are infiltrated with lymphocytes, large mononuclear and polymorphonuclear cells, and the same infiltration is present in the alveolar walls. The alveoli are filled with a serous exudate which rarely contains fibrin. Streptococci are abundant in the bronchi and peribronchial and perivascular lymphatics but are seen in minimal numbers in the alveoli. They are present in the pleural exudate which often forms even in the rapidly fatal cases, presumably through infection spreading to the pleura from the hilus region.

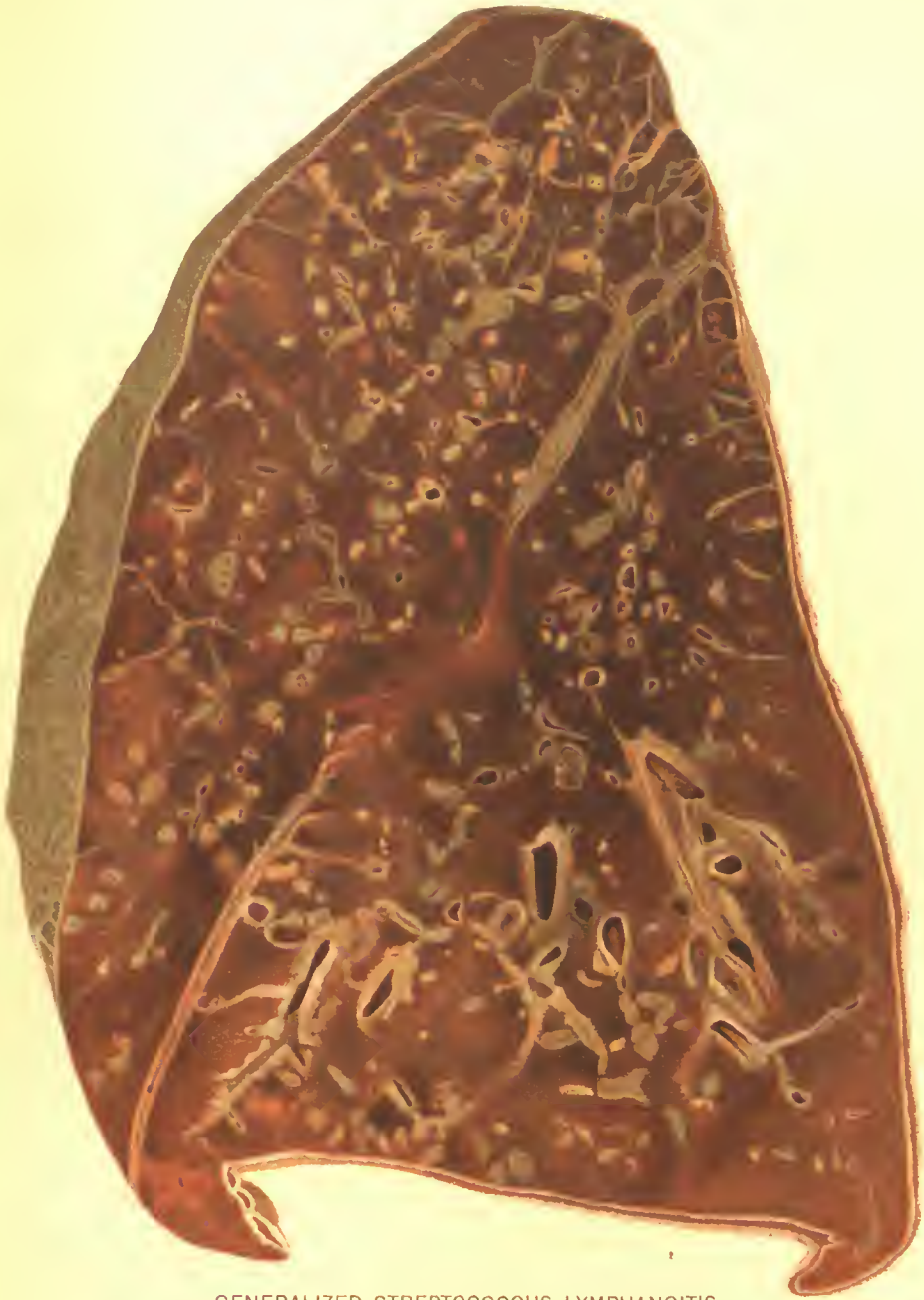Cases of interstitial pneumonia which live a longer period are accompanied by more involvement of the interstitial tissues and are relatively easy to diagnose macroscopically. The lungs of such cases are less distended and show areas of partial collapse. Areas of lobular pneumonia and of pneumonic consolidation extending from the peribronchial tissues, are always present. The bronchi show markedly thickened walls. The same type of thickening is present also along the vessels which frequently, except for the character of their lining, are indistinguishable from the bronchi. Fibrous tissue, separating lobules and groups of lobules which are involved in the process, shows marked thickening, is pale and opaque, the thickening being frequently of nodular character, due to irregular distention of the lymphatics with purulent exudate. (Plate II). All stages are seen from the acute hemorrhagic process, difficult to differentiate macroscopically, to advanced abscess formation in the interstitial tissues, accompanied by lobular and spreading bronchopneumonic consolidations, and empyema. In some instances the pneumonic consolidations are in excess, in others the interstitial reaction.

PERIBRONCHIOLAR PNEUMONIA

This is apparently the typical reaction of *B. influenzae* and is basically an involvement of the bronchi at their terminations in the respiratory bronchioles. At these terminal sites the infection extends to the alveoli grouped at the termi-



DIFFUSE, HEMORRHAGIC PNEUMONIA.
Streptococcus hemolyticus infection following influenza. Beginning consolidation.
Accession 2696, Army Medical Museum. Colored photograph.



GENERALIZED STREPTOCOCCUS LYMPHANGITIS.
Secondary to confluent lobular pneumonia following influenza.
Accession 16646, Army Medical Museum. Colored photograph.

A. MOHRE, L. C. 2111

nation of the bronchial radicles producing minute miliary nodules, primarily hemorrhagic, later becoming necrotic and resembling tubercles either single or in groups, at times practically uniformly consolidating the lobule, the lesion appearing more advanced centrally. (See frontispiece.)

In the acute fulminant type, which is described under Camp Devens (p. 42), practically every bronchial termination is involved and the gross picture is that of hemorrhagic inflammation. Much more frequently fewer areas are involved in the early stage and other organisms determine the majority of the terminal pictures. In the peripheral portion of such lungs, however, the lesions at the ductus alveolaris are still evident usually presenting alveoli filled with leucocytes, many of which are the large mononuclear types, while proliferative changes are practically always present and may appear advanced even in cases which died within two weeks after the clinical onset. Metaplastic types of change are seen in the bronchial epithelium even in the fulminant types of a few days' duration.

Where the patients live a longer time the bronchial inflammatory reaction becomes frankly purulent. The process originally does not involve the entire lung but is progressive, involving one portion and then a succeeding one, so that in parts of the lung the hemorrhagic type of reaction is present, in others a purulent reaction in the bronchi with secondary thickening of the wall, a loss of epithelium and an extension by continuity for greater or lesser distances in the surrounding alveoli. In such cases, the smaller bronchi and surrounding infiltration microscopically resemble nodular tubercles. The pus in such cases usually contains very numerous influenza bacilli not infrequently mixed with Gram-positive cocci, of which the most frequent is the streptococcus. With a mixture of streptococcus in which the organism is found in the peribronchial tissue, it is difficult to decide which organism preceded, as either alone may result in an interstitial reaction, while bronchi are also blocked and organizing processes occur in both varieties of infection, perhaps somewhat more frequently and rapidly in cases due to influenza bacillus. However, there is a reasonable doubt as to whether the influenza bacillus itself produces a definite interstitial reaction unless the organizing processes in areas of atelectasis are so considered.

The definitions given above appear to be necessary in order to avoid confusion. These are based on the pathological anatomy rather than on the clinical aspects of the case, because it appears that there is general agreement neither between clinicians and pathologists nor among pathologists. There was wide variation in the physical signs which clinicians considered indicative of the type of pneumonia present. An abrupt onset, with pleural pain, particularly if dullness involved most of a lobar area, was generally termed lobar pneumonia. If a crisis occurred practically all would so diagnose it. Lobar is an anatomical term, however, and depends on the pathologic anatomy of the disease. A slow onset and a termination by lysis made little difference to the diagnostician, while to many pathologists the fact that a lobe was involved to a large extent, whatever the type or variation in type of the pathological process, was sufficient to cause him to designate it as lobar pneumonia. Many of the pathologists, however, stated that any type designation was not adequate, since practically all the cases showed various types, and several preferred the term pneumonitis or

inflammation of the lung to pneumonia, with the various qualifying terms commonly used.

Every type of acute respiratory lesion noted during the World War occurred during the influenza pandemic and in sufficient numbers to enable one roughly to classify them. The rapidly fatal type which was such a prominent and spectacular feature will be described first and illustrated, as it is considered that the lesions seen were but modified in extent, intensity, or both, in practically all cases to which the clinical diagnosis influenza was applied, while other lesions, except primary lobar pneumonia, were later complicating infections. Whether the fulminant cases were the result of the action of the bacillus of Pfeiffer or of this organism as a secondary invader, or of symbiotic action is still to be determined. The evidence even now, nine years after the pandemic, does not allow a definite answer to the important question of etiology.

LESIONS ASSOCIATED WITH INFECTION BY *B. INFLUENZÆ*

With regard to the most numerous group—those who recovered in a few days—one may surmise a reaction less violent or less extensive than those seen in the fatal cases, but of similar type. Whether influenza is always primarily a respiratory disease or whether the infective agent may enter by other portals is not known. In the pandemic of 1918 the respiratory tract appeared always to be involved, at least in its upper portion.

Discussion of the lesions in these cases, in so far as these can be described from the Army material, follows:

Nose.—Grossly the redness, swelling, and mucous flow varied. In the earliest stages a sense of dryness and discomfort was followed by more or less profuse discharge of mucus. This might terminate the symptoms or more frequently a purulent inflammation followed.

Accessory sinuses.—The ethmoids usually were involved if there were any marked lesion in the nose. The frontal sinus, maxillary antrum, and sphenoid frequently presented symptoms and at necropsy purulent inflammations of the mucous membrane lining them (one or several) were found, not infrequently accompanied by hemorrhage into the mucous membrane and exudate. The bacteriology is uncertain as so few were carefully examined. *B. influenzae* was found both early and late and the same is true for both pneumococci and streptococci. Extension of the process along the Eustachian canal and to the middle ear and involvement of the mastoid antrum in a purulent inflammation was observed with varying frequency. In the mastoid antrum bone necrosis often was observed while extension to the bones from the other sinuses was not frequent. It was more often seen in cases from which streptococcus was isolated. By bone involvement, extension occurred to the membranes of the brain both primarily and subsequent to operations on these sinuses. (Fig. 9.)

Nasopharynx.—The mucous membrane here, so far as observed, was always reddened and the lymphatic structures swollen but not often to a great degree. No tissues were described.

Tonsils.—As a whole, little early change was seen except for hyperemia, especially in the crypts, which frequently showed red injected openings. The more pronounced changes seen in the cases of clinical influenza appear to have

been due to invasion by streptococcus and were not a part of the influenzal picture. The pillars of the fauces were reddened as was the uvula. Careful observation of the mucosa of the buccal cavity sometimes showed numerous reddened spots simulating an eruption; these were the inflamed openings of the buccal mucous glands.

Larynx.—The mucosa was swollen, reddened, and frequently showed smaller or larger hemorrhagic infiltrations of the superficial layers. The columnar

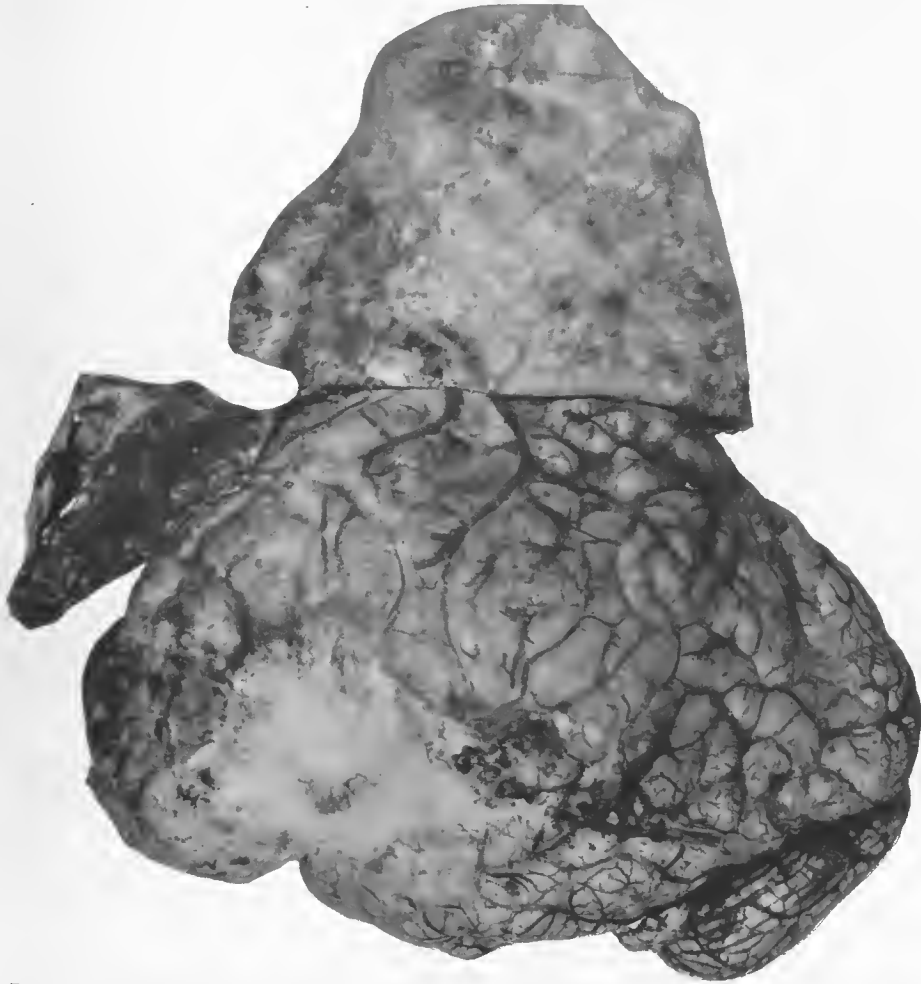

FIG. 9.—Subdural abscess following suppurative frontal sinusitis after influenza, *Streptococcus hemolyticus*. Accession number 12726, Army Medical Museum. Negative number 30804

cells were missing in some areas and the submucosa was edematous while the basement membrane was swollen and hyaline in appearance. On the surface small Gram-negative bacteria were seen and usually Gram-positive cocci having the morphology of pneumococci, streptococci, or both. In cases dying in the first few days the cellular exudate was often not abundant and contained a

large proportion of mononuclear cells. Occasionally, even early, the exudate along the surface was distinctly purulent and frequently contained numerous minute Gram-negative bacilli with a greater or lesser mixture of Gram-positive cocci.

Ulceration had not had the opportunity to form at this early stage and when present later it was probably due to organisms other than those of the primary infection. Atria of ingress, for whatever bacteria were present, were formed as a result of the denudation of the columnar cell layer.

Trachea.—The picture here was essentially the same as in the larynx. The mucous glands of the submucosa were more or less swollen and the ducts were filled with mucinous material containing mononuclear cells and occasionally frank pus. The gland cells appeared active and, as a rule, did not show marked degeneration or many bacteria in their vicinity. Rarely a few Gram-negative, small bacilli were found in the acini nearer the mucosa. Hemorrhages into the superficial mucosa were frequent and there were usually small areas filled with red blood corpuscles about smaller vessels in the submucous zone. The tissue between the ends of the cartilaginous tracheal rings was more or less infiltrated with mononuclear cells. Nodular accumulations of lymphocytes were reported occasionally as occurring in the submucosa and some of these showed the typical area of lymphocytic accumulation normally present at the bifurcation of bronchi within the lung, including a certain amount of reticular structure and reticulum cells. Ulceration was seen in patients who survived for some time but were not reported in the acute fulminant cases and were probably due in large part to secondary invasion. (Fig. 10.)

The tracheal lymph nodes were moderately swollen, moist, and red. The peripheral sinuses were dilated with fluid containing large mononuclear cells and lymphocytes while there was a general edema and an increased number of large mononuclear cells in the tissue. In a considerable number of cases the enlargement of these nodes was extreme. Such nodes dripped blood and serum on section and hemorrhages were visible. The blood vessels of small caliber showed swelling and proliferation of the intimal endothelium and capillaries were often distended by hyaline "thrombi." The large mononuclear cells had often phagocytosed leucocytes and occasionally contained red blood corpuscles, but it was unusual to find bacteria in their cytoplasm and when found the organisms were usually in phagocytosed polymorphonuclear leucocytes.

Proliferation of the reticulum cells, particularly those of the follicles, was usual and varied greatly in amount. It was most marked in cases surviving longest. (Fig. 11.)

Thorax.—On opening the chest the appearance of the thorax was rather characteristic. The lungs filled the pleural cavities and presented a large surface overlapping the heart, and decreasing the exposed area of the pericardium.

The loose tissues of the mediastinum were edematous and occasionally contained air. The pleural cavities contained a slight excess of fluid which was either clear or blood tinged.

The parietal pleura was more or less reddened and small hemorrhages into this membrane were observed. Definite pleural exudate in these fulminant cases was usually lacking. The lungs were a deep red or purplish color with

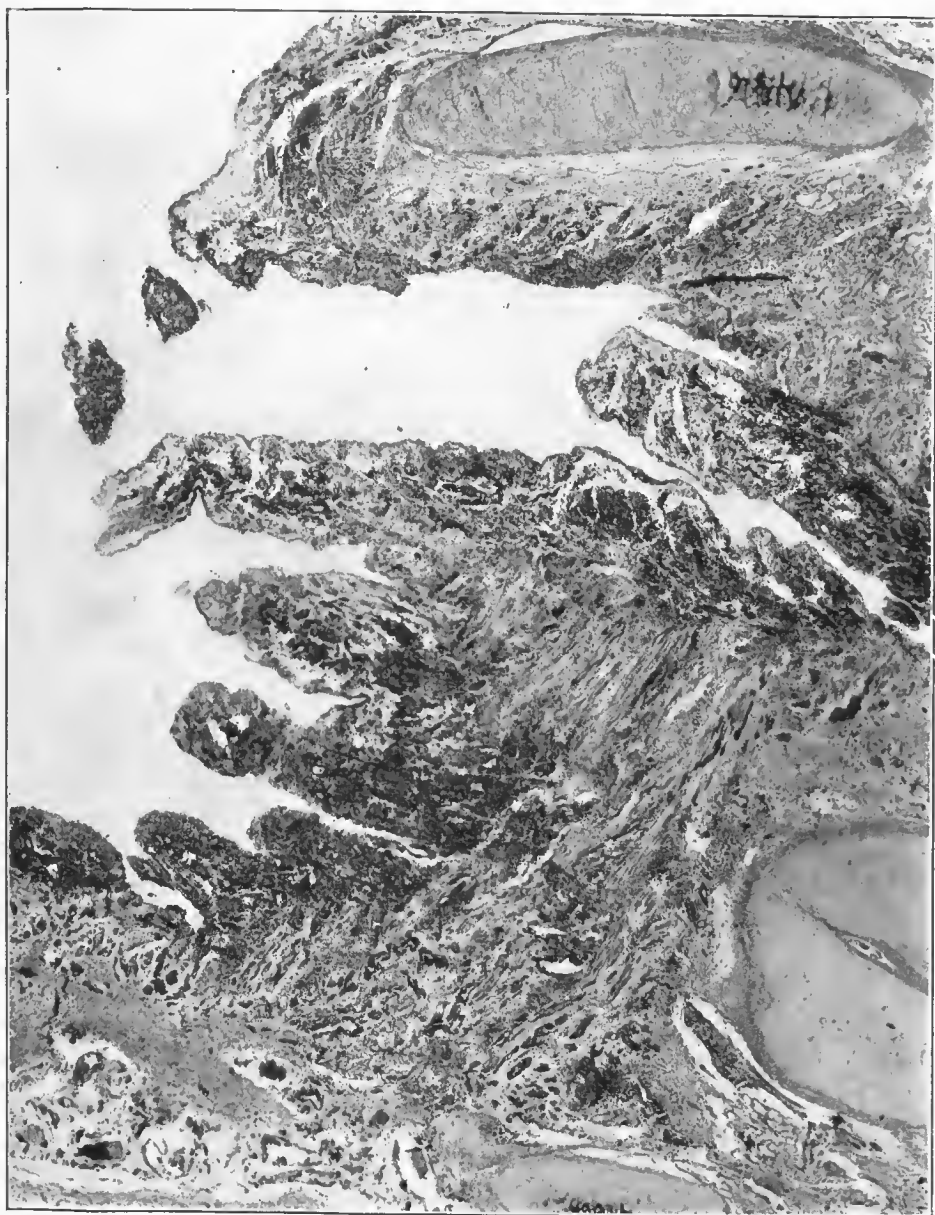


FIG. 10.—Hemorrhagic necrotic inflammation of the lining of the trachea in a fulminant case of acute, diffuse inflammation in both lungs. Both influenza bacillus and streptococcus were present in cultures. Accession number 3577 Army Medical Museum. Negative number 45910. Hematoxylin and eosin stain; $\times 21$

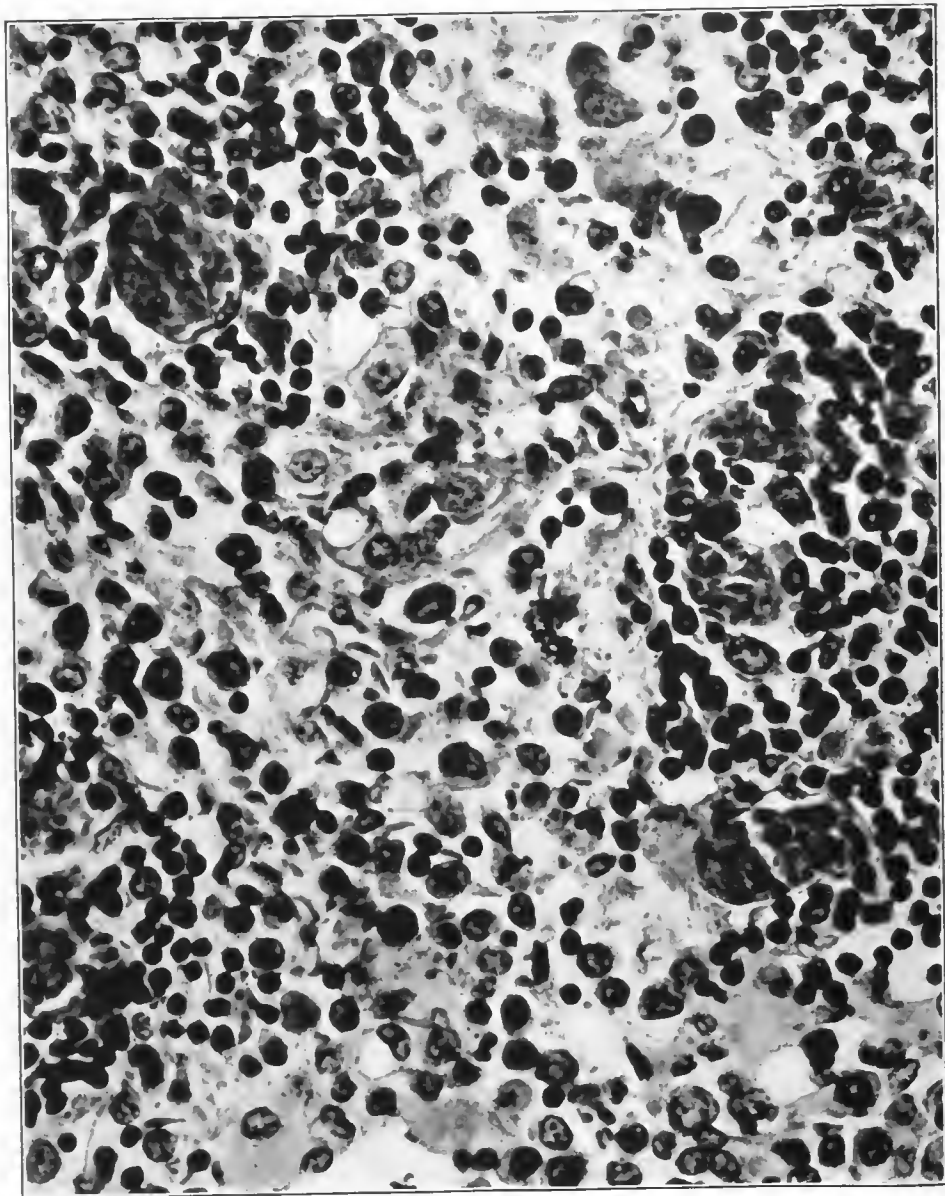


FIG. 11.—Cellular reaction in a bronchial lymph node in pneumonia following influenza, showing the character of the cell exudate along the reticular tissue of the node. Very few polymorphonuclear leucocytes are seen, lymphocytes are moderately numerous, while large mononuclear cells preponderate; they were evidently actively proliferating as indicated by mitotic figures. Accession number 1049, Army Medical Museum. Negative number 45170. Hematoxylin and eosin stain; $\times 580$

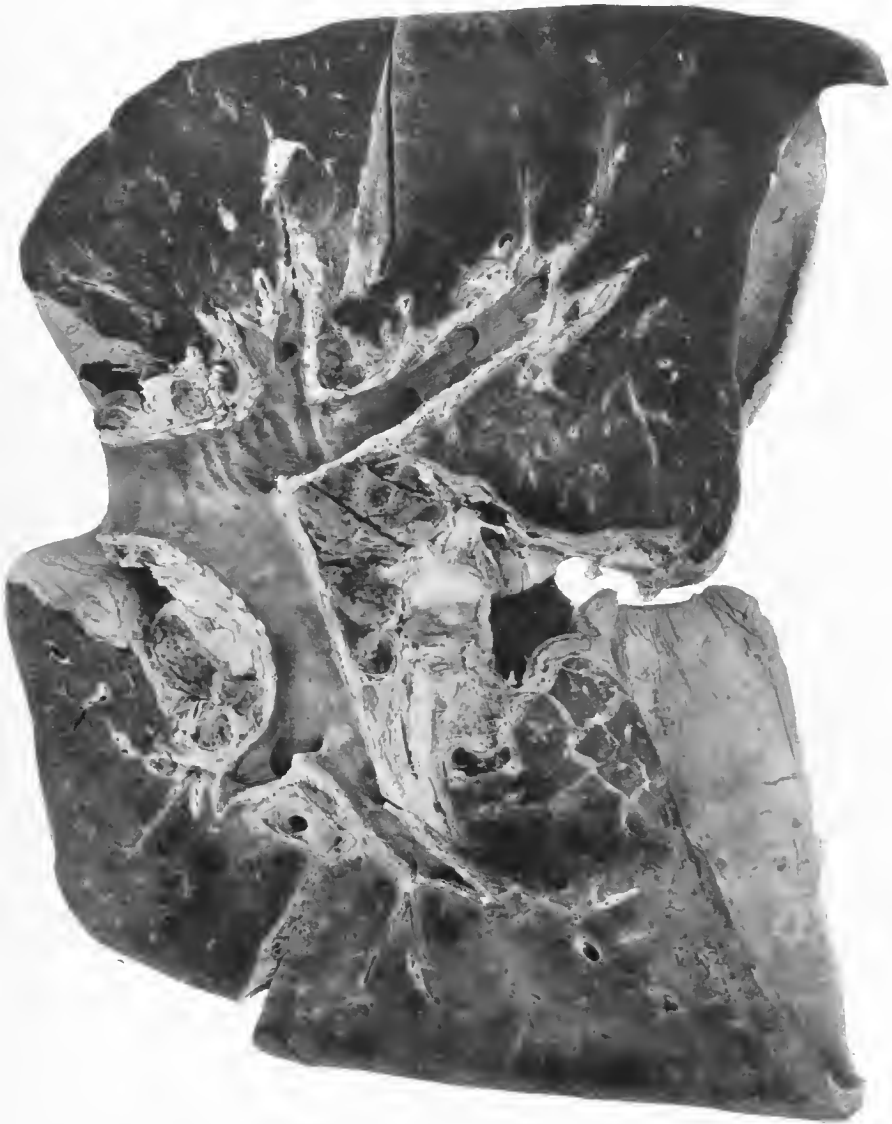

FIG. 12.—Pneumonia following influenza. Diffuse, hemorrhagic inflammation of the lungs. Minute Gram-negative bacteria and streptococci in sections. The onset of pneumonia was four days prior to death. Pneumococcus, Group IV, found in the sputum, hemolytic streptococcus in the heart and lungs at necropsy. Accession number 2707, Army Medical Museum. Negative number 30602

occasional flecks or small extravasations of blood beneath the serosa. The lymph nodes at the hilus were large, moist, dark in color, and dripped blood on section; occasionally minute punctate hemorrhages could be seen. The lungs showed no firm consolidation but were boggy or rubbery in consistency, crepitation though present being elicited only in slight degree. The lungs were heavy and showed, even in necropsies made within a few hours after death, a greater density in the lower and posterior portions. (Fig. 12.)

Blisterlike structures often were seen on the pleural surface, more abundant anteriorly, but small ones were scattered over the entire surface in some cases. Some of these contained fluid but the majority were filled with air.

On sectioning such lungs, a great deal of fluid welled up on the cut surface. This fluid appeared to be blood and serum mixed, the blood content varying considerably so that from some parts of the lung, particularly the anterior portions, serum predominated, while from other parts the fluid appeared to be thin, dark blood. Large quantities of fluid escaped and more could be squeezed out as from a sponge, leaving a brownish-red tissue without definite consolidation. The fluid was frothy from air admixture and this was especially true of that which bubbled up in the severed bronchi, which usually contained less blood than that from the parenchyma. The tissue, as seen after wiping off the fluid with the knife, appeared firmer than normal, and with a lens the walls of the alveoli appeared thickened. In some cases hemorrhagic consolidations, appearing like small infarcts, could be made out surrounded by the hemorrhagic edema. At the time of necropsy these areas showed little evidence of inflammatory consolidation, but after the lungs had been fixed the center of these areas showed as paler nodules of peribronchiolar consolidation surrounded by zones of hemorrhage. (Fig. 13.) Emphysema was indicated by air vesicles protruding from the surface. Although there was some variation in the intensity of the reaction, the mucosa of all the bronchi was reddened and somewhat swollen, with a velvety sheen flecked with small hemorrhages.

Primary bronchi.—The process being described appeared to extend along the respiratory passages with great rapidity. In a few hours an inflammation, apparently starting in the nose or pharynx, would involve successively the larynx, trachea, and entire bronchial tree. Thus the bronchi showed the same type of changes seen in the trachea and because of the uniform involvement present throughout the respiratory tract, little unchanged bronchial mucosa was seen in these fulminant cases at necropsy.

The mucus membrane, particularly of the larger bronchi, was usually intensely red, with a velvety sheen with occasional splashes or flecks of actual hemorrhage. These tubes were filled with a frothy somewhat viscid mucus, tinged and streaked with blood, little exudate of a purulent nature being evident, though pus quickly appeared in the mucus if the patient survived for a sufficient time. Microscopically the columnar cells were swollen, many individual ones being cast off while here and there small areas of cells were raised from the basement membrane in small vesicles by fluid exudate. (Figs. 14 and 15.) It was unusual in cases dying in the first two to four days to find either grossly or microscopically complete denudation of very large areas. Suitably fixed specimens show marked vascular engorgement particularly

of the capillaries just beneath the mucosa, while the lymphatic network in contact with the basement membrane was markedly dilated. The mucous glands appeared active and the nuclei as a whole stained well. Cellular infiltration was not marked. The majority of the infiltrating cells were of the lymphocytic type with rather numerous large mononuclear cells with pale cytoplasm, most abundant near the basement membrane.

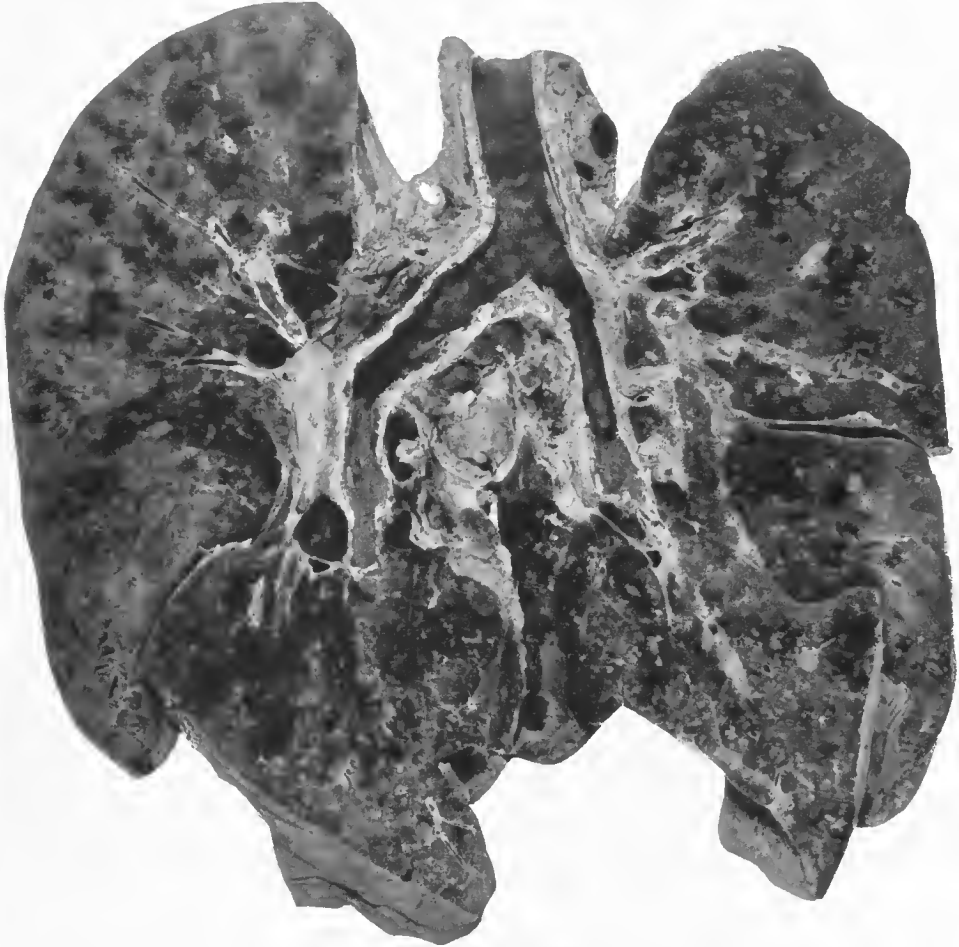

FIG. 13.—Postinfluenzal pneumonia. Both lobes contain numerous disseminated nodules of consolidation, most of which are surrounded by zones of hemorrhage. At necropsy the pale centers did not appear, being infiltrated with blood which masked the dense consolidation. The lesion in the left lung was a confluent lobular pneumonia superimposed on smaller foci of consolidation about the terminal bronchioles. Pneumococcus, Group IV, was isolated, but histological sections show minute Gram-negative bacilli. Acute tracheitis and bronchitis with flecks of hemorrhage into the mucosa. Accession number 2694, Army Medical Museum. Negative number 45879

In the well-fixed material minute Gram-negative bacteria were found, free along the mucosal surface, in the blisterlike areas and engulfed, sometimes in large numbers, by the large mononuclears. (Figs. 16, 17, 18, 19, 20, 21, and 22.) These organisms were not found deep in the tissues but were seen occasionally in phagocytes at 8 to 20 cells depth (50 to 200 μ) beneath the surface. The higher up the bronchial tree sections were made, the more organ-

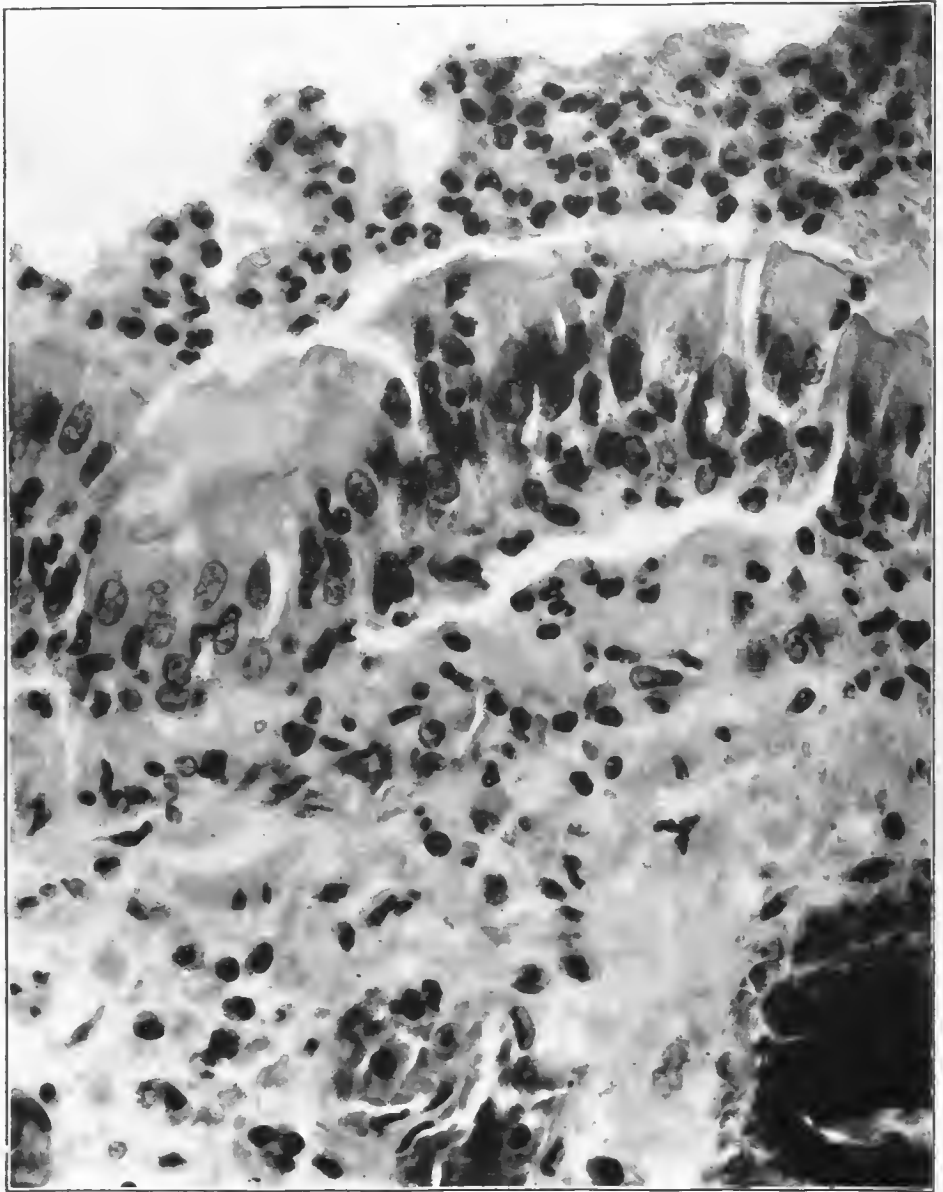


FIG. 14.—Early changes in bronchiolar epithelium. Cells show hypersecretion and beginning desquamation. Edema and cellular infiltration along the basement membrane and beneath it. Beginning purulent bronchitis. Accession number 1055, Army Medical Museum. Negative number 45195. Hematoxylin and eosin stain; $\times 600$

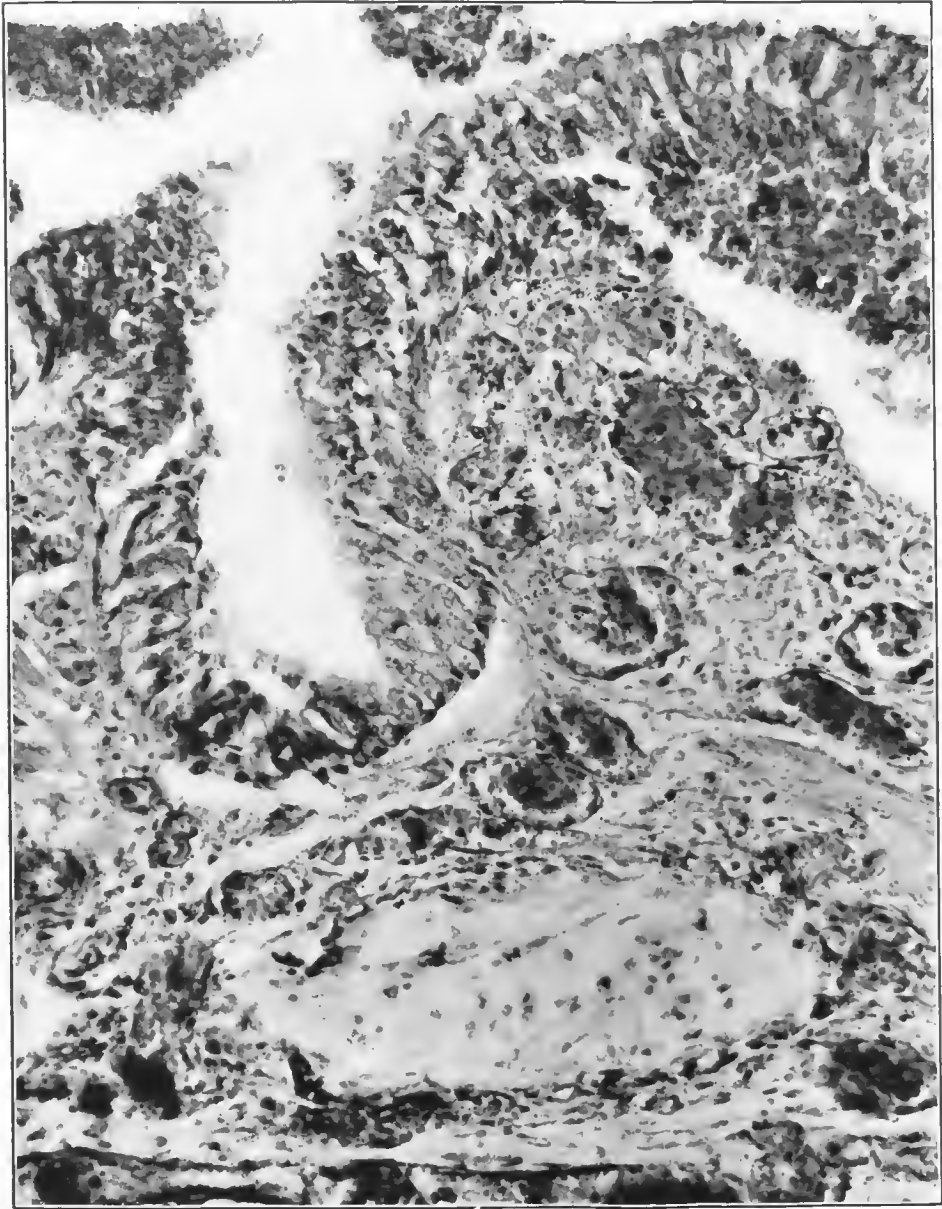


FIG. 15.—Degeneration of bronchial mucosa in an acute fulminant case of pneumonia following influenza; necrosis of the cells of submucosal glands; hemorrhagic inflammation. Accession number 16595, Army Medical Museum. Negative number 45907. Hematoxylin and eosin stain; $\times 235$

isms of the Gram-positive coccus type were found. These were rarely seen in the smaller tubes until later in the disease. Pus formed relatively early in the smaller bronchi and by the fifth or sixth day was usually abundant there. In this pus the Gram-negative bacilli were often present in enormous numbers, and as the disease continued the Gram-positive cocci increased in number as determined by stains of the tissue. (Figs. 23, 24, and 25.) These Gram-negative bacilli were not found as above described by all pathologists. They were present, however, in well-fixed tissue from all cases dying relatively early and subjected to necropsy soon after death which were examined in the studies on which this description is based.

Smaller bronchi.—The changes continued of the same intense character as seen in the larger bronchi though with less regularity. Some bronchioles showed what appeared to be earlier, or at least less intense reactions, with less cellular response, less edema and desquamation and few bacilli. These structures of the smaller type were filled with exudate containing air or open spaces as seen in the sections. (Figs. 26 and 27.) There was less casting off of the mucosa and in many in which the inflammatory reaction was less intense there was a piling up of the cells from the basal layer with a loss of the columnar type of cell and an appearance of beginning metaplastic-like change toward the stratified squamous type, even in cases the duration of which was less than a week. (Figs. 28 and 29.) Consequently, these smaller bronchi were completely plugged by viscous secretion, the plug continuing down to their terminal branches and containing fibrin strands. The tissue distal to such a block was atelectatic.

The most characteristic changes in the pulmonary inflammation being described occurred in the true lung unit of Miller.² This unit consists of the respiratory bronchiole opening into the ductuli alveolares which terminate in more or less spherical spaces beyond a dilated extremity. These spaces or atria lead from air sacs into which open the alveoli. In addition there are some alveoli along the respiratory bronchiole and ductuli which open directly into them.

The inflammatory reaction extends along the surface of the terminal bronchiole as a serous inflammation, the secretion filling the ductus alveolaris. It also extends into the alveoli leading off directly from the bronchiolar wall and to a greater or lesser extent into the atria and alveoli. In the fulminant cases many or most of these lung units are involved with a reaction varying from a serous to a hemorrhagic type accompanied by marked congestion and little cellular infiltration, giving rise to the edematous hemorrhagic picture seen macroscopically in the lung. (Pls. III and IV.) The distribution was rarely uniform but the more uniformly the lung as a whole was affected, the less varied the picture and the more rapid the death. Microscopically the ductuli alveolares were filled with viscid albuminous fluid containing air bubbles, while the atria contained more or less air, the exudate lying along the walls of the air sacs and alveoli. (Figs. 30 and 31.) The block by the exudate at the opening of the atria into the ductus alveolaris thus caused an increased pressure in the alveoli, a factor of undoubted relationship to the rupture of alveolar walls which so commonly occurred. The air sacs and alveoli opening from one ductus were rather

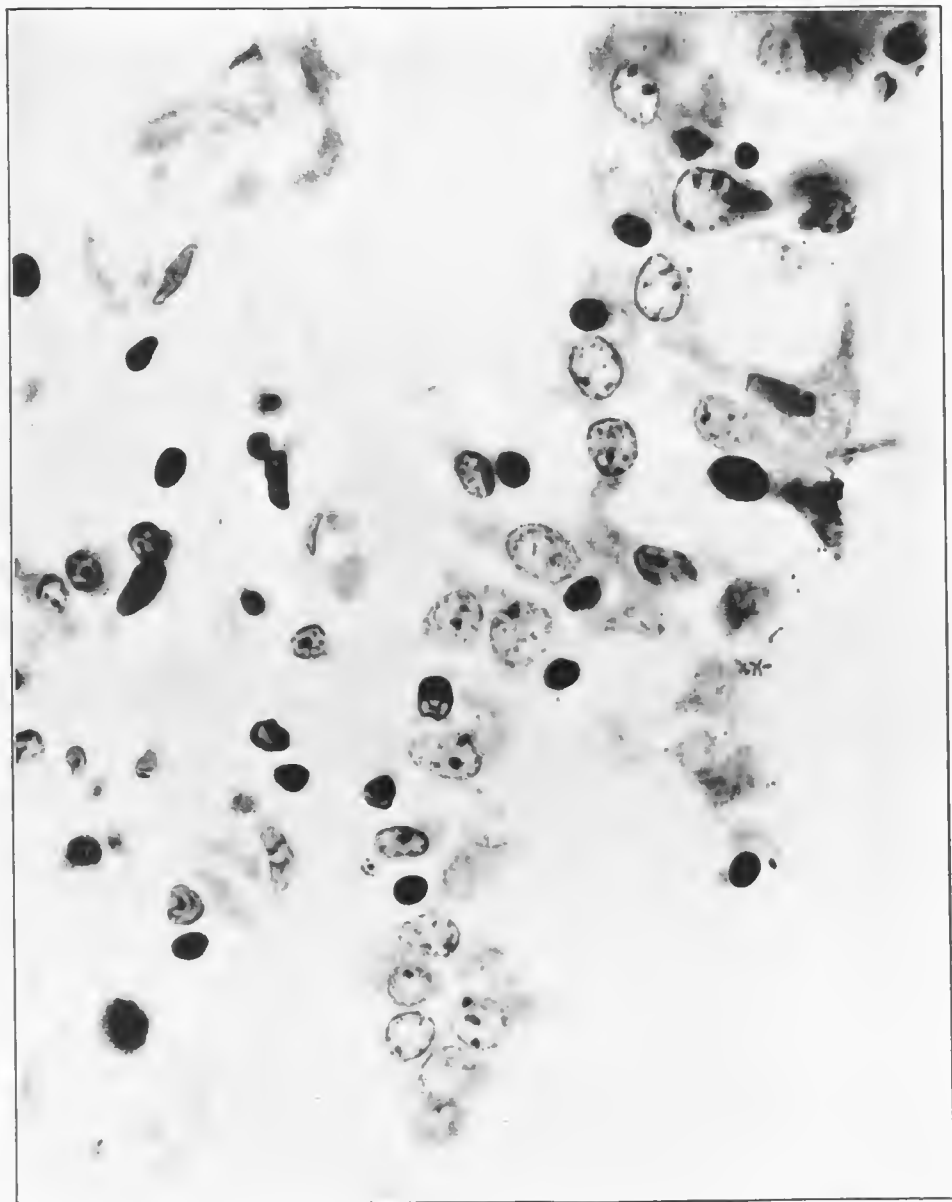


FIG. 16.—Gram-negative bacilli along bronchiolar epithelium in a case of lobular pneumonia. Streptococcus cultured from blood and lung. Duration eight days. Accession number 1519, Army Medical Museum. Negative number 45179. MacCallum stain; $\times 1070$

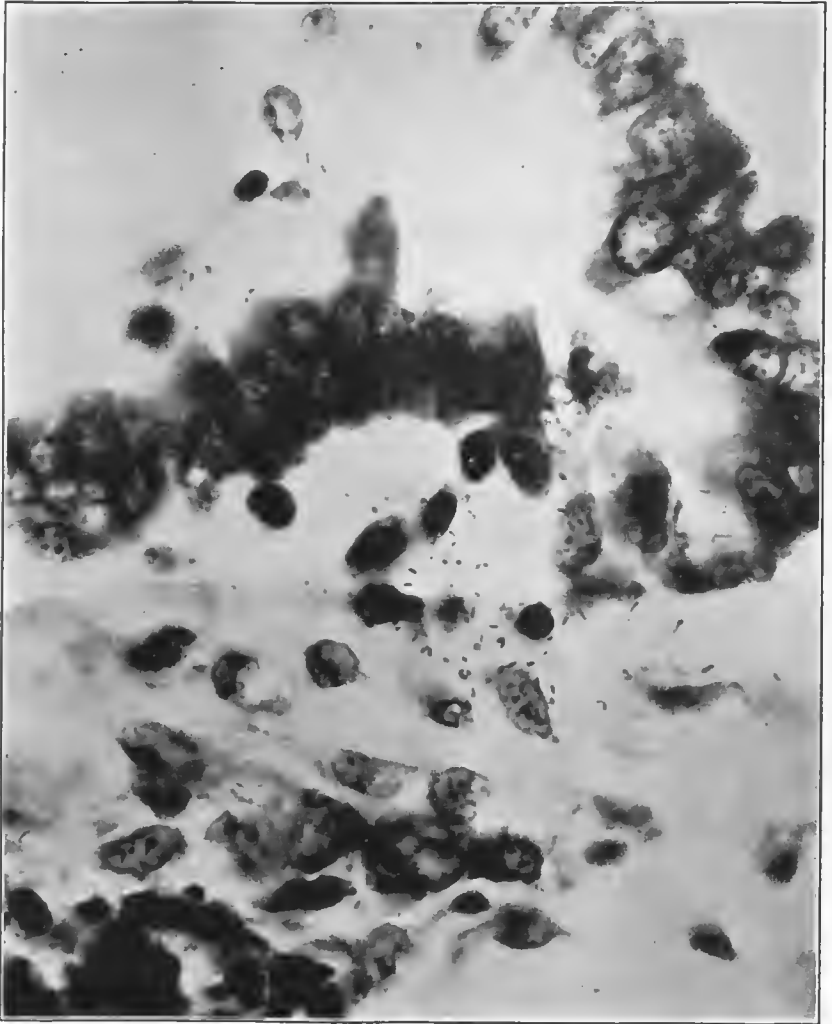


FIG. 17.—Wall of bronchiole. Epithelium being raised and separated by serous exudate beneath. Gram-negative minute bacilli and mononuclear cells in exudate. Accession number 3108, Army Medical Museum. Negative number 45270. MacCallum stain; $\times 1300$

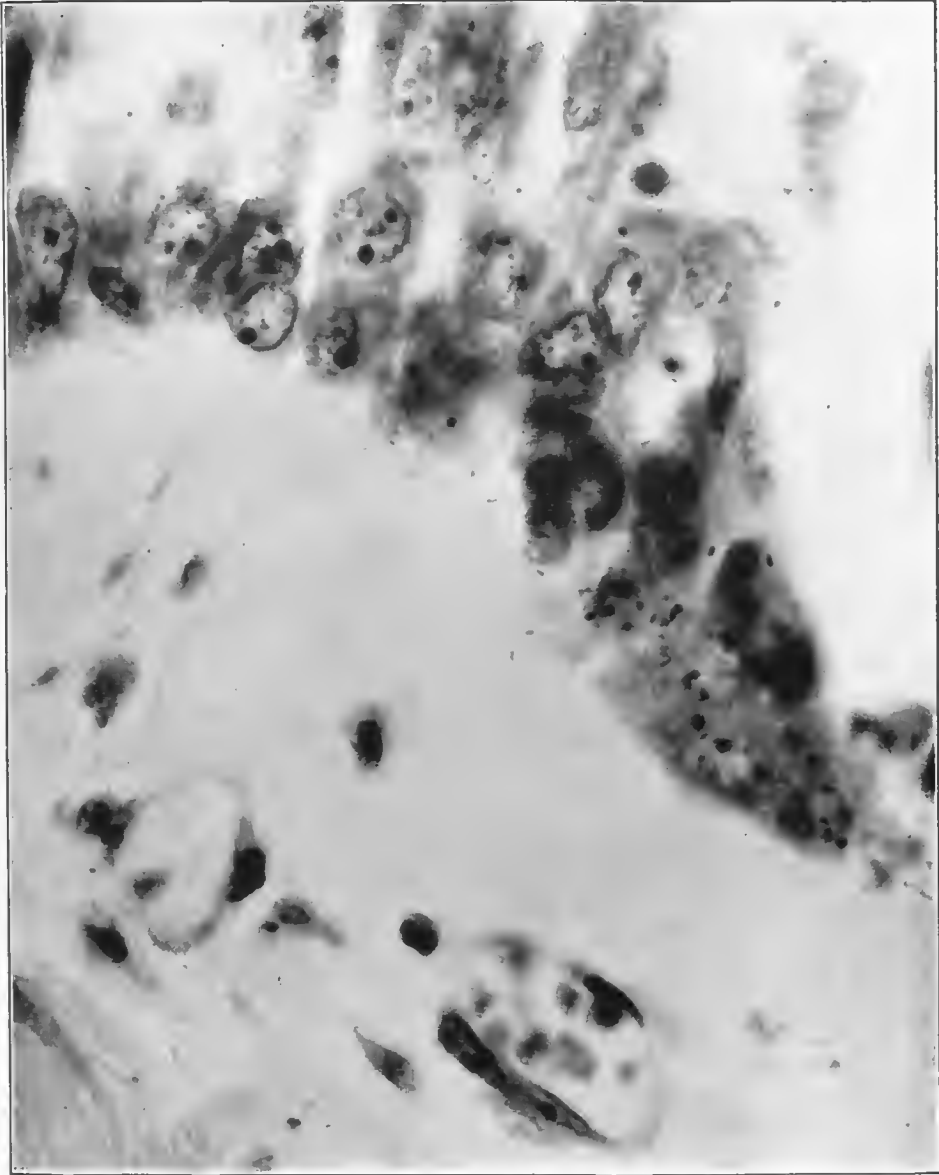


FIG. 18.—Lobular pneumonia. Hemolytic streptococcus in heart's blood, pleura, and lung. Pneumococcus, Type IV, regained at necropsy culture of lung. Minute Gram-negative bacillary and coccoid forms beneath the elevated mucosa of a bronchus. Accession number 3108, Army Medical Museum. Negative number 45198. MacCallum stain; $\times 1390$

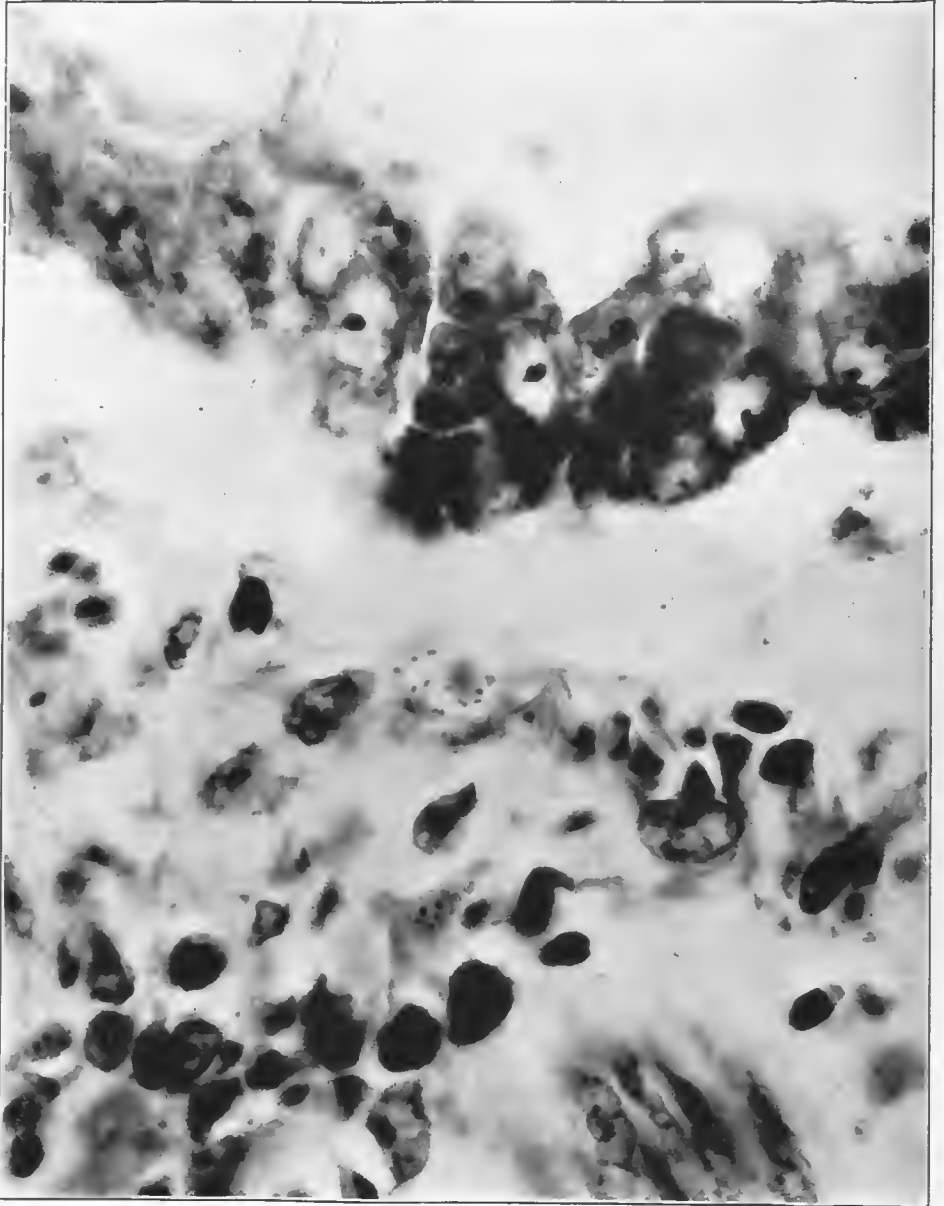


FIG. 19.—Lobular pneumonia. Hemolytic streptococcus in heart's blood, pleura, and lung. Pneumococcus, Type IV, in lung regained at necropsy culture. Gram-negative bacilli in macrophage cell beneath bronchial mucosa, which is raised by fluid exudate. Accession number 3105, Army Medical Museum. Negative number 45241. MacCallum stain; $\times 1390$

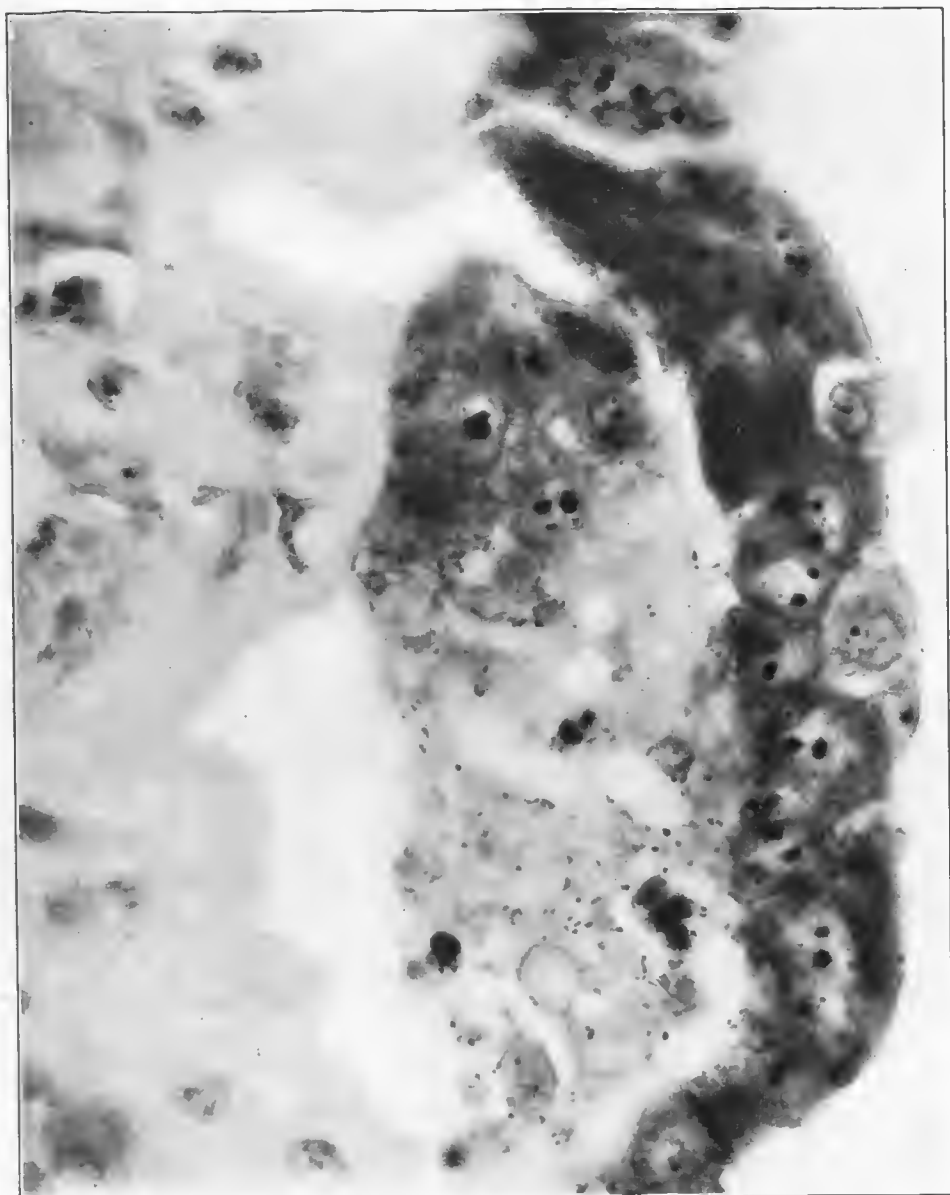


FIG. 20.—Minute Gram-negative bacteria in exudate of blisterlike elevation of bronchiolar mucosa. Accession number 3108, Army Medical Museum. Negative number 45237. MacCallum stain; $\times 1390$

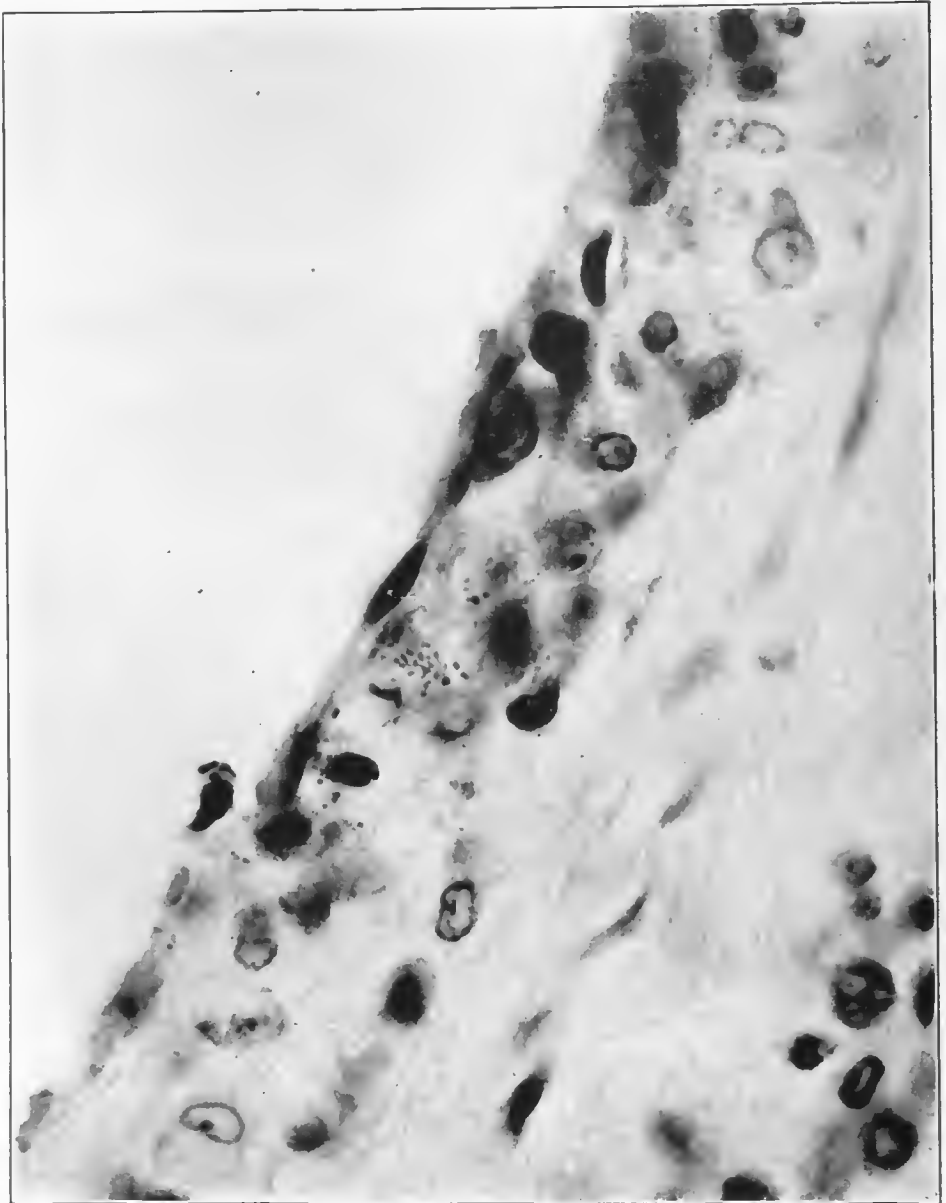


FIG. 21.—Minute Gram-negative bacteria, free and in phagocytes in the wall of a ductus alveolaris. *Streptococcus hemolyticus* recovered in cultures. Accession number 3101, Army Medical Museum. Negative number 45271. MacCallum stain; $\times 1390$

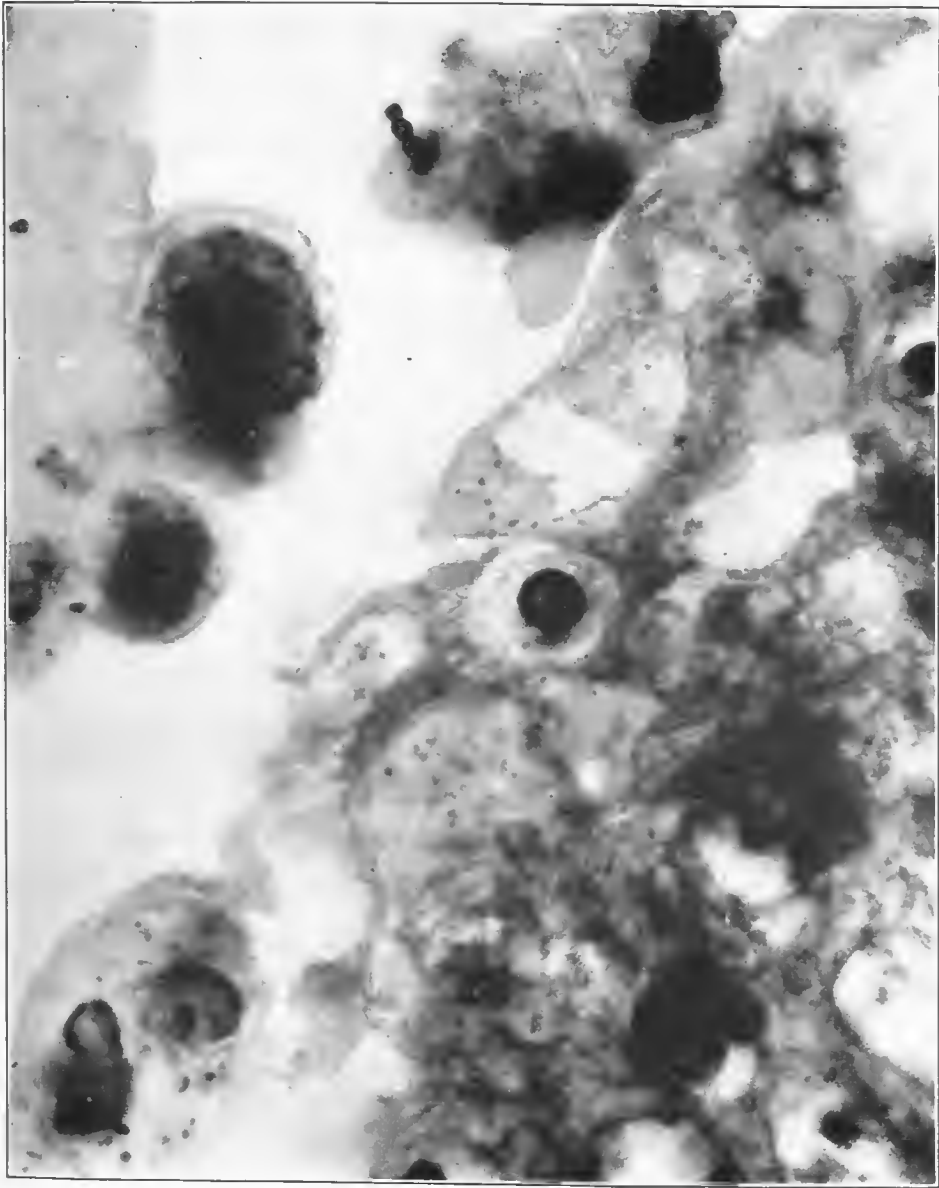


FIG. 22.—Margin of ductus alveolaris, showing a short chain of streptococci and numerous minute Gram-negative bacteria. Post-mortem bacteriology showed streptococci in the lung puncture, streptococcus, and pneumococcus in the pleural fluid. Accession number 3089, Army Medical Museum. Negative number 45236. MacCallum stain; X 3100

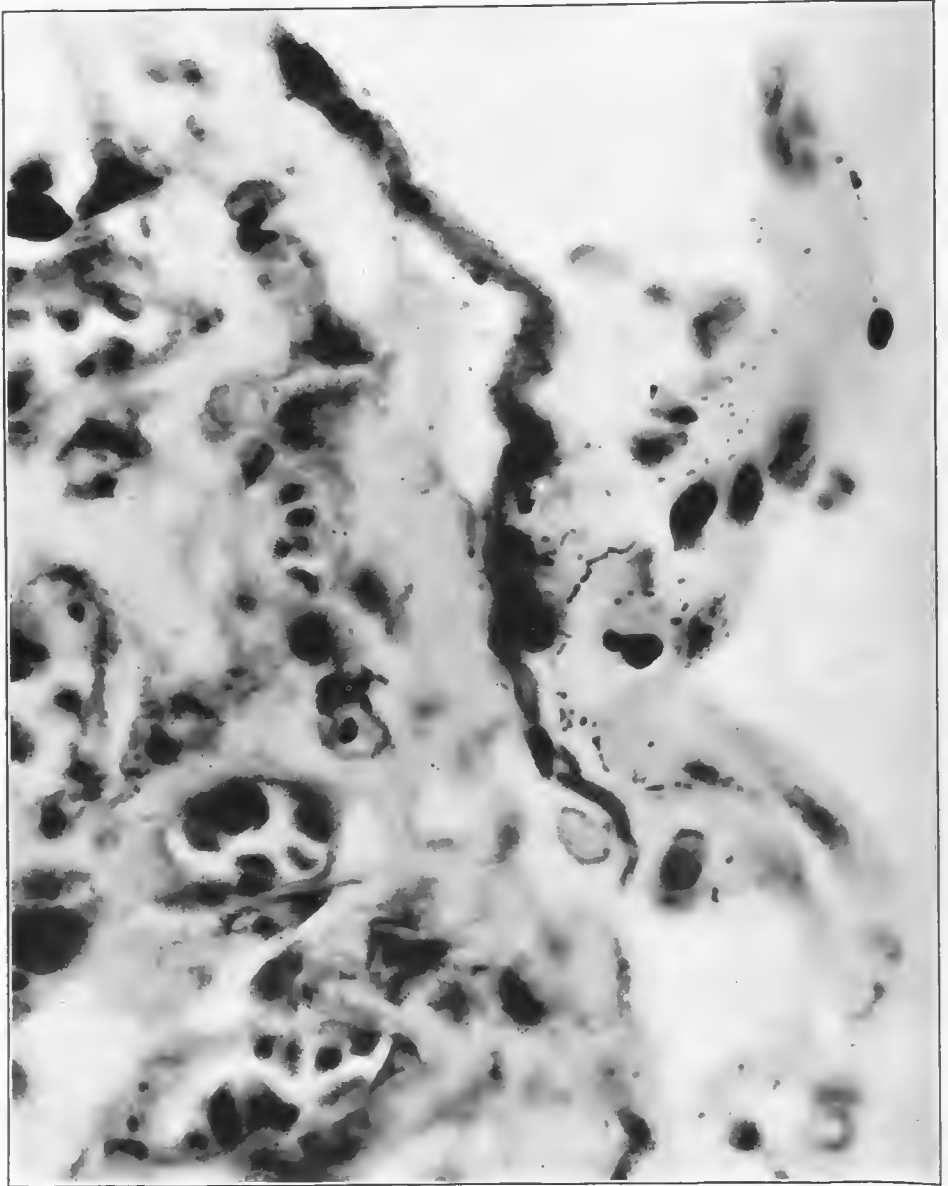


FIG. 23.—Beginning of ductus alveolaris. Minute Gram-negative bacteria and streptococci in the exudate along the epithelium. Epithelial cells partially desquamated; basement membrane thickened and hyalin in appearance. The Gram-negative bacteria preponderated in the exudate. Cultures from the lung and pleura showed pneumococcus, Group IV, and hemolytic streptococcus. Accession number 3103, Army Medical Museum. Negative number 45199. MacCallum stain; $\times 1390$

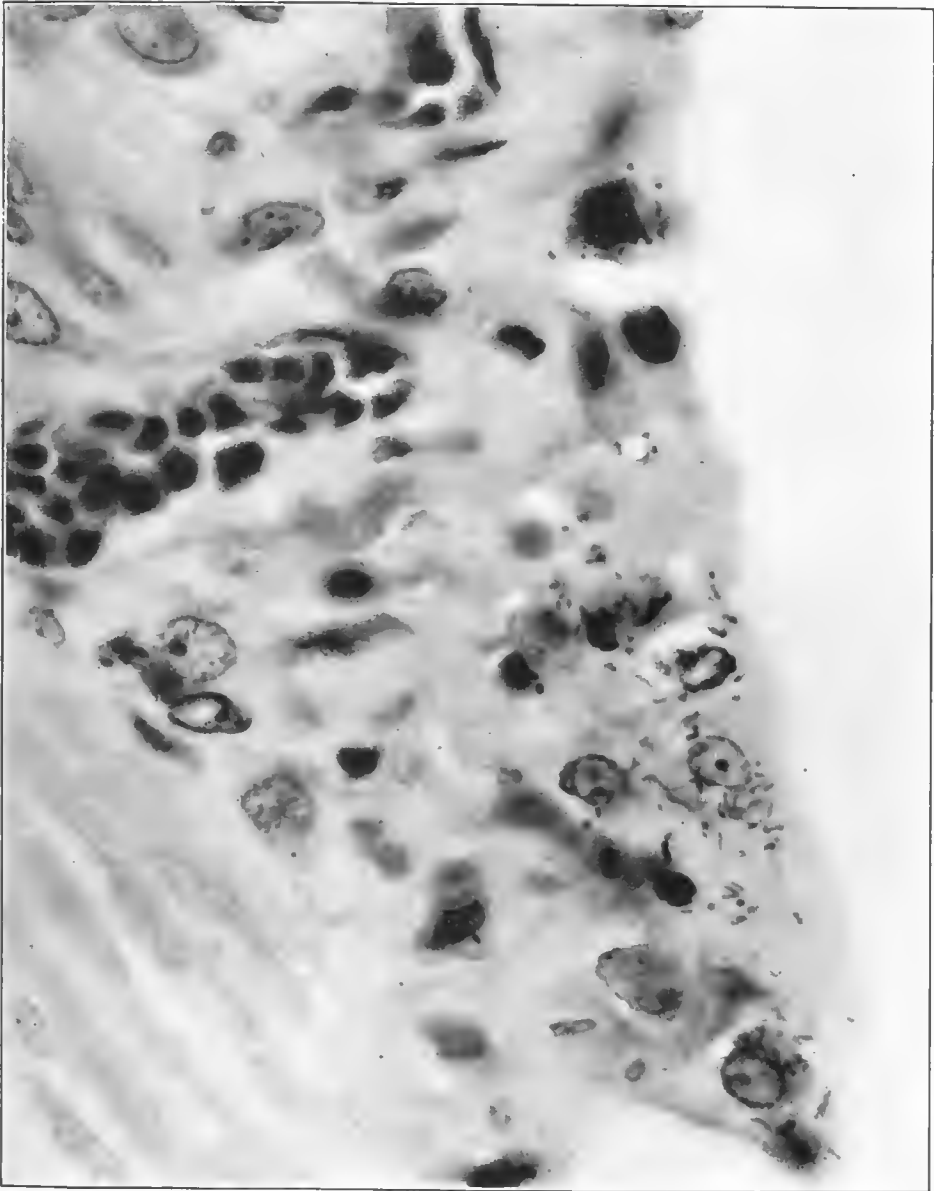


FIG. 24.—Gram-negative bacteria and a few streptococci along the wall of a ductus alveolaris, the epithelium of which is largely desquamated. *Streptococcus hemolyticus* in cultures from the lung at necropsy. Gram-negative bacteria were not cultivated. Accession number 1520, Army Medical Museum. Negative number 45188. MacCallum stain; $\times 1390$

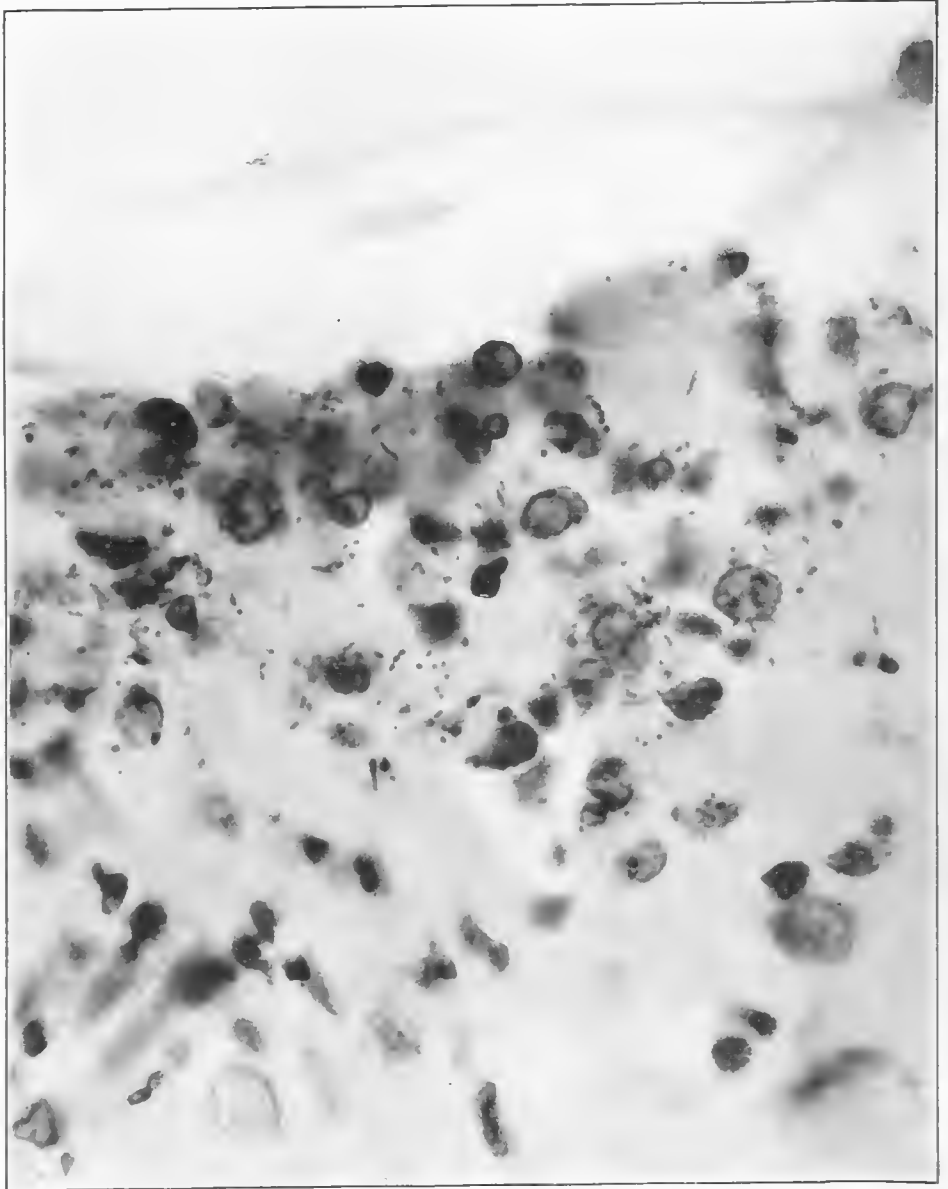


FIG. 25.—Wall of bronchiole infiltrated with leucocytes, Gram-negative bacteria and relatively numerous streptococcus forms. *Streptococcus hemolyticus* recovered in culture. Accession number 1520, Army Medical Museum. Negative number 45189. MacCallum stain; $\times 1390$

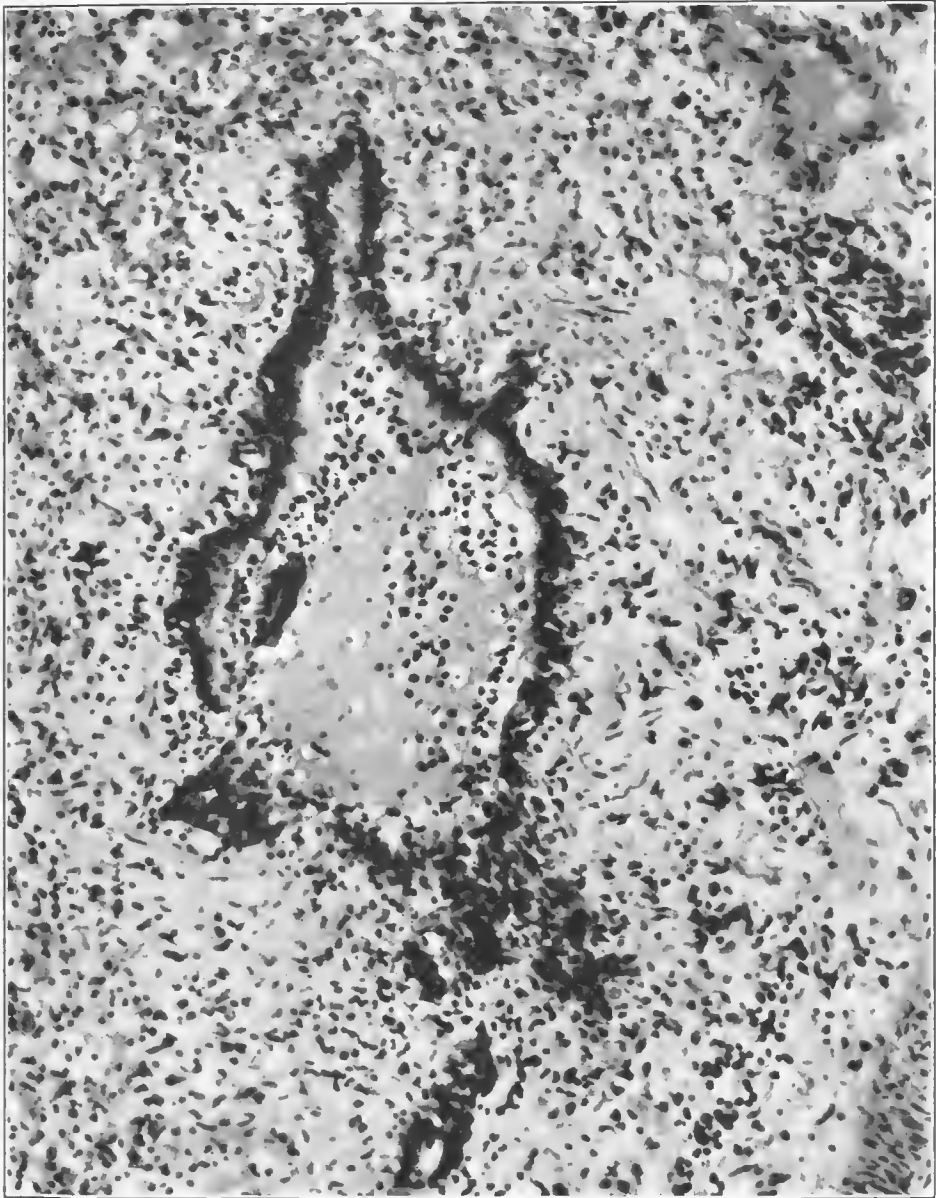


FIG. 26.—Bronchiole in the center of a peribronchiolar consolidation, showing a seropurulent exudate, some proliferation of the basal cell layer, with but little desquamation of the columnar cells. Basement membrane is thickened and the surrounding tissue edematous and infiltrated with leucocytes. "Hyalin thrombi" are seen in small vessels in the surrounding tissue. Accession number 2696, Army Medical Museum. Negative number 45999. Hematoxylin and eosin stain; $\times 235$

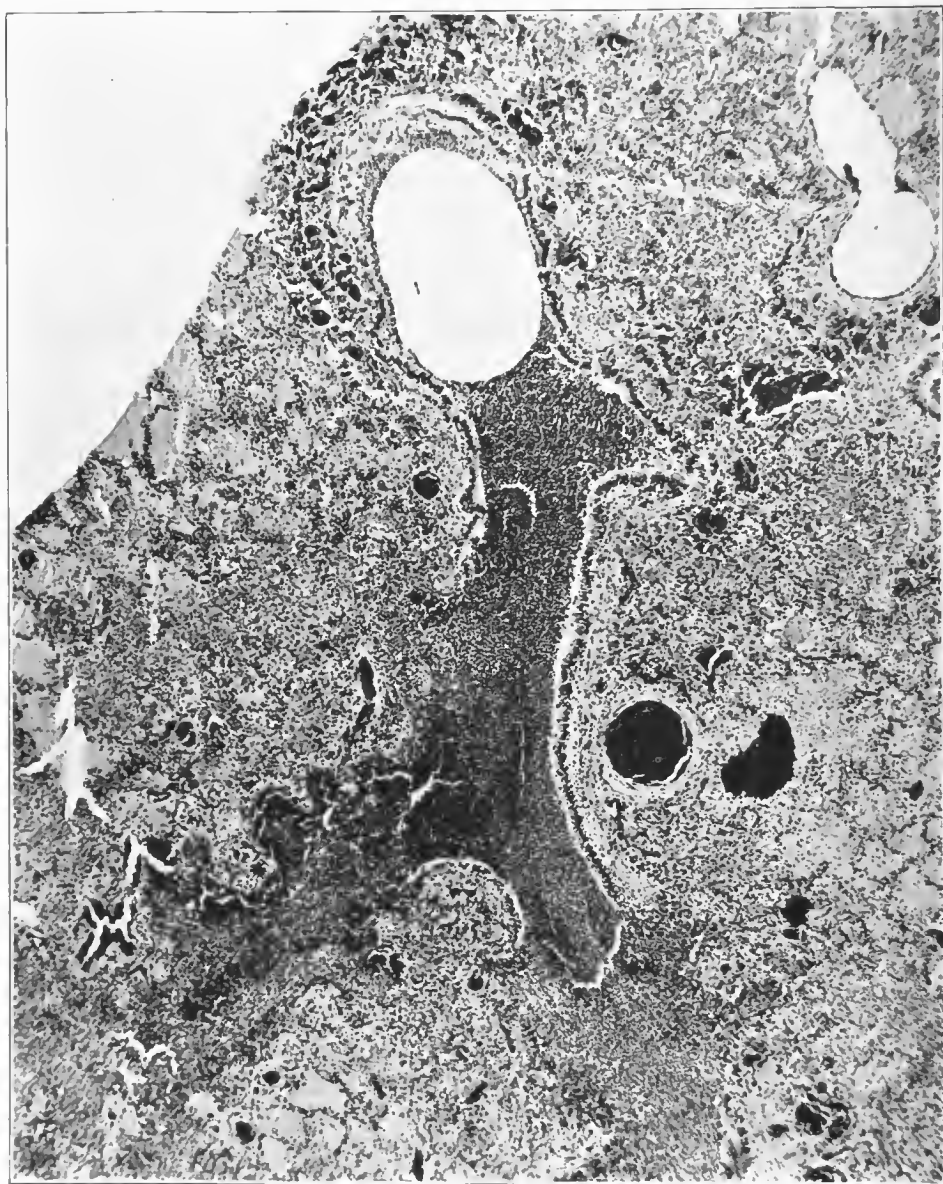


FIG. 27.—Longitudinal section of a bronchiole containing purulent exudate in which is one large space formerly the location of a bubble of air. No organism isolated; organisms of streptococci type in purulent exudate in the bronchi, Gram-negative bacteria in the ductuli. Surrounding lung tissue shows beginning consolidation, exudate being most dense near the bronchiolus from which it appears to have spread. Accession number 1049, Army Medical Museum, Negative number 45151. Hematoxylin and eosin stain; $\times 33$

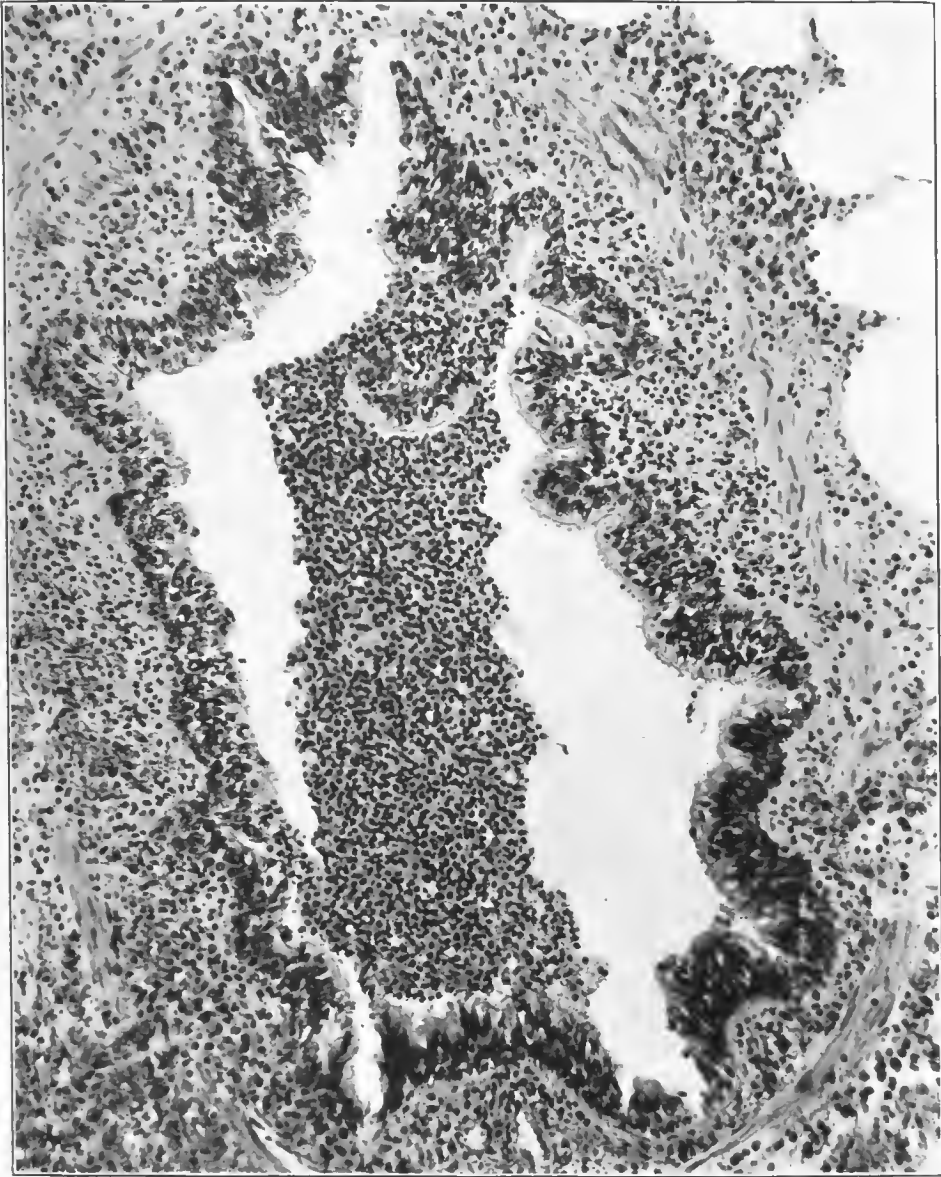


FIG. 28.—Bronchiole, showing purulent inflammation, proliferation of the basal layer and leucocytic infiltration. This is one of the larger bronchioles preceding the terminal divisions into the bronchioli respiratorii. Streptococci were present in the exudate in this bronchiole and Gram-negative bacilli in the peribronchiolar lesions of smaller size beyond it. Accession number 2694, Army Medical Museum. Negative number 46025. Hematoxylin and eosin stain; $\times 155$

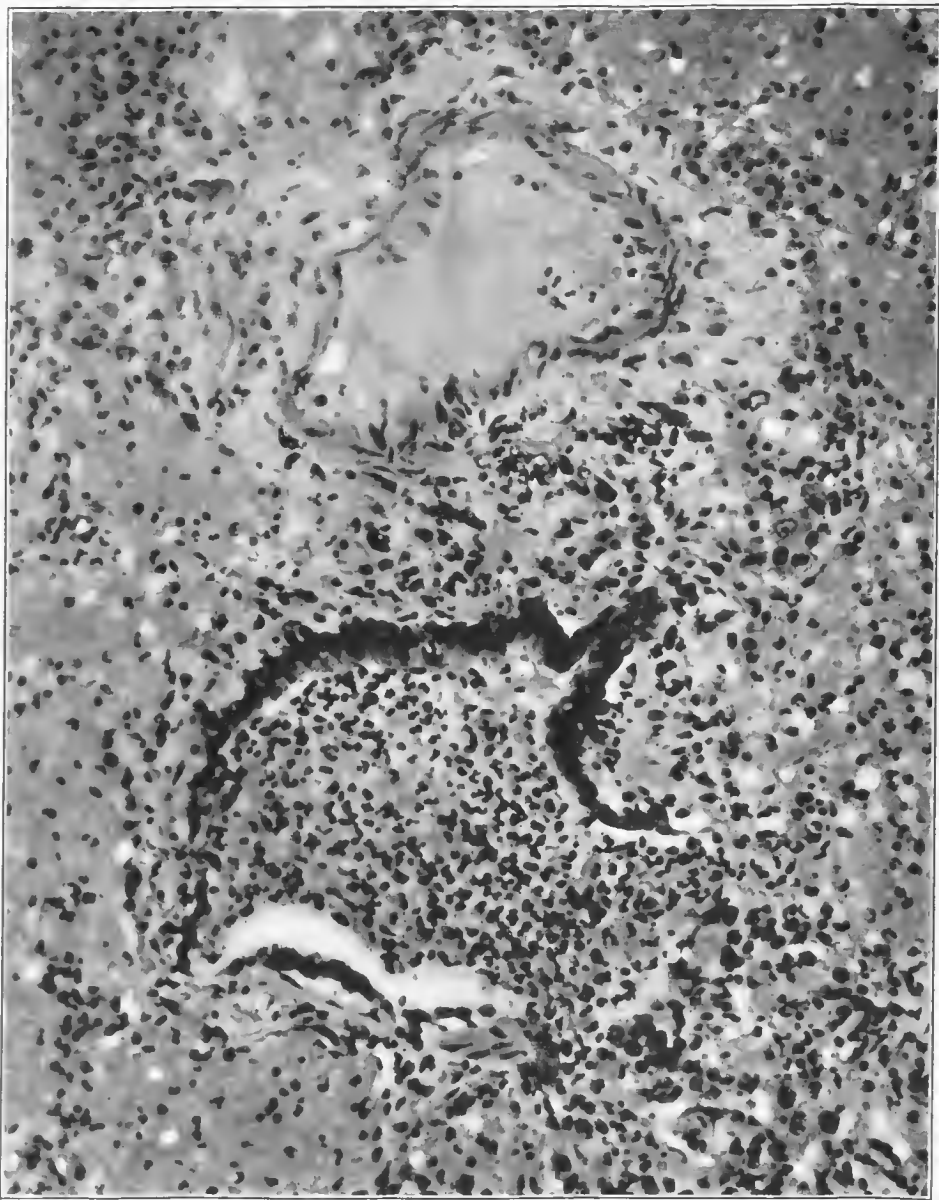


FIG. 29.—Respiratory bronchiole, showing purulent exudate which is continuous with that of the adjacent alveolar consolidation. A small group of alveoli open into the bronchiole on the right, where the wall is interrupted and the columnar cells merge with the flattened epithelium. So-called "hyaline thrombus" in vein near bronchiole. The lymph spaces around the vein are edematous. Accession number 2696, Army Medical Museum. Negative number 46010. Hematoxylin and eosin stain; $\times 265$

evenly involved and were often sharply defined by reason of the noninvolvement of the alveoli surrounding, and supplied by, other terminal bronchioles, though in the fulminant cases few of these terminal lung units escaped, most of them being filled with exudate mixed with air.

The exudate appeared to be viscid as it adhered along the alveolar walls as a homogeneous, eosin-staining, membranelike structure, the center of many alveoli being occupied by air. (Figs. 32 and 33.) In others a thinner serous exudate completed the filling of the alveoli as though the thin exudate had been thrown out early and was followed by the denser more viscid material which continued to adhere to the walls as a pseudomembrane. Beneath it the alveolar epithelium for the most part was lost, occasional cells and groups of cells remaining. Less of the viscid exudate was seen in alveoli the epithelium of which still remained. Fibrin stains revealed that there was little fibrin in this exudate, though occasional fibers were seen and the border of the membrane appeared more dense, stained more deeply with eosin, and reacted but slightly to the fibrin stain. The blood vessels of the alveolar wall were engorged with blood and there was escape of blood along the ductus alveolaris and about and into the alveoli. Rarely there was frank hemorrhage of considerable amount as occurred more often in lesions associated with streptococci. The hemorrhagic edema and universal vascular engorgement were responsible for the gross picture at necropsy.

The alveolar walls, due to edema and vascular engorgement, were prominent. Cellular infiltration, largely of cells of the lymphocyte type and large mononuclear cells from the tissue, was present in alveolar walls, and about the walls of the terminal bronchioles, while varying numbers were in the exudate. (Fig. 34 and Pl. V.) A frankly purulent exudate was rare in the fulminant case. The epithelium of the alveolar wall was lifted off by the exudate forming between it and the underlying reticulum and appeared in the alveoli as single cells or small groups of cells. (Fig. 35.) The epithelium apparently formed a barrier to the egress of the exudate which, as stated above, appeared to be more abundant in alveoli, the epithelium of which had been cast off.

There are certain areas in the walls of the atria and alveoli where no capillaries are seen and special stains reveal no reticulum or very few fibers. Stains which differentiate elastic and collagen fibers reveal that such walls are made up of elastic and collagenous fibers on which rest the epithelial plates, there being a minimum of loose alveolar tissue between. The anatomical location of this type of wall suggests that there is a point of physical stress which has been reinforced by elastic fibers. These areas even in the earliest cases showed a swelling of the loose tissue beneath the epithelium which appeared to have no definite structure, and where epithelium was desquamated it merged with the exudate in the alveoli. Reticulum fibers were minimal or absent. Elastic fibers in their collagenous matrix remained as the only formed elements, the rest appearing necrotic. (Fig. 36.) At such places the ruptures of acute emphysema occurred. It would appear that though fibrous and elastic tissue was here in excess, a small vascular supply, possibly only a lymphatic supply, favored the necrosis of the tissue which, being at points of stress in the structure, yielded to the increased tension from exudate blocking plus respiratory effort. Whatever may be the explanation, the ruptures of the walls of the air-containing tissue occurred most

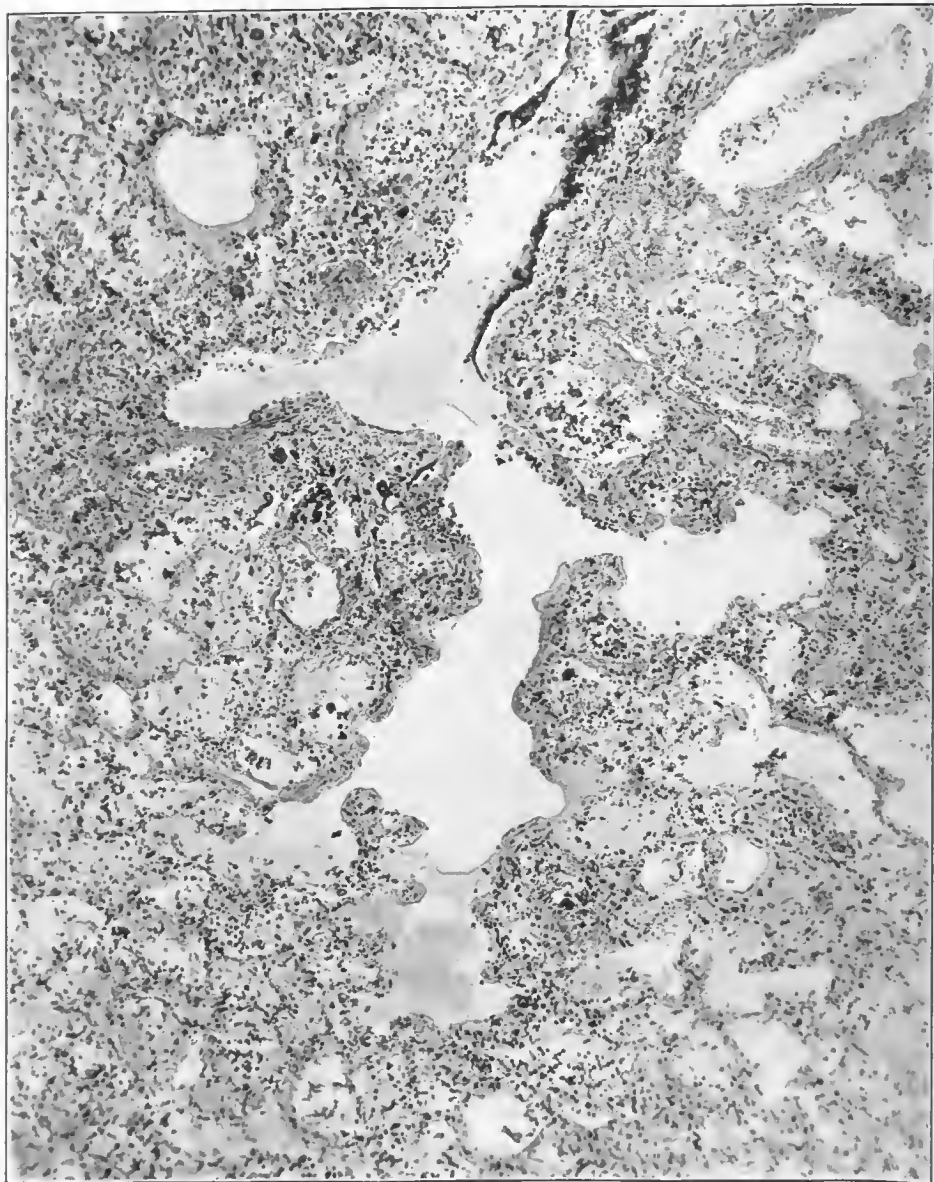
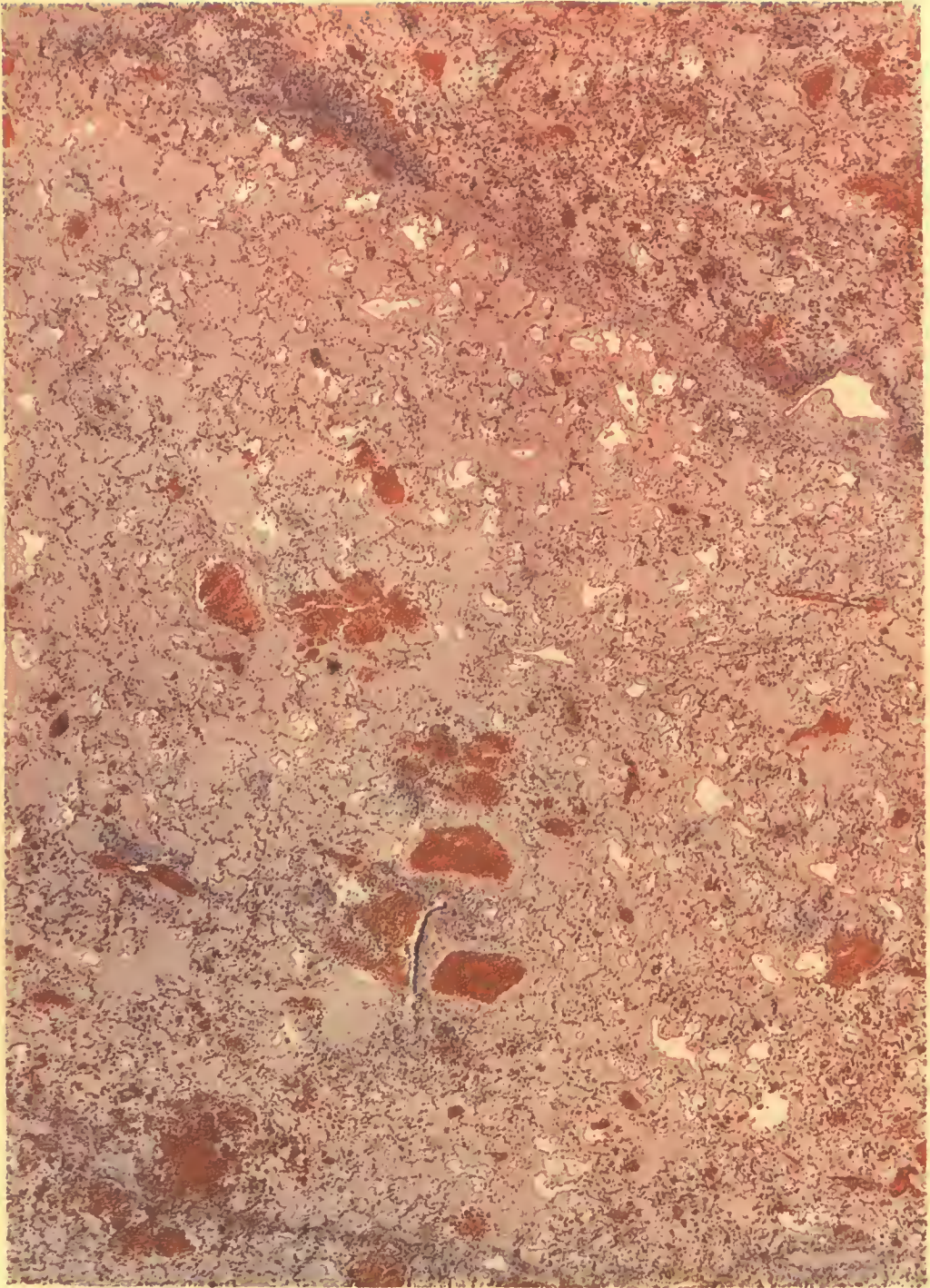


FIG. 30.—Longitudinal section of a ductulus alveolaris which is less involved than the alveoli and air sacs surrounding it. It contains a serous exudate filling the atria and air sacs, while the alveoli emptying into the air sacs and atria contain a few cells. The denser character of the exudate along the walls and in the termination of the middle branch of the ductulus is apparent. The respiratory bronchiole is plugged with a dense exudate containing leucocytes. Such a plug prevented the emptying of this lung unit, and the respiratory efforts producing increased pressure were responsible for its dilatation. Accession number 3113, Army Medical Museum. Negative number 45559. Hematoxylin and eosin stain; $\times 85$

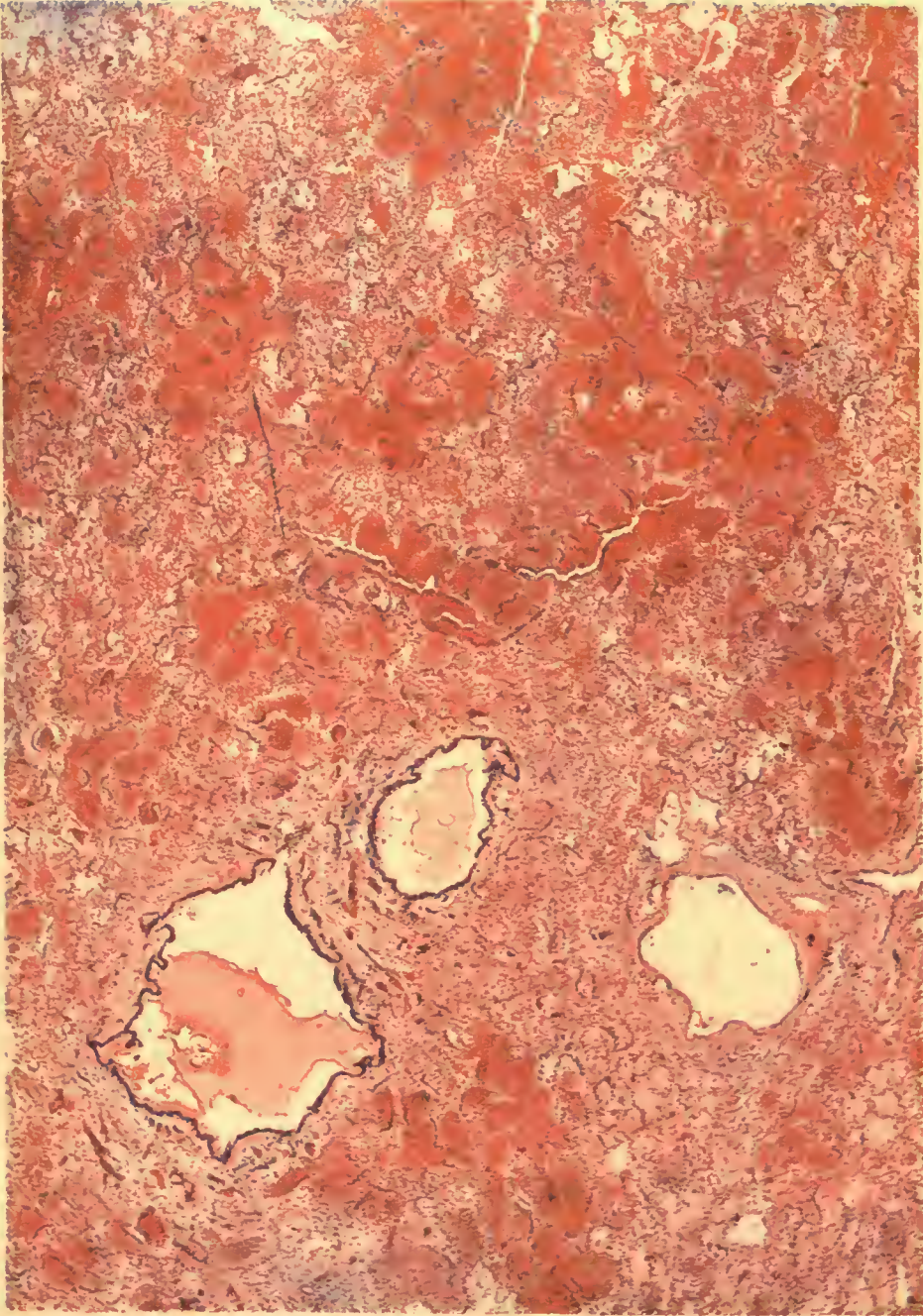


A. HOEN & CO.

HEMORRHAGIC EDEMA, ACUTE BRONCHIECTASIS.

Beginning purulent consolidation. Minute Gram-negative bacteria were seen in smaller air passages, a few streptococci were present in purulent exudate.

Accession 2696, Army Medical Museum. H. & E. stain. Autochrome.



A. HOEN & CO.

HEMORRHAGIC EDEMA.

With beginning leucocytic infiltration of interlobular septum and alveolar walls, beginning streptococcus infection, many Gram-negative bacteria were seen along the bronchioles a few streptococci were present in bronchi and interstitial tissue.

Accession 2696, Army Medical Museum. H. & E. stain. Autochrome.

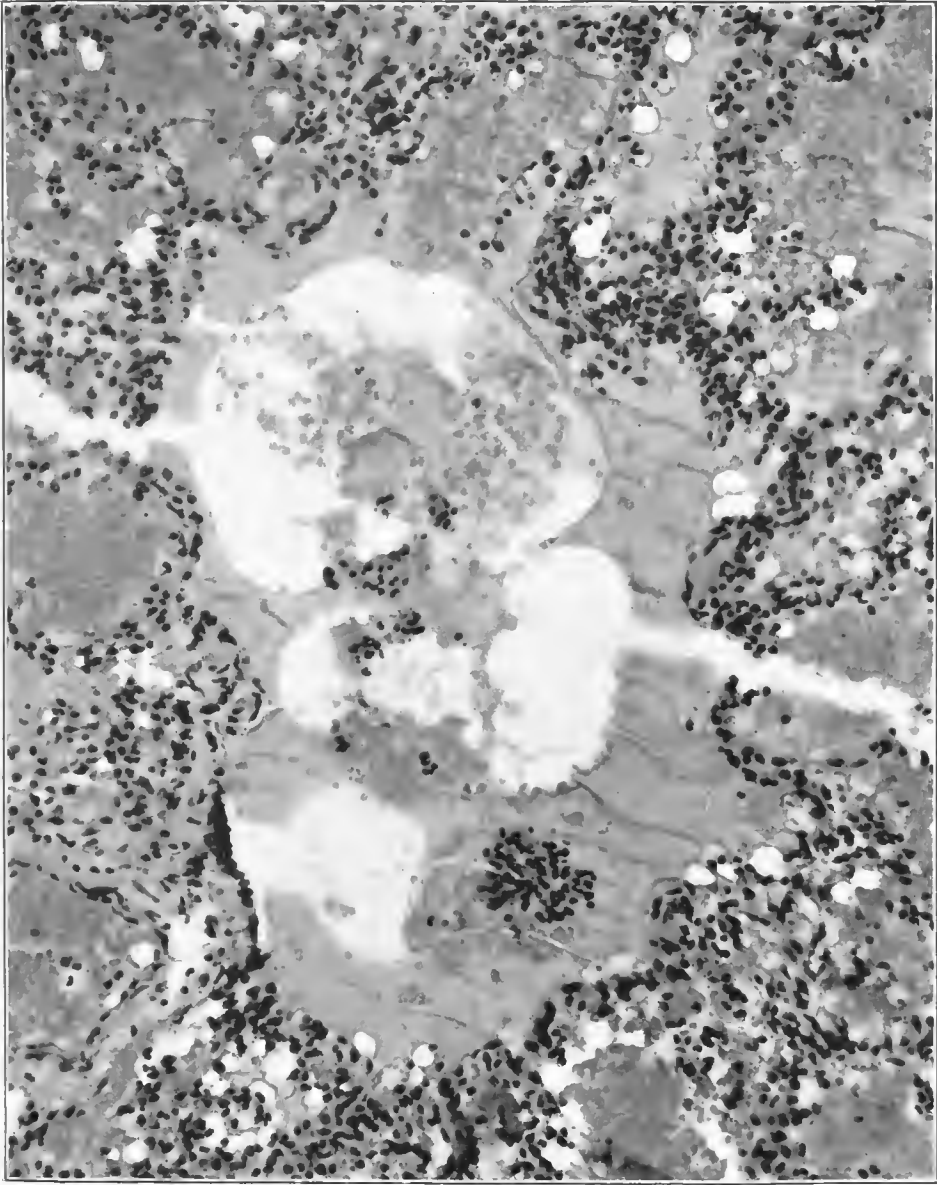


FIG. 31.—Cross section of an atrium, showing a few columnar cells at one corner, air and hemorrhagic exudate in the circular pale areas, and a dense viscid hyalin exudate (hyalin membrane), filling the rest of the structure and extending into the alveoli which open into it. The wall of the atrium is infiltrated with leucocytes, a considerable number of which are polymorphonuclear leucocytes. The primary reaction appears to have been an edema or practically universal involvement of the lung with a superimposed infection by streptococcus which produced the hemorrhagic inflammatory reaction. Streptococci were isolated and Gram-negative bacteria are seen along the respiratory bronchioles and in the atria. Accession number 2696, Army Medical Museum. Negative number 45960. Hematoxylin and eosin stain; $\times 235$

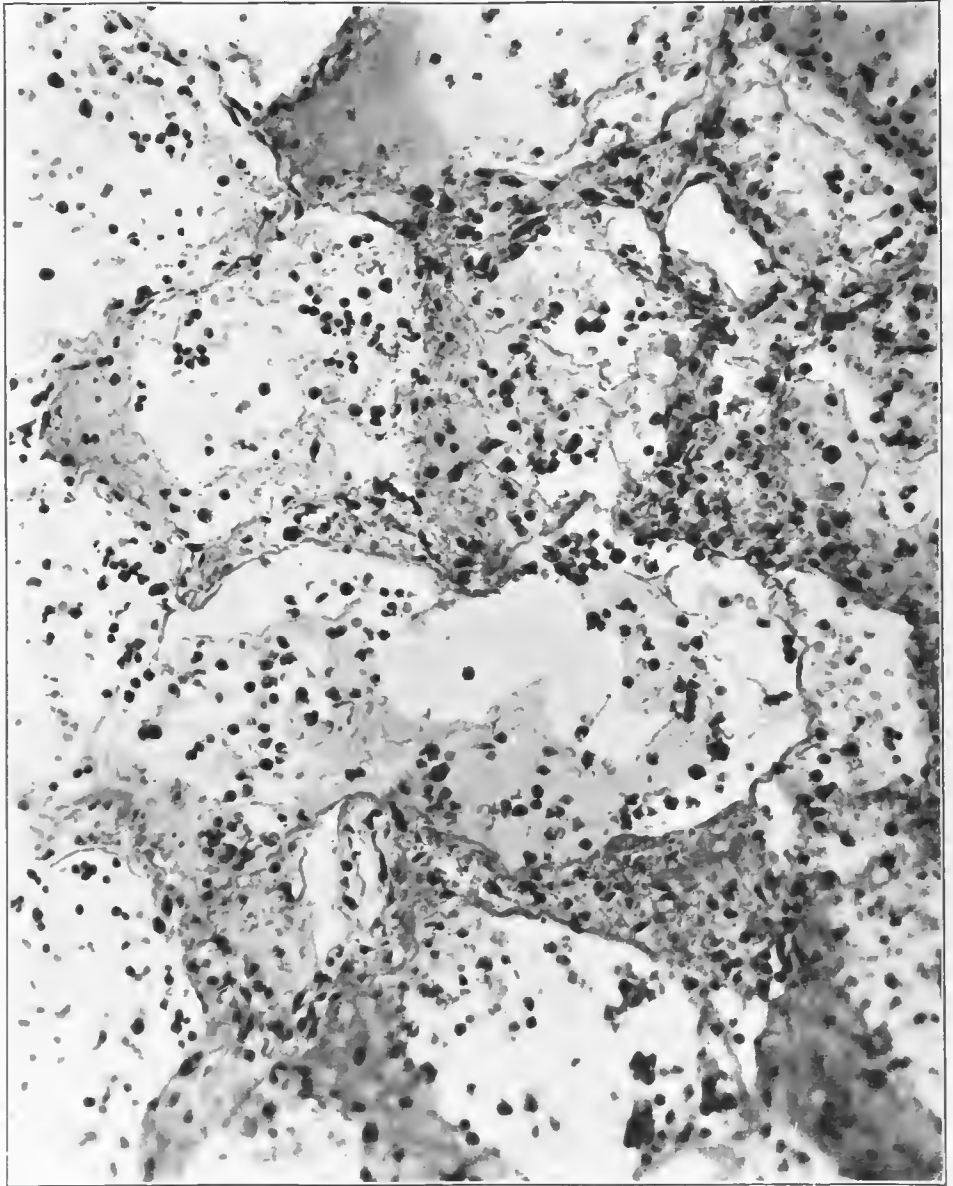


FIG. 32.—Early exudate in a diffuse inflammation of the lungs in which lobular consolidation was commencing. Section taken from an area at the edge of the beginning consolidation shows a viscid exudate being thrown out from the alveolar wall and a thinner fluid filling the rest of the spaces. The exudate contains a few red corpuscles and a few leucocytes, both mononuclears and polymorphonuclears. The epithelium is largely desquamated and a few strands of fibrin are evident. This presents one stage in the formation of the so-called hyalin membrane. Accession number 3113, Army Medical Museum. Negative number 45580. Hematoxylin and eosin stain; $\times 230$

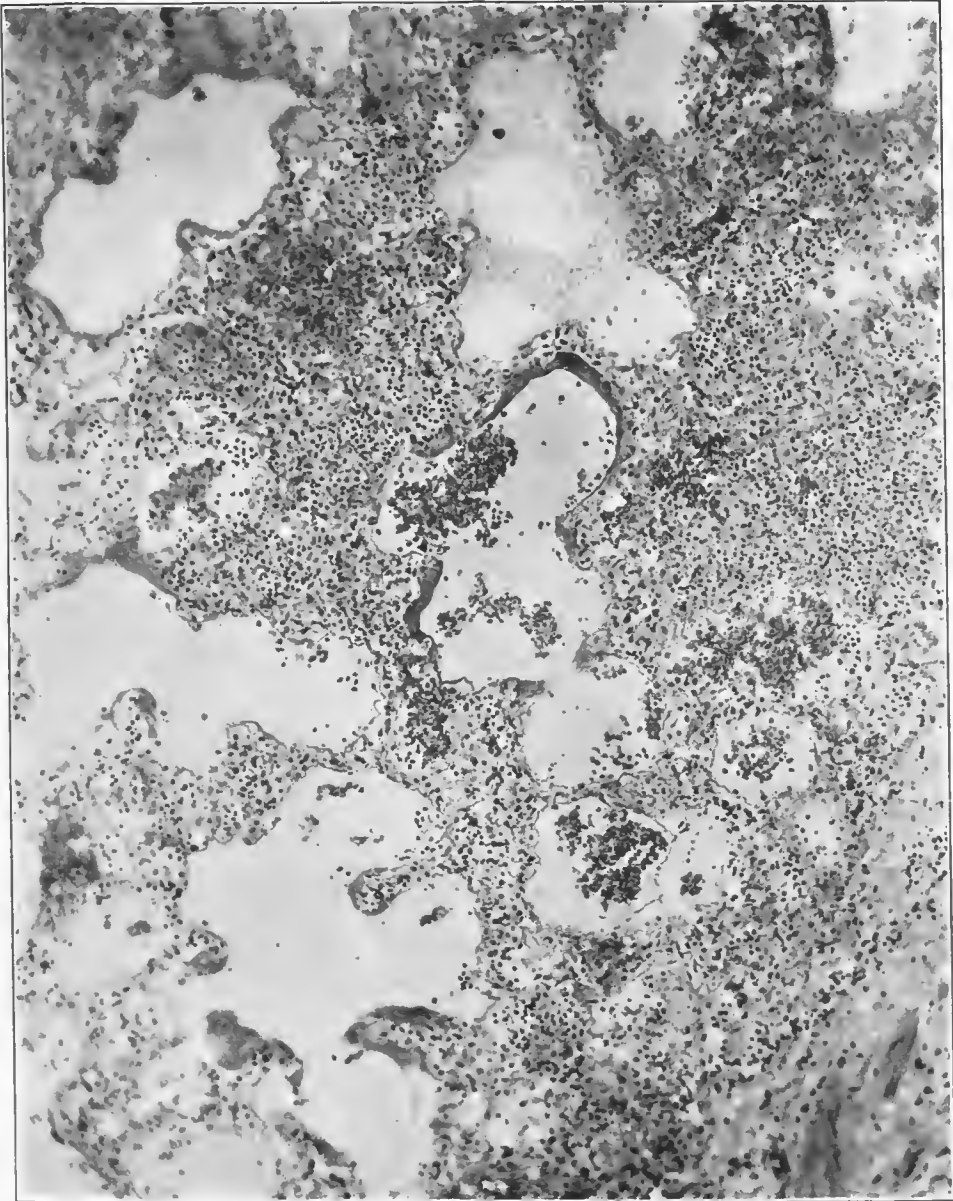


FIG. 33.—Early exudate in a confluent lobular pneumonia, with formation of the so-called hyaline membrane about the walls of the alveoli and air sacs. The inflammation is in part hemorrhagic. Gram-negative bacteria and Gram-positive cocci with the morphology of pneumococci were found in this lung, but in the area illustrated Gram-negative bacteria predominated along the walls of the alveoli, pneumococcus forms in the exudate and in the surrounding interstitial tissue. Accession number 1385, Army Medical Museum. Negative number 45278. Hematoxylin and eosin stain; $\times 100$

frequently at these points. Such ruptures caused emphysematous areas so that the atria and alveoli of one lung unit opened into adjacent ones. (Pl. VI.)

Ruptures occurring near the interlobular septa caused escape of air into this tissue. The air then extended along the septa to the pleura, giving rise to air "blisters" beneath the pleura, and by extending mesially reached the peribronchial and perivascular areolar tissues. From the latter structures access to the mediastinal tissues occurred, there being no endothelial barrier. From the mediastinal tissues to the subcutaneous tissues the air extended along vascular trunks giving rise to the cutaneous emphysema. Air may also have escaped into the interstitial tissues from rupture of the bronchioles in the acute dilatations or bronchiectases which occurred in these structures, and escaped along this interstitial tissue to the hilus in the same manner as along the septa. Several observers considered this the chief method of escape of the air which in quantity gave rise to emphysema of the mediastinal and subcutaneous tissues.

The general picture just described, was not a frequent one, but occurred occasionally throughout the period of the war. It is not distinguishable grossly from the acute fulminant cases, where apparently *Streptococcus hemolyticus* was the etiological agent and, in many cases, the only organism found. In the lungs of cases dying within the first 10 days to 2 weeks, and often in those of longer duration, the picture described above was present in some portion of the lung, and probably represented an extension or a reinfection occurring during the clinical course of the illness. The study of many cases who succumbed later in the course of the disease revealed the subsequent stages in this process. In such cases the amount of pulmonary tissue affected by this type of reaction varied but was usually found unaccompanied by other processes in a relatively small proportion of the lung substance. An entire lobe or more than one might thus escape; more frequently the inflammation spread along all the main bronchi but did not involve all of the terminal bronchioles, so that the foci of inflammation were separated one from the other by intervening spaces of relatively normal tissue. In other words, the bronchitis was universal but the extension to the parenchyma was in scattered foci. (Fig. 37 and Pl. VII.)

By studying portions of many lungs, it is possible to portray the various stages of the process. In the lungs of cases not dying during the stage of edema, the exudate gradually became more purulent; groups and single lung units became filled with pus in which polymorphonuclear leucocytes appeared in increasing numbers. While hemorrhage and engorgement predominated the foci were, macroscopically, small nodular areas, firmer than the surrounding air-containing tissue. The number of small Gram-negative bacilli increased and the inflammation extended to a limited extent into the alveoli and air sacs of lung units adjacent to the original process. (Figs. 38, 39, and 40.) The filling up of the air sacs and alveoli with exudate gradually caused a change in the gross picture. The nodular foci became paler and less hemorrhagic and finally a reddish or yellowish-gray color resembling submiliary tubercles from which, macroscopically, they were practically indistinguishable. (Figs. 41, 42, 43, 43, 44, 45, and 46.) Fibrin appeared in relatively small quantities and lymphocytes and large mononuclear cells formed a prominent part of the cellular exudate. Some of the large mononuclears were actively phagocytic for leucocytes

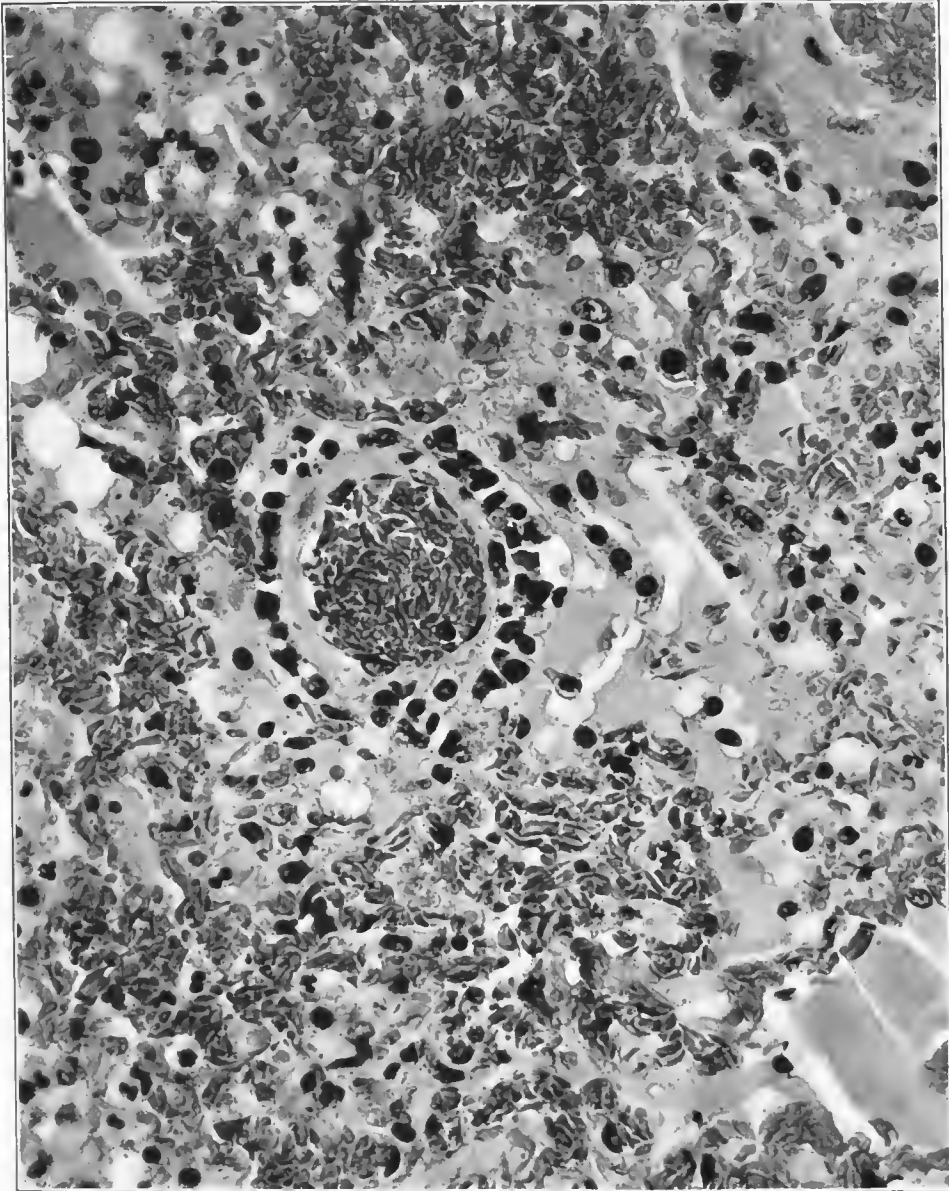


FIG. 34.—Small arteriole between alveolar ducts, showing a ring of mononuclear cells which have apparently proliferated from the cells of the adventitia or arrived by migration through the vessel wall. The apparent attachment of some of them to the tissue suggests the adventitia of the vessel as the probable point of origin of these cells. Accession number 1049, Army Medical Museum. Negative number 45672. Weigert iron hematoxylin and picro-eosin stain; $\times 515$

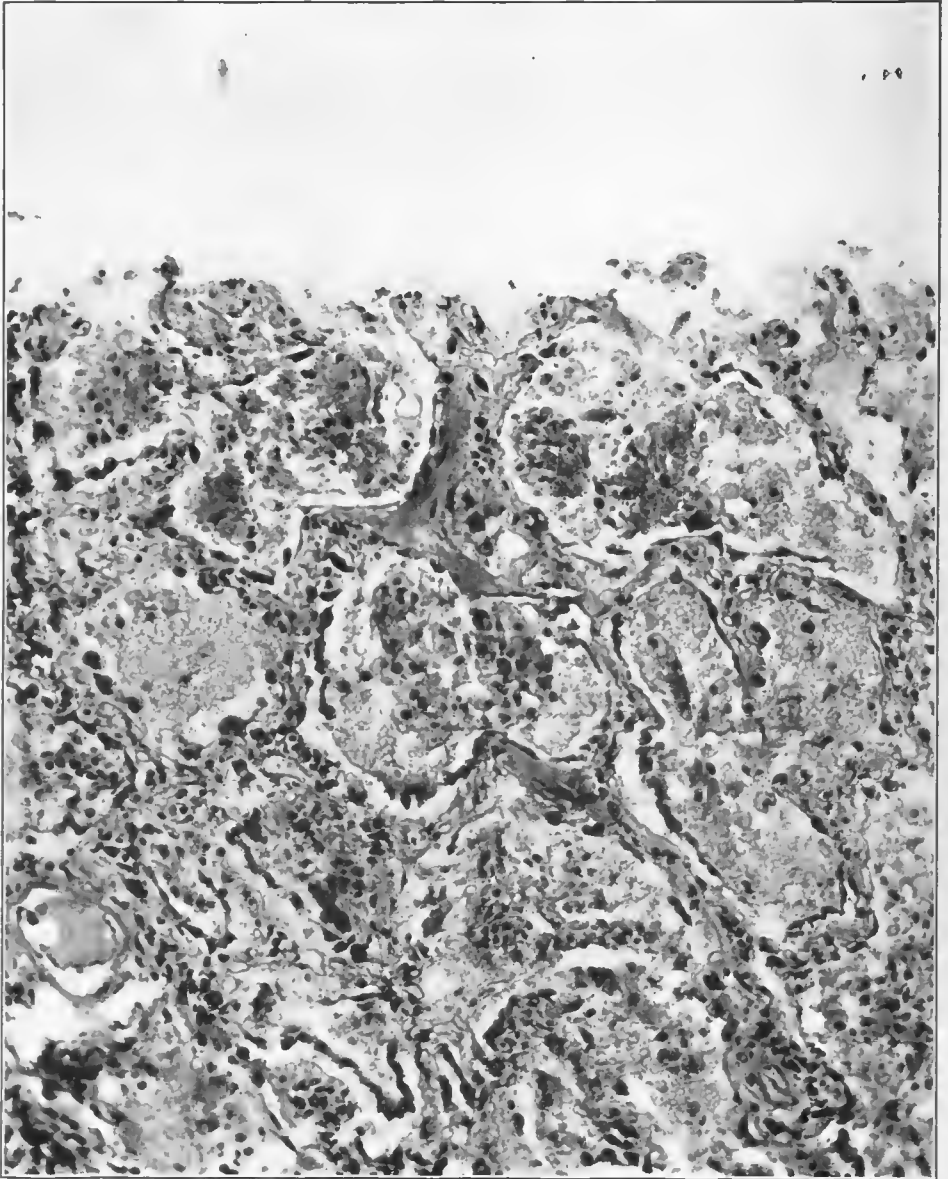
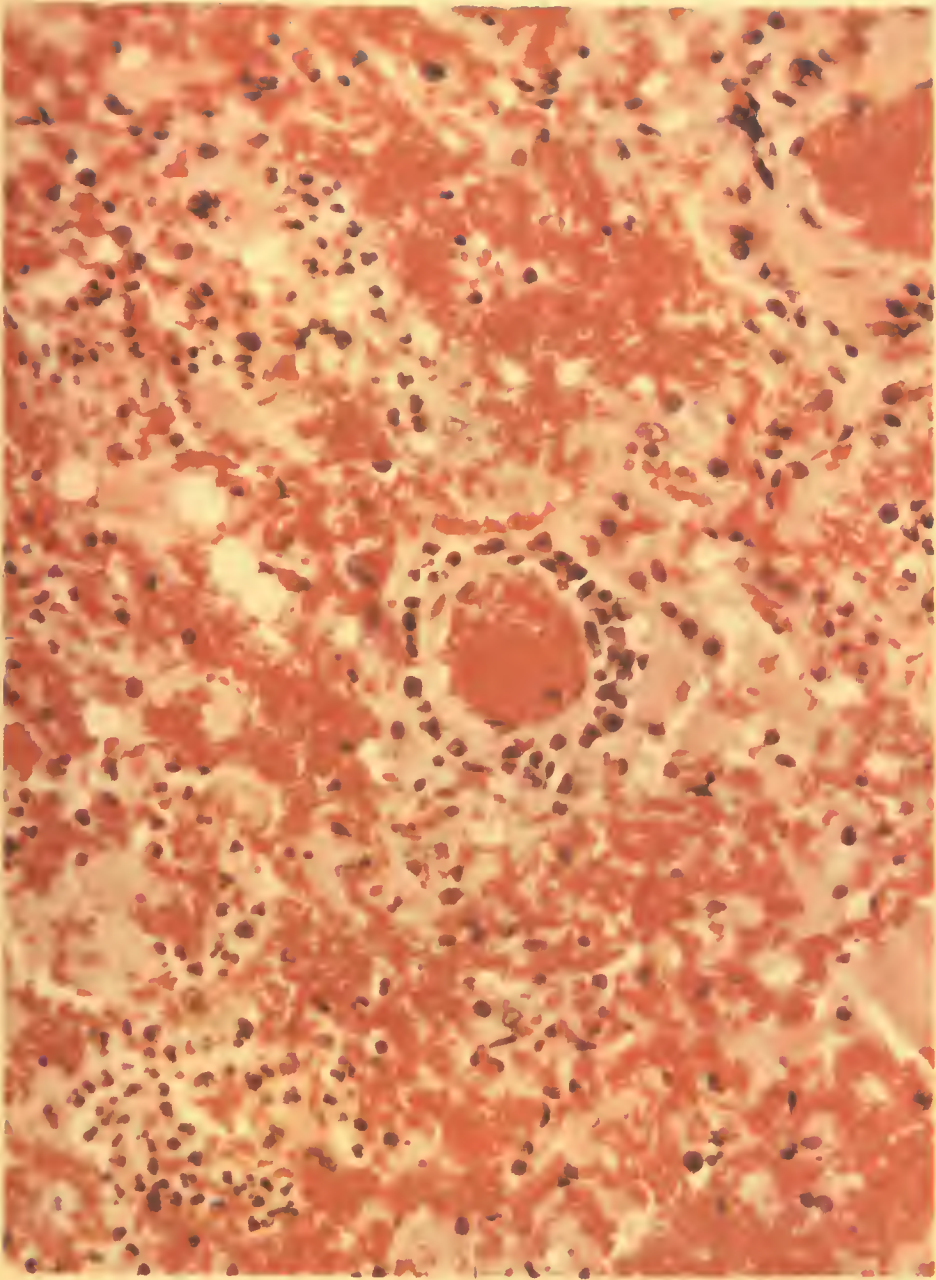


FIG. 35.—Early hemorrhagic lesion. Epithelium raised by underlying exudate from alveolar walls. Alveoli contain shadows of red corpuscles, a few lymphocytes and large mononuclears. Accession number 16571, Army Medical Museum. Negative number 45282. Hematoxylin and eosin stain $\times 205$

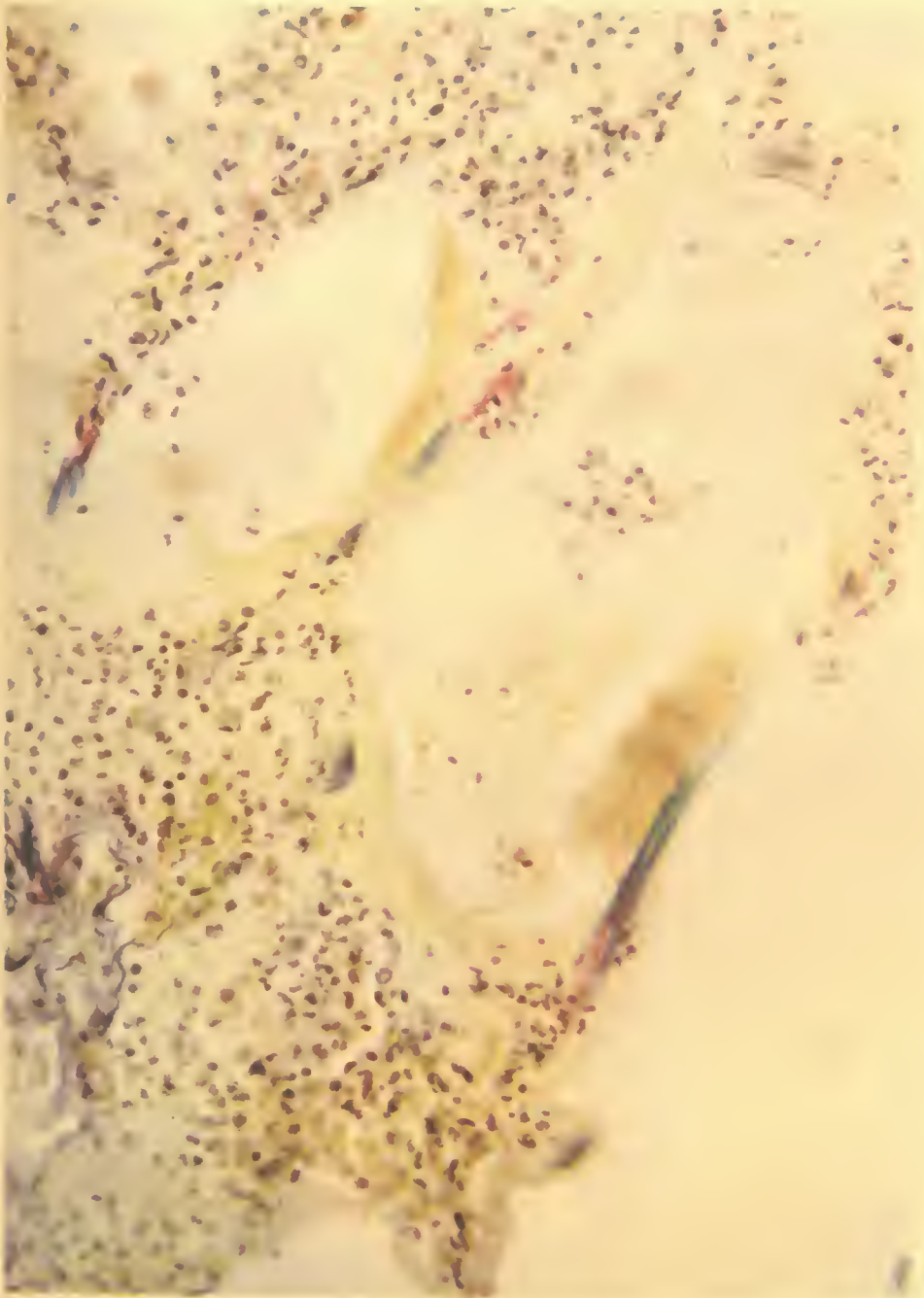


A. HOEN & CO.

PERIVASCULAR ADVENTITIAL PROLIFERATION AND INFILTRATION.

Hemorrhagic peribronchiolar pneumonia.

Accession 1049, Army Medical Museum. Weigert hematoxylin, picro-eosin stain. Autochrome.



A. HOEN & CO.

TWO RUPTURES IN AN ATRIAL WALL.

One of which involves the neighboring alveolus, the opposite wall of which is also ruptured.

Accession 1519, Army Medical Museum. Elastic stain. Autochrome.

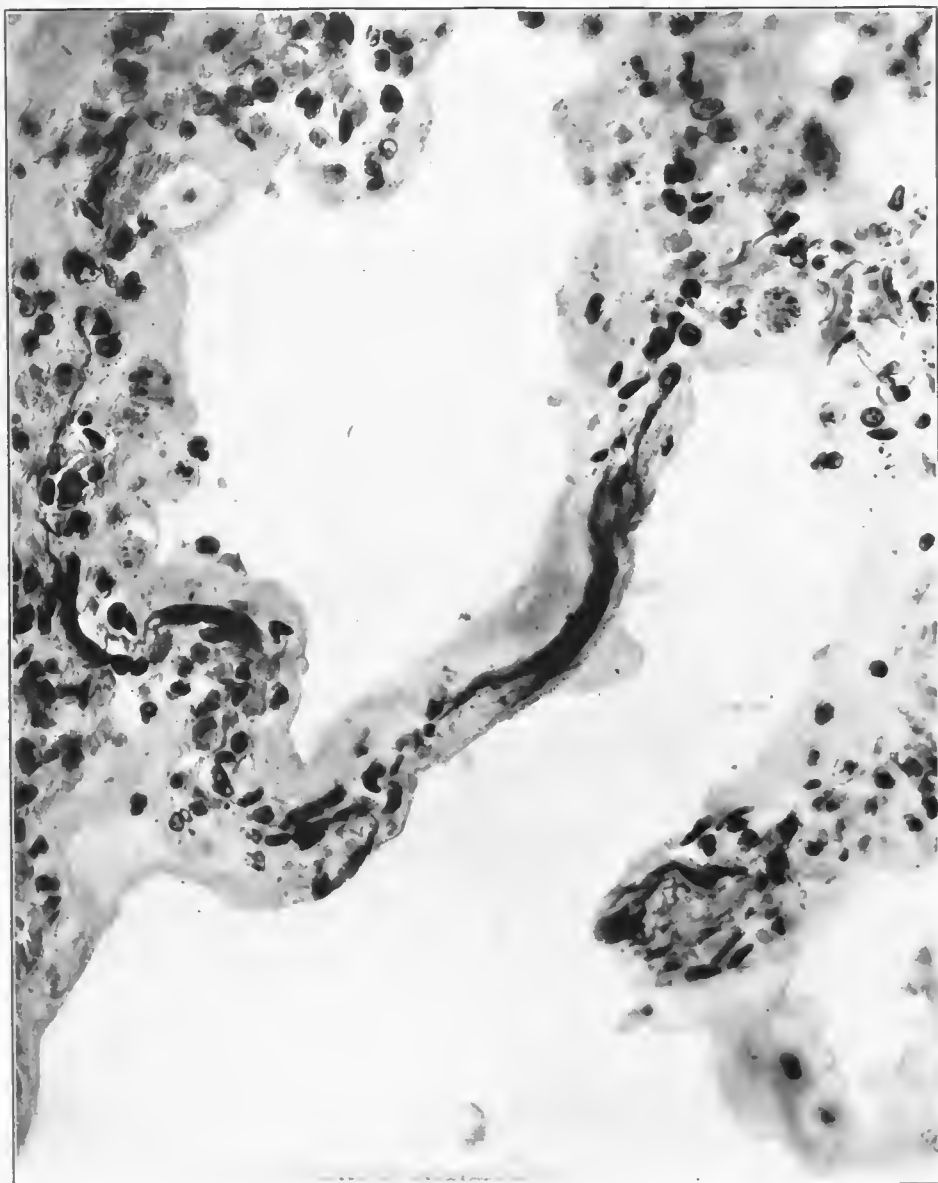


FIG. 36.—Degenerated wall of atrium. Swollen elastic tissue, stained dark, in a necrotic amorphous wall. Accession number 1519, Army Medical Museum. Negative number 45221. Elastic stain; $\times 555$

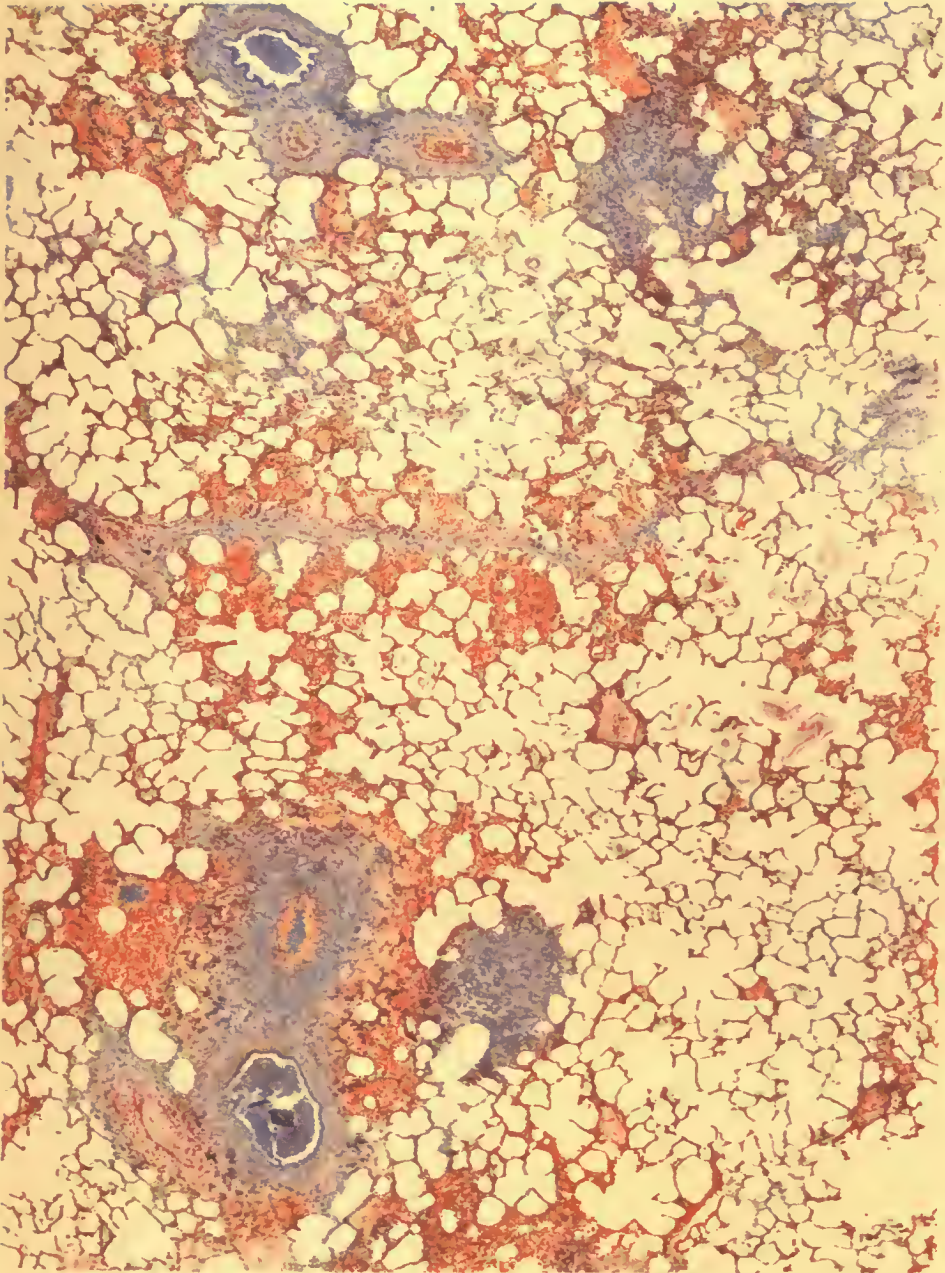
42706—29—17

and occasionally contained red blood corpuscles. Occasional ones contained several nuclei either of nuclear division without cell division or formed as the result of the fusion of several cells. (Fig. 47.) The epithelium of the trachea and bronchi proliferated and appeared in multiple layers (figs. 48, 49, and 50), the cells approaching the squamous type in morphology and in arrangement, while the epithelial cells of some of the air sacs, particularly those not filled with purulent exudate, proliferated, were distinct, and appeared more numerous than normal. (Fig. 51.)

In some instances the stratified, squamous type of epithelium extended from the bronchioles into the alveoli or else the alveolar epithelium underwent this metaplastic-like change and filled the alveoli with solid masses of cells resembling foci of carcinoma. (Figs. 52 and 53.) If no secondary infection occurred to complicate the picture, the proliferative changes continued. Large mononuclear cells which previously had been seen about the adventitia of the arteries of the terminal bronchioles increased in number, and wandered through the exudate preceding the formation of reticulum which extended out from the walls of the atria, air sacs, and alveoli and formed a network in the exudate. (Figs. 54, 55, 56, 57, 58.) Collagenous fibrils were then laid down along and between the strands of reticulum which gradually disappeared except about vessels. (Fig. 59 and Pl. IX; fig. 60 and Pl. X.) In the early stages reticulum was laid down in irregular lines often beaded and also formed basket-like networks around individual cells which were morphologically large mononuclears, while collagenous fibrils were laid down in more or less parallel lines between fusiform cells of the fibroblast type. (Figs. 61, 62, and 63.) In addition to the reticulum formed in the exudate this material increased in the walls of the alveoli not always surrounding additional capillaries, though it is probable that, to some extent, these were formed later, the whole appearing as a sort of granulation tissue increasing the thickness of the walls of the atria, air sacs, and alveoli. (Figs. 64, 65, and 66.)

The organizing process as seen in cases living several weeks, usually dying from other infections, appeared grossly as indurated areas not definitely nodular, extending into the tissue somewhat diffusely and rather cyanotic, like recently formed scar tissue. This organizing pneumonia or organization of pneumonic exudate which occurred with extreme rapidity was characteristic of this inflammatory process. While this organization is seen most beautifully in the air sacs and alveoli, it also occurred in the bronchi, though there it took the form of granulation tissue extending out into the lumens of the bronchioles from the capillary network beneath the basement membrane, no remnants of the latter being visible, thus indicating its complete destruction. (Figs. 67, 68, 69, and 70.)

The process described above in the terminal lung units was accompanied by similar changes in the bronchial tree. The bronchitis which early was of a catarrhal or serous type became purulent, the mucosa was desquamated from irregular areas and the infection extended into the peribronchial tissue. In the earliest stages the limiting membrane of the submucosa or basement layer became thickened and appeared hyaline and necrotic. The capillaries which terminated their loops at this membrane appeared increased in number. Ex-



A. HOEN & CO.

PERIBRONCHIOLAR, HEMORRHAGIC CONSOLIDATION.

Leucocytic infiltration of interlobular septa surrounded by hemorrhage. Minute Gram-negative bacteria and streptococcus forms were seen in the bronchioles, streptococci in the lymphatics of the septa.

Accession 2694, Army Medical Museum. H. & E. stain. Autochrome.

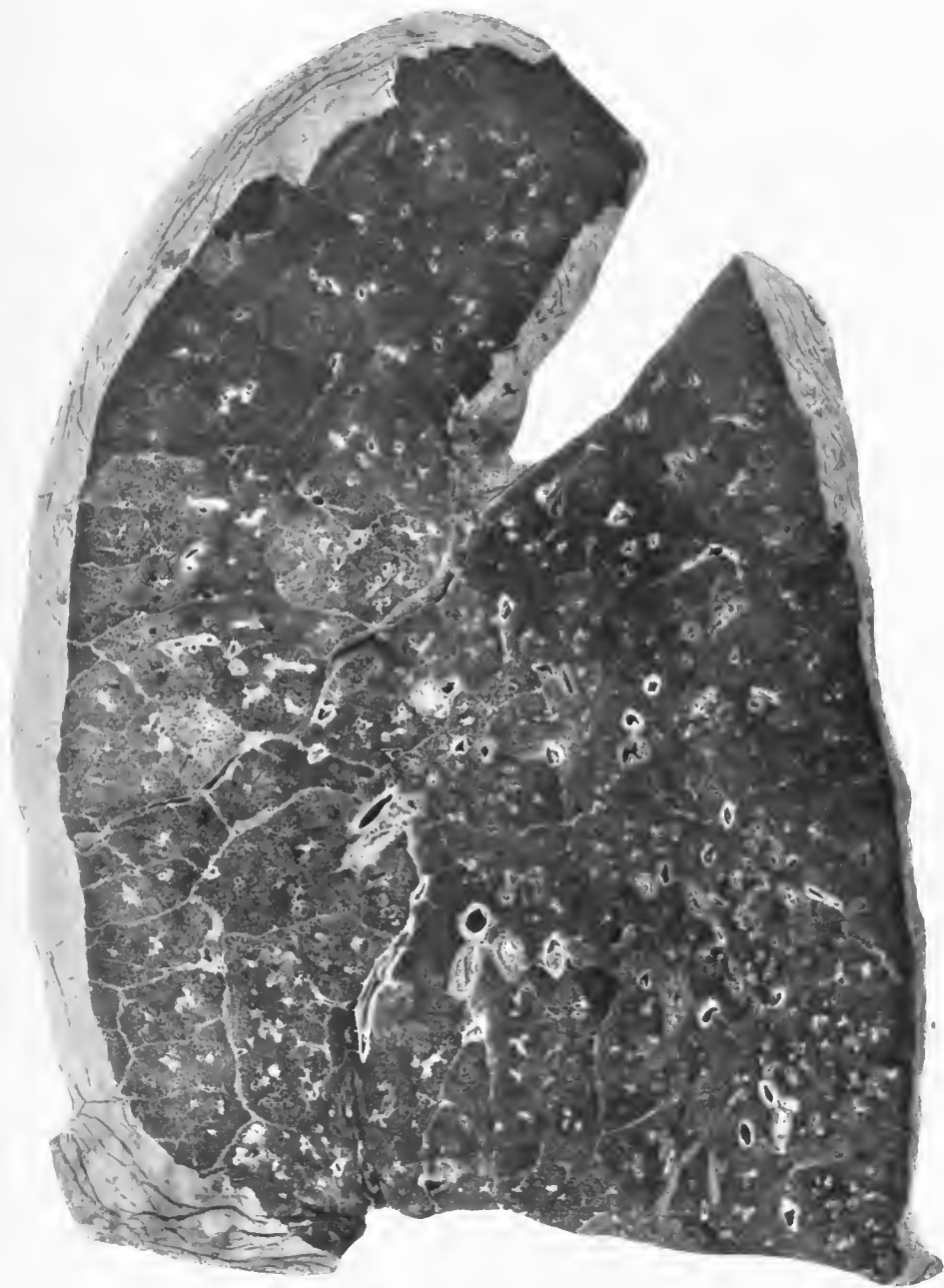


FIG. 37.—Peribronchiolar consolidation surrounded by zones of hemorrhage in the lower lobe. Peribronchiolar nodules in the lobules of the upper lobe surrounded by lobular consolidations due to *Streptococcus hemolyticus*. Minute Gram-negative bacteria and streptococci in the bronchioles. Only streptococci recovered in culture. Accession number 3092, Army Medical Museum. Negative number 30716

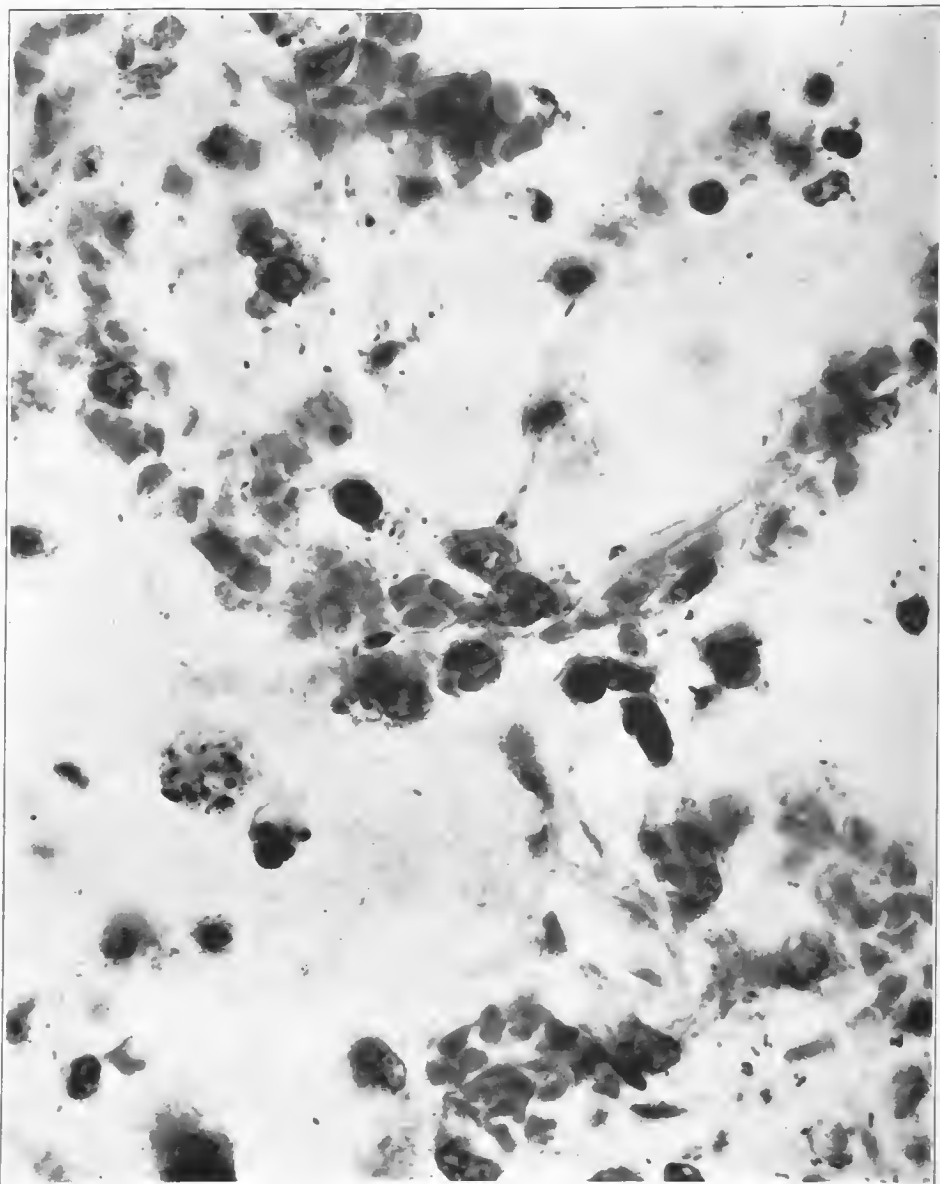


FIG. 38.—Gram-negative bacillary forms in the alveolar wall with partial desquamation of the alveolar epithelium. Accession number 3108, Army Medical Museum. Negative number 45257. MacCallum stain; \times 1150

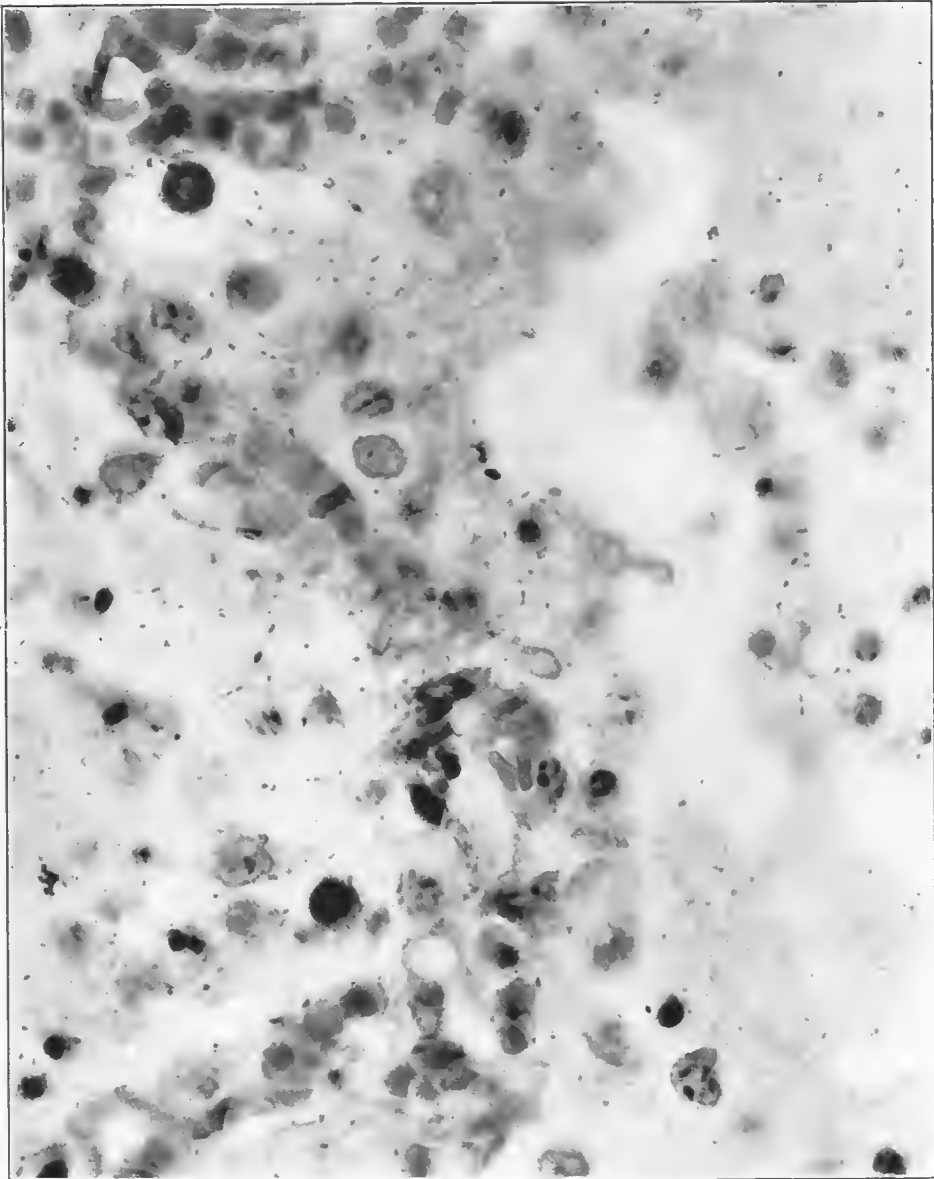


FIG. 39.—Minute Gram-negative bacteria in the alveoli. Pneumococcus, Group IV, in lung culture. *Hemolytic streptococcus* in heart's blood, pleura, and lung. Accession number 3108, Army Medical Museum. Negative number 45252. MacCallum stain; $\times 1200$

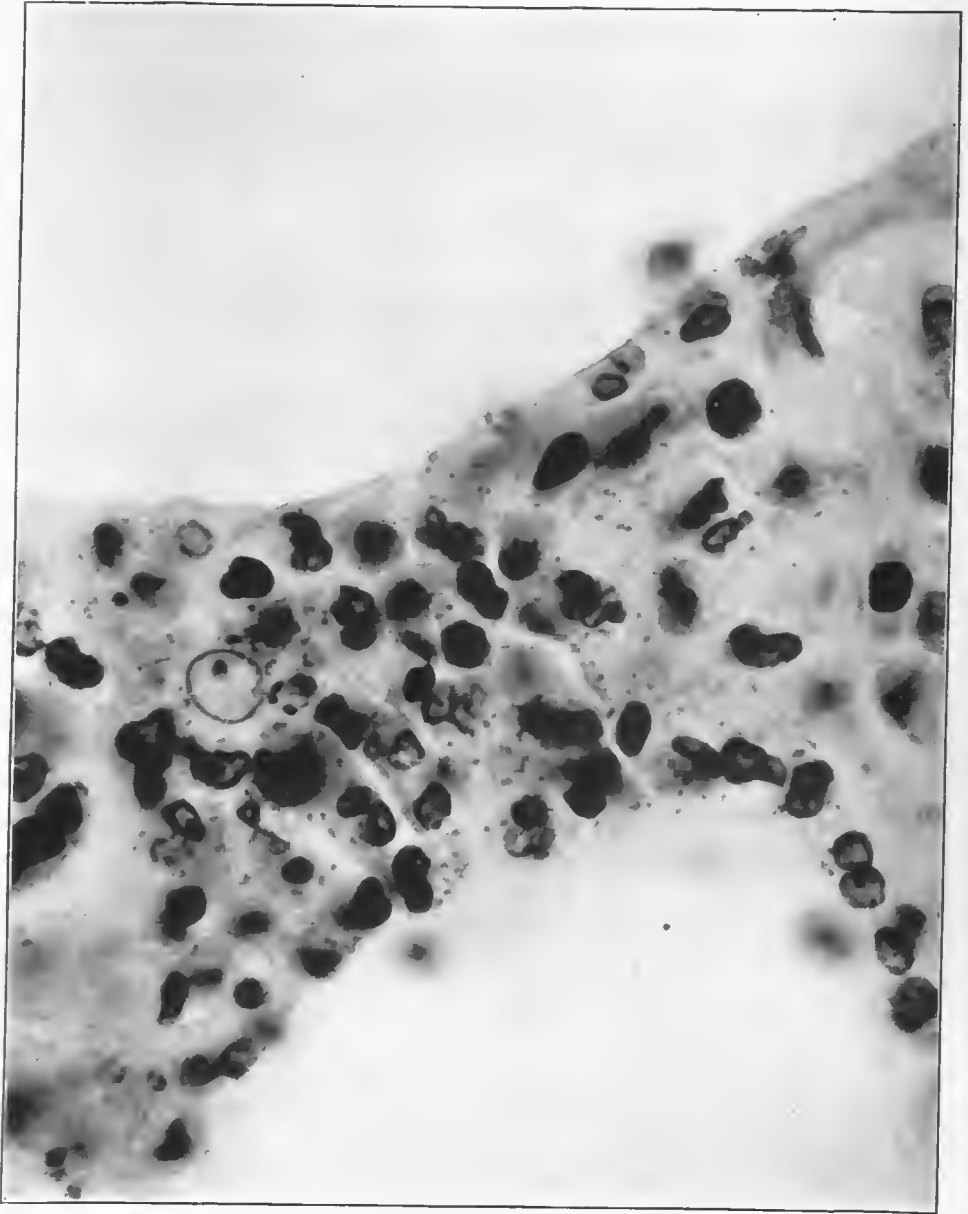


FIG. 40.—Minute Gram-negative bacteria in alveolar wall which is infiltrated with lymphocytes, large mononuclear cells and a few polymorphonuclear leucocytes. *Streptococcus hemolyticus* found in culture. Accession number 3101, Army Medical Museum. Negative number 45233. MacCallum stain; $\times 1560$

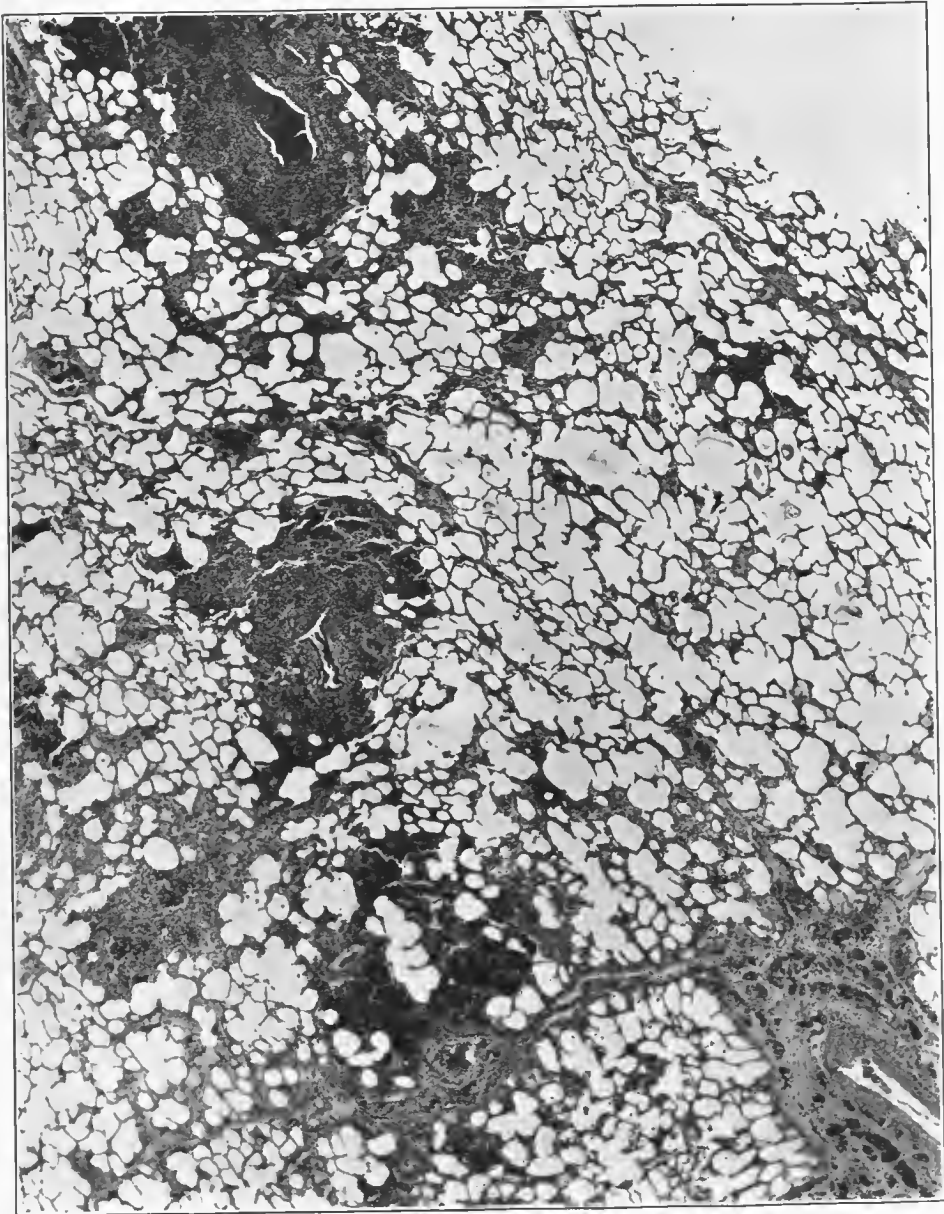


FIG. 41.—Peribronchiolar lesions in pneumonia following influenza. It is in this type of lesion that small Gram-negative bacilli most frequently are found. Streptococci were found in the bronchioles not far from these areas and in the interstitial tissue around the larger vessel seen in one corner of the illustration. Accession number 2694, Army Medical Museum. Negative number 45995. Hematoxylin and eosin stain; X 19

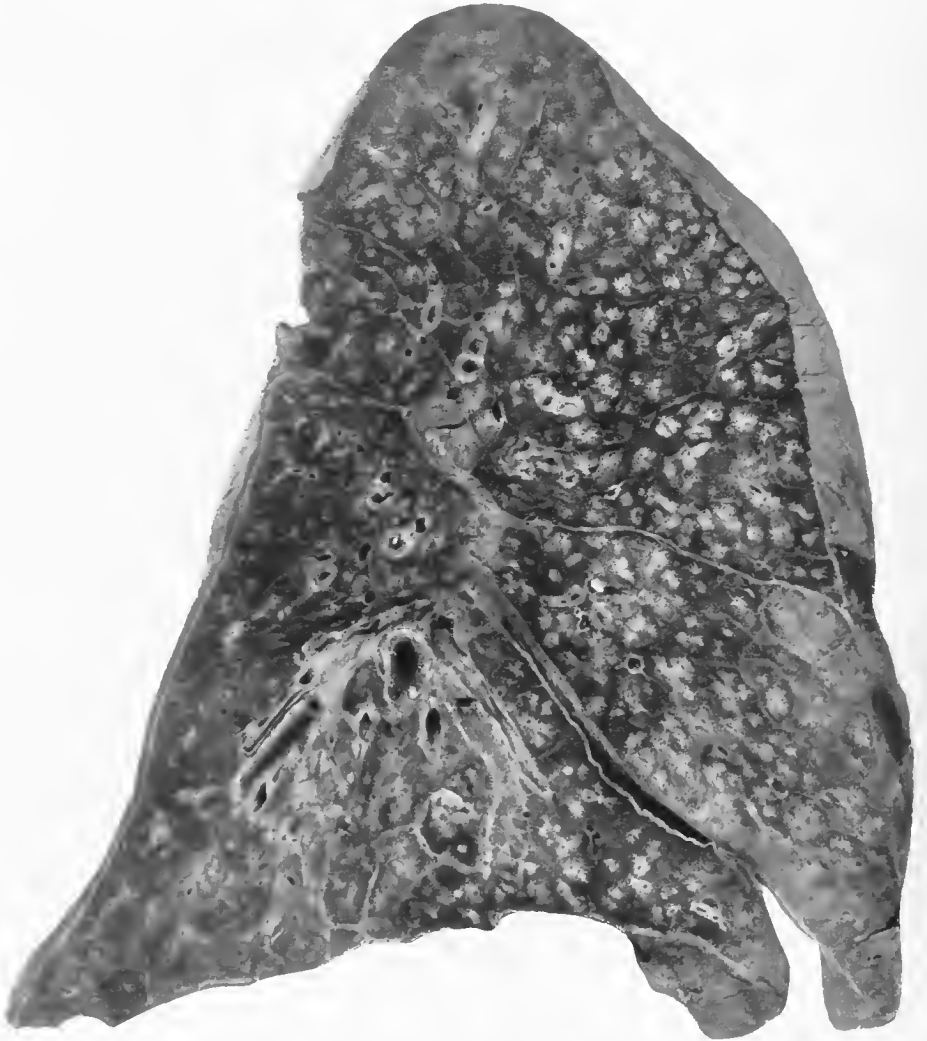


FIG. 42.—Pneumonia following influenza. Peribronchiolar nodular consolidations, with some spreading out of the lesion from the bronchioles so that a few lobules are filled with exudate. Considerable interstitial lymphangitis near the base of the lower lobe, with slight thickening of the interlobular septa and peribronchial tissue throughout the lung. Gram-negative organisms were present in sections of the peribronchiolar lesions; *Streptococcus hemolyticus* was cultivated from the areas of lymphangitis. Accession number 3036, Army Medical Museum. Negative number 42866

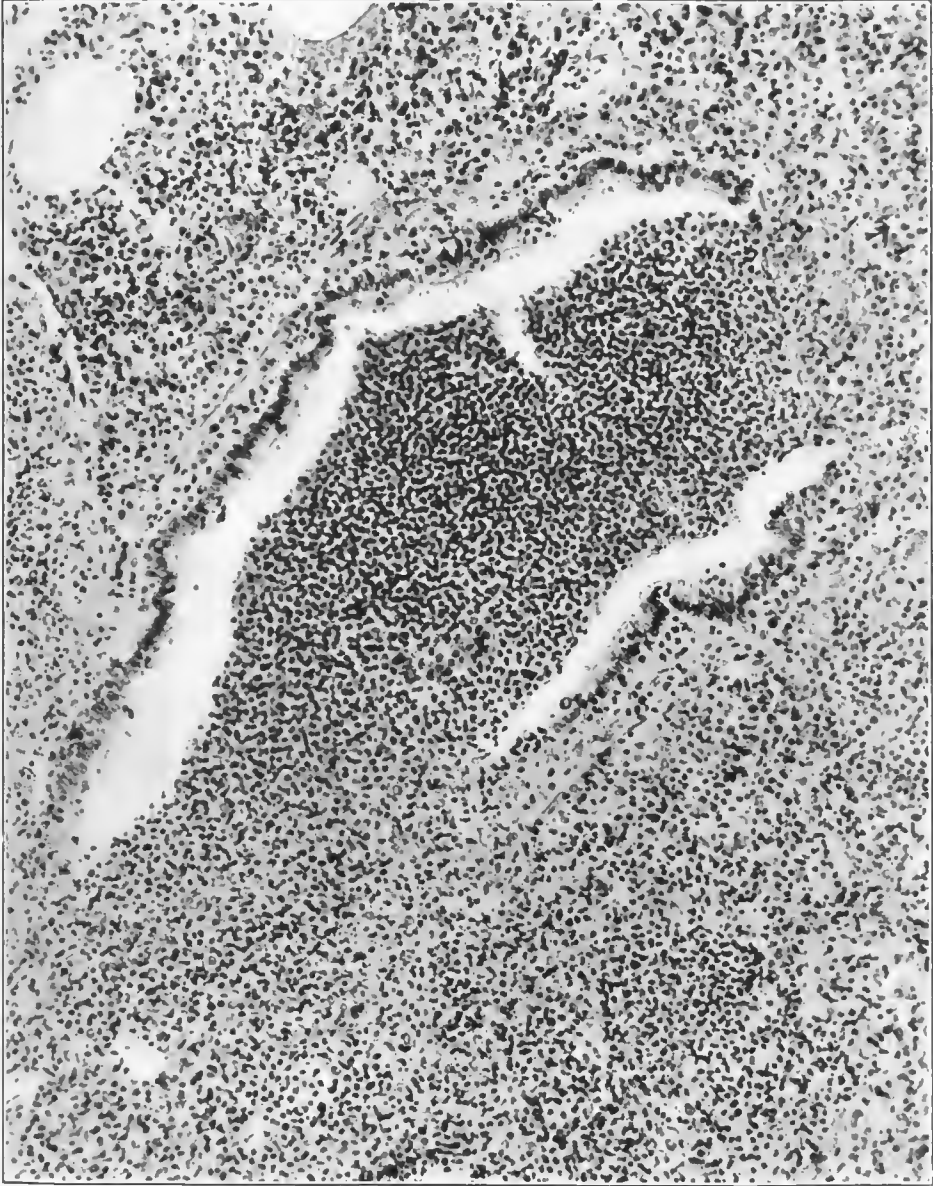


FIG. 43.—A bronchiole, showing absence of columnar cells at either side, the fibrinopurulent exudate being attached where epithelium is absent; the inflammation extends into the surrounding tissue. The places of attachment of the exudate were probably points where small groups or single alveoli opened into the bronchiole. Purulent infiltration of the submucosal tissues. Streptococci and Gram-negative bacteria in the pus. This bronchiole was the center of a peribronchiolar, nodular consolidation. Accession number 2694, Army Medical Museum. Negative number 46028. Hematoxylin and eosin stain; $\times 170$

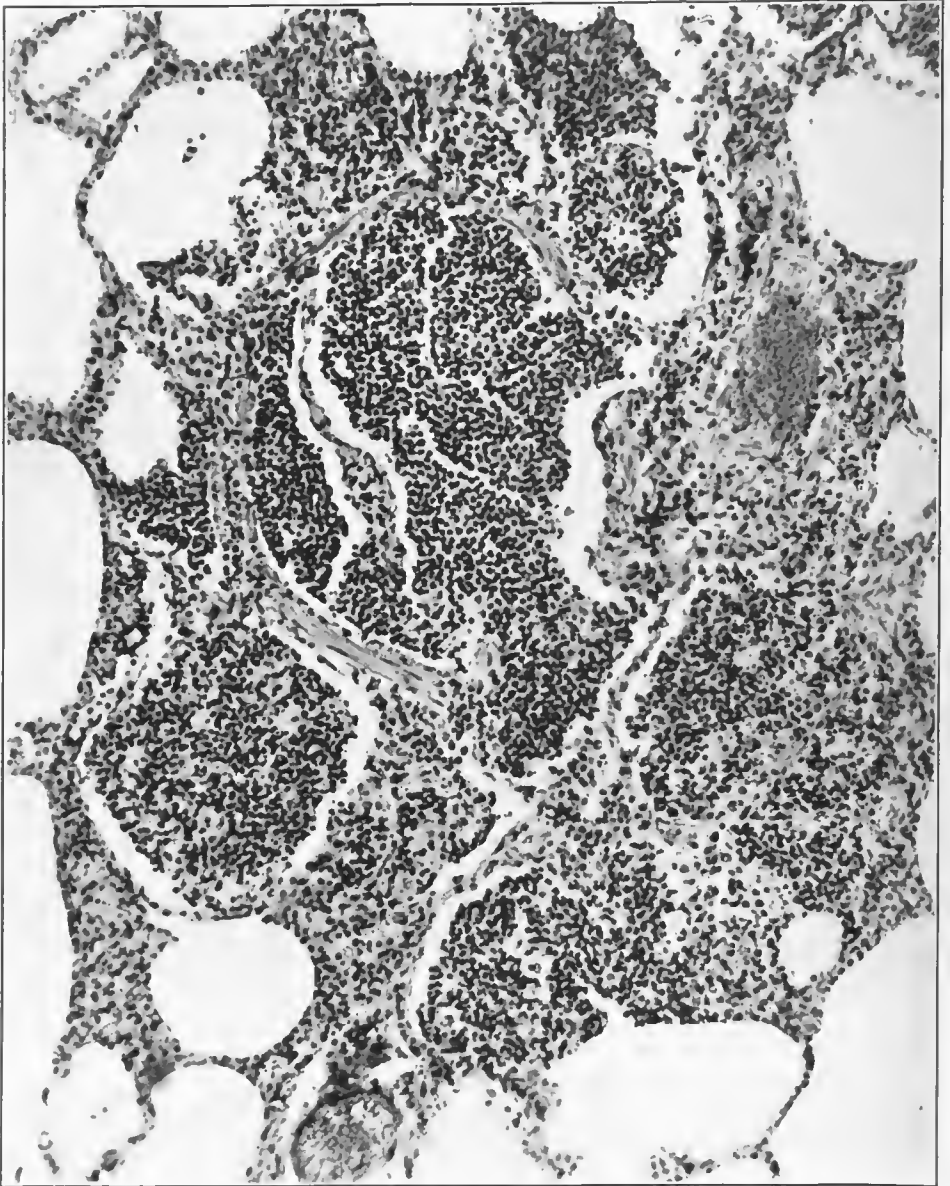


FIG. 44.—Section of a ductus alveolaris near its termination, which is surrounded by purulent exudate in the alveoli adjacent. Two of these alveoli open directly into the ductus. Accession number 2694, Army Medical Museum, Negative number 46038. Hematoxylin and eosin stain; $\times 170$

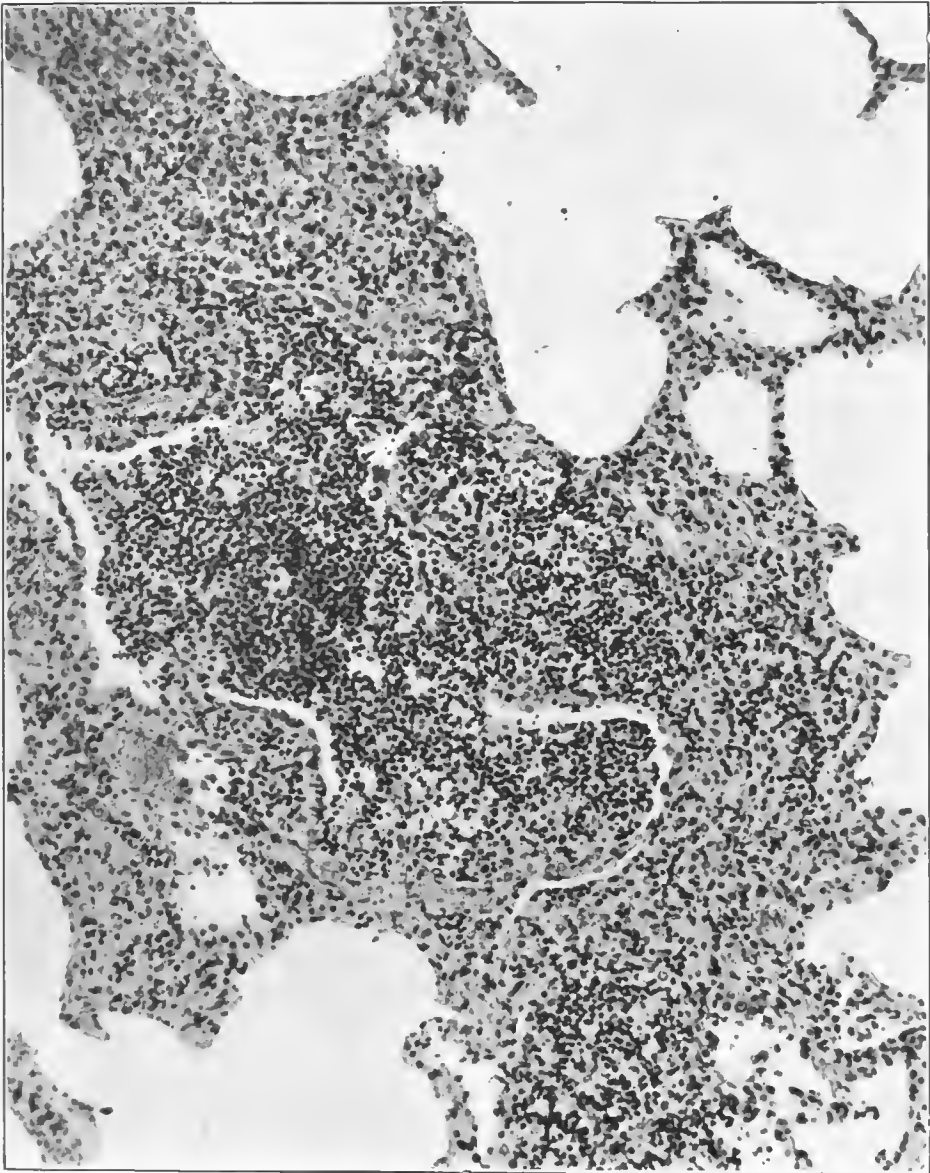


FIG. 45.—A small nodular consolidated area of peribronchiolar pneumonia. Section is taken through the division of a ductus respiratorius into atria. Atrial lumen filled with purulent exudate, as are the surrounding alveoli. The walls of alveoli adjacent to the tissue about the atria are swollen from inflammatory edema and are infiltrated with leucocytes. Accession number 2694, Army Medical Museum. Negative number 46032. Hematoxylin and eosin stain; X 170

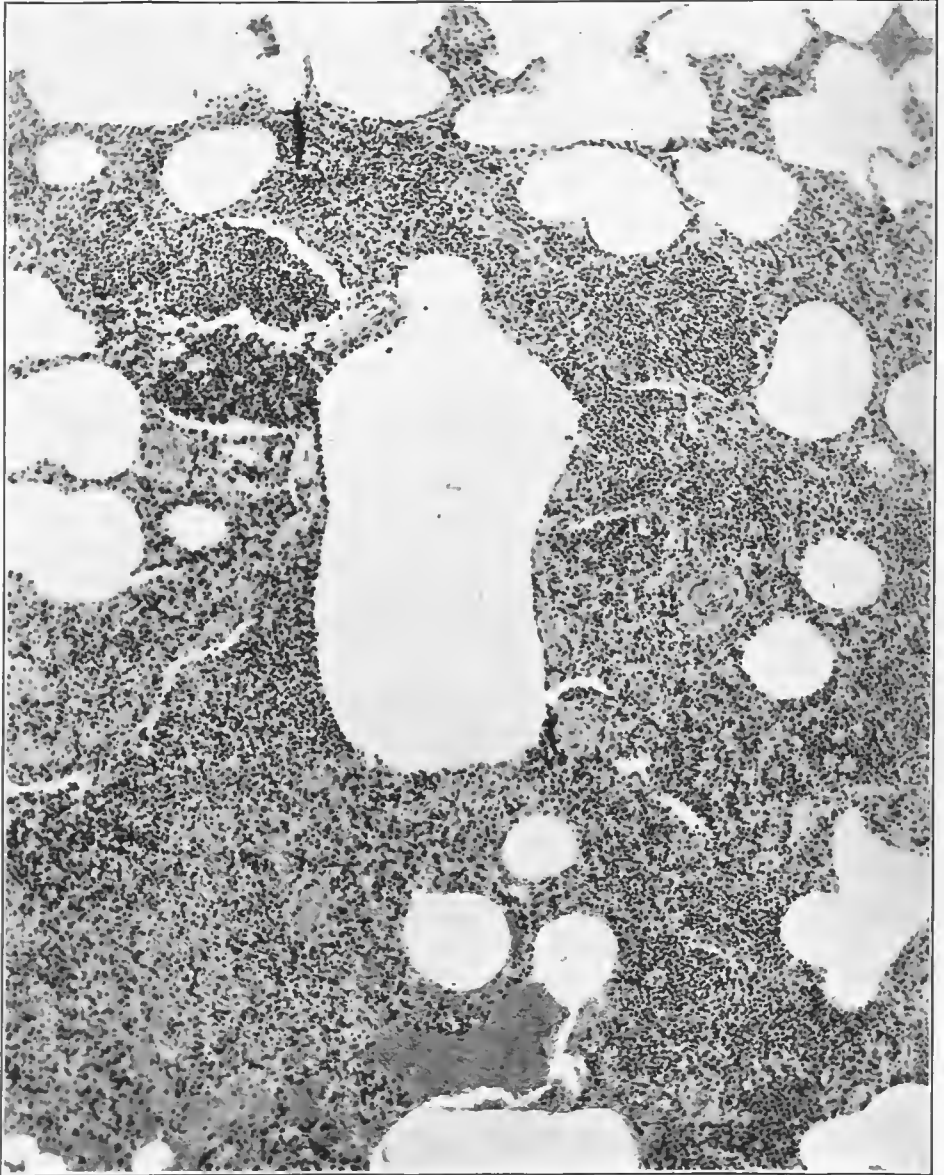

FIG. 46.—Consolidation about the division of a ductus alveolaris into its atria at about the termination of the ductus. Surrounding alveoli and air sacs filled with a purulent exudate. A small amount of columnar epithelium is seen at one end of the opening of the ductus. Some hemorrhage into the alveoli in the outer portions. The walls of the blood vessels are markedly thickened. Accession number 2694, Army Medical Museum. Negative number 46026. Hematoxylin and eosin stain; $\times 98$

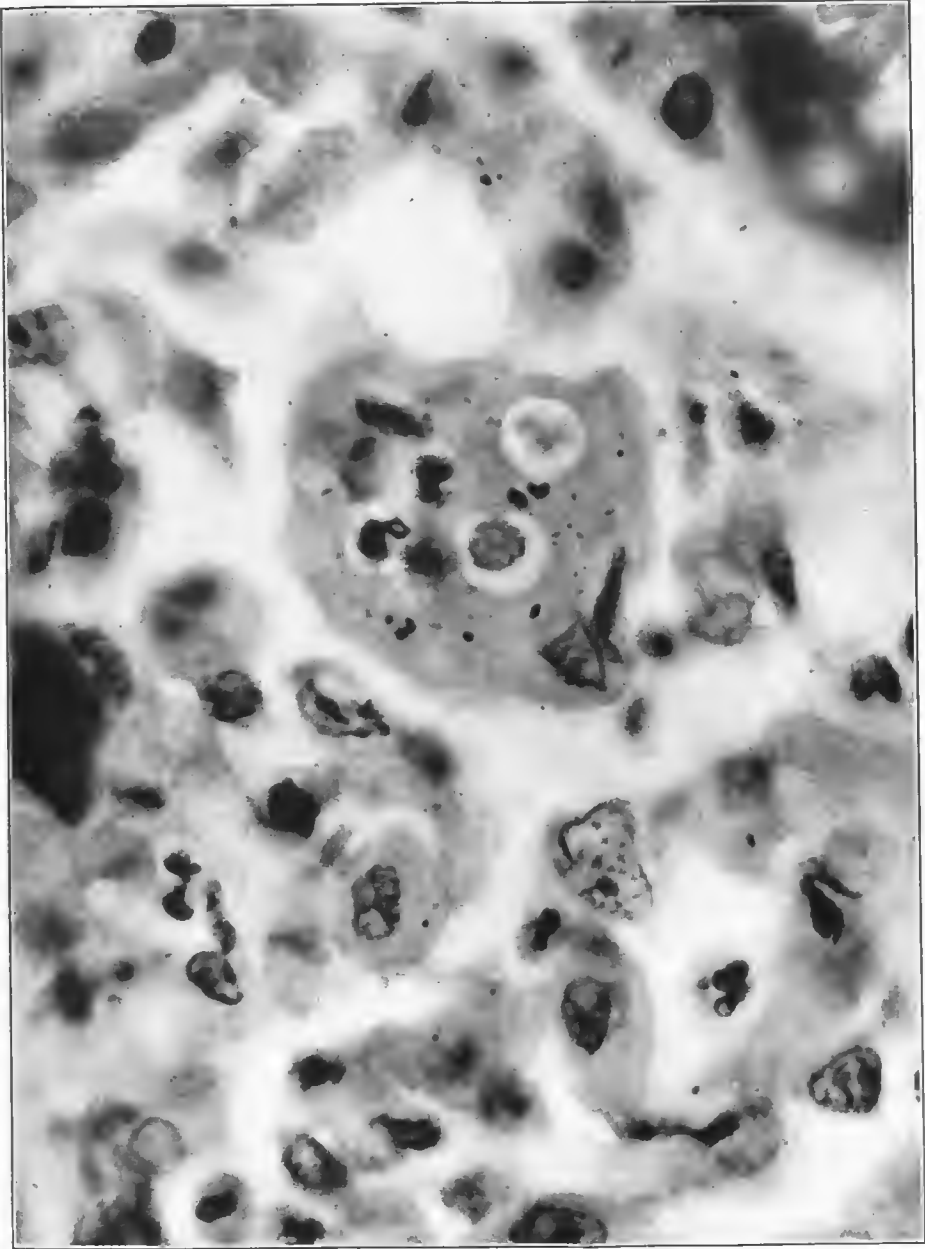


FIG. 47.—Infiltration of alveolar wall by mononuclear leucocytes, some of which have escaped into the alveolus. Large multinucleated phagocyte, which contains numerous leucocytes and some flecks of pigment. Accession number 22073, Army Medical Museum. Negative number 45565. Hematoxylin and eosin stain; $\times 650$

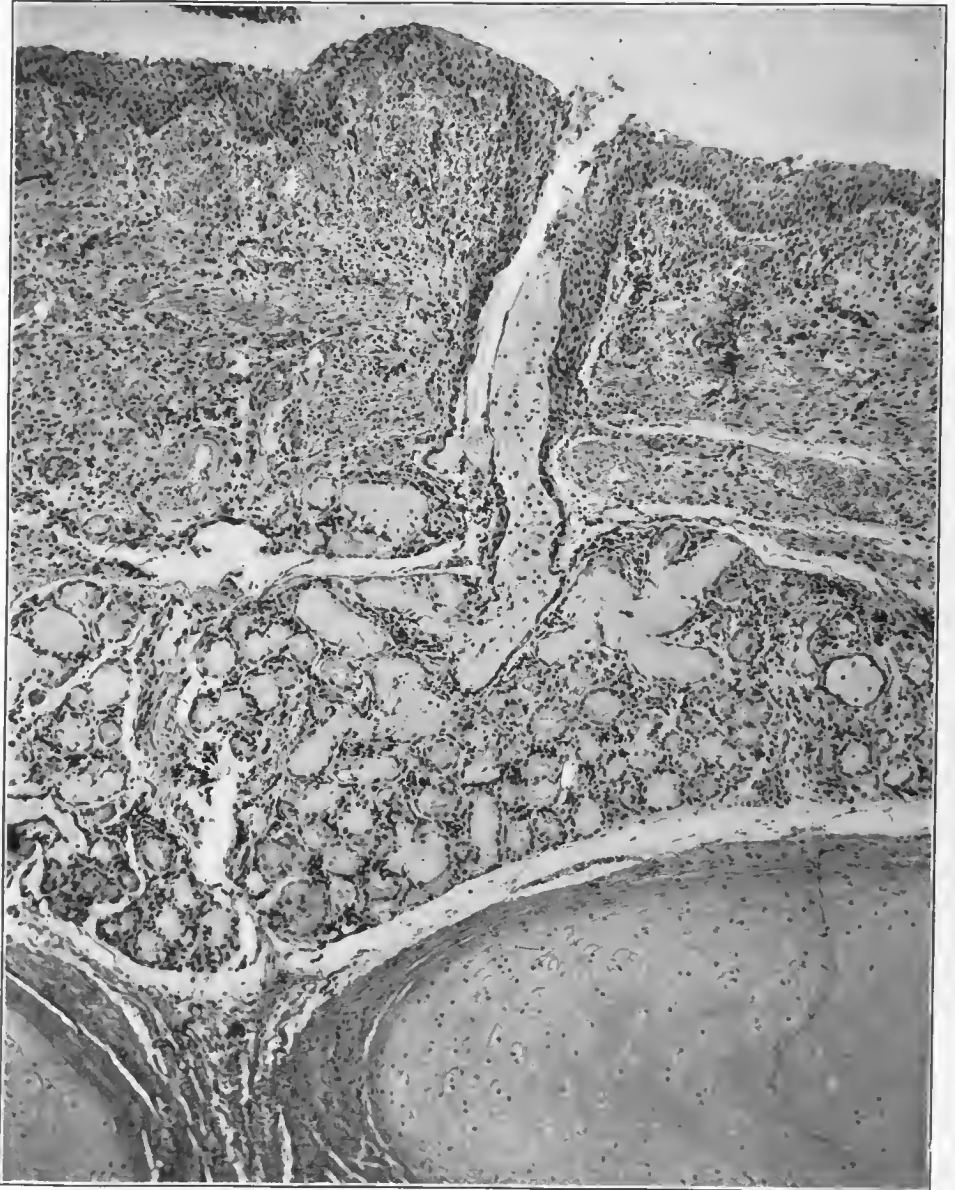

FIG. 48.—Section of the trachea, showing complete loss of the columnar cells, with formation of a thick epithelial surface of stratified squamous type which extends down into the lumen of the duct of the tracheal glands. The latter show hypersecretion but little degeneration. Accession number 2694, Army Medical Museum. Negative number 46020. Hematoxylin and eosin stain; $\times 97$

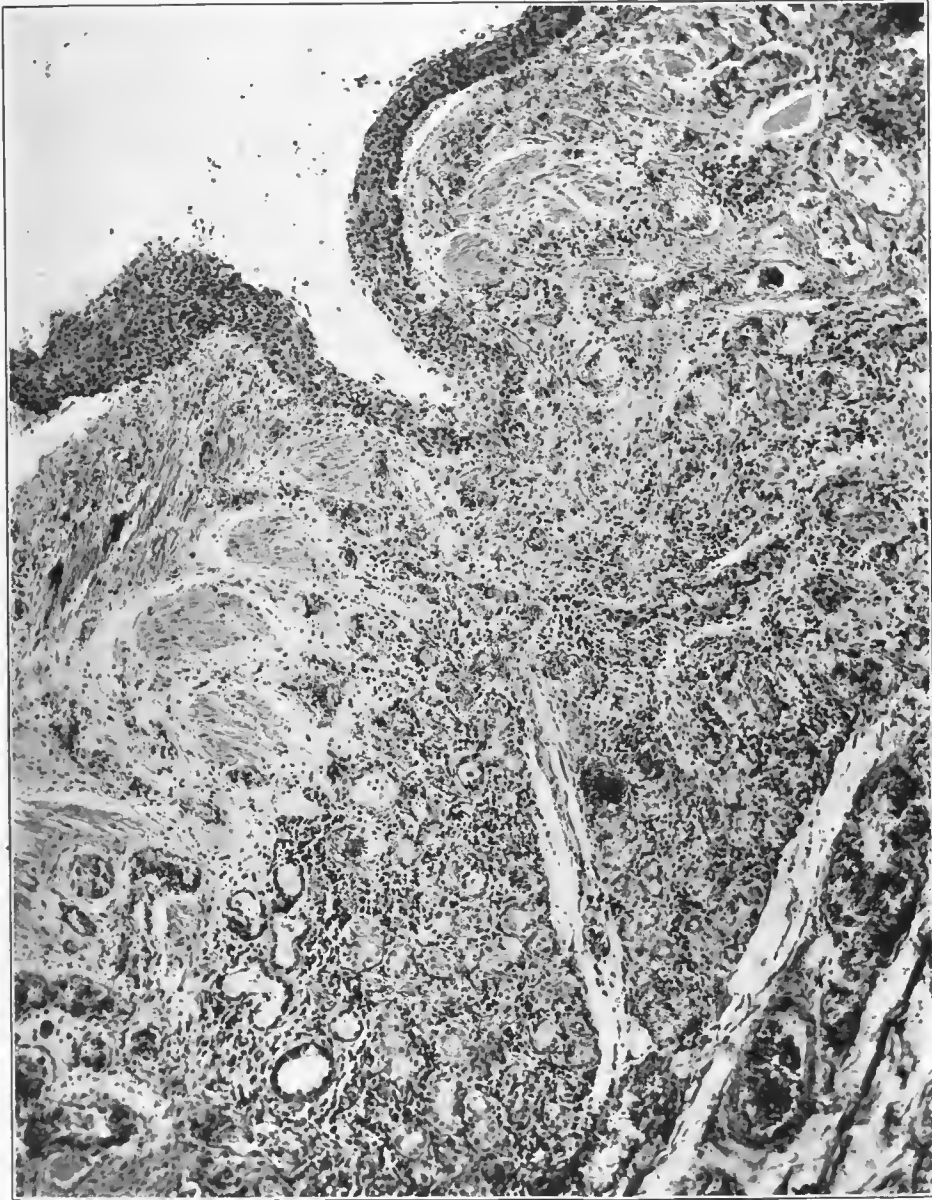


FIG. 49.—Section of trachea showing practically complete loss of columnar cells, with marked proliferation of the basal layer forming a mucosa which appears like the stratified squamous type. Inflammatory edema and leucocytic infiltration of the submucosa and glands with some degeneration of the latter and some hemorrhage from small capillaries. Accession number 2694, Army Medical Museum. Negative number 46043. Hematoxylin and eosin stain; $\times 85$

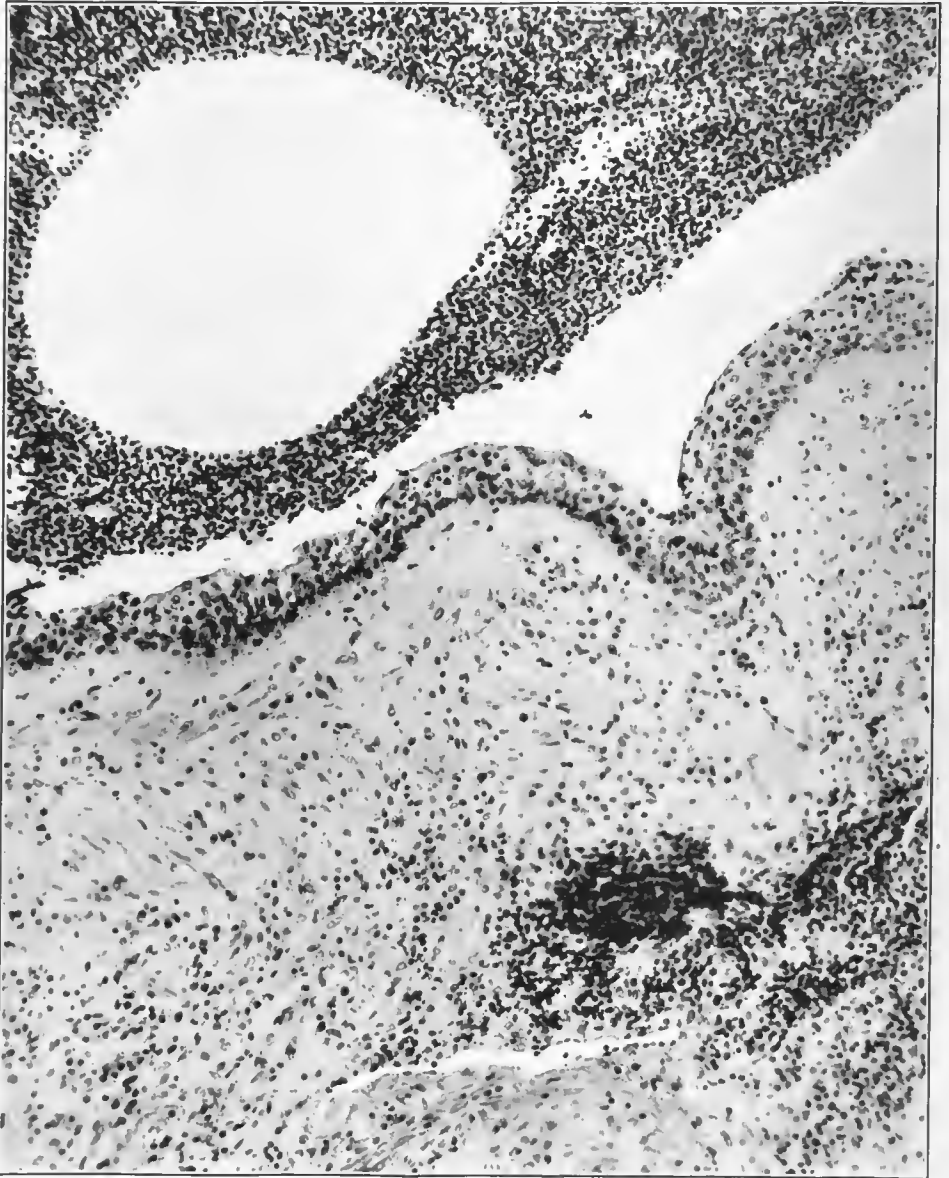
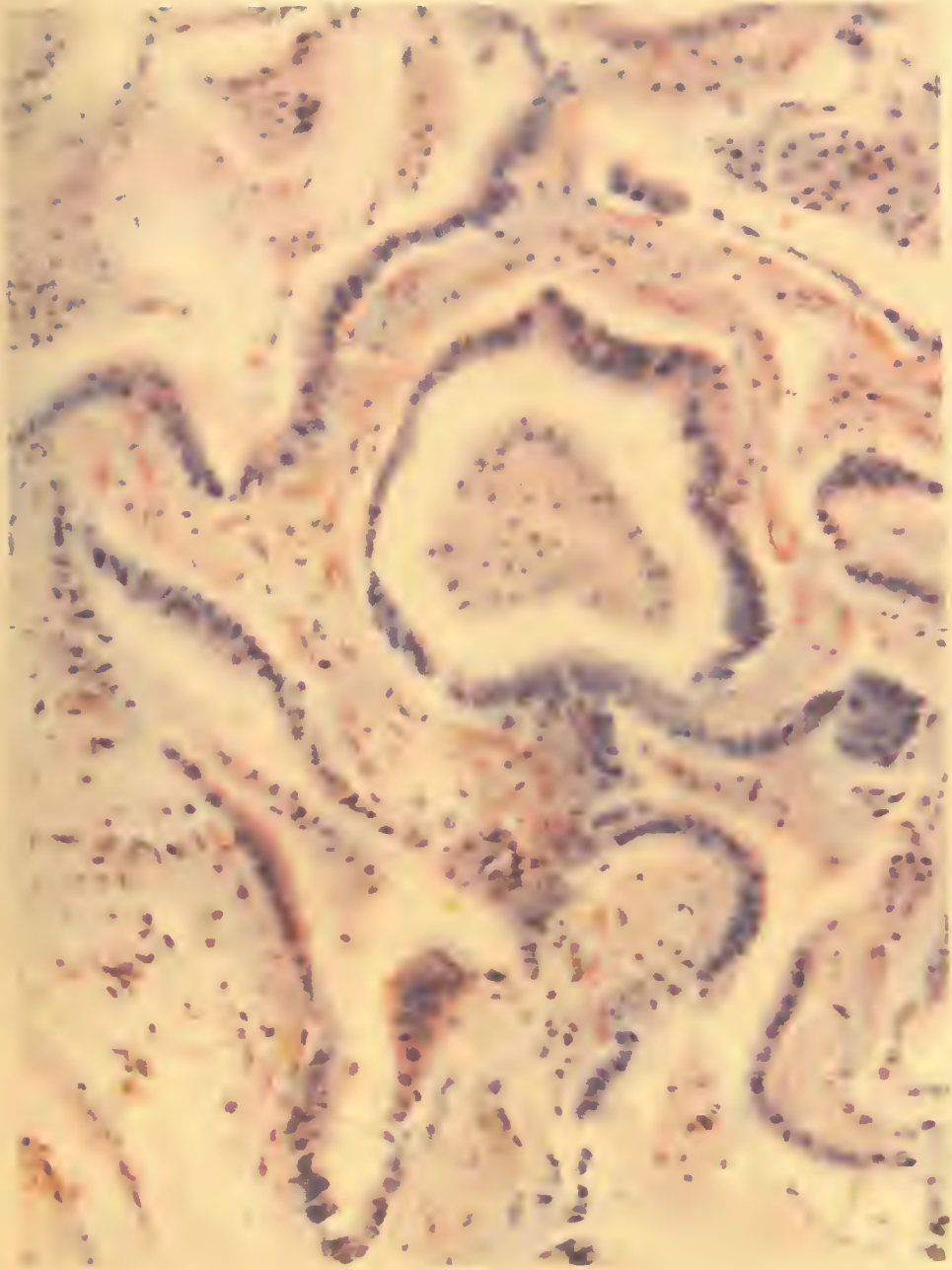


FIG. 50.—Bronchus showing purulent exudate and air in the lumen. Columnar cells are completely desquamated and the basal layers are proliferated, forming an epithelium of the stratified squamous type. This is infiltrated with leucocytes. Surrounding tissues show inflammatory edema and leucocytic infiltration with an increase in lymphocytes in the node which shows at one corner of the figure. This type of reaction occurred early in the influenzal process. Accession number 2694, Army Medical Museum. Negative number 46029. Hematoxylin and eosin stain; $\times 145$



A. HOEN & CO.

ORGANIZING PNEUMONIC PROCESS.

Alveoli lined by columnar cells.

Accession 22073, Army Medical Museum. H. & E. stain. Autochrome.

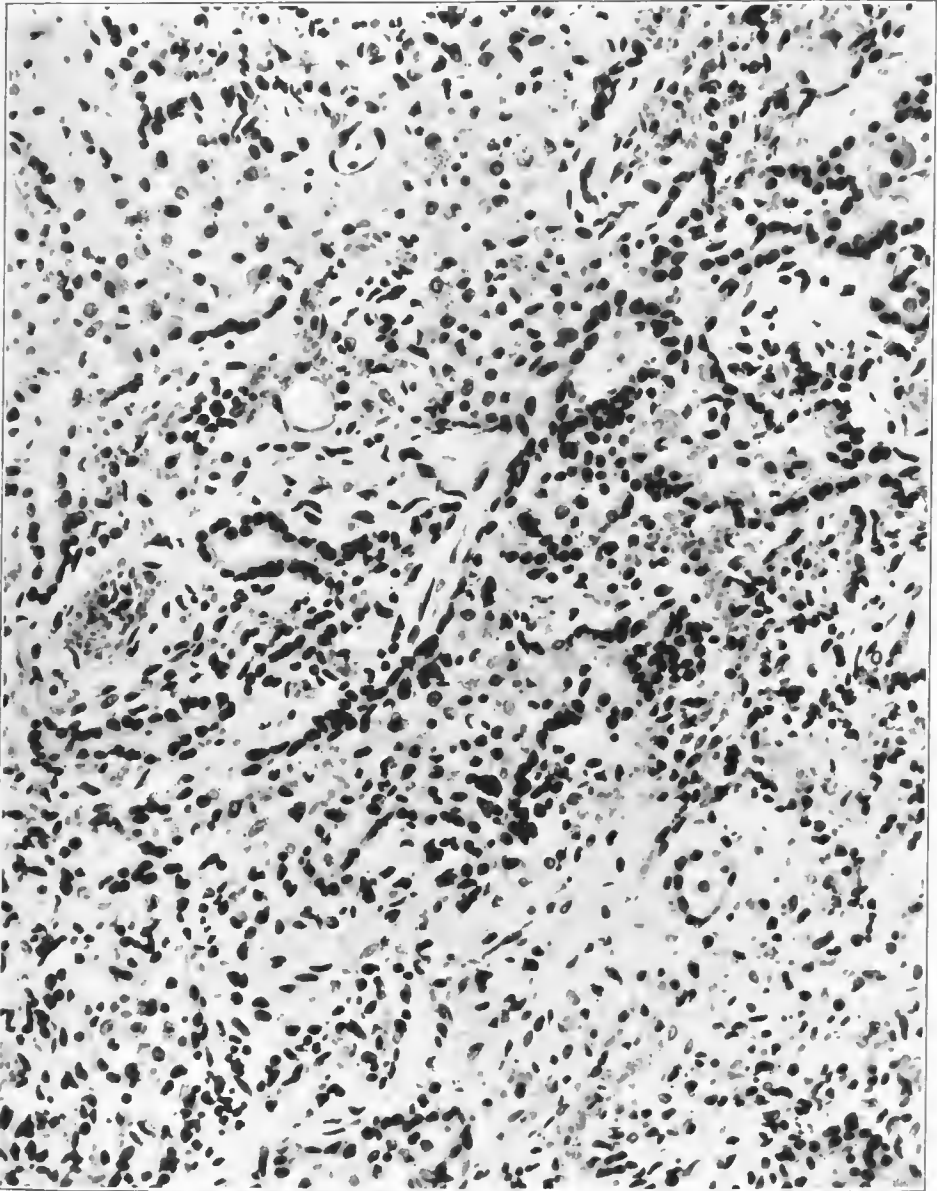


FIG. 51.—Area of atelectasis in influenza pneumonia. Proliferation of alveolar epithelium, connective tissue thickening of the alveolar walls, leucocytic infiltration of the walls with numerous leucocytes in the alveoli, most of which are large mononuclear types. Accession number 3038, Army Medical Museum. Negative number 45178. Hematoxylin and eosin stain; $\times 285$

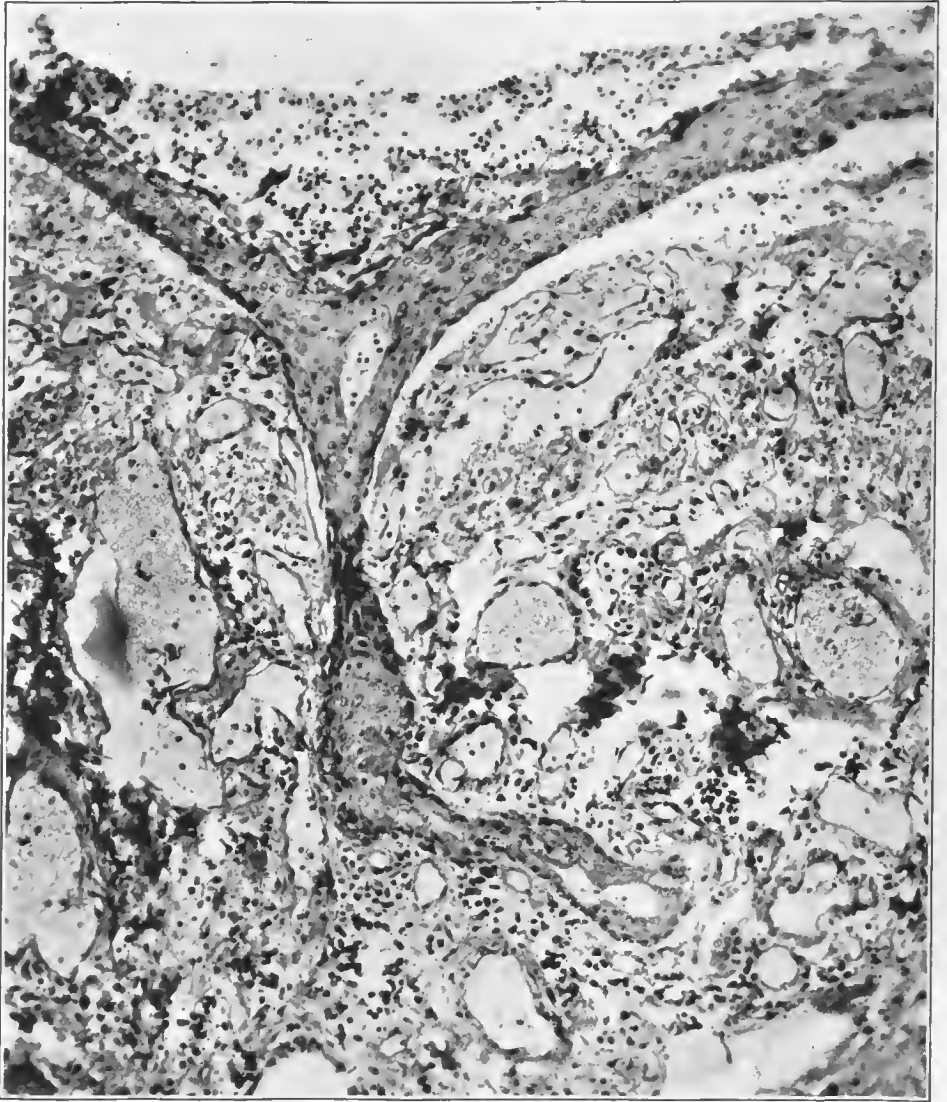


FIG. 52.—Section of wall of small bronchus, showing a loss of columnar cells, proliferation of basal layer into a stratified squamous type of epithelium which extends along a small branch of the bronchiole and into an alveolus. No definite rupture of tissue is present, but in bronchiectasis breaks in the bronchiolar walls are usually covered with this type of epithelium. Accession number 16571, Army Medical Museum. Negative number 45273. Hematoxylin and eosin stain; $\times 142$

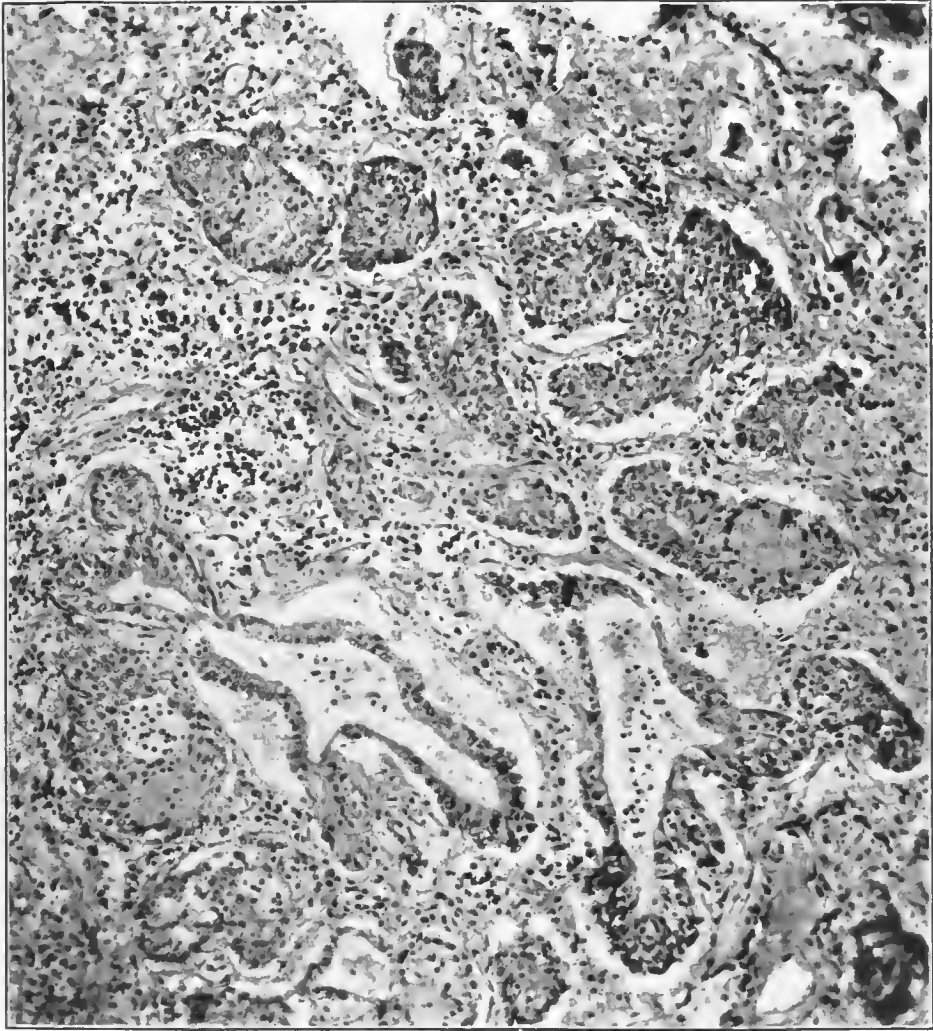


FIG. 53.—Alveoli and atria more or less completely filled with masses of epithelium of the type of the basal or regenerative layer of the bronchi. The masses have the appearance of the stratified squamous epithelium of mucous membranes. This represents part of the process of organization in a peribronchiolar consolidation following influenza. Proliferative changes of this type are seen in the bronchioles and have extended into the atria and alveoli, or the epithelium of these structures has piled up and differentiated into the stratified squamous type. Accession number 16571, Army Medical Museum. Negative number 45272. Hematoxylin and eosin stain; $\times 131$

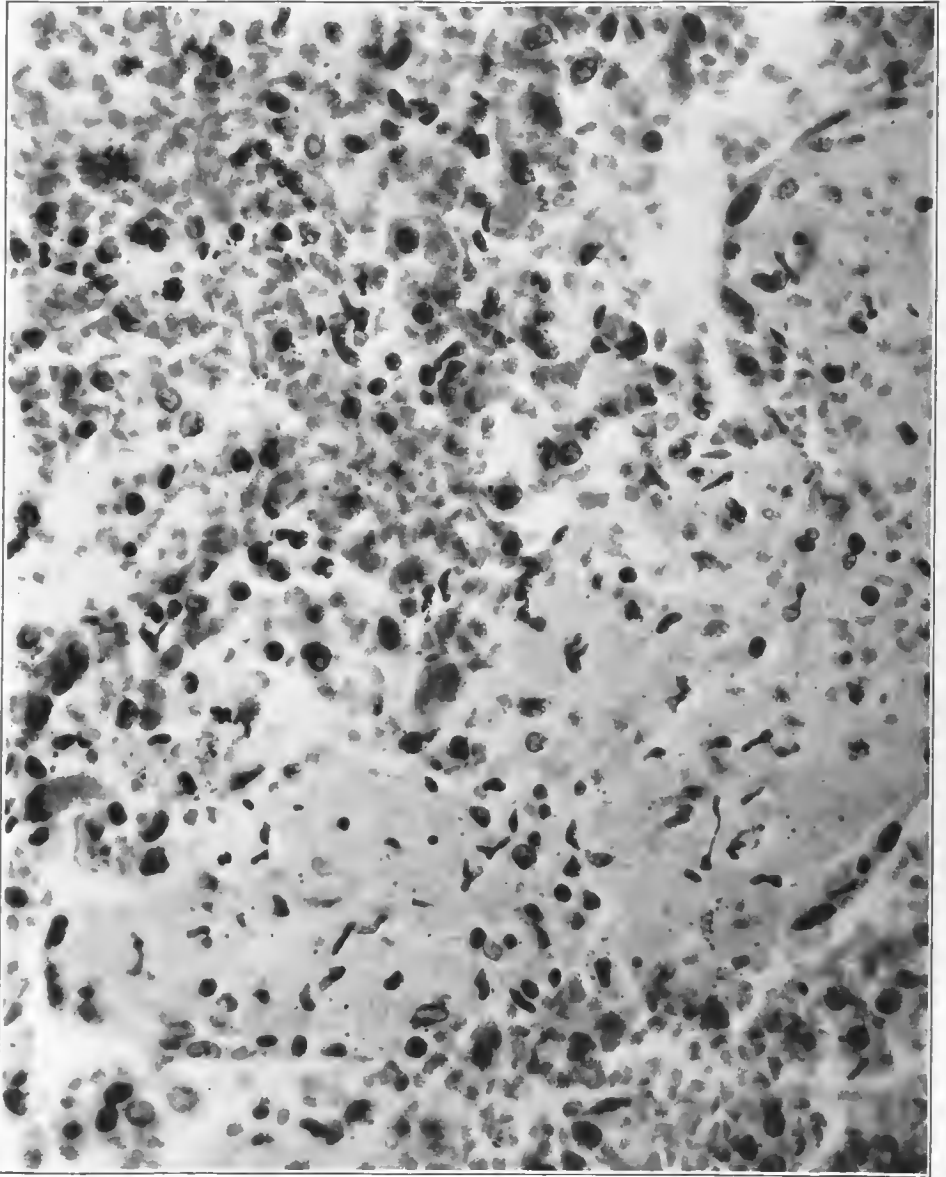


FIG. 54.—Exudate in an atrium in an early stage of the process of organization. Some of the wandering cells have elongated nuclei which can be clearly made out in the albuminous matrix. This beginning of organization is taking place in an area where a hemorrhagic inflammation is present. Accession number 1049, Army Medical Museum. Negative number 45672. Hematoxylin and eosin stain; $\times 505$

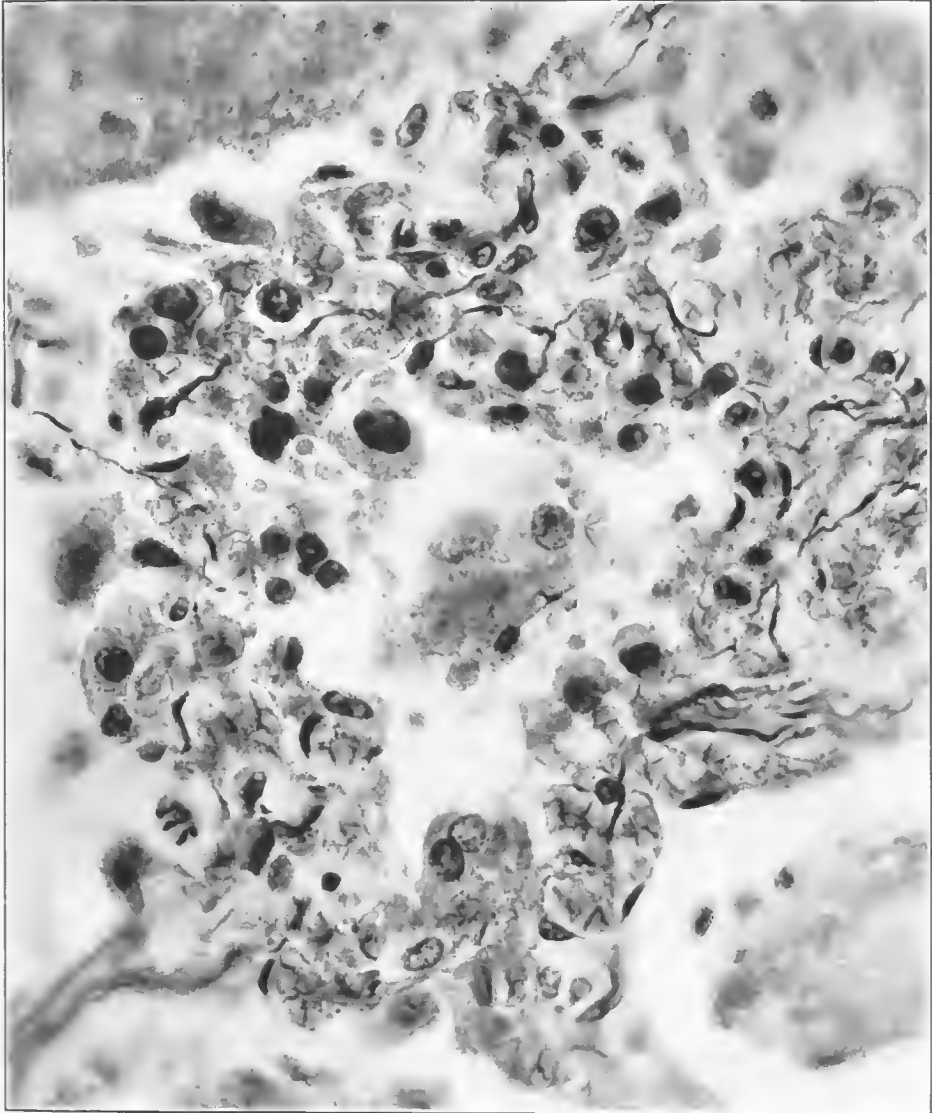


FIG. 55.—Wall of alveolus showing types of cells in the infiltration in an influenza pneumonia near an area where organization is beginning. Duration 14 days. Delicate reticulum forms a basketry about some of the cells in the alveolar wall. Accession number 3572, Army Medical Museum. Negative number 45306. Reticulum stain; $\times 845$

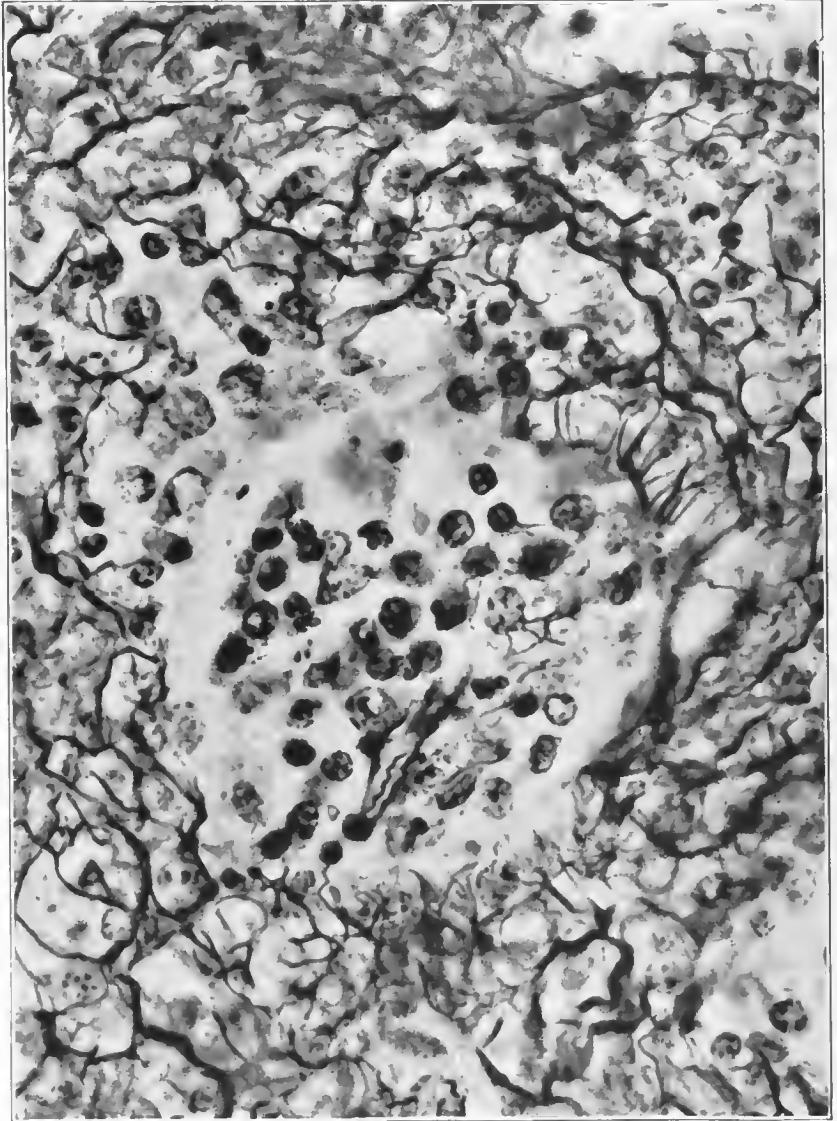


FIG. 56.—Early stage of organization of exudate in an alveolus. The reticulum is extending into the cellular mass and has formed a basketlike network about one of the cells. There is an increase in the number of capillaries causing a thickening of the alveolar wall. This same basketlike reticulum can also be seen about some of the cells in the alveolar wall. Accession number 3036, Army Medical Museum. Negative number 45668. Reticulum stain; $\times 810$

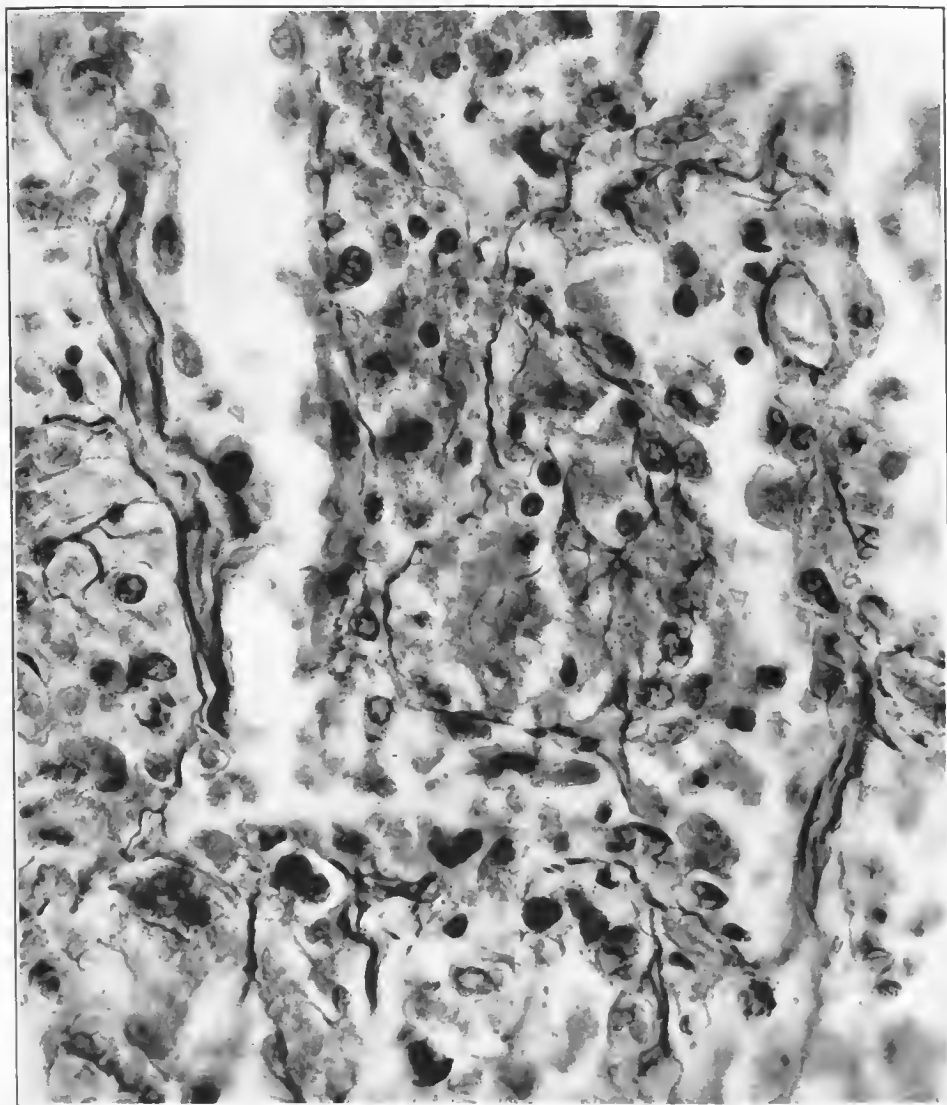


FIG. 57.—Early stage of organization of the exudate in a pulmonary atrium. Reticulum is extending into alveolar exudate which contains relatively little fibrin. The fibers extend throughout the exudate and no apparent connection with cells can be seen. There is some regeneration of epithelium along the atrial wall. In the exudate are round and polygonal cells the exact character of which can not be determined except that there are a few lymphocytes. Accession number 3572, Army Medical Museum. Negative number 45488. Reticulum stain; $\times 745$

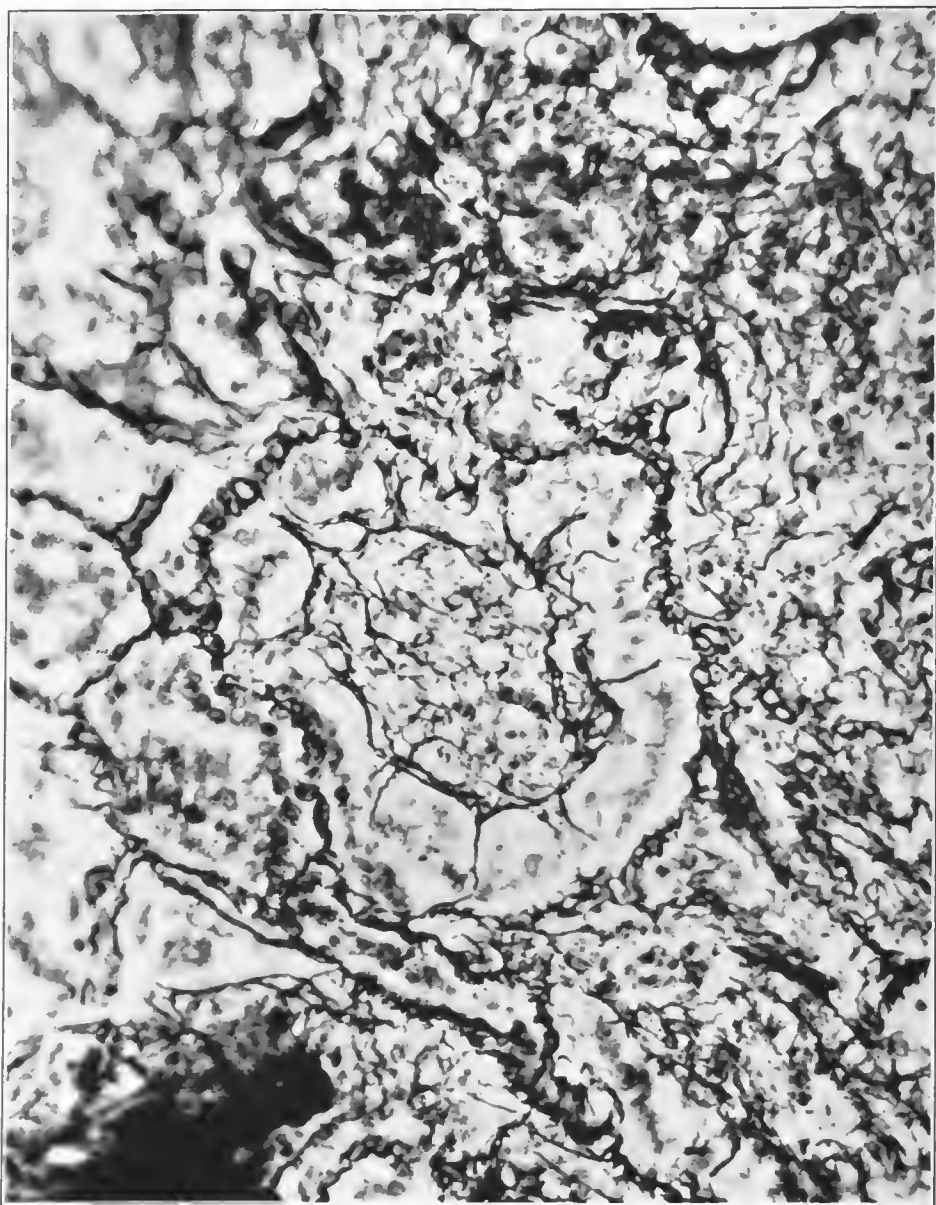
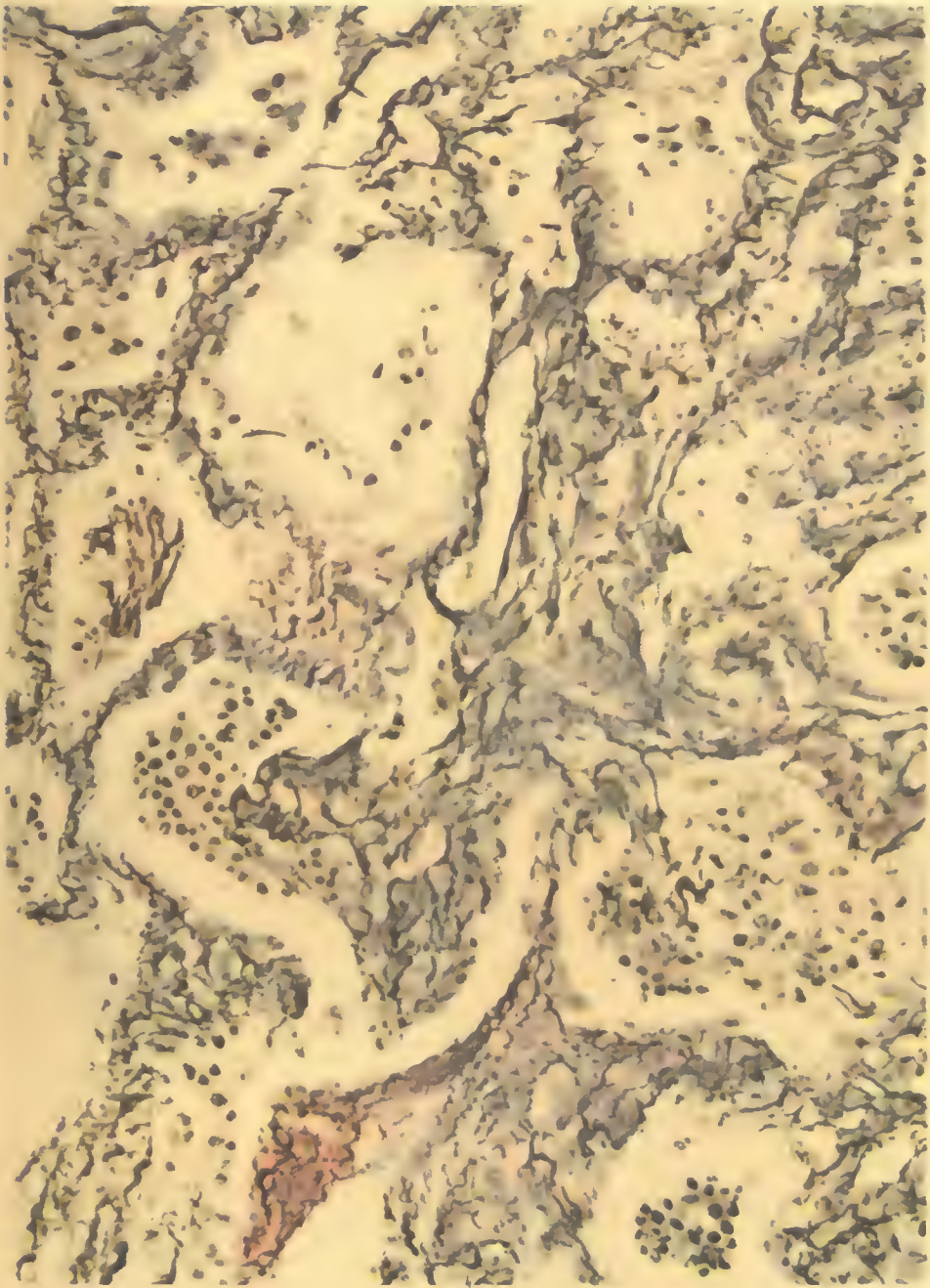


FIG. 58.—Early organization. Mass of cellular exudate in an atrium, infiltrated with reticulum fibers, showing radii of attachment to the atrial wall; no evidence of formation of collagen. Accession number 1390, Army Medical Museum. Negative number 45553. Reticulum stain; $\times 375$



A. HOEN & CO.

POST INFLUENZAL ORGANIZATION.

Accession 3036, Army Medical Museum. Reticulum stain. Autochrome.

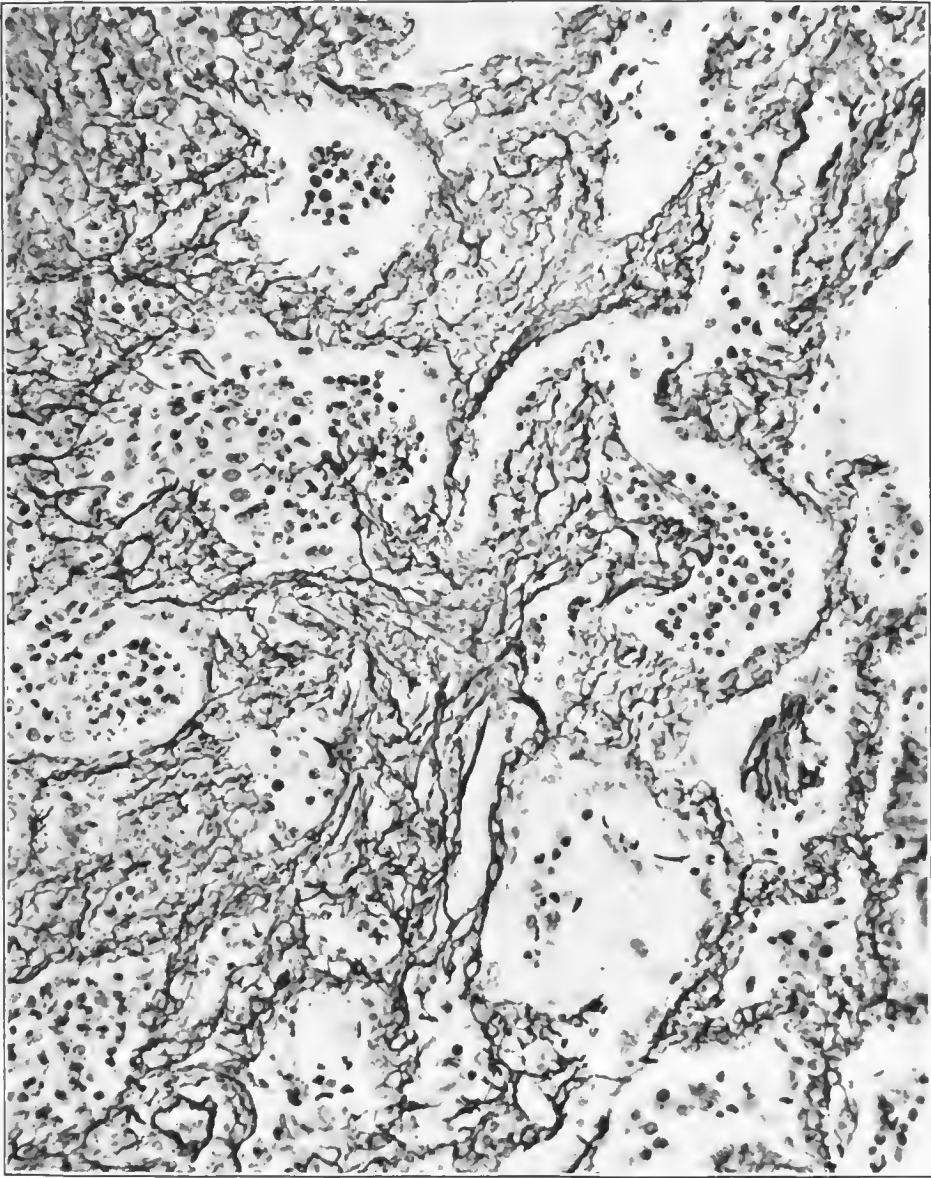


FIG. 59.—Organization of exudate in influenza pneumonia. The central mass of organization shows dense fibers of reticulum stained black; the lighter lavender fibers are collagen which appears to be laid down between the reticulum fibers, which gradually disappear. In the cellular exudate in two of the alveoli reticulum fibers are extending and in the advanced parts of the extending organization no collagenous fibers can be seen. Accession number 3036, Army Medical Museum. Negative number 45671. Reticulum stain; $\times 250$

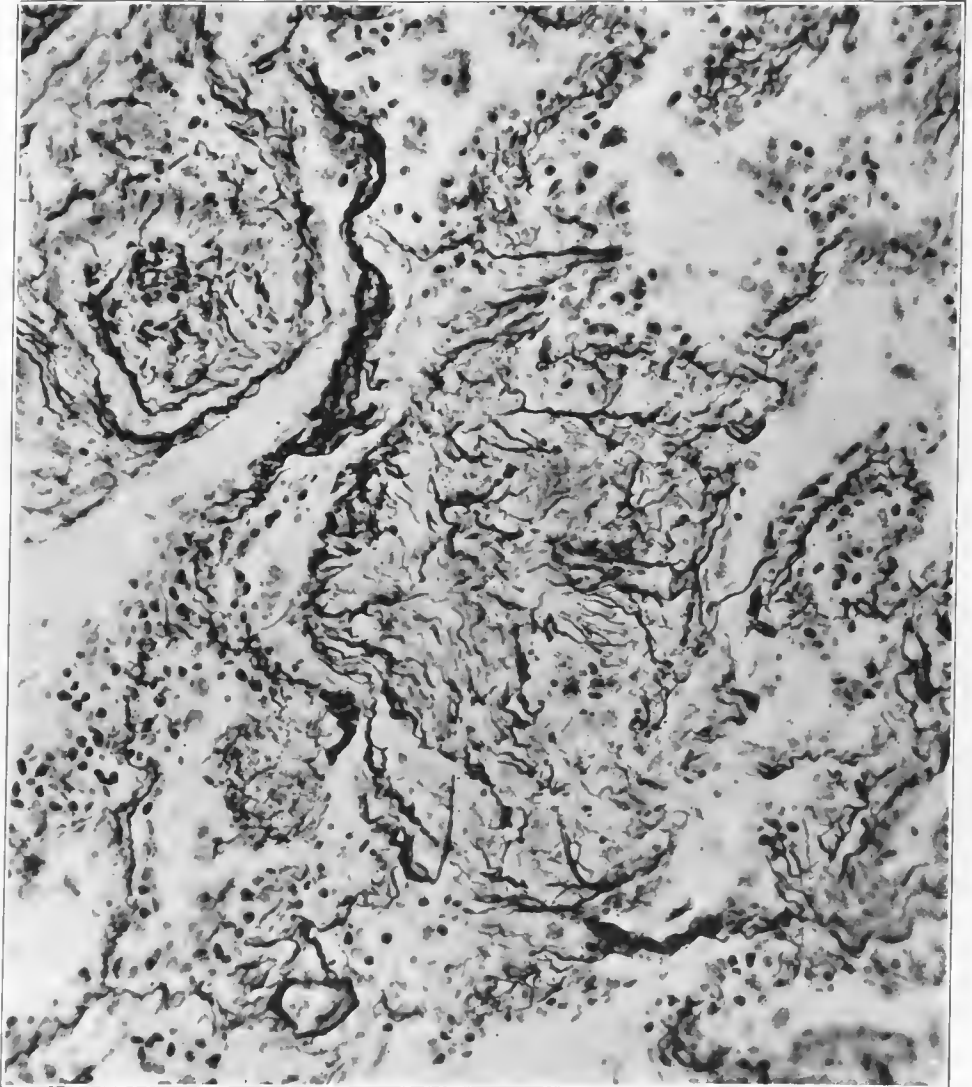
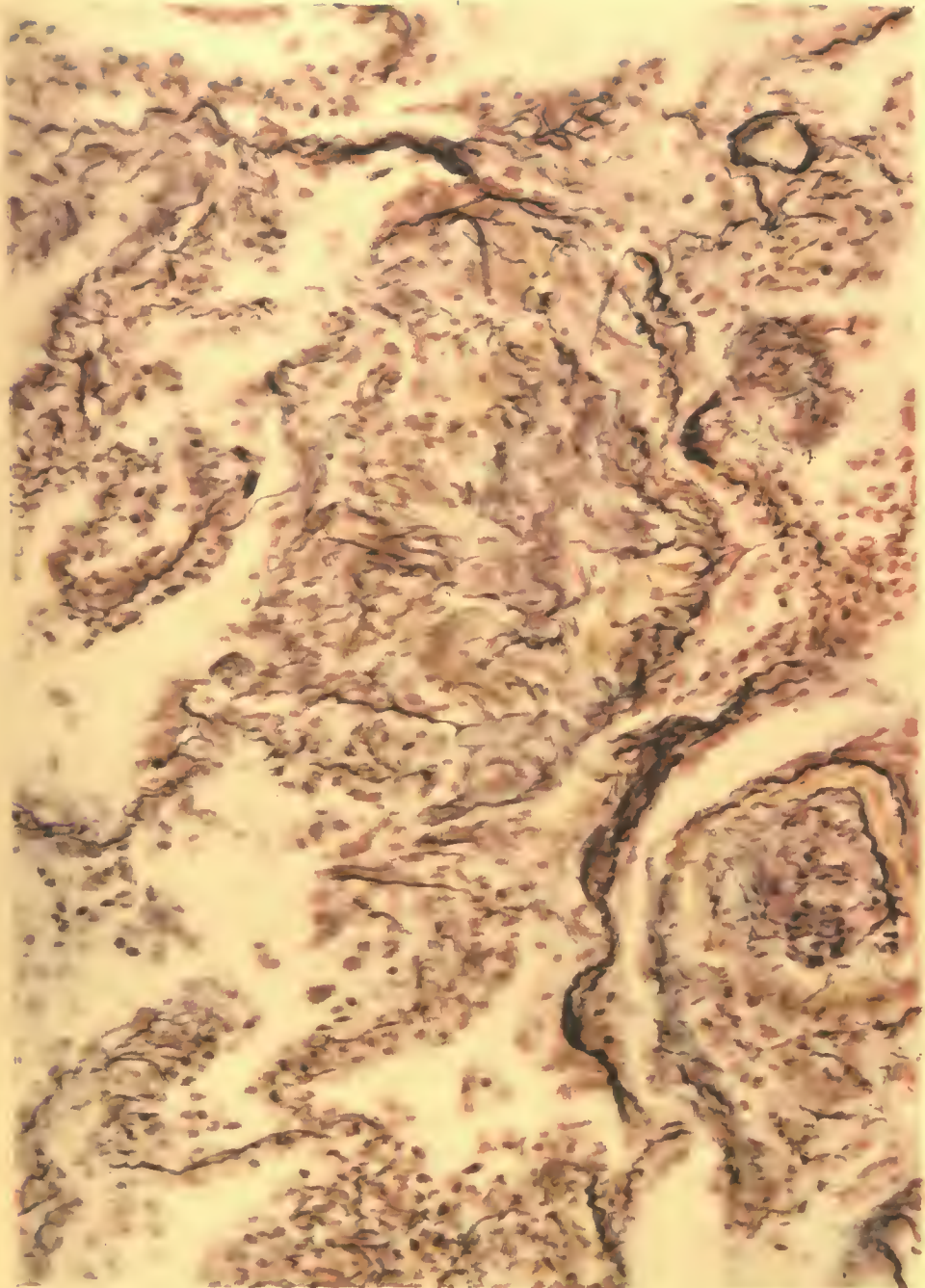


FIG. 60.—Organization in a pulmonary atrium following influenza pneumonia. Organized tissue has practically replaced the exudate. The reticulum fibers are stained black, collagenous fibers lavender. Accession number 1390, Army Medical Museum. Negative number 45552. Reticulum stain; $\times 250$



A. HOEN & CO.

POST INFLUENZAL ORGANIZATION.

Accession 1390, Army Medical Museum. Reticulum stain. Autochrome.

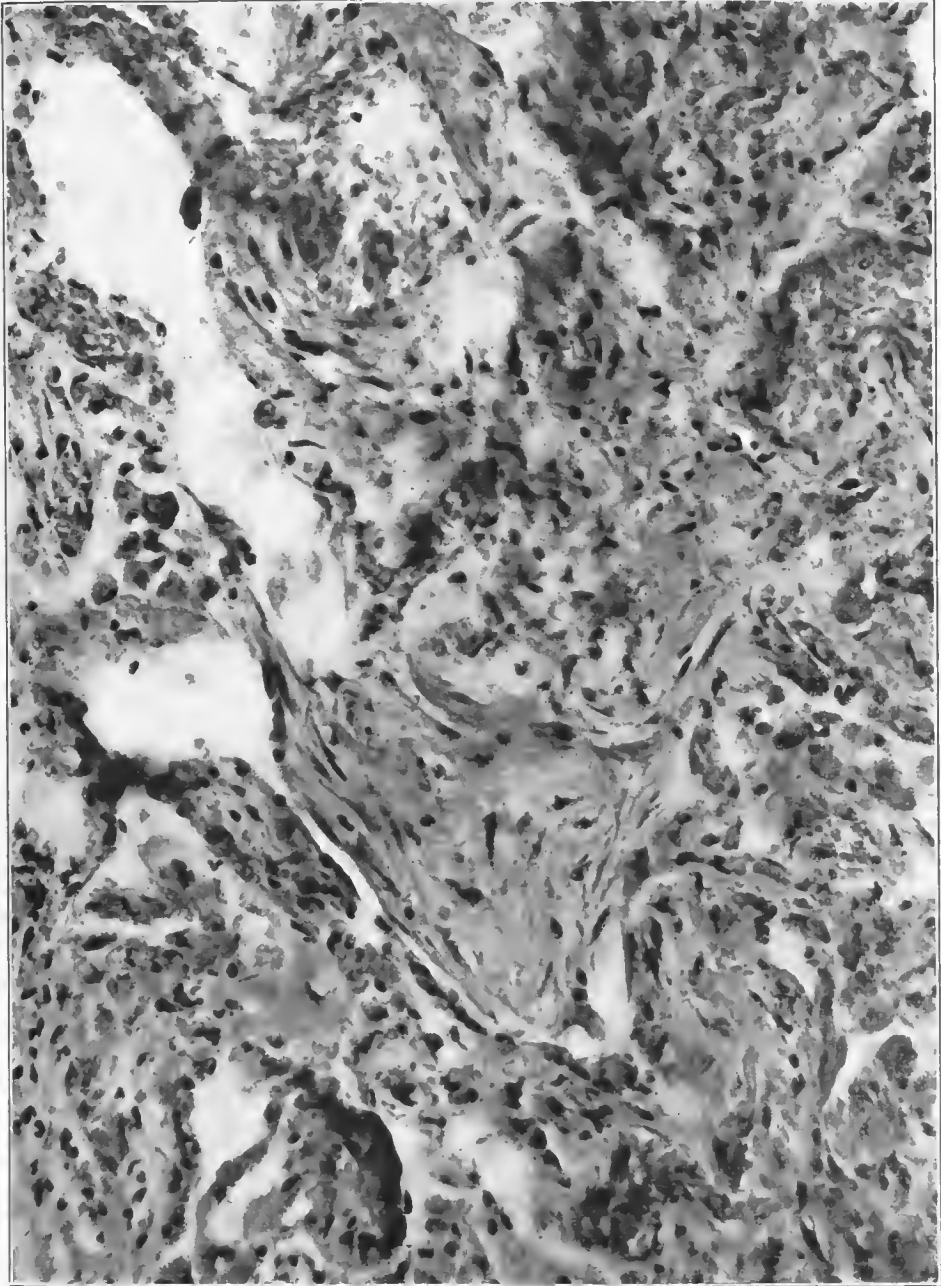


FIG. 61.—Organization complete in an alveolus, with fibers extending to a mass of cells in the atrium into which the alveolus opens. The cells are mononuclear, some of which have phagocytosed pigment. This type of organizing tissue shows few reticulum fibers and much collagen. Accession number 22073A, Army Medical Museum. Negative number 45439. Hematoxylin and eosin stain; $\times 340$

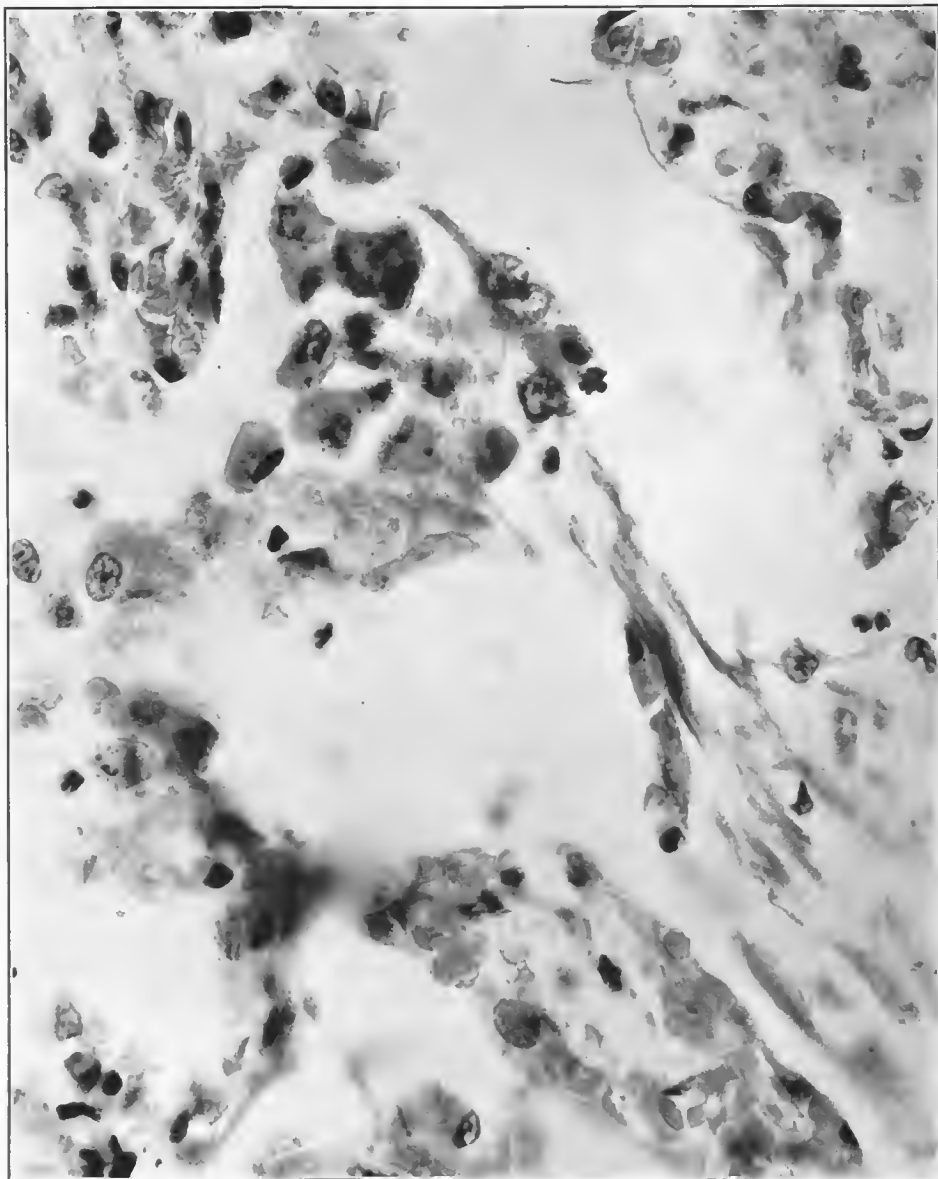


FIG. 62.—Higher power photograph of a portion of the field shown in Fig. 61, collagenous fibers extending to the group of mononuclear cells. Accession number 22073B, Army Medical Museum. Negative number 45437. Hematoxylin and eosin stain; $\times 920$

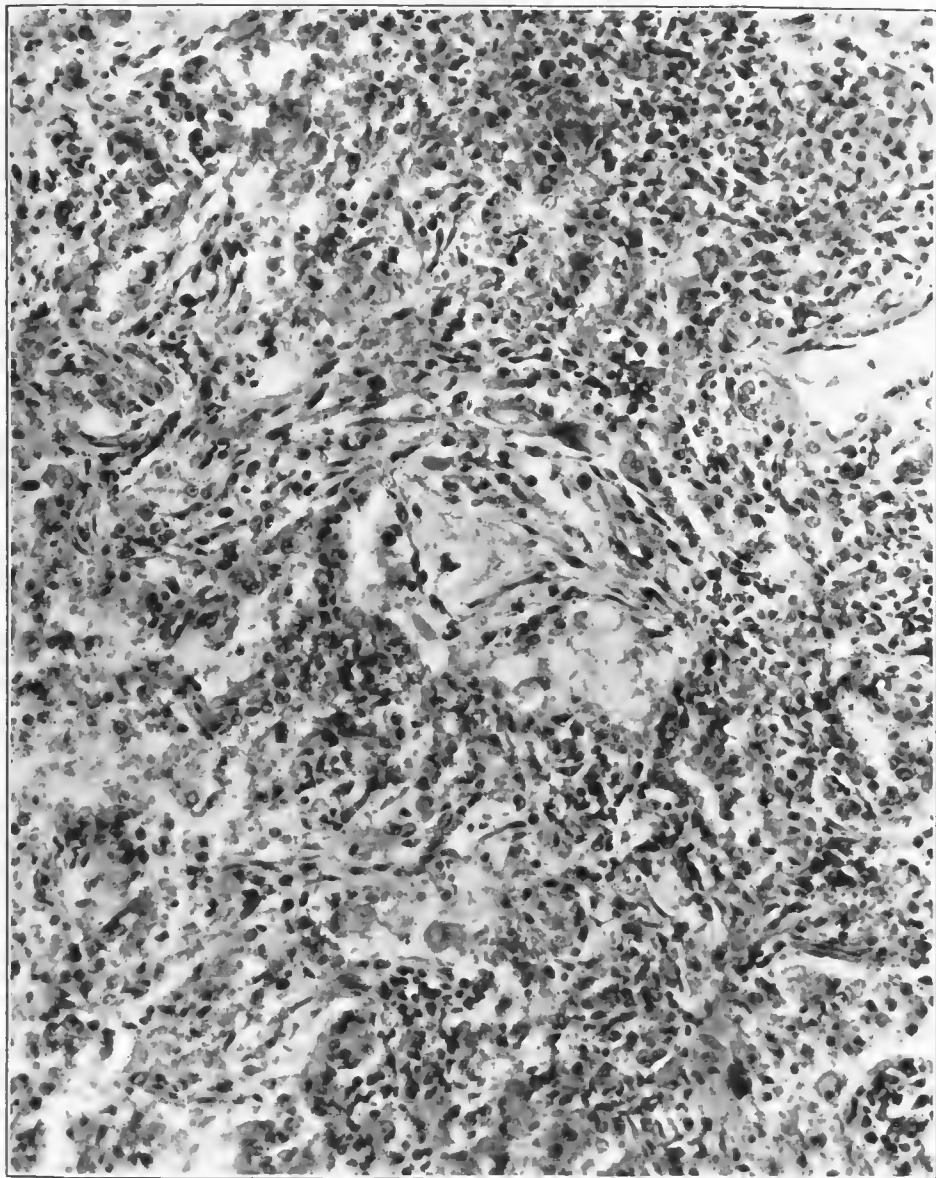


FIG. 63.—Practically complete organization of a group of alveoli, with the atrium in the center showing some vacant areas. The illustration shows the incomplete character of the organizing process. Inflammatory reaction is still present, as is indicated by the leucocytic infiltration. Accession number 1390, Army Medical Museum. Negative number 45307. Hematoxylin and eosin stain; $\times 250$

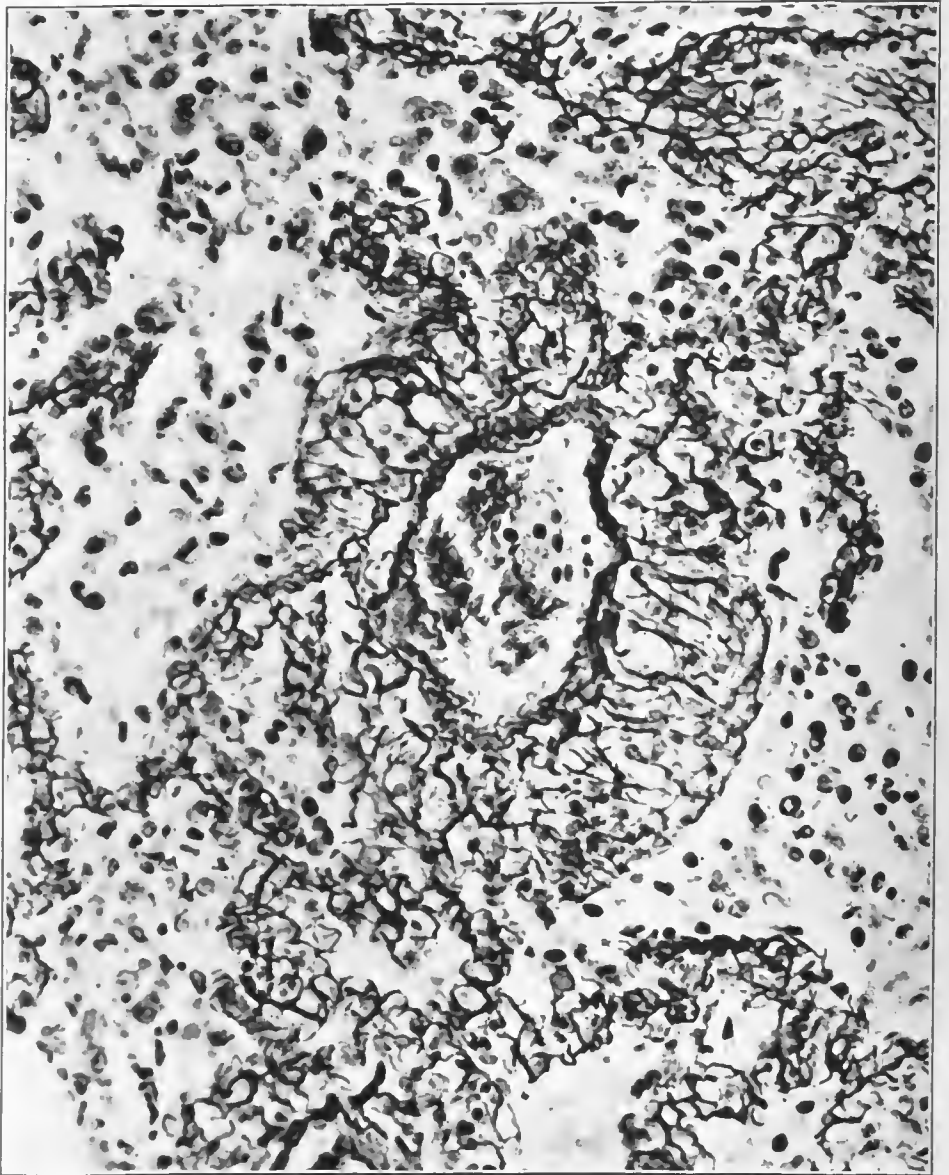

FIG. 64.—Newly formed capillaries about a small blood vessel in the wall of a respiratory atrium, with increase in the number of blood vessels in the alveolar and atrial walls in the vicinity. Accession number 3036, Army Medical Museum. Negative number 45674. Reticulum stain; $\times 335$

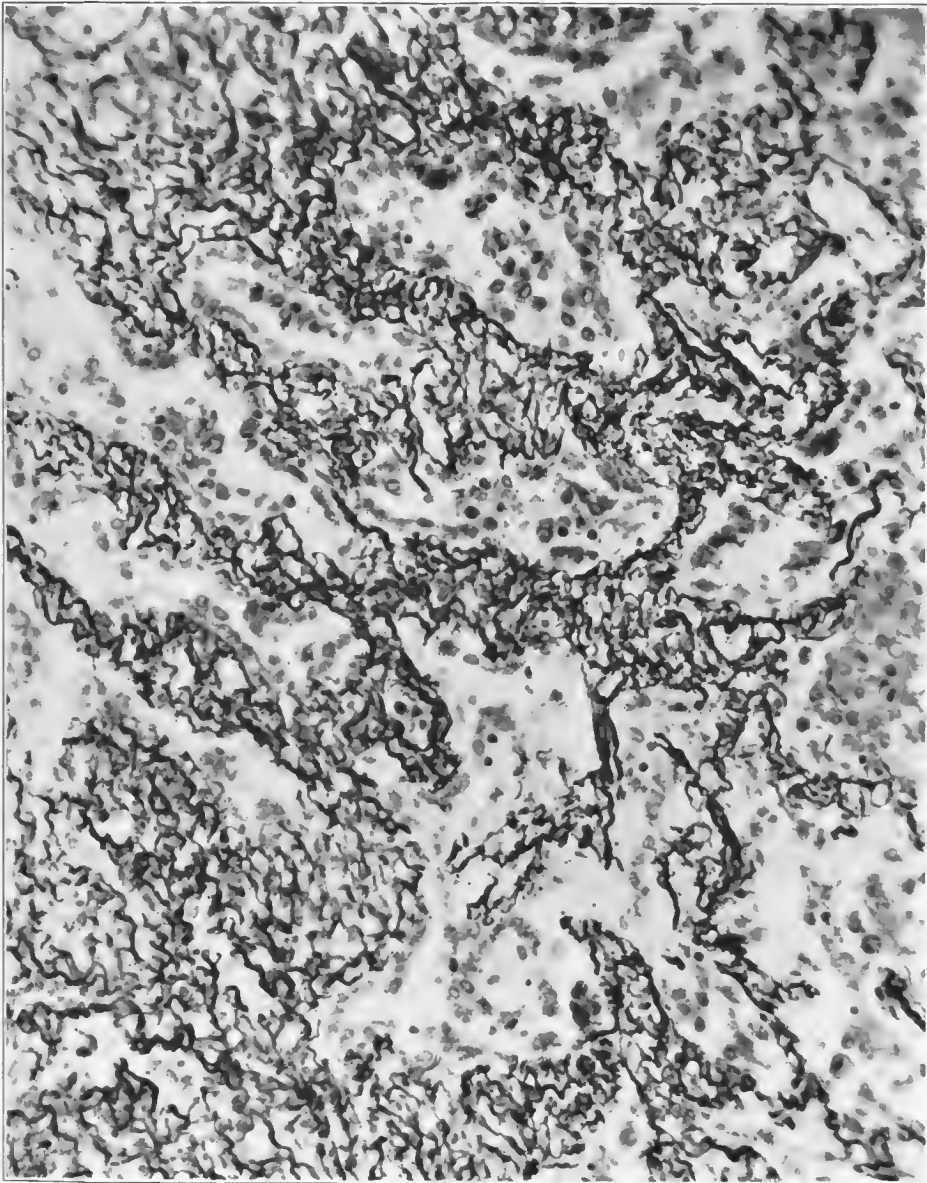


FIG. 65.—Increase in the number of capillaries in alveolar walls in the late stage of an interstitial inflammation of these structures. Accession number 3042, Army Medical Museum. Negative number 45564. Reticulum stain; $\times 255$

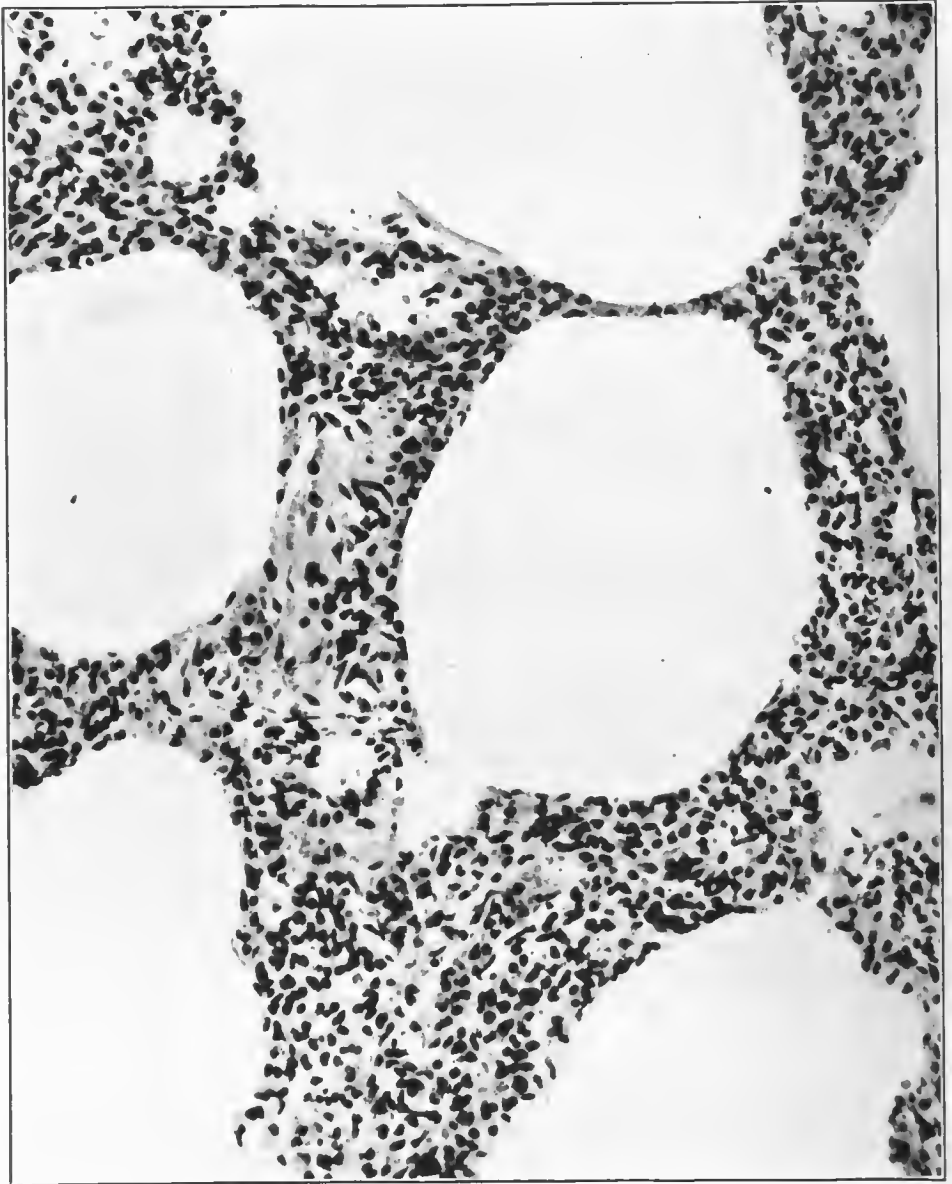


FIG. 66.—Alveolar walls, showing new formation of connective tissue infiltrated with leucocytes. Duration 50 days. Accession number 3038, Army Medical Museum. Negative number 45183. Hematoxylin and eosin stain; $\times 210$

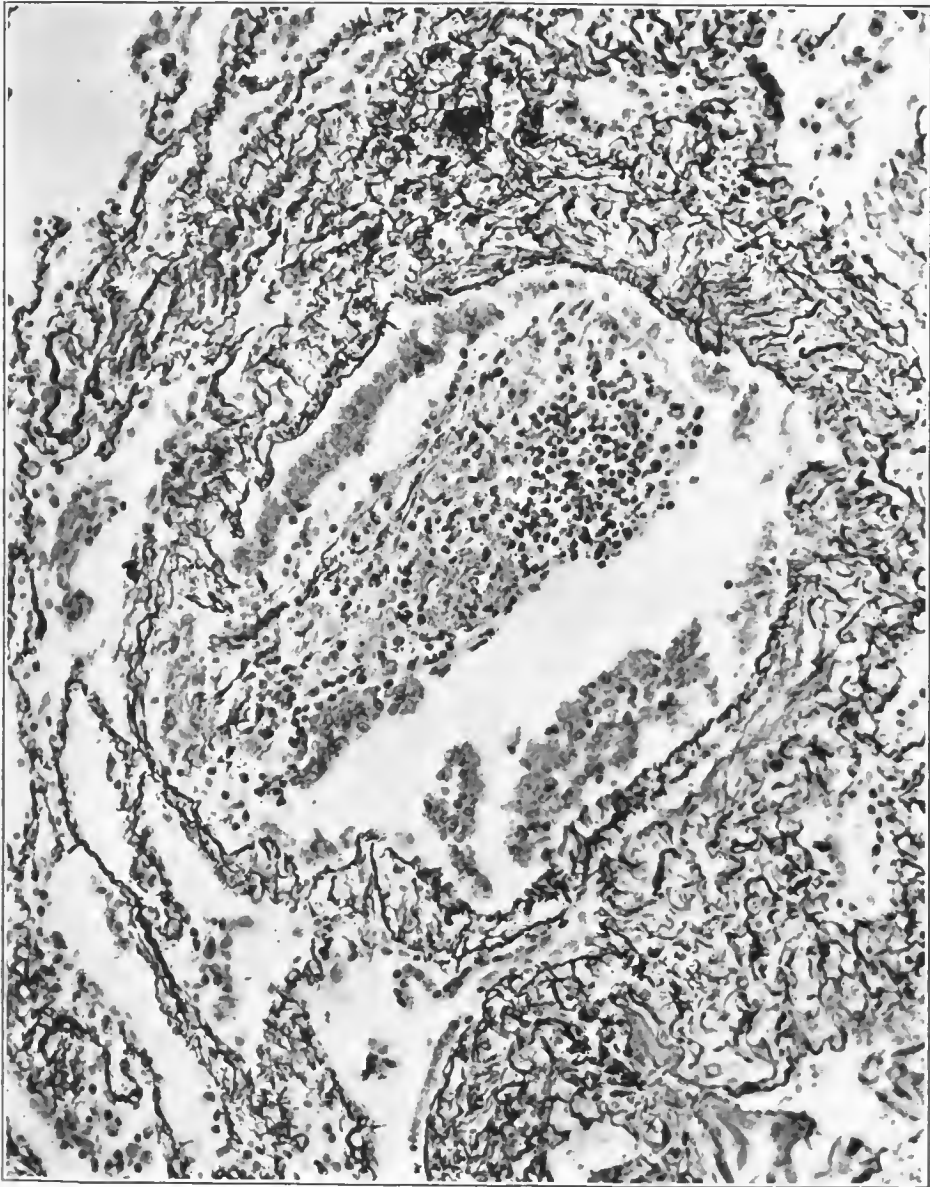


FIG. 67.—Organization extending from an ulcerated area in a bronchiole into the seropurulent exudate in the lumen. Very little fibrin was present, as shown by fibrin stain. Accession number 3042, Army Medical Museum. Negative number 45575. Reticulum stain; $\times 230$

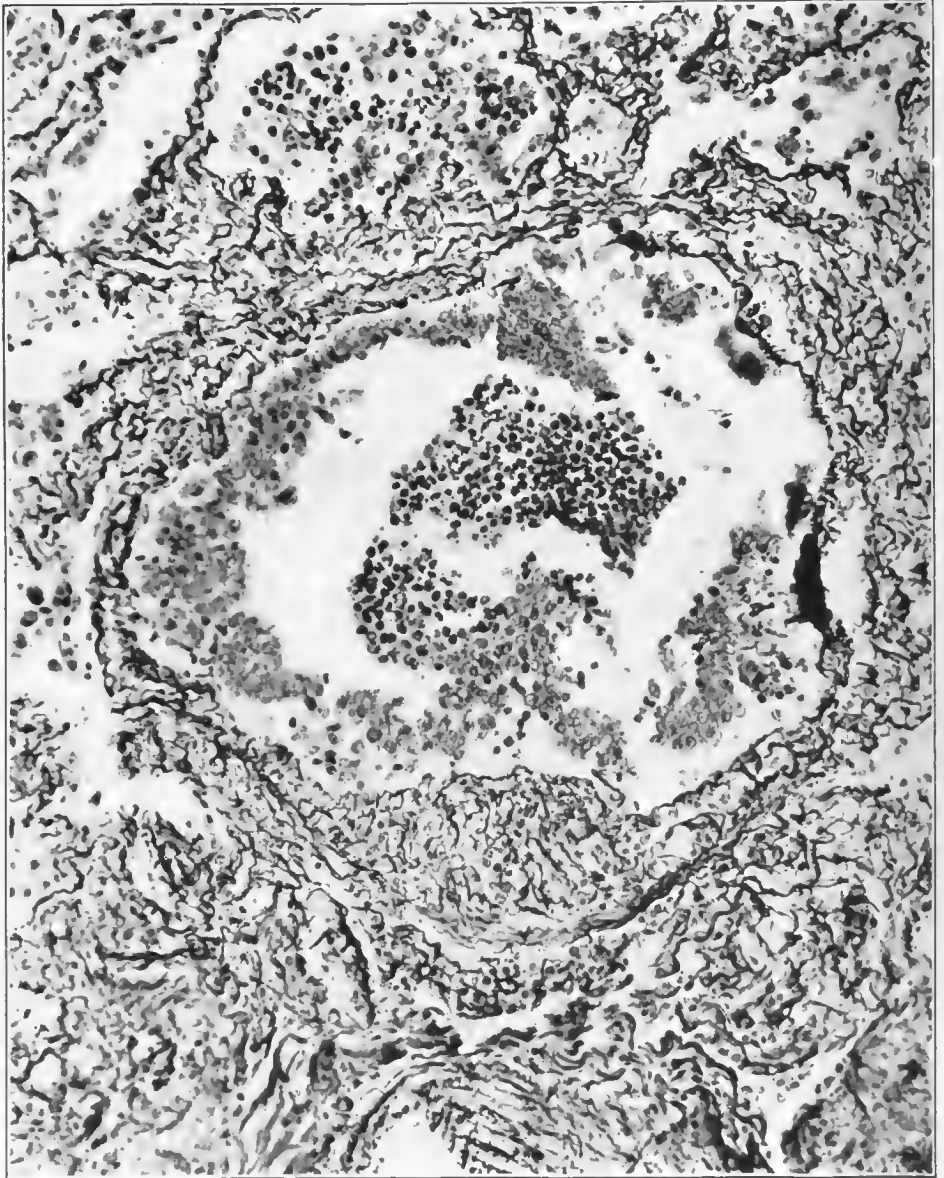


FIG. 68.—Granulation tissue in the wall of a bronchiole, projecting from an area previously ulcerated. It has been covered with a membrane made up of cells of the type of the basal layer of the mucosa. Columnar cells are not present. Accession number 3042, Army Medical Museum. Negative number 45584. Reticulum stain; $\times 230$

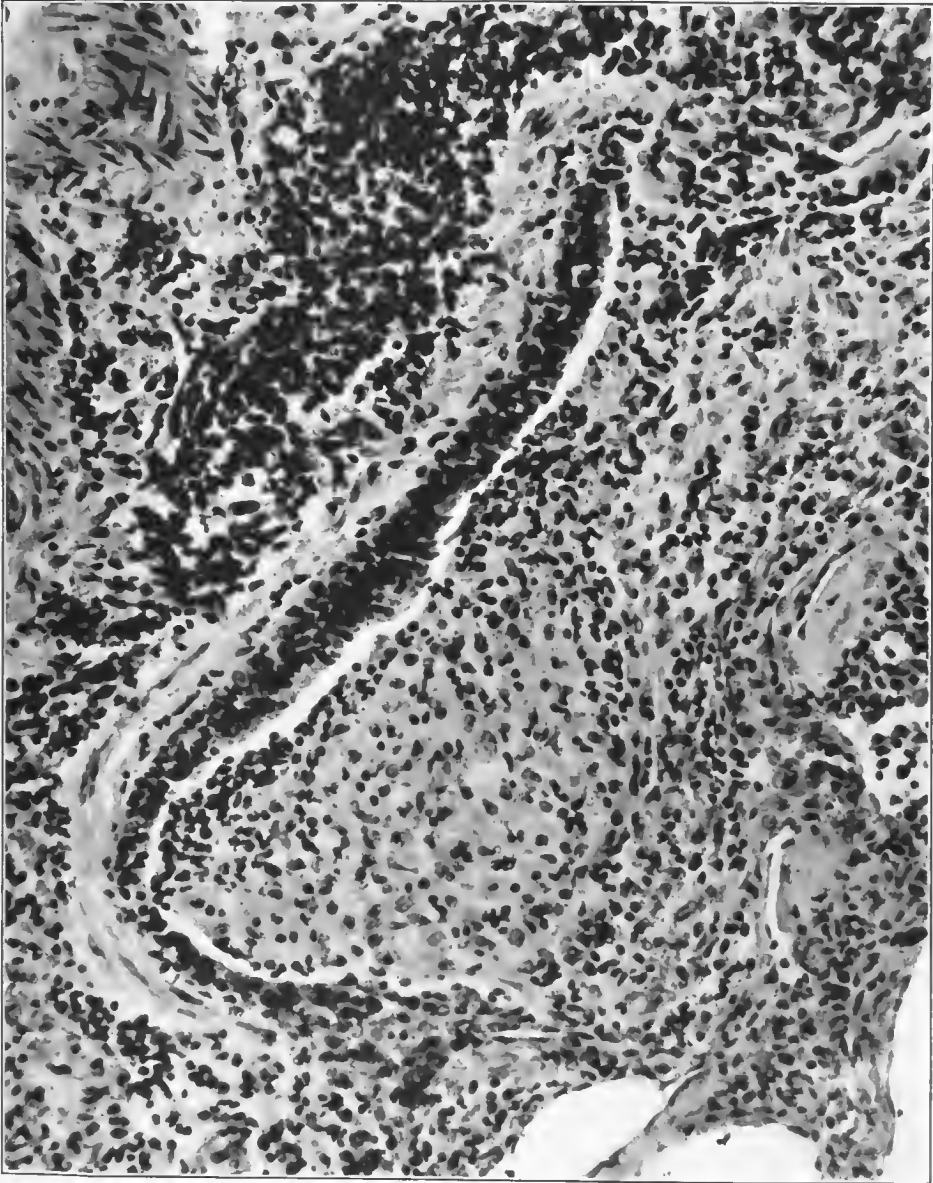


FIG. 69.—New fibrous tissue encroaching on the lumen of a bronchiole in the process of organization. The surface is still free of epithelium but a small lumen remains. Blocks of bronchioles of this character were responsible for atelectatic areas beyond the point of block, and represent the results of the organizing process arising from the ulceration of the bronchiolar mucosa or extending in from alveoli which opened into respiratory bronchioles. Accession number 3061, Army Medical Museum. Negative number 45193. Hematoxylin and eosin stain; $\times 300$

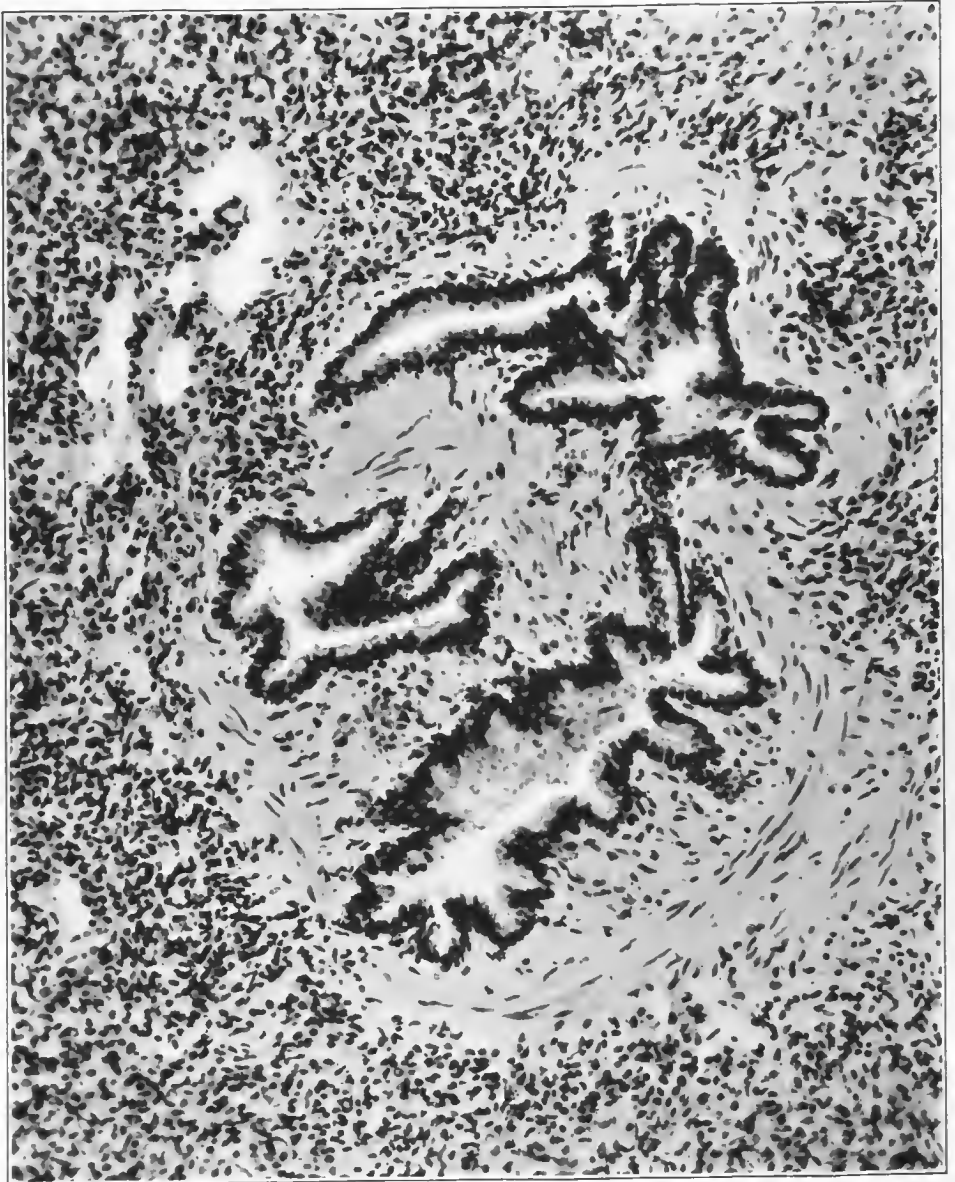

FIG. 70.—Late stage of interstitial reaction about bronchioles, showing the healing process well advanced, with overproduction of connective tissue, which, outside the immediate vicinity of the bronchi, is infiltrated with mononuclear leucocytes. The vascular submucosa is replaced with relatively avascular fibrous tissue. Accession number 3038B Army Medical Museum. Negative number 45202. Hematoxylin and eosin stain; $\times 210$

tension to the air cells adjacent to the bronchioles, plus the thickening of the bronchiolar wall, caused these lesions to stand out prominently on the cut section of the lung as hemorrhagic to yellowish-gray opaque foci with a central opening, the lumen of the bronchiole, the color depending on the stage of the process at death. Proliferation of fibroblasts occurred at an early period of the process in the walls of bronchi and bronchioles.

The edematous bronchial wall thus was infiltrated with granulation tissue which gradually became dense connective tissue in an amount far in excess of that normally found. The infiltrating cells in such forming tissue were predominantly lymphocytes, which were sometimes very numerous.

The smaller bronchioles showed considerable distention in all stages of the process and frequently fusiform, and irregular dilatations or bronchiectases occurred and were evident on the gross examination of the lung. Microscopically the dilated bronchioles usually showed complete desquamation of the columnar cells; the bundles of unstriated muscles were separated by more than the normal amount of intervening tissue which was edematous, the lymph spaces being widely dilated and the collagen fibers proportionately diminished. The hyaline layer of the basement membrane was interrupted and sometimes not visible in these dilated areas. The inflammatory reaction appeared more purulent, and the bronchial wall became infiltrated with leucocytes earlier than was the case of bronchioles not so affected. The alveoli adjacent to these bronchiectases were found in a more advanced stage of inflammatory reaction than those surrounding bronchioles whose walls were still relatively intact. Increased pressure was undoubtedly present in the terminal bronchioles due to the blocking of larger air passages by the viscid exudate of the disease plus respiratory effort. The focal character of these dilatations, however, is not readily explained. The presence of more advanced inflammatory reactions at these points may be either the cause or the result of the dilatation and injury of the tube. It is probable that the patchy distribution of the bronchiolar ulceration accounts for the focal character of the lesions. Proliferation of capillaries appeared to be unusually marked about bronchiectases and the fibrosis of the healing process was responsible for further distortion of the lumens of the bronchi and bronchioles. (Figs. 71, 72, 73, and 74.)

SECONDARY BRONCHOPNEUMONIA

In few cases which died of pneumonia during the influenza epidemic and in relatively few deaths during the World War were the lesions in the lungs found to be of only one type. Pneumonic consolidation spreading out about bronchi was present in some part of the lungs in a large proportion of the fatal cases of acute respiratory disease. This lesion was associated with or produced by many different organisms; in fact, practically every organism isolated from the lungs was believed to have caused this reaction. Histologically, there were two forms of the condition both of which, however, were found associated in many lungs; these are described under the definitions.

Spreading bronchopneumonia, in so far as can be determined from the material reviewed, was a secondary type of pneumonia. In every instance where adequate histories were obtained there was abundant evidence of a preceding

disease most often definitely diagnosed either measles or influenza. The organism found in the tissues of such cases by examining microscopical slides was morphologically most frequently a pneumococcus. From the cultural standpoint pneumococcus Group IV was the most frequent organism, pneumococcus Type II atypical, streptococci of the nonhemolytic varieties, the hemolytic streptococcus and the type pneumococci, pneumococcus Type III being distinctly more frequent than Types I and II, were recorded as present in this type of lesion.

With the exception of the lesions in which streptococci were found, the sequence of events appeared to be first, a preliminary infection, most often bronchitis, as described under the fulminant cases in which the exudate in the bronchi became more purulent, pneumococci were found in addition to Gram-negative bacilli, the wall of the bronchus was infiltrated with leucocytes, the peribronchial area frequently contained fibrin in addition to serum, while strands of fibrin were often present in the purulent exudate in the lumen of the bronchi. (Plate IX; Figs. 75, 76, 77, 78, 79, 80, 81, 82 and 83.) Inflammation extended by continuity outwards into the adjacent alveoli apparently directly across the tissues and thence by the same process involved alveoli farther separated from the bronchus. In this way smaller bronchioles were involved as well as alveoli, so that the distal portions of bronchi supplying the air sacs in the vicinity of another bronchus might be involved from without, appearing from the microscopical section to have had the process extend to them along the peribronchial tissues, the lumen and the mucosa being affected last. (Fig. 84.) This caused some confusion and resulted in the diagnosis of an interstitial type of reaction as the result of studying small microscopical sections when the actual process was an extension by continuity from purulent inflammation within another bronchus.

Macroscopically, the lungs were more voluminous than normal, collapsing to a greater or less degree, depending upon the amount of tissue involved in the consolidation. Early in the process the periphery of the lung was sometimes free of involvement; more often it presented nodular areas which projected above the surface of the rest of the lung, the latter being somewhat collapsed, as the result of opening the chest cavity. The pleural surface of such areas usually was covered with a fibrinous exudate, which later in the process extended to the rest of the pleura and still later terminated in empyema, the organism present being that found in the tissue or, in lesions due to other organisms than the hemolytic streptococcus, that organism was usually found as well. Streptococcus also appeared alone in such cases, having reached the pleura and involved it possibly before the consolidation caused by other organisms had reached the periphery.

On section, the parts of lung affected by this process varied in their consistency. If caused by the pneumococcus they were usually firmer than normal, and sometimes distinctly dry, presenting reactions much like that of lobar pneumonia, though more frequently, as the result of there being less fibrin in the exudate, the consolidation was more elastic and less fragile. The more dense consolidation was near the bronchi and toward the hilus of the lung where several bronchi and their surrounding consolidations made one pneumonic mass.

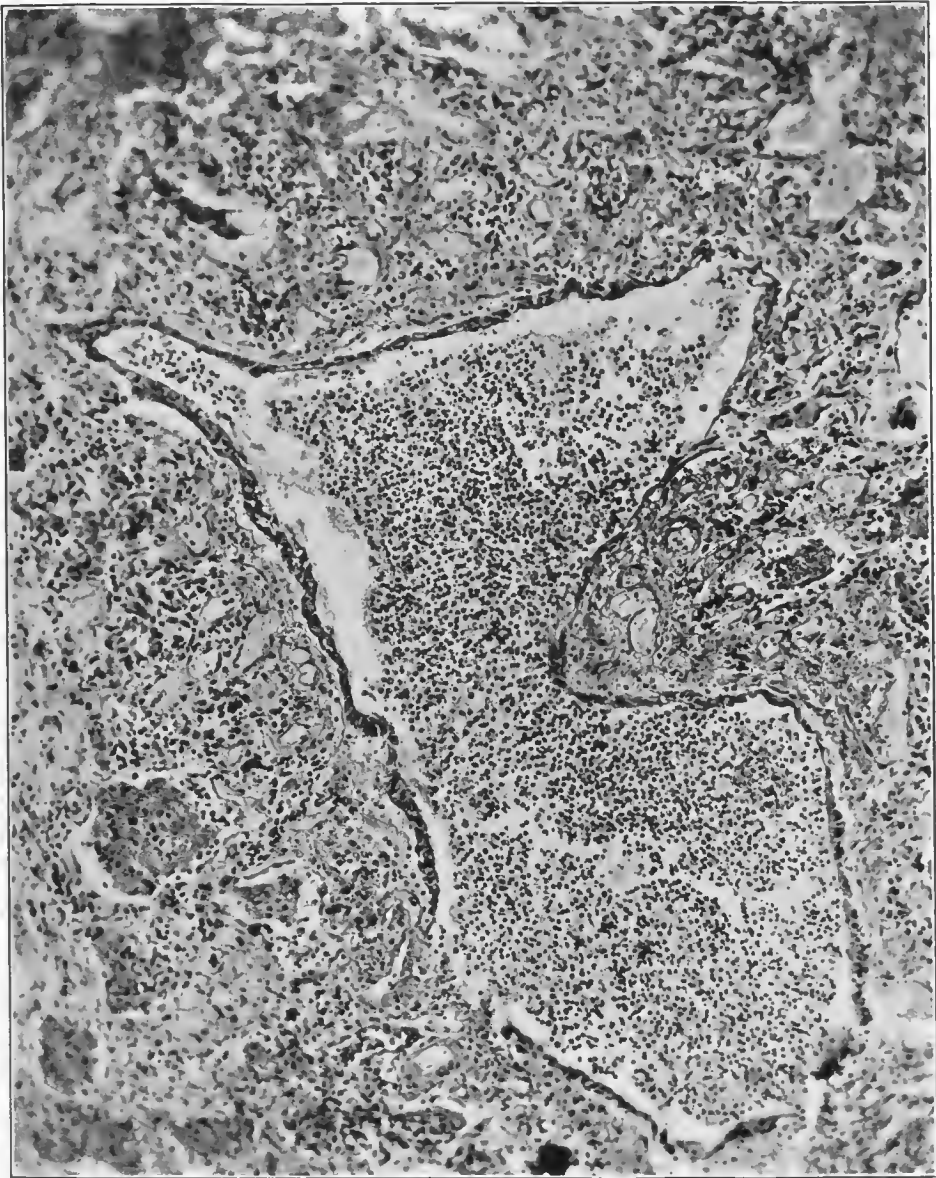


FIG. 71.—Purulent bronchiolitis with bronchiectasis following influenza. Columnar cells are desquamated, and there is considerable proliferation of the basal layer, forming a layer of cells of the stratified squamous type. Accession number 16571. Army Medical Museum. Negative number 45256. Hematoxylin and eosin stain; $\times 110$

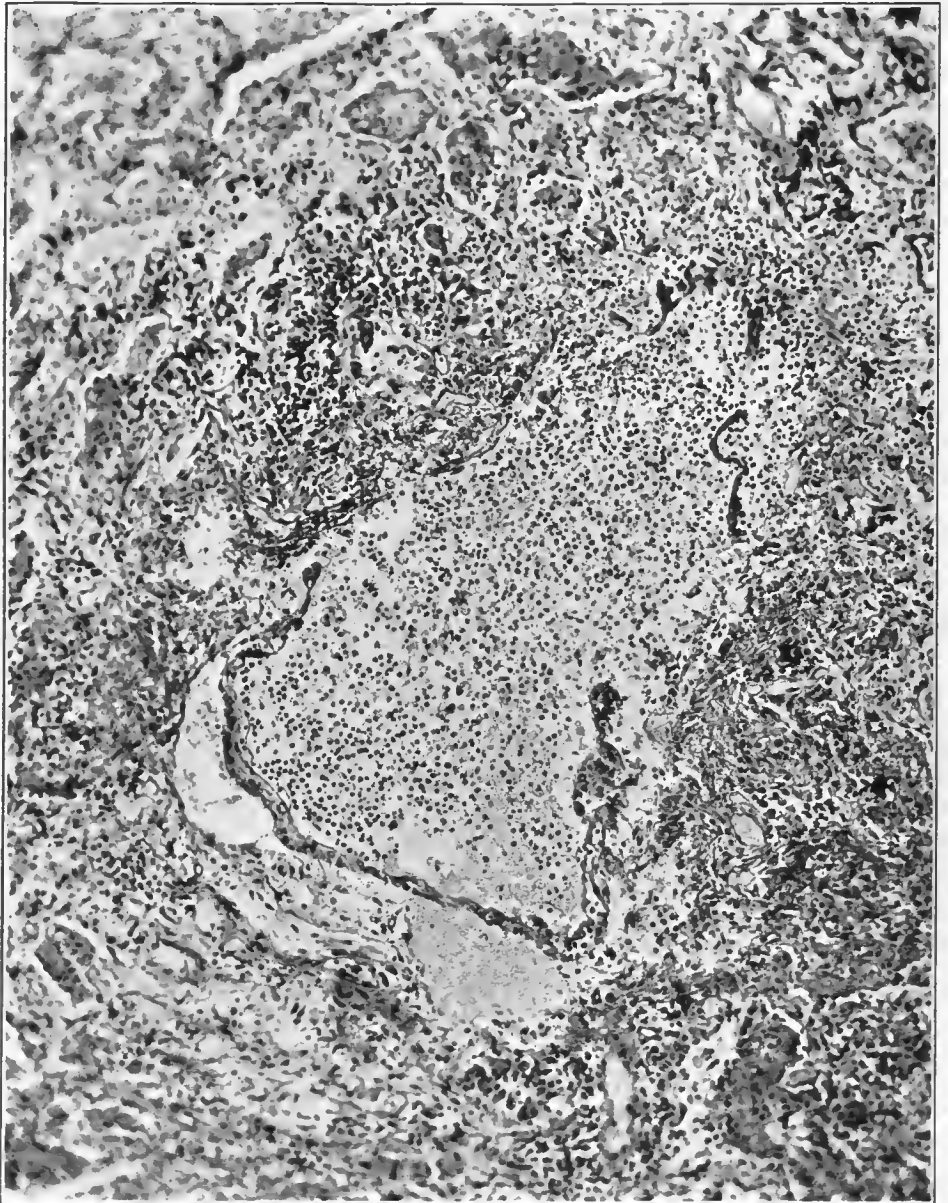

FIG. 72.—Purulent bronchitis with marked dilatation and bronchiectasis; complete desquamation of the columnar cells; proliferation and partial desquamation of the basal cells, the membrane being lifted off in part by serum and in part by hemorrhage. The fibers of the wall of the bronchiole are separated in several places and the wall is infiltrated with leucocytes. Accession number 16571, Army Medical Museum. Negative number 45259. Hematoxylin and eosin stain; $\times 110$

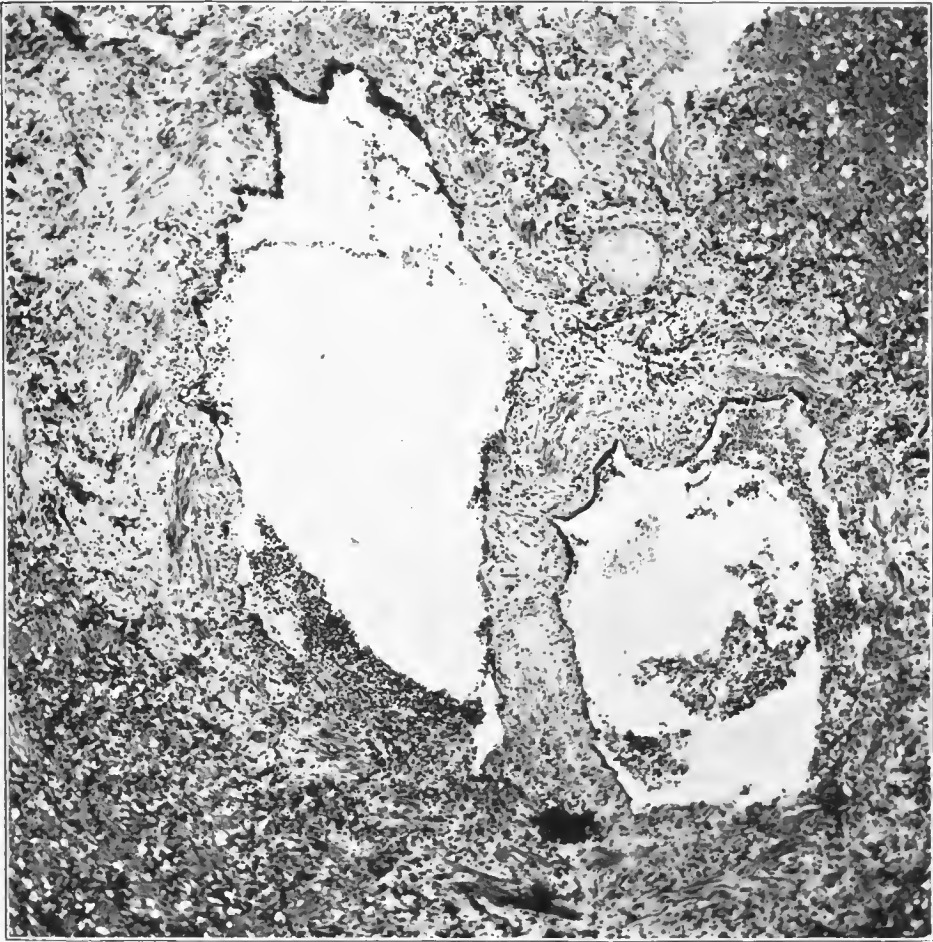


FIG. 73.—Acute, ulcerative bronchitis and bronchiectasis. Ulcerations are covered by purulent exudate, walls are edematous, and muscle fibers are separated; purulent infiltration of the walls. Accession number 2696, Army Medical Museum. Negative number 45962. Hematoxylin and eosin stain; $\times 125$

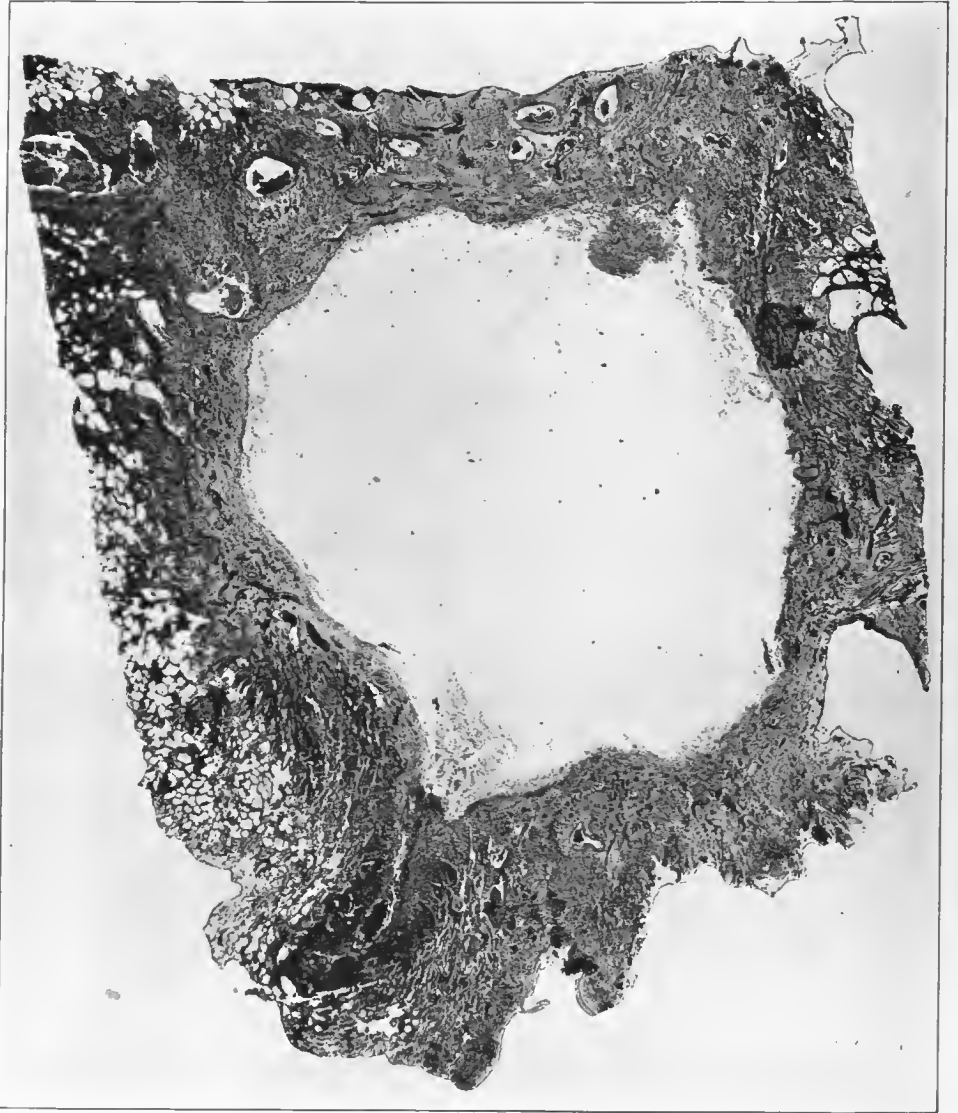
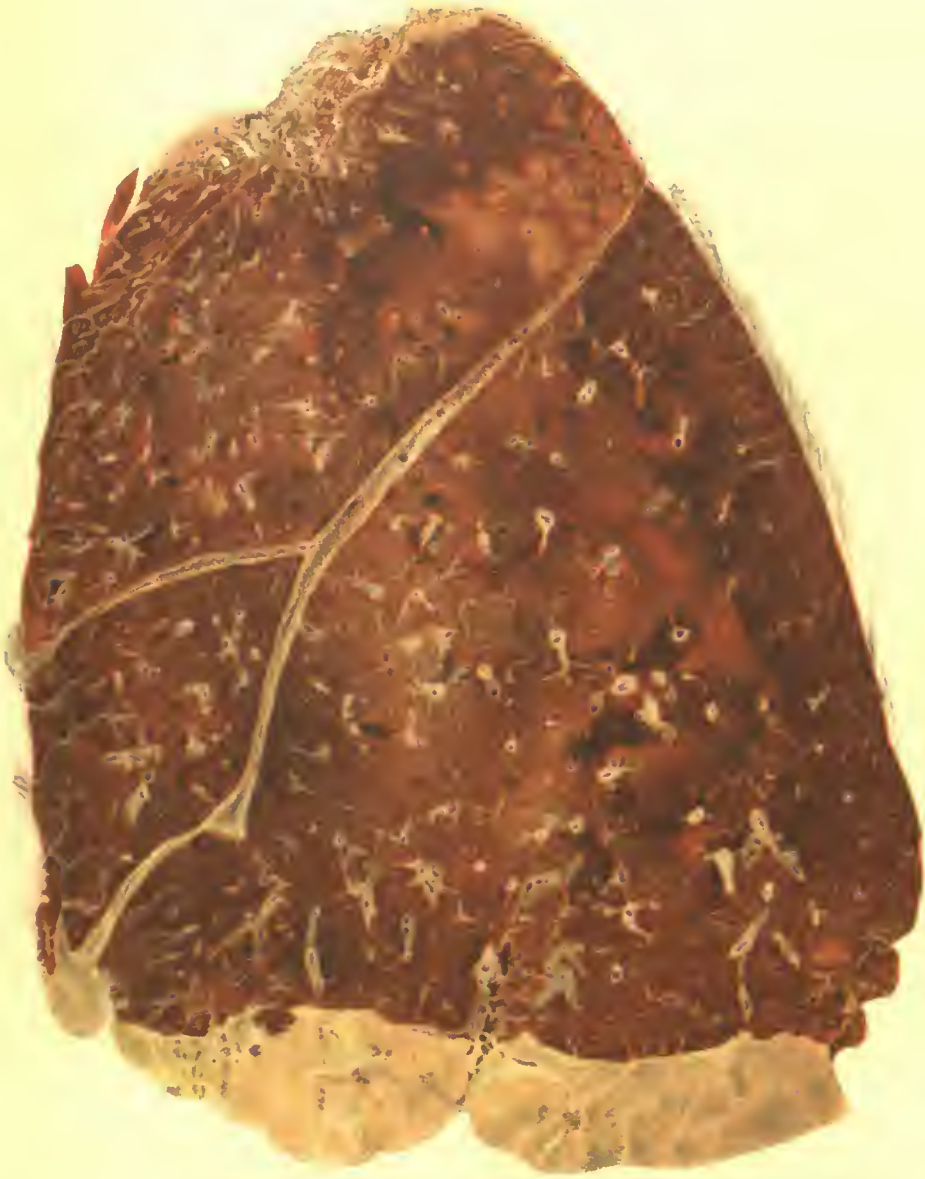

FIG. 74.—Bronchiectasis. Purulent bronchitis in a small bronchus showing practically complete destruction of the wall and dilation of the bronchus. The mucosa is replaced by granulating tissue, the site of purulent inflammation. Accession number 16398, Army Medical Museum. Negative number 45963. Hematoxylin and eosin stain; $\times 8\frac{1}{2}$



BRONCHOPNEUMONIA.

(Age 51). Spreading or confluent consolidation. Necrotic, lobular consolidation in upper lobe.
Accession 12623, Army Medical Museum. Colored photograph.

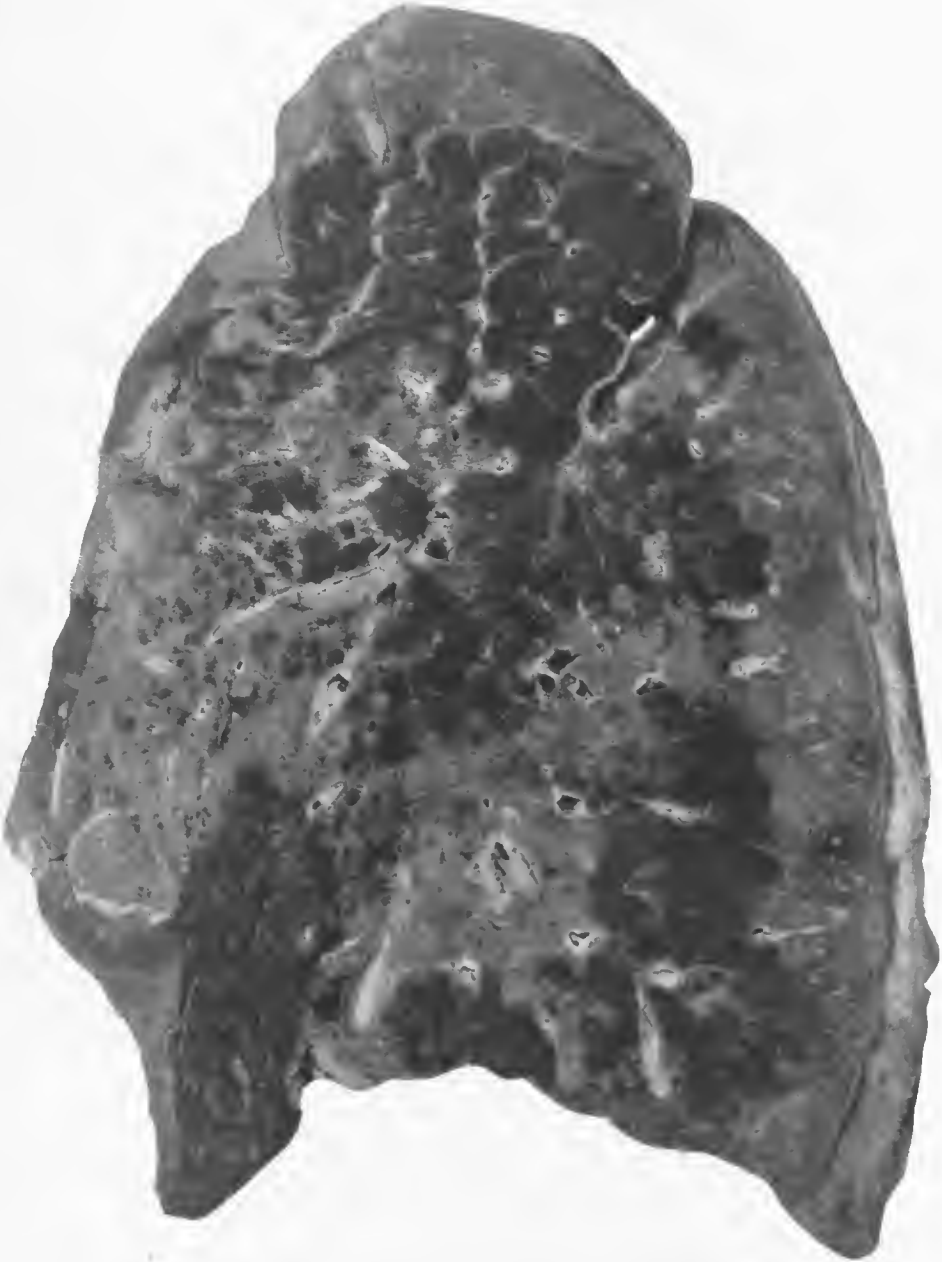

FIG. 75.—Pneumonic consolidation spreading out about the bronchi and extending to neighboring bronchi with confluent lobular consolidation about the periphery. Moderate interstitial lymphangitis. Organism isolated was designated as the streptococcus mucosus, but in the sections the organisms were morphologically pneumococci. Accession number 3058. Army Medical Museum. Negative number 42898

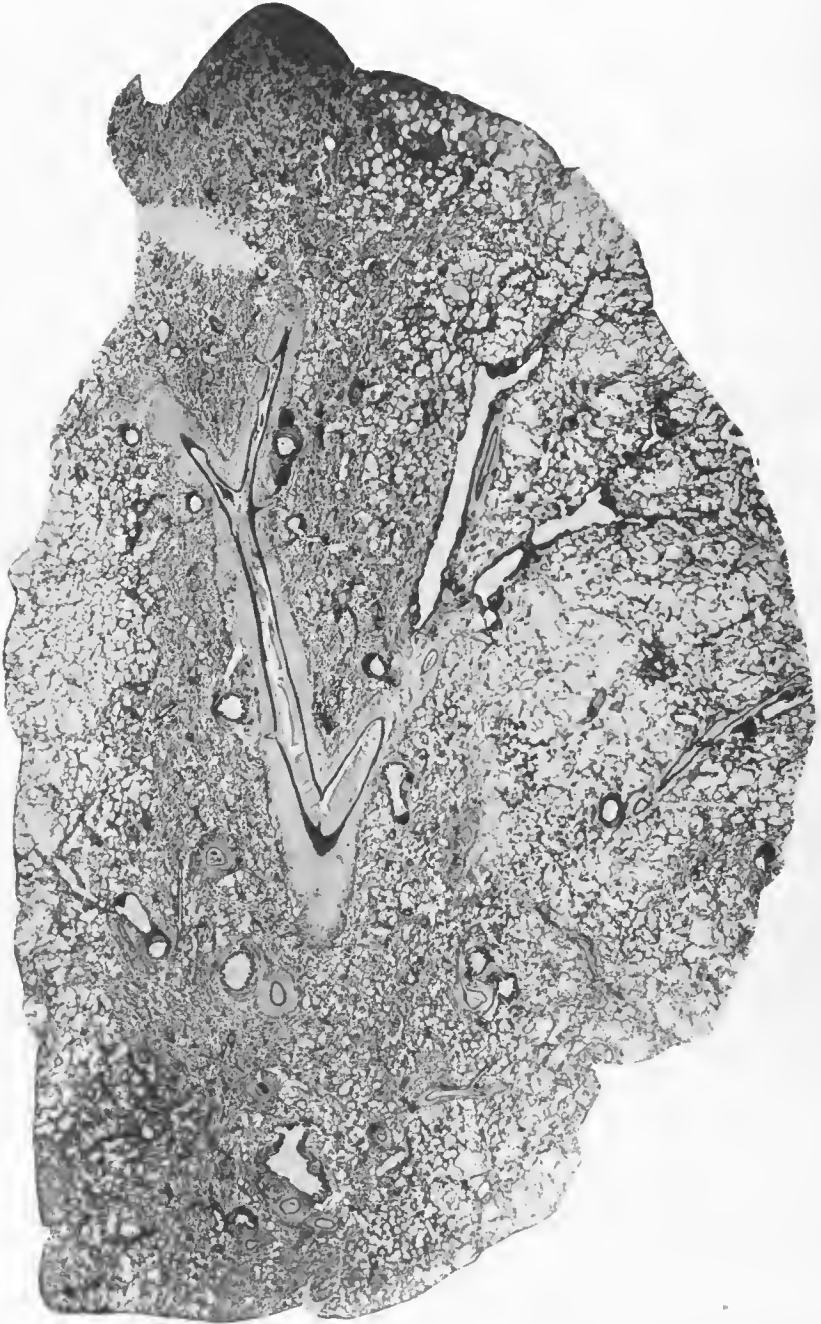

FIG. 76.—Experimental bronchopneumonia in a monkey (No. 107) caused by injection of 1 c. c. pneumococcus, Type III, into the trachea. Dense purulent infiltration about the bronchial and vascular walls, with extension into the surrounding alveoli. Extension continues to bronchi not yet involved in a purulent process in the lumen, but the walls of these structures show purulent infiltration. Accession number 2696, Army Medical Museum. Negative number 45489. Hematoxylin and eosin stain; $\times 5$

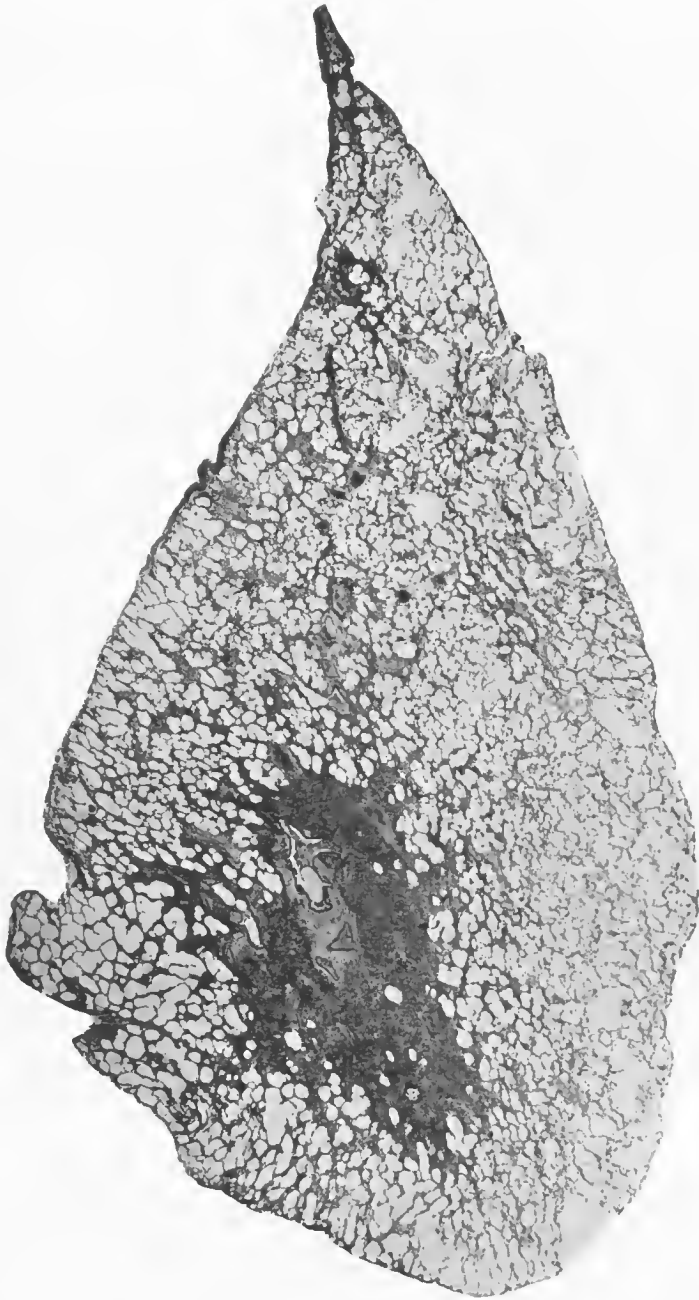


FIG. 77.—Experimental bronchopneumonia in a monkey (No. 112) following injection of 0.01 c. c. pneumococcus, Type I, into the trachea. Bronchopneumonia spreading out from a purulent bronchitis into the alveoli and involving neighboring bronchi. Army Medical Museum, negative number 45493. Hematoxylin and eosin stain; $\times 5$

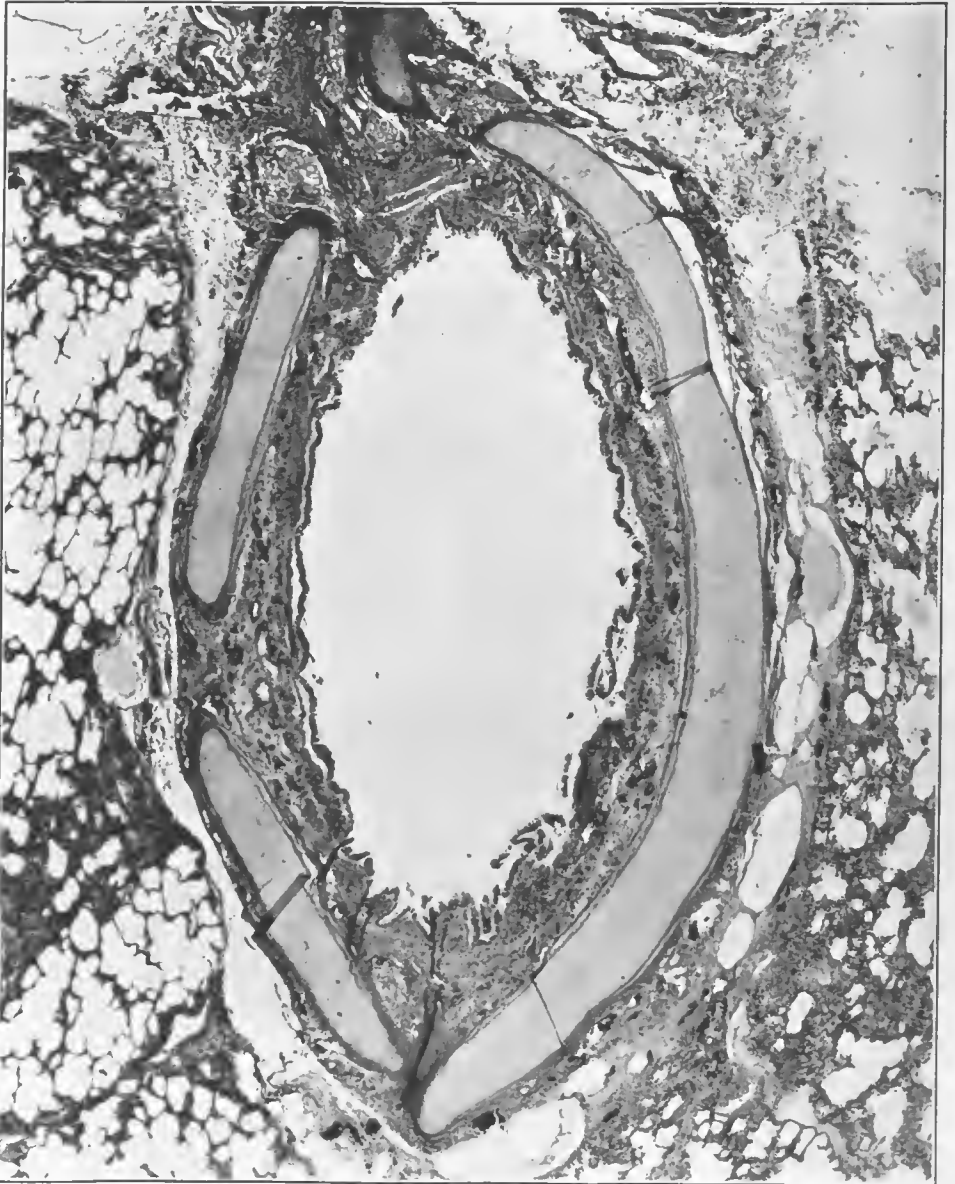


FIG. 78.—Acute bronchitis with desquamation of the epithelium of a bronchus recently involved in an inflammation by the extension of a pneumonic process from which pneumococcus, Type III, was isolated. Accession number 1521, Army Medical Museum. Negative number 45192. Hematoxylin and eosin stain; $\times 21$

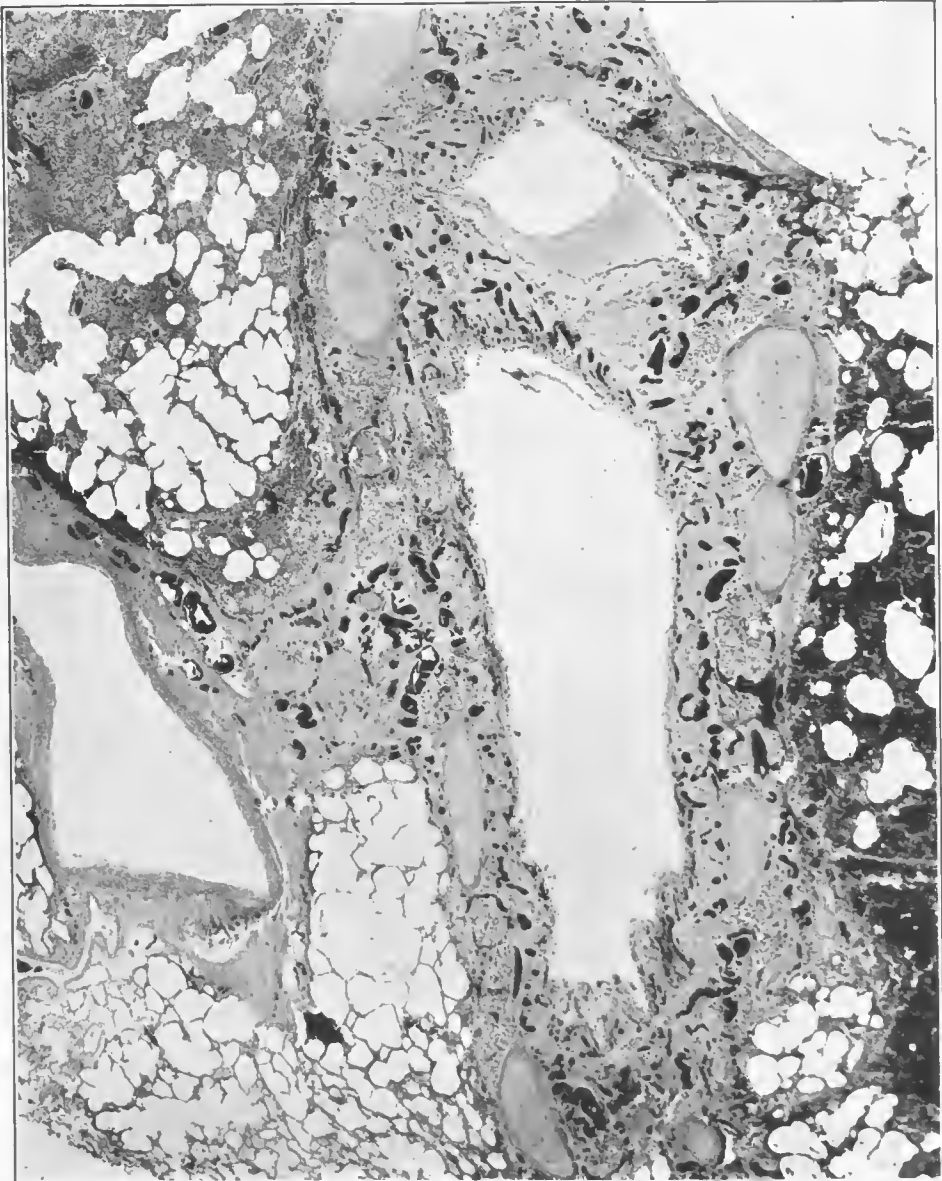


FIG. 79.—Bronchus showing an acute inflammatory reaction with practically complete desquamation of the epithelium. The inflammatory process is extending out of the bronchus between the cartilaginous rings. Oblique section. Accession number 1049, Army Medical Museum. Negative number 45207. Hematoxylin and eosin stain; $\times 25$

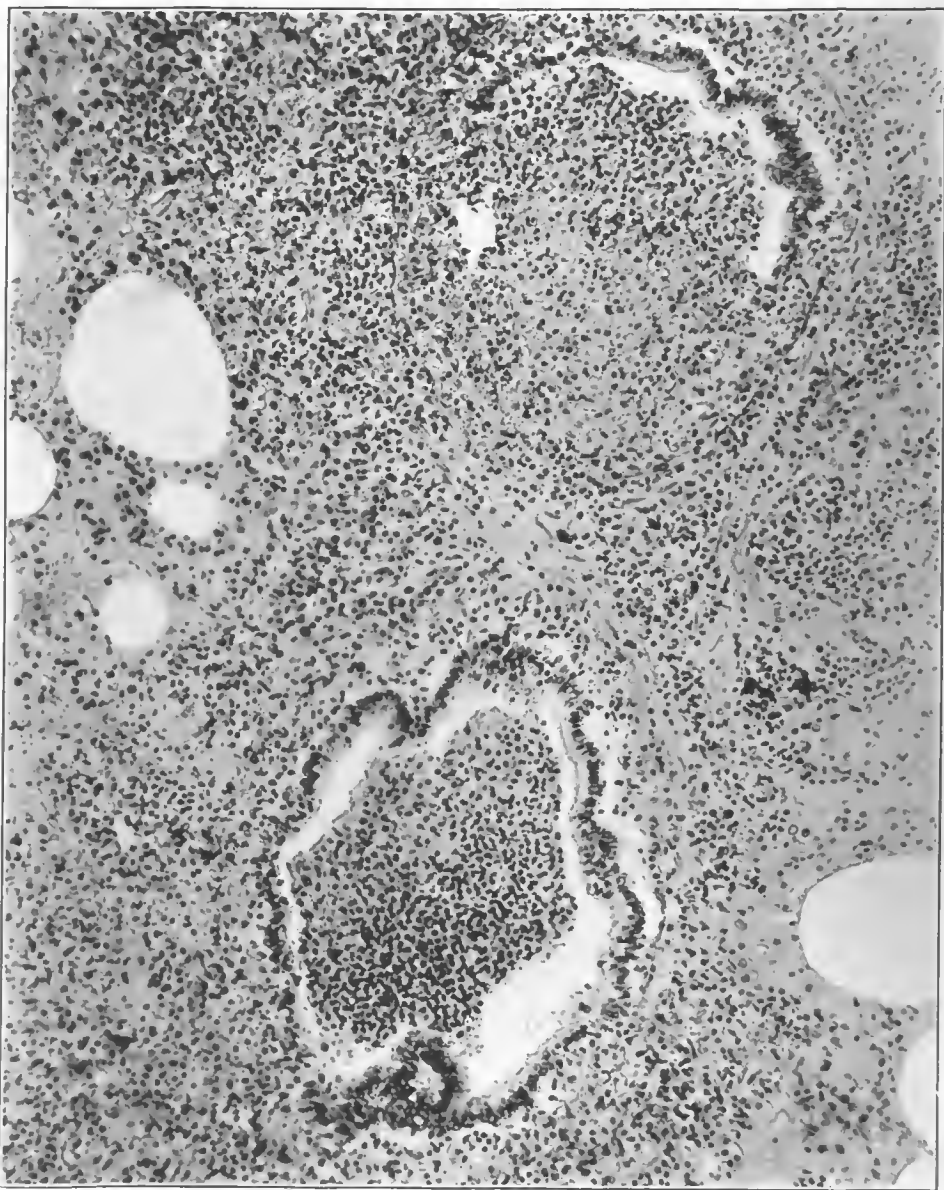


FIG. 80.—Purulent bronchiolitis with ulceration. Inflammation extending outward into the surrounding tissue. Accession number 2694, Army Medical Museum. Negative number 46027. Hematoxylin and eosin stain; $\times 155$

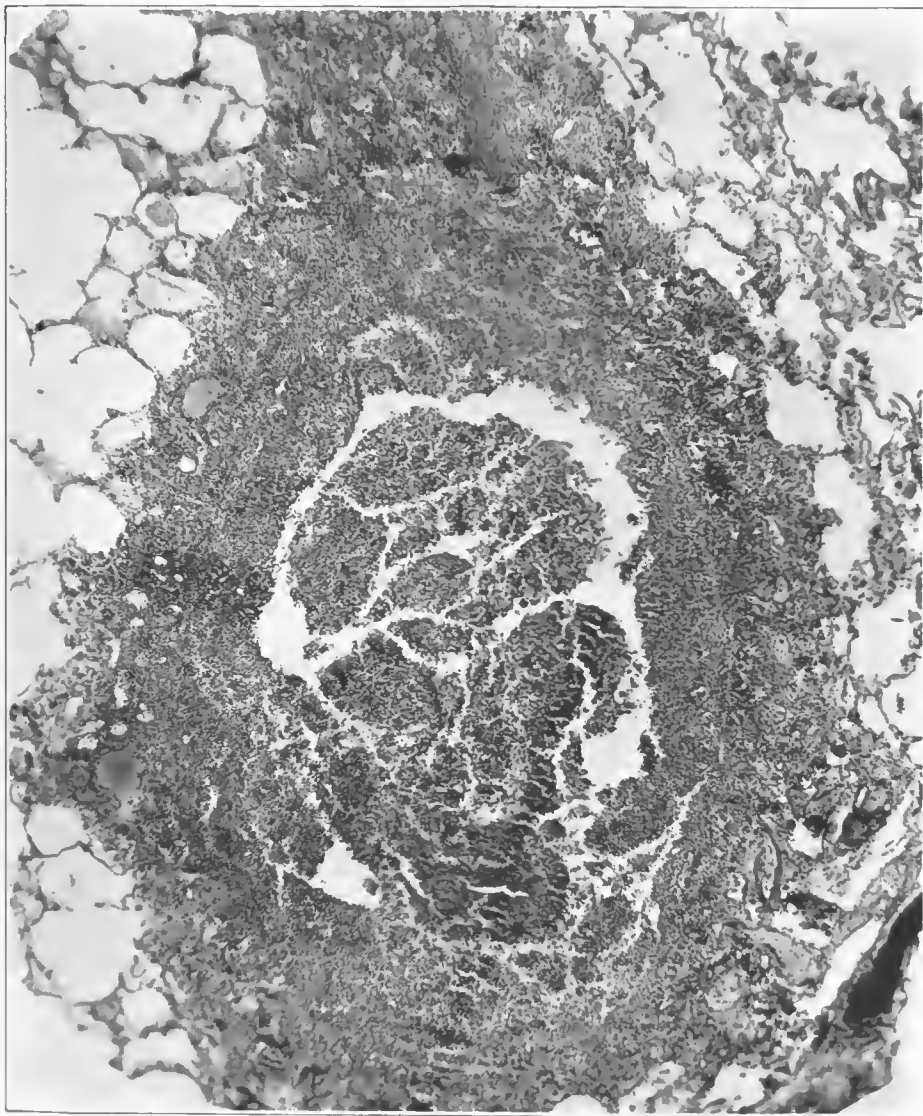


FIG. 81.—Purulent bronchitis. Phlegmonous infiltration of wall with extension into surrounding alveoli. Accession number 16648, Army Medical Museum. Negative Number 45222. Heinoxylin and eosin stain; X 53
42706—29—20

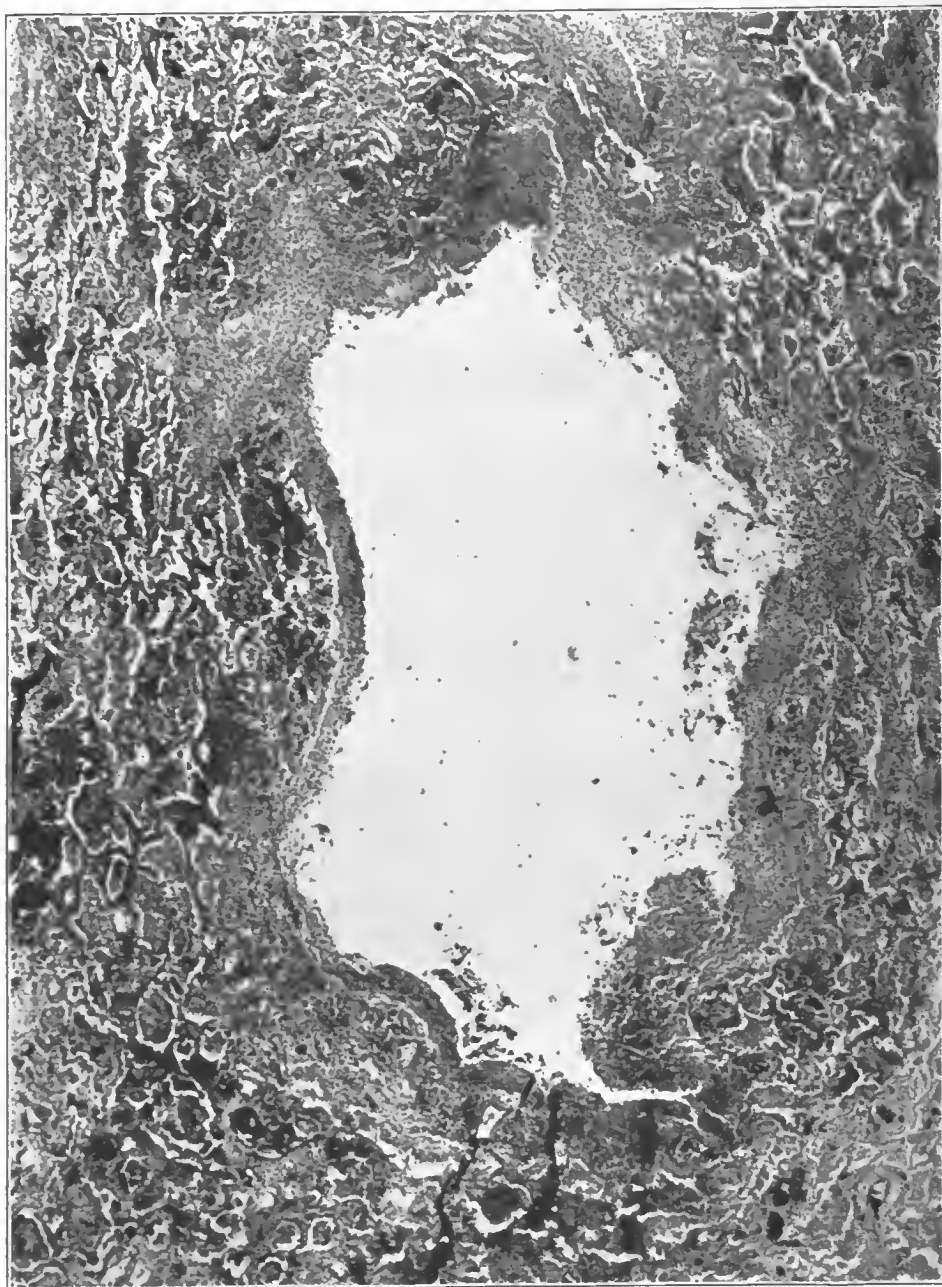


FIG. 82.—Purulent bronchitis and bronchiectasis in a small bronchus, showing practically complete destruction of the wall and dilatation of the bronchus. The mucosa is replaced by a granulating tissue, and the inflammation has extended outward into the surrounding tissue. Accession number 16618, Army Medical Museum. Negative number 45223. Hematoxylin and eosin stain; $\times 34$

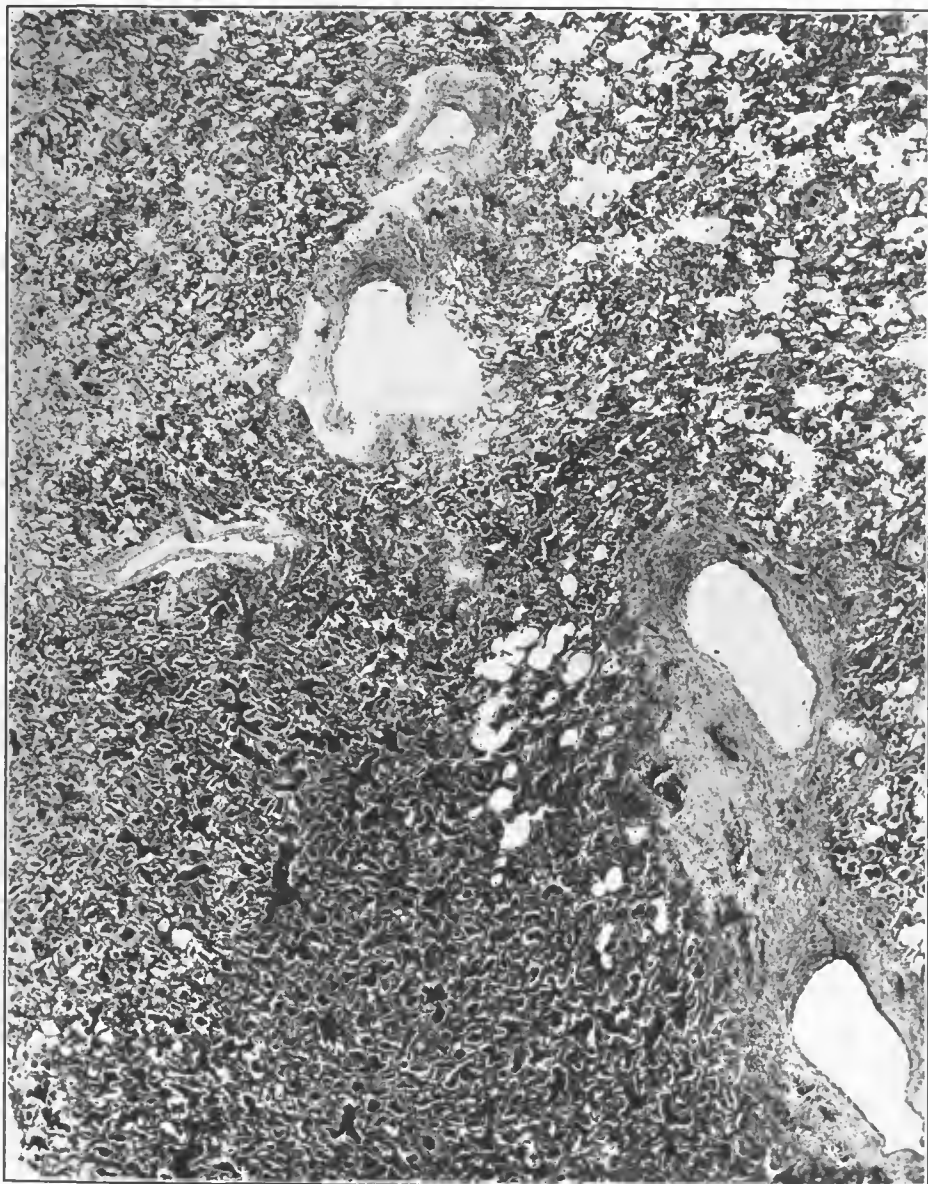


FIG. 83.—Bronchitis and bronchiectasis with break in the wall of one bronchus. Pneumonic consolidation surrounds the bronchi, the exudate being scanty and serous in the upper portion and dense fibrinous in the lower. Accession number 3572, Army Medical Museum. Negative number 45299. MacCallum stain; $\times 18$

The consolidation in the early stages of the involvement of the bronchus showed the greatest width of the extension into the parenchyma near the hilus, gradually diminishing if only the direct trunk was involved. The more usual picture, however, at death was an involvement most dense near the hilus which formed

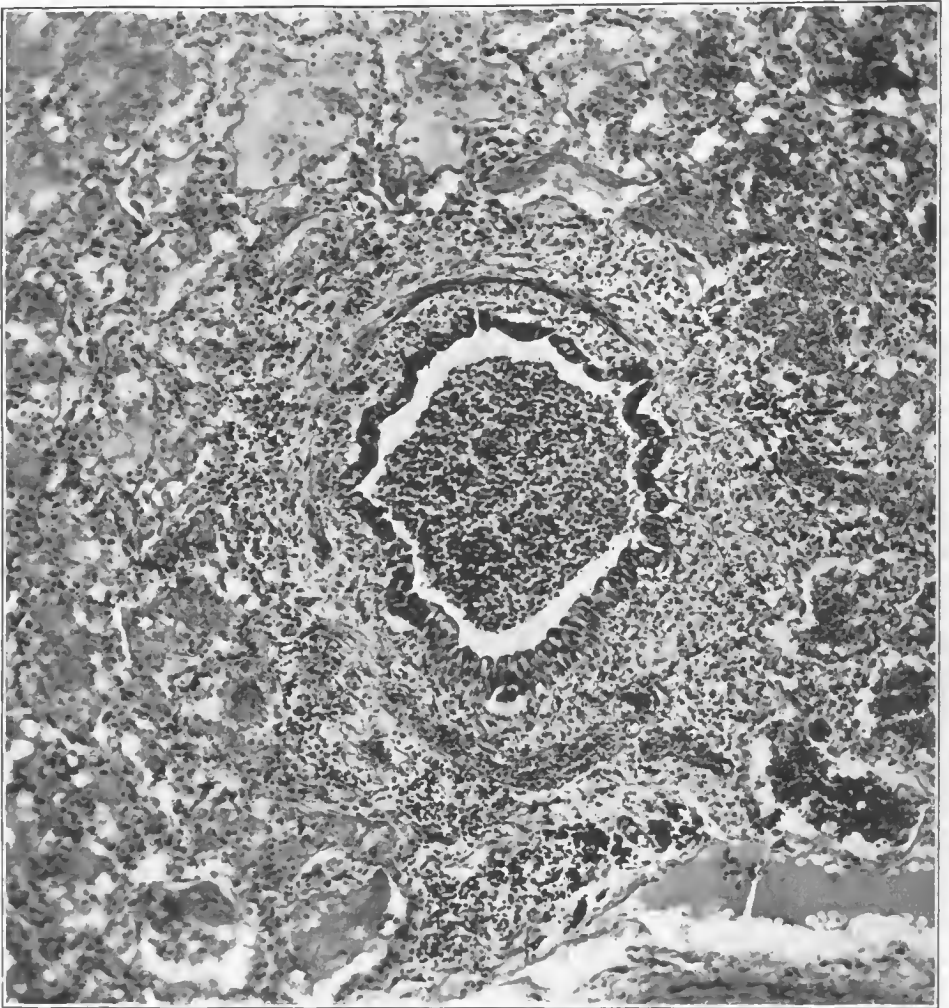


FIG. 84.—Bronchiole involved in an inflammatory reaction of the surrounding tissue, which extends to the submucosa. There is an early purulent bronchiolitis. Organisms which are morphologically pneumococci are present in the exudate in the alveoli surrounding this bronchiole. The inflammation in the alveoli is fibrinous in character. The reaction about the bronchiole is an interstitial type not distinguishable from that produced by the streptococcus. Accession number 1385, Army Medical Museum. Negative number 45277. Hematoxylin and eosin stain; $\times 130$

the apex of a cone, the cone being the area supplied by the main bronchus and most or all of its branches. There was considerable irregularity in the character of consolidation of the areas surrounding different branches of the bronchus, yet in all, the older or more dense portions of the consolidation appeared nearer the larger trunks or visible bronchi.

As a whole the consolidations were less uniform, less dense, and more crepitant toward the periphery of the lung and the most marked congestions were found at the periphery of such spreading areas. In this locality also one was more apt to find hemorrhages, recognizable as such on gross examination. The lower lobes were somewhat more frequently affected than the upper and sometimes most of a lower lobe would be so involved. In such cases, however, there was usually a layer of air-containing tissue beneath the pleura.

As previously stated, this type of reaction was more often associated with pneumococci and when members of this group were responsible, the lesions were apt to show considerable fibrin and a relatively dry exudate. (Fig. 85.) *Streptococcus viridans* produced less fibrin, as was also true of meningococcus, an organism occasionally found in this type of lesion. It also appeared sometimes to be produced by *Streptococcus hemolyticus*, and in such cases the appearance was that of a spreading bronchopneumonia along all the bronchi near the hilus and extending out a relatively short distance into the parenchyma. This consolidation was hemorrhagic in character and, on section, so full of blood that it appeared like a relatively fresh clot. In such cases death probably occurred before extension to the peripheral portions of the lung took place. The most common lesions in the periphery, however, in the streptococcus cases were lobular consolidations which were usually less hemorrhagic than the central areas.

Microscopically, spreading bronchopneumonia presented the most varied picture, including practically every type of acute inflammatory reaction in the lung which has ever been described. Even in a single section representing a surface area of two or three square centimeters purulent, hemorrhagic, fibrinous, and serous reactions were not infrequently seen.

The usual picture in cases due to the pneumococcus in which fibrin formation was a factor were first, a purulent bronchitis and desquamation of the mucous membrane, the lumen being filled with pus and desquamated epithelial cells. The submucosa was edematous and infiltrated with leucocytes, most of them being of the polymorphonuclear variety. The hyaline basement layer varied in its appearance, being swollen early, disappearing during the later stages. The submucous glands of the larger bronchi varied greatly in the degree to which they were affected. In some instances they were the site of a fibrinous inflammatory reaction, particularly those nearest to the mucosa. As a whole, the changes in these structures were not marked, capillary vessels were prominent, and the reticulum stain revealed an apparent excess of them, though such excess was observed in the fulminant cases heretofore described, the inflammatory reaction of which, in many instances at least, preceded the bronchopneumonia now being considered. Pus and inflammatory edema infiltrated the bronchial wall and extended out into the alveoli accompanied by more or less fibrin formation. In the alveoli the vessels became engorged and a serous exudate was poured out, accompanied by a few cells, polymorphonuclears and lymphocytes. This exudate escaped in small quantities through the epithelium and later, raised the epithelium of the alveoli and caused its desquamation. Strands of fibrin then appeared in the exudate, the leucocytes gradually increased as did fibrin until the typical picture of the fibrinous reaction of croupous pneumonia was attained. Adjacent alveoli were involved as the process extended, yet it was rare to have even several adjacent microscopical fields show a uniform

picture, the portions distal to the bronchus usually presenting an earlier stage in the inflammatory process.

The variation in the amount of fibrin in the exudate was very striking. Tissue surrounding one bronchus might contain considerable quantities of it,

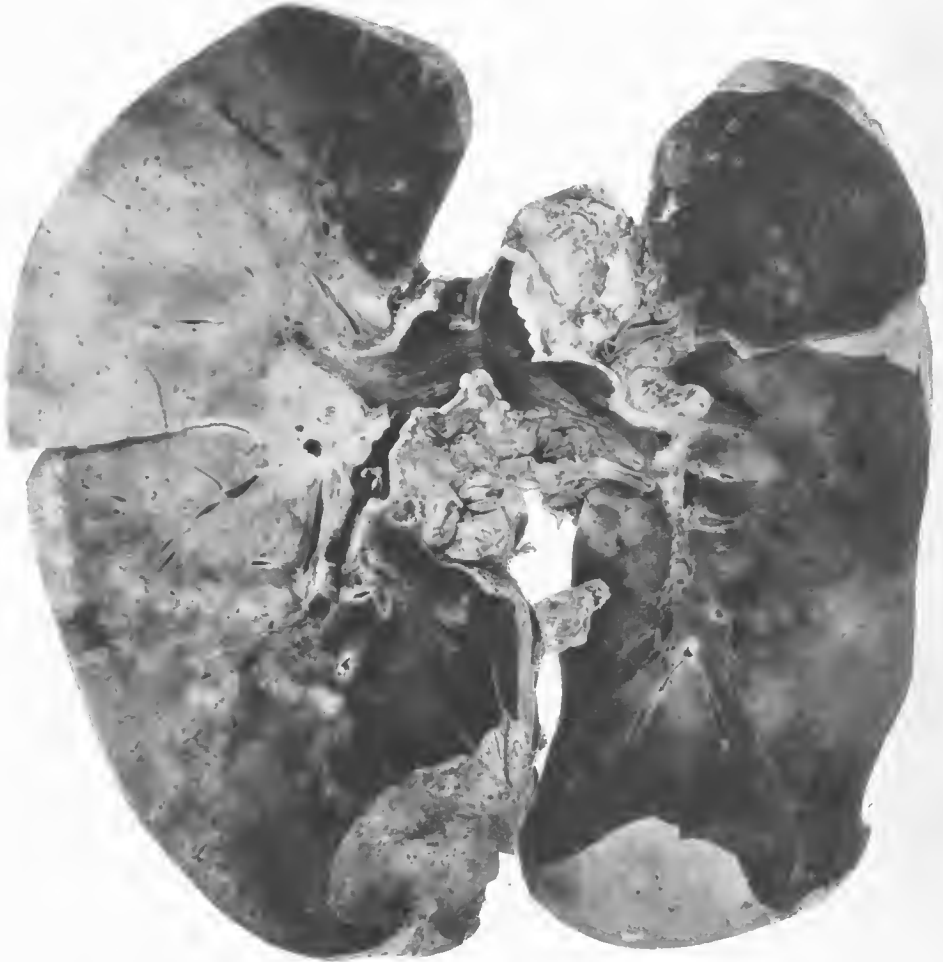

FIG. 85.—Postinfluenzal pneumonia. Pneumococcus, Type II, found in blood cultures, sputum, and cultures from the lung. Duration of pneumonic symptoms four days. The lesions are confluent lobular pneumonia, which is most advanced in the right lung, with necrosis near the hilum. There are a few peribronchiolar lesions in both lungs, not masked by the lobular consolidation. Acute hemorrhagic tracheitis and bronchitis was present, with hemorrhagic serofibrinous pleuritis. The amount of fluid in the pleural cavities was small. At necropsy, the lungs were moist and dripped blood with the exception of the lower portion of the right upper lobe which was drier. Foci of consolidation in the left lung were nodular in character and dusky red in color. The consolidations become paler and more distinct as the result of fixation. The peribronchial and mediastinal lymph nodes were enlarged, contained an increased amount of fluid, and showed necrotic areas about the periphery. Accession number 2551, Army Medical Museum. Negative number 30652.

and alveoli filled with fibrin surrounding this structure were contiguous with areas, the site of a purulent, serous or hemorrhagic reaction in which fibrin formation was scarcely visible. This may be explained by assuming either that the organism in one instance produced fibrin, in the other did not, or what

is distinctly more probable, that the two sets of tissue were affected by two distinct secondary invaders, the one affecting one bronchus, the other, a different one. It is true, however, that alveoli arising from the same terminal bronchiole not infrequently showed different types of inflammatory reaction and even though more than one organism was found in the exudate as examined in the sections, it seems unlikely that different organisms were the cause of these variations in response within so small a unit.

SPREADING BRONCHOPNEUMONIA (INTERSTITIAL)

In a certain number of the cases of this spreading type of bronchopneumonia the infection appeared to extend along the peribronchial and perivascular tissues as a phlegmonous inflammatory reaction following the lymphatic trunks. So far as can be determined from the material examined, there were always peripheral lobular lesions, sometimes of minor degree, which were drained by the peribronchial lymphatics of bronchi not affected by the inflammation of which the peripheral lesions were part. Lymphatics surrounding one bronchus receive tributaries from others and lymph flow is undoubtedly greater when, as was constant in these cases, the flow was retarded or blocked by inflammation in the lymphatics of bronchi primarily involved. This type of lesion was more frequently due to *Streptococcus hemolyticus*, but *Streptococcus viridans*, or at least organisms so identified, were occasionally the etiological factors, as were also Group IV pneumococci.

The reaction apparently occurred as a definite entity entirely apart from one almost indistinguishable from it produced, as has been described above, by direct extension from the neighboring bronchi. It was seen to greater or lesser degree about varying numbers of bronchi of all lungs in which the interstitial reaction formed a prominent part in the pulmonary inflammation. The tissues surrounding the bronchus and its surrounding areolar tissue were involved by the spreading of the inflammation to them by continuity, while at the same time the phlegmon involved the entire bronchial wall to and finally including the mucous membrane, producing first a sharp catarrhal reaction followed by desquamation of the cells and finally by a purulent bronchitis in which were large numbers of the organism which presumably caused the inflammation. (Figs. 86, 87, 88, 89 and 90.)

The reaction in the alveoli resembled that seen in the spreading pneumonias originating within the bronchus, except that as pneumococci were relatively infrequently the cause, fibrin production was less and frequently not apparent at all. Hemorrhage in smaller or larger amounts was usual and the bronchi and larger vessels were often surrounded by definite hemorrhagic zones, while hemorrhagic extravasations might consolidate a large portion of the central part of a lung or appear scattered here and there, usually relatively near larger bronchi where the lymphatic channels were larger and more tissue was present of the type apparently favoring this reaction, namely, the areolar tissue surrounding bronchi and blood vessels.

Abscesses formed in the peribronchial tissues and not infrequently the termination of the purulent inflammation of the alveoli was a complete destruction of the alveolar walls and abscess formation, a reaction relatively common with

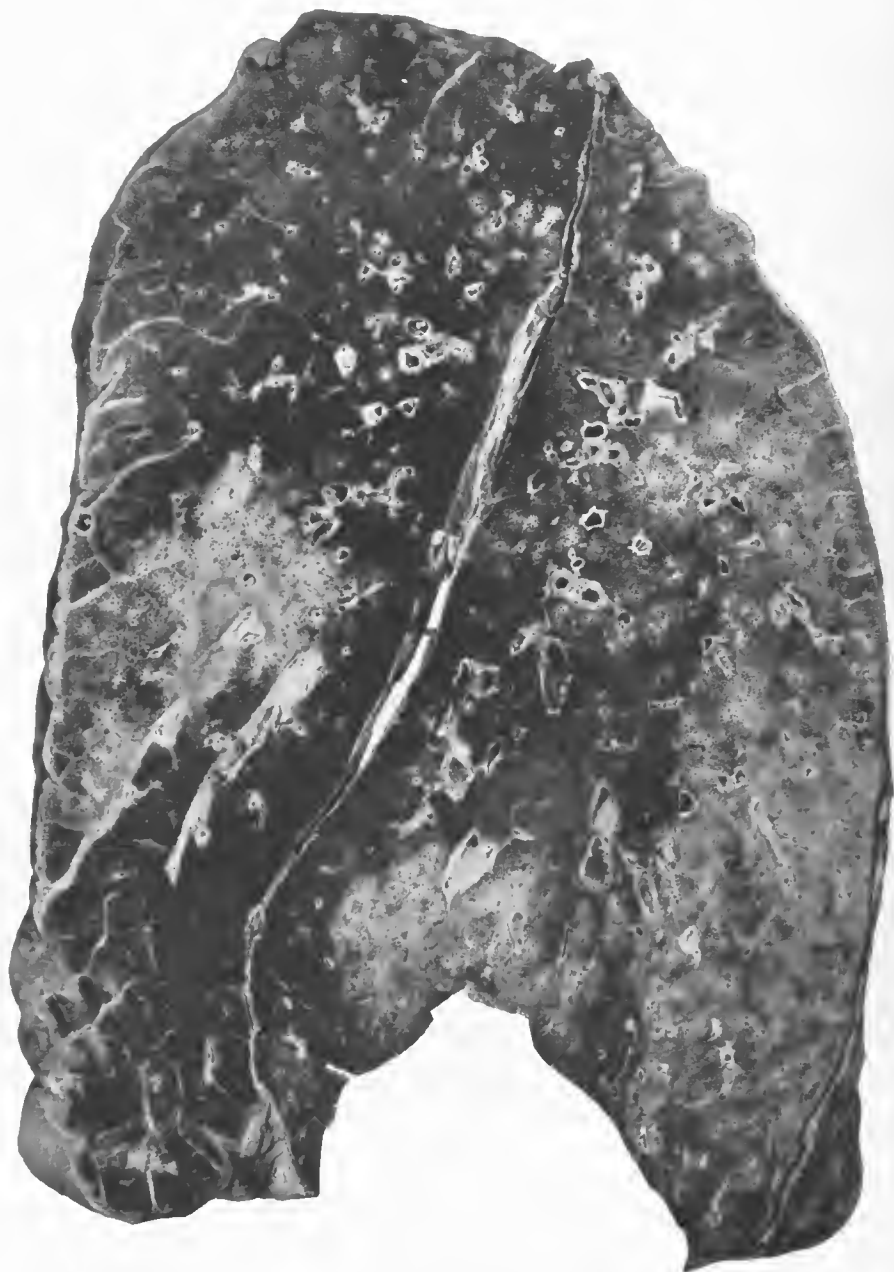


FIG. 86.—Bronchopneumonia spreading out about bronchi and blood vessels combined with peripheral lobular consolidations and peribronchiolar nodular lesions. The density of some of the interlobular and larger septa indicates that the lobular lesions occurred early and that the infection drained back along the lymphatics and then spread out from the bronchi or peribronchial tissues. The confluent area in the lower lobe near the base and interlobar pleura appears to have spread out about several small bronchi. This is possibly the focus, the drainage of which is responsible for the lymphangitis about the bronchus just above it which, in turn, is surrounded by a beginning consolidation. Microscopically, this bronchus showed a phlegmon of the surrounding tissues with little change of the mucosa. Accession number 3078, Army Medical Museum. Negative number 30725

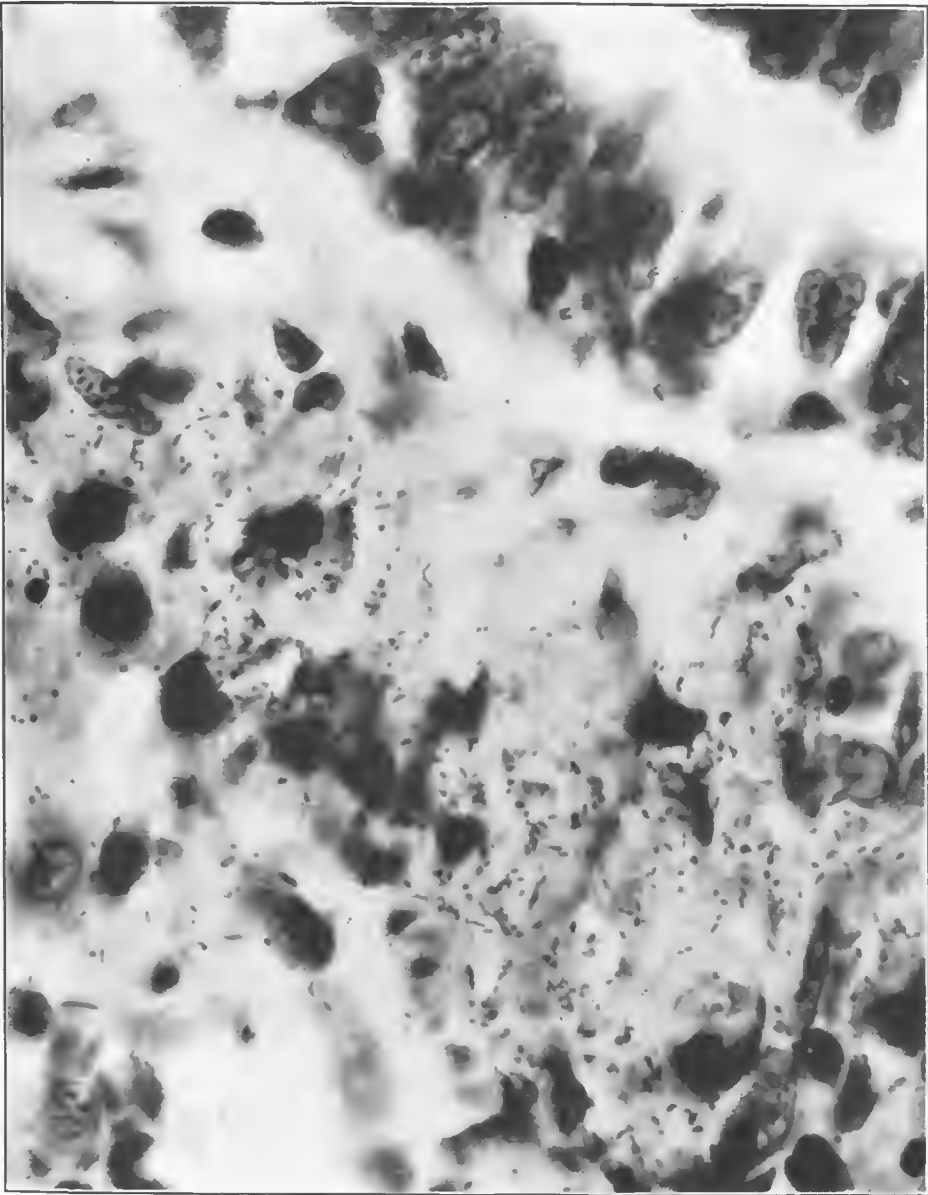


FIG. 87.—Wall of bronchiole containing numerous pneumococcus forms. There is practically no exudate in the bronchus, the infection having extended from surrounding consolidation. Accession number 3108, Army Medical Museum. Negative number 45184. MacCallum stain; $\times 1380$

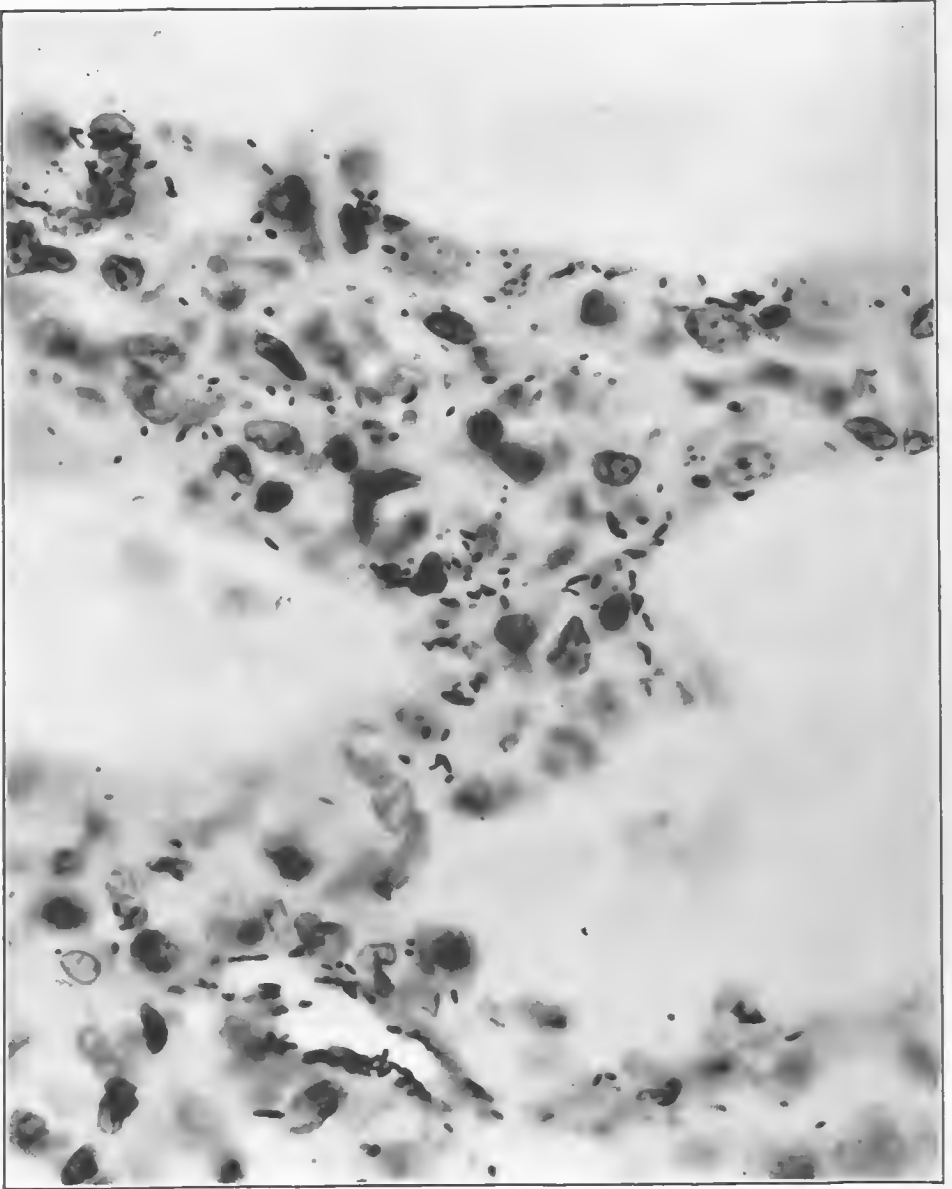


FIG. 88.—Alveolar walls containing numerous pneumococcus forms; scant exudate in the alveoli. Both pneumococcus and streptococcus cultivated from this lung. Accession number 3108, Army Medical Museum. Negative number 45213. MacCallum stain; $\times 1200$

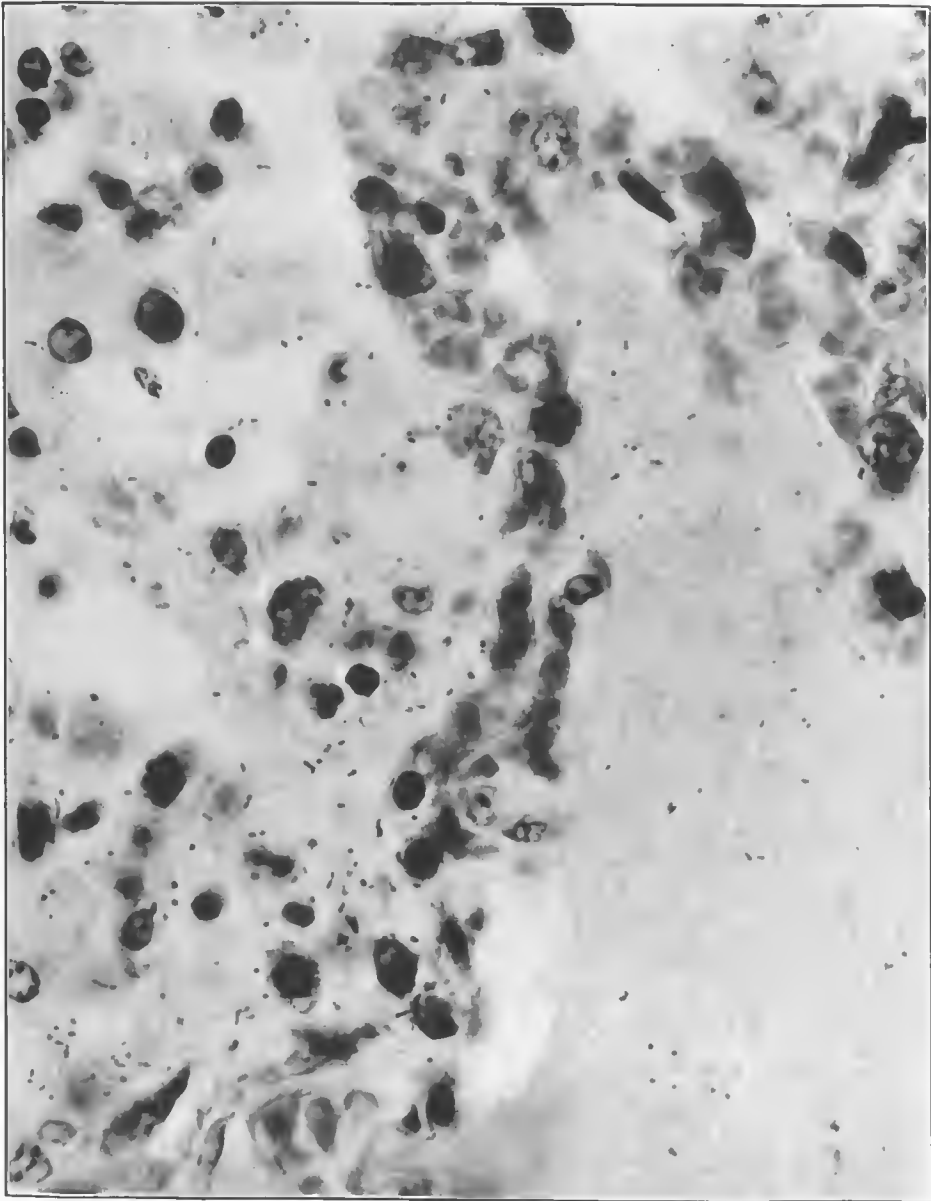


FIG. 89.—Walls of alveoli and exudate containing pneumococcus forms, scant fibrin, and moderately numerous leucocytes. Both pneumococcus and *Streptococcus hemolyticus* were cultivated from this lung. Accession number 3108, Army Medical Museum. Negative number 45260. MacCallum stain; $\times 1270$

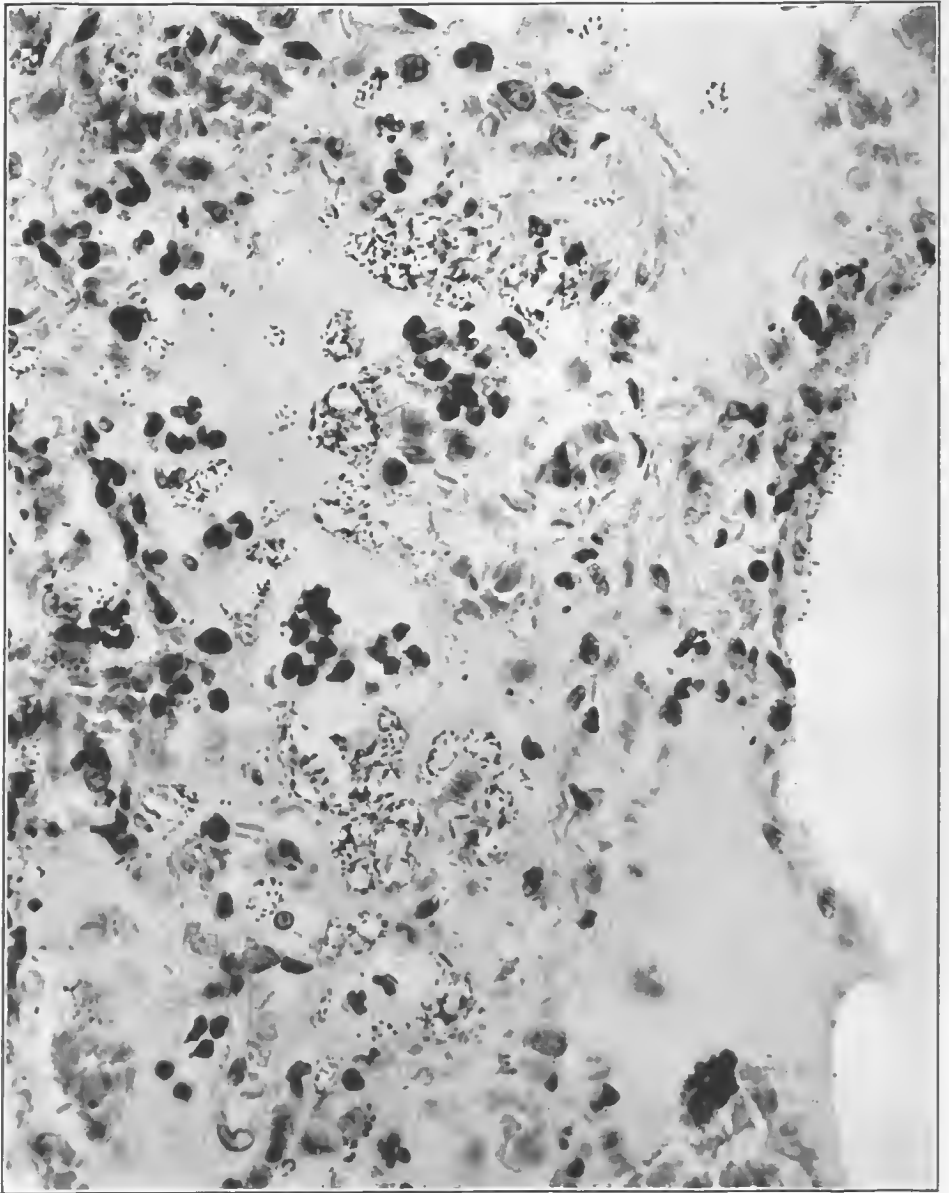


FIG. 90.—Early stage of reaction in the alveoli in a pneumonia due to pneumococci, showing large numbers of pneumococci about bubbles of air in the exudate. This proliferation is post-mortem, there being no motion in the fluid or tissues which accounts for the localization of the organisms. Accession number 3113, Army Medical Museum. Negative number 46041. MacCallum stain; $\times 645$

the streptococcus and rare with pneumococcus infection. This peribronchitis frequently was associated with pneumonic areas representing sections of lung supplied by relatively small bronchi or bronchioles and consisting of one or more anatomical lobules. These were usually relatively uniformly involved, the inflammation being at the same stage throughout. This stage was usually somewhat earlier than that reached by the consolidation in the central portion of the lung, and the general picture suggested strongly that these were pneumonia resulting from the inhalation of purulent material in bronchi, the terminal portion of which up to that time had been relatively slightly affected.

The phlegmon of the wall, in its later stages, was accompanied by considerable apparent increase in the number of blood vessels, fibroblasts increased, the wall of the bronchus was thickened by fibrous tissue, the contraction of which distorted the lumen, and in a certain proportion of the cases which died after many weeks, usually from empyema, rather extensive bronchiectases were found in relatively large bronchi. Not infrequently these communicated with abscesses in the parenchyma, the latter being of varying size from microscopical structures to large ones which had been recognized by their physical signs and X-ray appearances during life.

ACUTE BRONCHITIS AND PNEUMONITIS WITHOUT CONSOLIDATION

A few cases of an intense bronchitis were followed by an infiltration of the alveolar walls with leucocytes, slight inflammatory edema and very little exudate into the alveoli, death apparently occurring before such exudation took place. The lungs of such cases collapsed to a considerable degree on opening the chest, but were dark red in color and appeared more voluminous than normal lungs. On section, the bronchi showed a thin, serofibrinous exudate, the walls being dry, while the parenchyma was a somewhat dusky red, very slightly denser than normal, and showed an increased blood content but with little serum or froth escaping with the blood. Microscopically, a serofibrinous bronchitis was found with desquamation of the columnar cells. The ducts leading to the bronchial glands were usually plugged with serofibrinous exudate containing relatively few leucocytes and some blood. The submucosa showed leucocytic infiltration and edema and the glands usually showed a considerable degree of necrosis and fibrinous exudate. Small hemorrhages were present about the smaller vessels in the lower submucosa. Smaller bronchi did not show marked involvement of epithelium but the submucosa was infiltrated with leucocytes particularly about the capillaries. The alveolar walls showed engorgement of the vessels, with the escape of polymorphonuclear leucocytes into the walls, and occasional ones in the alveoli. In a few cases in which the tissues were well preserved pneumococcus-like forms occasionally were found in the alveolar walls and more rarely in the alveoli. They were seen occasionally also in the blood of the smaller vessels. In the cases in the Army Medical Museum, cultures of blood and lung showed pneumococcus Type II. Cases, apparently of this type, were described as having occurred in the Civil War and were then diagnosed simply as acute bronchitis. The most advanced process was in the bronchi and the distribution and character of the lesion suggest that the organisms found their way into the blood stream through the bronchial

veins and were distributed to the lungs by the pulmonary circulation. The organisms were present in the blood as well as in the lung, but the greatest intensity of the reaction appears to have occurred in the pulmonary tissues. The infection was apparently so overwhelming that death occurred before exudation could take place, and this would appear to be the logical result of a blood-stream dissemination. (Figs. 91, 92, 93, and 94.)

SECONDARY LOBULAR PNEUMONIA

This lesion was probably the most frequent type of secondary pneumonia though it was practically never the only type present. As stated previously, isolated anatomical lobules and groups of lobules frequently were involved in cases, the majority of the lesions in which were of other varieties. (See frontispiece.) Usually it was present in lungs, the seat of extensive interstitial inflammation, though often affecting lobes and parts of lobes not markedly involved in the interstitial process. When it affected the greater part of a lobe, difficulty was experienced in distinguishing it microscopically from the earlier stages of lobar pneumonia, but microscopical examination showed differences in the character of the reaction in different and often adjacent lobules. (Fig. 95, 96, 97, 98, 99.)

Pneumococci and streptococci were the organisms most frequently found in the cultures of the lesions. The types of the pneumococci varied in the different camps but organisms of Group IV predominated in all. The incidence of hemolytic streptococci varied and tended to increase toward the latter part of the epidemic waves of acute respiratory disease, including the influenza pandemic of 1918. At some camps, however, these organisms were abundant early in the pandemic and their proportion in such places did not vary markedly during its course.

This type or distribution of consolidation varied markedly in the character of the exudative process. This was due to two factors, the bacterium causing it and the relative duration. The sequence of events in the progress of the anatomical involvement, however, appeared to be the same. The infection appears to have extended along air passages and involved with greater or lesser rapidity and completeness an entire anatomical lobular sector of the lung. In some cases the cellulitis and lymphangitis of the perilobular tissue and the interlobar septa were undoubtedly the lesions from which infection spread to the lobules between and about them, as the densest parts of the lobular consolidations often were nearest these structures, the central part of the lobule or that part farthest from the affected septa being the least involved. (Figs. 100 and 101.)

Every type of appearance, gross and microscopic, was seen, varying from lobule to lobule, and, except for those lobular consolidations of fibrinous character, usually due to pneumococci, the microscopical reactions varied in the same lobules. In the lesions due to *Streptococcus hemolyticus* there was no regular sequence of events.

In the lobular pneumonias, the upper respiratory tract varied in the pathological picture presented according to the organism responsible for the pathological conditions. Thus the most intense reactions in the upper respiratory tract were found in those cases in which culture from the nasopharynx and

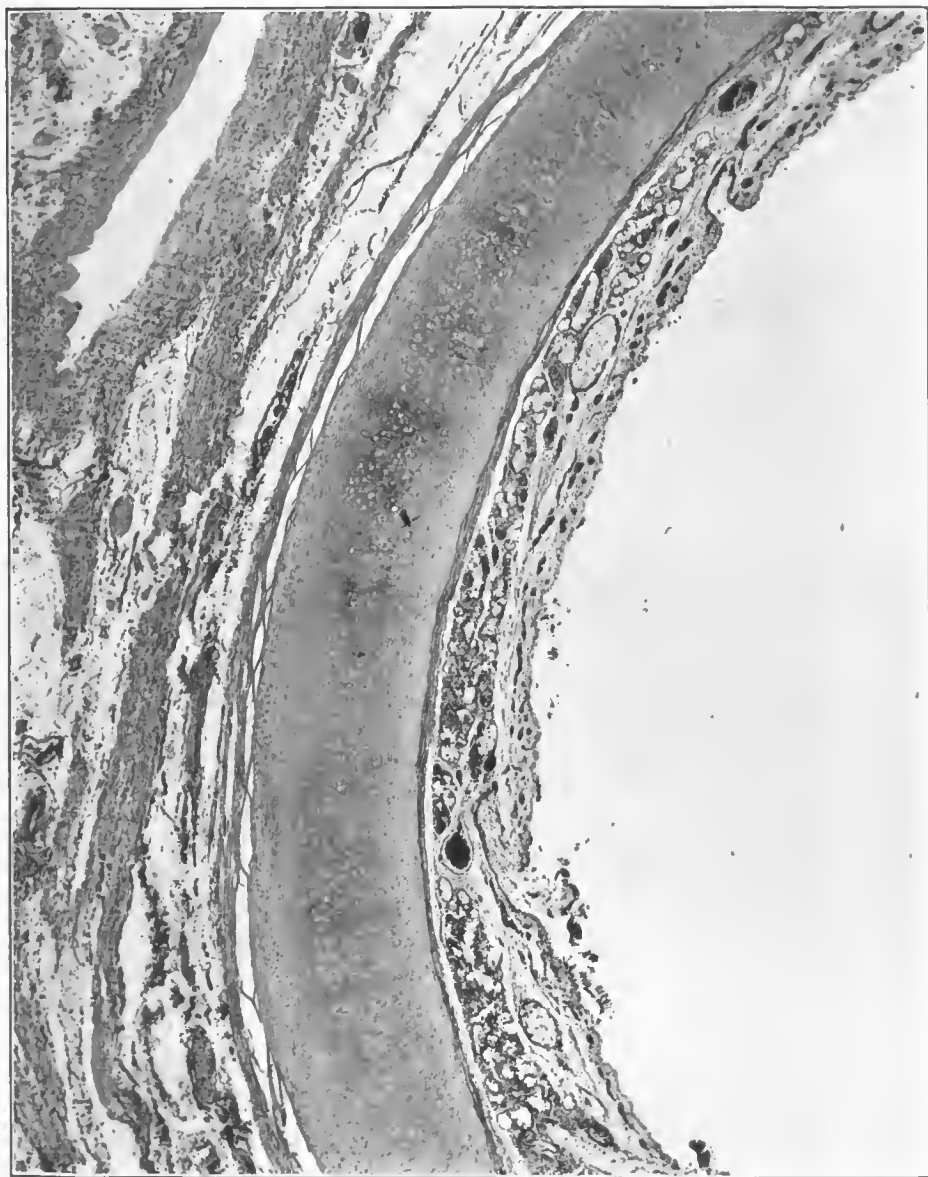


FIG. 91.—Section of wall of the main bronchus, showing desquamation of epithelium and fibrinous and hemorrhagic inflammation of the submucosa. The ducts from the submucosal glands are filled with a fibrinous exudate. Pneumococcus, Type II, isolated from the lung and blood. Accession number 16389, Army Medical Museum. Negative number 45581. Hematoxylin and eosin stain; $\times 25$

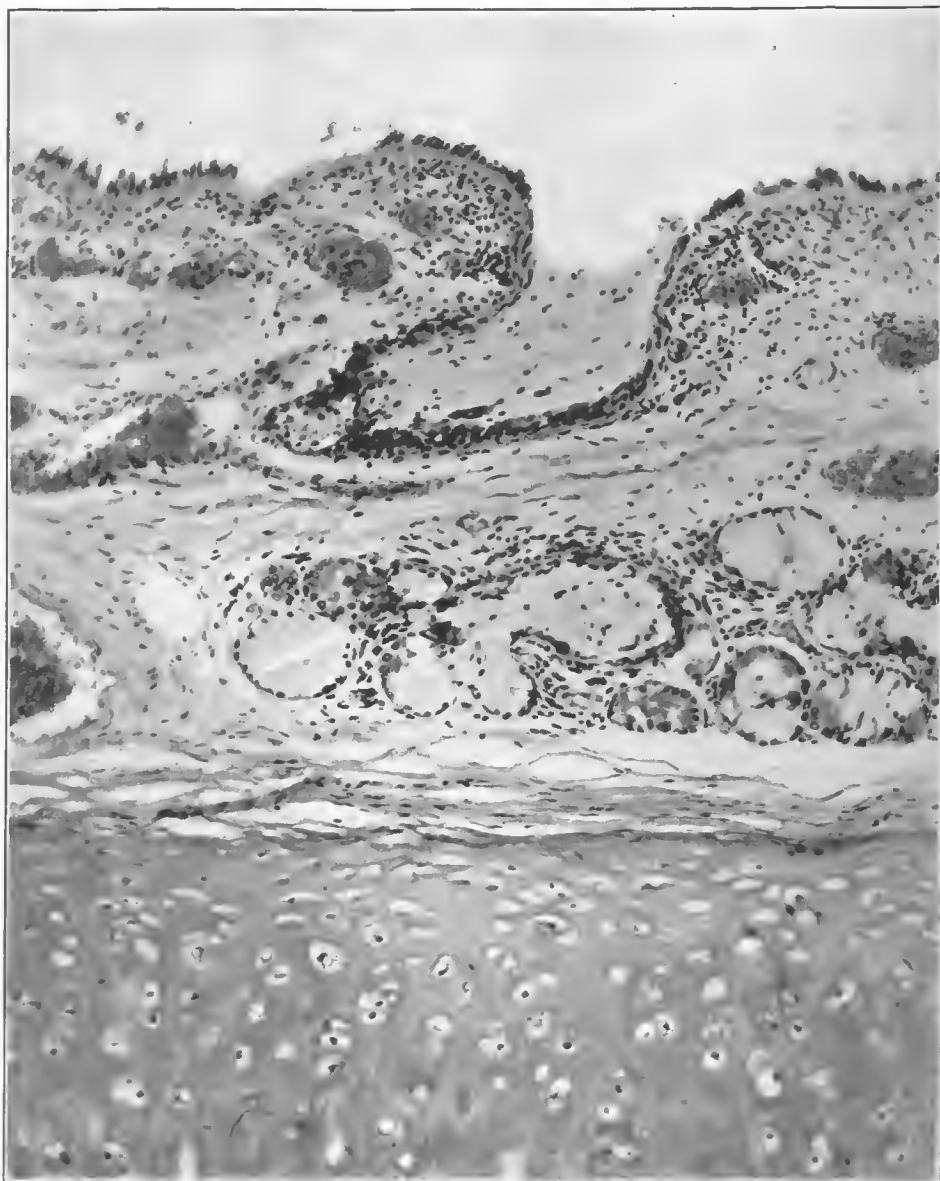


FIG. 92.—Section of wall of bronchus showing the lumen of a duct plugged with serofibrinous exudate. There is swelling and hyalination of the basal membrane, with partial desquamation of the cells. Submucosal glands degenerated. Pneumococcus, Type II, isolated from blood and lung. Accession number 16380, Army Medical Museum. Negative number 45677. Hematoxylin and eosin stain; $\times 150$

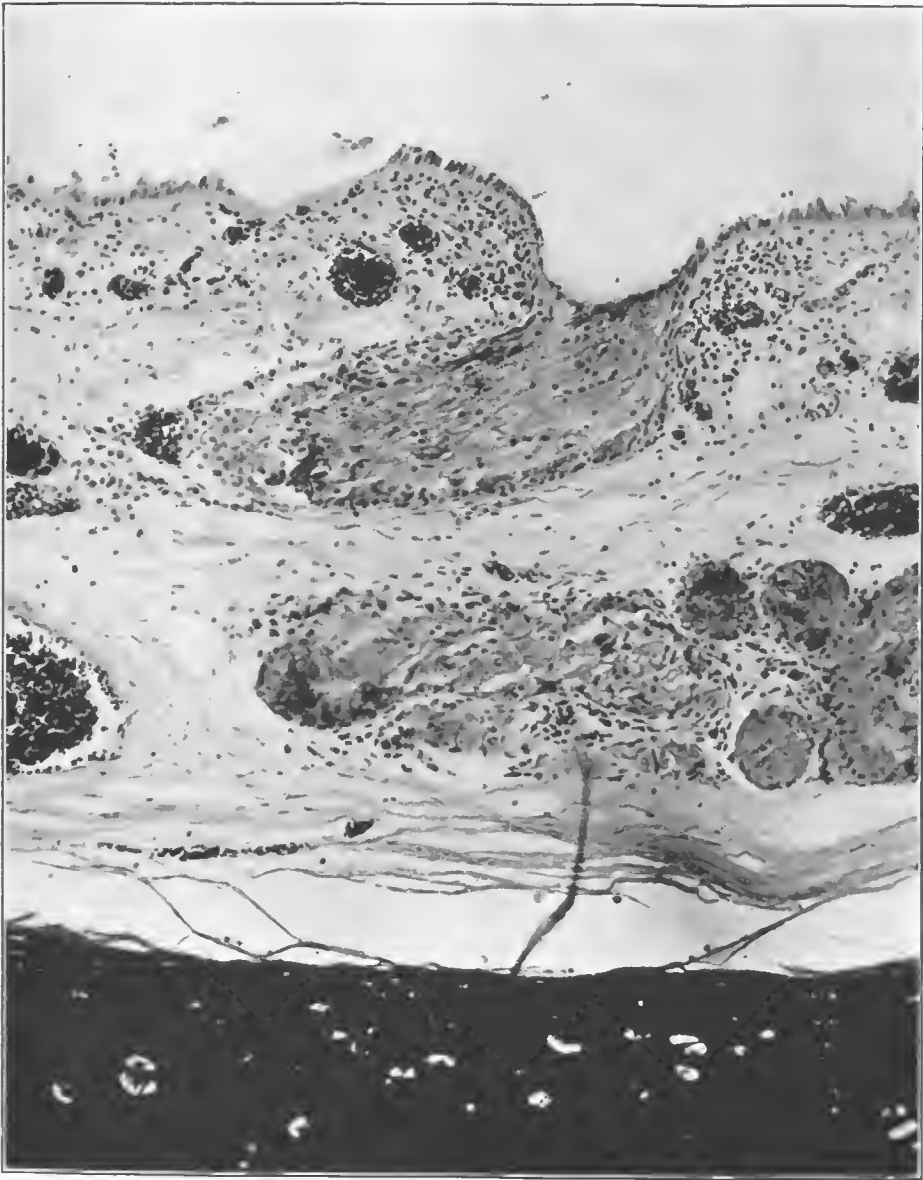


FIG. 93.—Section of wall of bronchus, showing fibrinous exudate plugging a duct from the submucosal glands. Fibrinous inflammation, degeneration, and necrosis of one of the glands shown in the lower portion of the picture. Some hemorrhage into the lumen of the duct. Pneumococcus, Type II, isolated. Accession number 16380, Army Medical Museum. Negative number 45676. MacCallum stain; $\times 150$

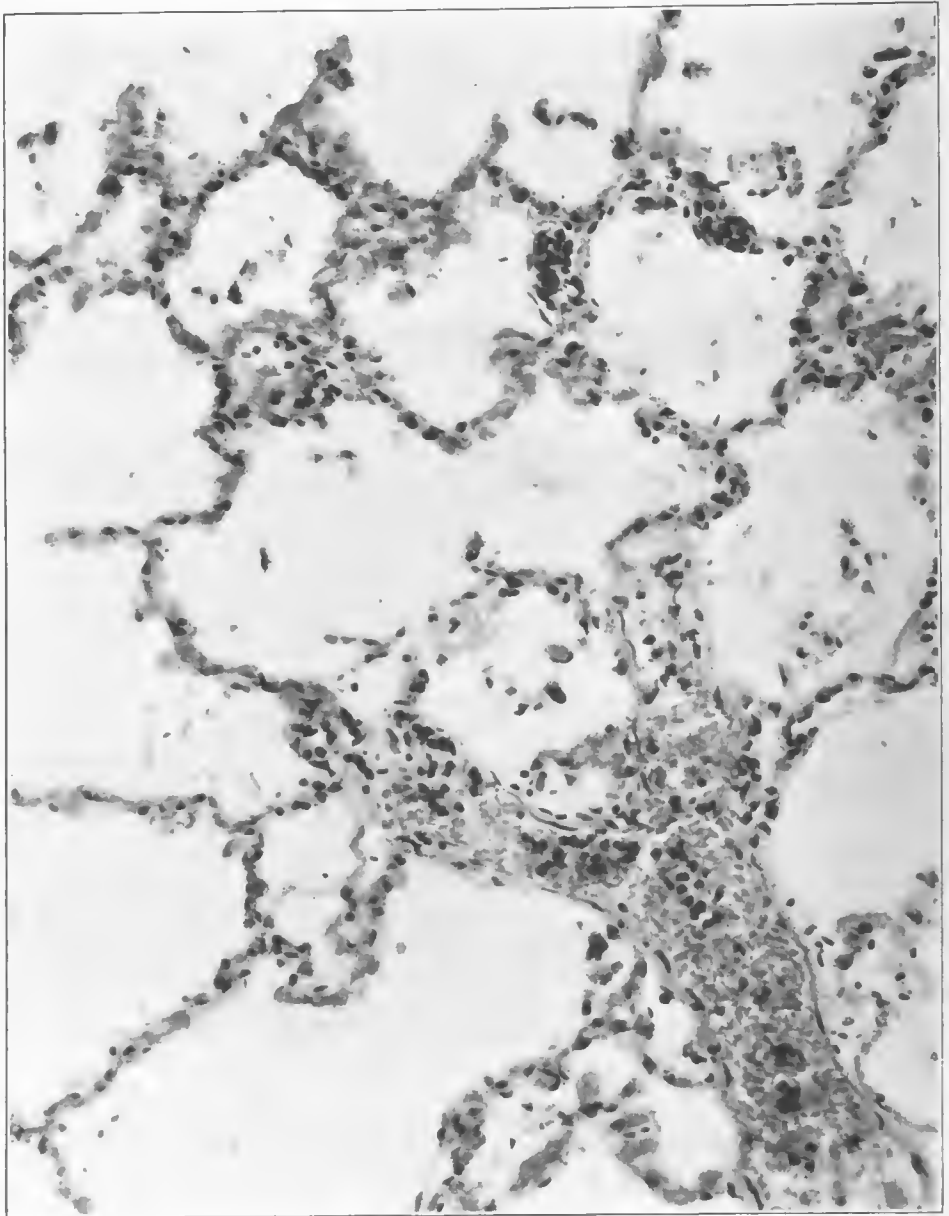


FIG. 94.—Blood vessels and alveoli in a case of pneumococcus, Type II, infection in which there was a severe bronchitis with fibrinous inflammation due to pneumococcus, Type II. A few organisms were present in the alveolar walls, rarely in the alveoli, and all alveolar walls show vascular engorgement and polymorphonuclear and mononuclear cell infiltration with practically no exudate in the alveoli. The condition was a pneumococcus, Type II, septicemia following an acute bronchitis without any pneumonia. Clinically, the case did not have a preceding influenza and illustrates the extreme virulence some of the pneumococci, particularly Type II, assume. Accession number 16380, Army Medical Museum. Negative number 45903. MacCallum stain; $\times 265$




FIG. 95.—Peribronchiolar consolidations of the lower lobe, with apparent extension out and involvement of the lobules in which the peribronchiolar consolidations are located. Confluent or universal lobular pneumonia of the upper lobe, peribronchiolar consolidations still being visible in some of the lobules. Considerable lymphangitis in the upper lobe, lower central portion, with necrosis. *Streptococcus hemolyticus* isolated from the lung, minute Gram-negative bacteria seen in sections along the bronchioles and in a few alveoli along the respiratory bronchioles. Accession number 3130, Army Medical Museum. Negative number 30712

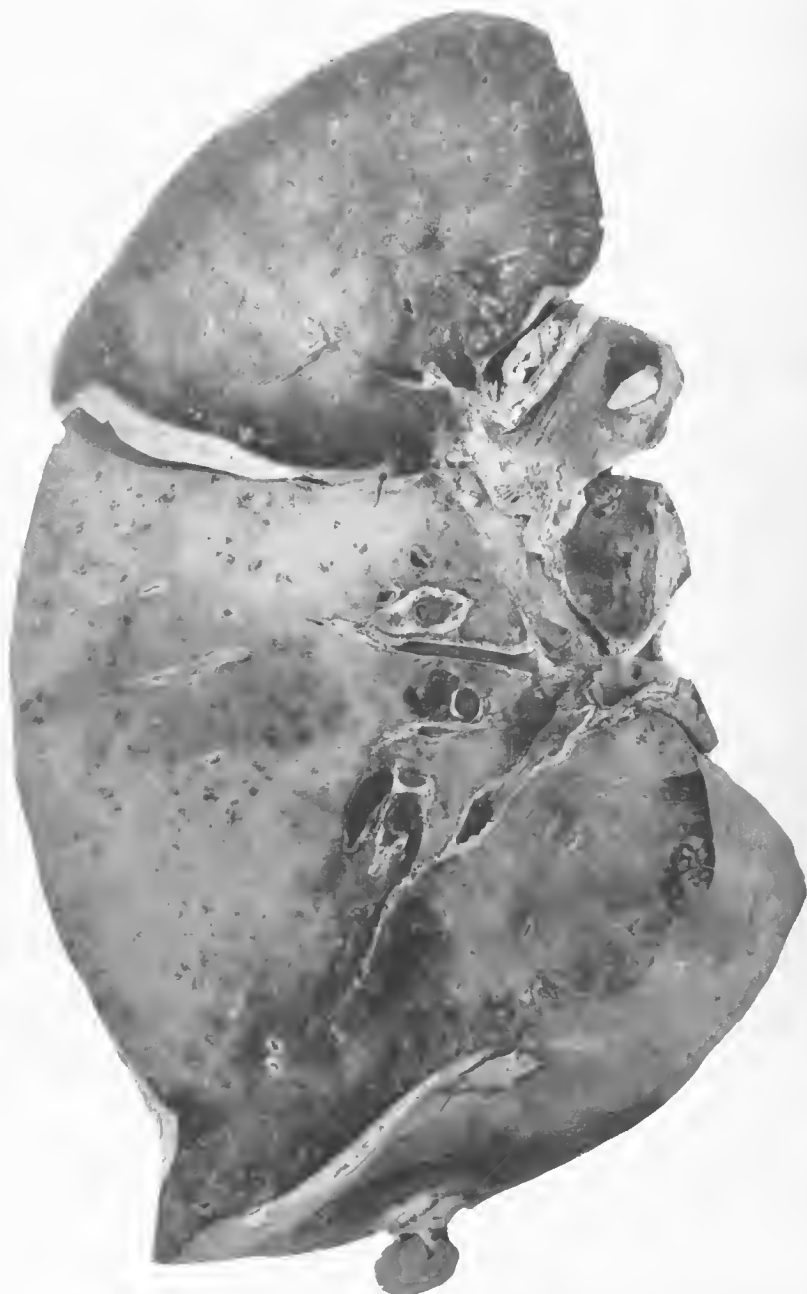

FIG. 96.—Postinfluenzal pneumonia. Confluent lobular pneumonia of both lobes with peribroncholar consolidations in the lower portion of the lower lobe and upper and mesial portions of the upper lobe, interlobar pleurisy. Pneumococci and Gram-negative bacilli were seen in sections. Accession number 1107, Army Medical Museum. Negative number 30337




FIG. 97.—Postinfluenzal pneumonia. Confluent lobular pneumonia simulating lobar pneumonia involving both lobes of the left lung. Microscopically there are distinct differences in the exudate in the different lobules. Pneumococcus, Group IV, was isolated from blood; cultures from the lung did not show growth. The exudate contained considerable fibrin, many polymorphonuclear neutrophils and pneumococcus forms. Accession number 1509, Army Medical Museum. Negative number 30606

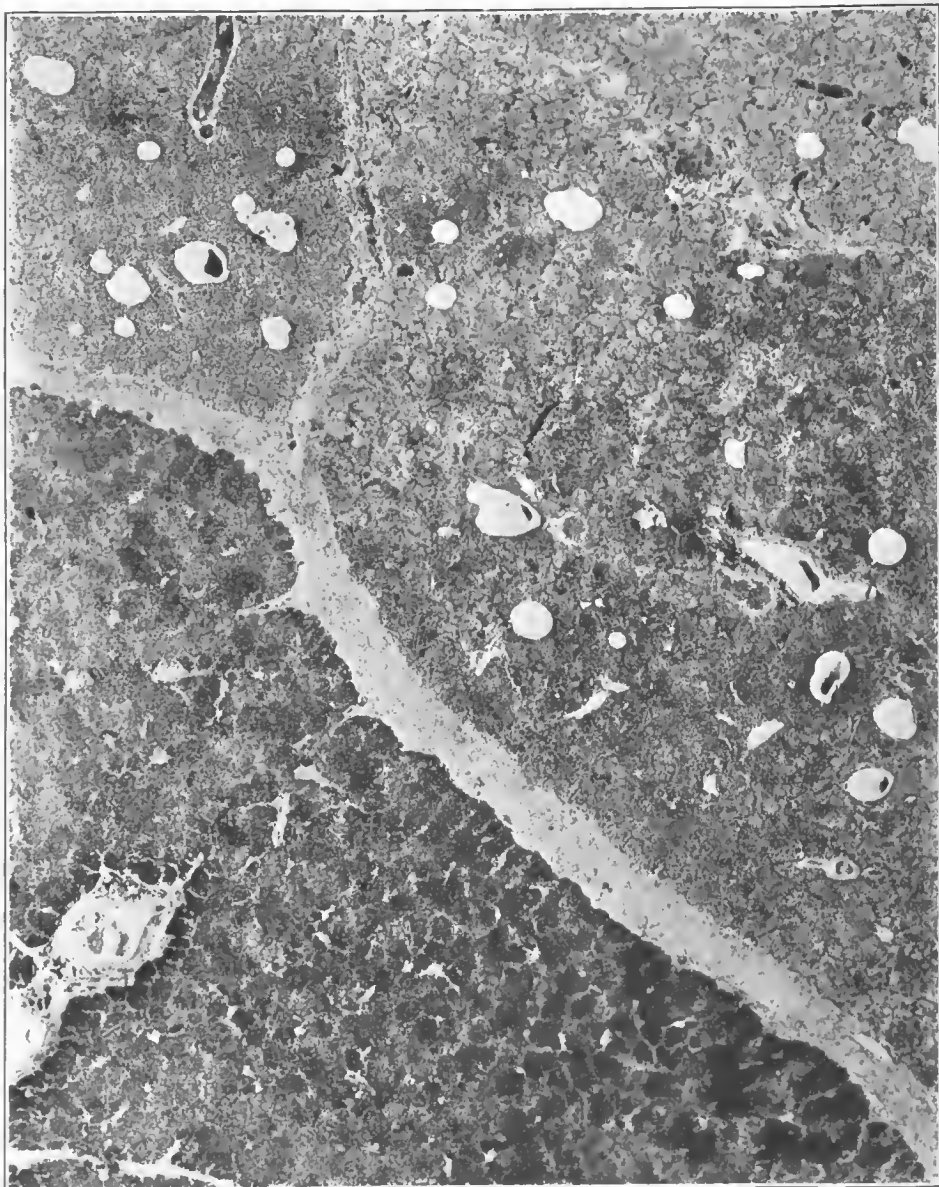


FIG. 98.—Lobular pneumonic consolidation showing variations in the character of the exudate in adjoining lobules. In the darkest area pneumococcus forms were abundant, both streptococcus and pneumococcus forms were present in the other two lobules. Streptococci were present in the interlobular septa where a purulent lymphangitis was present. Culture from the heart's blood contained pneumococci; culture from the lung contained pneumococci and hemolytic streptococci. Accession number 3115, Army Medical Museum. Negative number 45537. Hematexylin and eosin stain; $\times 11$

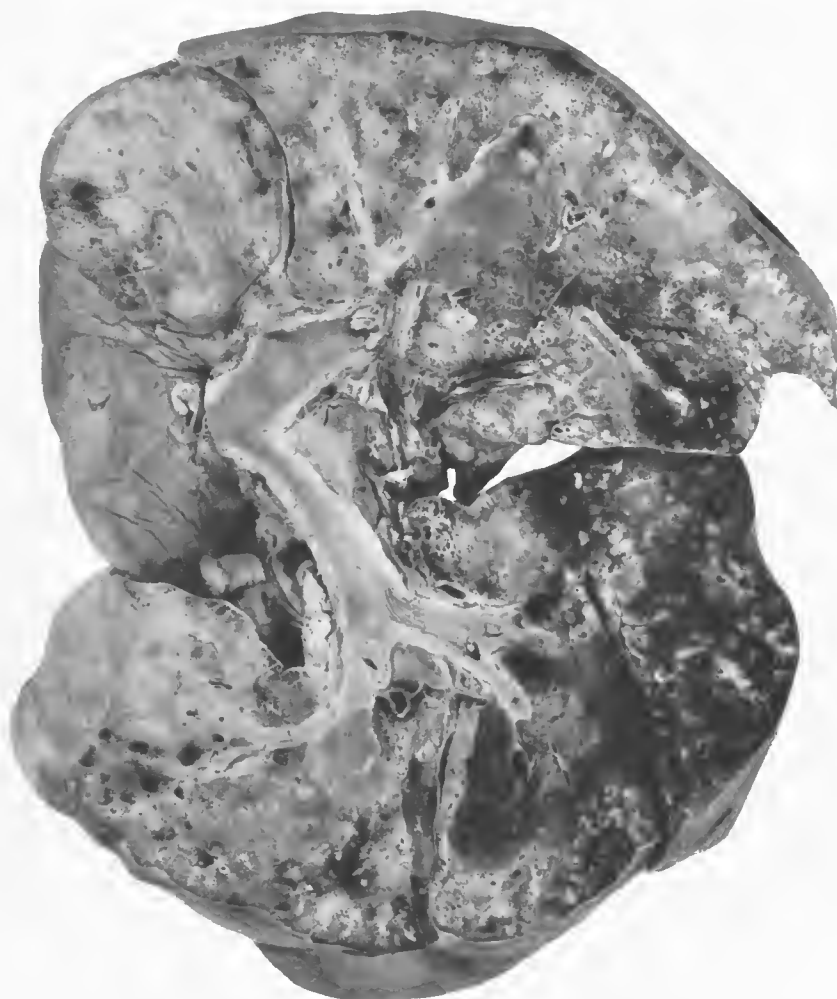


FIG. 99.—Pneumonia following influenza. Duration 15 days. Confluent lobular pneumonia of all lobes superimposed on peribronchiolar nodular consolidations with pneumonia spreading out along bronchi in the right lower lobe and occasionally in small areas in both left lobes. Pneumococcus, Type I, was the only organisms isolated. Accession number 1480, Army Medical Museum. Negative number 30650

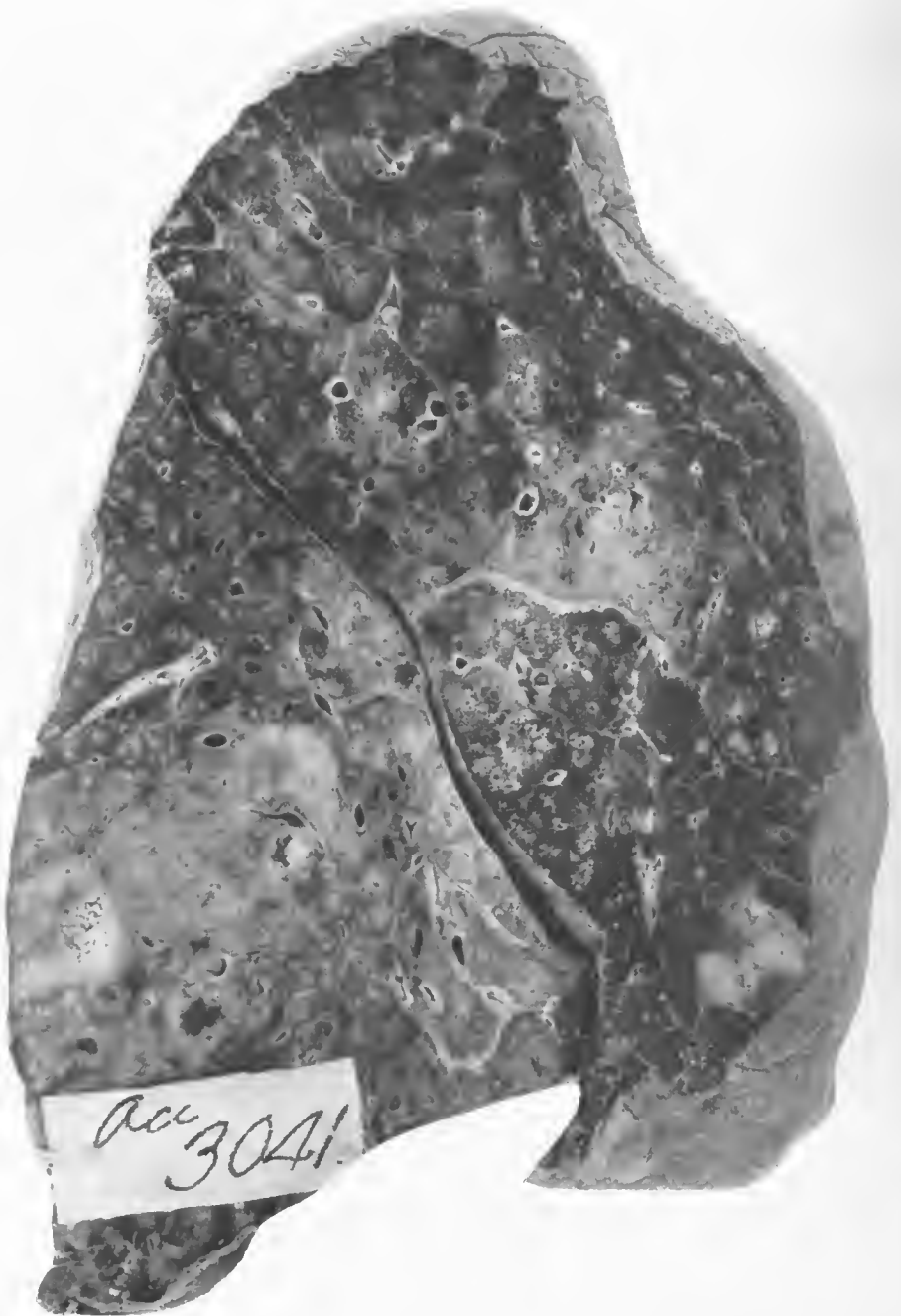

FIG. 100.—Postinfluenzal pneumonia. Peribronchiolar consolidations in both lobes; process is extending out from thickened interstitial tissue at about the middle of the upper lobe. *Streptococcus hemolyticus* in culture and in sections of the denser consolidations and along the bronchi. Gram-negative bacteria were seen in the peribronchiolar consolidations. Accession number 3041, Army Medical Museum. Negative number 30277

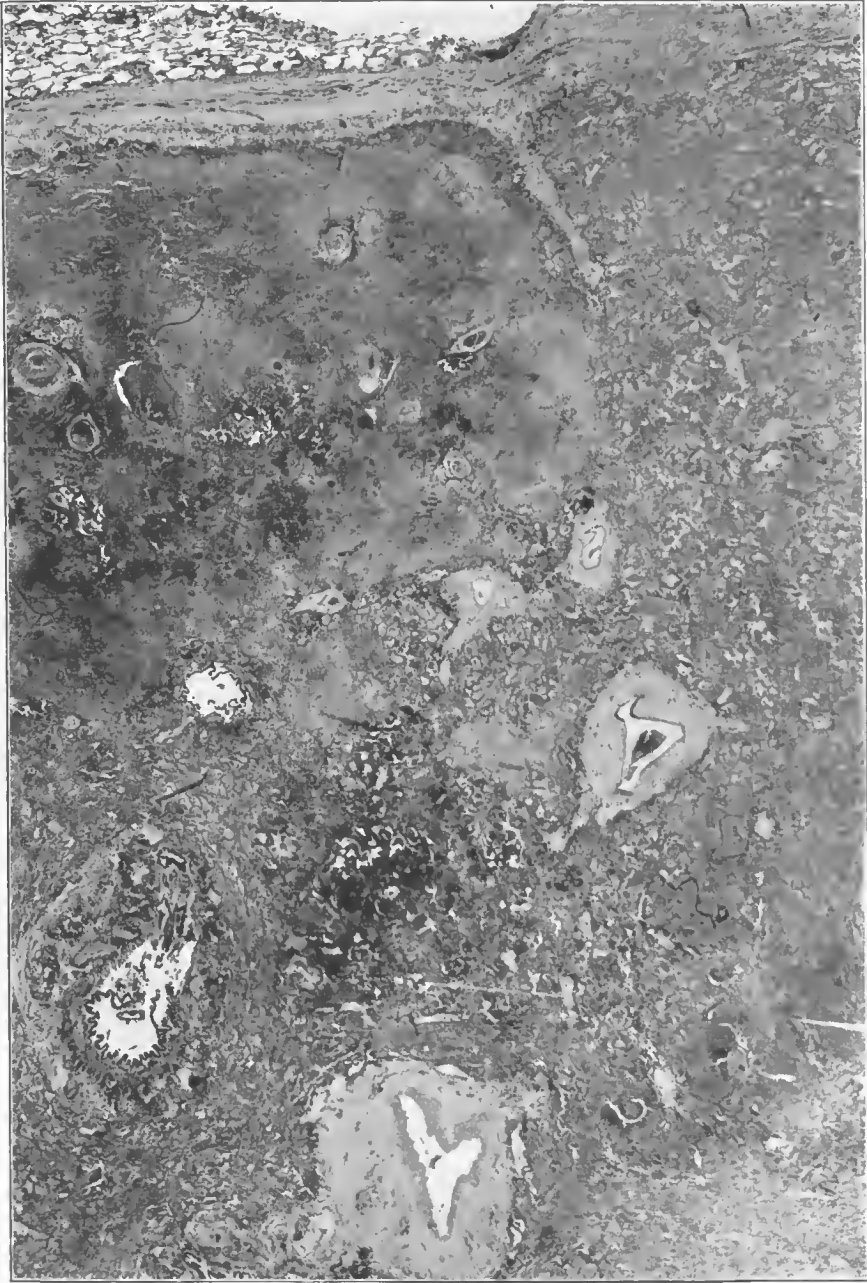


FIG. 101.—Lobular pneumonia. Nonhemolytic streptococcus in culture. Necrosis farther advanced near interlobular septum. Phlegmon about vessels and bronchioles. Accession number 3026, Army Medical Museum. Negative number 45219. Hematoxylin and eosin stain: $\times 24$

sputum showed hemolytic streptococci. The changes in the trachea, in the cases due to pneumococci, showed little more than the reaction found in those acute, fulminant cases which have been described previously, and there was usually some epithelium left on the surface. In the streptococcus cases the columnar cells, for the most part, were thrown off, the submucosa infiltrated with leucocytes and the lymphatics distended with polymorphonuclear cells. Except for the depths of the crypts the mucous membrane appears to have lost both the columnar and basal cells. Hemorrhages in the submucosa about the capillaries in the deeper portions were usual, the glands of the submucosa showing hypersecretion and usually some degenerative changes. (Figs. 102 and 103.) In the bronchi the same type of inflammatory reaction was seen in the mucosa and in addition the inflammation extended out between the cartilaginous rings into the surrounding lymphatics. (Fig. 104.) In the smaller bronchi and bronchioles in these streptococcus infections a thin exudate was thrown out accompanied by desquamation of the columnar cells and a moderate degree of proliferation of the basal layer, though in all of the cases in which tissues were well fixed small Gram-negative bacteria were likewise present in these locations, thus making it possible that the proliferative changes were not due to the streptococcus. In the thin, fibrinopurulent exudate the organisms were not particularly numerous and usually were found in the lymph spaces beneath the hyaline basement membrane as well as mingled with the cells of the mucosa, and contained in the serous exudate which sometimes raised the mucus membrane from the underlying reticulum. (Figs. 105, 106, and 107.) In the smaller bronchioles in the midst of lobular consolidations it is difficult or impossible to tell whether the inflammatory reaction extended along the bronchioles and spread out from them or extended to them from adjacent inflamed alveoli.

In the alveoli of lobular consolidations apparently caused by pneumococci, the changes approached those seen in typical lobar pneumonia, and in microscopical sections, small areas may be indistinguishable from the microscopical picture in the lobar type of distribution. Quite frequently, however, there was much less uniformity even in a lobule than is found in an entire lobe of lobar pneumonia. Usually there was less fibrin formation and more variation in amount and kind of exudate even in adjacent fields of a microscopical section. In the pneumococcus cases, however, leucocytic infiltration of the alveolar walls was relatively rare but was usual in the streptococcus infections. (Figs. 108, 109, and 110.)

The infiltration of the alveolar walls in the streptococcus pneumonias varied markedly in the amount of inflammatory edema, cellular infiltration and hemorrhage present. Leucocytic infiltration of the alveolar walls appeared to be characteristic of the process and usually was accompanied in the early stages by a serous exudate in the alveoli. (Fig. 111.) In some instances the leucocytic exudate of the alveolar walls appears to have been superimposed upon the typical alveolar reaction seen in the fulminant cases and associated with small Gram-negative bacteria, and in such, if the tissue was well fixed, these bacteria usually were found. (Fig. 112.) The amount of hemorrhage in the alveolar walls and in the alveoli varied in amount and distribution, sometimes being abundant in the walls with little escape in the alveoli; at other times the hemorrhage appeared to be practically entirely within the alveoli.

(Fig. 113.) In cases of the most fulminant type the leucocytic exudate frequently showed a preponderance of mononuclear cells most of which were lymphocytes. (Figs. 114, 115, 116, 117, and 118.) In the more rapidly fatal streptococcus cases hemorrhage was usually abundant, and in many the patients did not survive a sufficient time to allow a marked cellular infiltration to occur.

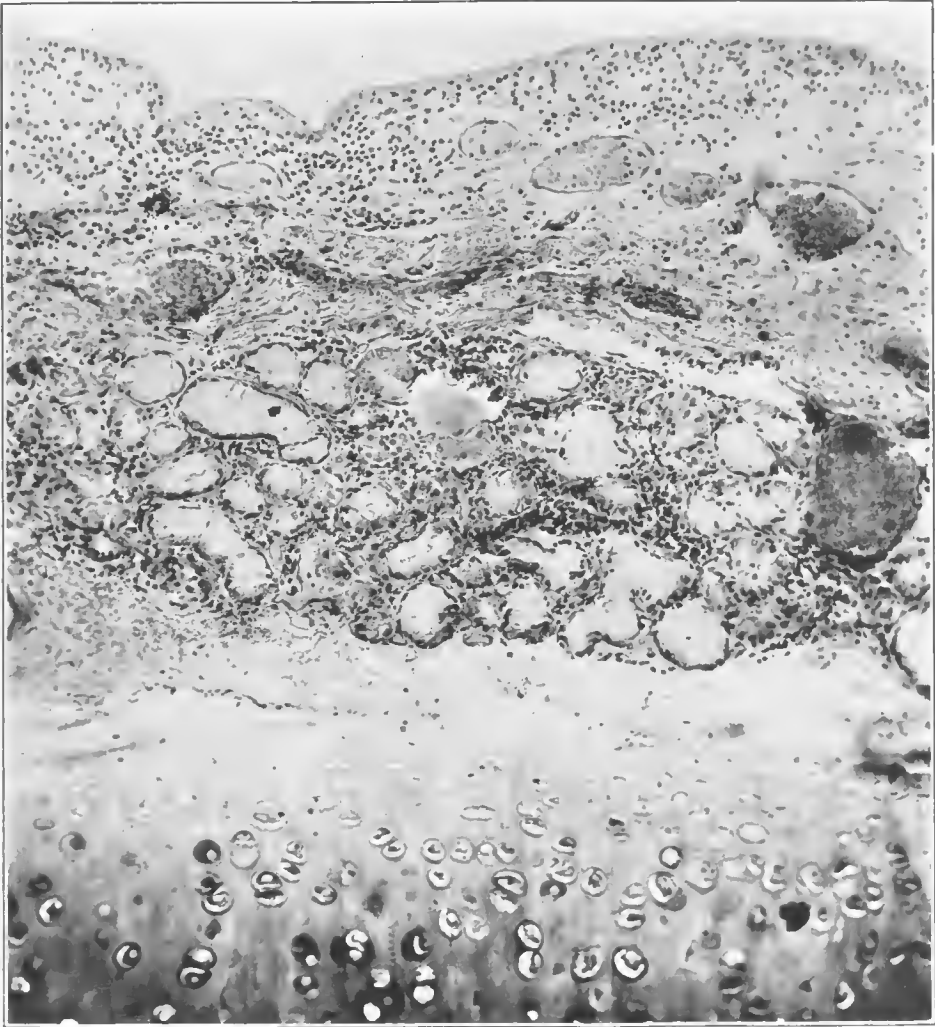


FIG. 102.—Section of bronchial wall including group of mucous glands in a streptococcus bronchitis. A number of glands show advanced degenerated changes of the cells while the mucosa of the bronchus is completely desquamated. Accession number 16657, Army Medical Museum. Negative number 45226. Hematoxylin and eosin stain; $\times 150$

In most cases where considerable portions of the lung were affected by lobular pneumonia there was found a spreading bronchopneumonia of the central portions of the lung where it was impossible to make out lobular areas, and the presumption is that the primary reaction was that of bronchitis and peribronchitis. (Fig. 119.)

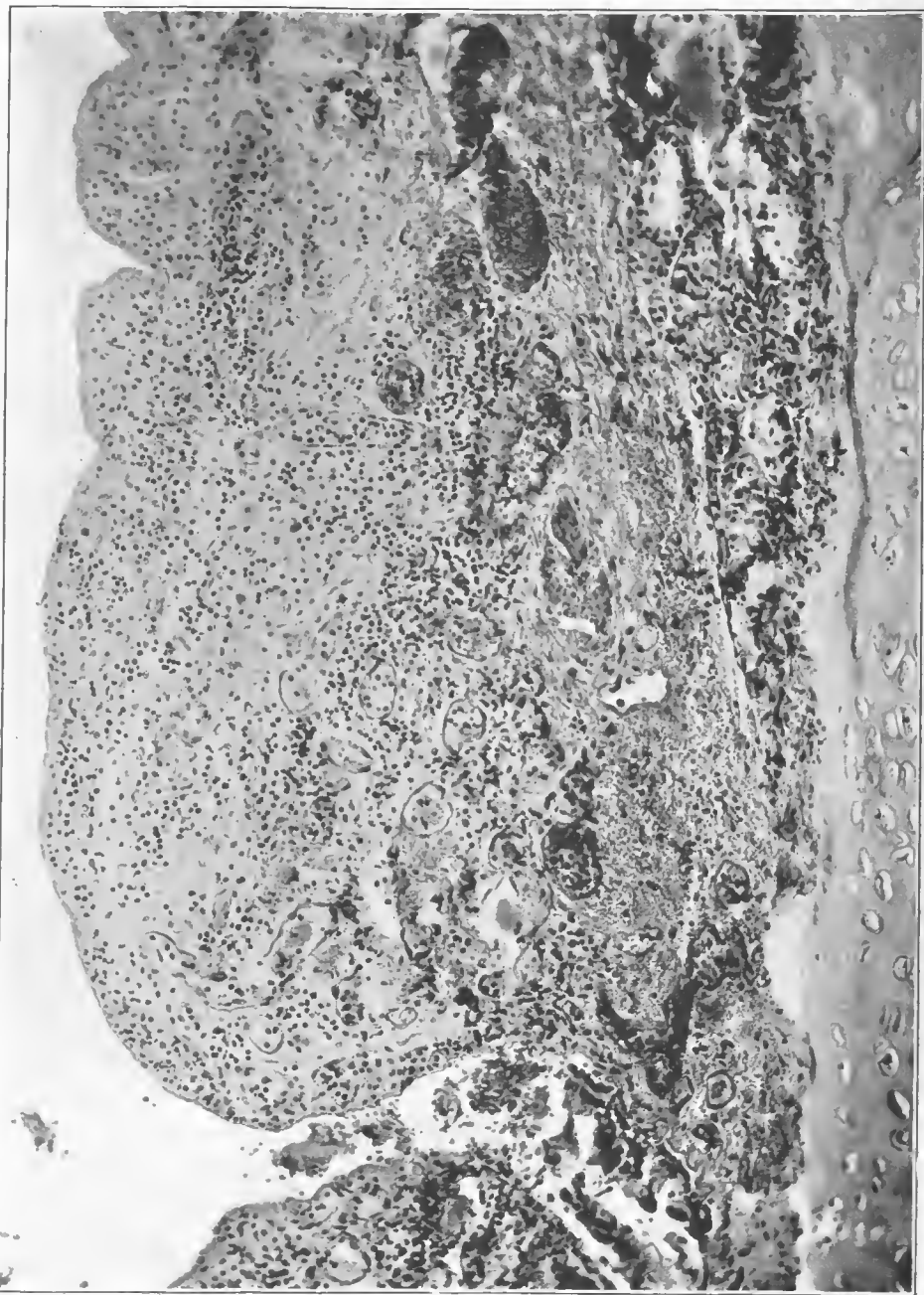

FIG. 103.—Wall of main bronchus in a case of streptococcus bronchitis and bronchopneumonia. Epithelium completely desquamated, submucosa appears as granulation tissue. Hemorrhage from the vessels in submucosa. A few columnar cells are seen at the base of the duct leading to the glands of the submucosa. Accession number 16657, Army Medical Museum. Negative number 45286. Hematoxylin and eosin stain; $\times 155$

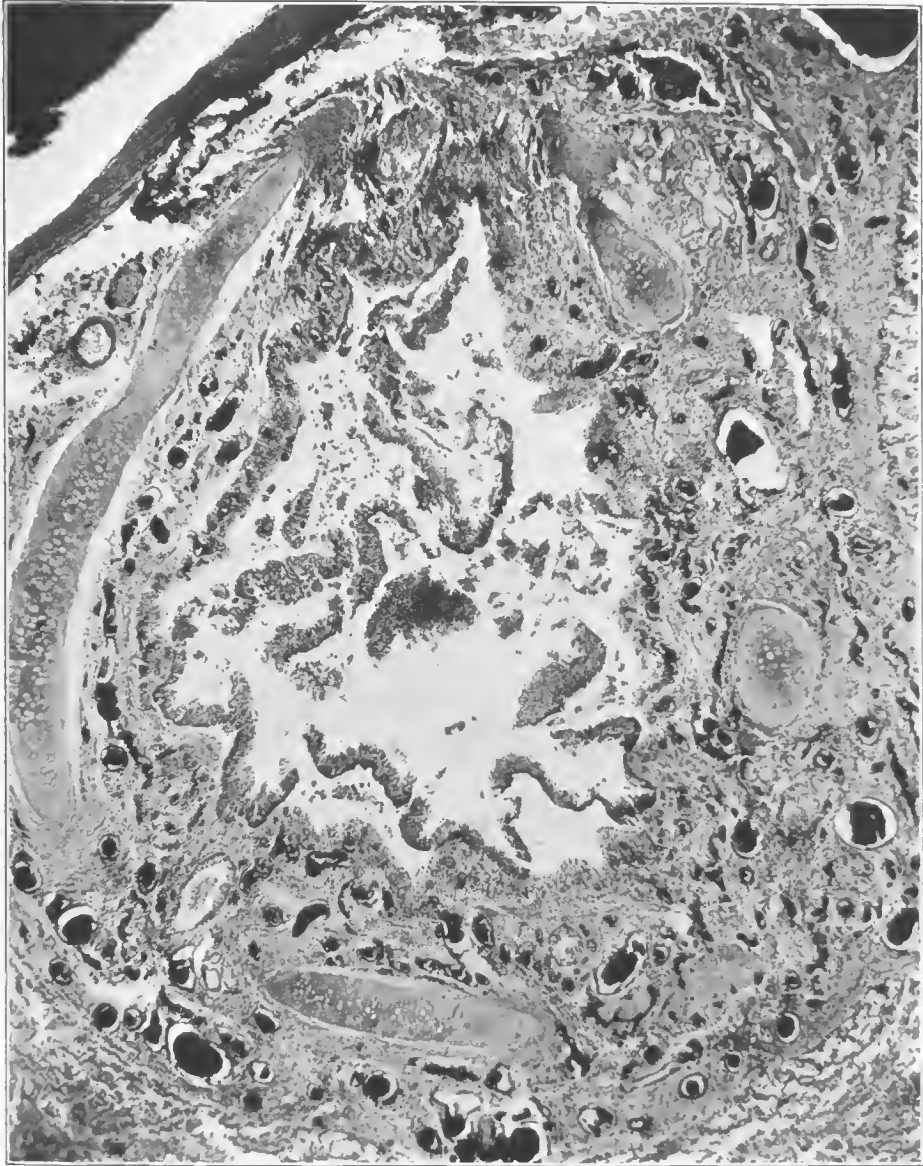


FIG. 104.—Bronchus showing the extension of inflammation through the tissue between the cartilages, with desquamation of the epithelium, in a case of streptococcus lobular pneumonia. The epithelium is thickened by proliferation, as seen in cases associated with influenza bacillus infection, which may have preceded the streptococcus infection. Accession number 16590, Army Medical Museum. Negative number 45230. Hematoxylin and eosin stain; $\times 32$

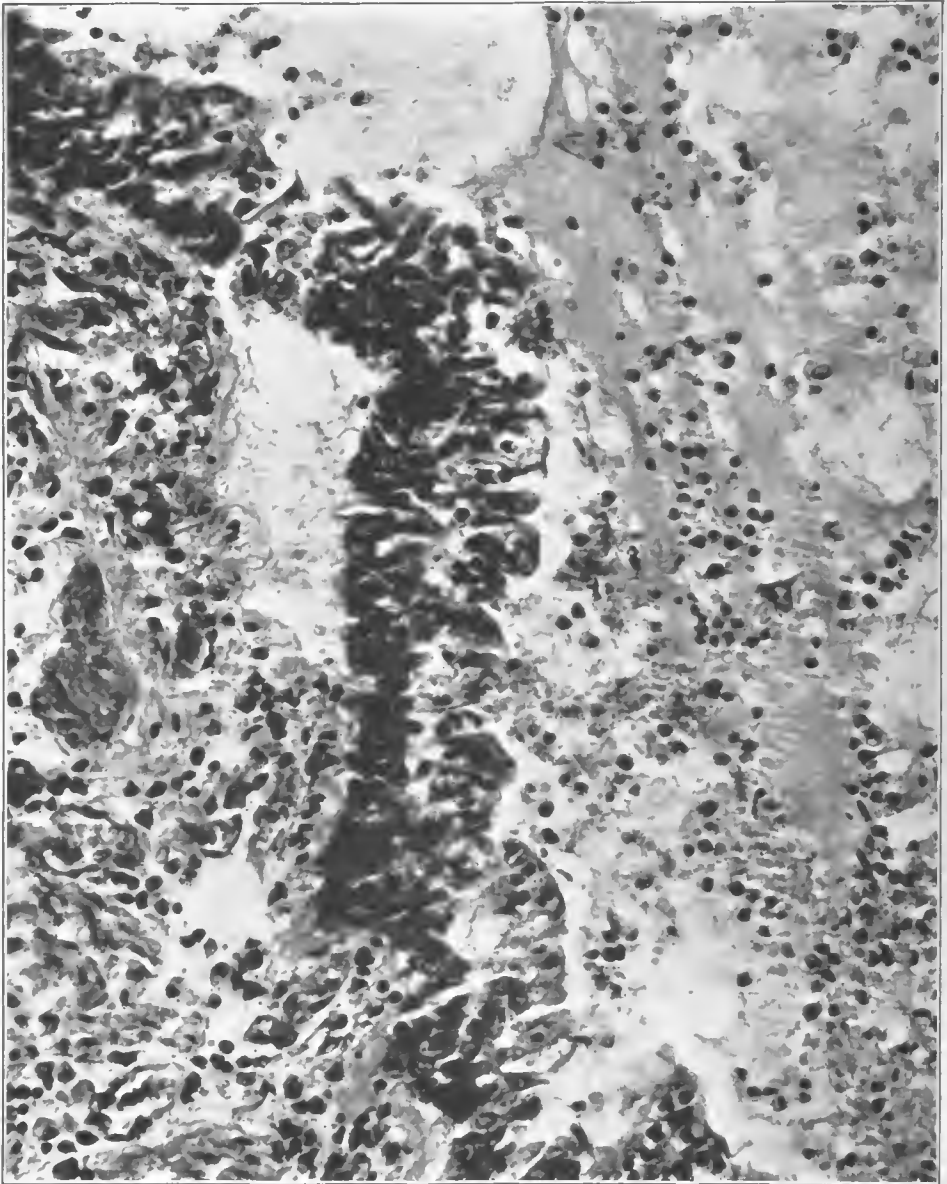


FIG. 105.—Bronchus containing serous exudate and moderate number of mononuclear and a few polymorphonuclear cells. The mucosa is raised by serum in a blisterlike structure. Peribronchial tissue is infiltrated with leucocytes and peribronchial lymphatics contain purulent exudate. Hemolytic streptococcus recovered in cultures of the pleura, lung, and heart's blood. Accession number 3105, Army Medical Museum. Negative number 45180. Hematoxylin and eosin stain; $\times 320$

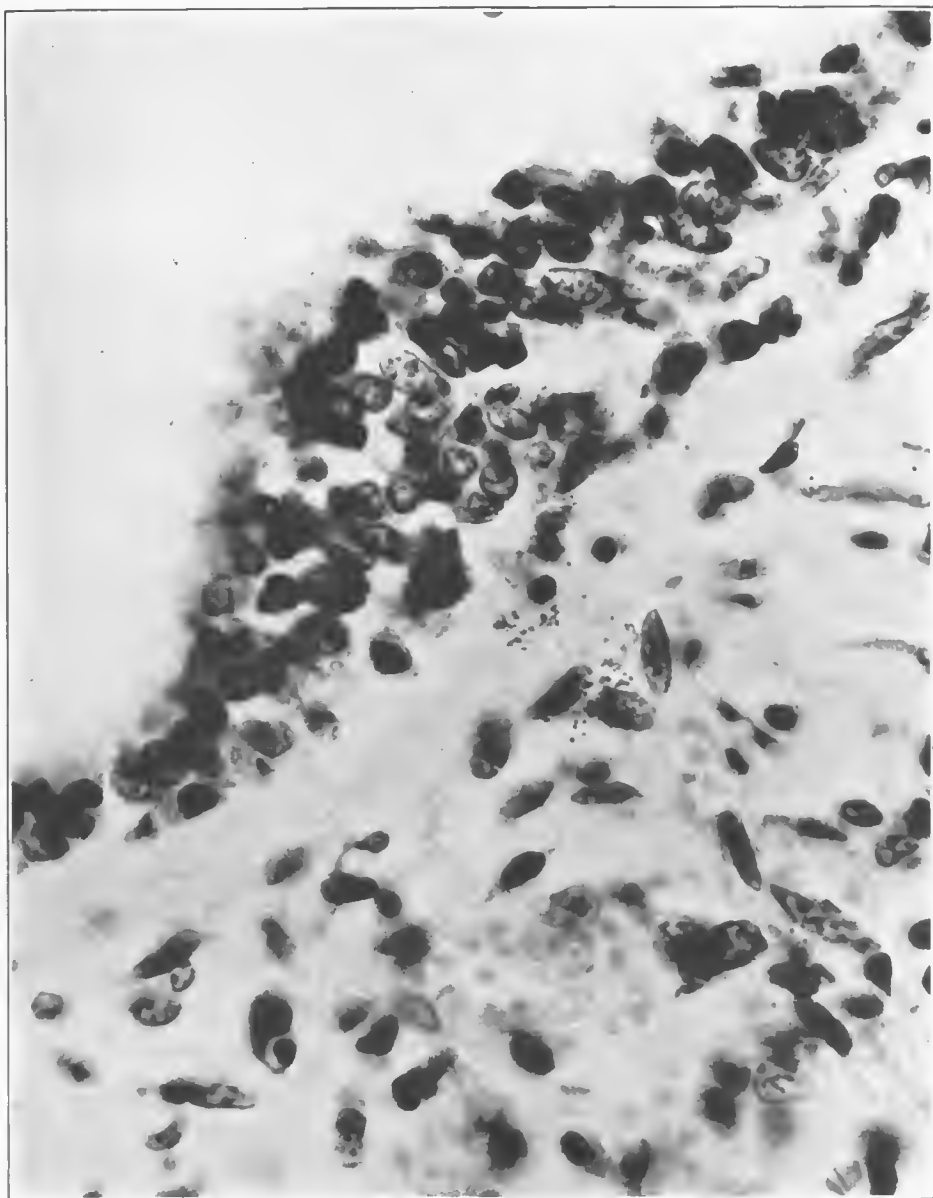


FIG. 106.—Groups of streptococci in lymph spaces beneath the mucosa of a bronchiole which is raised by an exudate of serum and an infiltration of mononuclear cells. There is no exudate in the lumen and the process appears to have extended from the neighboring infected lung. Accession number 3102, Army Medical Museum. Negative number 45263. MacCallum stain; $\times 1020$

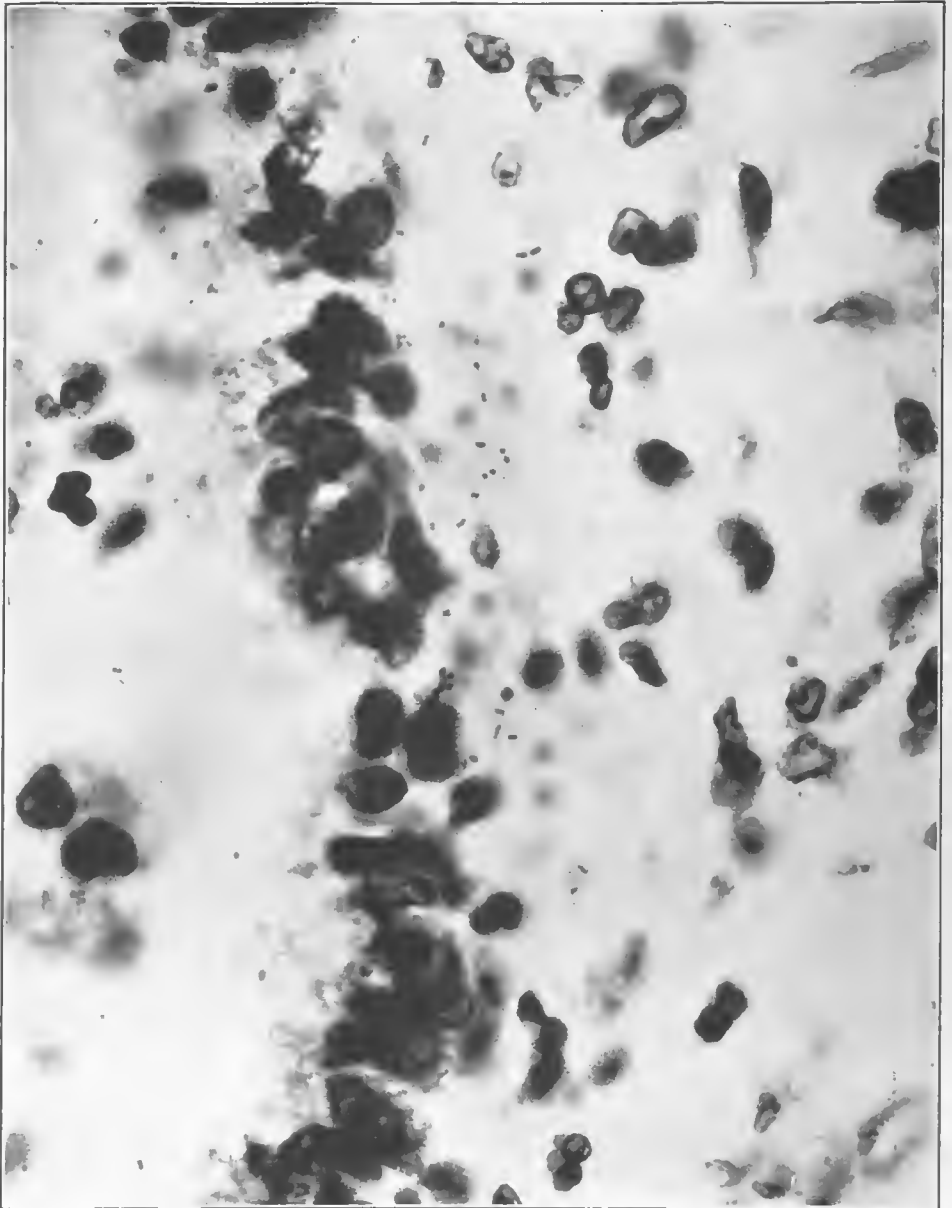


FIG. 107.—Wall of small bronchiole showing streptococcus forms beneath the bronchial mucosa, which is not much affected. Other bronchi in this case showed a purulent bronchitis with loss of mucosa. The bronchiole shown here appeared to have the involvement extend to it from neighboring areas. The bacteria were disseminated throughout the surrounding tissues between, but were few in the serous exudate in the lumen. Accession number 3102, Army Medical Museum. Negative number 45262. MacCallum stain; $\times 1270$

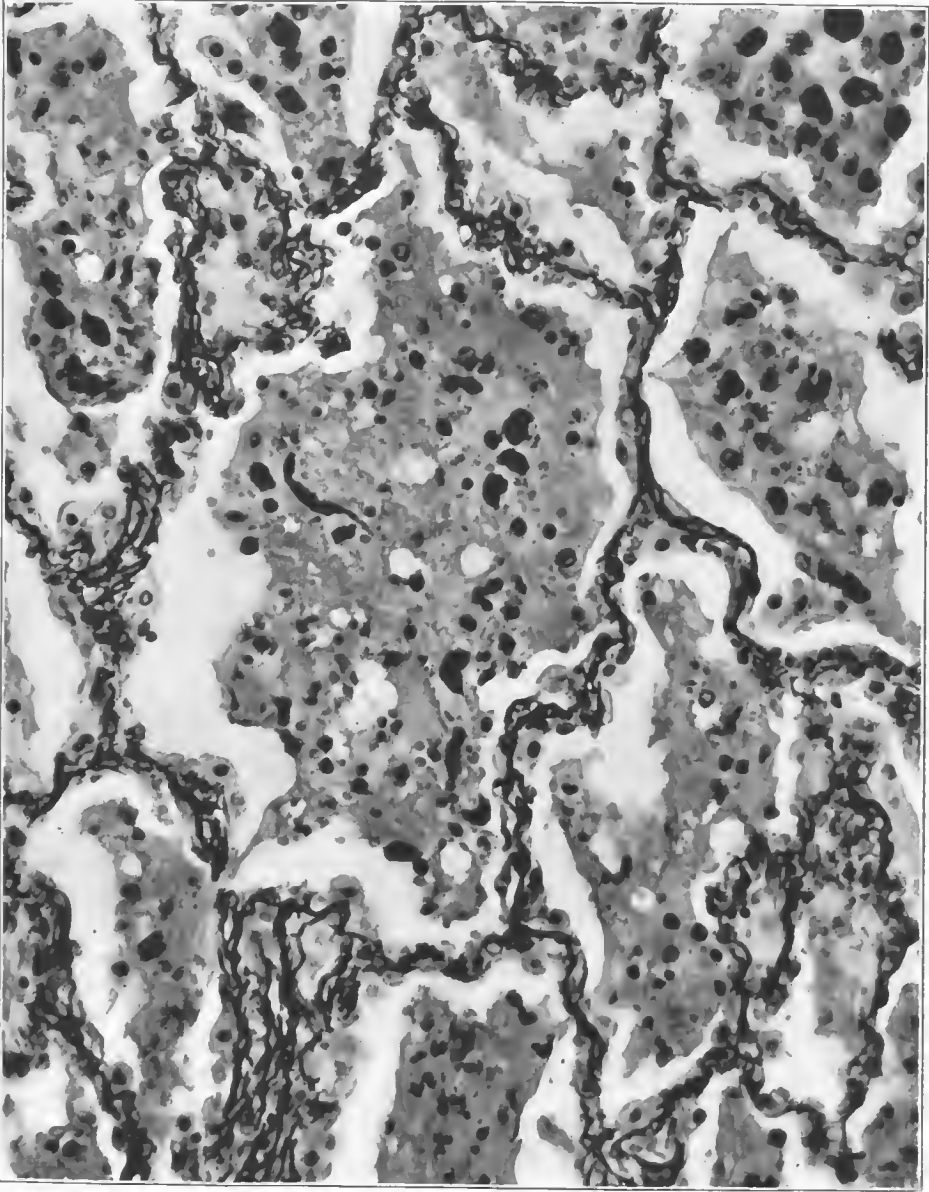


FIG. 108.—Serofibrinous exudate in an early stage of a lobular pneumonia caused by hemolytic streptococcus. The formation of fibrin extends out from areas where the epithelium is denuded; where the epithelium is gone on both sides of the alveolar wall, the fibrin strands project into the alveoli on either side, the reaction extending through the tissue of the wall. Accession number 20476, Army Medical Museum. Negative number 46044. MacCallum stain; $\times 300$

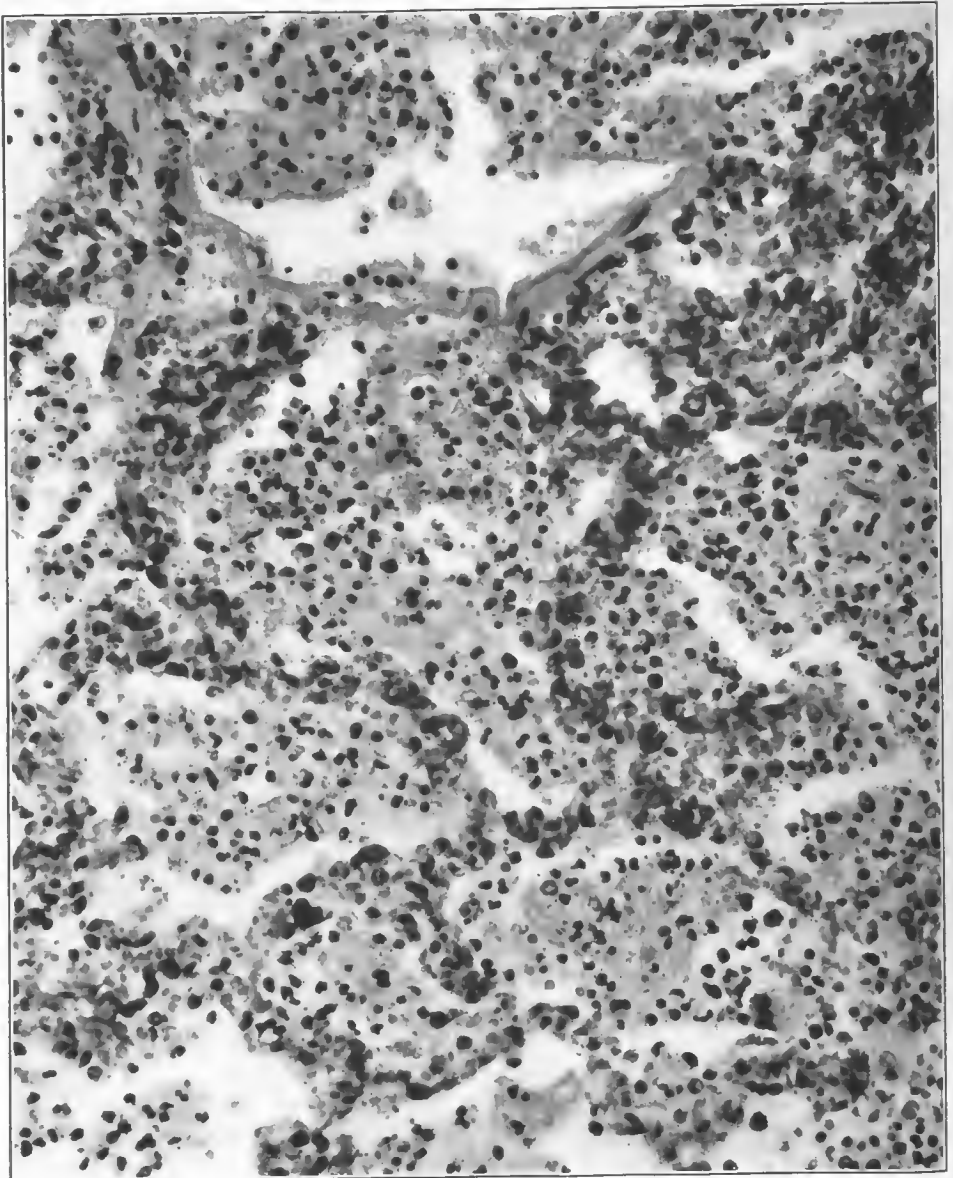


FIG. 109.—Early stage of consolidation in a lobular pneumonia which was grossly hemorrhagic in type. Cultures from the lung showed both hemolytic streptococci and pneumococci. In this section pneumococcus forms were numerous in the exudate and alveoli. A few Gram-negative bacilli were seen along the walls of the atrium, which appears at the lower part of the picture. In this structure there is a beginning formation of hyalin membrane. Accession number 3108, Army Medical Museum. Negative number 45165. Hematoxylin and eosin stain; $\times 650$

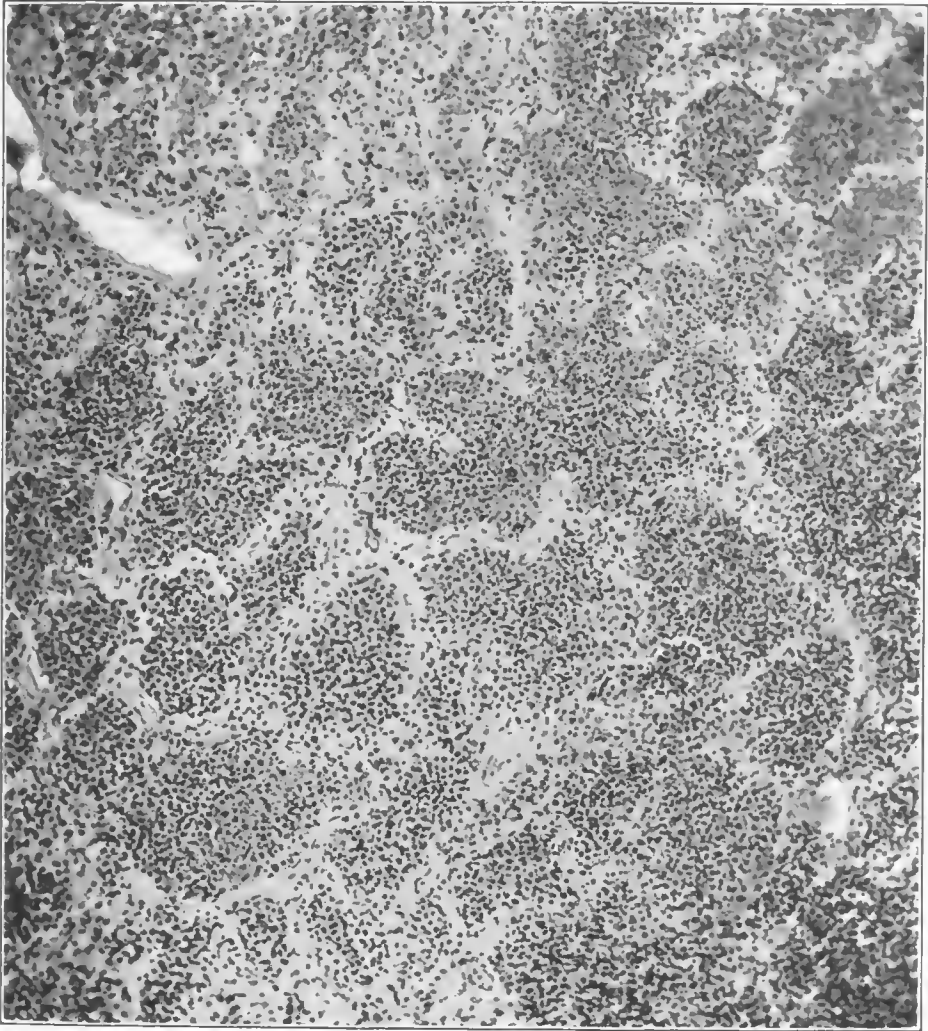


FIG. 110.—Purulent exudate containing blood and a little fibrin in a lobular pneumonia. Streptococci present in cultures but the alveolar walls show less leucocytic infiltration than is usual in streptococcus lobular pneumonia. Accession number 3090, Army Medical Museum. Negative number 45284. Hematoxylin and eosin stain; $\times 140$

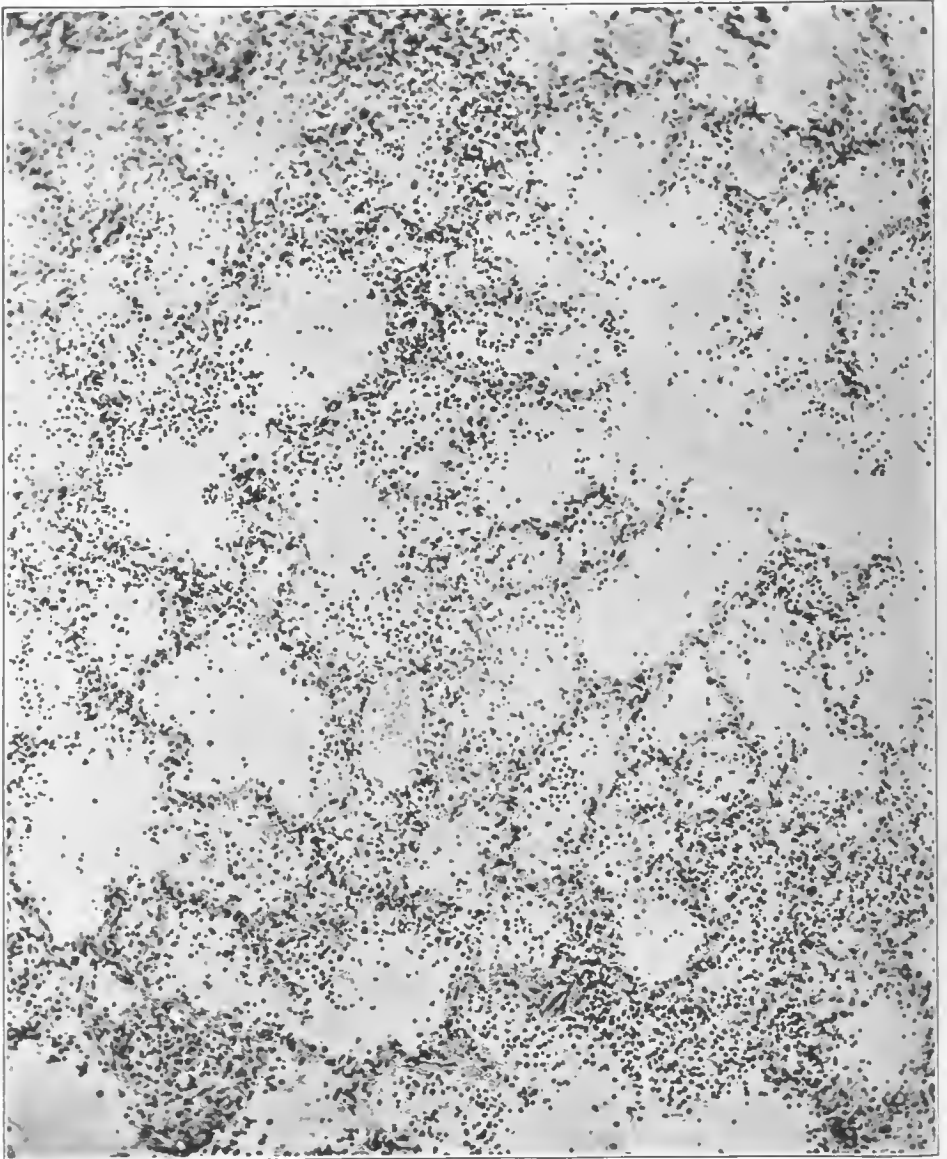


FIG. 111.—Early stage of streptococcus lobar pneumonia. Exudate is largely serous; the alveolar walls are infiltrated with leucocytes, are edematous, and appear to have been the first involved. The epithelium is partially desquamated, such desquamation being more marked in the wall of alveoli, the lumen of which contains many leucocytes. Extension in this case appeared to be outward from the walls of terminal bronchioles. Accession number 3102, Army Medical Museum. Negative number 45283. Hematoxylin and eosin stain; $\times 140$

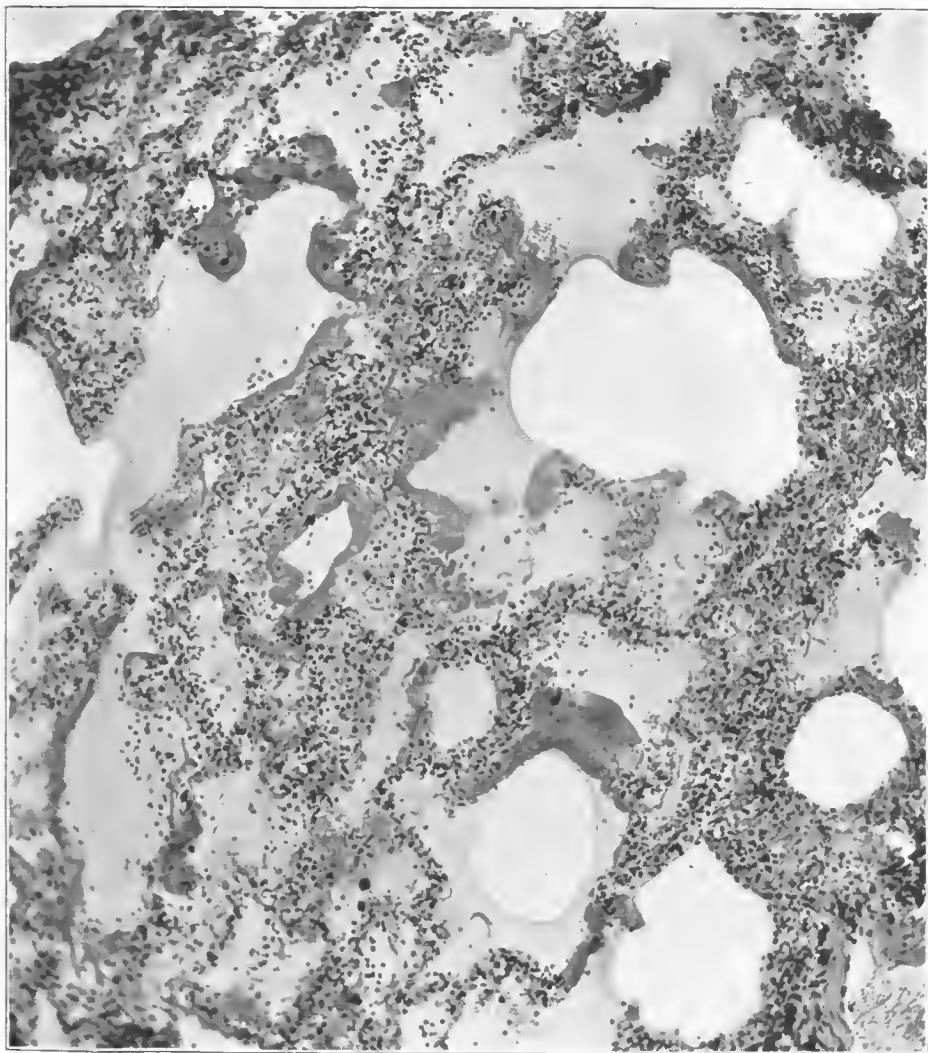


FIG. 112.—Air and serous exudate with formations of hyalin membrane in a group of atria and alveoli, the walls of which are infiltrated with leucocytes. Both pneumococci and streptococci were cultured from the lung; minute Gram-negative forms were found along atrial and bronchiolar walls of sections presenting this type of reaction, in addition to streptococci. Accession number 3117, Army Medical Museum. Negative number 45280. Hematoxylin and eosin stain; $\times 130$

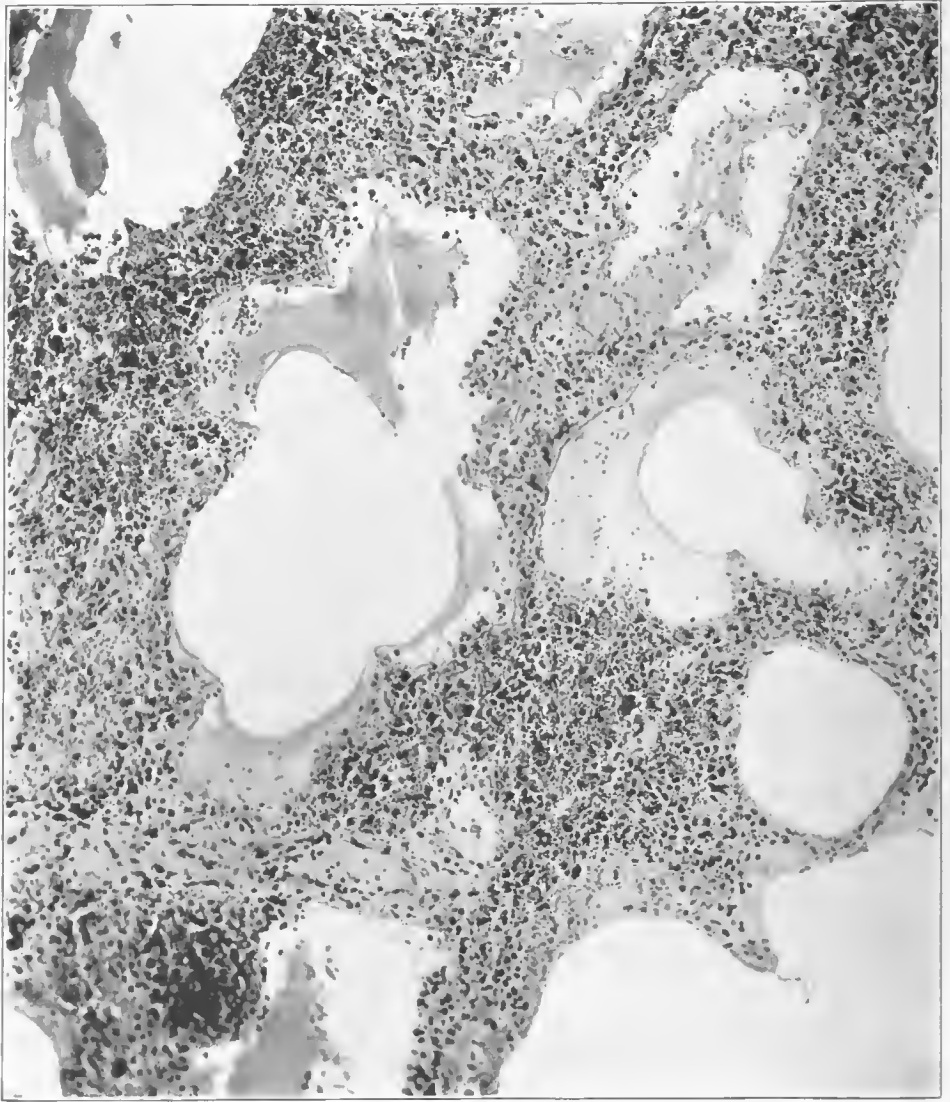


FIG. 113.—Hemorrhagic inflammation of alveolar walls with serous exudate in the alveoli. Streptococci in cultures and in sections. Gram-negative bacteria in sections of smaller bronchioles. Accession number 3109, Army Medical Museum. Negative number 45274. Hematoxylin and eosin stain; $\times 113$

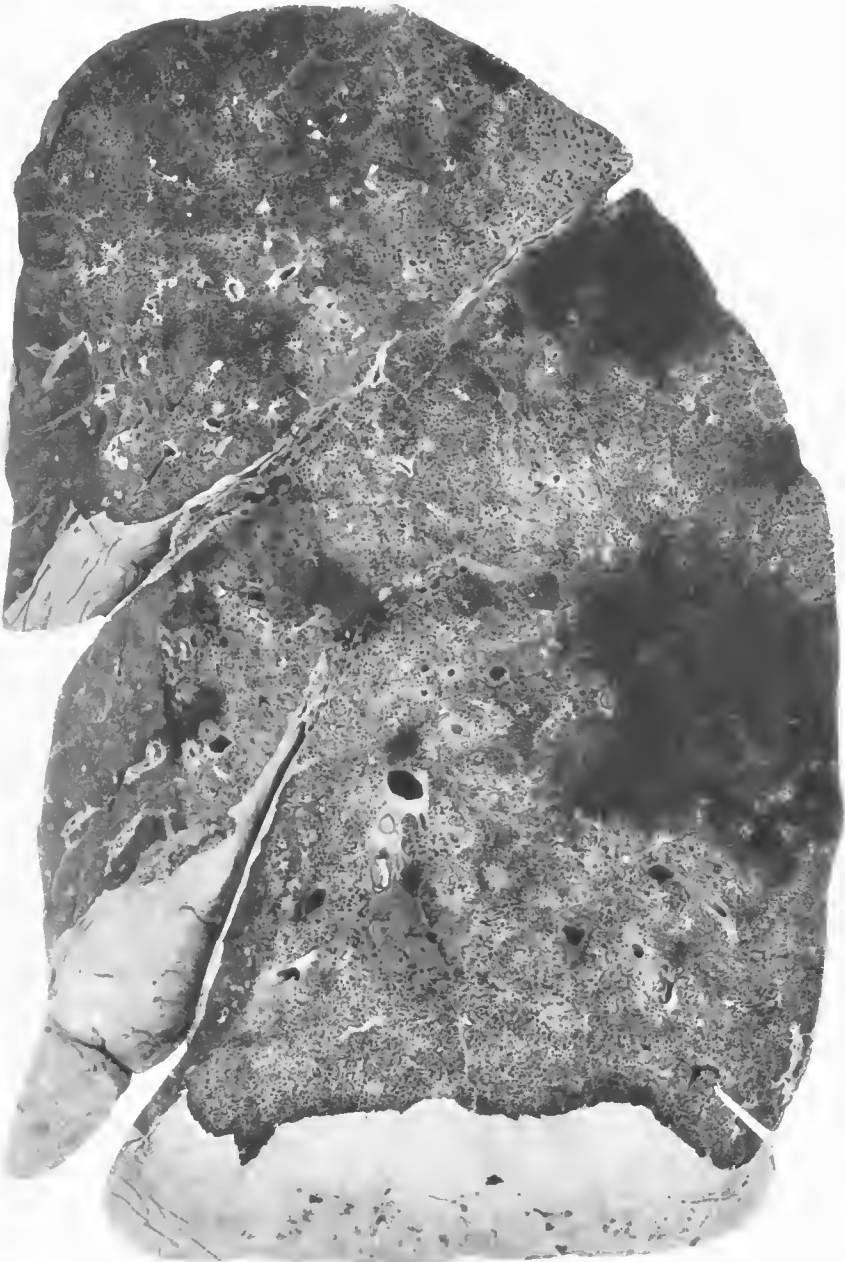


FIG. 114.—Universal or confluent lobular pneumonia, with extensive hemorrhage due to hemolytic streptococcus, very little lymphangitis, which is confined to perivascular lymphatic structures and is indicated by the small white spots most abundant in the upper lobe. Accession number 3100, Army Medical Museum. Negative number 30665

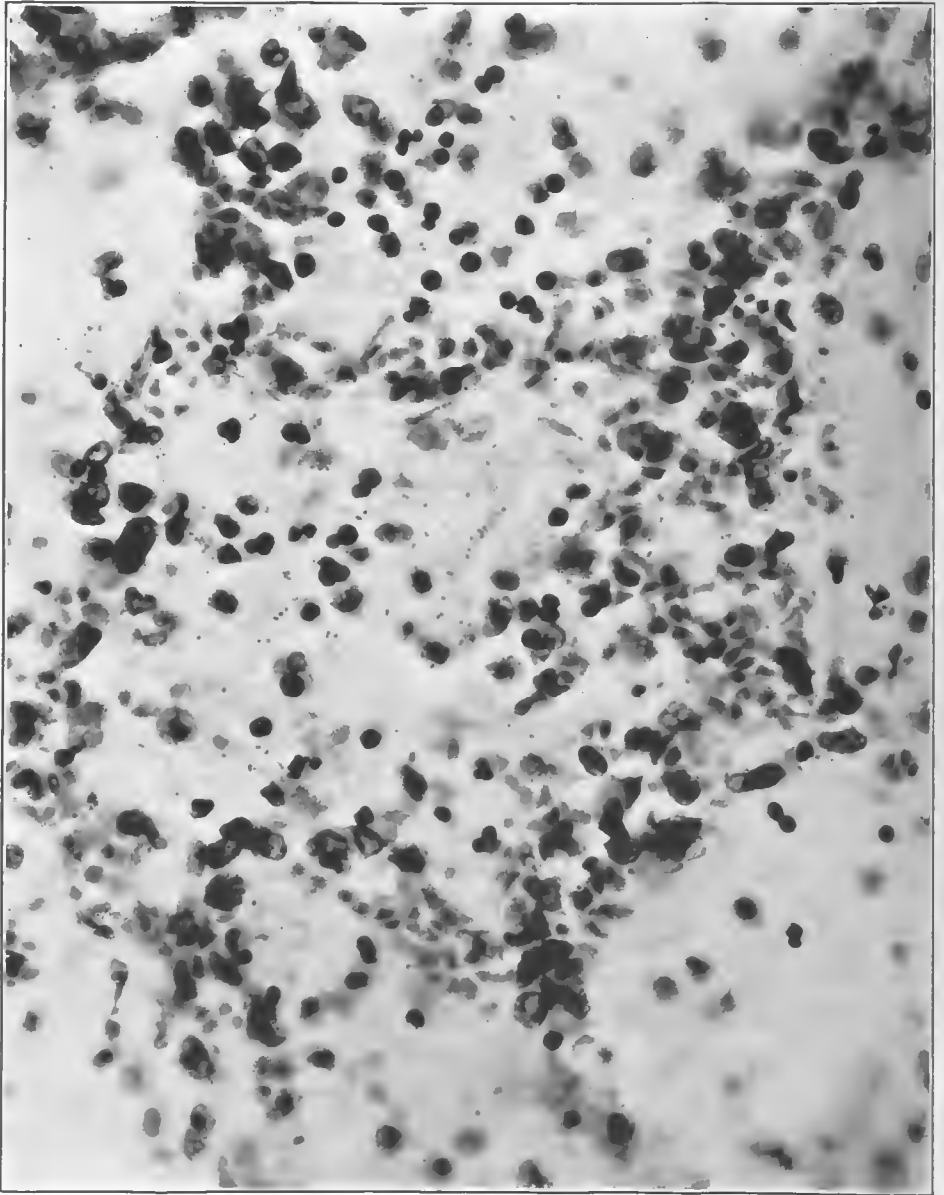


FIG. 115.—Alveolus with serous exudate containing streptococci. Walls show engorgement and leucocytic infiltration. Early stage of streptococcus lobular pneumonia. Accession number 3102, Army Medical Museum. Negative number 45265. MacCallum stain; $\times 650$

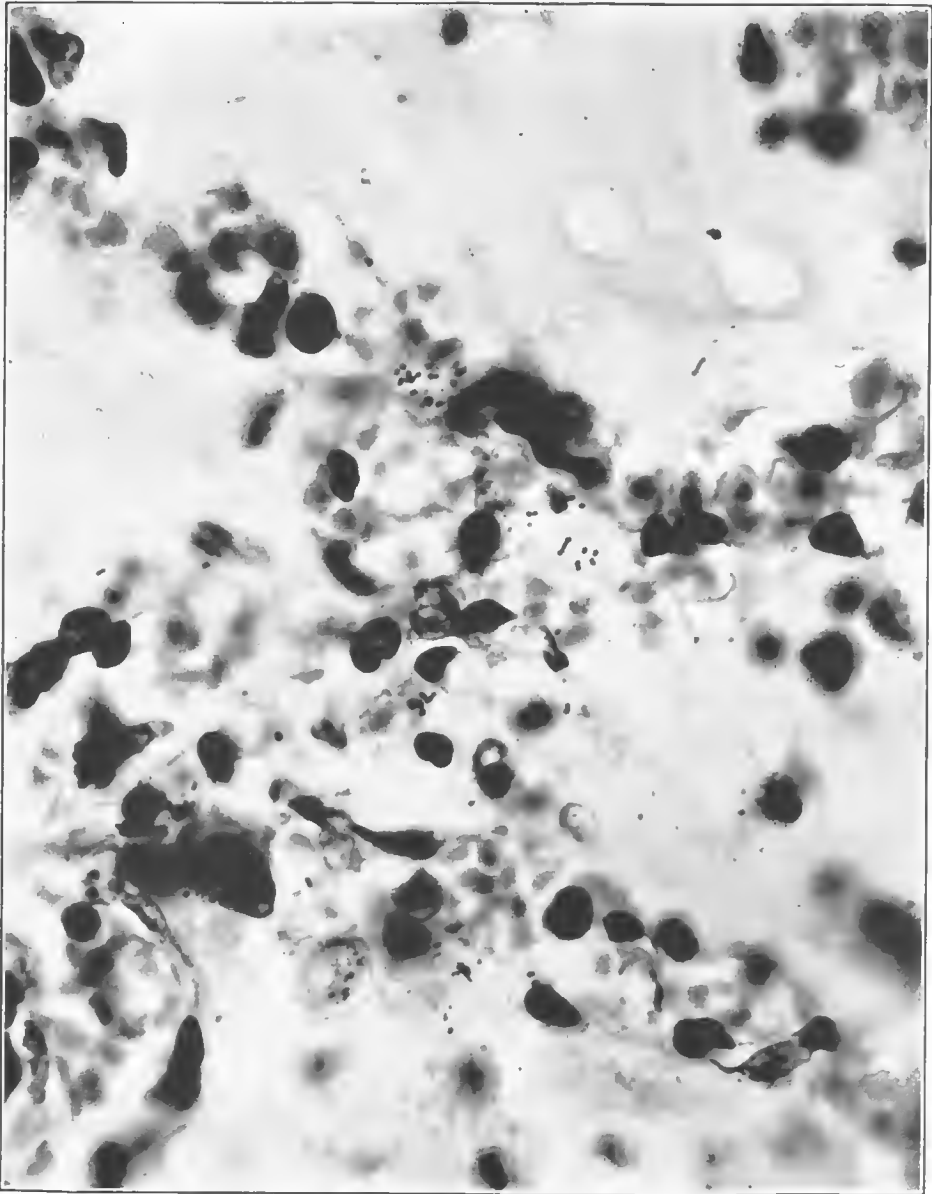


FIG. 116.—Alveolar walls at junction of four alveoli. Streptococci in lymph spaces in alveolar walls. Early streptococcus lobular pneumonia. Accession number 3102, Army Medical Museum. Negative number 45176. MacCallum stain; $\times 1020$

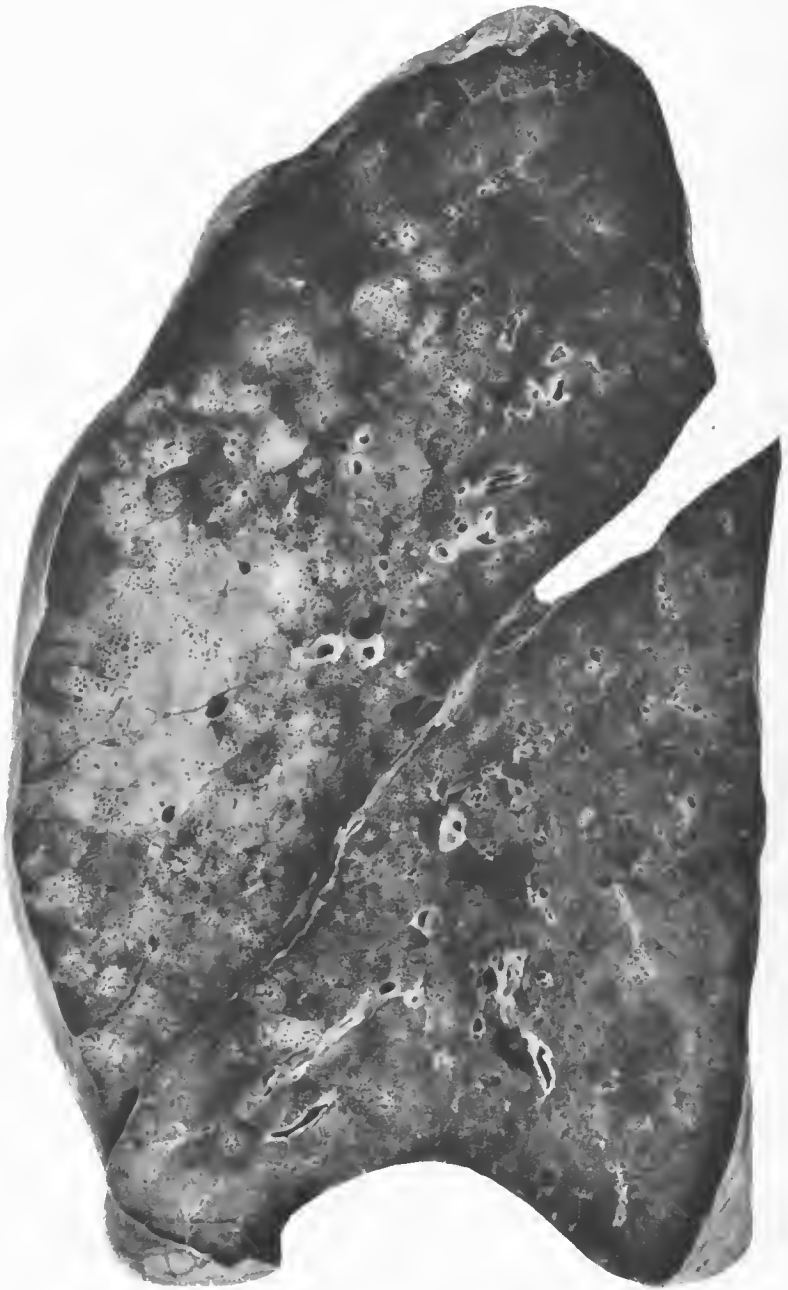


FIG. 117.—Postinfluenzal pneumonia. Hemolytic streptococci were isolated from the pleural fluid and influenza bacilli from the left lung. The lesion present is a lobular pneumonia in which the lesions are of varied age, no lobule seen in the cross section being free from involvement. Accession number 3172, Army Medical Museum. Negative number 30717

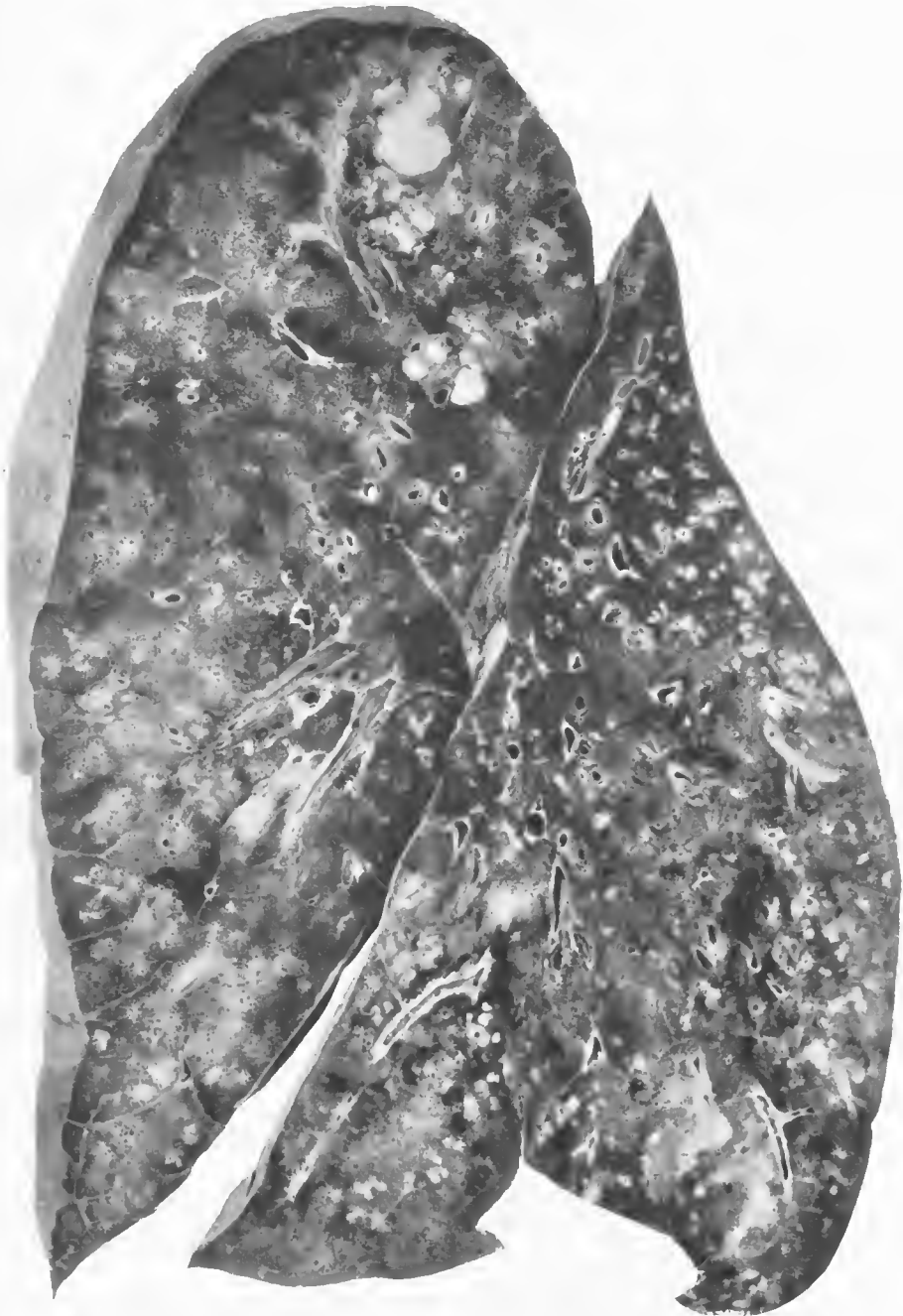

FIG. 118.—Postinfluenzal pneumonia. Peribronchiolar consolidations extending to involve lobules, with necrosis in areas in the apex and in the base of the lower lobe. Nonhemolytic streptococcus and influenza bacillus found on culture. Accession number 3133, Army Medical Museum. Negative number 30980



FIG. 119.—Postinfluenzal pneumonia. Confluent lobular pneumonia due to hemolytic streptococcus superimposed on peribronchiolar lesions probably due to the influenza bacilli. *Streptococcus hemolyticus* and *Staphylococcus albus* were found in cultures from this lung. Accession number 16598, Army Medical Museum. Negative number 45882

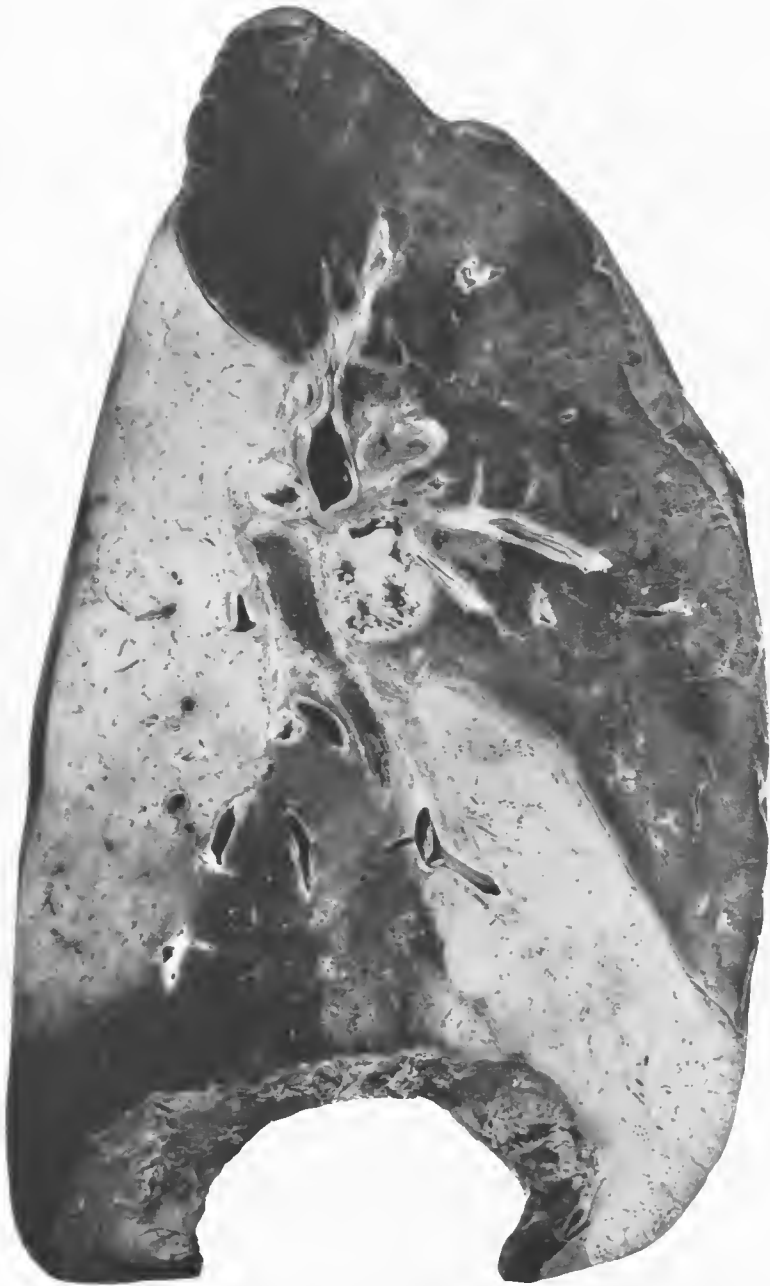

FIG. 120.—Postinfluenzal pneumonia. Confluent lobular pneumonia of the upper lobe with a few small peribronchiolar foci of older consolidation in the lower portion. *Streptococcus hemolyticus* cultivated from this lobe and influenza bacillus from the bronchi. Accession number 16524, Army Medical Museum. Negative number 45883

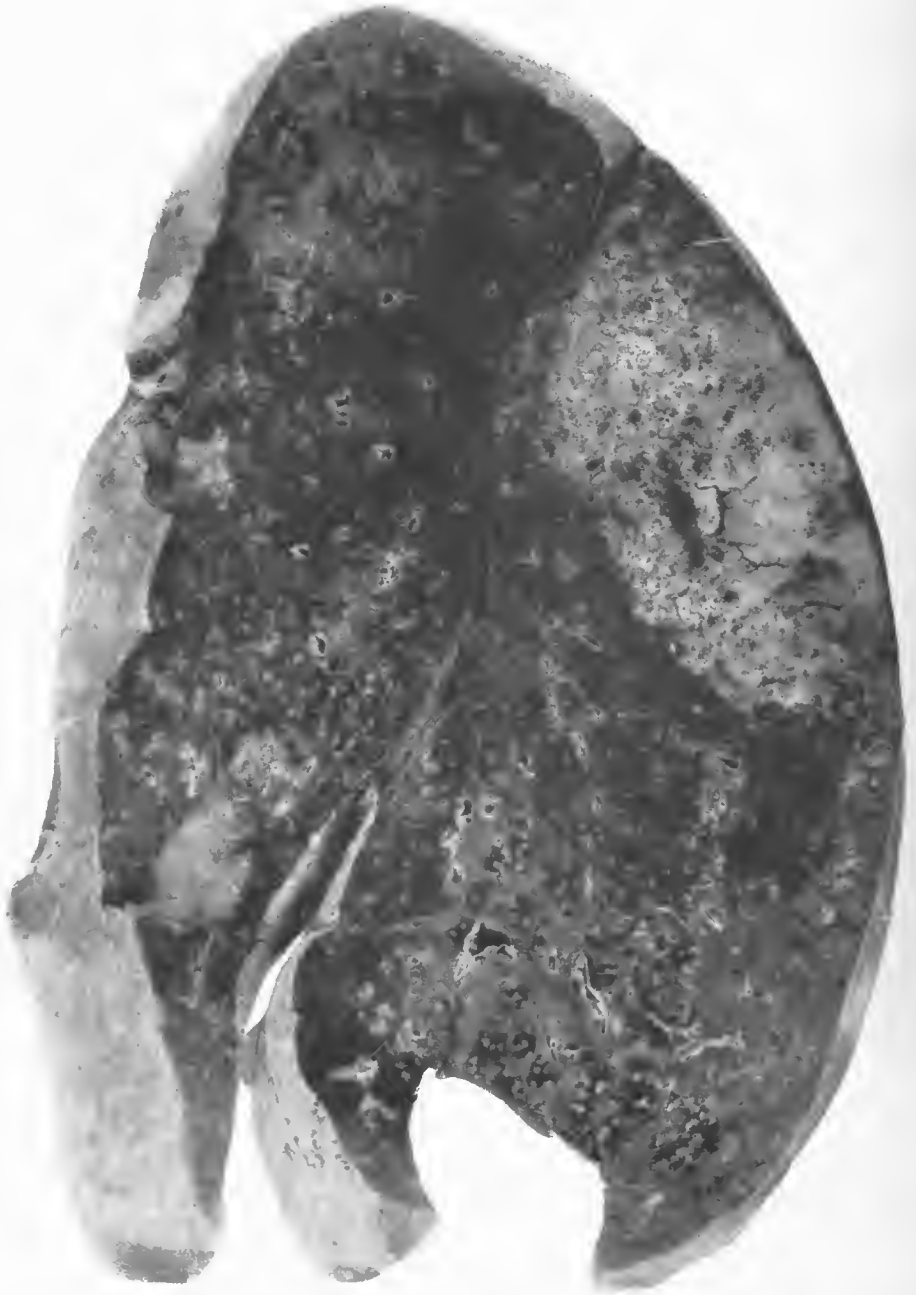

FIG. 121.—Left lung. Confluent lobular pneumonia of the upper portion of the lower lobe with central necrosis. Peribronchiolar consolidations throughout the rest of the lung. Hemolytic streptococci isolated. Sections show abundant streptococci but Gram-negative bacilli predominate in the ductuli alveolares and atria of the consolidations about terminal bronchioles. Accession number 3073 Army Medical Museum. Negative number 42900

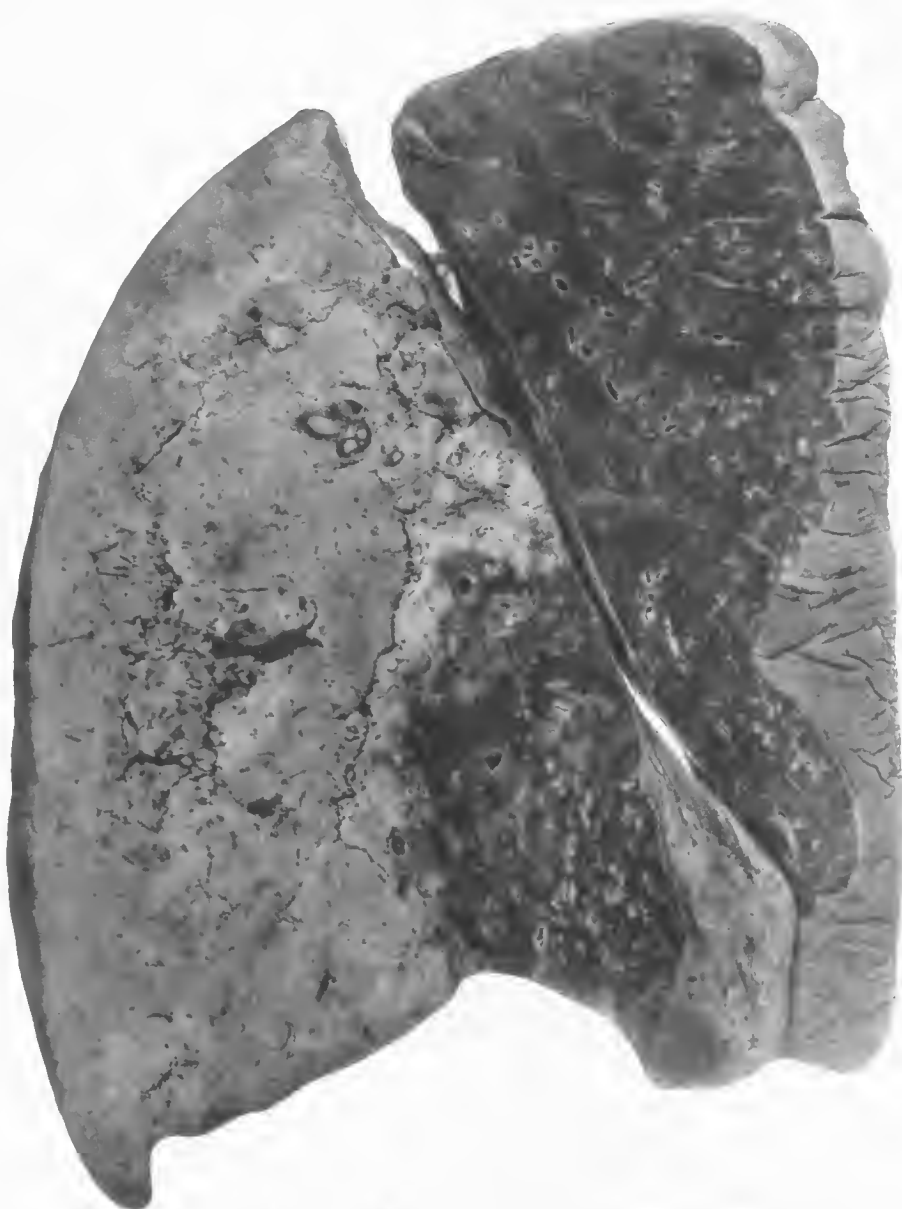

FIG. 122.—Right lung. Confluent lobular pneumonia of the lower lobe with extensive central necrosis. The lower mesial portion of this lobe contains peribronchial and peribronchiolar consolidations accompanied by hemorrhage. Peribronchiolar consolidations throughout the upper lobe. Accession number 3073, Army Medical Museum. Negative number 42912

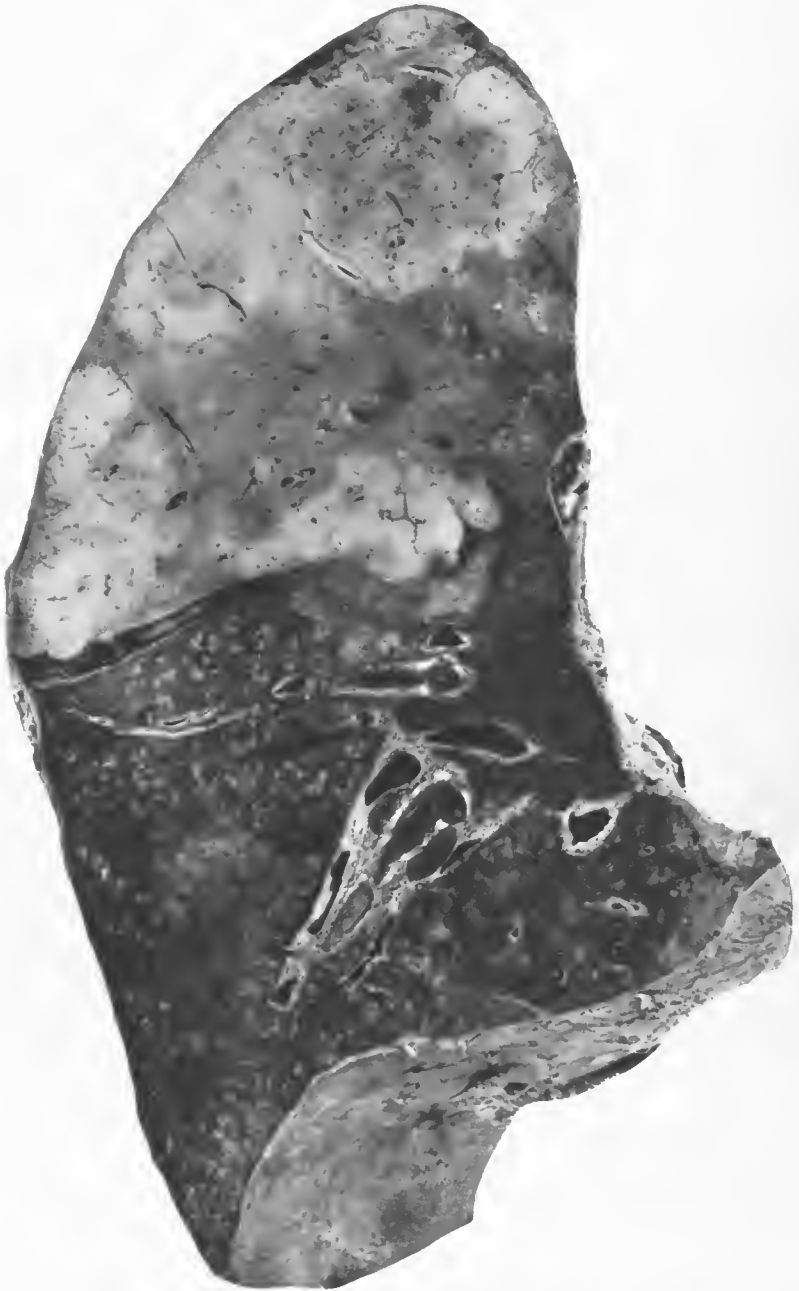


FIG. 123.—Postinfluenzal pneumonia. Necrotic confluent lobar pneumonia. Beginning evolution toward the hilum. The lower lobe shows peribronchiolar nodular lesions. Pneumococcus, Type III, isolated from the sputum. Accession number 2333, Army Medical Museum. Negative number 31001

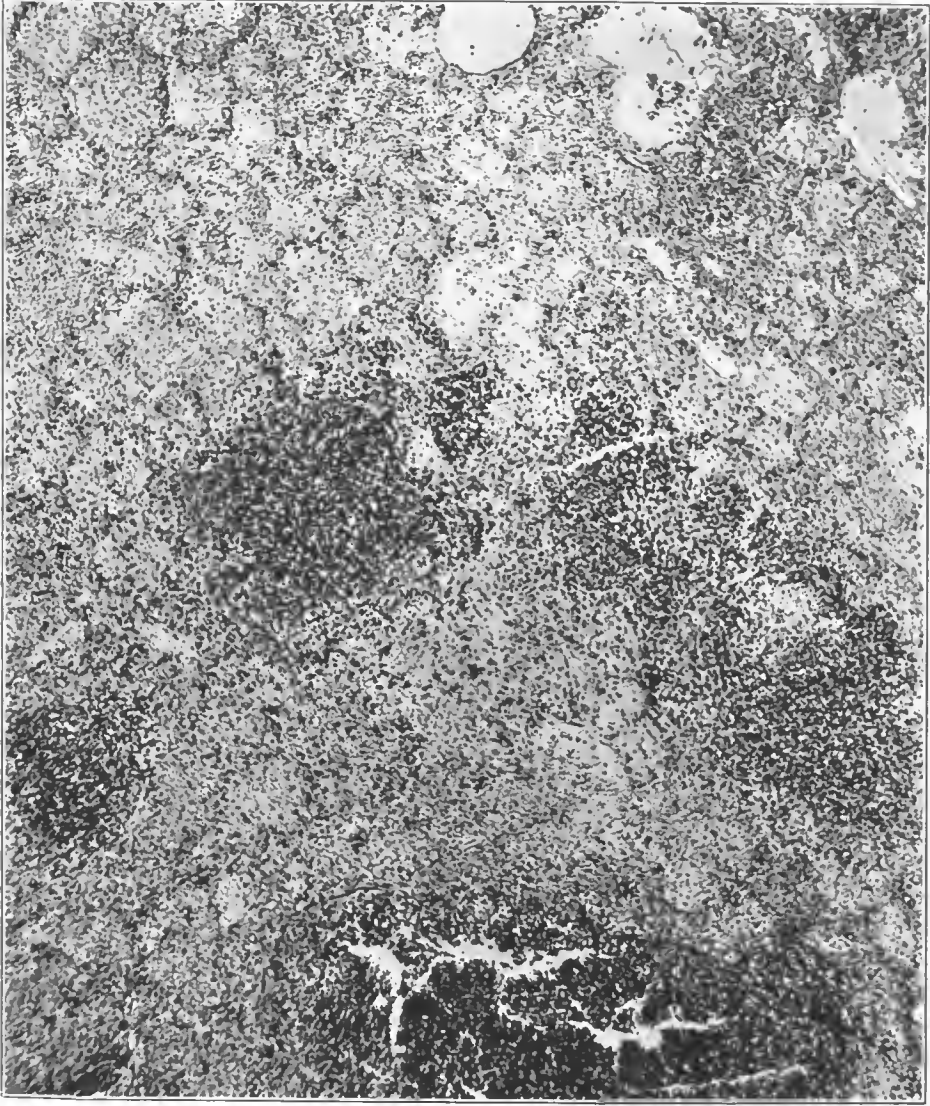

FIG. 124.—*Streptococcus lobular pneumonia* showing beginning abscess formation. Note the lack of uniformity in the consolidation. Accession number 3107, Army Medical Museum. Negative number 45228. Hematoxylin and eosin stain; $\times 70$

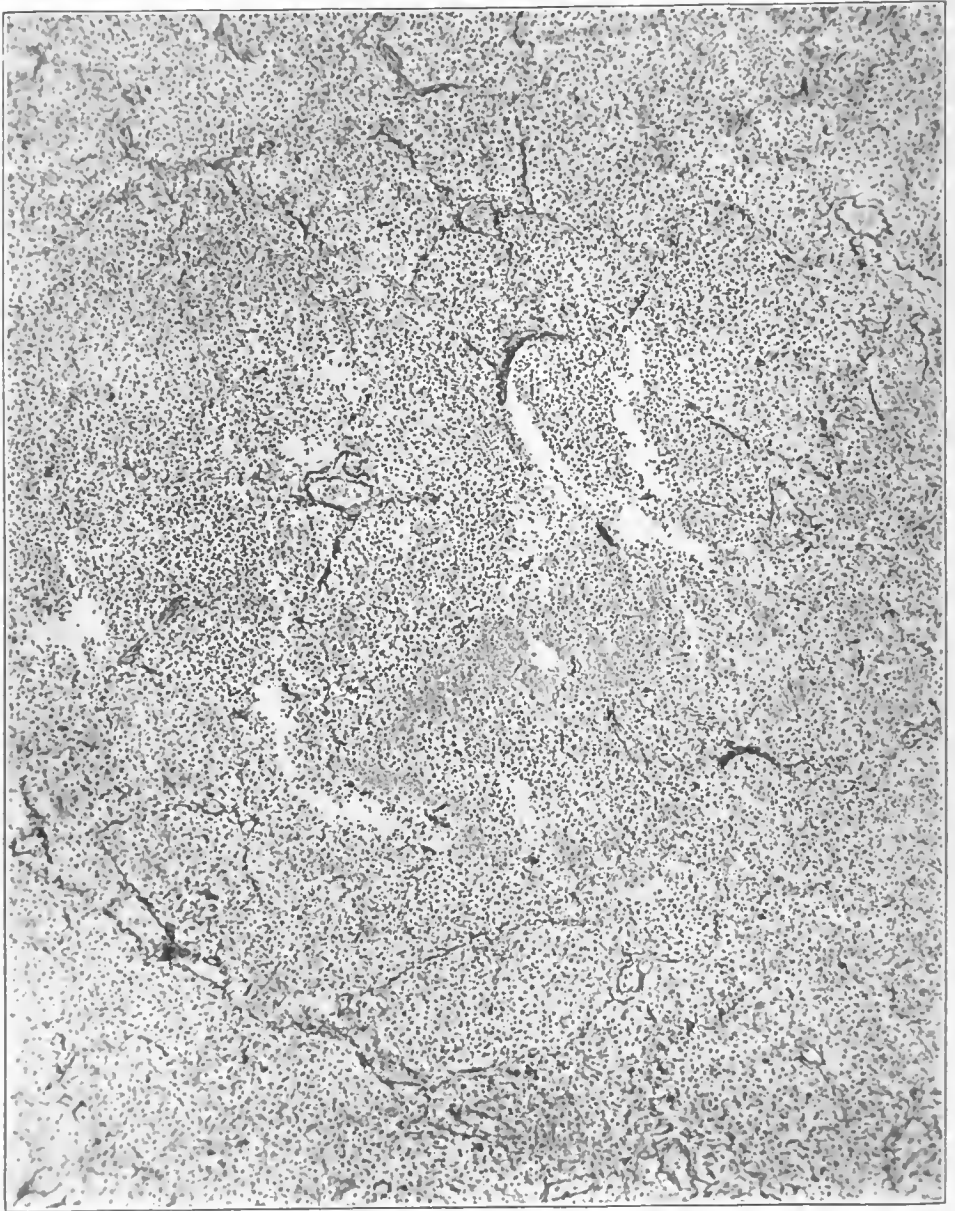


FIG. 125.—Abscess formation in the center of a lobule of streptococcus lobular pneumonia. Note the disappearance of the reticulum of alveolar walls in the center of the illustration. Reticulum persists after all other structures of the wall have disappeared; and its disappearance indicates complete destruction. Accession number 3047, Army Medical Museum. Negative number 45558. Reticulum stain; $\times 78$

If the cases survived a sufficient time the massive consolidations tended to become more uniform, particularly when they reached the purulent stage. (Fig. 120.) These massive consolidations usually showed necrosis in the central portions or, if located near the periphery of the lung, the necrosis appeared to start in the subpleural lobules. The density decreased toward the periphery in the earlier stages but began to return toward the normal in parts nearer the hilus of the lung, presumably as the result of the resumption of circulation. (Figs. 121, 122, and 123.) The continued extension of the process, thus maintaining the block of the lymphatic circulation, played an important part in the production of the necrosis and solution of the tissues. The necrosis occurred relatively early in lungs affected by *Streptococcus hemolyticus* and the rupture of such areas into the pleura was frequently the cause of empyema. Occasionally these ruptured into the bronchi and a pulmonary abscess formed which in some cases, as indicated by clinical and roentgenoscopical evidence, were healed, leaving a definite scar. Microscopically there appeared in the early stages of this abscess formation dense collections of polymorphonuclear leucocytes in the relatively loosely consolidated lobules. (Fig. 124.) A reticulum stain shows that in these areas the reticulum of the alveolar walls has been destroyed. (Fig. 125.) This finding is quite different from that of lobar pneumonia where similar stains show that, in spite of the almost uniform consolidation, fibers of the reticulum are still present outlining the air spaces.

In cases in which individual, isolated lobules were involved in the necrotic process the solution of tissue appeared to start in areas of denser consolidation instead of uniformly involving the entire lobule. This is explained by the variations in the circulation and lymphatic drainage still remaining. (Fig. 126.) Sometimes considerable areas of the lung showed scattered rather than confluent areas of necrosis with abscess formation, but the most frequent picture was that of a massive consolidation with necrosis of its central portion or that portion of the consolidation nearest the pleura.

Where scattered lobules were involved the tissue between was usually atelectatic and if the patient survived a sufficient time, the tissue between the abscesses became organized and a dense fibrous matrix filled with abscesses resulted. This maintained a focus of infection for an indefinite length of time and as it usually communicated with an empyema cavity the whole mass occasionally was involved in an organizing process extending from the parietal pleura irregularly into the pulmonary parenchyma. (Fig. 127.) In this dense tissue, even after what appeared to be complete organization, one found in the microscopical sections collections of mononuclear leucocytes with occasional polymorphonuclears, and it usually was possible to find Gram-positive cocci by means of bacterial stains. Ordinarily granulation tissue projected into the abscess cavities from walls of a greater or lesser density, but the contraction of the fibrous tissue about the veins and smaller vessels was responsible for necrosis and breaking down of the granulations just as is true of other healing abscesses. (Fig. 128.)

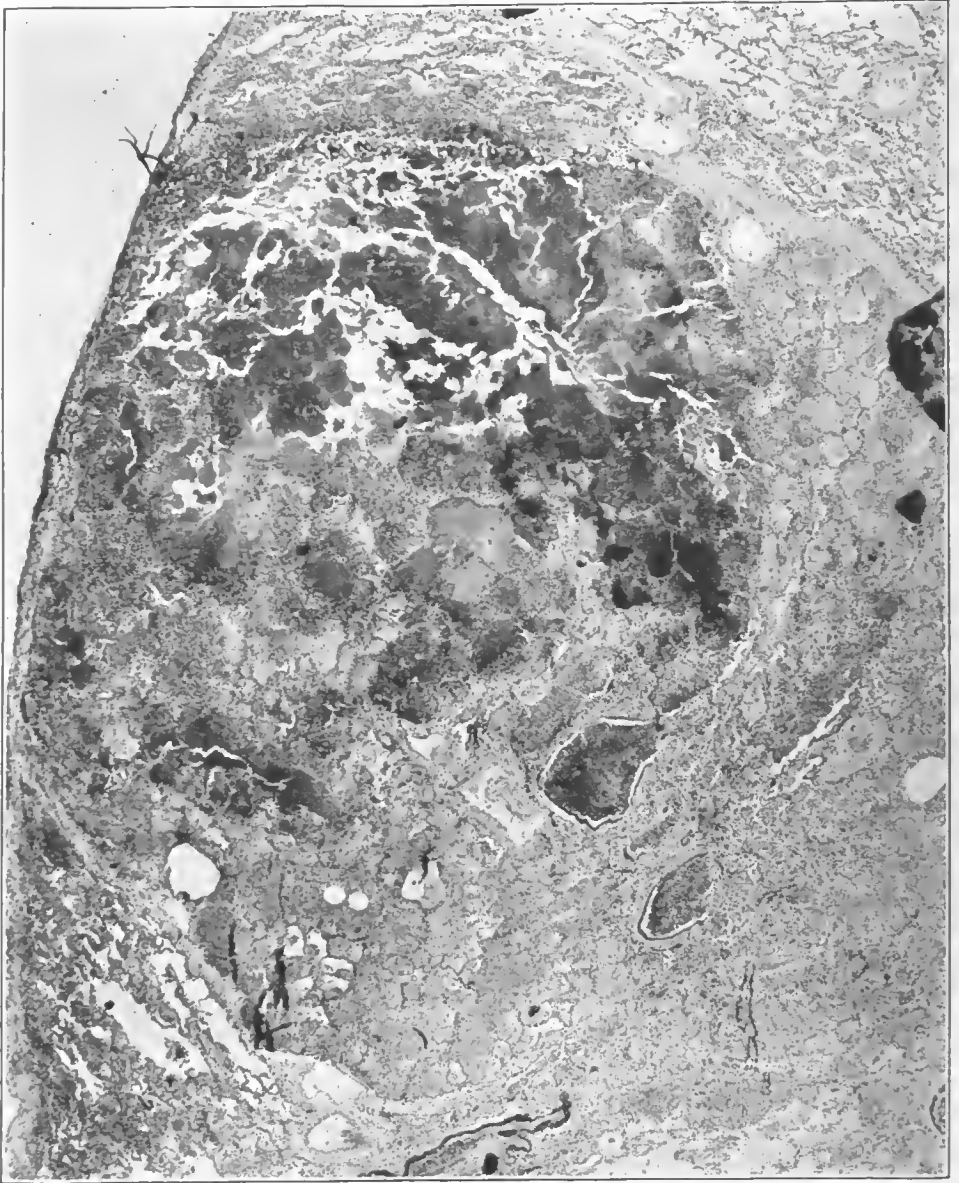
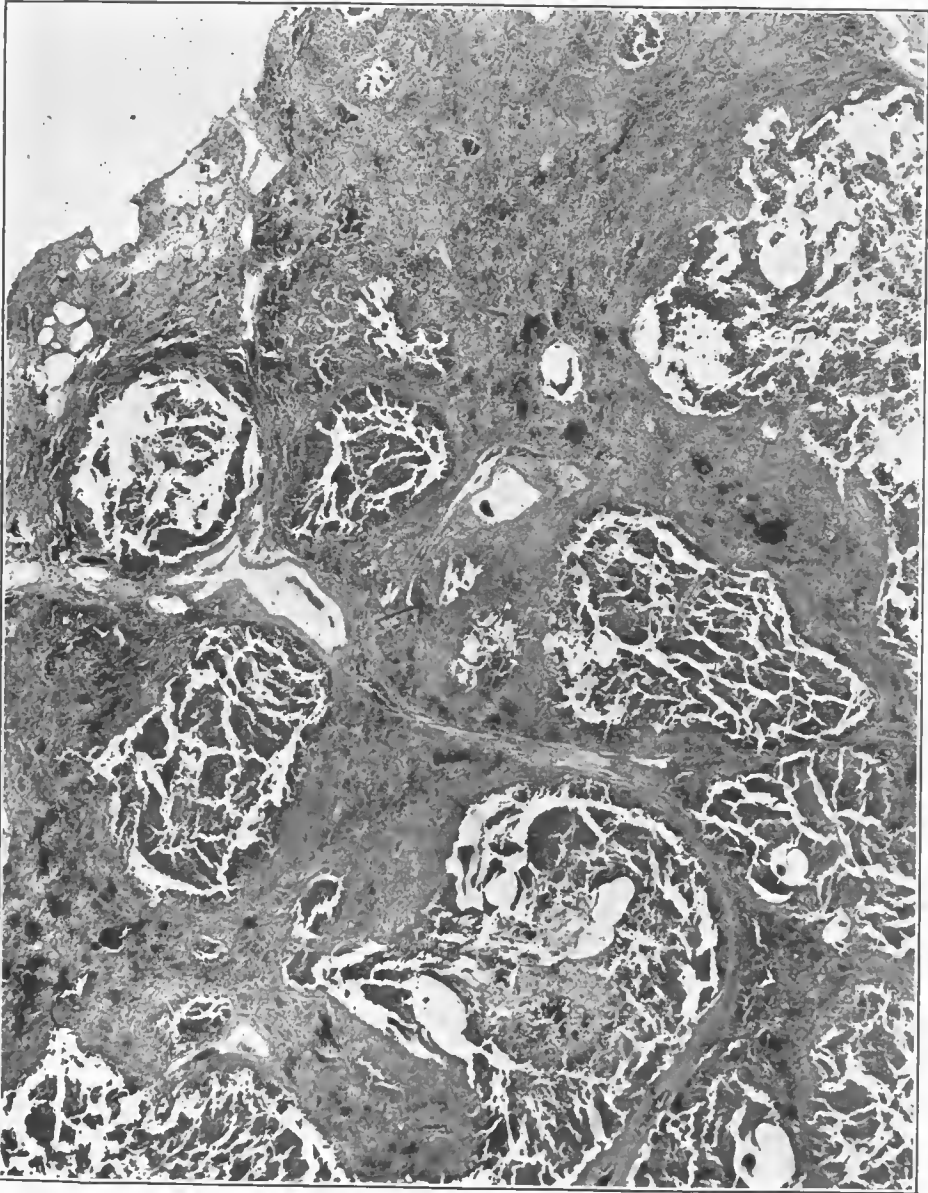


FIG. 126.—Pneumonia following influenza. Low power photograph of a lobule completely consolidated and going on to abscess formation at one side, where open spaces or faults in the section are visible. Interlobular septa where not involved in the necrosis are composed of fibrous tissue, the lymphatics having been obliterated. Duration 50 days. Death occurred from streptococcus empyema. Lung showed a resolving pneumonia with atelectasis of large areas and multiple abscesses throughout the lung. Accession number 3638, Army Medical Museum. Negative number 45201. Hematoxylin and eosin stain; $\times 20$



! FIG. 127.—Late stage in a pneumonia due to hemolytic streptococcus, showing abscess formation in the tissue, the abscesses representing lobules. The interlobular septa are markedly thickened with fibrous connective tissue. Death from empyema. Accession number 3057, Army Medical Museum. Negative number 45177. Hematoxylin and eosin stain; $\times 14$

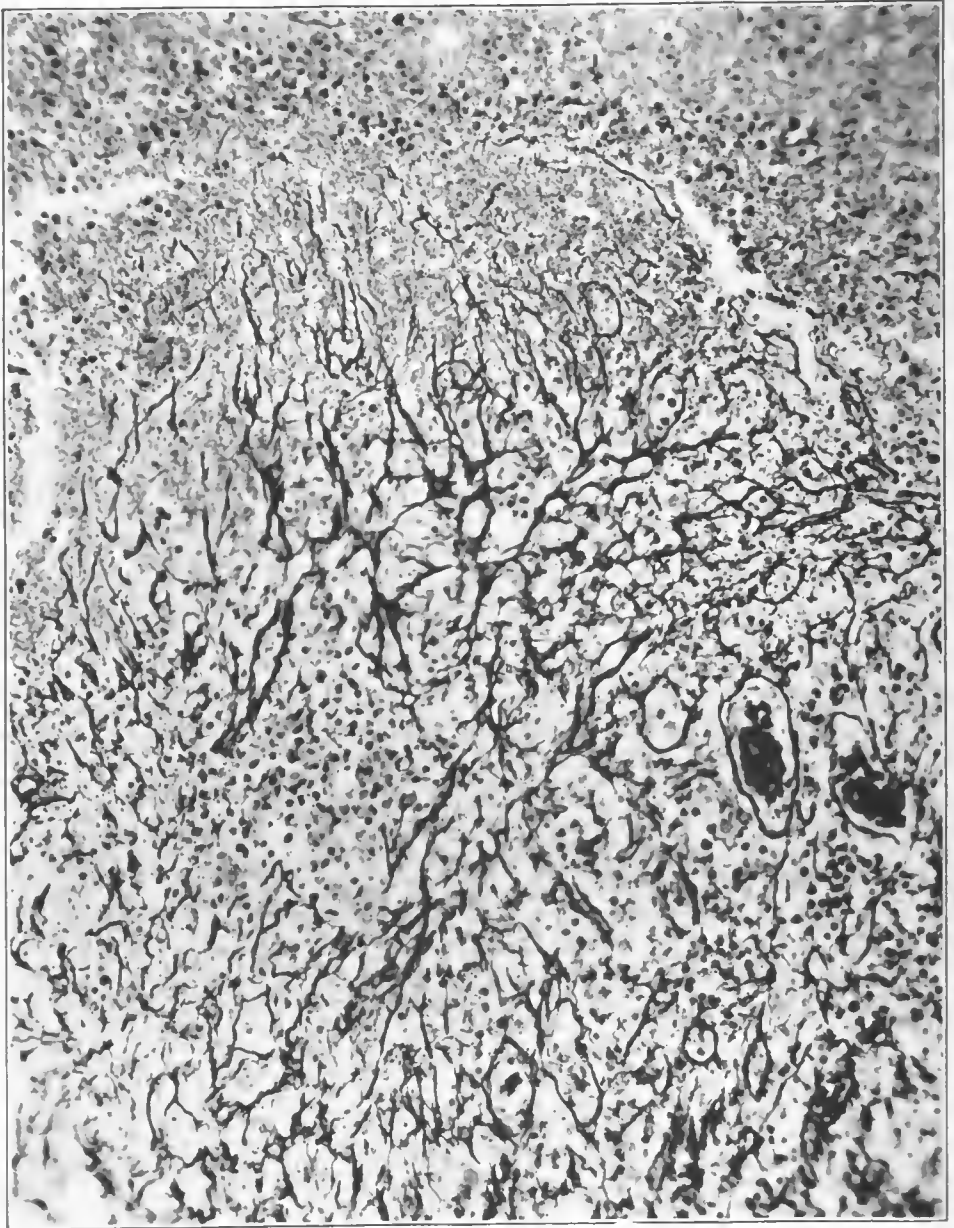


FIG. 128.—New capillaries in granulation tissue projecting into an abscess caused by streptococci. The dense vascular granulation tissue forms the wall of the abscess. Accession number 3042, Army Medical Museum. Negative number 45568. Reticulum stain; $\times 230$

INTERSTITIAL PULMONARY LYMPHANGITIS

Inflammatory reactions in interstitial tissues of the lung have been described from time to time, and indeed the term interstitial pneumonia has been used not infrequently, though more often as descriptive of chronic or proliferative types of reaction than of acute. It is doubtful if an acute interstitial inflammation ever occurs as a primary condition. In the material in the Army Medical Museum collections it was always associated with pneumonia, usually of the lobular variety. The designation in fact can be justified only in cases in which the interstitial reaction so preponderates among the factors leading to the death of the individual, that the pneumonic consolidation accompanying it appears insignificant.

There is extreme variation in the rapidity of the process in the amount of tissue involved and in the resistance of the host. The various stages found were dependent on the length of time the patient survived following the onset of the disease.

Following the onset of measles or influenza by relatively few days, the acute or fulminant hemolytic streptococcus infections lead to death in three or four days. Two types of such cases were found.

In one type there was an acute streptococcus infection of the upper respiratory passages, with intense involvement of the tonsils and nasal pharynx by an acute inflammation characterized by reddening, moderate swelling, and a pale, filmy exudate over the surface of the mucous membrane. It extended into the larynx where there was considerable swelling of the vocal cords; hoarseness was a prominent symptom, and not infrequently considerable respiratory difficulty resulted from the laryngeal edema. The acute inflammatory reaction extended down the trachea and into the bronchi, producing a seropurulent exudate. The inflammation then spread to the alveoli producing a diffuse hemorrhagic pneumonitis. This lesion followed both measles and influenza cases, and in the examination of some of these in the specimens at the Army Medical Museum, the purulent exudate in the bronchi was found to contain large numbers of Gram-negative bacteria as well as numerous streptococci, the latter organism decreasing in numbers toward the periphery of the lung. (Figs. 129, 130.)

The large amount of purulent material in the bronchi may not have been wholly due to the streptococcus. The purulent inflammation may have preceded it as a result of the action of either the measles or influenza virus, or of both. This possibility should be considered, because the reaction of the streptococcus elsewhere is not the production of large amounts of pus until later in the disease, the primary reaction being serous or hemorrhagic. (Figs. 131 and 132.) The frankly purulent exudate in the bronchi was associated with serous and hemorrhagic lesions in the lung and serofibrinous reactions in the pleura.

In the other type the organisms in the bronchi gained access to the mediastinal nodes causing a phlegmon in and about these nodes, extended directly to the pleura at the hilus and produced an intense pleuritis with rapid accumulation of fluid. This process was accompanied by an overwhelming toxemia and death resulted sometimes with no evidence of involvement of the parenchyma of the lung, though bronchitis always was found. The macroscopical appearance in such cases was striking. On opening the chest, large quantities

of fluid were found in the pleural cavities, frequently bilateral, which clinically had accumulated with great rapidity, so that during life aspirations had been necessary much more frequently than usual. The rapid accumulation of the fluid in the early hours or days of the disease, being so unusual, caused some cases to be considered pneumonia, and some of them came to necropsy without the presence of fluid having been ascertained. The lungs were found collapsed and dark in color, the mediastinal tissues were edematous, and the lymph nodes were enlarged, moist, and usually presented small hemorrhagic spots. On section, the compressed portions of the lungs were relatively dry and deep purplish red in color. Near the hilus the lung was moist, contained considerable fluid, and peribronchial thickening was usually evident. Here also there were frequently some hemorrhages and usually small areas of consolidation, though it was evident that the pleural and not the pulmonary involvement was responsible for the symptoms and death of the individual. (Fig. 133.)

In cases which were just as fulminant in character from the clinical standpoint, pleural involvement was slight or absent, but instead, the peribronchial and perivascular lymphatics containing areolar tissue were involved in a spreading phlegmon which extended to the interstitial tissues of both lungs. The bronchi always were involved in an inflammatory reaction, and it is probable that the interstitial reaction was secondary. Serial roentgenograms show the thickening beginning near the hilus and extending out into the periphery of the lung. This appearance is probably due more to the accumulation of exudate piling up more quickly in the numerous large lymphatics near the hilus draining from large peripheral areas while those in the periphery required a longer time to reach that degree of thickening necessary to produce shadows on the plate. The extension of the shadow outward, however, was exceedingly rapid, requiring a matter of hours only to produce definite lines reaching to the periphery.

Pleural symptoms frequently had their first appearance at about the time the roentgenograms showed that these lines had reached the vicinity of the pleura, though extension to this membrane from the vicinity of the hilus occurred at various stages of spread of the interstitial reaction in the lung. The pleura became involved and gave clinical signs before any lung was involved, as previously stated, and at any time during the spread of the process, or it might remain uninvolved until the interstitial reaction reached the pleura by way of the interlobular septa. In some instances, generalized involvement did not occur until interlobar empyema ruptured and discharged into the cavity. Sometimes several localized empyemata were found walled off by fibrinous exudate without general involvement of the entire pleura.

In the case predominantly interstitial the lung was slightly heavier than normal. The pleural surface rarely was uninvolved; usually there were patches of fibrinous inflammation overlying consolidated areas. The entire surface sometimes showed a thin layer of fibrin adherent, the cavity being dry. Usually irregular consolidations could be felt near the pleural surface, but rarely no definite consolidation of nodular character was evident. On section, in the rapidly fatal cases not accompanied by marked pleural involvement, the lung presented a moist, dripping surface from which frothy, bloody serum flowed. (Pl. I.) From the bronchi purulent secretion often streaked with blood could

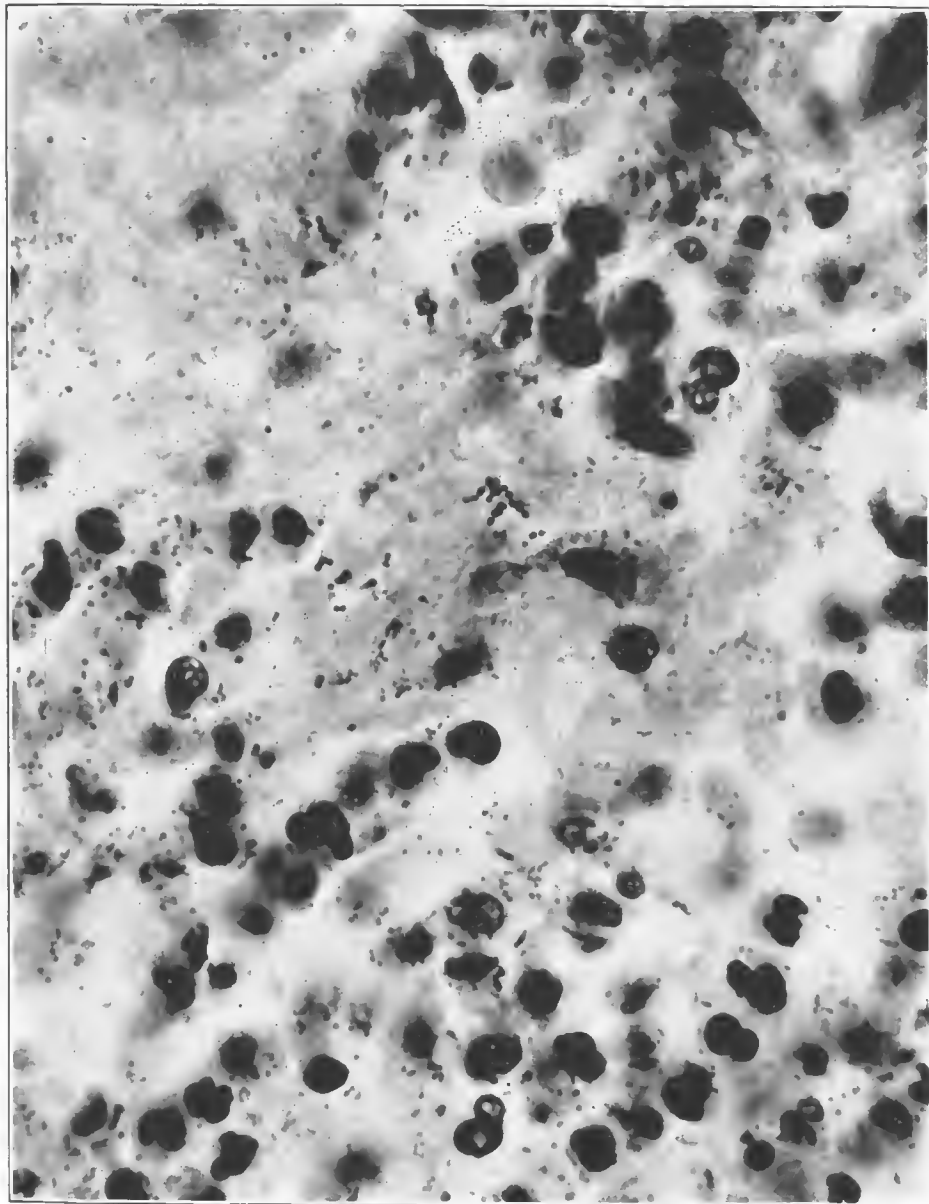


FIG. 129.—Purulent bronchitis. Lung showed lobular pneumonia from which streptococci were cultivated. The smaller forms shown in the illustration were Gram-negative bacteria, many of which were bacillary in shape. Accession number 3101, Army Medical Museum. Negative number 45250. MacCallum stain; $\times 1700$

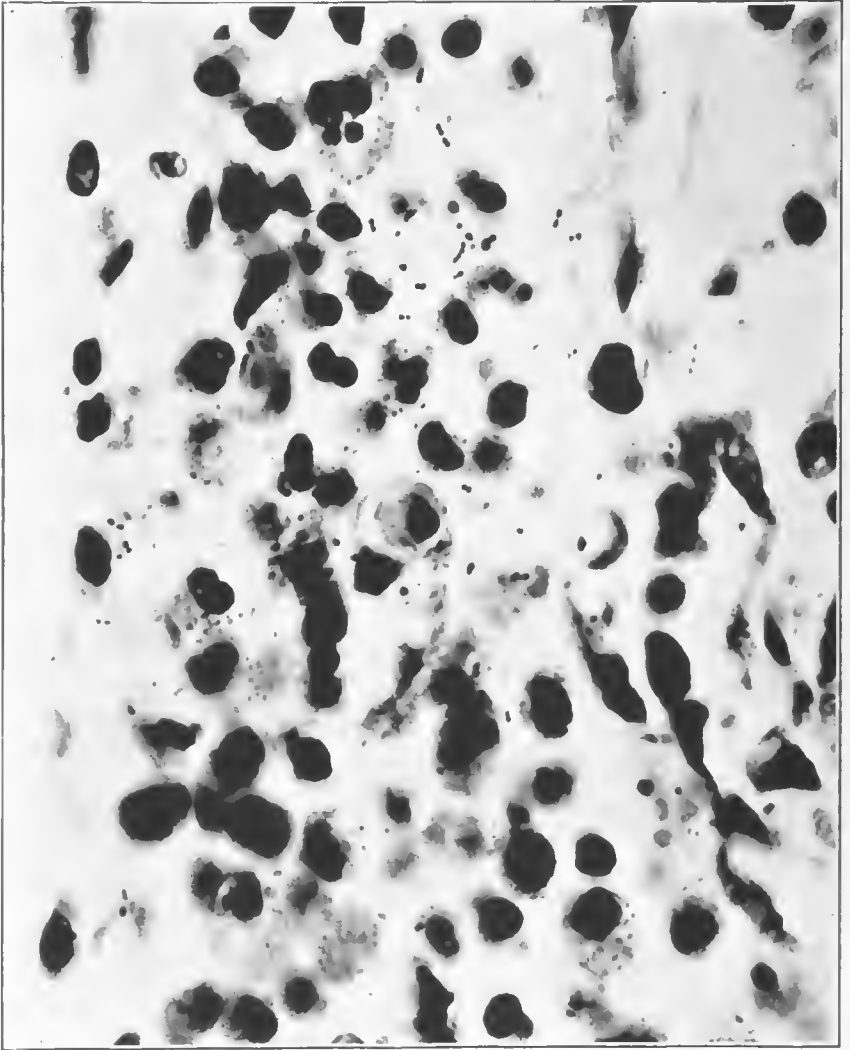


FIG. 130.—Exudate in bronchiole, fewer streptococci than in the previous illustration. Abundant Gram-negative forms (original photograph retouched to bring out the Gram-negative bacteria). Accession number 3089, Army Medical Museum. Negative number 45264. MacCallum stain; $\times 1950$

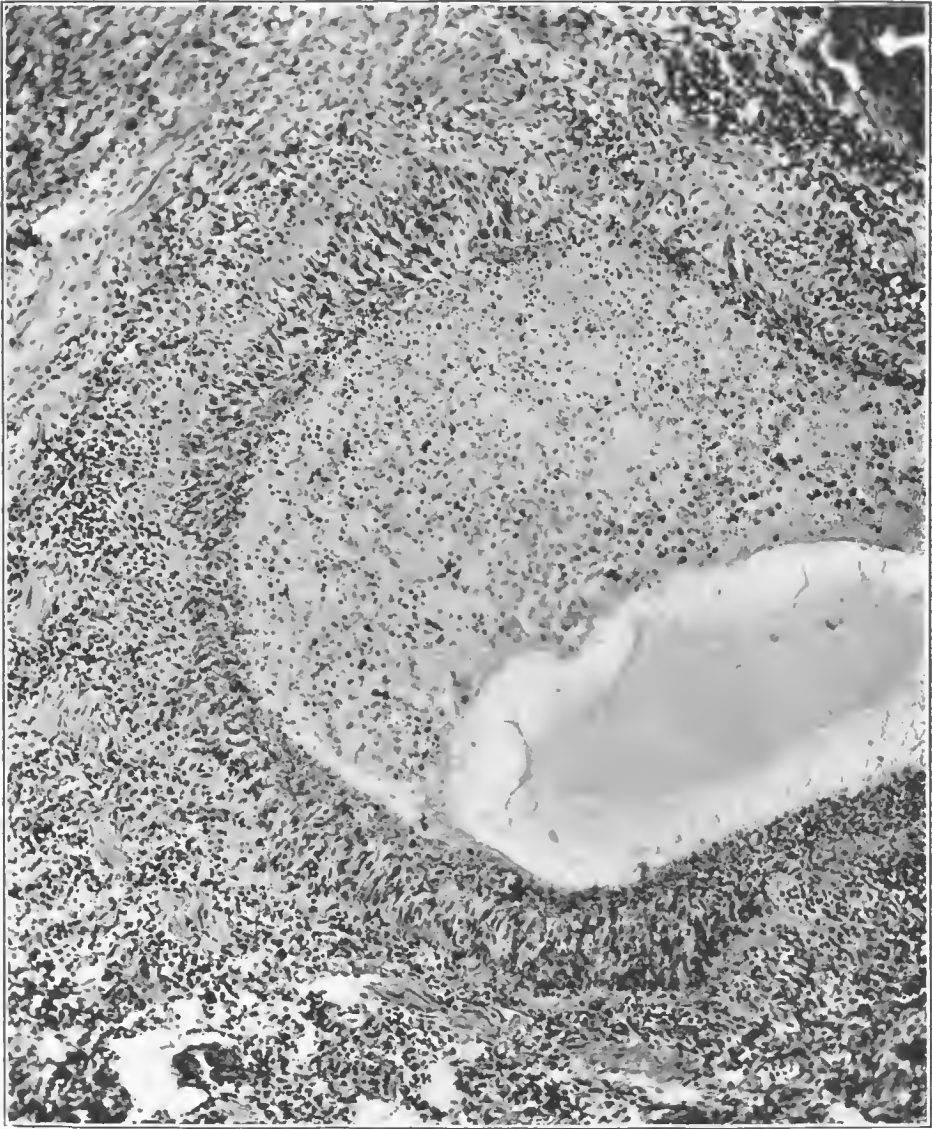


FIG. 131.—Small bronchus showing almost complete desquamation of columnar cells, proliferation of the basal layer thickening and hyalinization of the basement membrane, and a seropurulent exudate in the bronchus. Streptococcus infection following influenza. Accession number 3091, Army Medical Museum. Negative number 45290. Hematoxylin and eosin stain; $\times 125$

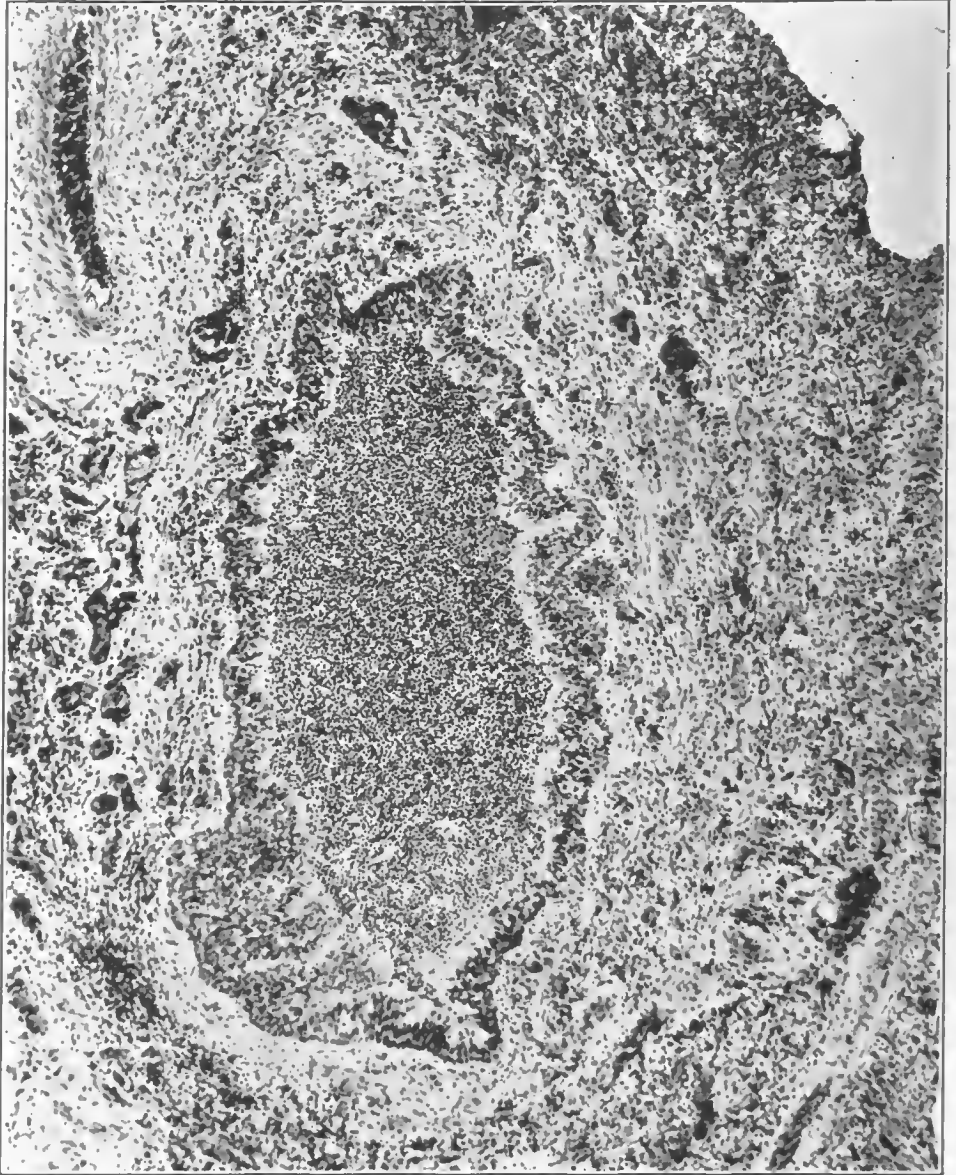


FIG. 132.—Small bronchus showing proliferation of basal layers and a purulent exudate with surrounding phlegmon due to streptococcus following influenza. The moderate involvement of the wall indicates that this is part of a recent extension of the process. Accession number 3065, Army Medical Museum. Negative number 45169. Hematoxylin and eosin stain; $\times 78$

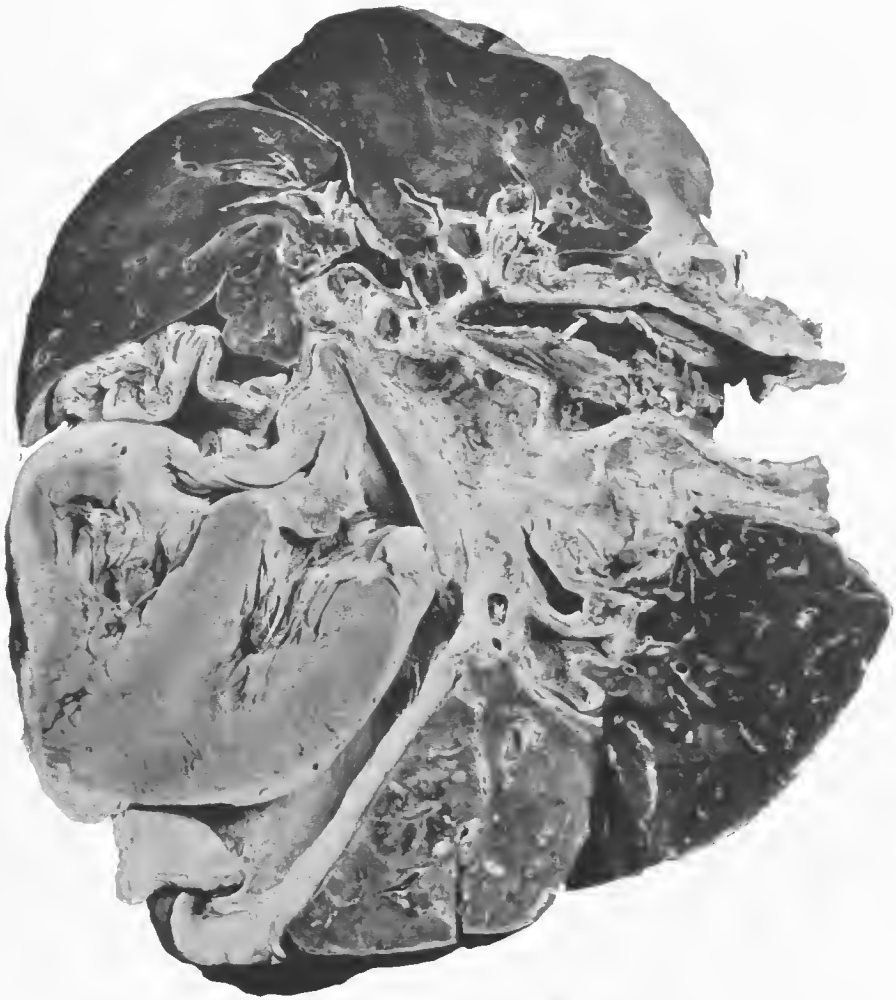


FIG. 133.—Postinfluenzal pneumonia and empyema. Lungs, heart, pericardium, pleura, and mediastinal tissues of a case of empyema, pericarditis, and mediastinitis. Mediastinal tissues were indurated and thickened; the lymph nodes showed necrotic areas which can be made out in the picture. The mediastinal tissues were the site of a phlegmonous inflammatory reaction extending through to the pleural cavities on both sides and into the pericardial sac. This patient entered complaining of tonsillitis; pneumonic consolidation diagnosed on seventh day. On tenth day the condition was improved; became rapidly worse on the eleventh, developing extreme dyspœa and cyanosis, and died on twelfth day before the presence of fluid in quantity was suspected. Both pleural cavities contained fluid, the left pleura being entirely filled. This case is an example of the rapid accumulation of fluid as the result of the invasion of the pleura by hemolytic streptococcus. Accession number 6152, Army Medical Museum. Negative number 32995

be expressed. Larger and smaller areas of frank hemorrhage with clotting were to be found scattered throughout the lung but most evident and largest in the vicinity of the main bronchial trunks. Other than these there was, in the typical case, no definite consolidation, though the tissue seemed somewhat stiffer than normal and under a hand lens the walls of the pulmonary structures appeared unduly prominent.

Microscopically the changes in the parenchyma were very distinctive. Purulent inflammation in the bronchi was present and this pus contained varying numbers of streptococci, the numbers being distinctly greater in proportion in the exudate in the larger trunks, decreasing toward the periphery, and being practically absent in many terminal bronchioles, where in well fixed tissues Gram-negative bacteria were found. In the fulminant cases the degree of destruction of the bronchial mucosa was never very great. The most marked changes were in the peribronchial areolar tissue and consisted of a phlegmonous inflammatory reaction characterized by inflammatory edema, a deposit of relatively small amounts of fibrin and an infiltration of leucocytes, many being of the mononuclear type. Cells of the character of large lymphocytes were frequent but there were considerable numbers of somewhat larger mononuclear cells, most of which had slightly basophilic cytoplasm; a certain proportion appeared eosinophilic, though rarely were granular cells present in numbers except polymorphonuclear neutrophiles. The lymph vessels were dilated with serum containing leucocytes, some fibrin, and streptococci (figs. 134, 135, 136), apparent clots being formed, in many instances, which took a deep eosin stain, and while they were for the most part granular, hyaline areas occurred in them. Capillary blood vessels were engorged and some of them contained masses of cells which appeared laked (conglutination thrombi) or contained deep eosin staining material without evidence of morphological elements (hyaline thrombi). Whether or not these thrombi were present during the life of the individual is open to question. Appearances similar in every way are certainly more frequent in poorly fixed tissue, but they are noted more frequently in descriptions of the various types of pulmonary inflammations of the World War than in those of the respiratory affections ordinarily met with. Interstitial changes involved equally the areolar tissue around the bronchi and blood vessels, though they were more noticeable about the tissue surrounding the pulmonary artery and bronchus than about the vein; in fact, the structures about the vein were rarely markedly involved. (Figs. 137, 138.)

In addition to the involvement of the peribronchial and perivascular structures the phlegmon extended to those bands of connective tissue which pass into the lobe, finally separating it into anatomical lobules. (Figs. 139, 140.) These septa were involved, the distribution of the involvement varying markedly in different cases; they were most characteristic, as seen in section, when the involvement was of those interlobular septa just beneath the pleura, particularly in the latter stages when frank pus was formed.

There is a valid question as to whether the lymphangitis—for such is the character of the reaction in the peribronchial and perivascular tissues and interlobar septa—precedes the changes in the parenchyma or alveoli and terminal bronchioles or is the result of drainage from these structures. It is generally

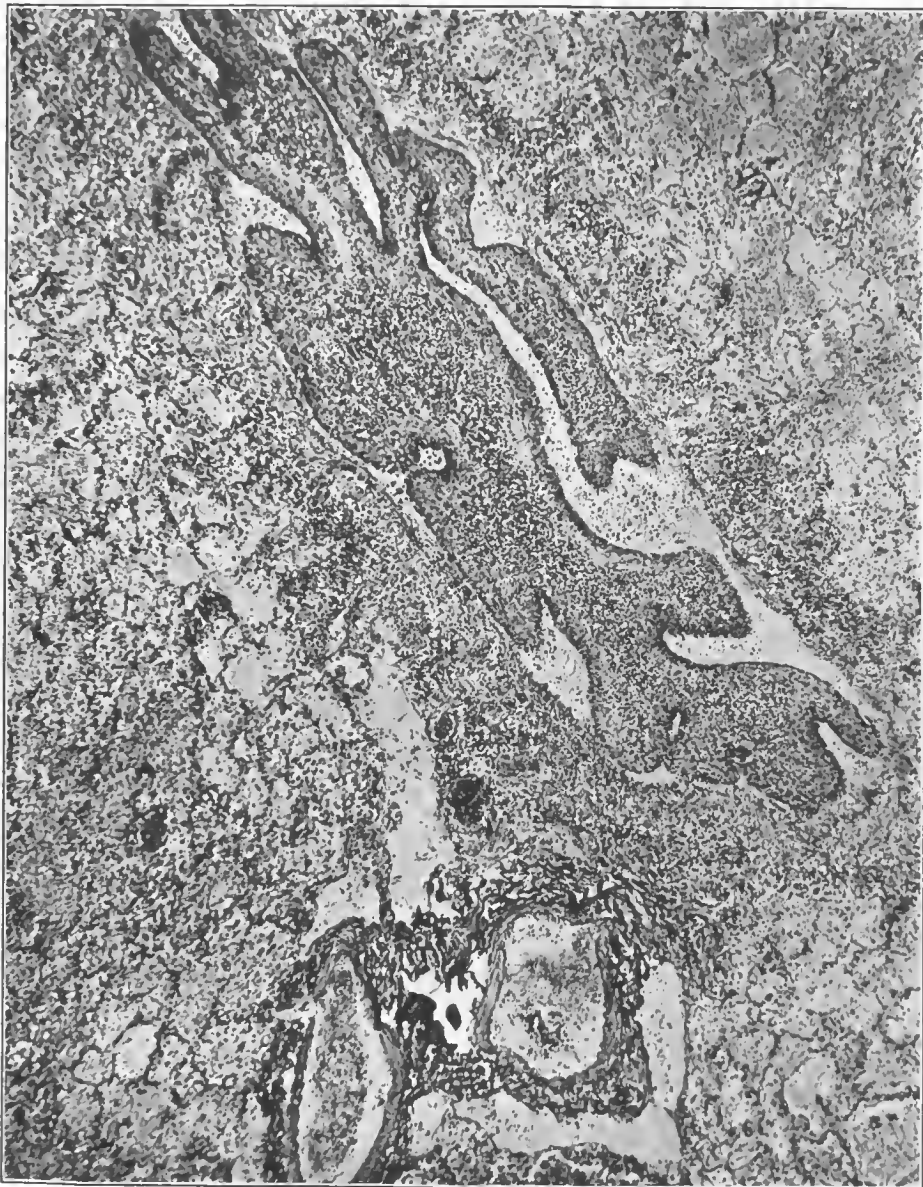

FIG. 134.—Oblique section of a bronchus in an area of lobular pneumonia from which streptococcus hemolyticus was cultivated. The peribronchial tissues are infiltrated with pus, the mucosa is raised from its basement membrane by seropurulent exudate, and there is considerable pus in the narrowed lumen of the bronchus. The infection appears to have reached this bronchus by extension from without. Accession number 3107, Army Medical Museum. Negative number 45229. Hematoxylin and eosin stain; $\times 115$

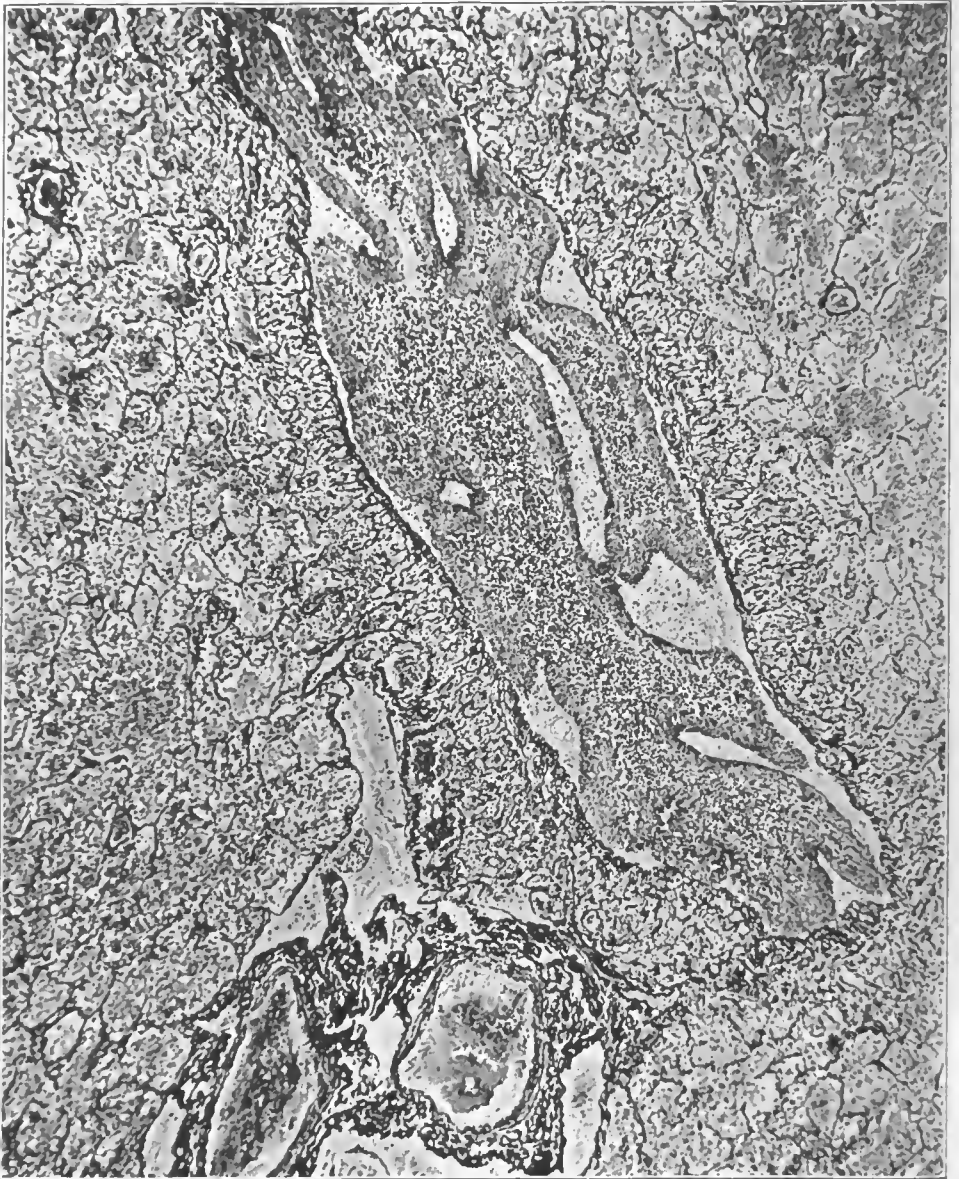
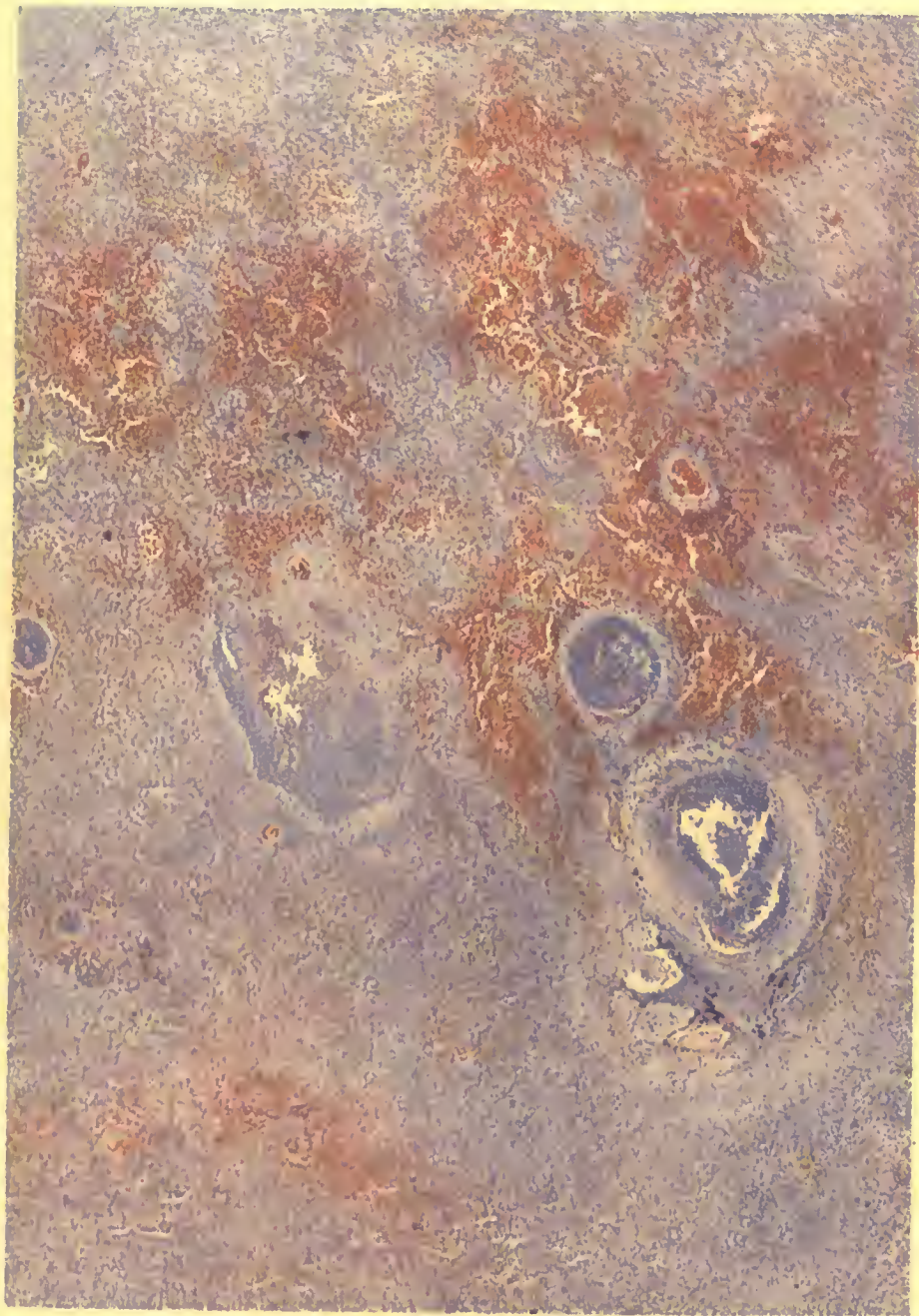


FIG. 135.—Note the apparent increase in vessels in the submucosa. Accession number 3107, Army Medical Museum. Negative number 45246. Reticulum stain; $\times 115$



STREPTOCOCCUS LYMPHANGITIS.

Hemorrhagic perivascular and peribronchial lesions. Streptococcus hemolyticus.
Thrombosis of vessel.

Accession 3026. Armv Medical Museum. H. & E. stain. Autochrome.

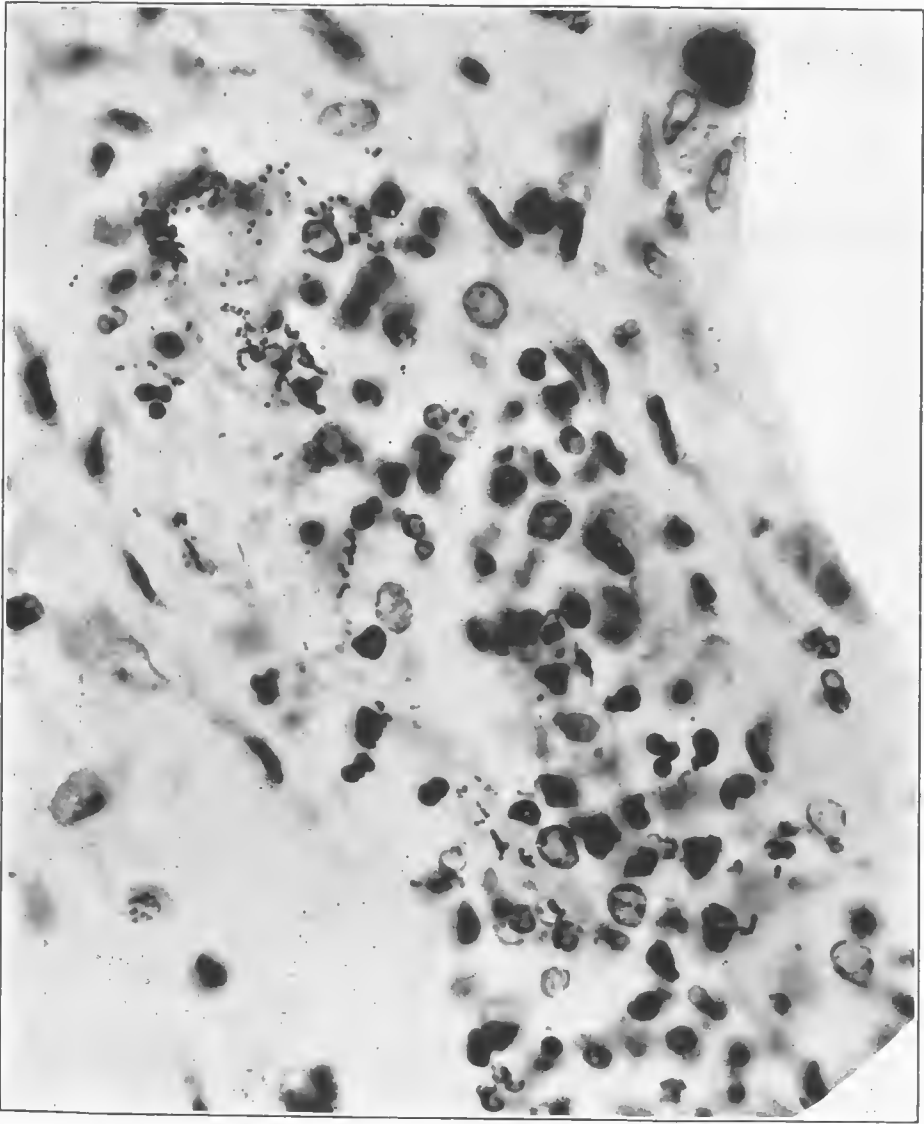


FIG. 136.—Peribronchial lymphangitis in the wall of a bronchiole. Figure shows a lymphatic filled with pus and containing numerous streptococci. Note the character of the cellular exudate. *Streptococcus hemolyticus* in culture. Accession number 3071, Army Medical Museum. Negative number 45214. MacCallum stain; $\times 1060$

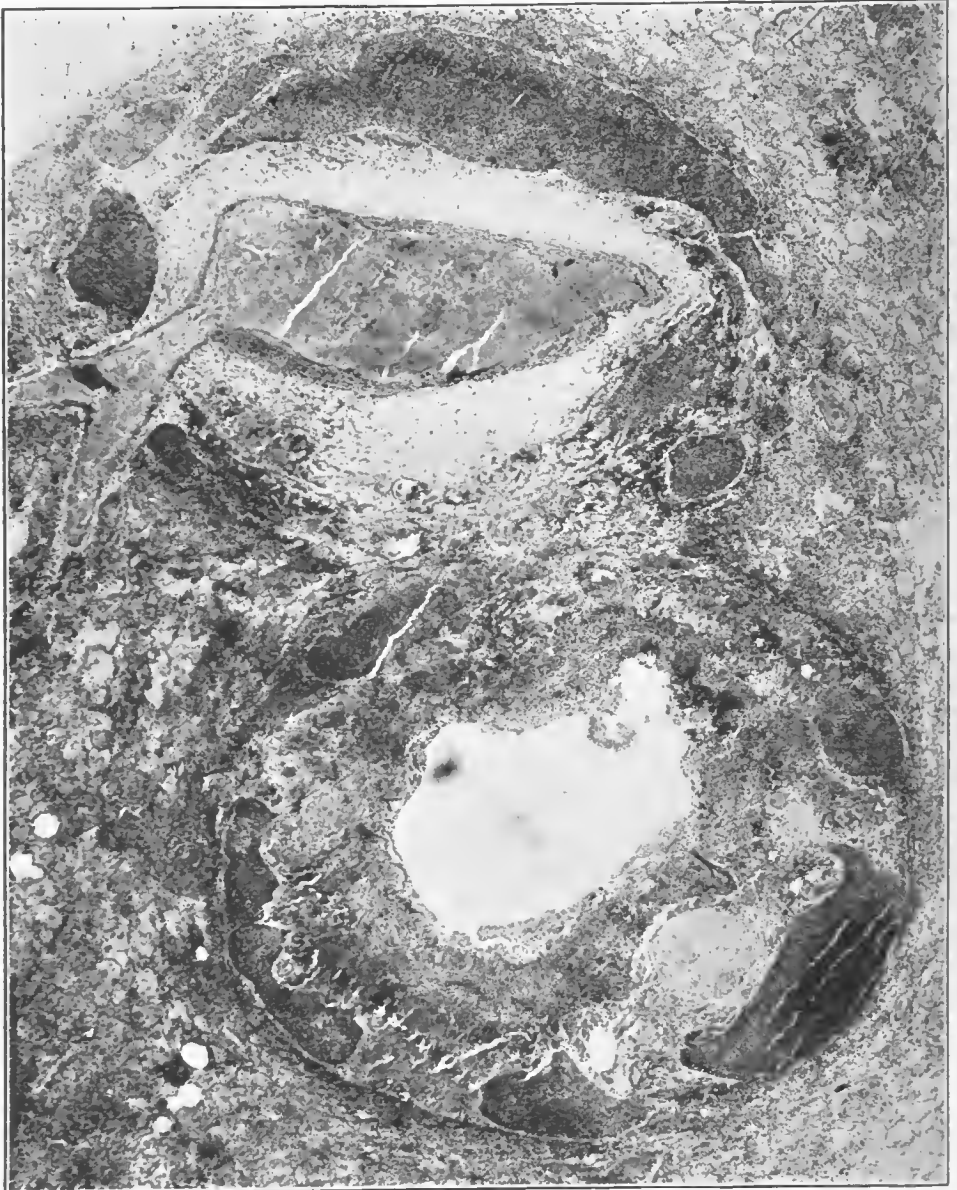


FIG. 137.—Peribronchial and perivascular lymphangitis in a streptococcus lobular pneumonia. Peribronchial and perivascular lymphatics filled with pus containing numerous streptococci. Submucosa of the bronchus and the perivascular tissue edematous and infiltrated to a greater or lesser degree with leucocytes. Bronchial epithelium largely desquamated. Accession number 3047, Army Medical Museum. Negative number 45200. Hematoxylin and eosin stain; $\times 21$

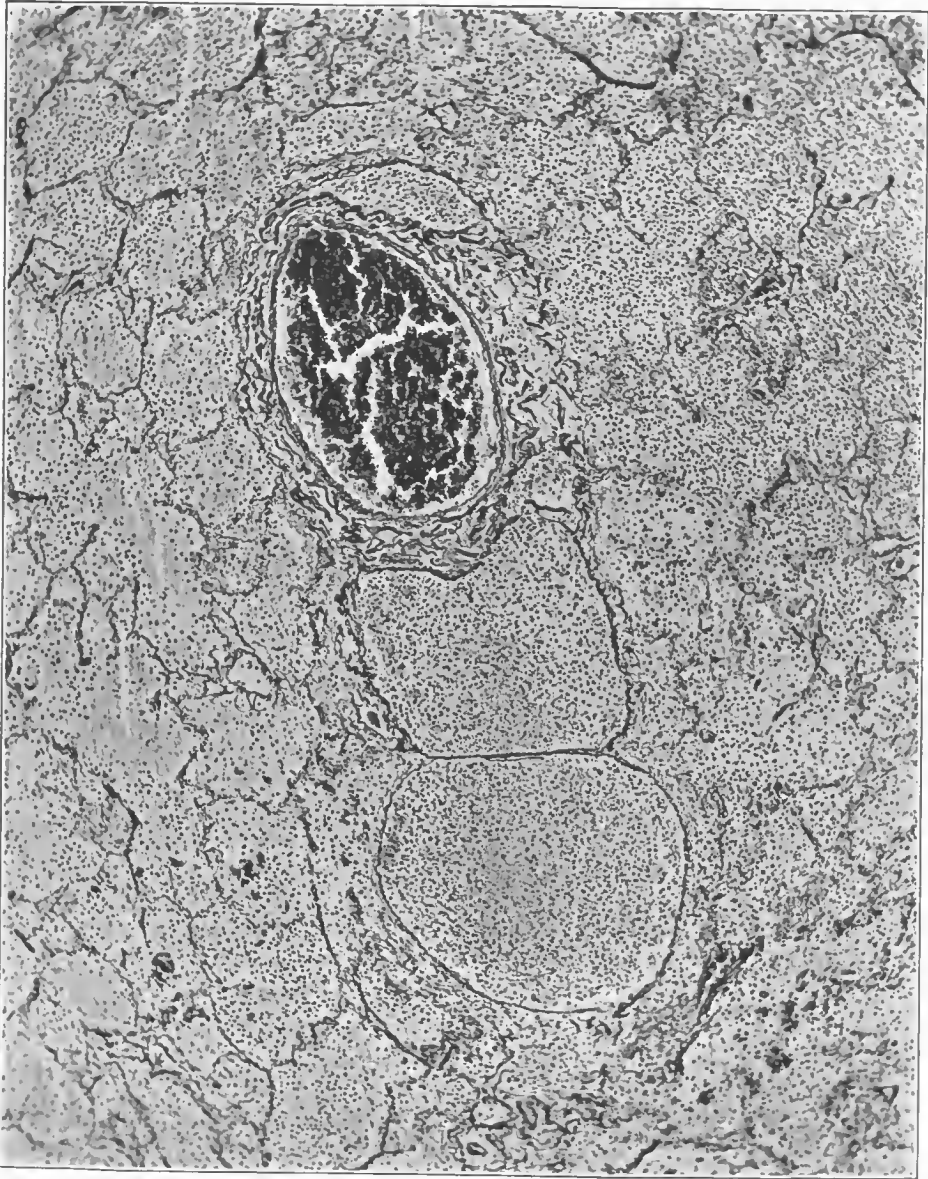

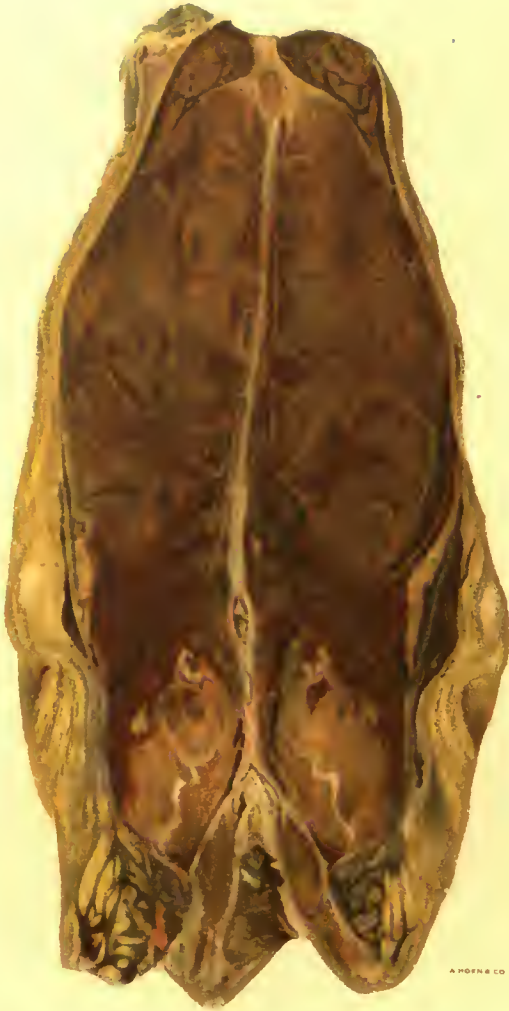FIG. 138.—Perivascular lymphangitis about a small pulmonary vein; the lymphatics are distended with a purulent exudate the outlines of which are shown sharply by the reticulum stain used to bring out their delicate walls. Accession number 3047, Army Medical Museum. Negative number 45579. Reticulum stain; $\times 78$

accepted that the bronchi and bronchioles are involved first, by the inflammation of the initial infection by the measles or influenza virus. The infection with the streptococcus spreads along the surface of the upper air passages just as does the infection seen in so many cases of clinical influenza. Indeed the wave of exudative inflammation characteristic of *Streptococcus hemolyticus* involvement of the pharynx and larynx was observed as a succeeding one to that of the initial influenzal or measles process. That the *Streptococcus hemolyticus* extended to the mediastinum directly from the hilus lymph nodes seems indubitable, but it is difficult to explain the extension of the process outward along the peribronchial and perivascular lymphatics against the normal or usual flow in these vessels. The small size of streptococcus lesions of the hand which give rise to marked lymphangitis extending up the arm and the rapidity with which such lymphangitis extends is well known. It seems probable that the interstitial lymphangitis is secondary to peripheral involvement, at least of the bronchi rather than that it extends outward and involves the parenchyma secondarily. If it is viewed in this light, it appears erroneous or misleading to coin the words "interstitial pneumonia" for the process. The correct term is interstitial lymphangitis and cellulitis or phlegmon secondary to bronchitis, bronchiolitis and lobular pneumonia of streptococcus origin; in other words it is secondary to the spread of this organism along the air passages. Infections by this organism in the early days of the preceding measles or influenza, sometimes produced extremely extensive pulmonary involvement which, however, might well be the result of its combination with the other virus, no division being possible between the lesions produced by the one and the other.

In cases that lived a longer time the changes in the interstitial tissues were recognizable on gross examination. The peribronchial and perivascular tissues became paler as the result of increase in the leucocytic infiltration and were more distended. The same is true of the septal tissues, so that there formed a mosaic-like pattern dividing the anatomical lobules. At first reddish, these became paler and the lymph vessels became visible as tortuous beaded striae distended with fluid or clotted purulent exudate. (Pl. II; figs. 141, 142, 143, 144, 145.)

The purulent inflammation extended out into the parenchyma and abscesses were formed in the tissue. Extension to the pleura caused generalized or local empyema. Often extensions to the interlobar pleura caused interlobar pus pockets which, as the result of fibrinous adhesions at the junction of visceral and parietal pleura, were retained in the interlobar clefts and were not evacuated when the pleura was drained by operative procedures.

Some of these interlobar pus pockets destroyed the adjacent parenchyma, forming abscesses extending into the lung. (Fig. 146.) The thickening along the bronchi and blood vessels made these structures appear as thick-walled tubes which, on gross examination, were differentiated one from the other with difficulty, unless section revealed the contents. On cross section they were even more difficult to differentiate. The cut ends protruded above the contracted parenchyma. (Figs. 147, 148.) Early there was a surrounding zone of hemorrhage but later the exudate became purulent so that the thickened walls were pale and opaque resembling cross sections of old water pipes encrusted

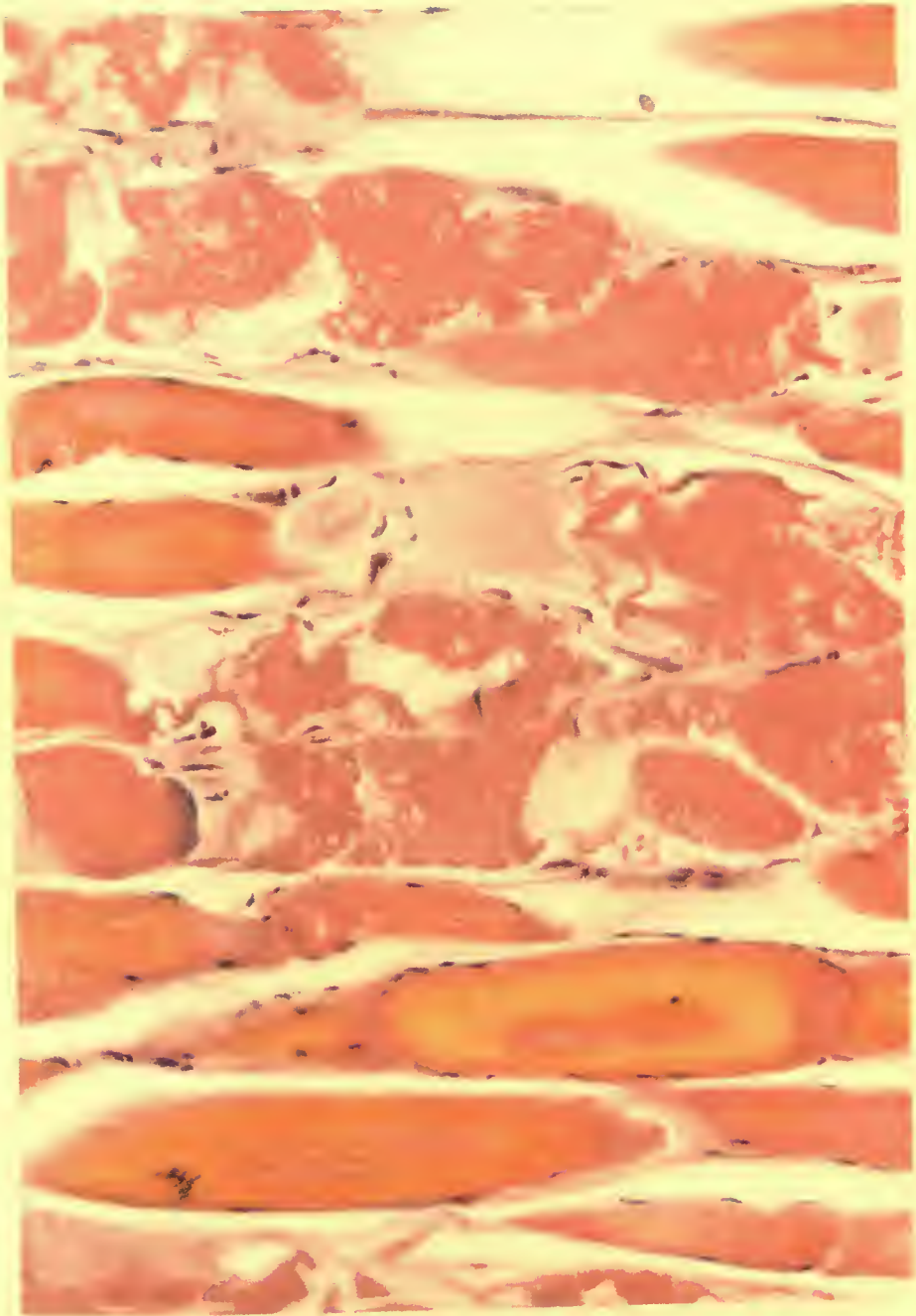


A. HOFER & CO. LITH.

ZENKER'S DEGENERATION OCCURRING IN INFLUENZA.

Rectus abdominis muscle.

Accession 6951, Army Medical Museum. Colored photograph.



ZENKER'S DEGENERATION OCCURRING IN INFLUENZA.

Accession 6951, Army Medical Museum. Weigert hematoxylin picro-eosin stain. Autochrome.

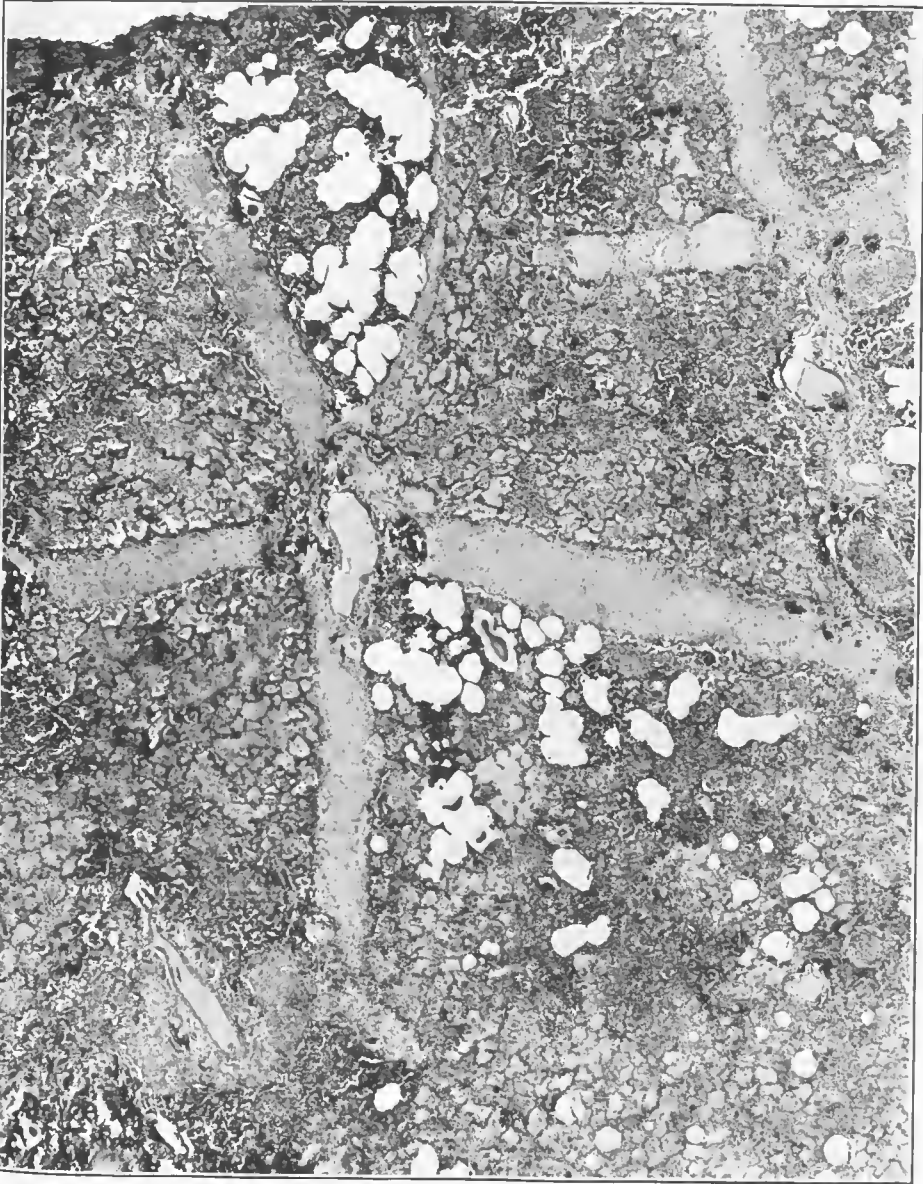


FIG. 139.—Interlobular lymphangitis in a lobular pneumonia due to hemolytic streptococci. The lymphatics and interstitial tissue are filled with inflammatory edema and leucocytes. Lobules are irregularly consolidated, with an exudate composed of serum, leucocytes and a small amount of fibrin. Accession number 3106, Army Medical Museum. Negative number 45215. Hematoxylin and eosin stain; $\times 21$

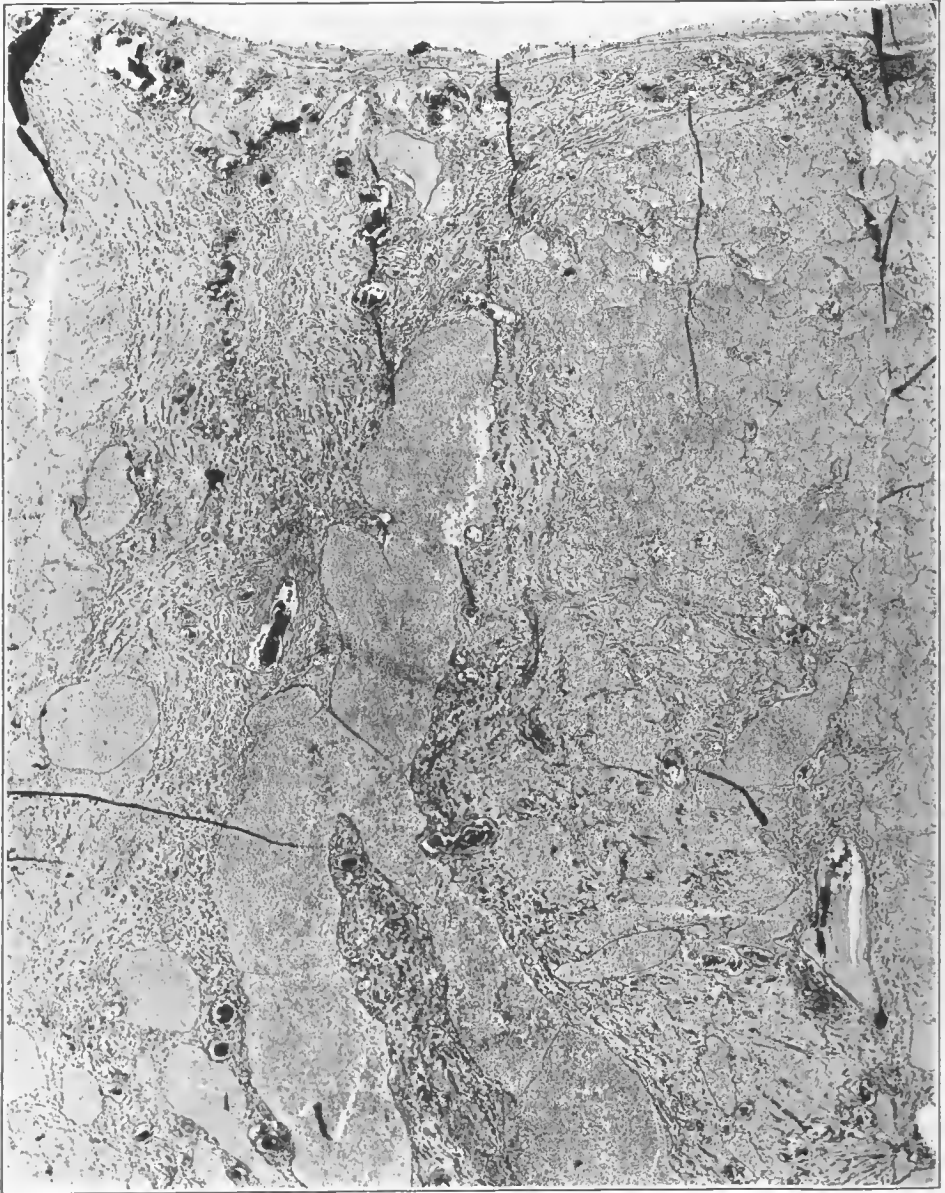

FIG. 140.—Lymphatics of an interlobular septum filled with fibrinopurulent exudate which appears to have clotted. The inflammation extended to the pleura which is the seat of a fibrinopurulent inflammation. Accession number 3047, Army Medical Museum. Negative number 45560. Reticulum stain; $\times 13$




FIG. 141.—Postinfluenzal pneumonia. Diffuse *Streptococcus hemolyticus* pneumonia, with beginning necrosis in areas surrounding smaller bronchi in the base of the lower lobe. Considerable peribronchial and perivascular lymphangitis, most marked about the bronchi and arteries in the upper lobe. The interstitial tissues show nodular areas of pus accumulation and necrosis, giving them a beaded appearance. Accession number 3082, Army Medical Museum. Negative number 42868

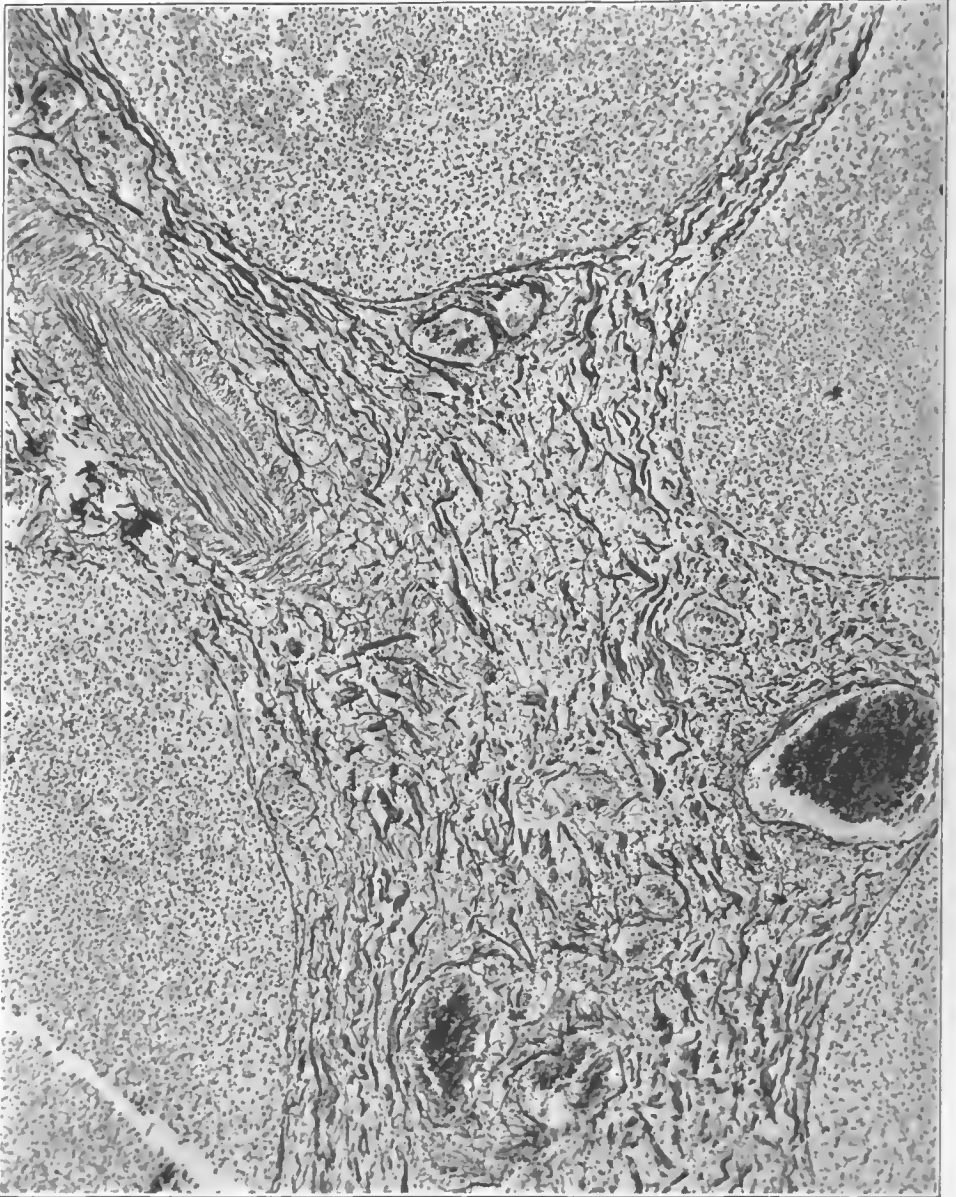

FIG. 142.—Plegmonous inflammation of interlobular septa. Reticulum stained to show separation of the reticulum and collagenous fibers by inflammatory exudate. Accession number 3047, Army Medical Museum. Negative number 45563. Reticulum stain; $\times 95$

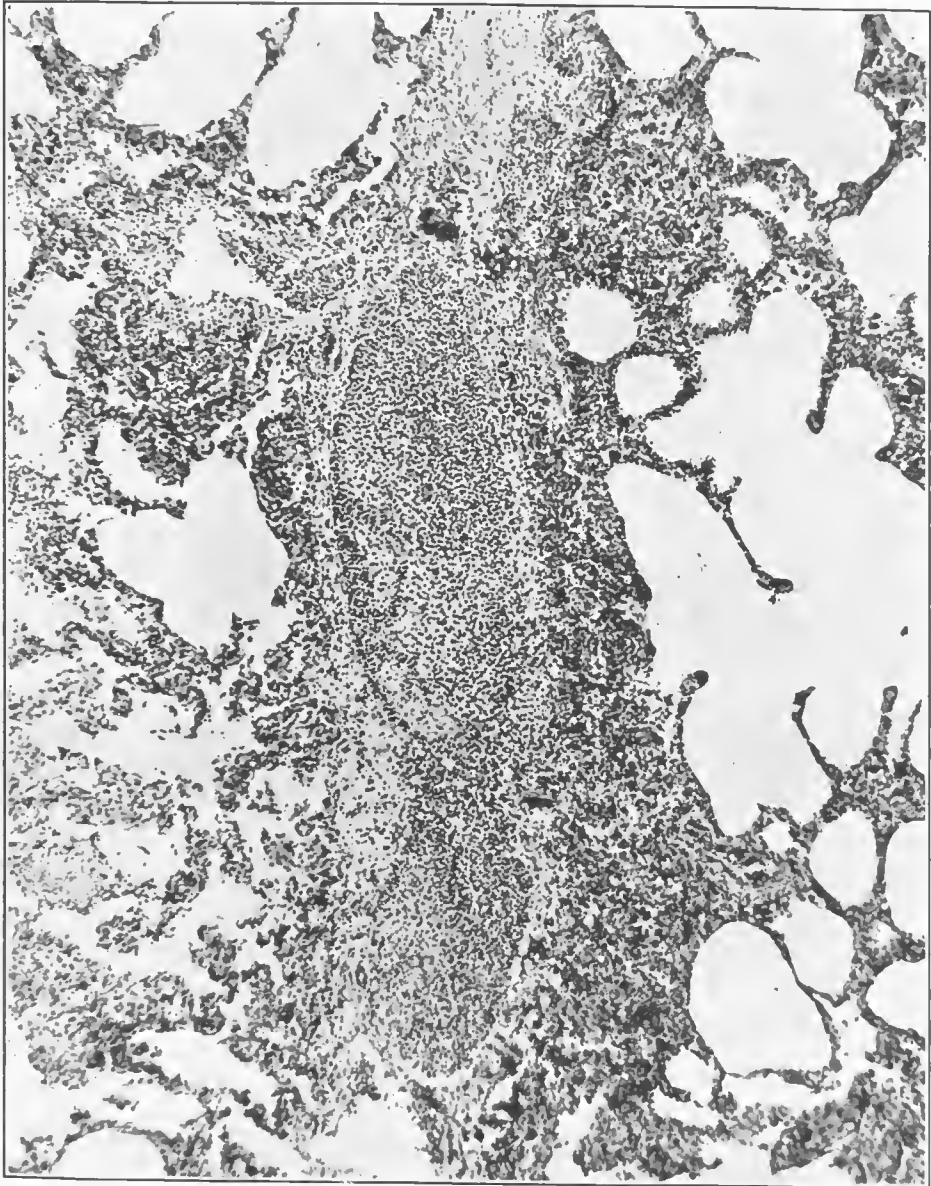


FIG. 143.—Purulent lymphangitis in an interlobular septum, the surrounding alveoli showing purulent infiltration of the walls. Case of lobular pneumonia due to streptococcus hemolyticus. Accession number 3071, Army Medical Museum. Negative number 45171. Hematoxylin and eosin stain; $\times 78$

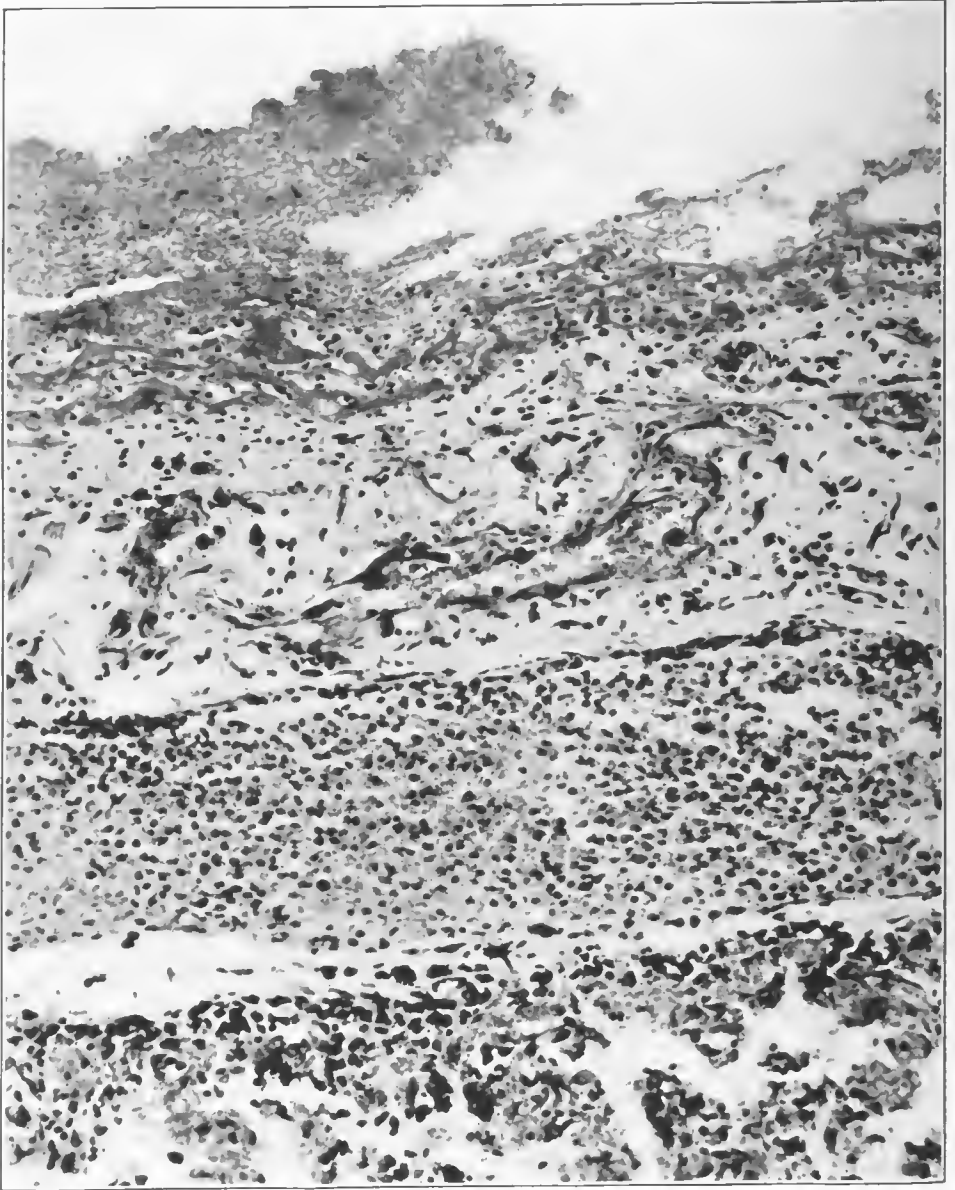


FIG. 144.—Fibrinopurulent pleuritis with subpleural lymphangitis due to hemolytic streptococcus. Extension to the pleura was from an underlying lobular pneumonia. Accession number 3069, Army Medical Museum. Negative number 45173. Hematoxylin and eosin stain; $\times 240$

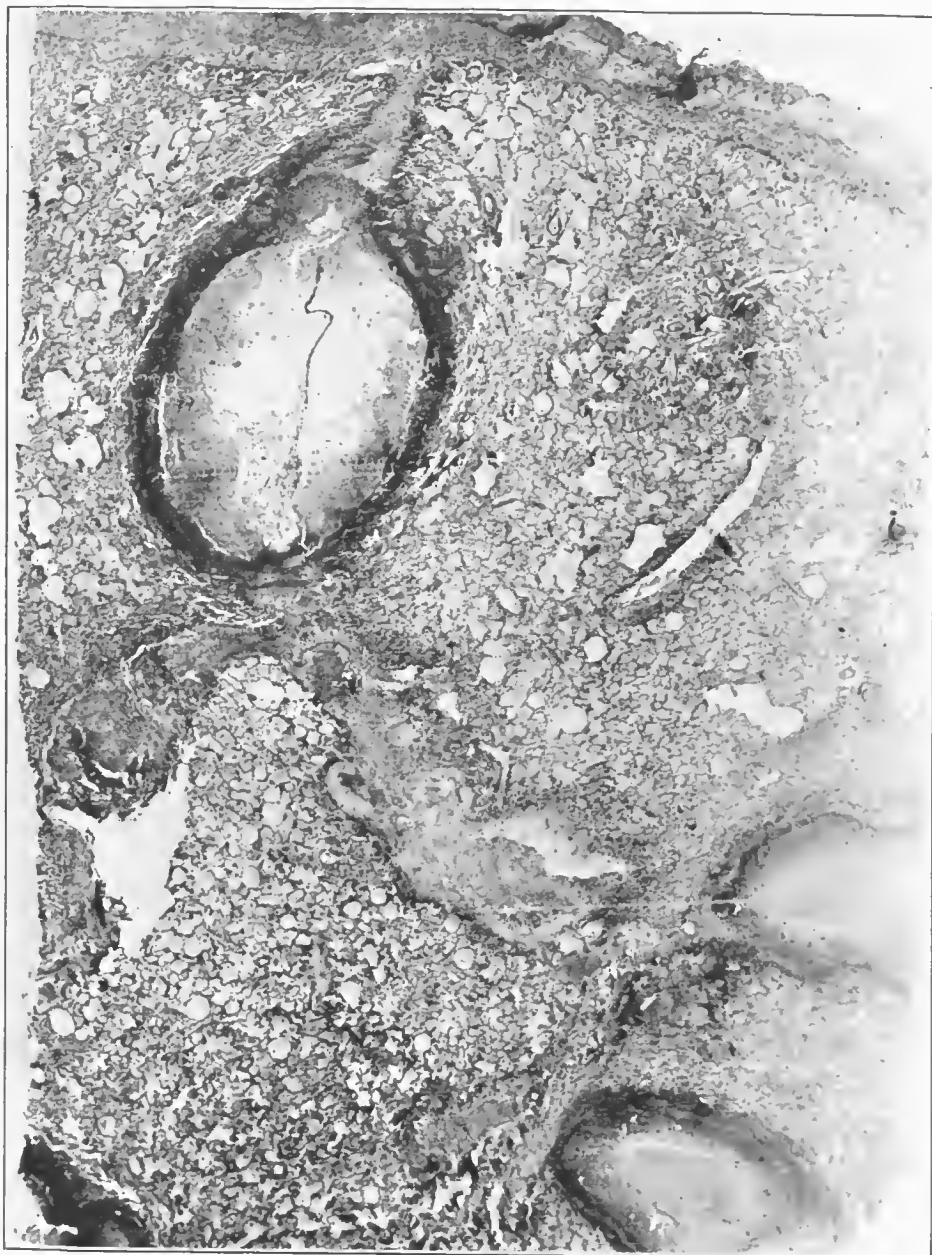


FIG. 145.—Abscesses in interlobular septa arising in thrombosed lymphatics in a streptococcus lobular pneumonia. Accession number 16648, Army Medical Museum. Negative number 45240. Hematoxylin and eosin stain; $\times 13$

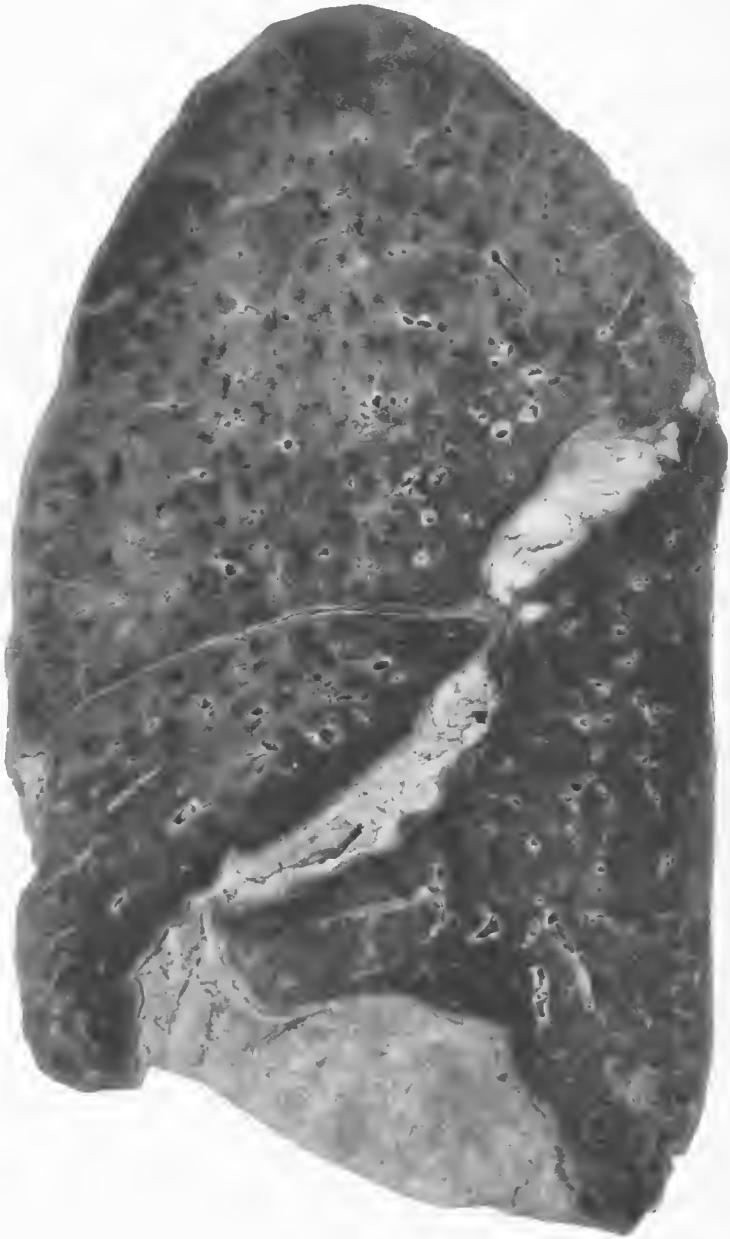

FIG. 146.—Postinfluenzal interlobular empyema. There was also a left empyema and purulent pericarditis. The organism present in the pus was *Streptococcus hemolyticus*. Accession number 3564, Army Medical Museum. Negative number 42869

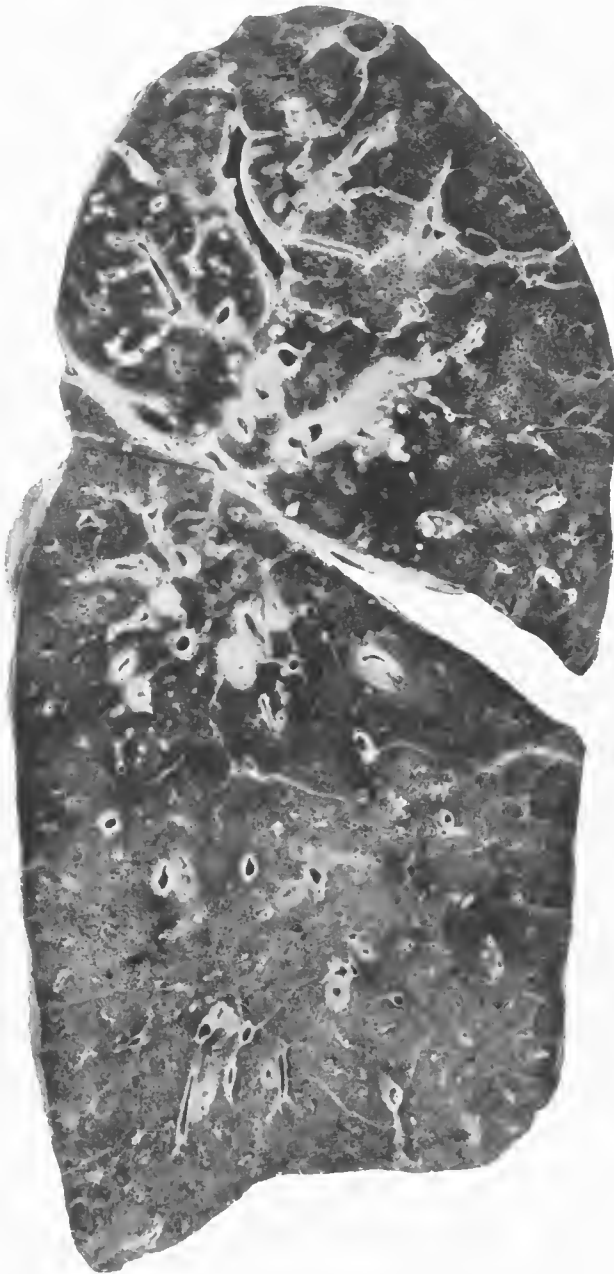


FIG. 147.—Pneumonia following measles. Confluent lobular pneumonia of the entire lung, with advanced interstitial lymphangitis of the interlobular septa, peribronchial and perivascular tissues of the upper lobe and upper part of the lower lobe and bronchiectasis due to *Streptococcus hemolyticus*. Accession number 620, Army Medical Museum. Negative number 30757

with calcareous deposit. Abscesses also formed along the bronchial tree and occasionally ruptured into the bronchi. Some abscesses destroyed sections of the bronchial wall and thus communicated by large openings into the bronchial lumen, producing in effect irregular or saecular bronchiectases. In other cases the phlegmonous inflammation, by weakening the entire circumference of a section of bronchial wall through destruction of its tissues, aided in the production of more even dilatations, the more common variety of bronchiectasis.

Abscesses in the periphery of the lung caused pleural involvement and empyema by extension, sometimes as the result of gross rupture. Abscesses nearer the hilus extended and sometimes produced large pulmonary abscesses before rupture into a bronchus resulted in drainage and relief of tension. The inflammation occasionally extended to the walls of vessels usually of pulmonary veins causing thrombosis which rarely completely blocked the larger vessels. Bacteriemia from which streptococci were cultured was found in cases where this was observed. (Figs. 149, 150.)

The abscesses compressed bronchi and produced atelectatic areas distally to the point of compression, where organizing processes quickly supervened. These atelectatic areas were sometimes the seat of inflammation at the time of the shutting off of the air and sometimes relatively unaffected. In the former case the exudate became organized and in the latter the epithelium of the alveoli became columnar and often piled up in masses of cells of squamous type imitating foci of epithelioma. In some of the cases of interstitial lymphangitis of considerable duration, organization of the exudate within the septa produced a very striking picture. The cause of death in these cases was usually empyema, the lung having recovered to a greater or lesser degree. It is probable that in many of the recovered cases patches of this organizing process were responsible for some of the opaque areas shown in the roentgenograms. The cross sections of such lungs show varying amounts of increased thickness of the walls of the bronchi and of the perivascular tissues. The most striking lesion is the thickening of the interlobular septa which stand out as pale areas surrounding the irregular lobular divisions of the lung. If the process involved a larger part of the lobules or a whole lobe, abscesses always were found in the interstitial tissue and also in the parenchyma, and practically constantly areas of recent lobular pneumonia representing a recent extension of the process were evident. (Figs. 151 and 152.) In some instances considerable organization was seen relatively soon after the apparent onset of pneumonia, and it was impossible to state the exact age of the processes on the macroscopic appearance, histological examination being necessary to demonstrate the relative amounts of fibrous tissue and phlegmonous infiltration present.

Histological examination showed a gradual increase of the reticulum throughout the interlobular septa. This reticulum was gradually replaced by collagenous fibers and the relatively large number of vessels of capillary size present in the early stages were replaced by fewer vessels of larger caliber. The varying stages of the process could frequently be studied by taking multiple sections from the same lung. (Figs. 153, 154, 155.)

Streptococcus lymphangitis, in addition to forming a prominent part in some cases, was seen in all types of pneumonia in camps where *Streptococcus*

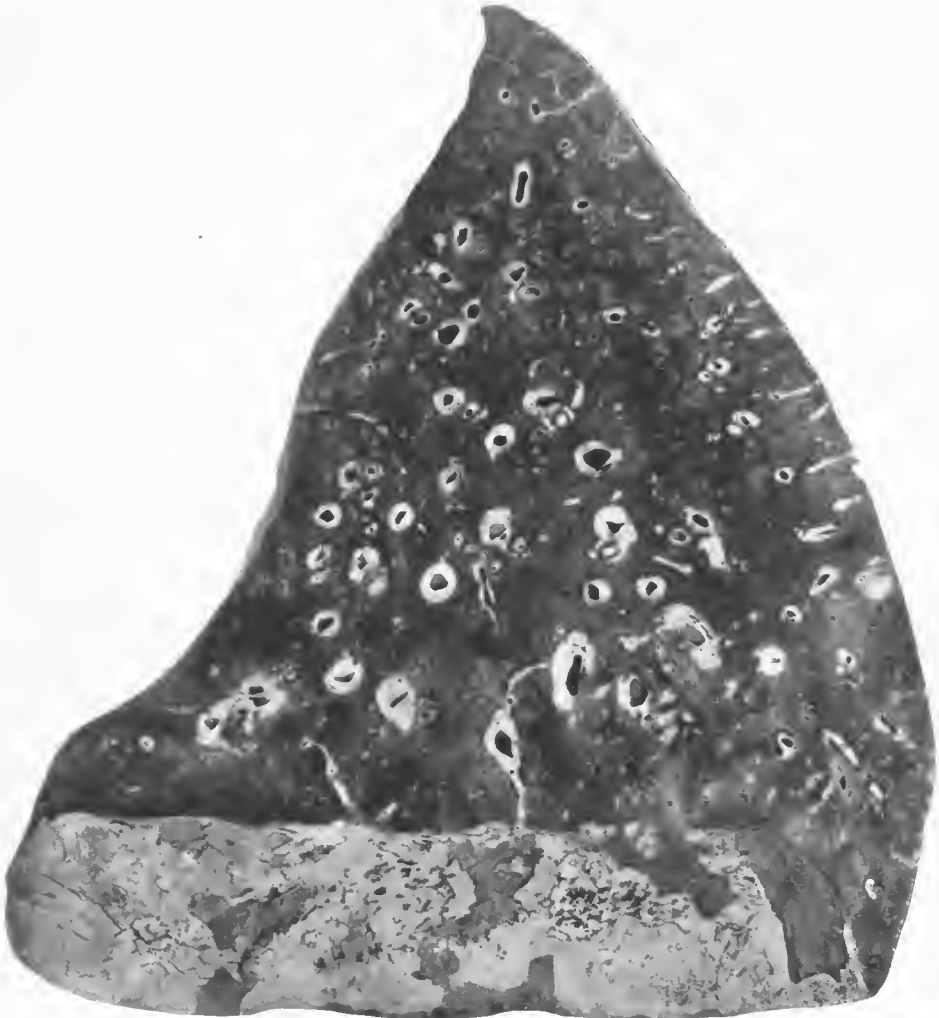


FIG. 148.—Pneumonia following influenza complicated by empyema. Hemolytic streptococci in cultures from the lung and pleura. Section shows bronchi and arteries cut in cross section to show the rings of peribronchial and perivascular lymphangitis. Accession number 3047, Army Medical Museum. Negative number 42905

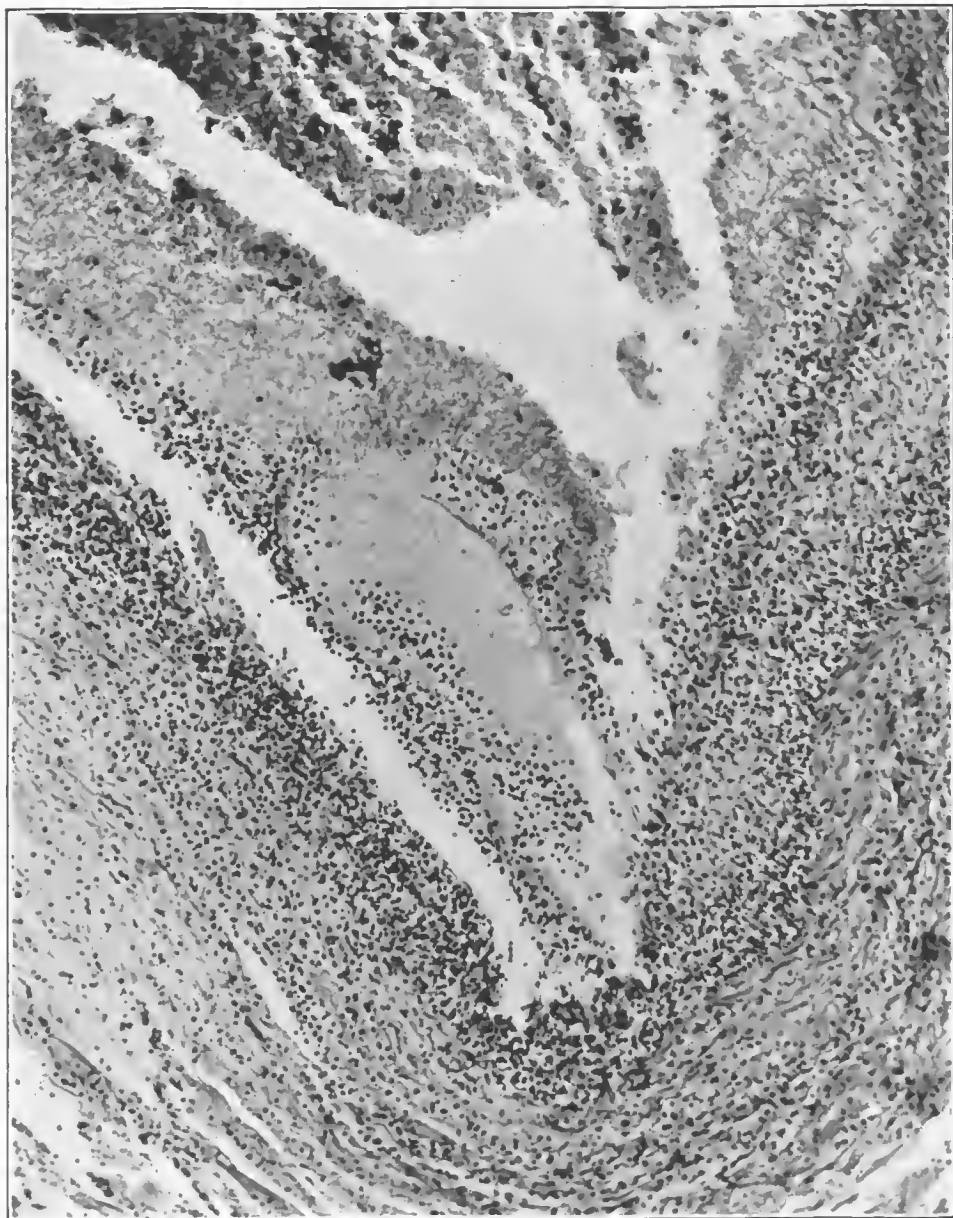


FIG. 149.—Purulent phlebitis of a pulmonary vein the result of extension from perivascular lymphangitis secondary to a bronchopneumonia caused by hemolytic streptococci. Accession number 3091, Army Medical Museum. Negative number 45216. Hematoxylin and eosin stain; $\times 225$

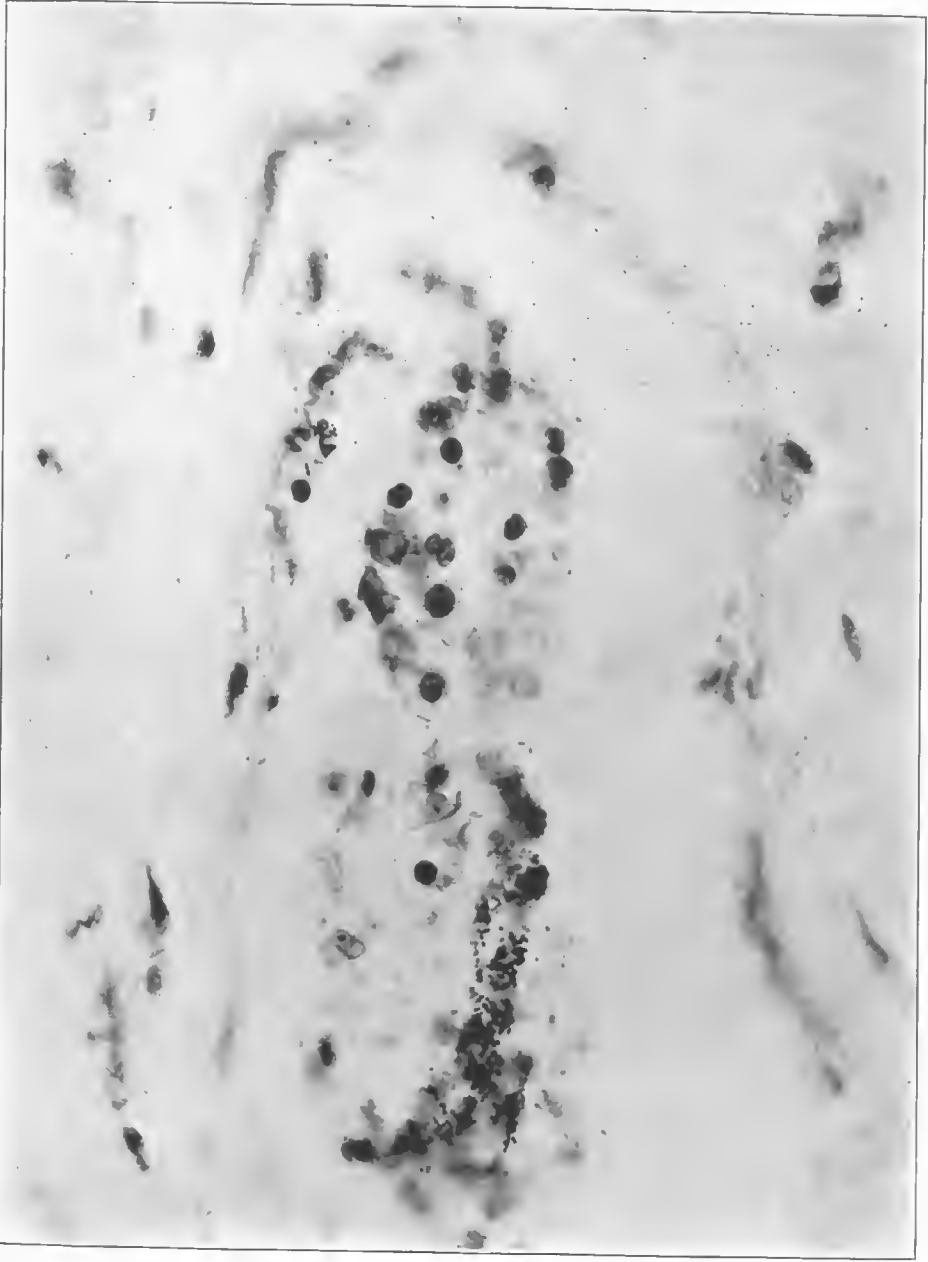


FIG. 150.—Dilated capillary in the mediastinal tissues in a case of mediastinitis complicating a lobular pneumonia due to hemolytic streptococcus. Pericarditis and bilateral empyema were also present. Accession number 3027, Army Medical Museum. Negative number 45225. MacCallum stain; $\times 82$

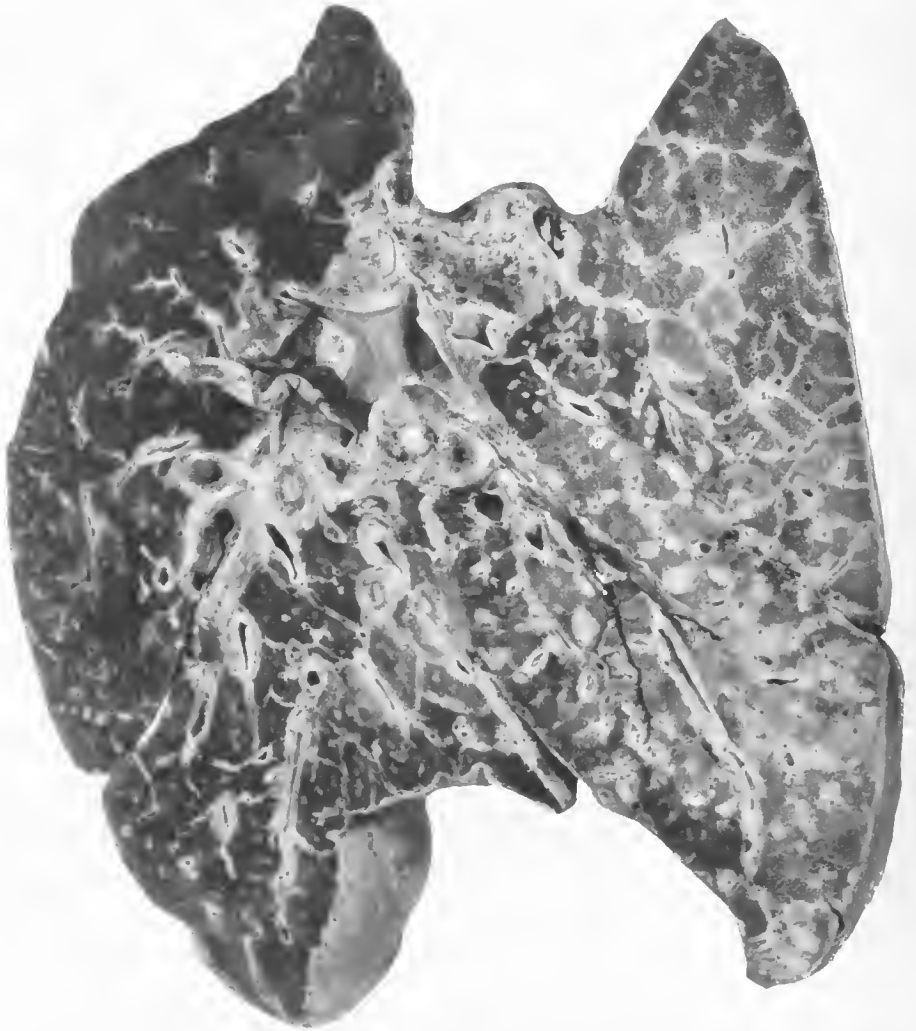


FIG. 151.—Pneumonia following measles, with fibrinopurulent pleuritis. Confluent lobular pneumonia with marked interstitial lymphangitis. *Streptococcus hemolyticus* present in cultures from the lung and pleural fluid. Process more advanced in the left lung. Accession number 606, Army Medical Museum. Negative number 30950

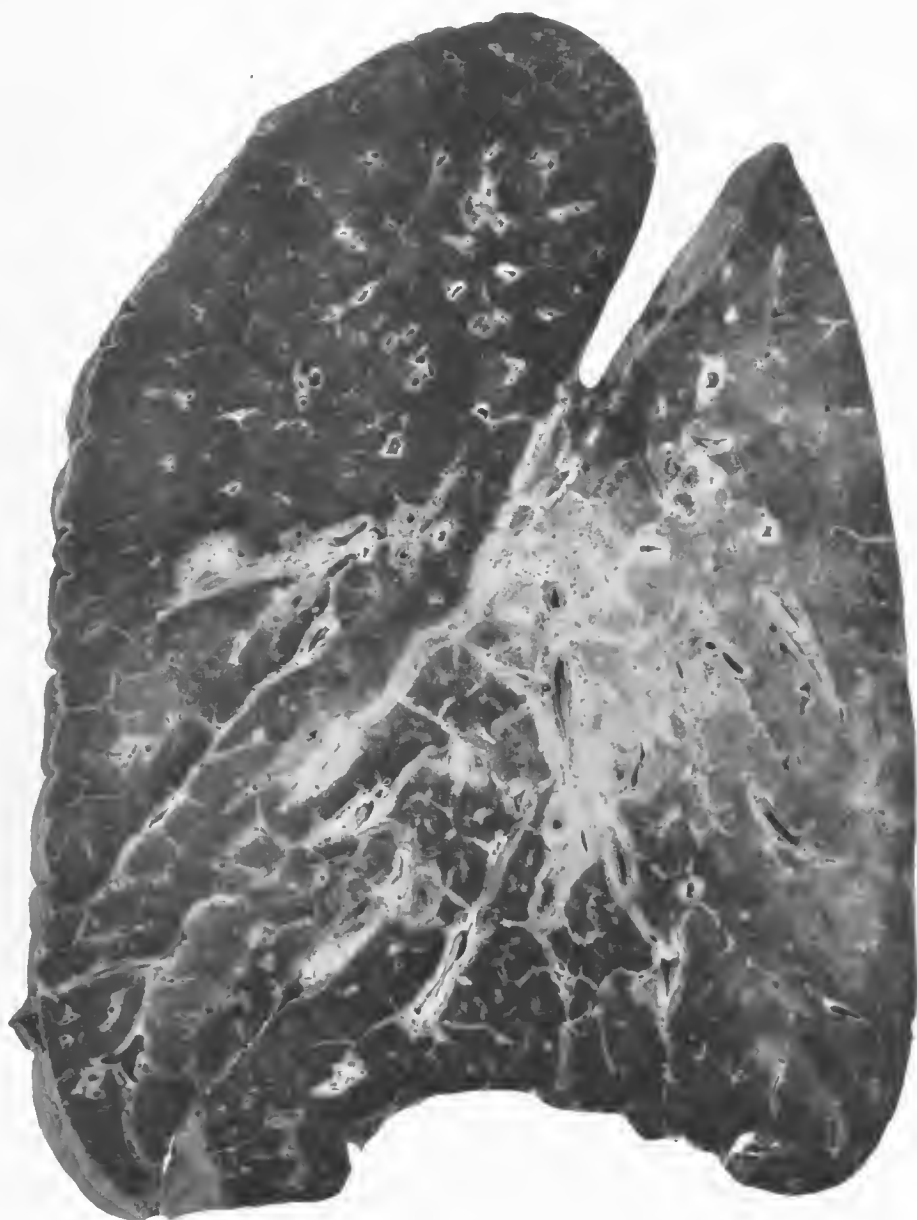


FIG. 152.—Postinfluenzal pneumonia. Late streptococcus lymphangitis following confluent lobular pneumonia. There is considerable phlegmon and moderately advanced organization of the interlobular septa near the central portion of the lung. Accession number 3105, Army Medical Museum. Negative number 30708

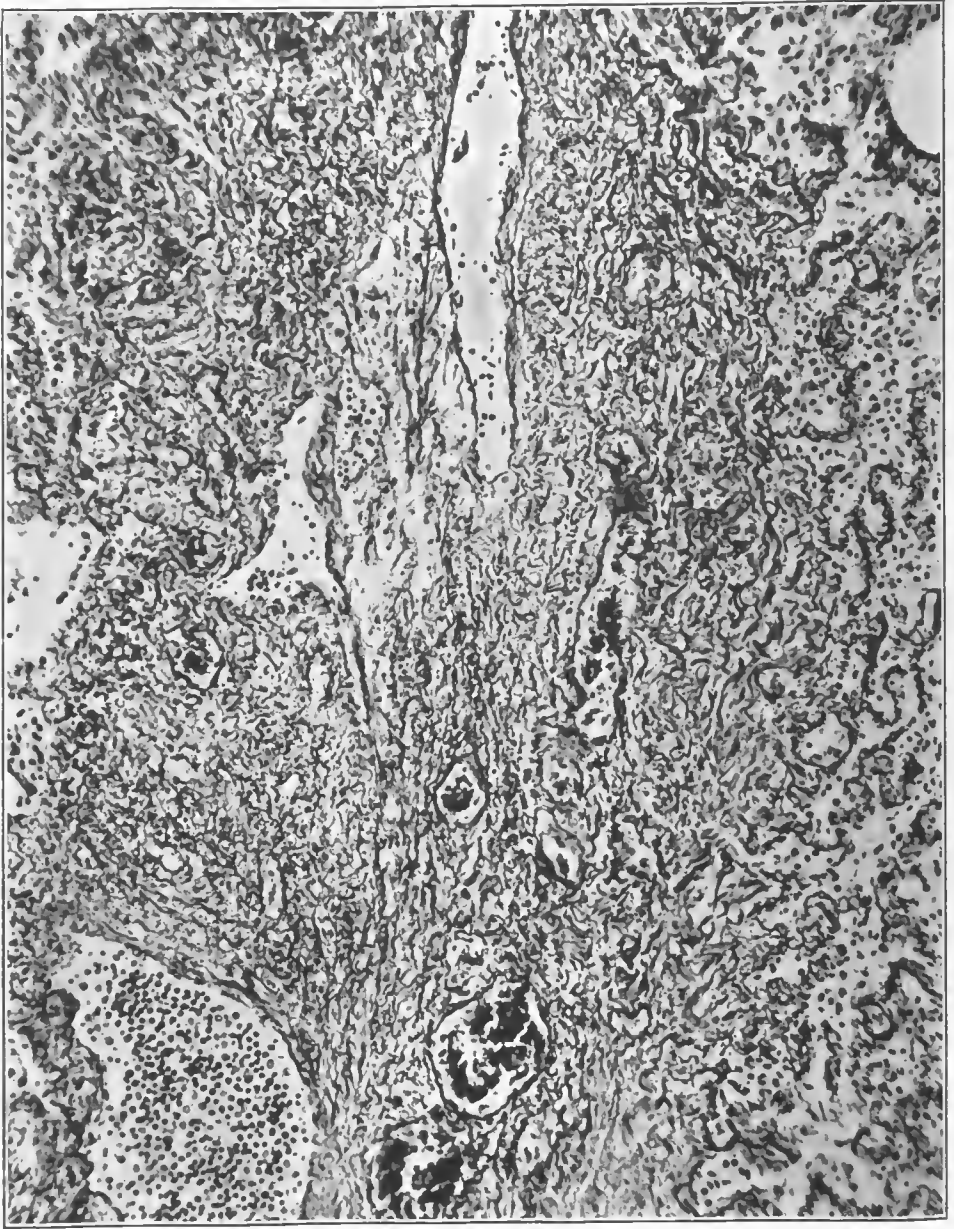

FIG. 153.—Organization in an interlobular septum. Reticulum stain showing collagenous gray and reticulum fibrils black. Lymphatics still visible and contain numerous leucocytes. Accession number 3036, Army Medical Museum. Negative number 45909. Reticulum stain; $\times 145$

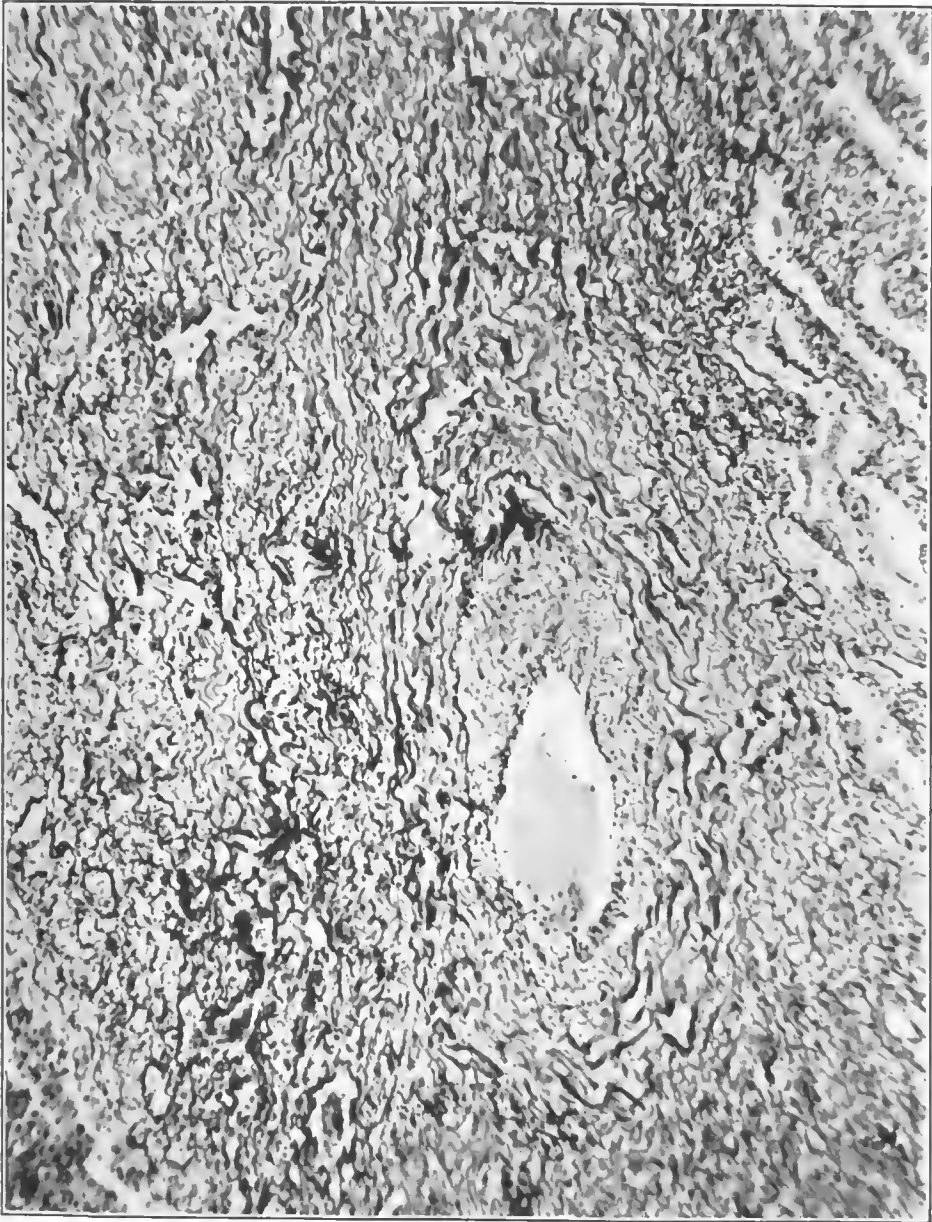


FIG. 154.—Advanced fibrosis in an interlobular septum, showing interstitial lymphangitis, collagenous fibers wavy and gray; reticulum fibrils black. Accession number 3042, Army Medical Museum. Negative number 45901. Reticulum stain; $\times 147$

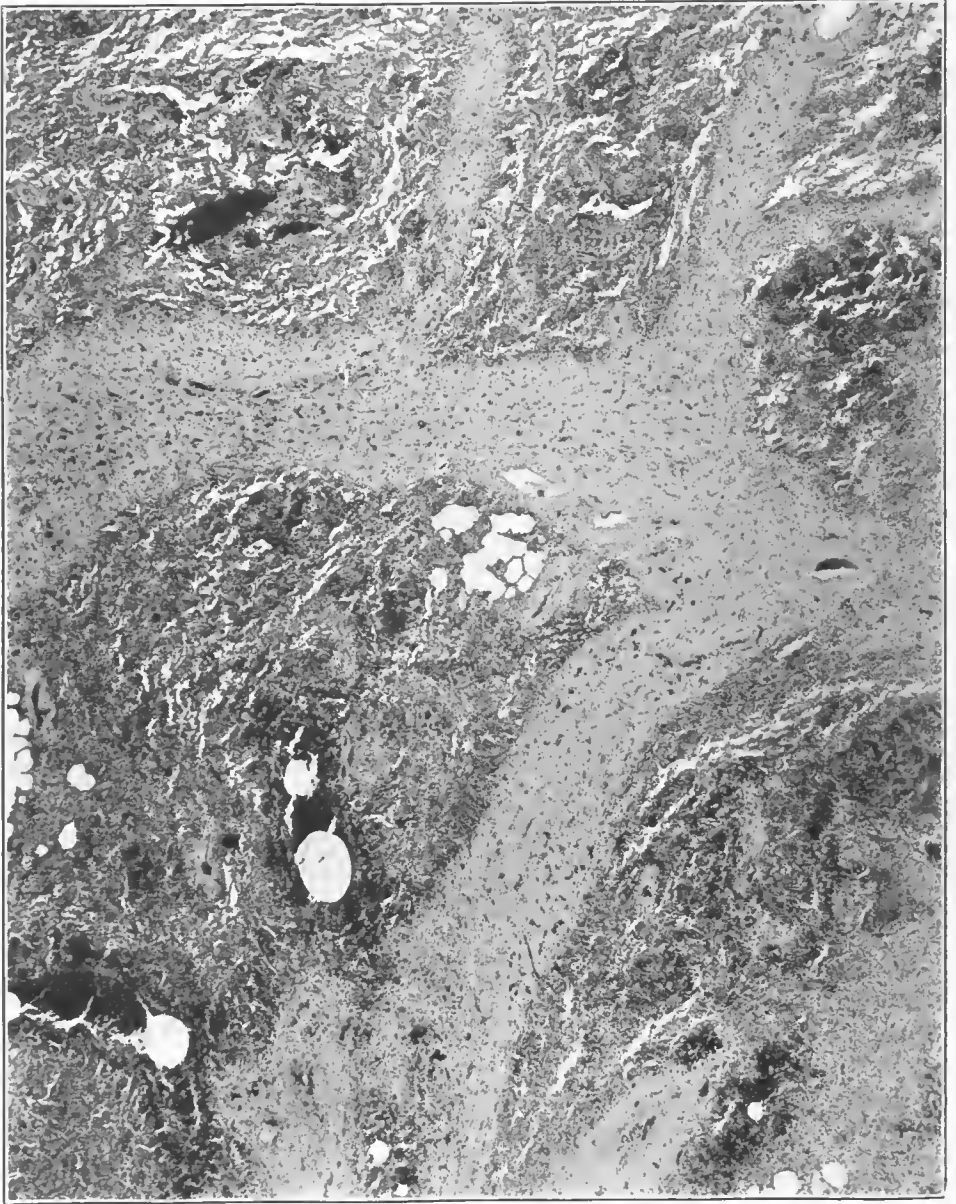


FIG. 155.—Organizing process in interlobular septa in a lobular pneumonia due to nonhemolytic streptococcus of 53 days' duration. The normal structure of the interlobular septa is replaced by granulation tissue. Accession number 3042 Army Medical Museum. Negative number 45190. Hematoxylin and eosin stain; $\times 18$

hemolyticus was prevalent. In spreading bronchopneumonia due to other organisms interstitial inflammation was seen affecting other parts of the same lung. Often it was found along the bronchi serving the posterior vertebral portion of the lower lobe, more rarely the upper lobe. The mediastinal tissues were infected by streptococci with subsequent empyema in cases the pulmonary lesions of which were apparently due to other organisms, principally pneumococci.

In empyema with lobar pneumonia the streptococcus was found in the exudate about as frequently as was the pneumococcus. In such cases it was not always possible to trace its path but sometimes the presence of a mediastinitis or interstitial lymphangitis in other lobes revealed its route.

STAPHYLOCOCCUS AUREUS PNEUMONIA °

Staphylococci were frequently found in cultures from the lung of pneumonia following influenza, but for the most part they were not believed to produce the pneumonic lesions. Pneumonia due to staphylococcus aureus was described at Camp Jackson and was occasionally reported from other camps. The lesions due to a septicemia or pyemia in which this organism was the etiologic agent were reported occasionally, but these can scarcely be considered pneumonia. The number of such cases as compared with the total cases of pneumonia was relatively few, but at Camp Jackson the clinical type was considered to be a distinct one. It is doubtful, however, if one could with surety diagnose *Staphylococcus aureus* pneumonia during life.

In the typical cases, the patients were extremely prostrated almost from the onset of their infection. After being ill from three to four days with influenza, their condition became critical. They exhibited an unusual type of cyanosis. The cherry-red, indigo-blue color was indeed very striking, though not pathognomonic of the infection.

The onset was rarely accompanied by the chill and localized pain of a typical lobar pneumonia though the course of the disease was extremely rapid. The facies, the anxious expression, and deep cyanosis suggested a grave prognosis from the onset, at a period when physical signs of pulmonary involvement were but scanty. Epistaxis was common. The fever on the whole was high, ranging between 104° and 106° F., with frequent remissions to 101° F. The pulse rate was usually low but poor, and in many cases almost imperceptible. Respirations usually ranged between 24 and 36 and in some cases rose to 50 or 60 without much obvious discomfort. These patients rarely had the painful and labored breathing seen in pneumococcus infections.

Of the patients studied at Camp Jackson, 12 died between the first and fifth day, and 73 between the sixth and tenth day of the disease.

The most characteristic feature of this type of pneumonia is the sputum. When typical, the sputum is friable, purulent material of a dirty salmon-pink resembling anchovy sauce or the contents of an overripe furuncle. Occasionally the sputum is hemorrhagic, at first suggesting an acute pulmonary hemorrhage;

° The following statements are based on a study by H. T. Chickering and James H. Park: *Staphylococcus Aureus Pneumonia*. *Journal American Medical Association*, 1919, lxxii, 617, and protocols and specimens in the collections of the Army Medical Museum.

but on close inspection its purulent character can be distinguished. Smears of such sputum stained according to Gram's method, showed many grouped Gram-positive cocci and pus cells. When such sputum was obtained the prognosis was grave; typical sputum, however, was not always procured; and frequently cases that ultimately resulted fatally produced only greenish yellow purulent material which on culture yielded the staphylococcus as the predominant organism.

If sputum containing the staphylococcus was streaked on glucose-free blood-agar plates, the colonies appeared as opaque, round shiny disks about 1 mm. in diameter, surrounded by a wide zone of hemolysis after 18 hours' incubation. On removal from the incubator, the colonies sometimes appeared white; but if the plates were allowed to remain a few hours in the daylight or sunlight, the yellow pigment appeared.

In the routine examination of hundreds of specimens of sputum, *Staphylococcus aureus* was encountered frequently from the throats of normal persons and from patients having a definite pneumococcus infection, but not usually as the predominating organism. It is impossible to say what proportion of men having pneumonic lesions and showing *Staphylococcus aureus* in the sputum were harboring the organisms in the alveoli of the lungs. A considerable number of individuals presenting these findings recovered, but it is doubtful that many of them actually had a staphylococcus infection of the lungs when one considers the pathology of the disease. In many cases, in addition to the predominating *Staphylococcus aureus* in the sputum, there were recovered various types of pneumococcus, *B. influenzae*, streptococcus, and other organisms. The presence of these bacteria in association with the staphylococcus in the lung was confirmed in many instances in the post-mortem examinations. Bacteriemia was an unfavorable prognostic sign.

Few cases showed clinical evidence of accumulation of fluid in the chest or pericardium. When present, the fluid was slightly cloudy-amber in color, sometimes with a tinge of blood, when discovered early in the disease. Later, frank greenish-yellow pus sometimes was obtained. Direct smears of the fluid stained by Gram's method showed many pus cells and grouped Gram-positive cocci. Many of the bacteria were phagocyted. Cultures of the fluid on plain or blood agar showed the typical colonies of *Staphylococcus aureus*. The culture plates were incubated for 72 hours before discarding; otherwise the small, colorless, dewdrop-like colonies of *B. influenzae*, which are prone to develop about the large staphylococcus colony, might have escaped notice after 18 hours' incubation, when they were pin-point in size and could be seen only with a hand lens.

If, in exploring the chest, no fluid is obtained, the needle penetrating solid or semiconsolidated lung tissue, the needle may be washed out by aspirating a little plain bouillon broth culture medium into the syringe and cultures made with the blood-tinged fluid. *Staphylococcus aureus* was frequently recovered by this method.

Leucocyte determinations were made in a considerable number of cases of *Staphylococcus aureus* pneumonia. Both the patients dying of pure *Staphylococcus aureus* infection and those having a mixed infection with *B. influenzae*,

pneumococcus or hemolytic streptococcus, in many instances showed leucopenia. The majority were about normal; a few showed moderate leucocytosis. Many of those having an increased number of white blood corpuscles had localized complications, as empyema or pericarditis.

Brief mention was made above of the lack of definite localized shadows in the lungs on fluoroscopic examination early in the disease. In many instances the diffuse mottling of the whole lung suggested miliary tuberculosis. In other instances, small multiple areas of consolidation were demonstrated. Occasionally whole lobes were involved, there being present a confluent bronchopneumonia or a lobar type of lesion caused by pneumococci with a *Staphylococcus aureus* infection superimposed.

Complications were rare, due largely to the high immediate mortality. Only three patients had discoverable empyema. Other complications were few in number. Seven patients had acute otitis media. One patient had a staphylococcus meningitis. Nine patients had signs of meningeal irritation, but examination of the spinal fluids proved them to be normal. One patient developed *Staphylococcus aureus* pericarditis. The pericardium, both parietal and visceral layers, were covered with a thick, shaggy coat of fibrin. A small amount of purulent fluid was found in the pericardial sac.

Subcutaneous emphysema, a complication rarely seen in primary lobar pneumonia, was encountered six times in the total series of about 1,400 cases of pneumonia. In two of these cases *Staphylococcus aureus* was isolated from the lung. The emphysema was very extensive, involving the head, neck, and trunk. In one case the eyelids were completely closed. It apparently embarrassed the respiration but little.

One patient had a complicating suppurative parotitis from which the staphylococcus was cultivated. Several patients had multiple furuncles.

At the necropsy examinations made during this epidemic in 14 cases it was possible to cultivate *Staphylococcus aureus* directly from the lung tissue, either as the sole organism or in association with other microorganisms.

From this material an unusual opportunity was presented to study the lesions associated with the presence of *Staphylococcus aureus* in the lung tissue. The lungs on gross inspection were not usually so voluminous as those seen in the hemolytic streptococcus infections, nor did they have the same shotty feeling on palpation. Usually the dependent portions of the lungs, the lower lobes, or very frequently the posterior portions of all the lobes, being the dependent parts with the body in the horizontal position, were involved.

Sometimes there was a pleural exudate. A fibrinous exudate was much less commonly found than in lobar pneumonia. The surface of the affected portions of the lung was deep purplish-blue. Careful examination of the pleura usually revealed, in addition to showers of petechiæ, small yellowish-white spots, pinhead in size, situated just beneath the pleura, which proved to be minute abscesses. The cut surface of the lung was either intensely hemorrhagic, resembling the cut surface of the spleen if the course of disease had been of brief duration, or had the appearance of a confluent bronchopneumonia. However, small bronchioles standing up above the cut surface and surrounded by a zone of dark red infiltrated tissue, as in the bronchopneumonias following

measles, were not seen. On the contrary, innumerable small abscesses, ranging in size from 1 to 10 mm. in diameter, were usual. In early processes, these minute white spots were not broken down. In those of longer duration, many small abscesses became confluent, having softened and become filled with thick, greenish-yellow pus. Nine of the 14 cases examined post mortem revealed these small abscesses. Of the cases not showing abscess formation, three were very early, the patients dying on the fourth, sixth and seventh days from the onset of the primary epidemic infection. The sections of these cases showed intense congestion, with rupture of the alveolar walls and exudation of serum and red blood corpuscles into the alveoli. Another case, in which the patient died on the eleventh day without abscess formation, was complicated by suppurative pericarditis. In the last case there was a mixed infection with *B. influenzae*, in which process *Staphylococcus aureus* apparently played a minor rôle. Direct smears of the abscesses showed pus cells and many grouped Gram-positive cocci. The majority of the abscesses were situated at the periphery of the lung near the pleura, though the whole lung was sometimes involved. The propensity of *Staphylococcus aureus* to form multiple small abscesses in the lung appeared to be characteristic of this organism. The gross appearances suggest that the abscesses resulted from a pyemic process, but microscopical examination revealed the fact that the abscesses had originated within the bronchial lumen, the resulting lesions resembling those of inhalation pneumonia. Extensions along peripheral lymphatics to the pleura gave rise to the minute foci seen beneath the surface of this membrane.

The inflammation extended along the bronchi, producing a purulent bronchitis with destruction of the mucosa and rapid extension through the walls of the bronchi and bronchioles, destroying these walls and extending into the surrounding alveoli. It thus formed abscesses, the center of which was the bronchus and the periphery those surrounding alveoli not dissolved by the lytic action. (Figs. 156, 157, 158, 159, 160, 161.) The alveoli surrounding these bronchial abscesses were involved in an inflammation of greater or lesser extent. Where the abscesses were surrounded by a relatively narrow zone of inflammation there was an exudate of serum, relatively few leucocytes and few bacteria, essentially a reaction surrounding a focal abscess in the lung and dependent more on the reaction secondary to the toxins of the abscess than on extension of the bacteria into the tissues.

In other cases the inflammation extended outward from the bronchus for considerable distances, apparently following along the air passages, causing a seropurulent reaction over wide areas of the pulmonary parenchyma. This reaction was a spreading bronchopneumonia, but was characterized by the occurrence of the focal abscesses about the bronchi which supplied or traversed the consolidated area. The organism, true to its characteristics, produced lysis of the tissue and abscess formation with a minimum of phlegmonous reaction about the lesions, but in addition spread along air passages and sometimes caused widespread pneumonic consolidation. Staphylococci were relatively abundant in the pus of the abscess but were few in the alveolar walls and exudate of the pneumonic areas. Lymphangitis, so prominent a part of the picture in streptococcus lesions, was not noticeable.

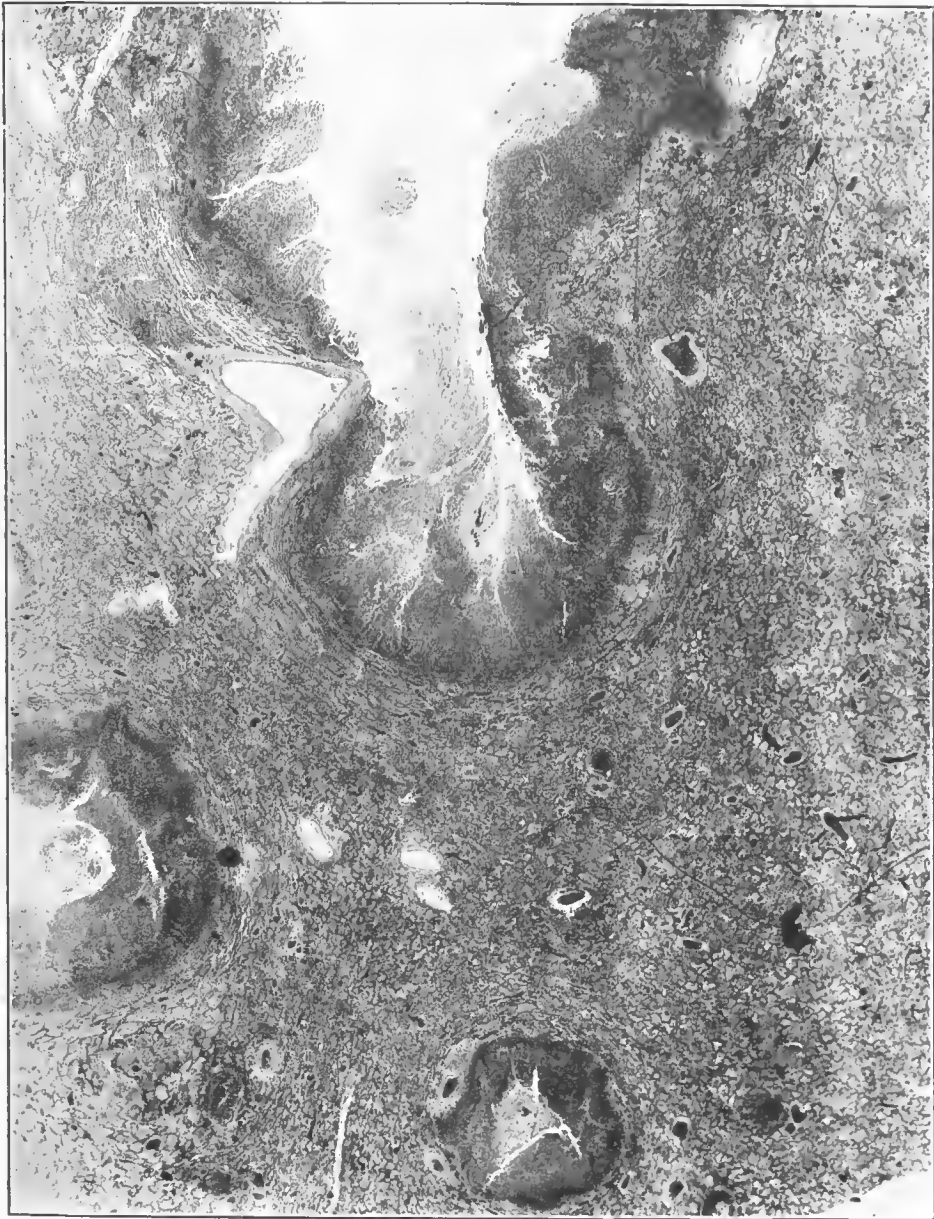

FIG. 156.—*Staphylococcus pneumonia*. Abscesses arising in the bronchioles, extending outward. Intervening tissue shows seropurulent exudate. Black masses in pus are grouped staphylococci. Accession number 1141, Army Medical Museum. Negative number 46201. Hematoxylin and eosin stain; $\times 14$




FIG. 157.—Staphylococcus pneumonia. Multiple abscesses in bronchi, with intervening lax consolidation. Accession number 1141, Army Medical Museum. Negative number 30723

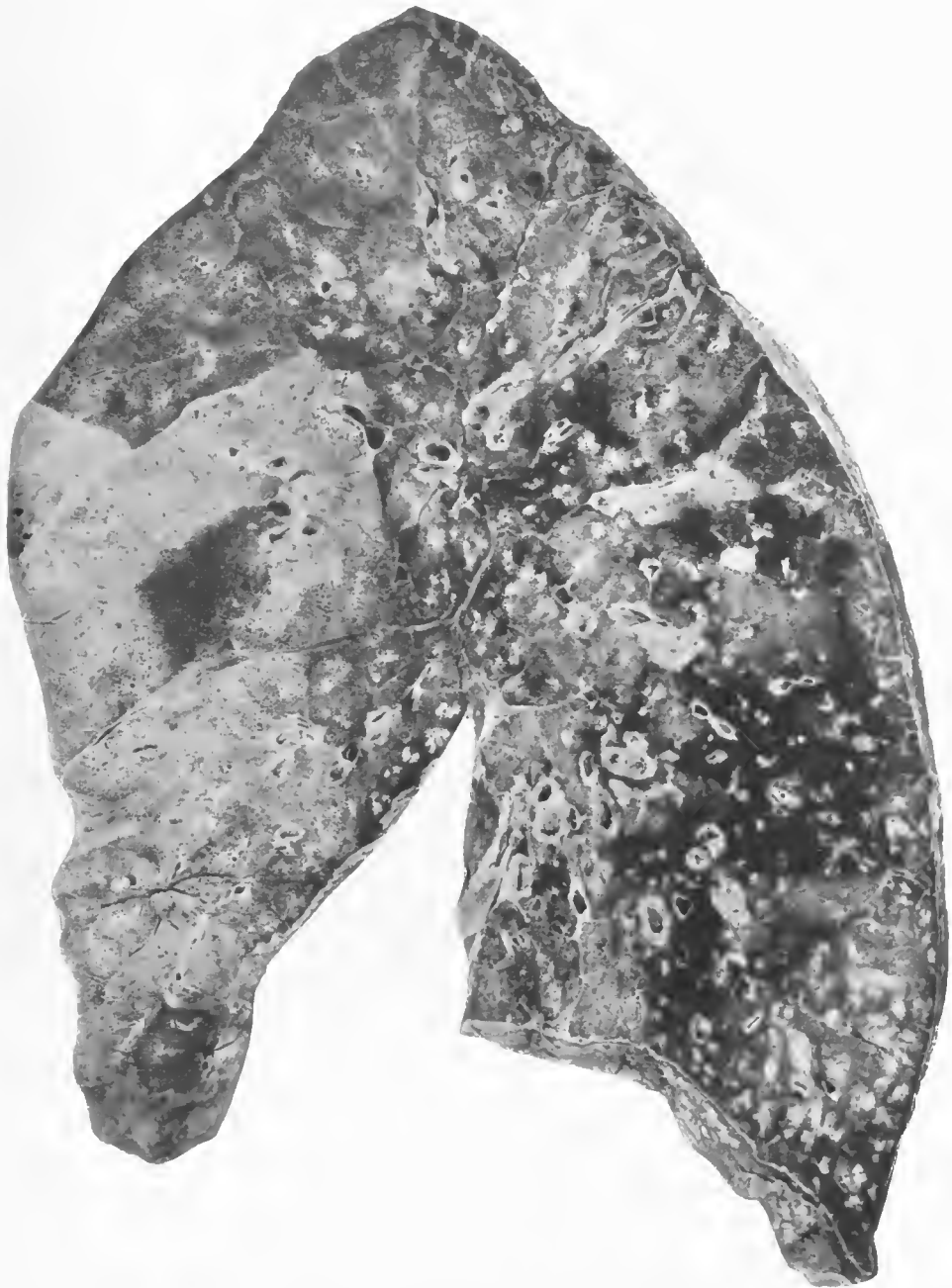


FIG. 158.—Confluent lobular pneumonia due to pneumococcus, Group IV. Multiple abscesses arising in bronchi due to staphylococcus. Accession number 3131, Army Medical Museum. Negative number 42863

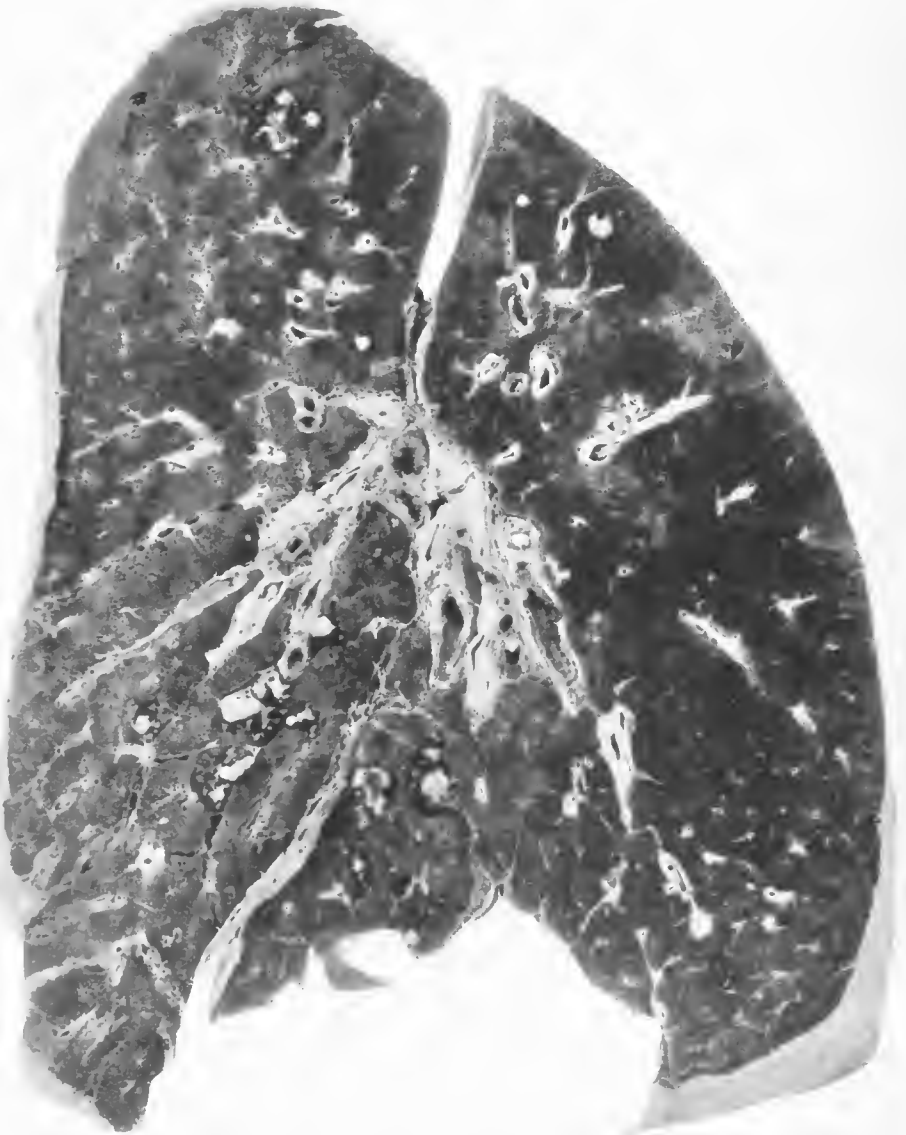

FIG. 159.—Confluent lobular pneumonia, with groups of staphylococcus abscesses. Pneumococci isolated from the lung, *Staphylococcus aureus* from abscesses. Accession number 3057, Army Medical Museum. Negative number 30701

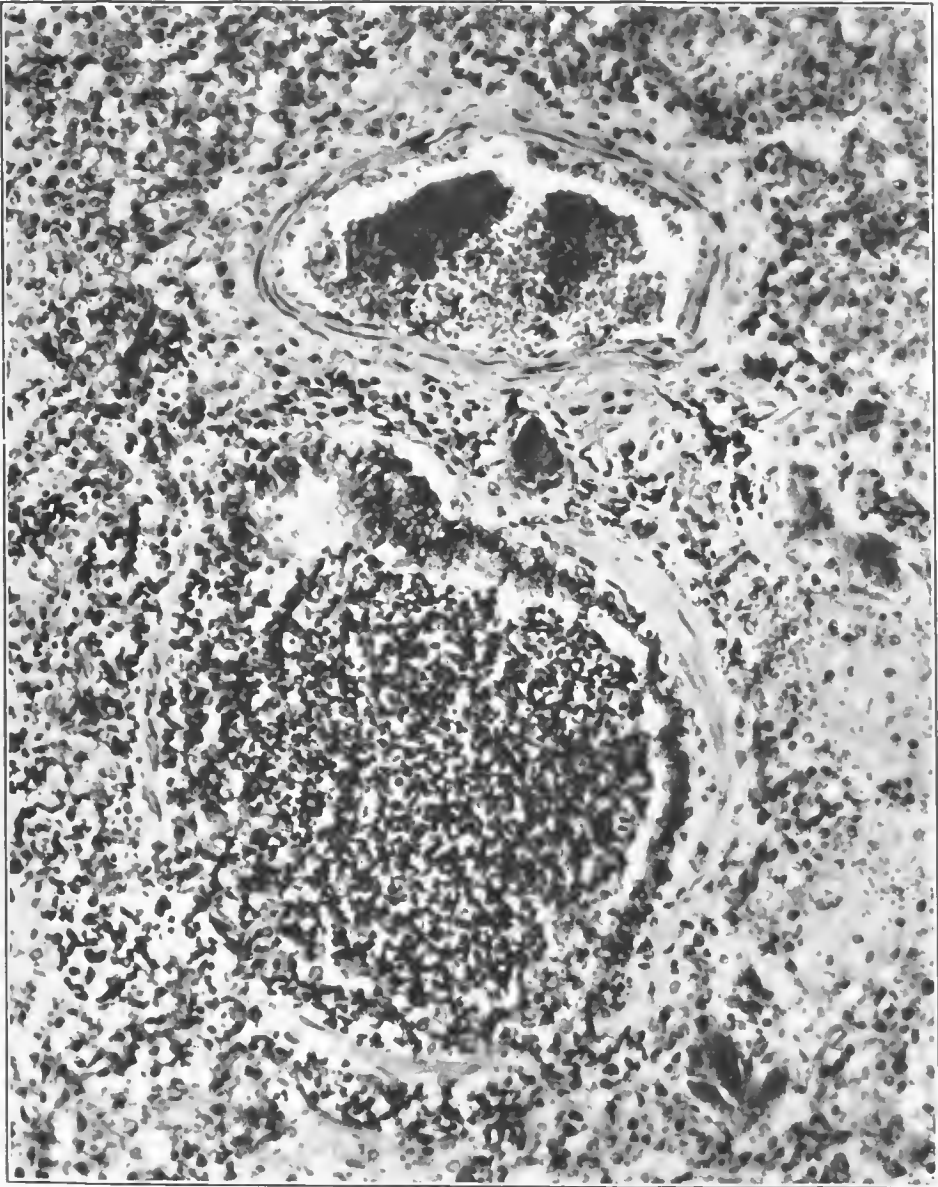


FIG. 160.—Purulent staphylococcus bronchiolitis. Epithelium partially destroyed. Large numbers of staphylococcus forms were seen in the pus. Accession number 1141, Army Medical Museum. Negative number 46200. Hematoxylin and eosin stain; $\times 235$

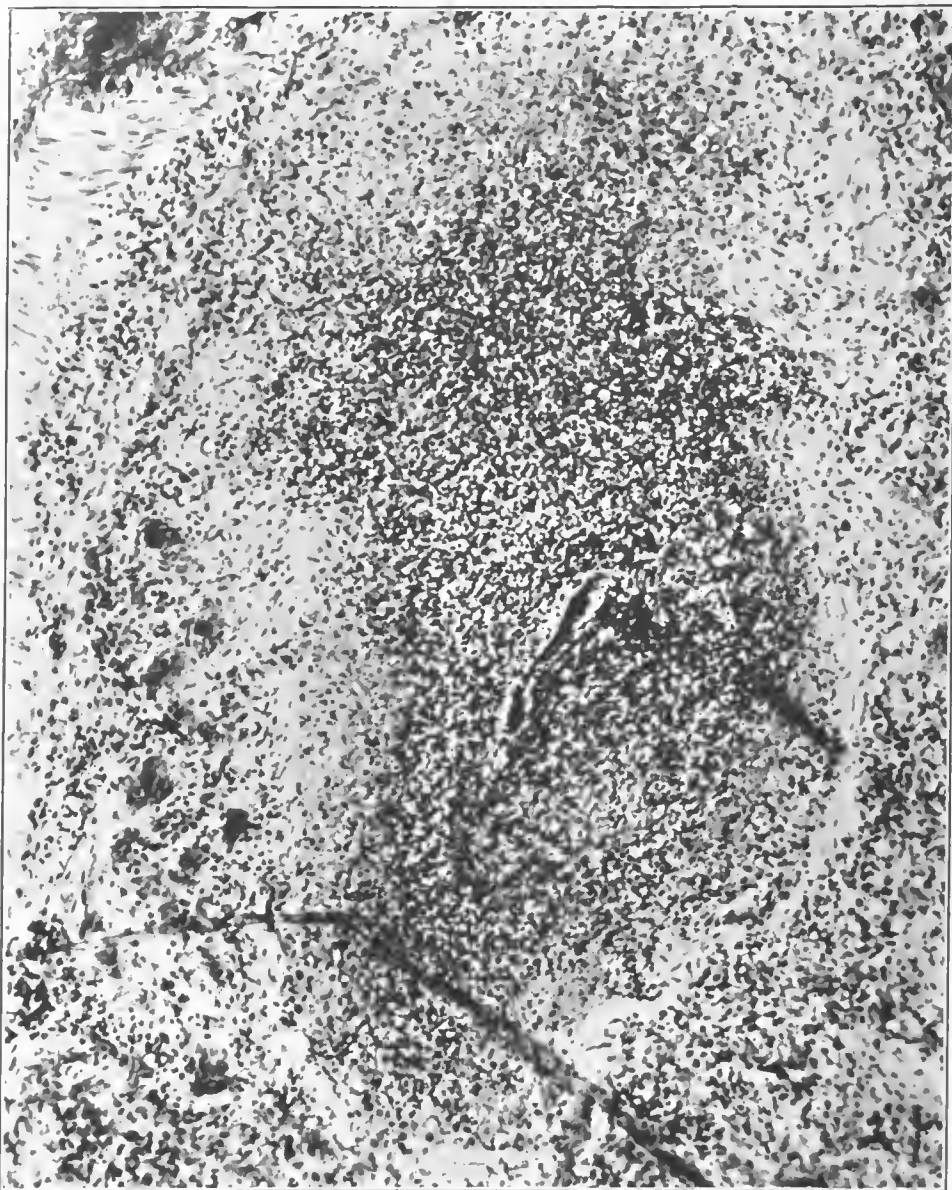

FIG. 161.—Purulent staphylococcus bronchitis. Bronchial wall is partly destroyed and the inflammation is extending through and dissolving it. Black mass in the pus is a group of staphylococci. Accession number 1141, Army Medical Museum. Negative number 46199. Hematoxylin and eosin stain; $\times 235$

A post-mortem examination of one of the two cases presenting signs of subcutaneous emphysema was made. It was impossible to discover the pathway of the escape of air from the lungs. The mediastinal tissue was filled with bubbles of air. Along the lappet of the inferior edge of the right upper lobe, the visceral pleura was distended with large bubbles of air varying in size from 1 to 10 mm. in diameter.

On account of the crowded condition of the morgue at Camp Jackson it became impossible to hold many post-mortem examinations. Consequently an attempt was made to learn more of the bacterial infection of the lungs of the fatal cases by exploring the lungs post mortem with an ordinary chest exploring needle and syringe. The syringes and needles were sterilized by boiling and the skin was sterilized by the application of tincture of iodine. The needle was thrust into the lung tissue and aspiration continued until about 1 c. c. of bloody fluid was obtained. This fluid was then cultivated on glucose-free blood-agar plates and slants and in plain broth, and in many cases direct smears of the lung juice were made. These smears checked closely with the cultures. The organisms recovered in this way were found as well in the sputa, blood cultures, and empyema fluids.

The occurrence of *Staphylococcus aureus* in the lungs in the fatal cases of pneumonia at Camp Jackson was striking; 49 per cent of the 312 cases cultivated showing this organism present alone, 92 cases; in association with the influenza bacillus, 22 cases; with the pneumococcus, 29 cases; with various streptococci, 12 cases. In many instances, death was predicted from the appearance of the sputum alone, and the post-mortem cultures verified the information obtained from the sputum examination.

The lesions were somewhat similar to some of those produced by streptococcus in other camps, though the breaking down into abscesses appeared to occur with greater rapidity. It differed from the abscesses due to streptococci in showing little or no evidence of lymphangitis in the lymphatics draining the affected area. It was associated usually with other organisms which undoubtedly were responsible in part for the pulmonary lesions.

REFERENCES

- (1) MacCullum, W. G.: Pneumonia in Army Camps. Monograph of the Rockefeller Institute for Medical Research, No. 10, April 16, 1919.
- (2) Miller, William Snow: Studies on the Normal and Pathological Histology of the Lung. *The American Review of Tuberculosis*, 1925, Vol. XI, 1.

CHAPTER IV

LESIONS IN ORGANS OUTSIDE OF THE RESPIRATORY TRACT

SKIN

Various skin lesions occurred during the course of influenza and the pneumonias which followed. In the absence of knowledge as to the etiology of influenza, it is impossible to state that these eruptions were due to the cause of influenza or to any of the organisms which were found in the respiratory tract as secondary invaders. It should be borne in mind that in a majority of the camps measles was endemic or epidemic at the time of the influenzal outbreak of the fall of 1918, and a rash occurring in patients whose clinical signs were those of epidemic influenza may have been measles. As is true in all epidemics, a certain proportion of the cases with other diseases were recorded as cases of the epidemic condition, and it appears impossible to state with any degree of positiveness that any eruption occurred in influenza uncomplicated by infections of other varieties. Exanthems resembling measles or scarlet fever were fairly frequent and in the absence of an epidemic of influenza the cases showing them might have been so diagnosed.

Miliaria was very frequent possibly as the result of profuse perspiration. Occasionally petechial hemorrhages were seen in the skin, sometimes larger areas of hemorrhagic extravasation, while an occasional case showed a more or less typical reaction of purpura hemorrhagica. At Camp Taylor hemorrhages into the papillæ accompanied by more or less inflammatory cell exudation were seen. Occasionally the eruption was vesicular and sometimes the vesicles were filled with pus.

Jaundice was present in some cases, though not in the very early stages of the disease. This condition varied considerably, being present more frequently in some camps than others, yet it is impossible to state that any particular organism caused the condition more frequently than another, though it appeared to be more frequent in cases infected with the hemolytic streptococcus.

Subcutaneous emphysema was noted in most of the camps but its incidence can not be arrived at from a study of autopsy material. Cultures of the emphysematous tissues were uniformly sterile. The pathogenesis of this condition is discussed under the pathology of the respiratory tract.

MUSCLES

Necrosis of muscles was met with fairly frequently and undoubtedly was present more often than it was reported. It was reported most frequently in the rectus abdominis muscle but was recorded in other muscles, particularly the accessory muscles of respiration. In appearance the muscles were smooth, moist, light reddish-brown in color with a peculiar translucency. Rupture of individual fibers was sometimes followed by hemorrhage and occasionally considerable

portions of the muscle were separated, the tear being filled with clotted blood. Leucocytic infiltration was usually minimal in amount but occasionally frank pus was formed and bacteria, pneumococci or streptococci, were found in a few cases. The etiology of this condition, which is not peculiar to this disease, is not clear, but the character of the lesion suggests a block in the arterial blood supply. As the condition appears most frequently in the muscles which are used in respiration the increased respiratory effort is probably partly responsible. (Pl. XIV; figs. 162, 163, 164, 165.)

PERITONEUM

Peritonitis occasionally occurred either from extension of the infection through the diaphragm or apparently independently of such extension, and when the latter occurred there was often a coexisting inflammation of the meninges and occasionally of the joints. The organisms found were usually pneumococci or streptococci, rarely both. Extensions from the pleura occurred relatively late during the course of the disease, but in cases of so-called polyserositis the spread to the serous membranes usually occurred relatively early.

HEART AND BLOOD VESSELS

Dilation of the heart, particularly of the right ventricle, was a common finding at necropsy. Various degrees of degeneration of the myocardium were reported, from a mild swelling and a slight obscuration of the cell markings to segmentation and fragmentation of the muscle fibers. In cases which were accompanied by a septicemic or pyemic condition occasionally small abscesses, the result of bacterial embolism, were found. Edema between the muscle fibers occasionally was reported.

In the endocardium in a few instances small petechial hemorrhages were seen, but as a whole endocardial change was rarely reported during the pandemic period. In the post epidemic period subacute bacterial endocarditis from which the influenza bacillus was isolated was occasionally reported. Streptococcus endocarditis was also rarely reported.

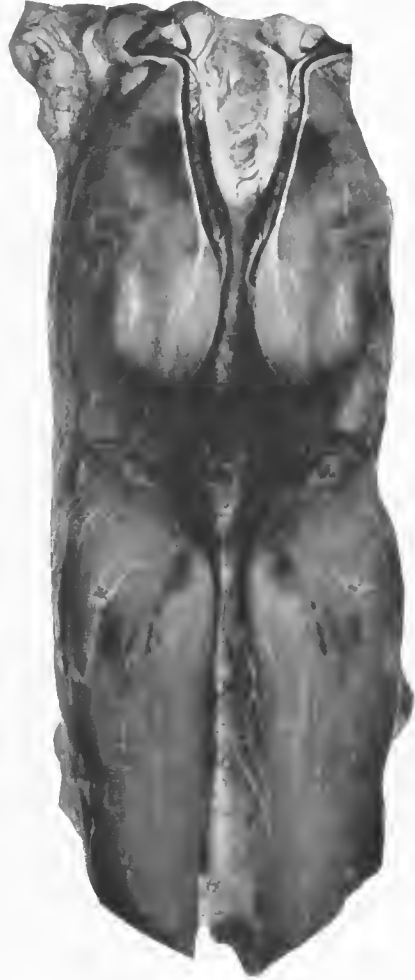

FIG. 162.—Zenker's degeneration of rectus abdominis muscle in a case of influenza and pneumonia. Accession number 6945, Army Medical Museum. Negative number 30512

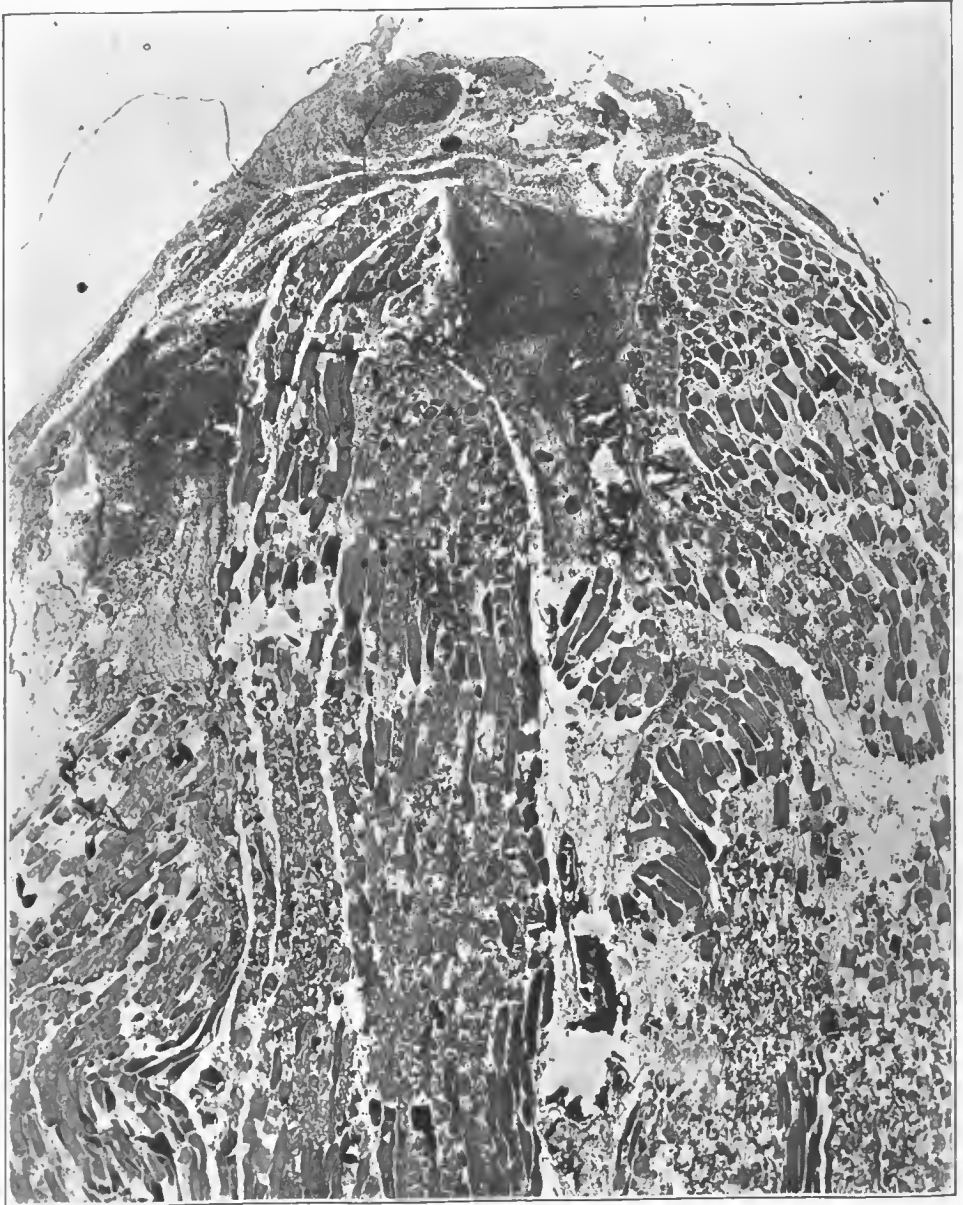


FIG. 163.—Zenker's degeneration of the rectus abdominis muscle in a case of pneumonia following influenza. Low power, showing broken end of the muscle bundle where considerable hemorrhage is present. Muscle fibers show varying stages of degeneration, necrosis, and lysis. Accession number 6951, Army Medical Museum. Negative number 45866. Iron Hematoxylin and picro-eosin stain; $\times 23$

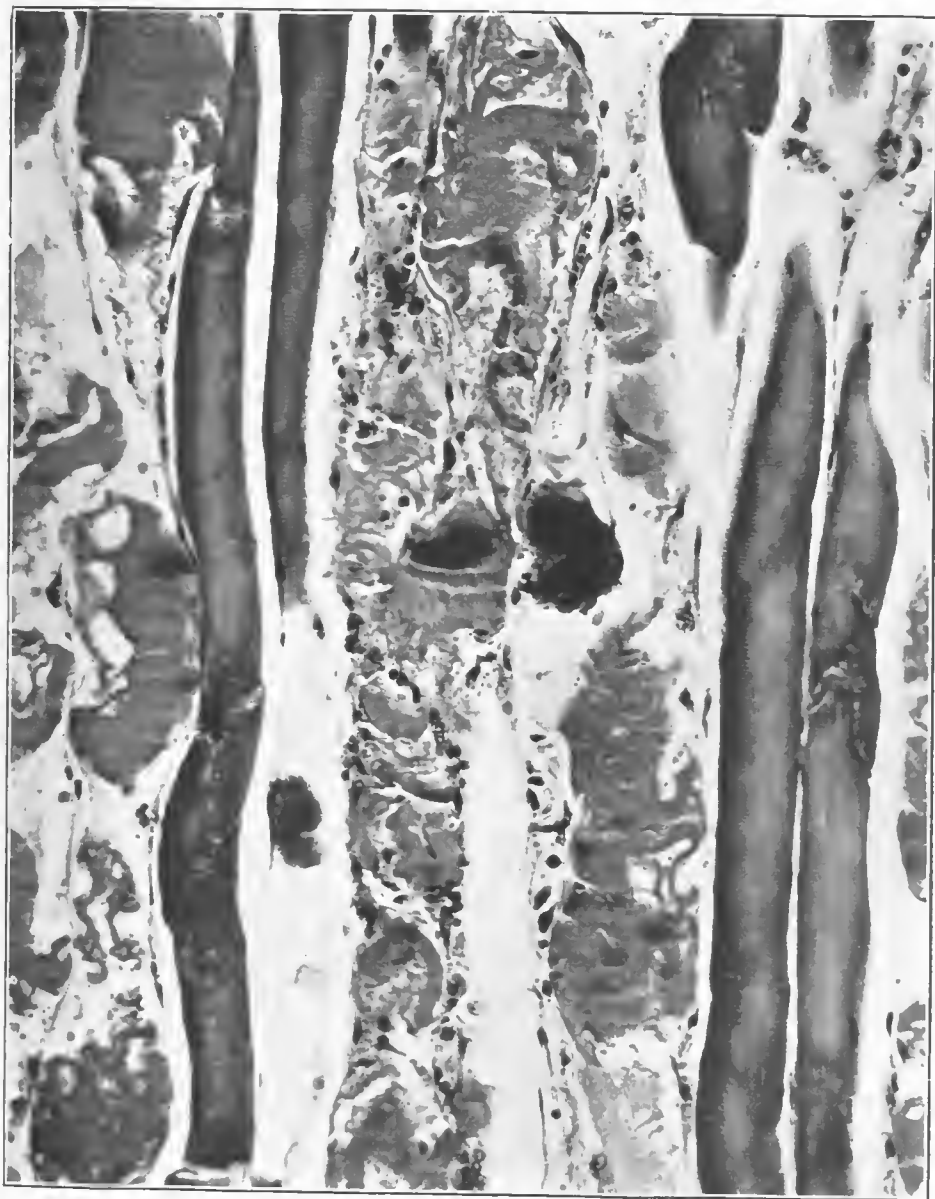


FIG. 164.—Zenker's degeneration in the rectus abdominis muscle. Striations still present in some areas along the fibers which show the least swelling. Accession number 6951, Army Medical Museum. Negative number 45896. Iron hematoxylin and picro-eosin stain; $\times 223$

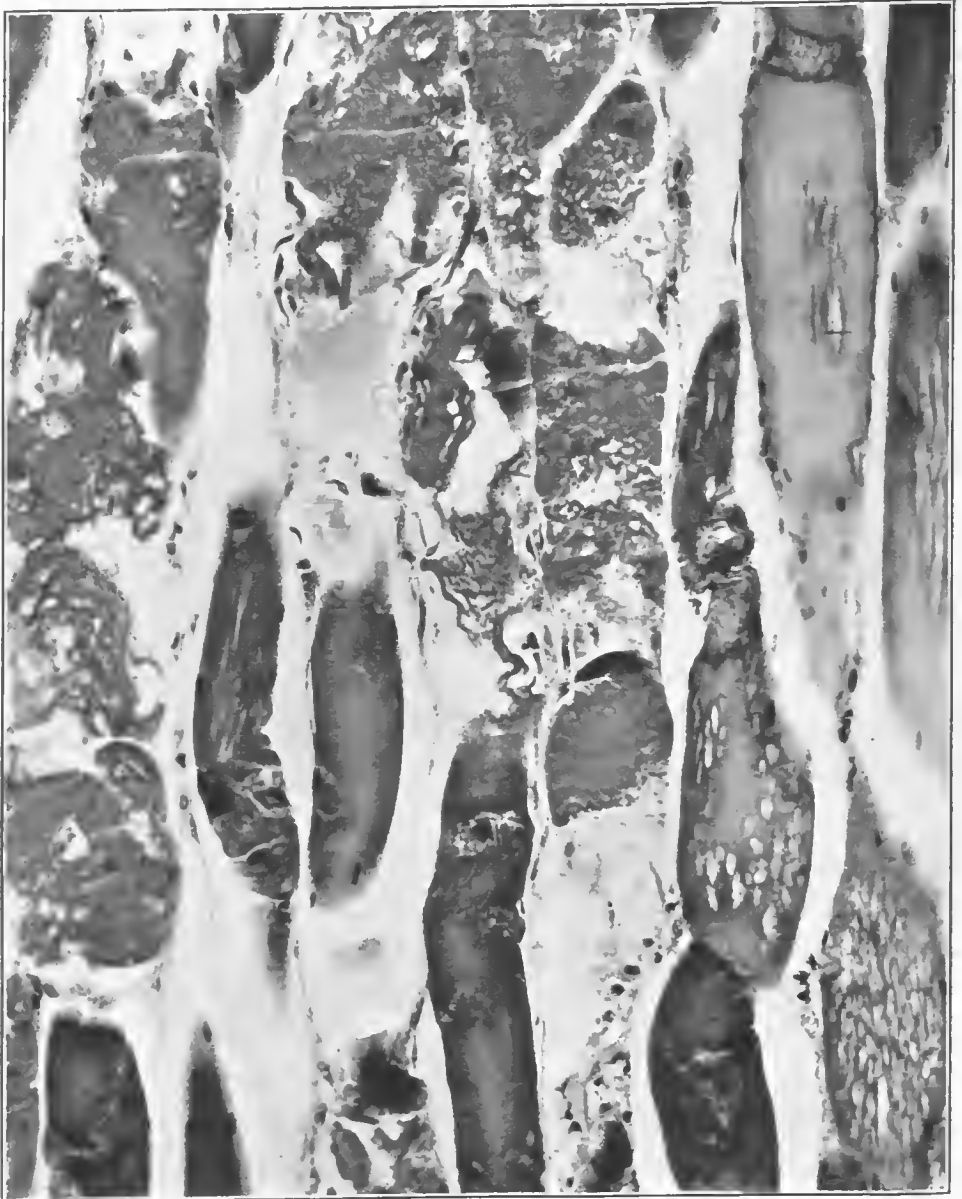


FIG. 165.—Zenker's degeneration in the rectus abdominis muscle. Lighter stained homogeneous muscle fibers are more alkaline and have taken up the picric acid of the combined picric acid-eosin stain. Few nuclei stain in the less swollen fibers. Accession number 6951, Army Medical Museum. Negative number 45895. Iron hematoxylin and picric acid-eosin stain; $\times 220$

Aorta.—Yellowish streaks longitudinally arranged along the intima of the aorta were seen in cases where death followed influenza, but can not be said to be peculiar to the condition, as they have been reported following other acute infectious diseases and are commonly found during the age periods when the acute infectious diseases, particularly the exanthemata, occur. Their color varies from a pale opaque cream color to a fairly bright yellow. Only exceptionally were further changes found and these were not attributed to the disease from which the patient died. Elasticity of the aorta as a whole did not appear to be decreased. Microscopically the condition appeared to be an edema of the tissues below the internal elastic membrane, with swelling of the cells and an accumulation of large cells with vacuolated cytoplasm. Frequently these cells contained no recognizable nuclei. This degenerative condition was not distinguishable from the early stages of ordinary atheroma.

Hemoglobin tinting of the intima of the aorta was observed occasionally, probably due to blood destruction as the result of secondary invading organisms, most frequently the hemolytic streptococcus.

Small blood vessels in the vicinity of lesions in the lung showed various types of degenerative change, the most prominent being a proliferation of the capillary endothelium. Occasionally the walls of small vessels were hyaline, apparently necrotic, and some observers have reported seeing the actual point of rupture of these structures. That this rupture of small vessels occurred is evidenced by the hemorrhagic extravasation in the lungs, but whether it was due to the virus of influenza or secondary infecting organisms can not be determined. The occurrence of the hyaline or conglutination thrombi, the latter consisting of red corpuscles which had lost their hemoglobin, is reported by most observers. Their significance is not entirely clear. Where outlines of red blood corpuscles are seen it seems probable that the condition is one of thrombosis or vascular block of some kind. The hyaline thrombi appeared to be little more than coagulated plasma and were more frequent in poorly fixed tissues. These may be sections across a vessel in the vicinity of a clot which has contracted, leaving serum only in that part of the vessel seen in the specimen. They were found in vessels of considerable size though most frequently in the capillaries of the alveolar walls.

BLOOD

Reports of blood examinations indicate that there is primarily a decrease in the white blood corpuscles, particularly a decrease in the polymorphonuclear neutrophiles. This leucopenia persists throughout the course of the disease in uncomplicated influenza but the picture changes when secondary infection takes place, the blood picture then conforming to the usual reaction accompanying the secondary invading organism. Bunting,¹ in a small series reported in 1921, found that in clinically uncomplicated influenza there was an early neutrophile increase followed by a sharp drop, and that thereafter there was a leucopenia, a deficiency in the cells of marrow origin, and of blood platelets. An early polymorphonuclear leucocytosis was not observed or recorded from the Army camps and stations during the pandemic period. A decrease in platelets often was seen.

Little was done on the physical characteristics of the blood, but it was the general experience at necropsy, particularly on cases dying early, that clotting was delayed.

Underhill and Ringer² reported a concentration of the blood in influenza and compared it with the changes found in the blood following poisoning with phosgene gas.

Symmers³ found that blood pressure was usually low and the pulse rate was frequently slow even in patients who had not received digitalis. He considered that the capillary dilatation and injection and the low blood pressure were possibly related to the changes in the suprarenal medulla.

SPLEEN

There is no agreement as to the changes in the spleen. In general, it may be said to have been somewhat enlarged, but not excessively so. Here, again, it is impossible to determine whether the changes were due to the primary infection by the influenza virus or to the secondary infections. In general, the picture was that of the spleen of acute infectious disease, and when not involved in other conditions such as previous splenitis, it was soft, the pulp more or less diffluent, occasionally mushy, while follicular markings were rarely prominent. Microscopically, there was an excessive blood content, endothelial hyperplasia of the vessels and the cells of the reticulum. Occasionally, there appeared to be an excess of phagocytic cells throughout the reticulum of the organ. In some cases focal necrosis was seen, sometimes of the toxic type, at other times apparently due to embolic lesions from a septicemic or pyemic condition. The lesions in the spleen could not be said to be in any way characteristic.

SUPRARENALS

Necrotic areas, frank hemorrhage and occasionally abscesses were reported in and about these organs and rarely streptococci were isolated from the lesions. They presented grossly with either hemorrhages within the substance of the organ or both in the substance of the cortex and out in the surrounding tissues. When not involved in the hemorrhagic process they usually showed considerable congestion, the cells of the cortex were usually swollen, sometimes hydropic, and some observers reported decrease in the lipid granules. Focal necroses were found occasionally, rarely considerable pus was present. (Figs. 166, 167.)

KIDNEYS

Usually the kidneys were involved in a parenchymatous degeneration of greater or lesser extent. Rarely glomerular nephritis was present, but it can not be considered at all characteristic of the disease. It was found more rarely than is usual in the acute exanthemata. The degree of degeneration varied markedly but some degree was practically constant.

LIVER

Degenerative changes in the liver cells was constantly present and varied markedly in degree. The differentiation between the changes due to influenza and those of secondary infecting organisms and the resultant toxemia, septicemia

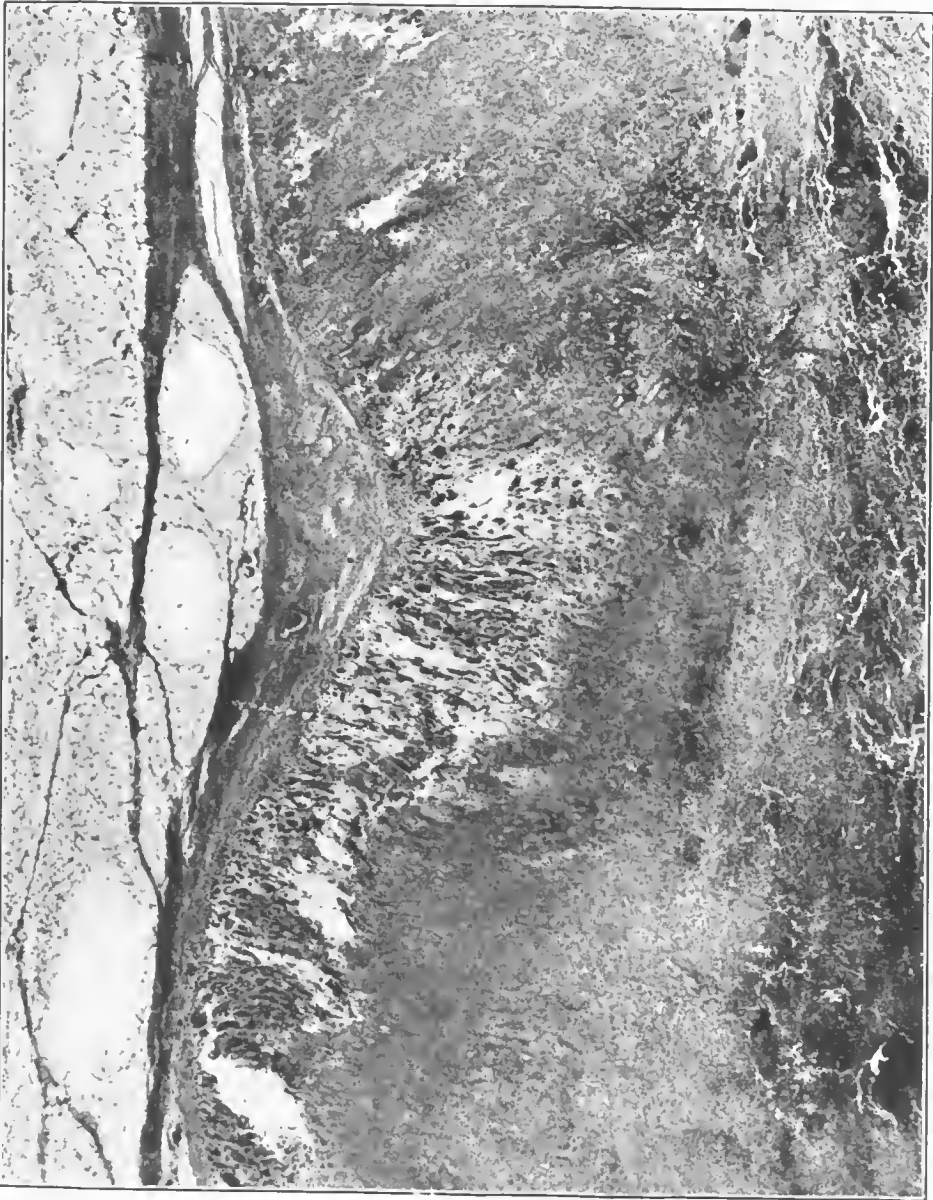

FIG. 166.—Hemorrhagic adrenitis in a case of bronchopneumonia following influenza. Ante-mortem cultures from the throat showed pneumococcus, Type I, hemolytic streptococcus, and influenza bacillus. Post-mortem culture from the blood and lung showed pneumococcus, Type I. Accession number 3045, Army Medical Museum. Negative number 45208. Hematoxylin-eosin stain; $\times 22$

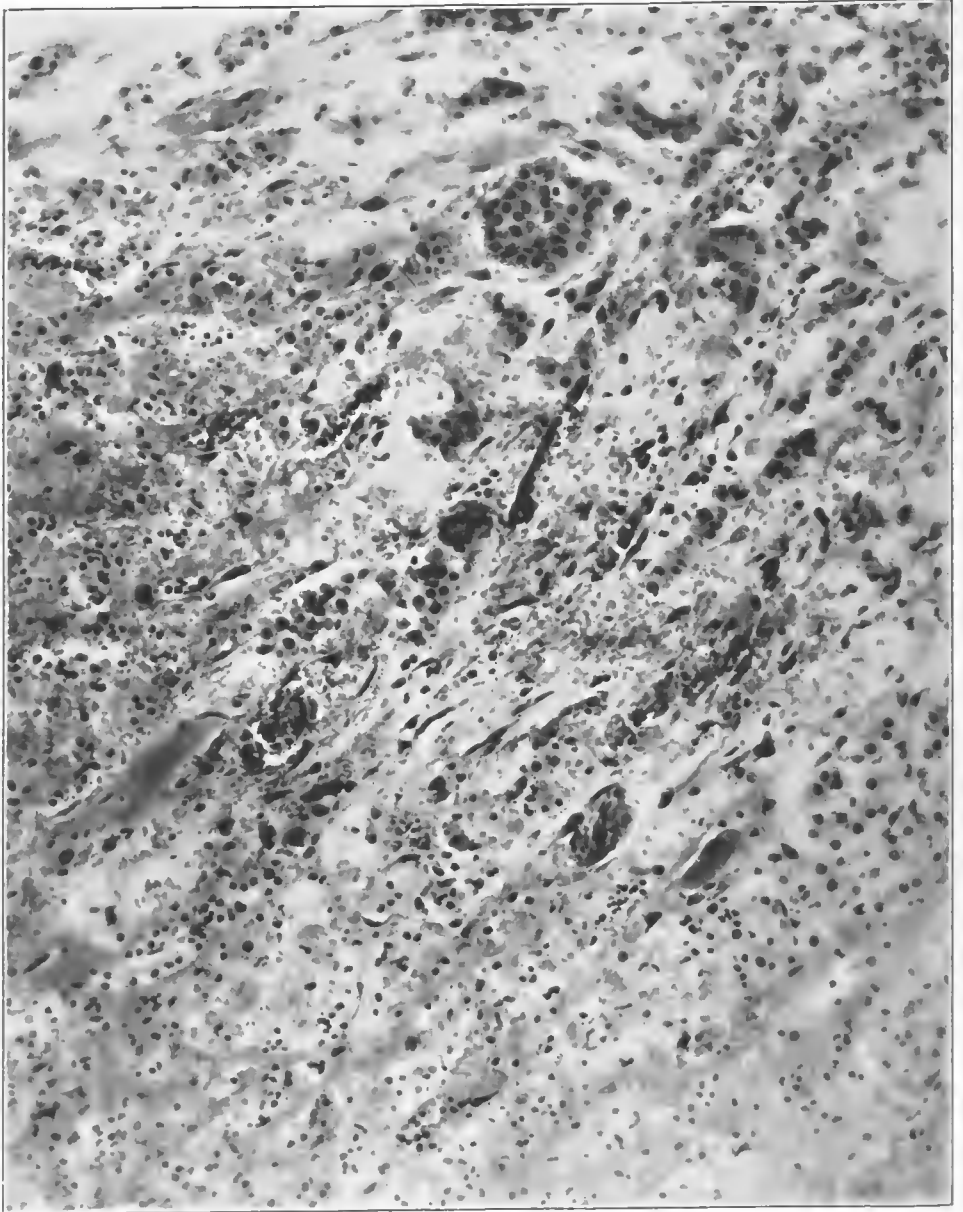


FIG. 167.—Hemorrhagic adrenitis in a case of bronchopneumonia following influenza. Ante-mortem cultures from the throat showed pneumococcus, Type I, hemolytic streptococcus, and influenza bacillus. Post-mortem culture from the blood and lung showed pneumococcus, Type I. Accession number 3045, Army Medical Museum. Negative number 45185. Hematoxylin-eosin stain; $\times 215$

or pyemia was not always possible, but in the cases dying quickly and showing little pneumonic consolidation the changes in the liver were rarely more than a mild parenchymatous degeneration. The liver was usually somewhat enlarged and congested while the parenchyma on section was dull and opaque, frequently with a yellow mottling near the capsule where microscopically some fatty degenerative changes were seen. Granular or albuminous degeneration was always seen and occasionally some fatty change was present. An occasional liver showed fatty infiltration, but that can scarcely be attributed to the disease itself. Focal necroses in the intermediate zones were found and not infrequently in these cases bacteria were cultivated from the blood stream. Necrosis of the cells about the hepatic veins occasionally occurred, usually accompanied by passive congestion of considerable degree. Occasionally the sinuses contained numerous polymorphonuclear leucocytes, indicating a general bacterial invasion of the liver, yet not all of such cases showed jaundice. The Kupfer cells throughout the liver usually appeared swollen and in some cases were apparently increased in number.

PANCREAS

There was no characteristic change in this organ. When general visceral congestion was present its vessels were likewise congested. Usually there were mild degenerative changes in the cells of the islands of Langerhans and also of the acini. No marked degenerative changes were reported.

GASTROINTESTINAL TRACT

In many cases irregular areas of hyperemia, occasionally small hemorrhages, and rarely superficial erosions were seen in the upper digestive tract. They were apparently not particularly frequent. Frank hemorrhage from the stomach was seen occasionally, and hemorrhage with partial necrosis of the colon was reported. The hyperemia and occasional small hemorrhages into the mucosa of the tract appeared with sufficient frequency to warrant their being considered. The other more extensive lesions can scarcely be attributed to influenza on the data presented. The mucosa in early autopsies was commonly more or less swollen particularly in the upper portion of the tract. The lymphoid follicles and Peyer's patches frequently were swollen or hyperplastic, and occasionally there was a definite hyperemia and in rare instances hemorrhage about these structures. Less change was seen in the lymphoid structures of the colon than in those of the lower ileum.

BLADDER

Hyperemia, small hemorrhages and necrosis of part of the bladder wall were reported, but their relation to the clinical disease, influenza, was not established.

TESTICLES

Cessation of spermatogenesis was reported by several investigators and occasionally focal necrosis of the parenchyma was seen.

MENINGES

Meningitis due to streptococci and pneumococci was reported frequently and was accompanied usually by infections of serous membranes. Congestion of the cerebral vessels was the rule and occasionally small hemorrhages were found. Some reports contained reference to lymphocytic infiltration in the meninges as occurring with relative frequency. This latter observation is noteworthy, since the conditions described are not unlike those seen in the meninges in lethargic encephalitis, a few cases of which were reported from Army camps and stations during the later stages of the epidemic and in the post-epidemic period.

PITUITARY

In relatively few cases in which observations were reported on this organ, it showed hyperemic changes, and at Camp Taylor it was considered that there was an increase in the colloid.

EYES

The subjective symptoms of pain in and behind the eyes was a rather characteristic complaint. The conjunctiva was commonly more or less reddened and occasionally conjunctivitis was diagnosed. The eyes were occasionally involved in pyemic processes.

Pericarditis and pleuritis are covered elsewhere^a and will not be considered at this place.

As previously stated, it is impossible from published reports to distinguish between the lesions due to influenza and to the organisms which were practically constantly present as secondary invaders. In the majority of reports the results of bacteriological investigations are not so recorded as to enable one to determine the frequency of the various visceral lesions in patients infected with the secondary invaders. Neither is it possible to coordinate the lesions in the viscera outside of the lungs with the positive blood cultures during life or at the necropsy table. In the absence of such data the occurrence of these conditions can be recorded as having occurred in patients who exhibited the clinical condition, influenza, and their etiology must remain, at least for the present, unknown.

REFERENCES

- (1) Bunting, C. H.: The Leucocytic Picture of Influenza. *American Journal of Medical Sciences*, Philadelphia, 1921, clxii, 1-9.
- (2) Underhill, F. P., and Ringer, M.: Blood-concentration Changes in Influenza; with Suggestions for Treatment. *Journal of the American Medical Association*, Chicago, 1920, lxxv, 1531.
- (3) Symmers, D.: The Significance of the Vascular Changes in the So-called Pandemic Influenza. *New York Medical Journal*, 1919, cx, 789.

^a Consult Volume XI, Surgery, Pt. 2, Sec. I, pp. 142, *et seq.*

CHAPTER V

BACTERIOLOGY

The bacteriological investigations which were carried out during the World War and the research in the period following showed the extreme variety of organisms which were concerned in the production of the various pneumonias or pulmonary inflammations. The results of cultural work on the secretions from the respiratory tract during life, together with the results of bacteriological examinations at necropsy, have shown that only extremely exhaustive investigation will define the bacterial flora and the relation of their components to the lesions in the lung. It was found that the various types of pulmonary inflammation were not produced by different organisms; rather, several different organisms apparently were each capable of producing practically all the varieties of inflammation which have been described. In general, however, the pneumococci produced a fibrinous type of inflammatory reaction, an exudate in which fibrin forms a prominent part, more often than other organisms, although varying amounts of fibrin were found in inflammations from which the streptococci, influenza bacilli, and rarely meningococci were isolated.

The streptococci, pneumococci, Friedlander's bacillus, *Micrococcus catarrhalis*, staphylococcus and meningococcus are conceded by practically all investigators to be the organisms which produced the pneumonic consolidation or pulmonary inflammation which was secondary to other acute respiratory diseases, principally measles and influenza. Certain members of the pneumococcus group, particularly Type I, probably Types II and III, produced primary pneumonia. Such pneumonia was most frequent following the mobilization of unseasoned troops, did not have a high mortality, and did not contribute much to the total of acute respiratory diseases of the war period.

No organism was proved to be the cause of the clinical disease, influenza, and in fact our ideas with reference to the etiology of this condition were perhaps more confused than clarified as the result of the numerous and varying reports of clinical and laboratory investigation. No new organisms were discovered until after the decline of the pandemic of influenza in the fall of 1918, though certain organisms were considered by some investigators to be new varieties because of their occurrence in diseases of a character not usually associated with bacteria of the same morphology, staining and cultural characteristics. *Bacterium pneumosintes* reported by Olitsky and Gates should be mentioned and the cultural methods used by these investigators should be utilized in future research to determine the etiology of clinical influenza with the idea that organisms of this character may be found to be responsible.¹ The influenza bacillus, described by Pfeiffer, was frequently found but in so far as can be determined from published reports was not constantly present. If one read selected reports from stations widely separated throughout this and other countries and ignored other reports one would decide that the influenza bacillus

was undoubtedly the proven cause of clinical influenza. On the other hand, one could likewise read as many reports from different stations also scattered and receive exactly the opposite impression. This suggests that the influenza bacillus was but another of the secondary invaders, which were extremely frequent in some stations and absent in others, yet at practically all stations bacteriologists isolated organisms which they considered to be influenza bacilli. Competent investigators studied bacterial flora at stations where this organism was found in abundance and at stations where it was seen relatively infrequently. In a careful perusal of the technique used for isolating the bacillus by the different workers it appears that the more thoroughly cultures were made, the more parts of the respiratory tract which were cultured, and the more care that was taken to provide a medium on which this organism grows, in other words, a selective medium, the greater was the number of cases from which the organism was isolated. It is impossible to decide from the various reports the ideal cultural medium for the isolation of this organism. Media containing hemoglobin appear to be essential, and the growth of the organism appears to be better in blood medium so heated as to destroy the normal complement of the serum. It is true, however, that high percentages were found by some investigators who used unchanged human blood.

The presence of colonies of streptococci or pneumococci appeared to hinder the growth of *B. influenzae*, while the presence of colonies of staphylococci apparently stimulated the growth. An inhibitory influence by pneumococci and streptococci possibly accounts in part for the failure to find *B. influenzae* in greater numbers, since the former organisms were practically always present in the cultures.

As the result of a review of the techniques used it is apparent that the failure to find the influenza bacillus does not prove that this organism was not present. At several places during the early part of the pandemic of the fall of 1918 *B. influenzae* was not found at all, in others rarely, and a change in technique resulted in securing high percentages of positive results.

In the histological examination of the tissues in the Army Medical Museum collection from the pneumonias secondary to clinical influenza it was found that small Gram-negative bacteria were present in practically every case which died after a short illness, the tissue of which was well fixed, whether or not cultures ante mortem and at necropsy had recorded their presence. They were not found in every case; but the fixation of the material in many instances was of such character as to preclude the possibility of finding any organism; in other cases advanced pulmonary lesions due to other organisms so filled the tissue that it was unreasonable to expect to find them by such examination. Of course, it is impossible to state that these Gram-negative bacteria were influenza bacilli. Morphologically they corresponded as they did also in their reactions to stains. This finding has little value in so far as it goes to prove the influenza bacillus an etiological factor in clinical influenza. It does show, however, that Gram-negative bacteria existed in the lung which were not found by the cultural examination. These small Gram-negative bacteria were seen most frequently along the smaller bronchioles, in the ductuli alveolares and in the atria; less frequently in the alveoli and rarely in the alveolar walls or peribronchial tissue.

In the early cases, they were found frequently in the terminal bronchioles without admixture of other organisms, while, in addition, in the bronchi near the hilus streptococci and pneumococci usually were seen. It was in the bronchioles also that bacteriologists found them most frequently in cultures. They were less apt to be present in cultures from definite consolidations involving lobules or larger portions of the lung. They were rarely found in the pleura or in the heart's blood. During life they were found most frequently in swabs from the posterior nasopharynx, much less frequently in the sputum. Organisms of identical morphology were found more frequently in smears from the nasopharynx and sputum than they were in the cultures.

The results in smears and culture plainly indicate that in order to determine the prevalence of the different organisms in the respiratory tract, all parts of this tract must be cultured and the media used for each part must be of such variety as to include those which have been found to favor the growth of each and every organism described. Unless this is done and each organism in the resulting cultures identified and worked out serologically with prepared immune serum and with the serum from the patient, dependable results will not be secured.

Investigations which have been undertaken during the last four decades have been scarcely adequate to show the prevalence of the influenza bacillus. Numerous reports, useful in determining the incidence of the organism during epidemics and in the preepidemic periods, have been accumulated and reviewed by Zinsser² and by McCloud, Ritchie, and Dottridge.³ Certain investigations of similar character, some intentionally made, others not, appear in the reports of the Army camps in the United States. Admitting that the cultural results are only relatively accurate and realizing the relative paucity of the material examined, it still appears that the influenza bacilli or organisms of similar morphology, staining reactions, and cultural characteristics are found in greater frequency during epidemic periods and were particularly frequent during the epidemic of the fall of 1918 in this country. It is further evident from bacteriological investigations that this organism increased both in the unaffected and in the affected population at the time of the influenza pandemic and gradually decreased after it. In fact, in many of the places where it would appear from reviewing the work that the best and most exhaustive bacterial research was made, this organism showed an increase until it was universally prevalent in those affected with clinical influenza. No other organisms increased to such an extent. Of course, we must ignore pneumococci of Group IV, organisms present in a very large proportion if not all normal mouths, practically as prevalent as the colon bacillus in the rectum.

In spite of this great prevalence, in the large number of cultures obtained of this organism the strains isolated did not show common immunological reactions. In fact, these small Gram-negative bacteria, culturally influenza bacilli, were immunologically of very many different strains. At one and the same place it could scarcely be said that there was a predominant type in so far as could be determined by serological reactions. Serological reactions are generally considered to be the most accurate method of separation of bacterial varieties, and thus the fact that no common strain was found is against the probability of the influenza bacillus being the cause of the pandemic disease.

A relatively small amount of work was done in testing strains for agglutination and complement fixation, using the serum of the persons affected with the clinical disease. Some investigators reported positive reactions in relatively low dilutions, others failed to find any reactions even with the sera of persons from whom the strains were isolated.

The experiments with influenza vaccines in the effort to protect from the clinical disease indicate that the vaccines so far utilized did not excite the production of protective bodies. Such a result has no influence either for or against the etiologic relationship of the influenza bacillus to the disease, as the methods of preparation of vaccine, the dosage, and the methods of giving it were various and may not have been of such nature as to yield the maximum in protective substances, while vaccines have been found of little value in protection against many diseases whose etiology is well known.

The influenza bacillus produces toxic substances of two varieties, one of which is found in culture media and appears to be at least in part a soluble toxin against which antitoxin can be produced. Extracts of the bodies of influenza bacilli yield a poisonous substance against which an antitoxin apparently can not be prepared. An antitoxin against the substance produced in cultures apparently has some protective action in experimental animals against infection by the influenza bacillus. The symptoms produced by the injection of the toxin were, in general, a congestion of the viscera and in some animals a relatively extreme prostration. While these symptoms are in accord with the lesions seen in the lungs in influenza and in experimental lesions with the influenza bacillus they are not dissimilar to reactions to the toxins of other organisms.

The virulence of this group of Gram-negative bacteria, morphologically and culturally the influenza bacillus, is very variable. Some strains appear virulent from the outset and retain their virulence, others can have their virulence raised by animal passage, while some strains apparently possess little virulence for the experimental animals and it has not been possible by animal passage to raise this virulence to any great degree. The possibilities of variants must be kept in mind as a possible explanation of changes in virulence not only among strains at a given time, as was seen in the numerous isolations of the influenza bacillus, but also those changes which sometimes occur in a virus independently of efforts to raise that virulence by animal passage.

There is thus no explanation, based on incontrovertible facts, of the variations in virulence and pathogenicity of the small Gram-negative organisms which are morphologically and culturally influenza bacilli. The variations in serological reactions suggest that we are dealing here with a group some members of which have much greater virulence than others in the production of disease. Like the pneumococcus group some of these Gram-negative bacilli may be analogous to the Group IV pneumococci, some of which appear to have extreme invasiveness and pathogenicity, while others appear little more than saprophytes.

Bacteriological studies on this group have not as yet reached that state of perfection which allow conclusions to be made; furthermore, the evidence presented by one group of workers may be the exact opposite of that of another. Difficulties in cultivation, isolation, and maintenance of the organisms, their low virulence in experimental animals, and their lack of resistance to deleterious

influences present in the culture media or environment, make the group an exceedingly difficult one to handle, which, up to date, has yet to be so handled as to permit definite conclusions as the result of investigations.

Inoculation experiments have been disappointing. Suggestive results have been obtained with filtered sputum and with cultures in both man and animals, yet the majority of results were absolutely negative. Many volunteers have been inoculated and suggestive results obtained in very few. Blake and Cecil,⁴ using monkeys as experimental animals, proved that *B. influenzae* would produce pneumonia of a more or less characteristic variety. In their work on human beings Cecil and Steffen⁵ report the production of influenza-like attacks of mild character by the use of one culture while another, though apparently from an infection of considerable intensity, did not result in a recognizable reaction. *Bacterium pneumosintes* of Olitsky and Gates is on no better footing in so far as proof of its connection with pandemic influenza or clinical influenza is concerned.

Organisms of the pneumococcus group are present in the cultures of a very large proportion of cases of the pneumonias following influenza. Organisms of Group IV preponderated to a marked degree, while organisms of Types I, II, and III and II atypical varied markedly from camp to camp and station to station. In some camps a considerable number of Type I infections were found, in others Type II showed a larger proportion than the average and the same was true of Type III. Type I produced typical lobar consolidations, but following influenza the consolidations rarely had the typical lobar distribution. Much more frequently many lobules were involved, but the consolidation was not uniform, though the appearances of the tissues in a given lobule showed considerable uniformity and presented some one of the stages characteristic of lobar pneumonia.

Type II pneumococcus produced lobular pneumonia and spreading bronchopneumonia and occasionally was found scattered throughout the lung in cases in which it was difficult to find any definite consolidations, there being present heavy soggy lungs with general thickening of the tissues and but little exudate in the alveoli except serum. Occasionally cases were seen with an intense hemorrhagic bronchitis and a leucocytic infiltration of the alveolar walls throughout the lung, with more or less serous exudate in the alveoli but with no consolidation; a pulmonary septicemic condition causing death with extreme rapidity.

Type III pneumococcus produced spreading bronchopneumonia, and lobular pneumonia in which fibrin formation was not a prominent feature. The consolidations were boggy and moist but not particularly bloody, while the exudate on the cut surface strung out like mucin from the knife edge. Occasionally small amounts of fibrin were seen but rarely was hepatization present.

Group IV pneumococci occasionally produced typical consolidations with lobar distribution, but following influenza and measles, bronchopneumonia and lobular pneumonia were the types of distribution most commonly found.

Streptococcus viridans, or organisms so classified, produced lobular and bronchopneumonia and usually caused considerable inflammatory reaction in the interstitial tissues. In the streptococcus group the bacteriological results

were not always of such a character as to allow accurate differentiation of the bacteria. Media requirements for this differentiation as between the viridans and the hemolytic streptococcus are such that unless one knows the exact technique used by the bacteriologist one is apt to doubt the diagnosis. Traces of sugar in media used to bring out the characteristic reaction on blood media of the hemolytic streptococcus will lead to an erroneous interpretation so that, in the absence of a definite statement as to the technique, including the method of preparation of the media used, bacteriological investigations do not justify any statement of a positive nature as to exactly what type of pulmonary inflammation resulted from infection with this group of organisms. These difficulties must be remedied before worth-while conclusions can be reached and few of the published reports give sufficient data. *Streptococcus hemolyticus* certainly produced the majority if not all of the lesions which we have described as lymphangitis of the pulmonary interstitial tissues and was responsible for many of the hemorrhagic lesions where considerable amounts of blood escaped into the pulmonary tissues. It was also responsible for a large proportion of the empyemas and for the extensions into the mediastinum.

All of the organisms above mentioned, Group IV pneumococci being considered as one organism, occasionally produce infection in the peritoneum, pleura, meninges, and pericardium. Whether these infections represent a marked increase in virulence whereby the infection extends readily, the tissues offering little resistance to its progress, or whether these lesions are the result of a pathological accident whereby large numbers of organisms gained the circulation in the form of small emboli which blocked capillaries and involved serous surfaces, is not known. Some cases appear best explained in one way, some in another. It does appear, however, that virulence and invasiveness account for at least part of the cases of polyserositis. Of the pneumococci, Type II appears to be most likely to produce such reaction, though at some camps many cases were reported from which organisms of Group IV were isolated.

Staphylococci frequently were found in the pulmonary tissues and in some camps were responsible for some of the pneumonic lesions present. Like other organisms there appeared to be virulent strains as lesions due to it were reported at some camps and not in others. It is an easily cultivated organism so that variations in technique should not interfere with its recognition, but many bacteriologists chose to ignore its presence in the cultures, considering it of little importance.

Micrococcus catarrhalis was occasionally found in the lungs, more particularly along the bronchi, but its pathogenic significance in these cases was not determined with sufficient clarity to make possible any statement with regard to its pathogenicity in the lungs.

Authentic reports of pneumonias of the lobular and spreading bronchopneumonic variety, caused by members of the meningococcus group are on record and it seems fairly definitely proven that this organism occasionally produced such lesions.

The bacillus of Friedlander was occasionally found and its lesions, except for the bacteria present, were scarcely to be distinguished from those due to

pneumococcus Type III. It occasionally was present in considerable numbers in some camps, but as a whole it was not often reported as a cause of inflammatory lesions in the lung.

Summarizing, one may say that the influenza bacillus has more evidence behind it to prove it the cause of pandemic influenza than any other organism, but that the proof is not final and convincing and awaits a great deal of further work, and that during a pandemic period. Its occurrence and frequency during interepidemic periods, particularly during the seasons of the increased prevalence of respiratory diseases, must be determined, as well as its incidence during the general epidemics or pandemics which occasionally visit us.

It is evident that more thorough bacteriological work must be done as practically every type of media known must be used and all parts of the tissues must be cultivated at practically all stages of the disease by competent bacteriologists associated with competent pathologists, so that the organisms and the lesions may be properly correlated. Because of the large variety of flora present in the respiratory tract, there is no other alternative than to investigate every organism that can be cultivated as some one, morphologically indistinguishable from the others and similar in cultural characteristics may be responsible. No absolute dependence can be placed on the results of bacteriological investigation during the pandemic of influenza of 1918, except that they showed the large numbers of different bacteria concerned in the production of the pulmonary inflammation and of the presence in one and the same lung of lesions due to different organisms.

REFERENCES

- (1) Olitsky, P. K., and Gates, F. L.: Experimental Studies of the Nasopharyngeal Secretions from Influenza Patients. *Journal of Experimental Medicine*, Baltimore, 1921, xxxiii, 125, 361, 375, and 713; *ibid.*, 1921, xxxiv, 1; *ibid.*, 1922, xxxv, 1, 553, and 813; 1922, xxxvi, 685.
- (2) Zinsser, Hans: The Etiology and Epidemiology of Influenza. *Medicine*, 1922, i, 213-309.
- (3) McLeod, J. W., Ritchie, A. G., and Dottridge, C. A.: Incidence of Infections with Pfeiffer's Bacillus before, during, and after the 1918 Epidemic. *Quarterly Journal Medicine*, Oxford, 1920-21, 327-338.
- (4) Blake, F. G., and Cecil, R. L.: Studies on Experimental Pneumonia. Experimental Streptococcus Hemolyticus Pneumonia in Monkeys. *Journal of Experimental Medicine*, Baltimore, 1920, xxxii, 1; xxxi, 403-1920.
- (5) Cecil, R. L., and Steffen, G. I.: Acute Respiratory Infection in Man Following Inoculation with Virulent *Bacillus Influenzae*. *Journal of Infectious Diseases*, Chicago, 1921, xxviii, 201-225.

SECTION II

PATHOLOGY OF GAS GANGRENE FOLLOWING WAR WOUNDS

Gas gangrene is a spreading, moist gangrene produced by gas-forming anaerobic bacteria in extensively traumatized tissues. It is characterized by a gaseous infiltration and edema of the part affected, and by changes in the color and contractility of the muscle. The infection may remain strictly localized or it may tend to spread and involve a single muscle group or an entire limb or other part of the body; in the latter type the onset and course are generally rapid and accompanied by profound toxemia and high mortality. The condition is practically always associated with a mixed infection and the clinical picture varies according to the combined characteristic activities of the etiologic agents present. With a certain type of bacterium dominant, we may have, as one extreme, a gaseous infiltration; as another, edema without gas; and as another, rapid digestion and dissolution of tissue with neither edema nor gas. Most frequently the dominance is only partial, and edema, gaseous infiltration, and rapid tissue destruction go hand in hand with profound intoxication. The aerobic bacteria which usually are present are either ancillary, through preparing a more favorable substratum for the anaerobic bacilli which constitute the determining factor in the production of gas gangrene, form a part of the process affecting the wounded tissues, or both.

The biology of the bacteria which are the etiologic agents in this most fatal of war wound infections gives us the key to the peculiarities of distribution and prevalence of gas gangrene during the World War. The anaerobic bacteria here in question are frequently, if not habitually, present in the intestines of man and of many of the lower animals. They thrive on decaying animal and vegetable matter, but not on living tissue, and through their resistant spores are able to retain their vitality through long periods of conditions unfavorable to their multiplication. They grow best in the absence of free oxygen and in their growth produce toxic substances. The type of wounds produced by high explosive shells was peculiarly suited to the development of such anaerobic bacteria, and the bacteria themselves were furnished by a soil, which for centuries had been fertilized with the feces of man and the lower animals.

Of the anaerobic bacteria, *B. welchii* (*Clostridium welchii*) claims first place through being the member of the pathogenic group most frequently present. The organism called by Pasteur *Vibrion septique* (*Clostridium septique*), commonly, although possibly erroneously, accepted as being identical with the *B. adematidis maligni* of Koch, is less frequently present in war wounds than *B. welchii*, but its presence is of more serious import. *B. adematiens* (*Clostridium novyi*) seems subject to greater variations than the others, but may be found more frequently than *Vibrion septique*. *B. histolyticus* (*Clostridium histolyticum*) was first isolated by Weinberg and Seguin,¹ and the frequency of its occur-

rence was not noted by other workers. These four anaerobes are recognized as the most important agents in the production of gas gangrene. Their characteristics are as follows:

One of the outstanding characteristics of *B. welchii* is the large amount of gas it produces. It is one of the most hardy of the anaerobes and one of the most widely distributed. *B. welchii* produces hemolysins for the blood corpuscles of man, rabbits, dogs, pigeons, white mice, hogs, cattle, sheep, horses, guinea pigs, white rats, and chickens. It dissolves hemoglobin out of the red cells of the guinea pig, rabbit, hen, and pigeon. It destroys the red cells of the other animals.

It has been possible to produce agglutinating substances by the injection of cultures of washed bacilli into rabbits or horses. McCampbell² produced precipitins in rabbits by parenteral injection. Korentchevsky³ claims to have produced precipitins successfully by administering broth culture filtrates to animals per rectum and by feeding them by mouth.

McCampbell² claims to have produced bacteriolysins against *B. welchii*. In 1915, Jablons⁴ succeeded in producing bacteriolysins in a horse injected serially with small quantities of first killed and then living cultures of *B. welchii*. This serum had a bacteriolytic titer of 1-100; in doses of 0.5 c. c. it protected against a lethal quantity of a 24-hour culture. McCampbell² found complement fixing bodies in the serum of animals injected with *B. welchii*. Korentchevsky³ claims similarly to have found complement fixing bodies in the serum of dogs fed with culture filtrates.

While Weinberg and Seguin¹ claim to have produced toxins in cultures of *B. welchii*, they state that the problem is surrounded with great difficulties. Korentchevsky³ found that filtrates of broth cultures were toxic for young rabbits, symptoms appearing in from one to three hours after intravenous or intraperitoneal injection. Klose⁵ claims to have demonstrated toxic substances in subcutaneous exudates from guinea pigs and in filtrates from 5 per cent glucose broth cultures after 14 days' incubation. It remained, however, for Bull and Pritchett⁶ to produce first a toxin of appreciable potency. This was done by growing a virulent strain of the bacilli in 0.2 or 0.3 per cent glucose broth to which fragments of fresh muscle had been added. To obtain the most potent toxin the culture was filtered after 18 to 24 hours' incubation. Tested by injection into the breast muscle of pigeons the lethal dose obtained from several individual strains ranged from 0.3 to 3 c. c. Weinberg and Seguin¹ at first injected whole cultures in the hope of preparing serums, at the same time anti-infectious and antitoxic. Tested upon animals the serums were shown to have a certain degree of potency. Bull and Pritchett⁶ produced antitoxins through the injection of horses with the toxins prepared by their method.

The virulence of *B. welchii*, in common with all the other anaerobes of gas gangrene, is extremely variable. Strains isolated from fatal cases of gas gangrene are usually very pathogenic for the guinea pig, and are able to retain their virulence over a period of months.

Observations upon animals infected with pure cultures of *B. welchii* have thrown much light on the pathogenesis of gas gangrene. Formerly it was believed that *B. welchii* was of itself always capable of producing so-called gas

baecillus infection. The injection of large quantities of washed bacilli, however, fail to produce lesions in laboratory animals. Lesions can be produced if either acid or powdered glass is injected with the bacilli, or if a slight injury to muscles precedes the injection. In other words, the Welch bacillus is not a true parasite but a saprophyte that can not grow in healthy tissues; it is able to thrive only if the body cells are first injured by some chemical or mechanical means. The lesions involve the muscles, the blood vessels, and the fat of the subcutaneous connective tissue.

The symptoms following injection of bacilli plus toxin, or following injection of bacilli after injury to muscles, are invariably the same. If the culture is virulent, it is not uncommon to see swelling and induration of the region injected within four to six hours after inoculation. The swelling increases and extends up to the abdomen; in about six to eight hours crackling is perceptible. The animal holds its limb in a flexed position to relieve the tension of the tissues. Swelling is due chiefly to edema, and to gas infiltration. As the bacteria multiply, the symptoms of intoxication become manifest and are the same as those observed when sublethal doses of toxin are injected into the circulation of susceptible animals. The nervous symptoms are tremor, slight convulsion, hiccough, bristling of the hair and paralysis of the bowel. The effect on the circulatory system is evidenced by the extreme rapidity of the pulse.

The injected animal, before death, shows paralysis of its hind legs, it remains hunched up and motionless, and its respirations are markedly increased. Death intervenes by respiratory failure rather than by cardiac paralysis.

Vibrio septique is nonproteolytic, but slightly peptolytic, and very saccharolytic. Specific agglutinins have been demonstrated in the serum of animals inoculated with cultures of *V. septique*. It produces both a hemolysin and a hemagglutinin. It hemolyzes the blood cells of the guinea pig, rabbit, sheep, goat, and man. The pathogenicity of various strains varies, so that it is sometimes necessary to inject fairly large quantities of culture to produce characteristic lesions.

The lesions in rabbits and guinea pigs are similar. The swelling and induration develop fairly rapidly but are never so extensive as those produced by *B. welchii*. Crepitation is very slight as the bacillus produces only a small amount of gas. The edema extends up the abdomen but is soft and compressible. Small blisters appear on the skin from which serosanguinolent fluid exudes. The hair does not fall out as it does in *B. welchii* infection. With some strains the swelling is slight but there is stiffness of the injected limb. Intravenous injection into a rabbit usually is followed by the same train of symptoms. Paralysis of the fore limbs is particularly to be noted.

B. œdematiens is saccharolytic and digests gelatin. Agglutinating serum has been produced. This organism, however, has a tendency to agglutinate spontaneously, and satisfactory suspensions can be made only with very young cultures. It produces hemolysis which destroys, in vitro, the red cells of man, sheep, and guinea pigs. Toxins fatal to guinea pigs in doses of $\frac{1}{10}$ to $\frac{1}{40}$ c. c. have been produced. The animals died within 48 hours following intravenous injection. There seems to have been little difficulty in obtaining antitoxins of a potency comparable to that of diphtheria antitoxin. According to the tests reported, the antitoxin likewise had anti-infectious power.

The lesions caused by different strains of *B. oedematiens* are not always the same. If a toxin-producing strain is used, the intramuscular inoculation is followed in a very short time by an appreciable swelling of the limb and this increases hour by hour. The thigh becomes cold, the skin pale and bluish, a firm elastic edema extends up the abdomen, often to the sternum. At autopsy, the muscles at the site of injection are congested and infiltrated with very fine gas bubbles. There is no putrid odor present. Bacteria are found seldom in the fluid of the wound, rarely in the blood stream, and with difficulty in the peritoneal fluid. Blood cultures made before or immediately after death are usually negative.

If the strain used is virulent but not very toxigenic it produces a different type of lesion. The thigh becomes swollen, the skin red and moist and a fine crepitation is noticeable, extending up the edematous abdomen. The edema on incision is gelatinous and deep pink or strawberry red, and is infiltrated with a few, relatively large, gas bubbles. The edematous fluid infiltrating between and around the muscles is usually hemorrhagic and is visible beneath the semitransparent edema. The muscles are markedly congested, deep violet-red in color, and infiltrated with large gas bubbles. No gangrenous necrosis and no putrid odor are present. A large number of Gram-positive bacilli are present, arranged in pairs, both in muscle fluid, peritoneal exudate, and on the liver surface. Blood cultures made before death are usually positive.

Subcutaneous injections produce the same type of lesion but require larger amounts. There is usually a very thick, lardlike edema infiltrating the subcutaneous connective tissue for a depth of from 3 to 4 cm. The lesions are never putrid. The abdominal muscles are congested but never gangrenous.

B. histolyticus is the most proteolytic of all the anaerobes. It is pathogenic for all laboratory animals (guinea pig, rabbit, white mouse, and rat). The pathogenicity varies with the strains studied. The intravenous injection of 1 to 2 c. c. of a 24-hour culture in Martin broth will kill a guinea pig in several minutes. The intraperitoneal injection is lethal in the same dose. Intramuscular injection into the thigh of a whole culture produces lesions characteristic of this microorganism. Immediately after injection of 1 or 2 c. c. the animal shows violent tetany of the muscles of the head and neck and cries out plaintively. After several hours, the thigh is swollen, the skin is violet-red, and a slight edema, which is soft and compressible, invades a part of the abdomen. If one kills the guinea pig at this time, incision of the lesion shows the presence of a hemorrhagic layer in the subcutaneous connective tissue, containing large red, cherrylike clots. The subcutaneous and perimuscular connective tissues are attacked and seem to be undergoing rapid digestion. The lesion is accompanied by a hemorrhagic edema, which invades the connective tissue of the peritoneal wall. If the process continues for several hours, the digestion of the perimuscular connective tissue is more evident, then the muscles and the muscular bundles become dissociated and liquefied.

To obtain a good toxin, it is necessary to use very young cultures. Beyond 24 hours at 37° C., both toxic power and virulence rapidly diminish and finally disappear. This toxin produces *in vitro*, as well as *in vivo*, all of the phenomena observed with the culture. The filtrate of *B. histolyticus* liquefies gelatin rapidly, just as does the bacterium itself. The guinea pig, the rabbit, and white mouse

injected with toxin present very extensive hemorrhagic lesions. Similar lesions have been observed in horses used for the preparation of an anti-histolytic serum. The *B. histolyticus* does not secrete hemolysins for the red cells of man, sheep, and guinea pigs. Horses immunized with the bacterial bodies injected intravenously and deprived of their toxin by centrifugalization produce a serum which strongly agglutinates homologous strains.

The activity of spores in soil has been made the subject of a special study by Joffe and Conn.⁷ From their results it is easy to see how in ground under constant cultivation, and especially terrain over which severe fighting had recently occurred, or where many men had been living, the activities of spore-forming bacteria would be enormously stimulated. The conclusions of Joffe and Conn, in part, are as follows:

There is reason to believe, therefore, that the rôle of spore-forming bacteria in soil is, under ordinary conditions, one of watchful waiting. They seize upon bits of organic matter and utilize periods of high moisture content to grow occasionally for a few generations before going back into the spore state, and thus maintain their numbers. When special conditions furnish them with some unusually available organic matter in the presence of considerable moisture, they immediately germinate in large numbers and carry on the initial stages of the decomposition of the organic matter more rapidly than the nonspore formers, which, under ordinary field conditions, are the active soil organisms.

The presence of the group of bacteria which produces gas gangrene upon the clothing and skin of the soldier always depends upon the bacterial flora of the geographic area in which he is and upon the character of fighting going on at the time of his wounding. These factors are also influenced by moisture, temperature, and the character of the terrain, an area with a stone or chalk subsoil being less favorable to the maintenance of this flora than a soft subsoil. The intensity of manure tillage and the recency of this cultivation are important factors. If the terrain is such that dugouts and bombproofs cannot be built in the ground and the trenches are practically built on top of it, the chances of the occurrence of gas gangrene are greater. The intensity of the fighting is another important factor, as the uncovering of buried bodies by constant shelling and the consequent inability to provide the area with proper sanitary conveniences also operate to increase the liability to this condition. The soldier cannot keep his uniform in a condition even approaching proper cleanliness, and infrequently has opportunity for bathing. Scabies is particularly important in this regard because of the habit of the female of boring into the skin to deposit her eggs. These borings, filled up behind her with dirt and bacteria, are veritable culture tubes that, carried deep into the muscle by high explosive shell, afford the presence of the exciting factor in an ideal situation for the production of the infection. Simple bathing cannot eradicate such foci.

These are the most important of the external causes of the production of this lesion. The same factors also influence the internal causes. Lack of water and proper food and loss of sleep produce those physiological conditions which increase the liability to shock by lowering blood pressure. This makes local vascular blocking easier.

Of the 224,080 officers and men of our Army who were wounded in battle in France, 13,691 died as a result of their wounds, the total death rate there-

fore being 6.11 per cent.⁸ The wounds complicated by gas gangrene may be divided among those who sustained injuries of the soft parts only and those whose wounds were complicated by bone fracture. Injuries to the soft parts as recorded here do not include those due to chemical-warfare gases. There were, with these exceptions, 128,265 wounds of the soft parts with 9,719 deaths; of the wounded in this group, 1,389 developed gas gangrene, which amounts to only a little more than 1 per cent (1.08). The death rate among those who received wounds of the soft parts which became complicated with gas gangrene was 48.52 per cent, the actual number of deaths being 674.

Among the 25,272 whose wounds included bone fracture there were 2,751 deaths.⁸ The incidence of gas gangrene among the bone-fracture cases was much higher than among those who sustained wounds of the soft parts only, the total being 1,329 with 593 deaths. The incidence in this group of the wounded was therefore 6.26 per cent and the case mortality rate 44.62 per cent.

A study was made at Base Hospital No. 15, A. E. F., of a series of 276 cases of gas gangrene with 73 deaths, a death rate of 26.45 per cent.⁹ The figures showed that the activity of the gas-gangrene group was self-limiting and practically confined to the first week after the wound was received, showing a drop of the anaerobes during the first 7 days from 38 to 7 per cent. It was shown, further, that as the self-limiting process of the gangrene went on, the aerobes, especially the common pyogens, streptococcus and staphylococcus, accumulated rapidly in the wound. The cases were charted according to the influence of the symbiosis of the various aerobes and anaerobes, and a summary of these charts indicates that the various organisms did not seem to alter the killing action of the gas-gangrene group. Although no deductions were made from the statistics because of the small totals, it was believed that the association of anaerobes with streptococcus produced a more virulent infection than with anaerobes alone, and that the association of staphylococcus seemed to produce less virulent infections than with anaerobes alone.

The following table gives a striking example of the etiology of gas infection. Of 16 fatal cases 9 showed gas infection and 4 showed the presence of staphylococcus, streptococcus, and anaerobes. Seven without clinical evidence of gas infection showed the same bacteriological incidence. It is possible that eight of these deaths were due to pyogenic septicemia, and the deaths which occurred after the fifth day were probably all due to pyogens. Among the nonfatal cases of this group, 18 of the cases without clinical gas infection showed the presence of *B. welchii* and other anaerobes, practically always accompanied by the pyogens, and four cases of the nine with gas infection showed the virulent gas bacilli, whereas six of these nine also showed the presence of the pyogens. The important feature of this analysis is that in 18 cases there were present the anaerobes concerned in the production of gas gangrene without the infection ensuing. This shows that the condition is not a concrete bacteriological entity but a pathological complex depending on numerous tissue factors.

Bacteriology of gas infections⁹

FATAL CASES

	Streptococcus present	Staphylococcus present	<i>B. welchii</i> present	<i>Vibrio septique</i> present	<i>B. sporogenes</i> present	<i>B. tetani</i> present	Other anaerobes present	<i>B. coli</i> or <i>B. proteus</i> present	Gram-positive aerobic bacilli present	Total cases
With gas infection.....	4	4	4	-----	1	1	-----	2	3	9
Without gas infection but with anaerobes.....	4	3	4	2	2	3	-----	5	1	7
Total, fatal.....	8	7	8	2	3	4	-----	7	4	16

NONFATAL CASES

With gas infection.....	6	6	2	2	-----	-----	1	2	5	9
Without gas infection but with anaerobes.....	15	20	18	2	3	-----	7	11	3	27
Total, nonfatal.....	21	26	20	4	3	-----	8	13	8	36
Grand total.....	29	33	28	6	6	4	8	20	12	52

From this study it appeared that anaerobes were prominent in the early bacterial picture of wounds, but began to disappear by the end of the fourth day, when the aerobes became progressively more prominent. Streptococcus had a fairly constant incidence, and was very persistent.

A combination of *Streptococcus hemolyticus* and *Staphylococcus aureus*, was the most prominent of all the bacterial associations in wounds at Base Hospital No. 15.⁹ This association was particularly prominent in fatal wounds. *Streptococcus hemolyticus*, *Staphylococcus aureus*, *Bacillus welchii*, *Bacillus coli communis*, *Bacillus proteus*, and, to a lesser extent, *Staphylococcus albus*, were the bacteria appearing most prominently in both the fatal and nonfatal cases.

The prognosis was good in cases showing *Staphylococcus aureus* or other aerobes excepting streptococcus. An association with *Staphylococcus aureus* seemed to lower the virulence of infection with anaerobes.

The presence of the frank pus producers had an important influence on checking the progress of gas gangrene. This seemed to be especially true of staphylococcus. In all probability the positive chemotaxis of these organisms for leucocytes may well account for the reverence with which the surgeons of the Civil, and other earlier wars, spoke of "laudable" pus in connection with gangrenous wounds.

Infections with anaerobes showed a high death rate, but a short period of danger to life, unless the anaerobes were in association with streptococcus.

Deaths from streptococcus infections were numerous, and occurred at least up to the end of the fourth month. The mortality was even higher, where streptococcus was associated with *Staphylococcus aureus* or with anaerobes. On the other hand, the association of streptococcus with both *Staphylococcus aureus* and anaerobes gave a lower death rate than the simple association with either *Staphylococcus aureus* or anaerobes. Moreover, for infections by the association of all three, the period of danger to life seemed to be shorter than that for infections, by streptococcus with either *Staphylococcus aureus* or anaerobes alone.

At Base Hospital No. 15, a streptococcus bacteriemia was by far the most important cause of death in cases of war wound.⁹ This was common where patients lived beyond the first week, the self-limiting period of the gangrenous process, and many deaths attributed to the anaerobes were in reality deaths due to streptococcus in the process of replacing them.

An important study was made at Evacuation Hospital No. 8, A. E. F., of cultures from wounds in an investigation into the causes of gas gangrene.¹⁰ In the fall of 1918, this hospital was near the forward areas, served a sector on the heights of the Meuse, which, because of the hinging operation in the retreat of the German forces, remained fairly stationary, and was practically confined to trenches and dugouts until the end of hostilities. It was an area that had been fought over throughout the war, and its soil was rich with the bacterial flora found in gas gangrene. Because of the forward position of this hospital, the evacuation of patients was very rapid and gas gangrene cases were encountered in their earliest stages. Between September 10 and November 13, 1918, 4,741 wounded were admitted to this hospital. Of these, 4,683 required surgical treatment. Two hundred and six of the wounded required amputation, 96 of these being performed for gas gangrene. Ninety-three amputations were done because of severity of injury, many probably being done as a prophylactic procedure for the prevention of gangrene. The following table shows the distribution of these amputations:

Part of body	Total number	For severity of injury		For simple infection		For gas gangrene	
		Number	Per cent	Number	Per cent	Number	Per cent
Arms.....	31	9	29.0	1	3.20	21	67.7
Forearms.....	16	11	68.7	1	6.25	4	25.0
Fingers.....	44	32	95.6	1	2.20	1	2.2
Thighs.....	60	5	8.33	10	16.60	45	75.0
Legs.....	38	12	31.5	4	10.6	22	57.8
Feet.....	6	4	66.6	0	0.0	2	33.3
Toes.....	11	10	90.9	0	0.0	1	9.1
Total.....	206	93	45.1	17	8.25	96	46.6

During this period the total number of deaths was 363. These deaths were due to the following causes:

Cause of death	Number	Per cent	Cause of death	Number	Per cent
Gas gangrene.....	61	17.0	Head injuries.....	50	14.0
Simple infection.....	7	2.0	Spinal injuries.....	12	3.3
Shock and hemorrhage.....	88	24.2	Multiple wounds.....	30	8.3
Chest wounds.....	53	15.0	Pneumonia.....	9	2.5
Abdominal wounds.....	47	10.2	Poison gas.....	6	2.0

It is thus seen that gas gangrene was the second most important cause of death. Of the 4,377 patients admitted to the hospital that had received wounds in action, 221, or 5 per cent, had gas gangrene. This incidence is high but since this hospital received only the seriously wounded, and since it was only approximately 10 hours from the front line, this is not unusual. This agrees with the carefully worked out figures of German and French authorities.

Of the 157 cases of gangrene in which satisfactory records could be obtained, the lesion was well developed on admission to the hospital in 141 cases, or 90 per cent. In 16 cases, or 10 per cent, the condition developed after operation. The average length of time between injury and operation in 162 cases of gangrene with satisfactory record, was 41.8 hours. In 349 cases of similar wounded which were nontransportable, and which did not develop gas gangrene, the average length of time between injury and operation was 24.67 hours. This indicates that many of those operations performed for extent of injury and the prevention of shock probably had the double effect of preventing, as well, the onset of gas gangrene.

The following table shows the relation between the interval before operation and the development of gas gangrene:

Time interval between injury and operation	With gan-grene	Without gan-grene	Total	Time interval between injury and operation	With gan-grene	Without gan-grene	Total
Received at hospital between—				Received at hospital between—			
0 to 6 hours	0	0	0	Continued.			
6 to 12 hours	12	80	92	60 to 72 hours	9	9	18
12 to 18 hours	15	90	105	72 to 96 hours	9	10	19
18 to 24 hours	27	55	82	96 to 120 hours	11	7	18
24 to 36 hours	30	56	86	120 plus	6	2	8
36 to 48 hours	20	17	37				
48 to 60 hours	23	23	46	Total	162	349	511

It is seen from this table that the delay in the modern surgical application of débridement had a marked influence in increasing the incidence of this condition.

The majority of these lesions occurred in the heavily muscled areas of the body and in one-third of the cases in this series they occurred in the lower leg. The anatomical reason for this high incidence is contained in the fact that the posterior tibial artery in a distance of about 1½ inches gives off the majority of its muscular branches to the calf. Machine gun and rifle bullets which fracture the tibia in this vascular area, necessitated the blocking of the bulk of the blood supply of the calf and presented the typical conditions of the failure of circulation, so important as the causative factor of this condition. Because of this vascular mechanics this is one area where bullets are almost as important factors as high explosive shell fragments in the production of gas gangrene.

Of 890 wound cultures, 478 or 53 per cent contained anaerobic bacilli. Of these 478 wounds, 321 or 67 per cent at no time showed clinical evidences of gas gangrene infection.

Of the remainder of the gas gangrene cases, 16 or 3 per cent developed gas gangrene after débridement, while in 141 cases, or 29 per cent, gas gangrene was clinically evident at the time the wound culture was made. It is thus seen that more than two-thirds of severe nontransportable wounds contaminated by anaerobic bacilli failed to develop gangrene, all of these cases being under observation at least five days, and many of them as long as two weeks. This fact involves a very important pathological principle. These bacteria are incapable of producing gas gangrene by their presence alone, and must be accompanied by the failure of circulation, the extensive cellular damage of large quantities of muscle, and in all probability by a constantly progressive increase of this series of factors.

Only a very small percentage of cases developed gas gangrene after operation. One hundred fifty-seven cases of gas gangrene were examined bacteriologically. In 18 of these the cultures were made at a distance from the wound, incisions above the wound, and from the amputation stump. In 139 cases in which cultures were made directly from the wounds, the relation of the *B. welchii* to the other anaerobes was as follows:

B. welchii was the only anaerobe in 20 cases, or 14 per cent; other anaerobes were found in 30 cases, or 21 per cent, and *B. welchii* and other anaerobes were found in 89 cases, or 65 per cent. In 139 cases of gangrene, streptococci were found in 44 cases, or 31.6 per cent. In 321 cases without gas gangrene, streptococci and anaerobes were found together in 97 cases, or 30 per cent. It is thus seen that the streptococcus was no more frequent in the gangrenous wounds than in those that failed to develop gas gangrene.

Previous wars had not prepared the medical departments of the various armies for the high incidence of gas gangrene which characterized the evolution of gunshot wounds received in France, during the World War, for the essential causative factors were heretofore not all cooperating so perfectly. Peace-time injuries so rarely produce the conditions which are favorable to the development of gas gangrene that our knowledge of it at the outbreak of the war in 1914 was both fragmentary and inaccurate. The chaotic state of our knowledge of the anaerobic bacteria was due very largely to the difficulty of obtaining and of maintaining them in pure culture.

In all probability the most important single factor in the production of gas gangrene is the intensive damage to muscle at a distance from the surface, under conditions that prevent the free access of oxygen. The next most important factor is the local ischemia produced by the damage to the circulation. There is histological evidence of immediate injury to muscles with a zone of disintegrated muscle around the missile tract, which closely resembles a freshly made beef emulsion, and makes an ideal culture medium for this group of bacteria. The lack of definite lymphatics within the mass of skeletal muscles, making a whole muscle bundle a true lymph space, determines the first actual interference to circulation. When a large muscle bundle is broken into, this single lymph space is destroyed, and the ebb and flow of nourishment is disrupted. Although the muscle in close relation to the missile tract is killed immediately it does not differ essentially in appearance from the muscle at a distance from this point, where its death is caused by the internal pressure of edema and gas gangrene, and the resulting interference to the circulation. The center of large muscles under these conditions, receives the greatest injury, since the muscles just beneath fascias get their lymph from lymphatics in these structures. A classical vicious circle is produced under these conditions. The traumatic opening of this main lymph space, produces an imbalance in the circulation and results in edema and the flow of serum into the damaged areas. The invasion of these collections of serum, of edema along dense fascial planes and of neighboring muscles by the members of this group of bacteria produces gas gangrene. The gas elaborated by the bacteria increases the internal pressure within the injured area. This pressure increases until it equals that in the lymphatics when it closes this avenue of release to the general circulation.

With the return lymph flow thus occluded the pressure mounts and approaches that of the pulse pressure. When this occurs the return of the circulation through the veins is impeded. At this point muscle degenerates from lack of nutrition, and the infection progresses rapidly so that the pressure may rise and approach first the level of the diastolic, then of the systolic level of the circulation. This completes the mechanics of the vicious circle and opens the malignant phase of the progress of gas gangrene into neighboring tissue. The pressure may be so great that reverse flow occurs in the lymphatics of neighboring muscles, and the bacteria spread back along perivascular lymph channels to involve more distant muscle groups.

Bashford¹¹ noted the spread of these bacteria at a point $5\frac{1}{2}$ inches from the wound tract in muscle fibers and capillaries. He found that when cultures were injected into the back of the thigh of a rabbit the organisms appeared halfway up the anterior abdominal wall $3\frac{1}{2}$ hours after injection, under favorable conditions for infection.

The muscles at a distance from the wound rapidly undergo cloudy swelling, fatty degeneration, necrosis, and the accompanying changes which alter their color and reactions to stains. They are penetrated by the spreading gases, and the mechanics of this vicious circle is so pyramided, that the infection can be well advanced in two hours, and death from massive gas gangrene of an entire limb can occur in less than 30 hours.

The reaction to these bacteria varies widely. Following the traumatism there is a definite period of delay before any increase in the number of bacteria present in the exudate. This period is rarely less than four hours and often not more than six. The only changes in the wound that may be noted during this period are due directly to the injury. There is a positive leucocytic reaction when the quantity of bacteria is small enough and the damage to the circulation is not great enough to prevent the constant renewal of these cells and the liquid elements of exudate that contain antibodies. With the development of a gangrenous process and the accompanying multiplication of the anaerobic group of microorganisms, the leucocytes diminish rapidly in number. The few that remain are quickly destroyed and converted into a homogeneous granular detritus which may bear no resemblance to white blood cells.

With favorable evolution of the wound considerable phagocytosis will be demonstrable. The leucocytes will be found to contain relatively large numbers of bacteria. This is usually a favorable sign and indicates increasing resistance. As the infection diminishes in intensity the polynuclear leucocytes decrease in number to be replaced by a corresponding increase in the mononuclear elements which are also phagocytic.

When, however, the evolution of the wound does not progress favorably and gangrenous changes begin, the cytologic picture is quite different. This difference concerns especially the leucocytes and may be revealed by vital staining and staining with Sudan III. Smears made at about the second hour show that out of 96 leucocytes only 8 show any evidences of fat content. After the tenth hour at least half the leucocytes show fatty changes.

After this period, with unfavorable evolution of the wound and with the development of gas gangrene, the bacterial content of the exudate and of the

surrounding tissues holds the center of the stage. The bacteria are aided in



FIG. 168.—Posterior aspect of left leg amputated for a mixed type of gas gangrene, with extensive putrefactive blackening of the inner and posterior aspect of the upper two-thirds of the calf. There are several high-explosive wounds on the posterior surface, around which there has been superficial dissection of the skin in the search for injuries to vessels and subcutaneous hemorrhages responsible for this zone of gangrene. Seven and one-half centimeters above the uppermost wound is a rupture of the long saphenous vein, probably produced by the missile through hydraulic transmission of its force. Arrow points to rupture. Accession number 4720, Army Medical Museum. Negative number 30237

producing damage by the hydraulic injury to the walls of blood vessels produced by the peculiar dynamics of high explosive shells. Ruptures of surface veins have been found more than 3 inches below the site of injury. (Fig. 168.) Large muscles, especially those under tension, because of the closed lymphatic space which they represent, produce an ideal situation for dissemination of injury to a distance because of the hydraulic action of this semifluid tissue within dense fascial envelopes. The force which ruptures smaller vessels tends to damage the intima, produces shredding of the inner coats of larger vessels and results in secondary or delayed gas gangrene, and many of the dramatic secondary hemorrhages which occurred in these conditions. Shredding of the inner coats accounts for the linear tears from which these massive hemorrhages occurred.

Hematomas were very important factors in the production of gas gangrene in the World War wounded. These hematomas, encircling the wound, checked hemorrhages by their own pressure within confining fascias. They interfered physically with lymphatic drainage, and augmented internal pressure and its influence on the progress of this condition. Fresh blood is an unfavorable medium for the growth of gas gangrene group but as the clot ages it becomes an ideal culture medium for these

organisms. (Fig. 169.) The formation of acids of this group of bacteria

forces them into the spore stage. This self-limiting action is neutralized by the alkalinity of the exudate. With complete blocking of the circulation the increased acidity stops proliferation, and gas gangrene no longer progresses.

The Welch bacillus forms spores in the presence of coagulable proteins, and produces quantities of gas and organic acids in the presence of glucose. These acids, which consist chiefly of the butyric group are inimical to the growth of this organism and are formed readily in muscle, on account of its glucose content. This, and the fact that pus is in part a coagulable protein and forces the organism out of the vegetative and into the sporulating stage, are important factors in the self-limiting character of this infection. It must do its damage in the first few days of its activity or be superseded by pus-producing bacteria.

Emery¹² used powdered chalk in his cultures in order to overcome this inhibition of growth by acids. The chalk neutralizes the acid as it forms and allows a sufficiently luxuriant growth for the study of pathogenicity. The protective power of serum and leucocytes is maintained only as long as they are fresh and constantly renewed, and fails when the circulation no longer furnishes the needed replenishment of these elements as determined by the extent of the infection. A preponderance of the bacilli and their products over the leucocytic response may result in a negative chemotaxis for these cells and they no longer phagocytose and destroy the organisms. It is readily seen then how important the blood supply is to a part subjected to the factors which produce gas gangrene. The normal blood supply may prevent infection but when this has already been started a much greater supply must be furnished.

As the gas gangrene group decreases, the more saprophytic organisms take their place. When this occurs the tissues of the muscle or the limb go on to ordinary gangrene and slough away. At those zones where the circulation is established, the more virulent members of the group are limited by local leucocytosis and give way to the members of the pyogenic group, especially hemolytic streptococcus and staphylococcus. Inflammatory reactions due to these organisms then replace the gangrenous process which does not reappear unless there occurs a thrombosis or other obstruction to circulation which renews the degenerative process in muscles, and again affords a suitable medium for the multiplication of these organisms. Many of the deaths attributed to gas gangrene which occurred after the fifth day of wounding probably should be credited to a blood invasion by streptococcus.

The clinical classification of Weinberg and Seguin¹ offers a convenient one in describing these lesions.

(a) Virulent gas gangrenes.

1. Emphysematous type.
2. Toxic or edematous type.
3. Mixed form.
4. Putrefactive type.

(b) Avirulent gas gangrenes.

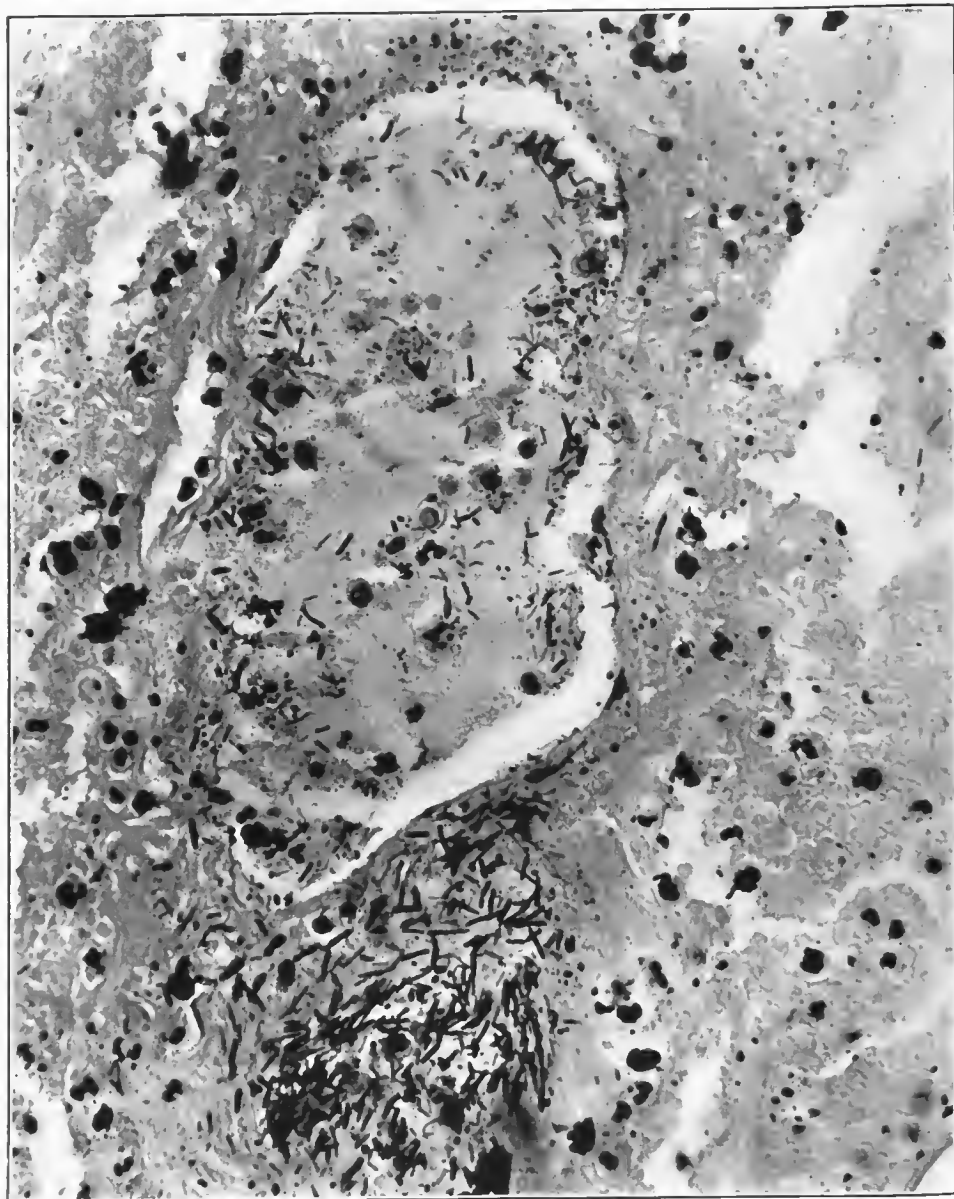


FIG. 169.—A section through a distended vein. The circulation had evidently ceased within this vein before amputation. The perivascular area at the lower end of the vein is filled with large bacteria of putrefactive type which are Gram-positive. Some of the bacteria which have invaded the recent clot do not appear like the putrefactive types and contain Gram-negative and Gram-positive rods, some of the latter appearing like Welch bacilli. Accession number 4717, Army Medical Museum. Negative number 46070. MacCallum stain; $\times 500$

The Welch bacillus is the greatest producer of gas, and the infections caused by it are usually the classical or emphysematous type. *B. œdematiens* and *Vibrio septique* produce less gas and more edema, and predominate in the edematous lesions. The mixed forms are caused by any combination of the above, while the putrefactive lesions may show any and all combinations of aerobes and anaerobes, including the ordinary pyogenic bacteria.

During the World War the emphysematous type of gas gangrene was the most virulent of this group. It usually showed a preponderance of *B. welchii* in all cultures of the wound, and occurred in relative purity in the depths of the muscles involved. It was responsible for the large collections of gas bubbles in muscle and the most extensive swelling of limbs occurred in this type of lesion. The type of wound producing the emphysematous form of gangrene was usually that of a small opening with massive internal injury of a well muscled portion of the limb. The small wound of entrance and exit served to keep the infection in relative purity in the deeper zones, and maintained the anaerobic conditions in these areas throughout the process. The small wound of entrance and exit tended to decrease the liability to contamination with the putrefactive members of this group of bacteria. The surface wound was dry, its edges were fairly clean, and the intense pressure produced by the gas and edema in the deeper portions forced the walls of the wound tract to protrude some distance above the level of the limb. The following cases illustrate the clinical and pathological characteristics of the virulent emphysematous type of gas gangrene.

CASE 1.—Soldier was wounded July 21, 1918, at Château Thierry, and was admitted to American Red Cross Military Hospital No. 5 on July 22, 1918, with a diagnosis of gunshot wound of the right thigh and of the left knee. There is a gaping wound on the anterior surface of the lower third of the right thigh and another wound on the external surface of the same thigh, just above the knee joint, with a compound comminuted fracture of the right femur in its lower third and a well advanced gas gangrene of the right thigh. Above the external condyle of the left femur is a superficial furrowed wound whose base is covered with a shaggy exudate. This specimen consists of the right thigh including the articular end of the femur. On both medial and lateral surfaces there are two wounds. The external wound measures 10 by 6 cm. and the internal one is approximately the same size. Both wounds have been debrided, the skin edges having been trimmed, and part of the muscle removed. Denuded bone fragments can be seen in the external wound. All muscles are infiltrated by gas. The X ray shows a large amount of comminution of the fracture of the femur with most of the muscle bundles separated by gas bubbles. (See Pls. XV and XVI and figs. 170 to 180, inclusive.)

CASE 2.—Amputation just above knee joint for gas gangrene following a resection of the head of the tibia for gunshot wound. Advanced gas gangrene of the muscles with putrefactive changes in the tissues in and about a superficial hemorrhage into the skin and subcutaneous tissues. (See figs. 181 to 188, inclusive.)

CASE 3.—Soldier was wounded July 17, 1918. Gunshot wound of left thigh and left shoulder. Left thigh amputated July 22, 1918. Secondary hemorrhage occurred July 31 at 10 a. m., because of which the femoral artery was ligated 2 inches above the stump. Patient died three hours after ligation. The amputated limb showed a compound comminuted fracture of the middle of the shaft of the femur. The surrounding tissues were infiltrated with gas, and the muscles were a characteristic brick red color, except in the immediate vicinity of the wound where there was some darker discoloration due to putrefactive bacteria.

At necropsy there was gas gangrene of the stump and gas in small quantities was seen in the liver. (See figs. 189 to 195, inclusive.)

CASE 4.—Soldier was wounded on July 17, 1918.

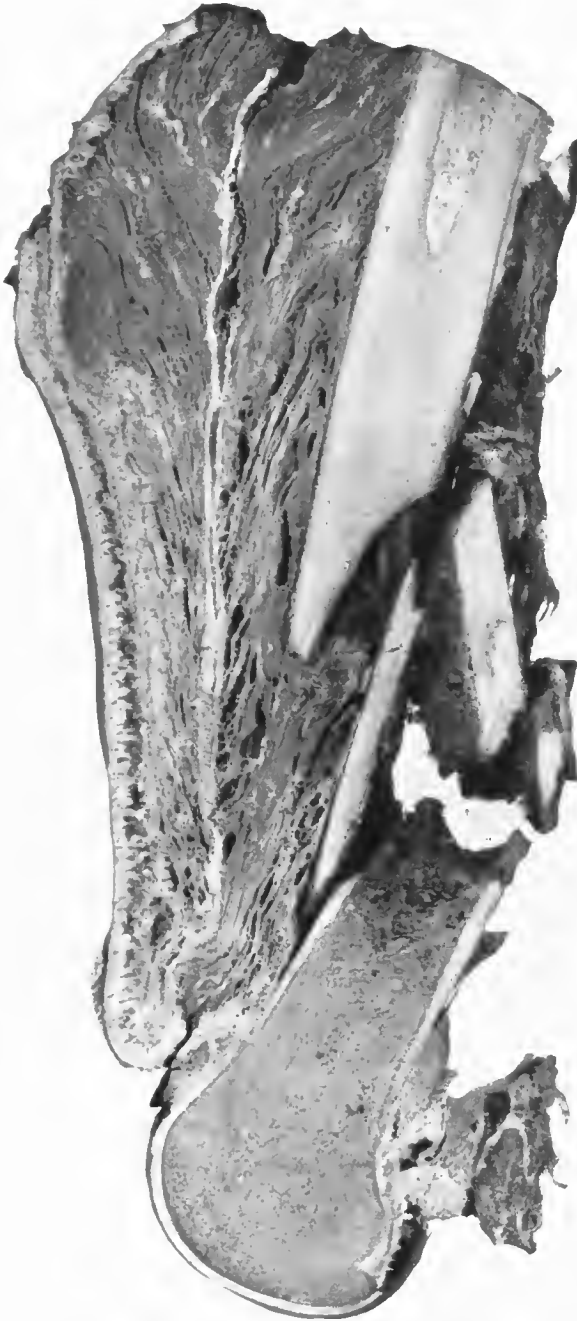

FIG. 170.—Vertical midsection through the femur. There is a massive comminution with putrefactive involvement of the marrow cavity. The muscles on the right of the bone show the same putrefactive reaction. Those to the left of it show almost no putrefactive changes but contain massive collections of gas bubbles. Accession number 2879, Army Medical Museum. Negative number 30890

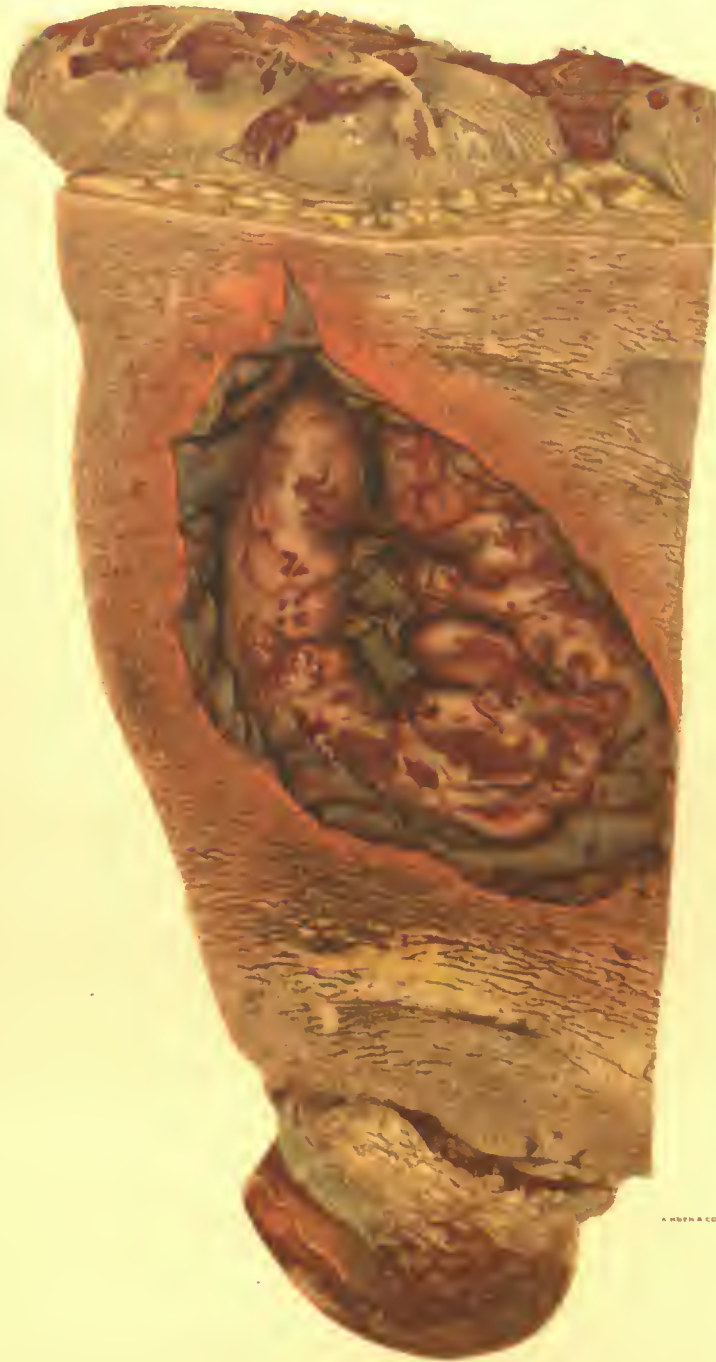He entered the hospital, July 20, with multiple wounds, from fragments of high explosive shell, of the right thigh, middle finger of left hand, neck and left thigh. The wound of the left thigh was extensive but did not fracture the femur. There were large debrided wounds of exit and entrance exposing dark colored, partially necrotic muscles. July 26, the left leg was amputated because of gas gangrene.

The amputated limb shows a diffuse infiltration with gas, the base of the wounds being covered by a greyish-green slough.

At necropsy the stump was seen to be involved in the gangrenous process. There was a purulent arthritis of the right knee. There was a perforating wound of the larynx just below the vocal cord, with a shell fragment the size of a pea in the cartilagenous tissue of the left side. This wound was accompanied by edema of the larynx and glottis and extensive peritrachial hemorrhage. Bacterial stains of sections of the wound of the left thigh, superficial portions, show numerous streptococci. (See figs. 196 to 203, inclusive.)

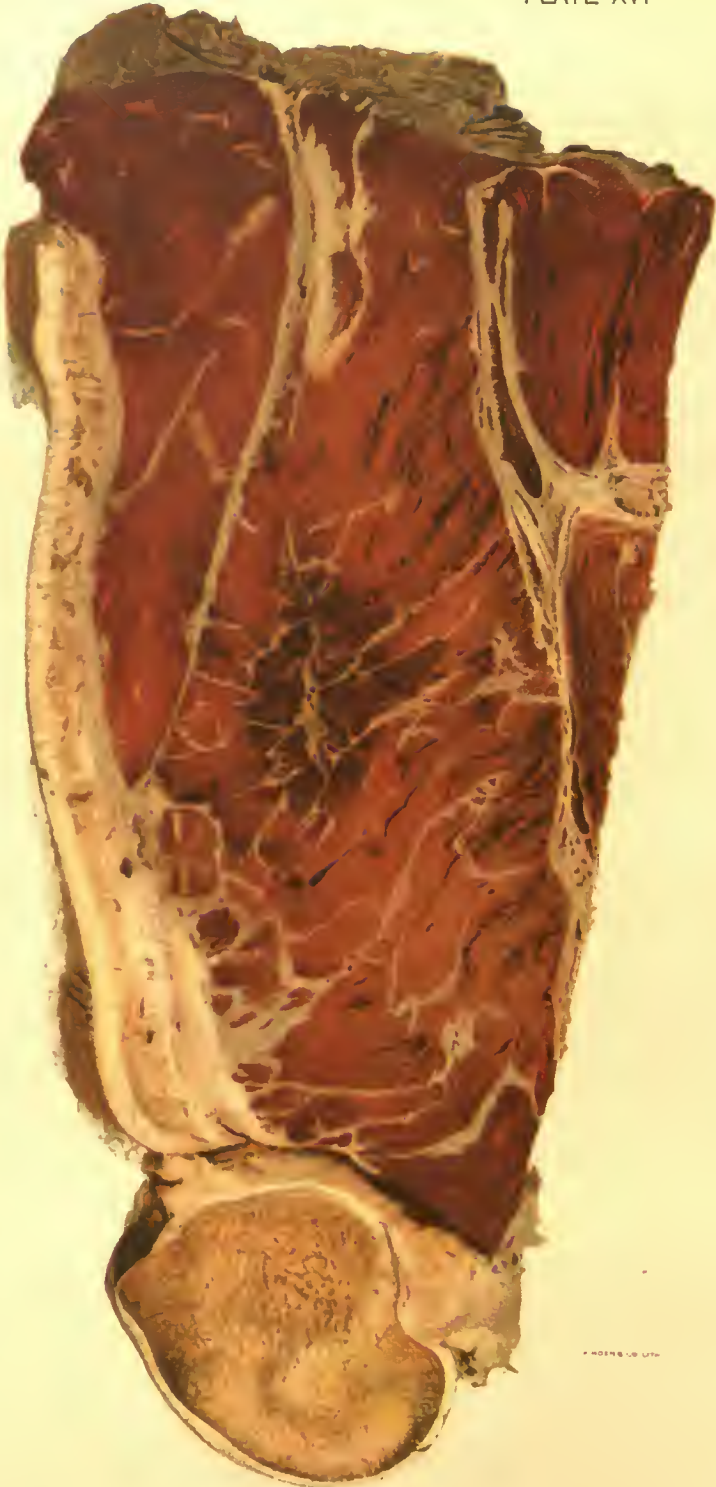CASE 5.—Soldier wounded October 16, 1918, by fragments of high explosive shell. October 18, 1918, the wound was debrided, and a free dissection of all the muscles of the calf was done. October 21, there was present an extremely emphysematous gas infection. The leg was amputated just above the knee on October 25, because of extension of the emphysematous gangrene, and secondary infection with pyogenic organisms.

Amputated leg shows a free dissection of the posterior muscle bundles which appear attached only by small bands of tissue bearing their blood supply. The muscles show extensive fragmentation as the result of gas emphysema, the gas being more abundant in the muscle tissue than



A. HENN & CO. LITH.

DEBRIDED WOUND OF ANTERIOR SURFACE OF THIGH.
Muscles extruded by pressure from below. Tension and pigmentation of skin from gangrenous process in muscles beneath.
Accession 2879, Army Medical Museum. Colored photograph.



GAS GANGRENE.

Vertical section behind femur of thigh shown in Plate XV. Muscle about wound shows the dark color of putrefactive gangrene. Surrounding this area the muscles are the brick red color of gas gangrene. Muscle fibers separated by gas.

Accession 2379, Army Medical Museum. Colored photograph.

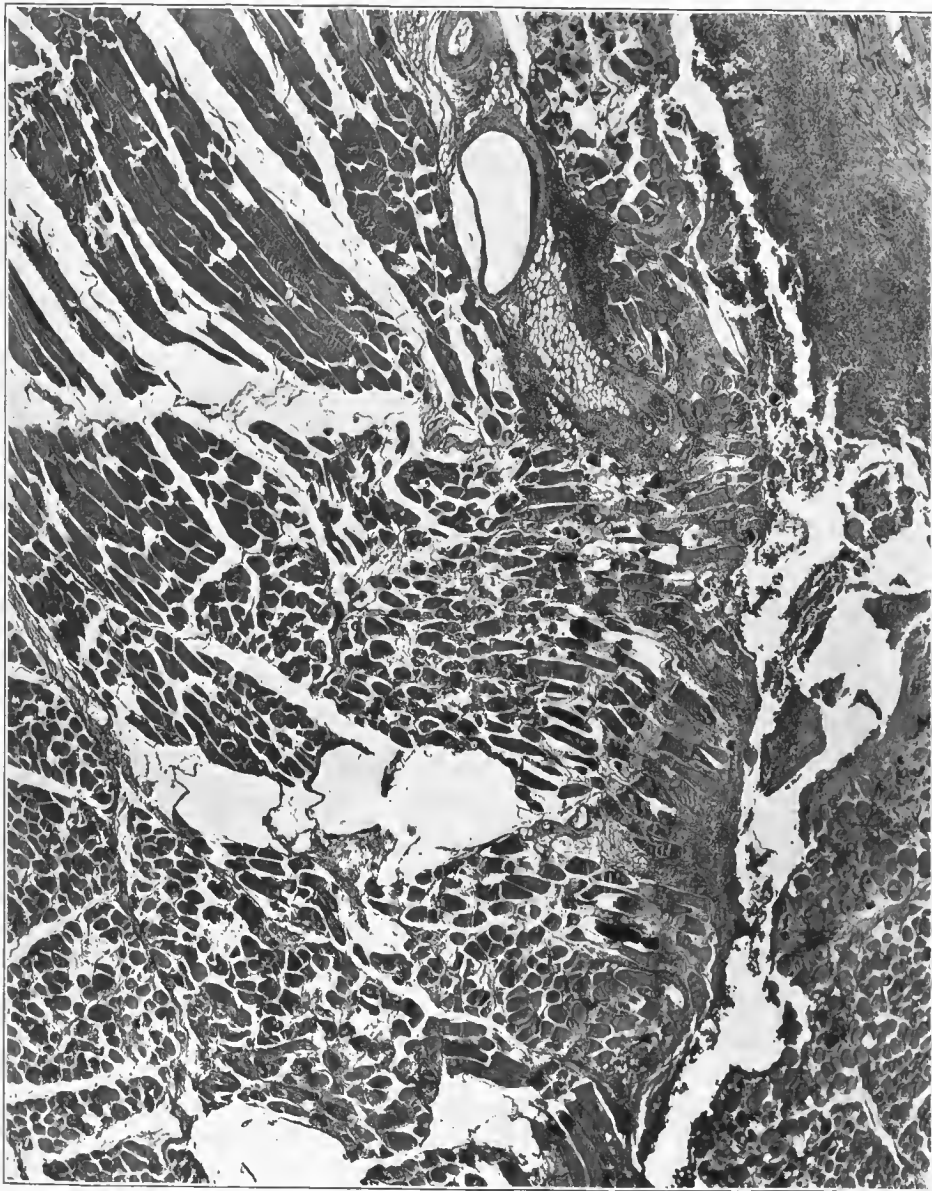


FIG. 171.—Section of the gangrenous muscle, showing massive bubbles between muscle bundles, with numerous muscle fibers containing small gas bubbles. There is a medium-sized vein in the upper part of the picture which shows a gas bubble between the adventitia and muscular layer. This vein is surrounded by hemorrhage. To the right of this hemorrhage is a larger one showing purulent softening. Muscle fibers in relation to the central gas bubble stain deeply with eosin and appear darker in the figure. Accession number 2879, Army Medical Museum. Negative number 46071. Hematoxylin and eosin stain; $\times 23$

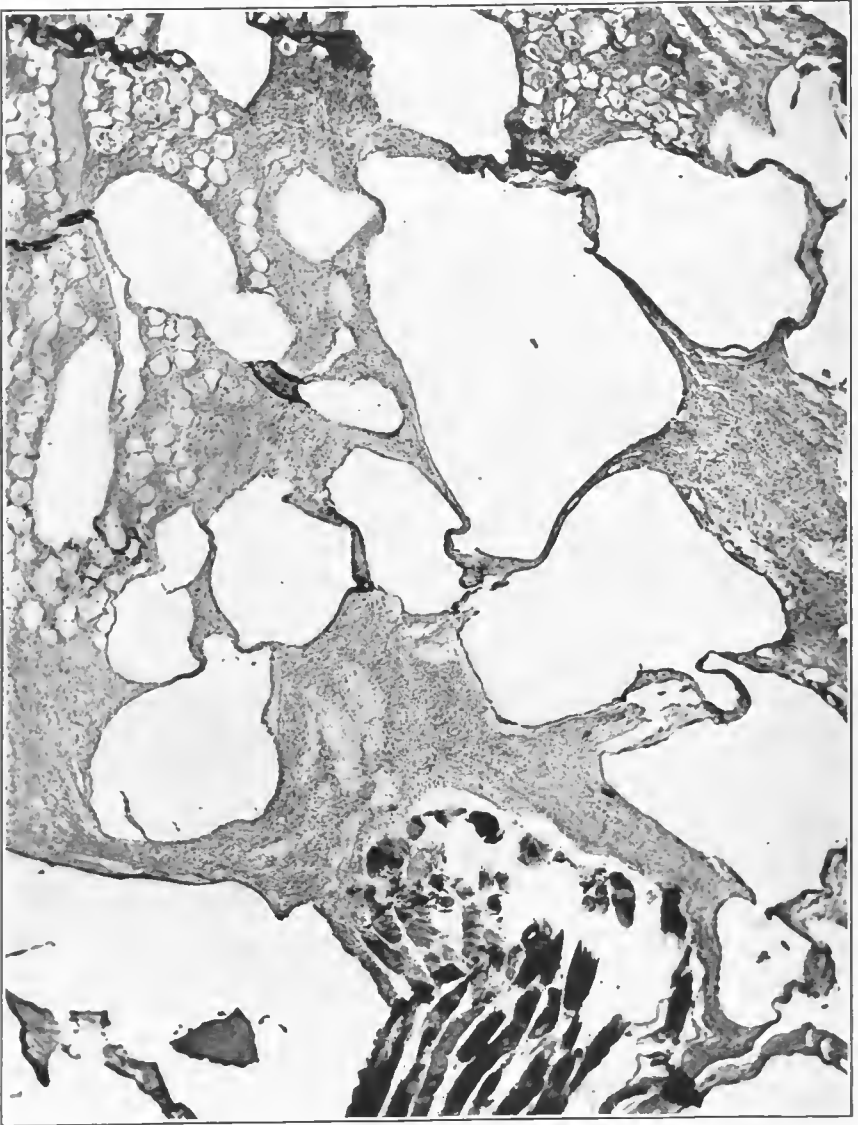


FIG. 172.—A gaseous area showing large accumulations of gas in fat connective tissue. Some fibers in the bundle of muscle at the lower margin of the picture stain intensely with the violet. There is a small fragment of bone near this muscle bundle. There is a moderate leucocytic reaction in the connective tissue. Accession number 2879, Army Medical Museum. Negative number 46047. MacCallum stain; $\times 76$

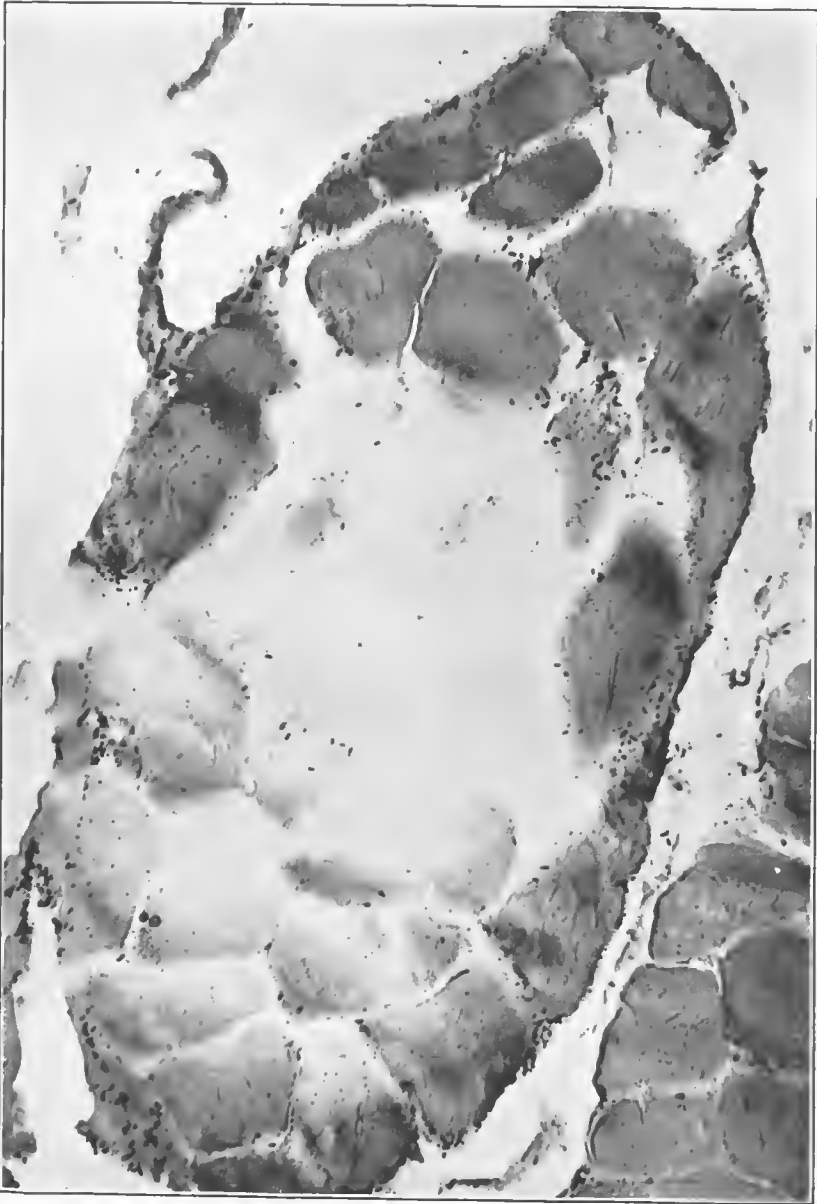

FIG. 173.—Gangrenous area, showing the central two-thirds of a small muscle bundle replaced by gas. The margins of the bundle contain numerous Gram-positive round-ended rods. These are less frequent in the central area. This appears to be a pure infection with *B. welchii*. There is no leucocytic infiltration in this section. Accession number 2879, Army Medical Museum. Negative number 46045. MacCallum stain; $\times 305$

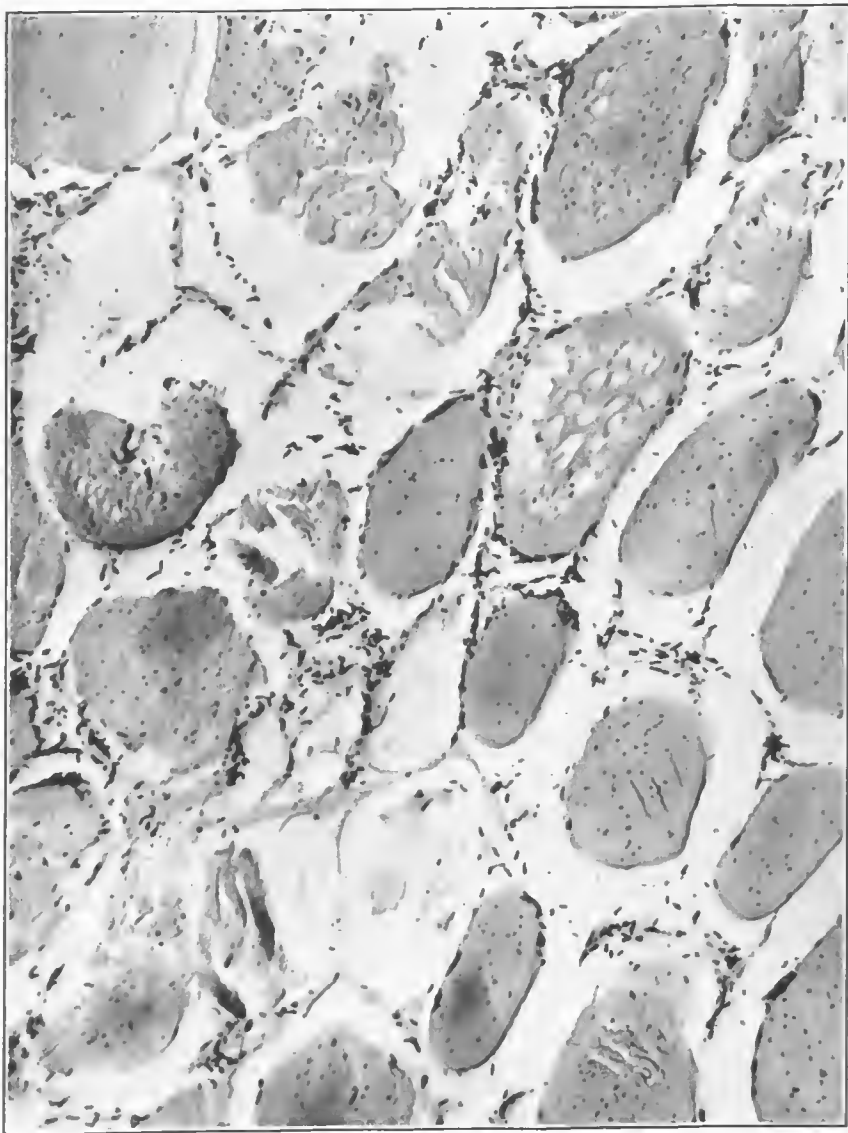


FIG. 174.—Numerous Gram-positive round-ended rods between muscle fibers. Numerous muscle fibers are dissolved and replaced by collections of gas. Others show fine bubbles in the act of producing this change. There is a moderate amount of gas between muscle bundles. The majority of the bacteria are found just within the sarcolemma. Accession number 2879, Army Medical Museum. Negative number 46046. MacCallum stain; $\times 350$

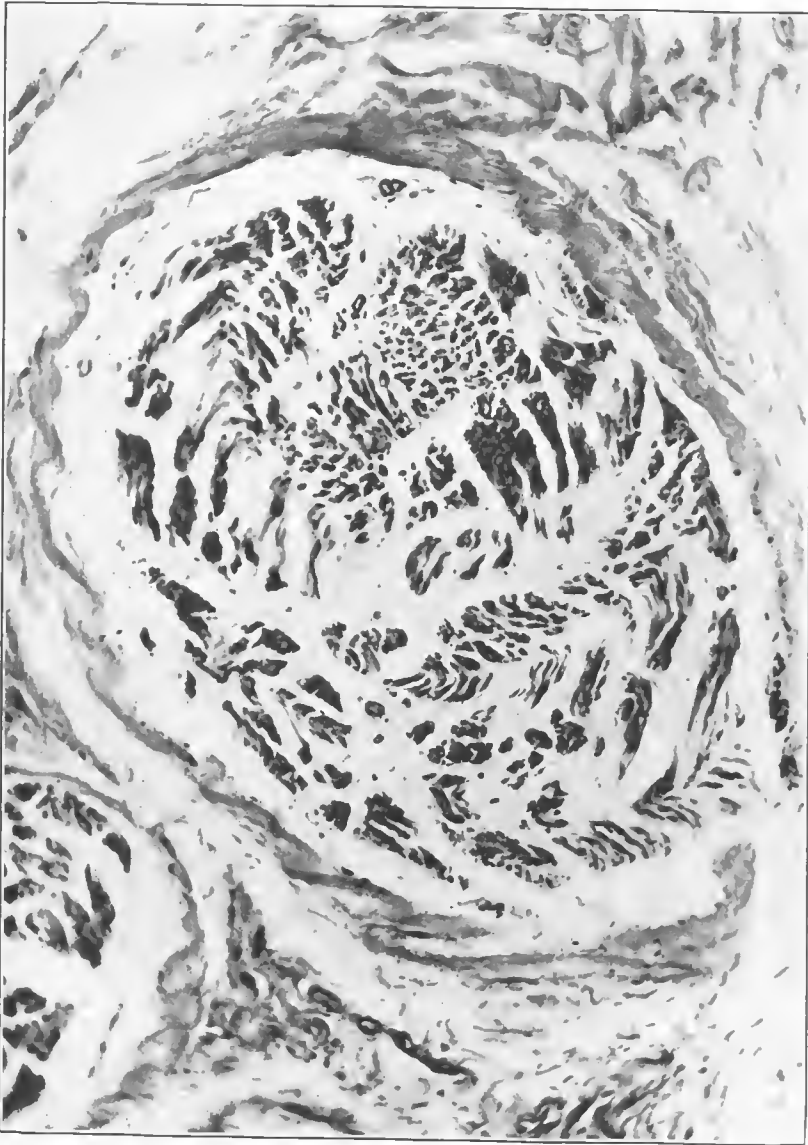


FIG. 175.—Cross section of a nerve the sheath of which shows a spiral rupture. The nerve fibers are separated by gas and edema. Gram-positive rod-shaped bacilli in the sheath. Accession number 2879, Army Medical Museum. Negative number 46049. MacCallum stain; $\times 125$

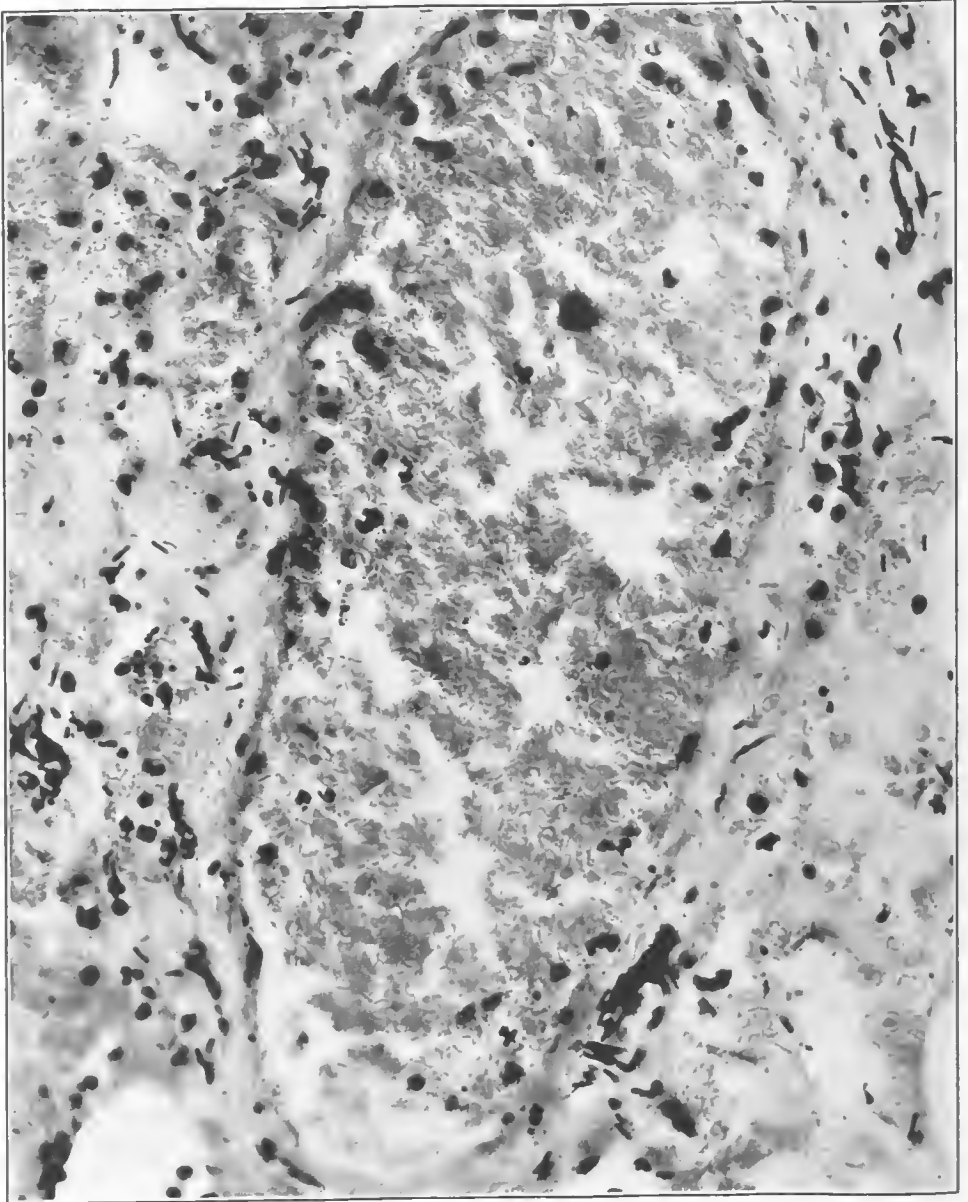


FIG. 176.—Medium-sized vein which shows no bacilli within its lumen. There are numerous Gram-positive rods in the muscularis and in the lymphatics. These bacteria seem to be of one variety, apparently, Welch bacilli in form and staining reaction. No spores are seen. Accession number 2879, Army Medical Museum. Negative number 4073. MacCallum stain; $\times 500$

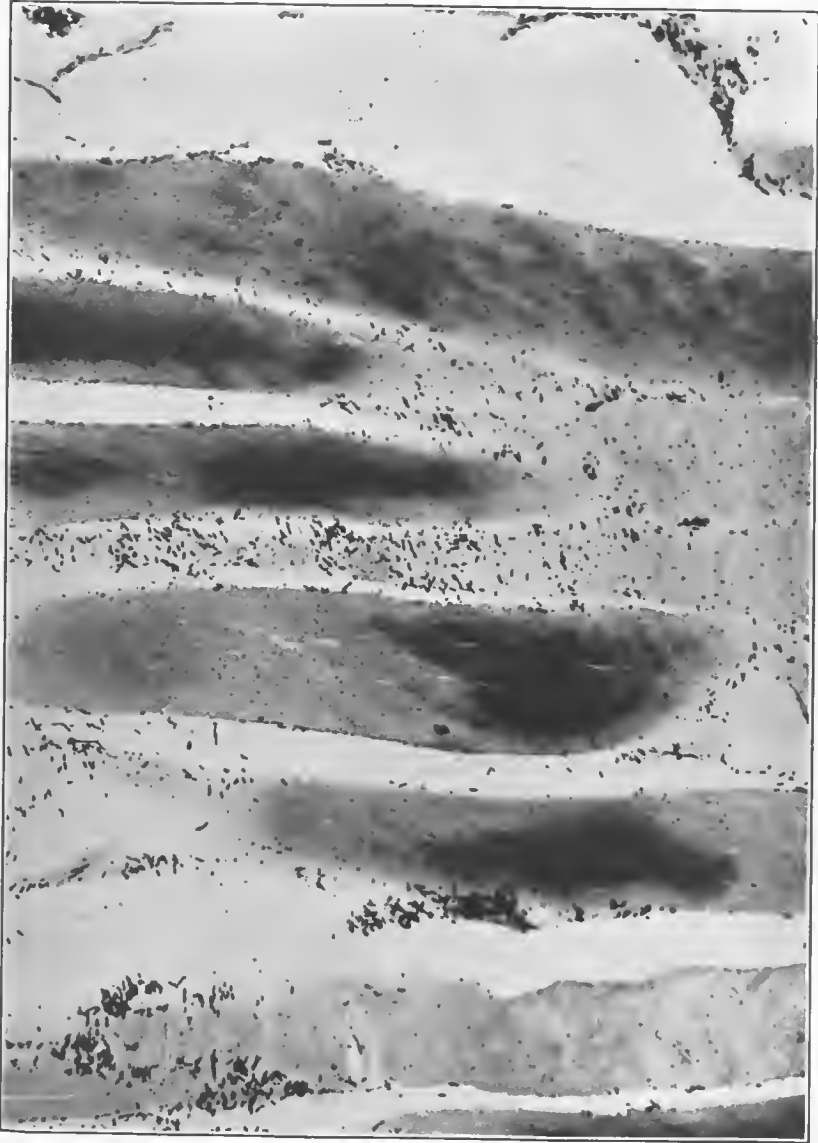


FIG. 177.—Longitudinal section of muscle fiber taken from the contaminated area of muscle infection near the débrided wound. The muscle fibers are dotted with a fine débris of blood pigment. The lesion is a gaseous one with a superimposed putrefactive process. The bacteria seem to be of one type and are probably Welch bacilli. The muscle fibers show a retention of the basic dye. Accession number 2879, Army Medical Museum. Negative number 46057. MacCallum stain; $\times 205$



FIG. 17b.—Section of muscle cut longitudinally. The fibers show a peculiar spiral rupture caused by the slowly increasing tension of accumulating gases within the muscle fascia. Accession number 2879, Army Medical Museum. Negative number 46069. Hematoxylin and eosin stain; $\times 280$

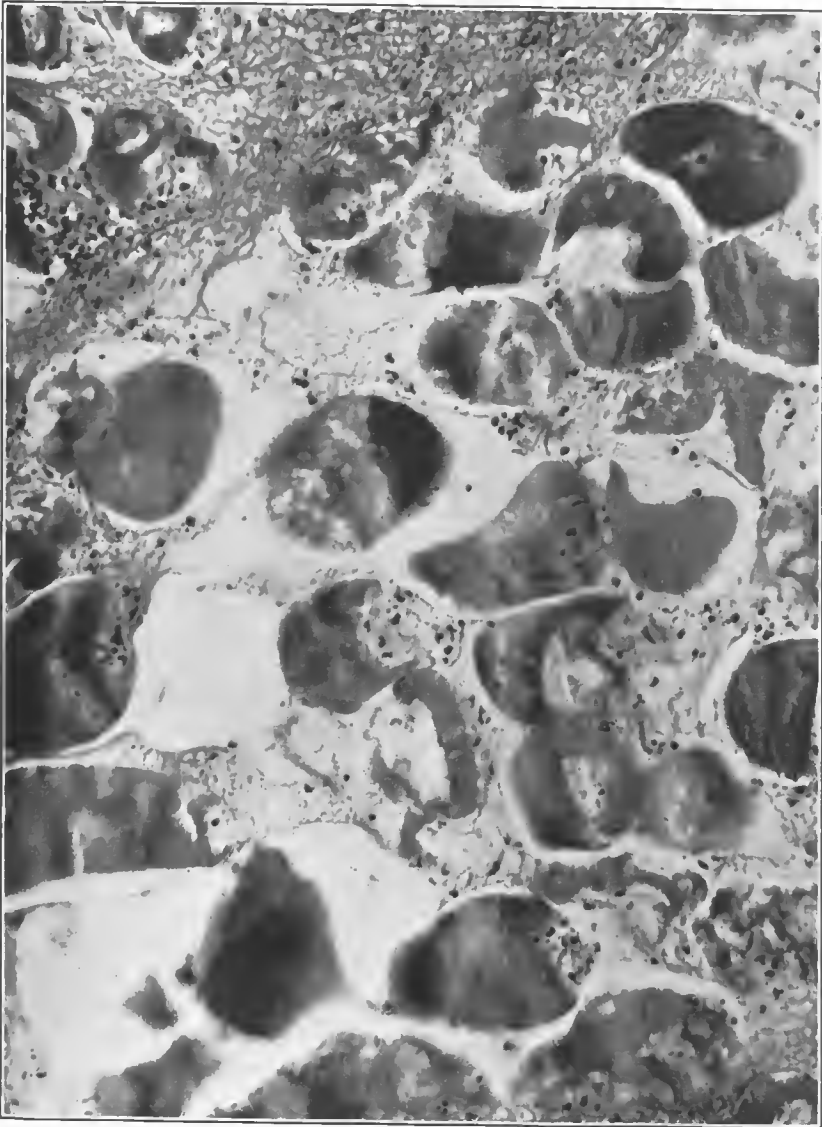


FIG. 179.—Cross section of muscle which shows accumulations of gas between muscle bundles and within muscle fibers, with extensive rupture. It is taken from an area near the wound tract and shows involvement with pyogenic and putrefactive bacteria. There is a moderate leucocytic infiltration. Some fibers retain the basic dye. Accession number 2879, Army Medical Museum. Negative number 46048. MacCallum stain; $\times 205$

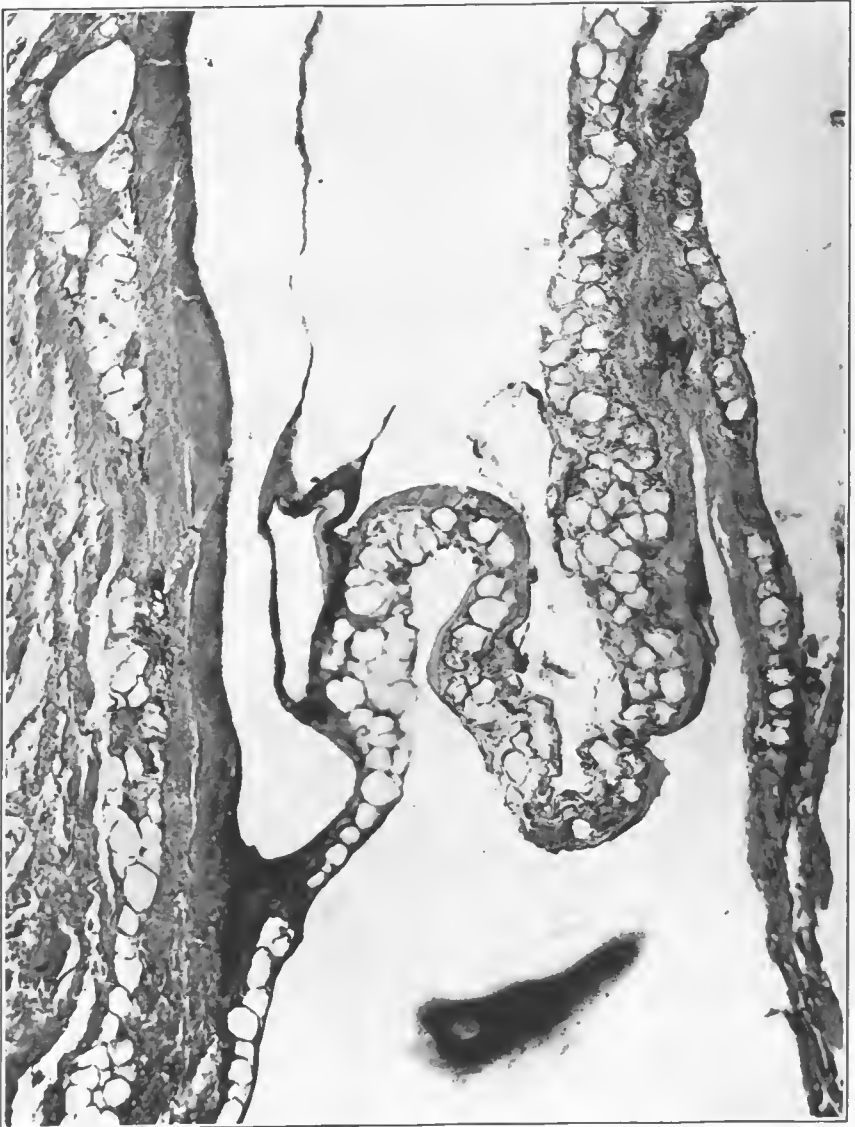

FIG. 180.—Connective tissue and fat, showing an accumulation of gas and edema and digestion of fat cells by the fat splitting enzymes elaborated by bacteria. This is the beginning of the formation of adipocere. Accession number 2879, Army Medical Museum. Negative number 46054. Hematoxylin and eosin stain; $\times 105$

between the muscles and in the subcutaneous tissues. Cross section above the dissected area shows the freedom of the muscles from marked emphysema but there is a marked superficial and deep lymphangitis. (See figs. 204 to 209, inclusive.)

CASE No. 6.—Soldier wounded June 7, 1918. Admitted to hospital the same date with bullet wound of shoulder. Operated June 8. Findings: Penetrating wound of the arm at about the level of the fold of the axilla. Almost complete severing of the brachial artery. Contusion of the brachial vein with thrombosis. Hemorrhage necessitated tying of the subclavian artery.

The tissues became infected with gas-producing bacilli, extended over the chest and the bacteria entered the circulation. Death occurred June 13.

Necropsy was performed 14 hours after death. The tissues of the arm and of the upper chest on the left are discolored, and present several incisions. The tissues of the upper arm are almost black. The forearm is swollen and tense but not discolored. Subcutaneous gas can be detected over the left arm and forearm, the left side of the neck and beneath both pectoral muscles. Necrosis and liquefaction are present in the left pectoral muscles. Bubbles of gas numerous in the tissues of the lungs, liver, and spleen. (See figs. 210 to 214, inclusive.)

CASE 7.—The following case is a typical one to show the influence that traumatized muscle has in the production of gas gangrene, and the speed with which this can develop. This soldier was hit by a 37 mm. shell which exploded on contact. The wound occurred about 4 a. m., October 27, 1918, and he was seen in the admitting room of Evacuation Hospital No. 6 at 8.30 p. m., walking about the room, smoking a cigarette and talking rather volubly. His diagnosis tag read "Gunshot wound right thigh, compound, comminuted fracture." A tight cotton cloth tourniquet had been applied and was still in position and tight enough to check hemorrhage. His ability to walk about with complete crushing of the lower thigh and fracture of the femur and tibia led the examiner to suspect that this soldier was in the excited stage of shock. He was sent immediately to the shock room and amputation was performed, after four and one-half hours of shock treatment, at 1 a. m., October 28, 1918, about 21 hours after being wounded. He answered very readily to shock treatment and it was thought by the members of the shock team, that the tight tourniquet had saved him from the shock and toxic products which the pulped muscles might have thrown into the circulation but for it. In all probability such shock as he had, was due to insult to the central nervous system, and the tourniquet had been applied quickly enough to prevent augmentation of this shock, first from hemorrhage and second from the toxic products of autolyzed muscles.

The amputation specimen consists of the right leg which had been removed by the guillotine operation at the middle of the thigh. The lower half of the leg at the lower third of the soleus muscle has been cut away as it showed no lesion. The cotton cloth tourniquet was still in place just below the line of amputation. All of the popliteal vessels have been ruptured by this direct explosion. There is a piece of 37 mm. shell casing measuring 1 by 2 by 5 cm. lying just under the skin over the patella. There is a compound, comminuted fracture of the tibia and fibula, at the middle of the upper third. The fracture through the femur was by secondary violence. The wound on the upper surface of the right calf measured 11 cm. in diameter. It is ragged and roughly circular in outline and the muscle is completely pulped throughout its extent. (Fig. 215.) It has driven the tibia through the skin on the opposite side of the leg, making a wound through the skin 7 by 3 c. m. in extent. (See figs. 215 to 225, inclusive. Pl. XVII.)

CASE 8.—Soldier wounded by high explosive shell July 19, 1918. Admitted to hospital July 20, 1918. On July 21, amputation was done through upper third right humerus for comminuted fracture of the femur in its middle third, complicated by extensive gas gangrene.

Right leg was amputated through the upper third of the femur for gas gangrene complicating two shell wounds of the right thigh. The gas extended above Poupart's ligament.

X-ray report: Gunshot wound of right thigh with numerous foreign bodies of various sizes, large cavity in the muscle with loss of substance, some separation of bundles of muscle with gas. (See figs. 226 to 235, inclusive.)

CASE 9.—Soldier received a shell wound of the right foot July 20, 1918. Admitted to hospital July 21.

On July 22, foot was amputated above the right ankle because of gas gangrene. The amputated limb shows a shell wound on the outer side of the instep of the right foot caused by a piece of shell 4 by 4 by 4 cm. The wound was infected with gas producing bacilli, the gas infection involving the plantar muscles. There was beginning gangrene of the fifth toe due to destruction of the vessel. (See figs. 236 to 242, inclusive.)

CASE 10.—Soldier wounded by high explosive shell fragments August 28, 1918. On this date an extensive wound of the left leg, with compound comminuted fracture of the upper half of the tibia, was debrided and 4 inches of tibia removed. There was considerable serous discharge at the time of operation. Length of time after injury not given. There were little dirt or fragments of clothing in the wound. September 6, 1918, amputation was performed in the lower third of the left thigh for gas gangrene, and severe secondary infection by pyogenic bacteria, which included the tibia. Hemolytic streptococci and Welch bacilli were recovered in cultures taken on this date. (See figs. 243 to 250, inclusive.)

CASE 11.—Soldier was wounded June 6, 1918. Admitted to hospital June 9, with gunshot wounds of both thighs. There was a compound comminuted fracture of the upper third of the left femur and a simple gunshot wound of the right thigh. The wound of the left thigh was debrided and bone sequestra were removed. The bone was infected with streptococci. Patient died August 5, 1918, the intervening history being unknown.

The necropsy, 16 hours after death, showed a partially healed wound of the left thigh, 9 by 5 cm., communicating with necrotic bone. There is another large open wound on the undersurface close to the perineum. The leg is markedly swollen. There are small perforating wounds on each side of the left knee, the outer one extending to the joint capsule. There is a large amount of exudate in the tissues. The tissues of the left thigh are distended with exudate and gas. The muscles are the characteristic brick red color of gas gangrene. Considerable young callus has been thrown out about the fractured bones. The edges of the wound show beginning epithelization. The lungs, spleen, liver and kidneys show infection with gas producing organisms, in the form of gas bubbles. The wound in the right thigh is nearly healed. (See figs. 251 to 255.)

The toxic or edematous type of virulent gas gangrene was usually caused by *B. adematians* and *Vibrion septique*, and showed less virulence than the emphysematous form. There was marked edema beneath fascias between muscle bundles, and even surrounding individual fibers. There was little or no gas in these lesions. The muscle was pale and moist instead of dry, and had a homogeneous, textureless character. As in the gaseous form, the fascias were swollen with a glairy, gelatinous exudate and they and the collections of edema beneath them were often stained a cherry red. Hemolysis of escaped blood was a prominent feature and most of the collections of exudate were stained by it. These cases showed abundant evidence of hemolysis in the wound, which was usually confined to the local focus. Jaundice and anemia from hemolysis rarely occurred. These cases died with toxic symptoms, often showing extremely high temperatures, and those respiratory failures which indicate toxicity for the heat regulating and respiratory centers in the brain. The following cases illustrate this form of the virulent type of gas gangrene:

CASE 12.—Soldier was wounded in the right arm by a machine-gun bullet which produced a markedly comminuted fracture of the humerus. An extensive débridement was done. The wound measures 15 by 18 cm. and occupies the inner aspect of the upper arm. The musculospiral nerve is severed in the upper portion of the wound. The brachial vein is severed in its middle portion and the brachial artery has been injured. Dissection of the wound shows a fragment of the humerus which has pushed the musculospiral nerve before it without breaking the sheath into which there is a moderate amount of hemorrhage. (See figs. 256 to 265, inclusive, and Pls. XVIII and XIX.)

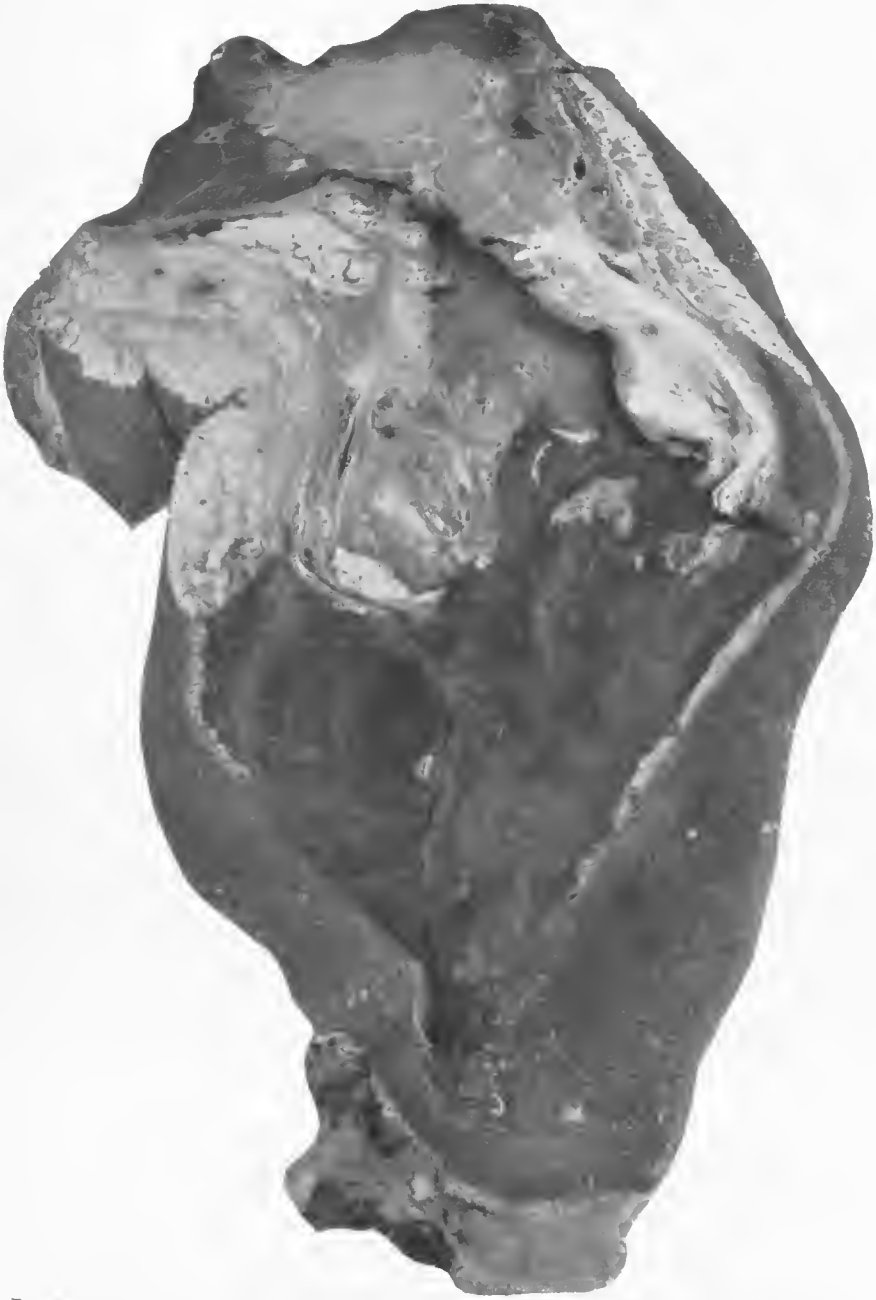

FIG. 181.—inner aspect of the left knee with a débrided wound 12 by 15 cm. in diameter. The central zone of the wound shows a base covered with a putrefactive exudate, while the margins show the muscles extruding above the level of the skin from the internal pressure of the accumulating gas. Accession number 2920, Army Medical Museum. Negative number 30854

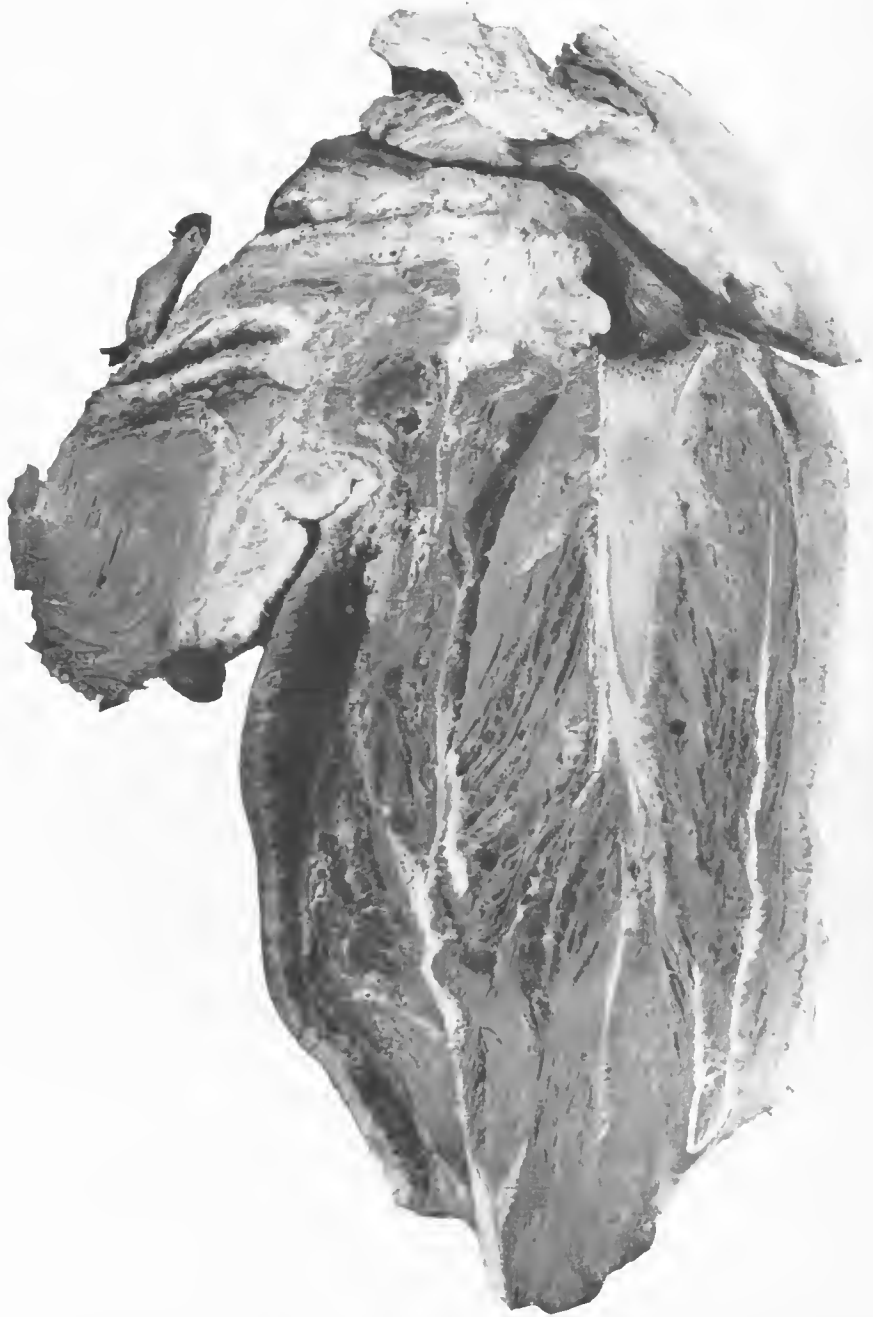

FIG. 182.—Mid section of the knee in Fig. 181, showing an extreme of gas formation in the type of gangrene, usually due to pure infections by the Welch bacillus. In the posterior margin of the calf and beneath the skin, apparently in close relation to the wound tract where a superficial hemorrhage has occurred, is a putrefactive gangrenous process. Accession number 2920, Army Medical Museum. Negative number 30852

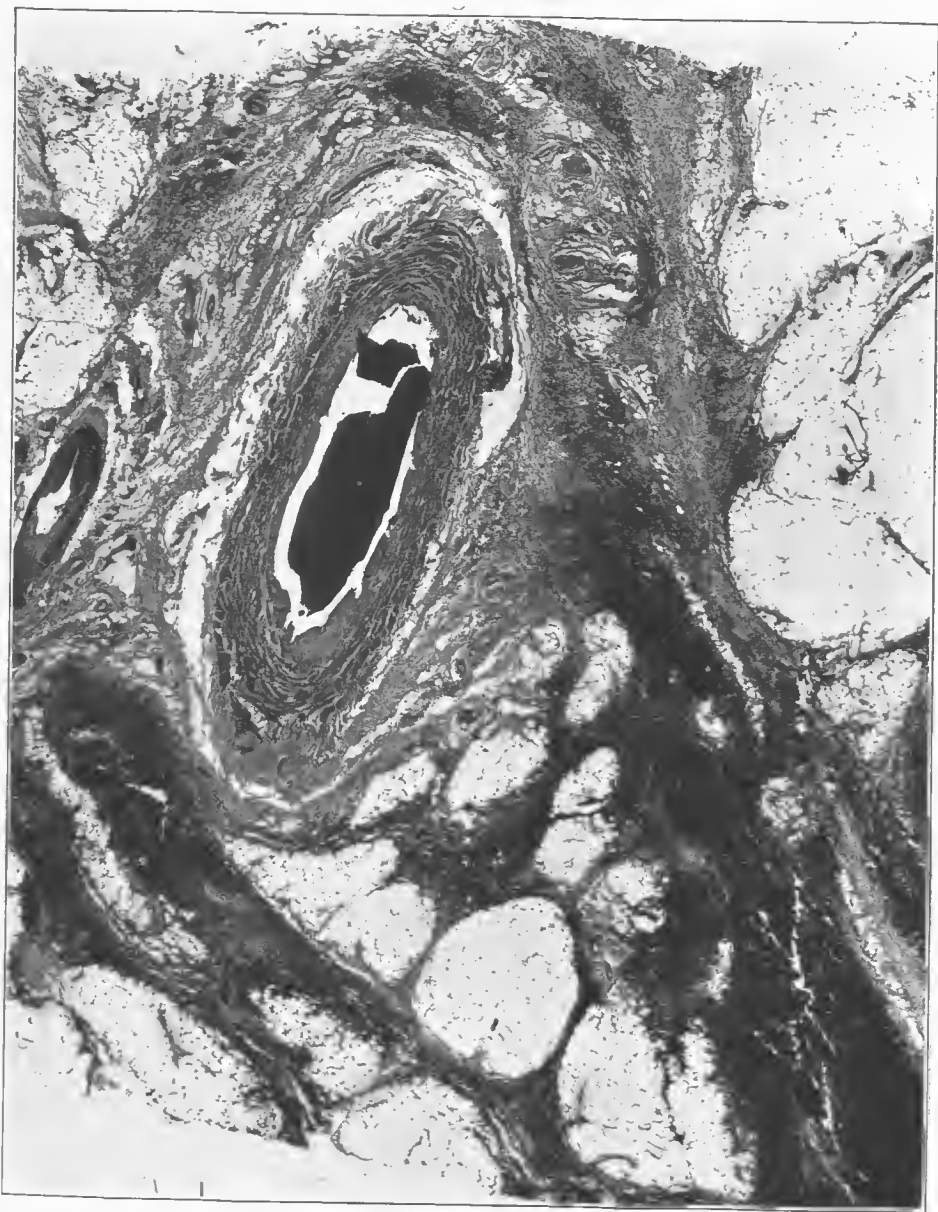


FIG. 183.—Section from the neighborhood of the hemorrhage. It shows a medium-sized artery with marked shredding of the adventitia and hemorrhage into the subcutaneous tissues. Accession number 2920, Army Medical Museum, Negative number 46228. Hematoxylin and eosin stain; $\times 25$

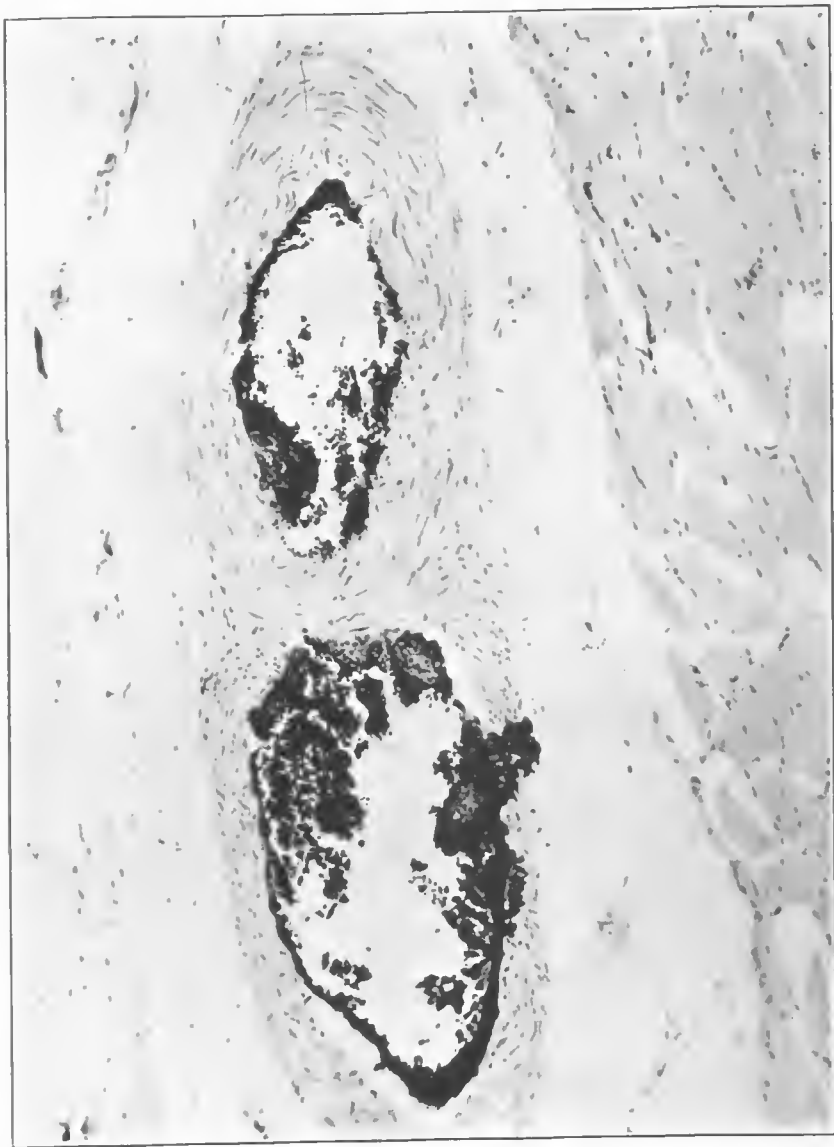

FIG. 184.—Medium-sized vein and artery which are branches of the vessels in Fig. 183. An invasion of the clot by putrefactive bacteria and gas producing anaerobes has occurred. Accession number 2920, Army Medical Museum. Negative number 46209. MacCallum stain; $\times 200$

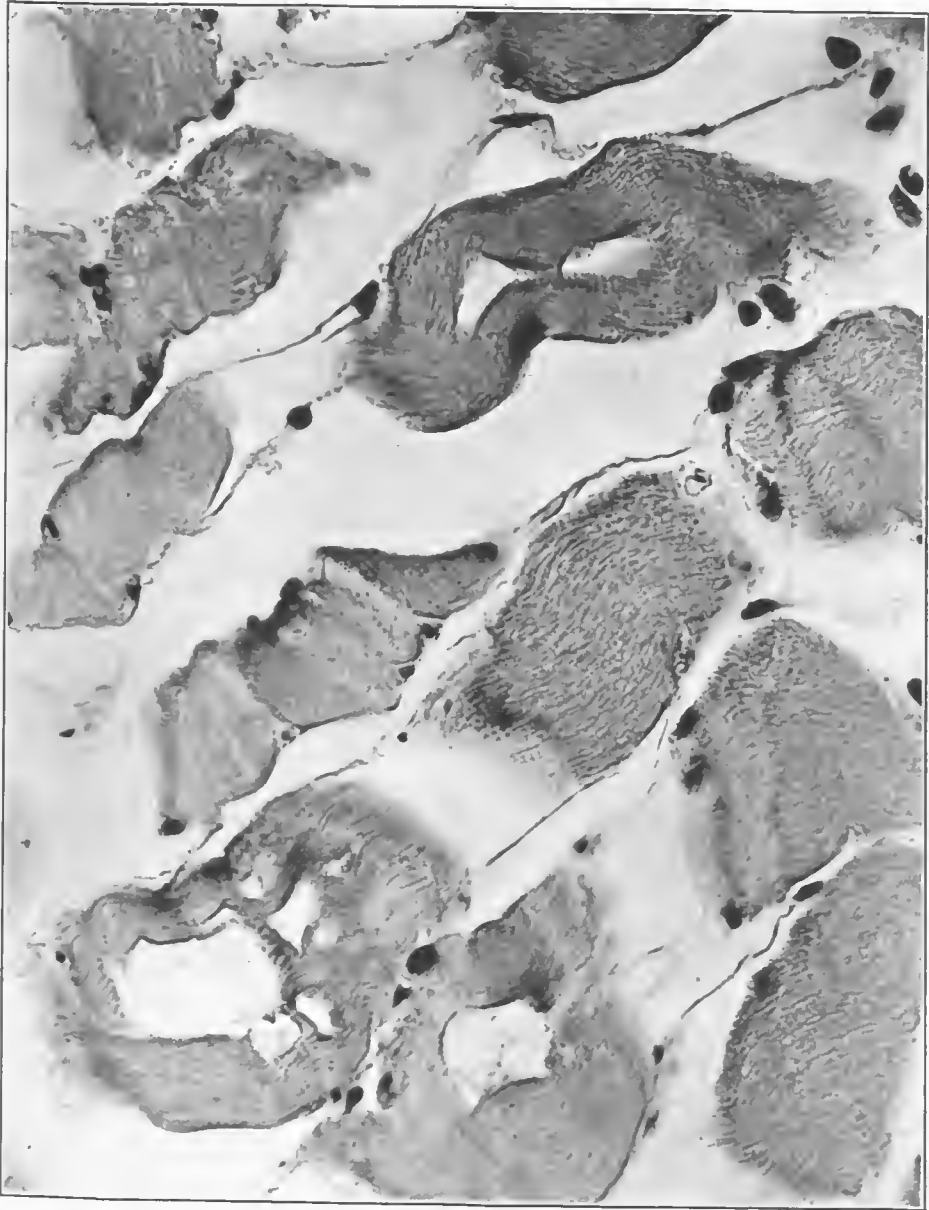


FIG. 185.—Section from the area of advanced emphysematous gangrene, showing gas between muscle bundles, between muscle fibers and their envelopes, and in the center of fibers. This is an extreme of gas accumulation in this type of lesion. Accession number 2920, Army Medical Museum. Negative number 46230. Hematoxylin and eosin stain; $\times 840$

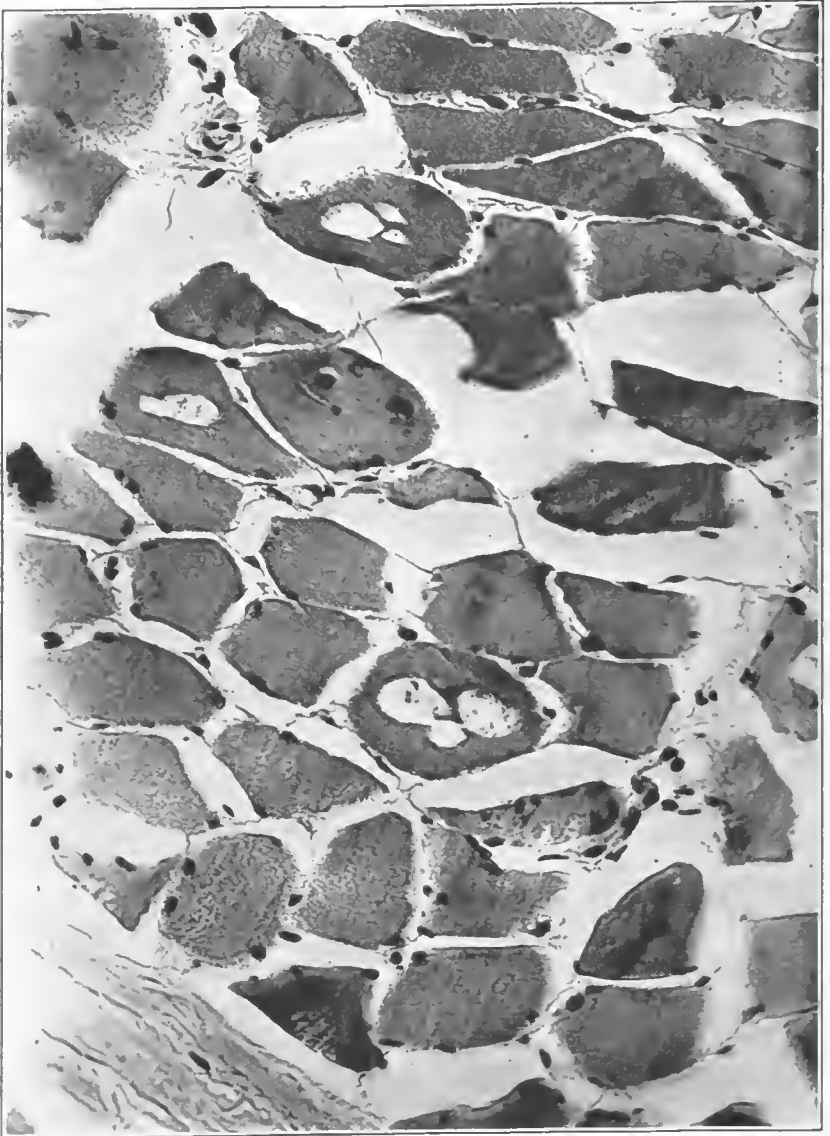

FIG. 186.—Individual muscle fibers with two-thirds of their diameter occupied by gas bubbles. Accession number 2920, Army Medical Museum. Negative number 46220. Hematoxylin and eosin stain; $\times 390$

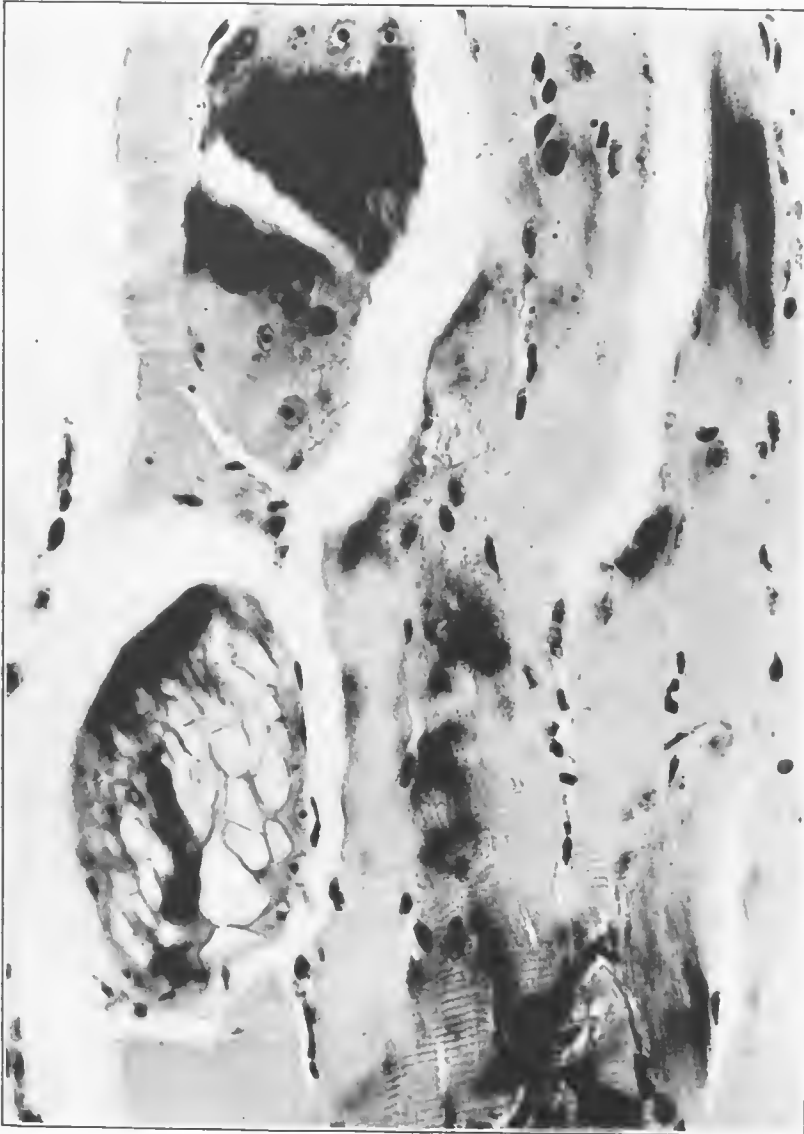

FIG. 187.—Gas infiltration of one muscle fiber which is swollen to four or five times its normal size. There is a retention of the basic dye in parts of the fibers. Accession number 2920, Army Medical Museum. Negative number 46214. MacCallum stain; $\times 540$




FIG. 188.—Gas gangrene change in muscle infiltrated with large coccobacilli. Accession number 2920, Army Medical Museum. Negative number 46238. MacCallum stain; $\times 760$

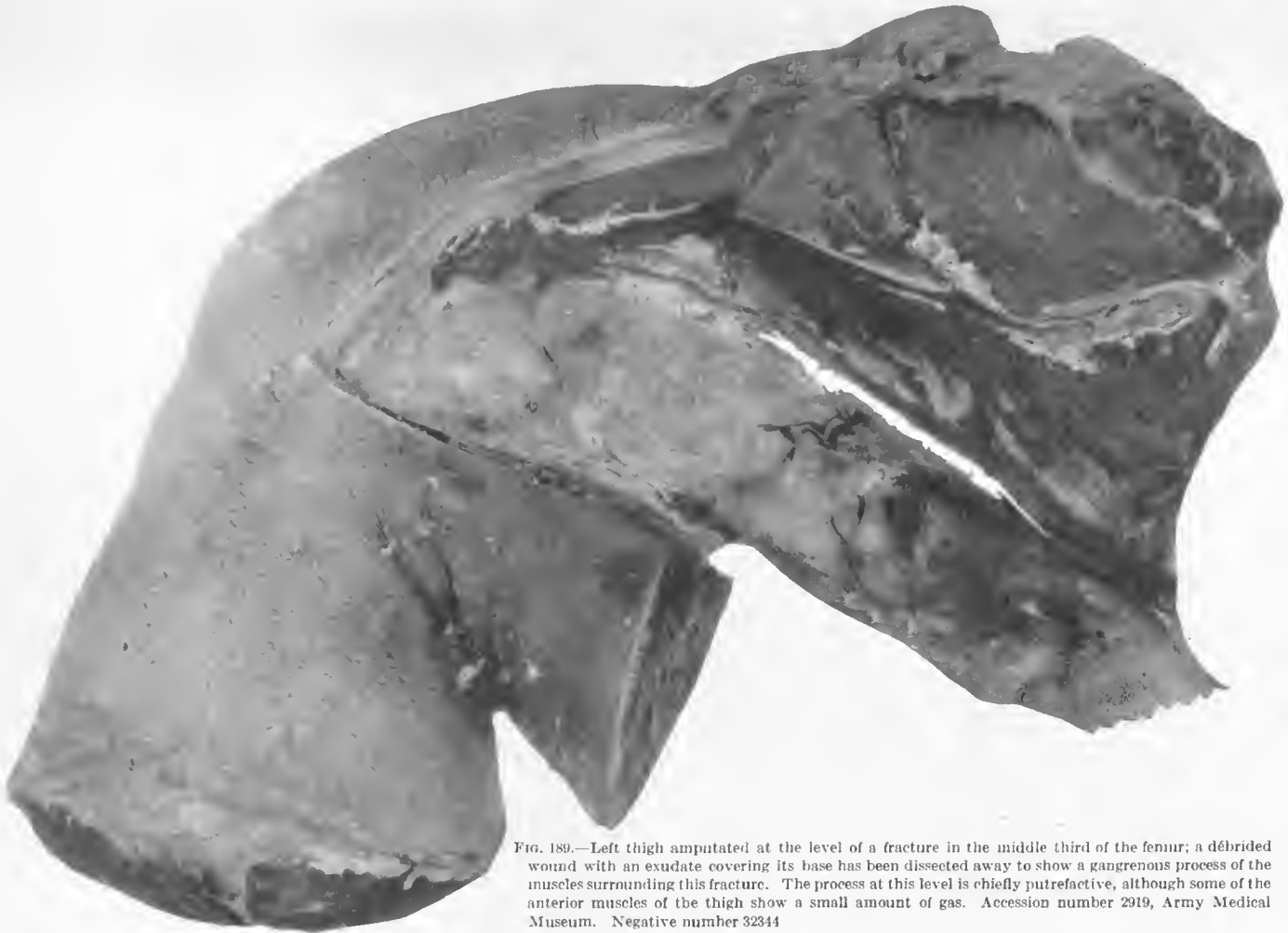

FIG. 189.—Left thigh amputated at the level of a fracture in the middle third of the femur; a débrided wound with an exudate covering its base has been dissected away to show a gangrenous process of the muscles surrounding this fracture. The process at this level is chiefly putrefactive, although some of the anterior muscles of the thigh show a small amount of gas. Accession number 2919, Army Medical Museum. Negative number 32344

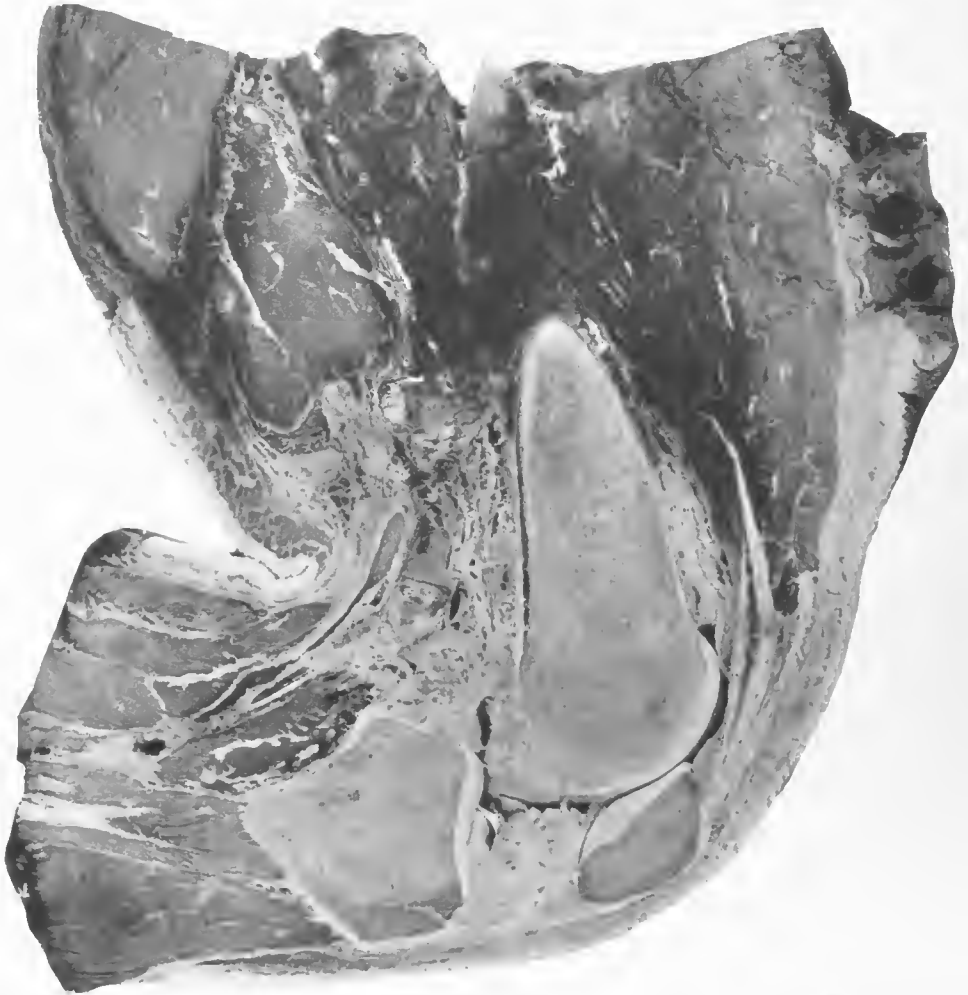

FIG. 190.—Vertical section of the limb in Fig. 189, showing putrefactive gangrene in all the muscles of the thigh just below the level of the base of the débrided wound. The section through the popliteal artery shows that it is empty of any clot. There is little or no gaseous involvement of the muscles at this level. Accession number 2919, Army Medical Museum. Negative number 32346

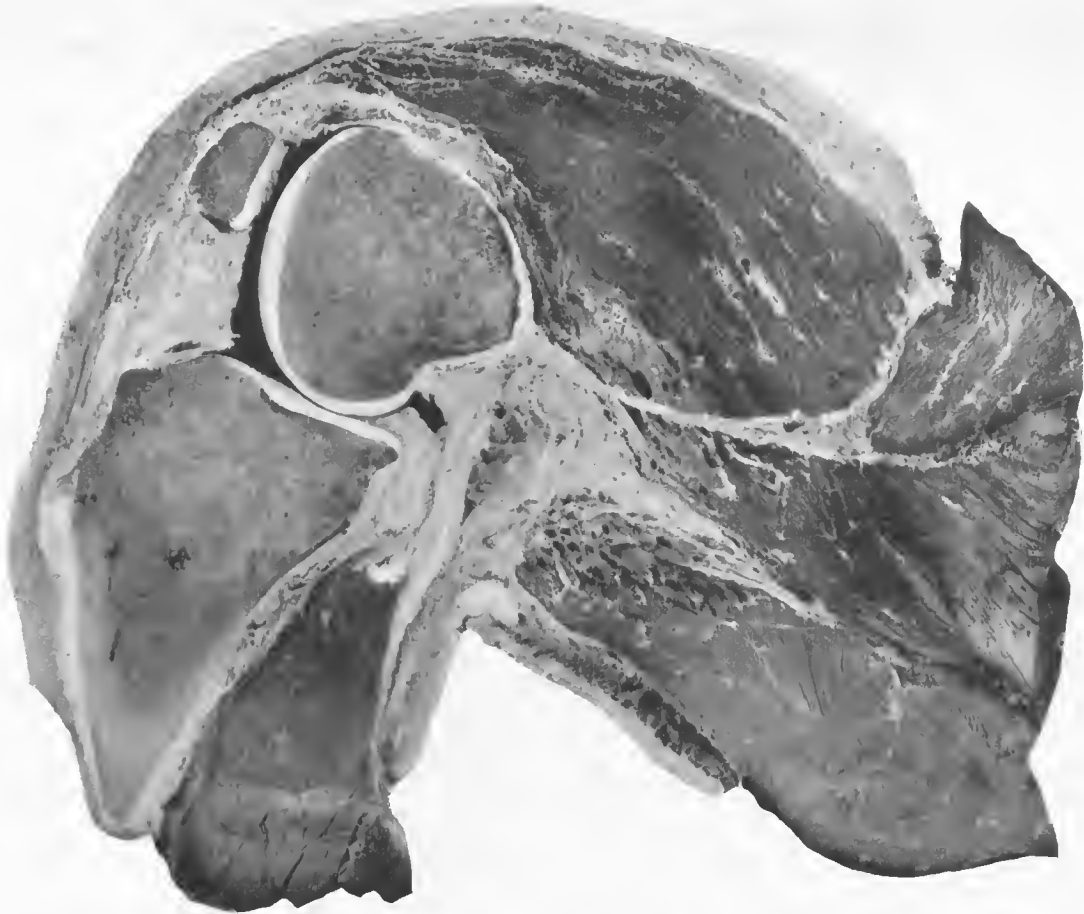

FIG. 191.—Mid section of the amputated limb shown in Fig. 189, with a massive accumulation of large gas bubbles at a level 2 cm. below the surface of the débrided wound. The muscles around this area show the characteristic brick-red color and where the wound tract is near this level there is putrefactive gangrene of the muscles. Accession number 2919, Army Medical Museum. Negative number 32347

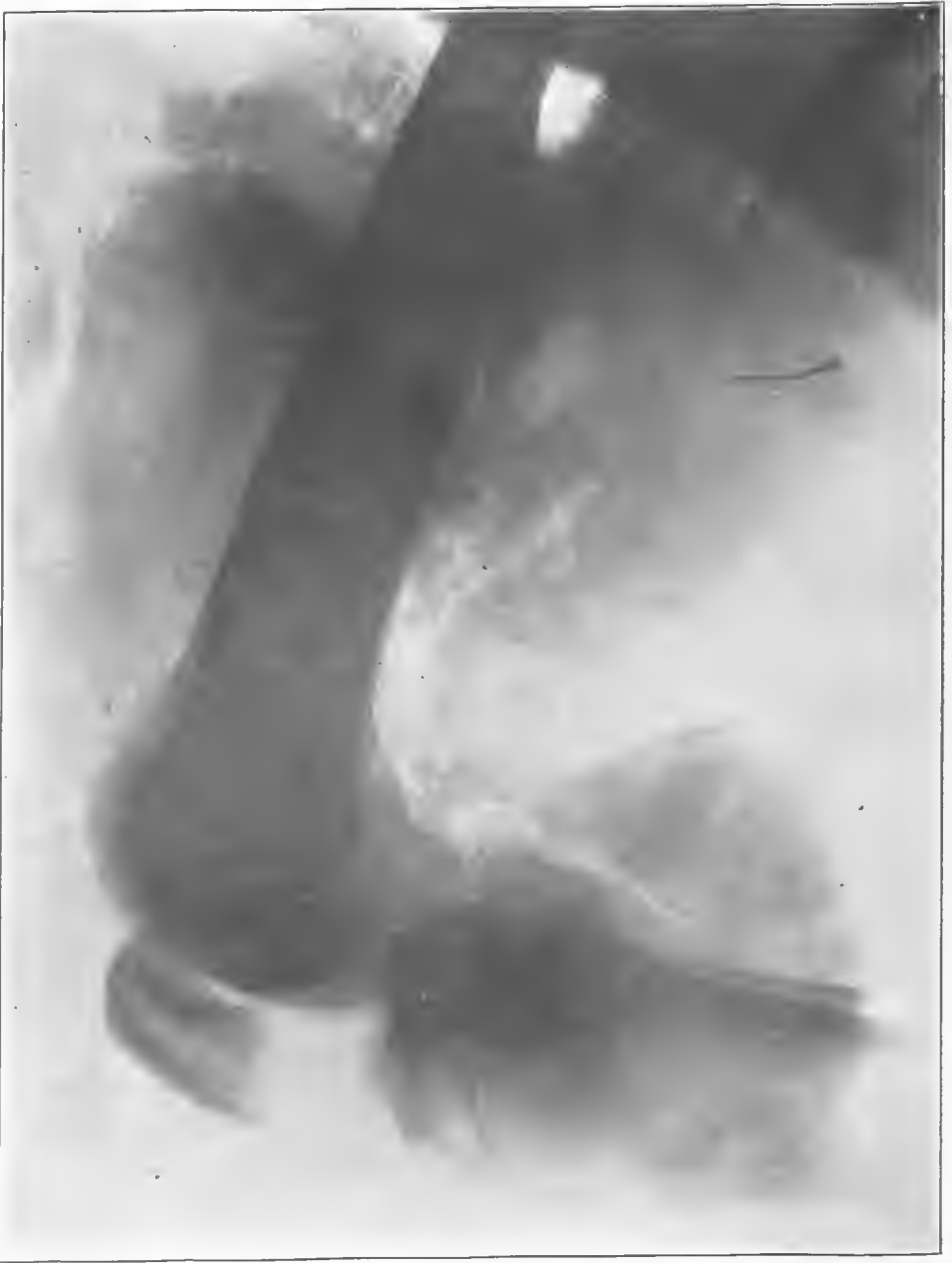

FIG. 192.—X ray of limb (fig. 189), showing plainly the accumulation of gas bubbles in the depths of the wound just posterior to the femur. This gas is at some distance from the débrided area of the wound around the upper end of the lower fragment of the femur. Accession number 2919, Army Medical Museum. Negative number 46263

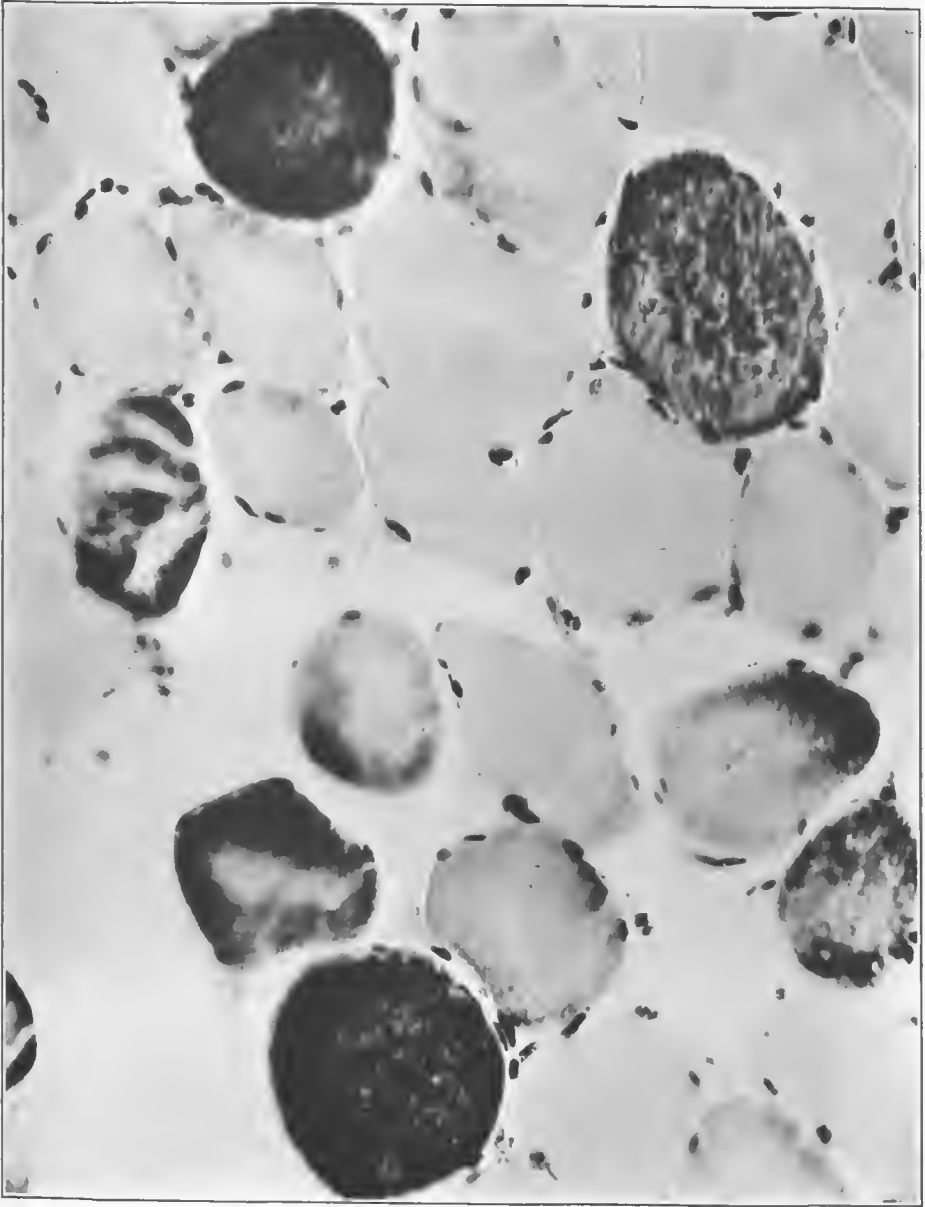


FIG. 193.—Section from the gangrenous area. Certain fibers show marked affinity for the basic dye. Accession number 2919, Army Medical Museum. Negative number 46118. MacCallum stain; $\times 450$



FIG. 194.—Section from the emphysematous area, showing Gram-positive rods with deeply staining centers and pale ends, as well as organisms which look like the Welch bacillus. This section shows the affinity for the basic dye which usually occurs in this gangrenous process. Since the section is from an area near the wound tract, it shows a mixed infection. Accession number 2919, Army Medical Museum. Negative number 46113. MacCallum stain; $\times 750$

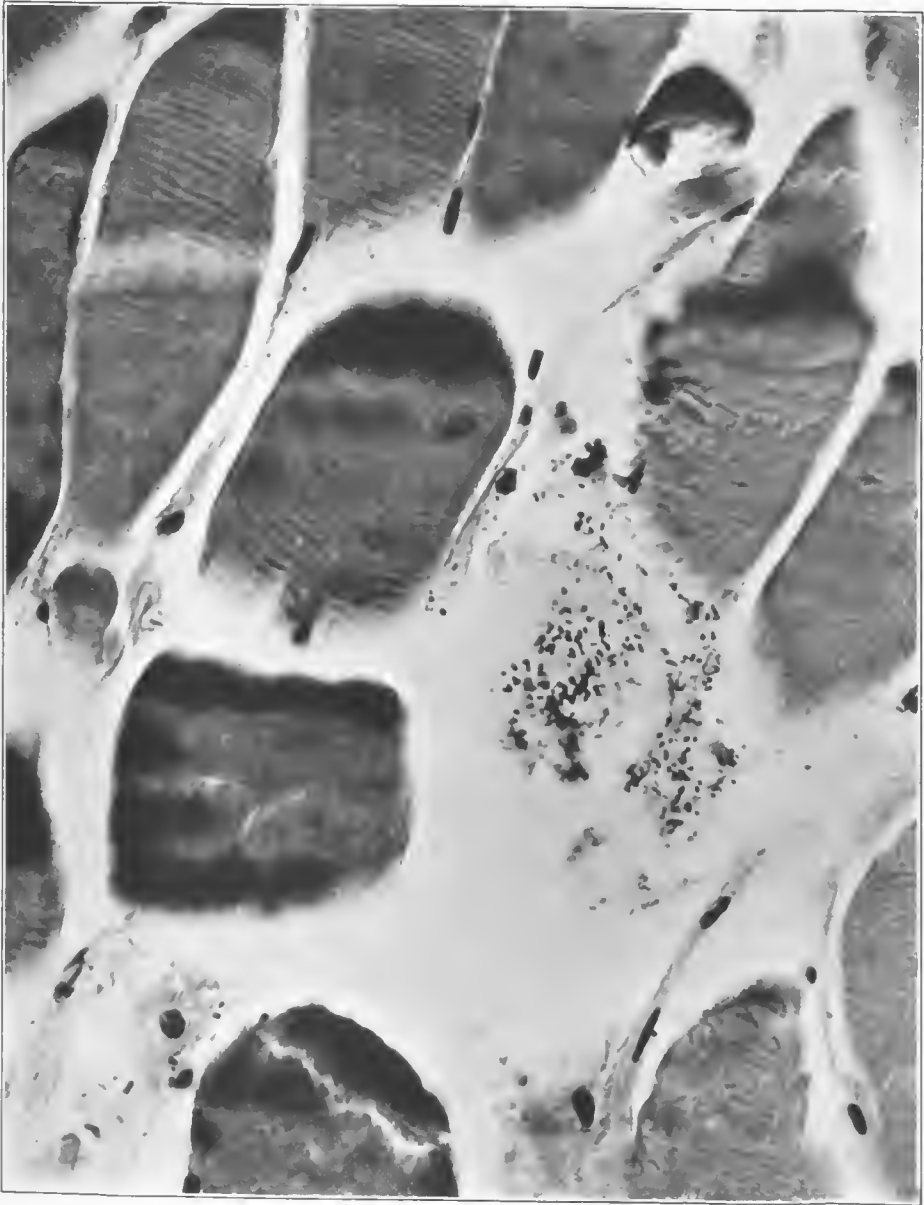


FIG. 195.—Section from the putrefactive gangrenous process. There was a high degree of contamination, rods, cocci, and coccobacilli being present. No leucocytic reaction is present. Accession number 2919, Army Medical Museum. Negative number 46119. MacCallum stain; $\times 750$

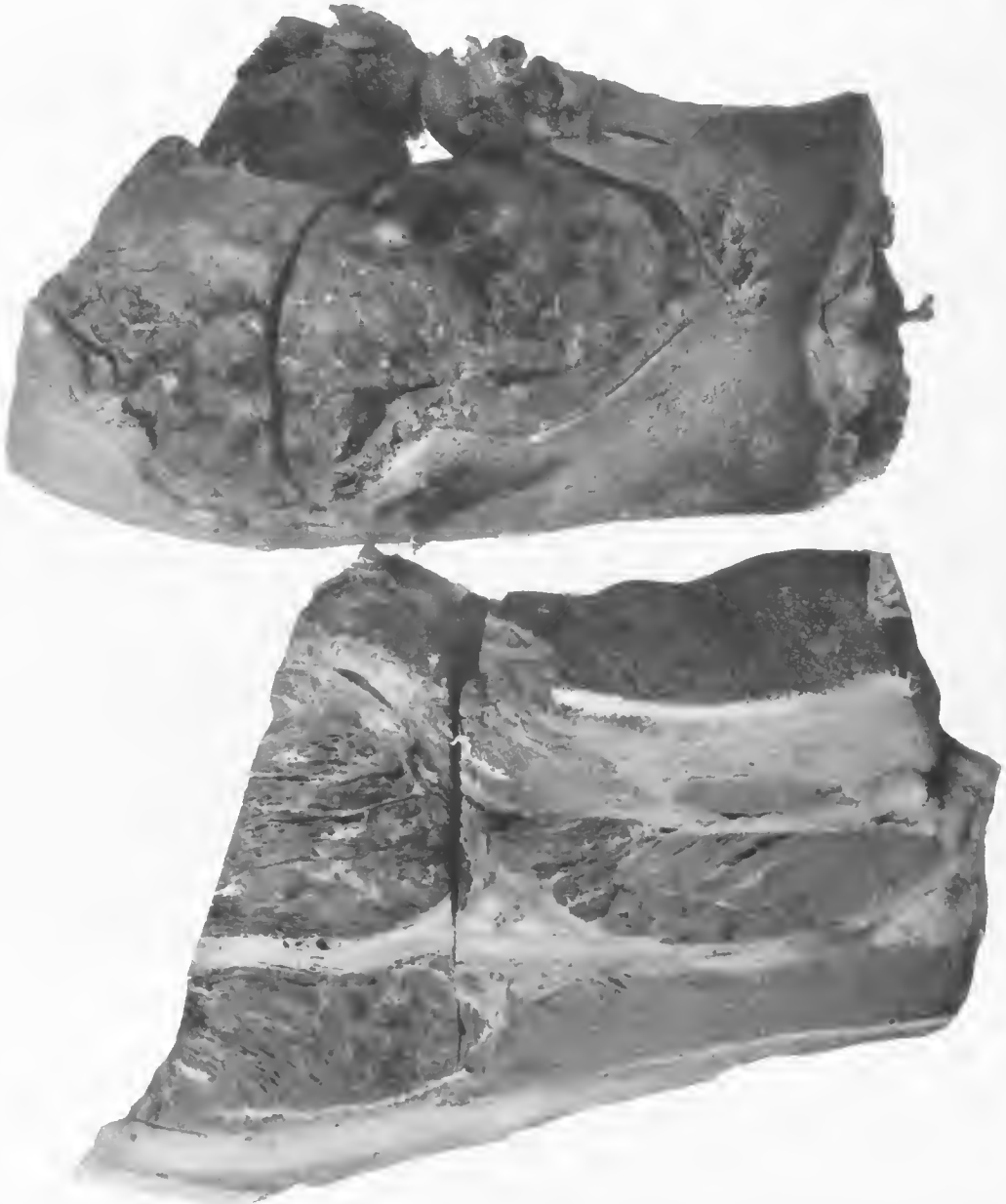


FIG. 196.—The upper illustration is the anterior surface of the right thigh with a debrided high-explosive wound. This wound had apparently been dakinized and is covered with a shaggy exudate. The muscles left after the débridement extrude into the wound and are apparently under extreme internal pressure from the formation of gas in the deeper muscles. The lower illustration is a mid section of the limb. Numerous gas bubbles are present in the undébrided muscle. Accession number 2914, Army Medical Museum. Negative number 30882

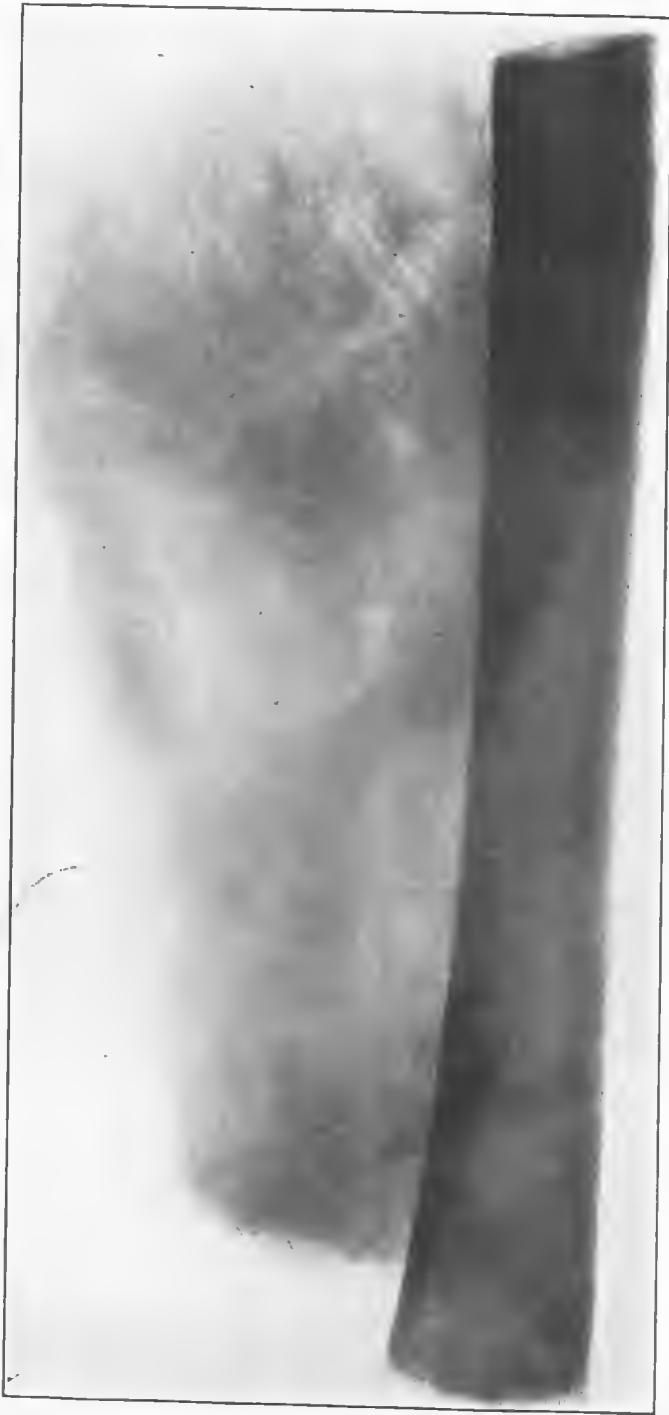

FIG. 197.—X ray of the thigh, showing gas in the muscle in the position corresponding to that shown in Fig. 196. Accession number 2914, Army Medical Museum. Negative number 46286

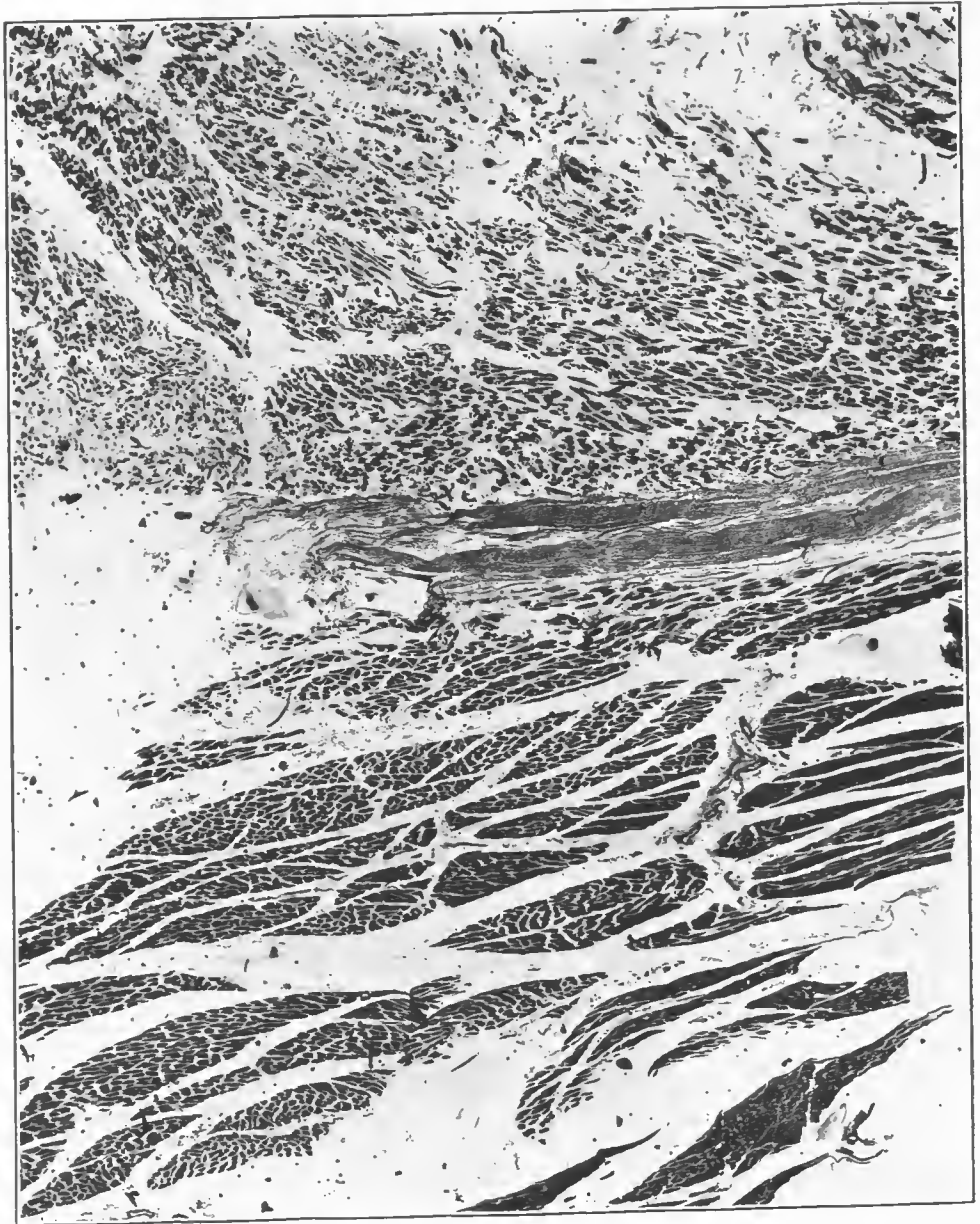


FIG. 198.—Section from the junction of two muscles, one of which shows a marked rupture of fibers with gas gangrene. The muscle on the other side of the fascia shows only a moderate accumulation of gas between bundles, the individual fibers being fairly well preserved. Accession number 2914, Army Medical Museum. Negative number 46225. Hematoxylin and eosin stain; $\times 25$

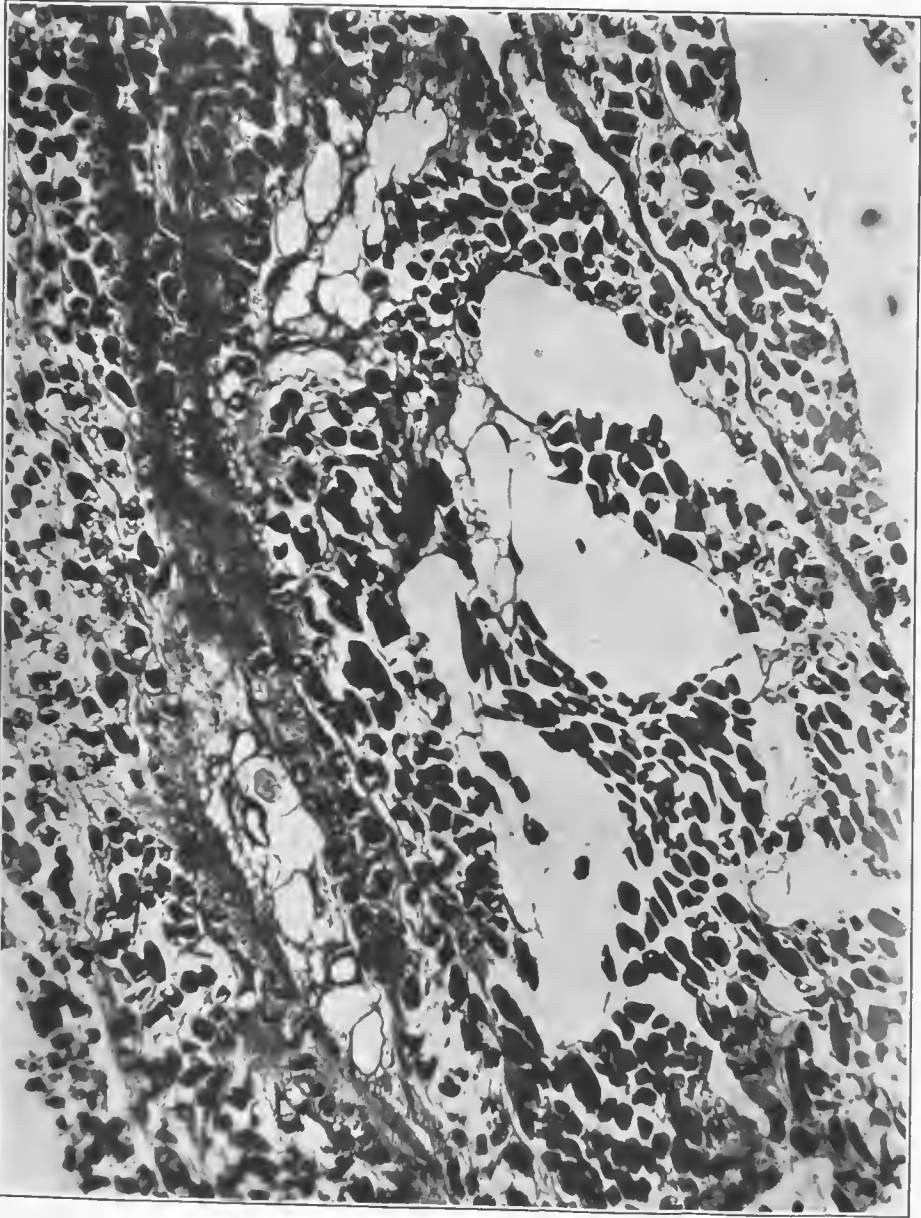


FIG. 199.—Section from an area of advanced emphysematous gangrene. Three bubbles occur in the center of the picture, and two other areas of large bubbles are found in and about perivascular lymphatics. There are small bubbles in some of the individual fibers. Accession number 2914, Army Medical Museum. Negative number 46158. Hematoxylin and eosin stain; $\times 32$

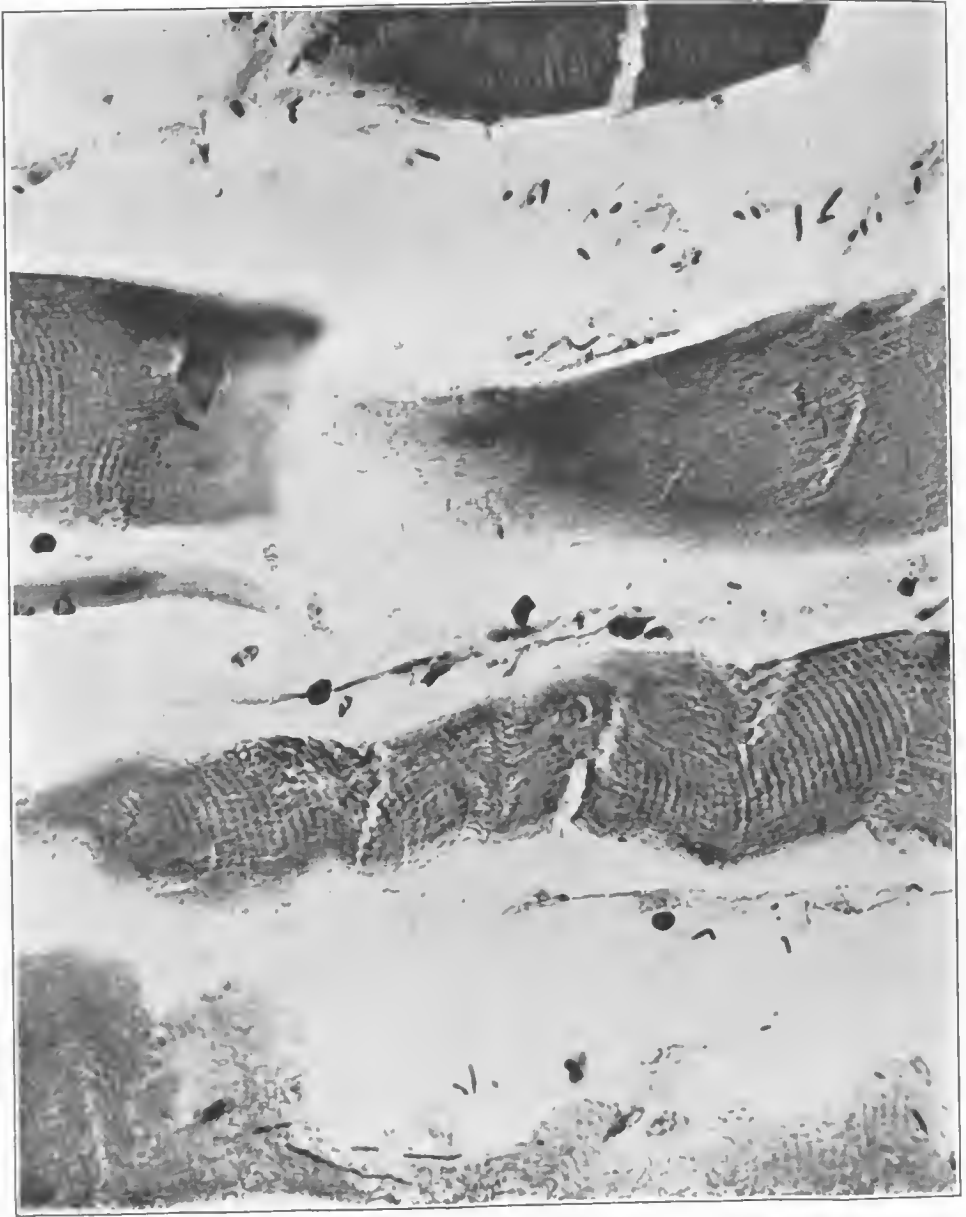


FIG. 200.—Section from the gangrenous area close to the wound tract. It shows gas bubbles, a lacking of some muscle fibers, and in others an accentuation of their cross striations. The numerous rod-shaped organisms of different sizes, both Gram-negative and Gram-positive, indicate the mixed infection with putrefactive bacteria which was present in this case. Accession number 2914, Army Medical Museum. Negative number 46223. MacCallum stain; $\times 840$

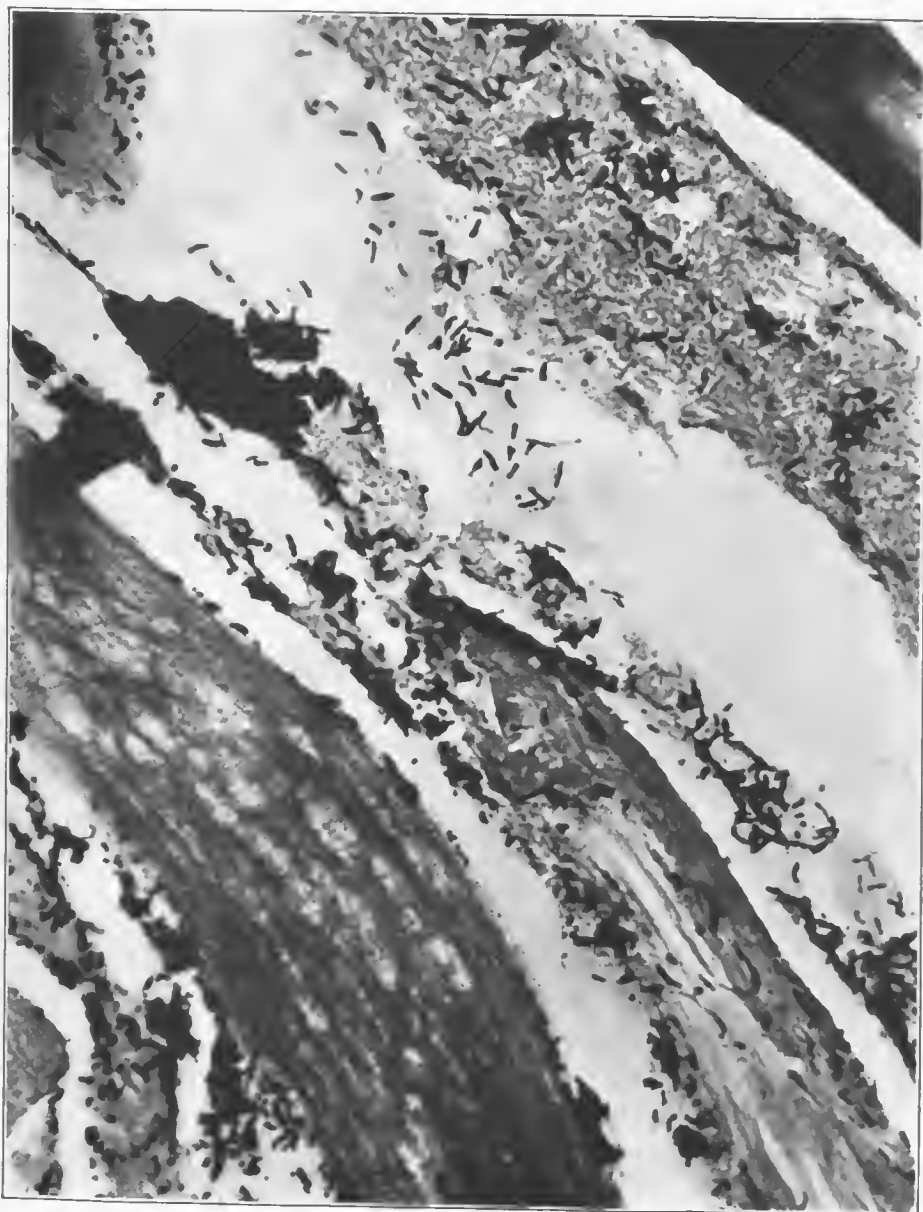


FIG. 201.—Section from a muscle close to the wound tract. It shows a muscle fiber cut longitudinally with numerous fine bubbles obscuring the cross striations. There is a wide variety of Gram-positive and Gram-negative rods, some of which are barred diptheroid forms. Accession number 2914, Army Medical Museum. Negative number 46164. MacCallum stain; $\times 725$

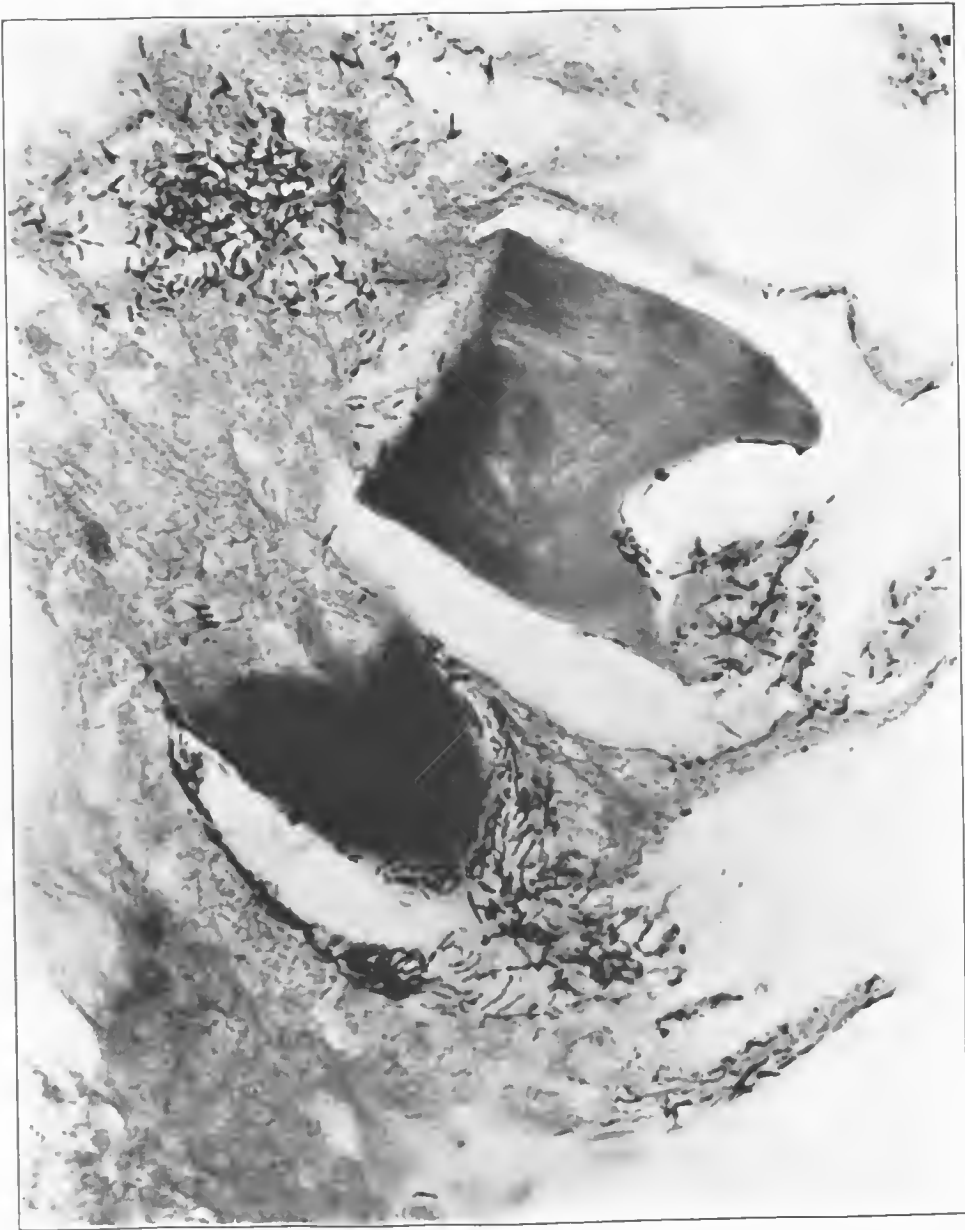


FIG. 202.—Section from vicinity of the wound tract. Two isolated muscle fibers which have been split by gas. The barring of the diphtheroid forms is distinct. Accession number 2914, Army Medical Museum. Negative number 46161. MacCallum stain; $\times 725$



FIG. 203.—Section taken from an area of comparatively pure emphysematous gangrene. It shows bubbles in muscle fibers and Gram-positive bacilli in comparative purity, most of which are probably Welch bacilli. There is an occasional sporulating form. One of these is found within a large bubble at the end of the muscle fiber. Accession number 2914, Army Medical Museum. Negative number 46153. MacCallum stain; $\times 745$

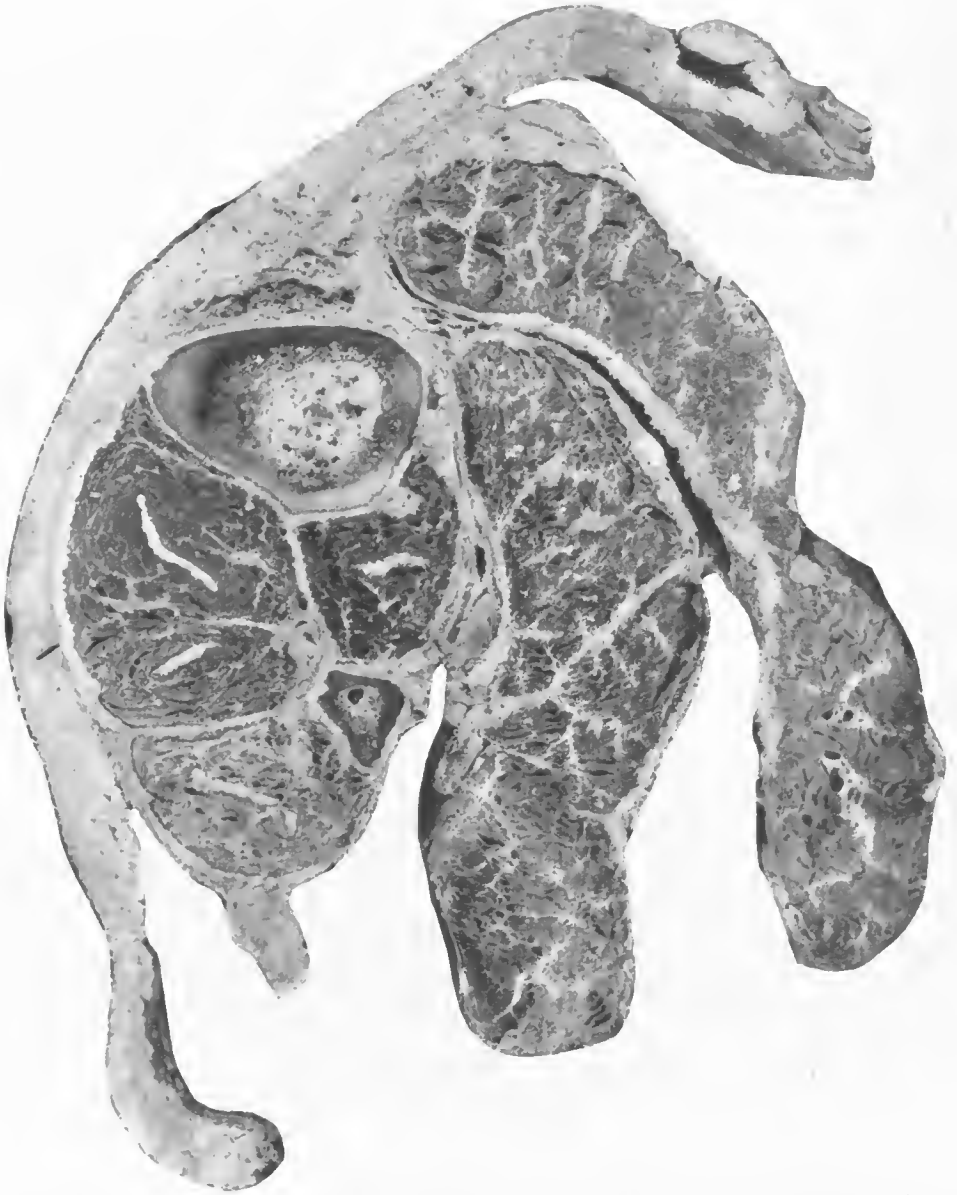

FIG. 204. —Cross section of the leg at the level of the middle of the calf showing the surgical free dissection of these muscles in the attempt to check the process. The presence of the gas within muscles rather than between them was the reason for the failure of the surgical treatment. Amputation, cutting across these long muscles, releases the gas pressure and checks the process. This leg was amputated at some distance above the knee because of extension of the emphysematous condition in spite of the free dissection. Accession number 4708, Army Medical Museum. Negative number 46270

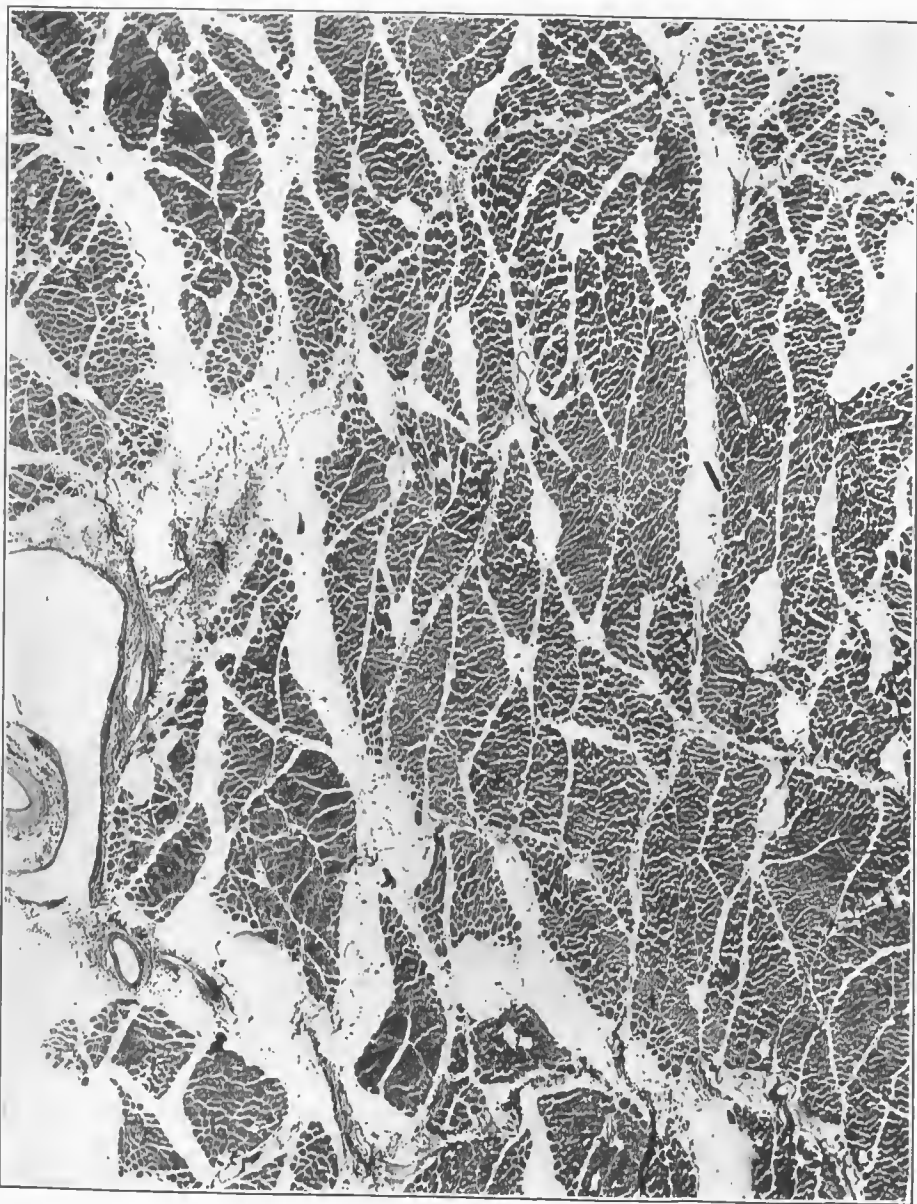


FIG. 205.—Section through muscles invaded by gas. The bulk of this gas is between muscle bundles and there is a marked distention of the perivascular lymphatics. Accession number 4708, Army Medical Museum. Negative number 46227. Hematoxylin and eosin stain; $\times 26$

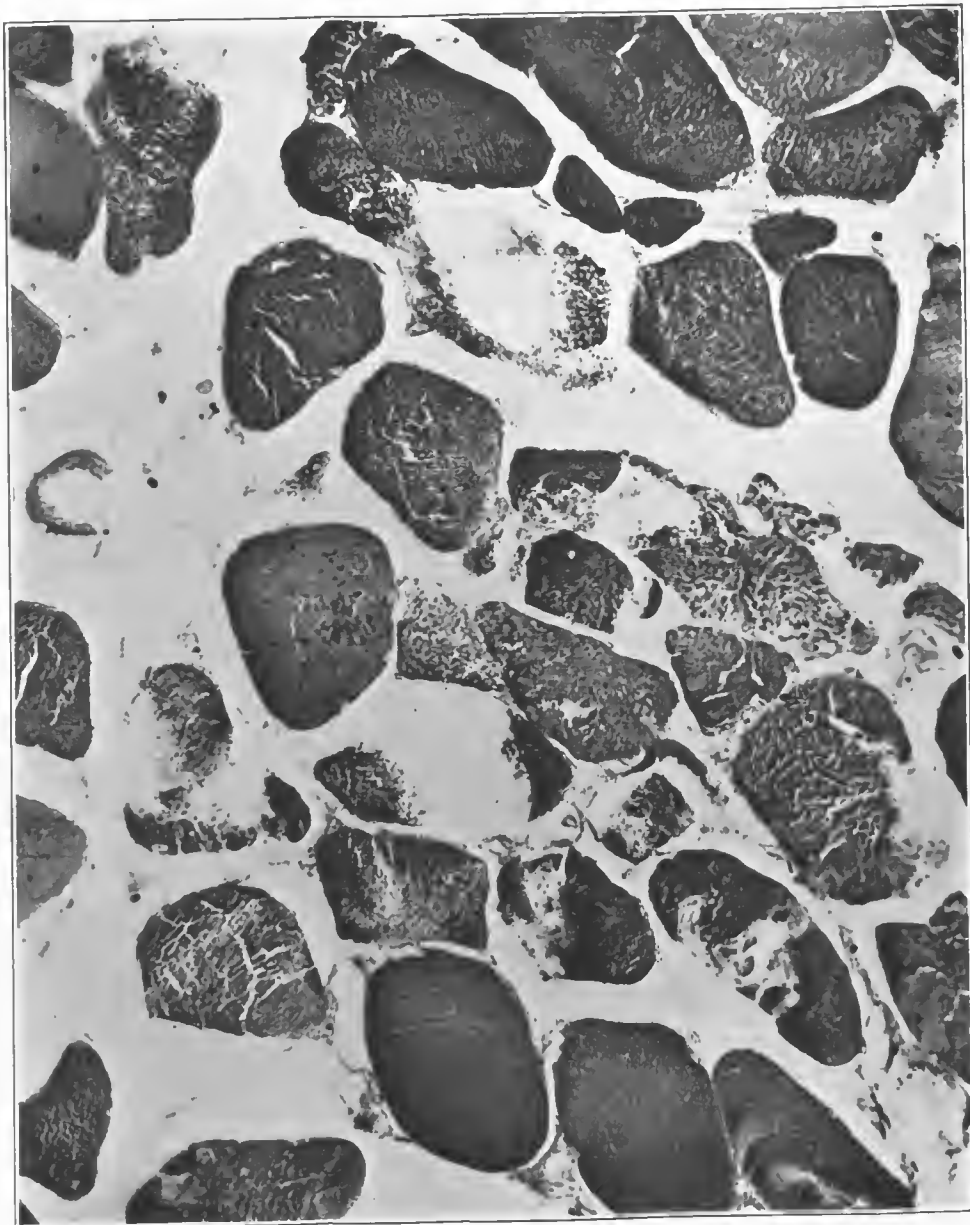


FIG. 206.—Higher magnification of an area of the preceding figure. It shows some infiltration of muscle fibers by gas, a moderate amount of hemoglobin detritus in fibers, and considerable gas between fibers. The muscle markings are obliterated. Accession number 4708, Army Medical Museum. Negative number 46226. Hematoxylin and eosin stain; $\times 450$

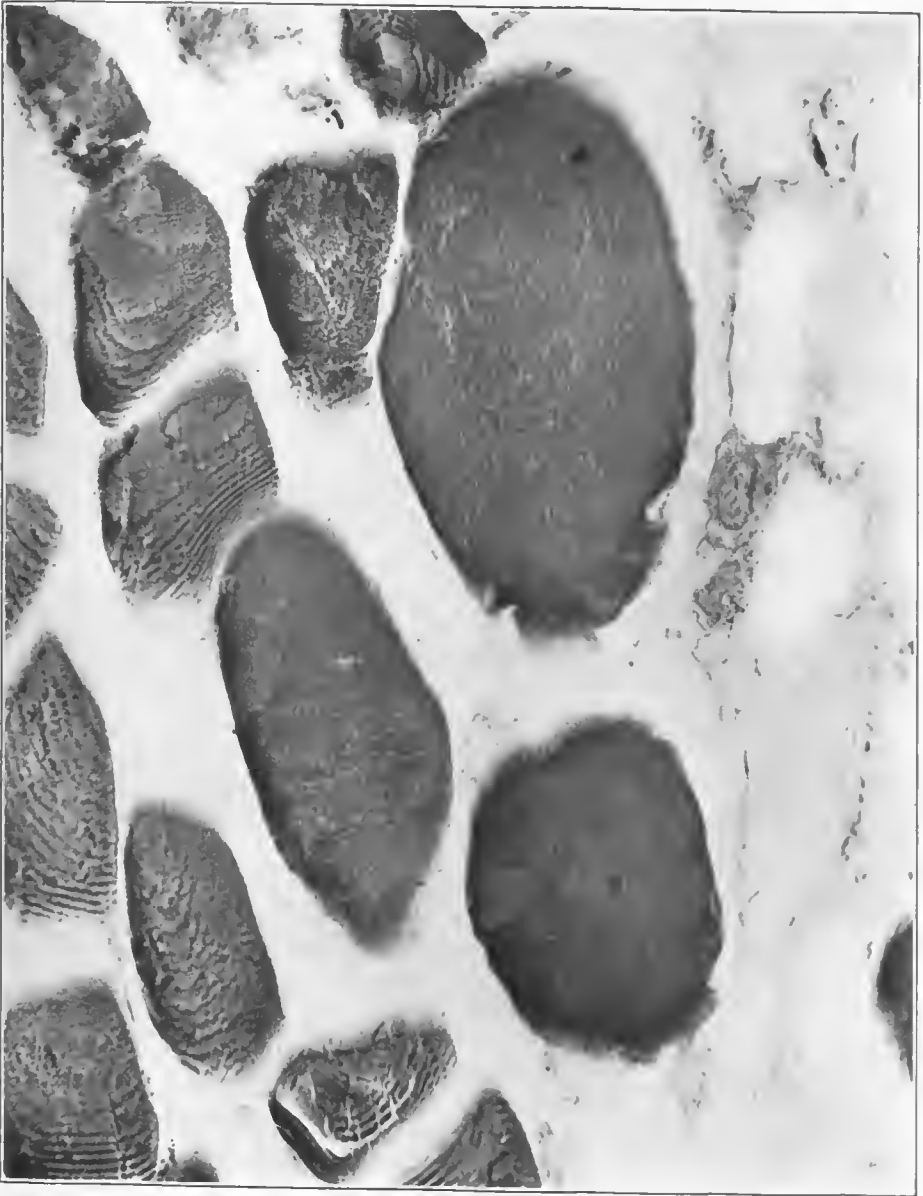


FIG. 207.—Section from the gangrenous muscles. Three of the fibers in the center of the picture are swollen to four or five times their normal diameter. Some of the fibers have lost their markings, while adjacent ones still retain them. There is one group of short Gram-positive bacilli in the field and numerous Gram-negative organisms scattered throughout. Accession number 4708, Army Medical Museum. Negative number 46236. MacCallum stain; $\times 750$

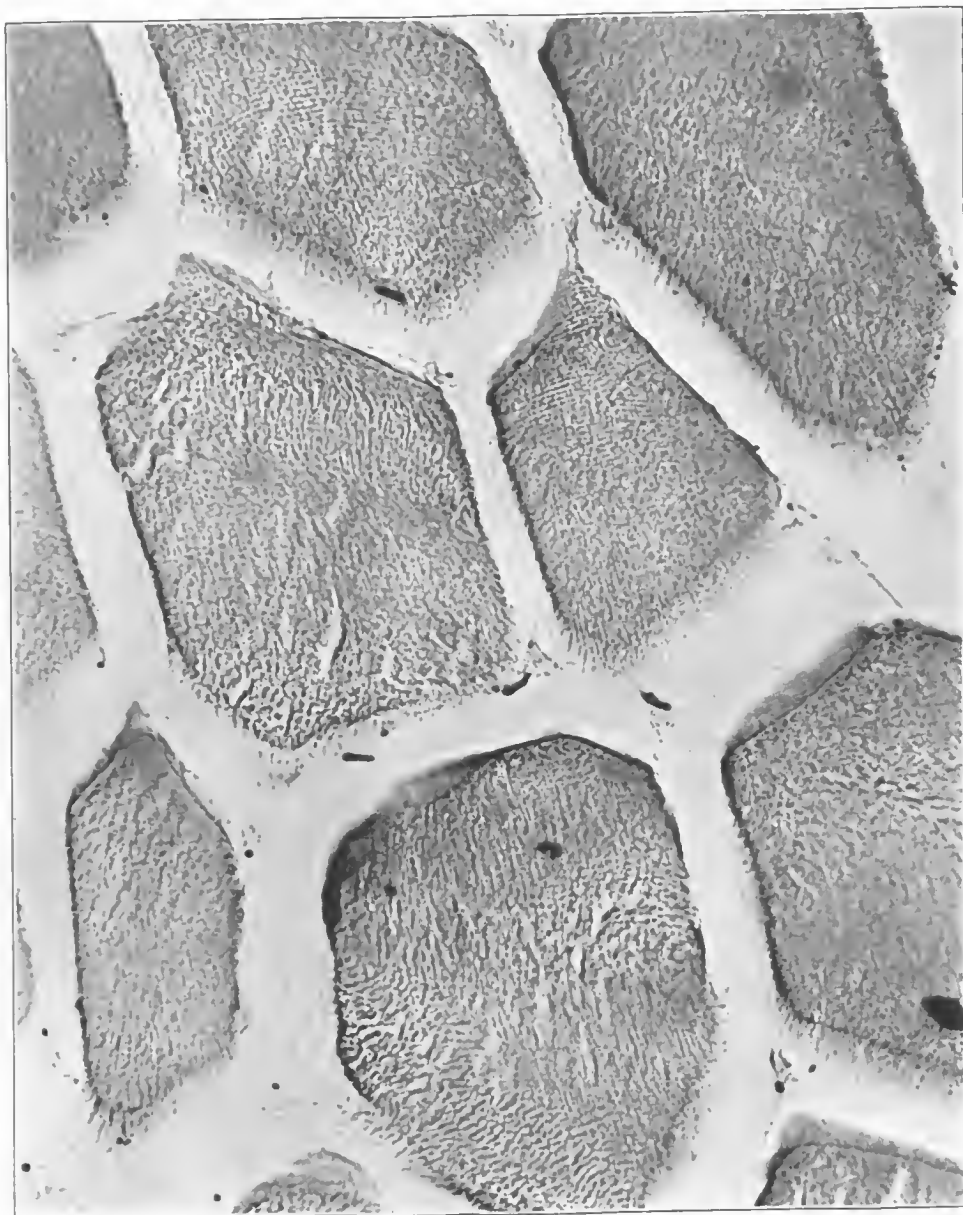


FIG. 208.—Section from the gaseous area, showing the loss of texture described as the ground-glass appearance in muscle fibers. There are occasional Gram-positive rods with end spores, and coccoid forms of bacteria. Accession number 4708, Army Medical Museum. Negative number 46234. MacCallum stain; $\times 720$

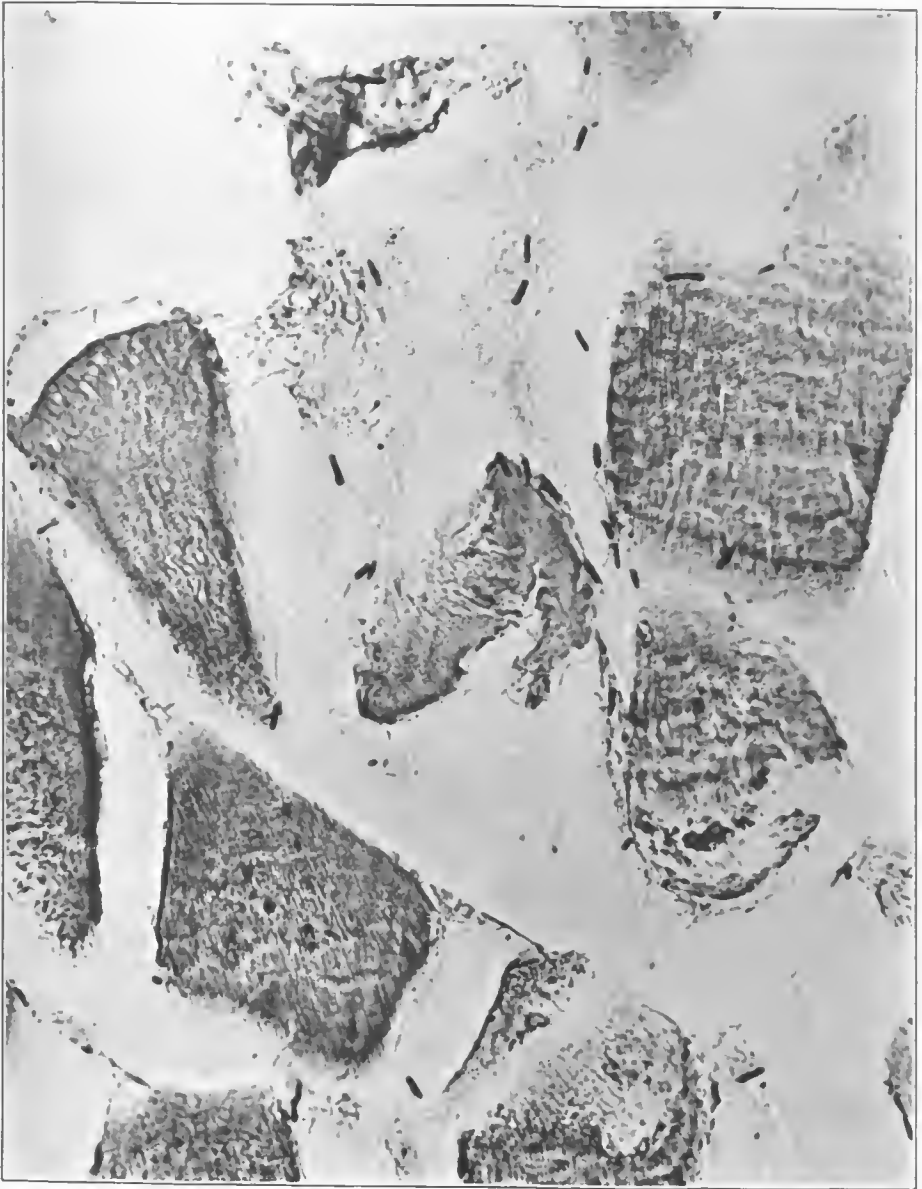

FIG. 209.—Section of muscle fibers in the putrefactive part of the gangrenous process. It shows a mixture of bacterial forms, end spores, drum stick and coccoid forms being present, most of which are Gram-positive. Accession number 4708, Army Medical Museum. Negative number 46229. MacCallum stain; $\times 720$

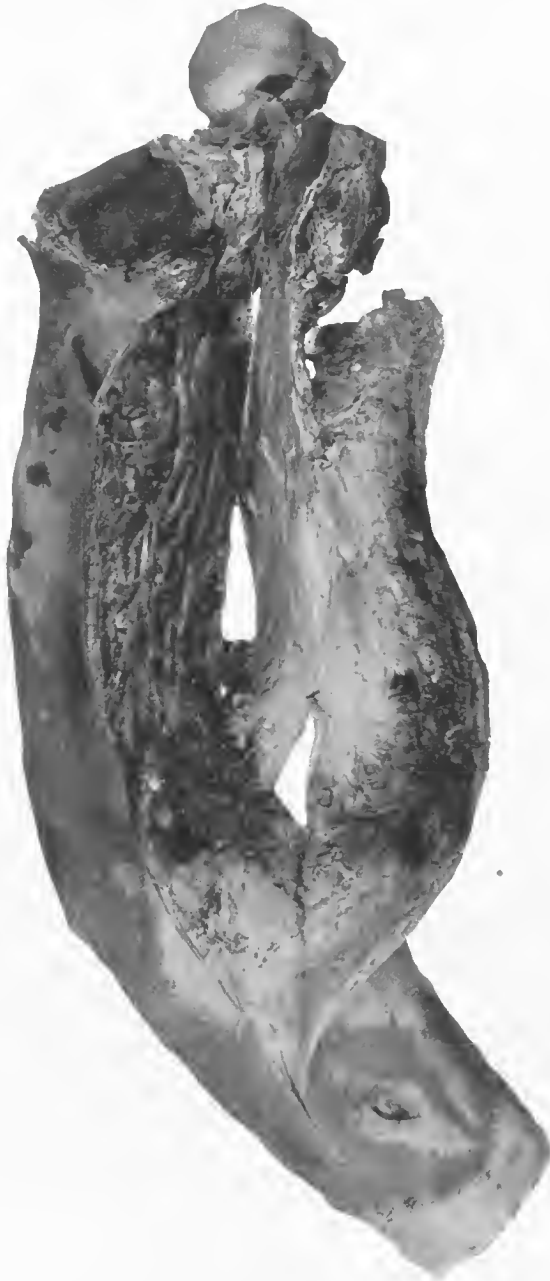

FIG. 210.—Left arm with a debrided bullet wound at the level of a fracture of the humerus, with rupture of the brachial vessels. The dissected tissues show an advanced putrefactive gangrene with blackening, blistering, and desquamation of the skin. Midsection of the arm at this level shows autolyzed muscles around an area of putrefactive gangrene. Accession number 2903, Army Medical Museum. Negative number 32348

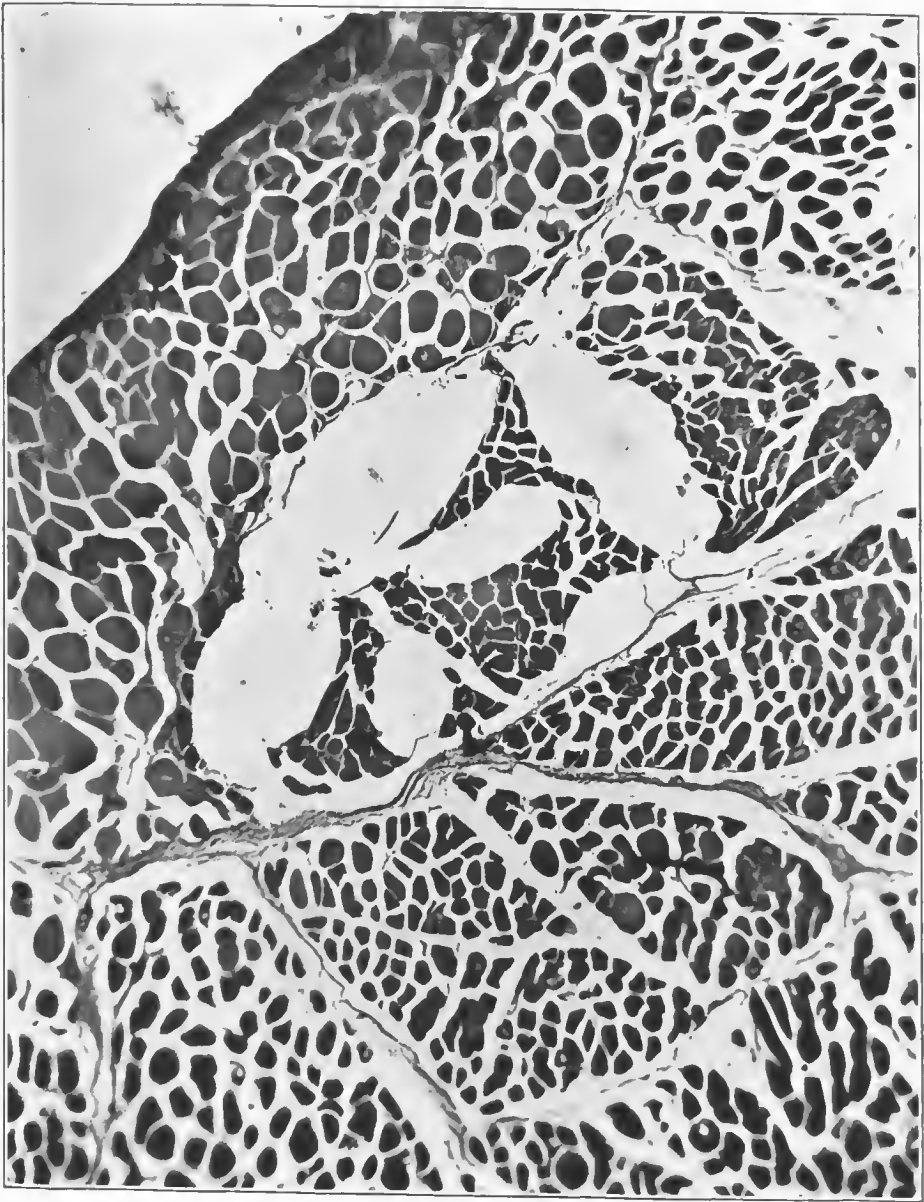


FIG. 211.—Large gas bubble between the fibers of an isolated muscle bundle. There is a beginning accumulation of fine gas bubbles in the center of numerous fibers. Accession number 2903, Army Medical Museum. Negative number 46169. Hematoxylin and eosin stain; $\times 54$

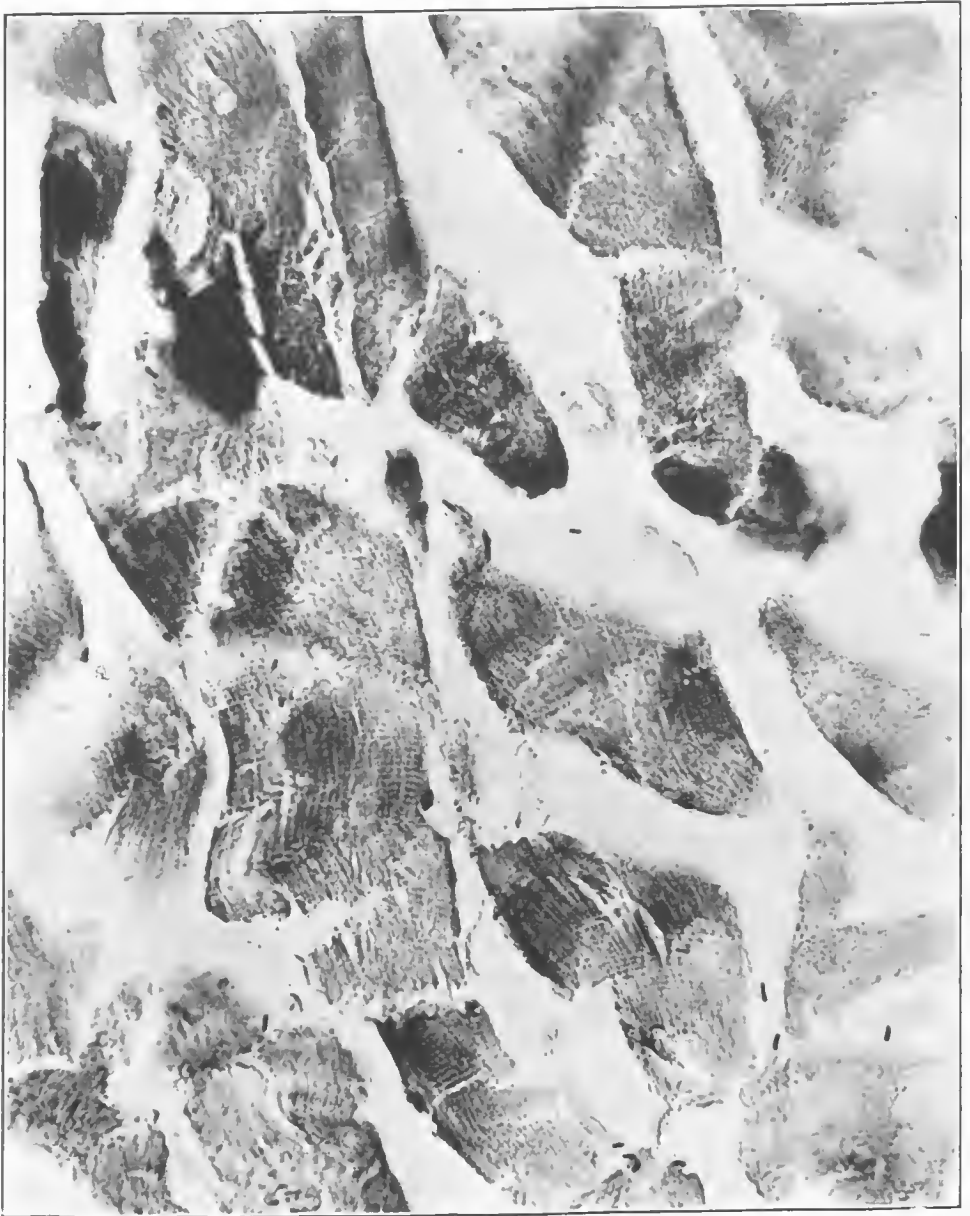

FIG. 212.—Section of muscle in the area of gas gangrene. It shows occasional round-ended Gram-positive rods, probably Welch bacilli. This infection appears to be a comparatively pure one. Accession number 2903, Army Medical Museum. Negative number 46179. MacCallum stain; $\times 505$

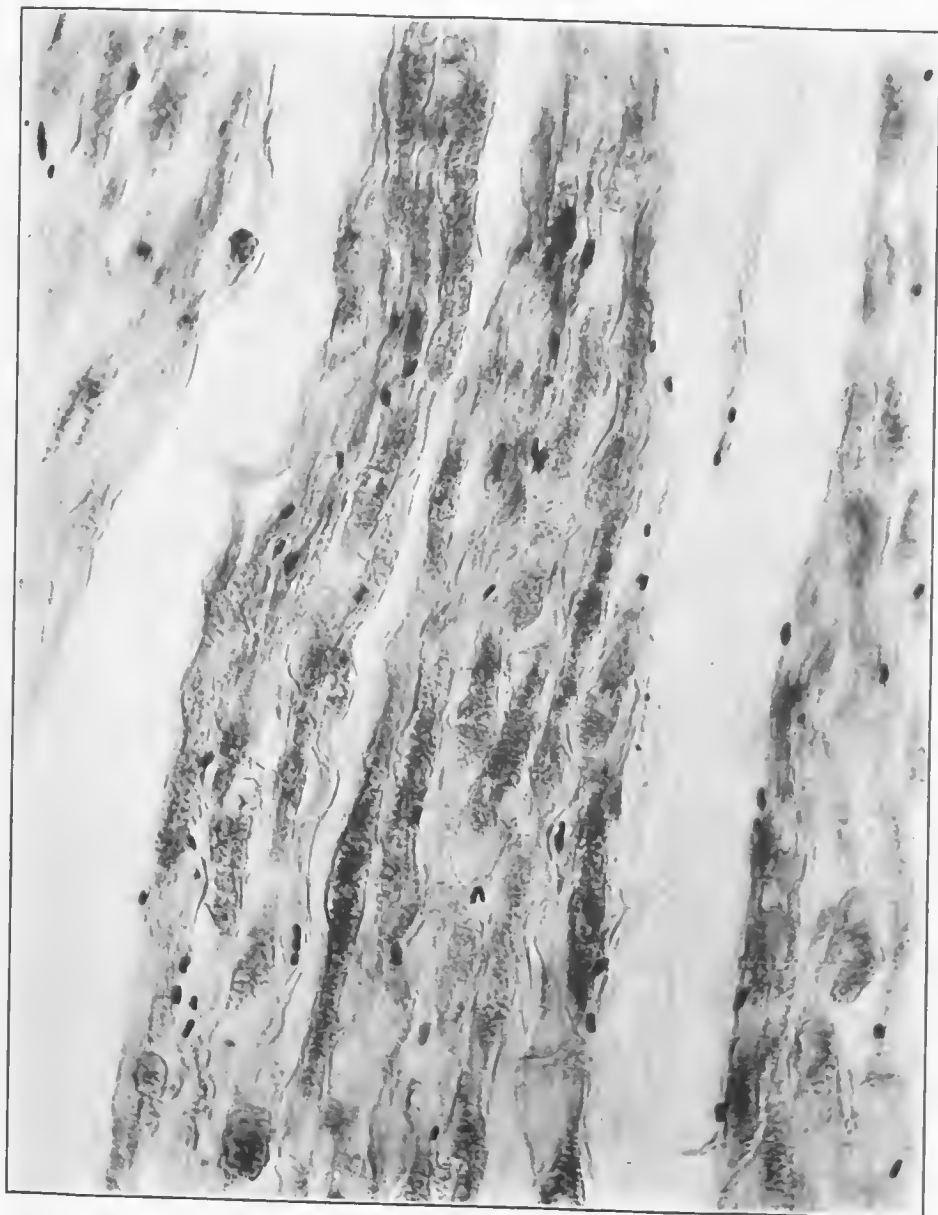


FIG. 213.—Section taken from the brachial nerve. It shows edema and gas and numerous round-ended Gram-positive rods, apparently Welch bacilli, between the fibers. Accession number 2903, Army Medical Museum. Negative number 46168. MacCallum stain; $\times 505$


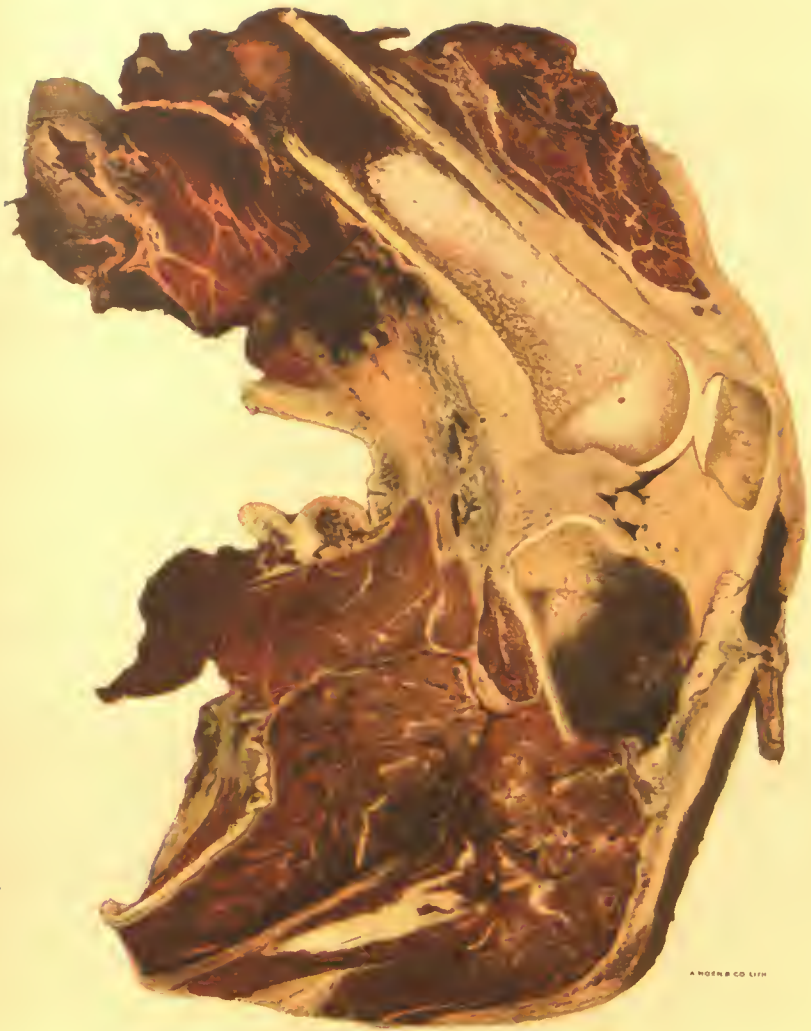


FIG. 214.—Section of fascia and fat from the area of putrefactive gangrene over the biceps muscle. It shows numerous Gram-positive rods of varying shapes and sizes, apparently an area of high contamination. The fat shows the early stage of the putrefactive change which forms adipocere. Accession number 2903, Army Medical Museum. Negative number 46171. MacCallum stain; $\times 505$



GAS GANGRENE OF THE CALF MUSCLES.

Beginning formation of gas bubbles and some putrefactive change in the clot around the tibia. Typical color of muscle of gas gangrene without secondary infection. Fragment of shell under skin below patella.

Accession 4707, Army Medical Museum. Autochrome.

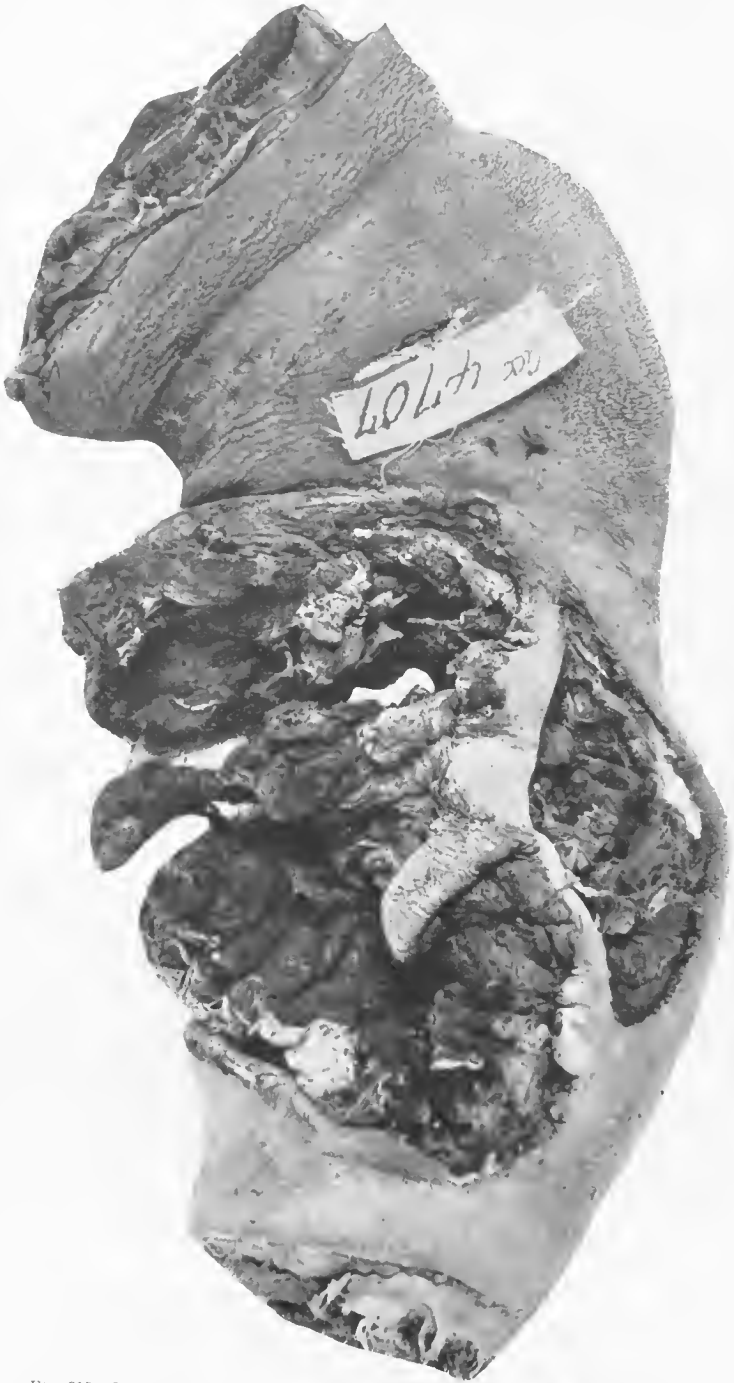

FIG. 215.—High-explosive shell wound caused by contact explosion. Muscle completely pulped. Accession number 4707, Army Medical Museum. Negative number 39236

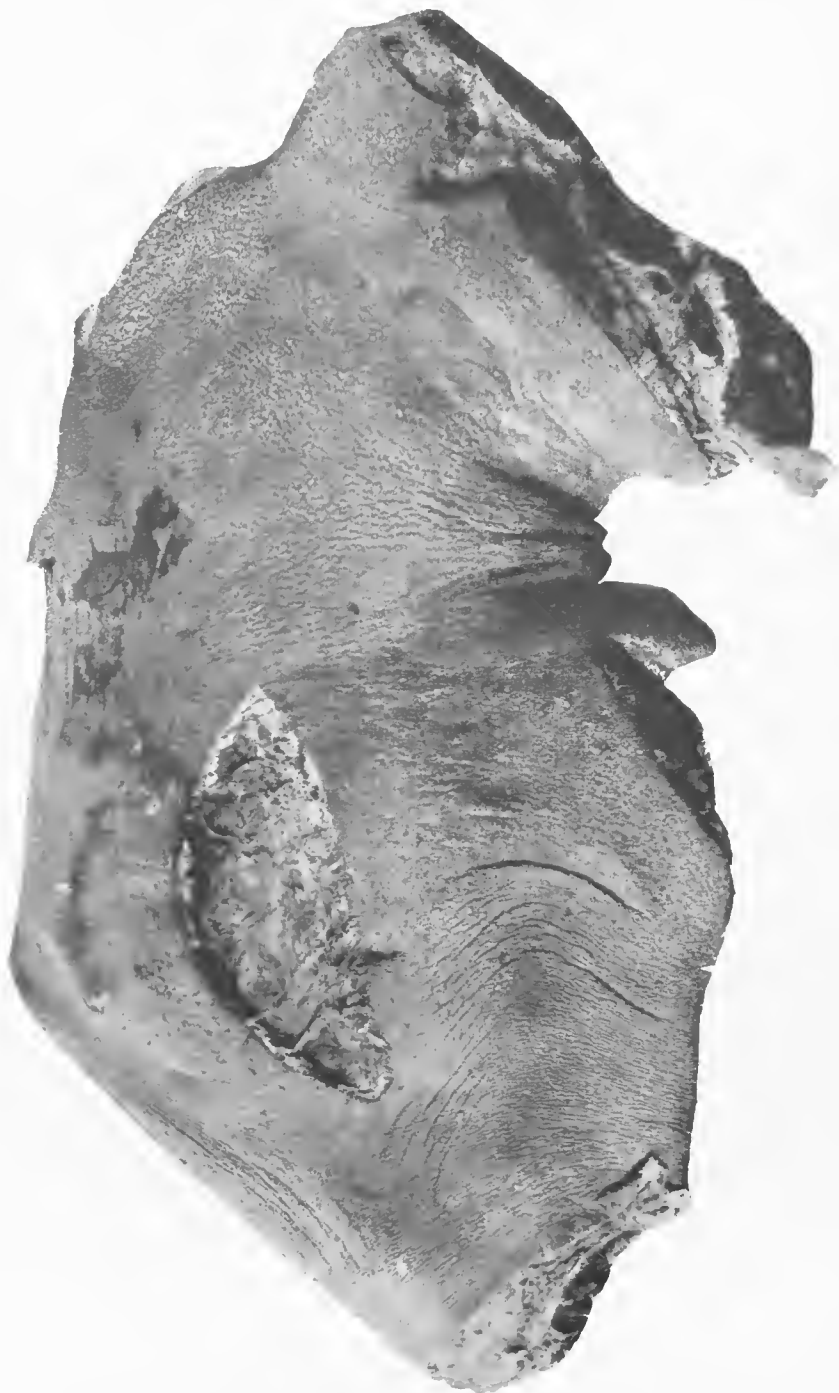

FIG. 216.—Ridge in thigh where cotton tourniquet had been placed just below the point of amputation. The inner aspect of the lower leg shows the formation of an exudate in the wound, some bronzing of the skin around the wound in the bend of the knee, and beginning gangrenous blisters in an area approximately 3 by 6 cm. above the wound of compounding. Accession number 4707, Army Medical Museum. Negative number 30229

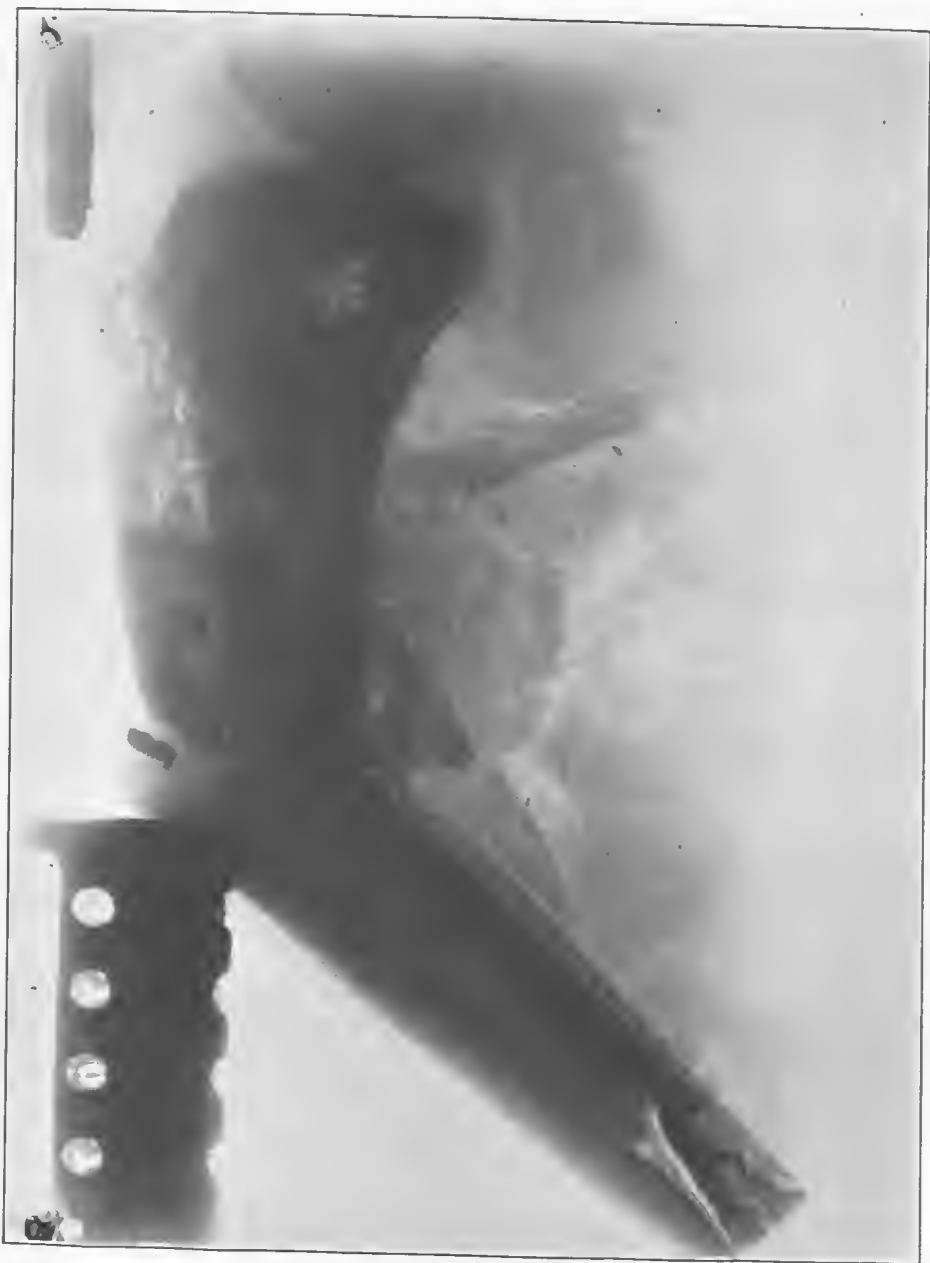

FIG. 217.—X ray, showing the fractured tibia and fibula displaced forward and a massive irregular gas gangrene of the calf muscles behind it. Accession number 4707, Army Medical Museum. Negative number 46245

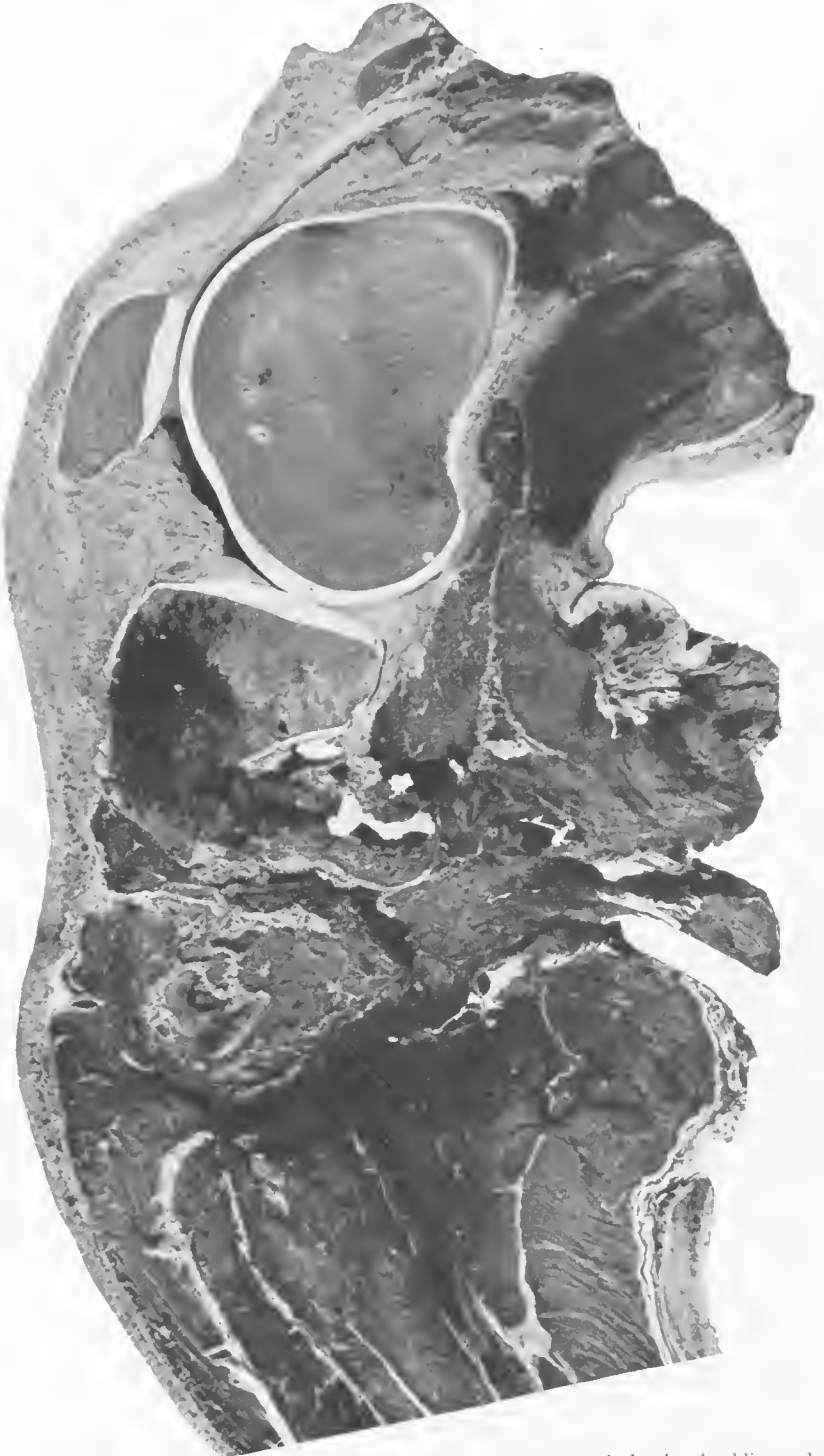

FIG. 218.—Vertical section toward the outer side and nearer to the wound, showing shredding and thrombosis of the popliteal vessels, with beginning putrefactive gas gangrene in the hemorrhage and muscles about this rupture. Accession number 4707, Army Medical Museum. Negative number 30222

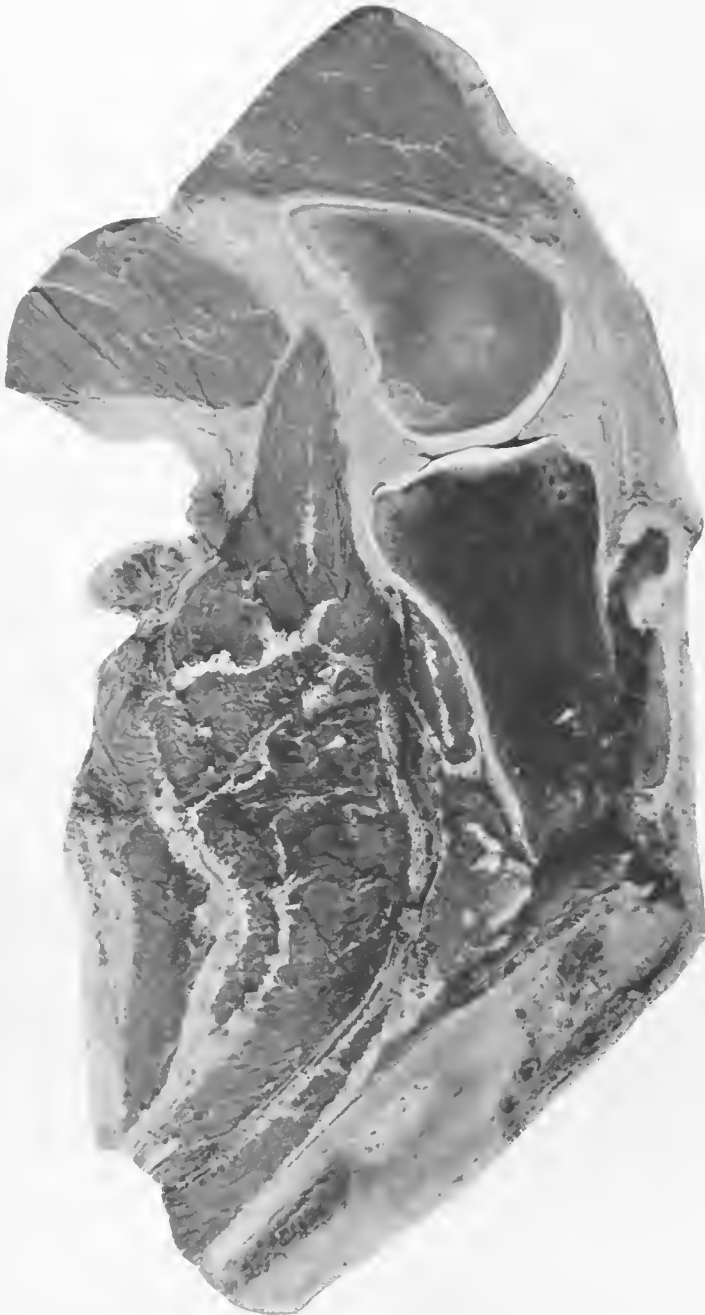

FIG. 219.—Gas gangrene of the calf muscles. Putrefactive change in the clot around the upper end of the fractured tibia. Accession number 4707, Army Medical Museum. Negative number 30233

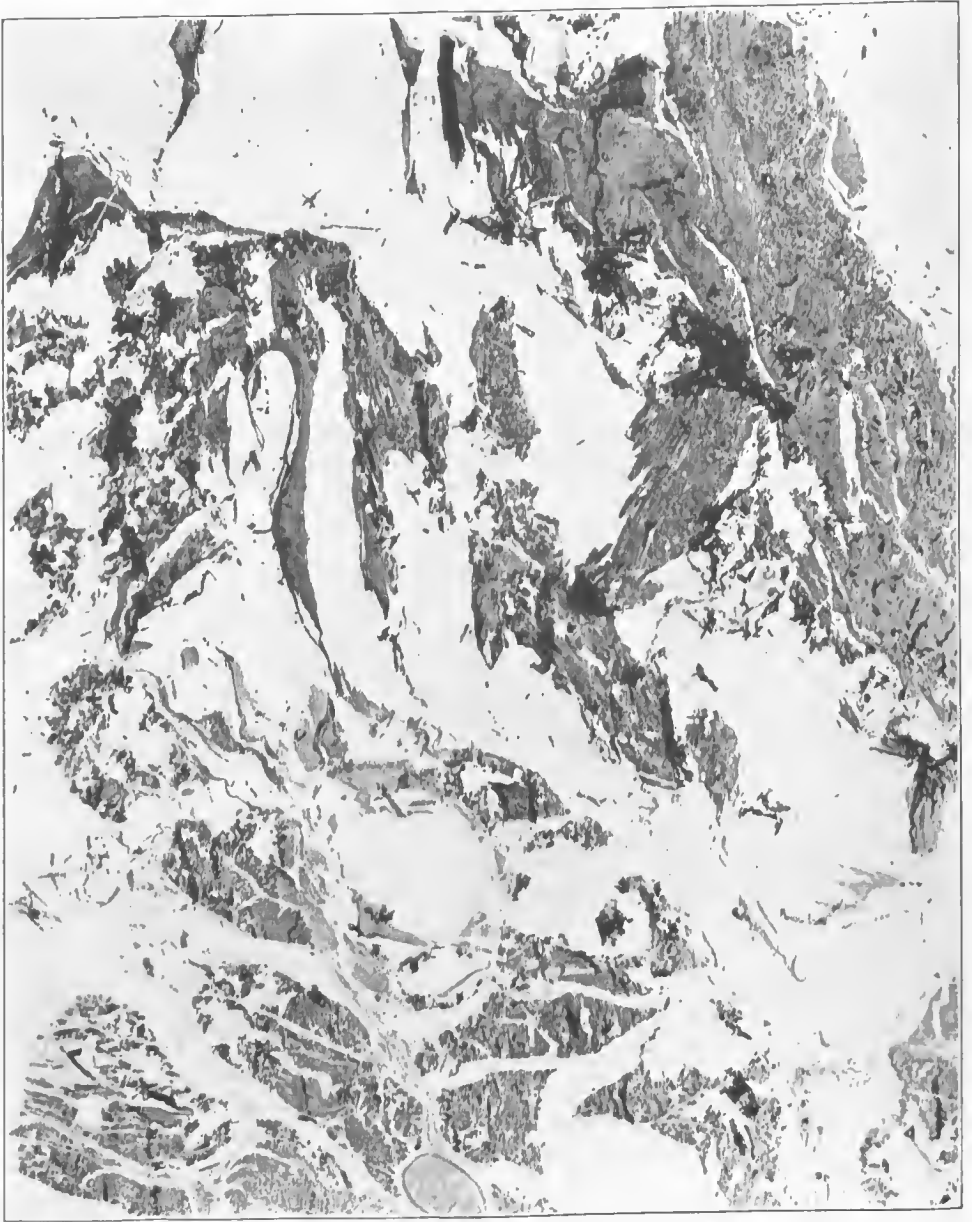

FIG. 220.—Section from the gangrenous area, showing massive destruction of muscle fibers and surrounding fascia, with serous exudate and large gas bubbles. Accession number 4707, Army Medical Museum. Negative number 45632 Hematoxylin and eosin stain; $\times 11$

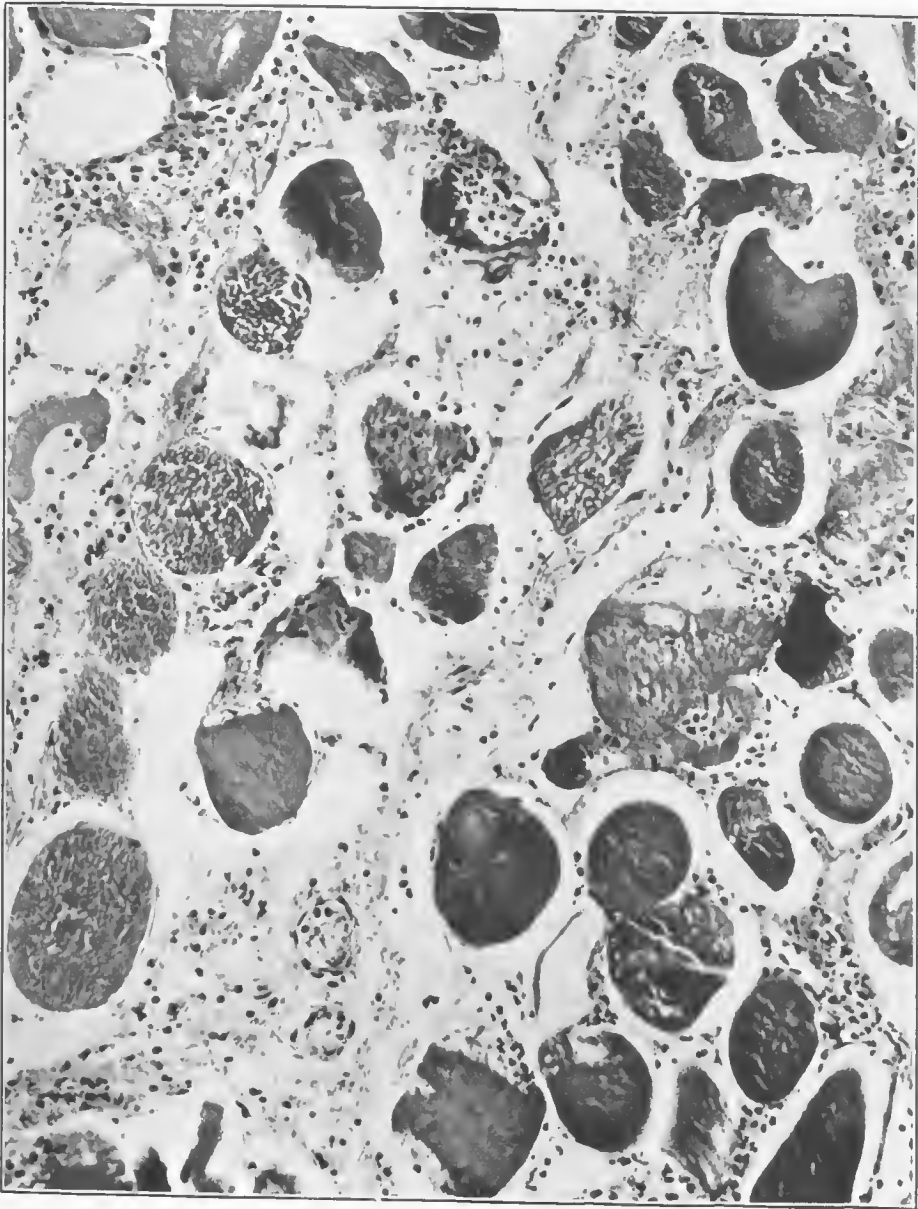


FIG. 221.—Section from the same area as in Fig. 220, cutting the muscle fibers in cross section, showing small bubbles of gas within the fibers and small collections of gas around them. This picture shows the leucocytic reaction secondary to trauma, produced by the positive chemotaxis which occurs when the anaerobic bacteria are few. At the right of the figure is a small foreign body (black). Accession number 4707, Army Medical Museum. Negative number 45898. Hematoxylin and eosin stain; $\times 220$

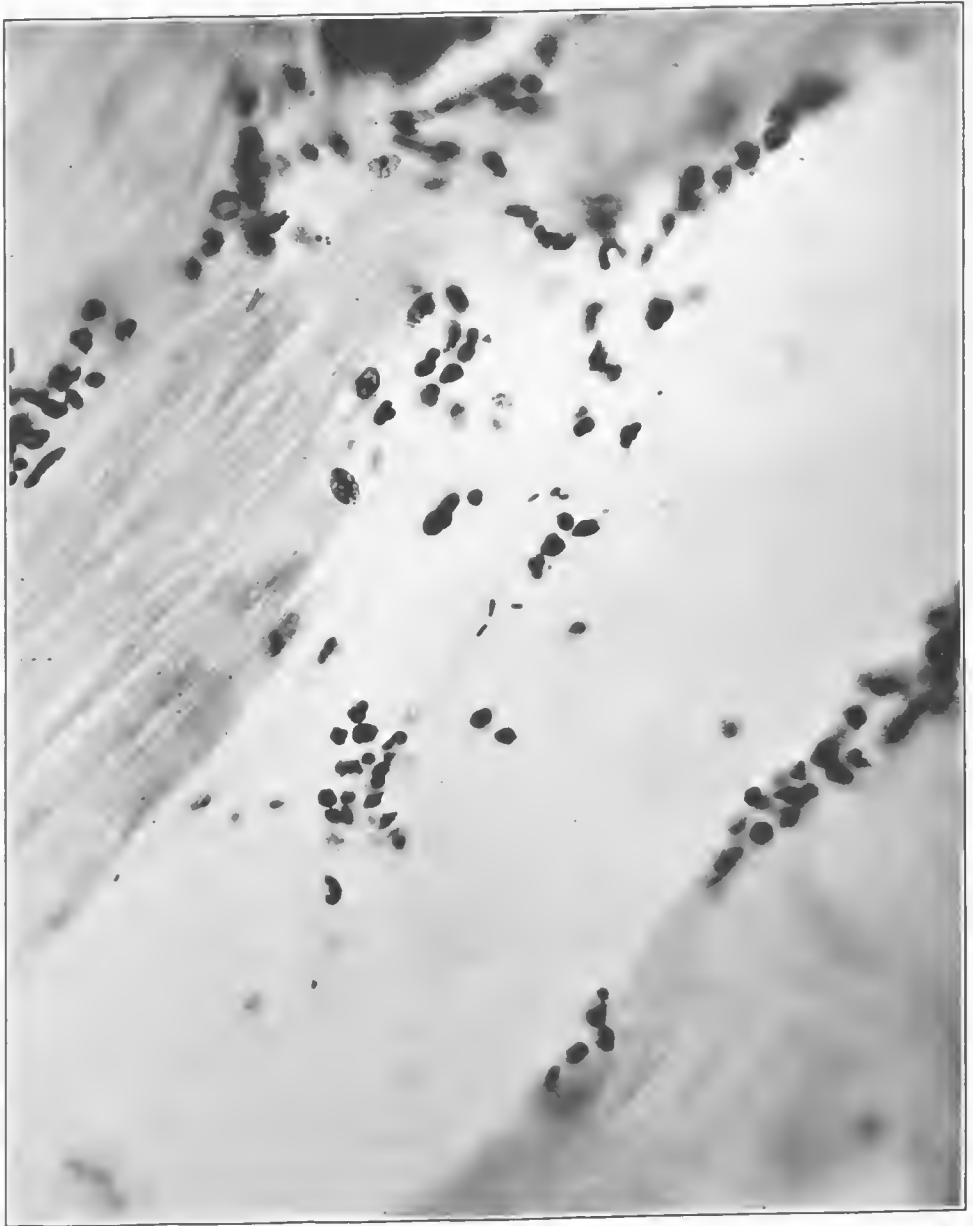


FIG. 222.—A section of the deeper portion of the wound which contained bacteria. These are apparently Welch bacilli, occurring in very small numbers. Accession number 4707, Army Medical Museum. Negative number 45629. MacCallum stain; $\times 1100$

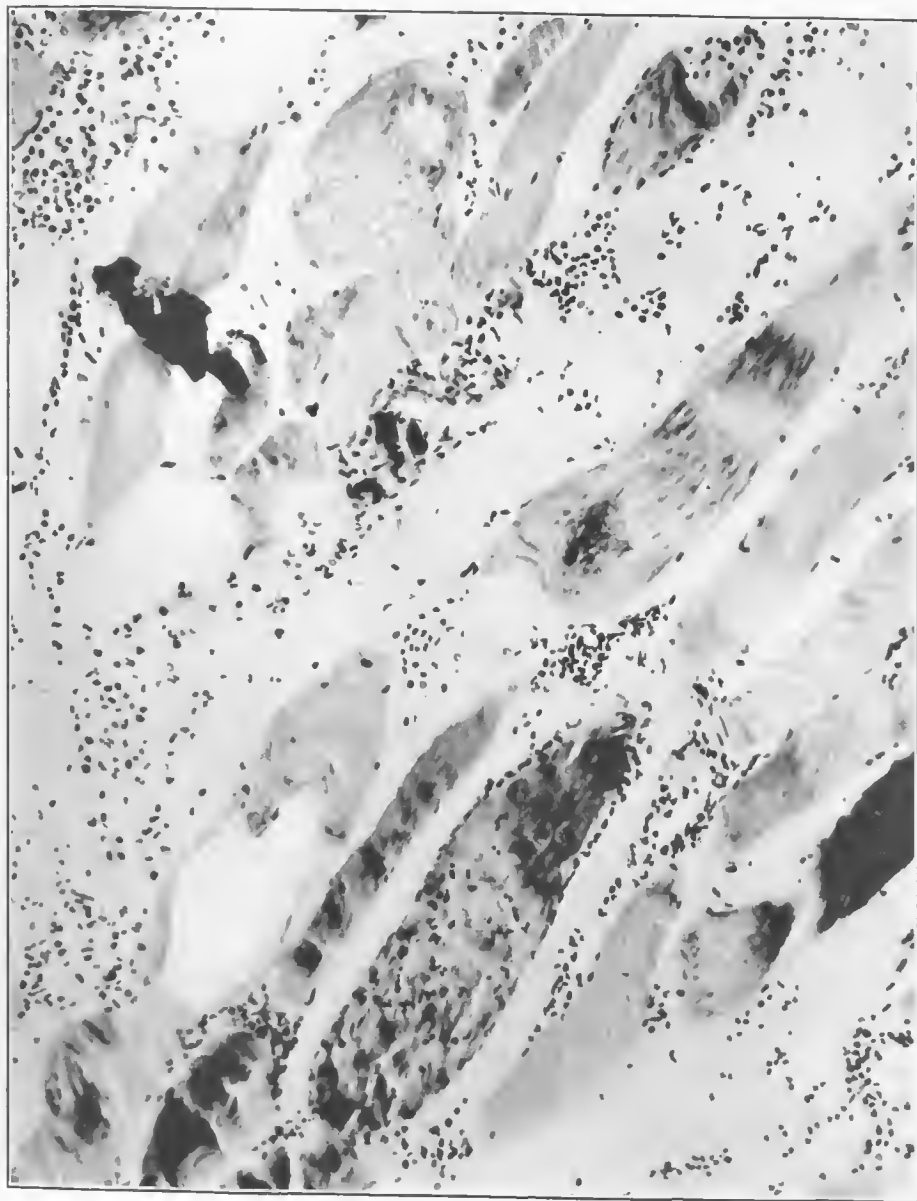


FIG. 223.—An area where muscles are cut almost longitudinally, with a moderate amount of leucocytic exudate. There is a small accumulation of gas within one ruptured fiber in the lower left part of the picture. One fiber at the top shows a single bubble of gas. In the upper left-hand portion is a small foreign body. Some fibers are ruptured, probably due to the trauma, since the gas accumulation is not marked. Accession number 4707, Army Medical Museum. Negative number 45728. MacCallum stain; $\times 195$



FIG. 224.—Marked variation in the way muscle fibers have retained the basic dye. The upper central portion of the picture shows the rupture of myomeres within a fiber which can be due to either trauma by the missile or accumulation of gas bubbles, or both. Accession number 4707, Army Medical Museum. Negative number 45717. MacCallum stain; $\times 200$

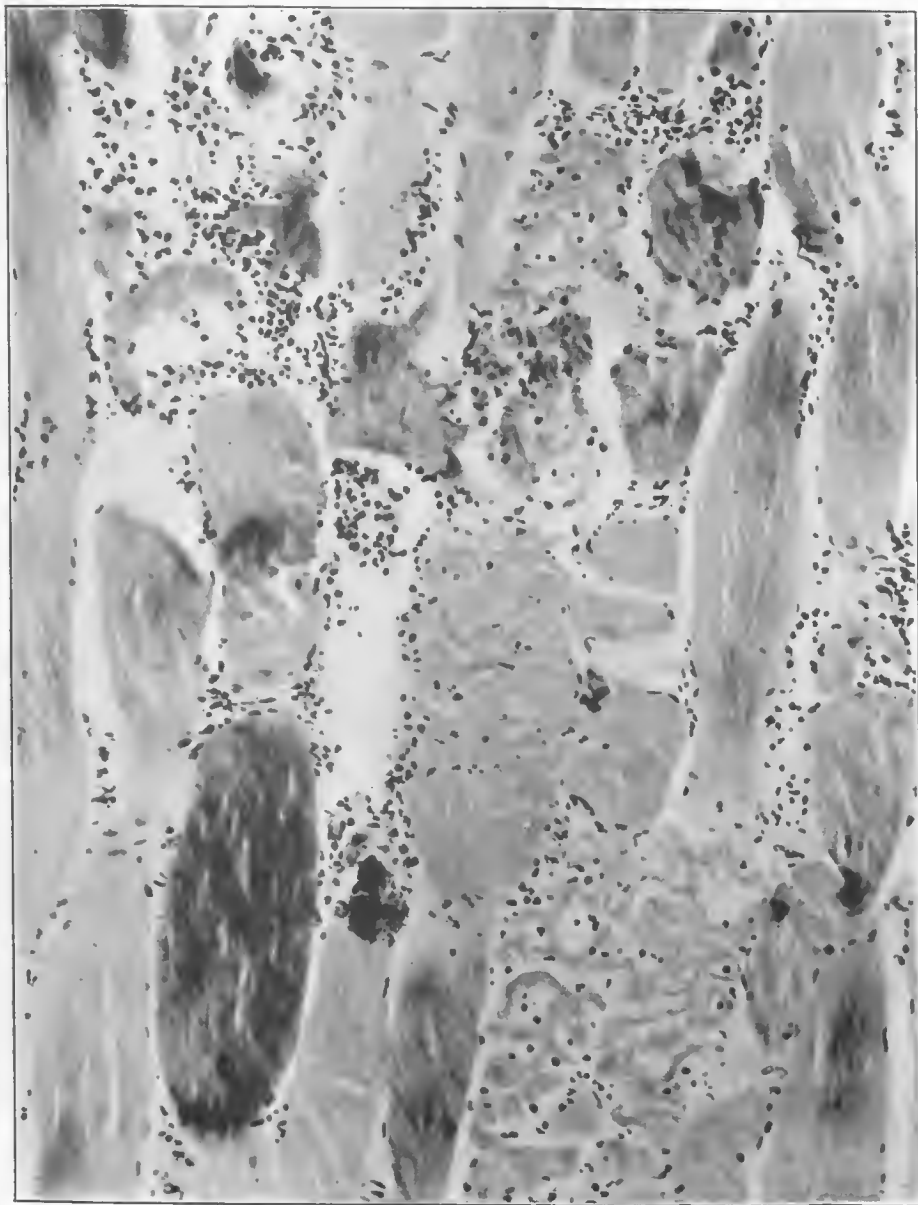


FIG. 225.—Marked separation of myomeres, moderate accumulation of gas, and leucocytic infiltration. One fiber in the lower left-hand portion retains the basic dye as well as small gas bubbles. Eight to twelve myomeres are separated in one muscle fiber. Several foreign bodies appear in the section. Accession number 4707, Army Medical Museum. Negative number 45725. MacCallum stain; $\times 215$

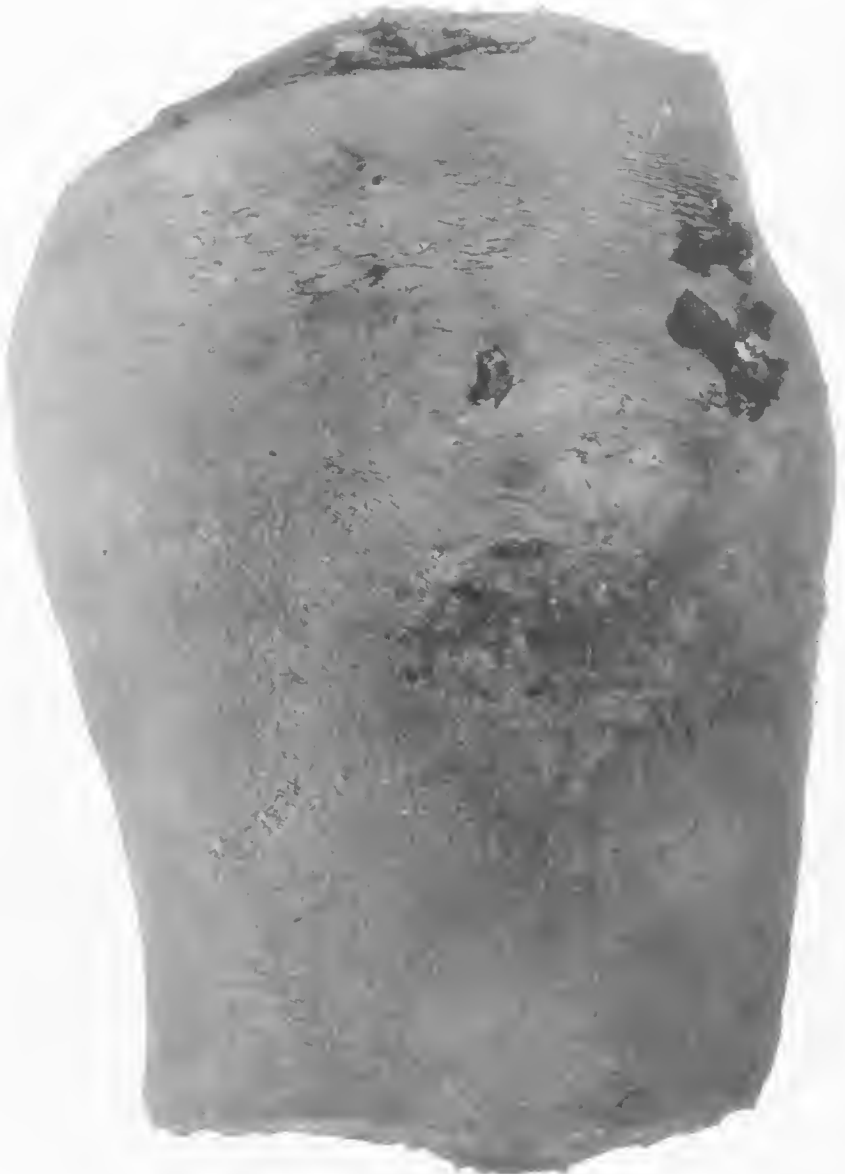

FIG. 225.—Anterior of right thigh. There is considerable swelling and several small wounds, probably due to high explosive. The skin, which is extensively blackened, indicates that there has been a putrefactive infection of superficial hemorrhages. Accession number 2881, Army Medical Museum. Negative number 31931. (See fig. 227)



FIG. 227.—Posterior aspect of thigh of Fig. 226. There is a débrided high explosive wound with projecting muscle masses. Skin is blackened from putrefactive bacterial infection of subcutaneous hemorrhage. Accession number 2881, Army Medical Museum. Negative number 31931



FIG. 228.—Vertical section of right thigh, cutting through the center of the femur showing advanced putrefactive infection around the wound tract and moderate accumulation of gas below the tract. The muscle throughout the limb is textureless, a type of change seen in cases which clinically showed marked toxemia. Accession number 2881, Army Medical Museum. Negative number 31929

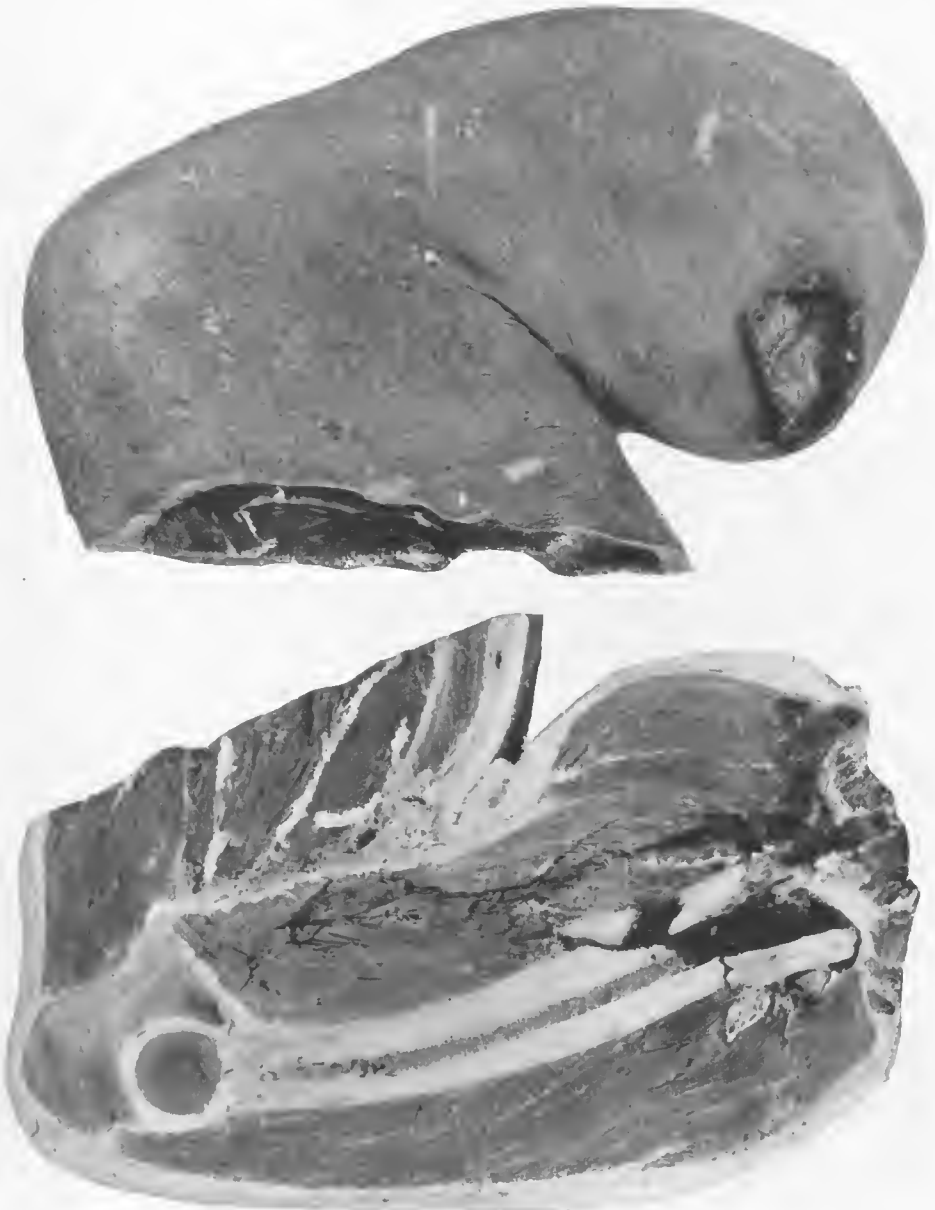


FIG. 229.—Internal aspect of the right upper arm. High-explosive wound of the middle of the biceps with marked swelling. The base of the wound is covered with a shaggy exudate and is surrounded by a raised zone of extruded muscle. The skin markings around the wound are obliterated by the tension upon the skin from below. The mid section through this arm shows a fracture of the humerus, a marked edema of the biceps, with little gas accumulation, and a putrefactive reaction about the wound tract and in the hemorrhage from the marrow. There is a loss of texture and color of the muscle secondary to the toxic type of gangrene. Accession number 2881, Army Medical Museum. Negative number 30856

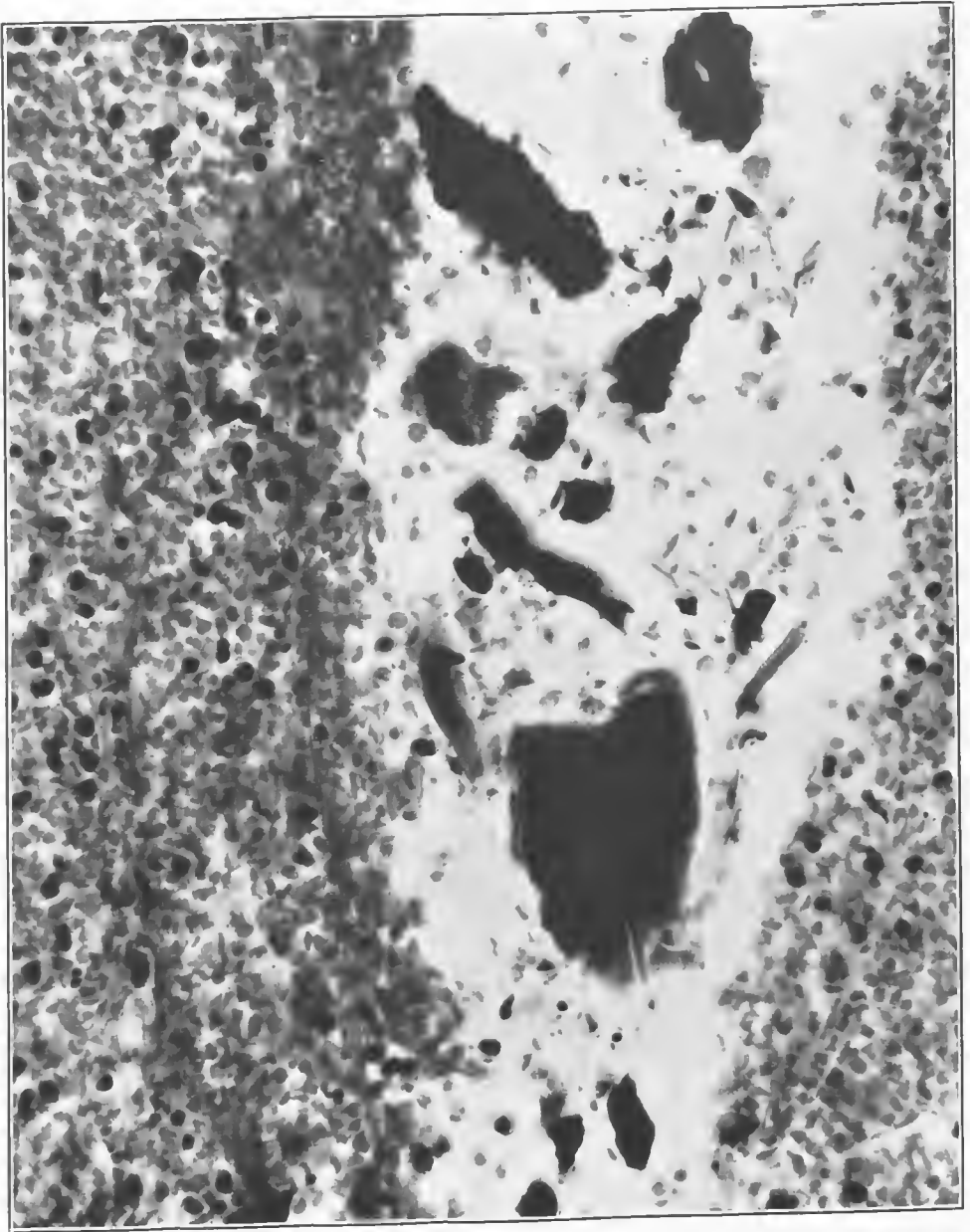


FIG. 230.—Section of the wound tract in the thigh which shows massive hemorrhage, fragments of bone, dirt, and foreign bodies carried in by the missile. Accession number 2881, Army Medical Museum. Negative number 45855. Hematoxylin and eosin stain; $\times 470$

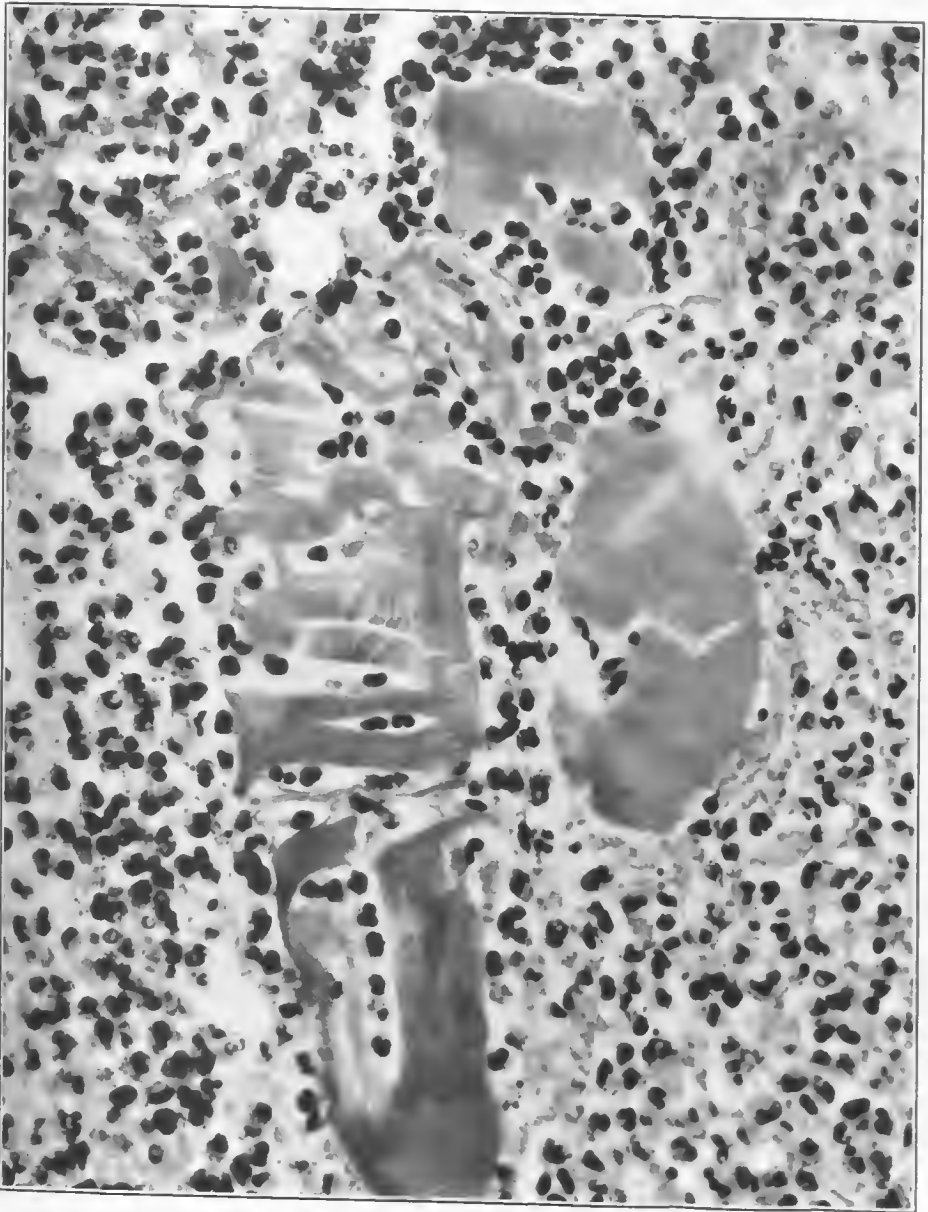


FIG. 231.—Section from the margin of the wound tract, showing rupture of a muscle fiber, a loss of its markings and separation into myomeres. The fiber is surrounded by a purulent exudate which indicates a contamination of the wound tract at this point by pyogenic organisms. Accession number 2881, Army Medical Museum. Negative number 45853. Hematoxylin and eosin stain; $\times 595$

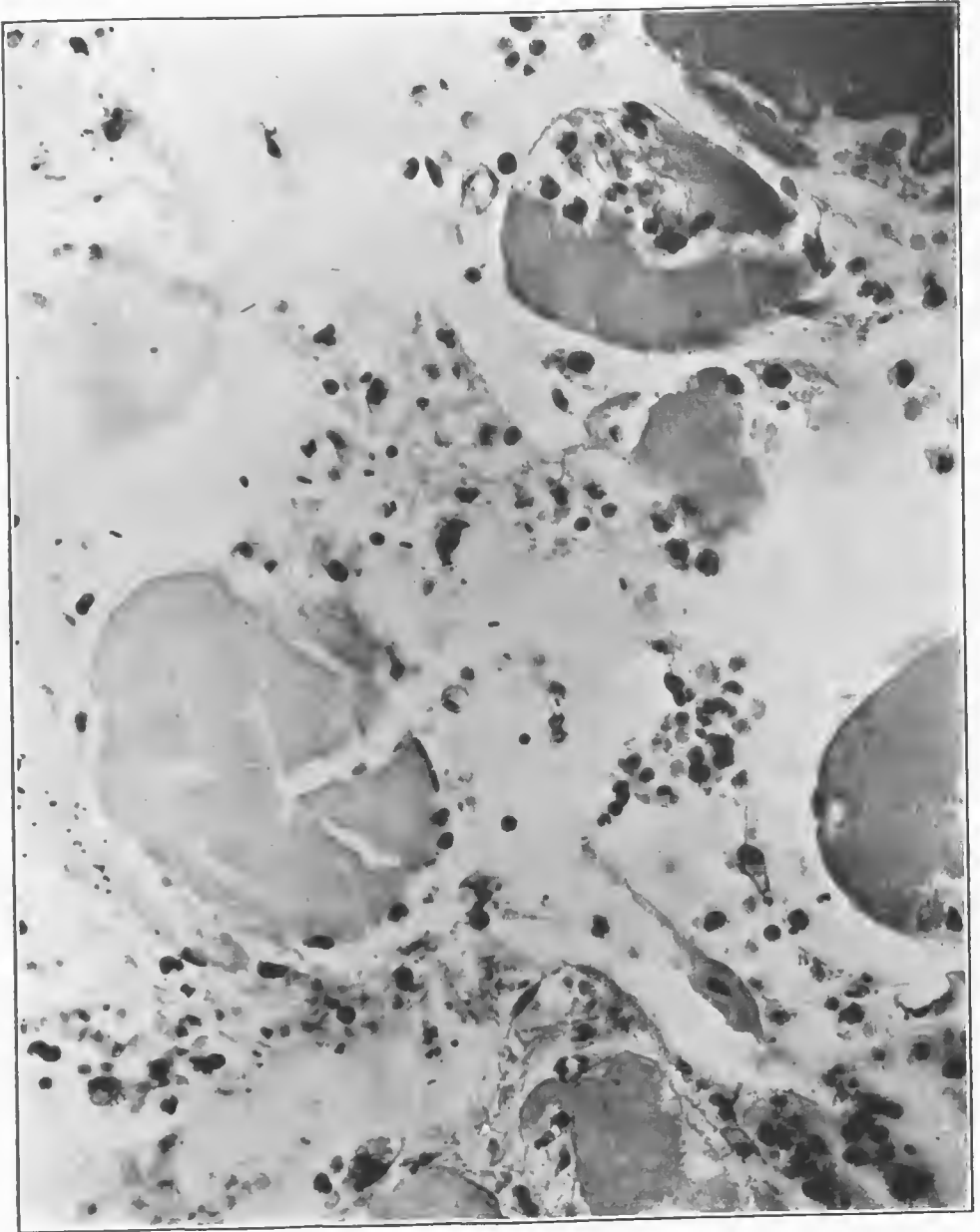


FIG. 232.—Section from the putrefactive gangrenous area in the thigh. This shows organisms that resemble Welch bacilli, others with central spores, and members of the pyogenic group. There is splitting of muscle fibers and small accumulations of gas. Some of the splitting of fibers is probably due to direct trauma, as this section was taken from the wound tract. Accession number 2881, Army Medical Museum. Negative number 45849. MacCallum stain; $\times 545$

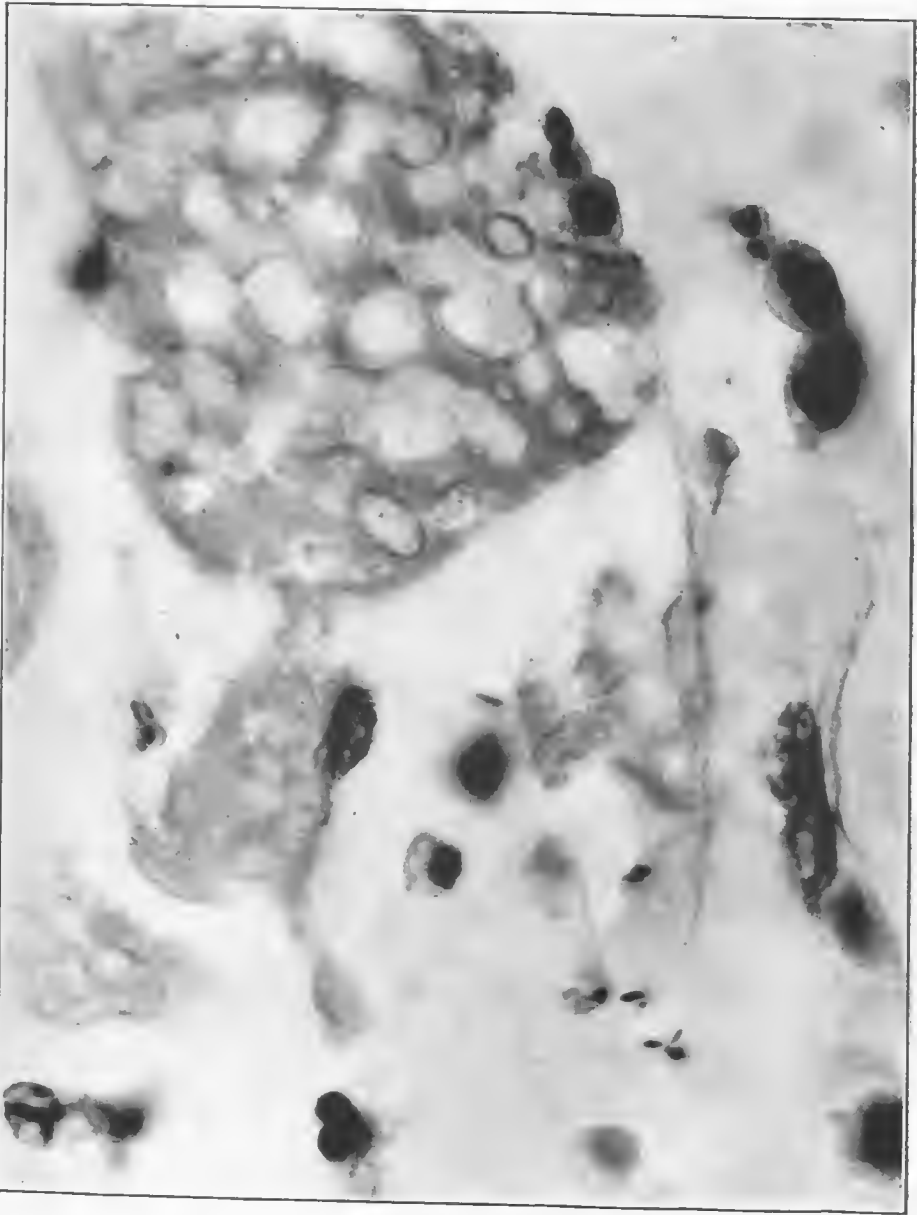


FIG. 233.—Section of the gangrenous tissue in the arm, showing a cross section of a muscle fiber completely honeycombed with fine bubbles. There are occasional leucocytes and a few Gram-positive rods whose morphology is not clear enough to indicate the type. Accession number 2881, Army Medical Museum. Negative number 46255. MacCallum stain; $\times 2100$

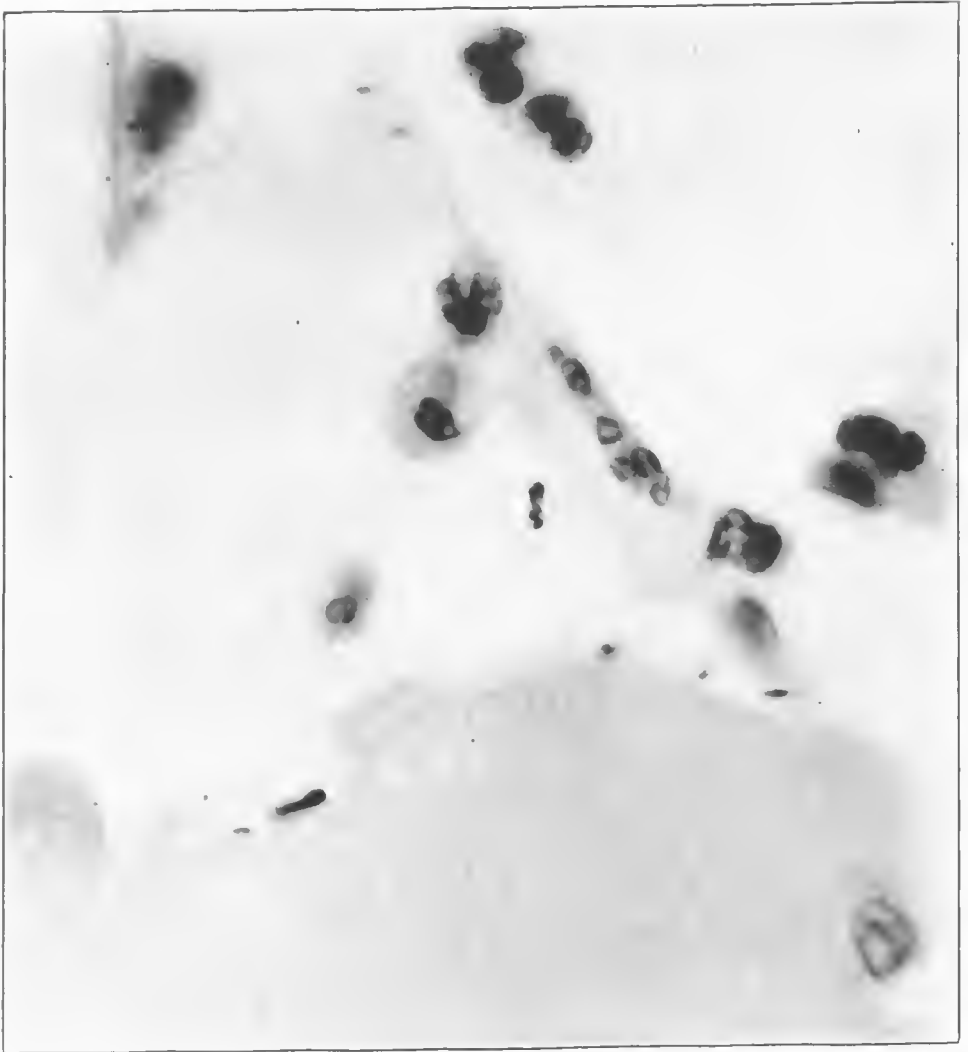


FIG. 234.—At the end of the muscle fiber there is a large rod-shaped organism with an end spore. There is solution of the fiber about this organism. Muscle markings are lost and there is a moderate accumulation of leucocytes. Accession number 2881, Army Medical Museum. Negative number 45850. MacCallum stain; $\times 2000$

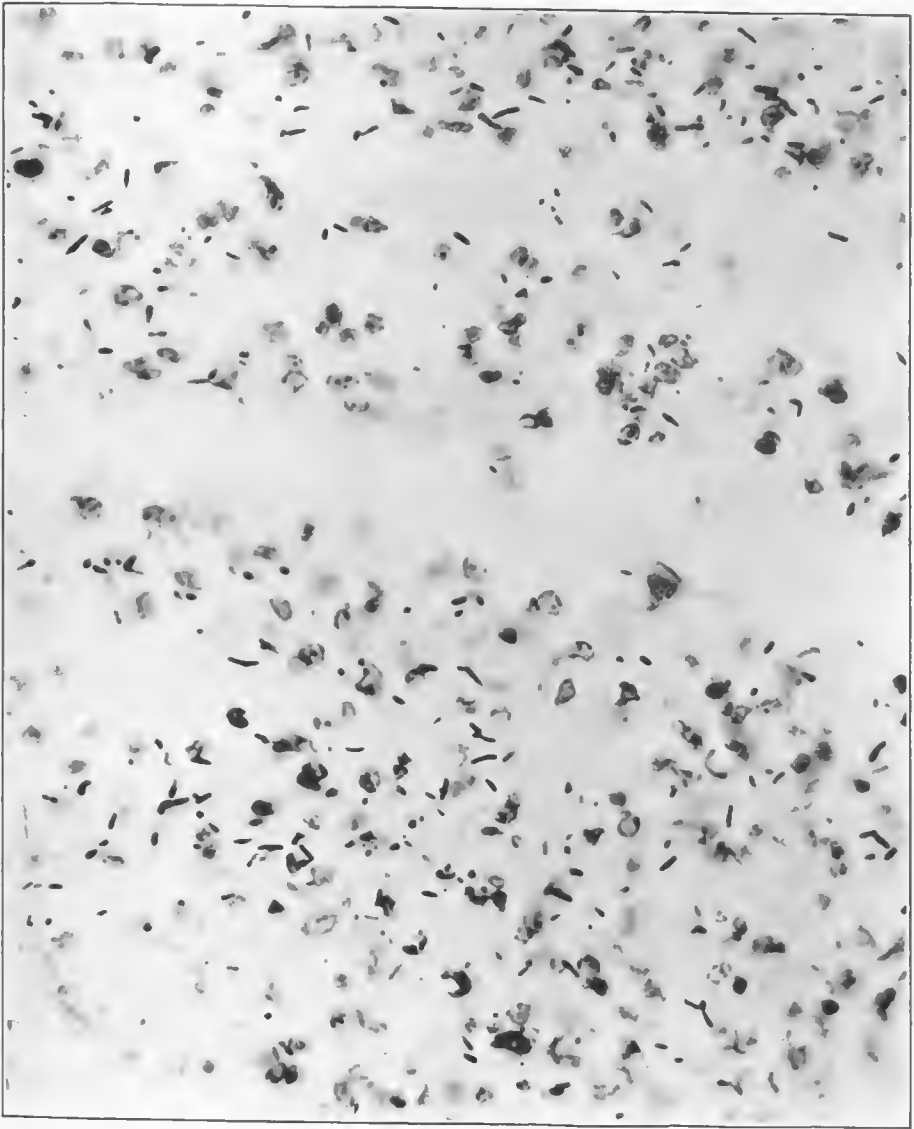


FIG. 235.—An area of hemorrhage around the wound tract in the thigh which showed a putrefactive gangrenous process. It is evidently a mixed infection with the gangrene group, the majority of which resemble Weib bacillus and vibrios septique. There are occasional diptheroids. Accession number 2881, Army Medical Museum. Negative number 46222. MacCallum stain $\times 950$



FIG. 236.—External surface of the right foot with a débrided wound below the external malleolus measuring 5 by 9 cm. There is an ordinary gangrene of the anterior third of the foot, including all the toes, due to vascular occlusion. The skin surface of the remainder of the foot shows the reaction due to putrefactive gangrene. Accession number 2934, Army Medical Museum. Negative number 30961

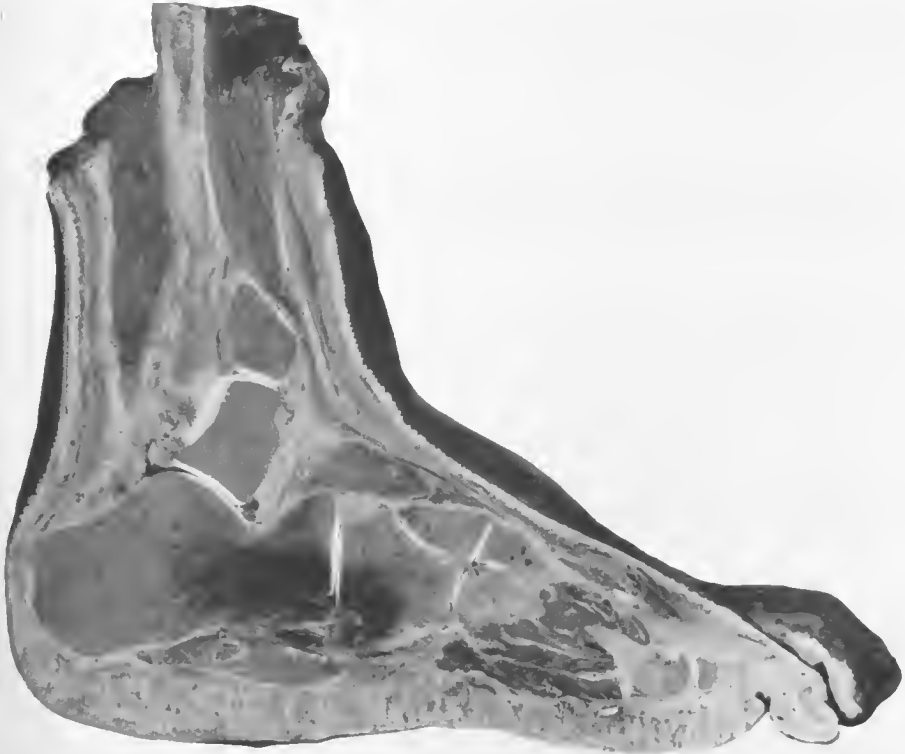


FIG. 237.—Mid section of the foot shown in the preceding figure. There is putrefactive gangrene of the os calcis and some of the neighboring bones and muscles around a hemorrhage in this area. There is a gaseous infiltration in the interosseus muscles about the level of the line of demarcation of the gangrene in the anterior portion of the foot. Accession number 2934, Army Medical Museum. Negative number 30961

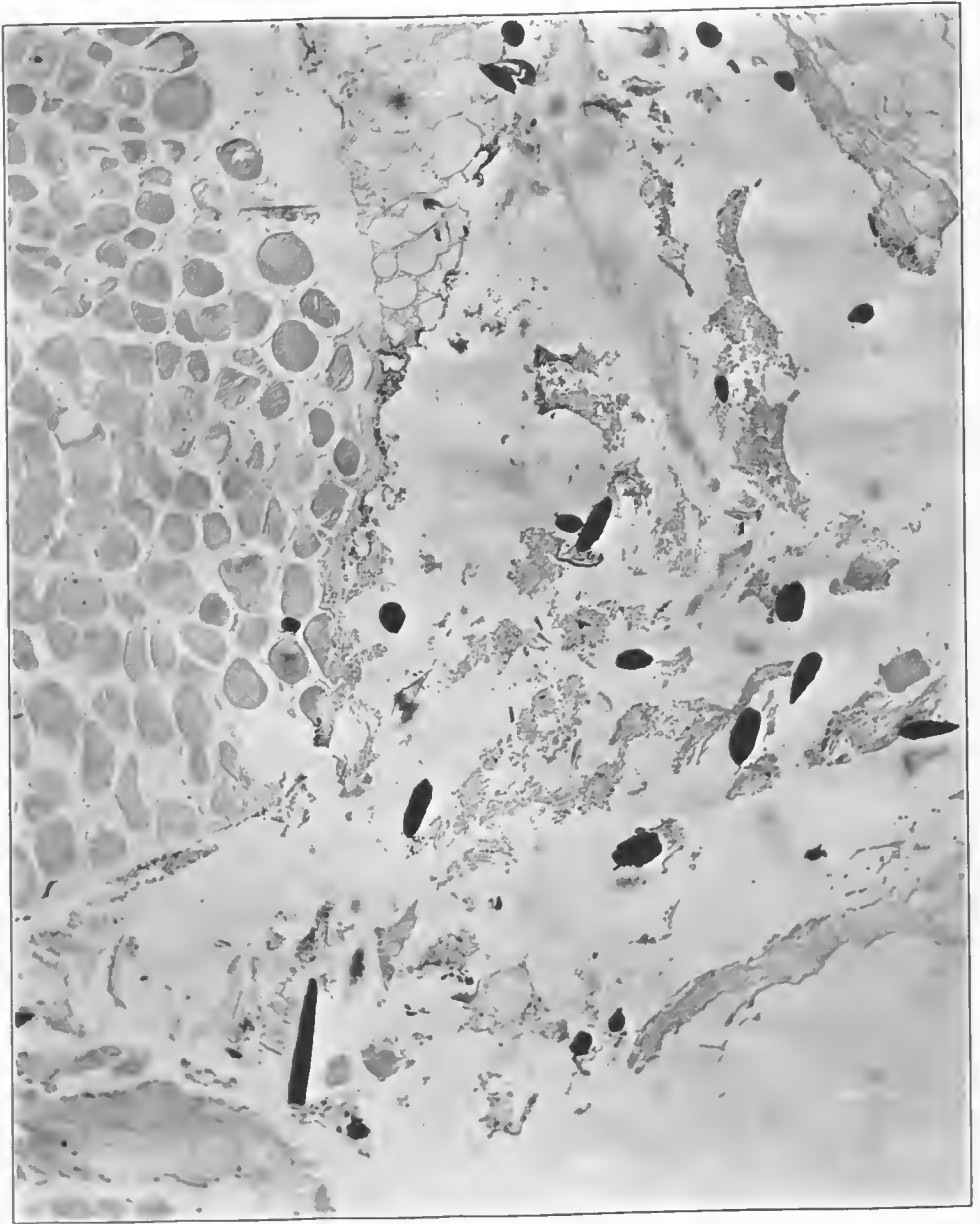


FIG. 238.—Section from the gangrenous area of muscle in close relation to the wound tract. It shows formation of gas bubbles within muscle fibers. There are numerous foreign bodies throughout this section which are portions of the bearding of a wheat head. Accession number 2934, Army Medical Museum. Negative number 46031. MacCallum stain; $\times 780$



FIG. 239.—Section from an area of emphysematous gangrene in the interosseus muscles. The cross striations of the muscles are accentuated as a result of swelling and also from chemical change. Accession number 2934, Army Medical Museum. Negative number 46017. Hematoxylin and eosin stain; $\times 200$

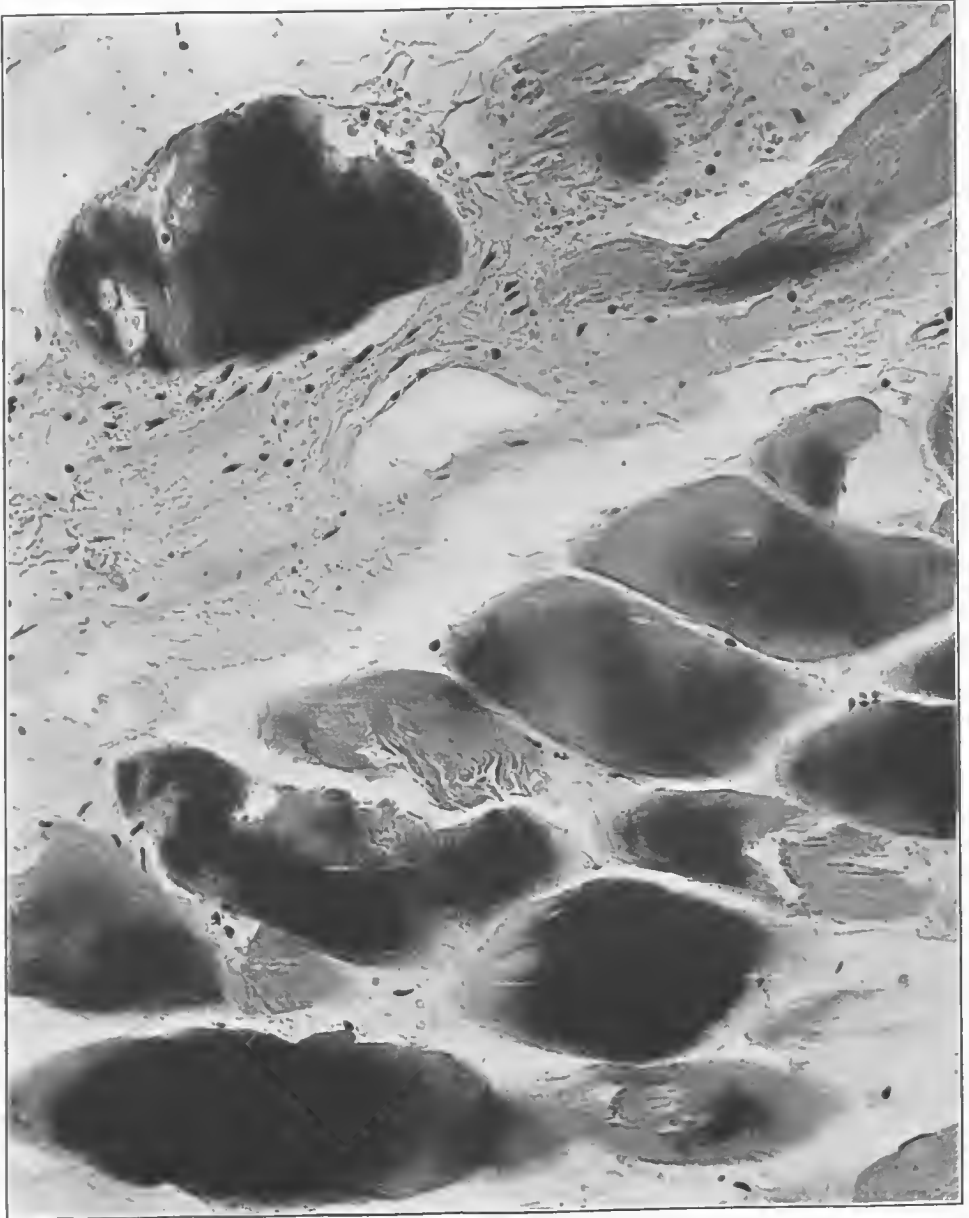


FIG. 240.—Section from near the same area as that of the preceding figure. There is gas in the swollen muscle fibers and a marked variation in their staining reaction. There is an occasional rod-shaped Gram-positive organism in close relation to muscle fibers. Accession number 2934 Army Medical Museum. Negative number 46023. MacCallum stain; $\times 265$

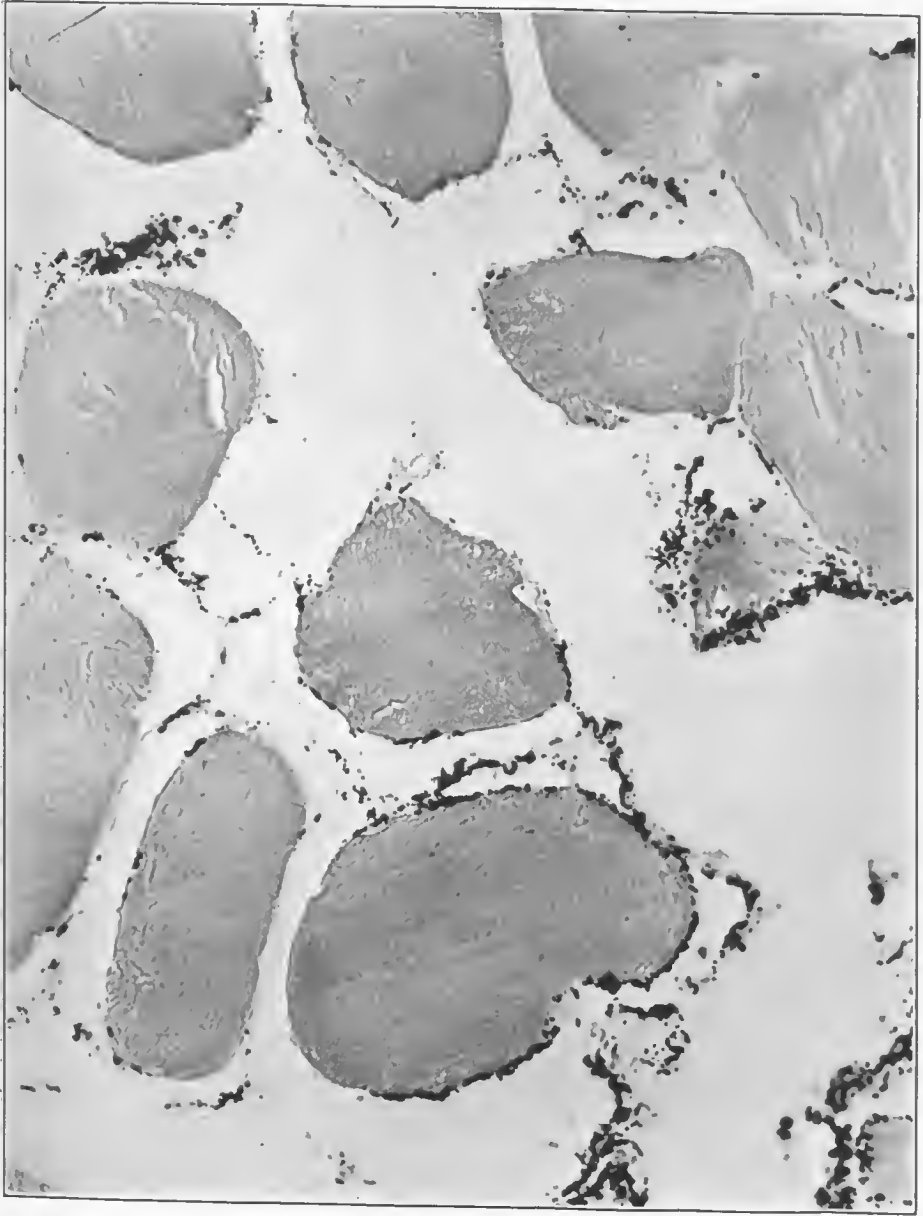

FIG. 241.—Section from the same area as the preceding figures, somewhat nearer the wound tract. It shows numerous Gram-positive and Gram-negative rods and coccoid organisms. Muscle fibers are swollen and markings lost. Accession number 2934, Army Medical Museum. Negative number 46036. MacCallum stain; $\times 575$

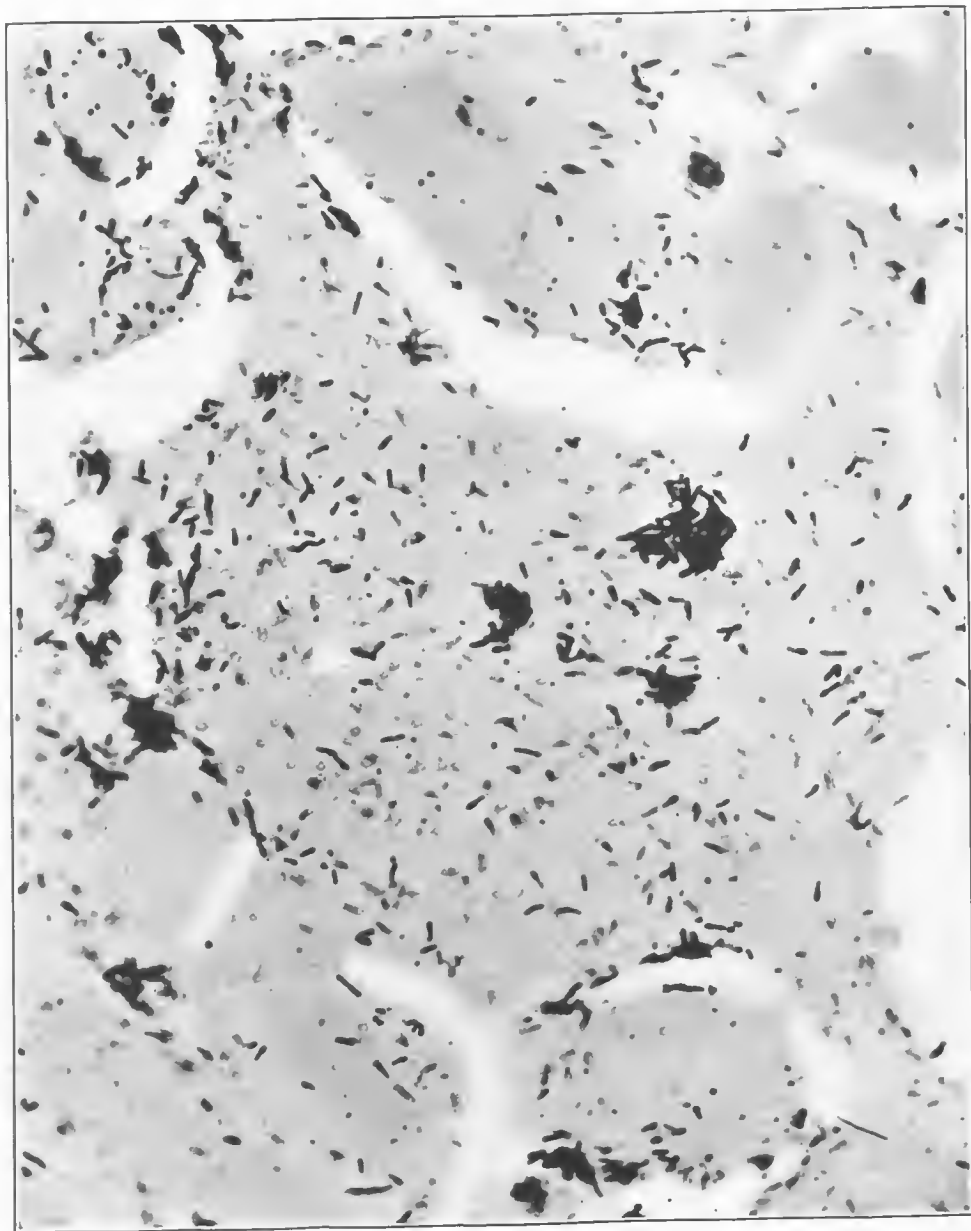


FIG. 242.—Section from a frankly putrefactive gangrenous area. There is marked degeneration of muscle with coarse granular detritus within fibers and many organisms with terminal and central spores, most of which are Gram-positive. The picture is typical of the putrefactive gangrenous process. Accession number 2934, Army Medical Museum. Negative number 46035. MacCallum stain; $\times 660$

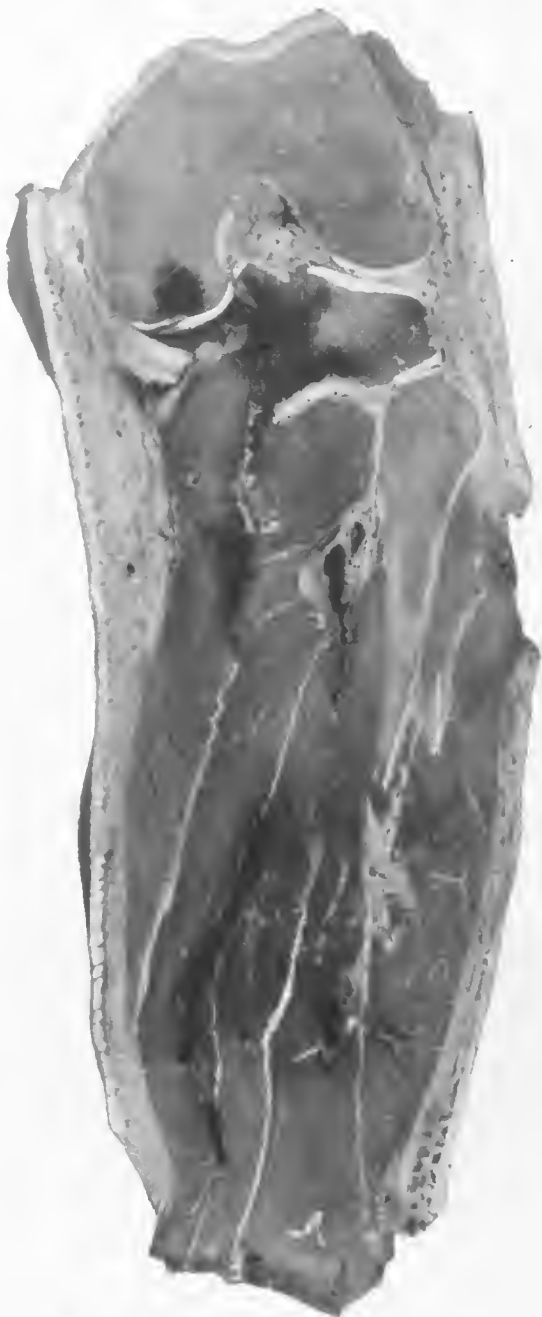

FIG. 243.—Vertical section of the left leg cut posterior to the tibia, the upper third of which has been shot away by high-explosive shell fragments. There is a thrombosis of the popliteal vessel and its branches. There is a putrefactive gangrene in the calf muscle around the tibial arteries. There is a small amount of gas in the inner aspect of the calf muscles. The remainder of the calf muscles show loss of muscle texture and color characteristic of the toxic type of gangrene. Accession number 2892, Army Medical Museum. Negative number 32110

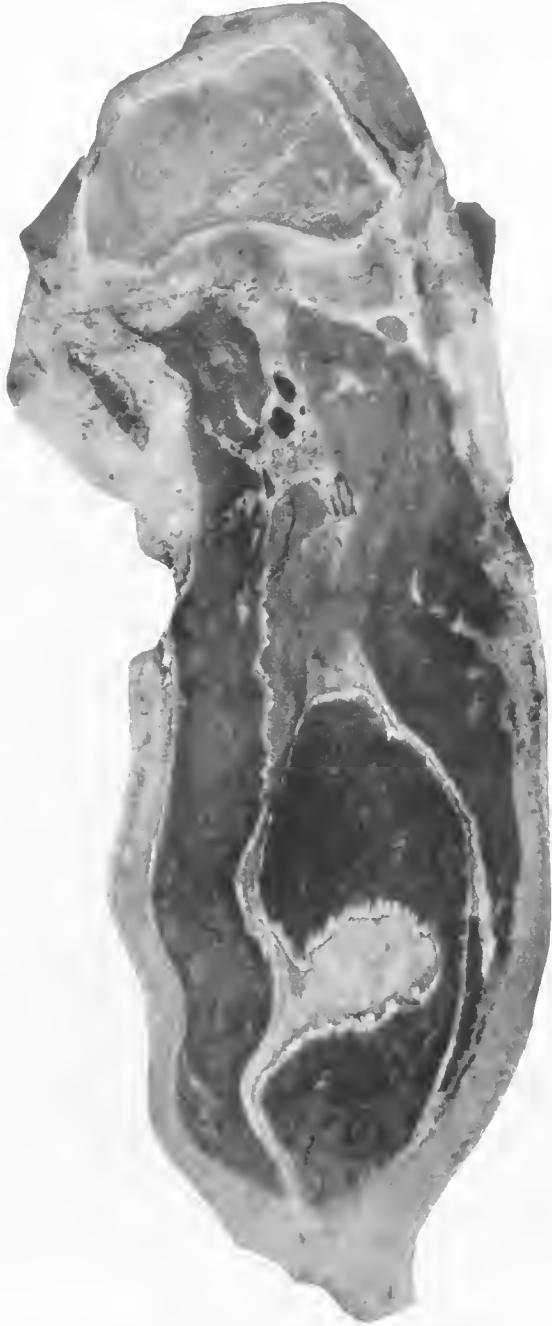

FIG. 244.—The surface shown is cut several centimeters posterior to the preceding section. It shows a portion of the wound tract with a surrounding putrefactive gangrene. The remaining muscles show the toxic type of gangrene, excepting the gastrocnemius, occupying the middle of the lower portion of the picture, which alone shows a well advanced emphysematous type of gangrene, with wide separation of muscle bundles by large bubbles of gas. Accession number 2892, Army Medical Museum. Negative number 32106

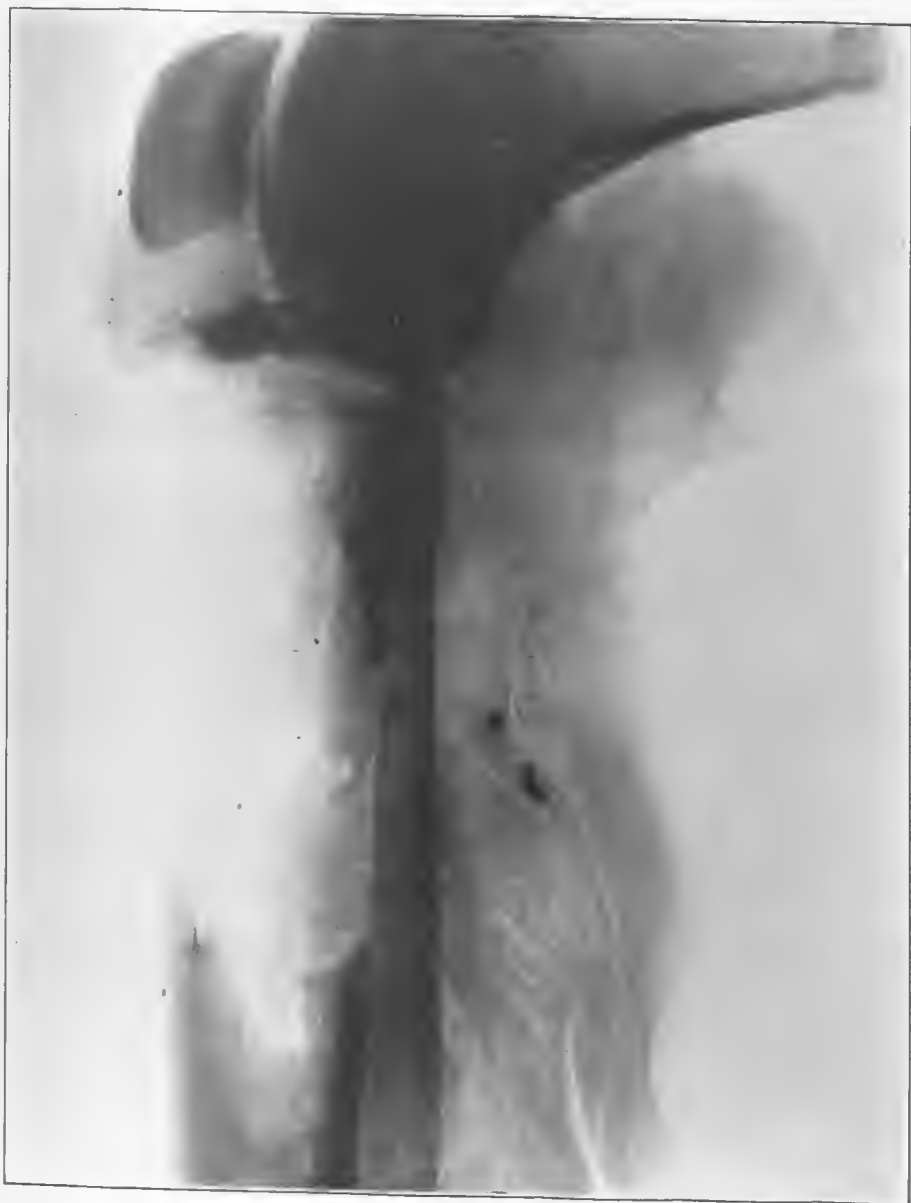

FIG. 245.—X ray of the left leg, showing numerous foreign bodies and evidence of emphysematous gangrene apparently confined to the single muscle shown in the preceding photograph. Accession number 2892, Army Medical Museum. Negative number 46817




FIG. 246.—Section from the gangrenous emphysematous gastrocnemius which shows at the margin of two gas bubbles muscle fibers which are split by gas yet retain their cross striations. There are a few round-ended rods, which appear from their morphology to be Welch bacilli. Accession number 2892, Army Medical Museum. Negative number 46296. MacCallum stain; $\times 750$

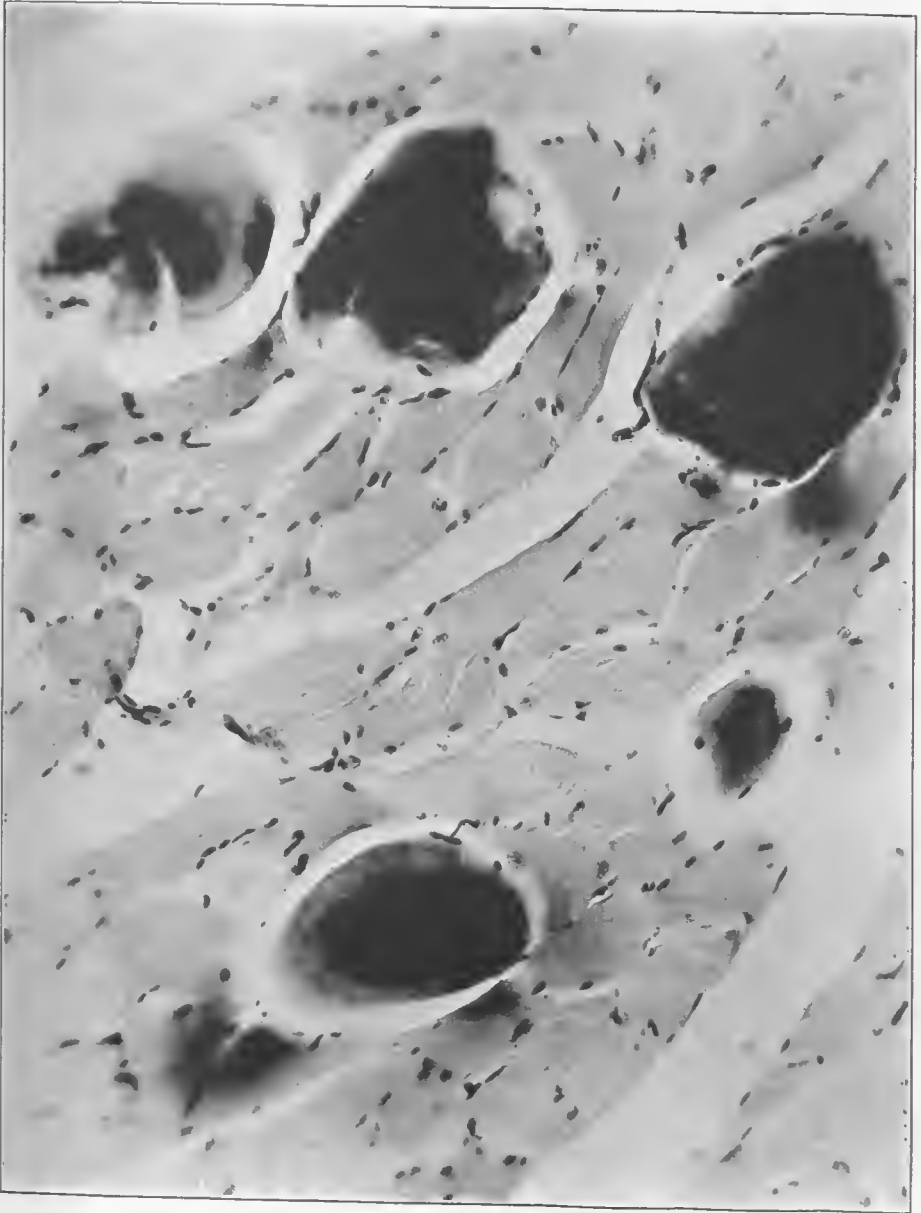


FIG. 247.—Section from the same area as the preceding figure. It shows accumulation of gas between muscle bundles, and around four separate fibers which are swollen approximately four times the size of neighboring fibers. These four fibers have undergone chemical alteration which makes them take the basic dye intensely. Accession number 2892, Army Medical Museum. Negative number 46299. MacCallum stain; $\times 230$

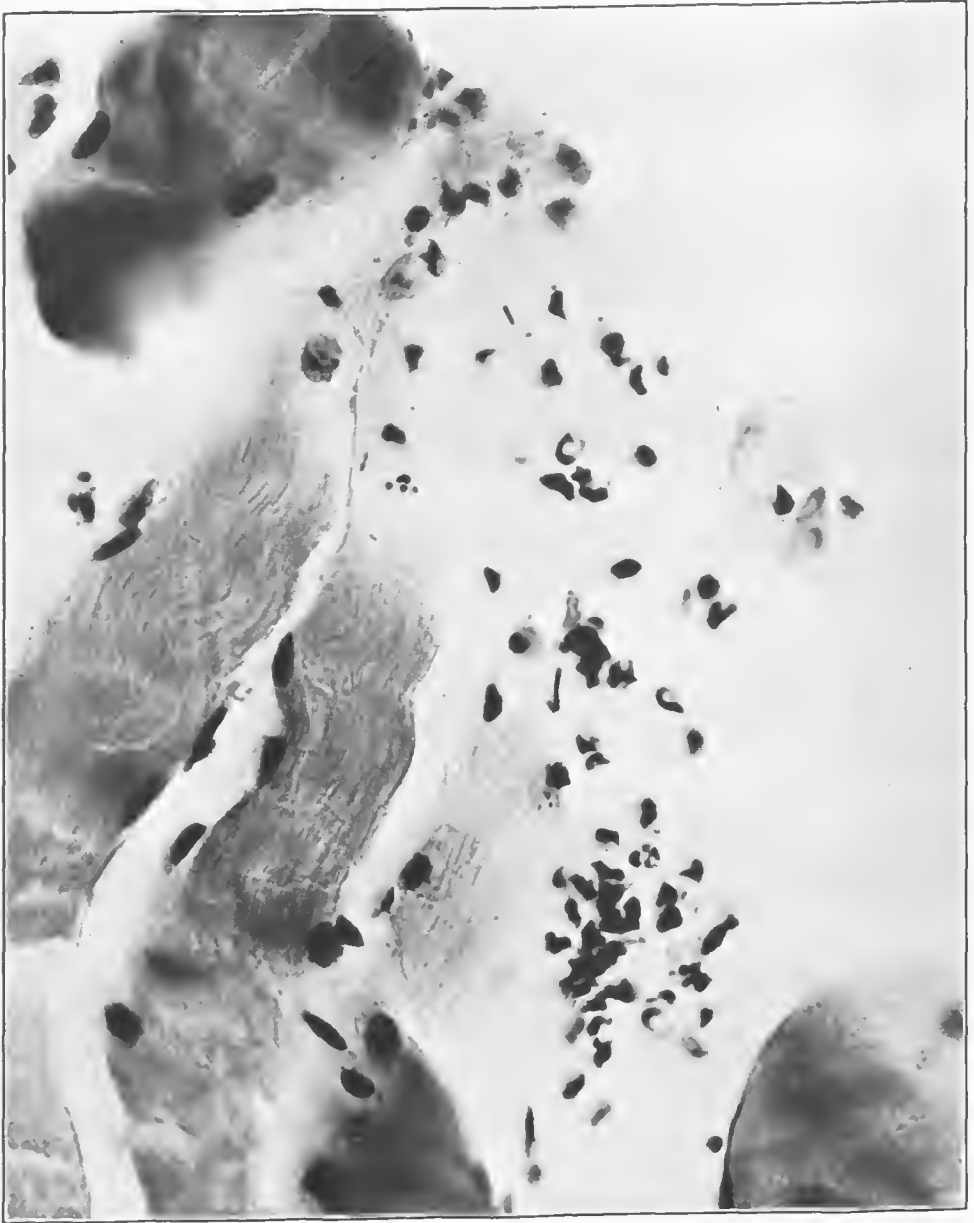

FIG. 213.—Section from around the tibial arteries, showing the putrefactive gangrenous process. There is fragmentation of muscle fibers, a variety of rod-shaped organisms, and an occasional coccoid form. There is a moderate accumulation of leucocytes. Accession number 2892, Army Medical Museum. Negative number 46297. MacCallum stain; $\times 730$




FIG. 249.—Section from the same area as the preceding figure, showing a lymphatic distended with gas and lined by masses of bacteria. Accession number 2892, Army Medical Museum. Negative number 46293. MacCallum stain; $\times 750$

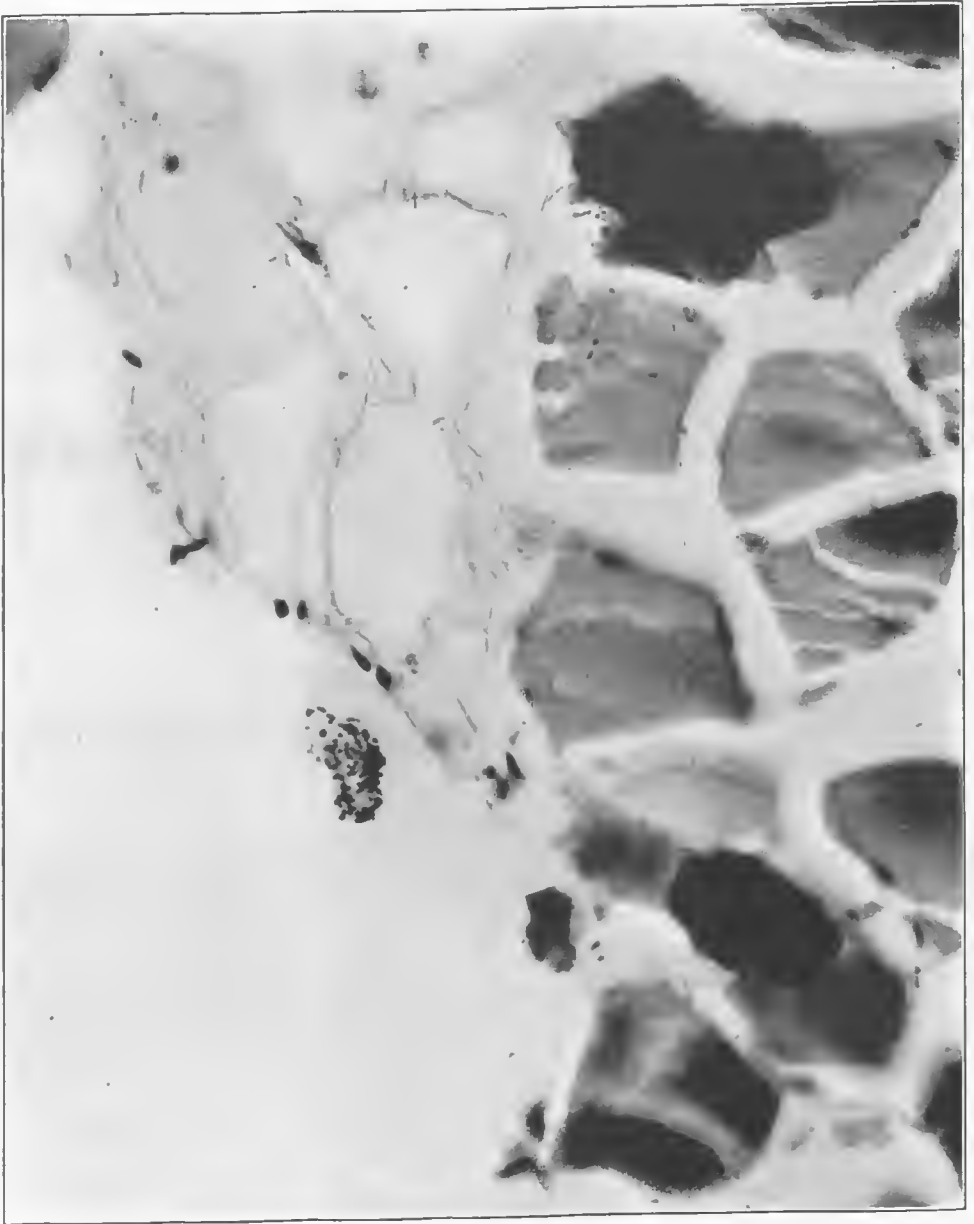


FIG. 250.—Section is from the gastrocnemius which shows the emphysematous reaction. The muscle is split by gas and there is a chemical change of the muscle fibers as indicated by retention of the basic dye. Numerous coccoid organisms are visible. Accession number 2892, Army Medical Museum. Negative number 46291. MacCallum stain; $\times 640$



FIG. 251.—Mid section of the thigh amputated in the upper third, with thrombosis of the femoral artery and vein and marked gaseous gangrene of muscle bundles on both sides of these vessels. Accession number 2789, Army Medical Museum. Negative number 30881



FIG. 252.—Mid vertical section in the upper portion of the thigh with fracture through the condyles. There is marked secondary infection of the bone marrow of all fragments, and an extensive gas gangrene with massive gas accumulation along fascial planes. Accession number 2789, Army Medical Museum. Negative number 30880

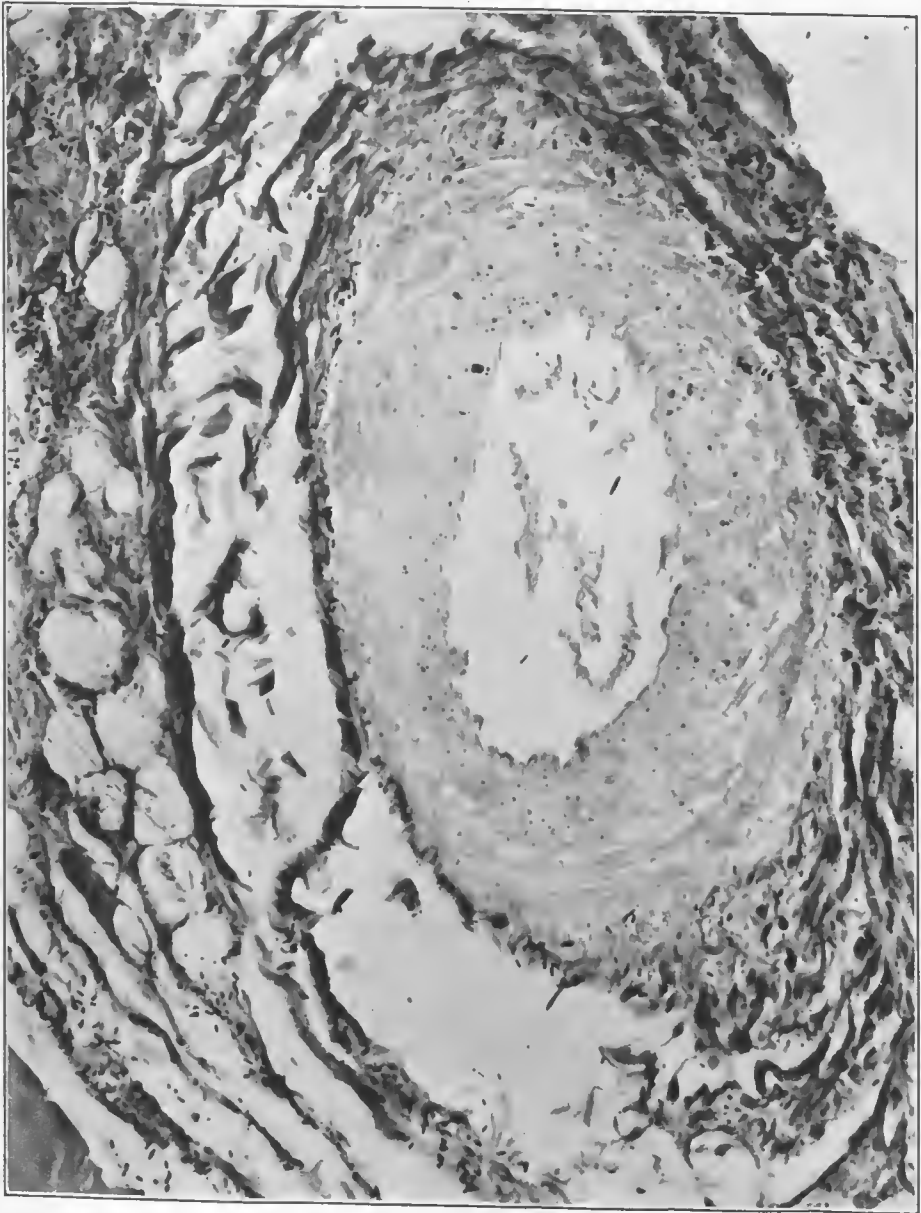


FIG. 253.—Cross section through a medium-sized artery. There is an extreme shredding of the adventitia of this vessel, with gaseous gangrene of the muscular coat. The bulk of this damage is probably due to the effect of the missile and indicates a rupture of the vessel above or below this point. With the rupture below, this is the typical form produced by the missile at a distance from the injury through hydraulic transmission of the force, which resulted in the massive secondary hemorrhages in these wounds. There are numerous bacteria in the walls of the vessel and its lymphatics. One rounded rod occupies a gas bubble in the muscular coat. Accession number 2789, Army Medical Museum. Negative number 46074. MacCallum stain; $\times 235$

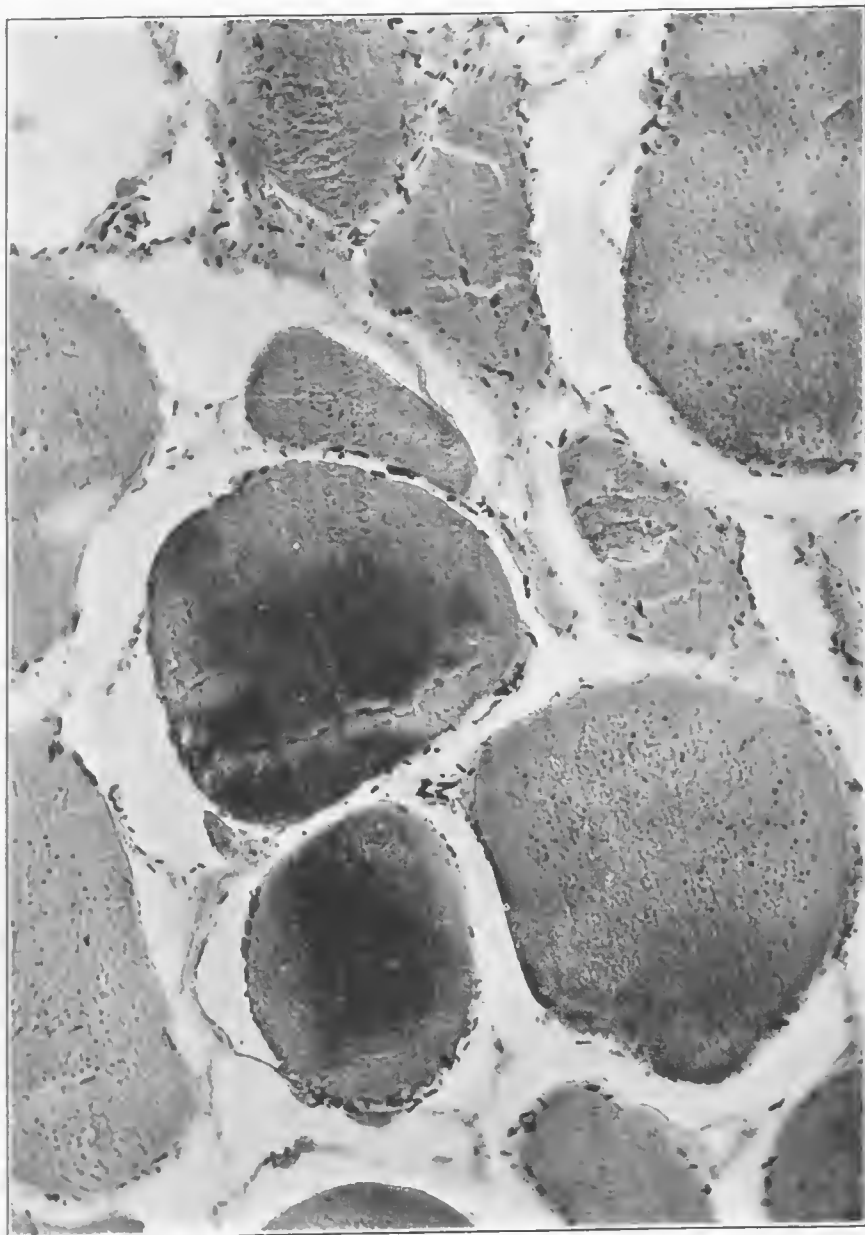


FIG. 254.—Cross section of muscle fibers from the putrefactive area. There is a granular hemoglobin detritus in all fibers, extensive chemical in the two central fibers, indicated by retention of the basic dye, and numerous accumulations of gas around muscle bundles. Bacteria are numerous and are all Welch bacilli, as is indicated by form and staining reaction. Accession number 2789, Army Medical Museum. Negative number 46053. MacCallum stain; $\times 465$

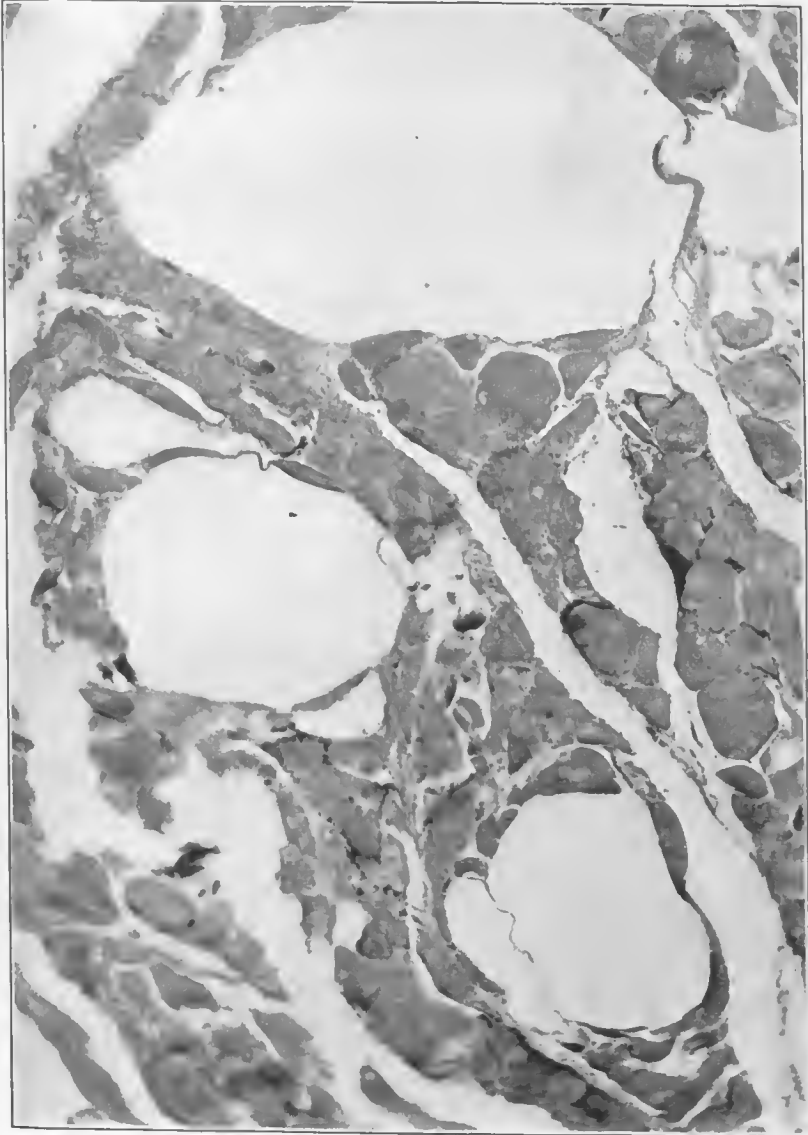


FIG. 255.—Muscle fibers from a gangrenous area showing large gas bubbles in muscle bundles. Accession number 2789, Army Medical Museum. Negative number 46056. MacCallum stain; $\times 125$

CASE 13.—Gunshot wound of left arm with comminuted fracture of the lower third of humerus, complicated by gas gangrene. Wound of entrance on posterior surface; large wound of exit on anterior surface with hernia of biceps muscle. Amputated limb shows gas gangrene in the muscles of the forearm with considerable putrefactive change in the tissues of the upper arm. The skin, over tissue filled with gas, is greenish in color and there is separation of the tissues along fascial planes as a result of the accumulation of gas. (See figs. 266 to 272, inclusive.)

CASE 14.—Soldier was wounded by fragment of high explosive shell, resulting in a compound comminuted fracture of the femur followed by the toxic type of gas gangrene. The specimen consists of the amputated thigh showing a debrided wound on the anterior surface whose base is covered with a shaggy exudate. (Fig. 273.) This thigh shows an extreme swelling due more to edema than to gas. The wound shows the extent of this swelling by the bulging of its edges. There is a moderate amount of blackening of the skin around this wound. This is a typical example of the toxic type of gas gangrene. (See figs. 273 to 275, inclusive.)

The mixed form of gas gangrene was a combination of the three types and presented all of their features. It stood third in the scale of virulence, and occasionally was found among the avirulent forms. There was usually a fairly pure infection of the deep muscles by either *B. welchii*, *V. septique* or *B. oedematiens*, with invasion of the edematous fascial planes and lymphatic structures by the putrefactive anaerobes. The deeper muscles were brick red or pale, and were dry or moist, according to the bacteria producing the lesion. The putrefactive infection blackened connective tissues around lymphatics, and only tended to involve the exposed muscles in the base of the débrided wounds of entrance and exit. The following cases illustrate this type of gas gangrene.

CASE 15.—Soldier was wounded October 25, 1918, by high explosive shell; died October 28, from sepsis and gas gangrene. Specimen consists of a left leg showing a severe, compound comminuted fracture of both bones, and penetrating gun-shot wounds.

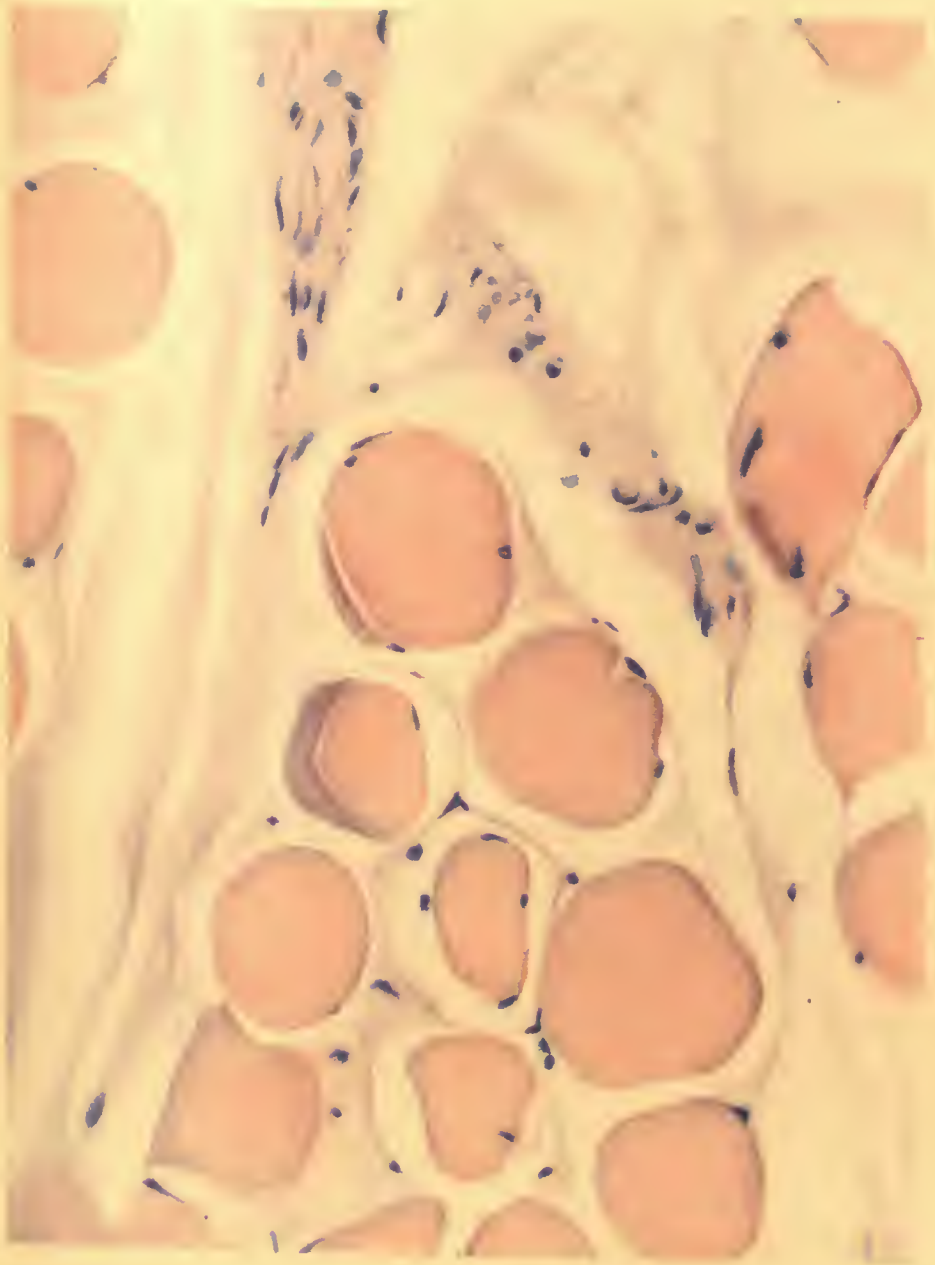
There is a wound, 3 by 5 cm., at the middle of the tibia in the anterior midline and another 2 by 3 cm., 2 cm. inferior and 3 cm. posterior to the internal malleolus.

The X ray shows many foreign bodies and shell fragments, posterior to an extremely comminuted fracture of the tibia, at the middle third, and oblique fracture of the fibula at the same level. There are multiple foreign bodies in the region of the os calcis, one measuring $1\frac{1}{2}$ by $2\frac{1}{2}$ cm. in the midline just below the posterior margin of this bone. (See figs. 276 to 283, inclusive, and Pls. XX and XXI.)

CASE 16.—Soldier received a high explosive shell wound of the popliteal space July 21, 1918. Wound of entrance was two inches above the popliteal space and there was a fragment of shell in the joint. The limb was amputated in the upper third of the right thigh on July 22, for gas gangrene, approximately 60 hours after receipt of the wound.

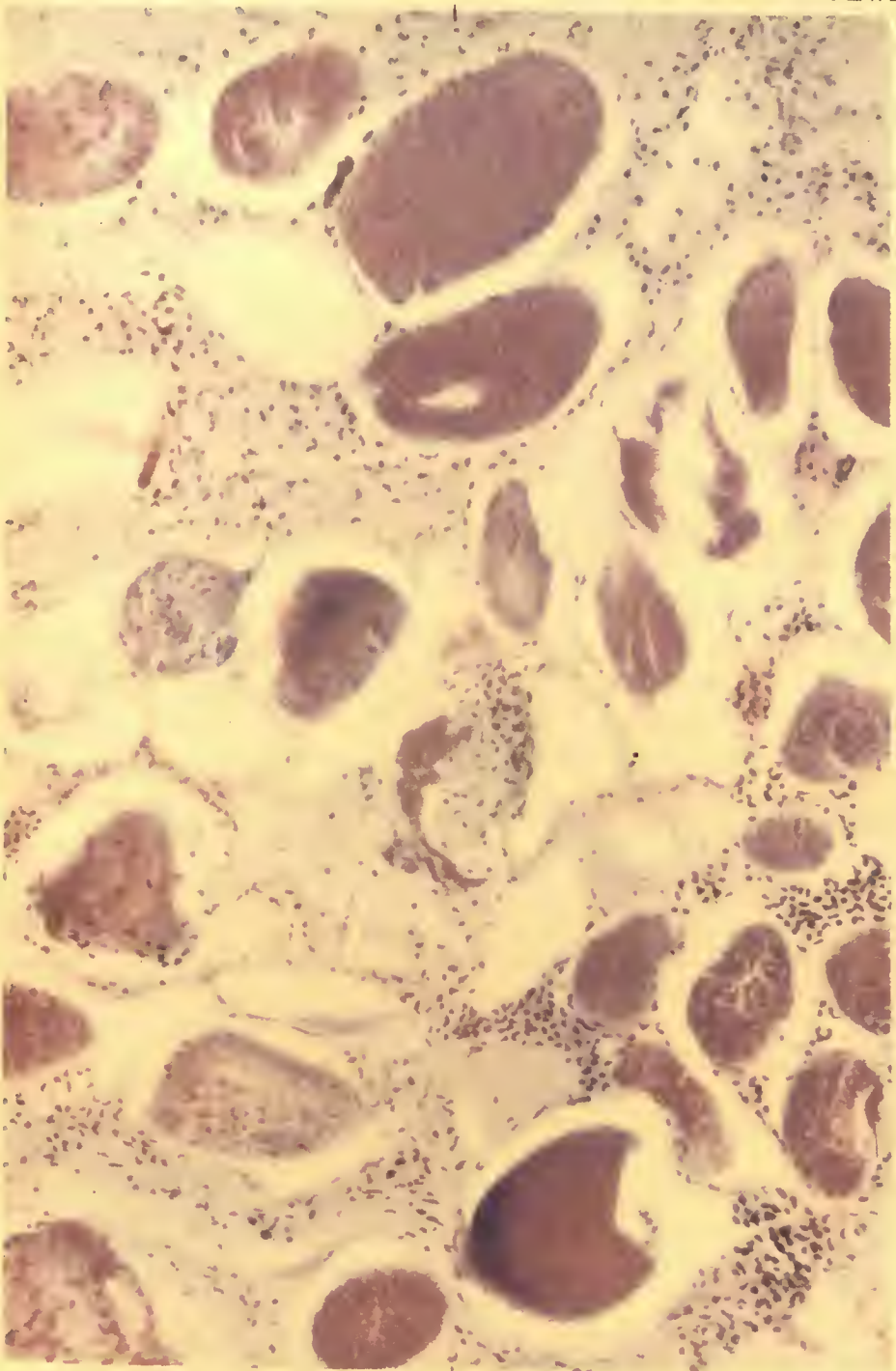
The amputated limb shows discoloration of the skin in the popliteal space and a small entrance wound. On dissection the popliteal nerve is found to be partially severed; the popliteal vein is ruptured laterally; the artery is completely severed and the surrounding tissues are impregnated with blood. The knee joint contains reddish fluid and the synovial membrane is red in color. There is some gas in the surrounding muscles and areolar tissue, which extends also into the muscles of the thigh and upper calf. (See figs. 284 to 287, inclusive.)

CASE 17.—Wound by high explosive shell fragment through the lower third of the leg. Specimen consists of the lower half of the leg from which the foot has been removed, by disarticulation at the ankle. On the internal side there is a large débrided wound. There is an oblique fracture of the tibia, 9 cm. from the lower end and a transverse fracture of the fibula at about the same level, the ends of this bone being separated by intervening muscle. The tissues show gas gangrene. There are several foreign bodies about the fractured bones including a shoe islet in the tissues a short distance from and opposite the lower end of the tibia. (See figs. 288 to 294, inclusive.)



NECROTIC MUSCLE FIBERS.

Variation in staining due to chemical changes. (See Fig. 262).
Accession 2891, Army Medical Museum. H. & E. stain. Autochrome.



A. HOEN & CO.

GAS GANGRENE.

Cross section of muscle from an area of toxic edema near the wound tract. Contamination with pyogenic bacteria. Necrotic muscle fibers show variations in their affinity for the dyes.

Accession 2891, Army Medical Museum. MacCallum stain. Autochrome.

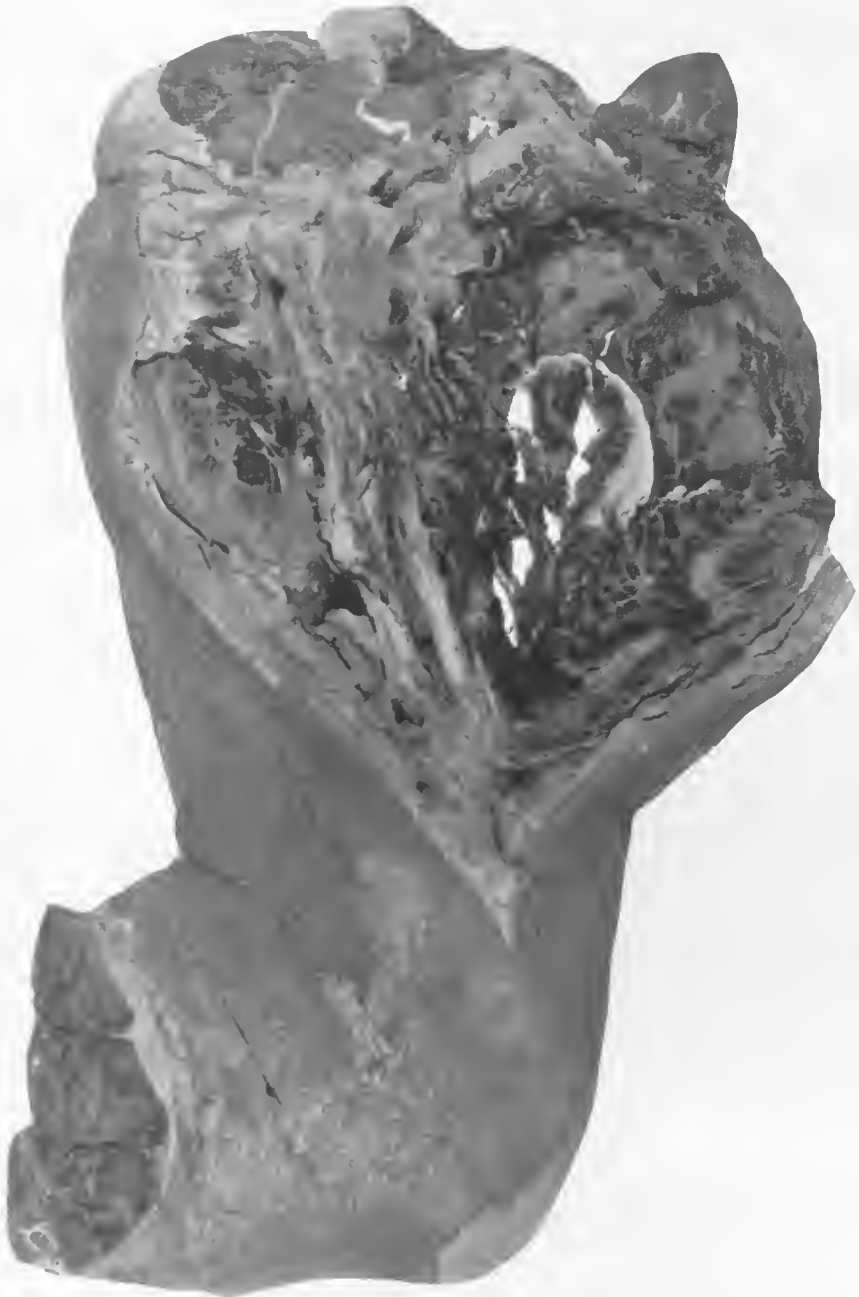

FIG. 256.—Right arm amputated through the surgical neck of the humerus, showing a large debrided wound of the inner aspect which runs from the site of amputation to the inner condyle. The lower arm has been cut away, as it showed no lesion. Débridement was apparently done to remove all the damaged muscle and to assure the operator of the condition of the main nerves and arteries. There is little exudate on this wound except over the belly of the biceps, which appears to be swollen and contains a few gas bubbles. Accession number 2891, Army Medical Museum. Negative number 32076



FIG. 257.—Anatomical dissection of the arm shown in the preceding figure done to illustrate the injury to the musculospiral nerve. It shows beginning gangrene of a putrefactive character around a hemorrhage opposite the upper end of the lower fragment of the humerus, which has extended into the musculospiral sheath at this level. Except for this hemorrhage the nerve at this point is uninjured. There is some blackening of the skin in the bend of the elbow, secondary to a putrefactive gangrene at this point. The X ray of this specimen does not reveal any gross evidence of gangrene. Accession number 2891, Army Medical Museum. Negative number 32077

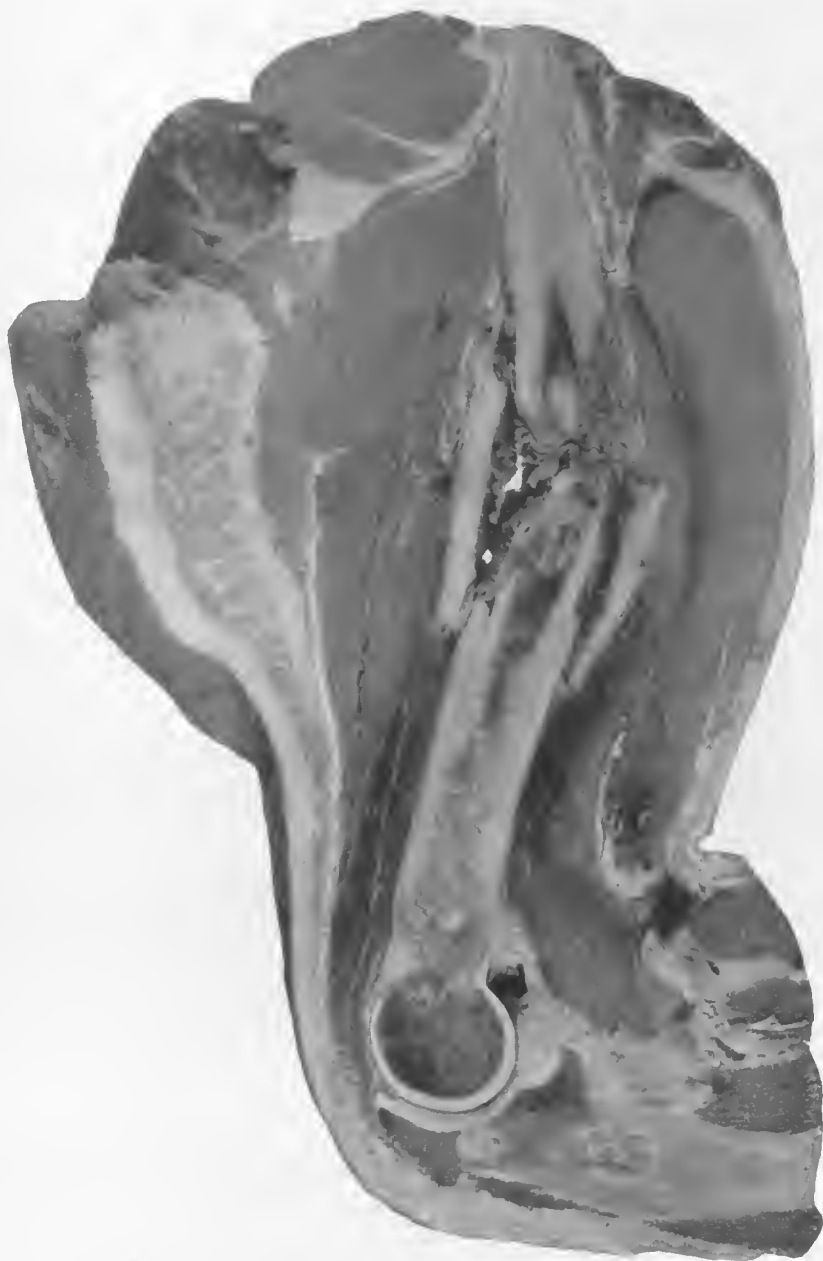

FIG. 258.—Mid section of the arm of the preceding figures showing a beginning putrefactive gangrene around the lower third of the humerus, with some accumulation of gas bubbles in the muscles above this area. There is a fibrinous exudate around the fracture which extends into the marrow of both fragments. The muscles around this point show lack of texture and color typical of the toxic or edematous type of gas gangrene. Accession number 2891, Army Medical Museum. Negative number 32072

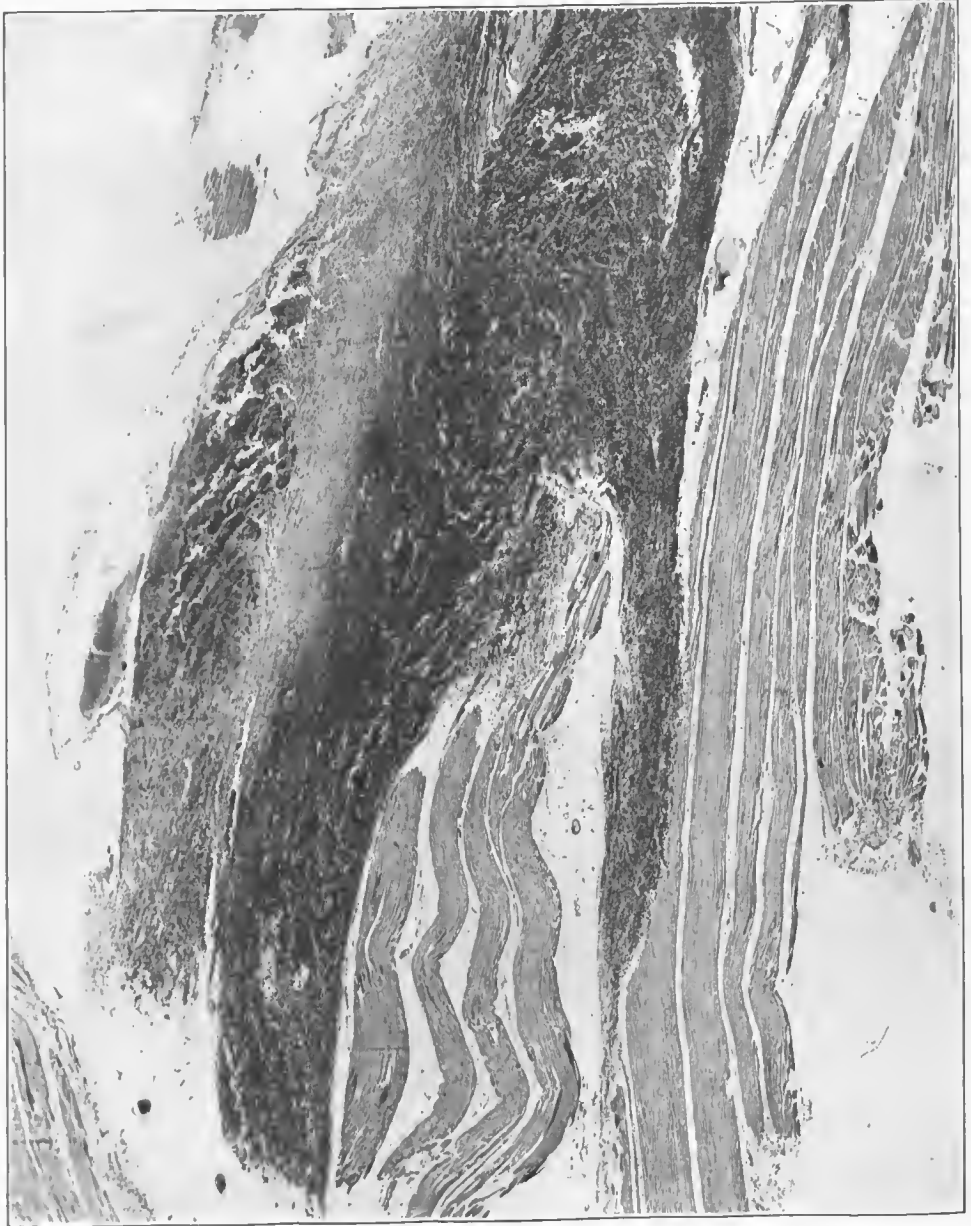

FIG. 259.—Section from the edematous muscle around the fractured humerus. There is evidence of gross damage to the muscle due to trauma, massive hemorrhage with edema, and beginning gangrene of the muscles, which are infiltrated with blood. There are numerous small accumulations of edematous fluid throughout. Accession number 2891, Army Medical Museum. Negative number 45628. Hematoxylin and eosin stain; $\times 13$

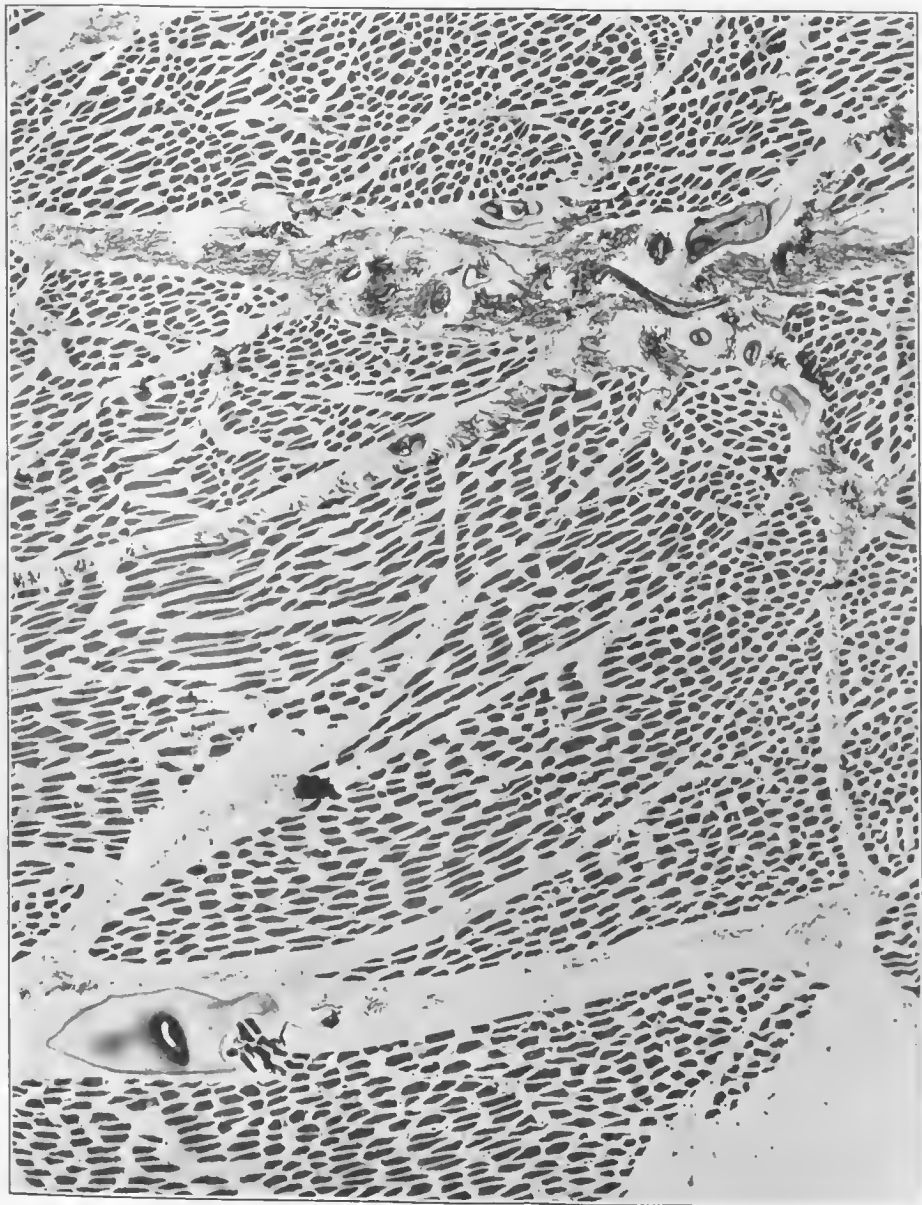

FIG. 260.—Section from the margin of the gangrenous reactions around the fracture. There is marked edema along the fascial plane in the upper portion of the picture and a large accumulation of edema fluid in the lower left-hand area. There is beginning accumulation of gas between muscle bundles. Accession number 2891, Army Medical Museum. Negative number 45631. Hematoxylin and eosin stain; $\times 23$

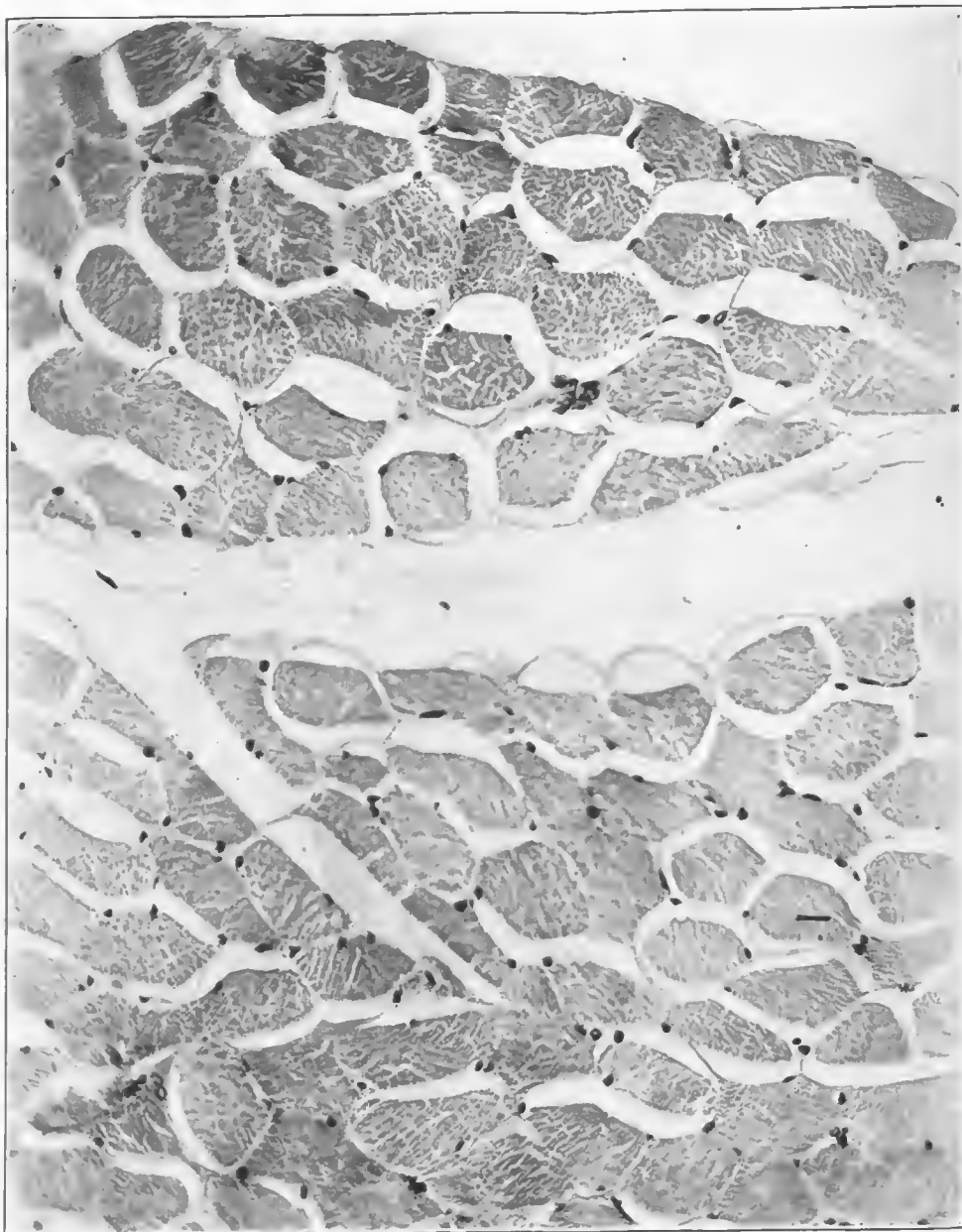


FIG. 261.—Section taken from the area between the emphysematous and edematous areas of gangrene. It shows extreme edema between muscle fibers and their envelopes, and between muscle bundles, and a beginning formation of gas within muscle fibers. It is a typical example of the tissue changes in the toxic form of gas gangrene which, if it does not cause amputation or kill, goes on to the pure emphysematous type. Accession number 2891, Army Medical Museum. Negative number 45626. Hematoxylin and eosin stain; $\times 290$

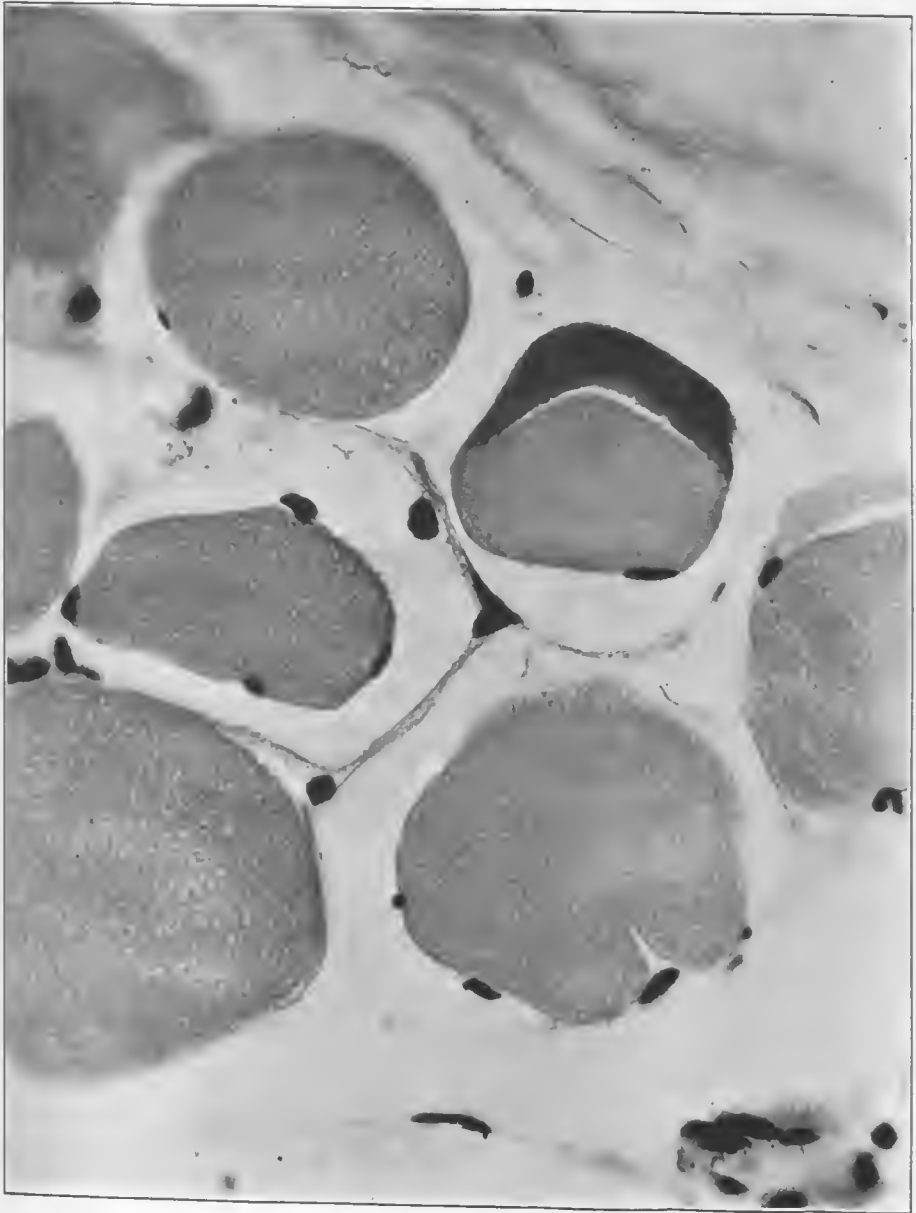


FIG. 262.—Cross section of muscle fibers from the typical edematous area of gangrene. It shows massive edema everywhere within muscle envelopes and between muscle bundles. There is a beginning accumulation of free gas bubbles within all of the fibers. There is pyknosis of muscle nuclei and a ground-glass appearance of the fibers, one of which shows a crescent of liquefied material within the fiber itself. This crescent has undergone a chemical alteration which results in an affinity for the basic dye. Accession number 2891, Army Medical Museum. Negative number 45624. Hematoxylin and eosin stain; $\times 710$.

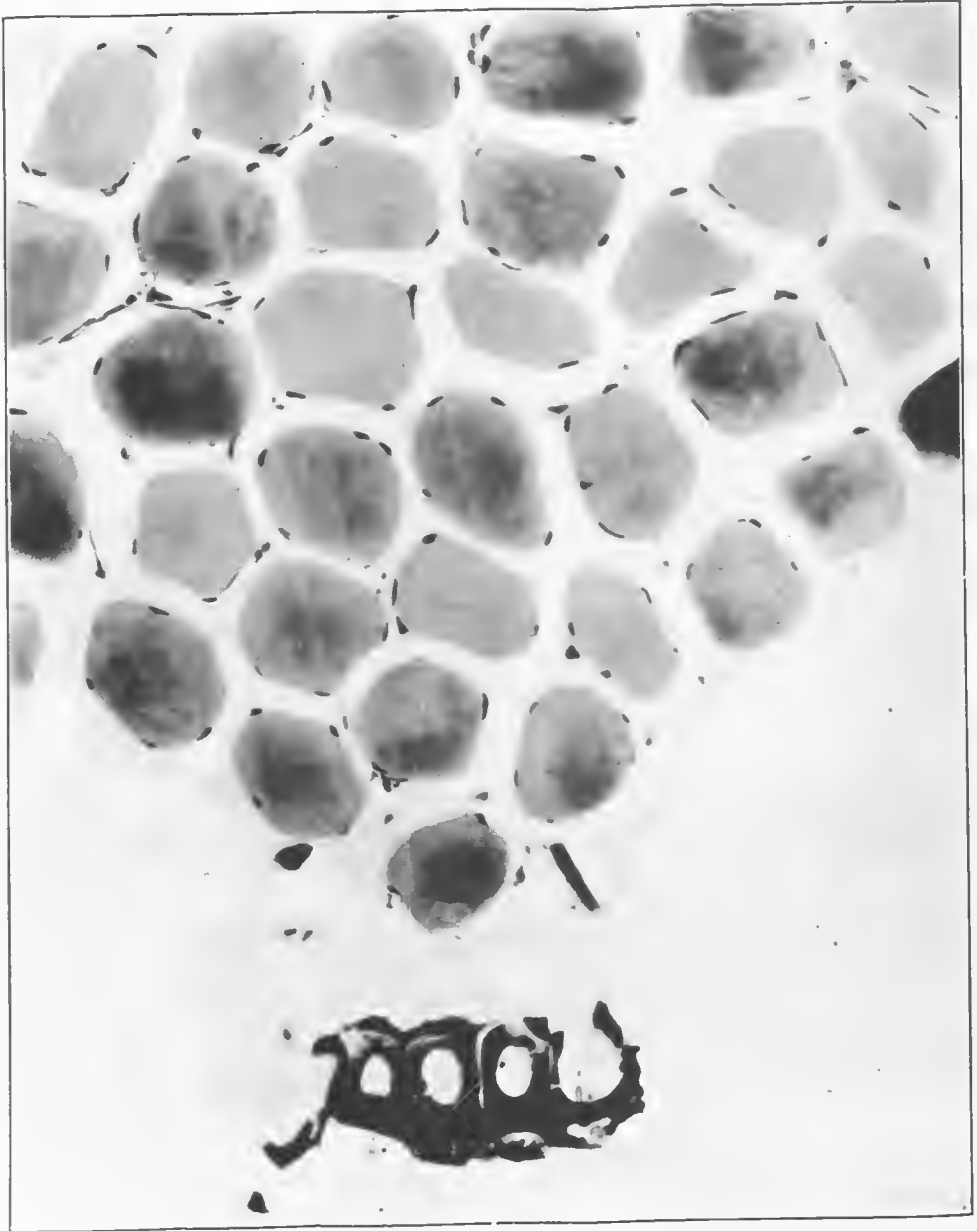


FIG. 263.—Section from an area near the wound tract showing a moderate amount of edema, a marked swelling and loss of markings in muscle fibers, with a moderate chemical alteration of these structures, as indicated by retention of the basic dye. The chemical change is secondary to a beginning emphysematous gangrene which forms acid in the tissues. The edema has separated muscle fibers about twice their normal distance, and the degeneration in them is marked by the intense pyknosis of the nuclei of the sarcolemma. In the lower portion of the picture is a cross section of a leaf carried in by the missile. Two other small foreign bodies lie near it. Accession number 2891, Army Medical Museum. Negative number 46000. MacCallum stain; $\times 285$

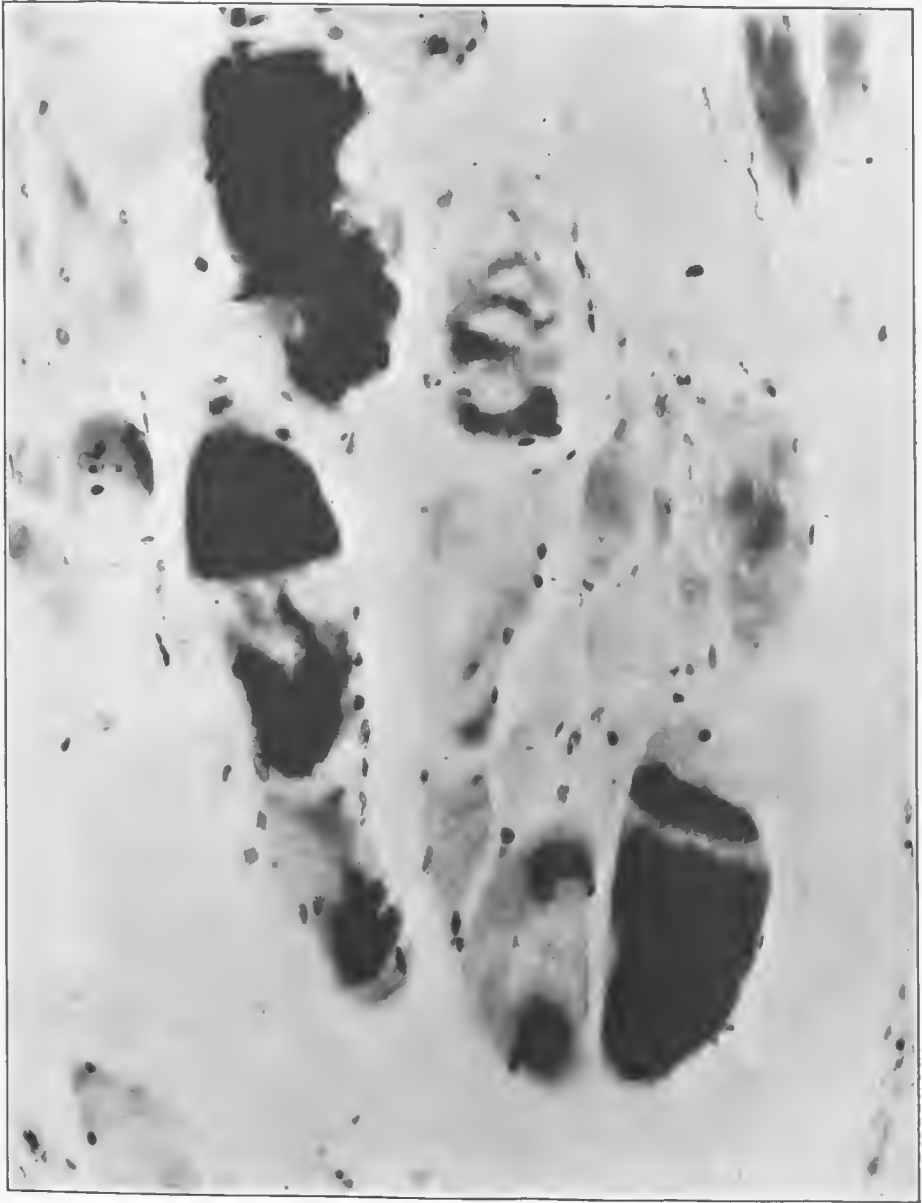


FIG. 264.—Section from the emphysematous area of gangrene in the biceps muscle, which shows a marked alteration in reaction of the muscle fibers to the basic dye. Portions of the myomeres in some of them appear jet black from the intensity of staining with crystal violet and basic fuchsin. Accession number 2891, Army Medical Museum. Negative number 46039. MacCallum stain; $\times 300$

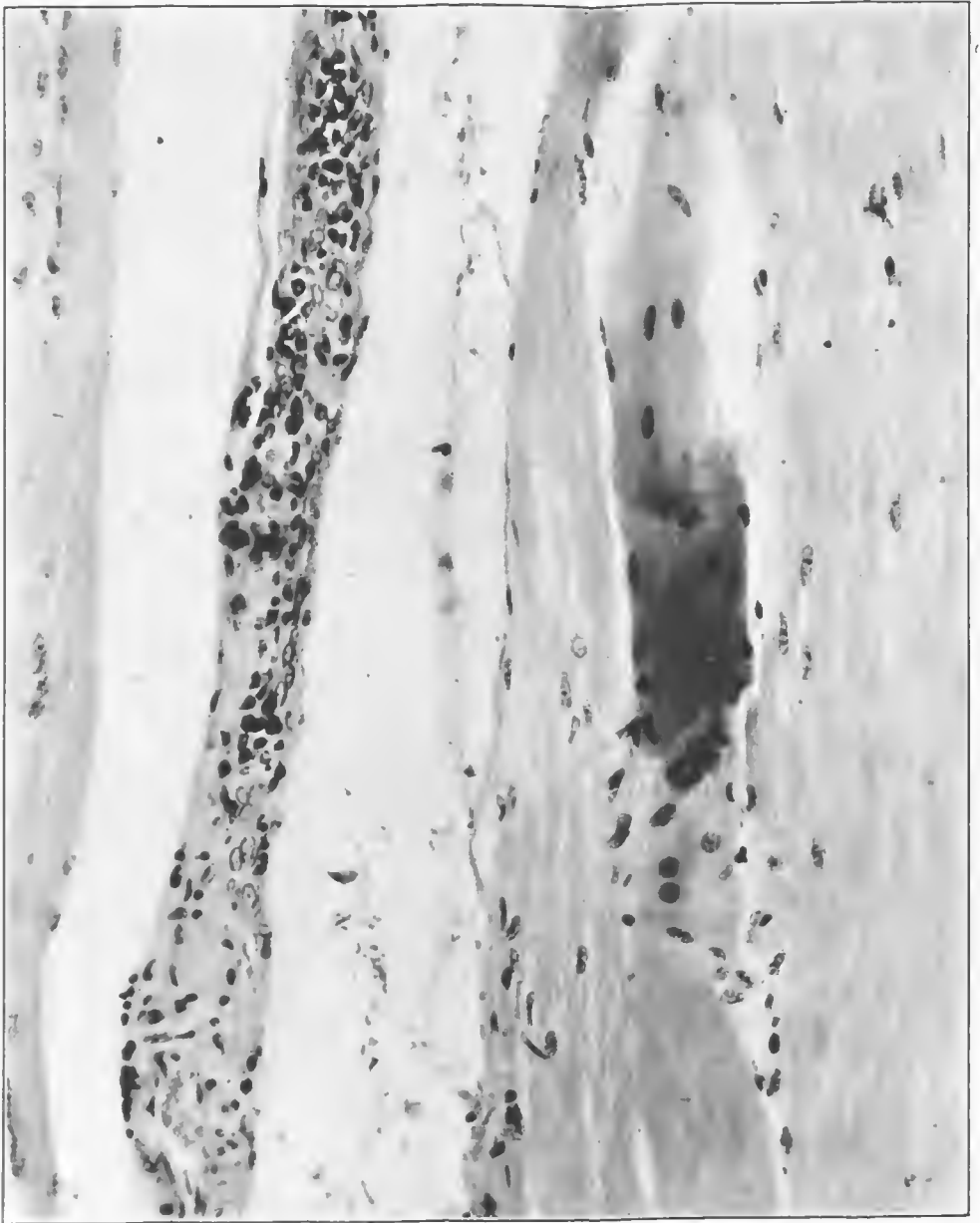


FIG. 265.—Section in close relation to the wound tract, showing an early regeneration of muscle fibers. Considerable edema is between muscle bundles. Accession number 2891, Army Medical Museum. Negative number 46037. Hematoxylin and eosin stain; $\times 250$

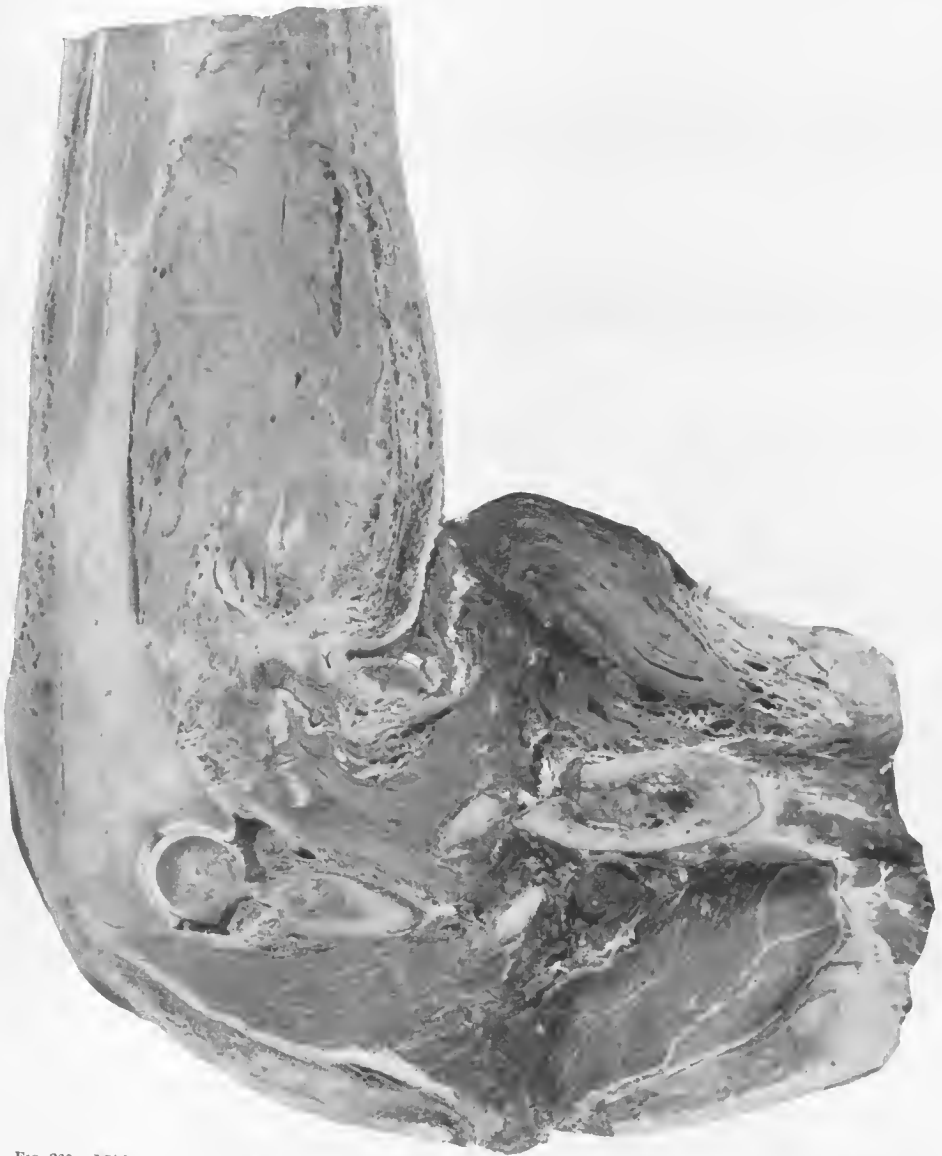

FIG. 236.—Mid section of the left arm showing an emphysematous gangrene around a fracture of the humerus. Numerous gas bubbles are in the biceps, and an advanced putrefactive and edematous process is in the triceps muscle. The muscles of the forearm show advanced autolysis, probably due to vessel injury at the site of fracture. Accession number 2797, Army Medical Museum. Negative number 32079

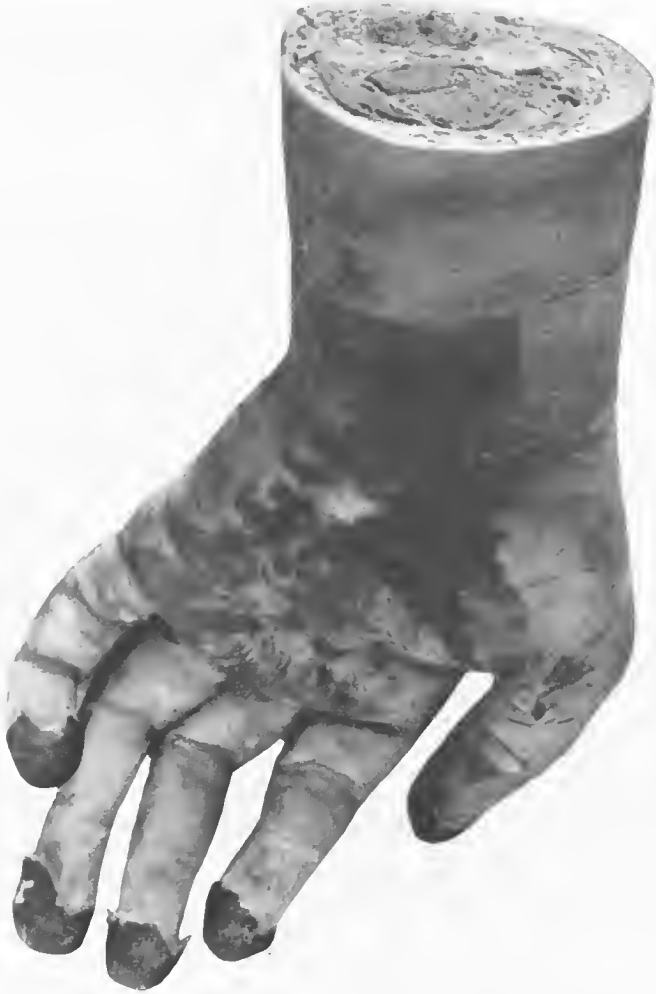

FIG. 257.—Palmar surface of the left hand with the typical gangrene due to complete failure of the blood supply, the end result of the process of autolysis of the muscles noted in the forearm in the preceding figure. Accession number 2797, Army Medical Museum. Negative number 46254.

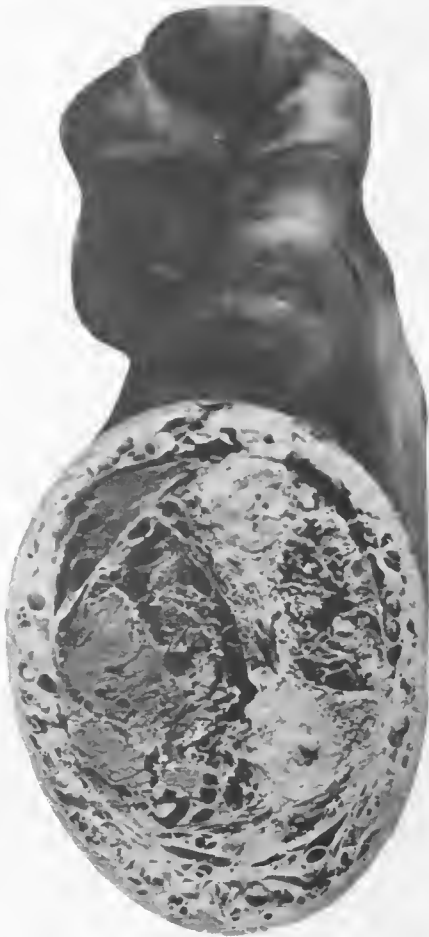

FIG. 268.—Cross section of the forearm showing the emphysematous process well established in the muscles and connective tissues of the wrist, as evidenced by the numerous gas bubbles. Accession number 2797, Army Medical Museum. Negative number 46252



FIG. 269.—X ray showing accumulations of gas around the point of fracture in the muscles of the upper arm and between the radius and ulna in the lower arm. Accession number 2797, Army Medical Museum. Negative number 46258

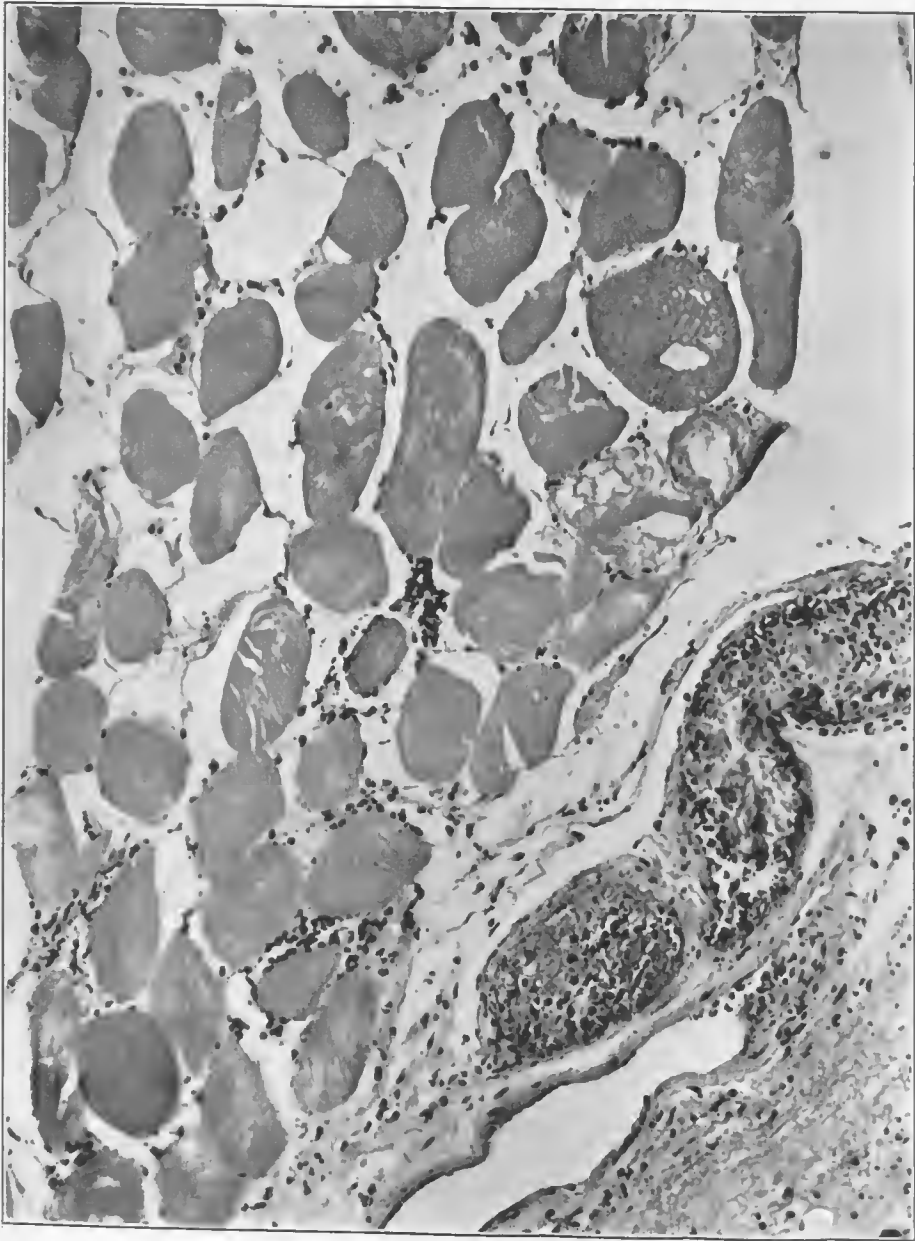


FIG. 270.—Muscle fibers cut in cross section near vessels. There is a loss of normal markings of muscle fibers. One fiber in cross section shows an accumulation of gas and hemoglobin detritus. Occasional gas bubbles are between the fibers. There is an infected thrombus in the vessel with surrounding edema and gaseous infiltration. Accession number 2797, Army Medical Museum. Negative number 45993. Hematoxylin and eosin stain; $\times 210$

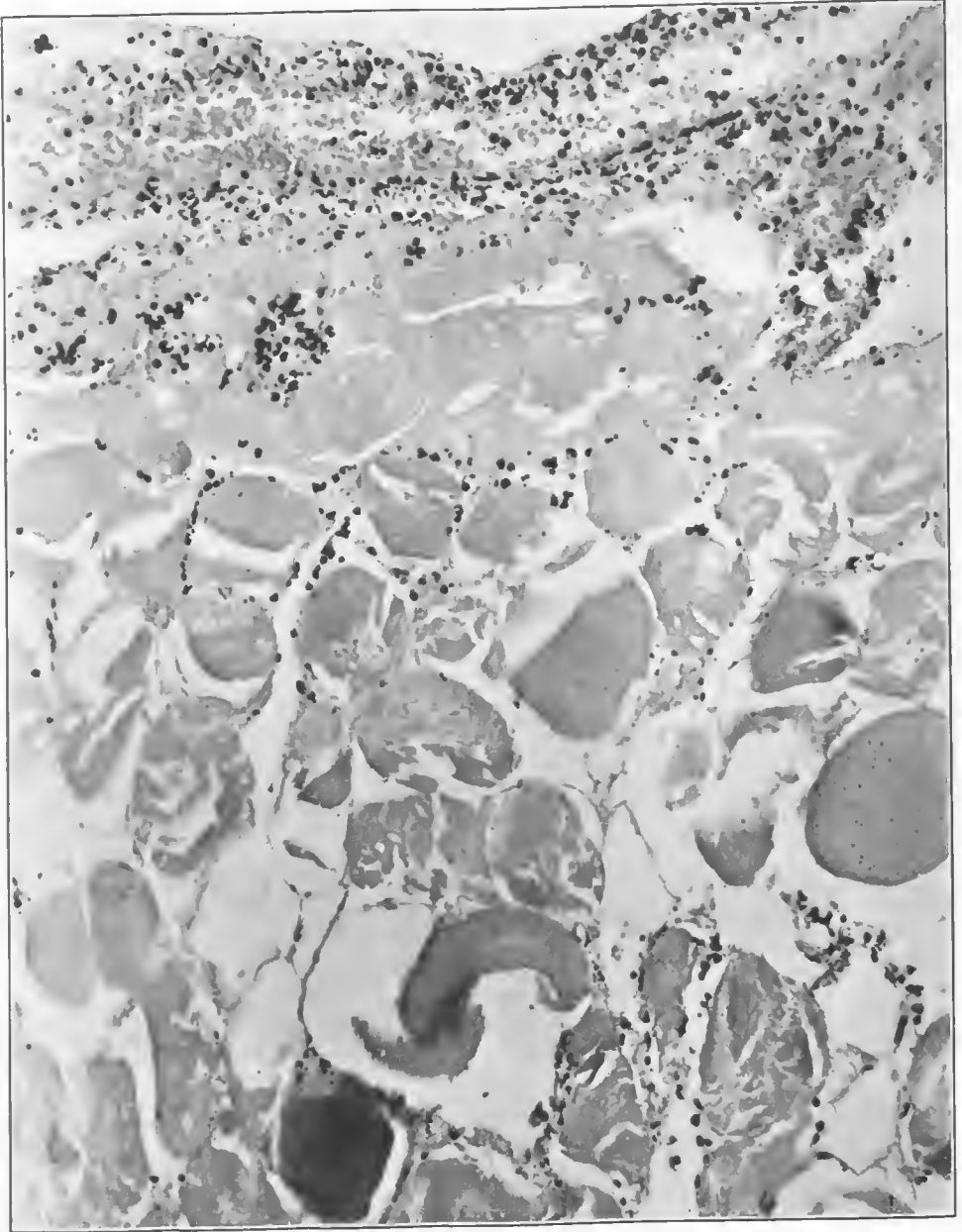


FIG. 271.—Section from the same area as the preceding figure, showing a leucocytic exudate in the débrided wound and considerable rupture of muscles due to gas bubbles. One muscle fiber shows coarse scattered hemoglobin detritus. Accession number 2797, Army Medical Museum. Negative number 45994. Hematoxylin and eosin stain; $\times 235$

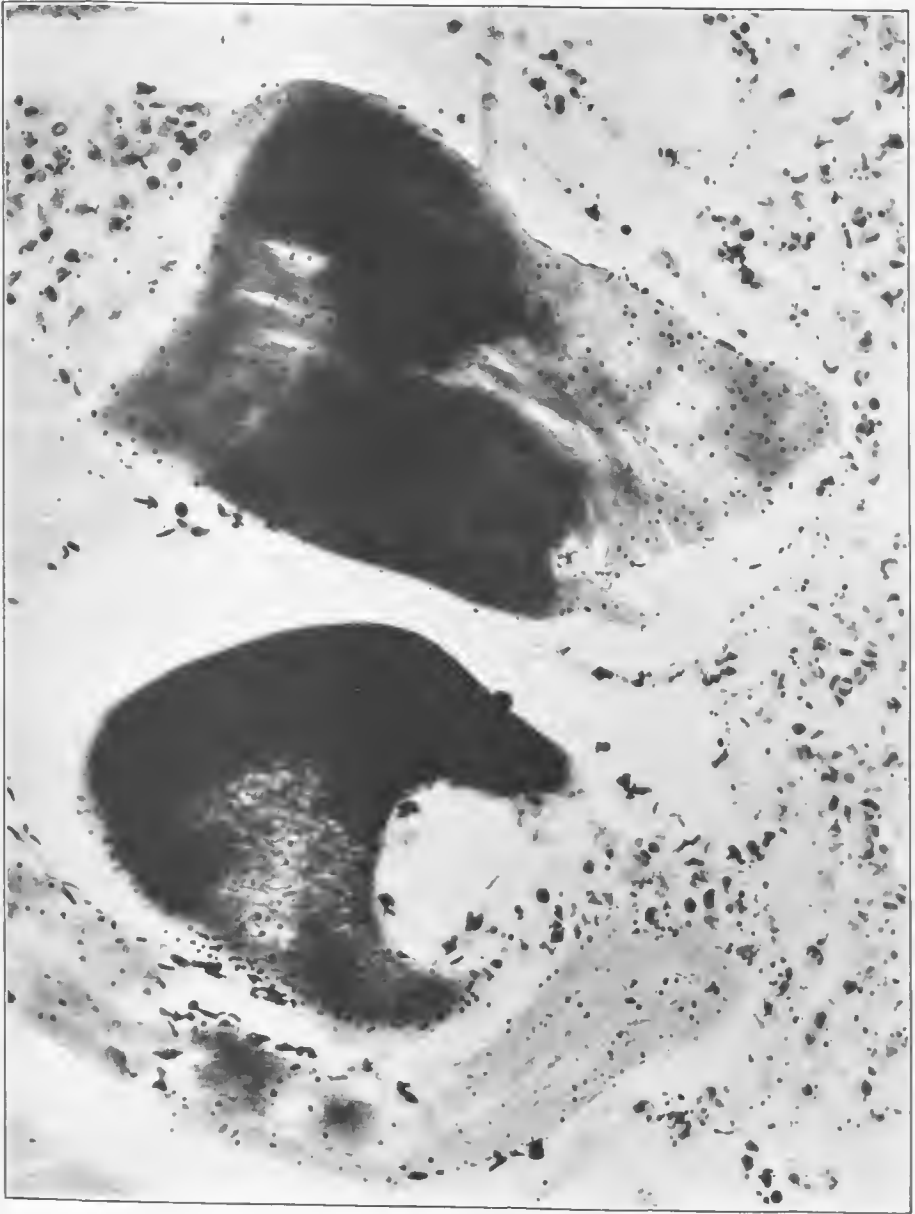


FIG. 272.—Section of gangrenous muscle, showing marked chemical alteration, probably due to the acid-forming power of these bacteria and evidenced by the intense basic staining of parts of the fibers. One fiber shows a solution of the muscle tissue, the cavity containing Gram-positive and Gram-negative rods. Both fibers show blood detritus. There is a moderate leucocytic reaction. Coccoid forms and various sizes of Gram-positive and Gram-negative rods are present. Accession number 2797, Army Medical Museum. Negative number 46009. MacCallum stain; $\times 570$

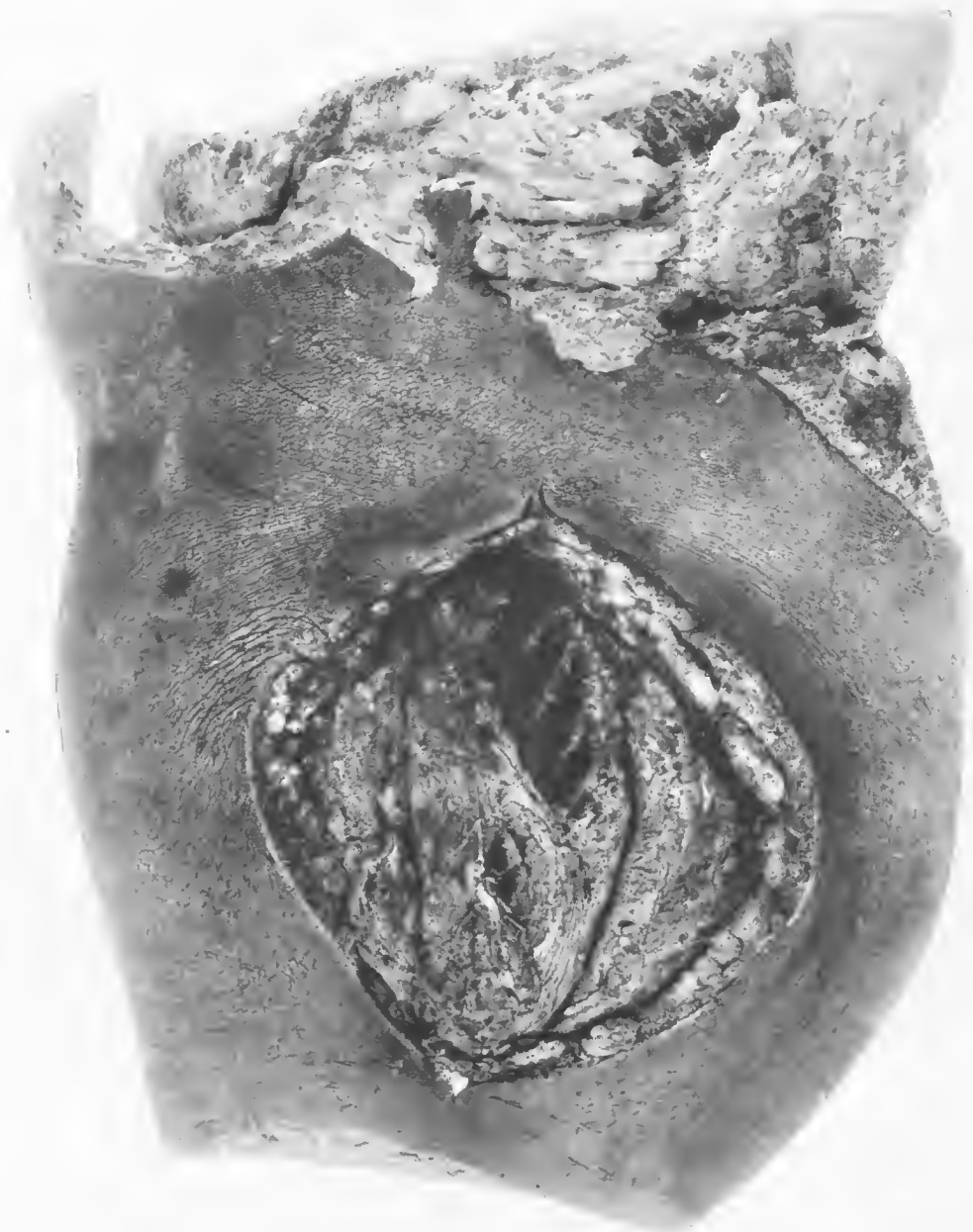

FIG. 273.—Debrided high-explosive shell wound of thigh. Secondary toxic edematous type of gangrene. Marked bulging of the muscles forcing the edges of the wound apart. Considerable blackening of the skin. Accession number 2923, Army Medical Museum. Negative number 31717

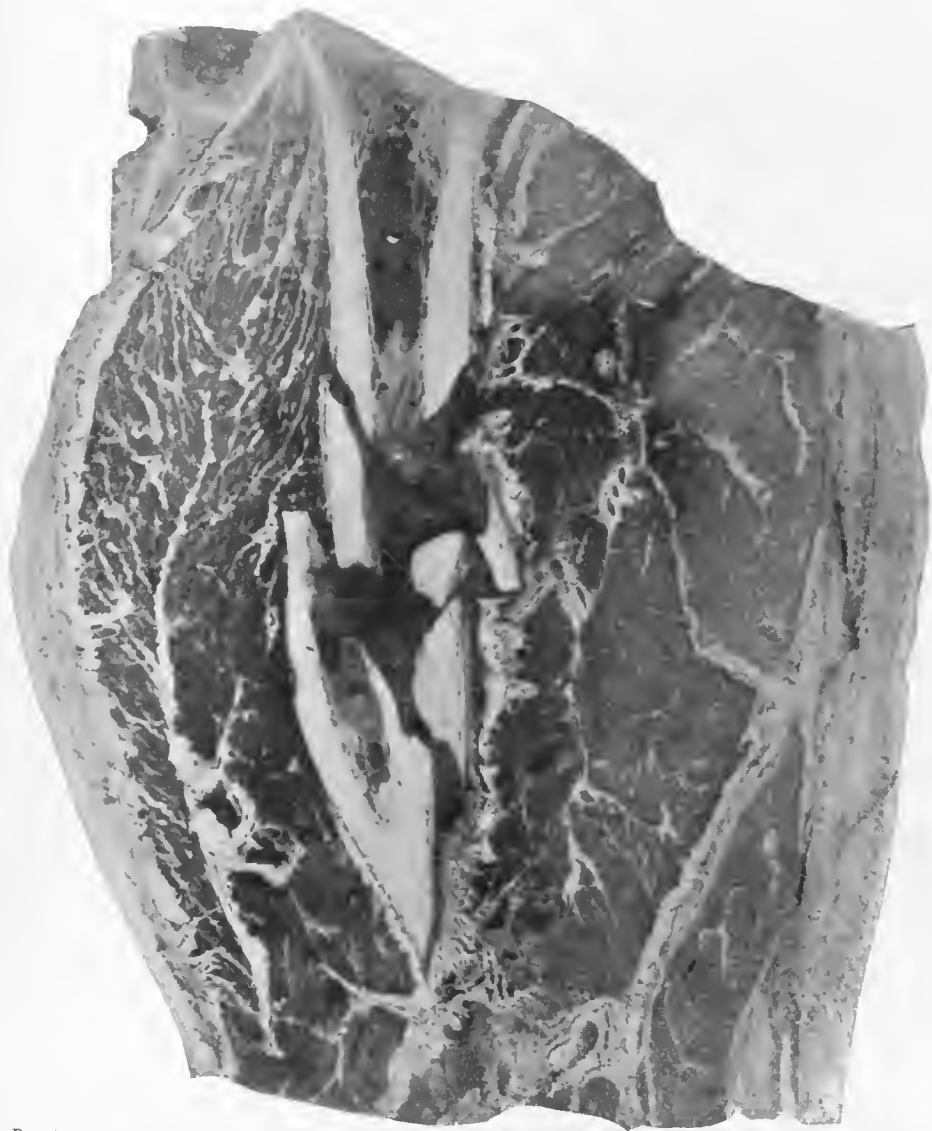


FIG. 274.—Mid section of the thigh through the fractured femur, showing a moderate amount of gas gangrene of the internal group of muscles and an extreme edema in the outer group. Accession number 2923, Army Medical Museum. Negative number 31716

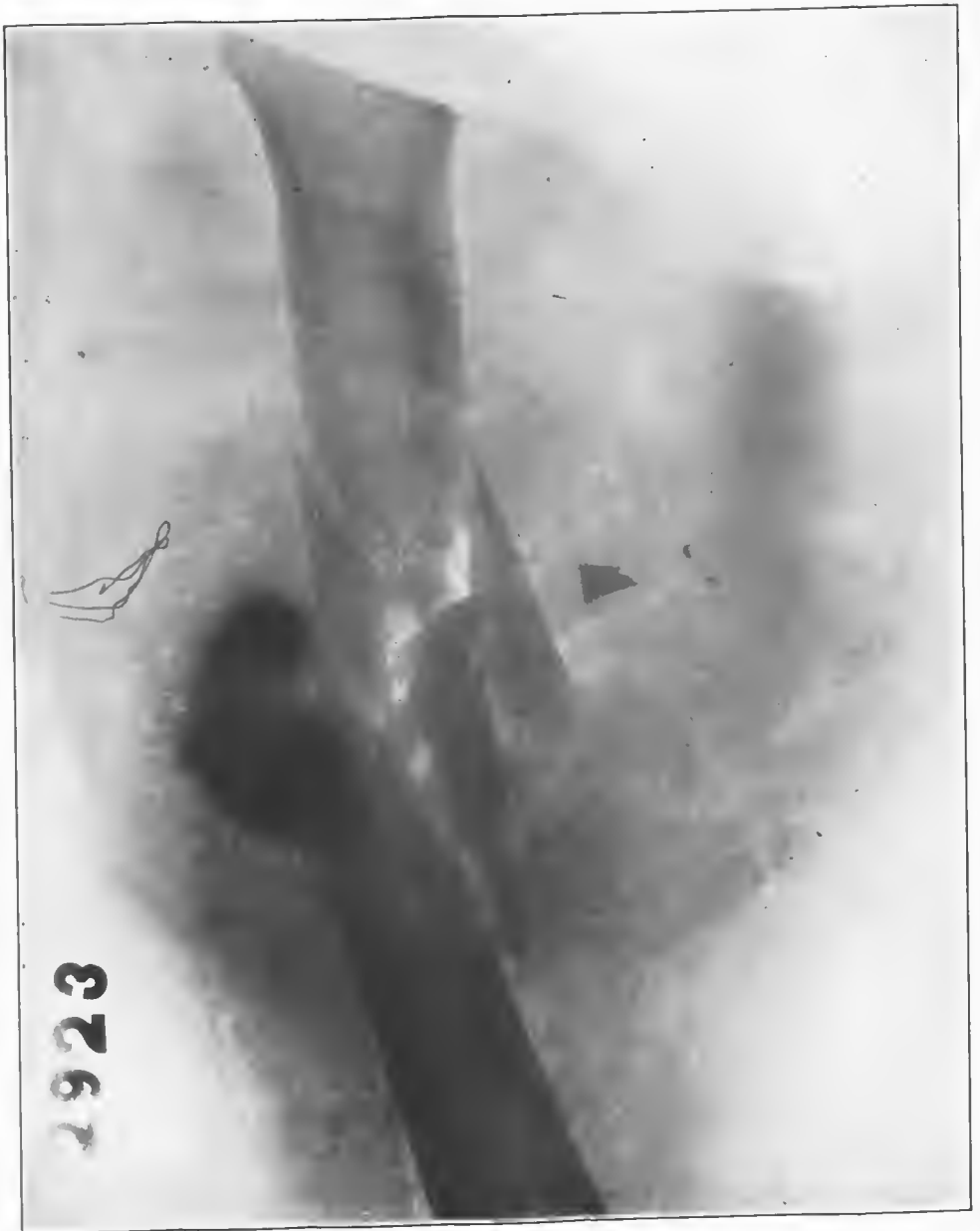


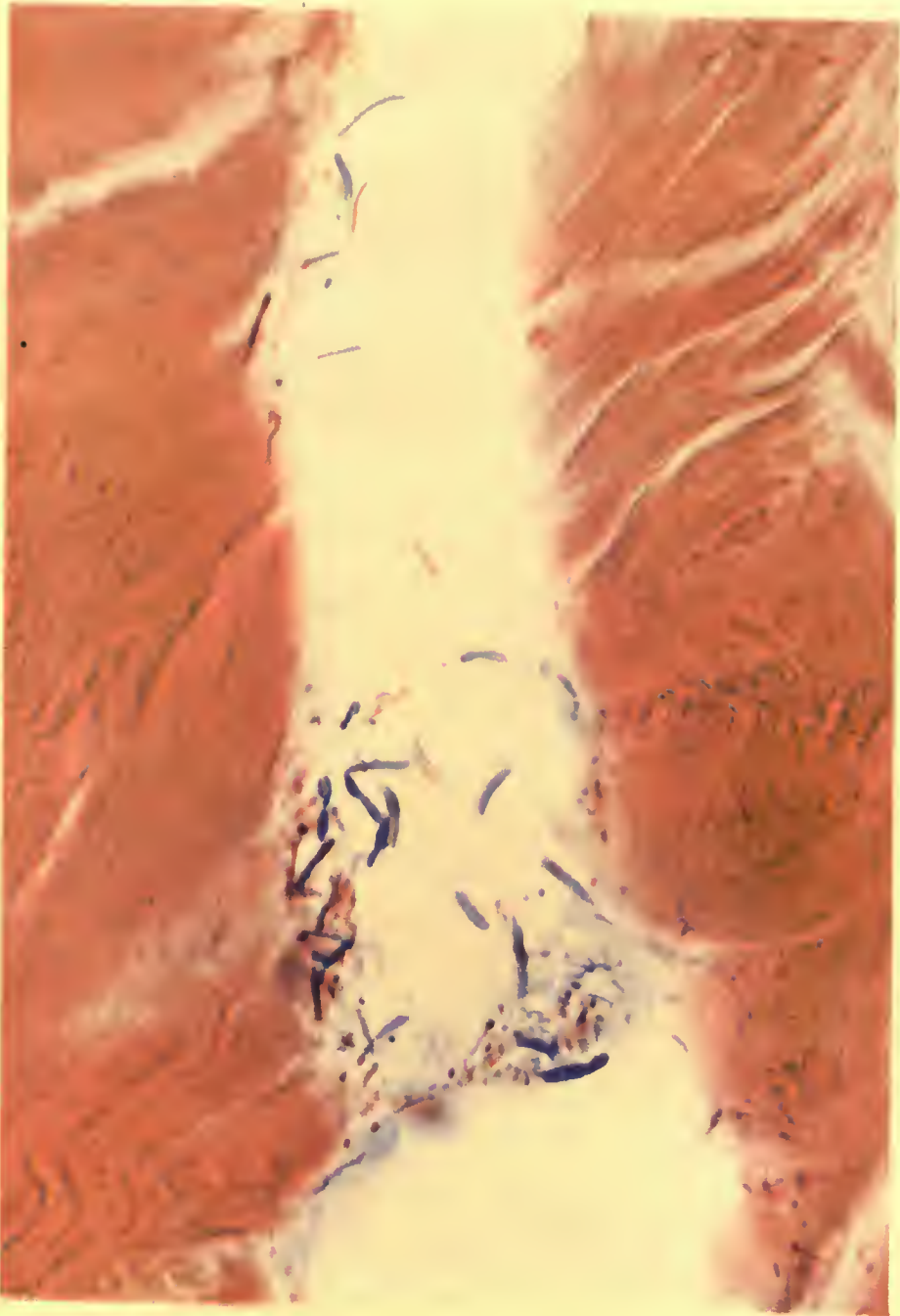
FIG. 275.—X ray of the specimen of the two preceding figures; shows a moderate amount of gas gangrene, comminution of the fracture, and a piece of high-explosive shell casing, probably of a small-caliber shell. Accession number 2923. Army Medical Museum. Negative number 46818



TYPICAL GAS GANGRENE OF CALF MUSCLES.

Darker color near bone produced by putrefactive organisms. Brick-red color of gas gangrene with separation of muscles by gas. Shell fragment 1 x 1½ cm. behind proximal fragment of tibia which shows purulent myelitis.

Accession 4711, Army Medical Museum. Colored photograph.



A HOEN & CO

PUTREFACTIVE GANGRENE.

Muscle fibers showing Gram-positive and negative rods and Gram-positive cocci.
Accession 4711, Army Medical Museum. MacCallum stain. Autochrome.



FIG. 276.—Anterior aspect of a vertical section of the left leg, showing a fracture of the fibula and tibia. A foreign body, apparently a piece of a medium-sized high-explosive shell, is internal to the lower end of the upper fragment of the fibula. The muscles of the calf above the fragment show a typical gas gangrene without much gas. The muscles and connective tissue below and internal to the foreign body show a putrefactive form of gas gangrene. Accession number 4711, Army Medical Museum. Negative number 30211

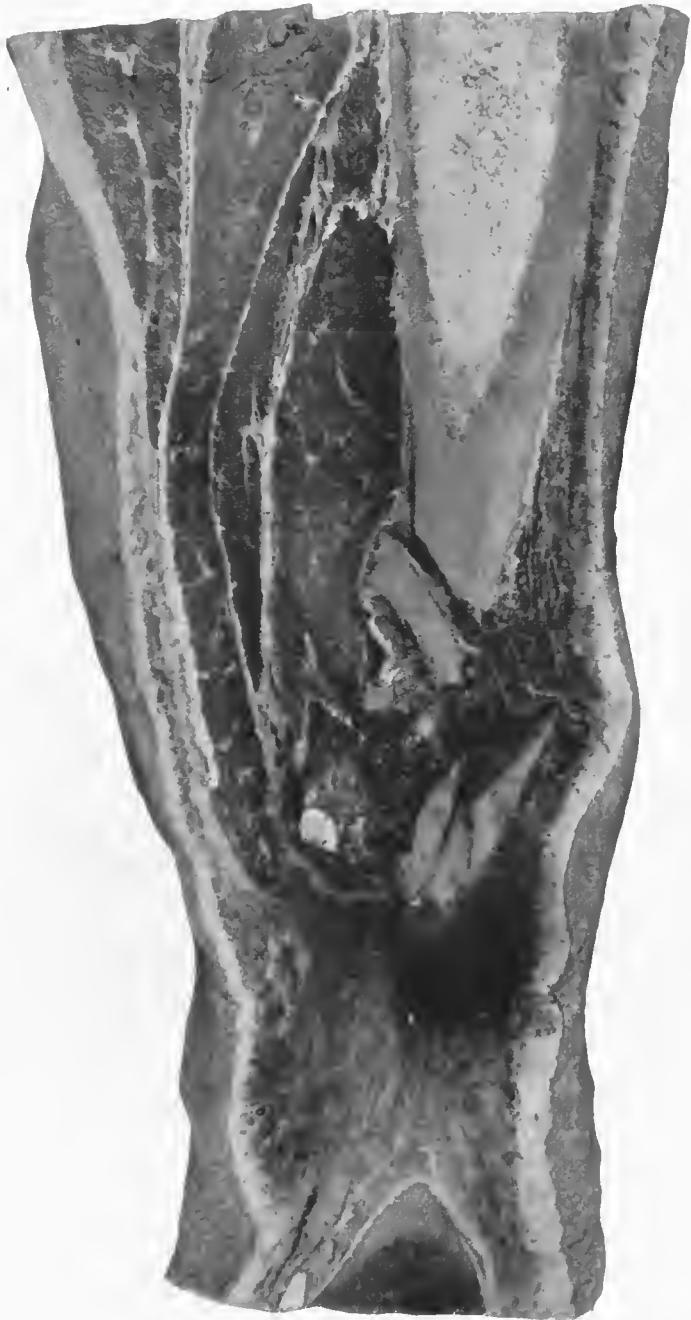

FIG. 277.—Posterior aspect of a vertical section through the middle of the tibia showing a comminuted fracture of this bone, with mixed putrefactive and edematous infection of the muscles about the upper end of the lower fragment and gas gangrene of the calf muscles above. The muscles show the typical brick-red change due to this process, though there are no massive accumulations of gas. Accession number 4711, Army Medical Museum. Negative number 30212

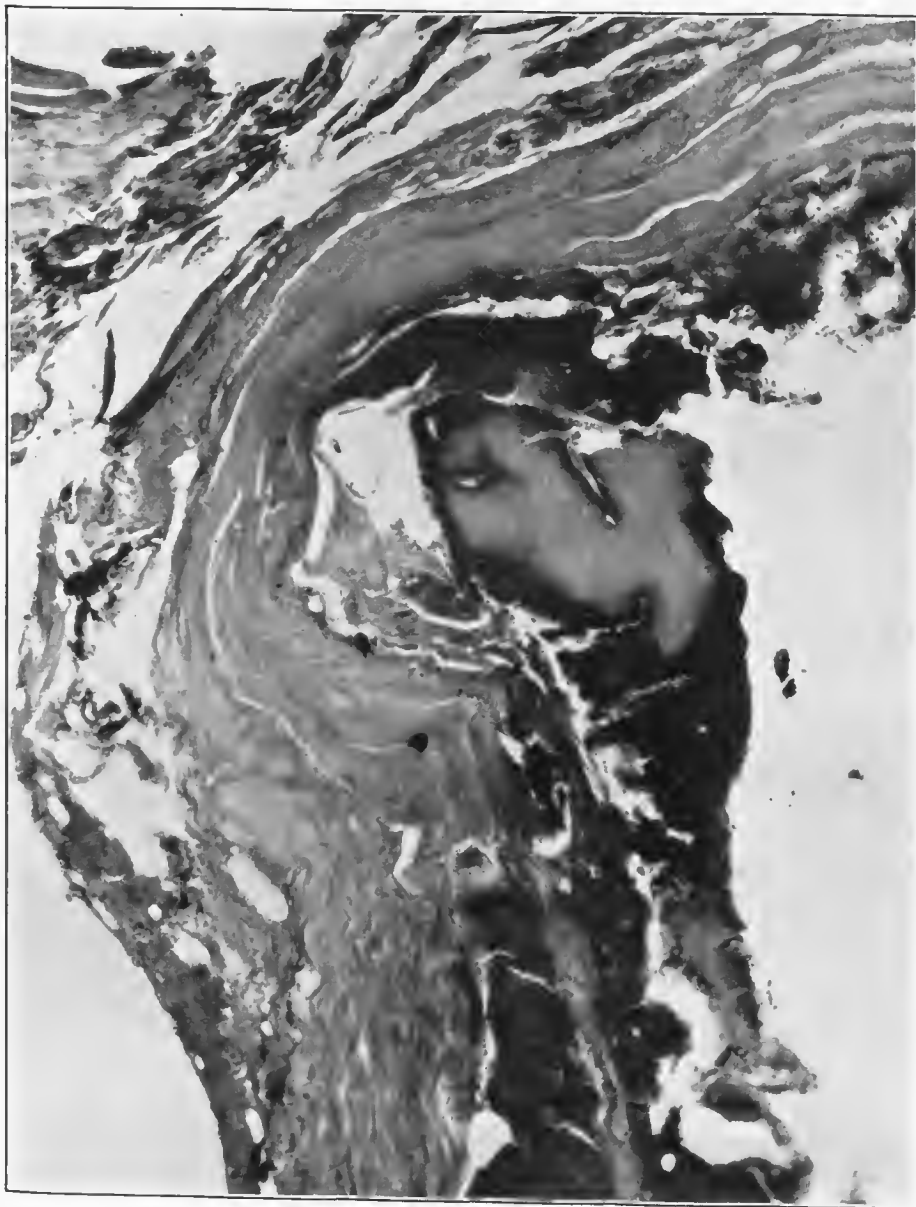


FIG. 278.—Fragment of bone surrounded by putrefactive gangrene. This section was taken from the deeper layers of the gangrene and at a distance from the shell fragment. Accession number 4711, Army Medical Museum. Negative number 46156. Hematoxylin and eosin stain; $\times 115$

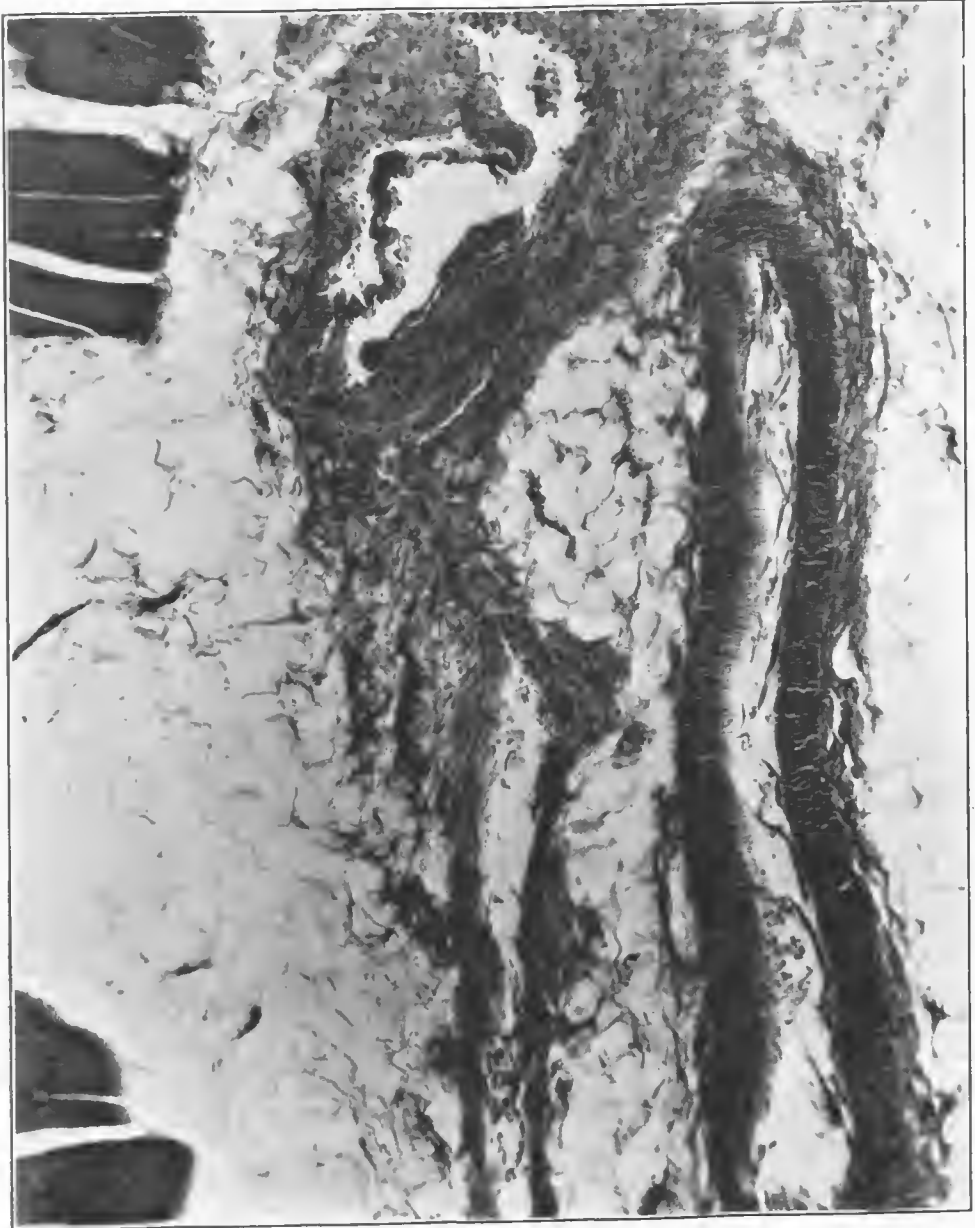


FIG. 279.—Section of the gaseous area showing a distinct shredding of the coats of a medium-sized vein of the type caused by the missile at a distance from the tract. The artery shows stripping of its intima, which could be caused by the infection. Lack of hemorrhage indicates that the force which shredded this vessel must have severed it considerably above this level. Accession number 4711, Army Medical Museum. Negative number 46159. Hematoxylin and eosin stain; $\times 115$




FIG. 280.—Muscle fibers from the gaseous area of gangrene. There is little gas formation; considerable damage of the fibers, probably from swelling, and some irregularity of staining due to the chemical changes produced by the gas gangrene. Accession number 4711, Army Medical Museum. Negative number 46145. Hematoxylin and eosin stain; $\times 810$

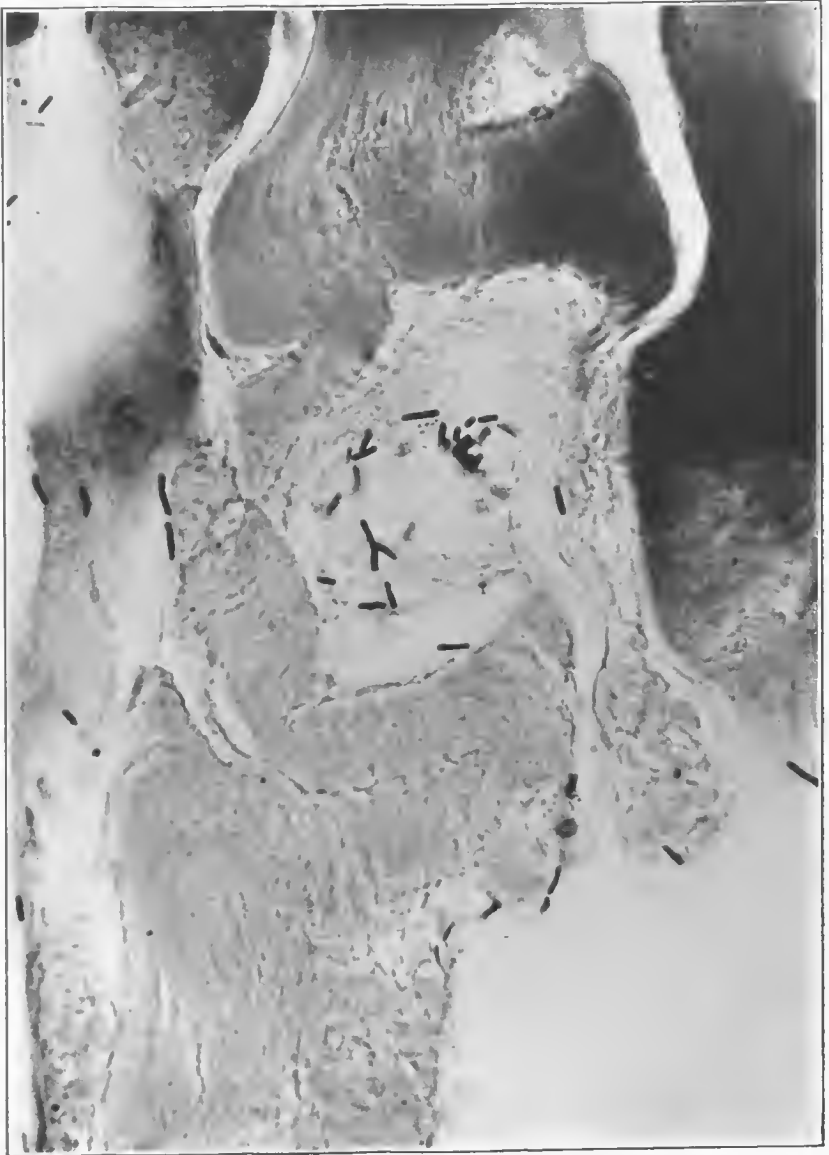


FIG. 281.—Muscle fibers in the putrefactive area of gangrene. The fibers are segmented and partially liquefied. There are two types of Gram-positive rods shown which appear to be Welch bacilli and one of the putrefactive group. The latter show terminal spores. Small amounts of gas were present. Accession number 4744, Army Medical Museum. Negative number 46154. MacCallum stain; $\times 810$

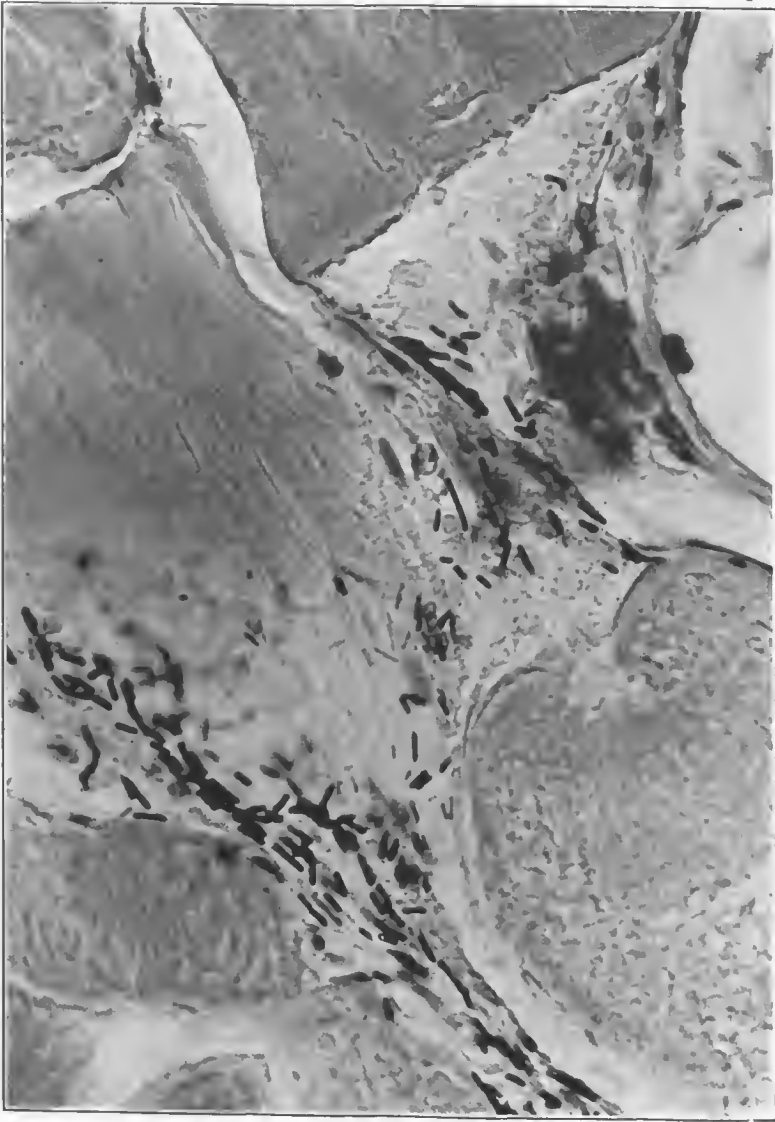


FIG. 282.—Muscle fibers from an area of putrefactive change in gas gangrene. There is a rupture across one fiber and a “ground-glass” degeneration of the lower right-hand fiber. The remaining fiber retains faintly some of its cross striations. This is a putrefactive area with marked mixed infection near the wound tract. There are present numerous Gram-positive and Gram-negative rods, diphtheroids, and cocci. Accession number 4711, Army Medical Museum. Negative number 46147. MacCallum stain; $\times 810$

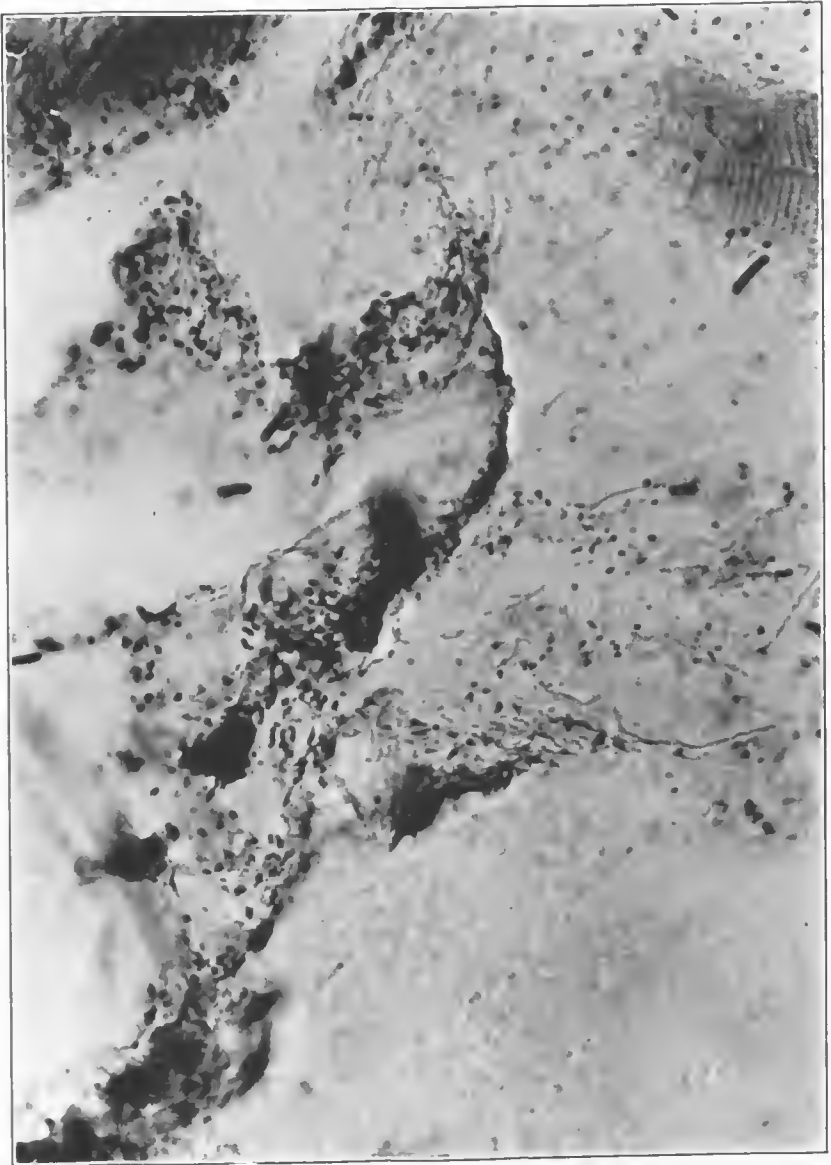


FIG. 283.—Muscle fibers from a contaminated area near the wound tract. There is a far greater variety of contaminating organisms and much more muscle change than is shown in Fig. 282. There are numerous Gram-positive and Gram-negative rods and a much greater number of cocci. Accession number 4711, Army Medical Museum. Negative number 46152. MacCallum stain; $\times 810$

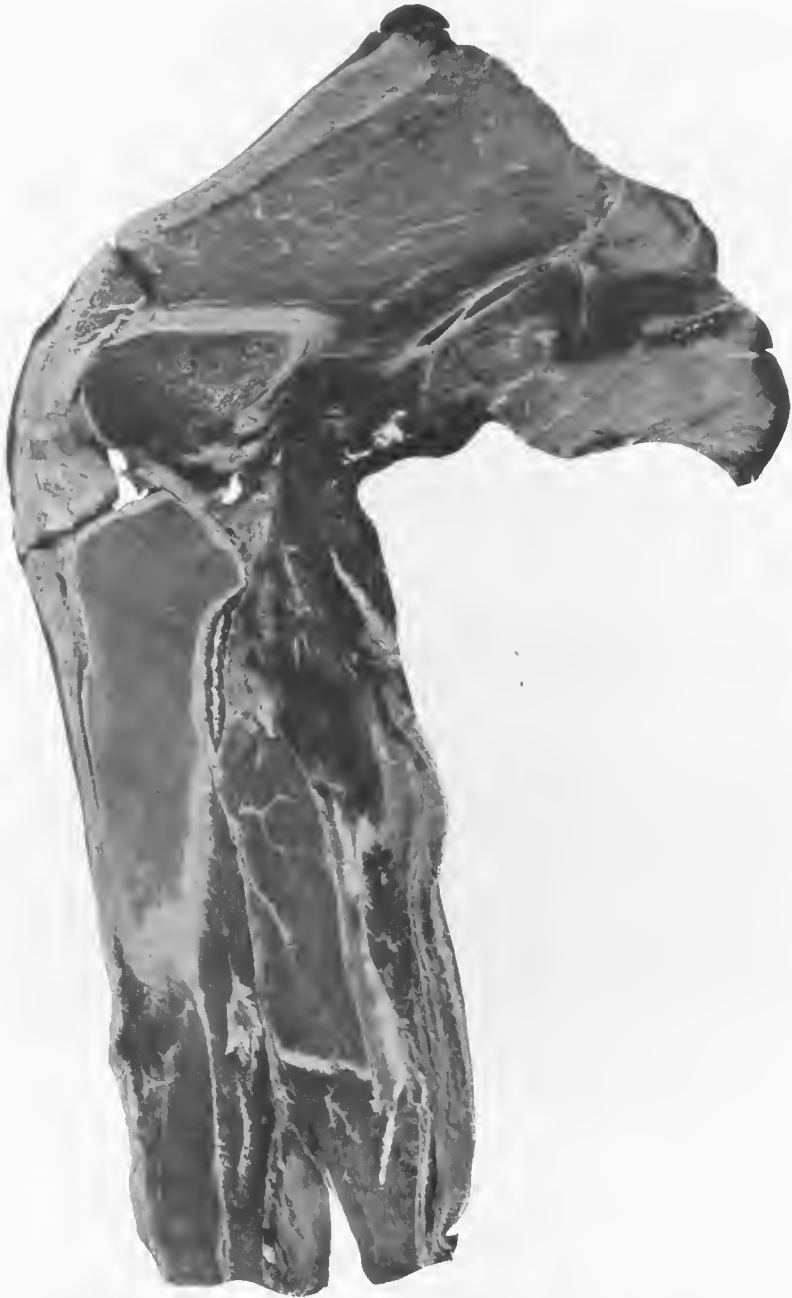

FIG. 284.—Mid section of the lower third of the thigh and upper two-thirds of the leg. There is massive damage to the muscles in the popliteal area and to the posterior thigh and calf muscles. The popliteal and thigh muscles appear to be affected by a putrefactive gangrene. There are small accumulations of gas in the calf muscles. Accession number 2918, Army Medical Museum. Negative number 32232

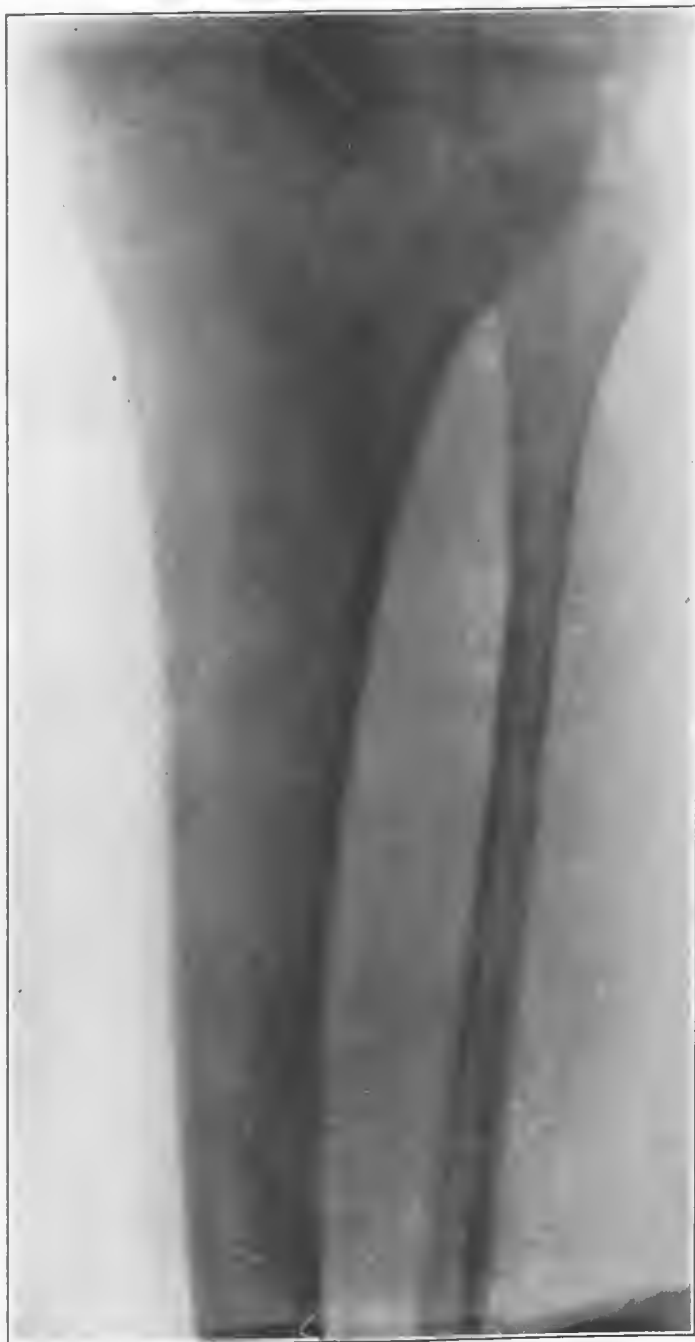

FIG. 285.—X ray of the leg shows a moderate accumulation of fine gas bubbles in the muscles extending to the middle third of the fibula. Accession number 2918, Army Medical Museum. Negative number 46260

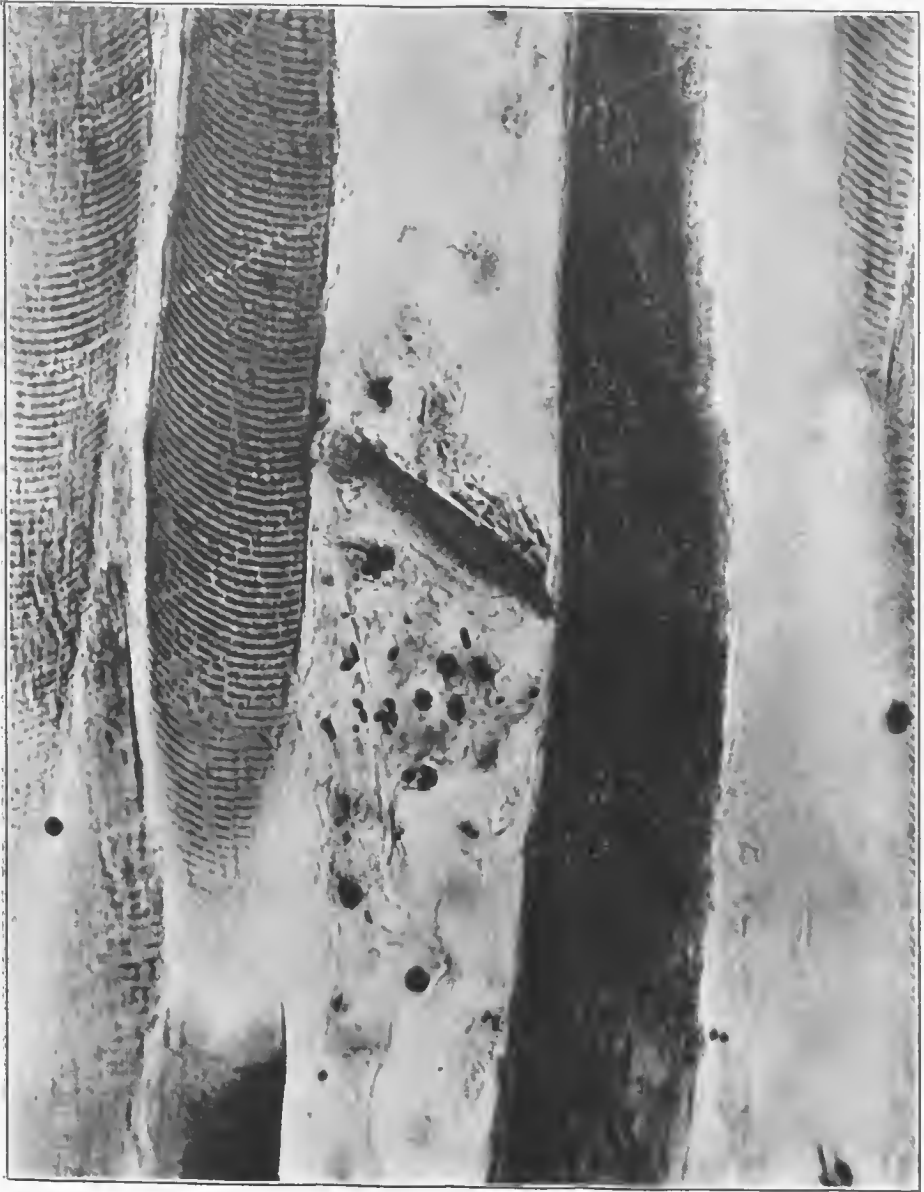

FIG. 286.—Muscle fibers from the putrefactive area in the popliteal region. There is considerable edema, probably secondary to the trauma. Fragment of muscle fiber in the edematous area in the center of the picture due rather to the missile than to gas formation. Occasional round-ended rods are seen, which are apparently Welch bacilli. A few leucocytes are present. Accession number 2918, Army Medical Museum. Negative number 46166. MacCallum stain; $\times 710$

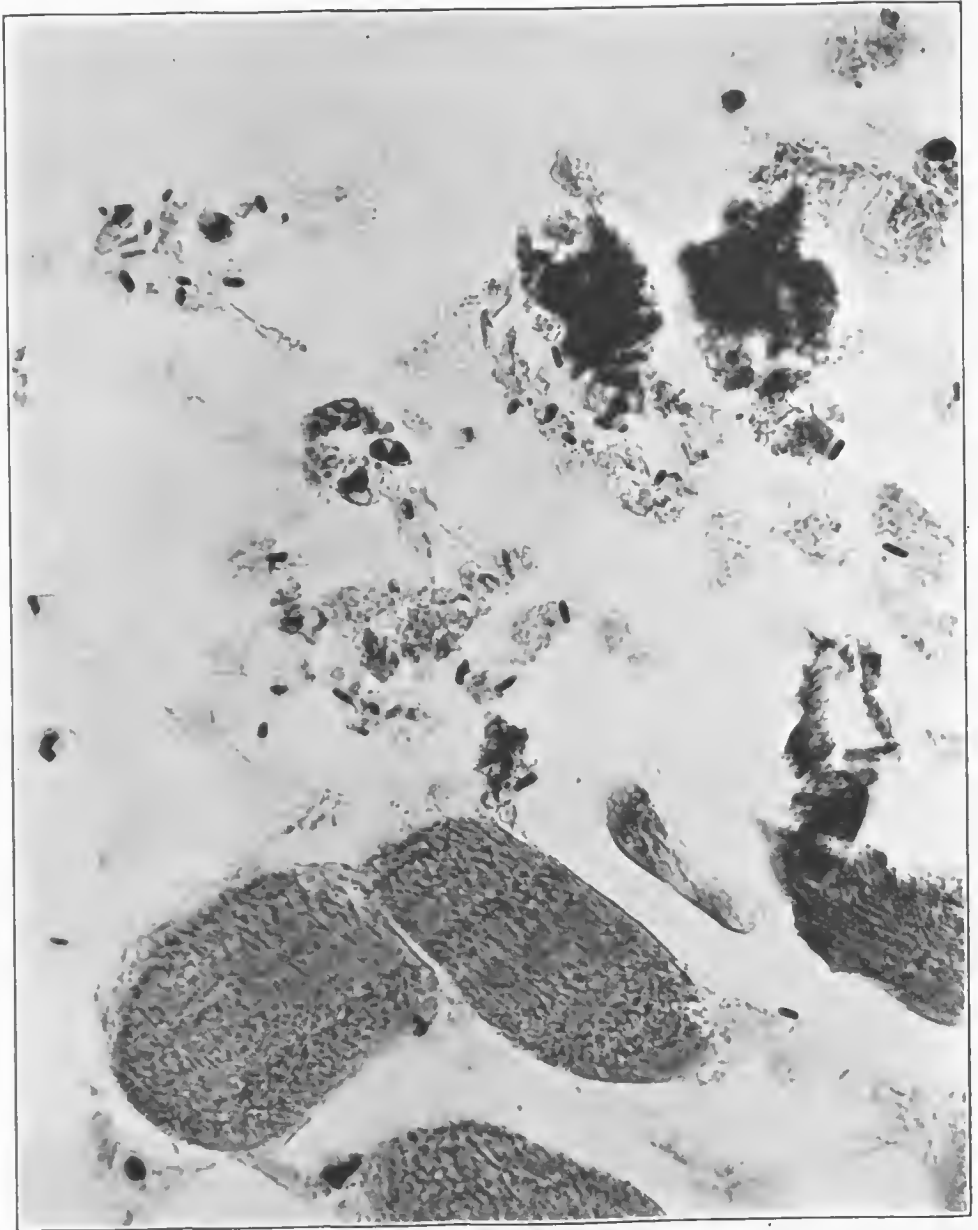


FIG. 287.—Section from the gaseous area of the calf muscle showing two masses of foreign bodies, evidently dirt, in accumulations of gas. There are occasional bacteria, rare leucocytes, and moderate "ground-glass" and blood detritus changes in the muscle fibers. The bacteria are all in vegetative form, and there is evidence that there is a mixed infection, forms like Weich bacilli being common. Barred forms of a diphtheroid character are seen near the foreign bodies. Accession number 2918, Army Medical Museum. Negative number 46167. MacCallum stain; $\times 710$



FIG. 288.—Outer aspect of the left leg with high-explosive wound about 2 cm. in diameter cm., above the external malleolus. The instep shows desquamation of the skin characteristic of the ordinary gangrene due to vascular occlusion. Above this the skin shows some of the blackening characteristic of putrefactive gangrene. Accession number 2802, Army Medical Museum. Negative number 32257

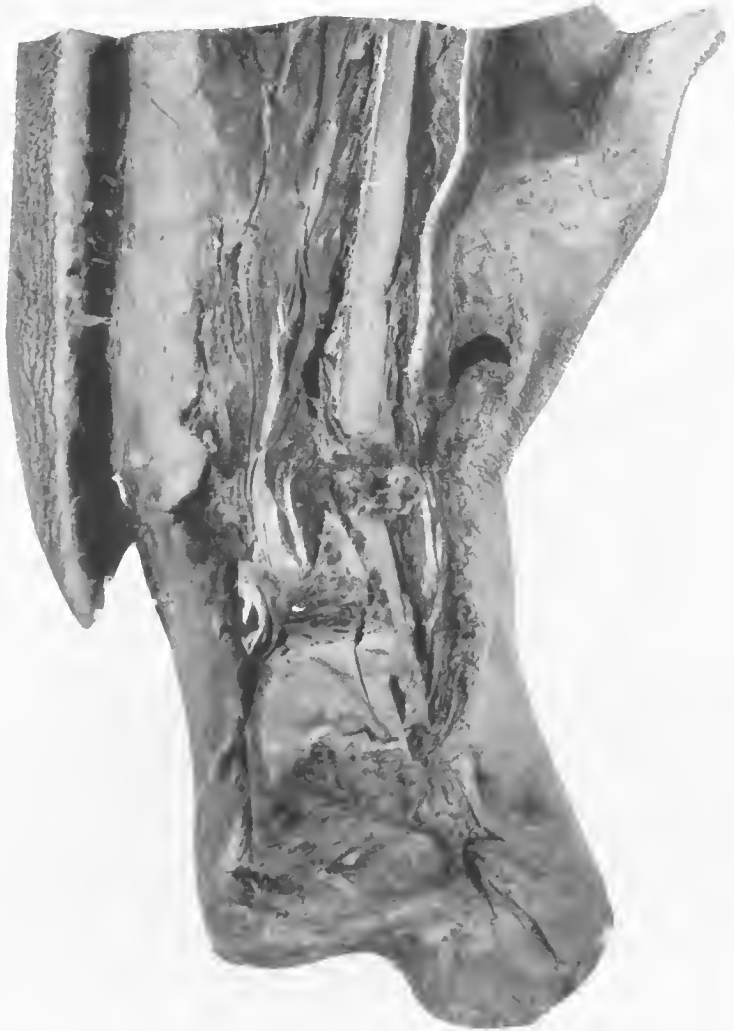

FIG. 289.—Anterior aspect of the left leg with the foot disarticulated at the ankle joint. A debrided wound approximately 8 cm. in length has been dissected away, exposing the fractured ends of the tibia and fibula. The muscles, especially those between the two bones, show gas bubbles. Beneath the skin in front of the tibia is a putrefactive reaction which parallels this bone. Accession number 2802, Army Medical Museum. Negative number 32256

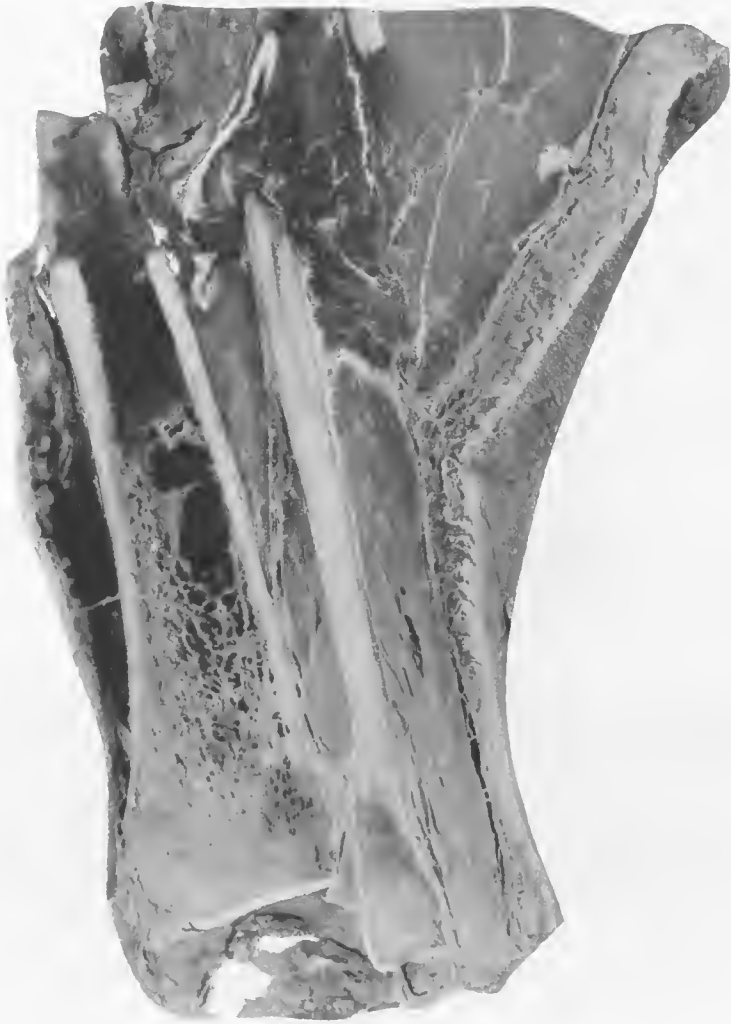

FIG. 290.—Mid section of the specimen through both bones, showing a massive clot in the marrow of the tibia undergoing a putrefactive process and putrefactive changes beneath the skin in front of the tibia. Some putrefactive gangrene is around the upper end of the lower fragment of the fibula. A moderate accumulation of gas is in the muscles about the fibula. Accession number 2802, Army Medical Museum. Negative number 32256

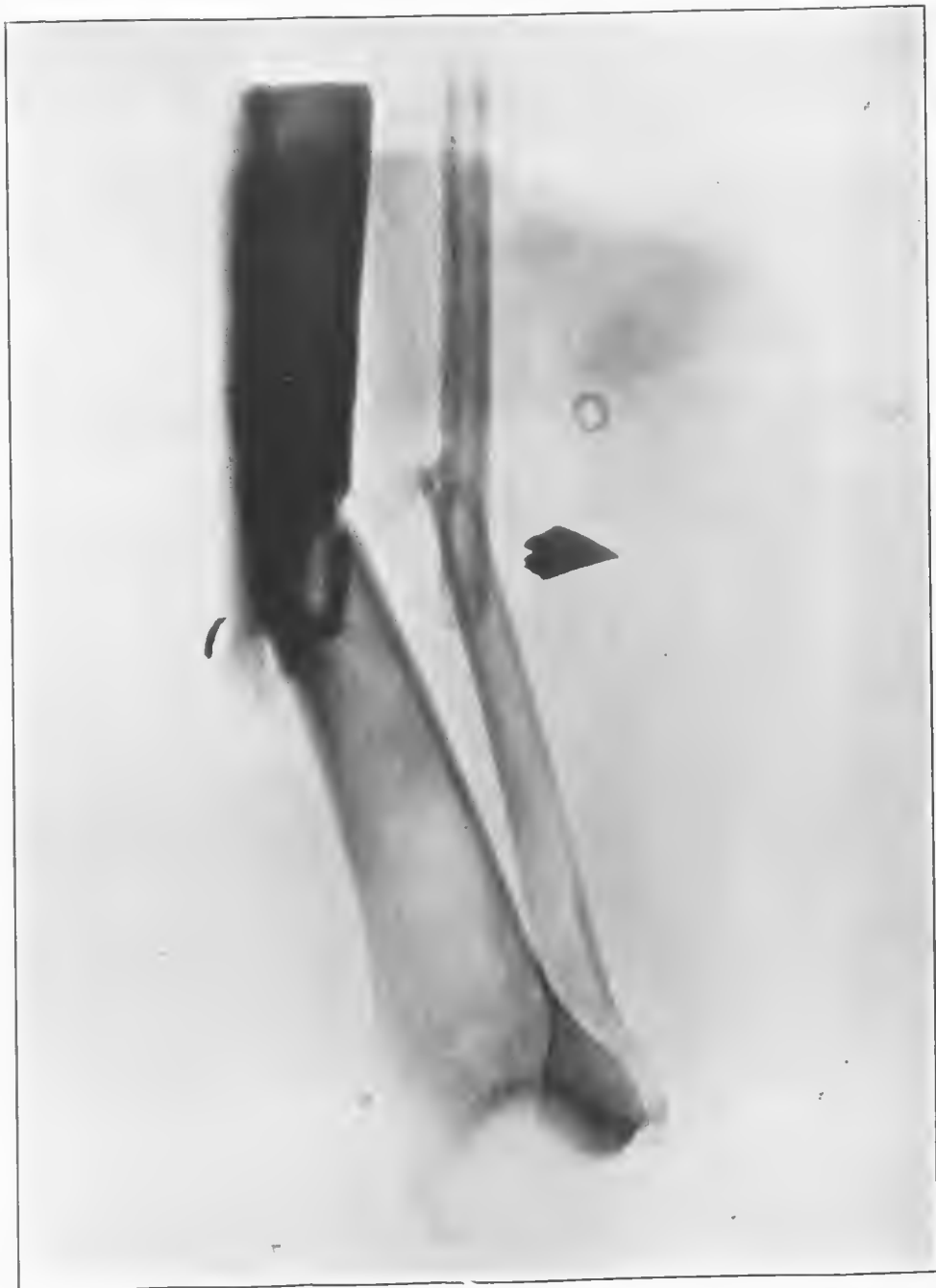

FIG. 291.—X ray showing fracture of both bones with foreign bodies, probably fragments of small-caliber high-explosive shell or a hand grenade. A legging eyelet appears buried in the depths of the muscle. Accession number 2802, Army Medical Museum. Negative number 46268

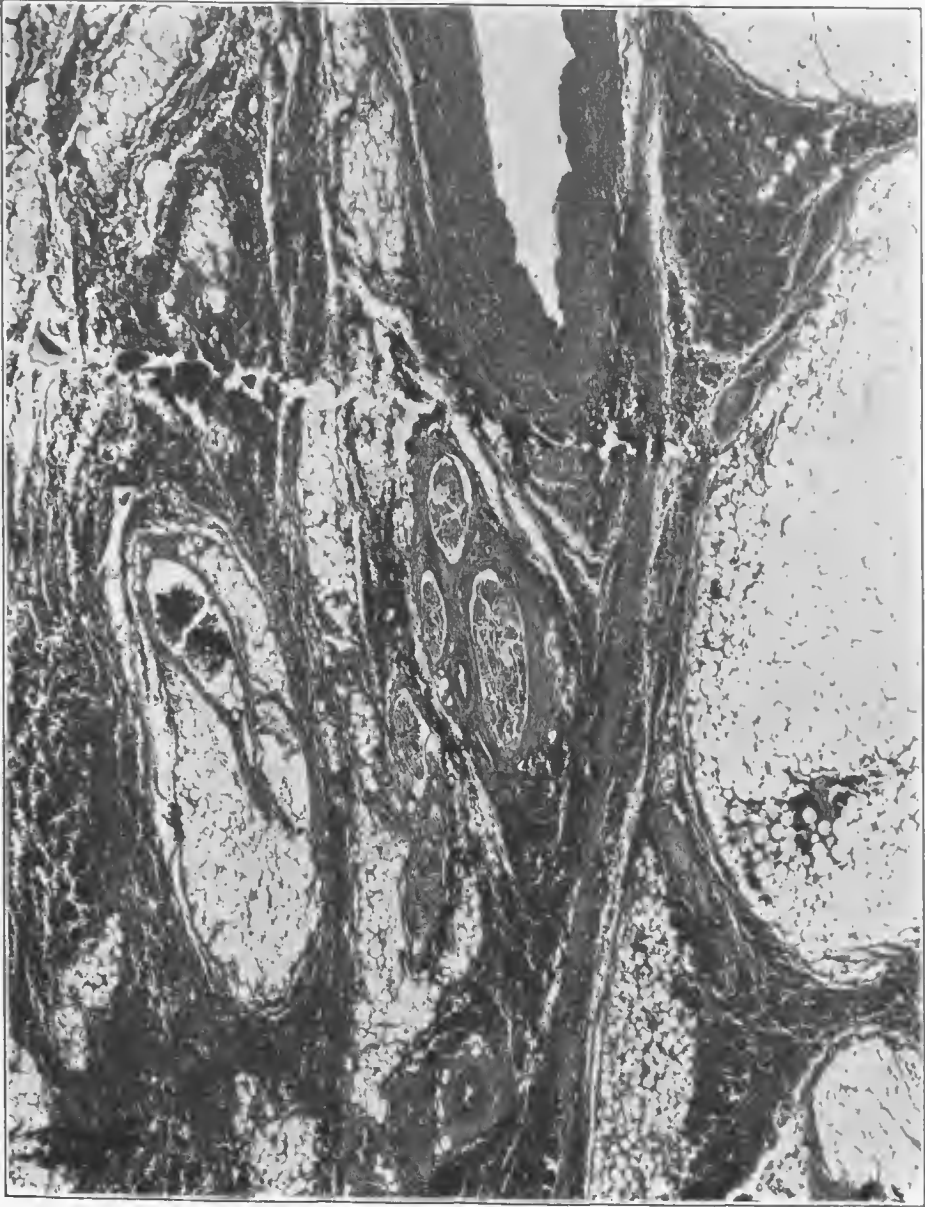

FIG. 292.—Section from the putrefactive area around the larger blood vessels. It includes a missile tract which scores the margin of the posterior tibial artery. The wall of the vessel is split at this point, and a small thrombus has formed on that part of the intima nearest the injury. Two small veins in the left-hand lower portion of the picture near the wound tract show rupture of their walls. This whole area showed considerable hemorrhage undergoing putrefactive changes. Edema and gas are along the wound tract, especially about a bundle of nerve fibers. Accession number 2802, Army Medical Museum. Negative number 46176. Hematoxylin and eosin stain; $\times 26$

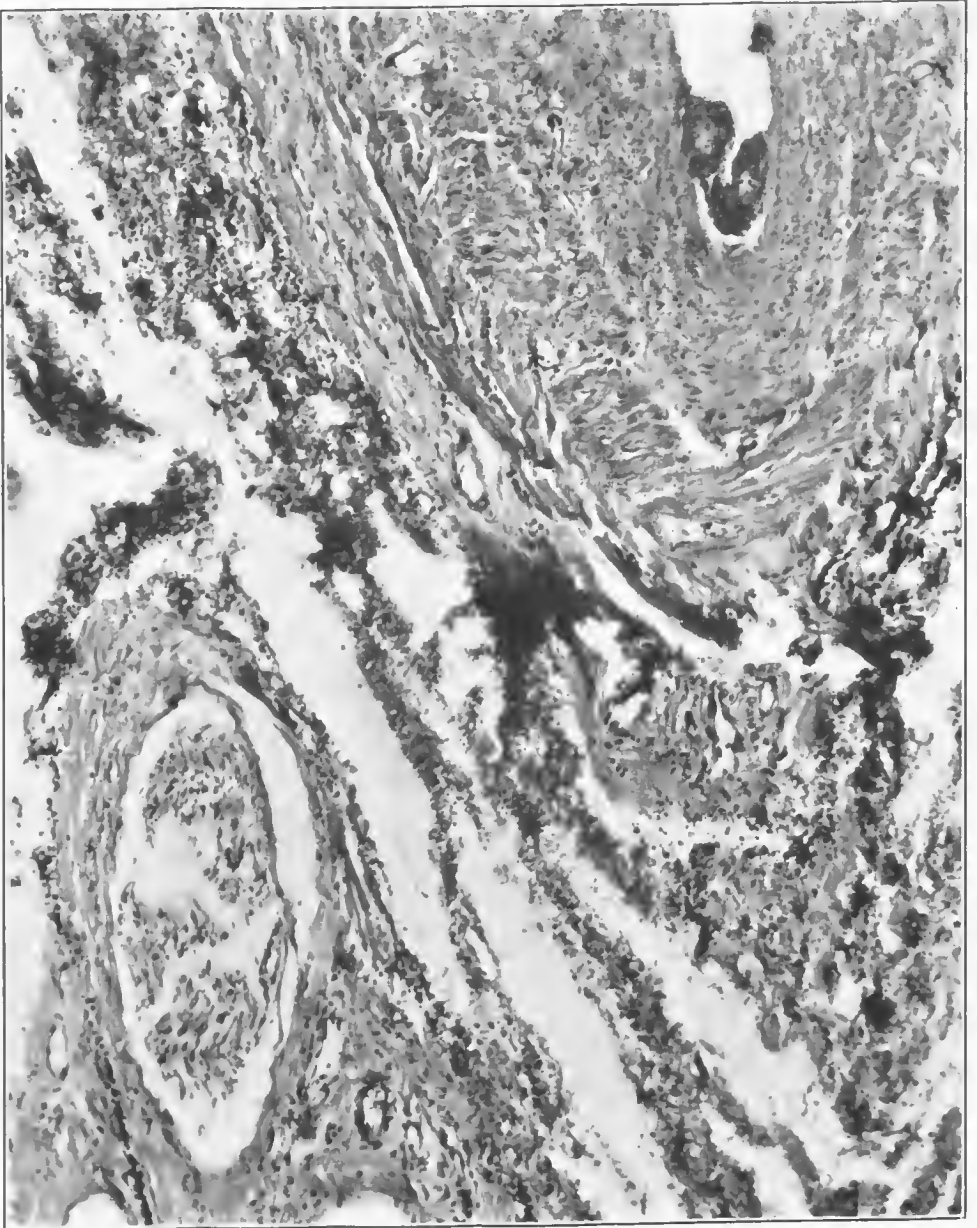


FIG. 293.—The missile tract showing a tear through the adventitia and media of the artery and a separation of the media from the internal coats and the small thrombus. There is a moderate hemorrhage, a low-grade infection, and some accumulation of gas. There is a rupture of a medium-sized nerve sheath, with accumulation of edema and gas between the nerve fibers. Accession number 2802, Army Medical Museum. Negative number 46178. Hematoxylin and eosin stain; $\times 105$

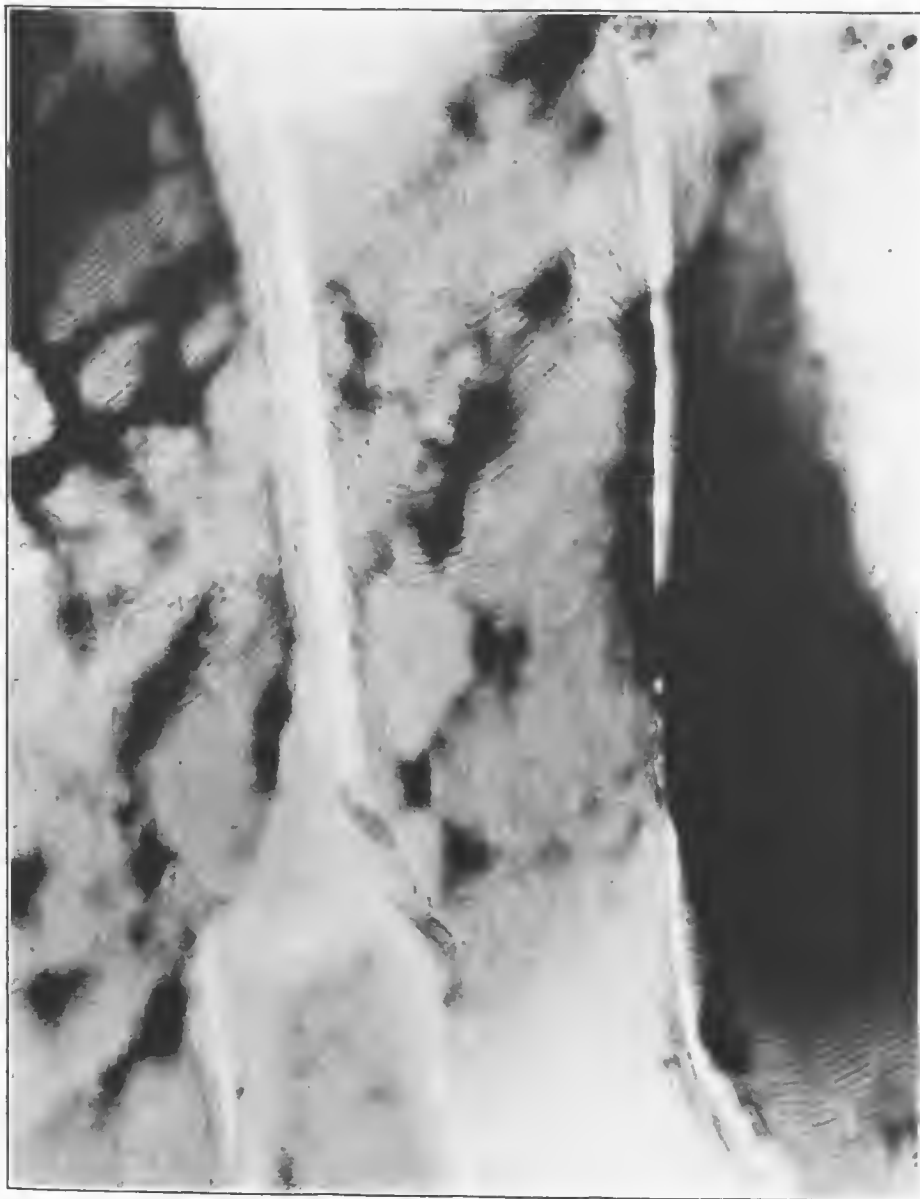

FIG. 294.—Beginning chemical change in the muscle fibers, resulting in retaining the basic dye in an irregular marbled distribution. Accession number 2802, Army Medical Museum. Negative number 46163. MacCallum stain; $\times 710$

The putrefactive form of gas gangrene rarely occurred in purity, but often involved the superficial lymphatics, and areolar connective tissue near the wound tract of avirulent as well as virulent forms. The avirulent form very often was accompanied by bronzed erysipelas, especially when the putrefactive bacteria invaded extremely superficial extravasations of blood, near enough to the surface to be seen through the skin. It only became virulent when accompanied by pyogenic bacteria or when it occurred late in shock cases, or those secondary anemias following severe hemorrhage. The following cases illustrate the putrefactive form of gas gangrene.

CASE 18.—Perforating machine gun bullet wound of the left thigh, with compound, comminuted fracture of the femur and gas infection. Débrided 48 hours after the injury. Amputation was done for gas gangrene, three days after the débridement.

The specimen consists of left thigh amputated at its middle third, with the leg cut away 8 cm. below the patella. There is a débrided wound of entrance on the inner aspect of the posterior surface of the thigh 4 cm. in diameter, 10 cm. above the internal condyle and 4 cm. internal to the midline. There is a débrided wound of exit 6 cm. in diameter on the outer aspect of the anterior surface of the thigh 6 cm. higher than the wound of entrance. Both wounds are lined by a greyish-green exudate, and bony fragments can be seen in the anterior wound. (See figs. 295 to 303, inclusive.)

CASE 19.—Soldier received a bullet wound of the right leg at 8 a. m., October 28, 1918. There was a perforating wound with compound comminuted fracture of both bones. The wound was débrided at 8 p. m., October 29. Amputation November 3 for gas gangrene.

Amputated limb shows a débrided wound on the external surface measuring 12 by 4 cm., beginning 5 cm. below the head of the fibula. There is a similar wound on the inner aspect. Both wounds are lined with a shaggy exudate and the tissues of the calf are swollen and boggy. A median vertical section shows a fracture of the tibia at the middle third with marked comminution and a fracture of the fibula at the same level. There is extensive gas gangrene of all the calf muscles with a secondary mixed infection of the muscles on the inner or tibial sides. There is also a myelitis of both fragments of the tibia. (See figs. 169 and 304 to 307, inclusive, and Pl. XXII.)

The avirulent gas gangrene is usually a mild form of the putrefactive type and is very often accompanied by bronzing of the skin over the lesion. This is produced by an oxidation of superficial subcutaneous hemorrhages, in which the blood is oxidizing and producing those variations of blue, black, and bronze, that occur in an ordinary "black eye." The mechanics is not unlike that of this condition, plus a mild form of infection. This bronzing is a valuable symptom since, unless there is a massive amount of swelling in an injured limb, it indicates that the infection is an avirulent one and ordinarily does not require any surgical interference. The following case illustrates the avirulent form of gas gangrene.

CASE 20.—This soldier entered an evacuation hospital 48 hours after receiving two machine gun wounds of the chest and one of the calf of the left leg. The wounds of the chest were cleaned and closed, and the leg wound was débrided. A bronzing of the whole of the calf of the leg began 48 hours after débriding, but the swelling was only moderate and since the symptom of bronzing indicates only mild forms of gas gangrene, the wound was Dakinized and amputation advised against.

A streptococcus empyema began on the fifth day and the patient sank rapidly. A delayed gangrene of the muscles of the leg began on the tenth day and amputation was performed. The soldier died on the fifteenth day.

Autopsy revealed that death was due to a streptococcus septicemia and the gas gangrene in the leg was secondary, being reestablished during the terminal process of the septicemia when hemolytic jaundice and failure of the circulation made it possible. (See figs. 308 to 312 and Pls. XXIII and XXIV.)



FIG. 295.—External surface of the left thigh amputated at the middle third. A machine-gun bullet wound 4 cm. in diameter, 9 cm. above the knee joint, has been debrided, is covered with a shaggy exudate, and the muscles surrounding the wound are under extreme pressure and extrude above the surface of the skin. There has been some bronzing of the skin in the fold of the knee joint. Accession number 4709, Army Medical Museum. Negative number 32107

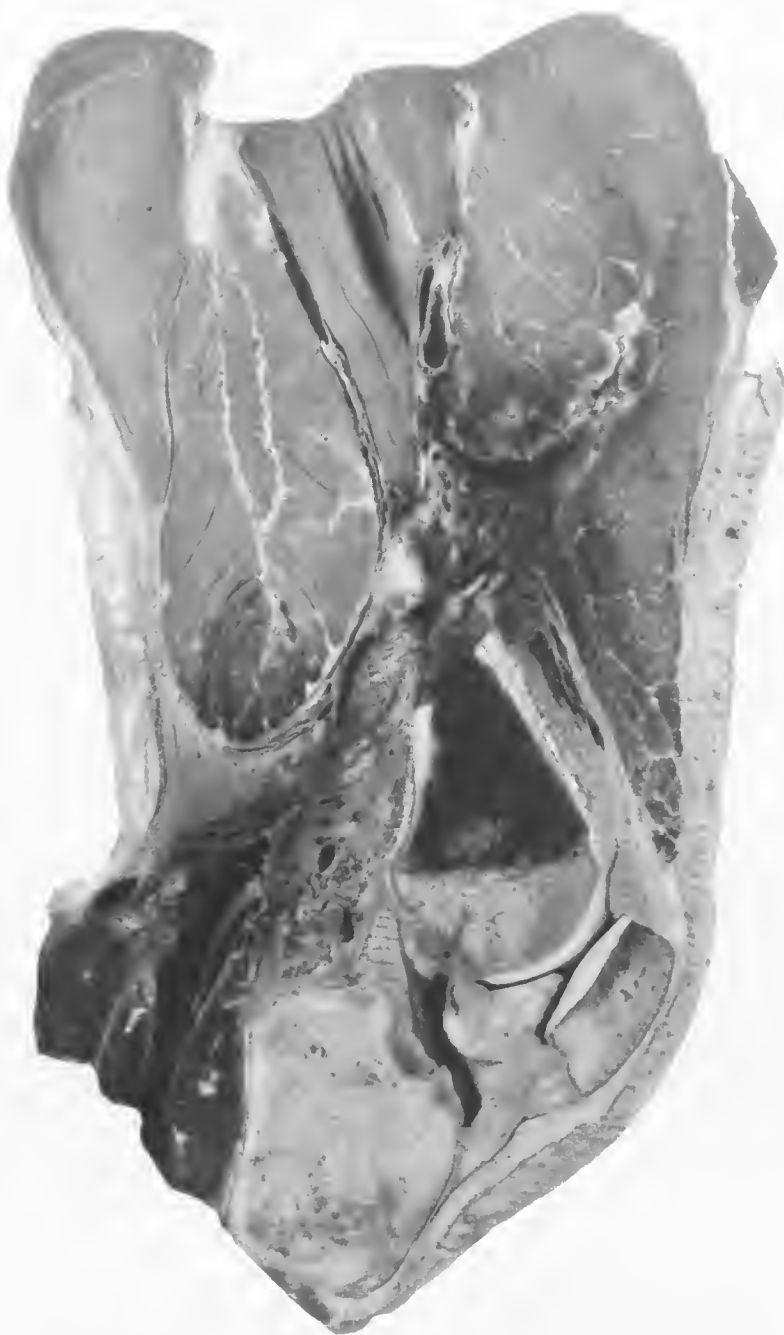

FIG 296.—Mid section of the thigh of Fig. 295. There is a wound tract running obliquely down from the wound of entrance and internally, making its exit in the posterior fold of the knee, rupturing the profunda femoris artery just above the popliteal vessels. All of these vessels are thrombosed. There is putrefactive change all along the wound tract, with exudate in the tract itself and blackening of the surrounding muscles. There is gas gangrene of the biceps muscle, which involves the lower fourth of that part of the muscle shown in the picture. There are gas bubbles in this area and a loss of normal color and markings in the neighboring muscles. Accession number 4709, Army Medical Museum. Negative number 32105

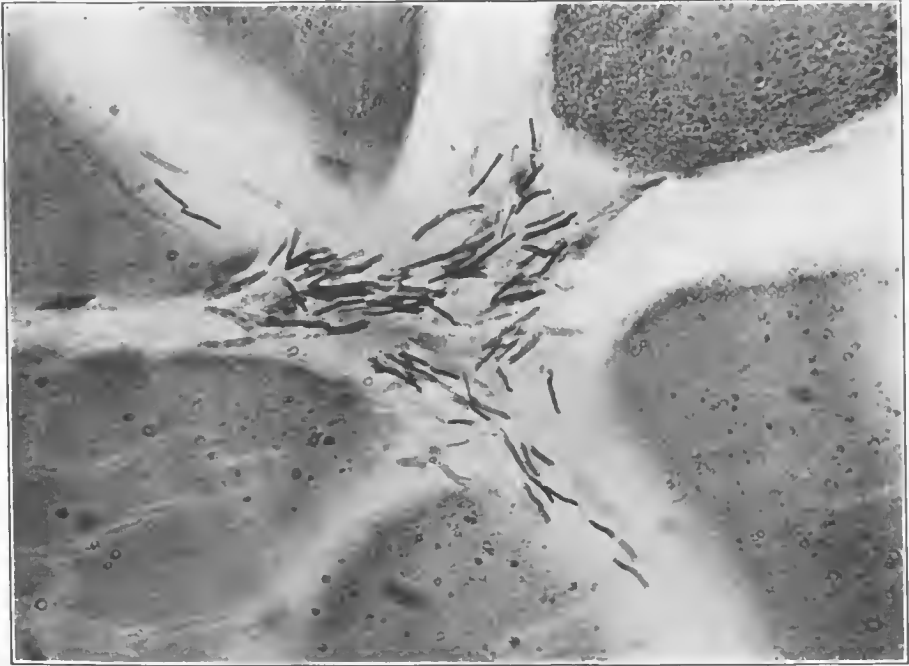

FIG. 297.—Section of muscle from the putrefactive area. There are numerous Gram-negative and Gram-positive rods, no leucocytic reaction, and a fine granular hemoglobin detritus in muscle fibers. Accession number 4709, Army Medical Museum. Negative number 30925. MacCallum stain; $\times 1200$

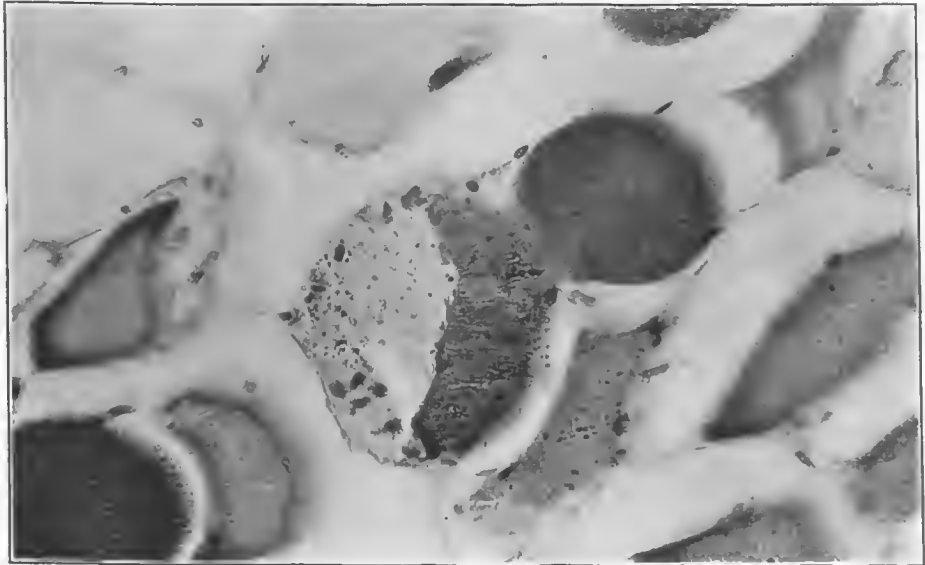


FIG. 298.—Liquefaction of approximately two-thirds of a muscle fiber. All fibers are separated by gas which has penetrated the muscle envelopes. Many of the fibers contain a fine hemoglobin detritus. Accession number 4709, Army Medical Museum. Negative number 31045. MacCallum stain; $\times 500$

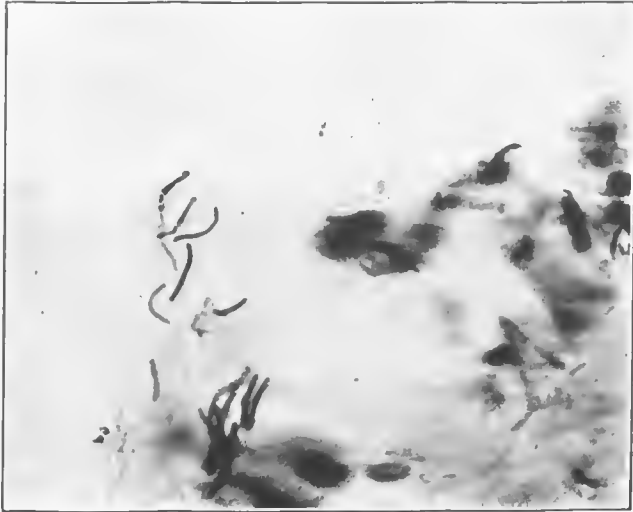


FIG. 299.—Gram-positive bacilli between muscle fibers from an area of putrefactive gangrene. Some of them show barred staining. Accession number 4709, Army Medical Museum. Negative number 31040. MacCallum stain; $\times 1000$

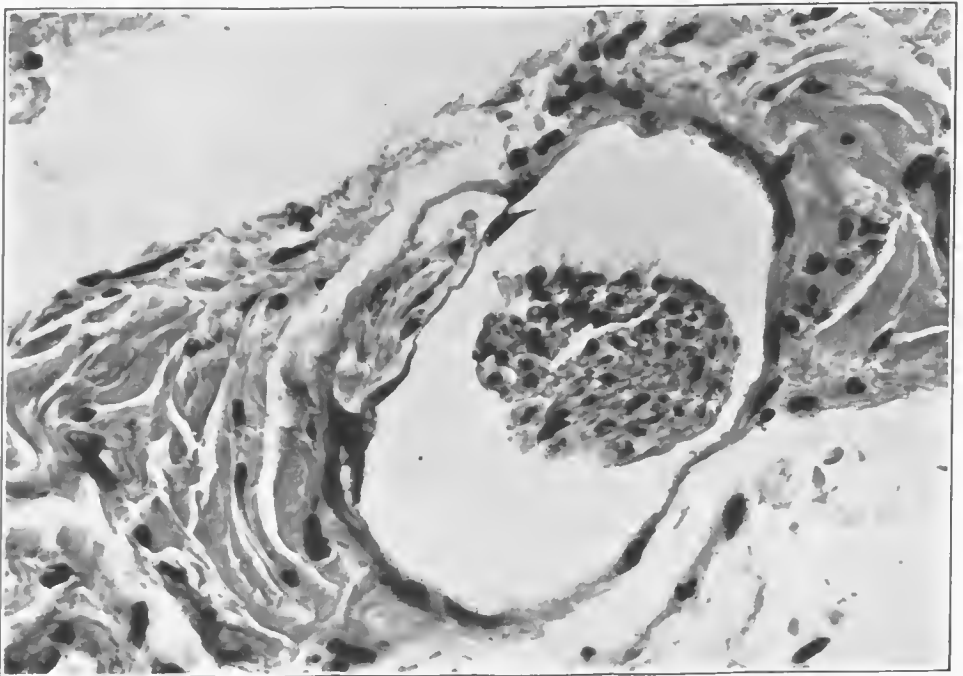


FIG. 300.—Cross section of a small nerve fiber with marked shrinkage and an accumulation of gas about them and within the nerve sheath. Accession number 4709, Army Medical Museum. Negative number 46110. Hematoxylin and eosin stain; $\times 700$

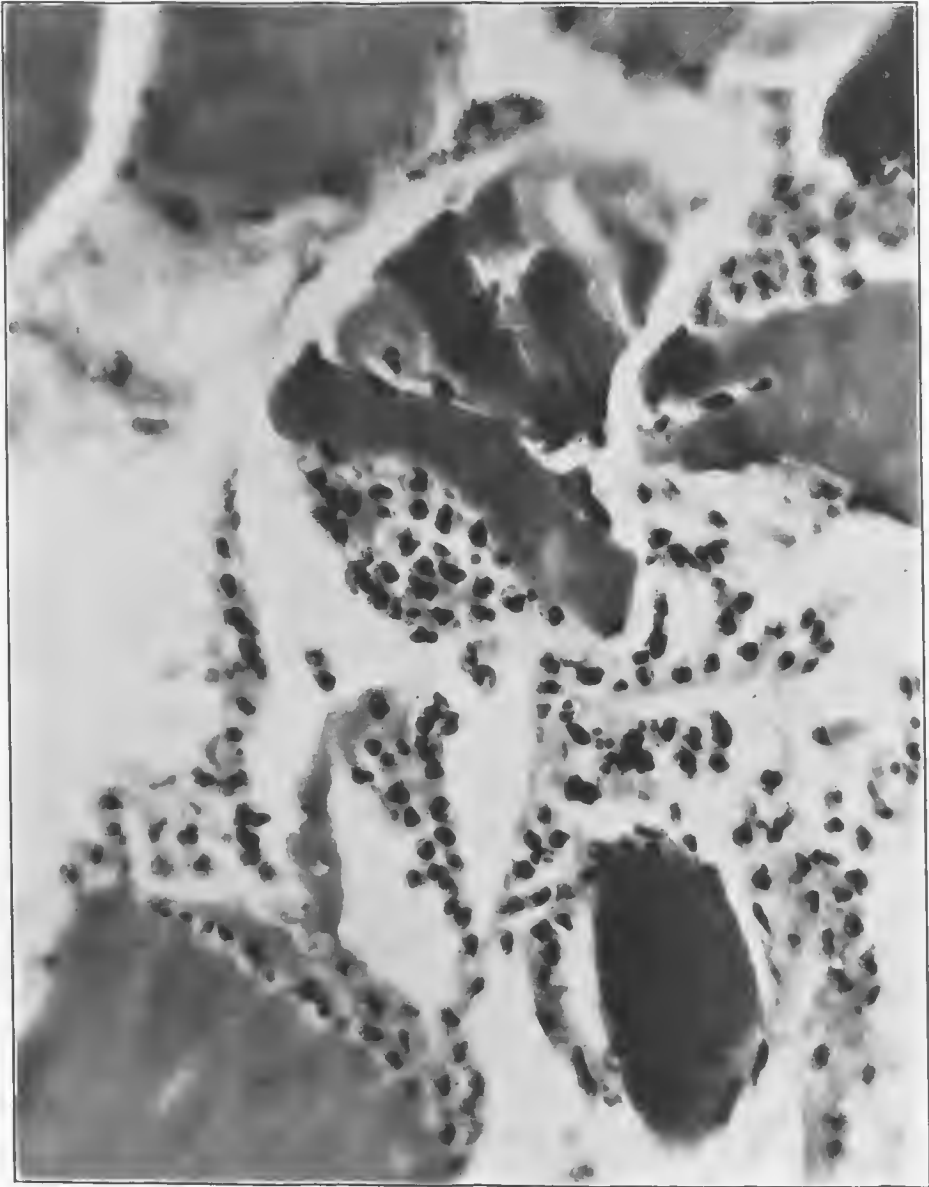


FIG. 301.—Muscle fibers in close relation to the wound tract. Rupture of fibers probably by the trauma of the missile. Numerous leucocytes indicate a pyogenic invasion. One muscle fiber in the lower right-hand corner shows chemical change, as indicated by retention of the basic dye. Accession number 4709, Army Medical Museum. Negative number 46117. Hematoxylin and eosin stain; $\times 900$

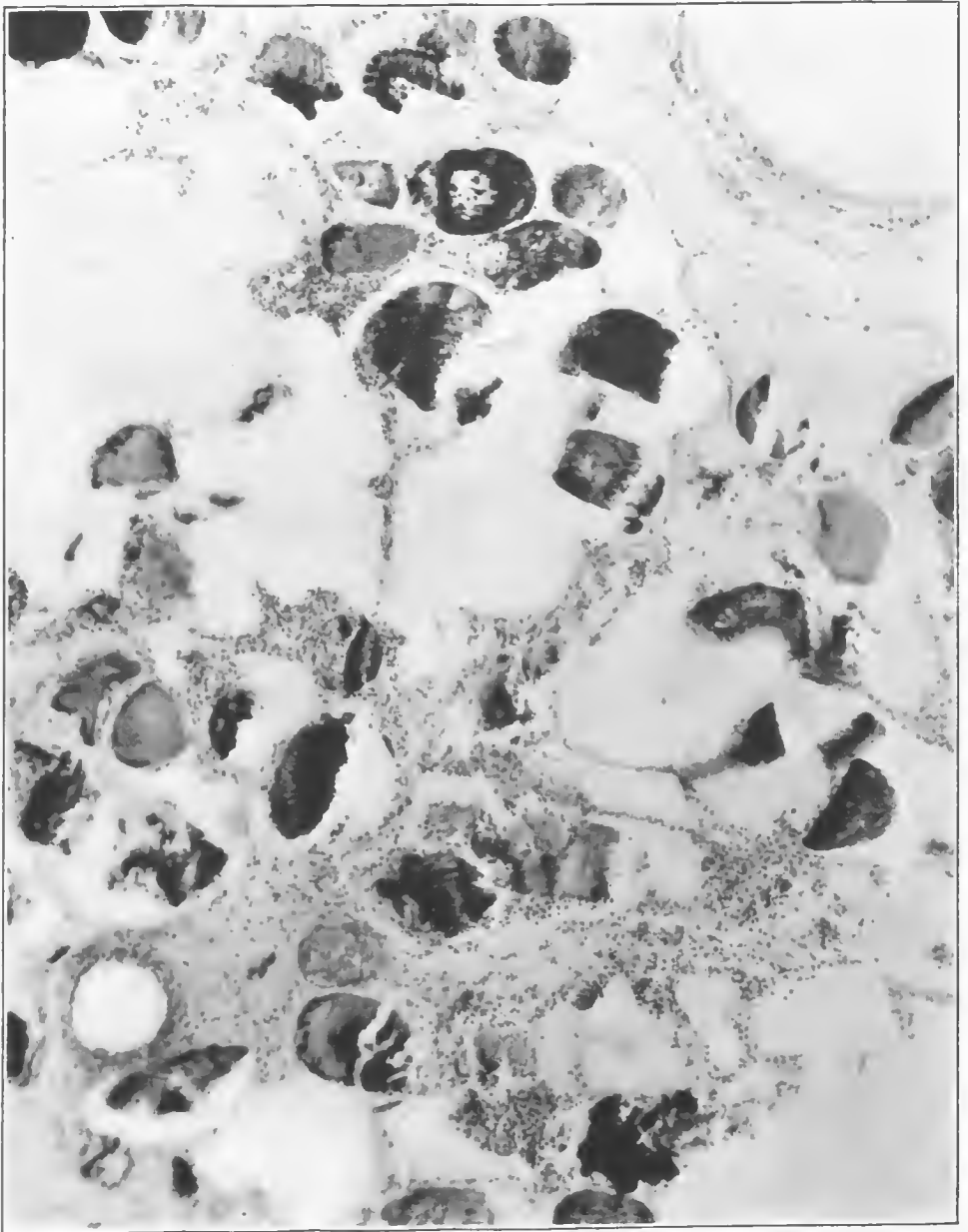
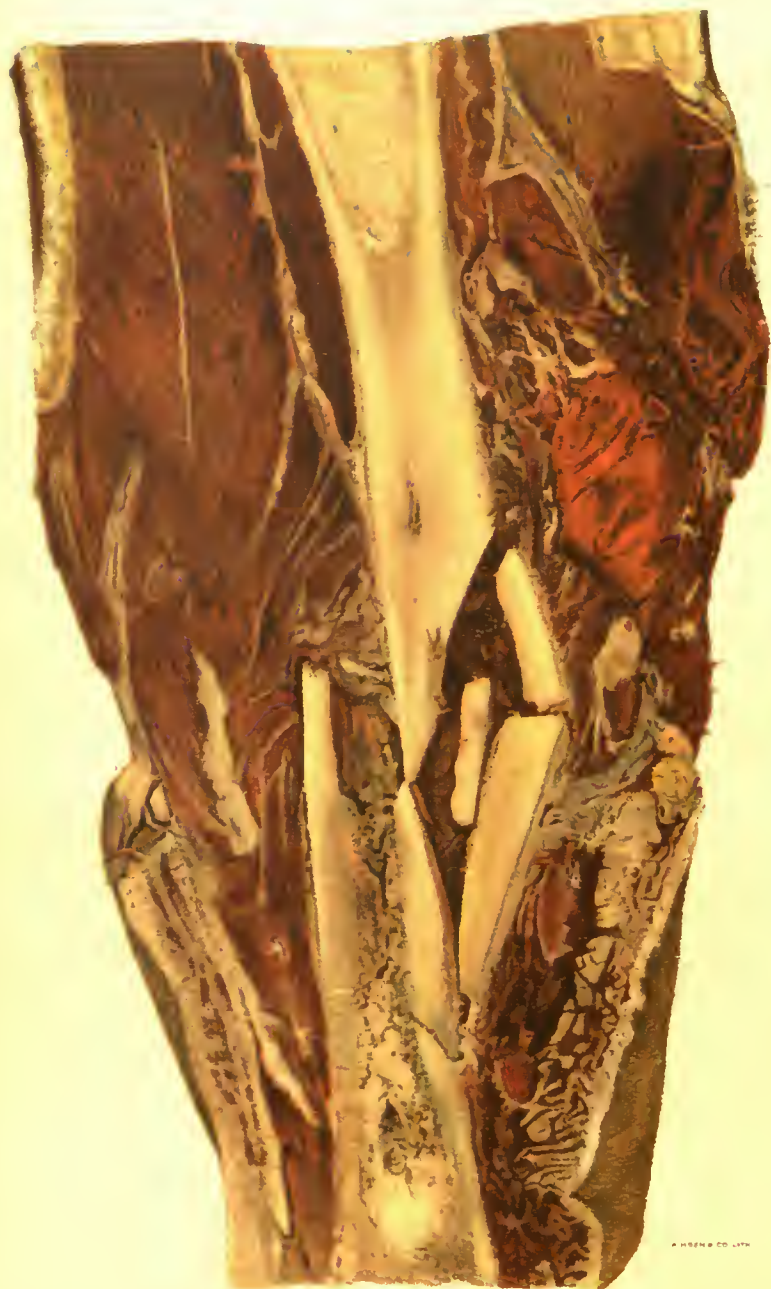

FIG. 302.—Muscle fibers separated by gas and exudate. This area was near the wound tract and shows a marked leucocytic infiltration, as well as a large amount of gas. There are marked chemical changes in muscle fibers, as evidenced by the marked variation in the way in which they take the stain. One fiber in the upper central area contains a relatively large gas bubble. Accession number 4709, Army Medical Museum. Negative number 46172. MacCallum stain; $\times 230$



COMMINUTED GUNSHOT FRACTURE OF TIBIA.

Putrefactive infection of the marrow cavity of the lower fragment. Putrefactive gangrene of muscles and connective tissues to the right of this fragment. The calf muscles show a mixed form of gangrene with little accumulation of gas.

Accession 4717, Army Medical Museum. Colored photograph.

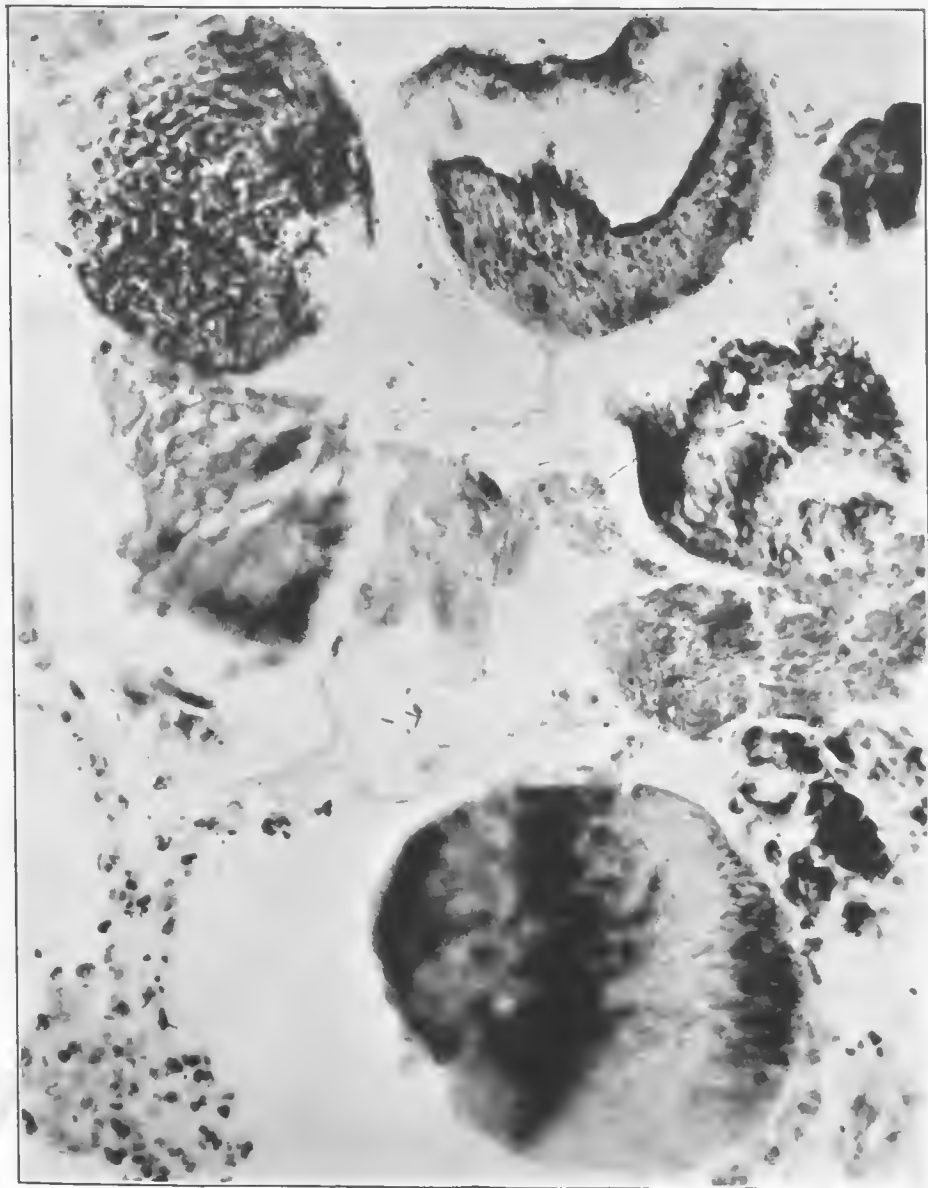


FIG. 303.—Necrotic muscle fibers in the gaseous area cut in cross section. They contain gas bubbles and show marked chemical alteration. There are a few bacteria and a moderate leucocytic infiltration. Accession number 4709, Army Medical Museum. Negative number 46111. MacCallum stain; $\times 545$

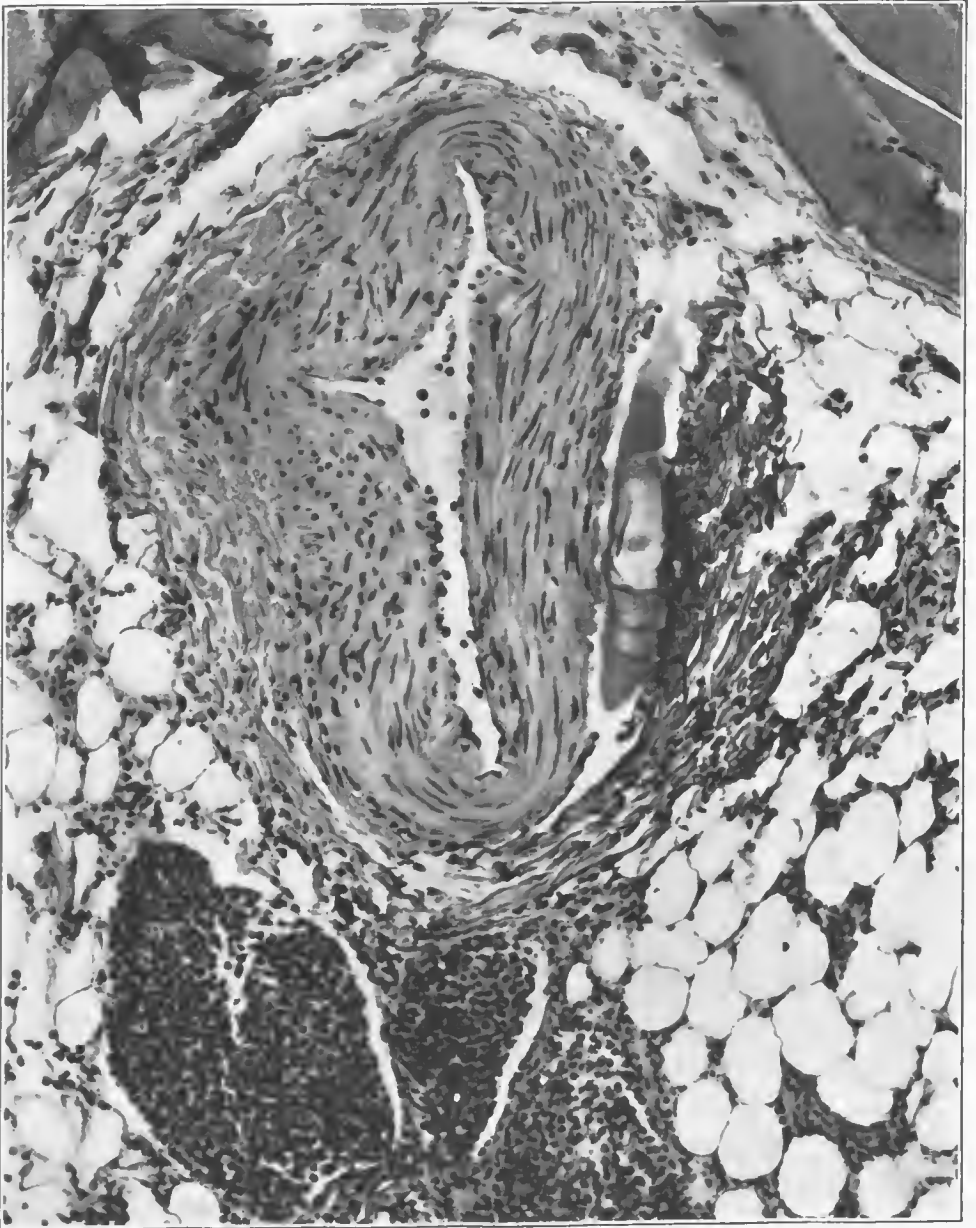


FIG. 304.—Cross section of a medium-sized artery showing marked shredding and swelling of the adventitia, with a zone of edema between it and the media. The perivascular lymphatics are filled with leucocytes. This is the type of injury to the blood vessels which, when accompanied by secondary pyogenic infections, undergoes thrombosis and gives rise to secondary hemorrhage. The vessel usually shows a linear tear when hemorrhage occurs. Accession number 4717, Army Medical Museum. Negative number 46072. Hematoxylin and eosin stain; $\times 180$

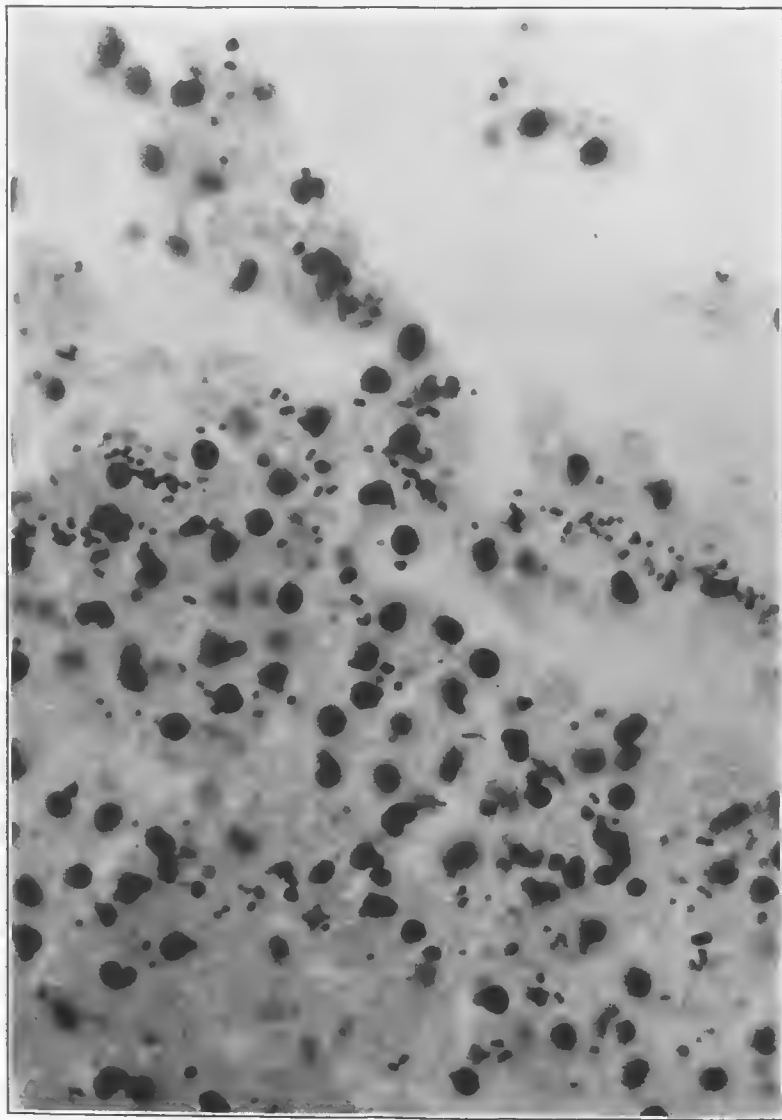


FIG. 305.—Clot in tissue near vessel shown in Fig. 304. It contains numerous leucocytes and diplococci, probably a mixture of pyogenic cocci. Accession number 4717, Army Medical Museum. Negative number 46149. MacCallum stain; $\times 830$

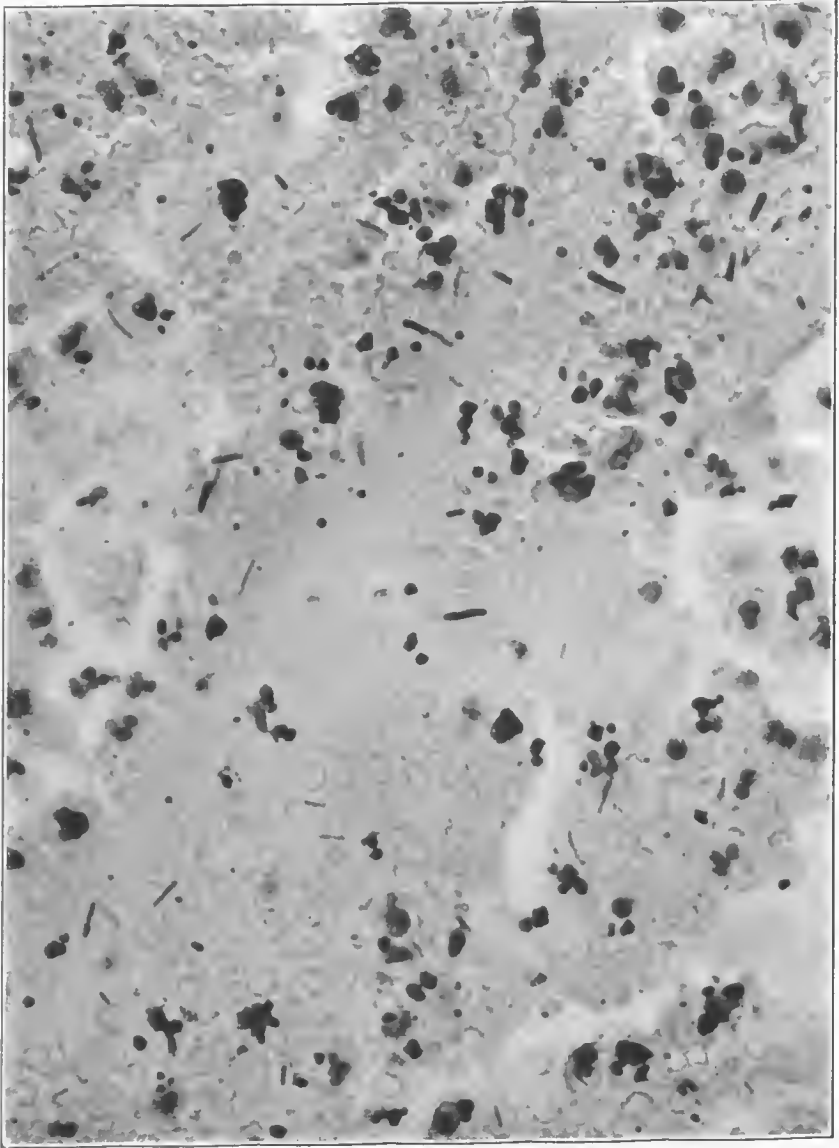


FIG. 306.—Field of the hemorrhage in the gangrenous area which contains numerous cocci and rod-shaped bacteria. There are no forms which appear like the uniform round-ended Welch bacillus, which probably accounts for the small amount of gas in this case. Accession number 4717, Army Medical Museum. Negative number 46068. MacCallum stain; $\times 870$

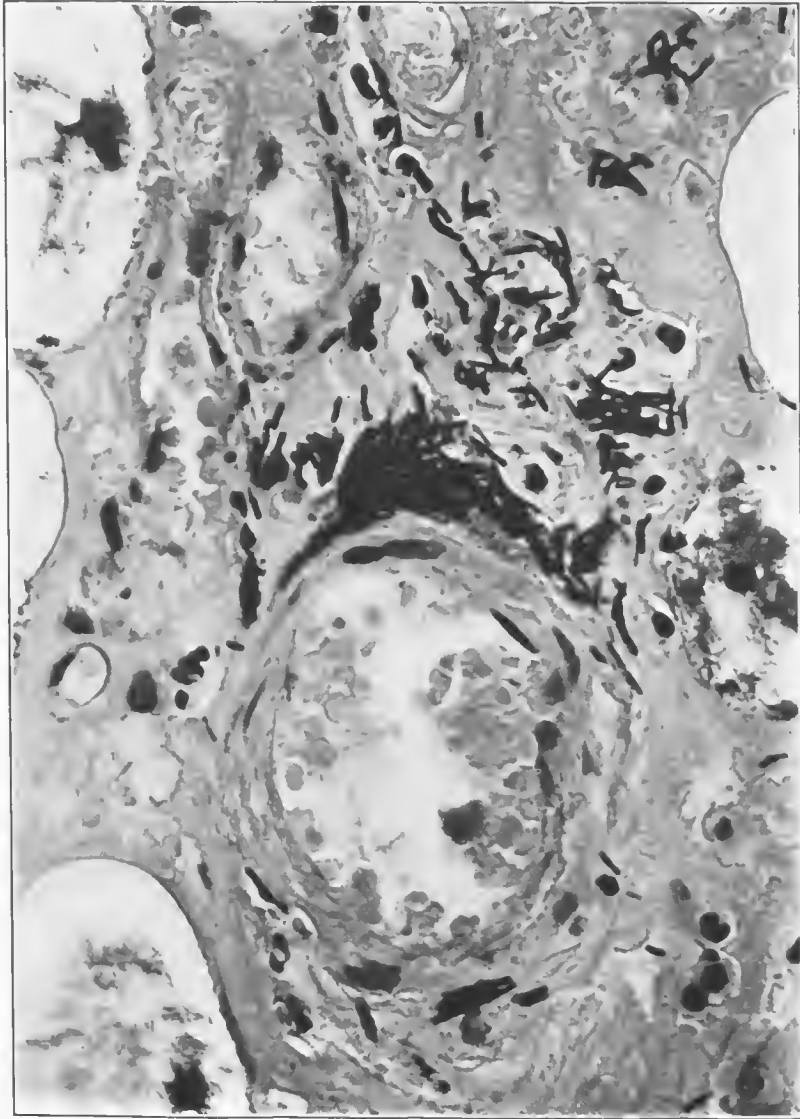


FIG. 307.—Cross section of a small vessel in the putrefactive area. There are many large, evenly staining, Gram-positive rods in the perivascular lymphatics. The circulation of this vessel remained intact to the time of amputation, and these organisms had not invaded its lumen. Accession number 4717, Army Medical Museum. Negative number 46067. MacCallum stain; $\times 870$

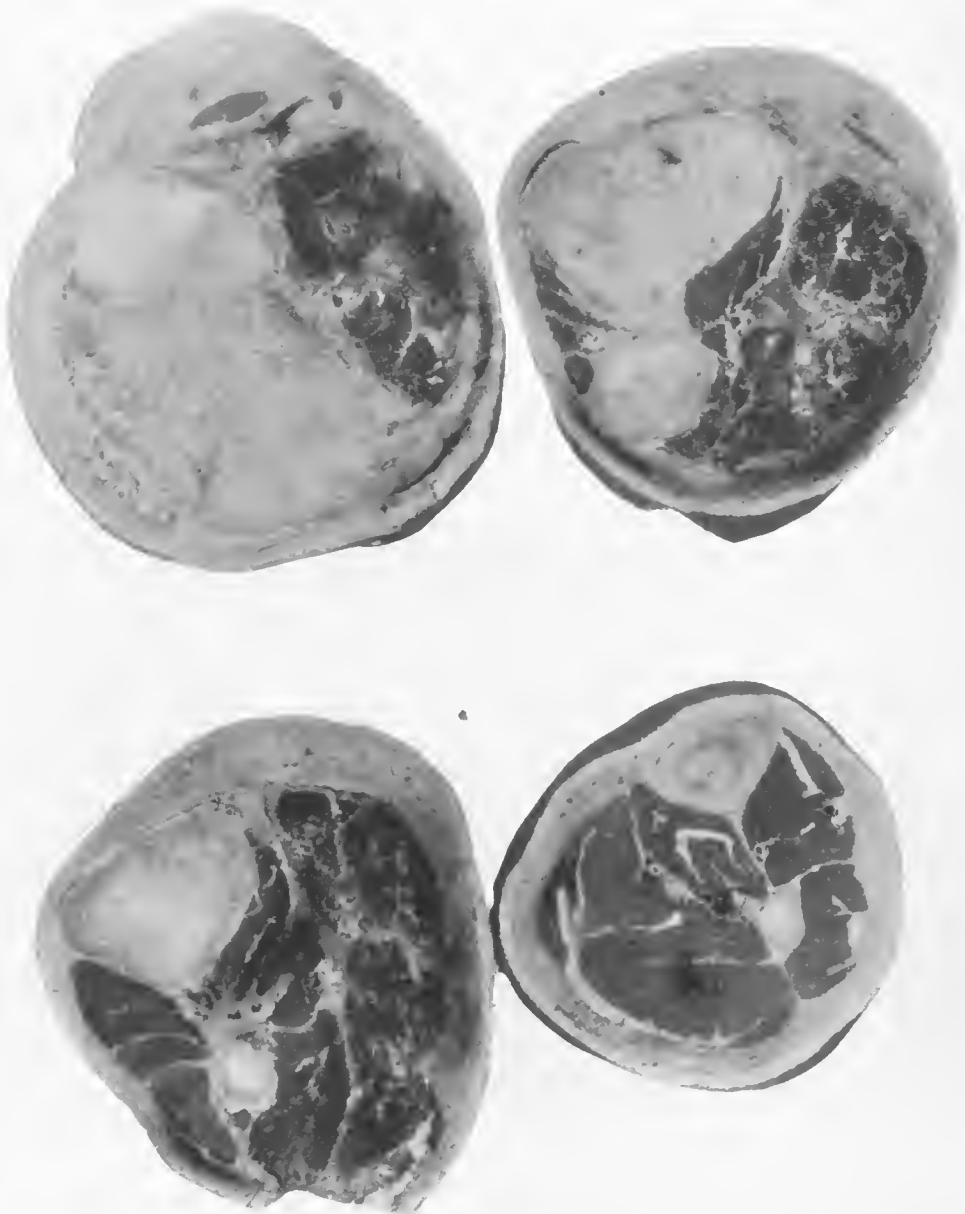
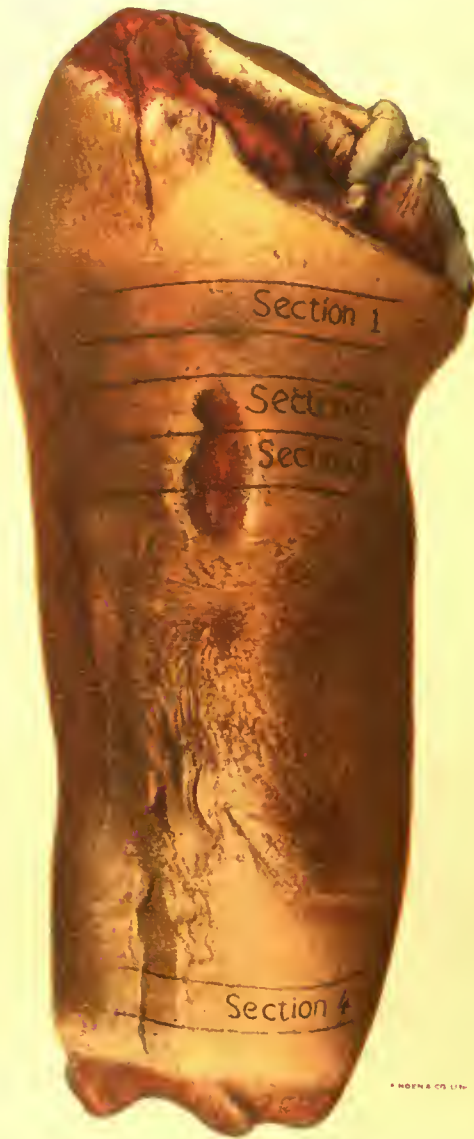

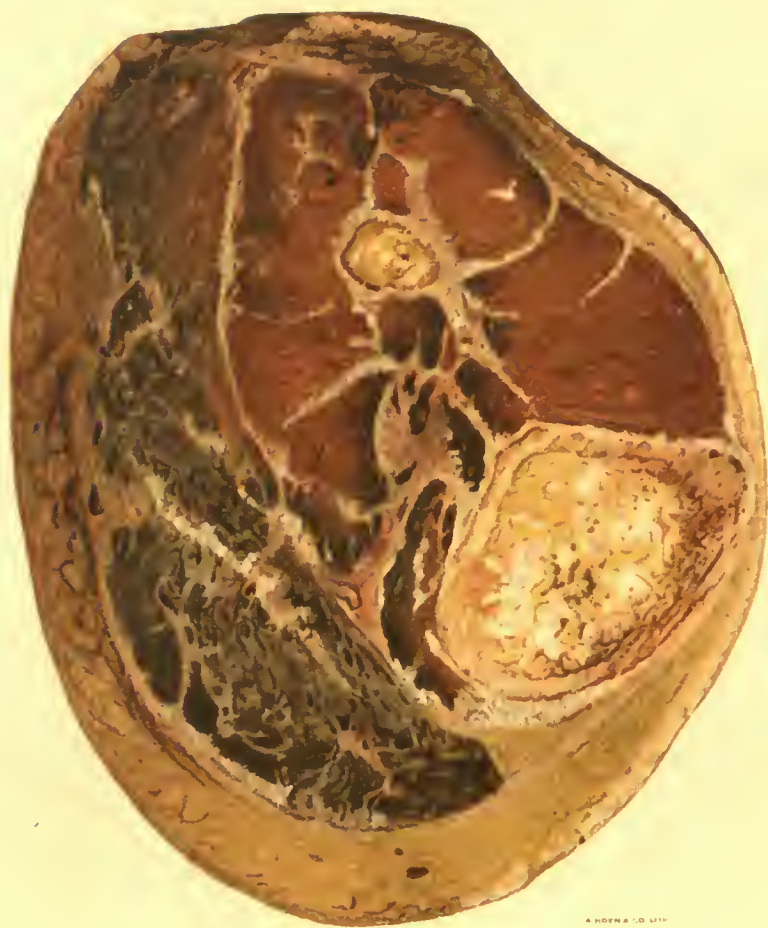FIG. 308.—Four cross sections of leg shown in Plate XXIII (black lines indicate areas): (1) Section from above the wound, showing almost complete involvement of the muscles; (2) section at the upper limit of the débrided wound in the skin, which shows complete involvement of all muscles at this level by the putrefactive process; (3) section taken at the level of the middle of the débrided skin wound. It shows extension of the putrefactive gangrene process to the heavy muscles of the calf and to the perivascular areas around the posterior tibial artery and the surrounding muscle. Anterior muscles appear free from the infection; (4) section from area indicated by the lowest black lines, showing a blackening around the perivascular lymphatics from reverse lymphatic flow and putrefaction. Accession number 4705, Army Medical Museum. Negative number 46253



BRONZING OF SKIN IN AVIRULENT GAS GANGRENE.

Bronze erysipelas. This is a valuable clinical sign, as it usually indicates that no further surgical interference is necessary when it appears.

Accession 4705, Army Medical Museum. Autochrome.



PUTREFACTIVE GANGRENE.

Cross section of leg shown in Plate XXIII. Putrefactive lesions are near the surface in relation to superficial hemorrhages near the debrided wounds.

Accession 4705, Army Medical Museum. Autochrome.

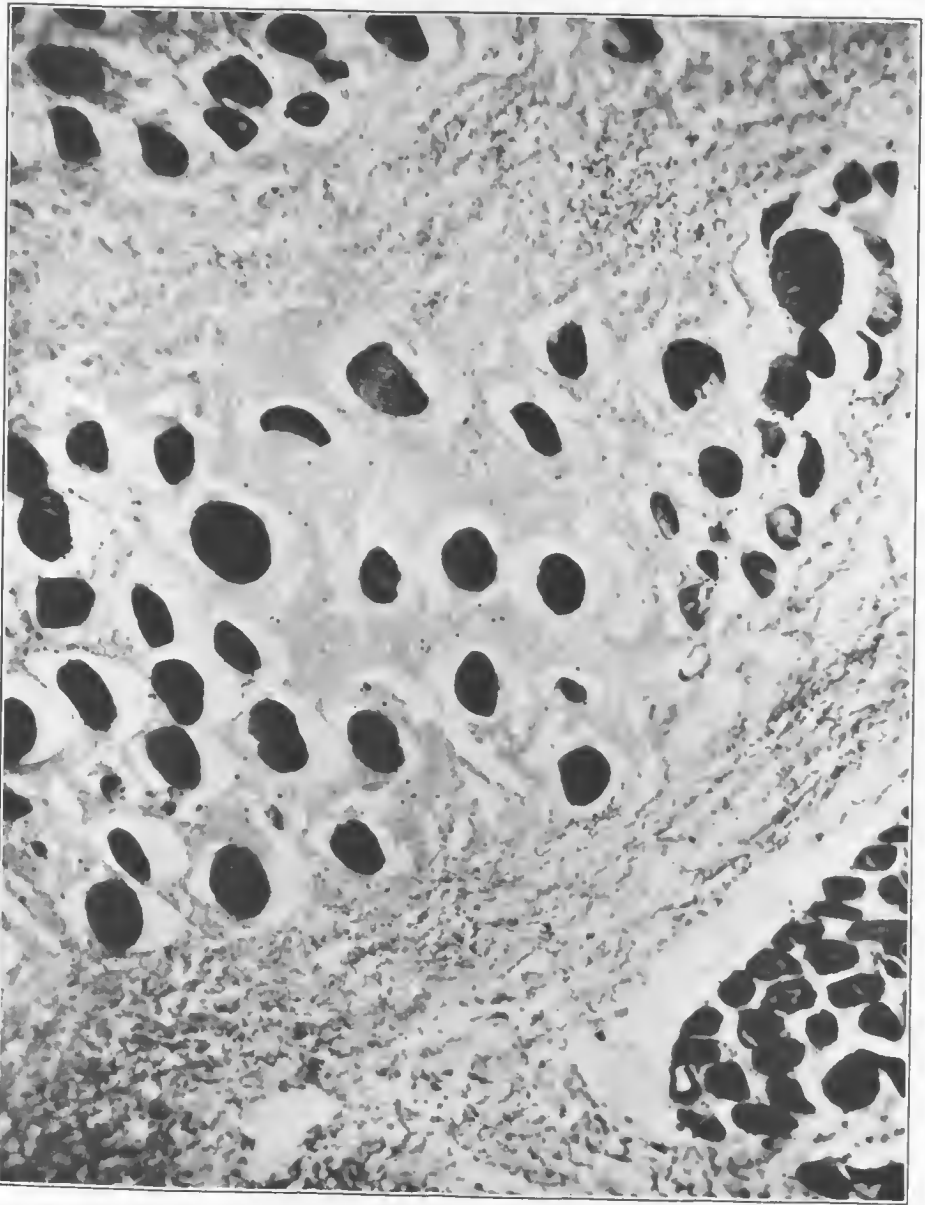


FIG. 309.—Area of putrefactive gangrene of the muscles with beginning gas gangrene in one or two fibers, while the group of muscle fibers in the upper left and lower right corners show a much more gaseous process, with gas bubbles in the center of fibers between them and around the muscle bundles. Accession number 4705, Army Medical Museum. Negative number 46237. MacCallum stain; $\times 250$

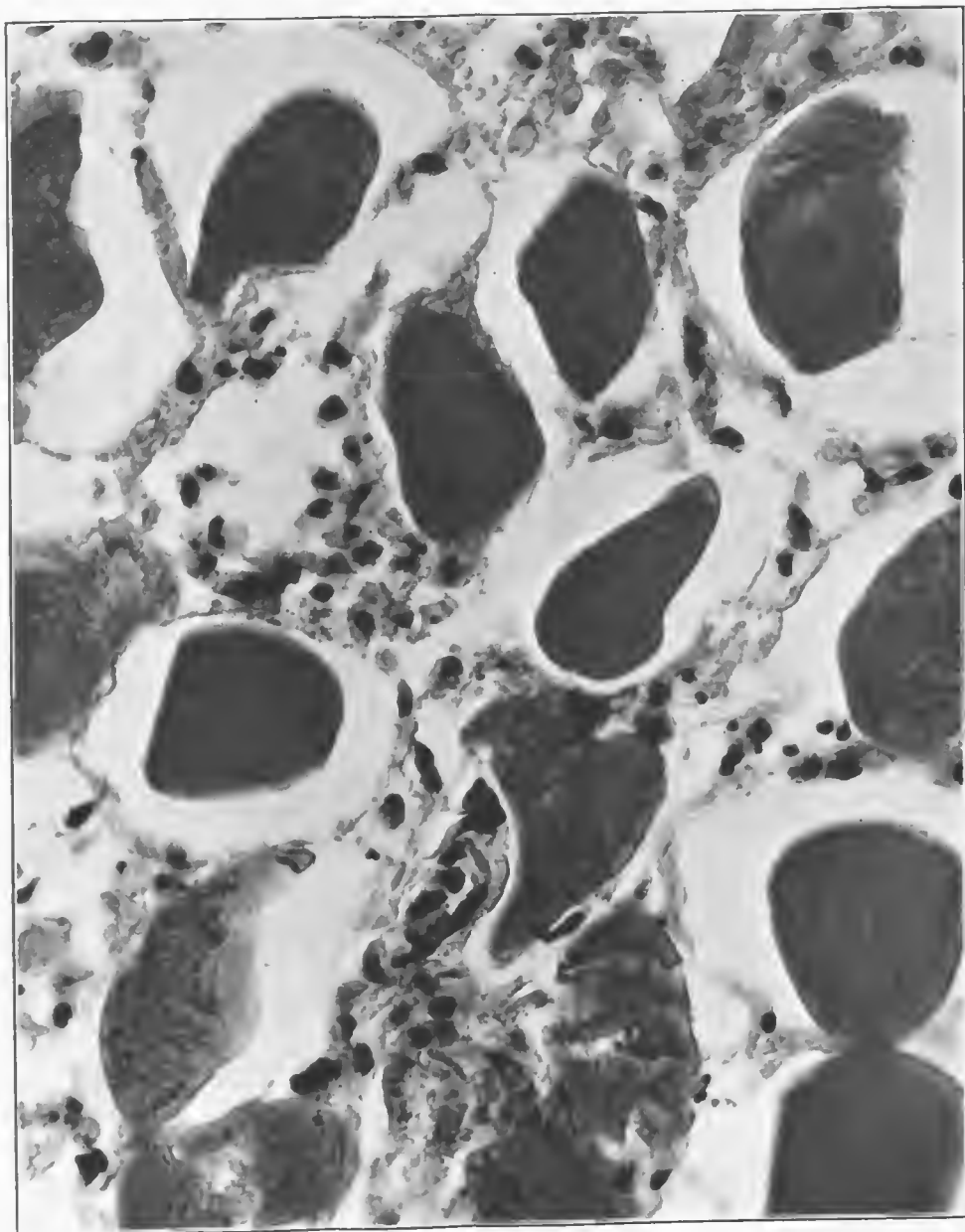


FIG. 310.—Field from the putrefactive gangrenous area with a beginning gaseous process. It shows a slight leucocytic reaction, some laking of muscle fibers, and in the lower left-hand corner a fiber containing a small gas bubble in its center. There is little chemical change. Accession number 4705, Army Medical Museum. Negative number 46235. Hematoxylin and eosin stain; $\times 195$

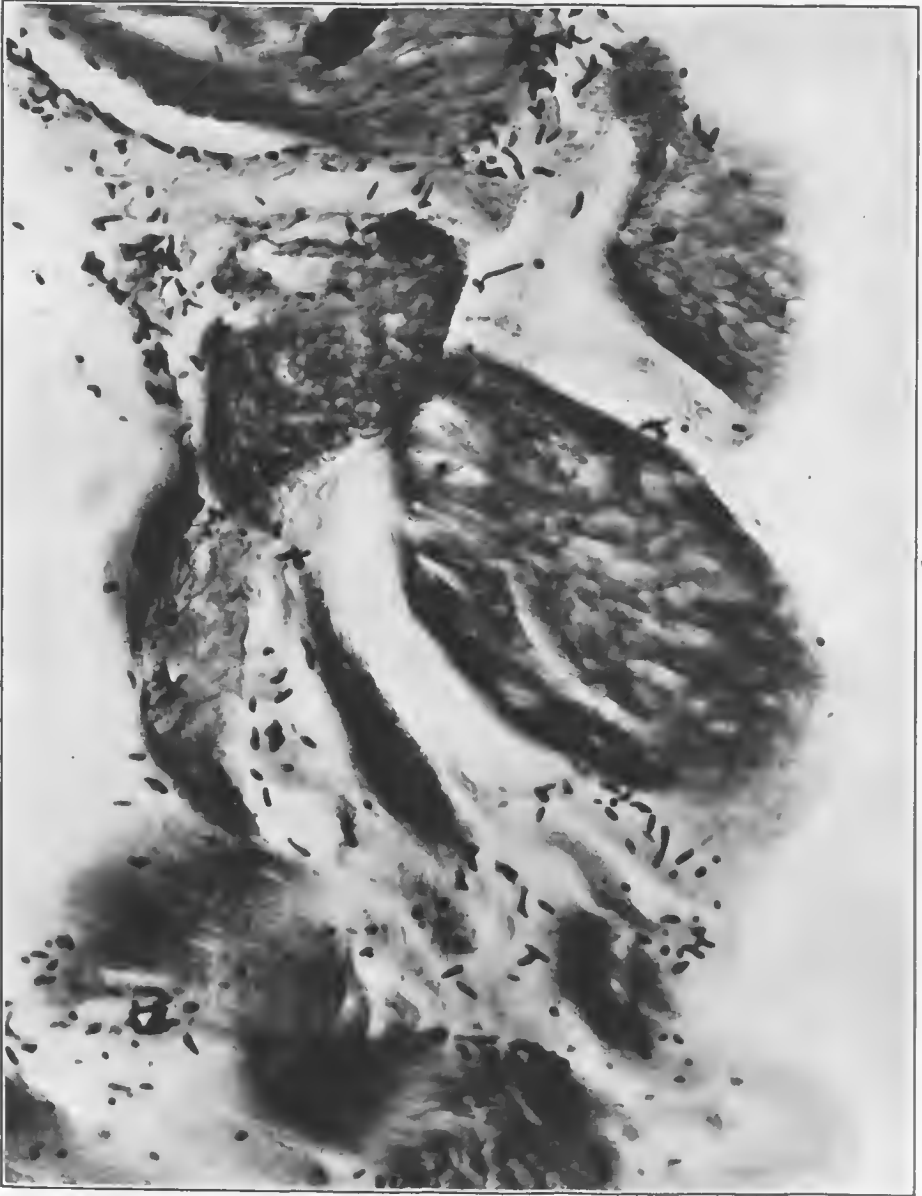

FIG. 311.—Section of muscle fibers. Fiber in the center, with comparatively few bacteria around it, has gas bubbles in its center and a collection of gas beneath its sarcolemma. The other fibers show numerous forms of bacteria—Gram-positive and Gram-negative rods with terminal and subterminal spores and occasional cocci. This is a typical picture in putrefactive gangrene and indicates why it is difficult to determine the bacteria which produce it. Accession number 4705, Army Medical Museum. Negative number 46232. MacCallum stain; $\times 846$

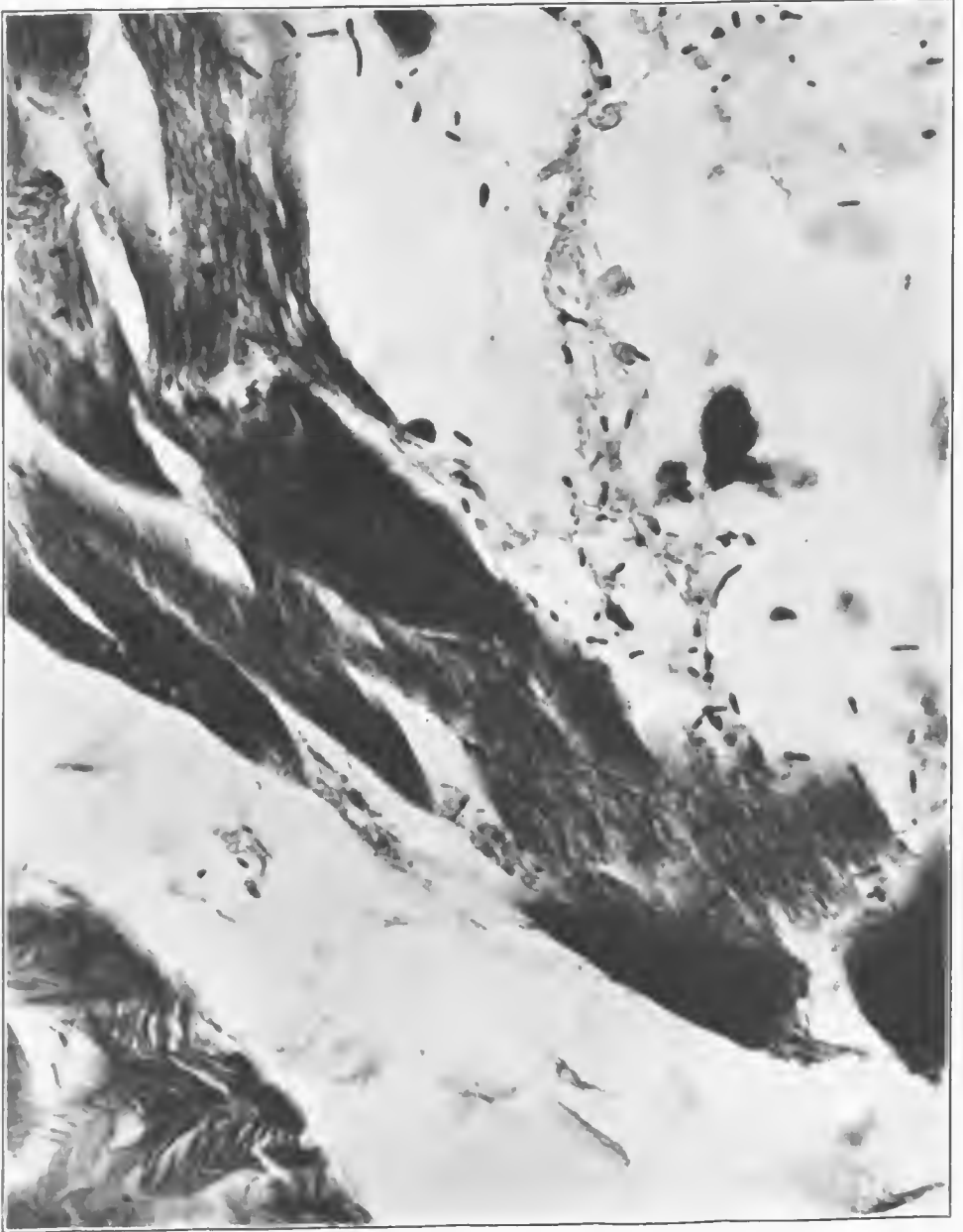

FIG. 312.—Field from a section of putrefactive gangrene of muscle with considerable gaseous change. The bacteria are few in number and variety, consisting chiefly of those bearing terminal spores. Accession number 4705, Army Medical Museum. Negative number 46224. MacCallum stain; $\times 835$

REFERENCES

- (1) Weinberg, M., et Séguin, P.: La Gangrène gazeuse. Bactériologie, Reproduction expérimentale, Sérothérapie. Monographes de l'Institut Pasteur, Paris, 1918, Masson et Cie.
- (2) McCampbell, E. F.: The Toxic and Antigenic Properties of Bacterium Welchii. *The Journal of Infectious Diseases*, Chicago, 1909, vi, No. 4.
- (3) Korentchevsky, W.: Contribution à l'étude biologique du "B. Perfringens" et du "B. Putrificus." *Annales de l'Institut Pasteur*, Paris, 1909, xxiii, No. 1, 91.
- (4) Jablons, Benjamin: Pathology of War Surgery. *Journal of the American Medical Association*, Chicago, 1915, lxiv, No. 25, 2045.
- (5) Klose, F.: Ueber toxin und antitoxin versuche mit dem Fränkelschen Gasbrandbaeillus. *Münchener medizinische Wochenschrift*, 1916, lxiii, 723.
- (6) Bull, Carroll G., and Pritchett, Ida W.: Toxin and Antitoxin of and Protective Inoculation against Bacillus Welchii. *Journal of Experimental Medicine*, New York, 1917, xxvi, No. 1.
- (7) Joffe, J. S., and Conn, H. J.: Factors Influencing the Activity of Spore-forming Bacteria in Soil. New York State Agriculture Experimental Station Technical Bulletin, 1923, No. 97.
- (8) Based on sick and wounded reports sent to the Surgeon General.
- (9) Sweetser, T. H.: Report to the director of laboratories, A. E. F. on wound bacteriology, at Base Hospital No. 15, A. E. F. On file, Historical Division, S. G. O.
- (10) Petit, R. T.: Report to the director of laboratories, A. E. F., on wound bacteriology at Evacuation Hospital No. 8, A. E. F. On file, Historical Division, S. G. O.
- (11) Bashford, E. F.: General Pathology of Acute Bacillary Gangrene Arising in Gunshot Injuries of Muscle. *The British Journal of Surgery*, London, 1916-1917, iv, 562-596.
- (12) Emery, W. d'Este: The Biology of Clostridium Welchii. *Journal of Bacteriology*, Baltimore, 1920, v, 375-429.

APPENDIX

TECHNIQUE USED IN THE PREPARATION OF THE PATHOLOGICAL TISSUES FOR STUDY

HEMATOXYLIN AND EOSIN STAINING

Sections, affixed to the slide, were brought through xylene and alcohols to water and stained two to five minutes in hematoxylin solution prepared as follows:

Hematoxylin.....	gram..	1.0
Alcohol.....	mil..	10.0
(Dye dissolved in the alcohol.)		
Alum (ammonium or potassium).....	grams..	20.0
Distilled water.....	mil..	200.0

The alum was dissolved in the water with the aid of heat, and the alcoholic solution of the dye added. The mixture was brought to a boil rapidly and 0.5 gram of mercuric oxide added. The solution at once assumed a dark purple color, and as soon as this occurred it was cooled by plunging the flask into cold water. For use, 4 per cent glacial acetic acid was added, since this increases the precision of nuclear staining.

Sections were then passed through 1 per cent hydrochloric acid in 70 per cent alcohol for 10 to 15 seconds, rinsed in water, placed in 0.5 of 1 per cent aqueous solution of lithium carbonate for 5 minutes, washed in water for 5 minutes, stained in 0.5 of 1 per cent eosin in 25 per cent alcohol for 30 seconds to 1 minute, dehydrated in alcohols, cleared in xylene, and mounted in euparal or balsam.

Euparal^a often was employed as a mounting medium in preference to balsam.

ELASTIC TISSUE STAINING

Sections affixed to the slide were brought through xylene and alcohols to water, and stained in the following elastic tissue stain^b for one-half to two hours:

	Grams
Crystal violet.....	2.0
Dextrin.....	0.5
Resoreinol.....	4.0
Water, distilled.....	200.0

This mixture was boiled in a flask and when boiling briskly 25 mil. of a 29 per cent aqueous solution of ferric chloride was added. Boiling was continued for two to five minutes. A heavy precipitate formed, and the mixture assumed a greenish cast. It was then cooled and filtered. The precipitate was dissolved by boiling with 200 mil. of 95 per cent alcohol over a water bath or electric hot plate. After cooling and filtering the volume was made up to 200 mil. with 95 per cent alcohol and 4 mil. of strong hydrochloric acid (33.8 per cent) added.

Sections were differentiated in 95 per cent alcohol, washed in water and stained for 10 to 15 minutes in Weigert iron hematoxylin prepared as follows:

	Mil.
30 per cent aqueous ferric chloride.....	1.0
Strong hydrochloric acid.....	0.25
Distilled water to make.....	25.0
1 per cent alcoholic solution of hematoxylin.....	25.0

This mixture kept satisfactorily for several weeks in a Coplin jar.

^a A trade name for a mixture of camsal, sandarac, eucalyptol, and paraldehyde.

^b For further details, consult: "Elastic fiber stain," by L. H. Prince. *United States Veterans' Bureau Medical Bulletin*, Washington, 1927; III, 83.

Sections were washed in water and stained in the following Van Gieson mixture for one to two minutes:

	Mil.
1 per cent aqueous acid fuchsin	2. 0
Saturated aqueous picric acid	38. 0

The nature of the acid fuchsin is important; a detailed description of it is given below in the discussion of dyes.

Sections were then differentiated in 95 per cent alcohol, dehydrated through alcohols, cleared in xylene, and mounted in euparal or balsam. Euparal was found to preserve a Van Gieson stain better than balsam.

Difficulty was experienced in the consistent preparation of an elastic stain, until it was noted that certain pre-war samples of dye were satisfactory while pure dyes produced since the war often failed. It formerly had been customary to weight dyes with dextrin as a diluent and it was found that the presence of dextrin was necessary for the production of the stain.

Prepared with crystal violet as the basic dye, this elastic stain shows elastin as a bright grass green, while the original technique of Weigert with basic fuchsin resulted in a bluish black elastin. It was noted further that by using both of these dyes in combination, in various proportions, a varying shade of green could be obtained in the elastin. For photography, a mixture of equal parts of basic fuchsin and crystal violet proved to be excellent.

MacCALLUM'S STAIN

Paraffine sections affixed to the slide were passed through xylene and alcohols to water, and stained for 10 minutes to one-half hour in the following mixture:

30 per cent alcohol	mil..	100. 0
Basic fuchsin	gram..	0. 59
Aniline	mil..	1. 0
Phenol, crystals	mil..	1. 0

They were then washed in water and differentiated in 40 per cent formaldehyde. This required only a few seconds, the bright red color being washed away and replaced by a clear rose. Sections were next washed in water and counterstained in a saturated aqueous solution of picric acid. The sections remained in this until they assumed a purplish color (three to five minutes); then they were washed in water and differentiated in 95 per cent alcohol, the red reappearing and some of it being washed out as was some of the yellow of the picric acid. The sections then were washed in water and stained for three to five minutes in the following solution:

Crystal violet	grams..	5. 0
Alcohol	mil..	10. 0
Aniline	mil..	2. 0
Water	mil..	88. 0

Following this, the sections were washed in water and immersed in iodine solution for one minute.

Iodine	gram..	1. 0
Potassium iodide	do..	2. 0
Water	mil..	300. 0

The slides were finally blotted dry without washing, treated in equal parts of xylene and aniline until no more color came away, passed through two changes of xylene, and mounted in balsam or euparal.

Gram-negative organisms were stained red; Gram-positive, blue. The stained preparations are easily bleached by the intense lights used in photomicrography, particularly by the carbon arc.

GIEMSA TISSUE STAIN

Paraffine sections affixed to the slide were brought through xylene and alcohols to water, and placed in the following stain, for two to three hours to overnight, in the incubator at 37° C.:

	Mil.
Giemsa substitute (see below).....	5.0
Distilled water pH 7.5 phosphate buffer.....	45.0

They were differentiated in 15 per cent solution of colophonium (rosin) in acetone for 20 to 30 seconds (until the free blue was completely washed out). A second change of 15 per cent colophonium in acetone for a few seconds and placed in the following mixture for 30 seconds to 1 minute:

	Mil.
Acetone.....	30.0
Xylene.....	70.0

Cleared in xylene and mounted in euparal or balsam.

GIEMSA SUBSTITUTE ^c

Methylene blue, zinc free.....	gram..	1.0
Eosin, yellowish.....	do.....	1.0
Azure C.....	do.....	0.6
Methylene violet (Berntshen).....	do.....	0.2
Anhydrous glycerin.....	mil..	100.0
Absolute methyl alcohol, acetone free.....	do.....	300.0

After the addition of the dry dyes to the glycerin-alcohol, the mixture was allowed to stand in the thermostat at 54° C. for from 12 to 24 hours or in the incubator at 37° C. for several days. This was necessary to permit of a chemical reaction between the basic and acid dyes and the subsequent solution of the reaction products in the alcohol-glycerine mixture.

While azure C^d was employed, similar results were obtained with azure A^e or a good grade of toluidine blue. Azure C stained a slightly deeper shade of blue than was obtainable with the other dyes.

Suitable buffers were employed to control the pH of the staining solution thereby affording control of the relative intensity of the acid and basic dyes (eosin and methylene blue, azure, etc.). Buffering on the acid side accentuated the eosin staining, while with reactions towards the alkaline side the blue staining was enhanced. For bacillary staining the alkaline reaction, pH 7.5, was employed as a more intense bacillary stain was desired, while the eosin staining was relatively unimportant.

Satisfactory buffer solutions were prepared with an M/15 solution of primary potassium phosphate containing 9.087 grams of KH₂PO₄ in the liter of distilled water and an M/15 solution of secondary sodium phosphate which contained 11.876 grams of Na₂HPO₄·2H₂O, in the liter of distilled water. The primary phosphate as received was of sufficient purity for the work while the general supply of sodium phosphate had 12 molecules of water of crystallization. This was readily changed to the two-molecule form by drying in an opened dish in the incubator at 37° C. for three or four days. For varying values of pH the following proportions of the two solutions were employed:

pH desired	Mil. secondary phosphate	Mil. primary phosphate
6.0	1.1	8.9
6.5	3.2	6.8
7.0	6.1	3.9
7.5	8.5	1.5

^c Consult: "Polychrome stains. 1. A substitute for Giemsa's stain," by R. W. French. *The Journal of Laboratory and Clinical Medicine*. St. Louis, 1926, xi, 352-354.

^d For method of production, consult: "The Oxidation Products of Methylene Blue," by W. C. Holmes and R. W. French. *Stain Technology*, Geneva, N. Y., 1926, I, 17-26.

^e For method of production, consult: "Methylene Violet and Methylene Azure A and B," by Ward J. MacNeal. *Journal of Infectious Diseases*, Chicago, 1925, xxxvi, 538-546.

Ten per cent of the buffer mixture in distilled water was employed with the Giemsa substitute.

Differentiation in the acetone-celophonium mixture was accomplished through the action of the abietic acid, the active ingredient of rosin. By increasing the percentage of the celophonium the eosin staining was improved, but at the expense of a good blue stain which was most important in studying bacteria. In general the stain was manipulated to obtain a strong blue stain as this was found to be specially necessary in the staining of Gram-negative, weakly staining organisms such as *B. influenzae*.

Euparal was employed almost exclusively as a mounting medium following the Giemsa stain as it had less bleaching effect than the average balsam.

RETICULUM STAINING¹

Paraffine sections affixed to the slide were passed through xylene and alcohols to water and placed in 0.25 per cent aqueous solution of potassium permanganate for 5 minutes, washed in water, placed in 5 per cent aqueous solution of oxalic acid for 10 minutes, washed in tap water, washed in distilled water and incubated at 37° C. for 10 to 15 minutes in the following freshly prepared silver-ammonium carbonate mixture:

To 10 mil. of a 10 per cent aqueous solution of silver nitrate were added 10 mil. of a saturated solution of lithium carbonate in distilled water. The resulting heavy white precipitate of silver carbonate was allowed to settle and the supernatant fluid poured off. The precipitate was then washed several times in from 25 to 30 mil. of distilled water, allowed to settle each time, and the supernatant fluid poured off. After the addition of 25 mil. of freshly distilled water the washed precipitate was almost dissolved by the addition of strong ammonia water while the container was constantly agitated. The precipitate turned a grayish brown as the ammonia was added. From 8 to 15 drops of ammonia were required depending upon the strength of the ammonia. Extreme care was taken not to overstep the end point of solution, and it was preferable to leave a few granules of the precipitate undissolved. The entire solution was then made up to 100 mil. with distilled water and heated to about 50° C. The slides were immersed in this solution and placed in an incubator at 37° C. Care was exercised lest the section become detached from the slide in the warm alkaline bath. It was found that sections properly affixed to the slide and thoroughly dried did not come off.

The sections were next rinsed quickly in distilled water, placed in 20 per cent neutral formalin (8 per cent formaldehyde) for 2 minutes; washed in tap water, placed in 1 to 500 gold chloride for 2 minutes, washed in tap water; placed in 5 per cent aqueous solution of hyposulphite of sodium 2 minutes and washed in water.

Following the above reticulum stain, sections were stained 3 to 5 minutes in Harris's hematoxylin, washed in tap water until blue, counterstained in Van Gieson's mixture for 45 seconds, differentiated in 95 per cent alcohol, dehydrated, cleared in xylene, and mounted in balsam or euparal.

IRON HEMATOXYLIN AND Picro-EOSIN

To show certain types of muscle degeneration the Weigert iron hematoxylin, as mentioned under elastic tissue staining, was employed, followed by a weak picric acid-eosin mixture. One part of saturated aqueous picric acid was mixed with nine parts of a 0.25 per cent aqueous eosin. If certain tissues had a tendency to show too much of a yellow stain the staining in the picro-eosin mixture was followed by a few seconds in the standard eosin described under hematoxylin and eosin staining. This technique afforded an excellent stain for the photography of muscle degeneration; fibers staining in tint from a rich red of the eosin through orange to a brown; the more alkaline portions taking the picric acid stain and the more degenerated acid fibers showing a pure eosin color.

¹ Based on: "Rapid Method for Silver Impregnation of Reticulum," by N. C. Foot, and M. C. Menard. *Archives of Pathology and Laboratory Medicine*. Chicago, 1927, iv, 211-214.

DYES

Acid fuchsin.^a—This dye was the disodium salt of sulphonated rosanilin. It was found that the corresponding sulphonated salts of para-rosanilin and new fuchsin were unsatisfactory, though sulphonated mixtures of para-rosanilin and rosanilin could be used when the relative proportion of the latter dye was 75 per cent or more. Spectrophotometrically the dye showed a clean cut maximum of absorption at a wave length 545 millimicrons with a specific absorptive index of 1.385 at 540 millimicrons. Satisfactory samples of sulphonated rosanilin with a dye content of 70 per cent showed an absorptive index of 0.969 at 540 millimicrons and consumed 2.53 mil. of normal titanous chloride per gram of dye.

Basic fuchsin.—This dye was the hydrochloride of rosanilin, or a mixture of the hydrochlorides of rosanilin and para-rosanilin containing at least 50 per cent of the former. Examined spectrophotometrically in solution in 50 per cent ethyl alcohol it showed a maximum of absorption at a wave length of 548 millimicrons. A solution of the dye of 10 parts in a million of 50 per cent ethyl alcohol when examined with the spectrophotometer showed absorptive indices of from 1.49 to 1.77 at 545 millimicrons and of from 1.36 to 1.60 at 540 millimicrons. One gram of the dye consumed not less than 4.15 mil. nor more than 4.23 mil. of normal titanous chloride.

Crystal violet.—This dye was the hydrochloride of hexamethyl para-rosanilin. Inasmuch as this dye was a definite chemical entity, it was uniformly substituted in all formulæ calling for gentian violet. Examined spectrophotometrically in a concentration of 10 parts of the dye in a million parts of 10 per cent acetic acid in water a well-defined maximum of absorption occurred at a wave length 591 millimicrons and such a solution showed an absorptive index of 1.87 and 590 millimicrons plus or minus 0.046 when examined in a layer of 1 cm. depth.

Hematoxylin.^b—This dye was the glucoside obtained through the ethereal extraction of logwood (*hæmatoxylin campechianum*). Satisfactory samples consisted of well-defined crystals of a sandy or light brown color and contained less than 0.1 of 1 per cent ash.

Methylene blue.^c—This dye was the hydrochloride of tetra-methyl thionin with a slight admixture of lower homologues (azures). Examined spectrophotometrically in a concentration of 10 parts of the dye to the million of M/150 phosphate buffer, pH 7, a well-defined maximum of absorption occurred at 660 millimicrons with a distinct secondary maximum at 610 millimicrons. The ratio between the absorptive indices at 610 millimicrons and 660 millimicrons was as 25 is to 39. Quantitatively absorptive indices of 1.575 at 660 millimicrons and of 1.01 at 610 millimicrons were determined.

Azure A.—This dye was the asymmetrical dimethyl thionin. It reacted as a thiazine dye on sulphuric acid and spectrophotometrically in aqueous solution showed a clean-cut maximum of absorption at 625 millimicrons.

Azure C.—This dye was monomethyl thionin. It reacted as a thiazine dye on sulphuric acid and spectrophotometrically in aqueous solution exhibited a clean-cut maximum of absorption at 615 millimicrons.

Methylene violet.—This dye was the dimethyl thionin or methylene violet (Bernthsen).

Eosin Y.—This dye was the disodium salt of tetrabromfluorescein. Spectrophotometrically in aqueous solution it showed a sharp absorptive maximum at 516 millimicrons.

^a For further details, consult: "Acid Fuchsin as a Stain: A Refinement in Manufacture," by John T. Scanlan, R. W. French, and W. C. Holmes. *Stain Technology*, Geneva, N. Y., 1927, ii, 50-55.

^b For further details, consult: "Standardization of Biological Stains: III, Eosin and Hematoxylin," by R. E. Scott and R. W. French. *Military Surgeon*, Washington, 1924, iv, 617-624.

^c For further details, consult: "Standardization of Biological Stains: II, Methylene Blue," by R. E. Scott and R. W. French. *Military Surgeon*, Washington, 1924, iv, 337-352.

PHOTOGRAPHY

PHOTOGRAPHY OF GROSS SPECIMENS

The gross specimens were photographed, using a commercial type camera in the vertical position. Illumination was obtained by nitrogen-filled bulbs of 75 watts each. The specimen was immersed in water to eliminate high lights and to record on the plate the maximum of detail. Commercial orthochromatic films were used in this work.¹

PHOTOMICROGRAPHY

Illuminant.—Three types of illuminant were employed, the carbon arc, the "Point-of-light" or "Tungsarc," and the ribbon filament. The source of power with the two former light sources was 110 volts direct current, while with the latter lamp 110 volts alternating current was transformed to 6 volts, the lamp employed requiring 108 watts of power at 6 volts. The arc lamp was employed for higher magnifications, while the majority of the work was accomplished with the ribbon filament lamp. A water cell was employed with the arc lamp at all times. The arc lamp afforded approximately six times as much illumination as either of the other lamps, which were about equal, but it was much more difficult to manipulate and dangerous to preparations on account of the heat and intense illumination.

Condensing system.—Immediately in front of the light source was a condensing system for the collection of the converging rays from the light source into a parallel beam of sufficient size to fill the collecting lens of the microscope substage condenser. With the microscope, an achromatic substage condenser was employed. This condenser complete with an equivalent focus of 3 millimeters was employed with 2 and 3 millimeter homogeneous oil immersion objectives. With the front lens removed, resulting in a condenser with an equivalent focus of 22 millimeters, the system was employed with the 8 and 16 millimeter objectives. In lower power work with microtessars, special simple condensers of the same equivalent focus as the objective were used. Careful centering and focusing of the condensers was found to be necessary at all times.

Objectives.—In low-power work microtessars, of 32, 48, and 72 millimeter equivalent focus, were used without oculars. In higher power work achromatic dry objectives with initial magnifications of 3, 5, and 6 were used, as well as dry apochromatic objectives with initial magnifications of 10 and 20. Homogeneous immersion apochromatic objectives, with initial magnifications of 60 and 120, were used. For satisfactory color work it proved necessary to have an objective which brought all of the spectral colors into a focus in the same plane.

Oculars.—Compensating oculars giving magnifications of 3, 5, 10, 12, and 18 times were used with the apochromatic objectives, while "homal" oculars with a magnification of about 12.5 times were used with both achromatic and apochromatic objectives. A few pictures also were made with a "Periplan" ocular (semicompensating) with a magnification of six times. For autochrome photography it was necessary to employ compensating oculars with properly corrected apochromatic objectives.

Camera.—Bellows extension up to 100 centimeters was available. Over-all magnification was determined with the aid of a stage micrometer, all objectives and oculars being calibrated and the magnifications determined for various camera extensions, as indicated on the camera bed, which was graduated in centimeters.

Photographic materials.—Commercial orthochromatic films and plates and process panchromatic plates were used for most of the photomicrographs. Where extreme contrast was desired, Wratten and Wainwright M. Panchromatic plates were used.

¹ For details, consult: "The Photography of Gross Pathological Material," by Theodore Bitterman. *Bulletin of the International Association of Medical Museums and Journal of Technical Methods*, No. viii, December, 1922.

Light filtration.—The following light filters and filter combinations were used:

Name of filter	Visual color	Spectral transmission
A.....	Scarlet.....	580 millimicrons to red end.
B.....	Green.....	460 to 600 millimicrons.
E.....	Orange.....	640 millimicrons to red end.
G.....	Strong yellow.....	610 millimicrons to red end.
B and G.....	Yellowish-green.....	510 to 600 millimicrons.
H.....	Blue.....	510 millimicrons to red end.

In computing exposures the following filter factors were employed:

Filters	Panchromatic material		Orthochromatic material	
	Nitrogen filled lamp	Arc lamp	Nitrogen filled lamp	Arc lamp
A.....	8	12	—	—
B.....	10	10	6	4
E.....	4	8	12	32
G.....	2	4	4	8
B and G.....	20	25	24	32
H.....	8	6	8	6

With the various stains the filters were used as follows:

Well balanced hematoxylin and eosin stain: B and G.

Hematoxylin and eosin with weak eosin stain: B.

Hematoxylin and eosin with weak hematoxylin stain: G.

Elastic tissue stain: A.

Giemsa stain: E.

MacCallum stain: B.

Reticulum stain: A.

Iron hematoxylin and piero-eosin: H.

In autochrome photomicrography light filters were not employed with the nitrogen-filled light sources while with the arc lamp filters were employed as indicated by the plate makers.

INDEX

	Page
Accessory nasal sinuses in acute influenza, Camp Taylor, Ky.....	163
Accessory sinuses, lesions associated with, infection by <i>B. influenzae</i> , pathological anatomy.....	210
Acute influenza, Camp Taylor, Ky.....	158
Acute respiratory diseases:	
bacteriology.....	399-405
lesions in organs outside of the respiratory tract.....	388-398
pathological anatomy.....	196-387
pathology of the.....	1-405
Civil War (1861-1865).....	4
in camps in the United States.....	7
in the American Expeditionary Forces.....	187-195
Mexican border mobilization (1915-16).....	6
War of 1812.....	3
American Expeditionary Forces, acute respiratory diseases in the.....	187-195
Anatomy, pathological. (See Pathological anatomy.)	
Aorta:	
lesions in, in acute respiratory diseases.....	393
thoracic duct and vena cava, in acute influenza, Camp Taylor, Ky.....	161
Appearance, external, in acute influenza, Camp Taylor, Ky.....	159
Appendix.....	571-577
<i>B. influenzae</i> , lesions associated with infection by, pathological anatomy.....	210
Bacteriology:	
acute respiratory diseases.....	399-405
in the American Expeditionary Forces.....	192
chronic influenza, Camp Taylor, Ky.....	179
Bladder:	
and ureter, in acute influenza, Camp Taylor, Ky.....	171
lesions in, in acute respiratory diseases.....	397
Blood, in acute respiratory diseases.....	393
Blood vascular system, in acute influenza, Camp Taylor, Ky.....	161
Blood vessels and heart, lesions in, in acute respiratory diseases.....	389
Brain:	
and meninges, in chronic influenza, Camp Taylor, Ky.....	179
in acute influenza, Camp Taylor, Ky.....	175
Bronchi:	
and trachea, in acute influenza, Camp Taylor, Ky.....	164
primary lesions associated with infection by <i>B. influenzae</i> , pathological anatomy.....	216
smaller, lesions associated with infection by <i>B. influenzae</i> , pathological anatomy.....	220
Bronchitis, acute, and pneumonitis without consolidation, pathological anatomy.....	303
Broncho-pneumonia:	
pathological anatomy.....	201
spreading (interstitial), pathological anatomy.....	297
secondary, pathological anatomy.....	279
Camps in the United States, pathology of the acute respiratory diseases in the.....	7-186
Camp—	
Beauregard, La.....	11
Bowie, Tex.....	21
Cody, N. Mex.....	31
Custer, Mich.....	37
Devens, Mass.....	42
Dix, N. J.....	54
Dodge, Iowa.....	62
Fremont, Calif.....	75
Grant, Ill.....	81
Greene, N. C.....	88
Lewis, Wash.....	98
MacArthur, Tex.....	107
Merritt, N. J.....	114
Pike, Ark.....	124
Sherman, Ohio.....	137
Taylor, Ky.....	144

	Page
Cases, particular, pathology of, acute respiratory diseases, in the American Expeditionary Forces	190
Chronic influenza, Camp Taylor, Ky	176
Civil War (1861-1865), pathology of the acute respiratory diseases	4
Course and outcome, acute respiratory diseases, in the American Expeditionary Forces	188
Cranial sinuses, in acute respiratory diseases, in the American Expeditionary Forces	190
Dura mater in acute influenza, Camp Taylor, Ky	174
Dyes used in the preparation of the pathological tissues for study	575
Ear, in acute influenza, Camp Taylor, Ky	176
Elastic tissue staining	371
Empysema, subcutaneous, in acute respiratory diseases, in the American Expeditionary Forces	190
Empyema at Camp Merritt, N. J.	121
Eosin, hematoxylin and, staining	571
Esophagus, pharynx, and stomach, in acute influenza, Camp Taylor, Ky	172
External appearance in acute influenza, Camp Taylor, Ky	159
Eye, in acute influenza, Camp Taylor, Ky	176
Eyes, lesions in, in acute respiratory diseases	398
Gas gangrene following war wounds, pathology of	407-567
Gastrointestinal tract, lesions in, in acute respiratory diseases	397
Giemsa:	
substitute	573
tissue stain	572
Gross specimens, photography of	576
Heart:	
and blood vessels, lesions in, in acute respiratory diseases	389
and pericardium in chronic influenza, Camp Taylor, Ky	176
in acute influenza, Camp Taylor, Ky	162
Hematoxylin and eosin staining	571
Infection by <i>B. influenza</i> , lesions associated with infection by, pathological anatomy	210
Influenza:	
acute, Camp Taylor, Ky	158
pathologic anatomy	159
chronic, Camp Taylor, Ky	176
bacteriology	179
pathologic anatomy	176
Inspection, general internal, in acute influenza, Camp Taylor, Ky	161
Interstitial pneumonia, pathological anatomy	208
Interstitial pulmonary lymphangitis, pathological anatomy	345
Intestines, in acute influenza, Camp Taylor, Ky	174
Introduction, pathology of the acute respiratory diseases	1
Iron hematoxylin and picro-eosin staining	574
Kidneys:	
in acute influenza, Camp Taylor, Ky	171
in chronic influenza, Camp Taylor, Ky	178
lesions in, in acute respiratory diseases	394
Larynx:	
in acute influenza, Camp Taylor, Ky	164
lesions associated with infection by <i>B. influenza</i> , pathological anatomy	211
Lesions:	
associated with infection by <i>B. influenza</i> , pathological anatomy	210
accessory sinuses	210
larynx	211
nasopharynx	210
nose	210
primary bronchi	216
smaller bronchi	220
thorax	212
tonsils	210
trachea	212
in organs outside of the respiratory tract, in acute respiratory diseases	388-398
aorta	393
bladder	397
blood	393
eyes	398
gastrointestinal tract	397
heart and blood vessels	389
kidneys	394
liver	394

	Page
Lesions—Continued.	
in organs outside of the respiratory tract, in acute respiratory diseases—Contd.	
meninges.....	398
muscles.....	388
pancreas.....	397
peritoneum.....	389
skin.....	388
spleen.....	394
suprarenals.....	394
testicles.....	397
Liver:	
in acute influenza, Camp Taylor, Ky.....	172
in chronic influenza, Camp Taylor, Ky.....	178
lesions in, in acute respiratory diseases.....	394
Lobar pneumonia, pathological anatomy.....	198
Lobular pneumonia, pathological anatomy.....	205
Lungs, in acute influenza, Camp Taylor, Ky.....	165
Lymph nodes:	
mesenteric, in acute influenza, Camp Taylor, Ky.....	174
peribronchial, in acute influenza, Camp Taylor, Ky.....	163
Lymphangitis, interstitial pulmonary, pathological anatomy.....	345
MacCallum's stain.....	572
Meninges:	
and brain, in chronic influenza, Camp Taylor, Ky.....	179
lesions in, in acute respiratory diseases.....	398
Mesenteric lymph nodes, in acute influenza, Camp Taylor, Ky.....	174
Mexican border mobilization (1915-16), pathology of the acute respiratory diseases.....	6
Muscles:	
in acute influenza, Camp Taylor, Ky.....	160
lesions in, in acute respiratory diseases.....	388
Nasopharynx, lesions associated with infection by <i>B. influenzae</i> , pathological anatomy.....	210
Necropsy findings, Camp Merritt, N. J.....	122
Nervous system, in acute influenza, Camp Taylor, Ky.....	174
Nose, lesions associated with infection by <i>B. influenzae</i> , pathological anatomy.....	210
Organs:	
other, in acute respiratory diseases, in the American Expeditionary Forces.....	190
outside of the respiratory tract, lesions in, in acute respiratory diseases.....	388-398
Pancreas:	
in acute influenza, Camp Taylor, Ky.....	173
lesions in, in acute respiratory diseases.....	397
Pathologic anatomy:	
acute influenza, Camp Taylor, Ky.....	159
chronic influenza, Camp Taylor, Ky.....	176
acute respiratory diseases.....	196-387
in the American Expeditionary Forces.....	189
broncho-pneumonia.....	201
interstitial pneumonia.....	208
interstitial pulmonary lymphangitis.....	345
lesions associated with infection by <i>B. influenzae</i> , in acute respiratory diseases.....	210
lobar pneumonia.....	198
lobular pneumonia.....	205
secondary broncho-pneumonia.....	279
secondary lobular pneumonia.....	304
spreading broncho-pneumonia (interstitial).....	297
staphylococcus aureus pneumonia.....	377
Pathology:	
of gas gangrene following war wounds.....	407-567
of particular cases, acute respiratory diseases, in the American Expeditionary Forces.....	190
of the acute respiratory diseases.....	1-405
Civil War (1861-1865).....	4
in camps in the United States.....	7
in the American Expeditionary Forces.....	187-159
introduction.....	1
Mexican border mobilization (1915-16).....	6
War of 1812.....	3
Peribronchial lymph nodes, in acute influenza, Camp Taylor, Ky.....	163
Peribronchiolar pneumonia, pathological anatomy.....	208
Pericardium:	
and heart, in chronic influenza, Camp Taylor, Ky.....	176
in acute influenza, Camp Taylor, Ky.....	162

	Page
Peritoneum:	
in acute influenza, Camp Taylor, Ky.....	161
lesions in, in acute respiratory diseases.....	389
Pharynx, esophagus, and stomach, in acute influenza, Camp Taylor, Ky.....	172
Photography.....	576
of gross specimens.....	576
Photomicrography.....	576
Pia-arachnoid, in acute influenza, Camp Taylor, Ky.....	174
Picro-eosin, iron hematoxylin and, staining.....	574
Pituitary gland:	
in acute influenza, Camp Taylor, Ky.....	175
lesions in, in acute respiratory diseases.....	398
Pleurae, in acute influenza, Camp Taylor, Ky.....	165
Pneumonia:	
interstitial, pathological anatomy.....	208
lobar, pathological anatomy.....	198
lobular, pathological anatomy.....	205
peribronchiolar, pathological anatomy.....	208
secondary lobular, pathological anatomy.....	304
staphylococcus aureus, pathological anatomy.....	377
Pneumonitis without consolidation, acute bronchitis and, pathological anatomy.....	303
Prostate, in acute influenza, Camp Taylor, Ky.....	172
Rectus abdominis, in acute influenza, in the American Expeditionary Forces.....	190
Respiratory organs, in acute respiratory diseases, in the American Expeditionary Forces.....	189
Respiratory system, in acute influenza, Camp Taylor, Ky.....	163
Respiratory tract:	
in chronic influenza, Camp Taylor, Ky.....	177
lesions in organs outside of the, in acute respiratory diseases.....	388-398
Reticulum staining.....	574
Semilunar ganglia:	
and suprarenals, in chronic influenza, Camp Taylor, Ky.....	178
in acute influenza, Camp Taylor, Ky.....	170
Seminal vesicles, spermatic cord, and testicles, in acute influenza, Camp Taylor, Ky.....	172
Serous cavities in acute respiratory diseases, in the American Expeditionary Forces.....	189
Sinuses:	
accessory, lesions associated with infection by <i>B. influenzae</i> , pathological anatomy.....	210
cranial, in acute respiratory diseases, in the American Expeditionary Forces.....	190
Skin:	
in acute influenza, Camp Taylor, Ky.....	159
lesions in, in acute respiratory diseases.....	388
Specimens, gross, photography of.....	576
Spermatic cord, testicles, and seminal vesicles, in acute influenza, Camp Taylor, Ky.....	172
Spleen:	
in acute influenza, Camp Taylor, Ky.....	169
in chronic influenza, Camp Taylor, Ky.....	177
lesions in, in acute respiratory diseases.....	394
Stain:	
Giemsa tissue.....	572
MacCallum's.....	572
Staining:	
elastic tissue.....	571
hematoxylin and eosin.....	571
iron hematoxylin and picro-eosin.....	574
reticulum.....	574
Staphylococcus aureus pneumonia, pathological anatomy.....	377
Stomach, pharynx and esophagus, in acute influenza, Camp Taylor, Ky.....	172
Subcutaneous emphysema, in acute respiratory diseases, in the American Expeditionary Forces.....	190
Subcutaneous tissues, in acute influenza, Camp Taylor, Ky.....	160
Suprarenals:	
and semilunar ganglia, in chronic influenza, Camp Taylor, Ky.....	178
in acute influenza, Camp Taylor, Ky.....	170
lesions in, in acute respiratory diseases.....	394
Technique used in the preparation of the pathological tissues for study.....	571
Testicles:	
lesions in, in acute respiratory diseases.....	397
seminal vesicles, and spermatic cord, in acute influenza, Camp Taylor, Ky.....	172
Thoracic duct, vena cava, and aorta, in acute influenza, Camp Taylor, Ky.....	161
Thorax, lesions associated with infection by <i>B. influenzae</i> , pathological anatomy.....	212

	Page
Thyroid and tonsils, in acute influenza, Camp Taylor, Ky-----	172
Tissue, elastic, staining-----	571
Tissues, pathological, for study, technique used in the preparation of the-----	571
Tongue, in acute influenza, Camp Taylor, Ky-----	172
Tonsils:	
and thyroid, in acute influenza, Camp Taylor, Ky-----	172
lesions associated with infection by <i>B. influenza</i> , pathological anatomy-----	201
Trachea:	
and bronchi, in acute influenza, Camp Taylor, Ky-----	164
lesions associated with infection by <i>B. influenza</i> , pathological anatomy-----	211
United States, camps in the, pathology of the acute respiratory diseases in-----	7-186
Ureter and bladder, in acute influenza, Camp Taylor, Ky-----	171
Vena cava, aorta, and thoracic duct, in acute influenza, Camp Taylor, Ky-----	161
War of 1812, pathology of the acute respiratory diseases-----	3
Wounds, war, pathology of gas gangrene following-----	407-563

