



This is a digital copy of a book that was preserved for generations on library shelves before it was carefully scanned by Google as part of a project to make the world's books discoverable online.

It has survived long enough for the copyright to expire and the book to enter the public domain. A public domain book is one that was never subject to copyright or whose legal copyright term has expired. Whether a book is in the public domain may vary country to country. Public domain books are our gateways to the past, representing a wealth of history, culture and knowledge that's often difficult to discover.

Marks, notations and other marginalia present in the original volume will appear in this file - a reminder of this book's long journey from the publisher to a library and finally to you.

Usage guidelines

Google is proud to partner with libraries to digitize public domain materials and make them widely accessible. Public domain books belong to the public and we are merely their custodians. Nevertheless, this work is expensive, so in order to keep providing this resource, we have taken steps to prevent abuse by commercial parties, including placing technical restrictions on automated querying.


We also ask that you:

- + *Make non-commercial use of the files* We designed Google Book Search for use by individuals, and we request that you use these files for personal, non-commercial purposes.
- + *Refrain from automated querying* Do not send automated queries of any sort to Google's system: If you are conducting research on machine translation, optical character recognition or other areas where access to a large amount of text is helpful, please contact us. We encourage the use of public domain materials for these purposes and may be able to help.
- + *Maintain attribution* The Google "watermark" you see on each file is essential for informing people about this project and helping them find additional materials through Google Book Search. Please do not remove it.
- + *Keep it legal* Whatever your use, remember that you are responsible for ensuring that what you are doing is legal. Do not assume that just because we believe a book is in the public domain for users in the United States, that the work is also in the public domain for users in other countries. Whether a book is still in copyright varies from country to country, and we can't offer guidance on whether any specific use of any specific book is allowed. Please do not assume that a book's appearance in Google Book Search means it can be used in any manner anywhere in the world. Copyright infringement liability can be quite severe.

About Google Book Search

Google's mission is to organize the world's information and to make it universally accessible and useful. Google Book Search helps readers discover the world's books while helping authors and publishers reach new audiences. You can search through the full text of this book on the web at <http://books.google.com/>

24503442808



LANE MEDICAL LIBRARY STANFORD STOR
E32 P98 1887
A compend of modern medical, therapeutic

QUIZ-COMPENDS

ANATOMY

DR. POTTER.

A NEW SERIES OF MANUALS FOR MEDICAL STUDENTS.

UNIFORM IN SIZE, PRICE AND BINDING.

Price of Each Book, Cloth, \$3.00; Leather, \$3.50.

MIDWIFERY. By ALFRED LEWIS GALABIN, M. A., M.D., Obstetric Phy.

LANE

MEDICAL



LIBRARY

Gift

Dr. J. Underwood Hall

alphabetical order, and the various drugs indicated are given, with the authority recommending them, and a great number of special prescriptions.

CHILDREN. By J. F. GOODHART, M.D., Physician to the Evelina Hospital for Children; Assistant Physician to Guy's Hospital, London. American Edition. Revised and Edited by LOUIS STARR, M.D., Clinical Professor of Diseases of Children in the Hospital of the University of Pennsylvania; Physician to the Children's Hospital of Philadelphia. 50 Formule, and Directions for preparing Artificial Human Milk, for the Artificial Digestion of Milk, etc. 738 pages.

"Nothing that concerns disease as found in childhood seems to have escaped the author's attention. From introduction to the end it is replete with valuable information, and one reads it with the feeling that Dr. Goodhart is writing of what he has seen at the bedside. It need scarcely be added that the revisions and additions by the American editor are of much value, neither too full nor too spare, and very judicious."—*Journal of the American Medical Association*

W & CO., Publishers and Booksellers,
ALNUT STREET, PHILADELPHIA.

Recd. from Dr. Underwood Hall

Graily Hall.
The New Series of Manuals.—Continued.

PRACTICAL THERAPEUTICS, with an Index of Diseases. By ED. JOHN WARING, M.D., F.R.C.P. Fourth Edition. Rewritten and Revised. Edited by DUDLEY W. BUXTON, Assistant to the Professor of Medicine, University College Hospital, London. 666 pages.

"Our admiration, not only for the immense industry of the author, but also of the great practical value of the volume, increases with every reading or consultation of it. We wish a copy could be put in the hands of every Student or Practitioner in the country. In our estimation, it is the best book of the kind ever written."—*N. Y. Medical Journal.*

"It is, indeed, one of the most practical works that has ever attracted our attention. Combining the merits of Wood, Beck, Stillé, and the U. S. Dispensary, it forms a volume which no young physician can afford to be without."—*Chicago Medical Journal.*

"This work is a monument of industry and perseverance. It is invaluable both to the Practitioner and Student."—*Canada Medical Journal.*

MEDICAL JURISPRUDENCE AND TOXICOLOGY. By JOHN J. REESE, M.D., Professor of Medical Jurisprudence and Toxicology, University of Pennsylvania, etc. 606 pages.

"The production of this admirable text-book by one of the two or three leading teachers of medical jurisprudence in America, will, we hope, give a new impetus to the study of forensic medicine, which, inviting and important as it is, has heretofore been strangely neglected in both legal and medical schools."—*American Journal of the Medical Sciences.*

"We heartily second the author's hope that this treatise may encourage an increasing interest in the students for that most important, but too much neglected, subject, forensic medicine."—*Boston Medical and Surgical Journal.*

"We lay this volume aside, after a careful perusal of its pages, with the profound impression that it should be in the hands of every doctor and lawyer. It fully meets the wants of all students. He has succeeded in admirably condensing into a handy volume all the essential points."—*Cincinnati Lancet and Clinic.*

ORGANIC CHEMISTRY. By Prof. VICTOR VON RICHTER, University of Breslau. Translated from Fourth German Edition by EDGAR F. SMITH, M.A., PH. D., Professor of Chemistry, Wittenberg College, Springfield, O., formerly in the Laboratories of the University of Pennsylvania, etc. Illustrated. 710 pages.

"I must say that this standard treatise is here presented in a remarkably compendious shape."—*J. W. Holland, M.D., Professor of Chemistry, Jefferson Medical College, Philadelphia.*

"This work brings the whole matter, in simple, plain language, to the student in a clear, comprehensive manner. The whole method of the work is one that is more readily grasped than that of older and more famed text-books, and we look forward to the time when, to a great extent, this work will supersede others, on the score of its better adaptation to the wants of both teacher and student."—*Pharmaceutical Record.*

"It presents in a concise form the most modern views of the theory, and gives, moreover, many very practical methods. The freshness of its information may be noted."—*Saml. P. Sadtler, Professor of General and Organic Chemistry, University of Pennsylvania, and Professor of Chemistry, Philadelphia College of Pharmacy.*

DISEASES OF WOMEN. By Dr. F. WINCKEL, Professor of Gynecology, etc., Royal University of Munich. The Translation Edited by THEOPHILUS PARVIN, M.D., Professor of Obstetrics and Diseases of Women and Children, Jefferson Medical College, Philadelphia. 117 Engravings, most of which are new. 674 pages.

This work has no superior as a text-book of Diseases of Women in regard to clearness and completeness, and in its presentation of the latest scientific knowledge, and of the best practical rules and methods of treatment.

* * * Other Volumes in Preparation. A complete illustrated circular, with sample pages, sent free, upon application.

Price of Each Book, Cloth, \$3.00 ; Leather, \$3.50.

P. BLAKISTON, SON & CO., Publishers and Booksellers.
1012 WALNUT STREET, PHILADELPHIA.

MEDICAL BRIEFS.

A series of short, concise compends for the medical student and practitioner.
12mo. Cloth. Each, Price, \$1.00.

No. I. POST-MORTEM EXAMINATIONS. Second Edition.
With Especial Reference to Medico Legal Practice. By Prof. RUDOLPH VIRCHOW, of Berlin Charité Hospital, author of Cellular Pathology; Translated by T. P. SMITH, M.D., Member of the Royal College of Surgeons of England. Second American, from the Fourth German Edition. With Four Lithographic Plates.

"We are informed in precise and exact terms how a post-mortem examination should be made, both with regard to the plan to be pursued, and the manner of making the several cuts into the various organs and tissues. The method of recording the results of the investigation is clearly indicated by the addition of the detailed account of the examination of four cases; and the value of the objective evidence is accurately stated in the form of the inferences drawn concerning the manner and cause of death."—*American Journal of Medical Sciences.*

"For thorough and systematic method in the performance of post-mortem examinations, there is no guide like it."—*London Lancet.*

No. II. MANUAL OF VENEREAL DISEASES. Fourth Edition.
A Concise Description of those Affections and of their Treatment, including a list of SIXTY-SEVEN PRESCRIPTIONS for Vapor Bath, Gargles, Injections, Lotions, Mixtures, Ointments, Paste, Pills, Powders, Solutions and Suppositories. By BERKELEY HILL, M.D., Professor of Clinical Surgery, in University College; Surgeon to University College and Lock Hospitals; and ARTHUR COOPER, M.D., formerly House Surgeon, Lock Hospital. Fourth Edition, Revised and Enlarged.

"I have examined it with care, and find it to be a practical and useful compendium of knowledge on the subjects discussed, well adapted to the use of medical students and those physicians in general practice who have occasional need to consult a work of this kind."—*James Neven Hyde, M.D., Professor of Skin and Venereal Diseases, Rush Medical College, Chicago.*

"It seems to contain much information in a condensed form. The names of the authors ensure its doctrinal accuracy."—*Ed. L. Keyes, M.D., Professor of Genito-Urinary Surgery, Syphilology and Dermatology, Bellevue Hospital Medical College, N. Y.*

"As the work of one of the highest living authorities, it is natural that it should have found such favor."—*Gaillard's Medical Journal.*

"If you wish to be well informed on this subject, we say, secure this little book."—*Medical Brief.*

No. III. MEDICAL ELECTRICITY. A Compend of Electricity and its Medical and Surgical Uses. By CHAS. F. MASON, M.D., Assistant Surgeon, United States Army, with an Introduction by CHAS. H. MAY, M.D., Instructor in Ophthalmology, New York Polyclinic. With Illustrations.
Just Ready.

From the large amount of literature upon the subject of Medical Electricity, Dr. Mason has selected and classified the facts and principles that are of practical use to the student and physician. It is a short, comprehensive statement of this important branch of therapeutics in clear, plain language, with illustrations where needed, to render the text distinct.

OTHER VOLUMES IN PREPARATION.

Price of Each Book, Bound in Cloth, \$1.00.

**P. BLAKISTON, SON & CO., Publishers and Booksellers,
1012 WALNUT STREET, PHILADELPHIA.**

POTTER'S COMPEND
OF
ANATOMY.

FOURTH EDITION.

THE ? QUIZ-COMPENDS ?

A NEW SERIES OF MANUALS FOR THE USE OF STUDENTS
AND PHYSICIANS.

Price of each, Cloth, \$1.00. Interleaved, for taking Notes, \$1.25.

These Compendes are based on the most popular text-books, and the lectures of prominent professors, and are kept constantly revised, so that they may thoroughly represent the present state of the subjects upon which they treat.

The Authors have had large experience as Quiz Masters and attachés of colleges, and are well acquainted with the wants of students.

They are arranged in the most approved form, thorough and concise, containing 231 illustrations, inserted wherever they could be used to advantage.

Can be used by students of any college.

They contain information nowhere else collected in such a condensed, practical shape.

Size is such that they may be easily carried in the pocket, and the price is low.

They will be found very serviceable to physicians as remembrancers.

LIST OF VOLUMES.

- No. 1. HUMAN ANATOMY.** Fourth Revised and Enlarged Edition. Including Visceral Anatomy formerly published separately. 117 Illustrations. By SAMUEL O. L. POTTER, M.D., Professor of the Practice of Medicine, Cooper Medical College, San Francisco, late A. A. Surgeon, U. S. Army. Revised and enlarged.
- No. 2. PRACTICE OF MEDICINE. Part I.** Second Edition. Revised and Enlarged. By DAN'L E. HUGHES, M.D., Demonstrator of Clinical Medicine, Jefferson College, Philadelphia.
- No. 3. PRACTICE OF MEDICINE. Part II.** Second Edition. Revised and Enlarged. Same author as No. 2.
- No. 4. PHYSIOLOGY.** Third Edition, with Illustrations and a table of Physiological Constants. Enlarged and Revised. By A. P. BRUBAKER, M.D., Professor of Physiology and General Pathology in the Pennsylvania College of Dental Surgery; Demonstrator of Physiology, Jefferson Medical College, Philadelphia.
- No. 5. OBSTETRICS.** Third Edition. Enlarged. By HENRY G. LANDIS, M.D., Professor of Obstetrics and Diseases of Women and Children, Starling Medical College, Columbus, Ohio. Illustrated.
- No. 6. MATERIA MEDICA, THERAPEUTICS, AND PRESCRIPTION WRITING.** Fourth Revised Edition. By SAMUEL O. L. POTTER, M.D., Professor of Practice, Cooper Medical College, San Francisco, late A. A. Surgeon, U. S. Army.
- No. 7. INORGANIC CHEMISTRY.** Revised Edition. By G. MASON WARD, M.D., Demonstrator of Chemistry, Jefferson College, Philadelphia.
- No. 8. DISEASES OF THE EYE, AND REFRACTION,** including Treatment and Surgery. By L. WEBSTER FOX, M.D., Chief Clinical Assistant, Ophthalmological Department, Jefferson Medical College Hospital, and GEO. M. GOULD, A.B. With 60 Illustrations.
- No. 9. SURGERY.** Third Edition. Enlarged and Improved. By ORVILLE HORWITZ, B.S., M.D., Demonstrator of Anatomy, Jefferson College, Chief of the Out-Patient Surgical Department, Jefferson College Hospital, late Resident Physician, Pennsylvania Hospital, Philadelphia. 90 Illustrations.
- No. 10. ORGANIC CHEMISTRY.** Including Medical Chemistry, Urine Analysis and the Analysis of Water and Food. By HENRY LEFFMANN, M.D., D.D.S., Professor of Chemistry and Metallurgy in the Pennsylvania College of Dental Surgery; and of Clinical Chemistry and Hygiene in the Philadelphia Polyclinic, etc., Philadelphia.
- No. 11. PHARMACY.** Second Edition. Based upon Prof. Remington's Text-book of Pharmacy. By F. E. STEWART, M.D., PH.G., Quiz Master in Pharmacy and Chemistry, Philadelphia College of Pharmacy; Lecturer at the Medico-Chirurgical College, and Woman's Medical College, Philadelphia. Second Edition, carefully revised.

Others in preparation.

Price, each, Cloth, \$1.00. Interleaved, for taking Notes, \$1.25.

P. BLAKISTON, SON & CO., Medical Publishers and Booksellers,
1012 WALNUT STREET, PHILADELPHIA.

? QUIZ-COMPENDS? No. 1.

A COMPEND
J. B. Hall
OF
June 1887
HUMAN ANATOMY,

INCLUDING THE

ANATOMY OF THE VISCERA.

BY

SAMUEL O. L. POTTER, M.A., M.D.,

PROFESSOR OF THEORY AND PRACTICE OF MEDICINE IN THE COOPER MEDICAL COLLEGE
OF SAN FRANCISCO; AUTHOR OF "A HANDBOOK OF MATERIA MEDICA, PHARMACY
AND THERAPEUTICS," "AN INDEX OF COMPARATIVE THERAPEUTICS,"
"A COMPEND OF MATERIA MEDICA," AND OF THE LEA PRIZE
ESSAY OF JEFFERSON MEDICAL COLLEGE, ON "DYSALALIA,
A STUDY OF SPEECH AND ITS DEFECTS;"
LATE A. A. SURGEON, U. S. ARMY.

FOURTH EDITION, REVISED AND ENLARGED.

WITH ONE HUNDRED AND SEVENTEEN ILLUSTRATIONS.

PHILADELPHIA:
P. BLAKISTON, SON & CO.,
No. 1012 WALNUT STREET.

1887.

TO THE MEMORY
OF
AN AMERICAN SURGEON AND ANATOMIST,
WHOSE FAME IS ACKNOWLEDGED THROUGHOUT
THE WHOLE CIVILIZED WORLD,
JOSEPH PANCOAST,
FORMERLY PROFESSOR OF ANATOMY IN JEFFERSON MEDICAL COLLEGE;
AND TO
WILLIAM H. PANCOAST,
LATE PROFESSOR OF ANATOMY IN JEFFERSON MEDICAL COLLEGE,
THE TALENTED AND COURTEOUS
REPRESENTATIVE OF A GREAT NAME,
WHOSE ENTHUSIASTIC TEACHINGS, NO LESS THAN HIS GENIAL SALUTATIONS,
ARE TREASURED IN LOVING REMEMBRANCE BY EVERY STUDENT
WHO HAS HEARD HIM,
THIS COMPEND OF HUMAN ANATOMY
IS
AFFECTIONATELY DEDICATED,
BY ONE OF HIS
"STAR ANATOMICAL MEN."

Copyrighted, 1886, by P. Blakiston, Son & Co.

1886

P86
1887

PREFACE.

THIS book contains the complete text of my two Compendis of Anatomy, namely—the “Human Anatomy,” and the “Visceral Anatomy,” heretofore published as separate volumes in this series of students’ manuals. The marked favor with which these Compendis were first received, some three and a half years ago, has since been continuously extended to them by teachers and students, both in America and in England. This has been manifested by the sale of a new and large edition every year, and has been extremely gratifying to the author. Upon the exhaustion of the third edition, the publishers resolved to acknowledge the universal appreciation shown these books, by incorporating the two in one volume; making this, the first of the now well-known “Quiz-Compendis,” a complete quiz-book on Human Anatomy. In carrying out this generous resolution, the original matter has not been curtailed anywhere; but, on the contrary, much new matter has been introduced wherever greater detail seemed to be desirable, and the number of the illustrations has been increased by eighteen new cuts.

Originally designed for the use of the medical student, in preparing for the exercises of the quiz-room and for his final examination, the text is confined to the essentials of each structure treated of, which are arranged in such a manner as to facilitate their rapid acquirement. All superfluities of description have been studiously avoided, and only such matter inserted as should be thoroughly known in order to pass a rigid examination on any organ or structure of the human body. The descriptions will be found to closely follow Gray, though Quain and other recognized authorities have been freely consulted during the preparation of the text. For many of the special arrangements

the author is indebted to the lectures of Professor W. H. Pancoast, late of Jefferson Medical College, and to the quizzes of Dr. Henry Morris, formerly assistant to the Chair of Anatomy in the same school.

While striving to carry out the object of this series in furnishing the medical student with a condensed Manual of Anatomy, the author has endeavored, from a strong appreciation of the importance of the subject, to make this volume deserving of first rank among its kind; and believing that a judicious condensation, which does not slight the essential features of the subjects treated, cannot fail to be of benefit in any department of science, he again commits his Compend to the teachers and students of Anatomy, in the hope that it may continue to be found worthy of a place alongside the more exhaustive and exhausting textbooks.

SAM'L O. L. POTTER.

San Francisco, January, 1887.

TABLE OF CONTENTS.

ANATOMY.

	PAGE
OSTEOLOGY	9
BONES OF THE HEAD	12
THE ORBITS.....	29
THE FOSSE.....	31
THE SUTURES AND FONTANELLES	33
THE WORMIAN BONES.....	33
THE HYOID BONE.....	33
TABLE OF THE FORAMINA AT THE BASE OF THE SKULL	34
BONES OF THE TRUNK	36
THE VERTEBRAL COLUMN.....	36
THE THORAX	38
THE STERNUM.....	38
THE RIBS	38
THE PELVIS	40
BONES OF THE UPPER EXTREMITY	43
THE SHOULDER.....	43
THE ARM.....	45
THE FOREARM.....	47
THE HAND.....	48
BONES OF THE LOWER EXTREMITY	50
THE THIGH.....	50
THE LEG	51
THE FOOT	53
ARTICULATIONS	55
MUSCLES AND FASCIAE OF—	
THE HEAD	68
THE EAR	71
THE NECK.....	71
THE LARYNX AND EPIGLOTTIS	75
THE BACK.....	76
THE ABDOMEN.....	80
THE THORAX.....	82
THE PERINEUM	83

	PAGE
THE SHOULDER AND ARM	85
THE FOREARM	87
THE HAND	90
THE HIP AND THIGH.....	91
THE LEG.....	95
THE FOOT.....	97
THE HEART	99
ARTERIES	102
THE CIRCLE OF WILLIS.....	106
ARTERIAL ANASTOMOSES	114
VEINS	115
ABSORBENTS	119
NERVOUS SYSTEM	120
THE BRAIN.....	120
THE SPINAL CORD.....	129
THE CRANIAL NERVES	129
THE SPINAL NERVES.....	133
THE SYMPATHETIC NERVE.....	136

VISCERAL ANATOMY.

DIGESTIVE ORGANS	141
ALIMENTARY CANAL	141
TEETH	141
STRUCTURE	142
DEVELOPMENT	143
MOUTH	144
PALATE	144
TONSILS	144
SALIVARY GLANDS	145
TONGUE	145
PHARYNX	146
ESOPHAGUS	147
STOMACH	148
SMALL INTESTINE	150
DUODENUM	150
JEJUNUM	150
ILEUM	150
LARGE INTESTINE	151
CÆCUM	151
APPENDIX VERMIFORMIS	151
COLON	152

CONTENTS.

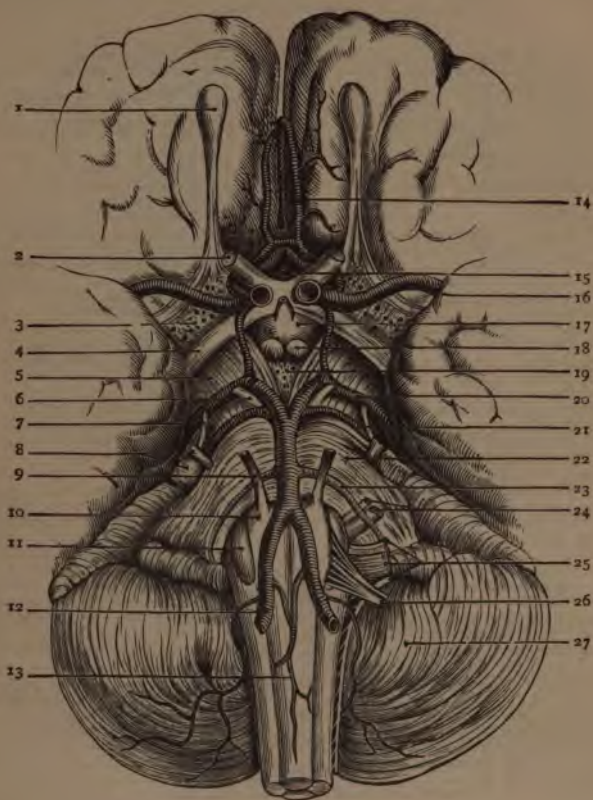
ix

	PAGE
RECTUM.....	152
LIVER.....	153
LIGAMENTS.....	154
FISSURES.....	154
LOBES.....	154
VESSELS.....	155
CAPSULE OF GLISSON.....	156
GALL-BLADDER.....	156
PANCREAS.....	157
DUCTLESS GLANDS.....	158
SPLEEN.....	158
THYROID GLAND.....	159
THYMUS GLAND.....	160
SUPRA-RENAL CAPSULES.....	160
ABDOMINAL CAVITY.....	161
BOUNDARIES.....	161
OPENINGS.....	162
REGIONS.....	162
PERITONEUM.....	163
FORAMEN OF WINSLOW.....	163
OMENTA.....	164
MESENTERIES.....	164
ORGANS OF VOICE AND RESPIRATION.....	165
LARYNX.....	165
TRACHEA AND BRONCHI.....	170
LUNGS.....	171
PLEURÆ.....	174
MEDIASTINUM.....	174
URINARY ORGANS.....	175
KIDNEYS.....	175
URETERS.....	177
BLADDER.....	178
MALE URETHRA.....	179
FEMALE URETHRA.....	181
MALE GENERATIVE ORGANS.....	181
PROSTATE GLAND.....	181
COWPER'S GLANDS.....	181
PENIS.....	182
TESTES AND APPENDAGES.....	183
DESCENT OF THE TESTES.....	186

	PAGE
FEMALE ORGANS OF GENERATION.....	187
VULVA.....	187
VAGINA.....	188
UTERUS AND APPENDAGES.....	188
FALLOPIAN TUBES.....	190
OVARIES.....	190
PAROVARIUM.....	192
MAMMÆ.....	192
ORGANS OF SENSE.....	193
SKIN AND ITS APPENDAGES.....	193
TONGUE.....	195
NOSE.....	195
SCHNEIDERIAN MEMBRANE.....	195
EYE.....	197
SCLEROTIC AND CORNEA.....	198
UVEAL TRACT.....	200
RETINA.....	202
HUMORS.....	204
VESSELS AND NERVES OF THE EYE.....	207
APPENDAGES OF THE EYE.....	209
EAR.....	212
EXTERNAL EAR.....	213
MEMBRANA TYMPANI.....	214
TYMPANUM.....	216
EUSTACHIAN TUBE.....	219
INTERNAL EAR.....	219
HERNIA.....	226
INGUINAL HERNIA.....	226
COVERINGS.....	227
FEMORAL HERNIA.....	228
COVERINGS.....	229
PERINEUM.....	230
MALE PERINEUM.....	230
LITHOTOMY.....	231
FEMALE PERINEUM.....	232

LIST OF ILLUSTRATIONS.

FIG.	PAGE	FIG.	PAGE
Base of the Brain.....	xii	59. The Femoral Artery.....	112
1. The Temporal Bone, external view,	15	60. The Venæ Cavæ and Azygos Veins.....	117
2. The Temporal Bone, internal view,	16	61. The Optic Nerves and Tract, etc.	130
3. The Sphenoid Bone, upper surface,	18	62. The Fifth Cranial Nerve.....	130
4. The Sphenoid Bone, lower surface.....	19	63. The Sacral Plexus, and its branches.....	135
5. The Ethmoid Bone.....	21	64. The Three Petrosal Nerves.....	138
6. The Superior Maxillary Bone.....	22	65. A Tooth.....	142
7. The Malar Bone.....	24	66. The Salivary Glands.....	144
8. The Palate Bone.....	25	67. The Tongue and Fauces.....	145
9. The Inferior Turbinated Bone.....	26	68. The Muscles of the Pharynx.....	147
10. The Vomer.....	26	69. The Stomach.....	148
11. The Inferior Maxillary Bone.....	27	70. Arteries of the Stomach, Pancreas, etc.....	149
12. The Cavity of the Orbit.....	29	71. The Duodenum.....	150
13. The Nasal Fossæ.....	31	72. The Colon and Rectum.....	152
14. The Base of the Skull.....	34	73. The Liver.....	153
15. A Vertebra.....	36	74. Structure of the Liver (vessels).....	155
16. The Sternum.....	38	75. Structure of the Liver (cells).....	156
17. Ribs.....	39	76. The Pancreas.....	157
18. The First Rib.....	39	77. The Spleen.....	158
19. The Pelvis.....	40	78. Regions of the Abdomen.....	162
20. The Sacrum.....	41	79. The Peritoneum.....	164
21. The Coccyx.....	41	80. The Thyroid Cartilage.....	166
22. The Innominate Bone.....	42	81. The Cricoid Cartilage.....	166
23. The Humerus.....	46	82. The Arytenoid Cartilages.....	166
24. The Radius and Ulna.....	47	83. Muscles of the Larynx.....	169
25. The Bones of the Carpus.....	48	84. The Lungs, Heart, etc.....	172
26. The Femur.....	50	85. Lobules and Alveoli of the Lung.....	173
27. The Tibia and Fibula.....	52	86. The Kidney.....	175
28. Bones of the Tarsus and Foot.....	53	87. A Malpighian Tuft.....	176
29. The Occipito-atloid Articulation, etc.	56	88. The Bladder.....	178
30. The Temporo-maxillary Articulation.....	57	89. The Male Urethra, etc.....	180
31. The Costo-vertebral Articulations.....	58	90. Section of the Penis.....	182
32. The Sacro-ischiatic Articulation, etc.	59	91. Section of the Testicle and Scrotum.....	184
33. The Shoulder-joint, etc.....	60	92. Ducts of the Testicle and Epididymis.....	185
34. The Elbow-joint.....	61	93. The Vulva.....	187
35. The Knee-joint, posteriorly.....	64	94. The Uterus and its Appendages.....	189
36. The Knee-joint, anteriorly.....	64	95. The Mammæ.....	192
37. Muscles of the Face and Forehead.....	69	96. The Skin and its Appendages.....	193
38. Muscles of the Neck.....	72	97. The Nose.....	196
39. Muscles of the Back.....	77	98. The Eye.....	198
40. Muscles of the Back, deep layers.....	79	99. The Iris.....	201
41. Muscles of the Chest and Abdomen.....	81	100. The Retina.....	203
42. The Diaphragm.....	83	101. The Crystalline Lens.....	205
43. Muscles of the Perineum.....	84	102. The Muscles of the Eyeball.....	206
44. Muscles of the Arm.....	86	103. Appendages of the Eye.....	209
45. Muscles of the Fore-arm and Hand (1).....	88	104. Structure of the Eyelids.....	210
46. Muscles of the Fore-arm and Hand (2).....	89	105. The Lachrymal Gland.....	212
47. Muscles of the Thigh, anteriorly.....	92	106. The Membrana Tympani.....	215
48. Muscles of the Thigh, posteriorly.....	93	107. The Tympanum.....	217
49. Muscles of the Hip-joint.....	94	108. The Internal Ear.....	220
50. Muscles of the Leg, anteriorly.....	96	109. The Cochlea.....	221
51. Muscles of the Leg, posteriorly.....	97	110. The Membranous Labyrinth.....	222
52. Muscles of the Foot.....	98	111. The Membranous Cochlea.....	223
53. The Heart.....	101	112. Rods of Corti.....	224
54. The Aorta.....	103	113. Auditory Cells.....	224
55. Arteries of the Face and Head.....	104	114. Poupart's Ligament.....	227
56. The Right Internal Maxillary Artery.....	104	115. Femoral Hernia.....	228
57. The Sub-clavian Artery.....	106	116. The Male Perineum.....	232
58. The Abdominal Aorta.....	109		



THE BASE OF THE BRAIN.

1. Olfactory Bulb. 2. Second, or Optic Nerves. 3. Anterior Perforated Space. 4. Optic Tract. 5. Crus Cerebri. 6. 3d Nerve. 7. 4th Nerve. 8. 5th Nerve. 9. 6th Nerve. 10. Pyramid. 11. Olivary Body. 12. Vertebral Artery. 13. Anterior Spinal Artery. 14. Anterior Cerebral Artery. 15. Lamina Cineria. 16. Middle Cerebral Artery. 17. Tuber Cinerium. 18. Corpora Albicantia. 19. Middle Perforated Space. 20. Posterior Cerebral Artery. 21. Superior Cerebral Artery. 22. Pons Varolii. 23. Inferior Cerebellar Artery. 24. 7th and 8th Nerves. 25. 9th, 10th and 11th Nerves. 26. 12th Nerve. 27. Cerebellum.

A

COMPEND OF ANATOMY.

Another definition - Dissection

Define the term Anatomy. Derived from the Greek *ana ana*, through, and *temnein*, to cut, it strictly means *dissection*, but is technically applied to that science which treats of the structure of organized bodies.

What are the divisions of Descriptive Human Anatomy? They are,—*Osteology*, the anatomy of the bones; *Syndesmology*, of the joints; *Myology*, of the muscles; *Angiology*, of the vessels; *Neurology*, of the nerves; *Splanchnology*, of the internal viscera; *Adenology*, of the glands; *Dermatology*, of the skin; *Genesisiology*, of the generative organs.

State the number of Bones in the Adult Human Skeleton. It is variously stated by different anatomists. Excluding the teeth, the Wormian and sesamoid bones, and the ossicles of the middle ear, the whole number would be 200; excluding also the 2 patellæ, and the hyoid bone, would leave in the skeleton proper 197 bones.

Describe the Long Bones. They number 90, act as supports, or levers, and are known by having a medullary canal in the centre of each, a shaft (*diaphysis*), and two extremities. They are developed by osseous deposit in cartilage.

Describe the Short Bones. Numbering 30, they are found where strength is required, but limited motion. They also are developed by osseous deposit in cartilage.

Describe the Flat Bones. They number 38, protect the viscera by forming walls around them, and afford extensive attachment for muscles. They are developed by osseous deposit in membranes, and consists of 2 dense layers, separated by a cellular or cancellated osseous tissue, the diploë.

What are the Irregular Bones? They are 39 in number, and include the vertebræ, sacrum, coccyx, the temporal, ethmoid, and sphenoid bones, and the bones of the face, except the *nasal*, *lachrymal*, and *vomer*.

Name the Bones of the Head. They number 22, and comprise the—
Cranial Bones (8)—the frontal, 2 parietal, occipital, 2 temporal, the sphenoid and the ethmoid bones.

Facial Bones (14)—2 superior maxillary, 2 malar, 2 nasal, 2 lachrymal, 2 palate, 2 inferior turbinated, vomer and inferior maxillary.

Name the Bones of the Trunk. They number 53, as follows, viz.—

Vertebræ (24)—7 cervical, 12 dorsal, and 5 lumbar vertebræ.

Thorax (25)—7 pairs of true ribs, 3 pairs of false ribs, 2 pairs of floating ribs, (articulating with the bodies of the dorsal vertebræ,) and the sternum.

Pelvis (4)—the sacrum, the coccyx, and 2 ossa innominata; each os innominatum consisting of 3,—the ilium, ischium, and pubes.

Name the Bones of each Upper Extremity. They number 32, as follows:—

Shoulder (2)—the clavicle and scapula.

Arm (1)—the humerus.

Forearm (2)—the radius and ulna.

Hand (27)—8 carpal bones,—the scaphoid, semilunar, cuneiform, pisiform, trapezium, trapezoid, os magnum, and unciform,—5 metacarpal, and 14 phalanges.

Name the Bones of each Lower Extremity. They number 29, viz.—

Thigh (1)—the femur.

Leg (2)—the tibia and fibula.

Foot (26)—7 tarsal bones,—the astragalus, os calcis, scaphoid, cuboid, external middle and internal cuneiform,—5 metatarsal, 14 phalanges.

Name the Unclassified Bones. They are the—

Patellæ (2), which are sesamoid bones, each developed in the tendon of the quadriceps extensor femoris muscle.

Hyoid Bone (1)—the tongue-bone, not articulated to the skeleton.

Malleus, Incus, Stapes (3 pairs)—the bones of the middle ear.

Sesamoid Bones, of variable number, situated in the tendons of the gastrocnemius and peroneus longus muscles, and in the flexor tendons of the great toe and the thumb.

Wormian Bones (ossa triquetra), sometimes found in the cranial sutures, are not constant in number or size.

Name the principal Eminences on Bones. *Heads*, are convex and smooth, for articulation in movable joints. *Condyles*, are irregularly-shaped heads. *Trochanters*, when for turning the bone. *Tuberosities*, are broad, uneven prominences. *Tubercles*, are small tuberosities. *Spines*, or *Spinous processes*, when sharp and slender. (*Apophysis*, is a process which has been an

Epiphysis, or separated from the shaft by cartilage, but has become united thereto by ossification) (P)

What other names are given to Bony Prominences? There are several adjectives applied to them from their fancied resemblances, such as—*Azygos*, without a fellow; *Clinoid*, like a bed; *Coracoid*, like a crow's beak; *Coronoid*, like a crown; *Hamular*, hook-like; *Malleolar*, like a mallet; *Mastoid*, like a nipple; *Odontoid*, tooth-like; *Pterygoid*, wing-like; *Rostrum*, a beak; *Spinous*, thorn-like; *Styloid*, pen-like; *Squamous*, scaly; *Vaginal*, en-sheathing, etc.

Name the Cavities of Bones. Articular cavities are called *Cotyloid*, cup-like; *Glenoid*, shallow; *Trochlear*, pulley-like; *Facet*, if smooth; *Alveolar*, or *Alveoli*, when socket-like. Non-articular cavities are named fossæ, sinuses, aqueducts, foramina, canals, fissures, notches, cells, grooves, depressions, etc.

What is the Composition of Bone? *Organic* or animal matter, about $\frac{1}{3}$, consisting of gelatin, vessels and fat. *Inorganic*, or mineral, about $\frac{2}{3}$, consisting of phosphate and carbonate of calcium ($62\frac{1}{2}$ per cent.), with fluoride of calcium, phosphates of magnesium, sodium, and chloride of sodium ($4\frac{1}{2}$ per cent.). *Heat* will remove the organic matter and leave the inorganic; dilute *Nitric* or *Hydrochloric acid* will remove the inorganic, and leave the organic. In old age the inorganic constituents predominate, and the bones are brittle; in youth the organic predominate, and epiphyseal dislocation is more common than fracture, especially in the long bones of the extremities.

Describe the Structure of Bone. Bone is composed of an outer compact layer, and an inner cellular or spongy structure. It is surrounded, except at the articular cartilages, by a vascular fibrous membrane, the *Periosteum*, which receives the insertions of all tendons, ligaments, etc.; and the central cavity of long bones is lined by a similar structure, the *Endosteum*. A transverse section of bone, examined microscopically, shows—

Haversian Canals, diameter $\frac{1}{800}$ inch, for the passage of vessels.

Canaliculi, diameter $\frac{1}{10000}$ inch, radiating from the canals, and connecting them with the lacunæ.

Lacunæ, arranged circularly around the canals, and contain the bone-cells, appearing as irregular dark spaces.

Haversian Spaces, connect the canals with the medullary spaces, and divide one Haversian system from another. An *Haversian System* comprises an Haversian canal with its lamellæ, lacunæ, and canaliculi.

Concentric Lamellæ of bone tissue, around the canals.

Circumferential Lamellæ, are bone layers binding the canals together.

Interstitial Lamellæ, woven in between the concentric lamellæ.

What is the Marrow of Bone? In young bones a tenacious, transparent fluid, free from fat. In adult bones of a yellow color, consisting of fat in varying proportion and extractive matters. It is found in the medullary canal, the cancellous texture, and the large Haversian spaces.

What Vessels are found in Bones? Arteries, veins, and some say lymphatics. *The Arteries* are,—the nutrient, entering at the nutrient foramen; the articular, nourishing the cancellous structure; and the periosteal, which supply the periosteum and the compact structure. *The Veins* emerge from the ends, the shaft, and from the nutrient foramen.

Describe the process of Ossification. The site of bone is first occupied by a mucoid substance, which becomes temporary cartilage (*blastema*) in the second month of foetal life. The young bone-cells (*osteo-blasts*) are then deposited in the cartilage at certain points, and their deposition and subsequent pressure cause the absorption of the cartilage. In most of the bones of the head and face, ossification is intra-membranous instead of intra-cartilaginous. *The first bones* in which ossification appears are the clavicle and inferior maxillary (5th to 7th foetal week); the *last* is the pisiform bone (12th year). *Epiphyses* ossify after birth and begin uniting to the bone from the age of puberty, and in the inverse order to that in which their ossification began, except the lower end of the fibula, which ossifies and is joined to the shaft earlier than its upper end.

THE BONES OF THE HEAD.

THE FRONTAL BONE.

Describe the points on its vertical portion. They are as follows:—
Externally,—

Frontal Eminences, one on each side of the median line.

Depression, marking the site of the frontal suture before obliteration.

Superciliary Ridges, behind which are the frontal sinuses.

Supraorbital Notches or Foramina, in the supraorbital arches, at about their inner third, for the supraorbital vessels and nerves.

Nasal Eminence, at lower end of the frontal depression.

External Angular Processes, articulate with the malar bones and form the anterior part of the temporal ridges.

Internal Angular Processes, articulate with the lachrymal bones.

Nasal Spine and Notch, between the internal angular processes.

Internally,—

Groove, for superior longitudinal sinus and the falx cerebri.

Frontal Crest, for attachment of the falx cerebri.

Foramen Cæcum, for a small vein to the longitudinal sinus.

Depressions and Elevations, for convolutions of the brain.

Between the two tables of the vertical portion in the adult are the—

Frontal Sinuses, two spaces at the anterior inferior part of the bone, which are lined with mucous membrane, and open into the middle meatus of the nose by means of an *Infundibulum* for each.

Describe its horizontal portion, or orbital plates. They each present the following points, viz.—

Fossa, for the lachrymal gland, near the external angular process.

Depression, at the nasal margin for the pulley of the superior oblique muscle.

Ethmoidal Notch, having the following foramina on its margin.

Anterior Ethmoidal Foramen, for anterior ethmoidal vessels and the nasal branch of the ophthalmic nerve.

Posterior Ethmoidal Foramen, for posterior ethmoidal vessels.

Grooves, on the cranial surface, for branches of the anterior and middle meningeal arteries.

Describe its articulations, development, and muscles. The frontal articulates with 12 bones,—the sphenoid, ethmoid, 2 parietal, 2 nasal, 2 superior maxillary, 2 lachrymal, and 2 malar. It is developed by 2 centres in membrane, 1 for each lateral half. The muscles attached to it are 3 pairs,—the temporal, corrugator supercillii, and orbicularis palpebrarum.

THE PARIETAL BONES.

Describe their general characteristics. They are 2 quadrilaterally-shaped bones situated at the superior and lateral regions of the cranium. The superior border of each joins the other by the *Sagittal Suture*; the anterior border joins the frontal bone by part of the *Coronal Suture*; the posterior border articulates with the occipital, forming the *Lambdoidal Suture*; the inferior border with the sphenoid and temporal bones. Forming the lateral walls of the skull they are named parietal, from *paries*, a wall.

Describe the points on each Parietal bone. Externally the bone is convex and presents for examination,—

Temporal Ridge, continuous with the same on the frontal bone.

Parietal Eminence, the point where ossification commenced.

Parietal Foramen, close to the upper border, transmits a vein to the superior longitudinal sinus. Is not constant.

Internally, the bone is concave, and marked by—

Depressions for the Pacchionian bodies, and for the cerebral convolutions.

Furrows, for branches of the middle meningeal artery.

Groove, for the lateral sinus, at the posterior inferior angle.

Half-groove, along the upper border, for the superior longitudinal sinus of the dura mater.

Describe their articulations, development, and muscles. Each parietal bone articulates with 5 bones,—the frontal, occipital, sphenoid, temporal, and opposite parietal. It is developed from 1 centre in membrane. The only muscle attached to it is the temporal.

THE OCCIPITAL BONE.

Describe its general features and surfaces. It is trapezoidal in form, curved upon itself, and placed at the posterior and inferior region of the cranium. Externally its surface is convex and presents for examination the following, viz.—

External Occipital Protuberance, and Crest, for the attachment of the ligamentum nuchæ.

Superior and Inferior Curved Lines, extending outwards on each side of the external occipital crest.

Foramen Magnum, transmitting the medulla oblongata and its membranes, the vertebral arteries, and the spinal accessory nerves.

Condyles, 2 in number, for articulation with the atlas vertebra.

Tubercles, 1 on each condyle, for the check ligaments.

Anterior Condylloid Foramina, 2, for the hypoglossal nerves.

Posterior Condylloid Foramina, 2, (often absent) for veins.

Jugular Processes, 2, each helping to form the foramen lacerum posterius basis cranii.

Internally, the surface is concave, showing—

Fossæ, 4, for the cerebellar and posterior cerebral lobes.

Internal Occipital Protuberance, where 6 cranial sinuses meet to form the torcular (wine-press) Herophili.

Crucial Ridge, the vertical portion for the falx cerebri and falx cerebelli; the transverse portion for the tentorium cerebelli, having also a groove for the lateral sinus.

Groove, for the lateral sinus, and the inferior petrosal sinus, along the postero-lateral border.

Internal Openings of the foramina described above.

Describe the Basilar Process of the Occipital. It lies in front of the foramen magnum, articulates with the body of the sphenoid bone, smooth and grooved internally for the medulla oblongata and pons varolii, which lie upon it; rough inferiorly for the attachment of muscles, and presenting the—

Pharyngeal Spine, for the attachment of the superior constrictor muscle of the pharynx and its tendinous raphé.

Describe its articulations and development. The occipital articulates with 6 bones,—the 2 parietal, 2 temporal, sphenoid, and atlas. It is developed by 4 centres, 1 each for the posterior part, the basilar process,

and the 2 condyles; its ossification being completed about the 6th year of age.

What muscles are attached to the Occipital Bone? There are 12 muscles attached on each side to the following portions, viz.—

Superior Curved Line 3—the occipito-frontalis, trapezius, and sterno-cleido-mastoid.

Space between the curved lines 2—the complexus and splenius.

Space below the inferior curved line 3—the obliquus capitis superior, rectus capitis posticus major and minor.

Basilar Process 3—the superior constrictor of the pharynx, rectus capitis anticus major and minor.

Jugular Process 1—the rectus capitis lateralis.

THE TEMPORAL BONES.

Describe their situation and divisions. They are situated at the inferior lateral portions of the skull, and contain the organs of hearing. Each bone is divided into 3 parts, the *Squamous*^a (scale-like), *Mastoid*^b (nipple-like), and *Petrous*^c (hard); and it is named from being the site of the first gray hairs (*tempus*, time).

Describe the Squamous Portion. It is a semicircular plate, smooth externally, and grooved internally for the middle meningeal artery, with depressions for the cerebral convolutions. Externally are seen the—

Zygomatic Process,^d or zygoma, arising by 3 roots, and extending forwards to articulate with the malar bone.

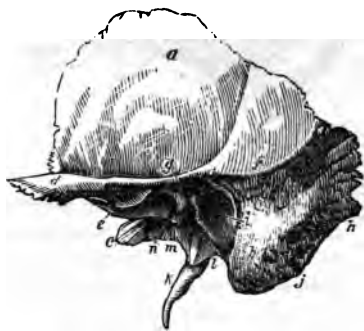Zygomatic Tubercle,^e at the base of the process, for the external lateral ligament of the lower jaw.

Eminentia Articularis, formed by the anterior root of the zygoma.

Glenoid Fossa,^g between the anterior and middle roots of the zygoma; its anterior part receives the condyle of the lower jaw, and is covered with cartilage; its posterior part lodges the parotid gland.

Glosserian Fissure, divides the glenoid fossa; it transmits the laxator tympani muscle, the tympanic artery, and the processus gracilis of the malleus.

FIG. 1.



Opening of the Canal of Hugier, lies in the angle between the squamous and petrous portions of the bone; and transmits the chorda tympani nerve.
Temporal Ridge, *f* in part.

Describe the Mastoid Portion. It projects like a nipple from the inferior portion of the bone posteriorly. Internally it is grooved for the lateral sinus; ⁹ externally are seen the—

Mastoid Foramen, *k* the largest of several foramina, for a vein.

Mastoid Process, at the tip, for the sterno-cleido-mastoid, splenius, and trachelo-mastoid muscles.

Digastric Fossa, *j* for the posterior belly of the digastric muscle.

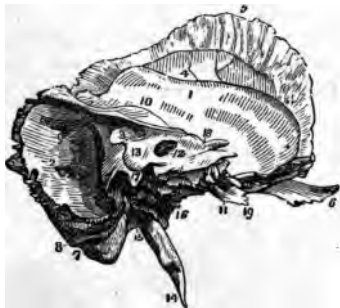Occipital Groove, ⁸ for the occipital artery.

Mastoid Cells, in the interior of the mastoid process, open on the posterior wall of the middle ear, and are lined with mucous membrane.

Describe the Petrous Portion. It is very hard, pyramidal in form, contains the internal and middle ear, projects inwards and forwards, and presents a base, an apex, three surfaces, and three borders.

On the Base are seen, the—

FIG. 2.



Meatus Auditorius Externus, *i* the external opening of the ear.

Auditory Process, a bony ring for the external cartilage of the ear.

Apex lies internally, at the base of the skull, forming the outer boundary of the foramen lacerum medium, and contains the internal carotid canal.

Anterior Surface, presents from within, outwards—

Opening of the Carotid Canal, ¹¹ for the internal carotid artery and plexus.

Depression, for the Gasserian ganglion of the 5th pair of cranial nerves.

Hiatus Fallopii, for great petrosal nerve and an artery.

Foramen, for small petrosal nerve.

Eminence, over the superior semicircular canal of the ear.

Depression, over the tympanum.

Posterior Surface, presents—

Meatus Auditorius Internus, ¹² transmits the 7th and 8th pairs of cranial nerves and the auditory artery, and lodges a process of dura mater.

Opening of the Aqueductus Vestibuli, ¹³ transmits to the vestibule a small artery and vein, and lodges a process of dura mater.

Inferior surface, presents from within outwards—

Rough Quadrilateral Surface,¹⁹ for the origin of the tensor tympani and levator palati muscles.

Opening of the Carotid Canal, transmitting the internal carotid artery, and the carotid plexus of the sympathetic nerve.

Aqueductus Cochleæ, transmitting a vein from the cochlea.

Jugular Fossa, a depression for the sinus of the internal jugular vein, forming with the occipital bone the foramen lacerum posterius, which transmits that vein and the 8th pair of cranial nerves, etc. (See page 35.)

Foramen for Jacobson's Nerve (tympanic branch of the glosso-pharyngeal), in the ridge between the jugular fossa and the carotid canal.

Foramen for Arnold's Nerve (auricular branch of the pneumogastric), in the outer wall of the jugular fossa.

Jugular Surface, for articulation with the jugular process of the occipital bone.

Vaginal Process,¹ ensheathing the root of the styloid process.

Styloid Process,¹⁴ a long projection for the stylo-pharyngeus, stylo-hyoid, and stylo-glossus muscles (3); and the stylo-hyoid and stylo-maxillary ligaments (2), which are attached thereto.

Stylo-mastoid Foramen,¹⁵ between the styloid and mastoid processes, for the exit of the facial nerve, and the entrance of the stylo-mastoid artery.

Auricular Fissure, for the exit of Arnold's nerve.

In the angle between the petrous and squamous portions, are seen the—

Septum Tubæ, a lamina separating the following canals. Its inner end projects into the tympanum, and is called the *Processus cochleariformis*.

Opening of the canal for the tensor tympani muscle.

*Osseous Opening of the Eustachian tube** inferiorly.

The Anterior Border articulates partly with the spinous process of the sphenoid bone.

The Posterior Border assists in forming the jugular foramen, and is grooved for the inferior petrosal sinus.

The Superior Border separates the anterior fossa of the skull from the middle fossa; to it is attached the tentorium cerebelli, and it is grooved for the superior petrosal sinus.¹⁰

Describe its articulations and development. The temporal articulates with 5 bones,—the occipital, parietal, sphenoid, malar, and inferior maxillary. It is developed by 4 centres, one each for the squamous portion, styloid process, and auditory process, and one for the petrous and mastoid portions. Its ossification is completed about the 2d or 3d year.

What muscles are attached to it? There are 14 muscles attached to the following-named portions. To the—

Squamous Portion 2,—the temporal and masseter.

2*

B

Mastoid Portion 6,—the occipito-frontalis, sterno-cleido-mastoid, splenius capitis, trachelo-mastoid, digastric, and retrahens aurem.

Petrous Portion 3,—the tensor tympani, levator palati, and stapedius.

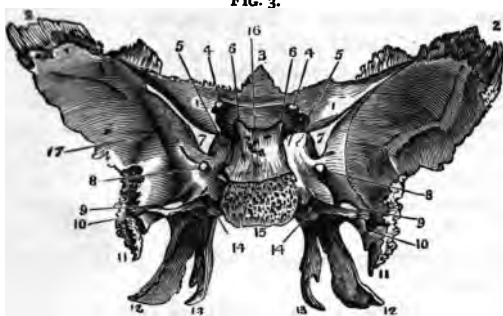
Styloid Process 3,—the stylo-glossus, stylo-hyoid, and stylo-pharyngeus.

THE SPHENOID BONE.

Describe its Position and Form. Wedged in between the bones of the skull anteriorly, it resembles a bat with out-stretched wings. It is named from the Greek word *σφήν sphane*, a wedge, enters into the formation of 5 cavities, 4 fossee, 3 fissures, and has—

A Body.	2 Pterygoid Processes.	12 Foramina.
2 Greater Wings. ²	2 Styloid Processes.	12 pairs of Muscles.
2 Lesser Wings. ¹	6 Clinoid Processes.	12 Articulations.
10 Points of Ossification.	3 Lesser Processes.	

Describe the Body of the Sphenoid Bone. Placed in the median line, cuboid in shape, it presents on its UPPER SURFACE from before backwards, the following points, viz.—



Ethmoidal Spine,⁹ articulating with the ethmoid bone.

A Smooth Surface, grooved for the olfactory nerves.

Optic Groove, supporting the commissure of the optic nerves.

Olivary Process, an olive-shaped eminence behind the optic groove.

Middle Clinoid Processes, bounding the sella Turcica in front.

*Sella Turcica*¹⁶ (Turkish saddle), lodges the pituitary body and the circular sinus of the brain.

Dorsum Sellæ (back of the saddle), grooved for the 6th nerves.

Posterior Clinoid Processes,⁶ for attachment of the tentorium cerebelli.

Grooves, laterally, for the cavernous sinus and internal carotid artery.

THE POSTERIOR SURFACE is rough and quadrilateral:¹⁵ it articulates with the basilar process of the occipital bone, ossification being completed from the 18th to the 20th year.

THE ANTERIOR SURFACE is nearly vertical, and presents the—

Lamella, in the median line, articulating with the perpendicular plate of the ethmoid bone, and forming part of the nasal septum.

Opening of the Sphenoidal Sinuses,^e or cavities in the body of the bone which exist in adults, not in children.

Sphenoidal Turbinated Bones (pyramids of Wistar), which partially close the sinuses, and articulate with the ethmoid and palate bones.

THE INFERIOR SURFACE helps to form the nasal fossæ, and presents the—

Rostrum,^d which articulates with a groove on the vomer.

Vaginal Processes, 1 on each side of the rostrum.

Pterygo-palatine Grooves, which, with the sphenoidal processes of the palate bones, form the pterygo-palatine canals, for the transmission of the pterygo-palatine arteries and nerves.

Describe the Greater Wings of the Sphenoid. Each wing, on its SUPERIOR SURFACE, presents the following points, viz.—

Foramen Rotundum,⁸ for the superior maxillary division of the 5th.

Foramen Ovale,⁹ for the inferior maxillary division of the 5th nerve, the small petrosal nerve, and the small meningeal artery.

Foramen Vesalii, transmitting a small vein.

Foramen Spinosum,¹⁰ transmitting the middle meningeal artery.

THE ANTERIOR SURFACE assists in forming the external wall of the orbit, the speno-maxillary and sphenoidal fissures. It articulates with the frontal and malar bones, and presents a—

Notch, transmitting a branch of the ophthalmic artery.

Spine, for part of the lower head of the external rectus muscle.

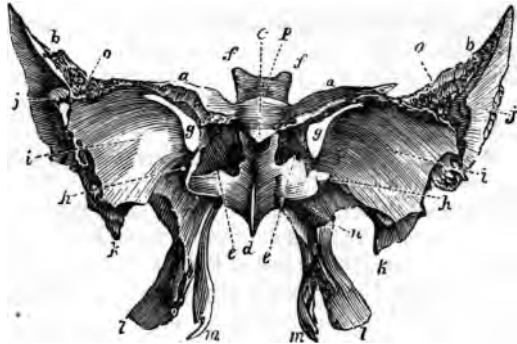
External Orbital Foramina, transmitting arterial branches.

THE EXTERNAL SURFACE presents the following points,—

Pterygoid Ridge, dividing the temporal fossa from the zygomatic.

Spine of the Sphenoid,¹¹ to which are attached the internal lateral ligament of the lower jaw, and the laxator tympani muscle.

FIG. 4.



THE NASAL BONES.

Describe them. They are 2 small bones forming the bridge of the nose by articulation with each other in the median line. They are convex externally, concave internally, and grooved for the external branch of the nasal nerve and for small arteries. They each articulate with 4 bones,—the frontal, ethmoid, superior maxillary, and the opposite nasal; are each developed by one centre of ossification, and have *no muscles* attached to them.

THE SUPERIOR MAXILLARY BONES.

Describe them. They are 2 hollow bones, together forming the upper jaw. Each bone consists of 4 processes, and a body which possesses a large cavity, the antrum of Highmore.

Describe the Antrum of Highmore. It is a pyramidal cavity in the body of the bone, and opens into the middle meatus of the nose by an aperture which is very small in the recent subject, admitting only a small probe. Its walls are very thin, and are covered internally by a mucous membrane. It presents the—
Aperture, partly closed by the articulation of the unciform process of the ethmoid with the ethmoidal process of the inferior turbinated; and that of the maxillary process of the palate with a fissure in the superior maxillary; also by the maxillary process of the inferior turbinated which hooks over the lower edge of the orifice.

Posterior Dental Canals, on the posterior wall of the cavity.

Processes in its floor, formed by the alveoli of the 1st and 2d molar teeth, the roots of which occasionally perforate it.

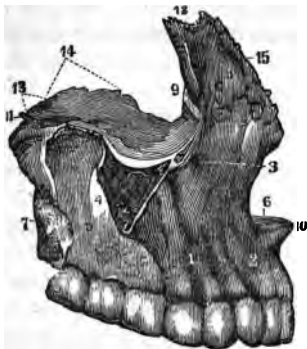
What other points are presented by the body? The body has 4 surfaces, the facial externally, the zygomatic posteriorly, the orbital superiorly, and an internal surface forming part of the outer wall of the nose and the cavity of the mouth. It presents the—

Incisive Fossa,² on the facial surface, above the incisor sockets, for the origin of the depressor alæ nasi muscle.

Canine Fossa,¹ more externally, for the levator anguli oris.

Infraorbital Foramen,³ above the canine fossa, transmitting the infraorbital vessels and nerve, from the *infraorbital canal* in the orbital surface of the bone.

FIG. 6.



Maxillary Tuberosity, articulates with the tuberosity of the palate bone.

Turbinated Crests, inferior and superior, on the inner surface, bounding horizontal grooves which correspond to the meati of the nose.

Vertical Grooves, on the inner surface, one assisting to form the nasal duct, the other to form the posterior palatine canal.

Rough Surface, for articulation with the palate bone.

Orbital Surface, articulating with the lachrymal, ethmoid, and palate bones inferiorly, partly bounding the sphenomaxillary fissure exteriorly, and forming the lower margin of the orbit anteriorly.

Infraorbital Groove, along the orbital surface, ending in the infraorbital canal and foramen. (See *ante*.)

Depression, for the origin of the inferior oblique muscle of the eye.

Describe its Processes. They number 4, as follows.—

MALAR PROCESS,⁴ is triangular, looks outwards from the body, and is rough for articulation with the malar bone.

NASAL PROCESS,⁸ is thin anteriorly and serrated superiorly for articulation with the nasal bone; posteriorly it is smooth and articulates with the lachrymal. It presents the—

- *Turbinated Crests*, superior and inferior, the former articulating with the middle turbinated process of the ethmoid bone.

Outer Surface, gives origin to the orbicularis palpebrarum and levator labii superioris aëque nasi muscles, and the tendo oculi.

Groove on the posterior border, helping to form the nasal duct.

ALVEOLAR PROCESS, forms the curved line of the teeth, and presents—

Alveoli, or sockets, for 8 teeth in the adult, 5 in the child.

PALATE PROCESS, forms part of the floor of the nasal cavity, and the roof of the mouth. It articulates with the vomer, the palate bone, and with its fellow process, and presents the—

Incisive Foramen, or foramen of Stenson, leading into the anterior palatine canal, for the anterior palatine vessels.

Foramina of Scarpa, 2, transmitting the naso-palatine nerves.

Groove on the under surface, for the protection of the vessels and nerves.

Orifice of the posterior palatine canal, at the posterior end.

Nasal Crest, at the articulation of the two processes with the vomer.

Anterior Nasal Spine, the anterior extremity of the nasal crest.

Describe its articulations and development. The superior maxillary articulates with 9 bones,—the frontal,¹² ethmoid,¹⁴ vomer,¹³ nasal,¹⁵ lachrymal, malar, palate, inferior turbinated, and opposite superior maxillary.¹⁰ It is *developed* probably by 4 centres,—1 for the facial and nasal parts, another for the orbital and malar, a 3d for the incisive, and a 4th for the palate portion.

What muscles are attached to it? There are 11, viz.—the orbicularis palpebrarum, and levator anguli oris *alæque nasi*, 2, to the *nasal process*;—the levator labii superioris, levator anguli oris, compressor naris, depressor *alæ nasi*, orbicularis oris, and inferior oblique of the eye, 6, to the *body*;—the buccinator, 1, to the *alveolar process*;—the masseter, 1, to the *malar process*;—and the external pterygoid, 1, to the *tuberosity*.

THE LACHRYMAL BONES.

Describe them. They are 2 small quadrilateral-shaped bones, situated in the anterior part of the inner wall of the orbit. Each presents a—

Groove, on the external surface, forming part of the nasal duct.

Ridge, also externally, for attachment of the tensor tarsi muscle.

Furrow, internally, corresponding to the ridge on the external surface.

Hamular Process, projecting downwards to articulate with the lachrymal process of the inferior turbinated bone.

Internal Surface, closes the anterior ethmoidal cells.

Describe its articulations, development, and muscles. The lachrymal articulates with 4 bones,—the frontal, ethmoid, superior maxillary, and inferior turbinated. It is *developed* from 1 centre, and has but 1 *muscle* attached to it, the tensor tarsi, or Horner's muscle.

THE MALAR BONES.

Describe them. The cheek bones are situated at the outer and upper part of the face, aiding to form the cavities of the orbits and the temporal and zygomatic fossæ. Each presents an—

External Surface, convex, for attachment of the zygomatic muscles.

Foramen, externally, for the malar branch of the temporo-malar nerve.

Foramen,^c internally, for the temporal branch of the same nerve.

Frontal Process,^a articulates with the external angular process of the frontal.

Orbital Process,^b projecting backwards, forming part of the floor and outer wall of the orbit, as well as part of the temporal fossa, and bounds the sphenomaxillary fissure anteriorly.

FIG. 7. *Zygomatic Process*,^f projecting backwards to articulate with the zygomatic process of the temporal bone by a serrated edge.

Upper Border,^b forms the outer and inferior margin of the orbit.

Lower Border, thick and rough, for the origin of the masseter muscle.

Anterior Border,^d articulates with the superior maxillary bone.

Posterior Border, terminates the temporal fossa below.



Name its articulations, centres, and muscles. The malar articulates with 4 bones,—the frontal, sphenoid, temporal, and superior maxillary. It is developed by one centre of ossification, and has 5 muscles attached to it,—the levator labii superioris, zygomaticus major and minor, masseter and temporal.

THE PALATE BONES.

Describe them. They are 2 irregularly-shaped bones, situated posteriorly in the nares. Each bone assists in forming the floor and outer wall of the nose, the roof of the mouth, the floor of the orbit, the inner wall of the antrum, the zygomatic, spheno-maxillary, and pterygoid fossæ, and presents the following points.—

HORIZONTAL PLATE,^a completes the nasal floor and hard palate; has a—

Ridge, on the inferior surface, for the tensor palati aponeurosis.

Groove, assisting to form the posterior palatine canal.

Foramina, transmitting the anterior and posterior palatine nerves.

Anterior Border, is serrated, and joins the superior maxillary bones.

Posterior Border, is free and concave, for the attachment of the soft palate.

Inner Border,^d is thick, and articulates with its fellow, forming a groove for the reception of the vomer.

Its posterior extremity is the—

Posterior Nasal Spine, for the origin of the azygos uvulæ muscle.

VERTICAL PLATE,^b a broad and thick lamella, presents the following :—

Superior Turbinate Crest, on the inner surface. Below it is the—

Inferior Turbinate Crest,^e dividing the middle meatus of the nose from the inferior, and articulating with the inferior turbinated bone.

Posterior Border, articulates with the pterygoid process of the sphenoid.

Groove, on the external surface, helping to form the posterior palatine canal.

Two Smooth Surfaces, externally, one forming the inner wall of the zygomatic fossa; the other, part of the inner wall of the antrum.

Two Rough Surfaces, also externally, one for articulation with the superior maxillary; the other with the pterygoid process of the sphenoid.

Deep Notch, which by articulation with the sphenoid bone, forms the *spheno-palatine foramen*,^h for the spheno-palatine nerves.

PTERYGOID PROCESS,^c is wedged into the notch between the plates of the pterygoid process of the sphenoid, with which it articulates laterally. In it are the—

Palatine Foramina, for the external and posterior palatine nerves.

Posterior Surface, aids in forming the pterygoid fossa.

FIG. 8.



ORBITAL PROCESS,ⁱ triangular in shape, large and hollow. It has—

Three Articular Surfaces, for the sup. maxillary, sphenoid, and ethmoid.

Two Free Surfaces, the orbital forming part of the floor of the orbit, the external aiding to form the zygomatic fossa.

Rounded Border, forms a part of the sphenomaxillary fissure.

SPHENOIDAL PROCESS,^j projects backwards, articulates superiorly with the body of the sphenoid, and externally with the pterygoid process of the sphenoid. On its upper surface is a—

Groove, which assists in forming the pterygo-palatine canal.

Inner Surface, forms part of the outer wall of the nasal fossa.

Describe its articulations, development, and muscles. The palate articulates with 6 bones,—the sphenoid, ethmoid, vomer, superior maxillary, inferior turbinated, and its fellow palate bone. It is *developed* by one centre at the junction of the two plates. There are 5 *muscles* attached to it,—the azygos uvulæ, internal and external pterygoids, superior constrictor, and tensor palati.

THE INFERIOR TURBINATED BONES.

Describe them. They are 2 thin curved osseous plates situated in the nasal fossæ, their convex surfaces presenting inwardly. Each bone is attached above to the inferior turbinated crests of the superior maxillary and palate bones, and presents the following, viz.—

*Lachrymal Process,*³ aiding to form the nasal duct, by articulation with the lachrymal and superior maxillary bones.

*Ethmoidal Process,*¹ articulating with the unciform process of the ethmoid, thus helping to partially close the aperture of the antrum.

*Maxillary Process,*⁴ also helps to partially close the aperture of the antrum, by hooking¹ over the lower edge of that orifice.

*Free Border,*² below, coming to about $\frac{1}{2}$ inch above the floor of the nose.

Name its articulations, centres, and muscles. The inferior turbinated articulates with 4 bones, the ethmoid, lachrymal, palate, and superior maxillary. It is *developed* by one centre, and has *no muscles* attached to it.

THE VOMER.

Describe it. The vomer (plough-share) forms the postero-inferior part of the nasal septum, but is usually bent to one side. Its—

Superior Border,^{1 2} has a groove and two alæ or wings, for articulation with the rostrum and vaginal processes of the sphenoid bone.

FIG. 9.



FIG. 10.



Anterior Border,³ is grooved for the ethmoidal plate and the nasal cartilage.
Inferior Border,⁴ the longest, articulates with the nasal crest of the superior maxillary and palate bones.

Posterior Border, is free and presents towards the pharynx.

Naso-palatine Grooves, laterally, for the naso-palatine nerves.

Furrows, on the lateral surfaces,⁶ for vessels and nerve-filaments.

Name its articulations, centres, and muscles. The vomer articulates with 6 bones,—the sphenoid, ethmoid, 2 superior maxillary, and 2 palate bones. It is developed by one centre, which appears about the 6th foetal week in cartilage between two laminae which coalesce after puberty. It has no muscles attached to it.

THE INFERIOR MAXILLARY BONE.

Describe its general characteristics. The inferior maxillary bone forms the lower jaw, receives the inferior teeth, and is the second bone of the body in which ossification appears, the clavicle being the first. It consists of a body and two rami.

Describe the Body of the bone. It is shaped somewhat like a horse-shoe, and presents for examination the following: viz.—

Alveolar Portion, above the oblique line, containing on its upper border *alveoli* for 16 teeth in the adult, for 10 in the child.

Symphysis, a vertical ridge on the median line, marking the junction of the two symmetrical portions of which the bone originally consisted.

Mental Process, a prominent triangular eminence, forming the chin.

Externally on each side from the symphysis backwards, are the—

Incisive Fossa, above the chin, for the origin of the levator menti.

Mental Foramen, below the 2d bicuspid alveolus, transmitting the mental artery and nerve.

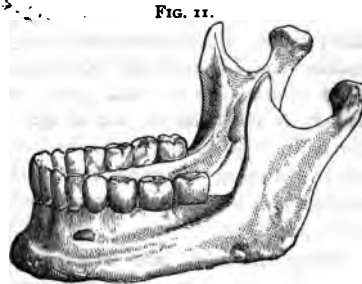
External Oblique Line, for the origins of the depressor labii inferioris and depressor anguli oris muscles from its anterior half.

Groove, near the angle, for the facial artery.

Internally, on each side from the median depression backwards, are the—

Genial Tubercles, the superior for the genio-hyo-glossus muscle; the inferior for the genio-hyoid.

Mylo-hyoid Ridge, obliquely backwards, for the mylo-hyoid muscle.



Sublingual Fossa, near the genial tubercles, for the sublingual gland.

Fossa, below the sublingual, for the anterior belly of the digastric muscle.

Submaxillary Fossa, below the ridge, for the submaxillary gland.

Describe the Rami of the Inferior Maxillary. The rami, or ascending portions of the bone, are 2 in number, and each present the—

Coronoid Process, anteriorly, for the insertion of the temporal muscle.

Condylod Process, posteriorly. Its condyle articulates with the glenoid fossa of the temporal bone, its *neck* receives the insertion of the external pterygoid muscle, its *tubercle* has attached to it the external lateral ligament of the lower jaw.

Sigmoid Notch, a deep depression separating the above-named processes from each other, and crossed by the masseteric vessels and nerve.

Groove, on the coronoid process internally, and prolonged downwards upon the body, for the attachment of the buccinator muscle.

Ridges, on the external surface, for the insertion of the masseter.

Spine, a projection on the internal surface, for the attachment of the internal lateral ligament of the jaw.

Inferior Dental Canal, opening behind the spine, lies within the ramus and body of the bone for the inferior dental vessels and nerve. It communicates with each alveolus and with the mental foramen.

Mylo-hyoid Groove, below the spine, for the mylo-hyoid vessels and nerve.

Rough Surface, behind the groove, for the internal pterygoid muscle.

Angle of the Jaw, at the junction of the posterior body of the ramus with the inferior border of the body, for the insertion of the masseter and internal pterygoid muscles, and the stylo-maxillary ligament.

Describe the Articulations and Development of the Inferior Maxillary bone. It articulates with one pair of bones,—the temporal. It is the earliest formed bone in the body except the clavicle, and is probably developed by 2 centres, one for each lateral half, the two halves coalescing at the symphysis about the 1st year of age. In *adult life* the ramus arises almost vertically from the body, and the dental canal lies about the middle of the body. In *old age* the ramus extends obliquely backwards, the angle becoming very obtuse; and the alveolar portion being absorbed, the dental canal is near the superior border.

What Muscles are attached to the Inferior Maxillary? They number 15 pairs,—the masseter, internal and external pterygoids and temporal, 4, to the ramus;—the genio-hyo-glossus, genio-hyoid, mylo-nyoid, digastric, and superior constrictor, 5, to the internal surface of the body;—the depressor labii inferioris, depressor anguli oris, levator menti, orbicularis oris, platysma myoides, and buccinator, 6, to the external surface of the body.

THE ORBITS.

Describe the Orbital Cavities. The orbits are 2 conoidal cavities, situated between the forehead and the face, their bases outwards, their apices pointing backwards, the lines of axial prolongation meeting at the sella turcica of the sphenoid bone. They contain the organs of vision with their appendages, and are each formed by 7 bones,—the frontal,¹ ethmoid,² sphenoid,³ ⁴ ⁵ lachrymal,⁶ superior maxillary,⁷ palate,⁸ and malar,⁹ of which the first three are common to both orbits. Each orbit communicates with 1 cavity and 4 fossæ, as follows, viz.—

Cavity of the cranium, by the optic foramen¹¹ and sphenoidal fissure.¹⁰

Fossæ (4)—the nasal, temporal, zygomatic, and speno-maxillary,—by the nasal duct¹² and the speno-maxillary fissure.¹³

What Foramina communicate with each orbit? Nine,—the optic foramen,¹¹ sphenoidal fissure,¹⁰ anterior²¹ and posterior²² ethmoidal foramina, supraorbital,¹⁴ infraorbital,¹⁵ and malar foramina,¹⁶ the nasal duct,¹² and the speno-maxillary fissure.¹³

Describe the Roof of the Orbit. Formed by the orbital plate of the frontal bone anteriorly,¹ and the lesser wing of the sphenoid⁴ posteriorly, it is concave, and presents the—

Lachrymal Fossa,¹⁷ at its outer angle, for the lachrymal gland.

Depression,¹⁸ at the inner angle, for the pulley of the superior oblique.

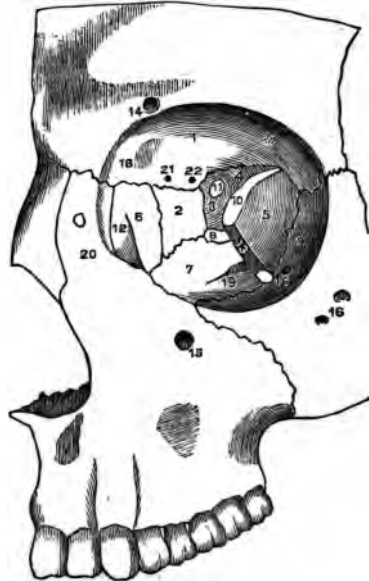Describe the Floor of the Orbit. Formed by the orbital surface of the superior maxillary bone,⁷ and the orbital process of the malar⁹ and palate bones,⁸ it is nearly flat and presents the—

Palato-maxillary Suture posteriorly.

Infraorbital Canal, and a *Depression* for the superior oblique muscle of the eye, anteriorly.

Infraorbital Groove,¹⁹ posteriorly.

FIG. 12.



Describe the Inner Wall of the Orbit. Formed by the nasal process of the superior maxillary bone,²⁰ the lachrymal,⁶ the os planum of the ethmoid,³ and the body of the sphenoid,³ it presents—

A Groove, for the lachrymal sac, and the *Lachrymal Crest*, anteriorly.
2 Sutures,—the ethmo-lachrymal, and the ethmo-sphenoidal.

Describe the Outer Wall of the Orbit. Formed by the orbital process of the malar bone,⁹ and the greater wing of the sphenoid,⁵ it presents the *Orifices*¹⁶ of the malar canals, and the *Spheno-malar Suture*.

Describe the Angles of the Orbit. They present the following points.

IN THE SUPERIOR EXTERNAL ANGLE.

Sphenoidal Fissure,¹⁰ or foramen lacerum anterius, transmits the 3d, 4th, ophthalmic division of the 5th, and the 6th nerves, the ophthalmic vein, branches of the lachrymal and middle meningeal arteries, filaments of the sympathetic nerve, and a process of the dura mater.

Articulations,—the fronto-malar, and fronto-sphenoidal.

IN THE SUPERIOR INTERNAL ANGLE.

Suture,—the lachrymo-ethmo-frontal, in which are the following foramina.
Anterior Ethmoidal Foramen,²¹ transmitting the anterior ethmoidal artery and the nasal nerve.

Posterior Ethmoidal Foramen,²² transmitting the posterior ethmoidal artery and vein.

IN THE INFERIOR EXTERNAL ANGLE.

*Spheno-maxillary Fissure*¹³ (described under the *Zygomatic Fossa*).

IN THE INFERIOR INTERNAL ANGLE.

A Suture, the ethmo-maxillo-palato-lachrymal.

What other points are connected with the Orbit? Two, the supra-orbital notch, and the optic foramen, as follows, viz.—

Supraorbital Notch or Foramen,¹⁴ at the junction of the inner and middle thirds of the upper circumference, transmitting the supraorbital artery, veins, and nerve. A line prolonged from this notch through the interval between the bicuspid teeth of either jaw, will cross both the infraorbital and mental foramina, and the canine fossa of the superior maxillary bone.

Optic Foramen,¹¹ at the apex, is formed by the 2 roots of the lesser wing of the sphenoid, and transmits the optic nerve and the ophthalmic artery. From around its margin arises a tendinous ring, the common origin of the 4 recti muscles of the eye.

What Muscles arise within the Orbit? The 4 recti and 2 oblique of the eye, the levator palpebræ, and the tensor tarsi (8 in all).

THE FOSSÆ.

Describe the Nasal Fossæ. Together they form the cavity of the nose, being separated from each other by the *Septum Nasi*.¹¹ They open in front by the anterior nares, behind by the posterior nares; and extend from the palate processes of the superior maxillary and palate bones,¹⁷ upwards to the base of the cranium. They are formed by 14 bones,—the ethmoid, sphenoid, frontal, vomer, 2 nasal, 2 superior maxillary, 2 lachrymal, 2 palate, and 2 inferior turbinated.

Describe the Septum Nasi.¹¹ It forms the inner wall of each nasal fossa, and is formed chiefly by the perpendicular plate of the ethmoid bone, the vomer, and the triangular cartilage of the septum; to a less extent by 5 other bones,—the rostrum of the sphenoid, the nasal spine of the frontal, and the crests of the nasal, palate, and superior maxillary bones.

Describe the points presented by each Nasal Fossa. They are—

ON THE ROOF.

Openings, posteriorly, into the sphenoidal sinuses.

Olfactory Foramina, and the *Nasal Slit*, in the cribriform plate of the ethmoid bone.

ON THE FLOOR.

Orifice, of the anterior palatine canal.

Suture, between the bones forming the hard palate.

Nasal Spines, anterior and posterior, and the *Ridge* connecting them.

ON THE OUTER WALL, from above downwards.

Superior Turbinated process of the ethmoid.

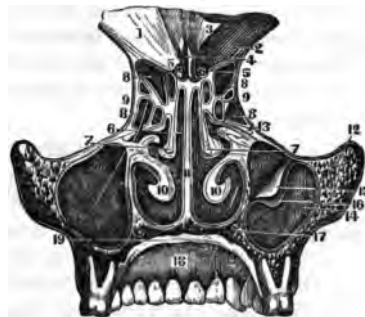
Superior Meatus of the nose, into which open 3 orifices,—those of the posterior ethmoidal and the sphenoidal sinuses, and the sphenopalatine foramen.

*Middle Turbinated*⁷ process of the ethmoid.

Middle Meatus of the nose, into which open 2 orifices,—those of the antrum¹⁴ and infundibulum,—the latter draining the anterior ethmoidal cells,⁸ and the frontal sinus.

Inferior Turbinated Bone,¹⁰ below which is the—

FIG. 13.



Inferior Meatus of the nose, the largest; into it open 2 orifices,—those of the lachrymal, and anterior palatine canals. To these may be added the anterior and posterior nares.

Describe the Temporal Fossa. Situated on each side of the cranium, it is shallow above and behind, but deep in front and below; and is formed by parts of 5 bones,—the frontal, sphenoid, temporal, parietal, and malar. It is bounded above and behind by the temporal ridge, in front by the malar frontal and sphenoid bones, and below by the zygoma and the pterygoid ridge on the greater wing of the sphenoid. It is traversed by 6 sutures,—the speno-malar, speno-frontal, speno-parietal, speno-temporal, fronto-parietal, and temporo-parietal. It opens below into the zygomatic fossa; and lodges the temporal muscle, and the deep temporal vessels.

Describe the Zygomatic Fossa. Extending downwards from the temporal fossa, it is thus bounded,—

In front, by the tuberosity of the superior maxillary bone.

Externally, by the zygoma, and the ramus of the inf. maxillary.

Internally, by the external plate of the pterygoid process.

Above, by the temporal fossa, the squamous portion of the temporal bone, and the greater wing of the sphenoid.

Below, by the alveolar border of the inferior maxillary bone.

What Fissures open into the Zygomatic Fossa. Two, the—

Spheno-maxillary Fissure, between the greater wing of the sphenoid externally, and the superior maxillary and palate bones internally. It connects the orbit with the zygomatic, temporal, and speno-maxillary fossæ; and transmits the infraorbital artery, the superior maxillary nerve and its orbital branches, and the ascending branches of Meckel's ganglion.

Pterygo-maxillary Fissure, between the tuberosity of the superior maxillary bone and the pterygoid process of the sphenoid. It transmits branches of the internal maxillary artery, and connects the zygomatic fossa with the speno-maxillary.

Describe the Spheno-Maxillary Fossa. It is a triangular cavity between the pterygoid process of the sphenoid bone and the tuberosity of the superior maxillary, and is situated at the junction of the speno-maxillary, pterygo-maxillary, and sphenoidal fissures. Into it open—

3 *Fossæ*,—the orbital, zygomatic, and nasal.

2 *Cavities*,—the cranial, and buccal.

5 *Foramina*,—the Vidian and pterygo-palatine canals, and the foramen rotundum, posteriorly; the speno-palatine foramen on the inner wall; and the posterior palatine canal inferiorly;—occasionally also the accessory palatine canals.

THE SUTURES AND FONTANELLES.

Name the Sutures of the skull. There are 17.

At the Vertex of the skull are 5, the—

Sagittal, or interparietal.

2 Coronal, or fronto-parietal. 2 Lambdoid, or occipito-parietal.

At the Sides of the skull are 4, the—

2 Spheno-parietal. 2 Temporo-parietal.

At the Base of the skull are 5, the—

2 Temporo-occipital. Basilar, in the central line of the base.

2 Temporo-sphenoidal.

In the Mesial line, besides the sagittal and basilar, are 3, the—

Spheno-ethmoidal. Spheno-frontal. Ethmo-frontal.

Describe the Facial Sutures. The most important are the following, but the sutures of the face are very numerous.

Zygomatic Suture, at the temporo-malar articulation.

Transverse Suture, extending from one external angular process of the frontal bone across to the other, and connecting that bone with the malar, sphenoid, ethmoid, lachrymal, superior maxillary, and nasal bones.

Symphysis of the Chin, the site of a foetal suture.

How are the Sutures formed? By indentations of the external tables interdigitating with each other, the adjacent edges of the internal tables lying in unjoined proximity. The sutures are not formed until a long time after the formation of the skull, probably to permit of the marginal growth of the bones.

What are the Fontanelles? They are 6 membranous intervals in the infant's skull, corresponding in situation with the angles of the two parietal bones. They are as follows, viz.—

Anterior, at the junction of the sagittal and coronal intervals.

Posterior, at the junction of the sagittal and lambdoid intervals.

Lateral Fontanelles, 4, two at the anterior inferior angles, and two at the posterior inferior angles of the parietal bones. •

Describe the Wormian Bones. They are supernumerary small pieces of bone, irregularly shaped, and developed by special centres in unclosed portions of the cranial sutures and fontanelles, being more frequent in the lambdoid suture. They are also called "*ossa triquetra*" from their triangular form.

Describe the Hyoid Bone. It is shaped like a horse-shoe, has no articulation with the skeleton, but supports the tongue. It consists of a *Body*, two greater, and two lesser *Cornua* or horns. On the body is a *Crucial Ridge*, with a *Tubercle* at the centre. It is *developed* by 5 centres,—one for the body and one for each horn. Attached to it are 10 muscles, 3 ligaments, and 1 membrane, as follows, viz.—

To the Body,—the genio-, mylo-, stylo-, sterno-, thyro-, omo-hyoid, the genio-hyo-glossus, and the hyo-glossus muscles; also the pulley of the digastric, the hyo-epiglottic ligament, and the thyro-hyoid membrane.

To the Greater Cornu,—the hyo-glossus, middle constrictor muscles, and part of the thyro-hyoid;—also the thyro-hyoid ligament.

To the Lesser Cornu,—the stylo-hyoid ligament.

TABLE OF THE FORAMINA AT THE BASE OF THE SKULL,

with the various structures transmitted by each.

Anterior Fossa contains 1 single foramen and 5 in pairs, viz.—

Foramen Cæcum,—lodges a fold of dura mater, and transmits a vein to the longitudinal sinus from the nose, sometimes one from the frontal sinus.

Ethmoidal Fissure,—the nasal nerve, and the anterior ethmoidal artery.

Olfactory,—olfactory nerves, and nasal branches of the ethmoidal arteries.

Anterior Ethmoidal,—anterior ethmoidal artery and the nasal nerve.

Posterior Ethmoidal,—posterior ethmoidal artery and vein.

Optic Foramen,—optic nerve and ophthalmic artery.

Middle Fossæ contain 8 pairs, viz.—

Foramen Lacerum Anterius, or *Sphenoidal Fissure*,[†]—the 3d, 4th, ophthalmic division of the 5th, and the 6th cranial nerves, and filaments of the sympathetic; ophthalmic vein, a branch of the lachrymal artery, orbital branches of the middle meningeal artery, and a process of dura mater.

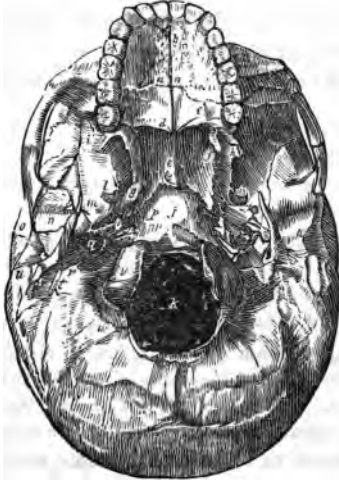Foramen Rotundum,—superior maxillary division of the 5th cranial nerve.

Foramen Vesalii,—a small vein. This foramen is often absent.

Foramen Ovale,[‡]—inferior maxillary division of the 5th nerve, lesser petrosal nerve, and the small meningeal branch of the internal maxillary artery.

Foramen Spinosum,[§]—middle meningeal artery, meningeal veins, and sympathetic filaments from the cavernous plexus.

FIG. 14.



Foramen Lacerum Medium,^g—internal carotid artery, carotid plexus, large petrosal nerve, and a branch from the ascending pharyngeal artery.

Small Foramen,—lesser petrosal nerve.

Hiatus Fallopii,—large petrosal nerve, branch of middle meningeal artery.

Posterior Fossa contains 6 pairs and 1 single, viz.—

Meatus Auditorius Internus,—facial and auditory nerves, auditory artery.

Aqueductus Vestibuli,—small artery and vein, process of dura mater.

Foramen Lacerum Posterius,^r—glosso-pharyngeal, pneumo-gastric, and spinal accessory nerves, internal jugular vein, meningeal branches of the ascending pharyngeal and occipital arteries.

Mastoid Foramen (often absent),—small vein, occasionally the mastoid artery.

Anterior Condyloid Foramen,—hypoglossal nerve, meningeal branch from the ascending pharyngeal artery.

Posterior Condyloid Foramen^w (often absent), posterior condyloid vein.

Foramen Magnum,^k—medulla oblongata and its membranes, the vertebral arteries, and the spinal accessory nerves.

Externally, at the base of the skull are 10 pairs, viz.—

Opening of the Eustachian Tube,—air to the middle ear.

Opening of Tensor Tympani Canal,—the tensor tympani muscle.

Orifice of the Vidian Canal,—the Vidian nerve, and vessels.

Glosserian Fissure,ⁿ—laxator tympani muscle, tympanic artery, processus gracilis of the malleus.

Orifice of the Canal of Hugier,—chorda tympani nerve.

Foramen for Jacobson's Nerve,—tympanic branch of glosso-pharyngeal.

Foramen for Arnold's Nerve,—auricular branch of pneumogastric.

Opening of the Aqueductus Cochleæ,—vein to the cochlea.

Stylo-mastoid Foramen,^t—facial nerve, stylo-mastoid artery.

Auricular Fissure,—exit of Arnold's nerve.

Face presents 3 pairs, viz.—

Supraorbital Foramen or Notch,—supraorbital artery, vein, and nerve.

Infraorbital Foramen,—infraorbital artery and nerve.

Mental Foramen,—mental artery and nerve.

Palate presents, on each side at least 6 pairs, viz.—

Incisive Foramina^b (one or two),—nerves and vessels to the incisor teeth.

Anterior Palatine,—anterior palatine vessels, naso-palatine nerves.

Posterior Palatine,—posterior palatine vessels, anterior palatine nerve.

Accessory Palatine Foramina (one or two),—posterior palatine nerves.

Pterygo-palatine Foramen,—pterygo-palatine vessels.

THE BONES OF THE TRUNK.

THE VERTEBRAL COLUMN.

What Characteristics are Common to the Vertebrae? Each vertebra consists of a body and an arch, the latter being formed by 2 pedicles and 2 laminae, which support 7 processes.

*Body*⁶ is thick and spongy, convex in front¹ from side to side, concave vertically, and on the upper and lower surfaces, which are surrounded by a bony rim. Anteriorly are small foramina for nutrient vessels, posteriorly a large foramen for the exit of the venae basis vertebrarum.

Pedicles, project backwards from the body, inclining outwards. They are notched above and below, thus forming, with the adjacent notches, the *Intervertebral Foramina* for the entrance of vessels and the exit of the spinal nerves.

Laminae,³ are 2 broad plates, meeting in the spinous process behind, and rough on their upper and lower borders for the attachment of the ligamentum subflava.

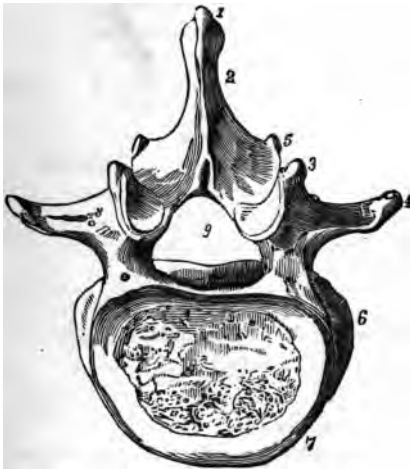Transverse Processes,⁴ one on each side, projecting outwards.

Articular Processes, two on each side, superior⁸ and inferior,⁵ project from the junction of the laminae and pedicles, and articulating above and below with the articular processes of the adjacent vertebrae. Their superior facets look upwards in the cervical region, outwards in the dorsal, and inwards in the lumbar.

Spinous Process,¹ projects backwards from the junction of the laminae with each other, sometimes very obliquely.

Spinal Foramen,⁹ is the space enclosed by the body, pedicles, and laminae; and which, when the vertebrae are articulated, forms part of the spinal canal.

FIG. 15.



How are the Vertebræ distinguished? As cervical (7), dorsal (12), and lumbar (5). Each of these divisions has several peculiar features, but their especial characteristics are as follows.

The Cervical Vertebræ are pierced at the bases of their transverse processes by the *vertebral foramina*, which transmit the vertebral artery, vein, and plexus.

The Dorsal Vertebræ have facets and demifacets on their bodies, for articulation with the heads of the ribs.

The Lumbar Vertebræ are marked by the absence of the foramina and facets which distinguish the other two classes.

What are the Peculiar Vertebræ? They are 9 in number,—the atlas or 1st cervical, the axis or 2d cervical, the vertebra prominens or 7th cervical, the 1st, 9th, 10th, 11th, and 12th dorsal, and the 5th lumbar.

The Atlas is a bony ring supporting the head. A bony arch takes the place of a body, and its spinous process is a mere tubercle. Its *Lateral Masses* form its chief bulk, supporting large *Articular Processes* which all look inwards, the superior articulating with the condyles of the occipital bone.

The Axis is marked by its *Odontoid Process* projecting upwards from the body into the anterior part of the spinal foramen of the atlas, where it articulates with the anterior arch, and receives the occipito-axoid and the check ligaments.

The Vertebra Prominens has a long and prominent spinous process which ends in a tubercle for the ligamentum nuchæ.

The Dorsal Vertebræ. The 1st has one facet and a demifacet. The 9th has a demifacet only. The 10th has but one facet on the body and one on the transverse process. The 11th and 12th have each but one facet on the body, and none on the transverse processes. The 12th resembles a lumbar vertebra in size and shape.

The 5th Lumbar is much deeper in front than behind; its spinous process is small, but its transverse processes are large and thick, and point slightly upwards.

What important Relations have Certain Vertebræ?

The 3d Cervical corresponds to—the bifurcation of the common carotid artery, and the superior cervical ganglion.

The 5th Cervical, to—the junctions of the larynx with the trachea, and the pharynx with the œsophagus, and the middle cervical ganglion of the sympathetic.

The 2d Lumbar, to—the junction of the duodenum with the jejunum, the commencement of the thoracic duct and the portal vein, the origin of the superior mesenteric artery, the lower margin of the pancreas, the opening of the ductus communis cholédochus, the lower end of the spinal cord, and the crura of the diaphragm.

[The false vertebræ are described as bones of the pelvis.]

THE THORAX.

What is the Thorax? An osseo-cartilaginous cage formed by the bodies of the dorsal vertebræ posteriorly, the ribs and costal cartilages laterally, and the sternum in front. Its shape is conical, the axis inclined forwards, the base below and closed by the diaphragm.

What Structures pass through its Apex? The trachea, œsophagus, large vessels of the neck, pneumogastric, phrenic and sympathetic nerves, thoracic duct, and in inspiration the apex of the lung.

What Structures are contained in its Cavity? The trachea, bronchi and lungs, the heart and great vessels, internal mammary arteries, azygos and bronchial veins, pneumogastric, phrenic, and splanchnic nerves, œsophagus, thoracic duct, lymphatic vessels, and glands.

THE STERNUM.

Describe it. The sternum, or breast-bone, consists of 3 parts,—the manubrium,^a or handle; the gladiolus,^b or sword; and the ensiform or xiphoid appendix.^c It presents the—



Interclavicular Notch, on its superior border.

Manubrium,^a articulates with the clavicle,^d 1st costal cartilage,^e and a part of the 2d.^f

Gladiolus, articulates with the costal cartilages from the 3d to the 6th inclusive, and partly with the 2d and 7th.

Ensiform Appendix (the tip), articulates with the cartilage of the false ribs, and in part with the 7th costal cartilage.^j

Describe its development and muscles. The sternum is *developed* by 6 centres, 1 each for the manubrium and ensiform appendix, and 4 for the gladiolus. The *muscles* attached to it are 9 pairs and one single muscle,—the sterno-cleido-mastoid, sterno-hyoid, and sterno-thyroid, 3, to its upper part;—the rectus abdominis, external and internal oblique, transversalis, and the diaphragm, 5, to its lower part;—the pectoralis major, 1, anteriorly;—and the triangularis sterni, 1, posteriorly.

THE RIBS.

Describe them. There are 12 ribs on each side, of which 7 are “true ribs,” being each connected to the sternum by a separate cartilage;—and 5 are “false ribs.” Three of the latter are connected by their cartilages to the cartilage of the 7th rib, while two are called “floating ribs,” having each one extremity free.

What are the Characteristics Common to most of the Ribs? They each consist of a head, neck, and shaft, and present the following points, viz.—

Head,^a is divided by a ridge into 2 facets, which articulate with the facets on the bodies of the dorsal vertebræ; the ridge giving attachment to the interarticular ligament.

Neck, about an inch long, having attached to its upper border the anterior costo-transverse ligament, to its posterior surface the middle costo-transverse ligament; its anterior surface is smooth.

Tuberosity,^b

at the junction of the neck with the shaft, has a facet for articulation with the transverse process of the next lower

vertebra, and a rough surface for the posterior costo-transverse ligament.

Shaft, twisted on itself, is concave internally, convex externally, its upper border round and smooth, its lower border grooved^d for the intercostal vessels and nerves. At its external extremity^e is an oval depression for the insertion of the costal cartilage.

Angle,^e just in front of the tuberosity, is marked by a rough line, to which are attached the muscles of the deep layer of the back.

How are they developed? Each rib has 3 centres, one each for the head, shaft, and tuberosity. The last 2 ribs, having no tuberosity, are developed each by 2 centres.

Describe the Peculiar Ribs. They are the 1st, 2d, 10th, 11th, and 12th. They respectively present the following peculiarities, viz.—

1st Rib, is broad, short, not twisted, has no angle, only one facet on the head;^a but on its upper surface are seen *two grooves* for the subclavian artery^d and vein,^e and between them a *tubercle* g for the scalenus anticus muscle.

2d Rib, is not twisted, its tuberosity and angle are very close together, and its upper surface presents rough surfaces for the serratus magnus and scalenus posticus muscles.

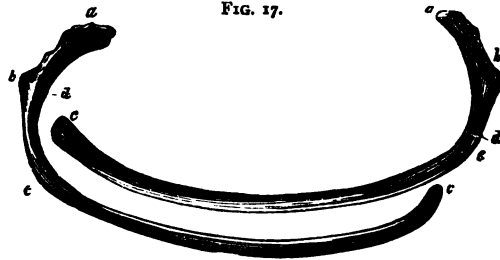


FIG. 17.

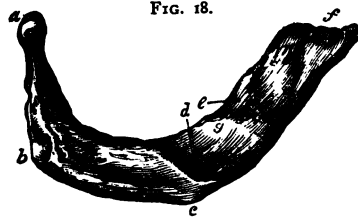


FIG. 18.

10th Rib, has but one facet on its head.

11th Rib, has no neck, no tuberosity, and but one facet on its head.

12th Rib, has neither neck, angle, tuberosity nor groove, and but one facet.

THE PELVIS.

Describe the Pelvis. It is formed by the sacrum, coccyx, and two ossa innominata, and is divided into,—the *false pelvis*, comprising the upper and expanded portion,—and the *true pelvis*, below the ilio-pectineal line. The false pelvis corresponds to the iliac fossæ, and is marked by its walls being deficient anteriorly between the iliac borders, and posteriorly between the sacrum and the posterior iliac spines. The true pelvis has a—

Brim, or inlet, bounded in front by the crest and spine of the pubes, behind by the promontory of the sacrum, laterally by the ilio-pectineal line. Its axis corresponds to a line from the umbilicus to the middle of the coccyx. Its average diameters in the female are,—4 inches antero-posteriorly,⁴ over 5 inches transversely,³ under 5 inches obliquely.³ In the male each of

these measurements is about $\frac{1}{2}$ an inch less.

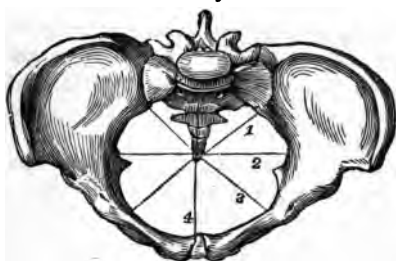Cavity, is a short curved canal, connecting the brim with the outlet. In front its depth is about $1\frac{3}{4}$ inch, posteriorly 4 to $4\frac{1}{2}$ inches in the female, $4\frac{1}{2}$ to $5\frac{1}{2}$ inches in the male. Its diameter is about $4\frac{1}{4}$ inches in the female, $4\frac{1}{2}$ inches in the male, all around.

Outlet, is bounded by the pubic arch above, the tip of the coccyx behind, and the tuberosities of the ischii laterally. Its axis, if prolonged, would touch the promontory of the sacrum. Its diameters in the female are each about $4\frac{1}{4}$ inches, in the male about $3\frac{1}{2}$ inches.

State the chief differences between the male and female pelvises. The *male pelvis* is marked by strength of the bones, prominence of the muscular impressions, a deep and narrow cavity, and large obturator foramina. The *female pelvis* has lighter bones, broader iliac fossæ, the spines being further apart, greater diameters at every point, the sacrum less curved, and the pubic arch wider.

Describe the Sacrum. The “sacred bone” is triangular, curved, with its convexity backwards, and is situated base upwards between the ossa innominata, forming with the coccyx the posterior wall of the pelvis. The bone is formed by the coalescence of 5 vertebræ, and presents the following points, viz—

FIG. 19.



4 *Ridges*,⁴ transversely across both surfaces, mark the union of its original segments.

8 *Anterior Sacral Foramina*, for the anterior sacral nerves.

8 *Grooves*,⁵ shallow and broad, for the aforesaid nerves.

Promontory, at its junction with the last lumbar vertebræ.

8 *Posterior Sacral Foramina*, for the posterior sacral nerves.

Tubercles, representing the spinous processes of the segments.

Groove, posteriorly, on each side of the spinous tubercles.

2 *Cornua*, at the posterior inferior portion of the bone.

Auricular Surface,⁸ on each side, articulates with the ilium.

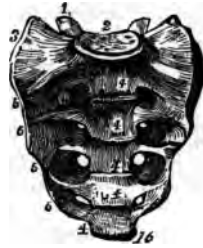Notch, laterally and inferiorly, for the 5th sacral nerve.

Base,² has all the characteristics of the lumbar vertebræ, with the last of which it articulates.

Apex,¹⁶ has an oval surface for articulation with the coccyx.

Sacral Canal, the continuation of the spinal, is incomplete posteriorly at its lower end. It transmits the *Cauda Equina*; into it open the sacral foramina laterally.

FIG. 20.



Describe the Coccyx. It consists of 4 or 5 rudimentary vertebræ coalesced into a triangular bone, the base¹ of which articulates with the apex of the sacrum. Its posterior surface is rough for muscles and ligaments, its anterior surface is smooth and marked by ridges at the junction of its constituent vertebræ. It presents the following points.—

2 *Cornua*,² superiorly, articulating with the sacral cornua to form foramina for the 5th sacral nerves.

Apex, is sometimes bifid and turned to one side.

FIG. 21.



Describe the Ossa Innominata. The unnamed bones are placed one on each side of the osseous pelvis, and are each formed by the union, about puberty, of 3 bones,—the ilium, ischium, and pubes. The innominate bone as a whole presents the following points, viz.—

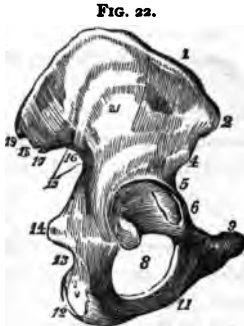
Acetabulum, or cotyloid cavity, receives the head of the femur. It is situated at the junction of the 3 bones, the ilium and ischium each forming about two-fifths, and the pubes one-fifth of it. A depression in its centre lodges a mass of fat containing vessels for the nourishment of the synovial

membrane. The *Cotyloid Notch* is a deficiency in its lower anterior margin, transmitting nutrient vessels to the joint; to the edges of the notch is attached the *ligamentum teres*, and it is bridged over by the *transverse ligament*, a continuation of the cotyloid ligament which surmounts the brim of the acetabulum.

Obturator, or Thyroid Foramen,⁸ on the anterior surface between the pubes and ischium, large and oval in the male, small and triangular in the female; is closed by the obturator membrane, except above where the obturator nerves and vessels pass through it.

Describe the Ilium. It is the superior part of the innominate bone, and presents the following points, viz.—

Crest,¹ along its upper border, having an outer and inner lip for muscular attachment, and ending in the superior spines.



Anterior Superior Spine,³ to which is attached the sartorius and tensor vaginæ femoris muscles, and Poupart's ligament.

Anterior Inferior Spine,⁴ for the straight tendon of the rectus femoris.

Notch, between the above-named spines, transmitting the external cutaneous nerve, and lodging some fibres of the sartorius.

Posterior Superior Spine,¹⁹ for the attachment of the erector spinæ muscle, and the oblique part of the sacro-sciatic ligament.

Posterior Inferior Spine,¹⁷ for the great sacro-sciatic ligament.

Great Sacro-sciatic Notch,¹⁶ below the last-named spine, transmits the great sciatic, superior gluteal, and pudic nerves, the pyriformis muscle, and the sciatic, pudic, and gluteal vessels; and a nerve supplying the obturator externus muscle.

Curved Lines,²¹ superior middle and inferior, on the outer surface of the bone, from the spaces between which arise the glutei muscles.

Groove, above the acetabulum, for the reflected tendon of the rectus femoris muscle.

Linea Ilio-pectinea, in part; on the inner surface, above which is a smooth surface, the *Venter of the Ilium*.

Auricular Surface,¹⁸ rough, articulates with the sacrum.

Describe the Ischium. It is the lowermost portion of the innominate bone, and presents the following points, viz.—

Body, forms two-fifths of the acetabulum, and the external margin of the

obturator foramen; on it is a broad groove for the tendon of the obturator externus muscle. Its posterior margin assists in forming the great sacro-sciatic notch.

Spine,¹⁴ for the gemellus superior, coccygeus, and levator ani muscles, and the lesser sacro-sciatic ligament.

Lesser Sacro-sciatic Notch,¹³ below the spine, transmits the obturator muscle, its nerve, and the pudic vessels and nerve as they re-enter the pelvis, having crossed the spine of the ischium. The sacro-sciatic notches are converted into foramina by the sacro-sciatic ligaments; the greater notch by the lesser ligament, the lesser notch by the greater ligament.

Tuberosity,¹² the lowest and most prominent part, gives attachment to the greater sacro-sciatic ligament, and to several muscles. On it one rests when sitting.

Ascending Ramus, bounds the obturator foramen inferiorly, articulates with the descending ramus of the pubes, and gives attachment to the obturator membrane and several muscles.

15) **Describe the Pubes.** The pubic or pectineal bone forms the anterior portion of the innominate. It presents the following, viz.—

Body, lies between the rami, with its fellow forms the *Symphysis*, giving origin to several muscles and ligaments.

Crest,⁹ is the upper part of the body, terminates externally in the *Spine*, and internally in the *Angle*.

Spine, affords attachment to one end of Poupert's ligament.

Linea Ilio-pectinea, in part; gives attachment to the conjoined tendon, Gimbernat's ligament, and the triangular ligament.

Horizontal Ramus, forms part of the brim of the pelvis, of the margin of the obturator foramen, and of the acetabulum. On its under surface is a groove for the obturator vessels and nerve.

Pectineal Eminence,⁵ gives attachment to the psoas parvus muscle.

Descending Ramus,¹¹ flat and thin, joins the ascending ramus of the ischium, and bounds the obturator foramen internally.

What Muscles are attached to the Os Innominate? 36, comprising those of the abdomen, thigh, perineum, floor of the pelvis, and rotators of the hip-joint.

BONES OF THE UPPER EXTREMITY.

THE SHOULDER.

What Bones form the Shoulder? The clavicle and scapula connecting the arm with the trunk, and in this respect homologous to the innominate bone in the lower part of the body.

Describe the Clavicle. The collar- or key-bone, is a short bone by structure, having no medullary canal; and is curved like the letter *f*, its inner two-thirds being cylindrical, and convex anteriorly; its outer third flattened, and concave anteriorly. It is placed horizontally between the sternum and the scapula, and is the most elastic bone in the body. It presents, from within outwards, the following points, viz.—

Facets, for articulation with the sternum and the cartilage of the 1st rib, at its sternal end.

Impression for the rhomboid, or costo-clavicular ligament.

Groove, on the lower surface, for the subclavius muscle.

Tubercle, for the conoid part of the costo-clavicular ligament.

Oblique Line, for the trapezoid part of the same ligament.

Facet, on the acromial end, for articulation with the scapula.

Nutrient Foramen, in the subclavian groove.

Describe the Scapula. The shoulder-blade is a large, flat, and triangular bone, situated on the posterior and lateral portion of the thorax, from the 2d rib to the 7th, inclusive.

THE VENTER, or anterior surface, presents from within outwards,—

Ridges, giving attachment to the subscapularis muscle.

Marginal Surface, along the inner border, for the attachment of the serratus magnus muscle.

Subscapular Fossa, and Angle, for the subscapularis muscle.

THE DORSUM, or posterior surface, presents the following, viz.—

Spine, a bony ridge, which affords attachment to the trapezius and deltoid muscles, and ends in the acromion process.

Supraspinous Fossa, above the spine, for the supraspinatus muscle.

Infraspinous Fossa, below the spine, larger than the supraspinous, convex at its centre, lodges the infraspinatus muscle, and the nutrient foramen.

Marginal Surface, along the external border, to which are attached the teres minor muscle above, the teres major below, and sometimes a few fibres of the latissimus dorsi at the lower angle.

Groove crossing the margin, for the dorsalis scapulae vessels.

Smooth Surface, behind the root of the spine, over which the trapezius muscle glides.

THE ACROMION PROCESS, or “summit of the shoulder,” extends from the spine, and projects over the glenoid cavity, articulating with the clavicle by an oval facet. It affords attachment to the deltoid and trapezius muscles, and by its apex to the coraco-acromial ligament.

THE CORACOID PROCESS, or “crow’s beak,” projects from the upper border and neck of the bone over the inner and upper part of the glenoid cavity.

Into it is inserted **I** muscle, the pectoralis minor; the coraco-brachialis, and the short head of the biceps arise from it by a common tendon; and 3 ligaments are attached to it,—the conoid, trapezoid, and coraco-acromial.

THE SUPERIOR BORDER presents the—

Suprascapular Notch, converted into a foramen for the suprascapular nerve by the transverse ligament, over which passes the suprascapular artery. The omo-hyoid muscle is attached to the border just internal to the notch.

THE AXILLARY BORDER is the thickest, and presents a—

Rough Surface, for the long head of the triceps muscle, just below the glenoid cavity.

Groove, the origin of a part of the subscapularis muscle.

THE VERTEBRAL BORDER is the longest, and presents an—

Anterior Lip, for the attachment of the serratus magnus.

Posterior Lip, for the supra- and infra-spinatus muscles.

Interspace, between the lips, for the levator anguli scapulæ, the rhomboideus minor, and the fibrous arch of the rhomboideus major muscles.

OTHER POINTS of interest on the bone are the—

Superior Angle, affords attachment to part of the serratus magnus, levator anguli scapulæ, and supra-spinatus muscles.

Inferior Angle, affords attachment to part of the serratus magnus and teres major muscles, and occasionally to a few fibres of the latissimus dorsi.

Glenoid Cavity, at the external angle or head of the bone, a shallow cavity for the reception of the head of the humerus. It is deepened by the glenoid ligament which is attached around its margin; and at its upper part gives origin to the long head of the biceps flexor cubiti muscle.

Neck, is the contracted part of the bone behind the glenoid cavity; from it arises the anterior root of the coracoid process.

THE ARM.

Describe the Humerus. It is the only bone in the arm, and articulates with the scapula above, and with the ulna and radius below. It presents the following points, viz.—

Head,^b is nearly hemispherical, and smooth for articulation with a glenoid cavity of the scapula.


Anatomical Neck,^c is a constriction in the bone, just below the head, for the attachment of the capsular ligament.

Greater Tuberosity,^d has 3 small facets for the insertion of spinatus, infraspinatus, and teres minor muscles.

Lesser Tuberosity, e, on the inner side of the bone, gives insertion to the subscapularis muscle.

Bicipital Groove, f lies vertically between the tuberosities for the upper third of the bone, and lodges the tendon of the long head of the biceps flexor cubiti. Into its inner or posterior lip *k* are inserted the teres major and latissimus dorsi muscles, while its outer or anterior lip *g* receives the insertion of the tendon of the pectoralis major, which covers the groove.

FIG. 23.



Surgical Neck, is situated immediately below the tuberosities, and is a slight constriction in the upper part of the shaft.

Shaft, a is cylindrical above, prismatic and flattened below.

Rough Surface, b for the insertion of the deltoid muscle, about the middle of the external surface of the shaft.

Musculo-spiral Groove, lodging the musculo-spiral nerve, and the superior profunda artery, is situated on the posterior surface of the shaft, separating the origins of the outer and inner heads of the triceps muscle.

Orifice, c of the nutrient canal, about the middle of the shaft.

Condyloid Ridges, d internal and external, arising from the respective condyles, extending upwards along the shaft.

External Condyle, m gives attachment to the external lateral ligament and the extensor and supinator group of muscles.

Internal Condyle, n lower and more prominent than the other, gives attachment to the internal lateral ligament and the flexor and pronator group of muscles of the fore-arm.

Radial Head, h forms the external part of the inferior articular surface; for articulation with the radius.

Trochlear Surface, i articulates with the greater sigmoid cavity of the ulna; is a deep depression between two borders, and extends from the anterior to the posterior surface of the bone.

Coronoid Fossa, j in front of the trochlea, receives the coronoid process of the ulna when the fore-arm is flexed.

Olecranon Fossa, behind the trochlea, receives the tip of the olecranon process, when the fore-arm is extended.

THE FORE-ARM.

Describe the Ulna. The elbow-bone is the internal bone of the fore-arm. It is larger and longer than the radius, forming the greater portion of the articulation with the humerus. It does not enter into the formation of the wrist-joint, being excluded therefrom by an interarticular fibro-cartilage. It presents the following, viz.—

Olecranon Process,^d at the upper extremity, forming the elbow. It is curved forwards, its apex being received into the olecranon fossa of the humerus when the fore-arm is extended. Its posterior surface gives insertion to the tendon of the triceps. In its function and structure it resembles the patella.

Coronoid Process,^e below the olecranon, projects forwards, its apex being received into the coronoid fossa of the humerus when the fore-arm is flexed. Its upper surface is concave for articulation with the humerus, its lower surface rough for the insertion of the brachialis anticus muscle. Its inner surface has a margin for the internal lateral ligament, a tubercle for the flexor sublimis digitorum, and a ridge for the pronator radii teres.

Greater Sigmoid Cavity,^b lies between the processes, and is divided by a vertical ridge into two unequal parts. It articulates with the trochlear surface of the humerus.

Lesser Sigmoid Cavity^c lies external to the coronoid process; is oval and concave, articulating with the head of the radius, and giving attachment to the orbicular ligament.

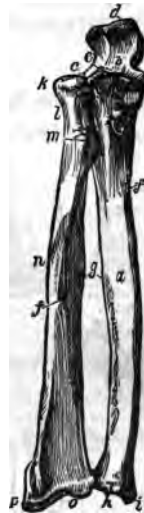
Shaft,^a large and prismatic above, smaller and rounded below, has the *Nutrient Foramen*^f on its anterior surface, and a prominent margin^g externally, to which is attached the interosseous membrane. The shaft gives attachment to 9 of the 12 muscles of the fore-arm.

Head,^h at the carpal end, articulates with the lesser sigmoid cavity of the radius, and the fibro-cartilage of the wrist-joint.

*Styloid Process,*ⁱ projecting from the head internally and posteriorly, its apex gives attachment to the internal lateral ligament, and a depression at its root to the fibro-cartilage of the joint.

Groove, for the tendon of the extensor carpi ulnaris muscle.

FIG. 24.



Describe the Radius. The radius lies externally to the ulna when the fore-arm is in supination; it is prismatic in form with the base below where it articulates with the carpus. The bone is curved outwards and is shorter than the ulna, by the length of the olecranon. It presents the following points from above downwards, viz.—

Head, *h* cylindrical and cup-shaped, articulating with the radial head of the humerus, and the lesser sigmoid cavity of the ulna, and playing within the orbicular ligament.

Neck, *l* the constricted part below the head.

Tuberosity, *m* rough behind for the insertion of the biceps, and smooth in front where it is covered by a bursa.

Shaft, *j* prismoid in form, presents a sharp border internally for the attachment of the interosseous membrane; the *Nutrient Foramen* is on its anterior surface. It gives attachment to 8 of the 12 muscles of the fore-arm.

Sigmoid Cavity, at the internal side of the carpal end, is shallow, and articulates with the head of the ulna.

Articular Surface, *o* is divided by a ridge into 2 facets for articulation with the semilunar and scaphoid bones of the carpus.

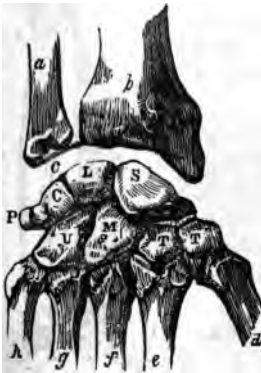Styloid Process, *p* externally, gives attachment by its apex to the external lateral ligament, and by its base to the supinator longus muscle.

Grooves, on the posterior and external surfaces of the lower extremity, for the tendons of the 8 extensor muscles of the thumb, and those of the radial side of the wrist, and fingers.

THE HAND.

How are the Bones of the Hand divided? Into the carpus (8), the metacarpus (5), and the phalanges (14). Total, 27 bones.

FIG. 25.



Name the Bones of the Carpus. They are placed in 2 rows, one row in front of the other, with 4 bones in each row, as follows,—the left hand being in supination, naming from without inwards, viz.—

1st, or Proximal Row,—Scaphoid, *S* Semi-lunar, *L* Cuneiform, *C* Pisiform, *P*

2d, or Distal Row,—Trapezium, *T* Trapezoid, *T* Os-magnum, *M* Unciform, *U*

State the number of Articulations in the Carpus. 34, as follows,—the number after each bone representing the number of its articulations, viz.—

Scaphoid, 5. Semilunar, 5. Cuneiform, 3. Pisiform, 1.
Trapezium, 4. Trapezoid, 4. Os-magnum, 7. Unciform, 5.

What peculiarities have the Carpal bones? The first three enter into the formation of the wrist-joint; the pisiform does not, but is wholly without it, and may be considered a mere appendage of the carpus. When the hand is in pronation—

The Scaphoid, or boat-shaped bone, has a tuberosity on its outer side, its largest auricular facet is uppermost, and a transverse groove crosses its posterior surface.

The Semilunar Bone has a crescentic facet externally, and a convex facet superiorly.

The Cuneiform Bone is wedge-shaped, its convex surface above, and has an isolated facet for the pisiform articulation.

The Pisiform Bone is the smallest, and has but one facet, which lies posteriorly when the bone is in position.

The Trapezium has a deep groove for the tendon of the flexor carpi radialis, and a saddle-shaped facet, inferiorly.

The Trapezoid is small and quadrilateral, bent on itself, with a saddle-shaped facet looking downwards.

The Os-magnum has a head looking upwards, a neck, and a body; is the largest bone of the carpus, and has a tubercle on the inner side of the base.

The Unciform Bone is triangular, with a concavity which lies to the outer side; and the unciform process, long and curved, projecting from its palmar surface.

Describe the Metacarpus. The 5 metacarpal bones are placed between the carpus and the phalanges, are long bones, and each has a head, shaft, and base. Their heads articulate with the respective phalanges.


1st Metacarpal Bone,^d articulates with the trapezium, is shorter than the others by one-third, and its base has but 1 articular facet. This bone is classed among the phalanges by Professor W. H. Pancoast.

2d Metacarpal Bone,^e articulates with 3 bones of the carpus,—the trapezium, trapezoid, and os-magnum; its base is large, and has 4 articular facets.

3d Metacarpal Bone,^f articulates with 1 bone of the carpus,—the os-magnum; its base has a projecting process on the radial side, and 2 small facets on the opposite side.

4th Metacarpal Bone,^g articulates with 2 bones of the carpus and with the adjacent metacarpal bones; its base is small, and has 2 circular facets, 1 on each side.

5th Metacarpal Bone,^h articulates with 1 carpal bone,—the unciform; its base has 1 lateral articular facet.



Describe the *Phalanges*. The finger-bones are 14 in number (15 according to Pancoast), 3 to each finger, and 2 to the thumb. They are long bones, and each has a base, a shaft, and a digital extremity. The *Bases* of the first row articulate with the heads of the metacarpal bones. The *Digital Extremities* of the first and second rows have each 2 small lateral condyles, while in the terminal row they are rough, for the attachment of the sensitive pulp of the fingers.

BONES OF THE LOWER EXTREMITY.

THE THIGH.

Describe the *Femur*. The thigh-bone is nearly cylindrical, and is the longest, largest, and strongest bone in the body. In the vertical position of the skeleton it forms one side of a triangle, of which the base is the breadth of the pelvis, and the apex at the knee-joints. The base of this triangle is longest in the female, and consequently that sex is usually knock-kneed.



Head, *b* articulates with the acetabulum, forms about two-fifths of a sphere, and has an oval depression *a* below its centre for the attachment of the ligamentum teres.

Neck, *f* connects the head with the shaft, is pyramidal and flattened; its obliquity varies with age, being less before puberty, about 120 to 125 degrees in the adult, and nearly horizontal to the shaft in old or debilitated subjects.

Great Trochanter, *d* a broad, rough, quadrilateral process directed outwards and backwards from the summit of the shaft to within three-fourths of an inch of the level of the head. On its outer surface the tendon of the gluteus maximus plays over a bursa. It gives insertion to the obturator internus, two gemelli, pyriformis, and gluteus minimus and medius muscles.

Digital Fossa, on the inner surface of the great trochanter, gives insertion to the obturator externus muscle.

Lesser Trochanter, *e* at the inferior root of the neck posteriorly, is small and conical, and affords insertion to the tendon of the psoas magnus muscle, the tendon of the iliacus being inserted immediately below it.

Inter-trochanteric Lines, anterior and posterior, the latter the most prominent; to the anterior is attached the capsular ligament of the hip-joint.

Linea Quadrati, extends from the middle of the posterior inter-trochanteric line about 2 inches down the shaft, and gives attachment to the quadratus

femoris muscle.

Shaft, is slightly curved forwards, broad and cylindrical at each end, and narrow and triangular in the centre. Its nutrient foramen perforates its posterior surface below the centre. From its anterior surface arise the crureus and sub-crureus muscles.

Linea Aspera,^g a crest lying along the central third of the shaft posteriorly; bifurcating above towards each trochanter, also below towards the 2 condyles. To its outer lip is attached the vastus externus, to its inner lip, the vastus internus; and between them, the pectineus, adductor brevis, and gluteus maximus above the short head of the biceps below, and the adductors longus and magnus along the greater portion of the space.

Groove, crossing the internal condyloid ridge, and lodging the femoral artery. *Popliteal Space*,^h triangular and smooth, lying between the condyloid ridges, for the popliteal artery.

External Condyle,ⁱ broader and shorter than the internal, so as to form a horizontal articulation, the bone being inclined towards the median line. It gives attachment to the external lateral ligament, and the popliteus and gastrocnemius muscles.

Internal Condyle,^l the longest by half an inch; it gives attachment to the internal lateral ligament and the gastrocnemius muscle.

Inter-condyloid Notch,^k lodges the crucial ligaments. In front the condyles are continuous with each other, forming a concave depression or trochlea for the patella.

Outer Tuberosity, on the external condyle, for the attachment of the external lateral ligament.

Groove, below the outer tuberosity, for the tendon of the popliteus muscle, terminating in a depression whence the muscle takes its origin.

Inner Tuberosity, on the internal condyle, for the attachment of the internal lateral ligament.

Tubercle, above the inner tuberosity, for the insertion of the tendon of the adductor magnus muscle.

Depression, behind the tubercle, for the tendon of the inner head of the gastrocnemius.

THE LEG.

Describe the Tibia. The shin-bone ranks next to the femur in respect to size and length. Its form is prismoidal, the upper extremity being much larger than the lower.

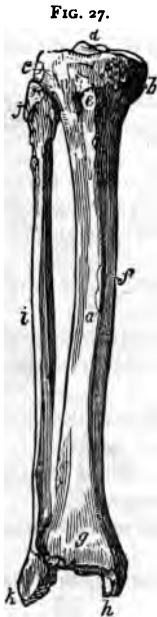Head, expands into 2 lateral tuberosities,^m which articulate with the condyles of the femur.

Spine,ⁿ projects vertically between the 2 articular surfaces, is bifid, affording attachment to the semilunar fibro-cartilages, and by depressions in front and behind its base to the crucial ligaments of the joint.

Tubercle, e anteriorly on the head, between the tuberosities, for the insertion of the ligamentum patellæ.

Popliteal Notch, posteriorly between the tuberosities, affords attachment to the posterior crucial ligament.

Groove, on the inner tuberosity posteriorly, for the insertion of the tendon of the semi-membranosus muscle.



Facet, on the outer tuberosity posteriorly and looking downwards, for articulation with the head of the fibula.

Popliteal Line, obliquely across the upper part of the shaft posteriorly, affords attachment to the fascia of the popliteus, and parts of the soleus, flexor longus digitorum, and tibialis posticus muscles.

Nutrient Canal, the largest in the skeleton, opens just below the popliteal line, its orifice looking upwards.

Shaft, a has 3 sharp ridges,—1 in front, the *Crest* or *Shin, f* and 1 on either side, to the external of which is attached the interosseous membrane.

Lower Extremity, g is smaller than the upper, grooved posteriorly for the tendon of the flexor longus pollicis; externally has a rough triangular depression for articulation with the fibula, and for the attachment of the inferior interosseous ligament. Its inferior surface is concave and smooth for articulation with the upper surface of the astragalus.

Internal Malleolus, k projects downwards from the internal side of the lower extremity. It articulates with the astragalus, is grooved posteriorly for the tendons of the tibialis posticus and flexor longus digitorum muscles, and affords attachment to the internal lateral ligament.

Describe the Fibula. It is a long slender bone, placed nearly parallel with the tibia on the outer side of the leg. It is also called the peroneous, or peroneal bone.

Head, j articulates with the external tuberosity of the tibia by a flat facet.

Externally it has a prominence for the attachment of the long external lateral ligament of the knee-joint.

Styloid Process, projects upwards from the head posteriorly, and gives insertion to the tendon of the biceps muscle, and the short external lateral ligament of the knee-joint.

Shaft i is triangular and twisted on itself, having 3 marked ridges, the

innermost of which is sharp for the attachment of the interosseus membrane. The shaft arches backwards, and gives attachment to 8 of the 12 muscles of the leg.

Nutrient Canal, opens about the centre of the shaft posteriorly, its orifice looking downwards.

External Malleolus,^k is the lower extremity of the bone. It is larger and longer than the internal, articulates with the astragalus by a triangular facet, and is grooved posteriorly for the tendons of the peroneus longus and brevis muscles. Its edge affords attachment to the external lateral ligament of the ankle-joint.

THE FOOT.

How are the bones of the Foot divided? Into the tarsus (7), metatarsus (5), and phalanges (14). Total, 26 bones.

Name the bones of the Tarsus. They are placed in 2 rows side by side, 2 bones in the external row, 5 in the internal, as follows—viz.—

Internally,— Astragalus.^a Scaphoid.^d 3 Cuneiform.^{e,f,g}

Externally,— Os calcis.^c Cuboid.^h

How many Art'culations are in the Tarsus? 28, each bone articulating with 4 others, except the os calcis, which articulates with 2, and the external cuneiform with 6 bones.

What Peculiarities have the Tarsal Bones?

They may be divided transversely at the astragaloscaphoid-calcaneo-cuboid articulation, the site of Chopart's operation.

The Astragalus,^a has a rounded head, a convex surface on which is a broad articular facet, and on its inferior surface a deep groove between 2 articular facets.

The Os Calcis,^c is a large bone, having on its upper surface a deep groove for the interosseous ligament, between 2 articular surfaces; anteriorly a large irregular portion, the head; and posteriorly an elongated portion forming the *Heel*. On its internal surface is a projection, the *Sustentaculum Tali*, which supports the internal articulating surface; below which process the bone is deeply grooved for the plantar vessels and nerves and the flexor tendons. To the os calcis are attached 8 muscles and the plantar fascia.

FIG. 28.



The Scaphoid Bone,^d is boat-shaped, has 3 facets anteriorly for the cuneiform bones, a concave surface posteriorly for the astragalus, and a facet externally for the cuboid bone. A tubercle is situated on the lower surface internally, for the insertion of the tibialis posticus muscle.

The Cuboid Bone,^h has 3 articular surfaces, and a groove inferiorly for the tendon of the peroneus longus.

The Internal Cuneiform Bone,^e the largest of the 3, has a tubercle on its plantar surface for the insertion of parts of the tendons of the tibialis anticus and tibialis posticus muscles.

The Middle Cuneiform Bone,^f is small and wedge-shaped with the narrow end downwards. Its anterior surface is considerably behind the line of the tarso-metatarsal articulation, thus forming a recess into which the base of the second metatarsal bone fits.

The External Cuneiform Bone,^g is also wedge-shaped, but longer than the middle one; and affords origin to 1 muscle, the flexor brevis pollicis.

Describe the Metatarsus. The metatarsal bonesⁱ are 5 in number, are long bones, having each a shaft and 2 extremities. Their bases articulate with the tarsal bones and with each other; their heads with the first row of phalanges.

1st Metatarsal, is large but shorter than the others, and forms the inner border of the foot, articulating with the internal cuneiform.

2d Metatarsal, is the longest; its base has 3 facets for articulation with the 3 cuneiform bones in the recess formed by the shortness of the middle cuneiform.

3d Metatarsal, has 2 facets on the inner side of its base, besides the facets for the internal cuneiform and the 4th metatarsal bone.

4th Metatarsal, articulates with the cuboid bone, and also with the internal cuneiform.

5th Metatarsal, articulates obliquely with the cuboid bone, and has a tubercular projection on the outer surface of its base, which forms the guide to Hey's operation.

Describe the Phalanges of the Foot. They number 14 as in the hand, the great toe having 2, the other toes 3 each. They are long bones, each having a base, a shaft, and an anterior extremity. They are convex above, concave below, and articulate by the bases of the first row with the bones of the metatarsus. The anterior extremities of the distal phalanges^{k, n} are expanded into surfaces for the support of the nails and pulp of the toes.

THE ARTICULATIONS.

Into what Classes are the Articulations divided? Into 3,—1. *Synarthro'sis*, immovable; 2. *Amphiarthro'sis*, *Synchondrosis*, or *Symphysis*, having limited motion; 3. *Diarthro'sis*, having free motion.

How are the Synarthroses subdivided? Into 3 divisions,—*Sutura*, by indentations; *Schindy'lesis*, by a plate of bone into a cleft in another; and *Gompho'sis*, by a conical process into a socket. The *Sutura* are again subdivided into—*S. Dentata*, having tooth-like processes; *S. Serrata*, with serrated edges; *S. Limbosa*, having beveled margins and dentated processes; *S. Squamosa*, with thin beveled margins overlapping each other; *S. Harmonia*, contiguous rough surfaces opposed to each other. The first 3 are also named *Sutura Vera* (true sutures) having indented borders; the last 2 *Sutura Notha* (false sutures) being formed by rough surfaces.

How are the Diarthroses divided? Into 4 divisions,—*Arthrodia*, gliding joint; *Enarthrosis*, ball-and-socket joint; *Ginglymus*, hinge-joint; and *Diarthrosis Rotatorius*, a ring surrounding a pivot.

Give an Example of each of the above-named articulations.

Synarthro'sis,—bones of cranium and face, except the lower jaw.

Sutura Dentata,—the inter-parietal suture.

Sutura Serrata,—the inter-frontal suture.

Sutura Limbosa,—the fronto-parietal suture.

Sutura Squamosa,—the tempora-parietal suture.

Sutura Harmonia,—the intermaxillary symphysis.

Schindy'lesis,—rostrum of sphenoid with the vomer.

Gompho'sis,—the teeth in their alveoli.

Amphiarthro'sis,—the bodies of the vertebræ, the sacro-iliac, and pubic symphyses.

Diarthro'ses,—

Arthrodia,—sterno-clavicular articulation.

Enarthrosis,—hip-joint, shoulder-joint.

Ginglymus,—elbow-joint, ankle-joint, knee-joint.

Diarthrosis Rotatorius,—the superior radio-ulnar, and atlo-axoid articulations.

Name the Varieties of motion in joints? There are 7 varieties, viz.—flexion, extension, adduction, abduction, rotation, circumduction, and gliding movement.

What Structures enter into the formation of joints? There are 5, viz.—the articular lamella of bone, ligaments, cartilage, fibro-cartilage, and synovial membrane.

Articular Lamella of bone differs from ordinary bone tissue in being more dense, containing no Haversian canals nor canaliculi, and having larger lacunæ.

Ligaments are bands of white fibrous tissue, except the ligamentum subflava and the ligamentum nuchæ, which are both composed purely of yellow elastic tissue.

Cartilage is temporary or permanent. The first forms the original framework of the skeleton, and becomes ossified. Permanent cartilage is not prone to ossification, and is divided into 3 varieties,—*Articular*, covering the ends of bones in joints; *Costal*, forming part of the skeleton; *Reticular*, arranged in lamellæ or plates to maintain the shape of certain parts.

Fibro-cartilage is *Interarticular* (menisci), separating the bones of a joint; *Connecting*, binding bones together; *Circumferential*, deepening cavities; *Stratiform*, lining grooves.

Synovial Membranes secrete the synovia, a viscid, glairy fluid, and resemble the serous membranes in structure. They are *Articular*, lubricating joints; *Bursal*, forming closed sacs (bursæ); *Vaginal*, ensheathing tendons.

Describe the Vertebral Articulations. They are formed by the adjacent surfaces of the bodies of the vertebræ, and their articular processes, and are connected by the following ligaments, etc.—(See FIG. 31.)

Intervertebral Fibro-cartilages, between the bodies of all true vertebræ, except the axis and atlas.

Anterior Common Ligament,¹ along fronts of the bodies.

Posterior Common Ligament, along backs of the bodies.

Ligamenta Subflava, connect the laminae of adjacent vertebræ.

Capsular,⁴ surround the articular processes, and are lined by synovial membrane.

Supra-spinous and Inter-spinous, connect the spinous processes.

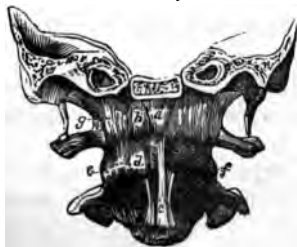Inter-transverse,³ connect the transverse processes.

Describe the Occipito-atloid Articulation. It is a double arthrodia formed by the condyles of the occipital bone with the superior articular surfaces of the atlas, and has 7 ligaments, viz.—

2 *Anterior Occipito-atloid*,² from the anterior margin of the foramen magnum to the anterior arch of the atlas.

Posterior Occipito-atloid, from the posterior margin of the foramen magnum to the posterior arch of the atlas. It is perforated by the vertebral arteries and suboccipital nerves.

FIG. 29.



a Lateral, from the jugular processes of the occipital bone to the bases of the transverse processes of the atlas.

a Capsular,^d around the articular surfaces, lined by synovial membrane.

Describe the Occipito-axoid Articulation. Formed by the occipital bone and the odontoid process of the axis, which do not articulate with each other strictly, but are connected by 4 ligaments.

*Occipito-axoid*¹ (*Apparatus Ligamentosus Colli*), a continuation of the posterior common spinal ligament to the basilar process of the occipital bone.

*a Lateral Occipito-odontoid*² (*Check Ligaments*), from the head of the odontoid process to the sides of the occipital condyles.

Vertical Occipito-odontoid (*Ligamentum Suspensorium*), from the anterior margin of the foramen magnum to the odontoid apex.

Describe the Atlo-axoid Articulation. It is a double arthrodia between the articular processes, a double diarthrosis rotatorius between the atlas and the odontoid process, and has 6 ligaments, and 4 synovial membranes.

a Anterior and 1 Posterior Atlo-axoid, continuations of the anterior and posterior common spinal ligaments.

a Capsular, surrounding the articular surfaces, each lined by a synovial membrane.

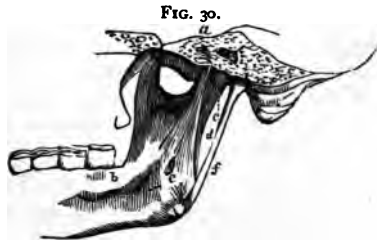Transverse, or Cruciform Ligament, divides the spinal foramen of the atlas into two portions, stretching across between the tubercles on the inner sides of the articular processes. It holds the odontoid process in place, having a synovial membrane interposed. Another synovial membrane is situated between the process and the anterior arch. The transverse ligament sends two vertical slips, one upwards, the other downwards, from which it is named the *Cruciform Ligament*.

Describe the Temporo-maxillary Articulation. A double arthrodia between the condyle of the lower jaw and the anterior part of the glenoid cavity of the temporal bone. It has 2 synovial membranes with an inter-articular fibro-cartilage between them, and 4 ligaments, viz.—

External Lateral, from the tubercle of the zygoma to the outer side of the neck of the condyle of the lower jaw.

Internal Lateral,^d from the spine of the sphenoid to the margin of the inferior dental foramen.

Stylo-maxillary,^f from the styloid process of the temporal bone to the angle of the inferior maxillary.



Capsular, from the edge of the glenoid cavity and the eminentia articularis to the neck of the inferior maxillary condyle.

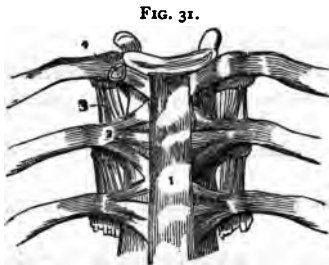
Nerves are derived from the auriculo-temporal and masseteric branches of the inferior maxillary.

Describe the Costo-vertebral Articulations. They are each a double arthrodia between the head of the rib and the bodies of 2 adjacent vertebræ, except in the 1st, 10th, 11th, and 12th ribs, which are each a single arthrodia, as they articulate with but 1 vertebra each. Their ligaments are 3, viz.—

Anterior Costo-vertebral, or *Stellate Ligament*, consists of 3 bundles, which fasten the anterior part of the head of the rib to the intervertebral disk and the 2 adjacent bodies.

Inter-articular Costo-vertebral, in the interior of the joint, from the crest on the head of the rib to the intervertebral disk; on each side there is a separate synovial membrane.

Capsular, surrounding the articular surfaces.



Describe the Costo-transverse Articulations. They are 10 arthrodiar articulations between the tubercles of the first 10 ribs and the transverse processes of the vertebræ next below. Their ligaments are 3, viz.—*Anterior, Middle, and Posterior Costo-transverse.*

Describe the Costo-sternal Articulations. One a synarthrodial, 6 are arthrodiar articulations, between the costal cartilages and the margin of the sternum. The first has no synovial membrane, the second only has an inter-articular fibro-cartilage. Each has 3 ligaments,—the *Anterior and Posterior Costo-sternal*, and a *Capsular*. The *Costo-xiphoid Ligament* connects the xiphoid appendix to the cartilage of the 6th or 7th rib.

How are the Costal Cartilages connected with the ribs and with each other? With the ribs by a depression on the end of each rib, strengthened by the blending together of the periosteum and the perichondrium. The cartilages of the lower ribs, sometimes from the 5th to the 10th inclusive, articulate with each other by their borders and for each a capsular and an intercostal ligament, with 3 synovial membranes for the 3 articulations between the 6th and the 9th cartilages.

What are the Ligaments of the Sternum? An anterior sternal and a posterior sternal ligament, with a layer of cartilage between the manubrium and the gladiolus.

Describe the Sacro-vertebral Articulation. It is similar to the other vertebral articulations, but has 2 additional ligaments on each side, viz.—

Lumbo-sacral, from the transverse processes of the 5th lumbar vertebra to the base of the sacrum laterally and anteriorly.

Lumbo-iliac, from the apices of the transverse processes of the 5th lumbar vertebra to the crest of the ilium.

Describe the Sacro-coccygeal Articulation. It is an amphiarthrodial joint, and has 3 ligaments, viz.—

Anterior Sacro-coccygeal.

Posterior Sacro-coccygeal.

Interarticular Fibro-cartilage, in the joint.

Describe the Sacro-iliac Articulation. It is an amphiarthrodial joint, formed by the auricular surfaces of the sacrum and ilium. Its ligaments on each side are as follows, viz.—

Anterior Sacro-iliac.

*Posterior Sacro-iliac.*⁸

Oblique Sacro-iliac.

Describe the Sacro-ischiatric Articulation. Its ligaments convert the sacro-sciatic notches into foramina, the greater notch by the lesser ligament, the lesser notch by the greater ligament. These foramina are described under the ilium and ischium bones.

Great Sacro-sciatic Ligament,^{13 14} from the posterior inferior spine of the ilium and the posterior surfaces and margins of the sacrum and coccyx, to the inner margin of the tuberosity and the ascending ramus of the ischium.

Lesser Sacro-sciatic Ligament,^{15 16} from the margins of the sacrum and coccyx, into the spine of the articulation.

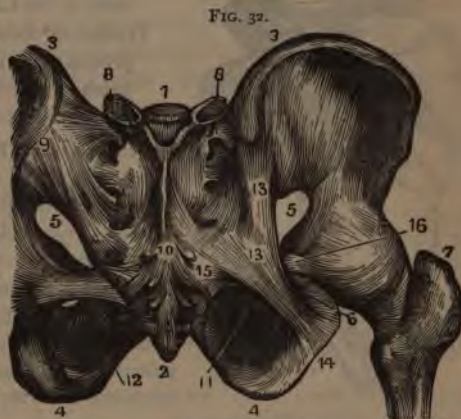Describe the Pubic Articulation. It is an amphiarthrodial joint, formed by the 2 pubic bones. It has an interarticular fibro-cartilage and 4 ligaments, viz.—

Anterior Pubic.

Posterior Pubic.

Supra-pubic.

Sub-pubic, forming a fibrous arch between the rami.



Describe the Sterno-clavicular Articulation. It is an arthrodial joint, formed by the sternal end of the clavicle with the sternum and the cartilage of the 1st rib. It has an interarticular fibro-cartilage, 2 synovial membranes, and 4 ligaments, viz.—

Anterior Sterno-clavicular.

Interclavicular.

Posterior Sterno-clavicular.

Costo-clavicular or Rhomboid.

Describe the Scapulo-clavicular Articulation. It is an arthrodial joint, formed by the outer extremity of the clavicle and the acromion process of the scapula. It frequently has an interarticular fibro-cartilage and 2 synovial membranes; usually but 1 synovial membrane is present, and 3 ligaments, viz.—

*Superior Acromio-clavicular.*¹

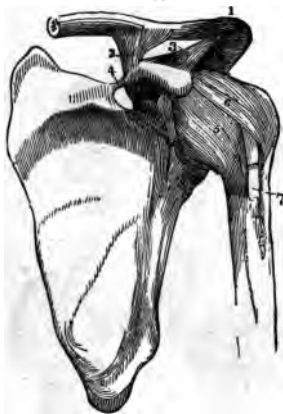
*Coraco-clavicular*²

Inferior Acromio-clavicular.

divided into— { Trapezoid, externally.
Conoid, internally.

What are the proper Ligaments of the Scapula? They are 2, the coraco-acromial, and the transverse, as follows.—

FIG. 33.



Coraco-acromial,³ completes the vault partially formed by the 2 processes over the head of the humerus.

Transverse,⁴ from the base of the coracoid process to the margin of the suprascapular notch, converting it into a foramen, for the supra-scapular nerve.

Describe the Shoulder-joint. It is an enarthrodial joint, formed by the head of the humerus and the glenoid cavity of the scapula. It has a *Synovial Membrane* which is reflected upon the tendons of the biceps, subscapularis, and infraspinatus muscles, and communicates with bursæ beneath the 2 latter tendons. Its *Arteries* are derived from the anterior and posterior circumflex and the suprascapular; its *Nerves* from the circumflex and the supra-

scapular. It has 3 ligaments, viz.—

Capsular,⁵ from the margin of the glenoid cavity to the anatomical neck of the humerus; has 3 openings for the reflexions of the synovial membrane over the tendons.

Coraco-humeral,⁶ intimately united with the capsular, extends from the coracoid process to the greater tuberosity.

Glenoid, a fibro-cartilaginous ring, continuous above with the tendon of the

long head of the biceps,⁷ and attached around the margin of the glenoid cavity in order to deepen the articular surface.

Describe the Elbow-joint. It is a ginglymus articulation, formed by the lower end of the humerus with the greater sigmoid cavity of the ulna and the head of the radius. Its *Synovial Membrane* is reflected over the ligaments, and dips down between the surfaces of the superior radio-ulnar articulation. Its *Arteries* are derived from the *anastomotica magna*, radial, ulnar, and interosseous recurrent, superior and inferior profunda arteries. Its *Nerves* are branches of the ulnar and the musculo-cutaneous. It has 4 ligaments,—

Anterior, from the inner condyle and anterior surface of the humerus to the orbicular ligament of the radius and the coronoid process of the ulna.

Posterior, from the posterior surface of the humerus to the olecranon process of the ulna.

External Lateral,⁴ from the external condyle of the humerus to the orbicular ligament of the radius.

Internal Lateral, from the internal condyle of the humerus to the coronoid and olecranon processes of the ulna.

Describe the Radio-ulnar Articulations. They are 3 in number, as follows, viz.—

SUPERIOR RADIO-ULNAR ARTICULATION is a lateral ginglymoid joint, formed by the head of the radius and the lesser sigmoid cavity of the ulna. Its synovial membrane is a continuation of that in the elbow-joint. It has 1 ligament, the—

Orbicular Ligament,⁵ forms four-fifths of a circle and surrounds the neck of the radius. It is attached to the margins of the lesser sigmoid cavity of the ulna, and to the external lateral ligament of the elbow-joint.

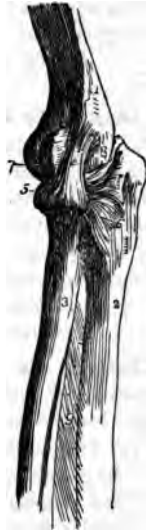MIDDLE RADIO-ULNAR ARTICULATION is formed by the shafts of the radius and ulna, which do not touch each other, but are connected by 2 ligaments, as follows, viz.—

Oblique Ligament, from the tubercle at the base of the coronoid process of the ulna to the shaft of the radius.

Interosseous Membrane,⁹ obliquely downwards from the interosseous ridge on the radius to that on the ulna. Through the interval between its upper border and the oblique ligament, the posterior interosseous vessels pass.

INFERIOR RADIO-ULNAR ARTICULATION is a lateral ginglymoid joint, formed by the head of the ulna and the sigmoid cavity of the radius. Its *Synovial Membrane* (membrana sacciformis) is very loose, and sometimes communicates

FIG. 34.



with that of the wrist-joint through an opening in the *triangular fibro-cartilage* which separates the head of the ulna from the wrist-joint, and acts as one of the ligaments of this articulation, which are 3, viz.—

Anterior Radio-ulnar.

Posterior Radio-ulnar.

Triangular Interarticular Fibro-cartilage.

Describe the Wrist-joint. It is chiefly an enarthrodial articulation, though incapable of rotation, and is formed by the lower end of the radius and the triangular fibro-cartilage, with the scaphoid, semilunar, and cuneiform bones of the carpus. Its *Arteries* are the anterior and posterior carpal from both the radial and ulnar, the anterior and posterior interosseous and ascending branches from the deep palmar arch. Its *Nerves* are derived from the ulnar; it is lined by a *synovial membrane*, and has 4 ligaments, viz.—

External Lateral (radio-carpal).

Anterior.

Internal Lateral (ulno-carpal).

Posterior.

Describe the Carpal Articulations. They are in 3 sets, (1) between the bones of the first row, (2) between the bones of the second row, (3) between the 2 rows of bones.

- (1) The scaphoid, semilunar, and cuneiform bones are connected together by 2 *Dorsal*, 2 *Palmar*, and 2 *Interosseous Ligaments*. The pisiform bone has a separate capsular ligament and synovial membrane and 2 *fasciculi* connecting it with the unciform and the 5th metacarpal.
- (2) The 4 bones of the second row are connected together by 3 *Dorsal*, 3 *Palmar*, and 3 *Interosseous Ligaments*.
- (3) The 2 rows of bones are united by a *Dorsal*, a *Palmar*, and 2 *Lateral Ligaments*, the last named being continuous with the lateral ligaments of the wrist-joint.

Describe the Carpo-metacarpal Articulations. That of the thumb with the trapezium is an enarthrodial joint, having a *Capsular Ligament* and a separate synovial membrane. The 4 inner metacarpal bones form 4 arthrodial joints with the adjacent carpal bones by 6 *Dorsal*, 8 *Palmar*, and 2 *Interosseous Ligaments*, irregularly disposed.

Describe the Synovial Membranes of the Wrist. They number 5, and are situated as follows, viz.—

The First, or Membrana Sacciformis, between the head of the ulna, the sigmoid cavity of the radius, and the triangular interarticular fibro-cartilage.

The Second, between the lower end of the radius, the triangular fibro-cartilage, and the scaphoid, semilunar, and cuneiform bones of the carpus.

The Third, between all the carpal bones except the pisiform, and between the bases of the inner 4 metacarpal bones; but it extends only halfway into the 2 intervals between the 3 proximal bones of the carpus.

The Fourth, between the trapezium and the metacarpal bone of the thumb.

The Fifth, between the cuneiform and pisiform bones.

Describe the Metacarpo-metacarpal Articulations. The 4 inner metacarpal bones are connected together at their bases by *Dorsal, Palmar, and Interosseous Ligaments*; and at their digital extremities by the *Transverse Ligament*.

Describe the remaining Articulations of the Hand. The metacarpophalangeal and the phalangeal articulations are all ginglymoid joints, and each has an *Anterior* and a *Lateral Ligaments*, the former being lined each with a synovial membrane. There are no posterior ligaments to these articulations, the extensor tendons of the hand supplying their places.

Describe the Hip-joint. It is a true enarthrodial articulation, formed by the head of the femur with the acetabulum of the os innominatum. Its *Synovial Membrane* is extensive, investing most of the head and neck of the femur, the capsular, cotyloid and teres ligaments, and the cavity of the acetabulum. Its *Arteries* are derived from the obturator, sciatic, internal circumflex, and gluteal. Its *Nerves* are branches from the sacral plexus, great sciatic, obturator, and accessory obturator. It has 5 ligaments, as follows, viz.—

Capsular, from the margin of the acetabulum and the transverse ligament, into the base of the neck of the femur above, the anterior inter-trochanteric line in front, and to the middle of the neck of the bone, behind.

Ilio-femoral or Y-ligament, from the anterior inferior spine of the ilium, into the anterior inter-trochanteric line by two fasciculi. It is a dissected portion of the capsular ligament which is very strong anteriorly.

Ligamentum Teres, from a depression on the head of the femur into the margins of the cotyloid notch of the acetabulum and into the transverse ligament, by two fasciculi.

Cotyloid, a fibro-cartilaginous band surrounding the margin of the acetabulum in order to deepen its cavity.

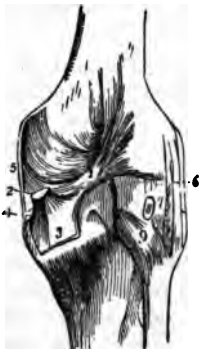
Transverse, that part of the cotyloid ligament which crosses over the cotyloid notch converting it into a foramen.

Describe the Knee-joint. It is a ginglymus articulation, formed by the condyles of the femur with the head of the tibia, and the patella in front. Its *Synovial Membrane* is the largest in the body, being reflected for 2 or 3 inches over the anterior surface of the femur, where it is supported by the subcrureus muscle, also over its condyles, the patella, semilunar cartilages, crucial ligaments, and head of the tibia; and is prolonged through an opening in the capsular ligament beneath the tendon of the popliteus. Its *Arteries* are derived from the anastomotica magna, the 5 articular branches of the femoral and the recurrent branch of the anterior tibial. Its *Nerves* are derived from the

obturator, anterior crural, external and internal popliteal. It has 14 ligaments, of which 6 are external and 8 internal, as follows:—

Anterior, or Ligamentum Patella, is a continuation of the tendon of the rectus femoris muscle, extending from the apex of the patella to the lower part of the tubercle of the tibia.

FIG. 35.



Posterior, or Ligamentum Winslowii,¹ from the inner tuberosity of the tibia to the external condyle of the femur, being partly derived from the tendon of the semimembranosus muscle.²

Internal Lateral,³ from the internal condyle of the femur to the internal surface of the tibia and semilunar cartilage.

External Lateral,⁴ from the external condyle of the femur to the head of the fibula. These ligaments are a *Long* anteriorly and a *Short* posteriorly, separated by the tendon of the biceps.

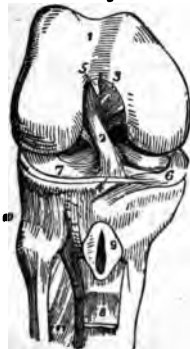Capsular, is only present where intervals are left by the preceding ligaments. It is thin but very strong.

The Internal ligaments are as follows:—

Anterior Crucial,⁵ from the depression in front of the spine of the tibia to the inner side of the *outer condyle* of the femur.

Posterior Crucial,⁶ from the same depression, to the outer side of the *inner condyle*. [To remember the positions and insertions of these crucial ligaments, let the student cross his index fingers over each knee in succession; when over the right knee placing the right finger in front, when over the left knee the left finger in front. The positions of the fingers will then in each case correspond with those of the respective crucial ligaments.]

FIG. 36.



Semilunar Fibro-cartilages,⁶ external and internal, are situated between the articular surfaces, and attached to the depressions in front and behind the spine of the tibia.

Transverse,⁶ is a connecting slip between the semilunar fibro-cartilages anteriorly.

Coronary,⁷ are short bands connecting the outer margins of the fibro-cartilages to the tibia and the adjacent ligaments.

Ligamentum Mucosum, is a triangular fold of the synovial membrane which at the lower border of the patella is given off to the intercondyloid notch of the femur.

Ligamenta Alaria, are fringes on the sides of the ligamentum mucosum, and are attached to the sides of the patella.

Bursa in the vicinity of this joint are 5, viz.—1 under the ligamentum patellæ,⁹ 1 between the patella and the skin; 1 between the internal lateral ligament and the tendons crossing it; sometimes 1 replacing the synovial pouch on the anterior surface of the femur; and occasionally 1 in the popliteal space replacing the synovial pouch usually situated therein.

Describe the Tibio-fibular Articulations. They are 3 in number, as follows, viz.—

SUPERIOR TIBIO-FIBULAR ARTICULATION, is an arthrodial joint, formed by the contiguous surfaces of the bones. It has a *Synovial Membrane* which is sometimes continuous with that of the knee-joint, and 2 ligaments, the—

*Anterior and Posterior Superior Tibio-fibular,*¹⁰ which connect the head of the fibula with the outer tuberosity of the tibia.

MIDDLE TIBIO-FIBULAR ARTICULATION. The shafts of these bones do not touch each other, but are connected by the *Interosseous Membrane* extending between their contiguous borders, and perforated, above for the anterior tibial artery, below for the anterior peroneal vessels.

INFERIOR TIBIO-FIBULAR ARTICULATION, is an amphi-arthrodial joint, formed by the contiguous rough surfaces on the bones. Its *Synovial Membrane* is derived from that of the ankle-joint, and it has 4 ligaments, viz.—

Inferior Interosseous, continuous with the interosseous membrane.

Anterior and Posterior Inferior Tibio-fibular, from the margins of the external malleolus to the front and back of the tibia.

Transverse, posteriorly between the 2 malleoli.

Describe the Ankle-joint. It is a ginglymoid articulation, formed by the lower ends of the tibia and fibula and their malleoli, with the astragalus. Its *Synovial Membrane* is prolonged upwards between the tibia and fibula for a short distance. Its *arteries* are derived from the malleolar branches of the anterior tibial and peroneal arteries; and its *Nerves* from the anterior tibial nerve. It has 3 ligaments, viz.—

Anterior, connecting the margins of the tibia and astragalus.

Internal Lateral, or Deltoid Ligament, from the internal malleolus to the 3 adjacent tarsal bones.

External Lateral, by anterior posterior and middle fasciculi, from the external malleolus to the astragalus and os calcis.

Describe the Tarsal Articulations. They are in 3 sets, (1) between the bones of the first row, (2) between the bones of the second row, (3) between the 2 rows of bones.

(1.) The astragalus and os calcis are united by 3 ligaments.

External Calcaneo-astragaloid.

Interosseous.

Posterior Calcaneo-astragaloid.

- (2.) The scaphoid, cuboid, and three cuneiform bones are united by an irregular number of *Dorsal* and *Plantar* and 4 *Interosseus* ligaments, which latter are arranged transversely.
- (3.) The 2 rows of bones are united by 7 ligaments viz.—
- | | |
|---|------------------------------------|
| <i>Superior Astragalo-scaploid.</i> | <i>Inferior Calcaneo-scaploid.</i> |
| <i>Superior Calcaneo-cuboid.</i> | <i>Short Calcaneo-cuboid.</i> |
| <i>Superior Calcaneo-scaploid.</i> | <i>Long Calcaneo-cuboid.</i> |
| <i>Interosseous, or Internal Calcaneo-cuboid.</i> | |

Describe the Tarso-metatarsal Articulations. They are 5 arthrodial joints formed by the bases of the metatarsal bones with the adjacent bones of the tarsus, the 2d metatarsal bone articulating with all 3 cuneiform in the recess formed by the shortness of the second cuneiform. They are united by *Dorsal, Plantar, and 3 Interosseous Ligaments*. The 2d metatarsal bone has 3 dorsal ligaments, 1 from each cuneiform bone. The interosseous ligaments pass from the 2d and 3d metatarsal bones to the internal and external cuneiform.

Describe the Synovial Membranes of the Tarsus and Metatarsus. They are 6 in number, and are situated as follows, viz.—

The First, between the os calcis and the astragalus, behind the interosseous ligament.

The Second, between the same bones in front of the interosseous ligament, also between the astragalus and the scaphoid.

The Third, between the os calcis and the cuboid.

The Fourth, between the scaphoid and the 3 cuneiform bones, running backwards between the scaphoid and the cuboid, forwards between the cuneiform bones, between the external cuneiform and the cuboid, between the middle and external cuneiform and the bases of the 2d and 3d metatarsal, passing also between the bases of these bones and the 4th metatarsal.

The Fifth, between the cuboid and the 4th and 5th metatarsal bones, also running forwards between their bases.

The Sixth, between the internal cuneiform and the base of the 1st metatarsal bone.

Describe the Metatarso-metatarsal Articulations. The metatarsal bones are connected together, except the first, at their bases by *Dorsal, Plantar, and Interosseous Ligaments*; and all 5 are connected at their digital extremities by the *Transverse Metatarsal Ligament*.

Describe the remaining Articulations of the Foot. The metatarso-phalangeal and the phalangeal articulations are similar to those in the hand, each having an *Anterior or Plantar*, and 2 *Lateral Ligaments*. The extensors of the foot supply the places of posterior ligaments.

THE MUSCLES AND FASCIAE.

What are the Muscles? They are the active organs of locomotion, formed of bundles of reddish fibres endowed with the property of shortening themselves upon irritation, which is called *muscular contractility*, and chemically consisting of syntonin, or muscular fibrin.

How are the Muscles divided? Into 2 great classes, (1) *Voluntary, Striped, or Muscles of animal life*, comprise those which are under the control of the will. (2) *Involuntary, Unstriped, or Muscles of organic life*, are those which are not under the control of the will.

Voluntary Muscular Fibre consists of fasciculi about $\frac{1}{400}$ inch in diameter, each surrounded by a tubular membranous sheath, the perimysium; and marked by fine striæ passing around them in curved parallel lines about $\frac{1}{1100}$ inch apart. These fasciculi are formed of *fibrilla*, each about $\frac{1}{1100}$ inch thick, also striated, presenting the appearance of a row of minute particles, the "sarcous elements" of Bowman, and surrounded by cellular tissue, the sarcolemma.

Involuntary Muscular Fibre consists of flattened fusiform or spindle-shaped fibres, averaging about $\frac{1}{400}$ inch in breadth, consisting of elongated cells, and bound together in bundles by areolar tissue. These fibres are found in the alimentary canal, in the posterior wall of the trachea, in the bronchi, the ducts of certain glands, in the ureters, bladder, urethra, genitalia of both sexes, walls of all arteries and most veins and lymphatics, in the iris and ciliary muscle, and in the skin.

What are Tendons and Aponeuroses? *Tendons* are white, glistening cords or bands formed of white fibrous tissue almost entirely, have few vessels and no nerves, and serve to connect the muscles with the structures on which they act. *Aponeuroses* are fibrous membranes, of similar structure and appearance, and serve the same purpose.

What are Fasciæ? They are laminae of variable thickness which invest (*fascia*, a bandage) the softer structures. The superficial fascia is composed of fibro-areolar tissue, and is found beneath the skin almost over the whole body. The deep fascia is of aponeurotic structure, dense, inelastic, and fibrous, sheathing the muscles and affording some of them attachment, also the vessels and nerves, and binding down the whole into a shapely mass.

To what Structures are Muscles attached? To the periosteum and perichondrium of bone and cartilage, to the subcutaneous areolar tissue, and to ligaments. In the latter case only are their tendons in direct contact with the tissue on which they are to act.

How many Muscles are Double-bellied? Five,—the occipito-frontalis, biventer cervicis, digastric, omo-hyoid, and the diaphragm.

muscles of expression, supplied by the nerve
of innervation
Temporal. Masseter & (Zinn's)

Describe each Muscle of the Body, giving its Origin, Insertion, Action, and Nervous supply.

MUSCLES OF THE HEAD.

Occipito-frontalis, *from* the external two-thirds of the superior curved line of the occipital bone and the mastoid process of the temporal; also from the pyramidalis nasi, corrugator supercilii, and orbicularis palpebrarum fibres,—*into* an aponeurosis or "galea capitis," which covers the vertex of the skull. *Action*, chiefly as a muscle of facial expression. *Nerves*, facial, supraorbital, small occipital.

Attollens Aures, *from* the occipito-frontalis aponeurosis,—*into* the pinna of the ear superiorly. *Action*, to raise the pinna. *Nerve*, small occipital branch of the cervical plexus.

Attrahens Aures, *from* the lateral cranial aponeurosis,—*into* the helix of the ear anteriorly. *Action*, to draw the pinna forwards. *Nerves*, facial, and auriculo-temporal branch of the inferior maxillary.

Retrahens Aures, *from* the mastoid process of the temporal bone,—*into* the concha. *Action*, to retract the pinna. *Nerve*, facial.

Orbicularis Palpebrarum, *from* the internal angular process of the frontal bone, the nasal process of the superior maxillary, and the borders of the tendo oculi,—*into* the skin of the eyelids, forehead, temple, and cheek, blending with the occipito-frontalis and the corrugator supercilii. *Action*, to close the eyelids. *Nerve*, facial.

Corrugator Supercilii, *from* the inner end of the superciliary ridge of the frontal bone,—*into* the orbicularis palpebrarum. *Action*, to draw eyebrow downwards and inwards. *Nerve*, facial.

Tensor Tarsi (Horner's muscle), *from* the crest of the lachrymal bone,—*into* the tarsal cartilages by two slips. *Action*, to compress the puncta lachrymalia against the globe of the eye, and to compress the lachrymal sac. *Nerve*, facial.

Levator Palpebræ Superioris, *from* the lesser wing of the sphenoid,—*into* the upper tarsal cartilage. *Action*, to lift the upper lid. *Nerve*, 3d cranial, or motor oculi.

Rectus Superior, *from* the upper margin of the optic foramen and the sheath of the optic nerve,—*into* the sclerotic coat. *Action*, to rotate the eyeball upwards. *Nerve*, 3d cranial.

Rectus Inferior, *from* the ligament of Zinn,—*into* the sclerotic coat. *Action*, rotates the eyeball downwards. *Nerve*, 3d cranial.

Rectus Internus, *from* the ligament of Zinn,—*into* the sclerotic coat. *Action*, rotates the eyeball inwards. *Nerve*, 3d cranial.

Rectus Externus, by 2 heads, the upper from the outer margin of the optic foramen, the lower from the ligament of Zinn and a bony process at lower margin of the sphenoidal fissure,—into the sclerotic coat. *Action*, to rotate the eyeball outwards. *Nerve*, 6th cranial, or abducens.

Between the 2 heads of the external rectus pass the 3d, nasal branch of the 5th, and the 6th cranial nerves, and the ophthalmic vein.

Obliquus Superior, from about a line above the inner margin of the optic foramen, its tendon passing through a "pulley" near the internal angular process of the frontal bone and thence beneath the rectus superior,—into the sclerotic coat at right angles to the insertion of the rectus superior. *Action*, to rotate the eyeball on its antero-posterior axis. *Nerve*, 4th cranial, or patheticus.

Obliquus Inferior, from the orbital plate of the superior maxillary,—into the sclerotic coat below the insertion of the external rectus and at right angles thereto. *Action*, to rotate the eye on its antero-posterior axis. *Nerve*, 3d cranial.

Pyramidalis Nasi,^c from the occipito-frontalis,—into the compressor naris. *Action*, to depress the eyebrow. *Nerve*, facial.

Levator Labii Superioris Alæque Nasi,^e from the nasal process of the superior maxillary bone,—into the cartilage of the ala of the nose and into the upper lip. *Action*, to elevate the upper lip, and dilate the nostril. *Nerve*, facial.

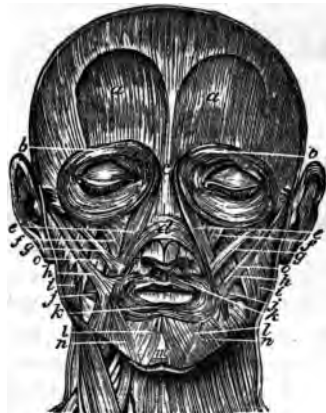Dilator Naris Anterior, from the cartilage of the ala,—into the border of its integument. *Action*, to dilate the nostril. *Nerve*, facial.

Dilator Naris Posterior, from the nasal notch of the superior maxillary and the sesamoid cartilages,—into the integument at the margin of the nostril. *Action*, to dilate the nostril. *Nerve*, facial.

Compressor Naris,^d from the superior maxillary above the incisive fossa,—into the fibro-cartilage of the nose, being continuous with its fellow and the pyramidalis nasi aponeurosis. *Action*, to dilate the nostril. *Nerve*, facial.

Compressor Narium Minor, from the alar cartilage,—into the skin at the end of the nose. *Action*, to dilate the nostril. *Nerve*, facial.

FIG. 37.



Depressor Alae Nasi, *f* from the incisive fossa of the superior maxillary,—into the septum and ala of the nose. *Action*, to contract the nostril. *Nerve*, facial.

Levator Labii Superioris, *f* from the lower margin of the orbit,—into the upper lip. *Action*, to elevate the lip. *Nerve*, facial.

Levator Anguli Oris, *o* from the canine fossa of the superior maxillary,—into the angle of the mouth. *Action*, as named. *Nerve*, facial.

Zygomaticus Major, *k* from the malar bone,—into the angle of the mouth. *Action*, to raise the lip outwards. *Nerve*, facial.

Zygomaticus Minor, *s* from the malar bone anteriorly,—into the angle of the mouth, blending with the levator labii superioris. *Action*, to raise the lip outwards. *Nerve*, facial.

Levator Labii Inferioris (Levator Menti), *m* from the incisive fossa of the inferior maxillary bone,—into the integument of the lower lip. *Action*, as named. *Nerve*, facial.

Depressor Labii Inferioris (Quadratus Menti), *l* from the external oblique line of the inferior maxillary bone,—into the lower lip. *Action*, as named. *Nerve*, facial.

Depressor Anguli Oris (Triangularis Menti), *n* from the external oblique line of the inferior maxillary,—into the angle of the mouth. *Action*, as named. *Nerve*, facial.

Orbicularis Oris, *k* by accessory fibres (accessorji orbicularis superioris and inferioris, and naso-labialis) from the nasal septum and the superior and inferior maxillary borders,—into the buccinator and other adjacent muscles, forming the sphincter of the mouth. *Action*, to close the mouth. *Nerve*, facial.

Buccinator, *j* from the posterior alveolar processes of both the maxillary bones and the pterygo-maxillary ligament,—into the orbicularis oris. *Action*, to compress the cheeks. *Nerves*, facial, and the buccal branch of the inferior maxillary.

Risorius, *r* from the fascia over the masseter muscle,—into the angle of the mouth. *Action*, the laughing muscle. *Nerve*, facial.

Masseter, *i* from the anterior two-thirds and the inner surface of the zygoma and the malar process of the superior maxillary,—into the angle, ramus, and coronoid process of the lower jaw. *Action*, to raise the back part of the lower jaw; a muscle of mastication. *Nerve*, inferior maxillary.

Temporal, *t* from the temporal fossa and temporal fascia,—into the coronoid process of the inferior maxillary. *Action*, to bring the incisor teeth together; the biting muscle. *Nerve*, inferior maxillary.

Internal Pterygoid, from the pterygoid fossa of the sphenoid bone, and the tuberosity of the palate,—into the angle and inner surface of the ramus of the jaw, as high as the dental foramen. *Action*, raises and draws forward the lower jaw; a triturating muscle of mastication. *Nerve*, inferior maxillary.

External Pterygoid, by 2 heads, *the upper*, from the pterygoid ridge on the greater wing of the sphenoid, *the lower* from the external pterygoid plate, and the tuberosities of the palate and superior maxillary bones,—into a depression in front of the condyle of the inferior maxillary, and the inter-articular fibro-cartilage. *Action*, to draw the jaw forwards; a triturating muscle of mastication. *Nerve*, inferior maxillary.

Between the two heads of the external pterygoid muscle passes the internal maxillary artery.

MUSCLES OF THE EAR.

Tensor Tympani, from the under surface of the petrous portion of the temporal bone, the cartilaginous Eustachian tube, and its own osseous canal,—into the handle of the malleus. *Action*, to draw the membrana tympani tense. *Nerve*, branch from otic ganglion.

Laxator Tympani Major, from the spinous process of the sphenoid and the cartilaginous Eustachian tube,—through the Glasserian fissure to the neck of the malleus just above the processus gracilis. *Action*, to relax the membrana tympani. *Nerve*, tympanic branch of the facial.

Laxator Tympani Minor, from the back of the external meatus,—passes between the layers of the membrana tympani into the handle of the malleus and processus brevis. *Action*, to relax the membrana tympani. Considered a ligament by many anatomists (the lig. mallei posticum).

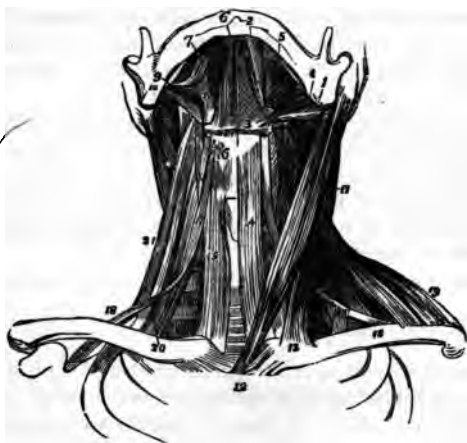Stapedius, from the interior of the pyramid,—through the orifice at its apex into the neck of the stapes. *Action*, to depress the base of the stapes. *Nerve*, filament from the facial.

MUSCLES OF THE NECK

Platysma Myoides, from the clavicle, the acromion, and the fascia covering the pectoral, deltoid, and trapezius muscles,—into the lower jaw, the angle of the mouth, and the cellular tissue of the face. *Action*, to wrinkle the skin, and depress the mouth. *Nerves*, facial and superficial cervical.

Sterno-cleido-mastoid,¹¹ by two heads from the sternum¹² and the clavicle¹³ at its inner third,—into the mastoid process of the temporal bone, and the superior curved line of the occipital. *Action*, to depress and rotate the head. *Nerves*, spinal accessory, and branches of the cervical plexus.

FIG. 38.



Between the sternal and clavicular origins is a fossa, the *fenticulus gutturis*, which rises and falls during labored breathing.

Sterno-hyoid,¹⁴ from *Mastoid* the posterior surface *of the* sternum and the sternal end of the clavicle,—into the body of the hyoid bone. *Action*, to depress the hyoid bone. *Nerve*, a branch from the communicating loop between the descendens and communicans noni.

Sterno-thyroid,¹⁵ from the posterior surface of the sternum and the cartilage of the 1st rib,—into the oblique line on the ala of the thyroid cartilage. *Action*, to depress the larynx. *Nerve*, a branch from the communicating loop between the descendens and communicans noni.

Thyro-hyoid,¹⁶ from the oblique line on the thyroid cartilage,—into the body and greater cornu of the hyoid bone. *Action*, to elevate the larynx. *Nerve*, hypoglossal.

Omo-hyoid,^{17 18} from the upper border of the scapula and the transverse ligament,—into the body of the hyoid bone. It has a tendon in its centre which is bound down to the cartilage of the 1st rib by a loop of the deep cervical fascia. *Action*, to depress the hyoid bone, and draw it backwards. *Nerve*, branch from the communicating loop between the descendens and communicans noni.

Digastric, by 2 bellies, the *posterior one*¹ from the digastric groove of the mastoid process of the temporal bone; the *anterior*² from a fossa on the inner surface of the inferior maxillary, near its symphysis,—into a central tendon³ which perforates the stylo-hyoid muscle, and is bound down to the body of the hyoid bone by an aponeurotic loop. *Action*, to raise the hyoid bone and tongue. *Nerves*, facial, and mylo-hyoid branch of the inferior dental.

Stylo-hyoid,⁴ from the styloid process of the temporal bone near its base,—into the body of the hyoid bone. *Action*, to elevate and retract the hyoid bone. *Nerve*, facial. This muscle is perforated by the digastric.

Genio-hyo-glossus Muscles of the Neck

Mylo-hyoid,⁵ from the mylo-hyoid ridge of the lower jaw,—into the body of the hyoid bone and a fibrous raphé in the median line running from the hyoid bone to the chin. *Action*, elevates the hyoid bone and draws it forwards, also forms the floor of the mouth. *Nerve*, mylo-hyoid branch of inferior dental.

Genio-hyoid,⁶ from the inferior genial tubercle of the inferior maxillary,—into the body of the hyoid bone. *Action*, same as the mylo-hyoid. *Nerve*, hypoglossal.

Genio-hyo-glossus, from the superior genial tubercle of the inferior maxillary,—into the body of the hyoid bone, the side of the pharynx, and the whole length of the under surface of the tongue, forming a fan-like muscle. *Action*, to retract and protrude the tongue. *Nerve*, hypoglossal.

Hyo-glossus⁹ (the basio-kerato-chondro-glossus), from the body of the hyoid bone, its lesser cornu, and the whole length of its greater cornu,—into the side of the tongue. *Action*, to draw down the side of the tongue. *Nerve*, hypoglossal.

Stylo-glossus,⁹ from the styloid process and the stylo-maxillary ligament,—into the side of the tongue and the hyo-glossus muscle. *Action*, to elevate and retract the tongue. *Nerve*, hypoglossal.

Lingualis, lies between the hyo-glossus and the genio-hyo-glossus, from the base to the tip of the tongue, along its under surface; some of its fibres being attached to the hyoid bone. *Action*, to elevate the centre of the tongue. *Nerve*, chorda tympani.

Inferior Constrictor, from the sides of the cricoid and thyroid cartilages,—into the fibrous raphé of the pharynx. *Action*, to contract the pharyngeal calibre. *Nerves*, glosso-pharyngeal, pharyngeal plexus, and external laryngeal.

Middle Constrictor, from the cornua of the hyoid bone and the stylo-hyoid ligament,—into the pharyngeal raphé. *Action*, to constrict the pharynx. *Nerves*, glosso-pharyngeal, pharyngeal plexus.

Superior Constrictor, from the lower third of the margin of the internal pterygoid plate and its hamular process, the contiguous part of the palate bone, the tendon of the tensor palati, the pterygo-maxillary ligament, part of the alveolar process of the lower jaw and the side of the tongue,—into the pharyngeal raphé and the pharyngeal spine of the occipital bone. *Action*, to constrict the pharynx. *Nerves*, glosso-pharyngeal, pharyngeal plexus.

Stylo-pharyngeus,¹⁰ from the inner side of the base of the styloid process,—into the constrictor and palato-pharyngeus muscles, and the thyroid car-

tilage. *Action*, to elevate the pharynx. *Nerves*, glosso-pharyngeal, pharyngeal plexus. The former nerve crosses this muscle in passing to the tongue.

Longus Cervicis
Levator Palati, ^{from the under surface of the apex of the petrous portion of the temporal bone and from the Eustachian tube,}—into the posterior surface of the soft palate. *Action*, to elevate the soft palate. *Nerve*, facial, through the Vidjan and petrosal.

Tensor Palati
Tensor Palati, ^{from the scaphoid fossa of the sphenoid bone and the Eustachian tube,}—reflected around the hamular process,—into the anterior surface of the soft palate, and the horizontal portion of the palate bone. *Action*, to tense the palate. *Nerve*, a branch from the otic ganglion.

Azygos Uvulae, ^{from the posterior nasal spine of the palate bone, and from the soft palate,}—into the uvula. *Action*, possibly to raise the uvula. *Nerve*, facial, through the Vidjan and petrosal. This muscle is wrongly named, as it is double.

Palato-glossus
Palato-glossus (anterior pillar of the fauces), ^{from the anterior surface of the soft palate laterally,}—into the side and dorsum of the tongue. *Action*, constrictor isthmi faucium. *Nerves*, palatine branches of Meckel's ganglion.

Palato-pharyngeus
Palato-pharyngeus (posterior pillar of the fauces), ^{from the soft palate,}—into the side of the pharynx and the posterior border of the thyroid cartilage, having joined the stylo-pharyngeus. *Action*, to close the posterior nares. *Nerves*, palatine branches from Meckel's ganglion.

Rectus Capitis Anticus Major
Rectus Capitis Anticus Major, ^{from the anterior tubercles of the transverse processes of the 3d, 4th, 5th, and 6th cervical vertebræ by 4 slips,}—into the basilar process of the occipital bone. *Action*, to flex the head. *Nerves*, sub-occipital and deep branches of cervical plexus. This muscle is a continuation of the scalenus anticus.

Rectus Capitis Anticus Minor
Rectus Capitis Anticus Minor, ^{from the anterior surface of the lateral mass of the atlas, and the root of its transverse process,}—into the basilar process of the occipital bone. *Action*, to flex the head. *Nerves*, sub-occipital and deep branches of the cervical plexus.

Rectus Lateralis, ^{from the upper surface of the transverse process of the atlas,}—into the jugular process of the occipital bone. *Action*, to draw the head laterally. *Nerve*, sub-occipital.

Longus Colli, 3 portions,—*the superior oblique*, from the anterior tubercles of the transverse processes of the 3d, 4th, and 5th cervical vertebræ, into a tubercle on the anterior arch of the atlas:—*inferior oblique*, from the bodies of the first 2 or 3 dorsal vertebræ, into the transverse processes of the 5th and 6th cervical:—*vertical portion* from the bodies of the lower 3 cervical and upper 3 dorsal vertebræ, to the bodies of the 2d, 3d, and 4th cervical.

Action, to flex the cervical vertebræ and slightly to rotate them. *Nerves*, branches from the lower cervical.

Scalenus Anti'cus,²⁰ *from* a tubercle on the upper surface of the 1st rib,—*into* the transverse processes of the cervical vertebræ, from the 3d to the 6th inclusive. *Action*, to flex the neck laterally, or to raise the 1st rib. *Nerves*, branches from the lower cervical. (See Fig. 38.)

Scalenus Medius,²² *from* the upper surface of the 1st rib, behind the subclavian groove,—*into* the transverse processes of the lower 6 cervical vertebræ. *Action*, same as scalenus anticus. *Nerves*, branches from the lower cervical. *Nerve of Bell* *from the subclavian*

Scalenus Posti'cus,²¹ *from* the outer surface of the 2d rib,—*into* the posterior tubercles on the transverse processes of the lower 2 or 3 cervical vertebræ. *Action*, to flex the neck laterally, or to elevate the 2d rib. *Nerves*, branches from lower cervical.

MUSCLES OF THE LARYNX AND EPIGLOTTIS.

Crico-thyroid, *from* the front and side of the cricoid cartilage,—*into* the lower and inner borders of the thyroid cartilage. *Action*, to elongate and make tense the vocal chords. *Nerve*, superior laryngeal.

Crico-arytenoideus Posticus, *from* the cricoid cartilage posteriorly,—*into* the outer angle of the base of the arytenoid cartilage. *Action*, to rotate the arytenoid cartilages outwards and open the glottis, while keeping the vocal chords tense. *Nerve*, recurrent laryngeal.

Crico-arytenoideus Lateralis, *from* the upper border of the cricoid cartilage laterally,—*into* the outer angle of the base of the arytenoid cartilage. *Action*, to rotate the arytenoid cartilages inwards and close the glottis. *Nerve*, recurrent laryngeal.

Thyro-arytenoideus, *from* the receding angle of the thyroid cartilage and the crico-thyroid membrane,—*into* the base and anterior surface of the arytenoid cartilage. *Action*, to shorten and relax the vocal chords by approximating the cartilages. *Nerve*, recurrent laryngeal.

Arytenoideus, *from* the posterior surface and outer border of one arytenoid cartilage,—*into* the corresponding parts of the opposite cartilage, filling up the posterior concave surface of these cartilages. *Action*, by approximating the arytenoids, to close the back part of the glottis. *Nerves*, superior and recurrent laryngeal.

Thyro-epiglottideus, *from* the inner surface of the thyroid cartilage,—*into* the margin of the epiglottis and the aryteno-epiglottidean fold. *Action*, a depressor of the epiglottis. *Nerve*, recurrent laryngeal.

Aryteno-epiglottideus Superior, from the apex of the arytenoid cartilage,—into the aryteno-epiglottidean folds. *Action*, to constrict the superior laryngeal aperture. *Nerve*, recurrent laryngeal.

Aryteno-epiglottideus Inferior, from the arytenoid cartilage anteriorly,—into the sacculus laryngis and the margin of the epiglottis. *Action*, to compress the sacculus laryngis. *Nerve*, recurrent laryngeal.

MUSCLES OF THE BACK.

First layer (2)—*Trapezius. Latissimus Dorsi.*

Second layer (3)—*Levator Anguli Scapulae. Rhomboideus Major and Minor.*

Third layer (3)—*Serratus Posticus Superior. Serratus Posticus Inferior. Splenius Capitis et Colli.*

Fourth layer (11)—in 4 sets, viz.—

LUMBAR (1)—*Erector Spinae.*

EXTERNAL (3).	MIDDLE (3).	INTERNAL (4).
<i>Sacro lumbalis.</i>	<i>Longissimus Dorsi.</i>	<i>Spinalis Dorsi.</i>
<i>Musculus Accessorius</i>	<i>Transversalis Colli.</i>	<i>Spinalis Colli.</i>
<i>ad Sacro-lumbalem.</i>	<i>Trachelo-mastoid.</i>	<i>Biventer Cervicis.</i>
<i>Cervicalis Ascendens.</i>		<i>Complexus.</i>

Fifth layer (12)—6 having the word *spinal* in them, viz.—

<i>Semi-spinalis Dorsi.</i>	<i>Inter-transversales.</i>
<i>Semi-spinalis Colli.</i>	<i>Rectus Capitis Posticus Major.</i>
<i>Multifidus Spinae.</i>	<i>Rectus Capitis Posticus Minor.</i>
<i>Rotatores Spinae.</i>	<i>Obliquus Capitis Superior.</i>
<i>Supra-spinales.</i>	<i>Obliquus Capitis Inferior.</i>
<i>Inter-spinales.</i>	<i>Extensor Coccygis.</i>

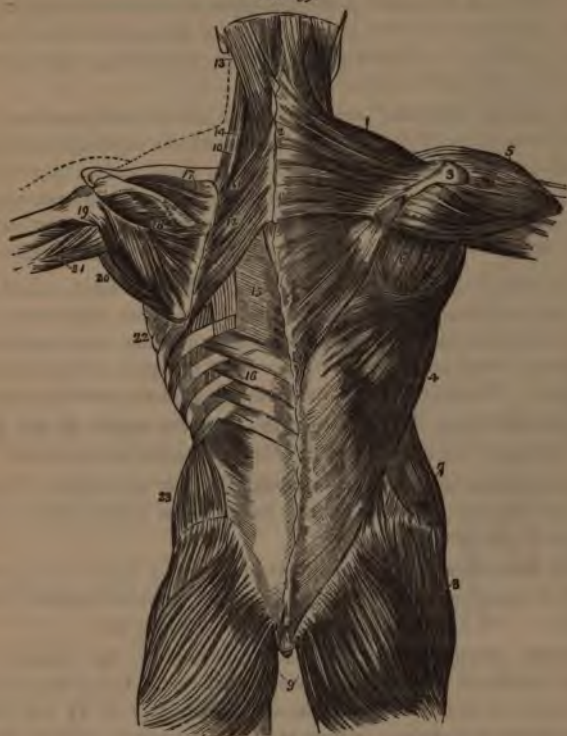Trapezius,¹ from the inner third of the superior curved line of the occipital bone, the ligamentum nuchæ,² the spinous processes of the last cervical and all the dorsal vertebræ, and the supra-spinous ligament,—into the outer third of the posterior border of the clavicle, the superior margin of the acromion-process, the whole length of the superior border of the spine of the scapula,³ and a tubercle at its inner extremity. *Action*, to draw the head backwards. *Nerves*, spinal accessory, cervical plexus.

LIGAMENTUM NUCHÆ, from the external occipital protuberance,—to the spines of the cervical vertebræ, from the 2d to the 7th inclusive.

Latissimus Dorsi,⁴ by an aponeurosis from the spines of the 6 lower dorsal and the lumbar and sacral vertebræ, the supra-spinous ligament, the crest of the ilium, and the 3 or 4 lower ribs,—into the bicipital groove of the humerus. *Action*, the *cursor ani* muscle, drawing the arm downwards and backwards; or raising the lower ribs and drawing the trunk forwards. *Nerves*, the subscapular.

Levator Anguli Scapulæ,¹⁰ by 4 slips from the transverse processes of 3 or 4 upper cervical vertebræ,—into the posterior border of the scapula. *Action*, as named. *Nerves*, branches from the 5th cervical and the cervical plexus.

FIG. 39.



Rhomboideus Minor,¹¹ from the ligamentum nuchæ and spines of the 7th cervical and 1st dorsal vertebræ,—into the smooth surface at the root of the spine of the scapula. *Action*, to draw the scapula backwards and upwards. *Nerve*, 5th cervical.

Rhomboideus Major,¹² from the spines of the 4 or 5 upper dorsal vertebræ and the supra-spinous ligament,—into the scapula at the root of its spine and inferior angle, by a tendinous arch. *Action*, to draw the scapula upwards and backwards. *Nerve*, 5th cervical.

- Serratus Posticus Superior**, from the ligamentum nuchæ, and spines of the 7th cervical and 2 or 3 upper dorsal vertebræ,—into the upper borders of the 2d, 3d, 4th, and 5th ribs, by 4 digitations. *Action*, to raise ribs in inspiration. *Nerves*, external posterior branches of the cervical nerves.
- Serratus Posticus Inferior**,¹⁶ from the spines of the last 2 dorsal and first 3 lumbar vertebræ,—into the lower borders of the 4 lower ribs, by 4 digitations. *Action*, to depress these ribs in expiration. *Nerves*, external branches of the dorsal nerves.
- Splenius Capitis**¹³ et Colli,¹⁴ from the lower half of the ligamentum nuchæ, the last cervical and 6 upper dorsal spines, and the supra-spinous ligament,—the *S. capitis* into the mastoid process and a rough surface below the superior curved line of the occipital bone,—the *S. colli* into the transverse processes of the 3 or 4 upper cervical vertebræ. *Action*, to draw the head backwards and the neck erect. *Nerves*, external posterior branches of the cervical nerves.
- Erector Spinæ**,¹ from the sacro-iliac groove, and by the lumbo-sacral tendon from the sacral, lumbar and 3 lower dorsal spines, the iliac crest, and the posterior eminences of the sacrum,—divides into the sacro-lumbalis² and longissimus dorsi³ muscles. *Action*, to erect the spine and bend the trunk backwards. *Nerves*, external posterior branches of the lumbar nerves.
- Sacro-lumbalis**,² from the erector spinæ,—into the angles of the 6 lower ribs. *Action*, as the erector spinæ. *Nerves*, branches of the dorsal.
- Musculus Accessorius ad Sacro-lumbalem**,² from the angles of 6 lower ribs,—into the angles of 6 upper ribs. *Action*, as the erector spinæ. *Nerves*, branches of the dorsal.
- Cervicalis Ascendens**,⁵ from the angles of 4 or 5 upper ribs,—into the transverse processes of the 4th, 5th, and 6th cervical vertebræ. *Action*, to keep the neck erect. *Nerves*, branches of the cervical.
- Longissimus Dorsi**,³ from the erector spinæ,—into the transverse and articular processes of the lumbar vertebræ, into the tips of the transverse processes of all the dorsal vertebræ, and into from 7 to 11 ribs between their tubercles and angles. *Action*, as the erector spinæ. *Nerves*, branches of the lumbar and dorsal nerves.
- Transversalis Colli**,⁸ from the transverse processes of the 3d, 4th, 5th, and 6th dorsal vertebræ,—into the transverse processes of the 5 lower cervical.⁹ *Action*, to keep the neck erect. *Nerves*, cervical branches.
- Trachelo-mastoid**,⁷ from the transverse processes of the 3d, 4th, 5th, and 6th dorsal vertebræ, and the articular processes of the 3 or 4 lower cervical,—into the posterior margin of the mastoid process. *Action*, to steady the head. *Nerves*, branches of the cervical.

Spinalis Dorsi, from the last 2 dorsal and first 2 lumbar spines,—into all the remaining dorsal spines. *Action*, to erect the spinal column. *Nerves*, branches of the dorsal.

Spinalis Colli, from the 5th and 6th cervical spines, sometimes from the 1st and 2d dorsal,—into the spine of the axis, or the 3d and 4th cervical spines. *Action*, to steady the neck. *Nerves*, branches of the cervical. [This muscle is frequently absent.]

Biventer Cervicis, from the transverse processes of 2 to 4 upper dorsal vertebræ,—into the superior curved line of the occipital bone. [Is but a portion of the complexus muscle.]

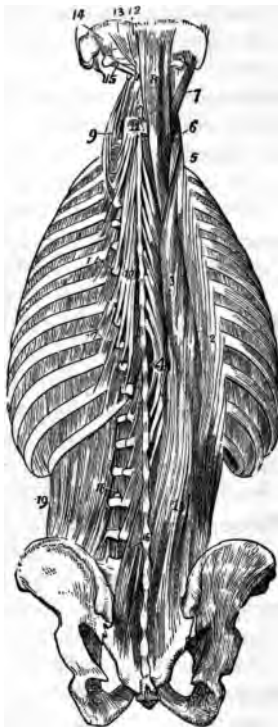
Complexus,⁸ by 7 tendons from the tips of the transverse processes of the 7th cervical and 3 upper dorsal vertebræ, and from the articular processes of the 4th, 5th, and 6th cervical,—into the inner depression between the curved lines of the occipital bone. *Action*, to retract and rotate the head. *Nerves*, suboccipital, great occipital, and branches of the cervical nerves.

Semispinalis Dorsi,¹⁰ from the transverse processes of the dorsal vertebræ, from about the 5th to the 11th,—into the last 2 cervical and 4 upper dorsal spines. *Action*, to erect the spinal column. *Nerves*, branches of the dorsal nerves.

Semispinalis Colli,¹¹ from the transverse processes of the 4 upper dorsal vertebræ, and the articular processes of the 4 lower cervical,—into the 2d, 3d, 4th, and 5th cervical spines. *Action*, to erect the spinal column. *Nerves*, branches of the cervical.

Multifidus Spinæ,¹⁶ from the back of the sacrum, posterior superior spine of the ilium, posterior sacro-iliac ligaments, articular processes of lumbar and cervical vertebræ, and the transverse processes of the dorsal,—into the laminæ and spines of the next 4 vertebræ above. *Action*, to erect and rotate the spinal column. *Nerves*, posterior spinal branches.

FIG. 40.



Rotatores Spinæ (11), *from* the transverse processes of the dorsal vertebræ, from the 2d to the 12th inclusive,—each *into* the lamina of the next dorsal vertebræ above. *Action*, to rotate the spinal column. *Nerves*, branches of the dorsal.

Supra-spinales, lie on the spinous processes in the cervical region. *Nerves*, branches of the cervical.

Inter-spinales, placed in pairs between the spines of contiguous vertebræ, 6 pairs in the cervical region, 3 in the dorsal, 4, sometimes 6, in the lumbar. *Nerves*, posterior spinal branches.

Inter-transversales,¹⁸ placed between the transverse processes of contiguous vertebræ, 7 in the cervical region, 12 in the dorsal, and 4 in the lumbar. *Nerves*, posterior spinal branches.

Rectus Capitis Posticus Major,¹⁸ *from* the spine of the axis,—*into* the inferior curved line of the occipital bone and the surface below. *Action*, to rotate the head. *Nerves*, sub- and great occipital.

Rectus Capitis Posticus Minor,¹² *from* the tubercle on the posterior arch of the atlas,—*into* a rough surface between the foramen magnum and the inferior curved line of the occipital bone. *Action*, to draw the head backwards. *Nerves*, sub- and great occipital.

Obliquus Capitis Inferior,¹⁵ *from* the spinous process of the axis,—almost horizontally to the transverse process of the atlas. *Action*, to rotate the atlas and cranium. *Nerves*, sub- and great occipital.

Obliquus Capitis Superior,¹⁴ *from* the transverse process of the atlas;—upwards and inwards *into* the occipital bone between the curved lines. *Action*, draws the head backwards. *Nerves*, sub- and great occipital.

Extensor Coccygis, *from* the last bone of the sacrum or first of the coccyx,—*into* the lower part of the coccyx, posteriorly. *Action*, as named. *Nerves*, posterior sacral branches.

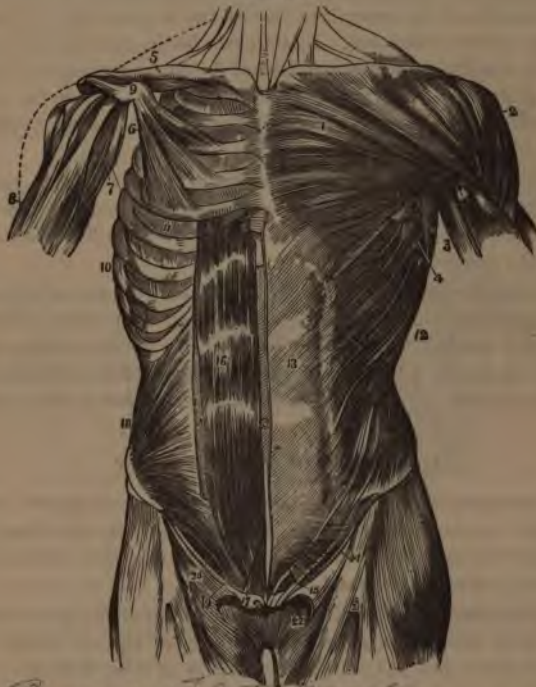
MUSCLES OF THE ABDOMEN.

External Oblique,¹² *from* 8 lower ribs by 8 fleshy digitations,—*into* the anterior half of the outer lip of the crest of the ilium, and by a broad aponeurosis,¹⁸ into the ensiform cartilage, linea alba, symphysis, and spine of the pubes, and the pectineal line. Its aponeurosis is continuous with that of the pectoralis major above, and below it forms Poupart's¹⁴ and Gimbernat's ligaments, and by the separation of its fibres, the external abdominal ring.¹⁶ *Action*, to compress the viscera, and flex the thorax on the pelvis, and *vice versa*. *Nerves*, lower intercostal, ilio-hypogastric, and ilio-inguinal.

Internal Oblique,¹⁸ *from* the lumbar fascia, the anterior two-thirds of the middle lip of the crest of the ilium, and the outer half of Poupart's liga-

ment,—into the cartilages of 4 lower ribs; by its aponeurosis into the linea alba; and leaving an arched border³⁰ over the spermatic cord, by the conjoined tendon¹⁹ with the transversalis into the pubic crest and the pectineal line. Its aponeurosis splits at the rectus abdominis for its upper three-fourths, one layer passing in front, the other behind that muscle, to unite again at the linea alba; for its lower one-fourth it passes in front of the rectus. *Action and Nerves*, same as the external oblique.

FIG. 41.



Broad, flat muscle
Transversalis, from the outer one-third of Poupart's ligament, the anterior two-thirds of the inner lip of the crest of the ilium, the cartilages of 6 lower ribs, and an aponeurosis from the spines and transverse processes of the lumbar vertebræ,—by its aponeurosis into the linea alba, and by the conjoined tendon¹⁹ with the internal oblique, into the pubic crest and the pectineal line. Its aponeurosis passes behind the rectus abdominis for its upper three-fourths, in front of that muscle for its lower one-fourth.

LUMBAR FASCIA, or vertebral aponeurosis of the transversalis, divides into 3 leaflets, *the anterior and middle* being attached to the apices of the transverse processes of the lumbar vertebræ, *the posterior* leaflet to the apices of their spines. The anterior and middle leaflets enclose the quadratus lumborum muscle, the middle and posterior enclose the erector spinæ.

Rectus Abdominis,¹⁶ by 2 tendons from the pubic crest and the ligaments covering the symphysis,—*into* the cartilages of the 5th, 6th, and 7th ribs. It lies in a sheath formed by the aponeuroses of the internal oblique and transversalis muscles for its upper three-fourths, and is crossed by 2 to 5 tendinous lines, the *Linea Transversa*. At its outer border is a similar line placed vertically, the *Linea Semilunaris*, formed by the aponeurosis of the internal oblique at its point of division. *Action*, to flex the thorax on the pelvis and *vice versa*, also to compress the abdominal viscera. *Nerves*, same as the external oblique.

Pyramidalis,¹⁷ lies in front of the rectus, but in the same sheath, arises from the front of the pubic bone and the anterior pubic ligament,—*into* the linea alba, half-way to the umbilicus. *Action*, a tensor of the linea alba. *Nerves*, same as the external oblique.

Quadratus Lumborum,¹⁸ *Plat. 40* from the ilio-lumbar ligament, adjacent 2 inches of the crest of the ilium, and transverse processes of the lower 3 lumbar vertebræ,—*into* one-half of the lower border of the last rib, and the transverse processes of the last 3 lumbar vertebræ. *Action*, to flex the thorax laterally on the pelvis and *vice versa*. *Nerves*, anterior branches of the lumbar.

MUSCLES OF THE THORAX.

External Intercostals (11), each from the outer lip of the groove in the inferior costal border,—*into* the upper border of the next rib below, directed obliquely downwards and forwards. *Action*, to raise and evert the ribs in inspiration. *Nerves*, intercostal.

Internal Intercostals (11), each from the inner lip of the groove in the inferior costal border,—*into* the upper border of the rib below, directed obliquely downwards and backwards. *Action*, at sides of thorax to depress the ribs in expiration; anteriorly they raise the costal cartilages. *Nerves*, intercostals.

Infra-costales (10), obliquely from inner surface of 1 rib,—*into* the inner surface of the 1st, 2d, or 3d rib below. *Action*, muscles of inspiration. *Nerves*, intercostal.

Triangularis Sterni, from the inner surface of the ensiform cartilage, inner surfaces of costal cartilages of 3 or 4 lower true ribs, and lower sides of the

sternum,—into the lower border and inner surfaces of the 2d, 3d, 4th, and 5th costal cartilages. *Action*, to draw down the cartilages in expiration. *Nerves*, intercostal.

Levatores Costarum,¹¹ *Fig.* 40 (12), each from the transverse process of a dorsal vertebra,—into the upper surface of the next rib below, near its angle. *Action*, to raise the ribs. *Nerves*, intercostal.

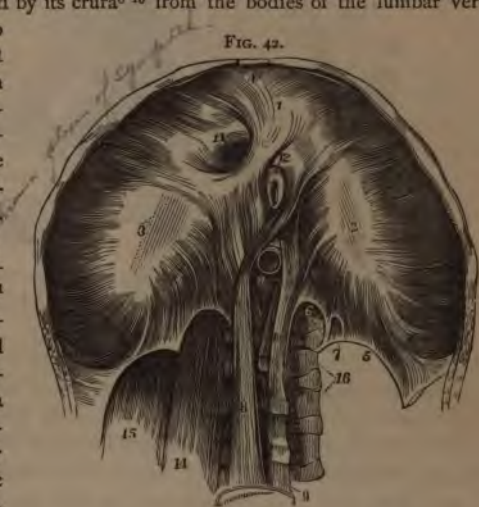Diaphragm, from the ensiform cartilage,⁴ inner surfaces of 6 or 7 lower ribs, ligamenta arcuata,⁵ and by its crura⁸⁻¹⁰ from the bodies of the lumbar vertebrae, from the 2d to the 4th on the right side, the 2d and 3d on the left,—into the central or cordiform tendon.²⁻³ *Action*, the great muscle of respiration and expulsion. *Nerve*, the phrenic.

Openings of the Diaphragm. *The Aortic*,¹¹ in the middle line posteriorly, and behind the diaphragm; transmits the aorta, vena azygos major, and thoracic duct, occasionally the left sympathetic nerve. *The Oesophageal*,¹² in the muscular structure, transmits the oesophagus and the pneumogastric nerves. *The Opening for the Vena Cava*¹³ is the highest, and has 4 tendinous margins. *The Right Crus*⁸ transmits the sympathetic and greater and lesser splanchnic nerves of that side. *The Left Crus*,¹⁰ the greater and lesser splanchnic nerves of the left side and the vena azygos minor.

Descent of the Diaphragm. Its central tendon does not descend during inspiration, being connected with the deep cervical fascia by the fibrous pericardium.

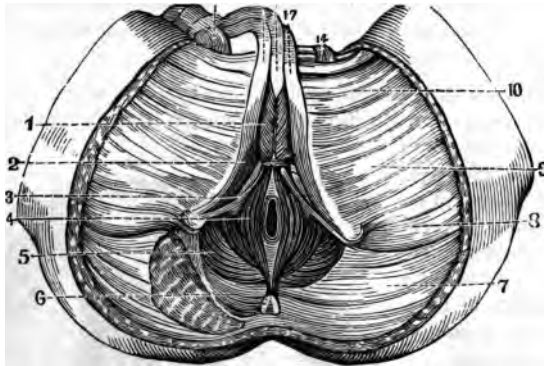
MUSCLES OF THE PERINEUM.

Sphincter Ani,⁴ from the tip of the coccyx and superficial fascia,—into the tendinous centre of the perineum. *Action*, to close the anus. *Nerve*, hemorrhoidal branch of the pudic.



Internal Sphincter, a muscular ring; half an inch broad, about an inch from the margin of the anus; is an aggregation of the involuntary circular fibres of the intestine.

FIG. 43.



Sphincter Tertius of Hyrtl, from the sacrum, encircling the rectum about 4 inches above the anal orifice. [Demonstrated by Hyrtl, Nelaton, and Velpeau, but denied by most anatomists.]

Accelerator Urinae,¹ from the central tendon of the perineum and the median raphé in front,—fibres spread over the bulb, corpus spongiosum, corpus cavernosum,¹⁷ and dorsal vessels. *Action*, to accelerate the flow of urine, and erect the penis. *Nerve*, perineal branch of pudic.

Erector Penis,² from the inner surface of the tuberosity of the ischium, the crus penis, and pubic ramus,—into the crus penis laterally and inferiorly. *Action*, to maintain erection. *Nerve*, perineal.

Transversus Perinei,³ from the ascending ramus of the ischium,—into the central tendon of the perineum. *Action*, to draw tense the central tendon. *Nerve*, perineal.

Levator Ani,⁵ from the body and ramus of the pubes posteriorly, pelvic fascia, and the spine of the ischium,—into the tendinous centre of the perineum, sides of the rectum (and vagina), apex of the coccyx, and a fibrous raphé extending from the coccyx to the anus. *Action*, to support the lower end of the rectum and vagina and the bladder, and assist in forming the floor of the pelvis. *Nerves*, inferior hemorrhoidal and 4th sacral.

Compressor Urethrae, from the upper part of the ramus of the pubes,—into its fellow of the opposite side after encircling the membranous portion of the urethra. *Action*, stop-cock muscle. *Nerve*, perineal.

- Coccygeus**,⁶ *from* the spine of the ischium and the lesser sacro-sciatic ligament,—*into* the margin of the coccyx and the side of the last sacral segment. *Action*, to support the coccyx, and close the outlet of the pelvis posteriorly. *Nerve*, 5th sacral, anterior division.
- Sphincter Vaginæ** (in the female), *from* the central tendon of the perineum,—*into* the corpora cavernosa and body of the clitoris. Represents the accelerator urinæ of the male.
- Erector Clitoridis** (in the female), replaces the erector penis.

MUSCLES OF THE SHOULDER AND ARM.

- Pectoralis Major**, *from* the sternal one-half of the clavicle, by an aponeurosis from the front of the sternum as low as the 6th or 7th rib, the cartilages of all the true ribs, and the aponeurosis of the external oblique,—the fibres converge, cross and are inserted by a flat tendon *into* the external bicipital ridge of the humerus, having crossed the bicipital groove. *Action*, to draw the arm forwards and downwards; also to elevate the ribs in forced inspiration. *Nerves*, anterior thoracic.
- Pectoralis Minor**, *from* the 3d, 4th, and 5th ribs, and the intercostal aponeurosis,—*into* the coracoid process of the scapula. *Action*, to depress the point of the shoulder, also to elevate the ribs in forced inspiration. *Nerves*, anterior thoracic.
- Subclavius**, *from* the cartilage of the 1st rib,—*into* the under surface of the clavicle, in a groove about its middle 3d. *Action*, to draw the clavicle downwards. *Nerve*, a branch from the 5th and 6th cervical.
- Serratus Magnus**, by 9 digitations *from* the 8 upper ribs (the 2d rib having 2) and from the intercostal aponeurosis,—*into* the whole length of the inner margin of the posterior border of the scapula. *Action*, to elevate the ribs in inspiration, also to raise the point of the shoulder. In lower animals the great sling-muscle, slinging the body between the upper extremities. *Nerve*, posterior thoracic.
- Deltoid**, *from* the outer one-third of the anterior and superior surfaces of the clavicle, the outer margin and upper surface of the acromion, and the whole lower border of the spine of the scapula,—*into* a prominence on the outer side of the shaft of the humerus, about its middle. *Action*, to raise the arm. *Nerve*, circumflex.
- Subscapularis**, *from* the inner two-thirds of the subscapular fossa,—*into* the lesser tuberosity of the humerus. *Action*, to rotate the head of the humerus inwards. *Nerves*, subscapular.
- Supra-spinatus**, *from* the inner two-thirds of the supra-spinous fossa,—*into* the upper facet of the greater tuberosity of the humerus. *Action*, to support the shoulder-joint, and to raise the arm. *Nerve*, supra-scapular.

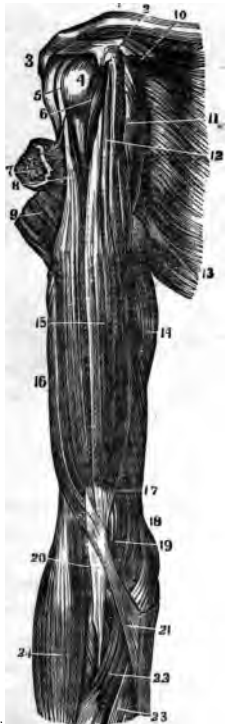
Infra-spinatus, from the inner two-thirds of the infra-spinous fossa,—into the middle facet on the greater tuberosity of the humerus. *Action*, to rotate the humerus outwards. *Nerve*, supra-scapular.

Teres Minor, from the upper two-thirds of the dorsal surface of the axillary border of the scapula,—into the lowest facet on the greater tuberosity of the humerus, and the bone below. *Action*, to rotate the humerus outwards. *Nerve*, circumflex.

Teres Major, from the dorsal aspect of the inferior angle of the scapula,—into the internal bicipital ridge of the humerus. *Action*, to assist the latissimus dorsi. *Nerve*, subscapular.

Coraco-brachialis,¹¹ from the apex of the coracoid process³ of the scapula,—into a ridge on the inner side of the shaft of the humerus, about its middle. *Action*, elevates the humerus forwards and inwards. *Nerve*, musculo-cutaneous, which perforates this muscle.

FIG. 44.



Biceps¹⁵ (Biceps Flexor Cubiti). *Long head*⁸ from the upper margin of the glenoid cavity, *short head*¹² from the apex of the coracoid process,³ in common with the coraco-brachialis,—into the back of the tuberosity of the radius, and the fascia of the forearm.²⁰ *Action*, to flex and supinate the forearm, and to make tense its fascia. *Nerve*, the musculo-cutaneous.

Brachialis Anti'cus,¹⁷ from the lower half of the shaft of the humerus anteriorly and laterally, embracing the insertion of the deltoid,⁹—into the base of the coronoid process of the ulna.¹⁹ *Action*, a flexor of the forearm. *Nerves*, musculo-cutaneous and musculo-spiral.

Triceps¹⁶ (Triceps Extensor Cubiti), by three heads, *the outer and inner* from the posterior surface of the shaft of the humerus, the outer above, the inner below the musculo-spiral groove; *the middle or long head* from a depression below the glenoid cavity of the scapula,—into the upper end of the olecranon process of the ulna. *Action*, to extend the forearm. *Nerve*, musculo-spiral.

Subanconeus, from the humerus above the olecranon fossa,—into the posterior ligament of the elbow-joint. *Action*, probably a tensor of the ligament. *Nerve*, musculo-spiral.

MUSCLES OF THE FOREARM.

Muscles of the forearm (20), arranged in groups of five and threes. (Pancoast.)

ANTERIORLY, 5 flexors, 2 pronators, 1 tensor of palmar fascia:—

<i>Flexor Carpi Radialis.</i>	<i>Pronator Radii Teres.</i>
<i>Flexor Carpi Ulnaris.</i>	<i>Pronator Quadratus.</i>
<i>Flexor Longus Pollicis.</i>	<i>Palmaris Longus.</i>
<i>Flexor Sublimis Digitorum Perforatus Manis.</i>	
<i>Flexor Profundus Digitorum Perforans Manis.</i>	

POSTERIORLY (12), in 4 sets of threes:—

<i>Supinator Longus.</i>	<i>Extensor Indicis.</i>
<i>Extensor Carpi Radialis Longior.</i>	<i>Extensor Communis Digitorum.</i>
<i>Extensor Carpi Radialis Brevior.</i>	<i>Extensor Minimi Digniti.</i>
<i>Extensor Ossis Metacarpi Pollicis.</i>	<i>Extensor Carpi Ulnaris.</i>
<i>Extensor Primi Internodii Pollicis.</i>	<i>Anconeus.</i>
<i>Extensor Secundi Internodii Pollicis.</i>	<i>Supinator Brevis.</i>

Pronator Radii Teres,⁴ by 2 heads, one from above the internal condyle of the humerus, the common tendon, fascia, and the intermuscular septum; the other from the inner side of the coronoid process of the ulna,—into a rough ridge on the outer side of the shaft of the radius, about its middle. *Action*, to pronate the hand. *Nerve*, median, which passes between the 2 heads of the muscle.

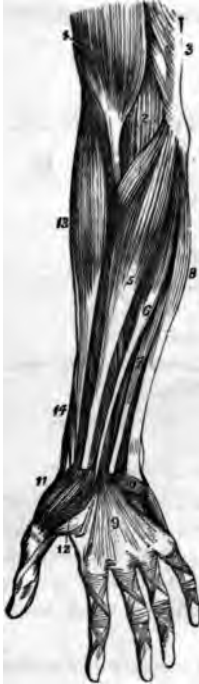Flexor Carpi Radialis,⁵ from the internal condyle by the common tendon, the fascia, and intermuscular septa,—into the base of the metacarpal bone of the index finger. *Action*, to flex the wrist. *Nerve*, median.

Palmaris Longus,⁶ from the same origin as the flexor carpi radialis,—into the annular ligament and the palmar fascia.⁹ *Action*, to make the palmar fascia tense. *Nerve*, median.

Flexor Carpi Ulnaris,⁸ by 2 heads, one from the internal condyle by the common tendon, the other from the inner margin of the olecranon, the upper two-thirds of the posterior border of the ulna, and the intermuscular septum,—into the pisiform bone, the annular ligament, and the base of the 5th metacarpal bone. *Action*, to flex the wrist. *Nerve*, ulnar.

Flexor Sublimis Digitorum (Perforatus),⁷ by 3 heads, one from the inner condyle by the common tendon, the internal lateral ligament, and the intermuscular septum; the 2d from the inner side of the coronoid process; the 3d from the oblique line of the radius,—into the lateral margins of the second

FIG. 45.



phalanges by 4 tendons which are split for the passage of the deep flexor tendons. *Action*, to flex the second phalanges. *Nerve*, median.

Flexor Profundus Digitorum (Perforans), *from* the upper two-thirds of the shaft of the ulna, a depression on the inner side of the coronoid process, and the interosseous membrane,—*into* the bases of the last phalanges, by 4 tendons which perforate the tendons of the superficial flexor. *Action*, to flex the phalanges. *Nerves*, ulnar, and anterior interosseous.

Flexor Longus Pollicis, *from* the upper two-thirds of the shaft of the radius, and the interosseous membrane,—*into* the base of the last phalanx of the thumb, which it flexes. *Nerve*, anterior interosseous.

Pronator Quadratus, *from* the oblique line on the lower one-fourth of the ulna, and the internal body of the ulna,—*into* the lower one-fourth of the external border of the shaft of the radius. *Action*, to pronate the hand. *Nerve*, anterior interosseous.

Supinator Longus,¹⁸ *from* the upper two-thirds of the external condyloid ridge on the humerus, and the intermuscular septum,—*into* the base of the styloid process of the radius. *Action*, to supinate the hand. *Nerve*, musculo-spiral.

Extensor Carpi Radialis Longior,^e *from* the lower one-third of the external condyloid ridge on the humerus, and the intermuscular septum,—*into* the base of the metacarpal bone of the index finger, *e* on its radial side. *Action*, to extend the wrist. *Nerve*, musculo-spiral.

Extensor Carpi Radialis Brevior,^f *from* the external condyle by the common tendon, the external lateral ligament, and the intermuscular septa,—*into* the radial side of the base of the 3d metacarpal bone. *Action*, to extend the wrist. *Nerve*, posterior interosseous.

Extensor Communis Digitorum,^h *from* the external condyle by the common tendon, the deep fascia, and the intermuscular septa,—*into* the 2d and 3d phalanges of all the fingers, by 3 tendons, one of which divides into two. *Action*, to extend the fingers. *Nerve*, posterior interosseous.

Extensor Minimi Digiti,ⁱ from the common tendon and the intermuscular septa,—into the 2d and 3d phalanges of the little finger, with the tendon derived from the common extensor. *Action*, as named. *Nerve*, posterior interosseous.

Extensor Carpi Ulnaris,^j from the common tendon, the middle one-third of the posterior border of the ulna, and the fascia of the forearm,—into the base of the 5th metacarpal bone. *Action*, to extend the wrist. *Nerve*, posterior interosseous.

Anconeus,^k from the external condyle of the humerus, posteriorly,—into the side of the olecranon, and upper one-third of the posterior surface of the shaft of the ulna. *Action*, to extend the forearm. *Nerve*, the musculo-spiral.

Supinator Brevis, from the external condyle of the humerus, the external lateral and orbicular ligaments, and an oblique line on the ulna,—into the inner surface of the neck of the radius, the outer edge of its bicipital tuberosity, and the oblique line. *Action*, to supinate the hand. *Nerve*, posterior interosseous, which pierces it.

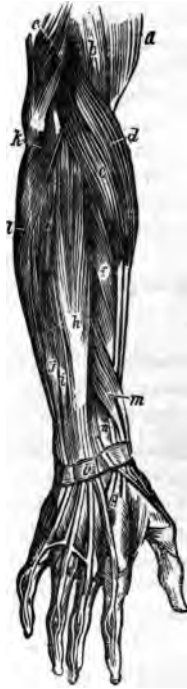Extensor Ossis Metacarpi Pollicis,^l from the posterior surfaces of the shafts of the radius and ulna, and the interosseous ligament,—into the base of the metacarpal bone of the thumb. *Action*, to extend the thumb. *Nerve*, posterior interosseous.

Extensor Primi Internodii Pollicis,ⁿ from the posterior surface of the shaft of the radius and the interosseous membrane,—into the base of the 1st phalanx of the thumb. *Action*, to extend the thumb. *Nerve*, posterior interosseous.

Extensor Secundi Internodii Pollicis,^m from the shaft of the ulna posteriorly and the interosseous membrane,—into the base of the last phalanx of the thumb. *Action*, to extend the thumb. *Nerve*, posterior interosseous.

Extensor Indicis, from the shaft of the ulna posteriorly and the interosseous membrane,—into the 2d and 3d phalanges of the index finger with the tendon of the common extensor. *Action*, to extend the index finger. *Nerve*, posterior interosseous.

FIG. 46.



FASCIÆ OF THE HAND.

ANTERIOR ANNULAR LIGAMENT, *from* the pisiform and unciform bones,—to the tuberosity of the scaphoid and the ridge on the trapezium. It is pierced by the tendon of the flexor carpi radialis, and beneath it pass the tendons of the superficial and deep flexors and the flexor longus pollicis, also the median nerve. It is continuous with the palmar fascia and the fascia of the forearm.

POSTERIOR ANNULAR LIGAMENT,⁹ *from* the ulna, cuneiform, and pisiform bones and the palmar fascia,—to the margin of the radius and the ridges on its posterior surface. It has 6 canals for the passage of the extensor tendons, each lined by a synovial membrane. It is continuous with the fascia of the forearm.

PALMAR FASCIA, ensheathes the muscles of the hand, and divides into slips for the four fingers, each slip dividing and forming tendinous arches for the passage of the flexor tendons.

MUSCLES OF THE HAND.

Abductor Pollicis,¹¹ *from* the ridge of the trapezium and annular ligament,—into the radial side of the base of the 1st phalanx of the thumb. *Action*, to draw the thumb from the median line. *Nerve*, median.

Opponens Pollicis, *from* the palmar surface of the trapezium and annular ligament,—into the radial side of the metacarpal bone of the thumb, for its whole length. *Action*, as a flexor ossis metacarpi pollicis. *Nerve*, median.

Flexor Brevis Pollicis,¹² *from* the trapezium, annular ligament, trapezoid, os-magnum, base of the 3d metacarpal, and the sheath of the tendon of the flexor carpi radialis,—into both sides of the base of the 1st phalanx of the thumb, by two tendons, each of which has a sesamoid bone in it. *Action*, to flex the thumb. *Nerves*, median and ulnar.

Adductor Pollicis, *from* the whole palmar surface of the 3d metacarpal bone,—into the ulnar side of the base of the 1st phalanx of the thumb, and the internal sesamoid bone. *Action*, to draw the thumb towards the median line. *Nerve*, ulnar.

Thenar Eminence, or ball of the thumb, is formed by the above-named 4 muscles. The following first 4 form the *Hypo-thenar Eminence*.

Palmaris Brevis,¹⁰ *from* the annular ligament and palmar fascia,—into the skin on the inner border of the palm of the hand. *Action*, to corrugate the skin of the hand. *Nerve*, ulnar.

Abductor Minimi Digni, *from* the pisiform bone and the tendon of the flexor carpi ulnaris,—into the ulnar side of the base of the 1st phalanx of the little finger. *Action*, as named. *Nerve*, ulnar.

11. Ext. pollicis longus
 12. Ext. pollicis longus
 10. Ext. pollicis longus
 9. Ext. pollicis longus

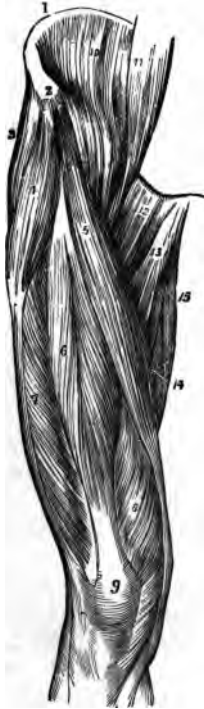
- Flexor Brevis Minimi Digiti**, from the tip of the unciform process and the annular ligament,—into the base of the 1st phalanx of the little finger, with the preceding muscle. *Action*, as named. *Nerve*, ulnar.
- Opponens Minimi Digiti**, from the unciform process and annular ligament,—into the whole ulnar margin of the 5th metacarpal bone. *Action*, a flexor of the 5th metacarpal bone. *Nerve*, ulnar.
- Lumbricales** (4), from the tendons of the deep flexor,—into the expanded tendons of the common extensor, on the dorsi of the phalanges. *Action*, probably to flex the 1st phalanges. *Nerves*, median and ulnar.
- Dorsal Interossei** (4), by 2 heads from the adjacent sides of the metacarpal bones,—into the bases of the 1st phalanges of the index, middle, and ring fingers, the middle finger having two. *Action*, abductors of the fingers from the median line. *Nerve*, ulnar.
- Palmar Interossei** (3), from the palmar surfaces of the 2d, 4th, and 5th metacarpal bones,—into the bases of the 1st phalanges of the same fingers. *Action*, adductors of the fingers. *Nerve*, ulnar.

MUSCLES OF THE HIP AND THIGH.

- Psoas Magnus**,⁹ from the bodies, transverse processes, and intervertebral substances of the last dorsal and all the lumbar vertebræ,—into the lesser trochanter of the femur, by a common tendon with the iliacus. *Action*, to flex and rotate the femur outwards, also to flex the trunk and pelvis on the thigh. *Nerves*, anterior lumbar branches.
- Psoas Parvus**,¹⁰ from the bodies of the last dorsal and first lumbar vertebræ, and the intervertebral substance,—into the ilio-pectineal eminence, and the iliac fascia. *Action*, when present it is a tensor of the iliac fascia. *Nerves*, anterior lumbar branches.
- Iliacus**,¹⁰ from the iliac fossa, inner margin of the iliac crest, ilio-lumbar ligament, base of the sacrum, anterior spinous processes of the ilium and the notch between them, and from the capsule of the hip-joint,—into the outer side of the tendon of the psoas magnus. *Action*, the same as the psoas magnus. *Nerve*, anterior crural.
- FASCIA LATA**, the deep fascia of the thigh, extends from Poupart's ligament to the prominent points around the knee-joint, and from the margin of the sacrum and coccyx around the limb to the pubic arch and pectineal line. It sends two strong intermuscular septa down to the linea aspera, and contains the *Saphenous Opening*, which is formed by the reflected margins of its pubic and iliac portions. *Poupart's Ligament* is made by the knife, and is only the line of junction between the aponeurosis of the external oblique

muscle and the fascia lata; extending from the anterior superior spine of the ilium to the spine of the pubic bone.

FIG. 47.



Tensor Vaginis Femoris,⁴ from the anterior part of the outer lip of the iliac crest, and the anterior superior spinous process,—into the fascia lata laterally, for one-fourth down the thigh. *Action*, a tensor of the fascia lata. *Nerve*, superior gluteal. *Sartorius*,⁵ from the anterior superior spine of the ilium² and half of the notch below it,—into the upper internal surface of the shaft of the tibia. *Action*, to flex and cross the legs. *Nerve*, anterior crural.

Quadriceps Extensor, includes the rectus, vastus internus and externus, and the crureus muscles. Its tendon contains the patella.

Rectus Femoris,⁶ by two tendons, the *Straight* from the anterior inferior spine of the ilium, the *Reflected* from a groove above the brim of the acetabulum,—into the tuberosity of the tibia by the tendon⁹ common to this and the next 3 muscles. *Action*, to extend the leg. *Nerve*, anterior crural.

Vastus Externus,⁷ from the anterior border of the great trochanter and the whole length of the linea aspera,—into the tuberosity of the tibia, by the common tendon.

Vastus Internus⁸ and **Crureus** are one muscle, arising from the inner lip of the linea aspera and nearly the whole of the shaft of the femur in front and laterally from the trochanters down to within the

lower one-fourth of the bone,—into the tuberosity of the tibia by the common extensor tendon. *Action*, to extend the leg. *Nerve*, anterior crural.

Subcrureus, from the lower part of the femur anteriorly,—into the synovial pouch behind the patella. *Action*, to draw up the synovial sac. *Nerve*, anterior crural.

Gracilis,¹⁵ from the inner margin of the rami of the pubes and ischium,—into the inner surface of the shaft of the tibia below the tuberosity. *Action*, to flex and adduct the leg. *Nerve*, obturator.

Pectineus,¹² from the ilio-pectineal line, and the bone in front thereof, also from an expansion of Gimbernat's ligament,—into the rough line extending

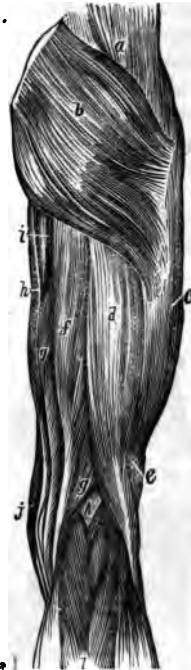
from the trochanter minor to the linea aspera. *Action*, to flex the thigh and rotate it outwards. *Nerves*, obturator, accessory obturator, and anterior crural.

Adductor Longus,¹³ from the front of the pubes,—into the middle third of the linea aspera. *Action*, to adduct the thigh and flex it. *Nerve*, obturator.

Adductor Brevis, from the descending ramus of the pubes,—into the upper part of the linea aspera. *Action*, to adduct and flex the thigh. *Nerve*, obturator.

Adductor Magnus,¹⁴ from the rami of the pubes and ischium, and the outer margin and under surface of the tuberosity of the ischium,—into the rough line leading from the great trochanter to the linea aspera, the whole length of the linea aspera, and by a tendon into the tubercle above the inner condyle of the femur. *Action*, to adduct the thigh and rotate it outwards. *Nerves*, obturator and great sciatic. This muscle is pierced by 4 apertures for the 3 superior perforating and the profunda arteries, and about the lower one-third of its insertion an angular interval is left therein, the lower opening of Hunter's canal, for the passage of the femoral vessels into the popliteal space.

FIG. 48.



Gluteus Maximus,^b from the curved line of the ilium, the crest behind it, the last piece of the sacrum, the side of the coccyx and the great and posterior sacro-sciatic ligaments,—into the fascia lata and the rough line leading from the great trochanter to the linea aspera. *Action*, to extend and abduct the thigh and rotate it outwards, also to maintain the trunk erect. *Nerves*, inferior gluteal and a branch from the sacral plexus.

Gluteus Medius,^a from the ilium between the superior and middle curved lines, the crest between them and the fascia of the part,—into the oblique lines on the great trochanter. *Action*, its posterior fibres rotate the thigh outwards, its anterior fibres rotate inwards. It also abducts the thigh and draws it forwards, and assists to maintain the trunk erect. *Nerve*, superior gluteal.

Gluteus Minimus,^b from the ilium between the middle and inferior curved lines, and the margin of the great sacro-sciatic notch,—into the anterior

border of the great trochanter. *Action*, to rotate the thigh inwards, also to abduct and draw it forwards, and to maintain the trunk erect. *Nerve*, superior gluteal.

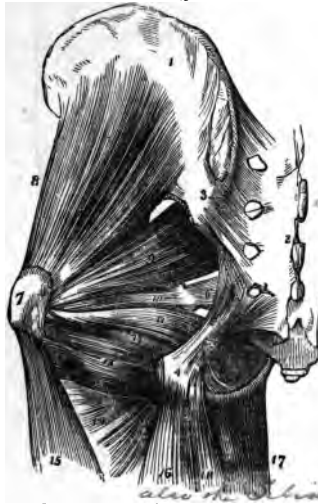Pyramiformis,⁹ by 3 digitations from the front of the sacrum, from the margin of the great sacro-sciatic foramen and the great sacro-sciatic ligament,—into the upper border of the great trochanter,⁷ having passed through the great sacro-sciatic foramen. *Action*, an external rotator of the thigh. *Nerves*, branches from the sacral plexus.

Obturator Internus,¹¹ from the posterior bony margin of the obturator foramen and the inner surface of the obturator membrane,—into the great trochanter,⁷ passing through the lesser sacro-sciatic notch. *Action*, an external rotator of the thigh. *Nerves*, branches from the sacral plexus.

Gemellus Superior,¹⁰ from the outer surface of the spine of the ischium,—into the great trochanter, being blended with the tendon of the obturator internus. *Action*, an external rotator of the thigh. *Nerves*, branches from the sacral plexus.

Gemellus Inferior,¹² from the tuberosity of the ischium,—into the tendon of the obturator internus and the great trochanter. *Action*, an external rotator of the thigh. *Nerves*, branches from the sacral plexus.

FIG. 49.



Obturator Externus, from the anterior inner bony margin of the obturator foramen, and the inner two-thirds of the anterior surface of the obturator membrane,—into the digital fossa of the femur at the inner base of the great trochanter. *Action*, an external rotator of the thigh. *Nerve*, obturator.

Quadratus Femoris,¹³ from the tuberosity of the ischium,—into the upper part of the linea quadrati on the trochanter major posteriorly. *Action*, an external rotator of the thigh. *Nerves*, branches from the sacral plexus.

Biceps,¹⁶ by 2 heads, the *Long Head*^d from the tuberosity of the ischium posteriorly, the *Short Head*,^e from the outer lip of the linea aspera, and the intermuscular septum,—into the outer side of the head of the fibula; its tendon embracing the external lateral ligament of the knee-joint, and forming the *Outer Hamstring*, the tendons of the semi-

tendinosus, semi-membranosus, gracilis, and sartorius, forming the *Inner Hamstring*. *Action*, to flex the leg and rotate it outwards. *Nerve*, great sciatic.

Semi-tendinosus, ^{from the tuberosity of the ischium by a tendon⁴ common to it and the long head of the biceps, and from the adjacent aponeurosis,} *into* the shaft of the tibia at its upper and inner surface, its tendon curving around the inner tuberosity. *Action*, to flex the leg upon the thigh. *Nerve*, great sciatic.

Semi-membranosus, ^{from the tuberosity of the ischium above the origin of the above-named muscles,} *into* the inner tuberosity of the tibia; its tendon dividing into 3 parts, one over the popliteus muscle, and another forming the posterior ligament of the knee-joint. *Action*, to flex the leg, and rotate it inwards. *Nerve*, great sciatic.

External Rotators of the Hip-joint are $12\frac{1}{2}$,—the 3 adductors, pyramiformis, 2 obturators, 2 gemelli, pectineus, psoas magnus, iliacus, sartorius, and posterior half of the gluteus medius.

Internal Rotators of the Hip-joint are $2\frac{1}{2}$,—the tensor vaginæ femoris, gluteus minimus, and the anterior half of the gluteus medius.

MUSCLES OF THE LEG.

Muscles of the leg arranged in groups of threes. (Pancoast.)

<i>Tibialis Anticus.</i>		<i>Tibialis Posticus.</i>
<i>Extensor Proprius Pollicis.</i>		<i>Flexor Longus Pollicis.</i>
<i>Extensor Longus Digitorum.</i>	1, 3,	<i>Flexor Longus Digitorum.</i>
<i>Gastrocnemius.</i>		<i>Peroneus Longus.</i>
<i>Soleus.</i>		<i>Peroneus Brevis.</i>
<i>Plantaris.</i>		<i>Peroneus Tertius.</i>

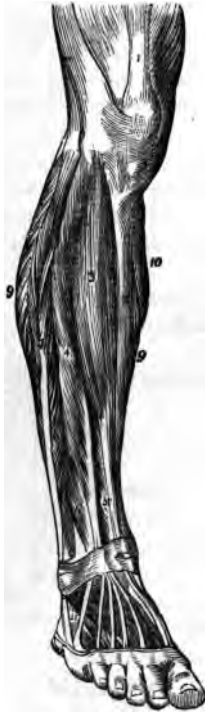
Tibialis Anticus ^(Flexor Tarsi Tibialis), ^{from the outer tuberosity and upper two-thirds of the shaft of the tibia externally, the interosseous membrane, deep fascia, and intermuscular septum,—through the inner canal in the anterior annular ligament} *into* the inner and plantar surface of the internal cuneiform bone, and the base of the 1st metatarsal. *Action*, to flex the tarsus on the leg, and elevate the inner border of the foot. *Nerve*, anterior tibial.

Extensor Proprius Pollicis, ^{from the middle two-fourths of the fibula anteriorly and the interosseous membrane,—through the 2d canal in the anterior annular ligament,—into the base of the last phalanx of the great toe.} *Action*, to extend that toe. *Nerve*, anterior tibial.

Extensor Longus Digitorum, ^{from the outer tuberosity of the tibia, the upper three-fourths of the shaft of the fibula anteriorly, interosseous membrane, deep fascia, and intermuscular septa,—into the 2d and 3d phalanges of the}

4 lesser toes, by 4 tendons which pass over the dorsum of the foot, from the outer canal in the anterior annular ligament. *Action*, to extend the lesser toes. *Nerve*, anterior tibial.

FIG. 50.



Peroneus Tertius (*Flexor Tarsi Fibularis*),⁶ from the outer lower one-fourth of the fibula, interosseous membrane, and intermuscular septum,—into the base of the 5th metatarsal bone. This muscle is a part of the last named, and passes through the same canal in the annular ligament. *Action*, to flex the tarsus. *Nerve*, anterior tibial.

Gastrocnemius, by 2 heads from the condyles of the femur, and the supra-condyloid ridges,—unites with the tendon of the soleus to form the *tendo Achillis*, into the posterior tuberosity of the os calcis. *Action*, to extend the foot. *Nerve*, internal popliteal.

Soleus, from the head and upper one-half of the shaft of the fibula posteriorly, the oblique line of the tibia, and the tendinous arch,—unites with the tendon of the gastrocnemius as the *tendo Achillis* (see above). *Action*, to extend the foot. *Nerve*, internal popliteal.

Plantaris, from the outer bifurcation of the *linea aspera*, and posterior ligament of the knee-joint, by a very long, delicate tendon,—into the posterior surface of the os calcis. *Action*, to extend the foot. *Nerve*, internal popliteal.

Popliteus,⁶ from a depression on the external condyle of the femur, and the posterior ligament of the knee-joint,—into the inner two-thirds of the triangular surface on the shaft of the tibia posteriorly and above the oblique line. *Action*, to flex the leg. *Nerve*, internal popliteal.

Flexor Longus Pollicis,⁹ from the lower two-thirds of the shaft of the fibula internally, the interosseous membrane, fascia, and intermuscular septum,—through grooves in the tibia, astragalus, and os calcis,—into the base of the last phalanx of the great toe. *Action*, to flex the great toe. *Nerve*, posterior tibial.

Flexor Longus Digitorum,⁷ from the shaft of the tibia posteriorly and below the oblique line, and the intermuscular septum,—passes behind the *inner malleolus* in a groove¹³ with the *tibialis posticus*,—into the bases of

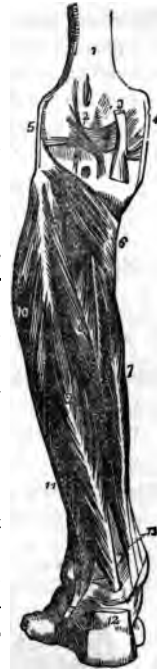the last phalanges of the lesser toes by 4 tendons which perforate the tendons of the flexor brevis digitorum. *Action*, to flex the phalanges and extend the foot. *Nerve*, posterior tibial.

Tibialis Posticus,⁸ by two processes between which pass the anterior tibial vessels, from the upper one-half of shaft of the tibia posteriorly, the upper two-thirds of the shaft of the fibula internally, the interosseous membrane, deep fascia, and intermuscular septa,—passes behind the inner malleolus in a groove¹⁸ with the long flexor, into the tuberosity of the scaphoid and internal cuneiform bones. *Action*, to extend the tarsus, and invert the foot. *Nerve*, posterior tibial.

Peroneus Longus,¹⁰ from the head of the fibula and the upper two-thirds of its shaft externally, the deep fascia, and intermuscular septa,—passes behind the outer malleolus in a groove with the peroneus brevis, through a groove in the cuboid bone, to the outer side of the base of the 1st metatarsal bone. *Action*, to extend and evert the foot. *Nerve*, musculo-cutaneous.

Peroneus Brevis,¹¹ from the middle one-third of the shaft of the fibula externally, and the intermuscular septa,—passes behind the external malleolus in a groove with the long peroneal, into the dorsum of the base of the 5th metatarsal bone. *Action*, to extend the foot. *Nerve*, musculo-cutaneous branch of external popliteal.

FIG. 51.



FASCIÆ OF THE FOOT.

ANTERIOR ANNULAR LIGAMENT, consists of vertical and horizontal portions, is attached to the lower ends of the fibula and tibia, the os calcis and the plantar fascia. It contains 5 sheaths lined by synovial membranes for the tendons of the extensor muscles, that of the extensor proprius pollicis passing beneath it, as also the anterior tibial vessels and nerve.

INTERNAL ANNULAR LIGAMENT, from the inner malleolus to the os calcis, converting 3 bony grooves into canals lined by synovial membranes for the flexor tendons and the posterior tibial vessels and nerve.

EXTERNAL ANNULAR LIGAMENT, from the outer malleolus to the os calcis, binding down the peronei tendons in one synovial sac.

PLANTAR FASCIA, the densest in the body, divided into a central and two lateral portions, and attached to the inner tuberosity of the os calcis, divides into 5 processes, 1 for each toe, and several intermuscular septa.

MUSCLES OF THE FOOT.

Extensor Brevis Digitorum, the only muscle on the dorsum of the foot, arises from the os calcis externally, the astragalo-calcanean and the anterior annular ligaments,—by 4 tendons, 1 into the 1st phalanx of the great toe, and the others into the outer sides of the long extensor tendons of the 2d, 3d, and 4th toes. *Action*, to extend the toes. *Nerve*, anterior tibial.

Muscles on the sole of the foot (19), by layers:—

1st Layer.

Flexor Brevis Digitorum.

Abductor Pollicis.

Abductor Minimi Digiti.

2d Layer.

Flexor Accessorius.

Lumbricales (4).

3d Layer.

Flexor Brevis Pollicis.

Flexor Brevis Minimi Digiti.

Adductor Pollicis.

Transversus Pedis.

4th Layer.

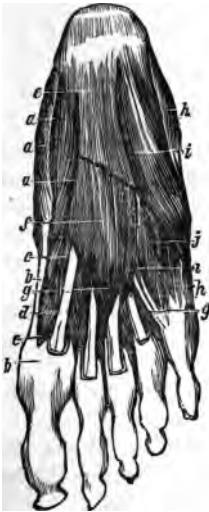Interossei (4 Dorsal, 3 Plantar).

} Pancoast's Triangle, the lowest in the body.

Abductor Pollicis,^a from the inner tuberosity of the os calcis, the internal annular ligament, plantar fascia, and intermuscular septum,—into the inner side of the base of the 1st phalanx of the great toe. *Action*, to abduct the great toe. *Nerve*, internal plantar.

Flexor Brevis Digitorum,^f from the inner tuberosity of the os calcis, the plantar fascia and intermuscular septa,—into the sides of the 2d phalanges of the lesser toes by 4 tendons which are perforated for the long flexor tendons. *Action*, to flex the lesser toes. *Nerve*, internal plantar.

FIG. 52.



Abductor Minimi Digiti,^k from the outer tuberosity and under surface of the os calcis, the plantar fascia and the intermuscular septum,—into the base of the 1st phalanx of the little toe with the tendon of its short flexor. *Action*, to abduct the little toe. *Nerve*, external plantar.

Flexor Accessorius, by 2 heads, from the os calcis and the calcaneo-scapoid and long plantar ligaments,—into the tendon of the flexor longus digitorum. *Action*, accessory flexor of the toes. *Nerve*, external plantar.

Lumbricales (4), from the long flexor tendons—into the inner side of the second phalanges of the lesser toes. *Action*, accessory flexors. *Nerves*, internal plantar to the two internal, external plantar to the others.

Flexor Brevis Pollicis,^c *from* the cuboid and external cuneiform bones, and the prolonged tendon of the tibialis posticus,—*into* both sides of the base of the 1st phalanx of the great toe, by 2 portions, of which one blends with the abductor pollicis, the other with the adductor pollicis. *Action*, to flex the great toe. *Nerve*, internal plantar.

Adductor Pollicis, *from* the tarsal ends of the three middle metatarsal bones, and the sheath of the tendon of the peroneus longus,—*into* the base of the 1st phalanx of the great toe, externally. *Action*, to adduct the great toe. *Nerve*, external plantar.

Flexor Brevis Minimi Digiti,ⁱ *from* the base of the 5th metatarsal bone and the sheath of the tendon of the peroneus longus,—*into* the base of the 1st phalanx of the little toe externally. *Action*, to flex the little toe. *Nerve*, external plantar.

Transversus Pedis, *from* the under surface of the head of the 5th metatarsal bone, and the transverse ligament of the metatarsus,—*into* the outer side of the 1st phalanx of the great toe, blending with the tendon of the adductor pollicis. *Action*, to adduct the great toe. *Nerve*, external plantar.

Dorsal Interossei (4), each by two heads *from* the adjacent sides of two metatarsal bones,—*into* the base of the 1st phalanx of the corresponding toe. *Action*, to abduct the toes. *Nerve*, external plantar.

Plantar Interossei^j (3), *from* the shafts of the 3d, 4th, and 5th metatarsal bones,—*into* the bases of the 1st phalanges of the same toes. *Action*, to adduct the toes towards the median line. *Nerve*, external plantar.

THE HEART.

What is the Pericardium? It is a conical membranous closed sac, containing the heart and the roots of the great vessels. It lies behind the sternum and between the pleuræ, its apex upwards, its base below and attached to the central tendon of the diaphragm. It is composed of an outer fibrous coat, and an inner serous one; the latter consisting of two portions, a parietal layer, lining the inner surface of the fibrous coat, and a visceral layer, which is reflected over the heart and vessels. The serous portion secretes a thin fluid, about 1 drachm in quantity normally, for the lubrication of its surfaces. The fibrous coat is prolonged on the outer surfaces of the great vessels, except the inferior vena cava, and becomes continuous with the deep layer of the cervical fascia.

Describe the Endocardium. It is a serous membrane which lines the inner surface of the heart, forming by its reduplications the cardiac, aortic, and pulmonary valves, and continuous with the lining membrane of the great vessels.

Describe the Heart. It is a hollow muscular organ, conoidal in shape, placed obliquely in the chest between the lungs, base upwards, apex towards the left and front, corresponding to the interspace between the 5th and 6th costal cartilages, one inch inside of and two inches below the left nipple. In the adult its size is about 5 inches by $3\frac{1}{2}$ by $2\frac{1}{2}$, and from 8 to 12 oz. in weight.

What are the Cavities of the Heart? They are 4 in number, an auricle and a ventricle on each side of the heart, separated by a longitudinal muscular septum, and indicated on the external surface of the organ by grooves, named, from their contiguous cavities, as the *Auriculo-ventricular Groove* transversely, and the *Inter-Ventricular Groove* longitudinally.

Describe the Right Auricle. It is larger than the left, can hold about 2 fluidounces, its walls being about 1 line in thickness. It receives the venous blood by the superior and inferior venæ cavæ and the coronary sinus, and presents interiorly the following points for examination:—

Appendix Auriculæ, a conical pouch projecting from the auricle to the front and left, its margins being dentated.

Openings of the superior and inferior venæ cavæ and the coronary sinus, the latter having a valve in two segments.

Foramina Thebesii, several minute orifices, the mouths of veins from the substance of the heart.

Tubercle of Lower, a very small projection on the right wall, supposed to influence the direction of the blood-current.

Eustachian Valve, at the anterior margin of the inferior vena cava; large in the fœtus, to direct the blood to the foramen ovale.

Fossa Ovalis, a depression on the inner wall, and the situation of the foramen ovale in the fœtus.

Annulus Ovalis, the oval margin of the fossa ovalis.

Musculi Pectinati, muscular columns on the inner surface of the appendix and the inner wall of the auricle.

Auriculo-ventricular Opening, communicates with the right ventricle, is oval, about an inch broad, surrounded by a fibrous ring, and is guarded by the tricuspid valve.

Describe the Right Ventricle. Its form is conical, its cavity containing about 2 fluidounces, its apex above the apex of the heart, and it presents interiorly the following, viz.—

Tricuspid Valve, consists of 3 triangular segments connected by their bases with the auriculo-ventricular orifice, and by their sides with each other, the largest being on the left side.

Chordæ Tendinæ, delicate tendinous cords which connect the margins and lower surfaces of the tricuspid valve with the columnæ.

Columnæ Carneæ, muscular columns projecting from the surface of the ventricle, of which 3 or 4, called *Columnæ Papillares*, give attachment to the chordæ tendinæ.

Semilunar Valves, are 3 in number, and guard the orifice of the pulmonary artery, each about the middle of its free margin has a fibro-cartilaginous nodule, the *Corpus Arantii*, which more perfectly closes the orifice.

Opening of the Pulmonary Artery, at the superior and internal angle of the ventricle, the *Conus Arteriosus*. It is circular in form, surrounded by a fibrous ring, and is guarded by the semilunar valves.

Sinuses of Valsalva, are 3 pouches, one behind each valve, between it and the commencement of the pulmonary artery.

Describe the Left Auricle. Its walls are about $1\frac{1}{2}$ lines in thickness, its capacity rather less than 2 fluidounces, has an appendix auriculæ, and receives the arterialized blood from the lungs. It presents the following internally:—

Openings of the Pulmonary Veins, are 4 in number, sometimes 3, as the two left veins frequently end in a common opening.

Left Auriculo-ventricular Opening, is smaller than the right one.

Musculi Pectinati, on the inner surface of the appendix.

Depression, corresponding to the fossa ovalis in the right auricle.

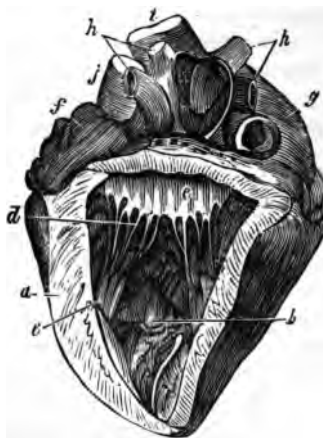
Describe the Left Ventricle.

It is longer, thicker, and more conical than the right, projecting towards the posterior aspect. Its walls^a are the thickest of those in the heart, being twice as thick as those of the right ventricle. Its interior presents the following:—

Aortic Opening, is small and circular, placed in front and to the right of the auriculo-ventricular, a segment of the mitral valve being between them. It is surrounded by a fibrous ring, and guarded by semilunar valves.

Mitral Valve,^c consists of two unequal-sized segments, and is attached to the fibrous ring which surrounds the auriculo-ventricular opening. Its margins are connected with the ventricular walls by *Chordæ Tendinæ*^d and *Musculi Papillares*.

FIG. 53.



Semilunar Valves, guard the aortic orifice, and are larger and stronger than those on the right side.

Sinus Aortici, or sinus of Valsalva, a pouch between each valve and the beginning of the aorta.

Columnæ Carneæ, are smaller and more numerous than on the right side; the *Musculi Papillares* are but two in number.

Describe the Structure of the Heart. The muscular fibres take origin from the four fibrous rings at the auriculo-ventricular and aortic openings. The fibres of the auricles are arranged in two layers, a superficial and a deep one, the latter having looped fibres and annular fibres. In the ventricles the fibres are superficial and deep, the latter being arranged circularly, the former spirally, coiling inwards at the apex of the heart into a whorl-like form, the *vortex*.

THE ARTERIES.

What are the Arteries? Cylindrical vessels which carry arterial blood to the body from the heart. Those going to the lungs with the returning veins, form the *Lesser or Pulmonic Circulation*. The aorta with its branches and the returning veins, constitute the *Greater or Systemic Circulation*. The arteries anastomose or communicate freely with each other everywhere throughout the body, permitting the establishment of collateral circulations.

Describe the Structure of the Arteries. They are dense, very elastic, preserving their cylindrical form, and are composed of 3 coats, an *Internal* or serous; a *Middle*, which is of muscular and elastic tissue; and an *External*, of connective tissue. They are generally included in a fibro-areolar investment, the *Sheath*, which also encloses the accompanying veins. The larger arteries are nourished by the *Vasa Vasorum*, blood-vessels which ramify in the external and middle coats; and are supplied with nerves, the *Vaso-motor*, derived from both the sympathetic and cerebro-spinal systems, and forming intricate plexuses on the larger trunks.

What are the Capillaries? Minute vessels forming a network throughout the tissues of the body between the terminating arteries and the commencing veins. Their average diameter is about the $\frac{1}{3000}$ of an inch, and their walls consist of a transparent homogeneous membrane continuous with the innermost layer of the arterial and venous walls.

[In the following pages, main branches are in italics, sub-branches in Roman.]

Describe the Aorta. It is the main trunk of the systemic arteries, commencing at the aortic opening of the left ventricle of the heart, arching backwards over the roof of the left lung into the thorax, where it descends on the left of the spinal column, and after passing through the aortic opening in the diaphragm, it terminates in the right and left common iliac arteries opposite

It is also crossed *above* by the facial, lingual, and superior thyroid veins, *below* by the anterior jugular vein, and on the left side often by the internal jugular vein. It bifurcates, at the level of the upper border of the thyroid cartilage, into the *External and Internal Carotids*, of which the internal is the most remote from the median line.

Name the Branches and Sub-branches of the External Carotid Artery.² (Fig. 55.) It has 8 branches, as follows, viz.—

Superior Thyroid,⁴ arising below the greater cornu of the hyoid bone.

Muscular.	Hyoid.	Superior Laryngeal.
Glandular.	Superficial Descending.	Crico-thyroid.

Lingual,⁵ under the hyo-glossus muscle to the tongue.

Hyoid.	Dorsalis Linguae.	Sublingual.	Ranine.
--------	-------------------	-------------	---------

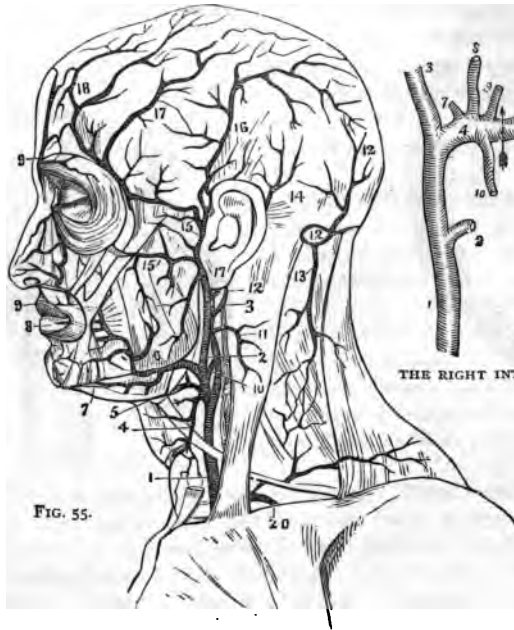


FIG. 55.

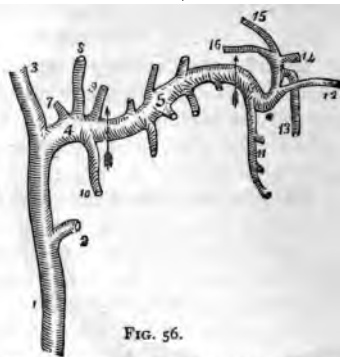


FIG. 56.

THE RIGHT INTERNAL MAXILLARY ARTERY

Facial,⁶ crosses the lower jaw at the anterior angle of the masseter.

Inferior or Ascending Palatine.	Submental. ⁷	2 Coronary. ^{8,9}
Tonsillar.	Muscular.	Lateralis Nasi.
Submaxillary.	Inferior Labial.	Angular.

Occipital,¹⁰ lies in the occipital groove of the temporal bone.

Muscular.	Inferior Meningeal.	Cranial Branches, over
Auricular.	Arteria Princeps Cervicis. ¹³	the occiput.

Posterior Auricular,¹⁴ ascends under cover of the parotid gland.

Stylo-mastoid.	Auricular.	Muscular.	Glandular.
----------------	------------	-----------	------------

Ascending Pharyngeal, lies on the rectus capitis anticus major.

External Branches.	Pharyngeal and Meningeal Branches.
--------------------	------------------------------------

Temporal,¹⁵ the smallest of the termini of the external carotid, begins in the parotid gland, crosses the zygomatic arch, and divides into anterior¹⁶ and posterior temporal.¹⁶

Transverse Facial. ¹⁵	Middle Temporal. ¹⁷	Anterior Auricular.
----------------------------------	--------------------------------	---------------------

Internal Maxillary,⁴ the other terminal branch of the external carotid,¹ is divided into three portions, Maxillary,⁴ Pterygoid,⁵ and Spheno-maxillary,⁶ which respectively give off the following branches: (Fig. 56.)

Deep Auricular, to the	Deep Temporal,	Alveolar. ¹¹
tragus and canal.	ant. and posterior.	Infra-orbital. ¹²

Tympanic, ⁷ entering	Pterygoid Branches,	Descending Palatine. ¹³
the Glaserian fissure.	to those muscles.	Vidian. ¹⁶

Middle Meningeal. ⁸	Masseteric, to the	Pterygo-palatine. ¹⁵
--------------------------------	--------------------	---------------------------------

Small Meningeal. ⁹	masseter muscle.	Spheno-palatine or Nasal. ¹⁴
-------------------------------	------------------	---

Inferior Dental, ¹⁰ divides	Buccal, to the buccino-
into Incisor and Mental.	nator muscle.

Describe the Internal Carotid Artery. It ascends in front of the transverse processes of the three upper cervical vertebræ, and close to the tonsil, traverses the carotid canal in the temporal bone, and after piercing the dura mater by the anterior clinoid process, divides into its terminal branches. Its branches are the

Tympanic, enters the tympanum from the carotid canal, and anastomoses on the membrana tympani with the tympanic branch of the internal maxillary, the stylo-mastoid, and the Vidian arteries.

Arteria Recaptaculi, numerous small vessels going to the walls of the sinuses, the Gasserian ganglion and the pituitary body; one of them, to the dura mater, is called the *Anterior Meningeal*.

Ophthalmic, arises from the cavernous portion, enters the orbit through the optic foramen, terminating at the inner angle of the eye into the frontal and nasal branches. It gives off,—

Lachrymal.	Short Ciliary.	Anterior Ethmoidal.
Arteria Centralis Retinæ.	Anterior Ciliary.	Palpebral.
Muscular Branches.	Supraorbital.	Nasal.
Long Ciliary.	Posterior Ethmoidal.	Frontal.

Anterior Cerebral, joined to its fellow by the anterior communicating branch, about 2 lines long.

Middle Cerebral, in the fissure of Sylvius; divides into 3 branches, anterior, median, and posterior.

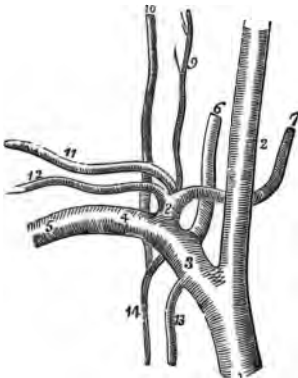
Anterior Choroid, to the choroid plexus, corpus fimbriatum, etc.

Posterior Communicating, anastomoses with the posterior cerebral, a branch of the basilar.

What is the Circle of Willis? An anastomosis at the base of the brain, between the branches of the internal carotid and vertebral arteries, to equalize the cerebral circulation. The 2 *Vertebral* arteries join to form the *Basilar*, which ends in 2 *Posterior Cerebral*. These are connected with the *Internal Carotid* by the 2 *Posterior Communicating*. The circle is completed by the connection of the 2 *Anterior Cerebral* branches of the internal carotid through the short *Anterior Communicating* artery.

Describe the Subclavian. It arises on the right side from the innominate, on the left side from the arch of the aorta, and is divided into 3 portions by the scalenus anticus, which crosses it just external to the origin of the thyroid axis, viz.—the parts internal, behind, and external to that muscle. At the outer border of the 1st rib, the subclavian becomes the axillary artery. Its upper border is a little above the clavicle, and it is separated from the subclavian vein by the scalenus anticus at its origin from the first rib. Its branches are all given off from its first portion, except the *Superior Intercostal*, which on the right side arises from the second portion.

FIG. 57.



Vertebral,⁶ passing up the neck, through the foramina in the transverse processes of six cervical vertebræ, and enters the skull by the foramen magnum, where it joins its fellow to form the *Basilar Artery*. Its branches are—

Lateral Spinal Branches.	Anterior Spinal.
Muscular Branches.	Posterior Spinal.
Posterior Meningeal.	Inferior Cerebellar.

The Basilar, formed by the junction of the vertebrals, gives off on each side a transverse, anterior, and superior cerebellar, and ends in the two posterior cerebral. (See *Circle of Willis*, above.)

THYROID AXIS,⁸ at oncé divides into the three following branches:—

*Inferior Thyroid,*⁷ to the thyroid gland, giving off,—

Laryngeal Branch.	Esophageal Branches.
Tracheal Branches.	Ascending Cervical. ⁹

*Transversalis Colli,*¹¹ divides beneath the margin of the trapezius into—

Superficial Cervical.	Posterior Scapular.
-----------------------	---------------------

*Suprascapular,*¹² to the shoulder-joint and the dorsum of the scapula, anastomosing there with the posterior- and sub-scapular.

*Internal Mammary,*¹³ arises opposite the thyroid axis, descends upon the costal cartilages, and ends at the 6th interval, in the musculo-phrenic and superior epigastric, the latter anastomosing with the deep epigastric branch of the external iliac. Its branches are the—

Comes Nervi Phrenici,	Pericardiac.	Perforating.
or Superior Phrenic.	Sternal.	Musculo-phrenic.
Mediastinal.	Anterior Intercostal.	Superior Epigastric.

*Superior Intercostal,*¹⁴ gives off branches in the intercostal spaces to the posterior spinal muscles and to the spinal cord.

*Profunda Cervicis,*¹⁰ supplies the muscles of the back of the neck, and anastomoses with the arteria princeps cervicis of the occipital.

Describe the Axillary.⁵ It is the continuation of the subclavian, extending from the edge of the 1st rib to the lower margin of the armpit muscles, where it becomes the brachial. It has 7 branches, viz.—

Superior Thoracic, to the pectoral muscles and walls of the thorax.

Acromial Thoracic, branches are thoracic, acromial, descending.

Thoracica Longa, to the muscles of the chest and mammary gland.

Thoracica Alaris, a small branch to the axillary glands.

Subscapular, to the inferior dorsum of the scapula. Its branches anastomose with the supra- and posterior scapular, and are the—

Subscapular.	Dorsalis Scapulæ.	Median Branch.
--------------	-------------------	----------------

Posterior Circumflex, to the deltoid muscle and the shoulder-joint.

Anterior Circumflex, to the joint and the head of the bone, anastomosing with the posterior circumflex and acromial thoracic.

Describe the Brachial. It is the continuation of the axillary from the lower margin of the teres major tendon to its bifurcation into the radial and ulnar, which is usually about one-half inch below the bend of the elbow. The median nerve crosses it from the outside to the inside at its centre. Its branches are the—

Superior Profunda, winds over the arm in the musculo-spiral groove, giving off the posterior articular to the elbow anastomosis.

Nutrient Branch, enters the nutrient canal.

Inferior Profunda, to the elbow-joint anastomosis.

Anastomotica Magna, anastomoses with the posterior articular, inferior profunda, anterior and posterior ulnar recurrent.

Muscular Branches, to the muscles in the course of the artery.

Describe the Radial. It extends from the bifurcation of the brachial to the deep palmar arch, and gives off the following branches respectively, in the forearm, the wrist, and the hand, viz.—

<i>Radial Recurrent.</i>	<i>Posterior Carpal.</i>	<i>Princeps Pollicis.</i>
<i>Muscular.</i>	<i>Metacarpal.</i>	<i>Radialis Indicis.</i>
<i>Superficialis Volæ.</i>	<i>Dorsalis Pollicis.</i>	<i>Perforantes.</i>
<i>Anterior Carpal.</i>	<i>Dorsalis Indicis.</i>	<i>Interossea.</i>

Name the Branches of the Ulnar. It extends from the division of the brachial to the superficial palmar arch. It has 8 branches, viz.—

<i>Anterior Ulnar Recurrent.</i>	<i>Muscular.</i>	<i>Deep or Communicating</i>
<i>Posterior Ulnar Recurrent.</i>	<i>Anterior Carpal.</i>	<i>Branch.</i>
<i>Interosseous</i> {	<i>Anterior.</i>	<i>Posterior Carpal. Digital.</i>
	<i>Posterior.</i>	

Describe the Palmar Arches. *The Superficial Palmar Arch* is that part of the ulna artery lying in the palm of the hand, and anastomosing with the superficialis volæ from the radial, and a branch from the radialis indicis, at the root of the thumb. It gives off 4 branches, the digital, to the sides of the fingers, except the inside of the index finger, which is supplied by the radialis indicis. *The Deep Palmar Arch* is formed by the palmar portion of the radial artery anastomosing with the deep or communicating branch of the ulna. It gives off the radialis indicis, palmar interossea, perforating and recurrent branches.

Describe the Thoracic Aorta. It begins on the left of the spine, at the lower border of the 12th dorsal vertebra, and ends at the aortic opening in the diaphragm directly in front of the last dorsal vertebra. Its branches are as follows :—

Pericardiac Branches, irregular in number and origin.

Bronchial, also vary in number and origin; generally one on the right side and two on the left. They nourish the lungs.

Œsophageal, 4 or 5, anastomose on the œsophagus with branches of the inferior thyroid, phrenic, and gastric.

Posterior Mediastinal, numerous small vessels.

Intercostals, usually 10 on each side, each dividing into an anterior and a posterior branch. The *anterior* divides again into two along the adjacent borders of the ribs, supplying the intercostal muscles and anastomosing with

branches of the internal mammary and axillary. The *posterior* divides into a spinal branch going to the vertebræ and the spinal cord, and a muscular to the muscles of the back.

Describe the Abdominal Aorta. It begins where the thoracic ends, and terminates at the 4th lumbar vertebra in the common iliacs. Its branches are as follows:—

CŒLIAC AXIS,² arises opposite the margin of the diaphragm, runs forwards for half an inch and divides into the Gastric, Hepatic, and Splenic arteries, occasionally giving off one of the phrenics.

Gastric,³ supplies the stomach along its lesser curvature, anastomosing with the aortic, œsophageal, splenic, and hepatic branches.

Hepatic,⁴ divides in the transverse fissure of the liver into the right and left branches, to the lobes of that organ; also the—

Pyloric.
Cystic.

Gastro-duodenalis { Gastro-epiploica Dextra.
Pancreatico-duodenalis.

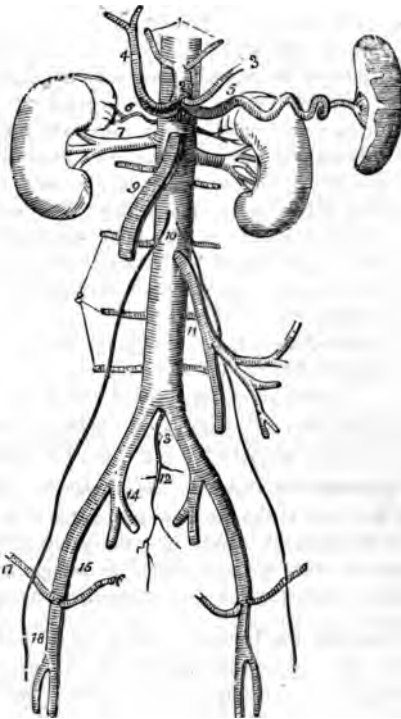
Splenic,⁵ the largest branch of the cœliac axis, passes by a very tortuous course to the spleen, giving off the following:—

Pancreaticæ Parvæ. Gastric (vasa brevia).
Pancreatica Magna. Gastro-epiploica Sinistra.

Phrenic,¹ one on each side, but usually only one arises from the aorta, the other springing from either the cœliac axis or the renal artery. They go to the under surface of the diaphragm.

Superior Mesenteric,⁶ supplies the small intestine, cæcum, ascending and

FIG. 58.



transverse colon. Arising about one-fourth inch below the cœliac axis, it arches forwards, downwards, and to the left, giving off—

Inferior Pancreatico-duodenal. Ileo-colic.

Vasa Intestini Tenuis. Colica Dextra and Media.

Inferior Mesenteric,¹¹ supplies the descending colon, sigmoid flexure, and most of the rectum, giving off the following branches:—

Colica Sinistra. Sigmoid. Superior Hemorrhoidal.

Supra-renal,⁶ arise one on each side, opposite the origin of the superior mesenteric, passing to the supra-renal capsules.

Renal,⁷ one from each side, just below the preceding, pass to the kidney, at the hilum having the middle place between the ureter behind and the renal vein in front. U. A. V. (you 'ave!)

Spermatic,¹⁰ one on each side, in the male through the inguinal canal to the testes; in the female to the ovaries, uterus, and the skin of the labia and groins.

Lumbar,⁸ usually 4 on each side, analogous to the intercostals. They each divide into two branches, the—

Dorsal, giving off a spinal branch. Abdominal.

Middle Sacral,¹² arises just at the bifurcation of the aorta; it descends along the sacrum and coccyx, giving off numerous branches.

Describe the Common Iliac Arteries. They extend from the bifurcation of the aorta at the 4th lumbar vertebra to near the lumbo-sacral articulation, where they each divide into the external¹⁵ and internal iliac.¹⁴ They are about 2 inches in length, the right being a little longer than the left one, and each is crossed by the ureter, just before its bifurcation.

Describe the Internal Iliac.¹⁴ It is about 1½ inches long, and extends from the lumbo-sacral articulation to the great sacro-sciatic notch, where it divides into an anterior and a posterior trunk. From the anterior trunk are given off from above downwards, the—

Superior Vesical, the remaining pervious part of the foetal hypogastric artery.

It sends branches to the vas deferens and the ureter; and one, the *Middle Vesical*, to the base of the bladder.

Obturator, through the canal in the obturator foramen to the thigh, where it divides into an internal and external branch. Within the pelvis it gives off an iliac, vesical, and a pubic branch. In one out of 3½ cases this artery arises from the epigastric.

Inferior Vesical, to the bladder, prostate gland, and vesiculæ seminales. In the female this artery is called the *Vaginal*.

Middle Hemorrhoidal, to the rectum.

Uterine, in the female, anastomosing with the ovarian.

Internal Pudic, the smaller of the terminal branches of the anterior trunk, supplies the external generative organs. Its branches in the pelvis are numerous and small, in the perineum they are—

Inferior Hemorrhoidal.	Artery of the Bulb.
Superficial Perineal.	Artery of the Corpus Cavernosum.
Transverse Perineal.	Dorsal Artery of the Penis.

Sciatic, the other terminal branch, supplies the muscles on the back of the pelvis. Its branches are as follows:—

Muscular Branches.	Coccygeal.	Muscular, external
Hemorrhoidal Branches.	Inferior Gluteal.	to the pelvis.
Vesical Branches.	Comes Nervi Ischiadici.	Articular Branches.

THE POSTERIOR TRUNK gives off the following:—

Ilio-lumbar, dividing into lumbar and iliac branches.

Lateral Sacral, superior and inferior on each side.

Gluteal, the continuation of the posterior trunk, divides into a superficial and a deep branch, to the glutei muscles, the skin over the sacrum, and the hip-joint. Before dividing it gives a nutrient branch to the ilium, and some muscular branches.

Describe the External Iliac. It extends to beneath the centre of Poupart's ligament, where it enters the thigh and becomes the *Femoral Artery*, lying between the femoral vein on the inside and the anterior crural nerve on the outside—V.A.N. Its branches are, small muscular and glandular, and—

Epigastric, which usually arises a few lines above Poupart's ligament, passes between the peritoneum and the transversalis fascia, to the sheath of the rectus which it perforates, and ascends behind that muscle, to anastomose by numerous branches with the terminal branches of the internal mammary and inferior intercostal. It gives off—

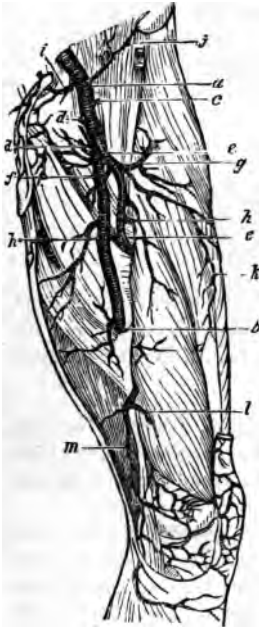
Cremasteric.	Pubic.	Muscular Branches.
--------------	--------	--------------------

Circumflex Iliac, arises opposite to the epigastric, passes along the crest of the ilium to anastomose with the ilio-lumbar, gluteal, lumbar, and epigastric arteries.

Describe the Femoral Artery. It extends from Poupart's ligament to the opening in the adductor magnus, where it becomes the popliteal artery. Its course corresponds to a line drawn from a point midway between the anterior superior spine of the ilium and the symphysis pubis, to the inner side of the inner condyle of the femur. It lies in a strong fibrous sheath with the femoral vein, but divided from the latter by a fibrous partition. It bisects Scarpa's triangle in the upper part of its course, where it is superficial, and rests on the inner margin of the psoas, which separates it from the capsule of the hip-joint. Its branches are as follows:—

Superficial Epigastric, f to the superficial fascia of the abdomen.

Fig. 59.



Superficial Circumflex Iliac, j to the skin over the iliac crest.

Superficial External Pudic, d to the integument of the lower abdomen, penis, and scrotum.

Deep External Pudic, d to the skin of the scrotum and perineum.

Profunda Femoris, e arises posteriorly about 1 or 2 inches below Poupart's ligament, and descends to the lower third of the back of the thigh, giving off the following branches:—

Ext. Circumflex. *g* Int. Circumflex. *f*
3 Perforating. *h*

Muscular Branches, k to the sartorius and vastus internus.

Anastomotica Magna, arises from the femoral in Hunter's canal, and divides into a superficial and deep branch, the latter anastomosing around the knee-joint with the superior external and internal articular arteries, and the recurrent tibial.

Describe the Popliteal Artery. It extends from the opening in the adductor magnus to the lower border of the popliteus muscle, where, having passed behind the knee-joint, it divides into the anterior and posterior tibial arteries. Its branches are as follows:—

Superior Muscular Branches.

Inferior Muscular, or Sural.

Cutaneous Branches.

Superior External Articular.

These are distributed around the knee-joint in a free anastomosis.

Superior Internal Articular. l

Azygos Articular.

Inferior External Articular.

Inferior Internal Articular.

The azygos branch perforates the posterior ligament of the joint to reach the internal ligaments and the synovial membrane.

Describe the Anterior Tibial Artery. It extends from the bifurcation of the popliteal to the front of the ankle-joint, where it becomes the *Dorsalis Pedis*. It passes between the two heads of the tibialis posticus, over the upper edge of the interosseus membrane and along its anterior surface, resting on

the tibia for its lower one-third. It is accompanied by the anterior tibial nerve close to it externally, and is crossed below by the tendon of the extensor proprius pollicis. Its branches are—

Recurrent Tibial. *Muscular.* *External and Internal Malleolar.*

Describe the Dorsalis Pedis Artery. It is the continuation of the anterior-tibial, extending from the front of the ankle-joint to the 1st interosseous space, where it terminates in the *Dorsalis Hallucis* and the *Communicating*. The anterior tibial nerve lies close to its outer side. Its branches are as follows:—

Tarsæa, passing outwards along the tarsus.

Metatarsæa, giving off 3 interosseæ, and they 7 digital.

Dorsalis Hallucis, to the great toe and the inner side of the second toe by its 3 digital branches.

Communicating, which dips down into the sole of the foot in the 1st interosseous space of the metatarsus, to inosculate with the external plantar; and gives off 2 digital branches to the plantar surface of the great and second toes.

Describe the Posterior Tibial Artery. It is a large vessel, extending from the bifurcation of the popliteal along the back of the tibia to the fossa below the inner malleolus, where it divides into the *Internal* and *External Plantar*. The posterior tibial nerve crosses it a short way below its origin and then lies close to its outer side for the rest of its course. Its branches are as follows:—

Peroneal, along the fibular side, giving off the anterior peroneal, muscular branches, ~~and the nutrient artery of the tibia.~~ *from Post. Tibial*

Nutrient of the Tibia, the largest nutrient artery of bone.

Muscular Branches, to the posterior muscles of the leg.

Communicating, a branch to the peroneal artery.

Internal Calcanean Branches, to the heel and sole of the foot.

Describe the Internal Plantar. This artery is the smallest of the terminating branches of the posterior tibial, and passes along the inner side of the foot and great toe.

Describe the External Plantar Artery. It sweeps across the plantar aspect of the foot in a curve, the convexity of which is directed outwards and forwards; and at the interval between the bases of the 1st and 2d metatarsal bones it inosculates with the communicating branch from the dorsalis pedis, forming the *Plantar Arch*, or the *Stirrup Anastomosis*. It gives off numerous muscular branches, and the—

Posterior Perforating, 3 small branches passing through the 3 outer interosseous spaces.

Digital, 4 branches supplying the sides of the 3 outer toes and the outer side of the 2d toe; its inner side, together with the great toe, being supplied by the *Digital Branches* of the *Dorsalis Pedis Communicating*.

Describe the Pulmonary Artery. It alone of the arteries carries venous blood, which it conveys from the right side of the heart to the lungs. It is only about 2 inches long, and nearly all within the pericardium; arising from the right ventricle in front of the ascending aorta, passing upwards and backwards to the under surface of the arch of the aorta, where it bifurcates, and is connected to the aorta by a fibrous cord, the remains of the ductus arteriosus of the fœtus. Its terminal branches are the—

Right and Left Pulmonary Arteries, the latter being the shorter of the two; pass horizontally outwards to the roots of their respective lungs, where each divides into two branches, which again and again subdivide to ramify throughout the lung tissue and end in the capillaries of those organs.

ARTERIAL ANASTOMOSES.

Describe the Anastomosis around the Shoulder-joint. It is formed by the following 8 arteries, viz.—

<i>Posterior Scapular</i> , br. of transv. colli.	<i>Suprascapular</i> , br. of thyroid axis.
<i>Subscapular</i> , br. of axillary.	<i>Ant. Circumflex</i> , br. of axillary.
<i>Dorsalis Scapulae</i> , br. of subscapular.	<i>Post. Circumflex</i> , br. of axillary.
<i>Infraspinous</i> , br. of dorsalis scapulae.	<i>Acromial</i> , br. of acromio-thoracic.

What Arteries Anastomose around the Elbow-joint? The—

<i>Superior Profunda</i> , br. of brachial.	<i>Radial Recurrent</i> , br. of radial.
<i>Inferior Profunda</i> , br. of brachial.	<i>Recurrent Interosseous</i> , br. of posterior interosseous.
<i>Anastomotica Magna</i> , br. of brachial.	<i>Anterior Ulnar Recurrent</i> , br. of ulnar.
<i>Posterior Articular</i> , br. of superior profunda.	<i>Posterior Ulnar Recurrent</i> , br. of ulnar.

What Arteries Anastomose around the Hip-joint? They are the *Gluteal*, *Ilio-lumbar*, and *Circumflex Iliac*, with the *External Circumflex*. *Obturator* and *Sciatic*, with the *Internal Circumflex*. *Comes Nervi Ischiadici*, with the *Perforating* branches of the *Profunda*.

Name the Arteries Anastomosing around the Knee-joint. The—

<i>Descending</i> , br. of ext. circumflex.	<i>Sup. Int. Articular</i> , br. of popliteal.
<i>Anastomotica Magna</i> , br. of femoral.	<i>Inf. Ext. Articular</i> , br. of popliteal.
<i>Inferior Perforating</i> , br. of profunda.	<i>Inf. Int. Articular</i> , br. of popliteal.
<i>Superior Ext. Articular</i> , br. of popliteal.	<i>Recurrent Tibial</i> , br. of anterior tibial.

How is the Collateral Circulation established after Ligature of the Carotid or Subclavian? By the following anastomoses, viz.—

Superior Thyroid, br. of external carotid, with the *Inferior Thyroid*, br. of the thyroid axis, from the subclavian.

Arteria Princeps Cervicis, br. of occipital, from the external carotid, with the *Vertebral*, br. of subclavian, and the *Profunda Cervicis*, br. of the superior intercostal, from the subclavian.

What is the Longest Anastomosis in the Body? That between the subclavian and the external iliac by the anastomosis of the *Superior Epigastric*, br. of the internal mammary, with the *Deep Epigastric*, br. of the external iliac.

[The circle of Willis has been described on page 106; the palmar and plantar arches on pages 108 and 113 respectively; and the anastomosis on the membrana tympani on page 105.]

THE VEINS.

What are the Veins? Vessels carrying blood towards the heart. Their walls are composed of 3 coats, an internal, serous; a middle, muscular; and an external, fibrous. They all carry carbonized or venous blood, except the pulmonary veins, which bring oxygenated blood to the left side of the heart. The deep veins accompany the arteries, generally in the same sheath, and are given the same names. The secondary arteries, as the radial, ulnar, brachial, etc., have each two veins, called *Venæ Comites*. The superficial veins are usually unaccompanied by arteries, and lie, as a rule, between the layers of the superficial fascia, terminating in the deep veins. Many veins are so irregular in their origin that they cannot be accurately described; they all anastomose with each other much more freely than do the arteries.

What are Sinuses? They are venous channels, differing from veins in structure, but answering the same purpose. Those of the cranium are formed by the separation of the layers of the dura mater.

How are the Veins divided? Into the *Pulmonary*, *Systemic*, and *Portal Systems*; the latter being an appendage of the systemic, its capillaries ramifying in the liver.

What Veins have no Valves? The *venæ cavæ*, hepatic, portal, renal, uterine, ovarian, cerebral, spinal, pulmonary, umbilical, and the very small veins.

Name the principal Veins of the Head and Neck. They are the—

(1.) Exterior veins.	(2.) Veins of the diploë and cranium.	
<i>Facial.</i>	<i>Veins of the Diploë.</i>	<i>Transverse Sinus.</i>
<i>Temporal.</i>	<i>Cerebral and Cerebellar.</i>	<i>Cavernous Sinus.</i>
<i>Internal Maxillary.</i>	<i>Superior Longitudinal Sinus.</i>	<i>Occipital Sinus.</i>
<i>Temporo-maxillary.</i>	<i>Inferior Longitudinal Sinus.</i>	<i>Superior Petrosal Sinus.</i>
<i>Posterior Auricular.</i>	<i>Straight Sinus.</i>	<i>Inferior Petrosal Sinus.</i>
<i>Occipital.</i>	<i>Circular Sinus.</i>	<i>Lateral Sinus.</i>

(3.) Veins of the neck draining the above-named.

External Jugular,⁶ terminating in the subclavian vein.⁴

Posterior External Jugular, opens into the external jugular.

Anterior Jugular,⁷ enters the subclavian vein near the external jugular.

Internal Jugular,⁸ formed by the junction of the two last-named sinuses at the jugular foramen, and uniting with the subclavian vein to form the innominate, at the root of the neck. In its course it receives the facial, lingual, pharyngeal, superior and middle thyroid veins, and the occipital.

Vertebral, descends the foramina in the transverse processes of the cervical vertebræ, and empties into the innominate vein.

Name the Veins of the Upper Extremity. They are in two sets, superficial and deep. The deep follow the arteries, generally as *venæ comites*, beginning in the hand as *Digital*, *Interosseous*, and *Palmar* veins, they unite in the *Deep Radial* and *Ulnar* which unite to form the *Venæ Comites* of the brachial artery at the bend of the elbow. The superficial veins lie in the superficial fascia; they are as follows:—

<i>Radial</i>	} <i>Median Cephalic. Cephalic.</i> }	} AXILLARY
<i>Median</i>		
<i>Anterior and Posterior Ulnar</i>		

Name the principal Veins of the Thorax. They are as follows, viz.—

<i>Internal Mammary.</i>	<i>Bronchial.</i>	<i>Right Azygos (major).</i>
<i>Inferior Thyroid.</i>	<i>Mediastinal.</i>	<i>Left Lower Azygos (minor).</i>
<i>Intercostal.</i>	<i>Pericardiac.</i>	<i>Left Upper Azygos (minimus).</i>

What are the Azygos Veins? They supply the place of the *venæ cavæ* in the region where these trunks are deficient, being connected with the heart. *The Right Azygos*¹⁷ begins by a branch from the right lumbar veins usually, passes through the aortic opening in the diaphragm, and ends in the superior vena cava, having drained 9 or 10 right lower intercostals, the vena azygos minor, the right bronchial, œsophageal, mediastinal, and vertebral veins. *The Left Lower Azygos*¹⁸ begins by a branch from the left lumbar or renal, passes the left crus of the diaphragm, crosses the vertebral column and ends in the right azygos, having drained 4 or 5 lower intercostals. *The Left Upper Azygos* drains 2 or 3 left intercostals and empties into either of the other two. It is often wanting, its place being filled by the left superior intercostal vein.²¹

Name the Spinal Veins. They may be arranged into 4 sets, as follows, viz.—

Medulli-spinal, the veins of the spinal cord, which lie in plexus form between the pia mater and arachnoid. They unite into 2 or 3 small trunks near the base of the skull, which terminate in the inferior cerebellar veins or in the petrosal sinuses.

Venæ Basis Vertebrarum, empty into the anterior longitudinal.

Longitudinal, in two plexuses, anterior and posterior, running the whole length of the spinal canal. The posterior join the dorsi-spinal veins, the anterior empty into the vertebral, intercostal, lumbar, and sacral veins in their various regions.

Dorsi-spinal, form a plexus around the spines, processes, and laminae of all the vertebræ. They empty into the vertebral, intercostal, lumbar, and sacral veins in their respective regions.

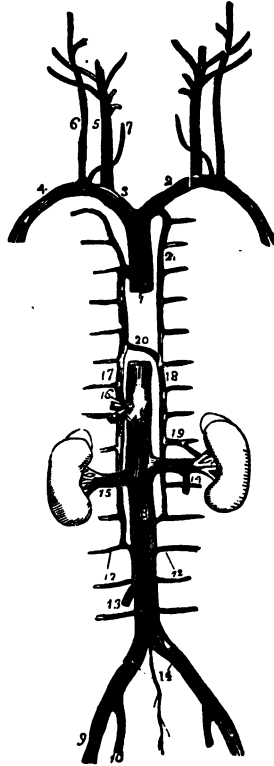
Describe the Subclavian Vein. It is the continuation of the axillary, extending from the outer margin of the 1st rib to the sterno-clavicular articulation, where it unites with the internal jugular to form the innominate vein. At the angle of junction enters the thoracic duct on the left side of the body and the right lymphatic duct on the right side. In its course it receives the external and anterior jugular veins and a branch from the cephalic.

Describe the Venæ Innominatæ. The two innominate veins are each formed by the union of the subclavian and internal jugular, and unite below the 1st costal cartilage to form the superior vena cava. *The Right Innominate*² is about 1½ inch long, and receives, besides its constituent branches, the right internal mammary, right inferior thyroid, and right superior intercostal veins. *The Left Innominate*³ is about 3 inches long, and in its course it receives the vertebral, inferior thyroid, internal mammary, and superior intercostal veins of the left side.

Describe the Superior Vena Cava.¹ It is a short trunk about 2½ or 3 inches in length, formed by the union of the venæ innominatæ, and receives all the blood from the upper half of the body, terminating in the right auricle of the heart. It is half covered by the pericardium, and receives the vena azygos major and small pericardiac and mediastinal veins.

Name the Principal Veins of the Lower Extremity. They are in two sets, superficial and deep. The deep are the *Venæ Comites* of the anterior and

FIG. 60.



posterior tibial and peroneal arteries, which collect the blood from the deep parts of the foot and leg, and unite in the—

Popliteal, which becomes the *Femoral*, and it the *External Iliac* in the same manner as the respectively-named arteries.

The superficial veins of the lower extremity are the—

Internal or Long Saphenous, on the inside of the leg and thigh, enters the femoral at the saphenous opening $1\frac{1}{2}$ inch below Poupart's ligament. In its course it receives the following:—

Cutaneous Branches.	Superficial Circumflex Iliac.
Superficial Epigastric.	Pudic.
	Communicating Branches.

External or Short Saphenous, formed by branches from the dorsum and outer side of the foot, it ascends behind the outer malleolus, up the middle of the back of the leg, and empties into the popliteal vein.

Describe the Internal Iliac Vein.¹⁰ It is formed by the venæ comites of the branches of the internal iliac artery, except the umbilical. It terminates with the external iliac, at the sacro-iliac articulation, to form the common iliac vein. It receives the following veins:—

<i>Gluteal.</i>	<i>Internal Pudic.</i>	<i>Hemorrhoidal and Vesico-</i>	<i>Uterine and Vagi-</i>
<i>Sciatic.</i>	<i>Obturator.</i>	<i>prostatic, in the male.</i>	<i>nal Plexuses, in</i>
			<i>the female.</i>

Describe the Common Iliac Veins.¹¹ They are each formed by the union of the two iliac veins as above described, and unite between the 4th and 5th lumbar vertebræ to form the inferior vena cava, the right common iliac being the shortest of the two. Each receives the *Ilio-lumbar*, sometimes the *Lateral Sacral*, and the left one in addition the *Middle Sacral Vein*, which sometimes ends in the vena cava.

Describe the Inferior Vena Cava.⁸ It extends from the junction of the two common iliac veins, passing along the front of the spine, through the tendinous centre of the diaphragm, to its termination in the right auricle of the heart. It receives the following veins:—

<i>Lumbar.</i> ¹²	<i>Renal.</i> ¹⁵	<i>Phrenic.</i>
<i>Right Spermatic.</i> ¹³	<i>Supra-renal.</i>	<i>Hepatic.</i> ¹⁶

Describe the Portal System. The portal system is formed by the *Superior and Inferior Mesenteric, Splenic, and Gastric Veins*, which collect the blood from the digestive viscera, and by their union behind the head of the pancreas form the *Portal Vein*, which enters the transverse fissure of the liver, where it divides into 2 branches, and these again subdivide, ramifying throughout that organ, therein receiving blood also from the branches of the hepatic artery. Its contents enter the inferior vena cava by the hepatic vein. The *portal vein* is about 4 inches long, receives the *Gastric and Cystic Veins*, and is

formed by the union of the superior mesenteric and splenic veins, the inferior mesenteric joining the splenic, which also receives one of the gastric, the other emptying into the portal.

Name the Cardiac Veins. They return the blood from the tissue of the heart into the right auricle. They are the—

Great Cardiac Vein.

Anterior Cardiac Veins.

Posterior Cardiac Vein.

Vena Thebesii.

Coronary Sinus, is a dilatation of the great cardiac vein, receiving the posterior cardiac and an oblique vein from the left auricle.

Describe the Pulmonary Veins. They alone of the veins carry arterial blood, beginning in the capillaries of the lungs, forming a single trunk for each lobule, which, uniting into a single trunk for each lobe, form two main trunks from each lung which open separately into the left auricle. Sometimes the 3 lobe-trunks of the right lung remain separate to their termination in the auricle, and not unfrequently a common opening serves for the 2 left pulmonary veins.

THE ABSORBENTS.

What are the Lymphatics? They are very delicate, transparent vessels, formed of three coats like arteries and veins, found in nearly every part of the body, except the brain, spinal cord, eyeball, cartilage, tendons, membranes of the ovum, placenta, umbilical cord, nails, cuticle, hair, and bone. They are nourished by nutrient vessels, and have valves, but no nerves, so far as known. They convey *lymph* to the blood.

What are the Lacteals? They are the lymphatics of the small intestine, conveying the *chyle* therefrom into the blood.

What are the Lymphatic Glands? Small solid bodies placed in the course of the absorbent vessels, and found chiefly in the mesentery, along the great blood-vessels, in the mediastina, axilla, neck, front of the elbow, groin, and popliteal space. The lymphatics and lacteals before entering these glands break up into smaller branches, the *afferent vessels*, which form a plexus in the gland, and pass out as *efferent vessels* to unite again in one trunk. They also contain spheroidal bodies about $\frac{1}{3000}$ inch in diameter. These glands are named after the regions in which they are situated, as the axillary, inguinal, mesenteric, etc.

Describe the Thoracic Duct. It is the main channel for the lymph and chyle from the whole body except the right arm and lung, right side of the head, heart, neck, and thorax, and the convex surface of the liver. It begins in the *Receptaculum Chyli*, in front of the 2d lumbar vertebra, passes through the aortic opening in the diaphragm, and at the upper border of the 7th cer-

vical vertebra it curves forwards, outwards, and downwards, terminating in the left subclavian vein at its junction with the internal jugular.

Describe the Right Lymphatic Duct. It is about an inch long, terminating in the right subclavian vein at its union with the internal jugular, and draining the lymphatics of those parts which are not connected with the thoracic duct.

THE NERVOUS SYSTEM.

How is the Nervous System divided? Into the *Cerebro-spinal*, or nervous system of animal life; and the *Sympathetic*, or nervous system of organic life.

What is the Structure of the Nervous tissue? It is formed of two substances essentially different from each other, the *White* or fibrous, and the *Gray* or vesicular matter. Chemically these contain phosphorized fat, albumen, and water. A third form, the *Gelatinous*, is yet a subject of disagreement among authorities.

Describe the White Nerve-matter. It is composed of a number of tubes, each consisting of a central *Axis-cylinder*, surrounded by the *White Substance of Schwann*, and this again enclosed in the tubular membrane, or *Nerve-sheath*. The whole arrangement is precisely analogous to that of a submarine telegraphic cable. A bundle of such tubes is invested by a covering, the *Neurilemma*, or perineurium, and is called a *Nerve*, and is nourished by a minute capillary system of blood-vessels.

How do Nerves terminate? Sensory nerves end peripherally as plexuses in their end-organs in the tissues. Motor nerves end peripherally in muscles as plexuses, or plates. Their central termination is not yet understood.

Of what does the Cerebro-spinal system consist? Of the brain, the spinal cord, the ganglia, and the cranial and spinal nerves.

THE BRAIN.

What are the Membranes of the Brain? The *dura mater*, the *arachnoid*, and the *pia mater*.

Describe the Dura Mater. It is a dense fibrous membrane lining the interior of the skull, and forming the internal periosteum of the cranial bones. It is continuous with the *dura mater* of the spinal cord, and is attached to many parts of the base of the skull. It presents the following for examination:—

Falx Cerebri, an arched process sent into the longitudinal fissure of the brain, contains in its upper and lower margins the superior and inferior longitudinal sinuses.

Tentorium Cerebelli, a lamina of dura mater supporting the posterior lobes of the brain, and covering the upper surface of the cerebellum. It incloses the lateral and superior petrosal sinuses.

Falx Cerebelli, projects between the lateral lobes of the cerebellum, from the tentorium to the foramen magnum.

Pachionian Bodies, clusters of white granulations situated on the outer and inner surfaces of the dura mater, in the superior longitudinal sinus, and on the pia mater, found only after the 7th year, and of unknown function.

Describe the Arachnoid. It is the serous sac which forms the middle membrane, having a visceral and a parietal layer, the latter being reflected over the interior surface of the dura mater. *The Anterior Sub-arachnoid Space* is the interval between it and the pia mater of the brain at the base, where it is extended across between the two middle lobes. *The Posterior Sub-arachnoid Space* is a similar interval between the hemispheres of the brain and the medulla oblongata. These spaces communicate together across the crura cerebri; and also with the general ventricular cavity, by an opening in the lower boundary of the 4th ventricle; and contain the cerebro-spinal fluid which forms a water-bed for the nervous centres. The sac of the arachnoid also contains a serous fluid in small quantity.

What is the Pia Mater? It is the vascular membrane, being supplied by the branches of the internal carotid and vertebral arteries. It covers the surface of the brain, dipping down into all the sulci, and forms the velum interpositum and choroid plexus of the 4th ventricle; and contains lymphatics and nerves.

How is the Brain divided? Into the cerebrum, cerebellum, pons Varolii, and medulla oblongata. Its average weight in the male adult is 49½ oz., in the female 44 oz., of which the cerebrum is about seven-eighths. The extreme weights in 278 male cases were 65 oz. and 34 oz.,—in 191 female cases, 56 oz. and 31 oz.

Describe the principal Lobes and Fissures of the Cerebrum. Each lateral half of the cerebrum, or hemisphere, has the following 5 lobes and 8 fissures, besides many of less importance.

Frontal Lobe, bounded internally by the longitudinal fissure, below by the fissure of Sylvius, and posteriorly by the fissure of Rolando.

Parietal Lobe, extending down to the fissure of Sylvius, and antero-posteriorly from the fissure of Rolando to the parieto-occipital.

Occipital Lobe, behind the parieto-occipital fissure.

Temporo-sphenoidal Lobe, lying in the middle fossa of the skull, and bounded in front by the fissure of Sylvius.

× *Central Lobe, or Island of Reil*, lies in the fissure of Sylvius, covered by the frontal and temporo-sphenoidal lobes.

✓ *Longitudinal Fissure*, separating the two hemispheres.

✓ *Fissure of Sylvius*, at the base of the brain, extending outwards on each side, and dividing into 2 branches, an ascending and a horizontal one. It lodges the middle cerebral artery.

Fissure of Rolando, on the superior surface, extending from the longitudinal fissure about its centre, downwards and forwards towards the fissure of Sylvius, separating the frontal and parietal lobes.

Parieto-occipital Fissure, extends from the longitudinal fissure outwards for about an inch between the parietal and occipital lobes. It is better marked in a longitudinal section of the brain.

Calloso-marginal Fissure, above the gyrus fornicatus on the inner surface of the hemisphere.

Transverse Fissure, between the middle lobe and the crus cerebri, at the base of the brain. It admits the pia mater to the lateral ventricle.

Calcarine Fissure, also seen on the inner surface, extending from the lower end of the parieto-occipital fissure outwards to the posterior border of the occipital lobe.

First Temporo-sphenoidal Fissure, below the fissure of Sylvius, on the lateral surface of the brain.

Name the principal Convolution of the Cerebrum. The superior and inner surfaces of each hemisphere are formed of convolutions (*gyri*) with intervening furrows (*sulci*) of various depths, both gyri and sulci being formed of gray matter thus arranged to enable it to present a great extent of surface. The convolutions are not uniform in all brains as to arrangement, nor are they symmetrical in the two hemispheres. The most constant are the following:—

Gyrus Fornicatus, the convolution over the corpus callosum, seen on the inner surface, arching from before backwards.

Convolution of the Longitudinal Fissure, along the edge of that fissure on the superior surface, curving over the front and back of each hemisphere, to the base of the brain.

Ascending Frontal, lies in front of the fissure of Rolando.

Ascending Parietal, lies behind the fissure of Rolando.

Angular Gyrus, or Pli Courbe, around the posterior end of the first temporo-sphenoidal fissure.

Many other convolutions are named by writers on the localization of cerebral functions, such as the temporo-sphenoidal, occipital, supra-marginal convolutions, etc. Their names will be found sufficiently explanatory of their several locations. The *Cuneus*, *Precuneus*, and *Paracentral Lobule* are names

given to the regions between the calcarine, parieto-occipital, and calloso-marginal fissures, the last-named locality lying in front of the last-named fissure.

Name the Points in view on the Inferior Surface of the Brain. From before backwards, excluding the cranial nerves, are the following:—

Longitudinal Fissure, its anterior portion.

Corpus Callosum, the great transverse commissure of the brain.

Lamina Cinerea, a thin, gray layer, beneath the optic tracts.

Fissure of Sylvius, between the anterior and temporo-sphenoidal lobes.

Anterior Perforated Space, for vessels to the corpora striata.

Optic Commissure, formed by the junction of the optic tracts.

Tuber Cinereum, a gray lamina behind the optic commissure, forming part of the floor of the 3d ventricle.

Infundibulum, a hollow process, connecting the pituitary cavity with the 3d ventricle in the foetus.

Pituitary Body, a vascular bi-lobed body, of glandular structure, projects from the infundibulum into the sella turcica of the sphenoid.

Corpora Albicantia, two round, white eminences, united together; they are the anterior crura of the fornix folded on themselves.

Posterior Perforated Space (Pons Tarini), for vessels to the optic thalami.

Crura Cerebri, or cerebral peduncles, connect the cerebrum with the cerebellum, spinal cord, and medulla oblongata; containing the fibres passing to the basal ganglia. They, with the optic tracts, form the boundaries of the *Inter-peduncular Space*.

Pons Varolii, to be described separately. [See page 127.]

What Ganglia are comprised in the Brain? Besides the gray matter of the cerebral hemispheres, of the cerebellum, and of the medulla oblongata, there are the following at the base of the brain:—

Olfactory Bulbs. Optic Thalami. Tuber Annulare.

Corpora Striata. Tubercula Quadrigemina.

Describe the Basal Ganglia. They are as follows, viz.—

Olfactory Bulbs are the ganglia of the sense of smell, lie one on each side of the median line, upon the cribriform plate of the ethmoid, and are connected with the hemispheres by the *Olfactory Tracts*.

Corpora Striata, the motor ganglia, are situated in the floor of the lateral ventricles, and therefore within the hemispheres. Each corpus striatum has a—

Caudate Nucleus,—the intraventricular part.

Lenticular Nucleus,—the extraventricular part.

Internal Capsule,—divides these two parts.

Optic Thalami, the sensory ganglia, are in the floor of the lateral ventricles,

behind the corpora striata. Each thalamus opticus is divided into an anterior tubercle seen in the lateral ventricle, and a posterior tubercle beneath the fornix.

Corpora Quadrigemina, or Optic Lobes (2 nates and 2 testes), lie beneath the posterior lobes, near the union of the cerebrum and cerebellum. They form two single ganglia for vision. [Described under Meso-cephalon.]

Tuber Annulare, a ganglion in the substance of the pons Varolii, the seat of indistinct sensation probably.

Name the Commissures of the Brain. These connecting bands number 19 in all, of which 10 are longitudinal, and 9 transverse in direction, viz.—

Longitudinal Commissures.

Olfactory Tracts.
Tænia Semicircularis.
Crura Cerebri.
Processes e Cerebello ad Testes.
Peduncles of the Pineal Gland.
Fornix.
Infundibulum.
Lamina Cinerea.
Gyrus Fornicatus.
Fasciculus Unciformis.

Transverse Commissures.

Anterior Commissure of 3d ventricle.
Middle Commissure of 3d ventricle.
Posterior Commissure of 3d ventricle.
Corpus Callosum.
Optic Commissure.
Pons Varolii.
Fornix, is a transverse commissure as well as a longitudinal one.
Posterior Medullary Velum.
Valve of Vieussens.

What are the Ventricles of the Brain? They are 5 cavities, each of which is situated as follows:—

Two Lateral Ventricles, within the substance of the hemispheres.

Third Ventricle, between the optic thalami, on the base of the brain.

Fourth Ventricle, between the cerebellum and the medulla oblongata.

Fifth Ventricle, between the two lateral, in the septum lucidum.

Ventricle of the Corpus Callosum, so called, is merely the space between the upper surface of that commissure and the margins of the hemispheres above (*labia cerebri*).

The *Foramina of Monroe* connect the two lateral ventricles with the 3d; the *Iter e Tertio ad Quartam Ventriculum*, or aqueduct of Sylvius, connects the 3d with the 4th.

Describe and bound the Lateral Ventricles. They each have 3 *Cornua*, the anterior, middle, and posterior, and are bounded as follows:—

Roof,—the corpus callosum.

Floor,—the corpus striatum, tænia semicircularis or horny band of Tarinus, optic thalamus, choroid plexus, corpus fimbriatum, and the fornix.

Internally,—the septum lucidum.

Externally, behind and in front,—the brain substance.

What are the parts above-named? Some, as the corpus striatum, optic thalamus, etc., have been described already; the others are—

Corpus Callosum, the great transverse commissure, arching backwards to become continuous with the fornix, reflected below, forming the *Peduncles* at the entrance of the fissure of Sylvius; and marked above by a depression, the *Raphé*, and longitudinal elevations, the *Striæ Longitudinales* or *Nerves of Lancisi*.

Tania Semicircularis, consists of commissural fibres between the corpus striatum and the optic thalamus.

Choroid Plexus of Veins, is the margin of a fold of pia mater which enters at the transverse fissure, passes up the descending cornu, passes through the foramen of Monroe, and as the *Velum Interpositum* spreads out over the roof of the 3d ventricle.

Corpus Fimbriatum, or *Tania Hippocampi*, is a white band, the edge of the posterior pillar of the fornix.

Fornix, is a commissure situated beneath the corpus callosum, but continuous with it posteriorly, the *Septum Lucidum* separating them in front. It is of triangular form with the apex in front. Its *Anterior Crura* curve downwards to the base of the brain, are there reflected, forming the *Corpora Albicantia*, and end in the optic thalami. Its *Posterior Crura* pass down the descending horns of the lateral ventricles, as the *Hippocampi Majores*. The *Lyra* is a series of markings on its under surface.

Septum Lucidum, consists of 2 layers of white and gray matter, lined by epithelium; is placed vertically between the lateral ventricles, from the raphé of the corpus callosum above to the fornix below. The cavity in its centre is the 5th ventricle.

Describe the Cornua of the Lateral Ventricles. The *Anterior Cornu* curves over the anterior end of the corpus striatum into the anterior lobe. The *Posterior Cornu* curves downwards and inwards in the occipital lobe, and contains a smooth eminence, the *Hippocampus Minor*. The *Middle Cornu* descends into the middle lobe to the transverse fissure at the base of the brain, curving backwards, outwards, downwards, forwards, and inwards (B. O. D. F. I.). On its floor are the following:—

Hippocampus Major, the doubled-in surface of the gyrus fornicatus.

Pes Hippocampi, rounded eminences at the end of the hippocampus.

Pes Accessorius, or *Eminentia Collateralis*, between the hippocampi, at the junction of the middle and posterior cornua.

Corpus Fimbriatum, a continuation of the posterior pillar of the fornix.

Choroid Plexus of Veins, a process of pia mater, already described.

Fascia Dentata, the gray serrated edge of the middle lobe.

Transverse Fissure, at the extremity of the cornu, extending to the median

line, between the hippocampus major and the optic thalamus. It opens at the base of the brain between the middle lobe and the crus cerebri, and admits the pia mater to the middle cornu.

Describe and bound the Third Ventricle. It is a mere fissure, situated between the optic thalami in the median line. It communicates with the lateral ventricles above by the foramina of Monroe, and with the 4th ventricle behind by the iter e tertio ad quartam ventriculorum. It is crossed by 3 bands, the anterior, middle, and posterior commissures, the middle one being of gray matter, the others of white. In the fœtus its cavity communicates with the 5th ventricle, and through the infundibulum with the cavity of the pituitary body. It is bounded as follows :—

Roof,—the velum interpositum, and above it the fornix.

Floor,—the parts comprised in the interpeduncular space at the base of the brain, viz.—the lamina cinerea, tuber cinereum, infundibulum, corpora albicantia, and posterior perforated space.

Anteriorly,—the anterior crura of the fornix, and the anterior commissure of the ventricle.

Posteriorly,—the posterior commissure, and the iter e tertio, etc.

Laterally,—the optic thalami and the peduncles of the pineal gland.

Describe and bound the Fourth Ventricle. The fourth, or ventricle of the cerebellum, lies between the medulla oblongata and the cerebellum. It is considered by some to be a dilatation of the central canal of the spinal cord, and is enclosed posteriorly by the pia mater; an opening in which admits the entrance and exit of the sub-arachnoid fluid from the sub-arachnoidean space of the brain and spinal cord, and a fold of the pia mater called the *Choroid Plexus*. It also communicates with the 3d ventricle by the *iter e tertio, etc.* Its boundaries are as follows :—

Roof,—the valve of Vieussens, and the cerebellum.

Anteriorly,—the medulla oblongata, and the pons Varolii.

Posteriorly,—the cerebellum.

Laterally,—the processus e cerebello ad testes, the posterior pyramids and the restiform bodies of the medulla oblongata.

Floor,—the posterior median fissure of the medulla, the orifice of the central canal of the cord, the locus ceruleus and tænia violacea (both of blue color), the fasculi teretes (2 spindle-shaped elevations) and eminences of origin of certain nerves.

Describe the Fifth Ventricle. It is situated between the two layers of the septum lucidum, and therefore between the lateral ventricles. Its roof is formed by the corpus callosum, and in the fœtus it communicates with the 3d ventricle by an opening between the pillars of the fornix. It usually contains fluid.

What is the Meso-cephalon? It comprises the parts which connect the cerebrum with the cerebellum and the medulla oblongata, and includes the following structures, viz. :—

X { *Pons Varolii*, a great transverse commissure seen at the base of the brain in front of the medulla. Its fibres connect the hemispheres of the cerebellum with each other and the medulla. *rests on floor of 4th ventricle*

• *Crura Cerebri*, or *Peduncles of the Cerebrum*, extend from the pons to the corpora striata and optic thalami, and consist of the *Peduncular Fibres* which pass from the medulla to the ganglia named, and thence upwards to the gray matter of the hemispheres as the *Corona Radiata*. Each crus contains in its centre a mass of gray matter called the *locus niger*.

X *Valve of Vieussens*, is a thin lamina forming the roof of the *iter e tertio ad quartam ventriculorum*, and stretched between the two *processus e cerebello ad testes*. Its *Frenulum* is a ridge descending on its upper part from the corpora quadrigemina.

Corpora Quadrigemina, or *Optic Lobes*, are 4 spherical eminences placed together above the valve of Vieussens, and behind the 3d ventricle beneath the posterior border of the corpus callosum. The anterior pair are called the *Nates*, the posterior, the *Testes*, and they are connected with the optic thalami and optic tracts by 4 bands, their *Brachia*; and with the cerebellum by a white cord on each side, the *Processus e Cerebello ad Testes*. They form two ganglia for the centre of vision.

Pineal Gland, is a small conical reddish body situated between the *nates*, on which it rests. Its 4 peduncles connect it with the anterior crura of the fornix, and the optic thalami. It is very vascular, and has a small cavity (said to communicate with the 3d ventricle) which contains a viscid fluid, and some concretions formed of the phosphates of lime, magnesia, and ammonia, etc., called the *Acerculus Cerebri*.

X Describe the *Medulla Oblongata*. This ganglion is the upper enlarged part of the spinal cord, extending from the upper border of the atlas to the pons Varolii. Its posterior surface forms the floor of the 4th ventricle, its anterior surface rests on the basilar groove of the occipital bone. It is divided into two lateral halves by the *Anterior and Posterior Median Fissures*, and contains gray matter scattered throughout it, from which the cranial nerves from the 5th to the 12th inclusive arise entirely or in part. In it are supposed to lie the centres for the vaso-motor and the cardiac nerves, also centres of respiration, phonation, deglutition, mastication, and expression. On each side it presents the following,—

Anterior Pyramid, formed by the anterior and lateral columns of the spinal cord.

Olivary Body, behind the pyramid, from which it is separated by the groove of the hypoglossal nerve. It contains a capsule of gray matter in its centre, the *Corpus Dentatum*.

Lateral Tract, continuous with the lateral column of the spinal cord, lies behind the olivary body and in front of the restiform.

Restiform Body, the posterior lateral portion of the medulla, also called the *Fasciculus Cuneatus*.

Posterior Pyramid, or Fasciculus Gracilis, the most posterior portion, is formed by the posterior median column of the spinal cord. It diverges from its fellow at the apex of the 4th ventricle and forms the lateral boundary of the *Calamus Scriptorius*.

What is the Cerebellum? It is that portion of the brain situated in the inferior occipital fossæ, beneath the posterior lobes of the cerebrum. It is an oblong flattened ganglion, divided into two lateral hemispheres, and a central portion, the *Vermiform Process*.

Name the Fissures of the Cerebellum. They are 3 in number,—2 vertical and 1 horizontal, viz.—

Incisura Cerebelli Anterior.

Great Horizontal Fissure, from which secondary fissures originate.

Incisura Cerebelli Posterior.

Name the Points on the surfaces of the Cerebellum. They comprise 15 lobes, 2 commissures, and 3 projections, as follows:—

On the upper surface of each hemisphere,—

Anterior or Square Lobe.

Posterior or Semilunar Lobe.

On the under surface of each hemisphere, from before backwards,—

Flocculus, Sub-peduncular Lobe, or Pneumogastric Lobule.

Amygdala Lobe, or Tonsil, projects into the 4th ventricle.

Digastric Lobe. Slender Lobe. Posterior Inferior Lobe.

On the vermiform process are the—

Lobulus Centralis.

Pyramid.

Monticulus Cerebelli.

Uvula.

Commissura Simplex.

Commissura Brevis.

} superiorly. } inferiorly.

The Vallecule, or valley of the cerebellum, is the central depression on its under surface between the two lateral hemispheres.

Name the Peduncles of the Cerebellum, They are 3 in number on each side, and from below upwards are as follows:—

Processus e Cerebello ad Medullam, to the medulla oblongata.

Processus e Cerebello ad Pontem, connect the hemispheres.

Processus e Cerebello ad Testes, to the cerebrum.

Describe the Gray Matter of the Cerebellum. It occupies the surface of

the mass in laminated shape, and is traversed by curved furrows, between the laminae. A vertical section gives an appearance called the *Arbor Vita*.

Corpus Dentatum, is a capsule of gray matter in the centre of the white and is open anteriorly. It is sometimes called the ganglion of the cerebellum.

THE SPINAL CORD.

Describe the Spinal Cord. It is that part of the cerebro-spinal axis which is situated in the spinal canal. Its length is about 16 inches, terminating at the lower border of the 1st lumbar vertebra in the *Cauda Equina*. It is cylindrical in general form, with 2 enlargements, one in the cervical region, the other in the lumbar. It is composed of gray and white matter, the gray being inside (instead of outside, as in the cerebrum), and arranged so as to present a crescentic appearance in horizontal section, joined by a transverse commissure, and forming, by their extremities, the *Anterior and Posterior Horns*, from which regions respectively the anterior and posterior roots of the spinal nerves have their apparent origin.

Membranes of the cord are 3, as in the brain,—dura mater, arachnoid, and pia mater. The *Dura Mater* is not adherent to the spinal column, but is connected thereto by fibrous tissue. The *Arachnoid* is arranged as on the brain, its sub-arachnoid space being filled with its fluid, for the protection of the cord. The *Pia Mater* has a fibrous band on each side, the ligamentum denticulatum, connecting it to the dura mater by some 20 serrations.

Fissures, number 8,—the anterior and posterior median, the anterior and posterior lateral on each side, and the two posterior intermediary in the cervical region.

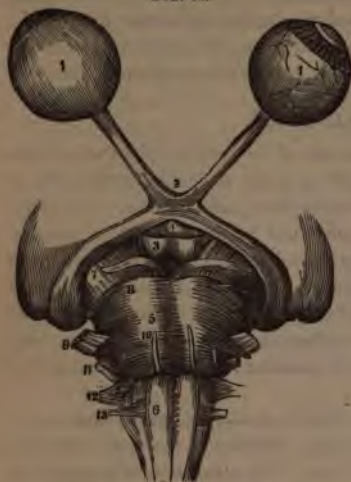Columns, are 8 in number, 4 on each side of the cord,—an anterior, lateral, posterior, and posterior median. The *Anterior* is continuous with the anterior pyramid of the medulla; the *Lateral*, with the lateral column of the medulla; the *Posterior*, with the restiform body; the *Posterior-median*, with the posterior pyramid.

Central Canal, or *Ventricle of the Cord*, extends through its entire length in the foetus and in some adults, but is usually closed except for one-half inch below its orifice in the floor of the 4th ventricle.

THE CRANIAL NERVES.

Describe each Cranial Nerve, stating its function, apparent and deep origin, foramen of exit, principal branches and distribution. There are 12 pairs of cranial nerves (9 according to Willis), of which those from the 6th to the 12th inclusive have their deep origin wholly or in part from the floor of the 4th ventricle. They are the—

FIG. 61.



—arises from the crus cerebri, *deeply* from the floor of the iter e tertio ad quartam ventriculium; *exit* through the sphenoidal fissure, to all the muscles of the orbit except the superior oblique and the external rectus, also to the iris.

FIG. 62.



1st, **Olfactory**, nerve of smell,—*arises* by 2 roots from the anterior cerebral lobe and 1 root from the middle lobe, *deeply* from the optic thalamus, island of Reil, corpus striatum, and anterior commissure; *exit* by 20 branches through the cribriform plate, to the Schneiderian membrane. Its bulb is a lobe of the cerebrum.

2d, **Optic**, nerve of sight,—*arises* from the optic commissure² and tracts, *deeply* from the optic thalamus, corpora geniculata, and corpora quadrigemina; *exit* through the optic foramen to the retina.

[This nerve and the Optic Tract are more fully described at the end of the volume, under the sub-title, **VESSELS AND NERVES OF THE EYE.**]

3d, **Motor Oculi**,⁷ motor of the eye, —*arises* from the crus cerebri, *deeply* from the floor of the iter e tertio ad quartam ventriculium; *exit* through the sphenoidal fissure, to all the muscles of the orbit except the superior oblique and the external rectus, also to the iris.

4th, **Patheticus**,⁸ motor of the eye, —*arises* from the outer side of the crus, *deeply* from the valve of Vieussens; *exit* through the sphenoidal fissure, to the superior oblique muscle of the eye.

5th, **Trigeminus**,⁹ nerve of sensation, motion, and taste,—*arises* by two roots,—from the side of the pons Varolii,⁵ *deeply* from the pyramidal body (motor root), lateral tract of the medulla, the pons, and cerebellum (sensory root). *Exit* of ophthalmic division by the sphenoidal fissure; of superior maxillary by the foramen rotundum; of inferior max-

illary division and motor root, by the foramen ovale. The *Gasserian ganglion*,⁵ is situated on the sensory root at the origin of its three divisions.

OPHTHALMIC DIVISION,⁶ goes to the forehead, eyelids, lachrymal gland, conjunctiva, iris, ciliary ganglion, and the nose. Its branches are—

Frontal,⁹ *Lachrymal*,¹⁰ *Nasal*,¹¹

SUPERIOR MAXILLARY DIVISION,⁷ goes to the temple, cheek, lower eyelid, nose, lip, upper teeth, and to Meckel's ganglion, thence to the palate. Its branches are the—

<i>Orbital</i> , ²⁰	<i>Posterior Dental</i> , ¹⁶	<i>Infraorbital</i> , ¹⁵ {	Palpebral.
<i>Spheno-palatine</i> .	<i>Anterior Dental</i> , ¹⁸		Nasal.
			Labial.

INFERIOR MAXILLARY DIVISION,⁸ includes the motor branch, and is therefore a nerve of common sensation, motion, and special sense (taste). Its motor filaments go to the muscles of mastication; its sensory to the auditory meatus, to the otic and submaxillary ganglia, the anterior part of the tongue, the cheek, teeth, and the lingualis muscle (sensation). Its branches are the—

<i>Masseteric</i> .	<i>Pterygoid</i> .	<i>Gustatory</i> , ²⁵	} Mylo-hyoid. ²⁶	
<i>Deep Temporal</i> (α).	<i>Auriculo-temporal</i> , ²⁶	<i>Inferior Dental</i> , ²⁴		Incisor.
<i>Buccal</i> .				Mental. ²⁵
				Dental.

6th, Abducens,¹⁰ motor of the eye,—*arises* from the medulla oblongata, *deeply* from the floor of the 4th ventricle; *exit* by the sphenoidal fissure, *to* the external rectus muscle of the eye.

7th, Facial, or Portio Dura,¹¹ motor of the face, ear, palate, and tongue,—*arises* from the groove between the olivary and restiform bodies of the medulla, *deeply* from the floor of the 4th ventricle. *Exit* by internal auditory meatus, through the aqueductus Fallopii, and stylo-mastoid foramen, *to* the muscles of expression, the tongue, muscles of the ear and palate, etc. It *communicates* with the carotid and meningeal plexuses, the spheno-palatine (Meckel's) and the otic ganglia, the auditory, great auricular, pneumogastric, glosso-pharyngeal, and 5th nerves. Its branches are the—

<i>Great Petrosal</i> , to Meckel's ganglion.	<i>Posterior Auricular</i> .
<i>Small Petrosal</i> , to the otic ganglion.	<i>Digastric</i> .
<i>External Petrosal</i> , to the meningeal plexus.	<i>Stylo-hyoid</i> .
<i>Tympanic</i> , to the muscles of the tympanum.	<i>Temporo-facial</i> .
<i>Chorda Tympani</i> , to the tongue, etc.	<i>Cervico-facial</i> .

8th, Auditory, or Portio Mollis of the 7th,¹¹ nerve of hearing,—*arises* just external to the facial, *deeply* from the floor of the 4th ventricle; *exit* by the internal auditory meatus, *to* the internal ear. Its branches are two, the—

Vestibular, to the vestibule. *Cochlear*, to the cochlea.

[This nerve is more fully described at the end of the volume, under the sub-title, THE INTERNAL EAR.]

9th, Glosso-pharyngeal,¹¹ nerve of sensation and taste,—*arises* from the medulla oblongata behind the olivary body, *deeply* from the floor of the 4th ventricle; *exit* by the jugular foramen, *to* the back of the tongue (taste), the middle ear, the tonsils, and pharynx. Branches are—

<i>Tympanic</i> (Jacobson's).	<i>Pharyngeal.</i>	<i>Tonsillar.</i>
<i>Carotid.</i>	<i>Muscular.</i>	<i>Lingual.</i>

10th, Pneumogastric, or Par Vagum,¹² the auriculo-laryngo-pharyngo-cesophago-tracheo-pulmono-cardio-gastro-hepatic nerve. A nerve of sensation and motion, probably receiving its motor influence from its *spinal* accessory. It *arises* from the medulla behind the olivary body and below the 9th nerve, *deeply* from the floor of the 4th ventricle; *exit* by the jugular foramen, *to* the parts indicated by the above euphonious appellation, supplying *sensation* to the external ear and larynx, *motion* to the other parts. Its branches are the—

<i>Auricular</i> (Arnold's).	<i>Recurrent Laryngeal.</i>	<i>Œsophageal.</i>
<i>Pharyngeal.</i>	<i>Cervical and Thoracic Cardiac.</i>	<i>Gastric.</i>
<i>Superior Laryngeal.</i>	<i>Ant. and Post. Pulmonary.</i>	<i>Hepatic.</i>

11th, Spinal Accessory¹³ (to the pneumogastric),—motor nerve,—*arises* by a double origin (1) from the lateral tract of the medulla, *deeply* from near the floor of the 4th ventricle; (2) from the lateral tract of the cord by several filaments, as low as the 6th cervical nerve, *deeply* from the anterior gray horn of the cord. *Exit* by jugular foramen, its spinal portion having first entered by the foramen magnum, *to* the sterno-cleido-mastoid and trapezius muscles, *communicating* with the pharyngeal and laryngeal nerves by its accessory portion in the same sheath with the pneumogastric; also with the 2d, 3d, 4th, and 5th cervical nerves by its spinal portion. Its branches are indicated by the above-described distribution.

12th, Hypo-glossal,¹³ (Nonus or 9th of Willis), motor of the tongue,—*arises* by 10 to 15 filaments from the groove between the pyramidal and olivary bodies of the medulla oblongata, *deeply* from the floor of the 4th ventricle; *exit* by the anterior condyloid foramen, *to* the thyro- and genio-hyoid, the stylo-hyo-, and genio-hyo-glossus muscles; and by the *descendens noni* branch to the sterno-hyoid, sterno-thyroid, and omo-hyoid muscles. It *communicates* with the pneumogastric, sympathetic, 1st and 2d cervical, and gustatory nerves. Its branches of distribution are the—

<i>Descendens Noni.</i>	<i>Muscular.</i>	<i>Thyro-hyoid.</i>
-------------------------	------------------	---------------------

What Nerves enter the Cranium before passing out of it? The spinal portion of the Spinal Accessory, and the Nasal branch of the Ophthalmic. The first enters by the foramen magnum, and then leaves by the jugular foramen. The second enters from the orbit by the anterior ethmoidal foramen, and leaves by the nasal slit at the side of the crista galli.

THE SPINAL NERVES.

Describe the Spinal Nerves. There are 31 pairs of spinal nerves, of which the cervical number 8, the dorsal 12, the lumbar 5, the sacral 5, and the coccygeal 1. The 1st cervical escapes above the 1st vertebra, each of the others below the corresponding vertebra through the intervertebral foramina. Each nerve arises by 2 roots, an anterior motor root, and a posterior sensory one, the latter having a ganglion on it. These unite, and the nerve then divides into 2 branches, both having motor and sensory fibres. The posterior branches are small and generally unimportant; they supply the muscles and integument of the back. The anterior branches supply the neck, front, and sides of the trunk, and the extremities, uniting in various regions to form plexuses from which important nerve-trunks originate.

How is the Cervical Plexus formed and distributed? It is formed by the anterior branches of the first 4 cervical nerves, and rests on the levator anguli scapulæ and scalenus medius muscles. Its branches (10) comprise 4 superficial to the integument of the head and neck, and the following deep branches, viz.—

Phrenic. Communicans Nomi. 2 Muscular. 2 Communicating.

Describe the Phrenic Nerve. It arises by 3 heads from the 3d, 4th, and 5th cervical, descends across the front of the scalenus anticus, crossing the subclavian and internal mammary arteries in the middle mediastinum, and is distributed to the inferior surface of the diaphragm. It is often called the Internal Respiratory Nerve of Bell. It sends filaments to the pericardium and pleura, and communicates with the plexuses of the sympathetic in the abdomen.

Describe the formation and distribution of the Brachial Plexus. It is formed by the union of the 4 lower cervical nerves and the 1st dorsal. The 5th, 6th, and 7th unite into one trunk externally to the scalenus medius, as also do the 8th cervical and 1st dorsal behind the same muscle. Below the line of the clavicle both these trunks bifurcate; the two adjacent branches unite behind the axillary artery making the *Posterior Cord*, and the remaining 2 form the *Outer and Inner Cords*, referred to the artery. Each of these cords bifurcates, but the 2 adjacent branches of the outer and inner cords unite over the artery, to form the *Median Nerve*, leaving 4 other branches, the *Ulnar, Musculo-cutaneous, Musculo-spinal*, and *Circumflex Nerves*, the last 2 being derived from the posterior cord.

THE BRANCHES of the brachial plexus are as follows, viz.—
Above the clavicle are given off 4, the—

Communicating, completing the phrenic nerve.

Muscular, to the longus colli, scaleni, rhomboidei, and subclavius muscles.

Posterior, or Long Thoracic, external respiratory nerve of Bell, to the serratus magnus, arising from the 5th and 6th cervical.

Suprascapular, from the 1st trunk of the plexus, to the scapular muscles.

Below the clavicle are 12, the,—

2 *Anterior Thoracic*, from outer and inner cords to the pectoral muscles.

3 *Subscapular*, from the posterior cord, to the subscapularis, teres major, and latissimus dorsi muscles.

Circumflex, from the posterior cord, to the muscles and integument of the shoulder, and the shoulder-joint.

Musculo-cutaneous, from the outer cord, to the forearm externally, piercing the coraco-brachialis muscle.

Internal Cutaneous, from the inner cord, to the arm and forearm.

Lesser Internal Cutaneous (nerve of Wrisberg), from the inner cord to the inner side of the arm. Is sometimes wanting, sometimes connected with the intercosto-humeral.

Median, from outer and inner cords, passes between the two heads of the pronator radii teres, supplying the pronators, flexors, first 2 lumbricales, and the integument of the thumb, $2\frac{1}{2}$ fingers, and the radial side of the palm. Its branches are all in the palm, the—

Muscular. Anterior Interosseus. Palmar Cutaneous.

Ulnar, from the inner cord, passes between the two heads of the flexor carpi ulnaris at the inner condyle of the humerus, supplying the elbow- and wrist-joints, several muscles, and the palmar and dorsal integument of the little finger and half of the ring finger. Branches are the—

2 Articular. Cutaneous. Superficial Palmar.

Muscular. Dorsal. Deep Palmar.

Musculo-spiral, from the posterior cord, accompanies the superior profunda artery and vein in the spiral groove of the humerus, and at the external condyle it divides into the radial and posterior interosseus nerves. Its branches are—

Muscular. Cutaneous. Radial. Posterior Interosseous.

The Radial supplies the outer side and ball of the thumb, and the dorsal integument of $2\frac{1}{2}$ fingers.

The Posterior Interosseus supplies all the muscles on the back of the forearm except 3, and also sends a filament to the wrist-joint.

What is the Intercosto-humeral Nerve? It is the lateral cutaneous branch of the 2d intercostal (anterior branch of the 2d dorsal); it pierces the external intercostal muscle and crosses the axilla, joining with a filament from the lesser internal cutaneous (nerve of Wrisberg), and supplying the skin of the upper half of the inside of the arm.

Describe the Lumbar Plexus. It is formed by communicating loops from the anterior branches of the first 4 lumbar nerves, in the following manner.

From the **FIRST** lumbar nerve are given off the—

Ilio-hypogastric, to the abdominal and gluteal regions.

Ilio-inguinal, to the inguinal region and the scrotum.

Communicating Loop, to the second lumbar nerve.

From the **SECOND** lumbar nerve are given off the—

External Cutaneous, to the integument of the outside of the thigh.

Genito-crural, to the spermatic cord and front of the thigh.

Communicating Branch, to the third lumbar nerve.

From the **THIRD** and **FOURTH** lumbar nerves are given off the following by a branch of origin from each, viz.—

Obturator, through the obturator foramen to the external obturator and adductor muscles and the hip and knee-joints.

Accessory Obturator (often absent), to the pectineus and hip-joint.

Communicating, from the 3d lumbar to the 4th.

Communicating, from the 4th lumbar to the 5th.

Anterior Crural, which descends through the psoas muscle, and beneath Poupart's ligament to the thigh, where it divides into an anterior and posterior division. Its branches are,—

To the Iliacus muscle. Long Saphenous.

To the Femoral artery. Muscular.

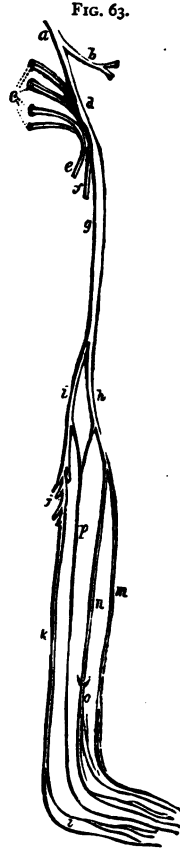
Middle and Internal Cutaneous. Articular.

Describe the Sacral Plexus. It is formed by the union of the upper 4 sacral nerves with the 5th lumbar and a loop from the 4th, the two latter forming the *Lumbo-sacral Cord*. It lies upon the pyriformis muscle and gives off the following 5 branches, viz.—

Superior Gluteal, from the lumbo-sacral cord, supplies the glutei and tensor vaginæ femoris.

Muscular Branches, to the pyriformis, obturator internus, gemelli, and quadratus femoris muscles.

Pudic, escapes by the great sacro-sciatic foramen, crosses the ischiatic



spinal system by intervening cords, beginning in the *ganglion of Ribes* on the anterior communicating artery, and ending in the *ganglion impar*, in front of the coccyx.

Name the Ganglia of the Sympathetic in the Cranium and its vicinity.

They are 9 in number, as follows :—

Ganglion of Ribes, on the anterior communicating artery.

Ganglion of Laumonier, on the internal carotid artery.

Ciliary, or Ophthalmic Ganglion, in the orbital cavity.

Spheno-palatine (Meckel's) Ganglion, in the spheno-maxillary fossa.

Otic (Arnold's) Ganglion, under the foramen ovale.

Submaxillary Ganglion, above the submaxillary gland.

Ganglion of Cloquet, in the incisive fossa, on the naso-palatine nerve.

Ganglion of Bidder, below the foramen spinosum, on the middle meningeal artery.

Ganglion of Bochdalek, on a branch between the spheno-palatine ganglion and the anterior dental nerve at their junction.

Describe the Ganglia connected with the 5th Cranial Nerve. There are 4 such, each having a motor, a sensory, and a sympathetic root, viz.—

Ciliary, or Ophthalmic Ganglion, is situated in the orbit, between the optic nerve and the external rectus muscle. Its sensory root is derived from the nasal branch of the ophthalmic, its motor root from the 3d nerve, its sympathetic root from the cavernous plexus. Its branches are the short ciliary nerves, and are distributed to the ciliary muscle and the iris.

Spheno-palatine, or Meckel's Ganglion, is a large ganglion situated in the spheno-maxillary fossa. Its sensory root is derived from the superior maxillary, its motor root from the facial by the Vidian and large petrosal, its sympathetic root from the carotid plexus, by the carotid branch of the Vidian. Its branches are the—

Ascending. Middle Palatine.

Anterior Palatine. Superior Nasal. Pharyngeal, or

Posterior Palatine. Naso-palatine. Pterygo-palatine.

Otic Ganglion (Arnold's), is situated on the inferior maxillary nerve, immediately below the foramen ovale. Its sensory root is derived from the auriculo-temporal branch of the inferior maxillary; its motor root from the internal pterygoid branch of the same, also from the facial and glosso-pharyngeal by the small petrosal; its sympathetic root from the middle meningeal plexus. Its branches are distributed to the tensor palati and tensor tympani muscles.

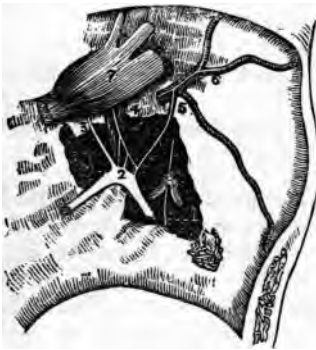Submaxillary Ganglion, is situated above the submaxillary gland. Its sensory root is derived from the gustatory branch of the inferior maxillary,

its motor root from the facial by the chorda tympani, its sympathetic root from the facial plexus. Its branches are distributed to the submaxillary gland, its duct, and the mucous membrane of the mouth.

What Nerves appear on removing the Gasserian Ganglion? The three Petrosal branches of the 7th nerve (see page 131), lying on the petrous portion of the temporal bone, and communicating with the sympathetic system as follows, viz., the—

*Large Superficial Petrosal,*³ (Great Petrosal),—a branch of the 7th nerve,

FIG. 64.



from its geniculate ganglion,² (intumentescia gangliiformis), which passes through the hiatus Fallopii, and thence through the foramen lacerum medium to the Vidian canal, where it joins the large deep petrosal from the carotid plexus, to form the Vidian nerve, as which it goes to Meckel's ganglion (page 137), forming its motor root.

*Small Superficial Petrosal,*⁴ (Small Petrosal), immediately external to the preceding, going from the geniculate ganglion of the 7th to the otic ganglion, and lying directly over the tensor tympani muscle.

*External Superficial Petrosal,*⁵ (External Petrosal),—going from the 7th to the sympathetic plexus on the middle meningeal artery.⁶

Describe the Cervical Ganglia. They are 3 in number on each side, of which the superior is the largest, communicate with each other, and are as follows, viz.—

Superior Cervical Ganglion, lies behind the carotid sheath opposite the 2d and 3d cervical vertebræ. Its branches are distributed to the carotid, cavernous, and pharyngeal plexuses, and one of its internal branches is the superior cardiac nerve going to the cardiac plexus.

Middle Cervical Ganglion, on the superior thyroid artery, opposite the 5th cervical vertebra, and gives off the middle cardiac nerve to the cardiac plexus, also communicating branches.

Inferior Cervical Ganglion, on the superior intercostal artery, between the neck of the 1st rib and the transverse process of the 7th cervical vertebra. It gives off several communicating branches and the inferior cardiac nerve to the cardiac plexus.

What are the other Ganglia of the Sympathetic? There are on each side of the vertebral column 11 or 12 dorsal ganglia, 4 or 5 lumbar, 5 sacral, besides the single coccygeal *Ganglion Impar* in which terminates the double chain. Connected with the viscera are many ganglia, from which branches ramify around the arteries in plexuses named from their locations.

Describe the Splanchnic Nerves. They are 3 in number on each side, and are derived from branches of the 6 lower thoracic ganglia, as follows, viz.—

Great Splanchnic, from branches of the 6th to the 10th, connecting with the upper six, passes through the posterior mediastinum, perforates the crus of the diaphragm, to the semilunar ganglion.

Lesser Splanchnic, from the 10th and 11th, passes through the diaphragm with the great splanchnic, to the coeliac plexus.

Smaller or Renal Splanchnic, from the last thoracic ganglion, also perforates the diaphragm, and ends in the renal and coeliac plexuses.

Describe the Solar Plexus. This plexus, called also the "abdominal brain," is a network of nerves and ganglia, chiefly formed by the splanchnic nerves and the right pneumogastric. It lies behind the stomach, and in front of the aorta and the crura of the diaphragm, surrounding the coeliac axis and the root of the superior mesenteric artery. Its two largest ganglia are the *Semilunar Ganglia* situated in front of the crura of the diaphragm. From it are derived branches which form *Plexuses* over most of the abdominal arteries, as follows :—

<i>Phrenic.</i>	<i>Gastric.</i>	<i>Splenic.</i>	<i>Renal.</i>	<i>Superior Mesenteric.</i>
<i>Cœliac.</i>	<i>Hepatic.</i>	<i>Suprarenal.</i>	<i>Spermatic.</i>	<i>Inferior Mesenteric.</i>

Describe the Carotid and Cavernous Plexuses. They are two plexuses of the sympathetic, situated on the internal carotid artery, the Carotid lying on the outer side of the artery, as it lies by the side of the body of the sphenoid bone; and the Cavernous being on the inner side of the artery, below its last bend, in the upper portion of the cavernous sinus. The—

Carotid Plexus,—is connected by numerous filaments with the 6th nerve and the Gasserian ganglion, and furnishes the *Large Deep Petrosal* to unite with the large superficial petrosal of the facial, to form the Vidian nerve; also the *Small Deep Petrosal*, to join the tympanic plexus probably.

Cavernous Plexus,—communicates with the 3d and 4th nerves and the ophthalmic division of the 5th, and gives a branch to the Ciliary ganglion in the orbit.

Mention some other Plexuses of the Sympathetic system. They are very numerous; besides those already mentioned, the most important are the following :—

Tympanic Plexus,—described under Nerves of the Tympanum.

Meningeal Plexus, on the middle meningeal artery.

Facial Plexus, surrounding the facial artery.

Cardiac Plexuses, the deep in front of the bifurcation of the trachea, the superficial in front of the right pulmonary artery; the first named lies behind the arch of the aorta, the latter beneath it.

Coronary Plexuses, anterior and posterior, accompanying respectively the left and right coronary arteries.

Aortic Plexus, on the sides and front of the aorta between the superior and inferior mesenteric arteries.

Hypogastric Plexus, on and between the common iliac arteries; supplying the viscera of the pelvic cavity.

Inferior Hypogastric or Pelvic Plexuses, two in number, one on each side of the rectum and bladder. Their branches are the—

Inferior Hemorrhoidal Plexus.	Small Cavernous Nerve.
Vesical and Prostatic Plexuses.	Large Cavernous Nerve.
Vaginal Plexus.	Uterine Nerve.

What is the Vidian Nerve? It has generally been described as a branch of the sphenopalatine (Meckel's) ganglion (see p. 137), running backwards through the Vidian canal, and dividing into a *Petrosal Branch* to the Facial nerve, and a *Carotid Branch* to the carotid plexus of the Sympathetic. It is now, however, more correctly described as a short nerve of communication, between the Facial and the Sympathetic on the one hand, and the Sphenopalatine Ganglion on the other, supplying that ganglion with its motor and vaso-motor roots. It is formed by the junction of the—

Large Superficial Petrosal, Br. of the Facial (p. 138), with the—

Large Deep Petrosal, Br. of the Carotid Plexus (p. 140), which occurs in the cartilage filling in the foramen lacerum medium (p. 35). It then enters the Vidian Canal (p. 20), in the pterygoid process of the sphenoid bone, passing through which to finally join the posterior part of the sphenopalatine ganglion (p. 137). Some filaments, the—

Upper Posterior Nasal Branches,—are apparently given off from the Vidian in the canal, to the septum and roof of the nose; but they are really branches from the ganglion, bound up in the same sheath with the Vidian nerve.

VISCERAL ANATOMY.

What is a Viscus? *Viscus, gen. visceris, pl. viscera*, is a term which is applied to any internal organ of the body. *The Viscera* are the organs contained in the three great cavities—cranium, thorax and abdomen—with their appendages. Of these the Heart and Brain have been described, with the circulatory and nervous systems respectively. [See pp. 99, 120; also the COMPEND OF PHYSIOLOGY in this series.]

THE DIGESTIVE ORGANS.

What is the Alimentary Canal? A musculo-membranous tube, from 25 to 30 feet in length, extending from the mouth to the anus, lined throughout with mucous membrane, furnished with several accessory organs, and performing the functions of ingestion, digestion, and egestion.

Name its Subdivisions. They are the Mouth, Pharynx, Œsophagus, Stomach, Small Intestine (duodenum, jejunum and ileum) and Large Intestine (cæcum, colon and rectum). The first three lie above the diaphragm, the rest below it.

Name the Accessory Organs of Digestion. They are—the Teeth, Salivary glands (parotid, sub-maxillary, sub-lingual), Liver, Pancreas and Spleen.

THE TEETH.

What are the Teeth? They are 32 organs of digestion (20 being temporary, or milk-teeth), situated one-half in each jaw, imbedded in the alveolar processes, and partly surrounded by the *Gums*, which are composed of fibrous tissue and covered with mucous membrane. In each half of each jaw there are—

Temporary Teeth (5)—2 Incisors, 1 Canine, 2 Milk-molars.

Permanent Teeth (8)—2 Incisors, 1 Canine, 2 Bicuspids, 3 Molars.

What are their General Characteristics? Each tooth presents a—
Crown, or Body,—the part seen projecting above the gum.
Neck,—the constricted portion between the crown and the fang.
Fang, or Root,—imbedded in the alveolus; and surrounded by the periodontal membrane or periosteum lining the alveolus.

Pulp-cavity,—in the interior, opening at the apex of the fang for the entrance of vessels and nerves.

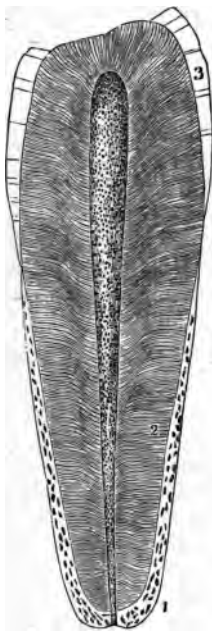
State the Characteristics of each class of Teeth.

Incisors, or Cutters.—Crown chisel-shaped, beveled posteriorly. Fang single, long, thickest antero-posteriorly.

Canines, or Tearers.—Crown thick and conical. Fang longest and thickest of all the teeth, forming a projection on the alveolar arch. The 2 upper canines are the “eye-teeth.”

Bicuspids.—Crown has 2 cusps. Fang single but grooved deeply, showing a marked tendency to bifurcate.

FIG. 65.



Molars, or Grinders.—Crown large, low and cuboid in shape, has 4 cusps on upper molars, 5 on the lower ones. Fangs multiple, usually 3 on the first two upper molars, 2 on the first two lower ones; the third molar of either jaw, having but one fang, is called the “wisdom tooth,” and is the smallest of the three.

The 2d or 3d Temporary Molar is larger than the first.

Describe the Structure of a Tooth. Each consists of—

Dentine or Ivory,²—composed of tubules surrounded by the inter-tubular tissue or Matrix, and opening into the pulp cavity. It resembles compact bone in appearance and in composition, consisting of 28 parts Animal matter and 72 Earthy matter. The *Tubules* are delicate wavy canals, diameter about $\frac{1}{15000}$ of an inch, which branch outwardly and anastomose with each other, forming concentric shadings or *Schreyer's Lines*.

Enamel,³—covers the crown; consists of very dense tissue, which contains but $3\frac{1}{2}$ per cent. of animal matter. It is covered by a very delicate epithelial cuticle, *Nasmyth's Membrane*, which when intact withstands the action of acids.

Crusta Petrosa or Cement,¹—the enamel of the fang; is a layer of true bony tissue, containing lacunæ, canaliculi, and Haversian canals.

Pulp.—fills the pulp-cavity and is prolonged into the dental tubules; is soft, vascular, and sensitive; and consists of connective and fibrous tissue,

nucleated cells, blood-vessels and nerves. The cells are caudate and anastomose with each other, those situated superficially being termed *Odontoblasts*.

What Arteries and Nerves supply the Teeth? *The Arteries* are derived from the inferior dental, and from the alveolar and infraorbital branches of the internal maxillary. *The Nerves* are derived from the inferior dental branch of the inferior maxillary division of the 5th, and also from the anterior and posterior dental branches of the superior maxillary division of the same nerve.

When do the Temporary Teeth appear? Their eruption begins about the 7th month after birth, with the central incisors, and ends with the appearance of the second molars, about the age of two years. The lower teeth slightly antedate the upper. Their formula is as follows:—

	Mo.	Mo.	Ca.	In.	In.	In.	In.	Ca.	Mo.	Mo.	
{ Upper... }	$\frac{x}{24}$	$\frac{x}{12}$	$\frac{x}{18}$	$\frac{x}{9}$	$\frac{x}{7}$	$\frac{x}{7}$	$\frac{x}{9}$	$\frac{x}{18}$	$\frac{x}{12}$	$\frac{x}{24}$	= 10
{ Lower... }	$\frac{x}{24}$	$\frac{x}{12}$	$\frac{x}{18}$	$\frac{x}{9}$	$\frac{x}{7}$	$\frac{x}{7}$	$\frac{x}{9}$	$\frac{x}{18}$	$\frac{x}{12}$	$\frac{x}{24}$	= 10
	} = 20 months.										

When do the Permanent Teeth appear? The first molars appear about the end of the 6th year, followed by the incisors about the 7th or 8th year, the bicuspidis from the 9th to the 10th year, the canines about the 11th or 12th year, the second molars from the 12th to the 13th year, and the third molars from the 17th to the 25th year. Those of the lower jaw are slightly in advance of the corresponding upper ones. Their formula is as follows:—

	Wis.	Mo.	Mo.	Bi.	Bi.	Ca.	In.	In.	In.	In.	Ca.	Bi.	Bi.	Mo.	Mo.	Wis.
{ Upper. }	$\frac{x}{18}$	$\frac{x}{12}$	$\frac{x}{6}$	$\frac{x}{10}$	$\frac{x}{9}$	$\frac{x}{11}$	$\frac{x}{8}$	$\frac{x}{7}$	$\frac{x}{7}$	$\frac{x}{8}$	$\frac{x}{11}$	$\frac{x}{9}$	$\frac{x}{10}$	$\frac{x}{6}$	$\frac{x}{12}$	$\frac{x}{18}$
{ Lower. }	$\frac{x}{18}$	$\frac{x}{12}$	$\frac{x}{6}$	$\frac{x}{10}$	$\frac{x}{9}$	$\frac{x}{11}$	$\frac{x}{8}$	$\frac{x}{7}$	$\frac{x}{7}$	$\frac{x}{8}$	$\frac{x}{11}$	$\frac{x}{9}$	$\frac{x}{10}$	$\frac{x}{6}$	$\frac{x}{12}$	$\frac{x}{18}$
	} = 32 years.															

What is the greatest Number of Teeth at one time in the jaws, and when? Forty-eight, namely, all the temporary and permanent teeth except the third molars,—occurring between the 5th and 7th years of age.

Describe the Development of the Teeth. They arise from the mucous membrane covering the maxillary arches, in which, about the 6th foetal week, appears a depression, the *Primitive Dental Groove*, from the floor of which arise papillæ of mucous membrane to form the pulp of the milk-teeth.

In the *Follicular Stage*, membranous septa form across the groove, and its margins become thick and prominent.

The Saccular Stage extends from the 13th week to the 16th, and is marked first by the projection of the papillæ from the follicles, next by the growth of the follicular margins, the formation of processes or *Opercula* thereon, which meet and close in the papillæ; and finally by the closing in of the dental

groove by the union of its margins. A *Cavity of Reserve* for each tooth is then formed by the closure of the secondary dental groove, from the floor of which another papilla arises to form the germ of the permanent tooth.

The dental pulps now take the forms of teeth, a thin lamina of dentine appears and increases from without inward, the enamel organ and membrane are formed, and when calcification has advanced sufficiently, the pressure of the teeth causes the absorption of the gum above them, the septa ossify and the eruption of the teeth occurs. *The Cement* is formed from the periodontal membrane, at a later period of life.

THE MOUTH.

Describe the Mouth. It is an oval cavity formed by the lips, cheeks, jaws, palate and tongue, forming the superior portion of the alimentary canal, and opening posteriorly into the pharynx by the fauces. It presents the teeth (already described), the tongue (to be described), and also the—

Hard Palate, formed by the palate processes of the superior maxillary and palate bones, and covered with mucous membrane; forms the roof of the mouth.

Soft Palate, formed by 5 muscles on each side, viz., the levator palati, tensor palati, palato-glossus, palato-pharyngeus, and the azygos uvulæ;—the latter forming with its fellow the *Uvula*, a descending muscular projection.

Anterior Pillars of the Fauces,—arch downwards and forwards to the base of the tongue, and contain the palato-glossi muscles.

Posterior Pillars of the Fauces,—arch downwards and backwards to the sides of the pharynx, and contain the palato-pharyngei muscles.

Isthmus Faucium,—the space bounded by the pillars, the free border of the palate, and the base of the tongue.

Tonsils,—are small, elongated, glandular bodies, situate done on each side of the fauces, between the anterior and posterior pillars. Each has 12 or 15

FIG. 66.



openings on its surface leading to follicular depressions within the gland, and lies close to the internal carotid artery.

Openings of Steno's Ducts,—from the parotid glands, are situated internally one on each cheek, opposite the 2d upper molar tooth.

Openings of Wharton's Ducts,—from the sub-maxillary glands, one at each side of the frenum of the tongue.

Openings of the Ducts of Rivinus,—8 to 18 on each side from the sublingual glands, near the frenum of the tongue. The longest is the *Duct of Bartholine*, which opens into the duct of Wharton.

Where are the Salivary Glands? The *Parotid Gland*¹ lies below and in front of the external ear,—the *Sub-maxillary*² and *Sub-lingual*³ Glands lie in the corresponding fossæ on the inner surface of the inferior maxillary bone. [See Fig. 66.]

Describe the Tongue. The tongue consists of extrinsic and intrinsic muscles, a hyo-glossal membrane and a mucous membrane, a median fibrous septum, vessels and nerves. Its *Base* is attached to the hyoid bone, the epiglottis, the soft palate and the pharynx. Its *Under Surface* is attached to the hyoid bone and the inferior maxillary. Its mucous membrane is reflected over the floor of the mouth to the inner surface of the gums, forming in front a fold, the *Frenum Linguae*.

The Tongue presents—

Filiform Papilla, along its sides, closely packed in rows.

Fungiform Papilla,² scattered over the anterior two-thirds of its dorsum.

Circumvallate Papilla,¹ 7 to 12 in number, in two rows, forming a V at the base of the tongue, meeting at the *Foramen Cæcum*, which contains the central papilla.

FIG. 67.

Follicular Glands, posteriorly to the circumvallate papillæ.

Racemose Glands, over the dorsum, sides, and under surface. Beneath the tip they form two small oblong masses.

Extrinsic Muscles, are the stylo-, hyo-, genio-hyo-, and palato-glossus muscles. [See pp. 73, 74.]

Intrinsic Muscles, are the several fibres of the lingualis muscle,—superior, inferior, transverse and perpendicular.

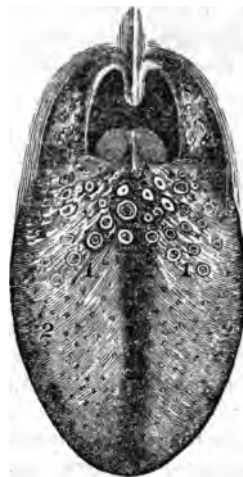Name the Arteries of the Tongue. They are the—

Lingual, branch of the external carotid,—with its branches, the—

Dorsalis linguæ. Sub-lingual. Ranine.

Sub-mental, branch of the facial,—anastomoses with the sub-lingual.

Ascending Pharyngeal, branch of the external carotid,—sends some small branches to the pharynx and tongue.



What Nerves are distributed to the Tongue ? The—

Gustatory Branch of the 5th,—to the mucous membrane of the sides and anterior two-thirds of the tongue, endowing it with general sensibility.

Chorda Tympani Branch of the 7th,—joins the gustatory, and is distributed to the same region, being the nerve of taste for the anterior two-thirds of the tongue.

Lingual Branches of the 9th or Glosso-pharyngeal,—to the mucous membrane of the base and sides of the tongue, being the nerve of taste for its posterior third.

Hypoglossal, or 12th,—to the intrinsic and extrinsic muscles of the tongue, being its nerve of motion.

Superior Laryngeal Branch of the 10th or Pneumogastric,—sends a few fibres to the base of the tongue from its internal branch.

What special Anatomical Features are presented by the Mouth ?

They are as follows, viz.—the—

Hamular Process of the Sphenoid Bone,—may be felt behind the last upper molar tooth ; also the *Internal Pterygoid Plate*, and part of the *Pterygoid Fossa*.

Coronoid Process,—of the lower jaw, its anterior border.

Posterior Palatine Artery,—at inner side of the last upper molar tooth, and in front of the hamular process.

Gustatory Nerve,—very near the last lower molar tooth.

Pterygo-maxillary Ligament,—felt as a fold posteriorly to the last lower molar tooth.

THE PHARYNX.

Describe the Pharynx. It is a conical, musculo-membranous bag, about $4\frac{1}{2}$ inches long, hung base up from the basilar process of the occipital bone, and extending to the lower border of the cricoid cartilage posteriorly, or the 5th cervical vertebra, where it becomes continuous with the œsophagus.⁵ It forms the part of the alimentary canal which lies behind the mouth, being incomplete in front.

What are its Relations ? It is connected with—

Posteriorly,—the longus colli and recti capitis antici muscles, and by loose areolar tissue to the first 5 cervical vertebrae.

Laterally,—the styloid processes and their muscles, the pterygoid muscles, the internal carotid arteries, the internal jugular vein, the 8th, 9th, and the sympathetic nerves.

Near its Apex,—the lobes of the thyroid gland, the common carotid and lingual arteries, the sterno-hyoid muscle, and the lingual nerves.

What are its Anterior Attachments?

The internal pterygoid plate, pterygo maxillary ligament, lower jaw, base of the tongue, cornua of the hyoid bone, stylo-hyoid ligament, thyroid and cricoid cartilages of the larynx.

Name the Openings into the Pharynx.

They are 7, viz.—

2 Posterior Nares,	Mouth.	Larynx.
2 Eustachian Tubes.		Œsophagus.

Describe its Structure. The pharynx is composed of 3 coats,—a mucous, a muscular and a fibrous, the latter lying between the other two, and sometimes called the *Pharyngeal Aponeurosis*. The mucous coat is covered with ciliated columnar epithelium above the level of the floor of the nares—below that level by squamous epithelium; and contains simple follicular glands, also compound follicular and racemose glands, the latter being most numerous in the upper part, between the two Eustachian tubes.

Name its Muscles, Arteries and Nerves.

Its—


Muscles, 5,—are the Superior, Middle and Inferior Constrictors, Stylo-pharyngeus, and Palato-Pharyngeus. [See pages 73, 74.]

Arteries number 4, as follows,—

Superior Thyroid Branches.	} Branches of Ascending Pharyngeal.	} Ext. Carotid.
Pterygo-palatine.		
Descending Palatine.	} Branches of the Internal Maxillary.	

Nerves,—Branches of the Pharyngeal Plexus, which is formed by the pharyngeal branches of the pneumogastric, glosso-pharyngeal, superior laryngeal, and superior cervical ganglion of the sympathetic.

FIG. 68.

**THE ŒSOPHAGUS.**

Describe the Œsophagus. It is a musculo-membranous tube, about 9 inches long, extending from the 5th cervical vertebra and the lower border of the cricoid cartilage of the larynx, through the Œsophageal opening in the

diaphragm to the cardiac orifice of the stomach, opposite the 9th dorsal vertebra, where it terminates. It lies in the neck, between the trachea and the vertebral column, resting in part on the longus colli muscle; then inclining to the left side it reaches the posterior mediastinum behind the left bronchus.

Describe its Structure. The Œsophagus has three coats, a—

Mucous,—in thick longitudinal folds, containing compound racemose glands, and covered with a thick layer of squamous epithelium.

Cellular,—forms a loose connection between the other two coats, and contains the œsophageal vessels.

Muscular,—having longitudinal fibres externally, circular fibres internally, which are continuous with the fibres of the stomach below, and with those of the inferior constrictor muscle above.

Name its Vessels and Nerves. The Œsophageal—*Arteries*, are chiefly branches from the thoracic aorta.

Veins, empty into the vena azygos minor.

Nerves, are branches of the pneumogastric and the cervical sympathetic, forming the Œsophageal Plexus.

THE STOMACH.

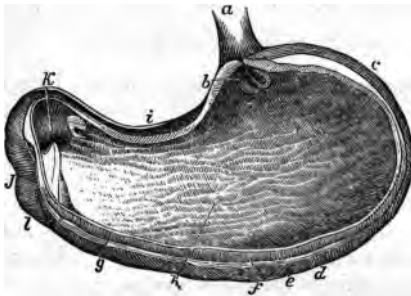
Describe the Stomach. It is the principal organ of digestion, pyriform in shape, of musculo-membranous structure, about 12 inches long by 4 inches in average diameter, held in position by the lesser omentum, and situated diagonally across the upper abdomen, in the epigastric and right and left hypochondriac regions, above the transverse colon, below the liver and diaphragm. It presents for examination a—

Fundus or Splenic End, c—connected to the spleen by the gastro-splenic omentum. (See under PERITONEUM.)

Pylorus or Lesser End,—lies in contact with the anterior wall of the abdomen, the under surface of the liver, and the neck of the gall-bladder, its position being near the end of the cartilage of the 8th rib.

Greater Curvature, d—is convex, and is connected to the colon by the gastro-colic omentum. (See under PERITONEUM.)

FIG. 69.



Lesser Curvature, i—is concave, and connected to the liver by the gastro-hepatic omentum, and to the diaphragm by the gastro-phrenic ligament.

Œsophageal Orifice, b—is situated between the fundus and the lesser curvature. It is funnel-shaped, and the highest part of the organ.

Pyloric Orifice, k—opens into the duodenum, *l* and is guarded by the circular muscular fibres of the pylorus, which are aggregated into a circular ring, projecting into the cavity, and with its covering fold of mucous membrane, forming the Pyloric Valve.

Describe its Structure. The Stomach has 3 coats, a—

Mucous Coat, g—lined with columnar non-ciliated epithelium, covered with polygonal *Alveoli*, $\frac{1}{10}$ of an inch in diameter, containing the orifices of the *Gastric Follicles*. When the stomach is contracted the mucous membrane lies in longitudinal folds or *Rugæ, h* one of which aids in forming the valve at the pyloric orifice.

Cellular or Sub-mucous Coat,—contains the gastric vessels.

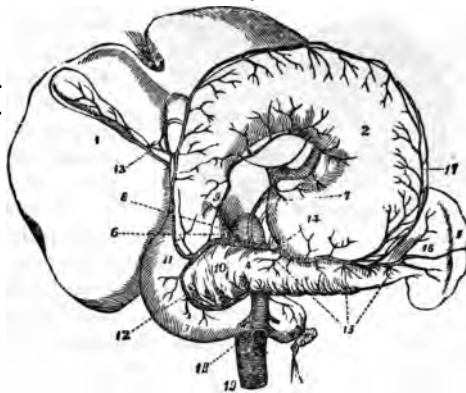
Muscular coat, f—consists of longitudinal, circular, and oblique fibres. *The Longitudinal* are continuous with those of the œsophagus and small intestine, and are the most superficial. *The Circular* lie deeper, and over the whole organ; they form a sphincter valve around the pyloric orifice. (See above.) *The Oblique Fibres* lie deepest, forming two sets around the œsophageal opening, in continuation of the circular fibres of the œsophagus.

THE SEROUS INVESTMENT of the stomach is derived from the peritoneum, and covers the whole external surface, excepting the points where the gastro-splenic, greater and lesser omenta are attached. It is usually, but incorrectly, described as a fourth coat of the stomach.

Describe the Gastric Glands. They are of 3 kinds, the—

Peptic Follicles,—situated all over the stomach, but most numerous towards the splenic end,—are tubules lined with columnar epithelium in their upper one-fourth, and filled with nucleated cells in their deepest parts.

FIG. 70.



Mucous Glands,—are most numerous at the pyloric end; are branched or sacculated, and lined throughout with columnar epithelium.

Simple Solitary Glands are found scattered along the lesser curvature, and near the pyloric end.

Name the Vessels and Nerves of the Stomach. Its—

Arteries are the—

Gastric, ⁷ Pyloric. ⁹	} Branches of the Hepatic Artery. ⁸
Right Gastro-epiploic. ¹¹	
Left Gastro-epiploic. ¹⁷	} Branches of the Splenic Artery. ¹⁴
Vasa Brevia. ¹⁶	

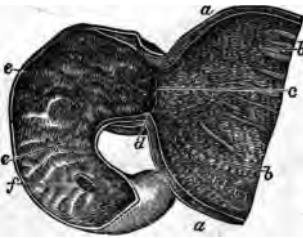
Veins, terminate in the splenic and portal veins.

Nerves, are terminal branches of the right and left pneumogastrics, and branches of the semilunar ganglia of the sympathetic, forming the *Gastric Plexus*.

THE SMALL INTESTINE.

Describe the Small Intestine. It is a convoluted, tubular, digestive organ, about 20 feet in length, held to the spinal column by the mesenteric portion of the peritoneum, and divided into 3 parts, the—

Duodenum,—about 12 fingers (10 inches) long, *ascends* for 2½ inches to the under surface of the liver and the neck of the gall-bladder,—*descends* for 3½ inches in front of the right kidney,—and passes transversely for 4 inches to the left, across the spinal column, to the left side of the second lumbar vertebra, where the superior mesenteric artery crosses its junction with the jejunum. The duodenum has no mesentery, is partially covered with peritoneum, and surrounds the



head of the pancreas. Into its descending portion open the ductus communis cholédochus *f* and the pancreatic duct.

Jejunum,—about two-fifths of the rest of the small intestine, its coils lying around the umbilical region. It is named from the fact that it is usually found empty (*jejunus*) after death.

Ileum,—comprises the remainder of the small intestine; is named from its twisted course, lying below the umbilicus, and terminating in the right iliac fossa, at the ileo-cæcal valve, or valve of Bauhin.

What Coats has the Small Intestine? Three, a mucous, a sub-mucous or cellular, and a muscular coat. Its peritoneal investment is sometimes described as a fourth coat, but incorrectly. The—

Mucous Membrane,—is covered with columnar non-ciliated epithelium, and thrown into crescentic transverse folds, the *Valvula Conniventes*, or valves of Kirkring. It also presents numerous vascular projections or *Villi*, each formed of basement membrane, epithelium, a lacteal vessel, a capillary plexus, granular corpuscles, and longitudinal muscular fibres, and numbering about four millions in the whole length of the intestine.

Cellular Coat,—contains the vessels of the intestine, and connects the other two coats together.

Muscular Coat,—consists of external longitudinal and internal circular fibres, the former being thinly distributed along the bowel, the latter forming a thick layer, but not making complete rings.

Describe the Glands of the Small Intestine. The mucous membrane of the small intestine contains—

Crypts of Lieberkühn, or Simple Follicles,—are minute tubular depressions, found all over the intestine and also in the stomach.

Brunner's Glands,—are small conglomerate glands, found only in the duodenum and the first part of the jejunum, being most numerous near the pylorus. In structure they resemble the pancreas.

Solitary Glands,—are lymphoid organs, situated throughout the intestine, though most numerous at the lower portion of the ileum. They are agminated into some 20 or 30 oval patches, named—

Peyer's Patches,—on the surface opposite to the mesenteric attachments, some of which are as much as 4 inches in length. They are most numerous and largest in the ileum, and are most developed during digestion.

THE LARGE INTESTINE.

Describe the Large Intestine. It is about five feet long, of large calibre, sacculated, consists of the same coats as the small intestine, the mucous being smooth, and without villi, the muscular having its longitudinal fibres collected into 3 narrow bands, producing a pouching of the tube. It presents the following PARTS and *points*, viz.—

CÆCUM, or Caput Cæcum Coli,^c—a dilated blind pouch behind the entrance of the small intestine.^a It is the beginning of the large intestine, lies in the right iliac fossa, and is two-thirds covered by peritoneum.

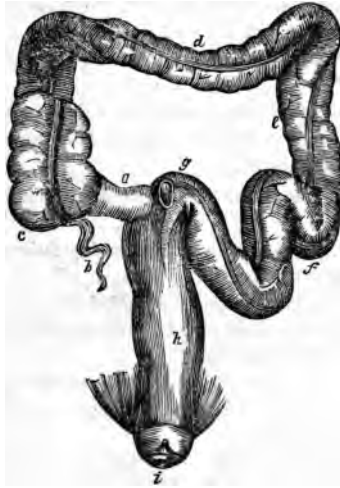Appendix Vermiformis,^b—a blind prolongation about 3 to 6 inches long, narrow and worm-like, directed backwards and upwards from the lower part of the cæcum, being retained by a fold of the peritoneum.

Ileo-cæcal Valve, or Valve of Bauhin,—guards the entrance of the small intestine, being formed by two crescentic folds of the mucous and cellular coats and circular muscular fibres, each covered with villi on the side toward the ileum, but smooth on the cæcal side.

ASCENDING COLON,—extends upwards to the under surface of the liver, where it forms the *Hepatic Flexure of the Colon*.

TRANSVERSE COLON, *d*—crosses the abdominal cavity just below the liver, gall-bladder, stomach and spleen, to the left hypochondrium, where it terminates in the *Splenic Flexure of the Colon*.

FIG. 72.



DESCENDING COLON, *e*—passes downwards in front of the left kidney to the left iliac fossa, where it forms the—

Sigmoid Flexure of the Colon, *f*—curved like an *f*, first upwards, then downwards; extending from the crest of the left ileum to the left sacro-iliac synchondrosis.

RECTUM, *h*—from the last-named point to the anus; is 6 to 8 inches long, not sacculated, and, though not straight, is straighter than the rest of the gut. It curves laterally to the middle of the sacrum, and backwards about an inch above its termination at the *Anus*, *i* where it is

distended into a pouch. This lower inch has no peritoneal investment.

Appendices Epiploica,—are small pouches of peritoneum containing fat, and found along the colon and part of the rectum. They are due to the incompleteness of the investment of the gut by peritoneum.

Sphincters of the Rectum are 3,—the sphincter ani, internal sphincter and sphincter tertius of Hyrtl. (See *ante*, pp. 83, 84.)

Folds of Houston,—three semilunar transverse folds, one in the upper part of the rectum on the right side, another about the middle on the left side, and the third in front, opposite the base of the bladder.

What Glands are found in the Large Intestine? The *Follicles of Lieberkühn* are more numerous here than elsewhere, also a few *Solitary Glands* and *Peyer's Patches* in its upper portion. The glands of Brunner are absent, the villi and *valvulae conniventes* are almost wanting.

State the Principal Relations of each of the three parts of the Rectum. They are as follows, viz.—

Upper Part (4 inches),—lies on the left pyriformis muscle and the left

sacral plexus; and to its left lie the left ureter and branches of the left internal iliac artery.

Middle Part (3 inches), in the male subject lies just behind the trigonum vesicæ and the vesiculæ seminales, and close below the under surface of the prostate gland. In the female it is adherent to the central portion of the posterior wall of the vagina.

Lower Part (1 inch),—is surrounded by the 3 sphincters and the levator ani muscle, and is separated by the perineum from the membranous portion and bulb of the urethra in the male, from the vagina in the female.

THE LIVER.

Describe the Liver. It is the largest gland in the body, weighing from 3 to 4 pounds, measuring transversely about 12 inches, antero-posteriorly 6 inches, in greatest thickness 3 inches. It is situated in the right hypochondriac, epigastric and part of the left hypochondriac regions; has 5 fissures, 5 lobes, 5 ligaments, and 5 sets of vessels, and is invested by peritoneum, except for a small space at the attachment of the coronary ligament. It is also surrounded by a fibrous coat which is continuous at the transverse fissure with the capsule of Glisson. Its—

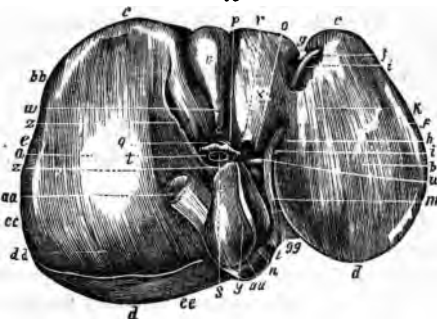
Upper Surface,—is convex, in relation with the under surface of the diaphragm and 6 or 7 lower ribs, and is divided into two lobes by the suspensory or broad ligament.

Under Surface (Fig. 73), is concave, covers the stomach, duodenum, hepatic flexure of colon, right kidney and supra-renal capsule, and is divided into 5 lobes by 5 fissures.

Anterior Border, c—sharp and notched opposite the fundus of the gall-bladder and the round and falciform ligaments. It corresponds to the lower border of the ribs and costal cartilages, descending a little lower during deep inspiration and in the upright posture.

Posterior Border, d—rounded, and deeply grooved (sometimes channeled) for the inferior vena cava. *aa*

FIG. 73.



Describe the 5 Ligaments of the Liver. Four are folds of peritoneum; one, the round ligament, is the obliterated umbilical vein and ductus venosus of the fœtus. The—

Suspensory or Falciform Ligament, j—called also the Broad and the Longitudinal Ligament,—is a sickle-shaped double fold reflected over the round ligament, and is attached to the sheath of the right rectus muscle as low as the umbilicus, and to the diaphragm.

Coronary Ligament, f—is a double fold, containing firm areolar tissue in its interspace, and extending from the posterior border of the liver to the diaphragm.

Lateral Ligaments, 2,—are the triangular extremities of the coronary ligament.

Round Ligament, i—ascends in the free margin of the suspensory ligament from the umbilicus to the longitudinal fissure, in which it is continued to the vena cava.

Describe the 5 Hepatic Fissures. They are all situated on its under surface, and separate the 5 lobes, one from another. They are the—

Longitudinal Fissure, h—its anterior two-thirds, in front of the transverse fissure, is called the *Umbilical Fissure*, from containing the umbilical vein; its posterior one-third is the *Fissure of the Ductus Venosus*, lodging the slender cord which represents that foetal vessel.

Transverse Fissure, o—about 2 inches long, running from the longitudinal towards the right; and transmit the portal vein, hepatic artery, bile-duct, lymphatics and nerves, surrounded by the *Capsule of Glisson*.

Fissure of the Gall bladder, v—on the right of the longitudinal fissure, and nearly parallel with it, extending from the anterior border, backwards to near the right end of the transverse fissure.

Fissure for the Vena Cava,—extends inwards from the posterior border, where it joins the fissure for the ductus venosus; and gives exit to the hepatic veins which here join the vena cava. This fissure is occasionally a complete foramen.

Describe the 5 Hepatic Lobes. Three are mere lobules, formed from the right lobe by the smaller fissures. The—

Right Lobe, a—is much the largest, and presents the three small fissures and two depressions, one anteriorly for the colon, the other posteriorly for the kidney.

Left Lobe, b—is divided from the right by the longitudinal fissure, and rests upon the stomach.

Lobulus Quadratus, x—in front of the transverse fissure, and between the umbilical fissure and that for the gall bladder.

Lobulus Spigelii, γ —behind the transverse fissure, and between the fissure for the ductus venosus and that for the vena cava.

Lobulus Caudatus, π —a connecting ridge from the lobulus Spigelii to the right lobe; it separates the transverse fissure from the fissure for the vena cava, and forms the roof of the foramen of Winslow.

Describe the 5 Hepatic Vessels. They are the — portal vein, r hepatic artery, g hepatic duct, p and lymphatics, situated in the transverse fissure, and surrounded by the capsule of Glisson,—also the hepatic veins in the fissure for the vena cava. The—

Portal Vein, r —formed by the superior and inferior mesenteric, splenic and gastric veins (all the main veins of the abdomen except the renal), is about 4 inches long. It enters the transverse fissure of the liver, where it divides into two branches, and these again divide and subdivide to ramify throughout the gland. Its branches are the—

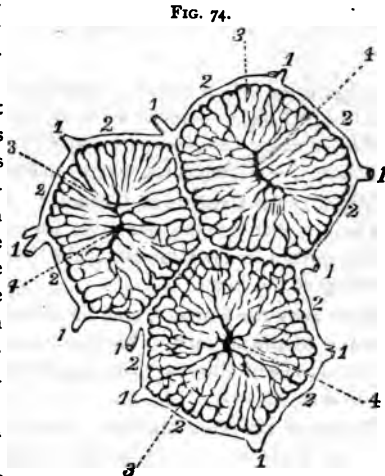
- | | | |
|-------------------|-----------------------------------|---------------------------------|
| Right Portal. | Inter-lobular Veins. ¹ | } Lobular Plexus.
(Fig. 74.) |
| Left Portal. | Lobular Veins. ² | |
| Vaginal Branches. | Intra-lobular Veins. ⁴ | |

Hepatic Veins,—are the continuations of the intra-lobular, beginning as the *Sub-lobular Veins* beneath each lobule, and entering the inferior vena cava in the fissure for that vessel.

Hepatic Artery, g —the nutrient vessel of the liver; arises from the coeliac axis, enters the transverse fissure, and divides into branches which supply the cellular tissue, the walls of the vessels, and the investing membranes of the liver, also forming a plexus in each lobule which anastomoses with the terminal branches of the portal vein.

Hepatic Duct,—about $1\frac{1}{2}$ inch long; is formed in the transverse fissure by the union of

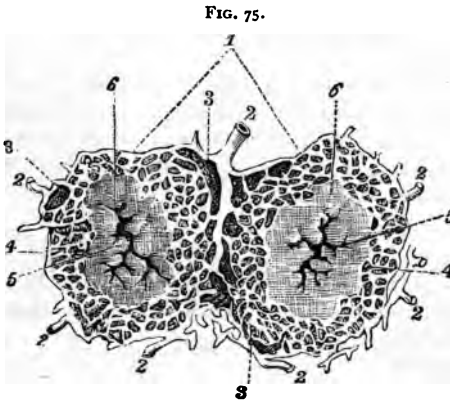
the two main biliary ducts, from the right and left lobes. It joins the cystic duct from the gall-bladder to form the Ductus Communis Cholédochus. (See next page.)



Lymphatics,—accompany the blood vessels in two sets, a superficial set and a deep one.

What Nerves supply the Liver? Branches of the Hepatic Plexus, which is formed by branches derived from the left pneumogastric, right phrenic and solar plexus.

Describe the Structure of the Liver. The substance of the liver is



composed of numerous *Lobules*,¹ of polygonal shape, and about $\frac{1}{8}$ of an inch in diameter, clustered around the sublobular branches of the hepatic veins, and connected together by connective tissue,³ blood vessels, ducts,² and lymphatics. Each lobule consists of—

Hepatic Cells,—each about the $\frac{1}{1500}$ of an inch in diameter, having a nucleus and

nucleolus, yellow coloring matter, glycogen granules, and oil globules.

Lobular Veins,³—forming a plexus in the lobule.

Intra-lobular Vein,⁴—in the centre of each lobule. } (See Figs. 74, 75.)

Plexuses,—of lymphatics, nerves, and bile-ducts.

What is the Capsule of Glisson? The areolar tissue which surrounds the hepatic vessels in the transverse fissure, and accompanies them in their course throughout the substance of the liver. It is continuous with the fibrous covering of the organ.

How may the Portal Veins be distinguished from the Hepatic, on section of the Liver? The portal veins remain closed, being surrounded by the capsule of Glisson. The hepatic veins gape open, being adherent to the liver substance.

Describe the Gall-bladder. It is a pear-shaped bag, 3 to 4 inches long, an inch in greatest diameter, holding from 8 to 12 fluid drachms, invested by peritoneum on its under surface and fundus, formed of a fibromuscular coat and lined by a mucous one, lying in a fissure on the under surface of the liver, close to its anterior border, and directed obliquely downwards, forwards, and to the right. Its—

Fundus,—touches the abdominal wall immediately below the 9th costal cartilage, and is completely invested by peritoneum.

Neck,—coils twice upon itself, and empties into the *Cystic Duct*, which is about an inch long, and joins with the *Hepatic Duct* to form the *Ductus Communis Cholédochus*.

What is the Ductus Communis Cholédochus? A fibro-muscular tube, covered by peritoneum and lined with mucous membrane, about 3 inches in length, formed by the junction of the Cystic and Hepatic ducts, and emptying its contents (bile) into the descending part of the duodenum at a point about 3 inches from the pyloric orifice of the stomach, generally in common with the duct of the pancreas. The three ducts above-named are often called the *Biliary Ducts*.

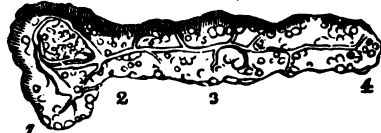THE PANCREAS. 6-8" x 1/2" x 1/2"

Describe the Pancreas. The Pancreas is a racemose gland, about 7 inches long, of a grayish-white color, situated behind the stomach and in front of the first lumbar vertebra. Its structure resembles that of the salivary glands, being composed of reddish-yellow lobules, united by cellular tissue, vessels and ducts, and ending in closed pouches surrounded by a capillary plexus. The—

WEIGHT. 2-3 3/4 oz or may reach 6 3/4

Pancreatic Duct, or Duct of Wirsung,⁵—extends the whole length of the gland, and opens into the duodenum about 3 inches below the pylorus, by an orifice common to it and the ductus communis cholédochus.

DESCRIBED BY REC. JOURNAL



Head, or Right Extremity,¹

is surrounded by the curve of the duodenum, the ductus communis cholédochus and the pancreatico-duodenal arteries.

Tail, or Left Extremity,⁴—lies above the left kidney and in contact with the lower end of the spleen.

*Body*³—is in relation *anteriorly* with the ascending layer of the transverse meso-colon, the posterior wall of the stomach and the transverse colon; *posteriorly* with the aorta, portal vein, inferior vena cava, splenic vein, origin of the superior mesenteric artery, crura of the diaphragm, left kidney and supra-renal capsule, and the left quadratus lumborum muscle.

Arteries, are the—

Pancreatica Magna, and *Pancreaticæ Parvæ*, from the splenic.

Pancreatico-duodenalis,—branch of the hepatic artery.

Inferior Pancreatico-duodenalis,—branch of the sup. mesenteric.

Veins,—open into the splenic and mesenteric veins.

Nerves,—from the solar plexus, forming a Splenic Plexus.

What is the Lesser Pancreas? A lobe of the head of the pancreas; sometimes detached therefrom, in which case it opens by a duct into the duodenum about an inch above the orifice of the pancreatic duct.

THE DUCTLESS GLANDS.

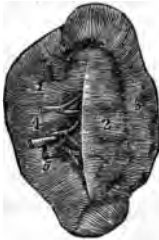Name the so-called Ductless Glands. They are the Spleen, Supra-renal Capsules, Thyroid and Thymus Glands. The first two are in the abdominal cavity, the thyroid gland is in the front of the trachea, and the thymus gland is in the anterior mediastinum of the thorax. These organs have no excretory ducts, and their functions are unknown.

THE SPLEEN.

Describe the Spleen. The spleen is a soft, spongy and very vascular organ, about 5 by 3 by 2 inches, from 6 to 10 ounces in weight, and situated deeply in the left hypochondrium, embracing the cardiac end of the stomach, to which it is connected by the gastro-splenic omentum. Its—

Outer Surface,—is convex, corresponds to the 9th, 10th and 11th ribs, and is in relation with the inferior surface of the diaphragm.

FIG. 77.



Inner Surface,—is concave, and embraces the cardiac or splenic end of the stomach.

Borders,—the anterior is thin and often notched; the posterior is thick and lies on the left kidney.

Suspensory Ligament,—attaches the upper extremity to the diaphragm, and is a fold of peritoneum.

Hilum,—a vertical fissure about the middle of the concave surface. It is pierced by the vessels, lymphatics and nerves.

Peritoneal, or Serous Coat,—covers the whole organ, except at the attachments of the suspensory ligaments and the gastro-splenic omentum.

Fibro-elastic Coat, or Tunica Propria,—is reflected at the hilum upon the vessels, and gives off numerous bands (*trabeculae*), which bound the lacunar spaces (*areolae*) of the organ.

Malpighian Corpuscles,—are lymphoid sphenoidal expansions of the outer coat of the small arteries, and average in diameter about the $\frac{1}{10}$ of an inch. They are attached to the arterioles of the organ in groups of 6 or 8, and are usually pierced by an artery. Their reticulum is slender and open, densely filled with lymphoid corpuscles, and well supplied with capillaries. They have no capsule.

Splenic Substance or Pulp,—a soft, pulpy, brown-red mass, surrounding the Malpighian corpuscles, and contained in the areolæ. It consists of a delicate net-work of connective-tissue corpuscles, containing pigment-granules (disintegrated blood-corpuscles), granular albuminous matter, nucleated and non-nucleated cells, and free nuclei, also red blood-corpuscles in every stage of metamorphosis. These are denominated the colored and colorless elements.

Splenic Artery,—is large and tortuous, and divides at the hilum into 5 or 6 branches, each supplying a segment of the organ, and terminating either directly in the venous radicles, or in the lacunar spaces.

Splenic Vein,—arises by radicles partly from the capillaries, partly from the lacunar spaces, and empties into the portal vein.

Nerves,—are derived from the semi-lunar ganglion of the solar plexus and the right pneumogastric, forming the *Splenic Plexus*.

THE THYROID GLAND.

Describe the Thyroid Gland. It is a bi-lobed organ, about 3 inches in length, situated on the sides of the upper 2 or 3 rings of the trachea, and consisting of minute closed vesicles containing a yellow-colored fluid, surrounded by a dense plexus of capillaries, and connected together by areolar tissue. Its—

Isthmus,—connects the lower third of each lobe together, passing in front of the trachea. It is occasionally absent.

Pyramid,—is a third lobe, which sometimes arises from the left lobe, or from the left upper border of the isthmus.

Levator Glandulae Thyroideæ,—are muscular bands occasionally found extending from the body of the hyoid bone to the isthmus of the gland or its pyramid.

Name the Arteries of the Thyroid Gland. They are very large, anastomose freely, and are the—

Superior Thyroid,—branch of the external carotid, arising therefrom below the greater cornu of the hyoid bone, and giving off the following branches, viz.—

Muscular.	Hyoid.	Superior Laryngeal.
Glandular.	Superficial Descending.	Crico-thyroid.

Middle Thyroid, Artery of Neubauer, or Arteria Thyroidea Ima,—is occasionally found arising from the innominate artery or directly from the arch of the aorta, passing upwards along the front of the trachea.

Inferior Thyroid, branch of the thyroid axis, gives off—

Laryngeal Branch.	Œsophageal Branches.
Tracheal Branches.	Ascending Cervical.

Enumerate the Veins and Nerves of the Thyroid Gland. The *Veins* form a plexus in front of the gland and the trachea, giving rise to the—

Superior Thyroid Vein.
Middle Thyroid Vein. } open into the Internal Jugular Vein.

Inferior Thyroid Vein, opens into the Innominate Vein.

Nerves—are branches of the pneumogastric, and of the middle and inferior ganglia of the sympathetic.

THE THYMUS GLAND.

What is the Thymus Gland? It is a temporary organ, attaining its full size about the age of 2 years, then being about 2 inches long, $1\frac{1}{2}$ inch broad, 3 lines thick, and weighing about half an ounce. It subsequently atrophies, and has almost disappeared at puberty. It is situated in the anterior mediastinum and the neck, behind the sternum and the sterno-hyoid and sterno-thyroid muscles, extending from the level of the 4th costal cartilage to the lower border of the thyroid gland. In the mediastinum it rests upon the pericardium, and is separated by the thoracic fascia from the arch of the aorta and the great vessels.

Describe its Structure. The Thymus gland consists of two lateral lobes (sometimes a third), together forming a pyramidal mass. It is surrounded by a fibrous capsule and is divided by *Trabeculae* into primary and secondary lobules, which consist of meshes of delicate retiform tissue closely packed with lymph-corpuscles, and pervaded with capillaries. The so-called *Central Cavity* and *Primitive Linear Tube*, are deceptive appearances of the multiplying cells in the interior of the gland.

Name its Vessels and Nerves. The Thymus—

Arteries,—are derived from the internal mammary, superior and inferior thyroid, subclavian and carotid. They ramify on the surface of each lobule, having smaller twigs converging toward the centre.

Veins,—open into the left innominate and the thyroid.

Lymphatics,—consist of intralobular and interlobular plexuses, and open into the anterior mediastinal glands.

Nerves,—are very minute and derived from the pneumogastric and the sympathetic.

THE SUPRA-RENAL CAPSULES.

What are the Supra-Renal Capsules? They are two small, crescentic-shaped bodies, situated one on each kidney. Each presents a small fissure or *Hilum* anteriorly, from which its vein emerges, and consists of a—

Fibrous Capsule,—which is very thin, closely adherent, and sends numerous septa inwards.

Cortical Substance,—composed of columnar and rounded cells, held together in layers by a fibrous stroma.

Medullary Substance,—is darker than the cortical portion, and pulpy.

Consists of cells in groups, supported by a delicate stroma, and believed by some anatomists to be prolonged into nerve fibres.

What are their Relations ? Their bases rest on the upper front parts of the kidneys, their posterior surfaces on the crura of the diaphragm, about the level of the 10th dorsal vertebra. The—

Anterior Surface,—of the right capsule is covered by the liver ; that of the left one by the spleen and pancreas.

Superior Surface,—of each is in relation internally with the great splanchnic nerve and semilunar ganglion.

Name their Vessels and Nerves. The *Lymphatics* of these bodies open into the lumbar glands, but are very imperfectly known. Their—

Arteries,—are the Supra-renal Branches of the aorta, renal, and inferior phrenic arteries, forming a dense capillary plexus in the cortical portion of the organ.

Veins,—of each open into a single trunk, the *Supra-renal Vein*, which on the right side of the body empties into the inferior vena cava, on the left side into the left renal vein.

Nerves,—are chiefly derived from the solar and renal plexuses, with some filaments from the phrenic and pneumogastric nerves, forming a complicated network in the medullary substance of the organ, and having numerous small ganglia developed upon them.

THE ABDOMINAL CAVITY.

What is the Abdomen ? An oval cavity, situated between the thorax above and the pelvis below, invested by peritoneum internally, and containing the—

<i>Stomach.</i>	<i>Pancreas.</i>	<i>Abdominal Aorta.</i>
<i>Intestines.</i>	<i>Kidneys and Ureters.</i>	<i>Inferior Vena Cava.</i>
<i>Liver.</i>	<i>Supra-renal Capsules.</i>	<i>Receptaculum Chyli.</i>
<i>Gall-bladder.</i>	<i>Bladder (when distended.)</i>	<i>Thoracic Duct.</i>
<i>Spleen.</i>	<i>Uterus (during pregnancy.)</i>	<i>Solar Plexus, etc.</i>

Name the Boundaries of the Abdomen. *Above*, it is bounded by the diaphragm;—*below*, by the brim of the pelvis;—*posteriorly*, by the vertebral column, and the fasciæ covering the psoæ and quadrati lumborum muscles;—*anteriorly and laterally*, by the transversalis fascia, the lower ribs, and the venter of the ilium.

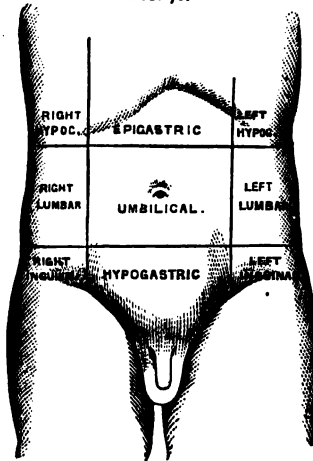
What Openings are found in its Walls? They are the—

- ✓ *Opening for the Vena Cava*,—in the diaphragm.
- ✓ *Aortic Opening*,—behind the diaphragm, for the aorta, vena azygos minor, the thoracic duct, and occasionally the left sympathetic nerve.
- ✓ *Œsophageal Opening*,—in the diaphragm, for the œsophagus, and the pneumogastric nerves.
- ✓ *Umbilical Opening*,—in the anterior wall, transmitting the umbilical vessels in the foetus, but obliterated after birth, leaving a puckered depression, the *Umbilicus*.
- ✓ *Internal Abdominal Ring*,—on each side, half an inch above Poupart's ligament, for the passage of the spermatic cord in the male, and the round ligament of the uterus in the female.
- ✓ *Femoral or Crural Ring*,—on each side, just below Poupart's ligament; for the passage of the femoral vessels. This opening is closed by the Septum Crurale. (See Femoral Hernia.)

Name the Regions of the Abdomen. The Abdomen is divided into 9 regions, by two horizontal lines,—one between the cartilages of the 9th ribs, another between the crests of the ilia,—and 2 vertical lines from the cartilages of the 8th ribs to the centre of Poupart's ligament. The 9 regions thus formed are named the—

<i>Right Hypochondriac.</i>	<i>Epigastric.</i>	<i>Left Hypochondriac.</i>
<i>Right Lumbar.</i>	<i>Umbilical.</i>	<i>Left Lumbar.</i>
<i>Right Inguinal.</i>	<i>Hypogastric.</i>	<i>Left Inguinal.</i>

FIG. 78.



What Parts are contained in each Region?

Right Hypochondriac Region,—contains the right lobe of the liver, gall-bladder, duodenum, hepatic flexure of the colon, upper part of the right kidney, and the right supra-renal capsule.

Epigastric Region,—contains the right two-thirds of the stomach, left lobe and lobus Spigelii of the liver, hepatic vessels, coeliac axis, solar plexus, pancreas, and parts of the aorta, inferior vena cava, vena azygos, and thoracic duct.

Left Hypochondriac Region,—contains the splenic end of the stomach, spleen, tail of the pancreas, splenic flexure of the colon, upper half of the left kidney and its supra-renal capsule.

Right Lumbar Region,—contains the ascending colon, lower half of the right kidney, and part of the small intestine.

Umbilical,—contains the transverse colon, transverse duodenum, part of the great omentum and mesentery, and part of the small intestine.

Left Lumbar Region,—contains the descending colon, lower half of the left kidney, and part of the small intestine.

Right Inguinal Region,—contains the right ureter, cæcum, appendix vermiformis, and the spermatic vessels of that side.

Hypogastric Region,—contains part of the small intestine, the bladder in children and when distended in adults, and the uterus during pregnancy.

Left Inguinal Region,—contains the left ureter and spermatic vessels, and the sigmoid flexure of the colon.

THE PERITONEUM.

What is the Peritoneum? A serous membrane, forming a closed sac, its *parietal layer* lining the walls of the abdomen and pelvis, its *visceral layer* being reflected more or less completely over all the abdominal and pelvic viscera. Its free surface is covered with squamous epithelium, and is smooth, moist, and shining. Its attached surface is connected to the viscera and the parietes of the abdomen by the sub-peritoneal areolar tissue.

Is the Peritoneum always a closed sac? No! In the female it is continuous with the mucous lining of the Fallopian tubes, which at their free extremities open into its cavity.

Name the Divisions of the Peritoneum. The—

Greater Sac,—extends over the anterior two-thirds of the liver, behind and above the stomach, below, behind, and in front of the great omentum, and below the meso-colon.

Lesser Sac, or Cavity of the Great Omentum,—extends behind and below the liver and stomach, above the meso-colon, and within the great omentum.

What is the Foramen of Winslow? A constriction of the peritoneal cavity connecting the two sacs, situated behind the right free border of the gastro-hepatic or lesser omentum, and formed by the gastric and hepatic arteries as they curve around to the cœliac axis. Its boundaries are as follows, viz.—

Anteriorly,—the lesser omentum, containing the duodenum, hepatic artery, portal vein, and the ductus communis cholédochus.

Posteriorly,—the inferior vena cava, and the right crus of the diaphragm.

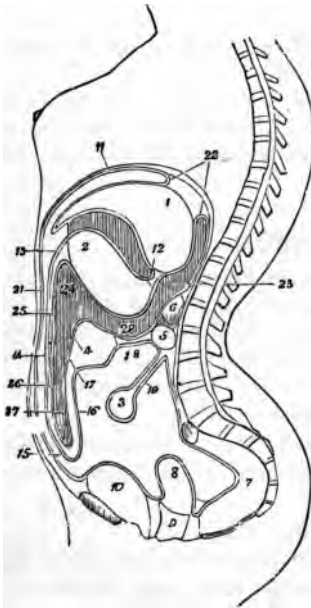
Superiorly,—the lobus Spigelii of the liver.

Inferiorly,—the hepatic artery, curving forwards from the cœliac axis

What passes through the Foramen of Winslow? Nothing.

What are the Omenta or Epiploa? They are folds of peritoneum connecting the stomach with other organs, and are 3 in number, namely, the—
Gastro-colic or Great Omentum,¹⁴—consists of four layers of peritoneum,

FIG. 79.



the most anterior and posterior of which belong to the greater sac, the two internal to the lesser sac. The two anterior layers descend from the stomach and the spleen, over the small intestines, and then ascend as the posterior layers, to enclose the transverse colon.

Gastro-hepatic or Lesser Omentum,—consists of two layers of peritoneum, the upper belonging to the greater sac, the lower to the lesser sac. It extends from the transverse fissure of the liver to the lesser curvature of the stomach, and contains in its right free margin the—

- 1 Hepatic Artery.
- 2 Portal Vein.
- 3 Lymphatics.
- 4 Ductus Communis Cholédochus.
- 5 First part of the Duodenum.
- 6 Hepatic Plexus of Nerves.

Gastro-splenic Omentum,—connects the stomach with the spleen, and is continuous by its lower border with the great omentum. It contains the Splenic Vessels and the Vasa Brevia.

What are the Mesos or Mesenteries? Folds of peritoneum connecting the various parts of the intestinal canal (except the duodenum) to the abdominal walls. Each one contains the vessels of the part which it supports. They are the—

Mesentery proper.¹⁹ *Meso-cæcum*. *Meso-colon*.²⁰ *Meso-rectum*.

What Ligaments are formed by the Peritoneum? They are 17 folds of peritoneum which support certain organs, viz.—

- 1 *Gastro-phrenic*,—from the stomach to the diaphragm.
- 4 *Hepatic*,—the longitudinal, coronary, and 2 lateral ligaments of the liver.
- 5 *Vesical*,—the false ligaments of the bladder.
- 6 *Uterine*,—2 vesico-uterine, 2 recto-uterine, and 2 lateral or broad ligaments of the uterus.
- 1 *Splenic*,—the suspensory ligament of the spleen.

Name the Viscera covered by Peritoneum. They are the—

- | | |
|--|--|
| ✓ <i>Liver</i> ¹ (almost wholly). | ✓ <i>Transverse Colon</i> . ⁴ |
| ✓ <i>Stomach</i> ² (almost wholly). | ✓ <i>Sigmoid Flexure</i> . |
| ✓ <i>Spleen</i> . | ✓ <i>Rectum</i> (upper $\frac{1}{3}$). |
| ✓ <i>Duodenum</i> ⁵ (first part). | ✓ <i>Ovaries</i> . |
| ✓ <i>Small Intestine</i> . ³ | ✓ <i>Uterus</i> . ⁸ |

Name the Viscera partially invested by Peritoneum. The—

- | | |
|--|--|
| <i>Duodenum</i> ⁵ (descending and transverse portions). | <i>Descending Colon</i> . |
| <i>Cæcum</i> . | <i>Rectum</i> ⁷ (middle third). |
| <i>Ascending Colon</i> . | <i>Vagina</i> ⁹ (upper part). |
| | <i>Bladder</i> ¹⁰ (posterior wall). |

What Viscera have no Peritoneal Investment? The—

- | | |
|---|--|
| <i>Rectum</i> ⁷ (lower third). | <i>Pancreas</i> . ⁶ |
| <i>Bladder</i> ¹⁰ (neck, base and anterior surface). | <i>Kidneys</i> . |
| | <i>Supra-renal Capsules</i> . |
| | <i>Vagina</i> ⁹ (lower part). |

What are the Appendices Epiploicæ? Pouches of peritoneum situated along the colon and upper third of the rectum, and filled with fat. They are chiefly found along the transverse colon.

A Demonstration of the Peritoneum is best made with a large bag of mosquito-netting, sewn up along all four sides, and having a central slit to represent the incision usually made in the laparotomy operation. Sponges of various sizes will represent the various organs, and may be pushed into folds of the bag and tied in by string, wholly covered or partially covered, as the case may be, for each. Professor Pancoast used this method of demonstration in his lectures, making the subject perfectly clear to many who never understood it before.

ORGANS OF VOICE AND RESPIRATION.

THE LARYNX.

What is the Larynx? A musculo-membranous-cartilaginous box placed between the trachea and the base of the tongue, and constituting the essential organ of voice.

Name its Cartilages. They are nine in number, 3 single and 3 in pairs, viz.—

- | | |
|---------------------------|--------------------------------|
| <i>Thyroid Cartilage.</i> | <i>2 Arytenoid Cartilages.</i> |
| <i>Cricoid Cartilage.</i> | <i>2 Cuneiform Cartilages.</i> |
| <i>Epiglottis.</i> | <i>2 Cornicula Laryngis.</i> |

Describe the Vocal Chords. They are in two sets, the—

Superior or False Vocal Chords,—containing the superior thyro-arytenoid ligaments,—extend from the angle of the thyroid cartilage around to the anterior surfaces of the arytenoids, and consist of two folds of mucous membrane, each having a free crescentic margin.

Inferior or True Vocal Chords,—containing the inferior thyro-arytenoid ligaments,—extend from the angle of the thyroid cartilage around to the anterior angles of the bases of the arytenoids, and consist of two thin layers of mucous membrane covering the ligaments named, each having the thyro-arytenoideus muscle external and parallel to it.

What is the Glottis? The Glottis or *Rima Glottidis* is a narrow chink or interval between the inferior vocal chords, formed by the projection into the cavity of the larynx of these chords and the thyro-arytenoidei muscles. Its greatest length is less than an inch, its greatest breadth about half an inch. Its form is a narrow fissure of varying size.

What is the Ventricle of the Larynx? An oval depression on each side of the larynx, between the true and false vocal chords, leading up to the sacculus laryngis by a narrow opening.

What is the Sacculus Laryngis? A blind pouch situated in each laryngeal wall at the level of the false vocal chord. It is of conical shape, and contains 60 or 70 small mucous glands which secrete a fluid for the lubrication of the true vocal chord. The sacculus is covered in by the aryteno-epiglottideus inferior muscle internally, and by the thyro-epiglottideus externally, both muscles compressing it to discharge its contents. The Sacculus Laryngis is also called the *Sinus of Morgagni*, and the lower part of the ventricle is sometimes named the *Sac of Hilton*.

What class of Epithelium lines the Larynx? Its mucous membrane is covered with *Ciliated Epithelium* below the level of the superior vocal chords, extending in front as high as the centre of the epiglottis. Over the rest of the larynx is *Squamous Epithelium*.

Describe the Laryngeal Muscles. They are 4 in number on each side and one in the median line, viz.—

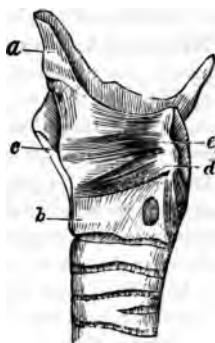Crico-thyroid (2),—from the front and side of the cricoid cartilage,^b—into the lower and inner border of the thyroid.^c *Action*, to tilt the thyroid cartilage forwards, thus elongating and making tense the vocal chords. *Nerve*, superior laryngeal.

Crico-arytenoideus Posticus (2),—from the cricoid cartilage posteriorly,—into the posterior angle of the base of the arytenoid cartilage. *Action*, to rotate the arytenoids outwards and open the glottis, while keeping the vocal chords tense. *Nerve*, recurrent laryngeal.

Crico-arytenoideus Lateralis *d* (2),—from the upper lateral border of the cricoid cartilage, —into the posterior angle of the base of the arytenoid. *Action*, to rotate the arytenoids inwards and close the glottis. *Nerve*, recurrent laryngeal.

Thyro-arytenoideus *e* (2),—from the angle of the thyroid cartilage and the posterior surface of the crico-thyroid membrane,—into the base and anterior surface of the arytenoid. *Action*, to shorten and relax the vocal chords by approximating the cartilages, and to compress the sacculus laryngis. *Nerve*, recurrent laryngeal.

FIG. 83.



Arytenoideus (1),—from the posterior surface and outer border of one arytenoid cartilage,—into the corresponding parts of the opposite cartilage; having oblique and transverse fibres, and filling up the posterior concave surfaces of the arytenoid cartilages. *Action*, by approximating the arytenoids, to close the back part of the glottis. *Nerves*, superior and recurrent laryngeal.

A small fasciculus, called the *Kerato-cricoideus*, is sometimes found below the arytenoideus, extending from the cricoid cartilage to the inferior cornu of the thyroid. It occurs once in 5 cases, usually on one side only; but occasionally on both, and acts to fix the lower horn of the thyroid cartilage backwards and downwards.

Another small muscle is found frequently, though rarely described in the books, the *Triticeo-glossus*. It arises from the cartilaginous nodule in the lateral thyro-hyoid ligament, and passes forwards and upwards to enter the tongue along with the kerato-glossus muscle.

Describe the Muscles of the Epiglottis. They are 3 double muscles, as follows, viz.—

Thyro-epiglottideus (2),—from the inner surface of the thyroid cartilage,—into the margin of the epiglottis, and the aryteno-epiglottidean fold. *Action*, to depress the epiglottis, and compress the sacculus laryngis. *Nerve*, recurrent laryngeal.

Aryteno-epiglottideus Superior (2),—from the apex of the arytenoid cartilage,—into the aryteno-epiglottidean fold. *Action*, to constrict the superior aperture of the larynx. *Nerve*, recurrent laryngeal.

Aryteno-epiglottideus Inferior (2),—from the arytenoid cartilage just above the attachment of the superior vocal chord,—into the sacculus laryngis

and the margin of the epiglottis. *Action*, to compress the sacculus laryngis. *Nerve*, recurrent laryngeal.

Name the Arteries and Veins of the Larynx. The—

Arteries,—are the Laryngeal Branches of the superior and inferior thyroid; and the Crico-thyroid Branches of the superior thyroid, which anastomose on the crico-thyroid membrane with their fellows of the opposite side.

Veins,—empty into the superior, middle and inferior thyroid veins.

Describe the Laryngeal Nerves. They are the Superior and Recurrent Laryngeal Branches of the pneumogastric, joined by filaments from the spinal accessory and the sympathetic. The—

Superior Laryngeal,—is the nerve of sensation. It enters the larynx by a hole in the thyro-hyoid membrane, and supplies the mucous membrane, and the crico-thyroid and arytenoideus muscles. It has the following branches, namely—

External Laryngeal.

Internal Laryngeal.

Recurrent Laryngeal,—is the motor nerve. It winds from before backwards, around the subclavian artery on the right side, around the arch of the aorta on the left side, and is distributed to all the laryngeal muscles except the crico-thyroid,—giving off, in its course, cardiac, œsophageal, tracheal and pharyngeal filaments, and finally anastomosing with the superior laryngeal nerve.

THE TRACHEA AND BRONCHI.

What is the Trachea? A membrano-cartilaginous, cylindrical tube, about $4\frac{1}{2}$ inches long, and $\frac{3}{4}$ to 1 inch in diameter, beginning at the lower border of the larynx,² opposite the 5th cervical vertebra, and ending opposite the 3d dorsal, by its bifurcation into the two bronchi. It is composed of a fibro-elastic membrane containing 16 to 20 imperfect cartilaginous rings, connected by muscular fibres. It is lined with mucous membrane covered with ciliated columnar epithelium, and furnished with glands. Its anterior surface is convex, its posterior surface flat.

State its Chief Relations in the Neck and Thorax.

Anteriorly,—it is covered from above downwards by the—

Isthmus of the Thyroid Gland.

Inferior Thyroid Veins.

Sterno-hyoid Muscle.

Sterno-thyroid Muscle.

Manubrium of the Sternum.

Thymus Gland.

Arch of the Aorta.

Innominate Artery.

Left Carotid Artery.

Deep Cardiac Plexus.

Posteriorly,—it is in relation with the—

Œsophagus.

Right Recurrent Laryngeal Nerve.

Laterally,—with the—

Common Carotid Arteries.
Thyroid Gland.
Inferior Thyroid Arteries.

Recurrent Laryngeal Nerves.
Pleuræ.
Pneumogastric Nerves.

Describe the Bronchi. They are two tubes similar in formation to the trachea, extending from its bifurcation into the lungs, where they divide and subdivide into bronchial tubes, losing their rings at the 2^d or 3^d subdivision, whence plates of cartilage extend in their walls to their minuter ramifications. The—

Right Bronchus,—is the widest, and the most horizontal, about 1 inch long, has 6 to 8 rings, and divides into 2 main divisions (though its lung has 3 lobes).

Left Bronchus,—is the narrowest and most oblique, nearly 2 inches long, has 9 to 12 rings, and divides into 3 main divisions (though its lung has 2 lobes).

What are the Relations of the Bronchi? Beginning opposite the 3^d dorsal vertebra, the right bronchus enters the lung opposite the 4th dorsal vertebra, the left bronchus opposite the 5th. *The Right Bronchus* lies behind the vena cava superior and the right auricle of the heart, having the right pulmonary artery at first below, then anterior to it, and the vena azygos major arching over it from behind forwards. *The Left Bronchus* passes beneath the arch of the aorta and in front of its descending portion, also in front of the cesophagus and the thoracic duct, having the left pulmonary artery above and in front of it.

Name the Vessels and Nerves of the Trachea and Bronchi.

Arteries,—Tracheal Branches of the inferior thyroid (br. of thyroid axis), and the Bronchial (brs. of thoracic aorta).

Veins,—open into the thyroid plexus and the bronchial veins.

Lymphatics,—terminate in the mediastinal glands.

Nerves,—are derived from the pneumogastric and its recurrent laryngeal branch, also from the sympathetic.

THE LUNGS.

Describe the Lungs. The lungs are the two essential organs of respiration, contained in the cavity of the thorax, covered by the pleuræ, and characterized by lightness (sp. gr. 0.345 to 0.746), sponginess, elasticity, and crepitation when pressed. They weigh together about 42 ounces, the right lung being the heaviest by about 2 ounces. At birth their color is a pinkish-white, mottled as age advances by slate-colored patches, from the deposit of carbonaceous granules in the areolar tissue of the organ. *The Right Lung* is the largest and has 3 lobes; the *Left Lung* has 2 lobes. Each lung presents for examination an—

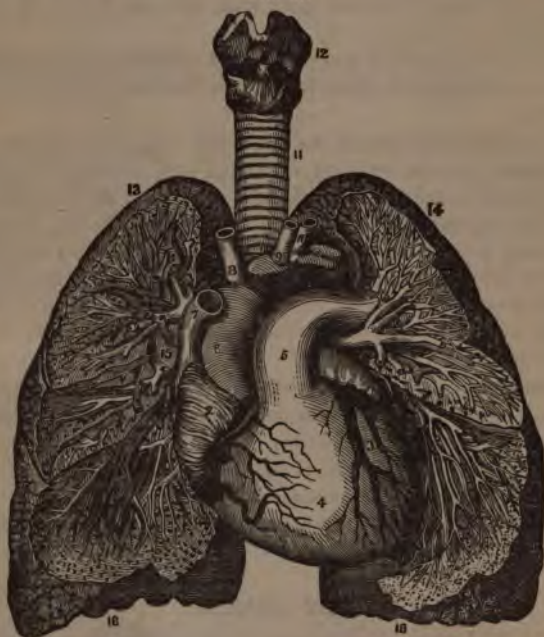*Apex,*¹³—projecting into the neck about an inch above the 1st rib, where it is in relation with the subclavian artery and the scaleni muscles.

*Base,*¹⁶—is broad, concave, and directed obliquely downwards and backwards, resting on the upper convex surface of the diaphragm.

External Surface,—is convex, smooth, marked by the fissures, and corresponds in form to that of the thorax.

Inner Surface,—is concave, the left lung excavated for the heart, the surface forming part of the walls of the middle mediastinum.

FIG. 34.



Root,—is where the bronchi, vessels, and nerves enter the lung, bound together by areolar tissue. In front of the root is the phrenic nerve, behind it the pneumogastric nerve. Its chief structures are arranged in the following manner:—

From before, backwards.

}	Pulmonary veins.	} V. A. B.
	Pulmonary artery. ³	
	Bronchus, etc.	

From above, downwards, on right side of body.	{ Bronchus, etc. Pulmonary artery. Pulmonary veins.	} B. A. V.
From above, downwards, on left side of body.	{ Pulmonary artery. Bronchus, etc. Pulmonary veins.	} A. B. V.

Describe the Structure of the Lung. The lung has a serous coat (the pleura); a sub-serous, elastic areolar tissue, investing the entire organ, and extending inwards between the lobules; and the parenchyma, or true lung-tissue, composed of—

Lobules,—each consisting of several air-cells or compartments, arranged around the termination of a bronchiole, and surrounded by 6 plexuses of pulmonary and bronchial arteries and veins, lymphatics and nerves. Each lobule is a miniature lung, pyramidal in form, with base outwards, and about $\frac{1}{8}$ inch in diameter.

Alveoli, or Air-cells,—are separated from each other by thin septa, are lined with pavement epithelium on a basement membrane, and vary in diameter from $\frac{1}{100}$ to $\frac{1}{70}$ inch. [See Fig. 85.]

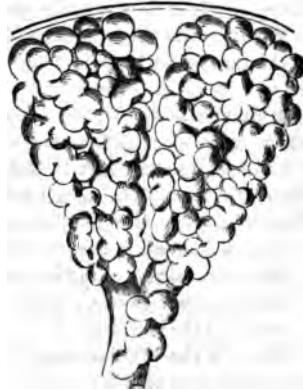

FIG. 85.

Name the Vessels and Nerves of the Lungs. The lungs are nourished by the bronchial arteries, and supplied with blood for oxygenation by the pulmonary arteries.

Bronchial Arteries,—are derived from the thoracic aorta.

Pulmonary Arteries,—are derived from the right heart.

Bronchial Veins,—open on the right side into the vena azygos, on the left side into the superior intercostal vein.

Pulmonary Veins,—open by 4 large orifices into the left auricle of the heart, carrying oxygenated blood from the lungs to the heart.

Lymphatics,—terminate in the bronchial glands.

Nerves,—are branches from the pneumogastric and the sympathetic, forming the Anterior and Posterior Pulmonary Plexuses, from which filaments are distributed to each lobule.

THE PLEURÆ.

What are the Pleuræ? Two delicate serous sacs, one surrounding each lung and reflected over the pericardium, the diaphragm, and the inner surface of the thorax.

Where do the Pleuræ meet? For a short space behind the middle of the sternum, at the approximation of the anterior borders of the lungs.

What Names are given to the parts of the Pleuræ? The—
Pleura Pulmonalis, or Visceral Layer,—covers the lung, and invests that organ as far as its root.

Pleura Costalis, or Parietal Layer,—lines the inner surface of the parietes of the chest.

Cavity of the Pleura,—is the space between the two layers.

What is the Ligamentum Latum Pulmonis? The Broad Ligament of the Lung is a triangular fold or reflection of pleura, which descends from the root of the lung posteriorly to the upper surface of the diaphragm.

State the Differences between the Pleuræ. The right sac is shorter, wider, and reaches higher into the neck than the left.

Enumerate the Parts in Relation with the Left Pleura. Its—
Visceral Layer,—is in contact with the left lung.

Parietal Layer,—is in relation with the vertebral column, the ribs, intercostal muscles and vessels, the sternum, the left sympathetic nerve, the diaphragm, the arched portion of the subclavian artery, and the origin of the left carotid, the left pneumogastric, phrenic and cardiac nerves, the trachea, œsophagus, aorta and the pericardium.

What is the Mediastinum? It is the space between the two pleuræ in the median line of the thorax, extending from the sternum to the vertebral column, and containing all the thoracic viscera except the lungs.

Enumerate the Contents of each of its Divisions. The—

Anterior Mediastinum, contains the—

Origins of the Sterno-hyoid and Sterno-thyroid Muscles.	
Triangularis Sterni Muscle.	Thymus Gland.
Left Internal Mammary Vessels.	Lymphatics.

Middle Mediastinum, contains the—

Heart and Pericardium.	Bifurcation of the Trachea.
Ascending Aorta.	Pulmonary Arteries and Veins.
Superior Vena Cava.	Phrenic Nerves.

Posterior Mediastinum, contains the—

Descending Aorta.	Pneumogastric Nerves.
Azygos Veins.	Splanchnic Nerves.
Superior Intercostal Veins.	Thoracic Duct.
<i>Œsophagus.</i>	Lymphatic Glands.

Describe the Tubuli Uriniferi. The uriniferous tubes begin at the Malpighian corpuscles in the Capsules of Müller, and end at the orifices on the surfaces of the papillæ. Their various portions are the—

Convolved Tubes of Ferrein,—in the cortical substance.

Looped Tubes of Henle,—descending from the former and ascending into the next mentioned.

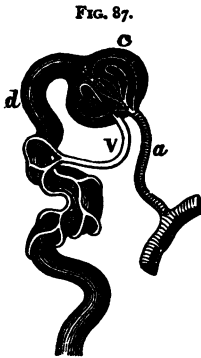
Straight Tubes of Bellini,—in the medullary substance, arranged in pyramids, the *Pyramids of Malpighi.*

What are the Pyramids of Ferrein? They are pyramidal arrangements of the tubes of Ferrein at the bases of the pyramids of Malpighi.

What are the Malpighian Bodies? They are small red bodies found in the cortical substance, each formed by the dilated extremity of a tube of Ferrein, about the $\frac{1}{10}$ inch in diameter, and consisting of the—

Malpighian Tuft,—a tuft of capillary vessels, the termination of some branches of the renal artery *a* and vein *v*.

Capsule of Müller, *c*—the dilated extremity of a tube of Ferrein, *d* investing the Malpighian tuft probably by two layers, similar to the pleural investment of the lungs.



How is the Kidney invested? By a dense fibrous Capsule, which is continued inwards at the hilum, to line the sides of the sinus and form sheaths around the vessels. The kidney is also surrounded by a large quantity of fat.

Enumerate the various Divisions of the Renal Vessels. They are all derived from the Renal Artery and the Renal Vein, but in their course have received different names, as follows, viz.—

Renal Artery,—branch of the abdominal aorta. Divides into the—

Primary Branches, 4 or 5,—arising just external to the hilum, again subdivide and enter in the columns of Bertin as the *Arteriæ Propriæ Renales*, which form—

Arterial Arches,—over the bases of the pyramids, and divide into ascending and descending branches.

Interlobular Arteries, or Ascending Branches,—supply the cortical substance, and end in the Stars of Verheyen. (See next page.)

Arteriola Recta, or Descending Branches,—supply the medullary pyramids, ending in venous plexuses therein.

Afferent Vessels,—to the Malpighian bodies, from the ascending branches.

Malpighian Tufts,—are capillary plexuses within the Malpighian bodies.

From them arise the—

Efferent Vessels,—whether arterial or venous, is undecided. They form

Venous Plexuses,—on the convoluted uriniferous tubes.

Stars of Verheyen,—are venous plexuses of stellate form, situated on the surface of the kidney, beneath its capsule, joining to form the—

Interlobular Veins,—from the cortical portion; which with the

Vena Recta,—from the medullary pyramids, making

Venous Arches,—over the bases of the pyramids, finally meet in the—

Vena Propria Renales,—and they end in the

Renal Vein,—which empties into the inferior vena cava.

Whence are the Nerves of the Kidney derived? From the Renal Plexus, which is formed by filaments from the solar plexus and the lesser splanchnic nerve.

THE URETERS.

What is the Ureter? The excretory duct of the kidney, forming, by its upper expanded portion, the cavity of that gland. It is a musculo-membranous tube, 16 to 18 inches long, as large as a small goose-quill; and ends at the base of the bladder, into which it opens obliquely by a constricted orifice, about 2 inches from the orifice of its fellow. The ureter commences in the—

Calices,—7 to 13 small tubes, embracing the papillæ of the kidney, and joining to form the—

Infundibula,—3 or 4 in number, which unite in the—

Pelvis,—a funnel-shaped dilatation of the upper portion of the ureter.

Describe its Course. It descends obliquely inwards along the posterior wall of the abdomen, enters the posterior false ligament of the bladder in the male, and that of the uterus in the female, through which it passes forwards and inwards to the posterior angle of the trigone vesicæ, lying between the muscular and mucous coats of the bladder, for about three-fourths of an inch.

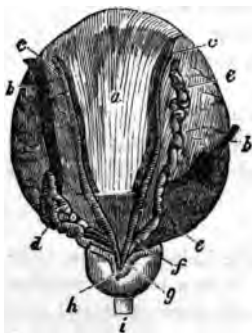
What are its Relations? It lies upon the psoas muscle, behind the peritoneum and below the spermatic vessels, over the common iliac or the external iliac artery, behind the ileum on the right side, behind the sigmoid flexure on the left. The right ureter lies close to the outer side of the inferior vena cava.

Describe its Structure. The ureter has 3 coats—a fibrous, a muscular, and a mucous; the epithelium of the mucous coat is different from that of the urethra, the bladder, or the uriniferous tubes, being spheroidal in shape.

THE BLADDER.

What is the Bladder? It is the urinary reservoir, a musculo-membranous sac, situated in the anterior portion of the pelvis, behind the pubes. When moderately distended it measures about 5 by 3 inches, and holds about a pint. Its—

FIG. 88.



Summit,—is connected to the umbilicus by the *Urachus* and the obliterated Hypogastric Arteries of the foetus, forming three fibrous cords, the Superior Ligament of the bladder.
Body,—is in relation in front with the triangular ligament, the symphysis pubis, and the internal obturator muscles,—behind it is covered by peritoneum, and is in relation with the rectum in the male, with the uterus and upper part of the vagina in the female. Each side is crossed obliquely by the obliterated hypogastric artery and the vas deferens, *c* the first passing from below forwards, the latter from below backwards.

Fundus or Base,—rests on the second portion of the rectum in the male, on the lower part of the cervix uteri and adherent to the anterior wall of the vagina in the female. It is partly covered by peritoneum.

Cervix or Neck,—is constricted and continuous with the urethra.^f It is surrounded in the male by the prostate gland,^h and is directed downwards and forwards.

Name the Ligaments of the Bladder. They number 10, of which 5 are true ligaments, and 5 are false, the latter being folds of peritoneum. They are named as follows,—

<i>True Ligaments.</i>	<i>False Ligaments.</i>
2 Anterior (pubo-prostatic).	2 Posterior.
2 Lateral.	2 Lateral.
Superior (the Urachus, etc.).	Superior.

What is the Urachus? It is the obliterated remains of a canal, which in the embryo connects the bladder with the allantois. It is situated between the two obliterated hypogastric arteries, and with them forms the superior ligament of the bladder, connecting the summit of that organ with the umbilicus.

What is the Trigonum Vesicæ? (? Fig. 89.) The Vesical Trigone is a triangular space, of pale color, at the base of the bladder interiorly, characterized by its smooth surface and the intimate adhesion between its mucous and muscular coats. Its boundaries are—

In Front,—the urethral opening.

Posteriorly,—a line connecting the orifices ³ of the ureters.

Laterally,—two ridges of mucous membrane, which extend from the urethral orifice back to the orifices of the ureters.

What is the Uvula Vesicæ? (⁴, Fig. 89.) A small elevation of mucous membrane projecting from the floor of the bladder into the urethral orifice. It is said to be lifted by the anterior fibres of the levator ani muscle.

Describe the Structure of the Bladder. It has a partial peritoneal investment, and its walls are composed of ~~4~~ ³ coats, ¹ a muscular, ² a cellular, and a mucous. The—

Muscular Coat,—consists of 5 sets of fibres, as follows,—

External and Internal Longitudinal fibres.

Intermediate Circular fibres, forming a *Sphincter Vesicæ* at the neck of the bladder.

Transverse fibres, connecting the orifices of the ureters.

Muscles of the Ureters, connecting their orifices with the middle lobe of the prostate gland.

Cellular Coat,—connects the other two coats together, and is closely attached to the mucous coat.

Mucous Coat,—is covered with epithelium intermediate in form between the columnar and the squamous; is loosely connected to the muscular coat, except at the trigone vesicale and the uvula vesicæ, where it is closely adherent.

What Nerves supply the Bladder? Branches from the hypogastric plexus supply its upper part,—from the sacral plexus its base and neck.

THE MALE URETHRA.

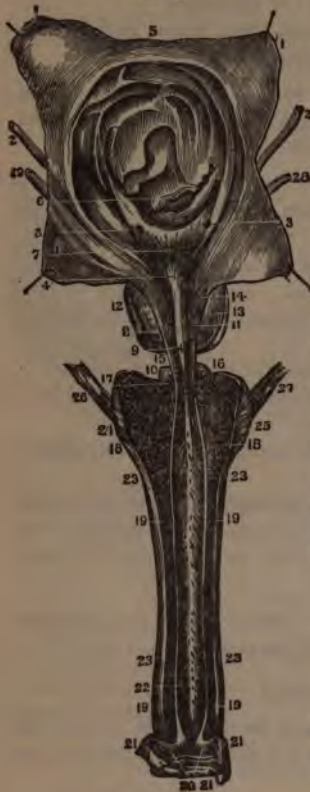What is the Urethra? It is the urinary canal from the neck of the bladder to the meatus urinarius; in the male it is chiefly within the penis, and from 8 to 9 inches in length.

Enumerate its Divisions. The male urethra is divided into 3 parts,—the prostatic, membranous and spongy.

Describe the Prostatic portion of the Urethra.¹⁴ It is that part of the canal which pierces the prostate gland,¹² is about $1\frac{1}{4}$ inch in length, of spindle-shape, and is the widest and most dilatable part of the urethra. Its floor presents the—

Veru Montanum, or Caput Gallinaginis,⁸—an elevation of the mucous membrane and its adjacent tissue, $\frac{3}{4}$ inch long, and supposed to contain muscular and erectile tissue.

FIG. 89.



Prostatic Sinus,¹¹—one on each side of the veru montanum, containing the orifices of the prostatic ducts.

Sinus Pocularis, or Uterus Masculinus,⁹—a small cul-de-sac situated at the front part of the veru montanum. It extends for $\frac{1}{4}$ inch upwards and backwards into the prostate gland, beneath its middle lobe.

Orifices of the Seminal Ducts,—open on the margins of the sinus pocularis.

Describe the **Membranous portion of the Urethra**.¹⁵ It is $\frac{3}{4}$ inch long above, and $\frac{1}{2}$ inch along its floor, being that part of the canal lying between the layers of the triangular ligament of the perineum. Its walls are very thin, and almost destitute of erectile tissue. It is surrounded by the compressor urethræ muscle, and except the orifice, is the narrowest part of the urethral canal. On its sides are the—

Ducts of Cowper's Glands,¹⁶—on their way to open into the bulb of the urethra. (See p. 182.)

Describe the **Spongy portion of the Urethra**. It is about 6 inches long, and has two dilatations, one at each end, named respectively the Bulb and the Fossa Navicularis. The—

Bulb of the Urethra,¹⁸—is the upper end of the spongy portion, projects backwards for $\frac{1}{4}$ inch, and contains the orifices of Cowper's glands.

Fossa Navicularis,—is the lower dilatation of the urethra, and is situated within the glans penis.

Lacuna Magna,—the largest of several orifices of mucous follicles, situated on the roof of the fossa navicularis.

Glands of Littrè,—are numerous mucous glands and follicles, opening into the urethral canal, their orifices being directed forwards.

Describe the Structure of the Urethra. It has 3 coats, a mucous, a muscular, and an erectile. The—

Mucous Coat,—is continuous with that of the whole urinary tract and the ducts of the glands opening therein. Its epithelium is columnar, except in the fossa navicularis, where it is squamous.

Muscular Coat,—consists of a layer of longitudinal fibres of the unstriped variety. [For the voluntary muscles of the urethra, see the Compressor Urethrae and Accelerator Urinae, page 84.]

Erectile Coat,—is the corpus spongiosum of the penis, and a thin layer continued therefrom around the membranous and prostatic portions.

THE FEMALE URETHRA.

Enumerate the Characteristics of the Female Urethra. It is about $1\frac{1}{2}$ inch long, imbedded in the anterior wall of the vagina, perforating the triangular ligament, and surrounded by the fibres of a compressor urethrae muscle. Its diameter is about $\frac{1}{4}$ inch, but it is capable of considerable dilatation, being surrounded by softer structures than those around the male urethra.

THE MALE GENERATIVE ORGANS.

THE URETHRAL GLANDS.

Where is the Prostate Gland? It encircles the neck of the male bladder, its apex touching the deep perineal fascia, its under surface resting on the rectum. It is perforated by the urethra and the common seminal ducts, and its ducts open into the prostatic portion of the urethra.

State its Dimensions and Characteristics. It measures about $1\frac{1}{2}$ inch by 1 inch by $\frac{3}{4}$ inch, weighs about $\frac{3}{4}$ oz., resembles a horse-chestnut in size and shape, and consists of three lobes, two being lateral and of equal size, the third or middle lobe being a small prominence situated in the notch between the lateral lobes.

Describe its Structure. The prostate gland is composed of glandular substance and muscular tissue, inclosed in a fibrous capsule.

How is it Held in Position? By the pubo prostatic ligaments of the bladder, the posterior layer of the deep perineal fascia, and by the anterior portion of the levator-ani muscle.

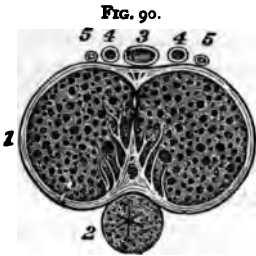
Where are Cowper's Glands? They are situated between the two layers of the deep perineal fascia, one on each side of the membranous portion of the urethra, close behind the bulb, and inclosed by the transverse fibres of the compressor urethrae muscle.

Where do their Ducts open? On the floor of the bulbous part of the spongy portion of the urethra, after traversing the wall of the urethra for about one inch, between its mucous and muscular coats.

THE PENIS.

Of what is the Penis composed? Of a mass of erectile tissue arranged in three compartments of cylindrical shape, each surrounded by a fibrous sheath which is prolonged inwards, forming numerous bands (*trabeculæ*), which divide the compartment into a number of spaces. The compartments are named the *Corpora Caverosa*¹ and the *Corpus Spongiosum*,² the latter lying between and beneath the former, like the ramrod of a double-barreled gun.

Describe the Corpora Caverosa. (¹, Fig. 89.) They lie side by side, forming the upper and lateral parts of the penis, are joined together along their anterior three-fourths, their posterior one-fourth forming the *Crura*, which arise from the tuberosities of the ischia and their descending rami, and meet beneath the symphysis pubis, forming two grooves, one above for the dorsal vessels³,⁴ and nerves,⁵ the inferior one for the corpus spongiosum.²



Bulb of the Corpus Caverosum,—is a slight enlargement on each crus, near its junction with its fellow.

Suspensory Ligament,—a fibrous membrane which connects the root of the organ to the symphysis pubis.

Septum Pectiniforme,—is a portion of the fibrous septum between the corpora cavernosa. This septum extends but two-thirds along the penis, and is wanting for its anterior third.

Describe the Corpus Spongiosum. It is an erectile tube lying in the inferior groove between the two corpora cavernosa, having within it the urethra, and being expanded at both ends to form the glans penis and the bulb. It is composed of trabecular (band-like) structure, derived from a fibrous sheath, and containing erectile tissue. The—⁴

Bulb of the Corpus Spongiosum,—receives the urethra and is surrounded by the accelerator urinæ muscle.

Glans Penis,—is the external expansion of the corpus spongiosum, and covers by its base the ends of the two corpora cavernosa. Its base presents a rounded border, called the *Corona Glandis*, behind which is a deep sulcus, the *Cervix*.

Meatus Urinarius,—the external orifice of the urethra, is situated at the summit of the glans penis.

Prepuce,—a prolongation of the integument of the penis, covering or partly covering the glans penis.

Frenum Preputii,—a fold of mucous membrane lying along the raphé of the glans penis, and connecting the prepuce thereto.

Glands of Tyson,—small lenticular sebaceous glands opening on the corona and cervix of the glans, and secreting an odorous sebaceous matter, which is easily decomposed.

Of what does Erectile Tissue consist? Of an intricate venous plexus, supplied by afferent arteries and emptied by efferent veins. Such are the essential features of the erectile tissue of the penis, which is lodged in the interspaces between the trabeculæ of the fibrous structure.

What are the Helicine Arteries? They are peculiar vine-like arterial branches, which project in a convoluted manner into the venous plexuses in the posterior portion of the penis.

Enumerate the Vessels and Nerves of the Penis. Its—

Arteries,—are derived from the internal pudic, and are the—

Artery of the Bulb,—to the corpus spongiosum.

Artery of the Corpus Cavernosum,—to that structure.

Dorsal Artery of the Penis,—to the glans, prepuce and skin.

Veins,—empty into the Dorsal Vein of the Penis, the prostatic plexus and the pudic vein. The venous plexuses of the erectile tissue are very intricate, and remarkably developed.

Lymphatics,—the superficial terminate in the inguinal glands; the deep set joins the deep lymphatics of the pelvis.

Nerves,—are derived from the internal pudic nerve, and the hypogastric plexus of the sympathetic.

THE TESTES AND THEIR APPENDAGES.

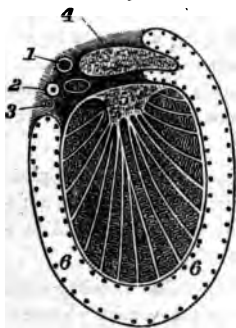
What are the Testes? The Testes or Testicles are the glandular organs which secrete the seminal fluid,—two oval bodies suspended obliquely in the scrotum by the spermatic cords, each measuring about an inch in diameter, and weighing $\frac{3}{4}$ oz. to an ounce.

What is the Scrotum? A cutaneous pouch, consisting of 2 layers—the integument and the *Dartos*,—the latter being a contractile vascular tunic, continuous with the superficial fascia of the thighs and perineum, and forming a septum in the scrotum between the two cavities for the testes.

Describe the Essential Coats of the Testis. They are 3 in number, as follows, viz. : the—

Tunica Vaginalis, the Serous Covering,—having a visceral layer (*tunica vaginalis propria*) and a parietal layer (*tunica vaginalis reflexa*). It was

FIG. 91.



originally derived from the peritoneum, and the upper part being obliterated, it remained a closed sac. (See ⁶ Fig. 91.)

Tunica Albuginea, the Fibrous Covering,—formed of white fibrous tissue, and forming an incomplete vertical septum within the gland, the *Corpus Highmorianum* or *Mediastinum Testis*,⁵ from which fibrous bands (*trabeculae*) cross the gland, dividing its interior into spaces for the lobules of the organ.

Tunica Vasculosa, the Pia Mater Testis,—is the vascular tunic, lying beneath the *tunica albuginea*, and giving off numerous processes between the lobules.

Name the Coverings of the Testicle. From without inwards they are 6 in number, as follows, the—

- (1) *Skin*,—of the scrotum, closely adherent to the dartos.
- (2) *Dartos*,—or superficial fascia.
- (3) *External Spermatic Fascia*, *Intercolumnar Fascia*,—derived from the margins of the external abdominal ring.
- (4) *Cremasteric Fascia*,—derived from the lower border of the internal oblique muscle. [Called also the *Cremaster Muscle*.]
- (5) *Internal Spermatic Fascia*, or *Fascia Propria*,—the infundibuliform process of the *transversalis fascia*.
- (6) *Tunica Vaginalis*,⁶—originally a process of peritoneum. [Shown by dots in Fig. 91.]

Describe the Structure of the Testicle. The glandular structure is composed of small, convoluted tubes, the *Tubuli Seminiferi*,³ (Fig. 92), which are collected into *Lobules*, about 300 in number, from which straight ducts, the *Vasa Recta*,⁴ enter the mediastinum and form an ascending plexus of anastomosing tubes, the *Rete Testis*,⁵ which gives off some 12 to 20 ducts, the *Vasa Efferentia*;⁶ these perforate the *tunica albuginea* of the testis, and form a number of conical masses, the *Coni Vasculosi*,⁷ which together constitute the *Globus Major*⁷ of the Epididymis.⁸

What is the Epididymis?⁸ It is an appendix to the testicle, lying along its posterior border, and consists of a single duct about 20 feet in length when unraveled, but which is wound upon itself so as to occupy a very small space. The—

Globus Major,⁷—is formed by the coni vasculosi, or efferent ducts of the testis, which therein open into the single duct which forms the epididymis.

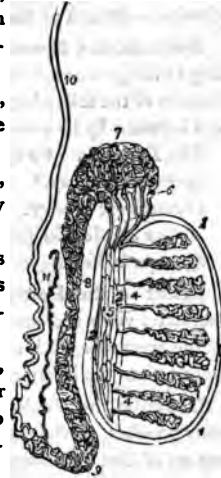
Body,⁸—is formed by the convolutions of the tube, held together by fine connective tissue, and is the central portion.

Globus Minor,⁹—the lower expanded portion, similarly formed, and connected to the testis by fibrous tissue.

Vasculum Aberrans,¹¹—a narrow tube, sometimes found opening into the canal of the epididymis near its lower end, and ending in a blind extremity.

Hydatids of Morgagni,—small pedunculated bodies, found attached to the epididymis or to the upper end of the testicle. One of them is believed to be the remains of the duct of Müller. (See COMPEND OF PHYSIOLOGY, page 131.)

FIG. 92.



Describe the Vas Deferens.¹⁰ It is the continuation of the epididymis, and is the excretory duct of the testicle. Beginning at the globus minor it ascends along the back of the spermatic cord to the external abdominal ring, where it enters the inguinal canal, and penetrates the abdominal cavity through the internal abdominal ring. Descending into the pelvis it passes between the bladder and the rectum, along the inner side of the vesicula seminalis, and at the base of the prostate gland it joins with the duct of the vesicula seminalis to form the ejaculatory duct. The vas deferens is about 2 feet long, and has a canal of only half a line in diameter. Its walls are very dense, making it feel like a piece of wire or whip-cord when grasped between the fingers. (2 Fig. 91.)

Name the Arteries of the Testicle. The *Spermatic Artery*¹ supplies the gland itself; but the coverings of the testicle are supplied by the—

Superficial External Pudic,
Deep External Pudic, } —branches of the Femoral.
Superficial Perineal,—br. of the Internal Pudic, from the Int. Iliac.
Cremasteric,—branch of the Epigastric, from the External Iliac.

Name the Nerves of the Testicle. They are the—

Ilio-inguinal,
Ilio-hypogastric, } —branches of the Lumbar Plexus.
Superficial Perineal,—branch of the Internal Pudic nerve.

Inferior Pudendal,—branch of the Small Sciatic nerve.

Genital,—branch of the Genito-crural nerve.

Describe the Spermatic Cord. It extends from the internal abdominal ring to the globus minor of the epididymis, and is about 4 inches long. It consists of the following-named 10 structures, bound together by areolar tissue and invested by its coverings. These structures are the—

Vas Deferens. ² Fig. 91.

Spermatic Plexus of Nerves.

*Spermatic Artery.*¹

Branch of the Ilio-inguinal Nerve.

Cremasteric Artery.

(1) O:

Branch of the Genito-crural Nerve.

*Artery of the Vas Deferens.*³

Vasculum Aberrans.

Spermatic Veins.

Lymphatics.

What is the Pampiniform Plexus? A venous plexus formed by the spermatic veins and branches from the epididymis. It forms the chief mass of the spermatic cord, and unites into a single trunk, which on the right side empties into the inferior vena cava, on the left side into the left renal vein.

Describe the Vesiculæ Seminales. They are two sacculated, membranous pouches, serving as reservoirs for the semen, and are filled by the backing up of that fluid from the vasa deferentia. They are about $2\frac{1}{2}$ inches in length, and are situated between the base of the bladder and the rectum. Their—

Ejaculatory Ducts,—one on each side, are formed by the junction of the vasa deferentia with the ducts of the vesiculæ seminales. They are about $\frac{3}{4}$ inch in length, and terminate in the prostatic portion of the urethra, by orifices on the sides of the veru montanum.

Describe the Descent of the Testes. In early foetal life the testes are situated in the abdominal cavity, just below and in front of the kidneys, and are each connected to the dartos of the scrotum and the tissues about the inguinal canal by the 3 processes of a cord named the *Gubernaculum Testis*, which is supposed to gradually shorten itself and draw the testis down. At the beginning of the 5th month the descent begins; during the 7th month the testicle enters the inguinal canal, and ordinarily arrives in the scrotum by the end of the 8th month. A process of peritoneum is supposed to be carried down in front of the testis; which process, by obliteration of the canal, becomes a separate structure, the *Tunica Vaginalis*. The structures of the inguinal canal are also supposed to be brought down with the testicle, and to constitute some of its coverings.

FEMALE ORGANS OF GENERATION.

THE VULVA.

Enumerate the Organs comprised in the Vulva. They are the Mons Veneris, the Labia Majora, Labia Minora, Clitoris, Meatus Urinarius, and the Orifice of the Vagina.

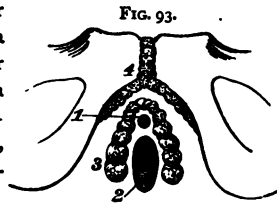
Describe the Labia Majora. They are two prominent folds formed of skin, mucous membrane, areolar and dartoid tissues;—are joined together at the mons veneris, forming the *Anterior Commissure*, and also in front of the perineum, where they form the *Posterior Commissure*.

What are the Labia Minora? The Labia Minora or Nymphæ are two folds of mucous membrane, lost posteriorly in the labia majora, but anteriorly they embrace the clitoris, forming the *Prepuce* of that organ.

Describe the other Parts comprised in the Vulva. The—

Mons Veneris,—is the eminence in front of the pubes. It is formed of adipose tissue, and at puberty becomes covered with hair.

Clitoris,⁴—is situated beneath the anterior commissure, its *Glans* only appearing as a small rounded tubercle between the anterior extremities of the labia minora. It is a diminutive penis in all but the urethra, having a body, two crura, a glans, prepuce, suspensory ligament and muscles, the *erectores clitoridis*.



Bulbi Vestibuli,³—are two oblong masses extending from the clitoris along the sides of the vestibule, and consisting of a venous plexus surrounded by a fibrous membrane.

Pars Intermedia,—is a small venous plexus situated between the glans clitoridis and the bulbi vestibuli.

Vestibule,—is a triangular depression in front of the vaginal orifice, bounded laterally by the labia minora.

Meatus Urinarius,¹—situated in the vestibule, about an inch below the clitoris, and close to the vaginal orifice.

Orifice of the Vagina,²—is surrounded by the sphincter vaginæ muscle, and in the virgin is sometimes partly closed by the hymen.

Hymen,—a fold of mucous membrane situated across the lower part of the vaginal orifice, of various shapes, but usually semilunar, the concavity upwards. It is frequently absent in virgins, and after sexual intercourse its rupture and cicatrization give rise to small eminences along the margin of the vaginal orifice, named the *Caruncula Myrtiformes*.

Fourchette,—a small transverse fold just behind the posterior margin of the vaginal orifice.

Fossa Navicularis,—the space between the fourchette and the posterior commissure of the vulva.

Glands of Bartholine,—one on each side of the vaginal orifice, their ducts opening on the inner sides of the labia minora. They are the analogues of Cowper's glands in the male.

THE VAGINA.

Describe the Vagina. It is a curved canal extending from the vulva to the uterus, placed between the bladder and the rectum. Its length is about 4 inches along its anterior wall, an inch longer posteriorly, and its walls are usually in contact with each other. It is very dilatable, especially at its upper part.

Describe its Structure. The vaginal wall consists of a muscular coat externally, a layer of erectile tissue, and a mucous lining covered with squamous epithelium, and furnished with mucous glands and follicles. The—

Columns of the Vagina,—are two longitudinal raphés situated along its mucous surface, connected by numerous transverse ridges, or *Rugæ*.

What are the Relations of the Vagina? They are—

Anteriorly,—the urethra and the base of the bladder.

Posteriorly,—the anterior wall of the rectum, and the recto-uterine fold of peritoneum which forms *Douglas' cul-de-sac* behind its upper fourth.

Laterally,—are attached the broad ligaments of the uterus, the levatores ani muscles, and the recto-vesical fascia.

Superiorly,—it is attached to the cervix uteri above the os, and higher on the posterior wall than anteriorly.

THE UTERUS AND ITS APPENDAGES.

Where is the Uterus situated? In the pelvic cavity, between the bladder and the rectum, and above the vagina.

Describe the Uterus. It is a hollow, pear-shaped, muscular organ, measuring about 3 inches long, 2 inches broad, and 1 inch thick, flattened from before backwards, placed base upwards, and forming an angle with the vagina, which partially receives its cervix. The—

Fundus, A,—is broad, convex, having walls $\frac{3}{8}$ inch thick, and is covered by peritoneum.

Body,—is about $1\frac{3}{8}$ inch long, walls $\frac{1}{2}$ inch thick, flat anteriorly, convex posteriorly, concave laterally, and joined to the bladder by its lower ante-

rior fourth. It is invested by peritoneum posteriorly, and in front for its upper three-fourths.

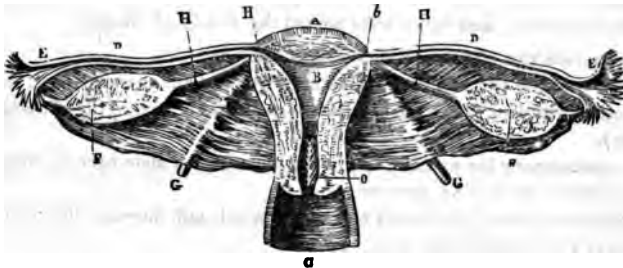
Cervix, or Neck,—is the lower constricted portion, about $1\frac{3}{8}$ inch long, walls $\frac{1}{4}$ inch in thickness, and is embraced for $\frac{1}{2}$ to $\frac{3}{4}$ inch by the upper extremity of the vagina.

Cavity of the Body, B—is small and triangular, flattened from before backwards, about $1\frac{1}{8}$ inch in length, and has two lateral *Cornua* above, and a constricted orifice—the *Os Internum Uteri*—at its lower angle, opening into the cavity of the cervix.

Cavity of the Cervix,—is spindle-shaped, about $1\frac{3}{8}$ inch long, and presents on its inner surface transverse folds of mucous membrane proceeding from a longitudinal fold, giving an appearance named the *Arbor Vitæ*.

Os Uteri or Os Tinæ,—is a transverse orifice at the lower end of the cervical cavity, opening into the vagina, and having an anterior and a posterior lip.

FIG. 94.



Enumerate the Ligaments of the Uterus. The proper ligaments of the uterus are 6 in number,—2 Anterior, or *Utero-vesico-pubic*, 2 Posterior, or *Utero-recto-sacral*, and 2 Lateral, or *Broad Ligaments*, all composed of peritoneum. The—

Broad Ligaments,—pass from the sides of the uterus to the lateral walls of the pelvis, and form a septum across the pelvic cavity. They contain, between the two folds of peritoneum of which they are composed, the Fallopian tubes, the Ovaries, and the so-called Round Ligaments.

What are the Round Ligaments of the Uterus? They are two cords, composed of areolar and fibrous tissue, muscular fibres, vessels and nerves, extending one on each side, from the lateral aspects of the fundus uteri, through the inguinal canals, to the labia majora, where they are lost. Each ligament lies, for a part of its course, between the two layers of the broad ligament, and is covered by a process of peritoneum. (*G* Fig. 94.)

Canal of Nuck,—is the extension of the above-named process of peritoneum into the inguinal canal. It exists in the foetus, and is usually obliterated in the adult.

Describe the Uterine Structure. The uterine wall has 3 coats—peritoneal, muscular and mucous. Its—

Peritoneal or Serous Coat,—invests the body of the organ, excepting on its lower anterior fourth.

Muscular Coat,—constitutes the chief bulk of the uterus. It consists of bundles of unstriped muscular fibres, disposed in 3 layers interlaced together; circular fibres predominating in the cervix, longitudinal fibres in the body of the organ.

Mucous Coat,—is very thick, $\frac{1}{2}$ to $\frac{1}{8}$ inch, and closely adherent to the muscular tissue, having no basement layer of connective tissue. It is covered with ciliated columnar epithelium, and studded with mucous follicles and glands, which are most numerous in the cervix. The latter, when distended by their own secretions, form sacs, which Naboth mistook for human ova, and hence were named the *Ovules of Naboth*.

Enumerate the Uterine Vessels and Nerves. Its—

Arteries,—are the Uterine, from the anterior trunk of the external iliac, anastomosing with twigs from the Ovarian—(spermatic branch of the abdominal aorta).

Veins,—accompany the arteries, and in the impregnated state become sinuses. They end in the uterine plexuses.

Lymphatics,—those of the cervix end in the sacral and internal iliac glands, those of the fundus in the lumbar glands.

Nerves,—are derived from the inferior hypogastric and ovarian plexuses, and from the 3d and 4th sacral nerves.

Describe the Fallopian Tubes or Oviducts. They are two tubes, each about 5 inches in length, and $\frac{1}{8}$ inch in calibre, situated in the free margin of the broad ligament, and extending from the superior angles of the uterus ^b outwards, to terminate in free, trumpet-shaped ends, the *Fimbriated Extremities*,^c surrounded by fringe-like processes, the *Fimbriae*, of which one or more are attached to the ovary of that side. Their structure is similar to that of the uterus, their mucous lining being continuous with the uterine mucous membrane and with the peritoneum. They open by one end into the uterus at its cornua, by the other end into the peritoneal cavity.

What are the Ovaries? Two oval bodies,^d of whitish color, situated in the broad ligament, behind and below the Fallopian tubes, one on each side of the uterus, to which they are attached by the *Ligaments of the Ovaries*.^h

They each measure about $1\frac{1}{2}$ inch by $\frac{3}{4}$ by $\frac{1}{3}$, and are invested by peritoneum, except posteriorly.

Describe the Structure of the Ovaries. They are composed of a vascular stroma containing the *Graafian Vesicles* or *Ovisacs*, in various stages of development, and are surrounded by a dense fibrous coat, the *Tunica Albuginea*.

Describe the Graafian Vesicles. They are the ovisacs containing the human ova, are very numerous (about 70,000 in each ovary), vary in diameter from $\frac{1}{8}$ to $\frac{1}{6}$ inch, but after puberty a few are found of from $\frac{1}{2}$ to $\frac{1}{4}$ inch or more. Each vesicle presents an—

External Coat,—of fibro-vascular structure.

Ovi-capsule,—or internal coat.

Membrana Granulosa,—a layer of nucleated cells, which at one point are heaped up around the ovum in a mature vesicle, forming the *Discus Proliigerus*.

Fluid,—of transparent, albuminous character, containing the ovum in immature vesicles.

What is the Ovum? It is a spherical mass of protoplasm, about $\frac{1}{10}$ inch in diameter when fully developed. It presents a—

Vitelline Membrane,—also called the *Zona Pellucida*,—a colorless envelope, in which is contained the—

Vitellus or *Yolk*,—composed of granules in a fluid substance, one of which is called the—

Germinal Vesicle,—which contains a smaller body named the *Germinal Spot*, measuring about the $\frac{1}{100}$ of an inch in diameter.

What is the Corpus Luteum? It is a puckered yellow spot in the substance of the ovary, produced as a result of the rupture of a Graafian vesicle and the discharge of an ovum, probably by the fatty degeneration of the extravasated blood. The—

True Corpus Luteum,—is that of pregnancy, and may increase in size, not disappearing until full term.

False Corpus Luteum,—occurs when impregnation has not taken place, and is absorbed in about three months.

What is the Pampiniform Plexus? A venous plexus near the ovary, formed by the veins of that organ.

Enumerate the Arteries and Nerves of the Ovaries. Their—

Arteries,—are the Ovarian (or Spermatic), from the aorta, which also supply the Fallopian tubes, anastomosing with the uterine arteries.

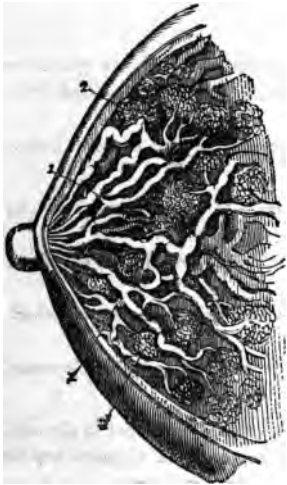
Nerves,—are derived from the Spermatic plexus.

What is the Parovarium? The Parovarium, or *Organ of Rosenmüller*, is a group of tubules, situated in the broad ligament, between the ovary and the Fallopian tube, and converging to a large duct, the *Duct of Gärtner*, which ramifies in the broad ligament, and descends along the side of the uterus. It is thought to be a remnant of the Wolffian Body of foetal life. (See "Reproduction," in COMPEND OF PHYSIOLOGY.)

THE MAMMÆ.

Describe the Mammæ. The breasts are two hemispherical eminences, situated one on each latero-anterior aspect of the chest, extending from the sternum to the axilla, and from the 3d rib to the 7th. Each breast contains the *Mammary Gland* and is surmounted by the *Nipple*, around the base of which is a zone of colored cutaneous tissue, the *Areola*, pink in virgins, darker in women who have borne children. In the male the mammæ are rudimentary organs, but capable of development under special circumstances.

FIG. 95.



Describe the Structure of the Mammary Gland. It is a compound conglomerate gland, composed of 15 or 20 lobes and their ducts,¹ with a packing of areolar and adipose tissue, and enveloped by a fibrous capsule which forms septa between the lobes. Each lobe is made up of lobules,² and these again are formed by the aggregation of the *Acini* or terminal vesicles, in which the milk is secreted. The—

Tubuli Lactiferi or *Tubuli Galactophori*,¹—are the excretory ducts of the lobes, one for each. They are formed by the junction of the ducts from each lobule, and converge towards the areola, beneath which they form *Ampullæ* or dilatations, and thence, piercing the nipple, open on its summit by separate orifices.

What is the Circulus Venosus? An anastomotic venous circle around the base of the nipple, from which larger veins run outwards and terminate in the axillary and internal mammary veins.

Name the Arteries of the Mammæ. They are derived from the Thoracic Branches of the axillary, the Intercostals, and the Internal Mammary arteries.

THE ORGANS OF SENSE.

THE SKIN AND ITS APPENDAGES.

Name the Divisions of the Skin. It is divided into the—

- | | | |
|--|---|--|
| <i>Epidermis, or Cuticle,</i> | { | <i>Superficial Epithelial layers.</i>
<i>Rete Mucosum, the pigmentary layers.</i> |
| <i>Derma, or Cutis Vera,</i>
the True Skin. | { | <i>Papillary Layer, c</i> next below the rete, from which it is separated by a homogeneous basement membrane.
<i>Corium, d</i> the deepest portion. |

What Structures lie in and beneath the Skin? The

Sensitive Papilla, containing the *Tactile Corpuscles* in very sensitive parts,—in the papillary layer of the Derma.

Sweat-glands, f, g. *Hair-roots, h.*
Sebaceous Glands, i. *Fat Cells, e.* } In the Sub-cutaneous Cellular Tissue.

Ducts of the Sweat-glands.

Hair-follicles,—into which most of the sebaceous ducts open. } Perforate both the Derma and the Epidermis.

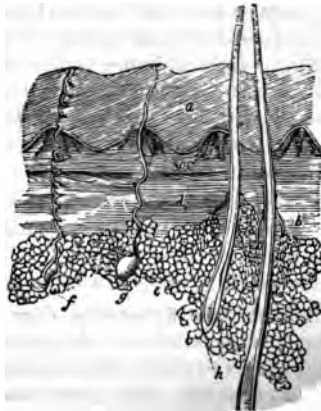Ducts of the Sebaceous Glands,—occasionally. }

Describe the Structure of the Epidermis. It is an unorganized epithelial structure, having no vessels or nerves. The cells of which it is composed are agglutinated together in a laminated arrangement, are flat and dry on the surface, round and softer in the central portion, columnar and softest in the deepest layers. The lowest and softest layers are named the—

Rete Mucosum,—which is closely moulded upon the papillary layer of the derma, and contains pigment cells, to which the color of the skin is due.

Describe the Structure of the Derma. The true skin is a highly organized, tough yet elastic tissue, and serves to protect the parts beneath, to perform the functions of excretion and absorption, and as the chief seat of the sense of touch. It consists of fibro-areolar tissue, vessels and nerves. The—

FIG. 96.



Papillary Layer,—situated next to the rete mucosum, is covered with minute conical elevations (papillæ), $\frac{1}{100}$ inch high $\frac{1}{250}$ inch in diameter at their base, very numerous and arranged in parallel curved lines wherever sensibility is greatest. Each papilla contains a capillary loop or plexus, the termination of one or more sensory nerves,—and in highly sensitive parts, an oval-shaped body, the *Tactile Corpuscle*.

Corium,—the lower layer of the derma, is composed chiefly of interlacing bundles of white fibrous tissue, in which are mingled some yellow elastic fibres, also plain muscular fibres wherever hairs are found,—and lymphatic vessels, blood-vessels and nerves, in plexiform arrangement.

Describe the Nails. They are flat, horny structures, a modification of the epidermis, molded upon the derma at the dorsal surface of the terminal phalanges of both fingers and toes. Each nail is convex on its outward surface, and is imbedded by its *Root* into a fold of the skin. Its—

Matrix,—is that portion of the derma directly beneath the nail. It is covered with highly vascular papillæ. The—

Lunula,—is a white crescentic portion of the nail nearest to its root, produced by the diminution in number and size of the papillæ beneath.

What are the Hairs ? They are also a modified form of the epidermis, found over nearly the whole surface of the body, much varied in size and color. Each hair consists of a *Root* and a *Shaft*. The—

Root,—is lodged in an involution of the epidermis called the *Hair-follicle*, which sometimes extends into the subcutaneous cellular tissue. The root rests on a vascular papilla at the bottom or *Bulb* of the follicle, which supplies it with the material for its growth.

Shaft,—is the projecting portion of the hair. It consists of a medulla in the centre, next a fibrous portion, externally a cortex of thin, flat scales. The finest hairs have no medulla.

Point,—consists of the fibrous portion and the cortex, the medulla being wanting.

Where are the Sebaceous Glands most abundant ? In the scalp, the face, around the anus, and the apertures of the nose, mouth and external ear. The largest are the—

Meibomian Glands,—situated in the eyelids (see Fig. 104).

Describe the Sebaceous Glands. They are small, glandular bodies situated in the corium or in the subcutaneous cellular tissue over most of the body, but not in that of the palmar surface of the hands nor on the plantar surface of the feet. Each gland consists of a single sacculated duct, usually opening into a hair follicle, but sometimes ending on the surface of the integument.

Describe the Sweat-glands. Each gland consists of a single convoluted tube, situated usually in the subcutaneous cellular tissue, and opening on the surface of the integument by a spiral duct which pierces the derma and the epidermis. It is formed of two coats, an external fibro-cellular, which is continuous with the corium, and an epithelial lining, continuous with the epidermis.

State the probable number of Sweat-glands and their Evaporating area. They are estimated as varying, in different parts of the integument, from 417 to 2800 to the square inch, giving for the whole body a total of nearly two millions and a half, representing an evaporating surface of about 8 square inches.

ORGANS OF TASTE.

What are the special Organs of Taste? The *Taste-buds*, small, flask-shaped bodies, each about $\frac{1}{100}$ inch long, situated in the fungiform and circumvallate papillæ of the tongue. The seat of the sense of taste lies, however, in the mucous membrane covering the dorsum of the tongue, the upper portion of the pharynx, the soft palate and the fauces.

Name the special Nerves of Taste in the Tongue. The—
Chorda Tympani Branch of the Facial,—for its anterior two-thirds; perceiving saline, acid and styptic qualities (Flint).
Lingual Branch of the Glosso-pharyngeal,—for its posterior third; appreciating alkaline, metallic, sweet and bitter tastes (Flint).

What is Sapolini's view of the Chorda Tympani Nerve? From repeated dissections, Dr. Sapolini, of Milan, believes the chorda tympani to be a separate cranial nerve, having its proximal end in the so-called intermediary nerve of Wrisberg, originating in the floor of the 4th ventricle, and terminating in a dense plexus with the lingual branch of the 5th nerve, in the muscles of the tongue. He further concludes that the chorda tympani is the nerve governing the movements of the tongue in speech, and that the nerves of taste are the Lingual Branches of the 5th and 9th nerves.

THE NOSE.

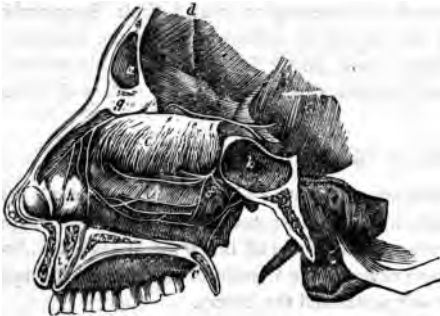
[For an osteological description of the Nasal Fossæ and Septum, see page 31.]

Where is the Organ of Smell situated? In the mucous lining of the upper portion of the nasal fossæ, which is the seat of distribution of the terminal filaments of the *Olfactory Nerve*, the special nerve of the sense of smell.

What is the Schneiderian Membrane? The Schneiderian or Pituitary Membrane is the mucous membrane of the nasal fossæ. It is continuous

the mucous lining of the pharynx, Eustachian tube, tympanum and mastoid cells; also with that of the frontal,^a ethmoidal and sphenoidal sinuses,^b the antrum, nasal duct, and the conjunctiva. It is covered with columnar epithelium, ciliated throughout most of its extent, provided with mucous glands, and in

FIG. 97.



its deeper layer with the—

Olfactory Cells of Schultze,—spindle-shaped, epithelial structures grouped around and between the columnar epithelial cells, and joined together by their anastomosing processes, to form an intricate plexus on which the terminal fibres of the olfactory nerve are supposed to be distributed.

Name the Arteries of the Nose. They are the—

Lateralis Nasi,—branch of the facial, to the *alæ* of the nose.

Nasal of the Septum,—from the superior coronary artery, to the septum.

Nasal,—branches of the ophthalmic and infra-orbital, to the dorsum and sides of the nose.

Name the Arteries of the Nasal Fossæ. They are the—

Anterior and Posterior Ethmoidal,—from the ophthalmic.

Spheno-palatine,—branch of the internal maxillary.

Alveolar,—branch of the internal maxillary, to the antrum.

What Nerves supply the Nose? Branches from the facial, infra-orbital and infra-trochlear, and a filament from the nasal branch of the ophthalmic nerve.

What Nerves supply the Nasal Fossæ? They are the—

Olfactory or 1st Cranial,^e—over the upper third of the septum nasi, and over the superior and middle turbinated bones.

Nasal Branch of the Ophthalmic,^f—to the septum and outer walls.

Anterior Dental Branch of the Superior Maxillary,^j—to the inferior meatus of the nose and the inferior turbinated bone.

Spheno-palatine Ganglion,—sends branches to the septum and the superior turbinated bone,—the *Superior Nasal Br.* to the same parts,—the *Naso-palatine* to the middle of the septum,—and the *Anterior Palatine* to the middle and lower turbinated bones.

THE EYE.

[For an osteological description of the Orbit, see page 29.]

What is the Visual Apparatus? It comprises the eyeballs and their appendages, which collect the luminous impressions,—and the optic nerves, which convey these impressions to the brain.

Describe the Eyeball. It is a spherical organ, situated in the anterior part of the orbital cavity, on a cushion of connective tissue and fat, where it is retained by its muscles, the optic nerve, the conjunctiva, etc., and protected in front by the eyelids and eyebrows. Projecting from its anterior surface is the segment of a smaller, transparent sphere, the Cornea. The eyeball has the following—

Diameters,—Antero-posterior, about .95 inch,—Transverse, .92 inch,—Vertical, .90 inch,—in the adult.

Anterior Pole,—is the geometric centre of the cornea.

Posterior Pole,—is the geometric centre of the fundus.

Optic Axis,—is an imaginary straight line connecting the poles.

Visual Axis,—an imaginary straight line from the yellow spot to the object, through the nodal point. It cuts the cornea above the optic axis, at an angle therewith of 3° to 7° , the *Visual Angle*.

Nodal Point,—the centre of curvature of the refracting surfaces.

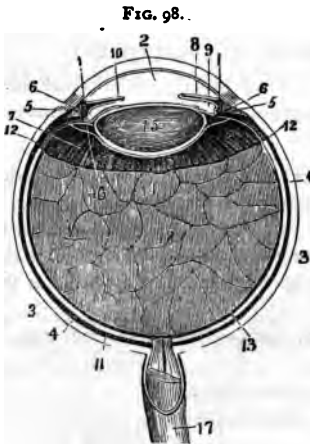
Equatorial Plane,—an imaginary plane through the centre of the eyeball, perpendicular to the axis, dividing the ball or globe into the anterior and posterior hemispheres. The *Equator* is the line where this plane cuts the surface of the globe.

Meridional Planes,—are imaginary planes coinciding with the axis of the eyeball. *Meridians* are the lines where these planes intersect the surface of the globe.

Describe the Tunica Vaginalis Oculi. It is a fibrous capsule, surrounding the eyeball and the intra-orbital portion of the optic nerve; arising from the optic foramen and being lost anteriorly on the sclerotic. It consists of two layers (parietal and visceral) enclosing a lymph-space which communicates with the lymph-space between the sclerotic and choroid coats. The tendons of the ocular muscles pierce it. The—

Capsule of Bonnet,—is the portion of tunica vaginalis posterior to the point where the tendons pass through it. This part is loosely attached to the eyeball, which rotates in it.

Capsule of Tenon,—is the portion of the tunica vaginalis anterior to the passage of the tendons. [The whole capsule or Tunica Vaginalis is by many anatomists named the Capsule of Tenon.]



Vitreous,¹³—in the posterior chamber of the eyeball.

Name the Tunics of the Eyeball.

They number 3, and are named as follows: the—

*Sclerotic*³ and *Cornea*,¹—the external and protective tunic.

Uveal Tract,—or vascular tunic, comprising the *Choroid*,⁴ *Ciliary body* and the *Iris*,⁵ within which is the—

Retina,¹¹—the innermost, nervous tunic.

Name the Humors of the Eyeball.

They also number 3, as follows:—

Aqueous,²—in the anterior² and middle⁹ chambers.

Crystalline,—forming the crystalline lens.¹⁵

THE SCLEROTIC AND CORNEA.

Describe the Sclerotic. The Sclerotic or hard coat is the posterior five-sixths of the external tunic of the eyeball, the anterior one-sixth being the Cornea. Externally it is of a white color, covered anteriorly by the conjunctival mucous membrane, posteriorly being continuous with the sheath of the optic nerve. Internally its color is brown, and its surface marked by grooves for the ciliary nerves. The optic nerve pierces it posteriorly, also the long and short ciliary arteries, posterior ciliary veins and short ciliary nerves. In the equatorial region it is pierced obliquely by the *venæ vorticosæ*, and around the corneal border by the anterior ciliary arteries and veins. It is composed of connective tissue with elastic fibres, intermixed with pigment cells, and cells resembling the corneal corpuscles. It presents for consideration the following points, viz. :—

Thickness,— $\frac{1}{25}$ inch posteriorly, $\frac{1}{40}$ inch anteriorly.

Lamina Fusca,—a layer of very fine connective tissue, connecting the sclerotic with the outer surface of the choroid.

Lamina Cribosa,—the posterior perforated portion of the sclerotic, which at this point is a thin, cribriform lamina. Its largest opening transmits the *arteria centralis retinæ*, and is named the *Porus Opticus*, or Optic Canal.

Sub-conjunctival Tissue,—connects the conjunctiva with the outer surface of the sclerotic.

Sulcus,—a slight circular depression around the junction of the sclerotic with the cornea.

Arteries,—from the Ciliary, are few and in a coarse net-work, uniting at wide intervals, but forming, however, the—

Posterior Vascular Zone, or *Zone of Zinn*,—an arterial zone around the optic nerve entrance, formed by twigs of the short ciliary going to the optic nerve to anastomose with branches of the central artery of the retina, forming the only connection between the ciliary and retinal systems.

Anterior Vascular Zone,—around the cornea, formed by sub-conjunctival branches of anterior ciliary vessels.

Nerves,—none have been yet found in the sclerotic.

What is the Cornea? The Cornea, or horny body, is the anterior transparent projecting portion of the external tunic of the eyeball, forming about one-sixth thereof. It is set into the sclerotic as a watch-crystal into its case, is of ellipsoidal base, the transverse diameter being the longest, and slightly more convex vertically than horizontally. Its—

Thickness,—is $\frac{1}{8}$ inch at centre, $\frac{1}{2}$ inch at periphery.

Index of Refraction,—1.342.

Vessels,—none, except the peripheral zone, $\frac{1}{5}$ inch wide, formed of capillary loops from Episcleral branches of the anterior ciliary, which terminate at its circumference; so that it is practically a non-vascular structure.

Nerves,—are numerous; 20 or 30 twigs from the Ciliary nerves form an intricate plexus throughout its laminated substance.

Describe the Structure of the Cornea. It consists of five layers,—centrally the true corneal tissue, having in front an anterior elastic lamina and the conjunctival epithelium; behind, a posterior elastic lamina and the epithelial lining of the aqueous chamber. The—

Layer of Conjunctival Epithelium $\frac{1}{80}$ inch thick, consists of two or three layers of transparent nucleated cells.

Anterior Elastic Lamina, also named the *Anterior Limiting Layer*, the Membrane of Bowman or Membrane of Reichert,—is $\frac{1}{300}$ to $\frac{1}{200}$ inch thick, a firm, elastic and transparent homogeneous membrane, consisting of closely-interwoven fibrils, similar to those in the corneal tissue proper.

True Corneal Tissue,— $\frac{1}{5}$ inch thick, a transparent, fibrous structure, formed of five connective-tissue fibrillæ, united in bundles, and these in laminæ, between which is a semi-fluid cement, filled with *Corneal Corpuscles* and wandering cells.

Posterior Elastic Lamina, Membrane of Descemet, or Demours,—is, like the anterior elastic lamina, a structureless basement membrane, of extreme thinness, resisting the action of water, alcohol or acids; very brittle, ex-

ceedingly elastic, and curls up inwardly upon itself, when detached from the true cornea. At the corneal margin it breaks up into fibres, which are continuous with the ligamentum pectinatum of the iris.

Posterior Epithelial Layer,—a single layer of flattened, polygonal, transparent, nucleated cells, forming the endothelium of the membrane of Descemet or Demours, and the epithelial lining of the aqueous chamber.

THE UVEAL TRACT.

Describe the Choroid. It is the posterior portion of the middle tunic of the eyeball, $\frac{3}{80}$ to $\frac{1}{10}$ inch thick, and extends from the optic nerve entrance to the ora serrata, a little in front of the equator. It is highly vascular, of dark-brown color, connected to the sclerotic by the *Lamina Fusca*, terminates anteriorly in the *Ciliary Processes*, and is composed of four layers, as follows:—

Tunica Vasculosa,—externally, consists of the venæ vorticosæ and the larger arterial branches.

Membrana Ruyschiana, or Chorio-capillaris, the middle layer—consists of a fine capillary plexus, formed by the short ciliary vessels.

Limiting Membrane,—a structureless hyaline membrane, covering the inner surface of the capillary layer.

Pigmentary Layer, internally,—a single layer of hexagonal nucleated cells, loaded with pigment of a brown-black color, which is absent in albinos, and of slight amount in blondes. [Considered by many anatomists the 10th layer of the retina.]

Arteries of the Choroid,—are the short posterior ciliary, and recurrent branches from the long posterior and anterior ciliary. (See p. 105.)

Veins,²—unite into 4 or 6 Venæ Vorticosæ,⁴ which pass out through the sclerotic near its equator.

Nerves,³—derived from 3d, 5th, and sympathetic, through the long and short ciliary nerves. (See p. 137.)

What are the Ciliary Processes? They are 70 or 80 folds, formed by the anterior prolongation of the middle and internal layers of the choroid on the inner surface of the ciliary muscle, being received into corresponding folds on the suspensory ligament of the lens. They are about $\frac{1}{16}$ inch in length, and form a curtain-like expansion behind the iris.

Describe the Ciliary Body.⁵ It is the portion of the uveal tract between the choroid and the iris,⁶ and consists of ciliary muscle covered by choroidal stroma and the ciliary processes. The—

Ciliary Muscle or Muscle of Bowman,—is a ring of involuntary muscular fibres, supplied by the 3d nerve; is thickest anteriorly, thin posteriorly.

Its fibres arise from the corneo-sclerotic junction, and pass backwards to

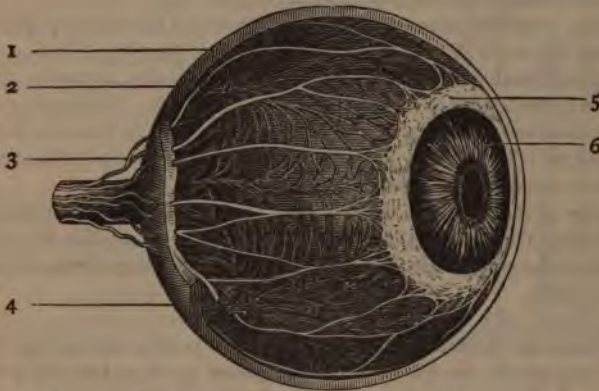
be attached to the choroid in front of the retina. Consists of meridional fibres drawing the choroid forwards, and circular fibres which relax the zonula and permit the lens to become more convex, from its own elasticity.

Annular Muscle of Müller,—consists of separate circular bundles at the anterior internal angle of the ciliary body.

Circulus Arteriosus Major and Minor,—are arterial circles on the ciliary muscle, formed by branches of the long posterior ciliary and anterior ciliary arteries.

What is the Iris? It is a perforated curtain, suspended in the aqueous humor behind the cornea and in front of the lens, and is the anterior portion of the middle tunic of the eyeball, being continuous with the ciliary muscle and the choroid coat. It is about $\frac{1}{8}$ inch wide, $\frac{1}{100}$ inch thick, and is com-

FIG. 99.



posed of radiating and circular muscular fibres, a fibrous stroma and pigment cells, covered by a layer of irregular cells continuous with those of the membrane of Descemet. The—

Pupil,—is the central opening in the iris, situated a little to the nasal side of the centre, diameter $\frac{1}{8}$ to $\frac{1}{4}$ inch.

Ligamentum Pectinatum Iridis, or Dollinger's band,—is the suspensory ligament of the iris, connecting its ciliary margin with the corneo-sclerotic junction. It is formed of strong fibrous prolongations from the membrane of Descemet and the posterior surface of the cornea.

Fontana's Spaces,—are spaces between the prolongations which form the ligamentum pectinatum. In some animals, as the ox, they form regular canals.

Uvea, or Tapetum,—a layer of purple pigment-cells on the posterior surface of the iris, continuous with the pigment layer of the ciliary processes.

Sphincter Pupille,—a layer of circular muscular fibres around the pupillary margin, supplied by the 3d nerve.

Dilator Pupille,—radiating muscular fibres from the pupillary margin toward the ciliary border, supplied by fibres of the sympathetic, from the ciliary ganglion. [See p. 137.]

Membrana Pupillaris,—a vascular membrane which covers the pupil in the fœtus, disappearing about the eighth month,—occasionally permanent. It is nourished by the *Hyaloid Artery*, through the *Canal of Stilling* (described under the VITREOUS HUMOR).

Arteries,—are derived from the long and anterior Ciliary, forming the *Circulus Major Iridis* at the ciliary border, and the *Circulus Arteriosus Iridis Minor* near the pupillary margin.

Veins,—empty into those of the ciliary processes and the anterior ciliary veins
Sinus Circularis Iridis, Canal of Schlemm, or Canal of Fontana,—is a minute canal at the internal corneo-sclerotic junction, extending around the circumference of the attached border of the iris. It is lined by endothelium and encloses a venous plexus, receiving veins from the sclerotic and the ciliary plexus. It communicates with the chamber of the aqueous humor and with the anterior ciliary veins.

Nerves of the Iris,—are derived from the 3d, 5th and the sympathetic, through the long and short ciliary nerves. The 3d supplies the circular fibres, the sympathetic the radiating ones, the 5th being nerves of common sensation.

THE RETINA.

What is the Retina? It is the innermost or nervous tunic of the eye,—a delicate, grayish, transparent membrane, about $\frac{1}{32}$ of an inch thick at the fundus, $\frac{1}{16}$ inch at the anterior margin. It is formed by a membranous expansion of the optic nerve elements, and extends from the termination of that nerve nearly as far forwards as the ciliary processes, terminating in a jagged margin, the *Ora Serrata*, though its fibrous stroma is continued as the *Pars Ciliaris Retinæ* over the ciliary body. The Retina presents for examination the following points, viz., the—

Macula Lutea, or Yellow Spot,—situated on the retina, exactly in the visual axis; is an elevated oval spot where vision is very acute, the retina being very thin and full of nerve elements closely packed together at the expense of its connective tissue. No rods, no nerve-fibre layer here, but the cones and ganglion-cells are very numerous.

Fovea Centralis,—a depression at the centre of the macula lutea, $\frac{1}{18}$ to $\frac{1}{16}$ inch in diameter, in which the sense of vision is most acute.

Optic Disc or Papilla,—the point where the optic nerve enters, the central artery of the retina piercing its centre. It lies about $\frac{1}{10}$ inch internal to and $\frac{1}{10}$ inch below the posterior pole of the eye, and is often called the *Blind Spot*, being the only part of the fundus oculi from which the power of vision is absent.

Pars Ciliaris Retinae,—the part of the retinal stroma which is prolonged over the ciliary body. It is destitute of nerve-elements.

Arteries of the Retina,—arise from the Arteria Centralis Retinae (br. of the ophthalmic), just behind the optic disc; run chiefly upwards and downwards, accompanied by veins, to terminate in capillary network. No vessels exist in the fovea centralis, and only the finest capillaries in the macula lutea.

Describe the Structure of the Retina. It is composed of nervous elements, blood-vessels, and modified connective tissue resembling the neuroglia of the brain, arranged in 9 or 10 layers, from within outwards, as follows, viz.—

Membrana Limitans Interna,—a perfectly transparent membrane, made up of the retinal connective tissue, and lining the inner surface of the retina (shown in the cut by the lowest line).

Optic Nerve Fibres,¹—composed of the terminal fibres of the optic nerve radiating from the papilla in all directions. They consist of the axis-cylinder only.

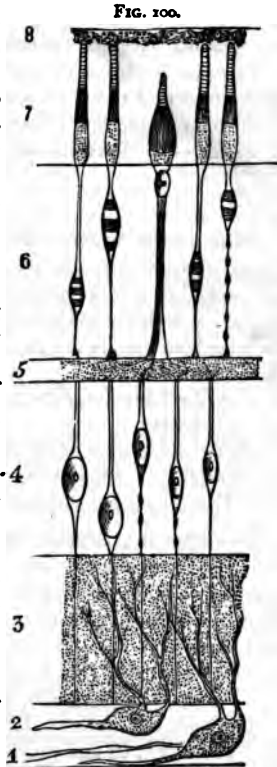
Ganglionic Layer,²—a very thin layer of large ganglion cells, having large nuclei and nucleoli, with branching processes to the optic nerve fibres of next layer.

Internal Molecular Layer,³—fine granules intersected by finest nerve fibres and connective tissue elements.

Internal Granular Layer,⁴—small, round cells with large nuclei, their processes uniting with the ganglion cells.

External Molecular Layer,⁵—a very thin layer of fine granules and nerve-fibrillae.

External Granular Layer,⁶—consists of ellipsoid cells, forming a nucleated enlargement of Jacob's membrane.



External Limiting Membrane,—a membranous expansion of radial connective tissue, perforated by foramina (shown in the cut by a line between 6 and 7).

Rods and Cones, or Jacob's Membrane,⁷—the perceptive layer of the retina, composed of rods and cones closely packed together, like palisades, the termini, probably, of the optic nerve fibres.

[A tenth layer is described by some anatomists, the pigmentary layer of the choroid.⁸ See *ante*, p. 200.]

Name the Essential Elements of the Retinal Structure.

PRINCIPAL ELEMENTS, are three, as follows, viz.—

Nerve fibres,—which in the molecular layers break up into very delicate plexuses. In their course are found—

Nerve cells,—ordinary bipolar or multipolar, and modified ones, the so-called granular layers of the retina.

Terminal Organs,—the rods and cones of Jacob.

SUBORDINATE ELEMENTS, are two, the—

Modified Connective Tissue,—of spongy nature.

Vessels,—blood vessels and lymphatics.

THE HUMORS.

What is the Aqueous Humor? It is a clear, alkaline, serous fluid, composed of water 96.7, albumen 0.1, chloride of sodium and extractive matters 3.2, weighing 4 to 5 grains, and filling the anterior and posterior aqueous chambers, which communicate with each other when the pupil is dilated sufficiently to remove the pupillary margin of the iris from the surface of the lens. The—

Anterior Chamber of the Aqueous Humor,—has the cornea in front and the iris behind.

Posterior Chamber of the Aqueous Humor,—has the iris in front, the lens, zonula and ciliary body behind. [The existence of any such space is denied by many authorities.]

Describe the Crystalline Lens. It is a bi-convex, elastic, transparent body, enclosed in a capsule, held in place by a suspensory ligament, and situated between the posterior aqueous chamber and the chamber of the vitreous humor, immediately behind the pupil. Its posterior surface is the most convex, and rests in the *Hyaloid Fossa* of the vitreous. Its—

Dimensions and Weight,—diameter, about $\frac{3}{8}$ inch,—axis about $\frac{1}{2}$ inch,—weight, 4 to $4\frac{1}{2}$ grains,—index of refraction, 1.44.

Composition,—water 60, soluble albuminous matter 35, insoluble albuminous matter 2.5, fat and cholesterine 2 per cent.

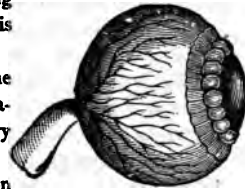
Capsule,—is transparent, elastic, $\frac{1}{1000}$ inch thick anteriorly, $\frac{1}{2000}$ inch posteriorly; has a layer of flat cells between its anterior portion and the lens, which, after death, break down into a fluid, the *Liquor Morgagni*.

Zonula of Zinn, or Suspensory Ligament,—connects the capsule with the ciliary body. It is formed by a splitting of the hyaloid membrane into two layers, one going in front of the lens, the other behind. It is shown exaggerated in the cut.

Canal of Petit,—is a triangular space around the circumference of the lens, formed by the separation of the two portions of the suspensory ligament (shown inflated in the cut).

Processus Zonula,—are small radiating folds on the anterior surface of the suspensory ligament, which are received between the ciliary processes.

FIG. 101.



Describe the Structure of the Crystalline Lens. It consists of flattened hexagonal fibres, united laterally into lamellæ, by serrated edges, and curving around the borders of the organ. Its centre or *Nucleus* is unstratified, and denser than the surrounding portion or *Cortex*. It is unorganized, having no vessels or nerves, but receives its nutriment by imbibition from the uveal tract, and possibly from the other humors of the eye.

What is the Vitreous Humor? The Vitreous Humor or Hyaloid Body is an apparently structureless substance, of gelatinous consistence, consisting of water with a little albumen and salts, and containing cells, nuclei, and connective-tissue filaments. It has no vessels or nerves, and is situated in the posterior chamber of the eye, behind the lens, which it supports, as also the retina. The—

Canal of Stilling, Canal of Cloquet, or Hyaloid Canal,—traverses the vitreous humor antero-posteriorly, being the channel for the transmission in the fœtus of the *Hyaloid Artery* to the *membrana pupillaris*. [See *ante*, p. 202.]

Hyaloid Fossa,—a depression on the anterior surface of the vitreous, receiving the posterior convexity of the lens.

What is the Hyaloid Membrane? It is a delicate capsule investing the vitreous, and supposed to send delicate septa into the substance of that humor. It divides anteriorly into two layers, which enclose the Canal of Petit and the Lens, forming the suspensory ligament of the latter, or *Zonula of Zinn*. [See above.]

The foregoing is the view of most anatomists, but some assert that this membrane is identical with the internal limiting membrane of the retina, extending only to the *ora serrata*. [Henle, Iwanoff, etc.]

Others admit a hyaloid membrane surrounding the vitreous, but deny that it splits to enclose the lens, and assign but one layer to the suspensory ligament, namely, that in front of the Canal of Petit. [Gray, etc.]

Describe the Muscles of the Eyeball. They number 6, of which 4 are Recti and 2 Oblique, as follows:—

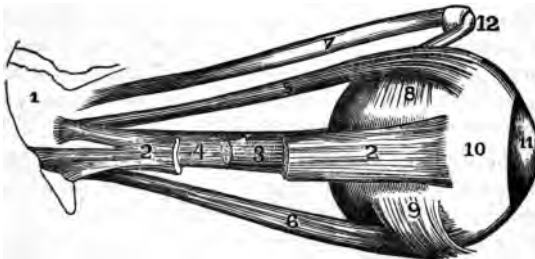
*Rectus Superior,*⁵—from the upper margin of the optic foramen and the sheath of the optic nerve,—into the sclerotic coat. *Action,* to rotate the eyeball upwards. *Nerve,* 3d cranial.

*Rectus Inferior,*⁶—from the ligament of Zinn,—into the sclerotic coat. *Action,* rotates the eyeball downwards. *Nerve,* 3d cranial.

*Rectus Internus,*⁴—from the ligament of Zinn,—into the sclerotic coat. *Action,* rotates the eyeball inwards. *Nerve,* 3d cranial.

*Rectus Externus,*²—by two heads, the upper from the outer margin of the optic foramen, the lower from the ligament of Zinn and a bony process

FIG. 102.



at lower margin of the sphenoidal fissure,—into the sclerotic coat.¹⁰ *Action,* to rotate the eyeball outwards. *Nerve,* 6th cranial, or abducens. Between the two heads of the external rectus pass the 3d, nasal branch of the 5th, and the 6th cranial nerves, and the ophthalmic vein.

*Obliquus Superior,*⁷—from about a line above the inner margin of the optic foramen, its tendon passing through a “pulley”¹² near the internal angular process of the frontal bone and thence beneath the rectus superior,—into the sclerotic coat, at right angles⁸ to the insertion of the rectus superior. *Actions,* to rotate the eyeball on its antero-posterior axis. *Nerve,* 4th cranial, or patheticus.

*Obliquus Inferior,*⁹—from the orbital plate of the superior maxillary,—into the sclerotic coat below the insertion of the external rectus and at right angles thereto. *Action,* to rotate the eye on its antero-posterior axis. *Nerve,* 3d cranial.

VESSELS AND NERVES OF THE EYE.

What Nerves supply the Muscles of the Eye? The—

3d Cranial, or Motor Oculi,—supplies the superior, inferior and internal recti, and the inferior oblique muscles.

4th Cranial, or Trochlear,—supplies the superior oblique muscle.

6th Cranial, or Abducens,—supplies the external rectus.

Describe the Arteries of the Eye. The Eye is supplied by the *Ophthalmic* and *Anterior Cerebral* branches of the internal carotid artery, and the *Infra-orbital* branch of the internal maxillary (from the external carotid). The—

OPHTHALMIC,—arises from the cavernous portion of the Internal Carotid, and enters the optic foramen, giving off the following-named branches:—

Lachrymal,—to the lachrymal gland, the upper eyelid, and the conjunctiva, anastomosing with the palpebral arteries.

Supra-orbital,—supplies the superior rectus and levator palpebræ muscles, the forehead and pericranial tissues.

Anterior and Posterior Ethmoidal,—to the dura mater, the nose, the anterior ethmoidal cells, and the frontal sinus.

Palpebral,—superior and inferior,—to the eyelids.

Frontal,—to the tissues of the forehead.

Nasal,—to the lachrymal sac, and the nose.

Short Ciliary, 12 or 15,—pierce the sclerotic at the lamina cribosa, supplying the choroid and the ciliary processes.

Long Ciliary, 2,—pierce the sclerotic, and pass forwards between it and the choroid, to supply the iris, forming two arterial circles thereon, the *Circulus Major Iridis* at the ciliary border, and the *Circulus Arteriosus Iridis Minor* near the pupillary margin.

Anterior Ciliary,—arise from the muscular branches, pierce the sclerotic, and join the great arterial circle of the iris.

Arteria Centralis Retinæ,—pierces the optic nerve obliquely, and is distributed to the retina.

Muscular Branches, 2,—superior and inferior, supply the muscles of the eyeball.

ANTERIOR CEREBRAL, branch of the Internal Carotid,—sends nutrient capillaries to the optic nerve.

INFRA-ORBITAL, branch of the Internal Maxillary artery,—sends branches to the inferior rectus and inferior oblique muscles, and to the lachrymal gland.

Name the Principal Lymph-spaces of the Eyeball. The—

Canal of Schlemm,—around the circumference of the iris.

Peri-choroidal Space,—between the choroid and the sclerotic.

Space of Tenon,—between the globe and its capsule.

Vaginal Spaces,—between the sheaths of the optic nerve.

What Veins has the Eye? It has two main trunks, the *Superior* and *Inferior Ophthalmic Veins*, which empty into the cavernous sinus, after collecting the blood from the smaller venous channels through the *Vena Vorticosa* of the choroid. The veins of the eye anastomose freely with the facial veins, thus permitting the escape of venous blood in either direction.

Describe the Nerves of the Eye. They are the—
Nerve of Special Sense,—the Optic, or 2d cranial nerve.

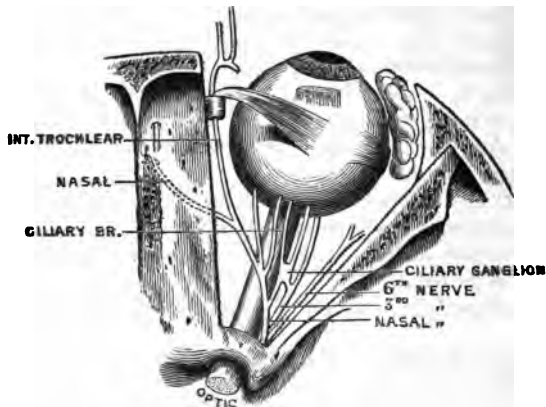
Motor Nerves,—the 3d, 4th, 6th, filaments of the 5th, and some fibres from the sympathetic.

Sensory Nerve,—the Ophthalmic Division of the 5th, giving off the—

Lachrymal,—to the lachrymal gland, the conjunctiva, and the integument of the upper eyelid.

<i>Frontal</i> ,	{	Supra-trochlear.	<i>Nasal</i> .	{	Ganglionic.
		Supra-orbital.			Long Ciliary.
					Infra-trochlear.

FIG. 103.



Sympathetic Branches,—arise from the medulla, cilio-spinal region, cavernous and carotid plexuses, and join the 3d, 4th, 5th, and 6th nerves, sending filaments to the dilator fibres of the iris, to the muscles of the orbit and lids, to the ciliary ganglion, and to the walls of the arteries.

Short Ciliary,—some 20 in number, arise from the *Ciliary Ganglion* [See *ante*, page 137], pierce the sclerotic and go to the ciliary muscle, choroid, iris, cornea, and to the sheath of the optic nerve.

Ascending,—from Meckel's ganglion [See *ante*, page 137], enter the orbit by the speno-maxillary fissure, going to the optic nerve, the 6th nerve, and the ciliary ganglion.

Describe the formation and course of the Optic Tract. The fibres which form the optic tract have their deep origin in the optic thalamus, corpora geniculata, and the anterior corpora quadrigemina. The tract winds around the crus cerebri as a flattened band, receiving from the crus a few fibres of attachment, and also fibres from the lamina cinerea and the tuber cinereum. In front of the latter body the two tracts join to form the *Optic Commissure* or *Chiasm*. [See ² on Fig. 61, page 130.]

What is the arrangement of the Fibres in the Optic Commissure? As generally described, the fibres undergo a partial decussation, as follows, viz., the—

Decussating Fibres,—are the most numerous. They lie in the centre of the commissure, and pass across to the opposite side, connecting the retina of each eye with the opposite cerebral hemisphere.

Longitudinal Fibres,—are the external fibres in the optic tracts, passing into the optic nerve of the same side, connecting each retina with the cerebral hemisphere of its own side.

Inter-cerebral Fibres,—situated posteriorly in the commissure, passing from one optic tract to the other.

Inter-retinal Fibres,—lie anteriorly in the commissure, passing from one optic nerve to the other, and connecting the retina of one eye with that of the other.

Describe the Optic Nerve. The Optic Nerve proper is the 2d cranial nerve, arises from the optic commissure, passes into the orbit by the optic foramen in company with the ophthalmic artery, is pierced by the central artery of the retina, and enters the eyeball posteriorly $\frac{1}{10}$ inch inwardly from its axis, piercing the sclerotic and choroid coats, and finally expanding in the retina. It is surrounded by a tubular process of dura mater, which as the nerve enters the orbit, subdivides to form both the sheath of the nerve and the periosteum of the orbit.

APPENDAGES OF THE EYE.

What are the Tutamina Oculi? They are the appendages of the eye, including the—

Eye brows, or Supercilia.

Eye lids, or Palpebræ.

Conjunctiva, or lining membrane.

Lachrymal Gland, and Ducts.

Lachrymal Sac.

Nasal Duct.

What are the Eyebrows? They are arched elevations of the integument over the supra-orbital arches, are covered with a row of short hairs, and are drawn downwards and inwards by the *Corrugator Supercilii* muscle. [See page 68.]

Describe the Eyelids. The Palpebræ, or Eyelids, are two thin, movable folds, placed in front of the eye, for its protection. The upper lid is the most movable one, having its own levator muscle, the *Levator palpebræ superioris*. [See page 68.] The—

Palpebral Fissure,—is the space between their free margins, its outer and inner angles being termed respectively the *External Canthus* and *Internal Canthus*.

Lacus Lachrymalis,—is a small triangular space at the internal canthus, between the lids and the globe.

Lachrymal Papilla,—on the edge of each lid, about $\frac{1}{4}$ inch from the internal canthus.

Punctum Lachrymale,—a minute orifice on each papilla, and the beginning of the lachrymal canal.

Describe the Structure of the Eyelids. They are composed externally of skin, internally of mucous membrane (the palpebral conjunctiva), and between these lie areolar tissue, the orbicularis muscle, tarsal cartilage, fibrous membrane, Meibomian glands, vessels and nerves. The—

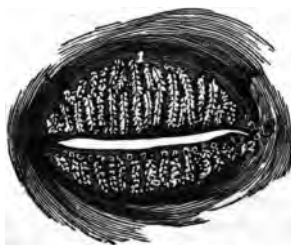Orbicularis Palpebrarum Muscle,—is very thin and pale. [See p. 68.]

Tensor Tarsi, or *Horner's Muscle*, [See p. 68]—is a portion of the orbicularis, compressing the punctum and the sac.

Tarsal Cartilages,—are plates of fibro-cartilage, forming the framework of the lids. The upper one is crescentic in shape, the lower one elliptical and smaller.

Tarsal Ligaments,—are fasciæ connecting the tarsal cartilages to the circumference of the orbit. Externally they connect with the malar bone, and are there called the *External Canthal Ligaments*.

FIG. 104.



Tendo Oculi,—connects the inner end of each tarsal cartilage to the nasal process of the superior maxillary bone.

Meibomian Glands,¹—are sebaceous glands imbedded in the tarsal cartilages, 30 to 40 in the upper lid, 20 to 30 in the lower one. They open along the inner edge of the free border of each lid, and furnish a sebaceous secretion, to prevent adhesion of the lids to each other.

Eyelashes, or Cilia,—are a double or triple row of short hairs, situated on the free margins of the lids; their follicles lying in the connective tissue beneath the tarsal cartilages.

Arteries,—are the *Palpebral* branches of the ophthalmic artery, forming the *Superior and Inferior Tarsal Arches*, and anastomosing with the angular, anterior temporal, lachrymal and transverse facial.

Nerves,—the 3d, facial and sympathetic to the muscles; the 5th to the skin and conjunctiva.

What is the Conjunctiva? It is the mucous membrane which lines the eyelids, and is reflected over the front of the sclerotic and cornea. It is continuous with the mucous lining of the Meibomian glands, canaliculi, lachrymal sac, nasal duct, lachrymal duct and gland. The—

Palpebral Conjunctiva,—consists of connective tissue covered by epithelium, is traversed by furrows, and has papillæ and follicular glands.

Ocular Conjunctiva,—is very thin and transparent, loosely attached on the sclerotic, firmly adherent over the cornea, where it has no vessels in its structure. It has very few papillæ, and no glands.

Retro-tarsal or Palpebral Folds,—superior and inferior,—are where the conjunctiva is reflected over the globe. They contain prominent papillæ, and conglomerate glands, called the accessory lachrymal glands.

Plica Semilunaris, or Semi-lunar Folds,—a crescentic fold of conjunctiva at the inner canthus, considered to be the rudiment of the *Membrana Nictitans* or 3d eyelid (of birds).

What is the Caruncula Lachrymalis? It is a small, red, conical body, situated in the lacus lachrymalis, at the inner canthus of the eye; consisting of hair follicles and sebaceous glands, and covered by conjunctiva. It is connected by tendinous fibres to the capsule of Tenon and to the rectus internus muscle.

Name the parts constituting the Lachrymal Apparatus. They are the lachrymal gland and its ducts, the accessory conjunctival glands, the canaliculi, lachrymal sac, and nasal duct.

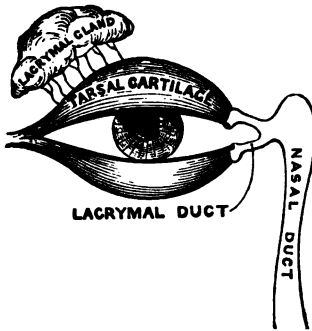
Describe the Lachrymal Gland. It is an oval gland situated in a fossa of the orbital portion of the frontal bone, at the outer angle of the orbit, its inferior surface resting on the eyeball, its lower margin or lobe being covered by conjunctiva. The—

Tarso-orbital Fascia,—connects the lachrymal gland to the bony roof of the orbit.

Ducts,—6 to 12 in number; open on the upper and outer portion of the palpebral conjunctiva.

Secretion—(tears),—lubricates the anterior surface of the eyeball. **Excess.**

FIG. 105.



evaporates, or collects in lacus and passes through puncta into canaliculi, and so to lachrymal sac, and thence, by the nasal duct, into the inferior meatus of the nose.

What are the Canaliculi? They are two minute canals, $\frac{1}{15}$ inch in diameter and $\frac{1}{3}$ inch long, which extend from the punctum in each lid to the lachrymal sac. They are lined with mucous membrane, and enveloped by fibres of the tensor tarsi muscle.

Describe the Lachrymal Sac. It is the superior dilated extremity of the nasal

duct, and is situated in the groove formed by the lachrymal bone and the nasal process of the superior maxillary. Its form is oval, flattened antero-posteriorly; its dimensions about $\frac{2}{3}$ inch long and $\frac{1}{8}$ inch wide. Its fundus is crossed by the tarsal ligament, and by the tensor tarsi muscle. Its junction with the nasal duct may be interrupted by folds of the lining mucous membrane.

What is the Nasal Duct? A membranous canal extending from the lachrymal sac to the inferior meatus of the nose. It is about $\frac{3}{4}$ inch long, $\frac{1}{8}$ inch in diameter, is contained in the osseous lachrymal canal, curving downwards, backwards and outwards, and its calibre is narrowest about its middle. Its mucous lining is thick, and continuous with the Schneiderian membrane of the nasal cavity. Surrounding it is a vascular network of connective tissue, and outside this, a tendinous sheath. At its lower end a fold of mucous membrane forms an imperfect valve.

THE EAR.

What Bone contains the Auditory Apparatus? The petrous and mastoid portions of the Temporal bone. [Described on page 16.]

Name the Divisions of the Auditory Apparatus. The organ of hearing consists of the following parts, viz.—

- | | |
|---|--|
| 1. <i>External Ear</i> | } <i>Auricle, or Pinna.</i>
<i>External Auditory Canal.</i> |
| 2. <i>Middle Ear, or Tympanum</i> | |
| | |
| | |

3. Internal Ear, or Labyrinth.....	{	Vestibule.
		Semicircular Canals.
		Cochlea.
		Auditory Nerve.

THE EXTERNAL EAR.

Describe the Auricle. The Auricle or Pinna is the external irregularly shaped appendage, fastened to the malar and temporal bones by elastic fibres. It consists of a broad plate of yellow cartilage, deficient in places where its parts are joined together by ligamentous tissue, and is covered by perichondrium and integument, the latter containing sebaceous and sweat glands, and provided with short, downy hairs. The Auricle presents several elevations and depressions, named as follows:—

Concha,—the central cavity leading into the canal.

Tragus,—a conical eminence in front of the concha, usually covered with hairs along its inferior border.

Anti-tragus,—a similar projection facing the tragus, from which it is separated by a deep fissure, the *Incisura Intertragica*.

Helix,—the outer curved edge of the pinna, beneath which is a deep groove, the *Fossa Navicularis*.

Anti-helix,—a curved ridge along the posterior boundary of the concha, bifurcating above to enclose a triangular depression, named the *Fossa Triangularis*.

Lobe or Lobule,—the soft, pendulous portion, composed of integumentary, adipose and connective tissues.

Name the Muscles of the Auricle. The—

EXTRINSIC MUSCLES are the—

Attolens Aurem, *Attrahens Aurem*, *Retrahens Aurem*.

[These muscles are described on page 68.]

INTRINSIC MUSCLES are but slightly developed. They are the—

Tragicus,—lies vertically on the outer surface of the tragus.

Anti-tragicus,—on the posterior wall of the auditory canal.

Helicis Major,—vertically on the anterior border of the helix.

Helicis Minor,—on lateral surface of the root of the helix.

Transversus Auriculæ,—on the posterior surface of the auricle, radiating outwards from the convexity of the concha.

Obliquus Auriculæ,—also on the posterior surface, radiating upwards from the convexity of the concha.

Dilator of Concha,—on the tragus.

Name the Arteries and Nerves of the Auricle. The—

ARTERIES,—are derived from the External Carotid. The—

Posterior Auricular,—a main branch of the external carotid.

Anterior Auricular, branch of the Temporal br. of the ext. carotid.

Auricular,—branch of the Occipital branch of the ext. carotid.

NERVES,—are the—

Auriculus Magnus,—from the cervical plexus. [See p. 133.]

Posterior Auricular,—from the facial nerve.

Auricular,—branch of the pneumogastric (also called Arnold's nerve).

Auriculo-temporal,—branch of the inferior maxillary div. of the 5th.

Describe the External Auditory Canal. It is an osseo-cartilaginous tube, about $1\frac{1}{4}$ inch long, extending from the concha to the membrana tympani, and curved irregularly in its course. The cartilaginous, or external portion, is about $\frac{1}{2}$ inch long, and deficient posteriorly and above, where it is filled by strong fibrous tissue. The canal is lined with integument, having numerous hair follicles, sebaceous and ceruminous glands.

Sulcus Tympanicus,—a groove at the bottom of the canal for the insertion of the membrana tympani. It is interrupted above by the—

Segment of Rivinus,—at the upper part of the sulcus tympanicus, each end having an osseous spine, the *Spina Tympanica Major* and *Minor*.

What are the Relations of the External Auditory Canal? *In front,* the articulation of the lower jaw; *below and in front,* the parotid gland; *behind,* the mastoid cells and the transverse sinus; *above,* the mastoid cells and the dura mater of the brain.

Name its Vessels and Nerves. Its—

Arteries,—are branches of the Posterior and Deep Auricular.

Nerves,—are chiefly derived from the Temporo-auricular Branch of the inferior maxillary division of the 5th nerve.

THE MEMBRANA TYMPANI.

What is the Membrana Tympani? The Membrana Tympani, or Drumhead, is an oval, inelastic, semi-transparent membrane, about $\frac{1}{16}$ inch in thickness, situated obliquely at the bottom of the external auditory canal, which it separates from the cavity of the tympanum. Seen through the canal, it is of a delicate blue-gray color, arched inwards, and presenting for consideration the following points, viz. :—A

Tubercle,—white in color at the upper border, made by the short process of the malleus.

Stripe,—also white, running downwards from the tubercle, and formed by the handle of the malleus.

Light-spot,—a triangular reflection, its apex at the tip of the malleus-handle, its base extending to the periphery of the membrane. It is due to the concavity of the drumhead.

Umbo,—or shadow, is the darker central portion.

Shrapnell's Membrane,—is the upper posterior part of the drumhead, where it is somewhat flaccid.

Rivinian Foramen,—a minute opening supposed to exist in the portion called Shrapnell's membrane.

FIG. 106.



In what direction is the *Membrana Tympani* placed? Obliquely inwards and forwards, almost forming a continuation of the posterior wall of the external auditory canal.

Describe the Structure of the *Membrana Tympani*. It is composed of 3 layers, as follows:—

External, or Dermoid Layer,—continuous with the integument lining the external auditory canal.

Middle Layer, or Lamina Propria,—formed of outer radiating fibres, and inner circular ones. Between these two sets of fibres are situated the short process and handle of the malleus.

Internal or Mucous Layer,—is continuous with the mucous lining of the tympanum.

Tendinous Ring (*At*, Fig. 106),—surrounds the margin of the membrane, being received into the sulcus tympanicus. Its anterior and posterior ends are shown by *v* and *h* in Fig. 106.

What Structures are presented by its Internal Surface? A fibrous fold descends from the upper portion of the marginal ring, for a short distance along the malleus-handle, forming the—

Anterior and Posterior Pouches,—one on each side of the malleus-handle, opening downwards.

Tendinous Bands,—4 or 5,—converge from the posterior margin to the middle of the malleus-handle.

What Arteries Supply the *Membrana Tympani*? The—

Deep Auricular, branch of the internal maxillary,—supplies the external layer, and forms with the Tympanic Branches a capillary plexus in the middle layer. (von Trölsch, Rossa, etc.)

Tympanic, branches of the internal maxillary and internal carotid arteries,—supply the internal layer, and anastomose on the *membrana tympani* with the—

Vidian and Stylo-mastoid,—branches respectively of the internal maxillary and posterior auricular branches of the external carotid.

What Nerves supply the Membrana Tympani? The external layer contains filaments from the *Superficial Temporal* branch of the 5th; the inner layer is supplied by the *Tympanic Plexus*. (See Nerves of Tympanum.)

THE TYMPANUM.

Describe the Tympanum. The Tympanum, Drum, or Middle Ear, is an irregularly-shaped cavity lying between the membrana tympani and the internal ear, and communicating with the pharyngeal cavity by the Eustachian tube. It contains the ossicles of the tympanum, part of the chorda tympani nerve, and air. Its average diameters are about $\frac{1}{2}$ inch antero-posteriorly, $\frac{1}{2}$ to $\frac{3}{4}$ inch vertically, and $\frac{1}{2}$ to $\frac{1}{4}$ inch transversely.

Name the Points on each wall of the Tympanum. Its—

ROOF,—is very thin, and corresponds to a depression on the anterior surface of the petrous portion of the temporal bone.

FLOOR,—is a thin plate, separating it from the jugular fossa and vein. **Has—**
Opening for Jacobson's Nerve,—in the floor.

OUTER WALL,—is formed by the membrani tympani and presents the—

Iter Chordæ Posterioris,—opens close to posterior edge of drumhead, for the entrance of the chorda tympani nerve.

Iter Chordæ Anterioris, or Canal of Hugier,—opening just in front of the drumhead, for the exit of the chorda tympani nerve. (See p. 16.)

Glaserian Fissure,—opens above and in front of the drumhead, receiving the long process of the malleus, the anterior ligament of the malleus, and the tympanic artery. (See *ante*, p. 15.)

INNER WALL,—is the outer wall of the labyrinth;—presents the—

Fenestra Ovalis,—an oval opening, leading into the vestibule, and closed by a membrane, to which is attached the base of the stapes.

Fenestra Rotunda,—a smaller opening, below the fenestra ovalis, leading into the scala tympani of the cochlea, and closed by the *Membrana Tympani Secundaria*.

Promontory,—an elevation corresponding to the first turn of the cochlea, situated between the fenestræ and in front of them.

Ridge of the Aqueductus Fallopii,—above the fenestra ovalis, behind which it curves downwards along the posterior wall.

Pyramid,—a conical eminence containing a canal which communicates with the aqueductus Fallopii and encloses the stapedius muscle.

ANTERIOR WALL,—presents the—

Opening of Canal for the Tensor Tympani Muscle,—above, situated on a small projection, the *Anterior Pyramid*.

Opening of the Eustachian Tube,—next below. These two canals being separated by a bony lamina, the *Septum Tubæ*.

Processus Cochleariformis,—the small end of the septum tubæ, projecting into the tympanum. (See p. 17.)

POSTERIOR WALL, separates it from the mastoid cells, and presents the—

Openings of the Mastoid Cells. Ridge of the *Aqueductus Fallopii*, curving downwards and nearly vertically. (See above.)

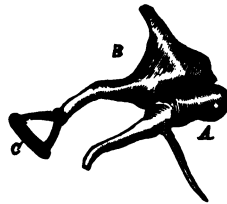
Describe the Ossicles of the Tympanum. They are three small bones, which form a chain across the tympanic cavity, connecting the membrana tympani with the fenestra ovalis, and named the—

Malleus, or Hammer, A—consists of a head, neck, short process, long process, or *Processus Gracilis*, and handle, or *Manubrium*. The short process and handle are fastened to the middle layer of the drumhead. The long process is received into the Glaserian fissure, and the head articulates with the head of the Incus.

Incus, or Anvil, B—has a head, also a long and a short process. The head articulates with the head of the malleus, the short process with the posterior wall of the tympanum, the long process with the head of the stapes, by the *Os Orbiculare*, its convex extremity.

Stapes, or Stirrup, C—presents a head, neck, base and crura. Its head articulates with the incus, its base rests on the membrane closing the fenestra ovalis, its neck receives the tendon of the stapedius muscle.

FIG. 107.



Name the Ligaments of the Ossicles. They are the—

Ligamentum Mallei Anterius,—from the spina tympanica major to the neck and long process of the malleus.

Lig. Mallei Externum,—from the border of the Rivinian segment (p. 214), to the neck of the malleus. Its posterior fibres are the—

Lig. Mallei Posticum,—(*Laxator tympani minor* muscle of Sömmering)—is simply the posterior group of fibres of the preceding ligament.

Lig. Mallei Superius,—(*Suspensory lig. of the malleus*) from the roof of the tympanum to the head of the malleus.

Lig. Incudis Superius,—from the roof of the tympanum to the head of the incus (Arnold).

Lig. Incudis Posticum,—from the posterior wall of the tympanum to the short process of the incus.

Lig. Obturatorium Stapedium,—a thin membrane which closes the opening between the crura of the stapes.

Annular Ligament,—connecting the base of the stapes to the margin of the fenestra ovalis.

Capsular Ligaments,—around the articulations between the ossicles themselves, which articulations are lined by synovial membranes, with articular cartilages between the contiguous surfaces.

Name the Muscles of the Tympanum. Three are usually described, —the *Tensor Tympani*, *Laxator Tympani*, and the *Stapedius*. A fourth, the *Laxator Tympani Minor*, is now generally omitted, being considered the posterior ligament of the malleus by most writers. Many otologists omit the *Laxator Tympani* from the list also. [These muscles are described on page 71.]

What Arteries supply the Tympanum? The—

Tympanic,—branch of the internal maxillary, entering the Glaserian fissure, anastomosing on the membrana tympani, in a vascular circle, with the Stylo-mastoid and Vidian arteries, and the Tympanic br. of the internal carotid.

Stylo-mastoid,—br. of the posterior auricular br. of the external carotid, entering at the stylo-mastoid foramen.

Petrosal,—br. of middle meningeal artery, entering by the hiatus Fallopii.

Tympanic,—br. from the internal carotid artery. (See p. 105.)

Vidian,—br. of the internal maxillary br. of the external carotid.

Branches,—from the ascending pharyngeal br. of the external carotid.

Name the Nerves of the Tympanum. The—

Tympanic Br. of the Glosso-pharyngeal (Jacobson's Nerve),—enters the tympanum through its floor, and supplies the two fenestræ and the mucous lining of the cavity, helping to form the *Tympanic Plexus* (see below).

Tympanic Branch of the Facial Nerve,—to the stapedius and laxator tympani muscles.

Branch from the Otic Ganglion,—to the tensor tympani muscle. [This ganglion is described on page 137.]

Chorda Tympani Br. of the Facial,—enters the tympanum by the iter chordæ posterioris, crosses the cavity between the handle of the malleus and the long process of the incus, and makes its exit by the iter chordæ anterioris, after passing close along the upper part of the membrana tympani.

How is the Tympanic Plexus Formed? By the—

Tympanic Br. of the Glosso-Pharyngeal,—or Jacobson's nerve.

Branch of the Superficial Petrosal, from the Facial,—entering from above.

Branches from the Carotid Plexus of the Sympathetic,—through the wall of the carotid canal.

The plexus lies in grooves on the inner wall around the promontory, and supplies the mucous membrane of the tympanum.

THE EUSTACHIAN TUBE.

What is the Eustachian Tube? It is an osseo-cartilaginous canal, about $1\frac{1}{2}$ inches long, $\frac{1}{2}$ inch in diameter at tympanic end, $\frac{1}{3}$ inch at pharyngeal, which leads downwards and forwards from the tympanic cavity into the pharynx. Of its length two-thirds is cartilaginous, one-third osseous. Above its bony portion is the canal for the tensor tympani muscle, from which it is divided by an osseous lamina, the *Septum Tubæ*. Its—

Cartilaginous Portion,—consists of two plates of cartilage, their non-approximated edges being connected by a membrane.

Pharyngeal Orifice,—is trumpet-shaped, and situated in the posterior nasal space, just above the nasal floor.

Mucous Membrane,—covered with the ciliated epithelium, and continuous with that of the pharynx and the tympanum.

Describe the Muscles of the Eustachian Tube. They are the—

Spheno-salpingo-staphylinus,—the abductor or dilator of the tube—is described as arising from the sphenoid bone and the cartilage of the tube, and being inserted into the convex border of the outer cartilage for its whole length.

Nerve,—internal pterygoid.

Levator Veli Palati,—arises from the temporal bone and the cartilage of the tube,—into the osseous tube, the cartilage, and the mucous membrane.

Action, to enlarge the transverse diameter of the tube. *Nerve*, pneumogastric.

Salpingo-pharyngeus,—a thin layer disposed along the median cartilaginous plate and the mucous membrane. *Action*, to fix the median cartilage. Called a fascia by some anatomists.

What Arteries supply the Eustachian Tube? The—

Ascending Pharyngeal,—branch of the external carotid.

Middle Meningeal,—branch of the internal maxillary br. of the ext. carotid.

Branch,—from the internal carotid artery.

Name its Nerves. Besides those which supply the muscles of the tube (see above), it has branches from the—

Superior Pharyngeal.

Glosso-pharyngeal.

THE INTERNAL EAR.

Name the Parts comprised in the Internal Ear.

Osseous Labyrinth, consists of the

{	<i>Vestibule.</i> <i>Semicircular Canals.</i> <i>Cochlea.</i>
---	---

Membranous Labyrinth, comprises the

{	<i>Utricula.</i>
	<i>Membranous Semicircular Canals.</i>
	<i>Sacculæ.</i>
	<i>Membranous Cochlea.</i>

Auditory Nerve,—the 8th cranial nerve, or the *Portio Mollis* of the 7th.

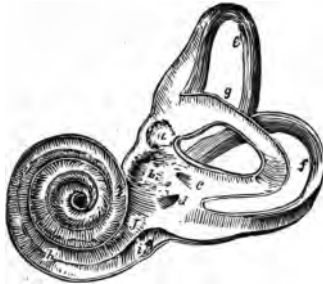Organ of Corti,—the terminal auditory apparatus.

Internal Auditory Canal,—by which the auditory nerve enters.

Describe the general arrangement of the Internal Ear. It lies internal to the tympanum, within the petrous portion of the temporal bone, and consists of a series of osseous chambers, the *Osseous Labyrinth*, containing a fluid, the *Perilymph*, or *Liquor Cotunnii*, in which lies a membranous reproduction of the chambers, the *Membranous Labyrinth*, which also contains a fluid, the *Endolymph*, or *Liquor Scarpæ*. Upon the membranous labyrinth are distributed the terminal filaments of the auditory nerve, which being suspended between two fluids, are not only protected from injury, but enabled to perceive the most delicate vibrations which may be communicated to the fluids surrounding them.

Describe the Vestibule. It is the common cavity of communication between the osseous parts of the internal ear, and measures in vertical diameter about $\frac{1}{8}$ inch, laterally about $\frac{1}{10}$ inch. It communicates in front with the scala vestibuli of the cochlea; and behind (by five openings) with the semicircular canals. It presents the following points, viz. :—the—

FIG. 108.



Fenestra Ovalis,—on its outer wall, closed by the base of the stapes and its annular ligament.

Fovea Hemispherica,^b—a small circular depression on the inner wall, for the sacculæ.

Macula Cricosa,—are groups of very minute orifices on the inner wall, admitting the nerve filaments.

Crista, or *Pyramidal Eminence*,—a vertical ridge on the inner wall, bounding the fovea posteriorly.

Aqueductus Vestibuli,^d—opens behind the crista, ending on the posterior surface of the petrous portion of the temporal bone. It contains a small blind canal opening by two arms, one into the utricule, the other into the sacculæ; also a small vein.

Fovea Semi-elliptica,^a—a small oval depression on the roof, above and be-

hind the fovea hemispherica. It lodges the utricle, and presents a *Macula Cribosa* for the entrance of branches of the vestibular nerve.

What are the Semicircular Canals? They are three C-shaped bony tubes, each about $\frac{1}{20}$ inch in diameter, situated above and behind the vestibule, into which they open by 5 apertures. Each canal lies at a right angle with the other two. The—

Superior and Posterior Canals,—are each nearly an inch long, vertically placed, joined together posteriorly where they open into the vestibule by a common orifice.^c

External Canal, *g*,—is $\frac{1}{2}$ inch long, horizontally placed, and directed outwards and backwards.

Ampulla,—is a flask-shaped dilatation of each canal at one extremity, having a diameter of about $\frac{1}{10}$ inch.

Describe the Cochlea. The Cochlea is a bony tube, about $1\frac{1}{2}$ inch long, tapering from $\frac{1}{10}$ to $\frac{1}{20}$ inch in diameter, coiled around a central conical axis for $2\frac{1}{2}$ turns, and resembling a snail shell in appearance. It measures about $\frac{1}{4}$ inch in length and the same in breadth at the base. It is situated in front of the vestibule, its apex pointing forwards and outwards, and is separated from the carotid canal in front by a thin wall. Its—

Modiolus, *a*,—is the central axis, conical in shape, channeled by small canals for the passage of arteries and nerves, and by a central one, the *Canalis Centralis Modioli*. Its apex is within the last coil of the cochlea, and is expanded into a funnel-shaped lamella, the *Infundibulum*.

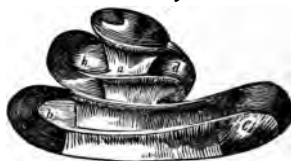

FIG. 109.

Lamina Spiralis, *b*,—is a thin, osseous plate, projecting from the modiolus half way across the spiral canal, and winding around the modiolus terminates near the apex in a hook-like or *Hamular Process*. Its deficiency in the last half turn of the cochlea forms the *Helicotrema*, a space in which the scalæ vestibuli and tympani unite. (See below.) It consists of two laminæ, ¹, ², between which pass the filaments of the cochlear nerve.¹⁰ From its free edge the structures composing the membranous cochlea pass to their attachment on the opposite wall of the cavity. (See Fig. III.)

Spiral Canal,—is the space between the modiolus and the outer wall of the cochlea. It makes $2\frac{1}{2}$ turns,—from left to right in the right ear, and right to left in the left ear; and terminates in the *Cupola*, a calyx at the apex of the cochlea. It is divided, by the osseous lamina

the membranous cochlea, into 2 Scalæ,—the *Scala Vestibuli*⁶ and the *Scala Tympani*.⁷ [Fig. 111.]

[A third scala is described by many authorities, the *Scala Media*,⁸ including the space occupied by the membranous cochlea. See Fig. 111.]

Describe the Scala Vestibuli. It is the portion of the spiral canal lying above the lamina spiralis and the membranous cochlea; communicates with the vestibule below, and with the scala tympani above at the Helicotrema. It is filled with perilymph.


What is the Scala Tympani? It is the portion of the spiral canal lying below the lamina spiralis and the membranous cochlea, communicates with the aqueductus cochlea (see below), and with the scala vestibuli at the *Helicotrema*. It terminates inferiorly at the fenestra rotunda, and is filled with perilymph.

What is meant by the Helicotrema? It is a space at the apex of the cochlea, formed by the deficiency of the lamina spiralis in the last half turn of the same. In this space the two scalæ are believed to open, thereby communicating with each other.

What is the Aqueductus Cochleæ? A small canal which begins by a small orifice in the lower wall of the scala tympani, and runs in the inner wall of the jugular fossa, ending at the edge between the inferior and inner surfaces of the petrous portion of the temporal bone. It transmits a vein from the cochlea to the jugular vein.

What Parts are comprised in the Membranous Labyrinth? It consists of two membranous sacs, the *Utricula*¹ and *Saccula*,² which lie in the vestibule, together with the *Membranous Semicircular Canals*,⁶ and the *Membranous Cochlea*.^{3, 5}

FIG. 110.



The utricle and saccule communicate with each other indirectly by a small canal contained in the aqueductus vestibuli. The saccule communicates with the membranous cochlea by the *Canalis Reuniens*,⁴ and the membranous semicircular canals open into the utricle; so that the membranous labyrinth presents an uninterrupted channel for the endolymph which it contains.

What is the Utricula? It is a flattened, elliptical membranous sac, fastened to the inner wall of the vestibule in the fovea semi-elliptica. It is filled with endolymph, nearly surrounded by perilymph, and communicates with the saccule through the small tube in the aqueductus vestibuli. The membranous

semicircular canals open into it by 5 orifices. The wall of the utricle has attached to it the—

Otoliths, or Ear-stones,—a powder, consisting of crystals of carbonate of calcium, $\frac{1}{8000}$ to $\frac{1}{20000}$ inch in diameter, held together by a mucoid substance.

Macula Acoustica,—See below, under *Sacculæ*.

Describe the Membranous Semicircular Canals. They are 3 canals, having the same shape as the osseous ones in which they are contained, being fastened thereto by their convex curves, and elsewhere surrounded by perilymph, except at the ampullæ, where they fill the osseous canals. They open into the utricle by 5 orifices.

What is the Sacculæ? It is a flask-shaped, membranous sac, about $\frac{1}{3}$ inch in diameter, attached at one point to the utricle, and also to the fovea hemispherica of the vestibule, being elsewhere surrounded by perilymph, and containing endolymph. It communicates with the utricle through the small canal in the aqueductus vestibuli, and also with the membranous cochlea by its neck, the—

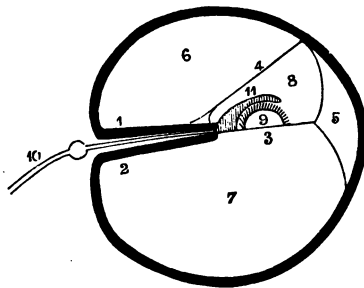
Canalis Reuniers,—about $\frac{1}{3}$ inch long and $\frac{1}{100}$ inch in diameter, is V-shaped, its arms opening respectively into the sacculæ and the vestibular end of the membranous cochlea.

Macula Acoustica,—is a dense, circular point, $\frac{1}{2}$ inch in diameter, on the wall of both the utricle and the sacculæ, formed by a thickening of the connective tissue where the fibres of the vestibular nerve enter it.

Describe the Membranous Cochlea. This portion of the membranous labyrinth, also called the *Ductus Cochlearis*, commences in the lower end of the osseous cochlea and send at its summit in a closed extremity. It is attached on one side to the lamina spiralis, on the other side to the outer wall of the osseous cochlea. It is formed by the *Membrana Basilaris* ³ below, the *Membrane of Reissner* ⁴ on one side, and the periosteum of the cochlear wall on the outer side, its cross section being of a triangular form. It is filled with endolymph, and contains the *Organ of Corti* ⁹ covered by the *Membrana Tectoria*.¹¹ The—

Limbus Laminae Spiralis,—is the soft structure on the edge of the lamina spiralis, and lies in the membranous cochlea. It has two lips,—an upper,

FIG. 111.



or *Labium Vestibulare*, a lower, or *Labium Tympanicum*, with a furrow between them, called the *Sulcus Spiralis Internus*.

Membrane of Reissner,⁴—extends from the edge of the lamina spiralis to the outer cochlear wall, forming the vestibular wall of the membranous cochlea. Its outer insertion is the *Angulus Vestibularis*.

Membrana Basilaris,³—is the tympanic wall of the membranous cochlea, extending from the labium tympanicum of the lamina spiralis to the outer cochlear wall, where its insertion is called the *Ligamentum Spirale*,⁵ or *Muscle of Todd and Bowman*. On it rests the *Organ of Corti*,⁹—covered by the —

Membrana Tectoria,¹¹—extends parallel to the membrana basilaris from the labium vestibulare to the outer cochlear wall, where, according to some authorities, it is inserted, according to others it is free and rests directly on the organ of Corti, perhaps to act as a damper to its vibrations.

Describe the Organ of Corti. It is a peculiar arrangement of cartilaginous rods and epithelial hair cells, which is supposed to constitute the essential organ of hearing.⁹ It lies on the membrana basilaris³ and is covered by the membrana tectoria.¹¹ The—

Rods of Corti,—are arranged in two rows, resting, by their pedestals, on the membrana basilaris, and uniting with each other by their heads, so as to form an arched tunnel all along the membrane. Number of rods in inner row about 6,000, in outer row 4,500. Average diameter of the rods, from $\frac{1}{250000}$ to $\frac{1}{330000}$ inch.

Head-plates,—are attached to the heads of the inner rods, for the reception of the rods of the opposite row.

Lamina Reticularis,¹—a perforated delicate membrane which extends from the articulations of the rods outwards to the external wall of the cochlea.

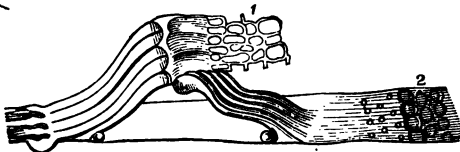
Auditory Cells,²—are epithelial structures covering the inner

surfaces of the walls and the floor of the membranous cochlea. Those which cover the inner rods by a single row number about 3,300, are nucleated, covered with tufts of cilia, and called the *Inner Hair-cells*. On the outer rods are 3 or 4 rows of similar cells, numbering about 18,000, and named the *Outer Hair-cells*.

FIG. 112.

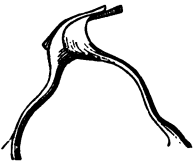

FIG. 113.



Rings and Phalanges,¹—are very minute structures which connect the ciliæ of the hair-cells together, and form the Lamina Reticularis. (See page 224.)

Describe the Origin, Course and Distribution of the Auditory Nerve. The 8th Cranial Nerve, or Portio Mollis of the 7th pair, arises by two roots from the medulla oblongata, one from the floor of the 4th ventricle, the other from a nucleus in the processus e cerebello ad medullam. It winds around the restiform body, from which it receives fibres, and emerges at the lower border of the pons, in company with the facial nerve. The two nerves pass into the internal auditory canal, at the bottom of which the auditory nerve divides into two branches, the vestibular and cochlear nerves. The—

Vestibular Nerve,—has a ganglionic swelling on it in the internal auditory canal, and then divides into 3 branches, which pass through the maculæ cribosæ, and are distributed to the utricle, saccule, and the ampullæ of the semicircular canals, respectively.

Cochlear Nerve,—gives off a small branch to the wall between the utricle and saccule, and then divides into numerous filaments which pass through the small canals into the modiolus, to form a plexus between the two plates of the lamina spiralis, from which filaments pass through the lower edge of the lamina to terminate in the spindle-shaped cells of the organ of Corti. (See page 224.)

Intumescencia Ganglioniformis Scarpæ,—is the ganglionic swelling on the vestibular nerve in the internal auditory canal.

Ganglion Spirale,—is a ganglion found on each filament of the cochlear nerve, just as it enters between the plates of the lamina spiralis.

What Arteries supply the Labyrinth? The—

Internal Auditory Artery, br. of the basilar (from the vertebral),—accompanies the auditory nerve into the internal auditory canal, where it divides into vestibular and cochlear branches.

Stylo-mastoid Artery, br. of the posterior auricular (from the external carotid),—sends some small branches to the internal ear.

Describe the Internal Auditory Canal. It begins by a large orifice on the posterior surface of the petrous portion of the temporal bone, and runs outwards for $\frac{1}{2}$ inch, to end in a blind fossa, the floor of which is marked by 4 depressions, which are perforated by fine foramina, for the passage of the filaments of the auditory nerve to the labyrinth. One of these depressions is the—

Tractus Spiralis Forminosus,—a spiral-shaped depression containing a number of the above foramina, situated opposite the base of the cochlea.

Maculæ Cribosæ,—are the other 3 depressions.

HERNIA.

What is a Hernia? A protrusion of any viscus from its natural cavity. The term, when unqualified as to the viscus, is understood to mean a protrusion of the intestines or mesentery, or both, from the abdominal cavity.

Name the Herniæ of most importance anatomically.

Oblique Inguinal Hernia,—in which the protrusion follows the spermatic cord through the inguinal canal; passing to the outer side of the epigastric artery, and through both the internal and external abdominal rings.

Direct Inguinal Hernia,—occurs at Hesselbach's triangle, escaping to the inner side of the epigastric artery, and through the external abdominal ring only.

Femoral Hernia,—in which the protrusion descends through the femoral or crural canal.

INGUINAL HERNIA.

Where is the Inguinal Canal? It is a passage in the abdominal wall, parallel to Poupart's ligament, and just above it. It commences at the internal abdominal ring⁵ and ends at the external abdominal ring,¹ being about 1½ inch in length. It serves for the passage of the spermatic cord in the male, and the round² ligament of the uterus in the female; and is directed downwards and inwards. The—

Internal Abdominal Ring,⁵—is an oval opening in the transversalis fascia, formed by the prolongation of this fascia around the cord, as the infundibuliform fascia. It lies ½ inch above Poupart's ligament and midway between the anterior superior spine of the ilium and the spine of the pubes. It is bounded above and externally by the arched fibres of the transversalis muscle; below and internally by the epigastric vessels.

External Abdominal Ring,¹—is a triangular opening in the aponeurosis of the external oblique muscle, situated just above and external to the crest of the pubes. It is about 1 inch long, and ½ inch wide, and is bounded laterally by its own margins, called the *Internal*⁴ and *External*³ Pillars of the ring. From these margins is given off the *Intercolumnar Fascia*, around the cord and testis.

What are the Boundaries of the Inguinal Canal?

Anteriorly,—the Skin, Superficial fascia, External oblique muscle, and the Internal oblique for its outer one-third.

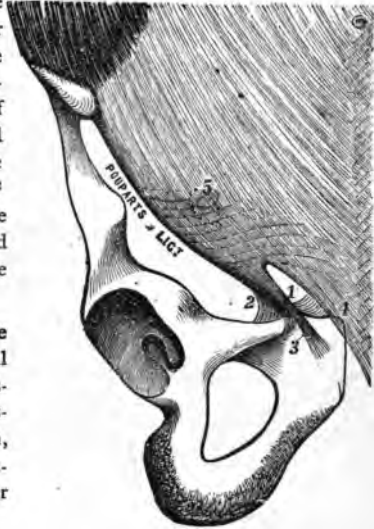
Posteriorly,—the Conjoined tendon, Transversalis fascia, Triangular ligament, Sub-peritoneal tissue, and Peritoneum.

Above,—the arched fibres of the Internal oblique and Transversalis muscles.

Below,—Poupart's ligament, and the Transversalis fascia.

What is Poupart's Ligament? The Crural Arch or Poupart's Ligament is that portion of the aponeurosis of the external oblique muscle which extends from the anterior superior spine of the ilium to the spine of the pubes. Its lower portion³ forms the external pillar of the external abdominal ring,¹ and its reflection along the pectineal line is called *Gimbernat's Ligament*.² Other fibres, reflected behind the internal pillar of the ring,⁴ upward to the linea alba, are termed the *Triangular Ligament*.

FIG. 114.



What is the Relation of the Epigastric Artery to the Internal Abdominal Ring? The Epigastric artery lies between the transversalis fascia and the peritoneum, passing obliquely upwards and inwards along the lower and inner margins of the internal ring.⁵

What is the Cremasteric Fascia? It consists of a series of muscular loops, united by areolar tissue, and forming a thin covering over the spermatic cord. The muscular fibres (Cremaster muscle) are supposed to have been originally part of the Internal oblique muscle, but carried down by the testicle in its descent to the scrotum. It does not exist in the female.

Name the Coverings of Inguinal Hernia. In the oblique form of Inguinal Hernia the coverings are—

1. *Skin*.
2. *Superficial Fascia*,—2 layers.
3. *Intercolumnar Fascia*,—from the external abdominal ring.
4. *Cremasteric Fascia*,—from the inguinal canal!
5. *Infundibuliform Process* of the transversalis fascia,—from the internal abdominal ring.
6. *Peritoneum*,—the proper hernial sac.

In the direct form of Inguinal Hernia, the coverings are precisely the same, except that the *Conjoined Tendon* is substituted for the Cremasteric fascia, and the *Transversalis Fascia* for its Infundibuliform process.

A 7th covering is sometimes enumerated, viz.: the *Sub-serous Areolar Tissue*,

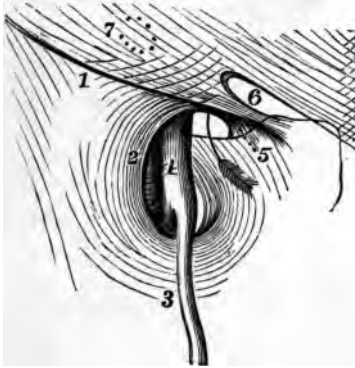which would come before the peritoneum in the above list. It is not sufficiently dense to make an appreciable covering.

FEMORAL HERNIA.

Where and What is the Femoral Canal? The Femoral or Crural Canal lies beneath Poupart's ligament,¹ close to the inner side of the femoral vein⁴; and extends from the *Femoral Ring* to the *Saphenous Opening* in the fascia lata of the thigh. It is a narrow interval between the femoral vein and the inner wall of the *Crural Sheath* or sheath of the vessels. The canal is $\frac{1}{4}$ to $\frac{1}{2}$ inch in length; is closed above by the *Septum Crurale*, below by the *Cribriform Fascia*; and contains only some loose areolar tissue and a few lymphatic vessels. The—

Femoral or Crural Ring,—is an oval-shaped opening, about $\frac{1}{2}$ inch in

FIG. 115.



diameter (larger in the female), situated below the internal abdominal ring⁷ and Poupart's ligament,¹ and between the inner side of the femoral vein and the margin of Gimbernat's ligament.⁵ It is closed by the *Septum Crurale* and a small lymphatic gland. The arrow in the figure goes into the femoral ring.

Saphenous Opening,²—is an oval-shaped structure, $1\frac{1}{2}$ inch long, $\frac{1}{2}$ inch wide, situated below the inner third of Poupart's ligament, and formed by a reflection inwards of

the fascia lata around the end of the internal saphenous vein.³ The outer margin curves over to the spine of the pubes, and is named the *Falciform Process*, or *Ligament of Burns*, its pubic end being often called the *Ligament of Hey*. The inner margin curves upwards behind the saphenous vein and under the outer margin, and is blended with the pubic portion of the fascia lata over the pectineus muscle. The opening is covered by the *Cribriform Fascia*.

What are the Boundaries of the Femoral Canal?

Anteriorly,—Poupart's ligament, Transversalis fascia, and the Falciform Process of the fascia lata.

Posteriorly,—Iliac fascia, and Pubic portion of the fascia lata.

Externally,—the Septum covering the femoral vein.

Internally,—Transversalis fascia, Iliac fascia, Gimbernat's ligament, and the deep Crural arch.

Name the Structures in relation with the Femoral Ring. The—*Spermatic Cord*,—in the male, lies directly above its anterior margin, replaced by the round ligament in the female.

Femoral Vein,⁴—lies next on its outer side.

Epigastric Artery,—crosses its upper and outer angle.

Oblurator Artery,—when arising from a common trunk with the epigastric, as it does once in $3\frac{1}{2}$ subjects, may lie close along its internal and superior margins.

What is the Septum Crurale? A layer of condensed cellular tissue, supporting a lymphatic gland, and perforated for the passage of lymphatic vessels. It lies across the femoral ring, and forms one of the coverings to any hernia escaping thereby. It is sometimes named the *Fascia of Cloquet*, or *Fascia of Cooper*.

Describe the Crural Sheath. It is the sheath which invests the femoral vessels below Poupart's ligament, and is formed by a prolongation of the transversalis fascia anteriorly, and the iliac fascia posteriorly. It is divided by two septa into 3 compartments, the exterior of which contains the *Femoral Artery*, the middle one the *Femoral Vein*, while the one most internal is the *Femoral Canal*. The sheath is perforated anteriorly by the genito-crural nerve, internally by the internal saphenous vein, and forms one of the coverings of a femoral hernia.

What is the Deep Crural Arch? It is the lower thickened border of the transversalis fascia, which arches across the front of the crural sheath, and is intimately connected therewith. It seems to be attached externally to the centre of Poupart's ligament; internally it is inserted into the pectineal line behind the conjoined tendon.

Name the Coverings of Femoral Hernia. From without inwards its coverings are the—

1. *Skin*.
2. *Superficial Fascia*,—2 layers.
3. *Cribriform Fascia*,—from the saphenous opening.
4. *Crural Sheath*,—from the transversalis fascia.
5. *Septum Crurale*,—from the femoral ring.
6. *Peritoneum*,—the proper hernial sac.

THE PERINEUM.

What is the Perineum? It is a triangular space containing the structures which close the pelvic outlet anterior to a line drawn between the tuberosities of the ischia. Posteriorly to this line the corresponding space is named the *Ischio-rectal Fossa*. The Perineum is bounded laterally by the rami of the pubes and ischia, anteriorly by the symphysis pubis, and posteriorly by the line above mentioned, which averages about $2\frac{3}{4}$ inches in length.

[For the Muscles of the Perineum, see *ante*, p. 83.]

THE MALE PERINEUM.

What Fasciæ are met with in the Perineum? The—

Superficial Layer of the Superficial Fascia,—is thick, loaded with fat, and continuous with the subcutaneous fascia of the thighs.

Deep Layer of the Superficial Fascia,—is thin but strong, continuous in front with the dartos of the scrotum, (?), attached on each side to the rami of the pubes and ischium; posteriorly it joins the deep perineal fascia under the transversus perinei muscle. It sends inwards a vertical septum which is incomplete in front. [This fascia is called by Professor Pancoast the “anterior leaflet of the triangular ligament.”]


Anterior Layer of the Deep Perineal Fascia,—is triangular in shape, and extends from the pubic arch and the sub-pubic ligament, laterally to the rami of the pubes and ischia, and posteriorly to the central tendinous portion of the perineum, where it becomes blended with the deep layer of the superficial fascia. It embraces the anterior part of the membranous portion of the urethra. [Called by Professor Pancoast, the “middle leaflet of the triangular ligament.”]

Posterior Layer of the Deep Perineal Fascia,—has the same attachments as the anterior layer above described, but in its course it embraces the posterior part of the membranous portion of the urethra, and is in connection with the apex of the prostate gland. [Called by Prof. Pancoast, the “posterior leaflet of the triangular ligament.”]

Obturator Fascia,—is the part of the pelvic fascia which covers the obturator internus muscle, and is continued on to the levator ani muscle as the *Ischio-rectal* or *Anal fascia*.

Recto-vesical Fascia,—is the portion of the pelvic fascia which invests the internal surface of the levator ani muscle, and the prostate gland, bladder, rectum, and vesiculæ seminales.

What is Buck's Fascia? It is a continuation of the Deep Layer of the Superficial Fascia of the Perineum, extending forwards upon the penis, and investing that organ completely as far as the glans. It is continuous above



with the suspensory ligament of the penis, and is held by some anatomists to prove that the deep layer aforesaid is not continuous in front with the dartos of the scrotum. This fascia was named from Dr. Buck, an American surgeon, who, in 1846, first insisted on the importance of this structure. It modifies the direction of urinary infiltration of the perineum, until perforated.

What is the Triangular Ligament of the Urethra? According to some authorities it is the anterior layer of the deep perineal fascia; according to others it includes the posterior layer also. Prof. Pancoast includes in the term "*Triangular Ligament*" all three layers which are united at the central tendinous portion of the perineum, including, therefore, the deep layer of the superficial perineal fascia.

Name the Structures which lie between the Layers of the Deep Perineal Fascia. In this space, which by some writers is termed the Cavity of the Triangular Ligament, are the—

Membranous Portion of the Urethra.

Compressor Urethræ Muscle. *Artery of the Bulb.*

Pubic Vessels and Nerve. *Nerve of the Bulb.*

Cowper's Glands and Ducts. *Plexus of Veins.*

What Structures lie behind the Posterior Layer of the Deep Perineal Fascia? They are the—

Bladder. *Rectum.*

Prostate Gland. *Levator Anti Muscle.*

Ischio-rectal, or Anal Fascia.

Enumerate the Structures situated between the Anterior Layer of the Deep Perineal Fascia and the Deep Layer of the Superficial Perineal Fascia. They are as follows, the—

Crura of the Penis. *Erector Penis Muscle.²*

Corpus Spongiosum. *Transversus Perinei Muscle.³*

Bulb of the Urethra. *Transversus Perinei Artery.*

Accelerator Urinæ Muscle.¹ *Superficial Perineal Vessels.*

Enumerate the Structures which are divided in the Lateral Operation of Lithotomy. If the knife is inserted $1\frac{1}{4}$ inch above the verge of the anus, and carried to a point $\frac{3}{4}$ inch below that orifice, and about half-way outwards to the tuber ischii (*Gross*), it will divide the

Skin and Superficial Fascia (1st Layer).

Inferior Hemorrhoidal Vessels and Nerves.

Deep Layer of the Superficial Fascia.

Superficial Perineal Vessels and Nerves.

Accelerator Urinæ Muscle¹ (posterior fibres).

Transversus Perinei Muscle³ and Artery.

Anterior Layer of the Deep Perineal Fascia.
Compressor Urethrae Muscle (a few fibres).
Levator Ani Muscle ⁵ (anterior fibres).
Membranous and Prostatic Portions of the Urethra.
Posterior Layer of the Deep Perineal Fascia.
Prostate Gland (in part only).
Neck of the Bladder.

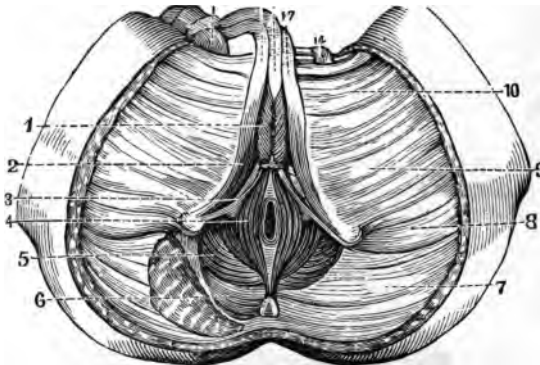
What Parts are to be avoided in the Lateral Operation of Lithotomy? They are the—

Bulb and its Artery,—in front.

Rectum,—inwardly and posteriorly.

Pudic Artery,—outwardly.

FIG. 116.



Prostate Gland and Veins,—by not carrying the deep incision too far backwards, the entire division of the left lobe of this gland will be avoided.

THE FEMALE PERINEUM.

What especial Function does the Female Perineum Perform? That of supporting the posterior wall of the vagina, and thereby aiding materially in the support of the whole vagina, uterus and bladder. The—

Perineal Body,—is the pyramidal-shaped prolongation of the female perineum upwards between the vagina and rectum.

Enumerate the chief points of Difference between the Female Perineum and that of the Male. The—

Orifice of the Vulva, including the vaginal orifice,—perforates the female

perineum, its posterior commissure approaching the anal margin within about an inch.


Superficial Fascia,—is incomplete, by reason of its perforation by the orifice of the vulva, but consists of two layers, as in the male.

Deep Perineal Fascia,—being also perforated by the vagina, is less apparent than in the male, though presenting two layers, with the urethra perforating them, as in the other sex.

Muscles,—the Sphincter Vaginæ takes the place, in the female, of the Accelerator Urinæ of the male.

Prostate Gland is wanting,—but its place is occupied by a number of minute glands disposed around the neck of the bladder.





A CATALOGUE OF BOOKS FOR STUDENTS.

CONTENTS.

	PAGES		PAGES
The Quiz-Compends,	2, 3, 4, 5	Pathology and Histology,	11
Anatomy,	6	Physical Diagnosis,	11
Chemistry,	6	Physiology,	11
Children's Diseases,	7	Practice of Medicine,	12
Dentistry,	8	Prescription Books,	13
Dictionaries,	8	Skin Diseases,	13
Eye Diseases,	8	Surgery,	13
Electricity,	9	Throat,	14
Gynæcology,	10	Urine and Urinary Organs,	14
Hygiene,	9	Veneral Diseases,	14
Medical Jurisprudence,	9	Medical Briefs. <i>A New</i>	
Miscellaneous,	10	<i>Series</i> ,	15
Obstetrics,	10	New Manuals,	16

PUBLISHED BY

P. BLAKISTON, SON & CO.,

Medical Booksellers, Importers and Publishers.

LARGE STOCK OF ALL STUDENTS' BOOKS, AT
THE LOWEST PRICES.

1012 Walnut Street, Philadelphia.

. For sale by all Booksellers, or any book will be sent by mail, postpaid, upon receipt of price. Catalogues of books on all branches of Medicine, Dentistry, Pharmacy, etc., supplied upon application.

QUIZ-COMPENDS?

A NEW SERIES OF COMPENDS FOR STUDENTS

For Use in the Quiz Class and when
Preparing for Examinations.

Price of Each, Bound in Cloth, \$1.00 Interleaved, \$1.25.

Based on the most popular text-books, and on the lectures of prominent professors, they form a most complete, practical and exhaustive set of manuals, containing information nowhere else collected in such a condensed, practical shape. Thoroughly up to the times in every respect, containing many new prescriptions and formulae, and over two hundred and thirty illustrations, many of which have been drawn and engraved specially for this series. The authors have had large experience as quiz-masters and attachés of colleges, with exceptional opportunities for noting the most recent advances and methods. The arrangement of the subjects, illustrations, types, etc., are all of the most improved form, and the size of the books is such that they may be easily carried in the pocket. They are constantly being revised, so as to include the latest and best teachings, and can be used by students of any college of medicine, dentistry or pharmacy.

No. 1. ANATOMY. 117 Illustrations.

FOURTH EDITION, ENLARGED.

A Compend of Human Anatomy, including Visceral Anatomy, formerly published separately as No. 8 of this series. By SAML. O. L. POTTER, M.A., M.D., Late A. A. Surg. U. S. Army; Professor of Practice, Cooper Medical College, San Francisco. 117 Illus.

"The work is reliable and complete, and just what the student needs in reviewing the subject for his examinations."—*The Physician and Surgeon's Investigator*, Buffalo, N. Y.

"The arrangement is well calculated to facilitate accurate memorizing, and the illustrations are clear and good."—*North Carolina Medical Journal*.

Nos. 2 and 3. PRACTICE.

NEW REVISED EDITIONS.

A Compend of the Practice of Medicine, especially adapted to the use of Students. By DAN'L E. HUGHES, M.D., Demonstrator of Clinical Medicine in Jefferson

Price of each Book, Cloth, \$1.00. Interleaved for Notes, \$1.25

Medical College, Philadelphia. Second Edition. Enlarged and thoroughly Revised. In two parts.

PART I.—Continued, Eruptive, and Periodical Fevers, Diseases of the Mouth, Stomach, Intestines, Peritoneum, Biliary Passages, Liver, Kidneys, Intestinal Parasites, etc., and General Diseases.

PART II.—Diseases of the Respiratory System, Circulatory System and Blood, Nervous System, etc.

* * * These little books can be regarded as a full set of notes upon the Practice of Medicine, containing the Synonyms, Definitions, Causes, Symptoms, Prognosis, Diagnosis, Treatment, etc., of each disease, and including a number of new prescriptions. They have been compiled from the lectures of prominent Professors, and reference has been made to the latest writings of Professors FLINT, DA COSTA, BARTHOLOW, ROBERTS, etc.

"It is brief and concise, and at the same time possesses an accuracy not generally found in compends."—*Yas. M. French, M.D., Ass't to the Prof. of Practice, Medical College of Ohio, Cincinnati.*

"The book seems very concise, yet very comprehensive. An unusually superior book."—*Dr. E. T. Bruen, Demonstrator of Clinical Medicine, University of Pennsylvania.*

"I have used it considerably in connection with my branches in the Quiz-class of the University of La."—*J. H. Bemis.*

"Dr. Hughes has prepared a very useful little book, and I shall take pleasure in advising my class to use it."—*Dr. George W. Hall, Prof. of Practice, St. Louis College of Phys. and Surgeons.*

No. 4. PHYSIOLOGY. Illustrated.

THIRD REVISED EDITION.

A Compend of Human Physiology. By ALBERT P. BRUBAKER, M.D., Demonstrator of Physiology in Jefferson Medical College, Philadelphia. Professor of Physiology, Pennsylvania College of Dental Surgery. Third Edition. Enlarged and Revised.

"Dr. Brubaker deserves the hearty thanks of medical students for his *Compend of Physiology*. He has arranged the fundamental and practical principles of the science in a peculiarly inviting and accessible manner. I have already introduced the work to my class."—*Maurice N. Miller, M.D., Instructor in Histology, formerly Demonstrator of Physiology, University City of New York.*

"Quiz-Compend No. 4 is fully up to the high standard established by its predecessors of the same series."—*Medical Bulletin, Philadelphia.*

"I can recommend it as a valuable aid to the student."—*C. N. Ellinwood, M.D., Professor of Physiology, Cooper Medical College, San Francisco.*

"This is a well written little book."—*London Lancet.*

Price of each Book, Cloth, \$1.00. Interleaved for Notes, \$1.25.

No. 5. OBSTETRICS. Third Edition.

A Compend of Obstetrics. For Physicians and Students.

By HENRY G. LANDIS, M.D., Professor of Obstetrics and Diseases of Women, in Starling Medical College, Columbus. Third Revised Ed. New Illustrations.

"We have no doubt that many students will find in it a most valuable aid in preparing for examination."—*The American Journal of Obstetrics.*

"It is complete, accurate and scientific. The very best book of its kind I have seen."—*J. S. Knox, M.D., Lecturer on Obstetrics, Rush Medical College, Chicago.*

No. 6. MATERIA MEDICA, THERAPEUTICS AND PRESCRIPTION WRITING.

Fourth Edition.

A Compend on Materia Medica, Therapeutics and

Prescription Writing, with especial reference to the Physiological Actions of Drugs. By SAML. O. L. POTTER, M.A., M.D., Professor of Practice, Cooper Medical College, San Francisco, Late Surgeon U. S. Army.

"I have examined the little volume carefully, and find it just such a book as I require in my private Quiz, and shall certainly recommend it to my classes. Your Compends are all popular here in Washington."—*John E. Brackett, M.D., Professor of Materia Medica and Therapeutics, Howard Medical College, Washington.*

"Part of a series of small but valuable text-books. . . . While the work is, owing to its therapeutic contents, more useful to the medical student, the pharmaceutical student may derive much useful information from it."—*N. Y. Pharmaceutical Record.*

No. 7. CHEMISTRY. Revised Ed.

A Compend of Chemistry. By G. MASON WARD, M.D.,

Demonstrator of Chemistry in Jefferson Medical College, Philadelphia. Including Table of Elements and various Analytical Tables.

"Brief, but excellent. . . . It will doubtless prove an admirable aid to the student, by fixing these facts in his memory. It is worthy the study of both medical and pharmaceutical students in this branch."—*Pharmaceutical Record, New York.*

No. 8. DISEASES OF THE EYE AND REFRACTION.

Compend on Diseases of the Eye and Refraction, including Treatment and Surgery. By L. WEBSTER

FOX, M.D., Chief Clinical Assistant, Ophthalmological Department, Jefferson Medical College Hospital;

Price of each Book, Cloth, \$1.00. Interleaved for Notes, \$1.25.

Ophthalmic Surgeon, Germantown Hospital, Philadelphia; late Clinical Assistant at Moorfields, London, England, etc., and GEO. M. GOULD, A.B. 60 Illus.

NO. 9. SURGERY.

THIRD REVISED EDITION. ILLUSTRATED.

A Compend of Surgery; including Fractures, Wounds, Dislocations, Sprains, Amputations and other operations, Inflammation, Suppuration, Ulcers, Syphilis, Tumors, Shock, etc. Diseases of the Spine, Ear, Eye, Bladder, Testicles, Anus, and other Surgical Diseases. By ORVILLE HORWITZ, A.M., M.D., Demonstrator of Anatomy, Jefferson Medical College, Philadelphia. Third Revised Edition. With 91 Illustrations.

* This compend has been prepared with great care, from the standard authorities on Surgery and from notes taken by the author during attendance on lectures by prominent professors.

"All the essential facts of surgery are presented in a well-arranged and condensed manner."—*Medical Brief*.

"Useful to the student in fixing the essentials firmly in his mind."—*Prof. G. F. Shears, Chicago*.

NO. 10. ORGANIC CHEMISTRY.

A Compend of Organic Chemistry, including Medical Chemistry, Urine Analysis, and the Analysis of Water and Food, etc. By HENRY LEFFMANN, M.D., Professor of Clinical Chemistry and Hygiene in the Philadelphia Polyclinic; Professor of Chemistry, Pennsylvania College of Dental Surgery.

"Compact, substantial and exact; well suited as a remembrancer to students."—*Pacific Medical and Surgical Journal*.

"It contains, in compact form, the most of modern organic and medical chemistry essential to the student of medicine, and will be of great value in bringing this subject within his grasp."—*C. C. Howard, Prof. of Chemistry, Starling Med. College, Columbus*.

"It has the decided merit of being written in a clear and understandable language."—*Dr. J. Sicksel, Instructor in Chemistry, University Medical College, New York*.

NO. 11. PHARMACOY. Second Ed.

A Compend of Pharmacy. Based upon "Remington's Text-Book of Pharmacy." By F. E. STEWART, M.D., PH.G., Quiz Master in Chemistry and Theoretical Pharmacy, Philadelphia College of Pharmacy; Demonstrator and Lecturer in Pharmacology, Medico-Chirurgical College, and Woman's Medical College;

* The ?Quiz-Compend? contains the latest and best information, in such a shape that it can be easily memorized.

Price of each Book, Cloth, \$1.00. Interleaved for Notes, \$1.25.

ANATOMY.

Holden's Anatomy. A manual of Dissection of the Human Body. Fifth Edition. Enlarged, with Marginal References and over 200 Illustrations. Octavo. Cloth, 5.00; Leather, 6.00

Bound in Oilcloth, for the Dissecting Room, \$4.50.

"No student of Anatomy can take up this book without being pleased and instructed. Its Diagrams are original, striking and suggestive, giving more at a glance than pages of text description. * * * The text matches the illustrations in directness of practical application and clearness of detail."—*New York Medical Record.*

Holden's Human Osteology. Comprising a Description of the Bones, with Colored Delineations of the Attachments of the Muscles. The General and Microscopical Structure of Bone and its Development. With Lithographic Plates and Numerous Illustrations. Sixth Edition. 8vo. Cloth, 6.00

Heath's Practical Anatomy. Sixth London Edition. 24 Colored Plates, and nearly 300 other Illustrations. Cloth, 5.00

CHEMISTRY.

Bartley's Medical Chemistry. A text-book prepared specially for Medical, Pharmaceutical and Dental Students. With 40 Illustrations, Plate of Absorption Spectra and Glossary of Chemical Terms. Cloth, 2.50

. This book has been written especially for students and physicians. It is practical and concise, dealing only with those parts of chemistry pertaining to medicine; no time being wasted in long descriptions of substances and theories of interest only to the advanced chemical student.

Bloxam's Chemistry, Inorganic and Organic, with Experiments. Fifth Edition, nearly 300 Illustrations. Cloth, 3.75; Leather, 4.75

Richter's Inorganic Chemistry. A text-book for Students. Second American, from Fourth German Edition. Translated by Prof. Edgar F. Smith, Ph.D. 89 Wood Engravings and Colored Plate of Spectra. Cloth, 2.00

Richter's Organic Chemistry, or Chemistry of the Carbon Compounds. Translated by Prof. Edgar F. Smith, Ph.D. Illustrated. Cloth, 3.00; Leather, 3.50

Watt's (Fowne's) Chemistry. 13th Edition. 2 Volumes.
Volume 1, Inorganic, 2.25; Volume 2, Organic, 2.25

. These volumes are based on Fowne's Chemistry, being, in fact, the 13th edition of Fowne, etc.

See pages 2 to 5 for list of ? Quis-Compendis ?

Chemistry:—Continued.

- Trimble. Practical and Analytical Chemistry.** A Course in Chemical Analysis, by Henry Trimble, Prof. of Analytical Chemistry in the Phila. College of Pharmacy. Illustrated. Second Edition. 8vo. Cloth, 1.50
- Wolff's Applied Medical Chemistry.** By Lawrence Wolff, M.D., Demonstrator of Chemistry in Jefferson Medical College, Philadelphia. Cloth, 1.50

CHILDREN.

- Goodhart and Starr. The Diseases of Children.** A Manual for Students and Physicians. By J. F. Goodhart, M.D., Physician to the Evelina Hospital for Children; Assistant Physician to Guy's Hospital, London. American Edition, Revised and Edited by Louis Starr, M.D., Clinical Professor of Diseases of Children in the Hospital of the University of Pennsylvania; Physician to the Children's Hospital, Philadelphia. Containing many new Prescriptions, a List of over 50 Formulæ, conforming to the U. S. Pharmacopœia, and Directions for making Artificial Human Milk, for the Artificial Digestion of Milk, etc. Just Ready. Demi-Octavo, 738 Pages.

Cloth, 3.00; Leather, 3.50

The NEW YORK MEDICAL RECORD says:—"As it is said of some men, so it might be said of some books, that they are 'born to greatness.' This new volume has, we believe, a mission, particularly in the hands of the younger members of the profession. In these days of prolixity in medical literature, it is refreshing to meet with an author who knows both what to say, and when he has said it. The work of Dr. Goodhart (admirably conformed, by Dr. Starr, to meet American requirements) is the nearest approach to clinical teaching, without the actual presence of clinical material, that we have yet seen. The details of management so gratefully read by the young practitioner are fully elucidated. Altogether, the book is one of as great practical working value as we have seen for many months."

- Day. On Children.** A Practical and Systematic Treatise. Second Edition. 8vo. 752 pages. Cloth, 3.00; Leather, 4.00

- Meigs and Pepper. The Diseases of Children,** Seventh Edition. 8vo. Cloth, 5.00; Leather, 6.00

- Starr. Diseases of the Digestive Organs in Infancy and Childhood.** With chapters on the Investigation of Disease, and on the General Management of Children. By Louis Starr, M.D., Prof. of Diseases of Children, Hospital of the University of Pennsylvania. Illus. Cloth, 2.50

See pages 2 to 5 for list of Quiz-Compend's

DENTISTRY.

- Flagg's Plastics and Plastic Filling.** 2d Ed. Cloth, 4.00
- Gorgas. Dental Medicine.** A Manual of Materia Medica and Therapeutics, by Professor F. J. S. Gorgas, M.D., D.D.S., Professor of the Principles and Practice of Dental Science, in Dental Dept., University of Maryland. Second Edition. Cloth, 3.25
- Harris' Principles and Practice of Dentistry.** Including Anatomy, Physiology, Pathology, Therapeutics, Dental Surgery and Mechanism. Eleventh Edition. Revised and enlarged by Professor Gorgas. 744 Illustrations. Cloth, 6.50; Leather, 7.50
- Richardson's Mechanical Dentistry.** Fourth Edition. 458 Illustrations. 720 pages. 8vo. Cloth, 4.50; Leather, 5.50
- Stocken's Dental Materia Medica.** Third Edition. Cloth, 2.50
- Taft's Operative Dentistry.** Dental Students and Practitioners. Fourth Edition. 100 Illustrations. Cloth, 4.25; Leather, 5.00
- Tomes' Dental Anatomy, Human and Comparative.** Second Edition. 197 Illustrations. Cloth, 4.25
- Tomes' Dental Surgery.** New Revised Edition. *Preparing.*

DICTIONARIES.

- Cleveland's Pocket Medical Lexicon.** Thirty-first Edition. Giving correct Pronunciation and Definition of Terms used in Medicine and the Collateral Sciences. Very small pocket size, red edges. Cloth, .75; pocket-book style, 1.00
- Longley's Pocket Dictionary.** The Student's Medical Lexicon, giving Definition and Pronunciation of all Terms used in Medicine, with an Appendix giving Poisons and Their Antidotes, Abbreviations used in Prescriptions, Metric Scale of Doses, etc. 24mo. Cloth, 1.00; pocket-book style, 1.25

EYE.

- Arlt. Diseases of the Eye.** Including those of the Conjunctiva, Cornea, Sclerotic, Iris and Ciliary Body. By Professor Fred. Ritter von Arlt. Translated by Dr. Lyman Ware. Illustrated. 8vo. Cloth, 2.50
- Macnamara. On Diseases of the Eye.** Fourth Edition, revised, with Marginal References, numerous Colored Plates and Diagrams, Wood Cuts and Test Types. Cloth, 4.00
- Meyer. Diseases of the Eye.** A complete Manual for Students and Physicians. With numerous Illustrations and two Colored Plates. 8vo. *In Press*
- Morton. Refraction of the Eye.** Third Ed. Illus. Cloth, 1.00
- See pages 2 to 5 for list of Quiz-Compend?*

ELECTRICITY.

Mason's Compend of Medical and Surgical Electricity.
With numerous Illustrations. 12mo. Cloth, 1.00

HYGIENE.

Parke's Practical Hygiene. Sixth Edition, enlarged. Illustrated. 8vo. Cloth, 3.00

Wilson's Handbook of Hygiene and Sanitary Science.
Sixth Edition. Revised and Illustrated. Cloth, 2.75

MATERIA MEDICA AND THERAPEUTICS.

Biddle's Materia Medica. Tenth Edition. For the use of Students and Physicians. By the late Prof. John B. Biddle, M.D., Professor of Materia Medica in Jefferson Medical College, Philadelphia. The Tenth Edition, thoroughly revised, and in many parts rewritten, by his son, Clement Biddle, M.D., Past Assistant Surgeon, U. S. Navy, assisted by Henry Morris, M.D., Demonstrator of Obstetrics in Jefferson Medical College. 8vo., illustrated. Cloth, 4.00; Leather, 4.75

"The larger works usually recommended as text-books in our medical schools are too voluminous for convenient use. This work will be found to contain in a condensed form all that is most valuable, and will supply students with a reliable guide."—*Chicago Med. Jl.*

Potter, Materia Medica, Pharmacy and Therapeutics.
Including Action of Medicines, Special Therapeutics, Pharmacology, etc. Cloth, 3.00; Leather, 3.50

The most complete compendium of its subjects published, containing information not hitherto collected in one volume.

Roberts' Compend of Materia Medica and Pharmacy. By the author of "Roberts' Practice." Cloth, 2.00

Headland's Action of Medicines. 9th Ed. 8vo. Cloth, 3.00

Waring. Therapeutics. With an Index of Diseases and an Index of Remedies. A Practical Manual. Fourth Edition. Revised and Enlarged. Cloth, 3.00; Leather, 3.50

MEDICAL JURISPRUDENCE.

Reese. A Text-book of Medical Jurisprudence and Toxicology. By John J. Reese, M.D., Professor of Medical Jurisprudence and Toxicology in the Medical and Law Departments of the University of Pennsylvania; Vice-President of the Medical Jurisprudence Society of Philadelphia; Physician to St. Joseph's Hospital; Corresponding Member of The New York Medico-legal Society. Cloth, 3.00; Leather, 3.50

"We might call these the essentials for the study of medical jurisprudence. The subject is skeletonized, condensed, and made

See pages 2 to 5 for list of Quiz-Compendis!

Medical Jurisprudence:—Continued.

thoroughly up to the wants of the general medical practitioner, and the requirements of prosecuting and defending attorneys. If any section deserves more distinction than any other, as to intrinsic excellence, it is that on toxicology. This part of the book comprises the best outline of the subject in a given space that can be found anywhere. As a whole, the work is everything it promises, and more, and considering its size, condensation, and practical character, it is by far the most useful one for ready reference, that we have met with. It is well printed and neatly bound."—*New York Medical Record.*

- Abercrombie's Students' Guide to Medical Jurisprudence.**
12mo. Cloth, 2.50
- Mann's Manual of Psychological Medicine, and Allied Nervous Diseases.** Their Diagnosis, Pathology and Treatment, and their Medico-Legal Aspects. Illus. Cloth, 5.00; Leather, 6.00
- Woodman and Tidy's Medical Jurisprudence and Toxicology.** Chromo-Lithographic Plates and 116 Wood engravings.
Cloth, 7.50; Leather, 8.50

MISCELLANEOUS.

- Beale. Slight Ailments.** Their Nature and Treatment. Illustrated. 8vo. Paper cover, .75; Cloth, 1.25
- Dulles. Surgical and other Emergencies.** Illustrated. Second Edition. 12mo. Cloth, .75
- Fothergill. Diseases of the Heart and Their Treatment.** Second Edition. 8vo. Cloth, 3.50
- Tanner. Memoranda of Poisons.** Their Antidotes and Tests. Fifth Edition. 12mo. Cloth, .75
- Allingham. Diseases of the Rectum.** Fourth Edition. Illustrated. 8vo. Paper covers, .75; Cloth, 1.25

OBSTETRICS AND GYNÆCOLOGY.

- Parvin's Winckel's Diseases of Women.** Edited by Prof. Theophilus Parvin, Jefferson Medical College, Philadelphia. 117 Illustrations. Cloth, 3.00; Leather, 3.50
- Galabin's Midwifery.** A New Manual for Students. By A. Lewis Galabin, M.D., F.R.C.P., Obstetric Physician to Guy's Hospital, London, and Professor of Obstetrics in the same Institution. 227 Illustrations. Cloth, 3.00; Leather, 3.50
- "The illustrations are mostly new and well executed, and we heartily commend this book as far superior to any manual upon this subject."—*Archives of Gynecology, New York, June, 1880.*
- Rigby's Obstetric Memoranda.** By Alfred Meadows, M.D. 4th Edition. Cloth, .50

☛ See pages 2 to 5 for list of *Quiz-Compend's*!

Obstetrics and Gynaecology:—Continued.

- Meadows' Manual of Midwifery.** Including the Signs and Symptoms of Pregnancy, Obstetric Operations, Diseases of the Puerperal State, etc. 145 Illustrations. 494 pages. Cloth, 2.00
- Swayne's Obstetric Aphorisms.** For the use of Students commencing Midwifery Practice. 8th Ed. 12mo. Cloth, 1.25

PATHOLOGY AND HISTOLOGY.

- Rindfleisch's General Pathology.** By Tyson. For Students and Physicians. By Prof. Edward Rindfleisch, of Würzburg. Translated by Wm. H. Mercur, M.D., of Pittsburg, Pa., Edited by James Tyson, M.D., Professor of Pathology and Morbid Anatomy in the University of Pennsylvania. 12mo. Cloth, 2.00
- Gilliam's Essentials of Pathology.** A Handbook for Students. 47 Illustrations. 12mo. Cloth, 2.00

. The object of this book is to unfold to the beginner the fundamentals of pathology in a plain, practical way, and by bringing them within easy comprehension to increase his interest in the study of the subject. Though it will not altogether supplant larger works, it will be found to impart clear-cut conceptions of the generally accepted doctrines of the day, and to prevent confusion in the mind of the student.

- Gibbes' Practical Histology and Pathology.** Third Edition. Enlarged. 12mo. Cloth, 1.75

PHYSICAL DIAGNOSIS.

- Bruen's Physical Diagnosis of the Heart and Lungs.** By Dr. Edward T. Bruen, Assistant Professor of Clinical Medicine in the University of Pennsylvania. Second Edition, revised. With new Illustrations. 12mo. Cloth, 1.50

. The subject is treated in a plain, practical manner, avoiding questions of historical or theoretical interest, and without laying special claim to originality of matter, the author has made a book that presents to the student the somewhat difficult points of Physical Diagnosis clearly and distinctly.

PHYSIOLOGY.

- Yeo's Physiology.** Second Edition. The most Popular Students' Book. By Gerald F. Yeo, M.D., F.R.C.S., Professor of Physiology in King's College, London. Small Octavo. 750 pages. Over 300 carefully printed Illustrations. With a Full Glossary and Index. Cloth, 3.00; Leather, 3.50

"The work will take a high rank among the smaller text-books of Physiology."—*Prof. H. P. Bowditch, Harvard Med. School, Boston.*

"The brief examination I have given it was so favorable that I placed it in the list of text-books recommended in the circular of the University Medical College."—*Prof. Lewis A. Stimpson, M. D., 37 East 33d Street, New York.*

☞ See pages 2 to 5 for list of ? Quia-Compends ?

Physiology:—Continued.

Kirke's Physiology. 11th Ed. Illus. Cloth, 4.00; Leather, 5.00

Landois' Human Physiology. Including Histology and Microscopical Anatomy, and with special reference to Practical Medicine. Second Edition. Translated and Edited by Prof. Stirling. 583 Illustrations. Cloth, 6.50; Leather, 7.50

"So great are the advantages offered by Prof. Landois' Text-book, from the exhaustive and eminently practical manner in which the subject is treated, that, notwithstanding it is one of the largest works on Physiology, it has yet passed through four large editions in the same number of years. Dr. Stirling's annotations have materially added to the value of the work. . . . Admirably adapted for the practitioner. . . . With this Text-book at his command, no student could fail in his examination."—*Lancet*.

Sanderson's Physiological Laboratory. Being Practical Exercises for the Student. 350 Illustrations. 8vo. Cloth, 5.00

Tyson's Cell Doctrine. Its History and Present State. Illustrated. Second Edition. Cloth, 2.00

PRACTICE.

Roberts' Practice. Fifth American Edition. A Handbook of the Theory and Practice of Medicine. By Frederick T. Roberts, M.D.; M.R.C.P., Professor of Clinical Medicine and Therapeutics in University College Hospital, London. Fifth Edition. Octavo. Cloth, 5.00; Leather, 6.00

. This new edition has been subjected to a careful revision. Many chapters have been rewritten. Important additions have been made throughout, and new illustrations introduced. Recommended as a Text-book at University of Pennsylvania, Long Island College Hospital, Yale and Harvard Colleges, Bishop's College, Montreal, University of Michigan, and over twenty other Medical Schools.

"I have become thoroughly convinced of its great value, and have cordially recommended it to my class in *Yale College*."—*Prof. David P. Smith.*

"I have examined it with some care, and think it a good book, and shall take pleasure in mentioning it among the works which may properly be put in the hands of students."—*A. B. Palmer, Prof. of the Practice of Medicine, University of Michigan.*

"A clear, yet concise, scientific and practical work. It is a capital compendium of the classified knowledge of the subject."—*Prof. J. Adams Allen, Rush Medical College, Chicago.*

"It is unsurpassed by any work that has fallen into our hands, as a compendium for students preparing for examination. It is thoroughly practical, and fully up to the times."—*The Clinic.*

Aitken's Practice of Medicine. Seventh Edition. 196 Illustrations. 2 vols. Cloth, 12.00; Leather, 14.00

Tanner's Index of Diseases, and Their Treatment. Cloth, 3.00

"This work has won for itself a reputation. . . . It is, in truth, what its Title indicates."—*N. Y. Medical Record.*

☛ See pages 2 to 5 for list of *Quiz-Compendis* !

PRESCRIPTION BOOKS.

- Wythe's Dose and Symptom Book.** Containing the Doses and Uses of all the principal Articles of the *Materia Medica*, etc. Sixteenth edition. 32mo. Cloth, 1.00; Pocket-book style, 1.25
- Pereira's Physician's Prescription Book.** Containing Lists of Terms, Phrases, Contractions and Abbreviations used in Prescriptions, Explanatory Notes, Grammatical Construction of Prescriptions, etc., etc. By Professor Jonathan Pereira, M.D. Sixteenth Edition. 32mo. Cloth, 1.00; Pocket-book style, 1.25

SKIN DISEASES.

- Anderson, (McCall) Skin Diseases.** A complete Text Book, with Colored Plates and numerous Wood Engravings. 8vo. *In Press.*

Van Harlingen on Skin Diseases. A Handbook of the Diseases of the Skin, their Diagnosis and Treatment. By Arthur Van Harlingen, M.D., Prof. of Diseases of the Skin in the Philadelphia Polyclinic; Consulting Physician to the Dispensary for Skin Diseases, etc. With colored plates. 12mo. Cloth, 1.75

*.*This is a complete epitome of skin diseases, arranged in alphabetical order, giving the diagnosis and treatment in a concise, practical way. Many prescriptions are given that have never been published in any text-book, and an article incorporated on Diet. The plates do not represent one or two cases, but are composed of a number of figures, accurately colored, showing the appearance of various lesions, and will be found to give great aid in diagnosing.

"This is an excellent little book, in which, for ease of reference, the more common diseases of the skin are arranged in alphabetical order, while many good prescriptions are given, together with clear and sensible directions as to their proper application."—*Boston Medical and Surgical Journal.*

Bulkley. The Skin in Health and Disease. By L. Duncan Bulkley, Physician to the N. Y. Hospital. Illus. Cloth, 50

SURGERY.

- Heath's Minor Surgery, and Bandaging.** Eighth Edition. 142 Illustrations. 60 Formulæ and Diet Lists. Cloth, 2.00
- Pye's Surgical Handicraft.** A Manual of Surgical Manipulations, Minor Surgery, Bandaging, Dressing, etc., etc. With special chapters on Aural Surgery, Extraction of Teeth, Anæsthetics, etc. 208 Illustrations. 8vo. Cloth, 5.00
- Watson on Amputation of the Extremities, and their Complications.** 2 colored plates and 250 wood cuts. 8vo. Cloth, 5.50

See pages 2 to 5 for list of *Quis-Compendis?*

A New Series of Manuals

FOR

Medical Students.

Price of each Book, Cloth, \$3.00; Leather, \$3.50.

MIDWIFERY. By ALFRED LEWIS GALABIN, M.A., M.D., Obstetric Physician to, and Lecturer on Midwifery and the Diseases of Women at, Guy's Hospital, London, etc. 227 fine Engravings. 753 pages.

PHYSIOLOGY. By GERALD F. YEO, M.D., F.R.C.S., Professor of Physiology in King's College, London. Second Edition, revised. 750 pages. 301 carefully printed Illustrations.

MATERIA MEDICA, PHARMACY AND THERAPEUTICS, including the Physiological Action of Drugs, Special Therapeutics, Official and Extemporaneous Pharmacy, with numerous Tables, Formulæ, Notes on Temperature, Clinical Thermometer, Poisons, Urinary Examinations and Patent Medicines. By SAM'L O. L. POTTER, M.A., M.D., Professor of Practice of Medicine, Cooper College, San Francisco, late Surgeon U. S. Army. 750 pages.

CHILDREN. By J. F. GOODHART, M.D., Physician to the Evelina Hospital for Children; Assistant Physician, Guy's Hospital, London. American Edition. Revised and Edited by LOUIS STARR, M.D., Clinical Professor of Diseases of Children in the Hospital of the University of Pennsylvania; Physician to the Children's Hospital, Philadelphia. 50 Formulæ, and Directions for preparing Artificial Human Milk, for the Artificial Digestion of Milk, etc. 738 pages.

PRACTICAL THERAPEUTICS, With an Index of Diseases. By ED. JOHN WARING, M.D., F.R.C.P. Fourth Edition. Rewritten and Revised. Edited by DUDLEY W. BUXTON, Assistant to the Professor of Medicine, University College Hospital, London. 744 pages.


MEDICAL JURISPRUDENCE AND TOXICOLOGY. By JOHN J. REESE, M.D., Professor of Medical Jurisprudence and Toxicology, University of Pennsylvania, etc. 6c6 pages.

ORGANIC CHEMISTRY. By Prof. VICTOR VON RICHTER, University of Breslau. Translated from Fourth German Edition by EDGAR F. SMITH, M.A., Ph.D., Professor of Chemistry, Wittenberg College, Springfield, O., formerly in the Laboratories of the University of Pennsylvania, etc. Illustrated. 710 pages.

DISEASES OF WOMEN. By Dr. F. WINCKEL, Professor of Gynæcology, etc., Royal University of Munich. The Translation Edited by THEOPHILUS PARVIN, M.D., Professor of Obstetrics and Diseases of Women and Children, Jefferson Medical College, Philadelphia. 117 Engravings, most of which are new. 700 pages.

. Other Volumes in Preparation. A complete illustrated circular with sample pages sent free, upon application.

Price of each Book, Cloth, \$3.00; Leather, \$3.50.





Medical Students' Handbooks.

BARTLEY'S MEDICAL CHEMISTRY. A Text-book for Medical and Pharmaceutical Students. By E. H. BARTLEY, M.D., Professor of Chemistry and Toxicology at the Long Island College Hospital; President of the American Society of Public Analysts; Chief Chemist, Board of Health, of Brooklyn, N. Y. With Illustrations, Glossary, and Complete Index. 12mo. Cloth, \$2.50.

"Probably the best chemistry for medical students."—*Journal of the American Medical Association.*

"I especially like the first part, dealing with chemical physics and elementary chemistry."—*Prof. J. W. Holland, Jefferson Medical College, Phila.*

VAN HARLINGEN ON SKIN DISEASES. Their Diagnosis and Treatment. By ARTHUR VAN HARLINGEN, M.D., Prof. of Diseases of the Skin in the Philadelphia Polyclinic; Consulting Physician to the Dispensary for Skin Diseases; late Vice-President American Dermatological Association, etc. Illustrated by Two Colored Lithographic Plates. 12mo. Cloth, \$1.75.

* * * This is a complete epitome of skin diseases, arranged in alphabetical order, giving the diagnosis and treatment. Many prescriptions are given that have never been published in any text-book, and an article incorporated on Diet. The plates do not represent one or two cases, but are composed of a number of figures, accurately colored, showing the appearance of various lesions, and will be found to give great aid in diagnosing.

"This is one of the best of the smaller handbooks of dermatology that we have seen."—*N. Y. Medical Journal.*

TYSON ON THE URINE. Fifth Edition. A Practical Guide to the Examination of Urine. For the Use of Physicians and Students. By JAMES TYSON, M.D., Prof. of Pathology and Morbid Anatomy in the University of Pennsylvania. With Colored Lithographic Plates and Numerous Illustrations Engraved on Wood. Fifth Edition, Revised and Enlarged. 12mo. Cloth, \$1.50.

"The practical man will find in this little book all that is absolutely necessary for him to know in order to utilize fully the data supplied by the urine."—*Chicago Medical Journal.*

GILLIAM'S PATHOLOGY. The Essentials of Pathology; a Handbook for Students. By D. TOD GILLIAM, M.D., Prof. of Physiology, Starling Medical College, Columbus, Ohio. With forty-seven Illustrations. 12mo. Cloth, \$2.00.

"Will be found useful by students who are commencing the study of pathology."—*Dublin Journal of Medical Sciences.*

"It is practically a student's book, and we have no hesitation in recommending it."—*The-rapeutic Gazette.*

WOLFF'S APPLIED MEDICAL CHEMISTRY. Containing a Description of the Apparatus and Methods Employed in the Practice of Medical Chemistry, the Chemistry of Poisons, Physiological and Pathological Analysis, Urinary and Fecal Analysis, Sanitary Chemistry and the Examination of Medicinal Agents, Foods, etc. By LAWRENCE WOLFF, M.D., Demonstrator of Chemistry in the Jefferson Medical College; Member of the Philadelphia College of Pharmacy, etc. 8vo. Cloth, \$1.50.

* * * The object of the author of this book is to furnish the practitioner and student a reliable and simple guide for making analyses and examinations of the various medicinal agents, human excretions, secretions, etc., without elaborate apparatus or expensive processes.

P. BLAKISTON, SON & CO., Publishers and Booksellers,
1012 WALNUT STREET, PHILADELPHIA.

Standard Text-Books.

LAN
ol
re
L
tu
wi
Pl
ch
fo:
O

"Wi
The L
"On
tween
concise
Journal
"Un
Practic
"La
been w

BID
Ec
Bt
Pl
rev
N;
M;
etc
set
Cl

"A r
esting t
ifest.
printed
just wh
"Th
Bellevu

MEY
m
M
fro
A-
ms
of

The
extern

LANE MEDICAL LIBRARY

To avoid fine, this book should be returned on or before the date last stamped below.

n Physi-
special
7 Dr. L.
al Insti-
Edition,
fessor of
ty, Man-
r of Ox-
trations.

ATION."—
Edge' be-
ness and
Medical

biology to
: has ever

. Tenth
OHN B.
College,
ay parts
n U. S.
efferson
elphia,
e other
Octavo.

be inter-
are man-
hich it is
ntaining
clinic.
books at

phthal-
Faculté
nslated
by Dr.
With
rection

ie eyes,

scopes, general considerations, on the treatment of ophthalmia, etc. Each disease is then taken up in its proper order; the anatomy of the part being presented first, followed by the diagnosis, causes, progress, prognosis, etiology and treatment. The arrangement of the work will thus be seen to be systematic, commending itself to all physicians and students for the logical and concise way in which the facts are given. The treatment in each case is thorough, often new, and includes many prescriptions.

P. BLAKISTON, SON & CO., Publishers and Booksellers,
1012 WALNUT STREET, PHILADELPHIA.

