

UC-NRLF




B 4 096 645

BNA

A. [redacted] D.
Omaha,
Nebraska

MEDICAL SCHOOL
LIBRARY




Medical Library Exchange

University of Nebraska
College of Medicine Library



Digitized by the Internet Archive
in 2007 with funding from
Microsoft Corporation



ANATOMICAL TERMINOLOGY

BARKER

ANATOMICAL TERMINOLOGY

WITH SPECIAL REFERENCE TO THE [BNA]

BY

LEWELLYS F. BARKER, M.D.

PROFESSOR OF MEDICINE, JOHNS HOPKINS UNIVERSITY, BALTIMORE; (FORMERLY PROFESSOR OF
ANATOMY, RUSH MEDICAL COLLEGE, UNIVERSITY OF CHICAGO).

With Vocabularies in Latin and English
and Illustrations

UNIVERSITY OF CALIF
MEDICAL SCHOOL

PHILADELPHIA:
P. BLAKISTON'S SON & CO.
1012 WALNUT STREET.

1907

M

COPYRIGHT, 1907, BY P. BLAKISTON'S SON & Co.

W. F. FELL COMPANY

ELECTROTYPERS AND PRINTERS

WM. F. FELL COMPANY
ELECTROTYPERS AND PRINTERS
1220-24 SANSOM STREET
PHILADELPHIA, PA.

PM81
B25
1904

CONTENTS

	PAGE
INTRODUCTION,	I
WHAT THE BNA IS,	2
WHY THIS REVIEW OF ANATOMICAL TERMINOLOGY WAS UNDERTAKEN,	2
THE SCOPE OF THE WORK AND THE WORKERS,	4
THE WAY THE WORK WAS DONE,	5
THE PRINCIPLES ARRIVED AT AS THE WORK PROCEEDED,	6
THE ADOPTION OF THE BNA IN AMERICA AND GREAT BRITAIN,	8
THE FUTURE OF ANATOMICAL TERMINOLOGY,	11
ANATOMICAL NAMES,	14
Terms Indicating the Position and Direction of Parts of the Body,	14
General Terms,	14
Terms Relating to the Extremities,	14
GENERAL ANATOMICAL TERMS,	15
PARTS OF THE HUMAN BODY,	17
Head,	17
Skull,	17
Face,	17
Eye,	17
Nose,	17
Mouth,	17
Neck,	17
Trunk,	17
Thorax,	17
Back,	17
Belly,	18
Pelvis,	18
Upper Extremities,	18
Lower Extremities,	18
OSTEOLOGY,	19
Vertebral Column, or Spine,	19
Atlas,	19
Epistropheus (O. T. Axis),	20
Sacrum,	20
Coccyx,	20
Thorax,	20
Ribs,	20
Breast Bone,	20
Thoracic Cavity,	20
Bones of the Skull,	20
Basilar Bone,	20
Occipital Bone,	20
Sphenoid Bone,	21
Temporal Bone,	22
Parietal Bone,	23
Frontal Bone,	23
Ethmoid Bone,	23
Inferior Turbinate Bone,	24
Lacrimal Bone,	24
Nasal Bone,	24
Vomer, or Ploughshare, Bone,	24
Bones of the Face,	24
Maxilla (O. T. Superior Maxillary Bone),	24
Palate Bone,	24

8503

	PAGE
OSTEOLOGY (<i>Continued</i>)	
Ligaments of the Girdle of Lower Extremity (O. T. Pelvic Girdle),	34
Sacro-Iliac Joint,	35
Symphysis of Pubic Bones,	35
Hip Joint,	35
Knee Joint,	35
Tibiofibular Joint (O. T. Superior Tibiofibular Articulation),	35
Tibiofibular Syndesmosis (O. T. Inferior Tibiofibular Articulation),	35
Joints of the Foot,	35
Ankle Joint,	35
Intertarsal Joints,	36
Talocalcaneonavicular Joint,	36
Taloalcalcanean Joint,	36
Chopart's Transverse Articulation of the Tarsus,	36
Talonavicular Joint,	36
Calcaneocuboid Joint,	36
Cuneonavicular Joint,	36
Interosseous Ligaments of Tarsus,	36
Dorsal Ligaments of Tarsus,	36
Plantar Ligaments of Tarsus,	36
Tarsometatarsal Joints,	36
Intermetatarsal Joints,	36
Metatarsophalangeal Joints,	36
Joints of the Toes,	37
MYOLOGY OR MUSCULATURE,	37
Muscles of the Back,	37
Muscles of the Head,	38
Muscles of the Hyoid Bone,	38
Muscles of the Neck,	38
Muscles of the Thorax,	39
Muscles of the Abdomen,	39
Coccygeal Muscles,	40
Muscles of the Upper Extremity,	40
Muscles of the Lower Extremity,	41
BURSÆ AND MUCOUS SHEATHS,	43
SPLANCHNOLOGY,	45
Digestive Apparatus,	45
Mouth Cavity,	45
Mucous Membrane of the Mouth,	45
Glands of the Mouth,	45
Teeth,	46
Tongue,	46
Fauces,	46
Muscles of the Palate and Fauces,	47
Pharynx,	47
Digestive Tube,	47
Oesophagus,	47
Stomach,	47
Small or Thin Intestine,	48
Large or Thick Intestine,	48
Rectum or Straight Gut,	49
Pancreas,	49
Liver,	49
RESPIRATORY APPARATUS,	50
Nasal Cavity,	50
External Nose,	51
Larynx,	51
Muscles of Larynx,	52
Cavity of Larynx,	52
Trachea and Bronchi,	52
Lung,	52
Thoracic Cavity,	53
Thyreoid Gland,	53
Carotid Skein (O. T. Intercarotid Gland),	53

CONTENTS

V

	PAGE
RESPIRATORY APPARATUS (<i>Continued</i>)	
Thymus,	53
UROGENITAL APPARATUS,	53
Uropoietic Organs,	53
Kidney,	53
Renal Arteries,	54
Renal Veins,	54
Ureter,	54
Urinary Bladder,	54
Suprarenal Gland,	54
Male Genital Organs,	55
Testicle,	55
Seminal Vesicle,	55
Spermatic Cord and Coats of the Testicle and Cord,	55
Prostate,	55
Bulbo-urethral Gland (O. T. Cowper's Gland),	56
Parts of External Genitals,	56
Penis,	56
Male Urethra,	56
Scrotum,	56
Female Genital Organs,	56
Ovary,	56
Uterine Tube (O. T. Fallopian Tube),	56
Uterus,	57
Vagina,	57
Epo-ophoron (O. T. Parovarium or Organ of Rosenmueller),	57
External Genital Parts,	57
Paro-ophoron,	57
Large Vestibular Gland of Bartholin,	57
Clitoris,	57
Female Urethra,	58
Perineum,	58
Peritoneum,	58
ANGIOLOGY,	60
Heart,	60
Right Atrium (O. T. right auricle),	61
Right Ventricle,	61
Left Atrium (O. T. Left Auricle),	61
Left Ventricle,	61
Arteries,	61
Pulmonary Artery,	61
Aorta,	61
Innominate Artery,	62
Common Carotid Artery,	62
External Carotid Artery,	62
Superior Thyreoid Artery,	62
Ascending Pharyngeal Artery,	62
Lingual Artery,	62
External Maxillary Artery (O. T. Facial Artery),	62
Sternocleidomastoid Artery,	62
Occipital Artery,	62
Posterior Auricular Artery,	62
Superficial Temporal Artery,	62
Internal Maxillary Artery,	62
Internal Carotid Artery,	63
Ophthalmic Artery,	63
Cerebral Arteries,	63
Subclavian Artery,	63
Vertebral Artery,	63
Basilar Artery,	63
Internal Mammary Artery,	63
Thyreocervical Trunk (O. T. Thyreoid Axis),	63
Inferior Thyreoid Artery,	63
Ascending Cervical Artery,	64

ANGIOLOGY, Subclavian Artery (<i>Continued</i>)	PAGE
Superficial Cervical Artery,.....	64
Transverse Artery of Scapula (O. T. Suprascapular),.....	64
Costocervical Trunk (O. T. Superior Intercostal),.....	64
Transverse Artery of Neck (O. T. Transversalis Coli),.....	64
Axillary Artery,.....	64
Highest Thoracic Artery (O. T. Superior Thoracic Artery),.....	64
Thoraco-Acromial Artery (O. T. Thoracic Axis),.....	64
Lateral Thoracic Artery (O. T. Long Thoracic),.....	64
Subscapular Artery,.....	64
Anterior Circumflex Artery of Humerus,.....	64
Posterior Circumflex Artery of Humerus,.....	64
Brachial Artery,.....	64
Deep Artery of Upper arm (O. T. Superior Profunda),.....	64
Superior Ulna Collateral Artery (O. T. Inferior Profunda),.....	64
Inferior Ulna Collateral Artery (O. T. Anastomotica Magna),.....	64
Radial Artery,.....	64
Ulnar Artery,.....	65
Thoracic Aorta,.....	65
Intercostal Arteries,.....	65
Abdominal Aorta,.....	65
Inferior Phrenic Artery,.....	65
Lumbar Arteries,.....	65
Middle Sacral Artery,.....	65
Coeliac Artery,.....	65
Superior Mesenteric Artery,.....	66
Inferior Mesenteric Artery,.....	66
Middle Suprarenal Artery (O. T. Middle Capsular Artery),.....	66
Renal Artery,.....	66
Internal Spermatic Artery,.....	66
Testicular Artery,.....	66
Ovarian Artery,.....	66
Common Iliac Artery,.....	66
Hypogastric Artery (O. T. Internal Iliac),.....	66
Iliolumbar Artery,.....	66
Lateral Sacral Artery,.....	66
Obturator Artery,.....	66
Superior Gluteal Artery,.....	66
Inferior Gluteal Artery,.....	66
Umbilical Artery,.....	66
Inferior Vesical Artery,.....	66
Deferential Artery,.....	66
Uterine Artery,.....	66
Middle Hemorrhoidal Artery,.....	66
Internal Pudendal Artery,.....	66
External Iliac Artery,.....	66
Inferior Epigastric Artery (O. T. Deep Epigastric),.....	66
Deep Circumflex Iliac Artery,.....	67
Femoral Artery,.....	67
Popliteal Artery,.....	67
Anterior Tibial Artery,.....	67
Posterior Tibial Artery,.....	67
Veins,.....	68
Pulmonary Veins,.....	68
Veins of the Heart,.....	68
Superior Vena Cava,.....	68
Right and Left Innominate Veins,.....	68
Internal Jugular Vein,.....	68
Sinuses of the Dura Mater,.....	68
Cerebral Veins,.....	69
Superior Ophthalmic Vein,.....	69
Common Facial Vein,.....	69
Anterior Facial Vein,.....	69
Posterior Facial Vein,.....	69

	PAGE
ANGIOLOGY, Veins (<i>Continued</i>)	
External Jugular Vein,.....	69
Subclavian Vein,.....	70
Axillary Vein,.....	70
Azygos Vein (O. T. Vena Azygos Major),.....	70
Inferior Vena Cava,.....	70
Portal Vein,.....	70
Common Iliac Vein,.....	71
Hypogastric Vein (O. T. Internal Iliac Vein),.....	71
External Iliac Veins,.....	71
Lymphatic System,.....	71
Lymphatic Vessels,.....	71
Thoracic Duct,.....	72
Lymph Glands,.....	72
Lymphatic Plexuses,.....	72
NEUROLOGY,	73
Central Nervous System,.....	73
Spinal Cord,.....	73
Sections of the Spinal Cord,.....	73
Brain,.....	74
Medullary or After-Brain,.....	74
Medulla Oblongata,.....	74
Sections of Medulla Oblongata,.....	74
Fourth Ventricle,.....	75
Hind-Brain,.....	75
Pons ("Bridge") Varolii,.....	75
Sections of the Pons,.....	75
Cerebellum or Small Brain,.....	75
Sections of Cerebellum,.....	76
Isthmus of Rhombencephalon,.....	76
Sections of Isthmus,.....	76
Cerebrum (Large Brain),.....	76
Midbrain,.....	76
Inferior Surface,.....	76
Peduncle of Cerebrum (O. T. Crus Cerebri),.....	77
Sections of Cerebral Peduncle,.....	77
Quadrigeminal Bodies (O. T. Optic Lobes),.....	77
Sections of Quadrigeminal Bodies,.....	77
Forebrain,.....	77
Interbrain,.....	77
Hypothalamus (O. T. Subthalamie Region),.....	77
Sections of the Hypothalamus,.....	77
Thalamic Brain,.....	78
Thalamus (O. T. Optic Thalamus),.....	78
Metathalamus,.....	78
Epithalamus,.....	78
Sections of the Thalamic Brain,.....	78
End-Brain,.....	78
Hemisphere,.....	78
Brain Mantle,.....	78
Medial Surface of Hemisphere,.....	79
Fornix,.....	79
Transparent Septum,.....	80
Lateral Ventricle,.....	80
Olfactory Brain,.....	80
Sections of End-Brain,.....	80
Membranes of Brain,.....	81
Peripheral Nervous System,.....	81
Cerebral Nerves,.....	81
Olfactory Nerves,.....	81
Optic Nerve,.....	81
Oculomotor Nerve (O. T. Third Nerve),.....	81
Trochlear Nerve (O. T. Patheticus or Fourth Nerve),.....	81
Trigeminal Nerve (O. T. Fifth Nerve),.....	82

NEUROLOGY, Peripheral Nervous System, Cerebral Nerves (<i>Continued</i>)	PAGE
Ophthalmic Nerve,.....	82
Maxillary Nerve (O. T. Superior Maxillary),.....	82
Mandibular Nerve (O. T. Inferior Maxillary),.....	82
Abducent Nerve (O. T. Sixth Nerve),.....	83
Facial Nerve,.....	83
Acoustic (O. T. Auditory Nerve),.....	83
Glossopharyngeal Nerve,.....	83
Vagus Nerve (O. T. Pneumogastric Nerve),.....	84
Accessory Nerve (O. T. Spinal Accessory),.....	84
Hypoglossal Nerve,.....	84
Spinal Nerves,.....	84
Cervical Nerves,.....	85
Brachial Plexus,.....	85
Median Nerve,.....	85
Ulnar Nerve,.....	85
Radial Nerve (O. T. Musculospiral),.....	86
Thoracic Nerves,.....	86
Lumbar, Sacral, and Coccygeal Nerves,.....	86
Lumbosacral Plexus,.....	86
Lumbar Plexus,.....	86
Iliohypogastric Nerve,.....	86
Ilio-inguinal Nerve,.....	86
Genitofemoral Nerve (O. T. Genitocrural Nerve),.....	86
Lateral Cutaneous Nerve of Thigh (O. T. External Cutaneous),.....	86
Obturator Nerve,.....	86
Femoral Nerve (O. T. Anterior Crural),.....	87
Sacral Plexus,.....	87
Sciatic Nerve (O. T. Great Sciatic),.....	87
Pudendal Plexus,.....	87
Coccygeal Nerve,.....	87
Sympathetic System of Nerves,.....	88
Cephalic and Cervical Portions of the Sympathetic System,.....	88
Thoracic Portion of the Sympathetic System,.....	88
Abdominal and Pelvic Portions of the Sympathetic System,.....	88
SENSE ORGANS AND COMMON INTEGUMENT,.....	89
Organ of Vision,.....	89
Eye,.....	89
Optic Nerve,.....	89
Eyeball,.....	89
Fibrous Tunic of Eye,.....	89
Sclera (O. T. Sclerotic Coat),.....	89
Cornea,.....	89
Vascular Coat of Eye,.....	89
Chorioid,.....	89
Ciliary Body,.....	90
Iris or Diaphragm of the Eye,.....	90
Layer of Pigment,.....	90
Retina,.....	90
Anterior Chamber of the Eye,.....	90
Posterior Chamber of the Eye,.....	90
Vitreous Body,.....	90
Crystalline Lens,.....	90
Ciliary Zonule (O. T. Zonule of Zinn),.....	91
Accessory Organs of the Eye,.....	91
Eye Muscles, Orbital Fasciae,.....	91
Eyebrow,.....	91
Eyelids,.....	91
Conjunctiva,.....	91
Lacrimal Apparatus,.....	91
Organ of Hearing,.....	92
Internal Ear,.....	92
Membranous Labyrinth,.....	92
Osseous Labyrinth,.....	92

SENSE ORGANS AND COMMON INTEGUMENT, Organ of Hearing (<i>Continued</i>)	PAGE
Vestibule,.....	92
Cochlea,.....	92
Internal Acoustic Meatus,.....	93
Cavity of Tympanum,.....	93
Membrane of the Tympanum (O. T. Drumhead),.....	93
Auditory Ossicles,.....	93
Joints of the Auditory Ossicles,.....	94
Ligaments of the Auditory Ossicles,.....	94
Muscles of the Auditory Ossicles,.....	94
Tympanic Mucous Coat,.....	94
Auditory or Eustachian Tube,.....	94
External Acoustic Meatus,.....	94
External Ear,.....	94
Organ of Smell,.....	95
Organ of Taste,.....	95
Common Integument,.....	95
Skin,.....	95
Epidermis or Scarf Skin,.....	95
Corium or Leather Skin,.....	95
Subcutaneous Tissue,.....	95
Terminal Corpuscles of the Nerves,.....	95
Hair,.....	95
Nails,.....	96
Glands of the Skin.....	96
Coil Glands,.....	96
Sebaceous Glands,.....	96
Breast,.....	96
REGIONS OF THE HUMAN BODY,.....	97
of the Head,.....	98
of the Face,.....	98
of the Neck,.....	98
of the Breast,.....	99
of the Abdomen,.....	99
of the Back,.....	99
of the Upper Extremity,.....	99
of the Lower Extremity,.....	100
EXPLANATORY NOTES TO CERTAIN TERMS,.....	101
COLORED PLATES OF REGIONS,.....	105-107



THE BASLE ANATOMICAL NOMENCLATURE [BNA].

Introduction.

Now that the BNA is being followed in medical and scientific schools throughout the world, and has been adopted as the language used in several of the newer English and American anatomical text-books and atlases, it has occurred to the publishers of Morris's Anatomy that a concise statement concerning the origin and exact nature of this list of anatomical terms would be interesting and helpful to anatomists, physiologists, biologists, pathologists, and clinicians. They have asked me to prepare this statement, and I do so gladly, in the hope that it may bring the terminology to the attention of many who do not yet know of it, and make clear, perhaps, certain misunderstandings that have existed in the minds of some who have heard of it, but are not yet really familiar with it. To know its origin, nature, and aims is, I feel sure, in the majority of instances at least, to decide to use it. That the sooner a general decision to adopt it is reached the better it will be for anatomical instruction and research, and the easier it will be for teacher and taught, it is the aim of the following paragraphs to show. They have not been difficult to write, for, aside from the experience I have gained by personally using the BNA in anatomical laboratories during the past ten years, the material for the account lay ready at hand in the articles of Krause* and His† and it has been necessary only to adapt it to the needs of readers in America and Great Britain. The article by Professor His has been followed especially closely, and parts of my account are no other than a free translation of his lucid paragraphs. The actual list of Latin names of the BNA is to be published at once by Messrs. P. Blakiston's Son & Co. and Messrs. J. & A. Churchill. It will be accompanied by a list of literal English equivalents which Dr. Benson A. Cohoe, Assistant Resident Physician in the Johns Hopkins Hospital, has been kind enough to help me to prepare. The English vocabulary is simply explanatory; in many instances it would be unwise to use the English synonyms given, and in many more instances anatomists would differ as to the most suitable English equivalent to be chosen. Each anatomist is of course at liberty to use whatever English equivalent he desires for the official Latin terms. Students are strongly advised, however, to use the original Latin terms as English words. The Latin terms are the only authorized ones.

*Krause, W.: Die anatomische Nomenclatur. Internat. Monatsschr. f. Anat. u. Physiol., 1893, x, 313.

†His, W.: "Die anatomische Nomenclatur. Nomina anatomica, Verzeichniss der von der anatomischen Gesellschaft auf ihrer IX. Versammlung in Basel aufgenommenen Namen Eingeleitet und im Einverständnis mit dem Redaktionsausschuss erläutert. Mit dreissig Abbildungen in Text und zwei Tafeln": Leipzig, Veit & Co., 1895. (Reprinted from the Arch. f. Anat. u. Physiol. anat. Abth. Leipzig, 1895, Supplement-Band.)

What the "BNA" is.

The expression BNA is a shorthand title for a list of some 4500 anatomical terms (*nomina anatomica*) accepted at Basle in 1895 by the Anatomical Society as the most suitable designations for the various parts of the human anatomy which are visible to the naked eye. The terms are all in correct Latin and have been selected by a group of the most distinguished anatomists in the world, working six years at their task, as the shortest and simplest available names for the different structures; the majority of the terms were already in use in the various text-books, but some of them were selected from anatomical monographs not considered in the text-books, and a few of them are brand-new, introduced into the list, where an examination of the literature and of anatomical preparations showed that none of the terms hitherto coined was satisfactory.

One name only is given to each structure, and the mass of synonyms which encumbered the text-books can thus be swept away. If one of the larger text-books of gross anatomy be examined, as many as 10,000 terms will be found employed, the half of which are synonyms; and if the anatomical terms used in the various standard text-books be collected into one list, the total number amounts to more than 30,000. It is no small achievement to have reduced the necessary number of terms in gross anatomy, as it is known to-day, to less than 5000,—an achievement for which both students and teachers of the subject must be thankful.

Even more important is the exclusion from the list of all obscure or ambiguous terms, each name employed having a definite and easily ascertainable meaning. The construction of the list has led, too, to the establishment of certain general principles regarding the formation and use of anatomical terms, and these principles promise to be of great service in simplifying terminology and keeping it uniform as anatomical science continues to develop.

Why this revision of anatomical terminology was undertaken.

Previous to undertaking this revision of the names used in gross anatomy, the burden of terms which had to be carried by text-book, teacher, and pupil had been growing progressively heavier. Anatomical structures had been christened in a most haphazard way. From the beginning of the science each investigator gave names as he would to the parts he studied, and as one investigator was often ignorant of the work done by others the same parts were frequently differently dubbed. The authors of anatomical text-books, especially those who read widely, gradually collected these terms, though each author selected and rejected names from the lists used by his predecessors as he thought fit.

It has thus come about that we have inherited from previous centuries an excess of anatomical terms, many single structures carrying double or even multiple designations. Examples come at once to mind: The pneumogastric nerve is also the vagus nerve as well as the tenth cerebral nerve; the trapezius muscle is known to some as the *musculus cucullaris*; the laryngeal prominence is also Adam's apple; the aqueduct of the cerebrum is also, in many books, the *iter tertio ad quartum ventriculium*; *m. levator palati* is synonymous with *m. petrosalpingostaphylinus*. These double and multiple terms were passed on from lecture to lecture and from text-book to text-book, and as a result of this anarchy in the creation and use of terms the weight became terribly grievous. Teachers and pupils writhed under it. Anatomical research was, to some extent at least, retarded by it. When the *valvula coli* was known also variously as the *valvula ileocecalis*, the *valvula Bauhini*, the *valvula Tulpii*, and the *valvula Falloppii*, a certain historical sense may have been aroused and opportunity

given, as His suggests, for the discussion of fossil questions of priority, but the inconveniences of such ballast were sufficiently obvious.

As this naming went on by the authors of individual text-books or monographs, a great many terms were proposed which never became current; others were gradually employed in a sense other than that originally intended; some attained to general anatomical parlance. It was the success that a name met with which justified its adoption in the science, although often, as examination has shown, it was fashion which in her imperious way decided, sometimes suddenly replacing an entirely suitable anatomical term by another, no better. The names arising, as it were, by chance and at totally different periods in the various anatomical systems, it was scarcely possible that anatomical terminology as a whole could manifest any general plan or have much uniformity of character; it was necessarily chaotic and incoherent,—full of inequalities, contradictions, and obscurities.

The distinguished German anatomist, J. Henle, when writing his well-known treatise, felt keenly the faults of the inherited terminology and made a great effort at improvement. In his text-book of anatomy he gave only one name to each structure, banishing all synonyms to the footnotes; he waged war against personal names, and replaced them by objective terms, urging that historical injustice was frequently done by their retention. It is to Henle, also, that we owe the introduction and consistent use of those excellent terms of orientation,—the words sagittal, frontal, medial, lateral, etc. But even as great an anatomist as Henle could not simplify anatomical terminology satisfactorily without the sympathetic coöperation of other anatomists. Each great medical school had to a certain extent its own anatomical language, and the physician who tried to read articles in which the terms of schools other than that in which he had been brought up were used met with irritating difficulties. A student going from one university to another often found that the anatomical expressions acquired with great difficulty in the one had to be supplanted by another set of terms, equally hard to learn, in the other.

This harmful and humiliating state of affairs stirred up in anatomists in various countries a strong feeling for the necessity of remedy. Anatomical societies in America, in Germany, and in Great Britain interested themselves much in the problem. In America it was Professor Burt G. Wilder, of Ithaca, who felt most keenly the need of reform in terminology. He deserves great credit for his efforts to stimulate other American anatomists to a realization of this need, as well as for the time and labor he has given to attempt to improve and simplify anatomical terms.* He writes me that the matter of terminology was definitely brought before the American Association for the Advancement of Science as long ago as 1880, and states that in connection with the revision of terminology in America the names of Messrs. Gage, Gerrish, Gould, Huntington, Leidy, and the Spitzkas, father and son, should be mentioned.

The movement for revision of terminology which originated in Germany in the enlarged Anatomical Society at its first meeting in Leipsic, in 1887, is the

* Cf. Wilder, B. G.: "The Fundamental Principles of Anatomical Nomenclature" (Med. News, Phila., 1891, December 19); "Macroscopical Vocabulary of the Brain," presented to the Association of American Anatomists at Boston, Mass., December 20, 1890; "American Reports upon Anatomical Nomenclature," 1889-1890, with notes by B. G. Wilder, Cornell University, February 5, 1892; "Anatomical Terminology," by B. G. Wilder and S. H. Gage, in the first edition of Wood's Reference Handbook of the Medical Sciences; "Neural Terms, International and National," 1896; "Some Misapprehensions as to the Simplification of the Nomenclature of Anatomy," 1898. The Reports of the Committee of the Association of American Anatomists may also be consulted.

one which resulted finally in the production of the BNA. The Society in that year voted that its officers undertake at once a revision of anatomical terms, with the hope of remedying the obvious evils existing. No sooner did these officers begin their work, however, than unforeseen difficulties began to appear, and these did not lessen in number or significance as the work progressed. Anatomists may rejoice that the difficulties were not insuperable. How they were overcome and what the results achieved were, I shall try to explain in the paragraphs which succeed.

The Scope of the Work and the Workers.

It soon became clear that a permanent commission on terminology could deal more effectively with the problem than the officers of the Society. Again, an editor-in-chief, who should devote himself almost entirely to the work for a number of years, must of necessity be appointed. These suggestions, emanating from Professor His, were adopted by the Society in 1889. The Commission on Nomenclature was at once appointed, with Professor von Kölliker as Chairman and Professors O. Hertwig, His, Kollmann, Merkel, Schwalbe, Toldt, Waldeyer, and v. Bardeleben as members,—a list of names as likely, surely, as any that could have been chosen to insure success from the start.

This Commission began its work most happily by securing the services of Professor W. Krause, of Berlin, as editor-in-chief. Krause's literary ability made the choice especially suitable. During the six years' work which followed his appointment he set an example, his collaborators tell us, of indefatigable diligence and inexhaustible patience. The necessary correspondence of such an editor was almost interminable; letters often passed to and fro for weeks in order to set a single term right or to get it into its proper place in the list.

The cost of the undertaking was a matter for early consideration. The work, while largely a labor of love, entailed unavoidably certain expenses. The original estimate of the Commission of 10,000 marks (\$2500) was exceeded only a little. It seems almost incredible that the work could have been accomplished with so small an outlay. A large proportion of the cost (some 8090 marks) was defrayed by the scientific academies of Munich, Berlin, Vienna, Leipsic, and Hungary; the rest of the amount (3800 marks) was contributed by the Anatomical Society itself.

The exact scope of the work had, of course, to be clearly before the minds of the members of the Commission from the outset. It was decided, therefore, to consider descriptive anatomy solely, and this only in as far as the structures are visible to the naked eye or through a simple hand lens. No attempts were to be made to settle the terminology in domains of lively contemporary investigation, nor were the terms of microscopic anatomy to be included. The list was to be constructed in one language—viz.: Latin; those who use the terminology were left, therefore, to translate, at will, the terms more or less freely, into their own tongues.

The question in how far the terminology should attempt to be international in character was a delicate one for the Commission to determine. The Anatomical Society, while organized in Germany and meeting usually only in cities in which the German language is spoken, has never been exclusively German in membership or character. Indeed, the list of members includes names from America, Austria, Belgium, Denmark, England, France, Hungary, Italy, Russia, Sweden, and Switzerland. The majority of members are German, it is true; in 1895 there were 145 German members to 129 members belonging to other countries. A society with such a membership might, perhaps, without criticism,

undertake the establishment of a terminology intended for international use. It was decided, however, not to make the undertaking too wide at the beginning, to try rather to form a list of terms which should, in the first place, be acceptable to German-speaking anatomists and, later on, to attempt to gain the coöperation of anatomists who speak other languages. Though the names of the Commission originally appointed are all those of German or Austrian anatomists, the lists of anatomical terms considered were, from the beginning, taken from French and English as well as from German books. In 1890 several anatomists from Great Britain and other European countries were invited to join the Commission, and, later, Professor Thane of London was included. It was partly owing, doubtless, to the relatively undeveloped state of anatomy at the time in American universities, partly to the fact that few, if any, of our anatomists then attended the meetings of the Anatomical Society, that no one from this country was invited to join the Commission. Were another revision to be made by the Society to-day, American anatomists would undoubtedly be requested to act. The terminology which the Commission prepared and which was accepted by the Society in Basle, in 1905, was, in origin and in execution, therefore, the affair of the Anatomical Society and is to be regarded as international only in as far as that Society and its affiliations may be so regarded.

The Way the Work was done.

It is interesting to learn the methods followed by the Commission in the accomplishment of its task. The plan adopted at the beginning was greatly modified as the work proceeded. Myology, as it promised to be much the easiest, was the first subject undertaken. The editor took as a basis the names used in the latest large text-book of gross anatomy.* These terms were written down in a vertical column and the synonyms from a number of other much-used text-books placed in parallel columns. The lists were manifolded and a copy sent to each commissioner with the request that he mark the term of his choice, or if he found none suitable to propose a new one for the structure concerned. Each commissioner was to return his list with comments to Professor Krause.

When the first vote on myological terms was counted it was found that the names of 85 per cent. of the structures had received a majority vote,—more than 40 per cent. receiving practically unanimous approval. This surprising result was most encouraging. A second list was then made out indicating the accepted names, the terms still not decided upon, and the list of new terms proposed, and it, together with the comments made by the various commissioners, was again distributed. After the second vote any terms left undetermined were discussed and settled in personal sittings of the Commission. By June, 1891, the myological terminology was complete with a list of some 300 terms.

As a result of its early experience the Commission found that a second and third vote made by correspondence gave results but little better than the first vote. Further, it was soon learned that the new terms proposed and the comments made by the members, often as a result of hard work and special knowledge, were insufficiently considered unless each new term and comment were verbally discussed in personal meetings of the commissioners. On attempting such verbal discussion, however, in 1892, it was found that progress was made too slowly in the full Commission and it became necessary to parcel out the work to special committees. Thus the list of terms in Angiology was assigned to Professors Merkel, Thane, and Toldt; that in Regional Anatomy to Pro-

* This happened to be C. Gegenbaur's "Lehrbuch der Anatomie des Menschen."

fessors Merkel, Rüdinger, and Toldt, while Professor Toldt was made a committee of one to consider the terminology of joints.

Another important step consisted in the appointment of a special editing committee consisting of Professors His, Krause, and Waldeyer. To this committee was delegated the task of giving a uniform character to the terminology as a whole, a matter of no little difficulty. Since the single systems had been voted upon at long intervals, the different terms accepted had received variable majorities. There was a considerable residue of terms still undetermined in the parts already considered and the whole list contained inequalities and even contradictions which had to be corrected. Indeed, this editing committee found itself deeply immersed in the hardest kind of work for no less than three years after it was appointed. The terminology of the nervous system and of the viscera proved to be the most difficult of all. In these chapters the completed list is deeply indebted especially to Professor His and to the support and advice he received from Professors von Kölliker, Toldt, and Waldeyer.

During the last three of the six years' work it was found that results were most quickly and satisfactorily reached by adopting the following program: First, the members of the Commission were asked to send in their special suggestions and comments for the unfinished lists even before the first vote was taken, so that they could be considered on the primary ballot. The editor-in-chief, after this vote had been made, rearranged the lists and turned them over to the editing committee, the members of which reconsidered each term separately and decided doubtful questions. This committee often found it necessary to refer to the bibliography and even to dissections to help it in its decisions. The lists thus edited were returned to the Commission for final comments. These, when received, were thoroughly studied by the editing committee, and in 1895 the definitive list was presented by the Commission to the Anatomical Society as a whole at its meeting in Basle. The Society voted its adoption.

The Principles arrived at as the Work proceeded.

As the six years' work of the Commission proceeded certain principles of terminology crystallized out and simplified the further revision. It was found, however, that while these principles were of value as general rules, none of them could be employed absolutely without exception. The more important decisions arrived at were the following:

- (1) Each part shall have only one name.
- (2) Each term shall be in Latin and be philologically correct.
- (3) Each term shall be as short and simple as possible.
- (4) The terms shall be merely memory signs and need lay no claim to description or to speculative interpretation.
- (5) Related terms shall, as far as possible, be similar—*e. g.*, Femur, Arteria femoralis, Vena femoralis, Nervus femoralis.

(6) Adjectives, in general, shall be arranged as opposites—*e. g.*, dexter and sinister, major and minor, anterior and posterior, superficialis and profundus.

The Commission was occasionally forced to deviate from these rules. Thus, the first one was violated with the mitral valve, which is named *valvula bicuspidalis* and *valvula mitralis*, neither term being omitted (a concession to clinicians). The third rule, while usually easily followed (few would care to retain the terms *crotaphitico-buccinatorius* or *petrosalpingostaphylinus*), could not always be obeyed; for instance, it did not seem wise to abolish that popular term, *sternocleidomastoideus*. The fifth rule was ignored in making the *arteria meningea media* go through a *foramen spinosum* (instead of through a

foramen meningeum medium), and other examples might be given. But only when compromise appeared to be unavoidable did the Commission consent to depart from the principles mentioned.

There was much difference of opinion regarding the retention of personal names. Some desired to continue their use; others wished to abolish them altogether. Much can be said on each side. The arguments pro and con have been marshalled by His. On the one hand (1) historical injustice is frequently done, the name borne by a part being not that of its real discoverer but of some later worker; (2) the personal names employed may vary in different countries, Lieberkühn's glands in Germany being Galeati's in Italy, Vater's corpuscles in the one country being those of Pacini in the other; (3) in the literature of the specialties personal names are often used in great excess, names of no importance figuring in the bibliography; and (4) no systematic plan seems to have been followed in adopting personal names; thus, even from among the immortals, the names of Eustachius and Malpighi have in more than one instance been chosen for anatomical structures, while the names of Vesalius and Harvey do not appear at all. On the other hand it is argued that (1) the personal names are usually good mnemotechnic material, a student easily retaining the names of Poupart's, Gimbernat's and Colles's ligaments and having the impulse to find out what each signifies; whereas, his interest is much less for a ligamentum inguinale, a ligamentum lacunare, or a ligamentum inguinale reflexum; (2) a certain feeling of piety should restrain us from sacrificing, to a principle arbitrarily established, terms which for centuries have been found good and useful; and (3) it is to the student's advantage in his first session in the medical school to become familiar with the names of Falloppia, Eustachius, Malpighi, etc., for through them his historical sense may be awakened; and it is, perhaps, matter of secondary importance whether or not the names are always rightly used, this being a function of the history of anatomy rather than of anatomical terminology. The Commission compromised by giving each part an objective name and putting widely used personal names in brackets. Though this makes the terms less simple, it has the advantage of leaving to time the final decision. The personal names are all put in the genitive case, following the precedent set by the Zoölogical Commission on terminology. Thus Poupart's ligament becomes Lig. inguinale [Poupart]. In time it will be known whether it is to be called ultimately the inguinal ligament or by Poupart's name.

Another matter which the Commission had to decide concerned the anatomical terms used in the medical specialties,—*e. g.*, in neurology, ophthalmology, otology, and laryngology. In recent years clinicians have been reworking the anatomy of their special domains quite independently of the anatomical laboratories. An examination of the literature of the specialties reveals an anatomical terminology and description which varies markedly from the language and presentation of the ordinary anatomical text-books. The Commission soon convinced itself that the creation of this special language was due to the insufficiency of the anatomies of the schools; it was its duty, therefore, to accept the terms introduced by the specialists or to supply better ones. While the average medical student cannot, in his course in anatomy, be expected to master completely the anatomical terms of all the medical specialties, still, as far as his training goes in that direction, he has the right to demand that it shall be correct and modern. For completeness' sake, therefore, the Commission has included a full list of the names of macroscopic structures in the special organs, being led to do so by the repeated assurance of distinguished specialists that they were ready to accept the nomenclature of the anatomists as soon as it covered their needs.

It is surprising to find how few really new terms were coined by the Commission. Indeed, the first plan was so conservative that it expected to make no new terms at all but only to choose the most suitable terms then in use in the text-books. Fortunately this plan was not adhered to. The only terms available in the text-books for some structures were antiquated and unworthy of retention; but, worse and oftener, among the terms used in the text-books are some that are employed by one author in one sense and by another in another, owing, in certain cases at least, to obscure or inexact views. The Commission was therefore sometimes compelled to search the bibliography, to study dissections, and even to make original investigations in connection with a given term. For the sake of clarity and accuracy a certain number of new terms had to be introduced, and in the explanatory notes which accompanied the publication of the BNA Professor His has indicated the exact meaning of these new terms. Now that the new anatomical text-books and atlases are being written in the language of the BNA the student and physician will have no difficulty in understanding the few terms which otherwise might have seemed unfamiliar to him. The fact, however, remains that the list consists chiefly of carefully selected old names; it gives quite a wrong impression, therefore, to speak of the BNA as the "new terminology" or "new nomenclature."*

The adoption of the BNA in America and in Great Britain.

Having reviewed the history of the origin and construction of the BNA let us now turn for a moment to the matter of its adoption in this and in other English-speaking countries. It was thought by some, at first, that there would be great difficulties in the way.

(1) Thus, though granting the desirability of an anatomical terminology which shall be the same in all civilized countries, some think that the time is not yet ripe for it; the needs of the anatomists of different countries as regards anatomical terms are, they argue, not yet fully identical. When it is remembered, however, that the terms of the BNA deal only with well-established gross anatomical structures and do not relate to microscopic parts or to parts concerning which views are still unsettled, it is not difficult to conceive of international coöperation in the use of them for the sake of uniformity. The work of all anatomists, physiologists, biologists, pathologists and clinicians would be made much easier thereby. The speed of progress in these days has compelled every scientific medical man to read articles on his subject appearing in several languages; unless he does so he falls hopelessly behind his colleagues. Even medical students, in the schools with the higher requirements, are now asked to read one or two modern languages other than their own before admission. How obviously the reading of medical articles in the international bibliography would be facilitated if all writers would make it a point to use the same anatomical terms in texts and at the sides of illustrative plates and figures! Certainly the vast majority of the terms of the BNA would be understandable of all and agreeable to all. Even if a small residue of names might be found objectionable and remain unused in each country, it would matter but little, though most of us, surely, would be willing temporarily, for the sake of uniformity, to use a few terms not wholly to our liking.

(2) There are, it is said, a few anatomists in America and in England who are prejudiced against the BNA because it was prepared by the German Anatomical Society and is largely the result of the work of German anatomists.

*Through an oversight in proof-reading, I have myself fallen into this error in my "Laboratory Manual."

Aside from the facts referred to above—that the Anatomical Society had almost as many non-German as German members and that the Commission on Terminology contained English, Belgian and Italian anatomists as well as German, Austrian and Swiss—it would not, it seems to me, have mattered much, or hindered its acceptance by us, if the BNA had been wholly German in origin. If anatomists of worthily world-wide fame like His, Toldt, Waldeyer, Krause, and their colleagues are willing and able to give a large part of their time and energies for six years to such a task, to secure the money to defray the expense thereof, and then to present it freely to the rest of us,—if what they have done is really excellent,—are we to be sulky and reject it simply because it was “made in Germany”? I cannot believe that any one who reflects for a moment can be other than extremely grateful for the very valuable gift these men have made us; such a Chauvinistic attitude as I have described can surely not be assumed by more than a minute minority. On the contrary, it is characteristic of the people of this country that they seek out and adopt as their own the “best” wherever it is to be found, even if it chance to be “made in Thibet” or in Timbuctoo.

(3) The fact that the list of terms is written entirely in the Latin language has been the ground of objection on the part of a few. But this, I feel sure, is due to a misunderstanding of the intention of the Commission. Its members had no idea that, in actual use, the Latin form would always be employed; it is matter of indifference whether one says “biceps muscle” or “musculus biceps,” “femoral nerve” or “nervus femoralis,” “temporal bone” or “os temporale,” “yellow spot” or “macula lutea.” As a matter of fact, a student learning an anatomical term for the first time will usually find that the Latin term goes as trippingly on the tongue, often more so, than its English equivalent. There are marked individual preferences, however, in this regard and I have known some teachers and students who would fly from a Latinized form as though from Satan. Certainly in this country fewer teachers than in Germany use the Latin consistently, though, as the feeling for precision and uniformity grows, it is possible that the custom may increase, in which event all the Latin names would actually become English words, as has already happened with *conjunctiva*, *retina*, *plexus*, *fornix*, *thalamus*, *ganglion*, *ependyma*, *cranium*, *abdomen*, *pelvis*, *perineum*, and of the like many more. The Commission at first had the idea of placing translations for the various languages in parallel columns with the Latin names, but wisely, I think, refrained therefrom, thus leaving everyone free to supply the equivalent in his own tongue as he will. In the German dissecting-rooms, even, the Latin forms are not strictly adhered to; one hears “Rückenmark” rather than “*Medulla spinalis*,” “Kopfnicker” (not “*Brustschlüsselzitzenfortsatzmuskel*”) rather than “*M. sternocleidomastoideus*.” It is in books, and more particularly in atlases, that it is especially desirable that the BNA be used in its Latin form. Where there is, too, any likelihood of international use of book or atlas, or of translation from one tongue into another, it would be helpful if this rule were followed.

(4) It has been objected, further, that since English and American textbooks have been written without regard to the BNA, students and teachers will only add the burden of a lot of additional names to their already overcrowded memories,—that we shall have a “confusion worse confounded” than before. It has been asserted, too, that students passing from anatomical laboratories in which the BNA is employed into the clinics which are manned by professors who learned their anatomy years ago will taken with them a tongue unintelligible to their instructors and will find in use there a form of anatomical language unknown to themselves.

There is a minimum of truth in these objections, but the difficulties to be encountered are far less real than would at first sight appear. For, in the first place, experience has taught that the use of the BNA along with the older text-books is not an impracticable task. The older books contain a majority of the BNA terms and a great many others besides, so that the use of the BNA resolves itself, in these circumstances, largely into an emphasizing of the names of choice and the omission of the unnecessary synonyms; the addition of the few new terms required meets with no difficulty if the instructors be well versed in them. Since Professor Mall called my attention to the BNA in 1895 and recommended it to me I have used it more or less consistently and with satisfaction ever since in my anatomical and clinical teaching in Baltimore and in Chicago. Other American teachers who have done the same tell me that they have found its employment easy and rewarding, and students, often unsolicited, express marked approval of the BNA terms where they differ from those formerly in use. The BNA is now used regularly in several of the American anatomical laboratories and, in large part though not exclusively, in others.

That the student's text-books and atlases should be written in the BNA is, nevertheless, obviously desirable. In 1899, in writing a book on the nervous system, I found it satisfactory to employ it (with minor exceptions), exclusively, for the domains which it covered. Soon after, in the dissecting-room teaching in Chicago, I was impressed with the idea that the student's task could be greatly simplified if a guide to dissection were written in terms of the BNA, each term being brought in at the moment the pupil meets with the structure named in his practical work. To meet this need, I prepared and had published, with the help of Drs. D. D. Lewis and D. G. Revell, in 1904, "A Laboratory Manual of Human Anatomy." Meanwhile, three excellent anatomical atlases,—those of Spalteholz, Sobotta and Toldt,—had appeared in Germany, each with the BNA terms printed at the sides of the figures. In order to make the task of students and teachers still lighter, and again encouraged by Professor Mall, I undertook during the years 1900–1904 the translation into English of the text of Professor Spalteholz's work, and since then its beautiful illustrations and brief, precise, anatomical descriptions have been available to American and English readers. The kind way in which these books have been received by American anatomists and clinicians makes it evident that there exists in this country a warm sympathy with the movement to render anatomical terminology more simple, less cumbersome, and more precise.

In 1902, Dr. Hardesty used the BNA exclusively in his useful "Neurological Technique," and in the small text of Dr. Whitehead (1900) and the monograph of Dr. Sabin (1901), both on the brain, it had also been adopted. Indications, indeed, now point to its general acceptance by American and British writers. Besides Spalteholz's Atlas that of Sobotta and that of Toldt are now available in English translation. The new edition of that popular text-book, Morris's Anatomy, edited by Mr. Henry Morris, of London, and Professor McMurrich, of Ann Arbor, just now being published, is couched in the BNA terms. It would take too long to cite all the books and important articles in which these names figure. A monograph recently published by Dr. Potter, of St. Louis, entitled "Topographical Anatomy of the Viscera of the Thorax and Abdomen," should not, however, be omitted, as it is most valuable as a companion to any one studying, for the first time, a series of cross-sections through the trunk of a human being; the BNA names are used throughout in its plates and descriptions. That biologists find the BNA satisfactory is indicated by its use in Professor J. B. Johnston's book, "The Anatomy of the Nervous System of

Vertebrates." And, now that the newest edition of Gould's Medical Dictionary is also to consider the BNA, there would seem to be no longer reason for delay in general recognition and employment.

The assumption that students who have been taught the BNA and their clinical teachers will be reciprocally embarrassed in one another's presence—that a sort of anatomical Babel will prevail—gives scarcely due credit to either student or clinician. For, on the one hand, the student is sure during this transition period to become acquainted quickly with the old synonyms of the few new anatomical terms foreign to the ordinary clinical vocabulary; he can scarcely escape, for instance, learning that clinicians almost invariably speak of the "atria" of the heart as its "auricles," or of the "omental bursa" as the "lesser peritoneum." And, on the other hand, we may be certain that the modern scientific clinician, worthy of a clinical chair in a medical school, will not be unfamiliar with those more recent studies in the anatomy of his field which are of sufficient permanent importance to have been reflected in the BNA. The internist who has not brought his anatomy of the lungs, the heart, the liver, the spleen, the kidneys and the peritoneum at least up to the level of precision indicated by the BNA list, handicaps himself in his work. So with the surgeon with regard to the bones, the articulations, the blood-vessels and nerves, the neck, the abdomen and the pelvis. There need be little fear, we may feel tolerably sure, of delinquency here. Should the nobler motives prove ineffective—they will not—the fierceness of competition among clinicians, the rivalry for prestige among the occupants of clinical chairs, would from now on, if it has not always so done in the past, compel the teachers of the practical branches to keep pace with progress in the fundamentals. We have seen above, as a matter of fact, how clinicians in the medical specialties have not only kept pace with the anatomists but, in part, have outstripped them in the race. Investigating the anatomy of their own special domains anew and independently, their inquiries have expanded knowledge and necessitated an enrichment of anatomical vocabulary. This process has begun in America. That it will go on and become an engine of great power in furthering the development of our knowledge of the human form in regions yet obscure, who can doubt?

The Future of Anatomical Terminology.

No matter how many revisions of terminology are made, and entirely independently of those who make them, we can be sure that, in the long run, only those names will survive which are wisely selected, which are precise in expression, and which are organically connected with whatever great general plan our anatomical nomenclature ultimately assumes. Anatomical terms, to live, must satisfy the needs of, and be adopted by, a majority of anatomists and clinicians. It would be folly to attempt to force the use of the BNA or any other list of anatomical terms upon any man or group of men. A terminology must rely upon its intrinsic merits, not upon the influence of authority. The better it satisfies the needs of teaching and investigation, the greater its chances of general acceptance and permanence. Those of us who are convinced of the value of the BNA should set an example by using it and may recommend its use to others. More than this we ought not to do.

The fact should be emphasized that the BNA makes no attempt to limit the language of research, but only to supply a list of simple terms, free from ambiguity, for common use in the medical schools. Research must, of course, retain absolute freedom of expression. Investigators, to make themselves understood, are compelled to use temporarily many expressions consciously

wholly provisional in character. Only when time has brought a certain repose to scientific activity in a given region do more permanent terms crystallize out.

It should be easy in a country like America, for anatomists to agree with their colleagues in the rest of the world upon the adoption of a common set of terms for school use. It is fair to assume that the tendency to coöperation, so characteristic of the energies of this country, notably manifest in industrial combinations no less than in the team-work of athletes, will not be found lacking among anatomists.

Even when compromises have to be made, there is a certain special honor and satisfaction to be derived from the sacrifices involved when they contribute to the common weal. That some concessions must necessarily be made in using the BNA cannot be denied; almost every coöperative measure demands some self-denial among participants. This need not, however, be great. Where the list does not supply in full the requirements of the individual teacher, there is no reason why he should not extend it at will. On the other hand, where the list contains terms in excess of the needs of a given instructor or school, it is an easy matter to omit those which seem superfluous. It may seem a little hard for one who has spoken of the "M. complexus" all his life to get used to calling it the "M. semispinalis capitis," or for another who has been brought up with an "anterior crural" to abandon it for the "femoral" nerve. But when the good reasons for the change are known and appreciated, good-will will carry one far. It is only when a term is found to be incompatible with one's scientific convictions that reasonable difficulty arises. The BNA has, however, been constructed with such great care and has so sedulously avoided affixing labels to structures still in dispute that we need have little fear on that score. Even should there be a few terms, or even a few hundred, which we find hard at this time to digest, the general acceptance of the other 4000 will be a great gain, cutting the labors of students, as it will, in two.

That conditions will arise, perhaps soon, when another revision will be desirable and demanded there can be no doubt. Investigation is ever extending; our criteria of values are constantly changing; scientific needs in terminology vary, in spite of us, with the years; at intervals revision becomes unavoidable. But with foundations so well laid as in the BNA, a subsequent review should be facilitated. The development of the BNA has taught us the necessity of observing certain rules in the coining of new anatomical terms. If these rules be good ones, the work of extension will be easy. It would not be difficult, for instance, to merge the names of this list into a nomenclature which considers, more satisfactorily than the BNA does, the needs to which a fusion of Human Anatomy with Comparative Anatomy gives rise. And I, for one, hope that such a "merger" may be promoted in our time. I trust too that, at another revision, the terms in Professor Wilder's lists which differ from those of the BNA may be carefully considered, and that his terms, where they are better than those of the present BNA, may be adopted.

Of one thing I am convinced,—coöperation is, from now on, essential for the welfare of a satisfactory anatomical language. Simplicity, accuracy, and serial connection will be favored if anatomists agree to use terms, in common, for the structures studied in the schools. The teacher's work will be simplified and the pupil's task will be lightened; instruction will be unhampered, research will flourish and anatomical science will gain in dignity and in precision.



Nomina anatomica¹

Termini, situm et directionem partium corporis indicantes

Termini generales

Verticalis	Anterior	Longitudinalis
Horizontalis	Medius	Transversus
Medianus	Posterior	Cranialis
Sagittalis	Ventralis	<i>Rostralis</i>
Frontalis	Dorsalis	Caudalis
Transversalis	Internus	Superior
Medialis	Externus	Inferior
Intermedius	Dexter	Superficialis [sublimis]
Lateralis	Sinister	Profundus

Termini ad extremitates spectantes

Proximalis	Ulnaris
Distalis	Tibialis
Radialis	Fibularis

¹ In the lists the following explanations are necessary:

1. Oval brackets () indicate variations (*Varietates anatomicæ*).
2. Angular brackets [] contain explanatory additions, among which are included double names and personal names.
3. Italics are used for ontogenetic expressions (e.g., *M. decidua*, *A. umbilicalis*, etc.)

Anatomical names¹

Terms indicating the position and direction of parts of the body

General terms

Vertical	Anterior	Longitudinal
Horizontal	Middle	Transverse
Median	Posterior	Cranial
Sagittal	Ventral	<i>Rostral</i>
Frontal	Dorsal	Caudal
Transversal	Inner	Superior
Medial	Outer	Inferior
Intermediate	Right	Superficial
Lateral	Left	Deep

Terms relating to the extremities

Proximal	Ulnar
Distal	Tibial
Radial	Fibular

¹ The letters O. T. following a name indicate that it belongs to the older terminology.

Termini generales

Accessorius	Corona	Glandula
Acinus	Corpus	Glomerulus
Aditus	Corpusculum	Glomus
Ala	Crista	Hilus
	Crus	Humor
Alveolus	Decussatio	Junctura
Ampulla	Dorsum	Impressio
Angulus	Ductulus	Incisura
Ansa	Ductus	Infundibulum
Antrum	Eminentia	Intestinum
Apertura	Endothelium	Isthmus
Apex	Epithelium	Labium
Appendix	Extremitas	Lacuna
Arcus	Facies	Lamina
Area	Fascia	Latus
Basis	Fasciculus	Ligamentum
Brachium	Fibra	Limbus
Canaliculus	Fibrocartilago	Limen
Canalis	Filum	Linea
Capsula	Fissura	Liquor
Caput	Flexura	Lobulus
Capitulum	Folium	Lobus
Cartilago	Folliculus	Macula
Caruncula	Foramen	Margo
Cauda	Formatio	Massa
Caverna	Fornix	Meatus
Cavum	Fossa	Medulla
Cellula	Fossula	Membrana
Circulus	Fovea	Membrum
Cisterna	Foveola	Mucus
Collum	Frenulum	Musculus
Columna	Fundus	Nervus
Commissura	Funiculus	Nodulus
	Geniculum	Nucleus
Cornu	Genu	Organon

General Anatomical Terms

Accessory	Wreath, garland, or crown	Gland
Berry	Body	Little skein
Entrance	Little body or corpuscle	Skein
Wing (contraction of axilla)	Crest	Hilus
Little hollow	Leg or limb	Liquid or fluid
Flask	Decussation or crossing	Joint
Angle	Back	Impression
Handle or loop	Little duct	Incision or notch
Cave	Duct	Funnel
Opening	Eminence or protuberance	Intestine or inward
Tip	Endothelium	Isthmus
Appendage	Epithelium	Lip
Arch	Extremity	Gap, defect
Space	Face or surface	Plate or layer
Base	Bandage or band	Broad; flank
Arm	A little bundle or packet	Ligament
Small channel	Fibre or filament	Border or fringe
Canal	Fibrocartilage	Threshold, boundary
Capsule	Thread	Line
Head	Fissure or cleft	Fluid or liquid
Little head	Bending	A little lobe
Cartilage	Leaf	Lobe
Small piece of flesh	Little sac or bag	Spot
Tail	Hole, aperture, or opening	Margin
Cavern	Formation	Mass
Hole or cavity	Arch or vault	Way or passage
Little chamber or cell	Ditch or trench	Marrow
Circle	Little fossa	Membrane
Cistern	Pit	Limb or member
Neck	Little pit	Mucus
Column or pillar	Cord or rein	Muscle
Connection or commissure	Bottom	Nerve
Horn	Thin rope, cord, or string	Nodule
	Little knee or knot	Nucleus or kernel
	Knee	Organ

Orificium	Septum	Tunica
Os [oris]	Sinus	Tunica propria
Os [ossis]	Spatium	Umbo
Ostium	Spina	Uvula
Papilla	Stratum	
Parenchyma	Stria	Vagina
Paries	Stroma	Vallecula
Perichondrium	Substantia	Vallum
Periosteum	Succus	Valvula
Plexus	Sulcus	Vas
Plica	Taenia	Velum
Polus	Tegmen	
Processus	Tela	Vertex
Prominentia	Tela conjunctiva	Vesica
Punctum	Tela elastica	Vesicula
Radix	Torus	
Ramulus		Vestibulum
Ramus	Trabecula	
Raphe	Tractus	Villus
Recessus	Trigonum	Viscus [viscera]
Regio	Trochlea	
Rete	Truncus	Vortex
Rima	Tuber	Zona
Rudimentum	Tuberculum	
Septulum	Tubulus	

Orifice	Partition	Coat or covering
Mouth	Sinus	Proper coat
Bone	Space	Boss or prominence
Entrance	Spine or thorn	Little cluster or
Papilla or nipple	Layer or covering	bunch
Parenchyma	Furrow, stripe, or ridge	Sheath
Wall	Stroma, or bed	Crevice
Perichondrium	Substance	Wall or fortification
Periosteum	Juice	Valve
Plexus	Sulcus or furrow	Vessel
Fold	Ribbon; tape-worm	Sail, covering or cur-
Pole	A cover	tain
Process	Web	Crown of head
Prominence or projection	Connecting web	Bladder
Point or small puncture	Elastic web	Vesicle or little blad-
Root	Round swelling or protuber-	der
Little branch or twig	ance	Vestibule or ante-
Branch	Little beam	chamber
Raphe or seam	Tract	Shaggy hair
Recess	Trigone or triangle	Organ, internal
Region or territory	Pulley	organ
Net or network	Trunk	Whirlpool
Slit or fissure	Swelling or hump	Girdle or zone
Rudiment	Tubercle	
Little septum	Tubule or little tube	

Partes corporis humani

Caput
Collum

Truncus
Extremitates

Caput Cranium

Vertex
Sinciput
 Frons
Occiput

Tempora
Auris
Auricula

Facies

Oculus

Palpebra superior
Palpebra inferior
Rima palpebrarum
Bulbus oculi
Supercilium
Sulcus infrapalpebralis

Nasus

Dorsum nasi
Apex nasi
Ala nasi

Os

Sulcus nasolabialis
Philtrum
Labium superius
Labium inferius
Rima oris
Cavum oris
 Lingua
 Fauces
Bucca [Mala]
Sulcus mentolabialis
Mentum

Collum

Cervix
Larynx
 Prominentia laryngea

Pharynx
Trachea
Oesophagus

Truncus

Thorax

Cavum thoracis
Pectus
Mamma
 Papilla mammae

Dorsum

Columna vertebralis
Canalis spinalis

Parts of the human body

Head

Neck

Trunk

Extremities

Head

Skull

Crown of the head

Sinciput; bregma

Forehead

Occiput

Temples

Ear

External ear, or pinna

Face

Eye

Upper eyelid

Lower eyelid

Lid-slit

Eyeball

Eyebrow

Infrapalpebral furrow

Nose

Back of the nose

Tip of the nose

Wing of the nose

Mouth

Nasolabial furrow

Infranasal depression

Upper lip

Lower lip

Mouth slit

Mouth cavity

Tongue

Throat

Cheek

Mentolabial furrow

Chin

Neck

Neck (posterior part)

Larynx

Laryngeal prominence (O.

T. Adam's apple)

Pharynx

Trachea

Oesophagus

Trunk

Thorax

Thoracic cavity

Breast

Mammary gland

Mammary nipple

Back

Vertebral column

Spinal canal

Abdomen

Cavum abdominis	Latus
Scrobiculus cordis	Lumbus
Umbilicus	Inguen

Pelvis

Cavum pelvis	Anus
Mons pubis	Crena ani
Coxa	Perineum
Nates [Clunes]	

Extremitas superior

Axilla	Manus
Plica axillaris anterior	Carpus
Plica axillaris posterior	Metacarpus
Acromion	Dorsum manus
Brachium	Vola manus [Palma]
Facies anterior	Thenar
Facies posterior	Hypothenar
Facies lateralis	Digiti manus
Facies medialis	Pollex [Digitus I]
Sulcus bicipitalis lateralis	Index [" II]
Sulcus bicipitalis medialis	Digitus medius [Digitus III]
Cubitus	Digitus annularis [" IV]
Antibrachium	Digitus minimus [" V]
Facies dorsalis	Facies dorsales
Facies volaris	Facies volares
Margo radialis	Margines radiales
Margo ulnaris	Margines ulnares

Extremitas inferior

Femur	Crus
Facies anterior	Facies anterior
Facies posterior	Facies posterior
Facies lateralis	Sura
Facies medialis	Malleolus lateralis
Sulcus gluteus	Malleolus medialis
Genu	Pes
Poples	Tarsus
Patella	Metatarsus

Belly

Abdominal cavity	Flank
“Heart fossa”; pit of stomach	Loin
Navel	Groin

Pelvis

Pelvic cavity	Anus
Pubic eminence	Anal cleft
Hip	Perineum
Buttock	

Upper extremity

Axilla; prominence of shoulder	Hand
Anterior axillary fold	Wrist
Posterior axillary fold	Metacarpus
Acromion; tip of shoulder	Back of the hand
Arm	Palm of the hand
Anterior surface	Thenar or radial palm
Posterior surface	Hypothenar or ulnar palm
Lateral surface	Fingers
Medial surface	Thumb
Lateral bicipital groove	Index finger
Medial bicipital groove	Middle finger
Elbow	Ring finger
Forearm	Little finger
Dorsal surface	Dorsal surfaces
Volar surface	Volar surfaces
Radial margin	Radial margins
Ulnar margin	Ulnar margins

Lower extremities

Thigh	Leg
Anterior surface	Anterior surface
Posterior surface	Posterior surface
Lateral surface	Calf
Medial surface	Lateral malleolus
Gluteal furrow	Medial malleolus
Knee	Foot
Posterior surface of knee	Root of foot
Knee-cap	Metatarsus

Dorsum pedis
 Planta
 Margo pedis lateralis
 Margo pedis medialis
 Calx
 Digiti pedis
 Hallux [Digitus I]

Digiti II–IV
 Digitus minimus [Digitus V]
 Facies dorsales
 Facies plantares
 Margines laterales
 Margines mediales

Osteologia

Os longum	<i>Synchondrosis epiphyseos</i>	Cavum medullare
Os breve	Apophysis	Medulla ossium
Os planum	Facies articularis	Medulla ossium flava
Os pneumaticum	Substantia compacta	Medulla ossium rubra
Epiphysis	Substantia corticalis	Foramen nutricium
Diaphysis	Substantia spongiosa	Canalis nutricius

Columna vertebralis

Vertebrae cervicales	Tuberculum anterius [vertebrarum cervicalium]
Vertebrae thoracales	Tuberculum caroticum [vertebrae cervicalis VI]
Vertebrae lumbales	Foramen transversarium
Vertebrae sacrales	Tuberculum posterius [vertebrarum cervicalium]
Vertebrae coccygeae	Processus articulares superiores
Corpus vertebrae	Facies articulares superiores
Fovea costalis superior	Processus articulares inferiores
Fovea costalis inferior	Facies articulares inferiores
Canalis vertebralis	Processus costarius
Foramen vertebrale	Processus accessorius [vertebrarum lumbalium]
Arcus vertebrae	Processus mammillaris
Radix arcus vertebrae	
Incisura vertebralis superior	
Incisura vertebralis inferior	
Foramen intervertebrale	
Sulcus n. spinalis	
Processus spinosus	
Vertebra prominens	
Processus transversus	
Fovea costalis transversalis	

Atlas

Massa lateralis
 Arcus anterior
 Tuberculum anterius
 Foveae articulares superiores
 Facies articulares inferiores
 Fovea dentis

Back of the foot	II-IV toes
Sole	Little toe
Lateral margin of the foot	Dorsal surfaces
Medial margin of the foot	Plantar surfaces
Heel	Lateral margins
Toes	Medial margins
Great toe	

Osteology

Long bone	<i>Epiphyseal synchondrosis</i>	Medullary cavity
Short bone	Apophysis ("excrescence")	Bone marrow
Flat bone	Articular surface	Yellow bone marrow
Hollow bone	Compact substance	Red bone marrow
Epiphysis ("accretion")	Cortical substance	Nutrient foramen
Shaft	Spongy substance	Nutrient canal

Vertebral column or spine

Cervical vertebrae	Anterior tubercle [of cervical vertebrae]
Thoracic vertebrae	
Lumbar vertebrae	Carotid tubercle [of sixth cervical vertebra]
Sacral vertebrae	
Coccygeal vertebrae	Foramen of transverse process
Body of vertebrae	Posterior tubercle [of cervical vertebrae]
Superior costal pit (O. T. demifacet for head of rib)	Superior articular processes
Inferior costal pit (O. T. demifacet for head of rib)	Superior articular surfaces
Vertebral canal	Inferior articular processes
Vertebral foramen	Inferior articular surfaces
Vertebral arch	Costal process
Root of vertebral arch (O. T. pedicle)	Accessory process of lumbar vertebrae
Superior vertebral notch	
Inferior vertebral notch	Mammillary process
Intervertebral foramen	
Groove for spinal nerve	
Spinous process	
Prominent vertebra (seventh cervical)	
Transverse process	
Costal pit of transverse process (O. T. facet for tubercle of rib)	

Atlas

Lateral mass
Anterior arch
Anterior tubercle
Superior articular pits
Inferior articular surfaces
Pit of the tooth

Arcus posterior
 Sulcus arteriae vertebralis
 Tuberculum posterius

Epistropheus

Dens
 Facies articularis anterior
 Facies articularis posterior

Os sacrum

Facies dorsalis
 Facies pelvina
 Basis oss. sacri
 Processus articularis superior
 Promontorium

Pars lateralis
 Facies auricularis
 Tuberositas sacralis
 Foramina intervertebralia
 Foramina sacralia anteriora
 Lineae transversae
 Foramina sacralia posteriora
 Crista sacralis media
 Cristae sacrales laterales
 Cristae sacrales articulares
 Cornua sacralia
 Canalis sacralis
 Hiatus sacralis
 Apex oss. sacri

Os coccygis

Cornua coccygea

Thorax

Costae

Costae verae
 Costae spuriae
 Os costale
 Cartilago costalis
 Capitulum costae
 Facies articularis capituli costae
 Crista capituli

Corpus costae
 Tuberculum costae
 Facies articularis tuberculi costae

Collum costae
 Crista colli costae
 Angulus costae
 Tuberculum scaleni [Lisfranci]
 Sulcus subclaviae
 Tuberositas costae II
 Sulcus costae

Sternum

Manubrium sterni
 Angulus sterni
 Synchronosis sternalis
 Corpus sterni
 Planum sternale
 Processus xiphoideus

Incisura clavicularis
 Incisura jugularis

Incisurae costales
 (Ossa suprasternalia)

T h o r a x

Cavum thoracis
 Apertura thoracis superior
 Apertura thoracis inferior
 Arcus costarum
 Spatia intercostalia
 Angulus infrasternalis
 Sulcus pulmonalis

Ossa cranii

Os basilare

Os occipitale

Foramen occipitale magnum
 Pars basilaris
 Sulcus petrosus inferior
 Pars lateralis

Posterior arch
Groove for vertebral artery
Posterior tubercle

Epistropheus ("a turning") (O. T. axis)

Tooth
Anterior articular surface
Posterior articular surface

Sacrum

Dorsal surface
Pelvic surface
Base of sacrum
Superior articular process
Promontory (O. T. sacrovertebral angle)
Lateral part
Auricular surface
Sacral tuberosity
Intervertebral foramina
Anterior sacral foramina
Transverse lines
Posterior sacral foramina
Middle sacral crest
Lateral sacral crests
Articular sacral crests
Sacral horns
Sacral canal
Sacral hiatus
Apex of sacrum

Coccyx

Coccygeal horns

Thorax

Ribs

True ribs
False ribs
Rib bone
Rib cartilage
Head of the rib
Articular surface of the head of the rib
Crest of the head

Body of the rib
Tubercle of the rib
Articular surface of the tubercle of the rib
Neck of the rib
Crest of neck of rib
Angle of rib
Scalene tubercle of Lisfranc
Subclavian groove
Tuberosity of the second rib
Costal groove

Breast Bone

Handle of sternum
Angle of sternum
Sternal synchondrosis
Body of sternum (O. T. gladiolus)
Sternal plain, or anterior surface
Xiphoid process (O. T. ensiform process)
Clavicular notch
Jugular notch (O. T. presternal notch)
Notches for the ribs
Suprasternal bones

T h o r a x

Thoracic cavity
Upper thoracic opening
Lower thoracic opening
Arch of the ribs
Intercostal spaces
Infrasternal angle
Pulmonary sulcus

Bones of the skull

Basilar bone

Occipital bone

Large occipital foramen
Basilar part
Inferior petrosal groove
Lateral part

Squama occipitalis
 Margo mastoideus
 Margo lambdoideus
 (Os interparietale)
 Clivus
 Tuberculum pharyngeum
 Condylus occipitalis
 Canalis condyloideus

Canalis hypoglossi

Tuberculum jugulare
 Incisura jugularis
 Processus jugularis
 Fossa condyloidea
 Processus intrajugularis
 Planum occipitale
 Planum nuchale
 Protuberantia occipitalis externa
 (Torus occipitalis)
 Crista occipitalis externa
 Linea nuchae suprema
 Linea nuchae superior
 Linea nuchae inferior
 Eminentia cruciata
 Protuberantia occipitalis interna
 Sulcus sagittalis

Sulcus transversus
 (Processus paramastoideus)

Os sphenoidale

Corpus
 Sella turcica
 Fossa hypophysaeos
 Dorsum sellae
 Tuberculum sellae
 Processus clinoides medius
 Processus clinoides posterior
 Sulcus caroticus

Lingula sphenoidalis

Crista sphenoidalis
 Rostrum sphenoidale
 Sinus sphenoidalis
 Septum sinuum sphenoidalium
 Apertura sinus sphenoidalis
 Conchae sphenoidales

Clivus

Ala parva
 Sulcus chiasmatis

Foramen opticum
 Processus clinoides anterior
 Fissura orbitalis superior

Ala magna
 Facies cerebralis
 Facies temporalis
 Facies sphenomaxillaris
 Facies orbitalis
 Margo zygomaticus
 Margo frontalis
 Angulus parietalis
 Margo squamosus
 Crista infratemporalis

Foramen rotundum
 Foramen ovale
 Foramen spinosum
 Spina angularis

Processus pterygoideus
 Lamina lateralis processus pterygoidei
 Lamina medialis processus pterygoidei
 Fissura pterygoidea
 Fossa scaphoidea
 Processus vaginalis
 Hamulus pterygoideus

Sulcus hamuli pterygoidei
 Fossa pterygoidea
 Canalis pterygoideus [Vidii]

Occipital squama ("scale")	Sphenoidal crest (O. T. ethmoidal crest)
Mastoid margin	Sphenoidal rostrum
Lambdoid margin	Sphenoidal sinus
Interparietal bone	Septum of sphenoidal sinuses
Clivus ("slope")	Opening of sphenoidal sinus
Pharyngeal tubercle	Sphenoidal conchae ("shell") (O. T. sphenoidal turbinated bones)
Occipital condyle	Clivus ("slope")
Condylloid canal (O. T. posterior condylloid foramen)	Small wing
Hypoglossal canal (O. T. anterior condylloid foramen)	Sulcus of the chiasma (O. T. optic groove)
Jugular tubercle	Optic foramen
Jugular notch	Anterior clinoid process
Jugular process	Superior orbital fissure
Condylloid fossa	
Intrajugular process	Large wing
Occipital plain	Cerebral surface
Nuchal plain	Temporal surface
External occipital protuberance	Sphenomaxillary surface
Occipital torus ("swelling")	Orbital surface
External occipital crest	Zygomatic margin
Supreme nuchal line	Frontal margin
Superior nuchal line	Parietal angle
Inferior nuchal line	Squamosal margin
Cruciate eminence	Infratemporal crest (O. T. pterygoid ridge)
Internal occipital protuberance	Round foramen
Sagittal sulcus (O. T. superior longitudinal sulcus)	Oval foramen
Transverse sulcus	Spinous foramen
Paramastoid process	Angular spine (O. T. spinous process)
Sphenoid bone	
Body	Pterygoid process
Turkish saddle	Lateral layer of pterygoid process
Hypophyseal fossa (O. T. pituitary fossa)	Medial layer of pterygoid process
Back of sella	Pterygoid fissure
Tubercle of sella or pommel	Scaphoid fossa
Middle clinoid process	Vaginal process
Posterior clinoid process	Pterygoid hamulus ("hook") (O. T. hamular process)
Carotid sulcus (O. T. cavernous groove)	Sulcus of pterygoid hamulus
Sphenoidal tongue	Pterygoid fossa
	Pterygoid canal (O. T. Vidian canal)

Canalis pharyngeus	Apertura externa aquaeductus vestibuli
Canalis basipharyngeus	Sulcus petrosus inferior
Sulcus tubae auditivae	Incisura jugularis
Sulcus pterygopalatinus	Processus intrajugularis
(Processus pterygospinosus [Civinini])	Fossa jugularis
	Canaliculus mastoideus
Os temporale	Sulcus canaliculi mastoidei
Pars mastoidea	Processus styloideus
Margo occipitalis	Vagina processus styloidei
Processus mastoideus	
Incisura mastoidea	Foramen stylomastoideum
Sulcus sigmoideus	Fossula petrosa
	Canaliculus tympanicus
Sulcus a. occipitalis	Sulcus tympanicus
Foramen mastoideum	Apertura inferior canaliculi tympanici
Pars petrosa [Pyramis]	Apertura superior canaliculi tympanici
Facies anterior pyramidis	
Facies posterior pyramidis	Canaliculus cochleae
Facies inferior pyramidis	Apertura externa canaliculi cochleae
Apex pyramidis	
Angulus superior pyramidis	Canalis caroticus
Angulus anterior pyramidis	Canaliculi caroticotympanici
Angulus posterior pyramidis	Canalis musculotubarius
Sulcus petrosus superior	Semicanalis m. tensoris tympani
Tegmen tympani	
Eminentia arcuata	
Canalis facialis [Fallopian]	Semicanalis tubae auditivae
Hiatus canalis facialis	
Geniculum canalis facialis	Septum canalis musculotubarii
Sulcus n. petrosi superficialis majoris	Cavum tympani (v. Organon auditus)
Sulcus n. petrosi superficialis minoris	Canaliculus chordae tympani
	Fissura petrotympanica [Glaseri]
Impressio trigemini	Fissura petrosquamosa
Porus acusticus internus	Pars tympanica
Meatus acusticus internus	Annulus tympanicus
Fossa subarcuata	Meatus acusticus externus
Aquaeductus vestibuli	(Spina supra meatum)
	Fissura tympanomastoidea

Pharyngeal canal (O. T. pterygo-palatine canal)	External opening of aqueduct of vestibule
Basipharyngeal canal	Inferior petrosal groove
Sulcus of auditory tube	Jugular notch
Pterygopalatine sulcus	Intrajugular process
Pterygospinous process	Jugular fossa
	Mastoid canaliculus
	Sulcus of mastoid canaliculus
	Styloid process
	Sheath of styloid process (O. T. vaginal process)
	Stylomastoid foramen
	Petrosal fossula
	Tympanic canaliculus
	Tympanic sulcus
	Inferior opening of tympanic canaliculus
	Superior opening of tympanic canaliculus (O. T. opening for smaller petrosal nerve)
	Canaliculus of the cochlea
	External opening of the canaliculus of the cochlea
	Carotid canal
	Caroticotympanic canaliculus
	Musculotubal canal
	Semicanal of the tensor muscle of tympanum (O. T. canal for tensor tympani muscle)
	Semicanal of auditory tube (O. T. canal for the Eustachian tube)
	Septum of the musculotubal canal
	Cavity of the tympanum (see <i>Organ of Hearing</i>)
	Canaliculus of cord of tympanum
	Petrotympanic fissure (O. T. Glaserian fissure)
	Petrosquamosal fissure
	Tympanic part
	<i>Tympanic ring</i>
	External acoustic meatus
	Spine above meatus
	Tympanomastoid fissure
Temporal bone	
Mastoid part	
Occipital margin	
Mastoid process	
Mastoid notch (O. T. digastric fossa)	
Sigmoid sulcus (O. T. fossa sigmoidea)	
Groove for the occipital artery	
Mastoid foramen	
Petrous part (pyramid)	
Anterior surface of pyramid	
Posterior surface of pyramid	
Inferior surface of pyramid	
Apex of pyramid	
Superior angle of pyramid	
Anterior angle of pyramid	
Posterior angle of pyramid	
Superior petrosal groove	
Roof of tympanum	
Arcuate eminence (O. T. eminence for superior semicircular canal)	
Facial canal (O. T. aqueduct of Fallopius)	
Hiatus of facial canal (O. T. hiatus Fallopii)	
Little knee of facial canal	
Groove for the greater superficial petrosal nerve	
Groove for the lesser superficial petrosal nerve	
Trigeminal impression (O. T. depression for Gasserian ganglion)	
Internal acoustic pore	
Internal acoustic meatus	
Subarcuate fossa	
Aqueduct of vestibule	

Spina tympanica major
 Spina tympanica minor
 Porus acusticus externus
 Squama temporalis
 Margo parietalis
 Incisura parietalis
 Margo sphenoidalis
 Facies temporalis
 Processus zygomaticus
 Fossa mandibularis

Facies articularis
 Tuberculum articulare
 Facies cerebralis
 Sulcus a. temporalis mediae

Os parietale

Facies cerebralis
 Facies parietalis
 Margo occipitalis
 Margo squamosus
 Margo frontalis
 Margo sagittalis
 Angulus frontalis
 Angulus occipitalis
 Angulus sphenoidalis
 Angulus mastoideus
 Foramen parietale
 Tuber parietale

Linea temporalis inferior

Linea temporalis superior
 Sulcus sagittalis
 Sulcus transversus

Os frontale

Squama frontalis
 Facies frontalis
 Margo supraorbitalis
 Pars orbitalis
 Incisura ethmoidalis

Pars nasalis
 Spina frontalis
 Margo nasalis
 Margo parietalis
 Processus zygomaticus
 Facies temporalis
 Linea temporalis
 Tuber frontale

Arcus superciliaris

Glabella
 Foramen sive Incisura supraorbitalis
 Incisura sive Foramen frontale
 Facies orbitalis
 (Spina trochlearis)
 Fovea trochlearis
 Foramen ethmoidale anterius
 Foramen ethmoidale posterius
 Fossa glandulae lacrimalis
 Facies cerebralis

Crista frontalis
 Sulcus sagittalis
 Foramen caecum
 Sinus frontalis
 Septum sinuum frontaliū

Os ethmoidale

Lamina cribrosa
 Crista galli
 Processus alaris
 Lamina perpendicularis
 Labyrinthus ethmoidalis

Cellulae ethmoidales
 Infundibulum ethmoidale
 Hiatus semilunaris
 Bulla ethmoidalis
 Lamina papyracea

Foramina ethmoidalia
 (Concha nasalis suprema)

Larger tympanic spine
 Smaller tympanic spine
 External acoustic pore
 Temporal squama ("scale")
 Parietal margin
 Parietal notch
 Sphenoidal margin
 Temporal surface
 Zygomatic process
 Mandibular fossa (O. T. glenoid cavity)
 Articular surface
 Articular tubercle
 Cerebral surface
 Groove for middle temporal artery

Parietal bone

Cerebral surface
 Parietal surface
 Occipital margin
 Squamosal margin
 Frontal margin
 Sagittal margin
 Frontal angle
 Occipital angle
 Sphenoidal angle
 Mastoid angle
 Parietal foramen
 Parietal tuber (O. T. parietal eminence)
 Inferior temporal line (O. T. temporal ridge)
 Superior temporal line
 Sagittal sulcus
 Transverse sulcus (O. T. groove for lateral sinus)

Frontal bone

Frontal squama ("scale")
 Frontal surface
 Supraorbital margin
 Orbital part
 Ethmoidal notch

Nasal part
 Frontal spine (O. T. nasal spine)
 Nasal margin
 Parietal margin
 Zygomatic process
 Temporal surface
 Temporal line
 Frontal tuber (O. T. frontal eminence)
 Superciliary arch (O. T. superciliary ridge)
 Glabella ("smooth")
 Supraorbital foramen or notch
 Frontal notch or foramen
 Orbital surface
 Trochlear spine
 Trochlear pit
 Anterior ethmoidal foramen
 Posterior ethmoidal foramen
 Fossa of lacrimal gland
 Cerebral surface (O. T. internal surface)
 Frontal crest
 Sagittal sulcus
 Blind foramen
 Frontal sinus
 Septum of frontal sinuses

Ethmoid bone

Cribriform plate
 Cock's comb
 Alar process
 Perpendicular plate
 Ethmoidal labyrinth (O. T. lateral mass of ethmoid)
 Ethmoidal cells
 Ethmoidal funnel
 Semilunar hiatus
 Ethmoidal bulla ("bubble")
 Papyrus or paper plate (O. T. os planum)
 Ethmoidal foramina
 Supreme turbinated bone

Concha nasalis superior
 Concha nasalis media
 Processus uncinatus

Concha nasalis inferior

Processus lacrimalis
 Processus maxillaris
 Processus ethmoidalis

Os lacrimale

Crista lacrimalis posterior

Sulcus lacrimalis
 Hamulus lacrimalis

Fossa sacci lacrimalis

Os nasale

Foramina nasalia
 Sulcus ethmoidalis

Vomer

Ala vomeris

Ossa faciei

Maxilla

Corpus maxillae
 Facies anterior

 Facies nasalis
 Facies orbitalis
 Facies infratemporalis

Sinus maxillaris

Margo infraorbitalis
 Canalis infraorbitalis
 Sulcus infraorbitalis
 Foramen infraorbitale
 Sutura infraorbitalis
 Fossa canina

(Fossa praenasalis)
 Incisura nasalis
 Tuber maxillare
 Foramina alveolaria
 Canales alveolares

Planum orbitale
 Margo lacrimalis
 Sulcus lacrimalis
 Canalis nasolacrimalis

Crista conchalis
 Processus frontalis
 Crista lacrimalis anterior
 Incisura lacrimalis
 Crista ethmoidalis
 Processus zygomaticus

Processus palatinus
 Crista nasalis
 Spina nasalis anterior
Os incisivum
 Canalis incisivus
 Sutura incisiva
 Spinae palatinae
 Sulci palatini
 Processus alveolaris
 Limbus alveolaris
 Alveoli dentales
 Septa interalveolaria
 Juga alveolaria
 Hiatus maxillaris
 Foramen incisivum

Os palatinum

Pars perpendicularis

Facies nasalis
 Facies maxillaris
 Incisura sphenopalatina
 Sulcus pterygopalatinus
 Processus pyramidalis
 Foramen palatinum majus

Superior turbinated bone
 Middle turbinated bone
 Uncinate process (O. T. unciform process)

Inferior turbinated bone

Lacrimal process
 Maxillary process
 Ethmoidal process

Lacrimal bone

Posterior lacrimal crest (O. T. lacrimal crest)
 Lacrimal sulcus
 Lacrimal hamulus ("hooklet") (O. T. hamular process)
 Fossa of lacrimal sac

Nasal bone

Nasal foramina
 Ethmoidal sulcus (O. T. groove for nasal nerve)

Vomer, or ploughshare bone

Wing of vomer

Bones of the face

Maxilla, or upper jawbone (O. T. superior maxillary bone)

Body of maxilla
 Anterior surface (O. T. external or facial surface)
 Nasal surface
 Orbital surface
 Infratemporal surface (O. T. zygomatic surface)
 Maxillary sinus (O. T. antrum of Highmore)
 Infraorbital margin
 Infraorbital canal
 Infraorbital groove
 Infraorbital foramen
 Infraorbital suture
 Canine fossa

Prenasal fossa
 Nasal notch
 Maxillary tuber
 Alveolar foramina
 Alveolar canals (O. T. posterior dental canals)
 Orbital plain
 Lacrimal margin
 Lacrimal sulcus
 Nasolacrimal canal (O. T. lacrimal groove)
 Turbinated crest
 Frontal process (O. T. nasal process)
 Anterior lacrimal crest
 Lacrimal notch
 Ethmoidal crest
 Zygomatic process (O. T. malar process)

Palatine process
 Nasal crest
 Anterior nasal spine
Incisive bone
 Incisive canal
 Incisive suture
 Palatine spines
 Palatine grooves
 Alveolar process
 Alveolar margin
 Tooth cavities
 Interalveolar septa
 Alveolar yokes
 Maxillary hiatus
 Incisive foramen

Palate bone

Perpendicular part (O. T. vertical plate)
 Nasal surface
 Maxillary surface
 Sphenopalatine notch
 Pterygopalatine sulcus
 Pyramidal process
 Larger palatine foramen

Foramina palatina minora	Linea mylohyoidea
Canales palatini	
Crista conchalis	Sulcus mylohyoideus
	Juga alveolaria
Crista ethmoidalis	Ramus mandibulae
Processus orbitalis	Angulus mandibulae
Processus sphenoidalis	(Tuberositas masseterica)
Pars horizontalis	(Tuberositas pterygoidea)
	(Crista buccinatoria)
Facies nasalis	Incisura mandibulae
Facies palatina	
Spina nasalis posterior	Processus condyloideus
Crista nasalis	Capitulum [proc. condyl.] mandibulae
	Collum [proc. condyloidei] mandibulae
	Fovea pterygoidea proc. condyloidei
	Processus coronoideus
	Foramen mandibulare
Os zygomaticum	
Facies malaris	Lingula mandibulae
Facies temporalis	Canalis mandibulae
Facies orbitalis	
Processus temporalis	
Processus frontosphenoidalis	Fovea sublingualis
	(Fovea submaxillaris)
(Processus marginalis)	
Foramen zygomaticoorbitale	Pars alveolaris
	Limbus alveolaris
Foramen zygomaticofaciale	Alveoli dentales
	Septa interalveolaria
Foramen zygomaticotemporale	
	Os hyoideum
	Corpus oss. hyoidei
	Cornu minus
	Cornu majus
	Cranium
	Calvaria
	Pericranium
	Lamina externa
	Diploë
	Canales diploici [Brescheti]
	Lamina interna
	Facies [ossea]
Mandibula	
Corpus mandibulae	
Basis mandibulae	
Protuberantia mentalis	
Tuberculum mentale	
Spina mentalis	
Foramen mentale	
Linea obliqua	
Fossa digastrica	

Smaller palatine foramen	Mylohyoid line (O. T. internal oblique line)
Palatine canals	Mylohyoid groove
Turbinated crest (O. T. inferior turbinated crest)	Alveolar yokes
Ethmoidal crest (O. T. superior turbinated crest)	Ramus of lower jaw (O. T. perpendicular portion)
Orbital process	Angle of lower jaw
Sphenoidal process	Masseteric tuberosity
Horizontal part (O. T. horizontal plate)	Pterygoid tuberosity
Nasal surface	Buccinator crest
Palatine surface	Mandibular notch (O. T. sigmoid notch)
Posterior nasal spine	Condylod process
Nasal crest	Head of condylod process of lower jaw
Zygoma, or yoke bone (O. T. malar bone)	Neck of condylod process of lower jaw
Malar surface	Pterygoid pit of condylod process
Temporal surface	Coronoid process
Orbital surface	Mandibular foramen (O. T. inferior dental foramen)
Temporal process (O. T. zygomatic process)	Mandibular tongue
Frontosphenoidal process (O. T. frontal process)	Mandibular canal (O. T. inferior dental canal)
Marginal process	Sublingual pit (O. T. sublingual fossa)
Zygomatico-orbital foramen (O. T. temporo-malar canal)	Submaxillary pit (O. T. submaxillary fossa)
Zygomaticofacial foramen (O. T. malar foramen)	Alveolar part
Zygomaticotemporal foramen	Alveolar margin
Mandible, or lower jaw bone (O. T. inferior maxillary bone)	Tooth cavities
Body of lower jaw bone	Interalveolar septa
Base of lower jaw	
Mental protuberance (O. T. mental process)	Hyoid bone
Mental tubercle	Body of hyoid bone
Mental spine (O. T. genial tubercle)	Lesser horn
Mental foramen	Greater horn
Oblique line (O. T. external oblique line)	
Digastric fossa	Skull
	Skull cap
	Periosteum of skull
	Outer plate
	Cancellous bone
	Diploic canals or canals of Breschet
	Inner table
	Bony portion of face

Cranium cerebrale
 Cranium viscerale
 Vertex
 Frons
 Occiput
 Basis cranii interna
 Basis cranii externa
 Fossa cranii anterior
 Fossa cranii media
 Fossa cranii posterior
 Juga cerebraalia
 Impressiones digitatae
 Sulci venosi
 Sulci arteriosi
 (Foveolae granulares [Pacchioni])

(Ossa suturarum)
 Planum temporale
 Fossa temporalis
 Arcus zygomaticus
 Fossa infratemporalis
 Fossa pterygopalatina

Canalis pterygopalatinus

Foramen sphenopalatinum
 Apertura piriformis
 Cavum nasi
 Septum nasi osseum
 Meatus nasi communis
 Meatus nasi superior
 Meatus nasi medius
 Meatus nasi inferior
 Meatus nasopharyngeus
 Choanae

Recessus sphenothmoidalis
 Foramen jugulare
 Fissura sphenopetrosa
 Fissura petrooccipitalis
 Fissura sphenoccipitalis
 Foramen lacerum

Fibrocartilago basalis
 Palatum durum
 (Torus palatinus)
 Orbita
 Aditus orbitae
 Margo supraorbitalis
 Margo infraorbitalis
 Paries superior
 Paries inferior
 Paries lateralis
 Paries medialis
 Fissura orbitalis superior
 Fissura orbitalis inferior

Suturae cranii

Sutura coronalis
 Sutura sagittalis
 Sutura lambdoidea
 Sutura occipitomastoidea
 Sutura sphenofrontalis
 Sutura sphenoorbitalis
 Sutura sphenothmoidalis
 Sutura sphenosquamosa
 Sutura sphenoparietalis
 Sutura squamosa
 (Sutura frontalis)
 Sutura parietomastoidea
 (Sutura squamosomastoidea)
 Sutura nasofrontalis
 Sutura frontothmoidalis
 Sutura frontomaxillaris
 Sutura frontolacrimalis
 Sutura zygomaticofrontalis
 Sutura zygomaticomaxillaris
 Sutura ethmoideomaxillaris
 Sutura sphenozygomatica
 (Sutura sphenomaxillaris)
 Sutura zygomaticotemporalis
 Sutura internasalis
 Sutura nasomaxillaris

Cerebral cranium or calvaria	Basal fibrocartilage
Visceral cranium or face	Hard palate
Vertex or crown of head	Palatine torus or protuberance
Forehead	Orbital cavity
Back of head	Orbital opening
Internal base of skull	Supraorbital margin
External base of skull	Infraorbital margin
Anterior cranial fossa	Superior wall
Middle cranial fossa	Inferior wall
Posterior cranial fossa	Lateral wall
Cerebral projections ("yokes")	Medial wall
Digitate impressions	Superior orbital fissure (O. T. sphenoidal fissure or foramen lacerum anterius)
Grooves of the veins	Inferior orbital fissure (O. T. sphenomaxillary fissure)
Grooves of the arteries	
Granular foveolae (O. T. Pacchionian depressions)	
Sutural bones (O. T. Wormian bones)	
Temporal plain	Sutures of the skull
Temporal fossa	Coronal suture
Zygomatic arch	Sagittal suture
Infratemporal fossa	Lambdoidal suture
Pterygopalatine fossa (O. T. sphenomaxillary fossa)	Occipitomastoid suture
Pterygopalatine canal (O. T. posterior palatine canal)	Sphenofrontal suture
Sphenopalatine foramen	Spheno-orbital suture
Piriform opening (O. T. anterior nares)	Spheno-ethmoidal suture
Nasal cavity	Sphenosquamosal suture
Bony nasal septum	Sphenoparietal suture
Common meatus of nose	Squamosal suture
Superior meatus of nose	Frontal suture
Middle meatus of nose	Parietomastoid suture
Inferior meatus of nose	Squamosomastoid suture
Nasopharyngeal meatus	Nasofrontal suture
Choanae ("funnels") (O. T. posterior nares)	Fronto-ethmoidal suture
Spheno-ethmoidal recess	Frontomaxillary suture
Jugular foramen	Frontolacrimal suture
Sphenopetrosal fissure	Zygomaticofrontal suture
Petro-occipital fissure	Zygomaticomaxillary suture
Spheno-occipital fissure	Ethmoideomaxillary suture
Lacerated foramen (O. T. foramen lacerum medium)	Sphenozygomatic suture
	Sphenomaxillary suture
	Zygomaticotemporal suture
	Internasal suture
	Nasomaxillary suture

Sutura lacrimomaxillaris
 Sutura lacrimoconchalis
 Sutura intermaxillaris
 Sutura palatamaxillaris
 Sutura palatoethmoidalis
 Sutura palatina mediana
 Sutura palatina transversa

Synchondroses cranii

Synchondrosis sphenoccipitalis
 Synchondrosis sphenopetrosa
 Synchondrosis petrooccipitalis
Synchondrosis intraoccipitalis posterior
Synchondrosis intraoccipitalis anterior
Synchondrosis intersphenoidalis
Fonticulus frontalis [major]
Fonticulus occipitalis [minor]
Fonticulus mastoideus
Fonticulus sphenoidalis

Ossa extremitatis superioris

Cingulum extremitatis superioris

Scapula

Facies costalis
 Lineae musculares
 Fossa subscapularis
 Facies dorsalis
 Spina scapulae
 Fossa supraspinata
 Fossa infraspinata
 Acromion
 Facies articularis acromii
 Margo vertebralis
 Margo axillaris
 Margo superior
 Angulus inferior
 Angulus lateralis
 Angulus medialis
 Cavitas glenoidalis
 Collum scapulae
 Tuberositas infraglenoidalis

Tuberositas supraglenoidalis

Incisura scapulae

Processus coracoideus

Clavicula

Extremitas sternalis
 Facies articularis sternalis
 Tuberositas costalis

Extremitas acromialis
 Facies articularis acromialis
 Tuberositas coracoidea

Skeleton extremitatis superioris liberae

Humerus

Caput humeri
 Collum anatomicum
 Collum chirurgicum
 Tuberculum majus

Tuberculum minus

Sulcus intertubercularis

Crista tuberculi majoris

Crista tuberculi minoris

Corpus humeri
 Facies anterior medialis

Facies anterior lateralis

Facies posterior
 Margo medialis
 Margo lateralis
 Tuberositas deltoidea
 Sulcus n. radialis

Lacrimomaxillary suture
 Lacrimoconchal suture
 Intermaxillary suture
 Palatomaxillary suture
 Palato-ethmoidal suture
 Median palatine suture
 Transverse palatine suture

Synchondroses of the skull

Spheno-occipital synchondrosis
 Sphenopetrosal synchondrosis
 Petro-occipital synchondrosis
Posterior intraoccipital synchondrosis
Anterior intraoccipital synchondrosis
Intersphenoidal synchondrosis
Larger frontal fontanelle
Smaller occipital fontanelle
Mastoid fontanelle
Sphenoidal fontanelle

Bones of upper extremity

Shoulder girdle

Shoulder-blade

Costal surface
 Muscular lines
 Subscapular fossa
 Dorsal surface
 Spine of the scapula
 Supraspinous fossa
 Infraspinous fossa
 Acromion, or acromial process
 Articular surface of acromion
 Vertebral margin
 Axillary margin
 Superior margin
 Inferior angle
 Lateral angle (O. T. anterior angle)
 Medial angle (O. T. superior angle)
 Glenoid cavity
 Neck of the scapula
 Infraglenoidal tuberosity

Supraglenoidal tuberosity (O. T. supraglenoid tubercle)
 Scapular notch (O. T. suprascapular notch)
 Coracoid ("crow's beak") process

Collar bone or clavicle

Sternal extremity
 Sternal articular surface
 Costal tuberosity (O. T. impression for rhomboid ligament)
 Acromial extremity
 Acromial articular surface
 Coracoid tuberosity (O. T. impression for conoid ligament)

Skeleton of free upper extremity

Humerus, or upper arm bone

Head of humerus
 Anatomical neck
 Surgical neck
 Larger tubercle (O. T. greater tuberosity)
 Smaller tubercle (O. T. lesser tuberosity)
 Intertubercular sulcus (O. T. bicipital groove)
 Crest of larger tubercle (O. T. posterior bicipital ridge)
 Crest of smaller tubercle (O. T. anterior bicipital ridge)
 Body of humerus, or shaft
 Medial anterior surface (O. T. internal surface)
 Lateral anterior surface (O. T. external surface)
 Posterior surface
 Medial margin (O. T. internal border)
 Lateral margin (O. T. external border)
 Deltoid tuberosity
 Groove for radial nerve (O. T. musculospiral groove)

Sulcus n. ulnaris
Capitulum humeri

Trochlea humeri
Epicondylus medialis

Epicondylus lateralis

Fossa olecrani
Fossa coronoidea
Fossa radialis
(Processus supracondyloideus)

Radius

Corpus radii
Capitulum radii
Fovea capituli radii
Collum radii
Circumferentia articularis
Tuberositas radii

Crista interossea

Facies dorsalis
Facies volaris
Facies lateralis
Margo dorsalis
Margo volaris
Processus styloideus
Incisura ulnaris
Facies articularis carpea

Ulna

Corpus ulnae
Olecranon
Processus coronoideus
Tuberositas ulnae
Incisura semilunaris

Incisura radialis

Crista interossea

Facies dorsalis

Facies volaris
Facies medialis
Margo dorsalis
Margo volaris

Crista m. supinatoris
Capitulum ulnae
Circumferentia articularis
Processus styloideus

Carpus

O s s a c a r p i
(Os centrale)
Os naviculare manus

Tuberculum oss. navicularis
Os lunatum
Os triquetrum

Os pisiforme
Os multangulum majus

Tuberculum oss. multang. majoris
Os multangulum minus

Os capitatum
Os hamatum
Hamulus oss. hamati
Eminentia carpi radialis
Eminentia carpi ulnaris
Sulcus carpi

Metacarpus

Ossa metacarpalia I—V
Basis
Corpus
Capitulum
Os metacarpale III
Processus styloideus

Phalanges digitorum manus

Phalanx prima
Phalanx secunda

Groove for ulnar nerve
 Capitulum or little head of humerus
 (O. T. capitellum or radial head)
 Trochlea ("pulley") of humerus
 Medial epicondyle (O. T. internal con-
 dyle)
 Lateral epicondyle (O. T. external
 condyle)
 Olecranon fossa
 Coronoid fossa
 Radial fossa
 Supracondyloid process

Radius ("spoke")

Body of radius, or shaft
 Head of radius
 Pit of head of radius
 Neck of radius
 Articular circumference
 Tuberosity of radius (O. T. bicipital
 tuberosity)
 Interosseous crest (O. T. internal or
 interosseous border)
 Dorsal surface (O. T. posterior surface)
 Volar surface (O. T. anterior surface)
 Lateral surface (O. T. external surface)
 Dorsal margin (O. T. posterior border)
 Volar margin (O. T. anterior border)
 Styloid process
 Ulnar notch (O. T. sigmoid cavity)
 Carpal articular surface

Ulna, or elbow bone

Body of ulna, or shaft
 Olecranon, or point of the elbow
 Coronoid process
 Tuberosity of the ulna
 Semilunar notch (O. T. greater sig-
 moid cavity)
 Radial notch (O. T. lesser sigmoid
 cavity)
 Interosseous crest (O. T. external or
 interosseous border)

Dorsal surface (O. T. posterior sur-
 face)
 Volar surface (O. T. anterior surface)
 Medial surface (O. T. internal surface)
 Dorsal margin (O. T. posterior border)
 Volar margin (O. T. anterior border)
 Ridge of supinator muscle
 Head of ulna
 Articular circumference
 Styloid process

Wrist

Bones of the wrist

Central bone
 Navicular bone of the hand (O. T.
 scaphoid)
 Tubercle of navicular bone
 Lunate bone (O. T. semilunar)
 Three-cornered bone (O. T. cuneiform
 bone)
 Pisiform bone
 Large multangular bone (O. T. tra-
 pezium)
 Tubercle of large multangular bone
 Small multangular bone (O. T. trape-
 zoid)
 Capitate bone (O. T. os magnum)
 Hooked bone (O. T. unciform)
 Hook of os hamatum
 Radial eminence of wrist
 Ulnar eminence of wrist
 Carpal sulcus

Metacarpus

Metacarpal bones I—V
 Base
 Body, or shaft
 Head
 Third metacarpal bone
 Styloid process

Phalanges of the fingers

First phalanx
 Second phalanx

Phalanx tertia
 Basis phalangis
 Corpus phalangis
 Trochlea phalangis
 Tuberositas unguicularis
 Ossa sesamoidea

Ossa extremitatis inferioris

Cingulum extremitatis inferioris

Os coxae

Foramen obturatum
 Acetabulum
 Fossa acetabuli
 Incisura acetabuli
 Facies lunata
 Sulci paraglenoidales

Os ilium

Corpus oss. ilium
 Ala oss. ilium
 Linea arcuata
 Crista iliaca
 Labium externum
 Linea intermedia
 Labium internum
 Spina iliaca anterior superior
 Spina iliaca anterior inferior
 Spina iliaca posterior superior
 Spina iliaca posterior inferior
 Linea glutaea anterior
 Linea glutaea posterior
 Linea glutaea inferior
 Facies auricularis
 Tuberositas iliaca
 Fossa iliaca

Os ischii

Corpus oss. ischii
 Ramus superior oss. ischii

Ramus inferior oss. ischii

Tuber ischiadicum

Spina ischiadica

Incisura ischiadica major

Incisura ischiadica minor

Os pubis

Corpus oss. pubis
 Pecten oss. pubis
 Eminentia iliopectinea
 Tuberculum pubicum
 Crista obturatoria
 Sulcus obturatorius
 Tuberculum obturatorium anterius
 (Tuberculum obturatorium posterius)
 Ramus inferior oss. pubis

Ramus superior oss. pubis

Facies symphyseos

Pelvis

Symphysis ossium pubis
 Arcus pubis
 Angulus pubis
 Pelvis major
 Pelvis minor
 Linea terminalis
 Pars sacralis
 Pars iliaca
 Pars pubica
 Apertura pelvis [minoris] superior
 Apertura pelvis [minoris] inferior

Axis pelvis

Conjugata

Third phalanx
 Base of phalanx
 Body of phalanx, or shaft
 Pulley of phalanx
 Ungual tuberosity
 Sesamoid bones

Bones of the lower extremity

Pelvic girdle

Hip bone (O. T. os innominatum)

Obturator ("closed") foramen
 Acetabulum ("cup")
 Fossa of the acetabulum
 Acetabular notch
 Lunate surface
 Paraglenoid grooves

Ilium, or flank bone

Body of ilium
 Wing of ilium
 Curved lines
 Iliac crest
 External lip
 Intermediate line
 Internal lip
 Superior anterior iliac spine
 Inferior anterior iliac spine
 Superior posterior iliac spine
 Inferior posterior iliac spine
 Anterior gluteal line (O. T. middle curved line)
 Posterior gluteal line (O. T. superior curved line)
 Inferior gluteal line (O. T. inferior curved line)
 Auricular surface
 Iliac tuberosity
 Iliac fossa

Ischium, or bone of the hip

Body of ischium
 Superior ramus of ischium

Inferior ramus of ischium (O. T. ascending ramus)
 Sciatic tuber (O. T. tuberosity of the ischium)
 Sciatic spine (O. T. spine of the ischium)
 Greater sciatic notch (O. T. great sacro-sciatic notch)
 Lesser sciatic notch (O. T. lesser sacro-sciatic notch)

Pubic bone

Body of pubic bone
 Pecten ("comb") of pubic bone
 Iliopectineal eminence
 Pubic tubercle (O. T. spine of os pubis)
 Obturator crest
 Obturator sulcus
 Anterior obturator tubercle
 Posterior obturator tubercle
 Inferior ramus of pubic bone (O. T. descending ramus)
 Superior ramus of pubic bone (O. T. ascending ramus)
 Symphyseal surface (O. T. symphysis pubis)

Pelvis ("basin")

Symphysis of pubic bones
 Pubic arch
 Angle of pubis
 Large pelvis (O. T. false pelvis)
 Small pelvis (O. T. true pelvis)
 Terminal line
 Sacral part
 Iliac part
 Pubic part
 Upper opening of lesser pelvis (O. T. pelvic inlet)
 Lower opening of lesser pelvis (O. T. pelvic outlet)
 Axis of pelvis
 Conjugate diameter

Diameter transversa

Diameter obliqua

Inclinatio pelvis

Skeleton extremitatis inferioris liberae in-

Femur

Caput femoris

Fovea capitis femoris

Collum femoris

Corpus femoris

Trochanter major

Fossa trochanterica

Trochanter minor

(Trochanter tertius)

Linea intertrochanterica

Crista intertrochanterica

Linea aspera

Labium laterale

Labium mediale

Linea pectinea

Tuberositas glutea

Fossa intercondyloidea

Linea intercondyloidea

Planum popliteum

Condylus medialis

Condylus lateralis

Facies patellaris

Epicondylus lateralis

Epicondylus medialis

Tibia

Facies articularis superior

Corpus tibiae

Condylus medialis

Condylus lateralis

Fossa intercondyloidea anterior

Fossa intercondyloidea posterior

Eminentia intercondyloidea

Tuberculum intercondyloideum mediale

Tuberculum intercondyloideum laterale

Margo infraglenoidalis

Tuberositas tibiae

Facies medialis

Facies posterior

Facies lateralis

Margo medialis

Crista anterior

Crista interossea

Linea poplitea

Malleolus medialis

Incisura fibularis

Sulcus malleolaris

Facies articularis inferior

Facies articularis malleolaris

Fibula

Corpus fibulae

Crista interossea

Crista anterior

Crista lateralis

Crista medialis

Facies medialis

Facies lateralis

Facies posterior

Capitulum fibulae

Facies articularis capituli

Apex capituli fibulae

Malleolus lateralis

Facies articularis malleoli

Patella

Basis patellae

Apex patellae

Facies articularis

Transverse diameter
 Oblique diameter
 Pelvic incline

Intercondyloid eminence (O. T. spinous process)
 Medial intercondyloid tubercle

Skeleton of free lower extremity

Lateral intercondyloid tubercle

Thigh bone

Head of femur
 Pit of the head of femur
 Neck of femur
 Body, or shaft, of femur
 Great trochanter
 Trochanteric fossa (O. T. digital fossa)
 Lesser trochanter
 Third trochanter
 Intertrochanteric line (O. T. spiral line)
 Intertrochanteric crest (O. T. intertrochanteric line)
 Rough line
 Lateral lip
 Medial lip
 Pectineal line
 Gluteal tuberosity
 Intercondyloid fossa
 Intercondyloid line
 Popliteal plain (O. T. popliteal space)
 Medial condyle (O. T. inner condyle)
 Lateral condyle (O. T. outer condyle)
 Patellar surface
 Lateral epicondyle (O. T. outer tuberosity)
 Medial epicondyle (O. T. inner tuberosity)

Infraglenoidal margin
 Tuberosity of the tibia (O. T. tubercle)
 Medial surface
 Posterior surface
 Lateral surface
 Medial margin
 Anterior crest
 Interosseous crest
 Popliteal line
 Medial malleolus (O. T. internal malleolus)
 Fibular notch
 Malleolar sulcus
 Inferior articular surface
 Malleolar articular surface

Calf bone

Shin bone
 Superior articular surface
 Body or shaft of tibia
 Medial condyle (O. T. internal tuberosity)
 Lateral condyle (O. T. external tuberosity)
 Anterior intercondyloid fossa
 Posterior intercondyloid fossa

Body or shaft of fibula
 Interosseous crest
 Anterior crest
 Lateral crest
 Medial crest
 Medial surface
 Lateral surface
 Posterior surface
 Head of fibula
 Articular surface of head
 Apex of head of fibula
 Lateral malleolus (O. T. external malleolus)
 Articular surface of malleolus

Knee-cap

Base of patella
 Apex of patella
 Articular surface

	Tarsus	
Ossa tarsi		Facies articularis media Facies articularis posterior Sulcus m. peronaei (Processus trochlearis) Facies articularis cuboidea
	Talus	
Caput tali		
Corpus tali		
Collum tali		
Trochlea tali		
Facies superior		
Facies malleolaris medialis		
Facies malleolaris lateralis		
Sulcus tali		
Processus lateralis tali		
Facies articularis calcanea posterior		
Facies articularis calcanea media		
Sulcus m. flexoris hallucis longi		
		Os naviculare pedis
		Tuberositas oss. navicularis
		Os cuneiforme primum
		Os cuneiforme secundum
		Os cuneiforme tertium
		Os cuboideum
		Sulcus m. peronaei Tuberositas oss. cuboidei
Facies articularis navicularis		Metatarsus
Facies articularis calcanea anterior		Ossa metatarsalia I—V
Processus posterior tali		Basis
(Os trigonum)		Corpus
		Capitulum
		Tuberositas oss. metatarsalis I
		Tuberositas oss. metatarsalis V
	Calcaneus	Phalanges digitorum pedis
Corpus calcanei		Phalanx prima
Tuber calcanei		Phalanx secunda
Processus medialis tuberis calcanei		Phalanx tertia
Processus lateralis tuberis calcanei		Tuberositas unguicularis
Sustentaculum tali		Basis phalangis
Sulcus m. flexoris hallucis longi		Corpus phalangis
		Trochlea phalangis
Sulcus calcanei		
Sinus tarsi		Ossa sesamoidea
Facies articularis anterior		

Root of the foot**Tarsal bones****Ankle bone (O. T. astragalus)**

Head of ankle bone
 Body of ankle bone
 Neck of ankle bone
 Trochlea ("pulley") of ankle bone
 Superior surface
 Medial malleolar surface
 Lateral malleolar surface
 Sulcus of ankle bone
 Lateral process of ankle bone
 Posterior calcanean articular surface
 Middle calcanean articular surface
 Groove for the long flexor muscle of
 the great toe
 Navicular articular surface
 Anterior calcanean articular surface
 Posterior process of ankle bone
 Triangular bone

Heel bone (O. T. os calcis)

Body of heel bone
 Calcanean tuber
 Medial process of calcanean tuber

 Lateral process of calcanean tuber

Support of ankle bone
 Groove for the long flexor muscle of
 great toe
 Calcanean sulcus
 Tarsal sinus
 Anterior articular surface

Middle articular surface
 Posterior articular surface
 Groove for peroneal muscle
 Trochlear process
 Cuboid articular surface

Scaphoid bone of foot

Tuberosity of scaphoid bone

First Cuneiform, or Wedge Bone**Second Cuneiform, or Wedge Bone****Third Cuneiform, or Wedge Bone****Cuboid bone**

Groove for peroneal muscle
 Tuberosity of cuboid bone

Metatarsus, or "after-root" of foot

Metatarsal bones I—V

Base

Body

Head

Tuberosity of first metatarsal bone
 Tuberosity of fifth metatarsal bone

Phalanges of toes

First phalanx
 Second phalanx
 Third phalanx
 Ungual tuberosity
 Base of phalanx
 Body of phalanx
 Trochlea ("pulley or block") of phalanx
 Sesamoid bones

Syndesmologia

Junctura ossium

Synarthrosis

Sutura

Sutura serrata

Sutura squamosa

Harmonia

Gomphosis

Synchondrosis

Symphysis

Diarthrosis

Articulatio

Articulatio simplex

Articulatio composita

Arthrodia

Articulatio sphaeroidea

Enarthrosis

Ginglymus

Articulatio cochlearis

Articulatio ellipsoidea

Articulatio trochoidea

Articulatio sellaris

Amphiarthrosis

Syndesmosis

Cartilago articularis

Cavum articulare

Discus articularis

Labrum glenoidale

Meniscus articularis

Capsula articularis

Stratum fibrosum

Stratum synoviale

Plica synovialis

Villi synoviales

Synovia

**Ligamenta columnae vertebralis
et cranii**

Fibrocartilagine intervertebrales

Annulus fibrosus

Nucleus pulposus

Ligg. flava

Capsulae articulares

Ligg. intertransversaria

Ligg. interspinalia

Lig. supraspinale

Lig. nuchae

Lig. longitudinale anterius

Lig. longitudinale posterius

Symphysis sacrococcygea

Lig. sacrococcygeum posterius superficiale

Lig. sacrococcygeum posterius profundum

Lig. sacrococcygeum anterius

Lig. sacrococcygeum laterale

Lig. pterygospinosum

Lig. stylohyoideum

Articulatio atlantooccipitalis

Capsulae articulares

Membrana atlantooccipitalis anterior

Membrana atlantooccipitalis posterior

Articulatio atlantoepistrophica

Capsulae articulares

Syndesmology, or Joint Articulation

Joining of bones
 Immovable articulation
 Suture or seam
 Serrated suture
 Scaly suture
 Apposition suture
 Socket articulation
 Cartilaginous articulation
 Bony coalescence or junction
 Movable articulation
 Joint
 Simple joint
 Compound joint
 Gliding joint
 Spherical joint
 Ball-and-socket joint
 Hinge-joint
 Spiral joint
 Elliptical joint
 Trochoid or pivot joint
 Saddle joint
 Mixed articulation
 Ligamentous union
 Articular cartilage
 Joint cavity
 Articular disk (O. T. interarticular fibrocartilage)
 Glenoid lip
 Articular crescent
 Joint-capsule
 Fibrous layer
 Synovial layer
 Synovial fold
 Synovial tufts
 Joint-oil

Ligaments of the spine and skull

Intervertebral fibrocartilages
 Fibrous ring
 Pulp-like nucleus
 Yellow ligaments (O. T. ligg. subflava)
 Joint-capsules
 Intertransverse ligaments
 Interspinous ligaments
 Supraspinous ligament
 Ligament of the nape
 Anterior longitudinal ligament (O. T. anterior common ligament)
 Posterior longitudinal ligament (O. T. posterior common ligament)
 Symphysis of sacrum and coccyx
 Superficial posterior sacrococcygeal ligament
 Deep posterior sacrococcygeal ligament
 Anterior sacrococcygeal ligament
 Lateral sacrococcygeal ligament
 Pterygospinous ligament
 Stylohyoid ligament

Joint between atlas and occipital bone

Joint-capsules
 Anterior atlanto-occipital membrane
 Posterior atlanto-occipital membrane

Joint between atlas and epistropheus or axis

Joint-capsules

Ligg. alaria

Lig. apicis dentis

Lig. transversum atlantis

Lig. cruciatum atlantis

Membrana tectoria

Articulationes costovertebrales

Articulationes capitulorum

Capsulae articulares

Lig. capituli costae radiatum

Lig. capituli costae interarticulare

Articulationes costotransversariae

Capsulae articulares

Lig. tuberculi costae

Lig. colli costae

Lig. costotransversarium anterius

Lig. costotransversarium posterius

Lig. lumbocostale

Foramen costotransversarium

Articulationes sternocostales

Capsulae articulares

Lig. sternocostale interarticulare

Ligg. sternocostalia radiata

Membrana sterni

Ligg. costoxiphoidae

Ligg. intercostalia

Ligg. intercostalia externa

Ligg. intercostalia interna

Articulationes interchondrales

Articulatio mandibularis

Capsula articularis

Discus articularis

Lig. temporomandibulare

Lig. sphenomandibulare

Lig. stylomandibulare

Ligg. cinguli extremitatis superioris

Lig. coracoacromiale

Lig. transversum scapulae superius

Lig. transversum scapulae inferius

Articulatio acromioclavicularis

Capsula articularis

Lig. acromioclaviculare

(Discus articularis)

Lig. coracoclaviculare

Lig. trapezoideum

Lig. conoideum

Articulatio sternoclavicularis

Capsula articularis

Discus articularis

Lig. sternoclaviculare

Lig. costoclaviculare

Lig. interclaviculare

Articulatio humeri

Capsula articularis

Labrum glenoidale

Lig. coracohumerale

Articulatio cubiti

Articulatio humeroulnaris

Articulatio humeroradialis

Alar ligaments (O. T. odontoid or check ligaments)

Ligament of apex of tooth (O. T. suspensory ligament)

Transverse ligament of atlas

Cruciform ligament of atlas

Tectorial ("roof") membrane (O. T. posterior occipito-axial ligament)

Joints between ribs and vertebrae

Capitular joints, or articulations between the heads of the ribs and the vertebrae

Joint-capsules

Radiate ligament of head of rib (O. T. anterior costovertebral or stellate ligament)

Interarticular ligament of head of rib

Costotransverse joints

Joint-capsules

Ligament of tubercle of rib

Ligament of neck of rib

Anterior costotransverse ligament

Posterior costotransverse ligament

Lumbocostal ligament

Costotransverse foramen

Sternocostal joints

Joint-capsules

Interarticular sternocostal ligament (O. T. interarticular chondrosternal ligament)

Radiate sternocostal ligaments (O. T. anterior and posterior chondrosternal ligaments)

Membrane of sternum

Costoxiphoid ligaments (O. T. chondroxiphoid ligaments)

Intercostal ligaments

External intercostal ligaments

Internal intercostal ligaments

Interchondral joints

Jaw=joint

Joint-capsule (O. T. capsular ligament)

Joint-disk (O. T. interarticular fibrocartilage)

Temporomandibular ligament (O. T. external lateral ligament)

Sphenomandibular ligament (O. T. internal lateral ligament)

Stylomandibular ligament (O. T. stylo-maxillary ligament)

Ligaments of the girdle of upper extremity

Coraco-acromial ligament

Superior transverse ligament of scapula

Inferior transverse ligament of scapula

Acromioclavicular joint

Joint-capsule

Acromioclavicular ligament

Intercalated disk of fibrocartilage

Coracoclavicular ligament

Trapezoid ligament

Conoid ligament

Sternoclavicular joint

Joint-capsule

Articular disk

Sternoclavicular ligament

Costoclavicular ligament (O. T. rhomboid ligament)

Interclavicular ligament

Shoulder=joint

Joint-capsule

Glenoid lip (O. T. glenoid ligament)

Coracohumeral ligament (O. T. accessory ligament)

Elbow=joint

Humero-ulnar articulation

Humero-radial articulation

Articulatio radioulnaris proximalis

Capsula articularis
Lig. collaterale ulnare

Lig. collaterale radiale

Lig. annulare radii

Recessus sacciformis
Membrana interossea antibrachii
Chorda obliqua

Articulatio radioulnaris distalis

Capsula articularis
Discus articularis

Recessus sacciformis

Articulatio manus

Articulatio radiocarpea

Articulatio intercarpea

Capsula articularis
Lig. radiocarpeum dorsale

Lig. radiocarpeum volare

Lig. carpi radiatum
Lig. collaterale carpi ulnare

Lig. collaterale carpi radiale

Ligg. intercarpea dorsalia
Ligg. intercarpea volaria

Ligg. intercarpea interossea

Articulatio ossis pisiformis

Capsula articularis

Lig. pisohamatum

Lig. pisometacarpeum

Canalis carpi

Articulationes carpometacarpeae

Capsulae articulares
Ligg. carpometacarpea dorsalia
Ligg. carpometacarpea volaria

Articulatio carpometacarpea pollicis

Capsula articularis

Articulationes intermetacarpeae

Capsulae articulares
Ligg. basium [oss. metacarp.] dorsalia

Lig. basium [oss. metacarp.] volaria

Lig. basium [oss. metacarp.] interossea

Spatia interossea metacarpi

Articulationes metacarpophalangeae

Capsulae articulares
Ligg. collateralia
Ligg. accessoria volaria

Ligg. capitulorum [oss. metacarpalium]
transversa

Articulationes digitorum manus

Capsulae articulares
Ligg. collateralia

Ligg. cinguli extremitatis inferioris

Membrana obturatoria
Canalis obturatorius
Lig. iliolumbale

Proximal radio-ulnar articulation (O. T. superior radio-ulnar)

Joint-capsule

Ulnar collateral ligament (O. T. internal lateral ligament)

Radial collateral ligament (O. T. external lateral ligament)

Annular ligament of radius (O. T. orbicular)

Sacciform recess

Interosseous membrane of forearm

Oblique cord (O. T. oblique, or round ligament)

Distal radio-ulnar articulation (O. T. inferior radio-ulnar)

Joint-capsule

Articular disk (O. T. triangular fibrocartilage).

Sacciform recess

Joint of the hand

Radiocarpal articulation (O. T. wrist-joint)

Intercarpal articulation (O. T. carpal joints)

Joint-capsule

Dorsal radiocarpal ligament (O. T. posterior ligament)

Volar radiocarpal ligament (O. T. anterior ligament)

Radiate ligament of carpus

Ulnar collateral ligament of carpus (O. T. internal lateral ligament)

Radial collateral ligament of carpus (O. T. external lateral ligament)

Dorsal intercarpal ligaments

Volar intercarpal ligaments (O. T. palmar intercarpal)

Interosseous intercarpal ligaments

Joint of the pisiform bone

Joint-capsule

Ligament between pisiform and hook-shaped bone

Ligament between pisiform and metacarpal bones

Carpal canal

Carpometacarpal joints

Joint-capsules

Dorsal carpometacarpal ligaments

Volar carpometacarpal ligaments

Carpometacarpal joint of the thumb

Joint-capsule

Intermetacarpal joints

Joint-capsules

Dorsal ligaments of basal extremities of metacarpal bones

Volar ligament of basal extremities of metacarpal bones

Interosseous ligament of basal extremities of metacarpal bones

Interosseous space of metacarpus

Metacarpophalangeal joints

Joint-capsules

Collateral ligaments

Volar accessory ligaments (O. T. palmar ligaments)

Transverse ligaments of the heads of the metacarpal bones

Joints of the fingers

Joint-capsules

Collateral ligaments (O. T. lateral ligaments)

Ligaments of the girdle of lower extremity (O. T. pelvic girdle)

Obturator membrane

Obturator canal

Iliolumbar ligament

Lig. sacrotuberosum

Processus falciformis

Lig. sacrospinosum

Foramen ischiadicum majus

Foramen ischiadicum minus

Articulatio sacroiliaca

Ligg. sacroiliaca anteriora

Ligg. sacroiliaca interossea

Lig. sacroiliacum posterius breve

Lig. sacroiliacum posterius longum

Symphysis ossium pubis

Lig. pubicum superius

Lig. arcuatum pubis

Lamina fibrocartilaginea interpubica

Articulatio coxae

Capsula articularis

Labrum glenoidale

Lig. transversum acetabuli

Lig. teres femoris

Zona orbicularis

Lig. iliofemorale

Lig. ischiocapsulare

Lig. pubocapsulare

Articulatio genu

Capsula articularis

Meniscus lateralis

Meniscus medialis

Lig. transversum genu

Ligg. cruciata genu

Lig. cruciatum anterius

Lig. cruciatum posterius

Plica synovialis patellaris

Plicae alares

Lig. collaterale fibulare

Lig. collaterale tibiale

Lig. popliteum obliquum

Lig. popliteum arcuatum

Retinaculum lig. arcuati

Lig. patellae

Retinaculum patellae mediale

Retinaculum patellae laterale

Articulatio tibiofibularis

Capsula articularis

Ligg. capituli fibulae

Membrana interossea cruris

Syndesmosis tibiofibularis

Lig. malleoli lateralis anterius

Lig. malleoli lateralis posterius

Articulationes pedis

Articulatio talocruralis

Capsula articularis

Lig. deltoideum

Lig. tibionaviculare

Lig. calcaneotibiale

Lig. talotibiale anterius

Lig. talotibiale posterius

Lig. talofibulare anterius

Sacro-tuberous ligament (O. T. posterior or great sacrosciatic ligament)
 Falciform process (O. T. falciform ligament)
 Sacrospinous ligament (O. T. anterior or small sacrosciatic ligament)
 Greater sciatic foramen
 Lesser sciatic foramen

Sacro-iliac joint

Anterior sacro-iliac ligaments
 Interosseous sacro-iliac ligaments
 Short posterior sacro-iliac ligament
 Long posterior sacro-iliac ligament

Symphysis of pubic bones

Superior pubic ligament
 Arcuate ligament of pubis
 Interpubic fibrocartilaginous lamina

Hip-joint

Joint-capsule
 Glenoid lip (O. T. cotyloid ligament)
 Transverse ligament of acetabulum
 Round ligament of the femur
 Orbicular zone (O. T. zonular band or ring ligament)
 Iliofemoral ligament (O. T. Y-shaped ligament of Bigelow)
 Ischiocapsular ligament (O. T. ischio-capsular band)
 Pubocapsular ligament (O. T. pubo-capsular band, or pubofemoral ligament)

Knee-joint

Joint-capsule
 Lateral meniscus (O. T. external semilunar fibrocartilage)
 Medial meniscus (O. T. internal semilunar fibrocartilage)
 Transverse ligament of the knee
 Crucial ligaments of the knee

Anterior crucial ligament
 Posterior crucial ligament
 Patellar synovial fold (O. T. ligamentum mucosum)
 Alar folds (O. T. ligamentum alaria)
 Fibular collateral ligament (O. T. long external lateral ligament)
 Tibial collateral ligament (O. T. internal lateral ligament)
 Oblique popliteal ligament (O. T. posterior ligament)
 Arcuate popliteal ligament
 Retaining band of arcuate ligament
 Ligament of the patella
 Medial retaining band of patella
 Lateral retaining band of patella

Tibiofibular joint (O. T. superior tibiofibular articulation)

Joint-capsule
 Ligaments of the head of the fibula (O. T. anterior and posterior superior tibiofibular ligaments)
 Interosseous membrane of leg (O. T. middle tibiofibular ligament)

Tibiofibular syndesmosis (O. T. inferior tibiofibular articulation)

Anterior ligament of lateral malleolus
 Posterior ligament of lateral malleolus

Joints of the foot

Ankle-joint

Joint-capsule
 Deltoid ligament (O. T. internal lateral ligament and anterior and posterior tibiotarsal ligaments)
 Tibionavicular ligament
 Calcaneotibial ligament
 Anterior talotibial ligament
 Posterior talotibial ligament
 Anterior talofibular ligament (O. T. anterior fasciculus of external lateral ligament)

Lig. talofibulare posterius

Pars calcaneonavicularis

Lig. calcaneofibulare

Pars calcaneocuboidea

Articulationes intertarseae**Articulatio talocalcaneonavicularis**

Capsula articularis

Lig. talocalcaneum laterale

Articulatio talocalcanea

Lig. talocalcaneum mediale

Lig. talocalcaneum anterius

Lig. talocalcaneum posterius

Articulatio tarsi transversa
[Choparti]**Articulatio talonavicularis**

Capsula articularis

Articulatio calcaneocuboidea

Capsula articularis

Articulatio cuneonavicularis**Ligg. tarsi interossea**

Lig. talocalcaneum interosseum

Lig. cuneocuboideum interosseum

Ligg. intercuneiformia interossea

Ligg. tarsi dorsalia

Lig. talonaviculare [dorsale]

Lig. cuneocuboideum dorsale

Lig. cuboideonaviculare dorsale

Lig. bifurcatum

Lig. calcaneonaviculare dorsale

Ligg. navicularicuneiformia dorsalia

Ligg. tarsi plantaria

Lig. plantare longum

Ligg. tarsi profunda

Lig. calcaneocuboideum plantare

Lig. calcaneonaviculare plantare

Fibrocartilago navicularis

Ligg. navicularicuneiformia plantaria

Lig. cuboideonaviculare plantare

Ligg. intercuneiformia plantaria

Lig. cuneocuboideum plantare

Articulationes tarsometatarseae

Capsulae articulares

Ligg. tarsometatarsea dorsalia

Ligg. tarsometatarsea plantaria

Ligg. cuneometatarsea interossea

Articulationes intermetatarseae

Capsulae articulares

Ligg. basium [oss. metatars.] interossea

Ligg. basium [oss. metatars.] dorsalia

Ligg. basium [oss. metatars.] plantaria

Spatia interossea metatarsi

Articulationes metatarsophalangeae

Capsulae articulares

Ligg. collateralia

Posterior talofibular ligament (O. T. posterior fasciculus of external lateral ligament)

Calcaneofibular ligament (O. T. middle fasciculus of external lateral ligament)

Intertarsal joints

Talocalcaneonavicular joint

Talocalcanean joint

Joint-capsule

Lateral talocalcanean ligament (O. T. external calcaneo-astragaloid ligament)

Medial talocalcanean ligament (O. T. internal calcaneo-astragaloid ligament)

Anterior talocalcanean ligament

Posterior talocalcanean ligament

Chopart's transverse articulation of the tarsus

Talonavicular joint

Joint-capsule

Calcaneocuboid joint

Joint-capsule

Cuneonavicular joint

Interosseous ligaments of tarsus

Interosseous talocalcanean ligament

Interosseous cuneocuboid ligament

Interosseous intercuneiform ligaments

Dorsal ligaments of tarsus

Dorsal talonavicular ligament (O. T. superior astragalonavicular ligament)

Dorsal cuneocuboid ligament

Dorsal cuboideonavicular ligament

Bifurcate ligament

Calcaneonavicular part (O. T. superior or external calcaneonavicular ligament)

Calcaneocuboidal part (O. T. internal calcaneocuboid ligament)

Dorsal calcaneonavicular ligament

Dorsal navicular cuneiform ligaments

Plantar ligaments of tarsus

Long plantar ligament (O. T. long calcaneocuboid ligament)

Deep ligaments of tarsus

Plantar calcaneocuboid ligament

Plantar calcaneonavicular ligament (O. T. inferior calcaneonavicular ligament)

Navicular fibrocartilage

Plantar navicular cuneiform ligaments

Plantar cuboideonavicular ligament

Plantar intercuneiform ligaments

Plantar cuneocuboid ligament

Tarsometatarsal joints

Joint-capsules

Dorsal tarsometatarsal ligaments

Plantar tarsometatarsal ligaments

Interosseous cuneometatarsal ligaments

Intermetatarsal joints

Joint-capsules

Interosseous ligaments of the bases of the metatarsal bones

Dorsal ligaments of the bases of the metatarsal bones

Plantar ligaments of the bases of the metatarsal bones

Interosseous spaces of metatarsus

Metatarsophalangeal joints

Joint-capsules

Collateral ligaments

Ligg. accessoria plantaria

Ligg. capitulorum [oss. metatars.]
transversa**Articulationes digitorum pedis**

Capsulae articulares

Ligg. collateralia

Myologia

Musculus

Caput

Venter

Musculus fusiformis

Musculus unipennatus

Musculus bipennatus

Musculus sphincter

Musculus orbicularis

Musculus articularis

Musculus skeleti

Musculus cutaneus

Tendo

Aponeurosis

Perimysium

Fascia

Fascia superficialis

Inscriptio tendinea

Arcus tendineus

Ligamentum vaginale

Vagina fibrosa tendinis

Vagina mucosa tendinis

Trochlea muscularis

Bursa mucosa

Musculi dorsi

M. trapezius

(M. transversus nuchae)

M. latissimus dorsi

M. rhomboideus major

M. rhomboideus minor

M. levator scapulae

M. serratus posterior inferior

M. serratus posterior superior

M. splenius cervicis

M. splenius capitis

M. sacrospinalis

M. iliocostalis

M. iliocostalis lumborum

M. iliocostalis dorsi

M. iliocostalis cervicis

M. longissimus

M. longissimus dorsi

M. longissimus cervicis

M. longissimus capitis

M. spinalis

M. spinalis dorsi

M. spinalis cervicis

M. spinalis capitis

M. semispinalis

M. semispinalis dorsi

M. semispinalis cervicis

M. semispinalis capitis

Plantar accessory ligaments	Joints of the toes
Transverse ligaments of the heads of the metatarsal bones	Joint-capsules
	Collateral ligaments

Myology, or Musculature

Muscle	Tendinous expansion
Head	Perimysium, or muscle sheath
Belly	Fascia ("band or swathe"), or fibrous covering
Fusiform muscle	Superficial fascia
Unipennate muscle	Tendinous inscription
Bipennate muscle	Tendinous arch
Sphincter muscle	Sheath ligament
Orbicular muscle	Fibrous sheath of tendon
Joint muscle	Mucous sheath of tendon
Skeletal muscle	Muscle pulley
Skin muscle	Mucous bursa or sac
Tendon	

Muscles of the back

Trapezius muscle	Iliocostal muscle of neck (O. T. cervicalis ascendens)
Transverse muscle of nape	Longest muscle
Broadest muscle of back	Longest muscle of back
Greater rhomboid muscle	Longest muscle of neck (O. T. transversalis cervicis)
Lesser rhomboid muscle	Longest muscle of head (O. T. trachelomastoid)
Levator muscle of scapula (O. T. levator anguli scapulae)	Spinal muscle
Inferior posterior serratus muscle	Spinal muscle of back
Superior posterior serratus muscle	Spinal muscle of neck (O. T. spinalis colli)
Splenius ("bandage") muscle of neck (O. T. splenius colli)	Spinal muscle of head
Splenius muscle of head	Semispinal muscle
Sacrospinal muscle (O. T. erector spinae)	Semispinal muscle of back
Iliocostal muscle	Semispinal muscle of neck (O. T. semispinalis colli)
Iliocostal muscle of loins (O. T. sacrolumbalis)	Semispinal muscle of head (O. T. complexus)
Iliocostal muscle of back (O. T. musculus accessorius)	

- M. multifidus
 Mm. rotatores
 M. rotatores longi
 M. rotatores breves
 M. interspinales
 Mm. intertransversarii
 Mm. intertransversarii laterales
 Mm. intertransversarii mediales
 Mm. intertransversarii anteriores
 Mm. intertransversarii posteriores
 M. rectus capitis posterior major

 M. rectus capitis posterior minor

 M. rectus capitis lateralis
 M. obliquus capitis superior
 M. obliquus capitis inferior
 Fascia lumbodorsalis
 Fascia nuchae
- Musculi capitis**
- M. epicranius

 M. frontalis
 M. occipitalis
 M. procerus

 M. nasalis
 Pars transversa
 Pars alaris
 M. depressor septi
 M. orbicularis oculi

 Pars palpebralis
 Pars orbitalis
 Pars lacrimalis [Horneri]

 M. auricularis anterior

 M. auricularis superior
- M. auricularis posterior

 M. orbicularis oris
 M. triangularis

 (M. transversus menti)
 M. risorius
 M. zygomaticus
 M. quadratus labii superioris
 Caput zygomaticum

 Caput infraorbitale

 Caput angulare

 M. quadratus labii inferioris

 M. caninus

 M. buccinator
 Mm. incisivi labii superioris
 Mm. incisivi labii inferioris
 M. mentalis
 M. masseter
 M. temporalis
 M. pterygoideus externus
 M. pterygoideus internus
 Galea aponeurotica

 Fascia buccopharyngea
 Fascia parotidomasseterica
 Fascia temporalis
- Musculi oss. hyoidei**
- M. digastricus
 Venter anterior
 Venter posterior
 M. stylohyoideus
 M. mylohyoideus
 M. geniohyoideus
- Musculi colli**
- Platysma

Multifidus ("much divided") muscle (O. T. multifidus spinae)	Posterior auricular muscle (O. T. retrahens auriculam)
Rotator muscles	Orbicular muscle of the mouth
Long rotator muscles	Triangular muscle (O. T. depressor anguli oris)
Short rotator muscles	Transverse muscle of the chin
Interspinal muscles	Muscle of laughing
Intertransverse muscles	Zygomatic muscle
Lateral intertransverse muscles	Quadrate muscle of upper lip
Medial intertransverse muscles	Zygomatic head (O. T. zygomaticus minor)
Anterior intertransverse muscles	Infraorbital head (O. T. levator labii superioris)
Posterior intertransverse muscles	Angular head (O. T. levator labii superioris alaeque nasi)
Larger posterior straight muscle of the head	Quadrate muscle of lower lip (O. T. depressor labii inferioris)
Lesser posterior straight muscle of the head	Canine muscle (O. T. levator anguli oris)
Lateral straight muscle of the head	Cheek muscle
Superior oblique muscle of the head	Incisive muscles of upper lip
Inferior oblique muscle of the head	Incisive muscles of lower lip
Lumbodorsal fascia	Chin muscle
Fascia of the nape	Masseter muscle

Muscles of the head

Epicranius muscle (O. T. occipitofrontalis)	Temporal muscle
Frontal muscle	External pterygoid muscle
Occipital muscle	Internal pterygoid muscle
Procerus ("prolonged") muscle (O. T. pyramidalis nasi)	Aponeurotic helmet (O. T. epicranial aponeurosis)
Muscle of the nose	Buccopharyngeal fascia
Transverse part	Parotideomasseteric fascia
Alar part	Temporal fascia
Depressor muscle of the septum	
Orbicular muscle of the eye (O. T. orbicularis palpebrarum)	
Palpebral part	
Orbital part	
Lacrimal part (O. T. tensor tarsi or Horner's muscle)	
Anterior auricular muscle (O. T. attrahens auriculam)	
Superior auricular muscle (O. T. attolens auriculam)	

Muscles of the hyoid bone

Digastric muscle
Anterior belly
Posterior belly
Stylohyoid muscle
Mylohyoid muscle
Geniohyoid muscle

Muscles of the neck

Platysma, or flat muscle (O. T. platysma myoides)

M. sternocleidomastoideus
 M. sternohyoideus
 M. omohyoideus
 Venter superior
 Venter inferior
 M. sternothyroideus
 M. thyreochoideus
 (M. levator glandulae thyroideae)

M. longus colli
 M. longus capitis

M. rectus capitis anterior

M. scalenus anterior
 M. scalenus medius
 M. scalenus posterior
 (M. scalenus minimus)
 Fascia colli
 Fascia praevertebralis

Musculi Thoracis

(M. sternalis)
 M. pectoralis major
 Pars clavicularis
 Pars sternocostalis
 Pars abdominalis
 M. pectoralis minor
 M. subclavius
 M. serratus anterior
 Mm. levatores costarum
 Mm. levatores costarum longi
 Mm. levatores costarum breves
 Mm. intercostales externi
 Mm. intercostales interni
 Mm. subcostales
 M. transversus thoracis

Diaphragma
 Pars lumbalis
 Crus mediale
 Crus intermedium

Crus laterale
 Pars costalis
 Pars sternalis
 Hiatus aorticus
 Hiatus oesophageus
 Centrum tendineum
 Foramen venae cavae
 Arcus lumbocostalis medialis [Halleri]

Arcus lumbocostalis lateralis [Halleri]

Fascia pectoralis
 Fascia coracoclavicularis

Musculi abdominis

M. rectus abdominis
 Falx [aponeurotica] inguinalis
 M. pyramidalis
 M. obliquus externus abdominis
 M. obliquus internus abdominis
 M. cremaster
 M. transversus abdominis
 M. quadratus lumborum
Annulus umbilicalis
 Linea alba
 Adminiculum lineae albae
 Inscriptiones tendineae
 Lig. suspensorium penis s. clitoridis
 Lig. fundiforme penis
 Vagina m. recti abdominis
 Linea semicircularis [Douglasi]
 Lig. inguinale [Poupartii]
 Lig. lacunare [Gimbernati]
 Lig. inguinale reflexum [Collesi]
 Annulus inguinalis subcutaneus

Crus superius
 Crus inferius
 Fibrae intercrurales

Sternocleidomastoid muscle
 Sternohyoid muscle
 Omohyoid muscle
 Superior belly
 Inferior belly
 Sternothyreoid muscle
 Thyreohyoid muscle
 Elevating muscle of the thyreoid gland
 Long muscle of the neck
 Long muscle of the head (O. T. rectus capitis anticus major)
 Anterior straight muscle of the head (O. T. rectus capitis anticus minor)
 Anterior scalene muscle
 Middle scalene muscle
 Posterior scalene muscle
 Smallest scalene muscle
 Cervical fascia
 Prevertebral fascia

Muscles of the chest

Sternal muscle
 Greater pectoral muscle
 Clavicular part
 Sternocostal part
 Abdominal part
 Smaller pectoral muscle
 Subclavius muscle
 Anterior serratus muscle (O. T. serratus magnus)
 Elevators of the ribs
 Long elevators of the ribs
 Short elevators of the ribs
 External intercostal muscles
 Internal intercostal muscles
 Subcostal muscles
 Transverse muscle of thorax (O. T. triangularis sterni)
 Diaphragm
 Lumbar part
 Medial crus
 Intermediate crus

 Lateral crus
 Costal part
 Sternal part
 Aortic opening
 Oesophageal opening
 Central tendon
 Opening of the vena cava
 Medial lumbocostal arch (O. T. ligamentum arcuatum internum)
 Lateral lumbocostal arch (O. T. ligamentum arcuatum externum)
 Pectoral fascia
 Coracoclavicular fascia

Muscles of the abdomen

Straight muscle of the abdomen
 Inguinal aponeurotic falx (O. T. conjoined tendon)
 Pyramidal muscle
 External oblique muscle of abdomen
 Internal oblique muscle of abdomen
 Cremasteric muscle
 Transverse muscle of abdomen
 Quadrate muscle of the loins
Umbilical ring
 White line
 Stay of the white line
 Tendinous inscriptions
 Suspensory ligament of the penis or clitoris
 Sling-like ligament of penis
 Sheath of the rectus muscle
 Semicircular fold of Douglas
 Inguinal ligament of Poupart
 Lacunar ligament of Gimbernat
 Reflex ligament of Colles (O. T. triangular fascia of the abdomen)
 Subcutaneous inguinal ring (O. T. external abdominal ring)
 Superior pillar
 Inferior pillar
 Intercrural fibres (O. T. intercolumnar fibres)

Trigonum lumbale [Petiti]
 Linea semilunaris [Spigelii]
 Fascia transversalis

Canalis inguinalis
 Annulus inguinalis abdominalis

Lig. interfoveolare [Hesselbachi]

Plica epigastrica
 Fovea inguinalis lateralis
 Fovea inguinalis medialis
 Fovea supravescicalis

Musculi coccygei

M. coccygeus
 M. sacrococcygeus anterior
 M. sacrococcygeus posterior

Musculi extremitatis superioris

M. deltoideus
 M. supraspinatus
 M. infraspinatus
 M. teres minor
 M. teres major
 M. subscapularis
 M. biceps brachii
 Caput longum
 Vagina mucosa intertubercularis
 Caput breve
 Lacertus fibrosus

M. coracobrachialis
 M. brachialis

M. triceps brachii
 Caput longum
 Caput laterale
 Caput mediale
 M. anconaeus
 (M. epitrochleoanconaeus)
 M. pronator teres

Caput humerale
 Caput ulnare
 M. flexor carpi radialis
 M. palmaris longus
 M. flexor carpi ulnaris
 Caput humerale
 Caput ulnare
 M. flexor digitorum sublimis
 Caput humerale
 Caput radiale
 M. flexor digitorum profundus
 M. flexor pollicis longus
 M. pronator quadratus
 M. brachioradialis

M. extensor carpi radialis longus
 M. extensor carpi radialis brevis
 M. extensor digitorum communis
 Juncturae tendinum

M. extensor digiti quinti proprius

M. extensor carpi ulnaris
 M. supinator

M. abductor pollicis longus

M. extensor pollicis brevis

M. extensor pollicis longus

M. extensor indicis proprius

M. palmaris brevis
 M. abductor pollicis brevis

M. flexor pollicis brevis
 M. opponens pollicis
 M. adductor pollicis
 M. abductor digiti quinti
 M. flexor digiti quinti brevis
 M. opponens digiti quinti
 Mm. lumbricales

Lumbar triangle of Petit
 Semilunar line of Spigelius
 Transversal fascia (O. T. transverse fascia)
 Inguinal canal
 Abdominal inguinal ring (O. T. internal abdominal ring)
 Interfoveolar ligament (O. T. Hesselbach's ligament)
 Epigastric fold
 Lateral inguinal fovea
 Medial inguinal fovea
 Supravesical fovea

Coccygeal muscles

Coccygeal muscle
 Anterior sacrococcygeal muscle
 Posterior sacrococcygeal muscle

Muscles of the upper extremity

Deltoid muscle
 Supraspinous muscle
 Infraspinous muscle
 Smaller round muscle
 Larger round muscle
 Subscapular muscle
 Biceps muscle of upper arm
 Long head
 Intertubercular mucous sheath
 Short head
 Fibrous lacertus ("muscle") (O. T. bicipital fascia)
 Coracobrachial muscle
 Brachial muscle (O. T. brachialis anticus)
 Triceps muscle of upper arm
 Long head
 Lateral head
 Medial head
 Elbow muscle
 Epitrochlear elbow muscle
 Round pronator muscle (O. T. pronator radii teres)

Humeral head
 Ulnar head (O. T. coronoid head)
 Radial flexor muscle of wrist
 Long palmar muscle
 Ulnar flexor muscle of wrist
 Humeral head
 Ulnar head
 Superficial flexor muscle of fingers
 Humeral head
 Radial head
 Deep flexor muscles of fingers
 Long flexor muscle of thumb
 Quadrate pronator muscle
 Brachioradial muscle (O. T. supinator longus)
 Long radial extensor muscle of carpus
 Short radial extensor muscle of carpus
 Common extensor muscle of fingers
 Junctions of the tendons; aponeurotic bridges
 Proper extensor muscle of fifth finger (O. T. extensor minimi digiti)
 Ulnar extensor muscle of wrist
 Supinator muscle (O. T. supinator brevis)
 Long abductor muscle of thumb (O. T. extensor ossis metacarpi pollicis)
 Short extensor muscle of thumb (O. T. extensor primi internodii pollicis)
 Long extensor muscle of thumb (O. T. extensor secundi internodii pollicis)
 Proper extensor muscle of index-finger (O. T. extensor indicis)
 Short palmar muscle
 Short abductor muscle of thumb (O. T. abductor pollicis)
 Short flexor muscle of thumb
 Opposing muscle of thumb
 Adductor muscle of thumb
 Abductor muscle of fifth finger
 Short flexor muscle of fifth finger
 Opposing muscle of fifth finger
 Lumbrical muscles

Mm. interossei dorsales		M. gemellus superior
Mm. interossei volares		M. gemellus inferior
Fascia axillaris		M. quadratus femoris
Fascia subscapularis		M. sartorius
Fascia supraspinata		M. quadriceps femoris
Fascia infraspinata		
Fascia brachii		M. rectus femoris
Septum intermusculare	[humeri]	M. vastus lateralis
mediale		
		M. vastus intermedius
Septum intermusculare	[humeri]	M. vastus medialis
laterale		
		M. articularis genu
Sulcus bicipitalis medialis		
Sulcus bicipitalis lateralis		
Fascia antibrachii		M. pectineus
Fascia dorsalis manus		M. adductor longus
Lig. carpi dorsale		M. gracilis
		M. adductor brevis
Aponeurosis palmaris		M. adductor magnus
Fasciculi transversi		M. adductor minimus
Lig. carpi transversum		M. obturator externus
		M. biceps femoris
Lig. carpi volare		Caput longum
Chiasma tendinum		Caput breve
Vinculum tendinum		M. semitendinosus
Vaginae mucosae		M. semimembranosus
Ligg. vaginalia digitorum manus		M. tibialis anterior
Ligg. annularia digitorum manus		
Ligg. cruciata digitorum manus		M. extensor digitorum longus
		M. peroneus tertius
		M. extensor hallucis longus
		M. peroneus longus
		M. peroneus brevis
		M. triceps surae
		M. gastrocnemius
		Caput laterale
		Caput mediale
		M. soleus
		Arcus tendineus m. solei
		Tendo calcaneus [Achillis]
Musculi extremitatis inferioris		
M. iliopsoas		
M. iliacus		
M. psoas major		
M. psoas minor		
M. gluteus maximus		
M. gluteus medius		
M. gluteus minimus		
M. tensor fasciae latae		
M. piriformis		
M. obturator internus		

- Dorsal interosseous muscles
 Palmar interosseous muscles
 Axillary fascia
 Subscapular fascia
 Supraspinous fascia
 Infraspinous fascia
 Brachial fascia
 Medial intermuscular septum of arm
 (O. T. internal intermuscular sep-
 tum)
 Lateral intermuscular septum of arm
 (O. T. external intermuscular sep-
 tum)
 Medial bicipital furrow
 Lateral bicipital furrow
 Antibrachial fascia
 Fascia of back of hand
 Dorsal ligament of wrist (O. T. pos-
 terior annular ligament)
 Palmar aponeurosis
 Transverse fibres (O. T. transverse
 superficial ligament)
 Transverse carpal ligament (O. T.
 anterior annular ligament)
 Palmar carpal ligament
 Crossing of the tendons
 Bands of union of the tendons
 Mucous sheaths
 Ligaments of the sheaths of the fingers
 Annular ligaments of the fingers
 Cruciate ligaments of the fingers
- Muscles of the lower extremity**
 Iliopsoas muscle
 Iliac muscle
 Greater psoas muscle
 Lesser psoas muscle
 Greatest gluteal muscle
 Middle gluteal muscle
 Least gluteal muscle
 Tensor muscle of broad fascia
 Piriform muscle
 Internal obturator muscle
- Superior twin muscle
 Inferior twin muscle
 Quadratus muscle of thigh
 Sartorius ("tailor") muscle
 Quadriceps ("four-headed") muscle of
 thigh
 Straight muscle of thigh
 Lateral great muscle (O. T. vastus
 externus)
 Intermediate great muscle (O. T.
 crureus)
 Medial great muscle (O. T. vastus
 internus)
 Articular muscle of knee (O. T. sub-
 crureus)
 Pectineus muscle
 Long adductor muscle
 Slender muscle
 Short adductor muscle
 Great adductor muscle
 Smallest adductor muscle (O. T. upper
 portion of adductor magnus)
 External obturator muscle
 Biceps ("two-headed") muscle of thigh
 Long head
 Short head
 Semitendinosus muscle
 Semimembranosus muscle
 Anterior tibial muscle (O. T. tibialis
 anticus)
 Long extensor of digits
 Third peroneal muscle
 Long extensor of great toe
 Long peroneal muscle
 Short peroneal muscle
 Triceps muscle of calf
 Gastrocnemius muscle
 Lateral head
 Medial head
 Soleus muscle
 Tendinous arch of soleus muscle
 Tendon of the heel (of Achilles) (O. T.
 tendo Achillis)

M. plantaris	Fossa iliopectinea
M. popliteus	Fascia pectinea
M. tibialis posterior	
	Canalis femoralis
M. flexor digitorum longus	Annulus femoralis
M. flexor hallucis longus	Septum femorale [Cloqueti]
M. extensor hallucis brevis	Fossa ovalis
M. extensor digitorum brevis	Margo falciformis
M. abductor hallucis	Cornu superius
M. flexor hallucis brevis	Cornu inferius
M. adductor hallucis	Fascia cribrosa
Caput obliquum	Fascia cruris
Caput transversum	Septum intermusculare anterius
M. abductor digiti quinti	[fibulare]
M. flexor digiti quinti brevis	
M. opponens digiti quinti	Septum intermusculare posterius
M. flexor digitorum brevis	[fibulare]
M. quadratus plantae	
Mm. lumbricales	Lig. transversum cruris
Mm. interossei dorsales	
Mm. interossei plantares	
Fascia lata	Lig. laciniatum
Tractus iliotibialis [Maissiati]	
Septum intermusculare [femoris]	Lig. cruciatum cruris
laterale	
Septum intermusculare [femoris]	Retinaculum mm. peronaeorum sup.
mediale	
Canalis adductorius [Hunteri]	Retinaculum mm. peronaeorum in-
	ferius
Hiatus tendineus [adductorius]	Fascia dorsalis pedis
Fascia iliaca	Aponeurosis plantaris
Fascia iliopectinea	Fasciculi transversi aponeurosis
Lacuna musculorum	plantaris
Lacuna vasorum	Vaginae mucosae
Trigonum femorale [Fossa Scarpae	Ligg. annularia
major]	Ligg. vaginalia
	Ligg. cruciata

- Plantaris muscle
- Popliteus muscle
- Posterior tibial muscle (O. T. tibialis posticus)
- Long flexor of the digits
- Long flexor of the great toe
- Short extensor of the great toe
- Short extensor of the digits
- Abductor of the great toe
- Short flexor of the great toe
- Adductor of the great toe
 - Oblique head
 - Transverse head
- Abductor of the fifth toe
- Short flexor muscle of fifth toe
- Opposing muscle of fifth toe
- Short flexor muscle of the toes
- Quadratus muscle of the sole
- Lumbrical muscles
- Dorsal interosseous muscles
- Plantar interosseous muscles
- Broad fascia
- Iliotibial band
- Lateral intermuscular septum of thigh (O. T. external intermuscular septum)
- Medial intermuscular septum of thigh (O. T. internal intermuscular septum)
- Adductor canal of Hunter (O. T. Hunter's canal)
- Tendinous adductor gap
- Iliac fascia
- Iliopectineal fascia
- Muscle gap
- Vessel gap
- Femoral triangle (greater fossa of Scarpa) (O. T. Scarpa's triangle)
- Iliopectineal fossa
- Pectineal fascia (O. T. pubic portion of fascia lata)
- Femoral canal (O. T. crural canal)
- Femoral ring (O. T. crural ring)
- Femoral septum of Cloquet
- Oval fossa
 - Falciform margin
 - Superior horn
 - Inferior horn
- Cribriform fascia
- Fascia of the leg
 - Anterior (fibular) intermuscular septum (O. T. anterior peroneal septum)
 - Posterior (fibular) intermuscular septum (O. T. posterior peroneal septum)
- Transverse ligament of the leg (O. T. upper or broad part of anterior annular ligament)
- Fringed ligament (O. T. internal annular ligament)
- Cruciate ligament of the leg (O. T. lower part of anterior annular ligament of leg)
- Upper retaining band of peroneal muscles
- Lower retaining band of peroneal muscles
- Dorsal fascia of the foot
- Plantar aponeurosis
 - Transverse bundles of plantar aponeurosis
- Mucous sheaths
- Annular ligaments
- Sheath ligaments
- Cruciate ligaments

Bursae et Vaginae mucosae

- | | |
|--|--|
| Bursa mucosa subcutanea | Bursa mucosa subtendinea |
| Bursa mucosa submuscularis | Vagina mucosa tendinis |
| Bursa mucosa subfascialis | |
|
 | |
| B. musculi trochlearis | |
| B. m. tensoris veli palatini | |
| B. subcutanea praementalis | Vagina tendinis m. extensoris digiti
minimi |
| B. subcutanea prominentiae laryngeae | Vagina tendinis m. extensoris carpi
ulnaris |
|
 | |
| B. m. sternohyoidei | B. m. extensoris carpi radialis brevis |
| B. m. thyreohyoidei | |
| B. subcutanea sacralis | Bursae subcutaneae metacarpophalan-
geae dorsales |
| B. coccygea | Bursae subcutaneae digitorum dorsales |
| B. subcutanea acromialis | |
| B. subacromialis | B. m. flexoris carpi ulnaris |
| B. subdeltoidea | |
| B. m. coracobrachialis | B. m. flexoris carpi radialis |
| B. m. infraspinati | |
| B. m. subscapularis | Vagina tendinum mm. flexorum com-
muniium |
| B. m. teretis majoris | Vag. tendinis m. flexoris pollicis longi |
| B. m. latissimi dorsi | |
| B. subcutanea olecrani | Bursae intermetacarpophalangeae |
| B. intratendinea olecrani | Vaginae tendinum digitales |
| B. subtendinea olecrani | B. trochanterica subcutanea |
| B. subcutanea epicondyli [humeri]
lateralis | B. trochanterica m. glutaei maximi |
| B. subcutanea epicondyli [humeri]
medialis | |
| B. bicipitoradialis | B. troch. m. glutaei medii anterior |
| B. cubitalis interossea | B. troch. m. glutaei medii posterior |
| Vagina tendinum mm. abductoris
longi et extensoris brevis pollicis | |
|
 | |
| Vagina tendinum mm. extensorum
carpi radialium | B. troch. m. glutaei minimi |
| Vagina tendinis m. extensoris pollicis
longi | B. m. piriformis |
| Vagina tendinum mm. extensoris digi-
torum communis et extensoris indicis | B. m. obturatorii interni |
| | Bursae glutaeofemorales |

Bursae and mucous sheaths

Subcutaneous mucous bursa	Subtendinous mucous bursa
Submuscular mucous bursa	Mucous sheath of tendon
Subfascial mucous bursa	
Bursa of the trochlear muscle	of the extensor muscle of the index finger
Bursa of tensor muscle of soft palate	
Subcutaneous premental bursa	Sheath of the tendon of the extensor muscle of the little finger
Subcutaneous bursa of the prominence of the larynx	Sheath of the tendon of the ulnar extensor muscle of the wrist
Bursa of the sternohyoid muscle	Bursa of the short radial extensor muscle of the wrist
Bursa of the thyreohyoid muscle	Dorsal subcutaneous metacarpophalangeal bursa
Subcutaneous sacral bursa	Dorsal subcutaneous bursae of the digits
Coccygeal bursa	Bursa of the ulnar flexor muscle of the wrist
Subcutaneous acromial bursa	Bursa of the radial flexor muscle of the wrist
Subacromial bursa	Sheath of the tendons of the common flexor muscles
Subdeltoid bursa	Sheath of the tendon of the long flexor muscle of the thumb
Bursa of the coracobrachial muscle	Intermetacarpophalangeal bursae
Bursa of the infraspinatus muscle	Digital sheaths of the tendons
Bursa of the subscapular muscle	Subcutaneous trochanteric bursa
Bursa of the greater round muscle	Trochanteric bursa of the great gluteal muscle
Bursa of the broadest muscle of back	Anterior trochanteric bursa of the middle gluteal muscle
Subcutaneous bursa of the olecranon	Posterior trochanteric bursa of the middle gluteal muscle
Intratendinous bursa of the olecranon	Trochanteric bursa of the smallest gluteal muscle
Subtendinous bursa of the olecranon	Bursa of the piriform muscle
Subcutaneous bursa of the lateral epicondyle of humerus	Bursa of the internal obturator muscle
Subcutaneous bursa of the medial epicondyle of humerus	Glutaeofemoral bursae
Bicipitoradial bursa	
Interosseous bursa of the elbow	
Sheath of the tendons of the long abductor and short extensor muscles of the thumb	
Sheath of the tendons of the radial extensor muscles of the wrist	
Sheath of the tendon of the long extensor muscle of the thumb	
Sheath of the tendons of the common extensor muscle of the digits and	

B. ischiadica m. glutaei maximi	Vag. tendinis m. tibialis anterioris
B. m. recti femoris	Vag. tendinis m. extensoris hallucis longi
B. iliopectinea	Vaginae tendinum m. extensoris digitorum pedis longi
B. iliaca subtendinea	
B. m. pectinei	
B. m. bicipitis femoris superior	Vaginae tendinum m. flexoris digitorum pedis longi
B. praepatellaris subcutanea	
B. praepatellaris subfascialis	
B. praepatellaris subtendinea	Vag. tendinis m. tibialis posterioris
B. suprapatellaris	
B. infrapatellaris subcutanea	Vag. tendinis m. flexoris hallucis longi
B. infrapatellaris profunda	
B. subcutanea tuberositatis tibiae	Vag. tendinum mm. peronaeorum communis
B. m. sartorii propria	Bursa sinus tarsi
B. anserina	B. subtendinea m. tibialis anterioris
B. m. bicipitis femoris inferior	B. subtendinea m. tibialis posterioris
B. m. poplitei	
B. bicipitogastrocnemialis	B. subcutanea calcanea
B. m. gastrocnemii lateralis	B. tendinis calcanei [Achillis]
B. m. gastrocnemii medialis	Vag. tendinis m. peronaei longi plantaris
B. m. semimembranosi	Bursae intermetatarsophalangeae
B. subcutanea malleoli lateralis	Bursae mm. lumbricalium pedis
B. subcutanea malleoli medialis	Vaginae tendinum digitales pedis

Sciatic bursa of the greatest gluteal muscle	Sheath of the tendon of the anterior tibial muscle
Bursa of the straight thigh muscle	Sheath of the tendon of the long extensor muscle of the great toe
Iliopectineal bursa	Sheaths of the tendons of the long extensor muscle of the digits of the foot
Subtendinous iliac bursa	Sheaths of the tendons of the long flexor muscle of the digits of the foot
Bursa of the pectineus muscle	Sheath of the tendon of the posterior tibial muscle
Superior bursa of the biceps muscle of the thigh	Sheath of the tendon of the long flexor muscle of the great toe
Subcutaneous prepatellar bursa	Common sheath of the tendons of the peroneal muscles
Subfascial prepatellar bursa	Bursa of the hollow of the ankle
Subtendinous prepatellar bursa	Subtendinous bursa of the anterior tibial muscle
Suprapatellar bursa	Subtendinous bursa of the posterior tibial muscle
Subcutaneous infrapatellar bursa	Subcutaneous calcanean bursa
Deep infrapatellar bursa	Bursa of the calcanean tendon of Achilles
Subcutaneous bursa of the tuberosity of the tibia	Sheath of the plantar tendon of the long peroneal muscle
Proper bursa of the sartorius muscle	Intermetatarsophalangeal bursae
Anserine bursa	Bursae of the lumbrical muscles of the foot
Inferior bursa of the biceps muscle of the thigh	Digital sheaths of the tendons of the foot
Bursa of the popliteus muscle	
Bicipitogastrocnemial bursa	
Lateral bursa of the gastrocnemius muscle	
Medial bursa of the gastrocnemius muscle	
Bursa of the semimembranosus muscle	
Subcutaneous bursa of the lateral malleolus	
Subcutaneous bursa of the medial malleolus	

Splanchnologia

Tunica albuginea	Ligamentum serosum
Tunica fibrosa	Serum
Tunica adventitia	Epithelium
Tunica mucosa	Endothelium
Lamina propria mucosae	Organon parenchymatosum
Lamina muscularis mucosae	Parenchyma
Tela submucosa	Stroma
Plica mucosa	Glandula
Mucus	Lobus
Tunica muscularis	Lobulus
Tunica serosa	Glandula mucosa
Tela subserosa	Musculus viscerum
Plica serosa	

Apparatus digestorius

Cavum oris	
Bucca	Frenulum labii inferioris
Corpus adiposum buccae	Gingiva
Vestibulum oris	Caruncula sublingualis
Cavum oris proprium	Plica sublingualis
Rima oris	Plicae palatinae transversae
Labia oris	Papilla incisiva
Labium superius	
Labium inferius	Glandulae oris
Commissura labiorum	Gl. labiales
Angulus oris	Gl. buccales
Palatum	Gl. molares
Palatum durum	Gl. palatinae
Palatum molle	Gl. linguales
Raphe palati	Gl. lingualis anterior [Blandini, Nuhni]
	Gl. sublingualis
Tunica mucosa oris	Ductus sublingualis major
Frenulum labii superioris	Ductus sublinguales minores

Splanchnology

Albugineous coat	Serous ligament
Fibrous coat	Serum
Adventitious (external) coat	Epithelium
Mucous coat	Endothelium
Proper layer of the mucosa	Parenchymatous organ
Muscular layer of the mucosa	Parenchyma
Submucous web	Stroma
Mucous fold	Gland
Mucus	Lobe
Muscular coat	Little lobe
Serous coat	Mucous gland
Subserous web	Muscle of the viscera
Serous fold	

Digestive apparatus

Mouth cavity	Check-cord of lower lip
Cheek	Gum
Fat body of cheek	Sublingual caruncle
Entrance to mouth	Sublingual fold
Mouth cavity proper	Transverse palatine folds
Mouth-slit	Incisor papilla
Lips of mouth	
Upper lip	Glands of mouth
Lower lip	Labial glands
Junction of lips	Buccal glands
Angle of mouth	Molar glands
Palate	Palatine glands
Hard palate	Lingual glands
Soft palate	Anterior lingual gland (O. T. gland of Nuhn)
Middle ridge of palate	Sublingual gland
	Larger sublingual duct
Mucous membrane of mouth	Smaller sublingual ducts
Check-cord of upper lip	

Gl. submaxillaris
Ductus submaxillaris [Whartoni]

Gl. parotis
Processus retromandibularis
Gl. parotis accessoria

Ductus parotideus [Stenonis]
Saliva

Dentes

Corona dentis
Tubercula [coronae] dentis
Collum dentis
Radix [Radices] dentis
Apex radices dentis
Facies masticatoria
Facies labialis [buccalis]
Facies lingualis
Facies contactus
Facies medialis } dentium incisivo-
Facies lateralis } rum et caninorum
Facies anterior } dentium praemola-
Facies posterior } rium et molarium
Cavum dentis
Pulpa dentis
Papilla dentis
Canalis radices dentis
Foramen apicis dentis
Substantia eburnea
Substantia adamantina
Substantia ossea
Canaliculi dentales
Spatia interglobularia
Prismata adamantina
Cuticula dentis
Periosteum alveolare
Arcus dentalis superior
Arcus dentalis inferior
Dentes incisivi
Dentes canini
Dentes praemolares
Dentes molares

Dens serotinus
Dentes permanentes
Dentes decidui

Lingua

Dorsum linguae
Radix linguae
Corpus linguae
Facies inferior [linguae]
Plica fimbriata
Margo lateralis [linguae]
Apex linguae
Tunica mucosa linguae
Frenulum linguae
Papillae linguales
Papillae filiformes
Papillae conicae
Papillae fungiformes
Papillae lenticulares
Papillae vallatae

Papillae foliatae
Sulcus medianus linguae
Sulcus terminalis
Foramen caecum linguae (Morgagnii)
(Ductus lingualis)
Ductus thyreoglossus
Tonsilla lingualis
Folliculi linguales
Septum linguae
M u s c u l i l i n g u a e
M. genioglossus
M. hyoglossus
M. chondroglossus
M. styloglossus
M. longitudinalis superior

M. longitudinalis inferior

M. transversus linguae
M. verticalis linguae

Fauces

Isthmus faucium

Submaxillary gland
 Submaxillary duct (O. T. Wharton's duct)
 Parotid gland
 Retromandibular process
 Accessory parotid (O. T. socia parotidis)
 Parotid duct (O. T. Steno's duct)
 Mixed mouth secretions

Teeth

Crown of tooth
 Tubercles of crown of tooth
 Neck of tooth
 Root of tooth
 Apex of root of tooth
 Chewing-surface
 Labial surface
 Lingual surface
 Contact surface
 Medial surface } of incisor
 Lateral surface } and canine teeth
 Anterior surface } of premolars
 Posterior surface } and molars
 Tooth cavity
 Tooth pulp
Papilla of tooth
 Root canal of tooth
 Foramen of apex of tooth
 Dentine
 Enamel
 Cement
 Smaller dental canals
 Granular layer
 Enamel prisms
 Cuticle of tooth
 Alveolar periosteum
 Superior dental arch
 Inferior dental arch
 Incisor teeth
 Canine teeth
 Premolar teeth (O. T. bicuspidis)
 Molar teeth

Late tooth (O. T. wisdom tooth)
 Permanent teeth
 Deciduous teeth

Tongue

Dorsum of tongue
 Root of tongue
 Body of tongue
 Inferior surface
 Fimbriated fold
 Lateral margin
 Tip of the tongue
 Mucous membrane of tongue
 Frenulum (check-rein) of tongue
 Lingual papillae
 Filiform papillae
 Conical papillae
 Fungiform papillae
 Lenticular papillae
 Vallate papillae (O. T. circumvallate papillae)
 Foliate papillae
 Median sulcus of tongue
 Terminal sulcus
 Blind foramen of tongue
 Lingual duct
Thyreoglossal duct
 Lingual tonsil
 Lingual folliculi
 Septum of tongue
 Muscles of tongue
 Genioglossus muscle
 Hyoglossus muscle
 Chondroglossus muscle
 Styloglossus muscle
 Superior longitudinal muscle (O. T. superficial lingual)
 Inferior longitudinal muscle (O. T. inferior lingual)
 Transverse muscle of tongue
 Vertical muscle of tongue

Fauces, or throat

Isthmus of fauces

Velum palatinum
 Uvula [palatina]
 Arcus palatini
 Arcus glossopalatinus

 Arcus pharyngopalatinus

Plica salpingopalatina
 Tonsilla palatina
 Fossulae tonsillares
 Sinus tonsillaris
 Plica triangularis
 Fossa supratonsillaris

Musculi palati et faucium

M. levator veli palatini
 M. tensor veli palatini
 M. uvulae
 M. glossopalatinus
 M. pharyngopalatinus

Pharynx

Cavum pharyngis
 Fornix pharyngis
 Pars nasalis
 Pars oralis
 Pars laryngea
 Ostium pharyngeum tubae
 Labium anterius
 Labium posterius
 Torus tubarius
 Plica salpingopharyngea
 Recessus pharyngeus [Rosenmuelleri]
 (Bursa pharyngea)
 Recessus piriformis
 M. stylopharyngeus
 Fascia pharyngobasilaris
 Tunica mucosa

Gl. pharyngeae
 Tonsilla pharyngea
 Fossulae tonsillares
 Tela submucosa

Tunica muscularis pharyngis
 Raphe pharyngis
 Raphe pterygomandibularis
 M. constrictor pharyngis superior
 M. pterygopharyngeus
 M. buccopharyngeus
 M. mylopharyngeus
 M. glossopharyngeus
 M. salpingopharyngeus
 M. constrictor pharyngis medius
 M. chondropharyngeus
 M. ceratopharyngeus
 M. constrictor pharyngis inferior
 M. thyreopharyngeus
 M. cricopharyngeus

Tubus digestorius

Oesophagus

Pars cervicalis
 Pars thoracalis
 Pars abdominalis
 Tunica adventitia
 Tunica muscularis
 M. bronchooesophageus
 M. pleurooesophageus
 Tela submucosa
 Tunica mucosa
 Lam. muscularis mucosae
 Gl. oesophageae

Ventriculus

[Gaster]

Paries anterior
 Paries posterior
 Curvatura ventriculi major
 Curvatura ventriculi minor
 Cardia
 Fundus ventriculi

Palatine curtain	Pharyngeal glands
Uvula	Pharyngeal tonsil
Palatine arches	Tonsillar crypts
Glossopalatine arch (O. T. anterior pillar of fauces)	Submucous web (O. T. pharyngeal aponeurosis)
Pharyngopalatine arch (O. T. posterior pillar of fauces)	Muscular coat of pharynx
Tubopalatine fold	Raphe of pharynx
Palatine tonsil	Pterygomandibular raphe
Tonsillar crypts	Superior constrictor muscle of pharynx
Tonsillar sinus	Pterygopharyngeal muscle
Triangular fold	Buccopharyngeal muscle
Supratonsillar fossa	Mylopharyngeal muscle
	Glossopharyngeal muscle
	Salpingopharyngeal muscle
	Middle constrictor muscle of pharynx
	Chondropharyngeal muscle
	Ceratopharyngeal muscle
	Inferior constrictor muscle of pharynx
	Thyreopharyngeal muscle
	Cricopharyngeal muscle

Muscles of palate and fauces

Levator muscle of palatine curtain (O. T. levator palati)	
Tensor muscle of palatine curtain (O. T. tensor palati)	
Muscle of uvula (O. T. azygos uvulae)	
Glossopalatine muscle (O. T. palatoglossus)	
Pharyngopalatine muscle (O. T. palatopharyngeus)	

Pharynx

Cavity of pharynx
Vault of pharynx
Nasal part (O. T. nasopharynx)
Oral part (O. T. oral pharynx)
Laryngeal part (O. T. laryngopharynx)
Pharyngeal opening of Eustachian tube
Anterior lip
Posterior lip
Tubal projection
Salpingopharyngeal fold
Pharyngeal recess of Rosenmueller (O. T. recessus infundibuliformis)
Pharyngeal bursa
Piriform recess (O. T. sinus piriformis)
Stylopharyngeus muscle
Pharyngobasilar fascia
Mucous membrane

Digestive tube

Oesophagus

Cervical part
Thoracic part
Abdominal part
Adventitious coat
Muscular coat
Broncho-oesophageal muscle
Pleuro-oesophageal muscle
Submucous layer
Mucous membrane
Muscular layer of mucosa
Oesophageal glands

Stomach

Anterior wall
Posterior wall
Greater curvature of stomach
Lesser curvature of stomach
Cardia
Fundus of stomach

Corpus ventriculi
 Pylorus
 Pars cardiaca
 Pars pylorica
 (Antrum cardiacum)
 Antrum pyloricum
 Tunica serosa
 Tunica muscularis
 Stratum longitudinale
 Ligg. pylori
 Stratum circulare
 M. sphincter pylori
 Fibrae obliquae
 Valvula pylori
 Tela submucosa
 Tunica mucosa
 Lam. muscularis mucosae
 Areae gastricae
 Plicae villosae
 Foveolae gastricae
 Glandulae gastricae [propriae]
 Glandulae pyloricae
 Noduli lymphatici gastrici
 Succus gastricus

Intestinum tenue

Tunica serosa
 Tunica muscularis
 Stratum longitudinale
 Stratum circulare
 Tela submucosa
 Tunica mucosa
 Lam. muscularis mucosae
 Plicae circulares [Kerkringi]
 Villi intestinales
 Gl. intestinales [Lieberkuehni]
 Noduli lymphatici solitarii
 Noduli lymphatici aggregati [Peyeri]
 Chymus
 Chylus

Succus entericus
 D u o d e n u m
 Pars superior
 Pars descendens
 Pars inferior
 Pars horizontalis [inferior]
 Pars ascendens
 Flexura duodeni superior
 Flexura duodeni inferior
 Flexura duodenojejunalis
 M. suspensorius duodeni
 Plica longitudinalis duodeni
 Papilla duodeni [Santorini]
 Gl. duodenales [Brunneri]
 I n t e s t i n u m t e n u e m e s e n -
 t e r i a l e
 Intestinum jejunum
 Intestinum ileum

Intestinum crassum

I n t e s t i n u m c a e c u m
 Valvula coli
 Labium superius
 Labium inferius
 Frenula valvulae coli
 P r o c e s s u s v e r m i f o r m i s
 (Valvula processus vermiformis)
 Noduli aggregati processus vermifor-
 mis
 C o l o n
 Colon ascendens
 Flexura coli dextra
 Colon transversum
 Flexura coli sinistra
 Colon descendens
 Colon sigmoideum
 Plicae semilunares coli
 Haustra coli
 Tunica serosa
 Appendices epiploicae

Body of stomach	Intestinal juice
Pylorus	D u o d e n u m
Cardiac part	Superior part
Pyloric part	Descending part
Cardiac antrum	Inferior part
Pyloric antrum	Horizontal part
Serous coat	Ascending part
Muscular coat	Superior duodenal flexure
Longitudinal layer	Inferior duodenal flexure
Pyloric ligaments	Duodenojejunal flexure
Circular layer	Suspensory muscle of duodenum (O.
Sphincter muscle of pylorus	T. muscle of Treitz)
Oblique fibres	Longitudinal fold of duodenum
Pyloric valve	Duodenal papilla
Submucous layer	Duodenal glands of Brunner
Mucous membrane	Mesenterial small intestine
Muscular layer of mucosa	
Gastric areas	Empty intestine (O. T. jejunum)
Folds of villi	Twisted intestine (O. T. ileum)
Gastric pits	
Gastric glands proper	
Pyloric glands	
Gastric lymph-nodules	
Gastric juice	
	Large or thick intestine
	Blind intestine
	Valve of the colon (O. T. ileocaecal valve)
	Superior lip
	Inferior lip
	Frenula of valve of colon
	Vermiform process, or appendix
	Valve of the vermiform process
	Aggregated nodules of the vermiform process
	Colon, or great gut
	Ascending colon
	Right colic flexure
	Transverse colon
	Left colic flexure
	Descending colon
	Sigmoid colon
	Semilunar folds of colon
	Sacculations of colon
	Serous coat
	Epiploic (fatty) appendages
Small or thin intestine	
Serous coat	
Muscular coat	
Longitudinal layer	
Circular layer	
Submucous coat	
Mucous coat	
Muscular layer of mucosa	
Circular folds (O. T. valvulae conniventes)	
Intestinal villi	
Intestinal glands (O. T. crypts of Lieberkuehn)	
Solitary lymph-nodules	
Aggregated lymph-nodules of Peyer (O. T. Peyer's patches)	
Chyme	
Chyle	

Tunica muscularis
 Taeniae coli
 Taenia mesocolica
 Taenia omentalis
 Taenia libera
 Tela submucosa
 Tunica mucosa
 Lam. muscularis mucosae
 Gl. intestinales [Lieberkuehni]
 Noduli lymphatici solitarii

Intestinum rectum

Flexura sacralis
 Flexura perinealis
 Ampulla recti
 Tunica muscularis
 M. sphincter ani internus
 M. rectococcygeus
 Tela submucosa
 Tunica mucosa
 Lam. m. mucosae
 Gl. intestinales [Lieberkuehni]
 Noduli lymphatici
 Plicae transversales recti

Pars analis recti
 Columnae rectales [Morgagnii]
 Sinus rectales
 Annulus haemorrhoidalis

Pancreas

Caput pancreatis
 Processus uncinatus [Pancreas Wins-
 lowi]
 Incisura pancreatis
 Corpus pancreatis
 Facies anterior
 Facies posterior
 Facies inferior
 Margo superior
 Margo anterior
 Margo posterior
 Tuber omentale

Cauda pancreatis
 Ductus pancreaticus [Wirsungi]
 Ductus pancreaticus accessorius
 [Santorini]
 (Pancreas accessorium)
 Succus pancreaticus

Hepar

Facies superior
 Facies posterior
 Facies inferior
 Margo anterior
 Incisura umbilicalis
 Fossae sagittales dextrae
 Fossa vesicae felleae
 Fossa venae cavae
 Fossa sagittalis sinistra
 Fossa venae umbilicalis
 Fossa ductus venosi
 Tunica serosa
 Lig. teres hepatis
 Lig. venosum [Arantii]
 Porta hepatis
 Lobus hepatis dexter
 Lobus quadratus
 Lobus caudatus [Spigelii]
 Processus papillaris
 Processus caudatus
 Lobus hepatis sinister
 (Appendix fibrosus hepatis)
 Impressio cardiaca
 Tuber omentale
 Impressio oesophagea
 Impressio gastrica
 Impressio duodenalis
 Impressio colica
 Impressio renalis
 Impressio suprarenalis
 Lobuli hepatis
 Capsula fibrosa [Glissoni]
 Rami arteriosi interlobulares
 Venae interlobulares
 Venae centrales

- | | |
|---|--|
| Muscular coat | Tail of pancreas |
| Bands of the colon | Pancreatic duct of Wirsung |
| Mesocolic band | Accessory pancreatic duct of Santorini |
| Omental band | |
| Free band | Accessory pancreas |
| Submucous coat | Pancreatic juice |
| Mucous coat | |
| Muscular layer of mucosa | Liver |
| Intestinal glands of Lieberkuehn | Superior surface |
| Solitary lymph-nodules | Posterior surface |
| | Inferior surface |
| Rectum, or straight gut | Anterior margin |
| Sacral flexure | Umbilical notch |
| Perineal flexure | Right sagittal fossae |
| Ampulla of rectum | Fossa for gall-bladder |
| Muscular layer | Fossa for vena cava |
| Internal sphincter muscle of anus | Left sagittal fossa |
| Rectococcygeus muscle | Fossa for umbilical vein |
| Submucous coat | Fossa for venous duct |
| Mucous membrane | Serous coat |
| Muscular layer of mucosa | Round ligament of liver |
| Intestinal glands of Lieberkuehn | Venous ligament of Arantius |
| Lymphatic nodules | Porta, or door of liver |
| Transverse folds of rectum (O. T.
valves of Houston) | Right lobe of liver |
| A n a l p a r t o f r e c t u m | Quadrate lobe |
| Rectal columns of Morgagni | Caudate lobe of Spigelius |
| Rectal sinuses | Papillary process |
| Hemorrhoidal ring | Caudate process |
| | Left lobe of liver |
| Pancreas | Fibrous appendix of liver |
| Head of pancreas | Cardiac impression |
| Uncinate process | Omental tuber |
| | Oesophageal impression |
| Notch of pancreas | Gastric impression |
| Body of pancreas | Duodenal impression |
| Anterior surface | Colic impression |
| Posterior surface | Renal impression |
| Inferior surface | Suprarenal impression |
| Superior margin | Lobules of liver |
| Anterior margin | Fibrous capsule of Glisson |
| Posterior margin | Interlobular arteries |
| Omental tuber | Interlobular veins |
| | Central veins |

Ductus biliferi	Lien
Ductus interlobulares	Facies diaphragmatica
Ductus hepaticus	Facies renalis
Vasa aberrantia hepatis	Facies gastrica
Fel [Bilis]	Extremitas superior
Vesica fellea	Extremitas inferior
Fundus vesicae felleae	Margo posterior
Corpus vesicae felleae	Margo anterior
Collum vesicae felleae	Hilus lienis
Ductus cysticus	Tunica serosa
Tunica serosa vesicae felleae	Tunica albuginea
Tunica muscularis vesicae felleae	Trabeculae lienis
Tunica mucosa vesicae felleae	Pulpa lienis
Plicae tun. mucosae v. felleae	Rami lienales [arteriae lienalis]
Valvula spiralis [Heisteri]	Penicilli
Ductus choledochus	Noduli lymphatici lienales [Malpighii]
Gl. mucosae biliosae	
	(Lien accessorius)

Apparatus respiratorius

Cavum nasi	Meatus nasi
Nares	Meatus nasi superior
Choanae	Meatus nasi medius
Septum nasi	Atrium meatus medii
Septum cartilagineum	Meatus nasi inferior
Septum membranaceum	Meatus nasi communis
Vestibulum nasi	Meatus nasopharyngeus
Limen nasi	Regio respiratoria
Sulcus olfactorius	Regio olfactoria
(Concha nasalis suprema [Santorini])	Gl. olfactoriae
	Sinus paranasales
Concha nasalis superior	Sinus maxillaris [Highmori]
Concha nasalis media	Sinus sphenoidalis
	Sinus frontalis
Concha nasalis inferior	Cellulae ethmoidales
	Bulla ethmoidalis
Membrana mucosa nasi	Infundibulum ethmoidale
Plexus cavernosi concharum	Hiatus semilunaris
Agger nasi	Gl. nasales
Recessus sphenothmoidalis	

Bile-ducts (O. T. bile canaliculi)	Spleen
Interlobular ducts	Diaphragmatic surface
Hepatic duct	Renal surface
Aberrant vessels of liver	Gastric surface
Bile	Superior extremity
G a l l b l a d d e r	Inferior extremity
Fundus of gall bladder	Posterior margin
Body of gall bladder	Anterior margin
Neck of gall bladder	Hilus of the spleen
Cystic duct	Serous coat
Serous coat of gall bladder	Albugineous coat
Muscular coat of gall bladder	Trabeculae ("cords") of spleen
Mucous coat of gall bladder	Spleen pulp
Folds of mucous coat of gall bladder	Splenic rami of splenic artery
Spiral valve of Heister	Arterial tufts
Common bile duct	Splenic lymph-nodules (O. T. Mal-
Glands of biliary mucosa	pighian corpuscles)
	Accessory spleen

Respiratory system

Nasal cavity	Meatuses of the nose
Anterior apertures	Superior meatus
Posterior apertures	Middle meatus
Nasal septum	"Entrance-hall" of middle meatus
Cartilaginous septum	Inferior meatus
Membranous septum	Common meatus
Vestibule of nose	Nasopharyngeal meatus
Threshold of nose	Respiratory region
Olfactory sulcus	Olfactory region
Highest nasal concha (O. T. upper-	Olfactory glands
most turbinated bone)	Sinuses near nose
Superior nasal concha (O. T. superior	Maxillary sinus (O. T. antrum of
turbinated bone)	Highmore)
Middle nasal concha (O. T. middle	Sphenoidal sinus
turbinated bone)	Frontal sinus
Inferior nasal concha (O. T. inferior	Ethmoidal cells
turbinated bone)	Ethmoidal bulla ("bubble")
Mucous membrane of nose	Ethmoidal infundibulum ("funnel")
Cavernous layer of conchae	Semilunar opening
Agger ("elevation") of nose	Nasal glands
Spheno-ethmoidal recess	

Nasus externus

Basis nasi
 Radix nasi
 Dorsum nasi
 Margo nasi
 Apex nasi
 Ala nasi
 Septum mobile nasi
 Cartilaginei nasi
 Cartilago septi nasi
 Processus sphenoidalis septi cartilaginei
 Cartilago nasi lateralis
 Cartilago alaris major
 Crus mediale
 Crus laterale
 Cartilaginei alares minores
 Cartilaginei sesamoidei nasi
 Organon vomeronasale [Jacobsoni]
 Cartilago vomeronasalis [Jacobsoni]
 (Ductus incisivus)

Larynx

Prominentia laryngea
 Cartilaginei laryngis
 Cartilago thyreoidea
 Lamina [dextra et sinistra]
 Incisura thyreoidea superior
 Incisura thyreoidea inferior
 Tuberculum thyreoideum superius
 Tuberculum thyreoideum inferius
 (Linea obliqua)
 Cornu superius
 Cornu inferius
 (Foramen thyreoideum)
 Lig. hyothyreoideum laterale
 Cartilago triticea
 Lig. hyothyreoideum medium
 Membrana hyothyreoidea
 Cartilago cricoidea
 Arcus [cartilaginei cricoideae]

Lamina [cartilaginei cricoideae]
 Facies articularis arytaenoidea
 Facies articularis thyreoidea
 Articulatio cricothyreoidea
 Capsula articularis cricothyreoidea
 Ligg. ceratocricoidea lateralia
 Lig. ceratocricoideum anterius
 Ligg. ceratocricoidea posteriora
 Lig. cricothyreoideum [medium]

Lig. cricotracheale
 Cartilago arytaenoidea
 Facies articularis
 Basis [cartilaginei arytaenoideae]
 Crista arcuata
 Colliculus
 Fovea oblonga
 Fovea triangularis
 Apex [cartilaginei arytaenoideae]
 Processus vocalis
 Processus muscularis
 Cartilago corniculata [Santorini]

Synchondrosis arycorniculata
 Articulatio cricoarytaenoidea
 Lig. cricopharyngeum
 Lig. corniculopharyngeum

Lig. ventriculare

Lig. vocale

(Cartilago sesamoidea)
 Capsula articularis cricoarytaenoidea
 Lig. cricoarytaenoideum posterius
 Epiglottis
 Petiolus epiglottidis
 Tuberculum epiglotticum

Cartilago epiglottica
 Lig. thyreoepiglotticum

External nose

Base of nose
 Root of nose
 Dorsum of nose
 Margin of nose
 Tip of nose
 Wing of nose
 Movable septum of nose
Nasal cartilages
 Cartilage of nasal septum
 Sphenoidal process of cartilaginous
 septum
 Lateral nasal cartilage
 Greater alar cartilage
 Medial crus
 Lateral crus
 Lesser alar cartilages
 Sesamoid cartilages of nose
 Vomer nasal organ of Jacobson
 Vomer nasal cartilage of Jacobson
 Incisor canaliculus

Larynx

Laryngeal prominence (O. T. Adam's
 apple, or pomum Adami)
Laryngeal cartilages
 Thyroid cartilage
 Right and left plates
 Superior thyroid notch
 Inferior thyroid notch
 Superior thyroid tubercle
 Inferior thyroid tubercle
 Oblique line
 Superior horn
 Inferior horn
 Thyroid foramen
 Lateral hyothyroid ligament
 Triticeous ("wheat-like") cartilage
 Middle hyothyroid ligament
 Hyothyroid membrane (O. T. thyro-
 hyoid membrane)
 Cricoid cartilage
 Arch of cricoid cartilage

Lamina of cricoid cartilage
 Arytaenoid articular surface
 Thyreoid articular surface
 Cricothyroid articulation
 Capsule of cricothyroid joint
 Lateral ceratocricoid ligaments
 Anterior ceratocricoid ligaments
 Posterior ceratocricoid ligaments
 Middle cricothyroid ligament (O. T.
 middle portion of cricothyroid mem-
 brane)
 Cricotracheal ligament
 Arytaenoid cartilage
 Articular surface
 Base of arytaenoid cartilage
 Arched ridge
 Nodule or hillock
 Oblong depression
 Triangular depression
 Tip or apex of arytaenoid cartilage
 Vocal process
 Muscular process .
 Corniculate cartilage (O. T. cartilage
 of Santorini)
 Arycorniculate synchondrosis
 Cricoarytaenoid joint
 Cricopharyngeal ligament
 Corniculopharyngeal ligament (O. T.
 Lig. jugale)
 Ventricular ligament (O. T. superior
 thyro-arytenoid ligament)
 Vocal ligament (O. T. inferior thyro-
 arytenoid ligament)
 Sesamoid cartilage
 Capsule of crico-arytaenoid joint
 Posterior crico-arytaenoid ligament
 Epiglottis
 Stem of epiglottis
 Epiglottic tubercle (O. T. cushion of
 epiglottis)
 Epiglottic cartilage
 Thyreo-epiglottic ligament (O. T.
 thyro-epiglottidean ligament)

Lig. hyoepiglotticum

Cartilago cuneiformis [Wrisbergi]

Tuberculum cuneiforme [Wrisbergi]

Tuberculum corniculatum [Santorini]

Musculi laryngis

M. aryepiglotticus

M. cricothyreoideus

Pars recta

Pars obliqua

M. cricoarytaenoideus posterior
(M. ceratocricoideus)

M. cricoarytaenoideus lateralis

M. ventricularis

M. vocalis

M. thyreoepiglotticus

M. thyreoarytaenoideus [externus]

M. arytaenoideus obliquus

M. arytaenoideus transversus

Cavum laryngis

Vallecula epiglottica

Aditus laryngis

Vestibulum laryngis

Rima vestibuli

Labium vocale

Glottis

Rima glottidis

Pars intermembranacea

Pars intercartilaginea

Ventriculus laryngis [Morgagnii]

Appendix ventriculi laryngis

Tunica mucosa laryngis

Membrana elastica laryngis

Conus elasticus

Plica glossoepiglottica mediana

Plica glossoepiglottica lateralis

Plica aryepiglottica

Plica nervi laryngis

Plica ventricularis

Plica vocalis

Macula flava

Aditus glottidis inferior

Aditus glottidis superior

Incisura interarytaenoidea

Gl. laryngeae

Gl. laryngeae anteriores

Gl. laryngeae mediae

Gl. laryngeae posteriores

Noduli lymphatici laryngei

Trachea et bronchi

Cartilagine tracheales

Ligg. annularia [trachealia]

Paries membranacea

Gl. tracheales

Bifurcatio tracheae

Bronchus [dexter et sinister]

Rami bronchiales

Ramus bronchialis eparterialis

Rami bronchiales hyperarteriales

Tunica muscularis

Tela submucosa

Tunica mucosa

Gl. tracheales

Gl. bronchiales

Pulmo

Basis pulmonis

Apex pulmonis

Sulcus subclavius

Hyo-epiglottic ligament (O. T. hyo-epiglottidean ligament)
 Cuneiform cartilage
 Cuneiform tubercle
 Corniculate tubercle of Santorini

Muscles of larynx

Aryepiglottic muscle (O. T. aryteno-epiglottidean muscle)
 Cricothyroid muscle
 Straight part (O. T. anterior or oblique part)
 Oblique part (O. T. posterior or horizontal part)
 Posterior crico-arytaenoid muscle
 Ceratocricoid muscle
 Lateral crico-arytaenoid muscle
 Ventricular muscle
 Vocal muscle (O. T. internal thyro-arytenoid muscle)
 Thyreo-epiglottic muscle (O. T. thyro-epiglottidean muscle)
 Thyreo-arytaenoid muscle (external)
 Oblique arytaenoid muscle
 Transverse arytaenoid muscle

Cavity of larynx

Epiglottic vallecula
 Laryngeal aperture
 Vestibule of larynx
 Slit of vestibule (O. T. false glottis)
 Vocal lip
 Glottis (O. T. glottis vera)
 Slit of glottis
 Intermembranous part (O. T. glottis vocalis)
 Intercartilaginous part (O. T. glottis respiratoria)
 Ventricle of larynx (O. T. laryngeal sinus)
 Appendage of ventricle of larynx (O. T. laryngeal pouch or sac)
 Mucous coat of larynx

Elastic membrane of larynx
 Elastic cone (O. T. cricothyroid membrane)
 Median glosso-epiglottic fold (O. T. middle glosso-epiglottidean fold, or fraenum of the epiglottis)
 Lateral glosso-epiglottic fold (O. T. lateral glosso-epiglottidean folds)
 Ary-epiglottic fold
 Fold of laryngeal nerve
 Ventricular fold (O. T. false vocal cord)
 Vocal fold (O. T. true vocal cord)
 Yellow spot
 Inferior entrance to glottis
 Superior entrance to glottis
 Interarytaenoid notch
 Laryngeal glands
 Anterior laryngeal glands
 Middle laryngeal glands
 Posterior laryngeal glands
 Lymph-nodules of larynx

Trachea and bronchi

Tracheal cartilages
 Annular ligaments
 Membranous wall
 Tracheal glands
 Bifurcation of trachea
 Right and left bronchus
 Bronchial rami
 Eparterial bronchial ramus
 Hyparterial bronchial ramus
 Muscular coat
 Submucous layer
 Mucous coat
 Tracheal glands
 Bronchial glands

Lung

Base of lung
 Apex of lung
 Subclavian sulcus

Facies costalis
 Facies mediastinalis
 Facies diaphragmatica
 Margo anterior
 Margo inferior
 Hilus pulmonis
 Radix pulmonis
 Incisura cardiaca
 Lingula pulmonis
 Lobus superior
 Lobus medius
 Lobus inferior
 Incisura interlobaris
 Lobuli pulmonum
 Rami bronchiales
 Bronchioli
 Bronchioli respiratorii
 Ductuli alveolares
 Alveoli pulmonum
 Lymphoglandulae bronchiales
 Noduli lymphatici bronchiales
 Lymphoglandulae pulmonales

Cavum thoracis

Fascia endothoracica
 Cavum pleurae
 Pleura
 Cupula pleurae
 Pleura pulmonalis
 Pleura parietalis

Pleura mediastinalis
 Laminae mediastinales
 Pleura pericardiaca
 Pleura costalis
 Pleura diaphragmatica
 Sinus pleurae
 Sinus phrenicocostalis
 Sinus costomediastinalis
 Lig. pulmonale
 Plicae adiposae
 Villi pleurales
 Septum mediastinale.
 Cavum mediastinale anterius
 Cavum mediastinale posterius

Gl. thyroidea

Isthmus gl. thyroideae
 (Lobus pyramidalis)
 Lobus [dexter et sinister]
 Lobuli gl. thyroideae
 Stroma gl. thyroideae
 (Gl. thyroideae accessoriae)
 (Gl. thyroidea accessoria supra-
 hyoidea)

Glomus caroticum

Thymus

Lobus [dexter et sinister]
 Tractus centralis
 Lobuli thymi

Apparatus urogenitalis

Organa uropoëtica

Ren

Margo lateralis
 Margo medialis
 Hilus renalis
 Sinus renalis
 Facies anterior
 Facies posterior
 Extremitas superior

Extremitas inferior
 (Impressio muscularis)
 (Impressio hepatica)
 (Impressio gastrica)
 Capsula adiposa
 Tunica fibrosa
 Tunica muscularis
 Tubuli renales
 Tubuli renales contorti

Costal surface
 Mediastinal surface
 Diaphragmatic surface
 Anterior margin
 Inferior margin
 Hilus of lung
 Root of lung
 Cardiac notch
 Lingula, or little tongue, of lung
 Upper lobe
 Middle lobe
 Inferior lobe
 Interlobar incisure
 Pulmonary lobules
 Bronchial rami
 Bronchioles
 Respiratory bronchioles
 Alveolar ductules
 Pulmonary alveoli
 Bronchial lymph glands
 Bronchial lymph-nodules
 Pulmonary lymph glands

Thoracic cavity

Endothoracic fascia
 Pleural cavity
 Pleura
 Dome or cupola of pleura
 Pulmonary pleura
 Parietal pleura

Mediastinal pleura
 Mediastinal layers
 Pericardiac pleura
 Costal pleura
 Diaphragmatic pleura
 Sinuses of the pleura
 Phrenicocostal sinus
 Costomediastinal sinus
 Pulmonary ligament
 Adipose folds
 Pleural villi
 Mediastinal septum
 Anterior mediastinal cavity
 Posterior mediastinal cavity

Thyreoid gland .

Isthmus of thyreoid
 Pyramidal lobe
 Right and left lobes
 Lobules of gland
 Stroma of gland
 Accessory thyreoid glands
 Suprahyoid accessory thyreoid gland

Carotid skein (O. T. intercarotid gland)

Thymus

Right and left lobe
 Central tract
 Lobules of thymus

Urogenital system

Uropoietic organs

Kidney .

Lateral margin
 Medial margin
 Renal hilus
 Renal sinus
 Anterior surface
 Posterior surface
 Superior extremity

Inferior extremity
 Muscular impression
 Hepatic impression
 Gastric impression
 Adipose capsule
 Fibrous coat
 Muscular coat
 Renal tubules
 Convoluted renal tubules

Tubuli renales recti
 Substantia corticalis
 Substantia medullaris
 Lobi renales
 Pyramides renales [Malpighii]
 Basis pyramidis
 Papillae renales
 Area cribrosa
 Foramina papillaria
 Columnae renales [Bertini]
 Lobuli corticales
 Pars radiata [Processus Ferreini]

Pars convoluta
 Corpuscula renis [Malpighii]

Glomeruli
 Capsula glomeruli
 Pelvis renalis
 Calyces renales
 Calyces renales majores
 Calyces renales minores
 Gl. pelvis renalis

Arteriae renis

Aa. interlobares renis
 Arteriae arciformes
 Arteriae interlobulares
 Vas afferens
 Vas efferens
 Rami capsulares
 Arteriolae rectae
 Aa. nutriciae pelvis renalis

Venae renis

Vv. interlobares
 Venae arciformes
 Venae interlobulares
 Venulae rectae
 Venae stellatae

Ureter

Pars abdominalis

Pars pelvina
 Tunica adventitia
 Tunica muscularis
 Stratum externum
 Stratum medium
 Stratum internum
 Tunica mucosa
 Gl. mucosae ureteris

Vesica urinaria

Vertex vesicae
 Corpus vesicae
 Fundus vesicae
 Lig. umbilicale medium
Urachus
 Tunica serosa
 Tunica muscularis
 Stratum externum
 Stratum medium
 Stratum internum
 M. pubovesicalis
 M. rectovesicalis
 Tela submucosa
 Tunica mucosa
 Gl. vesicales
 Noduli lymphatici vesicales
 Trigonum vesicae [Lieutaudi]
 Uvula vesicae
 Plica ureterica
 Orificium ureteris
 Orificium urethrae internum
 Annulus urethralis

Glandula suprarenalis

Substantia corticalis
 Substantia medullaris
 Hilus gl. suprarenalis
 Facies anterior
 Facies posterior
 Basis gl. suprarenalis
 Apex suprarenalis [gl. dextrae]
 Margo superior
 Margo medialis

Straight renal tubules
 Cortical substance
 Medullary substance
 Renal lobes (O. T. reniculi)
 Renal pyramids
 Base of pyramid
 Renal papillae
 Cribriform area
 Papillary foramina
 Renal columns
 Cortical lobules
 Radiate part (O. T. pyramid of
 Ferrein)
 Convoluted part (O. T. labyrinth)
 Renal corpuscles (O. T. Malpighian
 corpuscles)
 Glomeruli
 Capsule of glomerulus
Renal pelvis
 Renal calyces
 Greater renal calyces
 Smaller renal calyces
 Glands of renal pelvis

Renal arteries

Interlobar arteries of kidney
 Arciform arteries or renal arches
 Interlobular arteries
 Afferent vessel
 Efferent vessel
 Capsular branches
 Straight arterioles
 Nutrient arteries of renal pelvis

Renal veins

Interlobar veins
 Arciform veins
 Interlobular veins
 Straight venules
 Stellate veins

Ureter

Abdominal part

Pelvic part
 Adventitious coat
 Muscular coat
 External layer
 Middle layer
 Internal layer
 Mucous coat
 Mucous glands of ureter

Urinary bladder

Apex of bladder
 Body of bladder
 Fundus of bladder
 Middle umbilical ligament
Urachus
 Serous coat
 Muscular coat
 External layer
 Middle layer
 Internal layer
 Pubovesical muscle
 Rectovesical muscle
 Submucous layer
 Mucous coat
 Vesical glands
 Vesical lymph-nodules
 Lieutaud's trigone of the bladder
 Vesical uvula
 Ureteral fold
 Orifice of ureter
 Internal orifice of ureter
 Urethral ring

Suprarenal gland

Cortical substance
 Medullary substance
 Hilus of suprarenal gland
 Anterior surface
 Posterior surface
 Base of suprarenal gland
 Apex of right suprarenal
 Superior margin
 Medial margin

Vena centralis
(Gl. suprarenales accessoriae)

Organa genitalia

Organa genitalia virilia

Testis

Extremitas superior
Extremitas inferior
Facies lateralis
Facies medialis
Margo anterior
Margo posterior
Tunica albuginea
Mediastinum testis [Corpus Highmori]
Septula testis
Lobuli testis
Parenchyma testis
Tubuli seminiferi contorti
Tubuli seminiferi recti
 Tunica propria
Rete testis [Halleri]
Ductuli efferentes testis
Sperma [Semen]
Epididymis
Caput epididymidis
Corpus epididymidis
Cauda epididymidis
Lobuli epididymidis
Ductus epididymidis
Ductuli aberrantes
(Ductulus aberrans superior)
Appendices testis
 Appendix testis [Morgagnii]

(Appendix epididymis)
Paradidymis

Ductus deferens

Ampulla ductus deferentis
 Diverticula ampullae
 Tunica adventitia

Tunica muscularis
 Stratum externum
 Stratum medium
 Stratum internum
Tunica mucosa
Ductus ejaculatorius

Vesicula seminalis

Corpus vesiculae seminalis
Tunica adventitia
Tunica muscularis
Tunica mucosa
Ductus excretorius

Funiculus spermaticus et tunicae testis et funiculi spermatici

(Rudimentum processus vaginalis)
Tunica vaginalis propria testis
 Lamina parietalis
 Lamina visceralis
Lig. epididymidis superius
Lig. epididymidis inferius
Sinus epididymidis
Tunica vaginalis communis [testis et funiculi spermatici]
M. cremaster
Fascia cremasterica [Cooperi]
Descensus testis
Gubernaculum testis [Hunteri]

Prostata

Basis prostatae
Apex prostatae
Facies anterior
Facies posterior
Lobus [dexter et sinister]
Isthmus prostatae
 (Lobus medius)
Corpus glandulare
Ductus prostatici
Succus prostaticus
M. prostaticus

Central vein
 Accessory suprarenal glands

Genital organs

Male genital organs

Testicle

Superior extremity
 Inferior extremity
 Lateral surface
 Medial surface
 Anterior margin
 Posterior margin
 Albugineous coat
 Mediastinum of testicle
 Septules of testicle
 Lobules of testicle
 Parenchyma
 Convoluted seminiferous tubules
 Straight seminiferous tubules
 Proper coat
 Network
 Efferent ductules
 Sperm or semen
 Epididymis
 Head of epididymis
 Body of epididymis
 Tail of epididymis
 Lobules of epididymis
 Ducts of epididymis
 Aberrant ductules
 Superior aberrant ductule
 Appendages of the testicle
 Morgagni's appendage of testicle (O. T. hydatid of Morgagni)
 Appendage of epididymis
 Paraididymis (O. T. organ of Giraldes)
 Deferent duct (O. T. vas deferens)
 Ampulla of deferent duct
 Diverticula of ampulla
 Adventitious coat

Muscular coat
 External layer
 Middle layer
 Internal layer
 Mucous coat
 Ejaculatory duct

Seminal vesicles

Body of seminal vesicles
 Adventitious coat
 Muscular coat
 Mucous coat
 Excretory duct

Spermatic cord and coats of the testicle and cord

Rudiment of vaginal process
 Proper sheath of testicle
 Parietal layer
 Visceral layer
 Superior ligament of epididymis
 Inferior ligament of epididymis
 Sinus of epididymis
 Common sheath of testicle and spermatic cord
 Cremasteric muscle
 Cremasteric fascia
Descent of the testicle
Gubernaculum ("pilot") of testicle

Prostate

Base of prostate
 Apex of prostate
 Anterior surface
 Posterior surface
 Right and left lobe
 Isthmus of prostate
 Middle lobe
 Glandular body
 Prostatic ducts
 Prostatic fluid
 Prostatic muscle

Glandula bulbourethralis [Cowperi]

Corpus gl. bulbourethralis
Ductus excretorius

Partes genitales externae**Penis**

Radix penis
Corpus penis
Crus penis
Dorsum penis
Facies urethralis
Glans penis
 Corona glandis
 Septum glandis
 Collum glandis
Praeputium
Frenulum praeputii
Raphe penis
Corpus cavernosum penis
Corpus cavernosum urethrae
Bulbus urethrae
 Hemisphaeria bulbi urethrae
 Septum bulbi urethrae
Tunica albuginea corporum cavernosorum
Septum penis
Trabeculae corporum cavernosorum
Cavernae corporum cavernosorum
Arteriae helicinae
Venae cavernosae
Lig. suspensorium penis
Fascia penis
Gl. praeputiales
Smegma praeputii

Urethra virilis

Pars prostatica
Crista urethralis
Colliculus seminalis
Utriculus prostaticus
Pars membranacea
Pars cavernosa

Fossa navicularis urethrae [Morgagnii]
(Valvula fossae navicularis)
Orificium urethrae externum
Lacunae urethrales [Morgagnii]
Gl. urethrales [Littrei]

Scrotum

Raphe scroti
Septum scroti
Tunica dartos

Organa genitalia muliebria**Ovarium**

Hilus ovarii
Facies medialis
Facies lateralis
Margo liber
Margo mesovaricus
Extremitas tubaria
Extremitas uterina
Stroma ovarii
Folliculi oophori primarii
Folliculi oophori vesiculosi [Graafii]

Theca folliculi
 Tunica externa
 Tunica interna
Liquor folliculi
Stratum granulosum
Cumulus oophorus

Ovulum
Corpus luteum
Corpus albicans
Lig. ovarii proprium

Tuba uterina [Fallopii]

Ostium abdominale tubae uterinae
Infundibulum tubae uterinae
Fimbriae tubae
 Fimbria ovarica
Ampulla tubae uterinae
Isthmus tubae uterinae

Bulbo-urethral gland (O. T. Cowper's gland)

Body of gland
Excretory duct

Parts of external genitals

Penis

Root of penis
Body of penis
Crus of penis
Dorsum of penis
Urethral surface
Glans ("acorn") of penis
 Corona of glans
 Septum of glans
 Neck of glans
Prepuce
Frenulum of prepuce
Raphe of penis
Cavernous body of penis
Cavernous body of urethra
Bulb of urethra
 Hemispheres of bulb of urethra
 Septum of bulb of urethra
Albugineous coat of cavernous bodies

Septum of penis
Trabeculae of cavernous bodies
Caverns of cavernous bodies
Spiral arteries
Cavernous veins
Suspensory ligament of penis
Fascia of penis
Preputial glands
Smegma of prepuce

Male urethra

Prostatic part
Urethral crest
Seminal hillock
Prostatic utricle
Membranous part
Cavernous part

Navicular fossa of urethra
Valve of navicular fossa
External urethral orifice
Urethral lacunae of Morgagni
Urethral glands of Littre

Scrotum

Raphe of scrotum
Septum of scrotum
Dartos ("flayed") coat

Female genital organs

Ovary

Hilus of ovary
Medial surface
Lateral surface
Free margin
Mesovarian margin
Tubal extremity
Uterine extremity
Stroma of ovary
Primary ovarian follicles
Vesicular ovarian follicles (O. T. Graafian follicles)
Theca of follicle
 External coat
 Internal coat
Liquor of follicle
Granular layer
Ovarian mound (O. T. discus proligerus)
Ovule
Corpus luteum: "yellow body"
Corpus albicans: "white body"
Proper ligament of ovary

Uterine tube (O. T. Fallopian tube)

Abdominal mouth of uterine tube
Infundibulum of uterine tube
Fimbriae of tube
 Ovarian fimbria
Ampulla of uterine tube
Isthmus of uterine tube

Pars uterina

Ostium uterinum tubae
 Tunica serosa
 Tunica adventitia
 Tunica muscularis
 Stratum longitudinale
 Stratum circulare
 Tela submucosa
 Tunica mucosa
 Plicae tubariae
 Plicae ampullares
 Plicae isthmicae

Uterus

Corpus uteri
 Fundus uteri
 Margo lateralis
 Facies vesicalis
 Facies intestinalis
 Cavum uteri
 Orificium internum uteri

Cervix [uteri]
 Portio supravaginalis [cervicis]
 Portio vaginalis [cervicis]
 Orificium externum uteri

 Labium anterius
 Labium posterius
 Canalis cervicis uteri
 Plicae palmatae
 Gl. cervicales [uteri]
 Parametrium
 Tunica serosa [Perimetrium]
 Tunica muscularis
 Tunica muscularis cervicis
 Tunica mucosa
 Gl. uterinae
 M. rectouterinus
 Lig. teres uteri
 (Processus vaginalis peritonaei)

Vagina

Fornix vaginae
 Paries anterior
 Paries posterior
 Hymen [femininus]
 Carunculae hymenales
 Tunica muscularis
 Tunica mucosa
 Noduli lymphatici vaginales
 Rugae vaginales
 Columnae rugarum
 Columna rugarum posterior
 Columna rugarum anterior
 Carina urethralis [vaginae]

Epoophoron

Ductus epoophori longitudinalis [Gartneri]
 Ductuli transversi
 Appendices vesiculosi [Morgagnii]

Paroophoron**Partes genitales externae**

Pudendum muliebre
 Labium majus pudendi
 Commissura labiorum anterior
 Commissura labiorum posterior
 Frenulum labiorum pudendi
 Rima pudendi
 Fossa navicularis [vestibuli vaginae]
 Labium minus pudendi
 Vestibulum vaginae
 Bulbus vestibuli
 Gl. sebaceae
 Gl. vestibulares minores
 Orificium vaginae

Gl. vestibularis major [Bartholini]

Clitoris

Crus clitoridis
 Corpus clitoridis

Uterine part

- Uterine mouth of tube
- Serous coat
- Adventitious coat
- Muscular coat
 - Longitudinal layer
 - Circular layer
- Submucous tela
- Mucous coat
- Tubal folds
 - Ampullar folds
 - Isthmian folds

Uterus

- Body of uterus
- Fundus of uterus
- Lateral margin
- Vesical surface
- Intestinal surface
- Cavity of uterus
- Internal orifice of uterus (O. T. internal os)
- Neck of uterus
- Supravaginal portion of cervix
- Vaginal portion of cervix
- External orifice of uterus (O. T. external os)
 - Anterior lip
 - Posterior lip
- Canal of neck of uterus
- Palmate folds
- Cervical glands of uterus
- Parametrium
- Serous coat
- Muscular coat
- Muscular coat of neck
- Mucous coat
 - Uterine glands
- Rectouterine muscle
- Round ligament of uterus'
- Vaginal process of peritoneum (O. T. canal of Nuck)

Vagina ("sheath")

- Fornix of vagina
- Anterior wall
- Posterior wall
- Hymen
- Hymeneal caruncles
- Muscular coat
- Mucous coat
- Vaginal lymph-nodules
- Rugæ ("wrinkles") of vaginal wall
- Columns of the rugæ
 - Posterior column
 - Anterior column
- Urethral carina ("keel") of vagina

Epo-ophoron (O. T. parovarium or organ of Rosenmueller)

- Longitudinal duct of epo-ophoron (O. T. Gärtner's duct)
 - Transverse ductules
- Vesicular appendages of Morgagni (O. T. hydatids of Morgagni)

Paro-ophoron**External genital parts**

- Vulva ("wrapper")
 - Greater lip of vulva
 - Anterior labial commissure
 - Posterior labial commissure
 - Frenulum of pudendal labia
 - Pudendal slit
 - Navicular fossa of vestibule of vagina
 - Lesser lip of vulva
 - Vestibule of vagina
 - Vestibular bulb
 - Sebaceous glands
 - Lesser vestibular glands
 - Orifice of vagina

Larger vestibular gland of Bartholin**Clitoris**

- Crus of clitoris
- Body of clitoris

Glans clitoridis
 Frenulum clitoridis
 Praeputium clitoridis
 Smegma clitoridis
 Corpus cavernosum clitoridis
 Septum corporum cavernosorum
 Fascia clitoridis
 Lig. suspensorium clitoridis

Urethra muliebris

Orificium urethrae externum
 Corpus spongiosum urethrae
 Tunica muscularis
 Stratum circulare
 Stratum longitudinale
 Tunica submucosa
 Tunica mucosa
 Gl. urethrales
 Crista urethralis
 (Ductus paraurethrales)
 Terminis ontogenetici
Membranae deciduae
Decidua vera
Decidua capsularis
Decidua basalis
Placenta
Placenta uterina
Placenta foetalis
Funiculus umbilicalis
Corpus Wolffii
Ductus Wolffii
Ductus Muellieri
Sinus urogenitalis

Perineum

Raphe perinei
 Musculi perinei
 Diaphragma pelvis
 M. levator ani
 Arcus tendineus m. levatoris ani
 M. coccygeus [vide p. 40]
 M. sphincter ani externus

Lig. anococcygeum
 Fascia pelvis
 Fascia endopelvina
 Fascia diaphragmatis pelvis superior
 Arcus tendineus fasciae pelvis
 Lig. puboprostaticum [pubovesicale]
 medium

Lig. puboprostaticum [pubovesicale]
 laterale

Fascia diaphragmatis pelvis inferior
 Diaphragma urogenitale

M. transversus perinei profundus
 M. sphincter urethrae membranaceae

Fascia diaphragmatis urogenitalis superior

Fascia diaphragmatis urogenitalis inferior

Lig. transversum pelvis

Fascia prostatae

Fascia obturatoria

Fossa ischiorectalis

M. transversus perinei superficialis

M. ischiocavernosus

M. bulbocavernosus

Fascia superficialis perinei

Peritoneum

Tunica serosa
 Tela subserosa
 Peritoneum parietale
 Peritoneum viscerale

Glans of clitoris
 Frenulum of clitoris
 Prepuce of clitoris
 Smegma of clitoris
 Cavernous body of clitoris
 Septum of cavernous bodies
 Fascia of clitoris
 Suspensory ligament of clitoris

Female urethra

External orifice of urethra
 Spongy body of urethra
 Muscular coat
 Circular layer
 Longitudinal layer
 Submucous coat
 Mucous coat
 Urethral glands
 Urethral crest
 Para-urethral ducts
 Ontogenetic terms
Deciduous membranes
 True decidua
 Capsular decidua
 Basal decidua
Placenta ("cake")
 Uterine placenta
 Foetal placenta
Umbilical cord
Wolffian body
Wolffian duct
Muellerian duct
Urogenital sinus

Perineum

Perineal raphe
 Perineal muscles
 Pelvic diaphragm
 Levator muscle of anus
 Tendinous arch of levator ani muscle (O. T. white line of the pelvis)
 Coccygeus muscle
 External sphincter muscle of anus

Anococcygeal ligament
 Pelvic fascia
 Endopelvic fascia
 Superior fascia of the pelvic diaphragm
 Tendinous arch of pelvic fascia
 Middle puboprostatic or pubovesical ligament (O. T. anterior true ligament of bladder)
 Lateral puboprostatic or pubovesical ligament (O. T. lateral true ligament of bladder)
 Inferior fascia of the pelvic diaphragm
 Urogenital diaphragm (O. T. triangular ligament)
 Deep transverse muscle of perineum
 Sphincter muscle of the membranous urethra (O. T. compressor urethrae)
 Superior fascia of urogenital diaphragm (O. T. deep layer of triangular ligament)
 Inferior fascia of urogenital diaphragm (O. T. superficial layer of triangular ligament)
 Transverse ligament of pelvis (O. T. median puboprostatic ligament of Krause)
 Prostatic fascia
 Obturator fascia
 Ischiorectal fossa
 Superficial transverse perineal muscle
 Ischiocavernous muscle (O. T. erector penis [vel clitoridis] muscle)
 Bulbocavernous muscle (O. T. ejaculator seminis or accelerator urinae; sphincter vaginae)
 Superficial perineal fascia

Peritoneum

Serous coat
 Subserous tela
 Parietal peritoneum
 Visceral peritoneum

Cavum peritoneaei	Lig. triangulare sinistrum
<i>Mesenterium commune</i>	Lig. hepatorenale
Mesenterium	(Lig. duodenorenale)
Radix mesenterii	Recessus duodenojejunalis
Lamina mesenterii propria	Plica duodenojejunalis
Mesocolon	(Plica duodenomesocolica)
Mesocolon transversum	Recessus intersigmoideus
Mesocolon ascendens	Recessus iliocaecalis superior
Mesocolon descendens	Recessus iliocaecalis inferior
Mesocolon sigmoideum	Plica iliocaecalis
Mesorectum	Fossa caecalis
Mesenteriolum processus vermiformis	Recessus retrocaecalis
<i>Mesogastrium</i>	Plica caecalis
Omentum minus	Recessus paracolici
Lig. hepatogastricum	(Fossa iliacosubfascialis)
Lig. hepatoduodenale	(Recessus phrenicohepatici)
(Lig. hepatocolicum)	Plica umbilicalis media
Lig. gastrolienale	Plica umbilicalis lateralis
	Plica epigastrica
Lig. gastrocolicum	Plica pubovesicalis
Omentum majus	Plica vesicalis transversa
Bursa omentalis	<i>Mesorchium</i>
	<i>Processus vaginalis peritoneaei</i>
Vestibulum bursae omentalis	Lig. latum uteri
Recessus superior omentalis	Mesometrium
Recessus inferior omentalis	Mesosalpinx
Recessus lienalis	Mesovarium
Plica gastropancreatica	Bursa ovarica
Foramen epiploicum [Winslowi]	Lig. suspensorium ovarii
	Plica rectouterina [Douglasi]
Lig. phrenicocolicum	Excavatio rectouterina [Cavum Douglasi]
	Excavatio vesicouterina
Lig. phrenicolieneale	Excavatio rectovesicalis
Lig. falciforme hepatis	Spatium retroperitoneaeale
Lig. coronarium hepatis	
Lig. triangulare dextrum	

- Peritoneal cavity
Common mesentery
 Mesentery
 Root of the mesentery
 Proper layer of the mesentery
 Mesocolon
 Transverse mesocolon
 Ascending mesocolon
 Descending mesocolon
 Sigmoid mesocolon
 Mesorectum
 Meso-appendix
Mesogastrium
 Lesser omentum
 Hepatogastric ligament
 Hepatoduodenal ligament
 Hepatocolic ligament
 Gastrosplenic ligament (O. T. gastrosplenic omentum)
 Gastrocolic ligament
 Greater omentum
 Omental bursa (O. T. lesser peritoneal sac)
 Vestibule of omental bursa
 Superior omental recess
 Inferior omental recess
 Splenic recess
 Gastropancreatic fold
 Epiploic foramen (O. T. foramen of Winslow)
 Phrenicocolic ligament (O. T. costocolic ligament)
 Phrenicosplenic ligament
 Falciform ligament of liver
 Coronary ligament of liver
 Right triangular ligament
 Left triangular ligament
 Hepatorenal ligament
 Duodenorenal ligament
 Duodenojejunal recess
 Duodenojejunal fold
 Duodenomesocolic fold
 Intersigmoid recess
 Superior ileocaecal recess
 Inferior ileocaecal recess
 Ileocaecal fold
 Caecal fossa
 Retrocaecal recess
 Caecal fold
 Paracolic recess
 Iliaco-subfascial fossa
 Phrenicohepatic recess
 Middle umbilical fold
 Lateral umbilical fold
 Epigastric fold
 Pubovesical fold
 Transverse vesical fold
Mesorchium
Sheath process of peritoneum
 Broad ligament of uterus
 Mesometrium
 Mesosalpinx
 Mesovarium
 Ovarian bursa
 Suspensory ligament of ovary
 Recto-uterine fold
 Recto-uterine excavation, or cul-de-sac of Douglas
 Vesico-uterine excavation
 Rectovesical excavation
 Retroperitoneal space

Angiologia

Vas collaterale	Emissarium
Vas anastomoticum	Corpus cavernosum
Ramus communicans	Vas capillare
Plexus vasculosus	Vas lymphaticum
Rete vasculosum	Plexus lymphaticus
Rete mirabile	Lymphoglandula
Arteria	Nodulus lymphaticus
Arteriola	Cisterna
Vena	Tunica externa [adventitia]
Vena cutanea	Tunica media
Vena comitans	Tunica intima
Venula	Vasa vasorum
Plexus venosus	Vagina vasorum
Rete venosum	Sanguis
Sinus [venosus]	Lympha

Cor

Basis cordis	Epicardium
Facies sternocostalis	Myocardium
Facies diaphragmatica	Endocardium
Apex cordis	Ventriculus cordis
Incisura [apicis] cordis	Septum ventriculorum
Sulcus longitudinalis anterior	Septum musculare ventriculorum
	Septum membranaceum ventriculorum
Sulcus longitudinalis posterior	Atrium cordis
	Auricula cordis
Sulcus coronarius	Septum atriorum
	Pars membranacea septi atriorum
Pericardium	
Liquor pericardii	
Ligg. sternopericardiaca	Ostium venosum
Sinus transversus pericardii	Ostium arteriosum

Angiology

Collateral vessel	Emissary (vessel)
Anastomotic vessel	Cavernous body
Communicating branch	Capillary vessel
Vascular plexus	Lymphatic vessel
Vascular rete	Lymphatic plexus
Rete mirabile ("wonderful network")	Lymph gland
Artery	Lymph nodule
Arteriole	Cistern
Vein	External coat
Cutaneous vein	Middle coat
Accompanying vein	Inner coat
Venule	Vessels of the vessels
Venous plexus	Sheath of the vessels
Venous rete	Blood
Venous sinus	Lymph

Heart

Base of heart	Epicardium
Sternocostal surface	Myocardium
Diaphragmatic surface	Endocardium
Apex of heart	Ventricle of heart
Notch at apex of heart	Septum of ventricles
Anterior longitudinal sulcus (O. T. anterior interventricular groove)	Muscular septum of ventricles
Posterior longitudinal sulcus (O. T. posterior interventricular groove)	Membranous septum of ventricles
Coronary sulcus (O. T. auriculoventricular groove)	Forechamber (O. T. auricle)
Pericardium	Auricle (O. T. auricular appendix)
Pericardial fluid	Septum of atria
Sternopericardiac ligaments	Membranous part of septum of atria
Transverse sinus of pericardium	Venous orifice
	Arterial orifice

Trabeculae carneaе
 Vortex cordis
 Mm. papillares
 Chordae tendineae
 Trigona fibrosa
 Annulli fibrosi

Atrium dextrum

Mm. pectinati
 Sulcus terminalis atrii dextri
 Crista terminalis
 Sinus venarum [cavarum]
 Limbus fossae ovalis [Vieussenii]

Auricula dextra

Tuberculum intervenosum [Loweri]
 Valvula venae cavae [inferioris, Eustachii]
 Fossa ovalis
 Valvula sinus coronarii [Thebesii]

Foramina venarum minimarum [Thebesii]

Ventriculus dexter

Valvula tricuspidalis

Cuspis anterior

Cuspis posterior

Cuspis medialis
 Crista supraventricularis
 Conus arteriosus
 Valvulae semilunares a. pulmonalis
 Valvula semilunaris anterior
 Valvula semilunaris dextra
 Valvula semilunaris sinistra
 Noduli valvularum semilunarium
 Lunulae valvularum semilunarium

Atrium sinistrum

Auricula sinistra

Valvula foraminis ovalis

Ventriculus sinister

Valvula bicuspidalis [mitralis]

Cuspis anterior
 Cuspis posterior
 Valvulae semilunares aortae
 Valvula semilunaris posterior
 Valvula semilunaris dextra
 Valvula semilunaris sinistra
 Noduli valvularum semilunarium
 [Arantii]
 Lunulae valvularum semilunarium

Arteriae

A. pulmonalis

Ramus dexter
 Ramus sinister
Ductus arteriosus [Botalli]
 Ligamentum arteriosum

Aorta

Aorta ascendens

Bulbus aortae
 Sinus aortae [Valsalvae]
 Arcus aortae
 Isthmus aortae
 Aorta descendens
 A. coronaria [cordis] dextra
 Ramus descendens posterior
 A. coronaria [cordis] sinistra

Fleshy cords (O. T. columnae carnae)	Posterior cusp (O. T. marginal cusp)
Vortex of heart	Medial cusp (O. T. septal cusp)
Papillary muscles	Supraventricular crest
Tendinous cords	Arterial cone
Fibrous trigones	Semilunar valves of pulmonary artery
Fibrous rings	Anterior semilunar valve
	Right semilunar valve
	Left semilunar valve

Right atrium

Pectinate ("comb-like") muscles	Nodules of the semilunar valves
Terminal sulcus of the right atrium	Crescents of the semilunar valves
Terminal crest	
Venous sinus	

Edge of oval fossa (O. T. annulus ovalis)
 Right auricle (O. T. right auricular appendix)
 Intervenous tubercle of Lower

Left atrium (O. T. left auricle)
 Left auricle (O. T. left auricular appendix)
 Valve of the foramen

Valve of inferior vena cava (O. T. Eustachian valve)
 Oval fossa
 Valve of coronary sinus (O. T. coronary valve, or valve of Thebesius)
 Foramina of the smallest veins (O. T. foramina Thebesii)

Left ventricle

Bicuspid or mitral valve (O. T. left auriculoventricular valve)
 Anterior cusp
 Posterior cusp
 Semilunar valves of aorta
 Posterior semilunar valve
 Right semilunar valve
 Left semilunar valve
 Nodules of the semilunar valves (O. T. corpora Arantii)
 Crescents, or "sails" of semilunar valves

Right ventricle

Tricuspid valve (O. T. right auriculoventricular valve)
 Anterior cusp (O. T. infundibular cusp)

Arteries

Pulmonary artery

Right ramus
 Left ramus
Arterial duct
 Arterial ligament

Bulb of aorta
 Sinuses of aorta (O. T. sinus Val-salvae)
 Arch of aorta
 Isthmus of aorta
 Descending aorta
 Right coronary artery of heart
 Posterior descending ramus
 Left coronary artery of heart

Aorta

Ascending aorta

Ramus circumflexus
Ramus descendens anterior

A. anonyma

(A. thyreoidea ima)

A. carotis communis

A. carotis externa

A. thyreoidea superior

Ramus hyoideus
Ramus sternocleidomastoideus
A. laryngea superior
Ramus cricothyreoideus
Ramus anterior
Ramus posterior
Rami glandulares

A. pharyngea ascendens

A. meningea posterior
Rami pharyngei
A. tympanica inferior

A. lingualis

Ramus hyoideus
A. sublingualis
Rami dorsales linguae
A. profunda linguae

A. maxillaris externa

A. palatina ascendens
Ramus tonsillaris
A. submentalis
Rami glandulares
A. labialis inferior
A. labialis superior
A. angularis

A. sternocleidomastoidea

A. occipitalis

Ramus mastoideus
Ramus auricularis

Rami musculares
Ramus descendens
(Ramus meningeus)
Rami occipitales

A. auricularis posterior

A. styломastoidea
A. tympanica posterior
Rami mastoidei
Ramus stapedius
Ramus auricularis
Ramus occipitalis

A. temporalis superficialis

Rami parotidei
A. transversa faciei
Rami auriculares anteriores
A. zygomaticoorbitalis
A. temporalis media
Ramus frontalis
Ramus parietalis

A. maxillaris interna

A. auricularis profunda
A. tympanica anterior
A. alveolaris inferior

R. mylohyoideus
A. mentalis
A. meningea media
(Ramus meningeus accessorius)

Ramus petrosus superficialis
A. tympanica superior
A. masseterica
A. temporalis profunda posterior
A. temporalis profunda anterior
Rami pterygoidei
A. buccinatoria
A. alveolaris superior posterior

A. infraorbitalis
Aa. alveol. superiores anteriores

- Circumflex ramus
- Anterior descending ramus
- Innominate artery**
- Lowest thyroid artery
- Common carotid artery**
- External carotid artery**
- Superior thyroid artery**
- Hyoid ramus
- Sternocleidomastoid ramus
- Superior laryngeal artery
- Cricothyroid ramus
- Anterior ramus
- Posterior ramus
- Glandular rami
- Ascending pharyngeal artery**
- Posterior meningeal artery
- Pharyngeal rami
- Inferior tympanic artery
- Lingual artery**
- Hyoid ramus
- Sublingual artery
- Dorsal rami of tongue
- Deep artery of tongue (O. T. ranine artery)
- External maxillary artery (O. T. facial artery)**
- Ascending palatine artery
- Tonsillar rami
- Submental artery
- Glandular rami
- Inferior labial artery
- Superior labial artery
- Angular artery
- Sternocleidomastoid artery**
- Occipital artery**
- Mastoid ramus
- Auricular ramus
- Muscular rami
- Descending ramus
- Meningeal ramus
- Occipital rami
- Posterior auricular artery**
- Stylomastoid artery
- Posterior tympanic artery
- Mastoid rami
- Stapedial ramus
- Auricular ramus
- Occipital ramus
- Superficial temporal artery**
- Parotid rami
- Transverse artery of face
- Anterior auricular rami
- Zygomatico-orbital artery
- Middle temporal artery
- Frontal ramus
- Parietal ramus
- Internal maxillary artery**
- Deep auricular artery
- Anterior tympanic artery
- Inferior alveolar artery (O. T. inferior dental)
- Mylohyoid ramus
- Mental artery
- Middle meningeal artery
- Accessory meningeal ramus (O. T. small meningeal)
- Superficial petrosal ramus
- Superior tympanic artery
- Masseteric artery
- Posterior deep temporal artery
- Anterior deep temporal artery
- Pterygoid rami
- Buccinator artery (O. T. buccal)
- Posterior superior alveolar artery (O. T. posterior dental)
- Infraorbital artery
- Anterior superior alveolar arteries (O. T. anterior superior dental)

A. palatina descendens
 A. canalis pterygoidei [Vidii]
 A. palatina major
 Aa. palatinae minores
 A. sphenopalatina
 Aa. nasales posteriores laterales et septi

A. carotis interna

Ramus caroticotympanicus

A. ophthalmica

A. centralis retinae
 A. lacrimalis
 Aa. palpebrales laterales
 Rami musculares
 Aa. ciliares posteriores breves
 Aa. ciliares posteriores longae
 Aa. ciliares anteriores
 Aa. conjunctivales anteriores
 Aa. conjunctivales posteriores
 Aa. episclerales
 A. supraorbitalis
 A. ethmoidalis posterior
 A. ethmoidalis anterior
 A. meningea anterior
 Aa. palpebrales mediales
 Arcus tarseus superior
 Arcus tarseus inferior
 A. frontalis
 A. dorsalis nasi

Aa. cerebri

A. communicans posterior
 A. chorioidea

 A. cerebri anterior
 A. communicans anterior
 A. cerebri media

A. subclavia

A. vertebralis

Rami spinales
 A. spinalis posterior
 A. spinalis anterior
 Ramus meningeus

A. cerebelli inferior posterior

A. basilaris

A. cerebelli inferior anterior
 A. auditiva interna

Rami ad pontem

A. cerebelli superior
 A. cerebri posterior
 Circulus arteriosus [Willisi]

A. mammaria interna

Aa. mediastinales anteriores
 Aa. thymicae
 Rami bronchiales
 A. pericardiacophrenica

Rami sternales

Rami perforantes

Rami mammarii
 Rami musculares
 Rami cutanei

(Ramus costalis lateralis)

Rami intercostales

A. musculophrenica
 A. epigastrica superior

Truncus thyreocervicalis

A. thyreoidea inferior

A. laryngea inferior
 Rami pharyngei
 Rami oesophagei

Descending palatine artery
 Artery of pterygoid canal
 Greater palatine artery
 Lesser palatine arteries
 Sphenopalatine artery
 Posterior lateral arteries of the nose
 and of septum

Internal carotid artery

Caroticotympanic ramus (O. T. tym-
 panic branch)

Ophthalmic artery

Central artery of retina
 Lacrimal artery
 Lateral palpebral arteries
 Muscular rami
 Short posterior ciliary arteries
 Long posterior ciliary arteries
 Anterior ciliary arteries
 Anterior conjunctival arteries
 Posterior conjunctival arteries
 Episcleral arteries
 Supraorbital artery
 Posterior ethmoidal artery
 Anterior ethmoidal artery
 Anterior meningeal artery
 Middle palpebral arteries
 Superior tarsal arch
 Inferior tarsal arch
 Frontal artery
 Dorsal artery of nose

Cerebral arteries

Posterior communicating artery
 Chorioid artery (O. T. anterior cho-
 roidal)
 Anterior cerebral artery
 Anterior communicating artery
 Middle cerebral artery (O. T. arteria
 fossae Sylvii)

Subclavian artery

Vertebral artery

Spinal rami
 Posterior spinal artery
 Anterior spinal artery
 Meningeal ramus (O. T. posterior
 meningeal branch)
 Posterior inferior cerebellar artery

Basilar artery

Anterior inferior cerebellar artery
 Internal auditory artery (O. T. audi-
 tory artery)
 Rami to pons (O. T. transverse arter-
 ies)
 Superior cerebellar arteries
 Posterior cerebral artery
 Arterial circle of Willis

Internal mammary artery

Anterior mediastinal arteries
 Thymic arteries
 Bronchial rami
 Pericardiacophrenic artery (O. T.
 arteria comes nervi phrenici)
 Sternal rami
 Perforating rami
 Mammary rami
 Muscular rami
 Cutaneous rami
 Lateral costal ramus
 Intercostal rami (O. T. anterior inter-
 costals)
 Musculophrenic artery
 Superior epigastric artery

**Thyreocervical trunk (O. T. thy-
 roid axis)**

Inferior thyreoid artery

Inferior laryngeal artery
 Pharyngeal rami
 Oesophageal rami

Rami tracheales
Rami glandulares

A. cervicalis ascendens

Rami spinales
Rami musculares
Ramus profundus

A. cervicalis superficialis

A. transversa scapulae

Ramus acromialis

Truncus costocervicalis

A. intercostalis suprema

Rami dorsales

Rami spinales

A. cervicalis profunda

A. transversa colli

Ramus ascendens

Ramus descendens

A. axillaris

Rami subscapulares

A. thoracalis suprema

A. thoracoacromialis

Ramus acromialis

Rete acromiale

Ramus deltoideus

Rami pectorales

A. thoracalis lateralis

Rami mammarii externi

A. subscapularis

A. thoracodorsalis

A. circumflexa scapulae

A. circumflexa humeri anterior

A. circumflexa humeri posterior

A. brachialis

A. profunda brachii

Aa. nutritiae humeri

R. deltoideus

A. collateralis media

A. collateralis radialis

A. collateralis ulnaris superior

A. collateralis ulnaris inferior

A. radialis

A. recurrens radialis

Rami musculares

Ramus carpeus volaris

Ramus volaris superficialis

Ramus carpeus dorsalis

Rete carpi dorsale

Aa. metacarpeae dorsales

Aa. digitales dorsales

A. princeps pollicis

A. volaris indicis radialis

Arcus volaris profundus

Aa. metacarpeae volares

Rami perforantes

Tracheal rami
Glandular rami

Ascending cervical artery

Spinal rami
Muscular rami
Deep ramus

Superficial cervical artery

Transverse artery of scapula (O. T. suprascapular)

Acromial ramus

Costocervical trunk (O. T. superior intercostal)

Highest intercostal artery (O. T. superior intercostal proper)

Dorsal rami

Spinal rami

Deep cervical artery

Transverse artery of neck (O. T. transversalis colli)

Ascending ramus

Descending ramus

Axillary artery

Subscapular rami

Highest thoracic artery (O. T. superior thoracic artery)

Thoraco-acromial artery (O. T. acromiothoracic or thoracic axis)

Acromial ramus

Acromial rete

Deltoid ramus

Pectoral rami

Lateral thoracic artery (O. T. long thoracic)

External mammary rami

Subscapular artery

Thoracodorsal artery

Circumflex artery of scapula (O. T. dorsalis scapulae)

Anterior circumflex artery of humerus

Posterior circumflex artery of humerus

Brachial artery

Deep artery of upper arm (O. T. superior profunda)

Nutrient arteries of the humerus

Deltoid ramus

Middle collateral artery

Radial collateral artery (O. T. articular branch of superior profunda)

Superior ulnar collateral artery (O. T. inferior profunda)

Inferior ulnar collateral artery (O. T. anastomotica magna)

Radial artery

Radial recurrent artery

Muscular rami

Volar carpal ramus (O. T. anterior radial carpal)

Superficial volar ramus

Dorsal carpal ramus (O. T. posterior radial carpal)

Dorsal carpal rete (O. T. posterior carpal rete)

Dorsal metacarpal arteries (O. T. dorsal interosseous arteries)

Dorsal digital arteries

Principal artery of thumb

Radial volar artery of index-finger (O. T. arteria radialis indicis)

Deep volar arch (O. T. deep palmar arch)

Volar metacarpal arteries

Perforating rami

A. ulnaris

Aa. recurrentes ulnares

Rete articulare cubiti

A. interossea communis

A. interossea dorsalis

A. interossea recurrens

A. interossea volaris

A. mediana

Rami musculares

Ramus carpeus dorsalis

Ramus carpeus volaris

Ramus volaris profundus

Arcus volaris superficialis

Aa. digitales volares communes

Aa. digitales volares propriae

Aorta thoracalis

Rami viscerales

Aa. bronchiales

Aa. oesophageae

Rami pericardiaci

Rami parietales

Rami mediastinales

Aa. phrenicae superiores

Aa. intercostales

Rami posteriores

Ramus spinalis

Rami musculares

Ramus cutaneus medialis

Ramus cutaneus lateralis

Rami anteriores

Rami musculares

Rami cutanei laterales [pectorales
et abdominales]

Ramus posterior

Ramus anterior

Rami mammarii laterales

Rami cutanei anteriores [pecto-
rales et abdominales]

Rami mammarii mediales

Aorta abdominalis

Rami parietales

A. phrenica inferior

Rami suprarenales superiores

Aa. lumbales

Ramus dorsalis

Ramus spinalis

A. sacralis media

A. lumbalis ima

Glomus coccygeum

Rami viscerales

A. coeliaca

A. gastrica sinistra

Rami oesophagei

A. hepatica

A. gastrica dextra

A. hepatica propria

Ramus dexter

A. cystica

Ramus sinister

A. gastroduodenalis

A. pancreaticoduoden. superior

Rami pancreatici

Rami duodenales

A. gastroepiploica dextra

Rami epiploici

A. lienalis

Rami pancreatici

A. gastroepiploica sinistra

Aa. gastricae breves

Rami lienales

Ulnar artery

- Recurrent ulnar arteries
- Articular rete of elbow
- Common interosseous artery
- Dorsal interosseous artery (O. T. posterior interosseous)
 - Recurrent interosseous artery (O. T. posterior interosseous recurrent)
- Volar interosseous artery (O. T. anterior interosseous)
- Median artery
- Muscular rami
- Dorsal carpal ramus (O. T. posterior ulnar carpal)
- Volar carpal ramus (O. T. anterior ulnar carpal)
- Deep volar ramus
- Superficial volar arch (O. T. superficial palmar arch)
- Common volar digital arteries (O. T. palmar digital arteries)
- Volar digital arteries proper (O. T. collateral digital arteries)

Thoracic aorta

Visceral rami

- Bronchial arteries
- Oesophageal arteries
- Pericardial rami

Parietal rami

- Mediastinal rami
- Superior phrenic arteries

Intercostal arteries

- Posterior rami
 - Spinal rami
 - Muscular rami
 - Medial cutaneous ramus
 - Lateral cutaneous ramus
- Anterior rami
 - Muscular rami
 - Lateral cutaneous rami of breast and abdomen

Posterior ramus

Anterior ramus

Lateral mammary rami

Anterior cutaneous rami of breast and abdomen

Medial mammary rami

Abdominal aorta

Parietal rami

Inferior phrenic artery

Superior suprarenal rami

Lumbar arteries

Dorsal ramus

Spinal ramus

Middle sacral artery

Lowest lumbar artery

Coccygeal skein

Visceral rami

Coeliac artery

Left gastric artery

Oesophageal rami

Hepatic artery

Right gastric artery

Proper hepatic artery

Right ramus

Cystic artery

Left ramus

Gastroduodenal artery

Superior pancreaticoduodenal artery

Pancreatic rami

Duodenal rami

Right gastro-epiploic artery

Epiploic rami

Splenic artery

Pancreatic rami

Left gastro-epiploic artery

Short gastric arteries

Splenic rami

A. mesenterica superior

- Aa. intestinales
 - A. pancreaticoduodenalis inferior
 - Aa. jejunales
 - Aa. ileae
- A. ileocolica
 - A. appendicularis
 - A. colica dextra
 - A. colica media

A. mesenterica inferior

- A. colica sinistra
- Aa. sigmoideae
- A. haemorrhoidalis superior

A. suprarenalis media**A. renalis**

- A. suprarenalis inferior

A. spermatica interna**A. testicularis****A. ovarica****A. iliaca communis****A. hypogastrica****Rami parietales****A. iliolumbalis**

- Ramus lumbalis
- Ramus spinalis
- Ramus iliacus

A. sacralis lateralis

- Rami spinales

A. obturatoria

- Ramus pubicus
- Ramus anterior
- Ramus posterior
- A. acetabuli

A. glutea superior

- amus superior
- Ramus inferior

A. glutea inferior

- A. comitans n. ischiadici
- Rami viscerales

A. umbilicalis

- Aa. vesicales superiores
- [Ligamentum umbilicale laterale]

A. vesicalis inferior**A. deferentialis****A. uterina**

- A. vaginalis
- Ramus ovarii
- Ramus tubarius

A. haemorrhoidalis media**A. pudenda interna**

- A. haemorrhoidalis inferior
- A. perinei
- Aa. scrotales posteriores
- Aa. labiales posteriores
- A. penis
- A. urethralis
- A. bulbi urethrae
- A. bulbi vestibuli [vaginae]
- A. profunda penis
- A. dorsalis penis
- A. clitoridis
- A. profunda clitoridis
- A. dorsalis clitoridis

A. iliaca externa**A. epigastrica inferior**

- Ramus pubicus
- Ramus obturatorius
- A. spermatica externa

Superior mesenteric artery
 Intestinal arteries
 Inferior pancreaticoduodenal artery
 Jejunal arteries
 Ileal arteries (O. T. rami intestini tenuis)
 Ileocolic artery
 Appendicular artery
 Right colic artery
 Middle colic artery

Inferior mesenteric artery
 Left colic artery
 Sigmoid arteries
 Superior hemorrhoidal artery

Middle suprarenal artery (O. T. middle capsular artery)

Renal artery
 Inferior suprarenal artery

Internal spermatic artery
 Testicular artery
 Ovarian artery

Common iliac artery
Hypogastric artery (O. T. internal iliac)

Parietal rami
Iliolumbar artery
 Lumbar ramus
 Spinal ramus
 Iliac ramus

Lateral sacral artery
 Spinal rami

Obturator artery
 Pubic ramus
 Anterior ramus
 Posterior ramus
 Artery of acetabulum

Superior gluteal artery
 Superior ramus
 Inferior ramus

Inferior gluteal artery
 Companion artery of sciatic nerve
 Visceral rami

Umbilical artery
 Superior vesical arteries
 [Lateral umbilical ligament]

Inferior vesical artery

Deferential artery

Uterine artery
 Vaginal artery
 Ovarian ramus
 Tubal ramus

Middle hemorrhoidal artery

Internal pudendal artery
 Inferior hemorrhoidal artery
 Artery of perineum
 Posterior scrotal arteries
 Posterior labial arteries
 Artery of penis
 Urethral artery
 Artery of the bulb of urethra
 Artery of the vestibular bulb of vagina
 Deep artery of penis
 Dorsal artery of penis
 Artery of clitoris
 Deep artery of clitoris
 Dorsal artery of clitoris

External iliac artery

Inferior epigastric artery (O. T. deep epigastric)
 Pubic ramus
 Obturator ramus
 External spermatic artery (O. T. cremasteric)

A. lig. teretis uteri

A. circumflexa ilium profunda

A. femoralis

A. epigastrica superficialis

A. circumflexa ilium superficialis

Aa. pudendae externae

Aa. scrotales anteriores

Aa. labiales anteriores

Rami inguinales

A. profunda femoris

A. circumflexa femoris medialis

Ramus superficialis

Ramus profundus

Ramus acetabuli

A. circumflexa femoris lateralis

Ramus ascendens

Ramus descendens

A. perforans prima

A. nutritia femoris superior

A. perforans secunda

A. perforans tertia

A. nutritia femoris inferior

Rami musculares

A. genu suprema

Rami musculares

Ramus saphenus

Rami articulares

A. poplitea

A. genu superior lateralis

A. genu superior medialis

A. genu media

Aa. surales

A. genu inferior lateralis

A. genu inferior medialis

Rete articulare genu

Rete patellae

A. tibialis anterior

(A. recurrens tibialis posterior)

A. recurrens tibialis anterior

A. malleolaris anterior lateralis

A. malleolaris anterior medialis

Rete malleolare mediale

Rete malleolare laterale

A. dorsalis pedis

A. tarsea lateralis

Aa. tarseae mediales

A. arcuata

Rete dorsale pedis

Aa. metatarsae dorsales

Aa. digitales dorsales

Ramus plantaris profundus

A. tibialis posterior

Ramus fibularis

A. peronaea

A. nutritia fibulae

Ramus perforans

Ramus communicans

A. malleolaris posterior lateralis

Rami calcanei laterales

A. nutritia tibiae

A. malleolaris posterior medialis

Rami calcanei mediales

Rete calcaneum

A. plantaris medialis

Ramus profundus

Artery of round ligament of uterus

Deep circumflex iliac artery

Femoral artery

Superficial epigastric artery

Superficial circumflex iliac artery

External pudendal arteries (O. T. superficial and deep external pudic arteries)

Anterior scrotal arteries

Anterior labial arteries

Inguinal rami

Deep artery of thigh

Medial circumflex artery of thigh (O. T. internal circumflex)

Superficial ramus

Deep ramus

Ramus to acetabulum

Lateral circumflex artery of thigh (O. T. external circumflex)

Ascending ramus

Descending ramus

First perforating artery

Superior nutrient artery of femur

Second perforating artery

Third perforating artery

Inferior nutrient artery of femur

Muscular rami

Highest artery of knee

Muscular rami

Saphenous ramus

Articular rami

Popliteal artery

Lateral superior artery of knee (O. T. superior external articular artery)

Medial superior artery of knee (O. T. superior internal articular artery)

Middle artery of knee (O. T. azygos articular artery)

Sural arteries, or arteries of calf

Lateral inferior artery of knee (O. T. inferior external articular artery)

Medial inferior artery of knee (O. T. inferior internal articular artery)

Arterial network about knee-joint

Patellar network

Anterior tibial artery

Posterior recurrent tibial artery

Anterior recurrent tibial artery

Lateral anterior malleolar artery (O. T. external malleolar)

Medial anterior malleolar artery (O. T. internal malleolar)

Medial malleolar network

Lateral malleolar network

Dorsal artery of foot

Lateral tarsal artery

Medial tarsal arteries

Arcuate artery

Dorsal network of foot

Dorsal metatarsal arteries

Dorsal digital arteries

Deep plantar ramus

Posterior tibial artery

Fibular ramus

Peroneal artery

Nutrient artery of fibula

Perforating ramus (O. T. anterior peroneal)

Communicating ramus

Lateral posterior malleolar artery (O. T. posterior peroneal)

Lateral calcanean rami (O. T. external calcanean)

Nutrient artery of tibia

Medial posterior malleolar artery (O. T. internal malleolar)

Medial calcanean rami (O. T. internal calcanean)

Network of heel

Medial plantar artery (O. T. internal plantar)

Deep ramus

Ramus superficialis
A. plantaris lateralis

Arcus plantaris

Aa. metatarsae plantares

Rami perforantes
Aa. digitales plantares

Venae

Venae pulmonales

Vv. pulmonales dextrae
Vv. pulmonales sinistrae

Vv. cordis

Sinus coronarius
V. cordis magna

V. posterior ventriculi sinistri
V. obliqua atrii sinistri [Marshalli]

Lig. v. cavae sinistrae

V. cordis media
V. cordis parva
Vv. cordis anteriores
Vv. cordis minimae

Vena cava superior

Vv. anonymae dextra et sinistra

Vv. thyreoideae inferiores
V. thyreoidea ima
Plexus thyreoideus impar
V. laryngea inferior
Vv. thymicae
Vv. pericardiaca
Vv. phrenicae superiores
Vv. mediastinales anteriores
Vv. bronchiales anteriores
Vv. tracheales
Vv. oesophageae
V. vertebralis

V. cervicalis profunda
V. mammaria interna
Vv. subcutaneae abdominis
V. epigastrica superior
V. intercostalis suprema

V. jugularis interna

Bulbus venae jugularis superior
V. canaliculi cochleae
Bulbus v. jugularis inferior
Plexus pharyngeus
Vv. pharyngeae
Vv. meningeae
Vv. canalis pterygoidei [Vidii]
V. lingualis
Vv. dorsales linguae
V. sublingualis
V. comitans n. hypoglossi
(Vv. thyreoideae superiores)
V. sternocleidomastoidea
V. laryngea superior

Sinus durae matris

Sinus transversus
Confluens sinuum
Vv. auditivae internae
Sinus occipitalis
Plexus basilaris
Sinus sagittalis superior
Sinus sagittalis inferior

Superficial ramus	Plantar metatarsal arteries (O. T.
Lateral plantar artery (O. T. external	digital branches)
plantar)	Perforating rami
Plantar arch	Plantar digital arteries (O. T. collat-
	eral digital branches)

Veins

Pulmonary veins

Right pulmonary veins
Left pulmonary veins

Veins of heart

Coronary sinus
Large vein of heart (O. T. great
cardiac vein)
Posterior vein of left ventricle
Oblique vein of left atrium (O. T.
oblique vein of Marshall)
Ligament of left vena cava (O. T.
vestigial fold of Marshall)
Middle vein of heart
Small vein of heart
Anterior veins of heart
Smallest veins of heart (O. T. Vv.
Thebesii)

Superior vena cava

Right and left innominate veins

Inferior thyroid veins
Lowest thyroid vein
Unpaired thyroid plexus
Inferior laryngeal vein
Thymic veins
Pericardiac veins
Superior phrenic veins
Anterior mediastinal veins
Anterior bronchial veins
Tracheal veins
Oesophageal veins
Vertebral vein

Deep cervical vein
Internal mammary vein
Subcutaneous veins of abdomen
Superior epigastric vein
Highest intercostal vein (O. T. left
superior intercostal vein)

Internal jugular vein

Upper bulb of jugular vein
Vein of canaliculus of cochlea
Inferior bulb of jugular vein
Pharyngeal plexus
Pharyngeal veins
Meningeal veins
Veins of the pterygoid canal
Lingual vein
Dorsal veins of tongue
Sublingual vein
Companion vein to hypoglossal nerve
Superior thyroid veins
Sternocleidomastoid vein
Superior laryngeal vein

Sinuses of the dura mater

Transverse sinus (O. T. lateral sinus)
Confluence of the sinuses (O. T.
torcular Herophili)
Internal auditory veins
Occipital sinus
Basilar plexus (O. T. basilar sinus)
Superior sagittal sinus (O. T. superior
longitudinal sinus)
Inferior sagittal sinus (O. T. inferior
longitudinal sinus)

Sinus rectus
 Sinus petrosus inferior
 Sinus petrosus superior
 Sinus cavernosus
 Sinus intercavernosus anterior
 Sinus intercavernosus posterior
 Sinus circularis
 Sinus sphenoparietalis

Venae diploicae

V. diploica frontalis
 V. diploica temporalis anterior
 V. diploica temporalis posterior
 V. diploica occipitalis

Emissarium parietale
 Emissarium mastoideum
 Emissarium condyloideum
 Emissarium occipitale
 Rete canalis hypoglossi
 Rete foraminis ovalis
 Plexus venosus caroticus internus

Venae cerebri

Vv. cerebri superiores
 V. cerebri media
 Vv. cerebri inferiores
 Vv. cerebelli superiores
 Vv. cerebelli inferiores
 Vv. cerebri internae

V. cerebri magna [Galen]

V. septi pellucidi
 V. terminalis

V. basalis [Rosenthal]
 V. chorioidea
 V. ophthalmomeningea

V. ophthalmica superior

V. nasofrontalis
 V. ethmoidalis anterior
 V. ethmoidalis posterior

V. lacrimalis
 Vv. musculares
 Vv. vorticosae
 Vv. ciliares posteriores
 Vv. ciliares anteriores
 V. centralis retinae
 Vv. episclerales
 Vv. palpebrales
 Vv. conjunctivales anteriores
 Vv. conjunctivales posteriores
 V. ophthalmica inferior

V. facialis communis

V. facialis anterior

V. angularis
 Vv. frontales
 V. supraorbitalis
 V. palpebrales superiores
 V. nasales externae
 V. palpebrales inferiores
 V. labialis superior
 V. labialis inferior
 Vv. massetericae
 Vv. parotideae anteriores
 V. palatina
 V. submentalis

V. facialis posterior

Vv. temporales superficiales
 Vv. auriculares anteriores
 Vv. parotideae posteriores
 Vv. articulares mandibulae
 Vv. tympanicae
 V. stylomastoidea
 V. transversa faciei
 V. temporalis media
 Plexus pterygoideus
 Vv. meningae mediae
 Vv. temporales profundae
 V. thyreoidea superior

V. jugularis externa

V. occipitalis

Straight sinus
 Inferior petrosal sinus
 Superior petrosal sinus
 Cavernous sinus
 Anterior intercavernous sinus
 Posterior intercavernous sinus
 Circular sinus
 Sphenoparietal sinus (O. T. sinus alae
 parvae)
 Diploic veins
 Frontal diploic vein
 Anterior temporal diploic vein
 Posterior temporal diploic vein
 Occipital diploic vein
 Parietal emissary
 Mastoid emissary
 Condylloid emissary
 Occipital emissary
 Network of hypoglossal canal
 Network of oval foramen
 Venous plexus of internal carotid

Cerebral veins

Superior cerebral veins
 Middle cerebral vein
 Inferior cerebral veins
 Superior cerebellar veins
 Inferior cerebellar veins
 Internal cerebral veins (O. T. veins
 of Galen)
 Large vein of cerebrum (O. T. vena
 magna Galeni)
 Vein of septum pellucidum
 Terminal vein (O. T. vein of the cor-
 pus striatum)
 Basal vein (O. T. basilar vein)
 Chorioid vein
 Ophthalmomeningeal vein

Superior ophthalmic vein

Nasofrontal vein
 Anterior ethmoidal vein
 Posterior ethmoidal vein

Lacrimal vein
 Muscular veins
 Vortex veins
 Posterior ciliary veins
 Anterior ciliary veins
 Central vein of retina
 Episcleral veins
 Palpebral veins
 Anterior conjunctival veins
 Posterior conjunctival veins
 Inferior ophthalmic vein

Common facial vein

Anterior facial vein

Angular vein
 Frontal veins
 Supraorbital vein
 Superior palpebral veins
 External nasal veins
 Inferior palpebral veins
 Vein of upper lip
 Vein of lower lip
 Masseteric veins
 Anterior parotid veins
 Palatine vein
 Submental vein

Posterior facial vein

Superficial temporal veins
 Anterior auricular veins
 Posterior parotid veins
 Articular mandibular veins
 Tympanic veins
 Stylomastoid vein
 Transverse vein of face
 Middle temporal vein
 Pterygoid plexus
 Middle meningeal veins
 Deep temporal veins
 Superior thyroid vein

External jugular vein

Occipital vein

V. auricularis posterior
 V. jugularis anterior
 Arcus venosus juguli
 (V. mediana colli)
 V. transversa scapulae

V. subclavia

V. thoracoacromialis
 Vv. transversae colli

V. axillaris

V. thoracalis lateralis
 Vv. costoaxillares
 Vv. thoracoepigastricae
 Plexus venosus mamillae
 Vv. brachiales
 Vv. radiales
 Vv. ulnares
 V. cephalica
 V. cephalica accessoria
 V. basilica
 V. mediana cubiti
 (V. mediana antibrachii)
 (V. mediana basilica)
 (V. mediana cephalica)
 Rete venosum dorsale manus
 Vv. intercapitulares
 Arcus volaris venosus superficialis
 Arcus volaris venosus profundus
 Vv. digitales volares communes
 Vv. metacarpeae dorsales
 Vv. metacarpeae volares
 Vv. digitales volares propriae
 Arcus venosi digitales

V. azygos

V. hemiazygos

V. hemiazygos accessoria

Vv. intercostales
 Ramus dorsalis
 Ramus spinalis
 Vv. oesophageae
 Vv. bronchiales posteriores
 V. lumbalis ascendens
 Vv. basivertebrales
 Plexus venosi vertebrales externi
 Plexus venosi vertebrales anteriores
 Plexus venosi vertebrales posteriores
 Plexus venosi vertebrales interni
 Retia venosa vertebrarum
 Sinus vertebrales longitudinales
 Vv. intervertebrales
 Vv. spinales externae anteriores
 Vv. spinales externae posteriores
 Vv. spinales internae

V. cava inferior

Radices parietales

V. phrenica inferior
 Vv. lumbales

Radices viscerales

Vv. hepaticae
 Vv. renales
 Vv. suprarenales
 V. spermatica:
 V. testicularis
 V. ovarica
 Plexus pampiniformis

Vena portae

V. coronaria ventriculi
 V. mesenterica superior
 Vv. intestinales
 V. gastroepiploica dextra
 Vv. pancreaticae
 V. ileocolica
 Vv. colicae dextrae
 V. colica media
 Vv. pancreaticoduodenales

Posterior auricular vein
 Anterior jugular vein
 Venous jugular arch
 Median vein of neck
 Transverse vein of scapula (O. T. suprascapular vein)

Subclavian vein

Thoraco-acromial vein (O. T. acromiothoracic, or thoracic axis)
 Transverse veins of neck (O. T. transversalis colli)

Axillary vein

Lateral thoracic vein (O. T. long thoracic)
 Costo-axillary veins
 Thoraco-epigastric veins
 Venous plexus of mammary gland
 Brachial veins
 Radial veins
 Ulnar veins
 Cephalic vein
 Accessory cephalic vein
 Basilic vein
 Median vein of elbow
 Median vein of forearm
 Median basilic vein
 Median cephalic vein
 Dorsal venous network of hand
 Intercapitular veins
 Superficial venous volar arch
 Deep venous volar arch
 Common volar digital veins
 Dorsal metacarpal veins
 Volar metacarpal veins
 Volar digital veins proper
 Venous arches of digits

Azygos vein (O. T. vena azygos major)

Hemiazygos vein (O. T. v. azygos minor inferior)

Accessory hemiazygos vein (O. T. v. azygos minor superior)
 Intercostal veins
 Dorsal ramus
 Spinal ramus
 Oesophageal veins
 Posterior bronchial veins
 Ascending lumbar vein
 Basivertebral veins
 External vertebral venous plexuses
 Anterior vertebral venous plexuses
 Posterior vertebral venous plexuses
 Internal vertebral venous plexuses
 Venous networks of the vertebrae
 Longitudinal vertebral sinuses
 Intervertebral veins
 Anterior external spinal veins
 Posterior external spinal veins
 Internal spinal veins

Inferior vena cava

Parietal radicals

Inferior phrenic vein
 Lumbar veins

Visceral radicals

Hepatic veins
 Renal veins
 Suprarenal veins
 Spermatic vein
 Testicular vein
 Ovarian vein
 Pampiniform plexus

Portal vein

Coronary vein of stomach
 Superior mesenteric vein
 Intestinal veins
 Right gastro-epiploic vein
 Pancreatic veins
 Ileocolic vein
 Right colic veins
 Middle colic vein
 Pancreaticoduodenal veins

Vv. duodenales
 V. mesenterica inferior
 V. colica sinistra
 Vv. sigmoideae
 V. haemorrhoidalis superior
 V. lienalis
 Vv. gastricae breves
 V. gastroepiploica sinistra
 V. cystica
Vena umbilicalis
Ductus venosus [Arantii]
 Vv. parumbilicales [Sappeyi]

Vena iliaca communis

V. sacralis media

V. hypogastrica

Vv. glutaeae superiores
 Vv. glutaeae inferiores
 Vv. obturatoriae
 Vv. sacrales laterales
 V. iliolumbalis
 Plexus sacralis anterior
 Plexus haemorrhoidalis
 Plexus vesicalis
 Plexus pudendalis
 V. dorsalis penis
 Vv. profundae penis
 V. dorsalis clitoridis
 Vv. profundae clitoridis
 Vv. uterinae
 Plexus uterovaginalis
 V. haemorrhoidalis media
 Vv. haemorrhoidales inferiores
 Vv. scrotales posteriores

V. iliaca externa

V. epigastrica inferior
 V. circumflexa ilium profunda
 V. femoralis
 Vv. dorsales penis subcutaneae
 Vv. scrotales anteriores
 Vv. pudendae externae
 V. epigastrica superficialis
 V. saphena magna
 V. saphena accessoria
 V. circumflexa ilium superficialis
 Vv. circumflexae femoris mediales
 Vv. circumflexae femoris laterales
 Vv. comitantes
 Vv. profundae femoris
 Vv. perforantes
 V. saphena parva

V. femoropoplitea

Vv. peronaeae
 Vv. popliteae
 Vv. tibiales posteriores
 Vv. tibiales anteriores
 Rete venosum dorsale pedis
 Arcus venosus dorsalis pedis
 Vv. digitales communes pedis
 Vv. metatarsae dorsales pedis
 Vv. intercapitulares
 Rete venosum plantare
 Arcus venosus plantaris
 Vv. metatarsae plantares
 Vv. digitales pedis dorsales
 Vv. digitales plantares

Systema lymphaticum

Vasa lymphatica

Vasa lymphatica superficialia

Vasa lymphatica profunda

Truncus jugularis

Duodenal veins
 Inferior mesenteric vein
 Left colic vein
 Sigmoid veins
 Superior hemorrhoidal vein
 Splenic vein
 Short gastric veins
 Left gastro-epiploic vein
 Cystic vein

Umbilical vein

Venous duct of Arantius

Paraumbilical veins

Common iliac vein

Middle sacral vein

Hypogastric vein (O. T. internal iliac vein)

Superior gluteal veins
 Inferior gluteal veins
 Obturator veins
 Lateral sacral veins
 Iliolumbar vein
 Anterior sacral plexus
 Hemorrhoidal plexus
 Vesical plexus
 Pundental plexus
 Dorsal vein of penis
 Deep veins of penis
 Dorsal veins of clitoris
 Deep veins of clitoris
 Uterine veins
 Uterovaginal plexus
 Middle hemorrhoidal vein
 Inferior hemorrhoidal veins
 Posterior scrotal veins

External iliac veins

Inferior epigastric vein (O. T. deep epigastric)
 Deep circumflex iliac vein
 Femoral vein
 Subcutaneous dorsal veins of penis
 Anterior scrotal veins
 External pundental veins
 Superficial epigastric veins
 Large saphenous vein (O. T. internal saphenous)
 Accessory saphenous vein
 Superficial circumflex iliac vein
 Medial circumflex veins of thigh
 Lateral circumflex veins of thigh
 Accompanying veins
 Deep veins of thigh
 Perforating veins
 Small saphenous vein (O. T. external saphenous vein)
 Femoropopliteal vein
 Peroneal veins
 Popliteal veins
 Posterior tibial veins
 Anterior tibial veins
 Dorsal venous network of foot
 Dorsal venous arch of foot
 Common digital veins of foot
 Dorsal metatarsal veins of foot
 Intercapitular veins
 Plantar venous network
 Plantar venous arch
 Plantar metatarsal veins
 Dorsal digital veins of foot
 Plantar digital veins

Lymphatic system

Lymphatic vessels

Superficial lymphatic vessel

Deep lymphatic vessel

Jugular trunk

Truncus subclavius
 Truncus bronchomediastinalis dexter
 Ductus lymphaticus dexter

Ductus thoracicus

Trunci lumbales
 Truncus intestinalis
 Cisterna chyli

Lymphoglandulae

Vasa afferentia
 Vasa efferentia
 Substantia corticalis
 Substantia medullaris
 Hilus
 Lymphoglandulae occipitales
 " auriculares posteriores
 " auriculares anteriores
 " submaxillares
 " faciales profundae
 " parotideae
 " cervicales superficiales
 " cervicales profundae superiores
 " cervicales profundae inferiores
 " linguales
 " axillares
 " subscapulares
 " pectorales
 " epigastricae
 " cubitales superficiales
 " cubitales profundae
 " tracheales

Lymphoglandulae bronchiales
 " intercostales
 " mediastinales posteriores
 " mediastinales anteriores
 " sternales
 " iliaca
 " lumbales
 " coeliacae
 " gastricae superiores
 " gastricae inferiores
 " hepaticae
 " pancreaticolienales
 " mesentericae
 " mesocolicae
 " hypogastricae
 " sacrales
 " inguinales
 " subinguinales superficiales
 " subinguinales profundae
 " popliteae
 (Lymphoglandula tibialis anterior)

Plexus lymphatici

Plexus jugularis
 Plexus axillaris
 Plexus mammarius
 Plexus lumbalis
 Plexus aorticus
 Plexus sacralis medius
 Plexus hypogastricus
 Plexus coeliacus
 Plexus iliacus externus
 Plexus inguinalis

Subclavian trunk
 Right bronchomediastinal trunk
 Right lymphatic trunk

Thoracic duct

Lumbar trunks
 Intestinal trunk
 Chyle-cistern (O. T. receptaculum chyli)

Lymph glands

Afferent vessels
 Efferent vessels
 Cortical substance
 Medullary substance
 Hilus
 Occipital lymph glands
 Posterior auricular lymph glands
 Anterior auricular lymph glands
 Submaxillary lymph glands
 Deep facial lymph glands
 Parotid lymph glands
 Superficial cervical lymph glands
 Upper deep cervical lymph glands
 Lower deep cervical lymph glands
 Lingual lymph glands
 Axillary lymph glands
 Subscapular lymph glands
 Pectoral lymph glands
 Epigastric lymph glands
 Superficial lymph glands of elbow
 Deep lymph glands of elbow
 Tracheal lymph glands

Bronchial lymph glands
 Intercostal lymph glands
 Posterior mediastinal lymph glands
 Anterior mediastinal lymph glands
 Sternal lymph glands
 Iliac lymph glands
 Lumbar lymph glands
 Coeliac lymph glands
 Superior gastric lymph glands
 Inferior gastric lymph glands
 Hepatic lymph glands
 Pancreaticolienal lymph glands
 Mesenteric lymph glands
 Mesocolic lymph glands
 Hypogastric lymph glands
 Sacral lymph glands
 Inguinal lymph glands
 Superficial subinguinal lymph glands
 Deep subinguinal lymph glands
 Popliteal lymph glands
 Anterior tibial lymph glands

Lymphatic plexuses

Jugular plexus
 Axillary plexus
 Mammary plexus
 Lumbar plexus
 Aortic plexus
 Middle sacral plexus
 Hypogastric plexus
 Coeliac plexus
 External iliac plexus
 Inguinal plexus

Neurologia

Nervus	Nuclei originis
Ganglion	Nuclei terminales
Substantia alba	Ramus communicans
Substantia grisea	Ramus anastomoticus
Substantia gelatinosa	Ramus muscularis
Taenia telarum	Nervus cutaneus
Ependyma ventriculorum	Nervus articularis
Sulcus limitans ventriculorum	Plexus nervorum spinalium
Nuclei nervorum cerebralium	

Systema nervorum centrale

Medulla spinalis

Pars cervicalis
 Intumescencia cervicalis
 Pars thoracalis
 Pars lumbalis
 Intumescencia lumbalis
 Conus medullaris
 Filum terminale
 Ventriculus terminalis
 Fissura mediana anterior
 Sulcus medianus posterior
 Sulcus lateralis anterior
 Sulcus lateralis posterior
 Sulcus intermedius posterior

 (Sulcus intermedius anterior)
 Funiculi medullae spinalis
 Funiculus anterior
 Funiculus lateralis
 Funiculus posterior

Sectiones medullae spinalis

Canalis centralis
 Substantia grisea centralis
 Commissura anterior alba
 Commissura anterior grisea
 Commissura posterior
 Columnae griseae:
 Columna anterior
 Columna lateralis
 Columna posterior

 Cervix columnae posterioris
 Apex columnae posterioris
 Substantia gelatinosa [Rolandi]
 Nucleus dorsalis [Stillingi, Clarkii]

 Formatio reticularis
 Funiculus anterior
 Fasciculus cerebrospinalis anterior
 [pyramidalis anterior]

Neurology

Nerve	Nuclei of origin
Ganglion	End-nuclei
White matter	Communicating ramus
Gray matter	Anastomotic ramus
Gelatinous substance	Muscular ramus
Band of the telae ("web")	Cutaneous nerve
Ependyma ("cover") of ventricles	Articular nerve
Limiting sulcus of the ventricles	Plexus of spinal nerves
Nuclei of the cerebral nerves	

Central nervous system

Spinal cord

Cervical portion
 Cervical enlargement
 Thoracic portion (O. T. dorsal part)
 Lumbar portion
 Lumbar enlargement
 Medullary cone
 Terminal thread
 (Swelling due to) terminal ventricle
 Anterior median fissure
 Posterior median sulcus
 Anterior lateral sulcus
 Posterior lateral sulcus
 Posterior intermediate sulcus (O. T. paramedian furrow)
 Anterior intermediate sulcus
 Funiculi of spinal cord
 Anterior funiculus
 Lateral funiculus
 Posterior funiculus

Transverse sections of the spinal cord

Central canal
 Central gray matter
 Anterior white commissure
 Anterior gray commissure
 Posterior commissure
 Gray columns
 Anterior column (O. T. anterior horn)
 Lateral column (O. T. lateral horn)
 Posterior column (O. T. posterior horn)
 Neck of posterior column
 Apex of posterior column
 Gelatinous substance of Rolando
 Dorsal nucleus (O. T. Clark's column)
 Reticular formation
 Anterior funiculus
 Anterior cerebrospinal or pyramidal fasciculus (O. T. direct pyramidal tract)

Fasciculus anterior proprius [Flechsigi]	Fasciculus anterolateralis superficialis [Gowersi]
Funiculus lateralis	Fasciculus lateralis proprius [Flechsigi]
Fasciculus cerebrospinalis lateralis [pyramidalis lateralis]	Funiculus posterior
Funiculus cerebellospinalis	Fasciculus gracilis [Golli]
	Fasciculus cuneatus [Burdachi]

Encephalon

Rhombencephalon

Myelencephalon

Medulla oblongata

Fissura mediana posterior
 Fissura mediana anterior
 Foramen caecum
 Pyramis [medullae oblongatae]
 Decussatio pyramidum
 Sulcus lateralis anterior
 Sulcus lateralis posterior
 Oliva
 Corpus restiforme

Funiculus lateralis
 Funiculus cuneatus

Tuberculum cinereum
 Funiculus gracilis

Clava
 Fibrae arcuatae externae

Sectiones medullae oblongatae

Raphe
 Stratum nucleare
 Nucleus n. hypoglossi
 Nucleus ambiguus
 Nucleus alae cinereae

Tractus solitarius

Nucleus tractus solitarii
 Tractus spinalis n. trigemini

Nucleus tractus spinalis n. trigemini

Nucleus funiculi gracilis

Nucleus funiculi cuneati

Nuclei laterales

Nucleus olivaris inferior

Hilus nuclei olivaris

Nucleus olivaris accessorius medialis

Nucleus olivaris accessorius dorsalis

Nuclei arcuati

Fibrae arcuatae internae

Substantia reticularis grisea

Substantia reticularis alba

Fasciculus longitudinalis medialis

Stratum interolivare lemnisci

Decussatio lemniscorum

Corpus restiforme

Proper anterior fasciculus (O. T. anterior ground bundle)	Superficial anterolateral fasciculus (O. T. Gowers' tract)
Lateral funiculus	Proper lateral fasciculus (O. T. lateral ground bundle)
Lateral cerebrospinal or pyramidal fasciculus (O. T. crossed pyramidal tract)	Posterior funiculus
Cerebellospinal fasciculus (O. T. direct cerebellar tract of Flechsig)	Slender fasciculus (O. T. column or tract of Goll)
	Wedge-shaped fasciculus (O. T. column or tract of Burdach)

Brain

Lozenge-shaped brain

Medullary or after-brain

Oblong medulla

Posterior median fissure	Solitary tract (O. T. respiratory bundle)
Anterior median fissure	Nucleus of solitary tract
Blind foramen	Spinal tract of trigeminal nerve (O. T. ascending root of trigeminal nerve)
Pyramid of medulla oblongata	Nucleus of spinal tract of trigeminal nerve
Decussation of pyramids	Nucleus of slender funiculus (O. T. nucleus of Goll's column)
Anterior lateral sulcus	Nucleus of wedge-shaped funiculus (O. T. nucleus of Burdach's column)
Posterior lateral sulcus	Lateral nuclei
Olive (O. T. olivary eminence)	Inferior olivary nucleus
Restiform body (O. T. inferior cerebellar peduncle)	Hilus of olivary nucleus
Lateral funiculus	Medial accessory olivary nucleus
Cuneate funiculus (O. T. column of Burdach)	Dorsal accessory olivary nucleus
Gray or ashen tubercle	Arcuate nuclei
Slender funiculus (O. T. column of Goll)	Internal arcuate fibres
Club	Gray reticular substance
External arcuate fibres (O. T. superficial arcuate fibres)	White reticular substance
Transverse sections of medulla oblongata	Medial longitudinal fasciculus (O. T. posterior longitudinal bundle)
Median raphe	Interolivary layer of lemniscus
Nuclear layer	Decussation of lemniscus or fillet (O. T. sensory decussation of medulla oblongata)
Nucleus of hypoglossal nerve	Restiform body (O. T. inferior cerebellar peduncle)
Ambiguous nucleus	
Nucleus of ala cinerea	

Fasciculi corporis restiformis
 Fibrae cerebelloolivares
 Fasciculi pyramidales
 Fibrae arcuatae externae

Ventriculus quartus

Fossa rhomboidea
 Pars inferior fossae rhomboideae
 [Calamus scriptorius]
 Pars intermedia fossae rhomboideae
 Recessus lateralis fossae rhom-
 boideae
 Pars superior fossae rhomboideae
 Sulcus limitans [fossae rhomboideae]
 Fovea inferior
 Fovea superior
 Trigonum n. hypoglossi
 Striae medullares
 Eminencia medialis

Colliculus facialis
 Ala cinerea
 Area acustica

Locus caeruleus
 Tegmen ventriculi quarti
 Velum medullare posterius
 Taenia ventriculi quarti

Obex
 Lamina chorioidea epithelialis
 (Apertura medialis ventriculi quarti
 [Foramen Magendii])
 (Apertura lateralis ventriculi quarti)
 Fastigium

Metencephalon

Pons [Varolii]

Sulcus basilaris
 Fasciculus obliquus [pontis]
 (Fila lateralia pontis)
 Brachium pontis

Sectiones pontis

Pars dorsalis pontis

Raphe
 Nucleus n. abducentis

Nuclei motorii n. trigemini
 Radix descendens [mesencephalica]
 n. trigemini
 Tractus spinalis n. trigemini
 Nucleus tractus spinalis n. trigemini

Nucleus n. facialis
 Radix n. facialis
 Pars prima
 Genu [internum]
 Pars secunda
 Nuclei n. acustici

Nuclei n. cochlearis
 Nuclei n. vestibularis
 Nucleus olivaris superior
 Nucleus lemnisci lateralis
 Fasciculus longitudinalis medialis

Formatio reticularis
 Corpus trapezoideum
 Lemniscus
 Lemniscus medialis [sensitivus]
 Lemniscus lateralis [acusticus]
 Pars basilaris pontis
 Fibrae pontis profundae
 Fasciculi longitudinales [pyramidales]
 Nuclei pontis
 Fibrae pontis superficiales

Cerebellum

Gyri cerebelli
 Sulci cerebelli
 Vallecula cerebelli
 Incisura cerebelli anterior
 Incisura cerebelli posterior

Fasciculi of restiform body

Cerebello-olivary fibres

Pyramidal fasciculi

External arcuate fibres

Fourth ventricle

Rhomboid fossa

Inferior part of rhomboid fossa

Writing pen

Intermediate part of rhomboid fossa

Lateral recess of rhomboid fossa

Superior part of rhomboid fossa

Limiting groove of rhomboid fossa

Inferior pit

Superior pit

Trigone of hypoglossal nerve

Medullary striae

Medial eminence (O. T. eminentia teres)

Facial hillock

Ash-like wing (O. T. trigonum vagi)

Acoustic area (O. T. trigonum acustici)

Blue place

Roof of fourth ventricle

Posterior medullary velum

Taenia of fourth ventricle: junction of epithelial part of roof with compact nerve substance

Bar

Epithelial chorioid layer

Median aperture of fourth ventricle (foramen of Magendie)

Lateral aperture of fourth ventricle

Fastigium: "summit of roof"

Hind-brain

Pons ("bridge") Varolii

Basilar groove

Oblique bundle of pons

Lateral fibres of pons

Brachium ("arm") of pons

Sections of the pons

Dorsal part of pons

Median raphe

Nucleus of the abducent nerve (O. T. nucleus of sixth nerve)

Motor nuclei of the trigeminal nerve

Descending or mesencephalic root of trigeminal nerve

Spinal tract of trigeminal nerve

Nucleus of spinal tract of trigeminal nerve

Nucleus of facial nerve

Root of facial nerve

First part

Internal knee

Second part

Nuclei of acoustic nerve (O. T. auditory nucleus)

Nuclei of cochlear nerve

Nuclei of vestibular nerve

Superior olivary nucleus

Nucleus of lateral lemniscus

Medial longitudinal fasciculus (O. T. posterior longitudinal bundle)

Reticular formation

Trapezoid body

Fillet or lemniscus

Medial (sensory) fillet

Lateral (acoustic) fillet

Basilar part of pons

Deep fibres of pons

Longitudinal pyramidal fasciculi

Nuclei of pons

Superficial fibres of pons

Cerebellum, or small brain

Convolutions of cerebellum

Sulci of cerebellum

Cerebellar vallicula

Anterior notch of cerebellum (O. T. semilunar notch)

Posterior notch of cerebellum (O. T. marsupial notch)

Sulcus horizontalis cerebelli

Fissura transversa cerebelli

V e r m i s

Lingula cerebelli

Vincula lingulae cerebelli

Lobulus centralis

Monticulus

Culmen

Declive

Folium vermis

Tuber vermis

Pyramis [vermis]

Uvula [vermis]

Nodulus

H e m i s p h a e r i u m cerebelli

Facies superior

Ala lobuli centralis

Lobulus quadrangularis

Pars anterior

Pars posterior

Lobulus semilunaris superior

Facies inferior

Lobulus semilunaris inferior

Lobulus gracilis

Lobulus biventer

Tonsilla cerebelli

Flocculus

(Flocculi secundarii)

Pedunculus flocculi

Nidus avis

Sectiones cerebelli

Corpus medullare

Laminae medullares

Arbor vitae

Substantia corticalis

[Lamina basalis]

[Stratum cinereum]

[Stratum gangliosum]

[Stratum granulosum]

Nucleus dentatus

Hilus nuclei dentati

Nucleus fastigii

Nucleus globosus

Nucleus emboliformis

Capsula nuclei dentati

Isthmus rhombencephali

Brachium conjunctivum [cerebelli]

Lemniscus

Lemniscus lateralis

Lemniscus medialis

Trigonum lemnisci

Velum medullare anterius

Frenulum veli medullaris anterioris

Sectiones isthmi

[vide Pedunculus cerebri]

Ganglion interpedunculare

Nucleus n. trochlearis

Cerebrum

Facies convexa cerebri

Facies medialis cerebri

Basis cerebri

Mesencephalon

[Facies inferior]

Fossa interpeduncularis [Tarini]

Horizontal sulcus of cerebellum (O. T. great horizontal fissure)
 Transverse fissure of cerebellum
Vermis ("worm")
 Lingua ("tongue") of cerebellum
 Vincula of the lingua
 Central lobule (O. T. lobus centralis)
 Monticulus ("little mountain")
 Culmen ("summit")
 Declive ("slope or descent")
 Folium of vermis ("leaflet of worm")
 (O. T. folium cacuminis)
 Tuber of vermis (O. T. tuber valvulus)
 Pyramid of vermis
 Uvula of vermis
 Nodule
Hemisphere of cerebellum
 Superior surface
 Wing of central lobule
 Quadrangular lobule (O. T. quadrate lobule)
 Anterior part
 Posterior part
 Superior semilunar lobule (O. T. posterior crescentic lobule)
 Inferior surface
 Inferior semilunar lobule (O. T. postero-inferior lobule)
 Slender lobule
 Biventral lobule
 Tonsil of cerebellum
 Flocculus ("wool-tuft-like body")
 Secondary flocculi
 Peduncle of flocculus
 Nidus avis ("bird's nest")

Sections of cerebellum

Medullary body
 Medullary laminae
 Arbor vitae ("tree of life")
 Cortical substance
 Basal lamina
 Gray layer
 Ganglion-cell layer
 Granular layer
 Dentate nucleus
 Hilus of dentate nucleus
 Nucleus of fastigium ("roof")
 Spherical nucleus
 Emboliform nucleus (O. T. cork or plug)
 Capsule of dentate nucleus

Isthmus of rhombencephalon

Brachium conjunctivum ("connecting arm") of cerebellum (O. T. superior cerebellar peduncle)
 Fillet or ribbon
 Lateral fillet
 Medial fillet (O. T. ribbon of Reil)
 Trigone of fillet
 Anterior medullary velum (O. T. valve of Vieussens)
 Frenulum ("check-rein") of anterior medullary velum)

Sections of isthmus

[See *Cerebral peduncle*]

Interpeduncular ganglion
 Nucleus of trochlear nerve

Cerebrum (large brain)

Convex surface of cerebrum
 Medial surface of cerebrum
 Base of cerebrum

Midbrain

Inferior surface
 Interpeduncular fossa

Recessus anterior
 Recessus posterior
 Substantia perforata posterior

Pedunculus cerebri

Aquaeductus cerebri [Sylvii]

Sulcus lateralis
 Sulcus n. oculomotorii

Sectiones pedunculi cerebri

Tegmentum
 Stratum griseum centrale
 Formatio reticularis
 Fasciculus longitudinalis medialis

Radix descendens n. trigemini
 Nucleus radices descendentes n. trigemini
 Nucleus n. oculomotorii

Nuclei tegmenti
 Nucleus ruber
 Decussationes tegmentorum
 Decussatio brachii conjunctivi

Lemniscus lateralis
 Lemniscus medialis
 Substantia nigra
 Basis pedunculi

Corpora quadrigemina

Lamina quadrigemina
 Colliculus superior

Colliculus inferior

Brachium quadrigeminum superius
 Brachium quadrigeminum inferius

Sectiones corporum quadrigeminarum

Stratum zonale
 Stratum griseum colliculi superioris

Nucleus colliculi inferioris
 Stratum album profundum

Prosencephalon

Diencephalon

Ventriculus tertius
 Aditus ad aquaeductum cerebri

Commissura posterior [cerebri]
 Foramen interventriculare [Monroi]
 Sulcus hypothalamicus [Monroi]
 Massa intermedia

Recessus opticus
 Recessus infundibuli
 Commissura anterior [cerebri]
 Recessus triangularis

Hypothalamus

Pars mamillaris hypothalami

Corpus mamillare
 Pars optica hypothalami

Tuber cinereum
 Infundibulum
 Hypophysis
 Lobus anterior
 Lobus posterior

Tractus opticus
 Radix medialis
 Radix lateralis
 Chiasma opticum
 Lamina terminalis

Sectiones hypothalami

Nucleus hypothalamicus [Corpus Luysi]
 Pars grisea hypothalami
 Commissura superior [Meynerti]
 Commissura inferior [Guddeni]
 Nuclei corporis mamillarum

Anterior recess
 Posterior recess
 Posterior perforated substance
 Peduncle of cerebrum
 (O. T. crus cerebri)
 Aqueduct of cerebrum (O. T. iter e
 tertio ad quartum ventriculum)
 Lateral sulcus
 Sulcus of oculomotor nerve

Sections of cerebral peduncle

Tegmentum ("cover")
 Central gray layer
 Reticular formation
 Medial longitudinal fasciculus (O. T.
 posterior longitudinal bundle)
 Descending root of trigeminal nerve
 Nucleus of descending root of trigeminal
 nerve
 Nucleus of oculomotor nerve (O. T. nu-
 cleus of III. nerve)
 Nuclei of tegmentum
 Red nucleus
 Decussations of tegmenta
 Decussation of brachium conjunctivum
 Lateral fillet
 Medial fillet
 Black substance
 Base of peduncle
 Quadrigeminal bodies (O.
 T. optic lobes)
 Quadrigeminal layer
 Superior hillock (O. T. anterior body
 or nates)
 Inferior hillock (O. T. posterior body
 or testis)
 Superior quadrigeminal brachium
 Inferior quadrigeminal brachium
 Sections of quadrigeminal bodies
 Zonal layer
 Gray layer of superior colliculus

Nucleus of inferior colliculus
 Deep white layer

Forebrain

Interbrain

Third ventricle
 Entrance to the aqueduct of the cere-
 brum
 Posterior commissure of the cerebrum
 Interventricular foramen of Monroe
 Hypothalamic sulcus of Monroe
 Intermediate mass (O. T. middle, or
 soft, or gray, commissure)
 Optic recess
 Recess of infundibulum
 Anterior commissure of cerebrum
 Triangular recess

Hypothalamus (O. T. subthalamic region)

Mammillary part of hy-
 pothalamus
 Mammillary body
 Optic part of hypothalamus
 Tuber cinereum ("ash-like tuber")
 Infundibulum ("funnel")
 Hypophysis (O. T. pituitary body)
 Anterior lobe
 Posterior lobe
 Optic tract
 Medial root
 Lateral root
 Optic chiasm
 Terminal lamina

Sections of hypothalamus

Hypothalamic nucleus, or Luy's body
 (O. T. subthalamic nucleus)
 Gray part of hypothalamus
 Superior commissure of Meynert
 Inferior commissure of v. Gudden
 Nuclei of mammillary body

Fasciculus thalamomamillaris [Vicq'
d'Azyri]

Fasciculi pedunculomamillares

Pars tegmentalis

Pars basilaris

Ansa peduncularis

Ansa lenticularis

Pedunculus thalami inferior

Thalamencephalon

Thalamus

Pulvinar

Tuberculum anterius thalami

Taenia thalami

Stria medullaris

Lamina chorioidea epithelialis

Metathalamus

Corpus geniculatum mediale

Corpus geniculatum laterale

Epithalamus

Corpus pineale

Recessus pinealis

Recessus suprapinealis

Habenula

Commissura habenularum

Trigonum habenulae

Sectiones thalamencephali

Stratum zonale

Nucleus anterior thalami

Nucleus medialis thalami

Nucleus lateralis thalami

Laminae medullares thalami

Nucleus corporis geniculati medialis

Nucleus corporis geniculati lateralis

Nucleus habenulae

Fasciculus retroflexus [Meynerti]

Telencephalon

Hemisphaerium

Pallium

Fissura longitudinalis cerebri

Fissura transversa cerebri

Gyri cerebri

Gyri profundi

Gyri transitivi

Sulci cerebri

Impressio petrosa

Fossa cerebri lateralis [Sylvii]

Fissura cerebri lateralis [Sylvii]

Ramus posterior

Ramus anterior ascendens

Ramus anterior horizontalis

Lobus cerebri

Insula

Gyri insulae

Gyrus longus insulae

Gyri breves insulae

Sulcus circularis [Reili]

Operculum

Pars frontalis

Pars parietalis

Pars temporalis

Sulcus centralis [Rolandi]

Gyrus centralis anterior

Gyrus centralis posterior

Lobus frontalis

Polus frontalis

Sulcus praecentralis

Gyrus frontalis superior

Sulcus frontalis superior

Gyrus frontalis medius

Pars superior

Pars inferior

Sulcus frontalis inferior

Thalamomammillary fasciculus (O.

T. bundle of Vicq d'Azyr)

Pedunculomammillary fasciculi

Tegmental part

Basilar part

Peduncular loop

Lenticular loop

Inferior peduncle of thalamus

Thalamic brain

Thalamus ("bed") (O. T. optic thalamus)

Pulvinar ("cushion")

Anterior tubercle of thalamus

Thalamic taenia

Medullary stria (O. T. stria fornicis or stria pinealis)

Epithelial chorioid layer

Metathalamus

Medial geniculate body (O. T. internal geniculate body)

Lateral geniculate body (O. T. external geniculate body)

Epithalamus

Pineal body (O. T. conarium, or epiphysis cerebri)

Pineal recess

Suprapineal recess

Habenula ("strap") (O. T. peduncle of the pineal body)

Commissure of the habenula

Trigone of the habenula

Sections of the thalamic brain

Zonal layer

Anterior nucleus of thalamus

Medial nucleus of thalamus

Lateral nucleus of thalamus

Medullary layers of thalamus

Nucleus of medial geniculate body

Nucleus of lateral geniculate body

Nucleus of habenula

Retroflex fasciculus

End-brain

Hemisphere

Brain mantle

Longitudinal fissure of cerebrum

Transverse fissure of cerebrum

Convolution of cerebrum

Deep convolutions

Transitional convolutions (O. T. annectant gyri)

Grooves of cerebrum

Petrosal impression

Lateral fossa of cerebrum

Lateral fissure of cerebrum (O. T. fissure of Sylvius)

Posterior ramus

Ascending anterior ramus

Horizontal anterior ramus

Lobes of cerebrum

Island (O. T. island of Reil, or central lobe)

Convolution of island

Long convolution of island

Short convolutions of island

Circular sulcus of Reil (O. T. limiting sulcus of Reil)

Operculum ("cover")

Frontal part

Parietal part

Temporal part

Central sulcus of Rolando (O. T. fissure of Rolando)

Anterior central convolution

Posterior central convolution

Frontal lobe

Frontal pole

Precentral sulcus

Superior frontal convolution

Superior frontal sulcus

Middle frontal convolution

Superior part

Inferior part

Inferior frontal sulcus

Gyrus frontalis inferior

 Pars opercularis

 Pars triangularis

 Pars orbitalis

Gyrus rectus

Sulcus olfactorius

Gyri orbitales

Sulci orbitales

L o b u s t e m p o r a l i s

 Polus temporalis

 Sulci temporales transversi

 Gyri temporales transversi

 Gyrus temporalis superior

Sulcus temporalis superior

Gyrus temporalis medius

Sulcus temporalis medius

Gyrus temporalis inferior

Sulcus temporalis inferior

Fissura collateralis

Gyrus fusiformis

Gyrus lingualis

L o b u s o c c i p i t a l i s

 Polus occipitalis

 Sulcus occipitalis transversus

 Gyri occipitales superiores

 Sulci occipitales superiores

 Gyri occipitales laterales

 Sulci occipitales laterales

L o b u s p a r i e t a l i s

 Lobulus parietalis superior

 Sulcus interparietalis

Lobulus parietalis inferior

Gyrus supramarginalis

Gyrus angularis

Facies medialis hemisphaerii

Sulcus corporis callosi

Sulcus cinguli

 Pars subfrontalis

 Pars marginalis

Sulcus subparietalis

Fissura hippocampi

Gyrus fornicatus

 Gyrus cinguli

 Isthmus gyri fornicati

 Gyrus hippocampi

 Uncus [gyri hippocampi]

 Substantia reticularis alba [Arnoldi]

 Lobulus paracentralis

 Praecuneus

 Fissura parietooccipitalis

 Fissura calcarina

 Cuneus

C o r p u s c a l l o s u m

Splenium corporis callosi

Truncus corporis callosi

Genu corporis callosi

Rostrum corporis callosi

 Lamina rostralis

 Striae transversae

 Stria longitudinalis medialis

 Stria longitudinalis lateralis

 Fasciola cinerea

F o r n i x

Crus fornicis

Inferior frontal convolution
 Opercular part
 Triangular part
 Orbital part
 Straight convolution
 Olfactory sulcus
 Orbital convolutions
 Orbital sulci
 T e m p o r a l l o b e
 Temporal pole
 Transverse temporal sulci
 Transverse temporal convolutions
 Superior temporal convolution (O. T. first temporal gyrus)
 Superior temporal sulcus (O. T. parallel sulcus, or first temporal sulcus)
 Middle temporal convolution (O. T. second temporal gyrus)
 Middle temporal sulcus (O. T. second temporal sulcus)
 Inferior temporal convolution (O. T. third temporal gyrus)
 Inferior temporal sulcus (O. T. occipitotemporal sulcus)
 Collateral fissure
 Fusiform convolution (O. T. occipitotemporal convolution)
 Lingual convolution
 O c c i p i t a l l o b e
 Occipital pole
 Transverse occipital sulcus
 Superior occipital convolutions
 Superior occipital sulci
 Lateral occipital convolutions
 Lateral occipital sulci
 P a r i e t a l l o b e
 Superior parietal lobule
 Interparietal sulcus (O. T. intraparietal sulcus of Turner)
 Inferior parietal lobule
 Supramarginal convolution
 Angular convolution

Medial surface of hemisphere

Sulcus of corpus callosum (O. T. callosal sulcus)
 Sulcus of cingulum (O. T. callosomarginal fissure)
 Subfrontal part
 Marginal part
 Subparietal sulcus
 Fissure of hippocampus (O. T. dentate fissure, or fissura dentata)
 Fornicate convolution (O. T. limbic or falciform lobe)
 Convolution of cingulum (O. T. callosal convolution, or gyrus fornicatus)
 Isthmus of fornicate gyrus
 Convolution of hippocampus (O. T. hippocampal convolution)
 Hook of gyrus hippocampi
 White reticular substance of Arnold
 Paracentral lobule
 Precuneus
 Parieto-occipital fissure
 Calcarine fissure
 Cuneus ("wedge")
 C o r p u s c a l l o s u m (g r e a t t r a n s v e r s e c o m m i s s u r e o f c e r e b r u m)
 Splenium ("bandage") of corpus callosum
 Trunk of corpus callosum (O. T. body)
 Knee of corpus callosum
 Beak of corpus callosum
 Rostral lamina
 Transverse striae
 Medial longitudinal stria
 Lateral longitudinal stria
 Fasciola cinerea ("ash-like little bandage")

Fornix

Crus of fornix (O. T. posterior pillar of fornix)

- Corpus fornicis
 Taenia fornicis
 Columna fornicis
- Pars libera columnae fornicis
 Pars tecta columnae fornicis
 Septum pellucidum
 Lamina septi pellucidi
 Cavum septi pellucidi
- Ventriculus lateralis
- Pars centralis
 Cornu anterius
 Cornu posterius
 Cornu inferius
 Corpus striatum
 Nucleus caudatus
 Caput nuclei caudati
 Cauda nuclei caudati
 Stria terminalis
- Lamina affixa
 Taenia chorioidea
 Lamina chorioidea epithelialis
 Calcar avis
- (Bulbus cornu posterioris)
 Eminentia collateralis
 Trigonum collaterale
- Hippocampus
- Fimbria hippocampi
 Taenia fimbriae
 Digitationes hippocampi
- Fascia dentata hippocampi
- Commissura hippocampi
- Rhinencephalon
- Sulcus parolfactorius anterior
 Pars anterior [rhinencéphali]
- Lobus olfactorius
 Bulbus olfactorius
 Tractus olfactorius
 Trigonum olfactorium
 Stria medialis
 Stria intermedia
 Area parolfactoria [Brocae]
 Sulcus parolfactorius posterior
 Pars posterior [rhinencéphali]
- Gyrus subcallosus [Pedunculus corporis callosi]
 Substantia perforata anterior
 Stria olfactoria lateralis
 Limen insulae
- Sectiones telencephali
- Substantia corticalis
 Centrum semiovale
 Decursus fibrarum cerebralium
- Fibrae arcuatae cerebri
 Cingulum
 Fasciculus longitudinalis superior
 Fasciculus longitudinalis inferior
 Fasciculus uncinatus
 Radiatio corporis callosi
 Pars frontalis
 Pars parietalis
 Pars temporalis
 Pars occipitalis
- Tapetum
 Nucleus lentiformis
- Putamen
 Globus pallidus
 Claustrum
 Capsula externa
 Capsula interna
 Genu capsulae internae

- Body of fornix
 Taenia ("ribbon") of fornix
 Column of fornix (O. T. anterior pillar of fornix)
 Free part of column of fornix
 Covered part of column of fornix
 Transparent septum
 Layer of septum pellucidum
 Cavity of septum pellucidum (O. T. fifth ventricle)
 Lateral ventricle
 Central part
 Anterior horn
 Posterior horn
 Inferior horn (O. T. descending horn)
 Striate body
 Caudate nucleus
 Head of caudate nucleus
 Tail of caudate nucleus
 Terminal stria (O. T. taenia semicircularis)
 Lamina affixa ("fastened layer")
 Chorioid taenia
 Epithelial chorioid layer
 Calcar avis ("cock's spur") (O. T. hippocampus minor)
 Bulb of posterior horn
 Collateral eminence
 Collateral trigone (O. T. trigonum ventriculi)
 Hippocampus ("sea-horse") (O. T. hippocampus major, cornu Ammonis, or Ammon's horn)
 Fimbria ("fringe") of hippocampus
 Taenia of fimbria
 Digitations of the hippocampus (O. T. pes hippocampi)
 Dentate fascia of hippocampus (O. T. gyrus dentatus)
 Commissure of the hippocampus (O. T. lyra, or lyre of David)
 Olfactory brain
 Anterior parolfactory sulcus
 Anterior part of rhinencephalon
 Olfactory lobe
 Olfactory bulb
 Olfactory tract
 Olfactory trigone
 Medial stria
 Intermediate stria
 Parolfactory area of Broca
 Posterior parolfactory sulcus
 Posterior part of rhinencephalon
 Subcallosal convolution (peduncle of corpus callosum)
 Anterior perforated substance
 Lateral olfactory stria
 Threshold of island
 Sections of endbrain
 Cortical substance
 Semioval centre
 Decursus ("running down") of cerebral fibres
 Arcuate fibres of cerebrum
 Cingulum ("girdle")
 Superior longitudinal fasciculus
 Inferior longitudinal fasciculus
 Uncinate ("hooked") fasciculus
 Radiation of corpus callosum
 Frontal part (forceps minor)
 Parietal part
 Temporal part
 Occipital part (O. T. forceps major)
 Tapetum ("carpet," or "tapestry")
 Lentiform nucleus (O. T. lenticular nucleus)
 Putamen ("shell," or "paring")
 Globus pallidus ("pale sphere")
 Clastrum ("bulwark," or "barrier")
 External capsule
 Internal capsule
 Knee of internal capsule

Pars frontalis capsulae internae	Arachnoidea spinalis
	Arachnoidea encephali
Pars occipitalis capsulae internae	Cavum subarachnoideale
	Cisternae subarachnoidales
Nucleus amygdalae	Cisterna cerebellomedullaris
Corona radiata	
Pars frontalis	Cisterna fossae lateralis cerebri
Pars parietalis	[Sylvii]
Pars temporalis	Cisterna chiasmatis
Pars occipitalis	Cisterna interpeduncularis
Radiatio corporis striati	
Radiatio occipitothalamica	Cisterna venae magnae cerebri
[Gratioleti]	Granulationes arachnoideales [Pac-
Commissura anterior [cerebri]	chioni]
Pars anterior	Pia mater spinalis
Pars posterior	
	Lig. denticulatum
	Septum cervicale intermedium
	Pia mater encephali
	Tela chorioidea ventriculi quarti
	Plexus chorioideus ventriculi quarti
	Tela chorioidea ventriculi tertii
	Plexus chorioideus ventriculi tertii
	Plexus chorioideus ventriculi lateralis
	Glomus chorioideum
	Acervulus

Systema nervorum periphericum

Nervi cerebrales

Nn. olfactorii

N. opticus

N. oculomotorius

Ramus superior

Ramus inferior

Radix brevis ganglii ciliaris

N. trochlearis

Decussatio nervorum trochlearium

Frontal part of internal capsule (O. T. anterior limb)	Arachnoid ("spider-web") of spine
Occipital part of internal capsule (O. T. posterior limb)	Arachnoid ("spider-web") of brain
Amygdaloid ("almond") nucleus	Subarachnoid space
Corona radiata ("radiate crown")	Subarachnoid cisterns
Frontal part	Cerebellomedullary cistern (O. T. cisterna magna)
Parietal part	Cistern of the lateral fossa of the cerebrum
Temporal part	Cistern of the chiasm
Occipital part	Interpeduncular cistern (O. T. cisterna basalis)
Radiation of corpus striatum	Cistern of the great vein of cerebrum
Occipitohalamic radiation (O. T. optic radiation)	Arachnoideal granulations (O. T. Pacchionian bodies)
Anterior commissure of cerebrum	Pia mater of spine (soft membrane of cord)
Anterior part	Denticulate ligament
Posterior part	Intermediate cervical septum
	Pia mater of brain (soft membrane of brain)
	Chorioid tela of fourth ventricle (O. T. tela chorioidea inferior)
	Chorioid plexus of fourth ventricle
	Chorioid tela of third ventricle (O. T. velum interpositum, or tela chorioidea superior)
	Chorioid plexus of third ventricle
	Chorioid plexus of lateral ventricle
	Chorioid skein
	Brain sand

Membranes

System of peripheral nerves

Cerebral nerves	Inferior ramus
Olfactory nerves	Short root of ciliary ganglion (O. T. motor root of lenticular ganglion)
Optic nerve	
Oculomotor nerve (O. T. third nerve)	Trochlear nerve (O. T. patheticus or fourth nerve)
Superior ramus	Decussation of trochlear nerves

N. trigeminus

Portio major

Ganglion semilunare [Gasseri]

Portio minor

N. ophthalmicus

N. tentorii

N. lacrimalis

Ramus anastomoticus cum n. zygomatamico

N. frontalis

N. supraorbitalis

Ramus frontalis

N. supratrochlearis

N. nasociliaris

Radix longa ganglii ciliaris

Nn. ciliares longi

N. ethmoidalis posterior

N. ethmoidalis anterior

Rami nasales anteriores

Rami nasales interni

Rami nasales laterales

Rami nasales mediales

Ramus nasalis externus

N. infratrochlearis

Ramus palpebralis superior

R. palpebralis inferior

G. ciliare

Nn. ciliares breves

N. maxillaris

N. meningeus [medius]

N. zygomaticus

Ramus zygomaticotemporalis

Ramus zygomaticofacialis

Nn. sphenopalatini

Nn. alveolares superiores

Rami alveolares superiores posteriores

N. infraorbitalis

R. alveolaris superior medius

Rami alveolares superiores anteriores

Plexus dentalis superior

Rami dentales superiores

Rami gingivales superiores

Rami palpebrales inferiores

Rami nasales externi

Rami nasales interni

Rami labiales superiores

Ganglion sphenopalatinum

Rami orbitales

N. canalis pterygoidei [Vidii]

N. petrosus superficialis major

N. petrosus profundus

Rami nasales posteriores superiores laterales

Rami nasales posteriores superiores mediales

N. nasopalatinus [Scarpae]

Rami nasales posteriores inferiores [laterales]

Nn. palatini

N. palatinus anterior

N. palatinus medius

N. palatinus posterior

N. mandibularis

N. spinosus

N. masticatorius

N. massetericus

Nn. temporales profundi

N. temporalis profundus posterior

- Trigeminal nerve (O. T. fifth nerve)**
- Larger (sensory) root
 - Semilunar ganglion (O. T. Gasserian ganglion)
 - Smaller (motor) root
- Ophthalmic nerve**
- Nerve to the tentorium
 - Lacrimal nerve
 - Ramus anastomosing with zygomatic nerve
 - Frontal nerve
 - Supraorbital nerve
 - Frontal ramus
 - Supratrochlear nerve
 - Nasociliary nerve (O. T. nasal nerve)
 - Long root of the ciliary ganglion
 - Long ciliary nerves
 - Posterior ethmoidal nerve
 - Anterior ethmoidal nerve
 - Anterior nasal rami
 - Internal nasal rami
 - Lateral nasal rami
 - Medial nasal rami
 - External nasal ramus
 - Infratrochlear nerve
 - Superior palpebral ramus
 - Inferior palpebral ramus
 - Ciliary ganglion (O. T. lenticular or ophthalmic ganglion)
 - Short ciliary nerves
- Maxillary nerve (O. T. superior maxillary)**
- Middle meningeal nerve (O. T. recurrent)
 - Zygomatic nerve (O. T. orbital or temporomalar)
 - Zygomaticotemporal ramus
 - Zygomatofacial ramus
 - Sphenopalatine nerves
- Superior alveolar nerves**
- Posterior superior alveolar rami (O. T. posterior superior dental)
- Infraorbital nerve**
- Middle superior alveolar ramus (O. T. middle superior dental)
 - Anterior superior alveolar rami (O. T. anterior superior dental)
 - Superior dental plexus
 - Superior dental rami
 - Superior gingival rami
 - Inferior palpebral rami
 - External nasal rami
 - Internal nasal rami
 - Superior labial rami
- Sphenopalatine ganglion (O. T. Meckel's ganglion)**
- Orbital rami
 - Nerve of the pterygoid canal, or Vidian nerve
 - Larger superficial petrosal nerve
 - Deep petrosal nerve (O. T. great deep petrosal branch of carotid plexus)
 - Lateral superior posterior nasal rami
 - Medial superior posterior nasal rami
 - Nasopalatine nerve of Scarpa
 - Lateral inferior posterior nasal rami
- Palatine nerves**
- Anterior palatine nerve
 - Middle palatine nerve (O. T. external palatine)
 - Posterior palatine nerve
- Mandibular nerve (O. T. inferior maxillary)**
- Spinosus nerve (O. T. recurrent nerve)
 - Masticator nerve
 - Masseteric nerve
 - Deep temporal nerves
 - Posterior deep temporal nerve

- Anterior deep temporal nerve
 Buccinator nerve
 External pterygoid nerve
 Internal pterygoid nerve
 Auriculotemporal nerve
 Nerve of external auditory meatus
 Ramus to tympanic membrane
 Parotid rami
 Anastomotic rami to the facial nerve
 Anterior auricular nerves
 Superficial temporal rami
 Lingual nerve
 Rami to the isthmus of the fauces
 Anastomotic rami to the hypoglossal nerve
 Sublingual nerve
 Lingual rami
 Inferior alveolar nerve (O. T. inferior dental)
 Inferior dental plexus
 Inferior dental rami
 Inferior gingival rami
 Mylohyoid nerve
 Mental nerve
 Rami to chin
 Rami to lower lip
 Otic ganglion (O. T. ganglion of Arnold)
 Lesser superficial petrosal nerve
 Nerve of tensor muscle of palatine curtain
 Nerve of tensor muscle of tympanum
 Anastomotic ramus with spinosus nerve
 Anastomotic ramus with auriculotemporal nerve
 Anastomotic ramus with chorda tympani
 Submaxillary ganglion
 Rami communicating with lingual nerve
 Submaxillary rami
- Abducent nerve (O. T. sixth nerve)**
Facial nerve (O. T. seventh nerve)
 Knee of the facial nerve
 Ganglion of the knee (official nerve)
 Nerve to the stapedius muscle
 Ramus anastomosing with tympanic plexus (O. T. tympanic branch)
 Posterior auricular nerve
 Occipital ramus
 Digastric ramus
 Stylohyoid ramus
 Ramus anastomosing with glossopharyngeal nerve
 Parotid plexus
 Temporal rami
 Zygomatic rami
 Buccal rami
 Ramus of margin of jaw
 Ramus to neck
 Intermediate nerve (O. T. pars intermedia of Wrisberg, or sensory part of facial nerve)
 Cord of tympanum
Acoustic nerve (O. T. auditory nerve)
 Vestibular root
 Cochlear root
 Anastomotic fibres
Vestibular nerve
 Vestibular ganglion
 Utricular nerve
 Superior ampullar nerve
 Lateral ampullar nerve
 Inferior ampullar nerve
 Nerve of the cochlea
 Spiral ganglion
 Sacculus nerve
- Glossopharyngeal nerve**
 Upper ganglion (O. T. jugular ganglion)

Ganglion petrosum	Rami oesophagei
N. tympanicus	N. laryngeus inferior
	Ramus anterior
	Ramus posterior
Intumescencia tympanica	Rami bronchiales anteriores
Plexus tympanicus [Jacobsoni]	Rami bronchiales posteriores
N. caroticotympanicus superior	Plexus pulmonalis anterior
N. caroticotympanicus inferior	Plexus pulmonalis posterior
Ramus tubae	Rami oesophagei
R. anastomoticus cum ramo auriculari	Plexus oesophageus anterior
n. vagi	
Rami pharyngei	Plexus oesophageus posterior
Ramus stylopharyngeus	
Rami tonsillares	Rami gastrici
	Plexus gastricus anterior
Rami linguales	Plexus gastricus posterior
	Rami hepatici
	Rami coeliaci
	Rami lienales
	Rami renales
	N. accessorius
Ganglion jugulare	
	Ramus internus
Ganglion nodosum	
	Ramus externus
Ramus meningeus	
	N. hypoglossus
Ramus auricularis	Ramus descendens
	Ansa hypoglossi
R. anastomoticus cum n. glossopharyngeo	Ramus thyreochoideus
Rami pharyngei	Rami linguales
Plexus pharyngeus	
N. laryngeus superior	
Ramus externus	
Ramus internus	
Ramus anastomoticus cum n. laryngeo inferiore	
Rami cardiaci superiores	
(N. depressor)	
N. recurrens	
	N. spinales
	Fila radicularia
	Radix anterior
	Radix posterior
	Ganglion spinale
	Ramus anterior
	Ramus posterior
	Ramus communicans
	Ramus meningeus
	Cauda equina
	Ansae
Rami cardiaci inferiores	
Rami tracheales	

- Petrous ganglion (O. T. ganglion of Andersch)
- Tympanic nerve (O. T. Jacobson's nerve)
- Tympanic swelling
- Tympanic plexus
- Superior caroticotympanic nerve
- Inferior caroticotympanic nerve
- Tubal ramus
- Ramus anastomosing with the auricular branch of the vagus
- Pharyngeal rami
- Stylopharyngeal ramus
- Tonsillar rami (O. T. tonsillitic branches)
- Lingual rami (O. T. terminal rami)
- Vagus nerve (O. T. pneumogastric nerve)**
- Jugular ganglion (O. T. ganglion of the root)
- Knotty ganglion (O. T. ganglion of the trunk)
- Meningeal ramus (O. T. recurrent branch)
- Auricular ramus (O. T. Arnold's nerve)
- Ramus anastomosing with glosso-pharyngeal nerve
- Pharyngeal rami
- Pharyngeal plexus
- Superior laryngeal nerve
- External ramus
- Internal ramus
- Ramus anastomosing with inferior laryngeal nerve
- Superior cardiac rami
- Depressor nerve
- Recurrent nerve (O. T. recurrent laryngeal)
- Inferior cardiac rami (O. T. cardiac branches of recurrent laryngeal)
- Tracheal rami
- Oesophageal rami
- Inferior laryngeal nerve
- Anterior ramus
- Posterior ramus
- Anterior bronchial rami
- Posterior bronchial rami
- Anterior pulmonary plexus
- Posterior pulmonary plexus
- Oesophageal rami
- Anterior oesophageal plexus (O. T. plexus gulae)
- Posterior oesophageal plexus (O. T. plexus gulae)
- Gastric rami
- Anterior gastric plexus
- Posterior gastric plexus
- Hepatic rami
- Coeliac rami
- Splenic rami
- Renal rami
- Accessory nerve (O. T. spinal accessory)**
- Internal ramus (O. T. accessory portion)
- External ramus (O. T. spinal portion)
- Hypoglossal nerve**
- Descending ramus
- Loop of the hypoglossus
- Thyreohyoid ramus
- Lingual rami
- Spinal nerves**
- Radicular fibres
- Anterior root
- Posterior root
- Spinal ganglion
- Anterior ramus
- Posterior ramus
- Communicating ramus
- Meningeal ramus
- Cauda equina ("horse's tail")
- Loops

- Nn. cervicales**
- Rami posteriores
- Ramus medialis
 Ramus lateralis
N. suboccipitalis
- N. occipitalis major
- (N. occipitalis tertius)
- Rami anteriores
- Plexus cervicalis**
- N. occipitalis minor
N. auricularis magnus
 Ramus posterior
 Ramus anterior
N. cutaneus colli
- Rami superiores
 Rami inferiores
Nn. supraclaviculares
 Nn. supraclaviculares anteriores
- Nn. supraclaviculares medii
- Nn. supraclaviculares posteriores
- N. phrenicus
 Ramus pericardiacus
 Rami phrenicoabdominales
- Plexus brachialis**
- Pars supraclavicularis**
- Nn. thoracales posteriores
 N. dorsalis scapulae
- N. thoracalis longus
- Nn. thoracales anteriores
N. subclavius
N. suprascapularis
Nn. subscapulares
N. thoracodorsalis
- N. axillaris
 Rami musculares
 N. cutaneus brachii lateralis
Pars infraclavicularis
 Fasciculus lateralis
 Fasciculus medialis
 Fasciculus posterior
- N. musculocutaneus
 Rami musculares
 N. cutaneus antibrachii lateralis
- N. cutaneus brachii medialis
- N. cutaneus antibrachii medialis
- Ramus volaris
 Ramus ulnaris
- N. medianus**
- Rami musculares
N. interosseus [antibrachii] volaris
- Ramus palmaris n. mediani
- Ramus anastomoticus cum n. ulnari
Nn. digitales volares communes
Nn. digitales volares proprii
- N. ulnaris**
- Ramus cutaneus palmaris
Ramus dorsalis manus

Cervical nerves

Posterior rami (O. T. posterior primary divisions)

Medial ramus

Lateral ramus

Suboccipital nerve (O. T. posterior primary division of first cervical nerve)

Larger occipital nerve (O. T. great occipital, or medial branch of posterior primary division of second cervical nerve)

Third occipital nerve (O. T. third occipital, or medial branch of the posterior primary division of the third cervical nerve)

Anterior rami (O. T. anterior primary divisions)

Cervical plexus

Lesser occipital nerve

Great auricular nerve

Posterior ramus

Anterior ramus

Cutaneous nerve of the front of the neck (O. T. superficial cervical)

Upper rami

Lower rami

Supraclavicular nerves

Anterior supraclavicular nerves (O. T. suprasternal)

Middle supraclavicular nerves (O. T. supraclavicular)

Posterior supraclavicular nerves (O. T. supra-acromial)

Phrenic nerve

Pericardiac ramus

Phrenicoabdominal rami

Brachial plexus

Supraclavicular part

Posterior thoracic nerves

Dorsal nerve of scapula (O. T. nerve to the rhomboids)

Long thoracic nerve (O. T. external respiratory nerve of Bell, or posterior thoracic)

Anterior thoracic nerves

Subclavius nerve

Suprascapular nerve

Subscapular nerves

Thoracodorsal nerve (O. T. long subscapular nerve)

Axillary nerve (O. T. circumflex)

Muscular rami

Lateral cutaneous nerve of arm

Infraclavicular part

Lateral fasciculus (O. T. outer cord)

Medial fasciculus (O. T. inner cord)

Posterior fasciculus (O. T. posterior cord)

Musculocutaneous nerve

Muscular branches

Lateral cutaneous nerve of forearm (O. T. terminal cutaneous branch)

Medial nerve of upper arm (O. T. lesser internal cutaneous, or nerve of Wrisberg)

Medial nerve of forearm (O. T. internal cutaneous)

Volar ramus (O. T. anterior branch)

Ulnar ramus (O. T. posterior branch)

Median nerve

Muscular rami

Volar interosseous nerve of forearm (O. T. anterior interosseous)

Palmar ramus of median nerve (O. T. median palmar cutaneous)

Ramus anastomosing with ulnar nerve

Common volar digital nerves

Proper volar digital nerves (O. T. collateral palmar digital nerves)

Ulnar nerve

Palmar cutaneous ramus

Dorsal ramus of hand (O. T. dorsal cutaneous)

Nn. digitales dorsales
 Ramus volaris manus
 Ramus superficialis
 Nn. digitales volares communes
 Nn. digitales volares proprii
 Ramus profundus
 Rami musculares

N. radialis

N. cutaneus brachii posterior

Rami musculares
 N. cutaneus antibrachii dorsalis

Ramus profundus
 N. interosseus [antibrachii] dorsalis

Ramus superficialis

Ramus anastomoticus ulnaris

Nn. digitales dorsales

Nn. thoracales

Rami posteriores
 Ramus cutaneus lateralis
 Ramus cutaneus medialis
 Rami anteriores [Nn. intercostales]
 Rami musculares
 Ramus cutaneus lateralis [pectoralis et abdominalis]
 Ramus posterior
 Ramus anterior
 Rami mammarii laterales
 Nn. intercostobrachiales

Ramus cutaneus anterior [pectoralis et abdominalis]
 Rami mammarii mediales

Nn. lumbales, sacrales, coccygeus

Nn. lumbales
 Rami posteriores
 Ramus medialis
 Ramus lateralis
 Nn. clunium superiores
 Rami anteriores
 Nn. sacrales et coccygeus:
 Rami posteriores
 Ramus medialis
 Ramus lateralis
 Nn. clunium medii

Plexus lumbosacralis**Plexus lumbalis**

Rami musculares

N. iliohypogastricus

Rami musculares
 Ramus cutaneus lateralis

Ramus cutaneus anterior

N. ilioinguinalis

Rami musculares
 Nn. scrotales anteriores
 Nn. labiales anteriores

N. genitofemoralis

N. lumboinguinalis
 N. spermaticus externus

N. cutaneus femoris lateralis**N. obturatorius**

Ramus anterior
 Ramus cutaneus
 Ramus posterior

Dorsal digital nerves
 Volar ramus of hand
 Superficial ramus
 Common volar digital nerves
 Proper volar digital nerves (O. T. collateral palmar digital)
 Deep ramus
 Muscular rami

Radial nerve (O. T. musculospiral)

Posterior cutaneous nerve of upper arm (O. T. upper external cutaneous branch of musculospiral)

Muscular rami

Dorsal cutaneous nerve of forearm (O. T. lower external cutaneous branch of musculospiral)

Deep ramus

Dorsal interosseous nerve of forearm (O. T. posterior interosseous)

Superficial ramus (O. T. radial branch of musculospiral)

Ramus anastomosing with ulnar nerve

Dorsal digital nerves

Thoracic nerves

Posterior rami

Lateral cutaneous ramus

Medial cutaneous ramus

Anterior rami [intercostal nerves]

Muscular rami

Lateral cutaneous ramus (of breast and abdomen)

Posterior ramus

Anterior ramus

Lateral mammary rami

Intercostobrachial nerves (O. T. intercosto-humeral nerves)

Anterior cutaneous ramus (of breast and abdomen)

Medial mammary rami

Lumbar, sacral, and coccygeal nerves

Lumbar nerves

Posterior rami

Medial ramus

Lateral ramus

Superior clunial nerves

Anterior rami

Sacral and coccygeal nerves

Posterior rami

Medial ramus

Lateral ramus

Middle clunial nerves

Lumbosacral plexus

Lumbar plexus

Muscular rami

Iliohypogastric nerve

Muscular rami

Lateral cutaneous ramus (O. T. iliac branch of hypogastric)

Anterior cutaneous ramus (O. T. hypogastric branch)

Ilio-inguinal nerve

Muscular rami

Anterior scrotal nerves

Anterior labial nerves

Genitofemoral nerve (O. T. genitocrural nerve)

Lumbo-inguinal nerve (O. T. crural branch of genitocrural)

External spermatic nerve (O. T. genital branch of genitocrural)

Lateral cutaneous nerve of thigh (O. T. external cutaneous)

Obturator nerve

Anterior ramus

Cutaneous ramus

Posterior ramus

N. femoralis

Rami cutanei anteriores
 Rami musculares
 N. saphenus

Ramus infrapatellaris

Rami cutanei cruris mediales

Plexus sacralis

Truncus lumbosacralis

N. gluteus superior
 N. gluteus inferior
 N. cutaneus femoris posterior
 Nn. clunium inferiores
 Rami perineales

N. ischiadicus

Rami musculares
 N. peronaeus communis

Rami musculares
 N. cutaneus surae lateralis
 Ramus anastomoticus peronaeus

N. peronaeus superficialis

Rami musculares
 N. cutaneus dorsalis medialis
 N. cutaneus dorsalis intermedius
 Nn. digitales dorsales pedis
 N. peronaeus profundus

Rami musculares
 Nn. digitales dorsales hallucis lateralis et digiti secundi medialis

N. tibialis

Rami musculares
 N. interosseus cruris
 N. cutaneus surae medialis

[N. suralis]

Rami calcanei laterales
 N. cutaneus dorsalis lateralis
 Rami calcanei mediales
 N. plantaris medialis

Nn. digitales plantares communes
 Nn. digitales plantares proprii
 N. plantaris lateralis

Ramus superficialis
 Nn. digitales plantares communes
 Nn. digitales plantares proprii
 Ramus profundus

Plexus pudendus

Nn. haemorrhoidales medii
 Nn. vesicales inferiores
 Nn. vaginales
 N. pudendus
 Nn. haemorrhoidales inferiores
 N. perinei
 Nn. scrotales posteriores
 Nn. labiales posteriores
 N. dorsalis penis
 N. dorsalis clitoridis

N. coccygeus

Plexus coccygeus
 Nn. anococcygei

Femoral nerve (O. T. anterior crural)

- Anterior cutaneous rami
- Muscular rami
- Saphenous nerve (O. T. long saphenous)
 - Infrapatellar ramus (O. T. patellar branch or long saphenous)
 - Medial cutaneous rami of leg

Sacral plexus

- Lumbosacral trunk (O. T. lumbosacral cord)
- Superior gluteal nerve
- Inferior gluteal nerve
- Posterior cutaneous nerve of thigh
 - Inferior nerves of buttock
 - Perineal rami

Sciatic nerve (O. T. great sciatic)

- Muscular rami
- Common peroneal nerve (O. T. external popliteal)
 - Muscular rami
 - Lateral cutaneous nerve of calf
 - Peroneal anastomotic ramus (O. T. nervus communicans fibularis)
- Superficial peroneal nerve (O. T. musculocutaneous)
 - Muscular rami
 - Medial dorsal cutaneous nerve
 - Intermediate dorsal cutaneous nerve
 - Dorsal digital nerves of foot
- Deep peroneal nerve (O. T. anterior tibial)
 - Muscular rami
 - Dorsal digital nerves to lateral surface of hallux and to medial surface of second digit

Tibial nerve (O. T. internal popliteal nerve)

- Muscular rami
- Interosseous nerve of the leg
- Medial cutaneous nerve of the calf (O. T. nervus communicans tibialis)
- Nerve of the calf (O. T. short saphenous nerve)
 - Lateral calcanean rami
 - Lateral dorsal cutaneous nerve
 - Medial calcanean rami
- Medial plantar nerve (O. T. internal plantar)
 - Common digital plantar nerves
 - Proper digital plantar nerves
- Lateral plantar nerve (O. T. external plantar)
 - Superficial ramus
 - Common digital plantar nerves
 - Proper digital plantar nerves
 - Deep ramus

Pudendal plexus

- Middle hemorrhoidal nerves
- Inferior vesical nerves
- Vaginal nerves
- Pudendal nerve (O. T. pudic nerve)
 - Inferior hemorrhoidal nerves
 - Nerve of perineum
 - Posterior scrotal nerves
 - Posterior labial nerves
 - Dorsal nerve of penis
 - Dorsal nerve of clitoris

Coccygeal nerve

- Coccygeal plexus
- Anococcygeal nerves

Systema nervorum sympathicum

Truncus sympathicus
 Ganglia trunci sympathici
 Plexus sympathici
 Ganglia plexuum sympathicorum

Pars cephalica et cervicalis s. sympathici

Ganglion cervicale superius
 N. jugularis
 N. caroticus internus
 Plexus caroticus internus
 Plexus cavernosus
 Plexus arteriae cerebri anterioris
 Plexus arteriae cerebri mediae
 Plexus arteriae chorioideae
 Plexus ophthalmicus
 Radices sympathicae ganglii ciliaris
 Nn. carotici externi
 Plexus caroticus externus
 Plexus thyroideus superior
 Plexus lingualis
 Plexus maxillaris externus
 Radix sympathica ganglii submaxillaris
 Plexus occipitalis
 Plexus auricularis posterior
 Plexus temporalis superficialis
 Plexus maxillaris internus
 Plexus meningeus
 Plexus caroticus communis
 Rami laryngopharyngei
 Plexus pharyngeus ascendens
 N. cardiacus superior
 Ganglion cervicale medium
 N. cardiacus medius
 Ganglion cervicale inferius
 Ansa subclavia [Vicussenii]
 N. cardiacus inferior
 Plexus subclavius
 Plexus mammarius internus

Plexus thyroideus inferior
 Plexus vertebralis

Pars thoracalis s. sympathici

Ganglia thoracalia
 N. splanchnicus major
 Ganglion splanchnicum
 N. splanchnicus minor
 Ramus renalis
 (N. splanchnicus imus)
 Plexus aorticus thoracalis
 Plexus cardiacus
 Plexus coronarius cordis anterior
 Ganglion cardiacum [Wrisbergi]
 Plexus coronarius posterior
 Rami pulmonales
 Plexus pulmonalis

Pars abdominalis et pelvina s. sympathici

Ganglia lumbalia
 Ganglia sacralia
 Plexus aorticus abdominalis
 Plexus coeliacus
 Ganglia coeliaca
 Ganglion mesentericum superius
 Plexus phrenicus
 Ganglia phrenica
 Plexus hepaticus
 Plexus lienalis
 Plexus gastricus superior
 Plexus gastricus inferior
 Plexus suprarenalis
 Plexus renalis
 Plexus spermaticus
 Plexus arteriae ovaricae
 Plexus mesentericus superior
 Plexus myentericus

Sympathetic system of nerves

Sympathetic trunk
 Ganglia of the sympathetic trunk
 Sympathetic plexuses
 Ganglia of the sympathetic plexuses

Cephalic and cervical portions of the sympathetic system

Superior cervical ganglion
 Jugular nerve
 Internal carotid nerve
 Internal carotid plexus
 Cavernous plexus
 Plexus of anterior cerebral artery
 Plexus of middle cerebral artery
 Plexus of chorioid artery
 Ophthalmic plexus
 Sympathetic roots of ciliary ganglion
 External carotid nerves
 External carotid plexus
 Superior thyreoid plexus
 Lingual plexus
 External maxillary plexus
 Sympathetic root of the submaxillary ganglion
 Occipital plexus
 Posterior auricular plexus
 Superficial temporal plexus
 Internal maxillary plexus
 Meningeal plexus
 Common carotid plexus
 Laryngopharyngeal rami
 Ascending pharyngeal plexus
 Superior cardiac nerve
 Middle cervical ganglion
 Middle cardiac nerve
 Inferior cervical ganglion
 Subclavian loop
 Inferior cardiac nerve
 Subclavian plexus
 Internal mammary plexus

Inferior thyreoid plexus
 Vertebral plexus

Thoracic portion of the sympathetic system

Thoracic ganglia
 Greater splanchnic nerve
 Splanchnic ganglion
 Lesser splanchnic nerve
 Renal ramus
 Lowermost splanchnic nerve (O. T. smallest splanchnic)
 Thoracic aortic plexus
 Cardiac plexus
 Anterior coronary plexus of heart
 Cardiac ganglion of Wrisberg
 Posterior coronary plexus
 Pulmonary rami
 Pulmonary plexus

Abdominal and pelvic portions of the sympathetic system

Lumbar ganglia
 Sacral ganglia
 Abdominal aortic plexus
 Coeliac plexus
 Coeliac ganglia
 Superior mesenteric ganglion
 Phrenic plexus
 Phrenic ganglia
 Hepatic plexus
 Splenic plexus
 Superior gastric plexus
 Inferior gastric plexus
 Suprarenal plexus
 Renal plexus
 Spermatic plexus
 Plexus of the ovarian artery
 Superior mesenteric plexus
 Myenteric plexus (O. T. plexus of Auerbach)

Plexus submucosus	Plexus vesicalis
Plexus mesentericus inferior	Nn. vesicales superiores
Nn. haemorrhoidales superiores	Nn. vesicales inferiores
Plexus haemorrhoidalis superior	Plexus cavernosus penis
Plexus iliacus	N. cavernosus penis major
Plexus hypogastricus	Nn. cavernosi penis minores
Plexus haemorrhoidalis medius	Plexus cavernosus clitoridis
Plexus prostaticus	N. cavernosus clitoridis major
Plexus deferentialis	Nn. cavernosi clitoridis minores
Plexus uterovaginalis	Plexus femoralis
	Plexus popliteus

Organa sensuum et Integumentum commune

Organon visus

Oculus

N. opticus

Vaginae n. optici
Spatia intervaginalia

Bulbus oculi

Polus anterior
Polus posterior
Aequator
Meridiani
Axis oculi externa
Axis oculi interna
Axis optica
[Linea visus]
Vesicula ophthalmica
Caliculus ophthalmicus

Tunica fibrosa oculi

Sclera

Sulcus sclerae
Rima cornealis
Sinus venosus sclerae [Canalis
Schlemmi, Lauthi]
Lamina fusca

Lamina cribrosa sclerae
(Raphe sclerae)
(Funiculus sclerae)

Cornea

Annulus conjunctivae
Vertex corneae
Limbus corneae
Facies anterior
Facies posterior
Epithelium corneae
Lamina elastica anterior [Bowmani]

Substantia propria
Lamina elastica posterior [Demoursi,
Descemeti]
Endothelium camerae anterioris

Tunica vasculosa oculi

Chorioidea

Lamina suprachorioidea
Spatium perichorioidea
Lamina vasculosa
Lamina choriocapillaris

Lamina basalis
(Raphe chorioideae)

Plexus of submucosa (O. T. plexus of Meissner)	Vesical plexus
Inferior mesenteric plexus	Superior vesical nerves
Superior hemorrhoidal nerves	Inferior vesical nerves
Superior hemorrhoidal plexus	Cavernous plexus of penis
Iliac plexus	Larger cavernous nerve of penis
Hypogastric plexus	Lesser cavernous nerves of penis
Middle hemorrhoidal plexus	Cavernous plexus of clitoris
Prostatic plexus	Larger cavernous nerve of clitoris
Deferential plexus	Lesser cavernous nerves of clitoris
Uterovaginal plexus	Femoral plexus
	Popliteal plexus

Sense organs and common integument

Organ of vision

Eye

Optic nerve

Sheaths of the optic nerve
Intervaginal spaces

Eyeball

Anterior pole
Posterior pole
Equator
Meridian
External axis of eye
Internal axis of eye
Optic axis
Line of vision
Ophthalmic vesicle
Ophthalmic cup

Fibrous tunic of eye

Sclera (O. T. sclerotic coat)

Sulcus of the sclera
Cleft for the cornea
Venous sinus of the sclera, or canal of Schlemm
Brown layer

Perforated layer of the sclera
Ridge of the sclera
Funiculus of the sclera

Cornea

Ring of conjunctiva
Vertex of cornea
Border of cornea
Anterior surface
Posterior surface
Epithelium of cornea
Anterior elastic layer (O. T. Bowman's membrane)
Proper substance
Posterior elastic layer (O. T. Desmet's membrane)
Endothelium of anterior chamber

Vascular coat of eye

Chorioid

Suprachorioid layer
Perichorioideal space
Vascular layer
Choriocapillary layer (O. T. tunica Ruyschiana)
Basal layer
Raphe of chorioid

Corpus ciliare

Corona ciliaris
 Processus ciliares
 Plicae ciliares
 Orbiculus ciliaris
 M. ciliaris
 Fibrae meridionales [Bruecke]i
 Fibrae circulares [Mueller]i
 Plexus gangliosus ciliaris

Iris

Margo pupillaris
 Margo ciliaris
 Facies anterior
 Facies posterior
 Annulus iridis major
 Annulus iridis minor
 Plicae iridis
 Pupilla
 M. sphincter pupillae
 Stroma iridis
 M. dilatator pupillae
 Lig. pectinatum iridis
 Spatia anguli iridis [Fontanae]
 Circulus arteriosus major
 Circulus arteriosus minor
 Membrana pupillaris

Stratum pigmenti

Stratum pigmenti retinae
 Stratum pigmenti corporis ciliaris
 Stratum pigmenti iridis

Retina

Pars optica retinae
 Ora serrata
 Pars ciliaris retinae
 Papilla n. optici
 Excavatio papillae n. optici
 Macula lutea
 Fovea centralis

Vasa sanguinea retinae

Circulus vasculosus n. optici [Haller]i
 Arteriola [Venula] temporalis retinae superior
 Arteriola [Venula] temporalis retinae inferior
 Arteriola [Venula] nasalis retinae superior
 Arteriola [Venula] nasalis retinae inferior
 Arteriola [Venula] macularis superior
 Arteriola [Venula] macularis inferior
 Arteriola [Venula] retinae medialis

Camera oculi anterior

Angulus iridis

Camera oculi posterior**Corpus vitreum**

A. hyaloidea
 Canalis hyaloideus
 Fossa hyaloidea
 Membrana hyaloidea
 Stroma vitreum
 Humor vitreus

Lens crystallina

Substantia lentis
 Substantia corticalis
 Nucleus lentis
 Fibrae lentis
 Epithelium lentis
 Capsula lentis
 Polus anterior lentis
 Polus posterior lentis
 Facies anterior lentis
 Facies posterior lentis
 Axis lentis
 Aequator lentis
 Radii lentis

Ciliary body**Ciliary wreath**

Ciliary processes

Ciliary folds

Ciliary disk

Ciliary muscle

Meridional fibres

Circular fibres

Ciliary ganglionic plexus

Iris, or diaphragm of the eye

Pupillary margin

Ciliary margin

Anterior surface

Posterior surface

Greater ring of iris

Lesser ring of iris

Folds of iris

Pupil

Sphincter muscle of pupil

Stroma of iris

Dilator muscle of pupil

Pectinate ("comb-like") ligament of iris (O. T. pillars of the iris)

Spaces of the angle of the iris (O. T. spaces of Fontana)

Greater arterial circle

Lesser arterial circle

*Pupillary membrane***Layer of pigment**

Pigment layer of the retina

Pigment layer of ciliary body

Pigment layer of iris

Retina

Optic part of retina

Serrated edge

Ciliary part of retina

Papilla of optic nerve

Excavation of papilla of optic nerve

Yellow spot

Central fovea

Blood vessels of the retina

Vascular circle of the optic nerve

Superior arteriole (venule) of temporal retina

Inferior arteriole (venule) of temporal retina

Superior arteriole (venule) of nasal retina

Inferior arteriole (venule) of nasal retina

Superior macular arteriole (venule)

Inferior macular arteriole (venule)

Medial arteriole (venule) of retina

Anterior chamber of the eye

Angle of the iris (O. T. iridocorneal angle)

Posterior chamber of the eye**Vitreous body***Hyaloid artery*

Hyaloid canal (O. T. canal of Stilling)

Hyaloid fossa (O. T. fossa patellaris)

Hyaloid membrane

Vitreous stroma

Vitreous humor

Crystalline lens

Substance of the lens

Cortical substance

Nucleus of the lens

Fibres of the lens

Epithelium of the lens

Capsule of the lens

Anterior pole of lens

Posterior pole of lens

Anterior surface of lens

Posterior surface of lens

Axis of the lens

Equator of the lens

Radii of the lens

Zonula ciliaris [Zinni]

Fibrae zonulares
Spatia zonularia

Organa oculi accessoria**Musculi oculi, Fasciae orbitales**

M. orbitalis
M. rectus superior
M. rectus inferior
M. rectus medialis

M. rectus lateralis

Lacertus musculi recti lateralis
Annulus tendineus communis [Zinni]
M. obliquus superior

Trochlea

M. obliquus inferior
M. levator palpebrae superioris
Periorbita
Septum orbitale

Fasciae musculares
Fascia bulbi [Tenoni]
Spatium interfasciale [Tenoni]
Corpus adiposum orbitae

Supercilium**Palpebrae**

Palpebra superior
Palpebra inferior
Facies anterior palpebrarum
Facies posterior palpebrarum
Rima palpebrarum
Commissura palpebrarum lateralis

Commissura palpebrarum medialis

Angulus oculi lateralis
Angulus oculi medialis
Limbi palpebrales anteriores
Limbi palpebrales posteriores

Tarsus superior

Tarsus inferior

Lig. palpebrale mediale

Raphe palpebralis lateralis

Glandulae tarsales [Meibomi]

Sebum palpebrale

M. tarsalis superior

M. tarsalis inferior

Conjunctiva

Plica semilunaris conjunctivae
Caruncula lacrimalis
Tunica conjunctiva bulbi
Tunica conjunctiva palpebrarum
Fornix conjunctivae superior
Fornix conjunctivae inferior
Gl. mucosae [Krausei]
Noduli lymphatici conjunctivales
(Pinguecula)

Apparatus lacrimalis

Glandula lacrimalis superior
Glandula lacrimalis inferior
(Gl. lacrimales accessoriae)
Ductuli excretorii [gl. lacrimalis]
Rivus lacrimalis
Lacus lacrimalis
Puncta lacrimalia
Ductus lacrimales
Papillae lacrimales
Ampulla ductus lacrimalis
Saccus lacrimalis
Fornix sacci lacrimalis
Ductus nasolacrimalis
Plica lacrimalis [Hasneri]
Lacrimae

Ciliary zonule (O. T. zonule of Zinn)

Zonular fibres

Zonular spaces (O. T. canal of Petit)

Accessory organs of eye**Eye muscles, orbital fasciae**

Orbital muscle

Superior straight muscle

Inferior straight muscle

Medial straight muscle (O. T. internal rectus)

Lateral straight muscle (O. T. external rectus)

Lacertus of lateral straight muscle

Common tendinous ring of Zinn

Superior oblique muscle

Pulley

Inferior oblique muscle

Levator muscle of superior lid

Periorbit

Orbital septum (O. T. palpebral ligaments)

Muscular fasciae

Fascia of ball (O. T. capsule of Tenon)

Interfascial space

Fat body of orbit

Eyebrow**Eyelids**

Upper eyelid

Lower eyelid

Anterior surface of eyelids

Posterior surface of eyelids

Palpebral fissure

Lateral palpebral commissure (O. T. external canthus)

Medial palpebral commissure (O. T. internal canthus)

Lateral angle of the eye

Medial angle of the eye

Anterior palpebral margins

Posterior palpebral margins

Superior tarsus (O. T. superior tarsal plate)

Inferior tarsus (O. T. inferior tarsal plate)

Medial palpebral ligament (O. T. internal tarsal ligament)

Lateral palpebral raphe (O. T. external tarsal ligament)

Tarsal glands (O. T. Meibomian glands)

Palpebral sebum

Superior tarsal muscle

Inferior tarsal muscle (O. T. tensor tarsi)

Conjunctiva or connecting membrane

Semilunar fold of conjunctiva

Lacrimal caruncle

Conjunctival coat of eyeball

Conjunctival coat of eyelids

Superior fornix of conjunctiva

Inferior fornix of conjunctiva

Mucous glands of Krause

Conjunctival lymphatic nodules

Conjunctival fat

Lacrimal apparatus

Superior lacrimal gland

Inferior lacrimal gland

Accessory lacrimal glands

Excretory ductules of lacrimal gland

Lacrimal stream

Lacrimal lake

Lacrimal (punctate) openings

Lacrimal ducts

Lacrimal papillae

Ampulla of lacrimal duct

Lacrimal sac

Fornix, or summit of lacrimal sac

Nasolacrimal duct

Lacrimal fold of Hasner

Tears

Organon auditus**Auris interna****Labyrinthus membranaceus**

Ductus endolymphaticus
 Saccus endolymphaticus
 Ductus utriculosaccularis
 Utriculus
 Ductus semicirculares
 Ductus semicircularis superior
 Ductus semicircularis posterior
 Ductus semicircularis lateralis

Ampullae membranaceae
 Sulcus ampullaris
 Crista ampullaris
 Ampulla membranacea superior
 Ampulla membranacea posterior
 Ampulla membranacea lateralis

Sacculus
 Ductus reuniens [Henseni]
 Maculae acusticae
 Macula acustica utriculi
 Macula acustica sacculi

Otoconia
 Endolympha
 Perilympha
 Spatium perilymphaticum
 Ductus perilymphatici
 Ductus cochlearis

Caecum cupulare
 Caecum vestibulare
 Lamina basilaris
 Membrana vestibularis [Reissneri]
 Lig. spirale cochleae
 Prominentia spiralis
 Stria vascularis
 Sulcus spiralis
 Labium tympanicum
 Foramina nervosa
 Labium vestibulare

Ganglion spirale cochleae
 Organon spirale [Cortii]
 Vasa auris internae
 A. auditiva interna
 Rami vestibulares
 Ramus cochleae
 Glomeruli arteriosi cochleae
 Vv. auditivae internae
 V. spiralis modioli
 Vas prominens
 Vv. vestibulares
 V. aquaeductus vestibuli
 V. canaliculi cochleae

Labyrinthus osseus**Vestibulum**

Recessus sphaericus
 Recessus ellipticus
 Crista vestibuli
 Pyramis vestibuli
 Recessus cochlearis
 Maculae cribrosae
 Macula cribrosa superior
 Macula cribrosa media
 Macula cribrosa inferior
 Canales semicirculares ossei
 Canalis semicircularis superior
 Canalis semicircularis posterior
 Canalis semicircularis lateralis

Ampullae osseae
 Ampulla ossea superior
 Ampulla ossea posterior
 Ampulla ossea lateralis
 Crura ampullaria
 Crus commune
 Crus simplex

Cochlea

Cupula
 Basis cochleae

Organ of hearing**Internal ear****Membranous labyrinth**

Endolymphatic duct
 Endolymphatic sac
 Utriculosaccular duct
 Utricle
 Semicircular ducts
 Superior semicircular duct
 Posterior semicircular duct
 Lateral semicircular duct (O. T. external)
 Membranous ampullae
 Ampullary sulcus
 Ampullary crest
 Superior membranous ampulla
 Posterior membranous ampulla
 Lateral membranous ampulla
 Sacculae
 Uniting duct (O. T. canalis reuniens)
 Acoustic spots
 Acoustic spot of utricle
 Acoustic spot of sacculae
 Ear-stones
 Endolymph
 Perilymph
 Perilymphatic space
 Perilymphatic ducts
 Cochlear duct (O. T. membranous cochlea, or scala media)
 Cupular blind sac
 Vestibular blind sac
 Basilar layer
 Vestibular membrane of Reissner
 Spiral ligament of cochlea
 Spiral prominence
 Vascular stripe
 Spiral sulcus
 Tympanic lip
 Openings for nerves
 Vestibular lip

Spiral ganglion of cochlea
 Spiral organ of Corti
 Vessels of internal ear
 Internal auditory artery
 Vestibular rami
 Cochlear ramus
 Arterial glomeruli of cochlea
 Internal auditory veins
 Spiral vein of modiolus
 Prominent vessel
 Vestibular veins
 Vein of aqueduct of vestibule
 Vein of canaliculus of cochlea

Osseous labyrinth**Vestibule**

Spherical recess (O. T. fovea hemisphaerica)
 Elliptical recess (O. T. fovea hemieliptica)
 Crest of vestibule
 Pyramid of vestibule
 Cochlear recess
 Perforated spots
 Superior perforated spot
 Middle perforated spot
 Inferior perforated spot
 Osseous semicircular canals
 Superior semicircular canal
 Posterior semicircular canal
 Lateral semicircular canal (O. T. external)
 Osseous ampullae
 Superior osseous ampulla
 Posterior osseous ampulla
 Lateral osseous ampulla
 Ampullary limbs
 Common limb
 Simple limb

Cochlea ("snail shell")
 Cupola
 Base of cochlea

Canalis spiralis cochleae
 Modiolus
 Basis modioli
 Lamina modioli
 Lamina spiralis ossea
 Hamulus laminae spiralis
 Scala vestibuli
 Scala tympani
 Helicotrema
 Lamina spiralis secundaria
 Canalis spiralis modioli
 Canales longitudinales modioli

Meatus acusticus internus

Porus acusticus internus
 Fundus meatus acustici interni
 Crista transversa
 Area n. facialis
 Area cochleae
 Tractus spiralis foraminosus
 Area vestibularis superior
 Area vestibularis inferior
 Foramen singulare

Cavum tympani

P a r i e s t e g m e n t a l i s
 Recessus epitympanicus
 Pars cupularis
P a r i e s j u g u l a r i s
 Prominentia styloidea
P a r i e s l a b y r i n t h i c a

Fenestra vestibuli

Fossula fenestrae vestibuli
 Promontorium
 Sulcus promontorii
 Subiculum promontorii

Sinus tympani
 Fenestra cochleae

Fossula fenestrae cochleae

Crista fenestrae cochleae
 Processus cochleariformis
P a r i e s m a s t o i d e a

Antrum tympanicum

Prominentia canalis semicircularis
 lateralis

Prominentia canalis facialis

Eminentia pyramidalis

Fossa incudis

Sinus posterior

Apertura tympanica canaliculi
 chordae

Cellulae mastoideae

Cellulae tympanicae

P a r i e s c a r o t i c a

P a r i e s m e m b r a n a c e a

Membrana tympani

Pars flaccida

Pars tensa

Limbus membranae tympani

Plica malleolaris anterior

Plica malleolaris posterior

Prominentia malleolaris

Stria malleolaris

Umbo membranae tympani

Stratum cutaneum

Annulus fibrocartilagineus

Stratum radiatum

Stratum circulare

Stratum mucosum

Ossicula auditus

S t a p e s

Capitulum stapedis

Crus anterius

Crus posterius

Spiral canal of cochlea
 Modiolus ("screw")
 Base of modiolus
 Shelf of modiolus
 Osseous spiral shelf
 Hooklet of spiral shelf
 "Staircase" of vestibule
 "Staircase" of tympanum
 Helicotrema ("pore of the helix")
 Secondary spiral shelf
 Spiral canal of modiolus
 Longitudinal canals of modiolus

Internal acoustic meatus

Internal acoustic opening
 Bottom of internal acoustic meatus
 Transverse crest
 Area of facial nerve
 Area of cochlea
 Foraminous spiral tract
 Superior vestibular area
 Inferior vestibular area
 Isolated foramen

Cavity of tympanum

Tegmental wall
 Epitympanic recess
 Cupular portion
 Jugular wall (O. T. floor)
 Styloid prominence
 Labyrinthine wall (O. T. inner wall)
 Fenestra ("window") of vestibule (O. T. fenestra ovalis)
 Little fossa of fenestra of vestibule
 Promontory
 Sulcus of promontory
 Subiculum ("support") of promontory
 Sinus of tympanum
 Fenestra of cochlea (O. T. fenestra rotunda)
 Little fossa of fenestra of cochlea

Crest of fenestra of cochlea
 Cochleariform process
 Mastoid wall (O. T. posterior wall)
 Tympanic antrum (O. T. mastoidal antrum)
 Prominence of lateral semicircular canal
 Prominence of facial canal
 Pyramidal eminence
 Fossa of incus
 Posterior sinus
 Tympanic aperture of canaliculus of chorda
 Mastoid cells
 Tympanic cells
 Carotid wall (O. T. anterior wall)
 Membranous wall (O. T. outer wall)

Membrane of the tympanum (O. T. drumhead)

Flaccid part
 Tense part
 Border of membrane of tympanum
 Anterior malleolar fold
 Posterior malleolar fold
 Malleolar prominence
 Malleolar stripe
 Umbo ("prominent part") of tympanic membrane
 Cutaneous layer
 Fibrocartilaginous ring
 Radiate layer
 Circular layer
 Mucous layer

Auditory ossicles

Stirrup
 Head of stirrup
 Anterior limb
 Posterior limb

Basis stapedis

I n c u s

Corpus incudis

Crus longum

Processus lenticularis

Crus breve

M a l l e u s

Manubrium mallei

Capitulum mallei

Collum mallei

Processus lateralis

Processus anterior [Folii]

Articulationes ossiculorum auditus

Articulatio incudomalleolaris

Articulatio incudostapedia

Syndesmosis tympanostapedia

Ligg. ossiculorum auditus

Lig. mallei anterioris

Lig. mallei superioris

Lig. mallei laterale

Lig. incudis superioris

Lig. incudis posterioris

Membrana obturatoria (stapedis)

Lig. annulare baseos stapedis

[M. fixator baseos stapedis]

Musculi ossiculorum auditus

M. tensor tympani

M. stapedius

Tunica mucosa tympanica

(Gl. tympanicae)

Plica malleolaris posterior

Plica malleolaris anterior

Recessus membranae tympani anterior

Recessus tympani membranae superior

Recessus membranae tympani posterior

Plica incudis

Plica stapedis

Membrana tympani secundaria

Tuba auditiva [Eustachii]

Ostium tympanicum tubae auditivae

Pars ossea tubae auditivae

Isthmus tubae auditivae

Cellulae pneumaticae tubariae

Pars cartilaginosa tubae auditivae

Cartilago tubae auditivae

Lamina [cartilaginosa] medialis

Lamina [cartilaginosa] lateralis

Lamina membranacea

Tunica mucosa

Gl. mucosae

Noduli lymphatici tubarii

Ostium pharyngeum tubae auditivae

Meatus acusticus externus

Porus acusticus externus

Incisura tympanica [Rivini]

Meatus acusticus externus cartilagineus

Cartilago meatus acustici*

Incisurae cartilaginosa meatus acustici externi [Santorini]

Lamina tragi

Auriculae

Lobulus auriculae

Cartilago auriculae

Helix

Crus helices

Spina helices

Cauda helices

Anthelix

Fossa triangularis [auriculae]

Crura anthelices

Scapha

Concha auriculae

Cymba conchae

Cavum conchae

Antitragus

Base of stirrup (O. T. foot-piece)
 Anvil
 Body of anvil
 Long limb
 Lenticular process
 Short limb
 Hammer
 Handle of hammer
 Head of hammer
 Neck of hammer
 Lateral process (O. T. processus
 brevis)
 Anterior process (O. T. processus
 gracilis)

Joints of the auditory ossicles

Joint between anvil and hammer
 Joint between anvil and stirrup
 Junction of stirrup and tympanum

Ligaments of the auditory ossicles

Anterior ligament of hammer
 Superior ligament of hammer
 Lateral ligament of hammer (O. T.
 external ligament)
 Superior ligament of anvil
 Posterior ligament of anvil
 Obturator membrane of stirrup
 Annular ligament of base of stirrup
 Fixing muscle of the base of stirrup

Muscles of the auditory ossicles

Tensor muscle of the tympanum
 Stapedius muscle

Tympanic mucous coat

Tympanic glands
 Posterior maleolar fold
 Anterior malleolar fold
 Anterior recess of tympanic membrane
 Superior recess of tympanic membrane
 Posterior recess of tympanic membrane
 Fold of anvil

Fold of stirrup
 Secondary tympanic membrane

Auditory or Eustachian tube

Tympanic opening of auditory tube
 Bony part of auditory tube
 Isthmus of auditory tube
 Tubal air cells
 Cartilaginous part of auditory tube
 Cartilage of auditory tube
 Medial layer of cartilage
 Lateral layer of cartilage
 Membranous layer
 Mucous membrane
 Mucous glands
 Tubal lymphatic nodules
 Pharyngeal opening of auditory tube

External acoustic meatus

External acoustic opening
 Tympanic incisure
 Cartilaginous external acoustic meatus

Cartilage of acoustic meatus
 Notches in cartilage of external
 acoustic meatus
 Layer of tragus

External ear, or auricle (O. T. pinna)

Lobule of auricle
 Cartilage of auricle
 Coil
 Limb of coil
 Spine of coil
 Tail of coil
 Anthelix
 Triangular fossa of auricle
 Limbs of anthelix
 Scapha ("skiff")
 Concha ("shell") of auricle
 Cymba ("boat") of auricle
 Cavity of concha
 Antitragus

Tragus

Incisura anterior [auris]
 Incisura intertragica
 (Tuberculum auriculæ [Darwini])
 (Apex auriculæ [Darwini])
 Sulcus auriculæ posterior
 (Tuberculum supratragicum)
 Isthmus cartilaginis auris
 Incisura terminalis auris
 Fissura antitragohelicina
 Sulcus anthelicis transversus
 Sulcus cruris heliçis
 Fossa anthelicis
 Eminentia conchæ
 Eminentia scaphæ
 Eminentia fossæ triangularis
 Ligg. auricularia [Valsalvæ]
 Lig. auriculare anterius
 Lig. auriculare superius
 Lig. auriculare posterius
 M. heliçis major
 M. heliçis minor
 M. tragicus
 (M. pyramidalis auriculæ [Jungi])
 M. antitragicus
 M. transversus auriculæ
 M. obliquus auriculæ
 (M. incisuræ heliçis [Santorini])

Organon olfactus**Organon gustus**

Calyculi gustatorii

Integumentum commune**Cutis**

Sulci cutis
 Cristæ cutis
 Retinacula cutis
 Toruli tactiles
 Foveola coccygea
 Lig. caudale

Epidermis

Stratum corneum
 Stratum germinativum [Malpighii]

Corium

Tunica propria
 Corpus papillare
 Papillæ

Tela subcutanea

Panniculus adiposus

Corpuscula nervorum terminalia

Corpuscula bulboidea [Krausii]
 Corpuscula lamellosa [Vateri, Pacini]

Corpuscula tactus [Meissneri]
 Corpuscula nervorum genitalia
 Corpuscula nervorum articularia

Pili

Lanugo
 Capilli
 Supercilia
 Cilia
 Barba
 Tragi
 Vibrissæ
 Hirci
 Pubes
 Folliculus pili
 Fundus folliculi pili
 Collum folliculi pili
 Papilla pili
 Scapus pili
 Radix pili
 Bulbus pili
 Mm. arrectores pilorum
 Flumina pilorum
 Vortices pilorum
 (Vortex coccygeus)

Tragus ("goat")
 Anterior notch of ear
 Intertragic notch
 Darwinian tubercle of auricle
 Tip of ear
 Posterior sulcus of auricle
 Supratragic tubercle
 Cartilaginous isthmus of ear
 Terminal notch of ear
 Antitragohelicine fissure
 Transverse groove of anthelix
 Groove of crus of helix
 Fossa of anthelix
 Eminence of concha
 Eminence of scapha
 Eminence of triangular fossa
 Auricular ligaments of Valsalva
 Anterior auricular ligament
 Superior auricular ligament
 Posterior auricular ligament
 Larger muscle of helix
 Smaller muscle of helix
 Muscle of tragus
 Pyramidal muscle of ear
 Muscle of antitragus
 Transverse muscle of auricle
 Oblique muscle of auricle
 Muscle of notch of helix

Organ of smell

Organ of taste

Taste buds

Common integument

Skin

Grooves of skin
 Ridges of skin
 Retaining bands or folds of skin
 Tactile elevations
 Coccygeal depression
 Caudal ligament

Epidermis, or scarf skin

Horny layer
 Germinative, or Malpighian layer

Corium, or leather skin

Proper tunic
 Papillary body
 Papillae

Subcutaneous tissue

Adipose panniculus ("garment") (O.
 T. subcutaneous areolar tissue)

Terminal corpuscles of the nerves

Bulb-like corpuscles of Krause
 Lamellated corpuscles of Vater or
 Pacini
 Touch corpuscle of Meissner
 Genital corpuscles of the nerves
 Articular corpuscles of the nerves

Hairs

Woolly hair
 Hairs of the head
 Hairs of the eyebrows
 Eyelashes
 Hairs of the beard
 Hairs of the ear
 Hairs of the nose
 Axillary hairs
 Pubic hairs
 Hair follicle
 Fundus of hair follicle
 Neck of hair follicle
 Papilla of hair
 Shaft of hair
 Root of hair
 Bulb of hair
 Arrector muscles of the hairs
 Hair streams
 Hair whirlpools
 Coccygeal whirlpool

Ungues

Matrix unguis
 Cristae matricis unguis
 Sulcus matricis unguis
 Vallum unguis
 Corpus unguis
 Radix unguis
 Lunula
 Margo occultus
 Margo liber
 Margo lateralis
 Stratum corneum unguis
 Stratum germinativum unguis

Glandulae cutis**Gl. glomiformes**

Gl. sudoriferae
 Corpus gl. sudoriferae
 Ductus sudoriferus
 Porus sudoriferus
 Sudor
 Gl. ciliares [Molli]

Gl. circumanales
 Gl. ceruminosae
 Cerumen

Glandulae sebaceae

Sebum cutaneum

Mamma

Papilla mammae
 Corpus mammae
 Lobi mammae
 Lobuli mammae
 Ductus lactiferi
 Sinus lactiferi
 Lac femininum
 Colostrum
 Areola mammae
 Gl. sebaceae
 Gl. areolares [Montgomerii]
 Mamma virilis
 (Mammae accessoriae [muliebres et viriles])

Nails

Bed of the nail
 Crest of unguual matrix
 Sulcus of unguual matrix
 Wall of nail
 Body of nail
 Root of nail
 Lunule
 Hidden margin
 Free margin
 Latèral margin
 Horny layer of nail
 Germinative layer of nail

Glands of the skin**Coil glands**

Sweat glands
 Body of sweat gland
 Sweat duct
 Sweat pore
 Sweat
 Glands of the eyelashes of Moll

Circumanal glands

Wax glands

Wax

Sebaceous glands

Cutaneous sebum

Breast

Nipple of the breast

Body of the breast

Lobes of the breast

Lobules of breast

Lactiferous duct

Lactiferous sinus

Female milk

Colostrum

Areola of breast

Sebaceous glands

Areolar glands of Montgomery

M a l e b r e a s t

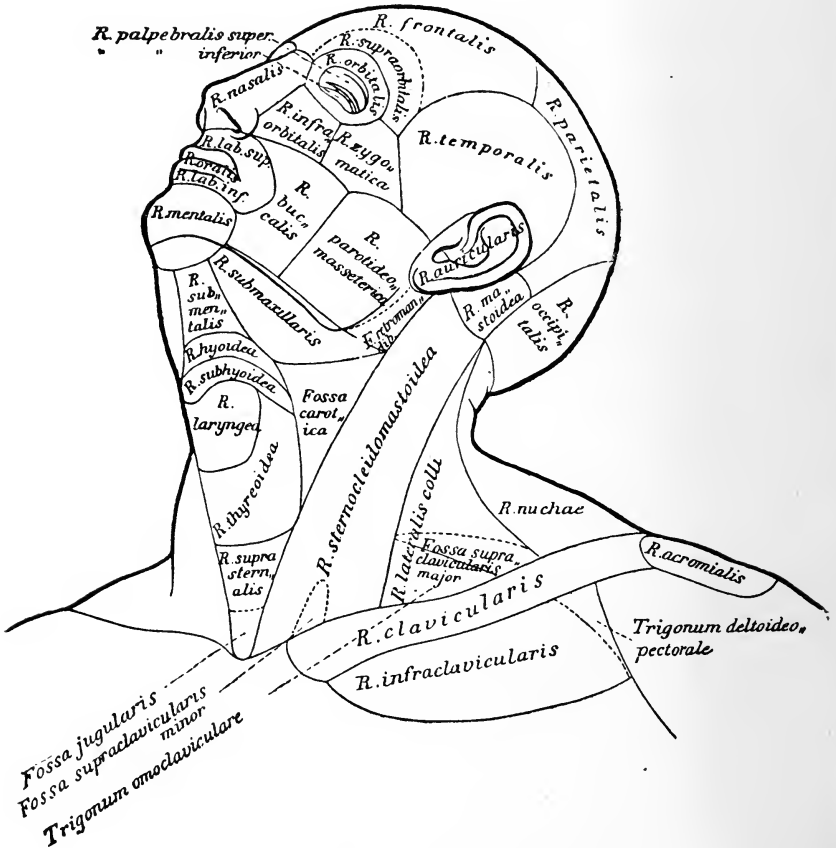
Accessory breasts, female and male

Regiones corporis humani

auctoribus Merkel, Rüdinger, Toldt.

Linea mediana anterior
 Linea mediana posterior
 Linea sternalis
 Linea parasternalis

Linea mamillaris
 Linea axillaris
 Linea scapularis



Regions of the human body

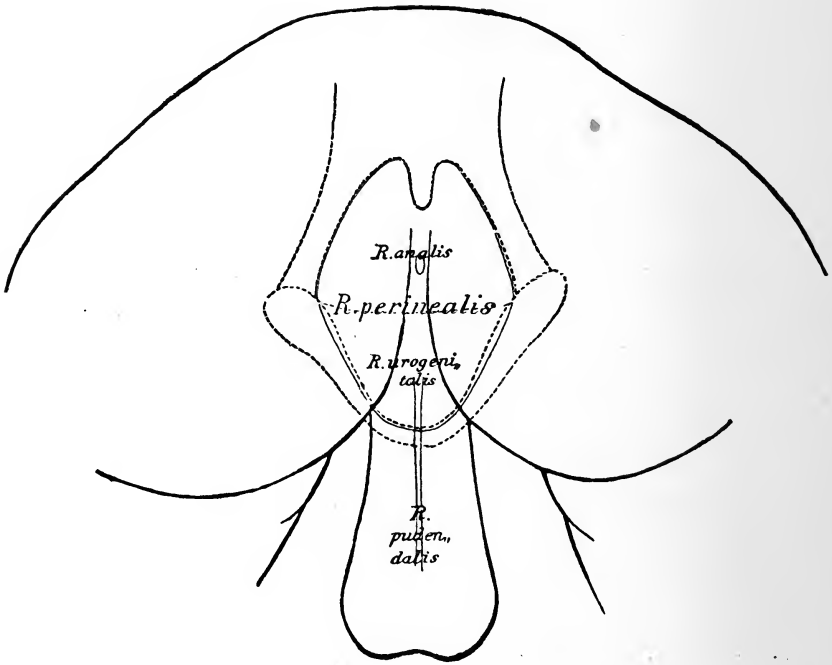
After the authors Merkel, Rüdinger, Toldt.

Anterior median line
Posterior median line
Sternal line
Parasternal line

Mammillary line
Axillary line
Scapular line

Regiones capitis
 Regio frontalis
 Regio supraorbitalis
 Regio parietalis
 Regio occipitalis
 Regio temporalis
 Regio auricularis
 Regio mastoidea
 Regiones faciei
 Regio nasalis

Regio parotideomasseterica
 Fossa retromandibularis
 Regiones colli
 Regio colli anterior
 Regio submentalis
 Regio hyoidea
 Regio subhyoidea
 Regio laryngea
 Regio thyroidea
 Regio suprasternalis



Regio oralis
 Regio labialis superior
 Regio labialis inferior
 Regio mentalis
 Regio orbitalis
 Regio palpebralis superior
 Regio palpebralis inferior
 Regio infraorbitalis
 Regio buccalis
 Regio zygomatica

Fossa jugularis
 Regio submaxillaris
 Fossa carotica
 Regio sternocleidomastoidea
 Fossa supraclavicularis minor
 Regio colli lateralis
 Fossa supraclavicularis major
 Trigonum omoclaviculäre
 Regio colli posterior
 Regio nuchae

Regions of the head

Region of the forehead

Supraorbital region

Parietal region

Region of the occiput

Region of the temple

Region of the ear

Region of the mastoid

Regions of the face

Region of the nose

Parotideomasseteric region

Retromandibular fossa

Regions of the neck

Anterior region of neck

Region under the chin

Region of the hyoid

Region below hyoid

Region of the larynx

Region of the thyreoid

Region above sternum

Region of the mouth

Region of the upper lip

Region of the lower lip

Region of the chin

Region of the eye

Region of upper eyelid

Region of lower eyelid

Infraorbital region

Region of the cheek

Region of the zygoma

Jugular fossa

Region below lower jaw

Carotid fossa

Region of the sternocleidomastoid

Lesser supraclavicular fossa

Region of the side of the neck

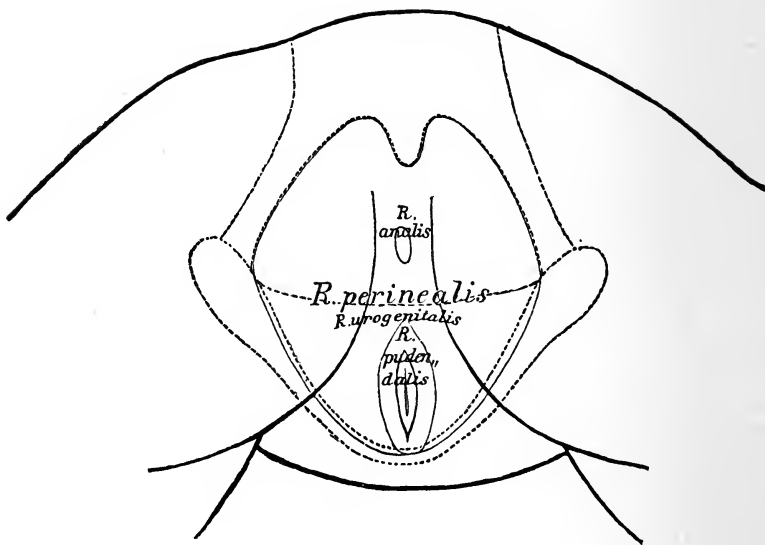
Larger supraclavicular fossa

Omoclavicular triangle

Region of the back of the neck

Region of the nape

Fovea nuchae	Regio mediana dorsi
Regiones pectoris	Regio interscapularis
Regio pectoris anterior	Regio scapularis
Regio sternalis	Regio suprascapularis
Regio clavicularis	Regio infrascapularis
Regio infraclavicularis	Regio lumbalis
Trigonum deltoideopectorale	Regio coxae
Regio mammalis	Regio sacralis
Regio inframammalis	Regio glutaea
Regio pectoris lateralis	Regio perinealis
Regio axillaris	Regio analis
Fossa axillaris	Regio urogenitalis



Regio costalis lateralis	Regio pudendalis
Regiones abdominis	Regiones extremitatis superioris
Regio epigastrica	Regio acromialis
Regio hypochondriaca	Regio deltoidea
Regio mesogastrica	Regio brachii lateralis
Regio umbilicalis	Regio brachii medialis
Regio abdominalis lateralis	Regio brachii anterior
Regio hypogastrica	Regio brachii posterior
Regio pubica	Regio cubiti anterior
Regio inguinalis	Fossa cubitalis
Regiones dorsi	

Nuchal depression	Median region of the back
Regions of the breast	Interscapular region
Anterior region of breast	Region of the scapula
Region of the sternum	Region above scapula
Region of the clavicle	Region below scapula
Region below clavicle	Lumbar region
Deltoideopectoral triangle	Region of the hip
Region of the mammary gland	Region of the sacrum
Region below mammary gland	Region of the buttocks
Lateral region of the breast	Region of the perineum
Region of the axilla	Anal region
Axillary pit	Urogenital region
Lateral region of ribs	Pundental region
Regions of abdomen	Regions of upper extremity
Epigastric region	Region of the acromion
Hypochondriac region	Region of the deltoid
Mesogastric region	Lateral region of upper arm
Region of umbilicus	Medial region of upper arm
Lateral region of abdomen	Anterior region of upper arm
Hypogastric region	Posterior region of upper arm
Region of the pubes	Anterior region of elbow
Region of the groin	Fossa of elbow
Regions of the back	

Regio cubiti posterior	Regio femoris medialis
Regio olecrani	Regio genu anterior
Regio cubiti lateralis	Regio patellaris
Regio cubiti medialis	Regio genu posterior
Regio antibrachii volaris	Fossa poplitea
Regio antibrachii dorsalis	Regio cruris anterior
Regio antibrachii radialis	Regio cruris posterior
Regio antibrachii ulnaris	Regio suralis
Regio dorsalis manus	Regio cruris lateralis
Regio volaris manus	Regio cruris medialis
Regiones digitales [manus]	Regio malleolaris lateralis
Regiones dorsales digitorum	Regio malleolaris medialis
Regiones unguiculares	Regio retromalleolaris lateralis
Regiones volares digitorum	Regio retromalleolaris medialis
Regiones extremitatis inferioris	Regio calcanea
Regio femoris anterior	Regio dorsalis pedis
Fossa subinguinalis	Regio plantaris pedis
Regio femoris lateralis	Regiones digitales pedis
Regio trochanterica	Regiones dorsales digitorum pedis
Regio femoris posterior	Regiones unguiculares
	Regiones plantares digitorum pedis

Posterior region of elbow	Medial region of thigh
Region of olecranon	Anterior region of the knee
Lateral region of elbow	Region of the patella
Medial region of elbow	Posterior region of knee
Volar region of forearm	Popliteal fossa
Dorsal region of forearm	Anterior region of the leg
Radial region of forearm	Posterior region of leg
Ulnar region of forearm	Region of the calf
Dorsal region of the hand	Lateral region of leg
Volar region of the hand	Medial region of leg
Regions of the digits of the hand	Region of lateral malleolus
Dorsal regions of digits	Region of medial malleolus
Regions of the nails	Lateral retromalleolar region
Volar regions of digits	Medial retromalleolar region
Regions of lower extrem- ity	Region of the heel
Anterior region of the thigh	Region of the dorsum of foot
Fossa below the groin	Region of the sole of the foot
Lateral region of thigh	Regions of the digits of the foot
Region of the trochanter	Dorsal regions of the digits of the foot
Posterior region of thigh	Regions of the nails
	Plantar regions of the digits of the foot

Explanatory Notes to Certain of the Terms.

While there can be no doubt as to the exact meaning of the majority of the names in the list, there are some names included which hitherto have been used with different meanings in different text-books, and here and there a new term, not to be found in any of the text-books, is included.

To indicate the exact meaning of these, Professor His, with the approval of the editing committee, wrote a series of brief explanatory notes. Thus, for example, the designations regarding the position and direction of parts of the body are explained, *transversalis* meaning across the axis of the body, *transversus* across the axis of the organ concerned. The word *intermedius* is used for the position midway between *medialis* and *lateralis* in order to avoid the juxtaposition of words sounding so much alike as *medius* and *medialis*; between *anterior* and *posterior* or between *externus* and *internus*, the adjective *medius* is retained. The notes contain a long discussion on the nomenclature of "glands" and "lymphglands." In connection with general terms it is noted that *discus* means "disc," while *meniscus* means "crescent." In the osteological notes the terms *glabella*, *infundibulum ethmoidale*, and *sulci paraglenoidales* are, among others, clearly defined. Comments on the *Pars lacrimalis m. orbicularis* or Horner's muscle, the *M. quadratus labii superioris* (the old "Mm. levator labii superioris proprius, levator labii superioris alæque nasi and zygomaticus minor" combined), the *Raphe pterygomandibularis*, the *Fasciculi transversi* of the palmar aponeurosis, the *Scalenus minimus*, the *Ligamentum fundiforme penis*, the *Falx inguinalis* (the old "conjoined" tendon or Henle's ligament), and the *Ligamentum interfoveolare* (Hesselbach's ligament) are made in connection with myology.

Some rather important notes accompany the splanchnological terms. Certain new terms have been adopted in the tonsillar region, partly on embryological grounds. The *Recessus pharyngeus* of Rosenmueller is exactly defined, as is also the *Bursa pharyngeus* (p. 128). In connection with the *Pars analis recti* attention is called to the excellent description given by the French anatomists, Sappey and Testut. A number of the names for parts of the nose and larynx have been drawn from the special literature. The less familiar of these in the nose—*Limen nasi*, *atrium meatus medii*, *agger nasi*, *Sulcus olfactorius*, *Recessus sphenothmoidalis*, *meatus nasopharyngeus*, *Meatus nasi communis*, *Processus sphenoidalis septi cartilaginei*—are explained. In the larynx marked precision has been arrived at and a great advance in nomenclature has been made. The old terms *Glottis vera* and *Glottis spuria* have been done away

with; the terms adopted throughout are exceedingly satisfactory. The names for the genitourinary organs are nearly all easily understood; the terms *Annulus urethralis vesicæ*, *Crista urethralis*, *Corpus glandulare prostatae*, *Isthmus prostatae*, *Colliculus seminalis* (the old *Caput gallinaginis*) are especially dealt with.

As might have been expected, there are numerous notes upon the pelvic floor and the pelvic fascia. After the notes were written the Commission changed *Trigonum urogenitale* to *Diaphragma urogenitale*. The floor of the pelvic cavity is formed by the *M. levator ani* and the *M. coccygeus*, and to this muscular funnel the name *Diaphragma pelvis*, suggested by H. Meyer, is given; the fascia above it is called the *Pars diaphragmatica fasciæ pelvis*, that below it the *Fascia inferior diaphragmatis pelvis*. The two parts of the Fascia pelvis are designated *Pars diaphragmatica* and *Pars endopelvina*, instead of, as of yore, *Pars parietalis* and *Pars visceralis*, the reason being that the latter terms are used only for serous membranes. The distinction between the *Arcus tendineus musculi levatoris ani* (the tendinous arch helping to give origin to the *M. levator ani* interwoven with the obturator fascia, whose two extremities reach to the upper margin of the pelvis) and the *Arcus tendineus fasciæ pelvis* is sharply drawn; the latter crosses the former and the two are easily separable from one another.

The *Diaphragma urogenitale*, the triangular mass of tissue stretching across between the pubic rami leaving a space at its upper end (beneath the *Lig. arcuatum*) open for the passage of the *Vena dorsalis penis* (s. *clitoridis*), is described as having a framework made up of two powerful fascial layers, the *Fascia diaphragmatis urogenitalis superior* (the old "deep layer of the triangular ligament"), and the *Fascia diaphragmatis urogenitalis inferior* (the old "superficial layer of the triangular ligament"). These two fasciæ are fused at their upper and lower margins, enclosing a flat slit-like space. The union of the upper margins gives rise to the *Lig. transversum pelvis*. The compartment between the two layers (middle perineal compartment) is traversed by the membranous urethra with its *M. sphincter urethrae membranaceæ*. In the compartment lie the *M. transversus profundus*, Cowper's glands, and numerous venous plexuses. The term "Fascia perinei propria" has been dropped; it was used in so many different ways that students were confused by it.

The revision of the names for the peritoneum seems satisfactory. By *Membrana mesenterii propria* is meant the layer of connective tissue remaining after removal of the two peritoneal layers; it carries the blood and lymph-vessels, lymph glands, and fat. The division of the *Bursa omentalis* (lesser peritoneal cavity) into a *Vestibulum*, *Recessus superior*, *Recessus inferior*, and *Recessus lienalis*, is important. The *Plica gastropancreatica* is explained.

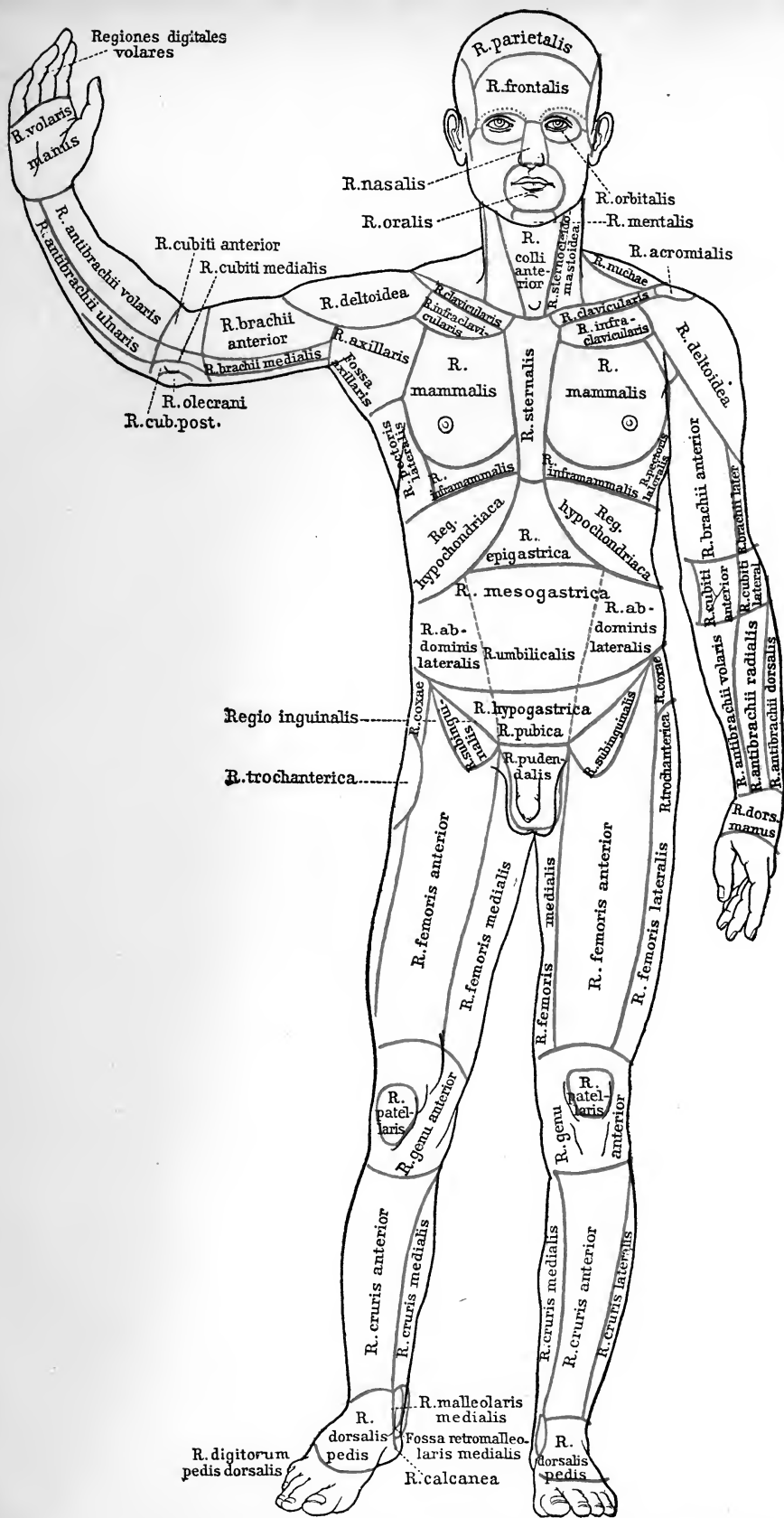
The old name of suspensory ligament of the liver has been changed to *Lig. falciforme hepatis* for obvious reasons.

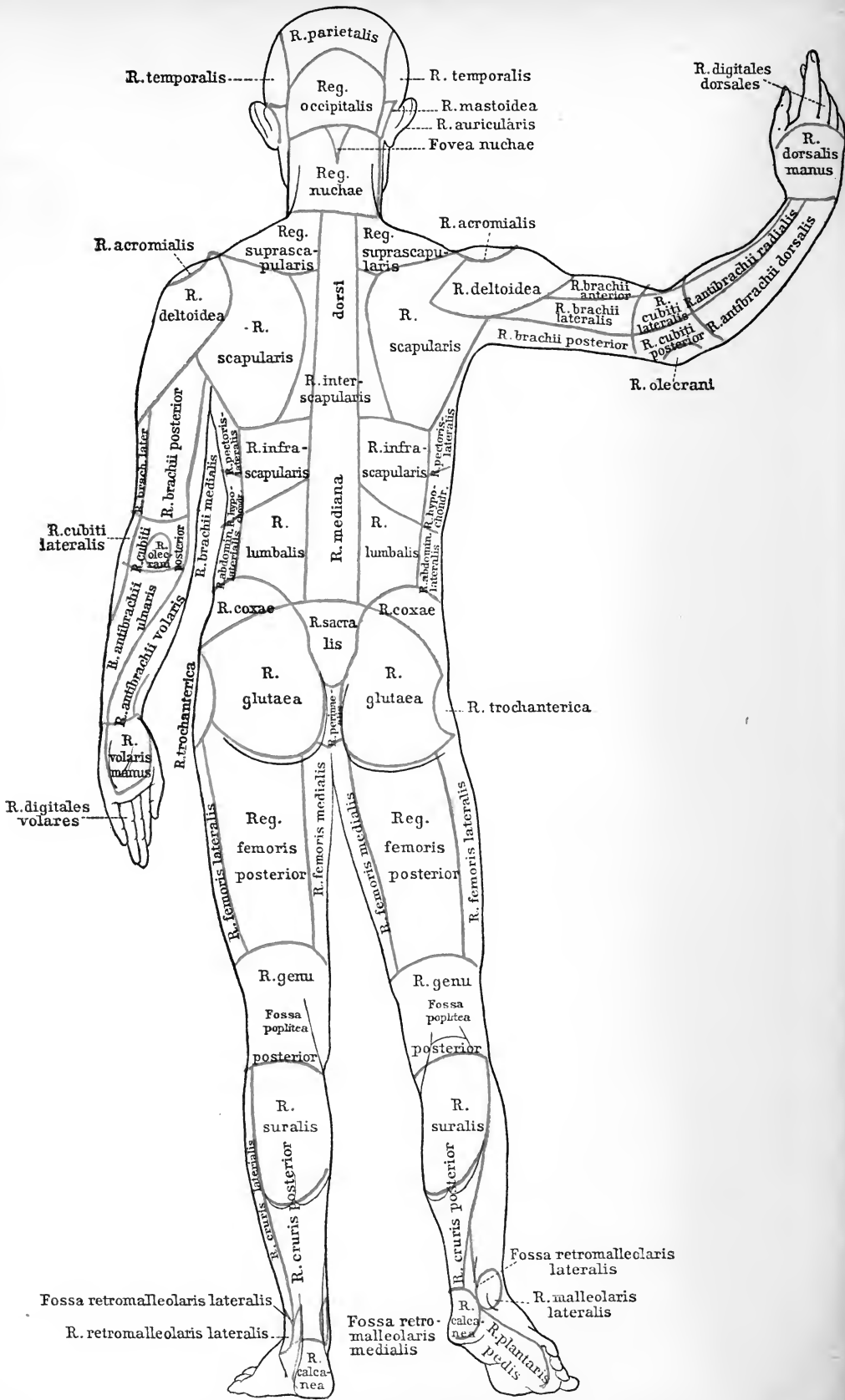
On the following terms of gynaecological anatomy comments are made: *Lig. suspensorium ovarii*, *Bursa ovarica*, and *Parametrium*.

The angiological notes are meagre, it being assumed that the names are in general wholly intelligible; a few names of parts of the heart are commented on and the question of the veins about the navel is thoroughly ventilated.

The neurological notes are in accord with the well-known nomenclature based on the embryological studies of His, and those familiar with his work will find but little new in them.

These notes are not more fully incorporated into this volume for two reasons: (1) They are easily accessible to those who desire to refer to them in the *Arch. f. Anat. u. Entwicklungs geschichte* (1895), and (2) they would have inconveniently enlarged the size and increased the price of the present publication.





A
LIST OF BOOKS

ON

**Anatomy, Physiology,
Histology, Biology,
Embryology, Zoology**



Published by
P. Blakiston's Son & Co.
Philadelphia.



Illustrated Circulars sent to
any Address upon Application

Arranged upon an Embryological Basis

Just Ready

Stohr's Histology

Sixth American, from the Twelfth German Edition.

Revised and Arranged by **FREDERIC T. LEWIS**

Assistant Professor of Embryology at the Harvard Medical School.

With 450 Illustrations, 45 in Colors. Octavo; ix + 434 pages. Cloth, \$3.00 net.

THE need of a text-book of histology arranged upon an embryological basis has long been felt, and the opportunity to accomplish this arrangement was promptly embraced when Professor Stohr's generous permission was given to adapt a new edition of his book to American needs. As a leading Professor of Histology says, "the book is now in its arrangement and treatment something adequate as a statement of the present knowledge of the subject. The illustrations *illustrate*; the text *instructs*."

The Basle Anatomical Nomenclature (BNA) is used throughout.

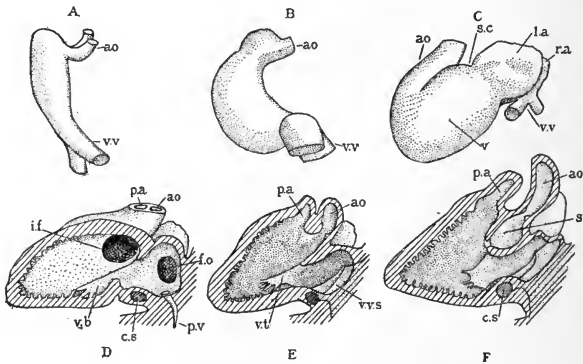


FIG. 159 (Reduced).—EMBRYONIC HEARTS.

A and B, from Rabbits 9 days after coitus, C, from a human embryo of 3 (?) weeks; D and E, from a 12 mm. pig (D sectioned on the left of the median septum, and E on the right of it); F, from a 13.6 mm. human embryo, sectioned like E.

Synopsis of Contents.—MICROSCOPIC ANATOMY. *Cytology:* The Cell; Form and Size of Cells; Vital Phenomena; Formation and Reproduction of Cells; Cytomorphosis. GENERAL HISTOLOGY: Histogenesis; Epithelia; Mesenchymal, Muscle, Nerve, and Vascular Tissues; Blood Forming and Blood Destroying Organs; Entodermal Tract; Urinary and Male and Female Genital Organs; Skin; Supra-renal Glands; Brain and Sense Organs. THE PREPARATION AND EXAMINATION OF MICROSCOPICAL SPECIMENS: Fresh Tissues; Isolation; Sectioning; Fixation; Decalcification; Imbedding; Staining and Mounting; General Stains; Special Stains; the Microscope; Drawings; Reconstruction.

An Americanized Fourth Edition Rewritten and Revised

NEARLY READY

Morris' Human Anatomy

A Complete, Systematic Treatise by American and English Authors

EDITED BY

HENRY MORRIS and **J. PLAYFAIR McMURRICH**
F.R.C.S. A.M., Ph.D.

Consulting Surgeon to, and formerly Lecturer on Surgery and Anatomy at Middlesex Hospital, London. and Examiner in Anatomy, University of Durham, etc.

Professor of Anatomy, University of Michigan; Member Association of American Anatomists; Member of Advisory Board, Wistar Institute of Anatomy, etc.

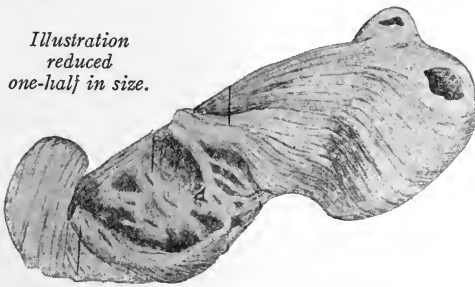
For the first time in the history of this famous work, American anatomists have been asked to contribute original articles and to rewrite and revise sections, the object in this being the desire to incorporate the very important results of recent investigations in the anatomical laboratories of the United States. The book has become international in scope, and with its widening

of view, of even greater usefulness to all English-speaking students.

Among the American contributors will be noted J. Playfair McMurrich, R. J. Terry, Irving Hardesty, G. Carl Huber, Abram T. Kerr, Charles R. Bardeen and Florence R. Sabin. Henry Morris, R. Marcus Gunn and W. H. A. Jacobson head the English contributors.

The text has been completely revised, and an additional feature of merit will be found in its **conformity with the new Anatomical Nomenclature (BNA)***

Illustration reduced one-half in size.



THE VENTRICLES UNROLLED. (After MacCallum.)

(Note:—It is not possible in this space to give a thoroughly representative illustration. That shown is one of a series depicting—according to Professor MacCallum, of Johns Hopkins University—the fact that the heart may be considered as three flat bands.)

Very especial attention, in this new edition, has been paid to the **illustrations**, with the result that the teaching value of the book has been very materially increased.

Containing about 1024 Illustrations, of which many are in Colors. One Handsome Octavo Volume. Cloth, \$6.00. Sheep or Half Morocco, \$7.00, net. Or in Five Parts, as follows, each part sold separately.

- PART I. Morphogenesis. Osteology. Articulation. Index.
- PART II. Muscles. Organs of Circulation. Index.
- PART III. Nervous System. Organs of Special Sense. Index.
- PART IV. Organs of Digestion; of Voice and Respiration. Urinary and Reproductive Organs. Ductless Glands. Skin and Mammary Glands. Index.
- PART V. Surgical and Topographical Anatomy. Index.

Entomology

With Special Reference to Its Biological and Economic Aspects

By Justus Watson Folsom, Sc.D. (Harv.)

Instructor in Entomology at the University of Illinois.

Five Plates, 1 Colored, and 300 other Illustrations. 8vo; 485 pages. Cloth, \$3.00 net.

“‘Entomology,’ by Dr. Justus W. Folsom, is an advance over all other American works of its kind. It should be in the hands of every entomologist or entomological student, and in every public library. A most careful work, containing much information that only an expert has heretofore known where to find.”—MR. F. M. WEBSTER, *in charge of the Cereal and Forage Crops Insect Investigations, Department of Agriculture at Washington.*

A comprehensive and concise account of insects, written to meet the growing demand for a biological treatment of entomology. The aim has been to introduce much material that, hitherto, has not appeared in the text-books; and though adapted for students and teachers of entomology and zoology (being the only book that fills the actual teaching requirements) it will also be valuable to the professional and amateur entomologists and to the general reader, especially on account of its consideration of economic subjects. The book contains, in small compass, authenticated facts that have had to be sought in many foreign languages. The new illustrations, which are many, have been prepared by the author; the others have been copied, by permission from various authoritative sources.

Synopsis of Contents: Classification.—Anatomy and Physiology.—Development.—Adaptations of Aquatic Insects.—Color and Coloration.—Adaptive Coloration.—Origin of Adaptations and of Species.—Insects in Relation to Plants; to other Animals.—Interrelations of Insects.—Insect Behavior.—Distribution.—Insects in Relation to Man.—Literature.—Index.

“This is an eminently satisfactory work on insects, both from the standpoint of the school and of the general reader. It is the first adequate treatment of this subject as adapted to the science of entomology, and at the same time to agriculture, horticulture and forestry. It teaches every fact about insects that it is desirable to know from the point of view of popular science, and literally all that need be known from the economic. This is an admirable realization of the dream of the schoolmaster and of the general reader for a book at once comprehensive, concise and attractive.”—*Journal of Education, Boston.*

“Of high, practical importance” (*Outlook*). “it is a complete and concise account of insect life, planned to meet the growing interest in biology” (*School*). “The book is a noteworthy one” (*Psyche*), “and is a very valuable addition to the general work on the subject. It covers much ground not touched by the other books on insects” (*Entomological News*). “It is a book to lean upon and draw upon” (*School Bulletin*). “Will be most useful to the general student” (*Science*).

Embryology

The Development of the Human Body

By J. Playfair McMurrich, A. M., Ph. D.
Professor of Anatomy in the University of Michigan.

Second Edition, Revised, Enlarged.
With 272 Illustrations.
12mo; 539 pages. Cloth, \$3.00 net.

A CONCISE statement of the development of the human body and a foundation for the proper understanding of the facts of anatomy. The comparative anatomy and development of the lower animals, too, is constantly referred to, a different style type being used for these references.

The assimilation of the enormous mass of facts which constitute what is usually known as descriptive anatomy has always been a difficult task for the student. Part of the difficulty has been due to a lack of information regarding the causes which have determined the structure and relations of the parts of the body, for without some knowledge of the "why" things are so, the facts of anatomy stand as so many isolated items, while with such knowledge they become bound together to a continuous whole and their study assumes the dignity of a science. The great key to the significance of the structure and relations of organs is their development, recognizing by that term the historical as well as the individual development.

Synopsis of Contents: PART I.—*General Development: The Spermatozoon and Spermatogenesis; the Ovum and Its Maturation and Fertilization; the Segmentation of the Ovum and the Formation of the Germ Layers; The Development of the External Form of the Human Embryo; The Medullary Groove, Notochord, and Mesodermic Somites; The Yolk-stalk, Belly-stalk, and the Foetal Membranes.* PART II.—*Organogeny: The Development of the Integumentary System; Connective Tissues and Skeleton; Muscular System; Circulatory and Lymphatic Systems; Digestive Tract and Glands; Pericardium and Pleuro-peritoneum, the Diaphragm and the Spleen; Organs of Respiration; Urinogenital System and the Suprarenal Bodies; Nervous System; Organs of Special Sense; Post-Natal Development; Index.*

"Right up to date."—*Lancet, London.*

A Laboratory Text-Book of Embryology

By Charles S. Minot, S. D., LL. D.
Professor of Histology and Human Embryology, Harvard University Medical School.

With 218 Illustrations, mainly original.
Quarto; 380 pages. Cloth, \$4.50 net.

This work is intended primarily for the use of students taking a practical laboratory course in Embryology. The author's experience has led him to believe that the study of carefully selected sections of embryos, accompanied by directions and explanations of the significant structures in each section, offers many advantages. This conviction has determined the arrangement of the book. Attention is given chiefly to such points as serve to explain adult anatomical relations, to illustrate general biological principles, and to afford insight into pathological processes.

Synopsis of Contents: General Conceptions.—The Early Development of Mammals.—The Human Embryo.—Study of Pig Embryos.—Study of Young Chick Embryos.—Study of the Blastodermic Vesicle and the Segmentation of the Ovum.—Study of the Uterus and the Foetal Appendages in Man.—Methods.—Index.

"This new laboratory text-book of Embryology is worthy of particular attention. It is a practical guide of a novel and original type, which is to be recommended as a valuable aid in laboratory teaching of a difficult nature. It is a valuable addition to the list of available text-books of Embryology. In fact, the book stands by itself and is an original departure in a very desirable direction, introducing the student to the subject by a practical method which promises excellent results. After a year's experience with it, we feel much confidence in its success."—*Bulletin of the Johns Hopkins Hospital.*

First Course In Zoology

A NEW TEXT-BOOK FOR SECONDARY SCHOOLS,
NORMAL SCHOOLS, AND COLLEGES

By **T. W. Galloway, Ph. D.**

Professor of Biology, James Millikin University, Decatur, Illinois.

With 240 Illustrations. Octavo; 460 pages. Cloth, \$2.50 net.

THE AUTHOR has endeavored in this book to present a balanced course in Zoology which will be suitable to beginning classes in the last years of the High School or the first year of College. **It provides specifically for class-room work, reference work in the library, laboratory work, and field work.** It includes a brief treatment of the fundamental principles of the science in the first part of the book; the second part, which contains a discussion of the great branches of the animal kingdom, is treated as a concrete illustration of these general principles.

Among many other distinctive excellences are seven features which give the work especial merit: (1) It follows no fads; (2) Because of the wealth of practical exercises suggested, it provides more work than any one class can cover in the time allotted; (3) Much collateral work in the library, field and laboratory is outlined; (4) The practical work is placed upon the broader problems of physiology, of the relations of animals to the environment, and of the adaptations of organic form to needs, rather than upon dissection and minute anatomy; (5) The practical (i. e. the laboratory, field and library) work is interspersed through the text in such a way as to illustrate and enforce the more abstract definitions; (6) Especial emphasis is put upon the illustrations; (7) There are numerous analytical reviews and summaries.

Synopsis of Contents:—Introduction.—Protoplasm: Its Morphology and Physiology.—The Animal Cell: Its Morphology and Physiology.—From the Simple Cell to the Complex Animal.—Cellular Differentiation.—Tissues.—General Animal Functions and Their Appropriate Organs.—Promorphology.—Individual Differentiation and Adaptation.—A General Preview of the Animal Kingdom.—Protozoa.—Porifera.—Coelenterata.—Unsegmented “Worms.”—Echinodermata.—Annulata: Segmented “Worms.”—Mollusca.—Arthropoda.—Chordata: Proto-vertebrata.—Chordata: Vertebrata.—Pisces.—Amphibia.—Reptilia.—Aves.—Mammalia.—General Summary.—A Review Outline.—Appendix.—Suggestions to Teachers.—Index.

“Galloway’s ‘First Course in Zoology’ is one of the authoritative text-books. The teacher may refer to it with confidence, and cannot fail to do so with profit.”—*School Bulletin.*

The Nervous System of Vertebrates

By J. B. Johnston, Ph. D.

Professor of Zoology in West Virginia University.

With 180 Illustrations, the majority from original drawings.

Octavo; xx+370 pages. Cloth, \$3.00 net.

THE attempt has been made in this book to give an account of the nervous system as a whole, to trace its phylogenetic history and to show the factors which have determined the course of evolution. The functional point of view, which is the chief characteristic of the present book, brings the treatment of the nervous system into close relation with the work of recent years on the behavior of animals. The study of behavior aims to give an account of the actions of animals in relation to the environment. The study of the nervous system aims to describe the mechanism by which actions are directed and adapted to the conditions of life. A text-book of comparative neurology at the present time must meet the needs of workers of all grades, students, investigators and instructors. Its descriptions should be intelligible to students who have had one year of work in zoology or medicine, including the anatomy and embryology of some vertebrate. On the other hand, there should be included all facts which are important for the functional and phylogenetic mode of treatment. Every effort has been made to bring out clearly the functional significance and relationships of the structures described, and to interest and train the student in the interpretation of structure in terms of function, adaptation and evolution. The (BNA) terms, which are now the most generally familiar, have been employed so far as possible. Much material has been collected which is published here for the first time.

Two prominent instructors say:

“It is an exceedingly useful piece of work,—well done.” “Professor Johnston’s text-book makes a valuable addition to our researches and represents the newer developments of neurological science in a way which, so far as I know, no other book has even attempted.”

Synopsis of Contents:—Study of the Nervous System.—General Morphology of the Nervous System.—Development of the Nervous System.—Nerve Elements and their Functions.—The Functional Divisions of the Nervous System.—Somatic Afferent Division; General Cutaneous Subdivision; Special Cutaneous Subdivision; Visual Apparatus.—Visceral Afferent Division.—Olfactory Apparatus.—Somatic Motor Division.—Visceral Efferent Division.—Sympathetic System.—Centers of Correlation.—Cerebellum.—Centers of Correlation; Mesencephalon and Diencephalon.—Evolution of the Cerebral Hemisphere.—Neopallium. Bibliography and Laboratory Work Suggestions at end of each Chapter.

Surgical Anatomy

A Treatise on Human Anatomy in its Application
to the Practice of Medicine and Surgery

By John B. Deaver, M.D.

Surgeon-in-Chief to the German Hospital, Philadelphia, etc., etc.

“The reader is not only taken by easy and natural stages from the more superficial to the deeper regions, but the various important regional landmarks are also indicated by schematic tracing. . . In summing up the general excellences of this remarkable work, we can accord our unqualified praise for the accurate, exhaustive, and systematic manner in which the author has carried out his plan, and we can commend it as a model of its kind, which must be possessed to be appreciated.”—*Medical Record, New York.*

Three Royal Octavo Volumes, of 2157 pages, containing 499 Full-page Plates engraved from original drawings made by special artists from dissections prepared for the purpose in the dissection-rooms of the University of Pennsylvania. *Sold by Subscription, in Complete Sets Only.* Leather or Half-Morocco, Marbled Edges, \$30.00; Half-Russia, Gilt, Marbled Edges, \$33.00 *net.*

Synopsis of Contents: (*Number of Illustrations in Parentheses.*)

Vol. I.—Upper Extremity (95); Back of Neck, Shoulder, and Trunk (24); Cranium, Scalp, Face (32). 632 pages; 151 Plates. **Vol. II.**—Neck (47); Mouth (3); Pharynx (6); Larynx (10); Nose (9); Orbit (8); Eye (14); Ear (12); Brain (32); Joints of Head and Neck (4); Male Perineum (17); Female Perineum (8). 709 pages; 170 Plates. **Vol. III.**—Abdomen (74); Pelvis (16); Chest (32); Lower Extremity (56). 816 pages; 178 Plates.

“In order to show its thoroughness, it is only necessary to mention that no less than twelve full-page plates are reproduced in order to accurately portray the surgical anatomy of the hand, and it is doubtful whether any better description exists in any work in the English language.”—*Journal of the American Medical Association.*

“The illustrations are lavishly supplied and are both helpful and informing. . . . No better text-book of surgical anatomy is in existence, and we can confidently predict that Dr. Deaver has satisfied the needs of the profession for at least a generation.”—*The British Medical Journal, London.*

THE LOOSE LEAF SYSTEM OF LABORATORY NOTES

FOR GUIDANCE IN THE DISSECTION AND
ELEMENTARY STUDY OF ANIMAL TYPES

Prepared by

THEO. H. SCHEFFER, A. M.

Assistant Professor of Zoology, Kansas State Agricultural College.

Octavo ; vi + 112 pages. Strong Adjustable Cloth Covers, Cloth, \$1.00 net.

Excerpts From the Preface:

INSTRUCTORS in biology very generally direct the laboratory work by means of written or printed guides placed in the hands of the student. These are sometimes hastily prepared for the occasion, or, if more elaborated, the sheets furnished the student at various times are not uniform in size and will not fit in with any system of notes which he may be keeping.


The LOOSE LEAF guides are the results of several years' experience in directing zoological work in high school and college laboratories. The sheets outlining the work on each type of animal are separate, so that they may be incorporated with the student's drawings and notes on that particular type. The recorded information on the subject is thus collected together, not only simplifying at the time the work of studying the specimen, taking notes, and indexing the drawings, but making future reference to the records an easy matter. Then, too, the laboratory guides being thus bound in with the student's notes, do not become scattered or lost.

The twenty-one types of animal life herein treated give the student a brief general survey of the field from Protozoan to Vertebrate. Similar treatment is accorded each type. It will be noted that the zoological position of each animal is given (*Parker and Haswell's classification*), that its habitat receives attention, and that there are hints on collecting the material for class study. Details of structure that are very obscure are either omitted, or, if essential, attention is called to them without demonstration.

Synopsis of Contents: PROTOZOA. *Amœba; Paramœcium; Vorticella.* PORIFERA. *Marine Sponge.* COELENTERATA. *Fresh-Water Hydra; Hydroid; Hydroid Medusa.* PLATYHELMINTHES. *Flat-Worm.* ECHINODERMATA. *Starfish.* ANNULATA. *Earthworm.* ARTHROPODA. *Water-flea; Lobster or Crayfish; Centipede; Grasshopper; Spider.* MOLLUSCA. *Fresh-water Mussel; Snail; Squid.* CHORDATA. *Catfish; Frog or Toad; English Sparrow.*

"The book will prove useful in high school and elementary college courses."—*The Nation*.

"It is a most capital idea" (*School Bulletin*), "and is a most excellent system of keeping notes."—*Country Life in America*.

 Scheffer's "Loose Leaf System" is not bound in the usual manner. Each leaf is separate and the whole tied into strong adjustable cloth covers, so that leaves may be removed or notes and drawings may be inserted at any place.

Blakiston's Manikins

A Series of Twelve Manikins of the Head, Nose, Throat, Eye, Ear, Lungs, Heart, Stomach, Kidney, Liver, Foot, and Hand, with Descriptions of each. ~ ~ ~ ~

One Volume. Octavo. Cloth, \$1.50 *net.*

The manikin of the HEAD shows 88 different structures; that of the ORAL CAVITY, with the PHARYNX, LARYNX, and TEETH, shows 61; the EYE, 44; the FOOT, 68; the HAND, 55; the LIVER, 47; the KIDNEY, 20; the STOMACH, 23; the NOSE, 32; the EAR, 24; the LUNGS, 18; and the HEART, 33,—A TOTAL OF 513 STRUCTURES.

The work is issued in book form, octavo in size, and embraces twelve manikins, some containing as many as ten flaps, lithographed in colors on heavy serviceable cardboard, the whole arranged to fold flat and compact when the volume is closed. Each manikin is cut to the exact shape of the organ illustrated, and the various flaps are intended to fold one upon the other in the order shown in nature, the deeper details becoming visible only when all the outer layers have been in their proper turn exposed. Every flap is printed on two sides, each side representing a different anatomical feature.

A Manual and Atlas of Dissection

By Simon Menno Yutzy, M.D.

Instructor in Osteology and Demonstrator of Anatomy in the University of Michigan.

With an Introduction by J. Playfair McMurrich, A.M., Ph.D.

Professor of Anatomy, University of Michigan; author of "A Manual of Human Embryology."

This work is a topographical index, providing the reader with a list of the structures to be found during dissection, together with concise directions for procedure.

With 314 Illustrations, many in Colors. Large Octavo; 256 pages. Cloth, \$2.50 *net.*

"The author's experience as a teacher has effected an arrangement likely to be very useful to the student."—*New York Medical Journal.*

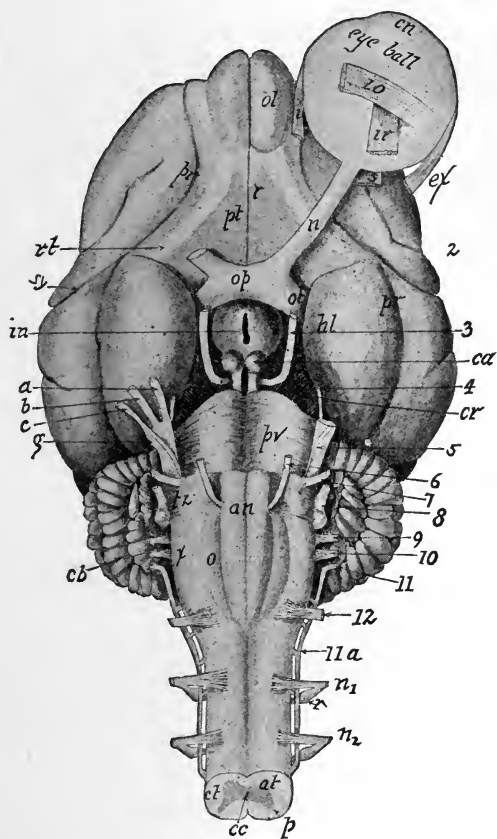
Mammalian Anatomy

With Special Reference to the Cat

By Alvin Davison, Ph. D.

Professor of Biology in Lafayette College.

With over 100 Illustrations made by
W. H. REESE, A. M., from the
author's dissections. 12mo; 250
pages. Cloth, \$1.50 net.



VENTRAL ASPECT OF THE BRAIN.

THIS work is intended to acquaint the student with the general structure of the cat, and at the same time introduce him to some of the most important morphologic features of the Mammalian. All eminent zoologists agree on the desirability of beginning zoological work by studying one of the higher animals. Again, since the majority of college students have not time for the acquisition of a fruitful knowledge of both vertebrates and invertebrates, the study of the former is a matter of vital importance, as it enables the student to become familiar with the anatomy and physiology of his own body. It also has the advantage of throwing light on the significant problem of organic evolution, such as is not to be derived from the study of invertebrate forms. Professor Davison's work has a distinct place in biological study.

Synopsis of Contents:—The Biological Sciences—Classification of the Animal Kingdom—Preparation and Preservation of Material—General Structure of a Vertebrate—The Skeleton—The Joints—The Muscles—Organs of Digestion—The Vascular System—Respiratory System—Excretory and Reproductive Systems—Nervous System—Index.

“It is designed to fill the gap between the more detailed works and those which are merely laboratory guides, and to afford the student who cannot pursue a lengthy course of zoological study, a general idea of the structure of a mammal and of the principles of mammalian anatomy. The book furnishes an excellent idea of the structure of the cat, free from a superfluity of detail. Throughout the book are frequent remarks of a comparative nature, and at the close of each chapter is a list of questions or suggestions, for the most part of a general nature, which will serve as excellent topics for comment by the teacher or for collateral investigation under his direction by the student. An introductory chapter is devoted to an account of useful methods by which the dissection may be facilitated, and the text is illustrated by numerous figures and diagrams.”—*Science*.

A Text-Book of
Anatomy for Nurses

Just Ready

By Elizabeth R. Bundy, M.D.

Member of the Medical Staff of the Woman's Hospital of Philadelphia, etc., etc.;
late Adjunct Professor of Anatomy, and Demonstrator of Anatomy in
the Woman's Medical College of Pennsylvania; formerly
Superintendent of Connecticut Training School
for Nurses, New Haven.

THE pupil-nurse in a training school has little time at command for the study of text-books, and conciseness, clearness and accuracy are essential requisites of any work written for her use. In this "Anatomy for Nurses" these requisites are observed, and nurses—pupil or graduate—will find in it a satisfactory aid to the acquirement of that knowledge of the human body which is necessary to the full understanding of their important duties.

Dr. Bundy, by reason of her positions, training and experience, is particularly well qualified to write such a book. It does not unnecessarily burden the mind of the student by endeavoring to reach into the domains of the physician, nor does it concern itself with useless abstract or theoretical matters. On the contrary, it fills a void for a work that is simple, terse, didactic,—one that, confining itself strictly to its own chosen field, is yet complete in all details of moment therein.

With a Glossary and 191 Illustrations, 34 of which are Colored.
12mo; viii + 252 pages. Cloth, \$1.75 net, postage prepaid.

Miscellaneous Books

Holden.

Holden's Anatomy

A Manual of the Dissections of the Human Body

By John Langton, F.R.C.S.

Surgeon to, and Lecturer on Anatomy at, St. Bartholomew's Hospital.

Seventh Edition, Carefully Revised by A. Hewson, M.D.

Demonstrator of Anatomy, Jefferson Medical College, Philadelphia, etc.

320 Illustrations. Two small compact volumes. 12mo.

Vol. I. Scalp, Face, Orbit, Neck, Throat, Thorax, Upper Extremity.
435 pages. 153 Illustrations. Oil Cloth, \$1.50 net.

Vol. II. Abdomen, Perineum, Lower Extremity, Brain, Eye, Ear, Mammary
Gland, Scrotum, Testes. 445 pages. 167 Illustrations.
Oil Cloth, \$1.50 net.

"The last edition of this standard work comes in two volumes instead of one as formerly. A few alterations have been made in the text, but the general character of the book is still maintained throughout, which is saying all of good that can be said of an anatomical classic."—*Medical Record, New York.*

Human Osteology

Comprising a Description of the Bones, with Colored
Delineations of the Attachments of the Muscles.

The General and Microscopical Structure
of Bone and Its Development

Eighth Edition. Carefully Revised.

Edited by Charles Stewart, F.R.S.

and R. W. Reid, M.D., F.R.C.S.

With Colored Lithographic Plates and Numerous Illustrations. Cloth, \$5.25 net.

Landmarks—Medical and Surgical

Fourth Edition. 8vo. Cloth, \$.75 net

Miscellaneous Books (Continued)

Gordinier.

The Gross and Minute Anatomy of the Central Nervous System

With a Chapter on the Embryology of the Central Nervous System

By H. C. Gordinier, A.M., M.D.

Professor of Physiology and of the Anatomy of the Nervous System in the Albany Medical College; Member American Neurological Association.

With 48 Full-page Plates and 213 other Illustrations, a number of which are printed in Colors and many of which are original. Large 8vo. Cloth, \$6.00; Sheep or Half-Morocco, \$7.00, net.

"It represents much painstaking research and bears also the stamp of original investigation. It is unusually well written, and the illustrations, many of which are original, are well chosen. It is destined to take its place among the standard books of its class."—*N. Y. Medical Journal.*

Broomell.

Anatomy and Histology of the Mouth and Teeth

By Dr. I. N. Broomell

Professor of Dental Anatomy, Dental Histology, and Prosthetic Technics in the Pennsylvania College of Dental Surgery.

Second Edition, Revised and Enlarged by 72 pages. 337 Handsome Illustrations, the majority of which are original. Large Octavo. Cloth, \$4.50; Leather or Half-Morocco, \$5.50, net.

"A most excellent manual and one of the most up-to-date textbooks upon the subject of the anatomy of the mouth which has appeared in recent years."—*The American Journal of Medical Sciences.*

Box and Eccles.

Clinical Applied Anatomy

or, the Anatomy of Medicine and Surgery

By Charles R. Box, M.D., F.R.C.S.

Lecturer on Applied Anatomy, St. Thomas's Hospital,

and W. McAdam Eccles, F.R.C.S.

Demonstrator of Operative Surgery, St. Bartholomew's Hospital.

With 45 Plates, 12 Colored; 6 figures. 8vo; 471 pages. Cloth, \$4.00 net.

"This excellent work is one of the most practical and applicable to the needs of the medical practitioner or senior student which has yet appeared on the subject of applied anatomy. The plan pursued by the authors in this book has been to treat the subject entirely from a clinical point of view rather than that of the anatomist, with the result of making the work delightfully readable. Any author who can accomplish this with an anatomical subject, and without detracting from the technical value of his work, deserves and is bound to receive great credit."—*Medical Record, New York.*

Miscellaneous Books (Continued)

Tomes.

Dental Anatomy

A Manual of Dental Anatomy, Human and Comparative
By C. S. Tomes, D.D.S.

263 Illustrations. Sixth Edition, Revised. 12mo. Cloth, \$4.00 net.

"This standard work on Dental Anatomy has been brought thoroughly up to date and is a distinct advance on any of the previous editions. At first written with a view of providing the dental student with the requisite knowledge for his qualifying examination it has since become a text-book for the student of biology in general. This fact, combined with the rapidly increasing literature on the subject, has, as the author points out, greatly enhanced the difficulty of bringing the book up to date. It is, however, needless to say that the work of editing has been carried out in an admirable way."—*Lancet, London.*

Ballou.

Equine Anatomy and Physiology

By Wm. R. Ballou, M.D.

Late Professor of Equine Anatomy, New York College of Veterinary Surgeons.

With 29 Graphic Illustrations. 12mo. *Blakiston's ? Quiz-Compend ? Series.*
Cloth, \$1.00; Interleaved for the Addition of Notes, \$1.25, net.

"One of Blakiston's series of Quiz-Compends. These Compends are based on popular text-books and the lectures of prominent professors, and are kept constantly revised, so that they represent the present state of the subjects upon which they treat. The one now before us supplies for students of veterinary anatomy and physiology a work which will answer their needs not only as a text-book, but also for work in the dissecting room."—*Science.*

Potter.

Compend of Anatomy **Including Visceral Anatomy**

By Samuel O. L. Potter, M.A., M.D., M.R.C.P.
(London)

Formerly Professor of the Principles and Practice of Medicine, Cooper Medical College, San Francisco; Major and Brigade Surgeon, U. S. Vol.

Seventh Edition, Revised and greatly enlarged. With numerous Tables, 16 Plates and 138 other Illustrations. *Blakiston's ? Quiz-Compend ? Series.*
Cloth, \$1.00; Interleaved for Taking Notes, \$1.25, net.

"Through the opportunity afforded a revision by the frequent editions of this manual, the author has given a concise and accurate work of anatomy. It makes an excellent text-book, permitting the teacher to enlarge upon the information given as the exigencies of the class-room demand."—*Bulletin of the American Academy of Medicine.*

A Text-Book of Human Physiology

By **A. P. Brubaker, M.D.**

Professor of Physiology and Hygiene at Jefferson Medical College; Professor of Physiology, Pennsylvania College of Dental Surgery, Philadelphia.

Second Edition. Revised and Enlarged. With Colored Plates and 356 other Illustrations. Octavo; 715 pages.

Cloth, \$3.00; Leather or Half-Morocco, \$4.00, *net*.

"An admirable exposition of the facts of physiology brought down to the latest date. . . . The author's style is lucid, concise, and pleasing. The work is one which may be warmly commended in every respect."—*New York Medical Journal*.

Landois' Human Physiology

Including Histology and Microscopical Anatomy,
with Special Reference to the Require-
ments of Practical Medicine

By **Dr. L. Landois**

Professor of Physiology and Director of the Physiological Institute in the University of Greifswald.

Tenth Edition. Revised and Enlarged.

Edited and Translated by **A. P. Brubaker, M.D.**

Professor of Physiology at Jefferson Medical College, Philadelphia, etc.,

and **Augustus A. Eshner, M.D.**

Professor of Clinical Medicine, Philadelphia Polyclinic, etc.

With 394 Illustrations. Octavo; 1027 pages.

Cloth, \$7.00; Leather or Half-Morocco, \$8.00, *net*.

"There is no other work of its kind in the English language which deals with the normal physiological processes so as to show where the physiological merges into the pathological, and how the facts of pathology are to be explained by, and how they are in reality of the same essence as, those of physiology. . . . The book will be useful to practitioners of medicine and to clinicians, while students reading for the higher examinations will find it a trustworthy guide to the fundamental facts of physiology and histology, and an encyclopædia of reference as well as an exposition of the latest discoveries and theories of physiology."—*The Lancet, London*.

"The author, editor, translator and publisher have unitedly produced a most valuable and attractive book which can in every way be depended upon as authoritative."—*American Medicine*.

DATE DUE SLIP

UNIVERSITY OF CALIFORNIA MEDICAL SCHOOL LIBRARY

**THIS BOOK IS DUE ON THE LAST DATE
STAMPED BELOW**

AUG 20 1923
JUN 24 1925

APR 7 1932

FEB 27 1980

774
p. 50 net

QM81	Barker, L.F.	8503
B25	Anatomical terminology	
1907	with special reference	
	to the (B N A) With	
	vocabularies in Latin	
	and English.	

8503

Library of the
University of California Medical School and Hospitals

