

UC-NRLF



B 4 096 736


5th Series

ANATOMY

BROOKWAY, OMAHA



UNIVERSITY OF CALIFORNIA
SAN FRANCISCO
LIBRARY



EX LIBRIS

HENRY I. FLEISSIG



Digitized by the Internet Archive
in 2007 with funding from
Microsoft Corporation

HENRY I. FLEISSIG

The Students' Quiz Series.

A series covering the essential subjects of a thorough medical education, arranged in form of question and answer. By qualified teachers and examiners in New York. Illustrations wherever desirable. Priced at uniform low rate of \$1.00, except double numbers on Anatomy and Surgery, which are priced at \$1.75 each.

ANATOMY (Double Number)—By FRED J. BROCKWAY, M.D., Ass't Demonstrator of Anatomy, College of Physicians and Surgeons, New York, and A. O'MALLEY, M.D., Instructor in Surgery, New York Polyclinic. \$1.75.

PHYSIOLOGY—By F. A. MANNING, M.D., Attending Surgeon, Manhattan Hospital, N. Y. \$1.00.

CHEMISTRY AND PHYSICS—By JOSEPH STRUTHERS, PH. B., Columbia College School of Mines, N. Y., and D. W. WARD, PH. B., Columbia College School of Mines, N. Y., and Chas. H. Willmarth, M.S., \$1.

HISTOLOGY, PATHOLOGY AND BACTERIOLOGY—By BENNETT S. BEACH, M.D., Lecturer on Histology, Pathology and Bacteriology, New York Polyclinic. \$1.00.

MATERIA MEDICA AND THERAPEUTICS—By L. F. WARNER, M.D., Attending Physician, St. Bartholomew's Dispensary, N. Y. \$1.00.

PRACTICE OF MEDICINE—By EDWIN T. DOUBLEDAY, M.D., Member N. Y. Pathological Society, and J. D. NAGEL, M.D., Member N. Y. County Medical Association. \$1.00.

SURGERY (Double Number)—By BERN B. GALLAUDET, M.D., Visiting Surgeon Bellevue Hospital, N. Y., and CHARLES DIXON JONES, M.D., Surgeon to Yorkville Dispensary and Hospital, N. Y. \$1.75.

GENITO-URINARY AND VENEREAL DISEASES—By CHAS. H. CHETWOOD, M.D., Visiting Surgeon, Demilt Dispensary, Department of Surgery and Genito-Urinary Diseases, New York. \$1.00.

DISEASES OF THE SKIN—By CHARLES C. RANSOM, M.D., Assistant Dermatologist, Vanderbilt Clinic, N. Y. \$1.00.

DISEASES OF THE EYE, EAR, THROAT AND NOSE—By FRANK E. MILLER, M.D., Throat Surgeon, Vanderbilt Clinic, N. Y., JAMES P. MACEVOY, M.D., Throat Surgeon, Bellevue Hospital, Out-Patient Department, New York, and J. E. WEEKS, M.D., Lecturer on Ophthalmology and Otology, Bellevue Hospital Medical College, New York. \$1.00

OBSTETRICS—By CHARLES W. HAYT, M.D., House Physician, Nursery and Child's Hospital, New York. \$1.00.

GYNECOLOGY—By G. W. BRATENAH, M.D., Assistant in Gynecology, Vanderbilt Clinic, New York, and SINCLAIR TOUSEY, M.D., Assistant Surgeon, Out-Patient Department, Roosevelt Hospital, New York. \$1.00.

DISEASES OF CHILDREN—By C. A. RHODES, M.D., Instructor in Diseases of Children, N. Y. Post-Graduate Medical College. \$1.00.

The Students' Quiz Series.

ANATOMY.

A MANUAL FOR STUDENTS AND PRACTITIONERS.

BY

FRED J. BROCKWAY, M. D.,

Assistant Demonstrator of Anatomy, College of Physicians and Surgeons, New York.

AND

A. O'MALLEY, M. D.,

Instructor in Surgery, New York Polyclinic.

SECOND EDITION, WITH FULL-PAGE PLATES.

SERIES EDITED BY

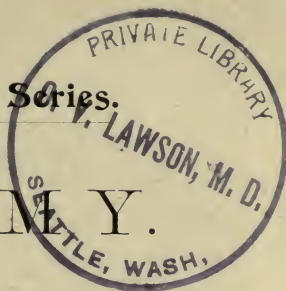BERN B. GALLAUDET, M. D.,


Demonstrator of Anatomy, College of Physicians and Surgeons, New York; Visiting Surgeon Bellevue Hospital, New York.

QM 28
B86
1893



PHILADELPHIA:
LEA BROTHERS & CO.





Entered according to Act of Congress, in the year 1893, by

LEA BROTHERS & CO.,

In the Office of the Librarian of Congress, at Washington. All rights reserved.

WESTCOTT & THOMSON,
Stereotypers and Electrotypers, Philada.

WILLIAM J. DORNAN,
Printer, Philada.

HENRY I. FLEISSIG

PREFACE.

THE opportunity afforded by the preparation of this book for the presentation of a brief Modern Anatomy has been deemed too valuable to sacrifice by duplicating existing "Anatomical Compendis." The science is steadily advancing in the discovery of new facts. Twenty years ago the German anatomists recorded discoveries which are only now coming to the notice of the American student. A hand-book can at most contain only the essentials of the science, and in the present instance the effort has been to select such knowledge as will be most useful to the student and the practitioner.

In the hope of presenting some new descriptions not accessible to all students, I have compiled the sections on Osteology, Arthrology, and Myology from Henle and from Quain, while Gray's *Anatomy* and notes on the lectures of Prof. George S. Huntington of the College of Physicians and Surgeons, New York, have also been largely consulted. The order and classification of Henle have been followed throughout: joints are mostly from his work, and where his descriptions of them differ greatly from those of English text-books, they have been described separately in fine print. Many muscular anomalies have been mentioned in fine print. New names for muscles as agreed upon by the German Anatomical Society have been marked "p. n." (proposed name). Illustrations from Gray, Quain, Henle, and Schwalbe have been reproduced to illustrate special points. English and metric measurements are both given, the English being approximately correct.

Space has been gained by conciseness and by the omission of many monosyllabic words. It is to be noted that the questions are, in a sense, headings introducing generally a large amount of information in the answers.

The Glossary has been written in the hope of promoting a correct pronunciation of anatomical terms.

I have to acknowledge the assistance of Dr. Andrew O'Malley and the Editor of the Series, who have written the sections on Angiology, Neurology, and Splanchnology. In the latter section the relations of the viscera are with slight modifications those given by Professor George S. Huntington, and the works of Quain and Gray serve as the basis for the general descriptions of the viscera, as well as for the sections on Angiology and Neurology.

This volume is not intended to replace text-books, but will be found serviceable in facilitating the remembrance of knowledge gained from more extended works and at the dissecting-table.

FRED J. BROCKWAY.

105 W. 74th St., }
NEW YORK. }

CONTENTS.

	PAGE
DEFINITION AND SUBDIVISIONS OF ANATOMY	17
EMBRYOLOGY	17
DESCRIPTIVE ANATOMY	19

OSTEOLOGY.

BONES OF THE TRUNK: The Vertebral Column; False Vertebrae; Ossification of the Vertebrae; The Thorax; The Hyoid Bone . .	23
BONES OF THE HEAD: Bones of the Cranium; Bones of the Face; The Skull as a Whole; The Wormian Bones; External Surface of the Skull; Ossification of the Bones of the Head	35
BONES OF THE UPPER EXTREMITY: The Shoulder; The Arm; The Forearm; The Hand	64
BONES OF THE LOWER EXTREMITY: The Pelvis; The Thigh; The Leg; The Foot	76

ARTHROLOGY.

Henle's Classification of Joints	93
ARTICULATIONS OF THE TRUNK AND HEAD: Henle's Vertebral and Costal Ligaments	95
ARTICULATIONS OF THE UPPER EXTREMITY: The Shoulder-girdle and Joint; The Elbow and Forearm; The Wrist and Carpus; Accessory Ligaments of the Wrist	104
ARTICULATIONS OF THE LOWER EXTREMITY: The Pelvic Girdle; Ligaments between the Bones of the Trunk and Hip-bone; The	

	PAGE
Hip-joint; The Knee-joint; Ligaments between the Bones of the Leg; The Ankle-joint; Joints of the Foot; Heule's Classification of the Ankle- and Foot-joints	120

MYOLOGY.

MUSCLES IN GENERAL	138
MUSCLES OF THE TRUNK: Muscles and Fasciæ of the Back; Muscles and Fasciæ of the Abdomen; Lining Fasciæ of the Abdomen; Muscles and Fasciæ of the Chest; Muscles and Fasciæ of the Neck; Muscles of the Head	139
MUSCLES AND FASCIÆ OF THE EXTREMITIES:	173
<i>The Upper Extremity</i> : The Shoulder; The Upper Arm; The Fore-arm; The Hand	173
<i>The Lower Extremity</i> : The Hip and Thigh; The Leg; The Foot . .	186
MUSCULAR HOMOLOGIES	202

ANGEIOLOGY.

THE HEART: Structure of the Heart	204
ARTERIES: The Pulmonary Artery	208
<i>Systemic Arteries</i> : Arch of the Aorta and its Branches; Arteries of the Head, Neck, and Upper Extremity; The Thoracic Aorta and its Branches; The Abdominal Aorta and its Branches; The Iliac Arteries and their Branches; Arteries of the Lower Extremity and their Branches	208
VEINS: The Pulmonary Veins	233
<i>Systemic Veins</i> : Superior Vena Cava and Innominate Veins; Veins of the Head and Neck; Veins of the Upper Extremity; Veins of the Trunk; Veins of Lower Extremity; Veins of the Pelvis; The Portal System	233
THE ABSORBENT SYSTEM	245


NEUROLOGY.

THE SPINAL CORD	249
THE BRAIN OR ENCEPHALON	252

	PAGE
CRANIAL NERVES	266
THE SPINAL NERVES	277
THE SYMPATHETIC NERVOUS SYSTEM	292
ORGANS OF SPECIAL SENSE: The Eye; The Ear; The Nose; The Tongue	297

SPLANCHNOLOGY.

ORGANS OF RESPIRATION: The Larynx; The Trachea; The Thyroid and Thymus Glands; Pleuræ and Mediastinum; The Lungs . .	310
THE ORGANS OF DIGESTION: The Mouth; The Teeth; The Palate; The Tonsils; The Salivary Glands; The Pharynx; The Œsopha- gus; The Stomach; The Small Intestine; The Large Intestine; The Liver; The Gall-bladder; The Pancreas	318
THE SPLEEN AND SUPRARENAL CAPSULES: The Spleen; The Supra- renal Capsules	335
THE URINARY ORGANS AND PERITONEUM: The Kidneys; The Ureters; The Bladder; The Peritoneum	336
ORGANS OF REPRODUCTION (MALE): The Prostate Gland; The Penis; The Male Urethra; The Testes	342
ORGANS OF REPRODUCTION (FEMALE)	348
<i>External:</i> The Vulva; The Vagina	348
<i>Internal:</i> The Uterus; The Fallopian Tubes; The Ovaries; The Parovarium	349
The Mammary Glands	352



ANATOMY.

DEFINITION AND SUBDIVISIONS OF ANATOMY.

What are the object and subdivisions of anatomy?

Its object is to find out the structure of organized bodies. This science includes Human, Comparative, and Vegetable Anatomy.

The animal possesses two tubes, the animal and vegetative: the former contains the spinal cord and brain, distinguishing in part the animal from the plant; the vegetative tube is common to both, and encloses the organs of nutrition and reproduction.

Human Anatomy is subdivided into Histology, or General Anatomy, and Descriptive, or Special Anatomy. The following pages treat of Descriptive Anatomy.

EMBRYOLOGY.

Briefly describe the process of development.

The human ovum is a small cell, $\frac{1}{125}$ th inch in diameter; its wall is the *vitelline membrane*, its body the *yolk*, its nucleus the *germinal vesicle*, and its nucleolus the *germinal spot*. If all the food-yolk undergoes changes, as in mammals, the ovum is *holoblastic*; if only part, as in fishes, it is *meroblastic*. When the ovum matures the germinal vesicle divides and extrudes two *polar globules*; inside the yolk is formed a *female pronucleus*.

These changes occur whether the ovum is fecundated or not. Should another cell, the *spermatozoön*, enter the yolk, its tail disappears and its head becomes the *male pronucleus*. The union of the two pronuclei forms the first *segmentation sphere*. Halves are formed of this sphere, each one again splits, and so on: when about ninety-six cells are formed, an upper group of sixty-four will completely enclose a lower group of thirty-two.

The outer group lines the vitelline membrane, and from it comes the *primitive ectoderm*, the *epiblast* or serous layer. From the enclosed group comes the *primitive entoderm*, the *hypoblast* or mucous layer; between them is later developed the *primitive mesoderm*, the *mesoblast* or vascular layer. On the outer layer there appears a shaded patch, the *area germinativa*, and in this come in order (1) the *primitive streak*, (2) the *medullary canal*, (3) the *chorda dorsalis* or *notochord*, and (4) the

mesoblastic somites: the first is transient; the third, round which the vertebral column forms, is more persistent; the second and fourth are permanent. The primitive streak soon acquires a *primitive groove*.

The medullary or neural canal is confined to the epiblast, and formed by two lateral ridges meeting dorsally. The chorda dorsalis is a thickening of the hypoblast, and its remains are the centres of the intervertebral disks. The lateral mesoblast cleaves into two plates: one clings to the epiblast, forming the *somatopleure*; the other to the hypoblast, forming the *splanchnopleure*. The former forms part of the wall of the body, the latter part of the wall of the alimentary tract, and between the two is the *cœlom*, or pleuro-peritoneal cavity.

In the paraxial mesoblast, in the region which afterward becomes the neck, is developed a linear series of quadrangular masses, the mesoblastic somites.

At the anterior end of the neural groove are formed three *primary cerebral vesicles*; later the anterior and posterior divide each into two, making five in all.

The steps to be noted are—(1) formation of polar globules and the male and female pronuclei; (2) segmentation of yolk; (3) arrangement of cells inside the vitelline membrane into two groups; (4) separation of cells into epiblast, mesoblast (two layers), and hypoblast; (5) formation of area germinativa; (6) primitive trace; (7) primitive groove caused by heaping up of "dorsal plates;" (8) neural canal formed by the meeting of dorsal plates; (9) under this canal formation of notochord from hypoblast; (10) a line of square segments, the mesoblastic plates; (11) somatopleure and splanchnopleure and body-cavity; (12) three primary cerebral vesicles; (13) curving of the embryo longitudinally and laterally, comparable to a canoe, the body-cavity corresponding to the well of the canoe; (14) the yolk-sac outside the body-cavity is the umbilical vesicle, providing nutrition until the placenta is formed.

What parts are derived from each blastodermic layer?

From *epiblast*, the whole nervous system, brain, spinal cord, peripheral and sympathetic nerves; epithelial structures of the organs of special sense; epidermis and appendages, as hair and nails; epithelium of glands which open upon the skin surface, as mammary, sweat, and sebaceous glands; muscular fibres of sweat-glands; epithelium of mouth, except that covering tongue, and of glands opening into it; enamel of teeth; epithelium of nasal passages and of glands and cavities opening into them.

From *mesoblast*, genito-urinary organs, except epithelium of bladder and urethra; all voluntary and involuntary muscles, except muscular fibres of sweat-glands; vascular and lymphatic systems; serous membranes and spleen; skeleton and all connective-tissue structures of body.

From *hypoblast*, epithelium of alimentary canal from back of mouth to anus, and of glands which open into this part of the tube; epithelium of Eustachian tube and tympanum; epithelium of bronchial tubes and

air-sacs of lungs; epithelium of the vesicles of the thyroid; epithelial nests of the thymus; epithelium of urinary bladder and urethra.

DESCRIPTIVE ANATOMY.

What are the systems of descriptive anatomy?

1. Osteology, the bones; 2. Arthrology, the articulations; 3. Myology, the voluntary muscles, fasciæ, and aponeuroses; 4. Angeiology, the heart, blood-vessels, and lymphatics; 5. Neurology, spinal cord, brain, nerves, and organs of the senses; 6. Splanchnology, the organs of respiration, digestion, reproduction, and urination.

An organ is capable of isolation: organs make up a system, and systems an apparatus.

What are some of the descriptive terms?

The body is always supposed to stand erect, with hands at the sides and palms to the front. *Superior* and *inferior* correspond to *cephalic* and *caudal*, anterior and posterior to *ventral* and *dorsal*. As the body is bilaterally symmetrical, it may be divided into similar halves by a *median plane* passing from before backward. The line along which this plane meets the surface of the body is the *median line*. The words *internal* and *external* refer to points nearer to or farther from the median plane. Henle uses *median* for internal, and *lateral* for external; the former looks toward the median line, the latter from it.

Sagittal denotes an antero-posterior direction in or parallel to the median plane; *coronal* or *frontal* denotes a transverse direction at right angles to the sagittal. Other terms applied to surfaces or borders, like *vertebral*, *sternal*, *radial*, *ulnar*, *flexor*, *extensor*, *proximal* (nearest the trunk or centre), *distal* (away from the trunk), are often convenient.

A surface is said to "look" in a certain direction when a perpendicular to the surface points in that direction.

OSTEOLOGY.

What is the skeleton?

The skeleton is the solid framework of the body, composed of bones completed by cartilage. In the lower animals there may be an *endoskeleton*, the deeper framework corresponding to the human skeleton, and an *exoskeleton*, comprising the integument and hardened structures connected with it. All vertebrate animals possess an endoskeleton; some have an exoskeleton. Most invertebrate animals possess an exoskeleton only.

What are the uses of bones?

(1) They serve as levers upon which attached muscles act; (2) support; (3) protection of delicate organs; (4) contribute to the formation of joints; (5) by elasticity of curvature tend to diminish shocks.

How are bones formed ?

They are formed by ossification in three ways: (1) *in* cartilage, not *from* it; (2) in membrane; (3) subperiosteally.

The bones of the vertex of the skull—*i. e.* the parietals, the frontal, the tabular part of the occipital, the squamous and tympanic parts of the temporal, the inner plate of the pterygoid process, the bones of the face except the inferior turbinate and part of the lower jaw—are formed in membrane. The base of the skull and the other bones of the body are formed in cartilage. A deposit of bone begins at one spot, the *primary centre*; the shaft or diaphysis is formed from this. Most bones have other centres of ossification, *secondary* or *tertiary*, and parts derived from them are the *epiphyses* (*growing upon*). The growth of bone in length depends largely upon the cartilage between the epiphysis and diaphysis; this cartilage acts as a buffer in concussions. The growth in circumference is by subperiosteal ossification.

Some bones ossify early, according to their function—*e. g.* the lower jaw and ribs, because suction and respiration come into play at birth. The first primary centre to appear is in the clavicle, at the fifth week of foetal life; the last secondary centre to appear is in the sternal end of the clavicle, at the eighteenth year. At birth nearly all primary centres have appeared (the pisiform not till the twelfth year), and only one secondary centre—*viz.* that for the lower extremity of the femur, possibly one for the upper extremity of the tibia.

What are the rules for the direction of medullary arteries ?

1. The medullary arteries run *from the knee* and *toward the elbow*.
2. The secondary centre *from* which the artery runs is the *first* to appear.
3. The epiphysis *first* to appear is *last* to unite (except in case of fibula, where its lower epiphysis appears first and unites first). If there is but one secondary centre in a bone, the artery runs from it. Rule 1 may be remembered by flexing the knees and elbows, and noting that the medullary arteries run *down* as though impelled by gravity.

The obliquity of the vascular canals is really due to the inequality of growth of the two ends: the one growing more rapidly carries the artery with it.

Briefly describe the structure of bone.

This description includes that of the periosteum, marrow, and bone proper.

The *periosteum*, or bone-skin, consists of two layers, an outer fibrous and an inner vascular one, beneath which are granular cells called *osteoblasts*. The periosteum serves as a nidus for vessels, and is related to the growth and renewal of bone. It is looser on young bone than on old, and looser on the shaft than on the extremities. The dura mater of the brain is allied to periosteum.

The *marrow* fills the medullary canal, cancellous spaces, and large

Haversian canals. The medullary canal is lined with *endosteum*. Marrow may be *yellow* or *red*: the former is in adult long bones and contains 96 per cent. fat. In the short and flat bones, in the cancellated ends of long bones, in the bodies of the vertebræ, in the cranial diploë, in the sternum and ribs, and in all bones of the fœtus and infant, the marrow is red and fluid, containing 72 per cent. water and a trace of fat. Marrow may possess five kinds of cells: (1) fat-cells; (2) marrow-cells proper, resembling white blood-cells, and possessing amœboid movement; (3) small nucleated reddish cells; (4) cells containing one or two red blood-corpuscles; (5) giant-cells (osteoclasts or myeloplaxes), which are concerned with bone-absorption. Marrow may help form and renovate blood, form bone, and has nutritive properties.

Bone proper may be compact or cancellous; the separate cancelli have the same structure as the compact bone. Long bones have an outer shell of compact substance, spongy tissue at the ends, with a dense layer beneath the articular cartilage, and a medullary canal.

Flat bones have two compact plates enclosing a spongy layer, the diploë.

Solid bone is made up of *Haversian systems* (Havers, an English physician). A central hole is the *Haversian canal*, $\frac{1}{500}$ inch in diameter, and five to fifteen concentric rings around it are the *lamellæ*. Between the lamellæ are dark specks, the *lacunæ*, which are connected with each other and the central canal by fine lines, the *canaliculi*. Lamellæ may be *concentric*, around Haversian canals; *interstitial*, between Haversian systems; and *circumferential*, surrounding the bone. The canals connect the medullary cavity with the surface of the bone, allowing free permeation of blood-vessels.

The lamellæ may be stripped up as thin films, and seem bolted together by the *perforating fibres of Sharpey*. In thin plates of bone there are no Haversian canals, but lacunæ and canaliculi are present.

What is the arrangement of the vascular and nerve supply?

The arteries are *periosteal*, *articular*, and *medullary* (all are *nutrient*). The veins emerge from the bone in the same places that the arteries enter. Lymphatics accompany the vessels. Nerves enter with the arteries, and are destined for the vessels: none are known to end in bony tissue itself.

What is the purpose of the medullary cavity?

To allow greater surface for muscular attachment with economy of weight; for strength, a hollow cylinder being stronger than a solid one of same weight. In some water animals the bones are nearly solid, acting as ballast. In birds the bones are light, with large medullary cavities filled with warm air from the lungs. In the human subject there are air-cells in a few bones.

What are the physical and chemical characters of bone?

Bone consists one-third of animal matter, giving tenacity and elasticity, impregnated with earthy salts, two-thirds, in the form of minute granules: this gives rigidity and brittleness. The analysis by Lehman is—

Gelatin and blood-vessels,	33	per cent.
Phosphate of calcium,	57	"
Carbonate of calcium,	8	"
Fluoride of calcium,	1	"
Phosphate of magnesium,	1	"
	100 per cent.	

Some add 1 per cent. of oily matter.

Pure bone is thought to be a definite compound, whether from a child or old person: it differs in compactness and arrangement. The petrous portion of the temporal, and the long bones as a whole, have an excess of inorganic matter compared with bones of the trunk—the upper extremity more than the lower. In rickets the earthy matter may sink to 20 per cent., instead of 66 per cent. Calcium phosphate forms more than half of bone and 88 per cent. of enamel of teeth. Bone is twice as strong as oak, three times as strong as elm, and twenty-two times as strong as freestone. A cubic inch will support 5000 pounds weight; it requires 800 or 900 pounds to fracture the femur.

What is the number of bones in the human skeleton?

200 in the adult; thus:

	Single bones.	Pairs.	Total.
Axial skeleton, . . .	{ The vertebral column	26	.. 26
	{ The skull	6	8 22
	{ The hyoid bone	1	.. 1
	{ The ribs and sternum	1	12 25
Appendicular skeleton,	{ The upper limbs		32 64
	{ The lower limbs		31 62
		34	83 200

The patella and pisiform are included, but not the ossicles of the ear or small sesamoid bones: the teeth belong to the epidermal layer.

Into what classes are bones divisible?

(1) *Long* or *cylindrical*, about 90 in number; (2) *tabular* or *flat*, for protection or muscular attachment, numbering 40; (3) *short*, for strength, numbering 30; (4) *irregular*, mostly situated symmetrically across the median plane of the body, numbering 40.

Mention some terms used in descriptions.

There are eminences and depressions, an articular and non-articular subdivision, of each variety.

Articular eminences are called *heads* and *condyles*; non-articular emi-

nences are *epicondyles*, *trochanters*, *tuberosities*, *tubercles*, *spines*, *lines*, *apophyses*, etc. An apophysis (*excrescence*) has never been separate from the surface of bone; an epiphysis is developed from a separate centre.

Certain adjectives used are—*clinoid*, like a bed; *coracoid*, like a crow's beak; *coronoid*, the tip of a curve; *hamular*, like a hook; *malleolar*, like a mallet; *mastoid*, like a nipple; *odontoid*, like a tooth; *pterygoid*, like a wing; *spinous*, thorn-like; *styloid*, like a pen; *vaginal*, ensheathing.

Articular cavities are *cotyloid*, like a deep cup; *glenoid*, like a shallow cup; *trochlear*, pulley-like; *sigmoid*, like the Greek letter for s.

Non-articular cavities are *fossæ*, *sinuses*, *fissures*, *grooves*, *canals*, *hiatuses*, etc.

BONES OF THE TRUNK.

The clavicle and scapula do not belong to the trunk; they form the shoulder girdle.

The os innominatum goes to form the pelvic girdle, completed behind by the sacrum, which belongs to the trunk. The animal tube is enclosed by the vertebral column; the vegetative tube is in front of this and behind the hyoid bone and sternum. The parts of the trunk are the vertebral column, the sternum and ribs, the hyoid, and bones of the skull.

THE VERTEBRAL COLUMN.

1. The *vertebral column* is composed of a series of vertebræ (*verto*, to turn), originally thirty-three in number. The upper twenty-four remain separate as movable or true vertebræ; these are succeeded by five united into the *sacrum*; then follow four dwindled segments united into the coccyx. These lower nine are the fixed or false vertebræ.

Beginning at the skull, there are seven cervical, twelve dorsal or thoracic connected with ribs, five abdominal or lumbar, five sacral, and four coccygeal vertebræ. The number in the cervical region is constant; those between the dorsal and lumbar may vary reciprocally. If there are but eleven pairs of ribs, the twelfth dorsal vertebra will have lumbar characteristics; if thirteen pairs, the first lumbar will have dorsal characteristics. A transitional *lumbo-sacral vertebra* is met with, one side connected with the sacrum, the other having a free transverse process.

Describe the characteristics of a vertebra.

The first two cervical vertebræ are called *rotation* vertebræ; all the other true ones, *flexion* vertebræ. A representative vertebra, like the tenth dorsal, presents a body for the purpose of support, an arch and spinal foramen for protection, and seven processes for leverage. The *body* or *centrum* is a short cylinder; the superior and inferior surfaces are flat, with a rim around the circumference. The front and sides are convex horizontally and concave from above down. The posterior surface is

slightly concave from side to side, and marked by one or two venous foramina. The *neural arch* consists of two symmetrical portions meeting in the median plane behind. The anterior part or pedicle rises from a point on the body where the lateral and posterior surfaces meet; the posterior part or *lamina* is broad and flat. The upper and lower borders of pedicles form *vertebral notches*, becoming *intervertebral foramina* between contiguous vertebræ. The *spinous process* projects back from the junction of the two laminae. The *transverse processes*, one on either side, project outward from the arch at the junction of the pedicle with the lamina. The *articular processes*, two superior and two inferior, project upward and downward at the point of origin of the transverse processes.

The *foramen* is bounded anteriorly by the body, posteriorly and laterally by the arch; the series of rings thus formed constitutes the spinal canal.

Describe a cervical vertebra.

The body is small and broad transversely; the upper surface is concave from the upward projection of lateral lips, and is sloped down in front. The under surface is rounded at the sides and lipped anteriorly, so there is interlocking at the sides to prevent lateral displacement—an anterior lip to prevent posterior, and articular processes to prevent anterior, dislocations. The laminae are long and flat. The superior and inferior notches are nearly equal in depth. The spinous processes are short and bifid. The transverse processes are directed outward, downward, and forward, and present at their extremities an anterior and a posterior tubercle. Each process is grooved above, and perforated vertically at its base by the *vertebrarterial foramen* for a vein, artery, and plexus of nerves. This foramen is between the two roots of the process, the posterior corresponding to a dorsal transverse process, and the anterior to a rib. The articular processes are placed at the extremities of a short vertical column of bone; the superior articular surface looks back and up. The foramen is triangular, and larger than in any other region. The peculiar cervical vertebræ are the first, second, and seventh.

Describe the atlas.

The atlas (supporting globe of head) has no body or spinous process, but is a large ring with articular and transverse processes. The posterior part of the ring corresponds to the neural canal of the other vertebræ; the anterior part is occupied by the odontoid process of the axis. The anterior boundary of the ring is the *anterior arch*, with a small tubercle in front for the longus colli muscle. Behind the tubercle is an articular surface for the odontoid. At the sides of the ring are the lateral masses bearing the superior and inferior articular processes. All the articular processes of the atlas and the superior ones of the axis are in front of the vertebral notches. The superior articular surfaces of the

PLATE I.

FIG. 1.—To face page 24.

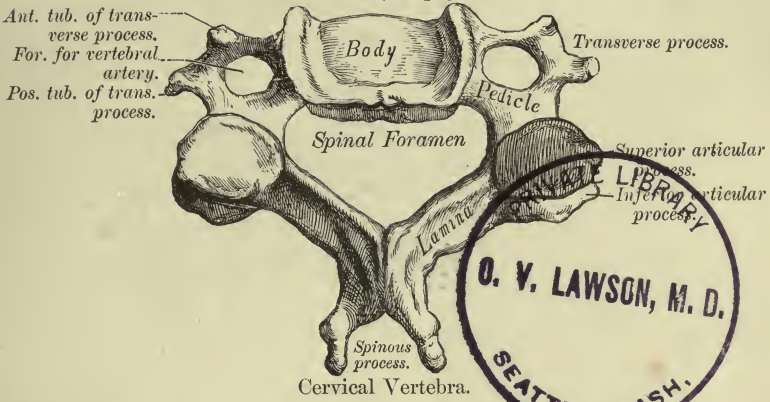


FIG. 2.—To face page 24.

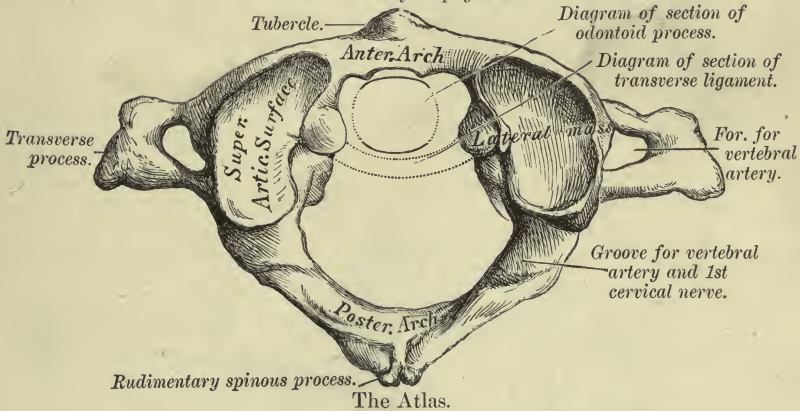


FIG. 3.—To face page 31.

By 4 primary centres.

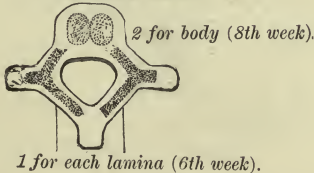
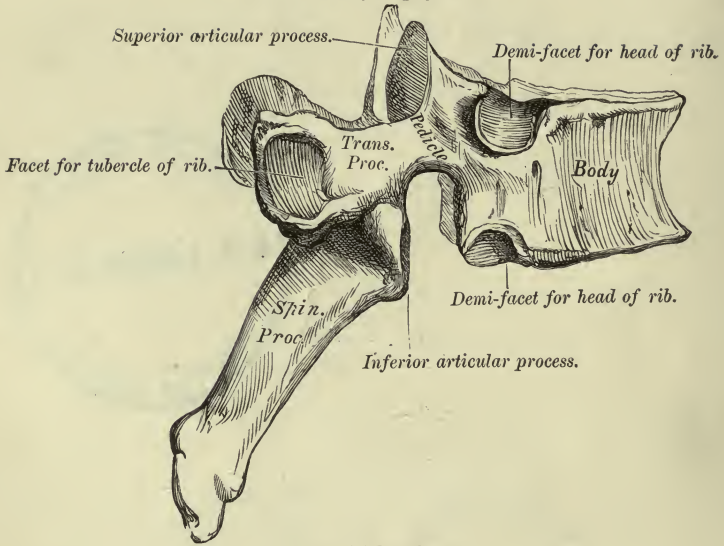


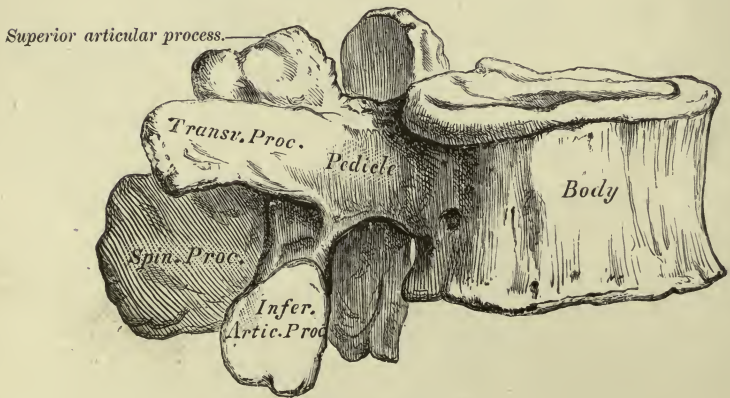
PLATE II.

FIG. 1.—To face page 26.



A Dorsal Vertebra.

FIG. 2.—To face page 27.



Lumbar Vertebra.

atlas are oval and converge in front. They look up and in, and form a cup for the occipital condyles. They may be partially subdivided by a transverse groove, and below the inner margin of each is a tubercle for the transverse ligament. The inferior articular surfaces are slightly convex, nearly circular, and do not wholly cover or fit the superior processes of the axis. The *posterior arch* presents in the median line either a ridge, hollow, or small tubercle. If a spinous process were well developed here, nodding of the head would be prevented. Just behind the lateral mass is a smooth sinus, the vertebral notch. The transverse processes are not bifid—are large and strong for attachment of rotatory muscles.

Varieties.—The posterior or anterior bony arch may be incomplete; the anterior root of the transverse process may be ligamentous. A spicule of bone may bridge over the superior vertebral notch, and the canal formed be subdivided by other spicules. The artery and vein go through the upper subdivision, the suboccipital nerve through the lower.

Describe the axis.

The second vertebra, *vertebra dentata* or *epistropheus* (to “turn round”), forms an axis upon which the atlas carrying the head rotates. The body of the atlas is joined upon that of the axis in form of a tooth-like process, the odontoid. Its apex is pointed, and just below is an enlargement or head, both giving attachment to bands of the check ligament.

The process has in front a smooth articular surface for the arch of the atlas, and behind a smooth groove for the transverse ligament. This makes a slight constriction, but hardly a neck.

The anterior surface of the body presents a slight ridge separating two depressions. The superior articular surface lies close to the odontoid, upon the body in part and upon the pedicles; they look up and out. The inferior articular surfaces are behind the upper, and resemble corresponding ones in the cervical region. The spinous process is grooved inferiorly—is very large and bifid, in contradistinction to that of the atlas. The transverse processes are short, with the anterior tubercle nearly suppressed. The inferior vertebral notch is in front of the articular surface, which is the rule for both notches below this in the column.

Describe the seventh cervical vertebra.

This has a long spinous process, non-bifurcated, tending to slope down, and projecting under the skin; hence the name *vertebra prominens*. The transverse processes are massive, slightly grooved, with a small foramen or none at all; the posterior tubercle is large and the anterior one very small. The vertebral artery and vein do not pass through these foramina: both veins may, sometimes the left artery does; the vessels may enter no foramina till the fourth vertebra is reached.

Varieties.—The spine of the sixth vertebra is not usually bifid; in the negro this is the rule also for the third, fourth, and fifth. Bifurcation of spines is peculiar to the human skeleton. The anterior tubercle of the sixth is large,

and called *Chassaignac's* and *carotid tubercle*. The common carotid artery may be compressed against it: opposite this level the omo-hyoid crosses beneath the sterno-mastoid muscle; the inferior thyroid artery crosses beneath the common carotid; the cricoid cartilage is opposite, also the beginning of the trachea and œsophagus, the end of the larynx and pharynx.

All known mammals have seven cervical vertebræ, except the sloth and manatee, which have six. There are two exceptions recorded in man. The number bears no relation to length of neck; that of the whale and giraffe each contains seven.

Describe the dorsal or thoracic vertebræ.

The body is relatively small, and heart-shaped; its antero-posterior and transverse diameters are nearly equal, and its depth is greater behind than in front. Where the arch joins the body there are articular surfaces for the heads of ribs, generally two on each side, one at the upper and one at the lower border. Between the neck of a rib and transverse process is the costo-transverse foramen. In the cervical region this is represented by the vertebral foramen, and in the lumbar region the space is filled by the bony mass of the transverse process. The cross-section of a dorsal body shows a slight median projection for purposes of strength, similar to the *linea aspera* of the femur. The laminae are broad and flat and overlap each other.

The superior vertebral notches are shallow or absent; the inferior are deep.

The spinous processes are bayonet-shaped, and terminate in a slight tubercle. They are longest and most oblique from the fifth to the eighth.

The transverse processes are directed out and back, and terminate in a clubbed extremity, which presents an articular surface for the tuberosity of a rib, and also two indistinct tubercles, one from the upper and one from the lower border. The articular processes are nearly vertical, with their smooth surfaces (superior) looking back and out, the inferior in a reverse direction.

The spinal foramen is nearly circular, and smaller than in other regions.

What dorsal vertebræ present peculiar characters?

The first, tenth, eleventh, and twelfth are to be distinguished. The *first dorsal* resembles the seventh cervical. Its body above is transversely concave and lipped. The superior vertebral notches are deep, the superior articular processes are oblique, and the spinous process is nearly horizontal. On the side of the body, close to the upper border, is a whole facet for the first rib, and a very small demi-facet below for the second rib.

The twelve ribs correspond to twelve joint surfaces, but these are divided, so that only the first, eleventh, and twelfth present single facets; the first in addition has a half-facet, and the tenth has one demi-facet.

The upper demi-facets become larger on succeeding vertebræ, and when the eleventh is reached it is a complete facet.

The *tenth dorsal* touches only one rib on a side, and has a nearly complete facet, mostly on the pedicle at its upper border. The transverse process has a small facet.

The *eleventh dorsal* has one complete facet on each side, but none on the transverse process.

The *twelfth dorsal* has a single facet on each side.

The inferior articular surfaces turn out, resembling the lumbar vertebræ. The spinous process is short and nearly horizontal.

The transverse processes are short, and present near their extremities the *external, superior, and inferior tubercles*, which correspond respectively to the *transverse, mammillary, and accessory processes* of the lumbar vertebræ. Rudiments of these tubercles may be seen on the tenth and eleventh vertebræ. The row of costal facets forms the anterior border of the intervertebral foramina. The ribs in moving intrude somewhat upon the vessels and nerves in those foramina; hence the "floating," most movable, ribs articulate with single vertebræ.

The ninth dorsal may be lacking in the lower demi-facet; the eleventh may take the lumbar type of articular process.

Describe the lumbar vertebræ.

These are the largest of the movable vertebræ. They have no costal articular surfaces, and no foramina through the transverse processes. The body is reniform in outline, broad transversely, and deeper in front than behind. The laminae are short and thick, the superior notches shallow, the spinous process horizontal, and broad and thickened at its extremity.

The transverse processes are slender and project directly out; they are in front of the articular processes, and are considered to be homologous with the ribs. Their extremities lie in series with the external tubercles of the lower dorsal transverse processes. The *accessory process (anapophysis)* lies behind each lumbar transverse process at its base, and points down. It is large in some animals, and locks the vertebræ together.

The articular surfaces are vertical, the superior concave looking back and in; the superior are farther apart than the inferior, and embrace an inferior pair above them.

The *mammillary process (metapophysis)* projects back from each superior articular process. The spinal foramen is triangular, larger than in the dorsal, and smaller than in the cervical regions.

The fifth lumbar is massive, the inferior articular processes wider apart than the upper; the transverse processes are broad and conical, and the laminae project into the spinal foramen.

In the European the bodies of the lumbar vertebræ are collectively deeper in front than behind, but the individual segments vary. In the negro the depth of the five bodies is greater behind than in front.

FALSE VERTEBRÆ.

Describe the sacral vertebræ.

These in the adult form the *os sacrum*: it is placed between the two hip-bones, and with the coccyx completes the pelvic wall above and behind. The bone may be likened to a shovel in shape, and is wedge-shaped in four directions: (1) is narrower from side to side at its apex than at its base; (2) is thinner antero-posteriorly at its apex than at its base; (3) the dorsal surface is narrower than the anterior; (4) a projection into the articular surface of the ilium (Fig. 12). The bone presents anterior, posterior, and two lateral surfaces, a base, an apex, and a central canal for description.

The *ventral surface* looks considerably downward, forming a projection with the last lumbar, the *sacro-vertebral angle* of about 120° . This surface is concave from above down and from side to side, and is crossed by four horizontal ridges, indicating the union of five vertebræ. At the ends of the ridges are four *anterior sacral foramina*, which lead externally into grooves on the lateral masses.

The two rows of foramina are vertical and parallel, not approaching below, as the width of the bodies are all equal.

The *dorsal surface* looks up and back, is convex and rough, and along the median line are three or four small spinous processes, more or less connected, forming a ridge. Below the ridge is a triangular opening, bounded by the imperfect laminæ of the fourth and fifth sacral, and by the inferior articular processes of the last sacral, which are prolonged down into *sacral cornua*, meeting corresponding ones from the coccyx. On each side of the median ridge the united laminæ are hollowed into the *sacral groove*, a continuation of the vertebral groove above; next externally is a row of tubercles representing articular and mammillary processes; next the four *posterior sacral foramina*, opposite to, but smaller than, the anterior. They correspond to the spaces between two transverse processes—the anterior to the spaces between two ribs.

The *lateral mass* is that part external to the foramina, broad above and narrow below. It is made up of broadened transverse processes, rudiments of which are seen outside the posterior sacral foramina: the first pair are large; the second are smaller and enter into the formation of the sacro-iliac joint; the third, fourth, and fifth give attachment to ligaments. Anteriorly are four shallow grooves, separated by ridges, which give attachment to slips of the pyriformis. Above and externally the lateral mass shows an uneven *auricular surface* with its convexity forward; it articulates with the ilium. Behind this the bone is still more rough for attachment of the posterior sacro-iliac ligament. The auricular surface rests on two and a half vertebræ, the larger part belonging to the first; the upper three are therefore called the true sacral vertebræ, and the other two the caudal. Lower down the bone terminates in the *inferior lateral angle*, below which is a half-notch, forming a foramen with the coccyx for the fifth sacral nerve.

The *base* shows the reniform first sacral body, behind which is the triangular aperture of the sacral canal; on each side of this is a large articular process bearing a large mammillary process. In front of this is a vertebral groove which helps form the last lumbar intervertebral foramen. Externally is a modified transverse process, and in front of that a smooth triangular surface continuous with the iliac fossa, the *ala* of the sacrum.

The *apex* is the body of the fifth sacral vertebra, transversely oval; it articulates with the coccyx. The *sacral canal* curves with the bone, and becomes smaller as it descends. A transverse section is triangular above, but flattened and then semicircular below. From it there pass out four pairs of intervertebral foramina, opening anteriorly and posteriorly into the anterior and posterior sacral foramina, and closed externally by the lateral masses.

The human sacrum is characterized by its great breadth compared to the length. The *sacral index* $\left(\frac{100 \times \text{breadth}}{\text{length}}\right)$ in the male European is 112, negro 106, gorilla 72. The sacrum may consist of six pieces, or rarely of four. The bodies of the first and second may not be united, forming a second "promontory" at this point. The sacral canal may be open more than usual or open throughout.

What are the differences in the sacrum of the male and female?

In the female it is wider, sacral index 116, is less curved, the upper half nearly straight, is more oblique, and forms a more marked promontory than in the male.

Describe the coccygeal vertebræ.

These are very rudimentary, usually four in number, often five, rarely three. Of the first one the pedicles and superior articular cornua project upward, and help form the last intervertebral foramen. The short transverse process usually bounds a notch for the anterior division of the fifth sacral nerve, or if it touches the inferior lateral angle of the sacrum, it forms a fifth anterior sacral foramen.

The second vertebra has rudiments of transverse processes, and two small eminences in line with the cornua, representing the last traces of a neural arch. The third and fourth are mere nodules, and represent vertebral bodies only. In adult life the first piece is usually separate, and the other three united. All four may form one bone, which occurs oftener and earlier in the male.

Steinbach observes that the male has most often five coccygeal vertebræ, and the female four or five with equal frequency.

Describe the vertebral column as a whole.

It is a central axis upon which other parts are arranged: above, it supports the head, laterally the ribs, and it rests on the hip-bones below. Its average length measured along the curves is 28 inches in the male,

and 27 inches in the female; persons seated in a row appear of about the same height.

Viewed from the front, the column is formed of two pyramids applied base to base at the junction of the last lumbar with the sacrum. The upper pyramid can be divided into three—viz. the six lower cervical, with base at first dorsal; the second is inverted, with the apex at fourth dorsal; and the third commences at the fourth dorsal and ends at the last lumbar. All three diameters of the vertebræ increase from the third cervical to the last lumbar: vertical diameter from $\frac{3}{8}$ – $1\frac{1}{5}$ inches (14 mm. to 29 mm.), sagittal from $\frac{3}{8}$ – $1\frac{2}{5}$ inches (14 mm. to 35 mm.), transverse (does not increase in dorsal region) from $\frac{1}{2}$ – $2\frac{1}{5}$ inches (21 mm. to 55 mm.).

The column presents a lateral curve convex to the right: this may be an indentation on the left side rather than a curve. Three theories are proposed: (1) liver draws right side over; (2) pulsating aorta pushes column over; (3) right-handedness. The last is most tenable. Viewed laterally, there are four curves, alternately convex and concave, the cervical, dorsal, lumbar, and pelvic; the first extends from the odontoid to the second dorsal; the dorsal curve is concave forward and ends at the twelfth dorsal; the lumbar ends at the sacro-vertebral angle, and the pelvic ends at the tip of the coccyx. The dorsal and pelvic curves are primary, exist at birth, enter into the formation of bone-walled cavities, and are due to the conformation of the vertebral bodies. The dorsal is produced by pressure of viscera and weight of head and thorax.

When the child begins to walk the ilio-psoas muscles pull the lumbar vertebræ forward, producing here and in the cervical region secondary or compensatory curves, mainly due to the shape of the intervertebral disks. Sitting and the weight of the head also induce the cervical curve.

The pathological curvatures are called *kyphosis* (humpbacked), *scoliosis* (crooked, bent to one side), and *lordosis* (bent forward).

Posteriorly, the *spines* occupy the median line or may be normally twisted a little from it. In the cervical region they are short, horizontal, and bifid; in the dorsal they are oblique above, vertical in the mid portion, and horizontal below; in the lumbar they are horizontal. A cross-section of a cervical spine is semilunar; of a dorsal, triangular; of a lumbar, oblong. On either side of the spines is the vertebral groove, bounded externally in the cervical and dorsal region by the transverse processes, and in the lumbar by the mammillary processes. The *transverse processes* of the atlas are long; of the axis, short, increasing to the first dorsal, thence diminishing to the last dorsal, and becoming suddenly much longer in the lumbar vertebræ. In the cervical region the transverse processes are in front of articular processes and between intervertebral foramina. In the dorsal region they are behind both. In the lumbar region they are in front of the articular processes and behind the intervertebral foramina.

Intervertebral foramina are always in front of articular processes, except those of the atlas and the upper ones of the axis. They are named

from the upper of the two vertebræ which go to form them, excepting in the cervical region, where there are eight, the fissure between the skull and atlas being called the first.

In the cervical region the superior articular surfaces look back and up.

In the dorsal region the superior articular surfaces look back and out.

In the lumbar region the superior articular surfaces look back and in. The inferior surfaces have an opposite direction.

The *spinal canal* has three sets of openings into it, the two rows of the intervertebral foramina and the *intervertebral fissures* between the laminae. It is narrowest in those parts having least motion—viz. in the dorsal and sacral regions. It is round and $\frac{3}{8}$ inch (17 mm.) in diameter in the dorsal region; is triangular with apex behind in the cervical and lumbar regions; and largest of all in the cervical.

OSSIFICATION OF THE VERTEBRÆ.

Each vertebra is developed from three primary centres—one on each side for the lamina and processes, appearing at the sixth week of fetal life, and one for the body at the eighth week. Five secondary centres are added—three for the tips of the spinous and transverse processes, and two for thin annular plates on the circumferences of the upper and lower surfaces of the bodies. These are not united till the twenty-fifth year. A lumbar vertebra has two others for the mammillary processes.

The atlas has three primary centres, the axis, six; there are two lateral ones for the odontoid, between which a bit of cartilage remains till advanced life; the apex of the odontoid has a separate centre. The seventh cervical usually has a separate centre in the anterior part of its transverse process, and likewise the first lumbar, though infrequently. The ossification of the laminae proceeds from above down, explaining the occurrence of spina bifida in the lower part of the column: ossification of the bodies appears first in the last dorsal and extends in both directions.

The sacrum as a whole is developed from thirty-five centres—fifteen for bodies and arches, ten for epiphysial plates, three for the upper part of each lateral mass, and two for an auricular surface and thin edge below. The coccyx has four centres—one for each piece, sometimes two for the first one.

THE THORAX.

The skeleton of the thorax comprises the dorsal vertebræ, the sternum, ribs, and costal cartilages.

Describe the sternum.

The breast-bone is an azygos bone in the median line at the front of the chest. It has attached the clavicles and seven upper costal cartilages. It originally consisted of six segments, and is likened to a sword. The upper segment remains distinct as the *manubrium* or *handle*; the next four fuse into the *body* or *gladiolus* (little sword); the sixth portion is the *ensiform* or *xiphoid process* (sword-like).

The sternum is flattened from before backward, and curved with a slight convexity, to the front. It is broad above, then narrow to the beginning of the gladiolus, then broad again, and narrow at the ensi-

form. The bone contains red marrow, confined in cancellous tissue between two thin layers of compact bone. The *manubrium* (presternum) is the thickest part, concavo-convex on cross-section. Superiorly are three deep notches: the middle one is the *semilunar* or *interclavicular* notch; the lateral ones look up back and out for articulation with the clavicles. Below the lateral notches on either side is a rough triangular surface for union with the first costal cartilage; next is a sloping concave surface; and at the lower angle a half notch for the second rib. The junction of the manubrium with the gladiolus is always prominent, and serves as a landmark for the second rib.

The *body* (mesosternum) is marked anteriorly by three slight transverse ridges. Each lateral margin presents four notches and two half-notches; they approach each other from above down. The half-notch above is for the second cartilage; the notches for the third, fourth, and fifth cartilages are opposite the lines of junction of the four segments; the notch for the sixth cartilage and the half-notch for the seventh belong to the inferior segment. So most of the cartilages of the true ribs articulate in front at junctions of segments, analogous to the connection of ribs with the vertebral column.

The *ensiform process* (metasternum) projects down between the cartilages of the seventh rib. It has various forms—may be bent forward, backward, or laterally, be forked or perforated, and is more or less cartilaginous. At its upper angle is a half-notch for the seventh cartilage. The sternum is subcutaneous in the median line, forming the floor of the *sternal groove*, with the *supra-* or *episternal notch* above and the *infra-sternal depression* at the ensiform process.

The body of the male sternum is more than twice as long as the manubrium; in the female it is less than twice the same length. The body at the junction of the third and fourth segments may be perforated by a *sternal foramen*, or rarely by a *sternal fissure*. Two small nodules, *ossa suprasternalia*, are sometimes found close inside the clavicular notches: they represent an episternal bone of lower animals, other remains of which are the interarticular fibro-cartilage of the sterno-clavicular joint. In flying birds a great keel exists along the middle of the sternum. In the male wild swan and guinea-fowl the sternum is tunnelled and contains the trachea.

Describe the general characters of the ribs.

The ribs (*costæ*) are twelve in number on each side. The first seven pairs, attached by costal cartilages to the sternum, are called *sternal*, *true*, or *vertebro-sternal* ribs; the remaining five pairs are *asternal* or *false* ribs: each of the upper three pairs of false ribs has its cartilage attached to the cartilage above it, *vertebro-chondral*; the last two pairs have no such attachment, and are *floating* or *vertebral* ribs.

Each rib presents three parts—a body, an anterior and a posterior extremity.

The *posterior extremity* is thickened into the *head* or *capitulum*: it has a superior and an inferior articular facet for articulation with two

vertebræ; the lower is the larger, and between them is a ridge for the interarticular cartilage.

Next externally is the flattened *neck*, 1 inch long (collum costæ), and next the *tuberosity*, divided into two parts by an oblique groove. The inner and lower part is articular for the transverse process of the lower of the two vertebræ, with which the rib is connected; the outer and upper part is rough for the posterior costo-transverse ligament.

The *body* is laterally compressed, and over its most convex part is a rough line corresponding to the outer border of the sacro-lumbalis muscle, marking the *angle*; still farther forward is another line, the *anterior angle*. The inferior border presents the subcostal groove, best marked at the angle and disappearing in front; it lodges intercostal vessels and nerves. Starting from the upper and inner border of the neck is a superior costal groove soon lost on the body.

The *anterior extremity* is hollowed into a pit for union with the costal cartilage. The ribs are curved on three axes—a vertical one near the angle; also a transverse one at this place, so that when the anterior part of the rib is horizontal the posterior will rise up; and a longitudinal one, so that the anterior part looks up and the posterior part looks down. The upper ribs are nearly at right angles with the spine, and reach their greatest obliquity at the ninth. The seventh or eighth rib is the longest, after which they decrease to the twelfth. The first is broadest, and the twelfth narrowest. The distance from the angle to the tuberosity increases from above down.

Describe the peculiar ribs.

The *first rib* is not twisted, and its surfaces look nearly up and down. The head is small and has a single articular facet: the neck is slender, and the angle coincides with the tuberosity. On the upper surface is a rough impression for the scalenus medius muscle, and in front of that two smooth depressions with an intervening ridge: the posterior depression is for the "third portion" of the subclavian artery, the ridge ending in the *scalene tubercle* (Lisfranc's tubercle) is for the attachment of the scalenus anticus muscle, and the anterior depression for the subclavian vein. There is no subcostal groove.

The *second rib* is not twisted and has no angle (Henle): it presents near the middle depressions for the scalenus posticus and serratus magnus muscles. It has a double articular facet.

The *eleventh* and *twelfth ribs* have single articular facets, and only slight elevations to mark the tuberosities which do not articulate with the transverse process.

The *eleventh* has a slight subcostal groove; the *twelfth* has no angle.

The number of ribs may be thirteen on one or both sides; the gorilla and chimpanzee have each thirteen pairs of ribs. The added rib is most often connected with the first lumbar transverse process, sometimes with the seventh cervical vertebra, where it has a double attachment—viz. to the body and to the transverse process. The pleura descends to the same spot whether

the twelfth rib be absent or not. The tenth rib may have but one articular facet. The twelfth rib varies in length from 8 inches to less than 1 inch.

Describe the costal cartilages.

They prolong the ribs to the sternum. Their breadth diminishes from the first to the last; they become narrow toward their sternal extremities; their length increases to the seventh; the first descends a little, the second is horizontal, the others, except the last two, ascend after following the direction of the rib for a short distance. Their external extremities are convex, and planted into the osseous tissue of corresponding ribs. The inner extremity of the first is united directly to the sternum without articular cavity; the succeeding six have rounded extremities for the sternal notches. Each cartilage of the first three false ribs is united to the lower border of the one above it. The fifth, sixth, seventh, and eighth cartilages articulate with each other; the eleventh and twelfth are pointed and unattached.

The eighth may articulate with the sternum. The seventh may meet its fellow of the other side in front of the ensiform. There may be no articulation between the fifth and sixth; there may be one between the eighth and ninth.

Describe the thorax as a whole.

The bony thorax is conical, and flattened from before backward. The short antero-posterior diameter is characteristic of man, but in the lower mammals and human foetus it is longer than the transverse diameter. The posterior wall is convex forward, and a broad furrow on either side, the *sulcus pulmonalis*, is formed by the ribs as they project backward, so that the weight of the body is more equally distributed around the column.

The anterior wall is convex and at an angle of 20° – 25° with the posterior.

A horizontal antero-posterior diameter from the base of the ensiform is 8 inches (20 cm.); the transverse at the eighth or ninth rib is 11 inches (28 cm.); the vertical anteriorly is 6 inches (15.5 cm.), and posteriorly is 12 inches (31.5 cm.). The upper border of the sternum is opposite the lower edge of the second dorsal (Henle), and the lower border opposite the tenth dorsal. The sides slope out to the ninth rib. The upper aperture is contracted and reniform, and sloped downward; the lower is irregular, and its margin ascends on each side from the tenth rib to the ensiform, forming the *subcostal angle*. The intercostal spaces are wider above than below.

The sternum is developed from six centres, one for each segment: the first to appear is at the sixth month in the manubrium; the ensiform centre does not appear till the sixth year. The manubrium may have two or more centres, and the third, fourth, and fifth segments may have two centres, each placed laterally: if the bony parts formed from these do not meet, there is left the sternal foramen or fissure. The manubrium and body exception-

ally join by bone, and usually remain separate till the twenty-fifth year. The ensiform unites in middle life.

A single centre, situated posteriorly, appears for each rib at the eighth week; after puberty two secondary centres appear in the cartilage of the head and tuberosity. The eleventh and twelfth ribs have none for the tuberosity.

In the adult the first costal cartilage usually shows superficial ossification or even a complete bony sheath. In advanced life the other cartilages may be covered by bone, especially anteriorly: this tendency is stronger in the male. The cartilage itself is seldom ossified.

THE HYOID BONE.

Describe the hyoid bone.

The hyoid, or os linguæ, is situated at the base of the tongue opposite the second or third cervical vertebra, and is shaped like the Greek letter *upsilon*. Its *body* is compressed from above down; the anterior surface looks up and forward, and is marked by a crucial ridge with a tubercle in the centre and depressions on either side for muscular attachment. Its posterior surface is concave and faces the epiglottis. The *great cornua* project back and are flat from above down. After middle life they have bony union with the body. The *small cornua* are short and conical, and project up and back from the junctions of the great cornua and body; they give attachment to the stylo-hyoid ligaments and have synovial articulations with the body. There are five centres of ossification for the five parts.

BONES OF THE HEAD.

The skull is divided into two parts, the *cranium* and *face*: the former protects the brain; the face surrounds the mouth, nasal cavities, and orbits in part.

Cranium has eight bones.

(a) unpairing:

Occipital,
Sphenoid,
Ethmoid,
Frontal.

(b) pairing:

Temporal,
Parietal.

Face has fourteen bones.

(a) unpairing:

Vomer,
Inferior maxilla.

(b) pairing:

Superior maxilla,
Palate,
Lachrymal,
Inferior turbinate,
Nasal,
Malar.

BONES OF THE CRANIUM.

Describe the occipital bone.

This bone (ob. caput, against the head) is flattened, lozenge-shaped, and bent on itself; the upper anterior surface is concave, the posterior

is convex. It *articulates* with six bones—two parietal, two temporal, the sphenoid and atlas.

Below and in front the bone is pierced by the foramen magnum (for. occipitale) for the passage of the spinal cord and membranes, spinal portions of the spinal accessory nerves, and two vertebral arteries: the part behind the foramen is the *tabular portion*, in front is the *basilar portion*, at the sides are the *condylar portions*.

The superior borders with the parietals form the lambdoid suture; the inferior borders from the lateral angles to the jugular processes articulate with the mastoid, thence with the petrous portion of the temporal; the basilar unites with the sphenoid by cartilage or by bone. The rhombic form may become eight-sided by secondary obtuse angles between the upper and lateral, the lateral and lower angles.

The *tabular portion* presents posteriorly near the centre the *external occipital protuberance*, from which the *superior curved line* arches outward on each side to the lateral angles; a little above this may usually be seen the *highest or supreme curved line*. Below the protuberance is a median *external occipital crest*, from the centre of which passes out the *inferior curved line* to the jugular processes.

To the supreme curved line is the bony attachment of the epicranial aponeurosis; to the superior curved line, most internally, the biventer cervicis, for the inner third the trapezius, next the occipitalis, sterno-cleido-mastoid, and splenius capitis. Between the superior and inferior lines are internally a large impression for the complexus, and externally a small one for the superior oblique. Below the lower line is an inner impression for the rect. cap. post. minor, and an outer one for the major. The ligamentum nuchæ is attached to the protuberance and crest.

The deep surface of the tabular portion shows two ridges crossing each other, one from the upper angle to the foramen magnum, one connecting the two lateral angles. Where these intersect is the *internal occipital protuberance*, not always opposite the external. The ridges mark off four hollows, the superior and inferior occipital fossæ, which lodge the posterior cerebral and the cerebellar lobes. The ridges are grooved for venous sinuses. The space where the longitudinal sinus is continued into a lateral one, generally the right, lodges the *torcular Herophili* (wine-press of Herophilus). Below this the vertical ridge is sharp, and named the *internal occipital crest*.

The *condylar portions* bear the articular surfaces for the atlas: these condyles converge toward the front, are doubly convex, and somewhat everted. At the inner side of each is a rough impression for a lateral odontoid ligament. Perforating the condyle from within out is the *anterior condylar foramen* for the hypoglossal nerve and a branch of the ascending pharyngeal artery. Immediately above this foramen is a heaping up of bone designated as the *eminentia innominata*. Behind the condyle is a *posterior condylar fossa*: it may be perforated by a foramen for the passage of a vein from the lateral sinus; both fossa and foramen are inconstant. External to the condyle is the *jugular process*, analogue

of a transverse process: it lies above the transverse process of the atlas, and it presents in front the *jugular notch*, which helps form the *jugular foramen*; the right notch is usually the larger. The extremity of the process presents an irregular facet for union with the temporal bone; this union is osseous at the twenty-fifth year. The upper surface presents the end of the lateral sulcus leading to the jugular notch: here the posterior condylar foramen opens if present. On the under surface is attached the rect. cap. lateralis muscle.

The *basilar process* projects forward and upward in the middle of the base of the skull and at the top of the pharynx, increasing in thickness and diminishing in width. Superiorly is a *basilar groove* for the medulla, and at either lateral margin a shallow sulcus for the inferior petrosal sinus. Inferiorly in the middle line is the *pharyngeal tubercle* for aponeurotic attachment of the superior constrictor of the pharynx: on each side of it are attached the rect. cap. anticus major and minor muscles.

The portion of bone above the superior curved line (intraparietal) is sometimes separated from the rest by a transverse suture. The bone between the supreme and superior curved lines may be very prominent and constitute the *torus occipitalis transversus* (transverse bulge). An *intrajugular process* may project into the jugular notch. From the under aspect of the jugular process the *paramastoid process* may descend to the transverse process of the atlas. There is a rare articulation between the basilar process and anterior arch of the atlas or odontoid. Birds and reptiles have only a single occipital condyle, placed in front of the foramen magnum. The external occipital crest is greatly developed in most animals.

Describe the parietal bone.

This bone is quadrilateral, convex externally and concave internally, a little broader above than below. It *articulates* with five bones—the opposite parietal, the occipital, frontal, sphenoid, and temporal. Near the middle of the outer surface, nearer the lower than upper border, is the *parietal eminence* or *boss*. This is very prominent in young bones.

Through or just below this are the *superior* and *inferior temporal lines*, $\frac{2}{5}$ inch apart: to the superior one is attached the temporal fascia, to the inferior the temporal muscle. The inferior line does not pass off the parietal upon the occipital bone; below it is the *temporal surface* for origin of the temporal muscle. Near the upper border, and $\frac{4}{5}$ inch (20 mm.) from the posterior angle, is the *parietal foramen* for the exit of a vein, and usually entrance of a branch of the occipital artery. The sagittal suture between the two parietal foramina is inclined to obliteration.

The deepest part of the inner surface opposite the parietal eminence is the *parietal fossa*. The inner surface is marked by furrows or canals for the meningeal vessels. A slight depression runs along the superior border, forming part of the sulcus for the longitudinal sinus. At the posterior inferior angle is a groove for the lateral sinus, which first runs

across the occipital, then this angle of the parietal, then the mastoid portion of the temporal, and finally the jugular process of the occipital. Near the upper border of the bone are *digital depressions* for the lodgment of Pacchionian bodies (modified tufts of arachnoid membrane).

The anterior border is alternately bevelled, so that the frontal rests upon it above and the parietal overlaps the frontal below, thus resisting the usual directions of violence. The inferior border is flattened and squamous, and divided into three parts, named from the bones overlapping it, sphenoid, squamous, and mastoid from before backward.

The parietal foramen may be absent on one or both sides or may be very large. This bone is bipartite in some Australian skulls.

Describe the frontal bone.

The frontal (*frons*, forehead) arches up and back above the orbits, forming the fore part of the cranium. It *articulates* with twelve bones—the parietals and sphenoid, the malars, the nasals, superior maxillæ, lachrymals, and ethmoid. Inferiorly are two thin horizontal laminae, the *orbital plates*, forming the roof of the orbits and separated by the *ethmoidal notch*. Three surfaces are presented for description. The *anterior surface* shows the greatest convexity on each side in the *frontal eminence*, separated by a slight depression below from the *superciliary ridge*, just above the orbit. In the middle line between the two ridges is a smooth surface, the *glabella* (without hair), also called *nasal eminence*. The *orbital arch* ends in extremities called the *internal* and *external angular processes*: the internal is slightly marked, and articulates with the lachrymal bone; the external is prominent, and articulates with the malar. At the junction of the inner and middle third of the arch is the supraorbital notch or foramen for the supraorbital nerve and vessels. The *temporal crest* springs from the outer angular process, and is continuous with the inferior temporal line on the parietal.

Inferior Surface.—The orbital plates are somewhat triangular, with their internal margins parallel. Close to the external angular process is the *lachrymal fossa*, and close to the inner process is the *trochlear fossa* for the pulley of the superior oblique. Between the internal angular processes is the *nasal notch*, and from its concavity the *nasal process* projects beneath the nasal bones and nasal processes of the superior maxillæ and supports the bridge of the nose. On the posterior surface of this process are two grooves which enter into the roof of the nasal fossæ; between the grooves is a median ridge, the *nasal spine*, which descends in the septum of the nose above the perpendicular plate of the ethmoid. Along the inner margins of the ethmoidal notch are irregular depressions forming the roof of cells in the ethmoid. Each border is marked inferiorly by two grooves, completing with the ethmoid the *anterior* and *posterior internal orbital canals*: the anterior transmits the nasal nerve from the orbit and anterior ethmoidal vessels; the posterior transmits the posterior ethmoidal vessels. The *frontal sinus* opens

at the root of the nasal process. It is between the outer and inner tables, over the root of the nose and divided by a bony septum. Outside and behind the orbital surface is a rough triangular area for articulation with the great wing of the sphenoid.

Cerebral Surface.—This forms a large concavity for the anterior lobes of the cerebrum. The orbital plates are convex and marked by ridges and depressions, and are so thin as to be transparent: these plates make an angle of about 60° with the upper part of the bone. From the upper margin descends the *frontal sulcus*, running into the *frontal crest* at the lower margin. At the base of the crest is usually a groove converted into the *foramen cecum* by the approximation of the ethmoid; this is usually open in children, but blind in adults. The sides of this surface present grooves for the meningeal vessels. The thin transverse edge bounding the surface behind articulates with the greater and lesser wings of the sphenoid.

The trochlear fossa may be absent or have in addition a trochlear spine. The bone may be divided by the frontal or metopic suture, the infantile halves having failed to unite: this occurs in 8 per cent. of European skulls, 5 per cent. of Mongolian, and 1 per cent. of African. A trace of the suture is seen in nearly all adult frontal bones just above the nasal notch.

Describe the temporal bone.

The temporal bone (*tempus*, time, as hair first becomes gray in this region, indicating age) helps form the side and base of the skull and contains the organ of hearing. It presents four parts—the *squamous*, *mastoid*, and *pyramidal*, which includes the *petrous* and *tympanic*. It articulates with five bones—posteriorly and internally with the occipital, above with the parietal, in front with the sphenoid and malar, and below with the inferior maxilla.

The **squamous portion** (scale), or squamo-zygomatic, presents a vertical portion and a narrow horizontal portion at the base of the skull. It is limited above by an arched border describing two-thirds of a circle. The *outer surface* is vertical, with a slight convexity, and forms part of the temporal fossa. This portion overlaps the mastoid. Above the aperture of the ear is a vertical groove for the middle temporal artery.

The *zygoma* is connected with the lower and outer part of the squamous portion: it is broad at its base, with surfaces looking up and down; it then twists on itself, so that it has inner and outer surfaces, upper and lower borders. The upper border is thin and longer than the inferior, which is short and arched; the anterior extremity articulates with the malar. The zygoma is attached by two roots: the *anterior*, continuous with the lower border, is a broad convex ridge directed inward, called the *eminentia articularis*. At the junction of this with the zygoma is a *tubercle* for the external lateral ligament of the lower jaw. The *posterior root* prolongs the upper border of the zygoma as the *supramastoid crest*, which becomes continuous with the lower temporal line; it is above the suture between the squama and mastoid. Between the two roots is

the *glenoid fossa*: its articular portion is bounded behind by the *post-glenoid process*, sometimes called the middle root of the zygoma. It is strongly developed in some mammals to prevent posterior dislocation of the lower jaw. The *inferior aspect* of the horizontal portion presents three districts—the auricular, articular, and zygomatic, from behind forward. The auricular part forms the upper concave margin of the external auditory meatus and a part of the roof of the external ear. The next portion is the *glenoid fossa*, which is divided into two parts by the transverse *fissure of Glaser*. The posterior part is non-articular, formed by the tympanic plate and lodging part of the parotid gland. The anterior part of the fossa is articular, bounded behind by the post-glenoid process and in front by the eminentia articularis; it is the *fossa mandibularis*, concavo-convex for the condyle of the lower jaw. The fissure of Glaser is a double cleft. The first fissure behind the articular fossa is the petro-squamous (FPS, Fig. 1), next comes a narrow projection of the *tegmen tympani* (TT') from the petrous, and next the petro-tympanic fissure or Glaserian fissure proper: it lodges the slender process of the malleus and tympanic branch of the internal maxillary artery. Farther in, and external to the Eustachian tube, is the canal of Huguier, by which the chorda tympani nerve enters. The outer part of the Glaserian fissure is entirely closed.

Sometimes a "false jugular foramen" is present in the squamous, by which, in the embryo and many animals, blood flows from the cranium to the external jugular vein. It is between the articular fossa and external auditory meatus.

In front of the articular eminence, and separated by a slight ridge from the temporal surface, is a small triangular *infratemporal surface*, entering into the zygomatic fossa.

The *inner surface* of the squamous is concave and presents cerebral impressions and meningeal grooves. A narrow horizontal part helps form the anterior wall of the tympanum.

The *superior border* is thin and fluted, and overlaps the parietal bone. The *parietal notch* marks the junction of the superior border with the mastoid: the squamo-mastoid suture passes from this notch to the posterior edge of the external auditory meatus.

The *antero-inferior border* is thick, and bevelled above continuously with the upper border at the expense of the inner surface, below at the expense of the outer—all for articulation with the great wing of the sphenoid.

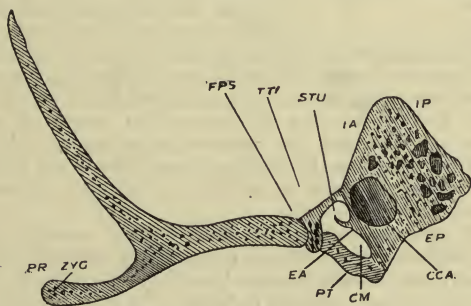
The *mastoid portion* (teat-like) is rough for muscular attachment, and prolonged down behind the auditory meatus as the *mastoid process*. At the posterior border is the *mastoid foramen*, sometimes foramina, transmitting veins from the lateral sinus and a mastoid artery from the occipital: the foramen is inconstant, and may be in the occipital bone or in the masto-occipital suture. On the inner side of the mastoid process is the *digastric fossa* for attachment of the posterior belly of the digastric,

and internal to this is the *sulcus occipitalis* for lodgment of the occipital artery.

The *internal surface* shows the *fossa sigmoidea*, which is a part of the sulcus for the lateral sinus: the mastoid foramen opens into it. A section of the mastoid portion shows a number of communicating cells; below in the mastoid process they are developed after puberty and are arranged vertically. Above these is the *antrum mastoideum*, which is a horizontal cellular cavity, a part of the middle ear: its roof and postero-lateral wall is formed from the petrous portion, and is continuous with the roof and side of the tympanum. Its antero-median wall belongs to the mastoid. Below it connects with the mastoid cells: its opening into the tympanum is large and on a level with the foramen ovale, so the floor of the tympanum passes in front into the Eustachian tube and behind into the mastoid antrum. The *superior border* of the mastoid is rough, slopes back, and articulates with the postero-inferior angle of the parietal: the *posterior border* articulates with the occipital between its lateral angle and jugular process.

The **pyramidal portion** includes the petrous (stone) and tympanic (drum). The *petrous portion* is a four-sided pyramid with its base turned out, and its long axis inward, forward, and slightly downward. The axes of the two portions if prolonged would meet at the posterior edge of the nasal septum. This portion presents four borders—*superior, inferior, anterior, and posterior*; and four surfaces—*antero-internal*

FIG. 1.



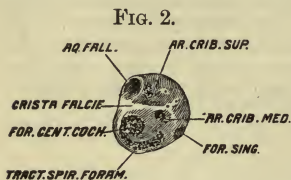
(IA, Fig. 1), *postero-internal* (IP), *antero-external* (EA), and *postero-external* (EP); also a *base* and an *apex*. The *base* is concealed in its upper half by the squamous and mastoid, and covered below, where these diverge, by the tympanic portion. The *apex* is received into the angle between the great wing of the sphenoid and the basilar process, and pre-

sents the anterior orifice of the carotid canal, and forms the postero-external boundary of the foramen lacerum.

The *antero-internal surface* is in the middle fossa of the skull, and separated from the squamous portion by the *fissura petro-squamosa* (FPS). This surface presents a little behind its centre the *eminentia arcuata*, covering the superior semicircular canal; in front of this is a groove leading to the *hiatus Fallopii*, which leads to the aqueduct of Fallopius; it transmits the large superficial petrosal nerve and the petrosal branch of the middle meningeal artery. Outside this is a groove and small foramen for the small superficial petrosal nerve. Near the apex the wall of the carotid canal is deficient; above this is a shallow depression for the Gasserian ganglion. Between the petro-squamous fissure externally and the hiatus Fallopii and eminence of the superior semicircular canal internally is a thin lamina which roofs in the tympanum and a common canal for the Eustachian tube and tensor tympani muscle: it is the *tegmen tympani*, TT', a process of the petrous.

The *postero-internal surface* is in the posterior fossa of the skull, and continuous with the inner surface of the mastoid. Near the centre, but

nearer the upper than the lower border, is a large orifice, the *porus acust. int.*, leading into a canal $\frac{1}{4}$ inch (6 mm.) long, which is the *internal auditory meatus*; this is terminated by the *lamina cribrosa* (Fig. 2). A transverse ridge, *crista falciformis*, separates a small superior from a large inferior fossa. A faint perpendicular crest divides these into four fossæ. The facial



nerve enters the aqueduct of Fallopius in the upper anterior fossa; the *area cribrosa superior* is the perforated part of the upper posterior fossa for auditory nerves going to the utricle, superior, and external auditory canals; below this is the *area cribrosa media*, conveying an auditory branch to the saccule; also the *foramen singulare* for a branch to the posterior auditory canal; in the lower anterior fossa is the *tractus spiralis foraminulentus*, for the cochlear division of the auditory nerve, ending at the *foramen centrale cochleæ*.

Behind the auditory meatus is a small slit, the opening of the *aqueduct of the vestibule*, transmitting a small artery and vein and lodging a process of the dura mater which encloses the *saccus endolymphaticus*; above and between these is a depression or fissure, the *subarcuate fossa*, which extends into the arch of the superior semicircular canal and represents the floccular fossa of animals.

The *postero-external surface* forms part of the base of the skull. Beginning at the apex, is first a quadrilateral surface for the origin of the levator palati and tensor tympani muscles, the lower aperture of the carotid canal, which is first vertical and then horizontal; vertically be-

neath the internal auditory meatus is the three-sided opening of the aqueduct of the cochlea, which in early life transmits a vein; next behind is the *jugular fossa*, which forms the jugular foramen when opposite the jugular notch of the occipital.

In front of the bony ridge, between the carotid canal and jugular fossa, is a small foramen for *Jacobson's nerve* (from the glosso-pharyngeal) to the tympanic plexus; this foramen usually splits to give exit to the small deep petrosal (*carotico-tympanicus superior*) from the tympanic to the carotid plexus. Externally in the ascending part of the carotid canal is a small foramen for the *carotico-tympanicus inferior*, a sympathetic nerve going from the carotid plexus to the tympanic. On the outside of the jugular fossa is a foramen for *Arnold's nerve* from the pneumogastric: its canal runs through the petrous transversely and out, and splits into two, an inner to meet the facial canal, $\frac{1}{8}$ inch (5 to 6 mm.) above the stylo-mastoid foramen, and the other to open at the tympanico-mastoid (auricular) fissure.

Behind the jugular fossa is the *jugular facet*, for articulation by synchondrosis with the jugular process of the occipital. Externally is the *styloid process*, enclosed between the layers of the *vaginal process*. It gives attachment to three muscles and two ligaments. Between the styloid and mastoid processes is the *stylo-mastoid foramen*, the end of the aqueductus Fallopii, which passes first out and back over the labyrinth, then in and back, and then down to terminate here: the stylo-mastoid artery enters this foramen.

The *antero-external surface* is free anteriorly for a short distance, and articulates with the great wing of the sphenoid; posteriorly it is concealed by the tympanic plate (PT, Fig. 1).

At the angle between the squamous and petrous portions is the opening of a canal the musculo-tubarius (CM), incompletely divided into two by a projecting lamella, the *cochleariform process* or *septum tubæ* (STU). The upper groove is for the tensor tympani muscle, and the lower is the bony wall of the Eustachian tube. This common canal is covered by the tegmen, its inner wall is the antero-external surface of the petrous, and its floor and outer wall are the tympanic plate. The septum tubæ rarely reaches the opposite wall, and rises from the anterior wall of the carotid canal (CCA). This wall is made of two thin lamellæ with diploë between, in which runs the small deep petrosal nerve. The *superior border* is grooved for the superior petrosal sinus, and gives attachment to the tentorium cerebelli. The *posterior border* presents on its inner portion a half groove for the inferior petrosal sinus, and externally the margin of the jugular fossa. From the apex, where a bony projection often overhangs the inferior petrosal groove, a fibrous band, the *petro-sphenoidal ligament*, extends to the side of the dorsum sellæ, and completes a foramen for the inferior petrosal sinus and sixth nerve. The *anterior border* has two parts—an outer, forming the petro-squamous fissure, and an inner free portion to form the petro-sphenoidal suture. The *inferior border* is largely concealed by the tympanic and petrous

portions: near the apex it is indistinct, and here the bone is rather three-sided.

The **tympanic portion** is beneath the petrous and between the mastoid and squamous. At birth it is a ring from which is developed the *tympanic plate*. The thickened outer extremity of this plate is the *external auditory process*, a curved, uneven lamina forming the anterior and inferior wall of the *external auditory meatus* and tympanum. The upper margin of the plate is concealed by the petrous and forms the posterior boundary of the fissure of Glaser. Its lower margin descends as a sharp edge, the *vaginal process*: it is continuous with the inferior border of the petrous portion.

Describe the sphenoid.

The sphenoid bone (wedge-like) is placed across the base of the skull near its middle, and binds the other cranial bones together. It helps form the cavities of the cranium, orbits, and nasal fossæ, and has to do with six pairs of cranial nerves. It resembles a bat with outstretched wings, and consists of a *body*, *greater* and *lesser wings*, and *pterygoid processes*. It articulates with twelve bones, all those of the cranium, and five of the face; posteriorly with the occipital and temporals, anteriorly with the ethmoid, palatals, frontal, and malars, laterally with the temporals, frontal, and parietals, inferiorly with the vomer and palatals, and sometimes with the superior maxillæ.

The *body* is hollowed into two cavities separated by the *sphenoidal septum*, and opening anteriorly into the upper and back part of the nasal fossæ behind the superior turbinate bone.

The *superior surface* presents in front the *ethmoidal spine*, articulating with the cribriform plate of the ethmoid. On either side of this surface is a slight depression for the olfactory lobe, and its posterior margin is the *limbus sphenoidalis*. Behind this, on a lower plane, is the *optic groove*, terminating on either side in the *optic foramen*. Next is the *olivary eminence (tuberculum sellæ)*, and next the *pituitary fossa*, or *sella Turcica* (Turkish saddle): it is occasionally bounded in front by two *middle clinoid processes*; behind is a square lamina, the *dorsum sellæ* or *dorsum ephippii* (back of saddle), which slopes posteriorly down and back into the basilar groove: this slope is the *clivus Blumenbachii* (Blumenbach's hill).

The upper angles of this lamella project over the fossa as the *posterior clinoid processes*; the sides are grooved for the sixth pair of nerves. The *sides* of the body present a winding groove curved like the letter *f* for the carotid artery in the cavernous sinus. Behind its commencement, at the lower lateral angle of the dorsum sellæ, is the *petrosal process* of the *sphenoid*, to fit against the apex of the petrous; opposite this, on the other side of the groove, is a tongue-like process, the *lingula sphenoidalis*.

The *posterior surface* is quadrilateral, and united to the basilar process by cartilage in early life, and by bone after the twenty-fifth year.

PLATE III.

FIG. 1.—To face page 44.

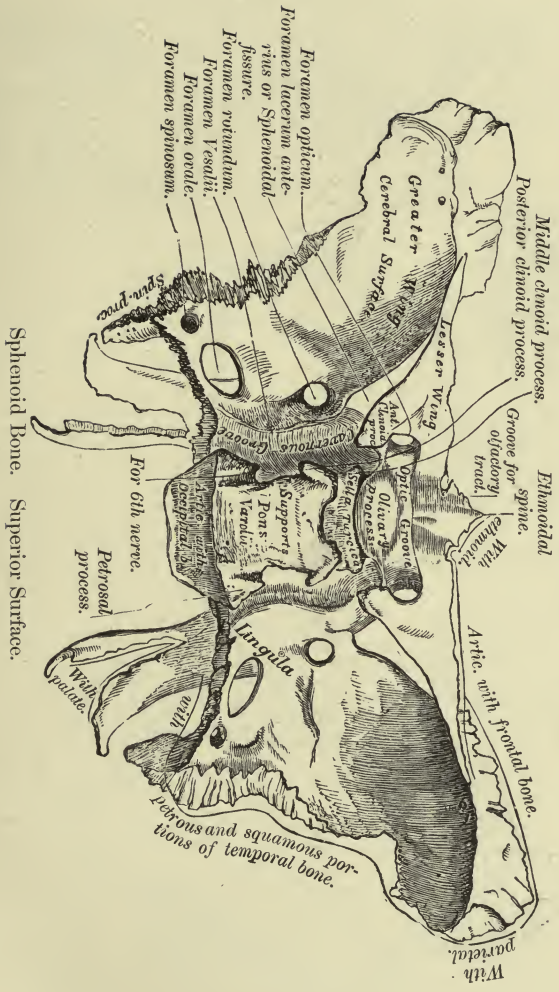


PLATE IV.

FIG. 1.—To face page 44.

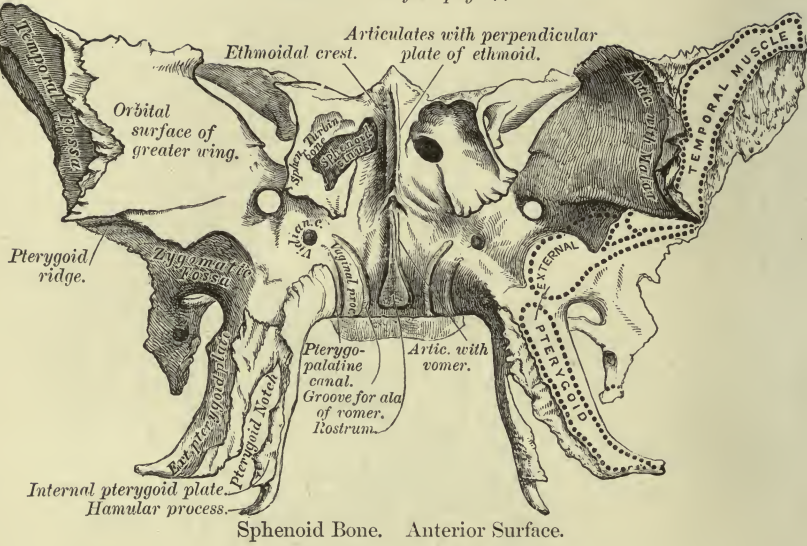
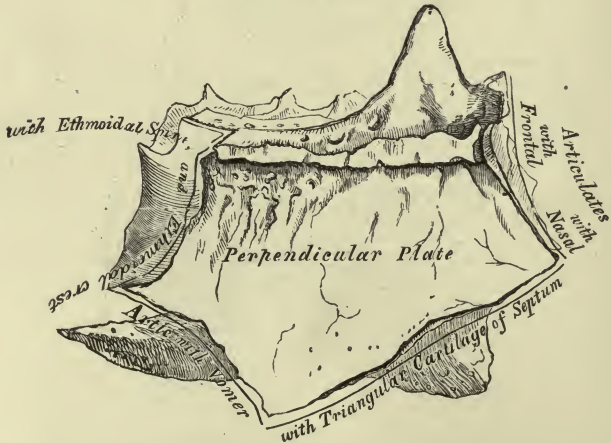


FIG. 2.—To face page 47.



Perpendicular Plate of Ethmoid (enlarged). Shown by removing the Right Lateral Mass.

The *anterior surface* is marked in the middle line by the *sphenoidal crest*, which articulates with the perpendicular plate of the ethmoid. On each side of the crest is a mesial and lateral part: the lateral shows half-cells, to be completed by the ethmoid and orbital plate of the palatal; the mesial part is smooth, and gives entrance anteriorly into the sphenoidal sinus, and forms part of the roof of the nose.

The *inferior surface* presents the *rostrum* (beak), which continues the sphenoidal crest and fits between the alæ of the vomer.

The *sphenoidal turbinate bones* (*spongy bones, conchæ sphenoidales, bones of Bertin*) form a considerable part of the anterior wall of the body of the sphenoid. They are curved and triangular, with apex backward. A small portion of them sometimes appears on the inner wall of the orbit between the ethmoid, frontal, sphenoid, and palate bones.

Each lateral surface of the body is mostly occupied by the attachment of the greater wings, except in front a free surface bounds the sphenoidal fissure and forms the hindermost part of the inner wall of the orbit.

The *small or orbital wings* (processes of Ingrassias) extend horizontally outward on a level with the fore part of the superior surface of the body: the extremity of each is pointed and comes almost into contact with the great wing. The inferior surface forms the upper boundary of the sphenoidal fissure and part of the roof of the orbit. The anterior border articulates with the orbital plate of the frontal; the posterior is free, and forms the boundary between the anterior and middle fossæ of the skull, and terminates internally in the *anterior clinoid process*. Between this clinoid process and the olivary eminence is a semicircular notch in which the carotid groove ends. The optic foramen perforates the base of the wing, the parts above and below being called its roots.

The *great or temporal wings* project out and up from the sides of the body: the back part of each is horizontal and fills the angle between the squamous and petrous portions of the temporal; from its extremity projects downward the *spinous process*. The fore part is vertical and three-sided, and lies between the cranial cavity, the orbit, and temporal fossa.

The *cerebral surface* is concave, and forms part of the middle fossa of the skull.

The *external surface* (temporo-zygomatic) is divided by the *infratemporal crest* into a lower part looking down into the zygomatic fossa, and an upper part looking out into the temporal fossa.

The *anterior surface* looks forward and inward, and consists of the *orbital plate* for the external wall of the orbit, and of a smaller portion above the pterygoid process which looks into the sphenomaxillary fossa and is perforated by the *foramen rotundum*.

The *posterior border* near the body bounds the foramen lacerum, and in its lateral part articulates with the petrous, forming a groove beneath for the cartilaginous portion of the Eustachian tube. The *external border*, commencing at the spinous process, articulates with the squamous, and above it overlaps the anterior inferior angle of the parietal bone.

In front of this is a triangular surface formed by the upper margins of the cerebral, orbital, and temporal surfaces. The *anterior margin* articulates above with the malar: below this is a free horizontal edge separating the zygomatic from the speno-maxillary surface. Above and internally the orbital and cerebral surfaces meet at a sharp border which forms the inferior boundary of the sphenoidal fissure, and often shows a bony projection for the lower head of the external rectus.

The *pterygoid* (wing-like) *processes* project downward and forward, angle of 110° to 115° , from the junction of the body and great wings. Some consider them to rise from two roots, one representing a transverse process, one a rib, and the Vidian canal, the costo-transverse foramen. Each consists of two plates united in front and diverging behind, forming the *pterygoid fossa* for the origin of the internal pterygoid muscle. The external plate is broad and extends out and back, and gives origin by its outer surface to the external pterygoid muscle. The internal plate is long and narrow, and prolonged below into the *hamular* (hook-like) process, round which plays the tendon of the tensor palati muscle. The upper part of the inner plate turns in beneath the body, and remains distinct as a slightly raised edge, the *vaginal process*, which meets the everted margin of the vomer. At the angle of the vaginal process with the internal plate is a groove which, with the sphenoidal process of the palate, forms the *pterygo-palatine canal*. Posteriorly, at the base of the inner plate, is the *pterygoid tubercle*, to the inner side of and below the Vidian canal: between this and the pterygoid fossa is the *scaphoid fossa* for the origin of the tensor palati muscle. Lower down, on the posterior margin of the plate, is the *processus tubarius*, which supports the cartilage of the Eustachian tube. Between the lower ends of the plates is the *pterygoid notch*, occupied by the pyramidal process of the palate bone.

Name the fissures and foramina of the sphenoid.

Each half presents a fissure, four foramina, and a canal. The *sphenoidal fissure* is the oblique interval between the great and small wings, closed externally by the frontal bone. It opens into the orbit and transmits the third, fourth, ophthalmic division of the fifth, and the sixth cranial nerves, some sympathetic filaments from the cavernous plexus, the orbital branch of the middle meningeal artery, recurrent branch of the lachrymal artery, and the ophthalmic vein. Above and to the inside of this fissure is the *optic foramen*, piercing the base of the small wing and transmitting the optic nerve and ophthalmic artery. The *foramen rotundum* pierces the great wing below the sphenoidal fissure and transmits the superior maxillary nerve. Behind and external to this is the *foramen ovale*, near the posterior margin of the great wing, sometimes incomplete: it transmits the inferior maxillary nerve, the small meningeal artery, and sometimes the small superficial petrosal nerve. The *foramen spinosum* pierces the great wing near the posterior angle, and transmits the middle meningeal artery and n. spinosus, a recurrent branch

of the inframaxillary. From the foramen spinosum projects backward a thin horizontal *spheno-petrosal lamina*, which reaches the upper border of the Eustachian canal on the petrous.

The *Vidian canal* pierces the base of the internal pterygoid plate antero-posteriorly; it passes from the foramen lacerum to the spheno-maxillary fossa, transmitting the Vidian nerve and vessels.

A spicule of bone may connect the middle clinoid process (when present) with the anterior, forming a *carotico-clinoid foramen* for the carotid artery. Interclinoid ligaments are normally present beneath the dura. The outer pterygoid plate may be connected by bone or ligament with the spinous process. The foramen of Vesalius for an emissary vein is sometimes present on the inner side of the foramen ovale. The *canaliculus immomimatus* is sometimes present for the small superficial petrosal nerve internal to the foramen spinosum.

Describe the ethmoid bone.

The *ethmoid* (sieve-like) projects down between the orbital plates of the frontal, and enters into the formation of the cranium, orbits, and nasal fossæ. It consists of thin plates enclosing irregular cells—a *vertical plate* and two *lateral masses* united above by the horizontal *cribriform plate*.

It *articulates* with thirteen bones—fifteen including the sphenoidal turbinate—the frontal, sphenoid, and vomer, the nasals, lachrymals, superior maxillæ, palatals, and inferior turbinate bones. The *vertical plate* forms the upper third of the nasal septum, and presents grooves and canals for olfactory nerves. Its superior border appears in the cranial cavity as the *crista galli* (cock's comb); posteriorly this process is thin, and anteriorly is broadened into two alar processes, between which is usually a groove completing the foramen cæcum with the frontal. If the vertical plate be deflected below the cribriform, the *crista galli* is inclined in the opposite direction. The anterior border of the plate articulates with the nasal spine of the frontal and with the nasal bones; the inferior border in front with the triangular cartilage of the nose, and behind with the vomer; the posterior margin with the sphenoidal crest.

Each *lateral mass* or *labyrinth* encloses three sets of spaces—the *anterior*, *middle*, and *posterior* ethmoidal cells: they do not communicate with each other. Externally is the paper-like *orbital plate*, or *os planum* (*lamina papyracea*), closing in the middle and posterior cells: it articulates in front with the lachrymal, behind with the sphenoid, above with the frontal, and below with the superior maxilla and palate bones. On this aspect below the plate is a groove belonging to the middle meatus of the nose: it turns up anteriorly, and is continued by the *infundibulum* through the anterior ethmoidal cells to the frontal sinus; the middle cells open into the horizontal part of the groove. The lateral mass in front of the orbital plate is covered in by the lachrymal: from this part the *uncinate process* curves back, down, and out,

helping to close the orifice of the antrum: it articulates below with the ethmoidal process of the inferior turbinate.

The *inner aspect* of each lateral mass is in the outer wall of the nasal fossa. Above is a channel, the *superior meatus*, passing from behind to about the middle of the bone: it communicates with the posterior cells. The plate overhanging it is the *superior turbinate process* or *superior spongy bone* (concha sup.); the space above that is in the roof of the nose. Below the groove is the *inferior turbinate process* of the ethmoid or *middle spongy bone* (concha inf.), rolling convexly toward the nasal fossa: it forms the lower border of the lateral mass.

Two grooves cross the upper margin of the lateral mass, forming with the frontal the two internal orbital canals. Posteriorly the mass is ankylosed with the sphenoidal spongy bone.

The *cribriform plate* occupies the ethmoidal notch of the frontal. It presents the *olfactory groove* on each side of the crista galli and foramina for the olfactory nerves; the foramina of the middle set are few and are simple perforations; in the external and internal sets they are more numerous, and are orifices of small canals which subdivide on the vertical plate and lateral mass. Anteriorly is a fissure close to the base of the crista galli, and external to it a notch connecting with the anterior internal orbital canal for the passage of the nasal nerve and anterior ethmoidal artery from the orbit to the cranium, and thence to the nasal fossa.

BONES OF THE FACE.

Describe the superior maxillary bone.

The superior maxilla is the principal bone of the face, supporting the upper teeth of one side, helping to form the hard palate, floor of orbit, floor and outer wall of nasal fossa. There are a body and four processes for description. The body is a hollow half-cylinder, presenting an external surface subdivided into an anterior and posterior, an internal and superior; the processes are nasal, alveolar, malar, and palatal.

The *body* encloses the *antrum* of Highmore, which opens into the middle meatus of the nose. The superior maxilla *articulates* with nine or ten bones—with its fellow, with the nasal, frontal, lachrymal, ethmoid, palate, malar, vomer, inferior turbinate, and sometimes with the sphenoid at the outer extremity of the spheno-maxillary fissure. The *anterior* or *facial* surface is marked below by eminences corresponding to fangs of the teeth. Internal to the eminence for the canine is the *incisor* or *myrtiform fossa*; external to it is the deeper *canine fossa*; above the latter, below the margin of the orbit, is the *infraorbital foramen*. The inner margin of this surface is cut by the *nasal notch*, the sharp edge of which is prolonged into the *anterior nasal spine*.

The *posterior* or *zygomatic* surface looks into the zygomatic and sphenomaxillary fossæ: it presents two or more apertures of the *posterior dental canals*; below and posteriorly is a rough *tuberosity*. At the junction

of this surface with the nasal and orbital is a small triangular space on which the orbital process of the palate rests, the *palatine trigone* (Henle).

The *internal* or *nasal* surface presents in front the *inferior turbinate crest*; below it is the smooth concavity of the inferior meatus; above it a small surface forming the *atrium* (entry) of the middle meatus. Behind the nasal process is the *lachrymal groove*, $\frac{1}{2}$ inch long, inclined down and out, opening into the inferior meatus; the groove is converted into the *canal of the nasal duct* by the lachrymal and inferior turbinate. Behind it is the opening of the antrum; above this are small half-cells belonging to the middle ethmoidal set. Behind the opening of the antrum the surface is rough for articulation with the palate bone, and traversed by a groove running down and forward, forming with the palate the *posterior palatine canal*.

The *orbital surface* is triangular and flat; externally is a rough surface for the malar; internally is first the *lachrymal notch*, and behind it a pretty straight margin for the ethmoid and orbital process of the palate. The postero-external border is free and bounds the sphenomaxillary fissure. The *infraorbital groove* commences well back on this surface, leading to a canal of the same name which opens anteriorly at the *infraorbital foramen*: from the canal are given off the *anterior* and *middle dental* canals in the substance of the bone.

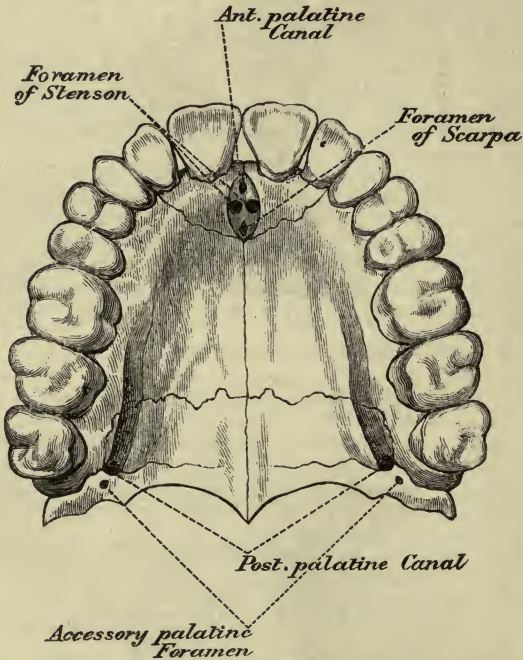
The *nasal process* projects up, in, and back; its external surface is smooth; the hinder part of the inner surface completes the anterior ethmoidal cells; below this the surface is crossed by the *superior turbinate crest* (agger nasi) for the inferior turbinate process of the ethmoid (middle spongy bone). The anterior border articulates with the nasal bones and above with the frontal; posteriorly is a continuation of the *lachrymal groove*, bounded internally by a sharp edge articulating with the lachrymal, and externally by a smooth border: where this border joins the orbital surface is the *lachrymal tubercle*.

The *alveolar process* is thick and hollowed into eight alveoli. The *malar process* is triangular, continuous in front and behind with the facial and zygomatic surfaces of the body. Superiorly it is rough for the malar: the inferior border forms a thick buttress opposite the first molar.

The *palate process* with its opposite forms three-fourths of the hard palate. Above it is concave transversely, and forms part of the floor of the inferior meatus. Below it is arched, and shows lateral grooves for nerves and vessels: its posterior extremity falls short of that of the alveolar arch and the space is filled by the palate bone. The inner border rises into a *nasal crest* which receives the vomer; in front a more elevated part is the *incisor crest*, prolonged into the anterior nasal spine. By the side of the incisor crest is a foramen, becoming a groove: when the bones are united there is one orifice below, with right and left branches above, called the *incisor foramina* or *foramina of Stenson*, for the transmission of arteries (Fig. 3). The lower aperture is the *anterior palatine fossa*; in the middle line, opening into it, are the *foramina of*

Scarpa, the left naso-palatine nerve passing through the anterior one and the right through the posterior. From the anterior palatine fossa are seen two sutures passing to the interval between the canine and lat-

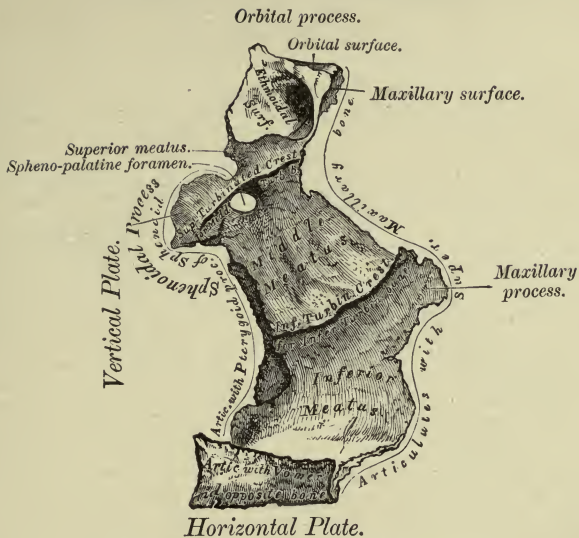
FIG. 3.



The Palate and Alveolar Arch.

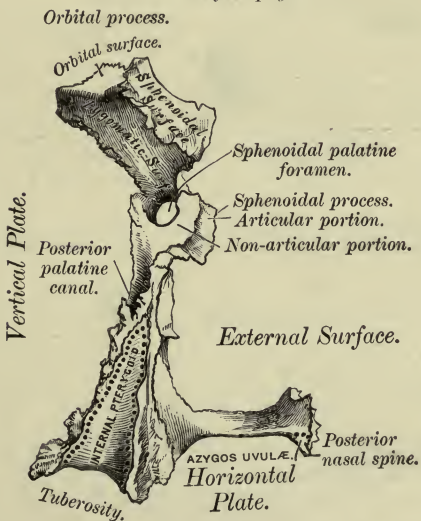
eral incisor tooth; the sutures are to be seen in the inferior meatus. They mark off the *intermaxillary bone*, and include the whole thickness of the alveolar processes, the nasal spine, and sockets for incisor teeth. No trace of the suture is seen on the facial surface, as an outgrowth, the *incisor process*, forms the front wall of the incisor sockets.

The *maxillary sinus*, or antrum, is irregularly pyramidal; the base is at the nasal surface of the body and the apex extends into the malar process. Its aperture is closed in part by the uncinatè process of the ethmoid, the ethmoidal process of the inferior turbinate, and the maxil-



Left Palate Bone, internal view (enlarged).

FIG. 2.—To face page 51.



Left Palate Bone, posterior view (enlarged).

PLATE VI.

FIG. 1.—To face page 52.

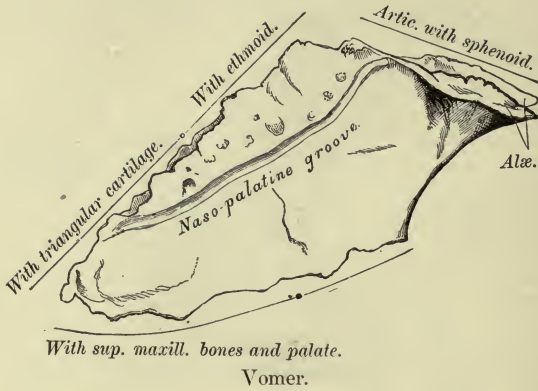
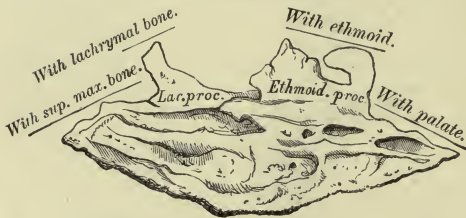
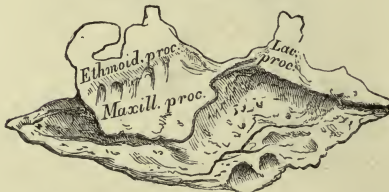

FIG. 2.—To face page 54.



Right Inferior Turbinate Bone, internal surface.

FIG. 3.—To face page 54.



Right Inferior Turbinate Bone, outer surface.

lary process of the palate behind; the lachrymal in front rarely assists. The alveolus of the first molar is most prominent in the floor.

Describe the palate bone.

This bone is L-shaped, and forms the back part of the hard palate and the lateral wall of the nose between the superior maxilla and internal pterygoid plate. It presents a horizontal, a vertical plate, and three processes. It articulates with six bones—its fellow, the superior maxilla, the ethmoid, sphenoid, vomer, and inferior turbinate. The *horizontal* or *palate* plate is concave above in the nasal fossa; near its posterior border is a transverse ridge for the tensor palati muscle. The posterior border is free and concave, gives attachment to the soft palate, and is prolonged internally into the *posterior nasal* or *palatine spine*, which continues the nasal crest of the superior maxillæ supporting the vomer. It is grooved externally by the *posterior palatine canal*. The *vertical plate* is thin; its nasal surface is divided into two parts by the inferior turbinate crest for the inferior turbinate bone; the middle meatus is above it and the inferior below. At the upper part is the *superior turbinate crest* for the middle spongy bone, and above this a groove in the superior meatus. The external surface presents above and behind a smooth surface, forming the inner wall of the pterygo-maxillary fissure, and leads to the *posterior palatine groove*. In front of the groove the surface is applied to the superior maxilla and sends the *maxillary process* forward. Behind the groove the surface articulates below with the maxilla and above with the pterygoid process.

The *pyramidal process* or *tuberosity* juts out behind and fits in between the pterygoid plates: it presents posteriorly a smooth middle district entering into the pterygoid fossa: internal to it is a groove for the internal pterygoid plate, and externally a rough area for the external plate. Part of the tuberosity appears in the zygomatic fossa. Inferiorly, close to the horizontal plate, are the *posterior* and *external accessory palatine canals*.

The *orbital process* rests on the anterior margin of the vertical plate: it has five surfaces, three articular, and two, the superior and external, are free.

The superior surface forms the posterior angle of the floor of the orbit; the external looks into the spheno-maxillary fossa; the anterior articulates with the maxilla, the internal with the ethmoid, and the posterior with the sphenoid. The process is usually hollow, and completes a posterior ethmoidal cell or may open into the sphenoidal sinus.

The *sphenoidal process* curves up and in from the posterior part of the vertical plate; it has three surfaces: the superior is in contact with the under surface of the body of the sphenoid, and is grooved for the *pterygo-palatine canal*; the internal surface looks into the nasal fossa and touches the ala of the vomer; the external looks into the spheno-maxillary fossa.

The *spheno-palatine notch* is between these two processes, converted by the body of the sphenoid into a foramen of the same name.

The posterior palatine canal may be wholly confined to the palate bone. The spheno-palatine notch may be converted to a foramen by union of the sphenoidal and orbital processes. The orbital process may be enlarged by a separate ossification from the ethmoid or sphenoid.

Describe the vomer.

The vomer (ploughshare) is thin and quadrilateral, and placed vertically between the nasal fossæ. The upper and posterior borders, the anterior and inferior, are of nearly equal lengths. It *articulates* with six bones—the sphenoid, ethmoid, two palate, two superior maxillary—and with the septal cartilage of the nose.

Each surface presents a groove leading the naso-palatine nerve to the foramen of Scarpa. The superior border divides into two alæ, which receive the rostrum of the vomer between them; each ala meets the vaginal process of the sphenoid and the sphenoidal process of the palate.

There are usually three vomero-basilar canals—a median, between ala and rostrum for nutrient vessels; an upper lateral one, between the body of sphenoid and root of vaginal process, carrying vessels to the sphenoidal cells; a lower lateral one, between the body of sphenoid and sphenoidal process of palate, carrying vessels and nerves from the nasal and spheno-maxillary fossæ to the upper pharynx.

The anterior border is grooved in its lower half for the septal cartilage; in its upper half it is ankylosed on one or both sides, usually the right, with the perpendicular plate of the ethmoid. At the inferior anterior angle is a short vertical edge to fit in behind the incisor crest of the maxillæ: from its upper end a process runs forward in the groove of the crest, and from its lower end a point may project down between the incisor foramina. The inferior border articulates with the nasal crest of the maxillæ and palate bones: the posterior border is thin and free and separates the posterior nares.

Describe the malar bone.

This cheek-bone separates the orbit from the temporal fossa and *articulates* with four bones—the frontal, sphenoid, temporal, and superior maxillary. It is quadrangular, with the angles directed vertically and horizontally: it may be thought of as formed of a triangular orbital plate united at a sharp angle to a quadrangular malar plate. The *outer surface* presents a little below the centre the *malar tuberosity*, and above this the orifice of the malar canal. The *inner surface* is concave, looks into the temporal and zygomatic fossæ, and presents a roughness for articulation with the superior maxilla. The *upper angle* or *frontal process* is serrated for the external angular process of the frontal. The *temporal* border behind this is sinuous and continuous with the upper border of the zygoma.

The *posterior angle* or *temporal process* has the zygoma resting upon and articulating with it. The postero-inferior border, the *masseteric*, completes the lower edge of the zygomatic arch; the antero-inferior border, *maxillary*, and a rough part of the inner surface, articulate with the malar process of the superior maxilla. The *orbital* border is excavated, and forms a great part of the orbital margin, ending internally just above or inside the infraorbital foramen. From this the *orbital process* projects back, forming the fore part of the outer wall of the orbit, articulating with the great wing of the sphenoid. On the orbital surface are the openings of two canals—the *temporal* opening on the temporal surface, and the *malar* opening on the facial: they transmit the temporo-malar branches of the superior maxillary nerve.

A horizontal suture may divide the bone into two unequal parts. The canals may have a common opening on the orbital surface. There may be a *marginal process* at the upper part of the temporal border (more often on the right side) for attachment of a band of temporal fascia. The anterior extremity of the speno-maxillary fissure may be completed in one of three ways: by the malar in more than half the cases, by the articulation of the sphenoid with the superior maxilla, or by a Wormian bone.

The antrum of Highmore may extend into the malar.

Describe the nasal bones.

The two form the bridge of the nose, and each *articulates* with four bones—the frontal, superior maxillary, ethmoid, and its fellow. They are narrow and thick above, broader and thinner below. They articulate above with the inner part of the nasal notch of the frontal.

The inferior border is free, and gives attachment to the lateral nasal cartilage: it usually has a small notch near the inner end. The external border is longest, and articulates by means of small teeth with the nasal process of the superior maxilla.

The internal border meets its fellow in a somewhat irregular internasal suture, which commonly deviates to one side at the upper end. Posteriorly the two form a crest which rests from above down on the nasal process of the frontal, the vertical plate of the ethmoid, and the septal nasal cartilage. The facial surface is convex below and concave above, and presents vascular foramina.

The posterior surface is concave, and a little external to its centre is a longitudinal groove for the nasal nerve.

These bones are relatively large in white races, small and flat in the black and yellow races. The internasal suture is obliterated in apes. There may be small internasal bones at the lower extremity of the internasal suture.

Describe the lachrymal bone.

The lachrymal, or *os unguis*, is a thin scale like a finger-nail at the anterior and inner part of the orbit. It *articulates* with four bones—frontal, ethmoid, superior maxilla, and inferior turbinate. Its *external surface* is divided by a vertical ridge, the *lachrymal crest*: in front of it

is the lachrymal groove, and this part is prolonged below as the *descending process* to articulate with the inferior turbinate; behind the crest the surface is smooth and forms part of the orbit, and it is produced below into the *hamular process*, which comes forward in the lachrymal notch of the superior maxilla and bounds the outer side of the orifice of the nasal duct. The *internal surface* is a depressed furrow completing above some of the anterior ethmoidal cells, and below it looks into the middle nasal meatus.

This bone may be absent, perforated, or divided into pieces; the hamular process may be wanting, small, or so long as to extend upon the face. A separate ossicle may take its place, the *lesser lachrymal bone*.

Describe the inferior turbinate bone.

The inferior turbinate or spongy bone projects like a shell into the nasal cavity, separating the middle from the inferior meatus. Its convexity looks in and its lower margin is rolled on itself. Its attached margin articulates in front with the inferior turbinate crest of the superior maxilla, and then ascends abruptly as the *lachrymal process* to complete the lachrymal canal. Behind this, and nearer the back than the front, the bone is folded down as the *maxillary process*, looking over the aperture of the antrum, and forming part of its inner wall: on the upper border of this process is the *ethmoidal process*, which articulates with the uncinæ of the ethmoid. Posteriorly, the bone is attached to the inferior turbinate crest of the palate: the posterior extremity is elongated and pointed, the anterior flat and broad.

The bone *articulates* with the superior maxilla, lachrymal, ethmoid, and palate. No muscle is attached to it. The negro may have four turbinate bones.

Describe the inferior maxillary bone.

The *lower jaw*, or *mandible*, is the strongest bone of the face, and *articulates* with the glenoid fossæ of the temporals. It consists of a curved horizontal portion or *body* and two ascending branches or *rami*. The *body* shows in front a faint vertical ridge, the symphysis of two originally distinct pieces: this expands into the *mental protuberance*, which becomes prominent on each side inferiorly as the *mental tubercles*. The superior or alveolar border is hollowed out into sockets for teeth. The inferior border, or *base*, is thick and rounded, and projects beyond the superior. Below the incisor teeth is the *incisor fossa*; more externally is the *mental foramen* midway between the upper and lower borders, under the interval between the two bicuspids: it is the anterior opening of the dental canal. Below the foramen the *external oblique line* runs up and back from the mental tubercle to the anterior margin of the ramus. The *deep surface* of the body presents inferiorly near the symphysis an oval fossa for the attachment of the digastric muscle: above it are the *mental spines*, the lower being a median ridge for the genio-hyoid muscles, and the upper a pair of tubercles for the genio-

hyoglossi: there may be four tubercles (:::) or two (..) or a vertical ridge (I) or one prominence (.). Above them a small foramen penetrates the bone and above this a narrow median groove marks the symphysis. Below the mental spines, and passing up and back to the ramus, is the *internal oblique line* or *mylo-hyoid ridge*, for the mylo-hyoid muscle and a slip of the superior constrictor of the pharynx. Above this line is a fossa for the sublingual gland, and below it another for the submaxillary.

The *ramus* is thinner than the body, and where its posterior border meets the base it forms the slightly everted *angle*. The *external surface* is flat, and near the angle it shows oblique lines for tendinous attachment of the masseter muscle. At the centre of the *internal surface*, on a level with the crowns of the molar teeth, is the *inferior dental foramen*, leading to the *dental canal*: the inner margin of the foramen is sharp anteriorly, and called the *lingula mandibulæ*. Beginning at the notch behind the lingula is the *mylo-hyoid groove* (sometimes a canal), terminating below the hinder end of the mylo-hyoid ridge. Behind this is a roughness for the internal pterygoid muscle. On the upper border of the ramus are two processes—the *condyle* for articulation and the *coronoid* for muscular attachment: they are separated by the *semilunar* or *sigmoid* notch. The *condyle* passes up from the posterior part of the ramus, supported on a constricted *neck*, on the front of which internally is a depression for the external pterygoid muscle. One-third inch (8 mm.) below the articular surface there may be an external tubercle for the external lateral ligament. The condyle is convex, transversely elongated, and the axes of the two would meet at the anterior margin of the foramen magnum. The *coronoid* process passes up from the fore part of the ramus, inclined out and somewhat beak-shaped: by its apex, sharp margins, and inner surface it gives attachment to the temporal muscle.

The anterior border of the ramus shows three oblique ridges—an external one to the end of the external oblique line; internal to that is a groove bounded posteriorly by a ridge passing from the internal oblique line to the middle aspect of the coronoid; at the lower part of the groove, extending a short distance to the outer side of the alveolus, is the third or *buccal* line.

The lower jaw consists of a thick shell of compact tissue enclosing cancellous tissue; the dental canal in its posterior two-thirds lies close to the inner compact layer; it is prolonged beyond the mental foramen under the canine and incisor teeth. There may be two dental canals. The angle of the jaw in the adult is about 120°, infancy 140° or more; in old and toothless jaws it is increased. These changes are due to development, absorption of alveolar arch, and strength of masseter muscles.

THE SKULL AS A WHOLE.

Describe the sutures.

The skull-bones are closely fitted by uneven edges, there being inter-

posed a little fibrous tissue continuous with the periosteum; the den-
tations are confined to the external table, the edges of the inner table
lying only in apposition. The lower jaw has a movable articulation,
differing from the others. The sutures around the parietal bones have
special names: between the two is the *sagittal*, behind them the *lamb-
doid*, in front of them the *coronal*.

All the sutures may be arranged in three groups—a *median longi-
tudinal*, a *lateral longitudinal*, and a *vertical transverse*. The first con-
sists of the sagittal, and in the infant the frontal; the second begins in
the median line in front, and includes on each side the fronto-nasal,
fronto-maxillary, fronto-lachrymal, fronto-ethmoidal, fronto-malar, fronto-
sphenoidal, spheno-parietal, squamo-parietal, and masto-parietal; the
third comprises the coronal and spheno-squamous, the lambdoid and
occipito-mastoid, and also the transverse sutures at the base of the
skull.

Sometimes the great wing of the sphenoid, the parietal, the squama, and
the frontal bones do not meet, and the short spheno-parietal suture is not
formed; the frontal and squama unite in a vertical fronto-temporal suture
continuing the coronal: this is the rule in the gorilla and chimpanzee. In
this situation is often developed the *epipteric bone*.

After about thirty years of age many sutures close, union taking place on
the inner surface first: the parts to close first are the sagittal suture between
the parietal foramina and the lower ends of the coronal suture.

THE WORMIAN BONES.

These, *ossa triquetra*, *ossa suturarum*, are irregular ossifications between
cranial bones rarely found in the face. They are usually symmetrical, and
are most common in the lambdoid suture, occupying the place of the superior
angle of the occipital bone; may be at either anterior angle of the parietals.
They usually include only one plate of the skull.

The *ossiculum jugulare* may be found at the jugular foramen.

EXTERNAL SURFACE OF THE SKULL.

The external surface may be divided into superior, inferior, anterior,
and lateral regions.

Describe the superior region.

This extends from the supraorbital margins to the superior curved
line of the occiput, bounded laterally by the temporal lines. It is a
smooth, convex surface covered by muscle and aponeurosis. The great-
est transverse diameter of the skull is at the junction of the posterior
and middle thirds—viz. $5\frac{3}{8}$ inches (140 mm.); the greatest longitudinal
diameter from the under margin of frontal bone to the external occi-
pital protuberance is $6\frac{1}{2}$ inches (170 mm.). As the head is usually held
it makes an angle of 20° with the horizon.

Describe the anterior region.

This region presents the openings of the orbits, the bridge of the nose,

below that the *anterior nasal aperture* (*apertura pyriformis*), presenting the anterior nasal spine below. Below the aperture are the incisor fossæ of the upper jaw, below the orbits the canine fossæ, and external to them the malar prominences. The lower jaw completes the skeleton of the face with its incisor fossæ, mental prominence, etc.

In a nearly vertical line on either side are three foramina for the exit of some part of the three divisions of the fifth cranial nerve—viz. the supraorbital, infraorbital, and mental. There are also the malar foramina on the malar bone.

The nose is rarely placed in the centre of the face, and the nasal aperture is often unsymmetrical, a deflection of the septum occurring toward the wider half.

Describe the orbits.

The orbits are pyramidal fossæ, somewhat quadrilateral, with their bases turned out and forward: their inner walls are nearly parallel, and their outer walls diverge at nearly right angles to each other. Each is formed of seven bones, or eleven for the two—the frontal, sphenoid, malar, superior maxillary, lachrymal, ethmoid, and palate. The *roof* of each is formed by the orbital plate of the frontal and small wing of the sphenoid; the *floor* by the malar, superior maxilla, and orbital plate of the palate; the *inner wall* by the nasal process of the superior maxilla, the lachrymal, ethmoid, and body of the sphenoid; the *outer wall* by the malar and great wing of the sphenoid. The *sphenoidal fissure* at its inner part occupies the apex of the orbit; its outer extremity lies between the roof and outer wall.

The *optic foramen* is internal to and above the fissure. In the angle between the external wall and floor is the *spheno-maxillary fissure*, bounded by the palate, superior maxilla, malar, and sphenoid bones: it leads into the spheno-maxillary fossa at its back part and zygomatic fossa at its fore part. Passing forward from the margin of this fissure is the commencement of the infraorbital canal. On the inner wall in front is the lachrymal groove, leading to the canal of the nasal duct, and farther back, between the frontal and ethmoid, are the *anterior* and *posterior internal orbital canals*. At the inner margin of the roof is the supraorbital foramen or notch. Within the external angular process is the *lachrymal fossa*, and on the outer wall are the temporal and malar canals.

Describe the lateral region of the skull.

This presents from behind forward the mastoid portion, the mastoid foramen, the external auditory meatus, the glenoid fossa with condyle of lower jaw, eminentia articularis, coronoid process, and *zygomatic arch*. Above this arch is the *temporal fossa*, and below it, separated by the infratemporal crest, is the *zygomatic fossa*.

The *temporal fossa*, occupied by the temporal muscle, is bounded above by the temporal crest of the frontal and the lower temporal line

of the parietal: the latter runs into the supramastoid crest, and that into the zygomatic arch.

The *zygomatic* or *infratemporal fossa* contains a part of the temporal muscle, the external and internal pterygoids, the internal maxillary artery, and the inferior maxillary nerve. Some of its boundaries are indefinite: externally is the ramus of the lower jaw; superiorly the great wing of the sphenoid, showing the foramen ovale and spinosum, also a small part of the squamous portion of the temporal; anteriorly is the lower part of the malar and zygomatic surface of the superior maxilla; the inferior limit is the extremity of the external pterygoid plate and alveolar border of the superior maxilla. The inner wall is formed by the external pterygoid plate; the posterior limit is the eminentia articularis and posterior border of the pterygoid plate.

Inferiorly the pterygoid process approaches close to the superior maxilla, but is prevented from meeting by the pyramidal process of the palate. Above they are separated by the *pterygo-maxillary fissure*, leading into the *spheno-maxillary fossa*. Running at right angles to the fissure is the spheno-maxillary fissure opening into the orbit.

Describe the spheno-maxillary fossa.

This is a small triangular space at the angle of junction of the above-named fissures, placed beneath the apex of the orbit. It is bounded above by the body of the sphenoid, in front by the superior maxilla, behind by the base of the pterygoid, and internally by the vertical plate of the palate. It has three fissures terminating in it—the sphenoidal, spheno-maxillary and pterygo-maxillary. It communicates with four fossæ—the orbital, nasal, zygomatic, and middle fossa of the base of the skull; and has opening into it five foramina—three from behind, the foramen rotundum, the Vidian, and the pterygo-palatine canals; internally is the spheno-palatine foramen, and inferiorly the posterior palatine canals, and occasionally the accessory posterior palatine canals.

Describe the external base of the skull.

("Base of skull" properly means base of the cranium, and does not include the facial bones; we have followed, however, the usual description, and include the inferior maxilla.)

It is divisible into three parts—anterior, middle, and posterior. The *anterior division* consists of the palate, alveolar arches, and body of the inferior maxilla. It is traversed longitudinally by a median suture, and transversely by that between the maxillary and palate bones. In front is the *anterior palatine fossa*, with the four foramina opening into it; farther back are the under surface of the tuberosity of the palate, the apertures of the posterior and external palatine canals, and the posterior nasal spine.

The *middle division* extends back to the foramen magnum, and is called the *guttural fossa* (relating to the throat). In the mid-line is the basilar process, and in front of that the body of the sphenoid covered

by the alæ of the vomer. On each side the petrous portion reaches to the extremity of the basilar process, and between the petrous and squamous is the back part of the great wing of the sphenoid. In front are the *posterior nares* or *choanæ* (funnels), separated by the vomer, bounded above by the sphenoid, below by the horizontal plates of the palate bones, and laterally by the internal pterygoid plates. On each side are the pterygo-palatine and Vidian canals, the scaphoid and pterygoid fossæ. A line from the external pterygoid plate to the spine of the sphenoid separates this surface from the zygomatic fossa: internal to this line is the groove for the cartilaginous part of the Eustachian tube. Between the apex of the petrous, the basilar process, and the sphenoid is the *foramen lacerum*. (This is the only foramen properly called "lacerated.") This with the petro-basilar fissure is filled with fibrous tissue, and may contain Wormian bones. Passing back and out from this is the petro-sphenoidal fissure, the styloid and vaginal processes, and the stylo-mastoid foramen; more internally are the anterior condylar foramina and the jugular fossa. This fossa is divided into three compartments by processes of dura mater. The inferior petrosal sinus is in the anterior one, the lateral sinus, some ascending pharyngeal and occipital arteries in the posterior one, and the ninth, tenth, and eleventh cranial nerves in the middle one.

Other points have been described with the temporal bone.

The *posterior division* presents on either side of the foramen magnum the occipital condyle, jugular process, occipital sulcus, digastric fossa, and mastoid process. Behind the foramen magnum is the tabular part of the occipital up to the superior curved line. Into this posterior division are inserted all the muscles running up to the skull from the ribs, spines, and transverse processes.

Henle describes for base of skull the base of the cranial bones: the foramen magnum is where the vertebral canal broadens out into the cranium; behind it is the part corresponding to the vertebral arches, in front the part corresponding to the vertebral body. The line of separation passes through the mastoid and jugular processes, the condyles, and the foramen magnum. In front of this line are two other regions: the "middle girdle" nearly corresponds to the middle fossa of the interior; its anterior border goes on either side from the pharyngeal spine, in front of the pterygoid process to the outer extremity of the *crista orbitalis*, which is the upper border of the sphenomaxillary fissure.

The anterior portion in front of the pharyngeal spine forms the roof of the "vegetative tube."

Describe the interior of the cranium.

The inner table presents impressions for cerebral convolutions. The thickness of the skull-cap, or *calvaria*, is $\frac{1}{8}$ to $\frac{1}{4}$ inch. The base of the skull varies in thickness, thinnest at the cribriform and orbital plates, where there is no diploë; also thin in the inferior occipital fossa, in the squama, and glenoid fossa. The inner surface of the calvaria is dome-like, formed by the frontal, parietal, and occipital bones. It is marked

by the superior longitudinal sulcus, small meningeal grooves, and Pacchionian fossæ. The only apertures are the inconstant parietal foramina.

Describe the internal base of the skull.

This surface is divided into three fossæ—anterior, middle, and posterior.

The *anterior fossa* is formed by the orbital plates of the frontal, the cribriform of the ethmoid, the small wings and part of the body of the sphenoid: it supports the frontal lobes of the cerebrum. It is convex laterally, with a hollow over the cribriform plate, where the crista galli stands up separating the olfactory grooves. There is here the foramen cæcum, the olfactory foramina, openings of the internal orbital canals, and the foramen for the nasal nerve.

The *middle fossa* is on a lower level than the anterior, and consists of a median and two lateral parts. The median part is narrow, presenting the olivary eminence, the sella Turcica, and limited behind by the dorsum sellæ. Laterally is the great wing of the sphenoid, the squama, and antero-internal surface of the petrous portion. This lodges the temporal lobe of the cerebrum. The foramina present are the optic, sphenoidal fissure, foramen rotundum, ovale, spinosum, lacerum, and hiatus Fallopii.

The *posterior fossa* is deeper and larger than the others, and lodges the cerebellum, medulla, and pons. The occipital bone, the petrous and mastoid portions, postero-inferior angle of the parietal, and body of the sphenoid enter into it. In the centre is the foramen magnum, and on each side, in a nearly vertical line, are the anterior condylar foramen, jugular foramen, and internal auditory meatus. Behind the jugular foramen is the posterior condylar (if present), and higher up the mastoid foramen, both opening into the lateral sulcus. By the internal auditory meatus the facial and auditory nerves, the portio intermedia, and the auditory vessels leave the cranium.

What grooves are there for blood-vessels?

That for the middle meningeal artery commences at the foramen spinosum, and passes anteriorly to the great wing of the sphenoid, and posteriorly upon the squama and parietal. There is also the groove for the internal carotid artery on the side of the body of the sphenoid, the groove for the superior longitudinal sinus terminating at the internal occipital protuberance, those for the lateral sinuses, and others for the superior and inferior petrosal sinuses on the petrous portion.

Describe the nasal cavities and communicating air-sinuses.

The *nasal fossæ* are placed one on each side of a median vertical septum. They open in front by the anterior nasal aperture and behind by the posterior nares. They communicate with the sinuses of the frontal, ethmoid, sphenoid, and superior maxillary bones. They are narrow transversely, especially above. The *internal wall*, or *septum nasi*, is

formed by the perpendicular plate of the ethmoid, the vomer, nasal spine of the frontal, crests of the nasal, rostrum of sphenoid, crests of the maxillary, and palate bones. There is an angular deficiency in front, filled by the septal cartilage, which usually deviates to one side.

The *roof* is horizontal in the middle part and sloping in front and behind. The middle part is formed by the cribriform, the fore part by the nasal and frontal bones, the back part by the body of the sphenoid, the ala of the vomer, and sphenoidal process of the palate. In the angle formed by the cribriform and body of the sphenoid is the *spheno-ethmoidal recess*: the sphenoidal sinus opens upon its posterior wall.

The *floor* is formed by the palate processes of the maxillary and palate bones; it is smooth and concave transversely, and shows the orifice of the incisor foramen. The *external wall* is formed by the nasal, superior maxillary, lachrymal, ethmoid, inferior turbinate, palate, and internal pterygoid plate. The superior and inferior turbinate processes of the ethmoid and the inferior spongy bone overhang the three meatuses. The *superior meatus* is very short, and placed between the superior and inferior turbinate processes; into it open in front the posterior ethmoidal cells, and behind the spheno-palatine foramen. The *middle meatus* is above the inferior spongy bone, and communicates with the anterior and middle ethmoidal cells, with the maxillary sinus, and in front by the infundibulum with the frontal sinus. The *inferior meatus*, longer than the others, lies between the inferior spongy bone and the floor of the cavity; in front is the orifice of the nasal duct.

The Air-Sinuses.

These communicate with the nasal cavities by narrow orifices: with the exception of the maxillary sinus (antrum) they are not present at birth. In old age they increase in size by absorption of neighboring cancellated tissue. The antrum begins to be formed about the fourth month. The frontal, ethmoidal, and sphenoidal excavate their respective bones in childhood, and at puberty undergo a great enlargement. Their purpose may be for resonance. They have been sufficiently described with the different bones.

OSSIFICATION OF THE BONES OF THE HEAD.

Ossifications at the base of the cranium take place for the most part in cartilage; those of the roof of the skull and of the face originate in membrane, excepting the inferior turbinate and part of the lower jaw. The diploë and air-sinuses are absent at first.

The *occipital bone* consists of four pieces at birth—a basilar, tabular, and two condylar parts. The basilar and condylar parts have each one nucleus; in the tabular part there are usually four, the upper pair deposited in membrane and representing the interparietal bone of animals. This subdivision may exist in the human skull.

The *parietal bone* begins to ossify in membrane at the seventh week: it has

two centres, which speedily unite into one mass at the position of the future parietal eminence. The radiating ossification leaves a notch in front of the upper posterior angle, giving rise when united to its fellow to the *sagittal fontanelle*. This closes during foetal life, but the parietal foramina are remains of the interval. Sometimes a *parietal fissure* persists. The two centres may develop separately.

The *frontal bone* is developed from two centres in membrane, appearing at the seventh week. At birth the bone consists of two lateral portions: the frontal suture ossifies from below upward, usually during the second year. The frontal sinuses appear about the seventh year and increase to old age.

The *fontanelles* are membranous intervals between the incomplete angles of the parietal and neighboring bones. They are six in number—two median and four lateral. The anterior is quadrangular, placed between four bones, with its most acute angle pointing toward the nose; the posterior is triangular, is filled at birth, but the bones are freely movable. The lateral ones, are irregular intervals at the inferior angles of the parietal. All traces of them should disappear before the age of four.

The *temporal bone* late in foetal life consists of three parts—squamo-zygomatic, petro-mastoid, and tympanic—developed from ten centres: the squamo-zygomatic is developed in membrane from a single centre. From the squamosal a post-auditory process grows down between the tympanic and petro-mastoid portions, and forms the upper part of the mastoid division of the bone. In the third month a nucleus appears in the membranous wall of the tympanum and forms the tympanic ring, an imperfect circle open above and enclosing the tympanic membrane. The petro-mastoid, or ear-capsule, is developed in cartilage.

The styloid process is formed from two centres in cartilage: the one near the extremity remains small till puberty, not joining the other till adult life or remaining separate. At birth the mastoid portion is flat, the antrum is present, the glenoid fossa shallow, the tympanic ring and membrane are even with the outer surface of the bone. The external auditory meatus is developed by an outward projection of the tympanic ring, commencing as two tubercles: these meet on the floor of the meatus, enclosing a foramen which is not obliterated till the fifth year. This part always remains thin, or a small aperture may persist.

The *sphenoid* is divided in the foetus into a post-sphenoid part, to which the sella Turcica, great wings, and pterygoids belong, and a presphenoid part, which includes the body in front of the olivary eminence and the small wings. It has twelve centres in all, one for each pterygoid plate, each lingula, each carotid groove. The sphenoidal spongy bones begin to ossify at the fifth month. They entirely surround the sphenoidal sinus by the third year; then their upper and inner parts absorb. They are ankylosed first to the ethmoid (fourth year); hence some regard them as parts of that bone; they join the sphenoid at the ninth to twelfth year.

The *ethmoid* has three centres, one for each lateral mass and one for the vertical plate; the cribriform comes from all three sources.

The *superior maxilla*, clavicle, and lower jaw begin to ossify at about the same time, fifth to the seventh week. The number of centres is uncertain, but there seem to be four pieces—a malar portion, orbito-facial, palatine, and a premaxillary for the bone carrying the incisor teeth. The antrum appears at the fourth month. The infraorbital canal begins as a groove, which is closed by the growing over of the outer margin: a fine suture remains to indicate the line of meeting.

The *palate bone* has a single centre.

The *vomere* has two nuclei in membrane; they unite below, but above and in front form two laminæ.

The *nasal* and *lacrimal* bones each have a separate centre: the lateral cartilage of the nose continues up beneath the nasals; it subsequently disappears.

The *malar bone* has three centres: a continued separation of one of them gives rise to a bipartite bone occasionally seen.

The *inferior turbinate* has a single centre in cartilage at the fifth month.

The *inferior maxillary bone* is developed in the fibrous tissue investing Meckel's cartilage: the largest part is formed in membrane outside this cartilage. A small part of the body near the symphysis ossifies directly from Meckel's cartilage; the condyle, part of the ramus, and the angle also ossify in cartilage, the last not connected with Meckel's, which runs up to the fissure of Glaser continuous with the slender process of the malleus, and it eventually forms the internal lateral ligament of the lower jaw.

What are some of the points of difference between human and animal skulls?

(1) The proportionally large expansion of the cranial bones in the human skull; (2) the smaller development of the face and jaws, all of which are under the brain-case; (3) adaptation of the cranium to the erect posture. The occipital condyles are at a point about $\frac{1}{10}$ of the distance from the posterior to the anterior extremity of the head, but this part is heavier than the anterior, and therefore nearly balanced. The foramen magnum looks down; in quadrupeds it is posterior and looks back; in anthropoid apes it is intermediate in direction. The downward openings of the nostrils, forward aspect of the orbits, vertical forehead, and oval face are in strong contrast with the small cranium and strong crests of the animal. In late years the *vertebrate theory* of the skull tends to be abandoned.

What are some of the various forms of skull?

According to Age: in the fœtus the posterior part is large and the face is not one-eighth of the cranial bulk, while in the adult it is one-half. The skull grows rapidly during the first seven years; at puberty there is a second period of growth affecting face and air-sinuses.

Sexual Differences: the female skull is smaller, smoother, and lighter than the male; the cranial cavity is less by one-tenth.

Race Differences: the capacity normally varies from 60 to 110 cubic inches (1000 cc. to 1800 cc.), with an average in all races of 85 cubic inches (1400 cc.).

Skulls exceeding 87 cubic inches (1450 cc.) are megacephalic—Europeans and Eskimos.

Skulls below 80 cubic inches (1350 cc.) are microcephalic—Australians.

Skulls between 80 and 87 cubic inches (1350 and 1450 cc.) are mesocephalic—Chinese.

What are the names of certain fixed points on the skull?

Alveolar point, centre of upper alveolar arch.

Subnasal point, middle of anterior nasal aperture.

Nasion, middle of naso-frontal suture.

Ophryon, middle of that supraorbital line which separates the face from the cranium.

Bregma, point of junction of coronal and sagittal sutures.

Obelion, point in the sagittal suture between the parietal foramina.

Lambda, point of junction of sagittal and lambdoid sutures.

Occipital point, median point of occiput most removed from glabella.

Inion, external occipital protuberance.

Opisthion, middle of posterior margin of foramen magnum.

Basion, middle of anterior margin of foramen magnum.

Pterion, spheno-parietal suture.

Lower stephanion, where lower temporal line crosses the coronal suture.

Upper stephanion, where the upper temporal line crosses the coronal suture.

Asterion, lateral angle of occipital bone.

Auricular point, centre of orifice of external auditory meatus.

What are some of the measurements of the cranium ?

Maximum circumference (horizontal), 21.7 inches (550 mm.); minimum, 17.7 inches (450 mm.); average in adult European male, 20.5 inches (525 mm.), in female, 19.5 inches (500 mm.).

The proportion of the breadth to the length on a scale of 100 is the *cephalic index*:

Skulls with a breadth-index above 80 are brachycephalic.

Skulls with a breadth-index from 75 to 80 are mesaticephalic.

Skulls with a breadth-index below 75 are dolichocephalic.

The breadth is usually taken as four-fifths the length.

The *gnathic index* expresses the degree of projection of the jaws. Similarly, there are the *nasal index*, *orbital index*, etc. Irregularities of form are a result of too early ossification of sutures: *scaphocephaly* is a result of obliterated sagittal suture; *acrocephaly* is due to obliterated coronal suture; *plagiocephaly* is oblique deformity.

BONES OF THE UPPER EXTREMITY.

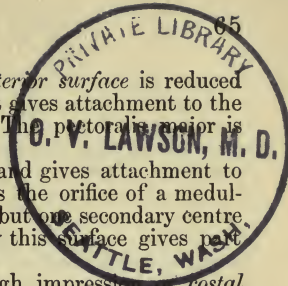
Upper limb,	{	Shoulder { clavicle } , forming shoulder-girdle.
		scapula }
		Arm (brachium), humerus.
		Forearm (antibrachium), radius and ulna.
Hand (manus)	{	carpus.
		metacarpus.
		phalanges.

THE SHOULDER.

Describe the clavicle.

The clavicle (key) passes out, back, and slightly upward from the summit of the sternum to the acromion, and connects the upper limb to the trunk. It is curved like the letter *f* for purposes of elasticity and admission of vessels behind it. The inner curve is convex forward, and occupies two-thirds of the bone: this part is prismatic. The outer third of the bone is concave in front and is flattened from above down.

The superior surfaces of these two portions are continuous; the inferior surfaces are continuous; the anterior border of the outer portion runs into the anterior surface of the inner; and the posterior border of the outer is continuous with the posterior surface of the inner. The *superior surface* is broad externally and largely subcutaneous; at its centre it may present a canal for the supraclavicular nerve; the sterno-cleido-



mastoid is attached to the inner part. The *anterior surface* is reduced to a rough border on the outer portion, where it gives attachment to the deltoid, and may present a *deltoid tubercle*. The *pectoralis major* is attached to the inner half.

The *posterior surface* is a border externally and gives attachment to the trapezius. In the middle of this surface is the orifice of a medullary canal directed outward. (In bones having but one secondary centre the medullary artery runs *from* it.) Internally this surface gives attachment to the sterno-hyoid muscle.

The *inferior surface* shows internally a rough impression or *costal tuberosity* about 1 inch long, for the rhomboid ligament; internal to it is a small facet for articulation with the cartilage of the first rib; external to it, a groove passing beyond the middle third for the subclavius muscle: the groove may show a longitudinal ridge for an intermuscular septum. On the posterior border, at the junction of the outer and middle thirds, is the *conoid tubercle* (scapular tuberosity), and passing out and forward from it the *trapezoid line*.

The *sternal end* is thick and projects in an angle down and backward, its triangular concavo-convex surface looking a little downward and forward. The *scapular end* is so bevelled as to rest upon the acromion, the small articular surface looking down and out: this end is normally a little higher than the acromion on which it rests.

This bone is a fulcrum to enable muscles to give lateral motion to the arm: it is absent in animals whose fore limbs are used only for progression—*e. g.* horse and bear; in carnivora it is not attached to bone; it is the furculum or “wish-bone” of birds. The female clavicle is smoother and more slender than the male. The right clavicle is usually rougher and shorter than the left. It is *developed* from two centres: one is the earliest in the body to appear, fifth week, and the secondary centre at the sternal end is the last in the body to appear, twentieth year.

Describe the scapula.

The scapula (spade) extends from the second to the seventh rib or seventh interspace. It is attached to the trunk only by muscles, is articulated with the clavicle, and from it is suspended the humerus in the shoulder-joint: its posterior border is about 1 inch from, and parallel with, the vertebral spines; its anterior surface looks forward, down, and in. The bone consists of a large triangular blade or *body*, and two processes, the coracoid and spine, and presents for examination two surfaces, three borders, and three angles. The *anterior surface*, or *venter*, presents the *subscapular fossa*, marked by three or four converging oblique lines, giving attachment to tendinous intersections of the subscapular muscle. The deepest part of the fossa is the *subscapular angle*, where the bone seems bent on itself, so that the thickest part of the muscle is perpendicular to the plane of the glenoid cavity, and can act most advantageously. Separated from this fossa are two flat surfaces, one at the upper angle and one at the lower: with the line connecting them close to the vertebral border they give attachment to the serratus magnus muscle.

The *posterior surface*, or *dorsum*, is divided by the spine into two unequal fossæ, the *supraspinous* and *infraspinous*. The *supraspinatus* muscle rises from the inner two-thirds of the upper fossa. The lower fossa is marked near the centre by a convexity corresponding to the concavity of the venter; on either side of this is a groove, the external one being deep and bounded by the axillary border. Near the inner border are short lines for intermuscular septa of the *infraspinatus* muscle, which rises from the inner two-thirds and covers the outer third. Along the outer part of this surface is a ridge passing down and back to the inner border, about 1 inch above the inferior angle: it gives attachment to the aponeurosis between the *infraspinatus* and *teres* muscles. On the upper third of the narrow surface between this line and the axillary border is a groove for the *dorsalis scapulæ* vessels; the middle third and part of the upper give attachment to the *teres minor*. Below this, including the inferior angle, is a raised surface for the *teres major*, over which the *latissimus dorsi* glides or attaches a few fibres. An oblique line separates the origins of the two *teres* muscles.

The *spine* of the scapula is a triangular plate projecting back and up from the *dorsum*. Beginning near the upper fourth of the vertebral border, it passes up across the *dorsum* to the middle of the neck of the scapula, and turns forward into the *acromion process*. The upper and lower surfaces are concave and form parts of the two dorsal fossæ. It has two unattached borders, a posterior subcutaneous one and an external axillary one. The former rises from the vertebral border by a triangular surface, over which a tendon of the *trapezius* glides as it passes to its insertion into a rough tubercle beyond. (This tubercle is very large in animals.) The rest of this border is rough and serpentine, and gives attachment by a superior lip to the *trapezius*, by an inferior lip to the *deltoid*. The external border is short, smooth, and concave, enclosing the *great scapular notch*.

The *acromion process* projects out and forward over the *glenoid fossa*: it is compressed from above down; its superior surface is rough, subcutaneous, and continuous with the prominent border of the spine. Anteriorly on its inner border is an oval articular facet for the *clavicle*: to this border is attached the *trapezius*, to the outer border the *deltoid*, marked by three or four tubercles for tendinous septa. This outer border terminates posteriorly in the *acromial angle*. The *coraco-acromial ligament* is attached to the apex of the *acromion*.

The *coracoid process* rises at first almost vertically from the upper border of the head, compressed from before backward: it then bends at a right angle forward and outward. Superiorly, toward its base, is the origin of the *conoid ligament*, and the *trapezoid* rises from an oblique line running forward and outward. The *coraco-acromial ligament* is attached to the outer border, the *conjoined tendon* of the *coraco-brachialis* and *biceps* to its apex, and the *pectoralis minor* to its inner border. The tip of the *coracoid* is about one and a half inches distant from the apex of the *acromion*.

The *external angle* of the scapula is the thickest part of the bone: it is called the *head*, supported on a *neck*. The head bears the *glenoid cavity*: this is slightly concave, looks outward, forward, and slightly upward. It is pyriform, with its narrow end above, and measures $1\frac{3}{8}$ inches by $1\frac{1}{8}$ inches (40 mm. by 30 mm.). Above it is a *supraglenoid tubercle* for the long head of the biceps. The "anatomical neck" is the part just behind the head.

The *superior angle* of the scapula is thin and rounded, and gives attachment to some fibres of the levator anguli scapulæ.

The *inferior angle* is thick and rough for the teres major attachment, sometimes the latissimus dorsi.

The *superior border* is shortest, and extends from the superior angle down to the coracoid, at the base of which is the *suprascapular* or *coraco-scapular notch*. A line through the suprascapular and great scapular notches marks the "surgical neck" of the bone.

The *axillary border* is the thickest. Beneath the glenoid fossa is a rough tubercle or ridge, *infraglenoid*, over an inch long, for the long head of the triceps. On the ventral aspect of this border is a longitudinal groove from which the subscapular muscle rises in part.

The *vertebral border* is the longest, and gives attachment above the triangular surface at the apex of the spine to the levator anguli muscle, opposite the triangular surface to the rhomboideus minor, and below this to the rhomboideus major.

The body of the scapula is mostly thin and translucent, and has no cancellated tissue in those spots. Vascular foramina pierce the upper and lower surfaces of the spine and the anterior surface near the neck. The human scapula is remarkable for its length. All mammals possess scapulæ. The coracoid reaches to the sternum in birds.

The bone is *developed* from seven centres and is ossified in two principal parts, one for the body and one for the coracoid, which represents the large coracoid bone of lower vertebrates. The various epiphyses should be joined to the bone at the age of twenty-five. Sometimes the acromion and spine do not unite, and a joint with hyaline cartilage and synovial membrane may here be present.

THE ARM.

Describe the humerus.

The arm-bone extends from the shoulder to the elbow. It is divisible into an upper extremity, including head, neck, great and small tuberosities, a shaft, and inferior extremity, which includes condyles, epicondyles, and articular surface. The *head* forms one-third of a sphere of $1\frac{1}{2}$ inches (32 mm.) radius, but the margin is not a true circle: a line from the upper part of the articular surface down and back to the lower part is 2 inches (50 mm.). A transverse diameter at right angles to this is $1\frac{1}{2}$ inches (44 mm.). The head is directed up, in, and a little backward, and makes an angle of 140° with the shaft. The "anatomical

neck" is the slight constriction at the circumference of the articular surface; the "surgical neck" is below the tuberosities.

The *great tuberosity* is a thick projection starting up from the external surface of the shaft. It is marked above by three facets, the upper for the supraspinatus tendon, the next for the infraspinatus, and the lowest for the teres minor, which also is attached to the shaft to the extent of 1 inch. Separated from this tuberosity by the *bicipital groove* (inter-tubercular sulcus, $\frac{2}{3}$ inch (10 mm.) broad) is the *small tuberosity*, looking forward and inward and giving attachment to the subscapularis.

The *shaft* is thick and cylindrical above, expanded transversely and three-sided below. It is divided into external, internal, and posterior surfaces by anterior and lateral borders. (Henle describes it as having two surfaces and two borders.) Superiorly is the bicipital groove lodging the long tendon of the biceps and a branch of the anterior circumflex artery. This groove, descending, is bounded by rough margins, the external or *pectoral ridge* (spina tuberculi majoris) for the pectoralis major muscle, and the internal for the latissimus dorsi and teres major muscles: these muscular attachments end at the junction of the upper with the lower three-fourths.

The *anterior border* is the pectoral ridge continued to the coronoid depression below. It becomes rounded and smooth below, and gives attachment to the brachialis anticus muscle.

The *inner border* is the inner bicipital ridge continued to the inner condyle, called below the *internal supracondylar ridge*. About the centre of this border is a rough linear mark for the coraco-brachialis muscle, and just below it the orifice of the medullary canal directed downward.

The *external border* runs from the back part of the great tuberosity to the external condyle. Its centre is traversed by the broad *spiral groove*, limited above by the *deltoid eminence* and below by the *external supracondylar ridge*. The ridge gives origin by its upper two-thirds to the supinator longus muscle; hence it is called the *supinator ridge*, which is very large in burrowing animals: its lower third attaches the extensor carpi radialis longior. The posterior lip of either supracondylar ridge is for the triceps, and a middle portion for intermuscular septa. The *external surface* presents near its middle the *deltoid eminence*.

The *internal surface* is narrow above, and forms the bicipital groove; near its centre is the insertion of the coraco-brachialis. Below this level the external and internal surfaces are occupied by the brachialis anticus.

The *posterior surface* is twisted, so that its upper part is directed a little inward, its lower part backward and outward. It is nearly all covered by the external and internal heads of the triceps, which are separated by the spiral groove running down and out. At the upper part of this groove is generally a second medullary foramen for a branch of the superior profunda artery.

The *inferior extremity* is flattened from before backward and curved

slightly forward. The two *condyles* include the articular surface, separated by a rounded ridge; the inner condyle is five-sixths articular. The prominent tuberosities situated on either condyle are the *epicondyles*, developed from separate centres. The *internal epicondyle* is the more prominent one, is inclined backward, and forms posteriorly a shallow groove for the ulnar nerve. It gives attachment to the pronator radii teres and the common tendon of the superficial pronator-flexor muscles of the forearm.

The *external condyle* presents (1) the epicondyle, which gives origin to some of the supinator-extensor muscles of the forearm; (2) below and internal to this on the condyle a small impression for the anconeus; and (3) a pit for the external lateral ligament.

The *inferior articular surface* is divided into two parts: the external part, rounded and directed forward, is the *capitellum* for articulation with the radius; it does not extend at all on the posterior surface. Internal to it is a groove for the inner margin of the head of the radius. The internal portion, or *trochlea*, articulates with the ulna, and extends from the anterior to the posterior surface of the bone; the external border is rounded and corresponds to the internal between the radius and ulna. The internal border is thick and prominent. Anteriorly these margins are inclined down and inward, posteriorly up and outward, so that the groove is obliquely inclined from without inward, and if continued would form the thread of a screw. The external part of the trochlea is the segment of a sphere, the internal part the segment of a truncated cone with base internal; at the junction of the cone and sphere is the groove.

Above the trochlea posteriorly is the *olecranon fossa*, above it anteriorly the *coronoid fossa*: the thin plate between them may be perforated by the *supratrochlear foramen*. This occurs more often in the lower races of man and in the gorilla. Above the capitellum is the *radial fossa* for the head of the radius in flexion.

The average length of the adult male humerus is 13 inches, female, 12 inches. It is nearly one-fifth the height of the individual. The right humerus with the radius is usually $\frac{1}{2}$ to $\frac{3}{4}$ inches longer than the left; no difference at birth.

The shaft of the humerus is twisted through about 135°. The twist is seen at the spiral groove, "groove of torsion," which does not exist in the fœtus; this allows the hand to serve the purposes of the head and mouth. A small hooked *supracondylar process* is sometimes found about 2 inches above the inner epicondyle. A fibrous band connects it to the inner epicondyle and gives origin to the pronator radii teres muscle; through the arch beneath pass the median nerve and brachial artery.

Remains of this foramen are seen in a fibrous band connected with the pronator muscle in about 45 per cent. of cases.

The humerus is *developed* from seven centres; the upper epiphysis unites last.

THE FOREARM.

Describe the ulna.

This is the internal of the two bones of the forearm. A line passing from the tuberosity of the humerus through the capitellum touches the lower end of the ulna. It is the arm-bone, while the radius is the hand-bone.

The *upper extremity* presents two processes and two articular concavities. The *great sigmoid cavity*, articulating with the trochlea, looks upward and forward, and is bounded above by the *olecranon* and below by the *coronoid processes*; it is concave from above down, and is traversed by a longitudinal ridge which is a half-circle of $\frac{2}{3}$ inch (10 mm.) radius. The part external to the ridge is broad and convex above, the part internal is broad and concave below. A slight constriction is seen across the middle of the cavity. Continuous with it is the *small sigmoid cavity* on the outer side of the base of the coronoid: it is concave from before backward for the head of the radius. The *olecranon* terminates in front in a beak which overhangs the great sigmoid cavity; behind it is a rectangular tuberosity, forming the point of the elbow. It has superiorly a ligamentous district, next a bursal, and next a tendinous one for the triceps. The posterior surface of the olecranon is triangular and subcutaneous, and continuous with the posterior border of the ulna. The extremity of the *coronoid process* is sharp and pointed. Its superior surface is a part of the great sigmoid cavity. At the inner part of the junction of the coronoid to the shaft of the ulna, also to the *tuberosity of ulna* at the angle of junction, is attached the brachialis anticus muscle, not *into* the process. Arising from the process is one head of the flexor sublimis digitorum, the flexor profundus, pronator radii teres, and occasionally the flexor longus pollicis.

The *shaft or body* tapers from above, is three-sided in its upper three-fourths, slender and cylindrical in its lower fourth. The upper three-fourths are convex backward; it is also convex externally above and internally below. The *anterior border* passes from the inner edge of the coronoid to the front of the styloid: it is thick and rounded, and gives attachment to the flexor profundus digitorum, and in its lower fourth to the pronator quadratus.

The *posterior border* begins below the olecranon, and runs with a sinuous curve to the back of the styloid. It is ill defined below and subcutaneous throughout, and affords attachment to an aponeurosis common to three muscles—the flexor carpi ulnaris, extensor c. ulnaris, and flexor profundus. The *external or interosseous border* is a sharp edge in the middle three-fifths of the shaft. Below it is faintly marked. The upper one-fifth is continued by two lines passing to the extremities of the small sigmoid notch: the posterior line is prominent, *supinator ridge*, for the supinator brevis muscle.

The *anterior surface* is concave above, and gives origin to the flexor profundus digitorum: the lower one-third is marked by the oblique *pro-*

nator ridge, which joins the anterior border. Above the middle is a medullary foramen directed upward.

The *internal surface* is smooth, and gives attachment to the flexor profundus digitorum muscle: it is subcutaneous in the lower one-third. The *posterior surface* looks outward and backward: an oblique line descending from the supinator ridge to the posterior border at the junction of its upper and middle thirds marks off a triangular area for the anconeus muscle. The ridge itself gives attachment to the supinator brevis. Below this is a longitudinal ridge dividing the surface into a smooth inner portion covered by the extensor c. ulnaris, and an outer part impressed from above downward by the extensor ossis metacarpi pollicis, extensor secundi internod. poll., and extensor indicis.

The *inferior extremity* presents a rounded *head*: from its inner and back part there projects downward the *styloid process*, giving attachment to the internal lateral ligament and to the triangular fibro-cartilage. Between the head and styloid process is a groove for the tendon of the extensor carpi ulnaris.

The *head* has two articular surfaces—an inferior one, upon which the triangular fibro-cartilage plays, and an outer narrow convex one, for the sigmoid cavity of the radius. With the hand supine the styloid process projects at the inner and back part of the wrist: if pronated, the outer and fore part of the ulnar head is prominent between the tendons of the extensor c. ulnaris and extensor min. digiti.

The ulna is *developed* from three centres: the greater part of the olecranon grows by an extension from the shaft.

Describe the radius.

This bone articulates with the humerus, ulna, scaphoid, and semilunar bones. The *superior extremity*, or *head* (*eminentia capitata*), is disk-shaped. On its summit is a depression for the capitellum of the humerus. It is surrounded by a convex part, broadest internally, which rotates in the small sigmoid cavity of the ulna within the orbicular ligament. The head is supported by a *neck*, which presents behind a ridge for part of the insertion of the supinator brevis.

The *shaft* is larger below than above, slightly curved, and convex outward and backward. Antero-internally below the neck is the *bicipital tuberosity*, rough posteriorly for the insertion of the biceps, and smooth in front for a bursa. Below this tuberosity the shaft has three surfaces and three borders.

The *anterior border* extends from the tuberosity to the base of the styloid: its upper part is called the *anterior oblique line*, and gives attachment to the supinator brevis, flexor longus pollicis, pronator radii teres, and flexor sublimis.

The *posterior border* runs from the back of the neck to the posterior part of the base of the styloid. It is well marked only in its middle third.

The *internal* or *interosseous border* becomes prominent below, and at

its lower part divides into two ridges which meet the margins of the sigmoid cavity, analogous to the division of a like border of the ulna.

The *anterior surface* is grooved longitudinally for the flexor long. poll. muscle: at the lower end is a flattened impression for the pronator quadratus, which also rises from a small surface at the inner side of the bone. A medullary foramen is above the middle of this surface.

The *posterior surface* shows at the junction of the upper and middle thirds the *posterior oblique line*, below which is attached the extensor ossis metacarpi poll., and below that the extensor primi internodii poll. The *external surface* is convex, and marked near the middle by an impression for the pronator radii teres: above this, on the area between the anterior and posterior oblique lines, is inserted the supinator brevis.

The *lower extremity* of the *radius*, broad and quadrilateral, presents a carpal articular surface and an ulnar articular surface. The former is divided by a line into a quadrilateral inner part for the semilunar, and a triangular outer part for the scaphoid. The articular surface for the ulna or *sigmoid cavity* is at right angles to the inferior surface, and concave from before backward. To the smooth border between these two articular surfaces is attached the base of the triangular fibrocartilage. Externally the *styloid process* projects downward. Anteriorly a transverse ridge forms the lowest limit of the pronator quadratus impression, which is continued into a vertical ridge external to that impression: between this ridge and the scaphoid facet is a triangular area for a strong band of the anterior ligament. The external and posterior aspects are marked by the following grooves from without inward: a flat groove for the extensor ossis met. poll. and extensor prim. internod. (next descends the styloid process); a broad groove, subdivided by a slight ridge, for the extensor carpi rad. longior and brevior; an oblique narrow groove, bounded externally by a *tubercle*, for the extensor secundi internod. poll.; a broad groove for the extensor indicis, extensor communis, and extensor min. dig. Just above the first groove is an impression for the supinator longus.

The relative length of the forearm to the arm is expressed by the *humero-radial index*: Eskimo, 71 (*i. e.* the radius is 71 if the humerus be taken as 100); European, 74; gorilla, 80; orang, 100. The index is higher in the fetus and infant. The radius in bats and birds is very long and supports the wing. The radius is *developed* from three centres. All the epiphyses around the elbow unite earlier than those at the opposite ends of the bones.

THE HAND.

The skeleton of the hand consists of three segments—wrist-bones, bones of palm, and bones of fingers.

Describe the carpus, or wrist-bones.

The carpus is composed of eight short bones arranged in two rows: the upper row, from radial to ulnar side, comprises the scaphoid, lunar

(semilunar), pyramidal (cuneiform), and pisiform; in the inferior row are the trapezium, trapezoid, os magnum, and unciform. The dorsal surface of the carpus is convex, and palmar concave transversely; the concavity is bounded by four prominences (*eminentiæ carpi*), one at each end of each row, to which the anterior annular ligament is attached. The superior surfaces of the scaphoid, lunar, and pyramidal form a meniscus for articulation with the concavity presented by the radius and triangular fibro-cartilage. The mid-carpal articulation is concavo-convex, the trapezium, trapezoid, and os magnum forming a concavity for the scaphoid, while the unciform and head of the os magnum rise up in a convexity. Each bone is more or less cubical and presents six surfaces.

The *scaphoid* (boat-like) has its long axis directed down and out. Internally it has two articular facets, a lower one for the os magnum and an upper crescentic one for the lunar. The superior surface is smooth and triangular, passes farther back than forward, and articulates with the radius. The inferior surface is smooth and convex, divided by a ridge, articulating externally with the trapezium and internally with the trapezoid. The anterior surface is concave above, and presents a conical *tuberosity* below. The external surface is rough and narrow. The posterior surface is a narrow transverse groove.

The *lunar* bone is characterized by a deep concavity from before backward on its inferior surface; it is for the head of the os magnum. This surface also presents a long narrow facet for the unciform. Externally it is crescentic and vertical for the scaphoid. Its internal surface looks down and in, is narrower than the external, and articulates with the pyramidal. The convex upper surface is four-sided, articulates with the radius, and extends farther back than forward, so that the anterior free surface is deeper than the posterior.

The *pyramidal* (cuneiform) bone directs its blunted apex down and in. The base shows a flat quadrilateral surface for the lunar. The inferior surface is concavo-convex from without inward, and articulates with the unciform. The anterior surface has a small articular facet on its inner half for the pisiform. The supero-posterior surface has near the base an articular facet for the triangular fibro-cartilage, but is mostly rough for ligaments.

The *pisiform* (like a pea) is anterior to the other bones of the carpus. It is spheroidal, with longest diameter directed vertically. Posteriorly it is an oval facet for the pyramidal, leaving a free portion below. The inner surface is convex and rough; the outer, toward the flexor tendons, is smoother and slightly concave.

The *trapezium* (a table) is the most external of the second row. The supero-internal surface is concave and articulates with the scaphoid. The inferior surface, directed down and out, is concavo-convex for the first metacarpal. The internal surface articulates with the trapezoid, and on its lower inner angle with the second metacarpal. The anterior surface is marked by a vertical groove for the flexor carpi radialis tendon,

external to which is a ridge or *tuberosity* for the annular ligament. The anterior, external, and dorsal surfaces are free.

The *trapezoid* is much smaller than the trapezium; its longest diameter is from before backward, and its posterior surface is larger than its anterior. The external inferior angle of the anterior surface is prolonged backward between the smooth surface for the trapezium and that for the second metacarpal bone. The superior surface is quadrilateral and articulates with the scaphoid; the external is convex for the trapezium; the internal articulates with the os magnum; and the inferior concavo-convex surface with the second metacarpal. Hold the bone with the larger non-articular surface toward you and the smooth quadrilateral articular surface upward (for scaphoid); the convex articular surface (for the trapezium) will point to the side to which the bone belongs.

The *os magnum* (os capitatum) is the largest of the carpal bones, rectangular below and rounded above. The upper extremity, or *head*, articulates with the lunar, its smooth surface extending farther behind than in front, and prolonged upon its outer side for the scaphoid. The *neck* is formed by depressions anteriorly and posteriorly. The anterior surface is narrower than the posterior. The posterior surface projects downward at its internal inferior angle. Externally, below the surface for the scaphoid, is a facet for the trapezoid. On the posterior part of the inner surface is a vertical facet for the unciform. Inferiorly there are three facets, the middle being the larger, for the second, third, and fourth metacarpal bones.

The *unciform* (hook-like) bone is wedge-shaped, with its base or inferior surface resting on the fourth and fifth metacarpal bones: its apex points up and out and articulates with the lunar. The external surface is vertical, and articulates with the os magnum by its upper posterior part. Its supero-internal surface is concavo-convex for the pyramidal: it is separated from the inferior surface by a rough border. The anterior surface at its lower and inner side presents the *unciform process*, projecting forward and curved slightly outward.

ARTICULATIONS OF CARPAL BONES.

	Superior.	External.	Inferior.	Internal.	Anterior.	Posterior.	Number.
Scaphoid . .	radius	free	trapezium trapezoid	os magnum lunar	free	free	5
Lunar . . .	radius	scaphoid	os magnum unciform	pyramidal	free	free	5
Pyramidal .	triangular fib. cart.	lunar	unciform	free	pisiform	free	3
Pisiform . .	free	free	free	free	free	pyramidal	1
Trapezium .	scaphoid	free	1st metacarp.	trapezoid 2d metacarp.	free	free	4
Trapezoid .	scaphoid	trapezium	2d metacarp.	os magnum	free	free	4
Os magnum	scaphoid lunar	trapezoid	2d, 3d, and 4th metacarp.	unciform	free	free	7
Unciform . .	lunar	os magnum	3d and 4th metacarp.	pyramidal	free	free	5

The carpus is wholly cartilaginous at birth: each bone is developed from a single centre except the scaphoid. The nucleus of the pisiform does not appear till the twelfth year, the latest of all primary centres. In the fœtus the scaphoid has normally a second cartilaginous element, which may develop into the *os centrale* placed on the back of the carpus between the scaphoid, os magnum, and trapezoid. The styloid process of the third metacarpal may be separated as a supernumerary bone.

Describe the metacarpus, or bones of palm.

The metacarpus supports the fingers and consists of five long, slightly divergent bones. They form the segment of a transverse arch: their carpal extremities are expanded bases and their digital ends are rounded heads. The first metacarpal is broad and short, the second longest of all, while the third, fourth, and fifth decrease regularly in length. The shafts are curved longitudinally, and are three-sided, presenting a posterior surface and anteriorly a median margin between two lateral surfaces. They are more slender near the carpal ends and thicker toward the heads. The dorsal surface is triangular, being bounded by lines which proceed from the sides of the head and converge in the second, third, and fourth metacarpals opposite the middle of the carpal extremity. The *heads* articulate with the proximal phalanges: their smooth surfaces broaden and extend farther on the palmar than on the dorsal aspect. On each side is a tubercle, with a hollow below it for attachment of the lateral ligament. The *carpal extremities* present distinctions. The *first* bone has a saddle-shaped articular surface, and externally a prominence for the insertion of the extensor ossis metacarpi poll. The shaft is compressed and dorsal surface convex. On the palmar surface the rounded ridge is nearer the inner than the outer border. The carpal extremity of the *second* is notched for the trapezoid. On the radial side is a facet for the trapezium, and close to it an impression for the extensor carp. rad. long. A prominent ulnar lip with two long facets is the distinguishing feature. The *third* bone presents a *styloid process* on the posterior radial angle, passing up behind the os magnum, and below it an impression for the extensor carp. rad. brev. The radial side has one facet and the ulnar side two. The carpal extremity of the *fourth* has two facets on the radial side, and a concave semielliptical one on the ulnar side. The *fifth* has a saddle-shaped surface for the unciform, and a *tuberosity* on the ulnar side for the extensor carpi ulnaris. There is only one oblique ridge on the dorsal surface, extending from the radial side of the head to the ulnar side of the base.

The first metacarpal articulates at its base with 1 bone.

The second metacarpal articulates at its base with 4 bones.

The third metacarpal articulates at its base with 3 bones.

The fourth metacarpal articulates at its base with 4 bones.

The fifth metacarpal articulates at its base with 2 bones.

It is interesting that the corresponding metatarsals articulate with exactly the same number.

Describe the digital phalanges.

The phalanges (internodia) are fourteen in number, three for each finger and two for the thumb. Those of the *first row*, five in number, are slightly curved. The dorsal surface is transversely convex, while the palmar is flat and bounded by rough margins. Their metacarpal extremities are thick and present a transversely concave surface; their distal extremities are smaller and divided by a median groove into two condyles. The bones of the *middle row* are four in number, and smaller than the preceding: their proximal articular surfaces show a middle ridge and two lateral depressions. The distal ends are like those of the first row. The *terminal* or *ungual* phalanges are five in number: their proximal extremities are like those of the middle, but with a depression in front for the deep flexor. Their free extremities are flat and expanded, and raised round the margins of the palmar aspect into an *ungual process*.

Where are the sesamoid bones of the hand?

One pair, each $\frac{1}{2}$ inch (5 mm.) in diameter, is placed in the palmar wall of the metacarpo-phalangeal joint of the thumb; others, single or double, may occur in the corresponding joint of the index and little fingers, more rarely in the third and fourth.

Collectively, the phalanges of the middle finger are longest, then those of the ring, index, little finger, and thumb. In some hands the index is longer than the ring, due wholly to the length of the metacarpal bone.

The metacarpals and phalanges are formed each from one centre for the shaft, and one for an epiphysis. In the four inner metacarpals the epiphyses are at the heads; in the metacarpal of the thumb and in the phalanges the epiphyses are at the bases. The so-called first metacarpal therefore resembles a phalanx. The unguinal phalanges are peculiar in beginning to ossify at the distal extremities instead of in the middle. In the metacarpals the medullary foramen is on the radial side of the palmar surface, and the canal runs toward the base; in the phalanges and first metacarpal the canal runs toward the head of the bone.

BONES OF THE LOWER EXTREMITY.

The lower limb consists of the haunch or hip, thigh, leg, and foot. In the haunch is the hip-bone, in the thigh the femur, in the leg the tibia and fibula, at the knee a large sesamoid bone, the patella, in the foot the tarsus, metatarsus, and phalanges. The pelvis and hip-bone are a part of the lower extremity.

THE PELVIS.**Describe the hip-bone.**

The *hip* or *innominate* bone (os coxæ), with its fellow, the sacrum, and coccyx form the pelvis. This bone is constricted in the middle and expanded above and below; it has been likened to the shape of a meat-chopper.

The *acetabulum* is on the outer aspect of the constricted portion, and the inferior expanded portion is perforated by the *thyroid* or *obturator foramen*. The bone above forms part of the abdominal wall, and below part of the true pelvis. In early life the *ilium*, *pubes*, and *ischium* are distinct.

The *ilium* (*ilia*, flanks; *ileum* is a part of the small intestine) is the superior expanded portion, and forms less than two-fifths of the acetabulum. This portion is limited anteriorly and posteriorly by margins which diverge at right angles from each other, and superiorly by the arched *crest of the ilium*. In front the crest is concave inward and behind it is concave outward: there is a marked external projection in the anterior third. On the crest are external and internal lips and a median ridge. The anterior extremity projects as the *anterior superior spine*; below it is a concavity, the *lesser iliac notch*, and below that the *anterior inferior spine*. Behind, the projecting extremity of the crest is called the *posterior superior spine*, separated by a small notch from the *posterior inferior spine*, below which is the *great sciatic* (ilio-sciatic) *notch*.

The *external surface* or *dorsum ilii* presents three curved *gluteal lines*. The posterior or *superior* one commences 2 inches in front of the posterior superior spine, and curves down and forward to the back part of the ilio-sciatic notch. The *middle gluteal line* begins in front about 1½ inches behind the anterior superior spine, and arches back and down to the upper part of the notch. The *inferior gluteal line*, less strongly marked, commences just above the anterior inferior spine, and passes back to the fore part of the notch. Behind the posterior line is a semilunar surface, rough above for the *gluteus maximus*: the sickle-shaped space between the posterior and middle lines and iliac crest is occupied by the *gluteus medius*; the *gluteus minimus* is between the middle and inferior lines. Just above the acetabulum is an elongated mark for the reflected head of the *rectus femoris*.

The *internal surface* is divided into two parts: the anterior part is the *iliac fossa* or *venter ilii*. To the inner side of the anterior inferior spine is a shallow groove, the *greater iliac notch*, which lodges the *ilio-psoas* muscle: the inner boundary of the groove is the *ilio-pectineal eminence*, marking the junction of the *pubis* and *ilium*. The posterior part (*sacral surface*) is again divided, presenting from below upward (1) a smooth surface in the true pelvis, separated from the iliac fossa by the *iliac portion of the ilio-pectineal line*; (2) the *auricular surface*, for articulation with the *sacrum*; (3) depressions on the *iliac tuberosity*, for the posterior *sacro-iliac ligament*; (4) a rough surface giving origin to the *erector* and *multifidus spinæ* muscles.

The iliac crest gives attachment by its outer lip to the *tensor vaginæ femoris*, *obliquus externus*, *latissimus dorsi*, and *fascia lata*; by its middle ridge to the *obliquus internus*; by its inner lip to the *transversalis*, *quadratus lumborum*, *erector spinæ*, and *iliac fascia*. To the anterior superior spine is attached externally the *tensor vaginæ femoris*, in front the *sartorius*, and internally *Poupart's ligament*. From the anterior inferior spine originates the straight

head of the rectus : just below this is an impression for the ilio-femoral ligament. The iliac part of the ilio-pectineal line gives attachment to the iliac and obturator fasciæ and tendon of the psoas parvus.

The *os pubis* forms the anterior wall of the pelvis, and bounds the thyroid foramen above. It forms about one-fifth of the acetabulum : at its inner extremity is a long oval surface marked by transverse ridges or nipple-like processes for articulation with the opposite bone ; the junction is the *symphysis pubis*. The part passing down and out from the symphysis is the *descending ramus* ; the upper part is the *superior* or *ascending ramus* ; and the flat portion between the rami is the *body*. The pelvic surface of the body is smooth, the anterior surface rough. The upper extremity of the symphysis is the *angle* ; extending out from this on the superior border is the *crest*, terminating in the *spine*. The *descending ramus* is thin and flat, and joins that of the ischium at the *pubo-ischiatic tuberosity*. The *superior ramus* becomes prismatic : its superior border is the *pubic portion* of the *ilio-pectineal line*, running from the spine of the pubis to the ilio-pectineal eminence. The triangular surface in front of this line gives origin to the pectineus muscle : below is the *obturator crest*, extending from the pubic spine to the margin of the acetabulum. Behind the outer part of the crest on the inferior surface of the ramus is the *obturator groove*, directed from behind forward and inward : it is limited by the *inferior* and *superior obturator tubercles*.

The pubic crest gives origin to part of the conjoined tendon, the pyramidalis and rectus abdominis. To the pubic spine is inserted Poupart's ligament and the outer pillar of the external abdominal ring. From the front of the pubis, in the angle between the crest and symphysis, rises the adductor longus muscle, and below this the adductor brevis and part of the adductor magnus. Internal to these the gracilis is attached, and external the obturator externus. Posteriorly the pubis gives attachment to the obturator internus : above this is sometimes a faint line passing from the upper margin of the obturator foramen to the lower end of the symphysis ; the levator ani muscle is attached to it, and the obturator and recto-vesical fasciæ.

The *ischium* forms the lower and back part of the hip-bone, bounds the thyroid foramen below, and forms over two-fifths of the acetabulum. It presents a *body*, and below this a *tuberosity* continued forward into the *ramus*. The body has three surfaces, external, internal, and posterior. The *external surface* helps form the acetabulum ; below this and above the tuberosity is a horizontal groove for the tendon of the obturator externus muscle. The *internal surface* is smooth, and forms part of the wall of the true pelvis. In front it is separated from the iliac fossa by the iliac portion of the ilio-pect. line, but behind the junction of the ischium and ilium does not reach that line. The *posterior surface* is quadrilateral, getting narrow below, and continuous with the tuberosity. It presents a part of the groove for the obturator externus, and supports the pyriformis, the two gemelli, and the obturator internus. On the posterior border is the *spine*, projecting back and in, and forming the inferior limit of the *ilio-sciatic notch*.

The *small sciatic notch* is between the spine and tuberosity. The *tuberosity* presents two lips and an intermediate space. The external lip gives attachment to the quadratus femoris and adductor magnus; the inner lip to the falciform portion of the great sacro-sciatic ligament, and more anteriorly to the transversus perinei and erector penis. The intermediate space is divided into two portions: the anterior part attaches the adductor magnus externally and great sacro-sciatic ligament internally; the posterior part has two facets, an upper and outer for the semimembranosus, a lower and inner for the biceps and semitendinosus.

The *ramus* joins the descending ramus of the pubis at the inner side of the thyroid foramen. Its outer surface gives attachment to the obturator externus, adductor magnus, and gracilis. The crus penis, and above that the constrictor urethræ, are attached to the inner border.

The *acetabulum*, or *cotyloid cavity*, is cup-shaped, and looks out, down, and forward. It is nearly surrounded by a prominent rim which presents three depressions—a slight one anteriorly and posteriorly, and the *cotyloid notch* below. In the lateral and upper parts of the cavity is a broad horseshoe-shaped articular surface. From the anterior corner of the horseshoe run two lines, one up and forward as the obturator crest to the pubic spine, the other backward to the superior obturator tubercle. The central part of the cup and the notch are depressed (*fossa acetabuli*), and contain fat and the interarticular ligament. This non-articular surface belongs mostly to the ischium.

The *thyroid* or *obturator foramen* (foramen ovale) is internal to and below the acetabulum. It is nearly oval in the male, more triangular in the female. It is closed by fibrous membranes, except in the region of the obturator groove in its upper margin.

The hip-bone is strongest along lines of greatest pressure. There is a thick bar on the ilium from the auricular surface to the acetabulum, also a second in the ischium and its tuberosity, and another running up from the acetabulum to the most prominent part of the crest. The iliac fossa and floor of the acetabulum are very thin: vascular foramina perforate the thickest parts of the bone. There may be an accessory ischial spine in the great sacro-sciatic notch. The pelves of most Javanese women present a *preauricular* sulcus for the anterior sacro-iliac ligament, rarely developed in European women.

The os innominatum is developed from eight or more centres in three principal pieces. By the seventh or eighth year the three pieces are separated by a Y-shaped cartilage in the acetabulum, which begins to ossify by the twelfth year from several centres: the most constant gives rise to a triangular *os acetabuli*, which forms the whole of the pubic portion of the articular cavity. Between the ilium and ischium are some irregular nodules, and a lamina spreads over the iliac and ischial portions of the articular surface. Secondary centres appear for the crest of the ilium, the tuber ischii, the anterior inferior spine, and symphysis: all are joined to the main bone by the twenty-fifth year.

Describe the pelvis as a whole.

The *pelvis* (basin) is composed of four bones—two ossa innominata, the sacrum, and coccyx. It is divided into two parts by a plane passing

through the sacral promontory, ilio-pectineal lines, and upper border of symphysis. This circle is the inlet or *brim* of the *true pelvis*: the space above it really belongs to the abdomen, but is called the *false* or upper pelvis. The pelvic outlet presents three large prominences, the coccyx and tuberosities of the ischia. Beneath the symphysis and between the ischial tuberosities is the *subpubic arch*; behind the tuberosities are the sacro-sciatic notches.

What is the position of the pelvis ?

In the erect attitude, with the heels together and toes turned out, the plane of the brim forms 60° with the horizontal, that of the outlet 16° . The base of the sacrum is about $3\frac{1}{2}$ inches above the upper margin of the symphysis, and the tip of the coccyx about $\frac{1}{2}$ inch above the apex of the subpubic arch. The sacrum looks down and forward, and is the inverted keystone of an arch, as its pelvic surface is broader than the dorsal: it is held in place chiefly by ligaments and by a slight bony projection into the iliac articular surface (Fig. 12).

What are the differences according to sex ?

In the female the bones are more slender and muscular impressions less marked; the height is less, breadth and capacity greater; but the false pelvis is relatively narrower than in the male. The sacrum is wider and flatter, less prominent, the subpubic arch is wider, about 90° (male is 75°), and the space between the ischial tuberosities is greater. The thyroid foramen is broader and more triangular in the female, nearly oval in the male.

The characteristics of the human pelvis compared with that of lower animals are its shallowness and breadth, great capacity of true pelvis, expansion of ilia, straightness of ischial tuberosities, and shortness of symphysis. The pelvis of the kangaroo is so small that the young are born when $1\frac{1}{4}$ inches long, and placed in a pouch on the abdomen of the mother, with the nipple firmly fixed in their mouths.

THE SACRUM AND COCCYX. (See *False Vertebrae*, p. 28.)

THE THIGH.

Describe the femur.

The *femur* (thigh-bone) is the largest, longest, and strongest bone of the skeleton. In the erect position it inclines inward and slightly backward. It is divisible into a *superior extremity*, including *head*, *neck*, and two *trochanters*; *shaft*; and *inferior extremity*, expanded into *external* and *internal condyles* and *epicondyles*.

The *neck* extends upward, inward, and slightly forward, being set upon the shaft at an angle of 125° . It is compressed from before backward, is broad at its base, becomes rounded at its summit, and enlarged as it joins the head. It is shorter above and in front than below and behind. Posteriorly it usually shows a shallow groove for the obturator externus

tendon. Reasons for a neck are—(1) to transmit shock through an arch; (2) room for adductor muscles; (3) room for pelvic muscles to femur.

The *head* forms more than half a sphere: its posterior inferior quadrant shows a depression (*fossa capitis*), the fore part of which gives attachment to the interarticular ligament (*lig. teres*) of the joint. In this hollow are one or two vascular foramina.

The *great trochanter* (to turn) is a thick process prolonged upward in a line with the external surface of the shaft to a level about $\frac{1}{2}$ or $\frac{2}{3}$ inch below the head. In front it is marked by a broad depression for the *gluteus minimus*. Externally an oblique line runs downward and forward, indicating the inferior border of the *gluteus medius* insertion. Lower down is a horizontal line continued to the *tubercle of the femur*, which is situated in front at the junction of the neck with the tuberosity: the tubercle is the meeting-place of five muscles—*vastus externus*, *gluteus minimus*, *obturator internus*, and two *gemelli*. Internally, at the base of the trochanter and rather behind the neck, is the *digital fossa*, giving attachment to the *obturator externus* tendon. Above and in front of this is the insertion of the *obturator internus* and *gemelli* muscles.

The upper border of the trochanter is narrow, and presents an oval mark for the *pyriformis*. The posterior border is prominent, and continuous with the *posterior intertrochanteric line*, limiting the neck posteriorly. Above the centre of this line is the *tubercle of the quadratus*, for attachment of the upper part of the *quadratus femoris*: sometimes a *linea quadrati* passes vertically down from the tubercle.

The *small trochanter* is a pyramidal eminence projecting from the postero-internal aspect of the bone at the junction of the neck with the shaft. Its apex gives attachment to the *ilio-psoas* tendon.

Anteriorly the neck of the femur is separated from the shaft by the *anterior intertrochanteric line*, which is the upper part of the *spiral line* (does not connect the trochanters): it commences at the tubercle of the femur, and runs down and in a finger's breadth in front of the small trochanter: it gives attachment to the capsular ligament, the united *crureus* and *vastus internus* muscles.

The *shaft* is arched with its convexity forward: toward the middle it is partly cylindrical, and expanded below. It presents anterior and lateral surfaces without definite lines of demarcation. All these surfaces are covered by the *crureus* and *vasti* muscles. Behind the lateral surfaces are separated by the *linea aspera*. This is a prominent ridge extending along the middle third of the shaft, bifurcating above and below. The external lip is prolonged up to the *great trochanter*: its upper end is strongly marked for the *gluteus maximus*, constituting the *gluteal ridge*. The inner lip winds round below the *small trochanter*, merging into the anterior intertrochanteric line and forming the lower part of the *spiral line*: rising from the inner lip, a third line passes up to the *small trochanter* and gives attachment to the *pectineus*.

Inferiorly two lips are prolonged to the condyles as the *internal* and *external supracondylar lines*, enclosing the flat *popliteal surface* of the

femur. The inner line is interrupted where the femoral vessels lie against the bone, and terminates below in the *adductor tubercle*. Above the centre of the *linea aspera* is the medullary foramen, directed upward; a second may exist near the lower end of the bone.

To the inner lip of the *linea aspera* is attached the *vastus internus*, to the outer lip the *vastus externus*, and diagonally between the two the *adductor magnus*. Between the *adductor magnus* and *vastus externus* are the *gluteus maximus* and short head of the *biceps*; between the *adductor magnus* and *vastus internus* are the *iliacus*, *pectineus*, *adductor brevis*, and *adductor longus*. At the lower part of the popliteal space above each condyle is the origin of one head of the *gastrocnemius*, and externally of the *plantaris*.

The *inferior extremity* presents two rounded *condyles*, united in front, but separated behind by the *intercondylar notch*: the external is broader and more prominent in front, the internal longer and more prominent internally. The inner aspect of this condyle and the head of the *femur* face nearly the same direction.

The inferior surfaces of the two condyles are on the same level in the natural position of the *femur*. Opposite the front of the *intercondylar notch* the whole articular surface is divided by a faint transverse groove on either side into three parts—a convex surface on either condyle for the tibia and a grooved anterior surface for the *patellar*.

The *patellar surface* is trochlear in form, marked by a vertical hollow and two lips: the external portion is wider, more prominent, and rises higher. The *tibial surfaces* are nearly parallel, but the internal one turns outward to meet the *patellar surface*. The exposed lateral surface of each condyle presents a tuberosity or *epicondyle* for ligamentous attachment. The external is the smaller: above it is the impression for the outer head of the *gastrocnemius*; below and behind it is an oblique groove ending inferiorly in a pit from which rises the *popliteus muscle*; its tendon sinks fully into the groove only when the knee-joint is flexed. The inner head of the *gastrocnemius* rises from the upper part of the inner condyle.

The *intercondylar fossa* presents two impressions for crucial ligaments: that for the anterior ligament is on the posterior part of the inner surface of the external condyle; that for the posterior ligament is on the fore part of the external surface of the inner condyle.

The cancellous tissue at the upper end of the *femur* is arranged in a system of "pressure lamellæ" and "tension lamellæ:" the former spring from the inner side of the neck and ascend to the head and to the great trochanter; these are crossed at right angles by the tension lamellæ, which start from the outer side of the shaft and pass upward and inward. The concave side of the neck is further strengthened by a vertical plate of compact tissue, the *calcar femorale*, just in front of the small trochanter.

The average length of the adult European *femur* is 18 inches for the male and 17 inches for the female; is .275 of the stature, and its proportion to the humerus is 100:71. The inclination of the *femur* is 9° with the sagittal plane (the two bones approach each other below) and 5° with the frontal; it is also twisted in a direction opposite to that of the humerus.

The angle of the neck with the shaft is open in the fœtus and child, then lessens under the weight of the body, but undergoes no change after growth is completed. The upper part of the gluteal ridge may form a *third trochanter*, always present in the horse.

In place of or in addition to the ridge there may be a *fossa hypotrochanterica*. A marked development of the *linea aspera* gives a *pilastered femur*. The adductor tubercle may be of large size.

The femur is *developed* from one primary centre and four epiphyses; more of growth in length depends upon the lower epiphysis, as it unites last.

Describe the patella.

The patella, or knee-pan, is a sesamoid bone developed in the tendon of the quadriceps extensor cruris. It is somewhat triangular, with its apex below. Its anterior surface is convex and striated and pierced by vascular foramina. The superior border is broad and sloped from behind downward and forward, and gives attachment to the rectus and crureus portions of the quadriceps extensor.

The posterior surface of the bone presents two vertical and two transverse ridges: one vertical ridge is close to the inner margin; the other is distinct and divides the surface into two parts, the external of which is the larger and transversely concave, the inner smaller portion is convex.

The faint transverse ridges divide the articular surface into an upper two-sixths, a middle three-sixths, and a lower one-sixth. In usual extension the lower one-sixth is in contact with the femur, in mid-flexion the middle three-sixths, and in extreme flexion the upper two-sixths; also in extreme flexion the thin marginal facet is the part in contact with the inner condyle. Below the articular surface is a rough triangular area; the ligamentum patellæ springs from the apex.

In the third month there is a deposit of cartilage in the quadriceps tendon; ossification begins from one centre in the third year and is completed at puberty.

THE LEG.

Describe the tibia.

The tibia (flute), or shin-bone, is the inner and anterior of the two bones of the leg, and transmits the weight of the trunk to the foot. It articulates with the femur, fibula, and astragalus; has a shaft and two extremities.

The *superior extremity*, or *head*, is thick and broad transversely. It forms on each side a *tuberosity*, on the upper aspect of which is a concave articular surface for the condyles of the femur. The *internal tuberosity* is larger than the external, and marked posteriorly by a horizontal groove for the semimembranosus. The *external tuberosity* at the junction of the anterior and outer surfaces forms a prominent tubercle for the insertion of the ilio-tibial band; below this are often attached a few fibres of the extensor longus digitorum and of the biceps. At the posterior and under part is a flat articular surface for the fibula, looking down, out, and back. The internal condylar surface is oval, more hol-

lowed than the external, and longer; the external is nearly circular, concave from side to side, and more or less convex from before backward; it is prolonged a little posteriorly where the popliteus glides. The periphery of each articular surface is flattened for the semilunar fibrocartilage.

Between the condylar parts is an interval depressed in front and behind for attachment of crucial ligaments, and elevated in the middle, forming the *spine*, the summit of which presents two compressed tubercles with an intervening hollow. The depression behind the spine is continued into the *popliteal notch*, which separates the tuberosities posteriorly. Anteriorly, at the junction of the head and shaft, is the *tubercle* or *anterior tuberosity* for attachment of the ligamentum patellæ.

The *shaft* is three-sided, diminishing in size as it descends for about two-thirds of its length, and then increasing again. The *internal surface* is convex and nearly subcutaneous. At the inner side of the tubercle are the insertions of the gracilis, semitendinosus, and double insertion of the sartorius. The *anterior border* runs sinuously from the tubercle to the front of the inner malleolus: its upper two-thirds is the *crest of the tibia*, its lower third is smooth. The *external surface* is hollowed in its upper two-thirds, where it lodges the tibialis anticus; below this the surface turns forward and is covered by the extensor tendons. The upper third of the posterior surface is crossed obliquely by the *popliteal* or *oblique line*, running down and inward: it gives origin to the soleus. Above it is a triangular area occupied by the popliteus; below it, in the middle third of the shaft, is a longitudinal ridge marking off two portions, an inner for the flexor long. dig., and an outer for the tibialis posticus. Below the oblique line a large medullary canal runs downward. The posterior surface is separated from the internal by the *internal border*, which is most distinct in the middle third, from the external surface by the *external border* or *interosseous ridge*.

The *inferior extremity* is broad from side to side, and projects downward internally to form the *inner malleolus*. This malleolus is marked posteriorly by a groove for the tibialis posticus tendon, and more externally by a depression for the flex. long. poll. The external surface of the extremity is hollowed for the fibula, and rough for ligaments except along the lower border. Below is an articular surface, quadrilateral, concave, narrower behind than in front. It shows a slight median elevation separating two lateral depressions. Internally the cartilaginous surface is continued upon the inner malleolus.

The ratio of the length of the femur to that of the tibia is 100:81 in the European, or 100:86 in the Bushman. The tibia is twisted with an angle of torsion of 5° to 20°. The shaft may be much compressed laterally, so that the skin and posterior longitudinal ridge are very prominent; such bone is *platycnemic*.

A facet at the anterior margin of the inferior extremity for articulation with the neck of the astragalus is rare in Europeans, but common in lower races of men.

The tibia is *developed* from three centres: the secondary one for the upper extremity usually appears before birth. The tubercle may have a separate centre.

Describe the fibula.

The fibula (clasp), or peroneal bone, nearly equals the tibia in length; its purpose in the leg is mainly for elasticity. Its shaft is convex backward, and its lower extremity is placed a little in advance of the upper.

The *upper extremity*, or *head*, is prolonged upward at its back part into the *styloid process*; inside this is a facet looking upward, inward, and forward for articulation with the tibia; more externally is a slight excavation for the biceps; the peroneus longus is attached in front and soleus behind. A somewhat constricted part below the head is the *neck*.

The *lower extremity*, or *external malleolus*, is pyramidal and longer than the internal malleolus; internally it shows a triangular, smooth, articular surface for the astragalus, and behind this a depression for the posterior band of the external lateral ligament.

Posteriorly is a shallow groove for the peroneus longus and brevis tendons. Externally this extremity is convex and subcutaneous.

The *shaft* presents four surfaces—*anterior*, *posterior*, *internal*, and *external*; and four borders—*antero-external*, *antero-internal*, *postero-external*, and *postero-internal* (Gray).

The *antero-external border* begins in front of the head and bifurcates below to embrace the triangular subcutaneous surface of the external malleolus: this border is between the peroneal and extensor muscles.

The *antero-internal border*, or *interosseous ridge*, is close to the preceding and parallel with it in the upper third. It terminates below at the apex of a rough surface just above the articular facet. The attached interosseous membrane separates the extensors in front from the tibialis posticus behind.

The *postero-external border* commences at the base of the styloid process and terminates below in the posterior border of the external malleolus. It is directed out above, then back, then slightly inward below. It separates the peronei from the flexor muscles. The *postero-internal border*, or *oblique line*, commences inside the head, and ends by joining the interosseous ridge in the lower fourth of the bone.

The *anterior surface* is very narrow above, broader and grooved below; to it is attached the extensor prop. poll., the extensor long. dig., and peroneus tertius.

The *external surface* is directed outward above and backward below, and is occupied by the peroneus brevis and longus muscles.

The *internal surface* between the antero-internal and postero-internal borders is grooved for the tibialis posticus.

The *posterior surface* looks backward above and directly inward below. Its upper third attaches the soleus muscle; its lower part is rough for interosseous ligaments; to the rest of the surface is attached the

flexor long. poll. The medullary canal opens on this surface and is directed downward.

The fibula is developed from three centres: the centre for the lower epiphysis appears first and unites first, contrary to the general rule; sometimes the medullary canal runs toward the knee. The fibula in the embryo is nearly as large as the tibia, is not twisted, and articulates with the femur. The tibial malleolus at first is larger than the fibular; the prominence of the latter is acquired after birth.

THE FOOT.

Name the bones constituting the tarsus.

The tarsus is composed of seven bones—the calcaneum or os calcis, and the astragalus, forming the hind-foot, the navicular or scaphoid, three cuneiform, and cuboid, forming the fore-foot.

Describe the os calcis.

The os calcis (heel) is the largest bone of the foot: it *articulates* with the astragalus above and cuboid in front; its principal axis runs downward and forward. The bone presents six surfaces. The *posterior extremity*, or *tuberosity*, presents inferiorly two tubercles: the inner is the larger. Its posterior surface presents three districts—a smooth one for a bursa, a ligamentous one for the tendo Achillis, and a lower convex part for the pad of the heel. The part in front of the tuberosity forms a slightly constricted *neck*.

The *internal surface* is deeply concave, and surmounted above by the *sustentaculum tali* (support of the astragalus): this projects inward on a level with the upper surface, and is grooved beneath for the flexor long. poll. The *superior surface* has two articular facets, separated by a groove which runs forward and outward for the interosseous ligament. The anterior facet, often subdivided into two, is on the sustentaculum, and is concave longitudinally; the other one is convex. At the fore part of the groove is a roughness for the extensor brevis digit. Behind the articular surfaces is a region convex from side to side and concave from before backward: above it is placed adipose tissue in front of the tendo Achillis.

The *anterior surface* is concavo-convex for articulation with the cuboid. The *inferior surface*, in front of the tuberosity, projects in an anterior tubercle with a transverse groove in front, and gives attachment to an inferior calcaneo-cuboid ligament.

The *external surface* is usually flat, and presents near the centre a tubercle for the middle fasciculus of the external lateral ligament, and anteriorly often a *peroneal spine*, separating two grooves—the upper for the peroneus brevis tendon, the lower for that of the peroneus longus.

Describe the astragalus.

The astragalus (a die), or talus, receives the weight of the body from the leg. It *articulates* with four bones—the tibia above and internally,

the fibula externally, os calcis below, and scaphoid in front. Its long axis is forward and inward. The main part is the *body*, the convex anterior portion the *head*, just behind which is the *neck*. The *superior articular surface* occupies the whole of the upper surface of the body and sends a prolongation down on either side. The trochlear part is convex and slightly concave from side to side, wider in front than behind; its outer margin is longer than the inner, and curved, while the inner is straight. The inner lateral part is sickle-shaped for the internal malleolus; the outer lateral part is concave and triangular and articulates with the external malleolus. *Inferiorly* there are two articular surfaces for the calcaneum: the posterior one is concave, separated by the interosseous groove from the anterior one, which is convex. The head articulates *anteriorly* with the scaphoid: at the lower and inner part, between this and the anterior articulation for the os calcis, is a facet resting upon the inferior calcaneo-scaphoid ligament, the three forming one continuous surface. The *posterior surface* is small and narrow, and marked by a groove for the flexor long. poll. Bounding the groove are two *tubercles*, the external more prominent and giving attachment to the posterior band of the ext. lat. ligament.

Describe the scaphoid bone.

The scaphoid, or navicular bone, is placed between the astragalus and cuneiform bones. It is long transversely, and presents posteriorly an articular cavity for the head of the astragalus, and anteriorly a convex surface divided into three facets. The superior surface is convex and rough for ligaments; the lower is narrower and irregular. At the outer end may be a facet for articulation with the cuboid. The inner end forms a prominent *tuberosity*, directed downward for insertion of the tibialis posticus tendon. It *articulates* with the astragalus, three cuneiform, and sometimes the cuboid.

Describe the cuneiform bones.

The cuneiform (wedge-shaped) bones are called first, second, and third from within out, or the internal, middle, and external: they are placed between the scaphoid and inner three metatarsals; the internal is the largest, the middle the smallest.

The *internal cuneiform* has its sharp border directed up, and its thick rounded base projects downward. The anterior articular surface for the first metatarsal is larger than the posterior, is kidney-shaped, and is convex. The internal surface is free and uneven, and marked by an oblique groove ending in an oval facet for the tendon of the tibialis anticus. On the outer surface, along the superior and posterior borders, is an L-shaped facet for the middle cuneiform, and anteriorly a facet for the second metatarsal. *Articulates* with four bones—scaphoid, middle cuneiform, first and second metatarsal.

The *middle cuneiform* has its base directed upward and sharp edge

downward: the anterior end is narrower than the posterior, and articulates with the second metatarsal. On the inner side is an L-shaped facet for the internal cuneiform, and on the outer side posteriorly a facet for the external cuneiform. *Articulates* with four bones—scaphoid, internal and external cuneiform, and second metatarsal.

The *external cuneiform* has its base upward. Its anterior end is triangular for the third metatarsal, and continuous with it are small lateral facets for the second and fourth metatarsal. On the posterior part of the inner surface is a facet for the middle cuneiform, and on the outer surface a larger one for the cuboid. *Articulates* with six bones—scaphoid, middle cuneiform, cuboid, second, third, and fourth metatarsal.

Describe the cuboid bone.

The *cuboid* is on the outer side of the foot between the calcaneum and fourth and fifth metatarsals. It is pyramidal rather than cuboid by the sloping of four surfaces to the short external border. If the base of the bone were external, the lateral thrust of the cuneiforms would throw it out of the arch.

Posteriorly it articulates with the os calcis by a concavo-convex surface, and its lower internal corner projects back beneath that bone.

The anterior surface, smaller than the posterior, shows an internal quadrilateral and an external triangular facet for the fourth and fifth metatarsals. In the middle of its internal surface is a facet for the external cuneiform, and behind this often a smaller one for the scaphoid. The superior surface is rough for ligaments. On the inferior surface is a thick ridge or *tuberosity*, at the outer end of which is a smooth facet where the peroneus longus tendon turns into the sole: in front of the tuberosity is a groove for the tendon, and behind it a depression for the calcaneo-cuboid ligament. *Articulates* with four bones—os calcis, external cuneiform, fourth and fifth metatarsal, and sometimes with the scaphoid.

A reduction in the number of tarsal bones may occur from a congenital synostosis of the os calcis and scaphoid, os calcis and astragalus, or astragalus and scaphoid. An increase may arise from the separation of the external tubercle at the back of the astragalus (os trigonum), a separation of the tuberosity of the scaphoid, or a division of the internal cuneiform into two pieces: a supernumerary ossicle may occur at the front of the os calcis or at the front of the internal cuneiform.

Describe the metatarsus.

The five metatarsals resemble the metacarpals; are slightly convex on the dorsum, are three-sided, and have rounded heads. The first is short, thick, and massive: on the *base* is a large kidney-shaped facet for the internal cuneiform, sometimes a lateral facet on the outer side for the second metatarsal. The lower part of the base forms the *tuberosity*, projecting down and out and presenting an impression for the peroneus longus. On the inner side is a small mark for the tibialis anticus. The

superior surface of the shaft looks inward: the inferior is concave, the external triangular and flat. The *head* is large, and shows inferiorly a median ridge separating two grooves in which the sesamoid bones glide. The remaining four bones are distinguished from the metacarpals by being more slender and compressed, corresponding to a form of foot narrower than that of the hand. Their *heads* are elongated from above down, and end below in two small projections. On each side are a tubercle and depression for the lateral ligament. Their *bases* furnish distinctions. The second has a triangular base articulating with the middle cuneiform: on its inner side is a small facet for the internal cuneiform, and sometimes a small one for the first metatarsal. On the outer side is an upper and lower facet, each subdivided into two, making four: the two posterior articulate with the external cuneiform; the two anterior with the third metatarsal. The third has a triangular base for the external cuneiform: on the inner side are two facets for the second, and on the outer side a single one for the fourth. The fourth has an oval or quadrangular base for the cuboid: on the inner side is usually a double facet for the third metatarsal and external cuneiform, and on the outer side a single one for the fifth. The fifth articulates internally with the fourth, and behind by an obliquely cut surface with the cuboid: it projects externally into a large *tuberosity* into which the peroneus brevis is inserted. An independent ossicle may take the place of this tuberosity.

Two *sesamoid* bones lie side by side in the plantar wall of the first metatarso-phalangeal joint. There may be small ones for the other toes.

Describe the phalanges.

The phalanges of the toes correspond closely to those of the fingers. Those of the four outer toes are smaller than those of the hand, but those of the great toe are larger than those of the thumb. The shafts of the first row are compressed laterally; those of the second row, especially in the fourth and fifth toes, are hardly longer than their breadth. The last two phalanges of the little toe may be ankylosed (36 per cent.) as frequently in the infant as in the adult.

Ancient art represents the second toe as longer than the great toe. This may have been copied from some lower race, but in the present white races the great toe is longer in nearly all cases.

Describe the bones of the foot as a whole.

The foot is narrowest at the heel, and broadens as far as the metatarsal bones. The astragalus overhanging the sustentaculum tali inclines inward so much that its external border is over the middle line of the os calcis. The foot is arched longitudinally from the heel to the heads of the metatarsals—a double arch in front and a common support behind. The internal division of the arch is most raised, and consists of the posterior two-thirds of the calcaneum, the scaphoid, cuneiform, and three

inner metatarsals; the outer arch consists of the whole length of the calcaneum, the cuboid, the fourth and fifth metatarsals. There is also a transverse arch formed by the cuboid and three cuneiform, and in front by the metatarsals.

In the infant the head of the astragalus is directed more inward than in the adult, and the foot is inverted. The first metacarpal is also short and inclined inward, the young foot resembling that of an ape.

The tarsal bones are all *ossified* in cartilage from a single nucleus, excepting the os calcis, which has an epiphysis on the posterior extremity. The metatarsals and phalanges agree with the corresponding bones of the hand, each from a principal centre, and one secondary one: the four outer metatarsals have the epiphysis at the distal extremity; in the metatarsal of the great toe and in the phalanges the epiphyses are at the proximal ends.

What are some of the homological comparisons of the upper and lower limbs?

The peripheral parts of both limbs in man and animals show a quinquefid division, but certain vestiges of suppressed digits give reasons for believing that this division was preceded by one of seven (heptadactyle). The nerves entering into the limb plexuses are in each case seven (crural plexus being composed of the lumbar and sacral).

The thoracic and pelvic limbs are constructed on the same general type, modified according to use—*e. g.* in the upper limb of man the free motion of the shoulder-joint, the eversion of the humerus, the forward flexion of the elbow, the pronation and supination of the hand, the opposability of the thumb, all show this to be an organ of prehension and touch and subservient to the head; in the lower limb the fixed condition of the pelvic girdle, the greater strength of bones, the close-fitting hip-joint, the backward flexion of the knee, and non-opposability of the great toe, all have relation to stability, locomotion, and support of weight.

Figs. 4 and 5 show the junctions of the limb-stalks to the trunk: the bones of the trunk are black, those of the girdles shaded. The *shoulder girdle* is imperfect in front, and completed by the sternum; it is wholly incomplete behind. The *pelvic girdle* is perfect in front, and is completed behind by the

Fig. 4.




Shoulder Girdle (Henle).

sacrum, giving solidity in marked contrast to the mobility of the upper girdle. The dorsal portions of the girdles are the scapula and ilium: the ventral portion is in each case double, including the clavicle and coracoid above, the

pubis and ischium below. The coracoid and ischium correspond: the clavicle may correspond to the reptilian precoracoid, which represents the pubis. The subscapular fossa represents the gluteal surface of the ilium, as the scapula has been rotated out and the ilium inward, in accordance with the rotation of the free parts of the limbs.

In the earliest stage the limbs bud out and have a dorsal and ventral aspect: in the next stage, when they come to be folded against the body, one border will look toward the head (preaxial) and one toward the tail (postaxial). Thus

Fig. 5.



Pelvic Girdle (Henle).

the great tuberosity of the humerus, its radial condyle, the radius, and thumb, the small trochanter of the femur, its internal condyle, the tibia, and great toe, are preaxial. In higher animals and man further changes occur according to function. The humerus in man is rotated out about 45°, so that its radial condyle becomes external; the femur is rotated in about 90°, bringing the tibial condyle to the inner side.

The pisiform of the carpus has been considered a sesamoid bone in the tendon of the flexor carp. uln.: it may be the representative of a suppressed digit. The tuberosity of the scaphoid of the carpus and of the navicular of the tarsus correspond, and may each represent a suppressed digit.

Table of Homologous Bones in Thoracic and Pelvic Limbs.

Thoracic Limb.	Pelvic Limb.
Scapula	Ilium.
Precoracoid	Pubis.
Coracoid	Ischium.
Glenoid cavity	Cotyloid cavity.
Clavicle	Absent.
Humerus	Femur.
Great tuberosity	Small trochanter.
Small tuberosity	Great trochanter.
External condyle and capitellum	Internal condyle.
Internal condyle and trochlea	External condyle.
Absent	Patella.
Radius	Tibia.
Ulna	Fibula.
Carpus	Tarsus.
Metacarpus	Metatarsus.
Pollex	Hallex.
Digital phalanges	Digital phalanges.

Homologues of Carpus and Tarsus.

Carpus.	Tarsus.
Pyramidal }	Os calcis.
Pisiform }	
Lunar }	Astragalus.
Scaphoid }	
Tuberosity of scaphoid }	Navicular.
<i>Os centrale</i>	
Trapezium	Internal cuneiform.
Trapezoid	Middle cuneiform.
Os magnum	External cuneiform.
Unciform	Cuboid.

Comparisons of Stability in Hand and Foot.

	Stability.	Intermediate	Mobility.
Hand {	carpus	2	
	metacarpus	3	
	phalanges		5
Foot {	tarsus	5	
	metatarsus	3	
	phalanges		2

Homologous Parts of Scapula and Ilium.

Scapula.	Ilium.
Supraspinous fossa	Sacral surface.
Infraspinous fossa	Iliac fossa.
Subscapular fossa	Gluteal surface.
Spine and acromion	Ilio-pectineal line.
Superior border	Posterior border.
Axillary or glenoid border	Anterior or cotyloid border.
Base (vertebral border)	Iliac crest.
Superior angle	Posterior superior spine.
Inferior angle	Anterior superior spine.

What facts show the adaptation of the skeleton to the erect attitude?

For maintaining this position the muscles passing over the ankle-joint must constantly act: at the knee- and hip-joints the ligaments are more concerned. A vertical plane through the vertex of the skull passes through the occipito-atlantoid, lumbo-sacral, sacro-iliac, hip-, knee-, and ankle-joints. In the infant the size of the head amounts to nearly one-fifth of the body, and the middle distance between the vertex and sole of the foot is above the umbilicus; in the adult a similar point is near the symphysis pubis. The skull is nearly balanced, and the plane of the foramen magnum is nearly horizontal. The face and orbits look forward, the nostrils down. The spinal column is pyramidal and fitted to sustain weight. The thorax is compressed antero-posteriorly, carrying the centre of gravity backward near the spine. The iliac portion of the pelvis supports the abdominal viscera. The femur is longer than the tibia, to give sufficient extent of stride and powers of balancing. The upper limb is adjusted for mobility, and not for support. The

foot of man alone among animals has an arched instep. The great toe is constituted not for grasping, but for support.

ARTHROLOGY.

What are the structures forming joints ?

Bones, cartilage, ligaments, and synovial membrane enter into the formation of joints.

The articular portions of bones are enlarged to form a joint of suitable size, and so that muscles passing over the joint can act at a greater angle. The layer of bone beneath the cartilage is a compact *articular lamella*. The *cartilage* is usually hyaline, may be fibro-cartilage or yellow elastic.

The *ligaments* are mainly white fibrous tissue ; some are yellow elastic.

The *synovial membrane* is like a short wide tube covering the inner surface of the ligaments ; its secretion is synovia, 95 per cent. water, 3.51 per cent. albumin and salts. There are three kinds of synovial membrane—articular, bursal, and vaginal. The former in the foetus is said to cover the articular cartilages as well as ligaments.

The *bursae* are *mucous* as between integument and bone, and *synovial* between muscles or tendons and bone.

Vaginal synovial membranes are sheaths for tendons.

What is the classification of joints ?

Gray classifies them as *synarthrodial*, immovable ; *amphiarthrodial*, mixed ; and *diarthrodial*, or movable.

Synarthrodial, immovable	Sutura	{ vera (true) { dentata— <i>e. g.</i> interparietal. serrata— <i>e. g.</i> interfrontal. limbosa— <i>e. g.</i> fronto-parietal. { notha (false) { squamosa— <i>e. g.</i> squamo-parietal. harmonia— <i>e. g.</i> intermaxillary.
Amphiarthro- dial, mixed		Gomphosis— <i>e. g.</i> tooth in alveolus.
		(1) Surfaces connected by fibro-cartilage, not separated by synovial membrane— <i>e. g.</i> bodies of vertebræ. (2) Surfaces covered by fibro-cartilage and partially lined by synovial membrane— <i>e. g.</i> pubic symphysis.
Diarthrodial, movable		<i>Arthrodia</i> gliding (not referable to any axis)— <i>e. g.</i> some movements in temporo-maxillary articulation.
		<i>Enarthrosis</i> , ball-and-socket— <i>e. g.</i> shoulder and hip.
		<i>Ginglymus</i> , hinge— <i>e. g.</i> elbow, knee ; no lateral motion.
		<i>Diarthrosis rotatoria</i> , or lateral ginglymus, a pivot within a ring— <i>e. g.</i> atlo-axoid.
		<i>Condylloid</i> , ovoid head in elliptical cavity— <i>e. g.</i> wrist.
		<i>Reciprocal reception</i> , saddle-shaped— <i>e. g.</i> carpo-meta-carpal joint of thumb.

What agents keep joint surfaces together ?

1. Atmospheric pressure—*e. g.* hip-joint; 2. synovial fluid; 3. ligaments to a small extent; 4. muscles, important. A short muscle may act on more than one joint; gluteus maximus extends the hip and also the knee through the rectus femoris.

What limits motion in joints ?

1. Extent of articular surfaces; 2. bony contact; 3. approximation of soft parts; 4. manner of articulation; 5. anatomical separation of joint into two, as the joints of a vertebra.

HENLE'S CLASSIFICATION OF JOINTS.

I. Synarthrodia; II. Diarthrodia.

I. Synarthrodia—a firm joint; characteristics are (1) junction along entire extent of adjacent surfaces by a third tissue; (2) motion is due to the gliding of this tissue; (3) bones do not touch.

(a) *Synchondrosis*, where intervening tissue is remains of embryonal tissue, not hyaline, but fibrous or elastic—*e. g.* (1) petrous bone and jugular process; (2) sacro-iliac and intervertebral articulations; (3) the band may ossify, *synostosis*—*e. g.* sphenoid and occipital or interfrontal suture; (4) small space hollowed out, so intervening cartilage is incomplete; *hemiarthrosis*, or false synchondrosis.

(b) *Syndesmosis*, a suture. Fibrous or membranous tissue intervenes and motion is practically *nil*; not an interlocking, as connective tissue is interposed, but the union is strengthened by serrations.

II. Diarthrodia, movable. In development two segments of bone will encroach upon a middle portion, so that the opposite articular surfaces come in contact. The enveloping perichondrium becomes periosteum, and ultimately capsular ligament. At the periphery of a concave surface may be developed a fibro-cartilaginous ring or glenoid ligament.

The capsule extends only to the hyaline cartilage, tough externally and differentiated internally into synovial membrane.

There may be only a partial deliquescence of blastema, and two articular cavities are formed with interarticular fibro-cartilage. Next the bones may be in actual contact by a liquefaction in part of the intervening substance, forming hemiarthrodia: the pubic symphysis is usually synarthrodial, but in pregnancy there may be a slight liquefaction, forming an hemiarthrodial joint. A continued liquefaction produces a diarthrodial joint, characterized by (1) direct touch of opposed surfaces; (2) bones covered by articular cartilage; (3) joint enclosed in a capsule. There is no proper synovial sac: a change occurs on the inner surface of the cartilage and capsule to small flat cells; the synovial fluid fills up irregularities and makes better coaptation. Liquefaction may occur in such a way as to produce a vertical layer, as the crucial ligaments.

To classify special joints various principles of subdivision may be employed: (1) coaptation of the bones forming joints; (2) extent of surfaces; (3) shape of surfaces. There are no special names given to the first variety: joints with non-coaptated surfaces are very numerous; the spaces are filled with interarticular cartilages or synovial folds. The cartilage may remain fixed or it may move on the joint-socket, and the head of a bone move on the cartilage—a sort of double joint, as at the temporo-maxillary and knee-

joints. Almost always the curve of the joint-head is of smaller radius than that of the joint-socket.

Joints named from the extent of articular surfaces are *amphiarthrodial* (arthrodia or gliding of Gray); characteristics are (1) surfaces plane or nearly so; (2) extent of surface the same; (3) firm, dense capsule; (4) motion slight: typical examples are petro-occipital and ilio-sacral. Joints may sometimes change from one variety to another by absorption or change in the interarticular tissue.

Joints named according to shape of articular surfaces are—(1) with *spherical surfaces*, ball-and-socket, arthrodial (enarthrosis, Gray); (2) with *elliptical surfaces*, *condylarthritis*, as radio-carpal; (3) with *saddle-shaped surfaces*, carpal joint of thumb; (4) with *cylindrical surfaces*: (a) *hinge-joint*, *ginglymus*, produced by a cylindrical surface at right angles to the shaft; the cylinder may be grooved or ridged antero-posteriorly; (b) *screw-like joint*, as at elbow, where central ridge is not antero-posterior, but if continued would form the thread of a screw; (c) *rotation-joint*, *trochoides* (lateral ginglymus of Gray), cylinder parallel to shaft. (5) *Mixed or ginglymo-arthrodial*, metacarpo-phalangeal: lateral ligaments control movement in certain directions.

The motions possible in joints are (1) radial, as flexion and extension; (2) rotatory; (3) circumduction; (4) gliding.

Flexion lessens the angles of bones, *extension* increases that angle. All ligaments besides the capsular and those within the capsule are called *accessory*: strengthening bands of the capsule, and separated from it by a layer of connective tissue, are regarded as accessory ligaments.

ARTICULATIONS OF THE TRUNK AND HEAD.

What are the articulations of the trunk and head?

- | | | |
|---|--|---|
| 1. Of the vertebral column. | | 4. Of ribs with vertebræ. |
| 2. Of the false vertebræ. | | 5. Of costal cartilages with sternum and with each other. |
| 3. Of rotation vertebræ with each other and with occiput: | | 6. Of sternum. |
| (a) atlas with axis; | | 7. Of hyoid bone. |
| (b) occiput with atlas; | | 8. Of skull. |
| (c) occiput with axis. | | 9. Of lower jaw. |

Articulations of the vertebral column comprise five sets: (1) those between the *bodies* of the vertebræ; (2) between the *laminae*; (3) between the *articular*; (4) the *spinous*; (5) and the *transverse* processes.

Describe the ligaments of the bodies.

Anterior common, posterior common, and intervertebral substance. The *anterior common* extends along the front of the bodies, filling up the concavities of the vertebræ from the axis to the sacrum: it is broader below than above, and thicker opposite the front of the body, where it is loosely connected, than opposite the intervertebral disk, where it is closely connected. It consists of several layers of fibres, the superficial set extending from a given vertebra to the fourth or fifth below it, and a third deep set from one to another. The ligament splits for the passage of vessels to the vertebral body.

The *posterior common ligament* is inside the spinal canal, along the posterior surface of the bodies, and extends from the axis to the sacrum. It is broader above than below, and laterally presents a series of dentations over the intervertebral disks, and concavities over the centres of the bodies, from which it is separated by the *venæ basis vertebræ*. It has denser fibres than the anterior ligament, and is similarly divided into sets.

The *intervertebral substances* are disks of fibro-cartilage placed between the bodies of the *vertebræ* from the axis to the sacrum. They vary in size and thickness in the different regions, being thicker behind than in front in the lumbar and cervical regions, and uniformly thick in the dorsal region. They form about one-fourth of the spinal column or one-third of the lumbar region, one-fourth of the cervical, and one-fifth of the dorsal. They are connected with the anterior and posterior common ligaments, and in the dorsal region with the heads of ribs. They are composed at the circumference of laminae $\frac{1}{100}$ to $\frac{1}{50}$ inch ($\frac{1}{4}$ to $\frac{1}{2}$ mm.) broad, of fibrous and fibro-elastic tissue and fibro-cartilage arranged concentrically one within the other, and surrounding in the centre a soft, pulpy mass. The laminae are not composed of different materials, but owe their difference in appearance to the fact that they are obliquely placed, crossing each other like an X, and the light strikes them differently: some fibres run horizontally. The most external fibres resemble those of a tendon.

The central part is pulpy, soft, and yellow, containing cells in a fibrous matrix: it rises up conically when pressure is removed. The intervertebral disks are compressible, and, according to one set of measurements, a man is $\frac{1}{2}$ inch taller in the morning than at night.

Describe the ligaments of the laminae and processes.

Those connecting the laminae are the *ligamenta subflava*, of yellow elastic tissue attached to the anterior surface of the lamina above and posterior surface and upper margin of the lamina below. They are analogous to the intervertebral substances in front. Each ligament consists of two lateral portions, which commence on each side of the root of either articular process and pass to the convergence of the laminae. They do not exist between the occiput and atlas, atlas and axis: they take the place of active material and help muscles pull back the flexed column.

The ligaments of the *articular processes* are *capsular*, thin, loose sacs attached to their margins and completed internally by the *ligamenta subflava*. They are lined by synovial membrane.

The *interspinous* ligaments are thin and membranous, extending from near the root to the summit of the spinous process. They are slightly developed in the neck, narrow in the dorsal region, and thicker in the lumbar.

The *supraspinous* ligament is a strong cord connecting the apices of the processes down from the seventh cervical. Its most superficial fibres connect three or four *vertebræ* and its deepest neighboring *vertebræ*.

The *ligamentum nuchæ* continues the *supraspinous* ligament upward

in the neck, and is attached to the external occipital protuberance. In the human subject it is only an intermuscular septum between the two trapezii. A fibrous slip is given off from its anterior surface to each cervical spinous process.

The *intertransverse* ligaments are scattered fibres in the cervical region, rounded cords in the dorsal, and membranous in the lumbar.

What are the movements of the spinal column ?

Flexion, éxtension, lateral movement, circumduction, and rotation—all on three axes, one transverse, one antero-posterior, and one vertical. Flexion is the freest of all movements: it compresses the disks in front and stretches the posterior common ligament and ligamenta subflava. Extension is not marked, and is limited by the anterior common ligament and spinous processes.

Flexion and extension are most free in the lower lumbar region and least in the upper dorsal: extension is greater in the neck than flexion. Lateral movement is most free in the cervical and lumbar regions, limited by the approximation of transverse processes. Circumduction is limited. Rotation is free in the upper dorsal and absent in the lumbar région. So the cervical region enjoys the greatest extent of each variety: the dorsal has greatest rotation, while the lumbar has none. We can turn the head and trunk through 180° on either side, head and neck through 79° —three-fifths of it is between atlas and axis; back and loins through 28° ; and in joints below this through 73° .

The movements are due largely to the shape of the disks, which limit the extent of motion, but not the direction; it is proportional to their height and inversely as their area.

The vertebral articulations are supplied by the spinal nerves in each region: by the vertebral and ascending cervical arteries in the neck, the intercostal and lumbar below.

What are the ligaments of the false vertebræ ?

The *lig. sacro-coccygeum articulare* connects the cornua of the sacrum and coccyx. The *lig. sacro-coccygeum ant.* is the analogue of the anterior vertebral. The *lateral sacro-coccygeal* ligaments correspond to the anterior costo-transverse, passing from the lateral edge of the sacrum to that of the coccyx. The *deep posterior sacro-coccygeal* ligament corresponds to the posterior common, and receives strengthening bands from the dura mater of the cord. The *superficial sacro-coccygeal* closes in the lower opening of the spinal canal, passing from the arch of the last sacral to the periosteum of the coccyx. This ligament may split below, leaving a median cleft.

Describe the articulations of the rotation vertebræ.

The ligaments connecting the atlas and axis are two anterior atlo-axoid, the posterior atlo-axoid, transverse, and two capsular. The two *anterior*

atlo-axoid (anterior obturator) comprise a superficial rounded cord in the median line, a continuation up of the anterior common ligament to the occiput, and a deeper portion on either side from the anterior arch of the atlas to the base of the odontoid and front of the body of the axis. In front of them are the *recti cap. ant. maj.* muscles.

The *posterior atlo-axoid* (posterior obturator) ligament is broad and thin, connecting the posterior arches of the two bones and supplying the place of the *ligamenta subflava*: it contains a little elastic tissue. Behind it are the inferior oblique muscles. The *transverse* or *cruciform* ligament passes across the ring of the atlas behind the odontoid. It holds the odontoid in place, but not with such firmness as often described: it is broad and firm in the middle, and in it is often developed a cartilaginous nodule; on each side it is attached to the lateral mass of the atlas. A small process passes up (superior crus) from its upper border to the basilar process, and another down (inferior crus) to the root of the odontoid posteriorly.

The *capsular ligaments* are thin and loose, strongest in front and externally: there is also a capsule for the anterior odonto-atloid articulation. The synovial membranes are four in number—one for each capsular ligament, one for the anterior articular surface of the odontoid, and one for its posterior surface, a sort of bursa which may communicate with the occipito-atloid joints. This joint possesses great mobility, the greater part of the rotation of the head occurring here, and none in the occipito-atloid joints. When the bones are covered by articular cartilage a sagittal section shows a convexity upon a convexity (Fig. 6). With the head equi-poised and eyes to the front the muscles are at rest and ligaments tense. When the head is rotated the point of the atlas sinks down off the axis and a part projects; otherwise an already tense ligament would become more tense in rotation, did not the points of attachment approach each other.

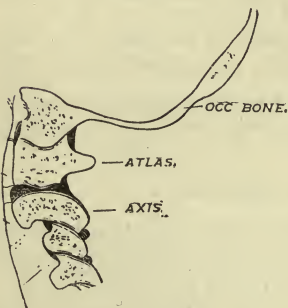
The spinal column is connected to the cranium by ligaments from the occiput to the atlas, from the occiput to the axis.

Describe the articulations of the occiput and atlas.

There are two *anterior occipito-atloid ligaments* (anterior obturator), a *posterior*, two *lateral*, and two *capsular*.

The *superficial anterior occipito-atloid* continues the anterior common and superficial atlo-axoid ligaments upward to the basilar process. The *deep* ligament is thin, and passes from the anterior margin of the fora-

FIG. 6.



men magnum to the anterior arch of the atlas; behind it are the odontoid ligaments.

The *posterior occipito-atloid* (posterior obturator) is membranous and blended with the dura mater of the cord: it passes from the posterior margin of the foramen magnum to the posterior arch of the atlas. Laterally, it is pierced by the vertebral artery and suboccipital nerve.

The *lateral ligaments* are fibrous bands passing from the transverse processes of the atlas up and in to the jugular processes of the occipital bone. The *capsular ligaments* are loose, and enclose a synovial membrane, which usually communicates with that between the posterior surface of the odontoid and transverse ligament.

The movements in the joint are flexion and extension, a nodding movement through about 45°: there is a slight lateral motion.

Describe the ligaments connecting the occiput and axis.

There are the *occipito-axoid* and three *odontoid*. To expose these the spinal canal must be opened. The *occipito-axoid* ligament prolongs the posterior common ligament to the front of the foramen magnum, and there blends with the dura. This is the *broad ligament* of the axis (lig. lata), and shows three sets of fibres: the posterior blends with the dura, the next is the continuation of the posterior common, and the most anterior or deepest set is confined to the back of the odontoid and body of axis: this deepest layer also joins the upper part of the posterior surface of the transverse ligament, and is called the *superior appendix* of the transverse ligament. A bursa is often between this broad and the transverse ligament.

From either side of the apex of the odontoid process an *alar* or *check* ligament passes up and out to the inner side of the condyle of the occiput. They limit the extent of rotation. From the apex of the odontoid a middle band passes to the front of the foramen magnum, the "suspensory" ligament, but it suspends nothing.

Should a section be made from behind forward just above the atlas, the knife would divide these ligaments in order: the lig. nuchæ, the posterior occipito-atloid (then the spinal cord), the occipito-axoid, the superior crus of the transverse, the odontoid, the deep and superficial anterior occipito-atloid.

Nerves of these joints are from the suboccipital and second cervical; *arteries* are from the vertebral.

Describe the ligaments connecting the ribs with vertebræ.

There are two sets: (1) connects heads of ribs with bodies; (2) connects necks and tubercles with transverse processes.

(1) *Anterior costo-vertebral* or *stellate, capsular, interarticular*. The stellate consists of three bundles of fibres radiating from the head of the rib: the upper bundle passes to the vertebra above, the lower to the vertebra below, and the middle to the intervertebral substance. The first rib articulates with one vertebra, sends up a slip to the seventh cer-

vical, a middle one to the first dorsal, but not a lower one: there is a similar arrangement with the eleventh and twelfth ribs. On the under edge of the stellate ligament a deep fasciculus passes from the side of the body to the under surface of the head of the rib.

The stellate ligament is continued into the cervical and lumbar regions: a slip from a next higher vertebral body and one from the adjacent intervertebral disk or body run to the root of the transverse process.

The *capsular* ligament is a loose bag, most distinct above and below, and firmly connected with the stellate ligament.

The *interarticular* ligament is a flat horizontal band of fibres passing from the intervertebral substance to the crest on the head of the rib: it divides the joint into non-communicating cavities, each lined by a separate synovial membrane. The first, eleventh, and twelfth ribs do not possess this ligament.

In many mammals a *conjugal ligament* unites the heads of opposite ribs across the back of an intervertebral disk.

(2) Articulations of necks and tubercles with the transverse processes—*superior*, *middle* (interosseous), and *posterior costo-transverse* ligaments and *capsular*.

The *superior* ligaments are two in number: the *anterior* passes from the upper border of the neck of each rib up and out to the lower border of the transverse process and neck of rib above. Its inner border completes an aperture between it and the articular process, corresponding to an anterior sacral foramen. Its external border is continued in a thin aponeurosis over the external intercostal muscle. The first rib does not possess this ligament.

The *posterior* band is less regular, and extends from the neck of the rib up and in to the transverse and lower articular process next above.

The *middle costo-transverse* is very short, and connects the neck of the rib to the front of the adjacent transverse and articular process. This is lacking in the case of the eleventh and twelfth ribs.

The *posterior costo-transverse* passes obliquely from the summit of the transverse process to the tubercle of the adjacent rib and is accessory to the capsule behind—wanting on the eleventh and twelfth ribs. The joint has a thin *capsular* ligament enclosing a synovial membrane. *Nerves* are anterior branches of spinal nerves, *arteries* the intercostals. *Action* of these joints is elevation and depression of ribs on a transverse axis through the head of a rib and its articular process—*i. e.* lengthwise through its neck: there are also eversion and inversion of ribs on an axis connecting their sternal and vertebral ends. No movement on a vertical axis.

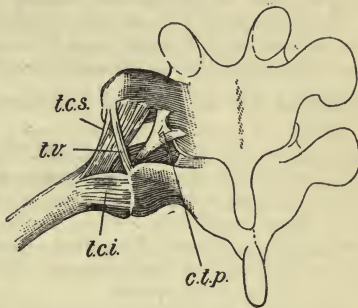
HENLE'S VERTEBRAL AND COSTAL LIGAMENTS.

A. Synchondroses and capsular ligaments. Synchondroses are intervertebral substances; capsular are three sets: (1) for articular processes; (2) for heads of ribs; and (3) for tubercles of ribs.

B. Accessory ligaments—(1) lig. commune vertebr. ant.; (2) lig. costo-vertebralia radiata (stellate).

C. Ligaments of the intertransverse and posterior parts of the intercostal spaces: (a) *Ligg. costo-transversaria*: (1) *antica*, (2) *postica*. The anterior costo-transverse is that of Gray; the posterior (*ctp*, Fig. 7) has the same origin as the anterior; passes up and back and bifurcates, the inner arm going to the articular process above, the lateral arm to the articular and transverse process above. Posterior vessels and nerves pass between its insertions and beneath its free edge. (b) *Ligg. colli costæ*—the *lig. colli costæ sup.* and *lig. c. c. inf.* form the middle costo-transverse of Gray. *Lig. colli costæ posticum* passes from the neck of rib near the head through the intervertebral foramen into the spinal canal to the posterior surface of an intervertebral disk: it meets its fellow from the other side beneath the posterior common ligament—*lig. costarum jugale* of animals. (c) *Ligg. tuberculi costæ*, superior and inferior. The inferior one (*tci*, Fig. 7) = the posterior costo-transverse. The *lig. t. e. sup.* (*tcs*, Fig. 7) passes from the tubercle of one rib to the apex of the transverse process next above. (d) *Ligg. tuberositatum vertebraliū* (*tv*, Fig. 7) = intertransverse of Gray.

FIG. 7.



The last internal intercostal muscle sends a band from the lower edge of the eleventh rib down to the twelfth, often to the twelfth dorsal vertebra; similar fibres go from the twelfth rib to the first lumbar, and from the transverse process of the first lumbar to the body of the second: it is the accessory costo-vertebral ligament (stellate), and serves for muscular origin, especially of the *psaos*.

The anterior costo-transverse ligaments of the lower intercostal spaces and two upper lumbar vertebræ unite into a shining aponeurosis, the *lumbo-costal ligament*. It passes transversely from the transverse processes of the two upper lumbar vertebræ to the end of the last rib; thence vertical fibres pass down to the ilio-lumbar ligament, usually behind the *quadratus lumborum* muscle.

D. Ligaments of the spinal canal. (1) *Lig. commune verteb. posticum*; (2) *ligamenta intercruralia* = *ligamenta subflava*.

E. Ligaments of spinous processes, *ligg. interspinalia*, *lig. supraspinale*, and *lig. nuchæ*.

Describe the articulations of the costal cartilages with the sternum.

Anterior chondro-sternal, *posterior chondro-sternal*, and *capsular*. The *anterior* one is a broad, radiating band with superior, middle, and inferior fasciculi. They intermingle with those of the opposite side and with the origin of the *pectoralis major*, forming a membrane over the sternum, *membrana sterni*. The *posterior* chondro-sternal ligaments are less distinct, and are composed of radiating fibres blending with the periosteum. The *capsular* ligaments are very thin, and connected with the anterior and posterior ones.

Synovial membranes, the first, sixth, and seventh cartilages, have none; the third, fourth, and fifth have one; the second has two and an interarticular cartilage resembling a vertebral articulation. In old age most of these articulations disappear.

From the sixth and seventh cartilages *chondro-xiphoid* (costo-xiphoid) ligaments pass down and in to the ensiform, strengthening the sheath of the rectus and limiting the aponeurosis of the external oblique.

Describe the intercostal ligaments.

There are *external* and *internal intercostal* ligaments. The former, *ligg. intercostalia ext.*, lie in the nine or ten upper spaces between the anterior end of the external intercostal muscle and the sternum. The fibres are partly oblique, vertical, and transverse. The vertical and oblique fibres constitute the *lig. corruscans* (shining), and seem to be undeveloped bundles of the external intercostal muscle: they are strongest in the third to the seventh spaces. The transverse fibres are present in the first to the seventh spaces.

The *internal intercostal ligaments*, *ligg. intercostalia int.*, are tendinous fasciculi of the *triangularis sterni* muscle, passing from rib to rib over one or two spaces: in the seventh and eighth spaces, sometimes sixth and ninth, they are nearly transverse.

Describe the interchondral ligaments.

The cartilages of the sixth, seventh, and eighth ribs, sometimes fifth and ninth, articulate by their lower borders with the margins of the adjoining cartilage; each articulation has a capsule and synovial membrane. All these articulations may be wanting.

In articulations of ribs with cartilages the cartilage is held in a depression in the sternal end of the rib by periosteum.

Describe the ligaments of the sternum.

The *gladiolus* is united to the *manubrium* by an interposed fibro-cartilage, *synarthrodial* (Henle), or it may be *diarthrodial* with a synovial membrane in 33 per cent. of cases—rarely so in childhood—and probably results from absorption. The ligaments are *anterior* and *posterior intersternal*: both consist of longitudinal fibres blending with the *chondrosternal* ligaments, the anterior with the *pectoralis major*.

The ligaments of the hyoid bone will be described with those of the *temporo-maxillary* articulation.

What are the ligaments of the skull?

(1) The *petro-occipital synchondrosis* possessed originally intervening hyaline cartilage, and was a true joint. (2) The *spheno-occipital synchondrosis* contains cartilaginous nodules till ossified at the age of twenty-five. The soft masses of connective tissue in the lacerated foramen, the *petro-occipital* and *petro-sphenoidal* fissures, are known as ligaments of the same names. (3) *Accessory bands*, a number of ligamentous bands bridging over grooves and bony points, completing canals: a *pterygo-pe-*

trosal ligament from the upper part of the posterior border of the external pterygoid plate to the spine of the sphenoid, sometimes ossified; another bridging over the supraorbital notch; an *intrajugular* ligament dividing the jugular foramen; a *petro-sphenoidal* ligament from the apex of the petrous to the posterior clinoid process under which passes the sixth nerve. A lack of bone between the foramen ovale and spinosum may be supplied by ligament; the clinoid processes of one side may be connected by ligament; one may pass from the anterior condylar foramen to the jugular notch of the occipital.

Describe the temporo-maxillary articulation.

The ligaments are—*capsular*, *interarticular fibro-cartilage*, and *accessory*, which include *external lateral*, *internal lateral*, *short internal lateral*, and *stylo-maxillary*.

The *capsule* is very thin and loose: it passes from the edge of the glenoid fossa to the interarticular cartilage, thence to the neck of the condyle.

The *interarticular disk* or *fibro-cartilage* is placed horizontally between the jaw and temporal bone, concavo-convex above and concave below. It is connected in front with the external pterygoid muscle: it is composed of concentric fibres; its circumference is thick, and its centre may be perforated.

There are two *synovial membranes*: the upper is the larger and prolonged in front, while the lower is smaller and prolonged behind.

The *external lateral ligament* (lig. accessorium laterale) passes from the outer surface of the zygoma and tubercle, their lower border, down and back to the posterior surface of the neck of the lower jaw. Externally it is in relation with the temporal fascia, and internally with the joint capsule.

The *internal lateral ligament* (lig. acces. mediale) has two parts: one passes from the inner margin of the glenoid fossa to the neck of the condyle behind the insertion of the external pterygoid muscle; this is in immediate relation to the capsule and known as the *short internal lateral ligament*. The other part passes from the spine of the sphenoid to the lingula and inner margin of the dental foramen (spheno-maxillary). Between these two ligaments are the internal maxillary artery and veins, and lower down the auriculo-temporal and inferior dental nerves; internal to the long band is the internal pterygoid muscle. Between the short internal lateral and the synovial membrane is a pad of soft elastic connective tissue united to the periosteum of the posterior half of the glenoid fossa: this is compressed or stretched according to the position of the condyle.

The *stylo-maxillary ligament* (stylo-myloid) has nothing to do with this articulation: it is a band of cervical fascia connected at one end by aid of the stylo-glossus muscle to the styloid process, and by the other to the angle and posterior border of the lower jaw. It separates the parotid from the submaxillary gland.

A hyoid ligament may be described here, the *stylo-hyoid*, which continues the styloid process down to the lesser cornu of the hyoid bone: it is often ossified in man, and usually is in many animals, as the *epihyal bone*.

The *pterygo-maxillary ligament* passes from the apex of the internal pterygoid plate to the posterior extremity of the internal oblique line of the lower jaw: it separates the buccinator from the superior constrictor of the pharynx.

	Origin.	Insertion.
Spheno-maxillary ligament,	spine of sphenoid.	Dental foramen.
Pterygo- “ “	int. pterygoid plate.	Alveolar border of lower jaw.
Stylo- “ “	styloid process.	Angle lower jaw.
Stylo-hyoid “ “	“ “	Lesser cornu of hyoid bone.

Nerves of the joint are the auriculo-temporal and masseteric from the inferior maxillary. *Arteries* are temporal, the deep auricular, and tympanic branches of the internal maxillary. *Actions* of the joint are protrusion and retraction, elevation and depression, or a rotation when one side acts. The movements in the superior and inferior compartments are of different kinds: in the upper the fibro-cartilage glides forward and backward, and in the lower the condyle rotates against it on a transverse axis. Elevation and depression take place on a transverse axis through the centres of the rami—some say through the interarticular cartilages. If the depression be considerable, the condyle also has a gliding motion, carrying the cartilage with it. Rotary movement to one or other side takes place on an axis through the opposite condyle. Depression is produced by the weight of the jaw, platysma, digastric, mylo-hyoid, and genio-hyoid muscles; elevation by the temporal, masseter, and internal pterygoid; protrusion by external pterygoid, internal pterygoid, and superficial fibres of masseter; retraction by deep fibres of masseter and posterior fibres of temporal.

ARTICULATIONS OF THE UPPER EXTREMITY.

THE SHOULDER GIRDLE.

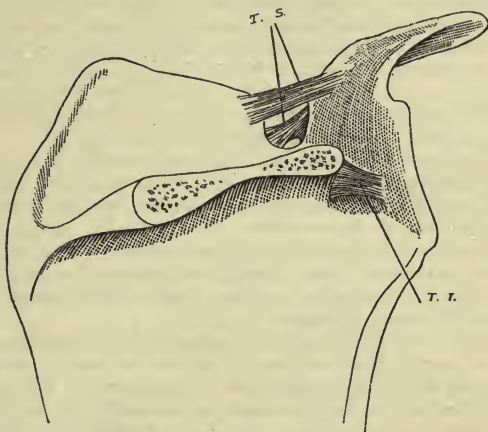
What are the proper ligaments of the scapula?

Coraco-acromial, superior and inferior transverse, and glenoid.

The *coraco-acromial ligament* is a thin triangular band attached by its apex to the summit of the acromion in front of and beneath the clavicular articulation, and by its base to the whole length of the outer border of the coracoid process: it completes a vault for the protection of the head of the humerus. Above it is the deltoid, and below it the supraspinatus muscle. The *subacromial bursa* separates it above from the acromion and acromial end of clavicle, and below the bursa covers the capsule over the head of the humerus and spreads out between the infraspinatus and supraspinatus muscles.

The *superior transverse ligament* (suprascapular) is a flat shining band passing between the inner margin of the scapular notch and the root of the coracoid. As a rule it has two parts (T. S., Fig. 8)—an upper, longer

FIG. 8.



Ligaments of Scapula.

and stronger and lying in a plane with the surfaces of the supraspinous fossa and somewhat oblique; a lower part, thin, horizontal, and more anterior than the upper. Above the ligament are the suprascapular artery and one of its venæ comites; between the two parts are the suprascapular nerve and the other suprascapular vein; beneath the lower arm of the ligament are two veins passing to a venous plexus in the subscapular fossa.

The *inferior transverse ligament* (T. I.) (spino-glenoid) is in the great scapular notch, and passes from the base of the spine of the scapula to the posterior surface of the head of the scapula. This may be a feeble band of fatty tissue or a strong one of connective tissue: beneath it anastomotic vessels run from one spinous fossa to the other. The *glenoid* ligament will be described with the shoulder-joint.

Describe the sterno-clavicular ligaments.

The ligaments are *capsular*, *interarticular fibro-cartilage*; *accessory* are *interclavicular* and *costo-clavicular*.

Henle describes a capsule for this joint made up mostly of strengthening bands: it is weakest at the lower anterior angle. In front a band called the *anterior sterno-clavicular ligament* passes from the inner ex-

tremity of the clavicle obliquely down and in to the upper part of the manubrium; the *post. sterno-clav. lig.* passes in a similar direction, and is related behind with the sterno-thyroid and sterno-hyoid muscles.

The *interarticular cartilage* is attached above to the upper and posterior border of the inner extremity of the clavicle, and below to the junction of the first costal cartilage with the sternum, and by its circumference to the capsule: thus the cartilage of the first rib is partly within this joint. Its circumference is thicker than its centre, which may be perforated: in size and shape it varies greatly. It lessens the inequalities of the two bony surfaces, and divides the joint into two parts, each provided with a synovial membrane. In young bones the interclavicular notch on the sternum is covered with hyaline cartilage.

The *interclavicular ligament* is a flat band passing in a curved direction between the inner extremities of the clavicles, and is closely attached to the upper border of the sternum. Some of its fibres are connected with the periosteum of the posterior surface of the sternal end of the clavicle, and some with the back of the capsule. So if we follow the course of the connective tissue from the upper border of the clavicle, some goes to the interarticular cartilage, some to the capsule, and some forms the interclavicular ligament.

The *costo-clavicular ligament* is of rhomboid form, ascending obliquely from the inner part of the cartilage of the first rib back to the depression on the under surface of the sternal end of the clavicle. To its outer side is the subclavian vein. This ligament encloses the tendon of insertion of the subclavius muscle, but most of the ligament is behind the muscle, its anterior part being continued as fascia over it. Between the muscle and the posterior part of the ligament is sometimes developed the "bursa of Monro." Cruveilhier describes this ligament and bursa as the *costo-clavicular articulation*.

Nerves, second and third cervical by *descendens noni*. *Arteries*, neighboring muscular branches. *Motion* is not a gliding, but axial on the fibro-cartilage. Elevation and depression of the shoulder produce movement here on a transverse axis through the costo-clavicular ligament; movement of shoulder forward or backward, on a vertical axis through the same point.

Describe the acromio-clavicular ligaments.

Ligaments are *capsular*, *interarticular fibro-cartilage*; *accessory* are *posterior coraco-clavicular* or *trapezoid* and *conoid*, and *anterior coraco-clavicular*.

There is a weak *capsule* to this joint, really a fibrous covering of the synovial membrane: it is strongest above, being strengthened above and below by bands designated by some as the *superior* and *inferior acromio-clavicular ligaments*. The *interarticular cartilage* is usually present in some form, either hanging from the edge of the clavicle in the upper part of the joint or covering the whole articular surface of the acromion, or in 3 out of 400 cases wholly dividing the joint into two cavities.

The *synovial membrane* is usually single, or double when the inter-articular cartilage is complete.

The *coraco-clavicular ligaments* connect the clavicle more firmly with the scapula: there are three. The *posterior coraco-clavicular* comprises the *trapezoid* and *conoid*. The trapezoid is external, and attached below to the upper surface of the coracoid, and above to the oblique line passing forward and outward on the under surface of the clavicle. Its outer border is free, and its internal border unites with the conoid, forming an angle projecting backward. This checks forward movement of the clavicle.

The *conoid* is posterior and internal, and attached by its apex to the base of the coracoid, and by an expanded base to the conoid tubercle and a line internal to it on the under surface of the clavicle. This checks backward movement of the clavicle. Between these two ligaments a bursa may be developed, and between them is also the extremity of the subclavius muscle.

The *anterior coraco-clavicular ligament* (Henle) is a shining thin band of connective tissue passing from the apex of the coracoid up and into the under surface of the clavicle. At its origin it is connected with the fascia over the pectoralis minor, and at its insertion with the fascia over the subclavius, from which it is separated in part by a layer of fatty tissue.

An occasional *scapulo-clavicular* ligament has been described passing from the upper border of the scapula internal to the notch to the acromial end of the clavicle.

Nerves, suprascapular and circumflex. *Arteries*, suprascapular and acromial thoracic. *Movements* of joint, gliding and rotation.

Describe the ligaments of the shoulder-joint.

The ligaments are, *capsular*, *glenoid*, *coraco-humeral*, *coraco-glenoid*, *transverse humeral*, *glenoideo-humeral* or *Flood's*, and the *glenoideo-brachial internal* and *inferior* of Schlemm.

The strengthening bands are parts of the capsule, and not accessory ligaments so called.

This is a ball-and-socket joint, peculiar (1) in the large size of the head of the humerus and shallowness of the glenoid cavity; (2) looseness of the capsule; (3) intimate relation of muscles with capsule; (4) relation of biceps tendon to joint. The glenoid articular cartilage is thinnest at its centre, $\frac{1}{25}$ inch (1 mm.); that on the head of the humerus is thickest at the centre, $\frac{2}{25}$ inch (2 mm.).

The *capsule* encircles the articulation, attached above to the margin of the glenoid beyond the glenoid ligament, and below to the anatomical neck of the humerus. It allows the bones to be separated more than an inch: it is strengthened by tendons of muscles which may be reckoned as ligaments—viz. above by the supraspinatus and tendon of biceps, externally by the infraspinatus and teres minor, below by the long head of the triceps, and internally by the subscapularis. There is a weak

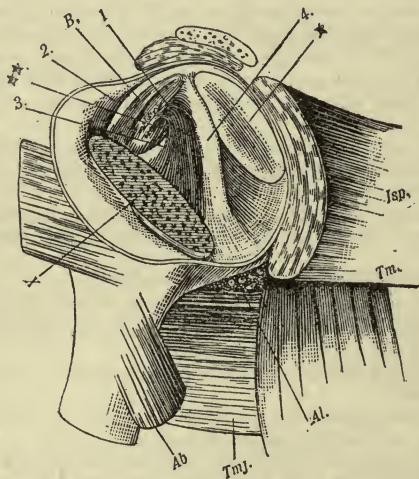
place in the capsule uncovered by muscle between the edges of the *teres major* and *subscapularis*; vessels and nerves enter here (*Al*, Fig. 9).

The superficial fibres of the capsule are longitudinal, and deeper ones are circular, forming a truncated cone with its narrow end toward the scapula. Below are folds in the capsule which become straight in raising the arm.

The *glenoid ligament* is a fibro-cartilaginous rim attached to the margin of the glenoid fossa to form a deeper cavity: it is triangular on section, and $\frac{3}{25}$ inch (3 mm.) broad at its base. It is partly formed by the biceps tendon above as it bifurcates at its attachment, and by the triceps below, the fibres being arranged in concentric rings. Its intrinsic fibres are fused with the capsule.

The *synovial membrane* lines the capsule and covers the outer side of

FIG. 9.



Left Shoulder-joint opened from Behind and Externally: 1, thickening of supraspinatus tendon; *B*, biceps tendon; 2, glenoid-humeral, or Flood's lig; 3, thickening of subscapular tendon; **, entrance to the subscapular bursa; 4, inf. glenoid-brachial of Schlemm, between 4 and 3, int. glenoid-brachial of Schlemm; * glenoid cavity; X cut surface of humerus; *Isp*, infraspinatus; *Tm*, teres minor; *Tmj*, teres major; *Al*, circumflex vessels; *Ab*, short head of triceps.

the glenoid ligament, and is continued a short distance over the cartilage on the head of the humerus. The long tendon of the biceps passing through the capsule is enclosed in a tubular sheath of synovial mem-

brane, and so does not really enter the synovial cavity. A rounded protrusion of synovial membrane, *bursa intertubercularis*, clothes the upper part of the bicipital groove as far as the insertion of the pect. major and latiss. dorsi. From within the tube of synovial membrane there passes to the tendon of the biceps a *retinaculum* of longitudinal bundles of connective tissue.

Among the strengthening bands of the capsule is the *coraco-humeral ligament*, rising from the outer border of the coracoid, spreading out upon the upper and posterior wall of the capsule, and inserted into the great tuberosity of the humerus. The *transverse humeral ligament* is a part of the capsule between the tuberosities. The *lig. coraco-glenoidale* is a part of the coraco-humeral, rising with it and passing backward and outward at right angles from it on the surface of the capsule to the upper margin of the glenoid cavity. When the joint is viewed from the inside (Fig. 9), the *glenoideo-humeral*, or Flood's ligament, is seen as a reflection of the fibres of the coraco-humeral ligament through the capsular opening, passing up internal to the tendon of the biceps.

The *internal glenoideo-brachial ligament of Schlemm* is a thin fold rising from a point above the entrance into the subscapular bursa, and, descending obliquely outward to be lost on the capsule beneath the subscapular tendon (is between (3) and (4) in Fig. 9), passes to the small tuberosity (Quain). The *lig. glenoideo-brachiale inf.*, or broad ligament of *Schlemm* (4), rises from the upper part of the glenoid ligament and passes down and out parallel to the internal lig. of Schlemm, and is lost on the circular fibres of the inner capsular wall.

Quain calls the three ligaments last described the superior, middle, and inferior gleno-humeral ligaments.

What holds the head of the humerus in place?

(1) Subscapular, supraspinatus, infraspinatus, deltoid, biceps, and triceps muscles; (2) adhesiveness; (3) atmospheric pressure.

What are the communications of the joint?

Subscapular, infraspinatus bursæ, biceps tendon, often the subcoracoid, coracoid, subacromial, and subdeltoid bursæ.

The *nerves* supplying the joint are circumflex and suprascapular.

The *arteries* are anterior and posterior circumflex and suprascapular.

The *movements* of the joint are in every direction.

Flexion is possible to 45° without involving other joints, produced by the pectoralis major, anterior fibres of the deltoid, coraco-brachialis, and by the biceps if the elbow is fixed. This occurs on a transverse axis through the great tuberosity and glenoid cavity. Flexion is limited by tension of the posterior part of the capsule and by the small tuberosity abutting against the coracoid; the movement is continued by rotation of the scapula.

Extension through 15° is produced by the latissimus dorsi, teres major, posterior fibres of deltoid, and the triceps if the elbow is fixed. Exten-

sion is hindered by superior muscles and approximation of the great tuberosity and acromion.

Abduction through 90° is performed by the deltoid, aided by the supraspinatus, on an antero-posterior axis through the anatomical neck of the humerus: further motion calls into play accessory joints—viz. the upper portion of the trapezius elevates the peak of the shoulder, and the lower fibres of the serratus magnus pull the inferior angle of the scapula forward, rotating that bone, which raises its external angle. Two other joints share the motion—the acromio-clavicular till its yielding is stopped by the coraco-clavicular ligaments, next the sterno-clavicular joint till its motion is checked by the costo-clavicular ligament. So three chief muscles are concerned in raising the hand above the head, and two joints besides the shoulder-joint. Freest motion is up and forward. The angle between the scapula and clavicle changes to secure adaptation of the former to the chest-wall.

Adduction is accomplished by the subscapularis, pectoralis major, latissimus dorsi, and teres major. Total rotation is through 90° , limited by capsule and muscles: it is freest externally and backward; *rotation in* is produced by the subscapularis, latissimus dorsi, and teres major; *rotation out* by the infraspinatus and teres minor. *Circumduction* is a combination of all the angular movements in succession.

THE ELBOW AND FOREARM.

Describe the elbow-joint.

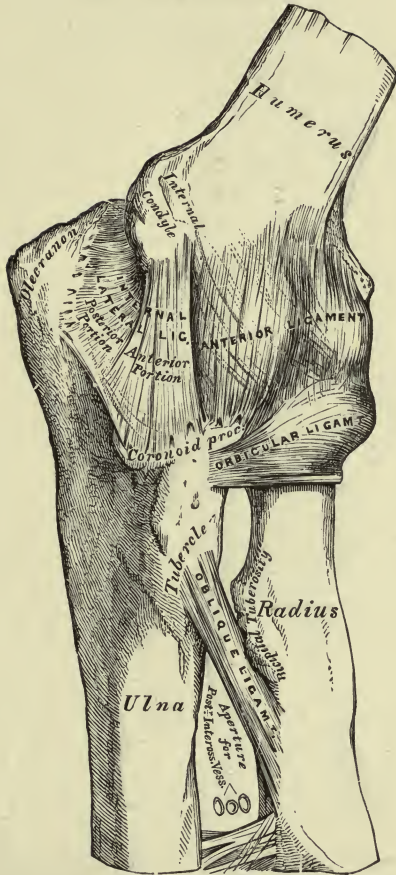
The elbow is a hinge joint with screw-like surfaces: really three joints are involved, the ginglymus screw, the radio-humeral, and the radio-ular. The lesser sigmoid of the ulna and the articular surface of the radius are parts of cylindrical surfaces, the latter an arc of 180° , the former of 90° and radius of $\frac{1}{2}$ inch (12 mm.). The diameter of the curve on the humerus at the inner edge of the trochlea is 16 mm., of the groove of the trochlea 11 mm., of the outer edge of the trochlea 13 mm., and of the capitellum 12 mm. The articular cartilage in the elbow-joint is hyaline and 2 mm. thick. Only so much of the trochlea is covered by cartilage as is embraced by the sigmoid cavity when the forearm is flexed to 90° : the parts remaining free, anteriorly and posteriorly, are covered with periosteum and fatty pads.

The *ligaments* are *capsular*, with thickened bands and the *orbicular ligament*; the thickened bands are known as *anterior* and *posterior, internal lateral* and *external lateral*. The radial insertion of the capsule is the orbicular ligament surrounding the head of the radius; the capsule includes the coronoid and part of the olecranon fossæ, a part of the internal epicondyle, but not the external, the tips of the coronoid and olecranon processes.

The *anterior* thickened portion of the capsule passes from the point of the inner epicondyle and from the front of the humerus above the coronoid fossa to the anterior margins of the coronoid process, and externally into

PLATE VII.

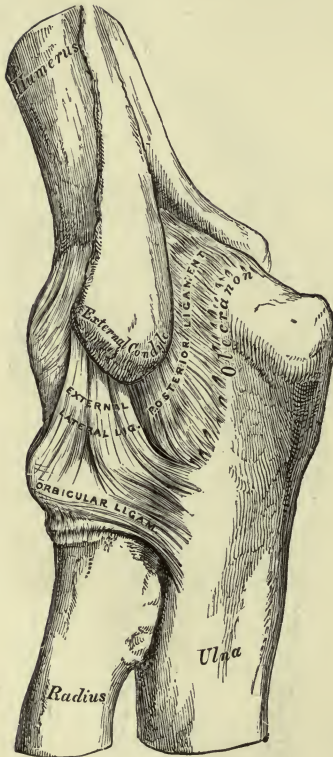
FIG. 1.—To face page 111.



Left Elbow-joint, showing anterior and internal ligaments.

PLATE VIII.

FIG. 1.—To face page 111.



Left Elbow-joint, showing posterior and external ligaments.

the orbicular ligament. Superficially is an oblique band passing down and out from the internal epicondyle to the orbicular ligament. The fibres under these are vertical, the *anterior ligament of Barkow*, and the deepest are transverse. The *posterior* part of the capsule passes to the margin of the olecranon process from the lower end of the humerus, leaving the upper part of the fossa exposed. The lowest fibres are transverse, bridging over part of the olecranon fossa; the upper fibres are vertical, thickest in the median line, and pass through a fatty pad in the upper part of the fossa. These vertical fibres are *Barkow's posterior straight cubital ligament*: on either side of it the capsule is as thin as a bursa.

The *internal lateral ligament* is fan-shaped, rises from the lower and back part of the root of the inner epicondyle, and consists of three portions: (1) a posterior *humero-olecranon* part, helping form the groove for the ulnar nerve; (2) an anterior *humero-coronoid* part; and (3) an *olecrano-coronoid* portion, deepening the sigmoid cavity.

The *external lateral ligament* is not so distinct as the internal, is attached above to a depression below the external epicondyle, and below to the orbicular ligament and posterior interosseous border of the ulna (not into the radius, or its rotation would be impaired). It gives some strengthening bands to the anterior ligament, forming a cruciform arrangement. The supinator brevis rises from this ligament in part. The brachialis anticus muscle inserts a band into the anterior ligament, the triceps a band into the posterior. The anconeus rises from the capsule between the external condyle and external border of the olecranon.

The *orbicular ligament*, lig. annulare radii, is the thickest part of, and is the inferior radial edge of, the capsular. It is $\frac{2}{3}$ inch (10 mm.) broad, and is the only ligament of the superior radio-ulnar articulation which is a lateral ginglymus joint. The ligament is attached by each end to the extremities of the small sigmoid cavity, surrounds the head of the radius, forming four-fifths of a circle. It is broader in the upper part of the circumference than below, grasping the head of the radius more firmly. The supinator brevis, extens. carpi uln., extens. min. dig., and extens. com. dig. rise in part from the orbicular ligament.

The *synovial membrane* is extensive, lines the capsule and orbicular ligament, entering into the articulation between all three bones.

There are inequalities between the sigmoid fossa and trochlea which are filled in with synovial membrane or fatty pads: there is another pad in the small sigmoid cavity. The capsule is reinforced by intra- and extracapsular pads, both in the coronoid and olecranon fossæ. This allows free gliding of muscles. The triceps pulls up the wrinkled capsule in extension, the brachialis anticus in flexion.

The *muscles in relation to the joint* are, in front, the brachialis anticus; behind, the triceps and anconeus; externally, the supinator brevis and supinato-extensor group; internally, the pronato-flexor group.

What bursæ are related to the joint?

- (1) Superficial olecranon between tendon of triceps and skin; (2) deep

olecranon, between tendon of triceps and bone; (3) at inner margin of brachialis anticus; (4) bicipital bursa, between tendon of biceps and bone; (5) epicondylar bursæ, subcutaneous; (6) sometimes a *retro-epitrochlear* behind the inner epicondyle, related to the ulnar nerve.

Nerves are from the ulnar, median, musculo-spiral, internal cutaneous, and nerve of Cruveilhier (from the branch of the musculo-cutaneous to the biceps).

Arteries are derived from an anastomosis between the inferior and superior profunda, anastomotica magna, anterior and posterior ulnar recurrent, interosseous recurrent, and radial recurrent.

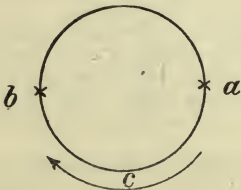Action.—The humero-ulnar joint possesses flexion and extension, no lateral movement or rotation.

Flexion of 150° is possible, produced by the supinator longus, biceps, brachialis anticus, and muscles from the inner condyle: it is checked by contact of soft parts, posterior part of capsule, and posterior part of internal and external lateral ligaments, not by bone.

Extension (after flexion) goes through 150° by the triceps, anconeus, extensors of the wrist, and common extensors of fingers: it is checked by the anterior part of the capsule and anterior parts of the external and internal lateral ligaments, not by bone.

Supination (rotation *out*) and *pronation* (rotation *in*) occur through 90° in the radio-ulnar and radio-humeral joints on an axis through the head and neck of the radius and styloid process of the ulna. Supination is performed by the biceps strongly, by the supinator longus and brevis and extensors of the thumb; pronation by the pronator radii teres and pronator quadratus: in this last motion there is a "winding up" of the biceps and supinator brevis. These rotary movements are checked by the oblique ligament, orbicular, and capsular, by the interosseous membrane, by the inferior articulation, and by muscles. If sliding of soft parts on the ulna is hindered, pronation and supination are largely checked.

Experiment.—Thrust the hand pronated through a round hole in a board: if it be the right hand, mark on the board the position of the styloid process of the ulna, as at *a*. Supinate the hand, and the ulnar styloid process will be found at *b*.



What is the explanation if the ulna has no lateral motion?

The first movement back from *a* is of extension, which occurs at the elbow-joint; the next, near *c*, is adduction, and occurs at the shoulder-joint; the final movement to *b* is flexion at the elbow. When rotated back again we have extension, adduction, and flexion in order. If now the humerus be firmly fixed as in a vice, so as to prevent ad- and abduction at the shoulder-joint, the styloid of the ulna will

not change position, and the experiment could not be done in the above aperture.

Describe the accessory ligaments of the bones of the forearm.

(1) *Oblique*; (2) *interosseous*. The *oblique ligament* (chorda transversalis) is a flatly-rounded cord running from the tubercle of the ulna on the coronoid process down and out to a point on the radius a little below the bicipital tuberosity. Its fibres have an opposite direction to those of the interosseous ligament. The oblique may be wanting, or may exist as a tendinous slip to the flexor long. poll.; it may be double, the upper band passing from the small sigmoid notch and orbicular ligament to a point above the bicipital tuberosity.

The *interosseous ligament* (membrane) connects the interosseous ridges of the radius and ulna. The fibres pass down and in to the ulna in such a direction that if the hand press against resistance the radius would drag the ulna after it. The ligament is divisible here and there into several layers, some fibres coming from the anterior surface of the radius. It is deficient above, commencing on the radius at the insertion of the oblique ligament, leaving a space between the two for the posterior interosseous vessels. Just above its lower end is an oblique opening between two layers of the ligament for the passage of the anterior interosseous vessels. The lower edge is almost vertical, the fibres ending higher on the ulna than on the radius and running in a direction opposite to the fibres above: this lowest split between the ligament and ulna is filled with fat and covered by the pronator quadratus muscle. Some fibres go to the posterior annular ligament. The object of the ligament is muscular attachment with economy of weight.

Describe the inferior radio-ulnar articulation.

A lateral ginglymus joint between the head of the ulna and sigmoid cavity of the radius. The ligaments are the *anterior* and *posterior radio-ulnar* and *triangular fibro-cartilage*. The anterior and posterior ligaments are narrow bands passing transversely over the joint, as indicated by their names. The triangular ligament is placed beneath the ulna, attached by its apex to the base of the styloid process; its under surface articulates with the cuneiform. The synovial membrane is very extensive, the *membrana sacciformis*.

Actions are supination and pronation.

THE WRIST AND CARPUS.

Describe the radio-carpal or wrist-joint.

This is a condyloid articulation between the radius and triangular cartilage above, the scaphoid, semilunar, and cuneiform below.

The ligaments are *external* and *internal lateral*, *anterior*, and *posterior*. The two former are rounded cords passing respectively from the styloid process of the radius and ulna to the end carpal bones of the first

row. The *anterior ligament* is a broad membranous band connecting the anterior surfaces of the bones forming the articulation. The *posterior ligament* is less strong than the anterior, and passes from the radius to the dorsum of the first three carpals.

Mention the ligaments of the carpus.

There are three sets: 1, articulations of first row have *two dorsal*, *two palmar*, and *two interosseous* ligaments; 2, articulations of the second row have *three dorsal*, *three palmar*, and *three interosseous* ligaments; 3, articulations of the two rows with each other have *anterior*, *posterior*, *external lateral*, and *internal lateral* ligaments.

What are the ligaments connecting the carpus with the metacarpus?

The first metacarpal bone and the trapezium have a capsule and separate synovial membranes. The joints between the carpus and four inner metacarpals have *dorsal*, *plantar*, and *interosseous* ligaments.

The synovial membranes of all the joints in the carpus and wrist proper are *five* in number.

What are the remaining ligaments of the metacarpus and phalanges?

Of the metacarpals with each other, there are the *dorsal*, *palmar*, and *interosseous* ligaments: their digital extremities are connected by a narrow band, the *transverse ligament*, presenting four grooves for tendons.

The metacarpo-phalangeal articulations have *anterior* and *two lateral* ligaments. The interphalangeal articulations also have *anterior* and *two lateral* ligaments.

Henle's Description of the Wrist- or Hand-joint.

This includes the lower radio-ulnar articulation, the articulation of the forearm with the carpus, the intercarpal and carpo-metacarpal articulations. Their movements are all mutually compensatory, and many ligaments are common. To the humerus is attached the ulna, to the ulna the radius, and to the radius the hand.

1. The lower radio-ulnar is a *rotation joint*. The curve of the ulnar articular surface and that of the sigmoid cavity are not concentric arcs, the former being a half-circle of $\frac{3}{8}$ inch (16 mm.) radius, and the latter an arc of 45° of 1 inch (26 mm.) radius. The ligaments are *capsular* and *interarticular*: the latter is not interarticular in the usual sense, but is an extension inward of the lower end of the radius. At its base it is attached to a prominent edge of the radius below the sigmoid cavity; at its apex it is attached by two bands, an upper to a little cavity at the base of the styloid, and a lower to the outer surface of that process: vessels pass between the two bands. Its upper surface articulates with the head of the ulna; its lower is concave and forms part of the carpal joint. It is perforated in the centre in 40 per cent. of cases, and is $\frac{1}{2}$ inch (5 mm.) thick at its apex.

The capsule is strong, and continuous below with that of the radio-carpal joint: anteriorly some fibres of the pronator quadratus are attached, by which

it is pulled forward in pronation; posteriorly it is strengthened by oblique and transverse fibres, and is covered on the ulnar side by the common carpal ligament (annular). It passes between the bones of the forearm about $\frac{1}{2}$ inch (5 mm.) above the cartilaginous surfaces, ending in a blind sac. The *synovial* processes vary in number and form: thin threads or tabs or strong folds rise from the posterior and inner capsular wall.

2. *Radio-carpal Joint*.—A line passing between the radius and ulna divides the lunar bone, so that the scaphoid and outer half of the lunar articulate with the radius; the inner half of the lunar and the pyramidal articulate with the triangular fibro-cartilage. The carpal bones of this joint are connected by strong interosseous ligaments flush with the upper articular surfaces. The extent of articular surface on the carpus is greater than that on the forearm, but the convexity is smaller than the concavity, so that contact is mesial, with room for lateral synovial pouches. The frontal arc of the joint-surface of the radius is 69° of $1\frac{3}{8}$ inches (42 mm.) diameter; the sagittal arc is 64° of $\frac{1}{2}$ inch (18 to 22 mm.) diameter.

The *capsule* is pretty firmly stretched from the edges of the upper to the edges of the lower joint-surfaces: it is shortest and least yielding between the radius and lunar, serving as an axis of rotation. The strengthening fibres of the capsule are continuous with those of the joint above. *Synovial folds* are in the posterior and ulnar corners of the joint-cavity: synovial bands with concave edges (ligg. mucosa), in connection with the interosseous ligaments of the first row, spring from the anterior and posterior parts of the capsule. This joint may communicate with that of the pisiform or with the carpal joint by the lack of an interosseous ligament.

3. *Carpal Joint*.—This is between the bones of the lower row and those of the upper, excepting the pisiform. The trapezoid and trapezium are connected at their lower edges by a thin interosseous ligament: there is none between the trapezoid and os magnum, where the carpal as a rule communicates with the carpo-metacarpal joint; the cleft between the os magnum and unciform is closed by a large mass of connective tissue prolonged as a thin membrane between their articular surfaces. The articular cartilages of all the carpal bones are hyaline, and $\frac{1}{25}$ inch ($\frac{1}{2}$ to 1 mm.) thick. The head of the os magnum projects into the cavity of the scaphoid and lunar, allowing flexion, extension, and rotation and lateral immobility: the axis of rotation is through the length of the os magnum, that of flexion and extension across its head.

The *capsule* of this joint includes the edges of the cartilaginous surfaces. It shows transverse folds anteriorly in flexion and posteriorly in extension.

Synovial folds fill the corners and clefts between the bones.

4. The *pisiform joint* has a weak capsule, attached at some distance from the articular surfaces of either bone (4 mm. distant from that of the pisiform).

5. The *General Carpo-metacarpal Joint*.—This is made up of very irregular joint-surfaces covered by hyaline cartilage $\frac{1}{4}$ to $\frac{1}{2}$ mm. thick.

The *capsule* is strong, and fastened immediately to the edge of the cartilaginous surfaces by which the bases of the metacarpals articulate with each other and with the carpus. The pouch between the bases of the third and fourth metacarpals is divided by an interosseous ligament into two parts, an anterior and posterior. In this same region a sagittal synovial fold passes up between the os magnum and unciform, and may completely divide the carpo-metacarpal joint.

6. The *thumb-carpal joint* is elliptical, saddle-shaped, so that the convexity of each surface seems to be received into the cavity of the other: it makes an angle of 45° with the horizontal, the external edge being the highest.

The *capsule* is attached close to the joint surface of the trapezium, but about

$\frac{1}{2}$ inch (5 mm.) away from that of the first metacarpal. A *synovial fold* 2 mm. broad extends around the joint-cavity, weakest on the radial side.

The *nerves* of the above joints are from the ulnar, median, and posterior interosseous.

Arteries of the radio-carpal joint are from the anterior and posterior carpal arches, the radial and ulnar; for carpal and carpo-metacarpal are anterior and posterior carpal arches, anterior and posterior interosseous, and deep palmar arch.

Actions.—In the *radio-carpal joint* there is flexion associated with adduction, extension associated with abduction: adduction is possible to 45°, as the ulna does not descend so low as the radius; abduction is slight; flexion is less than extension. When the hand is flexed, it cannot be ad- or abducted, as the lateral parts of the capsule are taut. There is no rotation provided, as the pronation and supination of the radius answer that purpose.

In the *carpal joint* flexion is freer than extension; rotation is present, but no lateral motion.

In the *carpo-metacarpal joint* there is some flexion and extension on a transverse axis, possibly a little rotation on a long axis. Movements are freest at the margins of the metacarpus and least in the centre; the excursion of the metacarpal of the middle finger does not exceed 6°.

The *synovial cavities* are five in number: (1) between radius and ulna, ulna and fibro-cartilage; (2) in radio-carpal joint; (3) in carpal joint and carpo-metacarpal; (4) in thumb-carpal joint; (5) in pisiform joint.

ACCESSORY LIGAMENTS OF THE WRIST.

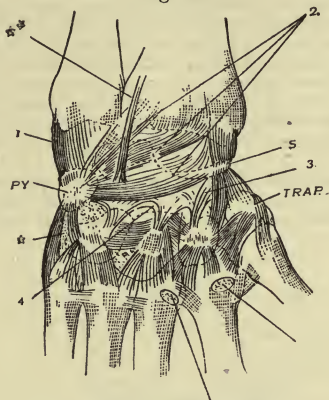
(a) What is generally known as the annular ligament is partly fascial and partly ligamentous. The fascial portion is only transverse bands of the fascia of the forearm, and is called the *lig. carpi commune*. There is no natural, but a practical, division into anterior and posterior parts (radial and ulnar). The highest bundles of the *ulnar portion* begin in the middle of the posterior surface of the forearm 1 inch above the radio-carpal joint, and run obliquely inward and down to the ulnar margin of the wrist, and are inserted into the extensor carpi ulnaris tendon. The next lower set of fibres rise from the prominent ridge on the radius, bounding externally the groove for the extensor sec. inter. poll., and pass around internally to the summit of the pisiform. Farther down follow fibres from the styloid process of the radius to the pisiform and ulnar edge of the fifth metacarpal. The fibres passing to the pisiform stop there; those above and below this are continued externally, so that a cleft is left through which the ulnar nerve and vessels pass from beneath the deep fascia.

The *radial portion* of the common carpal ligament passes from the ridge on the radius adjacent to the extensor secundi poll. tendon, over the other two extensors of the thumb, becomes continuous with the fascia over the ball of the thumb, passes over the radial vessels and tendon of the flexor carpi rad., and here unites in part with the tendinous layer of the "proper volar lig. of the carpus;" it passes on ulnarward, and divides into a superficial and deep layer, the former going to the summit of the pisiform, covering the ulnar nerve and vessels, the latter passing beneath them to join the ligamentous portion of the annular ligament—i. e. the *lig. c. volare proprium*. In front of the flexor tendons are therefore two ligaments, grown together, only separable by the knife in the region of the palmaris longus; the superficial one is fascia, *lig. c. commune*, the deep one is ligamentous, the *lig. c. vol. proprium*, and both together form the anterior annular ligament of Gray.

(b) *Accessory Bands of the Dorsal Surface*.—On the back of the wrist, between

the lig. c. comm. (posterior annular lig.) and the joints, is a layer of fatty connective tissue containing vascular network, cushioning the grooves and forming partition walls between some of the extensor tendons: some of it passes

Fig. 10.



Dorsal Surface of Wrist.

down into strengthening bands of the capsules. 1. *Deep dorsal ligament of the carpus* (lig. carpi dorsale profundum), Fig. 10. This consists of (1) nearly straight fibres from the ulna to the pyramidal (PY); (2) three bundles of converging and arched fibres to the pyramidal from the lower margin of the radius, its styloid process, and the scaphoid; (3) straight fibres from the styloid of the radius to the scaphoid (s); thence to the trapezium and trapezoid; (4) from the lowest arched band slips go to the os magnum and unciform; (5) a broad band (*) from the pyramidal to the unciform, thence to the base of the fifth metacarpal; (6) sometimes a narrow band (**) from the radius to the os magnum.

2. *Short Dorsal Ligaments of the Carpus* (ligg. carpi dorsalia brevia).—These include all which connect adjacent bones—viz. *ligg. intercarpea*, *carpo-metacarpa*, and *intermetacarpa*. The dorsal intercarpals are flat, transverse, or oblique, and only in the lower row; those seen in the upper row are posterior edges of interosseous ligaments. The dorsal carpo-metacarpals pass obliquely between the parts indicated (Fig. 10); as a rule each metacarpal is united to two carpals, only one for the first. These ligaments on the second, third, and fifth metacarpals are united with the radial and ulnar extensors. The dorsal intermetacarpals are transverse bands (Fig. 10) between the metacarpal bases, four in number; the one between the thumb and index is of varying strength.

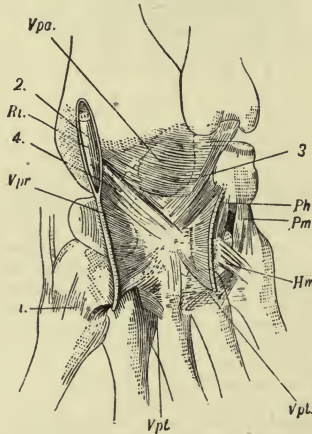
(c) *Accessory Bands of the Anterior Surface*.—1. The *proper volar ligament of the carpus* (lig. carpi volare proprium). This forms a bridge over the anterior hollow of the carpus, and a great support to the upper part of the hand; it may be called the ligamentous portion of the annular ligament. On the ulnar side it rises from the radial edge of the pisiform, from the hook of the unciform, and from the piso-unciform ligament, and sometimes from the

bases of the fourth and fifth metacarpals; radially it rises from the styloid process of the radius, the radio-carpal joint capsule, the tuberosity of the scaphoid and trapezium, and base of the first metacarpal. Besides these attachments, it is connected with the deep volar lig. on either side, the two together forming the canal for the passage of the flexor tendons. The middle third of the ligament is connected with the lig. c. comm. and palmaris long. tendon; below it is continuous with the deep layer of the palmar fascia.

2. The *deep volar ligament of the carpus* (lig. carpi volare profundum, Vpr, Fig. 11). There is a fascia continuous with that covering the pronator quadratus passing over the hand-joints to the anterior surface of the palmar interossei: if this be removed, there is left a shining, strong, ligamentous mass divisible into three parts—the *arcuate* above, the *radiate* in the middle, and the *transverse* below (lig. carpi v. profundum arcuatum, radiatum, and transversum).

(1) The upper fibres of the *arcuate* (Vpa) pass transversely on the capsule from the lower end of the radius to the triangular fibro-cartilage; (2) the next set pass in an arched manner from the styloid of the radius to the pyra-

FIG. 11.



Palmar Surface of Wrist.

midal; they there unite with (3) straight fibres from the base of the styloid process of the ulna to the os magnum; (4) fibres also pass from the styloid of the radius and from the cuneiform to converge upon the os magnum.

The *middle portion* of this deep ligament (Vpr) sends its fibres radially from the os magnum in three directions, internally, externally, and downward. Those going straight down descend to the third metacarpal; others, approaching a transverse direction, go to the second metacarpal on one side and the fourth and fifth on the other. The internal fibres go to the unciform and its process, and upward to the pisiform joint, and there turn forward to form the proper volar ligament (ligamentous part of the annular). The external

fibres go to the ulnar side of the flexor carpi radialis tendon, to the trapezoid and tuberosity of the scaphoid.

The *transverse portion* (Vpt) connects the bones of the lower row together, the bases of the metacarpals together, and these two sets of bones with each other. The bundles form a triangular mass with its apex down and attached to the third metacarpal; the base is formed of transverse bands covered by the radiate ligament which pass from bone to bone between the trapezium and unciform, between the second and fifth metacarpals. The fibres from the third metacarpal go externally in two layers, a superficial one in front of the tendon of the flexor c. radialis (R1, Fig. 11), and into the lig. c. vol. proprium; a deep one behind this tendon to the second metacarpal and trapezium; of the internal fibres, the deepest go to the fourth and fifth metacarpals, and the superficial to the unciform and piso-metacarpal ligament.

The height of the lig. c. vol. proprium is about 1 inch (28 mm.)—*i. e.* this is the length of the canal enclosing the flexor tendons and median nerve. The lower opening of the canal is $\frac{2}{5}$ inch (21 mm.) in a transverse direction, $\frac{2}{5}$ inch (11 mm.) in a sagittal direction. Diverging from the sides of this opening are the muscles of the little finger and those of the ball of the thumb.

A carpo-metacarpal band, Cm, passes from the tuberosity and ridge of the trapezium to the base of the first metacarpal.

(d) *Accessory Ligaments of the Ulnar Side.*—(1) Piso-hamatum (Ph, Fig. 11), from the apex of the pisiform to the hook of the unciform, united at its upper edge with the lig. c. vol. proprium; (2) lig. piso-metacarpeum (Pm), really a continuation of the flexor carpi uln. tendon, passes fan-shaped from the pisiform to the anterior surface of the base of the fifth, fourth, and third metacarpals; (3) lig. hamo-metacarpeum, Hm, passes from the ulnar surface of the hook of the unciform to the fifth metacarpal.

(e) *Accessory Ligaments of the Interspaces of the Metacarpals.*—Ligg. intermetacarpea interossea, connecting the bases of the metacarpals, strengthening the capsules below, and running from the posterior edge of the external bone to the anterior edge of the internal one.

Metacarpo-phalangeal Articulations.—The head of a metacarpal bone with its hyaline cartilage forms a half-sphere of $\frac{2}{3}$ inch (9 mm.) radius, with a segment cut off from each side. The concavity of the articulating phalanx is quite flat, and belongs to a curve of greater radius than the head it receives. (a) The capsule is very thin, but strengthened on all sides by ligaments or tendons, and is lined by synovial tissue. In the thumb, sometimes index and little finger, are to be found in the anterior wall of the capsule sesamoid bones: their surfaces, which lie in the joint-cavity, are covered with hyaline cartilage, and a synovial fold runs between them.

(b) *Accessory Bands.*—Two lateral ligaments, lig. accessorium (radiale and ulnare): these are rounded cords running on either side from the tubercle on the side of the head of the metacarpal and a little fossa in front of this to the base of the first phalanx.

The *anterior ligaments* (ligg. capitulorum volaria) are made of transverse bands coming from several directions: the connective tissue covering the interossei presents near the heads of the metacarpals strong transverse fibres which pass over the capsule and between the capsules of the four inner metacarpo-phalangeal joints. A part passes forward on either side, and forms a smooth tube for the flexor tendons over the joints, and for the lumbrical muscles over the ligg. capitulorum ant. The anterior walls of the tubes for the flexor tendons are the *ligg. vaginalia*, transverse bands fastened to the edges of the phalanx. These are also (*ligg. dorsalia*) connected with the anterior and side walls of the capsule, which pass back over the lateral ligaments

through some tendinous fibres of the interossei to the extensor tendons, which are enclosed by them, and thus held down for the protection of the back of the joint. Lower transverse dorsal bands (*ligg. capitulorum dorsalia*) are stretched from finger to finger between the *ligg. dorsalia*.

Sometimes there are bursæ between the adjacent joint-capsules at the lower ends of the metacarpals.

The *movements* of these joints are flexion, extension, ad- and abduction, circumduction, and rotation. When the finger is flexed, the lateral ligaments are tense and prevent ad- and abduction of fingers and rotation of the first phalanx on a long axis.

Articulations of the Phalanges.—*Capsular and accessory*—two lateral, *ligg. vaginalia*, *ligg. dorsalia*, and *retinacula tendinum* (folds of synovial membrane). Analogues of the *ligg. capitulorum* (transverse ligament, Gray) remain as fibrous septa passing laterally from the capsules to the skin of the fingers.

Movements are flexion and extension.

ARTICULATIONS OF THE LOWER EXTREMITY.

THE PELVIC GIRDLE.

Describe the special ligament of the hip-bone.

This is the *obturator ligament*, or membrane partly closing in the obturator foramen, presenting small holes here and there, in some places layers and a general horizontal direction. As it passes from one obturator tubercle to the other it forms the *obturator canal*, passing down and forward, filled with fat, the obturator vessels, and nerve. Above and anteriorly the ligament is attached to the margin of the foramen on a plane with the anterior (really inferior) surface of the os pubis; below and behind it is attached so as to be flush with the pelvic surface of the os pubis. From its inner margin rise fibres of the obturator internus muscle, and from the lower part of the outer margin fibres of the obt. externus. The upper part of the outer surface is filled by fat, which is covered by single flat bands going from the ligament to the external edge of the foramen and to the capsule of the hip-joint.

The *lig. iliacum proprium* is sometimes stretched across the concavity of the ilio-pectineal line.

Describe the ligaments between the two hip-bones.

The only articulation is the symphysis pubis, which shows many varieties. The bone-surfaces are covered by layers of hyaline cartilage connected to the bone by nipple-like processes: these plates often contain bony kernels. The space between the cartilages is filled in part with fibro-cartilage and in part with clear fibrous substance; the size of the space is greater in front and below where the edges diverge: in the posterior half of the synchondrosis the cartilages are parallel, and lie so close that the interposed substance looks like a fine white line. In the upper and back part of the interposed substance is a median split with smooth walls lined by elastic fibro-cartilage: up to the seventh year this cleft is occupied by fibrous substance containing little holes, which later unite into a larger cleft and may contain synovia. Whether this is more com-

mon in pregnancy is not settled: the cleft is not so often lacking in women as in men.

For ligaments Gray describes *anterior*, *posterior*, *superior*, and *subpubic*, and an interposed *fibro-cartilage*.

Henle finds that the cartilages are mainly continuous with the periosteum and muscle-tendons of the region. The upper edge and posterior surface of the joint are covered only by periosteum, $\frac{1}{8}$ inch ($\frac{1}{2}$ mm.) thick, consisting of transverse fibres. In front is a thick layer of connective tissue continuous with the periosteum, and the attachment of abdominal muscles and adductors of the thigh. In common with this is the *lig. arcuatum pubis* (posterior layer of triangular ligament), which is stretched between the rami of the pubis as a diaphragm to a point $\frac{2}{3}$ inch (9 mm.) below the bony subpubic arch: only the middle part of the lower edge is free, limiting the hole through which passes the dorsal vein of the penis; laterally it is continuous with the obturator internus fasciæ.

LIGAMENTS BETWEEN THE BONES OF THE TRUNK AND HIP-BONE.

Describe the ligaments of the ilio-sacral joint.

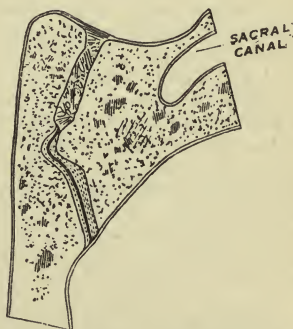
Capsule, accessory are—*ilio-lumbar*, *anterior*, *interosseous*, and *posterior ilio-sacral*, *great sacro-sciatic*, *small sacro-sciatic*.

The ilio-sacral joint (sacro-iliac) is between the auricular surface on the ilium and a corresponding one on the first three vertebræ of the sacrum: the cartilage is hyaline, 2 to 3 mm. thick on the sacrum and 1 mm. thick on the ilium. The sacrum is held in position mostly by ligament and partly by a sort of mortise between the bones (Fig. 12).

The *capsule* is firmly stretched over the joint-cavity, strengthened externally by horizontal fibres, within by soft vascular connective tissue covered by periosteum. On the pelvic surface the capsule is not attached immediately to the edges of the bones, but farther away, leaving a little space for synovia: small synovial tufts are found in this space and between the upper edges of the cartilaginous surfaces.

Accessory Bands.—(1) *Ilio-lumbar Ligament*.—The posterior layer of the sheath of the quadratus lumborum muscle is the lumbo-costal ligament, being a union of representatives of the costo-transverse and intercostal ligaments of this region. The anterior layer of this sheath is thin above, and may be a part of the lumbo-costal

FIG. 12.



Section through the Second Sacral Vertebra parallel to the Pelvic Inlet.

may be a part of the lumbo-costal

ligament, but below it is called the ilio-lumbar. It rises in part from the anterior surface of the fourth lumbar, some fibres descending to the fifth transverse process: a strong falciform band envelops at its origin the transverse process of the fifth and passes out upon the crest of the ilium; a part from the base of the fifth process descends into the pelvis, covers the upper part of the ilio-sacral joint, and is lost on the periosteum. These descending bands (lumbo-sacral of Gray) represent anterior costo-transverse ligaments, and form external boundaries to the openings through which pass the anterior branches of the fourth and fifth lumbar nerves. Internal to these run flat bands vertically from the root of a transverse process and intervertebral cartilage to corresponding points next below: they serve as bridges over vessels and as heads of origin for the psoas muscle.

(2) *Ilio-sacral Ligaments*.—The capsule of this joint is strengthened anteriorly by thin bands, the *anterior ilio-sacral ligament*. Posteriorly connecting the tuberosities of the two bones is a great number of flat and cylindrical bands separated by masses of fat: the whole mass is the *interosseous ilio-sacral ligament*. Two bands rise from the first and second articular processes of the sacrum, and a third very oblique one from the third process, and pass up to the posterior superior spine of the ilium: these are the *posterior ilio-sacral ligaments*. (3) The *great sacro-sciatic ligament* (posterior), or lig. sacro-tuberosum, is formed of several layers enclosing fat and muscle. It rises by a broad base from the posterior inferior spine and from a little of the adjoining iliac crest, from the fourth and fifth articular processes of the sacrum, the free lateral margin of that bone, and of the two upper coccygeal vertebræ. It passes down, out, and forward, becomes narrow and thick in the middle, and is inserted into the inner margin of the tuber ischii; thence it is prolonged forward as the *falciform ligament*, forming a groove with the bone for the internal pudic vessels and nerve. Some fibres of this ligament pass to the tendon of the biceps and semitendinosus: others from the posterior superior spine of the ilium pass straight down to the rudimentary transverse processes of the third, fourth, and fifth sacral vertebræ.

(4) The *small sacro-sciatic ligament* (anterior), lig. sacro-spinosum, is triangular and attached by its apex to the posterior surface of the spine of the ischium and by its base to the free lateral margin of the sacrum and upper coccygeal vertebræ: it is attached posteriorly to the great ligament, and forms the inferior boundary of the great sacro-sciatic foramen and upper boundary of the small foramen. It should hardly be called a ligament, as it is so intimately connected with the coccygeus muscle: ligamentous and muscular fibres cross each other at acute angles, and sometimes the ligament is almost wholly muscular.

A superior sacro-spinous ligament has been seen, forming a middle sacro-sciatic foramen.

The *great sciatic notch* is partly filled by the pyriformis muscle; above this pass the gluteal vessels and superior gluteal nerve, and below it the

sciatic vessels and nerve, internal pudic vessels and nerve, and muscular branches of the sacral plexus.

The small foramen transmits the tendon of the obturator internus muscle, its nerve, the internal pudic vessels and nerve.

THE HIP-JOINT.

Describe the hip-joint.

It is a ball-and-socket joint, with arcs of $\frac{4}{5}$ inch (22 mm.) radius: the radius of the circular edge of the acetabulum is about $\frac{2}{25}$ inch (2 mm.) smaller than that of the head of the femur. The articular surface of the head of the femur is more than a hemisphere: any section of the bony acetabulum through its centre is less than 180° .

The ligaments are—*cotyloid, transverse, teres, capsular*; *accessory* are—*orbicular zone, ilio-femoral, ilio-trochanteric, pubo-femoral, ischio-femoral, and ischio-capsular*.

The *cotyloid* consists of connective tissue arranged circularly: it is strengthened and fastened to the edge of the acetabulum by short fibres rising at different points and interlacing at acute angles. It is prismoid on section, and embraces the head of the femur so tightly that air does not enter the joint. Both its sides are covered with synovial membrane. Inferiorly the cotyloid becomes flat and bridges over the acetabular notch as the *transverse ligament*; it turns one surface upward and one down; one edge looks within and limits a split through which, enveloped in fat, blood-vessels enter the socket; the other edge passes uninterruptedly into the cotyloid ligament.

The articular cartilage of the acetabulum is 2 mm. thick, a little thinner toward the centre; that on the head of the femur is thickest at the centre, $\frac{1}{5}$ inch (4 mm.). The fossa acetabuli contains a fat pad.

The *ligamentum teres* is misnamed, being neither ligamentous nor round; it is somewhat triangular. It is planted by its apex into the fossa on the posterior inferior quadrant of the head of the femur, and rises from the notch and fossa acetabuli. Unoccupied space around it is filled with synovia. A cross-section of it discloses an outer firm and an inner loose part: it is made up of transverse fibres limited by the transverse ligament and longitudinal fibres, which rise from the acetabular fossa, and some pass in from the capsule under the transverse ligament. Its function may be (1) to check movement; (2) a remnant from lower animals; (3) to carry synovia and vessels (this is most probable). The motion it checks is a most unnatural one—viz. is tense with thigh flexed, adducted, and rotated in. Sometimes it is a mere synovial fold, and sometimes is wanting.

The *capsule* springs from the outer surface of the base of the cotyloid, from the edge of the acetabulum and margin of the transverse ligament; below it is attached to the anterior intertrochanteric line and to the back of the neck of the femur in a line parallel to the posterior intertrochanteric and about $\frac{1}{2}$ inch above it. The digital fossa is outside the capsule: it is im-

possible to have a true extracapsular fracture of the neck of the femur. At the attachment to bone the innermost layer of the capsule is reflected in smooth or longitudinal folds (retinacula) up the neck to the articular cartilage of the head, with which it fuses. This layer of the capsule lined by epithelium is a thin but firm membrane, seen by the microscope to be formed of parallel, transverse, or circular bands; outside this are connective-tissue layers separating it from the accessory bands.

The *accessory ligaments* are either circular or longitudinal. The circular bands form the *zona orbicularis*, which is most distinct on the under wall of the capsule, because less covered here by the longitudinal bands. It occupies the middle third of the capsule, and continues upon the upper and lower thirds as transverse or scattering bands of connective tissue.

The accessory longitudinal bands spring from each of the three bones forming the acetabulum, and are only lacking in that part of the capsule which rises from the transverse ligament. They go between the circular fibres, over them, or end in them.

The *ilio-femoral ligament* extends obliquely across the front of the capsule, attached above to the lower part of the anterior inferior spine, and from a point behind this, just above the acetabulum, and below to the whole length of the anterior intertrochanteric line. It is covered by a fine layer of circular fibres, and pierced by some fibres of origin of the outer head of the rectus femoris. At its insertion it is divided into two bands—one to the lower part of the line and base of the small trochanter, and one to the upper part. Sometimes it does not divide, forming then a triangular band. It is called the *inverted Y-ligament* of Bigelow and lig. of Bertin. It is of great importance in maintaining the erect position of the body, and requires 250 to 750 pounds for its rupture.

The *ilio-trochanteric ligament* rises from beneath the anterior inferior spine, and may be considered as the upper arm of the Y-ligament or as fibres parallel to it, and inserted into the anterior part of the base of the great trochanter.

The *pubo-femoral ligament* may be described in three parts at its origin: the first is a continuation of the fascia over the pectineus muscle, and goes from the ilio-pectineal eminence down between the ilio-psoas and pectineus muscles to the lowest part of the capsule; a second fasciculus (pubo-femoral of Barkow) comes beneath the pectineus from the whole length of the obturator crest, and joins the first set outside that muscle; a third set comes from the upper ramus of the pubis and upper obturator spine and joins the others: it gives origin to some fibres of the obturator externus.

The *ischio-capsular ligament* rises from the lower part of the edge of the acetabulum and neighboring portion of the ischium, and ends in the lower and outer portion of the orbicular zone.

The *ischio-femoral ligament* (Macalister) rises from the upper part of the ischial tuberosity, passes over the groove between this tuberosity and

the acetabulum, and is attached to the back of the neck at a point midway between the two trochanters. It is often fused with the capsule.

Synovial processes occupy the joint outside the fatty pad of the fossa acetabuli and in the region of the neck of the femur: broad flaps hang from the capsular covering of the neck, or thin tufts give a velvety appearance to the inner surface of the capsule.

The ilio-psoas bursa opens into the joint anteriorly, and is analogous to the subscapular bursa of the shoulder: it may act as an accessory pouch for synovial supply as needed. Where the capsule is thin, muscles strengthen it: in front is the ilio-psoas; above, the rectus and gluteus minimus; internally, the obturator externus and pectineus; behind, the pyriformis, two obturators, two gemelli, and quadratus femoris.

Nerves are from the sacral plexus, great sciatic, nerve to quad. fem. muscle, obturator, accessory obturator, and anterior crural.

The *arteries* are from the obturator, sciatic, gluteal, internal and external circumflex.

Movements are in every possible direction. Flexion and extension pass through 139° on the dead subject, about 86° on the living; ab- or adduction through 90°, and rotation through 51°. *Flexion is checked* by soft parts and by hamstring muscles (with knee extended), by posterior part of capsule and ischio-capsular ligament; *extension is checked* by the anterior part of the capsule and ilio-femoral ligament; *rotation out*, by upper arm of ilio-femoral; *rotation in*, by ischio-capsular and ischio-femoral ligaments; *abduction*, by pubo-femoral lig. and lower and inner parts of capsule and impact of head of femur; *adduction*, by upper arm of Y-ligament, by ilio-trochanteric lig., and by soft parts.

Ilio-femoral lig. checks extension and tendency to tip backward, rotation out, and adduction. *Pubo-femoral checks* abduction. *Ischio-femoral checks* rotation in, extraordinary flexion.

THE KNEE-JOINT.

Describe the knee-joint.

This is a double condylar joint, really consisting of three articulations, one between each condyle and the tibia, one between the patella and femur. The lig. mucosum indicates the original separation of the synovial sac into two.

The *ligaments* are—

External semilunar cartilage.
Internal semilunar cartilage.
Coronary.
Anterior crucial.
Posterior crucial.
Capsular.
Lig. alaria.

Accessory.

Anterior:
Fascia lata.
Lig. patellæ.
Lateral patellar ligaments.
Transverse.
Posterior:
Popliteal oblique.

Lig. mucosum.

Popliteal arcuate.

Retinaculum or short ext. lateral.

External:

External lateral.

Internal:

Long internal lateral.

Short internal lateral.

The bones are covered with hyaline cartilage to the average depth of $\frac{1}{8}$ inch (4 mm.). On the anterior part of the condylar surface is a transverse groove caused by the indentation of the fibro-cartilages: the part above this groove articulates with the patella. The free posterior part of the condyle corresponds to a radius of $\frac{3}{8}$ inch (17 mm.).

The joint-surface of the tibia is much flatter than that of the femur, and the disproportion is made up by the *internal* and *external semilunar fibro-cartilages* (meniscus medialis and lateralis). Their upper surfaces are concave, their outer edges $\frac{1}{2}$ inch (6 mm.) high, and lower surfaces flat. These ligaments are composed of horizontally arched fibres: near their outer edges they split into two layers, between which run nutrient vessels. Their upper surfaces are covered with a strong fibro-cartilaginous membrane 1 mm. thick.

The *external cartilage* is nearly circular, its anterior extremity being inserted in front of the spine of the tibia and its posterior into both the inner and outer peak of the spine. The width of this cartilage is about $\frac{3}{8}$ inch (13 mm.).

The *internal cartilage* forms nearly a half-circle, and is elongated from before backward. Its anterior extremity is in front of the anterior crucial ligament, its posterior extremity in front of the posterior crucial ligament. This is widest behind, 17 mm., and gets narrower in front.

Coronary ligaments connect the convex borders of these cartilages to the head of the tibia: they are derived in part from the lateral ligaments.

The *crucial ligaments* partly form a sagittal partition wall inside the joint, making a right and left chamber in its posterior half. They are not like the lig. teres, but are remains of original joints. Between them is loose connective tissue, sometimes little bursæ. They are named from their tibial origins. The *anterior* rises in front of the external meniscus, passes, fan-shaped, up, back, and out to the posterior part of the inner surface of the external condyle: the fibres rising most externally are inserted most posteriorly.

The *posterior ligament*, a little stronger than the anterior, rises from the floor of the popliteal notch on the tibia, and passes up and forward to the anterior part of the outer surface of the inner condyle—*i. e.* to the inner wall of the intercondylar fossa of the femur: this crosses behind the anterior one, forming an X, and its posterior surface becomes external.

The *crucial ligaments* receive fibres from the semilunar cartilages, rarely any from the inner to the anterior ligament: some pass from the

posterior end of the external semilunar to the posterior crucial (third crucial), either to its posterior or its anterior surface, or they surround it.

The *capsule* of the joint rises anteriorly to a point on the femur $\frac{3}{8}$ inch to 3 inches (1.5 to 8 cm.) above its articular surface; thence it slopes to the epicondyles; posteriorly it is attached just above the condyles and to a line between them and to the gastrocnemius and popliteus. On the anterior surface of the femur it is underlaid with rich masses of fat: on the patella it is attached close to the edges of its posterior surface, and on the tibia close beneath the articular cartilages, and is connected with the origin of the post-crucial lig.

Anteriorly, above the patella, the capsule is united with the extensor tendon: below this and the patella it is continued as a broad roll to the tibia, stretched in flexion, and in extension drawn forward by a special muscle. On the sides the capsule is united to the circumference of the semilunar cartilages: it presents two layers—one of vertical connective-tissue fibres to the edges of the cartilages, and an inner smooth vascular layer covering their upper surfaces: this also covers the crucial ligaments, so that really the semilunar cartilages and crucial ligaments are outside the sac of the capsule.

Synovial Bursæ and Ligaments.—By the semilunar cartilages is the joint divided into an upper and lower chamber, and by the crucial ligaments is each chamber divided into lateral halves: into one or other of these cavities the subcrural synovial pouch opens. There is a constant communication with the *popliteal bursa*, which is between the popliteus muscle and the posterior wall of the lower and outer chamber of the joint. In 1 out of 80 cases there is a communication with the upper tibio-fibular joint. The groove for the popliteus is covered with cartilage which is continuous with that of the upper tibio-fibular joint. The openings from the joint into the *subcrural pouch* are various in number and position, or, most rarely, are absent.

The *bursa semimembranosa* lies between the external surface of the semimembranosus tendon and the inner head of the gastrocnemius: it is about 2 inches (5 cm.) long, sometimes simple and sometimes split by septa. It communicates with the knee-joint in about one-half the cases, more often with the right knee, and more often in robust subjects, and never in children.

The knee-joint contains large fatty synovial folds and tufts: the most constant are the *ligamenta alaria* (plica synov. patellaris), which is separated in front from the capsule by a mass of fat, and rises up behind the articular surface of the patella to near its upper edge. By the vertical ridge on the posterior patellar surface it is divided more or less into its two wings (alæ): its upper edge is concave and unites with the lateral edges of the patella. In flexion of the joint it enters as a pad between the patella and tibia. Its position is secured by the *lig. mucosum* (lig. plicæ synov. patellaris), which rises from the bottom of the joint and passes free in a sagittal direction through it to the anterior edge of the intercondyloid fossa of the femur, rarely attached to the spine of the

tibia or anterior crucial ligament. At its insertion it is usually flat and broad, in the middle cylindrical. It may be no larger than a thread.

Synovial tufts are most numerous on the anterior wall of the joint above the patella. Small folds and strings and little follicles of the capsule lie near its insertion into the tibia. Synovia occupies the spaces not filled by synovial folds or fat pads.

Accessory bands are found upon the anterior, posterior, external, and internal walls.

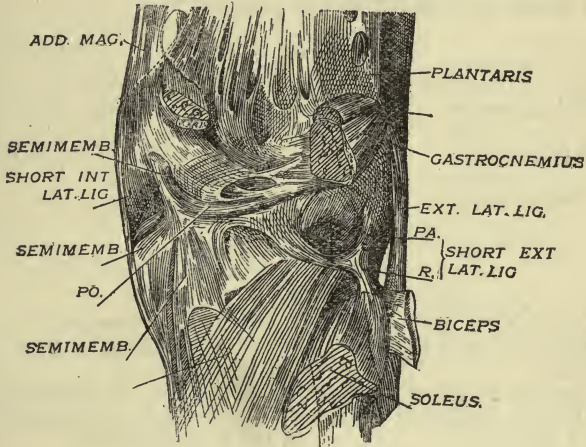
1. Anteriorly the accessory bands form three layers: (1) The most superficial is a continuation of the fascia lata, converging symmetrically on either side to be inserted into the tibia or lig. patellæ; some pass horizontally in front of the lig. patellæ and patella. (2) The middle consists of tendons and ligaments around the patella. (3) The deepest set is transverse. To the second set, the centre of which is the patella, belongs the extensor tendon of the leg and three bands: the lowest is the *lig. patellæ* (lig. patellare inf.), $\frac{1}{3}$ inch (4 mm.) thick, embracing the apex of the patella, and passing down and back to the tubercle of the tibia with undiminished size. Between this ligament and the capsule is a mass of fat; between it and the head of the tibia is the *subpatellar bursa*; between it and the tubercle of the tibia is a *pretibial bursa*. The *side bands* of the *patella* (lig. patellare laterale and mediale) are thin, membranous, and triangular. They rise by their apices from the epicondyles of the femur, and pass forward to the sides of the patella, to the posterior surface of the extensor tendon and lig. patellæ, often separated from the capsule by cellular bursæ. The deepest set forms the *transverse ligament*, more or less covered with fat, and passing from the upper surface of the internal semilunar cartilage near its anterior extremity to the anterior convexity of the outer. It is variable, may be round or flat, or lacking, or pass from one cartilage into synovial folds.

2. The *posterior capsular wall* has a complicated structure due to its connection with various muscle tendons. Above the condyles the capsule is compact, but lower it shows two transverse bands. The *oblique ligament* (posterior lig. of Winslow, PO, Fig. 13) is a part of the tendinous insertion of the semimembranosus. This muscle divides into four parts at its insertion—one to the front of the tibia in an arched direction, one straight down to the tibia, one to the popliteal fascia, and one on the posterior capsular wall up and out to the outer condyle. When the semimembranosus tendon is stretched this oblique ligament throws the wall into a fold.

The *arcuate ligament* (lig. popliteum arcuatum, PA) is composed of arched fibres, concave upward, springing from the external epicondyle and losing themselves on the capsule below the oblique ligament. This helps form the opening by which the popliteal bursa communicates with the joint. To the lower edge of this ligament are inserted a ligament and a muscle; the ligament rises from near the apex of the head of the fibula between the biceps and soleus, and spreads its fibres upon both sides of the arcuate ligament. It is the *retinaculum lig. arcuati* (R) or

short external lateral ligament. The muscle, rising from the arcuate is the inner half of the popliteus. When the knee is extended the retinaculum is stretched and the arcuate ligament kept convex: in the flexed

FIG. 13.



Posterior Surface of Knee-joint.

position the popliteus does the same, so that the ligament is tense in either case, and the canal held open by which the popliteal bursa communicates with the joint.

3. *Externally* is the long ext. lateral ligament (lig. accessorium laterale), a flat strand separated from the capsule by fat. It rises from the external epicondyle, receiving some fibres from the external intermuscular septum, and passes straight to the head of the fibula, splitting the biceps tendon at its insertion. The most anterior fibres of this ligament bend at right angles to the front, and are lost on the edge of the external semilunar cartilage: it is tense in extension and relaxed in flexion.

4. Internally are two ligaments, *long* and *short internal lateral* (lig. access. mediale longum and breve). Both are from the epicondyle below the lateral patellar ligament: the long one is the more superficial and attached to the posterior edge of the inner surface of the tibia 2 to 3 inches (5-8 cm.) below its articular surface. It covers the inferior articular vessels and the semimembranosus tendon, and is separated by a bursa from the tendons of the gracilis and semitendinosus; posteriorly it becomes very thin. As this rises from about the centre of the circle

formed by the posterior part of the condyle, it has an equal degree of tension in flexion or extension.

The *short internal lateral ligament*, placed behind the long internal, is a continuation of the semimembranosus fibres vertically to the inner semilunar cartilage.

What bursæ are related to the joint ?

Anterior Bursæ.

Prepatellar.	Pretibial.
1. Subcutaneous.	1. One in front of tubercle of tibia.
2. Subfascial.	2. One between lig. patellæ and tubercle of tibia.
3. Subaponeurotic.	3. Subpatellar.

Subcrural Bursa.

Lateral Bursæ.

Externally.	Internally.
1. Beneath outer head of gastrocnemius.	1. Beneath inner head of gastrocnemius.
2. Beneath tendon of popliteus.	2. Beneath semimembranosus.
3. Between tendon of popliteus and ext. lat. lig.	3. Between semimembranosus and semitendinosus.
4. Bicipital, between biceps, fibula, and ext. lat. lig.	

The *nerves* are from the obturator, anterior crural, by branches to the vastus externus, internus, and crureus, external and internal popliteal, three branches from each, and sometimes the great sciatic.

The *arteries* are—the anastomotica magna of femoral, five articular of popliteal, recurrent anterior tibial, posterior tibial recurrent, and a descending branch from the external circumflex.

Movements to be considered are those between each condyle and tibia, between femur and patella. It is a hinge, and owes its special motions to peculiarity of ligaments rather than to conformation of bone, as in case of elbow. *Flexion* and *extension* have a maximum of 140°: flexion is arrested mostly by the anterior crucial ligament; the anterior fibres of the posterior ligament are also stretched. At the beginning of flexion both crucial ligaments become relaxed: both are stretched in extension, especially the posterior short fibres of the posterior crucial. In extension the lateral ligaments are tense, and do not allow any motion but flexion. Flexion and extension do not occur in a pure hinge-like manner: the same part of one articular surface is not always applied to the same part of another; the axis of motion is not a fixed one. The motion

of the femur on the tibia is likened to that of a carriage-wheel on the ground: it advances or recedes while it rotates.

The semilunar cartilages are loosely attached, and move forward in extension and backward in flexion of the joint like movable wedges; as the condyles roll and present different curvatures, each cartilage contracts or expands to fit the surface above. The actual contact of the femur with the tibia is hardly more than linear.

In extension the anterior capsular wall is raised by the subcrural muscle; in flexion the posterior wall has two muscles to prevent its bulging into the joint. The semimembranosus acts through its oblique ligament when the flexors from the thigh and pelvis are in operation; the popliteus, through the arcuate ligament when the plantaris and those attached to the os calcis act.

As flexion increases, rotation is possible, and increases to a total of 39° , due to a relaxation of lateral and crucial ligaments. *Rotation out* (supination) is most extensive, as the external lateral ligaments are more loose than the internal; this occurs on an axis through the inner condyle and inner tuberosity of the tibia. This motion is checked by the internal lateral ligament and the winding of the posterior crucial around the spine of the tibia. *Rotation in* (pronation) on an axis through the outer condyle and outer tuberosity of the tibia is never more than 5° or 10° ; this motion is checked by the anterior crucial ligament and by the twisting of these crucial ligaments around each other.

At the close of full extension there is a *movement of adaptation*, or gliding back of the inner condyle upon the tibia: this axis is through the external condyle. At the beginning of flexion a reverse motion takes place.

The *movements of the patella* are partly gliding and partly those of adaptation. In extension only the lower one-sixth of the patellar articular surface is in contact with the femur; in semiflexion, the middle three-sixths; in full flexion, the upper two-sixths, as the lig. patellæ pulls it down in front of the joint.

LIGAMENTS BETWEEN THE BONES OF THE LEG.

Describe the ligaments between the bones of the leg.

In the *upper tibio-fibular articulation* is a capsule and two accessory bands.

The *capsule* rises from the tibia about $\frac{1}{2}$ inch (5 mm.) above the articular surface, elsewhere from its edge; it passes to the contiguous margins of the fibular surface, and generally encloses a little space at the lower part of the joint, covered only by periosteum, where the tibia and fibula rest upon each other.

Accessory bands are *anterior* and *posterior ligaments* (lig. capituli fibulæ ant. and post.). The former consists of one or more bands from the front of the head of the fibula to the front of the outer tuberosity of the tibia: some fibres of the peroneus longus and extensor long. digit.

rise from it. The posterior ligament connects the bones in a similar manner, and is covered by one head of the soleus. This joint-cavity may communicate with the knee-joint. Fat fills the space between the capsule and interosseous membrane.

The joint-surfaces move in a transverse and sagittal direction, more in the former; the purpose of the movement is to allow a gliding at the lower ends of the bones.

Between the bones is the *interosseous ligament* or *membrane*, its fibres passing down and out to the fibula; it separates the flexor from the extensor muscles. Above is an opening for the anterior tibial vessels, and below another for the anterior peroneal. Close to the upper tibio-fibular joint is a band of fibres analogous to the oblique ligament of the forearm, running in a direction opposite to the fibres of the rest of the membrane. If the forearm be pronated and compared with the leg, the two interosseous ligaments run in parallel directions.

The *inferior tibio-fibular joint* presents *interosseous*, *anterior*, *posterior*, and *transverse* ligaments. The *interosseous* is continuous with the interosseous membrane above. The *anterior* and *posterior* ligaments connect corresponding surfaces of the two bones. The *transverse* is under the posterior ligament, projects below and connects the margins of the bones, and forms part of the articulating surface for the astragalus.

THE ANKLE-JOINT.

Describe the ligaments of the ankle-joint.

The ligaments are *anterior*, *posterior*, *internal lateral*, and *external lateral*.

The *anterior* is broad and thin, and connects the tibia and astragalus. The *posterior* consists mostly of transverse fibres between the tibia and astragalus.

The *internal lateral* or *deltoid* has a superficial and a deep layer: the former rises from the apex, anterior and posterior borders of the internal malleolus, and passes forward to the scaphoid and inferior calcaneoscapoid ligament, downward to the posterior edge of the sustentaculum tali, and backward to the astragalus, all to different bones; the deep layer is strong and thick, and passes from the apex of the malleolus directly to the inner surface of the astragalus.

The *external lateral ligament* has three fasciculi—one from the anterior part of the external malleolus to the astragalus, a middle one from the apex of the malleolus to the os calcis, and a posterior one from the back of the malleolus to the astragalus. (For movements, etc. see p. 137.)

JOINTS OF THE FOOT.

What are the ligaments of the tarsus?

There are three sets—articulations of first row, of second row, of the two rows with each other.

Those of the first row, between the astragalus and os calcis, are *external*, *internal*, and *posterior calcaneo-astragaloid* and *interosseous*. The *external* is in front of and parallel with the middle fasciculus of the ext. lat. lig.: it is inconstant and connects the outer surfaces of the two bones. The *internal* passes from the inner tubercle of the astragalus to the sustentaculum tali. The *posterior* is narrow and connects the posterior borders of the two bones. The *interosseous* is thick and strong and fills the groove between the two bones.

The ligaments of the second row are *dorsal*, *plantar*, and four *interosseous*. These include the *scapho-cuboid* ligaments.

The ligaments connecting the two rows are of three sets—viz. (1) between os calcis and cuboid; (2) between os calcis and scaphoid; (3) between astragalus and scaphoid.

(1) *Superior, Internal, Long and Short Calcaneo-cuboid*.—The *superior* connects the upper surfaces of the two bones. The *internal* is somewhat interosseous. The *long plantar* (long calcaneo-cuboid) passes from the tuberosities of the os calcis to the ridge on the under surface of the cuboid, completing a canal for the peroneus long. tendon.

The *short plantar* extends from the anterior tubercle of the os calcis to the cuboid behind its peroneal groove.

(2) The ligaments are *superior* and *inferior calcaneo-scaphoid*. The *superior* and *internal calcaneo-cuboid* form the arms of a Y.

The *inferior* passes from the sustentaculum tali to the tuberosity of the scaphoid, forming an articular cavity for the head of the astragalus: it is supported below by the tibialis posticus tendon.

(3) There is a thin *superior astragalo-scaphoid* ligament: an inferior ligament is supplied by the inferior calcaneo-scaphoid.

What are the remaining ligaments of the foot?

Tarso-metatarsal joints have *dorsal*, *plantar*, and *interosseous* ligaments: the latter are three in number.

The intermetatarsal articulations have *dorsal*, *plantar*, and *interosseous* ligaments: the digital extremities are united by a *transverse metatarsal* ligament which connects the great toe to the others.

Metatarso-phalangeal and interphalangeal articulations have each *plantar* and *two lateral ligaments*.

HENLE'S CLASSIFICATION OF THE ANKLE- AND FOOT-JOINTS.

The articulations of the ankle, tarsus, etc. are all described under one head, the "foot-joints."

A division into capsular membranes and accessory bands cannot here be made just as in the hand: a ligament may pass over more than two bones, or one connecting two bones may help form a joint-socket. There are *three* distinct movable joints to be considered—that of the ankle, the anterior and posterior astragaloid joints: all the others are amphiarthrodial.

A. *Lower Tibio-fibular Joint.*

A thin *capsule* is mentioned. The interosseous ligament (membrane) ceases $\frac{2}{3}$ inch (10 mm.) above the lower extremity of the tibia: this distance between the tibia and fibula is a space hardly deserving the name "joint-cavity." The tibial surface is covered with periosteum, the fibular with a *flat pad of fat* ("valved pad") interposed in the chink between the bones. This allows a "give" in the joint: it is squeezed up between the bones and articulates below with the supero-external border of the astragalus, and prevents that bone from being pushed up between the tibia and fibula.

Accessory bands, anterior and posterior (lig. malleoli lateralis ant. and lig. mal. lat. post.), are continuous above with the interosseous ligament and below with the puffy edge of the capsule of the ankle. The *anterior band* is triangular, and passes down and out from the tibia in front of its articular surface to a corresponding point on the fibula. Anteriorly it is covered with fat and loose connective tissue: its posterior surface is in the ankle-joint, and its lower edge overhangs the astragalus.

The *posterior ligament* resembles the anterior in shape, but is stronger; rises not only from the posterior surfaces of the two bones, but also from their opposing surfaces and from a deep fossa behind the articular surface of the fibula. These lowest fibres (transverse lig. of Gray) run to the inner malleolus of the tibia or are lost on its posterior capsular wall. Both accessory bands are tense in flexion of the foot and relaxed in extension.

B. *Joints of the Astragalus.*

Capsular Ligaments.—1. *Talo-crural Articulation.*—Talus = astragalus, os naviculare = scaphoid. Surfaces are covered with hyaline cartilage 1 to 2 mm. thick; the accessory bands of the lower tibio-fibular joint help form these joint surfaces. The upper articular surface of the astragalus corresponds to a radius of $\frac{1}{4}$ inch (17 to 21 mm.) and an arc of 120° ; the extent of articular surface on the tibia is related to that on the astragalus as 2 : 3. Both head and socket diminish in a transverse direction toward the posterior from 32 to 28 mm. The *capsule* is tense on the sides and loose anteriorly and posteriorly, where it is thrown alternately into folds in flexion or extension: it is attached close to the articular surfaces except in front of that on the astragalus, where it encloses a rough space covered partly by fat and partly by thin periosteum. Vertical septa divide this little anterior pouch into compartments which communicate with the general cavity only by narrow mouths. On the posterior capsular wall are hernia-like protrusions. The strengthening fibres on the posterior wall pass down and in; on the anterior wall down and out. Thick fat pads lie upon the anterior and posterior capsular walls: the posterior is enclosed in fascia to which the plantaris is attached, so that this pad and the capsule are pulled back when that muscle contracts.

2. *Posterior Astragalus Joint* (astragalo-calcanea).—The surface on the os calcis is that of a cylinder of $1\frac{1}{2}$ inches (28 mm.) radius, whose axis passes from the posterior edge of the outer surface of the bone to the antero-inferior edge of the inner, making an angle of 30° with the long axis of the foot. The head of the joint is on the calcaneum, the socket in the astragalus; and motion here is a rotation of the foot on its long axis. The *capsular membrane* is close to the articular surfaces in the region of the interosseous groove, elsewhere is farther away: it is in relation to fatty masses, especially so near the canalis tarsi.

3. *Anterior Astragalus Joint* (astragalo-calcaneo-scaphoidea).—This is a joint of cylindrical surfaces: the head includes the anterior surfaces of the astrag-

alus and the anterior part of its lower surface; the socket is made of the inner articular surface of the os calcis, the posterior surface of the scaphoid, and the lig. tibio-calcaneo-naviculare (inferior calcaneo-scaphoid), and its fibro-cartilage. A horizontal section of the head shows an arc of 120° ; a vertical section is a little smaller. The lig. tibio-calcaneo-naviculare fills up the space in the plantar arch on the inner edge of the foot between the scaphoid and os calcis: it is made up of fibres which pass forward from the groove on the astragalus for the flex. long. poll. tendon, fibres passing down and forward from the tip of the inner malleolus, down and back from the scaphoid, up and forward from the sustentaculum tali. At the junction of all these fibres there is an elliptical ligamentous disk $\frac{1}{2}$ inch (6 mm.) thick, hard like cartilage, and may be ossified in spots. This supports the head of the astragalus, preserves the arch of the foot, and forms a groove for the tibialis posticus tendon.

The socket of this joint presents three zones: (1) corresponds to the postero-internal articular surface on the sustentaculum tali; (2) divided also into three parts, (2') the antero-internal articular surface on the calcaneum, (2'') the lig. tibio-calc.-naviculare, (2''') the ligamentous disk of this ligament; the third (3) zone is the anterior wall of the socket and belongs to the scaphoid. All these bony surfaces are marked off by deep furrows and fatty synovial folds. The joint-head also presents three zones nearly corresponding to the above.

The capsule of this joint springs inferiorly close from the edges of the articular surfaces, superiorly at some distance from the edges, and internally it reaches under the tibio-calc.-navic. lig. close to the ankle-joint.

Accessory Ligaments.—Of the astragalus joints there are three groups: (1) those connecting the astragalus with the bones of the leg; (2) those connecting the astragalus and os calcis; (3) that between the astragalus and scaphoid. The external are usually longer and stronger than the internal.

I. *Ligg. Talo-cruralia.*—These pass two from each malleolus obliquely down to the astragalus, one backward and one forward on each side. They hold the astragalus so firmly under the tibia that no rotation about a sagittal axis is possible. By flexion of the foot the two posterior are stretched, by extension the two anterior.

1. *Lig. Talo-fibulare Posticum*, the posterior fasciculus of the ext. lat. of Gray; origin, fossa on fibula behind its articular surface; insertion, posterior surface of astragalus near the outer tubercle of the flex. long. poll. groove.

2. *Lig. Talo-tibiale Posticum* (posterior superficial fibres of deltoid), from a little fossa behind the tip of inner malleolus to a smooth place on the astragalus below the posterior half of the joint-surface.

3. *Lig. Talo-fibulare Ant.* (anterior fasciculus of ext. lat. lig.), external malleolus to astragalus, 10 mm. broad; may divide into two at its insertion.

4. *Lig. Talo-tibiale Ant.*—Short band, 3 mm. broad, deeply placed under other ligaments; passes from apex of inner malleolus to a point behind the rounded apex of the inner joint-surface of the astragalus.

II. *Ligg. Talo-calcanea.*—1. *Lig. Talo-calcaneum Posticum* springs by a point from the outer tubercle of the flex. long. poll. groove, and is inserted broadly or by two arms into the upper and inner surface of the os calcis.

2. *Lig. Talo-calcaneum Laterale.*—Ext. calc.-astragaloid of Gray; from upper and outer surface of os calcis, covered by the short extensor muscle, passing through the fat at the entrance of the sinus tarsi, upward, inward, and backward to the rounded margin of the astragalus, which overlies the canalis tarsi. It is frequently doubled and frequently lacking.

3. *Lig. Talo-calcaneum Mediale*, a small nearly horizontal slip from the inner

margin of the flex. long. poll. groove to the posterior edge of the sustentaculum tali.

4. *Lig. Talo-calcaneum Interosseum* (interosseous calcaneo-astragaloid).—This fills the tarsal canal; consists of several layers and mostly short fibres. In the narrowest part of the canal two layers cross each other obliquely.

III. *Lig. Talo-naviculare* are dorsal fibres between the neck of the astragalus and middle of the scaphoid: it has two parts, which lie beside each other on the astragalus and overlap on the scaphoid, the external lying upon the inner ones, and some going on to the middle cuneiform.

IV. *Long Accessory Bands between Bones of the Leg and Tarsus*.—1. *Lig. Tibio-naviculare* (ant. superficial fibres of deltoid), from the anterior edge of inner malleolus down and out to the dorsum of the scaphoid.

2. *Lig. Calcaneo-fibulare* (middle fasciculus of ext. lat. lig.), from the apex of the external malleolus to a little tubercle in the middle of the external surface of the os calcis: it is covered by smooth membrane and helps form a groove for the peroneal tendons: it may be doubled.

3. *Lig. Calcaneo-tibiale* (middle superficial fibres of deltoid), from inner malleolus to posterior edge of sustentaculum tali.

C. Amphiarthrodia of Tarsus.

First row = astragalus and os calcis; second row = scaphoid and posterior half of cuboid; third row = the cuneiform bones and anterior half of cuboid.

Capsular membranes are variable in number, but should be nine; they are tense, and grow close to the edges of the joint-surfaces. The synovial folds are fatty and small. There is a capsule for (1) the calcaneo-cuboid joint; (2) the cuneo-navicular, which also includes the articulations of the cuneiform with each other, the external cuneiform with the cuboid, the navicular with the cuboid (sometimes); (3) tarso-metatarsal joints: capsules usually three in number—one for the internal cuneiform and first metatarsal, one for the middle and external cuneiform and second and third metatarsals, the third for the cuboid and fourth and fifth metatarsals.

Accessory Bands of Tarsus.—I. *On Dorsal Surface*.—1. *Transverse*: (a) in second row, *ligg. naviculari-cuboidea*, a superficial and a deep one; (b) in third row, (1) *ligg. cuneo-cuboid.*, an anterior and a posterior one; (2) between second and third cuneiforms; (3) between second and first. (c) In the metatarsus, *ligg. intermetatarsea dorsalia*, lacking between the first and second.

2. *Sagittal*: (a) between first and second rows, (1) *lig. calcaneo-naviculare dorsale* = superior calcaneo-scaphoid; (2) *ligg. calcaneo-cuboidea dorsalia*, two or three bands = superior and internal calcaneo-cuboid; (b) between second and third rows, (1) between scaphoid and outer cuneiform; (2) scaphoid and middle cuneiform, two bands; (3) scaphoid and inner cuneiform, two strong bands; (c) between third row and metatarsus, *ligg. tarso-metatarsea dorsalia*; one to the first metatarsal from the internal cuneiform; three to the second, one from each cuneiform; to the third are variable bands, may be two from the two outer cuneiform; to the fourth, one, sometimes two, from the cuboid; to the fifth, one from the cuboid.

II. *Accessory Bands of Plantar Surface*.—There are *long bands* which are superficial and pass over several bones; *short bands* which are deep and connect adjoining bones. (a) *Long Ligaments*.—*Lig. calcaneo-cuboideum plantare* = plantar ligaments of Gray. This rises from the whole rough under surface of the os calcis from the two posterior tubercles to the anterior one: it is divisible into three layers. The most superficial passes over the tuberosity of the cuboid to the flexor brevis poll. muscle, to the interossei and bases of the metatarsal. These last fibres are strengthened by single bundles rising

from the tuberosity of the cuboid: the fibres to the flexor brevis poll. are joined by transverse fibres from the tendon of the tibialis posticus, and are also connected with the plantar fascia.

The middle set of fibres extends to the tuberosity of the cuboid. The deepest set is inserted into the cuboid behind its tuberosity, passing mostly from the anterior tubercle of the os calcis: it comes to view internal to the upper layers.

The *lig. tarseum transversum laterale* goes from the external cuneiform, covered by the peroneus longus tendon, to the tuberosity of the fifth metatarsal.

The *lig. tarseum transversum mediale* runs from the inner surface of the inner cuneiform to the base of the third, sometimes fourth, metatarsal.

(b) *Short Ligaments*.—1. *Transverse*: (a) in second row, *lig. cuboideo-naviculare plantare*; (b) in third row, between the cuboid and outer cuneiform and between the cuneiforms is a continuous band or several separate ones; (c) in the metatarsus, *ligg. intermetatarsea plantaria*, only between the four outer bones: the lack of one between the first and second is supplied by a band from the internal cuneiform to the base of the second.

2. *Sagittal*: (a) between first and second rows, *lig. calcaneo-naviculare plantare*, a short round band running obliquely inward and forward to the navicular bone from the anterior inner corner of the os calcis; (b) between the second and third rows, from the scaphoid to the cuneiforms, a broad band covered by the tibialis posticus tendon; (c) between the third row and metatarsus, *ligg. tarso-metatarsea plantaria*, a broad and strong band to the first from the inner cuneiform; weak bands to the second from the middle and outer cuneiforms; to the third, short bands from the middle and external cuneiforms and cuboid; to the fourth, a band from the outer cuneiform or from the cuboid, or from both.

3. *Accessory Bands in the Interspaces of the Metatarsus*.—*Ligg. intermetatarsea interossea* lie in the spaces just in front of the capsules in which the side surfaces of the bases of the metatarsals articulate with each other.

What separate synovial cavities are there?

Usually six—one for the posterior calcaneo-astragaloid joint; one for the anterior and the astragalo-scaphoid joint; one for the calcaneo-cuboid; one for the cuneo-scaphoid, the cuneiform with each other, the external cuneiform with the cuboid, the middle and external cuneiform with the second and third metatarsals; one for the first metatarsal and internal cuneiform; one for the fourth and fifth and cuboid; sometimes one between the scaphoid and cuboid.

Nerves for ankle-joint proper are from anterior and posterior tibials: tarsal joints have the anterior tibial and plantars.

Arteries of ankle are anterior and posterior tibials, anterior and posterior peroneals; lower down are the plantars and dorsalis pedis.

The *movements* of the ankle-joint are *flexion* and *extension*—a little *lateral motion* in extension: this is possible because the astragalus and tibio-fibular mortise are a little wider in front than behind, and in extension the narrowest part of the astragalus is in the widest of the articular socket. In flexion, as in stepping upon a chair, where lateral motion would be dangerous, the two joint-surfaces fit closely. With flexion is associated a slight rotation out of the foot; with extension, a slight rotation in. Flexion, a lifting of the apex of the foot, is possible to 20° from the horizontal; extension, a depression of the apex of the foot, goes through 45°.

Eversion or *inversion* of the foot means a rotation *out* or *in* of the whole lower extremity. *Rotation out* or *in* is rotation of the whole foot on a longi-

tudinal axis: this occurs at the posterior calcaneo-astragaloid joint. The foot is rotated in when the sole looks in. *Adduction* or *abduction* refers to a displacement in or out of the fore-foot, motion occurring in the tarsal joints, especially mid-tarsal.

The movements between the lower ends of the tibia and fibula are those of elasticity.

What are the ligaments of the metatarso-phalangeal joints ?

Each has a capsule, which is connected with the other by *ligg. capitulorum plantaria* and *dorsalia*, which together form the transverse metatarsal ligament of Gray. It connects the great toe with the others. Under the joints it is developed into a thick *fibrous* or *sesamoid plate*. In the one for the great toe the plate is ossified into two bones held together by transverse bands: this may occur in other toes. Besides the above there are *two lateral ligaments*. As a rule, there is a bursa between the capsules in the three inner intermetatarsal spaces.

The *interphalangeal articulations* are practically the same as those of the fingers.

MYOLOGY.

How are muscles divided ?

Into—

- I. Voluntary, striated (animal life);
- II. Involuntary (vegetative life)—(a) smooth, non-striated, (b) striated (cardiac).

Describe the structure of muscle.

I. *Primitive muscle fibrillæ* form *fibres*; fibres, *fasciculi*; fasciculi, muscles or flesh.

Epimysium surrounds entire muscle, and sends partitions between fasciculi, called *perimysium*; *endomysium* is between the fibres, but not as a sheath.

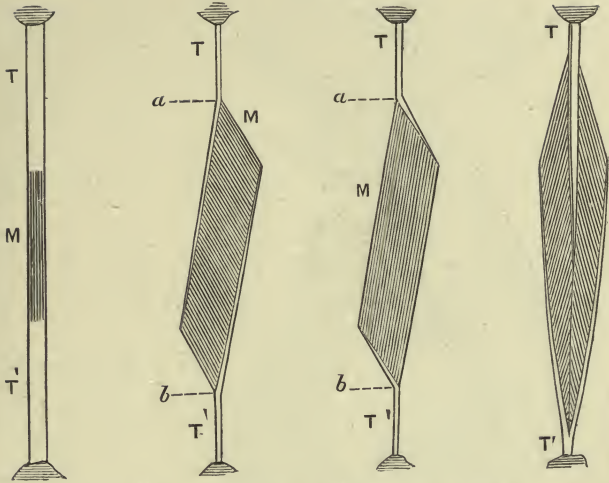
The fibres average $\frac{1}{400}$ inch in diameter, $1\frac{1}{4}$ inches long; by volition may contract one-fourth or one-third of its length, by electricity three-fourths. They consist of (1) central contractile substance, (2) nuclei, (3) tubular sheath or *sarcolemma*: they are divisible into the primitive fibrillæ, shown by longitudinal striations, and each fibrilla breaks into disks called *sarcous elements*, dark in the centre, with a lighter zone at each end; transversely through the light zone passes *Krause's line*, or membrane limiting with the sarcolemma each element; *Hensen's line* passes transversely through the central dark band.

Striated muscles comprise those of locomotion, respiration, expression; those of ear, larynx, pharynx, tongue, upper half of œsophagus, and walls of large veins near heart.

II. (a) Smooth, unstriated muscular fibres are made up of long nucleated cells, collected in bundles or layers, surrounded by connective tissue; the cell-body shows a longitudinal striation. This variety of

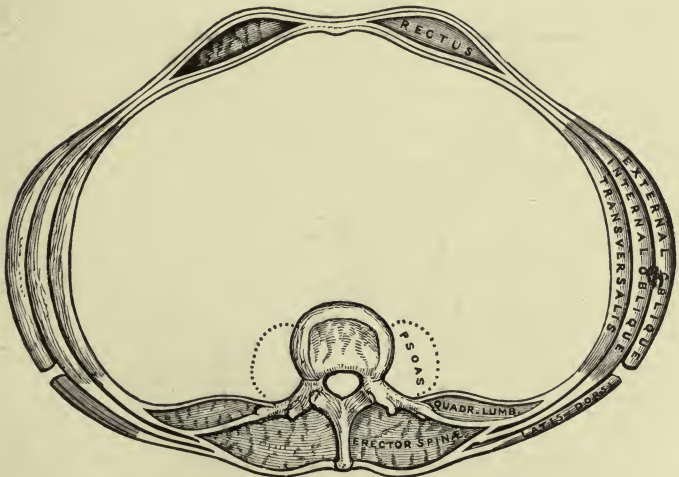
PLATE IX.

FIG. 1.—To face page 138.



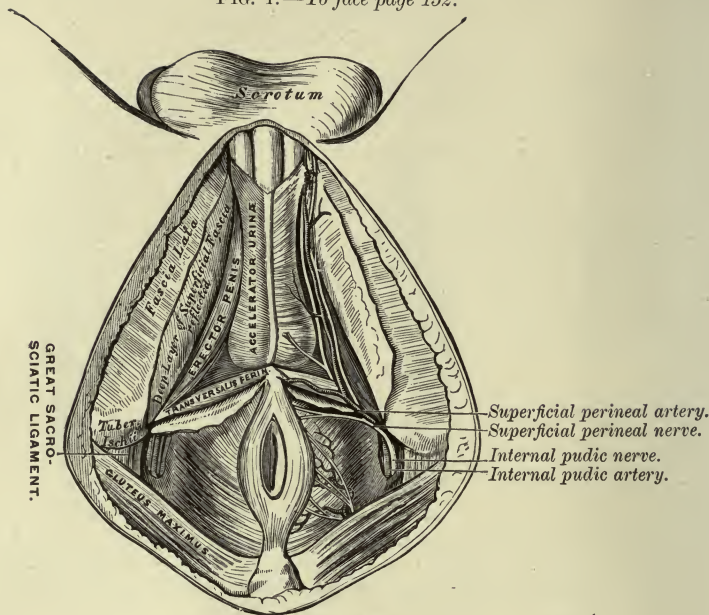
Arrangement of Muscular Fibres in Muscles in relation to the tendons and muscular aponeuroses: T, T', tendons of origin and insertion; M, muscular belly; a, b, length of muscular belly (Beaunis and Bouchard).

FIG. 2.—To face page 146.



A Transverse Section of the Abdomen in the Lumbar Region.

FIG. 1.—To face page 152.



The Superficial Muscles and Vessels of the Perinæum.

FIG. 2.—To face pages 158 and 159.

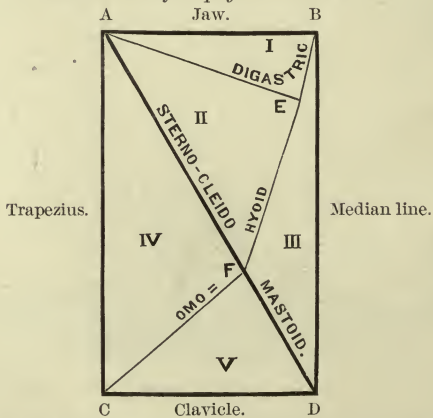


Diagram of the Triangles of the Right Side of the Neck.

muscle is found in the lower part of the œsophagus, stomach, intestinal canal, spleen, trachea, bronchial tubes, gall-bladder, bile-duct, ducts of large glands, of sweat-glands, uterus, appendages, vagina, ureters, bladder, urethra, corpora cavernosa, dartos, epididymis, prostate, ciliary muscle, iris, coats of veins, arteries, and lymphatics. (b) In striated heart-muscle the fibres anastomose and form a long-meshed network; no sarcolemma: transverse striæ are weak, fibres small, and made up of quadrangular cells joined end to end, each with a central nucleus.

MUSCLES IN GENERAL.

They are symmetrical in pairs, excepting the sphincters and a few others. They number about 311 (voluntary): head and front of neck = 82, vertebral column and back of neck = 60, thorax = 42, abdomen = 14, upper limb = 59, lower limb = 54. If a man weighs 150 pounds, his skeleton weighs 28 pounds; muscles, 62 pounds (over 40 per cent.); viscera, fat, blood, etc., 60 pounds.

How are muscles named?

(1) From *situation*, as tibialis; (2) *direction*, rectus; (3) *use*, flexors; (4) *shape*, deltoid; (5) *subdivision*, biceps; (6) *attachment*, sterno-cleido-masto-occipitoid; (7) *size*, magnus; (8) *bellies*, digastric; (9) *structure*, semimembranosus; (10) *relation to organs*, extrinsic or intrinsic; (11) *position*, superficial or deep; (12) *name of describer*, Horner's, Galen's.

Some muscles are synergists to others, some antagonists, some moderators.

The *origin* of a muscle refers to its more fixed, the *insertion* to its more movable or remote, attachment. The same nerves that supply joints generally supply the muscles and integument over those joints.

How are fasciæ arranged?

The *superficial fascia* is subcutaneous all over the body: its web contains subcutaneous fat, the *panniculus adiposus*, and often superficial muscles, the *panniculus carnosus*. There is no fat in this layer in the eyelids, penis, and scrotum. Beneath the fatty layer is usually another, devoid of fat, for the support of vessels and nerves.

The *deep fasciæ* or *aponeuroses* are made of strong fibrous tissue covering the body more or less, forming *aponeuroses of investment* or of *insertion* for muscles. Near some joints it is strengthened by transverse bands, forming *retinacula* or *annular ligaments* to hold tendons close to bone.

MUSCLES OF THE TRUNK.

MUSCLES AND FASCIÆ OF THE BACK.

Describe the muscles of the back.

(a) *Superficial, running out from spinous processes.*

FIRST LAYER.—*Musculus Trapezius* (cucullaris), or hood muscle.—

Origin, inner third superior curved line of occipital bone, lig. nuchæ, spinous processes of the seventh cervical, and all the dorsal vertebræ and supraspinous ligament; *insertion*, fibres converge to shoulder girdle; superior ones to outer third or half of posterior border of clavicle; middle fibres horizontally to inner margin of acromion and superior lip of scapular spine; inferior fibres up and out to a triangular tendon gliding over the inner extremity of the spine and inserted into a tubercle at its lower posterior margin. The aponeuroses of the two muscles form an ellipse widest at the seventh cervical spine.

Varieties.—May not rise from lower six dorsal spines; no occipital attachment; separation of cervical and dorsal parts; vestige of panniculus carnosus superficial to it.

SECOND LAYER.—1. *M. Rhomboideus Minor*.—*Origin*, seventh cervical and first dorsal spines and lig. nuchæ of that region; *insertion*, base of scapula opposite triangular surface at commencement of spine.

2. *M. Rhomboideus Major*.—*Origin*, spinous processes of four or five upper dorsal vertebræ and supraspinous ligament; *insertion*, base of scapula between spine and inferior angle. The greater part of its fibres is not fixed directly to bone, but ends in a tendon attached to the lower angle of the scapula, so that the muscle acts more especially upon this angle.

This muscle comes to view in the sixth intercostal space, with the scapula external, trapezius internal, and latissimus dorsi below. Variable in vertebral and scapular attachments; the division between the two indistinct. *M. rhomboideus occipitalis* (occipito-scapularis) above rhomb. min. from occiput beneath splenius to scapula, covering insertion of rhomb. min., normal in rabbits.

3. *M. Teres Major*, not round.—*Origin*, dorsal aspect inferior angle of scapula, slightly from axillary border, from septa between it, the minor and infraspinatus, from infraspinatus fascia; *insertion*, by flat tendon, 2 inches wide, behind latissimus dorsi into inner bicipital ridge of humerus. The two tendons are united below for a short distance, but separated by a bursa at their insertion.

May be connected with latissimus dorsi where it rises from the scapula; a slip to the fascia of the upper arm externally.

4. *M. Latissimus Dorsi*, broad and flat at its origin, narrow at its insertion.—*Origin*, spinous processes of lower six or seven dorsal vertebræ, posterior layer of lumbar aponeurosis, which attaches it to the lumbar and sacral spines and iliac crest, from external lip of iliac crest in front of lumbar aponeurosis; from last three or four ribs by digitations interposed between those of the external oblique; usually by a slip from inferior angle of scapula. Its upper fibres are nearly horizontal, middle, oblique, and lower, vertical: it winds round the teres major and in front of it, and is inserted by a tendon 1½ inches wide into floor of bicipital groove, a little higher than the teres major, and by its upper edge

into the inner lip of the groove limiting the insertion of the subscapularis.

Vertebral and costal attachments variable; muscular bands, *axillary arches* from near the insertion across the great vessels and nerves to either the great pectoral tendon, coraco-brachialis, biceps, or fascia; a slip from lower ribs to coracoid = *m. costo-coracoid*; a slip to triceps, fascia, or internal intermuscular septum = *m. dorso-epitrochlearis* of apes, usually present in man as a fibrous band.

THIRD LAYER.—*Serrati Muscles*.—1. *M. Serratus Posticus Superior*.—*Origin*, by a thin aponeurosis from two, rarely three, upper dorsal spines, supraspinous ligament, seventh cervical spine, lower part of lig. nuchæ; fibres pass down and out; *inserted* by four slips into the upper borders and outer surfaces of the second, third, fourth, and fifth ribs beyond their angles.

The slips may be three or increased to six.

2. *M. Serratus Post. Inferior*, broader than the above.—*Origin*, by part of the lumbo-dorsal aponeurosis from first two lumbar and last two or three dorsal spines; passing up and out; *inserted* by four slips into the lower borders of the last four ribs up to the origin of the lat. dorsi.

The two middle slips are broadest; the others may be lacking; they overlap each other from above.

FOURTH LAYER.—*Mm. Splenii*.—Named from strap-like action binding down underlying parts; rise from lower half of neck and upper half of back.

1. *M. Splenius Capitis*.—*Origin*, lig. nuchæ over third, fourth, fifth, and sixth cervical spines, from seventh cervical and first two dorsal spines; *insertion*, outer surface and posterior margin of mastoid process, outer part of superior curved line to insertion of trapezius.

2. *M. Splenius Cervicis* (colli).—*Origin*, below the above from third, fourth, fifth dorsal spines, not lower than the sixth; *insertion*, with slips of levator ang. scap. into tips of trans. proc. of first and second, often third, cervical vertebræ.

The splenii are covered in part by the trapezius, rhomboidei, and superior serratus; the complexus comes to view internal to them. The *m. rhombo-atloideus*, or *splenius colli access.*, rises from the lower one or two cervical spines superficial to the superior serratus, inserted into the trans. proc. of the atlas. *M. splenius capitis access.* is a similar slip ending on the occipital bone or mastoid.

Nerves.—Trapezius by spinal accessory, third and fourth cervical n.; rhomboidei by fifth cerv. n.; teres major by lower subscapular n. (6, 7 c.); latissimus dorsi by long subscapular n. (7, 8 c.); serrati by intercostals or upper slip of ser. post. sup. by cervical plexus; splenii by posterior spinal n.

Actions.—*Trapezius*, upper part supports shoulder, raises point of shoulder by rotation of scapula, acts in forced respiration; middle part adducts scapulæ, helps elevate shoulder, throws chest out; inferior part would alone depress and carry scapulæ in, but in concert with the upper two-thirds of the

muscle it raises acromion and carries lower angle out and up. Fixed below, one acting, draws head back and rotates face to opposite side; both acting, draw head back. The *rhomboidei* are special antagonists of the serratus magnus; they elevate the superior angle of the scapula and counteract the rotation of the trapezius; combined with the trapezius, the scapula is raised without rotation or drawn back and in. *Teres major*, fixed at humerus, rotates scapula; fixed at scapula, rotates raised humerus in and depresses arm. *Latissimus dorsi*, fixed at humerus, draws body forward as in using crutches or climbing; feebly in forced respiration; fixed below, carries elevated arm down, back, and rotates in; draws shoulder down and back; is used in swimming; keeps inferior angle of scapula close to chest-wall.

Serratus post. sup., muscle of forced inspiration; *serratus post. inf.*, muscle of forced expiration (Quain says of inspiration, as it holds the lower ribs fixed when the diaphragm tends to draw them up).

Splenii of one side draw head and neck back and rotate face to same side; help keep head erect.

What are the dorsal and lumbar fasciæ?

The *vertebral aponeurosis* represents the middle portion of the muscular sheet of the serrati; above, it passes beneath the superior serratus; below, it is blended with the lat. dorsi and inferior serratus, and binds down the long extensor muscles. The *lumbar aponeurosis* is usually described in three layers, enclosing the erector spinæ and quad. lumborum: its posterior layer is continuous with the vertebral aponeurosis, and by it the lat. dorsi and inferior serratus are attached to the vertebral spines.

(b) *Deep Longitudinal Muscles.*—LONG MUSCLES.—1. *M. Sacrospinalis*, p. n.* (erector spinæ).—*Origin*, lowest two or three dorsal, all the lumbar and sacral spines, posterior fifth of inner lip of iliac crest, lower and back part of sacrum, anterior surface of lumbar fascia: opposite the last rib this mass divides into middle and outer columns, and an inner one, *spinalis dorsi*, separates from the middle in the upper dorsal region. The outer and middle portions subdivide.

Middle Portion.

Longissimus dorsi (Longissimus dorsi, p. n.).

Transversalis cervicis (Longissimus cervicis, p. n.).

Trachelo-mastoid (Longissimus capitis, p. n.).

Outer Portion.

Sacro-lumbalis (Ilio-costalis lumborum, p. n.).

Accessorius (Ilio-costalis dorsi, p. n.).

Cervicalis ascendens (Ilio-costalis cervicis, p. n.).

M. ilio-costalis lumborum (sacro-lumbalis), from outer and superficial portion of common mass into angles of lower six or seven ribs.

M. ilio-costalis dorsi (accessorius), from ribs into which the preceding is inserted, but internal to it, into angles of the upper six ribs and trans. proc. of the seventh cerv. vert.

* A commission of anatomical nomenclature has suggested for universal use names here marked p. n. (proposed name). It is practically the nomenclature of Henle.

M. ilio-costalis cervicis (cervicalis ascendens) continues the series from angles of upper four or five ribs into posterior tubercles of fourth, fifth, and sixth cerv. trans. proc.

M. longissimus dorsi rises from common mass, has two sets of insertions—an inner row of round tendons into all the dorsal trans. proc. and lumbar accessory proc.; an outer row to the lowest nine or ten ribs between angles and tuberosities, and to whole length of lumbar trans. proc. and into lumbar fascia.

M. longissimus cervicis (transversalis cerv.), from highest four or five dorsal trans. proc. into posterior tubercles of trans. proc. of five cerv. vert., second to sixth inclusive.

M. longissimus capitis (trachelo-mastoid), by four tendons from the upper dorsal trans. proc., and from articular proc. of the lower three or four cervical vert., into the posterior margin of the mastoid process under the splenius cap. and sterno-mastoid. It shows a tendinous intersection near its insertion: it is the only muscle between the splenius and complexus.

2. *Musculi spinales*, spinous muscles, have an arched direction. (1) *M. spinalis dorsi*, close inside the longissimus dorsi and connected with it; origin, lowest two or three dorsal spines and from tendons passing from upper lumbar spines to long. dorsi; inserted by four to nine slips into the upper dorsal spines.

(2) *M. spinalis cervicis*, inconstant or different on the two sides from lig. nuchæ and seventh cerv. spine, and one or two above or below this; inserted into spine of axis or also into third and fourth cervical spines.

M. sacro-coccygeus posticus, or *extensor coccygis* (rare), from lower end of sacrum to coccyx, represents a strong extensor of lower animals.

3. *M. transverso-spinalis*, a common name for a group all inclined inward from transverse to spinous processes.

(a) *Mm. Semispinales* (half-spinous).—(1) *M. semispinalis dorsi*, by five or six tendons from the trans. proc. of the dorsal vert., from the sixth to the tenth, inclusive; inserted by just as many tendons into the spines of the upper four dorsal and lower two cervical vert. (2) *M. semispinalis cervicis*, covered by the complexus, rises nearly from the insertion vertebræ of preceding—viz. upper five or six dorsal trans. proc.; inserted into cervical spines from second to fifth, inclusive, being thickest into the axis. (3) *M. semispinalis capitis* (complexus) rises by two sets of heads: the inner, or *biventer cervicis*, rises from three or four dorsal trans. proc. between the second and sixth; its superficial fibres are inserted into the external occipital protuberance beside the lig. nuchæ; its deeper fibres join the external head. The outer head rises from upper dorsal and lower three or four cervical vert., on the dorsal and seventh cerv. from trans. proc., on the remaining cerv. vert. (fourth, fifth, or sixth) by two slips from each, one from the posterior tubercle of the trans. proc., and one from the lower articular process. These fibres unite, join part of the inner head, and are inserted into the inner im-

pression between the two curved occipital lines. A tendinous inscription crosses the muscle near the spine of the axis; another crosses the biventer lower down.

(b) *M. multifidus* (spinæ) occupies the groove beside the spinous processes from the sacrum to the axis; *rises from* deep surface of erector spinæ, from back of sacrum as low as fourth foramen, posterior extremity of ilium, and posterior sacro-iliac ligament; in lumbar region from mammillary processes; in dorsal, from trans. proc.; in cervical, from articular processes of the four lower vert. The bundles pass up and in, to be *inserted* into the whole length of the spines from the last lumbar to the axis: some fibres go to the fourth vertebra above, others to those nearer.

(c) *Mm. Rotatores*.—(1) *Mm. rotatores longi*, really a part of the multifidus, only in dorsal region, *from* upper edge of a trans. proc. *to* lateral edge of root of the second or third spinous process above.

(2) *Mm. rotatores breves* (rotatores dorsi of Quain), eleven in number, dorsal region, nearly horizontal, *from* upper edge of a trans. proc. *to* lower edge of the lamina above.

SHORT MUSCLES.—All those connecting adjacent vertebræ.

I. *Of Flexion-vertebræ*.—1. *Mm. interspinales*, vertical sets of fibres in pairs between contiguous spinous processes; in the neck they are round, in the back are usually absent, in the loins are flat from side to side.

2. *Mm. Intertransversales* (posterior, as there is also an anterior set in the neck).—In the lumbar region there are two parts—an inner, *intertransversalis post. medialis*, *from* a mammillary process *to* an accessory or mammillary process next above; an external, *intertr. post. lateralis*, between two contiguous trans. proc. In the back the inner portion is supplied by the intertransverse ligaments, the outer portion by the lev. costarum; in the neck and upper dorsal region they are single bands between the trans. proc. and behind the cervical nerves.

3. *Mm. levatores costarum*, twelve on either side, *rise from* the tips of the trans. proc. of the seventh cervical and upper eleven dorsal vert.; continued externally into the external intercostals, and *inserted* into the outer surface of the rib belonging to the vertebra below that from which it springs, between the tuberosity and angle. Those muscles passing to the adjacent rib are *lev. cost. breves*: in the lower dorsal region are lev. cost. longi, which pass over one rib.

II. *Short Muscles of Rotation-vertebræ and Occiput*.—Five on each side; two rise from the axis and three from the atlas. 1. *M. rectus capitis posticus major*.—*Origin*, spine of axis, upper border; *insertion*, into and below the middle third of the inferior curved line of the occiput. 2. *M. obliquus cap. inferior*, strongest of these muscles.—*Origin*, upper and posterior part of arch of axis (Henle); *insertion*, back part of trans. proc. of atlas. 3. *M. rectus cap. post. minor*.—*Origin*, posterior tubercle of atlas; *insertion*, into and beneath inner third of inferior curved line of occiput, covered partly by the major muscle. 4. *M.*

obliquus cap. superior.—*Origin*, upper surface of trans. proc. of atlas; *insertion*, impression between outer parts of the occipital curved lines.

5. *M. rectus cap. lateralis.*—*Origin*, anterior surface of apex of trans. proc. of atlas; passes nearly straight up to the jugular process of occiput.

The two oblique muscles, with the rect. cap. post. maj., form the *suboccipital triangle*.

Suboccipital muscles may be doubled. *M. atlanto-mastoid.*, from transverse process of atlas to hinder part of mastoid.

Nerves.—All the above back muscles by posterior primary branches of spinal n.

Actions.—The longitudinal muscles extend the back with a force of 200–400 pounds; some of the lower muscles may depress the ribs and aid in forced expiration; some of the upper, if fixed above, may act in forced inspiration. The muscles of one side produce lateral flexion of the spinal column. The *complexus* and *transverso-spinalis* rotate the head and spine to the opposite side. The *rectus minor* and *superior oblique* chiefly extend the head; the *rectus major* and *inferior oblique* rotate the atlas and skull on the axis; the *major* also extends the head. The *lev. costarum* have but little action on the ribs; are regarded as muscles of forced inspiration. The *rectus lat.* bends the head to one side.

MUSCLES AND FASCIÆ OF THE ABDOMEN.

Describe the abdominal muscles and fasciæ.

The *superficial fascia* of the abdomen has two layers: (1) *subcutaneous*, containing fat; (2) *deeper* contains yellow elastic tissue, corresponding to tunica abdominalis of animals for support of viscera. From the deeper layer is derived the *suspensory ligament of the penis*; its lower part, *fascia of Scarpa*, passes over Poupart's ligament and ends just below in the fascia lata. Both layers pass over the spermatic cord to the scrotum, become reddish and muscular, forming the *dartos*. There is no *deep fascia*.

The *abdominal muscles* fill the space between the chest, lumbar vertebræ, and pelvis.

(a) *Vertical Muscles.*—1. *M. rectus abdominis*, separated from its fellow by the linea alba.—*Origin*, cartilages of fifth, sixth, and seventh ribs, and usually bone of fifth, by three slips, sometimes from the ensiform; *insertion*, by two tendons, the inner smaller one into the front of the symphysis pubis, crossing its fellow of the opposite side, passing down and out to adductor fascia, down and in to fascia of penis; the outer head into the pubic crest or space in front of it if the pyramidalis is lacking. (Henle considers the insertion as below, as it passes into so much movable fascia.) The fibres are interrupted by zigzag tendinous inscriptions, the three most constant being one at the umbilicus, one at the lower end of the ensiform, and one between these two: if one or two more are added, they are incomplete and below the umbilicus. They do not penetrate the whole thickness of the muscle; may extend into the internal

oblique; are not vestiges of ribs, but of the septa between the original vertebral myotomes.

M. rectus lateralis abd., 1 inch (2.5 cm.) broad, between the external and internal oblique muscles, from the tenth rib down over the eleventh to the middle of the iliac crest.

2. *M. pyramidalis* rests on lower part of rectus inside its sheath, separated from it by a special fascia. *Origin*, front of pubis below insertion of outer tendon of rectus, passes over the lower third of the space between the umbilicus and pubis; *inserted* into the linea alba. Its inner fibres are vertical, outer ones oblique.

The height of the muscle is variable, unlike on both sides, one lacking; both lacking in every fourth case; doubled on one or both sides. When lacking the lower part of the rectus is increased in size.

The *linea alba* is a fibrous structure from the ensiform to the pubis, formed by the union of the oblique and transverse aponeuroses, broadest above, $\frac{1}{2}$ inch (4-7 mm.), and a little below its middle is the cicatrix of the *umbilicus*. At the lower end it passes in front of the recti, and here is detached posteriorly a band of longitudinal fibres = *adimaniculum lineæ albae*, spreading out triangularly behind the outer heads of the recti. The *linea semilunaris* is a narrow part of the internal oblique aponeurosis just before it divides into two layers. *Lineæ transversæ* correspond to the intersections of the rectus.

(b) *Transverse Muscles*.—1. *M. obliquus externus*, or descending oblique, muscular on the side, aponeurotic in front.—*Origin*, outer surfaces and lower borders of the lower eight ribs (seven, Henle) by slips in a serrated series, five interdigitating with the serratus magnus, the lower three with the lat. dorsi, from lumbo-dorsal aponeurosis connected with first lumb. vert. The slip from the eighth rib is broadest, the others diminish above and below that; upper and lower digitations rise from near the costal cartilages, the intermediate ones at some distance from them.

The fibres from the last two ribs pass nearly vertically down to the anterior half of the outer lip of the iliac crest; all the rest incline down and forward to the *aponeurosis*. This is wider below than above, meets its fellow in the linea alba, is connected with the costo-xiphoid ligament, gives origin to the lowest fibres of the pect. major, or is covered by a fascia derived from it; below it extends from the anterior superior spine of the ilium to the spine of the pubis as a thickened border called *Poupart's ligament*.

The aponeurosis is perforated by a large opening near the pubis for the spermatic cord in the male and round ligament in the female: this is the *external abdominal ring* (*annulus inguinalis cutaneus, p. n.*). It is oval or elliptical, 1 inch long, $\frac{1}{2}$ inch wide in the male, with its base at the pubic crest; its sides are the *pillars* (*crus superius* and *crus inferius, p. n.*); the *upper* or *inner* is flat and straight, attached to the anterior surface of the pubis, decussating with its fellow or passing to adductor

fascia and dorsum of penis; the *lower or external* is thin above, and below is formed by the inner end of Poupart's lig., attached to the spine of the pubis.

The deepest fibres of Poupart's lig. are sent back to the inner part of the ilio-pectineal line for $\frac{3}{4}$ inch, forming a layer called *Gimbernat's ligament*, presenting upper and lower surfaces and a concave margin toward the femoral ring and vein. Some of the fibres of Gimbernat's lig. or of the outer pillar are reflected up and in, under the spermatic cord, behind the inner pillar, in front of the conjoined tendon, covering the posterior wall of the external ring, and pass to the sheath of the rectus and linea alba or interlace with its opposite: this is the *reflected Gimbernat's ligament* or *triangular ligament of Colles*.

Transverse fibres bind together the oblique fibres of the aponeurosis, and where they cross the ring they are called *intercolumnar fibres*. From them a thin membrane is prolonged upon the spermatic cord, known as the *intercolumnar* or *spermatic fascia*.

Generally the ext. oblique and lat. dorsi leave a triangular space between them on the iliac crest, forming *Petit's triangle*, where thirty or forty cases of lumbar hernia have been recorded.

The *external inguinal ligament* of Henle (lig. inguinale ext.) is a strengthening band of fascia along the outer part of Poupart's lig. It springs from the anterior superior spine by two flat roots which form a short canal for the external cutaneous nerve: it runs transversely, and is fused with the iliac fascia at the lower edge of the ext. obl. aponeurosis as far as the crural arch; there it passes over the femoral vessels and is lost. It receives fibres from the ext. obl. aponeurosis, and sends fibres down to the fascia lata over the sartorius, so that a sagittal section of the ligament and connected fasciæ is in the form of a St. Andrew's cross. The superficial fascia, and with it the skin, are attached to the lig. ing. ext., and form the *inguinal sulcus* (fold of groin). Internally this ligament gives off the intercolumnar fibres, and may end in them or in the ext. obl. apon. or in the lig. ing. int.

2. *M. Obliquus Internus*.—*Origin*, outer half of Poupart's lig., anterior two-thirds of middle ridge of iliac crest, from lumbar fascia; *insertion*, lower margins of cartilages of last three ribs, its aponeurosis, and by *conjoined tendon* (with transversalis) arching over the inguinal canal to the front of the pubis and inner part of ilio-pect. line behind Gimbernat's lig. The *aponeurosis* splits at the outer border of the rectus; the anterior layer unites with the ext. obl. apon., the posterior with the transversalis apon., which reunite and form the *sheath of the rectus*; the posterior layer is attached above to the ensiform, seventh and eighth rib-cartilages. This division of aponeurosis stops a little above halfway between the umbilicus and pubis, and below this point the int. obl. apon. and transversalis apon. pass wholly in front of the rectus. This deficiency in the posterior wall of the sheath is marked by a lunated edge, concave downward, the *semilunar fold of Douglas* (linea Douglasii, *p. n.*); here the rectus is separated from the abdominal contents by

peritoneum, subperitoneal tissue, transversalis fascia, and a thin connective tissue which continues the trans. apon. (Note a difference between trans. fascia and apon.)

Int. obl. muscle may present a fibrous inscription or cartilaginous slip opposite the tenth or eleventh rib; fold of Douglas is often indistinct, may be lacking.

The *cremaster* muscle, peculiar to the male, is attached externally to the inner portion of Poupart's lig., and is continuous with the int. obl. fibres: its internal attachment (inconstant) is the spine and crest of the pubis; it descends in folds in front of the spermatic cord to the level of the testis, and spreads out in a *cremasteric fascia*. Some regard this muscle as a part of a foetal structure called *gubernaculum testis*. There are some remains of it in the female.

3. *M. Transversalis Abdominis*.—*Origin*, inner surface of the lower six rib-cartilages, interdigitating with the diaphragm, from lumbar trans. proc. by a *posterior aponeurosis*, from anterior three-fourths of inner margin of iliac crest, outer third of Poupart's lig. This muscle nearly surrounds the abdomen, and is inserted into the *anterior aponeurosis* and *conjoined tendon*. This apon. commences for the most part about 1 inch from the outer border of the rectus in the *linea Spigelii* (*p. n.*), but muscular fibres nearly meet behind the rectus above: the lower third of this apon. passes in front of the rectus.

The *posterior aponeurosis* is the middle layer of the lumbar fascia or lumbo-costal lig. (Henle), between the erector spinæ and quad. lumb. muscles. The highest part of this muscle is continuous with the triang. sterni.

Muscle may be absent; *m. pubo transversalis* behind conjoined tendon from ilio-pectineal line to trans. fascia or aponeurosis.

Nerves.—Supplied in general by lower intercostal n.; int. obl. and transversalis also by ilio-hypogastric and ilio-inguinal n.; cremaster by genital branch of genito-crural n.

Actions.—Upon thorax, viscera, or vertebral column; pelvis and thorax fixed, they aid vomiting, expulsion of foetus, feces, and urine; vertebral col. fixed, they raise diaphragm by pressing up viscera, and so aid expiration; flex thorax to front or laterally, or rotate it if vert. col. be not fixed; thorax fixed, draw up pelvis in climbing. Pyramidales make linea alba tense.

LINING FASCIÆ OF THE ABDOMEN.

The *transversalis fascia* covers the inner surface of that muscle, and is continued upon the under surface of the diaphragm: along the inner margin of the iliac crest it is attached to periosteum; for about 2 inches internal to the ant. sup. iliac spine it is attached to the back of Poupart's lig. and iliac fascia; next internally it passes down over the femoral vessels as the anterior portion of their sheath: as it passes under Poupart's lig. it is strengthened by the *deep crural arch* (*arcus cruralis*), a band of fibres inserted into the pubic spine and ilio-pectineal line behind the con-

joined tendon: it includes beneath it, between the femoral vein and Gimbernat's lig., the *femoral ring*, through which a femoral hernia may descend.

Halfway between the ant. sup. iliac spine and symphysis pubis is the *internal abdominal ring* (annulus inguinalis abdominalis, *p. n.*): its lower edge is vertically $\frac{1}{2}$ inch (8 mm.) above Poupart's lig. and $1\frac{1}{2}$ inches (4 to 5 cm.) from the outer ring.

From the inner end of the ilio-pectineal line fibres of transversalis fascia go in two directions—outward, beneath the internal ring and parallel with Poupart's lig., the *lig. inguinale int. laterale*; upward, on the inner side of the ring as the *lig. ing. int. mediale* (outer and inner parts of internal inguinal ligament). These two form a blunt angle, limiting the internal ring below and internally. From the margin of the ring is prolonged the delicate *infundibuliform fascia* (processus vaginalis fasciæ trans.) The ring is the entrance into this process, the lower sharp border of which is the *plica semilunaris fasciæ trans.* (frequently lacking).

In the region of the umbilicus are strengthening fibres covering the obliterated umbilical vein = *fascia transversalis umbilicalis*.

The *iliac fascia* covers the ilio-psoas muscle, stretched from the iliac crest to the iliac portion of the ilio-pect. line: it is continued up on the psoas, attached to the sacrum, vertebral disks, internal arched ligament of diaphragm, and externally to ilio-lumbar ligament (ant. layer of lumbar fascia). Below it passes beneath the femoral vessels, forming the hinder part of the femoral sheath: outside the vessels it unites with the transversalis fascia on Poupart's ligament and with the ext. ing. lig., which prolongs it to the fascia lata (iliac portion); internally it joins the pubic portion of the fascia lata. A strong band is attached to the ilio-pect. eminence between the psoas and pectineus, called the *ilio-pect. lig.*

Describe the fasciæ of the perineum and pelvis.

Fasciæ of Perineum, Superficial.—In the anterior half of the perineum, continuous with the dartos, is the *superficial perineal fascia*, or *fascia of Colles*, bound to the ischio-pubic rami as far back as the ischial tuberosities: on a line from this tuberosity to the central point of the perineum it turns round the transversus perinei muscle and becomes deep perineal fascia. There is an incomplete median septum, so that extravasated urine distends one side of the scrotum beneath the dartos, then penetrates to the other side, then to the front of the abdomen beneath the superficial fascia, but does not pass to the posterior half of the perineum nor down upon the thighs. *Buck's fascia* is the continuation forward of Colles' fascia, investing the penis as far as the glans, continuous with the dartos, and directing the urine as already stated.

The *deep perineal* or *subpubic fascia* or *triangular ligament of the urethra* is stretched across the subpubic arch on the deep surface of the crura and bulb, and consists of two layers: the *inferior* layer extends back to the central point of the perineum, attached to the ischio-pubic

rami, connected at its base with the other layer, and continuous with the recurved margin of the superficial perineal fascia. The *transverse lig. of the pelvis* is connected with this layer, and meeting from below the arcuate pubic lig. (subpubic) forms an aperture for the dorsal vein of the penis. This layer is perforated by the urethra, arteries of the bulb and of the corpora cavernosa. Between the two layers of the triangular ligament are the membranous portion of the urethra, the constrictor urethræ, Cowper's glands, pudic vessels, and dorsal nerves of penis.

The *superior* (deep) layer consists of right and left lateral halves, separated in the middle line by the urethra close to the prostate, and continuous on each side with the fascia covering the obt. int. muscle. The levator ani is between this layer and the recto-vesical fascia.

Fasciæ of the Pelvis.—This consists of two parts, obturator and recto-vesical fascia.

The *obturator fascia* covers the inner surface of the obturator internus muscle; it is attached to the iliac portion of the ilio-pect. line, to the body of the pubis, to the great sacro-sciatic notch and great sacro-sciatic ligament, and upper edge of obturator membrane; below it joins the falciform process of the great sacro-sciatic ligament and bounds the ischio-rectal fossa externally. Near its upper margin it gives off the *anal fascia*, which covers the lev. ani externally and bounds the ischio-rectal fossa internally.

The *fascia of the pyriformis* is continued back from the obturator in front of the pyriformis muscle and sacral plexus.

The *recto-vesical fascia* is attached in front to the back of the pubis, and laterally separates from the obturator fascia along a curved line from the upper part of the obturator foramen to the ischial spine: this is the posterior part of the *white line* which extends from the pubis to the ischial spine. This fascia, covering the upper surface of the lev. ani muscle, passes to the prostate gland, bladder, rectum, and from side to side across the median line. The part to the prostate and neck of bladder from the pubis consists largely of involuntary muscular fibres, the *anterior true ligaments of the bladder*, or *pubo-prostatic ligaments*; outside them are the *lateral true ligaments*, and the part going to the rectum is the *lig. of the rectum*. The anterior part of the fascia meets the bladder along its junction with the prostate, and divides into two layers: the upper (ascending) unites with the muscular coat of the bladder, and is attached just outside the vesiculæ seminales; the inferior layer (descending) forms the sheath of the prostate, and at its apex is continued into the upper layer of the triangular ligament; it also passes between the bladder and rectum and forms the front of the sheath of the latter. The vagina receives the recto-vesical fascia in a manner similar to the prostate.

Describe the muscles of the perineum.

Two groups—anal and genito-urinary, with a superficial and deep set in each.

A. *In the Male.*—(a) *Anal Muscles.*—The *internal* or *circular sphincter* is a thick ring of unstriated muscle continuous with the circular fibres of the rectum.

The *external sphincter*, 1 inch in depth, is elliptical, attached by a small tendon to the coccyx, encloses the anus, and superficial fibres end in skin; some decussate across the median line; a few deep ones are continuous from side to side, but a large part blend with the muscles at the "central point."

The *central point of the perineum* is the median part of a tendinous septum in which several muscles meet: it is 1 inch in front of the anus, behind the bulb of the urethra; may be absent.

The *levator ani* rises from the pubic body, adherent to and between the obt. and recto-vesical fasciæ, from the "white line," spine of the ischium, and upper layer of triangular ligament. The hinder fibres pass down and in to the coccyx. The foremost run almost directly back to the "central point," the intervening ones to the lower end of the rectum and median aponeurosis between coccyx and anus, common to the two muscles.

This muscle is divided by a cleft just below the obturator canal into two parts: the anterior *pubo-coccygeus* (Savage) is alone connected with the rectum; its outer fibres pass over the side of the prostate, continue the ext. sphincter upward, unite with its fellow behind the bowel, and are inserted into the coccyx; the inner fibres pass between the two sphincters and join the longitudinal fibres of the rectum and decussate in front of the anus. The hinder part of the muscle, *ischio-coccygeus* (Henle), passes from the pelvic fascia and ischial spine to the margin of the coccyx and median aponeurosis.

The *coccygeus*, or *levator coccygeus*, rises by its apex from the ischial spine and obturator fascia, and is inserted by its base into the margin of the coccyx and lower part of the sacrum. This with the above muscle, on both sides, constitute the *pelvic diaphragm*.

M. sacro-coccygeus anticus, curvator coccygis, from anterior surface of sacrum to anterior surface of coccyx.

(b) *Genito-urinary Muscles.*—Three on each side and a central deep one.

Transversus Perinei.—*Origin*, ischial tuberosity passes forward and inward to unite with its fellow, the external sphincter, and bulbo-cavernosus at the "central point."

Very variable, inconstant insertion, absent, composed of several slips. *M. gluteo-perinealis* from glut. max. to this muscle.

Ischio-cavernosus, or *Erector Penis.*—*Origin*, inner part of tuberosity and ramus of ischium, behind and on each side of the attachment of crus penis: its tendon spreads over the crus, and is inserted into the outer and under sides of that body at its fore part.

Houston describes the *m. compressor venæ dorsalis penis*, rising in front of the crus and erector penis, and joining its fellow above dorsal vein; it is well developed in the dog.

Bulbo-cavernosus, or *ejaculator urinae*, unites with its fellow in a median raphé continued forward from the "central point," the two covering the bulb and part of the corpus spongiosum. Its fibres ascend from the raphé and end on the dorsum of the corpus spong. by joining its fellow; at the fore part some pass to the outer side of the corpus cavernosum and send an expansion over the dorsal vessels; some of the posterior fibres unite with the under surface of the triangular ligament.

The fibres surrounding the bulb are somewhat distinct from the rest, and have been described as the *m. compressor hemisphaerum bulbi*.

The above three muscles and enclosed triangular space are between the superficial and deep perineal fasciæ—*i. e.* below the lower layer of the triangular ligament.

The *constrictor* or *compressor urethrae* rises from the ischio-pubic rami, from the two layers of the triangular ligament, between which it is placed, and surrounds the membranous portion of the urethra, forming a kind of sphincter. A median raphé sometimes divides the muscle. Its hindermost fibres have been described as the *trans. perinei profundus*.

Most of the fibres pass transversely, others obliquely, others circularly around the urethra, and on the inferior surface is a longitudinal slip from the base to the apex of the triangular ligament.

Nerves.—External sphincter by fourth sacral and inf. hemorrhoidal of pudic; lev. ani by fourth sacral and perineal branch of pudic; coccygeus by fourth sacral; the three superficial gen.-urinary muscles by the perineal branch of the pudic; constrictor urethrae by dorsal nerve of penis.

Actions.—*Int. sphincter* wholly involuntary, *external* usually involuntary, but made firmer by act of will; *lev. ani* and *coccygeus* support and raise floor of pelvis, and thus have to do with forced expiration; the levator also assists in emptying the lower rectum, raising and expanding its aperture, but some of its fibres act with the ext. sphincter in closing the anus; the *transversi* fix the "central point" and give support to the ejaculator muscles; the *ischio-cavernosi* compress the crus and help produce and maintain the erection of the penis; the *bulbo-cavernosi* forcibly eject fluid mostly voluntarily at the end of micturition, involuntarily in the emission of semen; they also are supposed to aid erection of penis; the *constrictor urethrae* assists the *bulbo-cavernosi* in clearing the urethra and erects penis (Henle).

B. In the female, the *transversus perinei*, *ext. sphincter*, *lev. ani*, *erector clitoridis* (*ischio-cavernosus*) correspond to similar muscles of the male, the *sphincter vaginae* to the *bulbo-cavernosi*. The *constrictor urethrae* is the *trans. perinei profundus*, and differs from that of the male by being divided into lateral halves by the vagina.

Describe the diaphragm or midriff.

A partition between the abdomen and thorax, rising by muscular fibres as *vertebral*, *costal*, and *sternal* portions.

The *crura*, or pillars of the vertebral portion, connected with the ant. common lig., rise from the bodies and intervertebral subs. of the lumbar vertebræ, the right from the second, third, and fourth, the left from the second and third; they arch over the aorta from right to left, and meet behind it from left to right. The muscular fibres from them form a figure 8, leaving an opening for the œsophagus. The *internal arched ligament* passes over the psoas muscle from the outer side of the first lumbar body to the second trans. proc. The *external arched ligament* passes over the quad. lumborum from the second trans. proc. to the last rib; they are the upper margins of fascia covering those muscles; an arched ligament may pass over both muscles; muscular fibres of the diaphragm rise from both.

The *costal portion* rises from the lower six cartilages, interdigitating with the transversalis abd. The *sternal portion* is very short—a single muscular slip, sometimes two, from the ensiform cartilage.

The *central tendon*, trefoil, forms the highest part, convex in front, concave behind; has three lobes, the right being the largest, the left the smallest; the tendinous fibres are interwoven in every direction.

There are three *foramina*: the *hiatus aorticus*, in front of the first lumbar, transmitting the aorta, thoracic duct, and vena azygos mag.; the *foramen for the œsophagus*, opposite tenth dorsal vert., entirely surrounded by muscle, oval, transmits œsophagus, pneumogastric nerves, and branches of the coronary artery; the *foramen quadratum* for vena cava is in the highest part of the central tendon, at level of disk between the eighth and ninth dorsal vert.; its sides are firmly attached to the vein. A sterno-diaphragmatic ligament passes to this foramen.

Small foramina are in the crura for splanchnics on both sides, for small azygos vein on left side: the sympathetic cord perforates the crus or passes under the internal arched ligament.

There are *four weak places*: (1) between costal and vertebral portions near quad. lumb.; (2) between costal and sternal portions = Larrey's spaces; (3) œsophageal opening; (4) where sympathetic cords pierce crura. Left side, as a whole, is the weaker: at Larrey's space is peritoneum below, then areolar tissue, then pericardium on left side and pleura on right side.

Highest point of diaphragm on right side in dead body is level of fifth rib-cartilage with sternum; on left side of sixth cartilage with sternum (Quain); mid-portion is flat, supports the heart, and is nearly immovable. A considerable extent of origin of diaphragm is in contact with the thoracic wall.

Relations are, above, pleuræ and pericardium, lungs, and heart; below, peritoneum, liver, stomach, pancreas, spleen, and kidneys.

Nerves.—Phrenics, lower intercostals, and sympathetic.

Actions.—By its contraction and descent the viscera are pushed down and thorax lengthened; it elevates the ribs when its vault is supported by the abdominal viscera: its anterior fibres oppose forward movement of the sternum.

MUSCLES AND FASCIÆ OF THE BREAST.

Describe the breast muscles and fasciæ.

Fascia of Pectoral Region.—*Superficial* contains the mammary gland, sending septa into it and supporting it. The *deep fascia* is thin: a part of it is the *costo-coracoid membrane* behind the pect. major; this ensheathes the subclavius, and its posterior layer blends with the sheath of the axillary vessels. The anterior layer from the coracoid to the first rib may be called the *costo-coracoid ligament*: it is prolonged down, invests the pect. minor, and merges into the axillary fascia at the border of the pect. major. The *axillary fascia* stretches between the two folds of the axilla, and is continuous with the sheath of the vessels and aponeurosis of arm.

a. *Superficial Breast-muscles.*

These muscles converge to their insertion into the upper extremity and its girdle: the deep ones belong to the bones of the trunk, and are in three layers like the transverse ones of the abdominal wall.

FIRST LAYER.—*M. pectoralis major*, two portions, *clavicular* and *sterno-costal*; the clavicular portion rises from the inner half of the anterior surface of the clavicle and sterno-clavicular capsule, the sterno-costal from the sternum (superficial part, Henle), and upper six rib-cartilages (deep part, Henle) and from anterior sheath of rectus and ext. obl. apon. The fibres converge to be inserted by two tendons, united along the lower margin, into the external bicipital ridge: the clavicular and upper sterno-costal parts form one tendon with straight fibres: the lower sterno-costal part twists so that its lowest fibres are inserted highest up; a bursa separates this from the other anterior tendon. This posterior layer also gives off three expansions—one over the biceps tendon to the capsule of the shoulder-joint, one lining the bicipital groove, and one to the fascia of the arm.

Variable in extent of origin and separation of heads. *M. chondro-epitrochlearis*, from one or two rib-cartilages below pect. maj., or from it or from ext. obl. apon. to fascia of arm, internal intermuscular septum, or inner epicondyle. *M. sternalis brutorum* lies on pect. maj. parallel to sternum; passes from sheath of rectus or third to seventh cartilages to sterno-mastoid, to upper cartilages, to sternum or pect. maj. If two are present, they may unite across the manubrium.

SECOND LAYER.—1. *M. subclavius* rises from the groove on the under surface of the clavicle and recess between the conoid and trapezoid ligaments; inserted into junction of first rib with its cartilage between fibres of costo-clavicular ligament.

May be attached to coracoid, and not to clavicle, or to both, or to scapula, as *m. sterno-scapularis*; *m. sterno-clavicularis anticus* from manubrium: if both are present, a digastric *interclavicular* muscle may connect them across the manubrium. Another variety of this is *m. supraclavicularis*, from upper edge of manubrium, either anteriorly or posteriorly, behind sterno-mastoid to upper

surface of clavicle (1 in 20). There may be the *scapulo-clavicularis* or *coraco-clavicularis*.

2. *M. pectoralis minor* from three ribs near their cartilages, usually third, fourth, and fifth, often second, third, and fourth or fifth, and from intercostal aponeuroses; *insertion*, inner border and upper surface of coracoid; a bursa is under its insertion (1 in 40 cases).

Each costal origin may remain separate in the muscle: its insertion may be continued into the capsule and great tuberosity; the insertion is represented normally by the coraco-humeral ligament. Absence of whole muscle. *M. pectoralis minimus* (rare), from first costal cartilage to coracoid.

THIRD LAYER.—*M. serratus anticus, p. n.* (*serratus magnus*), placed between ribs and scapula. *Origin*, first eight or nine ribs by as many slips: the first slip is attached to two ribs; *insertion*, posterior border of scapula and into the flat surfaces at upper and lower angles, not in the subscapular fossa. There are three sets of fibres: (1) first digitation, from first and second ribs, passes up to flat area at upper angle; (2) second and third digitations, from second and third ribs, pass down in a thin triangular layer to the whole line between the upper and lower angles; (3) the remaining five or six digitations converge, some up and some down, to the flat surface in front of the lower angle.

Varieties.—Slip from tenth rib; lower digitations or slip from first rib absent; may be united with levator scapulæ, as is the case in many mammals. May be a bursa at the upper angle of scapula or between the serratus and chest-wall.

Nerves.—The pectoralis major by the two anterior thoracics; the minor by the int. ant. thoracic n.; the subclavius by the fifth and sixth cervical; serratus anticus by the posterior thoracic, upper division by fifth c., middle by sixth c. (often fifth c. also), lower by sixth and seventh c.

Actions.—*Pect. major*.

Arm at Side.	Arm Abducted to 90°.	Arm Raised High.
First part of muscle draws arm up and in.	Draws arm forward and rotates in.	Draws arm forward to horizontal, and no farther.
Second part of muscle draws arm down and rotates in.	Draws arm down, in, and rotates in.	Adducts, draws down.

It assists the lat. dorsi in adduction, opposes it in flexion; lowest fibres are best adductors; succeeding ones draw forward; used in swimming. Fixed above the pectorales, draw body forward; the major does not draw up the ribs, the minor does not seem to, so that they have no inspiratory action.

The *subclavius* depresses clavicle or steadies it; may act in inspiration; supports sterno-clavicular joint. The *pect. minor* draws coracoid down and forward, depresses shoulder, throws lower angle of scapula backward, acts with levator and rhomboidei in rotating scapula. The scapula is slung by the *serratus magnus* and rhomboidei, is kept in equilibrium by them; lower portion of serratus, combined with trapezius, rotates scapula on an axis near its supe-

rior angle and elevates shoulder; upper fibres bring scapula forward and down, assisted by pect. minor; whole muscle brings scapula forward, acts in all movements of pushing, keeps scapula pressed to ribs; of no importance in respiration; middle fibres only might pull ribs down.

b. Deep Breast-muscles.

FIRST LAYER.—*Mm. intercostales externi*, thicker behind than in front, are directed obliquely downward and forward between the borders of two ribs: they extend from the tuberosities to the outer ends of the cartilages, not quite reaching them above, but continued along their borders in the lower two spaces. They are continued to the sternum as *anterior intercostal aponeuroses* or *ligg. intercostalia ext.*

M. supracostalis from anterior end of first rib, from cervical fascia or scaleni to fourth or to second and third ribs.

SECOND LAYER.—*Mm. intercostales interni*, thicker in front, incline down and back, but less obliquely than the external set; are attached to the inner surfaces of two ribs. Anteriorly they reach the sternum, and the last two are continuous with the int. obl. muscle; posteriorly they go to the angles or a little beyond. Their deficiency behind is supplied by the *post. intercost. aponeurosis*, which merge on one side into the ant. cost.-trans. lig., and on the other into a thin fascia between the muscles.

THIRD LAYER.—*Mm. Transversi Thoracis.*—1. *M. trans. thoracis posterior* (subcostal muscles) are small slips on inner aspect of thorax, connected with int. intercostals near angles of ribs; run in same direction as int. intercost., and extend over one or two spaces; *origins*, reach from twelfth rib to third; *insertions*, from tenth to second.

2. *M. Transversus Thoracis Ant.* (triangularis sterni).—Muscular and tendinous fibres behind the costal cartilages rise from ensiform, lower part of sternum, and cart. of lower two or three true ribs; fibres pass up and out; lowest are horizontal, middle oblique, and upper ones nearly vertical; *inserted* to inner surfaces and lower borders of sixth to second costal cartilages, inclusive. It is a continuation upward of the trans. abd. muscle; may be lacking on one or both sides.

Nerves.—All by intercostal n.

Actions.—Costal and diaphragmatic respiration are normally combined; the thorax is increased antero-posteriorly by a forward movement of the sternum, transversely by elevation and eversion of ribs, vertically by descent of diaphragm; extension of the vertebral column is also an agent. There are three views as to action of the intercostals: Hamberger's, that the external elevate and internal depress the ribs; Hutchinson's, that the external and anterior parts of the internal elevate, and the rest of the internal depress ribs; Haller's is best—that (1) ribs are not joined as by a pivot to vertebral col.; (2) are not parallel bars, but convex arches; (3) no two ribs can move as they please, being connected above and below, but all move as a system: if fixed point be above, both external and internal intercostals elevate the ribs and are inspiratory muscles; fixed below, they both depress and assist expiration.

Inspiration.

Typical Forces.
Elasticity of thorax.
Diaphragm.
Scaleni.
Intercostals.

Accessory Forces.
Sterno-mastoid.
Subclavius.
Muscles of back of neck.
Serratus post. sup.
Levatores costarum.

Expiration.

Typical Forces.
Elasticity of thorax.
Elasticity of lungs.
Weight of thorax and shoulder girdle.
Weight of abdomen.
Intercostals.

Accessory Forces.
Quadratus lumborum.
Triangularis sterni.
Serratus post. inf.
Abdominal muscles.
Levator ani and coccygeus.

MUSCLES AND FASCIÆ OF THE NECK.

Describe the neck-muscles.

Mostly vertical, a superficial or anterior group, some resembling the recti abd., a deep or posterior group corresponding to the intercostals and serratus anticus.

Anterior Neck-muscles.

Long Muscles.—1. *Platysma myoides* (M. subcutaneus colli) is a pale, thin muscular sheet over the front and side of the neck and lower part of face. *Origin*, skin and subcutaneous tissue over deltoid, pectoral and trapezius muscles in a line from anterior end of second rib to acromion; fibres pass up and in over clavicle, and are inserted into the lower jaw: the two muscles meet at the hyoid, and the right overlaps the left one; the posterior fibres blend with the depressor anguli and orbicularis muscles and fasciæ. The muscle does not rise from bone; inserted into bone, muscle, and fascia.

A slip to this muscle from the mastoid or occiput; the *m. occipitalis minor* from the fascia over the upper end of the trapezius transversely to the fascia over the insertion of the sterno-mastoid (8 out of 25 cases). *Platysma* represents the panniculus carnosus of mammals, a skin muscle.

Nerves.—Inframaxillary branch of facial, but as this unites with the superficial cerv. n., it may get some spinal innervation.

Action.—Draws angle of mouth down and out; may depress lower jaw; being curved, it tends to redress itself, carries skin of neck forward, and is said to be useful in singing by removing pressure from great vessels; used in swallowing and expressing sudden terror; some say propels saliva from parotid.

Describe the deep cervical fascia (anteriorly).

It passes from the trapezius muscle beneath the platysma over the posterior triangle of the neck, invests the sterno-mastoid, and passes over the anterior triangle to the median line. It is attached below to the clavicle, and perforated by the ext. jugular vein; attached above to

the lower jaw, and becomes the *parotid fascia* and *stylo-maxillary lig.* In front it is attached to the hyoid bone, and splits below the thyroid gland: the anterior layer goes to the anterior surface of the sternum, and the posterior, covering the sterno-hyoid and thyroid muscles, is attached to the interclavicular lig.; between these two layers is the *supra-sternal space*, extending a short distance on either side behind the sterno-mastoid as the *supraclavicular recess*. Prolonged from the deeper layer, a fascia invests the posterior belly of the omo-hyoid and holds it down to the first rib, there connected with the costo-coracoid membrane. A process also passes behind the depressors of the hyoid, invests the thyroid body, passes to the trachea, forms the carotid sheath, and extends to the pericardium. Deepest of all is the *prevertebral fascia*. Inside the pharyngeal muscles is the *pharyngeal aponeurosis*, outside them their proper fascial layer (bucco-pharyngeal), connected to the prevert. fascia by areolar tissue, forming the *retro-pharyngeal space*. A prolongation of the prevertebral fascia forms the *axillary sheath*.

Regions of Neck.—Suprahyoid, submaxillary, submental, infrahyoid, fossa suprasternalis; on either side the larynx are sulci carotidei, sterno-mastoid region, fossa supraclavicularis minor, above sternal end of clavicle, fossa supracl. major, between trapezius and sterno-mastoid.

2. *M. Sterno-cleido-mastoideus* (its full name should mention its insertion into the occipital bone).—*Origin*, sternal head, thick and round, from anterior surface of manubrium; *clavicular*, from inner third upper surface of clavicle. The two portions meet, pass up and back to the anterior border and outer surface of mastoid and outer half or more of the superior curved line of the occiput, to meet the trapezius. Spinal access. nerve pierces the under surface of the external portion.

Sterno-mastoid and cleido-mastoid parts may remain separate; the latter will be pierced by the sp. access. nerve. A third factor may be added, *cleido-occipital*, origin and insertion outside the cleido-mastoid. In animals without a clavicle the cleido-mastoid part is continued into the great pectoral or deltoid.

M. supraclavicularis proprius is attached to the clavicle at each end, forming an arch above the middle of the bone.

M. levator claviculæ, a misplaced part of the sterno-mastoid or scalenus, springs from the middle of the clavicle, and is inserted into the fifth and fourth, fourth and third, or third and second cervical trans. proc.

Connected with the insertion of the sterno-mastoid is the *M. Transversus Nuchæ* (18 out of 25 cases). It is covered by the insertion of the trapezius, lies below the superior curved line, concave above, *rises from* the inner part of this line and ext. occip. protuberance, and is *inserted* into this line externally and into the sterno-mastoid aponeurosis. When absent it is represented by tendinous fibres. Its purpose seems to be to prolong the sterno-mastoid insertion backward.

Nerves.—Both by spinal accessory, offsets of which are joined by the second cervical.

Actions.—The two sterno-mastoids draw the head and neck forward toward the sternum; one, acting slightly, flexes the head (extends, Henle) and flexes laterally and rotates, so that the face looks up and toward the opposite side. Fixed above, the muscles elevate thorax in forced inspiration.

3. *Digastric muscle* (m. biventer mandibulæ) has two bellies united by a rounded tendon: the posterior belly *rises from* the digastric fossa of the temporal bone, passes down, in, and forward toward the hyoid bone. The anterior belly is attached close to the symphysis of the lower jaw and directed down, back, and slightly outward: the intervening tendon is attached to the body and great cornu of the hyoid by an aponeurosis and by the stylo-hyoid muscle, which is pierced by the digastric tendon. The anterior bellies of the two muscles are connected by a dense aponeurosis.

Varieties.—Slip from styloid process to post. belly; slip from near angle of lower jaw to ant. belly; ant. belly may be split and some fibres cross the median line; muscle may be monogastric from mastoid to middle of lower jaw; digastric tendon may be in front of or behind the stylo-hyoid. The *mento-hyoid* is a median slip (or two parallel bands) from the hyoid to the chin.

Nerves.—Ant. belly by mylo-hyoid branch of inferior dental from third division of fifth nerve; post. belly by facial.

Actions.—Either an elevator of the hyoid or depressor of lower jaw, according to which is fixed; its insertion is not close enough to the hyoid to allow independent action of either belly.

Hyoid-bone Muscles.

I. BETWEEN BASE OF SKULL AND HYOID.—*M. Stylo-hyoideus.*—*Origin*, by narrow tendon from back of styloid process near its root; *insertion*, usually divided for transmission of digastric tendon, and the two portions pass ununited to the hyoid at the junction of the great cornu and body; almost always a slip ends in the digastric tendon.

May be wanting, may be double; inserted into digastric tendon; fibres continued to omo-, thyro-, or mylo-hyoid muscles. *M. stylo-hyoideus alter.* (stylo-chondro-hyoideus or stylo-hy. prof.), from styloid process to small cornu, accompanying or replacing the stylo-hyoid lig.

II. BETWEEN THORAX AND HYOID.—FIRST LAYER.—1. *M. Sterno-hyoideus.*—*Origin*, back of sternum and sterno-clavicular joint, or from joint and clavicle, from clavicle only, sometimes from first costal cartilage; *insertion*, inner half of lower border of hyoid body. Its inner border approaches its fellow; are far apart below.

Transverse intersection at level of omo-hyoid tendon, analogous to rect. abd.; muscle may be doubled or absent. *M. cleido-hyoideus* from clavicle to hyoid in front of sterno-hyoid.

2. *M. omo-hyoideus*, ribbon-shaped, has two bellies and an intermediate tendon. *Origin*, upper border scapula near notch or from transverse ligament; passes forward under trapezius across scaleni, beneath sterno-

mastoid, then vertically to lower border of hyoid, partly beneath and partly in front of the sterno-hyoid insertion. Its tendon beneath the sterno-mastoid at level of cricoid cartilage is enclosed in the deep cervical fascia, which is prolonged down to the sternum and first costal cartilage, while the fascia investing its posterior belly descends to the clavicle.

Varieties.—Frequent, doubled or absent; clavicle may be sole origin of post. belly (*m. cleido-hyoideus*); band of fascia may take the place of its ant. belly; the post. belly may have an accessory slip to the clavicle, first rib, or cervical fascia (*m. coraco-cervicalis*), others to the sterno-mastoid, sixth cerv. trans. proc., or fascia of scalenus, *M. cervico-costo-humeralis* has been seen, from small tuberosity of humerus, inserted by two tendons, one to sixth cerv. trans. proc., one to anterior end of first rib. The omo-hyoid and sterno-hyoid muscles are parts of the same muscular sheet; the fascia binding down the post. belly may contain striped muscular fibres; the varieties of the muscle come from the different degrees of cleavage of this sheet.

SECOND LAYER.—1. *M. sternothyreoideus* lies behind the sterno-hyoid, and rises from posterior surface of manubrium internal to the sterno-hyoid, variably from first and second costal cartilages, diverges from its fellow; inserted into oblique line of thyroid cartilage, covering some fibres of the inf. constrictor.

Muscles united at origin, absent or doubled; transverse inscriptions; a slip to fascia of neck (*costo-fascialis*), or one from the carotid sheath to the outer border of the muscle.

2. *M. thyreohyoideus*, a continuation of the preceding from the oblique line of the thyroid cartilage to the outer half of the lower border of the hyoid and anterior half of great cornu.

M. hyo-thyroideus lat. from apex of great cornu to apex upper horn of thyroid cart. *M. crico-hyoideus* between cricoid cart. and hyoid bone.

M. transversus colli, in the lower part of the neck, represents the mm. trans. abd. and thoracis; it springs from the upper edge of the first costal cartilage, and passes, fan-shaped, in many fine tendinous fibres between the sterno-hyoid and sterno-thyroid muscles, meeting or crossing its fellow in the middle line: some fibres end in the interclavicular ligament or sterno-clavicular capsule.

III. MUSCLES BETWEEN LOWER JAW AND HYOID BONE.

FIRST LAYER.—*M. Mylohyoideus.*—*Origin*, from mylo-hyoid ridge of lower jaw, extending from last molar tooth nearly to symphysis; fibres pass inward, back, and downward, hinder ones to body of hyoid, a larger number into the median raphé between the two muscles, which extends from near the symphysis to the hyoid; the posterior border is free; the two muscles form the "diaphragm of the mouth."

May be closely connected with or replaced by ant. belly of digastric; may receive slip from other hyoid muscles; may be deficient at fore part.

SECOND LAYER.—*M. geniohyoideus* has a narrow origin from the

inf. mental spine; fibres pass straight back to anterior surface of body of hyoid, and frequently send a small slip to the small cornu over the hyoglossus or another to the great cornu. It may be blended with its fellow or doubled.

Nerves.—Stylo-hyoid by facial, mylo-hyoid by mylo-hyoid branch of inf. dental of third div. of fifth; all the others of this group attached to the hyoid bone apparently by the hypoglossal, but really by the first, second, and third cerv. nerves *viâ* the communicans and descendens noni (so called).

Actions.—*Sterno-hyoid* and *omo-hyoid* depress the hyoid bone; the *sterno-thyroid* depresses that cartilage, may make vocal cords tense, but with the thyro-hyoid depresses the hyoid bone; the latter also draws up the larynx; may relax vocal cords, and produces descent of epiglottis. These muscles restore the larynx and hyoid after the act of swallowing, and depress them in utterance of low tones. The infrahyoid muscles may act in forced inspiration.

The *mylo-hyoid* and *genio-hyoid* elevate the hyoid and draw it forward, or depress the lower jaw, depending upon which is fixed: the former raises the floor of the mouth and forces food back. The *stylo-hyoid* acts only on the hyoid bone; aided by the mid. constrictor, it draws it up and back.

Describe the extrinsic muscles of the tongue.

M. genio-hyoglossus, fan-shaped, is placed vertically in contact with its fellow. *Origin*, superior mental tubercle; lower fibres pass to body of hyoid and side of pharynx, superior to tip of tongue, and intermediate to whole length of tongue, some decussating across the median line.

Slips may pass to the epiglottis, stylo-hyoid lig., or small cornu of hyoid bone.

M. hyoglossus is flat and quadrate. *Origin*, whole length of great cornu and lateral part of hyoid body; *insertion*, posterior half of tongue, where fibres spread forward and inward over the dorsum, joining the styloglossus. The fibres from the hyoid body may be called the *basio-glossus*, those from the great cornu the *keratoglossus*.

The *triticeo-glossus* rises from the cartilago triticea in the thyro-hyoid lig., and enters the tongue with the posterior part of the hyoglossus.

The *chondroglossus* is often described as a part of the above, but is separated from it by the pharyngeal fibres of the genio-hyoglossus. *Origin*, inner side of base of small cornu and from part of hyoid body; its fibres end on the dorsum of the tongue near the middle line.

M. Styloglossus.—*Origin*, front of styloid process near apex, and largely from stylo-maxillary lig.; *insertion*, side and under part of tongue as far as tip, decussating and blending with the hyoglossus and palatoglossus.

The *lingualis* is the intrinsic tongue-muscle, presenting inferior, superior, transverse, and vertical fibres, with a median fibrous septum.

M. myloglossus is an accessory slip of the styloglossus from angle of jaw or stylo-max. lig. to the tongue. *M. stylo-auricularis*, from cartilage of external auditory meatus to styloid process or styloglossus muscle: a fibrous band is often found here.

Nerves.—Motor supply by hypoglossal.

Actions—*Genio-hyoglossus*, hinder part protrudes the tongue, front part retracts, middle part or nearly whole muscle depresses and makes dorsum concave; in hemiplegia the sound fibres push apex over to paralyzed side. The *hyoglossus* and *chondroglossus* retract, depress, and make dorsum convex; the *styloglossus* draws tongue back, elevates the base, and makes dorsum concave.

Describe the muscles of the pharynx.

There are two layers: an outer, called *constrictors*, three in number, with a transverse direction; an inner, called *elevators*, two in number, with a longitudinal direction.

Inferior Constrictor (laryngo-pharyngeus).—*Origin*, cricoid cart. at lower and back part, inf. cornu, oblique line and upper tubercle of the thyroid cart.; some fibres continue into it from sterno-thyroid and crico-thyroid muscles. It unites with its fellow in the median line; its inferior fibres are horizontal, and a few enter the longitudinal layer of the œsophagus, and highest end on a raphé about 1 inch below the basilar process. Superficial fibres of one side become deep in the other, or may join the fibres of another constrictor. This covers the middle constrictor; the sup. laryngeal nerve and vessels enter the larynx above its upper border, and the inferior nerve and vessels beneath its lower border.

Middle Constrictor (hyo-pharyngeus).—*Origin*, large and small cornua of hyoid, from stylo-hyoid lig.; fibres diverge greatly, covering nearly the whole length of the pharynx, and meet behind in the median line: the lowest are beneath the inf. constrictor, the highest overlap the sup. constrictor, the intermediate ones are transverse. The stylo-pharyngeus muscle separates this from the sup. constrictor.

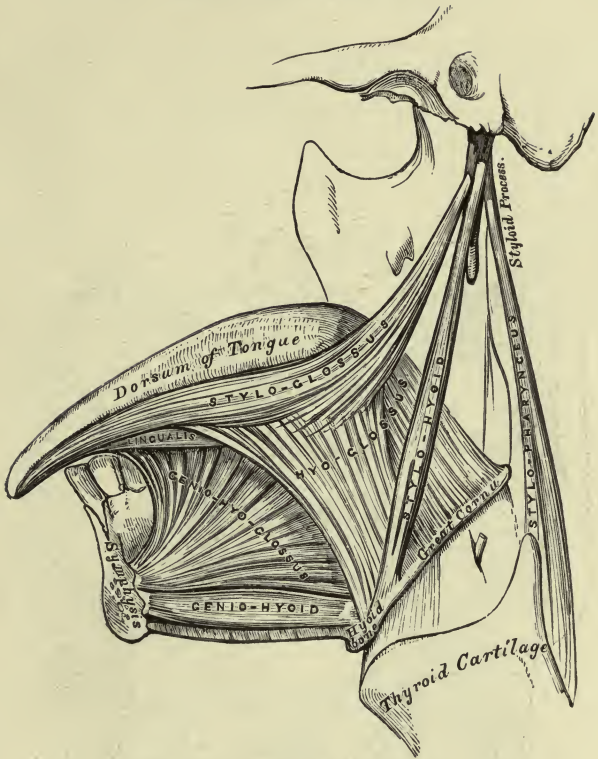
Fibres may come from the hyoid body, tongue, or mylo-hyoid ridge; a frequent slip from the lateral thyro-hyoid lig. is the *m. syndesmo-pharyngeus*.

Superior Constrictor (cephalo-pharyngeus).—*Origin*, side of tongue, mucous membrane of mouth, alveolus at end of mylo-hyoid ridge, pterygo-max. lig., hamular process, and lower third of internal pterygoid plate: the fibres curve back and blend with the opposite muscle or end in the aponeurosis which fixes the pharynx to the basilar process. Of all the constrictors, only the upper half of this muscle ends in a raphé (*linea alba*). The upper margin curves round the lev. palati and Eustachian tube; the space intervening, closed by fibrous membrane, is the sinus of Morgagni.

These muscles are covered externally by dense connective tissue, which is prolonged forward to the pterygo-max. lig., and is continuous with the membrane over the buccinator muscle; hence it is called the *bucco-pharyngeal fascia*. Next comes the muscular layers, next the pharyngeal apon., and next the mucous membrane.

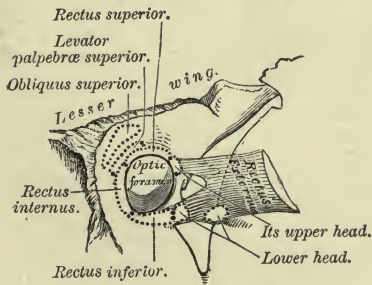
The *m. stylo-pharyngeus* rises from the inner surface of the styloid process near the root, passes down and in under cover of the middle constrictor, joined by the palato-pharyngeus, and ends on the superior and posterior borders of the thyroid cart. and lateral wall of the pharynx.

FIG. 1.—To face page 161.



Muscles of the Tongue, left side.

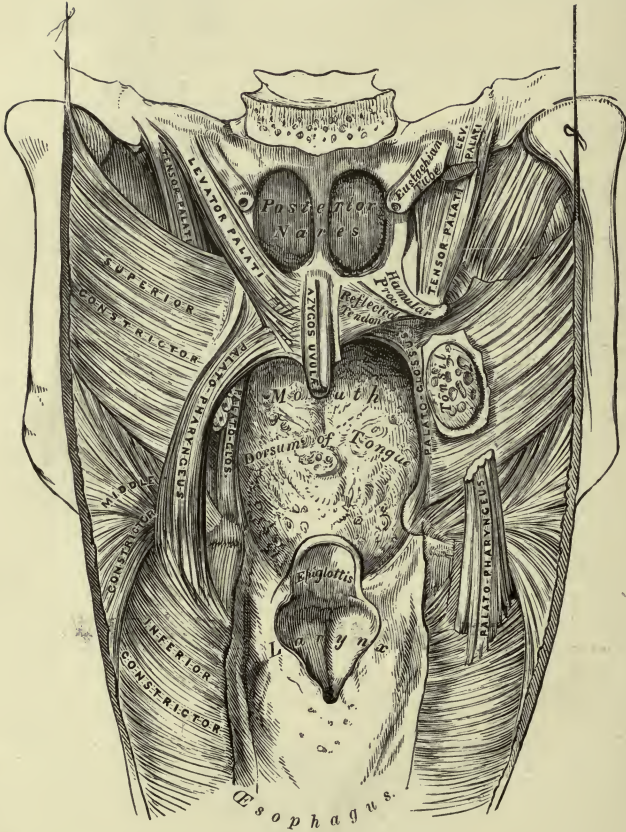
FIG. 2.—To face page 170.



The Relative Position and Attachment of the Muscles of the Left Eyeball.

PLATE XII.

FIG. 1.—To face page 163.



Muscles of the Soft Palate, the pharynx being laid open from behind.

The *m. palato-pharyngeus* will be described with the palatal muscles.

Varieties.—Splitting or doubling or a division into three parts; supernumerary elevators are common, passing to constrictors or fibrous wall of pharynx; from petrous portion or vaginal process = *petro-pharyngeus*, from spine of sphenoid = *spheno-pharyngeus*, from hamular process = *pterygo-pharyngeus ext.*, from basilar process = *occipito-pharyngeus*, from mastoid process (rare) = *pharyngo-mastoideus*; a small slip to raphé from pharyngeal spine = *azygos-pharyngis*.

Nerves.—Pharyngeal plexus and motor fibres from bulbar part of sp. access. n., glosso-pharyngeal also for mid. constrictor; inf. constrictor has in addition fibres from ext. and inf. laryngeal nerve. Stylo-pharyngeus is supplied by glosso-pharyngeal.

Describe the muscles of the soft palate.

The soft palate (*velum pendulum palati*) is continued back from the hard palate, pendulous posteriorly, prolonged in the middle into the *uvula*, and laterally into the *posterior pillars of the fauces*, which run to the side of the pharynx: another fold in front is the *anterior pillar of the fauces*, descending to the tongue; between them is the tonsil, and the constricted part between the anterior pillars is the *isthmus of the fauces*. There are five pairs of muscles—two superior, one intermediate, and two inferior.

The *palato-glossus* (constrictor *isthmi faucium*, glosso-staphylinus) occupies the anterior pillar of the fauces: at its origin it is below all the other palatal muscles, and continuous with its fellow; inferiorly it enters the side of the tongue and joins the transverse fibres.

M. amygdalo-glossus normally ascends from the side of the tongue to the tonsil.

The *palato-pharyngeus* (pharyngo-staphylinus) rises by two layers which embrace the *lev. palati* and *azygos uvulæ*: the superficial (posterior) layer is thin, the deep (anterior) layer is stronger, meets its fellow, and rises in part from the hard palate and apon. of the velum; it receives one or two fibres from the cartilage of the Eustachian tube (*salpingo-pharyngeus*). It passes down in the posterior pillar, mingling with the stylo-pharyngeus, is inserted into the upper and hinder borders of the thyroid cartilage and fibrous layer of pharynx, passing to or crossing the median line.

The *azygos uvulæ* (*palato-staphylinus*), supposed to be single, consists of two slips which rise from the soft palate and posterior nasal spine and descend into the uvula, separated above, united below.

Levator Palati (*petro-staphylinus*).—*Origin*, petrous portion of temporal bone in front of carotid canal, from lower margin of cartilage of Eustachian tube, passes forward over the sup. constrictor, and is inserted by its fore part into the apon. of the palate, and posteriorly it meets its fellow under cover of the *azygos uvulæ*.

Circumflexus, or Tensor Palati (*spheno-staphylinus*).—*Origin*, scaphoid fossa at root of int. pterygoid plate, spine of sphenoid, and outer side of Eustachian tube; descends vertically inside the int. pterygoid muscle;

its tendon turns round the hamular process, where there is a bursa, then passes horizontally to its *insertion* into the transverse ridge of the palate bone and apon. of soft palate.

From before backward in the soft palate is the palato-glossus, tensor palati, ant. part of palato-pharyngeus, levator palati, azygos uvulæ, post. part of palato-pharyngeus, and mucous membrane.

Nerves.—Sources not fully determined: tensor palati through otic ganglion from third division of fifth; lev. palati, azygos uvulæ, palato-glossus, and palato-pharyngeus probably by bulbar portion of sp. access. nerve through pharyngeal plexus.

Actions.—The *constrictors* are nearly immovable behind, and so carry back the anterior wall, the hyoid bone and larynx being carried up and back by the obliquity of the two lower constrictors. The upper part of the sup. constrictor cannot act directly upon the food, as it is attached at both ends to immovable parts. The *stylo-pharyngeus* is the chief elevator of the pharynx and larynx; the *palato-glossi* depress the soft palate, elevate the tongue, and shut off the mouth-cavity from the pharynx; the *palato-pharyngei* depress the soft palate, raise the pharynx, and bring the post. pillars together; the *azygos uvulæ* raises and shortens the uvula: the *lev. palati* raises the palate; the *tensor palati* tightens and supports the palate against the pull of other muscles and opens the Eustachian tube in deglutition. Some hold that the tube is closed in deglutition by the lev. palati pressing its floor against its upper and outer wall. The *first stage of deglutition* is effected by the mylo-hyoid, stylo-glossus, and palato-glossus pressing the tongue against the palate; the hyoid is also raised by its elevators; the larynx is then carried up beneath the hyoid by the thyro-hyoid and stylo-pharyngeus, root of tongue is drawn back by the stylo-glossi and epiglottis pressed down; at the same time the soft palate is raised and fixed by its proper muscles; the post. pillars and uvula shut off the posterior nares, and the food is guided into the lower pharynx, where it is grasped by the constrictors in succession and forced into the œsophagus.

Posterior Neck-muscles.

These are divided by the trans. proc. into two groups. The outer from the processes to the ribs corresponding to the intercostals, those from the processes to the shoulder-blade corresponding to the serratus magnus; the inner group passes from one process to another, long or short.

Outer group, four in number.—1. *M. Scalenus Anticus*.—*Origin*, anterior tubercles of trans. proc. of third, fourth, fifth, and sixth cerv. vert.; *insertion*, by a thick flat tendon into the scalene tubercle and upper surface of first rib to neighborhood of the cartilage; the pleura is attached to the lower part of the inner surface of this muscle.

2. *M. Scalenus Medius*.—*Origin*, tendinous above, muscular below, from posterior tubercles of trans. proc. of all the cerv. vert. (sometimes not of atlas); *insertion*, upper edge and outer surface of first rib from the tuberosity to the subclavian groove.

3. *M. Scalenus Posticus*, smaller than the others. *Origin*, by two or three tendons from the posterior tubercles of the lower two or three cerv.

vert.; *insertion*, by an aponeurotic tendon into the second rib external to the serratus post. sup.

Some regard the scalenus mass as one muscle with three insertions.

Varieties.—A slip from scalenus ant. may pass behind the subclavian artery. Scalenus post. may be absent or go to third rib. *Scalenus pleuralis*, from trans. proc. of seventh cerv. vert., spreads out in fascia, supporting the dome of pleura; inserted into inner border of first rib.

Scalenus minimus and *lateralis*, the former a slip of the anticus to the first rib, the latter of the posticus to the second rib. *M. transversalis cervicis medius*, between the scalenus medius and posticus, connecting the second and fourth with the sixth and seventh trans. proc.

4. *M. Levator Scapulæ* (lev. anguli scapulæ).—*Origin*, by distinct slips from the trans. proc. of the upper four cerv. vert. between the attachments of the splenius and scalmi; *insertion*, posterior border of scapula from spine to superior angle.

Vertebral attachments various: a slip to it from the occipital bone or mastoid process; parts from vertebræ may remain separate to insertion. In quadrupeds it unites with the serratus anticus (magnus), and forms one muscle; may send a slip to the scalmi, trapezius, serrated muscles, or first and second ribs.

Inner Group.—*Long Muscles*.—1. *M. longus colli* rests on the front of the vertebral column from the atlas to the third dorsal vert. There are three sets of fibres: (a) *vertical part*, from bodies of lower two cervical and upper two or three dorsal; on its outer border it receives slips from the lower three or four cerv. trans. proc.; *inserted* into bodies of second, third, and fourth cerv. vert.; (b) *lower oblique part*, from bodies of upper two or three dorsal, into anterior tubercles of fifth and sixth cerv. trans. proc.; (c) *upper oblique part* is the m. longus atlantis of Henle. *Origin*, anterior tubercles of trans. proc. of third, fourth, and fifth cerv. vert.; *inserted* into the vertical portion and lateral and lower part of anterior tubercle on arch of atlas.

Slip from lower oblique part may be inserted into head of first rib. *M. transversalis cervicis anticus*, from anterior tubercles of trans. proc. of lower four cerv. vert. to the body of the axis and trans. proc. of the atlas.

2. *M. Longus Atlantis* (see preceding muscle).

3. *M. Longus Capitis*, p. n. (rectus capitis anticus major).—*Origin*, anterior tubercles of trans. proc. of third, fourth, fifth, and sixth cerv. vert.; *insertion*, basilar process of occipital in front of the foramen magnum; it may show a tendinous inscription anteriorly; pharynx is closely attached to it.

Short Muscles.—1. *Mm. Intertransversarii Anteriores*.—Anterior intertransverse muscles pass as little fasciculi between the anterior tubercles of the trans. proc. of the cerv. vert.; they are in front of the nerve-trunks. The one for the axis is inserted broadly into its trans. proc. They may be lacking for the two upper vertebræ.

2. *M. Rectus Capitis Anticus*, p. n. (rect. cap. ant. minor).—*Origin*,

front of root of trans. proc. of atlas; *insertion*, basilar process, between foramen magnum and rectus major, $\frac{1}{2}$ inch from its fellow.

Nerves.—Rectus anticus minor by first cerv. nerve; scaleni and long prevertebral muscles by neighboring nerves; the levator scapulæ by the third, fourth, and fifth cerv. nerves.

Actions.—The *scalene muscles* are elevators of the ribs, muscles of inspiration; fixed at the ribs are lateral flexors of the neck, or both sides together bend it forward; the *recti antici* flex the head and throw forward the pharynx; the *longus colli* flexes the neck, and its oblique parts may rotate; the *levator scapulæ* elevates the superior angle and base of scapula, counteracting the rotation of the trapezius; fixed below, draws neck back and to one side.

MUSCLES OF THE HEAD.

Describe the head-muscles.

These belong to the skull and face; those of the face are in three groups and in three layers.

Epicranial Muscles.

M. Epicranius, p. n. (occipito-frontalis), comprises the occipital and frontal muscles on either side, united by the *Galea aponeurotica, p. n.* (epicranial apon.). This covers the upper surface of the skull without division, closely attached to integument and loosely to pericranium. Behind, it is attached to the occipitales muscles, to the occipital protuberance, and supreme curved lines; anteriorly it terminates in the frontales; laterally has no distinct margin, but beneath it a thin fascia springs from the superior temporal line and passes under the auricular muscles to the pinna. The *frontalis muscle* (m. epicr. frontalis) rises from the aponeurosis between the coronal suture and frontal eminence; inferiorly it ends in subcutaneous tissue at the root of nose (pyramidalis nasi is a part of it, Henle), inner canthus of eye, and whole length of eyebrow, continued into the pyramidalis nasi and interlacing with the corrugator supercillii and orbicularis; the margins of the right and left are united near the root of the nose, but separated higher up.

The *occipitalis muscle* (m. epicr. occip.) is attached to the outer two-thirds of the superior curved line and to the mastoid process: its fibres, 1 to 2 inches long, terminate in tendon, and that in aponeurosis; an interval between the muscles is occupied by aponeurosis.

Henle describes the *auricular muscles* as a part of the epicranium; the *m. epicr. temporalis* is the auricularis anterior of Quain; rises from the root of the zygoma and bony external auditory meatus; connected with the helix and capsule of lower jaw, its fibres pass up and forward to the edge of the frontalis muscle and orbicularis oculi, and meet the platysma below.

The *m. (epicr.) auricularis superior* rises from the Galea apon., and converges to the helix by one tendon, and by another to an eminence on the inner surface of the pinna.

The *m. (epicr.) auricularis posterior* rises from the mastoid, sterno-mastoid aponeurosis, and outer part of superior curved line, and is inserted into the vertical ridge at the back of the concha. All of the ear-muscles are more or less connected.

The post. auricular muscle may rise far back along the superior curved line. A deep anterior auricular muscle may pass normally from the zygoma to the tragus.

Actions.—The *frontales* elevate eyebrows, draw scalp forward, and wrinkle forehead transversely; *occipitales* draw scalp back or may alternate with the *frontales*. Most persons have only partial control, best in case of *frontales*. The actions of the *ear-muscles* are slight or nil; the anterior makes tense the temporal fascia, and has no effect on the ear; they may enlarge the entrance to the external ear.

Muscles of Eyelids and Eyebrow.

M. orbicularis oculi, p. n., has three parts, is thin and elliptical, covers the eyelid, and extends some distance on the forehead, temple, and cheek.

The *pars palpebralis, p. n.*, is contained in the eyelids, rises from the upper and lower margins of the int. tarsal lig., and passes out in a slight curve to the ext. tarsal lig. A thicker fasciculus along the free margin of each lid is the *ciliary bundle*.

The *pars orbitalis, p. n.*, is larger and stronger, attached to the nasal process of the superior maxilla, inner part of orbital arch, and externally to the cheek, forming a series of concentric loops. The *m. malaris* of Henle are the lower converging fibres of the orbital part, passing to the skin of the cheek and muscles of upper lip.

The *pars lachrymalis, p. n.* (tensor tarsi or Horner's muscle), extends from the lachrymal crest behind the sac, and divides into two slips behind the lachrymal canals for the ciliary bundles of the orbicularis.

The *internal palpebral ligament* (tendo oculi) is 2 lines long and attached to the nasal process of the sup. maxilla in front of the lachrymal groove; thence it passes to the inner commissure of the eyelids, splitting and terminating on the tarsi; it crosses the lachrymal sac in front, and gives off a process which passes behind the sac to the crest of the lachrymal bone.

The *external palpebral lig.* is weaker, and attaches the lids to the malar bone.

The *corrugator supercili* (described by Henle as a part of the orbicularis) rises from the glabella, and passes up and out to end at the middle of the orbital arch in the orbicularis and skin of eyebrow.

The *levator palpebræ sup.* will be described with the orbital muscles.

Actions.—Palpebral part closes the lids; upper half of orbital part depresses the eyebrow and opposes the frontalis, used in forcible closure of lids; in common winking the palpebral part carries forward the int. palpebral lig. and anterior wall of lach. sac, and sucks in tears; the *pars lachrymalis* (tensor tarsi) probably alternates with the palpebral part, draws back the palpebral lig., and compresses the sac. The *corrugator* produces vertical wrinkles at the inner end of the eyebrow.

Muscles of Face.

FIRST LAYER.—In muscular individuals this may be a continuous layer under the skin, converging to the corners of the mouth, but it is usually divided into—1. *M. zygomaticus*, from malar bone near zygomatic suture to angle of mouth, inserted into skin and mucous membrane by two layers, mingling with the levator and depressor anguli oris.

The so-called zyg. minor is very inconstant, and is best described as a head of another muscle.

2. *M. risorius* (Santorini), thin fasciculi from masseteric or parotid fascia passing over platysma to skin at angle of mouth; is not a part of the platysma.

May rise from skin over sterno-mastoid, from zygoma, external ear, or fascia over mastoid; may be double or triple.

3. *M. triangularis menti* (depressor anguli oris), from external oblique line of lower jaw; fibres converge partly to skin at angle of mouth, and partly to orbicularis of upper lip; anterior edge is concave and posterior convex.

M. transversus menti, from inner border of the depressor down and in below chin, across median line to corresponding point on other side.

At the corner of the mouth the various decussating muscular fibres give rise to a dense mass or knot external to the lip-commissure.

SECOND LAYER.—1. *M. quadratus labii sup.*, *p. n.*, lies along the side of nose from orbit to upper lip, and rises by three heads—*caput angulare*, *p. n.*, = levator labii sup. alæque nasi; *caput infraorbitale*, *p. n.*, = lev. labii sup. proprius; and *caput zygomaticum*, *p. n.*, = zygomat. minor. *Caput angulare* rises from nasal process of sup. max., generally connected with the frontalis, and separates into two fasciculi below—one to the skin of the wing of the nose, the other to the skin of the upper lip or cheek, blending with the orbicularis oris and the next head.

The middle head, *caput infraorbitale*, rises from the anterior surface of the upper jaw and its malar process in a line passing from above the infraorbital foramen down and out to the suture between the sup. maxilla and malar bones, and inserted behind the caput angulare into the skin of the wing of the nose and of the upper lip.

The outer head, *caput zygomaticum* (zygomaticus minor), rises from the tuberosity of the malar, strengthened by bundles of the malaris muscle, and passes to skin of upper lip and to the caput infraorbitale (lev. labii sup.).

2. *M. Caninus* (levator anguli oris).—*Origin*, canine fossa below infraorbital foramen, covered by the quadratus; passes down and out to skin at the angle of the mouth, and a large number of fibres decussate with the depressor anguli oris or are continued to the orbicularis of the lower lip; it almost always receives a slip from nasal process of the sup. maxilla close under the caput angulare.

3. *M. Quadratus Mentis* (depressor labii inferioris).—*Origin*, lower jaw from near symphysis to beyond the mental foramen; passes in to its fellow, and *inserted* into the skin of the lower lip and orbicularis; it is really a continuation of the platysma.

THIRD LAYER.—*Lateral Muscles*.—*M. buccinator* (trumpet muscle), a flat layer forming a large part of the wall of the mouth; attached at upper and lower margins to alveoli of maxillary bones opposite the molar teeth, posteriorly to the pterygo-maxillary lig., separating it from the superior constrictor of the pharynx; fibres become thickened at angle of mouth and join the orbicularis; higher and lower fibres are directed to corresponding lips, middle ones decussate, the upper to the lower lip, the lower to the upper lip.

Median Muscles.—1. *Sphincter oris*, or *m. orbicularis oris*, is an elliptical sheet making the foundation of the lips, composed largely of transverse and vertical fibres from the buccinator and elevators and depressors of the angle of the mouth; there are also sagittal fibres between the skin and mucous membrane. The deeper fibres and a distinct marginal band from the buccinator pass from side to side without interruption; the levator and depressor anguli fibres, which have crossed at the corner of the mouth, enter the more superficial parts and are inserted into the skin of the middle portion of the lip, mostly after crossing the median line and decussating with their fellows; these do not reach the free border of the lip.

2. *Mm. incisivi* attach the orbicularis to bone. The upper lip has two slips on each side, an outer, or *m. incisivus sup.*, from the incisor fossa, and an inner, *m. naso-labialis*, from the septum of the nares; the lower lip has one fasciculus on a side, *m. incisivus inf.*, from the incisor fossa. These all pass out toward the corners of the mouth.

The sagittal fibres are more developed in the infant, are in the marginal portion, and constitute the *m. labii proprius*.

3. *M. nasalis, p. n.*, includes slips usually distinguished as *compressor naris* and *depressor alæ nasi* (outer part). The former rises from the sup. maxilla by the side of the anterior nasal aperture, and meets its fellow in the median line over the cartilages of the nose in an expansion common to it and the pyramidalis nasi. The *depressor alæ nasi* rises from the incisor fossa, and is inserted by its outer part into the back of the ala of the nose, and by its *inner part* into the septum, called *depressor septi, p. n.*

The *pyramidalis nasi* is a prolongation of the frontalis, decussating with its fibres, and attached to skin at the lower median part of the forehead and to the tendinous expansion of the compressor naris below.

There are other indistinct fibres of nasal muscles—the *dilatator naris posterior* and *anterior*.

M. anomalus of Albinus is frequently present beneath the common elevator of lip and nose (*quadratus labii sup.*), passing from nasal process of sup. maxilla to same bone below, connected with comp. naris.

4. *M. mentalis, p. n.*, levator labii inf. or lev. menti, from incisor fossa of lower jaw, passing down between depressors of lower lip to integument of chin; it forms the furrow of the chin.

At the apex of the chin between the periosteum and soft parts is sometimes a bursa.

M. anomalus menti usually continues the above fibres to the region of the mental foramen.

Nerves.—All the muscles of head and face above described (muscles of expression) get their motor supply from the facial; perhaps the frontalis and orbicularis oculi are supplied from the oculo-motor nucleus, and not the facial.

Actions of the nasal muscles are indicated by their names: the *pyramidalis nasi* wrinkles the skin at the root of the nose and draws down that of the forehead; dilatation of the alæ is not usually seen unless in dyspnoea. Of the lip-muscles, the orbicularis oris draws the lips together vertically and transversely and presses them against the teeth; the *zygomaticus* draws the angle of the mouth up and back; the *risorius* retracts the angles of the mouth; the *buccinator* flattens the cheek, keeps food between the teeth, or expels air from the mouth: the *levator menti* draws up the chin integument, and so protrudes the lower lip. Actions of other muscles are indicated by their names; all have to do with the expression of passions.

Describe the muscles of the orbit.

There are seven for description. The *m. levator palpebræ superioris* (*origin*, above optic foramen and sup. rectus) ends in a membranous expansion; *inserted* into the fibrous tarsus of the upper eyelid.

A thin superficial layer is continued over the tarsus to the skin of the lid; some fibres are attached to the conjunctiva, to the wall of the orbit, and to the trochlea.

The *four straight muscles* have a continuous tendinous origin at the apex of the orbit from a ligamentous ring which encircles the optic foramen and crosses the sphenoidal fissure; most of the fibres spring from two *common tendons*: the upper one rises from the inferior root of the small wing of the sphenoid, and is prolonged into the internal, superior, and external recti; the lower (Zinn) rises from the body of the sphenoid and divides into three slips for the internal, inferior, and external recti. All the recti are inserted into the sclerotic 3 or 4 lines from the cornea; the external has two heads, between which pass the third, nasal branch of the fifth, the sixth nerve, and ophthalmic vein. The external and inferior recti are the longest, internal broadest, and superior smallest.

The *superior oblique, or trochlearis*, is internal to the lev. palpebræ, rises just in front of the optic foramen, and passes forward to a round tendon which plays through a fibro-cartilaginous ring attached to the trochlear fossa of the frontal: it is there bent out, back, and down between the sup. rectus and eye, and is inserted beneath the outer edge of the sup. rectus midway between the cornea and optic nerve. The pulley is lined by a synovial sheath.

The *inferior oblique* rises from the orbital plate of the sup. maxilla close outside the orifice of the nasal duct: the muscle passes out, back, and up between the inferior rectus and floor of orbit, and is *inserted* under cover of the ext. rectus at the back part of the eyeball, nearer to the optic nerve than to the cornea.

Varieties.—*M. tensor trochleæ* is a muscular slip from the lev. palpebræ to the trochlea; the occasional *gracillimus* rises with the sup. oblique and passes beneath it to the trochlea; the ext. rectus may have separate heads to the insertion. An *accessory inf. rectus* may pass from the inf. rectus to the inf. oblique; the *transversus orbitæ* is an arched muscle from the orbital plate of the ethmoid across the upper surface of the eyeball to the outer wall of the orbit.

Nerves.—External rectus by the sixth nerve, sup. oblique by the fourth, and the other five by the third nerve.

Actions.—*Lev. palpebræ* is the elevator of the upper lid and antagonist of the palpebral part of the orbicularis. The eyeball seems to move on a central fixed point without shifting its place as a whole within the orbit; four movements are possible: (1) lateral; (2) elevation and depression; (3) oblique movements of elevation and depression; (4) rotation about a sagittal axis. The *ext. and int. recti* produce only lateral movements; the *sup. and inf. recti* have their line of direction internal to the centre of motion, and so produce not only elevation and depression, but also inward direction and slight rotation: this is corrected by the oblique muscles, the *inf. oblique* being associated with the sup. rectus, and *sup. oblique* with the inf. rectus; the sup. oblique turns the cornea down and out, the inferior up and out.

Around the orbit is soft fat and the *capsule of Tenon*, forming a socket attached in front to the ocular conjunctiva: a large lymph-space is between it and the eye; it is pierced by the eye-muscles and sends a tubular prolongation upon each. The *suspensory ligament* of the eye is a thickening of the lower part of the capsule, attached at each end to the orbital margins and supporting the eye in its socket.

Muscles of Mastication.

There are four pairs, two outside and two inside the jaw-bone. The *masseteric fascia* is a part of the deep cervical, covers the masseter muscle, invests the parotid gland (parotid fascia), and forms the stylo-maxillary ligament.

1. *M. masseter*, a quadrate muscle with two parts: the *superficial part* rises from the sup. maxilla, malar, and lower border of zygoma for its anterior two-thirds by tendinous bundles which project between the muscular fasciculi; it passes down and back to lower half of jaw from angle to third molar tooth; the *deep part* is triangular, and passes nearly vertically from the posterior third of zygoma, lower border, and from all the deep surface of the arch; *inserted*, after uniting with the superficial part, into the upper half of the ramus and coronoid: this is almost wholly covered by the superficial portion.

There may be a bursa between these two parts.

The *buccal fat-pad* is between the fore part of the masseter and the bucci-

nator, and is prolonged into the zygomatic fossa: it is well developed in the infant, and inappropriately called the "sucking pad."

The *temporal fascia* is a dense apon. covering the temporal muscle above the zygoma: it is attached to the temporal crest of the frontal and upper temporal line, and below divides into two layers attached to the inner and outer surfaces of the zygomatic arch; it is separated from integument by a lateral projection of the Galea apon. and by the superior and anterior auricular muscles.

2. *M. temporalis* rises, fan-shaped, from the whole of the temporal fossa, not its anterior malar wall, which is covered with fat, from the deep surface of the temporal fascia, and may blend with some deep fibres of the masseter. The anterior fibres are nearly vertical, the posterior nearly horizontal; all converge to a tendon which is *inserted* into the upper and anterior borders of the coronoid, and deeper fibres have a fleshy insertion into its inner surface as far as the union of the ramus and body of jaw.

M. temporalis minor occasionally goes from the fibro-cartilage of the temporomaxillary articulation to the sigmoid notch of the lower jaw.

3. *M. pterygoideus externus* occupies the zygomatic fossa, and *rises* by two heads, the upper and smaller from the zygomatic surface of the great wing of the sphenoid and infratemporal crest; the lower and larger from the outer surface of the ext. pterygoid plate. The fibres from both pass back, converging to a fossa on the front of the neck of the lower jaw, to the interarticular cartilage and capsule. A venous plexus is between its upper surface and base of skull.

M. pterygoideus proprius is a vertical band from the infratemporal crest outside the ext. pterygoid to the outer pterygoid plate or tuberosity of palatobone or sup. maxilla.

M. pterygo-spinosus, from the spine of the sphenoid to the outer pterygoid plate between the two pterygoid muscles: this is frequently a *pterygo-spinous ligament*, and may be converted into bone.

4. *M. pterygoideus internus* rises also by two heads—one from the pterygoid fossa, mostly from the inner surface of the external plate, from the tuberosity of the palate between the two plates; a second small slip outside the ext. pterygoid muscle from the tuberosities of the palate and sup. maxilla: fibres pass down, back, and out to the inner surface of the ramus between the angle and dental foramen; it is disposed much like the masseter.

Nerves.—All from the inferior maxillary division of the fifth.

Actions.—*Masseter*, *temporal*, and *int. pterygoid* elevate the lower jaw; as depression is not much resisted, it is accomplished by smaller muscles, chiefly the digastric; *ext. pterygoid* protrudes the lower jaw, or alternately produces a grinding of molar teeth; it may also assist in opening the mouth when the condyles are carried forward upon the artic. eminences. The hinder portion of the temporal and the deep part of the masseter retract the jaw.

MUSCLES AND FASCIÆ OF THE EXTREMITIES.

The Upper Extremity.

THE SHOULDER.

Describe the scapular muscles and fasciæ.

The *deep fascia* is strong and tendinous over the back of the deltoid and infraspinatus; the infraspinatus fascia covers the teres minor and splits at the posterior border of the deltoid, a deep layer passing to the shoulder-joint under that muscle, a superficial layer to the spine of the scapula over the muscle.

(a) Vertical Scapular Muscles.

M. Deltoideus.—*Origin*, in three portions: an anterior from the front of the outer third of the clavicle, a middle from the point and outer edge of the acromion, a posterior from the lower border of the scapular spine and triangular surface at its inner end, and from infraspinatus fascia. These converge into the tendon of *insertion* into the deltoid tubercle of the humerus. The anterior and posterior parts run by long fasciculi into the marginal parts of the tendon: in the acromial portion most fibres rise in a bipenniform manner from the sides of four tendinous septa; the oblique fibres are inserted below into three septa which come up from the humerus to alternate with those above. Some fibres pass from the tip of the acromion to the tips of the lower septa, and some from the tips of the upper septa directly to the humerus.

Fibres continued into the trapezius, as in animals lacking clavicles; additional slips from ext. or int. border of scapula (*basio-deltoideus Meckelii*); a prolongation of its tendon to the insertion of the supinator longus, connected inseparably with the pect. major; *m. acromio-clavicularis lat.* from the acromial end of the clavicle to the acromion and origin of deltoid; may be a *subdeltoid* muscle.

(b) Posterior Scapular Muscles.

1. *M. supraspinatus*, from inner part of supraspinous fossa to region of the notch, from supraspinous fascia and trans. ligament; adherent to capsule and infraspinatus tendon; *inserted* into the upper of the three facets on the great tuberosity of the humerus.

2. *M. infraspinatus* rises from the inner two-thirds of the infraspinous fossa, from the infraspinatus fascia, and under surface of the spine; fibres converge to a tendon concealed within the muscle and *inserted* into the middle facet of the great tuberosity. It may be inseparably connected with the teres minor.

3. *M. Teres Minor.*—*Origin*, from narrow grooved surface or dorsum of scapula close to axillary border, from septa between it, the teres major, and infraspinatus; *inserted* into lowest facet on great tuberosity and into shaft for a short distance below.

May be a bursa under its insertion. It is behind the long head of the triceps and capsule; the dorsal scapular artery passes between it and bone.

(c) *Anterior Scapular Muscles.*

M. Subscapularis.—*Origin*, by muscular and tendinous fibres from venter of scapula and groove along the axillary border; *insertion*, small tuberosity of humerus and into shaft for a short distance. As in the deltoid, this muscle contains two sets of septa—one from the origin, and one from the insertion for attachment of oblique muscular fibres. Some fibres from the axillary border of the muscle are usually inserted into the capsule, known as the *subscapularis minor*.

There is a bursa between the muscle and the capsule, and often another on its anterior surface (bursa coraco-brachialis).

Nerves.—Supra- and infraspinatus by suprascapular nerve from fifth and sixth cervical; others from post. cord of brachial plexus, detoid, and teres minor from fifth and sixth cervical through circumflex nerve; subscapularis by fifth and sixth cervical through upper and lower subscapular nerves.

Actions.—*Deltoid* abducts arm to 90°, posterior fibres said to abduct only to 45°; insertion of trapezius corresponds to origin of deltoid, so that the two are continuous in action: anterior part of the deltoid draws the humerus forward and rotates in; of both deltoids crosses the arms over the chest; posterior part draws humerus backward and rotates out; supra-, infraspinatus, and subscapularis steady the capsule while deltoid acts. The *supraspinatus* only abducts. The *infraspinatus* rotates out and carries the arm back when it is raised. The *subscapularis* rotates in and carries the arm forward when it is raised. The *teres minor* rotates the raised humerus out and depresses it. All act as ligaments to the joint.

THE UPPER ARM.

Describe the muscles and fasciæ of the upper arm.

The *aponeurosis of the arm* (deep fascia) is thin over the biceps, strong over the triceps, and is attached to the humerus by *intermuscular septa* (*ligg. intermuscularia*). The *external intermuscular septum* extends from the outer epicondyle and supracondylar ridge to the deltoid insertion: it is pierced by the musculo-spiral nerve and sup. profunda artery. The *internal intermuscular septum* extends from the inner epicondyle and inner supracondylar ridge to behind the coraco-brachialis: it is pierced by the anastomotica magna artery.

The *internal brachial lig.* of Struthers is a fibrous band below the teres major insertion to the inner epicondyle: the ulnar nerve and inf. profunda artery pass between this band and the int. intermuscular septum.

(a) *Muscles of Anterior Surface.*

First Layer.—*M. Biceps* (brachii).—Its *short or inner head* rises with the coraco-brachialis from the coracoid; the *long head*, from the upper end of the glenoid cavity within the capsule by a tendon continuous on

each side with the glenoid ligament: these two heads form a belly in the middle and lower part of the arm. The tendon of *insertion* is slightly twisted and attached to the back part of the tuberosity of the radius, separated from the fore part by a bursa; may be a second bursa between the tendon and ulna. From the inner side of the tendon a part branches off as an aponeurotic band or *semilunar fascia* (lacertus fibrosus, *p. n.*), and blends with the deep fascia of the forearm stretched across the brachial vessels and median nerve.

One of the most variable muscles: a third head (10 per cent. of cases) rises from humerus, connected with brachialis anticus and coraco-brachialis, and inserted into coracoid portion of muscle and semilunar fascia: this is usually outside the brachial artery; a head may come from outer side of humerus, bicipital groove, or great tuberosity; may be two additional heads or even three. It may give off a slip to the internal intermusc. septum or inner condyle or pronator teres. Absence of long head: it was originally extracapsular, but has become covered by the coraco-humeral lig., a part of the pect. minor. The semilunar fascia represents an ulnar division and corresponds to the fascial insertion of the biceps fem.

Second Layer.—1. *M. Coraco-brachialis.*—*Origin*, tip of coracoid between pect. minor and short head of biceps, conjoined with the latter; *insertion*, inner border of humerus near its middle, between triceps and brachialis anticus; higher up some of its fibres are often inserted into a fibrous band arching over the lat. dorsi and teres major tendons, and attached close to the small tuberosity. It is usually pierced by the musculo-cutaneous nerve.

Many varieties, which seem to indicate it is formed of three parts—viz. (1) a superior short part, from coracoid to small tuberosity (*m. coraco-capsularis* to capsule); (2) middle part, corresponding to the muscle usually seen; (3) inferior part, to inner epicondyle or supracondylar process (*coraco-brachialis minor*). The middle part is most constant in man, but is usually accompanied by a part of the third, with the musculo-cut. nerve between them. It may send a slip to the brachialis anticus or internal septum or int. brachial lig.

2. *M. brachialis anticus* (brachialis internus, *p. n.*) rises from the lower half of the front of the humerus, nearly the whole of the int. intermuscular septum, and upper part of the external: it embraces the deltoid insertion by two processes, the outer of which is in the spiral groove as far as the upper limit of the deltoid tubercle. It is adherent to the capsule of the elbow-joint, and often sends a slip into it, and is inserted into the inner part of the rough surface at the junction of the coronoid with the shaft of the ulna.

The muscle may be subdivided into two, united with neighboring muscles, or send a slip to the semilunar fascia or radius.

(b) *Posterior Muscles of the Upper Arm.*

M. extensor triceps occupies the whole posterior brachial region. Three heads are inserted into a common tendon occupying the posterior surface

of the muscle from the middle of the arm to the elbow. The *middle or long head* (anconeus longus—*anconeus* was a term applied to any muscle attached to the olecranon) *rises from* the inf. glenoid tubercle of the scapula and adjacent portion of axillary border: this forms the middle and superficial part of the muscle and ends on the inner margin of the tendon. The *external head* (anconeus brevis) rises above the spiral groove and from an aponeurotic arch of the external intermusc. septum as it crosses it, extending to the teres minor insertion above, and *inserted* into the upper end and outer border of tendon. The *internal or deep head* (anconeus internus) *rises from* the whole posterior surface of the humerus below the spiral groove, from the lower part of the external intermusc. septum, from the whole of the internal, as high as the teres major: some of its fibres are *inserted* directly into the olecranon, but most join the deep surface of the tendon. The *common tendon* is *inserted* into the tuberosity of the olecranon, and externally a band is prolonged over the anconeus to the fascia of the forearm and posterior border of ulna: it may send a slip to the capsule.

On removing the triceps a few muscular slips are sometimes found from the bone to the capsule, analogous to the suberureus, and described by some as distinct from the triceps called the *subanconeus*.

There is a bursa between the tendon and olecranon or in the tendon, sometimes one between the integument and tendon, rarely one between the tendon and ulnar nerve (retro-epitrochlear).

Varieties.—Fourth head from inner part of humerus; a slip between triceps and lat. dorsi, the *anconeus quintus* or *dorso-epitrochlearis* of animals; the *anconeus-epitrochlearis* from the inner epicondyle to the olecranon, bridging over the ulnar nerve and generally present as a band of fascia.

Nerves.—Coraco-brachialis by branch from outer cord (7 c.), biceps by musculo-cut. (5, 6 c.), brachialis anticus by musculo-cut. and musculo-spiral, triceps by musculo-spiral (7, 8 c.).

Actions.—*Biceps* flexes arm at shoulder and forearm at elbow; after pronation of forearm it is a powerful supinator and makes tense the fascia of the forearm; its inner head and *coraco-brachialis* draw arm in as well as up. The *brachialis anticus* is a simple flexor at the elbow. *Triceps*, int. and ext. heads are extensors at the elbow; the long head extends the arm on the scapula, keeps the head of humerus in place, and assists in extending the forearm. These muscles may act from distal fixed points, as in climbing.

THE FOREARM.

Describe the muscles and fasciæ of the forearm.

The *superficial fascia* is most distinct at the elbow, contains the superficial veins, and below connects the skin with palmar fascia.

The *aponeurosis* of the forearm (deep fascia) is composed largely of transverse fibres, strengthened by expansions from the condyles of the humerus, olecranon, and fascia over biceps and triceps. The *anterior part* is weaker than the posterior, and continuous below into the ant. annular ligament (lig. carpi volare, *p. n.*): it sends in a thin layer be-

tween the superficial and deep muscles. The *posterior portion* sends off septa between the muscles and forms the post. annular ligament (lig. carpi dorsale, *p. n.*).

Anterior Group, Pronato-flexor.

Eight muscles, five superficial and three deep.

SUPERFICIAL LAYER.—All from a common tendon in the following order from without in:

1. *M. pronator teres* rises by two heads, the larger from the upper part of the inner condyle, common tendon, fascia, and intermuscular septum; second head, thin and deep, from inner margin of coronoid; *insertion*, middle of outer surface of radius. The ulnar artery is beneath this muscle, and median nerve between its heads.

Liabile to be injured in the "back stroke" of lawn tennis. Coronoid head may be absent; slip from intermusc. septum above inner condyle or from supracondylar process; additional head from biceps or brach. anticus.

2. *M. flexor carpi radialis* (*m. radialis internus*) rises from the common tendon, fascia of forearm, and septa between it and the pron. teres, palmaris longus, and flex. sublimis; tendon begins below middle of forearm, passes through a special compartment of the ant. ann. lig., through a groove in the trapezium; *inserted* into the base of the second metacarpal bone, anterior surface, and usually by a small slip to the base of the third.

Absence of muscle; inserted into ann. lig., trapezium, or fourth metacarpal; receives slip from biceps or its fascia, coronoid process, or oblique line of radius.

3. *M. palmaris longus* is placed between the ulnar and radial flexors of the carpus, resting upon the flex. subl.; rises from common tendon, fascia, and septa, forming a short muscular belly ending in a slender tendon, *inserted* into the palmar fascia, and sends a slip to the abductor poll., sometimes one to the little finger muscles.

Most variable muscle of body, lacking on both sides in one-third of the cases, on one side in one-half the cases (Hallett). Muscular belly may occupy the middle of the tendon, lower end, both ends, or be absent; may be double or have additional origin from coronoid or radius. Inserted into fascia of forearm, flex. carpi uln., pisiform, scaphoid, or little finger muscles. This muscle with the central part of the palmar fascia was a superficial flexor of the fingers, but has been reduced by the development of the other flexors.

4. *M. flexor carpi ulnaris* (*m. ulnaris int.*) is the innermost of the superficial group; rises by two heads, one from the common tendon, and one from the inner side of the olecranon and upper two-thirds of the post. border of the ulna, connected with the deep fascia of the forearm; muscular fibres end in a tendon along its anterior margin; *inserted* into the pisiform, by a small band to the ant. ann. lig., and prolonged by the

piso-metacarpal and piso-uncinate ligaments to the fifth metacarpal and unciform.

The ulnar nerve and post. ulnar recurrent artery pass between its two heads: the pisiform throws this tendon forward, so that the ulnar pulse cannot be felt so well as the radial.

Additional slip from coronoid; insertion into ann. lig. or fourth and fifth metacarpals. *Monro thinks there is a bursa between its tendon and the pisiform.

5. *M. flexor sublimis digitorum* (perforatus), placed behind the preceding, rises by three heads: (1) inner condyle by common tendon, fibrous septa, and int. lateral lig.; (2) inner margin of coronoid; (3) ant. oblique line of radius; divided below into four parts ending in tendons inserted into the second phalanges of the four inner digits. Through the ann. lig. they are placed in pairs: the anterior pair are for the ring and middle fingers, the posterior for the index and little fingers. In the palm they diverge and enter a sheath with the flex. prof.; opposite the bases of the first phalanges the tendon divides and folds round the deep flexor, and is reunited behind it; the two portions again separate and pass on each side to the middle of the lateral border of the second phalanx.

The arrangement into pairs corresponds to a division into layers, which can be separated nearly to the inner condyle; the middle finger receives the radial head, the ring-finger tendon is joined by a slip from the deep layer; this deep layer is a digastric muscle from the inner condyle, int. lat. lig., and coronoid; the conical belly ends in a tendon above the middle of the forearm, from which rise (1) a fleshy slip to the ring-finger tendon, (2) a belly for the index-finger tendon, (3) small belly furnishing the little-finger tendon. There is usually a slip from the condylo-ulnar head to the flex. long. poll. tendon.

Varieties.—Absence of radial head; of little-finger portion, which may be replaced by a slip from ann. lig., palmar fascia, flex. prof., or fourth lumbricalis; a frequent slip to the flex. prof. A bursa in its tendinous origin or between it and the pron. teres in 1 per cent. of cases.

Deep Muscles.

FIRST LAYER.—1. *M. flexor profundus digitorum* (perforans).—*Origin* (not from humerus), three-fourths of inner and anterior surface of ulna, from not quite the ulnar half of the interosseous membrane for the same distance, and from an aponeurosis attached to the post. border of the ulna, common to it and flex. c. ulnaris. Only one tendon (for index finger) separates above the wrist; in the palm, as the tendons diverge, they give origin to the lumbricales; over the first and second phalanges the tendon is bound down by an osseo-aponeurotic sheath, and opposite the first phalanx it passes through an opening in the flex. subl. tendon, and is finally inserted by an expanded end into the base of the last phalanx: over the middle and last phalanx its tendon is marked by a longitudinal furrow or cleft.

The index-finger portion is usually separate throughout, and comes mostly

from the interosseous membrane; between the ring- and little-finger portions a considerable part of the inner surface of the ulna is free from attachment.

M. accessorius, from the common tendon of the superficial muscles.

The *sheaths of the flexor tendons* are opposite the first and second phalanges, and formed of strong transverse bands, *lig. cruralia*; opposite the joints the bands change into a thin membrane strengthened by oblique decussating fibres, so that there are *annular* or transverse fibres, *crucial* and *oblique*. The sheath has a synovial lining containing small folds, *vincula tendinum* or *ligg. mucosa*, passing between tendons and bones. There are two sets: *ligamenta brevia*, broad, four-sided, and membranous, passing between both the superficial and deep tendons near their insertions and the lower part of the phalanx just above the joint-capsule; the *ligamenta longa*, less constant, join the tendons at a higher level. Contained in the *lig. breve* of the deep flexor is a small band of yellow elastic tissue, *lig. subflavum*, passing from the tendon to the head of the second phalanx.

2. *M. flexor longus pollicis* rises from the anterior surface of the radius, from its oblique line to the edge of the pron. quad., and from the adjacent part of the interosseous membrane, and usually (27 out of 36 cases) receives a slip (fasciculus exilis) from the inner epicondyle or coronoid. The tendon passes between the sesamoid bones of the thumb and enters a canal similar to that of the other flexors, to be inserted into the base of the last phalanx of the thumb. Its complete separation from the flex. prof. is characteristic of man.

May have a slip from flex. subl. or prof. or pronator teres; may be inserted into index finger or first lumbricalis.

M. flexor carpi radialis brevis or *profundus* (6 out of 70) rises from outer surface and anterior border of radius between insertions of pron. teres and supinator longus; *insertion*, very variable into tendon of flex. c. rad. or bones of carpus or metacarpus; more often present in the right arm.

M. ulnaris int. brevis (m. flex. c. ulnaris brevis) is a corresponding muscle from lower fourth of anterior surface of ulna to unciform.

SECOND LAYER.—*M. pronator quadratus*, close to bones behind the last two muscles, quadrilateral and flat, from pronator ridge and inner part of anterior surface of ulna for lower fourth, from radio-carpal joint; inserted into fore part and inner side of radius for less than its fourth.

May be absent, subdivided into two or three layers, extended further up than usual, prolonged down as radio-carpal or ulno-carpal muscle; a slip from ulna to trapezium or scaphoid = m. cubito-carpeus. Being bound to radio-ulnar capsule, it prevents its folding in pronation movements.

Nerves.—Six and one-half of the above muscles by the median nerve, one and one-half by the ulnar. Pron. teres, flex. c. rad., palm. longus, condylo-ulnar head of flex. subl. receive median branches near elbow; radial head of flex. subl. and belly for index finger have separate twigs; flex. long. poll., pron. quad., and outer half of flex. prof. by ant. interosseous br. of median. Flex. c. ulnaris and inner half of flex. prof. by ulnar.

Radial Group.

Three in number, from lower third of arm and upper third of forearm in an almost continuous row.

1. *M. supinator longus* (brachio-radialis) rises from the upper two-thirds of the ext. supracondylar ridge of the humerus and ext. intermuscular septum, limited above by the spiral groove: thin fleshy belly ends at middle of forearm in a flat tendon which expands at its insertion into the outer side of the radius at base of styloid process; its inner edge is united by fascia to the flex. c. rad.; it sends some fibres to the aponeurosis on the back of the forearm.

Muscle doubled or absent; united with brach. anticus; tendon splits into slips inserted together or at a distance from each other; inserted into middle of radius, tendon of biceps; slips to extensors of thumb.

M. sup. long. accessorius (1 per cent. of cases) rises either above or below the origin of the normal muscle and passes between it and the mm. radiales to the tuberosity of the radius.

2. *M. extensor carpi radialis longior* rises from the lower third of the ext. supracondylar ridge and ext. intermusc. septum and a few fibres from the common tendon; inserted into base of second metacarpal.

3. *M. Extensor Carpi Radialis Brevior*.—*Origin*, by common extensor tendon from outer condyle, septa, ext. lat. lig., fascia, and a fibrous arch over the radial n. and rad. recurrent vessels; *insertion*, base of metacarpal bone of middle finger.

Where these tendons are crossed by the first two thumb extensors a bursa is interposed; there is another under each tendon at its insertion; often one between the short rad. extensor and supinator brevis.

Each tendon may be split into two or three at its insertion; either may be inserted into both the second and third metacarpals or send a slip to the fourth. The two muscles may be united more or less completely.

M. extensor c. rad. intermedius, from humerus or normal extensors to second and third metacarpals or both.

M. extensor c. rad. accessorius, from humerus near attachment of long radial extensor, inserted by two slips into abd. poll. or first dorsal inteross. and into metacarpal bone of thumb.

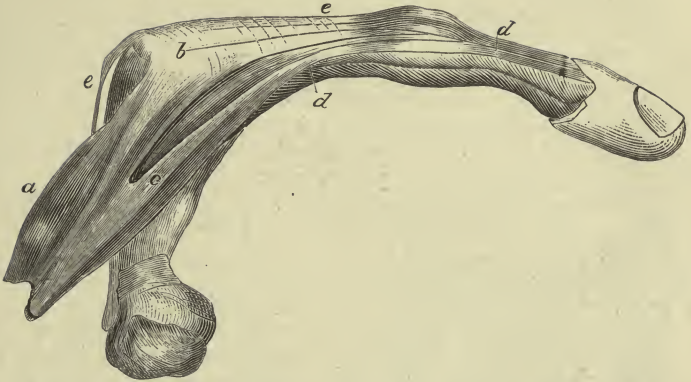
Posterior Group.

Two layers, muscles of superficial layer inserted into ulnar edge of forearm and hand and into fingers from fifth to second inclusive; of deep layer into radial edge of forearm and hand and two outer fingers.

SUPERFICIAL LAYER.—1. *M. Extensor Communis Digitorum*.—*Origin* (from neither ulna nor radius), common tendon, fascia, and septa; there are three fleshy bellies, the innermost divided into two, four passing under the post. ann. lig.; the first and second pass to the index and middle fingers connected by a weak band, always transverse; the first is joined by the extens. indicis tendon at the metacarpo-phalangeal joint; the third runs to the ring finger and sends a slip to the middle finger tendon; the fourth divides, the outer larger part going to the ring finger, the inner

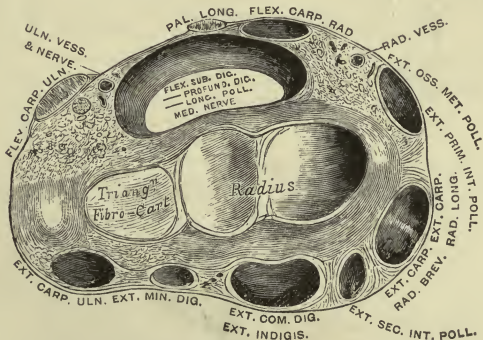
PLATE XIII.

FIG. 1.—To face page 180.



Ring Finger of the Right Hand, with its Adductor Interosseus Muscle : *a*, one belly of the Interosseous, attached at *b* to the first phalanx ; *c*, the other belly of the Interosseous, attached by *d, d*, its tendon, to the posterior surface of the second and third phalanges, and joined to *e, e*, the tendon of the Extensor communis (Duchenne).

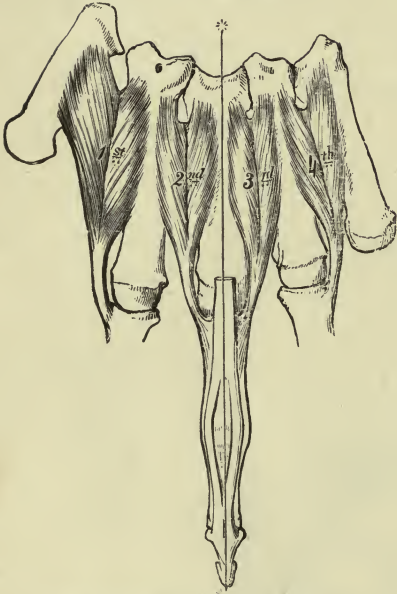
FIG. 2.—To face page 180.



Transverse Section through the Wrist, showing the annular ligaments and the canals for the passage of the tendons.

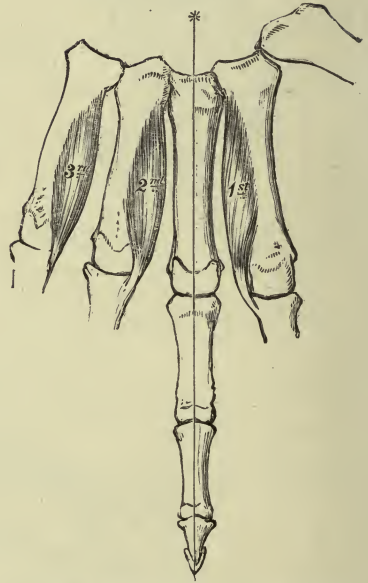
PLATE XIV.

FIG. 1.—*To face page 185.*



The Dorsal Interossei of Left Hand.

FIG. 2.—*To face page 185.*



The Palmar Interossei of Left Hand.

part joining the outer division of the extens. min. dig. tendon: this fourth is the smallest tendon, and receives muscular fibres as far as the wrist.

Opposite the metacarpo-phalangeal joints the tendons are bound down by transverse fibres from the front of the joint, *ligg. dorsalia*; the tendon expands, is joined by a slip from the interossei, and on the radial side by the insertion of a lumbrical muscle, forming a broad aponeurosis, which divides at the lower part of the first phalanx into three slips—a central thin one for the base of the second, while the two lateral parts join and are inserted into the base of the last phalanx.

Varieties.—Deficiency of one or more tendons, especially for fifth finger; more often an increase, especially for the index and middle fingers; a doubling or tripling of all the tendons; a slip to the thumb.

2. *M. extensor minimi digiti* (extens. dig. quinti propr.) rises from superficial and deep fascia of forearm, from septa between it and the common and ulnar extensors: its tendon is in a groove between the radius and ulna, and splits into two on the back of the hand, the outer being joined by a slip from the fourth common extens. tendon, and both parts end on the little finger, like the other extensor tendons.

Rises by a thin slip from the common tendon in 5 per cent. of cases; tendon of insertion undivided in 10 per cent. of cases; gives a slip to ring finger in 6 per cent.; fusion of belly with common extensor in 4 per cent.; absence rare.

3. *M. Extensor Carpi Ulnaris* (ulnaris externus).—*Origin*, common tendon, septa, fascia of forearm, which is connected with elbow-joint capsule and anconeus; its belly in its middle third is bound to the posterior border of the ulna by aponeurosis, and may receive fibres from this fascia; *insertion*, tuberosity of base of fifth metacarpal. A bursa is under its tendon of origin in one-fourth of the cases.

In 52 per cent. of cases a slip is continued anteriorly over the opponens min. dig. to the fascia over that muscle, to the metacarpal bone or first phalanx of the little finger (analogue of *per. brevis* of little toe).

Muscle may be double, reduced to a tendinous band, inserted into fourth or third metacarpal.

M. ulnaris quinti digiti, from post. surface of lower half of ulna to base first phal. of little finger: is represented in 44 per cent. by a dorsal slip from extens. uln. tendon to metacarpal bone, or first phal. or extens. tendon of little finger.

4. *M. anconeus* (quartus) fills the space between the triceps and extens. carp. uln.; is flat and triangular, covered by fascia connected with the triceps; rises by a narrow tendon from a fossa on the inner and posterior part of the ext. condyle; upper fibres are transverse, rest pass obliquely down and in to the radial aspect of the olecranon and adjacent upper third of the ulna. As a rule, its superior fibres are continuous with

those of the int. head of the triceps. A bursa is found under its tendon of origin, not in children.

DEEP LAYER.—1. *M. Supinator Brevis*.—*Origin*, ext. lat. lig., orbicular lig., supinator ridge, bicipital hollow of ulna, and for a short distance on outer border of ulna, from fascia covering it, which is connected with the ext. condyle: it regularly consists of two layers separated by the post. interosseous n.; fibres pass sling-like around upper part of radius to be inserted into a third of its length, limited by the ant. and post. oblique lines, to its neck and elbow-joint capsule.

Anterior fibres may have separate insertion into the orbicular lig.; insertion into biceps or tuberosity of radius.

2. *M. Extensor Ossis Metacarpi Pollicis* (abd. poll. longus).—*Origin*, upper part outer division of posterior surface of ulna below supinator brevis, from middle third of posterior surface of radius and interosseous membrane between; *inserted* into radial side of base of metacarpal bone of thumb, and commonly by a slip into the trapezium, its tendon usually splitting.

3. *M. extensor longus pollicis* (ext. secundi intern. poll.) *rises* below the extensor ossis on the middle third of the ulna and from the inteross. memb. for about 1 inch: its tendon passes over the radial extensors, and is *inserted* into the base of the last phalanx of the thumb. There is a tendency for it to divide into three parts, as in case of extensor comm. tendons, but all three converge to the base of the last phalanx.

4. *M. Extensor Indicis Proprius* (m. indicator).—*Origin*, from ulna below extensor long. poll., and slightly from interosseous membrane and fascia over extens. c. uln.; unites with the common extensor tendon for the index, and forms the usual insertion. This and the ext. min. dig. tendon are always on the ulnar side of the common extensor tendons.

Rarely absent, often double, and one slip may pass to the thumb, ring finger, or middle finger, forming an *extensor medii digiti* which can rise separately from the ulna or post ann. lig.

M. extensor brevis dig. manus, from back of wrist-joint, carpus, or metacarpus, sending tendons to one, two, or three fingers.

5. *M. Extensor Brevis Pollicis* (ext. primi internod. poll.).—*Origin*, small part of inteross. memb. and radius below the middle, next below the extensor ossis; *insertion*, proximal end of first phal. of thumb.

Varieties in thumb extensors in 1 out of 6 cases; most often in extens. ossis; insertion into short thumb-muscles. Extens. brevis poll. is peculiar to man, lacking in 5 per cent., fused as it were with the extens. ossis; it may be united with the long extensor. The long extensor is often double; may send a slip to the common extensor or indicator. May be another extensor between the indicator and extens. long. poll., with insertion into both digits; this is normal in the dog.

Nerves.—For the radial and posterior groups wholly by the musculo-spiral; the anconeus, sup. longus, and extens. carp. rad. long. by that nerve before it divides; all the others by its post. interosseous branch.

Three nerves, therefore, supply all the muscles of the forearm—*median* and *ulnar* anteriorly (flex. c. uln. and inner half of flex. prof. by ulnar), *musculo-spiral* externally and posteriorly.

THE HAND.

Describe the muscles and fasciæ of the hand.

Fascia of the dorsum is a thin layer prolonged from the post. ann. lig. and blending with the extensor expansions over the fingers; deeper than this the interossei are covered by thin aponeuroses.

Fascia of the palm (volar aponeurosis) consists of a strong central part and two lateral portions which cover the short muscles of the thumb and little finger. The central portion is the part commonly called *palmar fascia*: it consists of fibres mostly prolonged from the palm. long., some from the ann. lig., thus forming two superficial layers with vertical fibres, between which is the palm. brevis muscle; there is a deep layer of transverse fibres. Below the fascia divides into four processes to join the digital sheaths; offsets are sent back to the deep trans. lig. at the heads of the metacarpals, forming a short canal above each finger for the flexors. Between the processes the transverse layer of fascia covers the lumbrical muscles, digital vessels, and nerves, passing over to the thumb and forefinger. At the clefts of the fingers a transverse band is called the *superficial trans. lig.*, or Gerdy's fibres. The interossei muscles also have a separate fascia continued below into the deep trans. lig.

(a) *On the Dorsum.*

Extensor tendons already described.

(b) *Muscles of Volar Surface.*

SUPERFICIAL MUSCLES.—*M. palmaris brevis*, thin and subcutaneous, rises from ann. lig. and deep layer of longitudinal fibres of palmar fascia, and ends in a vertical line in the fascia covering the ball of the little finger, and sometimes in the skin.

DEEP MUSCLES.—*Median.*—*Carpal Bursa.*—As the superficial and deep flexors and flex. long. poll. enter the hollow of the hand they are bound into one tube lined by synovial tissue; a loose synovial sac is formed, passing up to the level of the radio-carpal joint and prolonged down the inner tendons to the digital sheath of the little finger, opening into it generally. The sheath for the tendon of the thumb is generally separated from the large sac by a sagittal septum behind the median nerve; the bursa extends but a short distance on the index and middle-finger tendons.

The *mm. lumbricales* (fiddler's muscles) are four tapering fasciculi passing from the deep flexor tendons each to the dorsal expansion of the common extensor on the radial side of the first phalanx: each rises from the radial side and radial part of the ant. surface of the deep

flexors, and the inner two also from their ulnar borders—*i. e.* have two heads.

Varieties.—A diminution or increase: one finger may have two inserted into it: the fourth may take the place of the fourth superficial flexor.

Muscles of the Ball of the Thumb.—These constitute the *thenar eminence*; great variety of description. (See Quain and Henle.)

1. *M. Abductor Pollicis* (*brevis*).—*Origin*, front of ann. lig., ridge of trapezium or tuberosity of scaphoid; *insertion*, base of first phal. of thumb, radial border, and sends a slip to the extensor tendons. (Henle calls this one belly, and what is described below as the outer head of the flexor *brevis* he calls the other belly of the abductor).

2. *M. Flexor Brevis Pollicis.*—Outer or superficial head from outer two-thirds of ann. lig. to outer side of base of first phalanx, having a sesamoid bone developed in it: *inner or deep head* is very small, and between the add. obliquus and outer head of first dorsal interosseous; *rises* from ulnar side of the first metacarpal; *inserted* into inner side of base of first phalanx.

3. *M. adductor pollicis* Quain describes in two parts, separated by the radial artery as it enters the palm. The *adductor obliquus pollicis* (*caput obliquum, p. n.*), largest of thumb muscles, rises from the upper ends of the second and third metacarpals, os magnum, ant. carpal ligaments, and sheath of flex. c. rad.: it passes on the inner side of the long flexor tendon to the inner side of the base of the first phalanx, uniting with the adductor transversus and deep head of flexor *brevis*. The inner sesamoid bone is developed in it. A considerable fasciculus passes behind the long flexor to join the superficial head of the flexor *brevis* and outer sesamoid bone. (This muscle is usually described as the inner head of the flexor *brevis*.)

The *adductor transversus poll.* (*caput transversum, p. n.*) *rises* from the lower third of the front of the third metacarpal bone; *inserted* into inner side of base of first phalanx of thumb, and the common insertion sends a slip to the long extensor.

4. *M. opponens pollicis*, beneath the abductor, *rises* from the ann. lig. and outer side of ridge of trapezium; *inserted* by an upper layer into the whole length of the first metacarpal bone, radial border, and by its deeper layer into the head of the bone and radial part of its palmar surface.

Muscles of Ball of Little Finger.—These three muscles constitute the *hypothenar eminence*.

1. *M. abductor minimi digiti* (*abd. dig. quinti*) *rises* from the lower border and inner surface of the pisiform, almost a continuation of the flex. c. uln.; *insertion*, base of first phalanx of little finger, ulnar side, and into a sesamoid bone, sending a slip to the extensor tendon.

2. *M. flexor brevis min. digiti* is separated from the abductor by deep branches of the ulnar nerve and artery, and *rises* from the annular lig. and tip of unciform process; *inserted* into the base of the first phalanx

by means of a tendinous arch passing over the flexors, attached to the radial and ulnar borders of the base. May be absent or fused with the abductor.

3. *M. opponens minimi digiti*, from ann. lig. and unciform process to whole length of ulnar side of fifth metacarpal and anterior surface of its head.

Mm. Interossei.—The *dorsal interossei* are four in number, one for each space, not rising above the level of the bones, and numbered from without inward. Each rises from the two bones between which it is placed, most extensively from that supporting the finger upon which it acts. The tendon is inserted partly into the base of the first phalanx and partly into the extensor tendon: they abduct the fingers from the middle line; two are inserted into the middle finger, one on either side, one into the radial side of the index, and one into the ulnar side of the ring. The first dorsal interosseous is larger than the others, called the *abductor indicis*: its outer head comes from the proximal half of the ulnar border of first metacarpal, its inner from the whole length of the radial border of second metacarpal.

The *palmar interossei* are three in number, are adductors, and each rises from the lateral surface of the metacarpal of the finger on which it acts. They terminate like the dorsal tendons. The first belongs to the ulnar side of the index, the second and third to the radial sides of the ring and little fingers. Henle describes four palmar interossei, the first being the inner head of the flex. brevis poll., as described above. Small bursæ are between the interossei tendons and metacarpo-phal. joints.

Varieties.—Palm. brevis seldom absent: a slip to abd. poll. from skin over thenar eminence; abductor divided into outer and inner parts, accessory head from parts above; abductor min. dig. divided into two or more slips, or accessory head from above; may be inserted into fifth metacarpal, representing the *m. pisi-metacarpeus*; there may also be the *m. pisi-uncinatus* and *m. pisi-anularis*.

Nerves of Hand-muscles.—Abductor poll., opponens poll., outer head of flexor brevis poll., and outer two lumbricales (outer three, Ziemssen) are supplied by the median nerve. The palm. brevis, muscles of little finger, inner two lumbricales (fourth, Ziemssen), all the interossei, adductores poll., inner head of flex. brev. poll., are supplied by the ulnar nerve.

Actions of Muscles of Forearm and Hand.—Pronation by pronator teres and quadratus and flex. c. rad. slightly; pron. teres flexes forearm; can only pronate when radius is intact.

Supination by supinator brevis, biceps, and sup. longus; the latter is a *flexor of the elbow* and brings the forearm into mid-supination. *Radial extensors of wrist* flex elbow; others from the ext. condyle extend. *Flexion of wrist* by flex. c. uln. and rad., by flexors of fingers, and palm. longus.

Extension of wrist by extens. c. uln., the two radial extensors, and extensors of fingers.

Abduction of wrist by radial flexor and radial extensors and extensors of thumb.

Adduction of wrist by the flexor and extensor c. uln. The flex. c. rad. and

extens. c. uln. act on the radio-carpal joint; the flex. c. uln. and radial extensors on the mid-carpal joint.

The extensors of the wrist are moderators of the long flexors of the fingers; the flexors of the wrist are moderators of the extensors of the fingers.

The dorsal interossei abduct the fingers from the middle one; the palmar adduct; the interossei and lumbricales flex the first phalanx and extend the last two (a movement in forming the hair-stroke in writing).

Flexion in Fingers.

1st phalanx, by interossei and lumbricales.

2d phalanx, by flexor sublimis.

3d phalanx, by flexor profundus.

Extension in Fingers.

By extensor communis.

By interossei and lumbricales.

By interossei and lumbricales.

When we flex fingers they tend to approach, due to lat. ligaments and obliquity of tendons.

The *palmaris longus* makes tense the palmar fascia, feebly flexes forearm and wrist; all the muscles from the inner condyle feebly flex forearm.

Palmaris brevis wrinkles the skin over the hypothenar eminence and protects the ulnar vessels and nerve from pressure when a foreign body is grasped.

Extension in the thumb is in the plane of abduction of the fingers, and its abduction is a movement forward. The action of its muscles and those of the little finger are indicated by their names: the flexors of the first phalanx in either case also extend the last, as the interossei would. The ulnar extensor and flexor of the carpus are moderators of the thumb extensors. There are three flexors of the wrist (including *palmaris long.*) and three extensors, three flexors of fingers and three extensors, three flexors of thumb and three extensors.

Muscles and Fasciæ of the Lower Extremity.

THE HIP AND THIGH.

Describe the fasciæ of hip and thigh.

The *superficial fascia* is continuous with that of other parts of the body. Thick over gluteal region, passes over Poupart's ligament into dartos of scrotum and superficial fascia of perineum. A deep layer of this fascia is continued across the saphenous opening, perforated by vessels and lymphatics, *cribriform fascia*.

The *deep fascia* or *fascia lata* is a strong membrane forming a continuous sheath around the limb: it is attached above to back of sacrum and coccyx, crest of ilium, Poupart's ligament, body and rami of pubis, ramus and tuberosity of ischium, and lower margin of great sacro-sciatic ligament. It descends on the glut. medius as far as the upper border of the glut. max., which muscle it encases, and over the great trochanter a great part of the muscle is inserted between its layers. From the fore part of the iliac crest to the outer tuberosity of the tibia is the *ilio-tibial band*, which receives the tensor vag. fem. and glut. max. insertions.

The fascia is thinnest at the inner part of the thigh over the adductors, and strengthened on each side of the patella by expansions from

the vasti. Posteriorly it is continuous over the hamstrings and popliteal space.

On the front of the thigh, below the inner end of Poupart's ligament, is the *saphenous opening*, bounded externally by the *falciform border* (ligament of Burns), more distinctly curved above and below as *sup.* and *inf. cornua*. The inner extremity of the *sup. cornu* passes to the inner side of the fem. sheath and to Gimbernat's ligament: it is the *femoral ligament* (Hey).

The parts external and internal to the saphenous opening are the *iliac* and *pubic portions*: the iliac is connected above with Poupart's and the deep layer of superficial fascia (of Scarpa), and internally forms the falciform margin of the saphenous opening.

The pubic portion, or pectineal fascia, is attached above to the iliopect. line, passes behind the femoral vessels, closely connected with the sheath, and merges into the iliac fascia and capsule of hip.

The fascia lata has various deep processes: one is internal to the tensor vag. fem. on the surface of the vastus ext.

There are *ext.* and *int. intermuscular septa* inserted into the linea aspera.

The femoral vessels are surrounded by the funnel-shaped *crural sheath*, made of transversalis fascia in front and iliac fascia behind; it is divided into three compartments—outermost for the artery, middle one for the vein, and innermost contains a lymphatic gland and fat, and when distended by a femoral hernia is the *crural canal*, $\frac{1}{2}$ to $1\frac{1}{2}$ inches (14 to 34 mm.) long. The *crural ring* (upper opening of the canal) is closed by the *septum crurale*.

Describe the muscles of the hip.

Internal Hip-muscles.—1. *M. Quadratus Lumborum*.—A quadrilateral muscle placed between the last rib and pelvis. *Origin*, ilio-lumbar ligament, crest of ilium for 2 inches, from two, three, or four lumbar trans. processes by fleshy slips passing up anteriorly (Gray says this is a separate portion); *insertion*, inner half last rib and upper four lumbar trans. processes.

Its sheath is formed behind by the costo-lumbar lig., and in front by part of the ilio-lumbar lig., middle and ant. layers of lumbar fascia. Henle describes its origin as above and insertion below. If the twelfth rib is lacking, it goes to the eleventh.

Nerves.—Last dorsal and upper lumbar.

Actions.—Lateral flexor or both may extend spine. Draws down the last rib, giving fixed point for diaphragm, and aids inspiration (Quain); muscle of forced expiration (Henle). Fixed above, draws pelvis to one side, or both draw it forward.

2. *M. Ilio-psoas*.—It has a broad outer head, iliacus, and a narrow inner head, psoas magnus.

Iliacus.—*Origin*, upper half of iliac fossa down as far as ant. inf. spine, posteriorly from ala of sacrum and sacro-iliac and ilio-lumbar liga-

ments. *Inserted* mostly into tendon of psoas; outermost fibres pass to femur in front of and below small trochanter.

Psoas Magnus (or Major).—*Origin*, by five fleshy slips from anterior surfaces and lower borders of the lumbar trans. proc., and by a series of processes, each from a disk and contiguous margins of two bodies; the highest is attached to the last dorsal and first lumbar, and lowest to fourth and fifth lumbar and intervert. subs. between them; fibres also come from the sacro-iliac joint and sacrum. These attachments are connected with arches passing over the middle of the vertebræ. The fibres all unite to a thick, long muscle running along the brim of the pelvis, passing under Poupart's, and inserted by a tendon into the small trochanter; separated by a bursa.

The common tendon is also separated from the capsule of the hip by a bursa.

M. iliacus minor, or ilio-capsularis: Henle calls the third head. *Origin*, ant. inf. spine; *insertion*, lower part of ant. intertrochanteric line or into the ilio-fem. ligament.

3. *M. Psoas Parvus (or Minor).*—Placed on the surface of psoas magnus; from bodies of last dorsal and first lumbar vert. and disk between; ends in a flat tendon merged into the iliac fascia and inserted into the ilio-pect. line and eminence. When present its origin is variable; was absent on both sides in 40 per cent. of cases.

External Hip-muscles.—FIRST LAYER.—*M. Gluteus Maximus.*—A quadrilateral, very coarse muscle. *Origin*, posterior fourth of iliac crest and rough surface between it and posterior gluteal line, back of last two pieces of sacrum and first three of coccyx, great sacro-sciatic lig., and aponeurosis of erector spinæ.

The upper half and superficial fibres of lower half are inserted into fascia lata and continued into the ilio-tibial band; the deeper portion of lower half into the gluteal ridge on the upper third of shaft of femur.

Between this and great trochanter is a multilocular bursa and one or two small ones, another between it and vast. ext.: may be another between it and tuber ischii.

Varieties.—*Agitator caudæ*, from coccyx to lower border of muscle. Fibres from sacro-sciatic lig. and sacrum are normally separated from the rest by areolar tissue, giving a bilaminar structure.

SECOND LAYER.—*M. Gluteus Medius.*—*Origin*, ilium between crest, post., and middle curved lines, and from fascia covering it, and from a band attached to the ant. sup. spine; fibres converge to an oblique impression going downward and forward on outer surface of the great trochanter; a small bursa between bone and tendon. There may be a separate tendon to the upper part of the trochanter.

THIRD LAYER.—1. *M. Gluteus Minimus* is covered by preceding, and rises from the whole surface on ilium between middle and inferior curved lines, and by a second head from the ant. sup. spine; fibres converge into an aponeurotic tendon on the outside of the muscle, *inserted* into

an impression on the front of the great trochanter. Tendon is bound down by band of capsule of joint from ilio-femoral lig. ; bursa between tendon and tubercle.

May be divided into anterior and posterior parts. The anterior fibres, if separate, represent the *scansorius* of apes (m. invertebrator femoris).

2. *M. Pyriformis*.—*Origin*, in pelvis by three digitations from second, third, and fourth pieces of sacrum, between and outside the ant. sacral foramina, from the hinder border of ilium below post. inf. spine, and from great sacro-sciatic lig. Emerges from pelvis by great sacro-sciatic foramen ; *inserted* into upper border of great trochanter.

May be divided by the ext. pop. nerve (high division of sciatic) ; inserted into capsule or absent. May be a bursa under its insertion.

3. *M. Obturator Internus*.—*Origin*, deep surface of obturator membrane, except below ; from the fibrous arch, completing the canal for the obturator vessels and nerve ; from hip-bone between thyroid foramen and sacro-iliac notch up to ilio-pect. line, and internally between foramen and subpubic arch ; from obturator fascia. Emerges by the small sacro-sciatic foramen, passes around the trochlear surface of ischium ; *inserted* with the gemelli into fore part of inner surface of great trochanter. It shows four or five tendinous bands on the surface turned toward bone, which receive pinnate fibres. A layer of cartilage covers the grooves on the ischium and a large synovial bursa. Another may be between the capsule and tendon. Henle describes the *gemelli* (gemini) as parts of this muscle, calling them its outer head.

The *gemellus sup.*, usually the smaller. *Origin*, outer and lower part of ischial spine. *Gemellus inf.*—*Origin*, upper part tuber ischii below obturator internus ; *inserted* with obturator int. into the great trochanter. They usually meet at origin beneath the obturator ; they overlap it at the insertion. The sup. gemellus may be absent or very small ; inf. gemellus is more constant.

4. *M. Quadratus Femoris*.—*Origin*, outer border tuber ischii ; *insertion*, horizontally outward into quadrate tubercle and back of femur to level of small trochanter. Bursa between it and small trochanter : it may be absent or replaced by the gemellus inf.

FOURTH LAYER.—*M. Obturator Externus*.—*Origin*, inner half of outer surface of obturator membrane, body of pubis, rami of pubis and ischium ; passes out in a groove between acetabulum and tuber ischii, then up and backward, close to lower and posterior surface of neck of femur to bottom of digital fossa. Sometimes bursa is between it and capsule.

Nerves.—Ilio-psoas by second and third lumbar ; those for iliacus are given off by ant. crural ; glut. max. by inf. gluteal nerve ; gluteus med. and min. by sup. gluteal nerve ; obturator int., gemelli, pyriformis, and quadratus fem. by sacral plexus ; obturator ext. by obturator nerve.

Actions of glutei on lower limb :

Flexion.	Extension.
Glut. med., anterior fibres.	Glut. maximus.
“ min., “ “	“ med., posterior fibres.
	“ min., “ “
Adduction.	Abduction.
Glut. med., anterior fibres } in sitting	Glut. max., slight.
“ min., “ “ } posture.	“ med., } strong, whole muscle, es-
	“ min., } pecially mid. portion.
Rotate in.	Rotate out.
Glut. med., anterior fibres.	Glut. max.
“ min., “ “	“ med., posterior fibres.
	“ min., “ “

The *gluteus maximus* extends trunk on thigh as in ascending stairs; in walking it is not used, as erect position is maintained by ligaments; steadies and supports knee by ilio-tibial band.

The *ilio-psoas* flexes thigh and rotates out; flexes body on thigh: the *psoas* bends the lumbar spine forward and laterally.

Psoas parvus makes tense the iliac fascia.

Pyriformis, *obturator int.*, and *gemelli* are external rotators after extension, abductors if thigh is flexed.

Quadratus femoris is an external rotator, and may assist adduction.

Obturator externus is an external rotator; may flex and adduct.

Describe the thigh-muscles.

There are three sets—anterior, posterior, and internal, with superficial and deep layers, the former passing over two joints, the latter over one.

Anterior Group.—**FIRST LAYER.**—1. *M. tensor vaginae femoris* (tensor fasciæ) lies in a groove between glut. med., rectus, and sartorius. *Origin*, anterior part of external lip of iliac crest, notch between the two spines, fascia over *gluteus med.*; *insertion*, between two layers of fascia lata 3 or 4 inches below the great trochanter, and from the insertion fibres are prolonged into the ilio-tibial band; the outer of the two laminae covers the muscle; the deeper is connected with the origin of the rectus.

2. *M. Sartorius* (tailor muscle).—*Origin*, anterior sup. spine of ilium and small part of notch below; *insertion*, inner surface of tibia near tubercle, sending an expansion from upper border to capsule, one from lower border to fascia of leg, and one to tibia behind the tendons of *gracilis* and *semitendinosus*. It is oblique at first, then vertical to the knee, and then curves forward.

Varieties.—Separate head from notch, ilio-pect. line, Poupart's, pubis close to symphysis; insertion into fascia lata, capsule of knee, or fascia of leg; an accessory insertion into fascia lata, femur, or lig. patellæ; tendinous inscription on muscle. There is a common bursa beneath its tendon and those of the *gracilis* and *semitendinosus*.

SECOND LAYER.—*M. Quadriceps Femoris*, *p. n.*—Largest muscle of

body, four parts closely united. (*a*) *Rectus femoris*, in a straight line from pelvis to patella. *Origin*, by two heads: anterior one from ant. inf. spine, and posterior from impression just above acetabulum; they join at an angle of 60° close below the acetabulum; tendon is anterior above, then in centre of muscle. From this are pinnate fibres ending in an inferior tendon covering the lower two-thirds of the posterior surface of the belly, and leaving a median cleft in the muscle. The lower tendon becomes free 3 inches above the patella; is attached to the upper margin of that bone, and helps form the common tendon.

Some regard the "reflected head" as the main tendon, and the "straight head" as the secondary attachment.

(*b*) The *vastus externus* (*vastus lateralis*, *p. n.*) is the outer part of the quadriceps. *Origin*, narrow from upper half of anterior intertrochanteric line, outer part of root of great trochanter, outer side gluteal ridge, upper half linea aspera, its outer lip, from ext. intermusc. septum, and a strong aponeurosis extending over the upper two-thirds of muscle. It rises in a succession of layers, the upper overlapping the lower. Aponeurosis of insertion occupies the deep surface of muscle, joins the common tendon, and sends expansion to lat. patellar ligaments and rectus tendon.

(*c* and *d*) *Vastus internus* (*vastus medialis*, *p. n.*) and *crureus* (*femoralis*, *p. n.*) seem to form one mass, but turn the rectus tendon well down, and above patella is an interval which can be followed up between the two tendons on line with lower end of anterior intertrochanteric line.

The *vastus internus* rises from a superficial aponeurosis and deeper fibres from the spiral line, inner lip of linea aspera, and from tendons of adductor longus and magnus: they end in a deep aponeurosis which enters the common tendon. Its muscular fibres pass lower than those of the externus, and are inserted into the inner margin of the patella, some into the rectus tendon.

Crureus, from upper two-thirds of anterior surface of femur, outer surface of femur in front of and below vastus ext., lower half of ext. intermuscular septum; fibres end in a superficial aponeurosis which forms the deepest portion of the common tendon. They rise from a series of transverse arches with intervening bare spaces on the front of the femur. Between this portion and the vastus int. most of the internal surface of the bone is free.

The *common or suprapatellar tendon* is inserted into the fore part of the upper border of the patella, and a few fibres are prolonged over its anterior surface into the lig. patellæ.

THIRD LAYER.—*M. subcruralis* (*articularis genu*, *p. n.*) is the name of a few fibres which may be regarded as the deepest layer of the crureus. *Origin*, anterior surface of femur; *insertion*, separated by a fat layer from vasti into the synovial membrane of knee-joint.

These muscles may be bilaminar.

Hunter's canal is a three-cornered passage in the middle two-fourths of the thigh, in the angle between the adductor magnus and longus and vastus internus. It is made a canal by a bridge of fascia, and contains the femoral artery, vein, and internal saphenous nerve.

Nerves.—Anterior crural for quadriceps and sartorius; superior gluteal for tensor vag. fem.

Actions.—*Sartorius* flexes hip and knee with eversion of thigh; rotates leg inward.

Quadriceps femoris extends leg; not necessary for maintenance of erect attitude.

Rectus fem. also flexes hip; its posterior head is tense when thigh is bent. Lower fibres of vastus int. draw patella in.

Tensor vag. fem. rotates in and abducts, assisted by glut. max.; counteracts the glut. max., which tends to draw the ilio-tibial band backward.

Posterior Group, or Hamstrings.—1. *M. Biceps Femoris*.—*Origin, long head* by a tendon common to it and semitendinosus from inner impression on lower part of ischial tuberosity, and from sacro-sciatic lig.; *short head* from middle third of outer lip of linea aspera and ext. intermuscular septum; fibres from both heads end in a tendon inserted into the upper and outer part of head of fibula by two portions embracing the ext. lat. lig.; some fibres pass forward and inward to the tuberosity of the tibia and to fascia of leg.

A bursa is almost constantly between the tendon and ext. lat. lig., or another between the long head and semimembranosus. Short head absent; additional one from various sources. A slip from long head to gastrocnemius or to tendo Achillis.

2. *M. Semitendinosus*.—From tuberosity of ischium and tendon common to it and biceps for 3 inches. Terminates in lower third of thigh in a long, slender tendon, and curves forward in an expanded form into upper part of inner surface of tibia or ant. crest of tibia, and sends a process to fascia of leg. It is below the gracilis tendon, covered by the sartorius, and a bursa separates the three from the int. lat. lig. It has a thin, oblique intersection in the middle of its belly.

3. *M. Semimembranosus*.—*Origin*, tuber ischii above and outside the tendon of biceps and semitendinosus, and its tendon is grooved posteriorly for the common tendon of those two muscles. Tendon of origin is on outer side of muscle for three-fourths the length of thigh; tendon of insertion, on opposite side of muscle, and turns forward and is inserted by four parts (1) into horizontal groove on back of inner tuberosity of tibia; (2) expansion is sent up and in as the posterior oblique lig. of the knee-joint; (3) down to the fascia over the popliteus muscle; (4) to form the short int. lat. lig. of the knee-joint.

The hamstring muscles descend mostly in contact with each other and bound down by the fascia lata; inferiorly they diverge the biceps to the outer side, semimembranosus and semitend. to the inner side, forming the upper borders of the popliteal space, the inferior margins of which are formed by the heads of the gastrocnemius.

Varieties.—Great reduction in size of semimemb. or absence.

M. ischio-aponeuroticus is a muscular slip from one or other hamstring to the fascia of the back of the leg.

Nerves.—Great sciatic, from its int. popliteal division, except that to the short head of the biceps, which is from the ext. popliteal division.

Actions.—Flex knee, and then can rotate tibia and drag it back under femur; biceps outward, other two inward. Powerful extensors of hip, and limit flexion of that joint when knee is extended.

Internal Group.—**FIRST LAYER.**—1. *M. Pectineus*—*Origin*, ilio-pect. line from ilio-pect. eminence and spine of pubis, and slightly from bone in front of this, and from fascia over the muscle; *insertion*, femur behind small trochanter and upper part of line passing to the trochanter. At origin surfaces are frontal, at insertion are sagittal.

2. *M. Adductor Longus* (add. fem. longus).—Flat and triangular, internal to the pectineus, on same plane. *Origin*, short tendon from body of pubis below crest and near angle; *insertion*, inner lip of linea aspera, united to vastus int. in front and adductor mag. behind.

3. *M. Gracilis*, or adductor gracilis.—*Origin*, inner margin pubic bone and whole length of its inferior ramus, thin and flat, then narrow and thicker. A round tendon in lower third of thigh, curving forward below, *inserted* into inner side of tibia just above semitend. and covered by sartorius.

SECOND LAYER.—*M. Adductor Brevis*.—*Origin*, body and inferior ramus of pubis below adductor longus, between gracilis and obturator ext.; *insertion*, into the whole of the line from small trochanter to linea aspera behind the pectineus. It lies between the adductor mag. and longus.

THIRD LAYER.—1. *M. Adductor Fem. Minimus*.—This is what is described with the add. magnus, usually as its anterior and superior portion. *Origin*, body of pubis and ischio-pubic rami; *insertion*, femur, in a line from quad. fem. to upper end of linea aspera, and a short distance along it.

2. *M. Adductor Magnus*.—*Origin*, ischial ramus internal to the above muscle and tuber ischii; fibres pass in two layers, one to the inner lip of linea aspera, and other on inner side of opening for femoral vessels by a distinct rounded tendon to the adductor tubercle on the inner condyle of the femur. The femoral attachment is interrupted by three or four tendinous arches for the perforating arteries.

Varieties.—*Pectineus* may be divided into two parts, supplied by different nerves, natural in many animals. May be inserted into capsule of hip.

Add. longus may extend to knee, inseparable from add. magnus.

Add. brevis may consist of two or three parts.

Add. magnus, condylar part may be distinct; usual in apes.

Nerves.—Adductors by obturator nerve, but add. magnus also by great sciatic; pectineus regularly by a branch from ant. crural, an offset from the obturator and accessory obt. nerve, only occasionally present.

Actions.—All adduct the thigh. *Pectineus*, *add. longus*, and *brevis* flex the hip, while part of the *add. magnus* from the ischial tuberosity to condyle

may extend the thigh and rotate in. *Gracilis* flexes knee and rotates leg inward. Adductors and oppositors, the gluteals; balance the body in walking.

What are the internal rotators of the thigh?

(1) Anterior fibres of glut. med. (2) and minimus; (3) tensor vaginae femoris; and some say (4), the condylar part of the add. magnus.

THE LEG.

Describe the muscles and fasciæ of the leg.

Three groups as in the forearm, only the extensors are on the anterior side and flexors posterior. The number of muscles passing over two joints is less in the leg; no muscle on the anterior and fibular side springs from above the knee.

Fasciæ.—The *aponeurosis* of the leg is not continued over the subcutaneous surface of the bones, but intimately blended with the periosteum. It is dense at the upper and front part. Posteriorly it is continuous with fascia lata, and receives accessions from the biceps, sartorius, gracilis, and semitendinosus and membranous tendons. Over the popliteal space are transverse fibres. It gives off intermuscular septa. In front of and on the sides of the ankle the apon. is strengthened by strong bands, forming the annular ligaments.

The *anterior annular ligament* includes two structures—an upper band, *lig. annulare, p. n.*, transversely between the anterior borders of the fibula and tibia. The tibialis anticus tendon alone has a synovial sheath under it. The lower band, *lig. cruciatum, p. n.*, resembles the letter Y placed on its side, one arm being external and two internal. The outer portion springs from the hollow of the os calcis, forming a strong loop, "*fundiform ligament of Retzius*," surrounding the peroneus tertius and extensor longus digit. The straight and most constant internal band passes to the internal malleolus over the extensor pollicis (hallicis), and practically beneath the tibialis ant. tendon; the lower band crosses both those tendons, and becomes continuous with plantar fascia on the inner side of the sole.

There are three synovial sheaths in all: a common one for the peroneus tertius and extensor longus, one for the extens. poll., and one for the tib. anticus; may be a bursa between the fundiform lig. and neck of astragalus.

Int. annular lig. (lig. laciniatum, p. n.) covers the flexor tendons, completing canals; it is attached to the inner malleolus and posteriorly to the inner side of the os calcis.

The *ext. ann. lg. (retinaculum peronæorum superius, p. n.)* forms sheaths for the long and short peroneal tendons, passing from the outer malleolus to the os calcis. May be subcutaneous bursæ over the malleoli and over the lower end of the tendo Achillis.

Anterior Group.—1. *M. Tibialis Anticus* ("chain muscle").—*Origin*, ext. tuberosity of tibia, upper half outer surface of that bone, and adjacent inteross. memb., fascia of leg, and intermusc. septum; *insertion*,

oval mark on inner and lower part of int. cuneiform and first metatarsal, dividing into two slips. A small bursa may be under it near insertion.

A part inserted into astragalus, a slip to head first metatarsal or first phalanx.

M. tibio-fascialis anticus, from lower part of tibia to ann. lig. and deep fascia.

2. *M. Extensor Longus* or *Proprius Hallicis*.*—*Origin*, middle two-fourths of narrow anterior surface of fibula and contiguous portion of interosseous membrane; *insertion*, base of terminal phalanx of great toe. It spreads in an expansion on each side over the metatarso-phal. articulation, and almost always sends a slip to base of first phalanx.

Extensor ossis metatarsi hallicis is sometimes found as a slip from some surrounding muscle.

M. extens. long. primi. internod. hall. is represented by the offshoot from the extensor proprius.

3. *M. Extensor Longus Digitorum Pedis*.—*Origin*, ext. tuberosity of tibia, head and upper two-thirds of ant. surface of fibula, very largely from septa and fascia. Tendon divides into four slips for the four outer toes. They are continued into expansions which are joined on the first phalanx by processes from the interossei and lumbricales. They divide into three parts—the middle inserted into middle phalanx; the lateral parts unite, and are inserted into the base of the terminal phalanx as in case of extensors of fingers.

Tendons to second and fifth toes may be doubled; extra slips from one or more tendons to metatarsal bones, to short extensor, or to interossei; a slip to great toe. Slip for little toe may be separable to origin.

4. *M. Peroneus Tertius*.—*Origin*, below extensor longus dig., and united with it; lower third or more of ant. surface of fibula, from inteross. membrane, from septum between it and per. brevis; *insertion*, upper surface of base of fifth metatarsal, sometimes fourth. This muscle is peculiar to man.

Nerves.—All by the ant. tibial nerve.

Fibular Muscles.—1. *M. Peroneus Longus*.—*Origin*, few fibres from outer tuberosity of tibia, head and upper two-thirds of ext. surface of fibula, fascia of leg, and septa on each side. It has an anterior and a posterior head with musc.-cut. nerve between. Tendon begins in lower half of leg, passes behind ext. malleolus; then forward on outer side of os calcis, winds round tuberosity of cuboid, and enters its groove, crosses the sole obliquely, and is *inserted* into outer side of tuberosity of first metatarsal, and slightly into internal cuneiform: a frequent offset to base of second metatarsal and first dorsal interosseous.

Both peroneal tendons are in the same sheath under the ann. lig., but on the os calcis each has its own sheath, separated by the peroneal spine, when it ex-

* *Allex* or *hallex*, genitive *hallicis*, thumb or great toe—there is no word *hallux* to form the genitive *hallucis*.

ists, and a fibrous septum. A single synovial sac sends two processes down into the special sheaths.

A second synovial membrane is in the cuboid groove. A sesamoid fibro-cartilage or bone is on the tendon, playing over the cuboid tuberosity. The special fascia binding down the peroneal tendons is the *retinaculum peroneorum inferius*, p. n.

2. *M. Peroneus Brevis*.—*Origin*, lower two-thirds ext. surface of fibula, overlapping the peroneus long., from septa and a flat tendon on the surface turned toward the bone; *insertion*, tuberosity at base of fifth metatarsal, sending a small slip to the outer edge of extensor of little toe or fore part of the metatarsal bone.

Varieties.—Fusion is rare. Slip from per. long. to base of third, fourth, or fifth metatarsal or to adduct. hall.

M. peroneus access. arises from fibula between brevis and longus, and joins the latter in sole of foot.

M. peroneus quint. digiti, from lower fourth of fibula under per. brevis, inserted into extensor apon. of little toe, commonly represented by slip of per. brevis. Occurs normally in many animals.

M. peroneus quartus (13 per cent.), from back of fibula between per. brevis and flexor hall., inserted into peroneal spine (peroneo-calcaneus) or tuberosity of cuboid (peroneo-cuboideus).

Nerves.—Musculo-cut. branch of ext. popliteal nerve.

Posterior Group.—*Superficial Muscles*.—1. *Mm. Gastrocnemius and Soleus* (m. triceps suræ).—Gastrocnemius has two large heads from the femur, terminating in the middle of the leg in a common tendon.

Outer head from depression on outer side ext. condyle above tuberosity, and from post. surface of femur just above that condyle. *Inner* head from upper part of int. condyle behind adductor tubercle, and lower end of supracondylar ridge. The two heads enlarge, and soon meet, do not join; separated superficially by a groove and deeply by a thin band.

The inf. tendon is broad and aponeurotic, and on the deep surface.

The lower edge of each muscular part is convex downward: the inner head is the broader and thicker, and descends the lower. A bursa is between it and the semimembranosus, and another between it and the femur.

Outer head may develop a sesamoid fibro-cartilage or bone over the condyle of the femur.

Soleus.—*Origin*, externally from post. surface of head and upper third of shaft of fibula; internally, oblique line and inner border of tibia to its middle, and from a tendinous arch over popliteal vessels and nerve; fibres rise to a large extent from two tendinous laminae which descend in the muscle, one from the fibula and one from the tibia. Fibres from the ant. surfaces of these laminae converge to a median septum; fibres from their post. surfaces pass down and back to an aponeurosis covering the back surface of the muscle. The tendon of insertion is prolonged from this aponeurosis, joined by the median septum. Muscular fibres

are continued down on the deep surface of the tendo Achillis near to the heel. The tibial head is almost peculiar to man.

Tendo Achillis, broad at first, contracts to within $1\frac{1}{2}$ inches of heel, then expands, and is inserted into middle of post. surface of tuberosity of os calcis, with a bursa between, having all the characters of a synovial membrane, with vascular and fatty synovial tufts.

2. *M. Plantaris*.—*Origin*, femur above external condyle and from post. lig. of knee-joint. Muscular belly 3 to 4 inches long, and the long, slender tendon turns in between gastrocnemius and soleus to inner border of tendo Achillis, and *inserted* by its side into calcaneum.

May join tendo Achillis, end in fascia of leg or int. ann. lig., or be enclosed in the tendo Achillis. Absent in 7.5 per cent. It is the remains of a superficial flexor of the digits, like the palmaris longus.

3. *M. Popliteus*.—*Origin*, round tendon, 1 inch long, from groove on outer surface of ext. condyle of femur, within capsule of joint, in contact with semilunar cartilage, and by muscular fibres from lig. popl. arcuatum. Fibres pass down and are inserted into triangular surface of tibia above oblique line, and into aponeurosis over the muscle. The tendon is in the groove on the femur only in full flexion. Henle gives origin below and insertion above.

M. popliteus minor (rare), from femur, inner side of plantaris, inserted into post. lig. of knee.

M. peroneo-tibialis (1 in 7), from inner side of head of fibula to upper end of oblique line of tibia beneath popliteus; constant in apes.

Deep Muscles.—1. *M. Flexor Longus Digitorum Pedis* (perforans).—*Origin*, inner portion post. surface tibia for middle two-fourths of length, from apon. over tibialis post., from inner border of fibula. Descends behind int. malleolus, passes forward and obliquely outward, having crossed the tibialis post. tendon in the leg, and now crossing that of the flex. longus hall., in each case superficially. It divides into four parts for terminal phalanges of the four lesser toes. The whole arrangement with vinculae access. etc. is as for the fingers.

M. flexor access. long. digitorum rises from fibula or tibia or deep fascia, and passes beneath int. ann. lig. and joins the long flexor or the accessorius.

2. *M. Tibialis Posticus*, beneath the two long flexors. *Origin*, post. surface of inteross. membrane, outer part of posterior surface of tibia to middle of bone, whole inner surface of fibula, and from aponeurosis over it. Tendon along inner border of muscle, free at level of lower tibio-fib. articulation, passes behind inner malleolus; *inserted* into tuberosity of scaphoid, with offsets to the three cuneiform, to cuboid, bases of second, third, and fourth metatarsal, and to trans. tarsal lig. and abd. hall. tendon, and sends a thin process back to the sustentaculum tali.

Varieties few. *Tibialis secundus*, or *tensor of capsule of ankle-joint*, from lower half outer surface of tibia, below flex. digitorum, to capsule of ankle or ann. lig. between tibia and fibula.

3. *M. Flex. Longus Hall.*—*Origin*, lower two-thirds post. surface fibula, septum between it and peronei; apon. common to it and flex. longus dig. Tendon at post. surface of muscle traverses groove on back of astragalus and under surface of sustentaculum, gives slip to flex. long. digitorum in sole of foot, and proceeds to the base of terminal phal. of great toe.

Nearly always a slip from flexor hall. to flex digit., and (1 in 5) another from flex. dig. to flex. hall.

Slip from flex. hall. passes to second and third toes, 52 per cent.; to second only, 28 per cent.; to second, third, and fourth, 19 per cent., or rarely to all four.

M. peroneo-calcaneus internus (rare), from back of fibula, passes over sustentaculum tali to os calcis.

Nerves.—Gastrocnemius, plantaris, and popliteus by int. popliteal n. Soleus by int. popliteal and post. tibial. Flex. long. digit., flex. long. hallucis, and tibialis post. by post-tibial nerve.

THE FOOT.

Describe the muscles and fasciæ of the foot.

Fascia of dorsum is a thin layer over the extensor tendons, with deeper layers over the short extensors and interossei.

Fascia of sole (superficial) forms a thick cushion of fatty lobules bound down by bands passing vertically from skin to deep fascia. Small bursæ over heel and first and fifth metacarpals.

Deep Fascia of Sole.—*Plantar fascia*, central and two lateral portions. The *inner* is thin and loose, covers the abductor hall., and is continuous with dorsal fascia and int. ann. lig. *Outer* part covers abductor min. dig., and forms a thick band, especially between outer tubercle of os calcis and tuberosity of fifth metatarsal, continuous with dorsal fascia, and sends a prolongation forward over short flexors of little toe.

Central portion has dense white, glistening fibres, from inner tubercle of os calcis to roots of toes; divides into five processes in front. Thin trans. fibres cover the lumbricals and digital nerves. Identical arrangement as in palmar fascia: fibres to digital sheaths, superficial trans. lig., and skin, and deep processes to the trans. metatarsal lig.

Two *intermuscular septa* are between the middle and lateral portions, giving partial origin to muscles.

Superficial trans. lig. of toes is in folds of skin at interdigital clefts, connected to tendon-sheaths beneath. Connects all five digits.

Muscles of Dorsum of Foot.

1. *M. Extensor Brevis Digitorum Pedis.*—From fore part and upper and outer surface of os calcis, in front of groove for peroneus brevis tendon, and from ant. lig. of ankle. The tendon has several vertical leaflets from which muscular fibres rise, dividing into three bellies which

unite with the outer border of the long extens. for the second, third, and fourth toes.

2. *M. Extensor Hallicis Brevis* (often described with the above).—*Origin*, two heads, outer from upper surface os calcis close by ant. edge, and connected with the extensor brevis digit. ; inner head from lowest arm of ann. lig. Tendon is free at tarso-metatarsal joint, passes under the tendon of the extensor long. hall., and is expanded and fastened to dorsum of first phalanx.

Access. slips from different bones of tarsus to tendon for second toe, or one from cuboid to third. Number of tendons vary; reduced to two, one doubled, or slip to little toe. A slip ending in a metatarso-phal. articulation or dorsal interos. muscle is rather common, especially between the great and second toe bellies. Deep slips, forming a transition to dorsal interossei, may occur; may be a bursa over the second and third metatarsal bases.

Muscles of the Sole.

None corresponding to the palmaris brevis: three groups as in the hand, middle group richer than that of hand. Great toe poorer than the thumb group. Little toe group, like number and arrangement.

IN THE MIDDLE.—1. *M. Flexor Brevis Digitorum* (perforatus).—*Origin*, inner tubercle of os calcis, plantar fascia, septa, and calc. cuboid lig. Terminates in four slender tendons inserted into sides of second phalanges of four outer toes; each divides and gives passage to the long flexor, as does the flex. subl. of the hand.

Muscle may pass to all toes. The tendon to the little toe is always smaller than the others, and wanting in 23 per cent.; may be replaced (5 per cent.) by a small muscle from the long flexor or flexor access.; origin of slip to fourth toe may be transferred to the long flexor. This is the rule for the outer toes of apes.

2. *Flexor Accessorius* (m. quadratus plantæ, *p. n.*).—Henle calls it the “plantar head of the flexor long. digit.” Flat quadrilateral muscle. *Origin*, two heads, internal and larger from inner surface of os calcis; external, narrow and tendinous, from outer surface os calcis and long plantar lig.; *insertion*, ext. border and upper surface of flex. long. digit. tendon.

Offsets can be traced to the second, third, and fourth toes, not always to the fifth. Muscle may end in flex. hall. tendon. May be absent.

3. *Mm. Lumbricales*.—Four in number. *Origin*, at points of division of flex. long. digit. tendon, each attached to two tendons, except the most internal one; they pass to inner side of four outer toes, *inserted* into bases of first phalanges (Henle).

One or more absent; doubling of third and fourth; insertion into extensor tendons. Bursæ between tendons and bases of first phalanges.

Muscles of Great Toe-side.—1. *M. Abductor Hallicis*.—*Origin*, inner tubercle os calcis, int. ann. lig., septum, plantar fascia; *insertion*,

inner border of base first phalanx great toe, inner sesamoid bone, and tendon of extens. long. hall. Slip to first phalanx second toe. May have a second head from scaphoid.

2. *M. Flexor Brevis Hallicis*.—*Origin*, flat process from cuboid inner border, from slip of tibialis post. tendon to the two outer cuneiform bones, from sheath flex. long. digit.; *inserted* by two heads into inner and outer borders of base of first phalanx, in connection with abductor hall. and adductors. Sesamoid bone in each head.

Origin from os calcis or long plantar lig. Sends slip to second toe, first phal. Inner head regarded by some as belonging to abductor.

3. *M. Adductor Hallicis* has two heads as in hand, an oblique and transverse, only more separated.

Caput Obliquum, p. n.—*Origin*, tarsal extremities of third and fourth metatarsals, sheath of peroneus long., calc.-cuboid lig., and third cuneiform; *insertion*, outer side of base of first phal. of great toe, somewhat above the tendon of the peroneus long.

Caput transversum, transversus pedis, is covered by flexor tendons. *Origin*, inf. tarso-metatarsal ligaments of three outer toes and trans. metatarsal lig.; *inserted* with the oblique head and flexor brevis into first phalanx of great toe and extensor tendon.

In the fœtus the muscle is close to the oblique head at bases of metatarsals; it subsequently travels forward along interosseous fascia. *Opponens hall.* into metatarsal of great toe is sometimes found.

Muscles of Little Toe-side.—1. *M. Abductor Min. Dig.*—*Origin*, both tubercles of os calcis, ext. septum, band of plantar fascia between external tubercle and base of fifth metatarsal; *inserted* into base fifth metatarsal and outer side base first phal. little toe. The tendon usually receives muscle-fibres from base fifth metatarsal.

M. abductor oss. metatarsi quinti, 18 per cent. from ext. tubercle of os calcis to tuberosity of fifth metatarsal.

2. *M. Flexor Brevis Min. Dig.*—*Origin*, base of fifth metatarsal, and calc.-cuboid lig., sheath of peroneus long.; *insertion*, base and ext. border first phalanx little toe; deeper fibres generally end on anterior half of fifth metatarsal.

3. *M. opponens min. dig.* is occasionally (3.5 per cent.) separate from the flex. brevis min. dig., especially at its origin. It better be considered the inner belly of the flex. brevis, attached to the metatarsal bone.

Mm. interossei, as in the hand, are seven in number, four dorsal and three plantar. The dorsal project downward as low as the plantar, and alternate with them. Only one muscle in the first space, two in the others. The second toe is their centre of insertion.

Each *dorsal interosseous* has two heads and a central tendon, which is inserted partly into the base of the first phalanx and into extensor aponeurosis. The first two are inserted, one on either side of the second toe,

the third and fourth into the outer sides of the third and fourth. Inner head of first is small, and rises from first metatarsal and int. cuneiform; the third and fourth receive fibres from sheath of peroneus long.

Plantar interossei, from inner and under surface of third, fourth, and fifth metatarsals, one-headed, and from sheath of peroneus long. Inserted to inner sides first phalanges of third, fourth, and fifth and extensor tendons of toes.

In the fœtus the dorsal interossei are on the plantar aspect, and have a single origin, corresponding to the outer head of the fully-formed muscle. As the metatarsals become separated they pass more to the dorsum and acquire another head.

Nerves.—Extensor brevis by ant. tibial. Flexor brev. digit., abductor and flex. brev. hall., and innermost lumbricalis by int. plantar; all the others by ext. plantar.

Actions.—*Popliteus* flexes knee and rotates leg in, pulls on capsule of joint, and keeps poplit. bursa open. The dorsum of the foot and ant. surface of leg is the *extensor surface*; the opposite side is the *flexor surface*, so that raising the foot on the front of the leg is really extension, and depressing it is flexion: it is customary to apply reverse terms to these acts.

Gastrocnemius flexes knee, extends ankle, combines with soleus and lifts heel or raises body on toes.

Tib. ant. and *peroneus tert.* flex ankle; the former rotates in, adducts, raises first metatarsal bone.

Tib. post., *peroneus long.* and *brevis* are extensors. *Tib. post.* and flexors of toes rotate foot in. The three peronei and extensors of toes rotate out.

Peroneus long. strengthens trans. arch, lifts outer border of foot in walking, extends foot, depresses first metatarsal, abducts fore foot, rotates out.

Flexors and extensors of toes, interossei, and lumbricalis act like the corresponding muscles of the hand.

Flex. accessorius modifies the action of the flex. long. dig., as those tendons cannot enter the foot in a straight line.

The *extensor brevis dig.* does the same for the extensor communis, though here they are not so much needed, and their function is not so evident.

Extensors of foot slightly rotate in; flexors of foot slightly rotate out; *plantaris* indirectly pulls up the capsule of ankle-joint and slightly aids the *gastrocnemius*.

Flexors of Foot.

Tibialis anticus.
Extens. communis dig.
Extens. propr. hall.
Peroneus tertius.

Adduction.

Tibialis post. (strongly).
Tendo Achillis (weakly).
Perhaps tendons behind inner mall.,
perhaps tibialis anticus.

Rotation in.

Tibialis anticus (strongly).
Tendo Achillis.

Extensors of Foot.

Tendo Achillis.
Peroneus long. and brevis.
Tibialis posticus.
Flex. long. digit. and hall.

Abduction.

Peroneus brevis.
Peroneus longus.

Rotation out.

Peroneus longus.
Extens. communis dig.
Peroneus tertius.

The muscles of the foot, especially of the little toe-side, are decreasing and the little toe becoming less important; those of the hand are increasing, corresponding to its complex movements over those of the foot.

In comparing muscles of leg with forearm we notice (1) a reduction in accordance with diminution of mobility; (2) disappearance of high origin of some superficial extensors; (3) development of tarsal attachment of superficial flexors of toes due to outgrowth of heel.

MUSCULAR HOMOLOGIES.

I. Muscles from Trunk to Limbs or from Girdle to Humerus or Femur.

Upper Limb.	Lower Limb.
Trapezius, Cleido-mastoid, Rhomboidi, Lev. ang. scapulæ, Serratus magnus,	} Ext. oblique and lumbar aponeurosis.
Deltoid,	
Teres minor. Latissimus dorsi, Teres major,	} Gluteus maximus, larger part.
Pectoralis major, Pectoralis minor. Subclavius.	
Supraspinatus. Infraspinatus,	Psoas.
Subscapularis,	Iliacus. Pectineus.
	Coraco-brachialis,
<i>Chondro-epitrochlearis</i> ,	

II. Muscles of Arm and Thigh.

Biceps,	} Ischial head of biceps fem. Semitendinosus. Semimembranosus.
<i>Humeral head of biceps</i> , Brachialis anticus, <i>Dorso-epitrochlearis</i> ,	
Triceps:	Quadriceps:
<i>a.</i> Scapular head.	<i>a.</i> Rectus femoris.
<i>b.</i> Humeral heads.	<i>b.</i> Vasti and crureus.
Anconæus.	

III. Muscles of Forearm and Leg.

Pronator teres,	Popliteus.	
Flexor carpi radialis,	} Gastrocnemius.	
Flexor carpi ulnaris,		
Palmaris longus,	Plantaris.	
Flexor sublimis digitorum,	Soleus and flexor brevis digit.	
Flexor longus pollicis,	} { Flexor longus hallicis.	
Flexor profundus digit.,		Flexor longus digit.
		Flexor accessorius.
		Lumbricales.
Lumbricales,		
Pronator quadratus.		
<i>Ulna-carpeus,</i>	<i>Peroneo-calcaneus internus.</i>	
<i>Radio-carpeus,</i>	Tibialis posticus.	
Supinator longus.		
Extensor carpi radialis longior.		
Extensor carpi radialis brevior.		
Extensor communis digit.,	Extensor longus digit.	
Extensor minimi digiti,	Peroneus tertius (?).	
	} Peroneus longus.	
Extensor carpi ulnaris,		Peroneus brevis.
Supinator brevis.		
Extensor ossis metacarpi poll.,	Tibialis anticus.	
Extensor longus poll.,	Extensor longus hall.	
Extensor brevis poll.,	First slip of extensor brevis digitorum.	
Extensor indicis,	} Second slip of extensor brevis digi- torum.	
<i>Extensor medii digiti,</i>		} Extensor brevis digit.
<i>Extensor brevis digitorum,</i>		

IV. Muscles of Hand and Foot.

Palmaris brevis.	Abductor hallicis.
Abductor pollicis,	Flexor brevis hallicis.
Flexor brevis pollicis,	<i>Opponens hallicis.</i>
Opponens pollicis,	Adductor obliquus hallicis.
Adductor obliquus pollicis,	Adductor transversus hallicis.
Adductor transversus pollicis,	Abductor minimi digiti.
Abductor minimi digiti,	
Flexor brevis minimi digiti.	
Opponens minimi digiti.	} Flexor brevis min. dig.
a. Superficial part.	
b. Deep part,	
First palmar interosseous.	First plantar interosseous.
Second palmar interosseous,	Second plantar interosseous.
Other interossei correspond.	

ANGEIOLOGY.

THE HEART.

Describe the pericardium.

The pericardium is a fibro-serous membrane which invests the heart and the great vessels at their origin for about 2 inches. Below it is attached to the diaphragm and its central tendon; in front it is separated from the sternum by the thymic remains, some areolar tissue, and overlapped by the margins of the lungs, especially of the left; behind it are the œsophagus, bronchi, and descending aorta; laterally it is covered by the pleuræ, with the phrenic nerve and vessels running between the two membranes.

The pericardium consists of a fibrous and a serous layer. The fibrous layer forms a tubular investment for the great vessels which is lost on the external coat, and can be traced afterward into the deep cervical fascia. It is attached below to the diaphragm and its central tendon. The vessels invested are the aorta, superior vena cava, both pulmonary arteries, and all the pulmonary veins.

The serous layer invests the heart and is reflected on to the fibrous layer. It also invests the great vessels for about 2 inches. The aorta and pulmonary artery are completely invested, the pulmonary veins and both the venæ cavæ only partially.

Describe the heart.

The heart is a hollow muscular organ, of a somewhat conical form, lying between the lungs and enclosed by the pericardium. It contains four chambers, an auricle and a ventricle on each side.

Give its general position and measurements.

It lies obliquely, the base being directed upward, backward, and toward the right, and extending from the level of the fifth to that of the eighth dorsal vertebra, and the apex looking downward, forward, and to the left, its impulse against the chest-wall being felt in the fifth left interspace, about $3\frac{1}{4}$ inches from the middle of the sternum. The heart lies more in the left than in the right side of the chest, its base being held in position by the great vessels which are connected with it; its posterior surface is flat, formed chiefly by the left ventricle, and rests on the diaphragm; and its anterior surface, formed chiefly by the right ventricle, but also partly by the left, is convex and covered to some extent by the lungs. Of the borders, the right is long and thin, and the left is shorter and thick. The length of the heart is 5 inches; its greatest breadth is $3\frac{1}{2}$ inches; its thickness is about $2\frac{1}{2}$ inches. Its weight is 10 to 12 ounces in the male, 8 to 10 in the female, and it increases with age.

How is the heart subdivided externally?

Externally it presents a deep transverse groove, the auriculo-ventricular, which marks off an upper or auricular and a lower or ventricular portion: this latter part presents a longitudinal furrow, of front and back, the former being somewhat to the left, the latter to the right.

How is the heart subdivided internally?

The interior of the heart is divided by a longitudinal septum into a right and left part, and these, in turn, are divided into an auricle and a ventricle.

Describe the right auricle.

The right auricle is larger than the left, its wall being about 1 line in thickness and its capacity two ounces. Its cavity is divided into two parts, the sinus venosus and the appendix auriculæ, the former lying between the entrances of the two venæ cavæ, the latter overlapping the commencement of the aorta. Within the auricle the following parts present themselves for examination:

(1) The orifice of the superior vena cava, looking downward and forward.

(2) The orifice of the inferior vena cava, at the lowest part, near the septum, looking upward and inward.

(3) Between the two caval openings a projection, the tuberculum Loweri.

(4) The opening of the coronary sinus, between the inferior cava and the auriculo-ventricular opening, and protected by the fold of endocardium forming the coronary valve.

(5) Numerous small openings (foramina Thebesii) of the venæ cordis minimæ.

(6) The auriculo-ventricular opening.

(7) The Eustachian valve, between the front of the vena cava and the above-mentioned orifice. It is semilunar in form, the free concave margin sending one cornu to join the front of the annulus ovalis and the other to the auricular wall.

(8) The fossa ovalis, at the back of the septum, in the situation of the foetal foramen ovale, its prominent margin being known as the annulus ovalis.

(9) The muscoli pectinati, small elevated columns which traverse the appendix and the adjacent part of the sinus.

Describe the right ventricle.

The right ventricle is triangular, and extends nearly to the apex of the heart. It is bounded internally by the convex surface of the septum ventriculorum, and prolonged above and internally into a pouch, the infundibulum, or conus arteriosus, from which springs the pulmonary artery. Its cavity has a capacity of three ounces. On opening the ventricle the following parts are presented for examination:

(1) The auriculo-ventricular orifice, oval in form and placed near the right side of the heart. Around its circumference is a fibrous ring, and it is guarded by the tricuspid valve.

(2) The opening of the pulmonary artery, circular in form, at the summit of the conus arteriosus, near the septum; is guarded by the pulmonary valve (semilunar).

(3) The tricuspid valve consists of three triangular flaps formed of fibrous tissue covered by endocardium. They are continuous with one another at their bases, and their free margins and ventricular surfaces give attachment to the chordæ tendineæ. Their central part is thick and strong, the lateral margins thinner and flexible.

(4) The chordæ tendineæ are attached as follows: several to the attached margin of each flap, blending with the fibrous ring; several to the strong central part; and the finest and most numerous to the margins of each curtain.

(5) The columnæ carneæ are projecting bundles of muscular substance found all over the ventricular wall excepting the conus arteriosus. They are of three classes: the first are mere ridges, attached by one side and both extremities; the second are attached only by both extremities; the third (musculi papillares) are attached by only one extremity, the free end having chordæ tendineæ attached to it.

(6) The three semilunar valves guard the pulmonary orifice. They are semicircular, their free margins being thick and tendinous and presenting at the middle a small fibrous nodule, the corpus Arantii. On each side of this body, just behind the free margin, the valve presents a small thinned-out interval, and when the valves are closed during diastole these intervals (*lunule*) are in contact, and so also are the three nodules. These latter prevent any leakage from the triangular space which would otherwise be left. At the commencement of the pulmonary artery are three pouches, the sinuses of Valsalva, placed one behind each valve. They resemble those of the aorta, but are smaller.

Describe the left auricle.

It is smaller and thicker-walled than the right, and consists, like the right, of a sinus and an appendix. The latter overlaps the pulmonary artery. Within it presents the following features of interest:

The orifices of the pulmonary veins, opening two into the right and two into the left side; the auriculo-ventricular orifice; and a few muscular pectination the inner side of the appendix.

Describe the left ventricle.

It is longer than the right, and enters into the formation of the apex. Its walls are three times as thick as those of the right. Within it presents for examination—

The auriculo-ventricular orifice, which is smaller than the right and guarded by the mitral or bicuspid valve; and the aortic opening, in front and to the right of the preceding, guarded by the semilunar valves.

PLATE XV.

FIG. 1.—To face page 205.

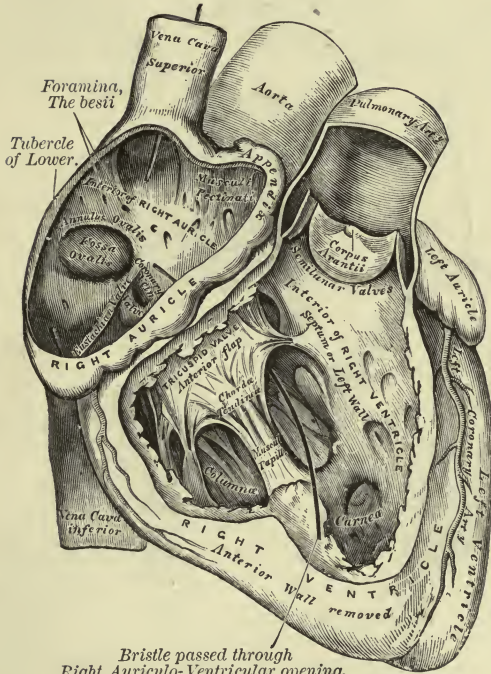
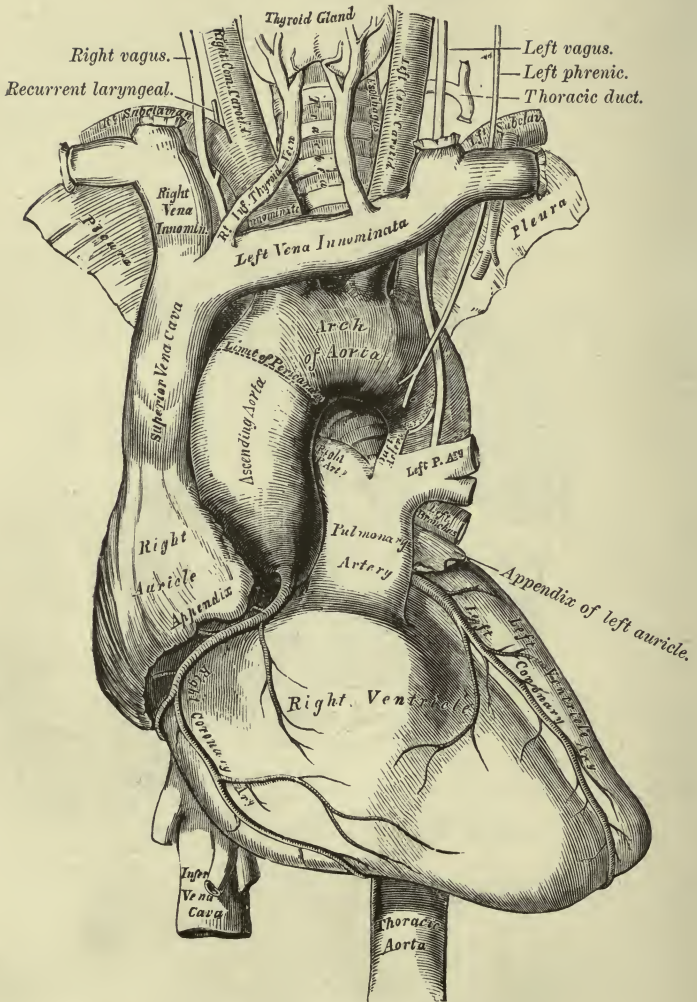


PLATE XVI.

FIG. 1.—To face page 209.



The Arch of the Aorta and its Branches.

The mitral valve is attached, like the tricuspid on the right side. It consists of two curtains which are larger and thicker than those of the tricuspid, and of two smaller segments, one at each angle of junction of the former. They are furnished with chordæ tendineæ.

The aortic semilunar valves are similar to but larger and stronger than the pulmonary valves.

Columnæ carneæ are found as in the right ventricle, and the musculi papillares consist of two groups and are very large.

The inner surface of the heart is lined by a thin membrane, the endocardium, continuous with the inner lining of the great blood-vessels, and helping to form by its folds the various valves.

The heart is supplied with blood by the coronary arteries, and with nerves by the cardiac plexuses, formed by branches of the pneumogastric and sympathetic nerves.

STRUCTURE OF THE HEART.

What are the two structures of which the heart is made up?

Fibrous rings and muscular fibres: the former serve as points of attachment of the latter.

What is the situation of the fibrous rings?

They surround the auriculo-ventricular and arterial orifices, and give attachment to the valves of the heart and great vessels, in addition to the muscular attachment.

How may the muscular fibres be divided?

1. Into those of the auricles; 2. those of the ventricles.

Describe the arrangement of the fibres of the auricles.

These are in two layers, a superficial and a deep. The former layer is common to both auricles; the latter is peculiar to each. The *superficial layer* passes across from one auricle to the other anteriorly, and back again posteriorly, thus enclosing them in a kind of ring. The *deep layer* is made up of looped and annular fibres. The looped fibres *arch over* the auricle; the annular fibres encircle each auricle.

Describe the arrangement of the fibres of the ventricles.

There are seven layers in each ventricle: in the left ventricle the fibres of the first or most external layer are continuous with the fibres of the seventh or most internal layer; those of the second with the sixth, those of the third with the fifth, while the fourth layer runs horizontally and continuously around the ventricle. The direction of the other layers is as follows: first layer, from above downward and from left to right; seventh layer, just the opposite; second layer, like the first, but more obliquely; sixth layer, just the reverse; while the third and fifth layers are nearly horizontal. The union of the first and seventh layers is at the apex of the heart, and forms the vortex or *whorl*. In the right

ventricle, arrangement exactly the same, except union of first and seventh layers, which takes place all along the anterior coronary groove. All the fibres are much more delicate than those of the left ventricle.

ARTERIES.

Describe the pulmonary artery.

It is a short, wide vessel, 2 inches in length. Commencing at the base of the right ventricle, it curves upward and backward, to end under the transverse aorta by dividing into a right and a left branch. Relations: in front, second left intercostal space and cartilage, left border of sternum; behind, origin of aorta, left auricle; above, transverse aorta, remains of ductus arteriosus; to the right, right appendix and coronary artery, ascending aorta; to the left, left appendix and coronary artery.

This vessel, with the ascending aorta, is enclosed in a sheath of pericardium. It winds around the aorta, being at first in front, and later to the left side, of the ascending portion. In foetal life the ductus arteriosus connects it a little to the left of its bifurcation with the transverse aorta.

Each branch enters the root of the corresponding lung; the right, the larger, passing behind the ascending aorta and superior vena cava; the left, in front of the descending aorta. The left divides into two branches for the lobes of the left lung; the right also divides into two primary branches for the upper and lower lobes. From the lower one of these is sent a branch to the middle lobe.

SYSTEMIC ARTERIES.

Describe the aorta.

The aorta is the main trunk from which spring the systemic arteries. From the base of the left ventricle it runs upward, forward, and to the right as far as the second right cartilage; then backward and to the left, over root of left lung, to the fourth dorsal vertebra; thence, along the spine, it descends through the thorax and abdomen to divide, at the fourth lumbar, into the common iliaes.

It has been divided, for convenience of description, into the arch and the descending aorta. The arch is subdivided into the ascending, transverse, and descending parts; the descending aorta, into the thoracic and abdominal portions.

ARCH OF THE AORTA AND ITS BRANCHES.

Describe the ascending part of the arch.

It runs upward, forward, and to the right, from a point opposite the lower border of the third left cartilage, to the upper border of the second

right cartilage. Close to its origin it presents three small dilatations, the sinuses of Valsalva, indicating the situation of the semilunar valves, and along the right side a bulging, the *sinus magnus*. Relations: in front, pulmonary artery, right appendix, thoracic fascia, right pleura, pericardium, remains of the thymus gland; behind, root of right lung, including right pulmonary vessels, left auricle; to the right, right auricle, superior vena cava; to the left, pulmonary artery.

Describe the transverse part of the arch.

This part passes backward and to the left as far as the left side of body of the fourth dorsal vertebra. Relations: in front, lungs and pleura, thymic remains, left vagus, phrenic and superficial cardiac nerves, left superior intercostal vein; behind, trachea, œsophagus, thoracic duct, deep cardiac plexus, left recurrent nerve; above, left innominate vein and the branches of this portion of the aorta—viz. innominate, left carotid, and subclavian arteries; below, left bronchus, bifurcation of pulmonary artery, ductus arteriosus, left recurrent nerve.

Describe the descending part of the arch.

It descends to lower border of fifth dorsal vertebra, ending in the thoracic aorta. Relations: in front, root of left lung covered by pleura; behind, left side of body of fifth dorsal vertebra; right side, œsophagus, thoracic duct; left side, left lung, covered by pleura.

Name and describe the branches of the arch of the aorta.

They are five: coronary, right and left, from the ascending part; and the innominate, left carotid, and left subclavian, from the transverse part. The descending part gives off no branches.

The coronary arteries supply the heart and the coats of the great vessels. They emerge on either side of the pulmonary artery, between it and the corresponding appendix auriculæ. Each arises from a sinus of Valsalva, just above the free margin of the corresponding semilunar valve, and is distributed to the muscular substance of the heart, its valves and septa, running along the grooves on its surfaces, and anastomosing freely with the other, and, by means of twigs to the aorta and pulmonary artery, with the pericardiac and bronchial vessels. Each divides into two primary branches, the right vessels running in the posterior and the left in the anterior grooves.

ARTERIES OF THE HEAD, NECK, AND UPPER EXTREMITY.

Describe the innominate artery (brachio-cephalic).

This is the largest branch. It arises in front of the left carotid, and runs obliquely to the right sterno-clavicular joint, where it divides into the right common carotid and right subclavian. Relations: in front, manubrium sterni, sterno-hyoid and thyroid muscles, thymic remains, left innominate and right inferior thyroid veins, inferior cervical cardiac

nerve from right vagus; behind, trachea and pleura; right side, pleura, right vagus, right phrenic nerve, and the right innominate vein; left side, remains of the thymus and trachea. The left carotid artery is behind and to the left of this vessel. The innominate regularly gives off no branches. Occasionally, however, a thymic or bronchial branch or the arteria thyroidea ima arises from it.

Describe the common carotid arteries.

They are identical in course, branches, and relations in the neck, but differ in their origin. Thus, the right is a branch of bifurcation of the innominate, while the left is a primary branch of the transverse aorta. From its origin the left carotid passes obliquely upward and outward to the left sterno-clavicular joint, and from that point follows a course corresponding to that of the right carotid. We describe, therefore, a *thoracic portion* of the left carotid artery. Its relations are as follows: in front, sternum, sterno-hyoid and thyroid, thymic remains, left innominate vein; behind, trachea, œsophagus, thoracic duct; left side, left subclavian artery, left vagus; right side, innominate artery, which is also somewhat in front.

In the neck each carotid ascends from the sterno-clavicular joint to the level of the upper border of the thyroid cartilage, there dividing into the external and internal carotids. Each is enclosed, with the internal jugular vein and vagus, in a sheath of deep cervical fascia, the several structures being partitioned from one another within the sheath. The artery is internal, the vein external, the nerve between them, but on a posterior plane. Relations: *in front*, integument, fasciæ, platysma, sterno-mastoid, hyoid, thyroid, and omo-hyoid muscles, descendens and communicantes noni nerves, sterno-mastoid artery, superior, middle thyroid, and anterior jugular veins, and a branch connecting anterior jugular with facial; *behind*, longus colli, rectus anticus major, spinal column, inferior thyroid artery, sympathetic and recurrent laryngeal nerves; *outer side*, internal jugular vein, vagus; *inner side*, trachea, œsophagus, larynx, pharynx, thyroid gland, inferior thyroid artery, and recurrent nerve. In the lower part of the neck the internal jugular diverges from the artery on the right side, but approaches, and may cross it, on the left. The common carotid regularly gives off no branches, but a vertebral, thyroid, or laryngeal branch may arise from it on either side.

Describe the external carotid artery.

This vessel runs from the bifurcation of the common carotid to the neck of the lower jaw, and there divides into the superficial temporal and internal maxillary. At its origin it is anterior and internal to the internal carotid, and at its termination is imbedded in the parotid gland. Relations: *in front*, integument and fasciæ, sterno-mastoid, digastric, and stylo-hyoid muscles, part of parotid, facial and hypoglossal nerves, lingual, facial, and temporo-maxillary veins; *behind*, styloid process with its remaining muscles, part of parotid gland, and the glosso-pharyngeal

nerve; *internally*, pharynx, hyoid bone, part of parotid, separating it from the lower jaw and stylo-maxillary ligament, and the superior laryngeal nerve.

Name and describe the branches of the external carotid.

Besides branches given off directly to the muscles in its course and to the parotid gland, they are the following: *Anterior branches*, superior thyroid, lingual, facial; *posterior branches*, occipital, posterior auricular; *internal branch*, ascending pharyngeal; *terminal branches*, superficial temporal and internal maxillary.

I. The **superior thyroid** runs beneath the omo-hyoid and sterno-hyoid and thyroid muscles to the gland, uniting with its fellow and with the inferior thyroid. It supplies the gland, the muscles in its course, and the following-named branches:

(a) *Hyoid*, to lower border of bone, joins its fellow.

(b) Superficial descending or *sterno-mastoid* crosses common carotid to the sterno-mastoid muscle.

(c) *Superior laryngeal*, beneath thyro-hyoid, pierces membrane to interior of larynx.

(d) The *crico-thyroid* runs across that membrane and joins its fellow.

II. The **lingual** ascends to the great cornu of the hyoid bone, runs forward parallel with it, ascends to the tongue, and runs along its under surface to the tip. It is at first superficial, lying on middle constrictor; later covered by digastric and stylo-hyoid, resting on the same muscle. It then ascends between the hyoglossus and genioglossus; finally, as the *ranine* artery, it runs on the lingualis to tip of tongue, along with the gustatory nerve, covered only by mucous membrane. The first part is crossed by the hypoglossal nerve. The second part is in the triangle formed by the diverging bellies of the digastric below and the hypoglossal nerve above. The artery lies above the central tendon of the digastric, below the nerve, and beneath the hyoglossus. *Branches*:

(a) *Hyoid*, to upper border of hyoid bone, joins its fellow.

(b) *Dorsalis linguee*, from beneath the hyoglossus, joins its fellow, and supplies the tonsil, epiglottis, and soft palate, besides the tongue.

(c) *Sublingual* runs on genio-glossus to the gland. Branches supply the mylo-hyoid and gums, and a twig joins its fellow across the middle line.

III. The **facial** runs under the lower jaw upon mylo-hyoid, and grooves the upper and back part of the submaxillary gland. It then crosses the jaw at the anterior border of the masseter, runs over the cheek by the angle of the mouth, and alongside of the nose to the inner canthus of the eye, ending in the angular artery, which anastomoses with the nasal branch of the ophthalmic. Its course is very tortuous.

This vessel lies at first beneath the digastric and stylo-hyoid, but is covered only by the platysma where it crosses the jaw. In the face it lies on the buccinator, levator anguli oris, and levator labii superioris, covered by the platysma, risorius, and zygomatici. The vein is external and at some distance from the artery, and pursues a straight course.

Branches of the facial nerve cross, and the infraorbital nerve is under, the artery.

Its *branches* are the following: a *cervical* group, including the inferior palatine, tonsillar, submaxillary, submental; and a *facial* group: the inferior labial, coronary upper and lower, lateralis nasi, and the angular.

(a) The *inferior* or *ascending palatine* runs at first between the styloglossus and pharyngeus; then between the internal pterygoid and pharynx. It crosses the superior constrictor to the soft palate, joins its fellow, and supplies the tonsil, Eustachian tube, palate, and the muscles along its course.

(b) The *tonsillar* pierces superior constrictor to tonsil and tongue.

(c) The *submaxillary* includes several glandular branches.

(d) The *submental*, the largest branch, runs beneath the jaw, sending twigs through the mylo-hyoid to join the sublingual. It turns over the symphysis, giving offsets to the chin and lower lip, and joins its fellow and the inferior dental. It supplies also the muscles along its course.

(e) *Muscular* branches are derived from the vessel at every point, both in the face and neck.

(f) The *inferior labial*, beneath the depressor anguli oris, joins mental, submental, and inferior coronary.

(g) The *coronary* arteries ramify between the orbicularis oris and the mucous membrane, the inferior joining its fellow and the inferior labial; the superior, arising from behind the zygomaticus major, gives off the artery of the septum, besides other nasal branches.

(h) *Lateralis nasi*, to side of nose.

(i) *Angular* is the terminal branch.

IV. The **occipital artery** is at first covered by the digastric and stylo-hyoid muscles and crossed by the hypoglossal nerve. It then crosses the internal carotid sheath and spinal accessory nerve to the interval between the atlas and mastoid process, lying here in the occipital groove, and then pierces the origin of the trapezius to ramify in the scalp as high as the vertex. *Branches*:

(a) *Muscular*, all along its course.

(b) The *sterno-mastoid* branch enters the muscle with the spinal accessory nerve.

(c) The *mastoid* branch, through the mastoid foramen.

(d) *Princeps cervicis* divides into a superficial branch, lying under the splenius, and sending twigs through it to anastomose with the superficial cervical; and a deep branch beneath the complexus, to join branches of the vertebral and profunda cervicis.

(e) A *meningeal* branch enters the jugular foramen.

V. The **posterior auricular artery**, resting on the styloid process, passes beneath the parotid to the groove between mastoid and auricle, and divides into two branches, the *auricular* and *mastoid*, the latter supplying the scalp. This artery crosses the spinal accessory and is crossed by the facial nerve. Besides branches to the various muscles and the parotid, it gives off the following:

(a) The *stylo-mastoid*, through the foramen, to the mastoid cells and tympanum. In the young subject a branch joins the tympanic from the internal maxillary artery to form a circle, from which twigs pass to the tympanic membrane. Another branch, in the aqueductus Fallopii, joins the petrosal artery of the middle meningeal.

(b) The *auricular*, anastomosing with branches of the temporal.

VI. The **ascending pharyngeal** ascends between pharynx and internal carotid to the base of the skull, giving off branches which may be divided into three sets—viz. (1) three or four *pharyngeal*, to the constrictors, the lower joining branches of the superior thyroid, and the largest to the superior constrictor, supplying also the palate and tonsil. (2) Several *meningeal* branches entering the foramen lacerum medium, jugular and anterior condylar foramina. (3) The *prevertebral* branches, to the muscles and glands in its course and to the vagus and sympathetic nerves, anastomosing with the ascending cervical.

The external carotid divides into the superficial temporal and internal maxillary while imbedded in the parotid gland, the former being the smaller.

VII. The **superficial temporal** ascends to about 2 inches above the zygoma, and divides into the *anterior* and *posterior temporal*. The former supplies the muscles, pericranium, and skin over the forehead, joining the supraorbital and frontal; the latter runs upward and backward over the side of the head, anastomosing with its fellow, the occipital, and posterior auricular. The temporal supplies the articulation of the jaw, the parotid, and the muscles in its course, and gives off the following-named *branches*:

(a) The *transverse facial*, lying at first between Stenson's duct and the zygoma upon the masseter, and accompanied by branches of the facial nerve. It joins branches of facial and infraorbital.

(b) *Middle temporal*, to the muscle, after perforating temporal fascia, grooves the squamous portion, and supplies an *orbital* branch. It anastomoses with the deep temporal.

(c) The *anterior auricular*, two or three, join branches of the posterior auricular after supplying fore part of pinna.

VIII. The **internal maxillary** is described in three portions—viz. maxillary, pterygoid, and spheno-maxillary. The first portion runs between the jaw and internal lateral ligament. The second runs forward and upward upon the external pterygoid. The third enters the spheno-maxillary fossa between the two roots of the external pterygoid.

Branches: from the first or maxillary portion the tympanic, middle and small meningeal, inferior dental; from the second or pterygoid part the deep temporal, pterygoid, masseteric, buccal; from the third or spheno-maxillary part the alveolar, infraorbital, superior or descending palatine, Vidian, pterygo-palatine, spheno-palatine.

(a) The *tympanic*, through the Glaserian fissure, joins the stylo-mastoid and the tympanic arteries, and supplies a *deep auricular* branch. (See *Stylo-mastoid Artery*.)

(b) The *middle meningeal* ascends between the roots of the auriculo-temporal nerve, through the foramen spinosum, and divides on entering the cranium into an anterior and a posterior branch. These ramify on the inner surface of the calvaria as far as the frontal and occipital bones, uniting with the posterior and anterior meningeal. Branches pass to the Gasserian ganglion and dura mater; through the sphenoidal fissure to the orbit; and through the hiatus Fallopii a petrosal branch passes to join a branch of the stylo-mastoid artery.

(c) The *small meningeal* enters the foramen ovale, sometimes arising from the preceding.

(d) The *inferior dental* traverses the dental canal, escaping at the mental foramen. It sends forward an incisor branch in the bone, gives off to the groove a mylo-hyoid branch, and unites with its fellow and with the submental and labial arteries. It supplies the teeth by small twigs to the roots from below.

(e) The two *deep temporal*, anterior and posterior, join other temporal branches. The anterior sends twigs through the malar bone to unite with the lachrymal.

(f) The *pterygoid* branches supply the muscles of that name.

(g) The *masseteric* crosses the sigmoid notch to the deep surface of the muscle.

(h) The *buccal*, on the buccinator, joins branches of the facial.

(i) The *alveolar* sends branches through the posterior dental canals to the molar and bicuspid teeth, the antrum, and gums.

(j) The *infraorbital* arises with the preceding, traverses the canal, supplying the orbital muscular branches and an anterior dental, and, escaping at the infraorbital foramen, supplies the lachrymal sac, sending branches also over the face. It joins branches of the facial and ophthalmic arteries.

(k) The *descending* (or superior) *palatine* enters the posterior palatine canal, and runs along the hard palate to the anterior palatine foramen,—thence through Stenson's foramen to join the naso-palatine artery. It sends branches through the accessory palatine canals to the soft palate.

(l) The *Vidian*, through its canal to the pharynx and Eustachian tube, and gives a branch to the tympanum.

(m) The *pterygo-palatine*, through its canal to the sphenoidal sinus and pharynx.

(n) The *nasal*, or *spheno-palatine*, through that foramen to the spongy bones, ethmoidal cells, and antrum. One large branch, the artery of the septum or naso-palatine, unites with the termination of the descending palatine artery.

Describe the internal carotid artery.

This is a very tortuous vessel, and at its origin is farther from the median line than the external carotid, deriving the name "internal" from its distribution. For description it is divided into four parts: The first, or cervical, extends from the bifurcation of the common carotid to

the carotid canal; the second, or petrous, is in the carotid canal; the third, or cavernous, runs in the cavernous sinus; and the fourth, or cerebral, is the terminal portion.

Cervical portion, relations: *in front*, skin and fasciæ, sterno-mastoid, digastric, and the styloid process with its muscles; external carotid artery and its occipital and posterior auricular branches; hypoglossal, glosso-pharyngeal nerves, and pharyngeal branch of vagus; *behind*, rectus capitis anticus major, sympathetic and superior laryngeal nerves; *externally*, internal jugular vein and vagus, both being in the same sheath with the artery, but having each a separate investment, the nerve being posterior to, and between, the artery and vein. Near the base of the skull the spinal accessory, glosso-pharyngeal, the vagus, and hypoglossal nerves emerge between the vein and artery. *Internally*, pharynx and tonsil, ascending pharyngeal artery, superior and external laryngeal nerves.

The *petrous portion* is at first in front of the tympanum and internal ear, and then runs forward and inward to the inner side of the foramen lacerum medium, and ascends, accompanied by the sympathetic, to the cavernous sinus.

The *cavernous portion* lies on the floor of the sinus, surrounded by the sympathetic, the sixth nerve being external.

The *cerebral portion* pierces the dura mater internal to the anterior clinoid process, lying at the inner extremity of the Sylvian fissure, between the second and third nerves.

Name and describe the branches of the internal carotid.

The first portion gives off no branches. The second sends a *tympanic* branch through a foramen in the carotid canal. The third gives off the *arteriæ receptaculi* to the pituitary gland, Gasserian ganglion, the cavernous and inferior petrosal sinuses. One of these branches is the *anterior meningeal*. It also gives off the *ophthalmic*.

The *ophthalmic artery* passes through the optic foramen, below and external to the nerve, then crosses the latter, and runs beneath the superior oblique muscle to the inner angle of the eye, and divides into the frontal and nasal. It gives off two sets of branches—viz. *orbital* and *ocular*. The orbital are the following:

(a) The *lachrymal* runs above the external rectus to the gland, sending several malar branches through the bone to the temporal fossa and cheek, a branch back through the sphenoidal fissure to join the middle meningeal, and several to the conjunctiva and upper lid to join other palpebral vessels.

(b) The *supraorbital*, through the notch, joining the temporal and facial branches.

(c) The *ethmoidal* branches, posterior and anterior, run through the ethmoidal canals to the ethmoidal cells. The former supplies also the roof of the nose; the latter runs with the nasal nerve, and divides into a meningeal and a nasal branch.

(d) The *palpebral* branches, superior and inferior, form arches on the lids between the orbicularis muscle and tarsal cartilages, the inferior sending a branch to the nasal duct. They anastomose with the orbital branch of the temporal and with the infraorbital artery.

(e) The *frontal*, at inner angle of the orbit, unites with the supra-orbital.

(f) The *nasal* crosses the tendo-oculi to lachrymal sac, and gives off the dorsalis nasi branch. It joins the angular artery.

(g) The *muscular* branches supply the muscles of the eyeball. They are superior and inferior, and belong to the ocular group. The other ocular branches are—

(h) The *arteria centralis retinae*, within the optic nerve to retina.

(i) The *ciliary* pierce the sclerotic to supply the iris, ciliary body, and choroid. They are derived from the ophthalmic directly or from some of its branches, and are divided into the anterior set, six to eight in number; the short, ten to fifteen; and the long, two in number.

The fourth portion of the internal carotid supplies the following branches:

(a) The *anterior cerebral*, along the front part of the great longitudinal fissure, and is joined, by the *anterior communicating*, with its fellow. The two vessels then, side by side, curve around the front of the corpus callosum and run back over its upper surface, breaking up into terminal branches which supply the anterior cerebral lobes, anterior locus perforatus, and the optic nerves.

(b) The *middle cerebral*, along the Sylvian fissure to the island of Reil, supplying the pia mater over the anterior and middle lobes, as well as the anterior perforated space.

(c) The *posterior communicating*, running back to join the posterior cerebral.

(d) The *anterior choroid*, to descending horn of lateral ventricle, sending branches to the choroid plexus, velum, and hippocampus major.

Describe the subclavian arteries.

Each vessel is divided into three parts, the first running to the inner margin of the scalenus anticus; the second, behind that muscle; the third, from its outer border to the lower border of the first rib, where it becomes the axillary artery. The right and left vessels differ only in their first portions, the right arising behind the sterno-clavicular joint, from the innominate; the left, from the aorta as a primary branch.

First Portion of the Right Subclavian.—Relations: *in front*, the sterno-mastoid, hyoid, and thyroid muscles; deep cervical fascia; internal jugular, vertebral, and right innominate veins; and superficially, the anterior jugular vein, some loops of the sympathetic nerve and its cardiac branches, the vagus and phrenic nerves; *behind*, the transverse process of the seventh cervical or first dorsal vertebra, longus colli, recurrent laryngeal, and sympathetic nerve and pleura; *below*, the pleura and recurrent nerve.

First Portion of the Left Subclavian.—Relations: *in front*, the left lung and pleura, left carotid artery; internal jugular, vertebral, and left innominate veins; vagus, phrenic, and cardiac nerves; and superficially, the sterno-thyroid, hyoid, and mastoid muscles; *behind*, sympathetic nerve, œsophagus, and thoracic duct, the longus colli separating it from the spine; *externally*, pleura; *internally*, trachea, œsophagus, and thoracic duct.

Second Portion of the Subclavian.—Relations: *in front*, the scalenus anticus, phrenic nerve, and the vein; *behind* and *below*, pleura.

Third Portion.—Relations: *in front*, the clavicle, subclavius, cervical fascia, suprascapular artery, external jugular, suprascapular and transverse cervical veins, supraclavicular nerves from cervical plexus, and the nerve to the subclavius; *behind*, the scalenus medius; *above*, omohyoid, brachial plexus; *below*, first rib.

Name and describe the branches of the subclavian.

They are the vertebral, thyroid axis, internal mammary, and superior intercostal. They are all derived from the first portion on the left side; on the right the superior intercostal arises from the second portion.

I. The **vertebral** enters the transverse foramen of the sixth cervical vertebra, ascends through those of the other cervical vertebræ, and, grooving the upper border of the atlas from without, backward, and inward, pierces the dura mater. It then ascends to the front of the medulla through the foramen magnum, uniting at the lower border of the pons with its fellow to form the basilar. The thoracic duct crosses the left artery. It is at first behind the internal jugular and its own vein; then between the scalenus anticus and longus colli. In the foramina it is accompanied by a sympathetic plexus, it is in front of the spinal nerves, and it crosses the suboccipital nerve on the atlas.

Branches: the *cervical* branches are *muscular*, to the deep cervical region, joining the occipital and deep cervical; and the *lateral spinal*, entering the intervertebral foramina.

The *cranial* branches include—

(a) The *posterior meningeal*, to the falx cerebelli and cerebellar fossæ.

(b) The *anterior spinal*, along the front of the medulla, joins its fellow to form the upper part of the anterior median artery of the cord. This is a small vessel which runs in the anterior median fissure of the cord, beneath the pia mater, as far as the cauda equina. It is formed below by offsets entering the intervertebral foramina, and dividing into ascending and descending branches. It is thus really a series of short vessels connected together. These branches are contributed by the vertebral and ascending cervical, intercostal, lumbar, ilio-lumbar, and lateral sacral from above downward.

(c) The *posterior spinal* descends along the posterior nerve-roots to the cauda equina. It is formed in a similar manner to the anterior, but it is bilateral.

(d) The *posterior inferior cerebellar* divides under the cerebellum into

two branches. The inner runs to the notch between the hemispheres; the outer, to their under surface and the choroid plexus of the fourth ventricle, joining the superior cerebellar.

The *basilar*, formed by the two vertebrals, runs to the upper border of the pons, and divides into the two posterior cerebrals. It gives off the following branches:

(a) Several *transverse arteries* on each side. One, the auditory, enters the internal meatus; another, the *anterior inferior cerebellar*, to the anterior border of the cerebellum.

(b) The *superior cerebellar*, to upper surface, joining the inferior cerebellar.

(c) The *posterior cerebrals*, to under surface of the posterior lobes, receiving the *posterior communicating*. They give off the *posterior choroid* branches and supply the posterior perforated space.

The circle of Willis is an important anastomosis, formed in front by the anterior cerebrals, which are connected by the short anterior communicating artery, which is only two lines in length, and behind by the two posterior cerebrals, united to the internal carotid, close to the origin of the anterior cerebrals, by the posterior communicating branches. Included in this circle are the lamina cinerea, the tuber cinereum, the infundibulum, the corpora albicantia, the optic commissure, and the posterior perforated space.

II. The *thyroid axis*, from the fore part of the subclavian, divides close to its origin into the inferior thyroid, suprascapular, and transverse cervical.

(1) The *inferior thyroid*, to the gland behind the sympathetic and the common carotid, joins its fellow and the superior thyroid, giving off the following branches:

(a) Laryngeal, runs with recurrent nerve; (b) tracheal, joining bronchial arteries; (c) œsophageal; (d) muscular, to the inferior constrictor and hyoid depressor muscles and the scaleni; and (e) the ascending cervical.

The last-named runs between the scalenus anticus and the rectus anticus major, joining the vertebral and giving other branches which, with the lateral spinal of the vertebral, help form the anterior median artery of the cord.

(2) The *suprascapular* runs at first between the scalenus anticus and the sterno-mastoid, crosses the subclavian, and runs behind the clavicle to cross the transverse ligament of the scapula. In the supraspinous fossa it runs beneath the muscle, which it supplies, and terminates in the infraspinatus where it joins the dorsal and posterior scapular artery. A supra-acromial branch joins the acromio-thoracic artery; a branch supplies the shoulder-joint, and another the subscapular fossa.

(3) The *transverse cervical* divides at the anterior border of the trapezius into a *superficial cervical* branch, ascending beneath and supplying that muscle, and a *posterior scapular* running along the posterior border of the scapula to join the subscapular artery at its inferior angle.

III. The **internal mammary** descends from the under surface of the subclavian along the hinder surface of the costal cartilages, $\frac{1}{2}$ inch from the sternum, as far as the sixth interspace, and divides into the *musculo-phrenic* and *superior epigastric*. At first, behind the subclavian vein and the phrenic nerve, it lies against the pleura, but separated from it below by the *triangularis sterni*.

Branches: (a) *Comes nervi phrenici*, to the diaphragm along with the nerve, joins the phrenic arteries.

(b) *Mediastinal*, to the glands in the anterior mediastinum, thymus gland, and areolar tissue.

(c) *Pericardiac*, to upper part of the pericardium.

(d) *Sternal*, to the bone and *triangularis sterni*.

The four preceding, with the bronchial and intercostal arteries, contribute branches which unite to form the subpleural mediastinal plexus.

(e) *Anterior intercostal*, to the six upper spaces, joining the aortic branches.

(f) *Anterior* or *perforating* branches, through the spaces, and supplying the mammary gland and pectoral muscles.

(g) *Musculo-phrenic* pierces diaphragm at eighth rib and runs behind the cartilages to the last interspace, giving off the lower intercostal branches.

(h) *Superior epigastric* pierces sheath of the rectus, sends a branch to join its fellow, and finally joins the deep epigastric.

IV. The **superior intercostal** crosses in front of the neck of the first rib, and supplies the first and part of the second interspace.

Its *profunda cervicis* branch passes backward between the seventh cervical vertebra and the first rib, ascends under the complexus to the axis, and joins the *princeps cervicis* and vertebral arteries.

Describe the axillary artery.

The continuation of the subclavian is called the axillary artery. It extends from the lower border of the first rib to the lower border of the *teres major* tendon, and there becomes the brachial. It is described in three parts: the first, above the *pectoralis minor*; the second, behind it; and the third, below it.

First Portion.—Relations: *in front*, *pectoralis major*, *subclavius*, *costo-coracoid* membrane, *acromio-thoracic* and *cephalic* veins, *external anterior thoracic* nerve; *behind*, *first intercostal* muscle, *first* digitation of *serratus magnus*, *posterior thoracic* nerve; *externally*, *brachial plexus*; *internally*, *axillary* vein.

Second Part.—*In front*, *pectoralis major* and *minor*; *behind*, *subscapularis*; *internally*, vein.

The posterior cord of the plexus is behind it, the outer cord outside, and the inner cord to its inner side. The plexus thus surrounds the second portion of the artery.

Third Part.—*In front*, integument, *fasciæ*, *pectoralis major*, *median* nerve, its inner head, *internal cutaneous* nerve; *behind*, *subscapularis*,

tendons of latissimus dorsi and teres major, musculo-spiral and circumflex nerves; *externally*, coraco-brachialis, musculo-cutaneous, and median nerves; *internally*, the vein, brachial venæ comites, ulnar and lesser internal cutaneous nerves.

Branches: first part, superior and acromial thoracic; second part, long and alar thoracic; third part, subscapular and circumflex, posterior and anterior.

(a) The *superior thoracic*, between pectorales to side of chest, joins the intercostals.

(b) The *acromial thoracic* divides into an acromial branch, to join the suprascapular; a thoracic, uniting with other thoracic branches; and a descending, along with the cephalic vein, between pectoralis and deltoid.

(c) The *long thoracic*, to pectorales, serratus, and mamma, joining the intercostal arteries.

(d) The *alar thoracic*, to axillary glands.

(e) The *subscapular*, along the lower border of the subscapularis, joining branches with the intercostal and posterior scapular arteries. Its *dorsalis scapulae* branch passes through a triangle formed by the two teretes and the triceps, and divides into three sets—viz. dorsal, to the infraspinous fossa; ventral, to the subscapular fossa; and descending, to run between the teretes muscles.

(f) The *circumflex* arteries encircle the neck of the humerus. The *posterior*, with the nerve and veins, passes through the quadrangular space formed by the triceps, teretes, and humerus, and ends in the deltoid and shoulder-joint. It joins the superior profunda and acromial arteries. The *anterior*, beneath the biceps and coraco-brachialis, to end under the deltoid, sends a twig to the shoulder-joint along the bicipital groove.

Describe the brachial artery.

The brachial artery extends from the end of the axillary, at the lower border of teres major, to $\frac{1}{2}$ an inch below the elbow-joint, dividing into the radial and ulnar arteries. Relations: *in front*, integument and fascia, bicipital fascia, median basilic vein, and median nerve; *behind*, triceps, coraco-brachialis, brachialis anticus, musculo-spiral nerve, and superior profunda artery; *externally*, coraco-brachialis, biceps, median nerve; *internally*, basilic vein, venæ comites, internal cutaneous, ulnar, and median nerves.

Name and describe the branches of the brachial artery.

(a) The *superior profunda*, along the musculo-spiral groove, sends a branch to the shoulder-joint, anastomosing with the circumflex; the posterior articular artery, to the back of the elbow, joining the interosseous recurrent; branches to muscles; and, finally, the continuation of the vessel joins the radial recurrent in front of the outer condyle.

(b) The *nutrient artery*, to the humerus, enters the foramen.

(c) The *inferior profunda*, on the inner head of the triceps, accompanies the ulnar nerve, and divides into a branch to the front of the inner

condyle and another to the back of it. The former joins the anterior, and the latter the posterior ulnar recurrent artery.

(d) The *muscular* branches, to the coraco-brachialis, biceps, and brachialis anticus.

(e) The *anastomotica magna* runs on the brachialis anticus inward to form an arch with the posterior articular under the triceps. This artery forms anastomoses with all the vessels around elbow, excepting only the radial recurrent.

The brachial divides, about $\frac{1}{2}$ an inch below the elbow, into the radial and ulnar arteries.

Describe the radial artery.

It runs from the bifurcation of the brachial along the radial side of the forearm to the wrist, and winds back to its posterior surface. It then enters the palm through the first dorsal interosseous, and runs across the hand to form the deep palmar arch by joining the deep branch of the ulnar.

In the forearm, relations: *in front*, integument, fascia, and supinator longus; *behind*, from above downward, it lies on the tendon of the biceps, supinator brevis, pronator teres, flexor sublimis, flexor longus pollicis, pronator quadratus, and radius; *on ulnar side*, flexor carpi radialis and pronator teres; *on radial side*, supinator longus and radial nerve, its middle third.

In the wrist it lies on the external lateral ligament, scaphoid, and trapezium, and is covered by the extensors of the thumb, cutaneous veins, and by filaments of the radial and musculo-cutaneous nerves.

In the hand it lies on the metacarpal bones and interossei, covered by the flexor tendons, opponens, flexor brevis minimi digiti, and flexor brevis pollicis.

Name and describe the branches of the radial artery.

In the forearm: (a) The *radial recurrent*, between the supinator longus and the brachialis anticus, joins superior profunda.

(b) The *muscular*, to the radial side of the forearm.

(c) The *superficialis volæ*, through the muscles of the thumb; sometimes it ends in them, or it may be very large, or may complete the superficial arch.

(d) The *anterior carpal* runs inward to join in the anterior carpal arch with the ulnar branch.

In the wrist: (e) The *posterior carpal* joins the ulnar branch, forming the posterior carpal arch. This arch gives off the third and fourth dorsal interosseous branches.

(f) The *metacarpal* runs on the second dorsal interosseous muscle, and joins, by branches, the first sup. perforating and palmar digital arteries. It divides into two dorsal digital branches for the index and middle fingers, their adjacent sides, and it also gives off an inferior perforating artery to the corresponding palmar digital.

(g) Two *dorsales pollicis*, along the sides of the thumb.

(h) The *dorsalis indicis*, along the radial side of the index finger.

In the hand: (i) The *princeps pollicis*, along the ulnar side of the first metacarpal to the first phalanx, where it divides into two branches for the palmar sides of the phalanges.

(j) The *radialis indicis*, along radial border, palmar surface of index finger.

(k) The superior perforating arteries pass back between the heads of the last three dorsal interossei muscles to join the dorsal interosseous arteries.

(l) Three or four palmar interosseous branches join the palmar digital arteries at the finger-clefts.

Describe the ulnar artery.

The ulnar artery runs along the inner side of the forearm to the wrist, crosses the annular ligament and the palm of the hand, and joins the superficialis volæ to form the superficial arch.

In the forearm, relations: *in front*, integument, fascia, and superficial flexor muscles, median nerve, and palmar cutaneous branch of the ulnar nerve; *behind*, brachialis anticus, flexor profundus digitorum; *ulnar side*, flexor carpi ulnaris, median nerve above and ulnar nerve below; *radial side*, flexor sublimis.

At the wrist the nerve is internal to the artery, and the pisiform bone is internal to the nerve.

In the hand, as the superficial arch, it is covered by the skin, palmaris brevis, and palmar fascia. It rests on the annular ligament, superficial flexor tendons, and divisions of the median and ulnar nerves.

Name and describe the branches of the ulnar artery.

Forearm: (a) The *anterior ulnar recurrent*, to front of inner condyle, joins the anastomotica magna and inferior profunda.

(b) The *posterior ulnar recurrent*, beneath flexor sublimis to back of inner condyle, and between the heads of the flexor carpi ulnaris along the ulnar nerve; joins the posterior interosseous recurrent and inferior profunda arteries.

(c) The *interosseous*, to the upper border of the interosseous membrane, where it divides into the anterior and posterior interosseous arteries. The *first* runs on the front of the membrane, which it pierces above the pronator quadratus, to join the posterior branch and the posterior carpal arch. It supplies the *median artery* to the nerve, muscular branches, and the nutrient vessels of the radius and ulna. A branch joins the anterior carpal arch. The *posterior interosseous* descends along the back of the forearm, between the superficial and deep muscles, and joins the anterior. It gives off the *interosseous recurrent*, which ascends beneath the anconeus to join, behind the olecranon, in the anastomosis at the elbow-joint.

(d) The *muscular*, to the ulnar side of the forearm.

(e) The *anterior* and *posterior carpal* join similar branches of the radial to form the carpal arches, the posterior giving a metacarpal branch to the little finger, ulnar side.

(f) The *deep branch* joins the radial to form the deep palmar arch.

(g) The *digital*, four, to little, ring, middle, and ulnar side of index finger.

THE THORACIC AORTA AND ITS BRANCHES.

Describe the thoracic aorta.

The thoracic aorta descends from the lower border of the fifth to the front of the last dorsal vertebra. Relations: *in front*, root of left lung, pericardium, and œsophagus; *behind*, azygos minor vein and spinal column; *to left*, left lung and pleura, and, below, œsophagus; *to right*, œsophagus above, vena azygos major, thoracic duct.

Name and describe the branches of the thoracic aorta.

(a) The *pericardiac*, to the pericardium.

(b) The *bronchial*, to the bronchial glands and the œsophagus; they are also the nutrient vessels of the lung. The right one arises from the front of the aorta together with the left upper. The left consist of an upper and lower branch. The bronchial vessels run along back of the corresponding bronchus and divide with the bronchi, entering the substance of the lung. The right sometimes arises from the first aortic intercostal.

(c) Four or five *œsophageal*, joining the inferior thyroid above, the gastric and phrenic below.

(d) The *posterior mediastinal*, to glands and areolar tissue.

(e) The *intercostal*. These are nine or ten, the superior intercostal from the subclavian supplying the upper space or two. They run under the pleura and sympathetic, the right behind the œsophagus and thoracic duct. They cross obliquely to the edge of the rib above, running at first on the external, and then between the two sets of intercostal muscles.

Each divides into two branches running along the contiguous borders of the two ribs, and each uniting anteriorly with the corresponding branch of the anterior intercostals from the internal mammary. The first joins the superior intercostal; the last two, the lumbar and epigastric. In general, each lies between the vein above and the nerve below.

A posterior branch runs from each, and divides into a spinal branch to the cord and a muscular branch.

THE ABDOMINAL AORTA AND ITS BRANCHES.

Describe the abdominal aorta.

It runs from the last dorsal to the left side of the middle of the body of the fourth lumbar vertebra, there dividing into the two common iliacs. Relations: *in front*, lesser omentum, stomach, pancreas, transverse duodenum, left renal and splenic veins, peritoneum forming mesentery,

aortic and solar plexuses; *behind*, receptaculum chyli, thoracic duct, left lumbar veins, and spine; *to the right*, crus of diaphragm, vena cava, great azygos vein, thoracic duct, right semilunar ganglion, splanchnic nerve; *to left*, splanchnic nerve, left semilunar ganglion.

Name and describe its branches.

The *parietal* are—I. The **phrenic**, a right and a left. Their origin is inconstant, from the aorta separately or in common, or from one of its branches. They run across the crura to the under surface of the diaphragm, and each passes outward, behind the vena cava on the right, the œsophagus on the left side, and divides into an *internal* branch, joining its fellow and the other phrenics, and an *external*, joining the intercostal arteries. Each supplies suprarenal capsular branches, the right sending branches to the liver and vena cava; the left, to the spleen and œsophagus.

II. The **lumbar**, five on each side, pass behind the psoas and sympathetic, and divide into a *dorsal* branch to the back, also sending twigs to the spinal anterior median artery (see *Anterior Spinal Branch of Vertebral*), and an *abdominal* branch running between the abdominal muscles, joining branches of epigastric, intercostal, ilio-lumbar, and internal mammary.

III. The **middle sacral**, along the middle of the front of the sacrum to the coccyx, joining the lateral sacral and entering Luschka's gland.

The *visceral* branches: IV. The **œliac axis**, $\frac{1}{2}$ inch long, divides into the *gastric*, *hepatic*, and *splenic*. It is covered by the lesser omentum, rests below on the pancreas; on each side is a semilunar ganglion, and on the right the lobus Spigelii, on the left the stomach.

(a) The *gastric* artery runs to the cardiac orifice, thence to the right, along lesser curvature, in the lesser omentum as far as the pylorus. It supplies both surfaces of the stomach and the œsophagus, anastomosing with the splenic, hepatic, and œsophageal arteries.

(b) The *hepatic* artery passes below the foramen of Winslow to the pylorus, then ascends in the lesser omentum, anterior to that foramen, to the transverse fissure of the liver, and divides into a *right* and a *left* branch. Its *pyloric* branch passes along the lesser curvature to meet the gastric. Its *cystic* branch from the right division ascends on neck of the gall-bladder and supplies it by two branches. The other branch of the hepatic, the *gastro-duodenalis*, divides behind the lower part of the duodenum into a *superior pancreatico-duodenal* branch, descending between the pancreas and duodenum to join the inferior artery of the same name; and the *gastro-epiploica dextra*, passing in the omentum toward the left, along the great curvature, to meet the sinistra.

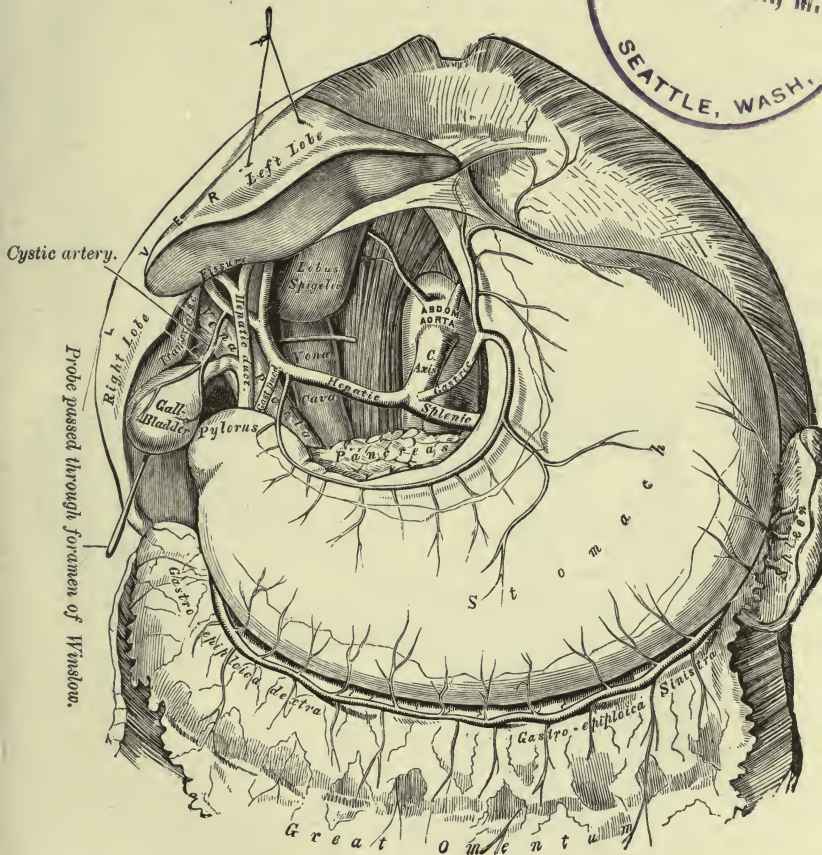
(c) The *splenic* runs tortuously to the left, along the upper border of the pancreas, and divides near the spleen into branches which enter at the hilus, some passing to the stomach.

Branches: *Pancreatic*, numerous, small; and one larger, the *pancreatica magna*, accompanies the duct of Wirsung.

PLATE XVII.

FIG. 1.—To face page 224.

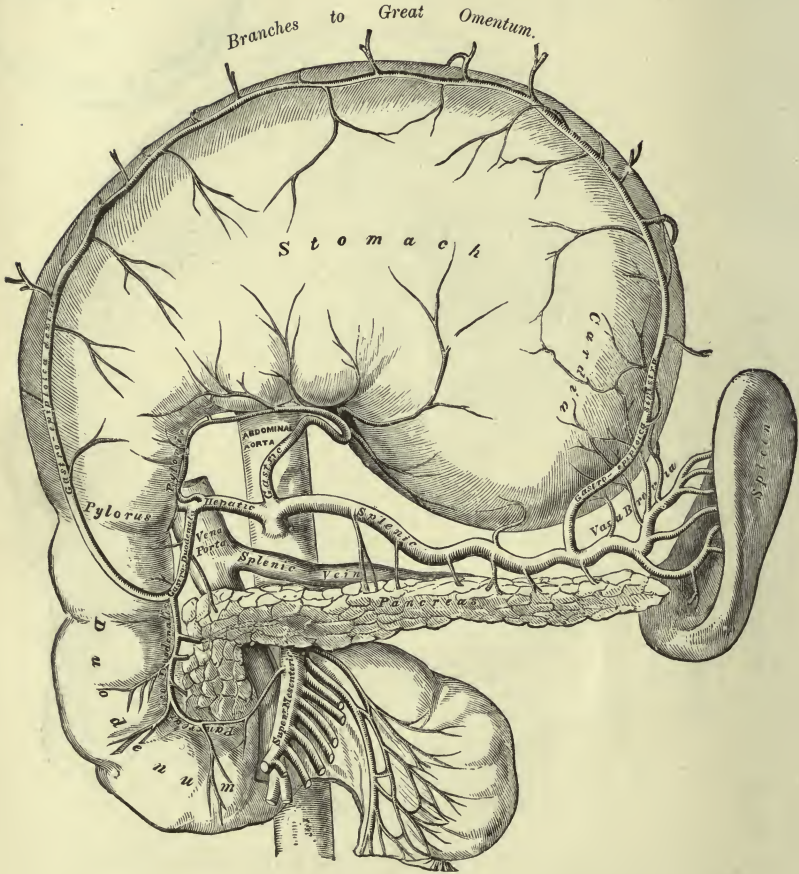
PRIVATE LIBRARY
O. V. LAWSON, M.D.
SEATTLE, WASH.



The Cœliac Axis and its Branches, the liver having been raised and the lesser omentum removed.

PLATE XVIII.

FIG. 2.—To face page 224.



The Cœliac Axis and its Branches, the stomach having been raised and the transverse mesocolon removed.

Five to seven *vasa brevia*, in the gastro-splenic omentum, to great end of stomach, joining the gastric and gastro-epiploic vessels.

The *gastro-epiploica sinistra* runs to the right, along the great curvature, to join the dextra.

V. The **superior mesenteric** supplies the small intestine except the first part of the duodenum, as well as the cæcum, and ascending and transverse colon. Emerging from between the transverse duodenum and pancreas, it crosses the former, and descends in the mesentery to the right iliac fossa with its vein and a plexus of nerves. It ends by anastomosing with its own ileo-colic branch.

Branches: (a) The *inferior pancreatico-duodenal*, joining the superior from the hepatic artery.

(b) Twelve to fifteen *vasa intestini tenuis* to jejunum and ileum, running parallel within the mesentery, each vessel bifurcating. These divisions, uniting on each side with their fellows, form a series of arches from which are formed, similarly, secondary arches until there are four or five tiers of such arches, which progressively diminish in size as they near the gut. The terminal arches send numerous straight vessels around the gut.

(c) The *ileo-colic* divides near the right iliac fossa into two branches. The inferior joins the termination of the superior mesenteric; the upper joins the colica dextra. It supplies the ileum, cæcum, appendix, and ascending colon.

(d) The *colica dextra*, to the middle of the ascending colon, divides into a lower branch joining the ileo-colic, and an upper, which joins the colica media. These branches form arches from which is supplied the colon.

(e) The *colica media*, to transverse colon, divides into a right branch joining the dextra; a left, the sinistra.

VI. The **inferior mesenteric** supplies the descending colon and its continuation. Arising from the left side of the aorta an inch or two above the bifurcation, it passes to the left iliac fossa, ending in the pelvis as the superior hemorrhoidal. It gives off—

(a) The *colica sinistra*, to the descending colon, dividing into an upper branch joining the media; a lower, the sigmoid artery.

(b) The *sigmoid*, to the flexure, joins the colica sinistra above and the superior hemorrhoidal below.

(c) The *superior hemorrhoidal*, in the meso-rectum, crosses the left common iliac artery and vein. It divides into two branches, one on each side of rectum, which finally join the middle and inferior hemorrhoidal arteries.

VII. The **suprarenals**, to the under surface of the suprarenal capsules, join branches of phrenic and renal arteries.

VIII. The **renal**, to the hilus, enters by four or five branches into which each vessel divides close to the kidney. They lie between the veins in front and the ureters behind. Branches pass to the suprarenal bodies and ureter.

IX. The **spermatic**, the **ovarian** in the female, to the testicles or ovaries respectively. Passing behind the peritoneum, they cross the ureter and psoas, and in front of the vena cava on the right, each crossing also the external iliac vessels. In the male the vessel then runs through the inguinal canal to the testis, joining the artery of the vas deferens. In the female it runs in the broad ligament to the ovary, and sends branches to the broad ligament, the tubes, and uterus.

THE ILIAC ARTERIES AND THEIR BRANCHES.

Describe the common iliac arteries.

Each runs downward and outward from the division of the aorta to the lumbo-sacral joint, and divides into the external and internal iliacs.

Relations: each has *in front* the peritoneum, small intestine, ureter, and sympathetic nerve; the left is crossed by the superior hemorrhoidal artery; *behind* and to the *inner* side of each is its vein, the right having both its own and the left vein between it and the last lumbar vertebra, and external to each is the psoas magnus. The right has also the vena cava posteriorly.

Branches: small twigs to the psoas, ureters, and lymphatic glands.

Describe the internal iliac artery.

It descends to the upper part of the great sacro-sciatic foramen, and divides into an anterior and a posterior trunk.

Relations: *in front*, ureter and peritoneum; *behind*, sacrum, lumbo-sacral cord, companion vein, and the external iliac vein at its upper part; *internally*, the vein; *externally*, psoas muscle.

Name and describe its branches.

The artery divides into two main trunks, the anterior and posterior. The posterior gives off the following branches:

(a) The **ilio-lumbar**, dividing behind the psoas into an iliac and a lumbar branch. The former supplies the iliacus and a nutrient branch to the bone. The latter supplies the psoas and quadratus, as well as the cord, by a *spinal* branch entering the last intervertebral foramen. It joins the last lumbar artery.

(b) The **lateral sacral**, upper and lower, unite with the middle sacral artery, and also give branches which enter the foramina supplying the contents of the sacral canal, and, emerging at the posterior foramina to supply the muscles and skin over the sacrum, join the sciatic and gluteal branches.

(c) The **gluteal**, through the great sciatic foramen, divides into a superficial and a deep branch. In the pelvis it gives off muscular branches and a nutrient artery to the ilium.

The *superficial* branch breaks up into twigs which ramify in the gluteus maximus. The *deep* subdivides into two others. Of these, one runs along the upper border of the gluteus minimus to the anterior su-

perior spine, joining the circumflex iliac; and the lower branch passes toward the great trochanter, giving a twig to the hip-joint and joining the external circumflex artery.

The anterior trunk of the internal iliac supplies the following:

(d) The **superior vesical** represents the pervious part of the foetal hypogastric artery. It runs to the apex and body of the bladder and to the ureter, joins its fellow, and gives off the *artery* of the *vas deferens*, which accompanies that structure to the testis. It also generally gives off the (e) middle vesical to the base of the bladder.

(f) The **inferior vesical—vaginal** in the female—joins its fellow. It supplies the bladder, prostate gland, and seminal vesicles; in the female, vagina and rectum.

(g) The **middle hemorrhoidal** arises with the preceding, and runs to the rectum to join other hemorrhoidal arteries.

(h) The **uterine** ascends in the broad ligament from the cervix along the side of the uterus and joins the ovarian artery.

(i) The **obturator** runs forward below the pelvic brim, between the peritoneum and pelvic fascia below the nerve, then through the upper part of the obturator foramen, dividing beneath the obturator externus into an *external* and an *internal* branch. Skirting the edges of the foramen, they join below with each other and the internal circumflex. The external also joins the sciatic, and sends a branch along the *ligamentum teres*, through the cotyloid notch, to the joint.

In the pelvis an *iliac* branch to the bone and *iliacus*, a *pubic* branch to the back of the pubes, joining its fellow and the pubic of the epigastric, and a *vesical* branch, are given off from the main trunk of the obturator artery.

The termination of the anterior trunk of the internal iliac then divides into two branches, the sciatic and internal pudic arteries.

(j) The **internal pudic** escapes from the pelvis through the great sciatic foramen, crosses the ischial spine, and re-enters the pelvis by the lesser foramen, then runs along the outer wall of the ischio-rectal fossa an inch and a half above the tuberosity, and upon the rami of the ischium and pubes, to the subpubic arch, where it divides into the artery of the corpus cavernosum and the dorsal artery of the penis.

This vessel is at first in front of the pyriformis, the sacral plexus intervening, and external to the rectum. On the ischial spine it lies beneath the gluteus maximus, the pudic nerve internally. In the ischio-rectal fossa it lies on the obturator internus, ensheathed by the obturator fascia, then between the layers of the perineal fascia.

Branches: (a) two or three *inferior hemorrhoidal*, to skin and muscles around anus.

(b) The *superficial perineal* runs over or under the *tranversus perinei* to the back of the scrotum, sending branches to the skin and muscles of the perineum.

(c) The *transverse perineal*, to the parts between the anus and bulb, joins its fellow.

(d) The *artery of the bulb* runs in the constrictor urethræ, pierces the bulb, and sends a branch to Cowper's gland.

(e) The *artery of the corpus cavernosum* runs forward in the centre of that body after piercing the crus penis.

(f) The *dorsal artery of the penis* runs between symphysis and crus penis, pierces the suspensory ligament, and runs along the dorsum of the penis to glans and prepuce. Here it is superficial, and lies between the median vein and the corresponding nerve.

In the female the pudic artery is smaller, but has analogous branches. The superficial perineal artery runs to the labia; that of the bulb, to the bulbus vestibuli; that of the corpus cavernosum to the corresponding part of the clitoris; and the dorsal artery to the glans clitoridis.

(g) The *sciatic* accompanies the pudic, resting on the pyriformis muscle and the sacral plexus, escapes by the great foramen, and descends, midway between the tuber ischii and the trochanter major, with the sciatic nerves. It is covered by the gluteus maximus, and joins the superior perforating, obturator, and internal circumflex arteries.

The branches are—

(a) The *coccygeal*, piercing the great sciatic ligament to supply the gluteus maximus and the skin over the sacrum and coccyx.

(b) The *muscular*, to the gluteus maximus, joining the other gluteal arteries within the substance of the muscle.

(c) The *comes nervi ischiadici*, in the substance of the great sciatic nerve.

(d) The *anastomotic*, to the muscles on the back of the hip, anastomosing with the superior perforating, internal circumflex, and gluteal arteries.

(e) The *articular* branches, to the capsule of the hip-joint, from the above.

Describe the external iliac artery.

It extends from the division of the common iliac to the mid-point between the crest of the pubes and the anterior superior spine of the ilium, behind Poupart's ligament.

Relations: *in front*, peritoneum, subperitoneal fascia, sigmoid flexure on left, ileum on right side, lymphatic vessels and glands, spermatic or ovarian vessels, deep circumflex iliac vein, genital branch of genito-crural nerve and, at times, ureter; *behind*, psoas muscle and iliac fascia and its vein; *internally*, its vein and the vas deferens; *externally*, psoas and iliac fascia.

Name and describe its branches.

(a) The *deep epigastric* descends to Poupart's ligament, then ascends, internal to the deep ring, between the transversalis fascia and the peritoneum. It then pierces the fascia and enters the sheath of the rectus, ascending on the posterior surface of the muscle, and dividing

into branches which join the superior epigastric. The vas deferens in the male, round ligament in the female, cross the vessel on its outer side at the internal ring.

Branches: the *cremasteric*, to cord; the *pubic*, to back of pubes, joining pubic of obturator; and the *muscular*.

(b) The **deep circumflex iliac** passes to the anterior superior spine in a sheath of the transversalis and iliac fascia, thence along inner margin of the crest, finally joining branches of the gluteal and of the ilio-lumbar arteries between the internal oblique and the transversalis. An ascending branch, between the same two muscles, joins the deep epigastric.

ARTERIES OF THE LOWER EXTREMITY AND THEIR BRANCHES.

Describe the femoral artery.

It continues the external iliac artery down into the thigh to end at the opening in the adductor magnus at the junction of the upper three-fourths and lower one-fourth of the femur. Its upper part lies in Scarpa's triangle, bounded above by Poupart's ligament, the inner side formed by the adductor longus, the outer by the sartorius. The lower part runs in Hunter's canal, a depression between the vastus internus and the adductores magnus and longus, covered by a strong fascia passing between them.

Relations: *in front*, fascia lata, crural sheath, fascia covering Hunter's canal, sartorius, internal cutaneous and long saphenous nerves, nerve to vastus internus, and filaments of the crural branch of genito-crural nerve; *behind*, psoas magnus, pectineus, adductores brevis, longus, and magnus, femoral vein and profunda vessels, branch of the anterior crural nerve to pectineus; *outer side*, anterior crural nerve, vastus internus, and femoral vein below; *inner side*, sartorius, adductor longus, femoral vein above.

Name and describe its branches.

(a) The **superficial epigastric**, through the saphenous opening, ascends in the superficial fascia over the abdomen, joining other epigastrics.

(b) The **superficial circumflex iliac**, parallel with Poupart's ligament to crest of ilium, joins deep circumflex and gluteal.

(c) The **superior external pudic** crosses to the lower abdomen over the cord, supplying the penis and scrotum (to labium in female), and joins the internal pudic terminal branches.

(d) The **inferior external pudic** crosses the pectineus, pierces the fascia lata, and supplies the perineum and scrotum (labium in female), joining the perineal arteries.

(e) The **muscular branches** all along its course.

(f) The **anastomotica magna** arises close to the adductor opening, and divides into two branches: a deep, to the inner side of the

knee, joins the recurrent tibial and articular arteries, and a superficial which runs with the long saphenous nerve.

(g) The **profunda artery** arises from the femoral at its outer and back part, 1 to 2 inches below Poupart's ligament. It at first runs outward, but afterward behind the femoral, then beneath the adductor longus, terminating at the lower third of the thigh by piercing the adductor magnus, becoming the lowest perforating artery.

Relations: *in front*, adductor longus, femoral and profunda veins; *behind*, iliacus, pectineus, adductores magnus and brevis.

Branches: the *external circumflex* runs beneath the sartorius and rectus, and divides into—ascending branches, under the tensor vaginae to join the gluteal and deep circumflex iliac arteries; descending branches, running upon the vasti, some passing beneath to the knee, to join the articular arteries; transverse, piercing the vastus externus to the back of the femur, and joining the superior perforating.

The *internal circumflex* runs between the psoas and pectineus, and supplies the adductor and obturator muscles and an articular twig to the hip-joint, under transverse ligament. It then joins in the crucial anastomosis.

The *perforating* pierce the short and great adductor muscles to the back of the thigh, anastomosing freely with each other and with the popliteal below. The superior enters into the crucial anastomosis. The first arises above the adductor brevis, the second opposite, the third below it. The second or third gives the nutrient artery to the femur. The termination of the profunda is called the fourth perforating.

Describe the popliteal artery.

It runs from the adductor opening to the lower border of the popliteus, where it divides into the anterior and posterior tibial.

Relations: *in front*, femur, ligamentum posticum, popliteus; *behind*, semimembranosus, fascia, gastrocnemius, plantaris, and soleus, popliteal and short saphenous veins, and the internal popliteal nerve; *outer side*, external condyle, outer head of the gastrocnemius, plantaris, internal popliteal nerve above; *inner side*, inner condyle, inner head of the gastrocnemius, semimembranosus, popliteal vein, and the internal popliteal nerve below.

Name and describe its branches.

(a) **Muscular superior**, three or four, to the lower part of the hamstring muscles to join the inferior perforating; **inferior** (sural), to the upper part of the gastrocnemius, plantaris, and soleus.

(b) **Cutaneous**, to the skin of the calf.

(c) **Articular superior**, two in number, an external and an internal, wind around above the condyles to the front. The external gives a branch to the external vastus and one to the joint, and also forms an arch with the anastomotica. The internal gives a branch to the internal

vastus, joining anastomotica and inferior articular, and another to the knee-joint, and also unites with the inferior articular.

(d) The **azygos articular** pierces the posterior ligament to the joint.

(e) **Articular inferior** wind around the tibia below the joint. They are external and internal, and anastomose with the tibial recurrent, anastomotica, and other articular branches.

Describe the anterior tibial artery.

It runs from the lower border of the popliteus, between the heads of the tibialis posticus and above the interosseous membrane, to the front of the leg, then descends as far as the ankle, ending in the *dorsalis pedis*.

Relations: *in front*, integument, fasciæ, tibialis anticus, extensores proprius pollicis and longus digitorum, anterior tibial nerve; *behind*, interosseous membrane, tibia, anterior tibio-tarsal ligament; *outer side*, extensores proprius pollicis and longus digitorum, anterior tibial nerve; *inner side*, tibialis anticus, extensor proprius pollicis.

Name and describe its branches.

(a) The **recurrent tibial**, through the tibialis anticus to the knee, joins other articular arteries.

(b) The **muscular**, to the muscles and skin; very numerous.

(c) The **malleolar**, to the ankle-joint. *Internal* joins corresponding branches of the posterior tibial; *external* joins the tarsal and anterior peroneal.

Describe the dorsalis pedis.

It is the continuation of the anterior tibial, and runs from the bend of the ankle to the first interosseous space, where it divides into the *dorsalis allicis* and *plantar digital*.

Relations: *in front*, skin, fascia, inner tendon of extensor brevis digitorum; *behind*, tarsal bones and their ligaments; *tibial side*, extensor proprius; *fibular side*, extensor longus digitorum, anterior tibial nerve.

Name and describe its branches.

(a) The **tarsal**, beneath the short extensor, supplying it and the tarsus and joining metatarsal and peroneal arteries.

(b) The **metatarsal**, over the bases of the metatarsal bones, joins the tarsal and external plantar, and gives off three *dorsal interosseous arteries* which run in the outer three intermetatarsal spaces, each dividing opposite the metatarso-phalangeal joint into two *dorsal digital* branches. These arteries anastomose at back part of spaces with the posterior perforating, and at front part with the anterior perforating.

(c) The **dorsalis allicis** lies along the first intermetatarsal space, and supplies both sides of the great toe and the inner side of the second dorsally.

(*d*) The **plantar digital** passes between the heads of the first dorsal interosseous, joins with the external plantar to form the plantar arch, and after supplying inner side of great toe divides into two branches for the adjacent sides of the great and second toes.

Describe the posterior tibial artery.

It runs from the lower border of the popliteus to divide, between inner malleolus and heel, into the *external* and *internal plantar* arteries.

Relations: *in front*, tibialis posticus, flexor longus digitorum, tibia, and ankle-joint; *behind*, skin, fascia, gastrocnemius, soleus, deep transverse fascia, posterior tibial nerve. This nerve is internal in its upper part, but lower down it is external to the artery.

Name and describe the branches of the posterior tibial artery.

(*a*) The **peroneal** runs from 1 inch below the popliteus to the lower third of the leg, and divides into the *anterior* and *posterior peroneal*. It is covered by the soleus and deep transverse fascia; in front of it are the tibialis posticus and interosseous membrane; external to it, the fibula; and externally, as well as behind, the flexor longus pollicis.

The peroneal gives off *muscular* branches and a *nutrient artery* to the fibula. The *anterior peroneal* passes beneath the interosseous membrane to the front of the leg, and runs to the outer ankle to join the tarsal and external malleolar. The *posterior peroneal* passes down behind the external malleolus, and terminates in branches (*external calcaneal*) which anastomose with the external malleolar.

(*b*) The **nutrient artery** for the tibia, from the posterior tibial close to its origin, is the largest nutrient artery of bone in the body.

(*c*) The **muscular branches** to the calf-muscles.

(*d*) The **communicating**, crossing back of the tibia to join the peroneal artery.

(*e*) Several **internal malleolar**, which join the inner malleolar of the anterior tibial.

Describe the plantar arteries.

They are the terminal branches of the posterior tibial. The **internal** is at first under cover of the abductor pollicis, and then between it and the flexor brevis digitorum, anastomosing at the inner border of the great toe with its digital artery.

The **external**, the larger, passes to the base of the fifth metatarsal, then to the space between the first and second metatarsals, and joins the plantar digital, from the dorsalis pedis, to form the plantar arch.

Describe the plantar arch.

It supplies the muscles, fascia, and skin of the sole of the foot, and gives off the *posterior perforating*. These pierce the three outer spaces between the heads of the dorsal interossei and join the dorsal interosseous arteries.

The *digital*, four in number, supply the three outer toes and the outer half of the second toe: the first runs to the outer side of the little toe, the others bifurcate to the adjacent sides of the fourth and fifth, fourth and third, third and second toes. At the point of bifurcation each sends a small branch to join the dorsal interosseous arteries (*anterior perforating*).

THE VEINS.

THE PULMONARY VEINS.

Describe the pulmonary veins.

These are four large trunks, two on each side, which return the blood from the lungs to the left auricle. On the right side they pass behind the right auricle and superior vena cava; on the left, in front of the descending aorta. The upper right vein receives the branch from the middle lobe.

THE SYSTEMIC VEINS.

Describe the veins of the heart.

The **great cardiac vein** ascends in the anterior interventricular groove from the apex of the heart to the left auriculo-ventricular groove; along this latter it runs to the posterior surface of the heart, to end in the coronary sinus. At its termination it is provided with a valve.

Three or four **posterior cardiac veins** ascend on the left ventricle to the sinus.

The **middle cardiac vein** ascends in the posterior interventricular groove to the sinus.

The **right (small) coronary vein** in the right auriculo-ventricular groove to the sinus.

The **coronary sinus**, 1 inch long, is placed at the back part of the auriculo-ventricular groove, on the left side, and opens into the right auricle in front of the inferior vena cava. Besides the foregoing veins, it receives the *oblique vein* of Marshall, which drains the back of the left auricle. Its opening is guarded by the Thebesian valve.

The other cardiac veins are several small vessels from the front of the right ventricle, the **anterior cardiac veins**, opening directly into the auricle, and the **venæ Thebesii**, in the muscular substance, which open by minute orifices, the foramina Thebesii, near the septum auricularum.

SUPERIOR VENA CAVA AND INNOMINATE VEINS.

Describe the superior vena cava.

This large trunk is formed by the union of the two venæ innominatæ, and returns the blood from the head and neck, the thoracic walls, and

the upper extremities. It is about 3 inches long, and descends from the junction of the first right cartilage with the sternum to its termination in the right auricle, opposite the upper border of the third right cartilage.

At first it is external to the innominate artery and internal to the right phrenic nerve, partly covered by the pleura. It then pierces the pericardium external to the ascending aorta, having descended in front of the right division of the pulmonary artery. It receives the azygos major and small pericardiac and mediastinal veins.

Describe the innominate veins.

The innominate veins, formed by the union of the subclavian and internal jugular of each side, behind the inner end of the clavicle unite to form the superior vena cava. The right vein, 1 inch long, descends vertically on the right side of the innominate artery, while the left, more than 2 inches in length, descends slightly, running to the right, behind the sterno-hyoid and thyroid muscles and upper part of sternum. The transverse aorta lies below it.

What are the tributaries of the innominate veins?

On each side the *vertebral*, *inferior thyroid*, and *internal mammary* veins. The left vein also receives the *superior intercostal* and some small *thymic*, *mediastinal*, and *pericardiac* veins and the thoracic duct, while the right is joined at its origin by the right lymphatic duct.

Describe the vertebral vein.

This vein descends with the artery through the foramina in the transverse processes of the upper six cervical vertebræ, crosses the subclavian artery, and opens into the back part of the vena innominata.

It receives branches: from the *muscles* in its course and from the *spinal canal* through the intervertebral foramina; a *small vein which accompanies the superior intercostal artery*, as well as the *anterior vertebral* and *deep cervical* veins.

The *anterior vertebral* arises from the plexus over the cervical part of the spine, and runs along with the ascending cervical artery. The *deep cervical* arises in the suboccipital triangle, runs between the complexus and semispinalis and below the transverse process of the seventh cervical vertebra to the vertebral vein. It receives branches from the deep spinal muscles, and the occipital veins empty into it.

Describe the inferior thyroid veins.

These arise by branches from the lateral lobes of the thyroid gland, and descend on the trachea beneath the sterno-thyroid muscles. They anastomose with the superior and middle thyroid veins, and receive *oesophageal*, *laryngeal*, and *tracheal* branches. The left joins the innominate on its own side, sometimes in common with the right. The

latter may empty into the junction of the two venæ innominatæ or join the right vena innominata.

Describe the internal mammary veins.

These are two on each side, and accompany the artery, receiving *corresponding branches*, finally uniting to form a single trunk which joins the corresponding innominate.

Describe the superior intercostal vein.

It drains the two or three spaces *below* the first, and enters on the right side the large azygos; on the left side it communicates with the left upper azygos and joins the innominate.

VEINS OF THE HEAD AND NECK.

Describe the facial vein.

The *facial vein* runs from the inner angle of the eye to the anterior border of the masseter muscle, then backward below the jaw, joining the anterior division of the temporo-maxillary trunk to form the common facial, which joins the internal jugular. It sends a *communicating branch* along the front of the sterno-mastoid to the anterior jugular. At its origin it is continuous with the *angular*, a vein formed by the union of the *frontal* and *supraorbital*.

The *frontal* runs from the forehead, parallel with its fellow and joined with it by cross-branches, to the inner side of the orbit, and joins the *supraorbital*, which drains the forehead, eyebrow, and upper lid, communicating with the temporal and ophthalmic veins.

The *angular* vein runs down and alongside of the nose near its root. It receives some *superior palpebral* and *nasal* veins, and communicates with the ophthalmic, becoming continuous with the facial.

The facial vein, in addition, receives the following tributaries:

Several *inferior palpebral* veins communicating with the infraorbital;

The *superior labial* vein and small *buccal* and *masseteric* twigs;

The *deep facial* from the pterygoid plexus, as well as some *parotid* veins;

The *submental*, receiving the veins from the lower lip and submaxillary gland and communicating with the anterior jugular vein;

The *submaxillary* veins from the gland, and the *inferior palatine* vein from the plexus around the tonsil and soft palate.

Describe the temporo-maxillary vein (posterior facial).

This short trunk, formed by the *temporal* and *internal maxillary* veins, runs from opposite the condyle of the lower jaw to the angle of the jaw, and divides into an anterior branch joining the facial and a posterior branch running backward to form with the posterior auricular the external jugular. This vein is imbedded in the parotid gland external to the external carotid artery.

Describe the temporal vein.

The **temporal** is formed by the union of the *superficial* with the *middle temporal* vein, and crosses over the zygoma and under the parotid to join the internal maxillary vein. It receives the *anterior auricular*, *parotid*, and *transverse facial* veins, and tributaries from a plexus around the articulation of the jaw.

The *superficial temporal* arises from a plexus at the side of the head from which proceed branches similar to those of the artery. These join to form the vein.

The *middle temporal* vein arises from a plexus in the temporal fossa, pierces the fascia near the zygoma, and joins the above. This vein receives an *orbital* branch and several *external palpebral* veins.

Describe the internal maxillary vein.

The **internal maxillary** vein arises from the pterygoid plexus and runs in company with the first part of the artery, joining the temporal vein behind the ramus of the jaw.

The pterygoid plexus corresponds to the second and third parts of the internal maxillary artery. It covers both pterygoid muscles, and receives veins corresponding to the branches of the artery—namely, several deep temporal, an alveolar, inferior dental, two middle meningeal, superior palatine, infraorbital, and sphenopalatine, and a communicating vein from the inferior ophthalmic. The blood leaves by the deep facial and the internal maxillary veins.

Describe the posterior auricular and occipital veins.

The **posterior auricular** vein descends over the mastoid process and sterno-mastoid and ends in the external jugular.

The **occipital veins**, two or three, join the deep cervical vein.

The emissary vein in the mastoid foramen connects the lateral sinus with the most external of the occipital veins.

Describe the external jugular vein.

It is formed by the union of the posterior auricular and the posterior division of the temporo-maxillary trunk. It descends obliquely across the sterno-mastoid, lying between the platysma and fascia. Above the clavicle it pierces the fascia and joins the subclavian at the outer border of the scalenus anticus; sometimes it joins the internal jugular. It receives the *posterior external jugular*, *anterior jugular*, *transverse cervical*, and *suprascapular* veins. The two latter correspond to the arteries of the same name.

The *posterior external* jugular drains the occipital and posterior cervical regions.

The *anterior jugular* descends along the front of the neck from the submaxillary region, pierces the fascia near the inner end of the clavicle, and joins the external jugular, sometimes the subclavian. This vein and its fellow are joined by a cross-branch just above the sternum, and it

receives branches of communication from the submental, external jugular, and facial.

Describe the internal jugular vein.

This vein commences at the jugular foramen just below the junction of the inferior petrosal with the lateral sinus, and descends with the internal carotid, then with the common carotid, to join at a right angle with the subclavian vein behind the clavicle, thus forming the innominate vein. It is placed external to the carotid vessels, lying in the same sheath with each in turn.

It receives the following tributaries:

The *common facial* (*vide antea*) and the *middle thyroid*.

The *superior thyroid*, which receives the *superior laryngeal* and *cricothyroid*, and sometimes joins the common facial.

The *pharyngeal veins*. These form a plexus on the outer side of the pharynx, from which several veins descend to join the internal jugular or common facial. Branches pass to join the pterygoid plexus.

The *lingual veins*, including the *ranine*, *dorsal vein of the tongue*, and the *venæ comites* of the lingual artery.

(The *inferior petrosal sinus* is regarded by some anatomists as the first tributary.)

Describe the cerebral veins.

These are divided into two sets, the superficial and the deep.

Superficial veins: the *superior*, ten to twelve on each side, consist of the anterior, middle, and posterior veins which run in the sulci, and, joining with branches from the mesial aspect of the brain, empty into the superior longitudinal sinus. The *inferior* consist of the middle cerebral vein, in the Sylvian fissure, which joins the cavernous sinus, and the great anastomotic vein, in the posterior branch of the same fissure, communicating with the middle meningeal veins and joining the superior petrosal sinus.

Deep veins: they finally converge to two trunks, the *venæ Galeni*. These run backward in the velum interpositum, the right and left, lying side by side, and unite into the *vena magna Galeni*, which joins the straight sinus. Each *vena Galeni* is formed by the union of the *choroid* vein and the *vena corporis striati*, and is joined by the *basilar* and other small veins, while the *vena magna* receives tributaries from the occipital lobes of each side and from the upper surface of the cerebellum.

Describe the cerebellar veins.

The *superior* join the straight sinus and the *vena magna* internally, and the superior petrosal and lateral sinuses externally.

The *inferior* enter the inferior petrosal, lateral, and occipital sinuses along with branches from the medulla and pons.

Describe the cranial sinuses.

(1) The **superior longitudinal sinus** is contained in the upper border of the falx cerebri, and extends from the crista galli to the torcular Herophili. Its section is triangular, and its cavity is crossed by several fibrous bands, the chordæ Willisii, and contains some Pacchionian bodies. It grooves the frontal, parietal, and occipital bones. In front a small vein in the foramen cæcum connects it with the nasal veins, and through the parietal foramen it communicates with the veins of the scalp. The superior cerebral veins open into the sinus, looking forward contrary to the direction of the blood-current. At its termination it enlarges and becomes continuous with the right (usually) or left lateral sinus. From this dilatation (the torcular Herophili) a cross-branch passes to join the straight sinus.

(2) The **inferior longitudinal sinus**, in the lower border of the falx cerebri, runs back to join the straight sinus.

(3) The **straight sinus** continues the inferior longitudinal along the line of junction of the falx with the tentorium backward, and joins the lateral sinus opposite to that in which the superior longitudinal ends. It receives the vena magna Galeni, some superior cerebellar veins, and a cross-branch from the torcular Herophili.

(4) The **lateral sinuses** run in the attached margin of the tentorium from the internal occipital protuberance to the jugular foramen, grooving, in order, the occipital, parietal, mastoid portion of the temporal, and the occipital a second time. Each sinus receives the superior petrosal sinus and emissary veins from the mastoid and posterior condylar foramina, as well as some cerebellar, diploic, and posterior cerebral veins.

(5) The **occipital sinus**, small, sometimes double, is contained in the falx cerebelli, and opens into the torcular above and the lateral sinus below by a branch on each side of the foramen magnum. It receives some cerebellar veins and branches from the posterior spinal veins.

(6) The **cavernous sinuses**, one on each side of the body of the sphenoid, run from the sphenoidal fissure to the apex of the petrous portion of the temporal, receiving the ophthalmic veins in front and joining the petrosal sinuses behind. It receives the sphenoparietal sinus, some inferior cerebral veins, and is joined with the opposite vessel by the circular sinus.

(7) The **circular sinus** consists of the anterior and posterior intercavernous sinuses, which join at each end the cavernous sinuses, thus surrounding the pituitary body.

(8) The **superior petrosal sinus** runs from the cavernous sinus, along the upper border of the petrous portion of the temporal, to end in the lateral sinus at the fossa sigmoidea. It receives the inferior cerebral, superior cerebellar, and some tympanic veins.

(9) The **inferior petrosal**, in the groove between the basilar process and petrous portion, runs from the cavernous to join the lateral sinus at

the jugular foramen, completing the internal jugular vein. (See under *Internal Jugular Vein*.) It receives the auditory and some inferior cerebellar veins.

(10) The **transverse (basilar) sinus** is a plexus in the dura mater over the basilar process. It joins the anterior spinal veins below and the two inferior petrosal sinuses laterally.

Describe the ophthalmic veins.

The **superior** passes back from the root of the nose with the ophthalmic artery through the sphenoidal fissure to the cavernous sinus. At its origin it connects with the *angular* and *supraorbital* veins, and receives the *ethmoidal*, *muscular*, and *lachrymal*, *vena centralis retinae*, *anterior*, and some of the *posterior ciliary* veins.

The **inferior** runs back, near the floor of the orbit, to open into the cavernous sinus, sometimes joining the superior. It arises by the union of some *muscular* and *posterior ciliary* veins, and is connected with the *pterygoid plexus* by a branch through the sphenomaxillary fissure.

Describe the diploic veins.

They run between the tables of the skull and open into the dural sinuses or externally. The larger consist, on each side, of a *frontal*, through an aperture in the supraorbital notch, joining the supraorbital vein; an *occipital*, to the occipital veins or torcular; and *two temporal*—the anterior, through an aperture in the great wing of the sphenoid to join a deep temporal vein, and the posterior, through a foramen in the parietal bone to the lateral sinus.

What are the emissary veins?

These small veins connect the cranial sinuses with the veins outside by means of foramina in the bones. These are the principal: one each—

(a) Through mastoid foramen, from lateral sinus to outermost occipital vein.

(b) Through posterior condylar foramen, from lateral sinus to cervical venous plexus.

(c) Through parietal foramen, from superior longitudinal to veins of scalp.

(d) Through a foramen in external occipital protuberance to occipital veins.

(e) Through foramen ovale, from cavernous to pterygoid plexus.

(f) Through foramen lacerum medium, from cavernous sinus to pharyngeal plexus.

(g) Through carotid canal, a small plexus from cavernous sinus to internal jugular.

(h) Through anterior condylar foramen, a plexus from occipital sinus to deep cervical veins.

VEINS OF THE UPPER EXTREMITY.

Describe the superficial veins.

They commence from a plexus on the dorsum of the hand mostly, but to some extent from the palm. They comprise the following :

The **ulnar**, *anterior* and *posterior*, occupy corresponding positions on the inner side of the forearm, and unite above in the common ulnar.

The **radial** vein is situated on the outer side, and the **median** ascends mesially, receives a *deep median* vein, and divides at the bend of the elbow into the median basilic and median cephalic.

The **median basilic** joins the common ulnar to form the basilic. The bicipital fascia separates it from the brachial artery.

The **median cephalic** crosses the external cutaneous nerve, and joins the radial to form the cephalic.

The **basilic** runs along the inner side of the biceps, pierces the fascia, and is continued upward into the axillary vein.

The **cephalic** runs along the outer side of the biceps, then between the pectoralis major and deltoid, piercing the costo-coracoid membrane to join the axillary vein below the clavicle.

Describe the deep veins.

The deep veins of the upper extremity are the **venæ comites**. They run one on each side of its artery from the digital to the brachial arteries. The **venæ comites** of the latter vessel, at the lower border of the subscapularis muscle, empty into the axillary vein.

The **axillary** vein runs internal to the artery, and receives veins corresponding to its branches, as well as the cephalic.

The **subclavian** vein is the continuation upward of the axillary, and runs, at a lower level than its artery, from which it is separated by the phrenic nerve and scalenus anticus, to the inner border of that muscle, to join the internal jugular, forming the innominate. It receives the *external jugular*, and occasionally the *anterior*.

VEINS OF THE TRUNK.

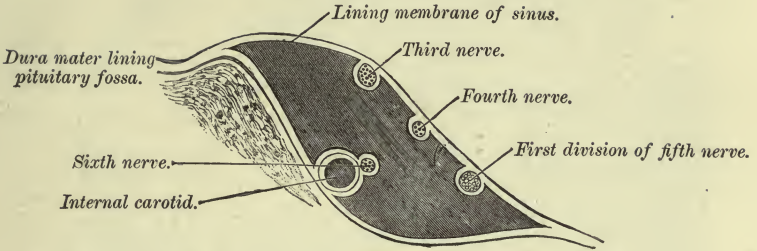
Describe the azygos veins.

The right or **vena azygos major** commences by the *right ascending lumbar vein*. Ascending to the thorax through the aortic opening and on the bodies of the dorsal vertebræ to the fourth, it arches over the root of the right lung and joins the superior vena cava above the pericardium. It receives the *right sup. intercostal vein* and the remaining *right intercostal* veins save the *first*, the *left azygos*, the *right bronchial*, and some *oesophageal*, *posterior mediastinal*, and *pericardiac* veins. Below it communicates with the common iliac by means of the ascending lumbar.

The **left lower** (small) **azygos** vein commences as the *left ascending lumbar*, and ascends through the left crus and along the spine to the

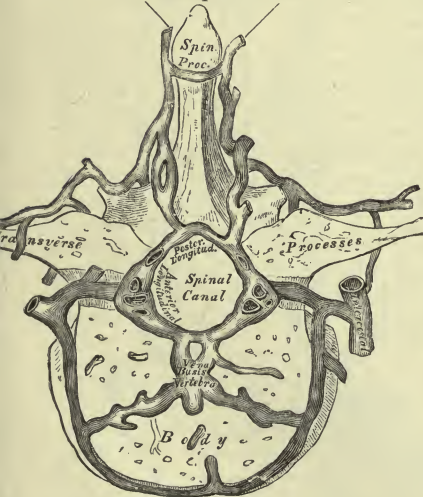
PLATE XIX.

FIG. 1.—To face page 238.



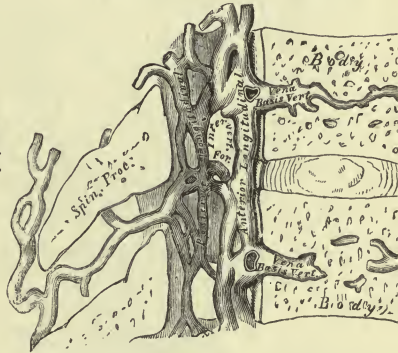
Plan showing the Relative Position of the Structures in the Right Cavernous Sinus, viewed from behind.

FIG. 2.—To face page 241.
The dorsi-spinal veins.



Transverse Section of a Dorsal Vertebra, showing the Spinal Veins.

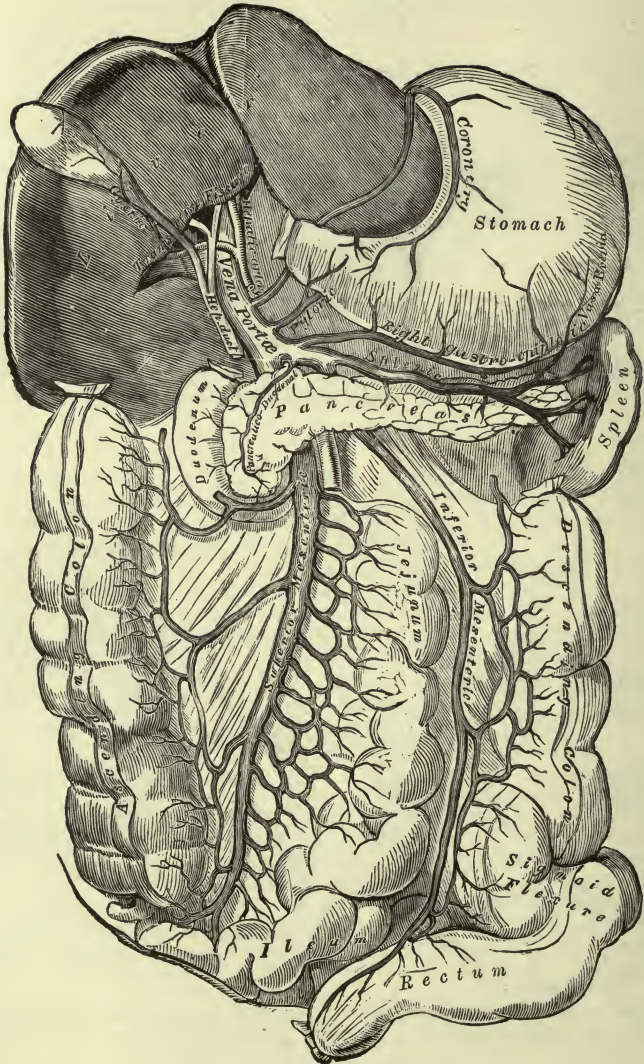
FIG. 3.—To face page 241.



Vertical Section of Two Dorsal Vertebrae showing the Spinal Veins.

PLATE XX.

FIG. 1.—To face page 244.



Portal Vein and its Branches.

ninth dorsal vertebra. It then crosses to the right, behind the aorta, and joins the vena azygos major. It receives the *lower three or four intercostals* and some *mediastinal* veins.

The **left upper azygos vein** is formed by the *fourth intercostal* to the *eighth*, inclusive, and joins the large azygos. It receives the *mediastinal* branches, *left bronchial* vein, and communicates above with the *left superior intercostal*.

The *intercostal veins* lie above the arteries. The first joins the innominate or vertebral; the rest join the azygos veins, the two or three upper uniting to form the superior intercostal. They receive branches from the vertebræ and the adjacent muscles.

The *bronchial veins* return part of the blood from the bronchial arteries. The right joins the vena azygos major; the left, the left upper azygos.

Describe the spinal venous system.

(a) The **dorsal spinal veins**, from the skin and muscles, form a plexus over the arches of the vertebræ, with a median longitudinal vessel over the spinous processes. Branches pass to the intercostal, lumbar, and vertebral veins.

(b) The **venæ basis vertebræ** run in canals in the bodies of the vertebræ, and emerge by a single or double orifice into the spinal canal to join the transverse branch which connects the anterior longitudinal veins.

(c) The **anterior longitudinal spinal veins** are two plexiform trunks, one on each side of the posterior common ligament throughout its whole length. They are dilated opposite the bodies, and joined by branches beneath the ligament. Above they communicate with the basilar sinus. Branches also pass out at the foramina on each side.

(d) The **posterior longitudinal spinal veins**, one on each side, run between the dura and the posterior wall of the spinal canal. Cross-branches join them, and they communicate with the occipital sinus and the dorsal spinal veins, and with the anterior longitudinal by branches through the same intervertebral notches.

(e) The **veins of the cord** run tortuously in the pia mater, one larger vein along the anterior fissure. They join into several trunks above, which empty into the cerebellar veins or the inferior petrosal sinus.

Describe the inferior vena cava.

This large trunk arises at the fifth lumbar, by the union of the two common iliacs. It ascends to the right of the aorta, grooves the posterior border of the liver, pierces the diaphragm, is enclosed by the serous layer of the pericardium, and empties into the right auricle. The Eustachian valve guards its orifice. It receives the following tributaries:

(a) The **lumbar**, corresponding to the arteries. Each arises by the union of an anterior branch from the abdominal wall and a posterior

from the dorsal plexus, muscles, and spinal canal. They run inward, beneath the psoas muscles, and on the left side behind the aorta, and open into the back of the inferior vena cava. Above and below, cross-branches unite these veins, forming the *ascending lumbar*, which is continued up into the azygos vein. This last also connects together the ilio-lumbar, lateral sacral, and common iliaes.

(b) The **spermatic** forms within the spermatic cord a plexus, the spermatic or pampiniform, which runs with the spermatic artery through the inguinal canal, ending in several vessels uniting into a single trunk. This vein, the spermatic, ascends on the psoas behind the peritoneum, and joins the vena cava on the right, the renal vein on the left side.

In the female its analogue, the **ovarian** vein, forms the pampiniform plexus in the broad ligament and runs with the artery.

(c) The **renal veins** run from the hilus of the kidney, in front of the arteries, to join the vena cava at a right angle. The left is longer and crosses the aorta. This vein receives some small suprarenal branches and also the spermatic and suprarenal veins.

(d) The **suprarenal** run from the suprarenal bodies to the vena cava on the right, the renal on the left side.

(e) The **inferior phrenic**, two on each side, run with their arteries. The left pair often joins the suprarenal vein.

(f) The **hepatic veins**, two or three, join the vena cava at the groove in the liver through which the latter passes. Several smaller veins empty separately. They return the blood from the liver brought by the portal vein and the hepatic artery.

Describe the common iliac veins.

Formed by the junction of the external and internal iliaes, they run from the base of the sacrum to the upper part of the fifth lumbar vertebra, and unite to form the inferior vena cava. The right is the shorter, and is at first behind, later to the right, of its artery, while the left is internal to its own artery, then behind the right iliac artery. The common iliaes receive the following tributaries:

The **ilio-lumbar**, from back of the abdomen, muscles, and spinal canal, runs beneath the psoas to the lower part of the common iliac. It communicates with branches of the lumbar above, lateral sacral below.

The two **middle sacral**, one on each side of the artery, anastomose with the lateral sacral and hemorrhoidal veins, and unite into a single vessel which joins the left common iliac vein.

VEINS OF LOWER EXTREMITY.

Describe the superficial veins.

On the dorsum of the foot is a plexus which receives the digital veins, and forms an arch from which emerge the internal or long and the external or short saphenous veins.

The **long saphenous**, from the inner part of the plexus, runs in

front of the inner malleolus, along with the long saphenous nerve, behind the inner border of the tibia and condyle of the femur; thence up along the antero-internal part of the thigh to join the femoral vein at the saphenous opening. It communicates with the deep plantar, both tibial, and the femoral veins, and receives superficial plantar and cutaneous branches, and the *superficial circumflex iliac*, *epigastric*, and *external pudic* veins.

The **short saphenous** vein ascends behind the outer malleolus, and external to the tendo Achillis, with the external saphenous nerve, and pierces the deep fascia in the popliteal space to join the popliteal vein. It receives branches from the heel and back of the leg and from the deep veins and the long saphenous.

Describe the deep veins.

The deep veins are the *venæ comites* of the arteries. The **posterior tibial veins** receive the **peroneal**, and join the **anterior tibial** to form the **popliteal**. This vessel then ascends, crossing superficial to the artery, from the inner to the outer side, and becomes the femoral at the adductor opening. It receives the *external saphenous* and veins corresponding to the arterial branches.

The **femoral vein** accompanies the artery, and becomes the external iliac at Poupart's ligament. It is at first outside, then behind, and at its termination internal to, the artery. It receives, in its lower part, veins corresponding to the branches of the superficial femoral artery; the *long saphenous*, and the *profunda* vein. The latter is formed by the union of the *venæ comites* of the offsets of the *profunda* artery.

The **external iliac** runs to join the internal iliac near the lumbosacral articulation, being at first internal to, later behind, the artery. It receives the *deep circumflex iliac*, the *deep epigastric*, and a *pubic* vein.

VEINS OF THE PELVIS.

Describe the internal iliac vein.

It accompanies the artery, lying behind and to its inner side, to join the external at the base of the sacrum, forming the common iliac. Its tributaries correspond to the branches of the artery in a general way. Thus, it receives the following:

The *gluteal*, *sciatic*, and the *obturator*; the *lateral sacral*, which form a plexus on the sacrum and open into the internal iliac at several points; the *internal pudic*, which receives branches corresponding to the *perineal* branches of the artery and commences as the *vein of the corpus cavernosum*.

The *dorsal vein of the penis*, at first two veins, these uniting into one, which runs back between the two dorsal arteries in a median groove, passes below the subpubic ligament, and divides into two veins, joining each side of the prostatic plexus, and each division communicating with the obturator and pudic veins of each side.

The visceral veins are larger than the arteries, and communicate freely with one another, so as to form a series of plexuses, as follows:

The *prostatic plexus*, continuous above with the vesical plexus, is formed by the dorsal vein of the penis and branches from the prostate and its vicinity. It communicates with the radicles of the pudic vein. This plexus has its analogue in the female around the urethra, which receives the *dorsal vein of the clitoris*.

The *vesical plexus* extends over the body and base of the bladder, and communicates with the prostatic and hemorrhoidal plexuses; vaginal in female.

The *hemorrhoidal plexus*, in the wall of the lower rectum, beneath the mucous coat, sends out *superior*, *middle*, and *inferior hemorrhoidal* veins, which follow the corresponding arteries, and communicates freely with the other plexuses.

The *vaginal plexus* surrounds the lower part of the vagina, and communicates with the vesical and hemorrhoidal plexuses, and the *uterine plexus* empties into the ovarian vein.

THE PORTAL SYSTEM.

Describe the portal system of veins.

The portal vein, 3 inches long, arises from the union of the splenic and superior mesenteric veins behind the head of the pancreas, and ascends behind the duodenum and between the layers of the lesser omentum. Here it runs behind hepatic artery and bile-duct. Accompanied by the hepatic plexus of nerves and lymphatics, all enclosed in Glisson's capsule, it then enters the transverse fissure, forming near the right end the "sinus," and divides into: a *right* branch, to the right lobe, which distributes branches entering the hepatic substance with hepatic arterial branches and ducts; and a *left* branch distributed like the right. To it are joined the obliterated umbilical vein and the ductus venosus.

The *vena portæ* receives the following tributaries:

The **superior mesenteric**, corresponding to the artery of the same name, receiving also the *right gastro-epiploic vein*, besides branches accompanying those of the artery. It joins the splenic vein.

The **splenic** arises by five or six vessels uniting after leaving the hilus, and runs to the right below the artery, joining the above at a right angle to form the *vena portæ*. It receives the *vasa brevia*, *left gastro-epiploic*, and *pancreatic branches*, and sometimes the inferior mesenteric vein.

The **inferior mesenteric** vein corresponds in branches and course to the artery, and empties into the angle of junction of the two preceding.

The **pyloric** runs with the pyloric branch of the hepatic artery, and joins the *vena portæ*; also the **vena coronaria ventriculi**, running with the gastric artery and receiving œsophageal branches, joins the *vena portæ* above the former.

THE ABSORBENT SYSTEM.

The absorbent system consists of vessels resembling thin-walled veins, the *lymphatics*, interrupted at intervals by the *lymphatic glands*. The lymphatics of the alimentary canal are called *lacteals*. All these vessels converge to two principal trunks, the *thoracic duct* and the *right lymphatic duct*, which open into the large veins at the root of the neck.

Describe the thoracic duct and right lymphatic duct.

The former begins by a dilatation, the *receptaculum chyli*, at the second lumbar vertebra, where the lacteals and lower lymphatics unite. It is placed behind or to the right side of the aorta at its origin, and ascends between it and the right crus to the thorax, lying on the front of the dorsal vertebræ, between the aorta and vena azygos major. It then runs upward toward the left, behind the arch of the aorta (at the fourth dorsal v.), then between the œsophagus and left subclavian artery, and at the seventh cervical vertebra it arches over the pleura to join the angle of union between the left subclavian and internal jugular veins. It receives the absorbents from the whole body excepting those of the right upper limb and right half of the head, neck, chest, heart, part of the upper surface of the liver and right lung.

The **right lymphatic duct** collects the lymph from the parts just mentioned above. It is only $\frac{1}{2}$ an inch or less in length, and empties on the right side, at a point corresponding to that where the thoracic duct empties on the left side.

Describe the lymphatics and lymphatic glands of the lower limb.

The lymphatics are arranged in a *superficial* and a *deep* set. The former open, in general, into the *superficial inguinal glands*; the latter into the *deep inguinal glands*. The superficial follow, in a general way, the course of the long saphenous vein; the deep accompany the deep blood-vessels, and in the leg enter the *popliteal glands*; in the gluteal and adductor region some enter the internal iliac glands.

The superficial lymphatics of the lower part of the trunk also join the superficial inguinal glands. The superficial lymphatics of the penis enter the superior set of superficial inguinal glands; the deep run under the pubic arch to join the internal iliac glands. The superficial lymphatics of the scrotum join the superficial inguinal glands. In the female external genitalia a similar disposition obtains.

The *superficial inguinal glands*, eight or ten, consist of a *superior* or oblique set in the line of Poupart's ligament, and an *inferior* or vertical set lying around the upper part of the saphenous vein. Efferent vessels join the deep inguinal and external iliac glands.

The four or five *popliteal glands* surround the vessels, and receive the deep and some superficial absorbents of the leg.

The *deep inguinal glands* lie around the femoral vessels; one at the crural ring is constant.

Describe the lymphatics and lymphatic glands of the pelvis and abdomen.

They include the following:

Six or more *external iliac* glands surround these vessels.

Numerous *internal iliac* glands, and sacral glands on the face of the sacrum.

The lymphatics of the *bladder* enter the internal iliac glands with the *prostatic* branches.

The lymphatics of the *uterus*, with those of the *vagina*, to the internal iliac glands.

The lymphatics of the *rectum* enter the sacral glands.

The *lumbar* glands comprise a middle and two lateral groups. The former lie around the aorta and vena cava, the latter beneath the psoas. Most of the efferent vessels join to form, on each side, the *lumbar lymphatic trunk*, which runs into beginning of thoracic duct.

The lymphatics of the *kidney*, deep and superficial, join the middle lumbar set after receiving the suprarenal lymphatics and some from the ureter.

The lymphatics from the *testicles*, superficial and deep, through the inguinal canal, in the cord, to join the lumbar glands.

The *deep lymphatics* of the *abdominal wall* receive others from the spinal canal and muscles, and join the lateral lumbar glands. At the upper part they enter the sternal glands.

About one hundred and fifty *mesenteric* glands lie between the layers of the mesentery in the arterial arches and around the superior mesenteric artery.

The *lacteals* form one plexus beneath the mucous membrane and one in the muscular coat, and leave the intestine at the attachment of the mesentery to enter the mesenteric glands, and, emerging, join the efferent vessels from the *cœliac* glands and form a single trunk. This intestinal lymphatic trunk joins the thoracic duct.

Sixteen to twenty *cœliac* glands, around the *cœliac* axis and adjacent aorta, receive the lymphatics from the stomach, spleen, pancreas, and a large part of the liver.

The lymphatics of the *stomach* traverse the gastric glands at the greater and lesser curvature and join the *cœliac* glands. From the left end they join the splenic lymphatics.

The lymphatics of the *spleen*, superficial and deep, enter the *cœliac* glands after receiving the pancreatic vessels.

The lymphatics of the *liver* are superficial and deep. The superficial on the upper surface are arranged in four groups: (1) The mesial, from both lobes, run through the diaphragm to the anterior mediastinal glands; (2) the lateral of each lobe to the *cœliac* glands; (3) the posterior, through

the diaphragm to the glands around the inferior vena cava; (4) an anterior group joins those on the inferior surface.

The superficial lymphatics on the lower surface run to the transverse fissure, for the most part, to join with the deep lymphatics. Some join the gastric lymphatics.

The deep hepatic lymphatics accompany the portal and hepatic veins. The former join the other vessels from the under surface at the transverse fissure, and traverse some small hepatic glands to join the coeliac glands. Those accompanying the hepatic veins form five or six trunks piercing the diaphragm, and join the glands around the vena cava.

Describe the lymphatic system of the thorax.

Six to ten *internal mammary* or *sternal glands* along the course of the vessels.

Along the line of the heads of the ribs, on each side of the spine, are the *intercostal glands*. They send vessels to both the thoracic and right lymphatic ducts.

Several *anterior mediastinal glands* lie between the sternum and the pericardium.

Eight or ten *superior mediastinal* or *cardiac*, around the great vessels, receive the lymphatics of the heart and thymus gland.

Numerous *bronchial glands*, between the bronchi and along their primary divisions, receive the lymphatics of the lung. They deepen in color as age advances.

Ten or twelve *posterior mediastinal*, along the œsophagus and aorta.

The *deep lymphatics* of the *chest-wall* are an anterior set, in the intercostal spaces, joining the internal mammary glands, and a posterior or intercostal set, along with the intercostal vessels, joining the intercostal glands.

The *cardiac lymphatics* run toward the base of the heart, and form a trunk on each side. Of these, the right enters a gland above the aortic arch; the left, the glands behind that vessel.

The *pulmonary lymphatics*, superficial and deep, end in the bronchial glands.

The *œsophageal lymphatics* form a plexus between the muscular and mucous coats and join the posterior mediastinal glands.

The *thymic lymphatics* enter the superior mediastinal glands.

Describe the lymphatics of the upper limb.

They consist of a superficial and a deep set, both converging to the axillary glands. The former have a somewhat similar distribution to that of the veins, some entering the infraclavicular glands; the latter correspond to the deep blood-vessels, communicate with the superficial lymphatics near the wrist, traverse the glands around the brachial artery near the elbow, and end in the axillary.

Describe the axillary glands.

They are ten to twelve in number, and lie mostly along the axillary vessels, but some, the *pectoral*, *subscapular*, and *infraclavicular*, occupy the positions indicated by their names. The efferent vessels from all these glands run along the subclavian vein, and may unite into a single axillary lymphatic trunk. They finally reach the thoracic or right lymphatic duct respectively, or they may enter the subclavian vein directly.

The *superficial lymphatics* of the *chest* drain the lymph from the pectoral muscles, skin, and mamma, and together with some superficial abdominal lymphatics, enter the axillary glands. Those from the *back* converge from all parts to reach the axillary glands.

Describe the absorbent system of the head and neck.

One or more *suboccipital* glands on the complexus send branches to the cervical glands.

Several *mastoid* glands over the insertion of the sterno-mastoid.

Some *parotid* glands, beneath the parotid fascia and imbedded in the gland, receive superficial temporal lymphatics, and send branches to the submaxillary and superficial cervical glands.

The *internal maxillary* glands, deep beneath the ramus of the jaw, around the artery and side of the pharynx, with branches to the deep cervical glands.

Eight or ten *submaxillary* glands beneath the base of the jaw drain the lymph from the floor of the mouth and the salivary glands and from the parotid lymphatic glands. The efferent vessels join the superficial and deep cervical glands.

The *superficial cervical* glands, four to six, along the external jugular beneath the platysma, receive the auricular lymphatics, efferent trunks from the suboccipital, mastoid, and some from the parotid and submaxillary glands. The efferent vessels enter the inferior deep cervical glands.

The *deep cervical*, twenty to thirty, consist of an upper and a lower set. The former run along the internal jugular vein; the latter around the lower part of the vein and into the supraclavicular fossa, and join the superior mediastinal and axillary glands; they receive afferent trunks from all the other cervical glands and the lymphatics of the lower part of the neck, and send out branches which unite into a *jugular lymphatic trunk*. This trunk then joins the thoracic or right lymphatic duct, or may open into a large vein.

The *lymphatics* of the *scalp* join the suboccipital, mastoid, and parotid glands.

The *lymphatics* of the *face* follow the course of the facial vein to the submaxillary glands, but there are others externally which join the parotid glands. The *deep* lymphatics from the *orbit*, *nasal cavity*, *palate*, and *cheek* join the internal maxillary glands.

The *cranial lymphatics* form a network in the pia mater, and run along the internal carotid, vertebral, and internal jugular veins to the deep cervical glands.

The *lingual lymphatics* run with the ranine vein, traverse several lingual glands, and join the upper deep cervical glands. One or two join the submaxillary.

NEUROLOGY.

THE SPINAL CORD.

What are the membranes of the spinal cord ?

The spinal cord is enclosed by three membranes, the dura mater, arachnoid, and pia mater.

Describe the dura mater.

This is a loose fibrous envelope which is attached closely to the margin of the foramen magnum above, but only loosely to the circumference of the vertebral canal below. Its inner surface is covered by a layer of epithelium, and it presents on each side a series of double orifices for the exits of the anterior and posterior roots of the spinal nerves. The dura is prolonged on to these nerves as a tubular investment.

Describe the arachnoid.

The arachnoid is a very delicate membrane which invests the cord between the dura and pia. It is continuous above with the cerebral arachnoid, and is connected by meshes of fibrous tissue with the pia, and to some extent also with the dura, from which it is separated by the subdural space. The subarachnoid space contains the subarachnoid fluid, which separates it from the pia mater. This space, by means of the foramen of Majendie, is continuous with the cavity of the ventricles of the brain.

Describe the pia mater.

The pia mater is closely connected to the cord, and sends a prolongation down into the anterior, and a very delicate process into the posterior median fissure. It ensheathes the spinal nerves, and ends below in the filum terminale, which joins the dura at the upper limit of the sacral canal.

Along the anterior median surface of the pia runs a prominent fibrous band, the *linea splendens*, and between the two nerve-roots on each side is a serrated band, the *ligamentum denticulatum*, the points of the serrations, about twenty on each side, being attached to the dura between the pairs of nerve-roots.

Describe the spinal cord.

It is about 18 inches long, weighs an ounce and a half, and occupies

about the upper two-thirds of the spinal canal— viz. from the foramen magnum to the upper border of the second lumbar vertebra. It ends in a narrow cord of gray matter which runs in the midst of the filum terminale.

What enlargements are found in the spinal cord ?

The spinal cord presents two enlargements—an upper or cervical, extending from the third cervical to the first or second dorsal vertebra, and a lower or lumbar, from the tenth dorsal to about the first lumbar. These enlargements correspond to the origin of the nerves which supply the upper and lower extremities respectively. The surface of the cord presents several *fissures*, which will now be described.

What are the fissures of the cord ?

The *anterior median* fissure extends through about one-third the thickness of the cord, as far as the anterior white commissure, and contains a fold of the pia.

The *posterior median* fissure extends about halfway through its substance to reach the posterior or gray commissure. It is not a real fissure, being filled up by connective tissue.

The antero-lateral fissure is merely the line of origin of the anterior nerve-roots, while the postero-lateral is in reality a groove, and runs along the line of origin of the posterior nerve-roots.

Lastly, a *slight groove* marks off the *posterior median column* on either side of the posterior median fissure.

How are the columns of the cord formed ?

These fissures divide the cord into four columns on each side.

The *anterior* column, between the anterior median and antero-lateral fissures, is continued above into the pyramid of the medulla. The *lateral*, between the antero- and postero-lateral fissures, runs up to become apparently the lateral column or tract of the medulla. The *posterior* column, between the postero-lateral and posterior median fissures, becomes divided, by the slight groove above mentioned, into the *posterior lateral* and *posterior median* columns. In the medulla the former becomes the funiculus cuneatus, the latter the funiculus gracilis.

What is the structure of the cord ?

The spinal cord is composed of white matter externally and of gray matter within. The latter presents on section the appearance of two crescents, the horns looking outward, united across the median line by the gray commissure, which is placed nearer to the apices of the anterior than to those of the posterior cornua. The posterior cornua are long and narrower than the anterior, and extend almost to the surface of the cord at the postero-lateral fissure, where they give off the posterior nerve-roots. The anterior are blunt and do not reach the surface; thus the

anterior roots pierce the white matter and emerge at the antero-lateral fissure. The gray commissure is separated from the anterior median fissure by the anterior white commissure, but the posterior median fissure quite reaches it.

Throughout the whole length of the cord in the gray matter runs a small central canal which opens above into the fourth ventricle and enlarges below, at its termination. It is lined by cylindrical epithelium.

The white matter is composed of medullated nerve-fibres of varying calibre, held together by a delicate reticular connective tissue, the *neuroglia*, containing numerous neuroglia-cells. This neuroglia sends in septa, along with which pass processes of pia mater, thus subdividing the columns into smaller tracts.

Describe the anterior column.

The anterior column is subdivided into the following :

(1) On either side of the anterior median fissure the *direct pyramidal tract*, forming above the uncrossed portion of the pyramids of the medulla, and (2) the *fundamental fasciculus*.

Describe the lateral column.

The lateral column is subdivided into (1) the *mixed lateral tract*, next to the concavity of the gray substance; (2) the *anterior radicular zone*, somewhat in front; (3) the *direct cerebellar tract*, behind peripherally; and (4) the *crossed pyramidal tract*, lying internal to the latter. Of these the first and second join the lateral tract or column of the medulla, the third traverses it to reach the restiform body, and the fourth joins the pyramid of the opposite side, forming, with its fellow, the decussation of the pyramids.

Describe the posterior column.

The posterior column is marked off into (1) the *column of Goll*, or *posterior median column*, and (2) *Burdach's column*, or the *posterior lateral column*. The first becomes the fasciculus gracilis; the second enters the medulla under its own name or as the funiculus cuneatus.

Mention some points in the structure of the gray matter.

The posterior cornu is constricted at its base (*cervix cornu*), and then expands (*caput cornu*) before narrowing to its extremity (*apex cornu*). Around the latter the neuroglia forms the *substantia gelatinosa*.

The gray matter of the cord consists of nerve-fibres, nerve-cells, and connective tissue (*neuroglia*). The nerve-cells are for the most part arranged in columns. Of these columns, one, at the inner side of the cervix cornu, is called the posterior vesicular column of Lockhart Clarke; a second, at the concavity of the gray matter, the tractus intermedio-lateralis; and a third is found along the anterior part of the anterior cornu.

THE BRAIN OR ENCEPHALON.

What is the encephalon ?

The encephalon or brain is that part of the cerebro-spinal axis which is contained in the cranium. It is composed of the cerebrum, cerebellum, pons Varolii, and medulla oblongata.

What are the membranes of the brain ?

They are the dura mater, pia mater, and arachnoid.

Describe the dura mater.

The dura is similar in structure to the dura of the cord, but differs from it in being closely attached to the cranial bones, forming, in fact, their inner periosteum. It is continuous with that of the cord at the foramen magnum, and with the external periosteum of the cranial bones by means of its prolongations into the many foramina. It sends in various processes to support and separate the different parts of the brain, and its layers separate to form the cranial sinuses. In the vicinity of the superior longitudinal sinus are to be found, on its outer surface, several glandulæ Pacchionii. They may also be seen on its inner surface and within the sinus, as well as on the pia mater.

The processes include the falces cerebri et cerebelli and the tentorium cerebelli.

The *falx cerebri* separates the cerebral hemispheres. In front it is narrow, becoming broader behind. Its upper convex margin is attached to the vault of the cranium from the crista galli in front to the internal occipital protuberance behind. Its lower margin is free and concave anteriorly, while it is attached posteriorly to the upper surface of the tentorium. Above it forms the superior, below, the inferior longitudinal sinus and part of the straight sinus.

The *falx cerebelli* is triangular, and separates, inferiorly, the lateral cerebellar lobes. It is attached above to the middle of the posterior border of the tentorium, behind to the internal occipital crust, below the torcular Herophili, and to the foramen magnum, where it often divides into two parts, which are attached to its margins.

The *tentorium* covers the upper surface of the cerebellum. Its posterior border, where it is attached to the transverse ridges of the occipital bone, encloses the lateral sinuses; along the superior border of the petrous portion it forms the superior petrosal sinus, and at the junction of its upper surface with the falx cerebri is the straight sinus. Besides these points, it is attached to the anterior and posterior clinoid processes. Its anterior concave edge is marked by an oval opening for the crura cerebri.

Describe the arachnoid and pia mater.

The arachnoid is a similar membrane to that of the cord, and is separated, as in the cord, by the subarachnoid fluid from the pia. It does

not dip into the sulci. In front it leaves a space between it and the pia mater, viz. along the pons and interpeduncular region, the anterior subarachnoidean space, and behind, between the medulla and the cerebellum, is a second interval called the posterior subarachnoidean space. Both are connected with the ventricles of the brain by the foramen of Magendie in the pia mater covering the fourth ventricle.

The subarachnoid fluid is a clear alkaline fluid containing 1.5 per cent. of solids, animal and mineral.

The pia mater is a very vascular, delicate membrane which dips into the sulci and forms the various choroid plexuses and also the velum of the third ventricle. The vessels of the brain run in the pia mater before entering the brain.

Describe the medulla oblongata.

It is a pyramidal body, 1 inch long, $\frac{3}{4}$ inch wide, and $\frac{1}{2}$ inch thick. Its larger extremity is continuous with the pons; its smaller extremity, directed downward and backward, blends with the spinal cord. The anterior surface lies on the basilar groove of the occipital bone, and the posterior in the vallecule, between the cerebellar hemispheres.

In front and behind it is marked by the continuation of the anterior and posterior median fissures of the cord, the former, with its process of pia mater, ending in a cul-de-sac just below the pons, the foramen cæcum. The posterior expands into the fourth ventricle.

Each lateral half of the medulla is divided into "columns."

Describe each of these "columns."

1. The *pyramid*. This contains internally the fibres of the crossed pyramidal tract from the lateral column of the opposite side of the cord; externally the pyramid contains the direct pyramidal tract from the anterior column of the cord of its own side.

2. The *lateral tract* is the apparent continuation of the lateral column of the cord. It is very short, and lies immediately under the

3. *Olivary body*. This is an oval mass of white matter enclosing the corpus dentatum, a gray nucleus which is hollowed out within and open at its upper part, admitting white fibres. Above and in front a groove separates it from the pons and pyramid. Crossing it are arched fibres which join the restiform body.

4. The *restiform body* is apparently continuous with the posterior columns of the cord, and diverges above from its fellow to form the lateral walls of the lower part of the fourth ventricle. It passes to the cerebellum, together with the direct cerebellar tract of the cord.

Immediately below the restiform body from without inward are: 5, the *funiculus of Rolando*; 6, the *funiculus cuneatus*; and 7, the *funiculus gracilis* or the column of Goll continued up. Its enlarged extremity, the *processus clavatus*, lies just under the restiform body. The angle of divergence from its fellow of the opposite side is called the *calamus scriptorius*.

Mention some points in regard to the deep structure of the medulla.

Numerous white fibres run in the median line, forming the so-called septum of the medulla. Some of these fibres emerge from the ant. med. fissure and cross the olivary body as the arciform fibres, which join the restiform body. Most of the remaining white fibres are the continuation upward of the *fundamental fasciculus*, the *mixed lateral tract*, and the *anterior radicular zone*. (See *Columns of the Cord*.) The crescentic arrangement of the gray matter which obtains in the cord is lost in the medulla. The caput cornu enlarges and appears close to the surface as the funiculus of Rolando, which swells above into the tubercle of Rolando. The gray matter of the base of the posterior cornu forms the nucleus gracilis in the funiculus gracilis and the nucleus cuneatus in the funiculus cuneatus. A part of the base of the anterior cornu forms the eminence of the funiculus teres, in which is the hypoglossal nucleus, while that part of the cornu which is left is known as the formatio reticularis.

Describe the pons Varolii (tuber annulare).

This part of the brain serves to connect its various divisions. Situated between the cerebellar hemispheres, it forms on each side the middle peduncles of the cerebellum. Its dorsal surface forms the upper part of the floor of the fourth ventricle. The ventral surface rests on the sphenoid and basilar groove of the occipital bone, and lodges the basilar artery in a median furrow, its branches running in smaller lateral depressions. The pons is arched above, below, and ventrally.

Describe the structure of the pons.

It is made up of nerve-fibres and gray matter. There are two sets of fibres, *transverse* and *longitudinal*, and each set has superficial and deep fibres. These four layers alternate with each other from below as follows: 1, superficial transverse fibres; 2, superficial longitudinal fibres; 3, deep transverse fibres; 4, deep longitudinal fibres. The first and third layers are prolonged into the middle peduncles of the cerebellum. The second layer is the prolongation upward of the fibres of the pyramids of the medulla. The fourth layer (immediately below the floor of the fourth ventricle) is the upward prolongation of the fibres in the "deep structure" of the medulla. (See above.)

The gray matter occurs chiefly as: 1, small points (nuclei pontis) scattered amongst the fibres; 2, the superior olivary nucleus, situated behind the third layer of white fibres (*trapezium*).

Describe the cerebrum.

The cerebrum is the largest part of the brain, and is composed of two symmetrical halves separated by the great longitudinal fissure. As a whole it is flattened below, convex above, broader behind than in front, and presents over its entire surface convoluted eminences, the gyri or

convolutions, separated by depressions, the sulci and fissures. The two hemispheres are connected by a great transverse white commissure, the corpus callosum.

The outer surface, including the gyri, is composed of gray matter, the cortical substance, while the interior is of white matter. The cortical layer is composed of alternate strata of white and gray matter.

The sulci vary from $\frac{1}{2}$ an inch to 1 inch in depth. Several well-marked sulci divide the surface into five lobes. They are the interlobar sulci or fissures, and include the fissure of Sylvius, fissure of Rolando, and the parieto-occipital fissure.

Describe the interlobar sulci.

The *fissure of Sylvius* runs outward from the anterior perforated space, and divides, on the outer side of the hemisphere, into an ascending limb, which runs upward and forward for about an inch, and a horizontal limb, which runs back between the parietal and temporo-sphenoidal lobes.

The *fissure of Rolando* (central sulcus), from its commencement ($\frac{1}{2}$ inch behind the mid-point between the glabella and external occipital protuberance), runs downward and forward, to end a little behind and above the bifurcation of the Sylvian fissure.

The *parieto-occipital* fissure commences at a point midway between the posterior extremity of the brain and the fissure of Rolando, and runs downward and forward on the mesial surface of the hemisphere nearly as far as the corpus callosum, and runs similarly also for nearly an inch on the convex surface. The first part is well marked, and is called the internal, the second the external, parieto-occipital fissure.

Describe the lobes and fissures on the external surface of the cerebrum.

The **frontal lobe** lies in front of the fissure of Rolando, and above and in front of the ascending limb of the Sylvian fissure. It rests on the orbital plate below.

The *precentral fissure* runs parallel with the lower part of the fissure of Rolando, marking off the *ascending frontal convolution*, and the part in front of it is divided by the superior and inferior frontal sulci, both running antero-posteriorly, into the superior or first, middle or second, and inferior or third frontal convolutions. The last is also called Broca's convolution. The under surface of the frontal lobe is grooved for the olfactory tract, a sulcus also separating the lower part of the first frontal convolution internally from the continuation of the second and third externally, the latter two being also separated by a sulcus. These gyri are called respectively the internal, middle, and posterior orbital convolutions.

The **parietal lobe** is bounded in front by the fissure of Rolando, behind by the parieto-occipital, and below by the horizontal part of the Sylvian fissure, which separates it from the temporo-sphenoidal lobe.

The *intraparietal fissure* runs up, at first parallel to the fissure of

Rolando, then turns backward, separating the superior and inferior parietal lobules. It marks off between it and the fissure of Rolando the *ascending parietal convolution*. The *superior parietal convolution* or lobule is continuous in front with the ascending parietal, and the *inferior parietal lobule* is subdivided by a vertical sulcus into the *supra-marginal gyrus* in front and the *angular gyrus* behind. The former is continuous in front with the superior temporo-sphenoidal, and the latter, behind, with the middle temporo-sphenoidal gyrus.

The **occipital lobe** is partly separated in front from the parietal by the parieto-occipital fissure, and forms, behind, the posterior extremity of the hemisphere. It is divided by the superior and middle occipital fissures into the superior, middle, and inferior occipital convolutions. These are connected by the annectant convolutions with the adjacent gyri as follows: the first annectant convolution connects the superior occipital with the superior parietal; the second connects the middle occipital with the angular; the third connects the middle occipital with the middle temporo-sphenoidal; and the fourth joins the inferior occipital and inferior temporo-sphenoidal convolutions. The inferior occipital fissure, at the side of the lobe, separates the inferior convolution from the occipito-temporal.

The **temporo-sphenoidal lobe** is bounded above and in front by the beginning of the fissure of Sylvius and its horizontal limb; is continuous behind with the occipital, and above with the parietal lobe. It lies in the middle fossa of the skull. The superior temporo-sphenoidal sulcus, with the middle and inferior, divides it into three convolutions, named, from above downward, the first, second, and third temporo-sphenoidal.

The **central lobe** (island of Reil, or insula) is triangular, and consists of five or six convolutions, the *gyri operi*. It lies in the fissure of Sylvius and beneath the inferior extremities of the ascending frontal and ascending parietal convolutions, which, joined by the inferior frontal, form the *operculum*. In front and externally a deep sulcus separates it from the orbital and frontal convolutions.

Describe the mesial and tentorial surfaces of the hemisphere.

The *calcarine fissure* commences at the back of the hemisphere by two branches, and as it runs forward is joined by the internal parieto-occipital fissure, ending near the back part of the gyrus fornicatus. It forms the calcar avis or hippocampus minor in the posterior horn of the lateral ventricle.

The *calloso-marginal fissure* runs from under the front of the corpus callosum, between the gyrus fornicatus and the upper margin of the hemisphere, then ascends to end in the upper part of the fissure of Rolando or close behind it.

The *hippocampal* or *dentate fissure* runs from within the back part of the gyrus fornicatus to the hook of the uncinate gyrus. It forms by its projection into the ventricle the hippocampus major.

The *internal parieto-occipital fissure* runs downward and forward to join the calcarine fissure.

The *collateral* or *occipito-temporal fissure* separates the superior and inferior occipito-temporal convolutions, and forms the eminentia collateralis.

The *cuneate* or *occipital lobule* lies between the parieto-occipital and calcarine fissures.

The *precuneus* (*quadrate lobule*) lies between the parieto-occipital and the termination of the calloso-marginal fissure.

The *marginal convolution* is the inner aspect of the first frontal, and runs along the margin of the longitudinal fissure from the anterior perforated space to the calloso-marginal fissure.

The *gyrus fornicatus* runs from the anterior perforated space around the genu of the corpus callosum, then back along its upper surface, around the posterior extremity, and lastly, as the *gyrus hippocampi*, runs forward to end in the *uncinate gyrus*. It is bounded above by the calloso-marginal fissure.

The *uncinate gyrus* is the terminal part of the preceding. It extends to the fissure of Sylvius. In front it bends back in the form of a hook, the uncus. The under and inner surface of the temporo-sphenoidal lobe presents two convolutions separated by the *collateral fissure*. They are the lateral and median occipito-temporal, or, respectively, the *fusiform* and *lingual convolutions*.

Describe the under surface of the cerebrum.

It presents three lobes: the *anterior*, composed of the under surface of the frontal, resting on the orbital plate; a *middle*, composed of the parietal and temporo-sphenoidal; and a *posterior*, the occipital lobe. The middle lies in the middle fossa, the posterior on the upper surface of the tentorium cerebelli.

From before backward the following parts come into view: longitudinal fissure, corpus callosum, lamina cinerea, olfactory bulb and tract, fissure of Sylvius, anterior perforated space, optic commissure, tuber cinereum, infundibulum, pituitary body, corpora albicantia, posterior perforated space, crura cerebri.

Describe each of these parts.

The *great longitudinal fissure* completely separates the anterior and posterior lobes, but is interrupted between these two points by the corpus callosum.

The *corpus callosum* is placed nearer the front than the back of the hemispheres, being convex from before backward above, concave below; the fibres run transversely, but along the middle line is a longitudinal raphé with a white band on each side, the *mesial longitudinal strice*, and near the margin some *lateral longitudinal strice*.

The *lamina cinerea* is a thin layer of gray matter lying between the chiasma and the corpus callosum, and continuous with the gray matter

of the anterior perforated space on each side. It forms part of the floor and anterior boundary of the third ventricle.

The *olfactory tract* runs in a groove close to the great longitudinal fissure on the under surface of the frontal, and ends in an enlargement, the bulb, from which the olfactory nerves descend through the cribriform plate. Behind, the tract divides into two roots. The outer runs back along the margin of the anterior perforated space to the Sylvian fissure; the inner to the longitudinal fissure. The triangular space between the two roots is occupied by gray matter forming part of the *tuber olfactorium*, which lies in a depression on the frontal lobe, and is composed internally of white matter.

The *fissure of Sylvius* lodges the middle cerebral artery. At its inner part is the fasciculus unciformis, connecting the frontal and temporo-sphenoidal lobes.

The *anterior perforated space* is a triangular depression at the inner side of the Sylvian fissure, of a grayish color, and is pierced by many small vessels passing to the corpus striatum, under which it lies.

The *optic commissure* or *chiasma* (see *Optic Nerve*) is formed by the union of the two *optic tracts*. It lies below the lamina cinerea and in front of the tuber cinereum.

Between the optic tracts and the crura cerebri is a diamond-shaped area, the *interpeduncular space*. This space includes the tuber cinereum, infundibulum, pituitary body, corpora albicantia, and the posterior perforated space.

The *tuber cinereum* is an elevation of gray matter between the optic tracts and corpora albicantia, and forms part of the floor of the third ventricle. From its under surface the *infundibulum* runs down to the pituitary body. The former is hollow and of a conical form, its cavity communicating with the third ventricle.

The *pituitary body*, or *hypophysis cerebri*, is a reddish-gray mass occupying the sella turcica. Its weight is from 4 to 10 grains. It consists of two lobes, the anterior and larger of which encloses the posterior. The former is of a yellowish-gray color; the latter in foetal life contains an aperture which communicates with the infundibulum.

The *corpora albicantia* are two bodies placed behind the tuber cinereum. They are composed of white matter, are about the size of a pea, and contain each a gray nucleus which is connected with its fellow across the median line. Each is formed by the corresponding anterior pillar of the fornix.

The *posterior perforated space* forms part of the posterior portion of the floor of the third ventricle, and is pierced by small vessels for the optic thalami. It occupies the interval between the corpora albicantia, the pons, and the crura cerebri.

The *crura cerebri* are broader in front than behind and less than 1 inch in length. They run from the upper border of the pons to the hemispheres of the cerebrum, under the optic tracts, which cross them.

The fourth nerve crosses the outer side, and the third issues from the inner side of each.

Each crus is composed of two parts separated by gray matter, the *locus niger*. The ventral part, or *crusta*, is a continuation of the *pyramidal fibres* from the medulla and pons, while the dorsal part, or *tegmentum*, is the continuation of the *deep longitudinal fibres* of the pons. The crustæ of the two sides are entirely separate, but the tegmenta are connected at the median line.

Describe the parts seen on two horizontal sections of the cerebrum.

A section of the hemispheres about $\frac{1}{2}$ inch above the corpus callosum brings into view the white matter constituting the *centrum ovale minus*. This is dotted with the *puncta vasculosa*, due to the divided blood-vessels. A section at the level of the corpus callosum is called the *centrum ovale majus* of Vieussens.

The anterior part of the *corpus callosum* forms in front a bend, the *genu*, and this extends back along the base of the brain up to the lamina cinerea as the *rostrum*. Here it sends off the peduncles of the corpus callosum. Behind it forms a thick border, the *splenium* or pad. The under surface of the corpus callosum is connected behind with the fornix and for the rest of its extent with the septum lucidum. It forms the roof of the lateral ventricles.

Describe the lateral ventricles.

These serous cavities have a thin lining membrane covered by a layer of epithelium cells (*ependyma*) which secretes a serous fluid. They are contained one in each hemisphere, separated by the *septum lucidum*, and each is divided into a *body* and *three cornua*, an anterior, posterior, and middle. The foramen of Monro connects them with the third ventricle.

The *central cavity* or *body* is roofed by the corpus callosum, and in the floor, from without inward, are found the caudate nucleus of the corpus striatum, tænia semicircularis, part of the optic thalamus, choroid plexus, and part of the fornix.

The *anterior cornu* projects into the anterior lobe and runs outward round the nucleus caudatus. Above and in front of it is the corpus callosum.

The *posterior cornu*, or digital cavity, runs back into the posterior lobe, its direction being backward, outward, and lastly inward. Its floor presents the eminence of the *hippocampus minor* or calcar avis. At the junction of the posterior and middle cornua is the *eminentia collateralis* or *pes accessorius*.

The *middle* or *descending cornu* curves round the back of the optic thalamus, descending at first backward and outward. It then runs downward, forward, and lastly inward. In its floor are the hippocampus major and pes hippocampi, corpus fimbriatum, and choroid plexus;

the fascia dentata lies within the hippocampal or dentate fissure, and the transverse fissure runs along the inner side of the cornu.

Describe these parts in detail.

The **corpus striatum** is a mass of gray matter, and consists of an extraventricular portion imbedded in the hemisphere and called the lenticular nucleus, and an intraventricular part in the body and anterior cornu, the nucleus caudatus.

The *caudate nucleus* is pyriform, projecting into the body and anterior cornu by its broad end, and by its smaller end into the roof of the middle cornu nearly to its tip.

The *lenticular nucleus* is divided into three zones, visible on transverse vertical section. It is separated from the caudate nucleus by the *internal capsule*, and the *external capsule* separates it from the *claustrum*. This nucleus and the caudate are joined together in front, and, behind, the lenticular is continuous with the gray matter of the anterior perforated space.

The *claustrum* is a gray lamina marked externally by ridges and furrows corresponding to the gyri and sulci of the island of Reil.

The *nucleus amygdalæ* is a small, yellowish-gray mass projecting into the apex of the middle cornu, and continuous with the cortical part of the apex of the temporo-sphenoidal lobe.

The *tænia semicircularis* lies in a groove between the caudate nucleus and the optic thalamus. In front it joins the anterior pillar of the fornix; behind it enters the nucleus amygdalæ. Beneath it is the *vena corporis striati*.

The **choroid plexus** is a very vascular fringe covered with epithelium continuous with that of the ependyma, and forms the border of the velum interpositum. It extends from the foramen of Monro, where it is continuous with the other, across the floor of the body of the ventricle and into the middle cornu.

The **corpus fimbriatum** is the narrow band of white matter on the hippocampus major into which is prolonged the posterior pillar of the fornix.

The **hippocampus major** is a curved white prominence in the floor of the middle horn. Its lower part presents the appearance of a paw from its grooves and eminences, hence called the *pes hippocampi*. The hippocampus major is caused by the dentate fissure, and the gray matter contained in this fissure (*dentate convolution*) projects as a free margin—the *fascia dentata*.

The **eminentia collateralis** (*pes accessorius*) is formed by the collateral fissure (occipito-temporal).

The **great transverse fissure** of Bichat, separating the cerebrum and cerebellum, lies between the fornix and the splenium of the corpus callosum above and the corpora quadrigemina below; laterally, it lies between the back part of the optic thalamus below and the corpus fimbriatum and fascia dentata above.

The **septum lucidum** separates the lateral ventricles. It is composed of two layers, a small space containing fluid being left between them called the fifth ventricle. It is attached above to the corpus callosum, below to the anterior part of the fornix and the reflected portion of the corpus callosum.

The **fornix** is an arched longitudinal commissure of white matter below the corpus callosum, its lateral margins forming part of the floor of the body of the lateral ventricles. In front its two lateral halves are divergent, and form the *anterior pillars*; behind they diverge into the two *posterior pillars*; the central part is the *body*. The body is triangular, attached above to the corpus callosum and septum lucidum; below the velum interpositum separates it from the third ventricle and optic thalami. On each side project the choroid plexuses.

The *anterior pillars* descend through the gray matter on the sides of the third ventricle and form the anterior boundaries of the foramen of Monro. Then they emerge at the base of the brain to form the corpora albicantia, from which each pillar turns upward and ends in the corresponding optic thalamus. In their course each communicates with the peduncle of the pineal gland and the tænia semicircularis.

The *posterior pillars* are connected with the corpus callosum, then enter the descending cornua, and are partly prolonged into the upper surface of hippocampus major and partly into the corpus fimbriatum.

The **foramen of Monro** is a foramen connecting each lateral ventricle with the anterior part of the third. In front it is bounded by the anterior pillar of the fornix; behind, by the anterior part of the optic thalamus; above, by the anterior extremity of the body of the fornix.

What is the velum interpositum?

The **velum interpositum** is a process of the pia mater which occupies the great transverse fissure, and hence separates the fornix from the third ventricle. In front it sends a process through the foramen of Monro to each lateral ventricle. From its under surface it supplies the two vascular processes which form the choroid plexuses of the third ventricle, and on each side the choroid plexuses of the lateral ventricles are found.

What are the optic thalami?

The **optic thalami** are two masses composed externally of white, internally of gray matter, and rest upon the tegmentum of the crura. The fibres of the crusta, forming the *internal capsule*, separate the outer surface of each from the lenticular nucleus of the corpus striatum. The inner surface of each forms the lateral boundaries of the third ventricle; its upper surface is grooved, and presents in front the projection of the anterior tubercle. Part of the under surface forms part of the roof of the descending cornu; the anterior extremity is the hinder boundary of the foramen of Monro.

Describe the third ventricle.

This is the expanded interval into which the Sylvian aqueduct opens, and which lies between the optic thalami. The *velum interpositum*, with the choroid plexuses, connected on each side with the *peduncles of the pineal gland*, forms its roof, together with the posterior commissure. Its floor presents the lamina cinerea, tuber cinereum, infundibulum, corpora albicantia, posterior perforated space, and tegumentum of crura. In front it is bounded by the anterior commissure and the lamina cinerea. Behind is the opening of the aqueduct of Sylvius.

In its cavity are three commissures: the *anterior*, in front of the anterior pillars of the fornix, piercing on each side the corpus striatum; the *middle* or soft, of gray matter, connecting the thalami; and the *posterior*, also connecting the optic thalami behind, and lying in front of and beneath the *pineal gland*.

In front are the two openings, one on each side, of the foramen of Monro.

Describe the parts in relation with the Sylvian aqueduct.

The *pineal gland* (epiphysis cerebri) is a small reddish body placed between and upon the upper pair of corpora quadrigemina. It has two peduncles, which run along the junction of the inner and upper surfaces of the optic thalami to join the anterior pillars of the fornix. Just before entering the pineal gland they are joined together, the connecting band joining, in front, the posterior commissure. This gland is a collection of follicles containing a clear, viscid matter and the brain sand (acervulus cerebri), a kind of phosphatic calculi.

The *corpora quadrigemina* are rounded masses of gray matter thinly covered with white, arranged as an upper and a lower pair. They lie above the Sylvian aqueduct and behind the posterior commissure, and upon the terminations of the superior peduncles of the cerebellum of each side. The anterior or upper pair are the larger. On each side they are connected with the thalami and optic tracts by white bands, the brachia, anterior and posterior.

The *geniculate bodies* lie against the under and back part of each thalamus, external to the corpora quadrigemina. They are named external and internal, and are separated by one of the roots of the optic tract.

Describe the cerebellum.

The cerebellum is that part of the cerebro-spinal axis which is contained in the inferior occipital fossæ. Its weight is about one-eighth that of the cerebrum, being proportionately large in the infant. It consists of gray matter externally, white internally.

Describe its upper surface.

The upper surface presents a median elevation, the *superior vermiform process*, which connects together the upper surfaces of the two

hemispheres of the organ. In front and behind the hemispheres are separated by two notches, the *incisura cerebelli anterior* and *posterior* respectively.

Describe the superior vermiform process.

It is divided into four lobes, the *lingula*, the *lobulus centralis*, *monticulus cerebelli*, and *commissura simplex*, or *folium cacuminis*. The first is on the valve of Vieussens, the second is in the anterior, the last in the posterior incisura, and the third is the most prominent part of the process.

Describe the under surface of the cerebellum.

The under surfaces of the hemispheres are separated by the *vallecula*, in which is found the *inferior vermiform process*, on which from behind forward are found the following: *commissura brevis* or *tuber valvulæ*, *pyramid*, *uvula*, lying between the amygdalæ and joined with them by the *furrowed band* and *nodule*, with the *inferior medullary velum* on each side.

Mention the lobes of the cerebellar hemispheres.

Each hemisphere presents numerous deep and curved fissures very close together. The largest, the *great horizontal fissure*, runs from the point of emergence of the peduncles on each side, to end at the same point as its opposite fellow in the *incisura posterior*. Secondary fissures proceed from it in various directions. The great fissure divides each hemisphere into an upper and a lower part, and the secondary fissures divide them into lobes. These lobes are the following:

Upper surface, anterior or square lobe; posterior or semilunar lobe.

Under surface, from before backward, the *flocculus* or *pneumogastric lobule*; *tonsil* or *amygdala*; *digastric* or *biventral lobe*; *slender lobe* (*gracilis*); and the *inferior posterior* or *postero-inferior lobe*.

Name and describe the peduncles of the cerebellum.

They connect the cerebellum with the other parts of the encephalon. They are the superior, middle, and inferior peduncles of the cerebellum.

The first run to and beneath the *corpora quadrigemina*, and form part of the roof of the fourth ventricle, the valve of Vieussens lying between the two; the second are the prolongation of the transverse fibres of the pons; and the third are simply the upper part of the *restiform bodies*. They are all of white matter.

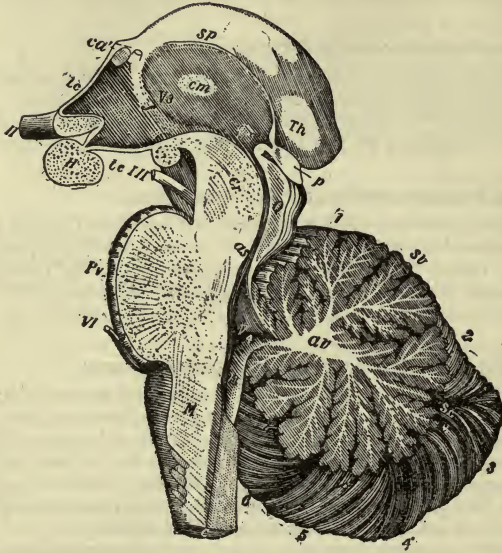
What is the arbor vitæ?

It is the name given to the arrangement of the white matter of the cerebellum as seen on a *median* section. (See Fig. 14.)

Describe the fourth ventricle.

The fourth ventricle is placed between the medulla and pons in front and the cerebellum behind. It is diamond-shaped, the lower triangle

FIG. 14.



Right half of the Encephalic Peduncle and Cerebellum as seen from the inside of a median section (Allen Thompson, after Reichert): *Pr*, pons Varolii divided in the middle; *m*, medulla oblongata; *c*, central canal, divided longitudinally, with gray substance surrounding it; *V₄*, middle of the fourth ventricle. In the cerebellum, *av*, stem of white substance in the centre of the middle lobe of the cerebellum, ramifying into the arbor vitæ; *sv*, superior vermiform process or upper portion of the middle lobe; *sc*, single folium (folium cacuminis), which passes across the postero-superior lobes; *v*, the tuber valvulæ; *p*, pyramid; *u*, uvula; *n*, nodule; 1 to 2, laminæ of the monticulus cerebelli; between *V₄* and 1 are seen the lingula and central lobe in section; 3, postero-inferior lobe; 4, lobulus gracilis; 5, biventral lobe; 6, amygdaloid lobe. *II*, right optic nerve; behind it the optic commissure divided; *III*, right third nerve; *VI*, sixth nerve; *V₃* third ventricle; *Th*, back part of the thalamus opticus; *H*, section of the pituitary body; *p*, pineal gland; below its stalk is the posterior commissure; *ca*, anterior commissure divided, and behind it the divided anterior pillar of the fornix; *tc*, lamina cinerea; *i*, infundibulum (cavity); *tc*, tuber cinereum; behind it the corpus albicans; *f*, mark of the anterior pillar of the fornix descending in the wall of the third ventricle; *Q*, pineal gland; *as*, aqueduct of Sylvius near the fourth ventricle; *cr*, crus cerebri.

being bounded *laterally* by the *clavæ* of the *funiculi graciles*, the *cuneate fasciculi*, and the *restiform bodies*; the upper by the *superior peduncles of the cerebellum*. Below it is continuous with the central canal of the cord; above, with the Sylvian aqueduct. Laterally it projects, as the

lateral recesses, to the point of contact of the medulla and cerebellum, this being its widest part. The lower pointed part of the ventricle is called the *calamus scriptorius*.

The roof of the lower triangle is formed by a *layer of epithelium* covering the *under surface* of the pia mater; that of the upper triangle is formed by the *valve of Vieussens*, together with the *superior peduncles*, in the upper part. The valve of Vieussens is streaked transversely by several laminae of gray matter separated by grooves, forming the *lingula*, which is a part of the superior vermiform process of the cerebellum.

Describe the valve of Vieussens.

The valve of Vieussens, or the *superior medullary velum*, is a white lamina between the superior peduncles of the cerebellum. Its upper part presents a ridge, the *frenulum*, on each side of which is the fourth nerve, joined by a transverse band with the opposite nerve.

Describe the floor of the fourth ventricle and accessory structures.

The epithelium forming the roof of the lower triangle is continuous with that covering the floor, and is thickened by some white matter, which runs for some distance along the edge of the lateral boundary, from the lateral recess above, nearly to the calamus scriptorius below. This constitutes the *tænia* or *ligula*. The epithelium is also thickened over the point of the calamus, and is here called the *obex*. The two choroid plexuses of the fourth ventricle depend from the roof, covered by epithelium. They send processes into the lateral recesses, around which part of the *ligula* is reflected, forming the *cornucopia*. The floor, medullary portion, presents several white lines, the *striæ acousticae*, which run outward from the median line across the restiform body to the auditory nerve. The floor presents also a *mesial groove*, on each side of which, below the striæ acousticae, toward which the apex is turned, is a small triangular depression, the *inferior fovea*. Its base sends off a *groove* from each angle, the inner of which runs toward the point of the calamus scriptorius, marking off between it and the median groove, the prominent lower portion of the *fasciculus teres*, triangular in shape with its base toward the striæ. The outer runs outward to the lateral boundary of the ventricle, and bounds a third triangular space with its base upward, ending near the striæ in the *acoustic tubercle*.

Between the two grooves just mentioned is a dark, somewhat triangular space, the *ala cinerea*, its narrower part at the inferior fovea, its broader side downward, forming the *eminentia cinerea*. Ventrally, this space practically includes the *nuclei* of the ninth, tenth, and eleventh nerves.

The upper part of the floor of the fourth ventricle presents, just above the inferior fovea on each side, a somewhat similar depression, the *superior fovea*. Between it and the mesial groove is the *upper part* of the *fasciculus teres*, and running from it toward the iter above is a groove,

the *locus cœruleus*. The color of the latter is due to a line of pigmented nerve-cells forming the *substantia ferruginea*.

In the floor of the fourth ventricle are also found the nuclei from which arise the fifth nerve, the seventh, eighth, and sixth. That for the fifth, its motor portion, lies below the lateral angle, and its sensory portion, more extensive, lies external to the latter; that for the seventh behind the superior olivary nucleus of the pons; that for the sixth, in a column of multipolar cells in the fasciculus teres, *above* the striæ acousticæ; and for the eighth the nuclei lie under the acoustic tubercle and striæ. The nuclei of the third and fourth nerves are in the floor of the aqueduct of Sylvius, and that of the twelfth is in the fasciculus teres *below* the striæ acousticæ.

CRANIAL NERVES.

How many cranial nerves are there? What are their names?

The cranial nerves consist of twelve pairs, as follows:

1st pair, Olfactory;	7th pair, Facial, portio dura;
2d pair, Optic;	8th pair, Auditory, portio mollis;
3d pair, Motor oculi;	9th pair, Glosso-pharyngeal;
4th pair, Pathetic;	10th pair, Pneumogastric;
5th pair, Trifacial;	11th pair, Spinal accessory;
6th pair, Abducens;	12th pair, Hypoglossal.

What are the origins of the cranial nerves?

These nerves have each a superficial and a deep origin. The former corresponds to its point of attachment at the surface of the brain; the latter to certain nuclei or collections of nerve-cells in the floor of the fourth ventricle and Sylvian aqueduct.

Describe the olfactory nerves.

The olfactory nerves, twenty on each side, descend from the under surface of the olfactory bulb through the cribriform plate to the nose. Internally they groove the vertical plate of the ethmoid; externally, the inner surface of the lateral mass. They are all non-medullated nerves.

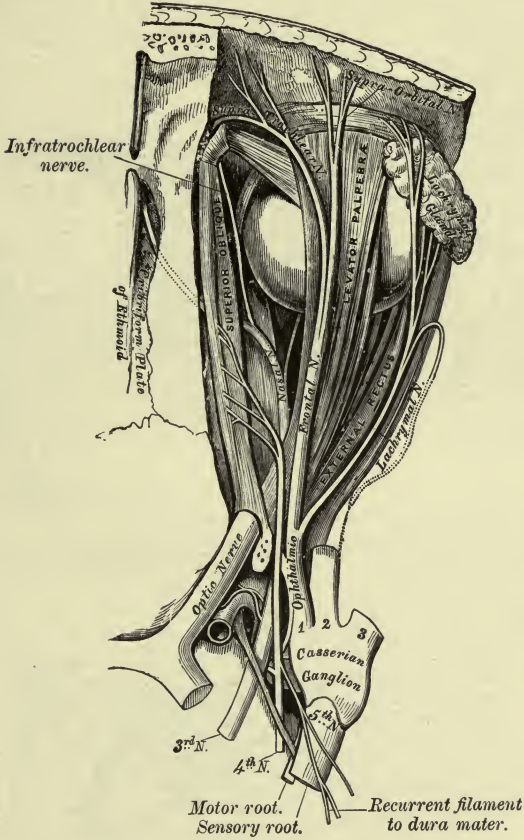
Describe the optic nerves.

The optic nerves of the two sides meet and partially decussate at the *commissure* or *chiasma*, back of which they enter the brain as the *optic tracts*. Each tract arises from the optic thalamus, corpora geniculata, and the superior corpus quadrigeminum as a flat band. This flattened band then crosses the crus cerebri, and, becoming rounded in form, is adherent to the tuber cinereum and lamina cinerea.

The *commissure* lies on the olivary eminence of the sphenoid bone, and in it most of the fibres decussate. The outer, however, are prolonged into the nerve of the same side. From the commissure each optic nerve runs through the foramen opticum, ensheathed by the dura mater and

PLATE XXI.

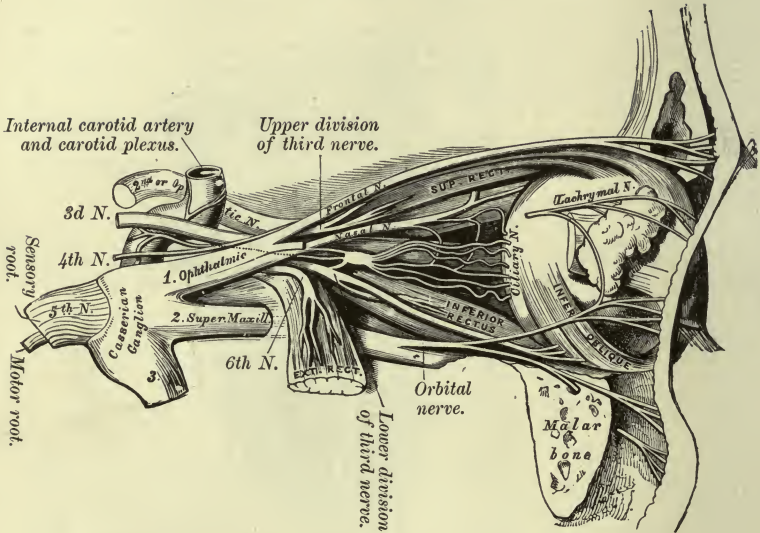
FIG. 1.—To face page 267.



Nerves of the Orbit, seen from above.

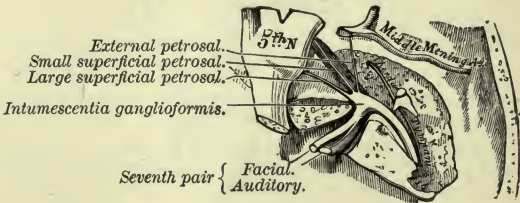
PLATE XXII.

FIG. 1.—To face page 267.



Nerves of the Orbit and Ophthalmic Ganglion (side view).

FIG. 2.—To face page 272.



The Course and Connections of the Facial Nerve in the Temporal Bone.

arachnoid, and pierces the eyeball just inside its centre, and, after running through the sclerotic and choroid, expands to form the retina.

Describe the motor oculi.

The motor oculi arises superficially from the crus anterior to the pons, its deep origin being a gray nucleus in the floor of the aqueduct of Sylvius. It runs to the outer side of the posterior clinoid process, enters the cavernous sinus, runs above the other nerves in its outer wall, and divides into *two branches*, which enter the orbit between the two heads of the external rectus. It is joined in the sinus by sympathetic filaments. The *superior* branch crosses the optic nerve to supply the superior rectus and levator palpebræ. The *inferior* divides into three parts—one for the inferior oblique, one to the inner and one to the lower rectus. The first supplies the motor root of the lenticular ganglion.

Describe the pathetic.

The pathetic nerve has an apparent origin from the upper side of the valve of Vieussens, and a deep from the floor of the aqueduct of Sylvius. The two nerves communicate by a transverse band on the valve of Vieussens. The nerve pierces the dura after crossing over the crus, enters the cavernous sinus, in whose outer wall it lies between the ophthalmic and third nerves, then crosses the latter to enter the orbit through the sphenoidal fissure above the external rectus, and enters the superior oblique after crossing over the levator palpebræ. It receives sympathetic filaments in the sinus, and sends a recurrent branch into the tentorium.

Describe the fifth nerve.

The fifth or trifacial is the largest of all the cranial nerves, and arises by two roots, a motor and a sensory. The former is small, and the latter has the Gasserian ganglion upon it. Both arise from the side of the pons superficially, the smaller root above the larger, some transverse fibres of the pons separating the two. This nerve confers both motion and sensation. At the apex of the petrous portion of the temporal the large root forms the *Gasserian ganglion*; the smaller does not join in the ganglion, but runs below it to join, just below the foramen ovale, the lowest trunk proceeding from the ganglion.

Describe the Gasserian ganglion.

The Gasserian ganglion lies in a hollow near the apex of the petrous portion of the temporal, the large superficial petrosal nerve, and the motor root lying below it. It receives branches from the carotid plexus. Small twigs pass to the dura mater. This ganglion sends off three large branches—viz. the ophthalmic, superior maxillary, and inferior maxillary.

The first two confer sensation, the third motion and sensation.

Describe the ophthalmic nerve.

The ophthalmic or first division of the fifth nerve is sensory, and the

smallest branch of the ganglion. It is flattened, about 1 inch long, and runs in the outer wall of the cavernous sinus, being the lowest of the nerves. It receives *filaments from the cavernous plexus*, and gives off *filaments* to the *third* and *sixth*, and sometimes to the *fourth* nerve, and a *recurrent* branch running in the tentorium with the fourth. Finally it divides into the frontal, lachrymal, and nasal nerves, which pass through the sphenoidal fissure into the orbit.

The **lachrymal**, the smallest, runs with the lachrymal artery above the external rectus muscle to the gland, which it supplies, as well as the conjunctiva, communicating with the superior maxillary nerve. It then pierces the palpebral ligament to end in the upper lid, joining branches of the facial.

The **frontal**, the largest branch, enters the orbit through the widest part of the sphenoidal fissure, just below the periosteum, and divides about the middle of the orbit into the *supratrochlear* and *supraorbital* nerves. The former runs in over the pulley of the superior oblique, and leaves the orbit between it and the supraorbital foramen. It then ascends beneath the muscles and ends in the skin of the forehead. It communicates in the orbit with the infratrochlear nerve. The frontal nerve continues as the supraorbital, which passes through the supraorbital foramen, supplies the upper lid, and divides into an inner and an outer branch. These ascend on the forehead and supply the pericranium and skin, the outer reaching nearly to the lambdoid suture.

The **nasal** enters the orbit between the two divisions of the third nerve, and between the heads of the external rectus, and then crosses over the optic nerve and runs to the anterior ethmoidal foramen. In the orbit it gives off a *branch* to the *ophthalmic ganglion*, several *long ciliary* to the eyeball, and an *infratrochlear* branch. It then re-enters the cranial cavity through the anterior ethmoidal canal. In the cranium it runs in a groove on the cribriform plate, and through a slit on the side of the crista galli into the nose, where it gives off an *external* and an *internal* branch. The latter supplies the mucous membrane of the septum, and the external the outer wall of the nasal fossa. The nerve then runs in the groove on the nasal bone to end as the *anterior* branch in the integument of the tip of the nose, joining facial branches.

Describe the ophthalmic ganglion.

It is found at the back of the orbit, between the optic nerve and the external rectus. It has three roots—viz. the long or *sensory*, from the nasal branch of the ophthalmic; a short or *motor*, from the branch of the third to the inferior oblique; and the *sympathetic* root, from the cavernous plexus.

Branches: six or eight *short ciliary*, which run with the ciliary arteries above and below the optic nerve, and are joined by the long ciliary from the nasal. They pierce the sclerotic to supply the ciliary muscle and iris.

Describe the second division of the fifth (superior maxillary) nerve.

It is sensory, and enters the foramen rotundum, crosses the sphenomaxillary fossa, and, as the *infraorbital*, traverses the canal, emerges from the foramen to end on the face in *palpebral*, *nasal*, and *labial* branches: the first, to lower lid; the second, to side of nose; and the third set, to upper lip. These branches join with the facial to form the infraorbital plexus. The superior maxillary nerve also gives off *two branches to Meckel's ganglion*, an *orbital* and *alveolar* branches, and a *recurrent* branch to the dura mater.

The *orbital* or temporo-malar branch enters the orbit by the sphenomaxillary fissure, and divides into two branches, which pierce the malar bone. The *malar* branch supplies the skin of the cheek, and joins the facial. The *temporal* branch, after piercing the malar bone, enters the temporal fossa, and ends in the skin over the fore part of the temporal region, joining the facial and auriculo-temporal nerves.

The *alveolar* or superior dental nerves are three. The *posterior* divides into two, which run on the zygomatic surface of the sup. maxilla, supplying the gum and the mucous membrane of the cheek, and enter the posterior dental canals to the molar teeth. The *middle* runs to the bicuspids along a canal in the antrum. The *anterior* descends in its canal, and gives a *nasal* branch to the pituitary membrane, and *dental* branches to the canine and incisor teeth.

Describe Meckel's ganglion.

It is also called the sphenopalatine, and lies in the sphenomaxillary fossa, close to the sphenopalatine foramen and below the superior maxillary nerve. Its *motor* root comes from the facial (see Vidian nerve), its *sensory* root from the two ganglionic branches of the superior maxillary nerve, and the *sympathetic* root from the carotid plexus. Its branches are as follows:

Ascending: *Several* through the sphenomaxillary fissure to the orbit. They may supply the periosteum.

Descending: The *small* or *posterior* runs with a *small* artery in the lesser palatine canal. It supplies the levator palati and azygos uvulae.

The *large* or *anterior* runs in the posterior palatine canal, thence in branches to the incisor teeth along grooves in the hard palate, and one joins the naso-palatine nerve. It gives off *inferior nasal* branches, through canals in the palate bone, to supply the spongy bones.

The *external*, to the outer part of the soft palate, through the external palatine canal.

The *internal* branches include the *naso-palatine* and the *upper nasal* nerves. The latter run through the sphenopalatine foramen to the spongy bones and septum. The *naso-palatine* nerve proceeds with the above, and then descends on the septum nasi, beneath the pituitary membrane, and through the mesial divisions of the anterior palatine canal, called

the foramina of Scarpa, the left anterior to the right. They supply the mucous membrane behind the incisor teeth.

The **posterior** branches are the *Vidian* and *pharyngeal* nerves. The *Vidian* passes back through the Vidian canal, and divides in the foramen lacerum medium into the *great superficial petrosal* and the *great deep petrosal*. The former passes through the foramen lacerum medium, runs in a groove on the anterior surface of the petrous portion of the temporal, enters the hiatus Fallopii, communicates with Jacobson's nerve, enters the aqueductus Fallopii, and joins the geniculate ganglion of the seventh nerve. The *deep* runs backward and joins the sympathetic in the carotid canal.

The *pharyngeal* nerve passes through the pterygo-palatine canal to the mucous membrane of the pharynx.

Describe the inferior maxillary nerve.

It is the largest branch, and arises by two roots—a large sensory root from the Gasserian ganglion and the motor root of the fifth. This nerve divides into two trunks, anterior and posterior. The *anterior* gives off the masseteric, the buccal the deep temporal and the two pterygoid.

The **masseteric** runs above the external pterygoid, crosses the sigmoid notch to masseter, supplying also filaments to the jaw.

The **deep temporal** are three, the posterior, middle, and anterior.

The **buccal** is a sensory nerve, and runs along the inner surface of the coronoid process to divide, on the buccinator, into branches to the muscles and skin joining the facial, and extending as far as the angle of the mouth.

The **pterygoid**, internal and external, supply those muscles respectively.

The *posterior* trunk of the inferior maxillary is mostly sensory. It divides into the auriculo-temporal, gustatory, and inferior dental.

The **auriculo-temporal** runs beneath the external pterygoid, the middle meningeal artery passing up between its two roots of origin to the inner side of the neck on the lower jaw. It then passes up under the parotid gland, and along with the temporal artery over the zygoma, and divides into temporal branches to the skin of the temporal region, joining the facial. This nerve communicates at its origin with the otic ganglion, and gives off the following branches:

Auricular, the inferior to the external meatus, the superior to the tragus and pinna.

Articular, one or two to the articulation of the jaw; several to the *parotid*, and the branches to the external auditory meatus send a filament to the membrana tympani.

The **inferior dental** nerve runs along with the artery, enters that canal, supplies the teeth, and at the mental foramen divides into an *incisor* and a *mental* branch. The former supplies the canines and incisors, the latter the skin of the chin and lower lip. The nerve is at first under the

external pterygoid; later, between the ramus of the jaw and the internal lateral ligament. Its branches are the *mylo-hyoid* and *dental*. The mylo-hyoid runs in the groove to supply the mylo-hyoid and anterior belly of digastric muscles. The dental supply the molars and bicuspid, interlacing to form a fine plexus, the inferior dental.

The **gustatory** or lingual nerve lies at first beneath the external pterygoid, internal to the dental nerve. Here a branch from the dental may cross the internal maxillary to join it. The chorda tympani also joins it. The nerve now runs along the inner side of the ramus of the jaw, and crosses the upper constrictor to the side of the tongue above the deep part of submaxillary gland; lastly, it runs below Wharton's duct, and superficially along the side of the tongue to its apex. It communicates with the facial through the chorda tympani, the submaxillary ganglion, inferior dental, and hypoglossal. It supplies the mucous membrane of the mouth and tongue (anterior two-thirds), the gums, sublingual gland, and the filiform and fungiform papillæ.

Describe the submaxillary ganglion.

It is placed above the deep part of the gland, and receives filaments from the gustatory and from the inferior maxillary nerve through the chorda tympani; also filaments from the sympathetic plexus around the facial artery.

Branches: Five or six to gland, Wharton's duct, and the mucous membrane of the mouth.

Describe the otic ganglion.

It is of a reddish color, oval and flattened in form, and $\frac{1}{4}$ inch in diameter. It lies on the inferior maxillary nerve (deep surface) below the foramen ovale, and behind it is the middle meningeal artery. It communicates with the inferior maxillary through its internal pterygoid branch, with the small superficial petrosal nerve, and with the plexus on the middle meningeal artery.

Branches: One to the tensor tympani, to tensor palati, to chorda tympani; and to the auriculo-temporal nerve two.

Describe the sixth nerve.

The **sixth** or **abducens** has an apparent origin in the groove between the pons and medulla, and a deep origin from the fasciculus teres. It runs to the lower and outer part of the dorsum sellæ, and traverses the floor of the cavernous sinus external to the carotid artery, and, receiving branches from the cavernous and carotid plexuses, enters the orbit by the sphenoidal fissure between the two heads of the external rectus; it receives a branch from the ophthalmic nerve, and supplies the above-named muscles.

What are the relations of the parts in the cavernous sinus and sphenoidal fissure?

In the *sinus*: the third, fourth, and the ophthalmic branch of the

fifth lie in the outer wall, in numerical order from above downward and from within outward; with the sixth nerve, on the floor and external to the carotid artery. In the *fissure*: the fourth, with the frontal and lachrymal divisions of the ophthalmic, lie in this order from within outward and just below the periosteum. All the rest enter between the heads of the external rectus in this order from above downward: the upper division of the third; nasal branch of the fifth; lower division of the third; and the sixth. The ophthalmic vein is below them all.

Describe the seventh nerve.

The **seventh** or **facial** has a superficial origin from the depression between the olivary and restiform bodies, and a deep from the fasciculus teres. Between it and the eighth is the *pars intermedia*, which joins the facial in the auditory canal. The nerve runs outward to the internal meatus, where it runs in a groove on the auditory nerve, enters the aqueductus Fallopii, and emerges at the stylo-mastoid foramen. It presents within the aqueduct, near the hiatus Fallopii, a reddish enlargement, the *geniculate ganglion*. Outside the cranium it runs forward in the parotid gland, and divides behind the ramus into the *cervico-facial* and *temporo-facial* divisions. In the parotid and vicinity the radiating branches form the *pes anserinus*.

Communicating branches: In the internal auditory meatus, one or two communicating with auditory nerve.

In the aqueduct it communicates with Meckel's ganglion by means of the *large superficial petrosal*; with the otic ganglion by a small branch to the *small superficial petrosal*; with the sympathetic, on the middle meningeal, by the *external petrosal*; and with the pneumogastric (auricular branch).

Outside the cranium: it sends branches to the glosso-pharyngeal, carotid plexus, auricularis magnus, auriculo-temporal, and facial nerves.

Branches of distribution: In the aqueduct: a *tympanic* branch to the stapedius, and the *chorda tympani*. The latter arises close to the stylo-mastoid foramen, ascends in a small canal to the posterior wall of tympanum, and then passes over the upper part of the membrane between the handle of the malleus and the incus, finally emerging through the canal of Huguier; it then descends on the inner side of the internal lateral ligament of the jaw, and joins the gustatory nerve, through which its fibres reach the submaxillary ganglion and lingualis muscle. It receives a branch from the otic ganglion before joining the lingual.

Outside the cranium: the *posterior auricular* ascends between the ear and the mastoid, receives a branch from the vagus, one from the auricularis magnus, and one from the occipitalis minor, and divides into an auricular branch to the back of the auricle and retrahens, and an occipital branch to the occipito-frontalis.

The *digastric* branches, to the posterior belly of the digastric, one joining the glosso-pharyngeal nerve; and a *stylo-hyoid* branch to the muscle, joining the carotid plexus.

The *temporo-facial division* crosses the external carotid artery and the temporo-maxillary vein in the upper part of the parotid, receives filaments from the auriculo-temporal nerve, and divides into three sets of branches—viz. temporal, malar, and infraorbital.

The *temporal* branches supply the atollens and attrahens, occipito-frontalis, orbicularis, and corrugator supercillii. They communicate with the auriculo-temporal, temporal branch of superior maxillary, and supra-orbital nerves.

The *malar* branches run to the outer angle of the orbit, supply the orbicularis and corrugator, joining the lachrymal and supraorbital, and some, to lower lid, join with the superior maxillary nerve (palpebral branches).

The *infraorbital* group, to the space between the orbit and mouth. They supply the buccinator, orbicularis oris, the levator labii superioris, the levator anguli oris, and nasal muscles. They unite with the cervico-facial branches, the nasal, infratrochlear, and with the superior maxillary nerve. The latter forms the infraorbital plexus.

The *cervico-facial* division descends through the parotid, joining branches of the great auricular, and divides, near the angle of the jaw, into buccal, supramaxillary, and inframaxillary branches.

The *buccal* cross the masseter, supply the buccinator and orbicularis oris, and join the infraorbital nerves and the buccal nerve from the inferior maxillary.

The *supramaxillary*, beneath the depressor anguli oris, supplies the inferior labial muscles, and joins branches of the inferior dental.

The *inframaxillary* pierces the deep cervical fascia, supplies the platysma, and forms arches in the suprahyoid region, joining the superficial cervical nerve.

Describe the auditory nerve.

The **eighth** or **auditory** is the special nerve of the sense of hearing. Superficially it appears at the lower border of the pons, external to the facial. It has two roots—one from the inner side of, and one from the front of, the restiform body. It runs to the internal auditory meatus with the facial nerve, the two being separated by the pars intermedia and the auditory artery. The nerve in the meatus divides into a *cochlear* and a *vestibular* branch.

Describe the ninth nerve.

The **ninth** or **glosso-pharyngeal** arises superficially by several filaments from the groove between the olivary and restiform bodies at the upper part of the medulla; deeply through the lateral tract to a gray nucleus in the floor of the fourth ventricle.

The nerve runs in front of the flocculus to pass through the middle part of the jugular foramen with the vagus and spinal accessory, in a separate sheath, and here presents two successive ganglionic enlargements, the jugular and the petrous ganglia. Outside the cranium it

passes between the jugular vein and the internal carotid artery, descending in front of the latter, and beneath the styloid process and its muscles, to the lower border of the stylo-pharyngeus. It then crosses this muscle and divides into branches beneath the hyoglossus. In the jugular foramen it grooves the lower border of the petrous portion of the temporal.

The *upper* or *jugular ganglion* is of small size, and is formed in the outer part of the nerve, some fibres passing over but not joining it.

The *petrous ganglion* is larger, and lies in a groove in the petrous bone, involving the entire trunk of the nerve. From it pass the *tympanic* nerve and branches of communication to the vagus and sympathetic. That to the sympathetic joins the upper cervical ganglion. To the vagus, one joins its auricular branch and one its upper ganglion. Another branch perforates the posterior belly of the digastric, from a point just below the petrous ganglion, to join the facial close to the stylo-mastoid foramen.

The *tympanic* (Jacobson's nerve) runs in a canal in the petrous portion to enter the tympanum through an aperture in its floor close to the inner wall, and divides into branches which groove the promontory and form the tympanic plexus. It gives a branch to the *fenestra rotunda*, *fenestra ovalis*, and to the Eustachian tube. The nerve finally emerges from the tympanum by a canal at its upper and back part, as the *small superficial petrosal* nerve. This latter enters the cavity of the skull by a small foramen on the anterior surface of the petrous portion external to the hiatus Fallopii, and escapes by a small foramen in the great wing of the sphenoid, sometimes the foramen ovale, to join the otic ganglion.

The tympanic nerve sends a communicating branch to the carotid plexus, the *small deep petrosal*.

Branches in the neck :

The *carotid* branches run on the internal carotid to its commencement at the common carotid, joining the pharyngeal branches of the vagus and the sympathetic.

The *pharyngeal*, three or four, pierce the superior constrictor to the mucous membrane of the upper pharynx.

The *muscular*, to the stylo-pharyngeus.

The *tonsillitic*, to the tonsil and soft palate, form the circulus tonsillaris and join the palatine nerves.

The *lingual* are the two terminal branches. One supplies the mucous membrane of the posterior third of the tongue and the circumvallate papillæ; the other, to the side of the tongue, joins the gustatory.

Describe the pneumogastric nerve.

The *tenth, vagus, or pneumogastric*, is both motor and sensory. Its apparent origin is by twelve to fifteen filaments below, and in the line of the origin of, the ninth; its deep origin is from a nucleus in the lower part of the fourth ventricle. It passes through the jugular foramen in the same sheath with the spinal accessory, a partition separating them

from the ninth, and develops the *ganglion of the root* of the vagus. Emerging from the foramen, it forms the *ganglion of the trunk* of the vagus.

The *ganglion of the root* (*ganglion jugulare*) is gray in color and spherical, its diameter about 2 lines. It has branches of communication with the accessory part of the spinal accessory, with the petrous ganglion of the ninth, with the facial, and with the superior cervical ganglion of the sympathetic.

The *ganglion of the trunk* (*ganglion cervicale*) is larger, of a reddish color and cylindrical form. Its surface is crossed by the accessory portion of the eleventh, and it communicates with the hypoglossal, the upper two cervical, and the sympathetic nerves.

The vagus then descends between the internal carotid artery and the jugular vein to the thyroid cartilage, then between the vein and the common carotid to the root of the neck.

On the right side the nerve crosses the first part of the subclavian artery, descends behind the right innominate vein and alongside of the trachea, and spreads out into the posterior pulmonary plexus behind the root of the lung. Below, two cords emerge from this plexus and ramify on the œsophagus, forming, with branches from the left, the œsophageal plexus. Again forming a single trunk, the nerve descends on the back of the œsophagus to ramify on the posterior surface of the stomach.

On the left side the nerve runs behind the left innominate vein, between the left carotid and subclavian arteries, and crosses the arch of the aorta. It forms the left posterior pulmonary plexus, assists to form the œsophageal plexus, and as a single trunk descends on the front of the œsophagus to ramify on the anterior surface of the stomach.

Branches: (a) In the jugular foramen: An *auricular* branch (Arnold's), from the jugular ganglion, receives a branch from petrous ganglion of the ninth, traverses a small canal in the petrous portion of the temporal, crosses the aqueductus Fallopii, and communicates with the facial. It escapes through the auricular fissure, then divides into a branch to the auricle, and a second which joins the posterior auricular. A *recurrent* branch from the jugular ganglion supplies the dura mater in the posterior fossa.

(b) In the neck: A *pharyngeal* branch from the cervical ganglion, deriving its fibres mainly from the spinal accessory, crosses the internal carotid, and joins with glosso-pharyngeal and sympathetic in the pharyngeal plexus. This plexus supplies the muscles and mucous membrane of the pharynx.

The *superior laryngeal*, from the lower ganglion, runs internal to the internal carotid vessels, receiving branches from the pharyngeal plexus and sympathetic, and divides into the external and internal laryngeal nerves.

The *external* runs beneath the sterno-thyroid to supply the crico-thyroid. It supplies the inferior constrictor, and sends branches to the pharyngeal plexus and superior cardiac nerve.

The *internal* branch pierces the thyro-hyoid membrane to supply the mucous membrane of the larynx, and by a long branch joins a similar offset from the recurrent nerve behind the ala of the thyroid cartilage. A twig supplies the arytenoideus.

The *inferior* or *recurrent laryngeal* on the right side arises in front of the subclavian artery and winds backward around that vessel; on the left it arises in front of the arch of the aorta and winds backward around it. Both nerves ascend between the trachea and œsophagus, behind the common carotid and inferior thyroid arteries, to the lower border of the cricoid cartilage. They enter the larynx beneath the inferior constrictor, supplying all its intrinsic muscles excepting the crico-thyroid, and join the superior laryngeal. Each gives off *cardiac* nerves which join those from the vagus and sympathetic; *tracheal* and *œsophageal* branches, and one to the inferior constrictor.

The *cervical cardiac* nerves, two or three, are divided into the *superior*, joining the cardiac branches of the sympathetic; and the *inferior*, one on each side. The right lies in front of the innominate artery, and joins the deep cardiac plexus. The left, in front of the arch of the aorta, joins the superficial cardiac plexus.

(c) In the chest: The *thoracic cardiac* branches, the right from the trunk of the vagus and from the recurrent branch, the left from the latter only. They join the deep cardiac plexus.

Pulmonary nerves, two or three anterior, join the sympathetic and form the anterior plexus on the root of the lung. The posterior, larger and more numerous, join branches from the second, third, and fourth thoracic ganglia to form the posterior plexus. Offsets from these nerves accompany the bronchi throughout the lung.

The *œsophageal*, above and below the preceding. The lower and larger branches come from the œsophageal plexus.

(d) *Gastric branches*: These are the terminal branches of the vagi. The right, to the posterior surface, join the cœliac, splenic, and left renal plexuses. The left, to the anterior surface and lesser curvature, join the right nerve, the sympathetic, and the hepatic plexus.

Describe the eleventh pair.

The *eleventh*, or *spinal accessory*, consists of a *spinal* portion and an *accessory part* to the vagus. The *latter* part arises as five or six filaments from the lateral tract of the medulla, below the origin of the vagus. It sends some filaments into the ganglion jugulare of the vagus, and joins that nerve below the ganglion cervicale, being continued, for the most part, into the pharyngeal and superior laryngeal branches.

The *spinal portion* arises from the lateral column of the cord as low as the sixth cervical nerve, the fibres being connected with the anterior horn of gray matter. This part then ascends, between the posterior nerve-roots and the ligamentum denticulatum, through the foramen magnum, then out again by the jugular foramen, lying in the sheath of the vagus, and here communicates with the accessory portion. After its exit from the

skull it crosses the internal jugular vein and pierces the sterno-mastoid to end in the trapezius.

Describe the hypoglossal.

The twelfth or hypoglossal nerve arises by ten to fifteen filaments from the groove between the pyramid and olivary body. The deep origin is from a nucleus in the floor of the fourth ventricle. The filaments form two bundles which pierce the dura separately and unite in the anterior condylar foramen. The nerve descends behind the internal carotid artery and internal jugular vein, closely bound to the vagus, then passes forward between the artery and vein, and becomes superficial below the digastric, curving around the occipital artery. It now crosses the external carotid and lingual arteries, runs between the mylo-hyoid and hyoglossus, communicates with the gustatory nerve, and after piercing the genio-glossus breaks up into filaments to the substance of the tongue.

Branches of communication pass to the vagus, superior cervical ganglion of sympathetic, to the loop between the first and second cervical, and to the gustatory nerves.

Branches of distribution:

Descendens noni leaves the nerve as it crosses the occipital artery, descends within or in front of the carotid sheath, and, joining the *communicantes noni*, forms a loop from which the sterno-hyoid and thyroid and both bellies of the omo-hyoid are supplied. Its origin can be traced to the first and second cervical nerves.

The *thyro-hyoid* branch crosses the great cornu of the hyoid bone, to supply the muscle.

Muscular branches pass to the stylo-glossus, hyo- and genio-hyoglossus, and genio-hyoid muscles.

Meningeal branches run to the posterior fossa, leaving the nerve at the foramen.

THE SPINAL NERVES.

Name and describe the origin of the spinal nerves.

The spinal nerves consist on each side, of eight cervical, twelve dorsal, five lumbar, five sacral, and one coccygeal, in all thirty-one pairs, which arise from the cord by two roots, *anterior* and *posterior*. The latter are the larger and are supplied with ganglia. The suboccipital or first cervical nerve has no ganglion. The two roots unite just beyond the ganglion, and the resulting *trunk* divides into *two divisions*, anterior and posterior, each containing fibres from both roots. The *posterior division* divides into an *external* and an *internal* branch. The *anterior divisions* in the dorsal region remain separate, but elsewhere they unite into plexuses.

Describe the posterior divisions of the cervical nerves.

That of the *first* or *suboccipital* does not divide into an external and internal branch. It crosses the atlas to the suboccipital triangle, and

supplies the complexus, the obliqui, and posterior recti, a branch joining the second nerve. Of the *other* nerves, the *external* branches supply the splenius, transversalis colli, cervicalis ascendens, and trachelo-mastoid. The *internal*, except that of the second, run inward: those of the third, fourth, and fifth, between the complexus and semispinalis, supply them and the multifidus and the skin over the trapezius. The *internal branches* of the sixth, seventh, and eighth run beneath the semispinalis, and supply no cutaneous branches. The internal branch of the second, known as the *great occipital nerve*, pierces the trapezius and complexus, supplies the latter, and runs with the occipital artery supplying the back of the head, and sends a branch to the small occipital.

Describe the posterior divisions of the other spinal nerves.

In the *dorsal* region the *external* branches increase in size from above downward, pierce the longissimus dorsi to supply the erector spinæ group, and those of the lower six, the skin. The internal branches of the six upper supply the multifidus and semispinalis dorsi and the skin. The six lower internal supply the multifidus, but not the skin.

In the *lumbar* region the *internal* branches end in the multifidus. The *external* supply the intertransverse muscles and erector spinæ, and the upper three the skin over the gluteal region.

In the *sacral* region, of the *upper three*, the *internal* branches end in the multifidus spinæ, and the *external* anastomose with the fourth sacral and last lumbar. They send off filaments over the great sciatic ligament, finally ending in the skin by two branches.

The *last two* do not divide, but join the coccygeal nerve.

The posterior division of the *coccygeal* nerve ends with the above, and supplies the skin over the coccyx.

Describe the anterior divisions of the spinal nerves.

They are larger than the posterior. Each division is connected with the sympathetic. Those of the *cervical*, *lumbar*, and *sacral* nerves form plexuses. Those of the dorsal nerves for the most part remain separate. (See *Brachial Plexus*.)

Describe the cervical plexus.

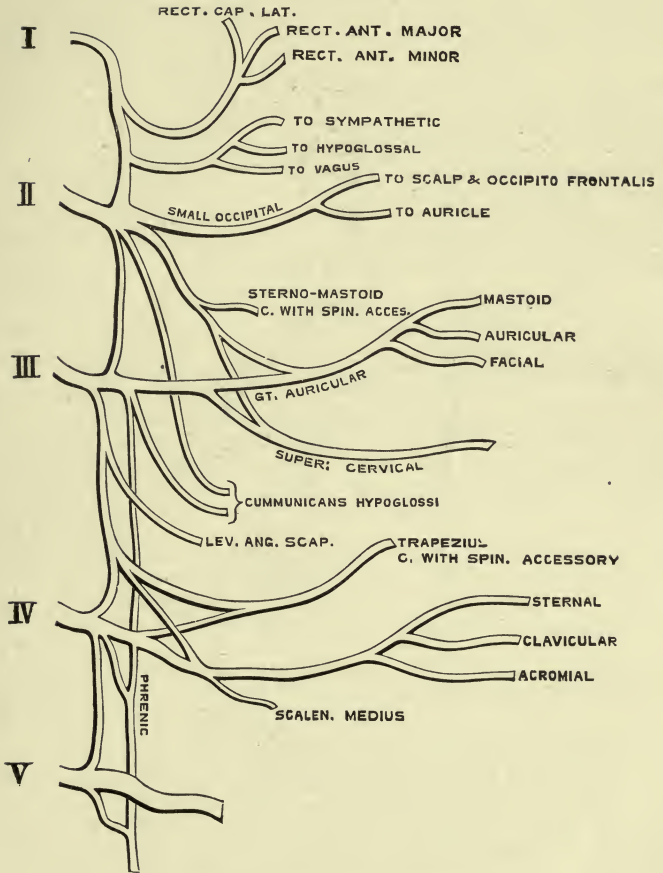
It is formed by the anterior divisions of the upper four cervical nerves, which emerge between the scalenus medius and rectus anticus major. It lies upon the scalenus medius and levator anguli scapulæ, beneath the sterno-mastoid. Each nerve except the first divides into a branch for the nerve above and one for the nerve below. The anterior division of the first (suboccipital) nerve grooves the atlas beneath the vertebral artery, and joins the second, supplying the rectus lateralis and recti antici. It communicates with the sympathetic, vagus, and hypoglossal nerves.

What are the branches of the cervical plexus?

Its branches are *superficial* and *deep*.

PLATE XXIII.

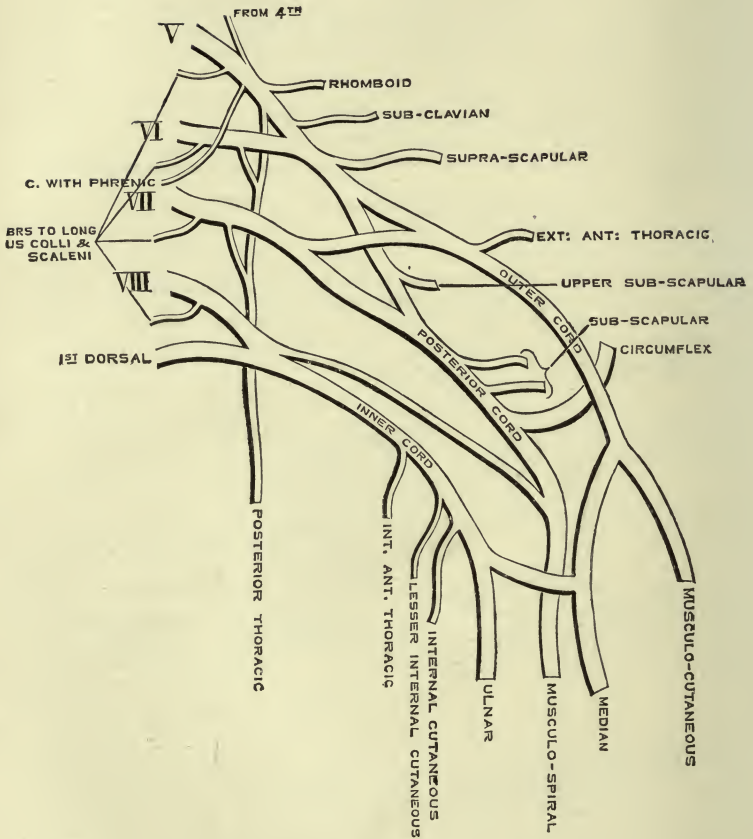
FIG. 1.—To face page 278.



Plan of the Cervical Plexus.

PLATE XXIV.

FIG. 1.—To face page 280.



Plan of the Brachial Plexus.

The *superficial* are divided into ascending and descending.

1. ASCENDING BRANCHES :

(a) The **superficialis colli**, from the second and third nerves, crosses the sterno-mastoid, and divides under the platysma into two branches, an upper and a lower, which ramify in the skin of the front of the neck, from the maxilla to the sternum.

(b) The **auricularis magnus**, from the second and third, runs over the sterno-mastoid to the parotid region, and supplies *facial* branches to the skin over the parotid, a *mastoid* branch to the skin in that region, and *auricular* branches to the lobule and back of the auricle. By these branches the nerve also communicates with the facial and small occipital.

(c) The **occipitalis minor**, from the second and third (sometimes only the second), runs along the posterior border of the sterno-mastoid to the head and supplies the scalp. It communicates with the great occipital and the great and posterior auricular nerves, and gives a branch to the auricle.

2. DESCENDING BRANCHES: these are the supraclavicular nerves. They arise from the third and fourth cervical, and divide into the *supra-sternal*, *supraclavicular*, and *supra-acromial* branches, which descend between the trapezius and sterno-mastoid to supply the skin over the regions indicated by their names.

The *deep* branches consist of an *external* and an *internal* series.

The **EXTERNAL** include **muscular**, to the sterno-mastoid (from the second); trapezius, scalenus medius, and levator anguli scapulæ (from the third and fourth), and **communicating**, which join the spinal accessory within the sterno-mastoid and trapezius, and also between these two muscles.

The **INTERNAL** are: **communicating**, from the loop between the first and second, to the vagus, hypoglossal, and sympathetic, and a branch from the fourth to the fifth;

Muscular, to the lateral and anterior recti muscles (from the first and second);

Communicantes noni, generally two, one from second and one from third, pass under or over the internal jugular to join the descending branch from the hypoglossal nerve;

Phrenic, from the third, fourth, and fifth, descends on the scalenus anticus, then between the subclavian artery and vein, and crosses the internal mammary artery. It then crosses the root of the lung and runs between the pericardium and mediastinal pleura to the diaphragm; it communicates with the sympathetic, descendens noni, and the nerve to the subclavius. The *right* is deeper than the left. It runs external to the innominate vein and superior vena cava. The *left* crosses the front of the aortic arch and the left vagus. Both phrenics supply the diaphragm, pleura, and pericardium. Filaments from the right, with the phrenic branches of the solar plexus, form a ganglion which sends branches to the suprarenal capsules and inferior vena cava and to the hepatic plexus; on the left side there is no ganglion.

Describe the brachial plexus.

Formed by the anterior divisions of the lower four cervical and first dorsal, as follows: the fifth and sixth form an upper; the seventh, a middle; and the eighth cervical with first dorsal a lower trunk. Each of these trunks then separates into an anterior and a posterior branch.

The anterior branches of the upper and middle trunks form the *outer cord* of the plexus; the anterior branch of the lower, the inner cord: of the posterior cord it is variously stated that the posterior branches of all three trunks form it, or that the posterior branches of the upper and middle trunks form it, while the posterior branch of the lower trunk joins the musculo-spiral nerve. It is altogether a matter of dissection.

The plexus is at first between the anterior and middle scalmi, then above and external to the subclavian artery. It passes behind the clavicle and subclavius, lying on the subscapularis and serratus magnus. The *cords* lie external to the first part of the axillary artery, but surround the second part of that vessel.

What are the branches of the brachial plexus?

BRANCHES ABOVE THE CLAVICLE: a *branch from the fifth* joins the phrenic, and **muscular** branches supply the scalmi, longus colli, rhomboidei, and subclavius. The *branch to the subclavius*, from the trunk formed by the fifth and sixth cervical, crosses the subclavian artery, its third part, and sends a branch to the phrenic nerve.

The **posterior thoracic** nerve from fifth and sixth cervical runs out of the scalmi medius and descends behind the clavicle upon the serratus magnus, which it supplies.

The **suprascapular** nerve, from the fifth and sixth, enters the supraspinous fossa by the notch, supplies an *articular* branch and one to the muscle, also a branch to the infraspinous fossa and muscle.

BRANCHES BELOW THE CLAVICLE: the *three cords* give off the following nerves: the outer, the musculo-cutaneous, outer head of median, external anterior thoracic; the inner, the internal anterior thoracic, inner head of median, internal and lesser internal cutaneous, and the ulnar; the posterior, the musculo-spiral and circumflex and subscapular.

Describe the thoracic and subscapular nerves.

The **anterior thoracic** nerves supply the pectoral muscles. The *external* crosses the axillary artery and gives a branch to the inner nerve, and the internal runs forth between the artery and vein, and joins the branch from the external, forming a loop around the artery.

The **subscapular**: the *upper* supplies the subscapularis at its upper part; the *middle* or *long* accompanies the subscapular artery to the latissimus dorsi; and the *lower* supplies the subscapularis and teres major.

Describe the internal "cutaneous" nerves.

The **internal cutaneous**, on the inner side of the axillary artery,

divides at the middle of the arm into an *anterior* branch, crossing over or under the median basilic vein, which supplies the forearm as far as the wrist, and a *posterior*, which winds above the inner condyle to back of humerus, and runs to lower part of forearm. This nerve communicates with the lesser nerve and the ulnar, and supplies the skin over the biceps.

The lesser internal cutaneous (of Wrisberg) runs behind and then internal to the axillary vein and joins the intercosto-humeral nerve. It then runs along the inner side of the brachial artery, and supplies the skin as far as the olecranon and internal condyle.

The intercosto-humeral bears a complementary relation, in point of size, to the lesser nerve, and may even replace it altogether.

Describe the circumflex and musculo-cutaneous nerves.

The **circumflex** nerve, behind the axillary artery, winds back through the space bounded by the triceps, humerus, and the two teretes muscles, gives a filament to the shoulder-joint, and divides into two branches, an *upper* and a *lower*. The *former* winds around the humerus to the anterior border of the deltoid, supplying it and the skin, and the *latter* supplies the skin over the lower two-thirds of the deltoid as well as the muscle, and gives a branch to the *teres minor* upon which a ganglion is developed.

The external or **musculo-cutaneous** nerve arises opposite the lower border of the pectoralis minor, and runs through the *coraco-brachialis* and over the *brachialis anticus* to pierce the fascia at the outer border of the *biceps*. It then runs behind the median cephalic vein and divides into two branches, *anterior* and *posterior*.

In the arm it supplies the three muscles mentioned above, a *filament* to the *elbow-joint*, and one to the *humerus*.

The *anterior* branch crosses the radial artery at wrist and joins a branch of the radial nerve and the palmar cutaneous branch of the median. It supplies the skin over the radius and twigs to the artery. The *posterior* branch descends along the back of the forearm to the wrist and joins branches of the radial and musculo-spiral nerves.

Describe the median nerve.

It arises by two roots, an outer from the outer cord and an inner from the inner cord, which unite in front of the axillary artery. It crosses over (or under) the brachial artery to its inner side. It enters the forearm between the two heads of the pronator *teres*, running on the flexor profundus and beneath the annular ligament into the hand. At the wrist it lies behind and to the ulnar side of the palmaris longus.

Describe its branches.

BRANCHES: in the arm, none.

In the forearm it supplies all the *superficial flexor muscles* except the flexor carpi ulnaris; some filaments to the elbow-joint;

The *anterior interosseous* nerve. This runs along the interosseous membrane with the artery of that name. It supplies the flexor longus pollicis and the outer half of the flexor profundus digitorum muscles, between which it lies, and also the pronator quadratus, in which it ends.

The *palmar cutaneous* branch pierces the fascia above the annular ligament, and supplies the skin over the ball of the thumb and the palm. It communicates with branches of the ulnar and external cutaneous nerves.

In the palm: the nerve lies on the flexor tendons, covered by the annular ligament, and becomes larger and reddish in color. It divides into two branches—the *external*, supplying some of the muscles of the thumb and digital branches to the thumb and index finger; and the *internal*, supplying digital nerves to the index, middle, and ring fingers.

The *muscular* branches supply the abductor, opponens, and outer head of the flexor brevis pollicis. The *first digital*, with the second, supplies the thumb, the former joining a branch of the radial. The *third*, along the radial side of the index finger, supplies it and the first lumbricalis. The *fourth* supplies the adjacent sides of the index and middle fingers and the second lumbricalis. The *fifth*, to the adjacent sides of the middle and ring fingers joins a branch of the ulnar. Each digital nerve divides at the tip of the finger into a branch to the pulp and one to the matrix of the nail. At the base of the first phalanx each sends a branch to the back of the second and third phalanges.

Describe the ulnar nerve.

The ulnar runs internal to the axillary and brachial arteries as far as the middle of the arm. It then passes to the groove between the olecranon and internal condyle with the inferior profunda artery, and runs between the two heads of the flexor carpi ulnaris, lying beneath the muscle above and to the radial side of it below. In the lower two-thirds of the forearm the ulnar artery is external. The nerve then crosses the annular ligament between the artery and pisiform bone, and divides into a *superficial* and a *deep* branch.

Describe its branches.

BRANCHES: In the arm, none.

In the forearm, several *articular* to the elbow. *Muscular*, to the flexor carpi ulnaris and inner half of the flexor profundus. *Two cutaneous*, by a common trunk. One joins a branch of the internal cutaneous, and the other, the *palmar cutaneous*, runs on the ulnar artery to the palm, joining branches of the median nerve.

The *dorsal cutaneous* runs backward beneath the flexor carpi ulnaris, and supplies dorsally the little and inner half of the ring finger. The latter communicates with the contiguous branch of the radial.

In the palm: the *superficial* and *deep* branches. The *former* supplies the skin and palmaris brevis and digital branches to the little and inner

half of the ring fingers, the latter joining a branch of the median. The *latter*, passing between flex. brev. and abductor min. digit., supplies all the muscles of the hand except those supplied by the median nerve, and sends filaments to the wrist-joint.

Describe the musculo-spiral nerve.

It runs behind the axillary and brachial vessels, and, later in the musculo-spiral groove with the superior profunda artery, then between the brachialis anticus and supinator longus. In front of the outer condyle it divides into the *radial* and *posterior interosseous* nerves.

BRANCHES: muscular and cutaneous.

Muscular branches: the *internal* supplies the inner and middle heads of the triceps; the *posterior* supplies the outer head of the triceps and the anconeus; the *external* supplies the supinator longus, extensor carpi radialis longior, and the brachialis anticus.

Cutaneous branches: the *internal* supplies the inner side of the posterior aspect of the arm; of the *two external*, the *upper* supplies the lower part of the upper arm; the *lower*, the lower half of the arm, forearm and wrist dorsally, joining the posterior branch of the musculo-cutaneous.

Describe the radial and posterior interosseous nerves.

The *radial*, beneath and parallel with the supinator longus, finally runs backward beneath its tendon, just above the wrist, pierces the fascia, and divides into two branches. Of these, the *external* supplies the radial side and ball of the thumb, and joins a branch of the musculo-cutaneous; the *internal*, after communicating with the musculo-cutaneous, supplies dorsally digital branches to the thumb and index, index and middle, middle and outer half of the ring fingers.

This last joins with the contiguous branch of dorsal cutaneous of ulna, and they all terminate at base of second phalanx.

The *posterior interosseous* pierces the supinator brevis, and runs beneath the superficial muscles on the back of the forearm and on the lower part of the interosseous membrane. It supplies all the muscles of the back and outer part of the forearm except the supinator longus, extensor carpi radialis longior, and the anconeus, and terminates at the wrist in a ganglion from which are supplied the carpal ligaments and joint.

Describe the anterior divisions of the dorsal nerves.

First dorsal: the anterior division in part joins the brachial plexus, and the remainder of the nerve forms the first intercostal, which has no lateral cutaneous branch.

THE UPPER SIX are called the pectoral intercostal nerves, and lie below the vessels. At first they run between the pleura and the external intercostal muscles, then between the two planes of muscles to the middle of the rib, here giving off the *lateral cutaneous* nerves. The nerves

now enter the substance of the internal intercostals as far as the cartilages, where they lie between the muscles and the pleura. Finally they cross the internal mammary vessels and the triangularis sterni, pierce the internal intercostals and pectoralis major, and end in the skin of the chest, as the *anterior cutaneous* nerves of the thorax.

Branches: *muscular*, to the intercostals, triangularis, levatores costarum, and serratus posticus superior.

The *lateral cutaneous* are given off about midway to the sternum, pierce the serratus magnus and external intercostals, and each divides into two branches, anterior and posterior.

The *anterior* runs to the skin over upper part of the external oblique, mamma, and skin; the *posterior*, to the skin over the scapula and latis-simus dorsi.

The lateral cutaneous of the *second dorsal* crosses to the arm, joins the nerve of Wrisberg, pierces the fascia, and supplies the skin of the upper half of the inner and back part of the upper arm, joining the cutaneous branch of musculo-spiral nerve. This nerve is generally called the *intercosto-humeral*. It has no *anterior* division.

The LOWER SIX, or abdominal intercostals, run from the intercostal spaces behind the cartilages, between the internal oblique and transversalis, to the rectus, which they enter. They supply the intercostals, serratus posticus inferior, abdominal muscles, and end in the skin, as the *anterior cutaneous* nerves of the abdomen.

The *lateral cutaneous* branches have a similar distribution to those in the chest.

The LAST DORSAL nerve is altogether abdominal. It crosses the quadratus lumborum and runs in the abdominal wall like the lower intercostals. It communicates with the ilio-hypogastric and with the first lumbar nerve (*dorsi-lumbar*). Its *lateral cutaneous* branch supplies the skin of the forepart of the gluteal region as low as the great trochanter.

Each dorsal nerve is joined by short communicating branches from the sympathetic.

Describe the anterior divisions of the lumbar nerves.

The *first* unites with a branch from the last dorsal, the *dorsi-lumbar nerve*, and then proceeds, together with the *second*, *third*, and *fourth*, to form the lumbar plexus. The *fifth* joins the sacral plexus. They are joined by sympathetic filaments, and furnish branches to the psoas and quadratus muscles.

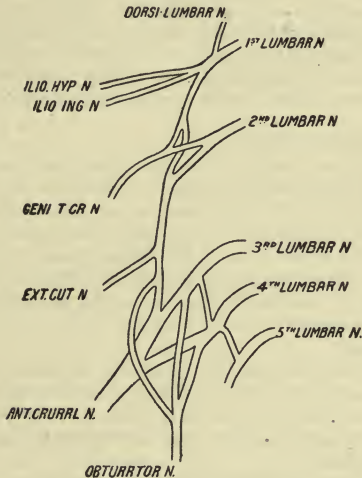
Describe the lumbar plexus.

It is formed in the substance of the psoas muscle, in the following manner: Each of the first four lumbar nerves divides into an *upper* and a *lower* branch. Just before dividing the *first* receives the *dorsi-lumbar* nerve, and the *third* and *fourth* send each a branch to the nerve below.

The *upper* branch of the first subdivides into the *ilio-hypogastric* and

ilio-inguinal nerves. The *lower* branch of the first passes downward and subdivides into two branches, one of which unites with the *upper* branch of the second to form the *genito-crural* nerve. The other unites with the *lower* branch of the second to form a cord. This cord passes downward, and gives off the *external cutaneous* nerve and a branch to the obturator, after which it unites with the upper branches of the third and fourth to form the *anterior crural* nerve. The lower branches of the third and fourth unite to form the *obturator* nerve. (See Fig. 15.)

FIG. 15.



Describe the ilio-hypogastric and ilio-inguinal nerves.

The ilio-hypogastric escapes at the upper part of the psoas, crosses the quadratus, pierces the transversalis at the iliac crest, and divides, between it and the internal oblique, into two branches. The *iliac* branch supplies the skin over the glutei, behind the lateral cutaneous of last dorsal; the *hypogastric* branch communicates with the ilio-inguinal, and pierces the oblique muscles to supply the skin of the pubic and hypogastric regions.

The ilio-inguinal crosses the quadratus and iliacus below the preceding, pierces the transversalis, communicating with the ilio-hypogastric, and runs in the inguinal canal, supplying the skin of the groin, scrotum, and penis (the labium in the female).

Describe the genito-crural and external cutaneous nerves.

The genito-crural runs downward through and on the psoas muscle,

and divides some distance above Poupart's ligament into a *genital* and a *crural* branch. The *former* lies on the external iliac artery, sending filaments around it, and runs with the cord through the inguinal canal to the cremaster muscle; in the female it runs on the round ligament. The *crural* branch runs under Poupart's ligament into the thigh, sending filaments around the femoral artery, and lying superficial to the artery in the femoral sheath. It supplies the skin of the upper thigh, and joins the middle cutaneous.

The **external cutaneous** crosses the iliacus and enters the thigh through the notch below the anterior superior spine of the ilium, dividing into an *anterior* and a *posterior* branch. The *former* runs in a canal within the fascia lata, and becomes cutaneous 4 inches below Poupart's ligament. It supplies the front and outer part of the thigh to the knee, sometimes joining in the patellar plexus. The *posterior* branch supplies the skin of the outer and back part of the thigh halfway to the knee.

Describe the obturator nerve.

The **obturator** nerve emerges from the inner border of the psoas at the pelvic brim. It runs above the obturator vessels to escape at the upper part of the obturator foramen, dividing into two branches separated by the adductor brevis. The *anterior* runs beneath the pectineus and adductor longus, joining at the lower part of the latter with branches of the long saphenous and internal cutaneous nerves to form a plexus. A *branch* supplies the *hip-joint*; *muscular branches* to gracilis and adductor longus, sometimes to the adductor brevis and pectineus; the terminal branch to the femoral artery.

The *posterior* branch pierces the obturator externus and runs behind the adductor brevis on the adductor magnus, and supplies these muscles. A branch to the knee-joint pierces the magnus, lies on the popliteal artery, sending branches to it, and pierces the ligamentum Winslowii to supply the synovial membrane.

The *accessory obturator* arises by branches from the second, third, and fourth nerves, or is a branch of the obturator. It runs along the inner border of the psoas, and, crossing the pubes, divides beneath the pectineus into three branches—one to the anterior branch of the obturator, another to the hip-joint, and a third to the pectineus. It is not constant.

Describe the anterior crural nerve.

It is the largest branch of the lumbar plexus. It enters the thigh between the psoas and iliacus, external to the femoral artery, and divides into an *anterior* (mainly cutaneous) and a *posterior* (mainly muscular) portion.

Branches:

Within the abdomen, three or more branches to the iliacus, and a branch to the femoral artery.

ANTERIOR PORTION:

(a) The *middle cutaneous* pierces the fascia lata 4 inches below Pou-

part's ligament, and divides into two branches which run on the front of the thigh to the patella. It joins the crural branch of the genito-crural and the internal cutaneous nerves.

(b) The *internal cutaneous* crosses the femoral artery and divides into two branches, anterior and posterior. It supplies several cutaneous filaments which follow the course of the long saphenous vein, one reaching to the knee. The *anterior* branch runs to the knee, perforating fascia lata low down, and, crossing the patella to its outer side, communicates with a branch of the long saphenous nerve. The *posterior* branch runs along the posterior border of the sartorius, communicates with the internal saphenous nerve, and supplies the skin of the inner side of the thigh (lower part) and leg. It perforates fascia lata at inner side of knee. It also joins branches of the obturator beneath the fascia.

(c) Branch to the pectineus passing behind the femoral vessels.

(d) Branches to the sartorius from the middle cutaneous.

POSTERIOR PORTION :

(a) Branch to the rectus femoris ; also sends a twig to the hip-joint.

(b) Branch to the vastus externus.

(c) Branches to the crureus : one of these sends a filament to the knee-joint.

(d) Branch to the vastus internus accompanies the saphenous nerve and sends a filament to the knee-joint.

(e) The *internal saphenous* nerve accompanies the femoral vessels, being at first external to, and later crossing, the artery. It then runs beneath the sartorius to the inner side of the knee, pierces the fascia, and accompanies the saphenous vein along the inner side of the leg. Passing in front of the inner ankle, it ends on the inner side of the metatarsus. It communicates with the obturator and internal cutaneous.

Branches supply the skin of the leg. The terminal branches communicate with the musculo-cutaneous, and a *patellar* branch spreads out over the knee and joins in the patellar plexus.

Describe the anterior divisions of the sacral and coccygeal nerves.

The anterior division of the *fifth lumbar* receives a branch from the fourth, and, under the name of the *lumbo-sacral* cord, joins the first sacral.

The anterior divisions of the *first four* sacral nerves escape by the anterior sacral foramina ; the *fifth*, between the sacrum and coccyx ; all join with filaments from the sympathetic.

The first *three*, with a branch from the fourth, enter into the formation of the sacral plexus.

The *fourth*, its remaining portion, sends branches to the bladder and adjacent viscera, and supplies the levator ani, coccygeus, external sphincter, and skin of the perineum. It also sends a branch to the fifth sacral. The visceral branches unite with occasional branches from the third sacral and with the sympathetic.

The *fifth* sacral pierces the coccygeus, supplying it and the skin over the coccyx. Branches from the fourth sacral and the coccygeal nerve join it.

The anterior division of the *coccygeal* nerve, very small, pierces the coccygeus and sacro-sciatic ligaments, and terminates by uniting with the fifth sacral.

Describe the sacral plexus and enumerate its branches.

It is formed by the anterior divisions of the *first, second, third,* and *part* of the *fourth* sacral nerves, together with the lumbo-sacral cord. The lumbo-sacral cord, with the first, second, and part of the third sacral nerve, is continued into the upper great branch of the plexus, and the remainder of the plexus forms the lower or smaller branch.

BRANCHES: besides these two principal branches, which are, respectively, the *great sciatic* and the *pubic* nerves, the upper nerves of the plexus give off the nerves of the *pyriformis, quadratus femoris, obturator internus,* and *gemelli*, as well as the *superior* and *inferior gluteal, small sciatic,* and a *perforating cutaneous* branch.

Describe the muscular branches.

The muscular branch to the *obturator internus* crosses the spine of the ischium and enters the small sciatic foramen to the inner surface of the muscle. It also supplies the *superior gemellus*. That to the *quadratus femoris* runs beneath the tendon of the obturator internus, and supplies also the *inferior gemellus* and hip-joint. Lastly, the *pyriformis* receives several filaments from the sacral nerves previous to the formation of the plexus.

Describe the gluteal nerves.

The *superior gluteal* emerges above the pyriformis, through the great sciatic notch, and divides into an *upper* branch, to the gluteus medius, and a *lower*, larger branch, which supplies both the medius and minimus, piercing the latter to end in the tensor vaginae femoris. It arises from the lumbo-sacral cord and first sacral nerve.

The *inferior gluteal* emerges below the pyriformis, dividing into numerous branches for the gluteus maximus. It sends a branch to join the small sciatic. It arises from the lumbo-sacral cord and first and second sacral nerves.

Describe the small sciatic and perforating cutaneous nerves.

The *small sciatic* appears below the pyriformis, and runs beneath the gluteus maximus upon the great sciatic nerve, thence beneath the fascia lata, which it pierces just below the knee. It communicates with the external saphenous nerve. It arises from the second and third sacral nerves.

Branches: *cutaneous*, to the calf of the leg, to the inferior gluteal region, and to the back and inner part of the thigh (*femoral cuta-*

neous); and the *inferior pudendal* nerve, derived below the tuber ischii, to the scrotum or labium majus and the skin of the upper and inner part of the thigh.

The **perforating cutaneous nerve**, from the fourth sacral nerve, pierces the great sciatic ligament and turns over the lower border of the gluteus maximus to supply the skin over its lower part.

Describe the pudic nerve.

The **pudic nerve** emerges between the coccygeus and pyriformis, and crosses the ischial spine to re-enter the pelvis by the lesser sacro-sciatic foramen. It divides, in the ischio-rectal fossa, into the *inferior hemorrhoidal*, *perineal*, and *dorsal nerve* of the *penis vel clitoridis*.

The *inferior hemorrhoidal* supplies the external sphincter and the skin of the back part of the perineum, communicating with the pudendal and perineal nerves.

The *perineal* runs in a sheath of the obturator fascia along the outer wall of the ischio-rectal fossa, and divides into *superficial* and *deep* branches. The *latter* supply the external sphincter and the muscles of the perineum, sending a branch to the mucous membrane of the urethra, which pierces the corpus spongiosum.

The *superficial* branches are external and internal. The former supplies the scrotum and inner side of the thigh, and the latter runs nearer to the middle line and supplies the skin of scrotum. Both the superficial perineal nerves communicate with the pudendal and hemorrhoidal branches, and in the female end in the labia majora.

The *dorsal nerve* of the penis (in the female of the clitoris) accompanies the pudic artery, and runs along the dorsum to the glans. It supplies branches to the constrictor urethræ, to the integument of the penis, and to the corpus cavernosum. On the penis it receives branches from the sympathetic. In the female the analogue of this nerve is smaller, with a like distribution.

Describe the great sciatic nerve.

This is the largest nerve in the body, and includes fibres from the greater part of the sacral plexus. From the lower border of the pyriformis it descends on the gemelli, obturator internus, and quadratus, then on the adductor magnus, being covered by the gluteus maximus and long head of the biceps, and accompanied by the small sciatic nerve and the sciatic artery. It divides at the lower third of the thigh into the *external* and *internal popliteal nerves*. It supplies the biceps, semitendinosus and semimembranosus, adductor magnus, and hip-joint.

Describe the internal popliteal nerve.

This is the larger branch of bifurcation of the great sciatic. It runs along the middle of the popliteal space to the lower border of the popliteus, where it becomes the posterior tibial. It is at first external to, then behind, and lastly internal to, the popliteal artery.

Branches: three *articular*, one accompanying the azygos articular artery, and one each the upper and lower articular arteries on the inner side of the knee-joint.

Muscular: one to each head of the gastrocnemius, to the plantaris, to the soleus, and to the popliteus. The latter gives filaments to the tibia and interosseous membrane, and turns beneath the lower border of the muscle.

Cutaneous: the *external* or *short saphenous nerve*, or tibial communicating. It runs between the two heads of the gastrocnemius, pierces the fascia about halfway down the calf, and receives the peroneal communicating nerve from the external popliteal. It then runs in company with the short saphenous vein, along the outer border of the tendo Achillis and below the outer malleolus, to end in the skin of the outer side of the foot and little toe, communicating with the musculo-cutaneous nerve.

Describe the posterior tibial nerve.

The posterior tibial nerve is the continuation of the internal popliteal from the lower margin of the popliteus. It is successively internal, behind, and external to the artery, and divides between the inner ankle and heel into the *two plantar nerves*.

Branches: *articular*, to the ankle.

Muscular: one each to the tibialis posticus, flexor longus digitorum, flexor longus pollicis, and the soleus.

A *cutaneous* branch pierces the internal annular ligament to supply the skin of the heel and back part of the sole.

Describe the plantar nerves.

The *internal plantar nerve* runs beneath the abductor pollicis, then between it and the flexor brevis pollicis, and divides into its digital branches.

Branches: *muscular*, to the abductor pollicis and flexor brevis digitorum.

Cutaneous, to the skin of the sole.

Digital branches as follows: the first, to the inner side of the great toe, supplies the flexor brevis pollicis; the second, to the great and second toes, supplies the first lumbricalis; the third, to the second and third toes, supplies the second lumbricalis; and the fourth, to the third and the inner side of the fourth toe, communicating with the external plantar. Each digital nerve supplies cutaneous and articular branches and terminates as in the hand.

The *external plantar* runs between the flexor accessorius and the flexor brevis digitorum, dividing between the latter and the abductor minimi digiti into a superficial and a deep branch. Before dividing it supplies the flexor accessorius and abductor minimi digiti.

The *superficial* gives a digital branch to the outer side of the little toe, which supplies its short flexor and sometimes also the interossei of the

fourth space, and another digital branch to the adjacent sides of this toe and the fourth.

The *deep* branch dips under the accessorius and flexor muscles, and supplies all the dorsal and plantar interossei except, occasionally, those of the fourth space; it also supplies the outer two lumbricales, the adductor pollicis, and the transversus pedis.

Describe the external popliteal nerve.

The **external popliteal** or **peroneal** nerve runs between the biceps muscle and outer head of the gastrocnemius, turns round the fibula below its head and beneath the peroneus longus, and divides into the anterior tibial and the musculo-cutaneous nerves.

Branches: articular, with the upper and lower external articular arteries, and occasionally a *recurrent articular* branch, with the recurrent tibial artery, reaches the joint.

Cutaneous, two in number, supply the skin of the outer and back part of the leg; and another, the *peroneal communicating*, joins the short saphenous nerve.

Describe the musculo-cutaneous nerve.

The **musculo-cutaneous** nerve runs between the extensor longus digitorum and the peronei, and pierces the fascia at the lower part of leg, dividing into two branches, *external* and *internal*, for the toes.

Branches: muscular, to the peroneus longus and brevis; *cutaneous*, to the lower part of the leg.

The terminal branches: of these, the *internal* runs on the dorsum of the foot and supplies the adjacent sides of the second and third toes and the inner side of the great toe. It communicates with the long saphenous and anterior tibial nerves.

The *external* supplies the fourth toe, together with the contiguous sides of the third and fifth. It communicates with a branch of the short saphenous nerve.

Describe the anterior tibial nerve.

The **anterior tibial** nerve, from between the peroneus longus and fibula, runs along the front of the interosseous membrane with the artery to the ankle, where it divides into an external and an internal branch. It is at first external, then in front, and below again external to the artery.

Branches: muscular, to the tibialis anticus, extensor longus digitorum, extensor proprius, and the peroneus tertius; *articular*, to ankle; and its terminal branches. Of these—

The *external* runs under the extensor brevis digitorum, and supplies it as well as the neighboring joints.

The *internal* accompanies the dorsal artery of the foot to the first interosseous space, and supplies the skin of the great and second toes, joining a branch of the musculo-cutaneous. Both these nerves send interosseous branches to the metatarso-phalangeal joints.

THE SYMPATHETIC NERVOUS SYSTEM.

Describe the general arrangement of the sympathetic nervous system.

The sympathetic nervous system consists of a series of ganglia, cords, and plexuses, with their communicating and distributing nerve-fibres. Its nerves supply all the viscera and the coats of the blood-vessels.

There are two principal **gangliated cords**, lying one on each side of the spine from the base of the skull to the coccyx. They consist of a series of ganglia connected by short single or double cords. The number of the ganglia corresponds in general to that of the vertebræ in the several regions, except in the neck, where there are but three.

Below, these cords end on the front of the coccyx by a loop on which is the ganglion impar, and above they are connected with the carotid plexus in the carotid canal.

The **ganglia** are *connected with the spinal nerves* by gray and white fibres, the former passing from the ganglia to the spinal nerves, and the latter *vice versâ*. The ganglia are also *connected together* by gray and white fibres, the latter being continuous with the fibres of the spinal nerves prolonged to the ganglia.

There are three great **plexuses**, consisting of nerves and ganglia. They are single and lie in front of the spine in the thoracic, abdominal, and pelvic regions, and each is named, from above downward, the cardiac, epigastric, and hypogastric plexus.

Describe the cervical part of the gangliated cord and the superior cervical ganglion.

The cervical part consists of three ganglia, named superior, middle, and inferior, on each side.

The *superior*, opposite the second and third cervical vertebræ, is reddish-gray in color, fusiform in shape, and lies on the rectus anticus major behind the internal carotid vessels.

Branches: an *ascending* branch runs alongside the internal carotid artery, and in the canal separates into an *outer* division, forming the carotid plexus, and an *inner*, forming the cavernous plexus.

The *carotid plexus* lies external to the artery. It sends one or more filaments to the sixth nerve as it lies alongside the artery, and some to the Gasserian ganglion; to the sphenopalatine ganglion it sends the large deep petrosal nerve, which joins the large superficial petrosal to form the Vidian; it also sends the small deep petrosal, which communicates with Jacobson's nerve by joining the tympanic plexus.

The *cavernous plexus*, in the cavernous sinus, lies below and internal to the internal carotid. It sends a branch to the third nerve, one to the fourth, several to the ophthalmic division of the fifth, the sympathetic root to the ophthalmic ganglion, and filaments to the pituitary body.

Both these plexuses supply terminal filaments which form plexuses on the ophthalmic and cerebral arteries and sub-branches:

A *descending* branch to the middle cervical ganglion.

External branches to the first four spinal nerves, to the ganglia of the vagus, the petrous ganglion of the glosso-pharyngeal, and to the hypoglossal.

Three *internal* branches—viz. pharyngeal, laryngeal, and the superior cardiac nerve. The *pharyngeal* runs to the pharynx and unites with the branches of the ninth and tenth cranial, forming the pharyngeal plexus.

The *laryngeal* branch joins the superior and external laryngeal nerves.

The *superior cardiac nerve* descends on the longus colli behind the common carotid sheath, and crosses the inferior thyroid artery and recurrent nerve. It rises from the upper ganglion, and receives filaments from a communicating branch between it and the middle ganglion. On the *right* side it crosses the subclavian, and runs along the innominate artery to join the deep cardiac plexus behind the aorta. It receives many branches from the vagus and sympathetic. The *left* descends along the left carotid to enter the superficial cardiac plexus in front of the aorta.

The *anterior* branches of the superior ganglion pass to the blood-vessels—viz. to the external carotid and its branches—forming gangliated plexuses named lingual, facial, temporal, meningeal, etc. They communicate with the submaxillary and otic ganglia and with the geniculate ganglion of the facial nerve (*external petrosal nerve*).

Describe the middle cervical ganglion.

The *middle* (thyroid ganglion) lies in front of the sixth cervical vertebra, on the inferior thyroid artery. It is connected with the superior and inferior ganglia and with the fifth and sixth cervical nerves. It also gives off the *thyroid branches* and *middle cardiac* nerves.

The *thyroid* branches run along the inferior thyroid artery to the gland, and join the recurrent and external laryngeal nerves. On the artery they connect with the upper cardiac nerve.

The *middle cardiac nerve* (deep or great), on the left side, descends between the carotid and subclavian arteries to join the deep cardiac plexus; on the right it runs in front of or behind the subclavian artery, then along the trachea, to join the deep cardiac plexus. In its course it joins the recurrent branch of the vagus and the upper cardiac nerve.

Describe the inferior cervical ganglion.

It lies between the transverse process of the seventh cervical vertebra and the neck of the first rib, behind the vertebral artery, and communicates with the seventh and eighth cervical nerves. It sends branches to the middle cervical and first thoracic ganglion (these branches may be derived from the *middle* cervical ganglion), and some along the vertebral artery, forming a plexus. It also sends off the *inferior cardiac nerve*. This descends behind the subclavian artery and along the trachea, and, after communicating with the middle cardiac and recurrent nerve, ends in the deep cardiac plexus.

Describe the thoracic portion of the gangliated cord.

The ganglia lie in a line along the heads of the ribs, beneath the pleura and in front of the intercostal vessels. They communicate with the spinal nerves. The upper five or six supply the aorta, the vertebræ and their ligaments, and enter into the posterior pulmonary plexus.

The lower six or seven unite to form the splanchnic nerves.

Name and describe the splanchnic nerves.

The **great splanchnic** arises from the fifth or sixth to the ninth or tenth, descends obliquely along the spine, and pierces the crus of the diaphragm to end in the semilunar ganglion, sending branches to the renal plexus and suprarenal capsule.

The **small splanchnic** arises from the tenth and eleventh, and, piercing the crus, ends in the cœliac plexus, communicating with the preceding and the renal plexus.

The **smallest splanchnic** arises from the last ganglion, and pierces the crus, joining the renal plexus and sending branches to the cœliac plexus.

Describe the lumbar portion of the gangliated cord.

The lumbar ganglia lie in front of the spine, along the inner side of the psoas. They communicate with the ganglia above and below, and by two branches with each of the spinal nerves. *Branches*: some cross the aorta to join the aortic plexus; some cross the common iliacs and enter the hypogastric plexus; others supply the vertebræ and their ligaments.

Describe the sacral portion of the gangliated cord.

Over the sacrum the ganglia lie internal to the anterior sacral foramina, sending branches to the ganglia above and below, and two branches each to the sacral nerves. The remaining branches join together and send filaments, some to enter the pelvic plexus and others to form a plexus on the middle sacral artery. The two lowest ganglia on each side are joined by a loop over the coccyx, on which is the *ganglion impar*.

Describe the cardiac and epigastric plexuses of the sympathetic.

The *cardiac plexus* lies at the base of the heart, and consists of a superficial and a deep part.

The **superficial cardiac plexus** lies between the aorta and the right pulmonary artery. It is formed by the left superior cardiac nerve and the lower cervical cardiac branch of the left vagus, a small ganglion (Wrisberg's) being found at their point of union. It forms a great part of the right coronary plexus, and sends filaments to the anterior pulmonary plexus. It receives filaments from the deep cardiac plexus.

The **deep cardiac plexus** lies between the trachea and the aorta,

above the bifurcation of the pulmonary artery. It receives all the cardiac branches of the sympathetic, excepting the left superior cardiac, and of the vagus and its recurrent branch, excepting the lower cervical cardiac branch of the left side.

From the left side of the plexus branches pass to the superficial cardiac plexus and to the left coronary plexus. From the right, the branches in part join those from the superficial plexus to form the right coronary plexus; some pass to the left coronary plexus, others to the right auricle. Both sides of the plexus furnish filaments to the anterior pulmonary plexuses.

The *left coronary plexus* surrounds the left coronary artery and its branches, and supplies the cardiac muscle. The *right* surrounds the right coronary artery in a similar way. The former receives its filaments from the deep plexus, the latter from both superficial and deep.

The *epigastric (solar) plexus* is placed in front of the aorta and crura of the diaphragm, behind the stomach, and between the suprarenal bodies. It receives the great splanchnic nerves, and the vagi send branches to it. It consists of a collection of nerves and ganglia, and its branches accompany the vessels to the principal viscera of the abdomen.

The largest of its ganglia are the *semilunar*, one on each side. They lie near the suprarenal bodies, in front of the crura, the right one beneath the inferior vena cava. They receive the great splanchnic nerves.

The branches of the solar plexus form secondary plexuses.

Describe these secondary plexuses.

The *phrenic plexus*, on the artery of the same name, to the diaphragm, supplies also the suprarenal capsules. It joins with branches from the phrenic nerve, and at the point of junction on the right side is a small ganglion, the diaphragmatic, on the under side of the diaphragm.

The *suprarenal plexus* receives branches from the phrenic plexus and great splanchnic nerves. At the point where the latter join is a ganglion.

The *renal plexus* receives filaments from the aortic plexus and the small and smallest splanchnics. The branches run along the renal artery, and send filaments to the spermatic plexus and to the inferior cava.

The *spermatic plexus* is derived from the renal and aortic plexuses, and runs on the spermatic vessels. In the female (*ovarian*) it supplies the uterus and ovaries.

The *celiac plexus* surrounds the celiac axis, and divides into the gastric, hepatic, and splenic plexuses, which accompany the corresponding vessels. It receives splanchnic branches; on the left side it receives also filaments from the right vagus.

The *gastric plexus* receives filaments from the vagi.

The *hepatic plexus* receives branches from the left vagus, and sends nerves to the right suprarenal plexus, and forms secondary plexuses, which follow the branches of the hepatic artery.

The *splenic plexus* is reinforced from the left semilunar ganglion and the right vagus.

All the above plexuses run along with the arteries, and subdivide into secondary plexuses, corresponding to the arterial branches, which form complex communications with one another. The same applies to the following:

The *superior mesenteric plexus* is reinforced by a branch from the union of the coeliac axis and right vagus.

The *aortic plexus*, on the abdominal aorta, is reinforced by filaments from the solar plexus and lumbar ganglia, renal plexuses and semilunar ganglia. It ends in the hypogastric plexus.

The *inferior mesenteric plexus* arises from the preceding, and runs on the artery, joining superior mesenteric branches and the pelvic plexus.

Describe the hypogastric plexus.

The *hypogastric plexus* is formed by lateral prolongations from the aortic plexus and lumbar ganglia. It lies between the two common iliac arteries. Below it bifurcates into the two pelvic plexuses.

Describe the pelvic plexuses.

The *pelvic plexuses* (inferior hypogastric) lie one on each side of the rectum, and in the female the vagina. They receive filaments from the second, third, and fourth sacral nerves, and where these join the plexus small ganglia are developed. The nerves from the plexus supply all the pelvic viscera, accompanying the branches of the internal iliac artery and forming secondary plexuses.

Describe these secondary plexuses.

The *hemorrhoidal plexus* joins the superior hemorrhoidal branches (from the inferior mesenteric plexus) to supply the rectum.

The *vesical plexus* contains many spinal nerves, runs with the vesical arteries, and sends nerves along the vas deferens.

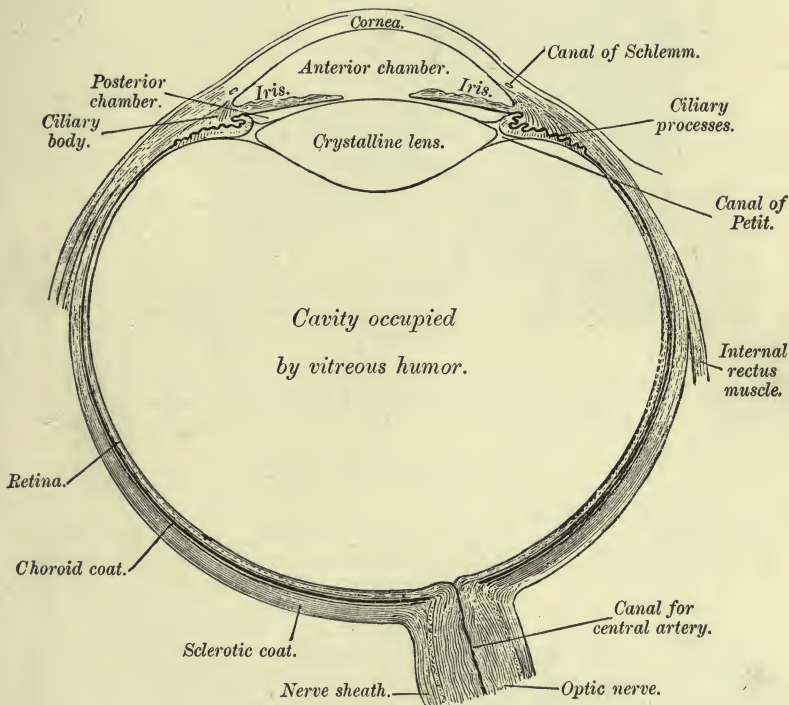
The *prostatic plexus* consists of large nerves from the lower part of the pelvic plexus, which supply the prostate, seminal vesicles, and cavernous bodies. These latter are divided into the small and large cavernous, and join the pudic branches. The small pierce the fibrous coat near the root of the penis and end in the erectile tissue. The large (single) runs forward on the dorsum, and supplies the corpora spongiosa and cavernosa.

The *vaginal plexus* runs in the vaginal walls and mucous membrane.

The *uterine plexus* sends some branches along the uterine artery, and others which directly pierce the cervix and lower part of the body. Branches pass also to the ovarian plexus and fundus uteri.

PLATE XXV.

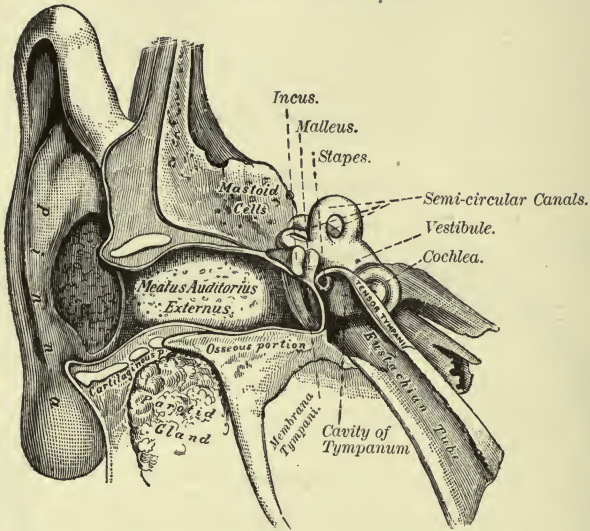
FIG. 1.—To face page 297.



Horizontal Section through the Left Eyeball (Allen).

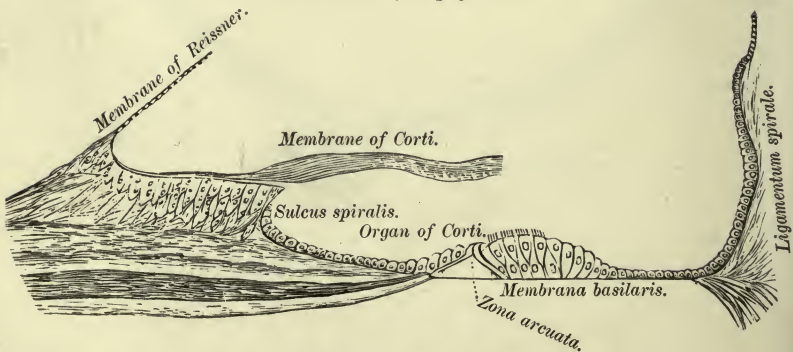
PLATE XXVI.

FIG. 1.—To face page 303.



A Front View of the Organ of Hearing, right side.

FIG. 2.—To face page 306.



Floor of Scala Media, showing the Organ of Corti, &c.

ORGANS OF SPECIAL SENSE.

THE EYE.

Give a general description of the eyeball.

The eyeball lies in the fat of the orbit, surrounded by a tunic of fascia, the *capsule of Tenon*. It is composed of segments of two spheres, an anterior smaller and a posterior larger, the junction of the sclerotic and cornea indicating their limits. It measures 1 inch transversely and vertically, and somewhat less from before backward. Behind it receives the optic nerve, and in front are the eyelids, eyebrows, etc., which comprise the so-called appendages of the eye.

Describe the appendages of the eye.

These include the eyebrows, eyelids, conjunctiva, the lachrymal gland and sac, and the nasal duct, the last three belonging to the "lachrymal apparatus."

The *eyebrows* (supercilia) are two prominent tracts of integument above the orbit, covered by thick hairs. They are connected with the orbicularis, corrugator supercillii, and occipito-frontalis muscles.

The *lids* (palpebræ) protect the eyeball. Each is composed of thin integument, areolar tissue, muscular fibres, the tarsal cartilage and ligament, Meibomian glands, and conjunctiva; the upper lid, which is also the more movable, contains, in addition, the aponeurosis of the levator palpebræ.

The *lids* are separated, when opened, by a space, the *fissura palpebrarum*, and are united at the angles (canthi). The outer canthus is sharp, and the inner is more obtuse. At the inner canthus, on each lid, is found the lachrymal tubercle, pierced by the *punctum lachrymale*, the upper opening of the lachrymal canal.

The *tarsal cartilages* (tarsi) are two plates of dense fibrous tissue, one in each lid. Into the anterior surface of the upper the levator palpebræ is inserted. Each is attached at the inner angle to the *tendo oculi* or internal tarsal ligament; at the outer angle to the external tarsal ligament, which is inserted into the malar bone.

The *tendo oculi* or palpebrarum is Y-shaped. The stem is attached to the nasal process of the superior maxillary, and each arm to one of the tarsal cartilages.

The *palpebral ligament* is a fibrous membrane attached to the tarsal cartilages and to the corresponding margin of the orbit.

The *Meibomian glands* lie on the inner surface of the lids, between the tarsal cartilages and the mucous membrane. In the upper lid there are about thirty; in the lower, fewer.

The *lashes* (cilia) are short, thick hairs forming a double row on the free margin of each lid. Above they are longer and more numerous.

The *conjunctiva* is the mucous membrane of the eye. The *palpebral* portion is very thick and vascular, and forms at the inner canthus a fold

known as the *plica semilunaris*. The *ocular* portion is loosely connected to the sclerotic, but over the cornea consists only of the conjunctival epithelium. The line of reflection from the lid on to the eyeball is called the *fornix conjunctivæ*.

Near the inner canthus there is also a collection of follicles constituting the *caruncula lachrymalis*, and external to this is the *plica semilunaris*.

Describe the lachrymal apparatus.

It includes the gland, the two canals, the sac, and the nasal duct.

The *gland* is about the size and shape of a small almond, and lies in a depression in the orbital plate of the frontal bone just inside the external angular process. Above it is attached to the periosteum, and below it rests on the eyeball and the upper and outer recti. In front it is closely connected to the upper lid and is covered by conjunctiva. Its ducts, ten or more in number, run beneath the conjunctiva and open separately at the outer part of the fornix.

The *lachrymal canals* commence by small orifices, the *puncta*, on the margin of each lid, and empty close together into the sac. The upper and longer ascends at first, then runs downward and inward; the lower ones downward, then inward.

The *lachrymal sac* is the upper dilated part of the nasal duct, and lies in a depression formed by the lachrymal and superior maxillary bones; it is invested by an aponeurosis derived from the *tendo oculi*, and is crossed by the *tensor tarsi*.

The *nasal duct* is contained in a canal formed by the superior maxilla, lachrymal and inferior turbinated bones, and runs from the lachrymal sac to the inferior meatus. It is lined by a mucous membrane continuous with the conjunctiva, is narrowest in the middle, and at its lower expanded orifice is the valve of Hasner. Its direction is downward, backward, and outward. Its epithelium is ciliated.

Describe the eyeball.

The eyeball consists of three coats enclosing the refractive media or humors. They are the sclerotic and cornea outside, the retina internally, and the choroid between them.

The *sclerotic coat* is a dense fibrous membrane, white and smooth externally, excepting where it receives the insertion of the recti and obliqui. Internally it is brown, grooved by the ciliary nerves, and united by a connective tissue, the *lamina fusca*, to the choroid beneath. It covers the posterior five-sixths of the eyeball. Behind it receives the optic nerve at a point just internal to the centre, the fibrous sheath of the former being continuous with the sclerotic. Here there is a number of small apertures (*lamina cribrosa*) for the funiculi of the optic nerve, and outside of these smaller foramina for the passage of vessels.

The *cornea* forms the anterior sixth of the external coat. It is transparent and projecting, and nearly circular in shape, the anterior surface being convex and the posterior surface concave.

Describe the choroid coat.

The second or intermediate coat is continued into the **choroid**, prolonged into the iris anteriorly, and forming the ciliary processes.

It is a chocolate-colored vascular structure lying between the sclerotic and retina and investing the posterior five-sixths of the eyeball, blending in front with the iris after forming a number of folds, the ciliary processes. Behind it is pierced by the optic nerve. It is smooth internally, and is connected to the lamina fusca of the sclerotic externally.

The *ciliary processes*, seventy or more in number, consist of a circle of folds or thickenings of the choroid received into pits in the vitreous and suspensory ligament of the lens. They are divided into a larger and a smaller set, the former being about $\frac{1}{10}$ inch in length. Their inner surface is covered by the layer of hexagonal pigmented cells of the retina.

The choroid is really a plexus of fine blood-vessels. Externally it presents a membrane, the *lamina suprachoroidea*, between which and the *lamina fusca* is a lymph-space which communicates with the capsule of Tenon through apertures in the sclerotic.

The *ciliary muscle* is a circular plane of unstriped muscle placed between the choroid and sclerotic at its anterior part. It consists of circular and radiating fibres. The latter arise near the union of the sclerotic and cornea, and are inserted into the choroid opposite the ciliary processes; the former surround the insertion of the iris.

The *iris* gives to the eye its color. It is a thin, contractile, circular membrane presenting, at about its centre, a circular aperture, the pupil. It is suspended in the aqueous humor behind the cornea and in front of the lens. Its circumference is continuous with the choroid and, through the *ligamentum pectinatum*, with the cornea. Its posterior surface is covered by dark pigment resembling that of a ripe grape; hence the term "uvea." The edges of the pupillary orifice are in contact with the lens, the size of the pupil varying from $\frac{1}{20}$ to $\frac{1}{8}$ inch across.

The muscle-fibres are radiating and circular. The latter form a sphincter for the pupil; the former constitute the dilator muscle.

Give the arterial and nervous supply of the iris.

The arteries are supplied from the long and anterior ciliary. The nerves are branches of the lenticular ganglion and the long ciliary from the nasal branch of the ophthalmic. They form a plexus around the circumference of the iris, and end in the muscular fibres and in a network on the front of the iris. The nerves to the circular fibres come from the motor oculi; those to the radiating, from the sympathetic.

Describe the retina.

It is a delicate nervous membrane on which the image of perceived objects is formed. It lies between the choroid and the hyaloid membrane of the vitreous, and is composed of ten layers. Behind, the optic nerve expands into it, and in front it terminates in a dentated margin,

the *ora serrata*, at the outer edge of the ciliary processes. It then sends off a thin, non-nervous membrane, the *pars ciliaris retinae*, to the tips of the ciliary processes. The inner surface of the retina presents at its centre an elliptical spot about $\frac{1}{20}$ inch across, the *macula lutea*. In the centre of this spot is a depression, the *fovea centralis*, which, on account of the extreme thinness of the retina, shows the pigmentary layer of the choroid, and hence presents the appearance of a foramen. About $\frac{1}{10}$ inch to the inner side of the yellow spot is the *porus opticus*, at which point the optic nerve enters, the nervous matter being heaped up here so as to form the *colliculus*.

What are Müller's fibres?

Passing through nearly the entire thickness of the retina, supporting its layers and binding them together, are the radiating fibres, or fibres of Müller. They form at one extremity the *membrana limitans interna*, and at the other the *externa*.

Describe the vitreous body.

The **vitreous** is a transparent gelatinous fluid enclosed in a transparent membrane, the *hyaloid*, and fills about four-fifths of the eyeball. In front it is hollowed out to receive the lens and its capsule, being adherent to the back of the latter. In the centre of the vitreous from the entrance of the optic nerve to the back of the lens runs a canal. It contains fluid, is about $\frac{1}{12}$ inch in diameter, and is called the canal of Stilling.

What is the crystalline lens?

It is a solid transparent biconvex body which lies, enclosed in its capsule, in front of the vitreous and behind the iris. The greater convexity is behind, and the lens measures antero-posteriorly $\frac{1}{8}$, transversely $\frac{1}{8}$, inch. It consists of concentric laminae which are progressively harder from without inward.

The *capsule* is an elastic, transparent, structureless membrane, in contact anteriorly with the iris and held in place by the *suspensory ligament*.

The *suspensory ligament* is a thin, transparent membrane placed between the vitreous humor and the ciliary processes, and presents externally a number of folds which receive those of the ciliary processes. It is really a part of the hyaloid membrane, which runs forward to the front of the margin of the lens. It is also called the *zonula of Zinn*, and is covered externally by the *pars ciliaris retinae*. Between its back part and the lens is a space, the canal of Petit. This canal is bounded in front by the suspensory ligament (*zonula of Zinn*), behind by the vitreous, and at its base is the capsule of the lens.

What is the aqueous humor?

It is the fluid which fills the space between the suspensory ligament and capsule behind and the cornea in front. That part of this space

which lies in front of the iris is called the *anterior chamber*, the part behind the iris is the *posterior chamber*. The latter is really only the small interval between the iris, suspensory ligament, and ciliary processes.

For a more complete description of the eye see *Histology* of this series.

THE EAR.

Describe the ear.

The ear is divided into the external ear, the middle ear or tympanum, and the internal ear or labyrinth.

Describe the external ear.

The external ear includes the projecting part, or *pinna*, and the *external auditory canal* and *meatus*. The pinna or auricle is concave externally and directed somewhat forward, presenting eminences and depressions to which various names have been given. Thus, the most external ridge is the *helix*; parallel and internal to this is the *antihelix*, a ridge which divides above to enclose the *fossa of the antihelix*; between these two ridges is the *fossa of the helix* (*fossa scaphoidea*); in front of the antihelix is a deep depression, the *concha*, which presents above and in front the commencement of the helix; in front of the concha is a small process, the *tragus*, which points backward; and behind this is the *antitragus*, a deep notch, the *incisura intertragica*, separating the two; and, lastly, below these is the *lobule*.

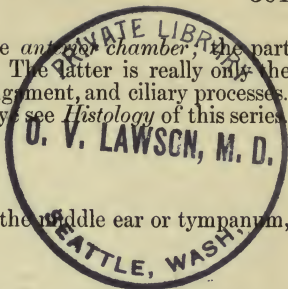
The pinna consists of a plate of yellow fibro-cartilage covered by skin and some adipose tissue. It enters also into the formation of the external meatus, being attached to the external auditory meatus of the temporal bone. The lobule contains only fat and strong fibrous tissue.

The *external auditory canal* is $1\frac{1}{4}$ inches long, and runs from the concha to the *membrana tympani*. It is directed somewhat forward, and presents an eminence in the floor of the osseous part, which makes the direction of the canal at first upward, then downward. It is narrowest at its middle. Its floor is longer than the roof, on account of the oblique position of the *membrana tympani*. It opens externally by means of the external auditory meatus.

Describe the middle ear or tympanum.

The tympanum is a cavity in the petrous portion of the temporal bone, extending from the *membrana tympani* to the outer wall of the labyrinth. Its width varies from $\frac{1}{12}$ to $\frac{1}{8}$ inch. It contains the ossicles of the ear, with their ligaments and muscles, and certain nerves. It is filled with air, and communicates by means of the Eustachian tube with the pharynx.

The *roof* of the tympanum is formed of very thin bone, which separates it from the cranial cavity. The *floor* is also of bone, and separates it from the jugular fossa beneath and the carotid canal in front. The *outer wall* is formed by the *membrana tympani* and the ring of bone



into which this is inserted, and presents, just in front of the bony ring, the Glaserian fissure, which lodges the processus gracilis of the malleus and transmits some tympanic vessels; at the back part, the iter posterius for the entrance of the chorda tympani, and the iter anterior, anteriorly, for its exit. The former leads to the aqueductus Fallopii, the latter to the canal of Huguier.

The *membrana tympani* is a thin membrane inserted into a ring of bone at the bottom of the external canal, which is grooved for its reception. It is ovoid in form and directed obliquely downward and inward. On its inner surface is the handle of the malleus, which extends to a little below its centre, covered by mucous membrane where it is attached. This process draws the membrane inward, making its outer surface concave and its inner convex. Externally, the membrane is covered with skin continuous with that of the meatus; internally, with mucous membrane continuous with that of the tympanum; and between these two is a fibrous layer, some of its fibres radiating from the handle of the malleus, others being circular and placed near the circumference. At the antero-superior part of the membrane is a notch in the bony ring, the notch of Rivini. That part of the membrane occupying it is called the *membrana flaccida*.

The *inner wall* of the tympanum is vertical and uneven. It presents the following: (a) The *fenestra ovalis*, leading into the vestibule, and occupied in the recent state by the base of the stapes and its annular ligament. (b) *Fenestra rotunda*, in a conical fossa leading into the cochlea, a rounded eminence, (c) the *promontory*, separating it from the preceding. It is closed, in the recent state, by the *membrana tympani secundaria*. This is composed of three layers, and is concave toward the tympanum. The middle layer is fibrous, the outer and inner being continuous with the lining membrane of the two cavities. The promontory indicates the first turn of the cochlea, and is grooved for branches of the tympanic plexus. (d) The *ridge* of the *aqueductus Fallopii*, running above the fenestra ovalis and descending on the posterior wall. (e) The *pyramid*, a hollow eminence containing the stapedius, the tendon of the muscle escaping through a foramen in its summit. A minute canal containing the nerve to this muscle runs from the aqueductus Fallopii to the cavity of the pyramid.

The *posterior wall* of the tympanum presents above one large and several small apertures leading to the *mastoid cells*.

The *anterior extremity* opens into two canals separated by a process of bone, the *processus cochleariformis*. The upper of these canals is the smaller and transmits the tensor tympani; the lower contains the Eustachian tube, an osseo-cartilaginous passage $1\frac{1}{2}$ inches long, leading to the pharynx. Both of these canals run in a direction downward, forward, and inward.

The osseous part of the Eustachian tube is $\frac{1}{2}$ an inch long, and to its lower end is attached the triangular piece of fibro-cartilage forming the remainder of the tube. The edges of the cartilage are not in contact,

but are joined by fibrous tissue. The tube is wide at its lower extremity, and opens at the upper and lateral part of the pharynx, above the hard palate and behind the lower turbinated bone. It is lined by epithelium continuous with that of the pharynx.

Describe the ossicula.

These are three small movable bones, named the malleus, incus, and stapes. The first is attached to the membrana tympani; the second is between the other two; the last-named is attached to the fenestra ovalis.

The **malleus** (a hammer) consists of a head, neck, and three processes—viz. the *processus gracilis*, the *processus brevis*, and the *manubrium*. The *head* articulates with the incus. The *neck* is below it, and rests on a *prominence* which is connected with the three processes. The *manubrium* tapers to its extremity, which is flattened, and it is connected with the membrana tympani. The tensor tympani is attached to its inner side near its upper end, and from its root springs the *processus brevis*. The *processus gracilis* is long and slender, and is connected by bone and fibrous tissue with the Glaserian fissure.

The **incus** (an anvil) has a *body* and *two processes*. The *body* presents a saddle-shaped articular surface for the malleus; the *short process* is conical, looks backward, and is attached to the opening which leads to the mastoid cells; the *long process* descends behind the manubrium of the malleus, to end in the *os orbiculare*, or lenticular process, which articulates with the head of the stapes.

The **stapes** (a stirrup) presents a *head*, which articulates with the *os orbiculare*; a *neck*, to which is attached the stapedius muscle; and *two crura*, diverging from the neck, and connected at their extremities by the *base*, which fills up the fenestra ovalis.

Describe the ligaments of the ossicula.

The articulations *between* the several bones are provided with synovial membranes; their surfaces are covered with cartilage and are connected by capsular ligaments. The following ligaments connect the bones with the walls of the tympanum:

The *anterior ligament* of the *malleus* is attached to the neck of the malleus at one end, and at the other to the anterior wall of the tympanum close to the Glaserian fissure, and its *suspensory ligament* runs from the roof of the tympanum to the head of the bone. An *external ligament* runs from the notch of Rivini to the body and lesser process, and the *accessory anterior ligament* is the thickened front portion of the sheath of the tensor tympani, which runs from the anterior wall to the manubrium and neck. An *inferior ligament* runs from the end of the handle to the outer wall of the tympanum.

The base of the stapes is fixed to the margin of the fenestra ovalis by an *annular ligament*.

The incus is provided with a *posterior ligament*, running from the

short process to the posterior wall, and a *suspensory ligament*, from the roof of the tympanum to the upper part of the bone near its articulation with the malleus.

Describe the muscles, mucous membrane, vessels, and nerves of the tympanum.

The **tensor tympani** runs in the canal previously mentioned. Arising from the under surface of the petrous portion, the cartilage of the Eustachian tube, and the margins of its own canal, its tendon is reflected over the *processus cochleariformis* and is inserted into the handle of the malleus near its root. It pulls on the malleus, thus drawing inward and making tense the *membrana tympani*. Its *nerve* comes from the otic ganglion.

The **stapedius** arises from the sides of its containing cavity within the pyramid, and, emerging from the apex, is inserted into the neck of the stapes. It draws the head of the stapes backward, thus pressing the base against the *fenestra ovalis* and compressing the contents of the vestibule. Its *nerve* is the tympanic branch of the facial.

The **mucous membrane** of the tympanum is pale and thin and its epithelium ciliated. It invests the contents of the cavity, the inner surface of the *membrana*, and covers the *fenestra rotunda*. It is continuous with that of the mastoid cells, Eustachian tube, and pharynx.

The **tympanic arteries** come from the internal maxillary, the stylo-mastoid branch of the posterior auricular, the petrosal branch of the middle meningeal, the Eustachian branch of the ascending pharyngeal, and from the internal carotid. The veins reach the internal jugular by means of the middle meningeal and pharyngeal veins.

The **nerves of the tympanum** are the *muscular*, already mentioned; the *nerves* to the *mucous membrane* from the tympanic plexus; the *communicating*, viz. between Jacobson's nerve, the sympathetic, and branches of the geniculate ganglion of the seventh; and the *chorda tympani*.

Jacobson's nerve (tympanic branch of the ninth) enters the tympanum in the floor and passes to the promontory. It forms the tympanic plexus, from which are supplied the *fenestræ*, Eustachian tube, and lining membrane, and sends off two communicating branches: one to the carotid plexus, one to the great superficial petrosal. It then receives a filament from the geniculate ganglion of the facial, and proceeds to join the otic ganglion as the lesser superficial petrosal nerve.

The *chorda tympani* arises from the facial near the stylo-mastoid foramen, enters at the base of the pyramid, crosses the tympanum between the long process of incus and handle of malleus, and runs through the *iter chordæ arterius* to the canal of Huguier.

Describe the internal ear.

This is the essential part of the hearing apparatus, since here the auditory nerve is distributed. It is contained in a cavity in the petrous

bone, and is made up of the osseous labyrinth and the membranous labyrinth.

Describe the osseous labyrinth.

The *osseous* labyrinth contains the *membranous* labyrinth, and is divided into three parts, the vestibule, semicircular canals, and cochlea. It communicates in the dry state with the tympanum by means of the fenestræ. Between the osseous and membranous labyrinth is a space occupied by a clear fluid, the perilymph, and within the membranous labyrinth is the endolymph.

The **vestibule** is the central cavity lying between the cochlea in front and the semicircular canal behind, the tympanum being external. Its *outer* or *tympanic wall* presents the *fenestra ovalis*.

Its *inner wall* has in front a depression, the *fovea hemispherica*, pierced by several minute holes for the auditory filaments, and, behind this, a ridge, the *crista vestibuli*. Behind this ridge is the opening of the *aqueductus vestibuli*. In the *roof* is a depression, the *fovea hemi-elliptica*.

Behind, the vestibule presents five foramina leading into the semicircular canals, and *in front* a larger foramen leading into the scala vestibuli of the cochlea.

The **semicircular canals** are three bony tubes of unequal length lying above and behind the vestibule, each forming about two-thirds of a circle. Their general diameter is $\frac{1}{20}$ inch, but at one end is a dilatation, the ampulla, $\frac{1}{10}$ inch in diameter. They empty into the vestibule by five apertures, in one of which two tubes join.

The *superior* is vertical and is set transversely, forming an eminence seen on the upper surface of the petrous bone. The ampulla of this tube opens into the upper part of the vestibule, the other end opening by a foramen into the back part, in common with the posterior canal.

The *posterior* is also vertical, but is set antero-posteriorly and is longer than the others, its ampulla being at the postero-inferior part of the vestibule, the other extremity joining with the preceding canal, as described.

The *external* is horizontal and the shortest, its ampulla being at the outer part, above the fenestra ovalis, and the other end at the upper and back part of the vestibule.

The **cochlea** resembles a snail-shell. Its apex looks forward and outward, and its base toward the internal auditory meatus. Within is a centre-piece, the *modiolus* or columella, around which the canal runs spirally for two and a half turns.

Within the canal, and attached to the modiolus, is the *lamina spiralis*. This plate of bone partially divides the spiral canal into two compartments or scalæ, the division being completed by a membrane (*see below*) which reaches the outer wall of the cochlea. The upper scala is known as the *scala vestibuli*; the lower is the *scala tympani*.

The *modiolus* or columella, the centre-piece of the cochlea, runs from base to apex. It is conical in form, the base corresponding to that of the cochlea, and is pierced by foramina for the cochlear branches of the

auditory nerve and for the vessels which pass to the lamina and spiral canal. One of these, larger than the rest, is the opening of the *canalis modiolii centralis*. Diminishing gradually in size, the modiolus terminates above in a bony process, the *infundibulum*, which blends with the cupola or last half turn of the spiral canal. Here the two *scalæ* communicate by a small opening, the *helicotrema*. Around the modiolus, along the attachment of the lamina spiralis, is the *spiral canal* of the modiolus, containing a gangliated portion of the cochlear nerve, the ganglion spirale.

The *spiral canal* is $1\frac{1}{2}$ inches long and $\frac{1}{10}$ inch in diameter at its widest part, which is below. The *scala vestibuli* communicates with the vestibule by the foramen above mentioned, and a part of it, marked off by a membrane, is called the *scala media* (see below). The *scala tympani* commences at the fenestra rotunda, and close to its commencement is the opening of the *aqueductus cochleæ*, by which it communicates with the subarachnoid space, and in which there is transmitted a small vein to the internal jugular. The *spiral lamina* ends above in a hook-like process, the *hamulus*, which partly bounds the *helicotrema*.

Describe the membranous labyrinth.

The membranous labyrinth is contained within the osseous labyrinth, having a similar form, though smaller and separated from it by the perilymph. It contains the endolymph and receives the distribution of the auditory nerve. In the vestibule it consists of the utricle and the saccule.

The *utricle* is in the upper and back part, its cavity communicating by five apertures with the membranous semicircular canals. It is in contact with the fovea hemi-elliptica.

The *saccule* is in the fovea hemispherica, and communicates with the utricle by means of a small tube which passes into the aqueductus vestibuli, and there joins a canal (*saccus endolymphaticus*), which canal is prolonged from the utricle and ends in a blind extremity; and with the *scala media* by means of the *canalis reuniens*.

The *membranous semicircular canals* are similar in shape to, but are only from one-fifth to one-third the diameter of, the bony canals; the ampullæ, however, are relatively large. Two small masses of calcium carbonate are found in the utricle and saccule. They are called the otoliths.

In the cochlea the membranous labyrinth is represented by the *scala media* and the parts therein, which are formed as follows:

Along the edge of the spiral lamina the periosteum on its upper surface is raised up like a C to form the *limbus laminae spiralis*. Thus there is a groove (the *sulcus spiralis*), the upper and lower lips of this sulcus being called respectively the *labium vestibulare* and *tympanicum*. From the latter the *membrana basilaris* extends to the outer wall, along the latter attachment forming the *ligamentum spirale*. Above the *limbus* to the outer wall stretches another membrane, *Reissner's*. The space below the osseous lamina and the *membrana basilaris* is the *scala tympani*; above the membrane of *Reissner* is the *scala vestibuli*; and that

space bounded by the two membranes and the outer wall of the cochlea is known as the *scala media*, or canal of the cochlea, which ends at the apex of the cochlea in a blind pointed extremity, and opens below into the saccule, as described above. Between the two membranes mentioned a third stretches across in the *scala media* to the outer wall. This is called the membrane of Corti, or *membrana tectoria*. Between the *membrana basilaris* and the last-named membrane is a space which contains the organ of Corti.

The *organ of Corti* lies on the basilar membrane. The central part is composed of two rows of peculiarly-shaped cells called the rods of Corti, outer and inner. These rods meet above by their extremities, and enclose an angular tunnel between them and the basilar membrane, the *zona arcuata*. The inner rods run close to the *labium tympanicum*, and along their inner side is a series of epithelioid cells continuous with the cubical epithelium of the *sulcus spiralis*. These present a row of short, stiff hairs, forming a sort of brush. External to the outer rods are several rows of similar cells. These are called the outer and inner hair-cells.

The *reticular lamina* is a delicate structure composed of small segments called phalanges arranged side by side and separated by holes, through which the hairs of the outer hair-cells project. The whole organ thus described is covered by the membrane of Corti (*membrana tectoria*).

Give the arterial and nervous supply.

The *arteries* of the internal ear are the auditory branch of the basilar, the stylo-mastoid branch of the posterior auricular, and branches occasionally from the occipital. The first named divides into a cochlear and a vestibular branch.

The *auditory nerve* divides at the bottom of the internal auditory meatus into a *superior* and an *inferior* branch. The former divides into branches, which are distributed to the utricle and to the ampullæ of the superior and external semicircular canals; the latter sends branches to the saccule, to the ampulla of the posterior canal, and to the cochlea.

The cochlear branch sends its filaments through the canals of the modiolus, and these form the *ganglion spirale*. This ganglion sends other filaments to the *sulcus spirale* and organ of Corti.

THE NOSE.

Describe the nose.

The nose is the organ of smell, and consists of an *external* part, the nose, and an *internal*, the nasal fossæ.

The *nose* is triangular, and is formed by the nasal bones and nasal processes of the superior maxillary bones, and of five cartilages—viz. the two upper and the two lower lateral cartilages, and the cartilage of the septum. The two openings; the anterior nares, are directed downward, and just inside of them are some short, stiff hairs, the vibrissæ. The bones

and cartilages are covered by skin on the outer side and by mucous membrane on the inner. Between the anterior nares is a fold of skin, the *columna nasi*, which continues the septum. The two lateral parts join in front to form the dorsum, and this ends below in the rounded lobe of the nose.

The *upper lateral cartilages* lie one on each side, below the nasal bones, and are triangular in form. The anterior margin joins its fellow above and the edge of the cartilage of the septum below. The inferior edge joins the lower lateral cartilage by means of fibrous tissue, and the posterior edge the nasal and superior maxillary bones.

The *lower lateral cartilages* are thin, and are curved so as to form the front and both walls of the nostrils. Behind it is attached to the superior maxilla, above to the upper cartilage. Between it and the former several smaller cartilages may be seen. It also joins a small part of the cartilage of the septum. In front it joins its fellow to form the tip of the nose.

The *cartilage of the septum* is quadrilateral, and thinner at the centre than at its borders. It forms the anterior part of the septum, and is joined superiorly to the nasal bones, and to the upper and lower lateral cartilages by its anterior margin. Its posterior margin is attached to the front of the perpendicular plate of the ethmoid, and its lower margin to a groove on the vomer and the ridge between the superior maxillæ.

The *arteries* are the *lateralis nasi*, artery of the septum from the superior coronary, infraorbital, and nasal branch of the ophthalmic.

The *veins* end in the facial and ophthalmic.

The nerves are from the facial, infraorbital, infratrochlear, and nasal branch of the ophthalmic.

Describe the nasal fossæ.

For the osseous part, see *Bones*. These fossæ open in front by the anterior nares, and into the pharynx behind by the posterior nares. The mucous membrane is called the pituitary or Schneiderian membrane, and is attached directly to the periosteum or perichondrium. It is continuous with that of the pharynx, conjunctiva, tympanum, and mastoid cells, antrum of Highmore, and with that of the different canals which connect these parts.

The epithelium is squamous near the nostril, columnar where the olfactory nerves are distributed, and columnar and ciliated elsewhere.

The nasal fossæ in the recent state present a different appearance from that seen in the skeleton. They are narrowed, and their component parts appear thicker, the turbinated bones being very prominent. The apertures of the various foramina are narrowed, or even closed, by the lining membrane.

The *arteries* of the nasal fossæ are the ethmoidal, the small meningeal, sphenopalatine, and alveolar.

The *veins* empty into the ophthalmic and facial, and through the foramen cæcum communicate with the cranial sinuses.

The *nerves* are the olfactory filaments distributed to the upper third of the septum and the surfaces of the superior and middle turbinated bone (these filaments do not reach the superior or middle meatus), the nasal branch of the ophthalmic, the anterior dental of the superior maxillary, and the Vidian, naso-palatine, and anterior palatine.

THE TONGUE.

Describe the tongue.

The tongue is composed of muscular substance covered by mucous membrane. Behind it is attached to the hyoid bone, and below by means of the genioglossus to the lower jaw. The mucous membrane is continuous with that of the gums, and forms on the middle line of the under surface a fold, the *frænum linguæ*. Along the middle line of the dorsum is a depression, the *raphé*, which ends in the *foramen cæcum*, 1 inch from the base. At its base three folds of mucous membrane, the glosso-epiglottic ligaments, connect it with the epiglottis.

The anterior two-thirds of the dorsum is covered with *papillæ*, as well as the tip and borders. These are of three kinds, circumvallate, fungiform, and conical, and are covered by minute *secondary papillæ*.

The *circumvallate* (*papillæ maximæ*), eight to ten in number, run from the foramen cæcum in two lines forward and outward, making a V. Each papilla lies in a depression which is surrounded, in turn, by an elevated ring.

The *fungiform* (*mediæ*) are smaller and more numerous. They occupy the middle and front part of the dorsum, and occur at the apex and near the borders.

The *conical papillæ* (*minimæ*) are the smallest and most numerous, and are found all over the dorsum. They run in lines which diverge from the *raphé* obliquely behind, nearly transversely in front.

The secondary papillæ send off fine processes, which give the appearance called filiform.

The *glands* of the mucous membrane are of two kinds, mucous and serous glands.

A quantity of *lymphoid tissue* is found between the epiglottis and *papillæ maximæ*, collected into masses, the *follicles*. The epithelium is stratified.

The tongue is divided by a *fibrous septum* into two symmetrical lateral halves: this septum is connected to the hyoid bone by the so-called hypoglossal membrane, which receives some of the fibres of the genio-hyoglossus muscle.

The tongue has extrinsic and intrinsic muscular fibres. The former include the hyoglossus, genioglossus, styloglossus, palatoglossus, and part of the superior constrictor. The intrinsic muscles are the various parts of the *lingualis*. These parts are the superior and inferior longitudinal, vertical, and transverse.

The *arteries* are the lingual and branches of the ascending pharyngeal and facial. The veins join the internal jugular.

The *nerves* are four in number: the lingual branch of the fifth (gustatory), to its anterior two-thirds; the lingual branch of the glosso-pharyngeal, to the base and papillæ maximæ; the hypoglossal, to the muscles; and the chorda tympani, to the lingualis. It also receives sympathetic branches.

The glosso-pharyngeal confers taste; the gustatory, common sensation; and the hypoglossal, motion; also the facial, by means of fibres from the chorda tympani.

SPLANCHNOLOGY.

Organs of Respiration.

THE LARYNX.

Give a general description of the larynx.

The larynx is the organ of voice, and is placed at the upper and fore part of the neck, between the trachea and base of the tongue. It has on each side of it the great vessels, and behind it the pharynx. In front are the cervical fascia mesially and the upper end of the thyroid gland, and on each side the sterno-hyoid and thyro-hyoid and the thyro-hyoid muscles. It consists of various cartilages held together by ligaments, and is lined internally by mucous membrane.

What are the cartilages?

The cartilages are nine: three pairs, the arytenoid, cornicula laryngis, and cuneiform; and three single, the thyroid, cricoid, and epiglottis.

Describe the thyroid cartilage.

It is the largest, and consists of two lateral parts or *alæ* uniting in front to form the projection of the pomum Adami. This is subcutaneous, more distinct above and in the male. Each ala is quadrilateral, and presents externally a tubercle from which a ridge descends obliquely forward. This ridge gives attachment to the sterno-thyroid and thyro-hyoid, and the surface behind it to the inferior constrictor muscle. Internally it is smooth, and in the angle the epiglottis, true and false vocal cords, and the thyro-arytenoid and thyro-epiglottic muscles are attached. The upper border is concavo-convex, and in front is notched over the pomum Adami, giving attachment throughout to the thyro-hyoid membrane. The lower border is joined to the cricoid cartilage by the crico-thyroid membrane. The posterior borders end in the *upper* and *lower cornua*: to the upper are attached the lateral thyro-hyoid ligaments, and the lower, which are shorter and thicker, present internally a facet for articulation with the cricoid cartilage. The stylo- and palato-pharyngei are attached also to the posterior border.

Describe the cricoid cartilage.

It resembles a signet ring, is narrow in front, and gives attachment to the crico-thyroid muscle, and behind it to some of the fibres of the inferior constrictor. It is broad behind, with a median ridge for the œsophagus, separating two hollows for the crico-arytenoideus posticus, and presents at about the middle of the lateral surface a prominence on each side which articulates with the corresponding inferior cornu of the thyroid cartilage. The lower border is joined to the upper ring of the trachea; the upper gives attachment in front and laterally to the crico-thyroid membrane and the lateral crico-arytenoideus muscle. Behind, at each end of its upper border, is an oval surface for the corresponding arytenoid cartilage, with a notch between.

Describe the arytenoid cartilages.

They are pyramidal in form, and rest by their bases on the highest part of the upper border of the cricoid cartilage behind, their curved apices approximating. To the posterior surface is attached the arytenoideus; to the anterior, the thyro-arytenoideus and the false vocal cord; and the internal is covered by mucous membrane. The apex is curved backward and inward, and surmounted by the corniculum laryngis. The base presents a concave surface to articulate with the cricoid cartilage, and to its external angle (*muscular process*) are attached the lateral and posterior crico-arytenoidei, and to the anterior angle (*vocal process*) the true vocal cord.

The *cornicula laryngis* (cartilages of Santorini) are two small, conical, yellowish bodies which prolong the apices of the arytenoid cartilages backward and inward.

The *cuneiform cartilages* (Wrisberg's) are two small, yellow, elongated bodies lying one in each fold of the mucous membrane which stretches between the arytenoid cartilage and the epiglottis.

The *epiglottis* is a fibro-cartilaginous lamella, shaped like a leaf, lying behind the tongue and in front of the upper orifice of the larynx. Above it is broad, below narrow and prolonged to the notch above the pomum Adami by the thyro-epiglottic ligament, or, rather, to the angular interval just below the notch, and is attached to the body of the hyoid bone by the hyo-epiglottic ligament. Laterally are attached the aryteno-epiglottic folds. The anterior surface is connected with the tongue by the lateral and median glosso-epiglottic folds. The posterior surface is concave transversely, convex longitudinally.

Describe the ligaments of the larynx.

These are extrinsic and intrinsic. The former connect it to the hyoid bone; the latter connect its parts together.

The *extrinsic* are the middle thyro-hyoid ligament, the two lateral thyro-hyoid ligaments, and the hyo-epiglottic ligament.

The *middle thyro-hyoid ligament* is a fibro-elastic structure attached to the entire border of the *notch* of the thyroid cartilage and to the

upper border of the posterior surface of the body of the hyoid bone. The lateral thyro-hyoid ligaments run between the upper cornua of the thyroid and the greater cornua of the hyoid bone. They sometimes enclose the cartilago triticea, a small cartilaginous nodule occasionally ossified. The hyo-epiglottic ligament runs from the front of the epiglottis near its apex to the upper border of the body of the hyoid bone.

Describe the intrinsic ligaments.

The ligaments connecting the thyroid and cricoid cartilages are the crico-thyroid ligament, the capsular ligaments, and the synovial membranes. The crico-thyroid ligament is of yellow elastic tissue, triangular, and consists of a mesial thicker portion connecting the adjacent borders of the two cartilages, and two lateral portions running from the upper border of the cricoid to be continuous with the inferior thyro-arytenoid ligaments (*true vocal cords*). In front this ligament is partly covered by the crico-thyroid muscles on each side, and in the subcutaneous interval there is a sort of plexus from the junction of the two crico-thyroid arteries. The lower cornua of the thyroid are connected with the sides of the cricoid by two ligamentous capsules each lined by a synovial membrane.

The cricoid and arytenoid cartilages are connected by loose capsular ligaments lined by synovial membranes, and by a posterior crico-arytenoid ligament running from the cricoid to the inner and back part of the base of the arytenoid.

The ligaments of the epiglottis are the hyo-epiglottic, the three glosso-epiglottic ligaments (mucous membrane), and the thyro-epiglottic. The latter is a long and slender cord between the apex of the epiglottis and the angle of the thyroid just below the notch.

Describe the interior of the larynx.

The cavity of the larynx is divided into an upper and a lower part by the rima glottidis. The upper opens into the pharynx by the *upper aperture* of the larynx, between which and the rima glottidis are the ventricles and their saccules and the false vocal cords. The lower aperture is continuous with the trachea.

The *superior aperture* is cordiform in shape, widest in front and narrow behind. In front it is bounded by the epiglottis, behind by the arytenoid cartilages (together with the fold of mucous membrane between them) and cornicula, and laterally by the aryteno-epiglottic folds.

The rima glottidis is the space between the true vocal cords and the bases of the arytenoid cartilages. It is somewhat less than 1 inch long, and, according to its degree of dilatation, from $\frac{1}{3}$ to $\frac{1}{2}$ an inch wide. In easy respiration its form is triangular with the base posterior, and when fully dilated it is lozenge-shaped.

What are the superior or false vocal cords?

They are two mucous folds, each enclosing the corresponding superior

thyro-arytenoid ligament. This latter is a thin band running between the angle of the thyroid and the anterior surface of the arytenoid cartilage.

What are the inferior or true vocal cords ?

They are two strong bands, the inferior thyro-arytenoid ligaments, covered by mucous membrane and attached to the depression between the alæ of the thyroid cartilage in front and the anterior angle of the base (vocal process) of the arytenoid cartilages behind. Below, each is continuous with the lateral part of the crico-thyroid ligament or membrane. Part of the thyro-arytenoidei is external and parallel to them.

Describe the ventricles of the larynx.

The ventricles of the larynx lie one on each side, between the upper and lower vocal cords, bounded externally by the thyro-arytenoidei. At the front a narrow opening leads into a blind pouch, the laryngeal sacculæ.

What is the sacculæ ?

The sacculus laryngis is a space on each side, between the false vocal cord and the inner surface of the thyroid cartilage, reaching upward as high as the upper border of that cartilage, and its mucous membrane presents the orifices of sixty or seventy glands. This space has a fibrous capsule. Its laryngeal surface is covered by the inferior aryteno-epiglottic muscle, or compressor sacculi laryngis, and its external surface by the thyro-arytenoideus and thyro-epiglottic muscles.

Name and describe the intrinsic muscles of the larynx.

They are the following :

(1) The *crico-thyroid* arises from the front part and sides of the cricoid cartilage, and is inserted into the lower border of the thyroid cartilage and the front of its lower cornu. Between the two muscles is the crico-thyroid membrane. The action of the two muscles is to approximate the cricoid to the thyroid and thus tense the vocal cords. The nerve-supply is from the superior laryngeal.

(2) The *thyro-arytenoid* is divided into two parts, outer and inner. It arises in front from the angle of the thyroid at its lower part, and its inner part is inserted into the vocal process and outer surface of the arytenoid cartilage; its outer part, into the outer border and muscular process of the same cartilage, above the internal part. The internal part is adherent and parallel to the true vocal cord; the outer is external to the sacculus laryngis. Their action is to advance the arytenoid cartilages and thus relax the vocal cords. The nerve comes from the inferior laryngeal.

(3) The *thyro-epiglottic* muscle arises from the inner surface of the thyroid cartilage, close to the angle, and is inserted into the sacculus laryngis, epiglottis, and aryteno-epiglottic fold. It is really a part of the preceding muscle. Its action is to depress the epiglottis and compress the sacculus laryngis. Its nerve is from the inferior laryngeal.

(4) The *superior aryteno-epiglottic* muscle arises from the apex of the

arytenoid, and is enclosed by the aryteno-epiglottic mucous folds bearing the same name. Additional fibres from each muscle decussate. These fibres extend from the apex of one cartilage to the muscular process of the other, and lie behind and on the arytenoideus. Its action is to diminish the size of the superior aperture of the larynx during deglutition. Its nerve is from the inferior laryngeal.

(5) The *inferior aryteno-epiglottic* muscle arises from the arytenoid cartilage, just above the false cord, and is inserted into the upper and inner part of the epiglottis. Its other name, compressor sacculi laryngis, indicates its action. It is really a part of the thyro-arytenoid muscle. Its nerve is from the inferior laryngeal.

(6) The *crico-arytenoideus posticus* arises from the back of the cricoid cartilage, and is inserted into the muscular process of the arytenoid. Its action is to rotate the corresponding arytenoid outward and thus to widen the glottis. The nerve is from the inferior laryngeal.

(7) The *crico-arytenoideus lateralis* arises from the upper border of the cricoid cartilage, and is inserted into the muscular process of the arytenoid cartilage. Its action is to rotate the corresponding cartilage inward, thus narrowing the glottis. The nerve is from the inferior laryngeal.

(8) The *arytenoideus* is attached to the posterior surface of each arytenoid cartilage. Its fibres run transversely. Its action is to close the back part of the glottis by means of the approximation of the arytenoid cartilages. Its nerve-supply is from both superior and inferior laryngeal nerves.

THE TRACHEA.

Describe the trachea.

The trachea is a membrano-cartilaginous tube, flattened behind, continuous above with the larynx, and below dividing into the two bronchi. Its upper limit is at the sixth cervical, its lower at the disk between the fourth and fifth dorsal vertebræ, and it measures about $4\frac{1}{2}$ inches in length; transversely, $\frac{3}{4}$ to 1 inch.

What are its relations?

In front: in the neck, the isthmus of the thyroid, the sterno-hyoid and thyroid and the cervical fascia between them, the arteria thyroidea ima, the inferior thyroid veins, and the communicating branches between the anterior jugulars; *in the thorax*, the manubrium sterni, thymic remains, the left innominate vein, arch of the aorta, innominate and left carotid vessels, and the deep cardiac plexus. *Behind* is the œsophagus. *Laterally:* in the neck, the common carotids, the lateral lobes of the thyroid, the inferior thyroid arteries, and the recurrent nerves; *in the chest*, the pleura of each side and the vagus.

Describe the bronchi.

The bronchi enter the root of the corresponding lung. The right is the shorter, wider, and more horizontal, and enters the lung opposite

the fifth dorsal vertebra, the larger azygos vein arching over it from behind, the right pulmonary artery being below and then in front of it. The left bronchus is about 2 inches long, and enters the lung opposite the sixth dorsal vertebra. It passes under the arch of the aorta and crosses in front of the œsophagus, thoracic duct, and descending aorta. The left pulmonary artery lies at first above, then in front of it.

What is the structure of the trachea ?

The trachea consists of sixteen to twenty incomplete cartilaginous rings connected by a fibrous membrane. Their free ends, which are directed posteriorly, are united similarly and by plain muscular tissue.

THE THYROID AND THYMUS GLANDS.

Describe the thyroid gland.

The thyroid gland is a highly vascular body situated at the upper part of the trachea, and consists of two lateral lobes connected by the isthmus. The lateral lobes are placed one on each side of the trachea.

In front it is convex and covered by the sterno-hyoid and thyroid and omo-hyoid muscles; laterally, also convex, it touches the common carotid sheath; behind it is concave and rests on the larynx and trachea.

The weight of this body is from 1 to 2 ounces, its color brownish-red, and each lobe is 2 inches long by $1\frac{1}{4}$ inches wide. There is sometimes a third and accessory smaller lobe, called the pyramid.

Describe the thymus gland.

The thymus is a temporary organ, attaining its greatest size at the end of the second year, and gradually dwindling thereafter to a mere trace. At its full growth it lies in the neck and superior mediastinum, and consists of two lobes extending behind the sternum from the level of the fourth cartilage below to the thyroid gland above.

In front are the sternum, sterno-, hyoid and thyroid; behind are the pericardium, the great vessels, and the trachea. For the *structure* of these bodies see *Histology* of this series.

PLEURÆ AND MEDIASTINUM.

Describe the pleuræ.

The pleuræ are two separate serous sacs which invest each lung to its root and are reflected on to the thoracic walls and pericardium. The first portion is the visceral layer, or pleura pulmonalis; the second is the parietal layer, or pleura costalis.

The two pleuræ are distinct from each other, and do not meet in the median line except behind the second piece of the sternum. At the root of the lung the visceral and parietal layer of the same side are continuous, and at the lower part of the root a fold, the ligamentum latum pulmonis, runs down to the diaphragm.

What is the mediastinum, and how is it subdivided?

The mediastinum is the space between the two pleural sacs, and extends antero-posteriorly from the sternum to the spine; it is divided into—a *superior* mediastinum, above the upper level of the pericardium; the *anterior*, in front of the pericardium; the *middle*, containing the pericardium; and the *posterior* mediastinum, behind the pericardium.

Describe each of these subdivisions.

The *superior mediastinum* is bounded by the manubrium sterni in front, the upper four dorsal vertebræ behind, and below by a plane passing from the lower border of the manubrium to the lower part of the fourth dorsal vertebra. It contains the lower part of the sterno-hyoid and thyroid and longus colli muscles, the transverse aorta, innominate, left carotid, and subclavian arteries, the superior cava (upper part), the two innominate and the left superior intercostal veins, the vagus, cardiac, phrenic, and left recurrent nerves, trachea, œsophagus, thoracic duct, thymic remains, and lymphatics.

The *anterior mediastinum* is bounded by the sternum and the pericardium before and behind, by the pleuræ laterally. It runs toward the left, is broader below than above, and contains the origins of the triangularis sterni, the left internal mammary vessels, some areolar tissue containing lymphatics, and the anterior mediastinal glands.

The *middle mediastinum* contains the heart and pericardium, ascending aorta, superior cava (lower part), bifurcation of trachea, pulmonary vessels, the phrenic nerves, and the arch of the vena azygos.

The *posterior mediastinum* is behind the pericardium and roots of the lungs, and in front of the lower eight dorsal vertebræ, the pleuræ bounding it on each side. It contains the descending part of the arch, the thoracic aorta, the azygos veins, and vagi, œsophagus, thoracic duct, and some lymphatic glands.

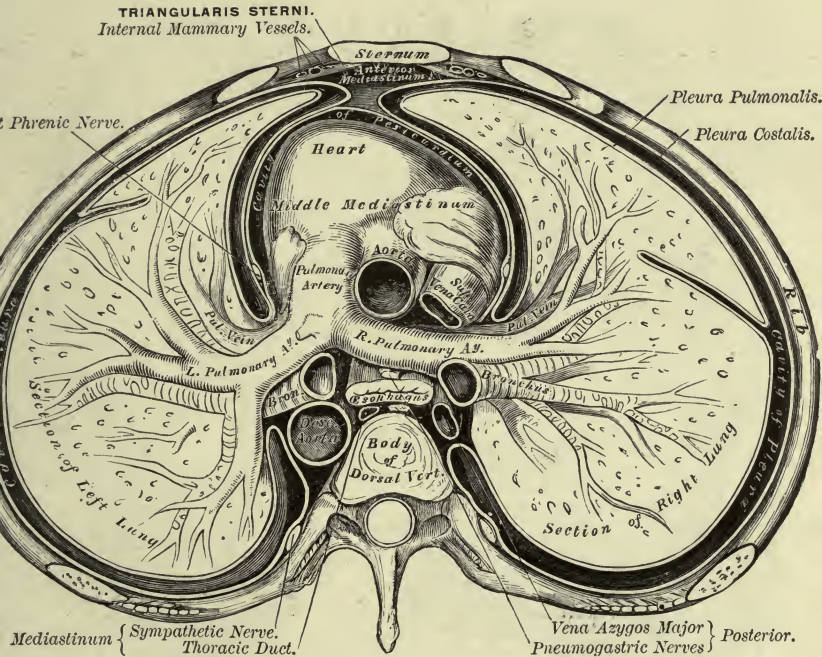
THE LUNGS.**Describe the lungs.**

The lungs are placed one in each side of the chest, in contact with its inner surface, and present each for examination an apex, a base, two borders, and two surfaces.

The *apex* extends 1 to 1½ inches above the first rib, and is marked by a groove for the subclavian artery. The *base* is concave and rests on the diaphragm, its thin margin fitting into the space between the ribs and diaphragm. The *outer surface* is smooth and convex; the *inner surface* is concave and adapted to the pericardium, and behind is marked by a fissure, the hilum pulmonis, for the root of the lung. The *posterior border* is rounded, fits into the concavity on either side of the spine, and is the longest part of the lung; the *anterior border* is sharp and overlaps the pericardium. That of the right lung runs mesially as far as the

PLATE XXVII.

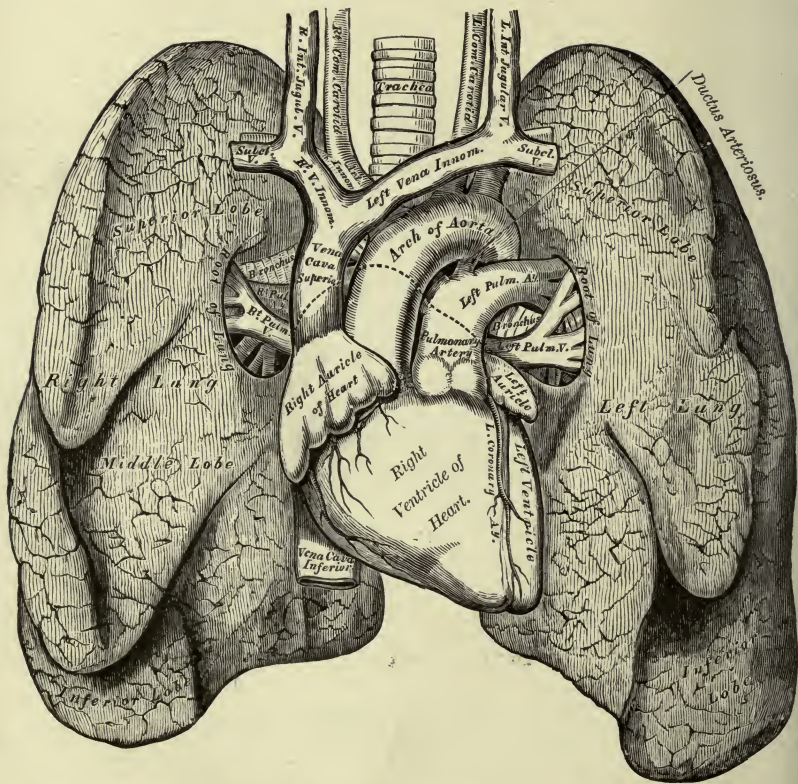
FIG. 1.—To face page 315.



A Transverse Section of the Thorax, showing the relative position of the viscera and the reflections of the pleura.

PLATE XXVIII.

FIG. 1.—To face page 317.



Front View of the Heart and Lungs.

sixth cartilage; the left only to the fourth cartilage, below which is a notch exposing the pericardium.

What are the fissures of the lungs?

Each lung is divided by a deep fissure, which runs from the upper part of the posterior border, 3 inches below the top, to the lower part of the anterior border, into two lobes. The upper lobe of the right lung is subdivided by a short fissure running from the middle of the preceding fissure, forward and upward to the anterior margin, the part below being the middle lobe.

The right lung is the larger, although the shorter, and it is also the heavier.

Describe the root of the lung.

The root of each lung is a little above and behind the centre, and includes the bronchus, pulmonary and bronchial vessels, pulmonary plexus, areolar tissue, lymphatics, and bronchial glands, these all being enclosed by a fold of the pleura. The root of the right lung is placed behind the superior cava and ascending arch and below the azygos major vein, and the left under the arch of the aorta and in front of the descending part of the arch. In front of each are the phrenic nerve and anterior pulmonary plexus, and behind each are the posterior plexus and the vagus.

The pulmonary vein, artery, and the bronchus and bronchial vessels lie in the order named from before backward; from above downward on the right side they run, bronchus, artery, vein; on the left side, artery, bronchus, vein.

What are the weight and general structure of the lungs?

The right lung weighs 22 ounces, the left 20 ounces, and their color, at birth a pink, darkens with age.

The lungs have an outer serous coat, under this a subserous coat, and under this latter the pulmonary parenchyma. The serous coat is the pleura; the subserous areolar tissue under it enters in between the lobules.

The lung is composed of lobules which are largest toward the periphery, and each is made up of a *lobular bronchial tube* with its ramifications, and includes branches of the pulmonary and bronchial vessels, nerves, and lymphatics, all connected together by areolar fibrous tissue.

What is the arrangement of the bronchi within the lung?

Both bronchi enter the lungs, the right giving off a branch to the upper lobe, dividing dichotomously, the cartilaginous rings becoming shorter until they are mere plates without regular distribution. The muscular coat is continuous around the tubes, and the mucous membrane throughout is columnar and ciliated. Each *lobular bronchial tube*, above mentioned, on entering a lobule becomes beset with *air-cells* or

alveoli. Finally, it ends as the *alveolar passage*, from which are given off blind ramifications or *infundibula*. These are also beset with air-cells.

What can you say of the blood-vessels of the lungs ?

The pulmonary artery divides, and its divisions accompany those of the bronchi. Finally a capillary plexus is formed on the walls of the air-cells and alveolar passages, which lies just beneath the mucous membrane, and from this plexus the pulmonary veins arise.

The bronchial arteries nourish the lungs, and in like manner accompany the tubes. They supply also the bronchial glands, and end in the bronchial veins. These veins do not receive all the blood from the corresponding artery, as the pulmonary veins return a part of it. The left empties into the superior intercostal; the right, into the azygos major vein.

THE ORGANS OF DIGESTION.

THE MOUTH.

Describe the mouth.

The mouth is the upper part of the alimentary canal. It is bounded by the lips, cheeks, tongue, hard and soft palate, alveolar processes of both jaws, with their contained teeth, and opens behind, through the isthmus faucium, into the pharynx. It is lined by mucous membrane continuous in front with the skin, behind with that of the fauces, its epithelium being stratified.

Describe the lips and cheeks.

They are formed of skin externally and of mucous membrane internally, enclosing between them muscles, vessels, nerves, areolar tissue, fat, and glands. In the cheeks are the buccal glands, similar to but smaller than the labial, and opposite the second upper molar tooth is a papilla, the summit of which presents the orifice of the parotid duct. Several larger buccal glands open opposite the last molar tooth. They lie between the buccinator and masseter, and are called the molar glands. The labial glands are about the size of small peas, and lie just beneath the mucous membrane. The inner surface of each lip in the middle line is joined to the gum of the corresponding jaw by a mesial fold of mucous membrane, the frænum. The upper is the larger.

Describe the gums.

They are formed of fibrous tissue intimately joined to the alveolar periosteum, and are covered by mucous membrane containing papillæ close to the teeth.

THE TEETH.

Describe the teeth.

There are in the human subject two sets of teeth, a temporary set, or

milk teeth, and a permanent set. The former are twenty in number, ten in each jaw; the latter, thirty-two, sixteen each above and below. Each tooth is made up of three parts: the root, consisting of one or more fangs, contained in the alveolus; the crown or body, above the gum; and the neck, between the two. The alveolar periosteum is reflected on to the fang as far as the neck.

How are the teeth divided?

The twenty *temporary* teeth are divided into four incisors, two canines, and four molars above and below. The thirty-two *permanent* teeth are, four incisors, two canines, four bicuspid, and six molars in each jaw. The temporary teeth are similar to but smaller than the permanent; of the temporary molars, the hinder one is the largest of all, and its place is afterward taken by the second permanent bicuspid.

Describe the permanent teeth.

Of the permanent teeth the **incisors** are the eight central cutting teeth, four each above and below, the former being the larger. They are bevelled at the expense of the posterior surface. The **canines** (*cuspidati*) are two in each jaw, being situated one behind each lateral incisor, the upper and larger being called the eye-teeth. The **bicuspid** (*premolars* or *false molars*), four in each jaw, lie two each behind the canines, the upper being the larger. The **molars** (*true molars* or *multicuspidati*) are the largest teeth, and number six in each jaw, three each behind the posterior bicuspid above and below. They present four tubercles on the upper, five on the lower crowns, and the root is subdivided into from two to five fangs. The first molar is the largest and broadest, the second is smaller, and the third (wisdom tooth) the smallest.

Give the structure of a tooth.

A vertical section of a tooth shows it to be hollow, the cavity being continuous with the aperture in the fang and filled up with the soft dental pulp, and is hence called the pulp-cavity. The pulp is sensitive, highly vascular, and consists of connective tissue with cells, vessels, and nerves. The hard substance of each tooth consists of three parts: the *ivory* or *dentine*, the *enamel*, and the *crusta petrosa* or *cement*.

The **dentine** forms the chief mass, consisting of fine tubes, the dental tubuli, imbedded in a homogeneous matrix, the intertubular tissue. These tubuli open into the pulp-cavity.

The **enamel** is a hard white substance which protects the crown of a tooth, being thickest at the cutting edge. It is the hardest part of the tooth, and consists of hexagonal rods, parallel and presenting one end to the dentine, the other to the crown. It also presents a series of brown lines, the parallel striæ.

The **crusta petrosa** covers the dentine of the root, which has no enamel. It resembles true bone of a somewhat modified structure, containing lacunæ, lamellæ, canaliculi, and some Haversian canals.

Give the different periods of eruption of the different teeth.

The period of eruption for the temporary teeth is from the seventh month to the end of the second year. They appear in the following order: central incisors, lateral incisors, anterior molars, canines, posterior molars. The lower precede the upper by a short period. The permanent teeth appear as follows: between the sixth and seventh year, first molars; seventh year, middle incisors; eighth year, lateral incisors; ninth year, first bicuspid; tenth year, second bicuspid; eleventh to twelfth year, canine; twelfth to thirteenth year, second molars; seventeenth to twenty-first year, wisdom teeth.

THE PALATE.**Describe the palate.**

The palate forms the roof of the 'mouth, and consists of a front part or hard, and a back part or soft palate. The periosteum of the hard palate (see *Bones*) is covered by and intimately connected with the mucous membrane of the mouth. In the middle line is a raphé ending in front at a small papilla, which marks the anterior palatine fossa which receives the terminal part of the anterior palatine and naso-palatine nerves. The mucous membrane is pale and corrugated, covered with squamous epithelioma, and furnished with a number of palatal glands which lie between it and the bone.

Describe the soft palate (*velum pendulum palati*).

It partially separates the mouth and pharynx. It consists of muscular, connective, and adenoid tissue, with vessels, nerves, and mucous glands, all enclosed in a fold of mucous membrane. Above it is joined to the back of the hard palate; laterally it blends with the pharynx; below it is free; in front it is concave, with a median ridge; and behind it is convex. Its mucous membrane is continuous with that of the roof of the mouth and of the posterior nares.

From its lower border a conical process depends, the *uvula*, from whose base descend the *pillars* of the soft palate, the anterior, formed by the *palato-glossi muscles*, to the sides of the base of the tongue; the posterior, formed by the *palato-pharyngei*, to the sides of the pharynx. These pillars are covered by mucous membrane and separated below by the tonsil, the space being called the isthmus of the fauces. The muscles of the soft palate are five on each side, and lie in the following relative position from before backward: the palato-glossus, tensor palati, anterior fasciculus of palato-pharyngeus, levator palati, azygos uvulæ, and, lastly, the posterior fasciculus of the palato-pharyngeus.

THE TONSILS.**Describe the tonsils.**

The tonsils (*amygdalæ*) lie between the anterior and posterior palatine pillars, and are about $\frac{1}{2}$ inch long and $\frac{1}{3}$ inch wide and thick, but vary

much in size. Externally they are separated by the superior constrictors from the internal carotid and ascending pharyngeal arteries; internally they project into the fauces, and present twelve or more orifices which lead into the crypts in their substance. Around the crypt-walls are numerous lymphoid follicles consisting of adenoid tissue.

THE SALIVARY GLANDS.

Describe the salivary glands.

There are three pairs, *parotid*, *submaxillary*, and *sublingual*.

The **parotid**, the largest, weighs $\frac{1}{2}$ to 1 ounce, and lies on the face below and in front of the ear. Its outer surface, lobulated, is covered by the skin and fascia, and partly by the platysma and several lymphatic glands; in front it runs over the masseter, is grooved for the ramus of the lower jaw, and extends beneath it, between the two pterygoids; above it is bounded by the zygoma; below by the angle of the jaw and a line joining it with the mastoid process; behind by the external meatus, mastoid process, and sterno-mastoid. The internal surface sends two processes into the neck: one behind the styloid process and beneath the mastoid process and sterno-mastoid; another in front of the styloid process, into the back of the glenoid cavity behind the jaw. Imbedded in the gland are found the external carotid, posterior auricular, temporal, transverse facial, and internal maxillary arteries, the temporo-maxillary vein and a branch from it to the internal jugular, the facial nerve with its branches, and the auriculo-temporal and great auricular nerves. The internal carotid artery and internal jugular vein lie under its deep surface.

The *duct* (Stenson's) is about $2\frac{1}{2}$ inches long and $\frac{1}{8}$ inch in diameter, and opens opposite the second molar tooth, thence runs backward beneath the mucous membrane, through the buccinator, and across the masseter to the front of the gland. It commences by numerous branches, and on the masseter receives the duct of a detached part of the gland, the *socia parotidis*, which sometimes is found beneath the zygomatic arch. Its epithelium is columnar.

The **submaxillary gland** is of an irregular form, weighs about 2 drachms, and lies below the jaw and above the digastric muscle. It is covered by the skin, platysma, and fasciæ, and grooves the inner surface of the lower jaw. It lies on the mylo-hyoid (partially embracing this muscle), hyoglossus, and styloglossus, and has in front of it the anterior belly of the digastric. Behind, the stylo-maxillary ligament separates it from the parotid, and the mylo-hyoid (its superficial part) from the sublingual gland in front. The facial artery grooves its upper and back part.

The *submaxillary duct* (Wharton's) is 2 inches long, and opens at the top of a papilla close to the frænum linguæ. Thence it runs back between the sublingual gland and the genio-hyoglossus, then between the mylo-hyoid and the hyoglossus and genio-hyoglossus.

The **sublingual gland**, the smallest of the salivary glands, lies at the

side of the frænum linguæ and against the inner surface of the lower jaw, beneath the mucous membrane. It is almond-shaped, weighs 1 drachm, and its ducts (*of Rivini*), ten to twenty in number, open separately, one or two joining to form the duct of Bartholin, which joins Wharton's duct. It is in relation below with the mylo-hyoid; in front with its fellow and the lower jaw; behind with the submaxillary gland; internally the gustatory nerve and Wharton's duct separate it from the genio-hyoglossus.

THE PHARYNX.

Describe the pharynx.

The pharynx extends from the base of the skull to the lower border of the cricoid cartilage; it is $4\frac{1}{2}$ inches long, wider transversely than antero-posteriorly, and widest opposite the hyoid cornua. Below it opens into the œsophagus; above it is connected with six openings—viz. the mouth, larynx, the two posterior nares, and the two Eustachian tubes.

The pharynx is formed of a fibrous coat, the pharyngeal aponeurosis, thick above, thinner below, lined by mucous membrane and covered by muscles. Above it is connected with the body of the sphenoid and the basilar process of the occipital bone; behind with the spine, the longi colli and recti capitis antici muscles; in front with the internal pterygoid plate, pterygo-maxillary ligament, lower jaw, tongue, larynx, and os hyoides; laterally are the styloid processes and their muscles, common and internal carotid arteries, internal pterygoid muscles, internal jugular veins, and the glosso-pharyngeal, vagus, hypoglossal, and sympathetic nerves. The pharyngeal aponeurosis is strengthened behind by a fibrous band which forms a median raphé, and is attached above to the pharyngeal spine on the basilar process of the occipital. Into it are inserted the constrictores pharyngis. A mass of lymphoid tissue at the back of the pharynx has been called the pharyngeal tonsil.

THE ŒSOPHAGUS.

Describe the œsophagus.

The œsophagus is the tube connecting the pharynx with the stomach, and extends from the level of the sixth cervical vertebra through the diaphragm, entering the stomach opposite the tenth or eleventh dorsal vertebra, a distance of 9 or 10 inches. At first in the median line, it runs to the left as far as the root of the neck, becomes again mesial, and lastly turns toward the left to pass through the œsophageal orifice in the diaphragm. It also corresponds to the cervical and dorsal curves of the spine. It is the narrowest part of the alimentary canal, and presents two constrictions, one at its commencement, the other at the diaphragm.

IN THE NECK it is in relation, *in front*, with the trachea; *behind*, with the longus colli and spinal column; *laterally*, with the common carotid

arteries and part of the thyroid gland. Between it and the trachea ascend the recurrent laryngeal nerves.

IN THE CHEST it is in relation, *in front*, with the trachea, left carotid artery, left bronchus, and pericardium; *behind*, with the spine, longus colli, thoracic duct, and aorta; *laterally*, with the pleuræ, and on the right side the large azygos vein, and on the left the aorta. The right vagus is behind, the left in front of, the œsophagus, but at first each is on the corresponding side.

What is the structure of the œsophagus?

The œsophagus has an external *muscular* coat, which is composed of an external longitudinal and an internal circular layer, an *areolar* coat between, and an internal *mucous* coat. This last is thick, paler below, and marked by longitudinal folds. Its surface presents numerous papillæ and is covered by stratified epithelium. Beneath it is a muscularis mucosæ, and in the submucous or areolar coat are numerous compound racemose œsophageal glands.

THE STOMACH.

Describe the stomach—situation, measurements, orifices, and borders.

The stomach lies in the epigastric and left hypochondriac regions, and is the most dilated part of the alimentary canal. Its shape is pyriform, the left or larger end being called the cardiac, the right the pyloric end. The left and right openings are termed respectively the cardiac or œsophageal orifice and the pyloric orifice. In a state of moderate distension it is 12 inches long and 4 inches in its vertical diameter, and weighs 4 to 5 ounces.

The *cardiac orifice* is the highest part of the stomach, and lies behind the seventh costal cartilage, 1 inch to the left of the sternum; the *pyloric orifice* is guarded by a valve, the *pylorus*. Between the two the stomach is curved, the upper concave border being known as the lesser, the lower convex border as the greater, curvature. The former gives attachment to the lesser, the latter to the great omentum. The left end (greater or splenic) extends 2 or 3 inches to the left of the cardiac orifice, forming the fundus or great cul-de-sac. The gastro-splenic omentum connects it to the spleen. The lesser or pyloric end lies inferior and anterior to the fundus, in contact with the liver and belly-wall, and its position varies according to the state of distension.

Describe the relations of the stomach.

ANTERIOR SURFACE.

Diaphragm.

Under surface of left lobe of liver.

Abdominal wall.

<i>Right End.</i>	<i>Left End.</i>
Abdominal wall.	Lower ribs.
Under surface of right lobe of liver.	Spleen (and behind).

POSTERIOR SURFACE.

Pancreas and pancreatic vessels.
 Abdominal aorta and inferior cava.
 Cœliac axis and branches.
 Crura of diaphragm and solar plexus.
 Superior mesenteric vessels.
 Left kidney and capsule.
 Spleen.

(*Below.*)

Transverse colon and transverse mesocolon, upper layer.

Describe the structure of the stomach.

The stomach has a *serous* peritoneal coat, a *muscular* coat comprising a longitudinal, circular, and oblique layer, an *areolar* coat of loose tissue (submucous coat), and a *mucous* coat. The latter is thickest near the pylorus, thinnest at the fundus, and presents, in the empty condition of the organ, numerous ridges or *rugæ* which run longitudinally along the great curvature. Studded over its surface are many small polygonally-shaped depressions which are the enlarged mouths of the gastric tubular glands. These are of two kinds, called pyloric and peptic glands; some are simply tubular, while others have several branches opening into a common duct. The *pyloric glands* are most numerous at the smaller end, but the *peptic glands* are found all over the stomach, the ducts of the latter being shorter. In the latter, between the basement membrane and the lining epithelium, are numerous peptic or parietal cells, the others being known as the central or chief cells. Between the glands the mucous membrane contains lymphoid tissue, collected here and there into little masses resembling the solitary intestinal glands, and called the lenticular glands. Beneath the membrane is a *muscularis mucosæ*.

THE SMALL INTESTINE.

Describe the small intestine—situation, division, and attachments.

The small intestine is about 20 feet long, and is a convoluted tube which forms that part of the alimentary canal between the pylorus and the cæcum. It occupies the central and lower part of the abdomen and part of the pelvis, and is surrounded by the large gut, being held in position by the peritoneal fold called the mesentery, which is attached behind to the spine. It is covered in front by the great omentum, and is divided into three parts, the duodenum, jejunum, and ileum.

Describe the structure of the small intestine.

The small intestine is made up of four coats :

An *external peritoneal* coat, which completely invests the jejunum and ileum except at the mesenteric or attached border behind, where the vessels pass, and which only partially invests the *duodenum*. Of this latter, the first portion is completely invested, the second portion only in front, and the third is covered in front by peritoneum derived from the inferior layer of the transverse mesocolon.

The *muscular* coat consists of an internal circular and an external longitudinal layer.

The *areolar* or *submucous* coat consists of loose connective tissue supporting the vessels.

The *mucous membrane* is closely covered by villi, and is of a red color at the upper part, but thinner and paler below. Its epithelium is columnar, and it is furnished with a *muscularis mucosæ*. The prominent features of the mucous membrane are (a) *valvulae conniventes* (Kerkring's), crescentic transverse folds extending one-half or two-thirds around the circumference, the largest being $2\frac{1}{2}$ inches long and $\frac{1}{8}$ inch wide. These folds are found from a point 1 to 2 inches from the pylorus to about midway through the ileum. (b) The *villi*, small projections set closely together over the entire mucous membrane surface of the small intestine, and about $\frac{1}{40}$ inch long. Each villus consists of a projection of the mucous membrane enclosing blood-vessels, a lacteal, and a part of the *muscularis mucosæ*, all held together by lymphoid tissue and surrounded by a delicate basement membrane beneath the epithelium. (c) *Lieberkühn's follicles*. These are small tubes found everywhere in the mucous membrane, and consist of a basement membrane lined by a layer of epithelium. (d) *Brunner's glands* are small granular bodies in the submucous tissue, their ducts opening on the mucous surface. They are found only in the duodenum and the commencement of the jejunum. (e) The *solitary glands* are small whitish bodies, most numerous in the lower part of the ileum. They are made up of very vascular retiform tissue, and on their surfaces are found villi and around them the openings of Lieberkühn's glands. (f) *Peyer's patches* are oblong aggregations of solitary glands, measuring from $\frac{1}{2}$ inch to 4 inches in length, and are situated on the border opposite to the attachment of the mesentery. Their surface is not covered by villi, and they are surrounded by Lieberkühn's crypts. They are most numerous in the lower part of the ileum.

Give a general description of the duodenum.

The duodenum is about 10 inches long (12 fingers), and runs in a curved direction from the pylorus to the jejunum, which it joins on the left side of the second lumbar vertebra. The concavity of the curve looks toward the left and embraces the head of the pancreas. It is divided, for description, into three parts.

Name these three parts, and give the relations of each.

FIRST OR ASCENDING PORTION.

Above and Front.

Liver.
Neck of gall-bladder.

Behind.

Hepatic artery.
Com. bile-duct.
Vena portæ.

Below.

Part of head of pancreas.

SECOND OR DESCENDING PORTION.

Front.

Hepatic flexure of colon.
Transverse mesocolon.
Pancreatico-duod. arteries.

Behind.

Right kidney and suprarenal capsule (at times).
Structures at hilus of kidney.
Com. bile duct (and to left).

Internally.

Head of pancreas.

THIRD OR TRANSVERSE PORTION.

Above.

Inf. border of pancreas.
Sup. mesenteric vessels.

Front.

Peritoneum derived from descending layer trans. mesocolon.
Sup. mesenteric vessels.

Behind.

Aorta and inf. cava.
Crura, diaphragm.
Second lumbar vert.

Describe the jejunum and ileum.

The *jejunum* includes the first two-fifths of the remaining part of the

small intestine, running from the left side of the second lumbar vertebra to the beginning of the ileum, and occupying the umbilical and left lumbar and iliac regions. Its coats are thicker and more vascular, and it is of a deeper color and larger calibre, than the ileum.

The remainder of the small intestine is the *ileum*, which ends by opening into the inner side of the commencement of the large gut in the right iliac fossa. Its coils occupy the hypogastric, umbilical, and right lumbar and iliac regions.

THE LARGE INTESTINE.

Describe the large intestine.

The large intestine is that part of the alimentary canal which extends from the end of the ileum to the anus; it is about $5\frac{1}{2}$ feet long, and surrounds the small intestine. It commences by a dilated part, the *cæcum*, in the right iliac fossa, ascends to the under surface of the liver, then runs transversely across the abdomen to the vicinity of the spleen, descends to the left iliac fossa, and forms the sigmoid flexure, and finally passes along back of the pelvis to end at the anus.

What is the cæcum?

The cæcum is the large cul-de-sac which is the beginning of the large intestine, and is about 3 inches broad and $2\frac{1}{4}$ long. It is variously situated, being found on the psoas, external to it, on the iliacus, internal to it, on the pelvic brim, or entirely within the pelvis. In any of these positions it is entirely surrounded by peritoneum.

Describe the vermiform appendix.

From the inner and back part of the cæcum, at its lower end, the vermiform appendix extends upward and inward behind it. This is a piece of gut of the diameter of a goose-quill, varying from 3 to 6 inches in length, curved upon itself, and ending in a blind extremity. It tapers gradually to its end, which is blunt, is completely invested by the peritoneum, which forms for it a mesentery, and at its connection with the cæcum is guarded by an imperfect valve.

Describe the ilio-cæcal valve.

The small intestine opens into the large gut about $2\frac{1}{2}$ inches above the lower extremity of the cæcum in an oblique direction. Its opening is guarded by a double fold forming the *ileo-cæcal valve*, which lies transversely to the long axis of the colon. Each fold of the valve is made up of the mucous and submucous coats, reinforced by some circular fibres from the muscular coat, of each portion of the gut, and is covered on the side toward the ileum with villi. At each end of the opening these folds run together and are prolonged some distance around the gut, forming the *retinacula*.

Describe the ascending colon.

This part of the large gut runs from the cæcum, above the ileo-cæcal valve, upward to the under surface of the liver on the right side of the gall-bladder, and then turns forward and to the left to form the *hepatic flexure*. The peritoneum rarely forms for it a mesocolon; generally it covers only the front part and the sides. It occupies the right lumbar and hypochondriac regions.

Describe the transverse colon.

This part arches across the abdomen, the convexity looking toward the belly-wall, and makes a sudden turn backward and downward beneath the spleen, forming the *splenic flexure*, and is completely invested by the peritoneum. It occupies the right hypochondriac, upper part of umbilical and left hypochondriac regions. At the splenic flexure is attached the *costo-colic ligament*, a fold of peritoneum extending to the diaphragm opposite the tenth or eleventh rib.

Describe the descending colon.

This part descends from the splenic flexure, to end at the left iliac fossa in the sigmoid flexure. It is covered in front and laterally by the peritoneum. It occupies the left hypochondriac and lumbar regions.

Give the relations of each of the three portions of the colon.**FIRST OR ASCENDING PORTION.***Front.*

Ileum.
Abdom. wall.
Great omentum.

Behind.

Quadratus lumborum.
Right kidney (lower part).
Second portion duod. (hepatic flexure).

SECOND OR TRANSVERSE PORTION.*Above.*

Liver and gall-bladder.
Stomach (gt. curvature).
Splenic flexure. { Spleen (lower end).
 { Pancreas (tail).

Below.

Small intestines.

Behind.

Transverse mesocolon.

THIRD OR DESCENDING PORTION.

*Front.*Jejunum.
Abdom. wall.*Behind.*Left kidney (along left border of lower part ant. surface).
Quadratus lumborum.**Describe the sigmoid flexure.**

The sigmoid flexure ends in the rectum. From the end of the descending colon it forms an S-shaped curve, ending opposite the left sacro-iliac joint. In front of it are the belly-wall and some coils of small intestine. The peritoneum forms a loose mesocolon for it. It is the narrowest part of the colon.

Describe the rectum.

The rectum is the lowest part of the large intestine, and extends from the sigmoid flexure to the anus. It has been divided into three parts: the first part extends from the left sacro-iliac joint to the centre of the third piece of the sacrum; the second part, to the tip of the coccyx; and the third part, to the anus.

The rectum is about 8 inches long and somewhat cylindrical in form, narrower above than the sigmoid flexure, but it enlarges as it descends, and just above the anus is remarkably dilated, forming the ampulla. The first part has a mesorectum; the second part is covered by peritoneum in front and laterally; the third part has no peritoneal covering.

Give the relations of the first and second part of the rectum.

The first part of the rectum is about one-half of its whole length, and has the following relations:

BEHIND.

Pyriformis,
Sacral plexus,
Int. iliac artery and branches, } of the left side chiefly.

FRONT.

Male.

Post. surface of bladder.

*Female.*Post. surface of uterus and
appendages.

(Small intestines intervening in both cases.)

The **second part** is about 3 inches long, and has the following relations :

BEHIND.

Concavity of sacrum.
Middle sacral artery.

FRONT.

Male.

Triangular part of bladder.
Vesiculæ seminales.
Vas deferens.
Under surface of prostate.

Female.

Post. vaginal wall.
Cervix uteri.

Describe the third or lower part of the rectum, and give its relations.

The *third part* is 1 to 1½ inches long, and curves backward and downward to end at the anus, where it is surrounded by the external sphincter. Higher up the internal sphincter surrounds it, and the levatores ani support it on each side. In front of it are the membranous and bulbous portions of the urethra, but separated from it by a triangular cellular space whose base is the central point of the perineum. In the female, in front, vagina and perineal body.

Describe the structure of the large intestine.

It has four coats—serous, muscular, submucous, and mucous.

The *serous coat* is peritoneum, and along the anterior margin of the gut it presents numerous little projections called *appendices epiploicæ*, which are filled with fat.

The *muscular coat* is divided into two layers, longitudinal and circular, the former being external. The *circular* layer is disposed generally over the surface.

The *longitudinal* layer is seen as three well-marked bands ½ inch wide and ½ line thick. These bands commence on the cæcum at the origin of the vermiform appendix, and have the following arrangement on the three divisions of the colon respectively: the *anterior* band runs along the anterior border of the ascending, the transverse, and descending colon: this band serves for the attachment of the great omentum to the transverse colon; the *posterior* band extends along the posterior border of the entire colon, and indicates the line along which the peritoneum leaves the ascending and descending colon, and along the transverse colon it is the line of coalescence of the two layers of the transverse mesocolon; the inner band is on the inner border of the ascending and descending colon and on the under border of the transverse colon. It is along this band that the *appendices epiploicæ* are found.

The *submucous coat* is made up of areolar tissue.

The *mucous coat* or mucous membrane is smooth, has no villi, contains crypts of Lieberkühm, and has lymphoid nodules scattered over its surface.

What can you say of the structure of the rectum ?

The longitudinal fibres of its muscular coat are disposed in a uniform layer. There are no bands. The mucous membrane has numerous folds, which near the anus are longitudinal in direction and are known as the columns of Morgagni. At and above the level of the prostate gland there are three other prominent folds, having more or less a horizontal direction. These are called the folds of Houston.

THE LIVER.

Give the general position and measurements of the liver.

The liver lies in the epigastric and right hypochondriac region, reaching partly into the left hypochondrium, weighs between 3 and 4 pounds, and measures 10 to 12 inches transversely, 6 to 7 inches from before backward, and $3\frac{1}{2}$ inches vertically at its thickest part.

Give the relations of the liver.

ABOVE.

Diaphragm.
Abdom. wall.

BELOW.

Stomach, duodenum (first part).
Hepatic flex. colon.
Right kidney and suprarenal capsule.
Gall-bladder and duct (cystic).

BEHIND.

Diaphragm.
Aorta and inf. cava.

How is the liver divided ?

The upper surface is divided by the suspensory ligament, and the lower by the longitudinal fissure, into a right and a left lobe. The anterior thin border is notched opposite the suspensory ligament. The right extremity is thick, the left thin and flattened.

Name and describe the ligaments of the liver.

They are all peritoneal folds excepting the round ligament, which is a foetal remnant. The *longitudinal* (suspensory or broad) *ligament* is broad and thin, runs from before backward, and is attached above to the diaphragm and sheath of the right rectus muscle as far as the umbilicus; below to the superior surface of the liver, from the posterior border to the notch in the anterior border. The free anterior border has between

its layers the *round ligament*, which is the shrivelled and impervious remains of the foetal umbilical vein. It runs along the longitudinal fissure from the umbilicus to the vena cava. The *lateral ligaments* are peritoneal folds which extend between the diaphragm and the corresponding borders of the liver, the left being to the left of the oesophageal opening. The *coronary ligament* is a process of peritoneum which is reflected on to the posterior surface of the liver in the situation of its apposition with the diaphragm. It is continuous with the lateral ligaments on each side and with the suspensory in front.

Name and describe the fissures of the liver.

They are five. The *longitudinal* separates the right and left lobes. It is joined by the transverse fissure, the part in front of that point being called the *umbilical fissure*, and lodging the umbilical vein or its remains, the round ligament. The *fissure of the ductus venosus* is the part of the longitudinal fissure behind the transverse. It lodges the ductus venosus or its remains. The *transverse* or *portal fissure* is the point of exit and entrance of the vessels, nerves, and ducts. It lies between the quadrate and Spigelian lobes. The fissure for the gall-bladder is parallel to the longitudinal on the under surface of the right lobe. The *fissure for the inferior vena cava*, sometimes a complete canal, lies to the right of the Spigelian lobule.

Name and describe the lobes of the liver.

These are also five in number. The *right* is the largest, being six times as large as the left, and is separated from the left above and below by the suspensory ligament and longitudinal fissure respectively, and in front by the interlobar notch. Its under surface is marked by the transverse fissure and that of the gall-bladder, and its posterior surface by that of the inferior vena cava, and anteriorly is the *impressio colica* for the hepatic flexure, and behind another, the *impressio renalis*, for the right kidney. The *left lobe* is flattened, lies in the epigastrium, and is in relation below with the stomach. The *lobus quadratus* is on the under surface of the right lobe, and is bounded in front by the free surface of the liver, behind by the transverse fissure, on the right by the fissure for the gall-bladder, on the left by the umbilical fissure. The *Spigelian lobe* lies behind and above the preceding, and is bounded in front by the transverse fissure, on the right by the fissure of the vena cava, and on the left by the fissure for the ductus venosus. The *caudate lobe* runs outward from the base of the Spigelian lobe to the under surface of the right lobe, lying between the transverse fissure and that for the inferior vena cava.

Describe the vessels of the liver.

The *hepatic artery* and *portal vein*, with nerves and lymphatics, pass to, and the *hepatic ducts* pass out from, the transverse fissure. These are all situated between the layers of the lesser omentum, lying in the

following relative position: the duct to the right, the artery to the left, and the vein between them and on a posterior plane. They are all enclosed in some loose areolar tissue, Glisson's capsule, and a prolongation of this tissue accompanies them through the liver.

The *hepatic veins*, three large and several small, empty into the inferior vena cava. The nerves come from the cœliac plexus, right phrenic, and both vagi.

THE GALL-BLADDER.

Describe the gall-bladder.

This is a pear-shaped sac lying in the impression of the right lobe, from the right end of the transverse fissure to the anterior free margin. It is 4 inches long and $1\frac{1}{2}$ inches broad, holding 8 to 12 drachms, and is held in place by areolar tissue and the peritoneum. The fundus looks downward, forward, and to the right; the body and neck upward, backward, and to the left.

What are the relations of the gall-bladder?

BODY.

Above.

Liver.

Below.

Ascending duod.

Pyloric end of stomach.

Hepatic flexure of colon.

FUNDUS.

Front.

Abdominal wall (ninth or tenth costal cart.).

Behind.

Transverse colon.

Describe the biliary ducts.

The *hepatic duct* is formed by the junction at an obtuse angle of a branch from each lobe, and runs downward and to the right for nearly 2 inches, and joins the cystic duct to form the common bile-duct. The *cystic duct* is $1\frac{1}{2}$ inches long, and descends toward the left and joins the above as described. The *common bile-duct* is nearly 3 inches long and 3 lines in diameter. It runs along the right border of the lesser omentum behind the first part of the duodenum, then between the pancreas and descending duodenum, then to the right of the pancreatic duct, with which it opens by a common orifice at the summit of a papilla just below the middle of the inner wall of the second portion of the duodenum.

THE PANCREAS.

Describe the pancreas.

This is a long gland, flattened from before backward, tapering to its left end, the *tail*, and enlarged at its right end, the *head*, between these two points being the *body*. It lies in the back part of the epigastric and left hypochondriac regions, being about 6 to 8 inches long, and less than 1 inch thick, and $1\frac{1}{2}$ inches broad. Its weight is variously stated at 2 to 6 ounces.

The head is curved upon itself, and often gives off a projection of its substance behind, which, with the remainder of the organ, encloses the superior mesenteric vessels. This portion is sometimes detached, and is called the lesser pancreas. The pancreas has two broad surfaces, anterior and posterior, and a narrow inferior surface.

Give the relations of the pancreas.

ABOVE.

Coeliac axis.
Splenic vessels (vein behind).
Hepatic artery.

FRONT.

Post. surface of stomach.
Peritoneum derived from superior layer trans. mesocolon.

Right Side.

Ascending duod. (*above*).
Com. bile-duct (*behind*).
Pancreatico-duod. artery (*in front*).
Descend duod. } abuts against.
Right kidney. }
Right suprarenal capsule (*behind*).
Trans. duod. (*below*).

Left Side.

Spleen.

BEHIND.

First lumbar vert.
Crura of diaphragm.
Sup. mesenteric vessels.
Inf. mesenteric vein.
Splenic vein.
Left kidney and suprarenal capsule.
Left renal vessels.
Thoracic duct.
Vena portæ.
Aorta and inf. cava.

BELOW.

Sup. mesenteric vessels.

Inf. mesenteric vein.

Splenic flex. colon.

Transverse duod.

Peritoneum derived from inferior layer trans. mesocolon.

The duct of the pancreas runs from left to right and empties into the duodenum as described. It is called the duct of Wirsung.

THE SPLEEN AND SUPRARENAL CAPSULES.

THE SPLEEN.

Describe the spleen.

The spleen is placed at the back of the left hypochondrium, and in the axillary line extends from the eighth to the eleventh rib. It is oval in shape, highly vascular, of a pulpy consistency, very brittle, and is of a peculiar purplish color. The anterior surface is marked by a vertical depression, the hilus, which affords entrance and exit to the vessels. Here the peritoneum, which invests the spleen, passes in a double fold to the stomach as the gastro-splenic omentum.

The organ consists of a fibrous trabecular framework containing and supporting the red splenic pulp and the vessels. Within the pulp, scattered here and there, are lighter-colored bodies, the Malpighian corpuscles. These are developed on one side of the arterial branches or entirely surround these vessels, and are composed of lymphoid tissue.

What are the relations of the spleen ?

EXTERNALLY AND POSTERIORLY.

Ninth, tenth, and eleventh ribs.

Costo-phrenic sinus and diaphragm.

Above.

Diaphragm.

*Below.*Splenic flexure of the colon.
Costo-colic lig.

INTERNALLY.

*Ant. Part.*Great end of stomach,
Tail of pancreas.*Post. Part.*

Left kidney and suprarenal capsule.

THE SUPRARENAL CAPSULES.

Describe the suprarenal capsules.

These are two flattened bodies, in shape resembling a cocked hat, which lie upon the upper border of the kidneys, to which they are united

by loose areolar tissue. They are concave below, convex above, and marked in front by the hilus, from which emerges the suprarenal vein. Each measures vertically about $1\frac{1}{4}$ inches, transversely $1\frac{1}{4}$ inches, and is about $\frac{1}{4}$ inch thick. They weigh each about 2 drachms.

Give the relations of the suprarenal capsules.

POSTERIORLY.

Diaphragm at junction of lumbar and costal parts, at level of eleventh or twelfth dorsal vertebra.

ANTERIORLY.

Right Capsule.

Post. surface of liver.

Peritoneum from liver to ant. surface of right kidney.

Left Capsule.

Spleen at upper and outer end.

Pancreas.

Peritoneum of lesser sac separating it from cul-de-sac of stomach.

INTERNALLY.

Vena cava (sometimes).

Suprarenal arteries and veins.

THE URINARY ORGANS AND PERITONEUM.

THE KIDNEYS.

Give the general shape, position, and measurements of the kidneys.

The kidneys lie one on each side of the vertebral column, behind the peritoneum, opposite the last dorsal and upper two or three lumbar vertebræ. Each is bean-shaped, measures about 4 inches in length, $2\frac{1}{2}$ in breadth, and 1 to $1\frac{1}{2}$ inches in thickness, and weighs about $4\frac{1}{2}$ ounces. The right is somewhat lower than the left, as well as somewhat shorter and broader.

The anterior surface of the kidney is convex and looks somewhat outward.

Give the relations of the kidneys.

FRONT.

(Right kidney.)

Post. part of under surface r. lobe of liver.

Descend. duod. (along left border).

Hepatic flexure colon (below).

(Left kidney.)

Great end of stomach.

Pancreas in the middle.

Splenic flexure of colon (at some distance).

BEHIND.

Crus diaphragm.

Quadratus lumborum.

Psoas (and internally).

EXTERNALLY.

Abdom. wall.
Spleen (left kidney).
Descend. colon (left kidney).

INTERNALLY.

Vessels at hilus and ureter.
Psoas magnus.
[The ureter lies behind and below
the vein and artery. The vein is
in front of the artery.]

ABOVE.

Suprarenal capsule (somewhat anteriorly and internally).

Describe the structure of the kidney.

The kidney has a distinct capsule, beneath which is some unstriped muscle, and contains within it a central cavity or sinus. The duct or ureter commences by a dilated part, the *pelvis*, which is itself made up of smaller tubules, the calyces. The kidney substance is made up of a cortical part and a medullary part. The latter is composed of pyramidal masses of a darker-colored tissue, their bases looking toward the periphery. They contain uriniferous tubules which at the apices of the pyramids open into the calyces, which, in turn, make up the *pelvis*.

(For a more detailed description of the structure of the kidney, see *Histology* of this series.)

THE URETERS.

Describe the ureters.

These tubes convey the urine from the kidneys to the bladder. Each is 16 to 18 inches long, of the diameter of a goose-quill, and runs downward, forward, and inward.

What are its relations ?

FRONT.

Peritoneum.
Spermatic vessels.
(Left ureter) sup. hemorrhoidal artery.
Ileum (right ureter).
Sigmoid flex. (left ureter).
Bladder.

The *pelvis* of the ureter is on a level posteriorly with the spinous process of the first lumbar vertebra.

BEHIND.

INTERNALLY.

Psoas.
Com. iliac artery at its bifurcation.

Inf. cava (right ureter).
Vas deferens.

Ureter enters post. false vesical ligament, with vas deferens between it and the bladder.

THE BLADDER.

Describe the bladder.

The bladder lies in the pelvic cavity behind the pubes, in front of the rectum (vagina and uterus coming between in the female). It is a musculo-membranous bag, and measures, when moderately distended, 5 inches in length and 3 in width, and holds about a pint.

How is the bladder divided?

It is divided into a summit, superior surface, base, inferior surface, and sides.

The *summit*, looking forward, is connected to the umbilicus by the urachus centrally and the obliterated hypogastric arteries laterally.

The *superior surface* extends from the summit to just above the bottom of the recto-vesical pouch. It is entirely covered by peritoneum.

The *base* extends from the superior surface to the prostate gland. It is triangular in shape, with the apex at the prostate, and is bounded laterally by the vasa deferentia and vesiculæ seminales. It has peritoneal covering only for a small distance just above the recto-vesical pouch.

The *inferior* (or *pubic*) *surface* extends from the prostate gland to the summit, and rests on the triangular ligament, posterior surface of body of pubes, and lower part of anterior abdominal wall.

The *sides* are in apposition with the recto-vesical fascia and obturator internus muscle.

When empty the bladder collapses into the pelvis, and in section presents a triangular outline with the apex toward the symphysis.

What are the relations of the bladder?

ABOVE.

Abdom. wall.
Small intestines.

Front.

Triangular lig.
Symp. pubis.
Abdom. wall.
Pre-vesical space of Retzius (when distended).
Prostatic plexus.

Behind.

Peritoneum.
Rectum.
Uterus (female).
Small intestines.

SIDES.

Hypogastric artery.
Ureter, obturator internus.
Vas deferens, recto-vesical fascia.

BASE.

Rectum (cervix uteri female).
Vesiculæ seminales (vagina female).
Vas deferens.
Prostate.

Name the ligaments of the bladder.

They are divided into true ligaments, or those formed by the rectovesical fascia, and in addition the urachus; and the false ones, or those formed of peritoneum.

The *true ligaments* include the two anterior or pubo-prostatic and the two lateral. The former run between the bladder and prostate; the latter between the bladder and sides of the pelvis.

The *false ligaments* are a superior, from summit of bladder to navel, two lateral, to the iliac fossæ, and two posterior. These latter run between the rectum and bladder (uterus and bladder in the female). They contain the ureters. The hypogastric arteries lie between each lateral ligament and the corresponding posterior ligament. The bladder has a serous or peritoneal coat, a muscular coat of three layers, a submucous areolar coat, and a mucous coat.

Describe the interior of the bladder.

The mucous membrane is loosely attached except over the *trigone*. This is a triangular area whose apex corresponds to the urethral opening, and whose base extends between the orifices of the ureters, indicated by a curved elevation due to a muscular band. Extending from the opening of the urethra is another elevation due to submucous thickening, the *uvula vesicæ*. In the female this is indistinct and the trigone is small.

THE PERITONEUM.**What is the peritoneum?**

The peritoneum is a closed serous sac which invests more or less completely the contents of the abdominal and pelvic cavities, sending in processes or diverticula between the adjacent viscera. These processes are attached to the surfaces of the viscera, forming their investment, and serving also to separate and allow a free movement between them without friction. Moreover, they confine the viscera in their proper relative positions.

The walls of the peritoneum are very thin, the attached surfaces being rough; the free, smooth and moist and covered with a layer of endothelium. That part which is attached to the inner surface of the abdominal walls is called the parietal layer, while that investing the viscera constitutes the visceral layer.

Describe the general arrangement of the peritoneum.

Starting from the anterior abdominal wall, the peritoneum passes around on the right side to completely invest the lower part of the cæcum and the vermiform appendix, but only partially (?) investing the rest of the cæcum, covering its front and sides, the back part being very often uncovered. It partially invests the entire ascending colon in a similar manner. Quite often, however, the back part of the cæcum is also

covered by the peritoneum, which thus forms a mesocæcum. It now covers the lower part of the front of the right kidney and the front of the third portion of the duodenum, passes thence to the spine, and, forming the right side of the mesentery, invests the jejunum and ileum, and returns, as the left layer of the mesentery, to the spine, thus completing the structure. The peritoneum now crosses the lower part of the left kidney, invests the descending colon in a manner similar to that on the right side, forms a long sigmoid mesocolon, and returns to the front of the abdomen.

Starting from the same place, we may trace the peritoneum downward to completely invest the rectum in its upper part and partially invest it below, at first covering it in front, and laterally lower down, only in front, and lastly leaving the gut altogether. It is then reflected on to the base and upper part of the bladder in the male, forming the recto-vesical pouch. This pouch presents on each side a fold, the *plica seminalis*. From the apex of the bladder it ascends, investing the urachus and obliterated hypogastric artery on each side. In the female it passes from the rectum to the upper part of the vagina, forming the pouch of Douglas, which presents *plicæ semilunares* similar to those found in the recto-vesical pouch in the male. It then covers both surfaces of the uterus, and forms the broad ligaments, investing the Fallopian tubes to the fimbriated ends, where it becomes continuous with their mucous membrane.

Above, the peritoneum runs on the under surface of the diaphragm as far back as the œsophageal opening, and meets the process of the *lesser sac*, which lies on the posterior surface of the liver. It also forms the coronary, lateral, and falciform ligaments. At the anterior border of the liver it is reflected on to the under surface, covers the quadratic lobe, and at the transverse fissure it meets the posterior layer of the lesser or gastro-hepatic omentum from the lesser sac, and passes with it to the lesser curvature of the stomach as the anterior layer, thus completing the omentum. From the quadrate lobe it invests the gall-bladder to a variable degree, the under surface of the right lobe of the liver, the front of the second portion of the duodenum, and the upper part of the right kidney, forming here the fold known as the hepato-renal ligament. Lastly, it invests the hepatic flexure of the colon, and proceeds to the right colon in the manner previously described.

To the left of the longitudinal fissure of the liver it covers the entire under and upper surface of the left lobe of the liver, forming the left lateral ligament. Tracing to the left the anterior layer of the lesser omentum, the peritoneum covers the front and left side of the œsophagus and left end of the stomach, passing thence to invest the spleen, and forming the anterior layer of the gastro-splenic omentum. Passing from the diaphragm to the stomach to the left of the gullet, there is formed the gastro-phrenic fold or ligament, and between the diaphragm and splenic flexure the costo-colic ligament.

Describe the lesser sac of the peritoneum.

This is a process of the peritoneum which lines the space bounded by the posterior surfaces of the liver and stomach and the upper surface of the transverse colon. It communicates with the greater sac by means of the foramen of Winslow, which is bounded in front by the lesser omentum, with the portal vein and hepatic artery and duct between its layers, behind by the vena cava inferior, above by the lobus caudatus, below by the duodenum. From this point the lesser sac lines the posterior abdominal wall, and adheres to the back of the greater sac except where the stomach comes between. Above it passes behind the liver, between the Spigelian lobule and the back part of the diaphragm, to meet the process from the greater sac already described. Here it is attached to the transverse fissure and the fissure of the ductus venosus, covering the œsophagus behind and on the right. At the transverse fissure it passes to the lesser curvature of the stomach, forming the posterior layer of the lesser or gastro-hepatic omentum, the anterior layer coming from the greater sac. It then invests the back of the stomach, and descends from the great curvature in front of the transverse colon and small intestine to a greater or less extent. Turning upon itself, it ascends, thus forming the internal layers of the great omentum, as far as the transverse colon, whose upper surface it invests, and passes thence to the spine, thus forming the upper layer of the transverse mesocolon. It now passes upward over the front of the pancreas, cœliac axis and its branches, upper part of left kidney, the left suprarenal capsule, and that part of the diaphragm between the aortic and caval openings, and is continuous with that part of the lesser sac lining the space back of the liver, already described. Traced to the left over the pancreas, the peritoneum is reflected to the hilus of the spleen, and thence to the stomach, forming the posterior layer of the gastro-splenic omentum. Traced to the right, it is reflected from the extreme end of the pancreas on to the back of the first portion of the duodenum, and becomes continuous with that covering the posterior surface of the stomach.

Describe the formation of the great omentum.

The anterior layer of the lesser omentum invests the front of the stomach to the greater curvature, from which it descends in front of and with the posterior layer, and thus in front of the transverse colon and small intestine, to a variable degree. Still outside of the posterior layer (from the lesser sac), it is reflected, in a manner similar to that layer, upon itself, and, ascending with it, completes the great omentum. Those layers, therefore, of the great omentum which are contributed by the lesser sac are continued within those from the greater sac. At the transverse colon the layers of the greater omentum separate and enclose the gut, meeting behind and completing the transverse mesocolon, which extends to the lower border of the pancreas. Here the inferior layer (from the greater sac) runs down along the posterior abdominal wall and

blends with the mesentery as described, and the superior layer (from the lesser sac) proceeds as already mentioned.

ORGANS OF REPRODUCTION (MALE).

THE PROSTATE GLAND.

The prostate gland surrounds the so-called neck of the bladder and the commencement of the urethra. It rests against the rectum behind, and lies on the subpubic fascia (posterior layer of triangular ligament). It resembles a chestnut in form, and measures transversely $1\frac{1}{2}$ inches, from base to apex $1\frac{1}{4}$ inches, and nearly 1 inch in thickness, its weight being 6 drachms. The *base* looks toward the neck of the bladder, its *apex* touches the deep perineal fascia (triangular ligament), the *posterior surface* is joined to the rectum by areolar tissue, and its *pubic surface*, grooved longitudinally, lies $\frac{3}{4}$ inch from the pubic symphysis. It is supported in its position by the pubo-prostatic ligaments, posterior layer of the deep perineal fascia, and the front of each levator ani (the levator prostatae).

The prostate consists of two lateral lobes and a middle lobe. The *lateral lobes* are separated behind by a deep notch, and are continuous in front of the urethra. The *middle* is smaller, lying between the lateral lobes, the bladder, and the adjacent portion of the urethra.

The urethra and common seminal ducts pierce the prostate. The gland has a dense, firm, fibrous capsule, which is derived from the recto-vesical fascia and the posterior layer of the triangular ligament, and it consists of glandular and muscular tissue.

THE PENIS.

Describe the penis.

The penis consists of three cylindrical masses of erectile tissue united together, the two upper of which, lying side by side and called the corpora cavernosa, form the chief bulk of the organ, and the lower, the corpus spongiosum, contains part of the urethra. The root is attached to the pubic rami by the crura, and to the symphysis by the suspensory ligament. The body is cylindrical when flaccid, triangular with rounded border and sides when erect, the upper side being the dorsum. It is covered by a very thin skin, which is dark in color and devoid of adipose tissue, being loosely connected to the organ. This skin folds upon itself in front to form the prepuce, the under layer of which joins the cervix and becomes very like a mucous membrane, covering the glans and blending into the mucous membrane of the urethra at the meatus. Around the cervix and corona glandis are small glands, the glandulae Tysoni odoriferae. The *glans* is conical and points anteriorly, its summit presenting a vertical slit, the *meatus urinarius*, from the lower part of which a fold of mucous membrane runs back to join the prepuce, and is called the *frænum præputii*. The base of the glans projects at its

circumference, forming the *corona glandis*, behind which is a constriction, the *cervix*.

The *corpora cavernosa* are closely connected for the anterior three-fourths, being flattened mesially, while behind they separate, and, enlarging at first to form the bulb of the corpus cavernosum, gradually taper, and under the name of *crura penis* are attached to the rami of the pubes and ischium. In front they form a single blunt extremity which is joined by fibrous tissue to the base of the glans. Below them is a groove for the corpus spongiosum, and above one for the dorsal vein of the penis.

The fibrous envelope is composed of longitudinal fibres common to both corpora, and circular fibres which are internal and belong to one corpus only. Mesially, where the circular fibres of both sides meet, they unite to form a septum. This septum is thick and complete behind, but in front many vertical slits allow of communication between the two bodies, and have given to the septum the name *septum pectiniforme*. From the inner surface of this envelope numerous fibrous trabeculæ pass in all directions. These trabeculæ support and enclose the arterial branches, which form a capillary network opening directly into the cavernous spaces, some of them forming convoluted vessels, the helicine arteries, which project into the trabecular spaces. The blood is returned by the dorsal vein, prostatic plexus, and pudendal veins.

The *corpus spongiosum* commences behind, between the two crura, and in front of the deep perineal fascia, as the *bulb*, and in front expands to form the glans. The bulb receives an investment from the anterior layer of the deep perineal fascia and is surrounded by the accelerator urinæ muscles. The urethra runs through the upper part of the corpus spongiosum, surrounded by a layer of erectile tissue, the part within the bulb being called the bulbous portion of the urethra. The fibrous envelope is white, thinner than that of the corpora cavernosa, and encloses a similar trabecular structure. Just beneath it, forming part of the outer coat, is a layer of muscular fibres, and a second muscular layer lies beneath the urethral mucous membrane.

THE MALE URETHRA.

Describe the urethra, and give its three divisions.

The male urethra extends from the neck of the bladder to the end of the penis, is about $8\frac{1}{2}$ inches long, and is lined throughout by mucous membrane supported by a submucous tissue and connected by it with the subjacent tissues in its three parts—viz. the prostatic, membranous, and spongy. Part of the submucous tissue is composed of a longitudinal muscular layer internally and a circular externally.

The **prostatic portion** is the widest part of the canal, and traverses the prostate gland, being about $1\frac{1}{4}$ inches long, widest at the middle, and lying above the middle lobe. It is very dilatable. On its floor is a slight elevation at the back part, which passes back to the uvula vesicæ, and

is placed in the median line, measuring $\frac{3}{4}$ inch long and about $\frac{1}{8}$ inch at its maximum height. This ridge has been variously named the *crista urethræ*, *colliculus seminalis*, *verumontanum*, and *caput gallinaginis*. On each side of it is a groove, the *prostatic sinus*, the floor of which presents the orifices of the numerous prostatic ducts.

In the fore part of the *verumontanum* is a depression, which leads into the *sinus pocularis* or *uterus masculinus*, upon or within the margins of which are the orifices of the *ejaculatory ducts*. This sinus forms a cul-de-sac running in the *verumontanum* and beneath the middle lobe of the prostate.

The **membranous portion** lies between the apex of the prostate and the bulb of the *corpus spongiosum*, and is the narrowest part of the canal. It is $\frac{3}{4}$ inch long. It pierces, lies between, and is invested by the anterior and posterior layers of the deep perineal fascia, and is surrounded by the compressor urethræ, one of Cowper's glands lying on each side.

Cowper's glands are yellowish, lobulated bodies, of the size of a pea, lying between the two layers of the deep perineal fascia, behind the membranous urethra, and between the arteries of the bulb above and the transverse fibres of the compressor urethræ below. The lobules are made up of acini and joined together by fibrous tissue. The ducts from the lobules unite outside the gland into a common duct, which runs forward beneath the mucous membrane for about an inch and opens on the floor of the bulbous portion of the urethra.

The **spongy portion** of the urethra is enclosed by the *corpus spongiosum*, and is about $6\frac{1}{2}$ inches long. The *bulbous portion*, or *sinus*, is dilated, but beyond the bulb the urethra is of uniform calibre as far as the glands, in which it is again dilated, forming here the *fossa navicularis*, and its long axis becomes vertical instead of transverse. At the meatus it is much contracted.

The mucous membrane presents the orifices of many small racemose glands (glands of Littre) and of many *lacunæ*. One of these latter, in the upper part of the *fossa navicularis*, is considerably dilated, and is called the *lacuna magna*.

THE TESTES.

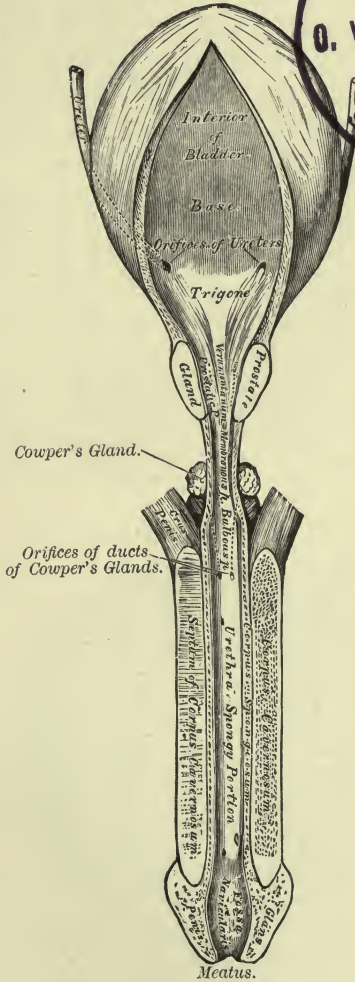
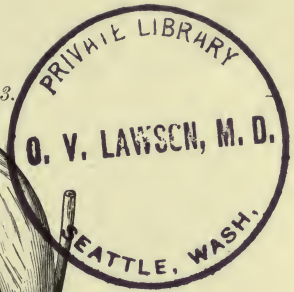
Describe the spermatic cord.

The testicles are two glandular organs suspended in the scrotum by the spermatic cord.

The *spermatic cord* extends from the internal ring to the back of the testis. Its various parts are connected together by areolar tissue, and are invested by the various processes of the fascia, which descends with the testicle. In its course through the inguinal canal it lies at first between the internal oblique and the fascia transversalis, the former at times arching over it; then between the aponeurosis of the external

PLATE XXIX.

FIG. 1.—To face page 343.



The Bladder and Urethra, laid open, seen from above.

oblique and the conjoined tendon; and Poupart's ligament is below. The left cord is the longer.

Of what is the spermatic cord composed?

It is composed of the spermatic artery, artery of the vas deferens, and cremasteric artery, the spermatic veins from the back of the testis, which receive the veins from the epididymis to form the pampiniform plexus, a number of large lymphatics, and the spermatic plexus of the sympathetic, together with the vas deferens, the layers of fascia which cover the testicle, and the remains of the peritoneal testicular process.

What are the boundaries of the inguinal canal?

The inguinal canal is bounded *behind* by the fascia transversalis and the conjoined tendon; *in front* by the transversalis and internal oblique above, and the external oblique aponeurosis below; its floor is formed by the curving back of Poupart's ligament; its roof by the arched fibres of the internal oblique in apposition with the aponeurosis of the external oblique.

Give the coverings of the testicle.

The testicle is covered from without inward by the following structures: the scrotum, composed of skin and dartos; the intercolumnar or external spermatic fascia; cremasteric fascia; infundibuliform fascia, or internal spermatic fascia; tunica vaginalis.

What is the scrotum?

The **scrotum** is a pocket which contains the testicles and part of the spermatic cords, and is marked superficially by a median ridge, the raphé, which runs from the penis along the scrotum and perineum to the anus. The scrotum consists of a layer of skin and the dartos.

The *skin* is thin and dark, and presents folds or rugæ, is covered with hairs thinly scattered, and is furnished with sebaceous glands.

The *dartos* is a thin contractile tunic, of a reddish color, continuous with the superficial fascia of the groin and perineum; it is very vascular, and is composed of loose areolar tissue and unstriated muscle. It sends in a partition, the septum scroti, which separates the two testes, and is attached to the under surface of the penis and to the raphé.

Give the fasciæ within the scrotum.

The *intercolumnar* fascia, separated by loose areolar tissue from the dartos, is attached to and descends from the margins of the pillars of the external ring.

The *cremasteric* fascia consists of scattered muscular loops or bundles (cremaster muscle), connected together by areolar tissue, the former being continuous with the lower border of the internal oblique.

The *infundibuliform* fascia is continuous above with the fascia trans-

versalis and the subserous areolar tissue of the peritoneum. These two together, the latter being underneath, form the fascia propria. It invests the surface of the cord and sends in septa between its component parts.

The *tunica vaginalis* (see *Testicle* proper).

Describe the testicle proper and epididymis.

Each testicle is ovoid, flattened from side to side, and suspended obliquely (the left being somewhat the lower), its upper end being directed forward, outward, and upward, the lower in the opposite direction. Each is $1\frac{1}{2}$ inches long, $1\frac{1}{4}$ inches wide, and less than 1 inch thick, and weighs $\frac{3}{4}$ to 1 ounce.

The front, sides, and both ends of the testis are free, smooth, and covered by the tunica vaginalis. At the posterior border the vessels and nerves enter and emerge, and to this border, as well as to the outer surface, is attached the epididymis.

The epididymis is a long, narrow structure, made up of a *body*, a *head* or *globus major*, and a *tail* or *globus minor*.

The globus major is large, and joined to the upper end of the testicle by the efferent ducts; the minor is small and pointed, and is joined to the lower end of the testicle by a reflection of the tunica vaginalis and some cellular tissue. The convex surface and anterior border of the epididymis are free and covered by the tunica vaginalis, as is also the concave or attached surface (except at the ends), the serous membrane here forming the *digital fossa*. On the front of the globus major are one or more small pedunculated bodies called the *hydatids of Morgagni*, believed to be the remains of Müller's duct. The epididymis is a convoluted canal whose lumen is continuous with that of the vas deferens.

The *tunica vaginalis* is a closed serous sac, and consists of a visceral layer and a parietal layer.

The *visceral layer* adheres to the outer surface of the tunica albuginea, surrounding the testis and epididymis, and joining them together by a fold. It forms between them the pouch known as the digital fossa.

The *parietal layer* is reflected on to the inner surface of the scrotum at the posterior border of the testicle.

The *tunica albuginea* is the fibrous coat which surrounds the soft substance of the testis and is reflected at the posterior border into its interior, forming a sort of septum, the *corpus Highmori* or *mediastinum testis*. This septum, wider above than below, extends from the upper nearly to the lower end of the gland, and sends off numerous trabeculae which join the inner surface of the tunica albuginea. These divide the organ incompletely into *lobules*. The *tunica vasculosa* (pia mater testis) is a vascular plexus supported by areolar tissue which covers the inner surface of the tunica albuginea and its trabeculae.

The *gland substance* consists of *seminiferous tubules*, which are contained within the lobules above mentioned, each lobule containing two

or three seminiferous tubules. Each of these latter is lined by several layers of epithelial cells, from which, by a process of division (karyokinesis), are finally developed the spermatozoa.

The *lobules* are conical, their bases being turned toward the circumference, their apices toward the mediastinum. In the latter situation the tubules become straighter, and unite to form twenty to thirty large ducts, the *tubuli recti*. These *tubuli recti* open into a vascular network, the *rete testis*, which lies in the substance of the mediastinum, and from this issue twelve to twenty *vasa efferentia*, which pierce the tunica albuginea and enter the globus major of the epididymis, where they now become tortuous and form conical masses, the *coni vasculosi*.

Describe the vas deferens, the vesiculæ seminales, and the ejaculatory ducts.

The **vas deferens**, the continuation of the epididymis, is the excretory duct of the testicle. From the globus minor it runs along the inner side of the epididymis and back of the testis, and in the spermatic cord to the internal ring: here it descends, crossing the external iliac vessels, and curving around the outer side of the deep epigastric artery. It now passes beneath the peritoneum to the side of the bladder, and runs downward and backward to its base, internal to the ureter and across the obliterated hypogastric artery. At the base of the bladder it lies between it and the rectum, internal to the seminal vesicle, the duct of which it joins (close to the base of the prostate) after having enlarged and again narrowed, forming with it the ejaculatory duct. Its length is about 2 feet and its diameter about $\frac{1}{10}$ inch. It has an external areolar coat, a middle muscular coat of two layers, longitudinal and circular, and an internal mucous coat covered with columnar epithelium.

The **vesiculæ seminales**, conical in form, the wider end looking backward, lie between the rectum and the base of the bladder, and are the reservoirs for the semen. They are 2 inches long and $\frac{1}{2}$ inch wide. In front they converge, and each joins the corresponding vas deferens at the base of the prostate to form the ejaculatory duct. The vesicle is a single tube 4 to 6 inches long, coiled up and giving off diverticula. It ends behind in a blind extremity, and is 2 inches long in its natural condition.

Each **ejaculatory duct** is $\frac{3}{4}$ inch long, and runs one on each side, forward and upward within the prostate, between its middle and lateral lobes, and along the walls of the sinus pocularis, close to the opening of which they empty. Each has an areolar, a muscular, and a mucous coat.

The **semen** is a whitish fluid composed of liquor seminis, seminal granules, and spermatozoa. The granules are $\frac{1}{40000}$ inch in diameter. The spermatozoa consist of a head, formerly the nucleus of a spermatoblast, a body, and a tail. The spermatoblasts constitute one of the layers of epithelial cells lining the seminiferous tubules.

ORGANS OF REPRODUCTION (FEMALE).

External.

THE VULVA.

Describe the vulva.

The term *vulva* or *pudendum* includes the mons veneris and labia, the nymphæ and clitoris, the hymen or its remains, the meatus urinarius, and the vaginal orifice.

Describe these various parts.

The *mons veneris* is a fatty cushion covering the front of the pubes, and after puberty is plentifully supplied with hairs. Below, it divides into the two *labia majora*, which, diminishing in size as they pass downward and backward, unite an inch in front of the anus. The two extremities are joined, and form the anterior and posterior commissures. Between the latter and the anus is the perineum, and just within the posterior commissure is a transverse fold, the *frænulum pudendi* or fourchette. Between this fold and the posterior commissure is a triangular space, the *fossa navicularis*.

The *nymphæ*, or *labia minora*, smaller than the above, run from the middle of the *labia majora* upward to the clitoris, each dividing into two folds, the upper pair of which join to form a prepuce for that organ, and the lower two to form its *frænulum*. They are continuous externally with the *labia majora*, internally with the vagina. The *mons veneris* is composed interiorly of fatty and fibrous tissue; the *labia*, of areolar fatty and dartoid tissue, with vessels and nerves; the *nymphæ*, of a plexus of vessels covered by mucous membrane.

The *clitoris* is the analogue of the penis, consisting like it of two corpora cavernosa united by a septum pectiniforme, and prolonged behind into two crura attached to the pubic and ischial rami. It also has a suspensory ligament and a glans enclosed by the *nymphæ*. Two *erectores clitoridis* muscles are attached to the crura. It has no *corpus spongiosum* nor urethra.

Between the clitoris and the vagina, bounded on each side by the *nymphæ*, is the *vestibule*, a triangular space, in which, just above the vagina, is the meatus urinarius, 1 inch below the clitoris.

The *hymen* is a mucous fold which more or less completely occludes the orificium vaginæ. It is generally semilunar in form, concave above, or it may be a complete membrane, perforate or imperforate, or it may be absent. After labor its remains form the *carunculæ myrtiformes*.

The *glands of Bartholin*, the analogues of Cowper's glands in the male, are two yellowish bodies on each side of the vaginal opening, each of which discharges by a single duct between the hymen and the *nymphæ*.

On each side of the vestibule, behind the *nymphæ*, is a leech-shaped mass, the *bulbus vestibuli*. Each consists of a venous plexus enclosed

by a fibrous capsule, and is about 1 inch long. In front of these, and connecting them with the vessels of the clitoris, is a small venous plexus, the *pars intermedia* of Kobelt.

THE URETHRA.

Describe the urethra.

The *female urethra* is a mucous canal, $1\frac{1}{2}$ inches long, running downward and forward in the anterior vaginal wall from the neck of the bladder to the meatus. As in the male, it pierces the triangular ligament, and is surrounded by the compressor urethræ muscle. It consists of a muscular, a mucous, and, between them, an erectile, coat. It is supplied with numerous glands, and just within the meatus near the floor are two ducts which extend upward for about $\frac{3}{4}$ inch. These are called Skene's tubules.

THE VAGINA.

Describe the vagina.

The *vagina* extends from the vulva to the uterus, lying behind the bladder and in front of the rectum, and is about 4 inches long on its anterior wall, 5 to $5\frac{1}{2}$ on its posterior, and is directed from the uterus downward and forward.

Above, it embraces the cervix uteri, and its walls are flattened from before backward. It is narrowest at the introitus, or orificium vaginæ. *In front* it is in relation with the urethra and base of the bladder; *behind* it is connected with the anterior wall of the rectum by its lower three-fourths, the cul-de-sac of peritoneum (Douglas's) separating them above; *laterally* the broad ligaments are attached above, and the levatores ani below, as well as the recto-vesical fascia. Its inner surface presents a mesial ridge or raphé on the front and back walls, the columnæ rugarum, and from them on both sides run out transverse folds or rugæ.

The vaginal mucous membrane is squamous, with papillæ here and there. The submucous coat holds many large veins and some muscular fibres, making a sort of erectile tissue. The veins form a sort of plexus. The muscular coat comprises an internal circular and an external longitudinal layer. At the lower part is the sphincter vaginæ, a muscle composed of striped fibres.

The *internal organs* include the *uterus, tubes, and ovaries.*

Internal.

THE UTERUS.

Describe the uterus.

The *uterus* or womb is a hollow muscular organ lying in the pelvis between the bladder and rectum. In the virgin it is pear-shaped, flattened from before backward, its upper end looking forward and upward, its lower downward and backward, forming an angle with the

vagina. Above, it is invested by the peritoneum, which covers its body before and behind; it covers also the cervix behind, but in front the peritoneum is reflected on to the bladder before reaching the cervix. Its upper and back part is in contact with the small intestine, its lower and front part with the bladder, the peritoneum separating them. The two folds of peritoneum after investing the uterus are applied to each other and form the broad ligaments.

The uterus is 3 inches long, 2 wide, and 1 thick, and it weighs about 1 ounce. It is divided into a body, fundus, and neck. The fundus is the convex part above the entrance of the tubes; the body is the part between this and the neck. In front of the Fallopian tubes, at the upper part of the lateral borders, the round ligaments are attached, and below and behind them are the ligamenta ovarica. The *cervix* is the lower constricted, rounded part, and around it is attached the vagina. At its vaginal end is a transverse opening, the os uteri, the posterior lip of which is thin and long, the anterior thick.

Describe the cavity of the uterus.

The cavity of the uterus is small; that part within the body is triangular, flattened antero-posteriorly, and presents at the superior angles the openings of the Fallopian tubes; also, at its junction with the neck it is constricted to form the os internum or isthmus. The cavity of the cervix is barrel-shaped and flattened antero-posteriorly, presenting on each wall a longitudinal column sending off oblique rugæ on each side; hence its name, *arbor-vitæ uterinus*.

Give the structure of the walls of the uterus.

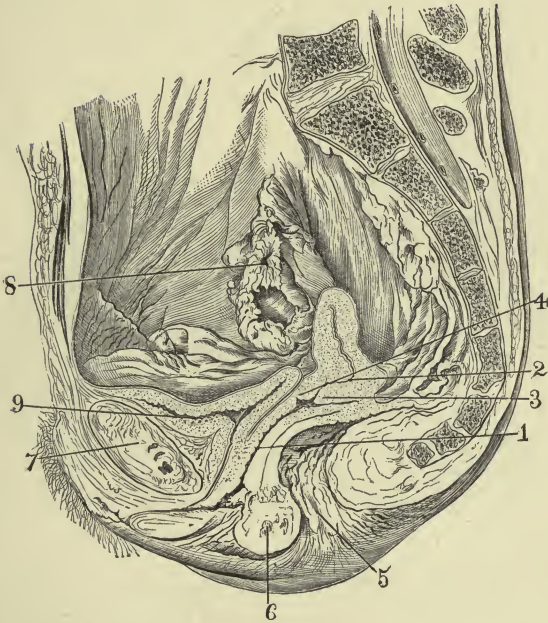
The walls of the uterus consist of an outer serous coat (already described), an inner mucous, and an intermediate muscular. The muscular coat forms the bulk of the uterus, and consists of bundles and layers of unstriped fibres which interlace, and of some areolar tissue supporting them, and of blood-vessels, lymphatics, and nerves. Three layers are described—an external transverse layer, some of the fibres being continued on to the Fallopian tubes, etc.; a middle layer of intermixed longitudinal, oblique, and transverse fibres; and an internal layer, which is circularly arranged at the cervix, forming the so-called external and internal sphincters. This layer is the *muscularis mucosæ* of the mucous membrane.

Describe the mucous membrane of the uterus.

The mucous membrane of the *body* differs from that of the cervix. The former is smooth, reddish, with columnar cells, and presents the ducts of a number of tubular glands which end by blind, sometimes forked, extremities. In the *cervix* it is firmer, and presents numerous saccular and tubular glands between the rugæ of the *arbor vitæ*, and, below, numerous papillæ. The glands are sometimes distended by their secretion, the ducts being choked, and present the appearance of vesi-

PLATE XXXI.

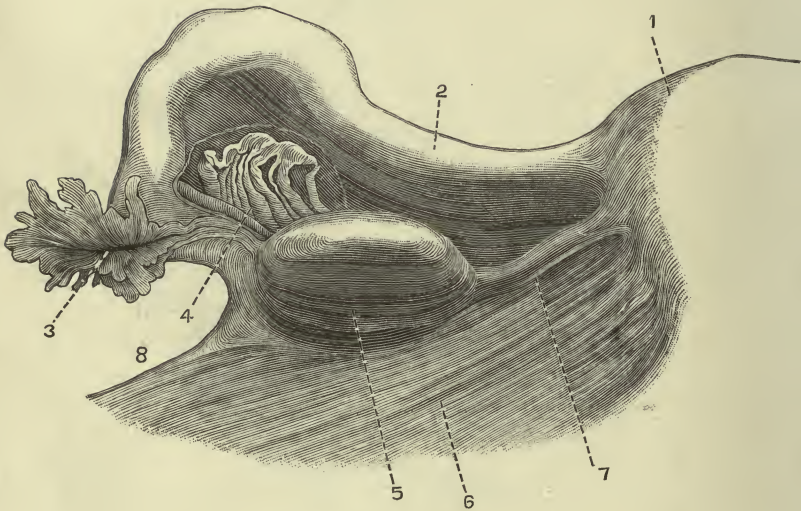
FIG. 1.—To face pages 349 and 350.



Antero-posterior (sagittal) Section of the Pelvic Organs of a Virgin : 1, $\frac{1}{4}$ vagina ; 2, uterus ; 3, posterior lip ; 4, anterior lip ; 5, anus ; 6, perineum ; 7, symphysis pubis ; 8, fimbriated extremity of the Fallopian tube ; 9, the empty bladder—note its Y shape, and also that the walls of the uterus, vagina, urethra, and bladder are in contact except when distended by their appropriate contents (D. Berry Hart).

PLATE XXXII.

FIG. 1.—*To face page 351.*



Posterior View of Uterine Appendages: 1, uterus; 2, Fallopian tube; 3, fimbriated extremity and opening of the Fallopian tube; 4, epoöphoron; 5, ovary; 6, ligament; 7, ligament of the ovary; 8, infundibulo-pelvic (broad) ligament (Henle).

cles; hence their name, ovules of Naboth. At the upper part of the cervix the cells are columnar and ciliated; below, stratified.

What are the ligaments of the uterus?

The ligaments of the uterus are the *round* ligaments and several *peritoneal folds*—namely, two each in front, behind, and laterally.

The *round ligaments* are two cord-like bundles of areolar, fibrous, and plain muscular tissue, with vessels and nerves, covered by peritoneum, which run from the upper angle of the uterus to the internal ring. Each then runs through the corresponding inguinal canal to end in the mons veneris and labia. Each measures about 4 or 5 inches in length, and their direction is upward, forward, and outward. The peritoneum, which invests them, is sometimes prolonged (as in the foetus) for some distance into the inguinal canal, and forms the canal of Nuck. Generally this canal is obliterated.

The *anterior* or *vesico-uterine ligaments* stretch between the bladder and the uterus; the *posterior*, between the uterus and rectum, hence called the *recto-uterine*, forming a pouch, the cul-de-sac of Douglas.

The two *lateral* or *broad ligaments* pass from the sides of the uterus to the sides of the pelvis, thus dividing the latter into two parts. They are formed by the coalescence of the peritoneal layers investing the anterior and posterior surfaces of the uterus, and contain between the two layers: the Fallopian tube at the upper margin; the round ligament below and in front of the tube; the ovary and its ligament enfolded by the posterior layer; and the uterine blood-vessels, lymphatics, and nerves.

THE FALLOPIAN TUBES.

Describe the Fallopian tubes.

The *Fallopian tubes*, or oviducts, run from the upper angles of the uterus toward the sides of the pelvis, and near their termination bend downward, backward, and inward. They are 3 to 4 inches long, are at first narrow, then enlarge near the extremity (ampulla), and end in a fimbriated margin, one of the fimbriae being attached to the ovary. The canal is very narrow at the uterine end (ostium uterinum), begins to widen in the outer half to form the ampulla, and at its termination again narrows (ostium abdominale).

The *tubes* consist of a peritoneal coat, a muscular coat composed of internal circular and external longitudinal fibres, and a mucous coat. The latter is continuous with that of the uterus and with the peritoneum, the epithelium being ciliated columnar, and it is thrown into longitudinal wrinkles, more marked in the outer half of the tube.

THE OVARIES.

Describe the ovaries.

The *ovaries* are analogous to the testes, and are flattened, oval bodies, measuring $1\frac{1}{2}$ inches long, $\frac{3}{4}$ inch wide, and $\frac{1}{2}$ inch thick, each weighing

60 to 100 grains. Of each, the two sides are free as well as the convex border, the straight border (hilus) being attached to the broad ligament and admitting the vessels, etc. Its outer end is attached by the fimbria ovarica to the Fallopian tube, its inner end to the uterus by the ligament of the ovary, a dense, fibro-muscular cord attached to the uterus below and behind the tube.

The *ovary* consists of a stroma in which are imbedded the Graafian follicles, and of a covering of columnar cells, the germinal epithelium. The stroma is invested beneath the epithelium by a dense fibrous layer, the tunica albuginea, and consists of connective tissue with numerous cells, as well as of elastic fibres, with some muscular tissue and blood-vessels.

The *Graafian follicles* consist of an external fibrous coat, and beneath it a coat called the ovi-capsule, lined internally by a layer of cells, the *membrana granulosa*. Within this last-named layer is the ovum, invested by the *discus proligerus*, a layer of cells derived from the *membrana granulosa*, together with the liquor folliculi.

For the structure of the ovum see *Histology*, or *Gynecology*, or *Obstetrics* of this series.

THE PAROVARIIUM.

What is the parovarium?

The *parovarium*, organ of Rosenmüller, is a foetal remnant lying in the broad ligament between the ovary and Fallopian tube. It consists of several vertical tubes, lined by epithelium, whose lower ends run toward the hilus of the ovary, and whose upper ends are united by a horizontal tube, the duct of Gaertner.

THE MAMMARY GLANDS.

Describe the mammary glands.

These are accessory to the generative system and secrete the milk. They are two rounded eminences, one on each side of the thorax, between the sternum and axilla and the third and seventh ribs. Just below the centre is a conical eminence, the nipple, which is dark, and is surrounded by a pinkish *areola* which darkens in pregnancy. It presents the orifices of the *lactiferous ducts*, and consists of vessels mixed in with plain muscular fibres, and by friction may be made to undergo erection.

The *mamma* consists of a number of lobes separated by fibrous tissue and some adipose tissue. The *lobes* are divided and subdivided into smaller lobules, which are in turn made up of alveoli. Each lobe has an excretory (galactophorous) duct, and these, about sixteen in number, converge to the areola, there dilating into *ampullæ* or sinuses. They then become smaller again, and, surrounded by areolar tissue and vessels, pass through the nipple to empty on the surface by separate orifices.

GLOSSARY.

F. = French; Gr. = Greek; L. = Latin; N. L. = New Latin; adj. = adjective; c. = common; dim. = diminutive; f. = feminine; m. = masculine; n. = neuter or noun; part. = participle.

- Abdo'men, inis, n. (L.) = venter.** [Etymology doubtful. Andrews: *Adipomen*, from *adeps*, fat, lard, the fat lower part of the belly; Foster: *Abdere*, to conceal, and *omen*, either a *sign* in ancient augury or a contr. of *omentum*—that which conceals the omen or omentum. This explanation of *omen* does not commend itself; *men* is a formative ending, the whole word meaning “the concealer.”] The belly, paunch.
- Acerv'ulus, i, m. (L.) (aserv'ulus)** [dim. of *acervus*, *i, m.*, a heap; root *ak*, perhaps related to *agitare*, to drive]. A little heap; applied to a collection of “brain-sand” in the pineal gland.
- Acetab'ulum, i, n. (L.) [ace'tum, vinegar].** A vinegar vessel, hence any cup-shaped vessel. The articular cavity of the innominate bone.
- Adminic'ulum, i, n. (L.) [ad, manus, upon the hand].** The stake around which the vine twines. A support.
- Af'ferent [afferens, part. from ad, to, ferre, to carry].** Conveying something from the periphery to the centre.
- Ag'ger, eris, m. (L.) [aggerare, to heap up].** A heap or prominence.
- Alve'olar (not alveo'lar).** Pertaining to or containing alveoli.
- Alve'olus, i, m. (L.) [dim. of alv'eus, a hollow].** Bone-socket for a tooth; an air-cell; a part of a gland.
- Anal'ogous [ἀνά, λόγος, according to due ratio].** Referring to a part in one organism which has the same function as another part in another organism; similarity of purpose. “When organs in different animals agree in structure they are ‘homologous;’ when they perform the same functions, they are ‘analogous.’ The wing of a bird and arm of a man are homologous, not analogous; the wing of a bird and the wing of an insect are analogous, not homologous.”
- Anas'tomo'sis, is, f. (L.) [ἀνά, of each, στομῶω, to furnish with a mouth, to contract to a narrow mouth, to whet the appetite].** The communication of an artery or vein with another artery or vein.
- Anat'omy [ἀνά, apart, τέμνειν, to cut].** A science of the structure of organized bodies.
- Anco'neus, a, um, adj. or n. m. (L.) [ancōn, ōnis, m. = ἀγκών, the bend of the arm].** Any muscle connected in any way with the olecranon; now applied to one muscle connected with the triceps and olecranon.
- Annec'tant [annecto, ad, to, necto, I fasten together].** Connecting. Applied to brain-tissue that connects adjacent gyri.
- Anti'cus, a, um, adj. (not an'ticus) (L.) [ante, before].** Anterior.
- Aor'ta, æ, f. (L.) [ἀορτή, in Hippocrates the bronchi; from ἀείρω, I lift or heave].** The common trunk of the systemic arteries.
- Apoph'ysis, is, pl. es, f. (L.) (apof'isis) [ἀποφύω].** An outgrowth.
- Aqu'educt (L. aquæductus, us, m.) [aqua, water, ducere, to lead].** A canal; it may or may not contain fluid.

- Arach'noid**, adj. and n. (arak'noid) (L. *arachnoid'us*) [*ἀράχνη*, a spider's web, εἶδος, resemblance]. The middle of the three membranes investing the brain and spinal cord.
- Are'olar** (not areo'lar) [*ἄρε'δλα*, æ, f. dim. of *ἄρ'εα*, an open space]. Pertaining to a tissue containing interspaces.
- Ar'tery** (L. *arte'ria*, æ, f. Gr. *ἀρτηρία*) [from *ἀρτήρ*, that which suspends; originally applied to the trachea, called the "rough artery," *τραχεῖα ἀρτηρία*, suspending the lungs; perhaps from *ἀήρ*, ἀέρος, air, *τηρέω*, I convey. The ancients believed it contained air, being found empty after death]. A vessel which conveys blood from the heart.
- Aryte'noid** (L. *arytænoid'us*, from *arytæ'na*) [*ἀρύταινα*, a ladle or pitcher, εἶδος, resemblance]. Shaped like the mouth of a pitcher. A cartilage of the larynx.
- Aste'rión**, ii, n. (L.) [*ἀστήρ*, star]. A sort of spider; point of junction of parietal, occipital, and temporal bones.
- Astrag'alus**, i, m. (L.) [*ἀστράγαλος*, a cervical vertebra; *ἀστράγαλοι* were dice made of the cubical ankle-bones; Lat. *tali* were stone dice]. The ankle- or sling-bone, the first of the tarsus.
- Az'ygos**, n. and adj. [*ἀ*, without, *ζυγόν*, yoke]. Without a fellow; unyoked.
- Basil'ic** [L. *basil'icus*; Gr. βασιλικός, royal, from βασιλεύς, king; perhaps from Arabic *al-basilik*, the inner]. A superficial vein of the arm. The name was applied by the ancients to important parts. The right basilic vein was called *hepatic*, as it was supposed to have some connection with the liver; for a similar reason the left basilic vein was called the *splenic*; the *cephalic* veins were thought to be connected with the head, and whenever the liver, spleen, or head was diseased, venesection was performed on the appropriate vein.
- Bifur'cate** (not bi'furcate) [*bis*, twice, *furca*, æ, f., a two-pronged fork]. To divide into two branches.
- Blast'oderm** [βλαστός, a germ, δέρμα, skin]. A membranous bag from which the embryo is formed.
- Breg'ma**, atis, n. (L.) [*βρέχειν*, to moisten, because the part is soft and moist in infants]. Junction of coronal and sagittal sutures.
- Cal'amus**, i, m. (L.) [*κάλαμος*, a reed or cane; a reed-pen]. *C. scriptorius*, writing-pen. A portion of the fourth ventricle, shaped like a pen.
- Cal'yx**, cal'ycis, m. (L.) [*καλύπτω*, I cover]. A cup. The outermost leaflets of a flower; a cup-like subdivision of the ureter.
- Canīne'** (kayneyn'), L. *canīnus* [*canis*, a dog]. Pertaining to or resembling some structure in a dog.
- Canthus**, i, m. (L.) [= *κάνθος*, the tire of a wheel]. The angle of junction of the upper and lower eyelids.
- Capillary** (kap'illary preferable to kapil'lary) [*capillus*, i, m or um, i, n., hair of the head, dim. of root *cap* (*caput*)]. Pertaining to hair or hair-like filaments.
- Carot'id** (L. *carō'ticus*) [*καρωτίδες* (pl.), the carotids, from *κάρος*, a deep, heavy sleep, from the fact that drowsiness can be produced by compression of these arteries in the neck].
- Caruncula**, æ, f. (L.) [dim. of *cāro*, *carnis*, f. flesh]. A little piece of flesh; caruncle.
- Cere'bral** (not cere'bral) [L. *cerebra'lis*]. Relating to the brain.
- Cer'ébrum**, i, n. (L.) (not cere'brum). The brain as a whole; the principal part of the brain, including the hemispheres.
- Cervi'cal** (not cer'vical) [*cervix*, *cervī'cis*, f., neck; L. *cervica'lis*]. Pertaining to the neck; neck of uterus.

- Cer'vix, cervi'cis** (servi'sis), gen. pl. cer'vicum, f. (L.) Neck, including the nape.
- Chias'ma, chias'matis**, n. (L.) (kiaz'ma) [χίασμα, from χιάζω, to mark with χ]. The crucial union of parts.
- Circumvallate** [circum, around, vallare, to surround with a rampart]. Surrounded with a prominence.
- Clit'oris** (not klit'oris), **clitor'idis**, f. (L.) [κλειτορίς, κλειτορίζειν, to titillate, or from κλείειν, to shut up, or from κλητήρ, a servant who invites guests]. A small erectile organ in the vulva, homologue of the penis.
- Coccygeal** (koksij'eal, not koksige'al) (L. *coccyg'eus*). Pertaining to the coccyx or tail.
- Coc'cyx** (kok'siks), gen. **coccy'gis** (not coc'cygis) (L.) [κόκκυξ, a cuckoo, whose beak it resembles]. The caudal end of the spinal column.
- Cœ'liac** (see'liak) [κοιλιακός from κοιλία, the belly]. Relating to the abdomen or its viscera.
- Com'es, eôm'itis**, m. or f. (L.) [cum, with, eo, I go]. A companion.
- Con'dyle**, L. *condylus*, *i*, m. (con'dyl) [κόνδυλος, a knot]. An articular process.
- Con'jugal** [conjux, ŷgis, c. spouse; con, together, jungo, to yoke]. *Lig. conjugal*, united with its fellow.
- Conniven'tes**, adj. pl. (L.) [connivens entis, from con-nīveo, I wink]. Folding on each other (*vulvulæ* c.).
- Coro'nal** (not cor'onal) [corō'na, æ, f. κορώνη, crown]. Relating to a crown.
- Crān'ium**, *ii*, n. (L.) [κράνος, helmet, or from κρανίον, skull]. The brain-case; the entire skull.
- Cremas'ter, cremaster'is**, m. (L.) [κρεμαστήρ, a suspender, κρεμάννυμι, I let hang down]. The suspensory muscle of the testicle.
- Crus'ta, æ, f.** (L.) crust, outer coating. Ventral portion of the crus cerebri.
- Cu'bitus, i, m., or cu'bitum, i, n.** (L.) [*cubo*, I lie down, κύβειτον]. Elbow (serving for leaning upon); ulna; forearm. An ell or cubit (originally the distance from the elbow to the end of the middle finger; the Roman, 17½ inches; the English, 18 inches; the Hebrew, 22 inches).
- Cu'neiform** [cunēus, *i*, m. wedge, *forma*, form]. Wedge-shaped.
- Decus'sate** (not de'cussate) [decus'sis, *is*, m. (*decem-as*), a ten-as piece, a coin; as was a pound weight, or 16½ cents. As the Roman numeral on the coin was X, *decussis* came to mean the intersection of two lines]. To cross; to place in the form of an X.
- Di'aphragm** [dy'afram], L. *diaphragma*, *atis*, n. (dyafrag'ma) [διάφραγμα, a partition-wall; διά, thoroughly, φράσσω, I fence in]. A partition between cavities. The partition between the thoracic and abdominal cavities.
- Diaph'ysis, is, f.** (diaf'isis) (L.) [διά, between, φύειν, to grow]. The part of bone formed from the principal centre.
- Digas'tric** [δύς, twice, γαστήρ, belly; L. *biventer*]. Having two bellies.
- Duodē'num, i, m.** (L.) [duodēni, twelve each]. Upper portion of the small intestine, about 12 finger-breadths (10 inches) long.
- Ef'ferent** [effereus, part., ex, from, ferre, to carry]. Carrying or leading from an organ.
- Em'bryo, o'nis** (L.) [ἐμβρυον, ἔν, within, βρῦω, to be full of anything]. The fecundated ovum in the first two or three months of its development. (See FŒTUS.)
- Em'issary** [e, out, mittere, to send]. Serving as an outlet.
- Ephip'pium** (effip'pium), **ephip'pii**, n. (L.) [ἐπί, upon, ἵππος, horse]. A saddle; a part of the sphenoid bone.
- Epiph'ysis** (epif'isis), *is, f.*, pl. **Epiph'yses** (L.) [ἐπί, upon, φύειν, to grow]. The portion of a long bone from a secondary or tertiary centre.

- Epiplo'ic** (L. *epiplo'icus*, a, um, adj.) [*ἐπίπλοον*, omentum, *ἐπί*, upon, *πλέω*, I float]. Pertaining to the omentum.
- Epipter'ic** (epipter'ik) [*ἐπί*, upon, *πτερόν*, wing]. Situated on the greater wing of the sphenoid.
- Eustach'ius** (Bartholomeo Eustachi), of the Italian school (1500), was the contemporary of Vesalius, and divides with him the merit of creating the science of anatomy. He studied especially the internal ear.
- Excre'tory** [*ex*, out, *cerno*, I choose]. Pertaining to excretion (the separation from the body of parts supposed to be useless).
- Fao'et** (not faset') (F.) [dim. of *face*]. A small face.
- Fallop'ius** was a pupil of Vesalius, and professor at Padua in 1551; studied bones, especially the internal ear and organs of generation.
- Ferrugin'eus**, a, um, adj. (L.); also *ferrūg'inus* [*ferrūgo*, iron-rust, from *fer-rum*, iron]. Of the color of iron-rust; dusky.
- Fœtus**, ūs, m. (strictly *fetus*) (L.) [from root *feo*, whence also *fecundus* and *felix*, fruitful; *femina*, fruit-bearer; *fenus*, interest or gain]. The unborn child. In the human subject this term is usually applied to the embryo only after the third month of gestation.
- Fontanelle** (fontanel') (F.) [*fontanella*, æ, f., dim. of *fons*, *fontis*, a fountain]. A membranous interspace between fetal skull-bones. Pulsation like a fountain is here seen.
- Fo'vea**, æ, f. (L.) [*fodio*, *ëre*, to dig]. A small pit, a pitfall. An old term for the vulva.
- Gal'ëa**, æ, f. (L.) [*γαλέη*, weasel, from the skin of which helmets were made]. Helmet; the amnion.
- Ga'len**, L. *Claudius Galenus* [*γαλανός*, calm]. The greatest anatomist of antiquity, lived in Pergamus and Rome; died, æt. 90, in 193 A. D. Wrote in Greek; he described the bones and sutures of the cranium, the vertebrae, the thorax, nearly in the same manner as at present. He described the facial, maxillary, and neck muscles, naming one the *platysma myoides*. He proved that arteries contained blood, not air. His death marked the downfall of ancient anatomy.
- Gallinag'o**, **gallinag'inis**, f. (L.) [*galli'na*, æ, hen]. The wood-cock. *Caput gal.*, syn. of *verumontanum*.
- Glabe'la**, æ, f. (L.) [*glabellus*, a, um, dim. of *glaber*, smooth, without hair]. The part of the frontal bone between the superciliary ridges.
- Glans**, **glandis**, f. (L.). An acorn. Any object resembling a nut, as the head of the penis or clitoris, a suppository, a pessary, a goitre.
- Hal'lex**, **hal'licis**, or **allex**, **allicis**, m. (L.) [*ἄλλομαι*, to leap]. The great toe or thumb. (There is no authority for *hallux*, *hallūcis*; *hallus* or *allus*, kindr. with *allex*, has the gen. *alli*. *Alex*, *alēcis*, f. and m., fish-brine or sediment.)
- Helicotre'ma**, **helicotre'matis**, n. (L.) [*ἕλιξ*, helix, spiral, *τρήμα*, hole]. An aperture at the apex of the cochlea.
- Hemorrhoid'al** [*hæmor'rhois*, *ïdis*, f., *αἰμορροΐς*, usually in pl. supply *φλέβες*, veins; *αἷμα*, blood, *ῥέω*, I flow, run]. Pertaining to hemorrhoids.
- Heroph'ilus**, i, m. [*ἕρωσ*, hero, *φιλέω*, I love]. An anatomist of the Alexandrian school, 304 B. C. He described the venous sinuses, and first applied the names *duodenum*, *choroid*, and *calamus scriptorius*.
- Hi'lum**, i, n. (L.), **hilus**, i, m. (N. L.) [from *nihilum* = *nihil*, nothing, a trifle]. The black spot on the base of a bean. The point, depressed or elevated, of an organ where the vessels and nerves enter it and its excretory duct leaves it.
- Hippocam'pus**, i, m. (L.) [*ἵπποκαμπος*, *ἵππος*, horse, *κάμπω*, I bend; a monster,

- with a horse's body and fish's tail, on which the sea-gods rode]. Sea-horse; projection of white matter into the lateral ventricle of the brain.
- Hippoc'rates**, **is**, **m.** [*Ἱπποκράτης*, ἵππος, horse, κράτος, strength, control]. A Greek physician of Cos, the father of medicine, 460-377 B. C.
- Homol'ogus** [ὁμός, common, λόγος, understanding]. Like a given standard; constructed on the same plan. (See **ANALOGOUS**.)
- Impar**, **aris** (**L.**) adj. [*im*, negative, *par*, equal]. Unequal, odd.
- I'mus**, **a**, **um**, adj. (**L.**) [*infērus*, that is below; *inferior*, lower; *infīmus* or *īmus*, lowest, last]. Lowest.
- Incisi'vus**, adj. and **n.** (**L.**) [*in*, *cædere*, to cut into]. Incisive; a muscle near the incisor teeth.
- Ingrassias**, **John Philip**, 1545-80, a Sicilian physician, made osteology a specialty; described the sphenoid and ethmoid, and first described the stapes.
- In'ion** (**N. L.**) [*ινίον*, back of the head]. External occipital protuberance.
- Intes'tine** (**L.** *intesti'num*, *i*, **n.**) [*intus*, within; cf. *έντερον*, from *έντός*, within]. The canal from the stomach to the anus.
- Ischiad'icus**, **a**, **um**, adj. (**L.**) [*ισχιαδικός*, subject to pains in the loins, *ισχίον*, hip-joint]. That has gout in the hip. Pertaining to the ischium. (See **SCIATIC**.)
- Is'ehium**; **ii**, **n.** (is'kĭum) (**L.**) [*ισχίον*, hip-joint, from *ισχύω*, I am strong, or from *ἴσχω*, I hold, I stop; supporting the trunk when seated]. The lower part of the os innominatum.
- Jeju'num**, neut. sing. of *jeju'nus*, **a**, **um**, adj. (**L.**) Fasting, hungry. The upper two-fifths of the small intestine below the duodenum; so called because it was supposed to be empty after death.
- Ju'gular** (not jug'ular) (**L.** *jugularis*, *e*) [*jugulum*, *i*, **n.**, the throat, dim. of *jugum*, the yoke, which was attached there]. Pertaining to the neck or throat.
- Laryn'geal** (not larynge'al). Pertaining to the larynx.
- Lateral'is**, **e** (**L.**) [*latus*, *ēris*, **n.**, the side]. Pertaining to the side (external, Henle).
- Lig'ula**, **æ**, **f.**, and **Lin'gula**, **æ**, **f.** (**L.**) [dim. of *lingua*, tongue]. A little tongue. Ligula is applied to white matter bounding the floor of the fourth ventricle.
- Ma'lar** [*māla*, **æ**, **f.**, cheek-bone]. Pertaining to the cheek-bone.
- Malle'olus**, **i**, **m.** (not malleo'lus) (**L.**) [dim. of *malleus*, mallet]. The projecting lower extremity of the tibia or fibula.
- Malpighi**, middle of seventeenth century, is the founder of histological anatomy, as he used the microscope. His name is associated with the deeper layer of the skin and the bodies in the kidney and spleen.
- Masse'ter**, **er'is**, **m.** (not mas'seter) (**L.**) [*μασσητήρ*, from *μασάομαι*, I chew]. (See **MAXILLA**.) Name of a muscle of the lower jaw.
- Maxil'la**, **æ**, **f.** (**L.**) [dim. of *māla*, **æ**, **f.**, the jaw or cheek, from *mando*, from *μασάομαι*, I chew, akin to *μάω* and *μάσσω*, I knead]. The jaw-bone. The upper jaw-bone, the lower being the mandible.
- Medial'is**, **e** (**L.**) [*medius*, middle]. Pertaining to the median part (internal, Henle).
- Mediasti'num**, **i**, **n.** (**L.**) [*mediasti'nus* is the same as *medius*, and more elegant than that short adj.; it is not a corruption of *per medium tensum*, something stretched between (Hyrtl)]. A partition. Properly the *cavum mediastini*.
- Med'ullary** (med'ullary preferable to medul'lary) [*medulla*, **æ**, **f.**, pith, *medius*, in the middle]. Pertaining to medulla or marrow.
- Menin'geal** (not meninge'al). Pertaining to the menin'ges.

- Mes'entery** [*μεσέντερον, μέσος, middle, έντερον, intestine*]. A fold of peritoneum by which the jejunum and ileum are attached to the abdominal wall; a fold by which any organ is attached.
- Modi'olus, i, m. (L.)** {dim. of *modius*, a peck}. The hub of a wheel; the central axis of the cochlea.
- Mus'cle** [dim. of *mus, muris*, a mouse, *musculus*, a little mouse, as muscles were said to resemble flayed mice; more probably from *μύειν*, to close]. Animal tissue composed of contractile fibres.
- My'lo-** [*μύλη*, a mill, from *μύω, μύζω*, to make the sound *μῦ μῦ* with closed lips, to murmur]. Referring to the jaw, especially the lower, or to the molar teeth.
- Myoi'des** [*μῦς, muscle, εἶδος, resemblance*]. Like a muscle.
- My'otomes** (L. pronunc. myot'mes) [*μῦς (μύω, to keep close), a muscle, τομή, a section, from τέμνω*]. A series of dark paired masses on each side of the notochord, producing the muscular segments of the body; provertebræ; mesoblastic somites.
- No'ni**, gen. sing. of *novus, a, um*, adj. (L.) [for *novenus*, from *novem*, nine]. Of the ninth; referring to the hypoglossal or ninth cranial nerve (old classif.).
- Nu'cha, æ, f. (L.)**. The hinder part or nape of neck.
- Obel'ion** (N. L.) [*ὀβελός, a spit, obelisk; a horizontal line with a point above and one below, +, was used to point out superfluous passages (kindr. with ὀβολός, a coin)*]. A point in the sagittal suture between the parietal foramina.
- Oph'ryon** (off'rion) (N. L.) [*ὄφρυς, eyebrow; L. supercilium*]. Where the supra-orbital line crosses the median line.
- Opis'thion** (N. L.) [*ὀπίσθιος, hinder part*]. Middle of posterior margin of the foramen magnum.
- Oppō'nens, entis** (not op'ponens) (L.) [part. from *ob*, against, and *pono*, I place]. Standing against; opposing.
- Os, ossis, pl. ossa, n. (L.)**. Bone. **Os, oris, pl. ōra, n. (L.)**. Mouth.
- Pal'pebral** (not palpe'bral) (L. *palpēbrā'lis*) [*pal'pebra, æ, f., or pal'pebrum, i, n., an eyelid*]. Pertaining to the eyelid.
- Papya'ceus, a, um, adj. (L.)** [*papyrus, i, m. or f., πάπυρος, an Egyptian rush or flag, from the inner rind of which paper was made*]. Like papyrus or paper.
- Pectin'eus** (not pectine'us), adj. and n. (L.) [*pecten, ἴνις, m., a comb, the hair of the privates*]. Name of a muscle rising from the os pubis.
- Peritonæ'um and Peritone'um, i, n. (L.)** = *περιτόναιον and περιτόνειον* [*περί, around, τείνω, I stretch*]. A serous membrane stretched over the abdominal viscera and lining the abdominal cavity.
- Pilas'tered** [*pilas'ter (pila, a pillar) is a square pillar inserted into a wall, projecting a little from its surface*]. Furnished with pilasters.
- Pī'neal** [*pi'nēa, æ, f., pine-cone*]. Resembling a pine-cone.
- Platys'ma** (L.) [*πλάτυσμα, anything spread out, from πλάτυς, wide*]. A muscle.
- Poplit'eal** (not poplite'al) [*poples, poplitis, m., ham of the knee (posterior part of knee)*]. That which relates to the ham.
- Por'ta, æ, f. (L.)** [root *por*, a place through which things are carried]. A gate; the part of the liver where vessels enter as by a gate. (*Vena portæ*, not *vena porta*.)
- Postī'cus, a, um, adj. (L.)** [*post, behind*]. That which is behind; posterior.
- Prē'puce** (L. *præputium*) [*πρό, before, πόσθη, penis (?)*]. The foreskin.
- Process** (prōc'es; prō'cess accord. to Lat. quantity) [*prōcēdere, to go forth*]. A prominence or projecting part.

- Pros'tate** [πρό, before, ἵστημι, I stand]. A gland situated before the neck of the bladder in the male.
- Pter'ion** (tēr'ion) or **Pte'ron** (N. L.) [πτερόν, a feather or bird's wing, from πέτομαι, I fly]. Spheno-parietal suture.
- Pū'bes, pū'ber, pū'bis, eris, adj.** (L.). That is grown up, adult. **Pū'bes, is, i.** The signs of manhood—i. e. the hair of the privates or the beard; the privy parts. **Os pubis**, the bone of the pubes (gen. case).
- Pyram'idal** (L. *pyramidal'is, e*), adj. [πυραμῖς, ἴδος (probably Egyptian). Ancients derived it from πῦρ, flame, because of its pointed shape, also from πυρός, wheat, as if pyramids had been granaries]. Shaped like a pyramid. Name of two muscles.
- Rā'nine** [ράνα, æ, f., a frog, a swelling under the tongue]. Frog-shaped. Applied to certain vessels of the tongue.
- Raph'e** (rāf'ē) (N. L.) [ράφή, a seam, ῥάπτω, I sew]. A ridge or suture.
- Rhomboid'eus, adj.** or n. (L.) [ῥόμβος, a figure whose sides are equal, with two acute and two obtuse angles; εἶδος, resemblance]. A muscle of the back.
- Rī'ma, æ, f.** (L.) [ρίγμα, from ringor, I open the mouth]. Chink, fissure.
- Sagit'tal** (not sag'ittal) [sagit'ta, æ, f., arrow]. Resembling an arrow. Pertaining to a vertical mesial plane of the body or any plane parallel to it.
- Saphe'nous** [σαφής, distinct, manifest]. Applied to some superficial veins of the lower extremity, to nerves, and to an "opening."
- Scāla, æ, f.** (L.) [scando, ἔρε, I climb]. A staircase; a ladder.
- Scanso'rius, a, um, adj.** (L.) [scando, scansum, I climb]. Of or for climbing.
- Sciat'ic** (syat'ik) (contraction of *ischiatric*) [ισχίον, strictly the acetabulum; the haunch or hip. Prob. from ισχύς, strength]. Related to or connected with the ischium.
- Secre'tory** [se, aside, cerno, I choose or put]. Pertaining to secretion (the separation from the blood of parts supposed to be useful to the animal economy).
- Sin'ister, tra, trum, adj.** (L.) (obs. sinis'ter). On the left hand; left. (In the Roman sense *lucky*; in the Greek sense *unlucky*. In consulting auspices the Romans turned the face to the south, and so had the eastern or fortunate side to the left; while the Greeks, turning to the north, had it on their right.)
- Sol'eus, i, m.** (L.) [solēa, æ, f., the sole of a shoe, sandal]. A muscle of the calf of the leg; named from its shape.
- Somat'opleure** [σῶμα, body, πλευρά, a rib, the side, lining membrane of the chest]. Outer leaf of blastoderm, producing the body-walls.
- So'mites** (L.) (L. pronunc. só'mi tes) [σῶμα, σῶματος, body]. Segments of the body or mesoderm.
- Splanchnol'ogy** [σπλάγχνον, pl. a, viscera, λόγος, treatise]. The part of anatomy relating to viscera.
- Splanchn'opleure** [σπλάγχνον, viscera, inward parts, πλευρά, the pleura]. Inner leaf of the blastoderm, forming the alimentary canal.
- Splē'nic** [splen, splēnis, m., also lien, ēnis, m.; σπλήν, ηνός, the milt, spleen]. Relating to the spleen.
- Splē'nium, ii, n.** (L.) [σπλήν, spleen]. A patch, pad (because like the spleen in shape).
- Splē'nium, a, um, adj.** or n. (L.) [σπλήνιον, a bandage, compress; σπλήν, σπληνός, spleen]. A muscle of the back and neck, said to resemble in shape the spleen of certain animals.
- Stapedius, ii, m.** (L.) [stā'pes, stā'pedis (sto, I stand; pes, pedis, a foot), stirrup]. A muscle of the middle ear attached to the stapes.
- Stephan'ion** (N. L.) [στέφανος, crown, from στέφω, I encircle]. The point where the coronal suture crosses either one of the temporal lines.

- Sutu'ra**, æ (not soot'ura), f. (L.) [*suo*, I sew or stitch]. Suture; a dovetail joint; an immovable articulation.
- Syl'vius**, **Jacobus** (*Jacques Dubois*), 1478–1555 A. D., was of the French school, and taught anatomy in Paris. He was coarse, envious, and jealous, made no original research, but acquired a great reputation. Parts of the brain bear his name.
- Syn'chondro'sis**, pl. **es** (N. L.) [σύν, with, χόνδρος, cartilage]. Union of bones by means of cartilage.
- Syn'desmo'sis**, pl. **es** (N. L.) [σύν, with, δεσμός, band (δέω, I tie)]. Union of bones by means of ligament.
- Tæ'nia**, æ, f. (L.) [ταινία, a band; τείνω, to stretch]. A band, ribbon, fillet; a tape-worm.
- Tā'lus**, i, m. (L.) [a die made of knuckle-bones, marked on four sides]. The ankle; the heel; the astragalus.
- Tento'rium**, ii, n. (L.) [tendo, I stretch]. A tent; the dura mater, which covers the cerebellum.
- Test'icle** [*testic'ulus*, dim. of *testis*, is, m.; pl. *testes*; a witness, because the testicles are witnesses of manly vigor]. A glandular organ in the scrotum which secretes sperm.
- Thal'amus**, i, m. (L.) [θάλαμος, an inner room, a bed, bridal-chamber, a den]. A central ganglion of the brain.
- Thy'roid** or **Thy'reoid** [θυρεός, an oblong shield, from θύρα, a folding-door, εἶδος, resemblance]. Applied to a cartilage of the larynx, also to a gland and various vessels.
- Trāche'a** (L. pronunc.) (L. *trāchīa*) [τραχεΐα, from τραχύς, rough]. The wind-pipe.
- Tri'gone** (try'gohne) (F.) [from *trigonium*, ii, n. = τρίγωνον, τρεῖς, three, γωνία, corner]. A triangle.
- Trique'trus**, a, um (trykwee'trus) (L.) [*trēs*, three]. Having three corners.
- Tritic'us**, a, um, adj. (L.) [from *trit'icum*, n., wheat, from *tero*, I rub or grind]. Like a kernel of wheat.
- Troch'lea**, æ, f. (L.) (trok'leah) [τροχός (τρέχω), a runner, anything round or circular]. A pulley; a surface grooved like a pulley.
- Tym'panic** (not tympan'ic) [τύμπανον, a kettle-drum, τύπτω, I beat]. Referring to the tympanum, ear-drum.
- Umbil'cal** (not umbil'ical). Relating to the navel.
- Umbil'cus**, i, m. (L.) [ὀμφαλός, navel, akin to ἄμβων, *umbo*, boss of a shield]. The navel; the centre.
- U'rachus**, i (N. L.) (not urak'us) [οὔρον, urine, ἔχειν, to hold]. A band from the bladder to the umbilicus; in the fœtus extended to the allantois.
- Ure'ter** (not u'reter), **eris** (N. L.) [οὐρητήρ = οὐρήθρα, from οὐρήω, I make water]. The excretory canal from the kidney to the bladder.
- Vagi'nal** (not vag'inal) [*vagina*, æ, f., a sheath]. Relating to the vagina; sheath-like.
- Vesalius**, **Andrew**, a native of Brussels, 1514–64, was a pupil of Sylvius. He was the first author of a comprehensive view of human anatomy; has been called its founder. He fully described the sphenoid, sternum, and vestibule of the internal ear; discovered and named the *ductus venosus*, and gave a full description of the brain.
- Ves'ical** (accord. to L. quantity vesi'cal; cf. cervi'cal, umbili'cal, vagi'nal) [*vesi'ca*, æ, f., a bladder, especially urinary]. Relating to the bladder.
- Ver'umonta'num** (L.) [*veru*, us, n., a spit, *montanus*, a, um, adj., mountain]. An elevation on the floor of the urethra.

INDEX.

A.

- Acetabulum, 77, 79
Adminiculum, 146
Agger nasi, 49
Air-sinuses, 61
Ala cinerea, 265
Amphiarthrodial joints, 93, 94
Angeiology, 19, 204
Angle of pubis, 78
 sacro-vertebral, 28
 subcostal, 34
Ankle-joint, 132
Annulus inguinalis, 146, 149
Antrum mastoideum, 41
 of Highmore, 48, 50
Aorta, 208
Aponeurosis, epicranial, 166
 intercostal, 156
 lumbar, 142
 of abdominal muscles, 147, 148
 of arm, 174
 of forearm, 176
 of leg, 194
 pharyngeal, 158
 vertebral, 142
Aqueduct of cochlea, 43
 of Sylvius, 262
 of vestibule, 42
Arch, crural, 149
 of aorta, 208
 palmar, 222
 plantar, 232
 subpubic, 80
Arachnoid, 249, 252
Area cribrosa, 42
Artery or Arteries, anastomotica magna, 221, 229
 angular, 212
 aorta, 208
 abdominal, 223
 thoracic, 223
Artery or Arteries, axillary, 219
 basilar, 218
 brachial, 220
 brachio-cephalic, 209
 bronchial, 223
 carotid, 210, 214
 centralis retinae, 216
 cerebellar, 217, 218
 cerebral, 216, 218
 cervical, 218
 choroid, 216, 218
 circumflex, 220, 230
 iliac, 229
 coeliac axis, 224
 colica, 225
 comes nervi ischiadici, 228
 phrenici, 219
 coronary, 212
 cremasteric, 229
 dental, 214
 dorsalis hallicis, 231
 indicis, 222
 pedis, 231
 pollicis, 222
 epigastric, 219, 228, 229
 facial, 211, 213
 femoral, 229
 gastric, 224
 gastro-duodenalis, 224
 gastro-epiploica, 224, 225
 gluteal, 226
 hemorrhoidal, 225, 257
 hepatic, 224
 iliac, 226, 228
 ileo-colic, 225
 ilio-lumbar, 226
 innominate, 209
 intercostal, 219, 223
 internal mammary, 219
 maxillary, 213
 interosseous, 222
 labial, 212

- Artery or Arteries, laryngeal, 211, 228
 lingual, 211
 lumbar, 224
 mastoid, 212
 median, 222
 medullary, 20
 meningeal, 212, 213, 214, 217
 musculo-phrenic, 219
 nasal, 214, 216
 obturator, 227
 occipital, 212
 ophthalmic, 215
 orbital, 213
 ovarian, 226
 palatine, 212, 214
 pancreatico-duodenal, 224, 225
 perineal, 227
 peroneal, 232
 pharyngeal, 213
 phrenic, 224
 plantar, 232
 popliteal, 230
 princeps cervicis, 212
 pollicis, 222
 profunda, 220, 230
 cervicis, 219
 pudic, 227, 229
 pyloric, 224
 radial, 221
 radialis indicis, 222
 ranine, 211
 receptaculi, 215
 renal, 225
 sacral, 224, 226
 scapular, 218, 220
 sciatic, 228
 sigmoid, 225
 spermatic, 226
 splenic, 224
 sterno-mastoid, 211, 212
 stylo-mastoid, 213
 subclavian, 216
 subscapular, 220
 superficialis volæ, 221
 suprarenal, 225
 suprascapular, 218
 temporal, 213, 214
 thyroid, 211, 218
 axis, 228
 tibial, 231, 232
 tonsillar, 212
 tympanic, 213, 215
 ulnar, 222
 uterine, 227
- Artery or Arteries, vaginal, 227
 vertebral, 217
 Vidian, 214
 Arthrology, 19, 93
 Articulations, ilio-sacral, 121
 of costal cartilages and sternum, 101
 of lower extremity, 120
 of ribs and vertebræ, 99
 of trunk and head, 95
 of upper extremity, 104
 of vertebral column, 95
 temporo-maxillary, 103
 Asterion, 64
 Auricles, 205
 Auricular point, 64
- B.**
- Basion, 64
 Bladder, 339
 Bone or Bones, analysis of, 22
 astragalus, 86
 atlas, 24
 axis, 25
 clavicle, 64
 cuboid, 88
 cuneiform, 73, 87, 88
 epiphyal, 104
 epipteric, 56
 ethmoid, 47
 femur, 80
 fibula, 85
 frontal, 38
 humerus, 67
 hyoid, 35
 iliac, 77
 incus, 303
 innominate, 76
 intermaxillary, 50
 ischium, 78
 lachrymal, 53
 lunar, 73
 malar, 52
 malleus, 303
 maxillary, 48, 54
 metacarpal, 75
 metatarsal, 88
 nasal, 53
 navicular, 87
 number of, 22
 occipital, 35
 of Bertin, 45
 of carpus, 72
 of cranium, 35

Bone or Bones of face, 35, 48
 of foot, 89
 of the head, 35
 of lower extremity, 76
 of palm, 75
 of tarsus, 86
 of trunk, 23
 of upper extremity, 64
 palate, 50
 parietal, 37
 patella, 83
 phalanges, 76, 89
 pisiform, 73
 pubic, 78
 pyramidal, 73
 radius, 71
 scaphoid, 73, 87
 scapula, 67
 semilunar, 73
 sesamoid, 78, 89
 sphenoid, 44
 spongy, 45, 48
 stapes, 303
 talus, 86
 temporal, 39
 tibia, 83
 trapezium, 73
 trapezoid, 74
 turbinate, 54
 ulna, 70
 unciform, 74
 vomer, 52
 Wormian, 56
 Brain, 252
 Bregma, 63
 Bronchi, 314
 Bursæ, carpal, 183
 intertubercularis, 109
 of elbow-joint, 111
 of hip-joint, 125
 of knee-joint, 127, 130
 of Monro, 106
 of shoulder-joint, 109
 prepatellar, 130
 pretibial, 128
 retro-epitrochlear, 112
 subacromial, 104
 subcrural, 127
 subpatellar, 128

C.

Calamus scriptorius, 265
 Calcar avis, 259

Calcar femorale, 82
 Calvaria, 59
 Canal, crural, 187
 dental, 49, 53
 Hunter's, 192
 internal orbital, 57
 malar, 53
 medullary, 18
 neural, 18
 of Huguier, 40
 of nasal duct, 49
 orbital, 38
 palatine, 49, 51
 pterygo-palatine, 46, 51
 sacral, 29
 semicircular, 305
 spinal, 31
 temporal, 53
 vomero-basilar, 52
 Canaliculus innominatus, 47
 Cerebellum, 262
 Chiasma, 258, 266
 Chordæ tendineæ, 206
 Circle of Willis, 218
 Claustrum, 260
 Clitoris, 348
 Clivus Blumenbachii, 44
 Coccyx, 29
 Cochlea, 305
 Cœlom, 18
 Colon, 328
 Concha, 301
 Conchæ sphenoidales, 45
 Conus arteriosus, 206
 Cornea, 298
 Cornucopia, 265
 Corpus albicans, 258
 Arantii, 206
 callosum, 257, 259
 fimbriatum, 260
 quadrigeminum, 262
 striatum, 260
 Costal cartilages, 33
 Crest, frontal, 39
 incisor, 49
 infratemporal, 45
 lachrymal, 53
 nasal, 49
 obturator, 78
 occipital, 36
 of pubis, 78
 of tibia, 84
 sphenoidal, 45
 supramastoid, 39

Crest, temporal, 38
 turbinate, 49, 51
 Crista falciformis, 42
 galli, 47
 orbitalis, 59
 Crus cerebri, 258
 Crystalline lens, 300

D.

Dartos, 145
 Deglutition, 164
 Development of ovum, 17
 Diaphragm, 152
 Diarthrodial joints 93, 94
 Duodenum, 325
 Dura mater, 249, 252

E.

Ear, 301
 Elbow-joint, 110
 Embryology, 17
 Eminence, deltoid, 68
 frontal, 38
 nasal, 38
 hypothenar, 184
 thenar, 184
 ilio-pectineal, 77
 olivary, 44
 Eminentia arcuata, 42
 articularis, 39
 capitata, 71
 cinerea, 265
 collateralis, 259, 260
 innominata, 36
 Epiblast, 17, 18
 Epididymis, 346
 Epiphysis, 20
 cerebri, 262
 Eustachian tube, 43, 302
 valve, 205
 Eye, 297

F.

Fallopian tubes, 351
 Fascia, 139
 anal, 150
 axillary, 154
 bucco-pharyngeal, 162
 Buck's, 149
 cervical, 157
 cremasteric, 148

Fascia dentata, 260
 iliac, 148
 infundibuliform, 148
 intercolumnar, 147
 lata, 186
 lumbar, 142
 masseteric, 171
 obturator, 150
 of abdomen, 145, 148
 of arm, 174
 of breast, 154
 of Colles, 149
 of forearm, 176
 of pelvis, 150
 of Scarpa, 145
 palmar, 183
 parotid, 158
 perineal, 149
 plantar, 198
 prevertebral, 158
 recto-vesical, 150
 semilunar, 175
 subpubic, 149
 temporal, 172
 transversalis, 148
 Fasciculus teres, 265
 Fat-pad, buccal, 171
 Fissure, calcareine, 256
 calloso-marginal, 256
 collateral, 257
 dentate, 256
 hippocampal, 256
 longitudinal, 257
 of Glaser, 40
 of Rolando, 255
 of Sylvius, 255
 parietal, 62
 parieto-occipital, 257
 petro-squamous, 40
 precentral, 255
 pterygo-maxillary, 58
 sphenoidal, 46, 57
 spheno-maxillary, 57
 Flocculus, 263
 Fontanelle, 62
 Foramen, aortic, 153
 cæcum, 39
 carotico-clinoid, 47
 carotico-tympanicus, 43
 centrale cochleæ, 42
 condylar, 36
 inferior dental, 55
 infraorbital, 48, 49
 intervertebral, 24, 30

- Foramen, Jacobson's, 43
 jugular, 37
 lacerum, 59
 mastoid, 40
 mental, 54
 obturator, 77, 79
 of Magendie, 253
 of Monro, 259, 261
 of Vesalius, 47
 optic, 44, 46, 57
 ovale, 46
 parietal, 37
 quadratum, 153
 rotundum, 45, 46
 sacral, 28
 singulare, 42
 spinosum, 46
 sternal, 32
 stylo-mastoid, 43
 supratrochlear, 69
 thyroid, 77, 79
- Foramina, incisor, 49
 of Scarpa, 49
 of Stenson, 49
 Thebesii, 205
- Fornix, 261
- Fossa acetabuli, 79
 anterior palatine, 49, 53
 canine, 48
 condylar, 36
 coronoid, 69
 digastric, 40
 digital, 81
 glenoid, 40, 67
 guttural, 58
 hypo-trochanterica, 83
 iliac, 77
 incisor, 48, 54
 infraspinous, 66
 infratemporal, 58
 intercondylar, 82
 jugular, 43
 lachrymal, 38, 57
 mandibularis, 40
 myrtiliform, 48
 nasal, 60, 308
 olecranon, 69
 ovalis, 205
 pituitary, 44
 pterygoid, 46
 radial, 69
 scaphoid, 46
 sigmoidea, 41
 spheno-maxillary, 58
- Fossa, subarcuate, 42
 subscapular, 65
 supraspinous, 66
 temporal, 57
 trochlear, 38
 zygomatic, 58
- Funiculus of Rolando, 253
 cuneatus, 253
 gracilis, 253
- G.**
- Galea aponeurotica, 166
- Gall-bladder, 333
- Ganglion, cervical, 292, 293
 Gasserian, 267
 geniculate, 272
 jugular, 274
 Meckel's, 269
 ophthalmic, 268
 otic, 271
 petrous, 274
 semilunar, 295
 submaxillary, 271
- Geniculate bodies, 262
- Gerdy's fibres, 183
- Glabella, 38
- Gland, mammary, 352
 parotid, 321
 prostate, 342
 sublingual, 321
 submaxillary, 321
 thymus, 315
 thyroid, 315
- Groove, basilar, 37
 bicipital, 68
 infraorbital, 49
 lachrymal, 49
 mylo-hyoid, 55
 obturator, 78
 olfactory, 48
 optic, 44
 posterior palatine, 51
 spiral, 68
 subcostal, 33
- Gyrus, angular, 256
 fornicatus, 257
 hippocampi, 257
 marginal, 256
 opertus, 256
 uncinatus, 257
- H.**
- Heart, 204

Hemiarthrosis, 94
 Henle's ankle-joint, 133
 classification of joints, 94
 vertebral ligaments, 100
 wrist-joint, 114
 Hip-joint, 123
 Hippocampus, 259, 260
 Homologies, muscular, 202
 of carpus and tarsus, 92
 of ilium and scapula, 92
 of upper and lower limbs, 91
 Hypoblast, 17, 18
 Hypophysis cerebri, 258

I.

Ilio-tibial band, 186
 Index, humero-radial, 72
 of cranium, 64
 sacral, 29
 Infundibulum, 47, 258, 306
 Inion, 64
 Intervertebral disks, 96
 Intestines, 324
 Iris, 299
 Island of Reil, 256

J.

Joints, classification of, 93

K.

Kidney, 336
 Knee-joint, 125

L.

Labyrinth, 47, 305, 306
 Lacertus fibrosus, 175
 Lambda, 63
 Lamina cinerea, 257
 cribrosa, 42
 papyracea, 47
 Larrey's space, 153
 Larynx, 310
 Ligament or Ligaments, accessory, 95
 of astragalus, 135
 of forearm, 113
 of hip, 154
 of knee, 128
 of tarsus, 136
 of wrist, 116
 tibio-fibular, 134

Ligament or Ligaments, accessorium
 laterale, 103, 129
 mediale, 103, 129
 radiale, 119
 ulnare, 119
 acromio-clavicular, 106
 alar, 99, 127
 annular, 116, 194
 anterior, 95, 110, 114, 128, 132
 arcuate, 118, 121, 128, 153
 astragalo-scapoid, 133
 atlo-axoid, 98
 Bertini, 124
 brachial, 174
 calcaneo-astragaloid, 133
 calcaneo-cuboid, 133, 136
 calcaneo-fibulare, 136
 calcaneo-naviculare, 136, 137
 calcaneo-scapoid, 133, 136
 calcaneo-tibiale, 136
 capituli fibulæ, 131, 132
 capitulum, 138
 dorsalia, 120
 volaria, 119
 capsular of elbow, 110
 of hip, 123
 of knee, 127
 of lower jaw, 103
 of shoulder, 107
 of vertebræ, 96
 of wrist, 115
 carpi commune, 116
 dorsale profundum, 117
 volare profundum, 118
 proprium, 117
 carpo-metacarpea, 117
 chondro-sternal, 101
 chondro-xiphoid, 102
 colli costæ, 101
 conjugal, 100
 conoid, 107
 coraco-acromial, 104
 coraco-clavicular, 107
 coraco-glenoidale, 109
 coraco-humeral, 109
 coronary, 126
 corruscans, 102
 costo-clavicular, 106
 costo-coracoid, 154
 costo-transverse, 100, 101
 costo-vertebral, 99, 100
 cotyloid, 123
 crucial, 98, 126, 194
 cuboideo-naviculare, 137

- Ligament or Ligaments, cuneo-cu-
boidea, 136
deltoid, 132
denticulatum, 249
dorsal, 114, 119, 120, 133
falciform, 122
Flood's, 109
fundiform of Retzius, 194
Gimbernat's, 147
 reflected, 147
glenoid, 108
glenoideo-brachial, 109
glenoideo-humeral, 109
hamo-metacarpum, 119
humero-coronoid, 111
humero-olecranon, 111
iliacum proprium, 120
ilio-femoral, 124
ilio-lumbar, 121
ilio-pectineal, 149
ilio-trochanteric, 124
inguinal, 147, 149
interarticular, 100
 fibro-cartilage, 103, 106
intercarpea, 117
interchondral, 102
interclavicular, 106
intercostal, 102
intercruralia, 101
intermetacarpea, 117, 119
intermetatarsa, 136, 137
intermuscularia, 174
interosseous, 113, 114, 132, 133
interspinous, 96
intersternal, 102
intertransverse, 97
intrajugular, 103
ischio-capsular, 124
ischio-femoral, 124
laciniatum, 194
lateral, 99, 103, 111, 113, 129, 132
latum, 99
lumbo-costal, 101
malleoli lateralis, 134
metatarsal, 133
metatarso-phalangeal, 138.
mucosum, 115, 127, 179
naviculari cuboidea, 136
nuchæ, 96
oblique, 113, 128
obturator, 98, 120
occipito-atloid, 98, 99
occipito-axoid, 99
odontoid, 99
- Ligament or Ligaments of ankle-
joint, 132
of Barkow, 111
of Bigelow, 124
of bladder, 150
of Burns, 187
of carpus, 114
of ilio-sacral joint, 121
of Colles, 147
of elbow-joint, 110
of Hey, 187
of hip-joint, 123
of knee-joint, 125
of larynx, 311
of metacarpus, 114
of phalanges, 114, 133
of rectum, 150
of scapula, 104
of shoulder-joint, 107
of skull, 102
of tarsus, 132, 136
of uterus, 351
of Winslow, 128
of wrist-joint, 113
of Zinn, 170
olecrano-coronoid, 111
orbicular, 111, 124
palmar, 114
palpebral, 167
patellæ, 128
petro-sphenoidal, 43, 103
piso-hamatum, 119
piso-metacarpum, 119
plantar, 133
plicæ synov. patellaris, 127
popliteum arcuatum, 128
posterior, 95, 111, 114, 128, 132
Poupart's, 146
pterygo-maxillary, 104
pterygo-petrosal, 103
pubo-femoral, 124
pubo-prostatic, 150
radiate, 118
radio-ulnar, 113
retinacula tendinum, 120
retinaculum, 109
 lig. arcuati, 128
 peronæorum, 194, 196
sacro-coccygeum articulare, 97
sacro-sciatic, 122
sacro-spinosum, 122
sacro-tuberosum, 122
scapho-cuboid, 133
scapulo-clavicular, 107

- Ligament or Ligaments, Schlemm's, 109
 semilunar fibro-cartilages, 126
 speno-maxillary, 104
 spino-glenoid, 105
 stellate, 99
 sterno-clavicular, 105
 stylo-hyoid, 104
 stylo-maxillary, 103
 stylo-myloid, 103
 subflava, 96, 179
 subpubic, 121
 suprascapular, 105
 supraspinous, 96
 suspensory of eye, 171
 of penis, 145
 talo-calcanea, 135
 talo-cruralia, 135
 talo-fibulare, 135
 talo-naviculare, 136
 talo-tibiale, 135
 tarseum transversum, 137
 tarso-metatarsea, 136
 teres, 123
 tibio-calcaneo-naviculare, 135
 tibio-fibular, 131, 134
 tibio-naviculare, 136
 transverse, 98, 105, 114, 119, 123,
 128, 132, 183
 humeral, 109
 of pelvis, 150
 trapezoid, 107
 triangular, 147, 149
 fibro-cartilage, 113
 tuberculi costæ, 101
 tuberositatum vertebrarium, 101
 vaginalia, 119, 120, 179
 vincula tendinum, 179
- Ligula, 265
 Lingual convolution, 257
 Lingula, 263
 mandibulæ, 55
 sphenoidalis, 44
 Limbus sphenoidalis, 44
 Line, buccal, 55
 gluteal, 77
 ilio-pectineal, 77
 intertrochanteric, 81
 oblique, 54, 71, 84, 85
 popliteal, 84
 spiral, 81
 temporal, 37
 Linea alba, 146
 aspera, 81
- Linea Douglasii, 147
 quadrati, 81
 semilunaris, 146
 Spigelii, 148
 splendens, 249
 transversa, 146
 Liver, 331
 Lobe, central, 256
 frontal, 255
 occipital, 256
 parietal, 255
 temporo-sphenoidal, 256
 Locus niger, 259
 Lungs, 316
 Lymphatic glands, axillary, 248
 cervical, 248
 inguinal, 245
 mesenteric, 246
 pelvic, 246
 thoracic, 247
 Lymphatics of lower limb, 245
 of abdomen, 246
 of head and neck, 248
 of pelvis, 246
 of thorax, 247
 of upper limb, 247
- M.**
- Malleolus, 84
 Mandible, 54
 Marrow, 21
 Meatus of nose, 48, 61
 Mediastinum, 316
 Medulla oblongata, 253
 Membrana sacciformis, 113
 tympani, 302
 Meniscus, 126
 Mesoblast, 17, 18
 Midriff, 152
 Modiolus, 305
 Mouth, 318
 Muscle or Muscles, abductor hallicis,
 199
 indicis, 185
 minimi dig., 184, 200
 ossis metatarsi quinti, 200
 pollicis, 182, 184
 accessorius, 179
 acromio-clavicularis, 173
 adductor brevis, 193
 gracilis, 193
 hallicis, 200
 longus, 193

- Musclev or Muscles, magnus, 193
 minimus, 193
 pollicis, 184
 agitator caudæ, 188
 amygdalo-glossus, 163
 anconeus, 176, 181
 quintus, 176
 epitrochlearis, 176
 anomalus, 169
 menti, 170
 articularis genu, 191
 aryteno-epiglottic, 313
 arytenoideus, 314
 atlanto-mastoideus, 145
 auricularis, 166, 167
 azygos pharyngis, 163
 uvulæ, 163
 biceps, 174
 femoris, 192
 biventer cervicis, 143
 mandibulæ, 158
 brachialis anticus, 175
 internus, 175
 brachio-radialis, 180
 buccinator, 169
 bulbo-cavernosus, 152
 caninus, 168
 cephalo-pharyngeus, 162
 cervico-costo-humeralis, 160
 chondro-epitrochlearis, 154
 chondroglossus, 161
 ciliary, 299
 circumflexus, 163
 cleido-hyoideus, 159
 cleido-occipital, 158
 coccygeus, 151
 complexus, 143
 compressor hemisph. bulbi, 152
 naris, 169
 urethræ, 152
 venæ dorsalis penis, 152
 constrictor of pharynx, 162
 coraco-brachialis, 175
 coraco-capsularis, 175
 coraco-minor, 175
 corrugator supercilii, 167
 costo-coracoid, 141
 costo-fascialis, 160
 cremaster, 148
 crico-arytenoideus, 314
 crico-hyoideus, 160
 crico-thyroid, 313
 crureus, 191
 cubito-carpeus, 179
- Musclev or Muscles, curvator coccygis,
 151
 deltoid, 173
 depressor alæ nasi, 169
 anguli oris, 168
 labii inferioris, 169
 septi, 169
 diaphragm, 152
 digastric, 159
 dilator naris, 169
 dorso-epitrochlearis, 141, 176
 ejaculator urinæ, 152
 epicranium, 166
 temporalis, 166
 erector penis, 151
 spinæ, 142
 extensor brevis digit., 198
 digit. manus, 182
 pollicis, 182
 carpi rad. access., 180
 brevior, 180
 coccygis, 143
 intermedius, 180
 longior, 180
 ulnaris, 181
 communis digit., 180
 digiti quinti, 181
 hallicis brevis, 199
 indicis proprius, 182
 longus hallicis, 195
 digit., 195
 primi internodii hall., 195
 pollicis, 182
 medii digiti, 182
 minimi digiti, 181
 ossis metac. poll., 182
 primi internod. poll., 182
 sec. intern. poll., 182
 flexor brevis digit., 199
 accessorius, 199
 hall., 200
 min. dig., 184, 200
 poll., 184
 carpi radialis, 177
 brevis, 179
 ulnaris, 177
 brevis, 179
 longus digitorum, 197
 access., 197
 hall., 198
 pollicis, 179
 sublimis digit., 178
 profundus digit., 178
 frontalis, 166

- Muscle or Muscles, gastrocnemius, 196
- gemelli, 189
 - genio-hyoglossus, 161
 - genio-hyoideus, 160
 - glosso-staphylinus, 163
 - glutei, 188
 - gluteo-perinealis, 151
 - gracilis, 171, 193
 - Horner's, 167
 - hyoglossus, 161
 - hyo-pharyngeus, 162
 - hyo-thyroideus, 160
 - iliacus, 187
 - minor, 188
 - ilio-costalis cervicis, 143
 - dorsi, 143
 - lumborum, 143
 - ilio-psoas, 187
 - incisivi, 169
 - indicator, 182
 - infraspinatus, 173
 - interclavicular, 154
 - intercostales, 156
 - interossei, 185, 200
 - interspinales, 144
 - intertransversales, 144
 - intertransversarii, 165
 - ischio-aponeuroticus, 193
 - ischio-cavernosus, 151, 152
 - ischio-coccygeus, 151
 - labii proprius, 169
 - laryngo-pharyngeus, 162
 - latissimus dorsi, 140
 - anguli oris, 168
 - labii sup., 168
 - levator ani, 151
 - claviculæ, 158
 - menti, 170
 - palati, 163
 - palpebræ, 170
 - scapulæ, 165
 - levatores costarum, 144
 - lingualis, 161
 - longissimus capitis, 143
 - cervicis, 143
 - dorsi, 143
 - longus atlantis, 165
 - capitis, 165
 - colli, 165
 - lumbricales, 183, 199
 - malaris, 167
 - masseter, 171
 - mentalis, 170
- Muscle or Muscles, mento-hyoid, 158
- multifidus, 144
 - myloglossus, 161
 - mylohyoideus, 160
 - nasalis, 169
 - naso-labialis, 169
 - oblique, inferior, 170
 - superior, 170
 - obliquus capitis, 144
 - externus, 146
 - internus, 147
 - obturator, 189
 - occipitalis, 166
 - minor, 157
 - occipito-frontalis, 166
 - occipito-pharyngeus, 163
 - occipito-scapularis, 140
 - of abdomen, 145
 - of arm, 174
 - of back, 139
 - of breast, 154
 - of foot, 198
 - of forearm, 176
 - of hand, 183
 - of head, 166
 - of hip, 187
 - of hyoid bone, 158
 - of leg, 195
 - of neck, 157
 - of orbit, 170
 - of palate, 163
 - of perineum, 150
 - of pharynx, 162
 - of scapula, 173
 - of thigh, 190
 - of tongue, 161
 - of trunk, 139
 - omo-hyoideus, 159
 - opponens hallucis, 200
 - minimi dig., 185, 200
 - pollicis, 184
 - orbicularis oculi, 167
 - oris, 169
 - palato-glossus, 163
 - palato-pharyngeus, 163
 - palato-staphylinus, 163
 - palmaris brevis, 183
 - longus, 177
 - papillares, 206
 - pectinati, 205
 - pectineus, 193
 - pectoralis major, 154
 - minor, 155
 - minimus, 155

- Muscle or Muscles, peroneo-calcaneus, 198
 peroneo-tibialis, 197
 peroneus access., 196
 brevis, 196
 longus, 195
 quartus, 196
 quint. digiti, 196
 tertius, 195
 petro-pharyngeus, 163
 petro-staphylinus, 163
 pharyngo-mastoideus, 163
 pharyngo-staphylinus, 163
 pisi-annularis, 185
 pisi-metacarpeus, 185
 pisi-uncinatus, 185
 plantaris, 197
 platysma myoides, 157
 popliteus, 197
 minor, 197
 pronator quadratus, 179
 teres, 177
 psoas magnus, 188
 parvus, 188
 pterygoideus, 172
 proprius, 172
 pterygo-pharyngeus, 163
 pterygo-spinosus, 172
 pubo-coccygeus, 151
 pubo-transversalis, 148
 pyramidalis, 146
 nasi, 169
 pyriformis, 189
 quadratus femoris, 189
 labii sup., 168
 lumborum, 187
 menti, 169
 plantæ, 199
 quadriceps femoris, 190
 radialis internus, 177
 radio-carpeus, 179
 recti of eye, 170
 rectus abdominis, 145
 capitis anticus, 165
 lateralis, 145
 posticus, 144
 femoris, 191
 lateralis abd., 146
 rhombo-atloideus, 141
 rhomboideus major, 140
 minor, 140
 occipitalis, 140
 risorius, 168
 rotatores, 144
- Muscle or Muscles, sacro-coccygeus, 143, 151
 sacro-lumbalis, 142
 sacro-spinalis, 142
 sartorius, 190
 scaleni, 164
 scalenus minimus, 165
 pleuralis, 165
 semimembranosus, 192
 semispinales, 143
 semitendinosus, 192
 serratus anticus, 155
 magnus, 155
 posticus, 141
 soleus, 196
 spheno-pharyngeus, 163
 spheno-staphylinus, 163
 sphincter ani, 151
 oris, 169
 spinales, 143
 splenius, 141
 capitis access., 141
 colli access., 141
 stapedius, 304
 sternalis brutorum, 154
 sterno-clavicularis, 154
 sterno-cleido-mastoid, 158
 sterno-hyoideus, 159
 sterno-scapularis, 154
 sterno-thyreoideus, 160
 stylo-auricularis, 161
 stylo-glossus, 161
 stylo-hyoideus, 159
 alter, 159
 profundus, 159
 stylo-pharyngeus, 162
 subanconeus, 176
 subclavius, 154
 subcruralis, 191
 subcutaneus colli, 157
 subdeltoid, 173
 subscapularis, 174
 minor, 174
 supinator brevis, 182
 longus, 180
 access., 180
 supraclavicularis, 154
 proprius, 158
 supracostalis, 156
 supraspinatus, 173
 temporal, 172
 minor, 172
 tensor palati, 163
 tarsi, 167

- Muscle or Muscles, tensor trochleæ, 171
 tympani, 304
 vaginæ femoris, 190
 teres major, 140
 minor, 173
 thyreo-hyoideus, 160
 thyro-arytenoid, 313
 thyro-epiglottic, 313
 tibialis anticus, 194
 posticus, 197
 secundus, 197
 tibio-fascialis, 195
 trachelo-mastoid, 143
 transversalis abd., 148
 cervicis, 143, 165
 transversi thoracis, 156
 transverso-spinalis, 143
 transversus colli, 160
 menti, 168
 nuchæ, 158
 orbitæ, 171
 pedis, 200
 perinei, 151
 profundus, 152
 trapezius, 139
 triangularis menti, 168
 sterni, 156
 triceps, 175
 suræ, 196
 triticeo-glossus, 161
 trochlearis, 170
 ulnaris externus, 181
 internus, 177
 brevis, 179
 quinti digiti, 181
 ulno-carpeus, 179
 vasti, 191
 zygomaticus, 168
 Myology, 19, 138
- N.
- Nasion, 63
 Nerve or Nerves, abducens, 271
 anterior crural, 286
 Arnold's, 275
 auditory, 273
 auricularis magnus, 279
 auriculo-temporal, 270
 cardiac, 276, 293
 chorda tympani, 272, 304
 ciliary, 268
 circumflex, 281
- Nerve or Nerves, communicans noni, 279
 cranial, 266
 descendens noni, 277
 dorsal, 283
 facial, 272
 genito-crural, 285
 glosso-pharyngeal, 273
 gluteal, 288
 gustatory, 271
 hypoglossal, 277
 ilio-hypogastric, 285
 ilio-inguinal, 285
 inferior maxillary, 270
 infraorbital, 269
 interosseous, 282, 283
 Jacobson's, 274, 304
 laryngeal, 275
 lingual, 271, 274
 lumbar, 283
 median, 281
 motor oculi, 267
 musculo-cutaneous, 281, 291
 musculo-spiral, 283
 nasal, 268, 269
 obturator, 286
 occipitalis minor, 279
 olfactory, 266
 ophthalmic, 267
 optic, 266
 orbital, 269
 pathetic, 267
 perineal, 289
 peroneal, 291
 petrosal, 270, 272, 274
 pharyngeal, 270, 275
 phrenic, 279
 plantar, 290
 pneumogastric, 274
 popliteal, 289, 291
 pudic, 289
 radial, 283
 saphenous, 287
 sciatic, 288, 289
 spinal accessory, 276
 splanchnic, 294
 suboccipital, 277
 superficialis colli, 279
 superior maxillary, 269
 suprascapular, 280
 sympathetic, 292
 thoracic, 280
 tibial, 290, 291
 trifacial, 267

Nerve or Nerves, tympanic, 272, 274
 ulnar, 282
 Vidian, 270
 Neural arch, 24
 Neuroglia, 251
 Neurology, 19, 249
 Nose, 307
 Notch, coraco-scapular, 67
 cotyloid, 79
 episternal, 32
 ethmoidal, 38
 great scapular, 66
 iliac, 77
 ilio-sciatic, 78
 intercondylar, 82
 jugular, 37
 lachrymal, 49
 nasal 38, 43
 parietal, 40
 popliteal, 84
 pterygoid, 48
 sciatic, 77, 79, 122
 semilunar, 32, 55
 sigmoid, 55
 spheno-palatine, 52
 suprascapular, 67
 vertebral, 24
 Notochord, 17
 Nucleus amygdalæ, 260
 caudate, 260
 lenticular, 260

O.

Obelion, 63
 Obex, 265
 Occipital point, 63
 Oesophagus, 322
 Olecranon, 70
 Olfactory tract, 258
 Ovary body, 253
 Omentum, 341
 Operculum, 256
 Ophryon, 63
 Opisthion, 64
 Optic commissure, 258, 266
 thalamus, 261
 tract, 258, 266
 Orbital plate, 38, 45, 47
 Orbits, 57
 Organ of Corti, 307
 Os acetabuli, 79
 capitatum, 74
 centrale, 75

Os coxæ, 76
 innominatum, 76
 planum, 47
 pubis, 78
 trigonum, 88
 Ossa supersternalia, 32
 triquetra, 56
 Ossiculum jugulare, 56
 Ossification, 20
 Osteology, 19
 Ovary, 351

P.

Palate, 320
 Palatine trigone, 49
 Pancreas, 324
 Panniculus adiposus, 139
 carnosus, 139
 Parietal boss, 37
 Parovarium, 352
 Pars intermedia, 272
 Patella, 83
 Peduncles of cerebellum, 263
 Pelvic girdle, 91, 120
 Pelvis, 76, 79
 position of, 80
 differences in, 80
 Penis, 342
 Pericardium, 204
 Perimysium, 138
 Periosteum, 20
 Peritoneum, 339
 Pes accessorius, 259, 260
 hippocampi, 260
 Phalanges, 76, 89
 Pharynx, 322
 Pia mater, 249, 252
 Pillar of fauces, 163
 Pineal gland, 262
 Pituitary body, 258
 Pleura, 315
 Plexus, brachial, 280
 cardiac, 294
 carotid, 292
 cavernous, 292
 cervical, 278
 epigastric, 295
 lumbar, 284
 pelvic, 296
 sacral, 288
 Pons Varolii, 254
 Porus acusticus, 42
 Posterior nares, 59

Precuneus, 257
 Primitive streak, 17, 18
 Process, accessory, 27
 alveolar, 49
 angular, 38
 articular, 24, 31
 clinoid, 44, 45
 cochleariform, 43
 coracoid, 66
 coronoid, 55, 70
 ensiform, 32
 ethmoidal, 54
 frontal, 52
 hamular, 46, 54
 incisor, 50
 intrajugular, 37
 jugular, 36
 lachrymal, 54
 malar, 49
 mammillary, 27
 marginal, 53
 mastoid, 40
 maxillary, 51, 54
 nasal, 38, 49
 odontoid, 25
 orbital, 51, 53
 palate, 49
 paramastoid, 37
 petrosal, 44
 pyramidal, 51
 sphenoidal, 51
 spinous, 24, 30, 45
 styloid, 43, 71, 72, 75, 85
 superior turbinate, 48
 supracondylar, 69
 transverse, 24, 30
 tubarius, 46
 uncinate, 47, 74
 ungual, 76
 vaginal, 43, 44, 46
 xiphoid, 32
 Processes of Ingrassias, 45
 pterygoid, 44, 46
 Pyramid, 253

R.

Radio-carpal joint, 115
 Radius, 71
 Receptaculum chyli, 245
 Rectum, 329
 Restiform body, 253
 Retina, 299
 Ribs, vertebro-sternal, 32

Ribs, vertebro-chondral, 32
 vertebral, 32
 Ridge, gluteal, 81
 mylo-hyoid, 55
 pectoral, 68
 pronator, 71
 superciliary, 38
 supinator, 68, 70
 supracondylar, 68, 81
 Ring, abdominal, 146, 149
 crural, 187
 femoral, 149
 Rostrum, 45, 259

S.

Saccus endolymphaticus, 42
 Sacrum, 28
 Sagittal plane, 19
 Saphenous opening, 187
 Sarcolemma, 138
 Scapula, 65
 Scarpa's triangle, 229
 Sclerotic coat, 298
 Scrotum, 345
 Segmentation sphere, 17
 Sella turcica, 44
 Semilunar valves, 206
 Septum crurale, 187
 lucidum, 259, 261
 nasi, 60
 tubæ, 43
 Sesamoid plate, 138
 Sheath, crural, 187
 of rectus, 147
 Shoulder, 64
 Shoulder-girdle, 90, 104
 Shoulder-joint, 107
 Sigmoid cavity, 70, 72
 Sinus, cavernous, 238, 271
 circular, 238
 coronary, 233
 frontal, 38
 lateral, 238
 longitudinal, 238
 magnus, 209
 maxillary, 50
 occipital, 238
 petrosal, 238
 straight, 238
 transverse, 239
 Skeleton, 19
 Skull, as a whole, 55
 fixed points on, 63

Somatopleure, 18
 Spermatic cord, 344
 Spheno-ethmoidal recess, 61
 Spheno-petrosal lamina, 47
 Spinal cord, 249
 Spine, 44
 iliac, 79
 nasal, 48, 51
 of ischium, 77
 of pubis, 77
 of scapula, 66
 of tibia, 84
 palatine, 51
 peroneal, 86
 Spines, mental, 54
 Splanchnology, 19, 310
 Splanchnopleure, 18
 Spleen, 335
 Splenium, 259
 Stapes, 303
 Stephanion, 64
 Sternum, 31
 Stomach, 323
 Striæ acusticæ, 265
 Subnasal point, 63
 Substantia ferruginea, 266
 gelatinosa, 251
 Sulci of brain, 255
 Suleus, frontal, 39
 occipitalis, 41
 preauricular, 79
 pulmonalis, 34
 Superior maxilla, 48
 Supination, 112, 131
 Suprarenal capsule, 335
 Sustentaculum tali, 86
 Sutures, coronal, 56
 lambdoid, 56
 sagittal, 56
 Symphysis pubis, 78, 120
 Synarthrodial joints, 93
 Synchronrosis, 94
 Syndesmosis, 94
 Synovial cavities of ankle, 137
 of wrist, 116
 membrane, 93

T.

Tænia semicircularis, 260
 Talus, 86
 Tarsus, 86
 Teeth, 318
 Tegmen tympani, 40, 42

Tegmentum, 259
 Tendo Achillis, 197
 oculi, 167
 Tentorium, 252
 Testis, 344
 Thigh, 80
 Thorax, 31, 34
 Tibia, 83
 Tongue, 309
 Tonsil, 263, 320
 Torcular Herophili, 36
 Torus occipitalis transversus, 37
 Trachea, 314
 Tractus spiralis foraminulentus, 42
 Tragus, 301
 Trapezium, 254
 Triangle of Petit, 147
 suboccipital, 145
 Trochanters, 81
 Trochlea, 69
 Tuber annulare, 254
 cinereum, 258
 olfactorium, 258
 Tubercle, adductor, 82
 carotid, 26
 Chassignac's, 26
 conoid, 65
 deltoid, 65
 infraglenoid, 67
 lachrymal, 49
 Lisfranc's 33
 mental, 54
 obturator, 78
 of femur, 81
 of radius, 72
 of the quadratus, 81
 of tibia, 84
 pharyngeal, 37
 pterygoid, 46
 scalene, 33
 supraglenoid, 67
 Tubercles of astragalus, 87
 Tuberosity, bicipital, 71
 costal, 65
 great, 68
 iliac, 77
 of ischium, 78, 79
 of scaphoid, 73, 87
 small, 68
 of superior maxilla, 48
 of the palate-bone, 51
 of tibia, 83
 of trapezium, 74
 of ulna, 70

Tuberosity, pubo-ischiatic, 78
 Tympanic plate, 44
 Tympanum, 301

U.

Ulna, 70
 Ureter, 337
 Urethra, 343, 349
 Uterus, 349

V.

Vagina, 349
 Valve of Vieussens, 263, 265
 Vas deferens, 347
 Vein or Veins, angular, 235
 axillary, 240
 azygos, 240, 241
 basilic, 240
 cardiac, 233
 cava inferior, 241
 superior, 233
 cephalic, 240
 cerebellar, 237
 cerebral, 237
 cervical, 234
 coronary, 233
 corporis striati, 237
 diploic, 239
 emissary, 239
 facial, 235
 femoral, 243
 hepatic, 242
 iliac, 242, 243
 innominate, 234
 intercostal, 235
 internal maxillary, 236
 jugular, 236, 237
 lumbar, 241
 magna Galeni, 237
 median, 240
 oblique of Marshall, 233
 ophthalmic, 239

Vein or Veins, popliteal, 243
 portæ, 244
 pubic, 243
 pulmonary, 233
 renal, 242
 saphenous, 242
 spermatic, 242
 spinal, 241
 subclavian, 240
 systemic, 233
 temporal, 236
 temporo-maxillary, 235
 thyroid, 234
 tibial, 243
 ulnar, 240
 vertebral, 234
 Velum interpositum, 261
 medullary, 263, 265
 palati, 163
 Ventricles, 205
 of brain, 259, 262, 263
 Vertebra dentata, 25
 prominens, 25
 Vertebrae, cervical, 24
 characteristics of, 23
 dorsal, 26
 false, 28
 lumbar, 26, 27
 sacral, 28
 Vertebral, 25
 column, 23, 29
 Vestibule, 305
 Vincula tendinum, 179
 Vitelline membrane, 17
 Vocal cords, 312
 Vulva, 348

W.

"White line," 150
 Wings of sphenoid, 44, 45
 Wrist-bones, 72
 Wrist-joint, 113

Lea Brothers & Co's
LIST OF THE
LEADING MEDICAL TEXT-BOOKS.

Anatomy.

GRAY'S ANATOMY.

13th Edition. In Colors or Black.

ANATOMY, DESCRIPTIVE AND SURGICAL.

BY

HENRY GRAY, F. R. S.,

LECTURER ON ANATOMY AT ST. GEORGE'S HOSPITAL, LONDON.

EDITED BY

T. PICKERING PICK, F. R. C. S.,

SURGEON TO AND LECTURER ON ANATOMY AT ST. GEORGE'S HOSPITAL, LONDON.

A NEW AMERICAN FROM THE THIRTEENTH ENLARGED AND IMPROVED
LONDON EDITION, THOROUGHLY REVISED.

In one imperial octavo volume of 1100 pages, with 635
large and elaborate engravings on wood.

Price of edition in black: cloth, \$6.00; leather, \$7.00. Price of edition
in colors: cloth, \$7.00; leather, \$8.00. *Just ready.*

A New Medical Dictionary—Ready Shortly.

**A DICTIONARY OF MEDICINE AND THE ALLIED
Sciences.** Comprising the Pronunciation, Derivation and Full Explan-
ation of Medical Terms; together with Much Collateral Descriptive
Matter, Numerous Tables, etc. By ALEXANDER DUANE, M. D., Assistant
Surgeon N. Y. Ophthalmic and Clinical Institute; Reviser of Medical Terms
for Webster's International Dictionary. In one very handsome square
octavo volume of about 600 pages. *Ready very shortly.*

LEA BROTHERS & CO., 706, 708 & 710 Sansom Street, Philadelphia.

NEW (TWENTY-FIRST) EDITION. JUST READY.

DUNGLISON'S MEDICAL DICTIONARY.

A DICTIONARY OF MEDICAL SCIENCE
CONTAINING

A FULL EXPLANATION OF THE VARIOUS SUBJECTS AND TERMS OF ANATOMY,
PHYSIOLOGY, MEDICAL CHEMISTRY, PHARMACY, PHARMACOLOGY,
THERAPEUTICS, MEDICINE, HYGIENE, DIETETICS, PATHOLOGY,
BACTERIOLOGY, SURGERY, OPHTHALMOLOGY, OTOTOLOGY,
LARYNGOLOGY, DERMATOLOGY, GYNECOLOGY,
OBSTETRICS, PEDIATRICS, MEDICAL JURIS-
PRUDENCE, DENTISTRY, ETC.

By ROBLEY DUNGLISON, M. D., LL. D.

New (21st) Edition, thoroughly Revised and greatly Enlarged and Improved.

**WITH THE PRONUNCIATION, ACCENTUATION
AND DERIVATION OF THE TERMS.**

By RICHARD J. DUNGLISON, A. M., M. D.

In one magnificent imperial octavo volume of 1200 pages.

Cloth, \$7; leather, \$8. *Just ready.*

TWENTY-ONE editions in sixty years corroborate the recognized position of *Dunglison's Dictionary* as being the standard in all matters of medical terminology. *Forty-four thousand* new words and phrases have been added in the new edition, and notwithstanding the omission of everything obsolete, the work has been enlarged by an amount of matter equal to one hundred pages of the previous edition; pronunciation has been introduced for the first time and is indicated by a simple phonetic spelling; derivation, an unequalled aid to memory, is fully given, and the definitions, for which "Dunglison" has always been distinguished, are full, clear and explanatory. The work abounds in information of practical importance, such as Diseases, symptoms and treatment; Poisoning, treatment, antidotes; Drugs, properties and doses, of which latter a full table is given; etc. Numerous tables enrich the alphabet and place an immense amount of knowledge clearly and conveniently at hand. In its present improved shape this standard work will be found indispensable to students, practitioners and pharmacists.

LEA BROTHERS & CO., 706, 708 & 710 Sansom Street, Philadelphia.

Anatomy • Dictionaries.

Billings' National Medical Dictionary.

THE NATIONAL MEDICAL DICTIONARY; including English, French, German, Italian and Latin technical terms used in Medicine and the Collateral Sciences, and a series of tables of useful data. By JOHN S. BILLINGS, M. D., LL. D., Edin. and Harv., D. C. L., Oxon., Member of the National Academy of Sciences, Surgeon U. S. A., etc. In two very handsome royal octavo volumes containing 1574 pages, with two colored plates. Per volume, cloth, \$6.00; leather, \$7.00; half Morocco, marbled edges, \$8.50. For sale by subscription only. Specimen pages on application. Address the publishers.

Its scope is one which will at once satisfy the student and meet all the requirements of the medical practitioner. It presents to the English reader a thoroughly scientific mode of acquiring a rich vocabulary and offers an accurate and ready means of reference in consulting works in any of the three modern continental languages which are richest in medical literature. There cannot

be two opinions as to the great value and usefulness of this dictionary as a book of ready reference for all sorts and conditions of medical men. So far as we have been able to see, no subject has been omitted, and in respect of completeness it will be found distinctly superior to any medical lexicon yet published.—*The London Lancet*, April 5, 1890.

Hoblyn's Medical Dictionary.

A DICTIONARY OF THE TERMS USED IN MEDICINE and the Collateral Sciences. By RICHARD D. HOBLYN, M. D. Revised, with numerous additions, by ISAAC HAYS, M. D., late editor of *The American Journal of the Medical Sciences*. In one large royal 12mo. volume of 520 double-columned pages. Cloth, \$1.50; leather, \$2.00.

It is the best book of definitions we have, and ought always be upon the student's table.—*Southern Medical and Surgical Journal*.

Holden's Landmarks, Medical and Surgical.

LANDMARKS, MEDICAL AND SURGICAL. By LUTHER HOLDEN, F. R. C. S., Surgeon to St. Bartholomew's and the Foundling Hospitals, London. Second American from the third and revised English edition, with additions by W. W. KEEN, M. D., Professor of Artistic Anatomy in the Pennsylvania Academy of Fine Arts. In one 12mo. volume of 148 pages. Cloth, \$1.00.

Ellis' Demonstrations of Anatomy—Eighth Edition.

DEMONSTRATIONS OF ANATOMY. Being a Guide to the Knowledge of the Human Body by Dissection. By GEORGE VINER ELLIS, Emeritus Professor of Anatomy in University College, London. From the eighth and revised London edition. In one very handsome octavo volume of 716 pages, with 249 illustrations. Cloth, \$4.25; leather, \$5.25.

LEA BROTHERS & CO., 706, 708 & 710 Sansom Street, Philadelphia.

Physics * Physiology.

Draper's Medical Physics.

MEDICAL PHYSICS. A Text-book for Students and Practitioners of Medicine. By JOHN C. DRAPER, M. D., LL. D., Professor of Chemistry in the University of the City of New York. In one octavo volume of 734 pages, with 376 woodcuts. Cloth, \$4.00.

No man in America was better fitted than Dr. Draper for the task he undertook, and he has provided the student and practitioner of medicine with a volume at once readable and thorough. Even to the student who has some knowledge of physics this book is useful, as it shows him its applications to the profession that he has chosen. Dr. Draper, as an old teacher, knew well the difficulties to be encountered in bringing his subject within the grasp of the average student, and that he has succeeded so well proves once more that the man to write for and examine students is the one who has taught and is teaching them. The book is well printed and fully illustrated, and in every way deserves grateful recognition.

agree that a knowledge of physics is desirable for the medical student, only those actually engaged in the teaching of the primary subjects can be fully aware of the difficulties encountered by students who attempt the study of these subjects without a knowledge of either physics or chemistry. These are especially felt by the teacher of physiology. It is, however, impossible for him to impart a knowledge of the main facts of his subject and establish them by reasons and experimental demonstrations, and at the same time undertake to teach *ab initio* the principles of chemistry or physics. Hence the desirability, we may say the necessity, for some such work as the present one.—*The Montreal Medical Journal*, July, 1890.

While all enlightened physicians will

Power's Physiology.

HUMAN PHYSIOLOGY. By HENRY POWER, M.B., F.R.C.S., Examiner in Physiology, Royal Collège of Surgeons of England. Second edition. In one 12mo. volume of 509 pages, with 68 illustrations. Cloth, \$1.50. See *Students' Series of Manuals*, at end.

Robertson's Physiological Physics.

PHYSIOLOGICAL PHYSICS. By J. MCGREGOR ROBERTSON, M. A., M. B., Muirhead Demonstrator of Physiology, University of Glasgow. In one 12mo. volume of 537 pages, with 219 illustrations. Limp cloth, \$2.00. See *Students' Series of Manuals*, at end.

Bell's Comparative Anatomy and Physiology.

COMPARATIVE ANATOMY AND PHYSIOLOGY. By F. JEFFREY BELL, M. A., Professor of Comparative Anatomy at King's College, London. In one 12mo. volume of 561 pages, with 229 illustrations. Limp cloth, \$2.00. See *Students' Series of Manuals*, at end.

Physiology—(Continued).

Foster's Physiology—New American Edition.

TEXT BOOK OF PHYSIOLOGY. By MICHAEL FOSTER, M.D., F R.S., Prelector in Physiology and Fellow of Trinity College, Cambridge, England. New (fourth) and enlarged American from the fifth and revised English edition, with notes and additions. In one handsome octavo volume of 1072 pages, with 282 illustrations. Cloth, \$4.50; leather, \$5.50.

The appearance of another edition of Foster's *Physiology* again reminds us of the continued popularity of this most excellent work. There can be no doubt that this text-book not only continues to lead all others in the English language, but that this last edition is superior to its predecessors. Every page bears evidences of careful revision. Although the work of the American editor in former editions has been by the author largely adopted in a modified form in this revision, much was still left to be done by the editor to render the work fully adapted to the wants of our American students, so that the American edition will undoubtedly

continue to supply the market on this side of the Atlantic. The work has been published in the characteristic creditable style of the Leas, and owing to its enormous sale is offered at an extremely low price.—*The Medical and Surgical Reporter*, January 9, '92.

Foster's *Physiology* would probably be placed by universal verdict at the head of all works of its class that the English-speaking world has yet produced. It appears to be a complete storehouse of physiological lore. The work is deserving of unstinted praise.—*American Practitioner and News*, March 12, 1892.

Dalton's Physiology—Seventh Edition.

A TREATISE ON HUMAN PHYSIOLOGY. Designed for the Use of Students and Practitioners of Medicine. By JOHN C. DALTON, M.D., Professor of Physiology in the College of Physicians and Surgeons, New York. Seventh edition, thoroughly revised. In one octavo volume of 722 pages, with 252 engravings. Cloth, \$5.00; leather, \$6.00.

From the first appearance of the book it has been a favorite, owing as well to the author's renown as an oral teacher as to the charm of simplicity with which, as a writer, he always succeeds in investing even intricate subjects. It must be gratifying to him to observe the frequency with which his work, written for students and practitioners,

is quoted by other writers on physiology. This fact attests its value, and, in great measure, its originality. It now needs no such seal of approbation, however, for the thousands who have studied it in its various editions have never been in any doubt as to its sterling worth.—*New York Medical Journal*, October, 1882.

Chapman's Physiology.

A TREATISE ON HUMAN PHYSIOLOGY. By HENRY C. CHAPMAN, M.D., Professor of Institutes of Medicine and Medical Jurisprudence in Jefferson Medical College of Philadelphia. In one octavo volume of 925 pages, with 605 engravings. Cloth, \$5.50; leather, \$6.50.

Matters which have a practical bearing on the practice of medicine are lucidly expressed; technical matters are given in minute detail; elaborate directions are stated for the guidance of students in the laboratory.

In every respect the work fulfils its promise, whether as a complete treatise for the student or for the physician; for the former it is so complete that he need look no farther.—*North Carolina Medical Journal*, Nov. 1887.

The Students' Quiz Series—PHYSIOLOGY, \$1. SEE P. 1

LEA BROTHERS & CO., 706, 708 & 710 Sansom Street, Philadelphia.

Chemistry.

Bloxam's Chemistry—Fifth Edition.

CHEMISTRY, INORGANIC AND ORGANIC. By CHARLES L. BLOXAM, Professor of Chemistry in King's College, London. New American from the fifth London edition, thoroughly revised and much improved. In one very handsome octavo volume of 727 pages, with 292 illustrations. Cloth, \$2.00; leather, \$3.00.

We know of no treatise on chemistry which contains so much practical information in the same number of pages. The book can be readily adapted not only to the needs of those who desire a tolerably complete course of chemistry, but also to the

needs of those who desire only a general knowledge of the subject. It is both a satisfactory text-book, and a useful book of reference.—*Boston Medical and Surgical Journal*, June 19, 1884.

Frankland & Japp's Inorganic Chemistry.

INORGANIC CHEMISTRY. By E. FRANKLAND, D. C. L., F. R. S., Professor of Chemistry in the Normal School of Science, London, and F. R. JAPP, F. I. C., Assistant Professor of Chemistry in the Normal School of Science, London. In one handsome octavo volume of 677 pages with 51 woodcuts and 2 plates. Cloth, \$3.75; leather, \$4.75.

This work should supersede other works of its class in the medical colleges. It is certainly better adapted than any work upon chemistry, with which we are acquainted, to impart that clear and full knowledge of the science which students of medicine should

have. Physicians who feel that their chemical knowledge is behind the times, would do well to study this work. The descriptions and demonstrations are made so plain that there is no difficulty in understanding them.—*Cincinnati Medical News*, January, 1886.

Luff's Manual of Chemistry—Just Ready.

A MANUAL OF CHEMISTRY. For the Use of Students of Medicine. By ARTHUR P. LUFF, M. D., B. Sc., Lecturer on Medical Jurisprudence and Toxicological Chemistry, St. Mary's Hospital Medical School, London. In one 12mo. volume of 522 pages, with 36 engravings. Cloth, \$2.00. See *Students' Series of Manuals*, at end.

Greene's Medical Chemistry.

A MANUAL OF MEDICAL CHEMISTRY. For the Use of Students. Based upon Bowman's Medical Chemistry. By WILLIAM H. GREENE, M. D., Demonstrator of Chemistry in the Medical Department of the University of Pennsylvania. In one 12mo. volume of 310 pages, with 74 illustrations. Cloth, \$1.75.

Chemistry—(Continued).

Simon's Manual of Chemistry—New (4th) Edition.

MANUAL OF CHEMISTRY. A Guide to Lectures and Laboratory Work for Beginners in Chemistry. A Text-book, specially adapted for Students of Pharmacy and Medicine. By W. SIMON, Ph. D., M. D., Prof. of Chemistry in the College of Physicians and Surgeons, Baltimore, Professor of Chem. in the Md. College of Pharm. New (fourth) edition. In one 8vo. volume of about 500 pages, with 44 woodcuts and 7 colored plates illustrating 56 of the most important chemical tests. Cloth, \$3.25. *Just Ready.*

A notice of the previous edition is appended.

While possessing all the usual qualities of an excellent text-book for the student or laboratory, this Manual presents the unique advantage of furnishing plates showing the variously shaded colors of certain chemicals, etc., and their reactions. This

Chemistry is especially valuable to medical students and practitioners, as devoting so much of detail to descriptions of analyses, tests, etc., of those things with which the doctor has mostly to deal.—*Virginia Medical Monthly*, January, 1892.

Attfield's Chemistry—Twelfth Edition.

CHEMISTRY, GENERAL, MEDICAL AND PHARMACEUTICAL; Including the Chemistry of the U. S. Pharmacopœia. A Manual of the General Principles of the Science, and their Application to Medicine and Pharmacy. By JOHN ATTFIELD, M. A., Ph. D., Prof. of Practical Chemistry to the Pharm. Soc. of Great Britain. A new American, from the 12th English edition, specially revised by the author for America. In one 12mo. volume of 782 pages, with 88 illus. Cloth, \$2.75; leather, \$3.25.

Attfield's *Chemistry* is the most popular book among students of medicine and pharmacy. This popularity has a good, substantial basis. It rests upon real merits. Attfield's work combines in the happiest manner a clear exposition of the theory of chemistry with the practical application of this knowledge to the everyday dealings of the physician and pharmacist. His discernment is shown not only in what he puts into his work, but also in what he leaves

out. His book is precisely what the title claims for it. The admirable arrangement of the text enables a reader to get a good idea of chemistry without the aid of experiments, and again it is a good laboratory guide and finally it contains such a mass of well-arranged information that it will always serve as a handy book of reference. This last edition shows the marks of the latest progress made in chemistry and chemical teaching.—*New Orleans Med. & Surg. Jour.*, Nov. 1889.

Fownes' Chemistry—Twelfth Edition.

A MANUAL OF ELEMENTARY CHEMISTRY; Theoretical and Practical. By GEORGE FOWNES, Ph. D. Embodying WATTS' *Physical and Inorganic Chemistry*. New American, from the twelfth English edition. In one large royal 12mo. volume of 1061 pages, with 168 illustrations on wood and a colored plate. Cloth, \$2.75; leather, \$3.25.

Of all the works on chemistry intended for the use of medical students, Fownes' *Chemistry* is perhaps the most widely used. Its popularity is based upon its excellence. This last edition contains all of the material found in the previous, and it is also enriched by the addition of Watts' *Physical and In-*

organic Chemistry. All of the matter is brought to the present standpoint of chemical knowledge. We may safely predict for this work a continuance of the fame and favor it enjoys among medical students.—*New Orleans Medical and Surgical Journal*, March, 1886.

The Students' Quiz Series—Chemistry, \$1. See P. 1.

LEA BROTHERS & CO., 706, 708 & 710 Sansom Street, Philadelphia.

Chemistry—(Continued).

Remsen's Theoretical Chemistry—NEW (4TH) EDITION.

PRINCIPLES OF THEORETICAL CHEMISTRY, with special reference to the Constitution of Chemical Compounds. By IRA REMSEN, M. D., Ph. D., Professor of Chemistry in the Johns Hopkins University, Baltimore. Fourth and thoroughly revised edition. In one handsome royal 12mo. volume of 325 pages. Cloth, \$2.00. *Just ready.*

No comment need be made on the excellence of this work. As a guide to the study of Theoretical Chemistry it remains unequalled. The favor which has been shown preceding editions of the work is sufficient proof that the object of the author in enabling students to obtain clear ideas in regard to the fundamental principles of chemistry has been successfully accomplished. Since the publication of the last edition in 1887, the work has been translated into German and into Italian—certainly no greater compliment could be desired by any author. The work will continue deservedly to hold the first place among the numerous treatises on Theoretical Chemistry.—*Pacific Medical Journal*, Oct. 1892.

Vaughan & Novy on Ptomaines and Leucomaines.

NEW (2D) EDITION.

PTOMAINES, LEUCOMAINES AND BACTERIAL PROTEIDS; or the Chemical Factors in the Causation of Disease. By VICTOR C. VAUGHAN, Ph. D., M. D., Professor of Physiological and Pathological Chemistry and Associate Professor of Therapeutics and Materia Medica in the University of Michigan, and FREDERICK G. NOVY, M. D., Instructor in Hygiene and Physiological Chemistry in the University of Michigan. New (second) edition. In one handsome 12mo. volume of 398 pp. Cloth, \$2.25.

The fact that a second edition appears within three years of the first is sufficient proof that it has been received by the profession with more than common interest. This may largely be accounted for by the systematic arrangement and the practical manner which the authors successfully adopted for it. This book is one of the greatest importance, and the modern physician who accepts bacterial pathology cannot have a complete knowledge of this subject unless he has carefully perused it. To the toxicologist the subject is alike of great import, as well as to the hygienist and sanitarian. It contains information which is not easily obtained elsewhere, and which is of a kind that no medical thinker should be without.—*The American Jour. of the Med. Sciences*, April, 1892.

Clowes' Chemical Analysis—Third Edition.

AN ELEMENTARY TREATISE ON PRACTICAL CHEMISTRY and Qualitative Inorganic Analysis. Specially adapted for use in Laboratories of Schools and Colleges and by Beginners. By FRANK CLOWES, D. Sc., London, Senior Science-Master at the High School, Newcastle-under-Lyme, etc. Third American from the fourth and revised English edition. In one 12mo. volume of 387 pages, with 55 illustrations. Cloth, \$2.50.

Ralfe's Clinical Chemistry.

CLINICAL CHEMISTRY. By CHARLES H. RALFE, M. D., F. R. C. P., Assistant Physician at the London Hospital. In one pocket-size 12mo. volume of 314 pages, with 16 illustrations. Limp cloth, red edges, \$1.50. See *Students' Series of Manuals*, at end.

LEA BROTHERS & CO., 706, 708 & 710 Sansom Street, Philadelphia

Chemistry * Pharmacy * Therapeutics.

Charles' Physiological and Pathological Chemistry.

THE ELEMENTS OF PHYSIOLOGICAL AND PATHOLOGICAL Chemistry. A Handbook for Medical Students and Practitioners. Containing a general Account of Nutrition, Foods and Digestion, and the Chemistry of the Tissues, Organs, Secretions and Excretions of the Body in Health and in Disease. Together with the methods for preparing or separating their chief constituents, as also for their examination in detail, and an outline syllabus of a practical course of instruction for students. By T. CRANSTOUN CHARLES, M. D., F. C. S., M. S., formerly Assistant Professor and Demonstrator of Chemistry and Chemical Physics, Queen's College, Belfast. Octavo, 463 pp., 38 woodcuts and 1 colored plate. Cloth, \$3.50.

Parrish's Pharmacy—Fifth Edition.

A TREATISE ON PHARMACY: Designed as a Text-book for the Student, and as a Guide for the Physician and Pharmacist. With many Formulæ and Prescriptions. By EDWARD PARRISH, Late Professor of the Theory and Practice of Pharmacy in the Philadelphia College of Pharmacy. Fifth edition, thoroughly revised, by THOMAS S. WIEGAND, Ph. G. Octavo volume of 1093 pages, with 256 illus. Cloth, \$5.00; leather, \$6.00.

There is nothing to equal Parrish's *Pharmacy* in this or any other language.—*London Pharmaceutical Journal*.

This treatise on *Pharmacy* is as indispensable to the dispensing or manufacturing druggist and student of pharmacy as Duglison's *Medical Dictionary* is to the doctor

and the student of medicine. It has ceased being a luxury, and has become a necessity. The work is not merely a text-book for pharmacy students and druggists, but is a valuable guide and compend for the physician and medical student.—*The Physician and Surgeon*, April, 1884.

Griffith's Universal Formulary.

A UNIVERSAL FORMULARY, containing the Methods of Preparing and Administering Official and other Medicines. The whole adapted to Physicians and Pharmaceutists. By ROBERT EGLESFIELD GRIFFITH, M. D. Third edition, thoroughly revised, with numerous additions, by JOHN M. MAISCH, Phar. D., Professor of Materia Medica and Botany in the Philadelphia College of Pharmacy. In one octavo volume of 775 pages, with 38 illustrations. Cloth, \$4.50; leather, \$5.50.

Bruce's Materia Medica and Therapeutics—5th Ed.

MATERIA MEDICA AND THERAPEUTICS. An Introduction to Rational Treatment. By J. MITCHELL BRUCE, M. D., F. R. C. P., Physician and Lecturer on Materia Medica and Therapeutics at Charing Cross Hospital, London. Fourth edition, 12mo., 591 pages. Cloth, \$1.50. See *Students' Series of Manuals*, at end.

The pharmacology and therapeutics of each drug are given with great fullness, and the indications for rational employment in

the practical treatment of disease are pointed out.—*Medical Chronicle*, May, 1891.

Therapeutics * Materia Medica.

Hare's Practical Therapeutics—NEW (3d) EDITION. JUST READY.

A TEXT-BOOK OF PRACTICAL THERAPEUTICS; With Especial Reference to the Application of Remedial Measures to Disease and their Employment upon a Rational Basis. By HOBART AMORY HARE, B. Sc., M. D., Professor of Materia Medica and Therapeutics in the Jefferson Medical College of Philadelphia. With special chapters by DRs. G. E. DE SCHWEINITZ, EDWARD MARTIN, J. HOWARD REEVES and BARTON C. HIRST. New (third) and revised edition. In one handsome octavo volume of 689 pages. Cloth, \$3.75; leather, \$4.75.

We find here directions for the use of the drugs of the most recent introduction, and the very latest results obtained in the treatment of disease by these newer remedies. There is also a list of drugs arranged according to their physiological action, and a list of definitions of the terms used to designate classes of drugs. In a word, this book is a treatise on drugs and other remedial measures, with especial reference to their practical uses; and also a treatise on diseases, with

full directions for the most approved treatment. The book closes with a table of doses and an index of diseases and remedies. There are some books that the student and practitioner alike would do well to purchase; there are others they must have. To this latter class belong the text-books on practical therapeutics. Certainly none can be found either more practical or more complete than this.—*The National Medical Review*, February 2, 1893.

Hare's System of Practical Therapeutics—3 Vols.

A SYSTEM OF PRACTICAL THERAPEUTICS. By American and Foreign Authors. Edited by HOBART AMORY HARE, M. D., Professor of Therapeutics and Materia Medica in the Jefferson Medical College of Philadelphia. In a series of contributions by seventy-eight eminent authorities. In three large octavo volumes containing 3544 pages, with 434 illustrations. Price, per volume: Cloth, \$5.00; leather, \$6.00; half Russia, \$7.00. *For sale by subscription only. Address the Publishers. Full prospectus free to any address on application.*

Stillé & Maisch's National Dispensatory—5th Edition.

THE NATIONAL DISPENSATORY. Containing the Natural History, Chemistry, Pharmacy, Actions and Uses of Medicines. By ALFRED STILLÉ, M. D., LL. D., Professor Emeritus of the Theory and Practice of Medicine and of Clinical Medicine in the University of Pennsylvania, and JOHN M. MAISCH, Phar. D., Professor of Materia Medica and Botany in the Philadelphia College of Pharmacy. New (5th) and revised edition. In one magnificent imperial octavo vol. of about 1750 pp., with about 315 elaborate engravings. *In Press.* A notice of the previous edition is appended.

The most comprehensive, elaborate and accurate work of the kind ever printed in this country. It is no wonder that it has become the standard authority for both the medical and pharmaceutical professions, and that four editions have been required to supply the constant and increasing demand

since its first appearance in 1879. The entire field has been gone over and the various articles revised in accordance with the latest developments regarding the attributes and therapeutical action of drugs.—*Kansas City Medical Index.*

The Students' Quiz Series—MAT. MED. AND THERAPEUTICS. \$1. SEE PAGE 1.

LEA BROTHERS & CO., 706, 708 & 710 Sansom Street, Philadelphia.

Therapeutics * Materia Medica—(Cont'd).

Brunton's Therapeutics and Mat. Med.—3d Edition.

A TEXT-BOOK OF PHARMACOLOGY, THERAPEUTICS and Materia Medica; Including the Pharmacy, the Physiological Action and the Therapeutical Uses of Drugs. By T. LAUDER BRUNTON, M. D., D. Sc., F. R. S., F. R. C. P., Lecturer on Materia Medica and Therapeutics at St. Bartholomew's Hospital, London, etc. Adapted to the U. S. Pharmacopœia by FRANCIS H. WILLIAMS, M. D., of Harvard Univ. Med. School. Third edition. Octavo, 1305 pages, 230 illus. Cloth, \$5.50; leather, \$6.50.

No words of praise are needed for this work, for it has already spoken for itself in former editions. It was by unanimous consent placed among the foremost books on the subject ever published in any language, and the better it is known and studied the more highly it is appreciated. The present edition contains much new matter, the insertion of which has been necessitated by the advances

made in various directions in the art of therapeutics, and it now stands unrivalled in its thoroughly scientific presentation of the modes of drug action. No one who wishes to be fully up to the times in this science can afford to neglect the study of Dr. Brunton's work. The indexes are excellent, and add not a little to the practical value of the book.—*Medical Record*, May 25, 1889

Farquharson's Therapeutics—Fourth Edition.

A GUIDE TO THERAPEUTICS AND MATERIA Medica. By ROBERT FARQUHARSON, M. D., F. R. C. P., LL. D., Lecturer on Materia Medica at St. Mary's Hospital Medical School, London. Fourth American, from the fourth English edition. Enlarged and adapted to the U. S. Pharmacopœia. By FRANK WOODBURY, M. D., Professor of Materia Medica and Therapeutics and Clinical Medicine in the Medico-Chirurgical College of Philadelphia. In one 12mo. volume of 581 pages. Cloth, \$2.50.

Farquharson's *Therapeutics and Materia Medica* has struck a happy medium between excessive brevity on the one hand and tedious prolixity on the other. It deals with the entire list of drugs embraced in the British Pharmacopœia in such a way as to give in a satisfactory form the established indications of each, excluding all irrelevant matter. An especially attractive feature is an arrangement by which the physiological

and therapeutical actions of various remedies are shown in parallel columns. This aids greatly in fixing attention and facilitates study. The American editor has enlarged the work so as to include all the remedies and preparations in the United States Pharmacopœia. Altogether the book is a most valuable addition to the list of treatises on this most important subject.—*The American Practitioner and News*, November 9, 1889.

Edes' Therapeutics and Materia Medica.

A TEXT-BOOK OF THERAPEUTICS AND MATERIA Medica. Intended for the Use of Students and Practitioners. By ROBERT T. EDES, M. D., Jackson Professor of Clinical Medicine in Harvard University, Medical Department. Octavo, 544 pages. Cloth, \$3.50; leather, \$4.50.

The present work seems destined to take a prominent place as a text-book on the subjects of which it treats. It possesses all the essentials which we expect in a book of its kind, such as conciseness, clearness, a judicious classification, and a reasonable degree of dogmatism. The student and young practitioner need a safe guide in this branch of medicine, such they can find in the present author. All the newest drugs of promise are treated of. The clinical index at the

end will be found very useful. We heartily commend the book and congratulate the author on having produced so good a one.—*N. Y. Medical Journal*, February 18, 1888.

Dr. Edes' book represents better than any older book the practical therapeutics of the present day. The book is a thoroughly practical one. The classification of remedies has reference to their therapeutic action.—*Pharmaceutical Era*, January, 1888.

Practice * Diagnosis.

Flint's Practice of Medicine—Sixth Edition.

A TREATISE ON THE PRINCIPLES AND PRACTICE of Medicine. Designed for the Use of Students and Practitioners of Medicine. By AUSTIN FLINT, M. D., LL. D., Professor of the Principles and Practice of Medicine and of Clinical Medicine in Bellevue Hospital Medical College, N. Y. Sixth edition, thoroughly revised and rewritten by the Author, assisted by WILLIAM H. WELCH, M. D., Professor of Pathology, Johns Hopkins University, Baltimore, and AUSTIN FLINT, JR., M. D., LL. D., Professor of Physiology, Bellevue Hospital Medical College, N. Y. In one very handsome octavo volume of 1160 pages, with illustrations. Cloth, \$5.50; leather, \$6.50.

No text-book on the principles and practice of medicine has ever met in this country with such general approval by medical students and practitioners as the work of Professor Flint. In all the medical colleges of the United States it is the favorite work upon Practice; and, as we have stated before in alluding to it, there is no other medical work that can be so generally found in the libra-

ries of physicians. In every state and territory of this vast country the book that will be most likely to be found in the office of a medical man, whether in city, town, village, or at some cross-roads, is Flint's *Practice*. We make this statement to a considerable extent from personal observation, and it is the testimony also of others.—*Cincinnati Medical News*, October, 1886.

Flint's Auscultation and Percussion—Fifth Edition.

A MANUAL OF AUSCULTATION AND PERCUSSION; Of the Physical Diagnosis of Diseases of the Lungs and Heart, and of Thoracic Aneurism. By AUSTIN FLINT, M. D., LL. D., Professor of the Principles and Practice of Medicine in Bellevue Hospital Medical College, N. Y. Fifth edition. Edited by JAMES C. WILSON, M. D., Lecturer on Physical Diagnosis in the Jefferson Medical College, Philadelphia. In one handsome royal 12mo. vol. of 274 pages, with 12 illustrations. Cloth, \$1.75.

The work has met with the favorable endorsement of the profession, a fifth edition being needed to meet the demand for it. Professor Flint's *Practice of Medicine* has met with a success that has never been equalled by any other work of the kind in this country. The one before us on Physical Diagnosis seems also to have become a favor-

ite text-book with medical students. As stated by the editor, its value is to be discovered in the clearness and appropriateness of its style, the accuracy of its statements, its scientific method, and the practical treatment of subjects at once difficult and essential to the student of medicine.—*Cincinnati Medical News*, February, 1891.

Hartshorne's Essentials of Practice—5th Edition.

ESSENTIALS OF THE PRINCIPLES AND PRACTICE of Medicine. A Handbook for Students and Practitioners. By HENRY HARTSHORNE, M. D., LL. D., Lately Professor of Hygiene in the University of Pennsylvania. Fifth edition, thoroughly revised and rewritten. In one royal 12mo. volume of 669 pages, with 144 illustrations. Cloth, \$2.75.

The Students' Quiz Series—PRACT. OF MED., INCLUDING NERVOUS DIS., \$1. SEE P. 1.

LEA BROTHERS & CO., 706, 708 & 710 Sansom Street, Philadelphia.

Practice * Electricity * Diagnosis.

Bristowe's Practice of Medicine—7th Edition.

A TREATISE ON THE SCIENCE AND PRACTICE OF Medicine. By JOHN SYER BRISTOWE, M. D., LL. D., F. R. S., Senior Physician to and Lecturer on Medicine at St. Thomas' Hospital, London. Seventh edition. In one 8vo. vol. of 1325 pages. Cloth, \$6.50; leather, \$7.50.

The remarkable regularity with which new editions of this text-book make their appearance is striking testimony to its excellence and value. This, too, in spite of the numerous rivals for the favor of the student, which have been put forth within the sixteen years since Bristowe's *Medicine* first ap-

peared. It is a work that is built on a stable foundation, systematic, scientific, and practical, containing the matured experience of a physician who has every claim to be considered an authority, and composed in a style which attracts the practitioner as much as the student.—*The Lancet*, July 12, 1890.

Fothergill's Handbook of Treatment—3d Edition.

THE PRACTITIONER'S HANDBOOK OF TREATMENT ; Or, the Principles of Therapeutics. By J. MILNER FOTHERGILL, M. D., EDIN., M. R. C. P., LOND., Physician to the City of London Hospital for Diseases of the Chest. Third edition. In one 8vo. volume of 661 pages. Cloth, \$3.75; leather, \$4.75.

This is a wonderful book. If there be such a thing as "medicine made easy," this is the work to accomplish this result.—*Virginia Medical Monthly*, June, 1887.

We do not know a more readable, practical and useful work on the treatment of disease than the one we have now before us.—*Pacific Medical and Surgical Journal*, Oct. 1887.

While the work should be attentively studied by every medical student, yet it is no less adapted to the wants of the experienced physician, who has been educated in his pro-

session with the impression from the beginning that the treatment of disease is entirely empirical. There is no work in the English language in regard to which we are so impressed that physicians should both read and study as this work.—*Cincinnati Medical News*, June, 1887.

It is an excellent practical work on therapeutics, well arranged and clearly expressed, useful to the student and young practitioner, perhaps even to the old.—*Dublin Journal of Medical Science*, March, 1888.

Bartholow's Medical Electricity—Third Edition.

MEDICAL ELECTRICITY. A Practical Treatise on the Applications of Electricity to Medicine and Surgery. By ROBERTS BARTHOLOW, A. M., M. D., LL. D., Professor of Materia Medica and General Therapeutics in the Jefferson Medical College of Philadelphia, etc. Third edition. In one very handsome octavo volume of 308 pages, with 110 illustrations. Cloth, \$2.50.

The fact that this work has reached its third edition in six years, and that it has been kept fully abreast with the increasing use and knowledge of electricity, demonstrates its claim to be considered a practical treatise of tried value to the profession. The matter added to the present edition embraces

the most recent advances in electrical treatment. The illustrations are abundant and clear, and the work constitutes a full, clear and concise manual well adapted to the needs of both student and practitioner.—*The Medical News*, May 14, 1887.

Broadbent on the Pulse.

THE PULSE. By W. H. BROADBENT, M. D., F. R. C. P., Lecturer on Medicine at St. Mary's Hospital, London. In one 12mo. volume of 312 pages. Cloth, \$1.75. See *Series of Clinical Manuals*, at end.

LEA BROTHERS & CO., 706, 708 & 710 Sansom Street, Philadelphia.

Practice of Medicine & Throat and Nose.

Lyman's Practice of Medicine.

A TEXT-BOOK OF THE PRINCIPLES AND PRACTICE of Medicine. For the Use of Medical Students and Practitioners. By HENRY M. LYMAN, M.D., Professor of the Principles and Practice of Medicine in Rush Medical College, Chicago. In one very handsome royal octavo volume of 926 pages, with 180 illus. Cloth, \$4.75; leather, \$5.75.

This is an excellent treatise on the practice of medicine, written by one who is not only familiar with his subject, but who has also learned through practical experience in teaching, what are the needs of the student, and how to present the facts to his mind in the most readily assimilable form. The reader is not confused by having presented to him a variety of different methods of treatment, among which he is left to choose the one most easy of execution, but the author describes the one which is in his judgment the best. What the student should be taught is the one most approved method of treatment.

We have spoken of the work as one for the student, and this because the author occupies so prominent a position as a teacher; but we would not be understood that it is adapted only for students. There is many a practitioner to whom this work will be of great use. He will find here each subject presented in its latest aspect. The practical and busy man who wants to ascertain in a short time all the necessary facts concerning the pathology or treatment of any disease, will find here a safe and convenient guide. —*Medical Record*, October 22, 1892.

Whitla's Dictionary of Treatment.

A DICTIONARY OF TREATMENT; OR THERAPEUTIC Index, including Medical and Surgical Therapeutics. By WILLIAM WHITLA, M.D., Professor of Materia Medica and Therapeutics in the Queen's College, Belfast. Revised and adapted to the United States Pharmacopœia. In one square, octavo volume of 917 pages. Cloth, \$4.00.

The several diseased conditions are arranged in alphabetical order, and the methods—medical, surgical, dietetic and climatic—by which they may be met, considered. On every page we find clear and detailed directions for treatment, supported by the author's personal authority and experience, whilst the recommendations of other competent observers are also critically

examined. The book abounds with useful, practical hints and suggestions, and the younger practitioner will find in it exactly the help he so often needs in treatment. The most experienced members of the profession may usefully consult its pages for the purpose of learning what is really trustworthy in the later therapeutic developments.—*The Glasgow Medical Journal*, April, 1892.

Seiler on the Throat and Nose—NEW (4th) EDITION. JUST READY

A HANDBOOK OF DIAGNOSIS AND TREATMENT OF Diseases of the Throat, Nose and Naso-Pharynx. By CARL SEILER, M.D., Lecturer on Laryngoscopy in the University of Pennsylvania. Fourth edition. In one handsome royal 12mo. volume of about 400 pages, with 107 illustrations and 2 colored plates. Cloth, \$2.25.

A notice of the previous edition is appended.

The object of the volume is to serve as a guide to students of laryngology in acquiring the skill requisite to the successful diagnosis and treatment of diseases of the larynx and naso-pharynx. The author has omitted

all purely theoretical considerations, and has discussed only points of practical importance as concisely as possible. The work may be used as a ready book of reference.—*The Cincinnati Medical News*, Jan. 1889.

The Students' Quiz Series—EYE, EAR, THROAT AND NOSE, \$1. SEE PAGE 1.

LEA BROTHERS & CO., 706, 708 & 710 Sansom Street, Philadelphia.

Diagnosis • Urinary & Renal • Treatment

Musser's Medical Diagnosis. In Press.

A PRACTICAL TREATISE ON MEDICAL DIAGNOSIS.
For the Use of Students and Practitioners. By JOHN H. MUSSER, M. D.,
Assistant Professor of Clinical Medicine, University of Pennsylvania, Phila-
delphia. In one octavo volume of about 650 pages.

Yeo on Food in Health and Disease.

FOOD IN HEALTH AND DISEASE. By I. BURNEY YEO,
M. D., F. R. C. P., Professor of Clinical Therapeutics in King's College,
London. In one 12mo. volume of 590 pages. Cloth, \$2.00. *Series of
Clinical Manuals.*

Dr. Yeo supplies in a compact form nearly all that the practitioner requires to know on the subject of diet. The work is divided into two parts—food in health and food in disease. Dr. Yeo has gathered together from all quarters an immense amount of useful information within a comparatively small compass, and he has arranged and digested his materials with skill for the use of the practitioner. We have seldom seen a book which more thoroughly realizes the object for which it was written than this little work of Dr. Yeo.—*British Medical Journal*, Feb. 8, 1890.

Yeo's Medical Treatment.—Just Ready.

A MANUAL OF MEDICAL TREATMENT OR CLINICAL Therapeutics. By I. BURNEY YEO, M. D., F. R. C. P., Professor of Clinical Therapeutics in King's College, London. In two 12mo. volumes, containing 1275 pages, with illustrations. Cloth, \$5.50.

Roberts on Urinary and Renal Diseases—4th Ed.

A PRACTICAL TREATISE ON URINARY AND RENAL Diseases, Including Urinary Deposits. By SIR WILLIAM ROBERTS, M. D., Lecturer on Medicine in the Manchester School of Medicine, etc. Fourth American from the fourth London edition. In one handsome octavo volume of 609 pages, with 81 illustrations. Cloth, \$3.50.

The constant aim of the author has been to make the book a valuable guide to the clinical student. It is doubtless the most generally accepted standard work. We do not see how any general practitioner of medicine can afford to be without the book. It is also either the text-book or the reference-book in most of the medical colleges of the country that have a special chair for renal and urinary diseases.—*Virginia Medical Monthly*, November, 1885.

The Year-Book of Treatment for 1893.

A COMPREHENSIVE AND CRITICAL REVIEW FOR Practitioners of Medicine and Surgery. In one 12mo. volume of 500 pages. Cloth, \$1.50 For special commutations with periodicals see page 32.

With comparatively little labor, the busy practitioner gets the gist of medical literature the world over. Every branch of medicine is covered—new remedies, old ones with new applications, new operations, all receiving attention.—*Medical Record*.

THE YEAR-BOOKS OF TREATMENT for 1891 and 1892; 485 pages, each \$1.50. The Year-Books for 1886 and 1887, 320-341 pages, each, \$1.25.

LEA BROTHERS & CO., 706, 708 & 710 Sansom Street, Philadelphia.

Pathology * Histology * Bacteriology.

Gibbes' Pathology and Histology.

PRACTICAL PATHOLOGY AND MORBID HISTOLOGY.

By HENEAGE GIBBES, M. D., Professor of Pathology in the University of Michigan, Medical Department. In one very handsome octavo volume of 314 pages, with 60 illustrations, mostly photographic. Cloth, \$2.75.

The important subject is brought fully up with the most recent advances. All the details of practical work in this department are given in the most lucid manner, so that as a guide it will prove exceedingly valuable. The value of the work is greatly enhanced by the numerous illustrations of morbid tissues displayed. These photo-engravings

are particularly accurate and impart to the work advantages not possessed by any other method of illustration. The section on Practical Bacteriology contains all the instruction necessary. It is a model of the kind, and deserves the fullest patronage of the medical-student world.—*Nashville Journal of Medicine and Surgery*, October, 1891.

Abbott's Bacteriology.

THE PRINCIPLES OF BACTERIOLOGY. A Practical

Manual for Students and Physicians. By A. C. ABBOTT, M. D., First Assistant, Laboratory of Hygiene, University of Pennsylvania, Philadelphia. In one 12mo. volume of 259 pages, with 32 illustrations. Cloth, \$2.60.

Now that practical bacteriology forms a specific portion of the medical student's labors, there will be a growing call for manuals of the science. In the book before us instruction is afforded in all laboratory manipulations, and sterilization, culture

media, inoculations, and staining, are all dealt with in a careful and specific manner. No college of medicine will be known for such that does not in the next few years provide for teaching bacteriology to its students.—*The Physician and Surgeon*, Mar. '92.

Klein's Histology—Fourth Edition.

ELEMENTS OF HISTOLOGY. By E. KLEIN, M. D., F. R. S.,

Joint Lecturer on General Anatomy and Physiology in the Medical School of St. Bartholomew's Hospital, London. Fourth edition. In one 12mo. volume of 376 pages, with 194 illustrations. Limp cloth, \$1.75. See *Students' Series of Manuals*, at end.

Crisp, concise, straightforward, his descriptions proceed from animal protoplasm and the simple cell, to the histology of every organ of the human body. The author gives just that information which the intelligent

student of anatomy wants and is justified in expecting, but which he is often denied. The illustrations are as excellent as is the matter they adorn.—*The Microscope*, January, 1890.

Green's Pathology and Morbid Anatomy—7th Ed.

PATHOLOGY AND MORBID ANATOMY. By T. HENRY

GREEN, M. D., Lecturer on Pathology and Morbid Anatomy at Charing Cross Hospital Medical School, London. Sixth American from the seventh revised English edition. Octavo, 539 pages, 167 engravings. Cloth, \$2.75.

This book presents the subject in so satisfactory a manner as to be not only favorably received by the medical profession, but to

be at once placed in the enviable position of a text-book in all medical schools.—*The Cincinnati Lancet Clinic*, Oct. 19, 1889.

The Students' Quiz Series—HISTOL. PATHOL. AND BACTERIOL. \$1. SEE P. 1.

LEA BROTHERS & CO., 706, 708 & 710 Sansom Street, Philadelphia.

Pathol. * Histol. * Bacteriol.—(Cont.)

Senn's Surgical Bacteriology—Second Edition.

SURGICAL BACTERIOLOGY. By NICHOLAS SENN, M. D., Ph. D., Professor of Surgery in Rush Medical College, Chicago. New (second) edition. In one handsome octavo of 268 pages, with 13 plates, of which 10 are colored, and 9 engravings. Cloth, \$2.00.

The book is valuable to the student, but its chief value lies in the fact that such a compilation makes it possible for the busy practitioner, whose time for reading is limited and whose sources of information are often few,

to become conversant with the most modern and advanced ideas in surgical pathology, which have "laid the foundation for the wonderful achievements of modern surgery."—*Annals of Surgery*, March, 1892.

Payne's General Pathology.

A MANUAL OF GENERAL PATHOLOGY. Designed as an Introduction to the Practice of Medicine. By JOSEPH F. PAYNE, M. D., F. R. C. P., Senior Assistant Physician and Lecturer on Pathological Anatomy, St. Thomas' Hospital, London. Octavo of 524 pages, with 152 illustrations, and a colored plate. Cloth, \$3.50.

The work has our heartiest commendation. Whether regarded as a text-book for the student, or as a work of reference for the scientific practitioner, it has no equal in our

language on the subject of which it treats.—*The American Journal of the Medical Sciences*, February, 1889.

Coats' Pathology.

A TREATISE ON PATHOLOGY. By JOSEPH COATS, M. D., F. F. P. S., Pathologist to the Glasgow Western Infirmary. In one octavo volume of 829 pages, with 339 illus. Cloth, \$5.50; leather, \$6.50.

The author, owing to his large experience as a practical pathologist, has written a book which is as instructive as it is complete, being brought up to the latest advances in that science. The plan of the book is one that will meet with universal approval. We commend the work as filling the wants of the practitioner and the

student. The illustrations are mostly new and are well executed. A novel feature, and one at the same time very useful, is the arrangement of the index, whereby the derivation of all technical terms is given, so that this portion of the work is, as it were, a medical lexicon in itself.—*New Orleans Med. and Surg. Journal*, Feb. 1884.

Schäfer's Histology—Second Edition.

THE ESSENTIALS OF HISTOLOGY. By EDWARD A. SCHÄFER, F. R. S., Jodrell Professor of Physiology in University College, London. New (second) edition. In one octavo volume of 311 pages, with 325 illustrations. Cloth, \$3.00.

This work now appears in its third edition, revised and enlarged. It has been used for some time past as the text-book on its subject in a large number of colleges, and is so well and favorably known by teachers and students of histology that a discussion of the book seems unnecessary. The matter is systematically arranged into forty-five lessons for the careful study of the minute

anatomy of the various tissues of the body. Unimportant details are omitted, the matter is clearly and concisely presented, and the large number of cuts employed to illustrate the text recommend this book to all interested in histology. An appendix containing directions for the preparation of sections for microscopic study is added.—*University Medical Magazine*, January, 1893.

Nerves * Eye * Ear * Throat * Nose.

Gray on Nervous and Mental Diseases.

A PRACTICAL TREATISE ON NERVOUS AND MENTAL Diseases. By LANDON CARTER GRAY, M. D., Professor of Diseases of the Mind and Nervous System in the New York Polyclinic. In one 8vo. volume of 681 pages, with 168 illus. Cloth, \$4.50; leather, \$5.50.

The symptomatology and etiology are very thorough and complete without being in the least verbose. The treatment of each disease is considered in all its details, and the usefulness of the most recent remedies demonstrated. The treatise on mental diseases is by no means the least important feature of the work. The student is not confused by a bewildering and interminable classification;

on the contrary, Dr. Gray has attempted to simplify this subject, with a success which, it is hoped, other authors will not be slow to recognize and imitate. The glossary at the end of the volume will materially assist those who are not conversant with neurological terms to a thorough comprehension of the text.—*Journal of Nervous and Mental Disease*, Dec., 1892.

Norris & Oliver's Ophthalmology—Just Ready.

A TEXT-BOOK OF OPHTHALMOLOGY. By WILLIAM F. NORRIS, M. D., Professor of Ophthalmology in the Medical Department of the University of Pennsylvania, and CHARLES A. OLIVER, M. D., Surgeon to Wills' Eye Hospital, Phila. In one octavo vol. of 641 pp., with 357 beautiful engrav. and 5 col. plates, test-types, etc. Cloth, \$5.00; leather, \$6.00.

It is safe to say that in the rich literature of Ophthalmology, no volume will be found which will give so clear and satisfactory an exposition of its subject in all practical bearings. Its exceptionally profuse and handsome series of illustrations will aid materially in constituting it a most satisfactory work for the student, practitioner and specialist.

Nettleship on the Eye—Fifth Edition.

DISEASES OF THE EYE. By EDWARD NETTLESHIP, F. R. C. S., Ophthalmic Surgeon at St. Thomas' Hospital, London. Fourth American from the fifth English edition, thoroughly revised. In one 12mo. volume of 500 pages, with 164 illus., selections from Snellen's test-types and formulæ, and a colored plate for detecting color-blindness. Cloth \$2.00.

Four large American editions testify to the fact that it is a favorite text-book in American colleges as well as to the extent of its use among practitioners in general and special branches. Its popularity as a reference-book is due to the practical nature of its text and to the inclusion of text-types,

color-blindness tests and a collection of formulæ. It is safe to predict that with the extended scope noted in its title, this handy volume will become more than ever a favorite with all classes of readers.—*Pacific Medical Journal*, December, 1890.

Burnett on the Ear—Second Edition.

THE EAR; ITS ANATOMY, PHYSIOLOGY AND DISEASES. A Practical Treatise for the Use of Medical Students and Practitioners. By CHARLES H. BURNETT, A. M., M. D., Professor of Otology in the Philadelphia Polyclinic. Second edition. In one handsome octavo volume of 580 pages, with 107 illustrations. Cloth, \$4.00; leather, \$5.00.

Students' Quiz Series—EYE, EAR, THROAT AND NOSE, \$1.
SEE PAGE 1.

LEA BROTHERS & CO., 706, 708 & 710 Sansom Street, Philadelphia.

Surgery. * Ophthal. * Neurol.—(Cont.)

Holmes' Treatise on Surgery—Fifth Edition.

A TREATISE ON SURGERY; ITS PRINCIPLES AND Practice. By TIMOTHY HOLMES, M. A., Surgeon and Lecturer on Surgery at St. George's Hospital, London. From the fifth English edition, edited by T. PICKERING PICK, F. R. C. S. In one octavo volume of 997 pages, with 428 illustrations. Cloth, \$6.00; leather, \$7.00.

The work is one of the best text-books for students and practitioners who have not the time to wade through the exhaustive systems and encyclopædias of surgery.—*Atlanta Medical and Surgical Journal*, August, 1889.

This work, which has now arrived at its fifth edition, still maintains its position as a

standard text-book on the principles and practice of surgery. Mr. Pick has performed his part of the work with rare judgment and skill. The book contains many original illustrations which add much to its merits as a whole.—*The Medical Record*, Nov. 2, 1889.

Carter & Frost's Ophthalmic Surgery.

OPHTHALMIC SURGERY. By R. BRUDENELL CARTER, F. R. C. S., Lecturer on Ophthalmic Surgery at St. George's Hospital, London, and W. ADAMS FROST, F. R. C. S., Joint Lecturer on Ophthalmic Surgery at St. George's Hospital, London. In one 12mo. volume of 559 pages, with 91 engravings, color-blindness test, test-types and dots and appendix of formulæ. Cloth, \$2.25. See *Series of Clinical Manuals*, at end.

This work belongs to the series of clinical manuals for practitioners and students of medicine, which Messrs. Lea Brothers & Co. have in process of publication. The works comprising this series, as we have mentioned before, are made in size, arrangement, etc., exceedingly convenient for the use of stu-

dents in attendance upon lectures, and for reference by practitioners of medicine. We know of no work upon ophthalmic diseases so well adapted for reference by physicians and for use of students in attendance upon lectures.—*Cincinnati Med. News*, April, 1888.

Ross on Nervous Diseases.

A HANDBOOK ON DISEASES OF THE NERVOUS System. By JAMES ROSS, M. D., F. R. C. P., LL. D., Senior Assistant Physician to the Manchester Royal Infirmary. In one octavo volume of 725 pages, with 184 illustrations. Cloth, \$4.50; leather, \$5.50.

This admirable work is intended for students of medicine and for such medical men as have no time for lengthy treatises. Dr. Ross holds such a high scientific position that any writings which bear his name are naturally expected to have the impress of a

powerful intellect. In every part this handbook merits the highest praise, and will no doubt be found of the greatest value to the student as well as to the practitioner.—*Edinburgh Med. Journal*, Jan. 1887.

Hamilton on Nervous Diseases—Second Edition.

NERVOUS DISEASES; Their Description and Treatment. By ALLAN MCLANE HAMILTON, M. D., Attending Physician at the Hospital for Epileptics and Paralytics, Blackwell's Island, N. Y. Second edition, thoroughly revised and rewritten. In one octavo volume of 598 pages, with 72 illustrations. Cloth, \$4.00.

We do not well see how the student or practitioner can afford to be without this book. It is in the highest sense what the

author claims for it—"a manual for students and practitioners."—*Virginia Med. Monthly*, May, 1882.

LEA BROTHERS & CO., 706, 708 & 710 Sansom Street, Philadelphia.

Surg.—(Cont.) * Minor Surg. & Bandaging.

Roberts' Modern Surgery.

THE PRINCIPLES AND PRACTICE OF MODERN Surgery. For the Use of Students and Practitioners of Medicine and Surgery. By JOHN B. ROBERTS, M. D., Professor of Anatomy and Surgery in the Philadelphia Polyclinic. Professor of the Principles and Practice of Surgery in the Woman's Medical College of Pennsylvania. In one octavo volume of 780 pages, with 501 illustrations. Cloth, \$4.50; leather, \$5.50.

It has been the effort of the author to prepare a volume that will be in every respect a thoroughly good surgical text-book. Being a teacher of surgery both in college and hospital, he understands just what sort of a text-book a student needs from which, with the aid of lectures, to acquire a knowledge of surgery; and he has prepared his manual in accordance with this knowledge. While he has drawn upon his own experience, he has

consulted, as he states, the latest literature of all kinds bearing upon his specialty. Though there are many works upon surgery of great excellence that have been before the profession for some time, yet there are none of a more practical character than that of Dr. Roberts. It is filled with illustrations that will aid much in elucidating the text.—*The Cincinnati Medical News*, October, 1890.

Ashhurst's Surgery—Fifth Edition.

THE PRINCIPLES AND PRACTICE OF SURGERY. By JOHN ASHHURST, JR., M. D., Barton Professor of Surgery and Clinical Surgery in the University of Pennsylvania. Fifth edition, enlarged and thoroughly revised. In one large and handsome octavo volume of 1144 pages, with 642 illustrations. Cloth, \$6.00; leather, \$7.00.

A complete and most excellent work on surgery. It is only necessary to examine it to see at once its excellence and real merit either as text-book for the student or a guide for the general practitioner. It fully considers in detail every surgical injury and disease to which the body is liable, and every

advance in surgery worth noting is to be found in its proper place. It is unquestionably the best and most complete single volume on surgery in the English language, and cannot but receive that continued appreciation which its merits justly demand.—*Southern Practitioner*, February, 1890.

Wharton's Minor Surgery and Bandaging.

MINOR SURGERY AND BANDAGING. By HENRY R. WHARTON, M. D., Demonstrator of Surgery and Lecturer on Surgical Diseases of Children in the University of Pennsylvania. In one very handsome 12mo. volume of 498 pages, with 403 engravings, many being photographic. Cloth, \$3.00.

Dr. Wharton has written a book especially designed for students and younger practitioners, superior in many respects to others on this subject. The portions of it devoted to bandaging and fracture-dressing are particularly good. Full and accurate verbal descriptions of the mode of applying all the important bandages, and of the best modern methods of treating and dressing fractures and dislocations, are supplemented and rendered still more valuable by a number of excellent illustrations, most of them new. These have been photographed from life,

and they combine the advantages of clearness of outline and accuracy in portraying the various turns of the bandages they represent. Thus the methods of application of the various dressings are rendered more easy of apprehension than by verbal description. The part of the work devoted to a description of the different substances and materials used in antiseptic dressings and operations and the mode of their preparation seems also excellent.—*Medical News*, November 28, 1891.

Surgery—(Cont.) • Fractures & Dislocations

Treves' Operative Surgery.

A MANUAL OF OPERATIVE SURGERY. By FREDERICK TREVES, F. R. C. S., Surgeon and Lecturer on Anatomy at the London Hospital. In two 8vo. volumes containing 1550 pages, with 422 original engravings. Complete work, cloth, \$9.00; leather, \$11.00.

We have no hesitation in declaring it the best work on the subject in the English language, and indeed, in many respects, the best in any language. It cannot fail to be of the greatest use both to practical surgeons and to those general practitioners who, owing to their isolation or to other circumstances, are forced to do much of their own operative work.—*Annals of Surgery*, March, 1892.

It is by far the most exhaustive, comprehensive and thorough work on the subject presented to the profession. It is a model text-book, and should be in the hands of every surgeon and physician who is called upon to perform surgical operations. It is decidedly the most perfect work of the kind ever published.—*The Nashville Journal of Medicine and Surgery*, March 1, 1892.

Erichsen's Science and Art of Surgery—8th Edition.

THE SCIENCE AND ART OF SURGERY; Being a Treatise on Surgical Injuries, Diseases and Operations. By JOHN E. ERICHSEN, F. R. S., F. R. C. S., Professor of Surgery in University College, London, etc. From the eighth and enlarged English edition. In two large 8vo. volumes containing 2316 pages, with 984 engravings on wood. Cloth, \$9.00; leather, \$11.00.

For many years this classic work has been made by preference of teachers the principal text-book on surgery for medical students, while through translations into the leading continental languages it may be said to guide the surgical teachings of the civilized world. No excellence of the former edition has been dropped and no discovery, device or improvement which has marked the progress of surgery during the last decade

has been omitted. The illustrations are many and executed in the highest style of art.—*Louisville Medical News*, Feb. 14, 1885.

We have always regarded the "Science and Art of Surgery" as one of the best surgical text-books in the English language, and this eighth edition only confirms our previous opinion. We take pleasure in cordially commending it to our readers.—*Medical News*, April 11, 1885.

Hamilton on Fractures and Dislocations—8th Edition.

A PRACTICAL TREATISE ON FRACTURES AND DISLOCATIONS. By FRANK H. HAMILTON, M. D., LL. D., Surgeon to Bellevue Hospital, New York. New (eighth) edition, revised and edited by STEPHEN SMITH, A. M., M. D., Professor of Clinical Surgery in the University of the City of New York. In one very handsome 8vo. volume of 832 pages, with 507 illustrations. Cloth, \$5.50; leather, \$6.50.

It has received the highest endorsement that a work upon a department of surgery can possibly receive. It is used as a text-book in every medical college of this country. Its great merits appear most conspicuously in its clear, concise, and yet comprehensive statement of principles, which renders it an

admirable text-book for teacher and pupil, and in its wealth of clinical materials, which adapts it to the daily necessities of the practitioner. We consider that the work before us should be in the library of every practitioner.—*Cincinnati Medical News*, February, 1891.

Students' Quiz Series—Surgery, \$1.75. See p. 1.

LEA BROTHERS & CO., 706, 708 & 710 Sansom Street, Philadelphia.

Surgery • Fractures & Dislocations—(Cont.)

Stimson's Operative Surgery—Second Edition.

A MANUAL OF OPERATIVE SURGERY. By LEWIS A. STIMSON, B. A., M. D., Professor of Clinical Surgery in the Medical Faculty of the University of the City of New York. Second edition. In one royal 12mo. volume of 503 pages, with 342 illustrations. Cloth, \$2.50.

There is always room for a good book, so that while many works on operative surgery must be considered superfluous, that of Dr. Stimson has held its own. The author knows the difficult art of condensation. Thus the manual serves as a work of reference, and at the same time as a handy guide. It teaches what it professes, the steps of operations. In this edition Dr. Stimson has sought to indicate the changes that have been effected in operative methods and procedures by the antiseptic system, and has added an account of many new operations and variations in the steps of older operations. We do not desire to extol this manual above many excellent standard British publications of the same class, still we

believe that it contains much that is worthy of imitation.—*British Medical Journal*, January 22, 1887.

It is a pleasure to call attention to such an admirable book from the pen of an American surgeon. It is full of good common sense, and may be taken as a guide in the subject of which it treats. It would be hard to point out all the excellences of this book, and it is not easy to find defects in it. We can heartily recommend this book to students and practitioners of surgery, who will find in it an amount of attention given to the details of operative methods which cannot be expected, and which certainly cannot be found in the larger works on general surgery.—*Amer. Jour. of Med. Sci.*, Apr. 1886.

Stimson on Fractures and Dislocations.

A TREATISE ON FRACTURES AND DISLOCATIONS.

By LEWIS A. STIMSON, M. D. In two octavo volumes. Vol. I., FRACTURES, 582 pages, 360 illus. Vol. II., DISLOCATIONS, 540 pages, 163 illus. Complete work, cloth, \$5.50; leather, \$7.50. Either volume separately, cloth, \$3.00; leather, \$4.00.

The appearance of the second volume marks the completion of the author's original plan of preparing a work which should present in the fullest manner all that is known on the cognate subjects of Fractures and Dislocations. The volume on *Fractures* assumed at once the position of authority on the subject, and its companion on *Dislocations* will no doubt be similarly received. The closing volume of Dr. Stimson's

work exhibits the surgery of dislocations as it is taught and practised by the most eminent surgeons of the present time. Containing the results of such extended researches it must for a long time be regarded as an authority on all subjects pertaining to dislocations. Every practitioner of surgery will feel it incumbent on him to have it for constant reference.—*Cincinnati Medical News*, May, 1888.

Gant's Students' Surgery.

THE STUDENT'S SURGERY. A *Multum in Parvo*. By

FREDERICK JAMES GANT, F. R. C. S., Senior Surgeon to the Royal Free Hospital, London. In one square octavo volume of 848 pages, with 159 engravings. Cloth, \$3.75.

The author of this work for students has succeeded admirably in his endeavor to present to the beginner his material in such a way that he may "acquire a sound matter-of-fact knowledge of injuries and surgical diseases, in their various forms, and of their diagnosis and treatment—including surgical operations; the knowledge of which, as divested of all theory, may be said to con-

stitute positive surgery." The work is, of course, not as exhaustive as larger and more ambitious ones, but will prove a great boon to the student who may want to get the kernel without much husk. The author is concise and pointed in his style, and we heartily recommend the work to the student of surgery.—*The Canada Lancet*, April, 1890.

Surgery * General and Operative—(Cont.).

Smith's Operative Surgery—Second Edition.

THE PRINCIPLES AND PRACTICE OF OPERATIVE SURGERY. By STEPHEN SMITH, M. D., Professor of Clinical Surgery in the University of the City of New York. Second and thoroughly revised edition. In one very handsome volume of 892 pages, with 1005 illustrations. Cloth, \$4.00; leather, \$5.00.

Professor Smith's *Operative Surgery* may be termed a model text-book in every respect. Everyone unites in regarding it as decidedly the best work upon operative surgery extant.—*Nashville Journal of Medicine and Surgery*, April, 1887.

This excellent and very valuable book is one of the most satisfactory works on modern operative surgery yet published. The book is a compendium for the modern surgeon. The present edition is much enlarged, and the text has been thoroughly revised, so as to give the most improved methods in aseptic surgery, and the latest instruments

known for operative work. It can be truly said that as a handbook for the student, a companion for the surgeon, and even as a book of reference for the physician not especially engaged in the practice of surgery, this volume will long hold a most conspicuous place, and seldom will its readers, no matter how unusual the subject, consult its pages in vain. Its compact form, excellent print, numerous illustrations, and especially its decidedly practical character, all combine to commend it.—*Boston Medical and Surgical Journal*, May 10, 1888.

Bryant's Practice of Surgery—Fourth Edition.

THE PRACTICE OF SURGERY. By THOMAS BRYANT, F. R. C. S., Surgeon and Lecturer on Surgery at Guy's Hospital, London. Fourth American from the fourth and revised English edition. In one imperial octavo of 1040 pages, with 727 illus. Cloth, \$6.50; leather, \$7.50.

The fourth edition of this work is fully abreast of the times. The author handles his subjects with that degree of judgment and skill which is attained by years of patient toil and varied experience. The present edition is a thorough revision of those which preceded it, with much new matter added. His diction is so graceful and so logical, and his explanations are so lucid, as to place the work among the highest order of text-books

for the medical student. The work is eminently clear, logical and practical.—*Chicago Med. Jour. and Examiner*, April, 1886.

That it is the very best work upon surgery for the use of medical students we think there can be no doubt. The author seems to have understood just what a student needs and has prepared the work accordingly.—*Cincinnati Medical News*, January, 1885.

Druitt's Modern Surgery—Twelfth Edition.

MANUAL OF MODERN SURGERY. By ROBERT DRUITT, M.R.C.S. Twelfth edition, thoroughly revised by STANLEY BOYD, F.R.C.S. In one 8vo. vol. of 965 pages, with 373 illus. Cloth, \$4.00; leather, \$5.00.

Every part of the book shows signs of careful and judicious revision, and while the well-known characteristics of Druitt's book, which have been appreciated by many generations of students, are preserved, all the chapters have been brought well up to date. The most important alteration made in this edition is the incorporation of a good account of antiseptic surgery in all its branches. It is in every way a trustworthy text-book.—*The London Lancet*, June 4, 1887.

An admirable edition of an old favorite. Few books have enjoyed a wider or longer

sustained popularity, or have more fully come up to the ideal of a *vade mecum* than Druitt's *Surgery*. No less than 50,000 copies have been sold in England alone, while in this country the book has had extensive collegiate recommendation and Federal patronage. We have no hesitation in saying that the book is abreast of the times, and desirable for students, and especially for those practitioners who wish their book for surgical reference to be in the most condensed form.—*Medical News*, Nov. 5, 1887.

Surgery * Orthopædics.

Treves' Manual of Surgery. Three Volumes.

A MANUAL OF SURGERY. In Treatises by Various Authors. Edited by FREDERICK TREVES, F. R. C. S., Surgeon and Lecturer on Anatomy at the London Hospital. In three 12mo. volumes containing 1866 pages, with 213 engravings. Price per set, cloth, \$6.00. See *Students' Series of Manuals*, at end.

This book is a successful attempt to represent the principles and practice of modern surgery, in the form and manner most acceptable to the greatest number of practitioners and medical students. All the articles are of a high order of merit. The *Manual* is destined to become popular both as a textbook and as a book of reference, and to take rank with the standard works on surgery.—*Chicago Med. Jour. and Examiner*, Dec. 1886.

Mr. Treves' *Manual* is a worthy compeer of the excellent manuals and handbooks of

surgery which have been given to us by Erichsen, Holmes, and Bryant. The names of the authors of the several treatises are a guarantee for the quality of the work. Each author has set himself to write a good, plain, lucid article on the subject assigned to him, and all appear to have succeeded. What is professed is well done, and the result is a book which students may well learn from and practitioners may well refer to.—*The Practitioner*, June, 1886.

Treves' Handbook of Surgical Operations.

THE STUDENT'S HANDBOOK OF SURGICAL OPERATIONS. By the same Author. In one square 12mo. volume of 508 pages, with 94 illustrations. Cloth, \$2.50. *Just ready.*

The present work is intended for the use of students who are preparing for the final examinations, or who need a handbook to assist them in carrying out operations upon the dead body. It concerns itself only with the most essential and most commonly performed operations. The volume contains the very latest teachings, so far as they concern

the technique of operative work. The operations are characterized throughout by surgical judgment, anatomical accuracy, and practical familiarity with the subjects under consideration. The illustrations are good and the size is convenient.—*Medical News*, Oct. 1, 1892.

Gould's Surgical Diagnosis.

ELEMENTS OF SURGICAL DIAGNOSIS. By A. PEARCE GOULD, F. R. C. S., Assistant Surgeon to Middlesex Hospital. In one 12mo. volume of 589 pages. Cloth, \$2.00. See *Students' Series of Manuals*, at end.

The simple, unpretending volume is, like its author, accurate and scholarly. No important facts with reference to surgical diagnosis have been omitted. To characterize Mr. Gould's system in a few words, we should say that it was eminently analytical and practical. He believes in using common sense above all in making a diagnosis, and, moreover, in following a method. In our

opinion his book will prove an invaluable aid to students, and it will be an excellent idea for practitioners to acquire the habits of care and accuracy which it inculcates. But the best thing about Mr. Gould's book is that it is not a compilation; it is the outgrowth of experience, and is correspondingly valuable.—*New York M. d. Jour.*, May 30, 1885.

Young's Orthopædic Surgery. Preparing.

A MANUAL OF ORTHOPÆDIC SURGERY, FOR STUDENTS and Practitioners. By JAMES K. YOUNG, M. D., Instructor in Orthopædic Surgery, University of Pennsylvania, Philadelphia. In one 12mo. volume of about 400 pages, fully illustrated.

LEA BROTHERS & CO., 706, 708 & 710 Sansom Street, Philadelphia.

Skin * Genito-Urinary and Venereal.

Jackson on the Skin

THE READY-REFERENCE HANDBOOK OF DISEASES of the Skin. By GEORGE THOMAS JACKSON, M. D., Professor of Dermatology, Women's Medical College, New York Infirmary. In one 12mo. volume of 534 pages, with 50 illustrations and a colored plate. Cloth, \$2.75.

The author's large experience as a practitioner and teacher has been brought to bear in producing a work admirably adapted to convey a practical knowledge of dermatology. It would be difficult to conceive of a work more exactly suited to the needs of both students and practitioners. Richly illustrated, issued in convenient form, and at a price within the means of all, the volume is assured of wide usefulness. The alphabetical arrangement of the different diseases has been adopted, making it exceedingly convenient for ready reference. An appendix of quite a number of formulæ for baths, combinations of drugs for internal

and external use is of no little value.—*The Southern Practitioner*, January, 1893.

This is a plain, practical survey of skin diseases, intended to present dermatology as it now exists. Symptomatology, diagnosis and treatment occupy the first place. To the general practitioner and the student of dermatology it is especially useful. Well-tryed and valuable formulæ are given, and there is a good index. Clearness, common sense and simplicity are the qualities that chiefly commend this admirable handbook to the student.—*The New York Medical Journal*, November 19, 1892.

Hardaway's Manual of Skin Diseases.

MANUAL OF SKIN DISEASES. With Special Reference to Diagnosis and Treatment. For the Use of Students and General Practitioners. By W. A. HARDAWAY, M. D., Prof. of Skin Diseases in the Missouri Med. Col., St. Louis. In one 12mo. vol. of 440 pages. Cloth, \$3.00.

This *Manual* is conveniently arranged to serve students and practitioners as a practical guide in the study of skin diseases. The subjects are arranged alphabetically for quick reference. The descriptions of the diseases are well made, and their causes and

diagnoses clearly given, while the sections on treatment of each of the diseases are based mostly on practical experience of many years of the author as a distinguished specialist.—*Va. Med. Monthly*, Sept. 1892.

Culver & Hayden on Venereal Diseases.

A MANUAL OF VENEREAL DISEASES. By E. M. CULVER, M. D., Pathologist and Assistant Attending Surgeon, Manhattan Hospital, N. Y., and J. R. HAYDEN, M. D., Chief of Clinic Venereal Department, Vanderbilt Clinic, College of Physicians and Surgeons, N. Y. In one 12mo. volume of 289 pages, with 33 illustrations. Cloth, \$1.75.

In this little volume the authors have succeeded admirably in giving the student and practitioner an epitome of our knowledge of the venereal diseases. The book contains nothing foreign to the subjects to be treated, and abounds in hints and suggestions of practical value. The authors

have had a wide range of experience, and that they have cultivated their opportunities a perusal of their work will testify. The book is one of the best manuals of its kind for the busy physician and for the student.—*New York Medical Journal*, Jan. 23, 1892.

The Students' Quiz Series.

GENITO-URINARY AND VENEREAL DISEASES, \$1.; SKIN DISEASES, \$1.
SEE PAGE 1.

LEA BROTHERS & CO., 706, 708 & 710 Sansom Street, Philadelphia.

Venereal and Skin Diseases—(Continued)

Taylor on Venereal Diseases—New Ed. Preparing.

THE PATHOLOGY AND TREATMENT OF VENEREAL DISEASES. Including the results of recent investigations upon the subject. By R. W. TAYLOR, A. M., M. D., Clinical Professor of Genito-Urinary Diseases in the College of Physicians and Surgeons, New York, Professor of Venereal and Skin Diseases in the University of Vermont. Being the sixth edition of Bumstead and Taylor, entirely rewritten by Dr. Taylor. Large 8vo. volume about 900 pages, with about 150 engravings, as well as numerous chromo-lithographs. *In active preparation.*

A notice of the previous edition is appended.

The character of this standard work is so well known that it would be superfluous here to pass in review its general or special points of excellence. The verdict of the profession has been passed; it has been accepted as the most thorough and complete exposition of the pathology and treatment

of venereal diseases in the language; admirable as a model of clear description, an exponent of sound pathological doctrine, and a guide for rational and successful treatment, it is an ornament to the medical literature of this country.—*Journal of Cutaneous and Venereal Diseases.*

Hyde on the Skin—Second Edition.

A PRACTICAL TREATISE ON DISEASES OF THE SKIN. For the Use of Students and Practitioners. By JAMES NEVINS HYDE, A. M., M. D., Professor of Dermatology and Venereal Diseases in Rush Medical College, Chicago. Second edition. In one octavo volume of 676 pages, with 2 colored plates and 85 illus. Cloth, \$4.50; leather, \$5.50.

In this volume the author has supplied the student with a work of standard value. While thorough and comprehensive in the description of disease, it is especially helpful in the matter of treatment. In this regard it leaves nothing to the presumed knowledge of the reader, but enters thoroughly into the most minute descriptions, so that one is not only told what should be done under given conditions, but how to do it as well. Care has been taken also to render the nomenclature as clear and unconfusing as the present state of dermatology will admit. The book is one we can heartily recommend as a

valuable and creditable addition to American dermatological literature and a reliable guide for students and practitioners.—*The Amer. Practitioner and News*, Sept. 29, 1888.

We can heartily recommend it, not only as an admirable text-book for teacher and student, but in its clear and comprehensive rules for diagnosis, its sound and independent doctrines in pathology, and its minute and judicious directions for the treatment of disease, as a most satisfactory and complete practical guide for the physician.—*The Amer. Jour. of the Med. Sciences*, July, 1888.

Fox's Epitome of Skin Diseases—Third Edition.

AN EPITOME OF SKIN DISEASES. With Formulæ. For Students and Practitioners. By TILBURY FOX, M. D., Physician to the Dep. for Skin Diseases, Univ. College Hospital, London, and T. COLCOTT FOX, M. R. C. S., Physician for Diseases of the Skin to the Westminster Hosp., London. Third edition, 12mo., 238 pages. Cloth, \$1.25.

The little handbook will prove alike valuable to the student and practitioner of medicine, being as it is, an epitome, yet quite full and complete. The pharmacopœia embraces a series of very valuable formulæ to

which reference is made in preceding pages. The work is most excellently arranged and will, we are satisfied, be highly appreciated.—*The Southern Practitioner*, February, 1884.

Gynecology.

Thomas & Mundé on Diseases of Women—6th Ed.

A PRACTICAL TREATISE ON THE DISEASES OF Women. By T. GAILLARD THOMAS, M. D., LL. D., Emeritus Professor of Diseases of Women in the College of Physicians and Surgeons, New York, and PAUL F. MUNDÉ, M. D., Professor of Gynecology in the New York Polyclinic. New (sixth) edition, thoroughly revised and rewritten by DR. MUNDÉ. In one large and handsome octavo volume of 824 pages, with 347 illustrations, of which 201 are new. Cloth, \$5.00; leather, \$6.00.

The profession has sadly felt the want of a text-book on diseases of women, which should be comprehensive, and at the same time not diffuse, systematically arranged so as to be easily grasped by the student of limited experience, and which should embrace the wonderful advances which have been made within the last two decades. Thomas' work fulfilled these conditions, and the announcement that a new edition was about to be issued, revised by so competent

a writer as Dr. Mundé, was hailed with delight. The result is what is perhaps, on the whole, the best practical treatise on the subject in the English language. It is, as we have said, the best text-book we know, and will be of special value to the general practitioner as well as to the specialist. The illustrations are very satisfactory. Many of them are new, and are particularly clear and attractive.—*Boston Medical and Surgical Journal*, January 14, 1892.

Davenport's Non-Surgical Gynecology—2d Edition.

DISEASES OF WOMEN; A MANUAL OF NON-SURGICAL Gynecology. Designed especially for the Use of Students and General Practitioners. By F. H. DAVENPORT, M. D., Assistant in Gynecology in the Medical Dept. of Harvard University, Boston. New (second) edition. In one 12mo. volume of 314 pages, with 107 illus. Cloth, \$1.75.

It teaches the physician or the student how to do the little things, or to remedy the minor evils in connection with gynecology. To those in the profession who are about to interest themselves particularly in this branch of surgery, and to the student who

in the future intends to make gynecology his life-work, we believe that Davenport's book will be essential to his success, because it will teach him facts which larger works sometimes ignore.—*The Therapeutic Gazette*, October 15, 1892.

May's Manual of Diseases of Women—2d Edition.

A MANUAL OF THE DISEASES OF WOMEN. Being a Concise and Systematic Exposition of the Theory and Practice of Gynecology. By CHARLES H. MAY, M. D., Late House Surg. to Mt. Sinai Hosp., N. Y. Second edition, by L. S. RAU, M. D., Attend. Gynecologist at Harlem Hosp., N. Y. In one 12mo. of 360 pages, with 31 illus. Cloth, \$1.75.

This is a manual of gynecology in a very condensed form, and the fact that a second edition has been called for indicates that it has met with a favorable reception. It is intended, the author tells us, to aid the student who after having carefully perused larger works desires to review the subject, and he adds that it may be useful to the prac-

itioner who wishes to refresh his memory rapidly but has not the time to consult larger works. We are much struck with the readiness and convenience with which one can refer to any subject contained in this volume. Carefully compiled indexes and ample illustrations also enrich the work.—*The Physician and Surgeon*, June, 1890.

The Students' Quiz Series—Gynecology, \$1. See P. 1.

LEA BROTHERS & CO., 706, 708 & 710 Sansom Street, Philadelphia.

Gynecology—(Continued)

Emmet's Gynæcology—Third Edition.

THE PRINCIPLES AND PRACTICE OF GYNÆCOLOGY; For the Use of Students and Practitioners of Medicine. By THOMAS ADDIS EMMET, M. D., LL. D., Surgeon to the Woman's Hospital, New York, etc. Third edition, thoroughly revised. In one large and very handsome octavo volume of 880 pages, with 150 illustrations. Cloth, \$5.00; leather, \$6.00.

The originality and amplitude of resource which characterize the operative procedures of the author are faithfully mirrored in the goodly volume before us. Dr. Emmet simplifies the treatment of diseases of women materially. The original and practical contributions form a pedestal upon which his fame must securely rest. The work is an inexhaustible fountain of clinic' information, which no practitioner who has the interest of his clientele at heart can afford to miss

from his library. Its practical teachings render it indispensable to the general practitioner, while its novel views and operations commend it to the progressive gynecologist.—*Medical Record*, December 20, 1884.

Medical students and physicians will find no work that better elucidates the etiology, pathology and treatment of diseases of women. It is a treasury of valuable practical knowledge set forth in a clear, interesting style.—*Cincinnati Med. News*, Jan. 1885.

Edis on Women.

THE DISEASES OF WOMEN. Including their Pathology, Causation, Symptoms, Diagnosis and Treatment. A Manual for Students and Practitioners. By ARTHUR W. EDIS, M. D., London, F. R. C. P., M. R. C. S., Assistant Obstetric Physician to Middlesex Hospital, late Physician to British Lying-in Hospital. In one handsome octavo volume of 576 pages, with 148 illustrations. Cloth, \$3.00; leather, \$4.00.

The special qualities which are conspicuous are thoroughness in covering the whole ground, clearness of description and conciseness of statement. Another marked feature of the book is the attention paid to the details of many minor surgical operations and procedures, as, for instance, the use of tents, application of leeches, and use of hot-water injections. These are among

the more common methods of treatment, and yet very little is said about them in many of the text-books. The book is one to be warmly recommended especially to students and general practitioners, who need a concise but complete *résumé* of the whole subject. Specialists, too, will find many useful hints in its pages.—*Boston Medical and Surgical Journal*, March 2, 1882.

Sutton on the Ovaries and Fallopian Tubes.

SURGICAL DISEASES OF THE OVARIES AND FALLOPIAN TUBES, including Tubal Pregnancy. By J. BLAND SUTTON, F. R. C. S., Assistant Surgeon to the Middlesex Hospital, London. In one crown octavo volume of 544 pages, with 119 engravings and 5 colored plates. Cloth, \$3.00.

If ever the writer of book reviews is to be pardoned for indulging in extravagant praise of a new work, it is in the review of the *Surgical Diseases of the Ovaries and Fallopian Tubes*. The author is recognized the world over as an authority on gynecological surgery, and his many contributions to medical literature have at once taken rank with the highest class of medical works. The book before us, exhaustive

of the subjects treated, breathes a spirit of conservatism which can but be beneficial to operators who look to the knife as the only rational treatment for almost all abdominal diseases. The work is profusely illustrated and the engravings are all splendidly executed, some of them being works of art. We more than commend the book to our readers, even going so far as to urge them to obtain it.—*Medical Fortnightly*, April 15, 1892.

Obstetrics.

Parvin's Obstetrics—Second Edition.

THE SCIENCE AND ART OF OBSTETRICS. By THEOPHILUS PARVIN, M. D., LL. D., Professor of Obstetrics and the Diseases of Women and Children in Jefferson Medical College, Philadelphia. Second edition. In one handsome 8vo. volume of 701 pages, with 239 engravings and a colored plate. Cloth, \$4.25; leather, \$5.25.

We regard it as the most valuable textbook for the student of medicine yet published. The author has been a most successful teacher for a long period, and the discipline and training of the lecture-room are observed in the clearness with which the often obscure principles of the science and art of obstetrics are presented to the comprehen-

sion of the undergraduate. We think this feature is one of the strongest in the work, and commends it especially to teachers. The present edition is greatly improved, and embodies all the advances made in this important department of medicine up to the time of its publication.—*Buffalo Medical and Surgical Journal*, December, 1890.

Playfair's Midwifery—Seventh Edition.

A TREATISE ON THE SCIENCE AND PRACTICE OF Midwifery. By W. S. PLAYFAIR, M. D., F. R. C. P., Professor of Obstetric Medicine in King's College, London, etc. Fifth American, from the seventh English edition. Edited, with additions, by ROBERT P. HARRIS, M. D. In one handsome octavo volume of 664 pages, with 207 engravings and 5 plates. Cloth, \$4.00; leather, \$5.00.

Truly a wonderful book; an epitome of all obstetrical knowledge, full, clear and concise. In thirteen years it has reached seven editions. It is perhaps the most popular work of its kind ever presented to the profession. Beginning with the anatomy and physiology of the organs concerned, nothing is left unwritten that the practical accoucheur should know. It seems that every conceivable physiological or pathological condition from the moment of conception to

the time of complete involution has had the author's patient attention. The plates and illustrations, carefully studied, will teach the science of midwifery. The reader of this book will have before him the very latest and best of obstetric practice, and also of all the coincident troubles connected therewith.—*Southern Practitioner*, December, 1889.

This work holds an enviable place in all medical colleges as a standard text-book.—*The Cincinnati Lancet-Clinic*, Nov. 2, 1889.

King's Obstetrics—New (5th) Edition. Just Ready.

A MANUAL OF OBSTETRICS. By A. F. A. KING, M. D., Professor of Obstetrics and Diseases of Women in the Medical Department of the Columbian University, Washington, D. C., and in the University of Vermont, etc. New (fifth) edition. In one very handsome 12mo. volume of 450 pages, with 150 illustrations. Cloth, \$2.50.

We cannot imagine a better manual for the hard-worked student; while its clean and practical teachings make it invaluable to the busy practitioner. The illustrations add much to the subject matter.—*The National Medical Review*, Oct. 1892.

It seems to be just the handy reference book physicians want, and they will not do without it. We are also acquainted with

teachers of obstetrics who are particular to recommend this manual to their students, and such advice based upon personal experience, is certainly the best encomium that could be made. We can heartily recommend this work to all of our readers as well as to students who desire to acquire a practical knowledge of obstetrics.—*The St. Louis Medical and Surgical Journal*, December, 1892.

The Students' Quiz Series—Obstetrics, \$1. See P. 1.

LEA BROTHERS & CO., 706, 708 & 710 Sansom Street, Philadelphia.

Obstetrics * Gynecological Surgery.

Barnes' Obstetric Medicine and Surgery.

A SYSTEM OF OBSTETRIC MEDICINE AND SURGERY, Theoretical and Clinical. For the Student and the Practitioner. By ROBERT BARNES, M. D., Physician to the General Lying-in Hospital, London, and FANCOURT BARNES, M. D., Obstetric Physician to St. Thomas' Hospital, London. The Section on Embryology by Professor Milnes Marshall. In one 8vo. volume of 872 pp., with 231 illus. Cloth, \$5.00; leather, \$6.00.

The immediate purpose of the work is to furnish a handbook of obstetric medicine and surgery for the use of the student and practitioner. It is not an exaggeration to say of the book that it is the best treatise in the English language yet published. Every

practitioner who desires to have the best obstetrical opinions of the time in a readily accessible and condensed form, ought to own a copy of the book.—*Journal of the American Medical Association*, June 12, 1886.

Tait on Diseases of Women and Abdominal Surgery.

DISEASES OF WOMEN AND ABDOMINAL SURGERY.

By LAWSON TAIT, F. R. C. S., Professor of Gynecology in Queen's College, Birmingham; late President of the British Gynecological Society; Fellow American Gynecological Society. In two octavo volumes. Volume I., 554 pages, 62 engravings and 3 plates. Cloth, \$3.00. Volume II., *preparing*.

Mr. Tait never writes anything that does not command attention by reason of the originality of his ideas and the clear and forcible manner in which they are expressed. This is eminently true of the present work. Germs of truth are thickly scattered throughout; single, happily-worded sentences express what another author would have expanded into pages. Useful hints on the

technique of surgical operations, ingenious theories on pathology, daring innovations on long-established rules—these succeed one another with bewildering rapidity. His position has long been assured; it is hardly possible for him to add to his great reputation as a daring and original surgeon.—*American Journal of the Medical Sciences*, June, 1890.

Landis on Labor and the Lying-in Period.

THE MANAGEMENT OF LABOR, AND OF THE Lying-in Period. By HENRY G. LANDIS, A. M., M. D., Professor of Obstetrics and the Diseases of Women in Starling Medical College, Columbus, O. In one handsome 12mo. vol. of 334 pp., with 28 illus. Cloth, \$1.75.

It is terse in its style, complete in its information, and clear in its text. The advanced student will find it a desirable companion to his larger text-books on obstetrics; and the "busy practitioner," as well as he who is not

so busy, will find when it is in his library that it is a book that will frequently be taken from its place for consultation.—*The Physician and Surgeon*, May, 1886.

Herman's First Lines in Midwifery.

FIRST LINES IN MIDWIFERY: A GUIDE TO ATTENDANCE ON NATURAL LABOR FOR MEDICAL STUDENTS AND MIDWIVES. By G. ERNEST HERMAN, M. B., F. R. C. P., Obstetric Physician to the London Hospital. In one 12mo. volume of 198 pages with 80 illustrations. Cloth, \$1.25. *Just ready.* See *Student's Series of Manuals*, at end.

Children * Jurisp. * Series of Manuals.

Smith on Children—Seventh Edition.

A TREATISE ON THE DISEASES OF INFANCY AND Childhood. By J. LEWIS SMITH, M. D., Clinical Professor of Diseases of Children in Bellevue Hosp. Med. Col., N. Y. Seventh edition, thoroughly revised and rewritten. Octavo, 881 pages, 51 illus. Cloth, \$4.50; leather, \$5.50.

We have always considered Dr. Smith's book as one of the very best on the subject. It has always been practical—a field book, theoretical where theory has been deduced from practical experience. The very practical character of this book has always appealed to us. One seldom fails to find here a practical suggestion after search in other works has been in vain. In the seventh

edition we note a variety of changes in accordance with the progress of the times. It still stands foremost as *the American textbook*. Its advice is always conservative and thorough, and the evidence of research has long since placed its author in the front rank of medical teachers.—*American Journal of the Medical Sciences*, Dec. 1891.

Taylor's Medical Jurisprudence—NEW (12th) EDITION. JUST READY.

A MANUAL OF MEDICAL JURISPRUDENCE. By ALFRED S. TAYLOR, M. D., Lecturer on Medical Jurisprudence and Chemistry in Guy's Hospital, London. New American from the twelfth English edition. Thoroughly revised by CLARK BELL, Esq., of the New York Bar. In one octavo vol. of 787 pages, with 56 illus. Cloth, \$4.50; leather, \$5.50.

The merits of this work are well recognized, and its value as a standard text-book for medical instruction and as a trustworthy guide in medico-legal emergencies is fully appreciated. It is enough to assert with confidence that as a manual upon the subject of which it treats it is not excelled by any

other work on medical jurisprudence in the English language. If the medical practitioner is obliged to limit his literature upon legal medicine to a single volume, he will not make a mistake if he gives his preference to this eleventh American edition.—*Boston Medical and Surgical Journal*, Jan. 5, 1893.

Students' Series of Manuals.

A Series of Fifteen Manuals, for the Use of Students and Practitioners of Medicine and Surgery, written by eminent Teachers or Examiners, and issued in pocket-size 12mo. volumes of 800-540 pages, richly illustrated and at a low price. The following volumes are now ready: LUFF'S *Manual of Chemistry*, \$2.00; HERMAN'S *First Lines in Midwifery*, \$1.25; TREVES' *Manual of Surgery*, by various writers, in three volumes, per set, \$6.00; BELL'S *Comparative Anatomy and Physiology*, \$2.00; GOULD'S *Surgical Diagnosis*, \$2.00; ROBERTSON'S *Physiological Physics*, \$2.00; BRUCE'S *Materia Medica and Therapeutics* (4th edition), \$1.50; POWER'S *Human Physiology* (2d edition), \$1.50; CLARKE and LOCKWOOD'S *Dissectors' Manual*, \$1.50; RALFE'S *Clinical Chemistry*, \$1.50; TREVES' *Surgical Applied Anatomy*, \$2.00; PEPPER'S *Surgical Pathology*, \$2.00; and KLEIN'S *Elements of Histology* (4th edition), \$1.75. For detailed Catalogue, address the Publishers.

Series of Clinical Manuals.

A collection of authoritative monographs on important clinical subjects in a cheap and portable form. The volumes contain about 550 pages and are freely illustrated by chromolithographs and woodcuts. The following volumes are now ready: YEO on *Food in Health and Disease*, \$2.00; BROADBENT on the *Pulse*, \$1.75; CARTER & FROST'S *Ophthalmic Surgery*, \$2.25; HUTCHINSON on *Syphilis*, \$2.25; MARSH on the *Joints*, \$2.00; OWEN on *Surgical Diseases of Children*, \$2.00; MORRIS on *Surgical Diseases of the Kidneys*, \$2.25; PICK on *Fractures and Dislocations*, \$2.00; BUTLIN on the *Tongue*, \$3.50; TREVES on *Intestinal Obstruction*, \$2.00; and SAVAGE on *Insanity and Allied Neuroses*, \$2.00. For detailed Catalogue, address the Publishers.

The Students' Quiz Series—Diseases of Children, \$1. See P. 1.

LEA BROTHERS & CO., 706, 708 & 710 Sansom Street, Philadelphia. /

Medical Periodicals and Combinations.



THE student cannot begin too early in his course a habit of reading current medical literature. In this way he will best acquire an intelligent interest in the vital questions of his profession, secure a vast fund of information which will constantly supplement the knowledge gained from text-books, and become familiar with the approved methods of calling public attention to such additions as he may make to medical science during his professional life. For these purposes the following periodicals are most admirably adapted:

THE MEDICAL NEWS (Weekly, \$4.00 per Annum).

THE NEWS contains each week twenty-eight quarto pages, comprising original articles, clinical lectures and notes on practical advances, latest hospital methods, summaries of progress condensed from the best medical journals of the world, full abstracts of important articles, able editorials on current topics, book reviews, medical correspondence from important centres, and news items of interest. Published for fifty years, THE NEWS is familiar with the needs of medical men and the best methods of meeting them.

THE AMERICAN JOURNAL OF THE MEDICAL SCIENCES

(Monthly, \$4.00 per Annum).

THE AMERICAN JOURNAL is a medical magazine affording, in the 112 pages of each issue, ample space for elaborate original articles on important medical discoveries, discriminating reviews on valuable medical literature, and classified summaries of progress. According to the highest literary authority of the profession, "from this file alone, were all other publications of the press for the last fifty years destroyed, it would be possible to reproduce the great majority of the real contributions of the world to medical science during that period."


COMMUTATION RATE.


Taken together, THE JOURNAL and NEWS form a peculiarly useful combination, and afford their readers the assurance that nothing of value in the progress of medical matters shall escape attention. To lead every reader to prove this personally the commutation rate has been placed at the exceedingly low figure of \$7.50.

SPECIAL COMBINATION OFFERS.

The MEDICAL NEWS VISITING LIST (regular price, \$1.25), or The Year-Book of Treatment (regular price, \$1.50), will be furnished to advance-paying subscribers to either or both of these periodicals for 75 cents apiece; or Journal, News, Visiting List and Year-Book, \$8.50. Circulars free on application.

LEA BROTHERS & CO., 706, 708 & 710 Sansom Street, Philadelphia.





THE LIBRARY
UNIVERSITY OF CALIFORNIA, SAN FRANCISCO
(415) 476-2335

THIS BOOK IS DUE ON THE LAST DATE STAMPED BELOW

Books not returned on time are subject to fines according to the Library Lending Code. A renewal may be made on certain materials. For details consult Lending Code.

14 DAY

FEB - 5 1993

RETURNED

JAN 28 1993

00513160



3 1378 00513 1605

2005/10/16
1378 00513 1605

