

Marine Biological Laboratory



Received July 14, 1949

Accession No. _____

Given By The Blakiston Co.

Place, Philadelphia, Pa.

MBL/WHOI



0 0301 0018265 5

PRACTICAL ANATOMY
OF THE RABBIT

BENSLEY'S
PRACTICAL ANATOMY
OF THE RABBIT

*An Elementary
Laboratory Text-Book
in Mammalian Anatomy*

*Eighth Edition
Fully Revised and Edited by*

*E. HORNE CRAIGIE, Ph.D.,
Professor of Comparative Anatomy and Neurology
in the University of Toronto*

THE BLAKISTON COMPANY
PHILADELPHIA

1948

Copyright, Canada, 1931, 1937, 1944, 1948
by the University of Toronto Press
Printed in Canada



Preface to the Fifth Edition

IN the preparation of the present edition of the *Anatomy of the Rabbit*, comparatively little alteration has been made in the body of the text. Many minor corrections and emendations have, however, been recorded.

As explained in previous editions, the main purpose of the text is to set forth in some kind of practical sequence a plan for the orderly study of a typical mammal, supplemented by a brief exposition of the relation of this kind of study to the content and outlook of cognate biological sciences.

The methods adopted by anatomical instructors are subject to wide variation, based no doubt upon personal preference and perhaps to some extent upon habit and upon laboratory facilities available. This is as it should be, though not capable of being covered by any system of texts. After all, a student must go through the process of acquiring a rather complex assortment of detached pieces of information before a comprehensive view of the ensemble of mammalian organization may be obtained. There is thus plenty of room for selection in the order of study, provided the requirement is met of avoiding the destruction of unidentified parts. One of the older difficulties of anatomical teaching, perhaps unintentionally fostered by all text-books, namely thorough, and often unstimulating, preliminary study of the skeleton before dissection, is being overcome by judicious division of skeletal studies into an introductory survey followed at suitable intervals with special study during dissection. The method of using a region under dissection as a basis for topical teaching of related physiological and morphological associations has also much to recommend it.


Teaching responsibility is ever an interesting issue but nevertheless so often overlooked that it becomes an important question as to whether the opportunities and obligations of anatomical teaching are being met. For the non-professional student perhaps the chief consideration is the avoidance of half-assimilated, unverified information. For the student looking forward to profes-

sional courses, time as well as instructional sequence and useful selection is equally important. It would be unfortunate if the high reputation always enjoyed by the anatomical sciences, of moving safely forward point by point were not used to the extent possible to counterbalance the rather observable tendency towards pedagogical confusion.

The writer appreciates the response of various instructors to his desire for information as to necessary and advisable emendations of the text. He is under particular obligation to Dr. E. H. Craigie, University of Toronto, for a critical revision of the account of the central nervous system which should add materially to the value of this section from both structural and functional points of view.

B. A. BENSLEY

University of Toronto
October 1, 1931



Preface to the Eighth Edition

IN the preparation of the eighth edition of the *Practical Anatomy of the Rabbit* use has been made of extensive notes recorded in the laboratory during successive years of employment of the previous edition. All relevant questions raised by students or other instructors for which an adequate answer was found not to be readily available in the text have been noted and an attempt has been made to provide answers for them in the revisions. Criticisms received have been carefully considered and the whole text has been searchingly surveyed, with the result that many small changes have been made, parts (e.g. the description of the larynx) have been expanded, and a few have been entirely rewritten. New sections have been added, for example, one on the foetal circulation. A considerable number of new illustrations have been included, some replacing ones which were felt to be unsatisfactory, but the total number in the book being further increased from 114 to 124. Functional aspects as well as developmental ones have been consistently emphasized.

Since some classes study briefly the microscopic structure along with the gross anatomy, the early chapter on "General Anatomy" has been somewhat expanded. For suggestions regarding this and for provision of some of the photomicrographs the writer is indebted to the co-operation of Dr. V. E. Engelbert. For the new figure 58 he is indebted to the kindness of Dr. C. C. Macklin. To these and to other colleagues from whom helpful comments have been received he wishes to express his gratitude.

E. HORNE CRAIGIE

Toronto
January, 1948

Contents

	PAGE
INTRODUCTION	xi
PART I. A GENERAL CONSIDERATION OF THE STRUCTURE OF THE RABBIT	
DIVISIONS AND METHODS	1
THE INTERPRETATION OF STRUCTURE	2
ZOOLOGICAL POSITION	5
GENERAL ANATOMY	11
The Tissues	13
1. Epithelial tissues	13
2. Connective tissues	18
3. Muscular tissues	25
4. Nervous tissues	29
5. Blood and lymph	32
SPECIAL ANATOMY	34
Terminology	34
THE GENERAL FEATURES AND GROUND PLAN OF THE ORGAN-SYSTEMS.	38
Classification of the Organ-Systems	38
General Organization	41
Embryonic Plan of the Systems	43
The Skeletal System	44
The Muscular System	63
The Nervous System	71
The Digestive System	93
The Respiratory System	104
The Blood-Vascular System	109
The Lymphatic System	118
The Urinogenital System	122
The Endocrine System	131
The Serous Cavities	135
REGIONAL SECTIONS	138
PART II. OSTEOLOGY OF THE RABBIT	
DIVISIONS OF THE SKELETON	156
THE VERTEBRAL COLUMN	156
Cervical Region	158
Thoracic Region	161

Lumbar Region	161
Sacral Region	163
Caudal Region	164
THE RIBS	164
THE STERNUM	166
THE SKELETON OF THE HEAD	166
The Skull as a Whole	166
The Bones of the Skull	180
The Hyoid Apparatus	197
THE SKELETON OF THE ANTERIOR LIMB	198
THE SKELETON OF THE POSTERIOR LIMB	206

PART III. DISSECTION OF THE RABBIT

I. EXTERNAL FEATURES	218
II. THE ABDOMINAL WALL	220
III. THE STOMACH AND SPLEEN	224
IV. THE LIVER	231
V. THE INTESTINES	234
VI. THE URINOGENITAL SYSTEM	242
The Urinary Organs	242
The Male Genital Organs	245
The Female Genital Organs	250
VII. THE ABDOMINAL AORTA, INFERIOR CAVAL VEIN, AND SYMPATHETIC TRUNKS	253
VIII. THE ANTERIOR LIMB	257
Blood-Vessels and Nerves of the Axillary Fossa	261
Blood-Vessels and Nerves of the Arm and Forearm	269
IX. THE POSTERIOR LIMB	272
Blood-Vessels and Nerves of the Thigh	279
Vessels and Nerves of the Leg and Foot	286
The Lumbosacral Plexus	288
The Articulations of the Posterior Limb	289
X. THE HEAD AND NECK	292
XI. THE THORAX	323
XII. THE VERTEBRAL AND OCCIPITAL MUSCULATURE	338
XIII. THE CENTRAL NERVOUS SYSTEM	344

APPENDIX

THE PRESERVATION OF MATERIAL	367
INDEX	375



Introduction

AS a laboratory exercise, the anatomical study of an animal is chiefly a matter of applying a certain practical method of exposition, the student's attention being concentrated on those facts which can be made out by direct observation. This method is educative in the technical sense because it involves accurate discernment of detail, and because, as a means of obtaining first-hand information, it is the foundation of laboratory practice. Within the range of natural science, which limits fact to what is reasonably demonstrable, laboratory practice takes its place as one of the principal methods by which first-hand knowledge of anything concrete is gained and it is important for the student as early as possible to form the habit of acquiring his knowledge in this way and of confirming thus information obtained otherwise.

In studying the structure of any organism, however, it is to be considered that the final object is not simply to determine in what its structure consists, i.e. its anatomy in a restricted sense, but also to understand what structure signifies, either as functional mechanism, or as the product of racial or evolutionary factors. While it is conceivable that a single organism, either as individual or as species, may be considered by itself, this provides only a much restricted point of view and a very superficial study suffices to show that the structure and function of no living creature can be adequately interpreted apart from the general arrangements of organized nature and, more especially, from the corresponding features of similar or nearly related organisms.

This being the case, it is a very pertinent question what is the best procedure. So far as the present book is concerned, it is expected that the study of the type will begin with at least a preliminary survey of the prepared skeleton (Part II). This will be followed by dissection (Part III), in which the order by sections will be found to be of less importance than that of details in any particular region and in which portions of the skeleton related to the part under examination may be included.

The regional method of approach is indicated rather than the more complete study of single systems, partly for the sake of

economy of material and partly in the belief that this aids understanding of the topographical and other interrelations between the systems, encouraging the building up of a conception of the individual organism as an integrated unit.

The general matter of Part I is purely accessory and, though necessarily incomplete in many ways, is designed to afford a comprehensive view of the various factors upon which mammalian structure depends. It will be found that only the first few chapters are introductory in most respects, the remainder being rather explanatory and hence most valuable if used to supplement the directions for dissection as this is carried out.

Regional sections of the foetus as figured in Part I, or frozen sections of the adult animal, are a useful adjunct, since they can be used either for points of general organization, or, being substantially correct for two dimensions, for the removal of erroneous impressions of the position of organs incidental to their displacement in dissection.



PART I

A General Consideration of the Structure of the Rabbit

DIVISIONS AND METHODS

BIOLOGY, the science or study of living organisms, includes several related sciences, fundamental among which are: **Anatomy**, the study of organized structure; **Physiology**, the study of function; and **Embryology**, the study of development. Anatomy is an essential foundation for the other branches. Comparative Anatomy, the comparative study of different organisms, and Embryology are also considered either as divisions, or as practical methods, of **Morphology**, the general science of the evolution of form.

The term "Anatomy," originally applied to the study of the structure of the human body, and still used as referring more especially to this, has come to be applied to the study of structure of living organisms generally.

It has been found convenient, especially in human anatomy, to distinguish as **Gross Anatomy**, the study of that kind of structure which is displayed by dissection, or is revealed by naked-eye appearances, and as **Microscopic Anatomy**, the study of finer structure through the application of the microscope; or, again, to distinguish as **Special** or **Descriptive Anatomy**, the study of the particular features of the organs of the body, and as **General Anatomy**, the study of its more fundamental composition. General Anatomy is practically equivalent to **Histology**, the latter considering the body from the point of view of the structure and arrangement of its cells and tissues.

These distinctions are of interest in the present case chiefly as defining more exactly the practical method and the kind of structure to be considered. Thus, **dissection** is a method of displaying structure of a gross and special kind. It consists in the orderly exposure and displacement of organs with the object of observing their features and their relations to surrounding parts. The plan is essentially one of analysis, since conceptions of structure are

based on the recognition of differences, the latter being estimated by various features, such as form, colour, texture, or position. On the other hand, because of the class of structure with which it deals, dissection should also be recognized as a method preliminary to others involving the use of the microscope. Further, the analysis should be followed at each step by a synthesis in the mind of the student, who must keep before him the unity of the individual organism as a whole.

THE INTERPRETATION OF STRUCTURE

Gross structure is, in a sense, only an expression of the finer microscopic structure underlying it. Since this relation is more fully discussed below under the head of "General Anatomy," it need only be mentioned here as an element in the interpretation of structure as viewed from the gross standpoint. All animal structure, however, may be considered from two points of view—physiological and morphological.

The **physiological** aspect of structure concerns the functions or activities of the living organism and of its individual parts. The contraction of a skeletal muscle is a change in the axial relations of a mass of living protoplasm, but the form and connections of the muscle are such that the contraction results in movement of one bone upon another. The excretion of urine by the kidneys is the final stage of a process which rids the body of soluble waste nitrogenous materials by discharging them into a system of tubes connected with the outside of the body. It is essential to recognize that in these, as in the multitude of analogous cases, structure and function are intimately related and serve to explain each other.

The **morphological** aspect of structure concerns various features of form and arrangement which, although they have been developed on a basis of utility, cannot be explained purely on that basis. The factors controlling them lie outside the body of the individual and comprise environmental influences and inherent characteristics of the whole race, the interaction of which only through a long series of gradually changing conditions has directed and determined the evolution of the type to which the individual belongs. As applied to a particular animal, the morphological method consists in explaining its adult structure by reference either to its embryonic

development or to the equivalent conditions in lower forms, existing or fossil. A recognized principle of embryology is that known as the **Law of Recapitulation**. It is based on the general observation that the definitive structure of an organism is attained through a series of embryonic stages, in which it not only develops from a simple or ground type to a more complex condition but also reflects in passing the features of lower forms which presumably represent its ancestors. These features are mingled with, however, and sometimes obscured by newer, purely embryonic characteristics which are not ancestral. Moreover, the adult condition of an advanced animal is sometimes reached by the retention of a characteristic which was only embryonic in its predecessors. The application of comparative anatomy depends on the comparison of higher, specialized animals with lower, or generalized ones, the latter being assumed, in one feature or another, to have remained in a backward or primitive state of specialization, and therefore to reflect in such features a grade of structure comparable with that possessed by the ancestors of existing higher forms. These relations form a basis for the comparison of the embryonic development of organisms with the evolution or history of the groups which they represent, the former being distinguished as **ontogeny**, the latter as **phylogeny**. The interpretation of the adult structure of an organism involves the distinction of its more general features from the more special ones and the application to them of ontogenetic and phylogenetic principles.

The present form common to the individuals of one kind of animal may be explained only by reference to ancestry. Apart from influences of accident, the sum of characters of the individual is the result of development, under more or less fixed environmental conditions, of the primordial cell which constitutes the fertilized egg. So long as the environment remains comparable with those normal for the species, such features as are impressed upon the animal during growth or maturity are negligible in this connection, the developmental possibilities of the fertilized egg having been transmitted to it through the succession of generations. Through this succession the continuity of life, as the fossil remains of organisms of the past reveal, has carried onward the structure of the body for countless millions of years.

With succession has come also modification, as is shown by the appearance on the earth at different geological times of progressively more specialized animals, which reveal in a large way the same kinds of differences observable among primitive and specialized animals living at the present day. That the entire skeleton of a mammal is patterned upon the primitive skeleton of the fossil amphibia of the Carboniferous and Permian is evident from a comparison of the components part for part, but it is equally evident from comparative anatomy that the viviparous condition of a higher mammal is founded upon an oviparous condition in lower forms even if no fossil evidence is forthcoming. That a mammal as an air-breathing vertebrate should develop gill pouches in the embryonic condition, though these are never used for functional gills, is in itself an important fact bearing on adult structure, but such a condition also illustrates how extensively a living animal carries ancestral features, whether functionally modified or not.

All characters of animals have thus an evolutionary basis, the general nature of which is easily understood although the process by which they have been developed is still a matter of uncertainty. In comparison with one another, animals present certain resemblances and differences—diagnostic features, which are used as a basis for classifying them into major and minor groups. In many cases characters of resemblance have been shown to be secondary, and are hence described as **convergent**. In some of these the resemblances are of a gross type, and the structures are described as **analogous**; in other cases they are exact or **homoplastic**. As a rule, however, characters of resemblance are broad marks of **affinity**, comparable to those seen on a small scale in human families, or in human races, and determined as in the latter cases by **heredity**. The chief basis of comparison of animals with one another is the general assumption that structures which are similar or identical are **homogenous**—of common origin—or **homologous**. On the other hand, their differences, particularly the differences in homologous parts, are chiefly marks of **divergence** in evolution. It is conceivable that many of the internal features of animals are the result of a general progressive development brought about by some inherent force in the constitution of the successive generations of organisms themselves, more conspicuous in comparison of a

series from primitive to specialized types. However, the majority of their differences are such as have resulted from adaptive modifications of structure, by which they have become differently adjusted to the particular conditions of their accepted habitats. **Adaptation** to environment is one great result of the modification of animal form, and is revealed in part by structural divergences, as between one type and its contemporaries; although such features may afterwards become settled in particular groups, and thus appear for these as **primitive, general, or group characters**. Adaptation, in other words, is not a matter of present conditions only. The rabbit as a gnawing mammal, a lagomorph, for example, is also an air-breathing, walking vertebrate, and shares these relatively large and ancient features with many other vertebrates of different kinds.

It is customary to include under the term **specialization** all those features in which an organism may be shown to be more highly modified in comparison with another type. If the latter is an ancestral type, or a lower form exhibiting ancestral features, its more primitive features are said to be **prototypal**, because they indicate the form from which the higher modification has been derived. Such comparisons not only reveal the fact that different animals are specialized in different degrees, but also show that a given form may be greatly specialized in some respects and primitive in others.

Moreover, it is to be considered that animals are at the present time, as they have been in the past, more or less changeable, or **plastic** types. Some of the most interesting features which they exhibit depend on the circumstance that the adjustment of structure which is rendered necessary by the opposing effects of heredity and specialization is gradual rather than exact or immediate. Thus, it is not difficult to find in any specialized animal, in addition to those organs which are **functional** or in full development, others which are **retrogressive** in character and reduced in size. It is also to be assumed, although difficult of proof among living forms, that there are also organs which are **sub-functional** or **progressive**.

ZOOLOGICAL POSITION

It will be evident from the foregoing statement that every specialized animal possesses in its organization a vast assemblage

of features which, if referred to their proper categories, are found to represent many grades of morphological value. In so far as the adult structure of a particular form is concerned, it is possible to consider them anatomically without discrimination; but, on the other hand, if they are to be explained, it is necessary to proceed on a basis of function, embryonic development, or evolution or, ultimately, of all three. The study of an animal as a **type** or representative of a group, however, concerns only in part the features common to the various members of the latter, since the majority of features present in any animal are of minor importance, and as such are significant chiefly as indicating the developments which may take place inside the group. What an animal actually represents is determined by comparison with other forms and is called its **zoological position**. This is expressed through the medium of **classification**, the latter being arranged to indicate, so far as is possible, the relationships of organisms one to another. In this connection the following statement of the zoological position of the rabbit may be found useful; and it may also be considered as illustrating, through the comparison of this animal with allied forms, some of the more general characters of animals as outlined above.

The domestic rabbit is represented by several races, of which the common variously-coloured forms, long-haired Angoras, Lop-ear Rabbits, and Belgian "Hares" are more familiar. They are all descendants of the wild rabbit (*Oryctolagus cuniculus*, *Lepus cuniculus*) of Europe. The latter is thought to have belonged originally to the countries bordering the western portion of the Mediterranean, but its distribution has been greatly extended northward and to other continents through human agency.

The European common rabbit (*Oryctolagus cuniculus*) belongs to the family **Leporidae**, which contains a large number of closely related species formerly included under the single genus *Lepus*, but now distributed among nine genera with living representatives and a larger number of extinct ones. In addition to *Oryctolagus cuniculus* and its derivatives, the more familiar species are the European Common Hare (*Lepus europaeus*) and in North America, the Cotton-tail Rabbit (*Sylvilagus floridanus*), the Northern or Varying Hare (*Lepus americanus*), and the Prairie Hare or White-

tailed Jack Rabbit (*Lepus campestris*). In recent decades, European hares have been several times introduced and liberated in North America, and are now established in certain parts of the Eastern United States and in Ontario, Canada. The two common European species differ in several well-marked features which form the basis of the recognized distinctions between "hares" and "rabbits." The rabbit is distinguished by its shorter ears and less elongated hind limbs; also by its burrowing habits, and by the circumstance that the young for a time after birth are blind and naked. The hair is more nearly a running or coursing type, and is distinguished by longer ears, which are, moreover, tipped with black, longer hind limbs, and prominent eyes. It inhabits an open "form" and the young directly after birth are clothed with hair and able to see. Upwards of one hundred species of *Leporidae* have been described in North America. They are variously known as hares or rabbits. It is generally considered that the American forms, aside from two aberrant genera, are hares, but in form and habits the Varying and Prairie Hares of the genus *Lepus* conform more closely to the type of the European Hare, while the Cotton-tails, members of the genus *Sylvilagus*, make at least some approximation to the European Rabbit.

The various species constituting this family are distinguished from the Picas or Tailless Hares (*Ochotonidae*) of the mountainous districts of Central Asia and of North America (Rocky Mountains), by several features, including the imperfect development of the clavicle, longer ears and limbs, and the presence of a distinct although greatly reduced tail. The two families are allied, however, in the possession of a common feature, namely, the presence in the upper jaw of a second pair of incisor teeth. This feature distinguishes what was formerly described as the suborder Duplicidentata from the suborder Simplicidentata, the latter containing the majority of rodents and embracing all forms with a single pair of upper incisors.

Authorities now tend to designate the Duplicidentata, to which the family Leporidae belongs, as the mammalian order **Lagomorpha** and to restrict the order Rodentia, which was formerly considered to include both the above suborders, to the larger assemblage of mammals with only one pair of upper incisors, such as squirrels,

marmots, cavies, beavers, mice, porcupines. Fossils of both lagomorphs and true rodents have been found in Palaeocene rocks and are reported not to be more similar than are modern representatives of the two orders. Their greater resemblance to each other than to other orders is recognized by a questionable association in a group designated "cohort *Glires*." In both these orders, the anterior incisors in both upper and lower jaws are modified to form chisel-like cutting organs, having their enamel layer disposed chiefly if not wholly on their front surfaces, so that they remain in a permanently sharp condition. This modification is associated with an extensive loss of intermediate teeth, involving posterior incisors, canines, and anterior premolars. There is also elaboration, often very considerable, of the remaining premolar and molar teeth, of the lower jaw, and, indeed, of the parts of the skull generally. Characteristic of these animals is the extension, both forward and backward, of the jaw-musculature. The articulation of the lower jaw has an antero-posteriorly elongated articular process fitting into a corresponding longitudinal fossa on the skull, the jaw being able to move forward and backward in addition to vertically and less from side to side. Further, the teeth are curved and the anterior or incisor teeth are provided with open roots, so that their growth is not limited, as it is in the majority of mammals. The cheek teeth of the rat and other rodents living on mixed diets have closed roots, but those of which the food is more difficult to masticate, including the Lagomorpha, have open roots as have the incisors. In these respects and in the elaboration of the intestine, especially the caecum, the rodents exhibit the characters of highly specialized herbivores, but in many particulars they are primitive types. For example, they tend to retain the five-toed (pentadactyl), plantigrade foot, characteristic of primitive mammalia and, indeed, of terrestrial vertebrates, and exhibit also unelaborated cerebral hemispheres in the brain.

Like all higher or **placental mammalia** (Infraclass Eutheria), the rabbit is viviparous, that is, the young are born in a more or less advanced stage of development, after being retained through a period of gestation in the maternal uterus, to the wall of which they are attached by a vascular connection, the placenta. In this feature the placental mammalia differ from the **marsupial mam-**

malia (Order Marsupialia of the Infraclass Metatheria) of Australia and South America, the latter being viviparous but, with one exception, lacking a placenta. The members of both these groups (which are associated in the subclass Theria) differ from those of the order **Monotremata** (subclass Prototheria) of Australia, which are not viviparous but oviparous, or egg-laying, like the majority of reptiles and other lower animals. These three divisions of mammals, however, are united by the common features of the class **Mammalia**. For example, they all are warm-blooded, are provided with a complete double circulation and a hairy investment for the surface of the body, and nourish the young for a time after birth by the secretion of cutaneous glands modified to produce milk, the mammary glands.

Many of the more general features of the rabbit are not characteristic of any one group but are shared with other terrestrial vertebrates, including mammals, reptiles, birds, and, in part, amphibians. Such features are the development of the lungs and associated respiratory tracts, both the true respiratory tracts and the accessory respiratory passages traversing the skull. Further, the loss of the branchial- or fish-type of respiration and the new disposition of the branchial structures; the development of a tri-segmented type of limb with a full complement of muscles, and originally a pentadactyl, plantigrade foot, for support of the body and for locomotion; the regional differentiation of the vertebral column, especially the mobility of the neck, the free occipital articulation, and the definition of the sacrum, the latter associated with the elaboration of the pelvic girdle, are all features of general significance in the terrestrial vertebrates.

The rabbit is like all **Vertebrata** or **Craniata** in the possession of an axial skeleton formed by the segmented vertebral column and of an organized head region with differentiated brain, special sense organs, and enclosing primary skull. Also, the vertebrates exhibit a basic transverse segmentation (metamerism) of a considerable part of the body.

Finally, the rabbit agrees with other members of the phylum **Chordata** in the ground plan underlying the most general features of its organs and the position, arrangement, and plan of development of its organ-systems. Particularly it possesses a dorsal,

tubular central nervous system; a notochord, a fundamental axial support which is only embryonic except in the lowest chordates; and a series of gill clefts, such as occurs in every chordate either in the adult condition, or in the embryo alone.

These facts may be set down in tabular form, as indicated below. A similar plan can be constructed for any group of organisms, but whether it constitutes a natural or an artificial classification depends on whether or not it is based upon an actual study of the affinities of the organisms concerned. A *natural classification* should show at a glance not only what the relative importance of any particular character may be, but also how it stands in the scale of specialization. For example, the placental stage of vertebrate development, i.e., the development of the placenta itself in the highest stage of vertebrate evolution, is the culmination of a series of arrangements for the care of eggs and young, and the adherence of human structure in the vast majority of features to the type of higher mammals is expressed by the fact that man is also a placental mammal.

Phylum **CHORDATA**. Animals with notochord and gills.

†PROTOZOA, ANNULATA, MOLLUSCA, *etc.*, invertebrate phyla.

Subphylum **CRANIATA**. (VERTEBRATA) Chordates with organized head region.

†ACRANIA. Lancelets. Also Ascidians and worm-like Chordates, sometimes separately classified.

Class **MAMMALIA**. Warm-blooded craniates, with hair coat.

Young nourished from mammary glands.

†CYCLOSTOMATA, PISCES, AMPHIBIA, REPTILIA, AVES, lower vertebrate classes.

Subclass **THERIA**. Viviparous mammals.

†PROTOTHERIA. Oviparous mammals.

Infraclass **EUTHERIA**. Placental mammals.

†METATHERIA. Viviparous mammals without placenta.

Order **LAGOMORPHA**. Gnawing placentals, with chisel-like incisors, of which there is in the upper jaw a small second pair directly behind the main pair.

†RODENTIA, CARNIVORA, PERISSODACTYLA, PRIMATES, *etc.* Various placental orders otherwise adapted.

Family **LEPORIDÆ**. Hares and Rabbits.

†OCHOTONIDÆ. Picas.

†*Equivalent groups.*

GENERAL ANATOMY

Although in every respect a continuous structure and forming a single organism, the body is differentiated into a large number of parts, or **organs**, which are more or less individual in form, composition, or function. Organs are arranged for the most part in **systems**, each of which is concerned with some general or fundamental function, to which several organs may contribute.

In a more general way the body may be considered as an assemblage of **tissues**, since these are the materials of which the organs are composed. Tissues may be defined as layers or aggregations of similarly differentiated cells. They are of several different kinds and are variously associated in the formation of organs. Being structures of intermediate rank, they may be considered either as organ components or as combinations of specialized cells.

As a body-unit a **cell** consists of a small mass of living **protoplasm**, containing a central body, the **nucleus** imbedded in a mass of **cytoplasm**. The latter is surrounded or enclosed on its free border by a **cell-membrane**. The nucleus is a highly organized body, having an important function in the reproduction of the cell and also in its general activity or metabolism. It contains a characteristic formed material, **chromatin**, and frequently also a minute spherical body, the **nucleolus**. The chief features of a typical cell are illustrated in the accompanying figure (1) of the developing ovum, the latter being a single cell, noteworthy for its large size, and also one in which the external form is not greatly modified, as it is in the majority of the cells of the body. Its enclosing membrane, the **zona pellucida**, by which in its natural position in the ovary it is separated from the surrounding follicular cells, is considered to belong in part to the latter.

As fundamental living matter, protoplasm possesses certain properties on which the functions of the body ultimately depend. Considered collectively, these functions are not so well illustrated in the higher or **multicellular** organisms, in which particular functions are assigned to particular cells, as in the lower **unicellular** organisms, in which all functions are discharged by a single cell. In simple or protozoan animals the protoplasm is seen to be capable

of ingesting food-materials, of discharging waste, of changing its form, and of reacting in one way or another to stimuli arising outside of the body. Moreover, the protozoan cell is capable of giving rise to new cells by division of its substance into two parts, which process originates in the nucleus, and is usually associated at some stage with union or **conjugation** of two parent cells.

All the cells of the body of a multicellular organism are products of a single cell, the **fertilized egg**, but the latter is a product of




FIG. 1. Photomicrograph of a developing ovum within the ovary of a rabbit, from a section. $\times 150$. ch, chromatin; cy, cytoplasm; fe, follicular epithelium; nm, nuclear membrane; tf, theca folliculi; zp, zona pellucida.

fusion of two primary elements, the **spermatozoon** of the male parent and the **ovum** of the female. The fertilized egg does not exhibit the functions of a one-celled body, but possesses the potential of these functions, and the latter appear, to a large extent individually, in the differentiation of its division-products into specialized tissue elements.

In this way, the processes which go on within the body of a multicellular animal and the structure underlying these processes are all based upon the same elementary functions of life as those appearing in one-celled organisms. But the repeated division of

the fertilized egg, in development toward the adult condition, gives rise by **division of labour** to a great variety of cells, each kind of which may be regarded as representing a minor aspect of some major function.

THE TISSUES

The primary tissues of the body are of four kinds—**epithelial**, **connective**, **muscular**, and **nervous**. To these—the **fixed** tissues—are to be added the fluid substances, **blood** and **lymph**, in which the cell elements, the red and white corpuscles, or in the latter case the white elements alone, are suspended in a fluid medium. The differences between these depend partly upon the characters of the cells composing them and partly upon the nature and quantity of the material between the latter, the intercellular matrix.

The following survey of the principal features of the tissues will serve to make clear the extent to which the gross appearance of organs depends upon tissue composition, though the account is in no way intended as a guide to the microscopic structure of the rabbit which is more properly part of the subject-matter of histology.

1. Epithelial Tissues

Epithelial tissues are distinguished chiefly as surface investments, such as those of the exterior of the body, and those of the interior of the alimentary canal, the lungs, the respiratory and accessory respiratory tracts, and the ducts of the urinogenital organs. In all epithelia the cellular feature is a prominent one, the amount of intercellular material being relatively small. With a few exceptions, they are not penetrated by blood-vessels. As constituents of lining membranes, they are not conspicuous in gross structure but they give rise to important derivatives, such as the hairs and the various kinds of secreting organs or **glands**.

Epithelium may be simple, i.e. one-layered, or it may be stratified, i.e. composed of several layers of cells. The cells composing it may be flattened or **squamous**, **cuboidal** or isoprismatic, or **columnar** and are packed together so closely that in free surface view each is seen to be pressed into a more or less hexagonal form. (See, for example, the epithelium lining the collecting tubule of the kidney in Fig. 73, p. 126.) The epithelium of the skin (Fig. 2),

which is known as the epidermis, or scarf-skin, is stratified, the deepest cells being columnar, formative, growing units which produce daughter cells that are gradually pushed outward and increasingly flattened so that those at the surface are squamous and are successively discarded. The several layers combined produce but a thin membrane. It extends over the entire surface of the body and connects at certain points with the epithelia of the internal surfaces. It is supported by a thick resistant layer of connective tissue which forms the true skin or **corium**. Between the epithelium and the underlying connective tissue there is usually a distinct basement membrane, derived from the inter-cellular substance of the connective tissue.

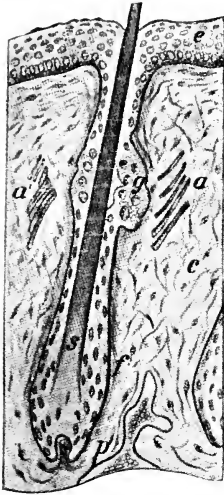


FIG. 2. From a section of the upper lip of a four-day-old rabbit: a,a', erector muscles of the hair; c, connective tissue of corium; e, epidermis; f, hair follicle; g, sebaceous gland; p, papilla; s, hair shaft.

In the greater portion of the alimentary tract the lining epithelial layer is **simple** or one-layered and is associated with a thin layer of smooth muscle to form a **mucous tunic** (Fig. 15, t.ms.). The cells are columnar and have on their free surfaces a zone of modified protoplasm, the striated border, which is important in absorption.

The free surfaces of the epithelial cells sometimes have delicate, hair-like outgrowths, which may be non-motile (brush border, as in the proximal convoluted tubules of the kidneys) or motile (cilia, as in the uterine tubes, respiratory passages, etc.).

Among secondary products of epithelial origin is the coating of hairs on the surface of the body, the presence of which is a strictly characteristic mammalian feature. It is a protective investment arising from the epidermis. Each **hair** is produced by the modification of the central portion of an ingrowth of the epidermis, termed the **hair follicle** (Fig. 2, f). The latter contains at its base a small elevation of the underlying vascular connective tissue, the **hair papilla**, through which the structure is nourished. On the general surface of the body of the rabbit the hair follicles are arranged in

groups, and on the lips certain large follicles are set apart for the production of the greatly enlarged sensory hairs or **vibrissae**. Connected with the hair follicles are thin strands of smooth muscle, the **arrectores pilorum** (Fig. 2, a, a'). They are placed in the broad angles formed by the inclined follicles with the corium and their contraction brings the hair into a more nearly erect position.

Important modifications are displayed in glandular epithelia and sensory epithelia.

Glandular Epithelia

Epithelial glands are composed of epithelial cells which have become greatly modified as secreting structures. In some cases the secreting element is a single cell, a **unicellular gland** lying directly in the general layer of epithelium. The mucus-secreting goblet cells of the intestinal wall are structures of this nature. In other cases

groups of secreting cells form ingrowths from the main layer, **multi-cellular glands**. The **lumen** or cavity of the gland, in most cases greatly complicated through the division of the gland substance, is connected with the general surface by a **duct** which serves to carry away its secretion. In some cases, however, the connection of a gland with the epithelial surface is only embryonic and, in the adult condition, the gland is found separated from the epithelium from which it was originally formed. This condition is represented by the thyroid and thymus glands of the neck and thorax respectively. Typical epithelial glands are accordingly external secreting, or **exocrine** glands, their secretions being discharged through ducts to free surfaces; while those which lose their ducts are internal secreting, or **endocrine** glands, their products being absorbed directly into the blood or lymph (cf. p. 131). There are many structures, such as the suprarenal gland and part of the pituitary body,

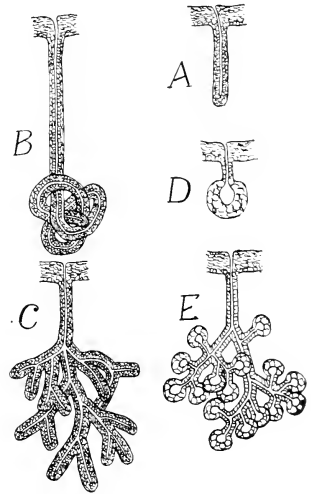


FIG. 3. Diagrams of main types of multicellular glands. A, simple tubular gland; B, coiled tubular gland; C, branched tubular gland; D, simple acinous gland; E, branched or compound acinous gland.

such as the suprarenal gland and part of the pituitary body,

commonly described as endocrine glands, which are not necessarily epithelial in origin and of which the resemblance to ordinary glands is often only a matter of superficial appearance and of the fact that both secrete, i.e. produce special substances in their cells and discharge them either on a free surface or towards the blood stream.

Most **multicellular glands** conform to one of two types, namely, the **tubular** gland, in which the secreting portions are of uniform calibre, and the **acinous** or **alveolar** gland, in which the secreting portions are sacculated (Fig. 3). Both types occur in simple, little branched, and greatly branched conditions (Figs. 3, 4), and the tubules of the former type may be elongate and greatly coiled.

Cutaneous glands of two types are commonly present in mammals in association with the hairs, namely, **sudoriferous** or sweat-glands, which are of the tubular type, and **sebaceous** glands, which are of the acinous type and produce an oily secretion. In the rabbit, glands are absent from the general surface, but are found in special situations, as, for example, in connection with the hair

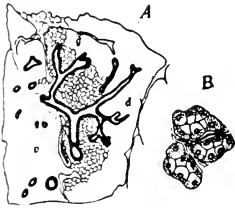


FIG. 4. From a section of the parotid salivary gland of the rabbit. A. Duct system in relation to body of gland: g. acini of gland body; d. interlobular duct. B. Three individual acini, highly magnified.

follicles of the lips, the internal surface of the ear, and the external genital organs. The **inguinal glands** comprise both tubular and acinous portions. The **mammary glands** of the female are greatly modified cutaneous glands of the sudoriferous type.

Besides the mucus-secreting cells of the general epithelium, the glands of the alimentary canal comprise the important but less elaborated glands of the wall, such as the **gastric glands** of the stomach; and the greatly elaborated, outstanding glands which lie beyond the wall and are connected with the interior of the canal only through their ducts. The latter comprise the **oral glands**, the **liver**, and the **pancreas**. The oral glands include chiefly the **submaxillary**, **parotid**, **sublingual**, **buccal**, and **infraorbital glands**—conspicuous structures in the dissection of the surrounding portions of the head and neck. Their ducts communicate with the cavity of the mouth.

The secretion of the oral glands has important mechanical functions in moistening the comminuted food in preparation for

The secretion of the oral glands has important mechanical functions in moistening the comminuted food in preparation for

swallowing. In mammals it also contains ferments or **enzymes**, chiefly ptyalin, which is capable of transforming starch into soluble materials, though the digestive action is probably not exercised to a great extent. Pancreatic secretion, on the other hand, has little or no mechanical action, but its enzymes are of the greatest importance in digestion. The pancreas is mainly an exocrine gland of compound acinous structure (Fig. 5). Imbedded among the acini, however, are numerous small solid groups of endocrine cells, the **islets of Langerhans**, which produce the important hormone, insulin.

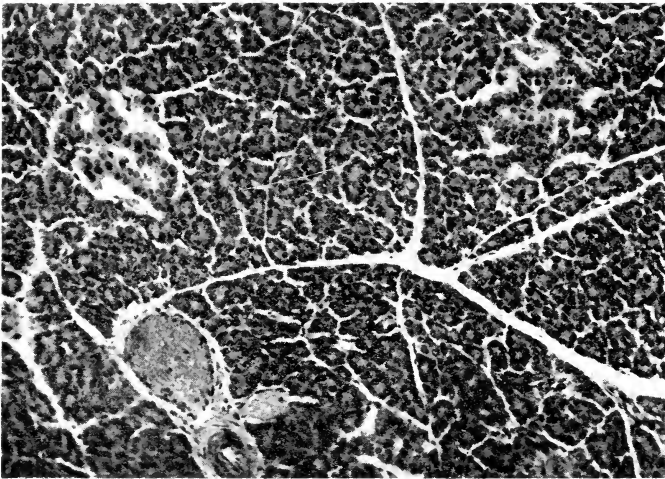


FIG. 5. Part of a section of the pancreas of the rabbit. $\times 130$. Two islets of Langerhans appear in the upper part of the field and a smaller, less conspicuous one near the bottom. The acini composing the greater (exocrine) portion of the gland are well shown and an artery and a vein also appear at the bottom.

The foregoing are all **secretory glands**. The term gland, however, is also applied to **excretory organs**, such as the kidney, which remove from the body, with little or no alteration, substances brought to them by the circulatory system. This process contrasts with secretion, in which the epithelial cells manufacture new products out of the materials brought to them. There are also **cytogenic glands**, which produce living cells, namely the ovaries, testes, and lymph glands.



Sensory Epithelia

There is a close association between the epithelia of the surface of the body and the nervous tissues. In the adult we may distinguish as **sensory epithelia** special aggregations of cells lying in either a deep or a superficial position, associated more or less closely with the central nervous system, and functioning for the reception of stimuli. That is, appropriate agencies set up in them states of excitation which are then transmitted along sensory nerves.

They comprise the **olfactory epithelium** of the nasal cavity, some of the cells of which are true nerve cells, the **gustatory epithelium** of the tongue, and the **auditory epithelium** of the membranous labyrinth of the ear. The **retina**—the nervous portion of the eye—is a modified portion of the central nervous system.

As linings of surfaces, the ordinary epithelia may be distinguished from certain special coverings of internal spaces, the **endothelia** and **mesothelia**. The two latter consist microscopically of thin pavement-like cells. They differ from epithelia in origin, being formed, not in connection with originally free surfaces, but in relation to spaces of the mesoderm or intermediate layer of the body. Endothelia form the linings of blood-vessels and lymph canals, while mesothelia are the chief layers of the smooth, moist **serous membranes** which line the peritoneal, pleural and pericardial cavities.

2. Connective Tissues

The **connective tissues** form the supporting elements of the body. As **ordinary connective** tissues they serve to connect organs or parts of organs, and as **skeletal** tissues they provide the rigid framework or skeleton from which all soft parts of the body are suspended. They are distinguished by the presence of two main components—the **cell basis**, and the **intercellular substance** or **matrix**. The cellular portion is formative, and is much more conspicuous in the embryonic than in the adult condition. All connective tissues are products of an embryonic tissue, the **mesenchyme** (Fig. 22, ms.), which consists of branched cells connected by their outstanding processes and typically suspended in a relatively large amount of tissue fluid. Through the activity of the

cells there is formed an intercellular material consisting of either a homogeneous matrix, or, more frequently, a matrix containing formed elements of a supportive nature.

Certain types of connective tissue cells occurring in various parts of the body have in common the function of phagocytosis and the property of taking up and storing minute particles of foreign materials brought to them in dilute colloidal solutions. These cells constitute the reticulo-endothelial or macrophage system and form an important constituent of the spleen, for example.

Ordinary Connective Tissues

In the adult condition the ordinary connective tissues, with few exceptions, consist of the cell basis with three kinds of fibrous elements, the **white**, the **yellow** (Fig. 6), and the **reticular fibres** all lying in a ground substance which is partly a watery fluid and partly more viscid in nature. White fibres are relatively coarse, single, unbranched, of various sizes, and of great strength, each constituted by a very compact bundle of fine fibrils. The yellow fibres are of smaller diameter. They branch and communicate, but are not associated to form bundles. They also differ from white fibres in being highly elastic. The reticular fibres are less conspicuous in most connective tissues. They are related to the white fibres but form a close-meshed network. The tissue produced in this way is known as **fibrous connective tissue**. It occurs in several forms according to the relative concentration of the different kinds of fibres or the admixture of other materials.

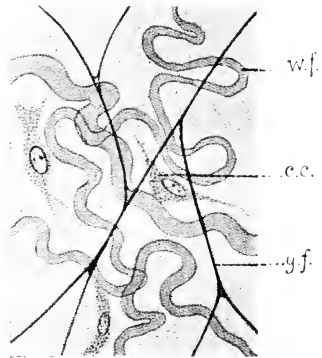


FIG. 6. Areolar connective tissue (subcutaneous tissue) of the rabbit; from an embalmed specimen: a diagrammatic representation to be compared with the photograph in Fig. 7: c.c. connective tissue cell; w.f., bundle of white fibres; y.f., yellow elastic fibre.

The commonest kind of fibrous tissue in the adult is that described as **areolar**. It is characteristic of the subcutaneous tissue (Fig. 7) which connects the skin with the body; but occurs also in various positions where it has a similar function of joining

structures loosely together. Subcutaneous connective tissue is a white material, the peculiar appearance and properties of which are due to the fact that the white and yellow fibrous elements are arranged in a loose felt-like network (Fig. 7) and reticular fibres are not important components. When stretched, it is found to yield up to a certain point, beyond which it is tough and resistant. It tends to regain its original shape when the tension is removed.

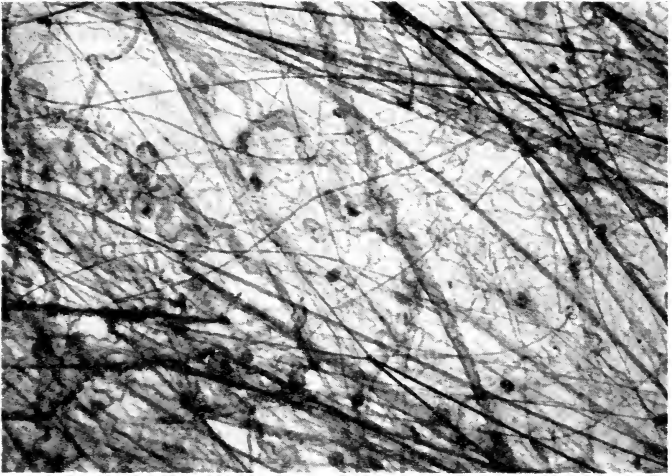


FIG. 7. Photomicrograph of stained preparation of areolar connective tissue—subcutaneous tissue of rabbit. $\times 150$.

Fibrous connective tissue may be greatly modified through the concentration of any one of the fibrous elements. Concentration of white fibres is, however, the common modification. This condition is illustrated in the thick connective tissue layer forming the true skin or **corium**, but is more conspicuous in the glistening white **tendons** (Figs. 8, 37) by which muscles are attached to bone surfaces, in the **ligaments** uniting bones with one another, and in the thin, broad **aponeuroses** which serve for muscular attachment. The cells are few and are squeezed between the closely packed white fibres. The structures known anatomically as **fasciae** are special sheets of connective tissue covering chiefly individual muscles or muscle groups. Concentration of yellow fibres occurs in

the dorsal ligament of the neck (ligamentum nuchae) where greater elasticity is required. The ligament is not so conspicuous in the rabbit as in larger mammals, where the yellow coloration is very noticeable. Elastic membranes composed chiefly of yellow fibres with scattered cells occur in the walls of blood vessels and of distensible viscera.




FIG. 8. Photomicrograph of small part of a longitudinal section of a muscle of a rabbit, showing part of the tendon, composed of connective tissue fibres, with coarse muscle fibres joining it obliquely at each side. $\times 100$.

Since the fibres are non-living and cells are few in tendons, ligaments, and elastic membranes, vessels also are few in these situations.

Fat or adipose tissue is a soft form of connective tissue in which the cells predominate over the intercellular components and are greatly enlarged by the inclusion of relatively enormous quantities of fat in the form of globules. Each globule is enveloped by a thin film of cytoplasm, which is slightly thickened at one side to contain the flattened nucleus of the cell. Such tissue tends to occur in certain definite situations, such as in association with the blood-vessels, but also is found in locations where areolar connective tissue might be expected to occur. Special fat masses, sometimes distinguished by unusually dark coloration, occur at the side of the neck and between the shoulder blades of the rabbit. In the foetus (cf. Plate VI) these are represented by large masses of vascular connective tissue. They correspond with the so-called storing or hibernating glands of certain other mammals.

Coloration or pigmentation of certain portions of the body, especially of the skin and hairs and of the retina, the ciliary body, and the iris of the eye, is due to the presence of pigment granules, partly in special connective tissue cells, chromatophores, and partly in epithelium. The absence of such granules in animals belonging to species normally coloured constitutes albinism, a condition indicated by the whiteness of the hair and by the pink colour of the eyes, the latter being due to the circumstance that the blood-vessels of the vascular tunic are not concealed by pigment.

Mesothelium, mentioned on page 18 as a type of epithelium, is related in embryonic origin (from mesenchyme) to connective tissue. It consists of a single layer of extremely flattened cells reinforced by some connective tissue fibres and cells. Endothelium also could be classified here both on account of its origin from mesenchyme and on account of the fact that its cells, though squamous, may under certain conditions differentiate into connective tissue cells.

Skeletal Tissues

The skeletal tissues are solid forms of connective tissue which, on account of their more permanent shape, are better adapted to form a support for the body. They are of two kinds—**cartilage** and **bone**.

Simple or **hyaline cartilage** (Fig. 9) is a semi-solid and somewhat resilient material of a bluish or pearly coloration. It consists

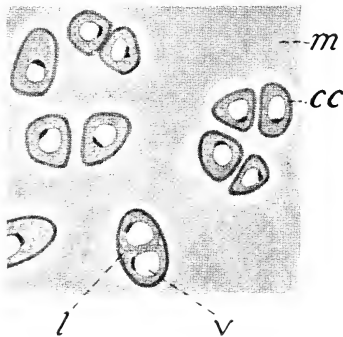


FIG. 9. Hyaline cartilage, from a fresh preparation of the costal cartilage of the rabbit: cc, cartilage cell; l, lacuna; m, matrix; v, vacuole.

of a **matrix** which appears homogeneous unless certain special techniques are applied to it and in which the cells are imbedded. The cells are distributed singly, or more often in groups of two to four, each cell, or occasionally two cells, being contained in a small oval space, the cartilage **lacuna**. The size of the spaces, and also their distance apart, are subject to great variation. The presence of large numbers of white fibres in the matrix produces a modification known as **fibro-cartilage**.

This occurs in certain definite situations, as in the symphysis of the pelvis, or in connection with the inter-articular menisci and at the capsular margins of the joints. Elastic cartilages, such as the epiglottic cartilage, contain many yellow fibres.

The surface of the mass of cartilage (except the articular surfaces within joint capsules) has a limiting membrane of fibrous connective tissue, the **perichondrium** (Fig. 10) which develops new cartilage,

adding it to that already present, during embryonic growth and may do so also in the adult in repair of injury.

In the adult skeleton cartilage is present only in small amount. It forms the articular surfaces of joints, the ventral portions or costal cartilages of the ribs, and a portion of the nasal septum; it is also found uniting the basal bones of the skull and supporting the walls of the respiratory passages. In the embryo, however, it forms the entire skeleton, with the exception of a small portion which, as described below, is composed of membrane bone. In the course of development, except in the situations indicated, the cartilage is replaced by bone.

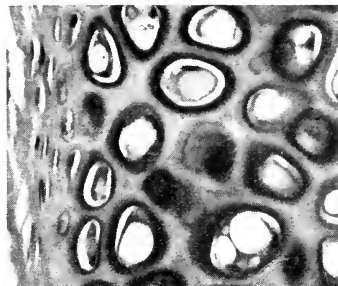


FIG. 10. Photomicrograph of a stained section of hyaline cartilage from the ear of the rabbit. $\times 230$. Shrinkage of the cells make the lacunae in which they lie conspicuous and the quantity of matrix is relatively small. The perichondrium appears at the left side.

Vessels and nerves may be absent in cartilage, the small amount of material exchange required to maintain the life of the cells taking place by diffusion through the ground substance.

Bone is a compact, resistant, but yet somewhat elastic tissue, possessing much greater strength than cartilage, and therefore forming a more perfect skeletal support. As indicated below, its appearance as a tissue differs somewhat according to its mode of formation. The more typical structure (intramembranous bone) is illustrated in the accompany-




FIG. 11. Intramembranous bone from a ground transverse section of a radius (human). $\times 120$. hc, Haversian canal; hl, Haversian lamella; il, interstitial lamella; lac, lacuna.

ing figure (11) of a ground transverse section of the dried shaft of a radius. Its dry weight consists of about one-third animal matter and two-thirds mineral matter, the latter being chiefly calcium phosphate. The bone materials are deposited in layers, or **lamellae**, which are comparable to highly modified white fibres of fibrous connective tissue. The lamellae enclose between them greatly branched spaces, the **lacunae**, which connect with each other and with the outer surface of the bone by very delicate canaliculi and in which during life the bone cells are accommodated. In the natural condition, each bone is enclosed, except on its articular surfaces, by a layer of connective tissue, the **periosteum**, derived in the case of replacing bones from the perichondrium of the original cartilage. During the period of growth, this membrane contains numerous bone-forming cells, the **osteoblasts**, through the activity of which the bone lamellae are deposited.

Compact bone of the adult develops in the embryo from spicules which become connected to form a spongy network, the marrow spaces in which are then gradually reduced by deposition of successive layers of bone-matrix until they appear as canals, the **Haversian canals**, surrounded by concentric lamellae. The concentric series of bone-cells and lamellae constitutes a **Haversian system** and the canal often contains an artery and a vein with a little connective tissue. Between the Haversian systems there may be bands of **interstitial lamellae** and over the outer and inner surfaces, parallel with them, zones of **circumferential** (respectively periosteal and endosteal) **lamellae**.

Bone may be formed either with or without a cartilage basis, being known in the former case as **cartilage** or **replacing bone**, in the latter as **membrane** or **derm bone**. The former is the more usual, replacing units of the primary cartilage skeleton, which appears earlier in the embryo. This it does both by surrounding and by invading the units

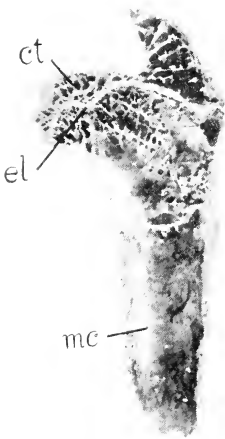

FIG. 12. Inner surface of proximal end of a dried femur of a rabbit divided longitudinally. ct, cancellous bone in proximal epiphysis; el, epiphysal line; mc, marrow cavity of shaft, enclosed by compact bone.

referred to. In only a few regions, as already indicated, the cartilage persists throughout life. The difference between the two types of bone is not fundamental, however, since both are formed by soft connective tissue, the latter invading a cartilage model when this exists and destroying it bit by bit previous to the deposition of bone-matrix.

Membrane bone occurs less extensively than replacing bone. It is exemplified by the roofing and facial bones of the skull, most of which have a flattened tabulate form, and by the clavicle. It is formed in connective-tissue membranes and may contain cartilage, but does not develop on a cartilage basis. Skeletal units of this type lie superficial to the other skeletal elements, a feature which is due to the fact that they represent surface plates which in lower vertebrates are associated with the skin.

Only in a few cases are the bones of the skeleton solid—as a rule they consist of a fairly thin shell of hard or **compact** bone surrounding a central mass of spongy or **cancellous** bone. This arrangement is one of great mechanical strength, combined with lightness, and at the same time provision is made in the interior of the bone for blood-vessels and marrow-spaces. Thus in a long bone (Fig. 12) the central portion or **shaft** consists of a cylinder of compact bone surrounding an extensive space, the **marrow-cavity**, filled with soft vascular tissue which, in the adult animal, is the most important region of red blood formation. The ends or **extremities** consist each of a thin shell of compact bone continuing that of the shaft and surrounding a mass of cancellous tissue. In the short, flat, or irregular bones of the skeleton no continuous marrow-cavity is formed.

It may be noted that, in addition to its function as a mechanically supporting or protecting material, bone serves as a reservoir for the important substance, calcium, which can be dissolved in the blood or redeposited in the bone as the needs of other parts of the organism may demand.

3. Muscular Tissues

Muscular tissues are the active portions of the individual muscles which move the skeleton and of the muscle coats of visceral

organs. Their chief feature consists in the elongation of the cells to form **fibres**. These fibres possess the contractile properties of simple protoplasm, but with the contraction limited to one direction. Except in a few cases, the fibres are arranged in a parallel fashion, so that the line of contraction of the muscle or muscle layer is the same as that of each of its fibres. The result of contraction in both the muscle and its individual fibres is the shortening of the longitudinal axis and the increase of the transverse axis. Muscles are important in the production of heat, which is liberated not only when the muscle is in action but also, though less rapidly, in repose.

Two chief types of muscle fibres occur in the body—the **smooth** or **unstriated** fibres, which are characteristic of the **involuntary muscles** or muscle coats of the visceral organs or of the skin, and the **striated fibres** which compose the individual or

voluntary muscles of the skeleton. Smooth fibres (Fig. 13) are elongated, spindle-like cells, the substance of which is longitudinally striated as a result of the presence within each of numerous fine myofibrils, but possesses no transverse markings. The single nucleus of the cell occupies a central position. The muscles which they form are distinguished as involuntary because their operation is not under the control of the will, their connections being with the autonomic nervous system. They respond slowly to stimulation but are capable of prolonged contraction. The striated fibres (Fig. 14) are very much larger, cylindrical structures, the substance of which possesses characteristic transverse striations in addition to the longitudinal ones. These are due to the myofibrils being composed of alternating light and dark portions, those of adjacent fibrils being placed side by side so as to give an appearance of transverse bands. Each fibre is

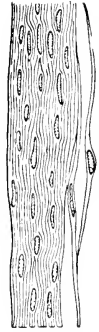


FIG. 13. Involuntary muscle, from a section of the muscular tunic of the intestine.




FIG. 14. Parts of two fibres from a teased preparation of a piece of striated (skeletal) muscle of a rabbit.

enclosed by a loosely attached, viscous, elastic membrane, the sarcolemma, and contains many nuclei. The presence of the latter indicates that the fibre is not a single cell but a syncytium, i.e., an association of cells unseparated by cell boundaries. The muscles formed by such fibres are under the control of the will, their connec-

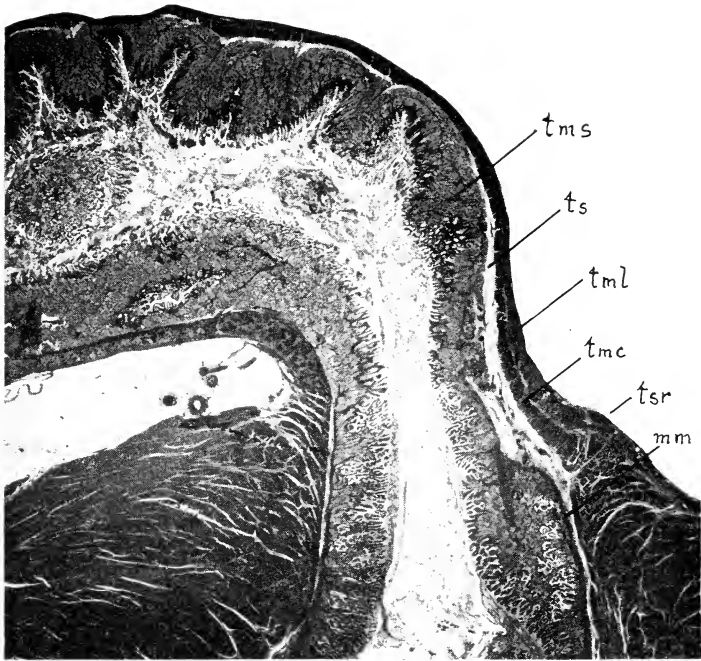


FIG. 15. Photomicrograph of a longitudinal section of the pyloric region of a rabbit. $\times 10$. The end of the pyloric antrum appears below, the beginning of the duodenum above. m.m., muscularis mucosae; t.m.c., circular layer of the muscular tunic; t.m.l., longitudinal layer of the muscular tunic; t.ms., mucous tunic; t.s., tela submucosa; t.sr., serous tunic.

tions being directly with the central nervous system. They comprise not only the typical muscles of the skeleton, but also the special muscles which serve to connect the skeleton with the skin.

Two kinds of striated muscle fibres occur, red and pale. Those

of the former kind have well defined myofibrils and rather inconspicuous transverse bands, are usually somewhat small in diameter, and contain a greater quantity than do the pale fibres of a reddish, iron-containing substance (myoglobin) related to the haemoglobin of blood. The pale fibres have less cytoplasm, more conspicuous transverse striations, and usually greater diameter, and their nuclei are more nearly confined to the inner surface of the sarcolemma. Red fibres contract more slowly than white but are more resistant to fatigue. The proportion of these two types varies in different muscles, and in many animals (as man) one never preponderates so greatly as to make an obvious difference in the appearance of the gross muscles. In the rabbit and many other animals, however, some muscles (e.g. the semitendinosus and the soleus) are definitely red and others (e.g. the adductor magnus) are pale or white.

The muscular substance of the heart differs from both striated and smooth muscle in being composed of branched anastomosing fibres, which apparently form a continuous network and which have their nuclei centrally placed. Like striated muscle, it possesses characteristic transverse markings, but, like involuntary muscle, it is under the control of the autonomic nervous system. Certain differentiated cardiac muscle cells, the Purkinje fibres, constitute a conducting system (bundle of His, etc.) which regulates the contraction of the chambers of the heart.

In the gross, voluntary muscles present a longitudinal striation which is roughly referred to as the **direction of the fibres**, and which is of great value in identification. The striation is due to the circumstance that the fibres are arranged in parallel groups or muscle bundles, each of which is surrounded and separated from the adjacent bundles by a connective tissue enclosure called the **perimysium**.

Involuntary muscle is distinguished by its white or greyish coloration and by its smooth or homogeneous appearance. It forms characteristic layers in connection with visceral organs or with the skin, and is thus much less individual than the voluntary muscles in its relations to particular parts. It forms the muscular portion (**muscularis mucosae**) of the mucous tunic of the alimentary canal, and also a separate **muscular tunic** lying in the outer portion

of its wall (Fig. 15). In the muscular tunic the fibres are arranged in both circular and longitudinal directions. Involuntary muscle also forms a small constituent of many organs, such as certain glands, in which contractility is not a chief function. It is a large constituent of the wall of the urinogenital tubes, particularly the bladder and the uterus. In association with elastic connective tissue, it is an important constituent of the walls of the blood-vessels.

The fundamental cause of the shortening of muscle fibres is not yet understood nor is the significance of the transverse striations, when these are present, known.



FIG. 16. Nerve-cell from the ventral grey column of the spinal cord (cf. Fig. 18): d., dendrites; c.g., chromatophile granules; nr., neurite.

4. Nervous Tissues

Nervous tissues are the essential components of the central nervous system and of the outlying nerves and ganglia. They comprise two kinds of elements—**neurons** or **nerve cells** and **neuroglia cells**. The former alone carry on the essential nervous functions, while the latter are supporting structures forming in the central nervous organs a mass of neutral tissue in which the neurons are imbedded.

Nerve cells differ greatly in form, but typically each consists of a **cell-body** (Fig. 16) bearing two kinds of processes—a single **axon**, **neurite**, or **neuraxis**, and a series of branched protoplasmic processes, the **dendrites**. The nerve-cell body is characterized by the presence in its cytoplasm of granular masses, the **chromatophile** or **tigroid bodies**, or **Nissl granules**, the size and arrangement of which are distinctive of certain types of nerve cells. These extend into the dendrites but not into the axon. The dendrites, which may be greatly elaborated and may be few or many, conduct nerve impulses towards the cell body and the axon conducts them away from it. The latter may traverse a relatively enormous dis-

tance before it ends. A **nerve fibre** consists of an axon with, in some cases, certain enclosing sheaths. Two kinds of nerve fibres are distinguished—**myelinated** and **unmyelinated** fibres. In the former, the axon is surrounded by a layer of fatty material, the medullary or **myelin sheath**. In peripheral nerves, a second sheath, the **neurilemma**, which is composed of independent cells, encloses the myelin, and as the latter is interrupted at certain points, the **nodes of Ranvier**, the neurilemma there comes into contact with the axon itself. Near the peripheral end of the axon, first the myelin and then the neurilemma disappears, so that the nerve-ending is devoid of either covering. The naked portion usually breaks up into numerous small branches which end on the dendrites or cell bodies of other neurons, on muscle fibres, etc. by terminals of various characteristic forms. Unmyelinated fibres lack the myelin sheath.

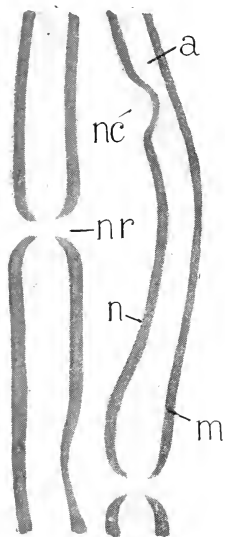


FIG. 17. Parts of two myelinated nerve fibres from a teased preparation of the sciatic nerve of a rabbit in which the myelin sheaths have been stained dark with osmic acid. a, axon; m, myelin sheath; n, neurilemma; nc, neurilemma cell; nr, node of Ranvier.

Both types of fibres are present, in varying proportions, in many peripheral nerves as well as in the central organs.

A **nerve** is an association of nerve fibres, the latter being disposed in a parallel fashion and united together into bundles of larger or smaller size by connective tissue, which also forms a general peripheral investment, the **epineurium**.

The dead-white coloration of most nerves is due to the fatty materials of the myelin sheaths, but nerves are commonly found imbedded in a fatty connective tissue which is associated with the epineurium and is also of white coloration.

Nerve fibres, and hence nerves, are organs of conduction and as such are designated **afferent** if they conduct impulses towards the central nervous system or **efferent** if they conduct away from it. Sensory nerves are afferent, while motor nerves are efferent. Nerves, however, usually contain both afferent and efferent fibres and when the proportions of both are considerable, they are described as mixed. In the central connections as well as in the

peripheral distribution of both afferent and efferent fibres, there is a marked difference between those associated with the external or somatic portions of the body and providing for external adjustments to the environment and those connected with internal or visceral portions and serving for the internal integration of processes within the body. Consequently **somatic** and **visceral** kinds of both afferent and efferent fibres are distinguished.

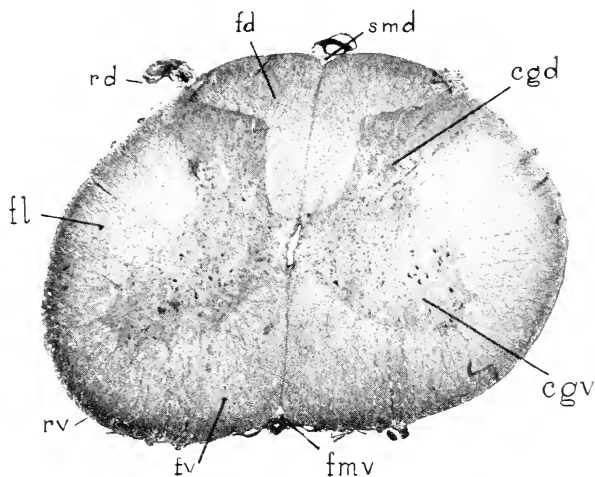


FIG. 18. Photomicrograph of transverse section of the spinal cord of a rabbit. $\times 15$. The central canal is visible in the middle of the picture. cgd, dorsal column (horn) of grey matter; cgv, ventral column (horn) of grey matter; fd, dorsal funiculus of the white matter; fl, lateral funiculus of the white matter; fmv, ventral median fissure; fv, ventral funiculus of the white matter; rd, dorsal root of spinal nerve; rv, position of ventral root of spinal nerve; smd, dorsal median sulcus.

Nerve fibres differ among themselves in such properties as calibre, thickness of the sheaths, and reaction to certain stains and it has been possible to associate some of these differences with the conduction of certain specific kinds of impulses.

While the nerve-cell bodies mostly lie within the central nervous organs, some are in the peripheral nerves. The majority of the latter are grouped into definite masses, each of which is called a **ganglion**.

On account of the difference in colour produced by the presence or absence of myelin, the cellular and the myelinated fibrous

constituents of the central nervous organs produce characteristic patterns according to their varying concentration. Where cell bodies, dendrites, and unmyelinated fibres preponderate, the tissue has a greyish colour and is hence distinguished as **grey matter**; while the concentration of myelinated fibres produces an opaque white appearance similar to that seen in the larger peripheral nerves, whence the tissue is described as **white matter**. In the spinal cord (Fig. 18) the grey matter is disposed as a central core, the white substance as a peripheral investment. An essentially similar though much elaborated distribution is found in the basal portion of the brain (Fig. 123), but the characteristic pattern in the cerebral hemispheres and in the cerebellum is one in which the grey substance forms a peripheral, investing, or cortical layer (Figs. 115, 117, 123).

In order that the conduction of excitation waves through the nerve cells and fibres may be effective, the neurons must be linked up in functionally useful patterns, the complexity of which is often almost inconceivably great. Each neuron receives or transmits impulses from or to others at special points of intimate contact, the synapses, through which the excitation can pass in only one direction though within a single neuron it can be propagated in all directions. The synapses occur almost entirely within the grey matter.

Neuroglia is a special type of connective tissue unrelated developmentally to the true connective tissues but having a common embryonic origin with the nerve cells. The neuroglia cells are much branched but lack the distinctive features of neurons. Among the true neuroglia elements occur small, phagocytic, migratory cells related in origin to ordinary connective tissue. These are known as microglia.

5. Blood and Lymph

Blood is fundamentally a cellular material, but owing to the fact that the intercellular matrix takes the form of a liquid medium, the **plasma**, in which the cells, or **corpuscles**, are suspended, its features largely differ from those of the ordinary tissues of the body. On account of its liquid character, the appearances presented by blood in dissection, especially of preserved animals, are almost

negligible, in spite of the importance of its functions. The cellular components comprise (a) erythrocytes, (b) leucocytes, and (c) platelets. The **erythrocytes** or red blood cells are microscopic biconcave, circular discs of uniform size and definite though not rigid contour, containing no nuclei in adult mammals. They are so soft and flexible that they squeeze readily through capillaries of diameter smaller than their own. They have a yellow colour when seen singly, or deep red when observed in bulk, on account of the presence of haemoglobin. The latter material is the specific carrier of oxygen, with which it forms a readily dissociated chemical compound. Arterial, oxygenated blood is bright red, while venous blood is dark red. The number of red blood cells is relatively somewhat greater in the rabbit than in man, there being over six millions contained in each cubic millimetre. The cells are formed first in the yolk-sac wall of the embryo, later in the spleen and liver, and in the marrow of bones. The **leucocytes**, also termed white or colourless blood cells, are amoeboid, nucleate cells, present in the blood in much smaller numbers than the erythrocytes, but occurring also in lymph. A number of different kinds is recognized and named. They are classified first as granular or agranular, the former comprising neutrophiles, eosinophiles, and basophiles, the latter comprising lymphocytes, monocytes, and some others apparently transitional. They are formed in the lymph glands, in the spleen, and elsewhere (cf. p. 121). Being capable of passing through the walls of the smaller vessels, they occur more or less throughout the tissues, where they have the function of carrying materials or of ridding the body of injurious substances and bacteria. The **platelets** are minute, non-nucleate masses of cytoplasm derived chiefly by fragmentation from cells in the bone marrow. They are related to coagulation of the blood and help to seal up small openings in the walls of the vessels.



FIG. 19. Red blood corpuscles of the rabbit: f, face; p, profile.

In all multicellular animals, large proportions of the tissues are necessarily more or less distant from the surfaces of absorption and excretion. Blood and lymph, circulating through the vascular system, are the media by which communication with these is kept up, providing for the transportation of materials essential for the

maintenance of life processes in the tissues. The composition of the blood varies from time to time according to the individual functions performed. Oxygen and food materials are carried to the tissues. Carbon dioxide and waste materials of other kinds are carried to organs from which they can be excreted. Blood, however, has been shown to vary in composition in different species of animals, and to be chemically homologous in related ones; and it can develop substances conferring immunity to bacterial diseases, which substances also differ in different species and individuals.

In most tissues there occurs a **tissue fluid** the amount and character of which differ in different localities. This is derived primarily from the blood by diffusion through the walls of the capillaries. All materials passing between the tissue cells and the blood stream are transmitted through it. It is taken up by the blind beginnings of the lymphatic capillaries within the tissue, within which vessels it is known as **lymph**. This is eventually poured into veins and thus mixed with the blood.

The peritoneal, pleural, and pericardial fluids and the synovial fluid in joints are special examples of tissue fluid and the cerebrospinal fluid also may be so regarded.

SPECIAL ANATOMY

TERMINOLOGY

In special or descriptive anatomy it is necessary to employ an extensive system of terminology in order that the various structures of the body may be individually designated, classified, and referred to their respective positions. The terms used for this purpose may be classified into four groups, as follows: (1) **general terms**—those included in the names of parts, but applicable in themselves to similar structures (arteries, nerves, *etc.*) in various parts of the body; (2) **specific terms** or **names of parts**; (3) **regional terms**—those defining areas (topographic); and (4) **terms of orientation**.

The terms of the first three groups will be defined so far as required wherever it seems necessary. The terms of orientation, however, being based on very general relations of the body, are of wider application and understanding of them is essential for any

anatomical description to be intelligible. For these reasons they are selected for definition here to the exclusion of others of a more restricting or individualizing kind.

In all vertebrates we may recognize a **longitudinal axis**, corresponding, in general, to the line formed by the vertebral column. In the usual or **prone** position of the body this axis is horizontal. The uppermost surface is then described as **dorsal**, the lowermost surface as **ventral**, the sides of the body as **lateral**. Any position forward, with respect to the long axis, is **anterior** in comparison with any position backward, which is **posterior**.

In relation to the long axis it is convenient to recognize a **median vertical plane**, which is one dividing the body into right and left halves, and transverse, coronal, and sagittal planes. **Transverse** planes are situated at right angles to the longitudinal axis. **Coronal** planes are longitudinal and horizontal, at right angles to the median vertical plane. **Sagittal** planes are longitudinal and vertical, parallel to and including (as midsagittal) the median vertical plane.

The median vertical plane is the centre of bilateral symmetry, each half of the body, as divided by it, being in a general way the reverse counterpart of the other. Structures or situations partly in the median plane are unpaired, and are described as **median**, while positions situated wholly outside of the plane are paired, right and left, or **dextral** and **sinistral**. In relation to the median plane and to the sides of the body, structures are described as **medial** when nearer the former, and as **lateral** when nearer the sides of the body. The term **intermediate** is applied especially to a position between medial and lateral, but this restriction is perhaps not justifiable.

In considering the extent of bilateral symmetry, it is necessary to bear in mind that, although a fundamental feature in vertebrates, it is not perfectly retained in the adult condition. Symmetry is destroyed by the migration of an unpaired structure from a median to a lateral position, as is seen, for example, in the case of the abdominal portion of the alimentary canal; or, again, by the reduction or disappearance of structures belonging to one side of the body, as, for example, in the case of the mammalian aortic arch.

Referring to centre and circumference, either in the body as a

whole, or in particular parts, the pairs of opposed terms **deep** and **superficial**, **central** and **peripheral**, or **internal** and **external** may be applied. It may be observed, however, that the terms internal and external are sometimes used in the sense of medial and lateral, both in descriptive language and in the names of parts.

In distinction from the terms medial (*medialis*) and median (*medianus*) the term **middle** (*medius*) may be used to designate the position of a structure lying between two others, the latter being otherwise designated, for example, as anterior and posterior, lateral and medial, or right and left.

The limbs being more or less independent structures, it is proper to apply to them certain terms not otherwise applicable to the main portion of the body. The chief terms which are used principally in this connection are **proximal**, meaning nearer the centre or base of attachment, and **distal**, toward the extremity. In the middle segment of the fore limb the respective positions of the bones (radius and ulna) are indicated as **radial** and **ulnar**. The terms **tibial** and **fibular** are also applicable, although with less reason, to the corresponding segment of the hind limb. The upper and lower surfaces of the fore foot are described respectively as **dorsal** and **volar**, those of the hind foot as **dorsal** and **plantar** (or volar).

In determining the identity of structures in a quadrupedal mammal, considerable difficulty may at first arise from the fact that descriptive terms, such as those just defined, are frequently included in the names of parts, the latter being, at the same time, terms applied in the first instance to the human body, in which the recognized relations are somewhat different. In contrast with that of a quadrupedal vertebrate, the human body occupies a vertical or erect position, and is to be considered as having been rotated upward through ninety degrees on the posterior limbs. The latter accordingly occupy for the most part their original position, and the human arm largely reassumes this position when allowed to hang freely at the side of the body. In all, however, the face retains its forward direction. Thus the terms anterior and posterior as used in human anatomy mean ventral and dorsal, provided they refer to parts of the body, such as the entire trunk region, which have been affected by rotation. The terms **superior** and **inferior** as applied to man are similarly equivalent to anterior

and posterior as applied to a lower form. Since it is unwise to change the form of the official terms of human anatomy, it becomes necessary to interpret all such terms when used for a quadrupedal mammal according to the relations exhibited by man. The human terms may in most cases be translated into terms acceptable for comparative anatomy by reading ventral for anterior, dorsal for posterior, **cranial** or **oral** for superior, and **caudal** or **aboral** for inferior. The exceptions then apply to those parts of the body unaffected by rotation.

On the other hand, in ordinary description of organs and their position, where it is not a matter of the official names of parts, little advantage is to be gained from adherence to this principle. The terms anterior and posterior apply with much greater force to a lower vertebrate than to man, while the terms superior and inferior are of interest only in the latter. In this case the rule here followed is to use the terms anterior and posterior *for descriptive purposes* without reference to the human relation. The same remark applies to the terms of direction, viz., upward, downward, forward, and backward.

In this connection it may be pointed out that the custom has become more or less general in comparative anatomy of employing the termination **ad** with words otherwise signifying position alone, in order to indicate position or course toward, e.g. dorsad = dorsalward. In the present case this form is used only for *course*, *position* being indicated by the adverbial termination **ly**, e.g. dorsally.

Reference may also be made here to the fact that the human structures to which identifying names are applied frequently fail in one way or another to correspond to structures in a lower form. Composite structures to which individualizing names are applied, for example, may be represented by independent parts. Also, structures which are similar in form or function may be convergent. Finally, although it is essential to endeavour to apply all terms as accurately as possible, it will be remembered that a terminology primarily arranged for one type cannot be exactly applied to another without considerable qualification.

THE GENERAL FEATURES AND GROUND PLAN OF THE ORGAN-SYSTEMS

It has already been stated as a general principle that the structure of an organism is the expression of an underlying plan and pattern, in the elaboration of which embryonic development and ancestry play a very large part. The manner in which the comparative method is applied in interpretation may be demonstrated by reference to any part of the body of an animal; and in the following pages will be found, under the head of the respective systems, a preliminary statement of how the origin of certain outstanding features of the rabbit may be explained and what grades of organization they may be presumed to illustrate. It will be recognized that the lower mammals are in many respects less specialized than man and must accordingly show in these respects various stages through which the human species must be assumed to have passed. Nevertheless, this principle is not applicable to all parts and cannot be assumed to be true in any particular case without critical examination.

CLASSIFICATION OF THE ORGAN-SYSTEMS

The term **organ-system** is employed in descriptive anatomy to designate a group of organs which co-operate in a general function. In many respects the systems represent primitive functions, and it is therefore largely on account of the independent elaboration of these that the systems may be recognized also on a structural basis as groups of organs allied in origin and development. The exact number of systems recognized depends on certain arbitrary distinctions, the following being those usually distinguished.

(1) The **integumentary system** comprises the skin, and its derivatives, such as the claws (or nails), hairs, and various glands of epidermal origin.

(2) The **skeletal system** comprises the cartilage and bone elements of the skeleton, with their connections.

(3) The **muscular system** comprises all contractile structures of the body. Since, however, the involuntary muscles are arranged as muscle layers in connection with visceral organs, the muscular

system is usually considered as including only the individual or voluntary muscles of the skeleton and skin.

(4) The **nervous system** comprises the **central nervous system** (the **brain** and **spinal cord**) and the **peripheral nervous system**, the latter consisting of the paired **cranial** and **spinal nerves** with their associated ganglia and the **autonomic nervous system**. The last is made up of a pair of ganglionated **sympathetic trunks**, with two series of ganglia, **collateral** and **peripheral**, interposed between these and the visceral organs, and of a set of visceral ganglia and nerves (**parasympathetic system**) connected with the cranial and sacral regions. Associated with the nervous system are the **special sense organs** of the head belonging fundamentally in part to the nervous system and in part to the surface layers of the body.

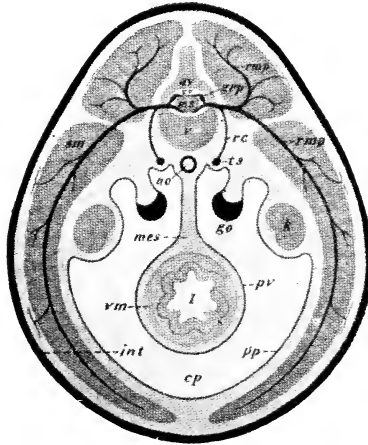


FIG. 20. Schematic representation of the chief organ-systems of a generalized vertebrate as seen in a transverse section of the abdominal region:

Integument—int.

Skeleton—v, vertebral body; av, vertebral arch; cv, vertebral canal.

Muscular system—sm, skeletal muscle; vm, visceral muscle.

Nervous system—ms, spinal cord, with the central canal, and the dorsal (posterior) and ventral (anterior) roots of the spinal nerves; grp, ganglion of the posterior root; rc, ramus communicans to sympathetic trunk; rma and rmp, ventral and dorsal rami of a spinal nerve; ts, sympathetic trunk.

Digestive system—i, intestine.

Vascular system—ao, aorta.

Urogenital system—k, kidney; go, gonad (ovary or testis).

Serous cavity—cp, general coelom, pleuroperitoneal, or peritoneal cavity; pv and pp, visceral and parietal parts of the serous tunic—visceral and parietal peritoneum; mes, mesentery.

(5) The **digestive system** comprises the **digestive tube** and its outstanding glandular appendages—the **oral glands**, the **liver**, and the **pancreas**.

(6) The **respiratory system** comprises the **lungs**, and **respiratory passages**, namely, the **bronchi**, the **trachea**, and the **larynx**. With this system may also be included the **accessory respiratory passages** formed by the **nasal fossae**.

(7) The **vascular system** comprises the organs of circulation of the blood and the lymphatic system. The former are the **heart**, the **arteries**, the **capillary vessels**, and the **veins**; the latter the lymph-conducting canals, which, though they ultimately empty into the veins and do not constitute an independent circulatory path, are sometimes considered as forming with their associated lymph glands a separate **lymphatic system**.

(8) The **urinogenital system** includes the reproductive and excretory organs, together with their common ducts—the **urethra** of the male and the **vestibulum** of the female—and the associated **bulbourethral gland**. The reproductive organs comprise, in the male, the central organs or **testes**, and the **deferent ducts**, both

of which are paired, the unpaired **seminal vesicle**, and the paired **prostatic** and **paraprostatic glands**. In the female, the reproductive organs comprise the paired **ovaries**, **uterine tubes**, and **uteri**, together with the unpaired **vagina**. The excretory organs of both sexes comprise the paired **kidneys** and **ureters** and the unpaired **urinary bladder**.

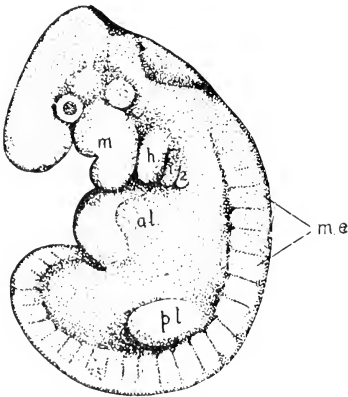


FIG. 21. Rabbit-embryo of 10½ days (4.8 mm.): m., manubrium; h., hyoid; 1 and 2, first and second branchial arches; a.l., anterior limb-bud; me., metamerites; p.l., posterior limb-bud. (After Minot and Taylor, in Keibel's Normentafeln, V; Fig. 12.)

Only included in part, or omitted in this classification are certain organs which physiologically at least may be grouped together because they have general regulatory and growth-controlling functions. They constitute the internal secreting, hormone, or

endocrine system, and include portions of the reproductive organs and pancreas, the *hypophysis*, *pineal body*, *suprarenal*, *thyroid*, *parathyroid*, and *thymus* glands.

GENERAL ORGANIZATION

It has already been pointed out that all chordates have a structural ground plan involving the possession of an axial skeleton in the form of a notochord, a dorsal tubular central nervous system, and a series of gill clefts leading from the alimentary canal to the exterior, and that all vertebrates (which constitute a subphylum of the chordates) are basically segmented.

The rabbit being a vertebrate, its organ-systems are disposed in conformity with these fundamental principles.

(1) **Axial orientation.** Associated with the elongated shape of the body in most animals there is a general lengthwise arrangement of the principal organ-systems, which thus lie more or less parallel to one another. This can be observed in invertebrates, such as the annulate worms, in respect of the more nearly original systems. In the vertebrates, the presence of the vertebral column establishes a structural axis, with reference to which the organ-systems are arranged (Figs. 20, 22).

(2) **Metamerism.** A large portion of the body, mainly dorso-lateral in position, is arranged on a segmented plan, in which parts are repeated serially and longitudinally around and to either side of the original axis. This segmentation, or metamerism, does not appear to any extent on the surface of the adult body, but becomes evident internally in the subdivision of the vertebral column into vertebrae, and the paired, serial arrangement of the related spinal nerves, vessels, and musculature. Metamerism is externally evident in embryos (Fig. 21, me.) and is founded upon the serial arrangement of parts of the mesoderm (Fig. 22, my., d.m.).

(3) **Branchiomerism.** This is a secondary segmentation, superposed upon the primary metamerism by the development of a series of gill clefts which do not always correspond precisely with the metameres. It is an adult feature of lower aquatic vertebrates, such as fishes (Fig. 32), where it is expressed in a series of true gill, or branchial structures, associated with gill filaments as functional

respiratory organs. In higher terrestrial animals it appears as an embryonic feature (Fig. 21, m., h., 1, 2) and is to be considered both as a determinant of adult form and as a mark of aquatic ancestry. It underlies the arrangement not only of structures which in the lower vertebrates belong to functional gills (branchial arches in the restricted sense) but also of modified branchial structures such as the first visceral, or mandibular arch (m.) and the second visceral, or hyoid arch (h.). The modification of these structures in passing

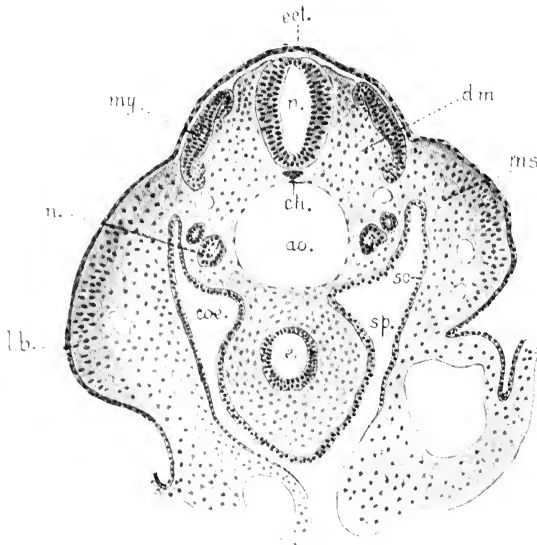


FIG. 22. Transverse section of a rabbit-embryo of about 10½ days, showing the arrangement of the organ-systems: a.o., aorta; ch., notochord; coe., coelomic cavity; d.m., dorsal mesoderm (myotomic and sclerotomic divisions); e., primitive alimentary canal (enteron); ect., ectoderm; l.b., limb-bud; ms., mesenchyme; my., external portion of a myotome; n., nephrotome of embryonic kidney; intermediate mass of mesoderm; sp. and so., splanchnic (visceral) and somatic (parietal) portions of the ventral mesoderm.

from the embryonic to the adult condition is very great, but their arrangement determines the position and relations of certain skeletal structures, including the auditory ossicles, the hyoid, and in part the laryngeal cartilages—a point of some value in the classification of the parts of the head skeleton. It also determines the succession of certain soft structures, including the fifth, seventh, ninth, and

tenth cranial nerves and the chief arterial vessels of the heart, which are more fully referred to below.

The fundamental significance of branchiomerism lies in the fact that respiration by means of gill perforations of the pharynx is characteristic of that branch of the animal kingdom designated Chordata. In the various invertebrate phyla are found respiratory surfaces of many kinds, such as thin surface membranes, external tufted, or invaginated tubes, and analogous structures, but these provide for diffusion without perforation of the body tube.

EMBRYONIC PLAN OF THE SYSTEMS

Governed by the broad principles of organization just indicated, the individual organ-systems are disposed according to a general plan the main features of which may be outlined as follows:

1. The formation of an axial skeletal support, consisting primarily of a strand of cellular tissue, the notochord, and secondarily of a segmented cartilaginous, afterwards bony, vertebral column.

2. The formation at the anterior end of this axial support of (a) a primary cartilage skull (chondrocranium) as a support for the brain, with capsules for the special sense organs (neurocranium or cerebral cranium); and (b) a series of cartilaginous visceral arches (splanchnocranium or visceral cranium).

3. The formation of the chief skeletal muscle in a dorsolateral position along the axis.

4. The formation of the central nervous system as a tube of nervous matter (neural tube), lying on the dorsal side of the axial support, and differentiated into a generalized posterior portion, the spinal cord, and an expanded and specialized anterior portion, the brain.

5. The formation of the digestive tube as a median structure, lying directly beneath the axial support, and of special glandular appendages arising from the epithelium of its wall.

6. The formation of the lungs as paired outgrowths of the ventral wall of the digestive tube, afterwards connected with the outside of the body by accessory respiratory tracts traversing the head.

7. The formation of the circulatory system primarily on an aquatic plan. This involves the formation of (*a*) the heart in a position ventral to the digestive tube and immediately behind the gills; (*b*) a ventral aorta, passing forward to the gills, and dividing into a paired series of branchial aortic arches; (*c*) a dorsal aorta, in which the upper ends of the aortic arches unite, and which passes backward along the ventral surface of the axial support; and (*d*) a series of paired veins returning the blood from various parts of the body to the heart.

8. The formation of the reproductive organs or gonads in association with the dorsal lining of the coelomic cavity, and their connection with the outside of the body by modified kidney ducts.

9. The formation of the kidneys, either as embryonic or as permanent structures, from an intermediate mass of tissue, lying in general between the dorsal musculature and the lining of the coelomic cavity (cf. position of embryonic kidney in Fig. 22).

10. The formation, in the ventral portion of the body, of an extensive space, the coelomic cavity or coelom, afterwards differentiated into pericardial, pleural, and peritoneal portions.

THE SKELETAL SYSTEM

The designation "vertebrate" has reference to a common feature of fishes, amphibians, reptiles, birds, and mammals—the possession of a backbone or **vertebral column**, composed of individual segments, the **vertebrae**. Vertebrates are, however, more properly described as animals having an internal skeleton.

Skeletal Architecture

The skeleton being composed of nearly rigid materials, it is necessary, in order that movement may be possible, that these should form many separate pieces, designated cartilages or bones according to the material composing them. In the embryonic condition, cartilage rudiments form a complete but primitive skeleton and in some lower vertebrates the skeleton remains entirely cartilaginous throughout life. The latter, however, is probably a degenerate condition for, although cartilage may actually have originated earlier than bone in the history of living beings, bone

was already present in many of the oldest known fossil vertebrates. In most vertebrates, the cartilage rudiments later are largely replaced by bone and membrane bones are added. In many cases the replacement of these elements by bone is not direct, certain readjustments being necessary both for purposes of growth and to meet the much more special functional requirements of the adult skeleton.

The way in which replacing bones are formed on the cartilage basis explains many peculiarities of the adult skeleton. In the embryonic condition the cartilage rudiments are enclosed by a connective tissue sheath, equivalent to the periosteum of a bone (p. 24), but described as the perichondrium. Like the periosteum, this sheath contains many osteoblasts, which form bone material both in the interior of the cartilage (endochondral bone) and on its surface (intramembranous bone). The formation of endochondral bone proceeds from certain localized areas, known as centres of ossification, into which active cells of the perichondrium are carried by vascular ingrowths, the periosteal buds. In the vicinity of these the cartilage matrix partly dissolves and the cells thereby set free die and disintegrate. The ingrowing buds extend into the spaces thus produced, constituting the primary marrow, and deposit layers of bone-matrix round the irregular calcified spicules of cartilage-matrix which still remain. Such deposition of bone material gradually extends from the centres of ossification through the remainder of the cartilage replacing it. This condition is partly illustrated in the distal epiphysis of the humerus shown in Fig. 26 A, where the area of endochondral bone (eb) appears in the centre of the mass of cartilage.

In long bones the formation of the first or **main centres** of ossification takes place in the shaft, and there are formed afterwards accessory or **epiphysial centres** for the extremities. A divided extremity, such as the proximal end of the femur (Fig. 24), may possess several such centres—a principal one for the chief epiphysis or actual extremity of the bone and several subsidiary centres for its outstanding processes. In the shaft the formation of endochondral bone is of short duration. Through the activity of the osteo-

blasts lying directly in the perichondrium, or later the periosteum,

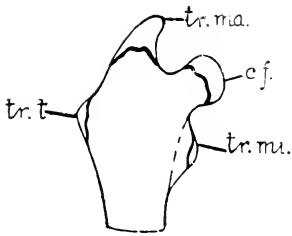


FIG. 24. Outline sketch of the proximal end of the femur of a young animal: cf., principal epiphysis for the head of the femur. The accessory epiphyses are for the great (tr.ma.), lesser (tr.mi.), and third (tr.t.) trochanters.

a process of formation of intramembranous bone goes on, continuing to the end of the period of growth, and the result of this peripheral deposition of bone lamellae is, that the transverse diameter of the bone is greatly increased. The enlargement of the marrow-cavity, with which this is associated, is produced by the absorption of bone from the interior.

In young animals both the epiphysial centres and the masses of cartilage in which they are formed

are sharply marked off from the body of the bone (cf. Fig. 26). This is largely because the formation of the epiphysial centres tends to lag behind that of the main centres, and thus the cartilage extremities of the bones are evident long after the formation of the shaft is under way. In the epiphysial centres the bone formation is endochondral. The bone masses which they form are distinguished as **epiphyses**. During the period of growth they are connected with the body of the bone by plates of epiphysial cartilage, into which the surrounding perichondrium extends as an ossification ridge. In this region bone formation takes place, with the result that the whole structure is greatly increased in length.

After the period of growth, the duration of which differs in different bones, the epiphyses become firmly co-ossified with the body of the bone, although the lines of junction or **epiphysial lines** may still be visible. Thus in the distal extremities of the radius and ulna, in the proximal extremities of the fibula, or in the bodies of the lumbar vertebrae, the epiphysial lines appear even in old animals. In figure 12, which represents a divided femur, it may be seen that the position of the epiphysial lines is indicated by bands

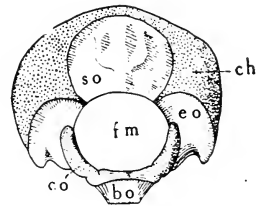


FIG. 25. The occipital portion of the skull in a three-day-old rabbit: bo, basi-occipital bone; ch, occipital portion of chondrocranium; co, occipital condyle; eo, exoccipital; fm, foramen magnum; so, supra-occipital.

of compact tissue. If the bones of young animals are thoroughly macerated, the epiphyses are usually found to be readily separable from the main parts of the bones.

In a comparison of the adult skeleton with the more primitive embryonic skeleton, several differences in the arrangement of the elements are evident. Thus many bones, notwithstanding their possession of several centres of ossification, are to be looked upon as individual structures, while in other cases, as in the basal portion of the skull, separate bone elements are produced in a mass of cartilage primarily continuous. These either remain distinct

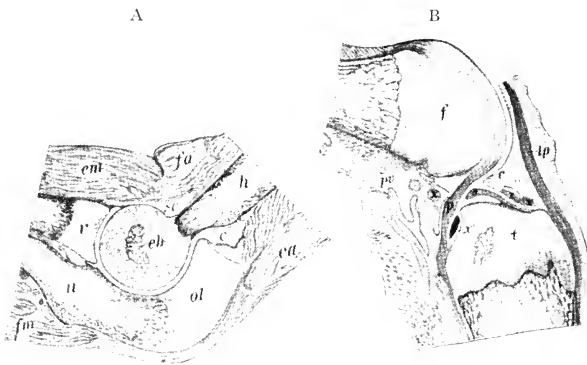


FIG. 26. Vertical sections of elbow and knee of four-day-old rabbit. A, elbow: c, capsule; eb, endochondral bone in the distal epiphysis of the humerus; ea, extensor muscles of the forearm; em, extensors of the hand; fa, flexors of the forearm; fm, flexors of the hand; h, humerus; ol, olecranon; r, radius; sc, synovial cavity; u, ulna. B, knee: a, anterior cruciate ligament; c, capsule; f, femur; lp, patellar ligament; p, posterior cruciate ligament; pv, popliteal vessels; t, tibia; x, x', anterior and posterior ligaments of the lateral meniscus; x'x', anterior and posterior ligaments of the medial meniscus.


throughout life, or, as in the occipital region (Fig. 25), become fused together to form compound or **composite bones**. In still other cases, as in the vertebrae, the apparently single elements of the adult condition are the products not only of originally distinct bones, but also of primarily separate cartilage masses.

The bones of the skeleton are united or **articulated** with one another by connective tissue in the form of ligaments, by cartilage, or in some cases by both together, i.e. by fibro-cartilage. The

articulations of bones are of two types—immovable articulations or **synarthroses**, and movable articulations, **diarthroses**, or joints. In the former, motion is either absent or, at least, greatly restricted. In the latter, it is definitely provided for through the presence of joint structures. Synarthrosis may be formed by ligamentous union, distinguished as **syndesmosis**. This is exemplified between carpal or tarsal bones and between the radius and the ulna. The articulation of the bones of the skull (except in the basal region as indicated below), which are fitted together by more or less uneven edges or surfaces, with usually only a small amount of fibrous tissue continuous with the periosteum between, is known as suture, which is thus a special case of syndesmosis. Cartilage union, or **synchondrosis**, occurs in certain situations, as in the basal region of the skull. Union by fibrocartilage, or **symphysis**, is found in the articulation of the two sides of the pelvis (symphysis pubis), and in that of the two halves of the mandible.

In a joint (Fig. 26), the apposed surfaces of the bones are accurately modelled in relation to each other, and are, moreover, covered by layers of cartilage, the **articular cartilages**, which form joint cushions. Between the two surfaces is a space, the cavity of the joint, containing a viscid material, the **synovia**, which serves for lubrication. The space is enclosed by a connective tissue **capsule** continuous with the perichondrium of the articular cartilage or with the periosteum of the bone. Within the capsule, perichondrium is present at the edges of the articular cartilages but thins out and is absent over the surfaces which actually rub together. The synovia is secreted by the inner or synovial layer of the capsule. The strength of the joint depends largely on the enclosing capsule, but it is usually greatly increased by the presence of accessory ligaments. In the more complex joints, such as that of the knee (Fig. 26, B), **interarticular cartilages** (menisci) are enclosed between the bone surfaces, and the latter are connected directly by short ligamentous cords. The various ligaments of a joint permit free motion of the bones, but only up to a certain point, which varies according to the functional needs of each particular joint.

Several differences are observable in joints according to the form of the apposed surface and the kind of motion provided for. Thus in the ball-and-socket joint or **enarthrosis**, exemplified by



those of the shoulder and hip, a bone is able to move in various directions about its base of attachment, although actually, in the limbs, this motion is almost restricted to an anteroposterior direction. In the **ginglymus** or hinge-joint, as exemplified by the distal articulations of the limb, motion is restricted to a single plane. The gliding joint or **arthrodia** is one in which a slight degree of motion is made possible by one surface slipping over the other; it is exemplified in the accessory articulations of the vertebral arches.

Skeletal Regions

The internal skeleton of a vertebrate nearly always consists of a principal or **axial** portion and an **appendicular** portion. The axial skeleton is formed by the vertebral column, the ribs, the sternum, and the skeleton of the head; the appendicular skeleton by the parts devoted to the support of the limbs, though in the case of terrestrial vertebrates it would be more precise to say that these are devoted to the support of the body on the limbs and to locomotion. In both fore and hind limbs, the skeletal support consists of a proximal portion lying within the contour of the body and forming the **pectoral** and **pelvic girdles**, and of a distal portion, lying beyond the general contour of the body and comprising the **skeleton** of the **free extremities**. The limbs of vertebrates present an extraordinary range of adaptations, being modified in the various groups into fins, paddles, wings, and walking or running limbs. In the majority of cases their adherence to a common ground plan is evident from their composition.

The Vertebral Column

The vertebral column of the rabbit consists of 7 **cervical**, 12 **thoracic**, 7 **lumbar**, 4 **sacral**, and 14-16 **caudal** vertebrae. The vertebrae are found to be gradually modified from any intermediate part of the column forward or backward, but a characteristic type of vertebra can be identified for each region. In fishes, which live in a medium of about the same weight as their bodies, the line of the vertebral column is straight, and there is little indication of regional differentiation. In terrestrial vertebrates, on the other hand, especially in mammals, the vertebrae are not arranged in a straight line but form a curve dorsad in the trunk or thoraco-

lumbar region. This constitutes an arch between the attachments to the fore and hind limbs for the support of the body in a light medium when the limbs raise it from the ground. The anterior and posterior ends of the body, which project beyond the supporting limbs, are sustained by the column curving ventrad in the cervical and caudal regions (with, of course, stout ligaments dorsally). In man, the curvatures are modified in relation to the assumption of an erect attitude, a lumbar curve ventrad developing to counteract the dorsal curve of the thoracic region, and the caudal region is reduced to a vestige, the **coccyx**, consisting of coalesced vertebrae.

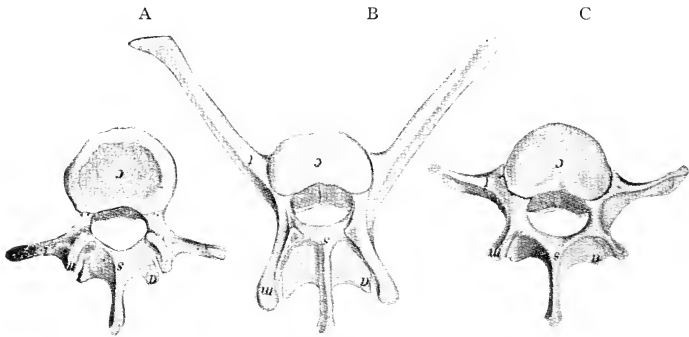


FIG. 27. Mid-lumbar vertebrae of bear (A, fifth), rabbit (B, fifth), and man (C, third): a, inferior articular process; c, body; m, mamillary and superior articular process; s, spinous process; t, transverse process.

The individual vertebra is made up of a massive ventral **body**, or **centrum**, and a dorsal **arch**, both composed of replacing bone (Fig. 28). Both body and arch bear processes which extend into the surrounding muscles and serve for their attachment. The principal processes are dorsomedian or **spinous**, lateral or **transverse**, and in the lumbar region, dorsolateral or mamillary. Less prominent processes bearing surfaces for mutual articulation are also present.

Generally speaking every vertebra has three principal functions—to support the body, to protect the spinal cord, and to provide a basis of attachment for muscles. In the support and movement of the body, the ventral part of the vertebra is subjected mainly to forces compressing it, the dorsal part to forces of tension. Hence

the ventral part, or centrum, is massive and the dorsal arch and processes are thinner and weaker.

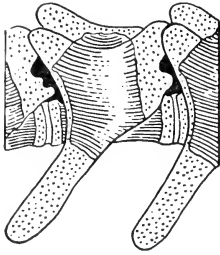


FIG. 28. Lumbar vertebra of four-day-old rabbit. Cartilage dotted, bone shaded. X5.

Any vertebra of the rabbit may be compared with the corresponding vertebra of any mammal or in a general way with those of any vertebrate, and will be found to show resemblances and differences corresponding with those of the precise functions performed by the bones compared. The fifth lumbar vertebra of the rabbit, for example, would be found distinguished by the great development of its processes, since the latter support powerful muscles used in leaping. The corresponding human vertebra, or the third as functionally more nearly equivalent, is weak in muscular expansion, but its body is massive for purposes of axial support. A corresponding vertebra of the bear will be found more or less intermediate between the two types (Fig. 27).

The two most cephalic vertebrae are very much modified to provide for the movements and the support of the head. The centrum of the first vertebra, or atlas, has lost its connection with the rest of this part and has fused with the anterior end of the centrum of the second vertebra, the epistropheus, to form a pivot round which the ring-like atlas can rotate. The ventral part of the adult atlas is derived from a small element, the intercentrum, which in other vertebrae has disappeared. These changes occurred in early reptiles but reach their most perfect expression in mammals.

The Notochord

The **axial line** of the vertebrae passes through the centres of the bodies, the position occupied in the embryo by the **notochord** (Fig. 22). Some of the lower aquatic chordates, such as lampreys, exhibit the notochord in both young and adult conditions, and show little indication of the development of the elements of vertebrae. Others, of slightly more advanced grade, such as sharks (Fig. 29), show the notochord surviving more or less to the adult condition with the vertebral elements developed round about it.

The Skull

Composition of the Skull

The head skeleton of a mammal, usually but inaptly called the skull, is a complex of individual bones and cartilage, the arrangement and functions of which may be determined with a little effort. The general disposition of the bone elements, demonstrable in the rabbit or any mammal is as indicated in Fig. 30. Briefly, there is a linear series of basal segments, comprising from behind forward **basioccipital**, **basisphenoid**, **presphenoid**, and **mesethmoid**. The three first-named form the floor of the brain-case, while the mesethmoid forms the nasal septum. Associated with the basioccipital are paired, lateral **exoccipital** bones, and a **supraoccipital** element, together forming an occipital ring enclosing the aperture for transmission of the spinal cord from the cranial cavity (Fig. 25). In ancestral tetrapods, the basioccipital and exoccipital bones took part in the formation of a single rounded condyle for articulation with the first vertebra. In mammals, however, the posterior end of the basioccipital has become reduced, leaving only the two lateral components of the original condyle to make this articulation. Hence the mammal has paired occipital condyles, borne upon the exoccipital bones only and constituting a stronger joint with motion practically restricted to the vertical plane. The basisphenoid and presphenoid bear lateral expansions, respectively the **greater** and **lesser wings**, or **alisphenoids** and **orbitosphenoids**, which assist in the formation of the side walls of the brain-case. The bony capsule (**periotic bone**) lodging the internal ear on either side is solidly built into the lateral cranial wall between the exoccipital and the alisphenoid, while further forward the light scroll-like surfaces of the **ethmoid bone**, or **ethmoturbinal**, representing the chief, or olfactory portions of the **nasal capsule**, are attached on each side of the base of the mesethmoid. The original extent of the nasal capsule is, however, more nearly commensurate with the general




FIG. 29. Transverse section of shark vertebra (cartilage stage), from young specimen of Atlantic dogfish, *Acanthias*: i. intercalary cartilage, completing arch; n. notochord; v. body of vertebra.

cavity of the nose; and additional turbinal surfaces, comprising the **nasoturbinals** and **maxilloturbinals**, are attached secondarily to the nasal and maxillary bones, the maxilloturbinals occupying only the respiratory or non-olfactory portion of the cavity.

To this foundation of cartilage bones there is added a series of enclosing membrane bones, for the most part thin and superficial, but nevertheless making up the greater part of the **facial** portion of the head skeleton as opposed to the **cranial** or brain-containing portion. The series comprises a median **interparietal** (absent in the hare and many other mammals), paired **parietal**, **squamosal**, **frontal**,

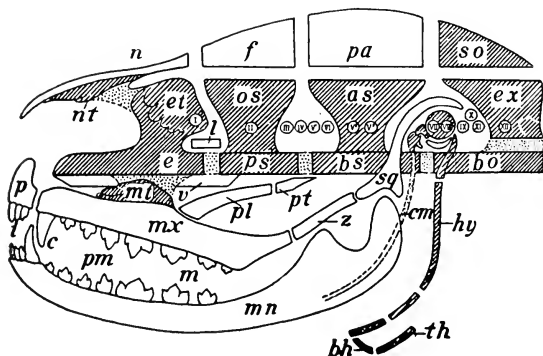


FIG. 30. Composition of the mammalian skull. Cartilage dotted, cartilage bone shaded, derm bones plain: I-XII, cranial nerves; as, alisphenoid; bh, body of hyoid; bo, basioccipital; bs, basisphenoid; c, canine teeth; cm, Meckel's (mandibular) cartilage (visceral arch I); e, mesethmoid; et, ethmoturbinal; ex, exoccipital; f, frontal; hy, hyoid (visceral arch II); i, incisors; l, lacrimal; m, molar teeth; mn, mandible; mx, maxilla; nt, maxilloturbinal; n, nasal; nt, nasoturbinal; os, orbitosphenoid; p, premaxilla; pa, parietal; pl, palatine; pm, premolar teeth; pt, pterygoid; sq, squamosal; so, supraoccipital; th, thyreo-hyal (visceral arch III); v, vomer; z, zygomatic.

and **nasal** bones as roofing structures, and paired **premaxillary**, **maxillary**, **palatine**, **pterygoid**, and **mandibular** bones forming the solid supports of the mouth. Several lateral elements also take part, including the **lacrimal**, at the anterior border of the orbit, the **zygomatic**, forming the central portion of the corresponding arch, for protection of the orbit and for muscular support, and finally the bladder-like **tympenic** bone, which forms the enclosure of the middle ear and protects the delicate bones of the **auditory chain**.

An important though inconspicuous portion of the head skeleton is formed by the **hyoid apparatus** supporting the tongue, and

certain cartilages of the larynx, with which the hyoid is intimately associated. The relation of this complex to the skull is indicated in a mammal by the suspension of the hyoid apparatus from its base. The three bones of the auditory chain (the series of small bones in the middle ear—**malleus**, **incus**, and **stapes**) and the elements just referred to, together with certain replacing or derm elements, constitute the modified remnant in the mammal of what is often regarded as a third main division of the internal skeleton, namely, the **visceral skeleton**.

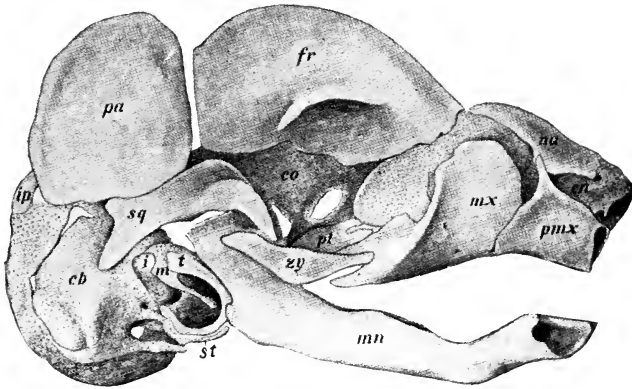


FIG. 31. Lateral view of skull of rabbit foetus, 45 mm: cb, co, cn, cranial, orbital, and nasal portions of primary chondrocranium; fr, frontal; pa, parietal; pl, palatine; pmx, premaxilla; sq, squamosal; st, styloid process; i, incus; ip, interparietal; m, malleus; mn, mandible; mx, maxilla; na, nasal; t, tympanic; zy, zygomatic. (Born plate model, after Voit.)

Chondrocranium and Osteocranium

The skull consists primarily in the embryo of a cartilage trough, the extent of which is roughly definable as the area occupied by the occipital, anterior and posterior sphenoidal, and ethmoidal portions (Fig. 31). As a cartilage skull it is designated as the **chondrocranium**, and after its conversion into bone as the **osteocranium**. It is no more than an enclosure for the brain, except that it has associated with it the cartilage capsules of the nasal, visual, and auditory organs, and, in the case of the first and last of these, the capsules are incorporated with the skull proper. This, the primary skull, is designated as the **neuro-cranium** or **cerebral cranium**, to

distinguish it from a second portion of the head skeleton, the **splanchnocranium** or **visceral cranium**, which includes the series of visceral arches suspended from the ventral surface of the neurocranium. The addition to the primary head skeleton of a large number of membrane bones results in more or less obscuring of the original divisions, since the membrane portions of the visceral cranium are, with the exception of the mandible, united by suture

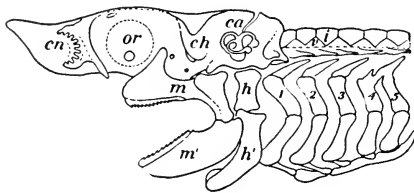


FIG. 32. The chondrocranium and visceral arches of the Atlantic dogfish, *Acanthias*: ca, auditory capsule; ch, chondrocranium; cn, nasal capsule; h, h', dorsal and ventral segments of hyoid arch (II); i, intercalary cartilage of vertebral column; m, m', dorsal and ventral portions of mandibular arch (I), functional upper and lower jaws; malleus and incus of mammalian ear; or, orbit depression for optic capsule; v, vertebra; 1-5, branchial arches.

with those of the cerebral cranium, while the true cartilage or cartilage bone portions of the former, occurring as the auditory ossicles, the hyoid, and the larynx (in part), although highly modified, remain in a more or less independent relation.

The components are strikingly distinct in the mammalian skull during the later stages of foetal development,

the cartilage of the chondrocranium and the bones ossifying in its interior forming a basal mass, from which, as a foundation, are suspended elements of the same nature, principally auditory and hyoid, in a somewhat arch- or rod-like form. The auditory arch is formed by the two more lateral bones of the auditory chain, incus and malleus, of which the incus is attached to the skull, while the malleus is extended as the **cartilage of Meckel** almost the whole length of the inner surface of the mandible. The bulk of the skull is formed already by the surface elements distributed in the characteristic fashion, but as yet only loosely associated (cf. Fig. 31).

Head Skeleton of Lower Vertebrates

This condition of the developing skull in a mammal finds its explanation far back in the history of the vertebrates and is made clear only by the study of some one of the lower fishes such as shark or sturgeon. In a shark (Fig. 32) the entire internal skeleton is formed in cartilage which persists throughout life. The principal

part of the head skeleton is a massive cartilaginous box (chondrocranium), enclosing the brain, and including, as a result of growth and fusion, the nasal and auditory capsules. The eye capsules are free, and are accommodated at the side of the cranium in an orbital depression, to be seen on the skull of all vertebrates. This type of structure is obviously the basis of the mammalian skull, except that in the latter the cartilage mass is more nearly restricted to its basal portion and at the same time is more specialized in its replacement by definite bone centres.

It is, however, in respect of the visceral arches suspended from the chondrocranium that the structure of the shark skull is most illuminating. The first or **mandibular** arch forms the upper and lower jaws. Its composition illustrates the phylogenetic basis of the origin of the external part of the auditory chain in the mammalian embryo, the two bones which this part comprises corresponding with the posterior ends of the two cartilaginous jaws of the sharks. Such a relation establishes the fact that in the history of mammals this arch has undergone a profound change of function. The second or **hyoid arch**, though developed to an extent out of keeping with the rudimentary state of the primitive tongue, is nevertheless obviously homologous with the hyoid arch of a mammal. In most sharks its upper portion has an important accessory function in the support of the jaws and this part probably becomes the third bone (stapes) of the auditory chain in the mammal. Following the hyoid arch are five ordinary or **branchial arches** supporting the filaments of the gills and serving as pillars of the gill apertures. These arches are the parts of an extensive system out of which have been formed by specialization part of the hyoid apparatus and most, if not all, of the laryngeal cartilages of mammals.

So far as the surface or roofing portion of the skull is concerned, it is represented in a shark only by dermal teeth or shagreen denticles (Fig. 33), uniformly distributed in the skin of the body, and slightly modified in shape and size at the aperture of the mouth to constitute definite teeth lining the jaws. In sturgeons and related fishes, however, these structures are already concentrated



FIG. 33. Shagreen denticles of the smooth dogfish, *Mustelus*; enlarged.

into a definite pattern of surface plates, having in general the same disposition as derm elements in the skull of all higher vertebrates, and distributed in such a way that they form an almost complete enclosure for those parts of the chondrocranium which they invest. The pattern of the dorsal elements is best indicated in fossil amphibia and early reptilia, in which the plan is almost diagrammatic.

The elements of the head skeleton may be classified as follows:

1. The **CEREBRAL CRANIUM** (cranium cerebrale or neurocranium), including:

- (a) The primary cartilage skull (chondrocranium), enclosing the brain, and containing in its wall the olfactory and auditory capsules (embryonic);
- (b) The secondary bone skull (osteocranium), replacing (a) and comprising the **occipital, sphenoid, ethmoid, inferior turbinal, and periotic** bones;
- (c) The associated derm elements, comprising the **interparietal, parietal, frontal, nasal, vomerine, lacrimal, tympanic,¹ and squamosal** bones.

2. The **VISCERAL CRANIUM** (cranium viscerale or splanchnocranium), including:

- (a) The primary mandibular and hyoid² visceral arches (embryonic);
- (b) The secondary elements, replacing (a)—the **malleus, incus, and stapes** of the auditory chain; the **hyoid** bone and its connections with the skull;
- (c) The associated derm elements of the face and palate, comprising the **premaxillary, maxillary, zygomatic, mandibular, palatine, and vestigial pterygoid** bones.

Dentition

Accessory structures intimately associated with the visceral skeleton, though related functionally to the digestive system, are

¹The identification of the tympanic as a derm element has been questioned.

²The thyreoid cartilage of the larynx and its connection with the hyoid (greater cornu) and possibly the other laryngeal cartilages are modified branchial arches, but the structure as a whole is not included with the head skeleton.

the teeth. Those of the rabbit present two characteristically mammalian features; they are **heterodont**, or differentiated in different regions of the jaw; and they are **diphyodont**, that is to say, the adult series are **permanent** teeth, which, excepting those designated as molars, replace **deciduous**, or **milk** teeth of the young animal. In lower vertebrates, in contrast with this condition, there is usually a multiple tooth change, new teeth being developed as required (polyphyodont type). Moreover, in the rabbit, as in all mammalia, the number is restricted, so that, considering the differentiation of the teeth, it is possible to express their relations by a **dental formula**. In the mammalia generally the teeth are differentiated into **incisors**, **canines**, **premolars**, and **molars**, and in placental mammals the full dental formula is indicated as i. $\frac{3}{3}$, c. $\frac{1}{1}$, pm. $\frac{4}{4}$, m. $\frac{3}{3}$. The incisors, the most anterior teeth, are more or less flattened into a chisel-like form; the canines are sharp, roughly conical, and sometimes elongated into prominent tusks; the premolars and molars, together designated cheek-teeth, are distinguished chiefly by the occurrence of the former in both sets and of the latter in the permanent set only. In the rabbit, as in other rodents, however, the dentition is greatly modified by the elaboration of two pairs of incisors for gnawing and the corresponding obliteration of intermediate teeth, the place of the latter being occupied by an extensive gap, or diastema, in which no teeth occur. The dental formula of the rabbit is i. $\frac{2}{1}$, c. $\frac{0}{0}$, pm. $\frac{3}{2}$, m. $\frac{3}{3}$. The specialization of the medial incisors retained by the rabbit is accomplished by the elimination of enamel from the posterior surfaces so that the posterior part of the tooth is worn away by use more rapidly than the anterior layer, which thus forms a sharp cutting edge. It will also be observed in this animal that the absence of the intermediate teeth allows the lips to be approximated behind the incisors, and since in this region the lips are also provided with hairs on their internal surfaces, the main part of the oral cavity is separated almost completely from a small space enclosing the incisor teeth. This adaptation, however, is not so perfectly developed in the rabbit as in certain members of the rodent order proper.

The cheek-teeth of the rabbit are modified for grinding by the formation of flattened ends with prominent transverse ridges.

Since the chewing motion of the mandible is almost entirely antero-posterior, these ridges are at right angles to the direction of movement in this activity.

The Human Skull

If the human skull be compared with that of the rabbit or other mammal, it is seen to differ most markedly in the enormous development of the cranial region, and in the anteroposterior compression of the face, with which is associated shortening of the jaw region, reduction of the nasal cavities, and rotation of the orbits to a forward position. A most instructive feature is the readjustment of the axes of the skull, coincident with the assumption of the erect position. In both quadrupedal and bipedal positions the face naturally retains its forward direction. In most mammals, as in vertebrates generally, the axial line of the cranium, known as the **basicranial axis**, and that of the face, the **basifacial axis**, tend to be nearly in a straight line or at least parallel; while in primates they tend to form an obtuse angle which is progressively reduced from lower to higher types, being smallest in man, where it approximates a right angle.

The Appendicular Skeleton

It will be evident from a study of the limb-skeleton of the rabbit that there is a general correspondence in structure between its anterior and posterior divisions. This not only applies to the distinction of girdle portions and the divisibility of the free extremity into proximal, middle, and distal portions, but extends to very many smaller details of composition. The relation in structure between anterior and posterior limbs is described as **serial homology**, since two structures in the same animal cannot be homologous in the usual meaning of the term.

The pelvic girdle is more uniformly and solidly developed than the pectoral girdle, as shown by its strength in the three principal directions about the point of attachment of the limb, the great development of the ventral union, and the strong attachment to the sacrum. These features correspond with the usually proportionally greater thrust of the hind limbs in support of the body-weight and in locomotion. On the other hand, the pectoral girdle is notable

chiefly for the strong development of the scapula as opposed to the weakness of the ventral, pectoral portion. In the rabbit the clavicle is vestigial, and in many mammals, such as the ungulates, it is entirely absent. In man, however, as well as in other mammals in which the fore limb is capable of much movement transversely instead of only anteroposteriorly, the clavicle is well developed and is articulated at its ends with the scapula and sternum. In this condition it acts as a prop upon which the well-developed pectoral muscles of adduction move the limb. The absence of direct articulation with the vertebral column and the attachment thereto by muscles and ligaments provide a shock-absorbing apparatus which is of evident value in a quadruped, like the rabbit, where locomotion is largely of a leaping character with the fore limbs reaching the ground first after each leap.

Both pectoral and pelvic girdles in terrestrial vertebrates conform more or less closely to a tri-radiate shape if the two halves are considered individually. The corresponding portions may be identified (Fig. 34), though in mammals the ventral portion in the case of the pectoral girdle is greatly reduced. Of the ventral elements, those commonly present in vertebrates are the coracoid, which forms the posterior ray, and the procoracoid, the anterior ray, the latter being partly covered in front by a derm splint, the clavicle. This condition, though not characteristic of mammals generally, is still found in monotremes and rudiments of the coracoid extension ventrally are identifiable in embryonic marsupials. Adult marsupials and placentals show only a small hook-like

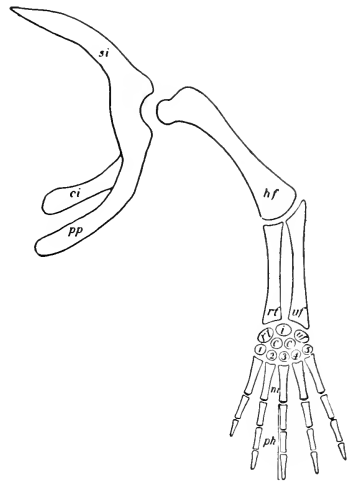


FIG. 34. Plan of the anterior limb skeleton in walking vertebrates, the equivalent elements of the posterior limb indicated in brackets: *si*, scapula (ilium), *pp*, procoracoid (pubis); *ci*, coracoid (ischium); *hf*, humerus (femur); *rt'*, radius (tibia); *uf'*, ulna (fibula); *rt*, radial carpal (tibial tarsal); *i*, intermedium; *uf*, ulnar carpal (fibular tarsal); *c.c.*, centrals; 1-5, distal carpals (tarsals); *m*, metacarpals (metatarsals); *ph*, phalanges of the digits.

coracoid process, and the clavicle in either perfect or less perfect development.

There is no more striking feature of homology than that shown by the free extremities in the different forms of vertebrates. This is **true homology** because it concerns the resemblances, part for part, in the anterior or in the posterior limb of any one vertebrate as compared with the corresponding elements in the same position in other forms. The front limb of the rabbit (Fig. 35,A) is slightly

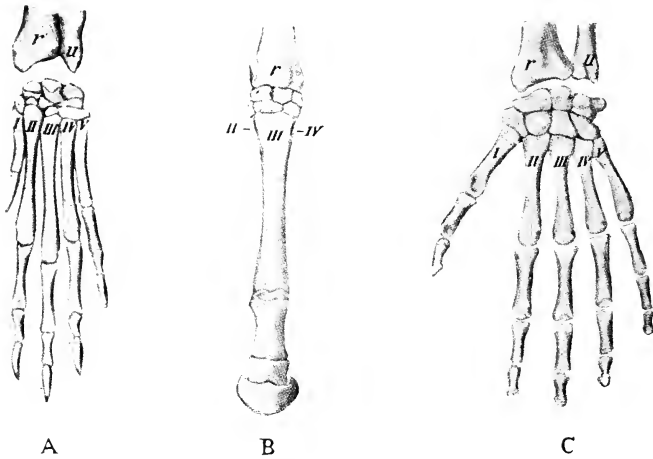


FIG. 35. Homologies of the mammalian limb. A, forefoot, rabbit. B, forefoot, horse. C, human hand. r, radius; u, ulna; I-V, metacarpa bones.

elongated and semi-digitigrade, the weight being supported on the tips of the bones of the palm (metacarpals), as shown in Fig. 23. These modifications make it more efficient for running than a more primitive limb, which is shorter and plantigrade (having the palm or sole applied to the ground), though it is less specialized and less efficient as a running organ than the limb of the horse (Fig. 35, B). The human hand retains a fairly primitive form as to its general proportions, but is modified into a seizing or grasping type, the thumb being opposable to the remaining digits. The limbs of the rabbit, of the horse, and of man, however, are all modifications of a primitive, five-toed limb, sometimes termed the ideal **pentadactyl plantigrade** type, in which the palm of the hand or sole of the foot is placed flat on the ground. The composition of this primitive

limb, traceable in one form or another throughout the higher vertebrates, and also the serial homologies of the parts are indicated in Fig. 34, while Fig. 36 illustrates the modifications which have occurred in the bones of the wrist and ankle in a few familiar species of animals. Such modifications (mainly reduction of the number of separate bones by fusion) are always greater in the

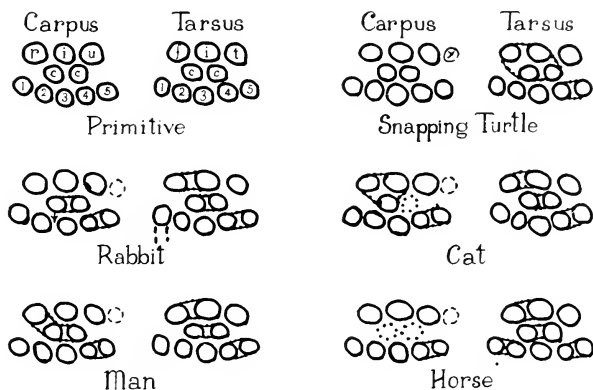


FIG. 36. Diagrams representing the carpal and tarsal bones in a primitive condition and in five adult animals: c, centrale; f, tibiale; i, intermedium; r, radiale; t, fibulare; u, ulnare; x, postminimus; 1-5, distal carpals or tarsals. In the tarsals of the snapping turtle four proximal and central elements are fused. In the carpus of the rabbit the two centrals are fused and displaced into the distal row, and, as in all the mammals, distal carpals 4 and 5 are fused to form the hamate bone. Also the mammals represented have a sesamoid bone, the pisiform, added to the proximal row in about the position of the postminimus of the turtle, but the pisiform and postminimus are not homologous. The tarsus in all cases has the tibiale and intermedium fused as the talus, and the fourth and fifth distal elements fused as the cuboid. In the rabbit the first distal tarsal is fused with the second metatarsal. Other fusions and losses are indicated in the representations of the other species.

posterior than in the anterior limb. In some kinds of turtles, the wrist shows the primitive pattern practically unmodified, with an extra element (the postminimus) which may possibly reflect an ancient condition when there were more than five digits represented.

THE MUSCULAR SYSTEM

Involuntary Muscle

As would be expected considering the nature of their functions, the contractile tissues are not arranged in a definite, continuous system as are most other organ complexes of the body. Smooth or **involuntary muscle** fibres, modified mesenchyme cells, of the

embryo, which are under the control of the sympathetic nervous system, form the muscle coats of the digestive tube, and are important not only for its repeated, peristaltic movements, but also for its elasticity and expansive power. Smooth muscle is also a constituent of many other visceral organs, especially glands, in the active secretion of which it appears to play a mechanical part. It is further distributed through the walls of the blood-vessels, especially the arteries, where it forms the mechanical organ of the **vasomotor function**. This consists in the control of the diameter of the vessels by **vasodilator** and **vasoconstrictor nerves** connected with the vagus nerve and the sympathetic nervous system. The constrictive action is stimulated by secretion of the suprarenal glands. Such regulation of the vessels is important, first, in maintaining tone of the vessel-walls and therefore blood-pressure, and, second, in controlling loss of heat from the surface of the body. Action of the vasomotor nerves may be demonstrated physiologically in a variety of ways. Transection of the cervical sympathetic nerve of one side in the living rabbit is followed by vasodilatation of the ear, the congestion of which can be seen, and the heat loss is demonstrable by feeling with the hand. Stimulation of the cut end which is attached to the head is followed by vasoconstriction.

Muscle of the Heart

Cardiac muscle, most nearly allied in action to smooth muscle, is the mechanical organ of the rhythmical contraction or beat of the heart. The contraction takes place according to the succession of the chambers or the course of the blood, and the rate and strength of the beat are regulated by a minute mass of highly specialized tissue, the sinu-atrial node, imbedded in the wall near the entrance of the right superior caval vein. A second, similar mass, the atrio-ventricular node, receives the impulse from the first and transmits it through a band of conducting tissue to the muscle of the ventricles. The excised heart in the case of lower vertebrates continues to beat for some time automatically or under stimulation. This behaviour has been interpreted as purely automatic action of the heart muscle, but may depend upon intracardiac nerve connections. The rate and strength of the beat in the intact animal may be modified through the vagus and the sympathetic nerves, the

former inhibiting, the latter accelerating, as may readily be demonstrated experimentally.

Voluntary Muscle

The **voluntary muscles** of the body form the nearest approach to a continuous system of all contractile tissues. They consist for the most part of parallel fibres, the association of which into fasciculi is responsible for the appearance of longitudinal striping when the gross muscle is viewed from the side, and more or less for the grained appearance of the cut surface when the muscle is divided approximately at right angles to the direction of the striping. The control of action is exercised directly from the spinal cord or from the brain.

A **muscle** is typically spindle shaped, consisting of a middle fleshy portion, termed the **belly** of the muscle, and of tapering ends which provide for attachment. The attachment is effected by a strong band of fibrous connective tissue, the **muscle tendon** (Figs. 8, 37). Some muscles, such as those of the abdominal wall, are disposed in the form of flattened sheets, the ends of which are attached by tendons in the shape of broad, thin sheets of connective tissue, the **aponeuroses**. In **unipennate** muscles the fibres are attached obliquely to the side of the tendon, or in **bipennate** muscles to both sides, like the vane of a feather. In the so-called **biceps**, **triceps**, and **quadriceps** muscles of the limbs, the origin is divided into two, three, or four portions.

A typical muscle of the skeleton has the disposition of parts illustrated in Fig. 37 by the biceps (a flexor of the forearm) and the long head of the triceps (an extensor of the forearm). The fixed tendon, or **tendon of origin**, of the biceps is attached to the glenoid border of the scapula, the movable tendon, or **tendon of insertion**, to the lower border of the ulna. Noting the position of the muscle in front of the elbow-joint, it will be seen that its contraction results in flexion, i.e., in bringing the forearm into a position nearer the arm, or in raising the forearm and hand from the ground. The analogous action of the triceps in producing an exactly opposite movement (extension) of the forearm is similarly demonstrated. It will be evident that the immediate result of contraction of the muscles is limited by the form of the joint between the bones to which they are attached. In this case a

hinge-joint confines motion to one plane, while in the cases of the shoulder and hip, a joint of the ball-and-socket type allows motion on points at various angles to a plane according to which muscle or group of muscles may be brought into action.

The recognition of origin and insertion depends on usual but not invariable relations. The exact effect of muscle contraction depends as a rule on the relative positions of the parts and on the synchronous action of other muscles. A muscle like that forming the diaphragm does not possess an insertion after the fashion of ordinary muscles; and in some cases, as in the intrinsic muscle of the tongue or the so-called **orbicular** or **sphincter** muscles, both origin and insertion may be absent.

In the study of the skeletal muscles, moreover, it should be borne in mind that the identification of "origin" and "insertion" is largely a matter of convention. Actually "fixed" and "movable" points depend upon the movement being effected at the moment. An excellent example of the necessity of convention in this respect is afforded by the human arm in which, as opposed to the ordinary use of the muscles, most of the relations would be reversed if the body is considered suspended by the hands, that is in the "brachiate" position commonly assumed by arboreal primates. Also the action commonly attributed to any muscle is usually an artificial abstraction, for in life muscles act in groups, not singly, and the precise effect of any given contraction will be modified by the other muscles acting at the same time. Finally, it should be noted that a muscle does not always act as a unit, but sometimes one part may contract independently of the remainder.

Embryonic Derivation

Voluntary muscle arises chiefly from the segmented areas or **myotomes** of the embryo. The extent to which segmentation is shown in the adult, however, depends for the most part on how far the definitive muscle is removed from the vertebral column or segmented portions of the skeleton. The vertebral muscles themselves show throughout their attachments to successive vertebrae the marks of segmental origin and the segmental character is obvious in the intercostal muscles and in the division of the rectus abdominis by "tendinous inscriptions." Many others, however, such as those of the abdomen, to a certain extent those of the limbs, and those

of the eye show practically no indications thereof, the connective tissue septa between segments having disappeared during development. The fusion indicated in the last sentence may, moreover, be accompanied by transformation of parts of the resulting sheets into connective tissue, forming "aponeuroses," and by splitting in new planes, for example, parallel with the surface.

A transverse septum of connective tissue extends laterally from the transverse processes and divides the trunk musculature into dorsal, or epaxial, and ventral, or hypaxial, portions supplied respectively by dorsal and ventral branches of the spinal nerves. This division is indicated in Fig. 20. The epaxial portions then produce the dorsal musculature, the hypaxial forming the prevertebral and lateral musculature of the trunk. In the neck region, the hypaxial portion is divided in early stages by the gill pouches, so that epibranchial and hypobranchial groups of muscles are produced. The muscles of each limb are developed from cells that have migrated from the ventral ends of several adjacent myotomes and those of the diaphragm have migrated from myotomes in the neck (corresponding with which fact, the phrenic nerve has its origin in the neck).

Distribution

While the bulk of voluntary muscle is **skeletal**, part at least is related to the skin. This forms a **cutaneous** sheet, divisible into the cutaneous maximus and platysma, and the facial, palpebral, and auricular muscles of the head. The first two and the last of these are commonly developed to a considerable extent in mammals, though reduced in man. The trunk musculature comprises a special group of **cervical** and **occipital** muscles in relation to the neck and head, and the general series which are more nearly **vertebral**. The **appendicular** muscles are distributed in special groups connecting the limb as a whole with the trunk and

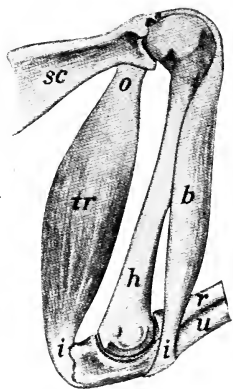


FIG. 37. Arm muscles of rabbit from the medial surface, illustrating muscle action, flexion, and extension: b, biceps (flexor); tr, long head of triceps (extensor); i, insertion; o, origin; sc, scapula; h, humerus; r, radius; u, ulna.

the various segments of the limb with one another. Individual muscles may be subject to considerable variation.

Equivalence of Limb Muscles

As already indicated, the skeletons of anterior and posterior limbs are serially equivalent part for part. This is true also of the related muscles and their actions upon the parts of the limb. The respective actual positions of the proximal, middle, and distal segments, however, are rather different in the front as compared with the hind limb of a mammal, a condition easily discernible from the fact that the elbow is directed backward, the knee forward. Similarly there are peculiarities of the muscles and muscle surfaces, owing to this difference in position and to a twisting which has occurred in the anterior limb but not in the posterior one, as ex-

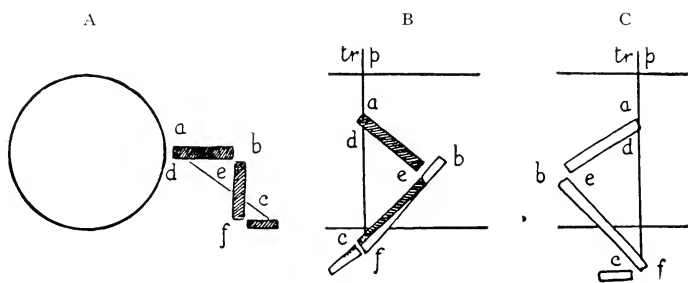


FIG. 38. Schematic representation of the respective positions of the segments in the mammalian limbs. A, neutral; B, anterior limb; C, posterior limb. Explanation in text: tr.p., transverse plane. Radial or tibial side of limb shaded, ulnar or fibular unshaded.

plained below. There are also conventional ideas prevailing in anatomy as to **flexion** and **extension**, that is bending or straightening parts of the limb, and as to flexor and extensor muscles and surfaces. For example, ventral bending of the hand is called flexion and the reverse movement is extension. A continuation of the latter movement, however, results in bending the hand dorsally and may be distinguished as dorsiflexion, which is accomplished by extensor muscles, the original flexion then being distinguished as ventral or palmar flexion. At the ankle, the foot in the normal position of rest is approximately at a right angle or at an acute angle to the leg. Further bending of the upper surface of the foot towards the leg is called flexion, or better dorsiflexion, while bringing the

foot more nearly into line with the leg is extension (or plantar-flexion). The muscles accomplishing the former movement, however, are classed as extensor muscles, and in so far as they are inserted distally in the digits actually do straighten these; while the muscles which extend the foot at the ankle are flexors and, when inserted distally in the digits, do bend the latter.

At the hip joint, movement of the thigh forward is flexion, movement backward is extension.

The corresponding surfaces and muscles and in general the differences presented by fore and hind limbs may be determined by a study of their embryonic relations, but it is simpler, even if less accurate, to refer the differences to the common basis of a more or less primitive or neutral type as illustrated in Fig. 38. In lower vertebrates, such as reptiles and amphibians, it is easily observable that the front and hind limbs are more nearly similar to each other than in mammals, especially in respect of the setting out from the body of the elbow and knee, so that the limbs are held nearly at right angles to the body axis. This common tendency is further expressed by the existence of a plantigrade condition of the hand and foot, and by a parallel arrangement of the bones of the forearm and leg. There is thus an approximation to a neutral plan as indicated in (A), where the animal is considered to be facing the observer or the limb viewed from in front. This neutral plan is, however, never quite realized, because, even in primitive vertebrates, where the limbs can scarcely be said to support the body, the adjustments for forward progression have already altered the respective positions of the segments.

It will be noted that as regards surfaces and angles in the neutral type, the radial side of the fore limb and the tibial side of the hind limb, shaded in the diagram, are anterior in position. Apart from the possible movements of the limb as a whole or of the segments upon one another, it will be seen that there are certain angle surfaces, *a*, *b*, *c*, dorsal and lateral in position, which may be identified as extension angles and certain others, *d*, *e*, *f*, ventral and medial, or flexion angles. In the relation of the limb respectively to dorsal and ventral surfaces of the body, *a* is likewise an "abduction" angle while *d* is an "adduction" angle. (Abduction may signify either the movement of a limb away from the median plane of the body or the movement of a digit away from

an imaginary extension of the axis of the limb through the hand or foot. Adduction is the reverse movement. The muscles bringing about such movements are then known as abductor or adductor muscles.)

In mammals the limbs are set in rather close to and more nearly underneath the body, a position better fitted for complete and permanent support. As compared with the neutral type, the elbow, as indicated in profile in (B), is rotated backward through ninety degrees, the hand forward through ninety degrees. The radius and ulna are crossed upon each other, the radial side of the limb being lateral at the elbow and medial at the hand. The extension angle b , at the elbow, is now posterior, that of the wrist, c , anterior. Many interesting observations may be made by placing the human arm in the corresponding positions. In most mammals, for example, the hand is fixed in a prone position with the radius and ulna crossed. In man and to a certain extent in some mammals the hand may be placed in a supine position or the limb held as in the neutral type. In either case the bones of the forearm are parallel. The human condition with respect to this character therefore appears to be rather primitive, and is in great contrast to that shown in specialized running animals such as the horse, where the radius takes over almost the entire support of the forearm and the ulna becomes simply an accessory of the elbow-joint.

The hind limb of a mammal (C) is rotated in its entirety forward through ninety degrees. The tibia and fibula retain their parallel position. The extension and flexion angles retain their mutual positions but the former become anterior and the latter posterior. The foot, in its more usual plantigrade condition, presents one of the striking cases of muscle arrangements in the limbs, in that, for example, as was pointed out above, an extensor muscle, originating on the front of the leg and terminating on the dorsum of the toes, will extend the toes and will bend the foot on the leg at the ankle joint. In a morphological sense, the foot is not thereby flexed and the muscles are named and classified accordingly. An attempt has been made in preceding paragraphs to clarify the apparent contradictions in terminology thus introduced.

From the mechanical point of view, each limb can act both as a strut and as a lever. When acting as a strut, it exerts forces along

its own mechanical axis only, as when it is in an approximately vertical position supporting the weight of the body at rest. When acting as a lever, it exerts both against the body and against the ground forces at right angles to its mechanical axis.

As a propulsive mechanism, the limb functions in both these ways. As a propulsive strut, it is extended by its own intrinsic musculature and its action may be compared roughly to that of a pole propelling a punt. As a lever, the limb is operated by the muscles which attach it to the body and its effect is somewhat analogous to that of a double paddle propelling a canoe while the outer end of its blade remains fixed.

THE NERVOUS SYSTEM

There is probably no other system of organs in which external form is so little suggestive of actual function as in the nervous system. This is perhaps less true of its peripheral portion, con-

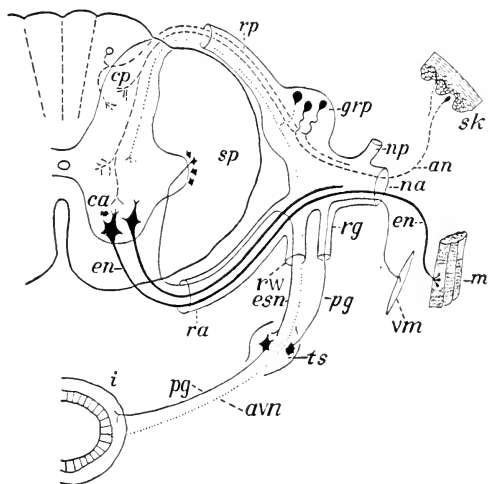


FIG. 39. Plan of the central and peripheral connections of a spinal nerve: an, afferent (sensory) neuron; avn, afferent visceral neuron; ca, cp, anterior (ventral) and posterior (dorsal) columns of gray matter; en, efferent (motor) neuron; esn, visceral efferent (preganglionic sympathetic) neuron; grp, dorsal root ganglion; i, intestine (visceral organs); m, skeletal muscle; na, np, anterior (ventral) and posterior (dorsal) rami of spinal nerve; pg, postganglionic sympathetic neuron; ra, rp, anterior and posterior roots of spinal nerve; rg, rw, gray and white rami communicantes (sympathetic); sk, skin; sp, white matter of spinal cord; ts, ganglion of sympathetic trunk; vm, smooth muscle. Modified, from Herrick.

sisting of nerves which can be seen ramifying through all parts of the body, than of the central portion comprising the brain and spinal cord. In examining the external form as a preliminary step to the study of the functional arrangements, it is advisable to bear in mind that the nervous system is a great correlating mechanism, consisting of centres where exceedingly complex inter-connections are made between the nerve elements, and of conducting paths to and from these centres connecting them with outlying parts of the body.

In accordance with its prime importance and at the same time the non-resistant character of the tissue of which it is composed, the central nervous system is protected within the canal of the vertebral column and cavity of the brain-case. It is furthermore surrounded by connective tissue membranes, **meninges**. In higher vertebrates, three of these are differentiated, the **dura mater**, which forms a tough external investment; the **arachnoidea**, which is a very delicate, somewhat spongy web lying internal to this; and the **pia mater**, a thin membrane lying next the nervous matter and richly supplied with blood-vessels from which branches penetrate the latter to provide for its nourishment and respiration. Still further protection is afforded by the cerebrospinal fluid, which fills the spaces between these membranes as well as the cavities within the brain. The nerves, on the other hand, are distributed freely throughout the body, and though not so adequately protected are more capable of withstanding or repairing mechanical injury. Also they are commonly found surrounded by connective tissue where mechanical injury is relatively little likely to occur. Each nerve has a tough sheath, the perineurium, composed of condensed connective tissue, and similar tissue extends between the fibres, binding them together in small bundles. Each has a relatively poor though indispensable blood supply received through small arteries which anastomose to form a continuous channel along the nerve.

The central nervous organs contain numerous blood vessels, the capillaries forming a continuous network the density of which differs considerably in different parts, but they have no lymphatics. The tissue spaces are continuous with narrow perivascular spaces which are nowhere lined with endothelium as are lymphatics.

The larger perivascular spaces acquire a thin lining of tissue from the arachnoid and pia mater and open into the subarachnoid space so that the tissue fluid mingles with the cerebrospinal fluid there. This fluid is mostly secreted by the chorioid plexuses (p. 83) and is eventually filtered into the venous sinuses which carry the blood from the brain.

Composition of a Spinal Nerve

The most typical of the structural arrangements of the nervous system may be made out from a study of the connections of any one of the paired nerves of the spinal series (Fig. 39). In the spinal cord the difference in appearance as between the white and the grey matter has already been described (p. 32). A spinal nerve arises by two **roots**, one of which is **dorsal** and bears a small **ganglion** containing nerve-cell bodies, the other **ventral** and without a ganglion. Impulses passing through the dorsal root are **centripetal** or **afferent** in that they pass only in the direction of the central nervous system and they are also in many cases **sensory** in that their effects may be consciously experienced. The most characteristic sensory impulses are those which come from the skin. Many afferent impulses do not enter consciousness and a majority of these come from deeper parts. In a similar fashion the impulses of the ventral root are **centrifugal** or **efferent**, in that they pass only in a direction away from the central nervous system, and are in most cases **motor** in that their effects are commonly observed as muscular contraction. The two roots, however, unite immediately outside the spinal cord, and subsequently redivide into a **dorsal ramus**, a **ventral ramus**, and either a **ramus communicans** or two rami communicantes. Each spinal nerve has a grey ramus communicans and the thoracic, the first five lumbar (in the rabbit), and the second to fourth sacral nerves (in the rabbit) have also a white ramus communicans. The dorsal and ventral rami are then distributed as somatic nerves to the body wall, each of them containing fibres from both dorsal and ventral roots and also fibres (for the blood-vessels) which have come from the sympathetic ganglia (see below) through the grey communicating rami. The white communicating ramus is a visceral nerve containing fibres derived from both dorsal and ventral roots and connecting through autonomic ganglia with the visceral organs.

Thus the grey ramus communicans differs from the other branches in carrying fibres to rather than from the trunk of the nerve and in that sense might better be designated as a root.

The Autonomic Nervous System

Unlike the somatic nerves, which take a direct course to their terminations, the communicating rami of each side unite in a position ventral to the vertebral column to form a longitudinal **sympathetic trunk** consisting of a connected series of **ganglia**. Of these trunk ganglia there are on each side two in the neck of the rabbit and a segmented series in the thoracic, lumbar, and sacral regions. The sympathetic trunk is similarly connected with an unpaired **collateral** series of ganglia, and through them with certain **peripheral** ganglia on the surface of the visceral organs. From these ganglia, fibres run to the visceral muscles and glands through plexuses which mostly accompany the blood-vessels. The longitudinal trunks and their connections with the thoracic and lumbar nerves form the sympathetic portion of the **autonomic division** of the peripheral nervous system. The corresponding connections of the sacral and certain cranial nerves (the third, seventh, ninth, tenth, and eleventh) constitute the parasympathetic portion of this division. The latter does not join the sympathetic trunk, and its fibres end only in the peripheral ganglia. The two divisions differ also in their responses to certain drugs. Most organs controlled by the autonomic system receive fibres from both, which usually produce opposite effects upon stimulation though in some cases they co-operate, acting upon different components of the organ. (For instance, mucous and serous cells in the submaxillary gland have respectively parasympathetic and sympathetic control.) It is usual to consider that only the visceral efferent elements constitute the autonomic division, though visceral afferent fibres run through the trunks and ganglia along with the efferent components and are thus included in the gross anatomical structures. The cell bodies of the afferent neurons, however, lie in the dorsal root ganglia of the spinal nerves as indicated in Fig. 39.

From the foregoing, it is apparent that the visceral efferent peripheral pathway, unlike the somatic one, always involves two successive neurons. One fibre springs from a cell body in the

central nervous system and ends in an autonomic ganglion—the **preganglionic** fibre—while the other arises from a cell body in the ganglion and ends in the organ to be controlled—the **postganglionic** fibre. Although either a preganglionic fibre or a postganglionic fibre may traverse several ganglia, the course between spinal cord and periphery is usually interrupted in only one. The preganglionic fibres, accompanied by visceral afferent elements, make up the white communicating rami but the grey rami are composed of postganglionic fibres destined to accompany the somatic branches and end in the walls of the blood-vessels, in other smooth musculature, or in glands.

The sympathetic trunk terminates anteriorly at the base of the head in a relatively large superior cervical ganglion, which receives its preganglionic fibres entirely from more posterior levels by way of the cervical portion of the trunk. The second ganglion in the rabbit is the inferior cervical, situated at the lower end of the neck. From the inferior cervical and the first thoracic ganglia, postganglionic fibres run as delicate grey rami along the vertebral artery, forming a plexus about the latter and giving off a branch to each cervical nerve as it crosses the artery.

Plexus Formation

In certain places, peripheral nerves, either spinal or autonomic, connect with each other so as to form a plexus, or network. This phenomenon is conspicuously exemplified by the nerves for each of the limbs (brachial and lumbosacral plexuses). The development of these limb-plexuses is probably an outcome of the manner of origin of the limb-muscles, which involves the fusion of material from the primary muscle-segments in the embryo and the subsequent differentiation of the resulting mass into units which may be derived from two or more segments. The originally segmented nerves then become interconnected in such a way that each definitive muscle will receive a nerve composed of the appropriate number of fibres belonging to each segment which has contributed to its formation. The patterns of the plexuses are subject to much individual variation.

Observation of these and other pertinent facts has led to the belief that the relation of nerves to their muscles is constant no

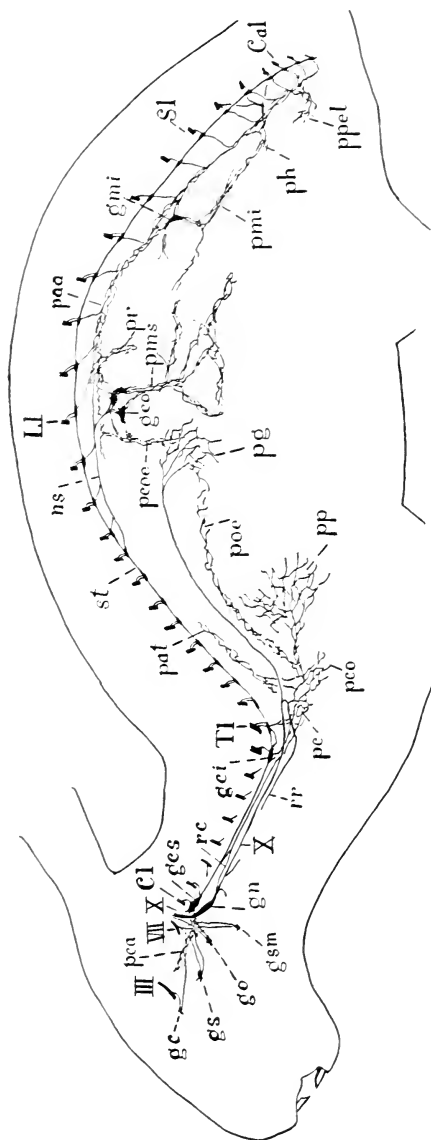


FIG. 40. Scheme of some of the principal portions of the autonomic nervous system. In the case of paired structures, only those of the left side are indicated. cl, first cervical nerve; cal, first caudal nerve; LI, first lumbar nerve; SL, first sacral nerve; TI, first thoracic nerve; III, oculomotor nerve; VII, facial nerve; X, vagus nerve; gc, ciliary ganglion; gci, inferior cervical sympathetic ganglion; geo, coeliac ganglion; ges, superior cervical sympathetic ganglion; gmi, inferior mesenteric ganglion; gm, ganglion nodosum; go, otic ganglion; gsm, splanchnic ganglion; gsm, submaxillary ganglion; ns, greater splanchnic nerve; pa, plexus aorticus abdominalis; pal, plexus aorticus thoracicus; pc, cardiac plexus; pca, carotid plexus; pcc, coronary plexus; pcc, coeliac plexus; pg, gastric plexus; ph, hypogastric plexus; pmi, inferior mesenteric plexus; pms, superior mesenteric plexus; pp, cesophageal plexus; pp, pulmonary plexus; ppel, plexuses in pelvic viscera; pr, renal plexus; rc, ramus cardiacus nervi vagi; rr, ramus recurrens nervi vagi; SL, sympathetic trunk.

matter what modifications the latter may undergo, though this principle is not now considered so absolutely rigid as it was formerly thought to be.

Reflex Action

It is difficult to determine what portion of a muscular contraction, even of one which is considered to be purely voluntary, results from an impulse actually originating in the central nervous system. The living body, however, affords many examples of muscular actions as direct **responses** to immediately previous in-

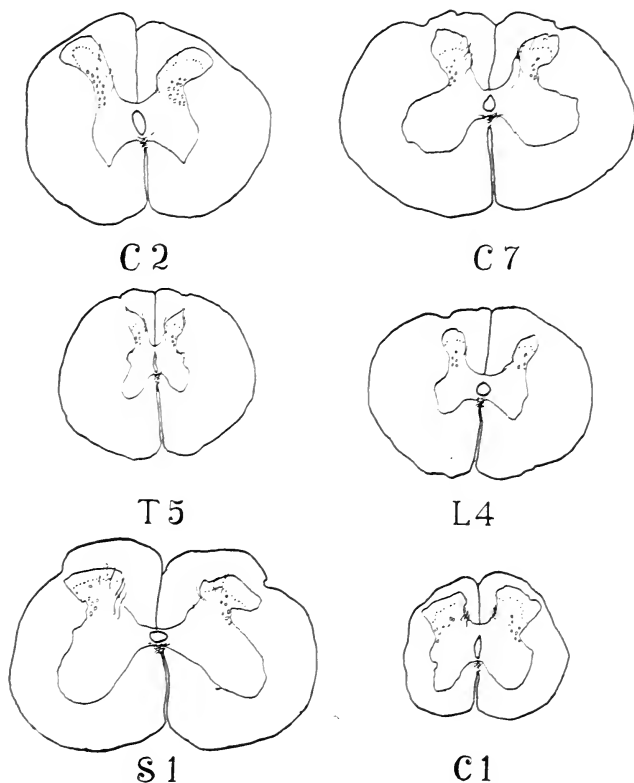


FIG. 41. Camera lucida tracings of transverse sections of the spinal cord of a rabbit to show the variations in the shape and in the proportions of grey matter and of white matter in representative segments: 2nd cervical, 7th cervical, 5th thoracic, 4th lumbar, 1st sacral, and 1st caudal.

coming **stimuli**, without conscious experience being a necessary factor in producing the result. In vertebrates in which the spinal cord is divided, the lower part thus being separated from the brain, stimulation of the skin below the level of the section is followed by co-ordinated movements. These are evidently brought about through direct connections within the spinal cord between the dorsal and ventral roots either of one spinal nerve or of neighbouring nerves. This is known as **reflex action**. Such responses, of which the well-known scratch reaction of the dog is an example, occur in all animals. The integration of reflexes and their purposeful control is performed by centres at various levels in a functionally superposed series, the cerebral cortex being the ultimate one and having become increasingly dominant in the mammalian scale.

The Spinal Cord

The spinal cord reflects in its form the basic architectural pattern of the vertebrate central nervous system, being developed in the embryo as a tube and retaining this condition throughout life. The inner part of the wall of the tube is composed of grey matter, the outer part of white matter. The cavity, however, is reduced to a very slender central canal while the walls become enormously thickened by proliferation of the cells and their fibre extensions, through which are established the nervous functions of the system, as a connected conducting mechanism. The cord traverses the vertebral canal, showing slight enlargements in the cervical and lumbar regions in relation to the nerve supply of the limbs, and at about the level of the second sacral vertebra narrows into the slender, thread-like **filum terminale**, by which it is continued almost to the middle of the length of the tail.

The sudden tapering of the cord into the filum terminale at the level indicated is a result of growth relatively less than that of the surrounding parts, the cord in the embryo extending through the region occupied in the adult by the filum. Such relative shortening of the cord by retardation of growth is more marked in some animals than in others, the lower tip of the human spinal cord, for example, being usually within the first lumbar vertebra.

The Brain

Superficial examination of the brain of the rabbit (Fig. 42) shows that its larger part is formed by the paired **cerebral hemispheres**. They are closely pressed together on the dorsal side but separated posteriorly on the ventral side. The external layer, the grey **cortex**, is important as the principal part of the physical substratum of intelligence. In the rabbit, as in all animals which have not large cerebral hemispheres, the cortex is smooth, contrasting with its condition in mammals with larger hemispheres, where it is corrugated. The amount of this corrugation is roughly related to the absolute size of the brain. Thus it is considerable in the cat and dog but reaches a high degree of elaboration in man and in the whale. At the anterior tips of the cerebral hemispheres in the rabbit are the slightly expanded **olfactory bulbs** which can be seen to be connected backwards with the posteroventral portion of the hemisphere, known as the pyriform lobe. These parts of the brain being directly related to the sense of smell, their size in different mammals corresponds with the degree of development of that sense and is markedly reduced in man. The development of the cerebral hemispheres even in lower mammals is such that important

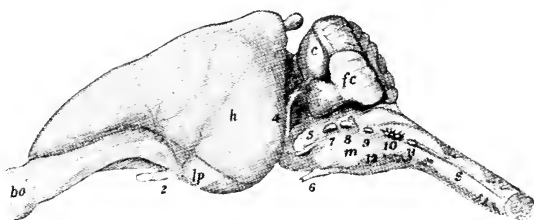


FIG. 42. The brain from the left side: bo, olfactory bulb; c, cerebellum; fc, paraflocculus cerebelli; h, cerebral hemisphere; lp, pyriform lobe; m, medulla oblongata; s, spinal cord. Numerals indicate the corresponding cranial nerves: 2, optic; 4, trochlear; 5, trigeminal; 6, abducens; 7, facial; 8, acoustic; 9, glossopharyngeal; 10, vagus; 11, spinal accessory; 12, hypoglossal.

parts of the brain, notably the diencephalon and mesencephalon (pp. 80, 81), are concealed dorsally and laterally. However, the chiasma or crossing of the optic nerves on the ventral aspect of the diencephalon is evident, while more posteriorly the convergent cords of the cerebral peduncles may be seen passing backwards on that of the mesencephalon. The posterior part of the brain is formed largely by the **cerebellum** above, the corrugation of which is one

of its outstanding features, and below by the somewhat tapering **medulla oblongata**, which is continuous caudally with the spinal cord. On the ventral side, the medulla oblongata is crossed in front by a bridge of fibres, not so conspicuous in the rabbit as in many mammals and in man, which is known as the **pons** and which appears to connect the two sides of the cerebellum. (Actually it is part of the path to the latter from the cerebral hemisphere.) These, the outstanding surface features of the brain, afford but a moderate conception of its details, the nature of which can be made out only by more thorough examination and by reference to the plan of development of the organ as a whole.

Like the spinal cord, with which it is continuous, the brain forms primarily a portion of the **neural tube**, containing a central cavity or **neurocoele**, but, unlike the spinal cord, it is greatly enlarged and elaborated to include both the highest controlling centres of the whole nervous mechanism and the special centres of the nervous mechanism for a variety of functions performed by organs in the head. It accordingly not only forms a more or less distinct division, known as the brain or **encephalon**, as opposed to the less elaborated spinal cord or **spinal medulla**, but also develops a series of paired and unpaired subdivisions containing portions of the original cavity distended to form **ventricles**.

The primary divisions of the brain are more or less similar and homologous in all vertebrates. The more elaborate condition of the organ in a mammal may be explained by reference to the general plan as indicated in Fig. 44, which is based upon general features of form in vertebrates and upon embryonic development. For comparison in the gross, the brain of the frog (Fig. 43) offers one of the best examples.

The brain as first formed in the embryo appears as three anterior expansions of the neural tube arranged in a linear series. They are described as the **primary cerebral vesicles**; or, as primary divisions of the future brain, they are designated in anteroposterior order as the **prosencephalon**, **mesencephalon**, and **rhombencephalon**.

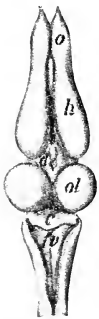

FIG. 43. The brain of the frog from the dorsal surface: c, cerebellum; d, diencephalon; fv, fourth ventricle; h, cerebral hemisphere; o, olfactory bulb; ol, optic lobe.

The first of the primary divisions, the **prosencephalon**, or **primary forebrain**, gives rise during development to a pair of hollow outgrowths and thus becomes divisible into an anterior portion, the **endbrain** or **telencephalon**, which is largely a paired structure, and a second portion, unpaired, the **diencephalon** or **interbrain**. The larger, paired portion of the telencephalon is

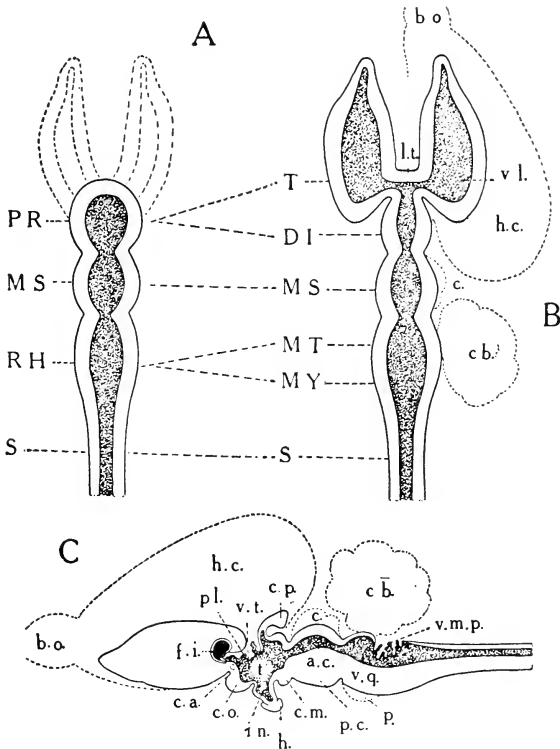


FIG. 44. Plan of the divisions of the vertebrate brain: A, embryonic; B, adult, projection from dorsal surface; C, adult, sagittal section. The contour of the mammalian brain is indicated by broken lines.

Primary divisions—PR, prosencephalon; T, telencephalon; DI, diencephalon; MS, mesencephalon; RH, rhombencephalon; MT, metencephalon; MY, myelencephalon; S, spinal cord.

a.c., cerebral aqueduct; b.o., olfactory bulb; c., corpora quadrigemina; c.a., anterior commissure; cb., cerebellum; c.m., mamillary body; c.o., optic chiasma; c.p., pineal body; f.i., interventricular foramen; h., hypophysis; h.c., cerebral hemisphere; in., infundibulum; l.t., lamina terminalis; p., pons; pl., chorioid plexus of third ventricle; p.c., cerebral peduncle; t., thalamus, also indicates position of massa intermedia; v.l., lateral ventricle; v.m.p., posterior medullary velum; v.q., fourth ventricle.

the basis of the **cerebral hemispheres**. It contains, as divisions of the primary cavity, a pair of cavities, the **lateral ventricles**. Originally, the whole of the telencephalon was concerned with olfactory functions, but it has been invaded by an increasing number of fibres from more posterior parts bearing non-olfactory nerve impulses. In the frog, a small part of it has already become free from olfactory connections and in the higher vertebrates the non-olfactory part becomes increasingly preponderant. In the mammalian brain, the olfactory portion, or **rhinencephalon**, is more or less definitely marked off from the rest. This portion, sometimes termed olfactory lobe or olfactory brain, includes the olfactory bulb and the pyriform lobe, already mentioned, with a number of related parts.

A primitive cerebral hemisphere like that of the frog or the young mammalian embryo comprises distinguishable dorsal and ventral halves, designated respectively pallial and basal. In the adult mammal, the basal portions have become massive and the pallium has spread partly over their lateral and ventral surfaces as well as constituting the dorsal wall of the hemisphere. The cells of the pallium have formed a highly specialized superficial layer, the cerebral cortex.

The unpaired portion of the prosencephalon is considered as belonging in part to the telencephalon and in part to the diencephalon. Its cavity, the **third ventricle**, is connected with each lateral ventricle through an **interventricular foramen**. Its anterior wall is formed by a transverse connection of the cerebral hemispheres, the **lamina terminalis**. In all vertebrates this portion of the brain is remarkable for the manner in which its wall is differentiated. The ventral portion extends downward as a slender funnel-like structure, the **infundibulum**, the tip of the latter being attached to the **pituitary body** or **hypophysis** and its base being connected with a small grey elevation, the **tuber cinereum**. Its cavity is the **recessus infundibuli**. Immediately in front of the infundibulum the **optic tracts** cross each other on the ventral surface of the brain, forming the **optic chiasma**, and immediately behind it the floor is thickened, forming externally a pair of rounded protuberances, the **mamillary bodies**. In the brain of the rabbit, the latter bodies are fused so that superficially they consist of a larger median

portion with faint lateral elevations appended to it. Collectively, these ventral structures are considered to form a major division of the fore-brain, the **hypothalamus**, the latter consisting of two portions, namely, an optic portion, comprising the optic chiasma and some adjacent tissue, and a mamillary portion, including the mamillary bodies, the tuber cinereum, the infundibulum, and the hypophysis. The optic portion belongs to the telencephalon and is better termed **telencephalon medium**, while the mamillary portion belongs to the diencephalon.

The more dorsal portion of the diencephalon, containing the major part of the third ventricle, is sometimes known as the **thalamencephalon**, a term now falling into disuse. Its lateral walls are greatly thickened, while its roof is extremely thin, especially in its anterior part. Here the actual roof of the ventricle is formed of a layer of tissue only one cell in thickness, the **epithelial chorioid lamina**, but the latter has associated with it a series of vascular ingrowths of the investing pia mater, the latter being described in this relation as the **chorioid web** (*tela chorioidea*). The two structures together form a **chorioid plexus**. This extends downward into the third ventricle, reaching out also into the lateral ventricles.

The dorsal portion of the diencephalon bears posteriorly the **pineal body** or **epiphysis cerebri**, an endocrine gland borne upon a stalk which is attached to certain other small dorsal parts of the brain, the **habenulae** and **habenular commissure**. These all together form the **epithalamus**. The lateral wall of the third ventricle is formed by the thalamus, which has become so massive in the mammal that it bulges medially to fuse with that of the other side and thus to produce a broad bridge across the middle of the ventricle, the **massa intermedia**. In the brain of the rabbit it will be seen that the thalamus is indicated externally chiefly by a rounded protuberance, the **lateral thalamic tubercle**. The latter is dorsal in position and is imperfectly marked off from a second protuberance, the **lateral geniculate body**, lying on its postero-lateral side. Postero-medial to this is a third protuberance, the **medial geniculate body**. The medial and lateral geniculate bodies as thus defined constitute the **metathalamus** (Fig. 116).

The second of the primary divisions, the **mesencephalon**, or

midbrain, is noteworthy in a mammal as lacking a cavity large enough to be designated a ventricle. Instead it has a narrow canal, funnel-shaped in the rabbit, the **cerebral aqueduct**, leading from the third ventricle backward to the fourth ventricle, or cavity of the rhombencephalon. Externally, its roof is differentiated into four rounded elevations, the **corpora quadrigemina**, of which the members of the anterior pair are much larger than the posterior ones and correspond with the optic lobes of the frog. Its floor is formed by the **cerebral peduncles**, the ventral surface of which is composed mainly of a pair of prominent bundles of nerve fibres converging from in front, having originated in the cerebral cortex and passing back into the rhombencephalon.

The parts of the mesencephalon and prosencephalon together constitute the large brain, or **cerebrum**.

The third primary division, the **rhombencephalon**, or primary **hindbrain**, is a greatly elaborated portion from which arise the majority of the cranial nerves. The constricted area joining it with the mesencephalon is known as the **isthmus rhombencephali**. It includes the **anterior medullary velum** and **brachia conjunctiva** (Fig. 122). The rhombencephalon itself is divisible into two portions, especially well defined in the mammalia, namely, the **metencephalon** and the **myelencephalon**. The former includes the **small brain**, or **cerebellum**, and a ventral region, the **pons**, which is marked by a thick transverse band of fibres on the surface. The myelencephalon is a transitional portion connecting the brain with the spinal cord. The cavity of the rhombencephalon is the **fourth ventricle**. It is a peculiarly shaped space, the floor and lateral walls of which are very greatly thickened, while the roof is for the most part thin. The roof appears at first sight to be formed largely by the cerebellum, but is in reality formed by two membranes underlying the latter, each being attached to it along a transverse line near the middle of its under surface (Fig. 124). One of these, the **anterior medullary velum**, is connected forwards with the mesencephalon, while the other, the **posterior medullary velum**, extends back from under the posterior margin of the cerebellum and covers a triangular space at the caudal end of the ventricle over which the cerebellum does not reach. The posterior medullary velum has the same structure as the chorioid plexus of the third ventricle, but is less well developed.

Most of the portions of the brain referred to in the foregoing paragraphs are not units homogeneous in respect of structure or function but are made up of constituents of varied significance. An attempt to indicate briefly the functions of various parts has been made in connection with the somewhat more detailed description in the directions for dissection (pp. 348-366).

Apart from its principal divisions, which, as indicated above, are more or less common to all vertebrates, the external form of the brain in various species is determined by the elaboration of certain parts in comparison with others. In the mammalia the cerebral hemispheres and the cerebellum are the chief form-determinants, although the pons and the corpora quadrigemina also are significant in this connection. It will be seen also that the form of the brain is more or less dependent on the existence at certain places of well-marked flexures (cf. Plate II). The first of these, the **cephalic flexure**, is in the region of the mesencephalon, the anterior portion of the brain being bent downward; the second, or **pontine flexure**, a bend in the opposite direction, is at the fourth ventricle; while the third, or **cervical flexure**, is at the point where the myelencephalon passes over into the spinal cord. By these flexures the overall length of the brain is kept within the dimensions of the cranial cavity.

The Cranial Nerves

The peripheral nervous system embraces two groups of paired and, for the most part, metamericly arranged nerves, namely, the **spinal nerves**—those arising from the spinal cord and leaving the

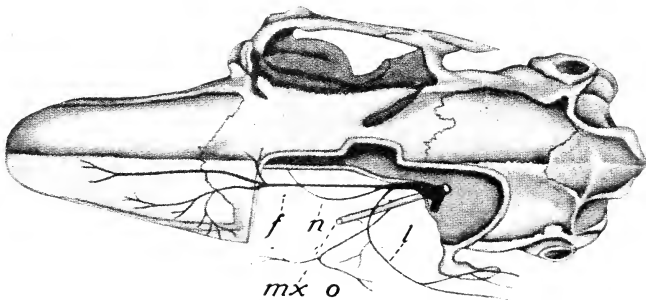
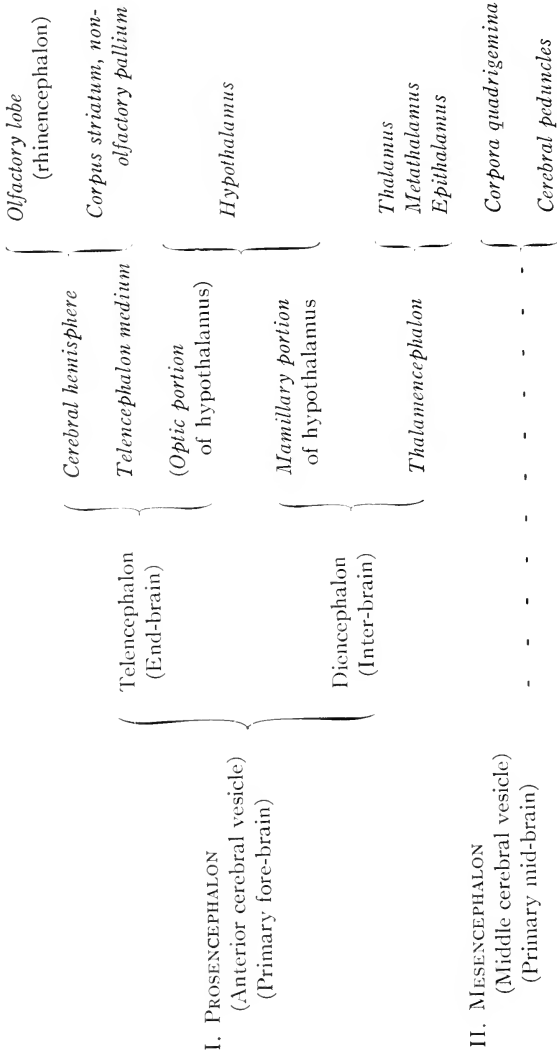


FIG. 45. Branches of the left ophthalmic nerve in the region of the orbit, dorsal view, after Winckler: f, frontal nerve; l, lacrimal nerve; mx, maxillary nerve; n, nasociliary nerve; o, orbital nerve.

Cerebrum

PLAN OF THE DIVISIONS OF THE BRAIN

(ENCEPHALON)



I. PROSENCEPHALON
(Anterior cerebral vesicle)
(Primary fore-brain)

II. MESENCEPHALON
(Middle cerebral vesicle)
(Primary mid-brain)

III. RHOMBENCEPHALON
(Posterior cerebral vesicle)
(Primary hind-brain)

Telencephalon (End-brain)

Cerebral hemisphere

Telencephalon medium

(Optic portion of hypothalamus)

Mamillary portion of hypothalamus

Hypothalamus

Olfactory lobe (rhinencephalon)

Corpus striatum, non-olfactory pallium

Thalamus

Metathalamus

Epithalamus

Thalamencephalon

Metencephalon

Myelencephalon

Cerebellum

Pons

Medulla oblongata

Corpora quadrigemina

Cerebral peduncles

vertebral column through the intervertebral foramina—and the **cranial or cerebral nerves**—those arising from the brain and passing through the foramina of the skull—in addition to the autonomic system, described on page 74. Of these the spinal nerves (p. 73) are less modified, in both structure and distribution.

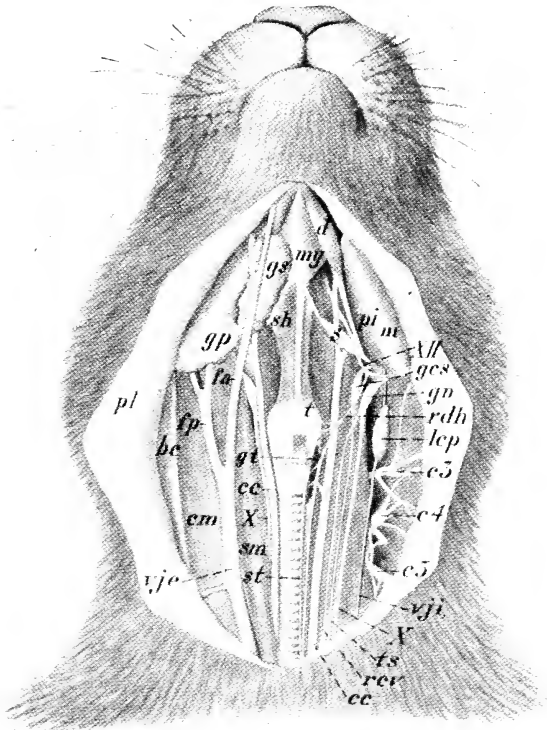


FIG. 46. Dissection from the ventral surface of the neck. On the right side the platysma and depressor conchae posterior are reflected with the skin. The vagus nerve is in proper relation to the external jugular vein and the common carotid artery. On the left side the external jugular vein, parotid and submaxillary glands, and the sternohyoid, sternomastoid, and cleidomastoid muscles are removed, the common carotid displaced medially and the nerves laterally, but otherwise in proper relation.

bc, basioclavicularis; cc, common carotid artery; cm, cleidomastoid; c3, c4, c5, cervical spinal nerves; d, digastricus; fa, anterior facial vein; fp, posterior facial vein; ges, superior cervical ganglion; gn, ganglion nodosum; gp, parotid gland; gs, submaxillary gland; gt, thyroid gland; lcp, deep cervical lymph gland; m, masseter; my, mylohyoid; pi, medial insertion portion of masseter concealing the pterygoideus internus; pl, platysma; rcv, cardiac branch of vagus nerve (n. depressor); rdh, descending branch of hypoglossal nerve; s, stylohyoid major; sh, sternohyoid; sm, sternomastoid; st, sternothyroid; t, thyrohyoid; ts, sympathetic trunk; vje, external jugular vein; vji, internal jugular vein; X, vagus nerve; XII, hypoglossal nerve. (From dissection by W. H. T. Baillie, drawing by E. B. Logier.)

The cranial nerves, those arising from the brain and making exit through the walls of the skull, are comparable in some respects to the spinal nerves, but in many ways are different in nature in addition to being in some cases highly specialized. Three pairs, respectively, **olfactory**, **optic**, and **acoustic**, or **first**, **second**, and **eighth** of the series are afferent nerves from the special sense organs of smell, sight, and hearing, the function of the acoustic nerve including also transmission of afferent impulses of equilibrium. The optic nerve differs from all others both structurally and developmentally, being really an outlying part of the brain itself. The **third**, **fourth**, and **sixth** nerves, respectively, **oculomotor**, **trochlear**, and **abducent**, are distributed as somatic motor nerves to the muscles of the eyeball, but also contain fibres of muscle sense.

Of the remaining cranial nerves the fifth, seventh, ninth, and tenth are branchiomeric (p. 41). Although the connections of these nerves are not fully considered in the dissection as here outlined, their chief characteristics as branchiomeric structures may be indicated. The **fifth**, or **trigeminal** nerve is the nerve of the mandibular arch and its branches are related to this arch with its associated structures and to the mouth in a manner comparable with the relations of a typical branchial nerve to its gill arch and the gill cleft in front of it when these structures are present. It arises in two parts, one of which, the portio major, is sensory, the other, the portio minor, motor. The portio major splits into three main branches, the ophthalmic (Fig. 45), maxillary, and mandibular nerves, and the portio minor unites with the last of these. Thus, while the terminal branches of all three divisions are distributed as somatic sensory nerves to the skin of the head, the mandibular nerve carries in addition visceral motor fibres for certain muscles (masticatory group, mylohyoid, and digastric) regarded as belonging to this, the first visceral arch. Visceral sensory fibres are carried from the anterior part of the mouth by the lingual branch of the mandibular nerve and by the palatine branches of the spheno-palatine ganglion, but both of these, despite their close peripheral association with the trigeminal, really belong to the seventh nerve, the connection of the former being through the chorda tympani, that of the latter through the great superficial petrosal.

The **seventh**, or **facial** nerve is the nerve of the second, or hyoid arch, the gill pouch in front of which is represented by the cavity of the middle ear. It is distributed chiefly as a motor nerve to the cutaneous muscles of the head, which are modified visceral muscles from the region of the hyoid arch, but contains also taste fibres from the front part of the tongue. The **ninth**, or **glossopharyngeal** nerve, belonging to the third visceral (first branchial) arch, and the **tenth**, or **vagus**, belonging to the fourth and succeeding visceral arches in lower forms, are distributed as visceral efferent nerves to the pharyngeal and laryngeal musculature, and as visceral afferent nerves to various visceral organs, the ninth nerve supplying the gustatory organs of the back part of the tongue. The vagus contains a variety of fibres, both afferent and efferent, the former from the larynx and respiratory organs, the latter distributed to the organs of circulation and digestion.

The **eleventh**, or **spinal accessory** nerve has apparently been formed by an association of certain motor components separated off from the vagus with others derived from the anterior spinal nerves. The spinal elements have a characteristic distribution to the cleidomastoid, sternomastoid, and trapezius muscles of the side of the neck and shoulder while the other components join the vagus and are distributed with it.

The **twelfth**, or **hypoglossal** nerve has the relation of the ventral or motor portion of a spinal nerve, and is distributed as a motor nerve to the muscles of the tongue.

The Sense Organs

The complete mechanism involved in the performance of an action comprises of necessity a receptor, an afferent conductor, an adjustor, an efferent conductor, and an effector. The effector may be a gland or a muscle, both of which have been considered in previous chapters; the afferent and efferent conductors are the nerve fibres which run through the peripheral nerves and are usually partly within the central nervous organs; the adjustor is in the spinal cord or in the brain; while the receptor is at the periphery and has been defined as an organ designed to lower the threshold of excitability for one kind of stimulus and to heighten it for all others.

Receptors, or sense organs, are classified as **exteroceptors**, which receive stimuli from outside the organism, **proprioceptors**, which are excited by events in the organism itself, such as contraction of muscles or movements of joints, and **interoceptors**, which are situated in visceral organs such as those of digestion, respiration, etc.

The simplest receptors, structurally, appear as free nerve endings in epithelium. These probably transmit impulses which are interpreted as pain. Several more specialized types of receptors, also of microscopic size, are stimulated by touch, pressure, or movement of various parts and others by heat, cold, or chemical irritation. A slightly enlarged portion of the internal carotid artery at the very beginning of that vessel, the carotid sinus, contains in its wall receptors for changes in arterial pressure and a minute organ between the bases of internal and external carotid arteries, the carotid body or glomus caroticum, is a receptor for chemical changes in the blood, both of these giving rise to reflex effects on blood-pressure and on breathing.

Of all receptors in the mammalian body, the most primitive, as regards structure are the olfactory cells. These are neuro-epithelial cells imbedded among the other elements of the nasal mucous membrane. Each has a free, ciliate outer end and gives rise at its inner end to an unmyelinated nerve fibre which runs through the olfactory nerve to terminate in the olfactory bulb.

The gustatory organs, or taste buds, are minute spindle-shaped groups of differentiated cells imbedded at certain regions in the stratified epithelial lining of the oral cavity. Sensory and supporting cells are distinguishable and round the former are the terminal ramifications of gustatory nerve fibres.

The Ear

The receptor for sound and for equilibratory stimuli resulting from movement or altered position of the head is the internal ear, which comprises two distinct though connected parts serving these respective functions. The actual sensory areas occur in the walls of a system of delicate canals, the **membranous labyrinth**, which are contained within corresponding bony canals imbedded in the petrosal bone. The equilibratory or **vestibular** por-

tion of the membranous labyrinth includes three **semicircular canals**, respectively anterior, posterior, and lateral or horizontal, lying in planes perpendicular to each other, so that movement in any direction will cause a tendency to flow in the contained fluid (the **endolymph**) of one or more canals.

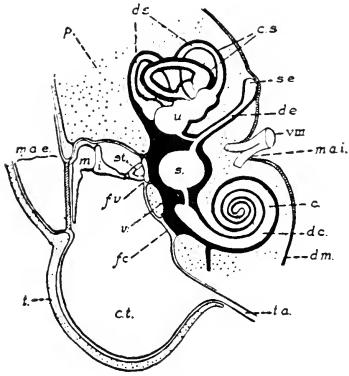


FIG. 47. Diagram of the parts of the ear in vertical projection. To show the general relations of the structures covered by the dissection.

p, petrous portion of the petrotympanic bone; t., tympanic portion (bulla tympani).

c., cochlea; c.s., bony semicircular canals; c.t., tympanic cavity; d.c., cochlear duct; d.e., endolymphatic duct; d.m., dura mater; d.s., semicircular ducts; f.c., cochlear fenestra; f.v., vestibular fenestra; i., incus; m, malleus; m.a.e., external acoustic meatus, terminating at the tympanic membrane; m.a.i., internal acoustic meatus; s., sacculus; s.e., endolymphatic sac; st., stapes; t.a., auditory tube; u., utricle; v, vestibulum; VIII, acoustic nerve.

Each canal has at one point an expansion, the **ampulla**, and all connect with a larger sac, the **utricle**, the endings of the vestibular nerve fibres being in the walls of these. The utricle connects with the endolymphatic duct, which runs to the cranial cavity and ends in a blind sac within the thickness of the dura mater. A narrow passage connects the utricle, further, with another relatively large space, the **sacculus**, which also has vestibular nerve endings, and this in turn is connected by a fine tube with the **cochlear duct**, the auditory portion of the membranous labyrinth. It appears that the receptors in the ampullae are stimulated essentially by movement,

those in the utricle and in the sacculus responding rather to position (gravitational stimuli).

While the vestibular parts of the labyrinth are completely surrounded by fluid, the **perilymph**, in the bony canals, the cochlear duct is attached to its bony enclosure along one side. It is also connected with the opposite wall by a membrane so that the cavity within the bony cochlear canal is divided into three parallel tubes, which are coiled in a close spiral and taper gradually towards the apex. Within the cochlear duct (which, like other parts of the membranous labyrinth, is filled with endolymph), is the complex structure containing the actual auditory sensory nerve endings, the **organ of Corti**.

Vibrations of the ear drum are transferred to a chain of ossicles in the middle ear (Figs. 47 and 90) the innermost of which fits loosely into an opening in the wall of the bony labyrinth and thus passes on the vibrations as pressure changes to the perilymph, which in turn transmits them to the organ of Corti.

The Eye

The eye is the special organ for the reception of stimulation by light and consists of a specialized portion of the brain, the **retina**, which has grown out on the end of a stalk of nervous tissue to come close to the surface and has been provided with a mechanism for focussing light rays upon it, the whole being enclosed in a supporting and protective capsule. The capsule is nearly spherical and is composed of exceedingly dense connective tissue which forms an opaque white coat, the **sclera**, except over the exposed outer surface of the eye.

On the exposed surface of the eye, the sclera is suddenly replaced by a transparent sheet of modified connective tissue which is fused with a thin outer layer corresponding with the epithelium of the conjunctiva (the lining layer on the inner surface of the eyelids). This outer layer of the eye is also perfectly transparent and along with the transparent

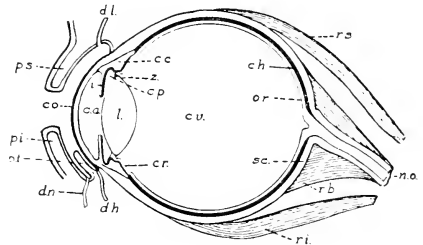


FIG. 48. Diagram of the parts of the eye in vertical section: c.a., anterior chamber; c.c., ciliary body; ch., chorioidea; co., cornea; c.p., posterior chamber; c.r., ciliary portion of the retina; c.v., vitreous body; d.h., Harderian duct; d.l., position of the lacrimal ducts; d.n., nasolacrimal duct; i., iris; l., lens; n.o., optic nerve; o.r., optic portion of the retina; p.i., lower eyelid; p.s., upper eyelid; p.t., third eyelid; r.b., retractor oculi; r.i., rectus inferior; r.s., rectus superior; sc., sclera; z., suspensory zonular fibres of the lens.

connective tissue constitutes the **cornea**, a highly refractive curved window. Internally, separated from the cornea by chambers containing a fluid, the **aqueous humour**, is suspended the **lens**, which is biconvex, somewhat more curved on its inner than on its outer surface, and composed of modified epithelium. This is suspended in a very thin capsule by a ring of fibres, the **zonula ciliaris**, which fibres are attached at their outer ends to a circular ridge of muscle, the **ciliary body**. The zonular fibres are under tension when the muscle is at rest, keeping the lens slightly flattened, and when the

muscle contracts this tension is reduced so that the elastic reaction of the lens causes its curvature to increase. The size of the aperture, the **pupil**, through which light reaches the lens is regulated by a deeply pigmented, muscular diaphragm, the **iris**.

By the structures described in the previous paragraph, light rays are brought to a focus upon the **retina**, the layer of nervous tissue lining the large cavity which occupies most of the eye. This cavity is filled with a gelatinous **vitreous body**.

The outermost layer of the retina (i.e. that nearest the sclera) is formed by a single row of deeply pigmented epithelial cells, which prevent the light from passing further. Into these project the rods and cones,* the actual receptive nerve endings. Internal to the rods and cones are several layers containing the cell bodies to which these endings belong and many other nerve cells of various kinds, together with supporting elements. Thus, in order to reach the rods and cones, the light must pass through these internal layers, which are almost perfectly transparent when alive. The most internal layer of nerve cells gives rise to the fibres of the optic nerve, and these converge over the inner surface to one point, where they turn abruptly outward, penetrating the whole thickness of the wall of the eye and proceeding to the brain.

In dissection, the nervous portion of the retina separates readily from the outer pigmented epithelial layer, but the latter is firmly adherent to a surrounding coat, the **chorioid membrane**, which is also deeply pigmented, contains very numerous blood vessels, and is loosely attached externally to the inner surface of the sclera. Towards the exposed side of the eye, the chorioid membrane passes over into the ciliary body and the iris, these three together constituting the **vascular tunic** of the eye.

THE DIGESTIVE SYSTEM

The digestive system comprises as its chief portions the **digestive tube** or alimentary canal and the **digestive glands**. The digestive tube is divisible into several parts, which, with the exception of the caecum and its vermiform process, are arranged in a linear series. The digestive glands comprise the **oral glands**, the

*The rabbit has very few cones. Correspondingly, it is reported to be colour-blind, the cones being the colour-sensitive receptors.

liver, and the **pancreas**. They are parts of an extensive series of epithelial glands, otherwise contained within the wall of the tube and for this reason not appearing as gross structures.

The parts of the digestive tube may be classified as follows:

- | | |
|--------------------|-----------------------|
| 1. ORAL CAVITY | 5. SMALL INTESTINE |
| Vestibulum oris | Duodenum |
| Oral cavity proper | Mesenterial intestine |
| | Jejunum |
| 2. PHARYNX | Ileum |
| Nasal portion | |
| Oral portion | 6. LARGE INTESTINE |
| Laryngeal portion | Caecum |
| | Vermiform process |
| 3. OESOPHAGUS | Colon |
| | Rectum |
| 4. STOMACH | |

Digestion as a Process

The digestive system performs a variety of functions, both mechanical and chemical, all connected directly or indirectly with the digestion of food. In the oral cavity, solid food is divided into small parts by the action of the teeth, and is mixed with salivary secretion, so that it is more easily swallowed and passed along the oesophagus to the stomach. The secretion of the oral glands is thus important chiefly for the lubricating properties of its mucous element, but that of the parotid especially contains an enzyme, **ptyalin**, which is capable of converting starch into soluble material. Food is further reduced to a pulp-like mass in the stomach, while the gastric secretion, containing **pepsin** and **rennin**, exercises a dissolving action upon protein, and a coagulating action upon milk. The liver secretion, known as bile, contains salts which co-operate with the pancreatic secretion in its action upon fats and which neutralize the acidity of the gastric secretion, thereby preparing the contents of the intestine for the action of the pancreatic juice and intestinal enzymes. The bile salts also aid in absorption of the products of the digestion of fats. The pancreatic secretion contains a variety of enzymes, degrading proteins and starches, and breaking fats into fatty acids and glycerin. The microscopic glands

in the lining of the small intestine also secrete enzymes capable of completing the action of those derived from the previous sources. The actions of the dissolving enzymes are successive, secretion being dependent to some extent on antecedent bodies by which the stimulus for secretion is determined. The preliminary processes of digestion refer in this way to the mechanical action of food passage along the canal and to the provision of converting enzymes. Absorption, which is the final object of the digestive process, is accomplished in the lower part of the small intestine and in the large intestine through the blood-vessels and lymphatics of the wall. The relatively great extent of the wall, including the enormous development of the caecum in the rabbit and other rodents, is related to the comparatively great bulk and low nutritive quality of the ingested food. The caecum also provides room for retention of materials long enough for bacterial action upon cellulose, which is not otherwise digested, to make resulting products available for assimilation.

The Liver

The liver has a variety of other functions besides those mentioned above. It stores nutritive material in the form of glycogen ("animal starch") and fat, and perhaps also protein, and plays an important part in fat metabolism. It removes various waste substances from the blood, eliminating some (bile pigments) in the bile and preparing others, the nitrogen-containing substances and toxic bodies absorbed from the colon, to be returned to the circulation for final excretion by the kidneys. It is one of the minor situations where red blood corpuscles are developed. From it, as well as from various other tissues, is obtained a substance (heparin) which prevents clotting of the blood. In the liver also there is stored an antianaemic substance, formed by the action of a specialized digestive enzyme on food protein, which stimulates the production of red corpuscles in bone marrow.

The liver is primarily a compound tubular gland, but during development it becomes associated with the vascular system in the formation of a structure quite peculiar. It is composed of numerous minute units, the **liver lobules**, indications of which may often be distinguished on the surface of a fresh or well-preserved liver.

Each of these is made up of innumerable cords of epithelial liver cells arranged in a radial manner around a **central vein**, which is a tributary of the hepatic veins draining the organ. Between the lobules, where several come together, there occurs a branch of each of the portal vein, the hepatic artery, and the bile duct, lymphatics, and nerves with a little connective tissue. These branch over the surface of each lobule, the branches of the vein and the artery both emptying into numerous **sinusoids** which pass radially through

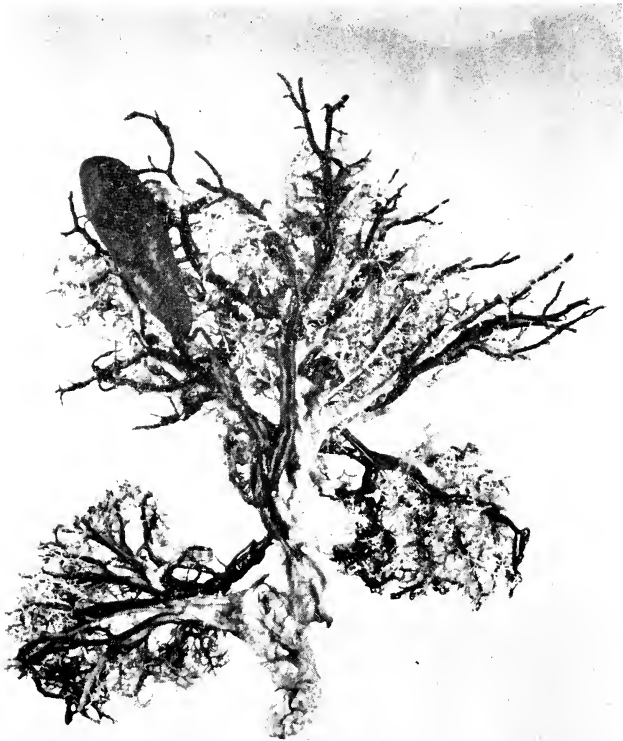

FIG. 49. Corrosion preparation of the right and left lobes of the liver of a rabbit, posteroventral view. The bile duct and the hepatic duct have been filled with a dark mass and the portal vein and its larger branches with a pale mass, following which the tissues have been dissolved away. The caudate lobe is not shown.

the substance of the lobule and enter the central vein (Fig. 50). The sinusoids differ from ordinary capillaries in being wider, and in the more extreme thinness and the irregularity of their endothelial walls, the cells of which are phagocytic and specially closely adherent to the glandular epithelium. In the cords of hepatic cells, delicate **bile capillaries** receive their secretion and carry it from the centre of the lobule towards the periphery, where they

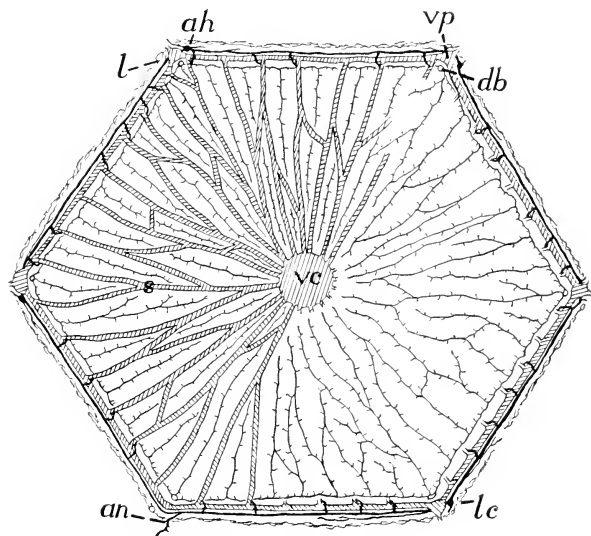


FIG. 50. Diagram of a cross section of a single liver lobule. The sinusoids are represented only in the left half of the diagram in order that the relations of the bile capillaries may be clearer on the right: ah, branch of hepatic artery; an, anastomosis between two branches of the hepatic artery; db, intrahepatic bile duct; l, lymphatic vessel; lc, lymphatic capillaries; s, sinusoids; vc, central vein; vp, branch of portal vein.

converge into the tributaries of the intrahepatic bile ducts which accompany the arteries and veins between the lobules and in turn unite to form the hepatic ducts. Lymphatic capillaries occur between the lobules but do not penetrate them. It is claimed that between the endothelium of the sinusoids and the hepatic cells there is an extremely thin film of tissue fluid which seeps out to the periphery of the lobule and is there absorbed by lymphatic capillaries, but some authorities deny this.

Form and Symmetry

In its most general features, the digestive system is significant as an epithelial tube in which the food is modified, by solution or otherwise, so that it is capable of being absorbed through the epithelial surface. In the form of the digestive tube as seen in a vertebrate, however, a number of gross mechanical features are evident, such as, for example, the increase in capacity, or in ab-

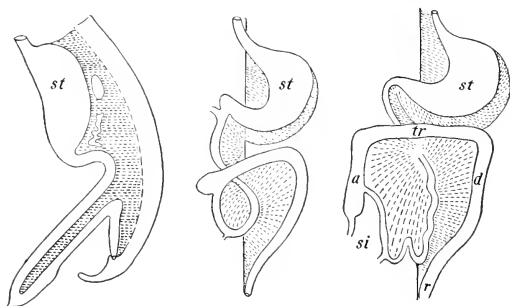


FIG. 51. Plan of successive embryonic stages in displacement of the digestive tube and common mesentery from the mid-line position (man): a, tr, d, ascending, transverse, and descending colons; r, rectum; si, small intestine; st, stomach. (Modified from figures by Toldt and Hertwig.)

sorptive area, through the folding of the mucous membrane, or the expansion of the wall; or again, the presence of a special muscular tunic, and its modification at certain places, as in the oesophagus, the pyloric limb of the stomach, and the first portion of the colon. Moreover, many features of the abdominal portion of the tube, and, indeed, certain of its recognized divisions, depend on its relation to an extensive serous sac—in a mammal the peritoneal cavity. In this connection it is to be considered that the digestive tube is primarily a median structure. It has this relation in the earlier stages of embryonic development (Figs. 22, 51), and in many of the lower vertebrates it does not deviate to a great extent from a median position. In all higher vertebrates, however, the tube becomes greatly elongated in comparison with the cavity in which it lies, and thus becomes extensively displaced to one side or other of the median plane. This development, while advanced in all mammals, may be said to reach an extreme in the herbivorous

mammalia; and in many cases it is further increased by the independent elaboration of the blind intestine or caecum. In the rabbit the combined length of the small and large intestines is approximately eleven times that of the body.

Principal Divisions

In considering the divisions of the digestive tube in the rabbit, the posterior, or post-cephalic portion, comprising the oesophagus and succeeding parts, may be distinguished from the anterior, or cephalic portion, the latter comprising the oral cavity and pharynx. The former is a free portion embracing the digestive tube proper, while the latter is a fixed portion exhibiting a variety of general mammalian features connected with the organization of the head.

The form of the anterior, or cephalic portion of the digestive tube (Plate II) depends on its fixed relation with respect to the enclosing parts of the head-skeleton. In the rabbit, as in mammals generally, the **oral cavity** is divisible into two portions, of which one is the oral cavity proper, while the other, the **vestibulum oris**, is a space enclosed between the alveolar processes of the jaws and the teeth on the one hand, and the cheeks and lips on the other. As in other vertebrates, the **tongue** is a muscular structure projecting upward and forward into the oral cavity from its base of attachment on the hyoid apparatus, but its greater elaboration and the differentiation of special processes, the circumvallate and foliate papillae, for the accommodation of the gustatory organs, are features characteristic of mammals. The roof of the oral cavity is formed by an extensive palatal surface, comprising the **hard palate**, and the **membranous, or soft palate**. These structures also form the floor of the accessory respiratory tracts of the nose, the posterior aperture being thus carried backward to a point almost directly above the aperture of the larynx.

The chief features of the **pharynx** depend on the fact that it is not merely a simple portion of the digestive tube but is also related structurally and functionally with the tubes of the respiratory system. It is divisible into an **oral portion**, representing the direct connection of the oral cavity with the oesophagus, a dorsal or **nasal portion**, connected with the nasal fossae, and also with the middle ear through the internal auditory tube, and a

ventral or **laryngeal portion**, containing the aperture of the larynx (Fig. 52).

The **oesophagus** is a slender but greatly expansible tube leading from the pharynx to the stomach. In its passage backward it traverses the neck and the thorax, and in both regions occupies a median position. In the thorax (Plate VII) it will be observed to lie between the heart and the dorsal aorta, thus exhibiting the original relation of the digestive tube to the aortic portion of the vascular system. The function of the oesophagus is that of a

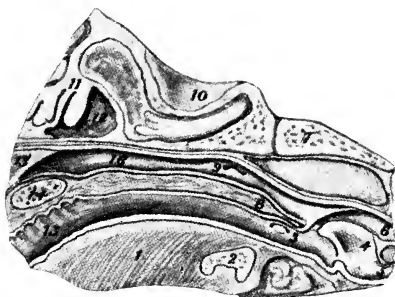


FIG. 52. The nasopharynx and related parts of the head as seen in median section (anterior end to the left): 1, tongue; 2, hyoid; 3, tonsil; 4, epiglottis; 5, entrance to trachea; 6, entrance to oesophagus; 7, basioccipital bone; 8, soft palate; 9, pharyngeal aperture of auditory (Eustachian) tube; 10, cranial cavity; 11, ethmoturbinal scrolls; 12, nasal cavity; 13, nasal septum; 14, hard palate; 15, oral cavity; 16, nasopharynx.

simple conveyer to the stomach. The succeeding portions of the digestive tube are those associated with the peritoneal cavity, and with the exception of the terminal portion, the rectum, are displaced from a median position. Consequently, the divisions which are recognized are based partly on the differential characters of the wall and partly on the position of structures, more especially in relation to the supporting peritoneum. Thus, the chief features of the **stomach** depend on the expansion of the organ and the rotation of its pyloric end forward and to the right. In the intestinal tract as a whole the chief, although by no means most conspicuous, feature of position depends on the looping of the entire structure on itself, so that the terminal portion, chiefly the transverse colon, crosses the ventral surface of the duodenum and then turns backward as the descending colon on the dorsal surface of the mesenterial small intestine (Fig. 51). In the development of this twisted arrangement and its many variants in different mammals the superior mesenteric artery has acted more or less as an axis of rotation (Fig. 53). The **duodenum** is marked off from the mesenterial intestine as an extensive loop containing the major part of the pancreas and its duct and lying on the right side of the

dorsal wall of the abdomen. The **common bile duct** enters its first portion immediately beyond the pylorus, so that in it materials received from the stomach are mixed successively with bile and with pancreatic juice. The **mesenteric intestine** is a greatly

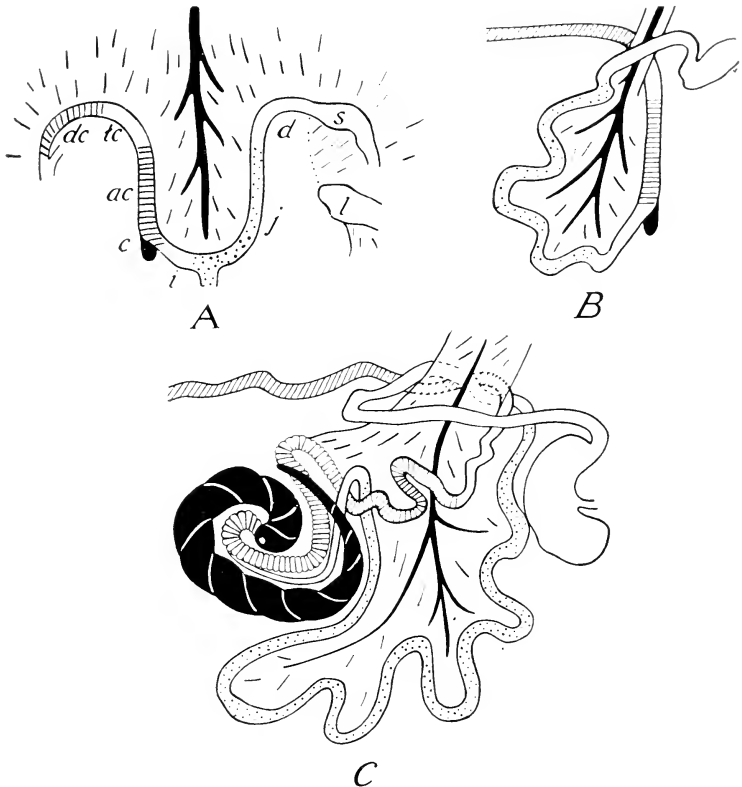


FIG. 53. Developmental stages in the coiling of the intestine. Redrawn with modifications after Zietzschmann. A. Primary intestinal loop. B. The loop twisted through 180° . C. The loop twisted through 360° , intestine differentiated as in rabbit. ac, ascending colon; c, caecum; d, duodenum; dc, descending colon; i, ileum; j, jejunum; l, liver; s, stomach; tc, transverse colon.

convoluted portion, lying chiefly on the left side of the abdominal cavity, and loosely supported by the broad, frill-like mesentery. Here the digestive processes are advanced greatly and a good deal of absorption takes place. From the pylorus to the end of the

small intestine there is generally no abrupt change in the character of the wall, although the first portion of the mesenterial intestine, that designated as the **jejunum**, and the duodenum may be considered together as a more vascular portion with thicker walls in comparison with the second portion, the **ileum**, in which the wall is less vascular and more transparent. The rabbit, however, presents an exception to the general statement at the beginning of the previous sentence in that the terminal portion of the ileum

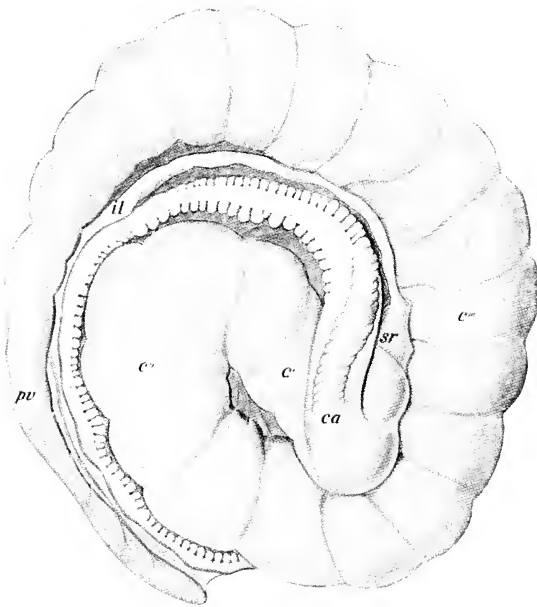


FIG. 54. The caecum and vermiform process: *c'*, *c''*, *c'''*, first, second, and third limbs of the caecum; *ca*, beginning of the ascending colon; *il*, ileum; *pv*, vermiform process (appendix); *sr*, sacculus rotundus.

forms a rather conspicuous rounded sacculus rotundus, a structure not found in other animals.

The main portion of the large intestine, the **colon**, although greatly specialized in the rabbit, may be considered to consist, as in man, of ascending, transverse, and descending parts, that is to say, the **ascending colon** lies on the right side of the body and passes in a general way from its point of origin on the caecum forward to a point where it becomes flexed to the left as the **transverse colon**;

the latter crosses the body and is flexed backward as the **descending colon**. In the rabbit, however, that portion definable as the ascending colon, which is the shortest in man, is greatly elongated, and is composed of five principal limbs, united by flexures. The last two of these are concealed in dissection from the ventral surface by the base of the superior mesenteric artery, since they lie on its right side. The descending colon is also only nominally related to the left side of the body-wall in the rabbit, its supporting peritoneum, the descending mesocolon, being fused with that of

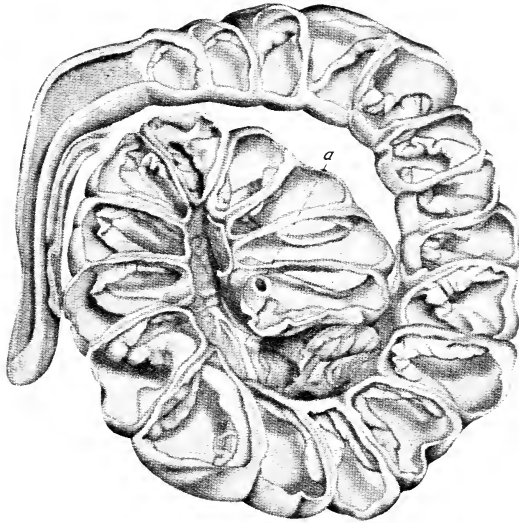


FIG. 55. The caecum with its ventral wall removed to show the lumen and the contained spiral valve: a. ileocolic aperture.

the ascending limb of the duodenal loop so that it is restored to an approximately median position. The **caecum**, like the colon, is much enlarged and particularly elongated, its course as it lies in the body being comparable to two turns of a left-hand spiral (Fig. 54). Its blind terminal portion, the thick-walled **vermiform process**, is also relatively large and, until the beginning of this portion is reached, its internal surface area is further increased by the presence of a long spiral fold or **spiral valve** (Fig. 55) comparable with that present in the intestines of sharks and skates.

It may be observed at this point that in their vascular supply the more typical divisions, namely, the transverse and descending colons, have arterial branches, respectively, the middle and left colic arteries, comparable to those of man; while on the other hand the supply to the parts on the right side, the ascending colon, caecum, and related portions, on account of their great elaboration, is represented by a large number of vessels, branches of a common ileo-caecocolic trunk. Each of these vessels anastomoses with its immediate neighbours so that the large intestine is supplied by a continuous series of arterial loops from which smaller branches are distributed to the intestinal walls.

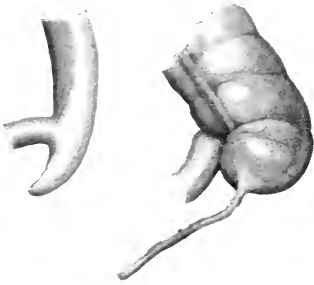


FIG. 56. Caeca of a cat and of a man, dorsal view. The former short, without a vermiform process, connecting with a smooth colon. The latter cup-like, with a vermiform process proportionally smaller than that of a rabbit, and having bands and haustra continuing those of the colon.

The elaborations of the ascending colon and of the caecum, which contrast markedly with conditions in carnivorous mammals, (figs. 54, 56), are highly instructive examples of adaptation to the character of the diet.

THE RESPIRATORY SYSTEM

In all air-breathing vertebrates, the **lungs** (Fig. 57) are paired sacs which arise embryonically as ventral outgrowths of the digestive tube, and are secondarily connected with the outside of the body through special perforations of the anterior portion of the head and through the oral cavity. The principal connection in a mammal is represented by an extensive nasal cavity bearing on its lateral walls the olfactory sense-organs. It is distinguished as an **accessory respiratory tract** from the true respiratory tract formed by the **trachea** and its terminal divisions, the **bronchi**. The respiratory system, as represented by the lungs and related tubes, being developed as a ventral outgrowth of the pharynx, is nominally ventral to the oesophagus, but in the adult animal this relation is actually true chiefly of the trachea. In the thorax (Plate VII) the bronchi are, in general, interposed between the oesophagus and

the heart, the lungs being expanded laterally into the paired pleural cavities.

In addition to the carrying of air over the sensory, olfactory surfaces, other accessory functions more closely related to respiration are the warming of the air and removal therefrom of particles of foreign material, both of which are performed by the mucous membrane of the nose, including that of the turbinated surfaces. The sole functions of the true respiratory tract and lungs are respiratory.

Respiration as a Process

In a mammal, respiration is both a physicochemical and a mechanical process. The former is fundamental, and consists in the supply of oxygen to the blood, and in this way to the tissues,

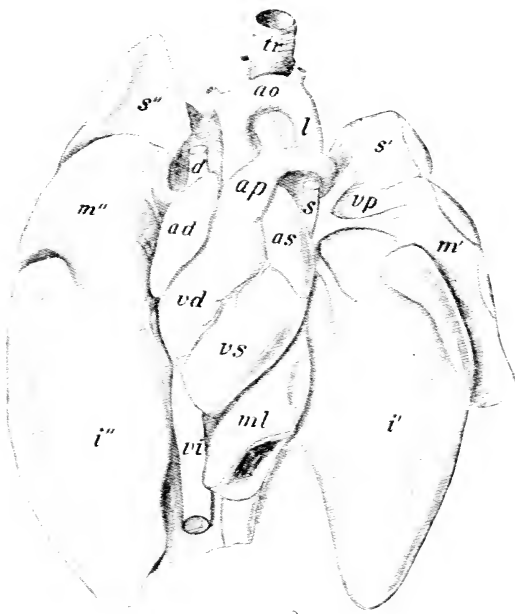


FIG. 57. The heart and lungs from the ventral surface: ad, right atrium; ao, aorta; ap, pulmonary artery; as, left atrium; d, right superior caval vein; i', i'', left and right inferior lobes of lung; l, aortic ligament; m', m'', middle lobes; ml, medial lobule of right inferior lobe; s, s', left superior caval vein; s', s'', superior lobes; tr, trachea; vd, right ventricle; vi, inferior caval vein; vp, pulmonary veins; vs, left ventricle. The right and left pulmonary arteries and the arch of the aorta are represented too high up—compare Fig. 62.

for the oxidative phases of metabolism; also in the discharge of waste gases, principally carbon dioxide, from the blood to the air. The absorption and transport of oxygen is a specific function of the red blood cells. Though the oxygen, of which a certain amount always remains in the lungs during the process of breathing, must pass through the thin epithelial lining of the terminal air sacs into

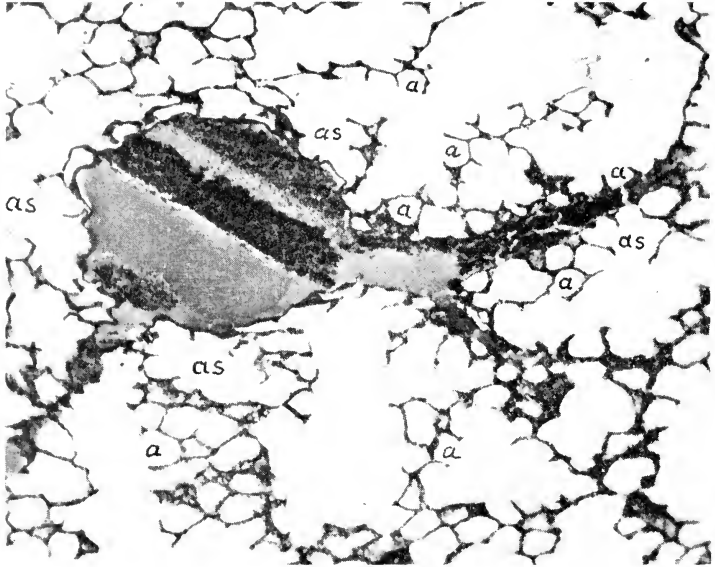


FIG. 58. Photomicrograph of part of a section of the lung of a rabbit 10 micra thick. $\times 50$. (Macklin and Hartroft.) A small venule is seen entering a larger one from the right. The venule is surrounded by alveolar sacs (as), each with small, cup-like alveoli (a).

the capillaries before it can be taken into the blood cells, the latter from their flattened shape and very great numbers present a relatively enormous surface for absorption, the process being thereby facilitated. Moreover, the epithelial lining referred to is so extremely attenuated that its completeness or even its presence in the adult mammal is a matter of active dispute. The lungs themselves are highly elastic, expansible sacs. They have the structure of greatly ramified saccular glands, except that the free internal surfaces are everywhere in contact with air (Fig. 58). The division

of the trachea into its bronchi, together with the bronchial ramifications, forms the trunk and main branch portions of a rather complex system of tubes (Fig. 60), of which the terminal air-spaces are the final and functional parts. The branching of the blood-vessels interlaced with the air passages is equally complex (Fig. 59, 63) and these vessels, besides providing for the aeration of the blood,

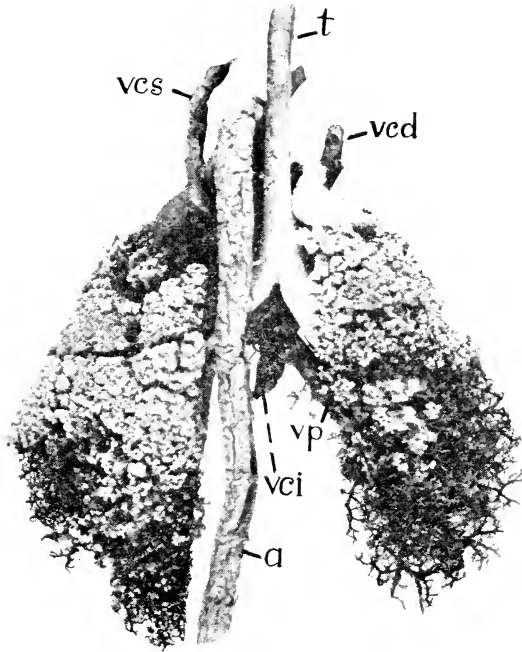


FIG. 59. Corrosion preparation of the lungs of the rabbit, dorsal view. The trachea, the bronchi, and most of the more anterior bronchioles have been filled with a pale mass, the veins with a dark mass, and the arteries with one of intermediate shade, the tissues then having been dissolved away: a, aorta; t, trachea; vcd, right superior vena cava; vci, inferior vena cava; vcs, left superior vena cava; vp, right pulmonary vein.

are said to form a blood-depot which assists in the regulation of the relative output of the two sides of the heart.

Breathing

What is commonly described as respiration, or the act of breathing, is a mechanical, muscular process accessory to the

fundamental exchange which really constitutes respiration. It consists in the expansion of the thorax, so that a partial vacuum is created and the lungs fill with air, the expansion being followed by relaxation, in which the air is expelled. The first portion of this action, known as **inspiration**, is brought about by the contraction of the intercostal and related muscles in such a way that the ribs are raised and by the simultaneous contraction of the dome-shaped diaphragm, by which the posterior wall of the thorax is flattened, and incidentally the abdominal viscera are displaced backward. On account of the oblique position of the ribs when at rest, these actions tend to enlarge the thoracic space in all three dimensions, in consequence of which air passes in from the pharynx and distends the lungs. The expulsion of air, or **expiration**, is accomplished by relaxation of the muscles mentioned above, assisted by contraction of the transverse thoracic muscles (p. 323) and the muscles of the ventral abdominal wall. The precise part played by the different muscles in the co-ordinated act of breathing has been shown to vary somewhat in different individual animals.

The action of the diaphragm is controlled directly by the phrenic nerves, but all respiratory movements are dependent upon the cervical and thoracic spinal nerves. The excitation of these nerves is regulated through a respiratory centre in the medulla oblongata, comprising inspiratory and expiratory portions and lying mainly under the back part of the fourth ventricle. The centre is stimulated both directly by carbon dioxide in the blood and reflexly by afferent impulses conveyed from the lungs, from chemoreceptors in the blood-vessels, and from other sources through fibres largely but not entirely in the vagus nerve.

Lungs and Gills

Respiration as a general function is common to all organisms. Though always constructed for easy diffusion, the organs by which the function is discharged differ profoundly in the various groups. This is true even within the limits of the vertebrates, where lower forms are characterized by **gills** for aquatic respiration, and the higher forms by **lungs** for air respiration. The occurrence of a great variety of intermediate and transitional growth stages, in which gills are replaced by lungs, with no modification from one to

the other, introduces a peculiar condition into the history of vertebrates. This condition is characterized by the appearance of gill structures in the embryos of all higher forms (Fig. 21), by the somewhat later development of air sacs in addition to these, and by the gradual elaboration of the latter in the vertebrate series from a simple type, as illustrated in the frog or better in lower tailed amphibians, to the greatly branched lung tubes of mammals and the highly complex and special arrangements in birds.



FIG. 60. The larger terminal ramifications of the left inferior bronchial ramus, from the dorsal surface; metallic cast of the interior. Cf. Figs. 57, 59, and 114. i.

THE BLOOD-VASCULAR SYSTEM

In the rabbit, as in all vertebrates, the **blood-vascular system** (Fig. 61) embraces a central, muscular organ of propulsion, the **heart**, and a series of branched tubes, the **blood-vessels**, the latter being of three different kinds: (*a*) thick-walled, elastic, distributing vessels—**arteries**; (*b*) microscopic terminal canals in the peripheral organs—**capillaries**; and (*c*) thin-walled collecting vessels—**veins**.

The chief mammalian feature in this system consists in the division of the heart into two portions, respectively left and right, each consisting of a receiving chamber, or **atrium**, and a driving chamber, or **ventricle**, and the arrangement of their vascular connections in such a way that two complete circulations are established. One of these is the **long**, or **systematic circulation**. It is concerned with the distribution of blood to the various parts of the body, with the exception of the conveyance of blood to the lungs for aeration (but including the supply of the deeper tissues of the lungs, through the bronchial arteries). It is established by the left ventricle, the aorta, the carotid and subclavian branches of its arch, and the parietal and visceral branches of its thoracic and abdominal portions. The blood is collected from the anterior portions of the body through paired internal and external

jugular and subclavian veins, communicating with the right atrium of the heart through paired superior cavals¹; from the posterior portions of the body through the unpaired and asymmetrical inferior caval vein, the latter passing forward on the right of the median plane and entering the posterior end of the right atrium. The second, **short**, or **pulmonary circulation**, is concerned with the distribution of the blood to the lungs for purposes of aeration (Fig. 63).

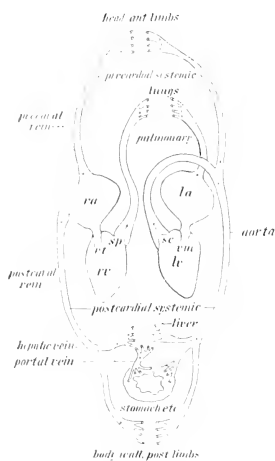


FIG. 61. The mammalian circulation: rv, lv, right and left ventricles; ra, la, right and left atria; sc, sp, semi-lunar valves of aorta and pulmonary artery; vt, vm, right and left atrioventricular valves.

It is established by the right ventricle, the pulmonary artery and its paired branches, and the capillaries of the lungs. The blood is delivered to the left atrium through several pulmonary veins. A similar division of the circulatory organs occurs as a homoplastic modification in birds, which, it will be observed, are also warm-blooded vertebrates.

In general, the blood which is distributed to the various parts of the body passes through but one set of capillary vessels,

and is then returned through the systemic veins to the heart. In all vertebrates, however, a special portion of the systemic venous circulation is set aside as the **hepatic portal system** distinguished by the possession of a second series of capillary vessels ramifying in the liver. Thus, in the rabbit and other mammals, the blood distributed to the stomach, spleen, and intestine through the coeliac and the superior and inferior mesenteric arteries, is collected into a main intestinal vessel, the **portal vein**, and the latter passes to the **sinusoids** of the liver, which take the place of true capillaries, differing from them as described on page 97. The liver receives also oxygenated blood, though in much smaller quantity, through the hepatic artery and the ultimate branches of this also empty

¹In many mammalian species, including man, there is a reduction of the left superior caval vein during development, blood from the left subclavian and jugular vessels all being diverted through the transverse jugular (p. 297) into the right superior caval, which thus appears unpaired in the adult.

into the sinusoids, which in turn unite in the tributaries of the hepatic veins. In lower vertebrates and in the embryos of mammals where the kidney is a mesonephros (p. 126), a second system of venous capillaries occurs in that organ and is known as the **renal portal system**.

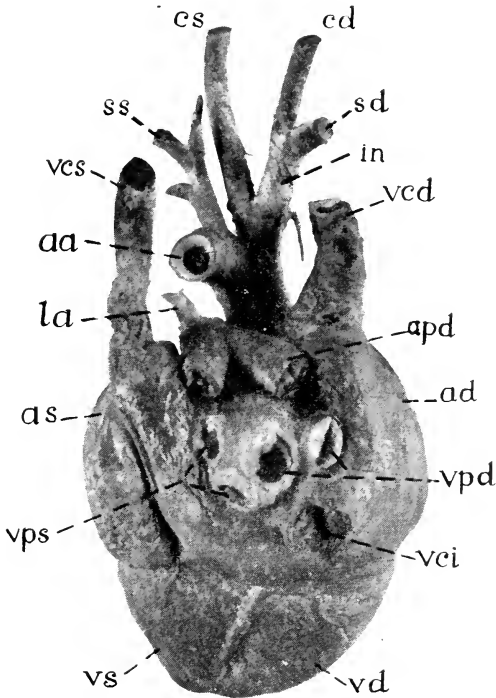


FIG. 62. Dorsal aspect of heart of rabbit: ad, as, right and left atria; apd, aps, right and left pulmonary arteries; cd, cs, right and left common carotid arteries; in, innominate artery; la, arterial ligament (cut); sd, ss, right and left subclavian arteries; vcd, vcs, right and left superior caval veins; vci, inferior caval vein; vpd, vps, right and left pulmonary veins.

The ultimate function of the vascular system is connected with interchange of materials between the tissues and the liquid flowing in the vessels. This is brought about through the medium of microscopic **capillaries**, the delicate walls of which act as semipermeable membranes permitting diffusion through them. The gross parts of the system are concerned with transportation of dissolved materials from one part of the body to another. The propulsive

action of the heart is muscular and rhythmic; contraction, or **systolic phases**, alternating with expansion, or **diastolic phases** (cf. p. 64). The flow is maintained in one direction principally by the atrioventricular valves of the heart and by the semilunar valves of the aorta and pulmonary arteries, though there are also valves in

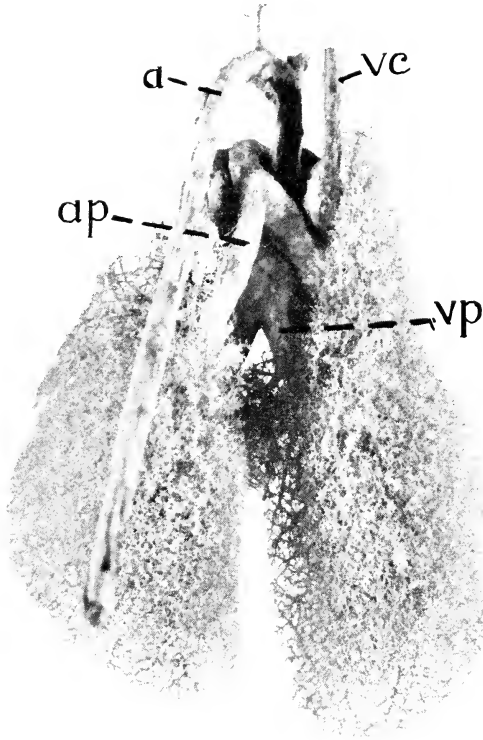


FIG. 63. Corrosion preparation of the blood-vessels of the lungs of a rabbit, dorsal view: a, aorta; ap, pulmonary artery; vc, right superior vena cava; vp, pulmonary vein.

the course of some of the veins. The arteries are tubes with thickened elastic walls. They are expanded by the impulse of blood from the heart, contraction of which is followed by a **pulse wave** in the arteries. The passage of blood into the capillaries takes place more slowly and uniformly, while the arteries contract to their previous diameter and the relative distribution of blood to various parts is

regulated both by changes in degree of contraction of the arterial walls and also by local closing and opening of the capillaries themselves. In the return of the blood the veins are largely passive, acting merely as closed channels connecting the capillaries with the heart. The control of the muscular action of the heart and arteries through the vagus and sympathetic nerves is an important element in maintaining tone in the walls of the vessels and thereby the pressure of the blood (cf. p. 64).

Many of the peculiar features of the mammalian circulation which at first sight do not appear to be general, but are so in reality, depend on the circumstance that the complete partition of the organs is a final stage of a general progressive development, observable in air-breathing vertebrates, in which the lungs and their vascular connections become perfected for **pulmonary respiration**. On the other hand, the vascular system in its earlier embryonic condition more especially in its aortic portion, is arranged according to the type of **branchial respiration** as found in fishes. In this condition the blood is sent forward from the heart through a ventral aorta. The latter is connected with a series of paired **branchial aortic arches**, traversing the rudimentary gill structures and thus passing upward around the sides of the primitive pharynx. The dorsal aorta is formed by the junction of the branchial aortic arches, and passes backward as a main distributing vessel on the ventral side of the axial support. The heart itself is formed primarily on a plan similar to that in fishes, where all the blood is received by a single atrium and is delivered forward to the gills by a single ventricle.

The definitive condition of the chief arterial vessels is arrived at by an extensive modification of the branchial plan. As indicated

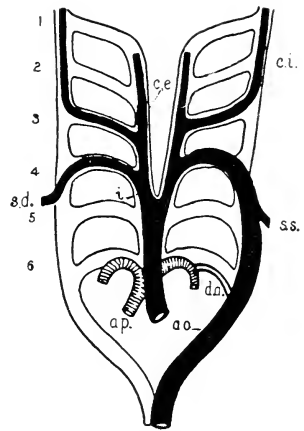


FIG. 64. Plan of the branchial aortic arches. The adult mammalian vessels are indicated in black (systemic) or shaded (pulmonary): 1-6, primary arches; ao., aorta; a.p., pulmonary artery; c.e., external carotid; c.i., internal carotid; d.a., ductus arteriosus (Botalli); i., innominate artery; s.d., right subclavian; s.s., left subclavian. (From Weber, after Boas.)

in the accompanying diagram (Fig. 64), the arched condition is retained by the aorta and by the pulmonary artery. It is interesting to note also that the primary connection of these vessels is represented in the foetus by an open canal, the ductus arteriosus (Bottalli), which closes shortly after birth but is indicated in the adult by a short fibrous cord between the left pulmonary artery and the aorta, the **arterial ligament** (Fig. 57, 1). It will be evident from an examination of Fig. 64 that this is a vestige of the dorsal part of the sixth aortic arch on the left side. The adult aortic arch represents the left one of a pair (the fourth) while that of the right side is represented only imperfectly by the base of the right subclavian artery (the innominate artery and the common carotids being derived from parts of the ventral aorta, as is apparent in Fig. 64). Hence a condition of asymmetry results, which is expressed mainly in the sinistral position of the aortic arch with reference to the oesophagus (Plate VII). By comparison with the embryonic plan, it is seen that the primitive features of the heart and the arterial vessels include the ventral position of the heart itself, the equivalence of the two atria and of the two ventricles—these structures being partitioned internally but imperfectly divided externally—the forward position of the first portion of the aorta (derived from the ventral aorta of the embryo), and the dorsal position of the descending part of the aorta (beyond its arch) as a median vertebral trunk.

The vascular system is noteworthy for several departures from the condition of symmetry, one of which has already been mentioned. In addition, it is seen that in a mammal, as in terrestrial vertebrates generally, the base of the pulmonary artery (Figs. 57, 62) is rotated in a spiral fashion about the base of the aorta, so that from its beginning on the right ventricle it passes across the ventral surface of the base of the aorta to divide on the dorsal side of the latter into its two main branches. Moreover, the separation of the ventricular portion of the heart into two chambers is associated with an enormous increase in the muscularity of the wall in the left ventricle, or, in other words, in that portion which is concerned with the larger, systemic circulation. The inferior caval vein (Plate VIII), a highly specialized vessel, is asymmetrical,

since from its beginning at the posterior end of the abdominal cavity to its termination on the right atrium it lies wholly to the right of the median plane. The azygos vein of the thorax (Plate VII), a vessel uniting the majority of the paired intercostal veins, and interesting as a remnant of the primitive circulation, is also asymmetrical, since the trunk lies to the right of the bodies of the vertebrae, and is connected at its base with the right superior caval vein. These dispositions have been derived from originally symmetrical ones through complicated embryological changes.

The Foetal Circulation and Its Transformation to the Adult Condition

Besides the features of the circulatory system discussed above, which are explained by their embryonic origin, others reflect later stages of prenatal development, when the aeration of the blood and the absorption of nourishment are accomplished in the peculiar organ characteristic of the higher, or placental mammals, the placenta. This organ is formed in part by the wall of the maternal uterus and in part by an outgrowth (the allantois) from the embryonic alimentary canal. It provides for a close interlacement of the maternal and embryonic bloodvessels so that, without any mixing of the two blood-streams, an exchange of dissolved material can occur between them by diffusion. The course of the foetal blood at this time is represented diagrammatically in figure 65.

After aeration in the placenta, the blood returns to the body of the foetus through the umbilical vein, unshaded in the diagram, and is carried by it to the liver, which it traverses through a wide channel, the ductus venosus. Here it is mixed with unoxygenated blood from the portal vein and is then emptied into the inferior vena cava, there mingling with a second stream of unoxygenated blood coming from the posterior parts of the body. This mixed blood is indicated in the diagram by stippling. Entering the right atrium of the heart, such blood mixes very little with that coming through the superior caval veins but mostly flows directly through the foramen ovale (Fig. 66), a wide passage leading through the median septum into the left atrium, whence the blood is pumped to the left ventricle and out through the aorta.

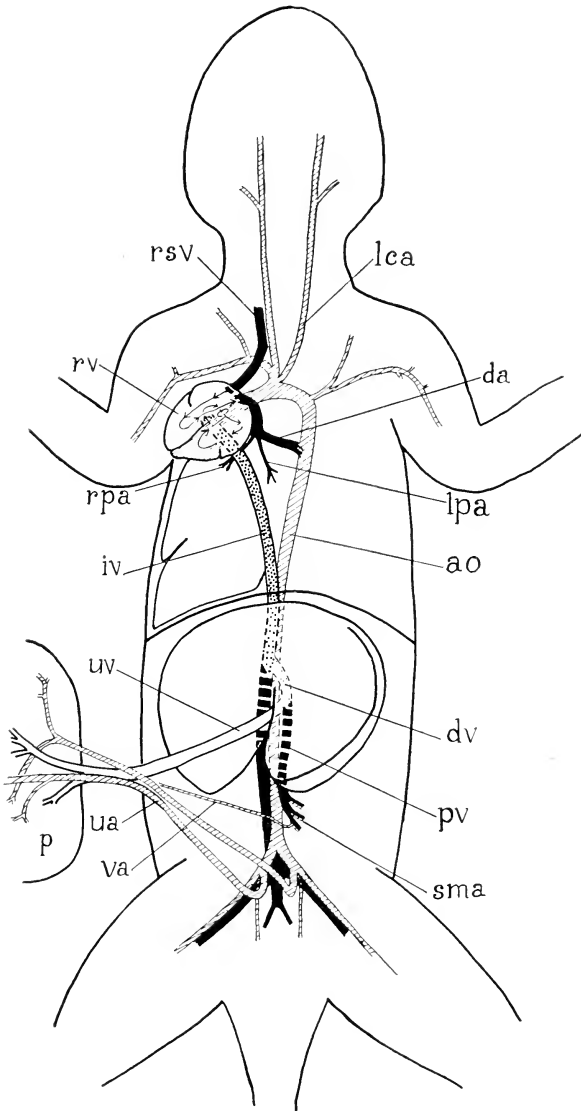


FIG. 65. Diagram of a ventral view of the blood-vascular system of a foetal rabbit, shortly before birth. ao, aorta; da, ductus arteriosus; dv, ductus venosus; iv, inferior vena cava; lca, left common carotid artery; lpa, left pulmonary artery; p, placenta; pv, portal vein; rpa, right pulmonary artery; rsv, right superior vena cava; rv, right ventricle; sma, superior mesenteric artery; ua, right umbilical artery; uv, umbilical vein; va, vitelline artery.

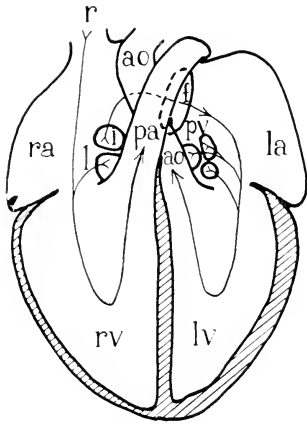


FIG. 66. Diagram of a ventral view of the course of the blood through the heart of a rabbit shortly before birth. ao, aorta; f, foramen ovale; i, opening of inferior vena cava; l, opening of left superior vena cava; la, left atrium; lv, left ventricle; pa, pulmonary artery; pv, openings of pulmonary veins; r, right superior vena cava; ra, right atrium; rv, right ventricle.

The unoxygenated blood from the regions in front of the heart enters the right atrium through the superior caval veins and, although there is no partition to separate it from the stream entering by the inferior caval, it is mainly directed through the right atrioventricular opening to the right ventricle and so into the pulmonary artery. The lungs being non-functional until birth, however, only a part of this current is carried to them, the greater portion passing through the wide ductus arteriosus (the retained dorsal part of the left sixth aortic arch) to the aorta. These vessels carrying unoxygenated blood appear black in the diagram. Some of the mixed blood which entered the aorta from the left ventricle has been

distributed through the carotid arteries to the head and through the subclavian arteries to the anterior limbs before this final admixture of unoxygenated blood through the ductus arteriosus occurs, so that these anterior parts receive blood better oxygenated than that which reaches the trunk and tail. At its caudal end, the aorta divides into a pair of large common iliac arteries, the greater part of the blood from which enters the umbilical arteries and so is returned to the placenta to have its load of oxygen renewed. The external iliac artery, which continues into the hind limb, is considerably smaller in the foetus than the umbilical, and the hypogastric (internal iliac) is smaller still.

Radical changes in these dispositions occur at birth. The placenta is suddenly lost and the flow of blood through the umbilical vein ceases, this vessel rapidly degenerating to a cord of connective tissue, the remains of which appear in the adult as the round ligament of the liver. The wide passage through the liver, the ductus venosus, also becomes obliterated so that all blood entering that organ has to flow through its sinusoids to reach the hepatic veins and enter the vena cava. Since no oxygenated blood now

reaches the liver except the small flow through the hepatic arteries, the blood in the inferior caval vein is now nearly devoid of oxygen.

The sudden expansion of the lungs with the first breath results in an immediate expansion of the pulmonary arteries and a simultaneous active contraction of the walls of the ductus arteriosus forces all the blood from the right atrium to flow through these. This contraction of the ductus arteriosus is maintained until the lumen is permanently obliterated and the vessel remains only as a solid cord, the arterial ligament of the adult.

The increased stream of blood through the lungs returns through the pulmonary veins to the left atrium, producing altered pressure-relations there such that the flaps at each side of the foramen ovale are pressed into contact. Thus an almost immediate functional closure of the foramen takes place. Later, the flaps fuse and the position of the foramen is indicated only by a thin area, the fossa ovalis, in the adult heart. Such closure of the foramen ovale diverts all the blood entering the right atrium into the right ventricle, whence it all is pumped to the lungs, as just indicated.

Thus all the regions of mixture of oxygenated and unoxygenated blood are closed off at birth and thereafter all blood in the right side of the heart is unoxygenated and all blood in the left chambers of the heart is oxygenated. Moreover, the oxygenated blood from the left ventricle is distributed through the aorta and its branches to all parts of the body without any dilution such as is brought about by the ductus arteriosus in the foetus, and even the most posterior parts receive blood with as much oxygen as in that to the head.

Although the placenta is lost, the basal part of the outgrowth of the embryonic alimentary canal which produced it remains and forms the urinary bladder; and the corresponding portions of the umbilical arteries also remain to supply that organ, though reduced in relative size and now carrying oxygenated blood.

THE LYMPHATIC SYSTEM

The **lymphatic system**, both in its functional relation and in origin, is an appendage of the venous portion of the vascular system. The system is an important one, of which, unfortunately, little may be seen by ordinary dissection, the structures which are revealed

in this way being mainly the lymph glands, or **lymph nodes**. Anatomically, the system may be regarded as comprising superficial and deep portions, the superficial nodes occurring under the skin either singly, as in the head and neck, or more or less grouped, as in the axillary and inguinal regions, their precise number and

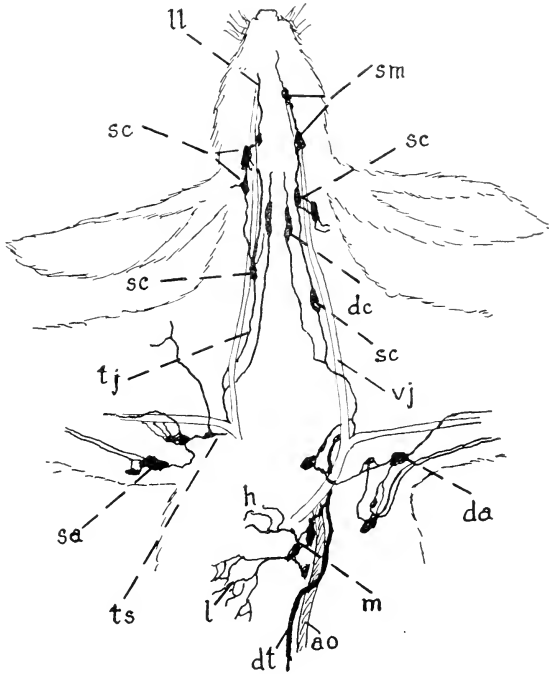


FIG. 67. Some of the lymph vessels and nodes of the anterior part of the rabbit, according to Jossifow (redrawn): ao, aorta; da, deep axillary lymph node; dc, deep cervical lymph node; dt, thoracic duct; h, lymph vessels of heart; l, lymph vessels of lungs; ll, lymph vessels from lips; m, mediastinal lymph nodes; sa, superficial axillary lymph nodes; sc, superficial cervical lymph nodes; sm, submaxillary lymph nodes; tj, jugular trunk; ts, subclavian trunk; vj, external jugular vein.

arrangement being somewhat variable. As deep structures they are conspicuous in the intestinal mesenteries and in the walls of the digestive tube, occurring in the latter chiefly as continuous masses of **lymph follicles**, as, for example, in the walls of the sacculus rotundus, the vermiform process, or the tonsil; or, again, as **aggregated lymph follicles** (Peyer's patches) at various points in the wall of the small intestine.



The conducting portion of the system comprises an extensive series of canals, beginning as **lymphatic capillaries** in peripheral organs, and ending as **lymphatic trunks** which empty into the great veins. The lymphatic capillaries are terminal vessels, differing from blood capillaries both in the character of their walls and in their relations to other portions of the system, since they are not interposed, as in the blood-vascular system, between vessels of a larger order. The lymphatic capillaries begin blindly in the tissue spaces, where they collect through their walls fluid derived from the blood plasma by exudation through the walls of the blood capillaries. The lymphatic capillaries unite to form larger vessels and these are connected as extensive plexuses, at important points in which the lymph nodes are distributed. The latter act as strainers for the lymph, removing bacteria or other foreign particles so that they will not be conveyed into the blood stream. They also add to it new white blood cells. From them the vessels convey the lymph to the lymphatic trunks.

The lymphatic trunks of the anterior portion of the body (Fig. 67) are designated from their association with the corresponding veins as **jugular** and **subclavian**. They enter the venous system on either side at the point of junction of the internal and external jugular veins or of the common jugular and subclavian (Fig. 111). The lymphatic vessels of the posterior portion of the body, including the intestine, usually largely unite in a lymph-reservoir at about the level of the first lumbar vertebra, and from this the lymph flows forward through a common canal, the **thoracic duct**. The latter lies for the most part between the aorta and the vertebral column, and traverses the thorax in this position to enter the venous system at the same point as the jugular and subclavian trunks of the left side. There are also retrosternal lymph-tracts accompanying the internal mammary blood-vessels and functional tests have shown that drainage from the abdominal cavity is largely through these. They enter the jugular veins of their respective sides just after the union of external and internal jugulars. All these trunks are so thin-walled that it is not usually possible to see them in ordinary dissection.

The **lymph** or fluid present in lymph vessels and in the spaces of lymph nodes and the tissue fluid in the tissues of the body are

comparable to the fluid part or plasma of the blood. While blood is a carrier for both in-going and out-going materials of metabolism, on account of being confined to the capillaries it is not brought into direct contact with the tissue-cells of the body. The cells are, however, bathed in tissue fluid, which can permeate the tissues by diffusion. It contains cells of a type that can migrate through the walls of vessels and when it enters the lymphatics it becomes lymph. The lymph is thus a general medium of transmission with special cell functions. The fat-carrying function of the intestinal lymphatics, in which the delivery of food materials directly to the blood is the principal consideration, is doubtless a very special phase of the transfer mechanism.

The cell contents of lymph vessels and spaces are amoeboid cells or leucocytes (cf. p. 33). Leucocytes of several kinds are found in various situations in the body. Since they are wandering cells, their situation at any one time reveals little of their points of origin. They are formed originally in lymph nodes, in the spleen, in the bone marrow, in endothelial linings, and by local proliferation of connective tissue cells. They serve a variety of purposes of which the phagocytic action, chiefly ingestion and destruction of bacteria, and disintegration of erythrocytes and other cell debris, is one of the chief.

Lymph nodes, which, as just indicated, are centres for the proliferation of certain types of leucocytes, concentration points for such cells, and local centres of phagocytic action, appear to be situated strategically with reference to parts of the body served. In local infection, the activity of leucocytes of various kinds at the point of injury can be correlated with that of leucocytes in the nearest lymph nodes and the general relation can be observed in the appearance and behaviour of the two regions themselves. The

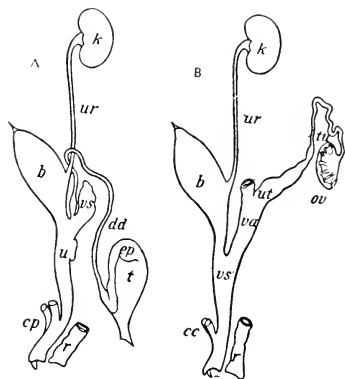


FIG. 65. Homologies of male (A) and female (B) urinogenital systems: b, urinary bladder; cc, crura clitoridis; cp, crura penis; dd, ductus deferens; ep, epididymis; k, kidney; ov, ovary; r, rectum; t, testis; tu, uterine tube; u, urethra; ut, uterus; ur, ureter; va, vagina; vs, seminal vesicle; vs', vestibulum, urethra.

spleen is a lymphatic organ, the largest in the body, with functions comparable to those of lymph nodes. It contains large vessels which act as reservoirs for blood and it also stores iron.

THE URINOGENITAL SYSTEM

The **urinogenital system** comprises two primary systems—**reproductive** and **urinary**—differing widely in their central organs, but associated to a certain extent by having common ducts. In the rabbit, as indicated in the accompanying diagram (Fig. 68), this association extends only to the presence in the two sexes of a urinogenital canal, or **urinogenital sinus** connecting both urinary and genital structures with the outside of the body. This canal is

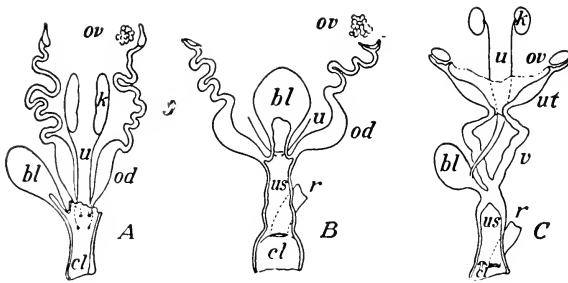


FIG. 69. The principal stages in specialization of the female urinogenital ducts in vertebrates. A, frog; B, monotreme; C, marsupial. bl, bladder; cl, cloaca; k, kidney; od, oviduct; ov, ovary; r, rectum; u, ureter; us, urinogenital sinus (vestibulum); ut, uterine tube; v, vagina. (Chiefly from figures of Gegenbaur and Wiedersheim.)

designated in the male as the **urethra**, but in the female as the **vestibulum**, since the structure known from the human relation as the female urethra is only a urinary canal leading from the bladder and does not serve as a reproductive duct.

In primitive vertebrates (Fig. 69), the urinary and genital ducts open into the posterior end of the digestive tube, the latter forming in this relation a common canal, the **cloaca**. In terrestrial vertebrates, the urinary bladder is developed as a ventral outgrowth of the digestive tube and, except in amphibians, both sets of ducts undergo a migration from their original position on to the wall of its canal, the latter being thus transformed into a urinogenital sinus. This development reaches its extreme in the placental mam-

mals, where the urinogenital sinus becomes completely separated from the digestive tube, and where the urinary ducts are also transferred from a posterior or **hypocystic** position on the wall of the urinogenital sinus to an anterior or **epicystic** position on the dorsal wall of the bladder.

The Kidneys

The chief organs of the urinary system are the **kidneys**. They are paired organs, lying against the dorsal abdominal wall, approximately in the position of the embryonic intermediate cell mass (Fig. 22, n.) from which they are formed. During development, one kidney is often displaced more than the other by the pressure of adjacent organs so that the symmetrical disposition of the pair is destroyed. Thus in the human adult the right kidney is situated lower than the left on account of the pressure of the right lobe of the liver. In the rabbit, on the other hand, the left kidney is displaced further back than the right by the posterior expansion of the greater curvature of the stomach.

The kidneys appear as solid organs, brownish in colour and bean-like in general shape, enclosed by a fibrous coat, and connected medially with the expanded end of the ureter. In the rabbit the kidney appears as an almost continuous mass, in which, however, slight traces of **lobulation** can be distinguished. In many mammals, such as sheep and bear, the organ is composed of distinct and separable lobules. This condition is clearly shown in the human kidney during foetal life, and though the organ is much more concentrated in the adult, the lobulated condition there appears internally in the division of the ureter into several **renal calyces**, each of them connected with a corresponding renal papilla. In the rabbit, however, there is only a single renal papilla and the expanded end of the ureter, the **renal pelvis**, is undivided. The pelvis has a lobulated form not readily displayed in dissection but striking-

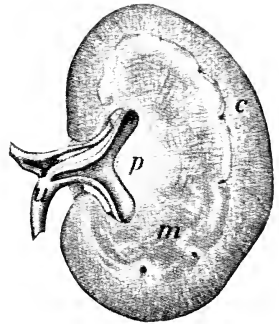


FIG. 76. The left kidney, divided horizontally lengthwise, cut surface of dorsal half: c, cortical substance; m, medullary substance; p, renal papilla; u, ureter.

ly shown in a cast of the cavity (Fig. 71). The suitability of the term calyx is evident.

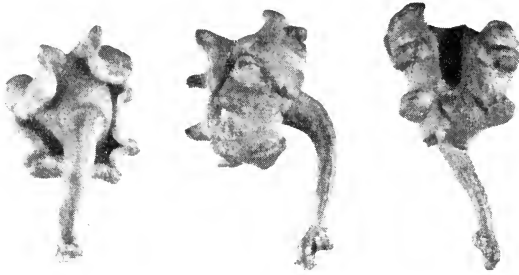

FIG. 71. Medial, dorsal, and posterolateral views of a cast of the renal pelvis and beginning of the ureter of a rabbit. The deep depression visible in the middle of the cast in the posterolateral view is occupied by the renal papilla. The pelvis is slightly distended by the pressure required to fill it with the mass.

Internal Structure and Function

When horizontally divided (Fig. 70), the kidney is seen to be made up of a more vascular and granular external layer, termed the **cortex**, and of a somewhat radially striated, central mass, termed the **medulla**. Notwithstanding the solid appearance of cortex and medulla, the kidney is made up of a system of **tubules**, the relation of which to the vascular system is such that water and certain soluble substances to be excreted are passed into them from the blood stream. The primary tubule, or nephron, (Fig. 73, B) begins in each case in the cortical substance with a cup-like structure, known as a **renal** or **Malpighian corpuscle**. This consists of a double capsule containing a **glomerulus** or knot of capillaries from the renal artery (Fig. 73, A). The blood in the glomerulus is separated from the cavity between the two layers of the capsule only by a very thin membrane composed of the lining of the capillary and that of the capsule, both of which linings are uninterrupted, and through this membrane fluid is filtered into the cavity of the capsule, whence it flows into the tubule. The nephron beyond the capsule is differentiated into portions known as the proximal and the distal tubules. The first of these comprises a convoluted portion, a straight portion, a thin portion, and a thick portion, of which the first with the renal corpuscle lies entirely in the cortex while the

others form a long loop, the loop of Henle, extending into the medulla and back to the capsule. Here commences the distal tubule, which is tortuous and leads into an initial collecting tubule. This, in turn, unites with others to form a collecting tubule that passes through the medulla to enter the pelvis through the surface of the papilla. Blood capillaries again come into contact with each tubule at certain points in its course, where further excretion and selective reabsorption occur. The excreted fluid, urine, contains characteristic nitrogenous waste materials, usually mainly urea but with smaller quantities of other nitrogenous substances such

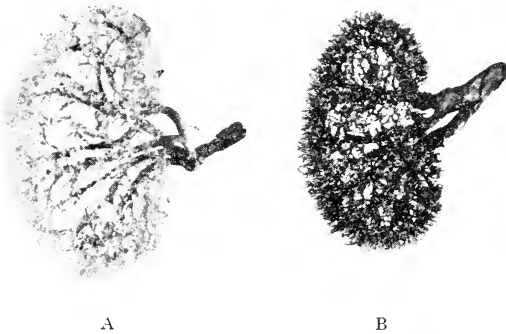


FIG. 72. Corrosion preparations of the larger blood vessels in the kidney of the rabbit: A, veins; B, arteries. The greater density of the vessels in the cortex as compared with the medulla is evident.

as uric acid or, in most mammals, allantoin. These are formed mainly in the liver and perhaps elsewhere in the body.

Homologies of Vertebrate Kidneys

Like all other parts of the urinogenital system, the mammalian kidney affords in its structure and embryonic development a remarkable illustration of the extent to which the adult form and relations of an organ may depend upon ancestry, and of the greatness of the changes which may occur before these adult conditions are attained. In the vertebrate subphylum, three successive pairs of kidneys have been recognized. They occur in antero-posterior order in the body, they are of increasing specialization, and their order of appearance and functional value are

directly associated with the degree of general specialization of the groups in which they occur. These organs have been designated

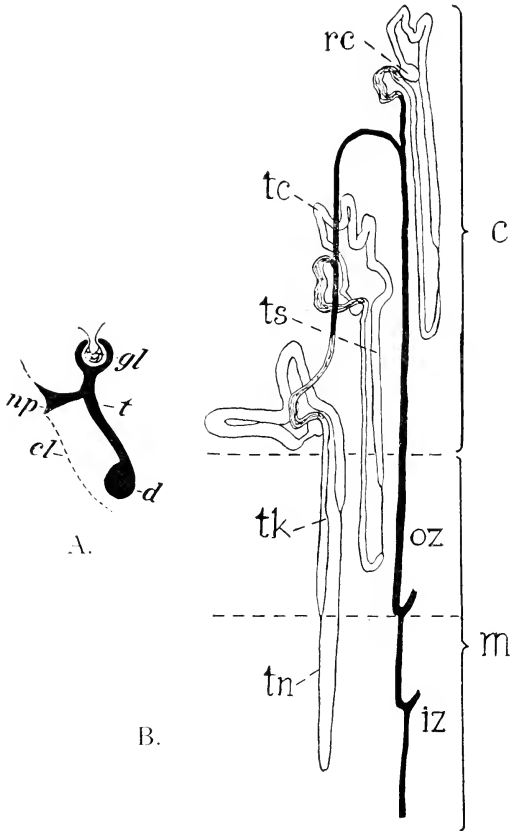


FIG. 73. A. Plan of a single primitive kidney tubule in a lower vertebrate, the cavity between the two layers of the capsule and the cavity of the tubule represented in solid black: gl, glomerulus; np, nephrostome; cl, coelomic epithelium; d, longitudinal duct; t, main portion of tubule.

B. Scheme of the parts of the nephrons and their situations in the mammalian kidney, after Sperber: c, cortex; iz, inner zone of the medulla; m, medulla; oz, outer zone of the medulla; rc, renal corpuscle; tc, convoluted portion of proximal tubule; tk, thick segment of proximal tubule; tn, thin segment of proximal tubule; ts, straight portion of proximal tubule. The proximal tubules are unshaded, the distal tubules grey, the collecting tubules black.

as **pronephros**, **mesonephros**, and **metanephros**. The metanephros is the adult kidney in mammals, while the other two are embryonic

in that class. The mesonephros is, however, the adult kidney in fishes and amphibians, where its duct serves in the male as both reproductive duct and ureter. The presence of this kidney and of its duct in embryonic mammals determines the form of the ductus deferens and its connections with the terminal portions of the urinary system. The pronephros, on the other hand, is in

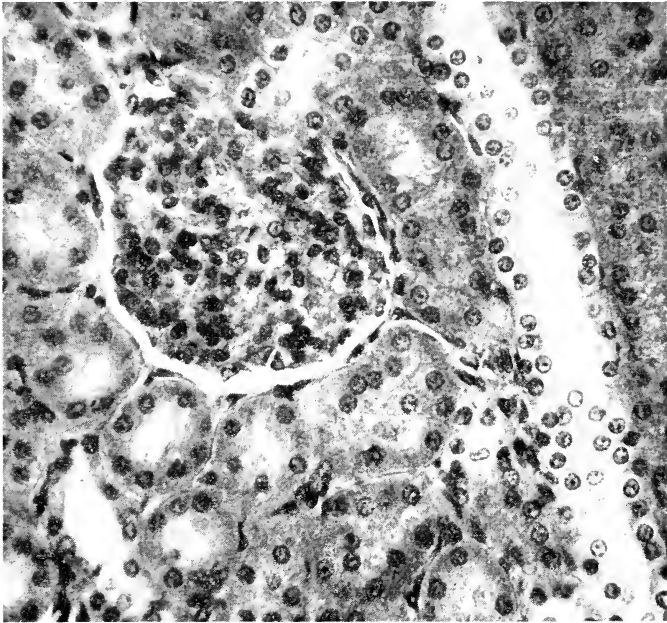


FIG. 74. Photomicrograph of a small part of a section of the kidney of a rabbit. $\times 360$. A collecting tubule appears at the right, the structure of its epithelial lining being distinct. At the left is a glomerulus lying within its Bowman's capsule and round it are several sections of convoluted tubules.

all vertebrates a vestigial kidney present only in embryos. Its duct system, however, which opens proximally to the body cavity, plays an important part in the formation of the oviduct in the female of all classes. The tubules of the pronephros and often those of the mesonephros connect with the coelom by ciliated openings, the **nephrostomes**, which do not occur in more specialized kidneys. Thus the development and structure of the pronephros and, in a less perfect way, those of the mesonephros show

that the primary connections of the kidney tubules are with the coelomic cavity (Fig. 73, B).

The Testis and its Duct

The male gonad, or testis (Fig. 81), is composed mainly of convoluted seminiferous tubules, held together by layers of connective tissue, and in the walls of these tubules the male germ cells, the spermatozoa, are developed. In a transverse section of a tubule, cells with dark nuclei appear in the outer or basal row (Fig. 76). These, known as spermatogonia, produce cells (spermatocytes) which are transformed through several intermediate steps into spermatozoa the latter then passing from the tubules to the epididymis. In the rabbit, as in all mammals, the testis is connected with the peripheral duct system (Fig. 75) by means of the **epididymis** and the **ductus deferens**, which are parts of the mesonephric connections of the embryo. While the ductus deferens is a

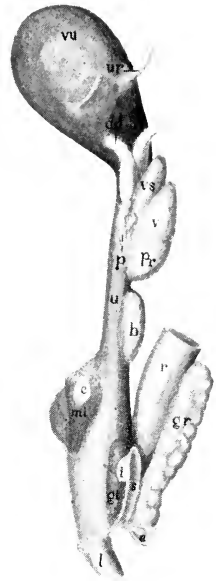


FIG. 75. The male urinogenital ducts and related structures viewed from the lateral surface: a, anal aperture; b, bulbourethral gland; c, end of crus penis cut from its attachment to the ischium; dd, ductus deferens; gi, brown portion of inguinal gland; gr, rectal gland; i, white portion of inguinal gland; l, pars libera penis; mi, ischiocavernosus muscle; p, paraprostatic glands; pr, prostate gland; r, rectum; s, inguinal space; u, urethra (membranous portion); ur, ureter (these stumps should be directed more backward, to pass under the deferent ducts); v, vesicular gland; vs, seminal vesicle; vu, urinary bladder.

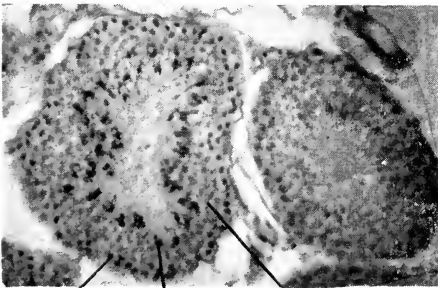


FIG. 76. Small part of a section of the testis of a rabbit showing two seminiferous tubules. sc, spermatocytes; sg, spermatogonia; sz, heads of newly formed spermatozoa.

single tube, the epididymis consists of an aggregation of small tubules, lying chiefly toward the anterior end of the testis, but with the tubules not individually discernible. In the embryo

of every vertebrate, the testis is formed in association with the dorsal abdominal wall, but in many mammals it moves backward either periodically or permanently in the course of development, to a position in a separate sac derived from the posteroventral part of the coelom, the scrotal sac. This change in position, known as the **descent** of the testis, has been shown to be an adaptation for temperature regulation in that organ. It is controlled by a cord of muscle and connective tissue, the **gubernaculum**, which is retained in the adult rabbit as a fibrous band attaching the testis to the end of the scrotal sac. The migration of the organ determines a number of peculiarities in the relations of its blood-vessels and peritoneal connections.

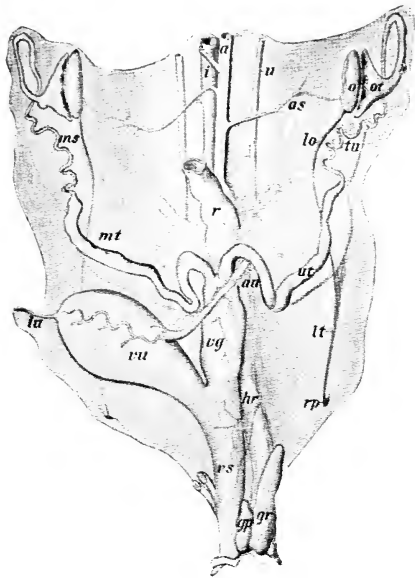


FIG. 77. The female urinogenital system; a, aorta; as, internal spermatic artery; au, umbilical artery; c, clitoris; gp, inguinal gland; gr, rectal gland; h, hydatid of uterine tube; hr, middle hæmorrhoidal artery; i, inferior caval vein; lo, ovarian ligament; lt, round ligament; lu, umbilical ligament; ms, mesosalpinx; mt, mesometrium; o, ovary; ot, ostium tubæ; r, rectum; rp, peritoneal recess (rudimentary vaginal process); tu, uterine tube; u, ureter; ut, uterus; vg, vagina; vs, vestibulum; vu, urinary bladder.

The Ovary and Oviducts

The female gonad or **ovary** (Fig. 77) lies on the dorsal wall of the abdominal cavity, thus retaining to a large extent the primitive position. It has, however, gubernacular connections corresponding with those of the testis and these are plainly discernible in the adult animal as the **ovarian** and **round ligaments**, of which the latter is inserted into a small pocket of the abdominal wall simulating the testis sac.

Though inconspicuous in gross size as compared with the testis, the ovary is concerned with the formation of cells of relatively large dimensions, the female germ cells or **ova** (Fig. 1), which, however, are

produced in much smaller numbers than the spermatozoa. The ova undergo their primary development as single cells in the tissue of the organ, but at times, through rupture of the enclosing **follicles**, they are released at the surface, and thence pass directly into the open mouth of the **uterine tube**, the narrow first part of the oviduct. In this tube the ova may come into contact with spermatozoa, fusion with one of which constitutes fertilization of the ovum. (Spermatozoa deposited in the vagina are carried into the uterus by muscular action of the duct, traverse the uterus by their own locomotor activity, and are carried up the uterine tube largely by the cilia lining it.) If fertilized, they begin their segmentation and further development into an embryo, the latter becoming attached to the wall of the more posterior part of the oviduct, which is enlarged to form the **uterus**. A **placental connection** is formed by which nourishment is carried to the embryo during the period of

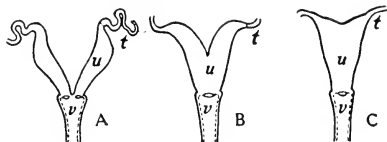


FIG. 78. Three stages of specialization of the uterus. A, uterus duplex; B, uterus bicornis; C, uterus simplex. t, uterine tube; u, uterus; v, vagina.

intra-uterine life, in the rabbit about thirty days. The rabbit has two complete uteri, the cavities of which are connected distally with the unpaired vagina, and through this with the urinogenital sinus or vestibulum. The size and appearance of the uteri depend upon the age of the animals examined, and upon whether or not they are pregnant or have borne young. The uteri of pregnant females are greatly enlarged and vascular. They contain from five to eight young, the position of which may be easily seen from the expansion of those parts of the tubes in which they lie.

The paired condition of the uteri in the rabbit is especially instructive because of its primitive nature as compared with the arrangement in many other mammals. **Paired oviducts** (Fig. 69, A) are the rule in lower vertebrates, where the function is simply to carry the eggs to the outside of the body. This condition is retained with minor modifications to the monotreme stage of mammals, but in higher forms of the latter the ducts are progressively coalesced. In marsupials the posterior part of each oviduct is differentiated as a vagina, which is still paired, while in placentals the

vaginae are fused to an unpaired tube. In the rabbit, as in many lower placentals, there are two complete uteri, and as an organ the whole structure represents the stage of **uterus duplex** (Fig. 78, A). A partly fused condition existing in some mammals, for example sheep, is known as **uterus bicornis** (Fig. 78, B), while the completely fused condition in man is known as **uterus simplex** (Fig. 78, C). It is characterized by the independent opening of the two uterine tubes into a single uterine cavity. The successive stages of coalescence are doubtless associated with progressive reduction of the number of young, the success of the species being determined by greater perfection of the placental apparatus.

THE ENDOCRINE SYSTEM

In contrast to the organ-systems usually recognized, which have a structural continuity and are associated with contributory but more or less separate functions, digestive, nervous, and the like, there are certain organs which have a detached distribution, belong structurally and embryonically to different systems and body-layers, and yet have common general functions in chemical and physical regulation, including growth. They are described as internal secreting, ductless, or **endocrine glands**. Their effects are exerted through relatively small quantities of very active substances, **hormones**, thrown into the circulation. In a physiological sense, they constitute an internal secreting or **endocrine system**. They include the **suprarenal bodies**, the **thyreoid**, the **parathyreoids**, the **thymus**, the **hypophysis**, the **pineal body**, and portions of the male and female gonads and of the pancreas as well as the epithelial lining of the duodenum. The occurrence of such endocrine organs is a feature peculiar to the vertebrates, in which they supplement nervous regulation, providing a duplicate mechanism for the maintenance of the all-important balance among the activities of the parts of the individual organism.

Both the testis and the ovary produce substances which have a pronounced effect upon metabolism and growth, especially the development of secondary sex characters in the young, and, in the adult female, changes connected with pregnancy. A more specific action is shown, for example, by the pancreas, imbedded in which are microscopic groups or islands of cells which are quite distinct

from those forming the main mass of the gland and have no connection with its duct (Fig. 5, p. 17). These islets produce insulin, a regulator of oxidation of starches, sugars, and fats.

The duodenal epithelium produces a hormone, named secretin, which stimulates the secretion of the digestive juice of the pancreas and also increases the discharge of bile from the liver.

The Suprarenal Gland

Each of the pair of suprarenal bodies is double, being composed, in mammals, of an inner medulla and an outer cortex which differ in origin, in structure, and in function. The medulla is an aggre-

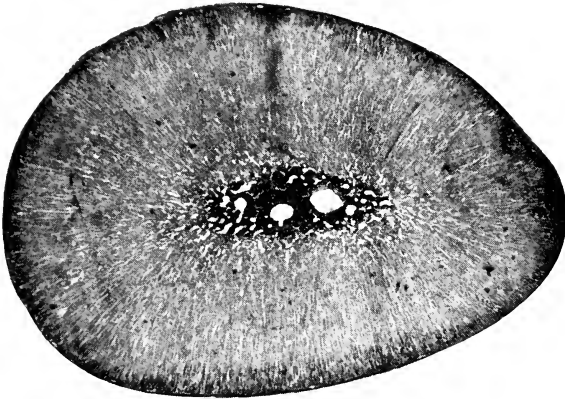


FIG. 79. Photomicrograph of transverse section of suprarenal body of rabbit, showing cortex and medulla. $\times 16$.

gation of cells which have a common origin with those of the sympathetic nerve ganglia, and the adrenalin or epinephrine which it secretes has an effect somewhat similar to that of stimulating these nerve cells, raising the blood pressure by vasoconstriction, causing release of glucose into the blood stream, and enabling the animal to meet emergency conditions. The discharge of adrenalin has emotional associations and its occurrence during a state of fear is regarded as an adaptive reaction preparing the animal for fight or flight. Actually, however, its effect in such circumstances appears to be rather enervating or even paralyzing.

The cortex is considerably more voluminous and is derived

from the lining of the body cavity. The homologous tissue forms a mass (interrenal gland) associated with the mesonephros in lower vertebrates. Its secretion is necessary for life. It appears to be concerned in maintenance of normal functioning of the kidneys, in the regulation of inorganic substances in the body, especially sodium and potassium, and in the conservation of muscular strength and ability to resist fatigue.

The Thyreoid Gland

Like the pancreas, the thyreoid gland develops as an outgrowth of the lining of the digestive tube, in this case from that of the pharynx, but it becomes completely detached therefrom. It gives directly into the blood a secretion (thyroxin) which takes part in the regulation of growth and stimulates metabolism in the body generally. This substance has a high content of iodine in combination with colloid material. Thyreoid deficiency in man is associated with the conditions known as cretinism and myxoedema, and hyperactivity with exophthalmic goitre.

The Parathyreoid Gland

The parathyreoid bodies are minute cell-masses lying in, or immediately outside of, the thyreoid. They are produced embryonically from the dorsal part of the epithelial lining of certain gill pouches. They have been shown to have essential functions in connection with calcium-phosphorus metabolism.

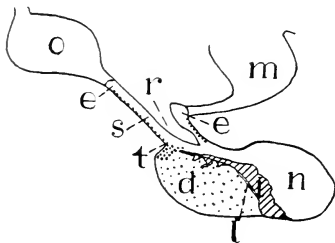


FIG. 80. The parts of the hypophysis of the rabbit and adjacent structures as seen in sagittal section: d, pars distalis (anterior lobe); e, median eminence of tuber cinereum; i, pars intermedia; l, residual lumen; m, mamillary body; n, infundibular process (neural lobe); o, optic chiasma; r, infundibular recess; s, infundibular stalk; t, pars tuberalis.

The Thymus Gland

The thymus is developed in mammals from the ventral part of the epithelial lining of the third pair of embryonic pharyngeal gill pouches. It is thus paired in origin, but in mammals the masses of the two sides become associated ventrally and migrate backwards to a position near the heart. The functions of the thymus are

still problematical, but an extract has been shown to increase fertility and when administered through successive generations to produce accruing precocity in development. The gland becomes lymphoid in character at some time after birth and is more or less reduced after the animal reaches maturity. There is some evidence which has been interpreted as indicating antitoxic activity.

The Hypophysis

The hypophysis is embryonically of double origin, while structurally three major divisions are recognized, viz: lobus glandularis, lobus nervosus, and infundibulum. The first of these comprises a pars distalis, a pars tuberalis, and a pars intermedia (Fig. 80), and the infundibulum is subdivided into the median eminence of the tuber cinereum and the infundibular stem. The glandular lobe is derived from the epithelium of the roof of the mouth, while the remaining parts are an outgrowth from the brain. Experimental removal of the pars distalis retards growth in young animals, the body retaining an infantile condition, and in normal circumstances the growth hormone produced is concerned in protein metabolism. Hyperactivity of this part in human adults is associated with the condition known as acromegaly, abnormal enlargement of the hands, feet, or parts of the head. The pars distalis also secretes hormones concerned in ovulation, in lactation, and in the stimulation of other endocrines. The neural lobe (lobus nervosus) produces a substance similar in some respects in its action to adrenalin and, like the latter, related functionally with the activity of the sympathetic system. It restricts cardiac output and oxygen consumption. Possibly, one component regulates passage of substances through the walls of capillaries, and another may stimulate uterine contractions in parturition.

The Pineal Gland

The pineal body is also an unpaired outgrowth of the brain, being the product of a part which in lower vertebrates displays the potentiality of developing into either a sense organ (a light-receptor) or a gland. In mammals it is always an endocrine gland. Its functions are not yet well understood but it has been reported to produce a growth-regulating substance, or one accelerating differentiation.

THE SEROUS CAVITIES

The organs collectively described as **visceral** are those associated with the serous cavities. They belong to several systems, but present the common feature of being projected into the membranous linings of these cavities so that they are more or less completely invested by them without interrupting them at any point.

The **serous sacs** are extensive body-spaces, derivatives of a primary body cavity or **coelom**. They are usually considered loosely as containing the visceral organs, but the condition is more accurately described as one in which the visceral organs encroach, chiefly from a dorsal position, on the enclosing membranes. The latter are thus divided into two portions, one of which is distributed as a **parietal** or peripheral layer, forming the enclosure of the sac, while the other is disposed as a visceral layer on the surface of the visceral organs (Fig. 24). The serous sacs are enclosed by thin, moist, **serous membranes**, consisting chiefly of mesothelium, which give to the visceral organs their characteristic appearance.

In lower vertebrates, where the diaphragm is absent or imperfectly developed, the coelom is divided into two chief portions—the **pericardial cavity**, enclosing the heart, and the **pleuroperitoneal cavity**, lodging the remaining visceral organs, including the lungs in terrestrial vertebrates. In the mammalia, the pleuroperitoneal cavity is completely divided into two portions by the diaphragm, the smaller pleural portion being again divided into **right** and **left pleural cavities** through the presence of certain structures filling the median portion of the thorax. There are thus recognizable in a mammal four large serous spaces, namely, the pericardial, the peritoneal, and paired pleural cavities.

The **pericardial cavity**, the smallest of these spaces, is situated between the paired pleural cavities. Its enclosing membrane, the **pericardium**, forms a capacious sac for the heart, and is reflected directly over the surface of the latter as a thin membrane, the **epicardium**.

The **pleural cavities** are those lodging the lungs, the latter being projected into them from a medial position. The lining membrane or **pleura** is divided into three chief portions—the **pulmonary pleura**, investing the greater part of each organ, the **costal pleura**, lining the internal surface of the thorax, and the **diaphragmatic pleura**, covering the anterior surface of the diaphragm,

the sac being completed medially by the **mediastinal pleura**. The two last mentioned are broadly connected with the pulmonary pleura through the **pulmonary ligament**.

The **peritoneal cavity**, the largest of the serous spaces, comprises in a mammal a general portion, the **abdominal cavity**, and its posterior extension into the pelvis—in the male also into the **sac of the testis** or **scrotum**. The general relation of the cavity to the abdominal organs is indicated diagrammatically in Fig. 20.

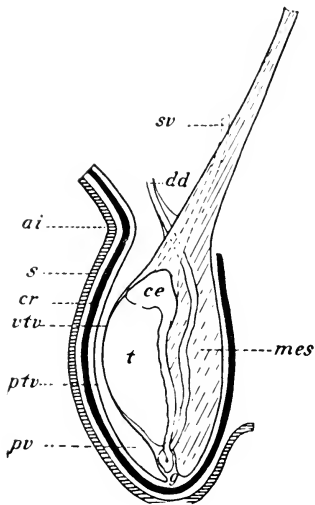


FIG. 81. Diagram showing the relation of the testis to its investments: ai, inguinal ring; ce, caput epididymidis; cr, cremaster muscle; dd, ductus deferens; g, gubernaculum; mes, mesorchium; ptv and vtv, parietal and visceral layers of the tunica vaginalis propria; pv, cavity of the vaginal process; sv, integument of the scrotum; t, testis.

Its lining membrane, the peritoneum, is divisible into two principal portions, the **parietal peritoneum**, lining the abdominal wall, and the **visceral peritoneum**, investing the visceral organs. Of the latter, the kidneys encroach only to a minor extent on the serous lining, so that they are covered by peritoneum only on their ventral surfaces. The digestive tube, on the other hand, is removed to such an extent from the abdominal wall that the peritoneum forms a complete serous coat, and is connected with the parietal peritoneum of the wall through a thin transparent membrane, the **mesentery**. The latter consists of two plates of peritoneum, enclosing between them a thin layer of connective tissue, the **lamina mesenterii propria**, for the transmission of nerves, blood-vessels, and lymph canals.

As indicated in an earlier chapter, the relations of the abdominal portion of the digestive tube are greatly modified by its elongation and displacement from a median position. Thus, while in the embryo the **common mesentery** (Fig. 51) is recognizable as a continuous median vertical fold, in the adult it follows the convolutions of the digestive tube, and is therefore considered as comprising corresponding parts. In many cases the relations of these are greatly complicated by secondary

adhesions. In the rabbit the **mesoduodenum**, **mesentery** of the jejunum, and **descending mesocolon** will be recognized as parts in which a more typical arrangement is retained. Moreover, in the anterior portion of the abdominal cavity the peritoneum is concerned not only with the investment of two large visceral structures, the stomach and the liver, but also with the formation of a lining for the posterior surface of the diaphragm. Thus the general condition is less simple than in the region of the small and large intestines. The peritoneum, passing from the dorsal wall, successively invests the spleen, the stomach, and the liver, and passes over from the last-named structure to the diaphragm and the ventral body-wall through the **coronary**, **triangular**, and **falciform ligaments**. A portion of the peritoneum passing between two organs, such as the stomach and the liver, rather than connecting either to the body-wall, is termed an **omentum** or sometimes a ligament. Thus the peritoneal attachments of the stomach are differentiated into the mesogastrium (connecting the stomach with the diaphragm and dorsal body-wall and divisible posteriorly into gastrosplenic and phrenicosplenic ligaments), the greater omentum (a broad fold connected to the greater curvature and to the transverse mesocolon), and the lesser omentum (passing between the lesser curvature and the liver). Similarly, in the posterior part of the body the peritoneum passes from the rectum to the urinary bladder, enclosing also in the female the vagina. It is then continued to the ventral body-wall as the **middle umbilical fold**. The falciform ligament and the middle umbilical fold represent respectively the anterior and the posterior ends of an originally continuous ventral mesentery, these parts being retained when the rest degenerates in early foetal life because through them run the umbilical blood-vessels (pp. 115, 117).

In the male, as indicated in the accompanying diagram (Fig. 81), the peritoneal relations of the testis are greatly modified by the migration of the organ from an abdominal to a scrotal position. The entire sac lodging the testis is an evaginated portion of the abdominal wall, and since in the rabbit the cavity is widely open throughout life to the abdominal cavity, the lining membrane—that designated as the **parietal layer** of the **tunica vaginalis propria**—is continuous with the parietal peritoneum of the abdomen. It

thus represents a permanent **vaginal process**, an outpouching of the peritoneum which in man becomes closed off. Like other structures of the abdominal cavity, the testis itself is covered by peritoneum, the latter being designated as the **visceral layer** of the **tunica vaginalis propria**. This investment is connected with the parietal layer by the **mesorchium**, and in the rabbit it will be observed that the latter is chiefly attached forwards on the dorsal wall of the abdomen, i.e., in a position indicating the original situation of the testis itself.

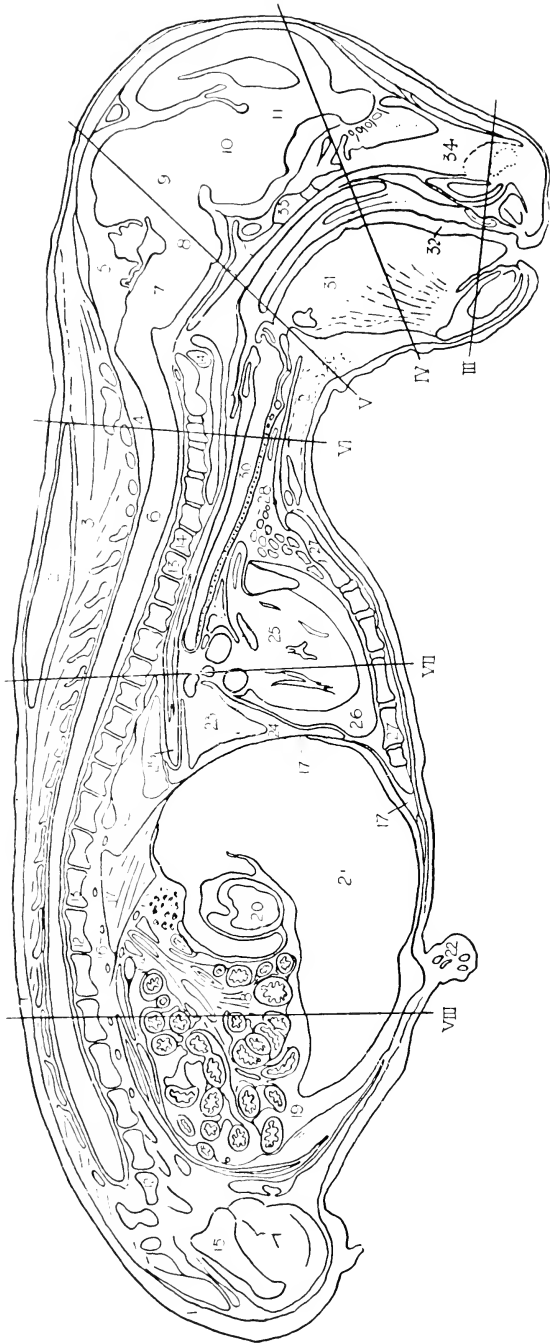
In the female the ovary is situated close to the dorsal wall of the abdomen, and its supporting peritoneum, the **mesovarium**, is insignificant. Its duct in passing backward, however, becomes greatly displaced from a dorsal position, and thus comes to be supported by a broad fold of peritoneum. The latter is considered to consist of two portions, one, the **mesosalpinx**, being the support of the uterine tube, the other, the **mesometrium**, that of the uterus. The entire fold, however, forms a continuous structure and is known in this relation as the **broad ligament**.

REGIONAL SECTIONS

The following plate-figures (I-VIII) are from characteristic sections of a rabbit-foetus of 56 mm., and may be used either in connection with the general features of topography as outlined above, or for the identification of various minor structures appearing in the dissection.

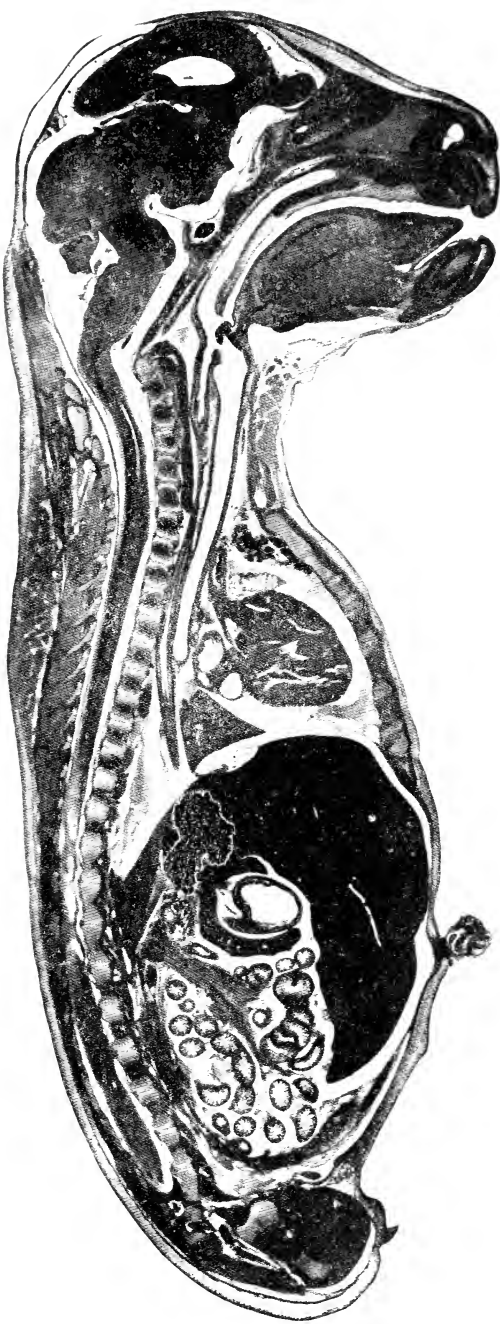
Certain points regarding the sections are perhaps worthy of notice. First, in the longitudinal section illustrated in Plates I and II it will be noticed that paired structures frequently appear; this being because of the fact that the section is not exactly median, at least in certain places. Second, in using sections of the foetus for gross anatomical features it is necessary to make allowance in some cases for the different proportions of organs, and consequent slight differences in position, in the foetal as compared with the adult condition. Finally, many of the features appearing in the original sections are such as could not be reproduced in the plates, although they are indicated in the accompanying skeleton figures, and may be referred to in this way.

PLATE-FIGURES



DESIGNATIONS FOR PLATE I

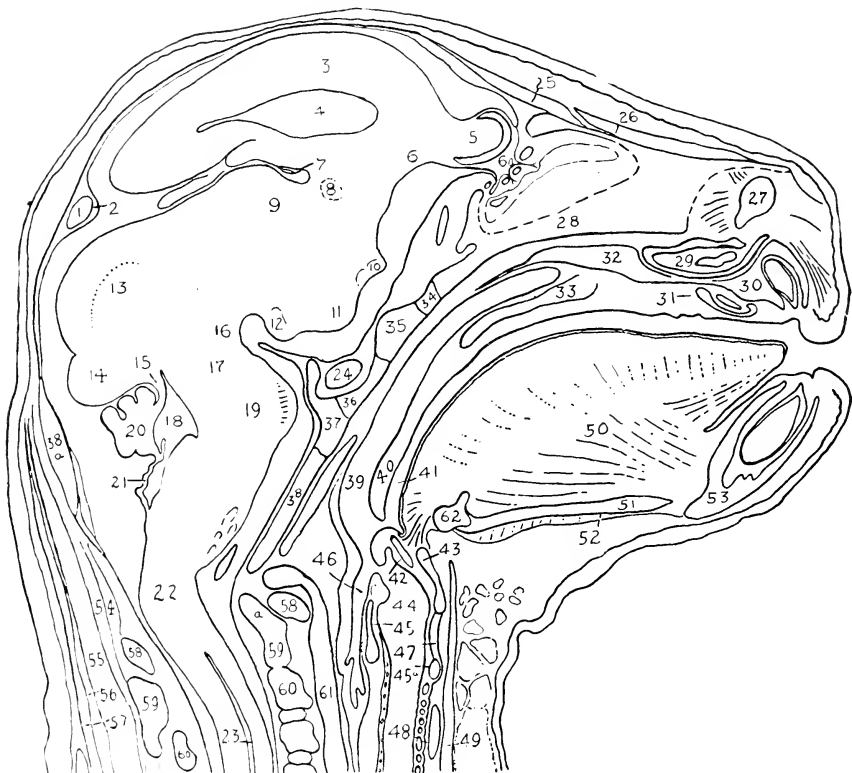
- | | |
|--|--|
| <ul style="list-style-type: none"> 1. Cutaneous maximus muscle. 2. Fat-masses of neck. 3. Spinal musculature. 4. Vertebral canal. 5. Cranial cavity. 6. Spinal cord. 7. Myelencephalon. 8. Metencephalon. 9. Mesencephalon. 10. Dienecephalon. 11. Telencephalon. 12. Lumbar vertebrae. 13. Thoracic vertebrae. 14. Cervical vertebrae. 15. Pelvis. 16. Ganglia of sympathetic trunk. 16A. Superior mesenteric ganglion 17. Diaphragm. 18. Intestines. 19. Abdominal cavity. 20. Stomach (pyloric portion). 21. Liver. 22. Umbilicus (base of cord and vessels.) 23. Lung. 24. Pleural cavity. 25. Heart and aorta. 26. Pericardial cavity. 27. Sternum. 28. Thymus gland. 29. Oesophagus. 30. Trachea. 31. Tongue. 32. Oral cavity. 33. Basicranium. 34. Nasal septum. | <ul style="list-style-type: none"> III-VIII indicate levels of corresponding transverse sections. |
|--|--|



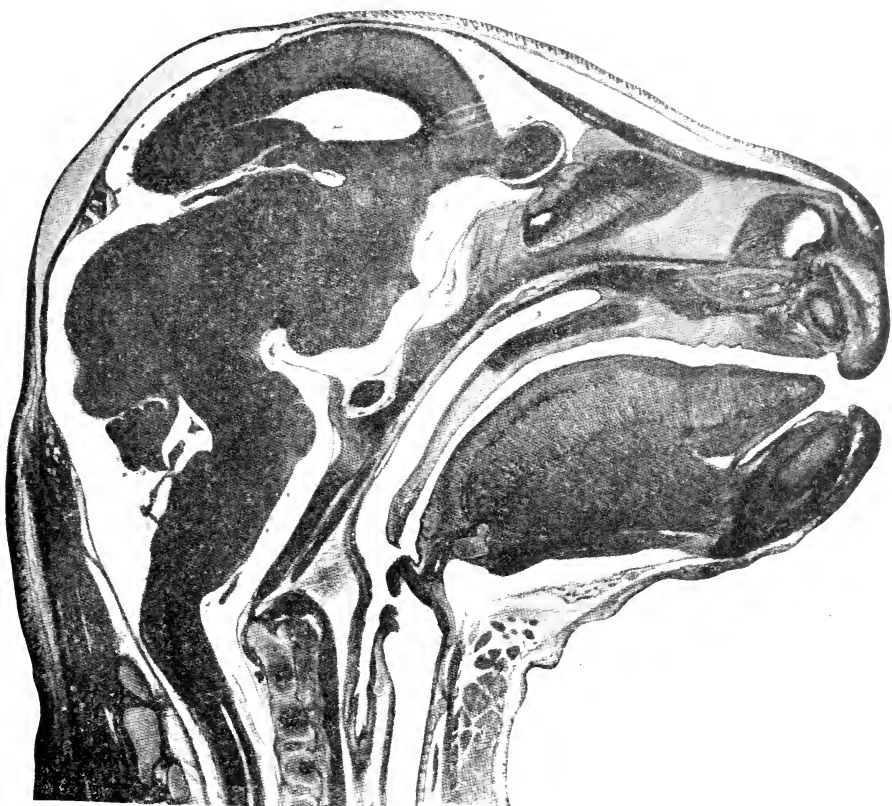
I
A MEDIAN VERTICAL SECTION OF THE ENTIRE BODY

DESIGNATIONS FOR PLATE II

- | | | |
|--|--------------------------------------|--|
| 1. Transverse sinus of dura mater. | 22. Cervical flexure. | 41. Oral portion of pharynx. |
| 2. Dura mater. | 23. Central canal of spinal cord. | 42. Epiglottis and epiglottic cartilage. |
| 3. Pallium of cerebral hemisphere. | 24. Hypophysis. | 43. Thyroid cartilage of larynx. |
| 4. Lateral ventricle. | 25. Frontal bone. | 44. Laryngeal cavity. |
| 5. Olfactory bulb. | 26. Nasal bone. | 45, 45a. Cricoid cartilage. |
| 6a. Divided olfactory nerve in the cribriform plate. | 27. Nasal fossa. | 46. Oesophagus. |
| 7. Choroid plexus of third ventricle. | 28. Mesethmoid cartilage. | 47. Cricothyroideus muscle. |
| 8. Anterior commissure. | 29. Cartilage of vomeronasal organ. | 48. Thyroid gland. |
| 9. Thalamus. | 30. Premaxilla. | 49. Sternohyoideus muscle. |
| | 31. Nasopalatine duct and cartilage. | 50. Genioglossus muscle. |
| | 32. Maxilla. | 51. Geniohyoideus muscle. |
| | | 52. Mylohyoideus muscle. |

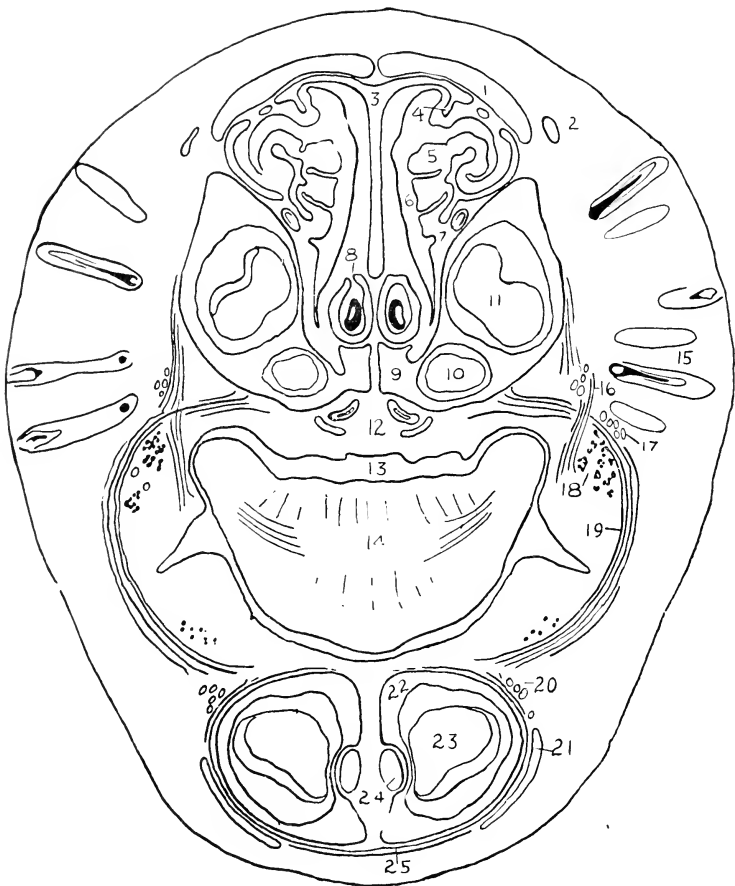


- | | | |
|--|---|------------------------------------|
| 10. Optic chiasma. | 33. Hard palate (palatine and maxilla). | 53. Mandible. |
| 11. Tuber cinereum. | 34. Presphenoid. | 54. Occipital musculature. |
| 12. Mamillary body. | 35. Intersphenoidal synchondrosis. | 55. Semispinalis capitis. |
| 13. Superior colliculus. | 36. Basisphenoid; hypophyseal fossa. | 56. Rhomboideus minor. |
| 14. Inferior colliculus. | 37. Sphenoccipital synchondrosis. | 57. Superior portion of trapezius. |
| 15. Anterior medullary velum. | 38. Basisoccipital. | 58. Atlas. |
| 16. Cerebral peduncle; cephalic flexure. | 38a. Supraoccipital. | 59. Epistropheus. |
| 17. Isthmus rhombencephali. | 39. Nasal portion of pharynx. | 59a. Odontoid process. |
| 18. Fourth ventricle. | 40. Soft palate. | 60. Third cervical vertebra. |
| 19. Pons; pontine flexure. | | 61. Median vertebral vein. |
| 20. Cerebellum. | | 62. Body of hyoid bone. |
| 21. Posterior medullary velum. | | |



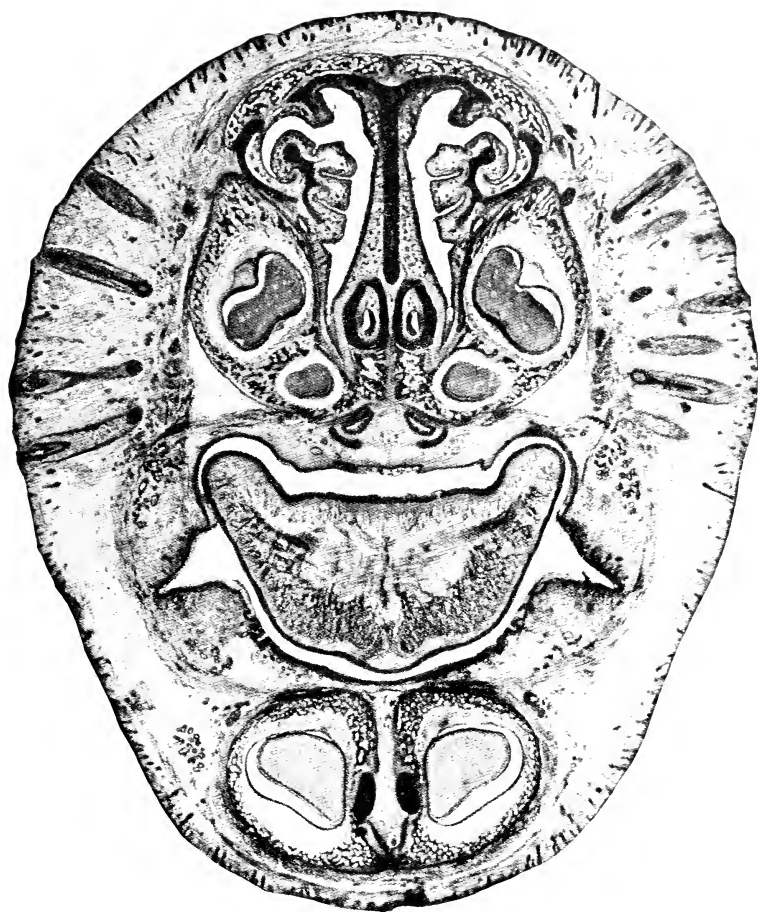II

A MEDIAN VERTICAL SECTION OF THE HEAD



DESIGNATIONS FOR PLATE III

- | | |
|---------------------------------------|---|
| 1. Nasal bone. | 14. Tongue. |
| 2. Levator alae nasi muscle. | 15. Vibrissae. |
| 3. Nasal septum. | 16. Caninus muscle. |
| 4. Nasoturbinial cartilage. | 17. Terminals of superior maxillary nerve. |
| 5. Maxilloturbinal (concha inferior). | 18. Buccal glands. |
| 6. Nasal fossa. | 19. Buccinator muscle. |
| 7. Nasolacrimal duct. | 20. Terminals of inferior alveolar nerve. |
| 8. Vomeronasal organ and cartilage. | 21. Quadratus labii inferioris muscle. |
| 9. Premaxilla. | 22. Mandible. |
| 10. Small upper incisor. | 23. Lower incisor. |
| 11. Large upper incisor. | 24. Meckel's cartilage (primary mandibular arch). |
| 12. Nasopalatine ducts. | 25. Mentalis muscle. |
| 13. Oral cavity. | |

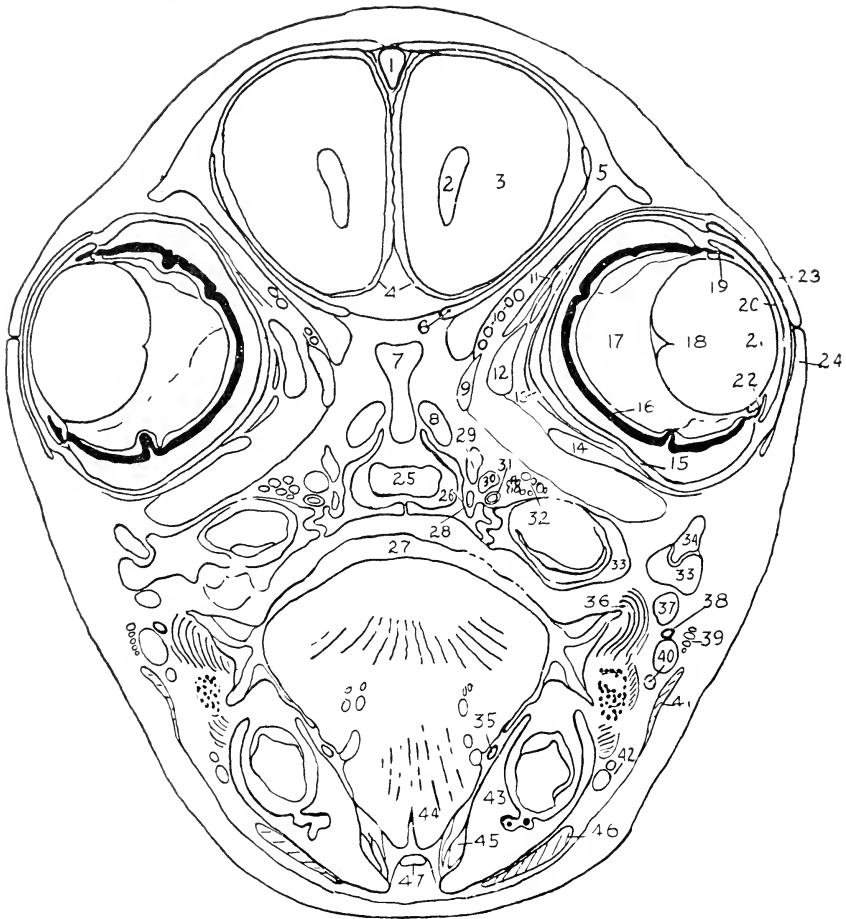


III

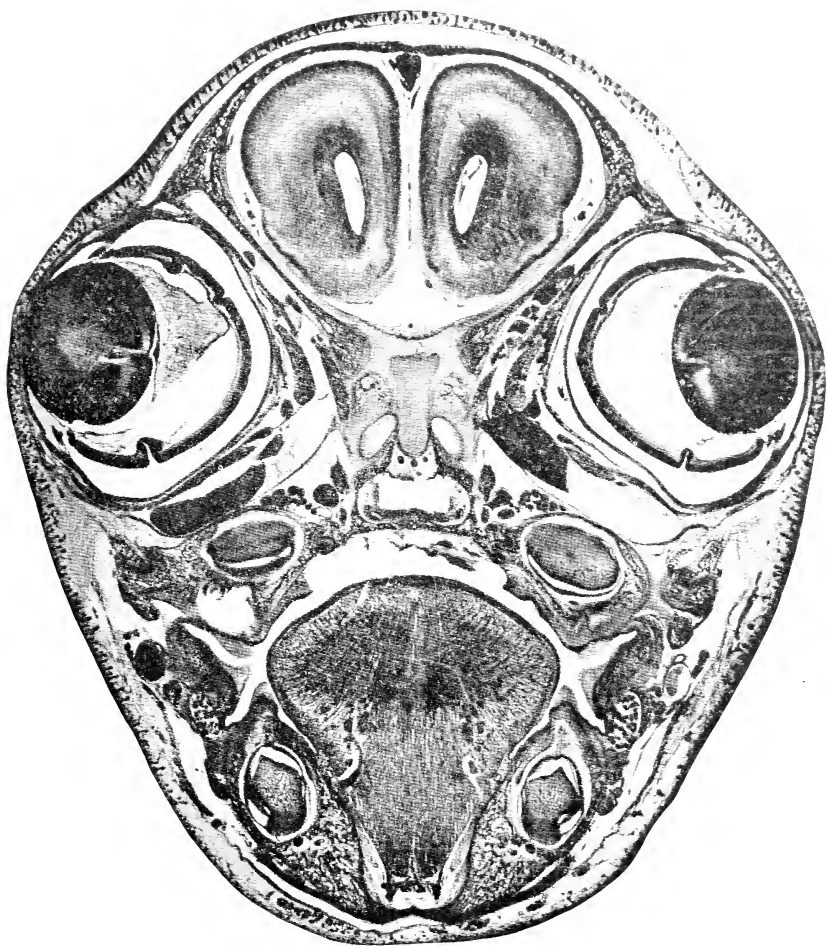
A TRANSVERSE SECTION OF THE ANTERIOR NASAL REGION

DESIGNATIONS FOR PLATE IV

- | | |
|---|--------------------------------|
| 1. Superior sagittal sinus of dura mater. | 25. Nasal tract; choana. |
| 2. Lateral ventricle. | 26. Palatine bone. |
| 3. Cerebral hemisphere. | 27. Oral cavity. |
| 4. Pia mater. | 28. Palatine nerve. |
| 5. Frontal bone. | 29. Sphenopalatine ganglion. |
| 6. Cartilage of orbital wing. | 30. Infraorbital vein. |
| 7. Mesethmoid cartilage. | 31. Internal maxillary artery. |
| 8. Cupula posterior cartilage. | 32. Maxillary nerve. |
| 9. Obliquus superior muscle. | 33. Maxilla. |
| 10. Ophthalmic vessels and nerves. | 34. Zygomatic bone. |
| 11. Levator palpebrae superioris muscle. | 35. Submaxillary duct. |
| 12. Rectus medialis muscle. | 36. Buccinator muscle. |



- | | |
|-------------------------------|---|
| 13. Retractor oculi muscle. | 37. Masseter muscle. |
| 14. Rectus inferior muscle. | 38. Parotid duct. |
| 15. Sclera. | 39. Facial nerve. |
| 16. Retina and chorioidea. | 40. External maxillary artery and vein
(anterior facial vein). |
| 17. Vitreous body. | 41. Platysma muscle. |
| 18. Lens. | 42. Inferior labial artery and vein. |
| 19. Posterior chamber of eye. | 43. Mandible. |
| 20. Anterior chamber. | 44. Genioglossus muscle. |
| 21. Cornea. | 45. Digastricus muscle. |
| 22. Ciliary body and iris. | 46. Quadratus labii inferioris muscle. |
| 23. Upper eyelid. | 47. Geniohyoideus muscle. |
| 24. Lower eyelid. | |

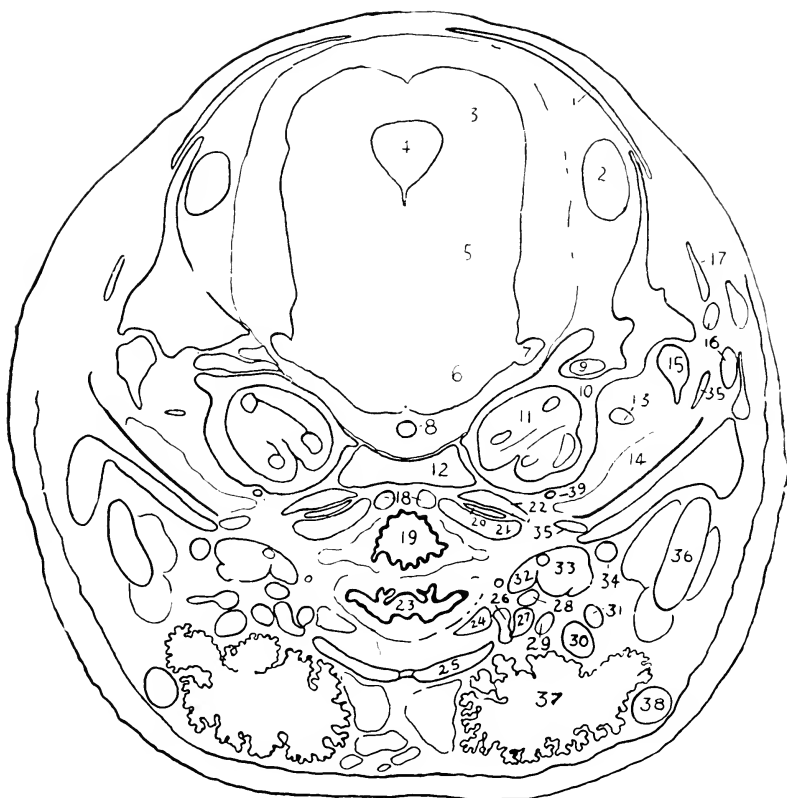

IV

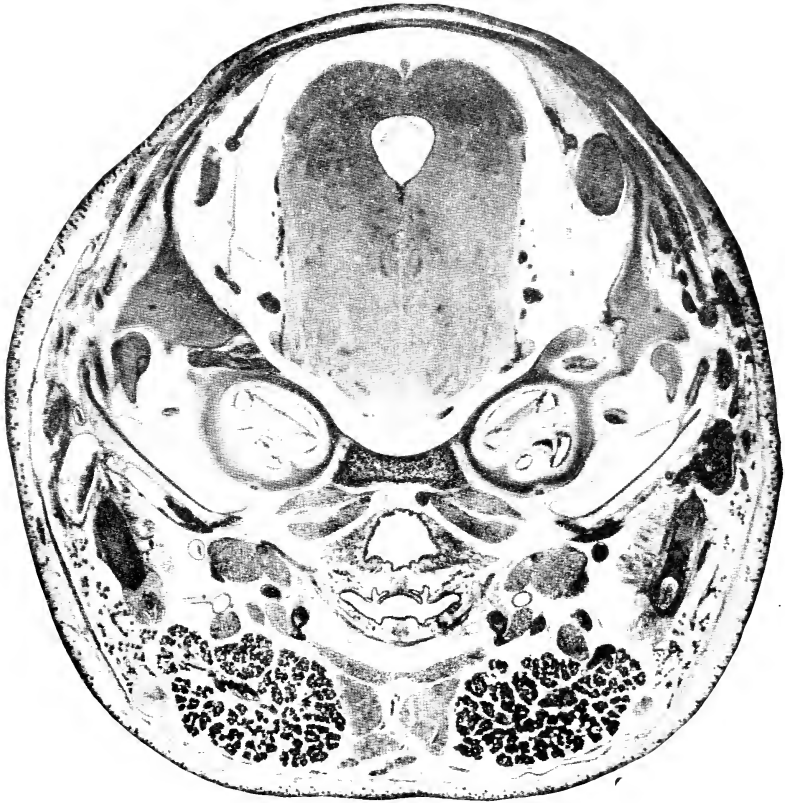
A TRANSVERSE SECTION OF THE ORBITAL REGION

DESIGNATIONS FOR PLATE V

- | | |
|--|--|
| <ol style="list-style-type: none"> 1. Parietal bone. 2. Transverse sinus of dura mater. 3. Superior colliculus. 4. Cerebral aqueduct. 5. Isthmus rhombencephali. 6. Pons. 7. Trigeminal nerve. 8. Basilar artery. 9. Facial nerve. 10. Cartilaginous auditory capsule. 11. Cochlea. | <ol style="list-style-type: none"> 21. Longus capitis. 22. Rectus capitis anterior. 23. Oral portion of pharynx. 24. Thyrohyoideus muscle. 25. Sternohyoideus muscle. 26. Greater cornu of hyoid. 27. Stylohyoideus major muscle. 28. Lingual artery. 29. Hypoglossal nerve. 30. Tendon of digastricus muscle. 31. External maxillary artery. |
|--|--|



- | | |
|---|--|
| <ol style="list-style-type: none"> 12. Basioccipital bone. 13. Tensor tympani muscle. 14. Tympanic cavity. 15. Malleus. 16. Tributaries of posterior facial vein. 17. Squamosal bone. 18. Cephalic portion of median vertebral vein. 19. Nasal portion of pharynx. 20. Origin of basioclavicularis and levator scapulae major muscles. | <ol style="list-style-type: none"> 32. Stylohyoideus minor. 33. Styloglossus. 34. Internal maxillary artery. 35. Tympanic bone. 36. Mandible. 37. Submaxillary gland. 38. Anterior facial vein. 39. Internal carotid artery. |
|---|--|

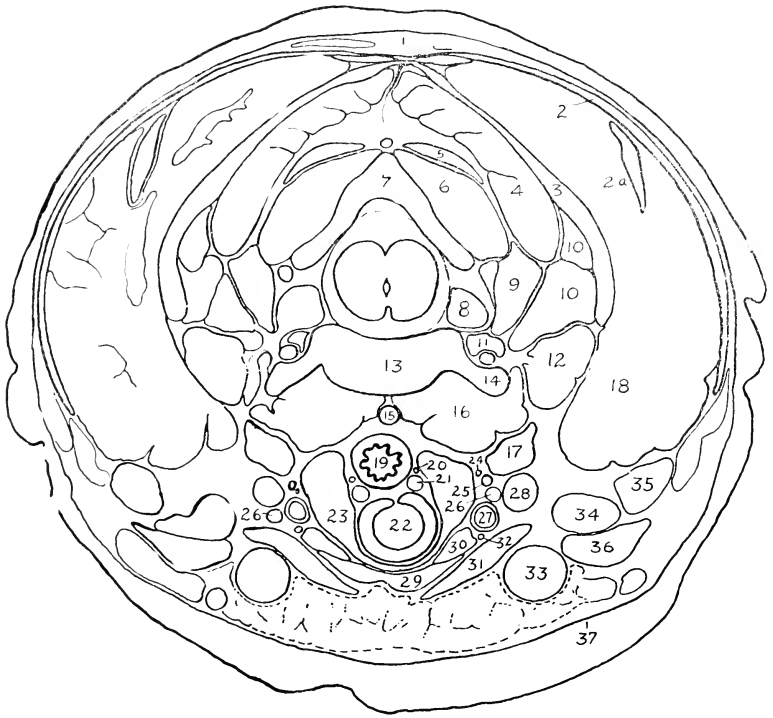


V

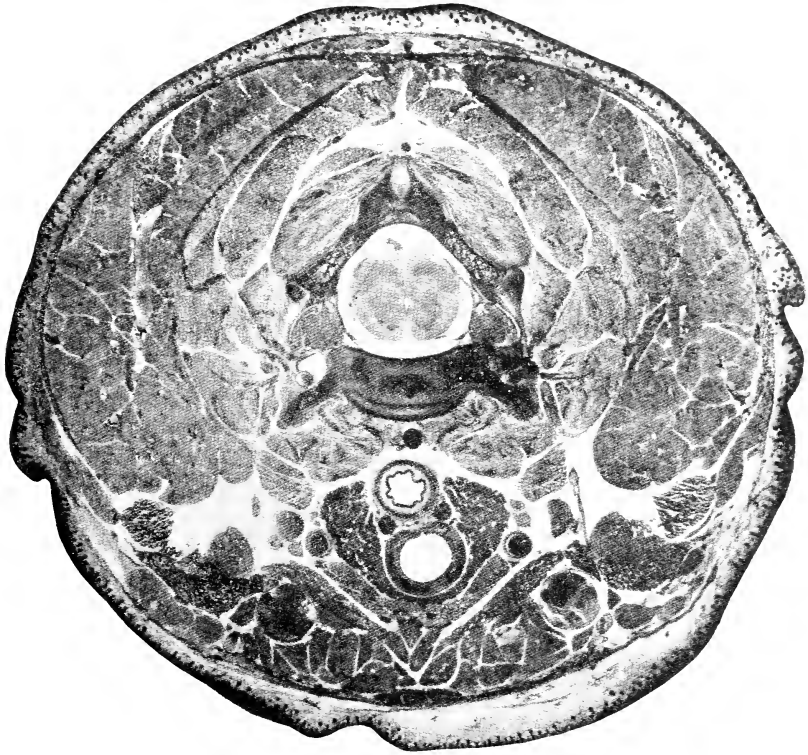
A TRANSVERSE SECTION OF THE AUDITORY REGION

DESIGNATIONS FOR PLATE VI

- | | |
|--|---|
| 1. Rhomboideus minor. | 19. Oesophagus. |
| 2. Superior portion of trapezius. | 20. Recurrent nerve. |
| 2a. Levator scapulae minor. | 21. Inferior thyroid vein. |
| 3. Splenius. | 22. Trachea. |
| 4. Semispinalis capitis. | 23. Thyroid gland. |
| 5. Rectus capitis posterior superficialis. | 24. Cardiac branch of vagus (n. depressor). |
| 6. Obliquus capitis major. | 25. Sympathetic trunk. |
| 7. Arch of epistropheus. | 26. Vagus nerve. |
| 8. Ganglion of posterior root. | 27. Common carotid artery. |
| 9. Longissimus cervicis. | 28. Internal jugular vein. |



- | | |
|---|--|
| 10. Longissimus capitis. | 29. Sternohyoideus muscle. |
| 11. Vertebral artery and vein. | 30. Sternothyroideus muscle. |
| 12. Longus atlantis. | 31. Sternomastoideus muscle. |
| 13. Vertebral body. | 32. Descending ramus of hypoglossal nerve. |
| 14. Transverse process (anterior root). | 33. External jugular vein. |
| 15. Median vertebral vein. | 34. Basioclavicularis muscle. |
| 16. Longus colli. | 35. Levator scapulae major muscle. |
| 17. Longus capitis. | 36. Cleidomastoideus. |
| 18. Fat-body. | 37. Platysma. |

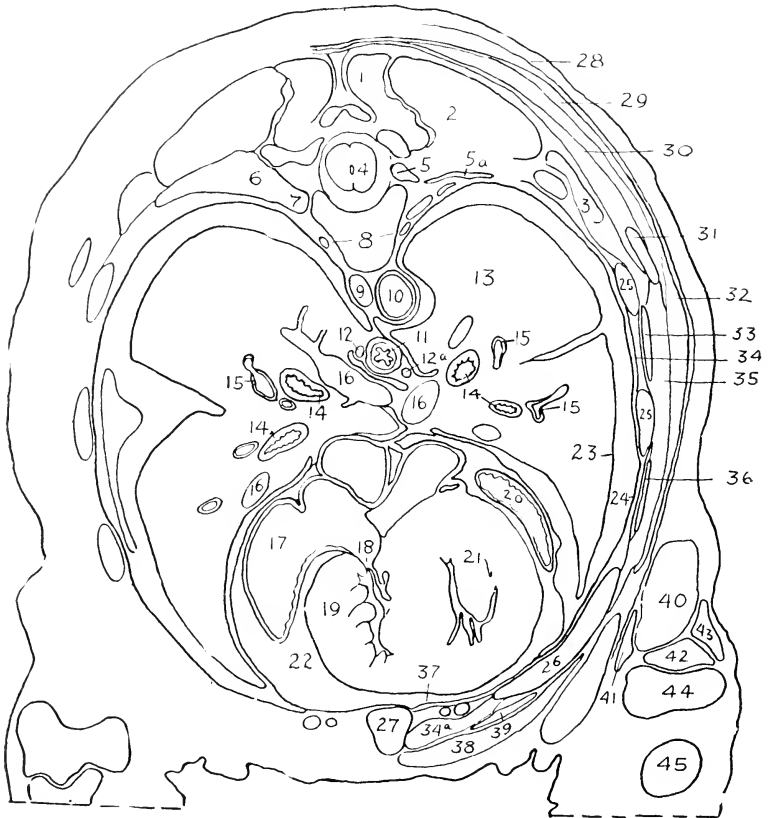


VI

A TRANSVERSE SECTION OF THE ANTERIOR CERVICAL REGION

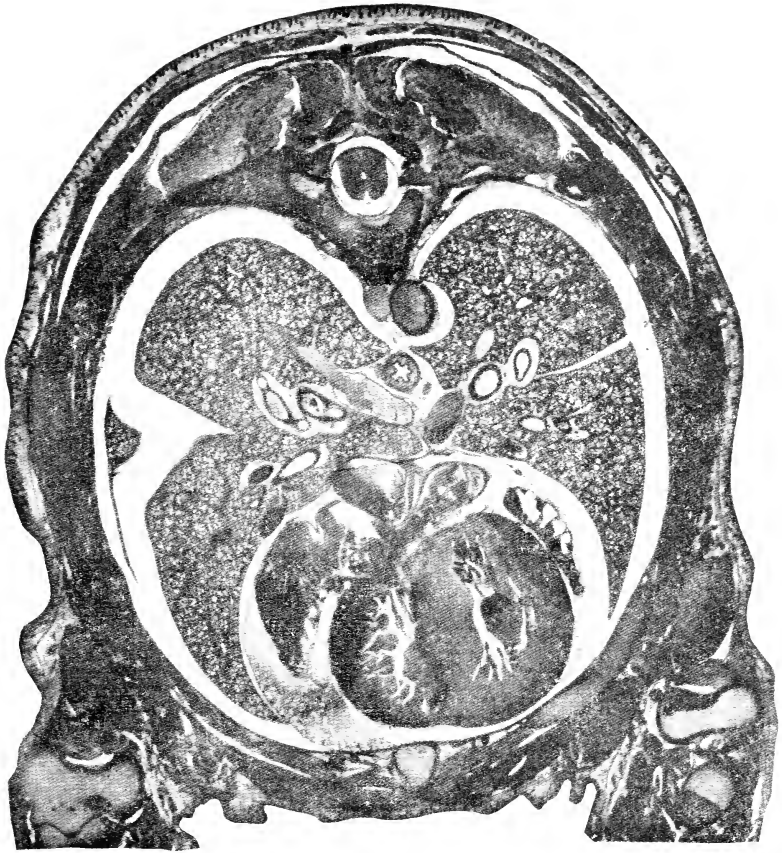
DESIGNATIONS FOR PLATE VII

- | | |
|--|--|
| 1. Semispinalis dorsi. | 24. Costal pleura. |
| 2. Longissimus dorsi. | 25. Bone ribs. |
| 3. Iliocostalis. | 26. Costal cartilage. |
| 4. Spinal cord. | 27. Sternum. |
| 5. Ganglion of posterior root and intercostal nerve. | 28. Cutaneus maximus muscle. |
| 6. Tubercle of rib. | 29. Inferior portion of trapezius. |
| 7. Head of rib. | 30. Rhomboideus major. |
| 8. Sympathetic trunks. | 31. Inferior angle of scapula. |
| 9. Azygos vein. | 32. Latissimus dorsi. |
| 10. Thoracic aorta. | 33. Serratus posterior. |
| 11. Oesophagus. | 34. Intercostales externi and interni. |
| | 34a. Intercostalis internus. |



- 12, 12a. Right and left vagi.
 13. Lung.
 14. Bronchi.
 15. Branches of pulmonary artery.
 16. Pulmonary veins.
 17. Right atrium.
 18. Tricuspid valve.
 19. Right ventricle.
 20. Left atrium.
 21. Left ventricle.
 22. Pericardial cavity.
 23. Pulmonary pleura.

35. Thoracic portion of serratus anterior.
 36. Obliquus externus abdominis.
 37. Transversus thoracis.
 38. Pectoralis major.
 39. Rectus abdominis.
 40. Long head of triceps.
 41. Extensor antibrachii parvus.
 42. Medial head of triceps.
 43. Lateral head of triceps.
 44. Distal extremity of humerus.
 45. Proximal portion of radius.



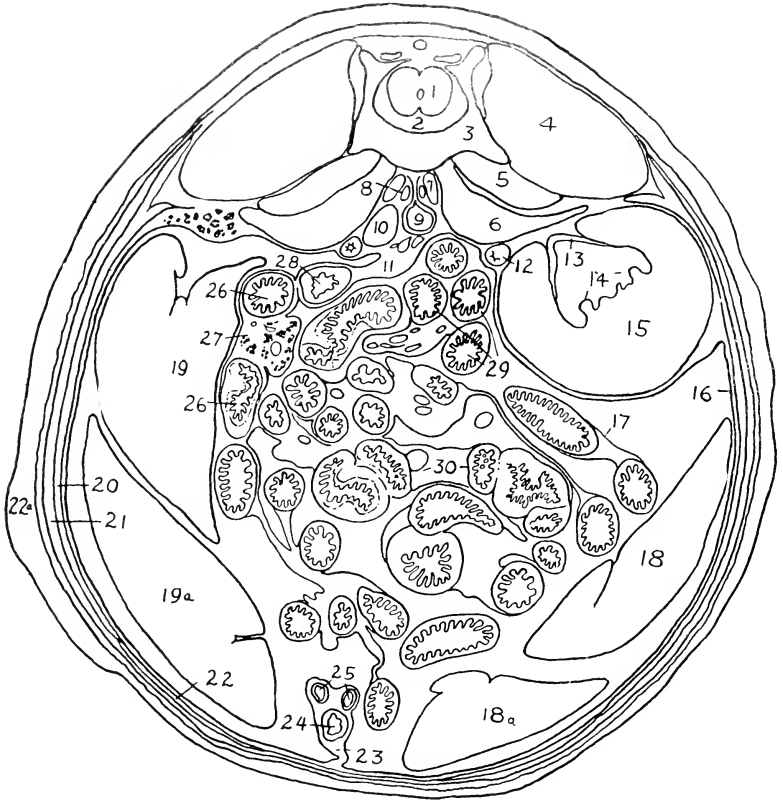VII

A TRANSVERSE SECTION OF THE THORAX

DESIGNATIONS FOR PLATE VIII

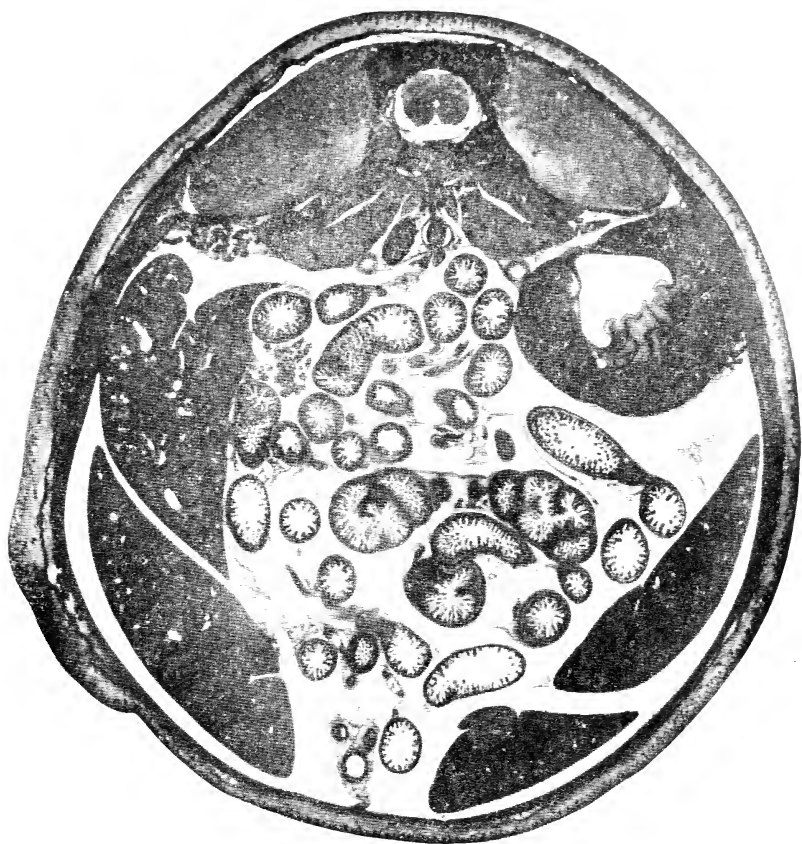1. Spinal cord.
2. Vertebral canal.
3. Vertebral body.
4. Sacrospinalis muscle.
5. Quadratus lumborum.
6. Psoas major.
7. Psoas minor.
8. Sympathetic trunk.

- 18, 18a. Posterior and anterior lobules of left lobe of liver.
- 19, 19a. Right lobe of liver.
20. Obliquus internus abdominis and transversus abdominis.
21. Obliquus externus abdominis.
22. Rectus abdominis.
- 22a. Cutaneus maximus.



9. Abdominal aorta.
10. Inferior caval vein.
11. Descending mesocolon.
12. Ureter.
13. Renal pelvis.
14. Renal papilla.
15. Left kidney.
16. Parietal peritoneum.
17. Visceral peritoneum.

23. Middle umbilical fold.
24. Urinary bladder (canal of foetal allantois).
25. Umbilical arteries.
26. Duodenum.
27. Pancreas and mesoduodenum.
28. Descending colon.
29. Parts of mesenterial small intestine.
30. Caecum.



VIII
A TRANSVERSE SECTION OF THE ABDOMEN

PART II

Osteology of the Rabbit

FOR a practical study of the rabbit's skeleton, a thoroughly cleaned, but otherwise rough, unmounted skeleton will be found most convenient. The skull should be divided with a fine saw at a little to one side of the median plane, or a second skull may be provided for this purpose (cf. Fig. 88). The most useful specimens for reference are: (1) a well-mounted skeleton of the adult animal, showing the natural relations of the bones; and (2) a rough skeleton of a young animal of from one to five weeks, showing the primary composition of cartilage bones. For the special study of the skull (pp. 180-195) a disarticulated specimen may be employed, but the majority of the features may be made out in the intact or divided skulls. The general account of the skull as given below will be found to cover most of the osteological points noted in the dissection.

DIVISIONS OF THE SKELETON

The skeleton is divisible into two main portions, namely, the **axial skeleton** and the **appendicular skeleton**. The former comprises the vertebral column, the ribs, the sternum, and the skeleton of the head; the latter, the supports of the anterior and posterior limbs, and the associated pectoral and pelvic girdles.

THE VERTEBRAL COLUMN

The **vertebral column** (*columna vertebralis*) is formed of a linear series of segments, the **vertebrae**. In accordance with its function as a general support of the body, and also its relations with the nervous system and the spinal musculature, the vertebrae, with minor exceptions, are constructed on the same plan. Those of particular regions, moreover, resemble each other specially closely in function and form, so that it is possible to classify them into cervical (neck), thoracic (chest), lumbar (abdominal), sacral (hip), and caudal (tail) groups.

A typical vertebra—for the characters of which any one of the thoracic or lumbar series may be taken (Fig. 82, D-F)—consists of

a somewhat massive basal portion, the **vertebral body** (*corpus vertebrae*) or **centrum**, and of a dorsal, **vertebral arch** (*arcus vertebrae*). The two portions enclose a large aperture, the **vertebral**

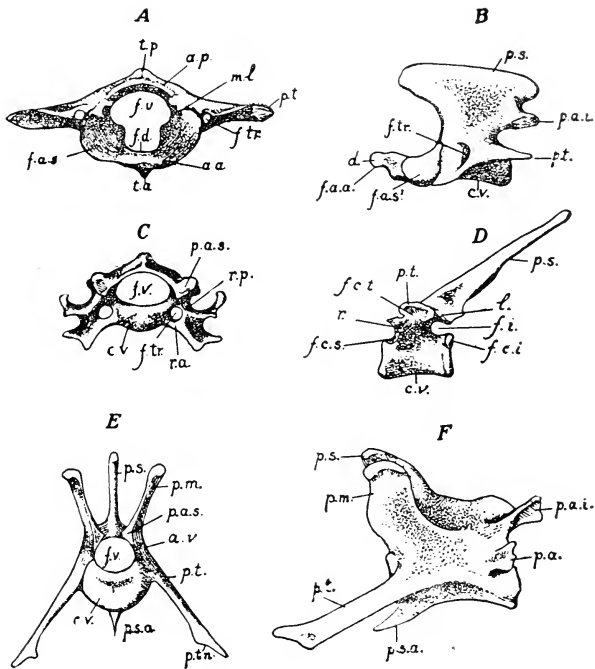


FIG. 82. Representative vertebrae: A, atlas, anterior surface; B, epistrophus, lateral surface; C, fifth cervical vertebra, anterior surface; D, fourth thoracic, lateral surface; E, F, second lumbar vertebra, anterior and lateral surfaces.

a.a., anterior arch of atlas; a.p., posterior arch of atlas; a.v., vertebral arch; c.v., vertebral body; d, dens epistrophei; f.a.a., anterior articular facet of epistrophus; f.a.s., superior articular pit of atlas; f.a.s., superior articular facet of epistrophus; f.c.i., inferior costal demifacet for head of rib; f.c.s., superior costal demifacet; f.c.t., costal facet of transverse process; f.d., fovea dentis; f.i., intervertebral foramen; f.tr., foramen transversarium; f.v., foramen vertebrale; l, lamina of vertebral arch; m.l., lateral mass of atlas; p.a., accessory process of lumbar vertebra; p.a.i., inferior articular process; p.a.s., superior articular process; p.m., mamillary process; p.s., spinous process; p.s.a., anterior spinous process; p.t., transverse process; p.t.n., triangular process; r., radix of vertebral arch; r.a., anterior and posterior radices of transverse process of cervical vertebra; t.a., t.p., anterior and posterior tubercles of atlas.

foramen (*foramen vertebrale*). The successive foramina form an almost complete tube, the **vertebral canal** (*canalis vertebralis*), for the accommodation of the spinal cord.

The body of a vertebra is a cylindrical, or somewhat dorso-ventrally flattened, mass of bone, which bears at either end an articular surface for attachment to the body of the adjacent vertebra. The articular surfaces are borne on thin plate-like epiphyses, the epiphysial lines being evident even in older animals, especially in the lumbar region. The arch of a vertebra is composed of a lateral, vertical portion, the **pedicle** or **root** (*radix arcus vertebrae*), at each side and a dorsal, transverse portion connecting the tops of the pedicles, distinguished as the **lamina**. Each pedicle is attached to one side of the dorsal surface of the body of the vertebra so that the latter forms the floor of the vertebral foramen, the pedicles constituting its sides and the lamina its roof. The anterior and posterior margins of the pedicle are notched, each notch or incisure being opposite that of the adjacent vertebra, so that together they form a rounded aperture, the **intervertebral foramen** (*foramen intervertebrale*), for the passage outward of a spinal nerve.

The arch of the vertebra bears various projections or **processes**. On either side is a horizontal plate of bone, the **transverse process** (*processus transversus*) and, dorsally, there is a median projection, the **spinous process** (*processus spinosus*), all three serving for the attachment of ligaments which hold the vertebrae together and for the attachment of the spinal musculature. Special surfaces for articulation with the adjacent vertebrae are borne on low **articular processes** (*processus articulares*) on the anterior and posterior margins of the arch. The anterior or **superior articular surfaces** are directed for the most part toward the dorsal surface, and are overlapped in the natural condition by the **inferior articular surfaces** of the next vertebra, which are directed more or less ventrad. A certain amount of movement is permitted by one surface slipping across the other, the mechanism illustrating the **arthrodia**, or gliding-joint.

CERVICAL REGION

The cervical vertebrae (*vertebrae cervicales*) are seven in number and serve mainly for the support of the head. As the latter has to be freely movable in a variety of directions, the articulations are such as to permit considerable flexibility in this

region and the first two cervical vertebrae (the atlas and the epistropheus) are specially modified to provide for movements of the skull. The posterior vertebrae (Fig. 82, C) are dorsoventrally compressed, with low arches and short spinous processes. In the seventh vertebra, however, the spinous process begins to be elongated as in the succeeding thoracic vertebrae. In each vertebra the transverse process is perforated by a **costo-transverse foramen** (foramen transversarium), which serves for the passage of the vertebral artery forward to the head. This aperture divides the base of the transverse process into a **dorsal**, or **posterior root** (radix posterior) and a **ventral**, or **anterior root** (radix anterior). The development of these parts shows that the anterior root is really a reduced rib which has become fused to the body and to the transverse process and is comparable in its general relations to the normal ribs of the thoracic vertebrae.

Atlas

The first vertebra is the **atlas** (Fig. 82, A). It is peculiar in lacking the vertebral body, the latter being represented by the odontoid process of the epistropheus (cf. Plate II); also in possessing special articular surfaces, and in having its transverse process greatly flattened dorsoventrally. It consists of a ventral half-ring, the **anterior arch** (arcus anterior), a dorsal half-ring, the **posterior arch** (arcus posterior), and paired **lateral masses** (massae laterales), the last being thickened regions of the bone uniting the arches at each side and forming the bases of the transverse processes. The anterior arch bears on its ventral side a small backwardly-directed process, the **anterior tubercle** (tuberculum anterius), named from its position in the human body, where the ventral surface is anterior. A similar **posterior tubercle** (tuberculum posterius) projects forward on the dorsal surface of the posterior arch and is comparable to the spinous process of an ordinary vertebra. The anterior surface of the atlas bears on either side an extensive concave smooth surface, the **superior articular pit** (fovea articularis superior), for articulation with one of the convex occipital condyles of the skull. Its posterior surface bears on either side a smaller, somewhat triangular, **inferior articular facet** (facies articularis inferior) for articulation with the epistropheus. These surfaces take the place of the arch

articulations of ordinary vertebrae. As a result of the flattening of the transverse process, the costo-transverse foramen is extended into a tubular canal. The anterior aperture of this is connected by a shallow groove, the **sulcus arteriae vertebralis**, with a foramen perforating the posterior arch (foramen obliquum). Through this latter foramen, represented in some mammals by separate alar and intervertebral foramina, the vertebral artery and the first cervical nerve enter the vertebral canal.

The space enclosed by the atlas is divided into a dorsal portion, corresponding to the vertebral foramen of other vertebrae, and a ventral portion which in the natural condition lodges the odontoid process of the epistropheus. The division is effected partly by a small tubercle on the inner side of each lateral mass, and partly by a transverse ligament which is stretched between these tubercles and over the dorsal surface of the odontoid process. On the floor of the ventral portion, a rounded articular surface, the **fovea dentis**, marks the point of articulation of the anterior articular facet of the odontoid process with the inner surface of the anterior arch.

Epistropheus

The second vertebra is the **epistropheus** or **axis** (Fig. 82, B). It resembles the succeeding cervical vertebrae more closely than does the atlas. It is noteworthy for its great size, for the lateral compression of its arch and spinous process, and for the possession of a stout forwardly-directed **odontoid process**, or **tooth** (dens epistrophei). It is articulated with the atlas through an **anterior articular facet**, borne on the ventral surface of the odontoid process, and by large paired **superior articular facets** borne on its base. The spinous process of this vertebra and the transverse processes of the atlas are three main points of attachment for the occipital musculature, which passes between the head and neck.

Consideration of the form and relations of the articular surfaces will make it evident that the articulation between skull and atlas provides chiefly for a nodding movement and that that between atlas and epistropheus allows mainly a pivoting movement of the head. Simple bending of the head to one side or the other is the main movement permitted between the remaining cervical vertebrae, in which the superior and inferior articular surfaces respectively face mainly dorsad and ventrad.

THORACIC REGION

The **thoracic vertebrae** (vertebrae thoracales) are twelve in number. They form the backbone of the chest region and provide attachment for certain muscles of the shoulder and muscles and ligaments of the neck, but are distinguished chiefly by the possession of **articular pits** for the attachment of ribs (Fig. 82, D). A typical rib is articulated at two points, namely, one on the body of the vertebra, the other on the transverse process. The former is marked by a small round depression, the **costal pit** (fovea costalis), or **costal facet**. In the last two vertebrae, the facet is borne wholly on the vertebral body to which the rib belongs, but in the remaining vertebrae, a complete articulating surface is formed by two **demi-facets**, one on the vertebra to which the rib belongs, the other on the vertebra immediately in front. The point of articulation of a rib with a transverse process is marked on the latter by an oval facet, the **costal pit of the transverse process** (fovea costalis transversalis). It is present only in the first ten of the thoracic vertebrae, the other two having the costal articulations on their bodies only.

In all vertebrae of the thoracic series, the spinous processes are well developed, mainly for attachment of the dorsal ligament of the neck, which supports much of the weight of the head. They increase in length to the third, and then become gradually shorter but wider, so that their surfaces are, on the whole, slightly increased in extent. The anterior ten are directed backward, the eleventh is almost vertical (anticlinal vertebra), while the twelfth is directed forward, like those of the succeeding lumbar vertebrae. The anticlinal vertebra is a centre about which the body bends in such movements as galloping.

Dorsolaterally, the more posterior vertebrae of the region have small mamillary processes corresponding with the more conspicuous ones of the lumbar region.

LUMBAR REGION

The **lumbar vertebrae** (vertebrae lumbales) are seven in number. As they not only support the longer part of the trunk but also provide the origins for some of the proximal muscles of the hind limb, they are large vertebrae, conspicuous for their extensive surfaces and processes for muscular attachment (Fig. 82, E, F). The transverse processes continue the general line of the ribs of

the thoracic region, being directed forward and downward, as well as outward. The tip of each is formed by a thin **triangular plate** (processus triangularis), which represents a vestigial rib fused with the original process. At the posterior side of the base of each is a short, flattened projection, the **accessory process** (processus accessorius). The spinous process is notably broad and is directed forward. The articular processes are rotated upward, so that their surfaces are directed more nearly toward, or away from, the median

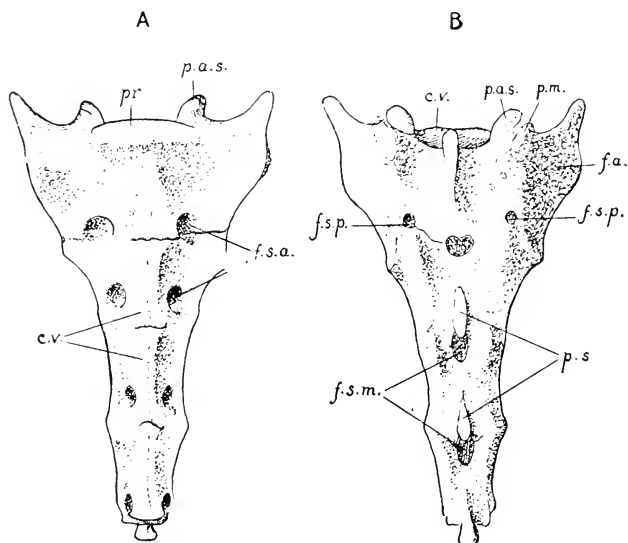


FIG. 83. The os sacrum: A, ventral (pelvic) surface; B, dorsal surface. c.v., bodies of coalesced vertebrae; f.a., auricular surface; f.s.a., anterior sacral foramina; f.s.m., median sacral foramina; f.s.p., posterior sacral foramina; p.a.s., superior articular process of first vertebra; p.m., mamillary process of first vertebra; pr., promontory; p.s., spinous processes.

plane, instead of to the dorsal or ventral surface, so that the movement provided for is chiefly a bending of the body dorso-ventrally. The anterior articular surfaces are borne on the bases of stout, upwardly-directed **mamillary processes** (processus mamillares) upon which the powerful muscles of the back originate (m. sacrospinalis, p. 339). The latter processes are most characteristic of the lumbar vertebrae, but, as mentioned above, appear in the posterior thoracic region as small elevations of the transverse

processes. Each of the first three of the lumbar vertebrae bears a median ventral projection, the **anterior spinous process** (processus spinosus anterior), for the attachment of the lumbar portion of the diaphragm.

SACRAL REGION

The **sacral vertebrae** (vertebrae sacrales) are four in number and are modified for the attachment of the pelvic girdle. In contrast to the **true** vertebrae—those united by ligament and articular surfaces—of the remaining portions of the vertebral column, they are **false** vertebrae, being united in the young by synchondroses, and in the adult coalesced to form a composite structure, the **os sacrum** (Fig. 83). The axis of the sacrum forms an obtuse angle with that of the lumbar vertebrae, the angle being indicated by a ventral projection, the **promontory** (promontorium), formed by the last lumbar and first sacral vertebrae where they articulate. The sacrum is the medium through which the vertebral column—in other words, the posterior portion of the trunk—is supported on the posterior limbs. Its anterior dorsal portion bears on either side a roughened area, the **auricular surface** (facies auricularis), for articulation with the pelvic girdle. This surface is borne for the most part on the transverse process of the first sacral vertebra.

The sacrum exhibits many features resulting from its formation through the fusion of originally distinct vertebrae. On the ventral or **pelvic surface** (facies pelvina), the lines of junction may be traced either between the bodies, or between the transverse processes. Four pairs of apertures on this surface, the **anterior sacral foramina** (foramina sacralia anteriora), lead into the intervertebral foramina, and give passage to the sacral spinal nerves. On the **dorsal surface** (facies dorsalis) a pair of posterior sacral foramina in the line of junction of the first and second vertebrae and minute foramina behind the second and third vertebrae transmit the dorsal rami of the first to third sacral nerves. The spinous processes are evident in all four vertebrae. The combined articular and mamillary processes are conspicuous only in the first two, but are represented in the succeeding two by low, roughened tubercles. In the middle line dorsally the vertebral arches are separated by conspicuous apertures, the **median sacral foramina**.

CAUDAL REGION

The **caudal** or **coccygeal vertebrae** (vertebrae caudales, s. coccygeae) are sixteen in number. They are segments of small size, increasing slightly to the third, and then gradually decreasing to the end of the column. As only the small tail muscles are attached to them, they lack any marked projections. The arches are complete in the first seven. The transverse processes are vestigial in all except the third. At the end of the column, the segments are reduced to slender cylinders of bone representing the vertebral bodies.

THE RIBS

The **ribs** (costae) are twelve in number on either side. Each is composed of a dorsal portion, the **costal bone** (os costale), or **bone-rib**, and a ventral portion, the **costal cartilage** (cartilago costalis) (Fig. 84). From their attachment on the vertebral column the bone-ribs are directed outward, downward, and backward. The costal cartilages are directed for the most part inward, downward, and forward. The first costal cartilage forms a pronounced angle with the corresponding bone-rib. In the succeeding ribs the angle is gradually replaced by a broad curve.

Ribs are classified as **true** or **sternal ribs** (costae verae) and **false** or **asternal ribs** (costae spuriae). The former—comprising the anterior seven—are those directly attached to the sternum. The latter—comprising the posterior five—are either indirectly attached, or unattached. Those unattached are designated as **floating ribs**.

Generally speaking, the bone-ribs are cylindrical; but the anterior five or six are more or less flattened, with their main surfaces respectively medial and lateral. The compression is most marked in old animals. The first rib is extremely short. The succeeding ribs increase in length to the sixth, and then decrease to the twelfth. Each rib is curved, not uniformly but so that its greatest convexity, or **angle**, is at some point toward the dorsal surface. Passing backward, in succeeding ribs the point of greatest convexity changes from a mediodorsal to a laterodorsal position. This, together with the elongation of the more posterior ribs, results in an enormous increase in the posterior extent of the thoracic cavity.

The vertebral end, or **head** of the rib (*capitulum costae*), is articulated with the body of the vertebra to which it belongs and also, in the case of the first ten, with the vertebra immediately in front. The articulation with a transverse process is marked by a small smooth elevation, the **costal tubercle** (*tuberculum costae*). It is present only in the first nine ribs.¹ Except in the first rib and in the last four, the tubercle bears a sharp, dorsally-directed process for muscular attachment. The slender portion of the rib intervening between the head and tubercle is the **neck** (*collum costae*), the remaining larger portion being distinguished as the **body** of the rib (*corpus costae*).

The **bony thorax** is formed by the ribs and the sternum with the assistance of the thoracic vertebrae. It encloses a large space, the **thoracic cavity** (*cavum thoracis*). The latter is conical in shape, with the apex directed forward. The dorsoventral diameter of the cavity is considerably greater than the transverse diameter. Apart from the **intercostal spaces**, the cavity is open at two points: anteriorly, the first thoracic vertebra, the first rib, and the manubrium sterni together enclose a small opening, the **superior thoracic aperture** (*apertura thoracis superior*); posteriorly, the seventh and succeeding ribs, together with the posterior thoracic vertebrae and the xiphoid process of the sternum, enclose a much larger opening, the **inferior thoracic aperture** (*apertura thoracis inferior*). In the natural condition it is largely closed by the diaphragm. The curved boundary formed by the ribs in this region is the **costal arch** (*arcus costarum*), the angle formed at the point of attachment of the xiphoid process being the **infrasternal angle** (*angulus infrasternalis*).

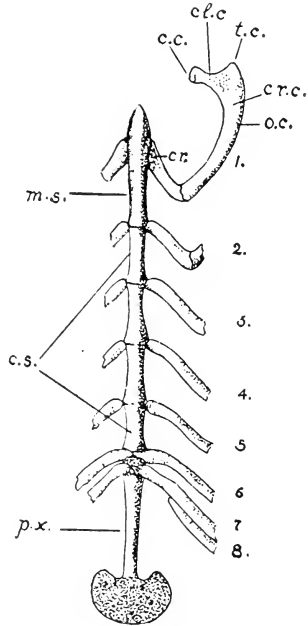


FIG. 84. The sternum and first rib, ventral view: 1-7, the true ribs; 8, first false rib; c.c., head of rib; c.l.c., neck of rib; cr., costal cartilage; c.r.c., body of rib; c.s., body of sternum; m.s., manubrium sterni; o.c., bone-rib; p.x., xiphoid process; t.c., costal tubercle.

As a result of their articulations with the vertebral column, and of the flexible nature of the costal cartilages, the ribs are capable of being moved, or rotated, forward. The movement brings about an increase of the extent of the thoracic cavity, and is of importance in breathing.

THE STERNUM

The **sternum** (Fig. 84) consists of a linear series of six segments, the **sternebrae**. The first segment is the **manubrium sterni**. It is about twice the length of the middle segments. It is somewhat triangular in section, two of its surfaces being ventrolateral, the third dorsal and directed toward the thoracic cavity. To its anterior tip is attached the **sternoclavicular ligament**, by which the greatly reduced clavicle is connected with the sternum.

The four middle segments are similar in appearance, and form the **body** (corpus sterni). The sixth segment, described as the **xiphoid process** (processus xiphoideus), is an elongated strip of bone with a broad, thin plate of cartilage attached to its posterior end.

The first costal articulation is situated at about the middle of the manubrium, the remaining six at the points of junction of the segments. Five of them occur singly, while the sixth and seventh costal cartilages are attached together at the point of junction of the last segment of the corpus sterni with the xiphoid process.

THE SKELETON OF THE HEAD

The head-skeleton comprises: (1) the series of elements constituting the **skull**; and (2) the **hyoid bone**, with its connections. The skull, or cranium—using that term in a general sense—includes the **cranium** proper, that portion enclosing the brain and containing in its wall the auditory capsules, and the **bones of the face** (ossa faciei), the latter including the series of elements related for the most part to the jaws and palate. The primary relations of the constituents of the head-skeleton have already been indicated above (p. 53).

THE SKULL AS A WHOLE

The **skull** (Figs. 85-88) is a composite structure, consisting of a large number of elements, which, with the exception of the man-

dible, are united by immovable articulations, so that they produce the effect of a continuous mass. In this, the sutures between component bones appear as fine lines of varying distinctness. The mandible is a more or less independent structure, articulated with the main body of the skull by a typical movable joint.

The posterior, cranial portion of the skull has a somewhat conical shape, its apex being directed forward. It is separated from the anterior, facial portion by a depression on either side of the skull, the **orbital cavity** (orbita), which serves for the accommodation of the optic bulb. Unlike the nasal and auditory sense-organs, the eye is not included within the skull-wall. The two portions are united both medially and laterally, the lateral connection being established by the **zygomatic arch** (arcus zygomaticus), which bridges the lateral portion of the orbit. The facial portion has also a somewhat conical shape, its apex being formed by the anterior extremity of the upper jaw and the incisor teeth. Its base is formed in part by the connection with the cranial portion, as already described, and also by the anterior walls of the orbits.

The **cranial portion** exhibits an extensive posterior surface, the **nuchal surface** (planum nuchale), situated in general at right angles to the cervical portion of the vertebral column and also to the dorsal, lateral, and ventral walls of the skull. This surface includes the external aspect of the **occipital bone**, with the exception, chiefly, of the basilar part of the latter. Its dorsal portion forms an area of attachment for the spinal and special occipital musculature. Its ventral portion is perforated by a large aperture, the **foramen magnum occipitale**, for the passage of the central nervous system from the cranial cavity into the vertebral canal. On either side of this is a smooth, ridge-like projection, the **occipital condyle** (condylus occipitalis), for articulation with the superior articular pits of the atlas. The single occipital bone of the adult is formed by the fusion of a dorsal, median **supraoccipital**, a ventral, median **basioccipital**, and paired, lateral **exoccipital** bones, the last of these bearing the main parts of the occipital condyles. At a little distance lateral to the occipital condyle, the nuchal surface is continued downward through the medium of a somewhat triangular, pointed **jugular** or **paramastoid process** (processus jugularis) of the exoccipital bone. This structure is separated

from the occipital condyle by a pronounced notch, the posterior boundary of a deep narrow excavation, the **jugular fossa** (fossa jugularis), which lies between the condyle and the tympanic bulla. The jugular process serves for the attachment of muscles belonging to the tongue, hyoid, and mandible, namely, the styloglossus, stylohyoidei major and minor, and the digastricus, the suspensory ligament of the lesser cornu of the hyoid also being

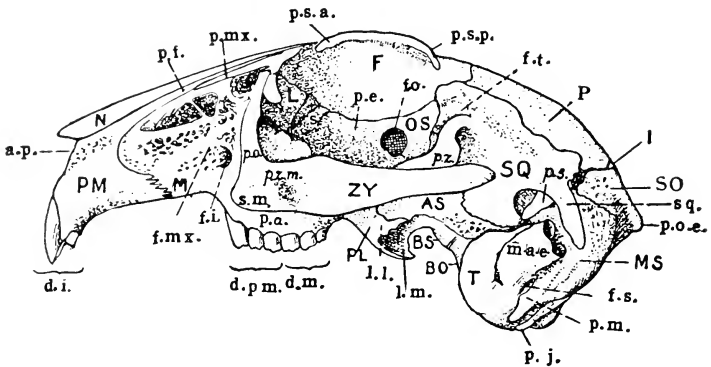


FIG. 85. Lateral surface of the skull; AS, alisphenoid (ala magna); BO, basioccipital (basilar portion of occipital); BS, basisphenoid (body of posterior sphenoid); F, frontal; I, interparietal; L, lacrimal; M, maxilla; MS, mastoid portion of petrosal (petromastoid); N, nasal; OS, orbitosphenoid (ala parva); P, parietal; PL, palatine; PM, premaxilla; SO, supraoccipital (squamous portion of occipital); SQ, squamosal; T, tympanic; ZY, zygomatic.

a.p., piriform aperture of nose; d.i., incisor teeth; d.m., molars; d.p.m., premolars; f.i., infraorbital foramen; f.mx., maxillary fossa; f.o., optic foramen; f.s., stylomastoid foramen; f.t., temporal fossa; l.l., lateral lamina of pterygoid process; l.m., medial lamina; m.a.e., osseous portion of external acoustic meatus; p.a., alveolar process of maxilla; p.e., ethmoidal portion of orbitosphenoid; p.f., frontal process of premaxilla; p.j., jugular process of occipital; p.m., mastoid process of mastoid; p.mx., maxillary process of frontal; p.o., orbital process of maxilla; p.o.e., external occipital protuberance; p.s., squamosal process of parietal; p.s.a. and p.s.p., anterior and posterior supraorbital processes of frontal; p.z., zygomatic process of squamosal; p.z.m., zygomatic process of maxilla; s, sphenoorbital process of maxilla; s.m., spina masseterica; sq., squamosal process of squamosal.

included in the ligament of the stylohyoideus minor. The nuchal surface is separated from the dorsal surface of the skull by a shield-shaped promontory and crest (crista nuchae). The lateral continuation of this crest is the **superior nuchal line** (linea nuchae superior). It forms a curved ridge, the position of which indicates the dorsal limit of the occipital musculature. The posterior, somewhat tri-radiate tip of the projection, together with a thin ridge extending ventrad from it, is the **external occipital protuberance**

(*protuberantia occipitalis externa*), an important median point of attachment for the occipital muscles and the dorsal ligament of the neck.

The ventral wall of the cranial portion is the basal part (**basicranium**) of the entire skull. Its axial line, the **basicranial axis**, continues, in general, that of the bodies of the vertebrae, and its posterior portion is equivalent, morphologically, to vertebral segments. It is formed by a linear series of three bones, namely, from back to front, the **basilar portion** of the **occipital**, the **body** of the **posterior sphenoid**, and that of the **anterior sphenoid** (respectively **basioccipital**, **basisphenoid**, and **presphenoid bones**). Its extremely narrow, anterior portion forms the roof of a deep groove which encloses the nasal portion of the pharynx. As viewed from the ventral surface, it is seen to disappear in the facial complex at some distance dorsal to the posterior margin of the bony palatine bridge. Laterally, it is separated from the orbit on either side by a vertical plate formed by the palatine bone, and also by two downward projections of the posterior sphenoid, the **medial** and **lateral laminae** of the **pterygoid process** (*processus pterygoideus*). These structures enclose between them the **pterygoid fossa** (*fossa pterygoidea*), the walls of which serve for the attachment of the external and internal pterygoid muscles of the mandible.

The lateral wall of the cranial portion of the skull forms anteriorly a large part of the boundary of the orbit. The components which do this are two upward projections of the basicranium, namely, the **lesser** or **orbital wing** of the **anterior sphenoid**, or **orbitosphenoid** and the **greater** or **temporal wing** of the **posterior sphenoid**, or **alisphenoid**, and two membrane elements, the **frontal bone** of the roof of the skull and the **squamosal bone**. The latter is distinguishable as the support of the posterior root of the zygomatic arch, which projects outward and then downward immediately behind the orbit. This root is formed by a **zygomatic process** (*processus zygomaticus*) of the squamosal bone, the tip of which process forms a vertical plate, united by a horizontal suture with the zygomatic bone. On the ventral side of the process, close to the cranial wall, is the **glenoid cavity** or **mandibular fossa** (*fossa mandibularis*), for articulation with the mandible. On its dorsal side, but more especially on the adjacent portion of the cranial

wall, there is a shallow, horizontal groove, lodging in the natural condition the temporalis muscle of the mandible, and therefore representing a greatly reduced **temporal fossa** (fossa temporalis). In the natural condition, the anterior portion of the groove is converted into a foramen through the presence of a stout ligament extending from the posterior supraorbital process to the base of the zygomatic arch and through this foramen the external ophthalmic vein emerges from the orbit. The dorsal boundary of the

fossa is formed by a pronounced ridge, the **temporal line** (linea temporalis), the latter forming also the lateral margin of the roof of the skull in this region.

Behind the posterior root of the zygomatic arch, the external surface of the lateral wall is largely occupied by the swollen **tympanic bulla** (bulla tympani), formed by the tympanic bone. It contains the capacious **tympanic cavity** (cavum tympani) and encloses the three small bones of the middle ear, the **auditory ossicles** (ossicula auditus), the relations of which are more fully dealt with below (p. 188). The dorsal portion of the

tympanic bulla is continuous with a short bony tube which opens at a short distance dorsally by a large oval aperture. This tube is part of a more extensive canal, the **external acoustic meatus** (meatus acusticus externus) which, in the natu-

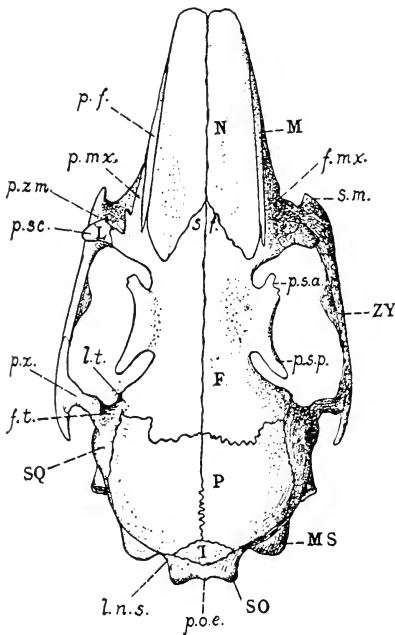


FIG. 86. Dorsal surface of the skull: F, frontal; I, interparietal; L, lacrimal; M, maxilla; MS, mastoid portion of petrosal (petromastoid); N, nasal; P, parietal; SO, supraoccipital (squamosal portion of occipital); SQ, squamosal; ZY, zygomatic.

f.m.x., maxillary fossa; f.t., temporal fossa; l.n.s., superior nuchal line; l.t., temporal line; p.f., frontal process of premaxilla; p.mx., maxillary process of frontal; p.o.e., external occipital protuberance; p.s.a. and p.s.p., anterior and posterior supraorbital processes of frontal; p.sc., subcutaneous process of lacrimal; p.z., zygomatic process of squamosal; p.z.m., zygomatic process of maxilla; s.f., frontal spine; s.m., spina masseterica.

ral condition, leads downward through the base of the external ear to the tympanic membrane. The tympanic bulla is not exposed to the cranial cavity. It is applied closely to the external surface of the **periotic** or **petromastoid bone** (os petrosum), which forms the lateral boundary of the cranial cavity, and contains the structures of the internal ear. The external or **mastoid portion** of this bone appears in the space enclosed between the tympanic bulla and the jugular process of the occipital bone, where it is readily distinguishable by its pitted appearance. Its ventral portion bears a slender projection, lying parallel to the jugular process, the **mastoid process** (processus mastoideus) which is the point of insertion of one of the neck muscles (sternomastoid).

A series of foramina, lying partly within the orbit and extending thence posteriorly along the boundary between the lateral and ventral walls to the occiput, puts the cranial cavity in communication with the outside, and serves for the passage of nerves and vessels. The first and largest of these openings, the **optic foramen** (foramen opticum), occupies the middle portion of the orbit, and, in the natural condition, transmits the optic nerve. Following this is a vertical slit-like aperture—not to be confused with the perforations of the external lamina of the pterygoid process—the **superior orbital fissure** (fissura orbitalis superior). It represents both the superior orbital fissure of the normal mammalian skull and the **foramen rotundum**, and provides for the passage outward of the third, fourth, and sixth cranial nerves, together with the first and second divisions of the fifth. The lateral lamina of the pterygoid process presents three foramina, of which the largest, anterior, and medial one, the **anterior sphenoidal foramen** (alar canal), serves for the transmission of the internal maxillary artery on its course dorsad into the orbit, while the remaining two, the **middle** and **posterior sphenoidal foramina**, transmit dorsally-directed muscular branches (massetericotemporal and pterygobuccinator) of the mandibular nerve. On the medial side of the base of the medial lamina of the pterygoid process there is a shallow longitudinal groove, representing the **pterygoid canal** (canalis pterygoidus) of the human skull. This accommodates a nerve (the Vidian, from the facial and the sympathetic). Immediately in front of the tympanic bulla, on

the ventral surface of the skull, an irregular aperture, the **foramen lacerum**, leads directly into the cranial cavity. It is incompletely divided into two parts by a slender bony splint. It contains, in addition to the foramen lacerum, which is ventral and transmits the internal carotid artery into the cranial cavity, the **foramen ovale** of the typical mammalian skull, which is the antero-dorsal part and serves to transmit the mandibular portion of the fifth nerve. Looking into the aperture from the front, it is seen to communicate not only with the cranial cavity, but also with two apertures in the anterior portion of the auditory complex. One of these—that toward the middle line—is the **internal carotid foramen** (foramen caroticum internum). It is the anterior end of a canal transmitting the internal carotid artery prior to the entry of that vessel to the cranial cavity through the foramen lacerum; the posterior end of this canal, the point at which the internal carotid artery enters the tympanic bone, or the **external carotid foramen** (foramen caroticum externum), being visible as a rounded aperture lying on the posteromedial surface of the tympanic bulla. The second, lateral aperture communicating with the foramen lacerum is that of the **auditory** (Eustachian) **tube** (tuba auditiva). It leads into the tympanic cavity, and in the natural condition the tube places this in communication with the nasal portion of the pharynx. Associated with the mastoid process is a small aperture, the **stylomastoid foramen** (foramen stylomastoideum), the external opening of the facial canal, which serves for the passage of the facial nerve. This foramen is named from the fact that in the human skull it is bounded in front by the styloid process, which is absent in the rabbit, and behind by the mastoid process. A slit-like aperture, the **jugular foramen** (foramen jugulare), lies in the jugular fossa, between the posterior ventral margin of the tympanic bulla and the occipital condyle. It transmits the first portion of the internal jugular vein from the transverse sinus of the dura mater, and also the ninth, tenth, and eleventh cranial nerves. Finally, immediately in front of the dorsal portion of the condyle, the occipital segment is perforated by several small apertures together representing the **hypoglossal canal** (canalis hypoglossi), and serving for the transmission of the hypoglossal nerve.

The roof of the cranial portion is largely formed by two pairs of thin membrane elements, the **frontal** and **parietal** bones. The

former occupy a general position between the orbits, while the latter are interposed between the frontal bones and the occipital segment. A small portion of the roof is formed posteriorly, however, by an unpaired, lozenge-shaped element, the **interparietal**

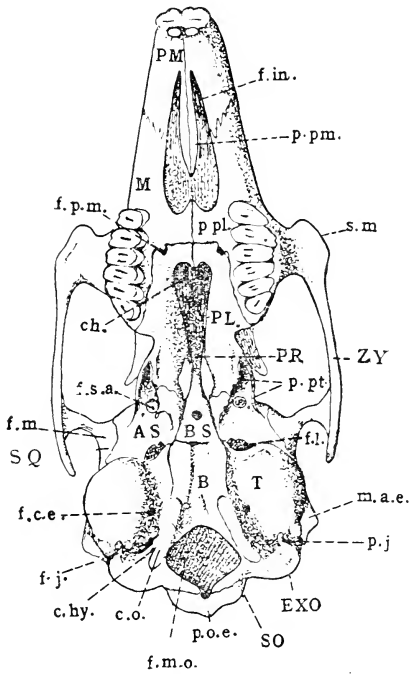


FIG. 87. Ventral surface of the skull: AS, alisphenoid (ala magna); B, basioccipital (basilar portion of occipital); BS, basisphenoid (body of posterior sphenoid); EXO, exoccipital; M, maxilla; PL, palatine; PMX, premaxilla; PR, presphenoid (body of anterior sphenoid); SO, supraoccipital (squamous portion of occipital); SQ, squamosal; T, tympanic; ZY, zygomatic.

ch, choana; c.hy., hypoglossal canal; c.o., occipital condyle; f.c.e., external carotid foramen; f.in., incisive foramen; f.j., jugular foramen; f.l., foramen lacerum; f.m., mandibular fossa; f.m.o., foramen magnum; f.p.m., greater palatine foramen; f.s.a., anterior sphenoidal foramen; m.a.e., osseous portion of external acoustic meatus; p.j., jugular process; p.o.e., external occipital protuberance; p.pl., palatine process of maxilla; p.pt., medial and lateral laminae of pterygoid process of posterior sphenoid; s.m., spina masseterica.

bone, and by the shield-shaped projection, described above, which is part of the occipital bone.

The **facial portion** of the skull is constituted largely by the investing bones of the upper jaw, palate, and mandible, but it encloses

also the entire olfactory region of the primary skull, including the nasal fossae and associated turbinal bones. The upper jaw—the **maxilla** of the human skull—is formed of two primary, and, in the rabbit, separate, elements, the **maxilla** and **premaxilla**. They together form the greater portion of the facial region—in the adult condition also a large portion of the lateral walls of the nasal fossae—and bear in a ventrolateral position low **alveolar processes** (*processus alveolares*) for the sockets or alveoli of the incisor and cheek-teeth. The maxilla bears the anterior root of the zygomatic arch, the latter being formed partly by a short **zygomatic process** arising from the lateral surface of the maxilla, by the **zygomatic** or **malar bone**, which is fused with it, and by the corresponding zygomatic process of the squamosal bone, constituting the posterior root. The anterior root of the zygomatic arch is perforated by a deep narrow **infraorbital canal** (*canalis infraorbitalis*), which opens on the facial surface by a vertical slit-like aperture, the **infraorbital foramen**. It serves for the transmission of the infraorbital vessels and nerves from the orbit to the face.

The ventral portion of the maxilla is associated with the **palatine bone** to form the **hard palate** (*palatum durum*). This structure is represented chiefly by a bony **palatine bridge** connecting the two sides of the skull between the more anterior cheek-teeth. It forms a portion of the roof of the oral cavity and a portion of the floor of the nasal cavity. Immediately in front of it, the palatal surface is perforated by a pair of large **incisive foramina** (*foramina incisiva*), which are broadly open to the nasal fossae.

A considerable portion of the anterior and dorsal wall of the orbit is formed by the facial complex. Dorsally, the roofing element of this region, the **frontal bone**, bears a curved lateral projection, the **supraorbital process** (*processus supraorbitalis*), which overhangs the orbit. Its narrower base expands into anterior and posterior tips, which lie parallel to the adjacent portion of the skull, and enclose with the latter corresponding **anterior** and **posterior supraorbital incisures**. Ligaments convert these incisures into foramina, the anterior for the passage from the orbit of the frontal nerve and the frontal artery, the posterior for the emergence of the lacrimal nerve and the lacrimal artery. The anterior wall of the orbit is formed in part by a loosely articulated element, the **lac-**

rimal bone, the lateral margin of which projects from the orbital rim as a blunt **subcutaneous process** (*processus subcutaneus*). This bone is frequently missing from the dried skull unless care has been taken to keep it in place. On the ventral side of the base of the subcutaneous process is the orbital opening of the **nasolacrimal canal** (*canalis nasolacrimalis*), the bony enclosure of the nasolacrimal duct, which in the natural condition leads from the corneal surface of the eye to the anterior portion of the nasal fossa. A smaller projection forming the ventral boundary of the nasolacrimal aperture is the **hamulus lacrimalis**. Finally, in the ventral anterior angle of the orbit, the bases of the three posterior cheek-teeth encroach to a considerable extent on the orbital space. They are separated from the orbital wall by a deep **infraorbital groove** (*sulcus infraorbitalis*), which leads forward into the canal of the same name. They partly conceal two important apertures of this region, the orbital opening of the **pterygopalatine canal** (*canalis pterygopalatinus*), leading to the palatal surface, and the **sphenopalatine foramen** (*foramen sphenopalatinum*), leading to the nasal fossa. The pterygopalatine canal opens ventrally in the palato-maxillary suture of the hard palate by a rounded aperture, the **greater palatine foramen** (*foramen palatinum majus*).

The **nasal cavity** (*cavum nasi*) is enclosed by the maxilla and premaxilla, with the assistance of paired roofing elements, the **nasal bones**. Apart from the incisive foramina, which are closed by soft tissue in the natural condition, the cavity is open at two points. Posteriorly it communicates with the ventral surface of the skull by the **choanae**, which, in the rabbit, are incompletely divided. Anteriorly it opens to the outside by the **piriform aperture** (*apertura piriformis*). The cavity is divided into right and left portions, the **nasal fossae**.

In a divided skull may be examined the space enclosed by the cranial portion, the **cranial cavity** (*cavum cranii*). Its form depends on that of the brain. It is divisible into three portions, known as the **cranial fossae**. The **anterior cranial fossa** (*fossa cranii anterior*) is a small division lodging in the natural condition the olfactory bulbs of the brain. The **middle cranial fossa**, the largest division of the cavity, accommodates the enlarged cerebral hemispheres. The **posterior cranial fossa** is a small division

extending backward to the foramen magnum and containing, in the natural condition, the cerebellum and related posterior portions of the brain. It is partly set off from the middle cranial fossa by a fold of the dura mater, the **tentorium cerebelli**, which projects inward from the dorsal and lateral walls of the skull. This fold is usually found adhering to the internal surface of the skull, unless the latter has been very thoroughly cleared, and in all cases its position is indicated by a low ridge of bone. The marked difference in diameter between the middle and posterior cranial fossae is accounted for by the great thickness of the auditory portion of the skull. The anterior surface of the petrotic bone will be observed to form an extensive posterior wall for the middle cranial fossa.

The floor of the middle and posterior cranial fossae is not smooth, like the external base of the skull, but presents in its anterior portion a prominent elevation, the **sella turcica**, which is borne on the body of the posterior sphenoid. The sella turcica contains a large central depression, the **hypophyseal fossa** (fossa hypophyseos), which in the natural condition lodges the hypophysis or pituitary body. The aperture of the fossa is partly enclosed laterally by a pair of pointed **posterior clinoid processes** (processus clinoides posteriores), the tips of which are directed forward; and a corresponding pair of **anterior clinoid processes** lie at the anterior end of the fossa, with the tips directed backward. The posterior, and also dorsal wall of the fossa, described as the **dorsum sellae**, leads by an abrupt curve backward on to the floor of the posterior cranial fossa, the sloping portion of the floor, or **clivus**, supporting in the natural condition the pons and medulla oblongata. Toward the anterior end of the middle cranial fossa, the lateral walls of the skull are greatly compressed, so that the anterior portion of the basicranium, especially the body of the anterior sphenoid, is largely excluded from the cranial cavity. The usually paired optic foramina are here confluent, there being a single aperture for the transmission of the optic nerves. The posterior ventral boundary of this aperture contains a broad groove, the **sulcus chiasmatis**, which in the intact animal lodges the optic chiasma.

In the anterior cranial fossa the floor is largely formed by a perforated area, borne on the **cribriform plate** (lamina cribrosa)

of the **ethmoid bone**, and serving for the transmission of the divided olfactory nerves. Its median portion projects slightly into the cranial fossa as a low ridge, the **crista galli**, which is interposed between the tips of the olfactory bulbs.

In the ventrolateral portion of the cranial cavity may be found the internal openings of the foramina described above, namely, the superior orbital fissure, the foramen lacerum, the jugular foramen, and the hypoglossal canal. The superior orbital fissure is almost ventral in position to the foramen opticum, and is connected back-

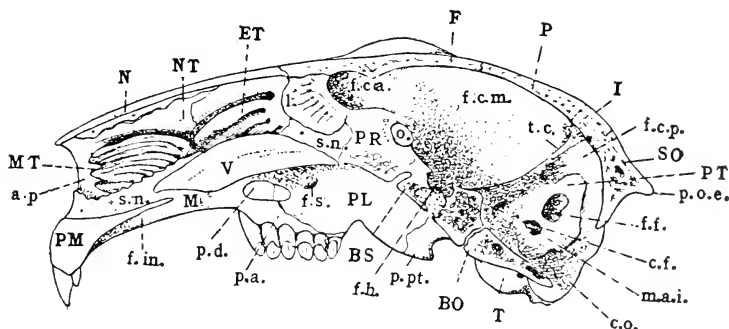


FIG. 88. The skull in vertical section: B.O., basioccipital (basilar portion of occipital); BS, basisphenoid (body of posterior sphenoid); ET, ethmoturbinal; F, frontal; I, interparietal; M, maxilla; MT, maxilloturbinal; N, nasal; NT, nasoturbinal; P, parietal; PL, palatine; PMX, premaxilla; PR, presphenoid (body of anterior sphenoid); PT, petrous portion of petromastoid; SO, supraoccipital (squamous portion of occipital); T, tympanic; V, vomere. a.p., piriform aperture of nose; c.f., internal aperture of facial canal; c.o., occipital condyle; f.c.a., f.c.m., and f.c.p., anterior, middle, and posterior cranial fossae; f.f., parafloccular fossa; f.h., hypophyseal fossa; f.in., incisive foramen; f.s., sphenopalatine foramen; l., perpendicular plate of the ethmoid; m.a.i., internal acoustic meatus; o., optic foramen; p.a., alveolar process of maxilla; p.d., hard palate; p.o.e., external occipital protuberance; p.pt., pterygoid process of posterior sphenoid; s.n., nasal septum; t.c., tentorium cerebelli.

ward with the foramen lacerum by a broad groove, the **sulcus sphenoidalis**, which, in the natural condition, lodges the roots of the fifth nerve. This groove continues to the medial surface of the petriotic bone, where it is bridged over by the tentorium cerebelli.

On the lateral wall of the posterior cranial fossa, and enclosed by the compact, white, **petrous portion** of the **petriotic bone**, is a series of three apertures leading into its substance. One of these, much larger than the remaining two, is the **parafloccular fossa** (fossa parafloccularis). It provides accommodation for the parafloc-

culus, a small stalked appendage of the cerebellum. Ventral to this fossa, and also somewhat in front of it, a thin ledge of bone extends over an oval opening, the internal aperture of the **facial canal** (canalis facialis), which serves for the transmission of the seventh cranial (facial) nerve. Immediately behind and below this aperture is the opening of the **internal acoustic meatus** (meatus acusticus internus) for the transmission of the eighth cranial (acoustic) nerve. The two apertures tend to be enclosed by a shallow bony ridge, largely formed by the projecting ledge described above, and resembling superficially the complete common tube represented by the internal acoustic meatus of the human skull.

In the bisected skull it is seen that the division of the nasal cavity into right and left fossae is effected chiefly through a median vertical, cartilaginous plate, the **nasal septum** (septum nasi), or cartilaginous portion of the **mesethmoid**. This is continuous posteriorly with a small crescentic vertical plate of bone, the **perpendicular plate** (lamina perpendicularis) of the ethmoid bone—the bony portion of the mesethmoid—and the latter is also the terminal element of the series of median bones constituting the basicranium. Posteriorly, the ventral portion of the cartilaginous nasal septum is supported by a vertical bony plate, the **vomer**, the dorsal margin of which is grooved to receive it. Anteriorly, the nasal septum bears on its ventral margin the paired enclosures of the vomeronasal organ, which are also supported by the grooved surface formed in the middle line by the adjacent dorsal surfaces of the palatine processes of the premaxilla. The relations of these structures, as well as of the cartilage supporting the nasopalatine duct, are best seen in very young animals (cf. Plate III).

The delicate, folded, or scroll-like **turbinated bones**, characteristic of the nasal cavity, are borne on its posterior and lateral walls. Occupying the anterior portion of the lateral wall of the nasal fossa is a finely-ridged mass of bone, the **concha inferior**, or **maxilloturbinal**. It is easily distinguishable from a more dorsal and posterior series of broader folds, which together constitute the **ethmoturbinal**. In the rabbit, as in mammals generally, the latter is divisible into a more dorsal elongated portion attached to the nasal bone, the **nasoturbinal**, and a more ventral and posterior portion, the **ethmoturbinal proper**, composed of several

shorter folds decreasing in length from above downward. In the natural condition, the turbinated bones bear a considerable portion of the nasal epithelium, the surface of which is greatly increased by the folding of the underlying bone. That covering the ethmo-turbinal contains the olfactory sense organs, while that covering the maxilloturbinal is non-sensory and possesses the mechanical function of freeing the air of the respiratory tracts from foreign materials, as well as of warming it slightly in its passage. On this account the respective structures are conveniently distinguished as **sensory (olfactory) turbinals** and **respiratory turbinals**.

The **mandible** (mandibula) is composed of two portions, united anteriorly by the **symphysis mandibulae**. Each half comprises

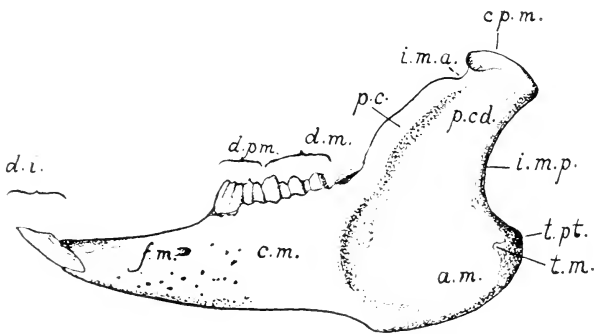


FIG. 89. Lateral surface of the left hand of the mandible: a.m., angle; c.m., body of mandible; cp.m., articular portion (head) of mandible; d.i., d.m., and d.p.m., incisor, molar, and premolar teeth; f.m., mental foramen; i.m.a. and i.m.p., anterior and posterior mandibular incisures; p.c., coronoid process; p.cd., condyloid process; t.m. and t.pt., masseteric and pterygoid tuberosities.

a horizontal portion, forming in conjunction with that of the opposite side the **body** of the mandible (corpus mandibulae), and a posterior, vertical portion, the **ramus mandibulae**, the latter serving for the insertion of the muscles of mastication and for articulation with the skull. The body of the mandible bears on its dorsal margin the alveoli of the lower teeth. The mandibular ramus forms a broad plate, the lateral surface of which is occupied in the intact animal by the masseter muscle, while the medial surface forms an area of insertion for the external and internal pterygoids. The surface of the ramus is greatly increased in its posteroventral portion through the expansion of the bone to form

the **angle** (angulus mandibulae), or **angular apophysis**. The elongated articular surface is borne at the end of a vertical, or slightly oblique, **condyloid process** (processus condyloideus). The nerve and vessels of the mandible enter at the **mandibular foramen** (foramen mandibulare), the latter being situated on the medial surface of the bone immediately behind the last cheek-tooth. Terminal portions of the same structures emerge on the lateral surface through the **mental foramen**, a little in front of the cheek teeth.

The mandible is described in greater detail starting on page 195.

THE BONES OF THE SKULL

The Occipital Bone

The **occipital bone** (os occipitale) is the first of the basicranial segments as numbered from the occipital articulation forward. It forms the posterior boundary of the skull and establishes the connection of the latter with the vertebral column. Its external surface is identifiable for the most part with the nuchal surface, but a portion of it falls in the horizontal plane of the basis cranii. The internal surface is partly exposed to the cranial cavity and forms the posterior, dorsal, and ventral boundaries of the posterior cranial fossa. The remaining portion is excluded from the cranial cavity, being applied instead to the broad posterior surfaces of the petrotympanic bones.

The occipital bone is divisible into four portions, namely, the **basilar portion** (pars basilaris) or **basioccipital**, the paired **lateral portions** (partes laterales), or **exoccipitals**, and the **squamous portion** (squama occipitalis), or **supraoccipital**. All four portions take part in the formation of the foramen magnum. In the young animal (Fig. 25) they are represented by separate elements, formed in a continuous mass of cartilage, and united for a time by synchondroses, but in the course of growth they become fused to form a single occipital bone.

The **basioccipital** is that portion lying below and in front of the foramen magnum. Its main surfaces are respectively dorsal and ventral. Its anterior margin is united with the posterior margin of the basisphenoid by a thin, transverse cartilage union,

the **sphenooccipital synchondrosis** (synchondrosis sphenooccipitalis). Posteriorly its dorsal and ventral surfaces come together in a thin concave edge which forms the ventral boundary of the foramen magnum. Laterally it is bounded by the petrotympanic bone and by the lateral portion of the occipital. The dorsal surface bears a median groove, deeper in its middle portion, where the lateral margins of the bone are raised to form a pair of rounded bosses for articulation with the petrotympanic. The groove represents the sloping portion or **clivus** of the occipital, and lodges in the natural condition, as described above, the ventral portion of the medulla oblongata. The ventral surface presents a similar groove, in the posterior portion of which there is a small ridge-like elevation, the **pharyngeal tubercle** (tuberculum pharyngeum).

The exoccipital is directed dorsad from the basioccipital in such a way that it falls in the plane of the nuchal surface. It is applied to the posterior surface of the petrotympanic bone, and also extends downward beyond the latter as the **jugular process**. The occipital condyle is borne on the exoccipital, with the exception, however, of its ventral tip, which belongs to the basioccipital. The portion of the occipital bone connecting the basioccipital and exoccipital contains the **jugular fossa** and the apertures representing the **hypoglossal canal**. Its anterior margin bears a **jugular incisure** (incisura jugularis), forming the occipital boundary of the jugular foramen, the remaining portion of the latter being formed by the petrotympanic.

The **supraoccipital** is the dorsal portion of the bone. Its dorsal margin is bent sharply forward, so that it tends to fall, like the basioccipital, in a horizontal plane. Its external surface bears the **nuchal crest** and the **external occipital protuberance**. Paired lateral wing-like expansions rest upon, and partly overlap, the dorsal margins of the petrotympanic bones. The anterior boundary is formed by the interparietal, parietal, and squamosal bones, but in young skulls the squamosal connection is represented by a vacuity. The internal surface bears a median longitudinal groove, lodging in the natural condition the vermis of the cerebellum. It is crossed at its anterior end by a shallow **transverse groove** (sulcus transversus), which marks the position of the transverse sinus of the dura mater.

The Posterior Sphenoid

The **sphenoid bone**, as identified from the human condition, is a complex of elements belonging to two segments, namely, the **posterior sphenoid** (os sphenoidale posterius) and the **anterior sphenoid** (os sphenoidale anterius). In the rabbit, as in mammals generally, these segments are separate throughout life.

The **posterior sphenoid** comprises: (1) a median portion, the **body**, or **basisphenoid**; (2) paired dorsolateral expansions, the **greater wings** (alae magnae), or **alisphenoids**; and (3) paired ventral projections, the **pterygoid processes**.

The **basisphenoid** continues the basis cranii forward from the basioccipital to the body of the anterior sphenoid. It is united with the latter by the **intersphenoidal synchondrosis**. Its surfaces correspond for the most part to those of the basioccipital. The ventral surface forms the chief part of the bony roof of the nasopharynx. It is perforated in its middle by a round aperture, the **foramen cavernosum**, which leads into the interior of the bone. The dorsal surface is occupied by the **hypophyseal fossa** and related structures, namely, the **dorsum sellae** and the **posterior clinoid processes**. On the lateral surface of the base of the posterior clinoid process a faint groove, the **sulcus caroticus**, marks the course of the internal carotid artery. The interior of the bone contains a cavity of considerable size, the **sphenoidal sinus** (sinus sphenoidalis), which communicates with both the foramen cavernosum and the hypophyseal fossa.

The **alisphenoid** extends laterad at first, but soon changes its direction so that its axis becomes dorsoventral. At the same time the bone is rotated in such a way that its surfaces tend to fall in a transverse plane. It is bounded anteriorly by the orbitosphenoid, dorsally by the squamosal, and posteriorly by the petrotympanic. The anterior margin of its root along with the basisphenoid, and to a certain extent with the orbitosphenoid, encloses the **superior orbital fissure**. The **foramen lacerum** is formed by the posterior margin of its root in association with the petrotympanic.

The external surface of the alisphenoid is convex, both toward the orbital and toward the ventral surface of the skull. In the posterior portion of the orbit this surface bears a jagged elevation, the **crista alae magnae**. The internal surface forms a portion of

the floor and anteroventral wall of the middle cranial fossa. At its base a broad groove, the **sulcus sphenoidalis**, indicates the position of the root of the fifth nerve and the related semilunar (Gasserian) ganglion.

The **pterygoid process** comprises the two plates described above as the **medial** and **lateral laminae**. The former is vertical and its medial surface is directed toward the nasopharynx. The latter is almost horizontal. The medial lamina ends ventrally in a hooked projection, the **hamular process** (hamulus pterygoideus). In the young animal this portion is formed of an elevation of cartilage tipped by a separate membrane element, the pterygoid bone. The **pterygoid fossa** is formed in part by the medial and lateral laminae and in part by the divided posterior end of the palatine bone. The posterior basal portion of the lateral lamina is extensively excavated, like the adjacent portions of the alisphenoid. It bears a shallow groove, representing a **pterygoid canal** (canalis pterygoideus), and is perforated by the three apertures described above as the **anterior, middle, and posterior sphenoidal foramina**.

The Anterior Sphenoid

The **anterior sphenoid** (os sphenoidale anterius) consists of two portions, namely, a median portion, the **body**, or **presphenoid**, and a pair of lateral expansions, the **lesser wings** (alae parvae), or **orbitosphenoids**.

The **presphenoid** is a constricted bony splint which continues the basis cranii forward from the basisphenoid. It is joined anteriorly with the perpendicular plate of the ethmoid and with the cartilaginous nasal septum. In the divided skull, or better in one from which the roof has been removed, the actual dorsal surface of the bone is seen to be exposed to the cranial cavity only in its posterior portion, where it is occupied by the **sulcus chiasmatis** and the **optic foramina**. That part of the floor immediately in front of the optic foramina is formed by the coalesced roots of the orbitosphenoids, the dorsal surface of the presphenoid being thus excluded.

The **orbitosphenoid** forms a long, low plate, lying in the ventral portion of the orbit, and divided by a shallow notch at the level of the optic foramen into a posterior portion, the orbitosphenoid proper, and an anterior portion, the **ethmoidal process** (processus

ethmoidalis). The orbitosphenoid proper lies behind the optic foramen. It is in contact dorsally with the orbital portion of the frontal, and ventrally with the alisphenoid; it assists the latter in the formation of the superior orbital fissure. Its posterior tip is in contact with the squamosal. Its internal surface forms a considerable portion of the anteroventral wall of the middle cranial fossa.

The **ethmoidal process** extends forward from the optic foramen. Its dorsal margin is articulated with the orbital portion of the frontal, and its ventral margin with the orbital portion of the palatine. Anteriorly it projects toward the lacrimal bone, thus occupying, in part, a space which, in the typical mammalian skull, is filled by the lamina papyracea of the ethmoid. Its internal surface is associated with the ethmoid bone and with the nasal cavity. It falls for the most part below the level of the cranial cavity.

The Squamosal Bone

The **temporal bone**, or **temporal complex**, as recognized from the human condition, is an association of three elements—**squamosal**, **tympanic**, and **periotic**—which in the human skull are coalesced to form a single bone. It is usually described as consisting of four portions, of which the **squamosal** and **tympanic portions** are two, while the periotic bone is considered to consist of two others, one of which, the **petrous portion**, is a solid white portion lodging the internal ear, while the second, or **mastoid portion**, is a mass of less compact character appearing externally in the wall of the skull. In the rabbit the original elements are not coalesced, but the periotic and tympanic bones are so closely associated that it is proper to describe them as forming a **petrotympanic bone**.

The **squamosal bone** (os squamosum) is a rectangular plate, forming part of the lateral wall of the cranium, and bearing the posterior root of the zygomatic arch. It is articulated anteriorly with the orbitosphenoid and with the orbital portion of the frontal, dorsally with the frontal and parietal, posteriorly with the supra-occipital and petrotympanic, and ventrally with the alisphenoid. Its posterior margin bears a prominent, slightly decurved **squamosal process** (processus squamosus). It lies on the lateral surface of the petrotympanic immediately above the opening of the bony external acoustic meatus. The posterior root of the zygomatic

arch is formed by a lateral and afterwards ventral projection, the **zygomatic process** of the squamosal. The base of this process bears ventrally the **mandibular fossa**, and dorsally, in association with the body of the squamosal, the **temporal fossa**. The internal surface of the squamosal forms a considerable portion of the wall of the cranial cavity, the middle cranial cavity being, in fact, broadest in this region.

The Petrotympenic Bone

The **petrotympenic bone** (*os petrotympenicum*) is a somewhat oblong bone lying in the lateral wall of the cranium between the posterior sphenoid and occipital bones. It is chiefly indicated externally by the **tympanic bulla** and the bony **external acoustic meatus**. It is articulated anteriorly with the alisphenoid and squamosal, dorsally with the supraoccipital, and posteriorly with the exoccipital. Except for the presence of the squamosal process of the squamosal bone, the lateral and ventral surfaces are exposed to the outside of the skull. The internal surface, with the exception of a small ventral portion which is articulated with the basioccipital bone, is exposed to the posterior cranial fossa. Only a small portion of the anterior surface is in contact with the squamosal bone, the larger part being applied to the tentorium cerebelli and forming with the latter a posterior wall for the middle cranial fossa. The dorsal portion of the bone corresponds in thickness with the wing of the supraoccipital with which it is articulated. The posterior surface is applied to the anterior surface of the exoccipital, and is thus excluded both from the cranial cavity and from the external surface of the skull. Viewing the skull from behind, however, it is seen that a small dorsal portion protrudes in a triangular space formed by the dorsolateral margin of the exoccipital and the ventrolateral margin of the supraoccipital wing. This portion is distinguishable by its pitted character. It forms the **mastoid portion** (*pars mastoidea*) as distinguished from the solid white **petrous portion** (*pars petrosa*), which is exposed to the cranial cavity, and which contains the structures of the internal ear. The mastoid portion lies for the most part above the tympanic cavity, but it is also continued ventrad between the external acoustic meatus and the exoccipital as the **mastoid process**. The

stylomastoid foramen lies between the latter and the external acoustic meatus.

The petrous portion, as viewed from its medial surface, is roughly oblong; it is placed obliquely with reference to the basioccipital and basisphenoid. The **parafloccular fossa** occupies its posterodorsal portion, and extends into the substance of the bone, forming a much larger depression than is indicated by the diameter of its rim. The related dorsal margin of the bone is occupied by a groove which leads into a canal at its posterior margin. It indicates the position of the lateral portion of the transverse sinus of the dura mater. The ventral, thicker portion of the bone, enclosing the apertures of the **internal acoustic meatus** and the **facial canal**, is also that lodging the vestibulum and cochlea of the internal ear. A small aperture at its anteroventral angle, visible only when the petrotympanic is freed from its connections, represents the **hiatus canalis facialis** of the human skull. It transmits the great superficial petrosal nerve, a branch of the facial nerve passing to the sphenopalatine ganglion.

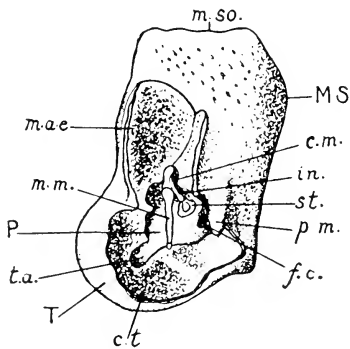


FIG. 90. Petrotympanic portion of the auditory complex of the left side $\times 3$. The lateral portions of the tympanic bulla and external acoustic meatus have been removed, exposing the structures of the tympanic cavity. MS, mastoid portion; P, petrous portion; T, tympanic portion (bulla tympani); c.m., mastoid cells; c.t., tympanic cavity; f.c., cochlear fenestra; in., incus; m.a.e., external acoustic meatus; m.m., manubrium of the malleus; m.so., supraoccipital margin of petromastoid; p.m., mastoid process; st., stapes; t.a., aperture of auditory tube.

It transmits the great superficial petrosal nerve, a branch of the facial nerve passing to the sphenopalatine ganglion.

The tympanic surface of the petrous portion is described below in connection with the structures of the tympanic cavity.

The **tympanic portion** forms the spherical, expanded, shell-like, tympanic bulla, which contains in its interior the **tympanic cavity**, and is continuous dorsally with the bony enclosure of the **external acoustic meatus**. The boundary between the two is indicated externally by a shallow oblique groove, the position of which indicates roughly that of the tympanic membrane within.

The medioventral margin of the bone is articulated with the basioccipital, but the swollen portion is separated from the latter by a broad groove terminating

posteriorly in the jugular fossa and the jugular foramen. Immediately in front of the jugular fossa, the rounded aperture of the **external carotid foramen**, transmitting in the natural condition the internal carotid artery, leads into the **carotid canal** of the interior of the tympanic portion. At the anterior end of the groove, communicating with the foramen lacerum, is the anterior opening of the carotid canal, the **internal carotid foramen**, and on its lateral side the much larger aperture of the **auditory** (Eustachian) **tube**. The relations of these apertures are seen to best advantage when the petrotympanic is disarticulated from the associated posterior sphenoid bone. The auditory tube is then seen to lead directly into the tympanic cavity. A fine bristle may be passed through the carotid canal from one foramen to the other.

The Structures of the Tympanic Cavity

The relations of the tympanic cavity and associated structures may be studied with advantage in a skull from which the lateral wall of the tympanic bulla and external acoustic meatus has been removed, the surface displayed being as indicated in Fig. 90. The **tympanum** or **middle ear** is enclosed by the tympanic and petromastoid portions of the temporal complex. The attached margin of the tympanic bulla encloses a roughly triangular area, into the ventral part of which the petrous portion of the petromastoid projects as a smooth, white, convex ridge, the **promontory** (promontorium). Above and behind the promontory the tympanic cavity is extended toward the mastoid portion of the bone as the **tympanic** or **mastoid antrum** (antrum tympanicum), and the interior of the mastoid portion is partly occupied by small extensions of the tympanic antrum, termed the **mastoid cells** (cellulae mastoideae). At the anteroventral angle of the area already described, a deep notch indicates the point of entrance of the auditory tube. The exposed surface of the petromastoid presents two apertures, one of which, situated posteroventrally, is open in the dried skull, and is the **cochlear fenestra** (fenestra cochleae). In the natural condition it is closed by a thin membrane which separates the tympanic cavity from the perilymphatic space containing the membranous labyrinth. The second aperture, the **vestibular fenestra** (fenestra

vestibuli), lies above and in front of that just described. It is closed by the base of the stapes.

The **auditory ossicles** (ossicula auditus) comprise three elements, namely, the **malleus**, **incus**, and **stapes**, which bridge the space intervening between the tympanic membrane and the opening to the internal ear as represented by the vestibular fenestra. They occupy the dorsal angle of the triangular area already described and lie immediately above the promontory. The malleus is the lateral element. The main portion, termed the **head**, is concealed by the projecting edge of the external acoustic meatus. It bears a stout vertical process, the **manubrium mallei**, which in the natural condition lies in contact with the tympanic membrane. The incus is the intermediate element; it is directly articulated with the malleus, and bears a downwardly-directed **long limb** (crus longum), for articulation with the minute head of the stapes. The latter element is a small stirrup-shaped bone, occupying an almost transverse position, and articulated at its base with the margin of the vestibular fenestra.

The Interparietal Bone

The **interparietal** (os interparietale) is a small, lozenge-shaped element, surrounded by the two parietal bones and the supraoccipital. It is the first of the membrane roofing elements of the cranium proceeding forward from the supraoccipital, and in the rabbit's skull is not fused with the occipital segment as it is in man.

The Parietal Bone

The **parietal bone** (os parietale) is a characteristic roofing bone covering a large portion of the middle cranial fossa. It is somewhat rectangular in shape, and is connected by serrate sutures with the surrounding elements and with its fellow of the opposite side, the sutures producing a characteristic pattern on the external surface of the skull. The sutures are medial, anterior, lateral, and posterior in position, and are designated respectively as **sagittal**, **coronal**, **squamosal**, and **lambdoidal**. The posterolateral angle of the bone is produced ventrally into a long, curved **squamous process** (processus squamosus), which lies in the angle formed by the tentorium

cerebelli and the lateral wall of the middle cranial fossa. It is not exposed to the external surface of the skull.

The Frontal Bone

The **frontal bone** (os frontale) is a paired element, lying directly in front of the parietal and forming with its fellow of the opposite side the anterior portion of the roof of the cranial cavity and also a considerable portion of its lateral, orbital wall. Unlike their homologues in the human skull, the two bones are separate throughout life, so that there is a permanent **frontal suture**. Each consists of a **frontal portion** (pars frontalis), the external or dorsal surface of which continues that of the parietal, and of an **orbital portion** (pars orbitalis), enclosing the dorsal part of the orbit. The two parts are connected at the **supraorbital border**, with which is also connected the base of the divided **supraorbital process**. The anterior end of the frontal portion is deeply notched where it comes in contact with the nasal and premaxillary bones. Two processes are thus formed, one medial, the other lateral to the nasal. The medial process is associated with that of the opposite side to form a triangular **frontal spine**, while the lateral or **maxillary process** (processus maxillaris) projects forward between the nasal and premaxillary bones, on the one hand, and the subcutaneous process of the lacrimal, the orbital process of the maxilla, and the body of the latter, on the other.

The **orbital portion** of the frontal forms a considerable portion of the orbital wall. Its anterior margin is in contact with the lacrimal bone, its ventral margin with the slender sphenoorbital process of the maxilla, the ethmoid process of the orbitosphenoid, and the orbitosphenoid proper. Its internal surface is divided by a vertical ridge into anterior and posterior portions, in relation respectively to the anterior and middle cranial fossae. The anterior cranial fossa is enclosed by the frontal bones, with the exception, however, of a small portion of the floor which is formed by the cribriform plate of the ethmoid.

The Ethmoid Bone

The **ethmoid bone** (os ethmoidale), the chief representative of the embryonic cartilaginous nasal capsule, is a delicate, greatly

sculptured structure, almost completely enclosed by the membrane bones of the face. Its features may be studied either in the divided skull, or in one from which the roof of the nasal and cranial cavities has been removed. It consists of three main portions, namely, the **cribriform plate**, the **perpendicular plate**, and the paired **lateral masses** or **ethmoidal labyrinths**.

The **cribriform plate** (*lamina cribrosa*) is exposed to the anterior cranial fossa. It is somewhat heart-shaped, with its apex in contact with the ethmoidal processes of the orbitosphenoids. Its lateral portions are perforated by numerous foramina, giving passage in the natural condition to the branches of the olfactory nerves. Its median portion forms a low vertical ridge, the **crista galli**, continuous in front with the perpendicular plate.

The **perpendicular plate** (*lamina perpendicularis*) is the bony, posterior portion of the nasal septum, and as such is exposed to the nasal cavity. It is united with the cartilaginous nasal septum and also with the presphenoid. It forms the terminal member of the chain of bones lying in the basicranial axis.

The **ethmoidal labyrinth** (*labyrinthus ethmoidalis*) occupies for the most part the posterior portion of the nasal fossa, but the **nasoturbinial** extends forward to its anterior end, and is attached for the greater part of its length to the internal surface of the nasal bone. It is broadest in its middle portion, where it projects into the space left between the ethmoturbinial proper and the maxilloturbinial, and contains at this point a pouch-like cavity, termed the **marsupium nasale**. The whole structure is comparable to one of the folds of the ethmoturbinial proper; but it is frequently seen to be divided into anterior and posterior parts by a thin vertical line of cartilage, the anterior division being probably allied to the maxilloturbinial. Its middle, ventral portion bears a stout, backwardly-directed **uncinate process** (*processus uncinatus*), which is applied to the medial surface of the maxilla.

The **ethmoturbinial proper** consists, as described above, of several shorter scrolls, decreasing in length from above downward. Like the posterior part of the nasoturbinial, they are attached directly to the cribriform plate, the perforations of which may be seen in the divided skull opening into the **ethmoidal scrolls** or spaces contained by them. They are roughly comparable to the

superior and middle turbinated bones of the human skull, but in the rabbit, as in most mammals, the ethmoturbinal surfaces are relatively much more extensive than in man.

In the typical mammalian skull the ethmoid bone is exposed to the orbit, where it forms a thin plate of bone, the **lamina papyracea**. In the rabbit, however, the space usually occupied by the lamina papyracea is partly filled by the lacrimal bone, the ethmoidal process of the orbitosphenoid, and the sphenoorbital process of the maxilla.

The Inferior Turbinated Bone

The **inferior turbinated bone** (concha nasalis inferior), or **maxilloturbinal**, is a finely ridged structure, situated anteriorly in the nasal fossa, and supported by the maxilla and premaxilla. It represents the similarly-named structure of the human skull, the lowermost of three scroll-like bones, of which the remaining two, the superior and middle turbinated bones, belong to the ethmoturbinal. In the natural condition it is covered by a non-olfactory epithelium, and is thus distinguishable in function as well as in position from the latter.

The Maxilla

The **maxilla**, the largest element of the facial region, is associated with its fellow of the opposite side to form the main portion of the upper jaw. It consists of a central portion, the **body** (corpus maxillae), and of five processes, namely, **alveolar**, **palatine**, **orbital**, **zygomatic**, and **sphenoorbital**. In the adult condition the zygomatic bone is fused with the maxilla, so that the extent of the zygomatic process appears to be greatly increased.

The **body** of the maxilla is greatly fenestrated on its external surface, the perforated area extending backward to the anterior rim of the orbit, and thus including the **maxillary fossa** and the **infraorbital foramen**. The dorsal boundary of the bone is formed by the frontal process of the premaxilla and by the maxillary process of the frontal. Anteriorly, it is united with the premaxilla, the ventral part of the suture appearing in the diastema separating the incisors from the cheek-teeth. The ventral portion of the bone forms part of the lateral boundary of the **incisive foramen**. Behind

the palatine bridge it is applied to the lateral surface of the palatine bone, and is projected into the orbit as a broad ridge enclosing the alveoli of the four posterior cheek-teeth.

In the divided skull, the medial surface of the body of the maxilla is found to be concealed by the ethmoturbinal. It contains a deep longitudinal excavation, the **maxillary sinus** (sinus maxillaris), widely open to the nasal fossa, but only seen to advantage when the ethmoturbinal is removed. The lateral wall of the sinus corresponds in position to the fenestrated area of the external surface. It bears the chief part of the **nasolacrimal canal**.

The **alveolar process** (processus alveolaris) is that portion of the maxilla lodging the sockets of the cheek-teeth. In the rabbit it is separated by the diastema, in which no teeth occur, from a corresponding but imperfectly differentiated process of the pre-maxilla.

The **palatine process** (processus palatinus) extends toward the median plane. It forms with its fellow of the opposite side about two-thirds of the palatine bridge.

The **orbital process** (processus orbitalis) is directed obliquely toward the dorsal surface of the skull. In conjunction with the lacrimal bone and the maxillary process of the frontal, it forms the anterior orbital rim. It is continuous with the fenestrated portion of the body, and its appearance as a process is largely due to its solid character as compared with the perforated surface lying in front of it.

The **zygomatic process** (processus zygomaticus) forms the anterior root of the zygomatic arch and, in the adult condition, is fused with the anterior end of the zygomatic bone. Its ventral angle bears a prominent **masseteric spine** for the attachment of the ligament of the masseter muscle.

The **sphenoorbital process** (processus sphenoorbitalis) lies on the medial wall of the orbit, in a position opposite to the middle portion of the ridge lodging the posterior cheek-teeth. It forms a stout buttress, the tip of which is applied to the anteroventral angle of the frontal bone. In this position it is visible from the orbit, lying between the lacrimal bone and the ethmoidal process of the orbitosphenoid.

The Premaxilla

The **premaxilla** or **incisive bone** (*os incisivum*) forms the anterior portion of the upper jaw. It comprises a central portion, the **body**—including with the latter the scarcely differentiated **alveolar portion** containing the large and small incisors—a **frontal process**, and a **palatine process**. The body forms a portion of the palatal surface of the skull and of the lateral boundary of the incisive foramen. Its dorsal surface forms part of the boundary of the **piriform aperture**, the remaining portion of this being formed by the nasal bone. The **palatine process** extends backward on the medial side of the bone, closely applied on the palatal surface to its fellow of the opposite side, and forms in this way a medial boundary for the incisive foramen. Its dorsal surface, in conjunction with that of the corresponding process of the other side, bears a broad **palatine groove** (*sulcus palatinus*), lodging a portion of the cartilage of the vomeronasal organ and nasopalatine duct. The **frontal process** (*processus frontalis*) is a thin bony splint, extending backward between the nasal and maxillary bones, and terminating between the former and the maxillary process of the frontal.

The Zygomatic Bone

The **zygomatic bone** (*os zygomaticum*) is a separate element only in very young animals. In the adult it is fused anteriorly with the zygomatic process of the maxilla, the position of the original suture being roughly identifiable as the point where the free horizontal portion of the zygomatic arch arises from the transverse zygomatic process. It forms an almost sagittal plate of bone bridging the orbit and serving for the attachment of the masseter muscle of the mandible. Its dorsal margin forms posteriorly a smooth, horizontal articulation with the zygomatic process of the squamosal, the end of the bone projecting considerably behind the articulation.

The Nasal Bone

The **nasal bone** (*os nasale*) is a thin, elongated bone forming the roof of the nasal fossa and, in conjunction with its fellow of the opposite side, the dorsal boundary of the piriform aperture. It is

loosely articulated with the maxilla and with the bone of the opposite side by smooth (harmonic) sutures. The medial margin is supported by the dorsal edge of the nasal septum. The internal surface bears the nasoturbinal scroll.

The Vomer

The **vomer** is the median, somewhat sickle-shaped, vertical plate of bone separating the ventral portions of the nasal fossae. It is visible from the palatal surface through the incisive foramina, but its extent is best shown in the divided skull. It forms a support for the ventral border of the nasal septum, and its posterior portion bears a shelf-like projection, the **ala vomeris**, which assists in the support of the ethmoturbinal.

The Lacrimal Bone

The **lacrimal bone** (os lacrimale) is a small element lying in the anterior wall of the orbit. It is loosely articulated with the surrounding bones. It consists of a very thin basal portion, somewhat rectangular on its orbital surface, and of two processes, namely, the **subcutaneous process** and the **hamulus lacrimalis**. The subcutaneous process is the prominent, somewhat thickened, hook-like projection extending laterad beyond the orbital rim. The hamulus lacrimalis is a small process, directed toward the nasal cavity. It bears a groove which, in association with a corresponding groove of the maxillary bone, forms the first portion of the nasolacrimal canal and the lateral end of which separates the hamulus below from the subcutaneous process above.

The Palatine Bone

The **palatine bone** (os palatinum) forms the posterior portion of the palatine bridge and the major portion of the lateral wall of the nasopharynx. It consists of two portions—**horizontal** and **perpendicular**. The **horizontal portion** (pars horizontalis) is that lying in the plane of the palatal surface. It is articulated in front with the palatine process of the maxilla, the suture between the two bones enclosing the greater palatine foramen, the ventral termination of the pterygopalatine canal. The **perpendicular portion** (pars perpendicularis) is the vertical plate extending

backward from the palatine bridge. Its medial surface is divided by a low ridge into a dorsal portion, in particular relation to the nasopharynx, and a ventral portion, in relation to the oral cavity, the ridge indicating the position of the soft palate. Its lateral surface is partly applied to the maxilla and partly exposed to the orbit. Its dorsal margin is articulated with the presphenoid and with the ethmoidal process of the orbitosphenoid, but a small posterior portion is free, so that the anterior portion of the basisphenoid is visible from the orbit. The free ventral margin forms posteriorly a thick projecting angle, the **pyramidal process** (*processus pyramidalis*), the base of which is cleft where it articulates with the medial and lateral laminae of the pterygoid process. Between the pyramidal process and the alveolus of the last cheek-tooth there is a conspicuous **palatine notch** (*incisura palatina*), connecting the orbit with the palatal surface. In the entire skull only the posterior portion of the lateral surface is visible from the orbit, the anterior portion being concealed by the projecting bases of the posterior cheek-teeth. The ridge of bone on which the alveoli of these teeth are borne is separated from the palatine bone by the **infraorbital groove**. The medial wall of the latter, formed by the palatine bone, contains the orbital opening of the pterygopalatine canal and the sphenopalatine foramen.

The Mandible

The **mandible** (*mandibula*) or lower jaw comprises the two **dentary bones** (*ossa dentalia*), which, in the rabbit, as in mammals generally, are united by a fibrous or fibrocartilaginous connection (*symphysis mandibulae*); not coalesced, as in the human skull, to form a continuous structure. As indicated above, each of the dentary bones comprises: (1) a horizontal, tooth-bearing portion which, in conjunction with that of the opposite side, forms the **body** of the mandible (*corpus mandibulae*); and (2) a posterior, vertical plate, the **mandibular ramus** (*ramus mandibulae*), for muscle attachment and articulation. The **horizontal portion** is deep posteriorly, where it lodges the alveoli of the cheek-teeth. Anteriorly, in the diastema separating the latter from the incisors, its dorsal surface is rounded and depressed, the space thus formed corresponding to a similar space in the upper jaw and serving

chiefly for the accommodation of the lips, which in this region encroach medially on the oral cavity. The medial surface of the horizontal portion forms an acute angle with that of the bone of the opposite side, except anteriorly, where it bears a roughened area for articulation with the latter. Running backward from the symphysis there is a broad horizontal ridge, representing the **mylohyoid line** (linea mylohyoidea), the line of attachment of the mylohyoid muscle. The **mandibular foramen**, through which, in the natural condition, the inferior alveolar nerve and artery gain access to the interior of the bone, and through which the inferior alveolar vein emerges, lies on this surface at the junction of the horizontal portion with the ramus. The corresponding **mental foramen** (foramen mentale), through which branches of these structures leave the mandible, is situated on the lateral surface in front of the first premolar. The mandibular foramen is closely connected with a second aperture lying at the ventral end of the sulcus ascendens, directly behind the last molar, and serving for the transmission of an anastomotic vein connecting the inferior alveolar and the deep facial veins (p. 298).

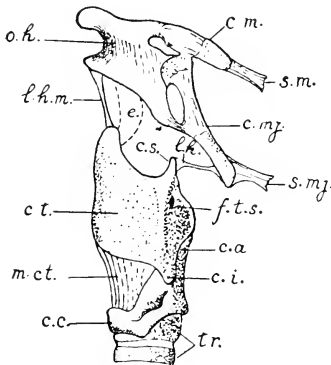


FIG. 91. Lateral surface of the hyoid and larynx: c.a., arytenoid cartilage; c.c., cricoid cartilage; c.i., inferior cornu of hyoid; c.m., lesser cornu of hyoid; c.mj., greater cornu of hyoid; c.s., superior cornu of thyroid cartilage; c.t., left plate of the thyroid cartilage; e., epiglottic cartilage; f.t.s., thyrohyoid foramen; l.h., lateral thyrohyoid ligament; l.h.m., median thyrohyoid ligament; m.ct., cricothyroid muscle; o.h., hyoid bone; s.m., stylohyoid minor muscle; s.mj., stylohyoid major muscle; tr., cartilaginous tracheal rings.

The **mandibular ramus** forms, in general, an obtuse angle with the horizontal portion. As in other herbivores, the ventral part, distinguished as the **angle**, is greatly increased in size at the expense of the condyloid process and to a still greater extent of the coronoid process, the latter being vestigial. In addition to a low **pterygoid tuberosity** (tuberositas pterygoidea), situated at the posterior projecting point of the angle, the posterior and ventral margins of the angle are excavated on the medial side of the bone, so that they form the boundary of a pronounced, though shallow, **inferior pterygoid depres-**

sion for the insertion of the pterygoideus internus muscle. The area occupied by the pterygoideus internus is separated by a low ridge from a more dorsally placed superior depression for the pterygoideus externus muscle. A somewhat similar depression, termed the **masseteric fossa**, occupies the lateral surface of the angle, its raised ventral margin terminating posteriorly in the **masseteric tuberosity** (tuberositas masseterica). The articular portion or **head** of the mandible is greatly elongated in the anteroposterior direction in accordance with the anteroposterior action of the lower jaw, this feature being one which is of general occurrence in the rodent order, and more fully expressed in the great extension forward and backward of the attachment areas of the muscles of mastication. The connection of the articulating portion with the **condyloid process**, the so-called **neck** of the mandible (collum mandibulae), is a thin plate of bone, the anterior and posterior margins of which are barely notched by the **anterior** and **posterior mandibular incisures**. Connecting the anterior incisure with the rim of the alveolus of the last cheek-tooth there is a deep groove, the **sulcus ascendens**, the lateral margin of which is formed by the reduced **coronoid process** (processus coronoideus). Its low medial margin is formed by a bony stay which extends to the medial surface of the horizontal portion opposite the last cheek-tooth and is continued forward into the mylohyoid line. The sulcus ascendens lodges in the natural condition the insertion portion of the greatly reduced temporalis muscle.

THE HYOID APPARATUS

The **hyoid bone** (os hyoideum) (Fig. 91) is a stout, somewhat wedge-shaped bone lying in front of the larynx and between the angles of the mandible. Its ventral portion is connected with the thyreoid cartilage of the larynx by the **median hyothyreoid ligament**. With its lateral portion are articulated two independent elements, termed the lesser and greater cornua. The **lesser cornu** (cornu minus) is a small, partly cartilaginous structure, attached to the anterodorsal angle of the hyoid, and connected through the stylohyoideus minor muscle with the jugular process of the skull. The muscle tendon contains, near the jugular process a small ossification representing a detached styloid process. The

greater cornu (*cornu majus*) is a larger element extending obliquely dorsad, and similarly suspended from the jugular process by the *stylohyoideus major* muscle. The connection of the lesser cornu with the styloid process through the *stylohyoideus minor* replaces the stylohyoid ligament of the human skull and the chain of elements commonly occurring in mammals and other vertebrates in this region. In most mammals the term "lesser", as applied to it, is inappropriate. The lesser cornu, the styloid process, and their connections, together with the hyoid bone itself, indicate the relation of the embryonic hyoid arch, from which the skeletal structures in question are derived. The greater cornu belongs to the succeeding visceral arch, and is connected with the superior cornu of the thyreoid cartilage of the larynx by the **lateral hyothyreoid ligament**. This cornu is commonly represented in mammals by a small thyreohyal process.

THE SKELETON OF THE ANTERIOR LIMB

The skeleton of the anterior limb is divisible into two portions, namely, a proximal portion, comprising the **scapula** and the **clavicle**, and a distal portion, comprising the supports of the **free extremity**. The scapulae and clavicles of the two sides together form the **pectoral girdle**. The pectoral girdle is lightly constructed and, apart from its muscular connections, which constitute its main support, is directly attached to the axial skeleton only through the sternoclavicular ligament. This arrangement may be regarded as providing a shock-absorbing mechanism.

The skeleton of the free extremity is divisible into proximal, middle, and distal segments. The proximal segment contains a single bone, the **humerus**; the middle segment two elements, the **radius** and **ulna**; while the distal segment comprises, in addition to the accessory **sesamoid bones**, twenty-eight elements of the regular series, of which nine form the **carpus**, five the **metacarpus**, and fourteen the **phalanges** of the digits.

The positions occupied by the principal parts in the natural state are shown in Fig. 23.

The Scapula

The **scapula** (Fig. 92) is a somewhat triangular plate of bone lying, in the natural position, on the lateral surface of the anterior

part of the thorax, with its apex directed downward and forward. In the rabbit, as in quadruped mammals generally, the main surfaces are respectively medial and lateral, and differ in this respect from the human condition, in which, from the transverse widening of the thorax, the corresponding surfaces are more nearly ventral and dorsal. Of its three borders, one, the **superior border** (margo superior), is directed toward the occiput; another, the **vertebral border** (margo vertebralis), toward the vertebral column; and the third or **axillary border** (margo axillaris), toward the armpit. The corresponding **angles** are called **medial** (superior—between the superior and vertebral borders), **inferior**, and **lateral**

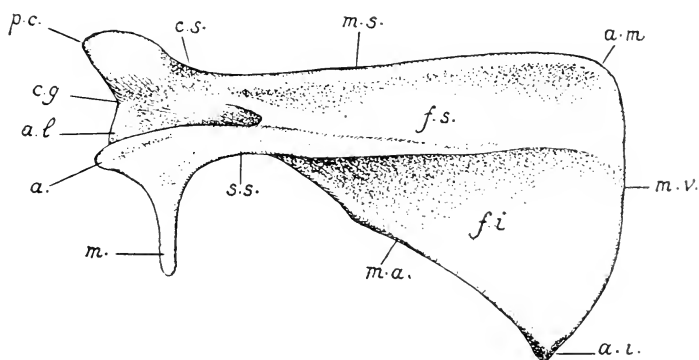


FIG. 92. Lateral surface of the left scapula; a., acromion; a.i., a.l., and a.m., inferior, lateral, and medial angles; c.g., glenoid cavity; c.s., neck of the scapula; f.s. and f.i., supraspinous and infraspinous fossae; m., metacromion; m.a., m.s., and m.v., axillary, superior, and vertebral borders; p.c., coracoid process; s.s., scapular spine.

(glenoid—between the superior and axillary borders). The lateral surface bears a stout bony plate, the **scapular spine** (spina scapulae), which arises from the body of the bone through about two-thirds of its extent, and ends ventrally in a free projection, the **acromion**. The posterior margin of the acromion bears a backwardly-directed process, the **metacromion** (processus hamatus). Through the presence of the scapular spine, the lateral surface of the bone is divided into two areas for muscular attachment. One of these, the **supraspinous fossa** (fossa supraspinata), lies in front of the spine, the other, the **infraspinous fossa** (fossa infraspinata), behind it. The infraspinous fossa is the more extensive one. The medial surface, on the other hand, presents a single large shallow depress-

ion, the **subscapular fossa** (fossa subscapularis), which is triangular in shape and occupies practically the entire surface. The apex or lateral angle of the scapula, sometimes termed the **head** of the bone, is expanded to a considerable extent in comparison with the slender portion—the so-called **neck** of the scapula (collum scapulae)—connecting it with the body of the bone. It bears a concave depression, the **glenoid cavity** (cavitas glenoidalis), for articulation with the humerus. The articulating surface is borne chiefly on that part of the bone corresponding to the axillary border, but it also extends in an anterior direction to the base of an overhanging projection, the **coracoid process** (processus coracoideus). The free portion of the latter forms a blunt, hook-like projection mediad. It represents the separate coracoid bone of lower terrestrial vertebrates (p. 61).

In the fresh condition, the vertebral border of the scapula bears a plate of cartilage, the **suprascapula**, which is about three-quarters of a centimetre wide near the inferior angle and tapers to a point towards the medial angle.

The Clavicle

The **clavicle** (clavicula) is imperfectly developed in the rabbit, consisting of a slender, curved rod of bone, tipped by cartilage, which lies in the interspace between the manubrium sterni and the head of the humerus. It occupies only a portion of this interspace, being attached medially by the **sternoclavicular ligament** and laterally by an **acromioclavicular** and a very slender **coracoclavicular ligament**, all three of which are considerably elongated. The sternoclavicular ligament is nearly two millimetres in diameter and fully twenty millimetres long, the acromioclavicular about two millimetres by thirty-five millimetres, and the coracoclavicular about twenty-five millimetres long. According to recent studies, the so-called cleidohumeral ligament to which certain muscles are attached (pp. 258 and 264) is merely a persistently fibrous intersection between tendons attached to the clavicle before reduction of the latter occurred but is not a vestige of the clavicle or its true ligaments.

The Humerus

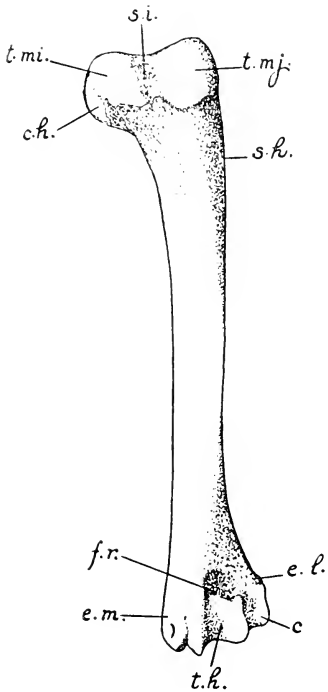


FIG. 93. Anterior surface of the left humerus: c., capitulum; c.h., head of humerus; e.l. and e.m., lateral and medial epicondyles; f.r., radial fossa; s.h., deltoid tuberosity; s.i., intertubercular groove; t.h., trochlea humeri; t.mi. and t.mj., lesser and greater tubercles.

lateral elevation, the **lateral tuberosity** or **greater tubercle** (tuberculum majus). Extending distad from the latter is a triangular area, the **deltoid tuberosity** (tuberositas deltoidea), the tip of which reaches almost to the middle of the bone and forms a pronounced angle on its anterior surface. These tuberosities are for muscle attachment, mainly for the insertion of muscles moving the shoulder-joint.

The distal extremity of the humerus bears a grooved articular surface, the **trochlea humeri**, for articulation with the radius and ulna. On its lateral side is a smaller surface, the **capitulum**

The **humerus** (Fig. 93) is typical of the long bones of the proximal and middle segments of the fore and hind limbs in consisting of a central portion, the **body** or **shaft** of the bone, and of **proximal** and **distal extremities** for muscle attachment and articulation. The proximal extremity bears on its medial side a smooth, convex projection, the **head** of the humerus (caput humeri), for articulation with the scapula. The articulation is nominally a ball-and-socket joint, or **enarthrosis**, but the articulating surfaces are somewhat restricted, and the muscular arrangements of the limb are such that the range of lateral motion (abduction and adduction) is small. Immediately in front of the head of the bone there is a small elevation, the **medial tuberosity** or **lesser tubercle** (tuberculum minus). It is separated by a longitudinal furrow of the anterior surface, the **intertubercular groove** (sulcus intertubularis), from a much larger

humeri, for articulation with the radius alone. Immediately above the trochlea the medial and lateral portions of the bone are thickened to form two areas for muscular attachment. One of these, the **lateral epicondyle** (epicondylus lateralis), is a general point of origin for the extensor muscles of the dorsal surface of the hand, while the other, the **medial epicondyle** (epicondylus medialis), is a similar point of origin for the flexor muscles of the ventral or volar surface. Between the epicondyles the extremity of the bone is greatly excavated, so that the projecting portions of the radius in front and of the ulna behind are received into depressions of the surface when the forearm is respectively flexed or extended. On the anterior side is the **radial fossa** (fossa radialis); on the posterior side the **olecranon fossa** (fossa olecrani), so-called because it accommodates the olecranon process of the ulna.

Between the radial and olecranon fossae the bone is reduced to a very thin lamina, which is sometimes pierced by an opening of very variable size, the **supratrochlear foramen**.¹

The Radius and Ulna

The **radius** (Fig. 94) is the shorter of the two bones of the forearm, since its proximal extremity does not extend backward beyond the front of the elbow-joint. It is anterodorsal in its general position, but crosses the ulna in such a way that its proximal extremity tends to be lateral, while its distal extremity is medial. The proximal extremity, termed the **head** of the radius (capitulum radii) is immovably articulated with the ulna. It bears an extensive articular surface, meeting both trochlea and capitulum of the humerus, and thus forming a considerable portion of the elbow-joint. The body of the bone is solidly united with the ulna by the **interosseous ligament** of the forearm. The distal extremity is largely formed by an epiphysis, which is well marked even in older animals. It bears a grooved, **carpal articular surface** (facies articularis carpea), for articulation with the navicular and lunate bones.

The **ulna** (Fig. 94) is a somewhat S-shaped bone, the shaft of which is vertically flattened, so that it possesses two main surfaces,

¹In an examination of 255 specimens, this was found in 173, or 68 per cent.

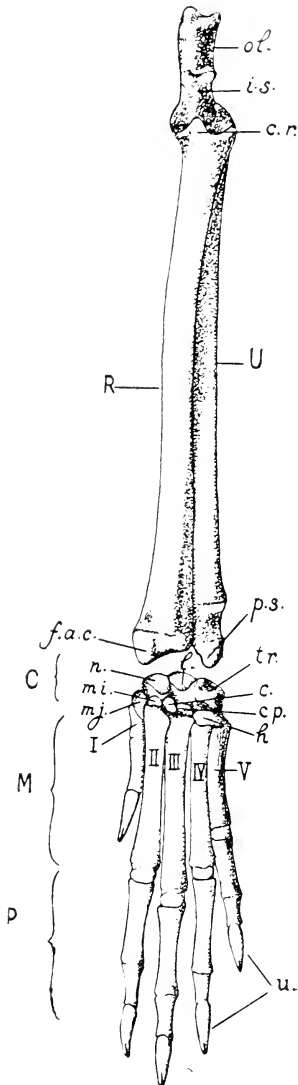


FIG. 94. Skeleton of the forearm and hand from the dorsal surface; R, radius; U, ulna; C, carpus; M, metacarpus; P, phalanges; I-V, metacarpal bones. c., central bone; cp., capitate; c.r., head of radius; f.a.c., carpal articular surface of radius; h., hamate bone; i.s., semilunar notch of the ulna; l., lunate bone; mi., lesser multangular; mj., greater multangular; n., navicular; ol., olecranon; p.s., styloid process of the ulna; tr., triquetrum; u., ungual phalanges.

respectively anterodorsal and posteroventral. The former, in conjunction with the related surface of the radius, continues the area of origin of the extensor muscles of the hand from the lateral epicondyle of the humerus distad on to the forearm, while the latter has a similar function with respect to the flexor muscles. The proximal portion of the bone is laterally compressed. It bears a crescentic depression, the **semilunar notch** (*incisura semilunaris*), the articulating surface of which continues that of the medial portion of the head of the radius, and is received into the trochlea humeri. Behind the elbow-joint, the bone forms the large projecting portion of the elbow, the **olecranon**, which is a strong process for the insertion of the extensor muscles (*anconaei*) acting on the forearm and provides leverage for their action. The distal extremity of the bone is formed by an epiphysis, similar to, but much longer than, that of the radius. It is immovably articulated with the radius and its tip is formed by a blunt **styloid process** (*processus styloideus*), which is articulated with the triquetral bone of the carpus.

The elbow-joint is formed by the trochlea and capitulum of the humerus in conjunction with the semilunar notch of the ulna and the corresponding articular surface of the head of the radius. It is a hinge-joint, or **ginglymus**, permitting motion in one plane, *i.e.*, extension and flexion of the forearm. The trochlear surface of the humerus, however, has a slight spiral trend, the anterior portion being medial in comparison with the posterior portion.

Through the immovable articulation provided by the respective proximal and distal ends of the bones, and also through the interosseous ligament, the radius and ulna are prevented from changing their positions with respect to each other; in other words, the radius is unable to rotate on an axis formed by the ulna as it does in man, the forefoot being fixed in a position comparable to that of pronation in the human hand (cf. p. 70).

The Carpus

The **carpus** (Fig. 94) comprises nine small elements, the wrist or **carpal bones** (*ossa carpi*), which are interposed between the forearm and the digits. They are arranged in two main rows, namely, a **proximal row**, the elements of which are articulated

with the radius and ulna; and a **distal row**, the elements of which are articulated with the five bones of the metacarpus. Enumerated from the medial side of the wrist laterad, the proximal row contains four elements, namely, the **navicular, lunate, triquetral, and pisiform bones**. The navicular and lunate are the radiale and intermedium of the primary terrestrial limb skeleton (p. 63) and are articulated with the distal extremity of the radius. The triquetral is the ulnare of the basic pattern and is articulated with the styloid process of the ulna. The pisiform bone lies on the ventral surface of the extremity of the ulna, and is therefore not exposed to the dorsal surface of the wrist. It is really a sesamoid bone (p. 206) added to the primary three proximal carpals. The distal row contains five elements, namely, the **greater multangular, lesser multangular, central, capitate, and hamate bones**. The first, second, and fourth are in association respectively with the first, second, and third metacarpals. The central bone lies to the lateral side of the articulation at the base of the second metacarpal. As its name implies, it is originally an element interposed between the proximal and distal rows. The hamate is a comparatively large element associated with the fourth and fifth metacarpals, but extending also to the articulation of the third, where it tends to replace the greatly reduced capitate. It represents the two lateral members of the original distal row of carpals (Fig. 36) fused together.

The Metacarpus and Phalanges

The **metacarpus** (Fig. 94) comprises five stout elements, the **metacarpal bones** (*ossa metacarpalia*), which form the basal supports of the digits. Each consists, in addition to a main portion or **body**, of a flattened proximal end, or **base**, and a rounded distal extremity, or **head**. The four lateral bones are normally developed, while the first, which belongs to a reduced digit, is of very small size.

The **phalanges**, or bones of the digits, are distributed according to the formula 2, 3, 3, 3, 3. They are similar in form to the **metacarpals**, with the exception, however, of the terminal, **ungual** phalanges, which are laterally compressed, pointed, and cleft at their tips for the attachment of the claws.

Sesamoid Bones

Accessory elements, **sesamoid bones** (*ossa sesamoidea*), developed in the ligaments or tendons of muscles, are found on the volar surface of the foot in association with certain of the joints. They occur in transverse pairs at the metacarpophalangeal articulations and in linear pairs at the articulations of the second with the third phalanges. The pisiform bone of the carpus is also a sesamoid, being formed in the insertion tendon of the flexor carpi ulnaris muscle.

THE SKELETON OF THE POSTERIOR LIMB

In the posterior limb, the proximal or girdle portion comprises the paired **coxal bones**, which are united ventrally at the pelvic symphysis, thus forming the **pelvic girdle**. Along with the sacrum, which is interposed between them dorsally, they constitute the **pelvis**. This rigid framework, involving part of the vertebral column, provides a strong basis for the powerful thrust of the hind limbs in locomotion and contrasts with the elastic attachment of the fore limbs to the trunk. The distal portion of the posterior limb, like that of the anterior, comprises the supports of the **free extremity** and is divisible into proximal, middle, and distal segments. The proximal segment contains a single element, the **femur**; the middle segment two elements, the **tibia** and **fibula**, which, however, are extensively coalesced; and the distal segment twenty-three elements, of which six form the **tarsus**, five the **metatarsus**, and twelve the **phalanges**.

The Coxal Bone

The **coxal bone** (*os coxae*) (Fig. 95) is a somewhat triradiate structure with one anterior ray and two posterior ones, the latter united so that they enclose a large aperture the **obturator foramen** (*foramen obturatum*). The bone is firmly articulated with the sacrum dorsally and is united ventrally with its fellow of the opposite side by a thin strip of cartilage containing a small amount of fibrous material. The latter connection is the **pubic symphysis** (*symphysis pubis*), better termed in the rabbit the **pelvic symphysis**, since it is somewhat more extensive than the correspond-

ing articulation of the human pelvis and involves the ischium as well as the pubis.

In the young animal each half of the pelvis consists of three elements, namely, the **ilium**, **ischium**, and **pubis**. They form the

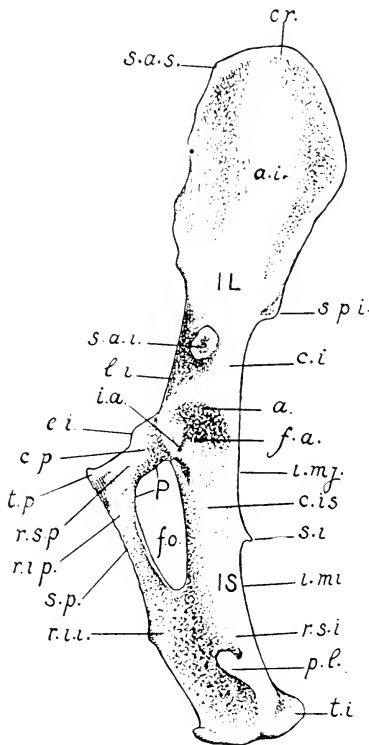


FIG. 95. Lateral surface of the left coxal bone: IL, ilium; IC, ischium; P, pubis. a., acetabulum; a.i., iliac wing; c.i., body of ilium; c.is, body of ischium; c.p., body of pubis; cr., iliac crest; e.i., iliopectineal eminence; f.a., acetabular fossa; f.o., obturator foramen; i.a., acetabular notch; i.mi., lesser sciatic notch; i.mj., greater sciatic notch; l.i., iliopectineal line; p.l., lateral process of ischial tuberosity; r.i.i., inferior ramus of ischium; r.i.p., inferior ramus of pubis; r.s.i., superior ramus of ischium; r.s.p., superior ramus of pubis; s.a.i., inferior anterior spine of the ilium; s.a.s., superior anterior spine; s.i., ischial spine; s.p., symphysis pubis; s.p.i., inferior posterior spine; t.i., ischial tuberosity; t.p., pubic tubercle.

three rays of the coxal bone and are united with one another in the region of the **acetabulum**, which is the basin-like depression for the articulation of the pelvis with the femur. Only two of the original elements, however, actually take part in the formation

of the acetabulum, the pubis being excluded through the development in the acetabular depression of a small triangular element, the **os acetabuli**. Although completely coalesced in the adult condition, and showing but few traces of their original separation, the three chief elements are nevertheless described as if distinct.

The **ilium** (os ilium) is the anterior, also somewhat dorsal, portion of the bone; that part extending forward from the acetabulum. It comprises a basal portion, the **body** (corpus oss. ilium), which includes the anterior portion of the acetabulum and the cylindrical part of the bone in front of it, and an expanded portion, the **iliac wing** (ala oss. ilium), for muscle attachment and articulation with the sacrum. The body is somewhat triangular in transverse section, its surface being divided into three areas, which are respectively medial, or **sacral**, ventrolateral, or **iliac**, and dorsolateral, or **gluteal**. The corresponding borders are respectively ventral, or **pubic**, lateral, or **acetabular**, and dorsal, or **ischial**. The acetabular border terminates a short distance in front of the acetabulum in an abruptly truncated projection, the **inferior anterior spine** (spina anterior inferior), which is the origin of an extensor muscle of the leg (second portion of the rectus femoris). The ischial border forms the anterior half of a long depression of the dorsal surface of the coxal bone, the **greater sciatic notch** (incisura ischiadica major) over which pass the sciatic nerve and artery as well as the piriformis muscle. The pubic border presents on its medial side a faint, ridge-like elevation, the **iliopectineal line** (linea iliopectinea), which connects the sharp anterior border of the pubis with the articular surface for the sacrum.

The wing of the ilium forms a shovel-like expansion, the natural position of which is almost sagittal. Its lateral surface provides a fairly extensive area for the origin of the gluteal muscles. Its medial surface is a muscle surface only in its anterior portion, the posterior portion being occupied by the roughened **auricular surface** (facies auricularis), for connection with the sacrum. The dorsal margin is thin and straight. Posteriorly, where it is associated with the greater sciatic notch, there is a small projection, the **inferior posterior spine** (spina posterior inferior), also termed the tuber sacrale. Anteriorly it passes by a broad angle into the anterodorsal margin of the bone, the latter forming the projecting

end of the wing, which is distinguished as the **iliac crest** (*crista iliaca*). This portion is considerably thicker than the related dorsal and ventral margins, and also bears on its medial side a somewhat hook-shaped process. Its anteroventral angle is the **superior anterior spine** (*spina anterior superior*) or *tuber coxae*. The ventral margin is slightly longer than the dorsal margin, and is also concave. It is associated with the pubic border of the body of the ilium, and is not connected with the inferior anterior spine. The anterior elongation of the ilium is an adaptation to the powerful anterior thrust of the hind limb in progression.

The **ischium** (*os ischii*) extends backward from the acetabulum, its axis continuing that of the ilium. It consists of a basal portion, or **body** (*corpus oss. ischii*), a **superior ramus**, and an **inferior ramus**. The body of the ischium is for the most part cylindrical. It forms the posterior part of the acetabulum and presents in connection with the latter a deep **acetabular notch** (*incisura acetabuli*), which tends to interrupt the articular surface. The acetabular notch leads forward into a depression of the centre of the articular basin, the **acetabular fossa** (*fossa acetabuli*). In the natural condition the combined depressions serve for the attachment of the round ligament of the head of the femur. The dorsal margin of the bone, belonging in part to the body and in part to the superior ramus, bears a short hook-like projection, the **ischial spine** (*spina ischiadica*), a point of muscle origin (p. 275). The spine divides this margin into two parts, one of which forms the posterior half of the greater sciatic notch, already described, while the other forms a similar, and, in the rabbit, scarcely less extensive, posterior depression, the **lesser sciatic notch** (*incisura ischiadica minor*). Through both notches pass muscles which move the femur (p. 275).

The **superior** or **acetabular ramus** of the ischium is the continuation backward of the body of the bone. It is a somewhat flattened plate of bone, the thicker dorsal portion of which terminates in two blunt projections. One of these, the **ischial tuberosity** (*tuber ischiadicum*), forms the posterior end of the bone, while the other extends in a lateral direction and is described as the **lateral process** (*processus lateralis*). The **inferior** or **symphyseal ramus** is that part of the ischium which extends from

the superior ramus downward and forward between the obturator foramen and the symphysis to meet the corresponding ramus of the pubis.

The **pubis** (os pubis) consists of a basal portion or **body** lying immediately below the acetabulum, a **superior** or **acetabular ramus** extending from the body to the symphysis, and an **inferior** or **symphyseal ramus** extending backward along the symphysis to its junction with the ischium. The anterior margin of the bone, described as the **pecten oss. pubis**, is thin and sharp. Near the symphysis it bears a minute elevation, the **pubic tubercle** (tuberculum pubicum), and laterally a more extensive elevation, the **iliopectineal eminence** (eminentia iliopectinea). The latter is more conspicuous in older specimens, where it is easily recognizable by its jagged outline. Its lateral margin is continuous with the iliopectineal line.

The Femur

The **femur** (Fig. 96) is a somewhat S-shaped bone, the body being very slightly curved, with the distal extremity bent downward, forming the articulation of the knee, while the proximal one, with its various processes, turns slightly upward in association with the pelvis. In considering the general form, it will be remembered that in the natural sitting posture of the rabbit, the position of the femur is approximately horizontal, the convex surface of the shaft, which is equivalent to the anterior surface in man, being uppermost.

The proximal extremity of the femur bears an extensive rounded portion or **head** (caput femoris), for articulation with the pelvic girdle. This portion is separated from the main part of the extremity by a constricted area or **neck** (collum femoris), so that, unlike the case of the anterior limb, the points of muscle attachment fall a considerable distance from the point of articulation. The actual extremity of the bone is formed by a large process for muscular attachment, the **great trochanter** (trochanter major). It is divided into two portions, one of which, the **first trochanter** (trochanter primus), forms the large terminal, hook-like projection, while the other, the **third trochanter** (trochanter tertius), is the smaller lateral crest. On the medial side of the bone, im-

mediately distal to the head, there is a triangular elevation, the **lesser** or **second trochanter** (trochanter minor s. secundus). Posteriorly, these projections form a smooth surface for muscle attachment, except, however, at the base of the trochanter major, where

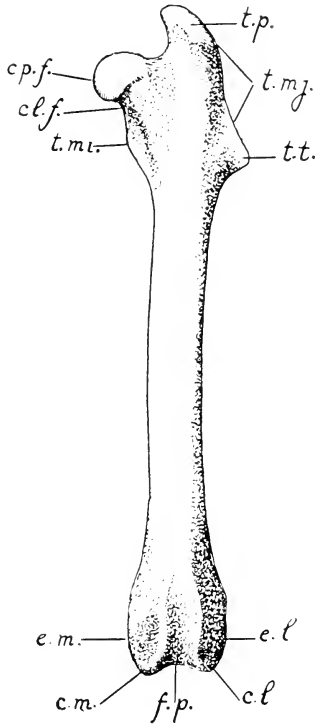


FIG. 96. Anterior surface of the left femur: c.l. and c.m., lateral and medial condyles; cl.f., neck of femur; cp.f., articular portion (head); e.l. and e.m., lateral and medial epicondyles; f.p., patellar surface; t.mi., trochanter minor; t.mj., trochanter major, including t.p. and t.t., the first and third trochanters.

the surface of the bone presents a deep, though narrow, depression, the **trochanteric fossa** (fossa trochanterica).

The distal extremity bears an extensive surface for articulation with the tibia. It is divided into two portions, known as the **medial** and **lateral condyles**, through the presence of a deep excavation, the **intercondyloid fossa** (fossa intercondyloidea). Imme-

diately above the condyles, on the anterior surface of the bone, the intercondyloid fossa is replaced by a broad groove, the **patellar surface** (facies patellaris), which, in the natural condition, accommodates the convex internal surface of the patella. The medial and lateral portions of the bone, intervening between the distal portion of the patellar surface and the tips of the condyles, provide slightly elevated, roughened surfaces, the **medial** and **lateral epicondyles**, for muscular attachment.

The Tibia and Fibula

The **tibia** (Fig. 97) is the larger of the two bones of the leg, lying on the medial side of the fibula, and fused with the latter, in the rabbit, for more than one-half of its length. Its proximal extremity is triangular in section, the main surfaces being respectively anterolateral, anteromedial, and posterior. The anterior border is formed by a stout, ridge-like elevation, the **tuberosity** of the tibia (tuberositas tibiae), which in the natural condition serves for the insertion of the quadriceps femoris, the extensor tendon by which this group of muscles is inserted being carried over the knee by the patella and the patellar ligament. The articular portion is slightly differentiated into **medial** and **lateral condyles** corresponding to those of the distal end of the femur. On the articular surface, the concave areas for the reception of the condyles of the femur are separated from one another by a small intervening, partly divided hillock, the **intercondyloid eminence** (eminentia intercondyloidea), and also posteriorly by a depression of the articular border, the **posterior intercondyloid fossa**. A corresponding

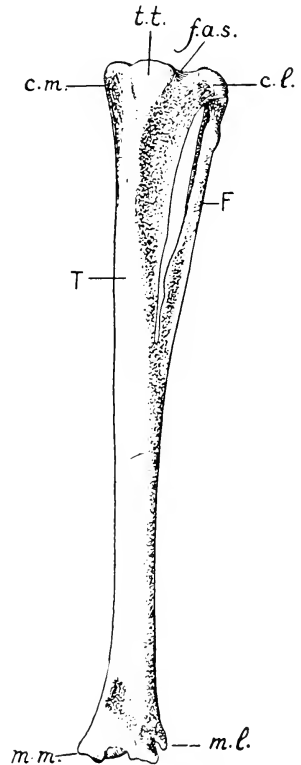


FIG. 97. Anterior surface of the left tibia (T) and fibula (F): c.l. and c.m., lateral and medial condyles; f.a.s., proximal articular surface for the femur; m.l. and m.m., lateral and medial malleoli; t.t., tuberosity of tibia.

A corresponding

anterior intercondyloid fossa lies in front of the intercondyloid eminence, but is poorly differentiated.

The **fibula** (Fig. 97) is the smaller, lateral bone of the leg, and in the rabbit is so extensively fused with the tibia that scarcely more than a third of it is distinguishable. The free portion forms a flattened bony splint, the medial margin of which is firmly united with the tibia by the **interosseous ligament** of the leg. Its proximal extremity is connected with the lateral condyle of the tibia by an elongated epiphysis, the latter, like those of the distal ends of the radius and ulna, being distinguishable even in older animals.

The combined distal extremities of the tibia and fibula bear a roughly rectangular articular surface for the tarsus. The tibial portion of this surface presents two grooves, separated by a ridge, for articulation with the trochlea tali. On its medial side is a small projection, the **medial malleolus** (malleolus medialis) round which, in the intact animal, passes the insertion tendon of the extensor hallucis longus muscle.

The fibular portion of the distal extremity projects distad a little further than the tibial portion, forming the **lateral malleolus**, the end of which presents a broad, shallow, transverse depression for the reception of the convex articular surface of the calcaneus, while its medial surface articulates with the lateral side of the trochlea tali. Immediately above it, on the lateral side of the bone, a prominent projection forms the anterior and lateral boundaries of a groove which in the natural condition lodges the insertion tendons of the peroneal muscles.

The Tarsus

The **tarsus** (Fig. 98) comprises six elements, the **tarsal** or **ankle-bones** (ossa tarsi), which, like the corresponding bones of the carpus, are arranged in proximal and distal rows. An exception is to be made, however, for one element, the navicular, which occupies an intermediate position. The proximal row contains two elements, the **talus** and **calcaneus**. The talus is medial and also slightly dorsal in position. It represents the tibial tarsal, or tibiale, fused with the intermedium (Fig. 36, p. 63) of the primary limb skeleton. Its proximal end, described as the **body** (corpus tali), bears an extensive pulley-like surface, the **trochlea tali**, for

articulation with the tibia, and forming with the latter the chief portion of the ankle-joint. Its distal end, termed the **head** of the talus (*caput tali*), provides a convex articular surface for the navicular bone, and is separated from the larger trochlear portion by a slightly constricted intermediate portion or **neck** (*collum tali*). Its ventrolateral border is extensively articulated with the calcaneus. The latter represents the ulnar tarsal, or **ulnare**, of the primary limb skeleton and is a cylindrical element, fully twice as long as the talus, since it is extended backward behind the ankle-joint as the **tuber calcanei**, or bone of the heel. Its dorsal surface bears a prominent elevation for articulation with the fibular side of the tibiofibula. Its medial surface bears a flat, shelf-like process, the **sustentaculum tali**, which forms a ventral support for the talus. The distal extremity of the bone articulates with the cuboid and also with the navicular.

The intermediate element, the **navicular bone** comes between proximal and distal tarsals and is the central bone of the primary pattern. Thus it does not correspond with the navicular bone of the wrist, which is the *radiale* (p. 205). It is a somewhat cubical bone, lying on the medial side of the tarsus between the talus, on the one hand, and the proximal end of the second metatarsal bone and the second and third cuneiform bones, on the other. It represents the central bone of the primitive tarsus (Fig. 36) and its position is more nearly that of a central element than is the case with the bone called by this name in the rabbit's carpus. In this connection it will be remembered that the carpus

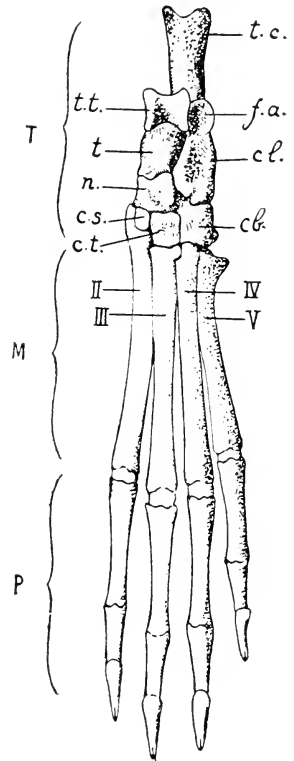


FIG. 98. The bones of the left foot, viewed from the dorsal surface: T, tarsus; M, metatarsus; P, phalanges. II-V, the four metatarsal bones. cb., cuboid; cl., calcaneus; c.s., second cuneiform; c.t., third cuneiform; f.a., articular surface for fibular side of the tibiofibula; n, navicular; t, talus; t.c., tuber calcanei; t.t., trochlea tali.

and tarsus, like other parts of the limb, are primarily constructed on the same plan.

The distal row of the tarsus contains three elements, namely, the **second** and **third cuneiform bones** and the **cuboid bone**. The two former, and especially the first, are smaller than the cuboid and articulate respectively with the second (first developed) and third metatarsals. In the rabbit the **first cuneiform bone**—the first element of the distal row in the usual condition—is fused with the proximal end of the second metatarsal. The cuboid is a larger element formed by fusion of the fourth and fifth distal tarsals and articulating, like the hamate bone of the carpus, with two distal elements, the fourth and fifth metatarsals. Its ventral surface bears a transverse elevation, the **tuberosity** of the cuboid (*tuberositas oss. cuboidei*), in front of which is a groove for the accommodation of the peculiar insertion tendon of the peroneus primus muscle.

The Metatarsus and Phalanges

The **metatarsus** (Fig. 98) comprises five elements, of which four are fully developed and greatly exceed in size the corresponding bones of the **metacarpus**, while one, the first metatarsal, is vestigial. The vestigial element lies on the plantar surface of the foot, for the most part ventral to the navicular and at the base of the second metatarsal. In each developed metatarsal there may be distinguished a main portion or **body**, a proximal extremity or **base**, and a distal extremity or **head**, the last-named portion articulating with the proximal phalanx of the digit. The base of the fifth metatarsal bears a **tuberosity** for the insertion of the peroneus secundus muscle.

The **phalanges** are distributed according to the formula 0, 3, 3, 3, 3, the terminal, **ungual** phalanges being modified like those of the anterior limb.

Sesamoid Bones

The sesamoid bones of the posterior limb occur at the knee-joint and on the plantar surface of the foot. On the anterior surface of the knee is the knee-pan or **patella**, through which, as indicated above, the tendon of the quadriceps femoris muscle is carried over the knee and continued as the **patellar ligament** to

the tuberosity of the tibia. On the posterior surface there are three sesamoid bones, of which one (in the medial head of the gastrocnemius) lies in association with the medial condyle of the femur, while the remaining two are associated respectively with the lateral condyle of the femur (imbedded in the lateral head of the gastrocnemius and the plantaris) and that of the tibia (contained in the popliteus muscle). The sesamoids of the foot are situated at the metatarso-phalangeal joints and at those connecting the second and third phalanges.

PART III

Dissection of the Rabbit

THE plan of dissection as outlined in the following pages presupposes in the first place that the entire dissection is to be made on a single specimen, and, second, that the latter has been prepared for gross dissection by embalming followed by arterial injection (see appendix). These points may be mentioned as explaining many details of procedure and also to a certain extent the selection in preference to others of those structures which are more readily made out by the method employed.

Because of the convenience of dissecting in circumscribed regions, the plan has been divided, although of necessity very unequally, into several parts. The order of these is such that the visceral dissection is introduced at an early stage. The somewhat more logical plan of completing first the dissection of the anterior and posterior limbs may be followed, but on account of the fact that it involves a lengthy muscular dissection to begin with, it is perhaps not to be recommended.

The account aims at a statement of the various structures as met with in order of dissection and the features by which they may be identified, rather than at a full description. The student should make his own observations and prove them by personal drawings and descriptions of selected parts. In this connection he will do well to bear in mind that, while dissection is nominally a means of obtaining anatomical information, its chief value as a laboratory exercise consists in the training to be acquired from critical observation and analysis. It is therefore of quite as much practical importance that he should make his observations extensive and accurate as that he should employ only good instruments or maintain the proper sequence in dissection.

The method of regional dissection, as here developed, lends itself particularly to the observation of inter-relations between the different organ systems and should help the student to keep in mind the essential dependence of each of these upon the others.

At the same time, it requires that a synthesis be made of the observations in various places in order that a conception of each system as a whole as well as of the total organism be obtained.

I. EXTERNAL FEATURES

The external structures, subdivisions of the body, and superficial skeletal points may be made out as follows:

1. The division of the body into **head** (caput), **neck** (collum), **trunk** (truncus), **tail** (cauda), and **anterior** and **posterior limbs** or **extremities** (extremitates).
2. In the head:
 - (a) The division into a posterior, **cranial portion** (cranium), and an anterior, **facial portion** (facies).
 - (b) The **mouth** (os), bounded by the cleft **upper lip** (labium superius) and the undivided **lower lip** (labium inferius). The external opening of the mouth is relatively narrow, having been reduced during development by the growth forward of tissue from each side to form the **cheek**.
 - (c) The large sensory hairs or **vibrissae**.
 - (d) The **nose** (nasus) and its ovoid external apertures, the **nostrils** (nares anteriores), which connect with the upper end of the groove dividing the upper lip into right and left halves and have the skin at their inner margins slightly folded.
 - (e) The **eye** (oculus) and its coverings, the eyelids, including the **upper eyelid** (palpebra superior), the **lower eyelid** (palpebra inferior), and the **third eyelid** or nictitating membrane (palpebra tertia). The third eyelid occupies the anterior angle of the eye, and is comparable to the conjunctival fold of the human eye. It is stiffened by a thin plate of flexible cartilage covered with a layer of glandular tissue and moulded to the exact curvature of the surface of the eyeball.

The eyes of the rabbit look more nearly straight laterally than do those of most mammals, the angle between the visual axes of the two eyes after death having been found to be over 141°. The fields of vision

of the two eyes at rest overlap in front only about 27° or less. On the other hand, they also overlap behind. The rabbit is one of the few mammals in which vision is not solely binocular.

- (f) The **external ear** (auricula) and its canal, the **external acoustic meatus** (meatus acusticus externus), leading to the tympanic membrane.
- (g) Points on the head skeleton, to be identified by feeling through the skin; zygomatic arch, supraorbital process, external occipital protuberance, angle of the mandible, symphysis of the mandible, and the hyoid bone.

3. In the trunk:

- (a) The division into **thorax**, **abdomen**, and **back** or **dorsum**.
- (b) The inclusion with the trunk of the proximal portions of the limbs. The angle formed by the anterior limb with the trunk represents in part the **axillary fossa** (fossa axillaris). The depression is much less evident than in man on account of the different positions of its enclosing folds formed by the pectorales and latissimus dorsi muscles. A corresponding **inguinal furrow** separates the posterior limb from the abdomen and pelvis.
- (c) The **anal aperture** (anus), and on either side of it the **inguinal spaces**, deep hairless depressions in which the ducts of the inguinal glands open.
- (d) In the male: the **urinogenital aperture** at the extremity of the **penis**; the latter enclosed by a fold of integument, the **prepuce** (praeputium); the **scrotal sacs** (scrotum), lateral sacs of the integument lodging the testes.
- (e) In the female: the urinogenital aperture, enclosed by folds of the integument, forming the **vulva**. The **clitoris**, the homologue of the penis, is a small, rod-like structure contained in its ventral wall. The **mammary nipples** (papillae mammarum), eight (to ten) in number, on the ventral surface of the breast and abdomen.
- (f) The following skeletal points: on the axial skeleton, the manubrium sterni, xiphoid process, costal arch, spinous processes of thoracic and lumbar vertebrae; on the pectoral girdle, the acromion, clavicle, and respective borders and

angles of the scapula; on the pelvic girdle, the iliac crest, pubic symphysis, and ischial tuberosity.

4. In the anterior limb:

- (a) The division of the free portion into three segments, the **arm** (brachium), **forearm** (antibrachium), and **hand** (manus).
- (b) The position of the **elbow** (cubitus) in comparison with the knee (cf. p. 70).
- (c) The five digits, designated from the medial side as: **first** (d. primus), or **pollex**; **second** (d. secundus), or **index**; **third**, or **middle** (d. tertius s. medius); **fourth** (d. quartus); and **fifth** (d. quintus s. minimus).

5. In the posterior limb:

- (a) The division into three segments, the **thigh** (femur), **leg** (crus), and **foot** (pes).
- (b) The **knee** (genu), and the **popliteal fossa** of its posterior surface, the latter not well defined. The projection of the heel (calx), and the angle formed by the foot with the leg.
- (c) The **four** digits (dd. secundus—quintus). The vestigial first digit, or **hallux**, is not distinguishable externally.

II. THE ABDOMINAL WALL

1. Place the animal on its back. Make a median incision of the skin of the ventral surface extending from the pubic symphysis to the manubrium sterni, being careful not to cut through more than the skin itself. Make two transverse incisions through the skin on the left side, the first passing just behind the arm, the second just in front of the thigh, both extending round to the dorsal surface. Work the flaps loose from the surface, using the handle of the scalpel, until the side of the trunk is well exposed, but leave them attached to the body. On the right side of the body it is sufficient to clear the middle line. Identify the structures as follows:

On the inner surface of the skin:

- (a) The thick compact connective tissue forming the **corium**.

- (b) the **hair-follicles** imbedded in it, appearing as dots.
- (c) The loose **subcutaneous tissue** (*tela subcutanea*) by which the skin is attached. In some animals, large amounts of fat are at times deposited in this layer. Some fat may be present in the rabbit but the quantity is not usually great.
- (d) In the female: the **mammary glands** (*mammæ*), forming a layer on the inner surface, and more or less closely aggregated about the mammary nipples.

On the exposed surface:

- (e) The **linea alba**, a white tendinous line extending from the pubic symphysis to the xiphoid process of the sternum.
- (f) The **cutaneus maximus muscle**, a thin sheet of muscle fibres covering the entire lateral surface of the thorax and abdomen. Origin: the linea alba, the ventral surface of the sternum in its posterior portion, and the deltoid tuberosity. The portion originating on the last-named appears on the medial surface of the humerus. Insertion: the skin of the trunk, mainly dorsolaterally but some fibres reaching the mid-dorsal line so that the muscles of the two sides are continuous across the back. The fibres are directed upward (in the natural position of the animal) and backward. The muscle is extended backward to the dorsum of the tail. It is used in shaking the skin.

The artery passing forward for a short distance in the inguinal region and lying in the subcutaneous tissue is the **superficial epigastric**, a branch of the femoral (p. 279). Passing into the ventral portion of the cutaneus maximus muscle, it anastomoses forward with the **external thoracic artery**, a branch of the lateral thoracic. The corresponding veins are usually conspicuous in the female, since the vessels supply the mammary glands. A second anastomosis in the cutaneus muscle is formed laterally by a branch of the subscapular artery which passes backward from the axillary border of the scapula, uniting with an anterior branch of the iliolumbar artery.

The **inguinal lymph nodes** (*lymphoglandulae inguinales*) are small, oval, brownish bodies lying in the inguinal furrow.

2. Separate the cutaneus maximus from the surface of the muscle

beneath. Identify the following points of attachment of the abdominal muscles proper:

- (a) The linea alba.
 - (b) The xiphoid process of the sternum, the ribs, and the costal arch.
 - (c) The **lumbodorsal fascia** (fascia lumbodorsalis), a broad, white sheet of connective tissue extending over the back in the posterior thoracic and lumbar regions.
 - (d) The **inguinal ligament** (ligamentum inguinale), a stout white cord, stretched between the symphysis pubis and the iliac crest.
3. Identify on the surface the **external oblique muscle** (m. obliquus externus abdominis). Origin: the xiphoid process, the posterior ten ribs by separate slips, and the lumbodorsal fascia. Insertion: the linea alba and the inguinal ligament. The fleshy portion, or muscle proper, covers the abdomen lateral to the tendinous portion, or aponeurosis, which appears as a longitudinal, whitish band attaching the muscle to its insertion. The fleshy portion and the aponeurosis meet along a slightly curved line a short distance lateral to the linea alba. The fibres are directed from an anterior dorsal origin downward and backward, the more dorsal ones almost directly backward, and the fibres of the aponeurosis continue the line of the muscular fibres attached to them. Some of the anterior slips of origin interdigitate with those of the thoracic portion of the serratus anterior muscle. Some are concealed by the pectoral muscles.

The muscle crossing the breast from the sternum to the arm is the pectoralis major. That passing forward from the lumbodorsal fascia to the medial surface of the humerus is the latissimus dorsi. The margins of these muscles may be raised where they conceal the external oblique.

4. Taking a line between the iliac crest and the xiphoid process, divide the external oblique muscle, and then separate it fully from the next, which may be distinguished by the markedly different direction of its fibres. Note the separate slips of origin and the difference in appearance between the fleshy portions of the muscle and its ventral tendinous expansion or aponeurosis; then remove it from the surface. This separation cannot

satisfactorily be carried quite to the linea alba as the medial part of the aponeurosis is fused with that of the internal oblique beneath it.

Examine the following muscles, proceeding in a similar manner:

- (a) The **internal oblique muscle** (m. obliquus internus abdominis). Origin: the inguinal ligament, a second sheet of the lumbodorsal fascia, and the posterior four ribs. Insertion: the linea alba. The fibres pass downward and forward. The ventral aponeurosis is much broader than that of the external oblique. Near the mid-ventral line it is split into dorsal and ventral leaves, containing between them the thin rectus abdominis muscle. Along the line of cleavage, which is known as the **linea semilunaris**, there is often a small deposit of fat.
- (b) The **rectus abdominis muscle**. Origin: lateral border of the sternum, including the xiphoid process; also the ventral surfaces of the first to seventh costal cartilages. Insertion: at the anterior end of the pubic symphysis. It is a thin, strap-like muscle, enclosed between two sheets of the aponeurosis of the internal oblique, and separated from its fellow of the opposite side by the linea alba.
- The artery passing forward, for the most part in this muscle, is the **inferior epigastric**, a branch of the external iliac (p. 255). It anastomoses with the **superior epigastric artery**, a continuation of the internal mammary (p. 326). It gives off the **external spermatic artery**, a small vessel which perforates the abdominal wall and extends backward, supplying the sac of the testis in the male and ending in the female in the wall of the vulva.
- (c) The **transverse muscle** (m. transversus abdominis), the deepest muscle of the abdominal wall. Origin: seven posterior ribs, the tips of the transverse processes of the lumbar vertebrae by a thin aponeurosis (also termed the middle layer of the lumbar fascia), and the inguinal ligament. Insertion: the linea alba, by an aponeurosis which fuses with the weakly developed dorsal leaf of the aponeurosis of the internal oblique to form the dorsal wall of the sheath of the rectus abdominis. The fibres are directed downward and slightly backward.

5. Divide the remaining portion of the abdominal wall on the left side, and its whole thickness on the right, by transverse and longitudinal incisions corresponding with those first made through the skin, so that the abdominal viscera are fully exposed. Note on the internal surface of the wall the smooth serous investment here forming the **parietal peritoneum** (peritoneum parietale).

III. THE STOMACH AND SPLEEN

The cavity disclosed by the division of the abdominal wall is the **peritoneal cavity** (cavum peritonei), the largest of the four great serous sacs representing the primary body-cavity or **coelom** (p. 135). The major portion of the cavity is abdominal, i.e. it lies between the diaphragm in front and the margin of the bony pelvic girdle behind, but it extends into the pelvis, the portion of the body enclosed by the skeletal ring of that name, and, in the male, also into the scrotal sacs. Its lining membrane is that appearing on the body-wall as the parietal peritoneum, noted above, and on the visceral structures as the **visceral peritoneum** (peritoneum viscerale). The visceral structures here include the major portions of the digestive and urinogenital systems.

The general relations of the visceral peritoneum should first be examined by raising a portion of the small intestine from the left side of the visceral mass. Note its enclosure by a complete **serous coat** (the visceral peritoneum), similar in appearance to the membrane covering the body-wall, and the extension of this coat into a **mesentery** for the attachment of the structure to the dorsal body-wall. Note the parallel arrangement of the arteries and veins, and also their frequent anastomoses. **Lymphatic vessels** (lacteal vessels) accompany the blood-vessels in the mesentery but, being transparent, are not readily recognizable. **Lymph nodes** also occur, but in this portion of the mesentery they are aggregated near its dorsal attachment or **root** (radix mesenterii).

For the general relations of the stomach see p. 100.

1. Displace the posteroventral portion of the liver forward, exposing in this way the ventral surface of the **stomach**. Without injuring the enclosing peritoneum, move the organ about

sufficiently to display its contour and divisions, as follows:

- (a) The **greater curvature** (*curvatura ventriculi major*), its convex posterior surface.
- (b) The **lesser curvature** (*curvatura ventriculi minor*), the contracted, concave anterior surface.
- (c) The main portion or **body** of the stomach (*corpus ventriculi*). It lies for the most part to the left of the median plane.
- (d) The **cardia** or area of junction with the oesophagus, largely concealed by the lesser omentum (2c, p. 226), a delicate sheet of peritoneum extending from the cardia to the liver. Through the semi-transparent omentum it is possible to see the pale-coloured oesophagus, which lies dorsal to it, approaching the stomach from in front and after careful examination the omentum may be torn to reveal these parts more clearly.
- (e) The **fundus**, a sac-like expansion of the stomach to the left of the cardia.
- (f) The **pyloric limb** (*pars pylorica*) forms the right portion of the organ.
- (g) The **pylorus**, the point of communication of the stomach with the intestine (*duodenum*). It is marked by an annular constriction, preceding which is a greatly thickened muscular portion of the pyloric limb, known as the **pyloric antrum** (*antrum pyloricum*).

2. Raise the posterior portion of the stomach and turn it forward. Note on the dorsal surface of the greater curvature at the left side a flat elongated body, the **spleen** (*lien*). It has sometimes a pale coloration in the embalmed animal, where the large amount of contained blood has been washed out by the preserving fluid, but is dark red in life. On the right side of the artery of the spleen, enclosed in the peritoneum, will be seen a diffuse, brownish, glandular mass, a portion of the pancreas. Trace the course of the peritoneum from the dorsal abdominal wall to the liver, as follows:

- (a) A broad fold of peritoneum, the **mesogastrium**, connects

the dorsal abdominal wall and the diaphragm with the left side and dorsal surface of the greater curvature of the stomach. Its posterior portion is divided into two parts by the spleen. The dorsal part, the **phrenicosplenic** ligament (lig. phrenicolienale) connects the spleen with the dorsal body-wall. The ventral part, the **gastrosplenic** ligament (lig. gastrolienale) connects the spleen with the greater curvature (cf. Fig. 51).

- (b) The peritoneum is projected backward from the greater curvature as a free fold, the **greater omentum** (omentum majus, epiploön) (cf. p. 137), which covers the surface of the intestines to a certain extent. It usually contains fat. It is composed of four layers, of which two, representing the ordinary layers of a mesentery, proceed backward from the surface of the stomach, and at the posterior free edge of the omentum turn forward as the other two in a more dorsal position to unite with the transverse mesocolon, the mesentery supporting the transverse colon (p. 239), a part of the large intestine. Fig. 51 shows how this arrangement develops.
 - (c) The **lesser omentum** (omentum minus) passes from the lesser curvature and the duodenum to the posterior surface of the liver. Its thickened margin on the right side forms the **hepatoduodenal ligament** (lig. hepatoduodenale) which carries three important structures, namely, the common bile duct, the hepatic artery, and the portal vein. Its left portion forms a thin membrane, the **hepatogastric omentum**, connecting the caudate lobe of the liver with the lesser curvature.
3. Working on the left side between the dorsal surface of the stomach and the body-wall, tear away sufficient of the peritoneum to expose the first portion of the abdominal aorta as it emerges from the diaphragm, and runs along the median line of the dorsal body-wall. In doing so, try to avoid damaging the slender greater splanchnic nerve (*g*). Passing in the direction of the stomach is a median ventral branch of the aorta, the **coeliac artery**, the distribution of which may be traced

(section 4 below). The following structures, however, should first be identified, especially the ganglia (*d*, *e*) which are likely to be damaged in disturbing the peritoneum, and may advantageously be examined first.

- (a) The **superior mesenteric artery** (a. mesenterica superior), a second and much larger, median branch of the aorta, given off a little distance behind the coeliac artery and passing in the direction of the intestine.
- (b) The **suprarenal gland** (gl. suprarenalis) of the left side, a pale flattened body about a quarter of an inch or more in length, a short distance medial to the anterior part of the kidney. If the gland is halved, examination of the cut surfaces will show it to be composed of a relatively thick outer **cortex** and a central **medulla**. These two portions, despite their close association, are both developmentally and functionally distinct organs (cf. p. 132).
- (c) The **inferior caval vein** (v. cava inferior), a large thin-walled vessel lying to the right of the aorta. It is not conspicuous if empty.

The following ganglia lie near the root of the mesentery and may be concealed by lymph nodes (p. 237, *d*) or by fat.

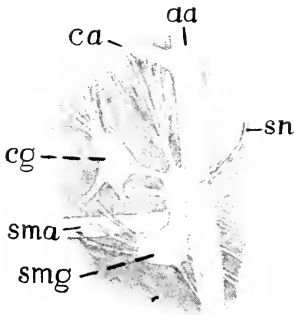


FIG. 99. Coeliac and superior mesenteric ganglia exposed and viewed from the left side. aa, abdominal aorta; ca, coeliac artery; cg, coeliac ganglion; sma, superior mesenteric artery; smg, superior mesenteric ganglion; sn, splanchnic nerve.

- (d) The **coeliac ganglion** (g. coeliacum), an unpaired, usually somewhat triangular ganglion of the sympathetic nervous system lies a short distance in front of the superior mesenteric artery (Fig. 99).
- (e) The **Superior mesenteric ganglion** (g. mesentericum superius) of the sympathetic system, which is also unpaired, is a curved body lying immediately behind the superior mesenteric artery. Its dorsal end projects forward on the left side of

that vessel and sometimes is nearly separated from the rest

of the ganglion. Delicate nerve strands connect the coeliac and superior mesenteric ganglia, which are the largest of those known as collateral (p. 74).

- (f) The delicate nerves proceeding from the coeliac and superior mesenteric ganglia accompany the corresponding arteries to the respective organs which they supply, forming the **coeliac** and **superior mesenteric plexuses**.

Through these plexuses run postganglionic fibres (p. 75) from the coeliac and superior mesenteric ganglia and from the ganglia of the sympathetic trunk, preganglionic fibres destined for the peripheral ganglia, and visceral afferent fibres. In the pancreas it has been shown that the gland-cells are innervated by parasympathetic fibres from cell-bodies in ganglia within the gland and the blood-vessels are controlled entirely by sympathetic fibres with their cell-bodies in the coeliac and superior mesenteric ganglia.

- (g) The (**greater**) **splanchnic nerve** (n. splanchnicus major) of the left side passes backward from its origin in the thorax (see p. 336), around the reduced left crus of the diaphragm, and, crossing the aorta obliquely, enters the coeliac and superior mesenteric ganglia as well as sending branches to the renal plexus. It is composed of preganglionic fibres (p. 75).

The ganglia just described transmit to the viscera nerve impulses received from the spinal cord through the splanchnic nerves but also probably transmit local reflex impulses received directly from the viscera.

Experimental section of the nerves in the living animal results in vaso-dilation, stimulation in vaso-constriction.

The lesser splanchnic nerve is absent as a distinct structure in the rabbit.

- (h) The beginning of the inferior mesenteric artery and the inferior mesenteric ganglion, with the related autonomic nerve plexus, all of which are described on pages 241-2, may be noted at this point.
- (i) An outlying portion of the **pancreas** (cf. p. 236) is seen in the peritoneum after the branches of the splenic artery have been severed (4, a). This is the part already pointed out in the first paragraph of section 2.
4. Trace the plan of branching of the coeliac artery, beginning at the point of origin, and exposing the vessels in order.

The details of this pattern vary considerably in different individuals but the parts supplied by the respective branches are constant.

The **coeliac artery** (a. coeliaca) is a short trunk, its first main branch, the splenic artery, being given off near its origin from the aorta. The remaining portion of the vessel passes to the right in the direction of the lesser curvature, and divides into two parts, the left gastric and hepatic arteries. Small vessels, the **inferior phrenic arteries** (aa. phrenicae inferiores), are given off from the anterior wall of the coeliac and are distributed to the diaphragm. The distribution of the main branches is as follows:

- (a) The **splenic artery** (a. lienalis) passes in the direction of the spleen, giving off small branches (**rr. pancreatici**) to the pancreas and one or more large vessels, the **short gastric arteries** (aa. gastricae breves), to the left portion of the greater curvature. Passing along the concave surface, or **hilus**, of the spleen, it gives off several **splenic branches** (rr. lienales) to that organ, and also several more short gastric arteries, to the greater curvature. Toward the end of the spleen the splenic artery passes into the free fold of the greater omentum as the slender omental artery, and near this point there is given off a large vessel, the **left gastroepiploic artery** (a. gastroepiploica sinistra), which passes to the right on the greater curvature and anastomoses with the right gastroepiploic artery.

The gastrosplenic ligament, together with its vessels, may be divided, the spleen being allowed to fall backward toward the intestine.

- (b) The **left gastric artery** (a. gastrica sinistra) forms a short trunk, or more commonly a group of vessels, the branches of which pass in a somewhat radiate manner toward the lesser curvature of the stomach, reaching in this way both dorsal and ventral surfaces. Two larger vessels appear on the ventral surface respectively to the right and left of the cardia. That on the left distributes small branches (rr. oesophagei) to the oesophagus, while that on the right bears a small pyloric branch which anastomoses across the lesser curvature with the right gastric artery.

The chief nerves of the **coeliac plexus** accompany the branches of the artery to the stomach where they are associated with the terminal ramifications of the vagus (see below). These two represent respectively the mutually antagonistic sympathetic and parasympathetic divisions of the nervous system, the latter exciting the former inhibiting gastric activity.

In dissecting the following arteries, care must be taken to avoid injuring the bile duct and the portal vein.

- (c) The **hepatic artery** (a. hepatica), the continuation of the coeliac, passes forward and to the right, giving off small branches to the pancreas. Its first main branch is the **gastroduodenal artery** (a. gastroduodenalis). The latter is distributed chiefly to the first portion of the intestine as the **superior pancreaticoduodenal artery** (a. pancreaticoduodenalis superior), but a recurrent branch, the **right gastroepiploic artery** (a. gastroepiploica dextra), traverses the greater omentum to the greater curvature where it anastomoses with the left gastroepiploic artery.

After giving off the gastroduodenal artery, the hepatic enters the lesser omentum on its way to the liver. A small branch, the **right gastric artery** (a. gastrica dextra) passes to the pylorus and anastomoses across the lesser curvature with a branch of the left gastric artery.

The veins of the stomach and spleen are tributaries of the **portal vein**. Accompanying the branches of the splenic artery are the tributaries of the **splenic vein** (v. lienalis), including the **left gastroepiploic vein**. Accompanying the branches of the left gastric artery are the tributaries of the **coronary vein** (v. coronaria ventriculi). The splenic and coronary veins enter the left wall of the portal vein through a short common trunk.

On the right side of the stomach, the **superior pancreaticoduodenal vein** is united with the **right gastroepiploic vein** to form a short trunk, the **gastroduodenal vein** (v. gastroduodenalis), which enters the right wall of the portal vein. The left gastroepiploic vein receives tributaries from the dorsal surface of the pyloric antrum.

The abdominal portion of the **tenth cranial, or vagus nerve** (n. vagus) may be traced from the oesophagus to the surface of the stomach. The left cord appears on the left wall of the oesophagus; crossing the ventral surface of the latter obliquely to the right, it ramifies on the ventral

portion of the lesser curvature. The right cord passes to the stomach in a similar manner from the dorsal surface of the oesophagus. These relations suggest the twisting which the stomach has undergone in developing its adult form and position.

5. Cut across the stomach at the pyloric antrum. Divide the oesophagus, and remove the stomach from the body. Open the organ by means of an incision extending around the greater curvature to the oesophagus.

On the cut end of the pyloric antrum the **mucous** and **muscular tunics** (cf. Fig. 16) may be distinguished and separated from each other by dividing the loose tissue of the tela submucosa. On the surface of the mucous tunic may be seen the **gastric areas** (areae gastricae), formed by the longitudinal folds and imperfect transverse ridges which tend to connect them. They are well marked only in the contracted condition of the stomach. The mucous tunic of the stomach is sharply differentiated from that of the oesophagus.

IV. THE LIVER

The **liver** (hepar) is noteworthy, first, as being the largest of the glandular structures of the body, and, secondly, as containing, in addition to the primary circulation formed by the hepatic artery and veins, the ramifications of the portal system. It is an appendage of the digestive tube, its connection with the latter being through the common bile duct, which marks the point at which it developed as an outgrowth from the embryonic endodermal canal.

For the general relations of the liver, see pp. 94, 95, and following pages.

1. Examine the contour and plan of division as follows:
 - (a) The anterior surface is convex, applied to the diaphragm; the posterior surface is concave, fitting the convexity of the stomach. The organ is thickened in its dorsal portion and tapers to a thin posteroventral margin.
 - (b) The liver is partially divided by a deep median cleft into **right** and **left lobes** and each of these comprises distinct **anterior** and **posterior lobules**. Variable indications of further subdivision sometimes appear, particularly in the

right posterior lobule. The latter lies close to the dorsal body-wall, is separated from the anterior lobule by a rather wide space which accommodates the pyloric end of the stomach, and fits round the anterior end of the right kidney.

- (c) The **gall bladder** (*vesica fellea*) is an elongated, rather thin-walled sac situated in a deep depression on the posterior surface of the right anterior lobule.
 - (d) The **quadrate lobe** (*lobus quadratus*) is a subdivision of the right lobe lying medial to the gall bladder. Its lateral limit is sometimes further indicated by a groove extending ventrally from the depression containing the gall bladder. It is frequently notched on its medial margin.
 - (e) The **caudate lobe** (*lobus caudatus*) is a small, well-separated, lobe with an almost circular portion fitting against the base of the left posterior lobule and an extension backwards which is accommodated in the natural condition in the space enclosed by the lesser curvature of the stomach. Dorsally, it blends with the posterior right lobule and passes over into the common dorsal mass wherein all the main lobules of the liver meet.
 - (f) The **portal fissure** (*porta hepatis*) is a large depression filled by the portal vein at its point of entrance and containing also the primary branches of the hepatic artery and tributaries of the common bile duct.
2. Trace the peritoneal connections as follows:
- (a) The lesser omentum, represented by the hepatoduodenal ligament and the hepatogastric omentum, previously divided.
 - (b) The **falciform ligament** (*lig. falciforme hepatis*), a broad median sheet connecting the anterior surface of the liver with the diaphragm and extending backward to the ventral abdominal wall. It is a remnant of a primitive ventral mesentery. The position of this ligament indicates the line of division of the liver into right and left lobes. The free curved border of the ligament contains a thin cord, the **round ligament** (*lig. teres hepatis*), which marks the position

of the umbilical vein in the foetus (p. 115). The corresponding **umbilical notch** is less conspicuous than in man because of the highly lobulated condition of the whole organ in the rabbit.

- (c) The **coronary ligament** (lig. coronarium hepatis), a short circular fold like a short section of a hollow cylinder, continuous with the dorsal extremity of the falciform, and connecting the anterior surface of the liver with the middle of the diaphragm. Within this the inferior vena cava reaches and pierces the diaphragm.
- (d) The **left triangular ligament** (lig. triangulare sinistrum), a lateral continuation of the coronary connecting the left lobe with the diaphragm.

In occasional individuals a smaller right triangular ligament also occurs.

3. Trace the branches of the common bile duct, the hepatic artery, and the portal vein. These structures traverse the lesser omentum side by side and their branches are similarly arranged.

- (a) The **common bile duct** (d. choledochus) is formed on the posterior surface of the liver by the union of a **left hepatic duct** (d. hepaticus) with a similar duct from the right anterior lobule (Fig. 49). The latter receives the **cystic duct** (d. cysticus) from the gall bladder. A duct from the quadrate lobe may join the left hepatic duct. Special ducts from the right posterior lobule and from the caudate lobe enter the common bile duct through a short common trunk and an additional duct from the anterior part of the caudate lobe may enter the common bile duct directly. The ducts from the caudate lobe run dorsal to the portal vein. The common bile duct passes backward on the right side of the portal vein and enters the digestive tube on the dorsal surface of the first (superior) portion of the duodenum immediately beyond the pylorus.
- (b) The **hepatic artery** (a. hepatica) approaches the liver by passing forward on the right side of the portal vein ventral to the bile duct. It distributes branches to the right posterior lobule, usually two in number, and from one of these a secondary branch crosses obliquely dorsal to the portal vein and enters the caudate lobe. At the common

base of the remaining portions of the liver, the hepatic artery divides into right and left rami, the right ramus sending a branch, the **cystic artery** (a. cystica), to the gall bladder.

- (c) The **portal vein** (v. portae), a vessel of large calibre, but usually found in a collapsed condition, enters the lesser omentum from the dorsal surface of the pyloric antrum, having been formed by the confluence behind this of the veins from the intestines and the stomach. It distributes branches to the right posterior lobule and the caudate lobe; then, passing directly forward to the base of the left lobe, is distributed to the latter, a right branch being given off to the right anterior lobule.
4. Divide the lesser omentum with the structures described above. Divide the falciform, the coronary, and the triangular ligaments, *cutting near (but not into) the liver so as not to injure the central tendon of the diaphragm*, which resembles the coronary ligament. Remove the liver and examine its dorsal surface for the following:
 - (a) The **inferior vena cava**, accommodated in a depression of the thickened dorsal portion of the organ. The vessel should be opened lengthwise.
 - (b) The **hepatic veins** (vv. hepaticae) open almost directly from the substance of the liver into the inferior cava. They are typically four in number, there being separate vessels for the anterior and posterior parts of the right lobe and for the caudate lobe in addition to a large vessel formed by the union of tributaries from the right anterior lobule and from both divisions of the left lobe.
 - (c) The **renal impression** (impressio renalis), an extensive excavation of the right posterior lobule for the accommodation of the right kidney.

V. THE INTESTINES

The posterior portion of the digestive tube, or that portion extending from the pyloric aperture of the stomach to the anal aperture, is divisible into two main parts, not wholly distinguish-

able in calibre, namely, the **small intestine** (intestinum tenue) and the **large intestine** (intestinum crassum). Both are greatly elongated and convoluted. In examining them, care must be taken to avoid injury to the blood-vessels and mesenteries, especially the dorsal attachments of the mesenteries, in which the chief plexuses and related ganglia of the sympathetic system will afterwards be traced.

For the general relations of the intestines and mesenteries, see pp. 100, 136. For study of mucous surface, see note p. 367.

1. Beginning at the pylorus, trace the course of the small intestine, as follows: Its first portion, the **duodenum**, curves round from the pylorus to turn back and form a U-shaped loop lying on the dorsal wall of the abdominal cavity to the right of the vertebral column. The distal end of this portion of the intestine, when traced from the right side, disappears in the peritoneum and may then be picked up in a forward position on the left side of the mass. This point marks the beginning of the second portion, the **mesenterial small intestine** (intestinum tenue mesenteriale), which may be traced to its termination on the greatly enlarged **caecum**. At its connection with the caecum, the small intestine forms a rounded, semi-expanded sac, the **sacculus rotundus**, a feature peculiar to the rabbit. The terminal portion of the small intestine is somewhat more difficult to follow on account of the adhesions of its peritoneum with that of the large intestine.
2. Examine the divisions of the duodenal loop and related structures as follows:
 - (a) The **superior portion** is the short part which curves round from the pylorus to lead into a long **descending portion**. The latter is then connected by a short, wavy, **transverse** (horizontal) **portion** with an **ascending portion** of intermediate length.
 - (b) The common bile duct, opening on the dorsal wall of the superior portion.
 - (c) The **mesoduodenum**, a fold of peritoneum joining the various parts of the loop.

- (d) The **pancreas** (Fig. 5, p. 17). Its principal portion is here seen as a diffuse brownish mass lying in the mesoduodenum (cf. pp. 94 and 131) sometimes associated with a considerable amount of fat. Its **duct** (d. pancreatis) opens into the posterior portion of the ascending limb.

The extraordinarily diffuse form of the pancreas and, more particularly, the wide separation of the opening of its duct from that of the bile duct (these two having a common termination in many mammals, including man) are associated with the lengthening of the duodenum as of other parts of the intestine in the herbivore.

- (e) The **superior pancreaticoduodenal artery**, a branch of the gastroduodenal (see p. 230), passes backward on the first portion of the descending limb.
- (f) The **inferior pancreaticoduodenal artery** (a. pancreaticoduodenalis inferior), a branch of the superior mesenteric (p. 240), enters the mesoduodenum from the left side and supplies the major portion of the loop. An anterior branch anastomoses with (e).

3. In the mesenterial small intestine, the following features may be identified:

- (a) The lighter coloration, due to the thicker wall and greater vascularity, of the first or duodenal portion, thus distinguished as the **jejunum** (intestinum jejunum).
- (b) The darker coloration, due to the thinner wall, which allows the contents to show through, and diminished vascularity of the terminal or caecal portion, thus distinguished as the **ileum** (intestinum ileum). The two portions are not distinctly separable. The **circular folds** (plicae circulares), or valvulae conniventes, of the mucous tunic, which in many mammals contribute to the thickness of the wall in the duodenum and jejunum, are, in the rabbit, not definitely expressed.

The colour differences are not usually well indicated in embalmed animals.

- (c) The **mesentery**, the peritoneal support of the mesenterial small intestine, is distinguished in its major portion by its broad frill-like character, which allows great freedom of

movement of this part of the digestive tube. Its terminal portion, however, beginning at a point where the intestine turns sharply forward on its way to the caecum, is adherent to the mesocolon.

- (d) The **mesenteric lymph glands** (lymphoglandulae mesentericae) are aggregated a short distance from the dorsal attachment of the mesentery, where they form a compact mass covering the left side of the superior mesenteric artery.
- (e) The wall of the sacculus rotundus shows externally a pattern of fine hexagonal markings, like the surface of a minute honeycomb, on account of the presence in it of a large number of lymph follicles. Structures of similar composition and similarly marked, forming oval areas about 3 mm. in diameter and 5 mm. in length, or somewhat larger, may be found along the wall of the small intestine (**aggregated lymph nodules of Peyer**).
- (f) The finger-like processes, or **villi**, of the mucous tunic of the small intestine may be seen by making an incision of the wall and examining its internal surface. A small portion of the wall may be excised and examined under water.

4. Trace the course of the large intestine, beginning at the sacculus rotundus, as follows:

Its first portion, the **blind intestine** or **caecum** (intestinum caecum), distinguished by its great size, is connected with the large intestine proper only in the region of the sacculus rotundus. Strictly speaking, the caecum begins at the opening from the small intestine, but in the rabbit and many other mammals its peculiar structure extends a short distance beyond this point along the other part of the large intestine, the colon. The caecum is so greatly elongated in the rabbit that it has become coiled in a spiral manner and may be considered to consist of three limbs (Fig. 54), the third terminating in the narrow but thick-walled **vermiform process** (processus vermiformis) or appendix. The latter lies in a dorsal position, and is directed backward.

The second portion, the **colon**, comprising the major portion of the large intestine proper, leaves the caecum in the region of the

sacculus rotundus, in which position it is distinguished by its greatly sacculated walls. As noted above, the first part of the colon of the rabbit has assumed the structure of the caecum, constituting the **ampulla caecalis coli**, beyond which the structure of the beginning of the colon appears suddenly. Such an ampulla is not present in mammals which, like man, have not an extensively developed caecum.

The third portion, the **straight intestine** or **rectum** (intestinum rectum), is a small terminal division situated in the middle line and enclosed for the most part by the pelvis. It is scarcely distinguishable from the related portion of the colon, so that the point of disappearance of the latter from the abdominal cavity may be regarded for convenience as the dividing line between them.

5. In the caecum the following features may be distinguished:
 - (a) The wall is notably thin and, though otherwise smooth, is divided by a spirally arranged constriction, the latter denoting the position, internally, of a fold of the mucous tunic, the **spiral valve**. Both of these features are continued into the ampulla caecalis coli.
 - (b) The vermiform process is a narrow, light-coloured tube of about five inches in length, the wall patterned externally by lymph follicles, in the same way as that of the sacculus rotundus, and greatly thickened in comparison with that of the caecum proper.
6. The colon, beyond the ampulla caecalis, is divisible into ascending, transverse, and descending portions, the relations of which may be traced as follows:
 - (a) The **ascending colon** (colon ascendens) passes from its origin on the caecum to a point forward on the right side of the dorsal body-wall. This portion is greatly elongated in the rabbit and, instead of passing directly forward (i.e., upward in man—see Fig. 51), follows more or less closely the course of the caecum. It is composed of five principal limbs, each of these being a portion which runs either forward or backward and is united by a flexure to the next, which has the opposite direction. Three of the limbs are

directed for the most part forward, the remaining two backward, and the third includes a pronounced secondary curvature in a lateral direction.

The first limb of the colon bears three rows of small sacculations, the **haustra**, separated by three longitudinal muscle-stripes, distinguished as the **bands of the colon** (*taeniae coli*). Two of these bands are free, while the third is enclosed by the supporting peritoneum, the **mesocolon**. The two free bands unite toward the anterior end of the first limb and the third or attached band joins them soon after, so that the second limb has but one row of haustra along most of its extent, this row continuing on to the beginning of the third limb. The modifications described, which are not observed in carnivores, serve to increase the storage capacity of the intestine and the area of its walls and to delay the passage of its contents.

- (b) The **transverse colon** (*colon transversum*) is a short segment, beginning forward on the right and crossing the middle line transversely to the left, where it bends sharply backward, and is replaced by the descending colon.
- (c) The **descending colon** (*colon descendens*) passes backward to a point in front of the pelvis, where it is replaced, without any definite demarcation, by the rectum.

The **descending mesocolon**, which connects this portion with the dorsal body-wall, should be noted on account of its relation to the inferior mesenteric artery and sympathetic plexuses. It is connected for a considerable distance with the mesentery of the ascending limb of the duodenum.

7. Displace the caecum, turning it over to the right side of the animal. Lay out the mesenterial small intestine, so that the mesentery and its blood-vessels are exposed. Remove the lymph glands from about the superior mesenteric artery, first noting their position a short distance from the root of the mesentery. They receive afferent lymphatic vessels from the wall of the intestine, and send off efferent vessels to one another and to the lymphatic trunks.

Trace the branches of the superior mesenteric artery as follows:

- (a) The **middle colic artery** (a. colica media), a small vessel (frequently two) arising from the left wall and passing to the transverse colon.
- (b) The inferior pancreaticoduodenal artery (p. 236) arises at the same level, but from the right wall.
- (c) The **ileocaecocolic artery** (a. ileocaecocolica), a large branch, equalling in size the superior mesenteric trunk, is distributed to the terminal portion of the ileum, the caecum (including the vermiform process), and the ascending colon. Its branches are arranged in two series, a **proximal group** being given off near the point of origin of the main vessel, and a **distal group**, including the terminal portion of the vessel, at about two inches from the point of origin.

The proximal branches of the ileocaecocolic artery include:

- (1) Small branches to the third, fourth, and fifth limbs of the ascending colon, each anastomosing with its neighbours, and the last with the middle colic artery.
- (2) The **appendicular artery** (a. appendicularis) to the vermiform process. This vessel also gives off several short branches to the immediately adjacent part of the ileum and a longer branch, arising from the appendicular near its point of origin, passes along the ileum to anastomose with an intestinal branch of the superior mesenteric trunk (top of p. 241).
- (3) An **anterior ileocaecal artery** to the terminal fourth (anterior part of the third limb) of the caecum proper and related portion of the ileum.
- (4) An **anterior right colic artery** to the flexure uniting the first and second limbs of the ascending colon.
- (5) A **posterior right colic artery** to the second limb of the ascending colon. This vessel anastomoses with (4) and with the special branch to the third limb (1).

The distal branches of the ileocaecocolic artery include:

- (6) A **posterior ileocaecal artery** to the middle portion of

the third limb of the caecum and the adjacent portion of the ileum; anastomosing with (3).

- (7) A **caecal artery** to the second limb and the posterior end of the third limb of the caecum.
- (8) Terminal branches to the parts of the ileum, caecum, and colon about the sacculus rotundus; anastomosing with (4).

(d) The **intestinal arteries** (aa. intestinales), about twenty in number, are given off from the superior mesenteric artery after the ileocaecocolic artery has left it, and are distributed to the free portion of the mesenterial small intestine. The successive vessels are connected by anastomoses the first connecting also with a branch of the inferior pancreaticoduodenal artery. All but two of the intestinal arteries arise from one side of the superior mesenteric artery, one forms the end of the latter, and one springs from its opposite side. The last anastomoses forward with a branch of the appendicular artery.

8. Locate in the descending mesocolon the **inferior mesenteric artery** (a. mesenterica inferior), a small median vessel arising from the abdominal aorta. It has two main branches—the **left colic artery** (a. colica sinistra) to the anterior portion of the descending colon (anastomosing with the middle colic), and the **superior haemorrhoidal artery** (a. haemorrhoidalis superior) to the posterior portion of the colon and the rectum, continuing caudad along the dorsal surface of the latter.
9. The **superior mesenteric vein** (v. mesenterica superior), the chief tributary of the portal, collects the blood distributed by the superior mesenteric artery, its tributaries being similar in arrangement to the branches of the artery. The **inferior mesenteric vein** (v. mesenterica inferior) collects blood from the descending colon and rectum and joins the superior mesenteric vein to form the portal vein (p. 234). It may be traced forward in the descending mesocolon, where it crosses the inferior mesenteric artery almost at right angles, only its more posterior part accompanying the arteries.

10. Sympathetic plexuses. In the descending mesocolon will be found the **inferior mesenteric ganglion** (g. mesentericum inferius), a narrow curved body situated in front of the inferior mesenteric artery. Surrounding the abdominal aorta and appearing in the mesocolon is the **abdominal aortic plexus** (plexus aorticus abdominalis). It is connected anteriorly with the coeliac and superior mesenteric plexuses (p. 213) accompanying the corresponding vessels, and with the **renal plexuses** accompanying the renal vessels to the kidneys; posteriorly with the **inferior mesenteric** and **spermatic plexuses** about the inferior mesenteric and internal spermatic arteries, and with the **hypogastric plexus** about the pelvic vessels.
11. By division of the rectum close in front of the pelvis and of the peritoneal attachments, the intestines may be separated and laid out in an extended condition. The relations to one another of the ileum, caecum, and colon are studied thus to much better advantage than in the natural position. The caecum should be opened lengthwise and the spiral valve examined (Fig. 55).
12. The lymphatic system can be studied adequately only in specially injected specimens, though the larger mesenterial lymph glands have been pointed out in the foregoing directions. The lymphatics from the liver and intestines converge in lymph nodes, of which there are usually two near the posterior end of the mesoduodenum, two associated with the portal vein near the lesser curvature of the stomach, and two near the junction of the splenic and superior mesenteric veins. These are all connected with the large mass of lymph nodes near the origin of the superior mesenteric artery, whence an intestinal trunk empties into one of the lumbar trunks, which run in the lateral walls of the abdominal aorta.

VI. THE URINOGENITAL SYSTEM

For the general relations of the urinogenital organs, see p. 122.

(A). THE URINARY ORGANS

The central organs of excretion, the **kidneys** (renes), occupy an anterior position on the dorsal wall of the abdomen. The right kidney is placed a little farther forward than the left and is largely covered by the right posterior lobule of the liver. In addition to a

fibrous coat immediately surrounding the kidney substance, each organ is imbedded in a mass of fatty material, the **adipose capsule** (capsula adiposa), and is also held in position by the peritoneum, which is stretched across its ventral surface.

1. If the peritoneum and adipose capsule are removed from the left kidney, the external features and vascular connections may be made out as follows:

- (a) The general convexity of contour.
- (b) The **renal hilus** (hilus renalis), a concavity of the medial surface of the organ.
- (c) The **ureter**, or duct of the kidney, a white tube passing backward from the hilus.
- (d) The **renal artery** (a. renalis), arising from the abdominal aorta and entering the kidney at the hilus. A branch of this vessel, the **suprarenolumbar artery** (a. suprarenolumbalis), passes to the body-wall in front of the kidney, giving off a small **suprarenal artery** to the suprarenal gland.
- (e) The **renal vein** (v. renalis), leaving the kidney at the hilus, and joining the inferior cava.

The **right** renal artery leaves the aorta about one-half centimetre in front of the origin of the left vessel, than which it is considerably shorter. The two renal veins have similar relative positions, but the distance between their proximal ends is a little greater.

2. Divide the kidney, beginning the incision at the hilus and removing the ventral half (Fig. 70). Examine the cut surface of the dorsal half for the following:

- (a) The **renal pelvis** (pelvis renalis), a cavity within the kidney, formed by the expanded funnel-like end of the ureter, which is fitted into the renal hilus. A central cone of kidney substance, the **renal papilla** (papilla renalis), projects into the pelvis.
- (b) The **cortical substance** (substantia corticalis); distinguishable as a narrow peripheral zone of the kidney substance.
- (c) The **medullary substance** (substantia medullaris), forming the central and medial portion of the kidney, including the renal papilla. It is distinguished by its radial striations.

- (d) The **fibrous coat** (*tunica fibrosa*) of the kidney may be stripped from the surface.

In the rabbit the kidney is not lobulated. Hence there is a single renal papilla, and the division of the kidney substance into **renal pyramids** is imperfectly expressed. The medullary substance, however, possesses a slightly divided margin.

The cortical substance is of darker coloration than the medullary in the natural condition, but in embalmed animals the colour relations are usually reversed.

3. The **urinary bladder** (*vesica urinaria*) lies in the ventral posterior portion of the abdominal cavity. It is a muscular sac, capable of a considerable amount of distension, but usually found in preserved animals in a greatly contracted condition. Its rounded anterior end, the **vertex**, projects forward into the abdominal cavity, while its posterior portion or **fundus**, narrows to a canal, the **urethra**, which receives on its dorsal wall the apertures of the genital ducts and those of the related glands.

The connections may be made out as follows:

- (a) The peritoneum is reflected from the dorsolateral surface of the rectum in the male and from the vagina in the female, to the bladder, and after investing the latter passes to the ventral abdominal wall. The peritoneum dorsal to the bladder forms in the male a paired **retrovesical fold** (*plica rectovesicalis*), and in the female a similar **vesicouterine fold**, the ureter in each case running in the edge of the fold and a recess of considerable extent (**rectovesical** or **vesicouterine pouch**) being left between the adjacent structures.

The ventral peritoneum forms a broad median vertical sheet, the **middle umbilical fold** (*plica umbilicalis media*) between the bladder and the ventral abdominal wall. The free edge of this fold, extending from the vertex of the bladder to the umbilicus, contains a slender cord, the **middle umbilical ligament** (*lig. umbilicale medium*). The latter marks the position of the peripheral portions of the umbilical arteries in the foetus, where they run beyond the bladder into the umbilical cord to reach the placenta (Fig. 65). The middle umbilical fold is often heavily laden with fat.

- (b) The **umbilical artery** (a. umbilicalis), a branch of the hypogastric, which has not yet been exposed (p. 255), passes along the side of the bladder to the vertex accompanied by the vesical vein. From the umbilical artery near its beginning, branches are given off to the ureter (a. ureterica) and related portions of the genital ducts.

THE MALE GENITAL ORGANS

1. Continue the median ventral incision of the skin backward along the symphysis to the free end of the penis. Reflect the skin on both sides and clear away the connective tissue so as to expose fully the body of the penis and its attachments to the ischium, and on one side continue the exposure to a point beyond the scrotum. Note the **cremaster muscle** (m. cremaster), a thin layer of muscle fibres forming the outer layer of each scrotal sac (sac of the testis) after removal of the skin and subcutaneous tissue. Though situated directly under the latter, it is continuous with the internal oblique muscle of the abdominal wall, and also contains fibres from the transverse muscle. It is supplied with blood from the **external spermatic artery** (p. 223). Make a longitudinal incision through this muscle, cutting forward into the abdominal cavity. After the two flaps are spread apart, the following features may be made out:
 - (a) The **parietal layer** (lamina parietalis) of the **tunica vaginalis propria**, a layer of peritoneum continuous with that of the abdominal wall, forms the internal lining of the sac of the testis (cf. p. 137 and Fig. 75). The sac is widely open to the abdominal cavity, so that the testis passes freely from one cavity to the other, a condition more primitive than that when the scrotal sac is closed off.
 - (b) The male reproductive gland, the **testis**, and its associated vessels and duct occupy the cavity of the sac, the testis being suspended from its dorsal wall. The gland has the form of an elongated oval, about two to three centimetres in length and seven or eight millimetres wide in the mature adult.
 - (c) The **gubernaculum**, a short connective tissue cord contain-

ing smooth muscle fibres, intimately associated with the lower end of the epididymis (*e*), joins the posterior end of the testis with the end of the sac.

- (*d*) The **visceral layer** (lamina visceralis) of the **tunica vaginalis propria** forms the peritoneal coat of the testis and is continuous with the **mesorchium**, a broad vertical fold of peritoneum connecting the testis dorsally and anteriorly with that of the body-wall.
- (*e*) The first portion of the duct of the testis, the **epididymis**, is very long, slender, and much coiled, the coils being bound together by connective tissue to form a thickened mass, usually imbedded in fat, fitting like a cap over the anterior end of the testis. It then extends back as a thinner cord along the side of the latter body and of the gubernaculum. The thickened anterior part is the **caput epididymidis**, the more slender part beside the posterior end of the testis and the gubernaculum is the **cauda epididymidis**, while the still thinner intervening portion is the **corpus epididymidis**. The second portion of the duct, the **ductus deferens**, leads forward from the cauda epididymidis, where it is firmly attached to the gubernaculum. The connection with the epididymis may be shown by carefully separating the duct from the gubernaculum and the side of the testis. The ductus deferens receives its blood supply mainly by the arteria deferentialis, which originates from the base of the umbilical artery or from the immediately adjacent part of the common iliac artery.
- (*f*) The **internal spermatic artery** (a. spermatica interna) arises from the abdominal aorta, in the neighbourhood of the inferior mesenteric artery, or opposite the sixth lumbar vertebra, the left artery usually behind the right. It sends branches to the epididymis and ductus deferens, and then follows a greatly contorted course to the anteromedial part of the testis, on the surface of which it then coils back and forth before finally entering its substance. The tortuous course of the artery appears to be an arrangement for slowing the blood flow.

(g) The **spermatic vein** (v. spermatica) is formed by a network of vessels, the **plexus pampiniformis**, which surrounds the internal spermatic artery as it approaches the testis. The left vein opens forwards into the inferior caval at the angle formed by the latter with the renal artery. That of the right side enters the inferior caval at about the level of the spermatic arteries.

Owing to the open communication of the testis sac with the abdominal cavity, the association of the ductus deferens with the spermatic vessels to form a **spermatic cord** (funiculus spermaticus) as in the human species is very imperfectly expressed.

2. The structure and attachments of the penis should be examined. Apart from the urethra, the soft-walled tube which traverses it ventrally and opens at its tip, the body of the penis is formed chiefly by a pair of hollow fibrous structures, the **cavernous bodies** (corpora cavernosa penis).

The cavernous bodies have thick white sheaths (tunicae albugineae) which fuse in a median septum and surround columns of spongy tissue which can be distended with blood i.e. erectile tissue. The fusion of the sheaths produces an apparently unpaired, median structure and the two contained corpora are best seen by cutting the penis transversely *after the study of the organs has been otherwise completed*. The wall of the associated portion of the urethra has a thin layer of similar erectile tissue.

The cavernous bodies diverge at their proximal ends, the diverging parts constituting the **crura penis**, and each crus is firmly attached to the ventromedial margin of the ischium, a little posterior to the symphysis, by a short cord of white fibrous connective tissue.

The crus is partly concealed by a short thick **ischiocavernosus** muscle, the origin of which is on the edge of the ischium both anteromedial and posterolateral to the attachment of the crus. The penis is also attached to the symphysis by a short but stout unpaired **suspensory ligament** (lig. suspensorium) and by a thick spindle-shaped **pubocavernosus muscle** lying in a median position ventral to the ligament and between the two ischiocavernosi.

Strictly speaking, a **glans penis**, which occurs in many mammals, is absent in the rabbit and the free extremity of the organ, occupying the position of that part, should be called simply **pars libera**. The glans, properly, is a swollen terminal portion of the erectile tissue (corpus spongiosum) in the wall of the urethra.

When the study of these parts has been completed, the attachments of the penis should be severed at the posterior border of the ischium and the symphysis should be divided. Pressing apart the two halves of the pelvis facilitates examination of the connections of the deferent ducts with the common urinogenital tube and related parts. Following this the urinogenital organs and pelvic portion of the rectum may be dissected out and removed from the body in a single piece without damage to anything except the vessels supplying these organs, which must be severed with the attaching connective tissue. The rectum should then be separated from the urinogenital structures.

The **middle haemorrhoidal artery** (a. haemorrhoidalis media), a branch of the hypogastric, passes to the side of the rectum, to the urethra, and to the seminal vesicle. The **internal pudendal artery** (a. pudenda interna), accompanied by the corresponding nerve and vein, passes to the side of the penis, giving off the **inferior haemorrhoidal artery** to the terminal portion of the rectum and to the associated **rectal** or **anal gland**. The latter is an elongated, paired organ enveloping the rectum a short distance in front of the anus and pouring into it an oily secretion. The rectum is connected with the root of the tail by the **rectocaudalis muscle**, a somewhat spindle-shaped aggregation of smooth muscle fibres, arising from the body of the second caudal vertebra, and inserted a short distance forwards on the dorsal surface of the rectum. The **sphincter ani externus** and **sphincter ani internus** are two closely related muscles enclosing the rectum and urethra, the former arising from the dorsum of the tail.

Immediately dorsolateral to the body of the penis and just under the skin lie the paired inguinal glands. At each side, a nearly spherical **white inguinal gland** and, closely associated, a **brown inguinal gland** pour their secretions into the hairless inguinal spaces. The former gland is sebaceous, the latter a modified sweat gland producing an odoriferous secretion.

The following parts of the urinogenital system may be made out :

- (a) The connection of the bladder with the outside of the body through the urethra. It comprises a short **prostatic portion** in relation to the genital ducts, a much longer **membranous portion** traversing the pelvis, and a terminal **cavernous portion** in the penis.
- (b) The **seminal vesicle** (vesicula seminalis) lies on the dorsal surface of the base of the bladder. It is a flattened median glandular pouch, the forward-directed tip of which has a relatively thick muscular wall and is slightly divided, corresponding with a bilobed character of the cavity within.

The organ as a whole is nearly 2.5 cm. long but is largely covered and compressed dorsally by the vesicular and prostate glands (Fig. 100). Its thin ventral wall adheres closely to the expanded terminal portions of the deferent ducts.

- (c) The somewhat dilated final portions (ampullae) of the deferent ducts lie between the seminal vesicle and the dorsal wall of the bladder. They terminate in the ventral wall of the seminal vesicle, where their point of entrance is marked by a pair of internal papillae.
- (d) The **vesicular gland** and the **prostate gland** lie in the dorsal wall of the more posterior part of the seminal vesicle, the former anterior to the latter, each enveloped in a connective tissue capsule. Macroscopically they are very similar and are associated in a single mass but histologically they are different and are separated by a thin connective tissue septum. In the fresh condition, the larger vesicular gland tends to be dull grey while the prostate is cream-coloured.

The vesicular gland has a pair of ventral ducts, one of them shown in Fig. 100 which enter the urethra at either side of the seminal colliculus (*vide infra*) and the prostate has four to six minute ducts at either side opening just behind them.

The **paraprostatic glands** are minute finger-like projections of the urethral lining imbedded in the outer part of its wall at either side of the base of the seminal vesicle. Their number is variable.

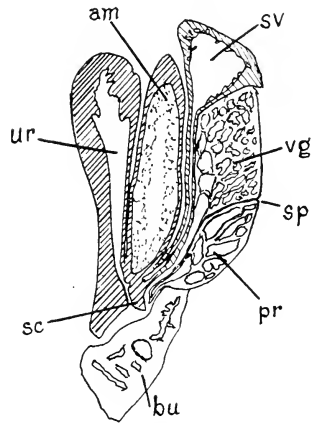


FIG. 100. Diagram of sagittal section of urethra with accessory sex glands and their ducts, from a seven-months old rabbit. (After Bern and Krichesky.) am, ampulla of ductus deferens; bu, bulbourethral gland; pr, prostate; sc, seminal colliculus; sp, septum between vesicular and prostate glands; sv, seminal vesicle; ur, urethra; vg, vesicular gland.

(e) The **bulbourethral** or Cowper's **gland** is a bilobed mass (deep pink in the living animal but usually dark coloured in the embalmed specimen) imbedded in the dorsolateral walls of the urethra immediately behind the prostate.

The above described glands, including the seminal vesicle, contribute to the liquid in which the sperms are transmitted. The seminal vesicle is not a reservoir for storage of sperms.

3. The internal surface of the dorsal wall of the urethra may be exposed by a longitudinal incision extending into the bladder. The crescentic aperture of the seminal vesicle lies immediately in front of an oval elevation, the **colliculus seminalis**, on either side of which some of the minute apertures of the prostate and vesicular glands may sometimes be made out. The seminal vesicle should also be cut open.

THE FEMALE GENITAL ORGANS

1. The organs may be traced from the abdominal cavity backward, as follows:
 - (a) The **ovary** (ovarium) is a small—in young animals minute—elongated, somewhat flattened, structure of greyish or yellowish coloration lying on the dorsal body-wall some distance behind the kidney. It is readily distinguished by the circular translucent dots representing the larger **vesicular ovarian follicles**. In some cases the darker radiate impressions (**corpora lutea**) left by extruded eggs are discernible.
 - (b) The **mesovarium**, a short fold of peritoneum suspending the ovary from the body-wall.
 - (c) The **internal spermatic artery** (a. spermatica interna) arises from the abdominal aorta, immediately behind the origin of the inferior mesenteric artery, and crosses the body-wall transversely to the ovary, giving branches also to the uterine tube.
 - (d) The **spermatic vein** (v. spermatica) leaves the medial side of the ovary and, crossing the body-wall, enters the inferior caval vein.

(e) The **uterine tube** (*tuba uterina*), the first portion of the oviduct, distinguishable by its narrow calibre, opens into the abdominal cavity through a broad funnel-like expansion, the **ostium abdominale tubae uterinae**. The margin bears a large number of short folds and processes, the **fimbriae tubae**, which tend to enclose the margin of the ovary. One of these is attached to the anterior end of the ovary.

A single cyst-like **hydatid** may be seen in the funnel-like expansion of the tube, but in embalmed animals is usually collapsed. It probably is a vestige of a part of the oviduct anterior to the ostium abdominale.

- (f) The **mesosalpinx** is the peritoneum supporting the uterine tube. It is continuous with the mesovarium.
- (g) The **uterus**, the second portion of the oviduct; distinguished by its greater diameter and muscular walls. The size of this portion is enormously increased in animals which contain or have borne young.
- (h) The **mesometrium** is the supporting peritoneum of the uterus, and is a continuation of the mesosalpinx. The mesometrium, mesosalpinx, and mesovarium together constitute the **broad ligament** (*lig. latum uteri*).
- (i) The **ovarian ligament** (*lig. ovarii proprium*) is a fine thread in the edge of a secondary fold of peritoneum which crosses the mesosalpinx from the posterior end of the ovary to the anterolateral end of the uterus.
- (j) The **round ligament** (*lig. teres uteri*) extends in line with the ovarian ligament behind the uterus. It is a fine fibrous cord which raises the peritoneum into a fold and which may be traced from the anterior end of the uterus to the body-wall ventral to the posterior portion of the inguinal ligament, where it is inserted into a small peritoneal recess, the homologue of the testis sac of the male. The ovarian and round ligaments together represent the gubernaculum of the male.
- (k) The **uterine artery** (*a. uterina*) runs through the mesometrium after originating from the umbilical artery. It

supplies the uterus and anastomoses anteriorly with the most posterior of the branches to the uterine tube from the internal spermatic artery.

- (l) The **vagina** is a flattened median tube with muscular walls; it receives anteriorly the apertures of the right and left uteri.
2. Preparatory to dissecting the urinogenital structures of the pelvis, the median incision of the skin of the ventral surface should be continued backward to the tip of the clitoris, which organ appears as a flexible median rod imbedded in the ventral wall of the vestibulum. Corresponding with the glans penis of the male, there is a short terminal portion, the glans clitoridis, covered by a fold of skin. The structure and attachments of the clitoris should now be examined.
- (a) The **clitoris**, like the penis of the male, is composed mainly of a pair of **cavernous bodies** (corpora cavernosa clitoridis), each consisting of an elongate mass of spongy vascular (erectile) tissue surrounded by a tough white sheath. The sheaths of the two cavernous bodies are fused in the median plane so closely that the double character of the organ is not evident except at the attached end, where the two bodies diverge as the **crura clitoridis**, and are connected to the posteroventromedial borders of the ischia by short fibrous cords overlain by muscles.
 - (b) The unpaired, median **pubocavernosus muscle**, originating at the symphysis and the paired **ischiocavernosus muscle**, originating on the posterior borders of the ischia, pass to the base of the clitoris.
 - (c) The **suspensory ligament** is a short median cord dorsal to the pubocavernosus muscle, joining the base of the clitoris with the posterior end of the symphysis. The crura clitoridis are largely covered ventrally by the ischio-cavernosus muscles, attaching the clitoris to the posterior edges of the ischia at each side.

The attachments of the clitoris should be severed and the symphysis should be divided. By pressing apart the two sides of the pelvis and cutting through the skin round the anus and the

tissue attaching the organs to the pelvis and the base of the tail, the urinogenital tube and the rectum may be dissected out in a single piece, their blood-vessels and the attaching peritoneum being the only other parts divided. The rectum should then be separated from the urinogenital organs.

The **middle haemorrhoidal artery** (a. haemorrhoidalis media), a branch of the hypogastric (p. 255), supplies the lateral walls of the rectum and the vestibulum. The **internal pudendal artery**, accompanied by the corresponding vein and nerve, passes over the side of the distal part of the vestibulum to the clitoris after giving off the **inferior haemorrhoidal artery** to the terminal portion of the rectum and to the **rectal or anal gland**. This gland is an elongated, paired organ, the pair almost surrounding the rectum a short distance in front of the anus and pouring into it an oily secretion. The rectum is connected with the base of the tail by the **rectocaudal muscle**, a somewhat spindle-shaped involuntary muscle originating on the body of the second caudal vertebra and inserted a little further forward on the dorsal side of the rectum. The external and internal anal sphincters are closely related thin muscles enclosing the rectum and the vestibulum, the former having its origin on the dorsum of the tail.

At each side of the external opening of the vestibulum, just under the skin, lie the paired inguinal glands. As in the male, each of these comprises a larger, medial, dark portion and a smaller lateral, white portion, the latter sebaceous, the former a modified sweat-gland secreting an odoriferous liquid. Ducts from both empty upon the hairless inguinal spaces.

In the urinogenital ducts, examine the extent of the vagina backward and its connection with the canal of the bladder (female urethra) to form the common **vestibulum**. The canal and the vestibulum together correspond with the male urethra (cf. Fig. 68, p. 121). The **bulbourethral gland** (gl. bulbourethralis) situated in the dorsal wall of the vestibulum, is similar to that of the male (cf. p. 250).

If the vestibulum be slit open and the incision be extended into the bladder and also forward into the left uterus the apertures of these structures may be examined from the interior. There is a separate **external uterine aperture** (orificium externum uteri) opening from each uterus into the vagina.

VII. THE ABDOMINAL AORTA, INFERIOR CAVAL VEIN, AND SYMPATHETIC TRUNKS

The dissection and removal of the intestines and urinogenital organs clear the dorsal body-wall for an examination of the

abdominal portion of the aorta, the inferior caval vein, and the sympathetic trunks. If the inferior cava does not contain blood, its tributaries should be cleared first, in order to keep them from being damaged; otherwise the branches of the aorta should first be traced. The anterior portion of the inferior cava has been removed with the liver.

1. The abdominal portion of the aorta, described as the **abdominal aorta** (*aorta abdominalis*) extends from the hiatus aorticus of the diaphragm to the seventh lumbar vertebra, where it is replaced by the paired common iliac arteries. It passes backward in a median position along the ventral surfaces of the bodies of the vertebrae. Its primitive continuation backwards on the sacrum and the caudal vertebrae is represented by the greatly reduced median sacral artery.

The branches of the vessel are distributed in two series: (1) **visceral branches** (*rami viscerales*) to the parts of the digestive tube and the urinogenital organs; and (2) **parietal branches** (*rami parietales*) to the body-wall.

The visceral branches comprise the paired **renal** and **spermatic** arteries, and the unpaired **coeliac**, **superior mesenteric**, and **inferior mesenteric** arteries, which have already been traced.

The parietal branches comprise:

- (a) The **superior phrenic arteries** (*aa. phrenicae superiores*), very small vessels arising by a common trunk in the hiatus aorticus and passing to the diaphragm (usually seen better on the right side).
- (b) The **suprarenolumbar artery** (*a. suprarenolumbalis*), arising

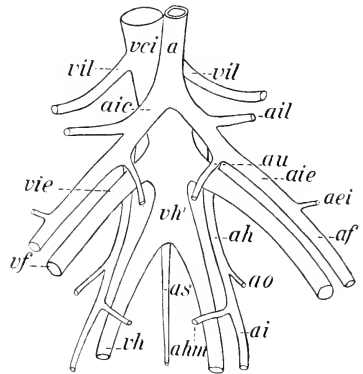


FIG. 101. Plan of the pelvic blood-vessels. Arteries: a, aorta; aei, inferior epigastric; af, femoral; ah, hypogastric; ahm, middle haemorrhoidal; ai, sciatic; aic, common iliac; aie, external iliac; ail, iliolumbar; ao, obturator; as, sacral; au, umbilical. Veins: vci, inferior cava; vf, femoral; vh, hypogastric; vh', common hypogastric; vie, external iliac; vil, iliolumbar.

on either side from the renal artery, and passing antero-laterad to the body-wall, supplying also the suprarenal body.

Occasionally the suprarenal artery originates separately, either from the renal artery or from the aorta itself.

- (c) The **lumbar arteries** (aa. lumbales), seven pairs of vessels distributed metamerically to the lumbar portion of the body-wall. Six pairs arise from the dorsal wall of the aorta, the seventh from the median sacral artery, each pair originating as a single trunk which branches to right and left.
 - (d) The **median sacral artery** (a. sacralis media) arises from the dorsal wall of the aorta near its posterior end, and passes backward on the ventral surface of the sacrum and of the caudal vertebrae in the middle line. Its first portion is concealed from the ventral surface by the common hypogastric vein.
2. The **common iliac artery** (a. iliaca communis) is a short paired trunk, the branches of which pass to the posterior limb, the wall of the pelvis, and the pelvic viscera. The first branch is usually the **iliolumbar artery**, which passes laterad to the body wall, though the point of origin of this vessel varies considerably and may be on the aorta itself. After giving off the iliolumbar artery, the common iliac divides into two branches, the external iliac and the hypogastric. The connections of these may be traced as follows:
- (a) The **external iliac artery** (a. iliaca externa) is the larger, lateral branch, directed toward the inguinal ligament, over which it passes to the medial surface of the limb, becoming the femoral artery. Near its crossing with the ligament it gives off the **inferior epigastric artery** (a. epigastrica inferior), the main portion of which passes forward in the medial portion of the abdominal wall.
 - (b) The **hypogastric artery** (a. hypogastrica formerly known also as internal iliac artery) is the smaller, medial branch, directed backward on the dorsal wall of the pelvis. Its course may be traced, care being taken not to injure the nerves of the lumbosacral plexus. Where it diverges from

external iliac the vessel gives off the **umbilical artery** (a. umbilicalis) to the bladder, or in the female first to the vagina and uterus (a. uterina). The next branch of the hypogastric is the **obturator artery**, which passes postero-laterad to the pelvic wall. About the same point arises the **medial femoral circumflex artery**, which runs more directly laterad into the muscles of the thigh. Slightly further back, the hypogastric gives rise to the **middle haemorrhoidal artery** to the side of the rectum and the urethra in the male or to the rectum and the vestibulum in the female. The hypogastric then leaves the pelvic cavity as the **sciatic artery** (a. ischiadica), passing to the lateral side of the abductor caudae anterior muscle. The sciatic artery reappears posteriorly, and divides into the **internal pudendal** and **lateral caudal** arteries.

3. The **inferior caval vein** (v. cava inferior) is formed on the dorsal surface of the posterior end of the aorta by the union of the paired external iliac veins with the **common hypogastric**, the latter a short median trunk receiving the **paired hypogastric veins**. From this position it passes to the right side of the aorta (rarely to the left) almost to its ventral surface, and then runs forward on the right side to the diaphragm. Its **visceral roots or tributaries** (radices viscerales) comprise the paired **renal** and **spermatic veins**, and the **hepatic veins** from the liver (p. 234). Its **parietal tributaries** (radices parietales) include the **inferior phrenic veins** (vv. phrenicae inferiores), which enter the inferior cava from either side of the diaphragm, the **lumbar veins** (vv. lumbales), a series of six pairs of vessels just in front of the corresponding first six lumbar arteries, and the paired **iliolumbar vein** (v. iliolumbalis). The members of each of the first two pairs of lumbar veins unite to form a single short trunk but the more posterior veins enter the vena cava separately. The suprarenolumbar vein at each side joins the renal vein or may enter the inferior vena cava directly.

The paired hypogastric vein receives as its largest tributary the sciatic vein from the back of the thigh. It also receives an external haemorrhoidal vein and a small obturator vein and

into either the right or the left vessel opens the unpaired median sacral vein. The seventh pair of lumbar veins opens into the dorsal side of the common hypogastric vein.

4. The **external iliac vein** (v. iliaca externa), the continuation of the femoral vein of the thigh, approaches the inferior cava from the dorsal side of the inguinal ligament. It receives the **inferior epigastric vein** from the abdominal wall and the **vesical vein** from the bladder, the latter accompanying the umbilical artery and receiving in the female also the veins of the uterus.
5. The **sympathetic trunk** (truncus sympathicus). Its lumbar and sacral portions, and, with due care, its caudal portions may be traced on either side by working between the abdominal aorta (or its continuation, the median sacral artery) and the body-wall. Except on the ventral surface of the sacrum, the ganglia of opposite sides lie close together. The **lumbar portion** of each trunk comprises seven ganglia with their connections. The ganglia lie on the lateral surfaces of the lumbar arteries near the points where the latter disappear dorsally in the body-wall. The **rami communicantes** may be found passing from the ganglia toward the spinal nerve-roots. The **sacral portion** comprises four ganglia of which the first is much larger than the others. The **caudal portion** of each trunk comprises two minute ganglia and an unpaired terminal ganglion unites the two trunks.

VIII. THE ANTERIOR LIMB

For this dissection the skin must first be reflected from the lateral surface of the limb and the side of the neck to the dorsal median line. It is advisable at first to divide the skin at the elbow, leaving the forearm and hand covered, so that the tendons of the muscles do not become dried out before they can be examined.

Covering the side and ventral surface of the neck is a broad thin sheet of muscle, the **platysma**, replacing the cutaneus maximus of the trunk. It forms a continuous layer over the dorsal surface of the neck, at which place it is also continuous with the cutaneus maximus. Passing forward from the manubrium sterni is a narrow band of fibres, closely associated with the platysma but lying beneath it, the **depressor conchae** (parotideoauricularis) **posterior**,

which is inserted into the external base of the ear. The entire sheet of muscle is so closely attached to the skin that it is sometimes removed with the latter. If in place, it should be raised from the surface, separated posteriorly from its attachment, and turned forward on the head.

The dissection is mainly muscular, but the arteries and nerves should be kept intact for later examination.

Identify the manubrium sterni by feeling. The muscle directed forward from it toward the angle of the mandible is the sternomastoideus, one of the muscles of the head. The external jugular vein lies on its lateral side and is joined by the transverse scapular vein from the lateral surface of the shoulder. Identify by feeling the clavicle rudiment and the cleidohumeral ligament attaching it to the humerus. Find the mid-dorsal line of the neck, indicating the position of the neck ligament (ligamentum nuchae). Then proceed to uncover the muscles, beginning with those on the ventral side and working around to the shoulder.

For the general relations of the muscles of the limbs, see pp. 68-70.

1. Muscles arising from the axial skeleton and inserted on the scapula and clavicle.¹

(a) The **cleidomastoideus**. Origin: Mastoid portion of the skull. Insertion: Middle portion of the clavicle.

The muscle lying on its medial side and arising from the manubrium sterni is the **sternomastoideus**, one of the muscles of the head.

(b) The **basioclavicularis** (basiohumeralis). Origin: Basioccipital bone. Insertion: Lateral third of the clavicle and the cleidohumeral ligament.

(c) The **levator scapulae major**. Origin: Cartilage union of basioccipital and basisphenoid (sphenooccipital synchondrosis). Insertion: Metacromion.

The **superficial cervical artery** (p. 325) passes obliquely forward and outward under cover of these muscles, ramifying beneath the superior portion of the trapezius in the fat-mass of the side of the neck. Its **ascending cervical** branch passes forward on the lateral surface of the external jugular vein.

¹The structures of Group 2 may be dissected first if preferred, the serratus anterior muscle being exposed from the lateral surface and divided together with the latissimus dorsi.

- (d) The **trapezius**. Origin in two portions. **Superior** (cervical) **portion**. External occipital protuberance and dorsal ligament of the neck (ligamentum nuchae). Insertion: Metacromion and supraspinous fascia. **Inferior** (thoracic) **portion**. Origin: Spinous processes of the thoracic vertebrae and the lumbodorsal fascia. Insertion: Dorsal half of the scapular spine. The muscle forms a broad triangular sheet on the dorsolateral surface of the shoulder.

The levator scapulae major, basioclavicularis, and trapezius should be divided.

On the ventrolateral surface of the superior portion of the trapezius and levator scapulae major may be found nerves from the ventral rami of the third, fourth, and fifth cervical spinal nerves. The **great auricular nerve** (n. auricularis magnus) passes from the third to the ear.

- (e) The **rhomboideus minor**. Origin: Ligamentum nuchae. Insertion: Anterior two-thirds of the vertebral border of the scapula.
- (f) The **levator scapulae minor**. Origin: Mastoid and supraoccipital portions of the skull. Insertion: Medial surface of the inferior angle of the scapula.
- (g) The **rhomboideus major**. Origin: Spinous processes of the first seven thoracic vertebrae. Insertion: Posterior third of vertebral border. The rhomboidei are almost continuous.

By dividing the rhomboidei, the scapula may be displaced laterad. The operation is facilitated by dividing the latissimus dorsi, the relations of which should, however, first be noted (2, a).

- (h) The **serratus anterior** consists of two portions. **Cervical portion**: Origin on the transverse processes of the posterior five cervical vertebrae and the anterior two ribs. Insertion on about the anterior four-fifths of the medial surface of the vertebral border of the scapula. **Thoracic portion**: Origin on the third to the ninth ribs by separate slips alternating with those of the external oblique. Insertion on the posterior two-fifths of the medial surface of the vertebral border of the scapula, overlapped medially by the cervical portion and the levator scapulae minor.

The transverse artery of the neck (*a. transversa colli*) lies on the medial side of the cervical portion.

The thoracic portion of the serratus anterior may function as an aid to breathing when the anterior limb is held firm and the muscle contracts so as to raise the ribs. In this case the relations of origin and insertion just described are thus reversed.

2. Muscles arising from the axial skeleton and the pectoral girdle and inserted on the humerus, for the most part at its proximal extremity.

Note the **axillary lymph glands** lying in the fat of the axillary fossa.

- (a) The **latissimus dorsi**. Origin: Lumbodorsal fascia and four posterior ribs. Insertion: Deltoid tuberosity. A long flat triangular muscle, covering a considerable portion of the lateral surface of the thorax; having its dorsal angle covered by the thoracic portion of the trapezius. Its insertion end passes to the medial side of the humerus.
- (b) The **pectoralis primus** (*p. tenuis*). Origin: Manubrium sterni. Insertion: Deltoid tuberosity.

A branch of the thoracoacromial artery appears between this muscle and the cleidohumeralis (3, *a*).

The muscle should be raised from the surface and divided.

- (c) The **pectoralis secundus** (*p. major*). Origin: Entire lateral portion of the sternum. Insertion: Anterior and antero-medial surfaces of the humerus, beginning below the greater tubercle and extending to near the boundary between the middle and distal thirds. The more anterior fibres are covered by those of (*b*). The more posterior fibres pass dorsal to the more anterior ones so that the muscle has a partly twisted form and its insertion is in two layers or separate slips. Some of the posterior fibres are inserted highest on the humerus. By working back from the clavicle, the muscle can be separated from those beneath and divided.

The more superficial layer is the thinner and is derived mainly from the anterior half of the origin. It is attached along a line extending distad from the greater tubercle along and beyond the medial part of the humeral spine. The deeper layer, derived mainly from the

posterior part of the origin, is attached more obliquely, just in front of the intertubercular groove and along the medial edge of the spine of the humerus, ending at the tip of that ridge.

- (d) The **pectoralis tertius** (p. minor). Origin consisting of two portions. First portion: The sternum from its anterior end to the attachment of the fourth rib. Second portion: On the manubrium sterni from its anterior end to a point a little behind the attachment of the first costal cartilage and on this cartilage, lying dorsal to the first portion. Insertion: The superficial fibres of the first portion are attached to the clavicle. The remaining fibres, combined with those of the second portion and those of the pectoralis scapularis, pass to the dorsal side of the clavicle and over the shoulder to be inserted on the ventral fourth of the scapular spine, the supraspinous fascia (p. 264), and both surfaces of the medial angle of the scapula. The muscle forms a broad fleshy mass covering the anterodorsal portion of the shoulder.
- (e) The **pectoralis quartus**. Origin: The sternum, from the attachment of the fourth to seventh costal cartilages. Insertion: Anterior surface of the head of the humerus, passing thence to its medial side. The muscle overlaps the posterior edge of the first portion of (d) and the thoracoacromial artery passes between them.
- (f) The **pectoscapularis**. Origin: The manubrium sterni at the point of attachment of the first costal cartilage. Insertion as indicated above. A slender muscle dorsal to the first portion of the p. tertius, which should be divided, and overlapping ventrally the posterior edge of the second portion.

BLOOD-VESSELS AND NERVES OF THE AXILLARY FOSSA

After division of the pectorals and the clavicle, the blood-vessels and nerves of the axillary fossa will be fully exposed.

During the examination of these, the axillary lymph glands may be noted. In specially injected preparations, these are found to receive superficial and deep lymphatic vessels from the anterior limb and to drain into the subclavian trunk, which accompanies the corresponding vein and opens into the superior vena cava.

The **axillary artery** (a. axillaris), the continuation of the subclavian, crosses from the first rib to the medial surface of the humerus, after reaching which it is called the brachial artery. Its branches are:

- (a) The **transverse scapular** (suprascapular) **artery** (a. transversa scapulae). It arises from the anterior wall and, taking a position dorsal to the clavicle, accompanies the p. tertius and pectoscapularis to the front of the shoulder, where, under cover of these muscles, it passes into the supraspinatus muscle (3, e).
- (b) The **thoracoacromial artery** (a. thoracoacromialis). It arises from the ventral wall or in common with (c), passes between the pectorales tertius and quartus, then between the p. primus and the cleidohumeralis. It distributes branches to these muscles and, taking a position ventral to the clavicle, passes to the platysma and the skin.
- (c) The **lateral** (long) **thoracic artery** (a. thoracalis lateralis) arises from the posterior wall or in common with (b), distributes branches chiefly to the p. secundus, and sends a long superficial branch, the **external thoracic artery**, backward through the cutaneus maximus muscle. This vessel is usually conspicuous in the female, where it distributes **external mammary branches** to the mammary glands. It anastomoses posteriorly with the superficial epigastric branch of the femoral.
- (d) The **subscapular artery** (a. subscapularis) is a large branch given off from the distal portion of the axillary artery. It distributes branches to the subscapularis muscle, and sends a **thoracodorsal branch** into the latissimus dorsi. Perforating the teres major muscle near the axilla, it appears on the lateral surface of the shoulder, where it sends a large branch into the inferior portion of the trapezius, and a second into the cutaneus maximus. The latter vessel supplies the proximal end of the long head of the triceps, but its chief portion passes backward uniting with an anterior superficial branch of the iliolumbar, and thus forming one of three anastomoses covering the abdominal

region and in the female the mammary glands (pp. 221 and 223).

- (e) The **circumflex arteries** of the head of the humerus. See p. 269.
- (f) The **deep artery** (a. profunda brachii). See p. 270.

The **axillary vein** (v. axillaris) begins at the medial side of the humerus and crosses the axillary fossa to the first rib whence it is continued as the subclavian. It receives the **lateral thoracic** and **subscapular veins**, which accompany the corresponding arteries, and also the **cephalic vein** (p. 271), which reaches the medial side of the shoulder from the anterior surface of the arm by passing between the teres major and subscapular muscles near the neck of the scapula.

The **brachial plexus** (plexus brachialis) is the network of nerves formed from the ventral rami of the posterior five cervical and first thoracic spinal nerves. The cervical nerves also take part in the formation of the more general **cervical plexus** embracing all nerves of the cervical series. The strands of the brachial plexus, which vary considerably in detail, cross the axillary fossa and at the medial surface of the humerus are largely replaced by the three chief trunks of the free extremity, the **radial, median, and ulnar nerves** (pp. 271, 272). These nerves are formed principally from a trunk produced by fusion of the ventral branches of the eighth cervical and first thoracic nerves, the latter crossing the inner surface of the first rib to meet the former, but adjacent nerves also contribute. The radial nerve separates first, the median and ulnar a little more distally.

The seventh cervical nerve gives a branch running mainly to the median and also connecting with the common trunk of the median and ulnar just before it divides into these nerves, and from the same source a slightly larger branch passes to the radial nerve. From the last-mentioned branch a **subscapular nerve** runs to the teres major, accompanied by a nerve to the latissimus dorsi, which latter frequently receives also a fascicle from the radial nerve. Another subscapular nerve to the muscle of that name arises mainly from the sixth cervical, these two being connected by a loop. A **supra-scapular nerve**, formed chiefly from the sixth cervical, passes to

the anterior border of the scapula, entering the supraspinatus muscle.

By dividing the axillary nerves and vessels and the two parts of the serratus anterior muscle, the limb may be removed from the body.

3. Muscles arising from the pectoral girdle and inserted on the humerus. These muscles act on the humerus through the shoulder-joint, and except for the unimportant difference in origin are similar to those of Group 2.

The course of the cephalic vein (p. 271) should be traced before separating the muscles of the front of the forearm.

Note the **supraspinous** and **infraspinous fasciae**, tough sheets of connective tissue covering the muscles lying in the supraspinous and infraspinous fossae of the scapula respectively.

(a) The **cleidohumeralis**.

Origin: Lateral portion of the clavicle and the cleidohumeral ligament.¹ Insertion: Anterior surface of the humerus in its distal third. The muscle is a continuation of the basioclavicularis, but represents the brachiocephalic muscle, which, in many mammals with reduced clavicle, extends from the mastoid portion of the skull to the front of the arm. The cervical part is the cleidomastoideus.

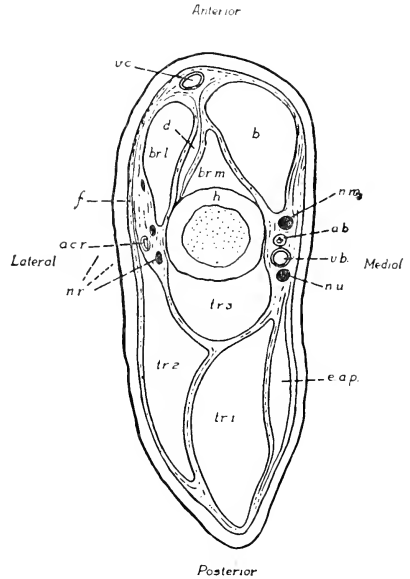


FIG. 102. Transverse section through the distal portion of the arm; semidiagrammatic; a.b., brachial artery; a.c.r., radial collateral artery; b., biceps; br.l. and br.m., lateral and medial heads of the brachialis; d., deltoideus (insertion); e.a.p., extensor antibrachii parvus; f., brachial fascia; h., humerus; n.m., median nerve; n.r., radial nerve; n.u., ulnar nerve; tr.l.tr.3, long, lateral, and medial heads of the triceps; v.b., brachial vein; v.c., cephalic vein.

¹Regarding this ligament, see p. 200.

- (b) The **deltoideus. Acromial portion.** Origin: The acromion. Insertion: Distal portion of the deltoid tuberosity. **Scapular portion.** Origin: Infraspinous fascia. The end of the muscle forms a curved line over the dorsal portion of the infraspinatus, leaving only a small triangular portion of the latter exposed. Insertion: The distal portion of the muscle passes beneath the metacromion, which also serves as a point of attachment, and is replaced on the lateral surface of the humerus, beneath the acromial portion, by a thin tendon, through which it is inserted beside the acromial portion.

The scapular portion of the deltoideus should be separated from the infraspinatus and divided, the distal end being reflected together with the metacromion.

- (c) The **infraspinatus.** Origin: Posterior portion of the lateral surface of the scapula, including the spine. Insertion: Greater tubercle of the humerus. The muscle fills the infraspinous fossa.
- (d) The **supraspinatus.** Origin: Anterior portion of the lateral surface of the scapula (supraspinous fossa), supraspinous fascia, and, to a certain extent, the subscapular fascia. Insertion: Greater tubercle of the humerus.

The extent of this muscle is evident only after removal of the loosely attached fleshy parts of the pectorals from its surface.

- (e) The **subscapularis.** Origin: Entire medial surface of the scapula. Insertion: Lesser tubercle of the humerus.
- (f) The **teres major.** Origin: Dorsal portion of the axillary border of the scapula. Insertion: In common with the latissimus dorsi on the anterior surface of the humerus.
- (g) The **teres minor.** Origin: Ventral portion of the axillary border of the scapula. Insertion: Greater tubercle.

The muscle is closely associated with the infraspinatus but is separated from the teres major by the tendon of origin of the long head of the triceps.

- (h) The **coracobrachialis.** Origin: Coracoid process. In-

sersion: Distal portion of the upper third of the humerus on its medial surface.

4. Muscles arising from the scapula and humerus and inserted on the proximal ends of the radius and ulna (extensors and flexors of the forearm) (Figs. 37, 38, 102).

A. **Extensor (anconaeus) group.** The muscles arise for the most part behind the axis of the humerus, and are inserted on the olecranon.

- (a) The **extensor antibrachii parvus** (anconaeus quartus). Origin: Fascia of the medial surface of the humerus. Insertion: Medial surface of the olecranon.

The muscle should be divided, or detached from its origin, and reflected.

- (b) The **anconaeus minimus** (epitrochleanconcaeus). Origin: Medial epicondyle of the humerus. Insertion: Medial surface of the olecranon.

- (c) The **triceps brachii**. Origin in three portions. **Caput longum** (anconaeus longus): Ventral portion of the axillary border of the scapula. **Caput laterale** (anconaeus lateralis): Greater tubercle and related portion of the lateral surface of the humerus. **Caput mediale** (anconaeus medialis): Posterior surface of the humerus.

The three portions are almost separate muscles. Insertion on the olecranon.

B. **Flexor group.** The muscles arise in front of the axis of the humerus and are inserted on the radius and ulna in front of the elbow-joint.

- (a) The **biceps brachii**. Origin: Anterior border of glenoid cavity. Insertion: Ventromedial surface of the ulna and medial surface of the radius. The muscle possesses only one head in the rabbit.

- (b) The **brachialis**. Origin: Anterior and lateral surfaces of the humerus, divided unequally into a larger lateral and a smaller medial portion by the insertion tendons of the deltoideus and cleidohumeralis muscles. Insertion: In common with the biceps.

5. Muscles arising from the distal end of the humerus and the radius and ulna and inserted on the hand (extensors and flexors of the hand and of the individual digits). The long insertion tendons pass through perforations of the **dorsal carpal** and **transverse** (ventral) **carpal ligaments** (Fig. 103).

A. **Extensor group.** The muscles have a general area of origin from the lateral epicondyle of the humerus and the antero-dorsal or anterolateral surface of the radius and ulna. Insertion dorsal.

- (a) The **extensor carpi radialis longus**. Origin: Lateral epicondyle. Insertion: Base of the second metacarpal.
- (b) The **extensor carpi radialis brevis**. Origin: Lateral epicondyle. Insertion: Base of the third metacarpal. The muscle is partly fused with the foregoing one, and the tendons are closely associated on the wrist.
- (c) The **abductor pollicis**. Origin: Anterolateral surface of the radius and ulna. Insertion: Base of the first metacarpal. The muscle is partly concealed by (e). Its tendon forms a conspicuous cross with those of (a) and (b).
- (d) The **extensor pollicis et indicis**. Origin: Anterolateral surface of the radius and ulna. Insertion: Ungual phalanx of the pollex and the head of the second metacarpal. Its tendon is the first of five in the centre of the carpus.
- (e) The **extensor digitorum communis**. Origin: Lateral epicondyle and proximal end of the ulna. Insertion: By four tendons on all phalanges of the four lateral digits.
- (f) The **extensor digiti quarti proprius**. Origin: Lateral epicondyle. Insertion: Ungual phalanx of the fourth digit.
- (g) The **extensor digiti quinti proprius**. Origin: Lateral epicondyle and lateral surface of the ulna. Insertion: Head of the fifth metacarpal and base of the first phalanx of this digit.
- (h) The **extensor carpi ulnaris**. Origin: Lateral epicondyle and proximal portion of the lateral surface of the ulna. Insertion: Base of the fifth metacarpal.

B. **Flexor group.** The muscles have a general area of origin from the medial epicondyle of the humerus and the posteroventral

or posteromedial surface of the radius and ulna. Insertion volar, the tendons (except that of *a*) passing under a very strong **transverse carpal ligament**, which stretches from the navicular and greater multangular to the pisiform and hamate bones.

- (a) The **pronator teres**. Origin: Medial epicondyle. Insertion: Ventral surface of the radius.
- (b) The **flexor carpi radialis**. Origin: Medial epicondyle. Insertion: Base of the second metacarpal.
- (c) The **flexor digitorum sublimis**. Origin: In common with the ulnar portion of the profundus from the medial epicondyle;

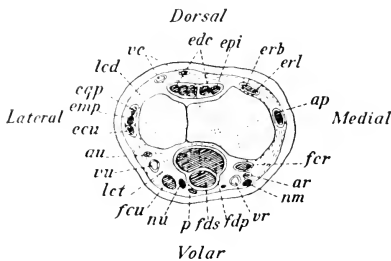


FIG. 103. Transverse section of the distal end of the forearm. Showing the relative positions of the muscle tendons: ap, abductor pollicis; ar, radial artery; au, ulnar artery; ecu, extensor carpi ulnaris; edc, extensor digitorum communis; emp, extensor digiti quinti proprius; epi, extensor pollicis et indicis; eqp, extensor digiti quarti proprius; erb, extensor carpi radialis brevis; erl, extensor carpi radialis longus; fer, flexor carpi radialis; fcu, flexor carpi ulnaris; fdp, flexor digitorum profundus; fds, flexor digitorum sublimis; lcd, dorsal carpal ligament; let, transverse carpal ligament; nm, median nerve; nu, ulnar nerve; p, palmaris; r, radius; u, ulna; vc, cephalic vein; vr, radial vein; vu, ulnar vein.

proximal portion of the ulna. Insertion: Bases of the second phalanges of the four lateral digits.

- (d) The **palmaris**. Origin: Medial epicondyle. Insertion: Superficially on the volar fascia. This extremely slender muscle lies between the superficial portion of the profundus and the flexor carpi ulnaris.

- (e) The **flexor digitorum profundus**. Origin in four portions. **Superficial portion:** Medial epicon-

dyle. **Radial portion:** Ventral surface of the radius. **Middle portion:** Ventral surface of the ulna. **Ulnar portion:** Medial epicondyle in common with (c). Insertion: By five tendons on the bases of the ungual phalanges. In exposing these, care should be taken not to destroy the flexor digiti quinti (6, a).

- (f) The **flexor carpi ulnaris**. Origin: Medial epicondyle and medial surface of the olecranon, forming two short but separate heads. Insertion: Pisiform bone.

6. Muscles arising from the bones of the hand and inserted on the individual digits.
- (a) The **flexor digiti quinti**. Origin: Pisiform bone and tendon sheath of the flexor digitorum profundus. Insertion: Sesamoid bones of the metacarpophalangeal joint of the fifth digit, extending to the unguis phalanx. This is a small muscle superficial to the most lateral division of the tendon of the flexor digitorum profundus. It represents both the flexor digiti quinti brevis and the abductor digiti quinti of some species.
 - (b) The **lumbricales**. Three in number. Origin: From the point of division of the tendon of the flexor digitorum profundus. Insertion: Medial side of the first phalanx in each of the third, fourth, and fifth digits.
 - (c) The **adductor digiti quinti, adductor digiti quarti, and adductor indicis**. Three slender muscles. Origin: Close together on the dorsal part of the tendon sheath of the flexor digitorum profundus. Insertion: By long thin tendons, respectively, to the radial sides of the fifth and fourth digits and the ulnar side of the second digit, just dorsal to the interossei.
 - (d) The **flexor pollicis brevis**. A minute muscle. Origin: The lateral part of the transverse carpal ligament. Insertion: The outer side of the base of the first phalanx of the pollex.
 - (e) The **interossei**. Origin: In pairs from the bases of the second to fifth metacarpals and related portions of the carpal bones. Insertion: Sesamoid bones of the metacarpophalangeal joints. The fibres of each pair interlace so that the members cannot be smoothly separated. Differentiation into volar and dorsal interossei is suggested, but they cannot be dissected apart.

BLOOD-VESSELS AND NERVES OF THE ARM AND FOREARM

The axillary artery gives rise to posterior and often anterior branches before turning into the arm as the brachial artery. The **anterior** and **posterior circumflex arteries** to the neck of the humerus and adjacent muscles may arise as one or several branches, of which

the largest (posterior) passes between the coracobrachialis and the teres muscles, giving branches to the deltoideus and to the proximal ends of the lateral and long heads of the triceps. It then continues (ramus descendens) on the lateral side of the medial head of the triceps and passes to the lateral head of the brachialis, near the elbow, as the **radial collateral artery**.

The distal part of the distribution of the vessel just described corresponds with the distal part of the deep or superior profunda artery of the human subject. The **deep artery** (a. profunda brachii) of the rabbit is a small and variable vessel originating from the beginning of the brachial artery. It lies behind the radial, median, and ulnar nerves, accompanying the first for a short distance, and supplies the long head of the triceps.

The **brachial artery** (a. brachialis), the continuation of the axillary, passes distad on the medial surface of the arm between the biceps and the medial head of the triceps. Crossing to the anterior surface of its distal extremity, it passes beneath the head of the pronator teres to the medial surface of the radius, dividing at this point—a short distance in front of the elbow—into the median and ulnar arteries. Its chief branches on the arm are the **ulnar collateral arteries** (superior, middle, and inferior) to the muscles and the elbow-joint. It soon gives off an interosseous branch which runs along between radius and ulna.


The **median artery** (a. medianus) passes distad on the ventromedial border of the radius, in company with the median nerve, lying at first between the flexor carpi radialis and the radial portion of the flexor digitorum profundus. A small radial artery may be given off before the bifurcation into median and ulnar and may run superficially distad in the forearm. Toward the distal end of the radius the median artery crosses the ventral surface of the tendon of the flexor carpi radialis, and appears in a superficial position on the medial border of the carpus after giving off a rather large branch, the medianoradial artery. Both vessels reach the volar surface of the hand, the median passing obliquely across the tendon of the flexor digitorum sublimis and curving laterad to anastomose with the ulnar artery. It thus forms a volar arch from which branches extend into the more lateral digits. (It may be noted that the parts supplied in man by the radial artery are here supplied mainly by the median vessel.)

The **ulnar artery** (a. ulnaris) crosses the ulna obliquely from its origin, reaching in this way the lateral border of the flexor carpi ulnaris, along which it passes to the end of the forearm and to the ulnar side of the pisiform bone. It passes to the ventral surface of the fifth digit, and then turns across the hand, forming the volar arch.

The single **brachial vein** (v. brachialis) accompanies the brachial artery and lies behind it. It is formed in front of the elbow by the union of two vessels, the **median** and **ulnar veins**, which accompany the corresponding arteries and join one another at the point of separation of the latter. The median vein anastomoses with the radial portion of the cephalic at a point distal to the middle of the forearm.

The **cephalic vein** (v. cephalica) is a large superficial vessel appearing on the dorsal surface of the forearm. From the radial side of the latter it receives a large tributary which anastomoses with the median vein. It is accompanied by branches of the superficial ramus of the radial nerve. It passes to the front of the arm across the angle of the elbow, lying at first on the anterior margin of the lateral head of the brachialis, and afterwards on the lateral surface of the arm between the acromial portion of the deltoideus and the lateral head of the triceps. It disappears from this surface in the triangular space enclosed by these muscles and the insertion of the levator scapulae major, receiving at this point a large tributary from the shoulder. It appears on the medial surface of the shoulder at the distal end of the axillary border of the scapula between the teres major and the subscapularis; entering the axillary vein at about the same place as the subscapular vein, or in common with the latter.

The **radial nerve** (n. radialis) passes behind the brachial artery to the posterior surface of the humerus. It perforates the medial head of the triceps, appearing afterwards on the lateral side of the brachialis in company with the collateral radial artery. A **superficial ramus**, given off on the distal portion of the arm, accompanies the cephalic vein: it passes along the surface of the extensor carpi radialis, dividing into branches for the dorsum of the hand. The remaining portion is chiefly distributed as the **ramus profundus** to the extensor muscles of the forearm.



The **median nerve** (n. medianus) passes distad along the medial surface of the arm, lying at first in front of the brachial artery and then on its medial side. It accompanies the brachial artery, passing beneath the head of the pronator teres, and then traverses the forearm, in company with the radial artery, to the volar surface of the hand.

The **ulnar nerve** (n. ulnaris) lies behind the brachial artery. Toward the distal extremity of the humerus it accompanies the inferior ulnar collateral artery. It passes from the medial surface of the elbow, between the anconaeus minimus and the base of the olecranon, to the dorsal surface of the olecranon head of the flexor carpi ulnaris, and then crosses the ulna obliquely, in company with the ulnar artery, to the lateral border of the muscle and along it to the insertion tendon. At the wrist it crosses the dorsal surface of the tendon, and passing between the tendon of the sublimis and the pisiform bone, reaches the volar surface of the hand.

IX. THE POSTERIOR LIMB

Dissect on the side opposite to that of injection. The dissection is largely a muscular one, to be conducted in the same way as in the anterior limb. The corresponding muscle groups should be compared with respect to the difference in orientation of the equivalent segments.

The skin should be removed first from the thigh and back to the mid-dorsal line, that on the leg and foot being stripped off later, when the muscles of these parts are to be examined.

1. Muscles arising from the ventral surface of the posterior thoracic and lumbar vertebrae and inserted on the pelvic girdle, or on the lesser trochanter of the femur. These muscles are chiefly distinguished by their vertebral position, on account of which, and on account of the fixed condition of the pelvic girdle, they combine the characters of vertebral and appendicular muscles.
 - (a) The **psoas minor**. Origin: Bodies of the four posterior lumbar vertebrae. Insertion: Pecten of the pubis. The flat, pointed tendon forms a right-angled cross with a ligamentous band which is stretched transversely from the

middle of the inguinal ligament to the centre of the ventral surface of the body of the first sacral vertebra. On this dorsal (sacral) continuation of the inguinal ligament some of the superficial fibres of the psoas minor tendon are inserted.

It is necessary to divide the inguinal ligament and reflect its sacral continuation, together with the tendon of the psoas minor.

- (b) The **psoas major**. Origin: Internal surfaces of the bases of the last three ribs and bodies of the corresponding thoracic vertebrae; also the lumbar vertebrae. Insertion: Lesser trochanter.
- (c) The **iliacus**. Origin: Bodies of the last lumbar and first sacral vertebrae, extending to the sacroiliac union and the body of the ilium behind it as far back as the ventral border of the acetabulum. Insertion: With the psoas major on the lesser trochanter. The two muscles together form the **iliopsoas**.

The **lumbar portion** of the **lumbosacral plexus**, beginning with the **fourth lumbar** nerve, lies on the ventral surface of the psoas major and between the latter and the iliacus, though, as an individual variation, the fifth lumbar nerve may be the most anterior to appear in this position. The fifth and sixth lumbar nerves usually together give rise to the greater part of the **femoral nerve** (p. 280), the trunk of which may be traced from a position between the two muscles distad over the dorsal surface of the inguinal ligament to the medial surface of the thigh. The remaining four nerves crossing the dorsal body-wall obliquely are the twelfth thoracic and first three lumbar.

The psoas major should be freed at its lateral margin and turned toward the median line, the fourth lumbar nerve being divided.

- (d) The **quadratus lumborum**. Origin: Bodies of the posterior five thoracic vertebrae and the bases of the corresponding five ribs; bodies and transverse processes of the lumbar vertebrae. Insertion: Triangular processes of six lumbar vertebrae and the posterior ventral angle of the iliac wing, together with the adjacent portion of its medial surface.

2. Muscles arising from the pelvic girdle and sacrum and inserted on the femur, for the most part at its proximal extremity.

The muscles of this group enclose the proximal portion of the femur on its lateral, posterior, and medial sides. They are partly covered by the flexors of Group 3, namely, the biceps, sartorius, and gracilis (p. 278), which must be examined and divided. To begin the dissection, identify the sciatic vein (p. 280) on the lateral surface of the thigh and cut the fascia along the proximal part of its course, where it runs in a nearly transverse direction. This procedure will free the first portion of the biceps in front from the superficial head of the semimembranosus behind. A continuation of the same incision distad and towards the front of the thigh along a line which is usually clearly visible, and which delimits the first portion of the biceps from the second, will separate these two portions. Now cut along the tendinous line which may be observed joining the tip of the great trochanter with the sacrum and carry the incision distad along the intermuscular septum of the lateral surface of the thigh to the knee. The first head of the biceps, having been freed both in front and behind by these manipulations, should now be raised slightly by working the handle of the scalpel under its distal portion. Divide the muscle, starting at its posterior margin and being careful not to injure the slender tensor fasciae cruris muscle and the branches of the sciatic nerve which lie beneath it. Reflecting the proximal end will expose the short muscles of the thigh.

Dissect on the lateral surface posteriorly.

- (a) The **glutaeus maximus**. Origin in two fleshy portions, joined by an aponeurosis. First portion: Fascia covering the sacrum in its entire length. This portion is triangular in shape, and is covered posteriorly by the first head of the biceps. Second portion: Anteroventral border of the iliac wing, fused with the tensor fasciae latae and the first head of the rectus femoris; also from the dorsal border and lumbar fascia through the aponeurosis mentioned above. Insertion: Third trochanter. The axis of the first portion is transverse, that of the second horizontal.

Both portions of the muscle should be divided. The sciatic nerve and artery are then exposed.

- (b) The **glutaeus medius**. Anterior border of the wing of the ilium and the iliac crest and fascia of the first two sacral vertebrae. Insertion: Greater trochanter. Some of the fibres pass around the medial surface of the tip of the greater trochanter and are inserted in the lateral wall of the trochanteric fossa.

The muscle should be divided.

- (c) The **glutaeus minimus**. Origin: Entire lateral surface of the body and wing of the ilium. Insertion: Greater trochanter.

Remove the entire muscle. The piriformis is in contact with its dorsal margin posteriorly.

- (d) The **tensor fasciae latae**. Origin: Anterior portion of the ventral border of the wing of the ilium. Insertion: Broad fascia of the lateral surface of the thigh. The muscle is fused with the first head of the rectus femoris in front, and with the second portion of the glutaeus maximus behind.

- (e) The **piriformis**. Origin: Lateral portions of the second and third sacral vertebrae. Insertion: Tip of the great trochanter. The muscle passes through the greater sciatic notch.

The muscle should be divided, care being taken to avoid injury to the nerves and blood-vessels beneath it.

- (f) The **gemellus superior**. Origin: Tendinous from the ischial spine and fleshy from the body of the ischium immediately in front of it. Insertion: Lateral wall of the trochanteric fossa, by a thick tendon common to this and the next two muscles.

The muscle extending from the ischial spine to the sacrum is the abductor caudae anterior (p. 343).

- (g) The **obturator internus**. Origin: Internal surface of the coxal bone all round the edge of the obturator foramen, extending forward along the medial surface of the ilium to the sacroiliac articulation, where a few fibres are attached to the sacrum. Insertion: Trochanteric fossa. The muscle passes over the ischium in the lesser sciatic notch, only its thick, white tendon of insertion appearing from the lateral surface. To see its origin, reflect the tendon through the lesser sciatic notch and examine the muscle from the internal surface of the pelvis.

- (h) The **gemellus inferior**. Origin: Posterior portion of the superior ramus of the ischium and the ischial tuberosity. Insertion: Trochanteric fossa.
- (i) The **quadratus femoris**. Origin: Ventral surface of the ischial tuberosity and the superior ramus of the ischium immediately in front of it. Insertion: The superficial fibres are inserted on and below the third trochanter, the remaining ones below the trochanteric fossa.
- (j) The **obturator externus**. Origin: External extent of the obturator foramen. Insertion: Trochanteric fossa. The muscle is largely concealed from this surface, but may be fully displayed by the division of the pectineus and adductores brevis and longus.

Dissect on the medial surface posteriorly, after examination and division of the sartorius and the gracilis (p. 278).

- (k) The **pectineus**. Origin: Pecten of the pubis. Insertion: Immediately below the lesser trochanter.
- (l) The **adductor brevis**. Origin: Anterior portion of the symphysis pubis. Insertion: Below the pectineus.
- (m) The **adductor longus**. Origin: Posterior portion of the symphysis and inferior ramus of the ischium. Insertion: Posterior surface of the shaft of the femur to its distal third.
- (n) The **adductor magnus**. Origin: Ventral surface of the ischial tuberosity. Insertion: Medial surface of the distal end of the femur, extending to the medial condyle of the tibia.

3. Muscles arising from the pelvic girdle and the femur and inserted on the proximal portions of the tibia and fibula (extensors and flexors of the leg) (Fig. 104).

A. **Extensor group (quadriceps femoris)**. The muscles lie for the most part in front of the axis of the femur. They have a common insertion on the tibial tuberosity through the patella and the patellar ligament (the stout ligament connecting the patella to the tuberosity of the tibia).

- (a) The **rectus femoris**. Origin in two portions. **First portion:** Superior anterior spine, fused with the tensor fasciae latae,

and ventral border of the iliac wing. **Second portion:** By a stout round tendon from the inferior anterior spine, immediately in front of the acetabulum. This part is cylindrical in shape and is almost a separate muscle.

The two portions of the muscle should be divided.

- (b) The **vastus lateralis**. Origin: Anterior surface of the great trochanter and the lateral intermuscular ligament (the thickened fascia attached to the lateral surface of the femur behind the proximal end of the muscle).

The muscle should be divided.

- (c) The **vastus intermedius**. Origin in two portions. **First portion:** Great trochanter, below the origin of the vastus lateralis. **Second portion:** Anterior surface of the femur.

- (d) The **vastus medialis**. Origin: Medially, at the base of the neck of the femur and the adjacent portion of the shaft. Common insertion (a-d): Tibial tuberosity.

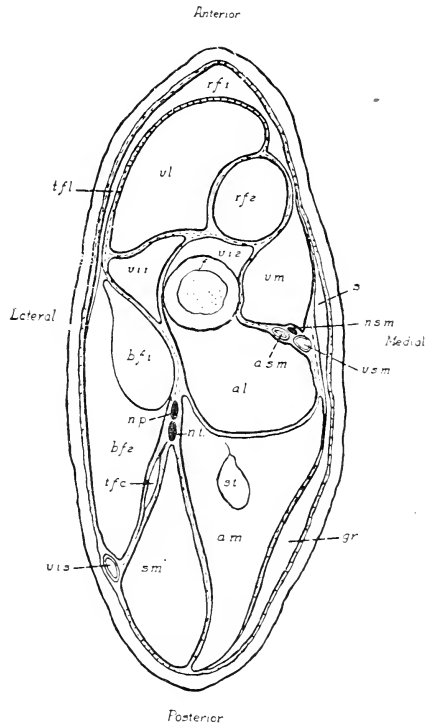


FIG. 104. Transverse section through the middle of the thigh: a.l., adductor longus; a.m., adductor magnus; a.s.m., femoral artery; b.f. 1 and b.f. 2, first and second heads of the biceps femoris; f., femur; gr., gracilis; n.p., peroneal nerve; n.s.m., greater saphenous nerve; n.t., tibial nerve; r.f. 1 and r.f. 2, first and second heads of the rectus femoris; s., sartorius; sm., semimembranosus; st., semitendinosus; t.f.c., tensor fasciae cruicis; t.f.l., tensor fasciae latae; v.i. 1 and v.i. 2, first and second heads of the vastus intermedius; v.s., sciatic vein; v.l., vastus lateralis; v.m., vastus medialis; v.s.m., great saphenous vein.

tions of the leg. They form the boundaries of the popliteal fossa.

- (a) The **sartorius**. Origin: Posterior portion of the inguinal ligament, especially its sacral extension. Insertion: Medial condyle of the tibia. This muscle is an extremely thin and narrow band of fibres, lying on the more anterior portion of the medial surface of the thigh. It is fused distally with the gracilis, and is a flexor only through its connection with the latter, since its position is that of a rotator.
- (b) The **gracilis**. Origin: The entire extent of the pubic symphysis. Insertion: Through a broad tendinous expansion ending in the fascia of the proximal portion of the medial surface of the leg. The muscle forms a broad, comparatively thin sheet, covering the posterior portion of the medial surface of the thigh. Its insertion tendon is perforated by the great saphenous artery and vein and the greater saphenous nerve.

The sartorius and gracilis should be raised from the surface and divided.

- (c) The **biceps femoris**. Origin in two portions. **First portion** (caput breve): Spinous processes of three posterior sacral and three anterior caudal vertebrae. This portion is triangular in shape, the distal end, or apex of the triangle, passing into a thin flat tendon which is inserted on the lateral margin of the patella. **Second portion** (caput longum): Dorsal surface of the ischial tuberosity, fused with the adductor magnus, and the lateral process, fused with the second, or deep portion of the semimembranosus (see below). This portion is also triangular, the base being distal and providing a broad insertion on the fascia of the proximal third of the lateral surface of the leg. The first, or superficial head of the semimembranosus, covers this portion at its origin, which is also crossed by the sciatic vein.

Directions for freeing the biceps and dividing its first portion have been given on page 274, this procedure being necessary to expose the short thigh muscles. The freeing of the second portion should now be completed, an incision first following the sciatic vein to the posterior margin of the muscle, and the muscle should be divided.

- (d) The **tensor fasciae cruris**. Origin: By a long slender tendon, from the transverse process of the fourth sacral vertebra. Insertion: Lateral fascia of the leg. This slender muscular slip underlies the biceps femoris.
- (e) The **semimembranosus**. Origin in two portions. **First** (superficial) **portion**: Fascia covering the first head of the biceps. **Second** (deep) **portion**: Lateral process of the ischial tuberosity. Insertion: In common with the gracilis on the fascia of the proximal portion of the medial surface of the leg. This fascia is contracted into two ligaments, one of which carries the insertion of the muscle to the distal end of the tibial tuberosity, the other to the distal end of the leg, where it joins the tendon of the heel (tendo calcaneus).
- (f) The **semitendinosus**. Origin: Ischial tuberosity. Insertion: Medial condyle of the tibia. The muscle is completely enclosed by the adductor magnus, which must be split to expose it.

BLOOD-VESSELS AND NERVES OF THE THIGH

The **femoral artery** (a. femoralis) traverses the medial surface of the thigh, beginning at the dorsal side of the inguinal ligament, where it continues the external iliac artery. Immediately distal to the inguinal ligament it gives off posteriorly the **deep artery of the thigh** (a. profunda femoris). The latter passes to the dorsal side of the pectineus and adductor brevis muscles and is distributed to the posterior proximal portion of the limb, chiefly to the adductores longus and magnus. A second branch, the **lateral circumflex artery** (a. circumflexa femoris lateralis), is given off from the anterolateral wall. It passes between the second head of the rectus femoris and vastus lateralis, on the one hand, and the two portions of the vastus intermedius, on the other. It supplies various parts of the quadriceps femoris group. A third branch of the femoral, the **superficial epigastric artery** (a. epigastrica superficialis), given off medially, and passing to the abdominal wall, has been divided (p. 221). At the beginning of the distal third of the thigh, a small branch, the **a. genu suprema**, passes over the medial condyle of the femur to

the knee-joint, and at about the point of origin of this vessel a large branch, the **great saphenous artery** (a. saphena magna), arises from the posterior wall. It passes across the medial surface of the distal end of the adductor longus, and through the tendon of the gracilis, to the medial surface of the leg. The femoral artery passes between the adductores longus and magnus, continuing as the **popliteal artery** (a. poplitea).

The hypogastric artery (p. 255) appears in the greater sciatic notch, continuing thence as the **sciatic artery** (a. ischiadica). The vessel passes backward to the dorsal surface of the superior ramus of the ischium, where it divides into **lateral caudal** and **internal pudendal** branches. Its smaller branches are distributed to the glutaei and biceps femoris muscles.

The **femoral vein** (v. femoralis) traverses the medial surface of the thigh in company with the femoral artery. It begins at the proximal end of the lower third of the thigh as a continuation of the **popliteal vein** (v. poplitea), which accompanies the corresponding artery. Its tributaries comprise the **great saphenous, superficial epigastric**, and **lateral circumflex**, and the **deep** vein of the thigh.

The **sciatic vein** (v. ischiadica) traverses the lateral surface of the thigh near its posterior margin, lying between the biceps and the semimembranosus proximally and, more distally, on the posterior margin of the former. At the dorsal border of the ischium, in front of the ischial tuberosity, before passing inwards to join the hypogastric vein, it receives the **lateral caudal** and **internal pudendal** veins.

The **femoral nerve** (n. femoralis) arises from the lumbo-sacral plexus, chiefly from the fifth and sixth lumbar nerves (p. 289). Its position between the psoas major and iliacus muscles has already been noted (p. 273). Immediately beyond the inguinal ligament it divides into two portions, one of which is distributed to the muscles of the anterior side of the thigh, while the other, the **great saphenous nerve** (n. saphenus major), passes to the medial surface of the thigh and leg in company first with the femoral artery and afterwards with the great saphenous artery.

The **sciatic nerve** (n. ischiadicus), formed chiefly from the seventh lumbar and first sacral nerves, appears laterally in the greater sciatic notch. It passes backward beneath the piriformis

muscle, and then turns and extends distad through the thigh, where it lies on the lateral surfaces of the adductores magnus and longus. It distributes branches to the posterior musculature of the thigh. In the proximal portion of the thigh it divides into two chief branches, which are closely associated as far as the knee. The anterior branch is the **peroneal nerve** (n. peronaeus), the posterior branch the **tibial nerve** (n. tibialis). The lesser saphenous nerve (p. 288) is a small branch given off from the tibial above the knee-joint.

For the origin of this and related nerves see p. 289.

The **superior gluteal nerve** (n. glutaesus superior) appears in the greater sciatic notch, leaving the sciatic close to the inferior posterior spine of the ilium. It passes between the glutaesus minimus and the lateral surface of the ilium, ending in the tensor fasciae latae. Its branches are distributed to the glutaesi medius and minimus and the piriformis muscles.

The **inferior gluteal nerve** (n. glutaesus inferior) perforates the posterior portion of the piriformis, and is distributed to the glutaesus maximus.

The **posterior cutaneous nerve** (n. cutaneus femoris posterior) accompanies the sciatic artery backward to the ischial tuberosity, where it turns to the posterior margin of the thigh and the medial surface of the sciatic vein, ending in branches to the skin.

The gluteal nerves originate from a loop connecting the seventh lumbar and the first sacral nerves and the posterior cutaneous nerve is described as having the same connection in the rabbit. The latter nerve may be found, however, connected chiefly with the second and third sacral nerves (as in various other mammals, such as the cat) and associated with the pudental and visceral branches. The last-mentioned arrangement is shown in figure 106.

The **pudental nerve** (n. pudendus) accompanies the sciatic artery and afterwards the internal pudental to the penis or clitoris.

The inguinal lymph nodes were observed at an earlier stage of the dissection (p. 221). These and a popliteal lymph node receive the subcutaneous lymph vessels of the hind limb, which can be seen only if specially injected. From them, lymph vessels run to a group of small iliac lymph nodes associated with the common iliac arteries and veins, into which nodes also the deep lymph vessels of the limb are emptied and from which arise lumbar trunks running forward in the lateral walls of the aorta.

In preparation for the muscular dissection of the leg, the insertion tendons of the biceps femoris, tensor fasciae cruris, gracilis, and semimembranosus muscles should be removed from about the knee-joint. The adductor magnus may be detached from the medial condyle of the femur, but the popliteal vessels must be kept intact. The superficial blood-vessels of the leg should be noted, since it is necessary to clear them away in separating the muscles. They include, medially, the great saphenous artery and vein and, laterally, the branches of the small saphenous artery to the insertion portions of the muscles of the thigh and its continuation on the posterolateral border of the leg; also the sciatic vein, with the anterior tibial vein, of which it is the continuation, and the accessory small saphenous vein (p. 287). The tibial and peroneal nerves may be cut, after first noting their position.

4. Muscles arising from the medial and lateral condyles of the femur and from the proximal portions of the tibia and fibula, including the tibial condyles; inserted on the foot. The group

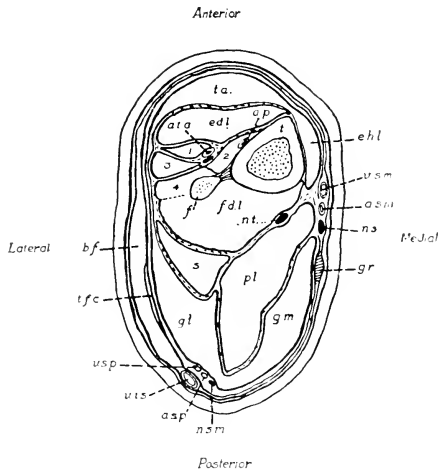


FIG. 105. Transverse section of the proximal portion of the leg: a.s.m., great saphenous artery; a.s.p., small saphenous artery; a.p., a.t.a., anterior tibial artery; b.f., biceps femoris (insertion); e.d.l., extensor digitorum longus; e.h.l., extensor hallucis longus; f., fibula; f.d.l., flexor digitorum longus; g.l., and g.m., lateral and medial heads of the gastrocnemius; gr., gracilis (insertion tendon); n.s., greater saphenous nerve; n.s.m., lesser saphenous nerve; n.t. tibial nerve; pl., plantaria; s., soleus; t., tibia; t.a., tibialis anterior; t.f.c., tensor fasciae cruris (insertion); v.s., sciatic vein; v.s.m., great saphenous vein; v.s.p., small saphenous vein; 1-4, the peronei (primus-quartus).

includes the typical extensors and flexors of the foot, together with the peronei muscles, which individually are extensors and flexors, but collectively have the relation of lateral tractors (Fig. 105).

A. **Extensor group.** Muscles occupying an anterior position on the leg and inserted on the dorsum of the foot.

- (a) The **extensor hallucis longus**. Origin: The medial condyle of the tibia just behind the tibial collateral ligament (p. 290) and the anteromedial surface of the same bone from about the level of the distal end of the tibial tuberosity to the middle of the length of the bone. Also the proximal half of the middle third of the posteromedial border of the tibia. Insertion: The tendon passes round the medial malleolus of the tibia, beneath the base and along the medial surface of the second (first functional) metatarsal, and to the dorsal surface of the basal phalanx of the corresponding digit, where it unites with the first tendon of the extensor digitorum longus.

This muscle is also identified as a tibialis posterior with displaced insertion tendon and is grouped with the flexors.

The posterior tibial artery, the continuation of the great saphenous, and the tibial nerve accompany the tendon in the malleolar groove.

- (b) The **tibialis anterior**. Origin: Lateral condyle of the tibia and corresponding surface of the tibial tuberosity. Insertion: Base of the second metatarsal. The tendon passes beneath the obliquely placed **crural ligament** of the lower portion of the leg.

The muscle should be divided and its head reflected.

- (c) The **extensor digitorum longus**. Origin: By a flattened tendon from the lateral portion of the patellar surface of the femur. This tendon passes through the capsule of the knee-joint, and the fleshy portion of the muscle lies on the anterolateral surface of the tibia. Insertion: The distal tendon passes beneath the crural ligament, then beneath the **cruciate ligament** of the dorsum of the foot, dividing into four portions for insertion on all the phalanges of the digits.

The muscle may be displaced by dividing the crural ligament.

The anterior tibial artery and its peroneal branch lie behind this muscle, the former in a medial position, in contact with the tibia, the latter on the peronei muscles in company with the peroneal nerve.

B. Peroneus group. These muscles arise from the lateral surface of the leg, and are inserted on all surfaces at the lateral side of the foot. The insertion tendons reach the foot from beneath the lateral malleolus. The muscles can be separated after the tendons are released from this position.

- (a) The **peroneus longus** (p. primus). Origin: Lateral condyle of the tibia and head of the fibula. Insertion: End of the reduced first metatarsal. The tendon crosses the plantar surface of the foot, passing around the distal end of the cuboid bone.

The muscle should be divided.

- (b) The **peroneus brevis** (p. secundus). Origin: Lateral condyle of the tibia and corresponding surface of the shaft; also the crural interosseous ligament joining the tibia and fibula. Insertion: Tuberosity of the base of the fifth metatarsal.
- (c) The **peroneus tertius** (p. digiti quinti). Origin: The head of the fibula and the crural interosseous ligament, fused with the flexor digitorum longus. Insertion: Head of the fifth metatarsal, and distally, united with the tendon of the extensor digitorum longus, on the phalanges of this digit.
- (d) The **peroneus quartus** (p. digiti quarti). Origin: The fibula and the interosseous ligament, fused with the peroneus brevis and with the flexor digitorum longus. Insertion: Head of the fourth metatarsal.

C. Flexor group. The muscles arise from the medial and lateral condyles of tibia and femur (the flexor digitorum sublimis from the posterior surface of the tibia). They lie behind the axis of the tibia, and are inserted both on the heel and on the plantar surface of the foot.

- (a) The **triceps surae** comprises:

(1) The **gastrocnemius**. Origin in two portions. **Caput laterale**: Lateral condyles of tibia and femur and related

femoral sesamoid. **Caput mediale:** The main origin is on the medial condyle of the femur and its sesamoid, but a smaller portion of the muscle originates in part with (immediately dorsal to) the caput laterale and in part by a flat tendon from the lateral edge of the patella.

(2) The **soleus:** Origin: By a strong tendon from the head of the fibula.

Insertion: Through the **Achilles' tendon** (tendo calcaneus). The latter passes over the posterior end of the tuber calcanei, and is attached to its ventral surface. The tendon is covered by that of the plantaris muscle.

The small saphenous artery and vein lie at the posterior margin of the lateral head of the gastrocnemius in company with the lesser saphenous nerve.

- (b) The **plantaris.** Origin: Lateral condyle of the femur and associated sesamoid. Insertion: The tendon passes over the heel to the plantar surface of the foot, and divides into four parts for insertion on the second phalanges of the four developed digits. Each of these parts is perforated near its termination by a tendon of insertion of the flexor digitorum longus.

The two muscles should be divided.

- (c) The **popliteus.** Origin: Lateral condyle of the femur. The tendon passes through the capsule of the knee-joint. The muscle contains the tibial sesamoid. It crosses the posterior surface of the tibia obliquely, and is inserted on the proximal portion of its posteromedial angle.
- (d) The **flexor digitorum longus.** Origin: Lateral condyle of the tibia and head of the fibula, extending to the posterior surface of the interosseous ligament and associated portions of the tibia and fibula. Insertion: The tendon passes beneath the sustentaculum tali, reaching the plantar surface of the foot, where it is partly covered by the plantaris tendon. It divides into four parts for insertion on the ungual phalanges of the four developed digits.

The tibial nerve lies on the medial surface of the head of the plantaris and afterwards on the medial surfaces of the popliteus and flexor digitorum longus.

5. Muscles arising from the foot and inserted on the individual digits.
- (a) The **lumbricales**. Origin: Tendon of the flexor digitorum longus. Insertion: Medial surfaces of the first phalanges of the three lateral digits.
 - (b) The **adductor indicis** and the **adductor minimi digiti**. Two extremely slender slips of muscle. Origin: Near the middle of the dorsal wall of the tendon-sheath of the flexor digitorum longus. Insertion: By long, thin tendons respectively to the lateral side of the first phalanx of digit two and the medial side of that of digit five.
 - (c) The **interossei** (metatarsi). Origin: From the dorsal portion of the tendon-sheath of the flexor digitorum longus, external and distal to the origin of the adductors. Insertion: Heads of the four metatarsals.

VESSELS AND NERVES OF THE LEG AND FOOT

The **great saphenous artery** passes distad on the medial surface of the leg, and is continued as the **posterior tibial artery** (a. tibialis posterior) around the medial malleolus to the plantar surface of the foot. Above the ankle-joint it gives off the **malleolar artery** (a. malleolaris) to the posterior surface of the distal end of the tibiofibula.

The **popliteal artery**, the continuation of the femoral, passes between the medial head of the gastrocnemius on the one hand and the lateral head and the plantaris on the other, reaching the anterior surface of the popliteus, and afterwards the anterior surfaces of the tibia and fibula by passing between their proximal ends. It distributes branches to the muscles about the knee-joint, including a branch to the distal portion of the vastus lateralis, which is given off near the same point as the small saphenous artery. It then continues as the **anterior tibial artery**. The vessel appears in front of the interosseous ligament of the leg and of the peroneus brevis, and continues to the dorsum of the foot after passing beneath the crural ligament. A large branch, the peroneal artery, given off in the upper part of the leg also reaches the dorsum of the foot from a more lateral position.

A branch of the popliteal artery supplying the flexor digitorum longus represents the posterior tibial artery of the human limb. In the latter, the great saphenous artery is lost and the peripheral part of its distribution (the posterior tibial artery as described above) has been taken over by the branch indicated. A comparable arrangement can occur as an individual variation in the rabbit. In man, the peroneal artery is a branch of the posterior tibial and runs distad behind the fibula.

The **small saphenous artery** (a. saphena parva) rises from the popliteal and appears on the proximal portion of the posterolateral margin of the leg, running along the border of the lateral head of the gastrocnemius in company with the corresponding vein and the lesser saphenous nerve. It continues in the thick lateral superficial fascia to the lateral aspect of the calcaneus and ramifies extensively to the structures about the dorsal, lateral, and plantar surfaces of the heel, passing mediad across the plantar surface of the tarsus to anastomose with a small branch of the posterior tibial artery. A branch given off about the level of the lateral malleolus accompanies the peroneal tendons to the dorsum of the foot.

The **great saphenous vein** (v. saphena magna), a large tributary of the femoral, accompanies the corresponding artery and the greater saphenous nerve. It is a continuation of the **posterior tibial vein** (v. tibialis posterior) from the plantar surface of the foot.

The **popliteal vein**, the root of the femoral, accompanies the corresponding artery in the popliteal fossa. It receives the **small saphenous vein** (v. saphena parva) from the posterior margin of the lateral head of the gastrocnemius, where this vein has been formed by tributaries accompanying the distal branches of the small saphenous artery.

The **sciatic vein** is the continuation of the **anterior tibial vein** (v. tibialis anterior), which runs along the lateral surface of the leg. The anterior tibial receives the **accessory small saphenous vein** (v. saphena parva accessoria) from the posterior surface and drains the dorsum of the foot, passing to the fibular side of the crural ligament. It reaches the region of the medial malleolus but does not pass this in the rabbit.

The **greater saphenous nerve**, the posterior branch of the femoral nerve, accompanies first the femoral artery and afterwards the great saphenous artery, passing distad to the medial surface of the leg to supply the skin.

The **tibial nerve**, the posterior division of the sciatic, passes between the medial and lateral heads of the gastrocnemius to the medial surface of the head of the plantaris. It traverses the leg, lying on the medial surface first of the popliteus and afterwards of the flexor digitorum longus, and passing beneath the medial malleolus reaches the plantar surface of the foot. In the proximal portion of the leg it distributes muscular branches to the flexor group.

The **lesser saphenous** or **sural nerve** separates from the tibial before it reaches the gastrocnemius muscle and accompanies the small saphenous artery and vein on the posterior margin of the lateral head of the gastrocnemius. It is distributed in the skin and fascia of the ankle and heel, one terminal branch passing under the external malleolus to the lateral and ventral surfaces of the calcaneus.

The **peroneal nerve**, the anterior division of the sciatic, passes distad, lying at first between the insertion of the biceps and the lateral head of the gastrocnemius, and thus appearing on the surface exposed by the removal of the former. It perforates the anterior portion of the lateral head of the gastrocnemius and afterwards the fused heads of the peronaeus tertius and flexor digitorum longus, traversing the leg at first behind the peronaeus longus and then around its medial margin to the front of its tendon, where it becomes associated with the peroneal artery. It passes with the latter over the fibular side of the crural ligament and branches over the whole dorsal surface of the foot (a distribution somewhat more extensive than in most animals). The nerve distributes branches to the tibialis anterior, to the extensor digitorum longus, and to the peronaeus muscles.

In man and most mammals, a common peroneal nerve divides into a superficial and a deep branch, but the latter appears to be absent in the rabbit.

THE LUMBOSACRAL PLEXUS

The structure of the lumbosacral plexus may be examined by breaking away the ventral portion of the pelvis, or by dividing the sacroiliac articulation in such a way that the two sides of the pelvis may be pressed apart, the ventral or pelvic face of the sacrum being thus exposed. The posterior portion of the psoas and iliacus muscles may be picked away with the forceps, and the

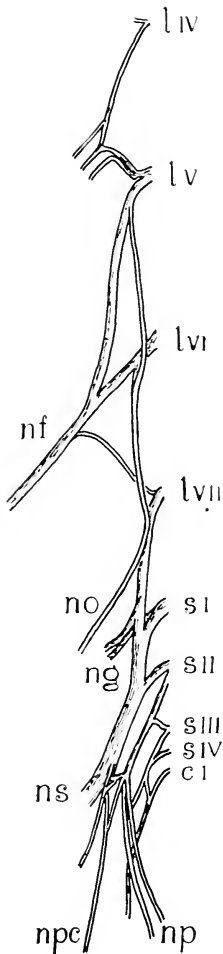


FIG. 106. Ventral view of right lumbosacral plexus. cI, first caudal nerve; lIV-VII, fourth to seventh lumbar nerves (ventral rami); nf, femoral nerve; ng, gluteal nerves; no, obturator nerve; np, pudendal nerve; npc, posterior cutaneous nerve; ns, sciatic nerve; s I-IV, first to fourth sacral nerves.

abductor caudae anterior muscle (p. 343) may be detached from its origin on the ischial spine.

The **lumbosacral plexus** (plexus lumbosacralis) is formed by the ventral roots of the four posterior lumbar and four sacral spinal nerves (Fig. 106). It is divisible into a **lumbar plexus** (plexus lumbalis), from which arises the femoral nerve, and a **sacral plexus** (plexus sacralis), from which arises the sciatic nerve. It is subject to certain variation.

The **femoral nerve** is formed usually from the fifth, sixth, and seventh lumbar, especially from the loop connecting the fifth and sixth (ansa lumbalis II). The **obturator nerve** (n. obturatorius), which accompanies the obturator artery, is formed from the fifth, sixth, and seventh lumbar but chiefly from the sixth, and is distributed to the obturatores, adductores, and gracilis muscles.

The **sciatic nerve**, together with the superior and inferior gluteal nerves, arises chiefly from the loop connecting the last lumbar and first sacral nerves (ansa lumbalis III).

The internal pudendal nerve is formed from the loop connecting the second and third sacral nerves (ansa sacralis II), but chiefly from the second, and the posterior cutaneous nerve may also connect with the same roots.

THE ARTICULATIONS OF THE POSTERIOR LIMB

The more perfect development and larger size of the joints of the posterior limb make them much more favourable for examination than the corresponding parts of the anterior limb.

The muscular attachments should be re-

moved from about the articular capsules and the structures examined as follows:

A. The **hip-joint** (*articulatio coxae*) is an enarthrosis, formed by the head of the femur with the parts of the ischium, ilium, and the *os acetabuli* enclosing the acetabulum, together with the **articular capsule** (*capsula articularis*) and accessory ligaments.

The articular capsule extends from the acetabular margin to the proximal end of the neck of the femur. It is strongest on its dorsal side, but is especially thickened at three points, forming the **ischio-capsular** (dorsal), **iliofemoral** (anterior), and **pubocapsular** (ventral) ligaments.

By dividing the capsule, the contents of the joint and the smooth articular surfaces may be examined; also the attachment of the head of the femur to the wall of the acetabular fossa through the **round ligament** (*lig. teres femoris*). The **glenoid lip** (*labrum glenoidale*) is the ring of fibrocartilage surrounding the margin of the acetabulum and connecting with the articular capsule.

B. The **knee-joint** (*articulatio genu*) is a hinge-joint or *ginglymus* with a slight spiral trend. It is formed by the articular surfaces of the medial and lateral condyles of the femur and tibia, with the associated articular capsule, ligaments, and interarticular fibrocartilages (see section, Fig. 27).

The **tibial collateral ligament** (*lig. collaterale tibiale*) is a stout band of connective tissue stretching from the medial condyle of the femur to the posteromedial angle of the medial condyle of the tibia.

The **fibular collateral ligament** is a similar structure connecting the lateral condyle of the femur with the anterior surface of the head of the fibula.

The sesamoid bones of the popliteal region have articular surfaces taking part in the formation of the joint. That on the medial condyle of the femur is contained in the medial head of the *gastrocnemius*, that on the lateral condyle of this bone in the lateral head of the *gastrocnemius* and the *plantaris*, and that on the lateral tibial condyle in the *popliteus*.

The common tendon of the *quadriceps femoris*, the *patella*, and the *patellar ligament* are associated with the capsule, forming the anterior wall of the joint, and a pad of soft fat underlies the *patellar*

ligament in such a way as to project into the joint cavity.

Between the apposed surfaces of the condyles, in the interior of the joint, there are two short, **cruciate** ligaments and two thin plates of fibrocartilage, the **medial** and **lateral menisci**. The **anterior cruciate ligament** (lig. cruciatum anterius) passes from the lateral wall of the intercondyloid fossa of the femur to the anterior end of the intercondyloid eminence of the tibia. The **posterior cruciate ligament** passes from the medial wall of the intercondyloid fossa of the femur to the posterior intercondyloid fossa of the tibia. The **medial meniscus** (meniscus medialis), a thin crescentic plate of fibrocartilage, lies on the articular surface of the medial condyle of the tibia, and is connected by ligament with the anterior and posterior intercondyloid fossae of the bone. The larger, **lateral meniscus** lies on the lateral condyle of the tibia, and is attached by ligament anteriorly to the medial portion of the articular surface, and posteriorly, to the medial wall of the intercondyloid fossa of the femur. The tendon of origin of the extensor digitorum longus traverses the anterior part of the joint on its way from the patellar surface of the femur to the front of the leg.

The **interosseous ligament** of the leg (lig. interosseum cruris) forms an almost complete sheet connecting the uncoalesced portions of tibia and fibula.

C. The **ankle-joint** (articulatio talocruralis) is a ginglymus with a considerable amount of spiral torsion. The articulating surfaces are formed chiefly by the tibia and talus, but also by the fibular side of the tibiofibula and the calcaneus. On the tibial side the **calcaneotibial ligament** (lig. calcaneotibiale) passes obliquely anteroventrad and then across the plantar surface to connect the medial malleolus with the sustentaculum tali and deep (lateral) to this a thick talotibial ligament connects the malleolus with the medial surface of the talus. On the fibular side the **calcaneofibular ligament** (lig. calcaneofibulare) connects the posterior portion of the groove for the peronei muscles forwards with the lateral surface of the calcaneus, and a second ligament extends from the anterior margin of the groove backward to the lateral surface of the calcaneus. The **tibionavicular ligament** (lig. tibionaviculare) connects the anterior surface of the distal end of the tibia with the dorsal surface of the navicular bone. The joint contains in its interior the short, strong **talofibular ligament** connecting the

medial side of the lateral malleolus with the lateral and ventral surfaces of the trochlea tali.

The Bone Marrow

Before the bones are discarded following the foregoing dissection, an instructive view of the marrow, which is not observed in the study of dried bones, may be obtained by breaking the femur and examining its interior. The marrow is a mass of reticular connective tissue with, in long bones such as the femur, a predominance of fat cells. It contains numerous vessels and is one of the principal sites of development of erythrocytes as well as producing white blood cells. The vessels are accompanied by sympathetic (efferent) and afferent nerve fibres.

X. THE HEAD AND NECK

This dissection includes the various structures of the region, with the exception of the cervical and occipital musculature and the central nervous system, which are treated in the succeeding parts, and the special musculature of the ear, which has been omitted.

To begin the dissection, the median ventral incision of the skin should be extended forward to the mandibular symphysis and the skin should be separated from the underlying platysma along the side of the head, and reflected until the surface is clear to a point near the dorsal median line of the skull. The more posterior part of the platysma has already been described on page 257. It is a very thin sheet of muscle originating in the skin over the first two ribs and extending over the neck and the ventral and lateral aspects of the head to be inserted in the skin over the cheek. Closely associated with this muscle and lying immediately beneath it, the depressor conchae posterior (p. 257) and the **depressor conchae anterior** (parotideoauricularis anticus), the latter originating on the ventrolateral surface of the mandible just in front of the masseter muscle, meet and are inserted together on the outer part of the base of the external ear.

The platysma proper is composed mainly of longitudinal fibres inserted in the skin about the angle of the mouth and the chin. A more superficial layer of roughly vertical and transverse fibres, which nearly always comes away with the skin, is the sphincter superficialis of the head. A specialized portion of the

platysma, the pars zygomatica platysmatis, has acquired an insertion on the zygomatic bone and is more or less separated from the main muscle. A deeper transverse layer, the sphincter profundus, is also distinguishable.

In removing the skin of the upper and lower eyelids, the dissector may observe the **orbicularis oculi**. This is a thin, somewhat ring-like band of muscle lying directly on the inner surface of the skin and forming a sphincter round both eyelids, which are closed by its contraction. The muscle fibres are concentrated at the anterior end, and, more particularly, at the posterior angles. The antagonistic action of raising the upper eyelid is accomplished by a muscle (levator palpebrae superioris) which arises from the orbital wall and, at this stage of dissection, is concealed by the projecting supraorbital process, while the depressor palpebrae inferioris consists of an extremely delicate group of muscle fibres described as originating on the zygomatic process of the maxilla and inserted in the anterior part of the lower eyelid.

Round the mouth, a very thin band of fibres on the skin constitutes the **orbicularis oris**, which in the rabbit is inconspicuous and forms a ring interrupted dorsally on account of the cleft upper lip. It is a special portion of the sphincter profundus mentioned above.

Small lymph glands of irregular occurrence are usually found ventral to the mandible. These receive the flow from subcutaneous lymphatic vessels and are drained by other vessels into the superficial lymph glands of the neck, of which usually two or three are associated with the external jugular veins and give rise to the jugular trunks. These last empty into the veins near the junction of the jugulars with the subclavians.

1. On the lateral surface of the head, the following structures may be made out after removal of the platysma without further dissection beyond the clearing of a little fascia.

- (a) The **parotid gland** (gl. parotis), a diffuse, white or brownish gland lying immediately behind the angle of the mandible. It expands dorsally to cover the lateral aspect of the base of the external ear and ventrally beneath the mandible (Fig. 46). Its **duct** (d. parotideus) passes forward across the lateral surface of the masseter muscle (*c*) in close association with the branches of the facial nerve (Fig. 107) and, perforating the mucous membrane of the cheek, opens into the oral cavity opposite the last upper molar tooth.

A lymph gland of some size is imbedded in the posterior aspect of the upper part of the parotid.

- (b) The chief part of the **seventh cranial** or **facial nerve** (n. facialis) appears in the anterior portion of the parotid gland, its branches crossing the masseter. They are distributed as motor nerves to the cutaneous muscles of the face, including the platysma.
- (c) The **masseter muscle**. Origin: The zygomatic arch; tendinous from its anterior angle and fleshy behind. Insertion: Lateral surface of the angle of the mandible. This muscle should not be disturbed at present. It is described in more detail on page 302.
- (d) The **external maxillary artery** (a. maxillaris externa) appears at the ventral border of the mandible immediately in front of the masseter. It passes dorsad to the region just in front of the eye, where it ends as the **angular artery** (a. angularis). Its chief branches to the anterior portion of the face are: (1) the **submental artery** (a. submentalis) to the chin, a small branch rising near where the external maxillary crosses the ventral margin of the mandible; (2) the **inferior labial artery** (a. labialis inferior) to the lower lip; and (3) the **superior labial artery** to the upper lip.

A small vessel, the **transverse facial artery**, crosses the cheek, running along the ventral border of the zygomatic arch. It is a branch of the superficial temporal (p. 307).

- (e) The **anterior facial vein** (v. facialis anterior) accompanies the external maxillary artery. It begins in front of the eye as the **angular vein**, and receives as tributaries the **superior** and **inferior labial veins**.

2. Dissection of the facial muscles. These muscles arise from the facial portion of the skull, and are inserted into the skin about the upper and lower lips.

- (a) The subcutaneous faciei, a thin muscle described as originating on the lateral border of the premaxilla, its frontal process, and the supraorbital process of the frontal bone and as being inserted on the skin of the dorsal surface of the nose, appears to vary in the degree of its development.

- (b) The **corrugator supercilii**, a conspicuous band closely associated at its insertion with the fore-going and probably operating in conjunction with the orbicularis oculi in firmly closing the eye. Origin: Anterodorsal margin of the zygomatic arch. Insertion: In front of and dorsal to the upper eyelid.

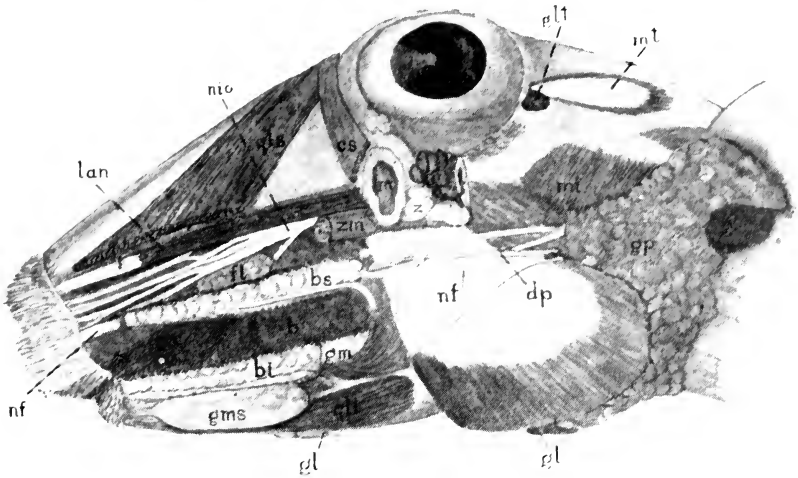


FIG. 107. Lateral view of the head. The insertion portions of the quadratus labii superioris and the zygomaticus minor, the origin of the caninus, and the anterior part of the zygomatic arch with the attached portion of the masseter have been removed, as have the more superficial structures. The buccinator muscle has been divided along two longitudinal lines to reveal the underlying buccal glands.

b, buccinator muscle; bi, inferior buccal gland; bs, superior buccal gland; c, caninus, remnant of insertion portion; cs, corrugator supercilii, insertion portion; dp, parotid duct; fl, facial lymph gland; gl, infraorbital gland; g, lymph glands; glt, temporal lobe of lacrimal gland; gm, masseteric gland; gms, superficial mandibular gland; gp, parotid gland; lan, levator alae nasi; m, cut end of zygomatic process of maxilla; ml, separable posterior part of internal division of masseter muscle; mt, temporal muscle, origin portion; nf, facial nerve; nio, infraorbital nerve; qli, quadratus labii inferioris; qls, quadratus labii superioris; z, zygomatic gland; zm, zygomaticus minor, origin.

- (c) The **quadratus labii superioris**. Origin: The postero-lateral corner of the nasal bone, the frontal process of the premaxilla, and the maxillary process of the frontal bone. Insertion: Skin of the upper lip.¹
- (d) The **zygomaticus minor**. Origin: Anterior surface of the zygomatic process of the maxilla. Insertion: Skin of the

¹The levator alae nasi and zygomaticus minor muscles may be considered to be subdivisions of this muscle.

- posterolateral part of the upper lip, in common with (c).
- (e) The **levator alae nasi**. Origin: Ventral part of the maxillary fossa. Insertion: Skin covering the lateral cartilage of the nose. The muscle is slender and is inserted by a long tendon which underlies the insertion portions of the two preceding muscles.
- (f) The **caninus**. Origin: Lateral border of the upper jaw. Insertion: Hairy portion of the mucous membrane of the mouth. The muscle is very broad, short, and thin and is closely applied to the lateral surface of the buccinator.
- (g) The **buccinator**. A broad stout sheet of fibres enclosing the cheek. Origin: The alveolar borders of the upper jaw and mandible as well as the anterolateral surface of the mandible. The insertion portion curves forward into each lip to be attached to the lining of the mouth.
- (h) The **quadratus labii inferioris**. Origin: Ventral border of the mandible. Insertion: Skin of the lower lip.
- (i) The **mentalis**. The muscle surrounds the anterior portion of the mandible behind the incisor teeth. It is attached externally to the skin of the lower lip through the insertion portion of the quadratus labii inferioris, which largely overlies it.

Because of the great size and mobility of the ears, the cutaneous auricular muscles, comprising some twenty different members, are especially well developed. These muscles are not individually described, but their extent should be noted in contrast to the vestigial character of the ear muscles in man.

Dissection of glands on the lateral aspect of the head (Fig. 107). The salivary glands are extensively developed in the rabbit. The largest is the parotid gland, described above (1a). The submaxillary gland is described on page 298, the sublingual gland on page 307, and the zygomatic gland on page 316.

- (j) The **superior buccal gland**, a long, narrow band of loosely connected lobules internal to the more dorsal part of the buccinator muscle, which must be divided to expose the gland. The lobules of the gland are associated with the superior labial artery and extend from a point just above

the terminal portion of the parotid duct to a position dorsal to the angle of the mouth.

- (k) The larger **inferior buccal gland** is also elongate but thicker, and comprises three portions. Two long, slender masses lie side by side internal to the more ventral part of the buccinator muscle, which must be cut lengthwise to expose them. The thicker, more dorsal of the two is replaced caudally by a third portion which has received the name **masseteric gland**.
- (l) The **superficial mandibular gland**, a flattened, oval mass closely applied to the ventrolateral surface of the mandible, covered by the anterior part of the platysma, is a cutaneous gland, from which the ducts open on the skin of the lower lip.
- (m) The **facial lymph gland** overlies the dorsal edge of the buccinator muscle and is covered laterally by the zygomaticus minor.

3. Dissection on the ventral surface of the neck to free the external jugular vein and its tributaries. The cervical fascia and a portion of the parotid gland must be removed.

The **external jugular vein** (v. jugularis externa) is formed behind the angle of the mandible by the union of the anterior and posterior facial veins. It passes backward in a superficial position to the superior thoracic aperture. Its connections in the lower part of the neck comprise the **transverse scapular vein** (v. transversa scapulae) of the shoulder and its union with the vein of the other side by the **transverse jugular vein** (v. jugularis transversa) (Fig. 111, p. 327). The last-mentioned vessel crosses ventral to the common carotid artery and the sternohyoid muscle a short distance anterior to the tip of the manubrium sterni.

The **posterior facial vein** is formed in front of the base of the ear by the union of the **superficial temporal vein**, which runs forward immediately dorsal to the external auditory meatus after emerging from the cranial cavity, and the **external ophthalmic vein**, which passes back from the orbit.

The superficial temporal vein receives blood from the brain through the transverse sinus, which emerges through a foramen between the squamosal and

petromastoid bones near the tip of the squamosal process of the parietal. As it runs along the lower margin of the temporal muscle, it is joined by one or more small **deep temporal veins** from the substance thereof. The posterior facial is joined by the **anterior auricular vein** from the ear and then passes downward through the parotid gland, receiving the small transverse facial vein and being crossed by the facial nerve. Immediately below the latter it receives the **posterior auricular vein** from the ear and the back of the head. At about the same level it is joined by a deep vessel, the **posterior internal maxillary**, emerging from behind the mandible.

In addition to the tributaries described above (p. 294), the **anterior facial vein** receives from beneath the anterior margin of the masseter the **deep facial vein** (v. facialis profunda). The latter arises in the lower anterior portion of the orbit, and passes downward beneath the masseter muscle. The anterior facial vein receives at the ventral border of the mandible the **internal maxillary vein** (v. maxillaris interna). The latter also begins in the orbit, where it is connected with the deep facial. It is also identified as the sublingual vein. At the medial surface of the mandible it receives the **inferior alveolar vein**—to be seen at a later stage—from the interior of the mandible.

An anastomotic branch connects the deep facial vein with the inferior alveolar vein through the foramen at the ventral end of the sulcus ascendens of the mandible. This provides an outlet through the latter vein for the blood from the former when its passage is obstructed by the pressure of the contracting masseter and internal pterygoid muscles.

A small, unpaired **median submental vein** enters the anterior facial of one side.

The external jugular vein may be divided and turned forward together with the parotid gland.

4. Examination of the more superficial structures of the ventral surface of the head and neck.

- (a) The **submaxillary gland** (gl. submaxillaris), one of the salivary series, is a somewhat compact rounded or oval gland lying at the medial side of the extreme ventral portion of the angle of the mandible. Its whitish-coloured **duct** (d. submaxillaris) may be seen running upward and slightly forward to enter the mouth (cf. p. 307). It crosses the lateral surface of the digastric muscle but is medial to the external maxillary artery and is approximately paralleled

by a branch from this artery to the gland and by a corresponding tributary of the anterior facial vein.

- (b) The angle of the mandible is covered by two muscles of mastication, the **masseter** lying on the lateral surface, and the **pterygoideus internus** on the medial surface, the latter being overlapped ventrally by a part of the former.
- (c) The **digastricus**. Only its insertion portion is visible (the origin being by a long, round tendon from the stylohyoid ligament, and so from the jugular process of the occipital bone

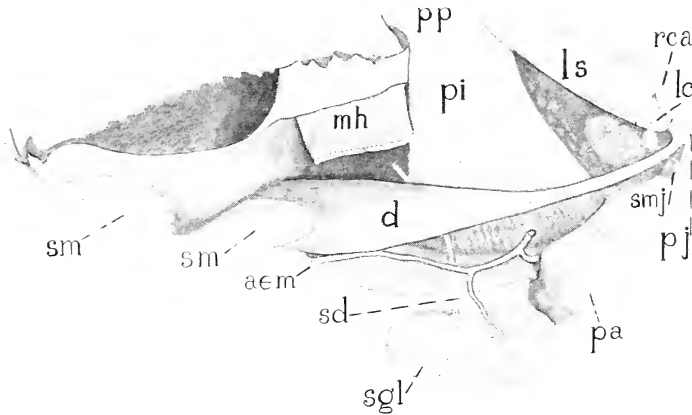


FIG. 108. Medial and somewhat ventral view of the muscles of the right half of the lower jaw. aem, external mandibular artery; d, digastricus muscle; lc, longus capitis muscle; ls, levator scapulae major (with basioclavicularis) muscle; mh, mylohyoid muscle (right half); mm, medial insertion-portion of masseter muscle; pa, parotid gland; pi, pterygoideus internus muscle; pj, jugular process; pp, pterygoid process; rca, rectus capitis anterior muscle; sd, duct of submaxillary gland; sg, styloglossus and stylohyoideus minor muscles; sgl, submaxillary gland (displaced ventrad); sm, mandibular symphysis; smj, stylohyoideus major muscle.

—Fig. 108). It passes forward along the medial surface of the mandible, on the anterior ventral portion of which surface it is inserted. In man and some lower primates, a second fleshy portion occupies the position of the posterior part of the tendon of origin, whence the muscle derives its name.

- (d) The **mylohyoideus** is a transverse sheet of muscle arising from the medial surface of the mandible on either side and inserted on the hyoid bone.
- (e) The **sternomastoideus**. Origin: In common with that of

the opposite side, from the manubrium sterni. Insertion: Mastoid process of the skull.

- (f) The **sternohyoideus**. Origin: In common with that of the opposite side, from the dorsal surface of the manubrium and anterior portion of the body of the sternum, extending to the third costal articulation. Insertion: Greater cornu of the hyoid.

The two muscles are closely associated in the middle line. They should be separated from each other and divided.

- (g) The **sternothyroideus**. Origin: In common with the sternohyoideus. Insertion: Lateral plate of the thyroid cartilage of the larynx. The muscle forms a thin band lying on the side of the trachea. It is continued from the thyroid cartilage to the greater cornu of the hyoid as the **thyreohyoideus**.
- (h) The trachea occupies a median position. It is supported by cartilaginous **tracheal rings**, each of which is incomplete dorsally thus allowing brief partial compression.
- (i) The **thyreoid cartilage** of the larynx; a saddle-shaped cartilage, composed of **right** and **left thyreoid plates** (Fig. 91) completely fused with each other ventrally.
- (j) The **cricoid cartilage**, a thick annular cartilage situated between the thyreoid cartilage and the first tracheal ring. It is connected ventrally with the thyreoid cartilage by the **cricothyreoides** muscle.
- (k) The **deep cervical lymph gland** (lymphoglandula cervicalis profunda) is a large, elongated, reddish-coloured gland in the upper portion of the neck, opposite the thyreoid cartilage.

This gland receives lymph vessels from the root of the tongue, the pharynx, and the larynx and empties into the jugular trunk through a vessel which accompanies the internal jugular vein.

- (l) The **thyreoid gland** (gl. thyroidea) lies on the ventral and lateral surfaces of the trachea behind the cricoid cartilage. It is composed of right and left portions connected across

the middle line by a thin median portion, the **isthmus** (cf. p. 133).

- (*m*) The **common carotid artery** (a. carotis communis) passes forward from the superior thoracic aperture along the side of the trachea. Its branches on the neck include the **superior thyreoid artery** (a. thyroidea superior), to the thyreoid gland, the oesophagus, the larynx, and the cricothyreoid muscle of the larynx (inferior laryngeal artery). The (**superior**) **laryngeal artery** rises from the upper end of the common carotid or the beginning of the external carotid artery near the level of the anterior edge of the thyreoid plate and accompanies the superior laryngeal nerve through the thyreoid foramen to the interior of the larynx after sending branches to the oesophagus, the hyothyreoid membrane, and the hyothyreoid, sternothyreoid, and sternohyoid muscles.
- (*n*) The **internal jugular vein** (v. jugularis interna) lies to the lateral side of the common carotid artery, traversing the neck from the jugular foramen of the skull to the superior thoracic aperture.
- (*o*) The **tenth cranial** or **vagus nerve** (n. vagus) is the largest of four nerves accompanying the carotid artery. It lies to the lateral side of the common carotid, between the latter and the internal jugular vein. It gives off the **n. laryngeus superior** to the larynx, this nerve crossing the dorsal side of the common carotid artery.

The superior laryngeal nerve passes through the thyreoid foramen (p. 313) into the larynx and supplies sensory fibres to the mucous membrane of the larynx and motor fibres to the cricothyreoid muscle.

The vagus is a mixed nerve, containing both afferent and efferent fibres. Its action on the heart is inhibitory, that on the stomach is excitatory. Section of the nerves increases heart beat.

- (*p*) The **ramus descendens** of the **twelfth cranial** or **hypoglossal nerve** (p. 309) crosses the root of the vagus from a lateral to a medial position. It passes backward on the ventral surface of the common carotid artery, and is distinguishable chiefly by its branches to the sternohyoideus and related muscles.

- (*q*) The **cervical portion** of the **sympathetic trunk** lies on the dorsal surface of the common carotid, and is slightly medial in relation to the vagus.

Section and stimulation of the sympathetic in the neck is one of the classic demonstrations of vaso-motor action. The result of section can be seen in reddening and loss of heat in the ear (vaso-dilatation), and contraction of the pupil of the eye. Stimulation has the opposite effect (vaso-constriction).

- (*r*) The **ramus cardiacus** of the **vagus** (n. depressor) lies on the dorsal surface of the common carotid on the medial side of the sympathetic trunk, arising at the level of the posterior margin of the thyroid cartilage. It is an afferent nerve. Its fibres are said to originate from cells in the upper pole of the jugular ganglion (a mass of nerve cells forming two slight swellings on the vagus nerve just before it emerges from the skull). Those of the left terminate peripherally in the arch of the aorta, those of the right in the subclavian, being distributed along with other nerve fibres in the cardiac plexus.

Occurring in the rabbit as a separate nerve, the depressor is important experimentally. Stimulation of the proximal end in the living animal produces fall of blood pressure and retardation of the heart beat. The former is due to reflex action on the blood-vessels (cf. p. 64), while the latter depends upon reflex inhibition by impulses passing through the vagus, as is shown by the fact that slowing of the heart does not take place if the vagi also are divided.

- (*s*) The **third** and **fourth cervical nerves** may be traced from their origin in the intervertebral foramina to the musculature of the neck. They encircle the basioclavicularis muscle, under cover of the sternomastoideus and cleidomastoideus.
5. Dissection of the muscles of mastication and related structures of the mandible.
- (*a*) The **masseter muscle**. Origin: The zygomatic arch. Insertion: Lateral surface of the angle of the mandible (1, *a*), also that of the ramus. Some of the most anterior fibres curve round the ventral edge of the mandible and pass back medial to it, covering the ventral part of the internal

pterygoid (*c*). They are inserted along the ventral edge almost to its posterior extremity.

The masseter muscle consists of external and internal divisions which are readily separable posteriorly but not anteriorly. The external originates from the lateral surface of the zygomatic arch along slightly less than the anterior half of its length, tendinous from its anterior angle and fleshy behind that. Its insertion is near the ventral edge of the mandible. The main part of the internal division takes origin from the internal surface of the same part of the arch and is inserted dorsal to the external division. In the rabbit a readily separable portion, probably to be included with the internal division, originates from the remainder of the inner surface of the arch and is inserted on the lateral surface of the ramus of the mandible.

The orbital structures should be freed from the zygomatic arch by passing a knife along its dorsal margin. The zygomatic processes of the maxilla and of the squamosal bone should then be divided and the zygomatic arch should be removed, together with the whole of the masseter muscle, which should be cleanly cut from its attachment to the mandible. Care should be taken not to injure the insertion tendon of the temporalis muscle just internal to the arch.

- (*b*) The **temporalis** is a slender muscle, being much smaller in the rabbit than in many mammals. It originates in the reduced temporal fossa (sulcus temporalis) of the skull back to about the posterior margins of the squamosal and parietal bones and is inserted by a long stout tendon on the edge and adjacent part of the lateral surface of the reduced coronoid process. Fibres from the masseter and the superior portion of the external pterygoid muscles are attached along the side of the tendon. The muscle may be exposed by dividing the temporal portion of the posterior supraorbital ligament which holds its tendon in place, and the muscles in front of the external ear if these are still in position. The temporal muscle itself may then be divided.

On account of the narrowness of the space between the two limbs of the mandible and the great depth of its angle, it is necessary, in order to expose the surface for the deep dissection of the ventral portion of the head and neck, to remove one-half of the

mandible. A better understanding of the attachments and relations of the muscles of mastication may be obtained, however, if this is done in steps, as follows.

Divide the mandibular symphysis and free one half of the mandible from its attachments to the lips and to the lining of the mouth. Pass a scalpel along the ventral part of the medial surface of the bone so as to detach the digastricus and mylohyoideus muscles and also the pterygoideus internus (see below). The insertion of the pterygoideus externus, which is more dorsally situated, should remain intact. The tip of the knife should be kept close to the bone so that the underlying soft parts, except in that they are divided at their attachments, will be kept uninjured, the medial surface of the mandible being clean when removed. The ventral edge of the mandible should then be turned laterad so as to rotate the bone towards a horizontal position, thereby exposing the following structures without further injury to any. (In order that this may be done, the zygomatic process of the squamosal bone must have been cut through its most dorsal part when the zygomatic arch was removed, as directed on the previous page.)

The structures appearing on the cut surface include the insertion of the digastricus and the margin of the mylohyoideus; also the following parts are exposed.

- (c) The **pterygoideus internus** muscle. Origin: Pterygoid process of the skull. Insertion: Ventral portion of the medial surface of the angle.

Still intact and attached to the mandible are:

- (d) The **pterygoideus externus**. The muscle comprises two portions. **Superior head.** Origin: Infratemporal surface of the alisphenoid. Insertion: Medial surface of the ramus of the mandible and sulcus ascendens.

This portion has also been described as a division of the temporalis.

Inferior head. Origin: Posterior edge and both surfaces of the lateral plate of the pterygoid process. Insertion: The depression in front of the neck of the mandible, the interarticular cartilage of the temporo-mandibular joint, and the whole medial edge of the head of the mandible.

It will be observed that the more powerful of the jaw-muscles are those which raise and protract the mandible, the combination of movements in these two directions being particularly important in animals with rodent habits. Raising is accomplished by the masseter, particularly its internal division, and the internal pterygoid, aided by the superior head of the external pterygoid and the temporalis. Protraction is the work of the masseter, particularly its external division, and of the inferior head of the external pterygoid. Retraction is a weaker movement accomplished mainly by the posterior part of the internal division of the masseter with some aid from the superior head of the external pterygoid and a little from the temporalis (all three pulling both upwards and backwards.) Lowering of the jaw is the work of the digastricus, aided by a simultaneous forward pull of the inferior portion of the external pterygoid on the head of the mandible.

- (e) The **inferior alveolar artery** (a. alveolaris inferior) lies between the two pterygoidei, and enters the mandible through the mandibular foramen. The corresponding **inferior alveolar vein** leaves the mandible at this point.
- (f) The **inferior alveolar nerve** (n. alveolaris inferior) accompanies the inferior alveolar artery to the mandible. The continuation of the nerve is the **mental nerve**. It appears at the mental foramen, and passes to the lower lip.

The displaced half of the mandible should now be freed from the foregoing structures and removed entirely.

The origin of the inferior alveolar nerve may be traced. It arises from the **mandibular nerve** (n. mandibularis), the third division of the **fifth cranial** or **trigeminal nerve** (n. trigeminus). The mandibular nerve also gives off anteriorly the stout **lingual nerve** to the tongue and posteriorly the slender **mylohyoid nerve** to the digastric and mylohyoid muscles. These structures, together with the inferior alveolar artery, may be freed from their loose connections with the pterygoidei, so that they may be left in place for further study. The two pterygoidei may then be detached at their points of origin from the skull and removed.

6. The branches of the common carotid artery may be traced in the anterior portion of the ventral surface of the neck as follows:
- (a) The **internal carotid artery** (a. carotis interna) is a small vessel given off from the dorsal wall (pp. 172, 361). The trunk then passes forward as the **external carotid** (a. carotis externa).

The internal carotid artery passes dorsad, medial to the styloglossal and stylopharyngeal muscles, to the base of the skull and enters the external carotid foramen, traverses the carotid canal, and enters the cranial cavity through the foramen lacerum to supply the brain.

At its very beginning, the internal carotid artery is very slightly distended as the carotid sinus, an organ which, though hardly noticeable in ordinary dissection, is important physiologically. It is a sensory receptor, stimulation of which by increased blood-pressure causes impulses to pass through fibres in the ninth, tenth, and eleventh cranial nerves and to produce reflex vasodilatation.

In the angle between the origins of the external and the internal carotid arteries is situated another organ too minute for observation in the gross, the carotid body or *glomus caroticum*. This is stimulated by chemical changes in the blood and sends impulses through a special branch of the glossopharyngeal nerve to alter blood-pressure, heart-beat, and respiration. The branch in question, the first to separate from the ninth nerve as it emerges from the cranium, is the intercarotid nerve or nerve of Hering.

- (b) The **occipital artery** (a. occipitalis) passes from the dorsal wall to the posterior portion of the head.

The **stylohyoideus major**, a slender muscle arising with the digastricus from the **stylohyoid ligament** and inserted on the greater cornu of the hyoid, should be divided. The tendon of the digastricus may be reflected.

- (c) The **lingual artery** (a. lingualis) arises from the ventral wall and passes forward into the tongue.

The hypoglossal nerve crosses the ventral surface of the artery and should be kept intact.

- (d) The **external maxillary artery** (a. maxillaris externa) is given off immediately in front of the lingual artery, sometimes in common with it. It passes forward on the medial surface of the ventral border of the mandible (medial to the digastricus), giving branches to the submaxillary gland and to the muscles of mastication. The vessel has been

divided at the point where it passes around the ventral border of the mandible to the lateral surface of the face.

- (e) The **internal maxillary artery** (a. maxillaris interna), one of the two terminal branches of the external carotid, passes in the direction of the orbit (p. 318), giving off the **inferior alveolar artery** to the mandible.
- (f) The **superficial temporal artery** (a. temporalis superficialis), the second terminal branch, passes dorsad to the temporal region, supplying the latter and the base of the ear. The **transverse facial artery**, which crosses the cheek, is an anterior branch of this vessel.

7. Dissection of the tongue and hyoid.

The mylohyoideus should be reflected. Note the position of the lingual nerve.

Dorsal to the anterior part of the mylohyoideus lies the **sublingual gland** (gl. sublingualis minor—the gl. sublingualis major is absent in the rabbit*) from which several small ducts run dorsad between the geniohyoid and the hyoglossus muscles to the floor of the mouth. The submaxillary duct turns forward behind the sublingual gland and runs along its dorsal surface to open on the floor of the mouth near the mandibular symphysis.

- (a) The **stylohyoideus major** muscle. Origin: Jugular process of the occipital bone. Insertion: Tip of the greater cornu of the hyoid. The muscle has been divided.

The superficial temporal and internal maxillary arteries should be divided.

- (b) The **styloglossus**. Origin: Jugular process. Insertion: The muscle passes downward and forward, expanding at the base of the tongue into a broad sheet, the fibres of which extend to its anterior tip.

The muscle should be carefully separated from two others on its dorsomedial side and divided.

- (c) The **stylohyoideus minor**. Origin: Jugular process. Insertion: Lesser cornu of the hyoid. A slender muscle having about the same direction, but ending on the more dorsal part of the hyoid apparatus.

*In many animals, the major sublingual gland is closely associated with the anterior end of the submaxillary gland and some authors have so designated the anterior lobes of the submaxillary in the rabbit. This has been denied, however, on the basis of critical embryological studies.

The remaining muscle is the **stylopharyngeus**, a thin delicate muscle, the insertion of which is on the lateral wall of the pharynx.

In man, the tendon joining the two portions of the digastric muscle usually passes through the stylohyoid muscle. In the rabbit, the tendon of the digastric passes between the major and minor stylohyoidei.

- (d) The **geniohyoideus**. Unpaired. Origin: Mandibular symphysis. Insertion: Ventral surface of the body of the hyoid.
- (e) The **genioglossus**. Origin: Medial surface of the mandible immediately behind the symphysis. The fibres pass upward and slightly backward into the substance of the tongue.
- (f) The **hyoglossus**. Origin: The body of the hyoid and the greater and lesser cornua by more or less separate heads. The muscle passes into the base of the tongue, enclosed on either side by the styloglossi.
- (g) The **lingualis**, or intrinsic muscle of the tongue, consists of a mass of fibres with no skeletal attachments.
- (h) The **lingual nerve** (n. lingualis), one of the chief branches of the **mandibular**, passes forward and downward to the side of the tongue and enters its substance immediately below the ventral border of the styloglossus.

The lingual is the sensory nerve of the tongue. It contains fibres for general sensibility and near its point of origin is joined by the chorda tympani (p. 322), the latter containing gustatory fibres.

- (i) The **twelfth cranial** or **hypoglossal nerve** (n. hypoglossus) enters the base of the tongue. It lies on the lateral side of the external carotid artery and on the medial side of the stylohyoideus major. It is distributed as a motor nerve to the lingual muscles.
 - (j) The **ramus lingualis** of the **ninth cranial**, or **glossopharyngeal** nerve (n. glossopharyngeus), enters the base of the tongue at a point dorsal to the hypoglossus and between the stylohyoideus minor and the stylopharyngeus. It is a gustatory nerve of the tongue.
8. Dissection of the extra-cranial roots of the ninth to twelfth nerves (Fig. 109).

These nerves, which for the most part have already been exposed, may be traced to their origin in the jugular and hypoglossal fora-

mina. The tympanic bulla should be cleared and the tendons of origin of tongue muscles removed from the jugular process.

- (a) The **ninth** (glossopharyngeal) nerve is farthest forward. Its two main branches are the **ramus lingualis** to the posterior part of the tongue, for taste, and the **ramus pharyngeus**, the latter entering the lateral wall of the pharynx.
- (b) The **tenth** (vagus) nerve bears an elongated ganglionic enlargement, the **plexus ganglioformis** or **ganglion nodosum**.

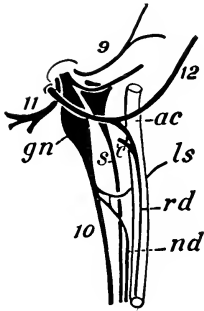


FIG. 109. Plan of the extra-cranial roots of the IX-XII cranial nerves and sympathetic trunk; ventral surface, right side, the sympathetic and depressor nerve shown as displaced from the dorsal surface of the artery. 9, 10, 11, 12, glossopharyngeal, vagus, spinal accessory, and hypoglossal nerves; ac, carotid artery; c, cervical root of ramus descendens XII; gn, ganglion nodosum vagi; ls, superior laryngeal; rd, ramus cardiacus vagi (depressor nerve); rd, ramus descendens hypoglossi; s, sympathetic.

It lies immediately below the jugular foramen. The **superior laryngeal nerve** and the **ramus cardiacus** (depressor nerve) are given off at the level of the origin of the internal carotid artery. Within the jugular foramen of the skull, the vagus bears a slight enlargement, usually double, the jugular ganglion, and gives off a minute auricular branch which connects with the ninth and seventh nerves and then emerges from the petromastoid bone just behind the external acoustic meatus to be distributed in the external ear.

- (c) The **eleventh cranial, or spinal accessory nerve** (n. accessorius), is dorsal to the vagus. The nerve passes dorsad to the medial side of the mastoid attachments of the sternomastoideus and cleidomastoideus muscles, giving branches to the latter, and then passes backward to the ventral surface of the trapezius to which it is distributed.

- (d) The **twelfth** (hypoglossal) nerve arises behind the foregoing nerves, since it comes from the hypoglossal foramina of the occipital. It crosses their roots, forming a broad curve on the lateral surface of the root of the external carotid artery, and enters the base of the tongue. The **ramus descendens** is given off at about the point where it crosses the artery. It has a slender root from the third cervical nerve.

The fibres composing the ramus descendens do not originate in the hypoglossal nucleus in the brain but are derived from the most anterior cervical nerves and are only secondarily included within the sheath of the hypoglossal.

- (e) The **cervical portion** of the **sympathetic trunk** begins in the **superior cervical ganglion** (g. cervicale superius). It lies to the medial side of the vagus ganglion and of the internal carotid artery. The nerves proceeding from the ganglion accompany the branches of the external and internal carotid arteries to the head.

9. The oral cavity and pharynx.

The glossopharyngeal nerve and the superior laryngeal nerve and artery may be divided, and the external carotid artery with the associated nerves separated from the oesophagus and trachea. The latter may be displaced downward to a slight extent by dividing the loose connective tissue along the ventral surface of the vertebral column. If a probe is inserted from the oral cavity backward into the oesophagus and an incision through the lateral wall is made following this guide, the internal surface of this portion of the digestive tube will be exposed sufficiently for the study of its features. The incision divides the **constrictor pharyngis muscle**, a broad band of muscle fibres enclosing the posterior portion of the pharynx.

The constrictor pharyngis has three heads of origin, not readily distinguished: (a) a very fine band from the base of the external acoustic meatus, (b) a larger mass from the tip of the medial lamina of the pterygoid process, and (c) a delicate band attached in the soft palate.

For the general relations of the oral cavity see p. 99 and Fig. 52.

- (a) The **oral cavity** (cavum oris) is divisible into the **oral cavity proper**, and the **vestibulum oris**, the latter lying between the alveolar processes and teeth on the one hand and the lips and cheeks on the other.
- (b) The **pharynx** comprises an **oral portion** (pars oralis), continuing the canal of which the first division is the oral cavity and connecting the latter with the oesophagus, and a dorsal and anterior **nasal portion** (pars nasalis) or **nasopharynx**, which lies above the soft palate, and receives the posterior aperture of the nose. Its ventral and posterior

laryngeal portion (pars laryngea), not well-defined, contains the aperture of the larynx, the **aditus laryngis**.

In the oral cavity:

- (a) The **hard palate** (palatum durum) forms the anterior portion of the roof; its mucous membrane is thrown into a series of transverse ridges.
- (b) The **soft palate** (palatum molle) is the thin, narrow, posterior, membranous portion of the roof. It is very long in the rabbit, extending from the bony palatine bridge backward to a point above the laryngeal aperture, where it ends with a concave free margin.

The soft palate contains a system of delicate muscles, including the tensor veli palatini (attached to the anteroventral part of the tympanic bulla and to the median process on the bony palatine bridge), the levator veli palatini (originating on the tympanic bulla and inserted in the free edge of the soft palate), the uvular muscle (origin on the median spine of the palatine bridge, insertion in the middle of the soft palate, underlying the buccal mucous membrane), the pharyngopalatine muscle (scattered fascicles from the dorsal wall of the pharynx spreading through the soft tissue of the palate), and the glossopalatine muscle (a very thin system of fibres curving round from the base of the tongue into the centre of the palate).

- (c) The **nasopalatine** or **incisive ducts** (dd. nasopalatini) open by small slits about a millimetre behind the secondary incisors, each opening being covered by a slight projection from its medial margin. The ducts connect the anterior portion of the nasal cavity with the mouth, and a probe may readily be passed backward along them from their oral apertures.
- (d) The **tongue** (lingua) projects upward and forward from its basal attachments on the hyoid into the floor of the mouth. Its connection with the latter is extended forward in the middle line by a vertical membranous fold, the **frenulum linguae**. Its dorsal surface is divided into a posterior smooth, hard portion, which forms a considerable rounded elevation, and an anterior softer and rougher portion. Both are covered by closely set fine processes, the papillae operariae, which correspond with the filiform and conical papillae of the human tongue. These are most typically

developed on the softer anterior part of the tongue, where single minute low elevations, the fungiform papillae, are scattered among them. At the posterior end of the smooth portion, there are on either side a minute spherical elevation, set low into the mucous membrane, the **vallate papilla** (papilla vallata), and in a more lateral and anterior position an oval area, the **papilla foliata**, the surface of which is marked by fine parallel ridges. Microscopic taste buds occur on the fungiform and, especially, on the vallate and foliate papillae.

In the pharynx:

- (a) The **tonsils** (tonsillae palatinae) are a pair of rounded masses of lymph follicles each lying on the anterior wall of a deep lateral depression, the **tonsillar sinus** (sinus tonsillaris). The vertical slit-like aperture of the sinus is bounded by low anterior and posterior folds.
- (b) The **epiglottis**, a valve-like fold guarding the entrance to the larynx, projects upward from the floor into the pharyngeal cavity, past the edge of the soft palate.
- (c) By removing the posterior portion of the soft palate, the connection of the nasopharynx with the nasal fossae will be exposed. Also, on the lateral wall of the nasopharynx, there will be visible the **pharyngeal aperture** of the **auditory tube** (ostium pharyngeum tubae), the other end of which opens into the middle ear.

10. Examination of the larynx.

By cutting around the base of the tongue on the opposite side of the body, the whole structure, together with the hyoid, larynx, and a portion of the trachea back to about the end of the thyroid gland may be removed. This affords a good opportunity of re-dissecting on the opposite side from the medial surface of the mandible outward. The hyoid apparatus, which supports the base of the tongue, should be cleared and examined (see p. 197).

The small, unpaired, median vertebral vein may be observed on the ventral surfaces of the vertebrae. This vessel, formed anteriorly by the veins of the nasal septum, receives a tributary through the foramen cavernosum from the basisphenoid bone, is joined by paired vertebral veins, and empties into the posterior end of the external jugular vein of either the right or the left side.

The laryngeal cartilages should now be thoroughly and carefully cleared externally by the removal of all soft tissues so that the following parts are clearly seen.

- (a) The **thyroid cartilage** (cartilago thyreidea) forms the largest portion of the structure. It is an unpaired saddle-shaped cartilage, described as consisting of **right** and **left laminae**. Its anterodorsal angle at each side projects forward as the **cornu superior**, connected by ligament with the greater cornu of the hyoid. The corresponding posterodorsal angle, the **cornu inferior**, overlies the dorsolateral portion of the cricoid cartilage. The anterior dorsal portion of each plate bears a small **thyroid foramen** (foramen thyreideum) for the entrance of the superior laryngeal nerve and just ventral to this a longitudinal ridge serves for the attachment of the sternothyroid, thyreohyoid, and thyreolaryngeal muscles.
- (b) The **cricoid cartilage** (cartilago cricoidea) is annular, surrounding the first tracheal ring. Its ventral portion, the **arch** of the cricoid cartilage, is situated some distance caudal to the thyroid cartilage, the intervening space being largely occupied by the **cricothyreoides muscles**. Its lateral part slants obliquely anterodorsad and expands into the dorsal portion, the **lamina** of the cricoid, which is partly enclosed at the sides by the posterodorsal angles of the thyroid laminae and has a firm ligamentous attachment to these. The lamina of the cricoid extends craniad and forms the larger part of the dorsal wall of the larynx, its anterior margin having a blunt median point and slanting obliquely laterocaudad at either side.
- (c) The paired **arytenoid cartilages** (cartilagine arytenoideae) lie obliquely one on each side of the anterior tip of the cricoid plate, closely articulated with its margin. Each appears curved and somewhat irregularly pear-shaped in dorsal view, tapering to a point anteromedially. From the lateral angle of the broader posterior end there is a prominent ventral projection for the attachment of one end of a vocal fold.

- (d) The **corniculate cartilages** (cartilagine corniculatae) are minute, slender, curved bodies composed of very flexible elastic cartilage and borne on the apices or anterior extremities of the arytenoid cartilages. Each projects cranial and lies in the dorsal end of the fold of mucous membrane extending to the edge of the epiglottis and forming the margin of the opening from the pharynx, the aditus laryngis.
- (e) The **epiglottic cartilage** (cartilago epiglottica) is a thin, very flexible, curved plate of elastic cartilage covered only by mucous membrane. It projects upward into the cavity of the pharynx just in front of the aditus laryngis and is attached ventrally to the internal surface of the thyroid cartilage. At the base of its posterior surface appears a pair of small but prominent projections, the hamuli.
- (f) The **vocal folds** (plicae vocales), which are rudimentary in the rabbit, may be seen as vertical folds of the internal surface of the larynx, especially prominent when the thyroid cartilage is bent downward on the cricoid. Each fold is attached at one end to the thyroid, at the other end to an arytenoid cartilage, and forms the posterior boundary of a shallow pouch, the **laryngeal ventricle** (ventriculus laryngis.)

In the rabbit the two laryngeal ventricles unite in a shallow median ventral depression which extends to between the hamuli epiglottici.

In addition to the cricothyroidei, the laryngeal cartilages are connected by several small muscles, including the cricoarytenoidei posterior and lateralis, the thyroarytenoideus and the arytenoideus transversus, the last named being an unpaired muscle connecting the arytenoid cartilages. These muscles acting together in various ways modify the shape of the laryngeal cavity and the degree of tension and of approximation of the vocal folds.

11. The eye and related structures of the orbital cavity.

The eyeball should be carefully separated from the bony orbital rim. The first portion of the nasolacrimal duct (d. nasolacrimalis), passing from its aperture, which may be observed in the anterior part of the medial surface of the lower eyelid, to the lacrimal bone, will be divided. The supraorbital process of the frontal bone may advantageously be broken away. The muscles and glands of the orbit may be made out as follows:

- (a) The **levator palpebrae superioris**. Origin: Wall of the orbit above the optic foramen. Insertion: Upper eyelid.

This thin sheet of muscle should be separated from the underlying rectus superior of the eyeball.

- (b) The **obliquus superior**. Origin: Anterior margin of the optic foramen. The muscle passes upward on the wall of the orbit, then beneath a fibrous cord, the trochlea, which bridges a small portion of the orbital wall and changes the course of the tendon by a considerable angle. Insertion: Anterodorsal portion of the eyeball.
- (c) The **obliquus inferior**. Origin: Lacrimal bone. Insertion: Posteroventral portion of the eyeball.

The oblique muscles are relatively large in the rabbit, a feature correlated with the lateral direction of the eyes.

- (d) The four **recti muscles, superior, inferior, medialis, and lateralis**, arise from the boundary of the optic foramen, and are inserted respectively on the dorsal, ventral, anterior, and posterior portions of the periphery of the eyeball.
- (e) The **retractor oculi, or retractor bulbi**, muscle (best seen after removal of the eye) originates on the posterolateral margin of the optic foramen, internal to the origin of the lateral rectus muscle, and is connected by a fibrous band through the foramen with the origin of the corresponding muscle of the other side. It has the form of a hollow cone with a cleft along its dorsal wall, in which the optic nerve lies upon a bed of fatty connective tissue. It is inserted on the medial portion of the eyeball around the optic nerve. Although the retractor oculi is described as consisting of four distinct parts, these are fused in the rabbit so that they are indicated only by sinuosities in the line of insertion alternating with the insertions of the recti muscles.
- (f) The **Harderian gland** (gl. Harderiana) is a large, compact, lobulated gland lying in the anterior portion of the orbit, internal to the inferior oblique muscle. It is composed, in the rabbit and the hare, of two parts, a large, pale, grey-reddish, posteroventral lobe and an almost white antero-dorsal lobe about one-third the size of the former. Both

lobes open by a common duct on the inner surface of the third eyelid. In embalmed rabbits, both parts may be brown so that the colour difference may not be very noticeable; though in the majority of cases the difference is extremely conspicuous. The presence of this gland, which is absent in Primates, is associated with that of a well-developed third eyelid.

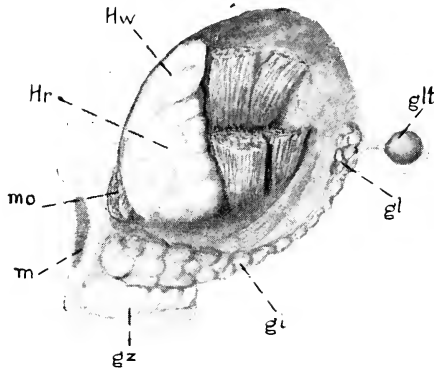


FIG. 110. Lateral view of the left orbit after removal of the eyeball. gi, infra-orbital gland; gl, lacrimal gland; glt, temporal lobe of lacrimal gland; gz, zygomatic gland; Hr, reddish portion of Harderian gland; Hw, white portion of Harderian gland; m, cut end of zygomatic process of maxilla; mo, cut end of inferior oblique muscle.

- (g) The **lacrimal gland** (gl. lacrimalis) is a much smaller, darker coloured, greatly lobulated structure lying close to the skull in the temporal angle of the orbit. An outlying portion is situated in the back part of the temporal foramen, where it overlies the tendon of the temporal muscle. The gland communicates by several fine ducts with the caudal part of the inner surface of the upper eyelid.

Described by some authors as inferior lobe of the lacrimal gland, a similar mass extends forward immediately internal to the zygomatic arch and near the anterior end of the orbit, where the gland expands considerably, lies dorsal as well as medial to the arch. This is the **infraorbital gland** of most authors. Its duct opens near those of the lacrimal gland proper, a short distance behind and below the posterior connection of the two eyelids.

The **zygomatic gland** (gl. zygomatica—infraorbital gland of earlier editions) is a rather small, white or yellow gland lying in the

anteroventral angle of the orbit immediately medial to the zygomatic arch and ventral to the anterior end of the infraorbital gland described above. The gland is one of the salivary series, its duct passing downward and opening through the mucous membrane of the cheek into the cavity of the mouth.

The application of the terms infraorbital and zygomatic to these two glands is reversed by some authors.

To examine the structure of the eye, the muscles of the eyeball should be divided at their insertions, and the whole structure should be removed. The **second cranial** or **optic nerve** (n. opticus) is divided; also the **ophthalmic artery**, a small branch of the internal carotid which accompanies the nerve outward from the optic foramen to the eyeball.

The eye may be divided into medial and lateral hemispheres by a circular incision, the lateral hemisphere, which contains the lens, being again divided vertically. The parts should be examined under water. The chief structures (Fig. 48, p. 92) comprise:

- (a) The **fibrous tunic** (tunica fibrosa oculi), the strong peripheral coat enclosing the whole structure. It is divisible into a medial portion, the **sclera**, or **sclerotic coat**, a thick white investment of fibrous connective tissue enclosing the greater part of the eyeball, and a smaller transparent lateral portion, the **cornea**, covering the exposed surface. The sclera is not so extensively exposed in the rabbit as it is in man (white of the eye), a condition related to the very small angle of movement in laterally placed eyes like those of the rabbit.
- (b) The **vascular tunic** (tunica vasculosa oculi), the thin middle coat of the eye; pigmented, except in albino animals. It is divisible into: (1) a general portion, the **chorioidea**, lying on the inner surface of the sclera; (2) a muscular portion, the **ciliary body** (corpus ciliare), composed of numerous, radially arranged ciliary folds (plicae ciliares) and forming an annular ridge about the periphery of the lens; and (3) the **iris**, the latter forming a circular fold suspended about the periphery of the lens and on its outer surface.

The ciliary body, which in man contains both radial and circular muscle, has only the former in the rabbit.

- (c) The **retina**, the innermost layer of the eye, forms a thin soft membrane covering the inner surface of the chorioidea. It is divisible into a larger **optic portion**, the sensory part of the eye, and a smaller **ciliary portion**, lying about the periphery of the lens and distinguishable by the radiate markings of its surface, the latter formed by the projecting ridges of the ciliary body, the inner surface of which it covers.

A little distance from the centre of the optic portion can be recognized the disc or "blind spot", where the nerve fibres in the retina converge and form the optic nerve.

- (d) The transparent **lens** of the eye is suspended by fine filaments, the **zonular fibres**, reflected from the margin of the ciliary body.

When the eye is at rest, the zonular fibres are in a state of tension sufficient to produce a slight flattening of the lens. Contraction of the muscles in the ciliary body reduces this tension so that the lens may become more convex by its own elasticity.

- (e) The **vitreous body** (*corpus vitreum*), a transparent mass, of gelatinous consistence, occupies the large space enclosed by the lens and the retina.
- (f) The space enclosed between the surface of the lens and the cornea is divisible into a large portion, the **anterior chamber** (*camera oculi anterior*), lying outside of the iris, and a smaller portion, the **posterior chamber** (*camera oculi posterior*), lying between the iris and the lens. These two chambers communicate through the central aperture enclosed by the free margin of the iris, the **pupil** (*pupilla*).
12. Following the removal of the eye, the blood-vessels and nerves of the orbit may be freed from the remaining portions of the eye muscles and examined. In order to see their connections in the anterior angle of the orbit, it is necessary to break away the anterior root of the zygomatic arch, and also the bony ridge which lodges the alveoli of the posterior cheek-teeth.
- (a) The **internal maxillary artery** enters the orbit through the anterior sphenoidal foramen in the root of the lateral lamina of the pterygoid process. At the posterior ventral

angle of the orbit it gives off the **inferior ophthalmic artery** (a. ophthalmica inferior). This vessel passes upward and forward on the medial wall of the orbit, giving branches to the eye muscles. It divides into two branches, the **frontal artery**, which leaves the orbit through the anterior foramen of the supraorbital process, and the **lacrimal artery**, which passes through the corresponding posterior foramen. The ethmoidal artery, a small branch of the frontal, passes through the minute ethmoidal foramen of the orbital portion of the frontal into the nasal cavity.

The internal maxillary artery passes forward along the ventral boundary of the orbit, and at the opening of the infraorbital canal gives off a branch, the pterygopalatine artery, continuing as the infraorbital artery. A small branch, the **superior dental artery** (a. dentalis superior) is given off laterally to the alveoli of the upper teeth.

The **infraorbital artery** (a. infraorbitalis) passes through the infraorbital canal to the face.

The **pterygopalatine artery** (a. pterygopalatina) divides almost immediately into the **anterior palatine artery**, which traverses the pterygopalatine canal to the mucous membrane of the hard palate, and the **sphenopalatine artery**, which enters the nasal cavity by the sphenopalatine foramen.

- (b) The divisions of the **third cranial**, or **oculomotor nerve**, supply the eye muscles, with the exception of the obliquus superior, rectus lateralis, and retractor oculi.

This nerve enters the orbit from the superior orbital fissure in company with certain parts of the trigeminal (see *e, f* below). The small nerves passing through the middle and posterior sphenoidal foramina of the pterygoid process are the **pterygobuccinator** and **masseterico-temporal** nerves, branches of the mandibular, passing to the muscles of mastication.

- (c) The **fourth cranial**, or **trochlear nerve** (n. trochlearis), is distributed to the obliquus superior muscle.
- (d) The **sixth cranial**, or **abducent nerve** (n. abducens), is distributed to the rectus lateralis and to the retractor oculi.

- (e) The **ophthalmic nerve** (n. ophthalmicus), the first division of the **fifth cranial**, or **trigeminal nerve** (n. trigeminus), accompanies the inferior ophthalmic artery on the medial wall of the orbit. It is entirely sensory. It gives off a **lacrimal nerve**, which passes upward through the posterior foramen of the supraorbital process, after giving off small branches to the lacrimal gland, and is distributed to the skin of the upper eyelid. The ophthalmic then passes forward a short distance and divides into two parts. One of these, the **frontal nerve**, leaves the orbit through the anterior supraorbital foramen and branches in the skin. The other, the **nasociliary nerve**, is distributed partly to the anterior portion of the orbit, while its main division leaves the orbit as the **ethmoidal nerve**, which passes through the small ethmoidal foramen of the orbital part of the frontal bone to supply the interior of the nose. The nasociliary nerve is also connected with the minute ciliary ganglion lying on the optic nerve by a very delicate **long root of the ciliary ganglion**.

The lacrimal, frontal, and nasociliary nerves appear as separate structures in the orbit, their origin being deep (Fig. 45, p. 85).

- (f) The branches of the **maxillary nerve** (n. maxillaris), the second division of the trigeminus, traverse the ventral portion of the orbit, passing forward in company with the internal maxillary artery. They include the **sphenopalatine nerve** (n. sphenopalatinus) and the **infraorbital nerve** (n. infraorbitalis). The latter gives off superior alveolar branches to the upper teeth, passing forward through the infraorbital groove and foramen to the face.

The connections of the sphenopalatine nerve may be examined by first dividing both nerves at the posterior angle of the orbit; then separating the slender sphenopalatine nerve from the ventral surface of the cord and turning the principal, infraorbital portion forward. A third nerve, the nerve of the pterygoid canal, should remain intact on the orbital wall. If the infraorbital nerve alone is divided, the sphenopalatine nerve will be found on the surface of

the bone below the nerve of the pterygoid canal, from which it may be distinguished by its lighter coloration.

The sphenopalatine nerve is continued forward as the **anterior** (major) **palatine nerve**, which passes through the pterygopalatine canal to the posterior portion of the hard palate, but the sphenopalatine nerve is also connected with the **sphenopalatine ganglion**. **Nasal rami** pass to the mucous membrane of the nose, and the **nasopalatine nerve** enters the nasal region, traversing the surface of the septum and reaching the anterior portion of the palate through the incisive foramina.

The **nerve** of the **pterygoid canal** (n. canalis pterygoidei), or Vidian nerve, is a slender cord which passes backward along the orbital wall from the posterodorsal angle of the sphenopalatine ganglion. It lies on the medial side of the sphenopalatine and infraorbital nerves and on the lateral surface of the palatine bone. Posteriorly, it enters the groove representing the pterygoid canal.

This nerve is composed of two parts, separated posteriorly. One of them, the **deep petrosal nerve** (n. petrosus profundus), is connected with the sympathetic plexus of the internal carotid artery, its fibres coming from the superior cervical ganglion. The other, the **great superficial petrosal nerve** (n. petrosus superficialis major), enters the skull at the foramen lacerum, passing into the petrosal bone, in the interior of which it is connected with the trunk of the facial. The nerve constitutes the motor root of the sphenopalatine ganglion, the sensory root being that provided by the sphenopalatine nerve.

The sphenopalatine ganglion is one of several representing the parasympathetic division of the autonomic system in the head, and having motor and sensory roots from the cerebral nerves in addition to autonomic connections. The series includes the **ciliary ganglion**, which lies on the optic nerve, the **sphenopalatine ganglion**, the **otic ganglia**, associated with the mandibular nerve, and the **submaxillary ganglion**, associated with the lingual nerve (Fig. 40).

13. Examination of the middle ear.

By breaking away the ventrolateral portion of the tympanic bulla and clearing the surface, the structures of the tympanic cavity

may be studied. They are chiefly those already described in connection with the skeleton (p. 186), but the following soft parts may be identified.

- (a) The **tympanic membrane** (*membrana tympani*) is stretched almost vertically across the lower end of the external acoustic meatus.
- (b) The **tensor tympani** is a slender muscle, the origin of which forwards from the alisphenoid is concealed. It is inserted on the manubrium mallei.
- (c) The **stapedius** is a minute muscle arising from the periotic bone above the cochlear fenestra and inserted on the stapes.
- (d) The **chorda tympani** is a delicate nerve which crosses the tympanic cavity, lying between the long crus of the incus and the manubrium mallei.

The nerve is a continuation of the **intermediate nerve**, a sensory root of the facial, which arises independently of the chief or motor root and joins the facial in the facial canal of the periotic bone. Its peripheral connections are with the lingual nerve and the submaxillary ganglion.

- (e) The **internal carotid artery** traverses the carotid canal of the tympanic bone. By breaking away the posterior portion of the bulla, the entrance of the vessel into the external carotid foramen may be seen.

The dissection of the parts of the ear as here outlined includes only the external and middle portions together with the associated acoustic nerve and its entrance to the periotic bone. The parts of the **internal ear** (Fig. 47, p. 91) are not readily made out without the use of special methods, though their position may be estimated by carefully breaking away the surface of the ventral portion of the periotic. They include (1) the bony **labyrinth**, consisting of a series of connected spaces lodged in the interior of the petrous bone, and comprising the **cochlea**, **vestibulum**, and the **bony semicircular canals**; and (2) the **membranous labyrinth**, consisting of a second series of spaces contained within the first, and comprising the **duct of the cochlea**, the **sacculus**, the **utricle**, and the **semicircular ducts**, together with their connections and the **endolymphatic duct** and **sac**. The membranous labyrinth contains the sensory portion of the ear and its cavity is occupied by a fluid material, the **endolymph**. The wall is separated from that of the bony labyrinth by an extensive **perilymphatic space** also occupied by a fluid material termed the **perilymph**.

XI. THE THORAX

1. Examination of the thoracic wall.

For this purpose the lateral surface of the thorax may conveniently be cleared, on the side from which the anterior limb has been removed, by dissecting away the attachments of the muscles already examined in the previous dissections. These include the origins of the pectorales, pectoscapularis, serratus anterior (thoracic portion), obliquus externus, and rectus abdominis.

The dorsal portion of the exposed surface is occupied by the spinal musculature, to be examined at a later stage. On the ventral portion appear the ribs, and between them, filling the intercostal spaces, the intercostal muscles. The **external intercostals** (mm. intercostales externi) arise from the posterior margins of the bone ribs, the fibres passing obliquely downward and backward to be inserted on the anterior margins of the next succeeding ribs. The **internal intercostals** (mm. intercostales interni), the fibres of which are disposed in the opposite direction, are concealed for the most part from this surface, but appear ventrally between the costal cartilages, where they are not covered by the external intercostals. They are best examined at a later stage from the interior of the thorax.

In preparation for the removal of a section of the thoracic wall, the pectorales should be divided on the opposite side of the thorax, close to the sternum, so that the limb may be displaced.

The nerves and vessels of the neck must be kept intact until the following dissection accounts for their thoracic connections.

The scaleni muscles (p. 343) should be examined, since it is necessary to destroy their costal insertions.

A triangular section of the wall, including the sternum and the costal cartilages, may be removed by making three incisions, one on either side extending from the middle of the first rib backward to the end of the ninth bone rib, or a point on this rib a little more dorsal, and the third across the ventral surface close in front of the diaphragm. *Do not cut into the diaphragm.*

The **transversus thoracis** muscle appears on the inner surface of the section removed. It is a thin sheet of fibres arising from the body and xiphoid process of the sternum and inserted on the ribs,

from the second to the sixth, at the junctions of the bone ribs with the costal cartilages.

A very thin layer of muscle fibres passing in the same direction as those of the internal intercostal muscles has been described as lying immediately internal to them in the lateral wall of the thorax and is named **intracostal** (more dorsal) and **subcostal** (more ventral) muscles. These, however, are not present as a distinct layer in the rabbit. They and the **transversus thoracis** muscle together represent a thoracic continuation of the **transversus abdominis**. The main branches of the intercostal nerves run between these and the internal intercostal muscles.

The artery passing along the ventral wall between the transverse thoracic muscle and the internal intercostals is the **internal mammary** (p. 326).

The importance of the above described muscles in the act of breathing is indicated on p. 108. For the general relations of heart and lungs, see pp. 106 and 109.

2. Dissection of structures in the superior thoracic aperture.

The nerves and blood-vessels of this region are concealed by the **thymus gland**, a large triangular flattened structure of fatty consistence, lying partly ventral to the heart and extending forward from its base to the anterior end of the thorax (cf. p. 133). The thymus should be carefully raised from behind and dissected away, all vessels except those of the gland itself being kept intact.

The following structures, including the aortic arch and the arteries arising from it, the superior caval veins, and the vagus, phrenic, and sympathetic nerves, cannot be dissected exactly in the order given below, but must be separated from one another and identified as they appear. The left superior caval vein is superficial, crossing the ventral surface of the aortic arch. Care should be taken not to injure the nerves (*c-f*) in exposing the branches of the subclavian artery.

- (a) The **arch of the aorta** (*arcus aortae*). Beginning at the anterior end of the heart, the aorta at first passes forward, and then describing a curve, in the course of which it lies slightly to the left of the median plane, turns backward along the ventral surfaces of the bodies of the thoracic vertebrae. With the exception of the coronary arteries (p. 330) the first branches are the large vessels arising from the convex surface of the arch. They comprise the **common carotid** and **subclavian arteries**. On the right side the carotid and subclavian arise from a short common trunk, the **innominate artery** (*a. anonyma*). The left common

carotid arises immediately to the left of this vessel or from its base. The left subclavian arises some distance farther out along the arch. The **subclavian artery** (a. subclavia) is the first portion of the artery of the anterior limb. It passes from its point of origin laterad to the anterior margin of the first rib, where it becomes the axillary artery. Near its point of origin it gives off several branches, the relations of which are subject to considerable variation. They include:

- (1) The **vertebral artery** (a. vertebralis). This vessel passes into the costotransverse foramen of the sixth cervical vertebra, and, traversing the canal formed by this and the corresponding foramina of the vertebrae anterior to it, reaches the interior of the cranial cavity. Its union on the ventral surface of the medulla oblongata with its fellow of the opposite side to form the basilar artery will be seen at a later stage (p. 360).
- (2) The **superficial cervical artery** (a. cervicalis superficialis)—divided in a previous dissection (p. 258)—is a small vessel which passes forward and outward beneath the insertions of the cleidomastoideus, basio-clavicularis, and levator scapulae major muscles, ramifying extensively in the fat mass of the side of the neck under cover of the superior portion of the trapezius. Its **ascending cervical** branch lies on the lateral side of the external jugular vein.
- (3) The **transverse artery of the neck** (a. transversa colli), also divided in a previous dissection (p. 260), passes laterad around the neck of the first rib to the wall of the thorax. It passes through the loop formed by the eighth cervical and first thoracic spinal nerves. It runs dorsad, first on the medial side of the scalenus anterior, then on the medial side of the cervical portion of the serratus anterior. A strong branch passes to the inferior angle of the scapula. The artery supplies the serratus anterior and the rhomboidei.
- (4) The **highest intercostal artery** (a. intercostalis suprema)

passes backward to the internal surface of the thoracic wall, giving off the first three (or four) **intercostal arteries** in the intercostal spaces, and also small branches to the oesophagus, the trachea, and the bronchi.

- (5) The **internal mammary artery** (a. *mammaria interna*), the first portion of which runs along the inner surface of the ventral wall of the thorax and has been removed with it, passes backward to the ventral abdominal wall as the **superior epigastric artery** (a. *epigastrica superior*) anastomosing with the inferior epigastric (p. 223).
- (b) The **superior caval vein** (v. *cava superior*) is formed at the base of the neck by the union of the internal and external jugular veins, the latter vessel receiving at this point the **subclavian vein** (v. *subclavia*). The right superior caval passes almost directly backward, crossing the ventral surface of the right subclavian artery, and enters the anterior portion of the right atrium. The left vessel crosses both the left subclavian artery and the arch of the aorta and turns mediad over the dorsal surface of the heart to reach the posteromedial part of the right atrium (Fig. 62, p. 111). The transverse terminal portion of the left superior caval vein constitutes the coronary sinus and is retained in reduced size in species, such as man, where the rest of the left superior caval vessel degenerates during development.
- (c) The **vagus nerve** on the right side crosses the ventral surface of the subclavian artery, passing dorsad over the dorsal surface of the bronchus to the wall of the oesophagus. It gives off the **recurrent nerve** (n. *recurrens*), which curves round the subclavian artery and passes forward dorsal to the latter and then along the side of the trachea to the muscles of the larynx (except the cricothyreoideus). On the left side the vagus descends dorsal to the superior vena cava, crosses the ventral surface of the arch of the aorta to the point of connection of the arterial ligament (p. 330), where it gives rise to the recurrent branch, and

then continues backwards between the arch of the aorta and the base of the heart. It passes dorsal to the pulmonary vessels and the bronchus (where it gives off pulmonary branches) to continue along the ventrolateral wall of the oesophagus. The recurrent nerve passes forward dorsal to the arterial ligament and over the dorsal side of the aortic arch to proceed craniad along the lateral surface of the trachea.

Near its beginning, the recurrent branch gives off efferent rami to the **cardiac plexus** (plexus cardiacus), a network of autonomic nerve fibres lying between the aortic arch and the pulmonary artery and distributed to the heart (coronary plexus) and the immediately adjacent arteries.

- (d) The **ramus cardiacus** of the vagus has already been observed running along the dorsal surface of the common carotid artery (p. 302).

In front of the subclavian artery, this sensory branch is at first closely associated with the vagus trunk, lying on its medial side. On the right side it passes to the dorsal surface of the subclavian, and on the left to the dorsal surface of the aortic arch. Its posterior end connects with the **cardiac plexus** through which its fibres come from the walls of the adjacent vessels and of the heart.

- (e) The **phrenic nerve** (n. phrenicus) is a stout cord arising chiefly from

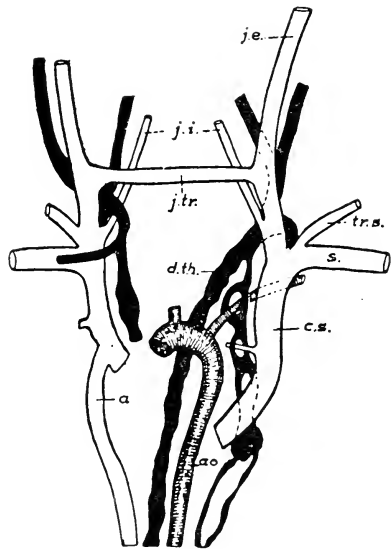


FIG. 111. Plan of the venous and lymphatic trunks of the anterior portion of the body. After McClure and Silvester.
a., azygos vein; ao., aorta; c.s., left superior caval vein; d.th., thoracic duct; j.e., j.i., and j.tr., external, internal, and transverse jugular veins; s., left subclavian vein; tr.s., transverse scapular vein.

the fourth cervical spinal nerve. That of the left side crosses the ventral surface of the subclavian artery but dorsal to the subclavian vein, then, lying just lateral to the superior vena cava, crosses ventral to the aortic arch and passes along the pericardium to the diaphragm (Fig. 112). That of the right side passes back along the dorsolateral wall of the superior caval vein, then along the pericardium, and accompanies the thoracic portion of the inferior caval vein. The phrenic nerves control the respiratory movements of the diaphragm, each turning laterad when it reaches that organ and being distributed in the muscular portions thereof on its own side.

- (f) The **sympathetic trunk**. At the base of the neck the cervical portion of the sympathetic trunk enters the **inferior cervical ganglion** (g. cervicale inferius). The latter lies in front of, and somewhat dorsal to, the subclavian artery. The **first thoracic ganglion** lies behind the artery and is connected with the inferior cervical by the **ansa subclavia**, a loop formed by two cords, one of which passes to the dorsal, the other to the ventral side of the subclavian artery.

The nerves proceeding from the inferior cervical ganglion enter the cardiac plexus and the sympathetic plexuses of the subclavian and its branches.

If desired, a useful view of the relations of the nervous structures may be obtained before proceeding to the next section by cutting away the left lateral wall of the thorax and examining from that side the parts described in section 5 (pp. 335-337).

3. Dissection of the heart.

The character and relations of the sac enclosing the heart, the pericardium, should first be noted. The relation to the heart of the pericardium proper, or **serous pericardium**, is similar to that of the peritoneum and pleura to the visceral organs which they invest (p. 135). The serous pericardium comprises a **parietal layer**, which lines the inner surface of a strong loose sac commonly known as the pericardium, and a **visceral layer**, or **epicardium**, which forms an intimately attached investment over the outer surface of the heart

substance. The two layers are continuous through sheaths surrounding the vessels which enter and leave the heart. The parietal layer of the serous pericardium is applied to the inner surface of a thicker and much tougher sac, the **fibrous pericardium**. This, in turn, is partly attached by loose connective tissue to surrounding organs and partly covered by the serous mediastinal pleurae, the linings of the cavities for the lungs.

The paired pleural cavities containing the lungs are broadly separated by a longitudinal vertical partition, the **mediastinum** or **mediastinal septum**, the space enclosed by the latter being largely occupied by the heart and by the cavity of the pericardium. For a considerable area ventrally the pericardium is loosely

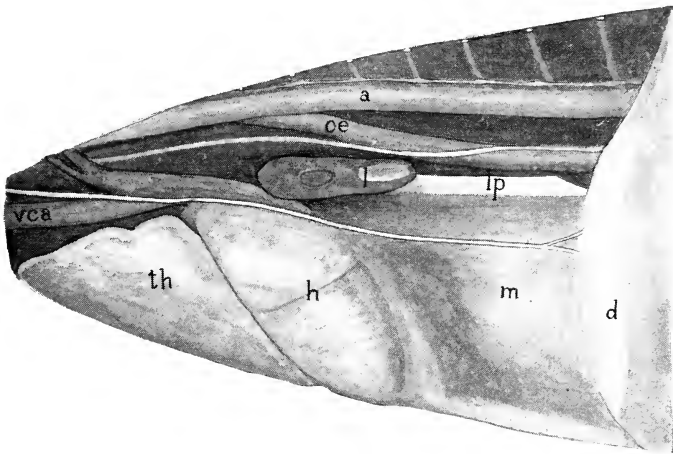


FIG. 112. Interior of the left pleural cavity with the lung removed to show the mediastinum, lateral view. a, thoracic aorta; d, diaphragm; h, heart in pericardium; l, remnant of base of lung; lp, pulmonary ligament; m, posterior mediastinum; oe, oesophagus; th, thymus gland; vca, left superior caval vein. The phrenic nerve is visible crossing the pericardium and the mediastinal septum and branching into the diaphragm, more dorsally the vagus nerve crosses the lateral surface of the oesophagus, and the sympathetic trunk appears on the dorsal wall.

applied to the thoracic wall, the intervening space, which is bounded laterally by the membrane lining the pleural cavities (pleura, p. 334), being known as the **anterior mediastinum**. A corresponding dorsal space lying between the heart and the bodies of the thoracic vertebrae, and also bounded laterally by the pleura, is the **posterior mediastinum**. It is occupied by several structures, namely, the oesophagus, the thoracic aorta, the bronchi, and the pulmonary blood-vessels, and caudally forms a thin septum similar to mesentery. In the rabbit and most quadrupedal mammals, unlike man, the pericardium does not reach the diaphragm, so that, in the rather narrow space between the caudal end of the pericardium and

the diaphragm, the posterior mediastinum widens into a thin vertical sheet extending from the dorsal thoracic wall to the internal surface of the sternum (Fig. 112).

The pericardium should be removed, and the external features of the heart¹ and its great vessels examined. These are as follows:

- (a) The posterior, somewhat conical, **ventricular portion** of the heart. The **left ventricle** (ventriculus sinister) may be distinguished both by its position and by the more solid character of its wall. The **right ventricle** (ventriculus dexter) is less muscular, and the wall is readily pressed inward. The line of division is indicated on the ventral surface by a faint depression, the **anterior longitudinal sulcus**.
- (b) The **pulmonary artery** (a. pulmonalis) leaves the base of the right ventricle, passing forward and to the left and then dorsad and caudad in a somewhat spiral fashion around the aorta. On the dorsal surface of the latter it divides into the **right and left pulmonary arteries**, one for each lung. Close to the point of division the left pulmonary artery is connected with the aorta by a short fibrous cord, the **arterial ligament** (lig. arteriosum), representing the foetal connection of the two vessels through the ductus arteriosus (pp. 114, 118).
- (c) The **left coronary artery** (a. coronaria sinistra) emerges from between the root of the pulmonary artery and the left atrium and divides into two main branches, one passing backward in or near the anterior longitudinal sulcus, the other ramifying over the left side of the heart. The **right coronary artery** (a. coronaria dextra) runs ventrad between the pulmonary artery and the right atrium and along the right atrioventricular groove, giving off branches to supply the whole right side of the heart. Both vessels supply the walls of the aorta, of the pulmonary arteries, and of the

¹The heart is relatively small in the rabbit, as in most animals not capable of prolonged severe muscular effort but depending upon hiding for safety. Its weight is given as about 0.003 of that of the body, which may be compared with values of about 0.006 in man and 0.01 in a deer.

great veins as well as the muscular substance of the heart itself. They arise from the aortic sinuses (p. 333), the right artery from the ventral sinus, the left one from the left dorsal sinus.

The blood distributed to the walls of the heart is collected by four groups of freely anastomosing **cardiac veins**. Those draining the left side unite in a left cardiac vein, which passes round in the left atrioventricular groove and enters the caudal part of the left superior vena cava, or the coronary sinus. The right cardiac vein, receiving the vessels from the right side, lies in the right atrioventricular groove and opens into the coronary sinus. The veins draining the dorsal surface of the heart join the right cardiac vein as it enters the sinus. Minute veins from the terminal portion of the right ventricle open directly into the right atrium.

- (d) The **left atrium** (atrium sinistrum) is the thin-walled chamber lying to the left at the base of the heart. The **pulmonary veins** (venae pulmonales), passing from the medial portions of the lungs, usually unite into two main vessels on each side and these four vessels enter a short, wide, funnel-shaped diverticulum on the left atrium. (This diverticulum is a feature of more primitive mammals.)
- (e) The **right atrium** (atrium dextrum) resembles the left in the character of its wall. It receives the **right** and **left superior caval veins** and the unpaired **inferior caval vein**.

The heart may be removed by dividing the great blood-vessels. The arch of the aorta should be removed with the heart by dividing the vessel at a point beyond the origin of the left subclavian, and then severing the carotids and subclavians at their bases. This exposes the surface for the subsequent examination of the posterior end of the trachea and its connections with the lungs.

Open the right ventricle by a longitudinal incision of the ventral wall, extending the incision forward into the pulmonary artery. Open both atria by transverse incisions. By washing out the cavities, the internal features of the wall, including the arrangement of the valvular structures, may be examined as follows:

In the right ventricle:

- (a) The **trabeculae carneae**; muscular ridges of the internal surface of the wall.

In the most primitive vertebrate hearts, the ventricular wall is composed almost entirely of a spongy mass of muscular trabeculae with a thin layer of compact muscle on the outer surface. There is a progressive change in the vertebrate series to the mammalian condition, where there is a thick, compact muscular wall with relatively few internal trabeculae.

- (b) The **tricuspid valve** (*valvula tricuspidalis*). The thin membranous flaps composing the valve enclose the atrio-ventricular aperture, and project into the cavity of the ventricle. Their margins, which are otherwise free, are connected by slender fibrous cords, the **chordae tendineae**, with the **papillary muscles** (*mm. papillares*), the latter being thick muscular projections, of somewhat conical shape, arising from the opposite walls.

In the rabbit the valve is composed of only two flaps, of which the ventral one is very free, and has large papillary muscles, while the dorsal one is closely attached to the wall, with the papillary muscle reduced or absent. For this reason the term **right atrioventricular valve** is more appropriate than "tricuspid."

- (c) The **semilunar valves** (*valvulae semilunares*) of the pulmonary artery are three extremely thin folds guarding the entrance to the vessel from the right ventricle. Each fold forms a pocket opening towards the artery and the cavity of the pocket is a pulmonary sinus. Two of the valves are usually found intact, the third being destroyed on opening the vessel.

In the atria:

- (a) The respective positions of the pulmonary and systemic veins at their points of entrance.
- (b) The complete separation of the two chambers. In the partition separating them may be seen a thin fibrous portion, the **fossa ovalis**, denoting the position of the embryonic **foramen ovale**.

Open the left ventricle by a ventral longitudinal incision, cutting well through the tip of the ventricle and extending the incision across the pulmonary artery and into the aorta. On account of the greater thickness of the wall the internal structure is not so easily examined as in the right ventricle. The interventricular

partition is approximately of the same thickness as the rest of the wall of the left ventricle.

- (a) The **bicuspid** or **left atrioventricular valve** (*valvula bicuspidalis*) is similar in general structure to the tricuspid valve of the right ventricle, but is more nearly circular in form, with stout, closely grouped papillary muscles.
- (b) The **semilunar valves** of the aorta are three in number, and are similar to those of the pulmonary artery. Opposite

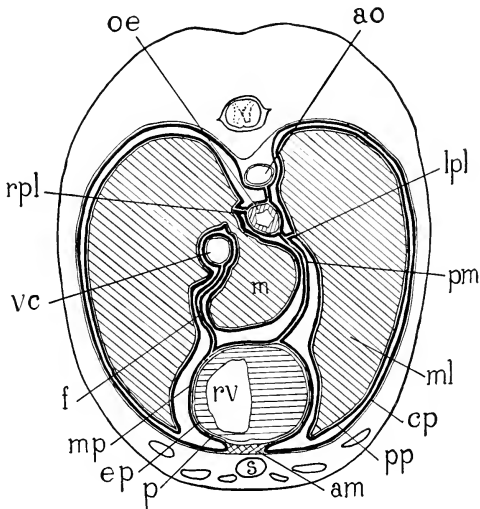


FIG. 113. Diagram of a transverse section of the thorax of a rabbit, passing through the posterior tip of the heart. am, anterior mediastinum; ao, aorta; cp, costal pleura; ep, epicardium; f, fold of mediastinal pleura containing the inferior caval vein; lpl, left pulmonary ligament; m, medial lobule of inferior lobe of the right lung; ml, middle lobe the left lung; mp, mediastinal pleura; oe, oesophagus; p, pericardium; pm, posterior mediastinum; pp, pulmonary pleura; rpl, right pulmonary ligament; rv, right ventricle; s, sternum; vc, inferior caval vein.

each, the wall of the aorta is slightly excavated so that the valve will not adhere to it. The cavity enclosed by each valve is known as an **aortic sinus** (of Valsalva).

4. Examination of the lungs and their connections (Figs. 57, 114).

The removal of the ventral wall of the thorax opens the pleural cavities by taking away a considerable portion of the costal pleura, which is adherent to the internal surfaces of the ribs. The chief features may be made out as follows:

- (a) Each **pleural cavity** (cavum pleurae) is a closed serous sac, the lining membrane, or **pleura**, being distributed over the costal surface as the **costal pleura**, partly over the anterior surface of the diaphragm as the **diaphragmatic pleura**, and over the surface of the lung as the **pulmonary pleura**, and entering into the formation of the mediastinum as the mediastinal pleura.

A secondary fold on the right side of the mediastinal septum contains the inferior vena cava and forms a pocket in which lies the medial lobule of the inferior lobe of the right lung. The attachment of the posterior margin of the septum to the diaphragm is displaced to the left so that it and the secondary fold are approximately symmetrical and the pleural pocket is median. Posteriorly, the pulmonary pleura passes from the medial margin of the left lung and from the medial margins of both inferior lobules of the right lung to the mediastinal septum and backward to the diaphragm, forming the **pulmonary ligament** (lig. pulmonale). These relations may be understood more clearly by reference to a transverse section such as that represented diagrammatically in Fig. 113.

- (b) The **lungs** (pulmones) are paired expansible structures, the surfaces of which are free, except medially, where they are connected with the respiratory passages and the pulmonary blood-vessels, and posteromedially, where they are attached to the mediastinum and to the diaphragm by the pulmonary ligaments.

- (c) The right lung is divided by deep fissures into superior, middle, and inferior lobes, the inferior lobe consisting of a large lateral lobule and a smaller medial lobule, the last frequently further subdivided. The inferior caval vein passes between these lobules. The left lung is only about two thirds of the size of the right lung and, although the middle and inferior lobes are well developed, the superior lobe is very imperfectly represented.

The inferior lobe of the left lung is not subdivided.

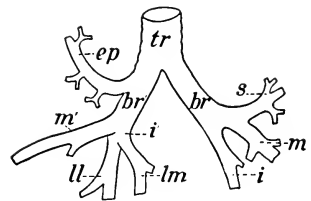


FIG. 114. Plan of the respiratory tubes as seen from the ventral surface. tr, trachea; br, br', left and right bronchi; ep, eparterial bronchus; s, m, m', i, i', bronchial rami to superior, middle, and inferior lobes; ll, lm, bronchial rami to lateral and medial lobules.

- (d) The trachea divides at its posterior end into two portions, the **right** and **left bronchi**, one for each lung. Each bronchus is again divided into smaller portions, the **bronchial rami**, which penetrate the substance of the organ and redivide into smaller tubes within it. On the right side a small **eparterial bronchus** is given off from the right bronchus to the well-developed superior lobe, entering the lung anterior to the right pulmonary artery.
- (e) The branches of the pulmonary artery and the pulmonary veins may be traced for a short distance on the medial portion, or **hilus**, of each organ. The artery penetrates deeply almost at once, anterior and then dorsal to the main bronchus, but some large venous tributaries have a considerable superficial course.
- (f) The vagus nerve passes to the dorsal side of the bronchus, giving off a number of branches, which accompany the bronchus to the lung.

These branches contain both afferent nerve fibres for the mucous membrane and efferent fibres to the smooth muscles of the bronchioles, the latter producing bronchoconstriction when stimulated and assisting expiration.

The lungs may be removed, together with a portion of the trachea, care being taken to leave the vagus nerves in place. The lungs may then be examined to better advantage, and the surface also may be prepared for the next dissection.

5. The following structures may now be traced on the dorsal wall of the thorax:
- (a) The oesophagus. It traverses the thorax in a median position, entering the diaphragm at the hiatus oesophageus.
- (b) The vagus nerves. The right and left nerves pass backward along the lateral walls of the oesophagus, and are connected with one another through nerve plexuses lying on its dorsal and ventral surfaces. In the posterior part of the thorax, both cords lie dorsolateral to the oesophagus and after passing through the diaphragm in this position the left nerve crosses to the ventral surface of the stomach. The right cord occupies a corresponding dorsal position and passes to the dorsal surface of the stomach (p. 230).

- (c) The **thoracic aorta** (aorta thoracalis) passes backward on the ventral surface of the vertebral column, leaving the thorax through the hiatus aorticus, the latter being the aperture enclosed by the crura of the diaphragm. Its branches in the thorax are the **intercostal arteries** (aa. intercostales), beginning with the fourth, which are given off metamERICALLY in the intercostal spaces, and pass laterad to the thoracic wall.
- (d) The **thoracic portions** of the **sympathetic trunks** lie on the lateral surfaces of the bodies of the thoracic vertebrae, the left trunk reaching this position by extending backward, dorsal to the aorta, from the first thoracic ganglion, to which it has already been traced. The posterior ganglia give origin to the **splanchnic nerve**, the latter usually separating at about the eighth thoracic ganglion and passing backward into the abdominal cavity (p. 228).
- (e) The **levatores costarum**; a series of small muscles arising from the transverse processes of the vertebrae and the heads of the ribs and inserted on the anterior margins of the next succeeding ribs. They assist the intercostals in respiration.
- (f) The **intercostal nerves** (nn. intercostales) accompany the intercostal arteries to the lateral wall of the thorax, their trunks running mainly between the internal intercostal muscles and the vestigial intracostal and subcostal muscles but partly enclosed by the internal intercostals.
- (g) The **azygos vein** (v. azygos) is a small, asymmetrical, venous trunk lying to the right of the dorsal surface of the aorta. It receives from both sides the majority of the **intercostal veins** which accompany the corresponding arteries and nerves, the tributaries extending backward to the first lumbar veins. It opens forward into the right superior caval at about the level of the second intercostal space. The more anterior intercostal veins are tributaries of the **right and left supreme intercostal veins** which open into the corresponding superior cavals.

The azygos vein lies ventral to the more anterior intercostal arteries but dorsal to the more posterior ones, the change of relation

occurring most frequently at the eighth intercostal space but often in the ninth, tenth, or eleventh.

- (h) The **thoracic duct**, which is not readily observed in ordinary dissection, is formed between the crura of the diaphragm by the union of the two lumbar lymphatic trunks and the intestinal trunk. It passes forward between the azygos vein and the aorta to the level of the second intercostal space, where it crosses to the left between the aorta and the oesophagus. It then follows the left superior vena cava and enters into the junction of the jugular and subclavian veins. A variable series of lymph nodes lies between the aorta and the oesophagus, receiving vessels from the organs in the thorax and draining either into the thoracic duct or separately into the vein. The arrangement of the lymphatic vessels and their connections with the veins show marked individual differences.

6. The **diaphragm** (diaphragma) is a muscular and tendinous sheet forming the posterior wall of the thorax and separating the pleural cavities from the peritoneal cavity. It is somewhat dome-shaped and contraction of its muscles partially flattens the dome in such a way that the space occupied by the lungs is considerably increased, while the liver and related structures of the abdominal cavity are displaced backward.

As a muscle, the diaphragm arises in three portions. The first, or **lumbar portion**, consists of two muscular and fibrous cords, the **crura**, the right much larger and stronger than the left, arising from the anterior spinous processes of the first three lumbar vertebrae. The second, or **costal portion**, arises from the internal surfaces of the posterior ribs by slips separated by small triangular aponeurotic areas. The third, or **sternal portion**, arises from the xiphoid process of the sternum. The insertion of the muscles of the diaphragm is represented by its own tendinous central portion, or **centrum tendineum**, although the latter is virtually attached forward to the lungs and pericardium through the broad mediastinum and the pulmonary ligaments. The centrum tendineum is shaped somewhat like a trefoil, its margin being indented dorsally by the crura and at each side at the position of the inferior phrenic veins. The fibres of the costal and sternal portions converge radially to its margin. The connection of the lumbar portion is somewhat asymmetrical, the two crura combining ventral to the aorta and ending largely to the left of the median plane.

The following may be made out on the posterior surface:

- (a) The cut margins of the falciform, coronary, and left triangular ligaments, which were severed in the removal of the liver.
- (b) The **hiatus aorticus**, an aperture enclosed by the dorsal parts of the two crura and serving for the transmission of the aorta.
- (c) The **hiatus oesophageus**, more ventral than the foregoing, and serving for the passage of the oesophagus. The muscle fibres of the right crus of the lumbar portion diverge at the dorsal side of this opening, a few passing to the right of it but the great majority ending in the central tendon to the left of it.
- (d) The **foramen venae cavae**, situated slightly to the right and slightly ventral to the hiatus oesophageus. It serves for the transmission of the vena cava inferior and is surrounded by the coronary ligament.
- (e) The **superior phrenic arteries** (aa. phrenicae superiores) arise from the aorta at about the point of origin of the eleventh intercostals or from one of the latter, and enter the crura.

The inferior phrenic arteries are minute branches arising at the base of the coeliac.

- (f) The **inferior phrenic veins** (vv. phrenicae inferiores), one on either side of the foramen venae cavae, at which point they enter the inferior cava.

The small **superior phrenic veins** run close to the phrenic nerves, pass forward from the centrum tendineum of the diaphragm along the mediastinum, ventral to the roots of the lungs, and open into the superior caval veins.

XII. THE VERTEBRAL AND OCCIPITAL MUSCULATURE

Dissect on the dorsal surface of the body from the occiput backward; also on the lateral and ventral surfaces of the neck.

The **serratus posterior muscle** lies on the dorsolateral surface of the thorax. It arises from the dorsal spinous ligament of the neck (ligamentum nuchae) and from the lumbodorsal fascia back

to the last rib, and is inserted on the lateral surfaces of the eight posterior ribs.

The **splenius muscle** is a somewhat triangular sheet arising from the ligamentum nuchae and inserted on the supraoccipital and mastoid portions of the skull, extending also to the transverse process of the atlas.

These two muscles should be divided, the serratus posterior being removed from the surface.

These and the muscles described in the next two sections constitute the epaxial musculature (p. 67).

1. The long muscles of the vertebral column.

Apart from the iliopsoas, psoas minor, and quadratus lumborum—muscles of appendicular insertion lying on the ventral surface of the vertebral column—the vertebral musculature comprises chiefly modified segmental muscles lying on the dorsal surface, for the most part in the area enclosed by the spinous and transverse processes of the vertebrae. They include the sacrospinalis, semispinalis, and intertransversarii. Their insertions are extended in part laterad to the ribs. In the cervical region they are represented by short muscles, separated for the most part from the thoracic and lumbar portions, and arising by accessory bundles from the anterior ribs, the corresponding thoracic, and the posterior cervical vertebrae. In the cervical region the muscles are easily separated from one another, but in the posterior part of the body it is necessary to dissect away the tough investment of lumbodorsal fascia which covers them.

(a) The **sacrospinalis**. Origin: Crest of the ilium and dorsal surface of the sacrum; mamillary processes of the six posterior lumbar vertebrae; investing lumbodorsal fascia.

This muscle is the largest and strongest muscle of the body. It extends forward over the surface of the ribs. Its medial border is separated from the middle line by a space of considerable width, in which the semispinalis and multifidus muscles are accommodated. In the lumbar region it is inserted in a continuous mass on the long transverse processes of the vertebrae and in the interspaces. In the thoracic region the muscle divides into two portions, name-

ly, a thin lateral portion, the **iliocostalis** or **longissimus costarum**, and a thick medial portion, the **longissimus**. The latter receives in the posterior portion of the thorax strong accessory bundles from the semispinalis muscle on its medial side, the two muscles being inseparable at this point.

The iliocostalis is inserted laterally on the ribs as the **iliocostalis dorsi**. Medially, it receives from the ribs a number of accessory bundles, which are inserted forwards to the seventh cervical vertebra as the **iliocostalis cervicis**.

The longissimus is inserted by broad fleshy bands on the posterior margins of the ribs, medial to the accessory origins of the iliocostalis, this portion of the muscle forming the **longissimus dorsi**. Continuing to the neck it is inserted on the transverse processes of the three posterior cervical vertebrae, medial to the origin of the cervical portion of the serratus anterior, but a number of accessory slips carry the insertion forward to the transverse process of the atlas. This portion is the **longissimus cervicis**. A separate band of fibres arising chiefly from the transverse processes of the second to fourth thoracic vertebrae joins the lateral, ventral portion of the splenius, and forms the **longissimus capitis**. It is inserted with the splenius on the mastoid portion of the skull.

- (b) The **semispinalis** and **multifidus**. The band of muscle lying between the longissimus and the middle line, is composed of partly fused slips, arising for the most part by very long tendons from the mamillary and transverse processes, and inserted forwards on the spinous processes. It is divisible into two portions, which are superficially separated by a constricted area lying at the level of the last thoracic vertebra, this being also the point where the muscle is fused with the longissimus. The anterior portion, the **semispinalis dorsi**, is inserted by a series of fleshy slips on the spinous processes of the more anterior thoracic vertebrae, but extends to the spinous process of the third or fourth cervical vertebra. The posterior portion, the **multifidus**, increases

in size backward to the sacrum, where it is continuous with the abductor caudae posterior.

An almost separate muscle, covering the neck as a broad sheet immediately beneath the splenius and longissimus capitis, is the **semispinalis capitis**. It arises from the transverse processes of the five posterior cervical and the transverse processes of the first four thoracic vertebrae. It is lightly attached on a line from the transverse process of the atlas to the external occipital protuberance, but is inserted on the lateral surface of the latter. The more posterior and medial portion of the muscle is composed of separate slips arising in common with the longissimus capitis, two closely applied slips, however, at the free margin of the muscle, arising from the semispinalis dorsi and the longissimus. The principal, lateral portion is crossed by a tendinous inscription.

A second muscle, the **semispinalis cervicis**, is covered by the foregoing one. It arises from the articular processes of the posterior cervical and first thoracic vertebrae, and is inserted on the spinous processes of the cervical vertebrae, chiefly on that of the epistropheus.

- (c) The **intertransversarii** are short muscles connecting the lateral portions of the vertebrae. They are distinguishable in part by their darker coloration. They increase in size backwards, being most conspicuous in the lumbar region, where they form thick muscular pads interposed between the mamillary and accessory processes. The last slip is attached to the crest of the ilium.
2. The following muscles constitute an occipital group, composed of short muscles arising from the atlas and axis and inserted on the atlas and the occipital portion of the skull.
- (a) The **rectus capitis posterior superficialis**. Origin: Spinous process of the epistropheus. Insertion: External occipital protuberance.
- (b) The **obliquus capitis superior**. Origin: Transverse process of the atlas. Insertion: Lateral surface of the occipital protuberance.

The foregoing muscles should be divided.

- (c) The **rectus capitis posterior minor**. Origin: Posterior tubercle of the atlas. Insertion: External occipital protuberance.
- (d) The **rectus capitis posterior major**. Origin: Spinous process of the epistropheus. Insertion: Laterally on the supraoccipital bone.
- (e) The **obliquus capitis inferior**. Origin: Spinous process of the epistropheus. Insertion: Dorsal surface of the transverse process of the atlas.
- (f) The **rectus capitis lateralis**. Origin: In common with the obliquus capitis superior, which covers it. Insertion: Base of the jugular process of the occipital.

3. Muscles of the lateral and ventral surfaces of the neck:

(These belong to the epibranchial portion of the hypaxial musculature—p. 67. The hypobranchial portion comprises the sternohyoid, sternothyroid, thyrohyoid, and geniohyoid muscles.)

- (a) The **scalenus ventralis** or **anterior**. Origin: Transverse processes of the four posterior cervical vertebrae. Insertion: Anterior and lateral surfaces of bony first rib.
- (b) The **scalenus medius**. Origin: Transverse process of the fifth cervical vertebra. Insertion: Lateral surfaces of the third to fifth ribs (with sometimes a slip to the second rib).
- (c) The **scalenus dorsalis** or **posterior**. Origin: Transverse processes of the fourth to sixth cervical vertebrae. Insertion: More dorsal part of first rib.

The medius is superficial; the ventral more or less separated from the dorsal by the origin on the first rib of part of the cervical portion of the serratus anterior.

- (d) The **obliquus thoracis** or **transversus costarum**. Origin: Lateral surface of the bony first rib just ventral to the insertion of the scalenus ventralis. Insertion: Side of the sternum from the attachment of the second costal cartilage to that of the fourth, by a triangular aponeurosis which is fused with that of the anterior end of the rectus abdominis

muscle. This muscle has been shown to be morphologically a part of the same sheet as the external oblique muscle of the abdomen.

The foregoing muscles, comprising the scalenus group, are destroyed by the removal of the ventral thoracic wall (p. 323).

- (e) The **longus colli**. Origin: Bodies of the first six thoracic vertebrae. Insertion: The muscle passes forward on the ventral surface of the bodies of the vertebrae, giving off insertion fibres, and also receiving strands of origin. It terminates on the anterior tubercle of the atlas.
- (f) The **longus capitis** is partly fused with the foregoing muscle, but its origin is in a more lateral position from the transverse processes of the first six cervical vertebrae. Insertion: Sphenooccipital synchondrosis.
- (g) The **longus atlantis**. Origin: Lateral to the longus capitis, from the transverse processes of the third to sixth cervical vertebrae. Insertion: Transverse process of the atlas.

The longus capitis should be divided near its insertion.

- (h) The **rectus capitis anterior**. Medial portion of the ventral surface of the transverse process of the atlas. Insertion: Basioccipital bone.
4. The **caudal musculature** in the rabbit comprises, in addition to the posterior extension of the cutaneus maximus, the following axial muscles:
- (a) The **extensor caudae medialis**. It lies in the furrow between the spinous and articular processes of the posterior sacral and anterior caudal vertebrae, and is inserted on the transverse processes and dorsal surfaces of the caudal vertebrae.
 - (b) The **abductor caudae posterior** lies in the groove between the articular and transverse processes and is inserted on succeeding vertebrae. It appears to continue the multifidus, but corresponds to the more medial portion of the longissimus.
 - (c) The **abductor caudae anterior**. Origin: Ischial spine. Insertion: Lateral surface of the sacrum and the transverse processes of the caudal vertebrae.
 - (d) The **flexor caudae**. Origin: Ventral surface of the sacrum and anterior caudal vertebrae. Insertion: Ventral surfaces of succeeding vertebrae.

These muscles are also known as sacro-coccygei, dorsalis, lateralis, and ventralis (*a, b, d*), and coccygeus (*c*).

XIII. THE CENTRAL NERVOUS SYSTEM

1. The spinal cord and nerve roots.

To expose the whole cord or a portion of it from the dorsal surface, the muscles should be removed from the dorsal aspect and both sides of the vertebral arches and the latter should be broken away with bone forceps. The following features may be made out when the extent of exposure is sufficient:

- (a) The spinal cord is enclosed in a set of three protective membranes, the **meninges**, the outermost of which is a relatively thick, tough, fibrous sheet, the **dura mater**. Unlike that of the brain, the dura mater of the spinal cord is not firmly attached to the inner surface of the surrounding bone and it is exposed in an intact condition by the removal of the vertebral arches. The **epidural space** between this membrane and the inner surface of the bone contains a little fat.

If the dura mater is now cut open, it is found to be separated by a narrow space from a much thinner, vascular membrane, the **pia mater**, which is closely applied to the surface of the spinal cord. Between the dura mater and the pia mater and attached to both lies a very delicate web of connective tissue, the **arachnoidea**.

The arachnoidea and the pia mater together are frequently designated leptomeninges, whereas the dura mater is distinguished as the pachymeninx.

The spaces between these membranes are filled, in the living condition, with cerebrospinal fluid, the same liquid which fills also the cavities within the central nervous organs.

- (b) The **spinal cord** (*medulla spinalis*) is a thick, subcylindrical, white cord traversing the vertebral column in the vertebral canal. Its diameter is not uniform, as it exhibits two slight enlargements, one in the cervical, the other in the lumbar region. These enlargements are the regions from which the nerves to the limbs arise and are due to the increased number of nerve elements present on that account. At about the middle of the sacrum, the cord contracts to a

slender filament, the **filum terminale**, which may be traced backward to the middle of the tail, and which is produced in development by the more rapid growth of the bony canal than of the spinal cord within it.

A faint median groove, most distinct towards the cephalic end of the cord, divides it into right and left halves. This is the dorsal or posterior median sulcus. A short distance to each side of this, the dorsal roots of the spinal nerves enter the cord along a still fainter groove, the dorsolateral or posterior lateral sulcus.

- (c) The nerve roots have a regional distribution—eight cervical, twelve thoracic, seven lumbar, four sacral, and six caudal.

Since the first spinal nerve emerges between the skull and the atlas, the cervical nerves are numbered to correspond with the vertebrae lying behind the intervertebral foramina from which they proceed, though the remaining spinal nerves are designated according to the vertebrae lying in front of the corresponding intervertebral foramina. The nerve transmitted by the intervertebral foramen between the seventh cervical and first thoracic vertebrae is described as the eighth cervical.

The disproportionate growth which produces the filum terminale also carries the connections of the posterior spinal nerves with the spinal cord to levels further forward than their emergence from the vertebral column. Hence a group of these nerves runs backward at each side of the filum terminale, constituting the formation known as the cauda equina. These features are less pronounced in the rabbit than in the human species, in which the spinal cord terminates near the boundary between the first and second lumbar vertebrae in the adult.

- (d) The origin and primary divisions of the nerve roots may be worked out by removing carefully the lateral portions of the arches of one or two vertebrae. Each spinal nerve has a **posterior** or **dorsal root** (radix posterior), composed of afferent nerve fibres (p. 73), which enters the dorsolateral surface of the spinal cord as a linear series of rootlets. These

extend ventrolaterally close to the cord and unite just lateral to it, where the root expands into a **spinal ganglion**. The more slender **anterior** or **ventral root** (radix anterior) lies directly ventral to the dorsal root and, like it, consists of a row of separate filaments. These are composed of efferent fibres emerging from the ventrolateral surface of the cord. They converge dorsolaterad to meet and combine with the dorsal root close to the spinal ganglion, thus forming a single nerve, which breaks up a little further laterally into three primary branches, the posterior or dorsal, the anterior or ventral, and the communicating ramus. Each branch contains fibres from both roots. The roots lie within the dura mater and this extends into each intervertebral foramen there to become continuous with the connective tissue sheath of the nerve.

The **posterior (dorsal) ramus** is an inconspicuous branch (except in the first two cervical nerves) passing to the dorsal musculature and skin. The **anterior (ventral) ramus** is the chief portion of the spinal nerve, the successive anterior rami appearing as the components of the cervical and lumbosacral plexuses or as individual spinal nerves. The **ramus communicans** is a slender filament passing ventrad to join the sympathetic trunk.

Each spinal nerve has a grey ramus communicans and certain ones have also a white ramus communicans. In the rabbit, the latter are all the thoracic and the first five lumbar nerves and similar parasympathetic white rami occur in the second, third, and fourth sacral nerves (see pp. 73-75).

2. A small portion of the spinal cord may be excised and examined (preferably under water) for the following (see Fig. 18, p. 31).
 - (a) The cord is divided into lateral halves by two median depressions, the **ventral** or **anterior median fissure** (fissura mediana anterior) and the **dorsal** or **posterior median sulcus** (sulcus medianus posterior).
 - (b) Each half of the cord is further marked off into three columns by shallow grooves, the **ventrolateral** and **dorso-**

lateral or **anterior** and **posterior lateral sulci**, of which only the latter are at all distinct. The grooves are marked by the attachments of the ventral and dorsal nerve roots. The three columns of each half of the cord are the **ventral** (anterior), the **lateral**, and the **dorsal** (posterior) **funiculi**.

- (c) On the cut surface the **white substance** (substantia alba) is seen to form a peripheral investment enclosing the **grey substance** (substantia grisea) of the centre of the cord. The grey portion is somewhat H-shaped in section, each half being composed of ventral larger and dorsal smaller masses, known in section as the **horns** of the grey matter, or, as complete structures, the **ventral** and **dorsal grey columns**. These grey columns are situated opposite the ventrolateral and dorsolateral sulci of the surface and separate internally the three funiculi mentioned in the previous paragraph. The white substance is composed of ascending and descending nerve fibres and, when a large proportion of these connect the brain with the various levels of the spinal cord, their number necessarily increases in a caudocephalic direction. In the rabbit, however, the proportion of such fibres is not great enough for the caudocephalic increase of the white matter to be marked (Fig. 41, p. 77). In the median plane is the minute **central canal** (canalis centralis), the cavity of the spinal cord.
- (d) The ventral (anterior) spinal artery runs along the cord in the ventral median fissure, giving off branches into the fissure and smaller branches over the surface.

3. The brain may be exposed by breaking away the supraorbital processes of the frontal bones and then removing the roof of the skull with bone forceps. In order to clear the brain and the roots of the cerebral nerves, it is necessary to remove the entire lateral wall of the skull on both sides. The part of the operation requiring most care is the removal of the temporal portion of the skull by successive steps, exposing first the paraflocculus of the cerebellum (Fig. 42, p. 79), a small stalked body which is almost completely enclosed by the dorsal portion of the petrosal bone. The entire petrotympanic bone is easily detached, and

if it is removed *en masse* the paraflocculus and probably also the roots of the facial and acoustic nerves will be destroyed.

The arches of the first three or four cervical vertebrae should be removed if the anterior portion of the cord has not already been exposed in the previous dissection.

The spinal cord may be divided at about the level of the third vertebrae. The brain should then be raised very gently from the ventral wall of the skull and the nerve roots should be divided with fine, sharp scissors. This operation requires considerable care not to pull upon the nerves since these are strongly attached at their points of exit from the skull but very lightly attached to the brain, so that they are in danger of being torn away from the latter.

The anterior end of the brain may be freed by cutting close to the bone under and in front of the small anterior expansions formed by the olfactory bulbs.

The dura mater is adherent to the inner surface of the cranium but may be stripped away from it in the process of removal of the bone. Portions which remain attached to the brain may be cut away with scissors. Such attachment will be found chiefly along two lines: one, where the membrane extends down into the longitudinal fissure between the cerebral hemispheres, as the falx cerebri, the other the tentorium cerebelli, a transverse fold extending inward between the cerebral hemispheres and the cerebellum. These parts contain wide vessels which receive most of the blood from the brain, the **superior sagittal** and the **transverse venous sinuses**, from the latter of which the blood passes into the superficial temporal vein (p. 297). On the ventral surface of the brain as removed appear the basilar and internal carotid arteries and their branches. These vessels should be kept intact for examination at a later stage.

4. The primary divisions of the brain are explained in a previous chapter (p. 80). The prosencephalon or forebrain, the mesencephalon or midbrain, and the rhombencephalon or hindbrain, though much elaborated in form, are still to be recognized in the adult animal. Their superficial features may be identified as follows:

THE PROSENCEPHALON:

- (a) The greatly enlarged **cerebral hemisphere** (hemisphaerium cerebri), the dominant portion which correlates and coordinates the activities of all the rest of the nervous system, forms with its fellow of the opposite side the largest portion of the brain. The two structures are separated by the **longitudinal cerebral fissure**, but are connected with each other by the commissures indicated below. Each hemisphere has a superficial layer of grey matter, the **cerebral cortex**, which in larger brains is thrown into numerous folds but in the rabbit is practically smooth.
- (b) The **olfactory bulb** (bulbus olfactorius) is a small expansion lying at the anterior end of each hemisphere. Its anterior and ventral surfaces receive the fascicles of the **first cranial** or **olfactory nerve**, which is not a compact structure but is represented by numerous separate threads coming from the mucous membrane of the nose. These may be found in the skull, where they may be traced into the perforations of the cribriform plate.
- (c) The olfactory bulb is the anterior portion of the **olfactory brain**. When traced backward on the ventral surface of the brain it is seen to be replaced by a white band of fibres, the **olfactory tract** (tractus olfactorius) and a somewhat wider strip of grey matter underlying the tract. This strip expands caudally into a portion of the brain which, from its shape, is known as the pyriform lobe (lobus piriformis) and here the olfactory tract spreads out and most of its fibres terminate. The lateral margin of the olfactory brain, which includes the olfactory bulb and the related parts just described is delimited superficially from the remaining portions of the cerebral hemisphere by a longitudinal furrow, the **limbic fissure** (fissura limbica). The anterior portion of the furrow, known as the **anterior rhinal fissure**, separates the grey matter underlying the olfactory tract superficially from the narrow anterior end of the non-olfactory part of the cerebral hemisphere. The corresponding posterior portion of the furrow, the **posterior rhinal fissure**, marks off the pyriform lobe from the posterior,

more expanded part of the cerebral cortex. The slight angle formed at the junction of the anterior and posterior rhinal fissures is the point of origin of a faint depression extending upward on the lateral surface of the cerebral hemisphere. This represents a rudiment of the **lateral cerebral (Sylvian) fissure**, which is a conspicuous feature in the brain of man and other mammals with convoluted hemispheres.

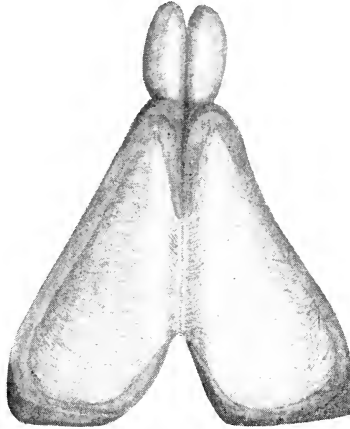


FIG. 115. Dissection to show the radiation of the corpus callosum from a dorsal viewpoint. The longitudinal white line close to the median plane is the position of a delicate band of hippocampal fibres, the medial longitudinal stria.

- (d) The **corpus callosum** is a broad, white commissural¹ band passing transversely between the hemispheres (Fig. 115) to connect the cortex of each with that of the other and thus providing for the co-ordination of their action. Its median portion lies at the bottom of the longitudinal cerebral fissure and may be exposed dorsally by pressing apart the medial margins of the hemispheres so as to open up the fissure.

The foregoing parts belong to the telencephalon, those which follow belong to the diencephalon (p. 86).

¹Though the term is sometimes loosely used, a commissure may be defined as a structure connecting corresponding parts on opposite sides. It contrasts with a decussation, which is a system of nerve-fibres crossing the median plane to connect different parts on the two sides.

- (e) The **pineal body** (*corpus pineale*) is a small, somewhat conical structure lying between the dorsal posterior tips of the cerebral hemispheres (cf. p. 134). It is connected by a hollow stalk with the unpaired portion of the brain (the diencephalon) lying below it. The connection is concealed by a mass of pigmented vascular tissue, the beginning of the chorioid plexus of the third ventricle, and usually also by a small portion of the dura mater containing part of the sagittal venous sinus. The latter may be carefully detached.

By raising and pressing apart the tips of the hemispheres and pulling away the pineal body with the tissue to which it is attached, the dorsal surface of the diencephalon will be sufficiently exposed to make out the following features:

- (f) The slit-like aperture appearing in the middle line after the removal of the pineal body represents the dorsal portion of the **third ventricle** (*ventriculus tertius*) (Fig. 116), the roof of which is formed by tissue just torn away with the pineal body. This roof consists of a thin membrane over which lies a dense network of fine blood vessels contained in pia mater, the **chorioid plexus**. Folds of the membrane and plexus dip down into the ventricular cavity and here cerebrospinal fluid is secreted.
- (g) The lateral margins of the aperture are largely formed by minute spindle-shaped masses, one on either side, the **habenulae**. Their posterior ends are united by a slender transverse band, the **habenular commissure** (*commissura habenularum*). The fibres constituting this band are faintly traceable forward, where they form a pair of thin whitish filaments (medullary

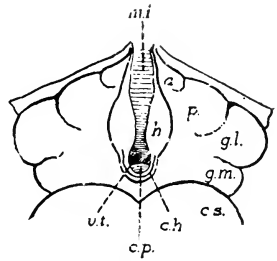


FIG. 116. Diagram, showing the arrangement of the parts of the thalamencephalon as viewed from the dorsal surface, after removal of the pineal body: a., anterior thalamic tubercle; c.h., habenular commissure; c.p., rostral edge of posterior commissure; c.s., superior colliculus (of mesencephalon); g.l. and g.m., lateral and medial geniculate bodies; h., habenula; m.i., massa intermedia; p., lateral thalamic tubercle; v.t., third ventricle.

striae) composed of fibres from olfactory correlation centres. The habenulae receive impulses from various olfactory regions of the cerebral hemisphere and tactile and other related sensory impulses which they correlate with them, sending resultant excitation impulses to motor centres, especially those concerned with feeding.

- (h) The **posterior commissure** (commissura posterior) crosses the posterior portion of the roof immediately behind and below the habenular commissure, so that only its rostral edge is visible from above, as indicated in Fig. 116. It is a composite structure which, like other commissures, connects parts on the two sides of the brain.
- (i) The very thick masses of nervous tissue which form the lateral walls of the third ventricle are the **thalami**. They are broadly connected by the **intermediate mass** (massa intermedia) or **middle commissure**, which may be seen from the dorsal surface crossing and largely filling up the ventricular cavity. This is not a true commissure (a band of nerve fibres connecting corresponding structures bilaterally), but is simply a fusion of the grey matter lining the walls of the ventricle, brought about by the increased thickness of the thalami. The latter contain various reflex centres and serve especially as a relay station through which pass all impulses proceeding to the cerebral hemisphere, except the olfactory ones.
- (j) On either side, lateral to the habenula, the dorsal portion of the thalamus forms a low, somewhat oval projection, the lateral thalamic tubercle. This swelling represents superficially a mass of grey matter through which pass most of the sensory impulses to the hemispheres from lower parts of the nervous system other than visual and auditory.

The anterior tubercle of the thalamus is a faint elevation of very small dimensions lying in the angle enclosed between the lateral tubercle and the anterior portion of the aperture of the third ventricle. It also is a relay station for impulses to the cerebral cortex, in this case mainly ones coming from olfacto-visceral correlation centres.

- (k) The parts of the **metathalamus** are distinguishable externally as two rounded projections of the lateral surface at each side of the thalamic region. One of them, the **lateral geniculate body** (*corpus geniculatum laterale*), lies external to the lateral thalamic tubercle, marked off from it superficially only by a faint depression, and constitutes the most lateral part of the thalamic mass. It contains the

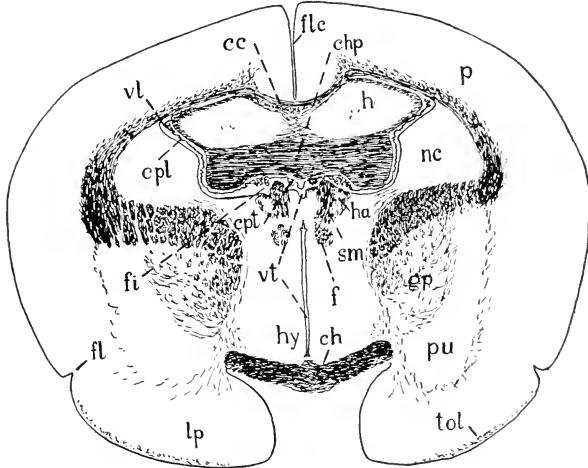


FIG. 117. Transverse section of the forebrain passing through the inter-ventricular foramina. The drawing represents a section stained by the method of Weigert, which gives the white nerve fibres a dark colour. The large mass of fibres dividing the corpus striatum into dorsal (nc) and ventral (gp + pu) parts (the internal capsule) contains the fibres which form the basis of the cerebral peduncle and the pyramid further back.

cc, corpus callosum; ch, optic chiasma; chp, hippocampal commissure; cpl, chorioid plexus of lateral ventricle; cpt, chorioid plexus of third ventricle; f, fornix; fi, inter-ventricular foramen; fl, limbic fissure; flc, longitudinal cerebral fissure; gp, part (globus pallidus) of corpus striatum; h, tapering anterior end of hippocampus; ha, habenula, anterior tip; hy, hypothalamus; lp, pyriform lobe; nc, part (caudate nucleus) of corpus striatum; p, cerebral cortex; pu, part (putamen) of corpus striatum; sm, stria medullaris thalami; tol, olfactory tract; vt, lateral ventricle; vt, third ventricle.

vestibule of the hemisphere for visual impulses. The **medial geniculate body** is less prominent and occupies a position immediately medial and posterior to the lateral geniculate body. It relays auditory excitations to the cerebral cortex.

- (l) The **optic tract** (*tractus opticus*) passes obliquely over the lateral surface of the brain from the ventrally situated optic chiasma to the lateral geniculate body, part of it

ending there and part continuing to the superior colliculi of the midbrain. The lateral geniculate body is a relay station for visual impulses to the cerebral cortex, the fibres which convey from the eye impulses producing conscious visual experiences being among those which terminate here. The fibres to the superior colliculus of the mammal are concerned entirely with the production of reflex adjustments.

- (*m*) On the ventral surface, the **optic chiasma** (chiasma opticum), forms a conspicuous median cross-like elevation, the posterior portion of which is traceable into the optic tracts, the anterior portion into the bases of the **second cranial**, or **optic nerves**. Thus the optic tracts are simply the direct continuation of the optic nerves after they have crossed in the chiasma.

While all mammals (and only mammals) have a certain proportion of optic nerve fibres which do not cross in the chiasma, the number of these is at a minimum in the rabbit, in which the eyes have an extreme lateral direction. In mammals generally, the number of uncrossed fibres is roughly proportional to the amount of overlapping of the fields of vision of the two eyes.

- (*n*) The **hypophysis**, or **pituitary body**, lies immediately behind the optic chiasma (cf. p. 134). It is a somewhat elongate, rounded, glandular organ attached to the base of the brain by a slender stalk.

On account of its enclosure by the walls of the hypophyseal fossa, and of the relative weakness of the stalk connecting it to the brain, the hypophysis is commonly detached in removal of the brain from the skull, in which case a slit-like aperture representing the ventral portion of the third ventricle is exposed.

The meninges fuse in a collar-like ring round the transition between the hypophyseal body and the infundibular stalk. Thence the dura continues so as to form a complete lining for the bony hypophyseal fossa, fused externally with the periosteum and over its whole inner surface with the fibrous capsule of the gland. Thus the subdural and subarachnoid spaces do not extend round the gland.

- (*o*) The **tuber cinereum** is a small elevation of grey matter appearing on the ventral surface after the removal of the hypophysis. It is the base of attachment of the **infundi-**

bulum, the latter being the slender stalk of the hypophysis which connects it to the brain. When the hypophysis is removed, the infundibulum which attaches it to the brain is, naturally, broken, exposing the cavity in its base as the slit mentioned above. The region of the tuber cinereum contains centres concerned chiefly with the correlation of olfactory with visceral sensory impulses.

- (p) The **mamillary body** (*corpus mamillare*) forms a conspicuous rounded elevation, lying at the posterior end of the tuber cinereum. The structure is externally single in the rabbit, but there is an indication of lateral lobes. It also receives impulses from the olfactory correlation regions of the cerebral hemisphere and combines them with others, chiefly visceral.

The tuber cinereum and the mamillary body belong to the **hypothalamus**, a region which includes centres for the control of the visceral organs through the autonomic system and for the regulation of highly integrated vegetative functions such as the metabolism of water, carbohydrate, and fat and the maintenance of body temperature.

THE MESENCEPHALON:

- (a) The boundary between prosencephalon and mesencephalon is marked dorsally by the anterior edges of a pair of prominent rounded elevations, which are associated with a second pair just behind them to form the roof of the midbrain. These four elevations are the **corpora quadrigemina**. The anterior pair, distinguished as the **colliculi superiores**, is much larger than the posterior pair, the **colliculi inferiores**. The superior colliculi correspond to the optic lobes of sub-mammalian vertebrates and receive many of the fibres of the optic tracts as well as fibres conveying impulses of other sensory types to be correlated with the visual ones. The inferior colliculi are important reflex centres belonging to the auditory system.
- (b) The ventral part of the midbrain is shorter anteroposteriorly than the dorsal one and is occupied by a pair of thick ridges converging from in front, the **cerebral peduncles**.

These are separated by a faint median depression, the **interpeduncular fossa**, just behind the mamillary body. The superficial portion of each peduncle is composed of a broad white band of longitudinal nerve fibres and contains the main descending pathways carrying impulses from the cerebral cortex to the cerebellum and to the motor centres of the brain and spinal cord.

- (c) The **third cranial**, or **oculomotor nerve** (n. oculomotorius), which controls the majority of the eye-muscles, emerges from the ventral surface of the cerebral peduncle.

THE RHOMBENCEPHALON:

- (a) The **cerebellum** forms a dorsal arch over the anterior part of the hindbrain and is supported by stout pillars at its sides. The dorsal part of the arch has become very massive, is moulded into several lobes, and has a superficial layer of grey matter, the **cerebellar cortex**. This is thrown into numerous transverse folds. The subdivisions recognized include a median portion, the **vermis**, a **cerebellar hemisphere** at each side of this, and a stalked body, the **paraflocculus**, arising ventrolaterally beneath each hemisphere.

The flocculus is a small fold ventral to the stalk of each paraflocculus.

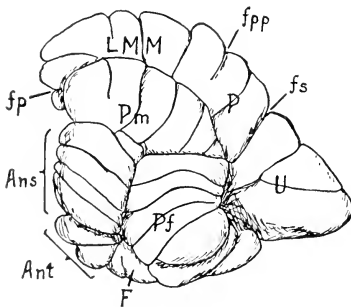


FIG. 118. Left lateral surface of cerebellum of the rabbit.

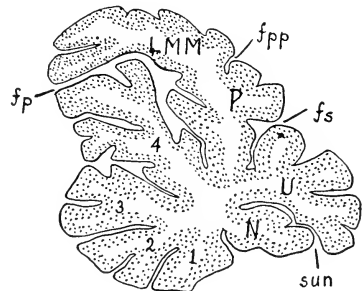


FIG. 119. Median section of cerebellum, the cortex stippled. Both figures after Brodal. Ans, lobulus ansiformis; Ant, lobus anterior; F, flocculus; fp, fissura prima; fpp, fissura prepyramidalis; fs, fissura secunda; LMM, lobus medius medianus; N, nodulus; P, pyramis; Pf, paraflocculus; Pm, lobulus paramedianus; sun, sulcus uvulonodularis; U, uvula; 1, lingula; 2, lobulus centralis; 3, 4, culmen; 1-4, lobus anterior.

The various folds of the cerebellar surface are designated as indicated in Figs. 118 and 119. The parts named lobulus ansiformis and lobulus paramedianus together make up the cerebellar hemisphere.

The cerebellum is concerned chiefly with the co-ordination of muscular action, the regulation of the "tone" of the muscles, and the preservation of the equilibrium of the body. The cerebellar hemispheres are specially related to the cerebral hemispheres and receive large numbers of fibres (from the pons) bearing impulses from the latter so that they may co-ordinate the contractions of muscles activated by direct impulses from the same source.

The areas of the two crura of the ansiform lobule indicated by hatching in Fig. 120 have been shown to be proportional to the weight of the muscle masses of the fore and hind limbs respectively in the rabbit and the remainder of the hemisphere appears to be related to ability to perform quick, powerful movements of the hind limbs and trunk.

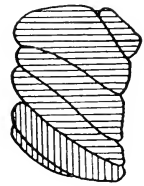


FIG. 120. Lateral view of the ansiform lobule as in Fig. 118, the superior crus hatched transversely and the inferior crus hatched vertically. The areas of the two crura are proportional to the weights of the muscles of the anterior and posterior limbs respectively, indicating a probable functional relation to these muscles.

- (b) The **anterior medullary velum** (velum medullare anterius) is the thin membrane underlying the anterior portion of the cerebellum, attached to the ventral surface of the latter and connecting it with the inferior colliculi (Fig. 124). It forms a small anterior portion of the roof of the fourth ventricle.
- (c) The **fourth cranial, or trochlear nerve** (n. trochlearis), which supplies the superior oblique muscle of the eye, emerges from the anterior medullary velum and runs transversely on to the lateral surface of the cerebral peduncle. Here the cut end of the proximal portion of the nerve is usually to be found.

- (d) The **posterior medullary velum** (velum medullare posterius) underlies the posterior margin of the cerebellum, and extends backward over the triangular space enclosed by the walls of the fourth ventricle. It is a more delicate membrane than the anterior medullary velum and supports a **chorioid plexus** similar in character to that of the third ventricle but much less extensive. It is commonly torn away in the preparation of the brain, in which case the interior of the fourth ventricle is exposed.
- (e) On the ventral surface (Fig. 121), the **pons** forms a broad band extending transversely across the brain and upward into the supports (peduncles) of the cerebellum, its fibres being distributed to the cortex of the cerebellar hemispheres. Its surface is divided into two parts by a median depression, the **sulcus basilaris**, occupied by the basilar artery. It is not really a commissure but is part of the pathway connecting the cerebral hemispheres with those of the cerebellum.

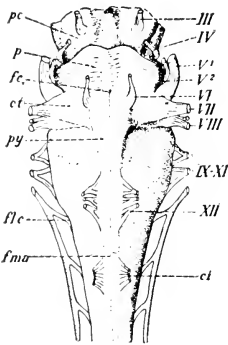


FIG. 121. The rhombencephalon. Ventral view (the cerebellum not figured).

ct, trapezoid body; fc, foramen caecum; flc, cervical flexure; fma, anterior median fissure; p, pons; pc, cerebral peduncle (mesencephalon); py, pyramid.

III, oculomotor nerve; IV, trochlear; V¹, portio major of the trigeminal; V², portio minor; VI, abducens; VII, facial; VIII, acoustic; IX-XI, glossopharyngeal, vagus, and spinal accessory group; XII, hypoglossal; ci, first cervical spinal.

The portion of the brain caudal to the posterior margin of the pons is the medulla oblongata.

- (f) The anterior median fissure of the spinal cord ends at the posterior margin of the pons in a faint depression, the **foramen caecum**.
- (g) The anterior funiculus of the spinal cord is continuous with a narrow band on the ventral surface of the hindbrain, the **pyramid**, which may be observed extending backwards on each side of the middle line from the posterior margin of the pons. The pyramids are really the reduced continuation backwards of the fibre-


- bands on the surface of the cerebral peduncles, which have been reduced by the ending of many fibres in the pons.
- (h) The **trapezoid body** (*corpus trapezoideum*) is another, smaller, superficial transverse band just behind the pons, and is part of the auditory pathway. It lies in the angle formed by the lateral margin of the pyramid with the posterior border of the pons, its fibres passing through the deeper part of the pyramid (Fig. 123) so that they are concealed by the latter.
- (i) The **fifth cranial, or trigeminal nerve** (*n. trigeminus*), arises by two roots, a larger sensory root, the **portio major**, and a smaller motor root, the **portio minor**. The two parts appear at the lateral border of the pons, whence they are directed forward.

The portio major is the common trunk of the ophthalmic, maxillary, and mandibular nerves, providing for the cutaneous sensibility of most of the head. The portio minor (motor, to muscles of mastication) joins the mandibular, so that the latter becomes a mixed nerve. The cut end of the portio major may be identified on the cranial wall and traced forward into the **semilunar ganglion**, the latter lying in a depression at the anterior ventral end of the petrosal bone.

- (j) The **sixth cranial, or abducent nerve** (*n. abducens*), which controls the lateral rectus muscle of the eye, is a slender cord arising by several very delicate rootlets along the lateral edge of the anterior end of the pyramid.
- (k) The **seventh cranial, or facial nerve** (*n. facialis*), and the **eighth, or acoustic nerve** (*n. acusticus*), appear to rise from the lateral margin of the trapezoid body.

The two nerves are closely associated, the former being slightly anterior in position. Its chief portion is the motor root which controls the facial muscles. In addition the nerve receives a sensory filament, the **portio intermedia** or **intermediate nerve**, bearing gustatory and related impulses. The eighth nerve is purely sensory but comprises two portions conveying respectively auditory and equilibratory impulses from the corresponding parts of the internal ear. The trapezoid body is composed of fibres transmitting impulses from the auditory portion of the nerve, which fibres decussate and eventually reach the inferior colliculus and the medial geniculate body.

- (l) The **glossopharyngeus, vagus, and accessorius** arise by several roots arranged in a linear series along the lateral



margin of the medulla. The trunk of the accessorius extends backward on the spinal cord, its roots, about ten in number, arising as far back as the fifth cervical spinal nerve. It is an efferent nerve, while the two former are mixed nerves to various visceral organs.

- (*m*) The **twelfth cranial, or hypoglossal nerve** (n. hypoglossus), which controls the movements of the tongue, arises by several roots from the ventral surface of the more posterior part of the medulla oblongata at the lateral margin of the pyramid, its point of origin corresponding to that of the ventral root of a spinal nerve.
5. The arteries of the brain may be traced on its ventral surface as follows:
- (*a*) The **basilar artery** (a. basilaris) is a median trunk formed on the ventral surface of the medulla oblongata by the union of the **vertebral arteries**, the latter here represented by their cut ends. It passes forward as far as the anterior edge of the pons, giving off an irregular series of transversely directed branches on the surface of the brain as well as median branches which are concealed from view as they run directly dorsad into the brain substance.
- (*b*) The **inferior cerebellar artery** (a. cerebelli inferior) is the largest of the transverse branches arising from the basilar on the ventral surface of the hindbrain. It originates about half way along the basilar artery and passes laterad and up the side of the brain to the posterior part of the cerebellum.
- (*c*) The **posterior cerebral artery** (a. cerebri posterior) is a paired vessel formed at the level of the anterior margin of the pons by the bifurcation of the basilar. It passes at each side laterad and dorsad to the posterior portion of the cerebral hemisphere, giving secondary branches to the diencephalon.
- (*d*) The **superior cerebellar artery** (a. cerebelli superior) is a relatively large branch of the posterior cerebral, arising near the origin of the latter and passing to the anterior portion of the cerebellum after giving branches to the midbrain.

- (e) The cut end of the **internal carotid artery** lies on either side of the tuber cinereum. It turns forward but is connected backwards with the posterior cerebral by a **posterior communicating artery**.
- (f) The **middle cerebral artery** (a. cerebri media) is given off from the internal carotid, branching over the middle portion of the hemisphere to supply most of its lateral and dorsal surfaces.
- (g) The **anterior cerebral artery** (a. cerebri anterior) is the continuation of the carotid after the origin of the middle cerebral artery. It passes to the anterior portion of the ventral surface of the cerebral hemisphere and to the olfactory bulb. The anterior cerebral unites with that of the other side to form a short common trunk between the hemispheres which redivides into paired vessels supplying the medial surfaces. A complete anastomotic loop is thus formed round the hypothalamus by the internal carotid, anterior cerebral, posterior communicating, and posterior cerebral arteries. This is the **circle of Willis**.

The fusion of the anterior cerebral arteries replaces an interconnection by an anterior communicating artery, which occurs in man and many other mammals and occasionally appears in rabbits as an individual variation.

6. By dividing the supports of the cerebellum on either side, the entire structure may be removed and the surface may be exposed, as in Fig. 122, for an examination of the structures of the dorsal surface of the rhombencephalon. The posterior medullary velum is removed with the cerebellum, but the anterior medullary velum should be cut so that a small portion of it remains in place.
 - (a) The **fourth ventricle** (ventriculus quartus) is the extensive space enclosed by the rhombencephalon. It is connected forwards with the cerebral aqueduct (the cavity in the midbrain) and backwards with the central canal of the spinal cord. Its roof is formed principally by the anterior and posterior medullary vela, these being attached to the cerebellum close to each other so that they underlie it.

(b) The **rhomboid fossa** (fossa rhomboidea) is the shallow depression enclosed by the thick lateral and anterior walls and floor of the ventricle. The middle line shows a narrow depression, the **median fissure** (sulcus medianus fossae rhomboideae), on either side of which the floor is raised into a low ridge, described as the **medial eminence** (eminentia medialis). The posterior end of the fossa forms with the enclosing wall the somewhat triangular figure described as the **calamus scriptorius**.

(c) The lateral supports of the cerebellum, now represented by their cut ends, are formed by fibre-bands connecting the cerebellum with adjacent portions of the brain. In each there are three main bands or peduncles, though these cannot usually be distinguished in the cut surfaces. A middle peduncle, the **brachium pontis**, represents the direct continuation of the pons into the cerebellum, bringing

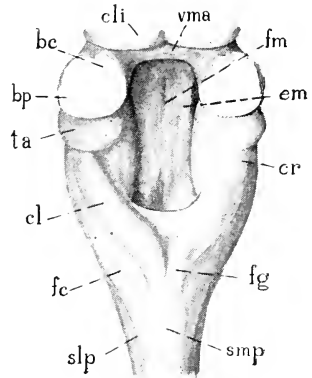


FIG. 122. The rhombencephalon. Dorsal view, after removal of the cerebellum; bc, brachium conjunctivum; bp, brachium pontis; cl, clava; cli, inferior colliculus (mesencephalon); cr, restiform body; em, medial eminence; fc, fasciculus cuneatus; fg, fasciculus gracilis; fm, median fissure of the rhomboid fossa; smp, dorsal median sulcus of the medulla; slp, dorso-lateral sulcus; ta, acoustic tubercle; vma, anterior medullary velum.

impulses to the latter from the cerebral cortex. An anterior band, the **brachium conjunctivum**, contains chiefly (not exclusively) fibres leading out of the cerebellum and running into the floor of the midbrain. A third band, the inferior cerebellar peduncle or **restiform body** (corpus restiforme), comes from behind as a thick ridge continuous with the dorsal part of the lateral funiculus of the spinal cord. It forms the lateral wall of the more caudal portion of the rhomboid fossa. Before turning dorsad into the cerebellum it passes under a rounded elevation, the **acoustic tubercle**, where part of the auditory nerve ends. The restiform body conveys impulses from various centres in

the spinal cord and medulla oblongata to the cerebellar cortex.

- (d) The dorsal funiculus of the spinal cord, as it passes forward into the medulla oblongata, is divided into medial and lateral portions. The medial portion, the **fasciculus gracilis**, forms a narrow band terminating rostrally in a club-shaped expansion, the **clava**. The lateral portion, the **fasciculus cuneatus**, appears to pass into the restiform body but does

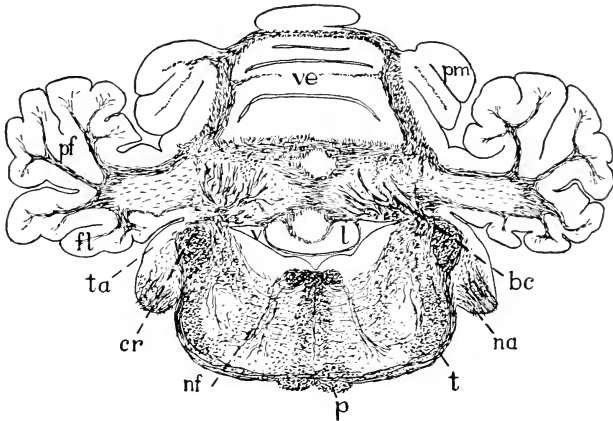


FIG. 123. Transverse section of the hindbrain passing through the posterior edge of the attachment of the cerebellum. The white nerve fibres are stained black by the method of Weigert. bc, bundles of nerve fibres proceeding to the brachium conjunctivum; cr, restiform body; fl, flocculus; l, lingula (part of vermis cerebelli, see Fig. 119) na, cochlear root of acoustic nerve; nf, root fibres of facial nerve which emerge from the brain a little further forward; p, pyramid; pf, paraflocculus; pm, cerebellar hemisphere (lobulus paramedianus); t, trapezoid body, composed of nerve fibres originating in the acoustic tubercle and crossing to the opposite side of the brain, where they turn forward towards the inferior colliculus and the medial geniculate body; ta, acoustic tubercle; v, fourth ventricle; ve, vermis cerebelli.

not actually do so. Both fasciculi end at this level. They convey from the trunk and limbs impulses of muscle- and joint-sensibility as well as tactile and related discrimination, these being then transmitted to more anterior parts of the brain by deeply situated fibres.

7. The brain may be divided by a median vertical section, and the medial surface of one-half (Fig. 124) may then be examined. In addition to many of the features already observed from other points of view, the following may be noted:

- (a) The deep but extremely narrow cavity formed by the third ventricle is the most anterior space appearing in the brain, the paired lateral ventricles, which are reckoned as the first two without either being specifically designated as first, lying laterally in the hemispheres. Each of these paired ventricles is connected with the third ventricle by a narrow transverse canal, the **interventricular foramen** (foramen interventriculare), situated a short distance dorsal to the position of the anterior commissure (Fig. 124).

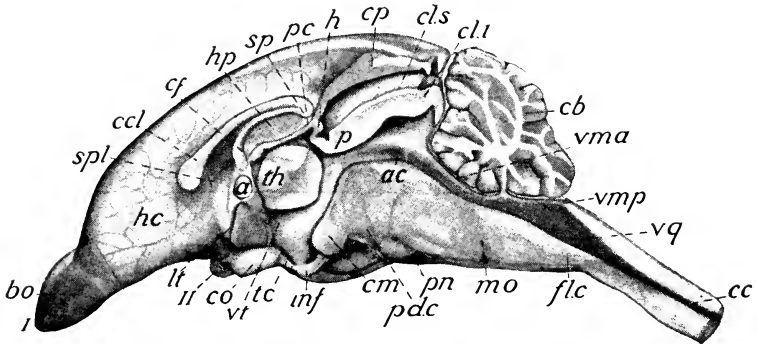


FIG. 124. The brain in median section: a, anterior commissure; ac, cerebral aqueduct; bo, olfactory bulb; cb, cerebellum; cc, central canal of spinal cord; ccl, corpus callosum; cf, body of the fornix; cl.i, inferior colliculus; cls, superior colliculus; cm, mamillary body; co, optic chiasma; cp, pineal body; fl.c, cervical flexure; h, habenular commissure; hc, cerebral hemisphere; hp, hippocampus; inf, infundibulum; lt, lamina terminalis; mo, medulla oblongata; p, posterior commissure; pc, choroid plexus of the third ventricle; pd.c, cerebral peduncle; pn, pons; sp, splenium; spl, septum pellucidum; tc, tuber cinereum; th, thalamus, massa intermedia; vma, anterior medullary velum; vmp, posterior medullary velum; vq, fourth ventricle; vt, third ventricle; I, olfactory nerve (origin); II, optic nerve.

- (b) The anterior boundary of the third ventricle is formed ventrally by the narrow transverse wall passing across from one hemisphere to the other, the lamina terminalis, in the dorsal portion of which is the small **anterior commissure** (commissura anterior), a connection between the olfactory portions of the brain on one side and those on the other. The ventral portion of the ventricle is projected above the optic chiasma forming the **recessus opticus**, and into the infundibulum, forming the **recessus infundibuli**.
- (c) The mesencephalon contains no ventricular expansion, its substance being perforated only by a tube, narrow an-

teriorly but wider posteriorly in the rabbit, the **cerebral aqueduct** (aquaeductus cerebri), which connects the third ventricle with the fourth.

- (d) The corpus callosum is shown in section. Anteriorly it appears to end in a somewhat club-shaped expansion, though actually it is extended as a thin sheet of fibres downward toward the lamina terminalis. Posteriorly it bends downward, forming the **splenium**, the latter being attached to the body of the fornix, which lies below it.

The **fornix** consists of a pair of greatly curved longitudinal fibre-bands, fused for a short distance in the middle line to form the unpaired **body of the fornix** (corpus fornicis). They begin in the hippocampus (p. 366) and end in the mamillary body, conveying to the latter impulses resulting from the correlation of olfactory with other stimuli.

- (e) Between the body of the fornix and the anterior portion of the corpus callosum is a thin area of the wall, the **septum pellucidum**, the lateral ventricles approaching the medial surface in each hemisphere and so lying close together in this region.
8. The cerebral cortex may be removed from part of one hemisphere by carefully scraping away the grey matter over most of the dorsal and lateral surfaces until the white surface of the corpus callosum is well exposed. By removing the corpus callosum, the interior of the hemisphere may then be examined.
- (a) The **lateral ventricle** (ventriculus lateralis) is the extensive cavity enclosed by the hemisphere. It reaches forward into the olfactory bulb and backward into the posterior free end of the hemisphere, passing a considerable distance behind the opening of the interventricular foramen.
- (b) The excised portion of the hemisphere, forming the moderately thick roof and dorsolateral wall, consists largely of the superficial grey cortex. The extensive portion of the hemisphere wall containing this cortex and the white matter immediately under it is termed the **pallium**.

- (c) The floor of the lateral ventricle is formed by two somewhat oblique, convex ridges. One of these, posterior and medial in position, is the **hippocampus**, a part of the pallium which has become folded inwards to form the ridge observed projecting into the ventricle. The other, anterior and lateral in position, has a smaller ventricular exposure but is a greatly thickened solid mass of nervous matter, the **corpus striatum** (Fig. 117). Between the two ridges, the pigmented vascular tissue of the **chorioid plexus** of the lateral ventricle may be made out. The hippocampus is a region where olfactory stimuli coming from the pyriform lobe and from more medial secondary olfactory areas are correlated with others, chiefly of visceral origin. The corpus striatum is related to the control of bodily movements.
- (d) On the medial wall, the thickened posterior portion forms the body of the fornix, immediately in front of which is the thinner portion of the wall, described above as the septum pellucidum.
9. The passage of the olfactory nerves to the ethmoturbinal surfaces may be traced by removing the nasal bones and working downward toward the cribriform plate, or the remaining portion of the skull containing the nasal region still intact may be divided vertically for a more extended examination of the nasal fossae. The features to be observed are largely those described in connection with the skeleton (pp. 178, 190).

APPENDIX

The Preservation of Material¹

THE method commonly used in the preparation of material for dissecting purposes consists in first embalming the body with suitable preserving fluids; afterwards filling the arteries with a coloured injection mass, so that they are more easily traced. The objects served by embalming are: (1) preserving the body from decomposition for a sufficient length of time to complete the dissection; (2) keeping the body as nearly intact as possible; and (3) having the organs in good condition for study. The point last mentioned is an important one, since much depends on having the parts of the animal in such condition that they are easily and comfortably handled, and also easily observed. The desired results are accomplished, first, by introducing the preserving fluid through the blood-vessels, instead of by immersing the animal, as was formerly the practice;² secondly, by using in the preserving fluid such materials

¹The methods here given apply only to the preservation of specimens for ordinary dissection, either singly, or in numbers for a laboratory course; with a few observations on the difficulties which are likely to be experienced. Especially in the matter of injections, the student who has acquired some knowledge of the vascular system will be able to make complete injections of the portal system and also satisfactory injections of the systemic veins, though the latter are somewhat more difficult on account of the presence of valves in the vessels. Finer vascular injections and injections of the lymphatic system according to the directions given in the anatomical text-books may also be suggested.

Owing to imperfect preservation of the contents of the digestive tube, examination of the inner wall in embalmed animals does not usually reveal its essential features. It is well to have at hand a demonstration specimen prepared as follows: Remove stomach and intestines from a freshly killed animal. Wash out the parts with weak salt solution. Fill, without distending, with 3 per cent bichromate of potash, formalin-bichromate, or any of the standard fixing agents, and tie the ends. Immerse the parts in the solution, and after a time examine by slitting them lengthwise.

²For sometimes convenient but less uniform preservation of small mammals ordinary immersion methods may be employed, the animal being placed in a preserving solution after making small incisions in the thoracic and abdominal walls. Formaldehyde solutions of 2 per cent or better, and graded alcohols be-

as will leave the organs in a condition as near the natural one as possible and at the same time keep them moist and flexible throughout dissection.

A suitable fluid for the purpose is that recommended by Keiller¹ for the preservation of human subjects. The formula is as follows:

Formalin.....	1.5 parts
Carbolic acid.....	2.5 "
Glycerin.....	10.0 "
Water.....	86.0 "
	100.0

A convenient method of making up the fluid, especially when embalming the animals in numbers, is to prepare the mixture of formalin, carbolic acid, and glycerin as a stock-solution, to be diluted for use by adding to each part of stock six parts of water. The amount required varies according to the size of the animal, the flow of the fluid in the vessels, the length of time during which the animal is left under the action of the fluid, and the height of the pressure column. Not less than 1500 cc. should be allowed for each specimen.

The apparatus needed for embalming includes a reservoir for the fluid, provided with an exit pipe to which a rubber tube may be attached; about six feet of rubber tubing to connect with the operating table; several three-way pieces to divide the stream in case several specimens are to be handled at the same time; selected rubber tubing of the size indicated below to attach the cannulae; clamps for the tubing; and, finally, glass or metal cannulae for insertion into the femoral artery.

Glass cannulae suitable for the purpose are readily made by heating ordinary glass tubing over the Bunsen flame and drawing it out to the desired thinness. The tubing used for the purpose should be of about 6 mm. outside diameter. The cannula when

ginning with 30 per cent and changing to 60 or 70 per cent are useful for this purpose. The addition of small quantities of glycerine or carbolic acid or both improves the brightness and flexibility of the tissues.

¹W. Keiller, "On the Preservation of Subjects, etc." (*American Journal of Anatomy*, vol. II, 1902-3). Several modifications, apparently successful, have been employed.

completed should be about 7 cm. long; and its narrow end should have a uniform diameter of 1.5-2 mm. for about 2 cm. at the tip. A slanting tip, produced by careful grinding on an emery stone aids insertion into the vessel. The tip should be touched lightly in the flame in order to round the margin by fusion, otherwise it might damage the wall of the vessel.

The rubber tubing used to connect the cannula with the main tube should be of the best quality of soft rubber, and should have an inside diameter of 4 mm., i.e., of proper size to slip on and off the cannula easily, but yet to retain its hold on the latter under moderate pressure.

The reservoir for holding the embalming fluid may be an aspirator or irrigator bottle, an enamel fountain, percolator, or ordinary funnel. It may have a capacity of one or two quarts. The capacity, however, is immaterial, so long as the operator keeps the fluid replaced. The reservoir is suspended in such a way that it may be moved up and down within a distance of four feet above the top of the operating table.

When large numbers of animals have to be prepared, it is useful to connect the reservoir by wide rubber tubing to a horizontal brass pipe six feet long, which is provided with five jets with taps. A short length of quarter-inch rubber tubing connects each jet to a Y-tube of glass or brass, which is in turn connected by slightly smaller tubing to two cannulae. Thus ten animals may be embalmed simultaneously.

At the time of beginning the embalming process the operator should have before him the reservoir, suspended at a height of about three feet, and a column of fluid, free from air-bubbles or foreign material to the tip of the cannula. This condition must be maintained throughout the operation. If at any time the pressure falls in the apparatus sufficiently to admit air, or allow coagulated blood to run back through the cannula, there is almost certain to be trouble, not only with the specimen under treatment, but also others which come after. The column of fluid is held back until the proper time by a clamp placed on the rubber tubing.

The animal is killed by administering ether or illuminating gas. It is placed on its back on the table, with the head away from the operator. The skin is first divided by a small incision on the inner

side of the right thigh.¹ By inserting the fingers well down into the incision, the skin may be torn backward and toward the ventral middle line, and at the same time the superficial epigastric vessels will be carried with the subcutaneous tissue well out of the operator's way. Small portions of the inner surface of the thigh and of the abdominal wall will be exposed. The white cord representing the inguinal ligament lies in the bottom of the inguinal furrow. Appearing from beneath the ligament in this position, and passing to the surface of the thigh, are the femoral nerve, artery, and vein, covered by an exceedingly thin layer of muscle belonging to the sartorius. The three structures may be separated from one another, and the muscle pulled away at the same time, by working lengthwise along the structures with fine forceps. The artery must be thoroughly cleared for about 3 cm. from the inguinal ligament. Care must be exercised in this operation to avoid breaking its branches or the tributaries of the vein. The artery lies in front of the vein and is distinguishable by its smaller size, its flattened or collapsed condition, and its white coloration. The vein will be found greatly distended with blood. The nerve lies in front and partly on the lateral side of the artery.

When the femoral artery has been fully exposed, a ligature of coarse thread, previously moistened, may be passed around its base, close to the inguinal ligament. An ordinary single knot may be placed on the ligature, but must be left loose until the cannula is inserted. By grasping the bare edge of the artery at about 2 cm. from the ligament, the operator may make a V-shaped incision in the vessel with fine scissors. The tips of the scissors are directed toward the ligament. The incision must be clean-cut, and care must be taken not to cut more than half-way through the vessel. By taking up the little angular flap with fine forceps, the cannula may be worked into the vessel and pushed well down into it beyond the inguinal ligament. The knot is then tightened by a gentle even pull on the ends of the thread. The knot should never be pulled very tight or doubled.

¹The embalming may be done from the common carotid artery of the neck, a vessel much larger than the femoral artery and therefore easier of manipulation. This is not recommended, however, because of the damage done to various important structures of the cervical region.

At the moment when the cannula is securely fastened into the vessel, the clamp is to be removed from the connecting tube and the fluid allowed to run in. At the beginning of the process a little care in arranging the animal will be amply rewarded by convenience in dissection. The hind limb on the side opposite the incision should be drawn backward. The front limbs should be drawn apart, so that the breast is well exposed, and held in this position by a thick cord, or, better, a stout flexible wire, passing around the back of the animal. The body should be turned slightly to the operator's left.

The animal is sufficiently embalmed in two hours. About eight animals may easily be kept on the table by one operator, provided he has at his disposal a sufficient number of cannulae, one for each specimen, since the first may be taken off the apparatus after the eighth has been put on. After some practice the number can be greatly increased.

Since small difficulties frequently occur in the process, especially in placing the cannulae and in keeping them clear of obstruction, a number of points may be mentioned which indicate to the operator just how the operation is succeeding. The entrance of the cannula into the artery, in the first place, is usually accompanied by a slight rise of blood into its tip. General muscle contractions in the recently killed animal are a safe indication of uniform flow of the fluid to these and also other parts of the body, and no clogging of the vessels need be feared. The fluid may usually be observed running in the cannula, and, of course, falling in the reservoir. Finally, there are characteristic changes in the body. The abdomen becomes greatly distended, the subcutaneous tissue swollen, the eyes protrude, and there is usually more or less frothing at the nose. Leakage, either in the area of the incision or at the nose, is sometimes a sign of too much pressure. In the former case the leakage is frequently behind the cannula, and may be stopped by artery forceps. In the latter case there is no recourse but to confine the fluid to the nasal cavity by tying the nostrils.

After the embalming process, the rubber tube is disconnected from the cannula, the latter being left carefully in place and closed by a stopper made by tying a short piece of rubber tubing in a knot. The animal is then set aside, preferably for twenty-four hours to

several days, but if the specimen is wanted for use immediately the injection of the coloured mass into the vessels may be made after several minutes, usually with satisfactory results.

The injection mass may be made by mixing ordinary starch and water to the consistence of thin cream; then adding a finely-ground colouring material, such as vermilion or a very small quantity of carmine. There is some advantage in using a 5 per cent or even stronger formalin and about one part in seven of glycerin instead of water alone in making up this mass, the arteries having afterwards a brighter appearance, which is doubtless due partly to better preservation and partly to the fixing of the starch in the vessels. The glycerin keeps the starch suspended better. The mass must be thoroughly strained before use, in order to avoid the presence in it of particles which are too large to go through the cannula. The injection is made with a syringe, the latter being provided with a rubber tube of the same kind as that used in the embalming process. The mass is sent in by applying a gentle, even pressure, and it is sometimes advantageous to allow the injection to run backward and forward in the tube, each time applying a little more pressure. When the vessels have been filled in this way, the tube is clamped. By drawing on one cord of the ligature the knot is loosened sufficiently to withdraw the cannula, and by keeping a finger pressed on the end of the vessel, the knot may then be drawn tight without loss of injection.

It sometimes happens, despite ordinary precautions, that the cannula becomes clogged either with settled starch or with coagulated blood. In this case it may easily be removed, cleaned, and replaced. The same cannula should always be used.

During recent years, coloured latex has largely replaced other masses for injection of the blood-vessels in animals to be dissected. It has the advantage of forming a strong, tough, elastic body within each vessel. The material may be obtained from commercial supply houses, which will also provide advice regarding minor precautions that facilitate its use.

Material prepared according to the directions given above will keep indefinitely, provided, however, that precautions are taken to avoid contamination from the surface. These are especially necessary in view of the thick coating of hairs. It is a good plan,

therefore, to sponge the animal with a preserving fluid which will penetrate the coat immediately, or if many specimens are being prepared, to immerse the whole animal for a moment. A suitable fluid for this purpose is formalin-alcohol, made by adding 2 per cent of formalin to a mixture of equal parts of ordinary spirit and water. The alcohol ensures immediate penetration and assists the formalin in preservation. The fluid should be squeezed out of the coat so far as practicable. An excess is undesirable because the alcohol tends to withdraw fluid from the body if the animals are kept for some time before dissection, but more especially because the fluid is likely to get into the material during dissection where it has the effect of removing glycerin, so that the tissues become brittle and dry rapidly on exposure.

For the storage of material, either before or during dissection, no precaution is necessary except that of protecting the body from undue exposure to evaporation. The animals may be stored in a spirit tank if raised above the level of the fluid, or may be kept individually in special prepared boxes for convenience in the laboratory. A zinc-lined copper box with sliding top, or a paraffin-wax-lined galvanized box with slip over cover, of dimensions 7 x 7 x 24 inches, will be found to be adequate and of proper proportions for animals of average size. If less costly individual containers are required, ordinary water-proofed paper sheets or bags may be employed, the latter being now obtainable through regular trade channels.

INDEX

When several references occur, the page containing the main or definitive description is indicated in bold-faced type.

- Abduction, 69
Acetabulum, 207
Acromion, 199
Adaptation, 5
Adduction, 69
Aditus laryngis, 311, 314
Adrenalin, 132
Albinism, 21
Allantois, 115
Ampulla caecalis coli, 238
Ansa subclavia, 328
Antrum, pyloric, 225, 231
 tympanic (mastoid), 187
Aorta, 113, 114, 117, 226, **254, 324**, 326
 ventral, 113, 114
Aperture, piriform, 175
 thoracic, 165
Aponeurosis, 20, 65, 67
Aqueduct, cerebral (Sylvian), 84, 148,
 365
Arachnoidea, 72, 344
Arch, costal, 165
 hyoid, 57, 89, 198
 mandibular, 57
 vertebral, 51
 volar, 270
 zygomatic, 167, 174
Arches, aortic, 113, 114,
 branchial, 57
 visceral, 55, 57, 198
Arteries, 109, 113
Artery, alveolar inferior, 305, 307
 angular, 294
 appendicular, 240
 axillary, 262
 basilar, 360
 brachial, 262, **270**
 bronchial, 109, 325
 caecal, 241
 carotid, common, 114, 117, 301,
 306, 324
 external, 306
 internal, 172, **306**, 317,
 322, 361
 caudal, lateral, 256, 280
 cerebellar, inferior, 360
 superior, 360
 cerebral, anterior, 361
 middle, 361
 posterior, 360
 cervical, ascending, 258, 325
 superficial, 258, 325
 circumflex, lateral of femur, 279
 medial of femur, 256
 of humerus, 263, 269
 coeliac, 226, **229**, 254
 colic, left, 241
 middle, 240
 right, 240
Artery, collateral, radial, 270
 ulnar, 270
communicating, anterior, 361
 posterior, 361
coronary, 324, 330
cystic, 234
deep of arm, 263, **270**
 thigh, 279
deferential, 246
dental, superior, 319
epigastric inferior, 223, 255
 superficial, 221, 262,
 279
 superior, 223, 326
ethmoidal, 319
facial, transverse, 294, 307
femoral, 279
frontal, 174, 319

- gastric, left, 229
 - right, 229, 230
 - short, 229
- gastroduodenal, 230
- gastroepiploic, left, 229
 - right, 229, 230
- genu suprema, 279
- haemorrhoidal, inferior, 248, 253
 - middle, 248, 253, 256
 - superior, 241
- hepatic, 230, 233
- hypogastric, 117, **255**, 280
- ileocaecal, 240
- ileocaecocolic, 240
- iliac, common, 117, 255
 - external, **255**, 279
 - internal, 255
- iliolumbar, 221
- infraorbital, 319
- innominate, 114, 324
- intercostal, 326, 336
 - highest, 325
- intercostalis suprema, 325
- intestinal, 241
- labial inferior, 294
 - superior, 294
- lacrimal, 174, 319
- laryngeal, inferior, 301
 - superior, 301
- lingual, 306
- lumbar, 255
- malleolar, 286
- Artery, mammary, external, 263
 - internal, 326
- maxillary external, 294, 306
 - internal, 307, 318, 319
- median, 270
- medianoradial, 270
- mesenteric, inferior, **241**, 254
 - superior, 227, **240**, 254
- obturator, 256
- occipital, 306
- omental, 229
- ophthalmic, 317
 - inferior, 319
- palatine, anterior, 319
- pancreaticoduodenal, inferior, 236, 240
 - superior, 230, 236
- peroneal, 283, 286, 287
- phrenic, inferior, 229
 - superior, 254, 338
- popliteal, 280, 286
- pterygopalatine, 319
- pudendal, internal, 248, 253, 256, 280
- pulmonary, 114, 117, 118, 330, 335
- radial, 270
- renal, 243
- sacral, median, 254, 255
- saphenous, great, 280, 282, 283, **286**, 287
 - small, 282, 285, **287**
- scapular, transverse, 262
- sciatic, 256, **280**
- spermatic, external, 223, 245
 - internal, 246, 250
- sphenopalatine, 319
- spinal, ventral (anterior), 347
- splenic, 229
- subclavian, 114, 117, 324, 325
- submental, 294
- subscapular, 221, 262
- suprarenal, 243, 255
- suprarenolumbar, 243, 254
- temporal, superficial, 307
- thoracic, external, 221, 262
 - lateral, 221, 262
- thoracoacromial, 260, 262
- thoracodorsal, 262
- thyreoid, superior, 301
- tibial, anterior, 284, 286
 - posterior, 283, 286, 287

- transverse facial, 294
 of neck, 260, **325**
 scapular, 262
 ulnar, 271
 umbilical, 118, 245, 246
 uterine, 251
 vertebral, 325, 360
- Articulations, 48, 49
 of posterior limb, 290
- Autonomic nervous system, 74, 321, 355
- Atlas, 52, 159
- Atrium, 331
- Axes of skull, 60
- Axis, 160
- Bladder, gall, 232
 urinary, 118, **244**
- Blood, 32
- Body, carotid, 90, 306
 cavernous, 247, 252
 ciliary, 92, 317
 geniculate, lateral, 353, 354
 medial, 353
 mamillary, 355
 pineal. *See* gland, pineal
 pituitary. *See* hypophysis
 restiform, 362
 spongy of urethra, 247
 trapezoid, 359
 vitreous, 93, 318
- Bone, 22, 23
 acetabular, 208
 alisphenoid, 53, 169, **182**
 atlas, 159
 axis, 160
 basioccipital, 53, 167, 169, **180**
 basisphenoid, 53, 169, **182**
 calcaneus, 214
 carpal, 63, 204
 clavicle, 61, 62, 200
 coracoid, 61, 200
 costal, 164
 coxal, 206
 dentary, 195
- Bone, epistropheus, 160
 ethmoid, 53, 58, 177, 178, **189**
 ethmoturbinal, 53, 178, **190**, 191
 exoccipital, 53, 167, 180, **181**
 femur, 210
 fibula, 213
 frontal, 54, 58, 169, 172, **189**
 humerus, 201
 hyoid, 54, 58, **197**
 ilium, 207, 208
 incisive, 193
 incus, 55, 58, **188**
 inferior turbinal, 58, 191
 interparietal, 54, 58, 173, 188
 ischium, 207, 209
 lacrimal, 54, 58, 174, **194**
 malar, 174
 malleus, 55, 58, 188 (*See also*
 ossicles, auditory)
 maxilla, 54, 58, 174, 175, **191**
 maxilloturbinal, 54, 178, **191**
 mesethmoid, 178
 metacarpal, 205
 metatarsal, 215
 nasal, 54, 58, 175, 178, **193**
 nasoturbinal, 54, 178, 190
 occipital, 58, 167, 180
 orbitosphenoid, 53, 169, **183**
 palatine, 54, 58, 169, 174, **194**
 parietal, 54, 58, 172, **188**
 patella, 215
 periotic, 53, 58, 171, 176, 177,
 184
 petromastoid, 171, 187
 petrotympanic, 184, **185**
 phalanx, 205, 215
 pisiform, 205
 postminimus, 63
 premaxilla, 54, 58, 174, 175, 178,
193
 presphenoid, 53, 169, **183**
 procoracoid, 61
 pterygoid, 54, 58, 183
 pubis, 207, 210
 radius, 202

- Bone, sacral, 163
 scapula, 61, 198
 sesamoid, 206, 215, 290
 sphenoid, 58, 170, 182, 183
 squamosal, 54, 58, 169, **184**
 stapes, 55, 57, 58, **188**
 sternum, 166
 supraoccipital, 53, 167, 180, **181**
 talus, 213
 tarsal, 63, 213
 temporal, 184
 tibia, 212
 turbinal, 58
 turbinated, 178, 191
 tympanic, 54, 184, **187**
 ulna, 202
 vomer, 58, 178, 194
 zygomatic, 54, 58, 169, 174, **193**
- Bones, of auditory chain, 54, 55, 56,
 57, 170, **188**
 carpal, 204
 limb, 50, 60, 198
 metacarpal, 205
 metatarsal, 215
 phalanges, 205, 215
 sesamoid, 206, 215
 tarsal, 213
- Brachium conjunctivum, 362
 pontis, 362
- Branchiomerism, 41
- Breathing, 107, 166
- Bridge, palatine, 174
- Bronchus, 335
- Bulb, olfactory, 349
- Bulla, tympanic, 168, 170, 171, 185, 186
- Caecum, 103, 235, **237**
- Calamus scriptorius, 362
- Canal, facial, 172, 178, 186
 hypoglossal, 172, 177, 181
 infraorbital, 174
 nasolacrimal, 175, 192
 pterygoid, 171, 183
 pterygopalatine, 175, 195
 vertebral, 157
- Capillaries, 109, 111, 120
 lymphatic, 120
- Capsule, auditory, 53, 55, 57, 58
 joint, 49, 290
 nasal, 53, 55, 57, 58
- Cartilage, 22
 articular, 49
 arytenoid, 313
 corniculate, 313
 costal, 164
 cricoid, 300, 313
 cupula posterior, 146
 epiglottic, 314
 laryngeal, 57
 of Meckel, 56, 144
 mesethmoid, 142, 178
 nasopalatine, 142
 nasoturbinal, 144
 suprascapular, 200
 thyroid, 300, 313
 vomeronasal, 142, 144
- Cauda equina, 345
- Cavity, cranial, 175
 glenoid of scapula, 200
 skull, 169
 nasal, 175
 oral. *See* oral cavity
 orbital, 167
 peritoneal, 136, 224
 pleural, 135, 334
 serous, 135, 224
 thoracic, 165
 tympanic, 136, 158, 170, 174,
175, 186, 187, 300,
- Calyx, renal, 123, 124
- Cell, 11
- Centre, respiratory, 108
- Cerebellum, 356
- Cerebral hemisphere, 82, 349
- Cerebrum, 84
- Chiasma, optic, 354
- Choana, 175
- Chondrocranium, 55, 57, 58
- Chorioidea, 317
- Chromatophores, 21

- Circle of Willis, 361
 Clava, 363
 Clitoris, 219, **252**
 Clivus, 176
 Cloaca, 122
 Cochlea, 91, 148, 322
 Coccyx, 51
 Coelom, 135, 224
 Colliculus, inferior, 355
 seminalis, 250
 superior, 354, 355
 Colon, 102, **237**, **238**
 Column, vertebral, 44, 50, 156
 Commissure, 350
 anterior, 364
 habenular, 351
 middle, 352
 posterior, 352
 Condyle, occipital, 167, 181
 Conjugation, 12
 Connective tissue, 18
 Convergence, 4
 Cord, spermatic, 247
 Cord, spinal. *See* spinal cord
 Cords, vocal. *See* vocal folds
 Corium, 14, 20, 220
 Cornea, 92, **317**
 Corpora lutea, 250
 quadrigemina, 355
 Corpus callosum, 350, 365
 striatum, 366
 Cortex, cerebellar, 356
 cerebral, 82, 349, 365
 Cranium, 166
 cerebral, 55, 58
 visceral, 55, 58
 Crest, nuchal, 168, 181
 Crista galli, 177, 190
 Crus clitoridis, 252
 penis, 247
 Cytoplasm, 11

 Denticles, shagreen, 57
 Descent of the testis, 129
 Diaphragm, 66, 67, 108, 140, **337**

 Diastema, 59, 192, 195
 Diencephalon, 83, 350
 Digestion, 94
 Digits, 220
 Divergence, 4.
 Duct, bile, 233, 235
 cystic, 233
 deferent, 127, 128, 246, 249
 hepatic, 233
 incisive. *See* duct, nasopalatine
 nasolacrimal, 175, 314
 nasopalatine, 311
 pancreatic, 236
 parotid, 146, 293
 submaxillary, 146, 298, 307
 thoracic, 120, 337
 Ductus arteriosus (Botalli), 314, 317, 318
 Ductus venosus, 115, 117
 Duodenum, 100, 154, 235
 Duplicidentata, 7
 Dura mater, 72, 344

 Ear, 90, 219, 321, **322**
 middle, 187
 Endothelium, 18, 22
 Epaxial musculature, 67, 339
 Epibranchial, 78, 342
 Epicardium, 135, 328
 Epidermis, 14
 Epididymis, 128, **246**
 Epiglottis, 312
 Epineurium, 30
 Epiphysis, 47
 cerebri, 83
 Epiploön, 226
 Epistropheus, 52, 160
 Epithalamus, 83, 86
 Epithelium, 13
 glandular, 15
 nasal, 90, 105, 179
 sensory, 17

 Erythrocytes, 33
 Evolution, 4
 Excretion, 17
 Extension, 68

- Exteroceptors, 90
 Eye, **92**, 218, **317**
 Eyelids, 218
- Falx cerebri, 348
- Fascia, 20
 - infraspinous, 264
 - lumbodorsal, **222**, **223**
 - supraspinous, 264
- Fasciculus cuneatus, 363
 - gracilis, 363
- Fat, 21
- Fat masses of neck, 21, 140, 150
- Fenestra, cochlear, 187
 - vestibular, 187
- Fertilization, 12
- Fibre, nerve, 30
- Filum terminale, 78, 345
- Fissure, cerebral, lateral, 350
 - cerebral, longitudinal, 349
 - limbic, 349
 - orbital, superior, 171, **177**, 182
 - portal, 232
 - rhinal, anterior, 349
 - posterior, 349
 - Sylvian, 350
- Flexion, 68
- Flexures of embryonic brain, 85, 142
- Flocculus, 356
- Fluid, cerebrospinal, 344, 351
- Foetal circulation, 115
- Fold, middle umbilical, 244
 - rectovesical, 244
 - vesicouterine, 244
 - vocal, 314
- Follicle, hair, 14, 221
- Follicles, lymph, 119
 - vesicular ovarian, 250
- Foot, 8, 9
- Foramen caecum, 358
 - carotid external, 172
 - internal, 172, 187
 - cavernosum, 182
 - costotransverse, 159, 160
 - greater palatine, 175
- Foramen incisive, 174, **175**, 191
 - infraorbital, 174, 191
 - interventricular, 364
 - intervertebral, 158
 - jugular, 172, **177**, 186
 - lacerum, 172, **177**, 182
 - magnum occipitale, 167, 180
 - mandibular, 180, 196
 - mental, 180, 196
 - obliquum, 160
 - obturator, 206
 - optic, 171, 176, 177
 - ovale, 115, 118, 172, 332
 - palatine, greater, 175
 - rotundum, 171
 - sphenoidal, 171, 183
 - sphenopalatine, 175, 195
 - stylomastoid, 172, 186
 - supratrochlear, 202
 - thyreoid, 313
 - transversarium, 159
 - vertebral, 157
- Fornix, 365, 366
- Fossa, acetabular, 209
 - axillary, 219
 - cranial, 175
 - hypophyseal, 176
 - infraspinous, 199
 - interpeduncular, 356
 - jugular, 168, 181, 186
 - mandibular, 169, 185
 - maxillary, 191
 - nasal, 174, 175
 - ovalis, 332
 - parafloccular, 186
 - popliteal, 220
 - pterygoid, 169, **183**
 - rhomboid, 362
 - subscapular, 200
 - supraspinous, 199
 - temporal, 170, 185
 - trochanteric, 211
- Frenulum linguae, 311
- Funiculi, 347, 363
- Furrow, inguinal, 219

- Ganglia of sympathetic trunk, 74, 257
- Ganglion, 31
- cervical, inferior, 75, 328
 - superior, 75, 309, 321
 - ciliary, 320, 321
 - coeliac, 227
 - dorsal root, 73, 346
 - jugular, 302, 309
 - mesenteric, inferior, 242
 - superior, 227
 - nodosum, 309
 - otic, 321
 - semilunar, 359
 - sphenopalatine, 321
 - spinal, 73, 346
 - submaxillary, 321
 - thoracic, 328
- Girdle, pectoral, 61, 198
- pelvic, 61, 206
- Gland, 15
- acinous, 16
 - alveolar, 16
 - anal, 248, 253
 - buccal, inferior, 297
 - superior, 296
 - bulbourethral, 250, 253
 - Cowper's, 250
 - cutaneous, 16
 - cytogenic, 16
 - ductless, 131
 - endocrine, 15, 131
 - exocrine, 15
 - Harderian, 315
 - hibernating, 21
 - infraorbital, 316
 - inguinal, 248, 253
 - interrenal, 133
 - lacrimal, 316
 - lymph, 119, 121
 - axillary, 260, 261
 - deep cervical, 300
 - facial, 297
 - iliac, 281
 - inguinal, 221, 281
- Gland, lymph, mesenteric, 237, 239, 242
- popliteal, 281
 - superficial cervical, 293
- mammary, 16, 221
- mandibular, superficial, 297
- masseteric, 297
- oral, 16
- paraprostate, 249
- parathyroid, 133
- parotid, 293
- pineal, 134, 351
- pituitary. *See* hypophysis
- prostate, 249
- rectal, 248, 253
- salivary, 296
- sebaceous, 16
- sublingual, 307
- submaxillary, 298, 307
- sudoriferous, 16
- suprarenal, 132, 227
- thymus, 133, 324
- thyreoid, 133, 300
- tubular, 16
- types, 15, 16, 17
- vesicular, 249
- zygomatic, 316
- Glans clitoridis, 252
- penis, 247
- Glomus caroticum, 90, 306
- Groove, infraorbital, 175
- Gubernaculum, 129, 245
- Habenula, 351
- Hair, 14
- Hallux, 220
- Haustra, 239
- Heart, 109, 112, 114, 115, 117, 330
- Hemisphere, cerebellar, 356, 357
- cerebral, 82, 349
- Hippocampus, 366
- His, bundle of, 28
- Homology, serial, 60
- true, 4, 62
- Hydatid, 251

- Hyoid apparatus, 197
 Hypaxial musculature, 67, 432
 Hypobranchial musculature, 67, 432
 Hypophysis, 134, 354
 Hypothalamus, 83, 355
- Ileum, 102, 236
 Incisure, supraorbital, 174
 Infundibulum, 354
 Inguinal space, 219, 248, 253
 Insulin, 132
 Interoceptors, 90
 Intestine, 100, 234
 blind. *See* caecum
 large, 237
 length, 99
 mesenterial, 101, 235, 236
 small, 235
 straight. *See* rectum
- Iris, 317
 Isthmus (rhombencephali), 84
- Jejunum, 102, 236
 Joint, ankle, 291
 hip, 290
 knee, 290
 Joints, 49
- Kidney, 123, 242
- Labyrinth of ear, 90, 322
 ethmoidal, 190
 Lagomorpha, 7
 Lamina papyracea, 191
 terminalis, 364
 Larynx, 300, 312
 Lens, 92, 318
 Leporidae, 6
 Leptomeninges, 344
 Leucocytes, 33, 121
 Ligament, 20
 acromioclavicular, 200
 arterial, 114, 118, 330
 broad, 138, 251
 calcaneofibular, 291
 Ligament, calcaneotibial, 291
 carpal, 267, 268
 cleidohumeral, 200
 coracoclavicular, 200
 coronary, 233
 cruciate of foot, 283
 knee, 291
 crural, 283
 dorsal of the neck, 169
 falciform, 232
 fibular collateral, 290
 gastrosplenic, 226
 hepatoduodenal, 226, 232
 hyothyroid, 198
 iliofemoral, 290
 inguinal, 222
 intermuscular, lateral, 277
 interosseous of forearm, 202
 leg, 284, 291
 ischiocapsular, 290
 ovarian, 129, 251
 patellar, 215, 290
 phrenicosplenic, 226
 pubocapsular, 290
 pulmonary, 334
 round, of hip, 290
 liver, 232
 uterus, 129, 251
 sternoclavicular, 166, 200
 stylohyoid, 198, 299, 306
 suspensory, 247, 252
 talofibular, 291
 talotibial, 291
 tibial collateral, 290
 tibionavicular, 291
 triangular, 233
 umbilical, middle, 244
 Ligamentum nuchae (dorsal ligament
 of the neck), 169
 Line, epiphysial, 47
 superior nuchal, 168
 temporal, 170
 Linea alba, 221, 222, 223
 semilunaris, 223
 Liver, 95, 231

- Lobe, optic, 355
 piriform, 349
- Lung, 334
- Lymph, 34, 120
 nodes. *See* gland, lymph
- Lymphatic vessels, 120
- Macrophage system, 19
- Malleolus, lateral, 213
 medial, 213
- Mammalia, 9, 10
- Mandible, 8, 54, 56, **179, 195**
- Manubrium sterni, 166
- Marrow, 25, 292
- Marsupium nasale, 190
- Mass, intermediate, 352
- Mastoid portion of petrotympanic bone,
 171, 185
- Meatus, acoustic, external, 170, 185
 219
 internal, 178, 186
- Mediastinum, 329
- Medulla oblongata, 358
- Membrane, basement, 14
 nictitating, 218
 serous, 18, 135
 tympanic, 322
- Meninges, 72, 344
- Meniscus, 49
 of knee joint, 291
- Mesencephalon, 80, **355, 364**
- Mesenchyme, 18
- Mesentery, 135, 224, 236
 ventral, 232
- Mesocolon, 239
- Mesoduodenum, 137, **235**
- Mesogastrium, 225
- Mesonephros, 126, 127
- Mesometrium, 138, 251
- Mesorchium, 138, 246
- Mesosalpinx, 138, 251
- Mesothelium, 18, 22, 135
- Mesovarium, 138, 250, 251
- Metacromion, 199
- Metamerism, 41
- Metanephros, 126
- Metathalamus, 353
- Microglia, 32
- Mucous membranes (tunics), 14, 231,
 236, 237
- Muscle, 25, 63
 abductor caudae anterior, 343
 posterior, 343
 digiti quinti, 269
 pollicis, 267
 adductor brevis, 276
 digiti, 251
 quarti, 269
 quinti, 269
 indicis, 269, 286
 longus, 276
 magnus, 28, 276
 minimi digiti, 286
 anconaeus, 266
 minimus, 266
 arrectores pilorum, 15
 arytenoideus transversus, 314
 auricular, cutaneous, 296
 basioclavicularis, 258
 biceps brachii, 266
 femoris, 274, 278
 brachialis, 266
 brachiocephalic, 264
 buccinator, 296
 caninus, 296
 cardiac, 28, 64
 cleidohumeralis, 264
 cleidomastoideus, **258, 264**
 coccygeal, 343
 constrictor pharyngis, 310
 coracobrachialis, 265
 corrugator supercillii, 294
 cremaster, 245
 cricoarytenoideus, 314
 cricothyreoideus, 300, 313
 cutaneus maximus, **221, 257**
 deltoideus, 265

- Muscle, depressor conchae anterior, 292
 posterior, 257, 292
 palpebrae inferioris, 293
 digastricus, 168, **299**, 305
 epaxial, 67, 339
 extensor, 68
 antibrachii parvus, 266
 carpi radialis brevis, 267
 longus, 267
 ulnaris, 267
 caudae medialis, 343
 digiti quarti proprius, 267
 quinti proprius, 267
 digitorum communis, 267
 longus, **283**, 291
 hallucis longus, 283
 pollicis et indicis, 267
 facial, 294
 flexor, 68
 capri radialis, 268
 capri ulnaris, 268
 caudae, 343
 digiti quinti, 269
 digitorum longus, 285
 profundus, 268
 sublimis, 268
 pollicis brevis, 269
 gastrocnemius, 284
 gemellus inferior, 276
 superior, 275
 genioglossus, 308
 geniohyoideus, 308
 glutacus maximus, 274
 medius, 274
 minimus, 275
- Muscle, gracilis, 274, 278
 hamstring, 277
 hyoglossus, 308
 hypaxial, 67, 342
 iliacus, 273
 iliocostalis, 340
 iliopsoas, 273
 infraspinatus, 265
 intercostal, 323
 interosseus, 269, 286
 intertransversarius, 341
 intracostal, 324
 involuntary, 26, 28, 63
 ishiocavernosus, 247, 252
 of jaw, 6
 of larynx, 314
 latissimus dorsi, 222, **260**
 levator alae nasi, 296
 costarum, 336
 palpebrae superioris, 315
 scapulae major, 258
 minor, 259
 lingualis, 308
 longissimus, 340
 capitis, 340
 cervicis, 340
 costarum, 340
 dorsi, 340
 longus atlantis, 343
 capitis, 343
 colli, 343
 lumbrical, 269, 286
 masseter, 179, 294, 299, **302**, 305
 mentalis, 296
 multifidus, 340
 mylohyoideus, 299
 obliquus capitis inferior, 342
 major, 150
 superior, 341
 externus, 222
 inferior, 315
 internus, 223
 superior, 315

- Muscle, thoracis, 342
 obturator externus, 276
 internus, 275
 orbicularis oculi, 293
 orbicularis oris, 293
 palmaris, 268
 papillary, 332
 pectineus, 276
 pectoralis major (secundus),
 222, 260
 pectoralis (primus—quartus),
 260, 261
 pectoscapularis, 261
 peronaeus, brevis, 284
 longus, 284
 quartus, 284
 tertius, 284
 piriformis, 275
 plantaris, 285
 platysma, 257, 292
 popliteus, 285
 pronator teres, 268
 psoas major, 273
 minor, 272
 pterygoid, external, 304, 305
 internal, 299, 304,
 305
 pubocavernosus, 247, 252
 quadratus femoris, 276
 labii inferioris, 296
 superioris, 295
 lumborum, 273
 quadriceps femoris, 276
 rectocaudalis, 248, 253
 rectus abdominis, 223
 capitis anterior, 343
 lateralis, 342
 posterior major,
 342
 minor,
 342
 superficialis,
 341
 femoris, 276
 inferior, 315
- Muscle, lateralis, 315
 medialis, 315
 superior, 315
 red, 28
 retractor oculi (bulbi), 315
 rhomboideus major, 259
 minor, 259
 sacrococcygeal, 343
 sacrospinalis, 339
 sartorius, 274, 278
 scalenus anterior, 342
 dorsalis, 342
 medius, 342
 posterior, 342
 ventralis, 342
 semimembranosus, 279
 semispinalis capitis, 341
 cervicis, 341
 dorsi, 340
 semitendinosus, 28, 279
 serratus anterior, 222, 259
 posterior, 338
 soleus, 28, 285
 sphincter ani, 248, 253
 splenius, 339
 stapedius, 322
 sternohyoideus, 300
 sternomastoideus, 171, 258,
 299
 sternothyroideus, 300
 styloglossus, 168, 307
 stylohyoideus major, 168, 198
 306, 307
 minor, 168, 197,
 198, 307
 stylopharyngeus, 308
 subcostal, 324
 subcutaneus faciei, 294
 subscapularis, 265
 supraspinatus, 265
 temporal, 170, 303, 305
 tensor fasciae cruris, 274, 279
 fasciae latae, 275
 tympani, 322

- Muscle, teres major, 265
 minor, 265
 thyreoarytenoideus, 314
 thyreochoyoideus, 300
 tibialis anterior, 283
 posterior, 283
 transversus abdominis, 223
 costarum, 342
 thoracis, 323
 trapezius, 259
 triceps brachii, 266
 surae, 284
 vastus intermedius, 277
 lateralis, 277
 medialis, 277
 voluntary, 26, 65
 white, 28
 zygomaticus minor, 295
- Myelin, 30
- Myofibrils, 26
- Nasal epithelium, 105, 179
- Nasopharynx, 99, 310, 312
- Nephron, 124
- Nerve, 30, 73
 abducent, 319, 359
 accessorius. *See* nerve, spinal
 accessory
 acoustic, 178, 359
 alveolar, inferior, 305
 superior, 320
 auricular, 259
 chorda tympani, 322
 cranial, 88
 cutaneous, posterior, 281, 289
 depressor. *See* nerve, vagus,
 cardiac branch
 ethmoidal, 320
 facial, 89, 176, 178, 186, 294,
 359
 femoral, 273, 280, 289
 frontal, 174, 320
 glosso-pharyngeal, 89, 306, 308,
 309, 359
 gluteal, inferior, 281, 289
 superior, 281, 289
 of Hering, 306
 hypoglossal, 89, 301, 308, 309,
 360
 ramus descendens,
 301, 309, 310
 infraorbital, 320
 intercarotid, 306
 intercostal, 336
 intermediate, 322, 359
 lacrimal, 174, 320
 laryngeal; superior, 301, 308
 lingual, 305, 308
 mandibular, 88, 172, 179, 305,
 308, 319
 massetericotemporal, 319
 maxillary, 320
 median, 263, 272
 mental, 305
 mylohyoid, 305
 nasociliary, 320
 nasopalatine, 321
 obturator, 289
 oculomotor, 319, 356
 olfactory, 177, 349
 ophthalmic, 320
 optic, 88, 317, 318, 354
 palatine, 146
 anterior, 321
 peroneal, 281, 284, 288
 petrosal, deep, 321
 great superficial, 186,
 321
 phrenic, 327
 pterygobuccinator, 319
 of the pterygoid canal. *See*
 nerve, Vidian
 pudendal, 281, 289
 radial, 263, 271
 recurrent, 326, 327
 saphenous, greater, 280, 287
 lesser, 281, 285, 288
 sciatic, 280, 289
 sphenopalatine, 320, 321

- Nerve, spinal, 73, 345
 accessory, 89, 309, 359
 splanchnic, 226, **228**
 subscapular, 263
 suprascapular, 263
 sural, 288
 tenth. *See* nerve, vagus
 tibial, 281, 283, 285, 288
 trigeminal, 88, 305, 320, **359**
 trochlear, 319, 357
 ulnar, 263, **272**
 vagus, 89, 230, 301, 302, 309,
 326, 335, 359
 cardiac branch, **302**, 309
 327
 recurrent branch, 326,
 327
 vasomotor, 64
 Vidian, 171, 320, 321
- Nerve fibre, 30
- Nervous system, autonomic, 74, 321,
 355. (*See also* sympathetic trunk)
- Neural tube, 80
- Neurilemma, 30
- Neurocoele, 80
- Neurocranium, 55, 58
- Neuroglia, 29, 32
- Neuron, 29
- Nipples, 219
- Node, atrioventricular, 64
 lymph. *See* Gland, lymph
 of Ranvier, 30
 sinuatrial, 64
 Notch, acetabular, 209
 sciatic, greater, 208
 lesser, 209
 umbilical, 233
- Notochord, 52
- Nuchal surface, 167
- Nucleus, 11
- Nucleolus, 11
- Oesophagus, 100, **335**
- Olecranon, 204
- Omentum, 137
 greater, 226
 hepatogastric, 226, 232
 lesser, 226, 232
- Ontogeny, 3
- Oral cavity, 99, **310**
- Orbit, 167, 169, 175
- Organ of Corti, 91
 vomeronasal, 178
- Ossicles, auditory, 54, 55, 56, 57, 170,
 188
- Ossification, 46
- Osteocranium, 55, 58
- Ovary, 129, 131, 250
- Oviduct, 130
- Ovum, 12, 129
- Pachymeninx, 344
- Palate, hard, 174, 311
 soft, 195, 311
- Pallium, 82, 142, 365
- Pancreas, 131, 225, 228, 236
- Papilla, circumvallate, 99
 conical, 311
 filiform, 311
 foliate, 99, 312
 fungiform, 312
 operaria, 211
 vallate (circumvallate), 99,
 312
- Paraflocculus, 356
- Parasympathetic, 321
- Peduncle, cerebellar, 362
 cerebral, 355
- Pelvis, 206, 224
 renal, 123, 243
- Penis, 219, 247
- Pericardium, 135, 328
- Perichondrium, 22, 46, 49
- Perimysium, 28
- Perineurium, 72
- Periosteum, 24, 46, 49
- Peritoneum, 136, 224, 244
- Petrous portion of petrotympanic bone,
 177, 186

- Peyer, aggregated lymph nodules of, 237
- Pharynx, 99, **310**, 312
- Phylogeny, 3
- Pia mater, 72, 344
- Pigment, 21
- Placenta, 8, 10, 115, 130
- Plate, cribriform, 176, **190**
- Platelets, 33
- Pleura, 135, 329, 334
- Plexus, aortic, 242
 - brachial, 263
 - cardiac, 327, 328
 - cervical, 263
 - chorioid, 83, 351, 358, 366
 - coeliac, 228, 230
 - coronary, 327
 - formation in nerves, 75
 - gangliiformis, 309
 - hypogastric, 242
 - lumbar, 289
 - lumbosacral, 273, **288**
 - lymphatic, 120
 - mesenteric, inferior, 242
 - superior, 228
 - pampiniformis, 247
 - renal, 228, 242
 - sacral, 289
 - spermatic, 242
- Pollex, 220
- Pons, 358
- Portal system, 110, 111
- Pouch, rectovesical, 244
 - vesicouterine, 244
- Prepuce, 219
- Process, alveolar, 174, 192
 - clinoid, 176
 - condyloid, 180, 197
 - coracoid, 62, 200
 - coronoid, 197
 - ethmoidal, 184
 - jugular, 167, 181
 - mastoid, 171, 185
 - odontoid, 160
 - orbital, of maxilla, 191, **192**
 - Process, palatine, of maxilla, 191, **192**
 - of premaxilla, 193
 - paramastoid, 167
 - pterygoid, 169, 171, 182, **183**
 - pyramidal, 195
 - sphenoorbital, 191, 192
 - styloid, 204
 - supraorbital, 170, 174
 - thyreoehyal, 198
 - vermiform, 103, 237, 238
 - xiphoid, 166
 - zygomatic, 169, 174, 185, 191, 192
- Promontory, 163, 187
- Pronephros, 126, 127
- Proprioceptors, 90
- Prosencephalon, 80, 81, 349
- Protuberance, external occipital, 168, 181
- Purkinje fibres, 28
- Pylorus, 225
- Pyramid, 358
 - renal, 244
- Recapitulation, 3
- Receptors, 90
- Rectum, 238, 239
- Reflex action, 77
- Reproduction, 8
- Respiration, 105
- Reticulo-endothelial system, 19
- Retina, 92, 93, 318
- Rhinencephalon, 82
- Rhombencephalon, 80, **356**, **361**
- Rib, 164
- Rodentia, 7
- Rotation of forearm, 70, 204
- Sac, scrotal (sac of testis), 129, 136, **137**, 219, 223, 224, **245**
 - serous, 135, 224
- Sacculus rotundus, 235, 237
- Sacrum, 50, 163
- Sarcolemma, 27
- Sclera, (sclerotic), 92, 317

- Scroll. *See* bone, turbinated
 Scrotum. *See* sac
 Secretin, 132
 Secretion, 15, 17
 Sella turcica, 176
 Sense organs, 89
 - auditory, 90, 219, 321, 322
 - gustatory, 90, 99
 - olfactory, 90
 - visual, 90, 92, 218, 317
 Septum, nasal, 178
 - pellucidum, 365
 Sinus, aortic, 333
 - carotid, 90, 306
 - coronary, 326
 - maxillary, 192
 - pulmonary, 332
 - sphenoidal, 182
 - superior sagittal of dura mater, 348
 - tonsillar, 312
 - transverse of dura mater, 172, 181, 186, 297, 348
 - urinogenital, 122, 130
 Sinusoids, 97, 110
 Skull, 53, 166
 - human, 60
 Space, epidural, 344
 - inguinal, 219, 248, 253
 - perivascular, 72
 Specialization, 5
 Spermatoocytes, 128, 130
 Spermatogonia, 128
 Spermatozoön, 12, 128
 Spinal cord, 31, 78, 344
 Splanchnocranium, 56, 58
 Spleen, 122, 225, 229
 Sternum, 166
 Stomach, 100, 224
 Sulcus arteriae vertebralis, 160
 - ascendens of mandible, 197, 298, 304
 - basilaris, 358
 - caroticus, 182
 Sulcus chiasmatis, 183
 - sphenoidalis, 177, 183
 Suprascapula, 200
 Sustentaculum tali, 214
 Suture, 49
 - coronal, 188
 - frontal, 189
 - harmonic, 194
 - lambdoidal, 188
 - sagittal, 188
 - squamosal, 188
 Sympathetic system, 73, 74
 - trunk, 257, 302, 309, 328, 336
 Symphysis, 49
 Synapse, 32
 Synovia, 49
 Taste buds, 90
 Teeth, 59
 Telencephalon, 81, 350
 Tendon, 20, 65
 Tendon of Achilles, 285
 Tentorium cerebelli, 176, 177
 Testis, 128, 129, 131, 245
 Thalamencephalon, 83
 Thalamus, 352
 Thorax, 165
 Tissues, 11, 13
 - adipose, 21
 - connective, 18
 - epithelial, 13
 - fluid, 34
 - muscular, 25
 - nervous, 29
 - skeletal, 22
 - subcutaneous, 20, 221
 Tongue, 311
 Tonsil (palatine), 312
 Trachea, 300
 Tract, olfactory, 349
 - optic, 353
 Trochanters (of femur), 210

- Trochlea humeri, 201
 orbital, 315
 tali, 213
- Trunk, lymphatic, 120, 281
 jugular, 293
 sympathetic. *See* Sympathetic trunk
- Tube, auditory, 172, 187, 312
 Eustachian, 172, 187, 312
 neural, 80
 uterine, 130, 251
- Tuber cinereum, 354, 355
- Tubercle, acoustic, 362
 pharyngeal, 181
- Tuberosity, deltoid, 201
- Tubules, renal, 124
 seminiferous, 128
- Tunica albuginea, 247
- Tunica vaginalis propria, 137, 245, 246
- Tympanum, 187
- Umbilicus, 140
- Ureter, 243, 244
- Urethra, 122, 244, 247, **248**, 250, **253**
- Uterus, 130, 251, 253
- Vagina, 130, 252, 253
- Valve, spiral, 103, 238
- Valves, atrioventricular, 332, 333
 bicuspid, 333
 semilunar, 332, 333
 tricuspid, 332
- Vas deferens. *See* duct, deferent
- Vein, alveolar, inferior, 298, 305
 angular, 294
 auricular, anterior, 298
 posterior, 298
 axillary, 263
 azygos, 336
 brachial, 271
 cardiac, 331
 caudal, lateral, 280
 caval, inferior, 115, 117, 227,
 234, **256**, 326, 331
 superior, 115, 117, 261,
326, 331
 cephalic, 263, **271**
 circumflex, lateral, 280
 coronary, 230
 deep, of thigh, 280
 epigastric, inferior, 257
 superficial, 280
 facial, anterior, 294, 298
 deep, 298
 posterior, 297
 transverse, 298
 femoral, 280
 gastroduodenal, 230
 gastroepiploic, 230
 haemorrhoidal, external, 256
 hepatic, 117, 234
 hypogastric, common, 256, 257
 paired, 256
 iliac, external, 257
 iliolumbar, 256
 infraorbital, 146
 intercostal, 336
 jugular, external, 258, **297**
 internal, 172, 301
 transverse, 297
 labial, inferior, 294
 superior, 294
 lumbar, 256
 maxillary, external, 146
 internal, 298
 posterior internal, 298
 median, 271
 mesenteric, 241
 obturator, 256
 ophthalmic, external, 170, 297
 pancreaticoduodenal, superior,
230
 phrenic, inferior, 256, 338
 superior, 338
 popliteal, 280, 287
 portal, 110, 115, 230, 234
 pudendal, internal, 280
 pulmonary, 331, 335
 renal, 243

- Vein, portal, 111
 sacral, median, 257
 saphenous, great, 280, 282, 287
 small, 285, 287
 accessory small, 282
 287
 scapular, transverse, 258, 297
 sciatic, 256, 282, 287
 spermatic, 247, 250
 splenic, 230
 subclavian, 326
 sublingual, 298
 submental, 298
 subscapular, 263
 suprarenolumbar, 256
 temporal, deep, 298
 superficial, 297
 thoracic, lateral, 263
 thyreoid, inferior, 150
 tibial, anterior, 287
 posterior, 287
 ulnar, 271
 umbilical 115, 117
 vertebral, 312
 median, 144, 148, 150,
 312
 vesical, 245, 257
- Veins, 109, 112, 113
- Velum, anterior medullary, 357, 361
 posterior medullary, 358, 361
- Ventricle, of brain, 80
 fourth, 361
 of heart, 330, 331, 332
 laryngeal, 314
 lateral, 364, 365
 third, 351, 364
- Vertebrae, 50, 51, 156
 caudal, 164
 cervical, 158
 coccygeal, 164
 false, 163
 lumbar, 161
 sacral, 163
 thoracic, 161
 true, 163
- Vertebral column, 44, 50, 156
- Vertebrates, 9, 10
- Vesicle, cerebral, 80
 seminal, 248
- Vestibulum, 122, 130, 253
- Vestibulum oris, 99, 310
- Vibrissae, 15, 144, 218
- Vocal folds, 314
- Vomeronasal organ, 178
- Vulva, 219, 223
- Zona pellucida, 11
- Zonula ciliaris, 92
- Zonular fibres, 318

