



19.7.156

No. ~~116.271~~

**BOSTON  
MEDICAL LIBRARY  
ASSOCIATION,**

119 BOYLSTON PLACE,

---

Received

February 10, 1897

By Gift of

purchase





# BRAIN SURGERY

BY

M. ALLEN STARR, M.D., PH.D.

PROFESSOR OF DISEASES OF THE MIND AND NERVOUS SYSTEM, COLLEGE OF PHYSICIANS  
AND SURGEONS, MEDICAL DEPARTMENT OF COLUMBIA COLLEGE, NEW YORK;  
PRESIDENT OF THE NEW YORK NEUROLOGICAL SOCIETY; CON-  
SULTING NEUROLOGIST TO THE PRESBYTERIAN,  
ORTHOPÆDIC AND BABIES HOSPITALS

---

WITH FIFTY-NINE ILLUSTRATIONS

---

NEW YORK  
WILLIAM WOOD & COMPANY

1893

1465

COPYRIGHT, 1893, BY  
WILLIAM WOOD & COMPANY



## PREFACE.

---

BRAIN surgery is at present a subject both novel and interesting. It is within the past five years only that operations for the relief of epilepsy and of imbecility, for the removal of clots from the brain, for the opening of abscesses, for the excision of tumors, and for the relief of intracranial pressure have been generally attempted. These operations are the practical outcome of the acceptance of the facts of localization of brain function established by the combined labor of physiologists, clinical observers, and pathologists.

Brain surgery has as its essential basis the accurate diagnosis of cerebral lesions, which was impossible until the localization of cerebral functions had been determined. And this diagnosis must be made by the physician before the surgeon is called in to remove the disease.

It is the object of this book to state clearly those facts regarding the essential features of brain disease which will enable the reader to determine in any case both the nature and the situation of the pathological process in progress, to settle the question whether the disease can be removed by surgical interference, and

to estimate the safety and probability of success by operation.

The facts have been reached by a careful study of the literature of the subject and by a considerable personal experience. The number of articles written upon brain surgery, the number of cases recorded and of operations reported in this country and in Europe during the past ten years is enormous. This literature is accessible to those only who have a large medical library at their command and who have the time for literary research. I have undertaken to bring together and to sift the scattered facts, to arrange them in an orderly sequence, and to deduce such conclusions from their analysis as seem warranted by critical study. While in no way disregarding the work of foreign observers, I have endeavored to utilize American observations and to cite American cases in preference to others. And this has in no way hampered me, for it is to the industry and genius of American surgeons that much of the great advance in this department of surgery is due.

To this collection of facts I am able to contribute a considerable number of cases of cerebral disease, operated upon under my direction. My own experience in the clinical study of brain diseases and my observation of the method and results of operations performed by different surgeons have enabled me to estimate the statements of other writers with some degree of critical judgment, and to arrive at certain convictions of my own.



I have to express my deep obligation to Dr. McBurney for placing at my entire disposal the large number of cases in which he has operated for me, and for a revision of the chapter upon the operation of trephining; and also my thanks to Drs. Weir, Hartley, Poore, and Briddon for permission to cite the cases which I have seen with them. I am indebted to Dr. Van Gieson for the very careful investigation of pathological material placed in his hands and for the drawings which illustrate his descriptions.

It is my hope that this work may aid the physician to diagnosticate brain diseases with more accuracy, and to select such cases as are properly open to surgical treatment by trephining; and also that it may enable the surgeon to perform his delicate task with more precision and with a fuller knowledge of those principles of local diagnosis which should form his constant guide.

M. ALLEN STARR.

NO. 22 WEST 48TH STREET, NEW YORK.

March 27th, 1893.



# CONTENTS.

---

## CHAPTER I.

### THE DIAGNOSIS OF CEREBRAL DISEASE.

	PAGE
Diagnosis is Preliminary to Operation and must be Made by the Physician before Surgical Treatment is Attempted. The Diagnosis of the Nature of the Cerebral Lesion. The Diagnosis of the Situation of the Cerebral Lesion. The Facts of Localization Essential to Diagnosis. Cranio-Cerebral Topography, . . . . .	1

## CHAPTER II.

### TREPHINING FOR EPILEPSY.

The Varieties of Epilepsy. Jacksonian Epilepsy. The Motor Form of Attack. The Sensory Form of Attack. The Aphasic Form of Attack. The Psychological Form of Attack. Traumatic Epilepsy. The Operation for Epilepsy. Records of Cases of Epilepsy operated upon, Personal and Selected. The Pathology of Jacksonian and Traumatic Epilepsy. The Results of Trephining for Epilepsy. Conclusion, . . . . .	19
--	----

## CHAPTER III.

### TREPHINING FOR IMBECILITY DUE TO MICROCEPHALUS.

Clinical Types of Microcephalic Children: (1) Paralytic Cases; (2) Imbeciles; (3) Cases of Sensory Defect. The Occurrence of Epilepsy in these Children. The Pathology of these Clinical Types. The Operation of Craniotomy and its Results. Table of Cases. Report of Personal Cases. Conclusions, . . . . .	114
---	-----

## CHAPTER IV.

## TREPHING FOR CEREBRAL HEMORRHAGE.

	PAGE
Records of Cases of Clots Removed from the Brain. Report of Personal and Selected Cases. The Symptoms of Traumatic Cerebral Hemorrhage. The Differential Diagnosis Between Intra-Dural and Extra-Dural Hemorrhage. Operations for Non-Traumatic Hemorrhage, . . . . .	157

## CHAPTER V.

## TREPHING FOR ABSCESS OF THE BRAIN.

The Surgical Treatment of Brain Abscess. The Varieties of Brain Abscess. (1) Traumatic Abscesses. Surgical Indications for Trephining, General and Local. Report of Cases. (2) Abscesses Secondary to Ear Disease. Symptoms. Differential Diagnosis between Abscess, Meningitis, and Sinus Thrombosis. The Situation for Trephining after Ear Disease. Illustrative Cases. Conclusions, . . . . .	179
---	-----

## CHAPTER VI.

## TREPHING FOR TUMOR OF THE BRAIN.

The Frequency and Varieties of Tumors in the Brain. Analysis of Six Hundred Tumors. Tumors in Children Contrasted with Tumors in Adults. The Diagnosis of the Nature of the Tumor. The Diagnosis of the Situation of the Tumor. The Percentage of Brain Tumors Open to Operation. The Results of Operation for Brain Tumors. Analysis of Ninety-seven Cases. I. Cerebral Tumors. Selected American Cases. Personal Case. Tumor of Frontal Lobes. II. Cerebellar Tumors. Diagnosis. Difficulties of Operation. Three Personal Cases. Table of all Brain Tumors Operated upon. Conclusions, . . . . .	200
---	-----

## CHAPTER VII.

## TREPHING FOR HYDROCEPHALUS AND FOR THE RELIEF OF INTRACRANIAL PRESSURE.

Hydrocephalus. Tapping the Lateral Ventricles. Keen's Cases. Robson's Cases. Broca's Cases. General Conclusions. Methods of Operation. Trephining to Relieve Intracranial Pressure, . . . . .	256
---	-----

## CHAPTER VIII.

## TREPHINING FOR INSANITY.

	PAGE
Traumatic Insanity in Relation to Insanity in General. Report of Cases Operated Upon. Trephining in General Paresis. Uselessness of the Operation, . . . . .	267

## CHAPTER IX.

TREPHINING FOR HEADACHE, AND OTHER CONDITIONS, .	273
--	-----

## CHAPTER X.

## THE OPERATION OF TREPHINING.

The Necessity of Antiseptic Precautions. The Preparation of the Patient. The Choice of an Anæsthetic. Marking the Scalp. The Incision in the Scalp. Methods of Opening the Skull. The Treatment of Hemorrhage. Opening of the Dura. The Exploration of the Brain. The Closure of the Wound, . . . . .	275
---	-----



# LIST OF ILLUSTRATIONS.

---

FIG.	PAGE
1. Diagram of the Functional Areas of the Right Hemisphere, . . . . .	4
2. Diagram of the Functional Areas of the Left Hemisphere, . . . . .	5
3. Diagram of the Median Surface of the Right Hemisphere, . . . . .	7
4. The Projection Tracts within the Brain, . . . . .	9
5. The Association Tracts within the Brain, . . . . .	10
6. Photograph of the Head and Brain (Fraser), . . . . .	12
7. Photograph of a Cast of the Head, . . . . .	13
8. Diagram of the Cranial Measurements to Locate the Fissures, . . . . .	14
9. Diagram of the Relations of the Skull and the Brain (Reid), . . . . .	15
10. Diagram, to Show the Relation of the Skull and the Functional Areas of the Right Hemisphere, . . . . .	16
11. Diagram to Show the Relation of the Skull and the Functional Areas of the Left Hemisphere, . . . . .	17
12. Diagram to Show the Opening in the Skull in Case I., . . . . .	30
13. Diagram to Show the Opening in the Skull in Case II., . . . . .	32
14. Diagram to Show the Opening in the Skull in Case III., . . . . .	36
15. Diagram to Show the Opening in the Skull in Case IV., . . . . .	37
16. Diagram to Show the Opening in the Skull in Case V., . . . . .	39
17. Diagram to Show the Opening in the Skull in Case VI., . . . . .	42
18. Diagram to Show the Opening in the Skull in Case VII., . . . . .	43
19. Diagram to Show the Opening in the Skull in Case VIII., . . . . .	45
20. Diagram to Show the Opening in the Skull in Case IX., . . . . .	47
21. Diagram to Show the Opening in the Skull in Case X., . . . . .	48
22. Diagram to Show the Opening in the Skull in Case XI., . . . . .	50
23. Diagram to Show the Opening in the Skull in Case XII., . . . . .	53
24. Diagram to Show the Opening in the Skull in Case XIII., . . . . .	54
25. Section through Pia and Cortex Showing Meningitis, . . . . .	71
26. Section Showing Spiculum of Bone in the Brain in Case III., . . . . .	84
27. Degeneration of Brain Cells in Epilepsy, . . . . .	87
28. Degeneration of Brain Cells in Epilepsy, . . . . .	89
29. Degeneration of Brain Cells in Epilepsy, . . . . .	90
30. Changes in the Neuroglia in Epilepsy, . . . . .	98
31. Changes in the Neuroglia in Epilepsy, . . . . .	99
32. Neuroglia Cells Undergoing Changes in Epilepsy, . . . . .	100

FIG.	PAGE
33. Adhesion of Scalp and Cortex in Case II., . . . . .	103
34. Section Showing Changes in Membranes and Brain in Case II., . . . . .	105
35. Changes in the Cortex in Case II., . . . . .	107
36. The Capillaries and the Neuroglia in Case II., . . . . .	109
37. The Neuroglia in Case II., . . . . .	110
38. Porencephalic Brain (Shattenberg), . . . . .	125
39. Porencephalic Brain (Ferraro), . . . . .	126
40. Porencephalic Brain (Ferraro), . . . . .	127
41. Hemiatrophy of the Brain, Superior Surface, . . . . .	130
42. Hemiatrophy of the Brain, Inferior Surface, . . . . .	131
43. Hydrocephalus (Delafield and Prudden), . . . . .	132
44. Diagram to Show the Opening in the Skull in Case XIV., . . . . .	142
45. Diagram to Show the Opening in the Skull in Case XV., . . . . .	145
46. Diagram to Show the Opening in the Skull in Case XVI., . . . . .	147
47. Diagram to Show the Opening in the Skull in Case XVII., . . . . .	149
48. Diagram to Show the Opening in the Skull in Case XVIII., . . . . .	164
49. Diagram to Show the Situation of the Clot in Case XVIII., . . . . .	165
50. Diagram to Show Relation of Skull and Functional Areas of the Left Hemisphere, . . . . .	170
51. Diagram to Show the Opening in the Skull in Case XIX., . . . . .	175
52. Diagram to Show the Opening in the Skull in Case XX., . . . . .	186
53. Photograph of the Brain Abscess in Case XX., . . . . .	187
54. Lateral Aspect of the Skull with Trephine Openings (Balance), . . . . .	193
55. The Cerebral Axis (Allan Thompson), . . . . .	210
56. Photograph of the Skull and Brain (Fraser), . . . . .	211
57. Diagram to Show the Opening in the Skull in Case XXI., . . . . .	234
58. Photograph of a Tumor Removed from the Brain in Case XXI., . . . . .	235
59. Hydrocephalus (Delafield and Prudden), . . . . .	265





# BRAIN SURGERY.

---

## CHAPTER I.

### **THE DIAGNOSIS OF CEREBRAL DISEASE.**

Diagnosis is Preliminary to Operation and must be Made by the Physician before Surgical Treatment is Attempted. The Diagnosis of the Nature of the Cerebral Lesion. The Diagnosis of the Situation of the Cerebral Lesion. The Facts of Localization Essential to Diagnosis. Cranio-Cerebral Topography.

THERE are two essential preliminaries to any operation upon the brain. The first is the diagnosis of the nature of disease which is present, and the second is the diagnosis of its situation. Both are purely medical questions, and until they are decided the surgeon cannot be asked to operate.

The diagnosis of the nature of disease in the brain is usually one of no great difficulty. The general cerebral symptoms characteristic of meningitis, either of the dura mater or of the pia mater, of hydrocephalus, of cerebral hemorrhage, of cerebral softening from embolism or thrombosis, of cerebral abscess, of cerebral tumor, and of sclerosis of the brain are in the majority of cases quite evident. The differential diagnosis between these conditions is elaborately dis-

cussed in every text-book on practice and on neurology. A careful study of the various symptoms, of the order and manner of their development, and of the general history of the case will usually lead with little difficulty to a diagnosis of the nature of the lesion present.

It is not my purpose to enter upon the discussion of the diagnosis of cerebral disease in general. In the course of the following chapters and in the recital of certain cases the essential facts will be carefully considered. But it should not be forgotten that surgical interference is by no means warranted in any case unless the nature of the disease is well determined.

The second essential preliminary to operation is a knowledge of those facts regarding the localization of brain functions, so far as they are at present determined, which may lead to a correct diagnosis of the situation of the disease. These facts may be stated briefly.

### *The Facts of Localization.*

There are certain areas upon the cortex of the brain, not necessarily co-extensive with either lobes or convolutions, whose functions are accurately known.

These areas are: (1) the sensori-motor area. (2) The speech areas. (3) The visual area. (4) The auditory area. (5) The area of sensations of smell and of taste.

(1) *The sensori-motor area* (Figs. 1 and 2) includes the cortex of the anterior and posterior central convolutions which border the fissure of Rolando and the adjacent cortex in front and behind these convolutions.

Each hemisphere controls movement on the opposite side of the body, but as the right hand is more generally used and is better trained than the left, this area is larger on the left hemisphere than on the right.

The cortex of the posterior part of the second frontal convolution controls the movements of the eyes and head. Impulses starting from this area produce conjugate movement of these parts toward the opposite side. The eye district is below, the head district above.

The lower third of the anterior and posterior central convolutions governs the movements of the face, tongue, larynx, and pharynx. The eyebrows and cheeks are controlled by the upper and forward part of this area; the tongue and larynx by the lower and forward part; the mouth, pharynx, and platysma by the hinder part.

The middle third of the anterior and posterior central convolutions governs the movements of the upper extremity; the shoulder motions being controlled in the anterior and upper part of this area, the elbow motions in its middle part, and the hand and finger motions in its posterior and lower part.

The upper third of the anterior and posterior central convolutions including their junction in the paracentral lobule controls the motions of the lower extremity; the thigh, knee, foot, and toes being governed by various parts of this area from before backward in the order named.

It will be noticed that the parts susceptible of the

finest and most delicate movements, those directed by the most acute sensations, the lips, the fingers, and the toes, lie furthest back in the motor area, chiefly in the posterior central convolution. Lesions in this convolution almost always cause some loss of tactile sensation as well as paralysis, and hence this area is thought to be the seat of tactile sensations as well as of movements, while some cases point to the localiza-

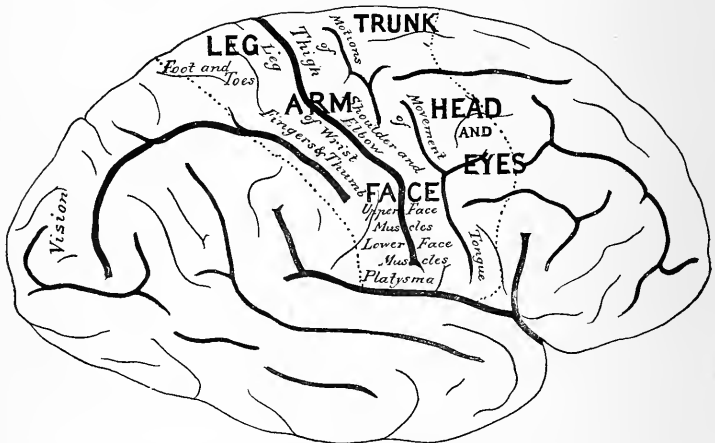


FIG. 1.—Diagram (after Eberstaller) of the Fissures and Convulsions of the Convexity of the Right Hemisphere of the Brain. The relative depth of the fissures is indicated by the shading. The extent of the functional areas is indicated by the dotted lines.

tion of muscular sensations in the area just behind that of motion.

The median surface of the hemisphere in front of the paracentral lobule is known to be related to movements of the trunk in monkeys, but these movements are rarely affected by disease in man and their cortical representation is still uncertain, though

a case reported by Horsley<sup>1</sup> points to the cortex in front of the leg area on the convexity as the probable location of the trunk area.

There are no sharply defined sections of the motor area to be assigned to special motions. Each motion, each part of a limb, has a wide general representation over the cortex and a special representation at a limited area. Horsley says that the areas of representa-

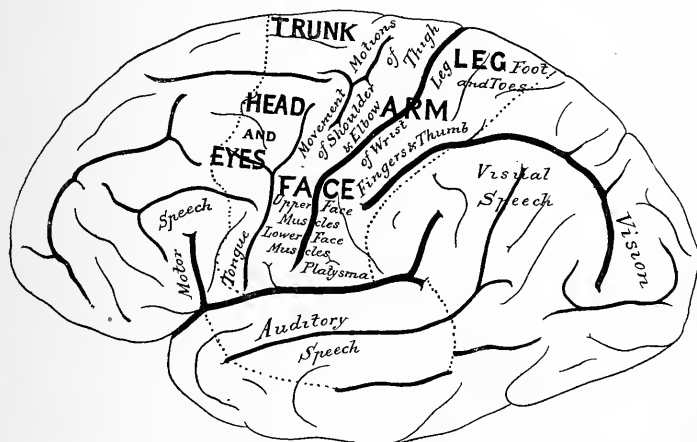


FIG. 2.—Diagram of the Fissures and Convulsions of the Convexity of the Left Hemisphere of the Brain. The speech areas are shown on this hemisphere. The motor area is more extensive than on the right hemisphere.

tion of different limbs merge into one another; thus in the representation of the thumb we find that there is a focus, but that the thumb is represented over a great deal of the upper limb region, and that this representation diminishes in intensity gradually as we pass from the focus upward. This explains the fact that the excision of a small area does not totally para-

<sup>1</sup> Amer. Jour. Med. Sci., April, 1887, Case III., Fig. 18.

lyze the portion of the limb represented chiefly on that area. The adjacent areas represent to some extent that limb and hence can govern it if need be.

(2) *The speech areas* (Fig. 2) are of four kinds and in four locations. They are limited to the left hemisphere in right-handed persons and to the right hemisphere in left-handed persons. There is *the motor speech area* in the posterior part of the third frontal convolution, in which the movements concerned in the act of speaking are controlled. The use of language and the power of talking are affected when this region is destroyed. There is *the auditory speech area* in the first and second temporal convolutions, in which the memories of word sounds are stored up. The understanding of language and the power of recollecting the names of objects are lost when this region is destroyed. There is *the visual speech area* in the lower parietal region, in which the memories of printed words are stored up. The understanding of written language and the power to read are lost when this region is destroyed. *The power of writing* is a part of speech and is usually lost when the motor speech area is destroyed, but its exact location is not fully determined; some cases pointing to the second frontal convolution, others to the lower parietal convolution near the hand centre as its probable cortical position. -

(3) *The area of sensations of sight* (Fig. 3) is located in the occipital lobe of the brain, including the cuneus on the median surface and the occipital convolutions on the convexity. The cortex lying in the

calcarine fissure is the part primarily reached by the visual impulses,<sup>1</sup> but the parts named are also concerned in vision. Each occipital lobe receives impressions from one-half of both eyes, hence a lesion in one lobe produces hemianopsia, a half-blindness in both eyes,

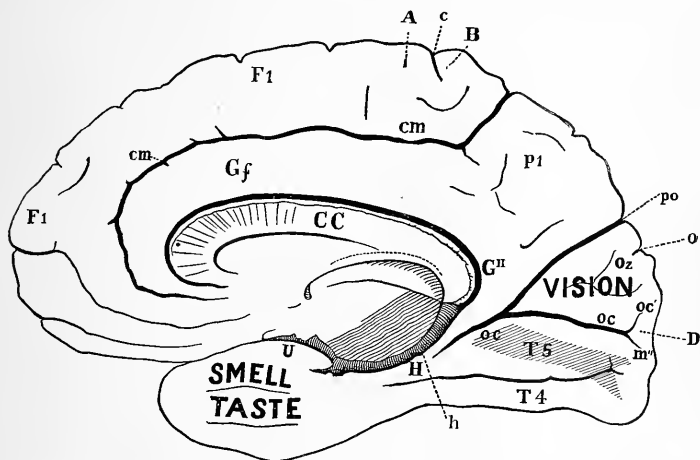


FIG. 3.—The Median Surface of the Right Hemisphere (after Ecker). The visual centre is in the cortex lying within the calcarine fissure, *OC*, and in the cuneus, *OZ*. The sensations of smell and taste are received in the uncinat convolution, *U*, and at the tip of the temporo-sphenoidal lobe. *AB* shows the position of the paracentral lobule, which is included in the motor area of the leg.

the blind field of vision being on the opposite side to the lesion.

(4) *The area of sensations of sound* (Fig. 2) is located in the first and second temporal convolutions of the brain. Each ear is connected with both hemispheres; hence deafness from a unilateral lesion is only partial and is not generally noticed. But if both temporal lobes are destroyed the patient becomes totally deaf.

<sup>1</sup> Henschen: "Pathologie des Gehirns," ii., 358, 1892.

(5) *The area of sensations of smell and taste* (Fig. 3) is located at the tip of the temporal lobe on its under and inner surface, which rests on the sphenoid bone. Each lobe is related to sensory organs on both sides, and a unilateral lesion does not often produce noticeable symptoms.

There are large areas of the cortex of the brain whose function is undetermined. These are much more extensive on the right hemisphere than on the left. There are no definite symptoms produced, so far as we now know, by lesions in these areas; but the negative fact is certain, that lesions in them do not cause disturbances of motion, of sensation, or of speech.

There appears to be a certain relation between the frontal lobes of the brain and the higher forms of intellectual activity, the powers of fixing the attention and of reasoning and of self-control. But disease here does not cause a loss of any one mental faculty, and for the higher powers of the mind a general integrity of the entire brain, not of any one part, is necessary. When it is considered that every concept is made up of numerous memory pictures joined together, each of which has a separate location in the brain cortex, it becomes evident that to the process of thought a healthy state of the entire cortex is necessary and also of the white matter beneath it, through which the associating fibres pass. And it is therefore impossible for a single lesion anywhere to cause a loss of memory or of imagination or of judgment. Yet for the co-ordination of facts into orderly



series, for comparison, and for analysis of knowledge gained through the senses, the healthy state of the frontal lobes appears to be necessary. And lesions in

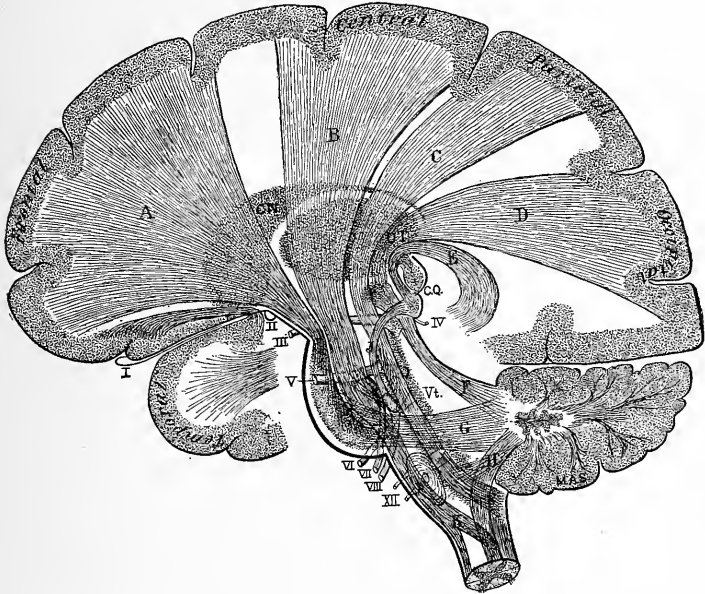

FIG. 4.—The Projection Tracts joining the Cortex with Lower Nerve Centres. Sagittal section showing the arrangement of tracts in the internal capsule. *A*, Tract from the frontal lobe to the pons, thence to the cerebellar hemisphere of the opposite side; *B*, motor tract from the central convolutions to the facial nucleus in the pons and to the spinal cord; its decussation is indicated at *K*; *C*, sensory tract from posterior columns of the cord, through the posterior part of the medulla, pons, crus, and capsule to the parietal lobe; *D*, visual tract from the optic thalamus (*OT*) to the occipital lobe; *E*, auditory tract from the inter-geniculate body (to which a tract passes from the viii. n. nucleus (*J*) to the temporal lobe; *F*, superior cerebellar peduncle; *G*, middle cerebellar peduncle; *H*, inferior cerebellar peduncle; *CN*, caudate nucleus; *CQ*, corpora quadrigemina; *Vt.*, fourth ventricle. The numerals refer to the cranial nerves.

the frontal region, especially upon the left side, are quite uniformly attended by mental dulness, apathy, lack of power of concentration, and imperfect self-control.

The cortex of the hemispheres upon the base of the brain lying on the orbital plate, on the sphenoid and temporal bones, and on the tentorium cerebelli has as yet no assignable functions, and lesions in these regions do not produce recognizable symptoms.

As to the functions of the centrum ovale, it is known

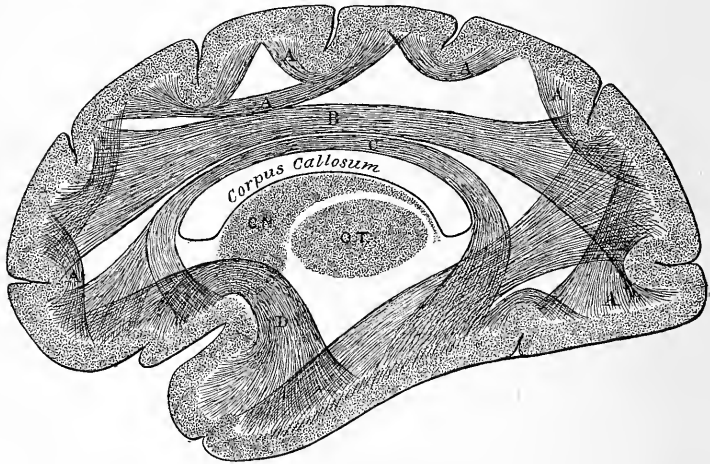


FIG. 5.—The Association Fibres in the Centrum Ovale. *A*, Between adjacent convolutions; *B*, between frontal and occipital lobes; *C*, between frontal and temporal lobes, the cingulum; *D*, between temporal and frontal lobes—lesion of this tract causes paraphasia; *E*, between occipital and temporal lobes—lesion of this tract causes word-blindness; *CN*, caudate nucleus; *OT*, optic thalamus.

that through this region the great brain tracts pass in various directions (Fig. 4). Many of these connect the various areas of the cortex with their respective sensory or motor mechanisms in the base of the brain and spinal cord. Others join the different areas of the cortex with each other, this bringing about a combination of sensory impressions into a single mental image (Fig. 5). Others again unite the two hemi-

spheres of the brain with one another, it being certain that symmetrical areas must act in unison on the two sides.

The basal ganglia, the corpora striata, and optic thalami, lying deep within the hemispheres, are masses of gray matter whose function is undetermined. Lesions in them frequently affect the various tracts which pass between them in the internal capsule, thus cutting off afferent or efferent impulses to and from the cortex and causing sensory and motor symptoms of the nature of hemianæsthesia, hemianopsia, and hemiplegia (Fig. 4). But if disease in the ganglia does not invade the internal capsule it cannot be detected during life.

The crura cerebri, pons, and medulla contain the centres of the various cranial nerve nuclei, and hence cranial nerve palsies are caused by disease in them. They transmit motor and sensory tracts to the spinal cord, hence numerous symptoms appear when they are injured.<sup>1</sup>

The cerebellum, lying in the posterior cranial fossa beneath the tentorium cerebelli, controls the equilibrium of the body; hence disturbances of the nature of staggering and vertigo are produced by lesions affecting it, especially if its median lobe is involved.

These local symptoms of brain disease must form the chief guides to the physician in his diagnosis and

<sup>1</sup> For a fuller statement of these facts of localization the reader is referred to my book, "Familiar Forms of Nervous Disease."

to the surgeon in operations. When they are present they point to a particular area of the organ which must be involved. When they are absent both neu-

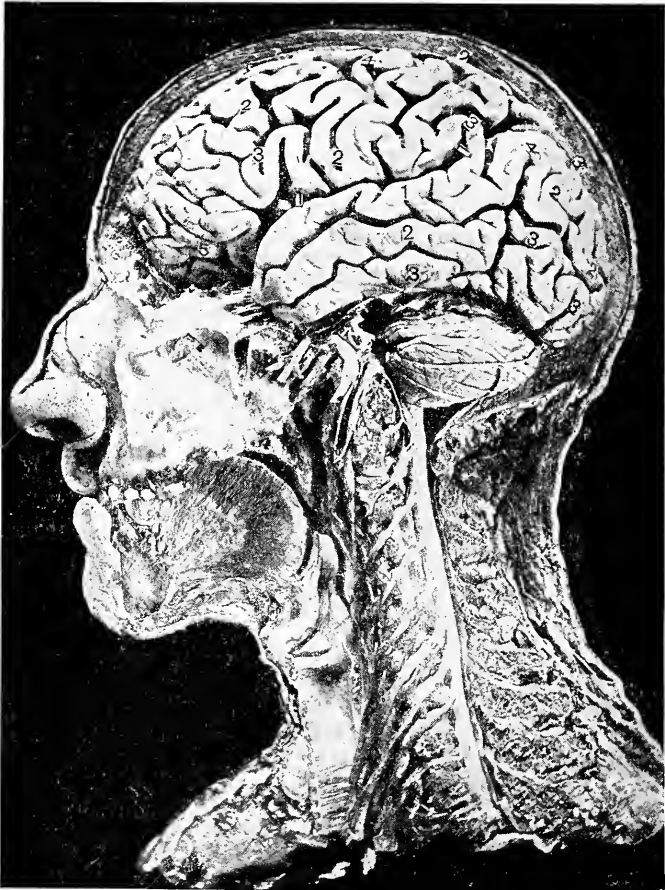


FIG. 6.—Photograph (Fraser) Showing the Relations of the Cerebral Hemisphere, the Cerebellum, the Cranial Nerves, the Upper Spinal Cord and Cervical Nerves to the Surface of the Head. The figures 1, 2, 3, are placed upon the chief convolutions of the frontal, parietal, occipital, and temporal lobes of the hemisphere.

rologist and surgeon are as helpless as they were before any of these facts of localization were determined.

*Cases open to Operation.*

There are many cases in which it is evident that brain disease is present, but in which it cannot be

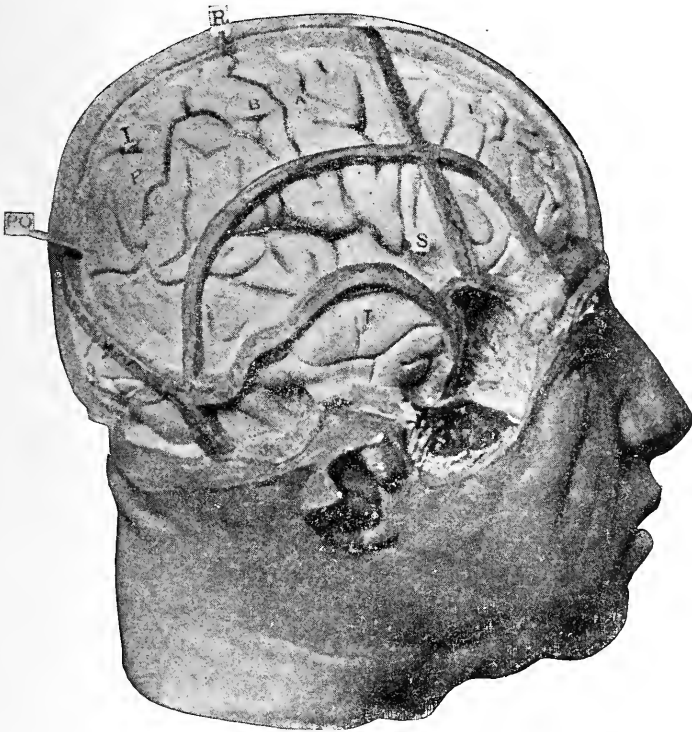


FIG. 7.—Photograph of a Cast of a Head showing the Relation of the Cranial Sutures to the Cerebral Fissures and Convolutions. *F*, Frontal; *P*, parietal; *O*, occipital; *T*, temporal lobes; *S*, fissure of Sylvius; *R*, fissure of Rolando; *I*, interparietal fissure; *P O*, parieto-occipital fissure; *A B*, anterior and posterior central convolutions.

located because the necessary symptoms to determine its location are absent.

There are other cases in which it is evident that the disease is located deep within the hemispheres or on the base of the brain entirely beyond the reach of the surgeon.

It is therefore evident that only in a limited number

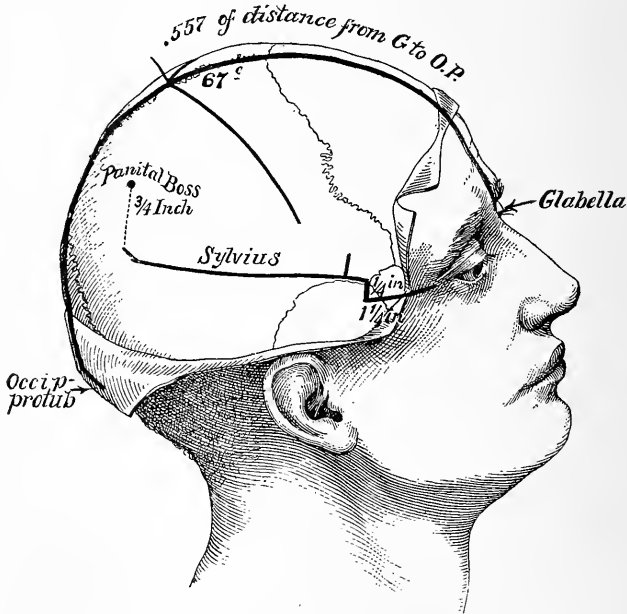


FIG. 8.—Diagram Showing the Measurements Required to Determine the Position of the Fissures of Rolando and Sylvius.

of cases of brain disease can any operative interference be considered with favor.

Operations may be performed for the relief of epilepsy, for the cure of imbecility, for the removal of clots, for the opening of abscesses, for the excision of tumors, for the relief of intracranial pressure—with or without drainage of the lateral ventricles—and for the cure of traumatic insanity. In the following

chapters each of these conditions will be discussed, the pathology of the disease being especially considered, and the results of operations hitherto done being fully described.

*Cranio-Cerebral Topography.*

The fact that the brain may be exposed for the removal of diseased parts in appropriate cases has made

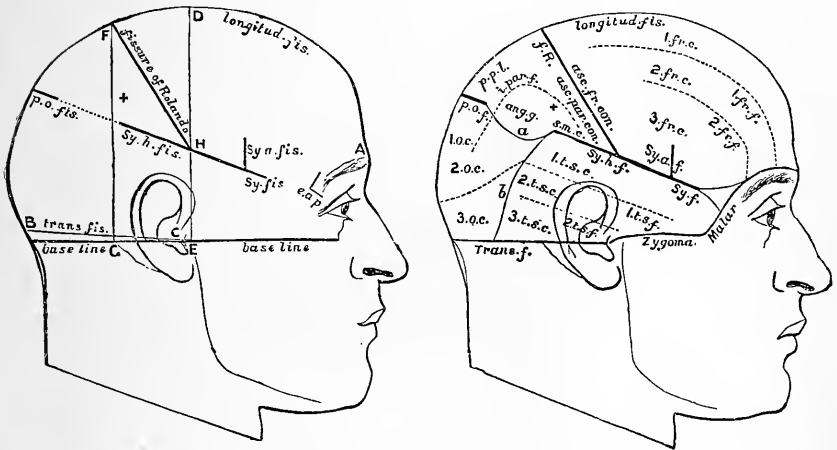


FIG. 9.—The Guiding Lines of Reid and the Relation of the Chief Convolution to them.

it necessary to ascertain the relation of its different fissures and convolutions to the cranial sutures, or to certain landmarks upon the surface of the head. These relations are well shown in the figure (Fig. 7), which is a photograph of a cast of a head made immediately after death by Dr. Cunningham, of Dublin.<sup>1</sup> Numer-

<sup>1</sup> See Dublin Journ. Med. Sc., 1888, p. 157. For an opportunity of photographing this cast I am indebted to Dr. F. Ferguson, Curator of the Museum of the New York Hospital.

ous rules have been laid down for the determination of the location of various parts of the convex surface of the hemisphere upon the head. The most important are the following, which may be compared with the diagram (Fig. 8), and with Reid's figures (Fig. 9).

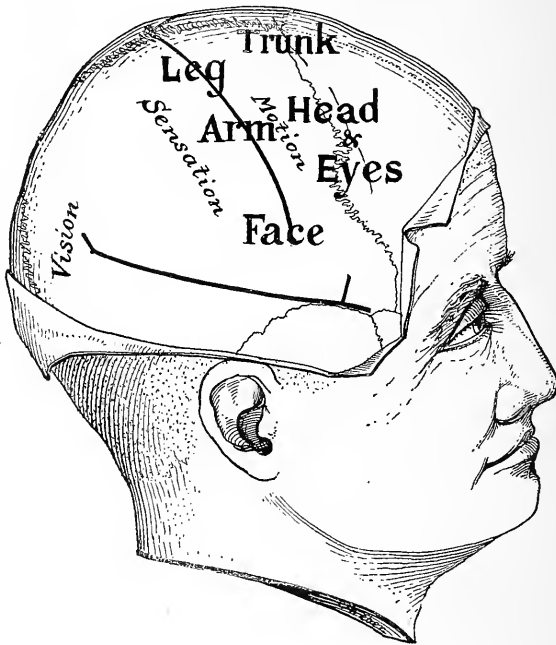


FIG. 10.—The lines indicating the fissures of Rolando and Sylvius laid down on the skull according to the rules given in the text and the relative situation of the functional areas of the cortex to these lines: the right hemisphere.

To find the fissure of Rolando, lay down a line from the root of the nose to the occipital protuberance over the top of the head, and take a point 0.557 of the distance back upon this line. This point will correspond to the upper end of the fissure. The fissure makes an angle of  $67^\circ$  with the median line just



measured. Hence if two strips of metal fixed to one another at this angle be placed on the head with their junction upon the upper end of the fissure, when one strip is on the median line the other strip, pointing forward and downward, must lie over the fissure of

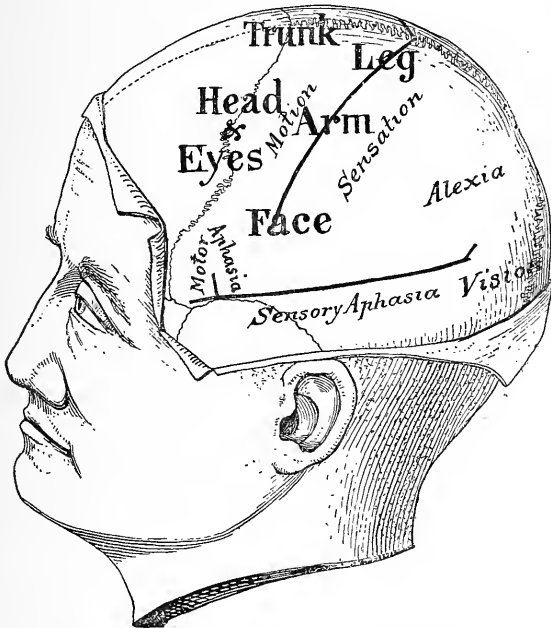


FIG. 11.—The lines indicating the fissures of Rolando and Sylvius laid down on the skull according to the rules given in the text and the relative situation of the functional areas of the cortex to these lines: the left hemisphere.

Rolando. In its lower third the fissure becomes a little more vertical than the strip. The fissure is about three and a half inches long.

To find the fissure of Sylvius, lay down a base line from the lower margin of the orbit to the auditory meatus. Lay down a second line parallel to the base line

from the external angular process of the frontal bone backward one inch and a quarter and then measure upward one quarter of an inch; this gives point one. Find the most prominent part of the parietal eminence and from it draw a line downward perpendicular to the base line, and on this take a point three-quarters of an inch below the eminence; this gives point two. Join these two points and the line will lie over the fissure of Sylvius. The anterior limb of the fissure will be two inches behind the external angular process. The fissure of Sylvius is about four inches long.

To find the parieto-occipital fissure, continue the line of the fissure of Sylvius to the median line. At their junction lies this fissure. Since all areas now open to surgical operation can be located with a definite relation to these three fissures, no further rules are necessary. Since in opening the skull it is customary to make a fenestra of at least an inch in diameter, and it is frequently necessary to enlarge the opening much more, a procedure in no way dangerous under aseptic conditions, there is no difficulty in recognizing the fissures and convolutions exposed if the rules are closely followed. Prior to the large incision of the scalp it is well to mark certain points upon the skull by the sharp point of a scalpel, so that when the bone is laid bare surface landmarks may still be kept in view.

## CHAPTER II.

### TREPHINING FOR EPILEPSY.

The Varieties of Epilepsy. Jacksonian Epilepsy. The Motor Form of Attack. The Sensory Form of Attack. The Aphasic Form of Attack. The Psychical Form of Attack. Traumatic Epilepsy. The Operation for Epilepsy. Records of Cases of Epilepsy operated upon, Personal and Selected. The Pathology of Jacksonian and Traumatic Epilepsy. The Results of Trephining for Epilepsy. Conclusion.

THE operation of opening the skull for the relief of epilepsy is supposed to be one of the oldest in the history of surgery. That its results were unfavorable is demonstrated by the fact that it fell into disuse and for several hundred years was entirely abandoned. It is within the past decade that it can be said to have become a rational operation, for it is only within that time that a definite guide to the surgeon has been offered by the facts of the localization of brain functions.

#### *The Varieties of Epilepsy.*

Hughlings Jackson was the first to point out a radical distinction to be observed between two classes of epileptic patients. In one class the convulsion begins suddenly with little or no warning but usually with a cry, and at once the patient loses consciousness and falls in a general convulsion which involves all the

muscles of the body simultaneously. This lasts several minutes and is followed by a deep sleep for some hours. This is ordinary idiopathic epilepsy, the origin of which is still unknown.

In the second class of cases the attack begins with a conscious sensation in some particular region of the body, either in one-half of the face or in one extremity. The sensation is followed by a twitching of the muscles of the part and the sensation and spasm advance gradually from the part originally affected to other parts in a definite order of progress; thus, from the right half of the face down the right side of the neck to the right arm and lastly to the right leg; or in the reverse order, from leg to arm and then to face; or from the arm upward to the face or downward to the leg. During such an attack consciousness is not usually lost, though it may be lost when the attack culminates in a general convulsion. Such an attack is very often followed by a feeling of great weakness in the part convulsed, which weakness gradually passes away. This form of attack is known as Jacksonian epilepsy.

#### *Jacksonian Epilepsy.*

As far back as 1864 Jackson maintained that this form of epilepsy was uniformly due to organic disease of some kind, situated in the convolutions adjacent to the fissure of Rolando. The discoveries of physiologists, made between 1872 and 1880, that electrical irritation of the corresponding convolutions in ani-

mals would produce spasms of a similar character, afforded startling confirmation of Jackson's statements. And the subsequent collections of carefully observed cases of disease in man accompanied by records of autopsies made by Charcot,<sup>1</sup> by Nothnagel,<sup>2</sup> by Wernicke,<sup>3</sup> by Ferrier,<sup>4</sup> by Roland,<sup>5</sup> and by myself<sup>6</sup> prove conclusively that disease of an organic character located in the motor region of the brain, of a character to produce irritation, will uniformly cause Jacksonian attacks. The character of these attacks, their mode of onset, and the order of their progress depend entirely upon the exact position of the initial irritation in this motor area. If the irritation is slight it may be limited to a small region, if more severe it extends to adjacent regions. This extension may be likened to the ripple on a pond when a stone is thrown into it. The ripple spreads from the centre to the very limits of the pond, but the little waves get lower as they get farther away from their point of starting. Irritation in the brain is likewise always more intense at the seat of excitation and grows less severe as the irritation reaches other centres at a distance. The order of progress of the spasm depends entirely upon the rela-

<sup>1</sup> Charcot et Pitres: "Localizations Cérébrales," *Rev. de Méd.*, 1879 and 1883.

<sup>2</sup> Nothnagel: "Topische Diagnostik der Gehirnkrankheiten," 1879.

<sup>3</sup> Wernicke: "Gehirnkrankheiten," 1881.

<sup>4</sup> Ferrier: "Localization of Brain Disease," 1878.

<sup>5</sup> Roland: "De l'Epilepsie Jacksonienne," Paris, 1887.

<sup>6</sup> Starr: "Cortical Lesions of the Brain," *Amer. Jour. Med. Sci.*, 1884, Jan., April, July.

tive situation of the motor centres to one another. Thus the fact that the motor centres for the arm lie between those of the face and leg determines the fact that a spasm beginning in the face always extends to the arm before it reaches the leg, or vice versa. It has already been stated that Jacksonian attacks usually begin with a sensation of tingling or numbness in the part convulsed. This tingling is thought to be evidence of an irritation of the centres of tactile sensation of the cortex, which coincide in situation with the motor centres. The paralysis which follows the attack and is evidence of exhaustion of the motor centres is often found to be associated with partial loss of sensation, which is evidence of a similar exhaustion of the sensory centres.

What is true of these tactile centres has been found to be true also of the sensory centres of sight, and hearing, and taste, and smell. Each of these centres may be irritated by disease, with the result of producing hallucinations, and then be exhausted, with the result of producing loss of the power of perception. It is thus possible to recognize what has been termed a sensory equivalent of a Jacksonian attack, and such a sensory equivalent or sensory epilepsy in any one sense is just as diagnostic of a localized disease in the brain as is a Jacksonian spasm. Sensory epilepsy beginning with a sound indicates irritation in the temporal region; sensory epilepsy beginning with light before the eyes or an hallucination of sight indicates irritation in the occipital region; sensory epilepsy be-

ginning with smells or taste indicates irritation in the temporo-sphenoidal region. These facts are so abundantly confirmed by clinical observation followed by autopsies that it is needless at present to cite cases in proof.<sup>1</sup>

Another form of attack requires mention. It is the aphasic form. It has been frequently observed that when a Jacksonian attack begins with spasm in the right side of the face it is usually associated with an immediate inability to speak. This continues until the attack is over, and even for several hours afterward. In a number of cases such an inability to speak coming on suddenly is the only symptom of the attack. This then may be termed an aphasic form of epilepsy. It is due to irritation followed by arrest of function in the motor speech area, which in right-handed persons is in the third frontal convolution of the left hemisphere of the brain, and in left-handed persons in the right hemisphere. There is probably a form of aphasic attack due to suspension of function of the sensory areas of speech, characterized by a sudden but temporary inability to understand language and to read. But such attacks have not to my knowledge been recorded.

The last form to be noticed is the psychical epileptic equivalent, a form of attack consisting of a temporary mental aberration either of the nature of maniacal excitement or of simple bewilderment followed by

<sup>1</sup> See Pitres: "Des épilepsies partielles sensitives," Arch. Clin. de Méd. de Bordeaux, 1892, Jan.

stupor and loss of memory of what has happened in the attack. This probably indicates an irritation followed by suspension of function in the frontal region, but any more definite statement is as yet unwarranted.

The facts just stated prove that Jacksonian attacks, either motor or sensory, or aphasic or psychical in nature, are to be regarded as symptoms of disease and are very different in their significance from attacks of ordinary epilepsy. Their character denotes the exact position of the disease in the brain, and hence such an attack may be regarded as a guide in the surgical treatment of epilepsy.

#### *Cases open to Trephining.*

It is evident, then, that the surgeon of the present day is no longer in the position of the surgeon in the past centuries, when asked to trephine in a case of epilepsy. For now it is possible to make a rational selection of cases, to choose those which are due to local disease, and to put one's finger on the diseased spot before the knife is used. It is these cases in which such a guide is afforded by our knowledge, which are open to surgical interference. The ordinary idiopathic epilepsy is as far removed from surgical treatment today as it was in the past.

It is difficult to make any general statement regarding the relative number of cases of epilepsy which are open to surgical treatment. I can only state that of 427 consecutive cases of epilepsy of which I have personal records, 26 were considered of organic origin and



suitable for operation because it was possible to locate the lesion with approximate certainty.

The disease in the brain which gives rise to Jacksonian epilepsy may be of various kinds. Any affection of the meninges, whether pachymeningitis or leptomeningitis, of traumatic or of syphilitic or of tubercular origin; or new growths upon or in the cortex of the brain; or cysts formed as the result of small circumscribed hemorrhages, or of spots of softening from embolism or thrombosis of a cerebral artery; or circumscribed encephalitis or sclerotic patches may act as centres of irritation in the cortex of the brain. The majority of these forms of disease when exactly localized in a small area appear to be traceable to traumatism, either to a blow or fall on the head, or to a fracture of the skull with or without depression. In the cases soon to be studied some of these pathological conditions will be described which have been found at the time of operation.

The discovery of the fact that such pathological results of traumatism will produce localized spasms when situated in the motor area of the brain has naturally led to the conclusion that similar products anywhere in the brain may give rise to epilepsy.

### *Traumatic Epilepsy.*

It is well known that many cases of ordinary epilepsy are traceable to injuries of the head and that many cases of fracture of the skull have been followed by the development of epilepsy. These cases have

been grouped together under the term "traumatic epilepsy," and it has been thought that the traumatism could be taken as the guiding indication to the surgeon for the operation of trephining. That wounds about the head are much more likely to produce epilepsy than wounds in the rest of the body is very well proven by statistics of the Franco-Prussian war. The records of that war show that among 8,985 individuals wounded on the head 46 developed epilepsy; that among 77,461 persons wounded in the body or extremities only 17 became epileptic. The records of our own war do not give any statements that bear upon this subject. There seems to be no doubt among surgeons that epilepsy develops subsequently to injuries of the head more often than after injuries of other parts. In these cases the same distinction already considered between general convulsions and localized motor, or sensory or aphasic attacks is frequently observed. If the character of the attack indicates disease in a definite area of the brain, and if the injury of the skull is so located as to coincide with this area, then the surgeon has a double indication to guide him in the operation. When, however, the injury and the localizing symptoms do not coincide, it is better to follow the localizing symptoms rather than the surgical injury. Thus in two cases operated upon by Dr. McBurney depressed fractures existed, epileptic attacks had developed subsequently to them, but the fit which began in both patients in the arm indicated disease in the middle third of the motor area, while the position of

the fracture was at least two inches away from this spot. In both cases trephining demonstrated the presence of splinters of bone cracked off from the inner table of the skull and embedded in the brain in the motor area for the arm, with the development of cysts at the same place. And the removal of the irritating focus of disease produced a cure. In these cases had the surgical indication—the depressed fracture—been followed the actual cause of the epilepsy would not have been found and removed. It is, therefore, far better when both medical and surgical indications exist, but do not coincide, to follow the medical indication.

In any case of localizable epilepsy when no removable lesion is discovered at the time of operation, it is the practice of some surgeons to determine accurately the area in the cortex irritation of which by a mild faradic current will cause a spasm similar to that occurring in the disease, and then to excise this area. The resulting paralysis due to excision of a small part of the motor area gradually passes away, and the result of the excision is in some cases to remove the centre of irritation, and thus to cure the attacks.

There is, finally, a class of cases following traumatism in which the epilepsy is of the general type and in which there are no localizing symptoms. When these are attended by depressed fracture, it is the practice of surgeons to trephine at the area of injury, that being the only guide obtainable. Lesions are sometimes discovered involving the meninges or brain,

and occasionally the fits are relieved by the operation. More often nothing is found at the place of trephining, and no result is obtained. In this class, where definite symptoms pointing to a focus of disease do not exist, the operation must be regarded as entirely exploratory.

### *The Danger of Trephining.*

The records of cases of epilepsy in which the operation of trephining has been undertaken are at present very numerous. The operation has been done over 300 times within the past five years, with very few deaths. Laurient (*Jour. de Méd., de Chirur. et de Pharmac.*, May 20th, 1891) collected 102 cases of trephining for epilepsy, with the result as follows: 54 cured; 20 improved; 17 not improved; 2 made worse; 7 died. Agnew (*Trans. Amer. Surg. Assoc.*, Sept., 1891) collected 57 additional cases with result as follows: 4 cured; 32 improved; 9 not improved; 4 unknown result; 4 died.

The cases collected here number 42, with result as follows: 13 cured; 11 improved; 15 not improved; 3 died. Of these cases thirteen are my own.

The statistics are chiefly of value in demonstrating the safety of the operation. The average mortality is 7%. It seems needless to relate very many cases in full. The essential features will be illustrated in the histories of cases which have been under my own observation. For the sake of presenting a sufficient number of cases to secure some credence for the statements made, I have appended an account of about 30

cases in which the reports are sufficiently exact and sufficiently reliable. These have been selected entirely from American reports. In some of these cases the fits were so exactly localized that a diagnosis could be made without difficulty. In others the existence of a depressed fracture or scar of the scalp was taken as a guide to the surgeon. The majority of the cases were traumatic in their origin.

*Cases of Epilepsy Trephined.*

CASE I. *Trauma—Spasms of right hand—Splinter of bone in motor area—Cyst of the Pia mater—Recovery.*

A. B., aged 18, was perfectly well until April, 1891, when he was struck by a heavy block of wood falling on his left parietal bone. His skull was fractured and he was taken to a hospital and treated there for several weeks, but not trephined. Three weeks later he began to suffer from peculiar attacks which had continued at frequent intervals until the day of operation, November 9th, 1892. His attacks are all of the same character. They begin with a tingling and numbness in his right hand which extend up the arm to the shoulder, down the trunk and down the leg; the tingling is never felt in the face. Soon after the tingling begins in the fingers a twitching motion is felt in the hand, and the clonic spasm extends up to the shoulder, involving the entire arm; it never extends to the leg or face. He does not lose consciousness during the attacks; the attacks last about a minute and subsequently he feels a little weak in the arm for a short time; he has no difficulty with his speech. Between the attacks there is neither paralysis nor anæsthesia; he does not suffer from headache; his eyesight is good.

Examination of the head showed the existence of a de-

pression about an inch long parallel to the longitudinal fissure and about an inch to the left of the median line anterior to the vertex. When the fissure of Rolando was laid down upon the head, this depression was found to lie over the first frontal convolution. A second scar was found below the first at a position over the hand area. It was determined to disregard the surgical indication, viz., the fracture, and to trephine over the hand centre of the

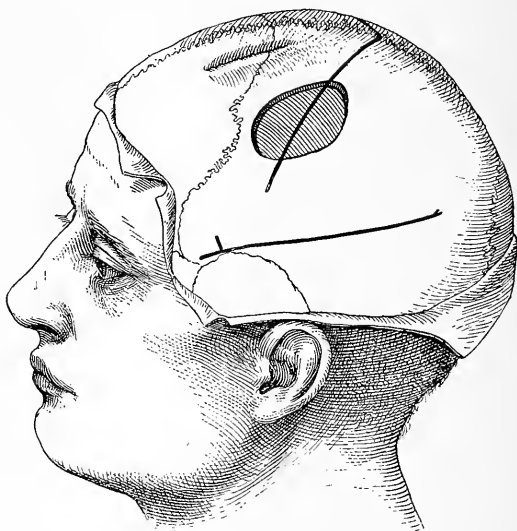


PLATE 12.—The Situation of the Opening made in the Skull in Case I. The position of the fracture is also shown.

cortex. This was done November 9th, 1892, by Dr. McBurney.

After the scalp was retracted the attempt to strip up the periosteum revealed the fact of its close adhesion to a fissure in the bone passing directly forward from the junction of the middle and lower thirds of the fissure of Rolando. It was evident that at this line there had been a fracture of the skull which could not be detected by palpation of the scalp. A trephine opening of one and one-

quarter inches in diameter was made at the point indicated in the figure over the hand centre (Fig. 12).

When the button was removed the dura was found to be closely adherent to it, and in the dura was found imbedded a splinter of bone one inch long and three-fourths of an inch wide. This lay partly outside of and partly inside of the dura, it having evidently been thrust through the dura at the time of the fracture. The dura about it was thickened to one-sixteenth of an inch. The splinter of bone was cut out and removed. A thickened connective-tissue strip which formed the external wall of a cyst was found adherent to its inner surface and removed with it. During the removal about a drachm of clear serous fluid escaped from the cyst, and a vessel of the pia was unavoidably torn in the removal of the cyst wall, giving rise to considerable hemorrhage. The appearance of the brain as seen through the opening in the dura was normal, though some œdema of pia over it was evident. The bone was not replaced. The wound was closed and healed by first intention within a week.

The situation of the splinter of bone was such as to have produced irritation in the hand area of the cortex.

The boy had two very slight attacks subsequently to the operation, but after that up to March, 1893, had none whatever and was apparently well.

CASE II. *Trauma—Spasms of right hand—Cyst removed—Recovery for six months. Recurrence—Second trephining—Recovery.*

Male, aged 14, at the age of 4 had a severe fall fracturing his skull over the left coronal suture. As a result of this he developed right hemiplegia with partial right hemianæsthesia, but without any aphasia. Traces of this hemiplegia still remain. At the age of 12½ he had a second fall, hit upon his head, and soon after this he began to suffer from Jacksonian epilepsy. His fits always began with a tingling and spasm in the right hand which extended to the arm and then down the right

leg, the face being very rarely involved, though occasionally the head turned to the right. There was no loss of consciousness during the attack. It lasted about a minute and he felt slightly weaker in the arm and leg after it. He has had as many as six attacks in a day. The boy was mentally very bright and had no headache.

Evidence of an old depressed fracture was found in the skull, the depression extending forward over the first

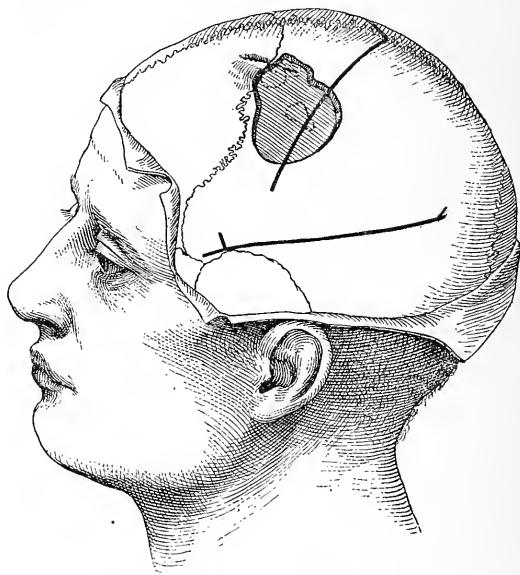


FIG. 13.—The Situation of the Opening made in the Skull in Case II.

frontal convolution so that its position was decidedly anterior to the motor area of the arm. Medical treatment having failed to relieve these attacks, it was resolved to trephine. The point selected was the arm centre in the middle third of the central convolutions, though its position was an inch and a half posterior to the position of the old fracture (Fig. 13). Dr. McBurney operated at Roosevelt Hospital, January 30th, 1892.

On exposing the dura it was found adherent to the bone



and did not pulsate. When the dura was dissected back it was found adherent to the pia, which was thickened and opaque so that the brain was not visible beneath it. On dividing the pia a cyst was found lying upon the surface of the brain and from this a drachm of clear fluid was evacuated. The cyst had lain in the pia itself. The walls of the cyst were removed. A strand of thickened pia was found running forward toward the old scar. The opening in the bone was, therefore, enlarged in the direction of the old fracture until this was reached and a second cyst was found beneath the old fracture. This cyst was also evacuated of about two drachms of fluid and its walls taken away. The brain beneath the cysts appeared to be somewhat atrophied but pulsated normally. It had an appearance of being slightly more yellow than normal brain tissue, and the number of blood-vessels and capillaries over its surface seemed to be rather increased. The wound was closed and healed well, and from January 30th, 1892, the date of operation, until April the boy had no fits at all. He then returned to my clinic, complaining of a return of his old attacks. On examination of the head it was found that there was a small collection of pus beneath the scalp over the site of the opening in the bone. This pus was evacuated and the small abscess cavity at once healed. From that date until August, 1892, the boy had no attacks. Then his attacks began again, and increased in frequency until in December he was having three or four daily. These attacks began with tingling and twitching in the right hand which extended up the arm and shoulder, then down the side to the leg, arm and leg twitching together for the space of five to fifteen minutes. Subsequently to the attacks both arm and leg were slightly paretic, the face never being involved, and consciousness not being lost. The use of bromides during this period had no effect upon the increase of the attacks; he was, therefore, again advised to go into the hospital for operation. On January 7th, 1893, Dr. McBurney operated. On

exposure of the shaven head the scalp was seen to be thick and tense so that at no place was there any perceptible depression around the old scar or over the defect in the bone. Pulsation of the brain was perceptible by palpation over the area from which the bone had previously been removed, and which corresponded to the arm centre. The tissues were very much thickened and it was thought best to avoid their direct incision. A semilunar incision was therefore made, the summit of which passed somewhat more to the left of the median line than the preceding incision, and by dissecting up its anterior and posterior portions the healthy bone below the old trephine opening was reached, the scalp being carefully dissected away from the old scar tissue. A triangular opening was then chiselled in the bone about one and one-half inches long and three-fourths of an inch wide. The bone was found to be closely adherent to the dura. The dura was seen to be thickened and on being divided and turned back it was closely adherent to the pia. The pia and brain were found to be welded together in a thick connective-tissue mass. Palpation of this gave the impression of fluid beneath it. Puncture with a hypodermic syringe brought away a small amount of clear serous fluid from a cavity about half an inch beneath the cortex. Incision was made into this cavity through the brain above it. When the brain tissue was incised it was found to present an abnormal appearance. There was no clear line of demarcation between the cortex and the white matter beneath it, but a connective-tissue mass had taken the place of the cortex. This mass of tissue was therefore excised, a piece of a lens shape about an inch long by half an inch wide being removed. It appeared to be scar tissue.<sup>1</sup> The second puncture with a hypodermic needle at a point an inch further forward revealed the presence of another cyst, and the incision in the brain was, therefore, carried forward so as to

<sup>1</sup>The microscopical appearances of this tissue are described by Dr. Van Gieson on page 102.

empty this. Hemorrhage was pretty free, but after the scar tissue had been excised the sides of the wound in the brain were seen to consist of fairly normal gray and white substance. The wound was packed with iodoform gauze and dressed antiseptically. The next day the boy was very comfortable, had no paralysis or anæsthesia. Within two weeks the wound had healed. He has had two attacks up to March, 1893.

CASE III. *Trauma—General convulsions beginning in left arm—Splinter of bone in the brain removed—Brain sclerotic—Recovery.—Recurrence of fits.*

A. G., male, aged 24, met with an injury in April, 1888, which produced a fracture of the skull on the right side about at the middle of the coronal suture. After the injury he was ill with fever and delirium about six weeks, but gradually recovered. Three years after this injury he began to have convulsions, from which he had suffered at intervals up to April, 1892, when he was first seen. The attacks began with a movement of the left arm and sensation of numbness in the left hand and with a turning of the head to the left; he then lost consciousness and the convulsion became general. He has had as many as two fits in a day, and the longest interval during the year was nine weeks. He had three fits in March, 1892. He was very dull mentally, and had been treated by very large doses of bromide of potassium, which diminished the frequency of but did not arrest the fits.

Operation by trephining was performed by Dr. McBurney on the 2d of April, 1892. The skull was opened at the point of fracture over the arm centre on the right side (Fig. 14). The external table was found to be fractured but the internal table appeared to be uninjured, but a small splinter of bone was found indenting the dura. The dura was very much thickened and the pia and brain were decidedly œdematous and yellower than normal. The pulsation in the brain was greater around the discolored area than in it. The discolored area pitted

upon pressure and to the touch gave the impression as if a cyst lay beneath, but puncture in all directions with a hypodermic needle failed to reach any cyst. A portion of the softened area was cut out. It was exam-

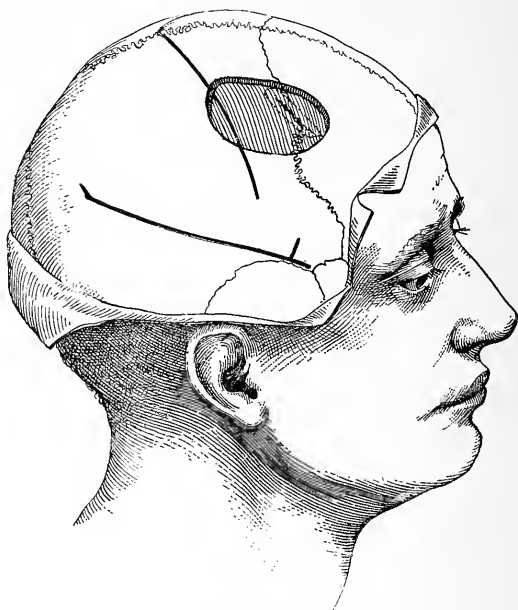


FIG. 14.—The Situation of the Opening made in the Skull in Case III.

ined by Dr. Van Gieson, who reported as follows: "I find that a splinter of bone has been driven down into the dura; the dura is thickened at this place and matted together with the pia. Dura is also sharply indented where the splinter is impacted. I think that the splinter has been much reduced in size by rarefying osteitis (only a few interlacing delicate trabeculæ remain of the bone). The splinter was probably originally much larger. Brain substance is much changed, there are too many glia cells. The cortex seems to have come from the motor region: this I gather from the presence of the very large

ganglion cells in the third layer.”<sup>1</sup> The wound healed easily. He had no paralysis and in three weeks he was discharged from the hospital. At that time he had improved very much mentally, and had had no fits. Soon after leaving the hospital the fits began again, and in the summer they occurred with greater frequency than before the operation, and at the present time they are as severe as ever.

CASE IV. *Trauma—Spasm of right leg—Trephining—Death.*

A. D., male, aged 30, had been perfectly well until a fall which occurred in 1888. He hit upon his head

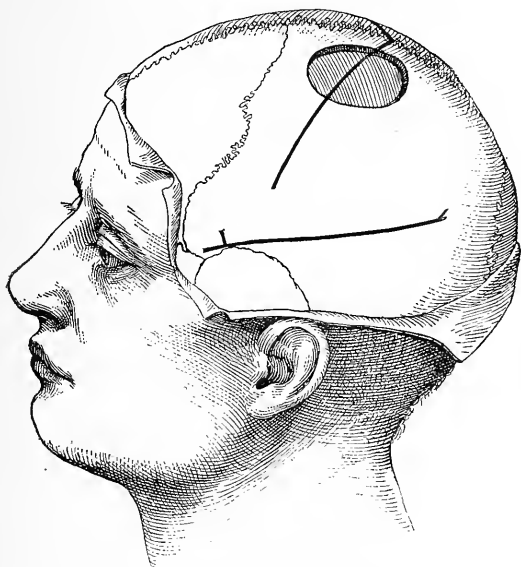


FIG. 15.—The Situation of the Opening made in the Skull in Case IV.

on the left side, near the vertex, but had no scar remaining as evidence of the fall. Since the fall he had begun to have attacks which consisted of a spasm begin-

<sup>1</sup>The microscopical appearances of this tissue are more fully described on page 83.

ning in the right leg, with a stamping motion of the foot, after which he would rise from the chair, if seated, and turn to the right, or would turn to the right if the fit came on when he was standing. After turning he lost consciousness, and fell in a general fit. These fits had become frequent during the past two years, so that he was having as many as six a day when he was first seen by me at Dr. Weir's request.

On the 17th of January, 1890, Dr. Weir trephined at the New York Hospital. The opening (Fig. 15) was made over the upper third of the motor region, exposing the area corresponding to the leg centre. The skull was found to be unusually thick, but no evidence of fracture was discovered. Small white specks resembling miliary tubercles were found scattered over the pia and over the motor area of the leg on the median surface of the brain. The dura was not thick nor adherent. The thickness of the skull made the operation a long one, and the hemorrhage was considerable, and the patient died of shock.

CASE V. *Traumatic Epilepsy—Hemiplegia with athetosis—Subcortical cyst emptied—Recovery.*

H. L. J., aged 12, was well until the age of 2, when he had a fall upon his head followed by convulsions lasting eleven hours. On recovering from convulsions he was found to be hemiplegic on the right side and aphasic; he recovered slowly during the following year, but has never been entirely relieved from the condition of right-sided paralysis, and has always been slow in his speech and mentally dull. For several years subsequently to the fall he was subject to slight attacks of the nature of petit mal; two years ago he had his first attack of grand mal, and since that time has had several recurrences. The fits begin by twitching of the eyes and head, the right side being always more affected than the left side in the convulsion; and he loses consciousness.

He was examined by me on the 22d of November, 1892. A condition of right hemiparesis with athetosis of the

right hand was found, the paralysis being greater in the hand than in the face or leg. Mentally he was very deficient, being able to read but little and being very dull and stupid; his speech was slow but he was not aphasic; there was no affection of sensation in the paralyzed limbs.

The diagnosis was made of a traumatic hemorrhage or a cyst in the cortex of the brain in the motor zone affecting especially the arm area. Trephining was recom-

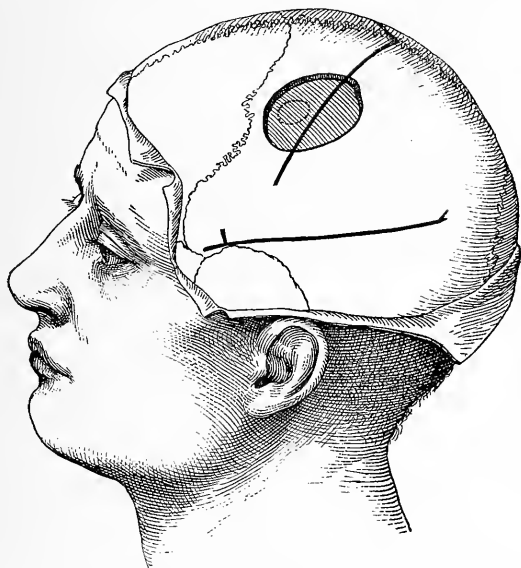


FIG. 16.—The Situation of the Opening made in the Skull in Case V.

mended with a view of removing the clot or the cyst which was considered the cause of the symptoms.

On December 2d, 1892, he was trephined by Dr. McBurney at Roosevelt Hospital, an opening of one and one-half inches in diameter being made over the arm area (Fig. 16). The bone and the dura appeared to be normal. On exposing the brain the fissure of Rolando was seen crossing the opening; the cortex appeared to be normal, but palpation indicated a collection of fluid beneath, and puncture with

a hypodermic needle resulted in the evacuation of about a drachm of clear serous fluid from a cavity three-fourths of an inch below the cortex. Incision through the summit of the anterior central convolution gave entrance to this cavity, and an attempt to drain it was made by inserting a small bit of rubber tissue. The dura was replaced but not stitched and the scalp was left open over the part of brain exposed. The day after the operation the boy was found to be in about the same condition so far as power went, but the right hand as high as the wrist was decidedly anæsthetic to touch, temperature, and pain, but there was no affection of the muscular sense. The athetosis had ceased. One week after the operation this condition of anæsthesia was much less but still remained. It did not affect his face, or his leg, or his body, or his arm, above the wrist. He seemed bright, had no temperature, but had had two attacks of petit mal. The wound healed readily and he went home at Christmas and has had no attacks up to March, 1893. He is said to be much brighter mentally and the athetosis has not returned.

CASE VI. *Trauma — Spasm in face — Temporary aphasia—Trephining—Scar in brain—Recovery—Recurrence of attacks.*

J. R., aged 40, was struck upon the left temple and sustained a fracture of the skull in August, 1889. When he recovered consciousness he was found to be paralyzed upon the right side and aphasic. In the course of the following six months the hemiplegia gradually subsided and the speech gradually improved so that he was able to go about but was still unfit for work. About a year after the accident he began to have convulsions; some of these were general with loss of consciousness, but later they became localized and have remained so for the past two years. They have gradually increased in frequency until, when seen in December, 1892, he was having several attacks every week. The attacks began



with a twitching of the muscles about the mouth upon the right side; a drawing of all of these muscles toward the right with a twitching of the eyes, a gradual extension of the spasm to the right side of the neck and to the right arm and hand. During the attack he did not lose consciousness but he could not speak, and had a sensation of tingling in the face and mouth. After an attack he appeared to be weak and was not able to talk as well as before the attack.

Examination on December 10th, 1892, demonstrated a slight paresis of the right side of the face, the tongue not deviating, and some weakness in the right arm, but no affection of the leg; no disturbance of sensation; increased reflexes upon the right side. His mental processes seemed to be slow; he understood perfectly what was said to him, but his replies were slow and his use of language evidently imperfect; he admitted that he could not express himself as he formerly did. He did not suffer from headache, but there was tenderness over the left temporal region. A depressed fracture of the skull running backward two inches about over the position of the Sylvian fissure was evident upon palpation. The posterior limit of the fracture was an inch below the location of the motor area of the face.

It was thought that beneath the fracture and about it some thickening of the meninges had occurred with the possible formation of a cyst, as the remains of an old hemorrhage, and that by an operation some relief could be had. On December 19th, 1892, Dr. Briddon trephined at the Presbyterian Hospital. A small trephine opening was made over the motor centre of the face and a larger one an inch below over Broca's convolution. The intervening bridge of bone was removed and the opening enlarged in all directions by the rongeur, the size of the opening being two and one-half by two inches (Fig. 17). On removal of the bone a perceptible thickening of the dura, especially over the face centre, was seen. When

the dura was divided it was found to be three times its ordinary thickness and closely adherent to the pia. It was stripped off carefully. The pia was found adherent to the brain and very œdematous. The brain substance at the

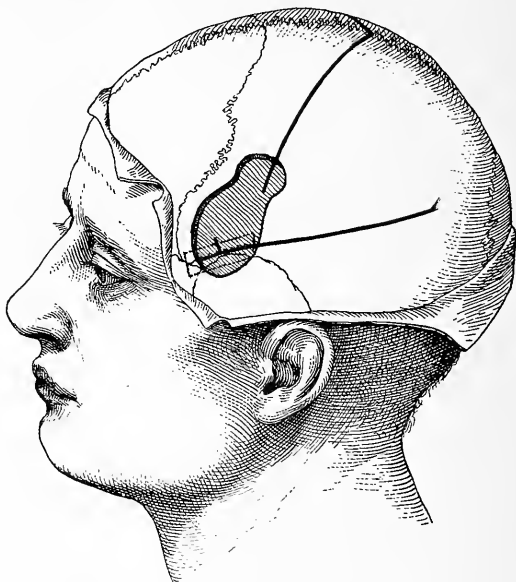


FIG. 17.—The Situation of the Opening made in the Skull in Case VI.

lower part of the anterior central convolution was apparently replaced by a connective-tissue mass. Where the dura was most thickened and its adhesion to the pia and the brain closest the brain exposed in the lower half of the opening appeared softer, darker, and abnormal. A hemorrhage had probably taken place, and as the result there remained a mass of scar tissue, chiefly connective tissue, beneath the pia mater. When the pia was divided it was found to be about a line in thickness. The gray matter of the brain had been reduced in its thickness so that the incision into the pia showed at once the white matter lying beneath it. This condition extended forward beneath the seat of the fracture, occupying a space about half an inch wide by an

inch long just above the fissure of Sylvius. The adhesion between the dura and the pia was broken up by the handle of the scalpel, but it was not thought best on account of hemorrhage to attempt the removal of the altered pia and brain. The wound was immediately closed and healed well by primary union within ten days.

The patient had two very slight attacks during the following two months and complained of some stiffness in the motion of his jaw. The pathological condition found precluded any hope of cure.

CASE VII. *Traumatic epilepsy—Trephining—No result.*

Male, aged 23, had a fall five years ago, hit upon the vertex to the right of the median line and somewhat

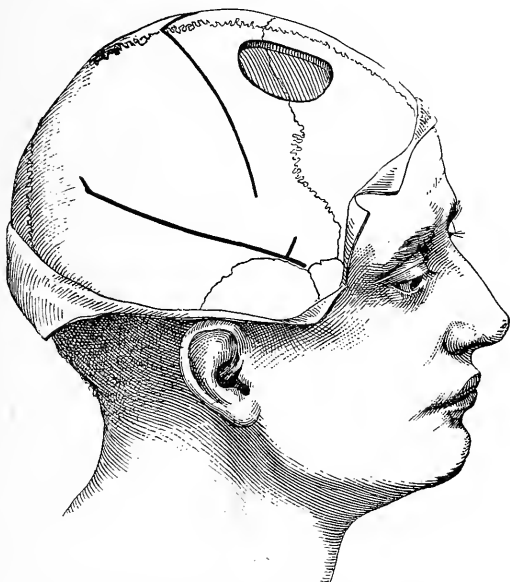

FIG. 18.—The Situation of the Opening made in the Skull in Case VII.

anterior to the fissure of Rolando. He soon developed general epileptic convulsions which began with a visual

aura, consisting of a green light before his eyes. The attack was of the nature of a general convulsion, with a total loss of consciousness; there was no localized movement. In addition to the general convulsion he had occasional attacks of petit mal. Physical examination failed to show any disturbance of sensation or of motion. He was trephined by Dr. McBurney, June 10th, 1892, over the seat of the fracture. The depression was found in the external table, not extending to the internal table (Fig. 18). The dura and pia were found to be normal, and the brain presented a normal appearance. The patient recovered from the operation, was out of the hospital in two weeks. At his last visit, October, 1892, he was still having his fits, having had five in the past four months.

CASE VIII. *Traumatic epilepsy—Spasm in right hand—Trephining—Improvement—Relapse—Death.*

P. B. C., male, aged 30, was hit in April, 1890, over the left side of the head by a sand-bag and was taken to the Roosevelt Hospital, where he lay for twelve days in a state of unconsciousness. There was no fracture of the skull. He gradually recovered and was able to return to his home in the South in July, and on July 23d had two fits. Each fit began with tingling and movement in the right hand, extending to the face, which was drawn to the right, and the mouth was opened and closed, then the speech was lost. In five minutes the attack had passed off and he felt pretty well. Such attacks were repeated in August, September, and October; all of the attacks being of the same character, excepting that on two occasions he lost consciousness for a few minutes. Examination in October, 1890, failed to reveal any deformity of the skull or any evidence of hemiplegia. He was rather slow and deliberate in his speech, with some slight hesitation for words, but this he maintained was his usual manner. His discs were clear, and his pupils equal. He was put upon bromide and belladonna, which he continued until March, 1891, during which time he had no attacks.

Between March and June, he averaged one severe attack and three slight attacks every month, all of which were similar to the attack first described. After each attack he noticed a decided difficulty in his speech, and the slowness of speech previously noticed still persisted. While there was no apparent clumsiness or anæsthesia in his right side, the power in his right hand was 100 as compared with 110 in his left. His personal equation was about

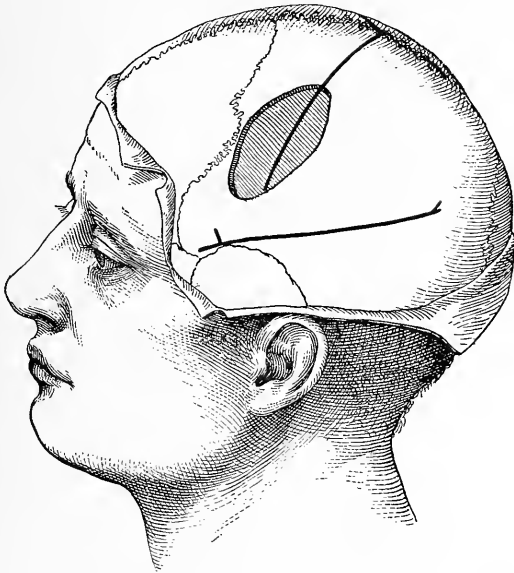

FIG. 19.—The Situation of the Opening made in the Skull in Case VIII.

normal, hearing being  $\frac{1}{100}$  of a second, sight  $\frac{1}{100}$  of a second, an average of seven tests being taken.

It being thought that the injury had probably produced a small hemorrhage upon the surface, the remnants of which might be removed, it was decided to trephine him. The operation was performed in June, 1891, by Dr. McBurney, an opening being made over the arm centre, and extending downward toward the face and motor

speech centres (Fig. 19). No evidence of fracture was found in the skull, and the dura was not adherent, and the brain appeared to be normal. The wound healed perfectly, and by December the hole in the skull had become filled up by a tense membrane, so it could not be depressed to any extent by the finger. He had two attacks between June and December. These attacks were of the same character as those occurring before the operation. He still talked slowly. During 1892, his attacks became more frequent, he developed severe headaches and optic neuritis, and he finally died in November, 1892. He was not under my observation after December, 1891. It is probable that there was present in this case a small subcortical tumor at the time of the operation, which escaped detection and afterward grew until it finally caused his death.

CASE IX. *Trauma—Spasms in left hand—Cyst evacuated—Recurrence of fits.*

A child, aged 3, had had a fall, hitting upon the right side of the head, and three months subsequently had developed spasms in the left arm which occurred at first occasionally, and later sometimes as frequently as seven a day. The arm was slightly weak. An apparent defect in the bone was felt in the right mid-parietal region. It was decided to make an exploratory operation. This was done by Dr. Poore in October, 1889, at St. Mary's Hospital. On exposing the bone a triangular defect was found in it with a thick connective-tissue membrane filling it (Fig. 20). Beneath this membrane was a cyst which was evacuated. The bone was not trephined on account of evidence of shock following the evacuation of the cyst; the operation was terminated. The child recovered from it, was free from her spasms for a year; recovered in the mean time the power in the arm. At the end of that time, however, the attacks began again. The probability is that this cyst has refilled with fluid and a second operation is contemplated.

CASE X. *Trauma—Depressed fracture—Spasm beginning with turning of the head—Trephining—Recovery—Recurrence of fits.*

T. M., male, aged 21, had a fall at the age of 7, producing an extensive fracture of the left parietal and frontal bones, which was immediately followed by right hemiplegia and motor aphasia, lasting a year and passing off. At the age of 14 he began to have

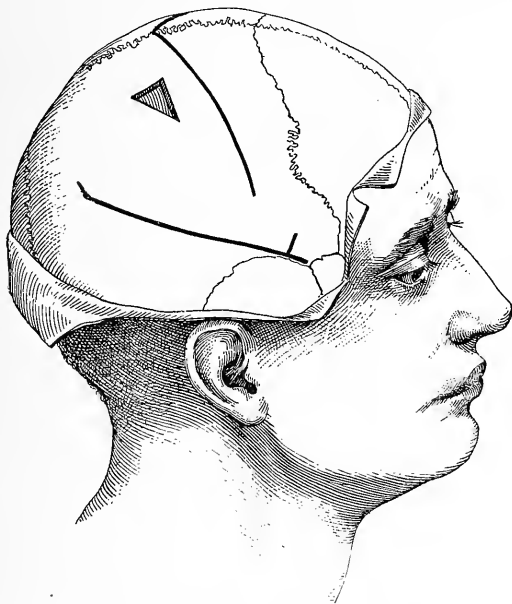

FIG. 20.—The Situation of the Defect in the Skull in Case IX.

general convulsions, which always began with a turning of the head to the right and were followed by a loss of consciousness. For the past seven years he has had such fits at intervals, having had as many as five in one day, but under bromide the rate has been about one in three weeks. He has not developed mentally in a proper way. He has little self-control, is irritable, quarrelsome, and ugly. He has fair intelligence, being able

to read and write, but is not fit to do any but simple work.

Examination October 14th, 1892, showed a trace of the old hemiplegia, the right side being smaller and somewhat weaker than the left. His speech was fair but he talked with some hesitancy. A depressed fracture of the frontal and parietal bones was found over the junction of the third frontal and anterior central region on the left side.

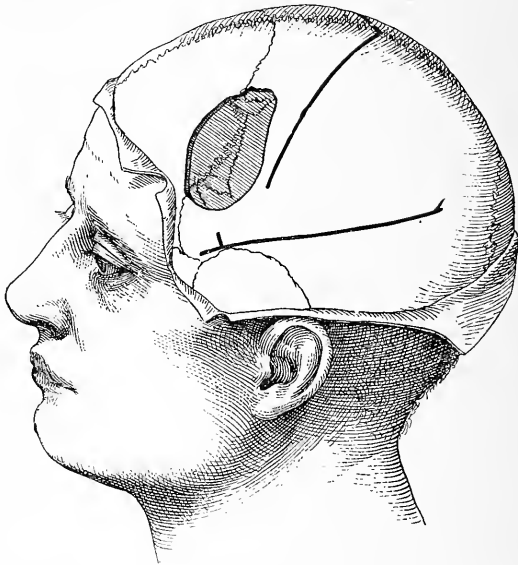


FIG. 21.—The Situation of the Opening made in the Skull in Case X.

On October 18th, 1892, he was trephined by Dr. Hartley, at Roosevelt Hospital. On laying back the scalp two deep depressions in the skull were found with a long angular depression between them (Fig. 21). This lay in front of the fissure of Rolando, about opposite to its lower third. The skull was very much thickened at the site of the old fracture. The bone was cut away over an area about two and one-half inches square. It had evidently made considerable pressure upon the tissue beneath. The



bone was adherent to the dura, and when the dura was divided and reflected it was found to be adherent to the pia. The pia was thickened and clouded and formed a cover of thin white connective tissue upon the brain. The cortex beneath the pia looked abnormal. It was rough on the surface, appeared redder than the adjacent cortex, the pia was closely adherent to it and contained an unusual number of capillary vessels. The appearance suggested an increase in the connective-tissue elements of the cortex with a high degree of vascularization. The brain pulsed normally. Puncture through this abnormal tissue failed to reveal any cyst beneath it. The wound was closed and healed readily, the man being up within a week of the time of operation. He had one fit on December 28th, 1892, and none since up to March 1893, though he had five the week before the operation. His mental condition is certainly much better than before the operation.

CASE XI. *Trauma—Spasm in the right arm—Trepthing—Recovery—Return of attacks.*

E. W., male, aged 11, was perfectly well until January, 1890, when he fell, striking upon the left parietal region of the skull, cutting the scalp but not fracturing the bone. This area was tender some weeks subsequently to the fall, and he has had pain in it at times ever since. Soon after the fall he began to have attacks, which became frequent, which always occurred at night, and which were always alike. The attacks began with a closing of the fingers and thumb of the right hand and a twitching of the same. The arm was then flexed and trembled, and the hand was brought to the face by a movement at the shoulder; the face upon the right side then began to twitch, and the head turned slightly toward the right. At this point he wakened from his sleep, perceived a sensation as if his mouth were full on the right side, felt a slight numbness in his cheek, but at the moment of waking the spasm ceased. The spasm never extended to the leg or to the muscles of the other side of the body. The attacks never

occurred when he was awake or in the day-time, but as many as six have occurred in one night.

Examination on February 10th, 1892, failed to reveal any evidence whatever of disturbance of sensation or motion. His mental condition was perfect, his eyes were normal, and he had no symptoms to complain of.

The condition was, therefore, one of pure Jacksonian epilepsy in the right hand developing subsequently to a

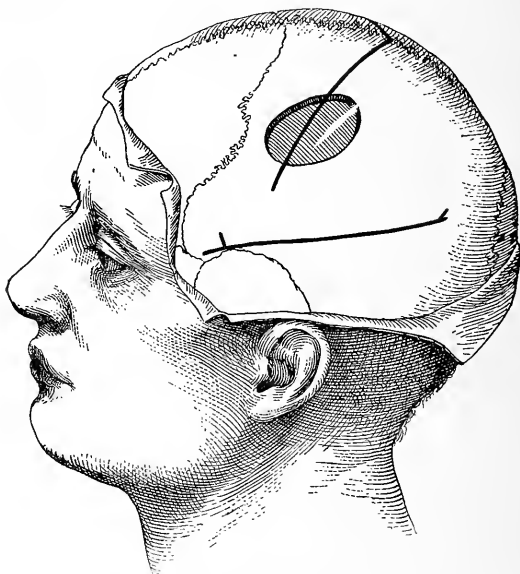


FIG. 22.—The Situation of the Opening made in the Skull in Case XI.

blow upon the head, but without any permanent defect of power or sensation.

The patient was trephined by Dr. McBurney, on February 25th, 1892, at St. Luke's Hospital. The opening was two by one and one-half inches over the middle third of the fissure of Rolando, and exposing the adjacent central convolutions (Fig. 22). The bone was found to be normal, the dura was adherent to the bone, and a small, whitish plaque of connective tissue was found on the

dura. The dura was not adherent to the pia, and the brain appeared to be perfectly normal; no cyst and no remnants of a clot were found. The wound was closed and within two weeks the boy was as well as before the operation.

During the month of March he had six slight attacks, the face only being affected. During April he had one attack; during June he had two attacks; since June he has had no attacks of the former character.

During August and between August and October he developed a new kind of attack at night which at first appeared to be of the nature of somnambulism. These were at first occasional, but by October had become as frequent as three or four in a night. They could be brought on by disturbing him in his sleep, either by noise in the room or by shaking him. The attacks consisted of the following motions: he closed his eyes tightly for a moment, then opened them and looked around, but evidently saw nothing consciously, as he did not recognize any one present or reply to a question addressed to him. His lips then twitched slightly, as if an attempt were being made to whistle, and the mouth then opened slowly and was held wide open for a few seconds; he then apparently tried to rise up in bed, and sometimes succeeded in getting up upon his knees. There was no convulsive movement of the limbs whatever. Usually after a few seconds he lay down again, took a long breath, followed by two or three short breaths, and then the attack was over. Occasionally he woke up, and if so he always knew that something had occurred, but was unable to give any account of what the sensation was which enabled him to distinguish such a waking from that from ordinary sleep. He was perfectly well in the day-time, and is a very bright and active boy. I witnessed two of these attacks.

The boy's father was for many years a sleep-walker, and the boy is known to have walked in his sleep. He is a restless sleeper, and frequently talks in his sleep. For

this reason these attacks were thought to be of a somnambulistic nature. But during November they become more severe and a decided convulsive movement of the arms and legs developed. The limbs were all rigidly extended and trembled violently, the right hand was flexed, the left hand extended, and after the attack he drooled at the mouth and breathed stertorously for a minute or two.

Treatment by gradually increasing doses of tincture of belladonna, from five drops every night up to thirty-five drops every night, had little or no influence upon the attacks. On December 20th, 1892, he was put upon bromides which immediately reduced their number and severity, and he is upon bromides at the present time, March 1893, and is entirely free from attacks.

CASE XII. *Traumatic epilepsy—Trephining—No result.*

Male, aged 50, had had a fall several years before the time when he was first seen, March, 1892. Subsequently to the fall he had developed fits, beginning in the right hand. He had been trephined in 1891, in Burlington, Vt. The hand centre had been exposed, but nothing had been found and the fits had continued. On examination an old fracture of the skull was found in the frontal bone anterior to the motor region of the brain. As he was anxious to be operated upon, trephining was done by Dr. McBurney at the seat of this fracture. The fracture was found to involve the external table only, the internal table not being affected (Fig. 23). The dura appeared to be normal, as did also the pia and brain. The wound healed readily and he was discharged from the hospital in two weeks. At the date of last report, October, 1892, his fits continued as before.

CASE XIII. *Trauma—Epilepsy.—No result.*

J. F., aged 32, had a severe fall when a boy about nine years of age, leaving a scar over the left parietal bone. When 23 years of age he began to have epileptic attacks,

consisting of general convulsions with epigastric aura. He had had since that time as many as five fits a day, and was having two or three every week when first seen by me, March 1st, 1890. The attacks did not begin uniformly, in any one set of muscles, but were general. In addition to the convulsions he had attacks of petit mal, daily. His attacks were so frequent as to unfit him absolutely for work of any kind, but had not apparently

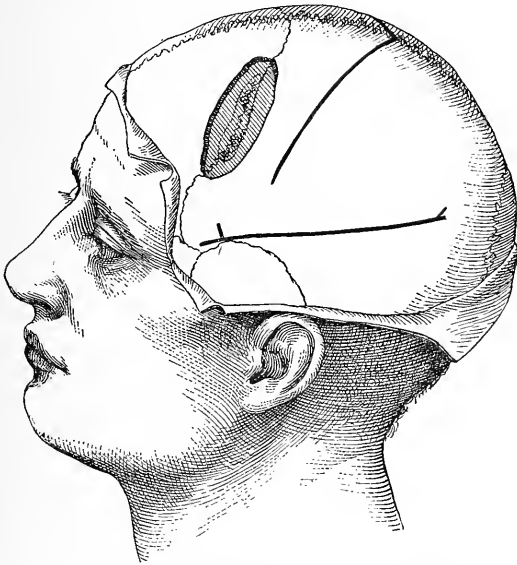


FIG. 23.—The Situation of the Opening made in the Skull in Case XII.

affected his intellect to any extent. Examination showed no evidence whatever of disturbance of sensation or of motion. Bromides had failed to control the attacks, though reducing their frequency somewhat. He was trephined on the 8th of March, 1890, at the Roosevelt Hospital, by Dr. McBurney. The old scar was exposed, the fracture in the external table was found (Fig. 24). A section of bone two by three inches in diameter was

removed. There was no fracture of the internal table. There was no affection of the dura and pia and the brain appeared to be normal.

He recovered from the operation and was able to leave the hospital in two weeks. On April 1st his attacks re-

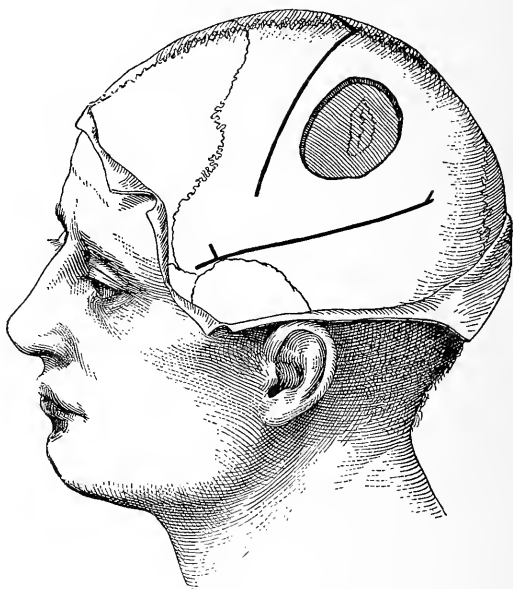


FIG. 24.—The Situation of the Opening made in the Skull in Case XIII.

turned, and have been as frequent up to October, 1892, as they were before the operation.

The result of these cases may be summarized as follows; cured 3; improved 5; not improved 4; died 1.

To these cases of my own I append short summaries of a number of cases of epilepsy which have been operated upon within the past few years in this country.

(1) D. B. L., m., 25, Keen, *Amer. Jour. Med. Sci.*, October, 1888.

*History.*—Fall on right side of head, November, 1886, unconscious for several hours. Some days after found left fingers anæsthetic. Six months after had sudden attack of vertigo followed by temporary paralysis of left hand. These attacks continued during following year. Depressed fracture found over middle third right motor area.

*Date of operation.*—April 18th, 1888.

*Character of operation.*—Trepined over depressed fracture. Adhesion of membranes. Spicula of bone projecting into brain. Cyst found under the fracture. Brain about it altered in color and thickened, was excised. Microscopic examination showed a chronic meningo-encephalitis of the excised brain.

*Result.*—Temporary paralysis of hand. No return of the fits up to four months after operation.

(2) I. G. W., m., 35, Lloyd and Deaver, *Amer. Jour. Med. Sci.*, November, 1888.

*History.*—Struck on head at age of 16. From age of 21 to 35 had fits beginning with numbness and spasm in left hand and arm extending to left side of face. These became frequent and were followed by paresis of left hand and face. Consciousness not often lost in attack.

*Date of operation.*—June 12th, 1888.

*Character of operation.*—Trepined over junction of middle and lower thirds of motor area. Brain normal. Hand centre located by faradism and excised.

*Result.*—Convulsions continued at first, but after three weeks ceased and had not returned at end of three months. Paralysis and anæsthesia in left hand permanent.

(3) P. H., m., 39, Frank and Church, *Amer. Jour. Med. Sci.*, July, 1890.

*History.*—For a year had attacks beginning with pain and spasm in right index finger, involving rest of hand, wrist and arm, then loss of consciousness and general con-

vulsion. Pain in right hand and increasing paralysis with contracture. Right leg slightly weak. Some aphasia.

*Date of operation.*—May 21st, 1889.

*Character of operation.*—Trephined over left motor area middle and lower third. Thick cicatricial mass found on cortex and removed. Brain excised one and one-half inches in diameter, one-fourth of an inch thick. Mass found to be sarcoma.

*Result.*—Some improvement, followed by return of fits in three months, at much longer intervals than before the operation. Paralysis much improved.

(4) C. T., f., 39, Keen, *Amer. Jour. Med. Sci.*, September, 1891.

*History.*—Fall, on left side of head. Two convulsions in 11 years. Then frequent attacks from age of 13 to 31. Fits began by flexion of right hand followed by spasm of arm and then general convulsion. No paralysis. Depressed fracture on left side over arm centre and defect in bone.

*Date of operation.*—October 29th, 1890.

*Character of operation.*—Bone and membranes taken away about the depression. Projecting pieces of bone removed. Brain beneath disorganized and depressed. Hand centre located by faradism and excised.

*Result.*—Paralysis of the hand with anæsthesia gradually passing off. No attacks at end of eight months.

(5) G. H., m., 23, Keen, *Amer. Jour. Med. Sci.*, September, 1891.

*History.*—Fracture of skull. Fits two years later from age of 9 to 32. General convulsions. Marked depressed fracture.

*Date of operation.*—November 21st, 1890.

*Character of operation.*—Depressed fracture over lower parietal convolutions on right side found. Bone deficient. Dura absent. Brain adherent to scalp tissue. When this adhesion was divided the brain surface sank away from the skull one-third inch. No effect of faradism on brain.



*Result.*—Recovered. Two attacks after operation within two weeks. Since then none. Report six months after operation.

(6) S. W., f., 27, Mills and Keen, *Amer. Jour. Med. Sci.*, December, 1891.

*History.*—For ten years had attacks of numbness and spasms beginning in the left arm and leg and frequently limited to them, but occasionally becoming general, usually without loss of consciousness. No permanent paralysis.

*Date of operation.*—December 10th, 1890.

*Character of operation.*—Trepined over right motor area. Bone thick. Membranes adherent. Small sarcoma found and removed. Also a small portion of cortex which was found to be normal on microscopic examination.

*Result.*—Paralysis, which passed off in a few weeks. Attacks continued as before for six months up to report.

(7) G. G., m., 8, Morrison, *Trans. Phil. Co. Med. Soc.*, May 25th, 1892.

*History.*—No traumatism. Convulsions from age of 2 to 8, at first slight, later severe, beginning with face and head turning to right.

*Date of operation.*—August 29th, 1891.

*Character of Operation.*—Trepined over junction of temporal ridge and coronal suture. Dura and brain normal.

*Result.*—Recovery. Fits recurred three weeks after operation and continued.

(8) A. C., f., 11, Diller, *Pitts. Med. Rev.*, November, 1892.

*History.*—Fall at six months; convulsions and left hemiplegia. From age of 4 to 11 convulsions beginning in left arm, then face, then leg with unconsciousness. Left hemiplegia worse in arm. Sensation diminished in left arm.

*Date of operation.*—January 9th, 1891.

*Character of operation.*—Trepined over motor area of arm, on right side. Fissure in bone; cyst found under cortex contained three ounces clear fluid. Drained.

*Result.*—Recovery. Accumulation of fluid in the cyst when drain was removed. It was replaced and cyst drained for forty days when fluid became purulent. She died on forty-third day.

(9) A. N., f., 31, A. B. Shaw, *Amer. Jour. Med. Sci.*, December, 1892.

*History.*—General convulsions occurring spontaneously, alternating with local spasms and always preceded by numbness in right hand and arm. The spasm often extended from arm to leg. Pain and paræsthesiæ continuous in right arm and increasing paralysis in arm and later in leg. Duration two years before operation.

*Date of operation.*—December 14th, 1891.

*Character of operation.*—Trepined over arm area of left side. Bone thick, adherent to dura, veins large in pia. Softened pigmented brain tissue found under dura and partly washed away. No pus found and no cyst.

*Result.*—Recovery from operation. Relief of pain and paræsthesia. Permanent paralysis of arm. No convulsions up to seven months after operation.

(10) W. H., m., 18, Knapp and Post, *Boston Medical and Surgical Journal*, January 7th, 1892.

*History.*—Struck over right temple in 1882. In 1883 convulsions began and have continued until the operation, four or five daily. Fit begins with turning of head to the left, then left side of face and neck and the left arm are convulsed, sometimes general convulsion follows.

*Date of operation.*—May 1st, 1891.

Scar over posterior portion of second frontal convolution on right side. Trepined here by Dr. Post. Opening two inches in diameter through the bone was made. Bone was very thin. Dura normal and pia cedematous and opaque. Brain markedly bluish.

*Result.*—Recovery from the operation. Recurrence of the fits as before during following six months.

(11) K. F., f., 16, Knapp and Post, *Boston Medical and Surgical Journal*, January 7th, 1892.

*History.*—Was struck on the head in 1885. Since then constant severe headache. In November, 1891, convulsions began, general in character, commencing with turning of head and eyes to the right. Depressed fracture over left second frontal convolution.

*Operation.*—November 24th, 1890.

Bone adherent to dura and much thickened. Dura adherent to the brain. Dura and a portion of the brain substance excised.

*Result.*—Subsequent history during following four months showed a continuance of convulsions.

(12) L. C., m., 6, Sachs and Gerster, *Amer. Jour. Med. Sci.*, November, 1892.

*History.*—Said to have had brain fever at age of 10 months; at age of 5½ years first right-side convulsion, repeated at interval of one week; right hemiparesis since first attack; athetoid and associated movements.

*Operation.*—December 29th, 1890.

Exposure by chiselling of motor area of right arm, determined by faradization. Dura tense and adherent; puncture; no cyst found.

*Result.*—Recovery excellent; no convulsions up to February 2d, 1891, when boy was discharged from hospital; after leaving hospital had one mild attack; not heard from since.

(13) W. C. H., m., 20, Sachs and Gerster, *l.c.*

*History.*—At age of 12 years was pushed back over pole of a wagon; supposed to have struck back of head (?); unconscious for a few minutes, but worked as usual; one week later general epileptic convulsions; has petit mal, and above all Jacksonian epilepsy involving muscles around right half of mouth. Occasionally eyes are involved. No loss of consciousness with majority of attacks.

*Operation.*—February 13th, 1891.

Exposed centre for representation of angle of mouth according to Horsley; adhesions under the button of bone; small cysts on dura; on puncture a little bloody fluid.

Faradization over dura caused contraction only of right angle of mouth. Large opening; button not replaced.

*Result.*—Attacks returned after operation and have not been diminished, and eyes are more frequently involved. No improvement.

(14) M. K., m., 16, Sachs and Gerster, *l.c.*

*History.*—At age of 18 months fell out of window; since that time epileptic attacks at varying intervals; has had tremendous doses of bromides; ill-tempered and stupid; stopped bromides; no attacks for three weeks, then left-sided convulsions becoming general.

*Operation.*—February 23d, 1891.

Large trephine opening over motor area for arm and leg, right side of skull.

*Result.*—Good recovery, but no cessation of attacks. No improvement.

(15) E. L. M., m., 30, Sachs and Gerster, *l.c.*

*History.*—Traumatic injury to right side of head; general epileptic attacks.

*Operation.*—July 24th, 1892.

Trephining over occipital depression; adhesions over the depression.

*Result.*—Did very well except that he developed delusions of persecution. Attacks returned within two weeks; alcoholic excesses.

(16) J. D., m., 8, Sachs and Gerster, *l.c.*

*History.*—Traumatism at seven months; six months previous to operation began to develop auditory and olfactory auræ and then general epileptic spells; chronic ear discharge; if ear ceased discharging spells became worse.

*Operation.*—August 14th, 1891.

Opening of mastoid and removing two sequestra of bone.

*Operation.*—November 17th, 1891.

Mastoid opened again and silver canula introduced to secure permanent drainage.

Facial palsy of left side. September 10th, attack; re-

peated attacks of convulsion of right side until second operation, but none since; last report August 15th, 1892.

*Result.*—Great improvement after second operation; no attacks up to date.

(17) T. C., m., 26, Sachs and Gerster, *l.c.*

*History.*—At age of 11½ years was severely kicked by a man over the right side of occiput; six months later epileptic attacks which have continued nocturnally about every six weeks since. No hemianopsia. Marked depression in skull; was eight weeks without any attack; attacks then returned.

*Operation.*—November 20th, 1891.

Trephining and chiselling over scar; tremendous exostosis indenting underlying part of brain.

November 22d, short spells; none while in hospital; discharged December 15th; has gone out West; has attacks every six weeks, but milder; reports that his memory is better.

*Result.*—Some improvement in severity of attacks eight months after operation.

(18) H. L., m., 24, Sachs and Gerster, *l.c.*

*History.*—Six years ago fell down; thinks he struck on right side of occiput; one year later first attack, right hand and leg convulsed. At first had attacks six times daily, lately three or four times in two weeks.

*Operation.*—January 29th, 1892.

Motor arm centre on left side exposed; part of dura but no cortical tissue removed.

Second operation March 8th, 1892.

Removed arm centre as determined by electrical tests, with slight resulting paresis.

*Result.*—Repeated attacks after both operations. No improvement worth mentioning.

(19) C. D., f., 9, Sachs and Gerster, *l.c.*

*History.*—Fell out of bed at six months, striking head against bare floor; at ten months a tedious illness, slow in development; at age of five years began to have in-

numerable convulsions (at least fifty per day). Idiocy. Parents insisting on operation.

*Operation.*—February 15th, 1892.

Large trephine opening over left side of head (motor area).

*Result.*—Attacks not quite so frequent as before. Slight improvement.

(20) K. A., m., 9, Sachs and Gerster, *l.c.*

*History.*—At age of five years had a “congestive chill” and spasms; no paralysis at the time; two or three years later developed Jacksonian epilepsy beginning in left hand without loss of consciousness; no evidence of palsy; boy feels left hand drawn up in cramp.

*Operation.*—April 12th, 1892.

Excision of hand centre in right hemisphere; removed considerable tissue; hand was paretic for a few days.

Did very well in hospital for six weeks, but as soon as he left hospital and ran about had severe attack with loss of consciousness and involuntary passage of urine.

*Result.*—Some immediate improvement, but no lasting benefit from operation; in later attacks right arm was also involved.

(21) J. B. G., m., 34, E. D. Fisher; personal communication.<sup>1</sup>

*History.*—Habits intemperate; no history of syphilis; family history negative; a history of injury to the head fourteen years ago; had epileptic seizures for the past twelve years. Following the attacks, he became maniacal, destructive, and homicidal.

On examination, the patient was found to be well nourished, intelligent, quiet; he had a slight depression on the left side of the head corresponding to the hand centre of the motor area.

*Operation.*—May, 1892, at Bellevue Hospital, by Dr. J. D. Bryant.

<sup>1</sup> I am indebted to Prof. Fisher for the five following cases unpublished.

The skull was trephined, the opening enlarged to a diameter of about three inches. There was no evidence of internal fracture or of adhesions of the membranes. The dura was opened, and the hand centre located by the faradic current. The patient made a good recovery from the operation, although for two or three days there was a considerable elevation of temperature without evidence of any suppuration having occurred in the wound.

*Result.*—The attacks at first increased in frequency, and were not changed in character; later they decreased somewhat in number, but finally resumed their old frequency and nature. The patient was recommitted to the insane asylum on Ward's Island.

(22) J. H., m., 22, E. D. Fisher.

*History.*—Family history negative. He gave an indefinite history of having received an injury on the head. The attacks were characterized by always commencing in the fingers of the left hand with a sensory aura passing toward the face, with resulting loss of consciousness, after which the convulsions became general. Patient's mental condition showed signs of dementia—never violent.

*Operation.*—May, 1892, at Bellevue Hospital, by Dr. George Woolsey.

The patient was trephined over the right arm centre, and a considerable portion of the skull removed. Nothing abnormal was found. The dura was opened, and again united. The hand centre was located by the faradic current, but was not excised. The patient made a good recovery without elevation of temperature.

*Result.*—The attacks, however, continued to be as frequent as before, but no longer commenced on the left side, being general in character. Patient's mental condition was unimproved. Admitted to the Ward's Island insane asylum, December, 1892.

(23) A. B., m., 38, E. D. Fisher.

*History.*—Negative family history. He was a moderate drinker. He gave a history of injury to the head re-

ceived five years previously from a club. About one year after this, he began to have slight attacks of an epileptic nature, which finally developed into complete seizures. Severe attacks occurred about once a month, and slight attacks every day. His memory became somewhat impaired.

On examination of the patient a depression over the parietal bone was found behind the motor area.

*Operation* in March, 1892, at the City Hospital, by Dr. J. E. Kelly.

The patient was trephined over the site of the depression. The inner table was found depressed and pressing the dura, but there was no evidence of internal fracture. The dura was not opened. The patient made a good recovery, and leaving the hospital in the summer, continued at work for two months.

*Result.*—Up to date reports that he has had no seizures of any kind unless light attacks of dizziness when exposed to the sun may be counted as such.

(24) A. D., f., 20, E. D. Fisher.

*History.*—Family history negative. She gave a history of attacks from childhood. The attacks have been almost continuous, and limited usually to the left side. Patient very much demented. The attacks at times, and just previous to the operation, were as frequent as one hundred in a day.

*Operation* at the City Hospital in June, by Dr. J. E. Kelly.

The patient was trephined over the right motor area, and a considerable portion of the skull removed. Nothing found. The hand centre was located by the faradic current. A small portion of this centre was excised.

*Result.*—The patient died six hours after the operation, probably from the combined effects of her previous excessive seizures and the shock of the operation.

(25) A. C., m., 26, E. D. Fisher.

*History.*—Family history negative. The attacks were



very frequent, general; patient demented and given to excessive masturbation. He gave a history of an injury received from a fall when 12 years of age. On examination, a considerable depression was found over the left frontal bone, at the margin of the hair.

*Operation* at the City Hospital in May, by Dr. J. E. Kelly.

The patient was trephined, and a considerable area over the frontal bone removed, but no sign of fracture nor any adhesion of the dura was found.

*Result.*—The patient made a good recovery without elevation of temperature and for some weeks after the operation seemed much improved in this mental state; the attacks were very much decreased in number, and he ceased masturbating. Later, his condition became about the same as previous to the operation, and he was transferred to the insane asylum.

There are many patients suffering from traumatic epilepsy who manifest mental symptoms either associated with the fits or developing in place of the fits. C. F. MacDonald reports the following cases:

(26) J. M., m., 29, MacDonald, *Jour. Nerv. and Ment. Dis.*, XIII., August, 1886.

A patient in the Auburn asylum, suffering from mania which had developed after a blow on the head with depressed fracture of the skull over the right ear, corresponding to the superior parietal lobule, was found to be the subject of severe general convulsions. Dr. MacDonald trephined, removing the bone, which was thick, roughened, and adherent to the dura. The patient subsequently remained entirely free from his epileptic attacks, and gradually recovered from the condition of mania, so that he was discharged cured seven months after the operation.

(27) J. C., m., 24, MacDonald, *l.c.*

The patient had been a chronic epileptic with periods of

insanity for eight years, each attack being followed by a period of mania. He was found to have a depressed fracture over the right occipital region said to have occurred at the age of six, and he suffered from pain at this location. He was trephined August 25th, 1885, a button of bone being removed and the dura not opened. A year later he had had no fits at all, and though partly demented, was free from delusions.

Park has recently reported two such cases, as follows:<sup>1</sup>

(28) The first was in a man of 31, who, on July 20th, 1891, was kicked in the left side of the head by a horse, and who some time later was found unconscious. He was carried into the house, and was aroused. He had no paralysis, but in three days began to act strangely and soon became wilful and almost violent. He developed erotic tendencies, and growing rapidly worse could not be kept at home. On July 28th, he was sent to me by Dr. Krehbiel, of Yorkshire Centre. At this time the patient was difficult to control and mildly maniacal. July 29th, I found a depressed area on the left side near the parietal eminence and a little anteriorly to it; yet he had absolutely no motor symptoms. At this point there was an H-shaped scar. Immediate operation was done under chloroform. Beneath the scalp I found a depression about the size of a half-dollar, around which I chiselled so as to entirely lift and remove the depressed portion. The bone was well comminuted; there was a small clot beneath the bone, but none beneath the dura. The bone was not replaced and the wound was closed without drainage. He made a rapid recovery; returned home in one week with his mind nearly clear and his disposition as it had been before the injury.

(29) The second case was in a man of 45, who, when a

<sup>1</sup> Roswell Park: Med. News, Dec. 10th, 1892.

young man, had had an extensive compound fracture of the skull, and who for a while was under the observation of the late Dr. Gray, of Utica, who advised against operation, in accordance with the practice of his day. Of late years the man has developed distinct epileptiform seizures followed by violent maniacal attacks, during which he was positively dangerous, so that his family lived in constant fear; moreover, his disposition and temper seemed to be gradually changing under this stress, and it got to be a question whether he should submit to an operation or be sent to an asylum. He was placed in my hands for operation by Dr. Putnam. This was made during October, 1891, the depressed bone being removed, adhesions separated, and a portion of the scar exsected. The change in this case for the better has been most marked and most gratifying. While it is too much to say that he has not had a single seizure since the operation, they have been reduced to very mild and very rare attacks, and I believe it is now some months since he had anything that could be called a fit. In temper and disposition he is also quite his old self again.

The result in these cases may be summed up as follows: cured 10; improved 6; not improved 11; died 2.

These cases are sufficient to show that in many cases of epilepsy the attack begins with a clearly localizable spasm which extends from the part in which it begins to other parts in a definite order of progression. The majority of such cases have developed subsequently to an injury. The operation of trephining often reveals decided pathological conditions in these cases which require special notice.

*Pathological Changes Observed.*

In studying the cases here described the most interesting feature is the pathological conditions which have been revealed during the operation. These have been mentioned in connection with each case, but some general discussion seems warranted. We may consider these changes in the order in which they have been met with during the operation.

I. *Scalp*.—Exposure of the scalp by close shaving very frequently reveals scars hitherto undiscovered. Such scars are rarely found to be tender, and, in fact, in no case has pressure upon the scar been followed by a fit. Some years since considerable notice was taken of a few cases in which the epilepsy was clearly traceable to compression of nerves in the scar tissue of the scalp, and it was thought to be characteristic of these cases that pressure upon the scar would lead to a fit. I have tested carefully very many patients, but have failed to find such tender scars upon the scalp. Two years ago I saw a little girl afflicted with left-sided convulsions, each convulsion being preceded by a sharp pain in the left supra-orbital nerve, and pressure upon this nerve produced sensations in the entire left side and the feeling of anxiety identical with that which usually preceded the fit. But in this case the division of the supra-orbital nerve, performed by Dr. McBurney, in the hope of removing peripheral irritation, failed to relieve the fits. From my experience I

consider that true reflex epilepsy from scars in the scalp is a very rare occurrence.

II. *Periosteum*.—In a number of cases when the scalp has been divided and laid back a perceptible thickening of the periosteum over the fractured bone has been noticed. In one case this was so extreme that the periosteum could be likened to a piece of canton flannel. It is often found to be very vascular and more closely adherent to the skull than normal. I have never seen any apparent bony deposit beneath the periosteum as an evidence of repair of a broken skull.

III. *The Skull*. In the cases operated upon fractures of all kinds have been met with. It is impossible, as a rule, to determine whether the fracture involves the external table only or the internal table as well; it is only by trephining that this fact can be settled. It is not always safe in operating for epilepsy to be guided by the position of a fracture unless that fracture coincides quite closely with the spot selected for trephining from the character of the fit.

Thus, in one of my cases a depressed fracture lay over the left first frontal convolution, but the spot selected for trephining was over the middle of the posterior central convolution where the bone was normal (Fig. 12, page 30). When the button of bone was removed, however, a splinter of bone from the internal table was found penetrating the dura and brain. Thus the medical indication was proved to be the correct one to follow in spite of the fact that at the spot selected for trephining there was no evidence of fracture.

In many cases there is a fracture of both tables with decided depression of bone. Usually when the trephine opening is made a very distinct thickening of the skull is revealed and the density of bone is greater in and about these fractures.

IV. *The Dura*.—In many cases the dura has been found roughened upon its external surface, more vascular than normal and more adherent to the bone than in a state of health. It is not uncommon to see white lines and bands running across the dura of white connective tissue, the remains of chronic inflammation.

When the dura is divided and reflected, adhesions to the pia are quite commonly found. These may be in the form of little thread-like attachments which are easily broken as the dura is reflected. They may be very close and vascular adhesions which have to be dissected up with care. The dura itself is quite commonly thickened and that to a very great degree, so that I have seen a dura three millimetres in thickness. Under these circumstances the thickening appears to have been upon the under surface of the dura.

Not infrequently the dura forms a part of the external wall of a cyst.

V. *The Pia*.—When the pia is exposed in an operation, it is almost always found to present the appearance of œdema and only after the wound has been opened for a few minutes and the pressure of a sponge or finger has been made upon the pia does the subpial fluid disappear, revealing the vascular surface of the brain beneath it. It would appear that in a state

of health a thin layer of fluid is normally interposed between the cortex of the brain and its dense coverings.

As the result of pathological changes the pia may be altered in its appearance. Small white dots of the size of the head of a pin have been seen many times, resembling tubercles, but not at all tubercular in their structure or nature. Again there may be white

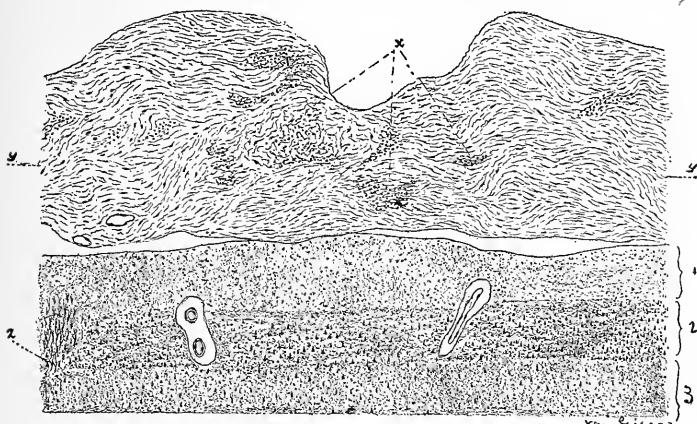


FIG. 25.—Section through Pia Mater and Cortex to show Thickening of the Pia. The normal thickness of the pia is indicated at *yy*. *x*, groups of small round cells—fibroblasts. 1, 2, 3, indicate the chief layers of the cortex. At *z* a wedge-shaped mass of neuroglia tissue is seen. Such a sclerotic patch may form a focus of irritation sufficient to cause a local spasm.

lines or narrow bands whiter than normal pia in its tissue. Again the pia may be much thickened, very vascular, and so closely adherent to the cortex that any attempt to elevate it with a fine forceps fails. Under these circumstances it is very difficult to avoid hemorrhage from these new vessels. But such hemorrhage can usually be checked by pressure maintained for a

few minutes evenly, or else by a light touch with the Paquelin cautery. The appearances of a localized patch of chronic meningitis with thickening are shown in Fig. 25, which was drawn by Dr. Van Gieson. He writes: "The pia mater is about three times thicker than in the normal condition, which is approximately indicated by the lines at *y*. The thickened pia mater is composed of fairly dense connective tissue, and as more and more fibro-blasts are developed apparently from the groups of small round cells at *x*, the membrane slowly grows thicker and thicker. Hand in hand with this localized growth of connective tissue of the pia mater, there is a disappearance or obliteration of the blood-vessels, and in Fig. 25 it is to be noted that there are very few blood-vessels and there is no distinction between the two layers of the membrane. The effect of all this upon the structure of the subjacent cortex cannot be described in this case, for the material was not especially well prepared. One important change in the cortex associated with this condition of the pia mater is the production of a wedge-shaped mass of neuroglial hyperplasia, Fig. 25, *z*, which passes inward from the outer margin of the cortex, and is composed of spindle-shaped and branching cells. The neuroglia cells of the barren layer are also slightly increased in number."

The pia not infrequently forms the inner wall of a cyst, and under these circumstances it is usually so much congested and thickened as to be quite opaque. When the pia is closely adherent to the brain and is



very vascular, the appearance of the cortex as seen through it is different from that of the normal cortex. It is blue instead of being red, and capillary vessels, which in the normal cortex are seen to radiate toward the summit of a convolution from the two sulci in which the chief pial vessels lie, are no longer visible.

In some cases there has been found beneath the pia but closely connected with it a delicate mesh-work of new connective tissue and vessels, making a mass resembling honeycomb, usually of the thickness of a centimetre.<sup>1</sup> This connective-tissue formation is usually full of fluid and collapses when the pia is incised. It is probably a relic of an old hemorrhage.

VI. *The Brain.*—Normal cortex during life has evidence of a vascular supply most profuse and perfect. Everywhere over the cortex a fine network of capillaries is visible, the larger capillaries running toward the summit of each convolution from its sides. It has a firm feel and a double pulsation, the pulsation of the heart and the pulsation on respiration. As the result of fractures or of meningitis the cortex may be changed in its appearance. It may have undergone compression and be indented. It may be stained with hæmatin as a remainder of an old hemorrhage. It may be changed in color to a darker tint and perceptibly hardened by new connective tissue growing into it from

<sup>1</sup> In an old case of right hemiplegia with contractures of twenty years' standing the entire motor area of the left hemisphere was replaced by such a honeycomb mesh of connective tissue. Secondary degeneration could be traced into the spinal cord.

an adherent pia. Or finally, it may be softened and lose its firm consistency and present a flat or depressed appearance very different from the normal. It may be actually destroyed and disintegrated by bony splinters projecting into it, and then it is semi-fluid in character or else hardened by sclerosis.

The microscopical changes are described later by Dr. Van Gieson.

It is not uncommon to find cysts in the brain. These may have a distinct connective-tissue wall, or may merely be surrounded by normal brain tissue. They are usually the remains of a hemorrhage or of a spot of softening from thrombosis or embolism of a small vessel. The fluid in them is usually clear serum. If they are divided the walls unite and the fluid does not collect again. If they are merely emptied the fluid re-forms. As we shall see in the chapter on tumors, cysts are not infrequent in the midst of gliomata. It is possible that some of the cases of epilepsy in which cysts were found were really cases of beginning glioma. For the presence of a cyst can hardly be thought sufficient to cause irritation of the surrounding tissue, while a growing tumor might easily do so.

The facts just stated in regard to the pathological conditions found in the brain at the time of operation prove conclusively that in these cases of epilepsy there was an organic basis for the disease, and this fact makes it seem very probable that in all cases of epilepsy commencing after injuries there is at some point

in the brain an actual pathological change. It is evident from what has already been stated that in some cases this focus of disease lies immediately beneath the point of injury; it is evident that in other cases it lies near the cortex at some distance from the point of injury. It is evident that when the part of the cortex involved is a part the function of which is known, the local symptoms will indicate the situation of the focus of disease. It is evident, finally, that in traumatic epilepsy when the disease is not found under the point of injury, and when it does not give rise to any local symptoms, we have no means of knowing where it is in the brain, even though we are sure of its existence, and we have no means of treating it surgically.

I think it may be stated, as a result of the facts derived from pathological studies of the conditions found at operations in epilepsy, that Jacksonian and traumatic epilepsy are always due to a pathological change in the brain.

When the pathological change is not apparent to the naked eye at the operation, and yet the approximate situation of it can be determined by the local symptoms, Horsley proposed to determine by the application of faradism to the cortex the exact spot irritation of which will set up a fit like the one spontaneously occurring, and then cut this spot out. This has been frequently done, in some cases with success, in others with a return of the symptoms. Several cases are mentioned in the collection given. The chief objection to this method—an objection which has been

urged by numerous operators—is that excision of brain cortex is necessarily followed by the formation of a cicatrix which becomes the centre of a sclerotic patch in the brain. Such a patch or even a cicatrix may act as an irritant and give rise to localized epilepsy when arising from other causes. It is not unreasonable to fear that it may act as an exciting cause of a continuance or renewal of the fits when it is produced by the surgeon. Later experience rather confirms this fear, for even in two of Horsley's cases the fits returned in spite of the excision of the cortex. Hence the excision of the focus of irritation, when such a focus is not apparently abnormal tissue, is not to be recommended, since to do so is to produce a brain lesion comparable to that found in the cases reported.

The exact pathological changes which take place in the brain after wounds have been studied by Ziegler<sup>1</sup> and by Coen.<sup>2</sup>

Ziegler describes them as follows:

“If a pointed instrument is thrust into the brain at any point a hemorrhage occurs at that point and the neighboring tissue is destroyed in greater or less extent. In this way there is produced a necrotic anæmic or hemorrhagic focus, and the pia and sub-arachnoid space over this is infiltrated with blood. At the border of the dead and living tissue there occurs a more or less intense inflammation in the first few days,

<sup>1</sup> Ziegler: “Lehrb. d. Path. Anat.,” Spec. Theil, 1887, 5te Auflage, S. 358.

<sup>2</sup> Coen: “Ueber d. Heilung von Stichwunden des Gehirns.” “Beiträge zur Path. Anat. u. Phys.,” ii., p. 107, 1888.

which soon results in a well-marked line of demarcation between them. At the spot of inflammation, which extends especially along the course of the vessels which enter the brain vertically from the pia mater, the brain tissue becomes softened and simultaneously the cell infiltration advances toward the necrotic focus. This latter in the course of time becomes dissolved and absorbed. It may take months, even years, for the products of inflammation to be finally removed.

“Other changes meantime go on in the adjacent tissue. The nervous tissue undergoes a degeneration in consequence of the change of nutritive conditions, and the ganglion cells and nerve fibres swell, become fatty, become disintegrated and destroyed. The focus of inflammation is thus surrounded by a zone of degeneration.

“In the first weeks the focus of inflammation consists of vessels, small round cells, larger corpuscles, and fatty and pigment granules. The last are in large numbers so long as the absorption of the dead tissue and of the extravasated blood are in progress. The fatty granules are also found in the zone of degeneration. After weeks and months there occurs a gradual formation of connective tissue, which evidently commences along the vessels which penetrate the inflammatory focus from the pia, and this surrounds the necrotic tissue or takes its place. The connective tissue is partly radiating in character and thick, partly areolar and meshlike in structure, and develops out of

the cells of the pia and of the vessels of the pia. The formation of connective tissue requires a long time, and even months or years after it has begun it may be rich in round cells."

Authorities differ as to the possibility of reproduction of ganglion cells of the brain after destruction (see Coen, *l. c.*). Coen denies that it can occur and holds that after a wound the new tissue found is entirely connective tissue containing no nerve elements. He says: "A true regeneration of the central nervous system was never observed in my experimental investigation; the tissue which developed at the spot wounded, replacing the destroyed brain tissue, contained no newly-formed nervous elements. The ganglion cells are, however, able to resist the traumatic attack and this they do very early by indirect division of their nuclei. This inclination to division subsides and ceases when healing begins. A reproduction of brain tissue fails to occur in the region where brain was destroyed, and connective tissue fills its place which forms a scar in the true sense of that word" (*l. c.*, p. 125).

*Microscopical Appearances of the Brain Tissue  
Excised, in Cases III. and II.*

BY DR. IRA VAN GIESON,

First Assistant in Histology, College of Physicians and Surgeons.

In describing these morphological changes in the motor cortex which harmonize very well with the symptoms of epilepsy, it is of especial importance to preface the details of the examination with some gen-

eral remarks about the technical limitations of investigations in the finer pathology of the cortex, and the extreme difficulties of detecting and attaching significance to the very early and subtle changes in the cortical elements. In such a preface the investigator should indicate the great caution and most refined technique which a study of minute cortical changes demands; for then the reader will appreciate that the observer has guarded against mistaking for lesions entirely artificial changes, or normal structures which, especially in the cortex, are by no means easy to define.

The difficulty in the way of research in cortical pathology is the complexity of the brain cortex; it is most highly organized, and is far beyond all other organs and tissues in the textural delicacy of its anatomical elements and complexity of their arrangement. In most of the other organs the structure of the parenchyma is comparatively simple, and the stroma is arranged in such a way that there is a contrast between the two in the sections; thus in the kidney or liver, for example, the changes in the stroma or in the parenchyma attending a chronic inflammation may be determined very accurately. The stroma is so distinct from the parenchyma and its distribution is so readily followed, that a very beginning of an increase in its substance may usually be easily and positively recognized. In the same way the distinctive distribution of the comparatively simple parenchyma cells permits early changes in them to be determined with but little difficulty.

When we come to the brain cortex, however, the contrast between stroma and parenchyma which in other organs affords most valuable topographical aid is lost, and the determination of changes in either stroma or parenchyma is correspondingly difficult. For in the brain cortex the neuroglia and ganglion cells, corresponding respectively to the stroma and parenchyma of other organs, are not only more intricately constructed but are diffusely arranged. The neuroglia and ganglion cells are mingled together in a most intricate way, and are surrounded by a great wilderness of processes derived from both, which forms a very large part of what is conveniently called the basement substance of the gray matter.

Thus it can be understood what a difficult matter it is to determine any beginning increase or proliferation of the neuroglia, which in ordinarily stained sections presents itself as multitudes of small round nuclei scattered all through the gray matter without any boundaries or limitations. This problem of the determination of a very early increase in the neuroglia becomes the more baffling because, as a rule, this tissue grows so slowly that the all-important criterion of the proliferation of cells, namely, the phases of karyokinesis, are difficult to find.

The investigation of minute and early changes in the other intrinsic element of the cortex—the ganglion cell—is rendered difficult by the presence of artefacts or artificial changes occurring after death. The structure of the ganglion cell is so delicate and intri-



cate and the cortex is so slowly permeable to the bichromate solutions that a number of post-mortem changes are liable to occur in the cell or are induced by the action of the hardening agents. Such artificial changes may simulate very closely the results of disease, and when these artificial changes are present in a cortex with suspected disease of the ganglion cells it becomes exceedingly difficult to understand the lesions, or to determine in what degree the changes are due to disease and in what degree to artificial conditions.

With the best of care we can recognize after all but the coarser and grosser lesion in the ganglion cell body, which is only a part of the cell. Changes in the great forest of processes of the cell, representing a volume of protoplasm fully as large if not larger than the cell body itself, are beyond our cognizance even with Golgi's methods, which seem to be of little service in showing minute changes in the ganglion cells. The aid of mitosis as an index of pathological changes in the ganglion cells is also absent, since the latest studies on this subject show that the ganglion cells seldom if ever proliferate.

Thus owing either to perplexing artefacts, or to the inherent complexity of the cortex, its more minute changes seem beyond recognition at present, and when we do detect cortical disease processes it is only after they have gone on to some considerable extent beyond the initial stages and have become rather coarse, extensive, or materially destructive. Since the wonder-

ful revelations of the Golgi methods, one can reasonably enough conceive that changes may occur in the cortex which are of the greatest etiological significance, but so subtle that they are entirely hidden from our view.

It certainly seems appropriate, therefore, to speak with all this detail about these peculiar difficulties in the way of pathological investigation of the cortex, for if real advances are to be made in the finer pathology of the cortex its difficulties of investigation should be appreciated, and if the lesions to be described in these particular cases are to be at all considered as underlying the phenomena of epilepsy we must approach the problem with all possible caution. I also wish to show that the material placed at my disposal by Professor Starr has such great advantages for investigation both in its structure and preparation, that the difficulties and errors in determining early cortical changes are considerably reduced.

From the fact that these minute fragments of the cortex were immediately transferred from the living body to the hardening fluid the changes in the ganglion cells are especially significant, for the element of artificial change incident to post-mortem alteration or the process of hardening larger portions of the cortex, which frequently interferes with making positive statements about the minute changes in the ganglion cells, is more thoroughly excluded than in the material from an ordinary post-mortem examination. Even allowing for the fact that Müller's fluid does not pre-

serve the ganglion cells perfectly, the damage to the ganglion cells, presently described, must have existed during life.

*Microscopic Examination of Case III.*

We may now go on with the detailed microscopical examination of the removed portion of the brain in Case III., and this comprises a description of (1) A rigid plate of connective tissue acting as a foreign body and pressing against the brain. (2) Changes in the pia mater. (3) Certain lesions of the cortex of the brain consisting of both changes in the ganglion cells and in the neuroglia.

*Description of the Inwardly Projecting Plate of Connective Tissue Indenting the Surface of the Brain.*

—The removed portion was hardened in Müller's fluid plus one-sixth its volume of strong alcohol for three weeks. The specimen was very small, measuring about ten by six millimetres in diameter, and its central portion furnished about one hundred sections which were cut in series and stained double with hæmatoxylin and eosin and by the picro-acid-fuchsin method.

Sections from the centre of the specimen when reconstructed show that a tiny plate of very dense partially calcified connective tissue projected obliquely downward apparently from the dura mater against the surface of the brain. Here the plate is firmly attached to a minute localized patch of thickened pia mater and seems directly or indirectly to have pressed

on the brain, for the cortex shows an abrupt little pit or depression (see Fig. 26) just beneath the inwardly projecting plate. This cortical depression corresponding to the plate is cone-shaped (with the apex projecting inward) and has approximately an altitude of

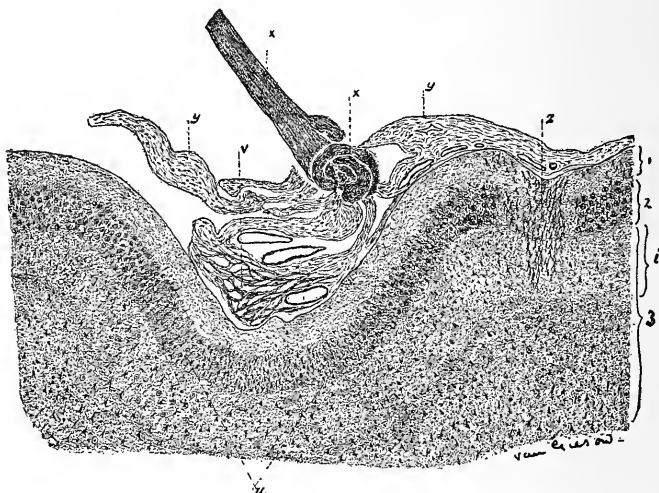


FIG. 26.—A Section from the Centre of the Removed Portion of the Brain in Case III. The topographical relations of the rigid calcified spiculum of connective tissue, the thickened pia mater, and the depressed region of the cortex. *xx*, Calcific spiculum of connective tissue. *yy*, Moderately thickened pia mater. *z*, Anastomosing wedge-shaped group of capillaries passing into the cortex from the pia mater. 1, 2, and 3, First, second, and third layers of the gray matter. *i*, Upper portion of the third layer.

three and three-fourths millimetres and a base four to five millimetres in diameter.

In the individual sections from the centre of the specimen the plate of connective tissue appears as a very dense, finely lamellated, partially calcified spiculum about three-fourths of a millimetre broad and three-fourths of a millimetre long (see Fig. 26, *xx*). At its inner extremity the spiculum has a globular

enlargement and the lamellæ do not run parallel as in the outer portion, but pass in various directions mostly concentrically arranged about a tiny central nodule or core. The outer end of the spiculum is entirely free in all of the sections, so that it is difficult to determine what the spiculum is a part of or where it grew from. The inner end of the spiculum is attached in all directions by many diverging fascicles of the thickened pia mater.

As the sections approach the margin of the specimen at one side, the plate grows a trifle smaller, but still persists to the free edge, so that it seems probable that not all of the plate was removed at the operation. At any rate it may be said that the removed portion was not large enough to completely surround the plate. From the very dense structure of this connective tissue, and from the fact that the edge of the microtome knife was turned in cutting the sections, this plate must have formed a fairly rigid body.

*The Changes in the Pia Mater.*—The pia mater not only at the attached end of the spiculum, but for some little surrounding distance (say three to four millimetres), shows the lesions of chronic meningitis, or productive or hyperplastic inflammation of the pia mater (Fig. 26, *yy*). The pia mater in the region contains an increased amount of connective tissue, which consists of fibro-blasts in different stages of development, but most of them show the more mature or final stages. The resultant thickening of the pia mater, however, is only of a moderate degree, and has not

gone on to the extent of obliterating the two layers of the membrane. The inner vascular layer still presents its normal features, although in places (see right-hand portion of the pia mater in Fig. 26) the vessels appear to be somewhat diminished in number.

The meshes of the inner layer of the pia mater in the depressed region of the cortex are distended and form a network (Fig. 26, *vv*) filled with extravasated red blood cells. This extravasation of blood as well as some minute hemorrhages in the gray matter seem to be of artificial origin, and are very likely referable to the manipulation in the removal of the specimen at the operation.

*The Lesions of the Cortex.*—The lesions of the cortex in this case might easily escape detection without the most careful scrutiny and technique. There are hardly any gross changes in the cortex which would attract attention with the low power, and it is only with the oil immersion lens that slight changes in the neuroglia cells and scattered damaged ganglion cells become fully apparent. These cortical changes are very minute and not at all striking, and yet they are none the less definite and significant.

*The Ganglion Cells.*—The ganglion cells are affected by a series of degenerative changes which in their most advanced stages result in an almost complete dissolution of the cell, and yet this degeneration is not extensive enough to involve the cells so universally as to interfere with their topographical distribution. Besides this, most of the damaged cells are in the

earlier stages of the degeneration so that they still retain their form and appropriate position. Thus in reconnoitering the sections with the lower powers the ganglion cells do not appear deficient in number; they are properly arranged and their several layers are perfectly distinct. The following description applies to all of the ganglion cells excepting the layer of small

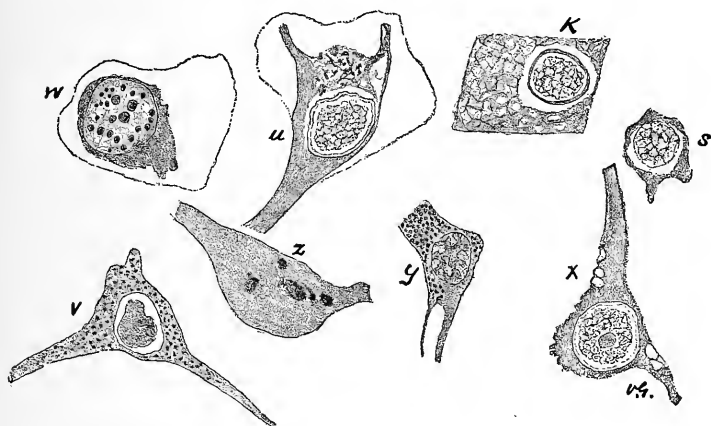


FIG. 27.—Various Phases of the Earlier Stages of the Degeneration of the Ganglion Cells. The thin lines enclosing the cells *u* and *w* represent the pericellular spaces; the cells *x* and *y* show the earliest stages, *w* and *s* later stages, and *K* shows the ultimate destruction of the whole of the ganglion cell body, leaving nothing but the nucleus lying in an empty space.

pyramids. For especial reasons this layer will be dealt with separately later on.

It will be convenient to describe the appearances of the nucleus and protoplasm of the degenerated ganglion cells separately. The prevailing form of nuclei shows a distinct peripheral zone, indicating the nuclear membrane; just inside of the nuclear membrane is a narrow clear zone surrounding the chromatic elements

of the nucleus, appearing in the form of a skein of finely dotted interlacing filaments which show the usual thickened appearances at the nodal points and surround unstained interstices. The nucleolus is seen in most of these skein-like nuclei, and both the nucleolus and the character of the skein show no variations relating to the different degrees of dissolution of the ganglion cells. In both the early and ultimate stages of the degeneration the form of nucleus as shown in Figs. 27, 28, and 29 remains about the same in all of the cells.

This particular form of nucleus in some of the cells is a trifle suggestive of one of the initial stages of karyokinesis, but none of the other stages of mitosis are present, so that this appearance of the nucleus must be regarded as an indication of retrogressive changes. There are no indications of mitosis in any of the ganglion cells, and this agrees with one of the latest papers on the ganglion cell reproduction by Fürstner and Knoblauch (*Archiv für Psych.*, XXIII., 135).

Some different appearances of the nucleus are shown in Fig. 27, in the cells *v*, *w*, and *y*. The nucleus of the cell *w* has its chromatic elements resolved into a number (some twenty to twenty-five in optical section) of larger and smaller globules or discs resembling very much the ordinary nucleolus. In the cells *y* and *v* the chromatic substance is collected into thickened strands or large lump-like masses.

The protoplasm of the cells shows a series of changes



which finally result in an entire disappearance of the cell body—for a very complete series of intermediate stages can be observed between the slightly and most completely degenerated cells. The earlier stages of degeneration consist in larger and smaller solutions of the substance of the cell so that hollow-looking vesicles appear in the cell body. Such cells are shown in Fig. 27, *x* and *y*, Fig. 28, *x*, and Fig. 29, *a*. The cell *x* in Fig. 27 also shows a ragged or roughened profile

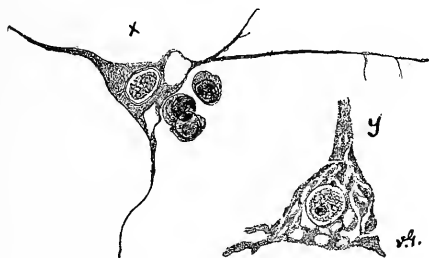


FIG. 28.—Shows Other Phases of the Degeneration of the Ganglion Cells. The cell *x* shows liquefied vesicles at the junction of two processes with the cell body and three small round cells crowded in the pericellular space; the cell *y* shows a series of liquefying seams or channels.

at one margin of the cell body. These vesicles frequently appear at the junction of one of the larger processes with the cell body as in Fig. 28, *x*, Fig. 29, *a*, or in the process itself some little distance from the cell (Fig. 29, *a*).

In a somewhat later stage, by the increase of these vesicles, and by their apparent coalescence, the cell body becomes more reduced in volume, deformed in its contours, and loses its processes. Besides the vesicles, liquefied seams and communicating channels also

appear and contribute their share toward the destruction of the cells.

A very beautiful example of these channels or seams is shown in Fig. 28, *y*. This is one of the very large ganglion cells peculiar to the deeper layers of the motor zone and it was situated on the extreme edge of the section, so that it must have been immediately fixed by the hardening solution, and may be regarded

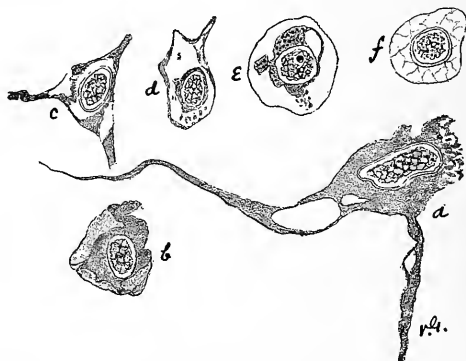


FIG. 29.—Other Variations of the Phases of Degeneration of the Ganglion Cells described in Figs. 27 and 28.

therefore as showing very nearly the same condition possessed during life.

The cell *c*, Fig. 29, also shows a somewhat similar condition and illustrates how the apical process is being separated from the cell; the protoplasm surrounds the nucleus as a deformed or deficient mass such as is shown in Fig. 27, *w* and *s*, and Fig. 29, *b*.

In some of the degenerated cells the protoplasm at the bounding surface becomes frayed out, or loosened from the cell body in little granular islands or cord-

like masses, while the remainder of the cell body may be comparatively intact. This is represented in Fig. 27, *u*, and in Fig. 29, *a*. The cell *a*, Fig. 29, is again one of the very large cells in the deeper layers and was situated just at the free edge of the section so that it must have been fixed in a perfectly natural condition.

In still others of the ganglion cells the protoplasm is studded with irregularly distributed shining dots. In most of the cells affected in this way, and they are comparatively few in number, these dots seem akin to and react like hyaline material, and their appearance is shown in Fig. 27, *v*, *y*. These hyaline dots are present in both the slightly and severely damaged cells (Fig. 29, *e*).

In focussing on the surface of the cell *z* in Fig. 27, some larger lump-like hyaline masses were noted.

Thus far, to the rather restricted extent that we are able to recognize them, the beginning and most limited changes in the ganglion cell body have been described. There were larger and smaller vesicular or channel-like solutions of the substance of the cell body, and a tendency toward disappearance or separation of the processes.

We may now go on with the consideration of the final and more grossly destructive phases of the ganglion cell degeneration. Some of these cells undergoing the later stages of the degeneration are reduced to a mere shell or skeleton of the former cell; the outline of the cell is preserved, but the cell is hollow; the

bounding surfaces are intact, and enclose the nucleus lying in an empty space or surrounded by a few shreds or granules of the former protoplasm (see Fig. 27, *k*, and Fig. 29, *f*). This condition seems to result from the extension and coalescence of the liquefactive seams and vesicles already described, and it is easy to trace the extension of the changes in the cell *y*, Fig. 28, to the cell *d*, Fig. 29.

These skeleton cells, when followed still farther in their degenerative course, show gradual dissolution and disappearance of the bounding shell, so that ultimately nothing remains of the cell but the nucleus, which lies bereft of protoplasm in the space once occupied by the ganglion cell (Fig. 27, *k*; Fig. 29, *f*).

Another way in which the ganglion cell ultimately becomes reduced to a mere nucleus is not so much by a solution of the protoplasm internally, as just described, but by a direct abstraction of portions of the external zones of the cell body. There is at first a slightly roughened surface of the cell, at some portion of its extent, with a fraying out of shreds and most minute fragments of protoplasm into the pericellular space. Then there is a tendency toward a distinct sequestration of a portion of the protoplasm (Fig. 29, *b*, *e*), so that the cell body grows smaller and smaller as the solution of its substance proceeds from without inward. Thus the cell becomes deformed and atrophied; it loses its processes, and the pericellular space sometimes contains minute fragments of the loosened protoplasm (Fig. 29, *e*). Ultimately the cell becomes

reduced to a naked nucleus lying in the pericellular space, as just described (Fig. 27, *k*; Fig. 29, *f*).

Very often this wasting away of the cell body from without inward is also combined with the liquefactive vesicles and channels or other forms of degeneration in the interior of the cell body (Fig. 29, *a*).

The ultimate fate of these nuclei bereft of the ganglion cell body cannot be determined positively, but some of them become destroyed. The nuclear membrane and chromatin skin become disintegrated and finally nothing is left but some fragments of the chromatin elements, surrounded by a complete or incomplete ring, which still take up the color of the nuclear dyes.

The description of the changes in the ganglion cells refers to the deeper layer of cells, and especially to the very large ganglion cells of the fourth layer, characteristic of the motor zone. The very large size of the cells renders the detection of the degenerative changes much more positive than in the other small cells. To be more certain of the ante-mortem origin of these lesions in the cells as many as possible were selected for study in glycerin mounts at the extreme edge of the specimen where they must have been immediately fixed in a natural condition. The spaces about these cells are small, and altogether the element of artificial changes may be more thoroughly excluded from them than in the much smaller cells.

One of the most striking features of this degeneration of the ganglion cells is the extensive involvement

of these very large cells of the fourth layer. It may be that this feature is so evident, from the fact that the degenerative changes are so much easier to recognize in these cells, but it would appear as if they were especially selected by the degeneration. At any rate very few of the large cells are left intact, they show quite universally one phase or another of the degenerative changes. In cutting out the fragment at the operation, the knife seems to have sliced it off just at or below this layer of cells, so that very many of them lie right at the edge of the sections. Many of the smaller cells of the third and fourth layers, however, show precisely similar degenerative changes. There are many normal ganglion cells in deeper layers, and the degeneration affects apparently, excepting the very large cells, only isolated or small groups of cells here and there, and yet the aggregate number of the damaged cells must be very large.

Still another feature about the ganglion cells remains to be described. This consists in the accumulation of clusters of from one to four or five small round cells crowded together in the pericellular spaces of both the diseased and normal cells. These cells have a very thin envelope of protoplasm and they are generally situated at the base of the cell. These cells are not infrequently found in brains with normal ganglion cells, and which have given no symptoms, and in the present case I am unable to interpret their meaning or determine what kind of cells they are.

We may now describe the layer of small pyramids

which has been held apart from the deeper layers, because the element of artificial changes cannot be as positively excluded. The small pyramids are quite universally altered, and but a very small number of natural cells are found in the sections. The nucleus surrounded by little if any protoplasm lies in a rather large empty pericellular space, as shown in the right-hand portion of Fig. 31. But just such a picture of the small pyramids as this is generally found in any cortex unless prepared by especial methods, and is generally to be regarded as largely of an artificial character. The small pyramids are especially prone to artificial changes, apparently from their very small size which seems to render them correspondingly liable to shrinkage. Artificial changes in this case, however, must be considered reduced to a minimum, and these alterations in the small pyramids in this case are not present in sections of the motor cortex of an electrically executed criminal, prepared in the same way and studied along with this case as normal control sections. So that while there may be reason in this instance for regarding these changes in the small pyramids as the results of actual disease, there is still doubt about it, and I prefer to disregard or exclude the small pyramids entirely from the larger, deeper cells where the lesions are definite, positive, and significant.

*The Pericellular Spaces.*—There is very little to say about the lymph spaces of the ganglion cells. They show no striking changes and are not enlarged. The space about the deeper cells fits fairly closely, and the

relations of the cells and spaces is especially well preserved. The spaces of many of the degenerated cells appear very large, but this effect is produced by the atrophy of the enclosed cell.

*The Basement Substance* of the cortex, consisting, as it does, largely of the processes of the ganglion cells, must contain changes corresponding to the degenerated and destroyed ganglion cells, but such a lesion is entirely too subtle to be recognized at present even with Golgi's methods. Some of the larger isolated processes in the basement substance show with the very highest powers an irregularity of outline of the process. These processes show minute nickings or a jagged outline of the edges. In one such process a clear vesicle was found like those described in the bodies of the degenerating ganglion cells (Fig. 29, a).

As regards the *distribution of these ganglion cell changes*, they are not especially concentrated about the region of the foreign body, but are scattered all through the sections, even to the lateral boundaries.

There is no positive support for making statements about *the duration of the ganglion cells degeneration*, but the impression is conveyed that the process is an exceedingly slow and gradual one. The cells do not show the swollen and other appearances of rapid degeneration such as are seen in the acute processes of the spinal cord. It seems probable that these damaged cortical cells may persist for a long time in the earliest stages of degeneration before advancing to the later or final stages.



*The Changes in the Neuroglia.*—There is a limited and very early stage of hyperplasia of the neuroglia tissue. This statement, however, can be better relied upon if the excessive difficulties attending the detection of this stage of a slowly growing neuroglia hyperplasia are indicated. The neuroglia cells appearing in ordinarily stained sections as small round cells are very profusely scattered throughout all of the cortical layers except in the barren layers, and their true form is only apparent by Golgi's methods. Then again, these cells are irregularly distributed, and vary somewhat in different cortical regions. In some layers they are very thickly aggregated together, and in other layers more sparsely arranged. Thus in this diffusely arranged tissue, without contrast to the surrounding tissues, in determining a slight increase of newly formed neuroglia cells which look exactly like their surrounding progenitors we often have an insoluble problem. When the young neuroglia cells have become more mature, and possess a larger cell body with beginning branches, a new difficulty arises in their identification, for frequently they cannot be distinguished from the surrounding ganglion cells of the same size. So the earlier diffuse increase of neuroglia is unfortunately liable to escape recognition until the process has become fairly extensively developed.

Notwithstanding these difficulties there are a few places in the sections which show quite distinctly clusters of an increased number of a very young and seemingly proliferated neuroglia cells. These are most

distinctly seen in the layer of small pyramids. In a few places in the layer there are groups of small round cells, which, although they are not sharply circumscribed, are still so closely aggregated that they stand out more clearly than the remainder of the rather sparsely distributed neuroglia cells of this layer (see Fig. 30). The contrast of the barren layer is also an aid in distinguishing these cell groups. These cells are often arranged in groups of twos or ill-defined

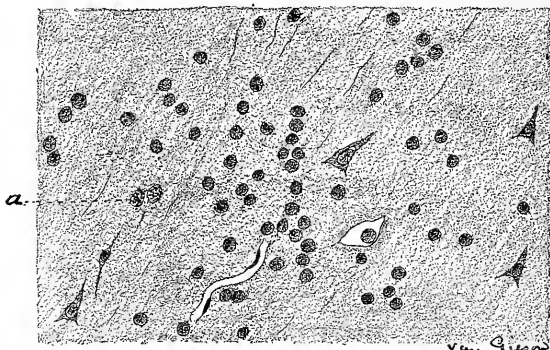


FIG. 30.—A Group of Young Neuroglia Cells Situated in the Layer of Small Pyramids

strings of four to six in number. In two cells only were positive evidences of mitosis discovered, and these are shown in Fig. 30, *a*, and more highly magnified in Fig. 32, *b*.

In the deeper layers there are some similar groups of increased neuroglia cells, but they are much less clearly defined. Thus the production of neuroglia in the deeper layers is hidden from view, because the normal neuroglia cells are so thickly aggregated that

the newly formed cells cannot be distinguished from them. In one single instance in all of the sections, a cluster of neuroglia cells on the edge of the specimen, in the deeper layers, was quite circumscribed from the surrounding cells and grouped differently and seemed to be a cluster of proliferated young neuroglia cells. These young neuroglia cells at first seem to be indifferent cells. They have a thin, spherical envelope of

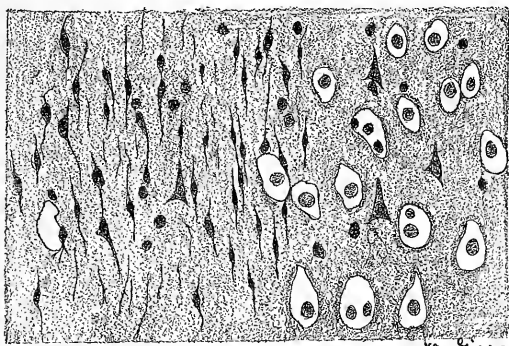


FIG. 31.—A Group of more Mature Neuroglia Cells in the Layer of Small Pyramids.

protoplasm, which at first appears to have no processes.

At a later stage of development the protoplasm increases in volume and they lengthen out into spindle or oval-shaped masses and send out branching processes. Groups of these more mature neuroglia cells were also found in the sections, and they could be identified most clearly in the layer of small pyramids, because here there was no danger of mistaking them for small ganglion cells, for the small pyramids were so universally and thoroughly shrunken (see Fig. 31).

If there are other groups of these more mature neuroglia cells in the deeper layers, they cannot be distinguished plainly because of their close resemblance to the small or polymorphous ganglion cells.

Fig. 30 at *a* shows this difficulty of distinguishing newly formed neuroglia cells from ganglion cells. These two sets of cells seem to be neuroglia cells; they have large, glassy cell bodies, and suggest a phase of cell division. Both of these two groups of neuroglia cells were found among the larger ganglion cells of the fourth layer, and are significant in evidencing an overgrowth of neuroglia in this important layer of the motor zone. Finally, in a single instance, a very large mature branching neuroglia cell was found in

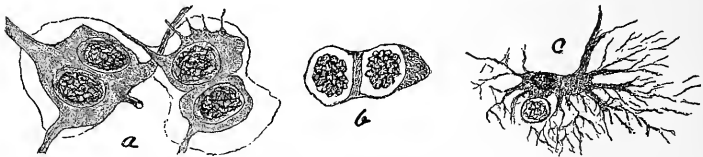


FIG. 32.—Isolated Neuroglia Cells from Different Layers of the Cortex. *A*, Two neuroglia cells from the deeper layers, apparently undergoing proliferation. *B*, The cells indicated at *a* in Fig. 30 more highly magnified, which show Karyokinetic figures. *C*, A large spider cell lying alongside of the nucleus of a completely degenerated ganglion cell.

the deeper layers, as shown at Fig. 32, *c*. Lying alongside of this large spider cell is the remains of the nucleus of a degenerated ganglion which may, perhaps, convey a suggestion as to the destiny of the previously described small round cells crowding the spaces of the ganglion cell, but there is no real evidence to connect these two sets of cells together.

There is then an increase of neuroglia in these sections, and it is of a very early and limited stage of development, and yet the impression is conveyed that only a portion of this growth is apparent in certain favorable situations, as in the narrow layer of the small pyramids. Still there are several indications of neuroglial growth in the deeper layers, as for example in Fig. 32, inviting the belief that the process is not limited to the region where it may be recognized most easily, but is a diffuse growth and involves the layers beneath the small pyramids, but possibly to a less extent.

The *neuroglial hyperplasia* is *irregularly distributed* throughout all of the sections, even at a distance from the foreign body, and often occurs in spots or patches. Most of the sections of the depressed region of the cortex show a slight concentration of the neuroglial growth as young, small, round cells or more mature spindle-shaped cells scattered about among the lesser pyramids.

This growth of the neuroglia, like the degeneration of the ganglion cells, seems to take place exceedingly slowly.

*The blood-vessels* of the *cortex* are normal in structure, but in places they are not properly arranged. In places anastomosing networks of capillaries penetrate the cortex from the pia mater and, accompanied by and surrounded by more or less neuroglial increase, appear as wedge-shaped areas in the section. This is shown schematically at Z, Fig. 26.

*Microscopical Examination of Case II.*

In this case there is a development of rather a large mass of connective tissue which has altered very materially the structure and topography of the convolutions which it has grown into. In this way the gray matter at the seat of the operation has been irregularly replaced by connective tissue, and has been rather largely converted into neuroglial tissue.

The removed portion was a flattened disc and measured about two cm. in diameter and was from five to seven mm. thick; it was hardened in strong alcohol and the celloidin sections were stained in the same way as in the preceding case.

The specimen consists of two layers, an outer layer of connective tissue and beneath it a layer of damaged cortex. At one side of the specimen a new layer makes its appearance, from the fact that a bit of the scalp is adherent to the specimen and has been removed with it. Throughout the remaining extent of the specimen the scalp is absent and the connective-tissue mass referred to is the outermost layer. Sections from the region of the specimen where the scalp is attached show the appearances in Fig. 33. The scalp (*a*) with its clusters of fat cells and obliquely cut hair follicles covers and partly surrounds a bit of damaged cortex (*c*). The scalp shows atrophic changes of a moderate degree and the attachment to the brain is rather a loose one. The brain, in this particular part of the specimen at any rate, simply lies against

the scalp rather than being attached to it, and there are no blood-vessels passing from the one to the other.

A tongue-like projection of rather dense connective tissue (Fig. 33, *b*) passes inward from the scalp at one place—just at the edge of the specimen—and tends to partially surround the degenerated fragment of the cortex. This tongue-like mass blends with, or is perhaps a portion of, the extensive lamina of connec-

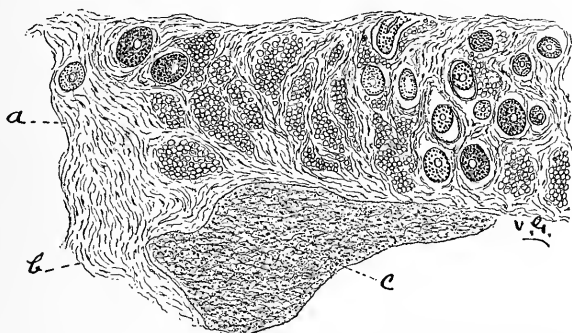


FIG. 33.—A Section through the Scalp in Case II., and Degenerated Cortex beneath showing their Loose Attachment.

tive tissue forming the upper layer throughout the rest of the specimen (see Fig. 34).

The bit of cortex lying underneath the scalp is very extensively changed. The ganglion cells are severely degenerated, many of them are reduced to mere hollow shells or skeletons surrounding the nuclei, and many others must have disappeared entirely. There is also a very perceptible increase in the size and number of the neuroglia cells. Both of these changes have reached such advanced stages that there is no difficulty attending their positive recognition.

Sections through the centre of the specimen show in a general way masses of dense connective tissue which encroach upon and cause material changes in the convolutions, as depicted in Fig. 34. Such a section from the centre of the specimen shows three convolutions, *A*, *B*, and *C*, two of which are involved by the connective-tissue growth, while a third, *A*, has escaped this encroachment.

The convolution *A*, although uninvolved by the connective-tissue growth and retaining its proper form and volume, is yet considerably changed. The ganglion cells are fairly extensively affected by various phases of a series of degenerative changes. Very many of the cells show the earlier and less well-pronounced stages of the degeneration, while a lesser number show the more extensive changes in the cell body tending toward complete disintegration of the cell as described in the previous case. Altogether the degeneration of the ganglion cells in this convolution is so well marked as to do away with the difficulties attending the recognition of the very early stages of the same process.

The neuroglia of the gray matter does not seem to be increased to any appreciable extent, but the white matter (*x*) is quite extensively involved by a growth of spindle-shaped and branching neuroglia cells. At the apex of the convolution this neuroglial increase extends a little distance into or seems to follow the passage of the nerve fibres into the gray matter.

In the convolution *B* the dense growth of connec-



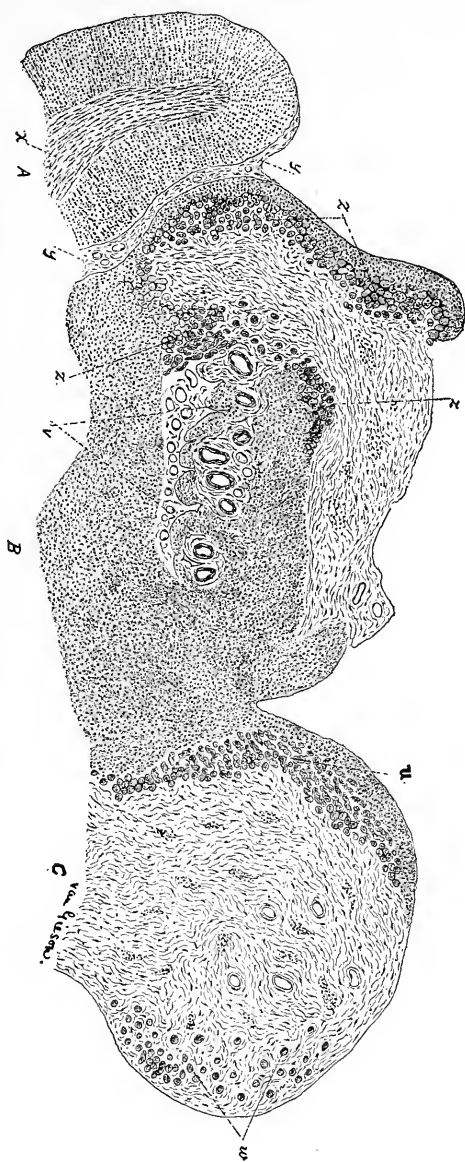


Fig. 34.—From a Section through the Centre of the Removed Portion, showing the Distribution of the Dense Connective-Tissue Masses which Replace Portions of the Convolutions. The convolution *A*, while retaining its normal shape and volume, shows extensive minute structural changes. The convolution *B*, partly replaced by connective tissue, is very extensively damaged in the remaining portions by the neuroglial hyperplasia. At *ZZZ* the cortex is converted into single or clustered islands of neuroglial tissue. *F* indicates a region where the cortex converted into neuroglial tissue is disintegrating and liquefying. The convolution *C* is still more extensively involved by the growth of connective tissue, and at *u* and *w* again shows the conversion of the cortex into insular masses of neuroglia.

tive tissue appears, hollowing out the apex of the convolution, and in many places at its junction with the gray matter fashions the latter into curious little islands or tubular plugs (Fig. 34, *Z, Z, Z*) often more or less surrounded by connective tissue. The brain tissue of the convolution *B* shows a tendency to become converted into neuroglia tissue, especially in the regions *Z, Z, Z*, where it consists entirely of neuroglia cells with their branching and tangled processes. In the other portions of the convolution there are quite a few degenerated ganglion cells scattered about among the proliferating or much-increased neuroglial elements, so that the rest of the entire convolution is extensively damaged, and the gray matter cannot be distinguished from the white matter except by the presence of the degenerated ganglion cells.

In the convolution *C* there is a still greater production of connective tissue and a corresponding diminution in the substance of the cortex. At (*u*) the plane of the section has cut the insulated masses of the cortex lengthwise, so that they appear as rather short convoluted cylinders. Some of these cylinders or plugs persist, completely isolated in the dense connective tissue, as little islands of neuroglial tissue (see Fig. 34, *w*).

When the process of insulation of clustered or isolated masses of the cortex is examined with more detail in a section at the junction of the connective-tissue masses with the cortex, the features shown in Fig. 35 (taken from the convolution *B*) are presented.

In such a section four tolerably distinct layers may be recognized. Proceeding from without inward toward the brain, there is at first the very thick extensive layer of dense connective which has already been topographically studied in the preceding paragraph. The first layer is apparent in Fig. 35 at *a*.

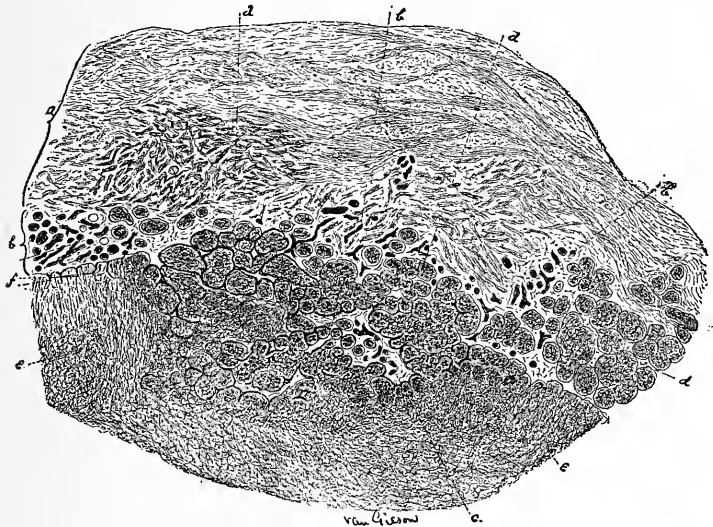


FIG. 35.—(From the convolution *B*) shows a more detailed view of the formation of islands of neuroglia tissue from the changed cortex at the junction with the connective-tissue masses, and consists of four layers, viz.: *a*, Layer of dense connective tissue; *bbb*, vascular layer; *ddd* and *c*, layer of clustered neuroglia islands; *ee*, the compact cortex largely converted into neuroglia.

It is composed of ordinary connective tissue, rather densely arranged, with its fibre bundles interlacing and running in various directions, and contains very few blood-vessels. The second and next layer is a vascular zone and lies immediately beneath the preceding layer. It is composed of a congeries of thin-

walled vessels, which give the impression that many of them are newly formed. This second layer is shown in Fig. 35 at *bbb* and *c*. Still proceeding inward, the third layer, *ddd*, is the one which consists of the clustered or discrete islands and plugs of neuroglial tissue. Finally, the fourth and last layer is the compact substance of the brain, *ee*, which has its neuroglia much increased and its ganglion cells quite thoroughly replaced or degenerated. In fact, this fourth layer represents brain cortex largely converted into neuroglial tissue.

Now the third layer of the insular masses seems in great part, if not entirely, to owe its origin to the agency of the newly formed vessels of the second or vascular layer. These thin-walled vessels appear to pass into the compact brain substance, and by anastomosing with each other and by sending off secondary offshoots surround little island-like masses of the brain, which has already been largely converted into neuroglial tissue. In Fig. 35, at *f*, the early stages of such a process can be observed. Here are delicately walled small vessels or capillaries growing into the brain, and by the course they pursue and by their tendency to unite with each other they exclude little island-like masses of the cortex.

Thus the layer of insular neuroglial masses seems to be formed from the compact brain by a peculiar segregating action of newly formed blood-vessels. It is further to be noted that following quite universally the layer of insular neuroglial masses, there is always

this vascular zone, intimately associated with them, and it lies between the dense masses of connective tissue and the islands. So the capillaries seem to determine the separation of neuroglial masses from the changed solid cortex and mould them into tiny islands or short cylinders (Fig. 36). In Fig. 36 (taken from

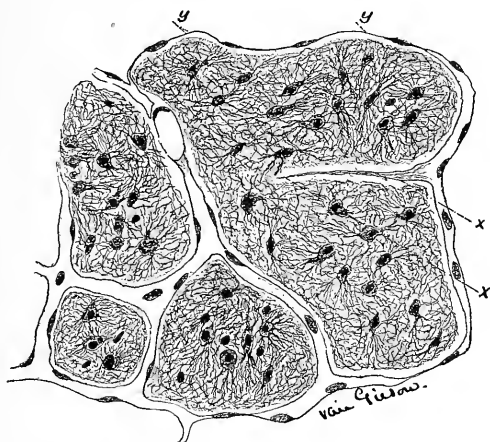


FIG. 36.—The Relation of the Capillaries to the Insular Masses of Neuroglia. *yy* is a collapsed capillary; *xx* indicates a solid protoplasmic offshoot of a capillary, which is destined to become a new vessel and subdivide one of the insular masses into two portions.

the region *C*, in Fig. 35) a still more detailed exposition of this relation of the vessels to the neuroglial islands is presented. Here the capillaries, one of them collapsed at *yy*, are seen surrounding the plugs and islands. But at *xx* is shown a stage of subdivision of one of these islands by a solid protoplasmic offshoot of a capillary destined to become hollowed out into a new blood-vessel. Care was taken not to confound this solid protoplasmic process with a collapsed capil-

lary, and it can be observed how it would divide the mass in two nearly equal parts by uniting with the opposite capillary.

Some of these masses of neuroglia persist as isolated little islands even in the midst of dense connective tissue, as shown in Fig. 37. In such instances, con-

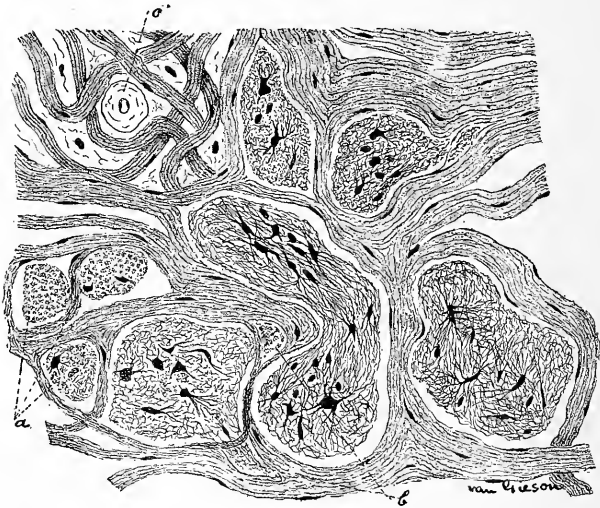


FIG. 37.—The Minute Structure of these Neuroglial Islands and their Persistence in the midst of Dense Connective Tissue. At *a* the filaments of the neuroglia cells are cut transversely, and at *b* two tongue-like extensions of a neuroglial island fill up two inter-fibrillary spaces.

nective-tissue fasciculi have apparently followed the course of the capillaries and have grown about the neuroglial islands. Fig. 37 also shows very faithfully the minute structure of these islands. They consist of rather large, glassy neuroglia cells completely enveloped by their own tangled and matted process. In the mass indicated at *a* the filamentous processes are

cut vertically, and at *b* two tongue-like processes of neuroglia pass beneath connective-tissue fascicles and fill up two inter-fibrillary spaces. The vessel, *c*, has a thickened or hyaline wall.

Finally, it is to be noted that the cortex for some little distance surrounding the connective-tissue growth is considerably damaged by a degeneration of the ganglion cells and an overgrowth of neuroglia.

*Remarks.*—It is exceedingly difficult to follow out the connected history of this process without having the opportunity to study the whole of the involved territory of the brain. The rather limited material examined in the removed specimen fails to show the lateral border zones of the process or the relations of the brain membranes, and in general the whole topographical distribution of the lesion. Thus there is no distinct clew to the origin of the process or to the formation of the cyst discovered at the operation. Still it may be said that this dense mass of connective tissue seems to have grown down rather slowly, apparently from the membranes of the brain, and by disintegrating portions of the brain beneath has contributed to the formation of the cyst, for there is in places distinct evidence of disintegration of the cortex beneath the overgrowth of connective tissue. The peculiar segregation of the little islands of the neuroglial cortex is seen in meningoceles of very young children, but whether any congenital deflection is behind the process in this case is a question which may be merely presented, but not commented upon.

*Results of Trephining in Epilepsy.*

When the result in these cases is reviewed, it is evident that in the majority there has been a failure to permanently cure epilepsy by operative interference. When we raise the question why the operation has failed, the obvious reply is offered that the original condition which gave rise to the fits has not been removed. This is evident from a study of the pathological changes already enumerated. It is, of course, quite possible to elevate depressed bone, to remove a cyst, or to take away any mass of connective tissue or tumor which compresses the brain. But on the other hand it is useless to break up adhesions between dura and pia or between pia and brain, because they will inevitably re-form immediately after the operation. Nor is it possible to accomplish anything when the pia and cortex are together affected by such connective-tissue changes as have been described. Fine trabeculæ of connective tissue entering the cortex from the pia and forming a dense scar tissue in and about the motor cells give rise to an irritation which can only be removed by the excision of the mass. But excision of such a mass together with the brain, or excision of a softened mass of brain, is inevitably followed by a formation of a connective-tissue cicatrix which in turn will act as an irritant.

Thus the pathological conditions met with in these cases are frequently such as to make any possibility of a relief by an operation out of the question.



I think the fact that the underlying organic brain disease producing the epilepsy cannot always be eradicated by an operation fully explains the failures which have been recorded by so many observers.

The question then arises, Shall we continue to trephine any cases of traumatic or localized epilepsy? Judging by general results which are unfavorable, we should be inclined to stop. But when it is taken into consideration that in no case is it possible without an operation to determine the exact pathological condition present, and that a certain proportion of the pathological conditions are removable, it is evident that an operation if not attended with danger may be reasonably undertaken. Some patients have undoubtedly been cured.

The statement should be made to the patient: You have a brain disease; that disease is causing fits; that disease may be curable by operation; we cannot tell whether it is curable until we operate; we cannot promise that the operation will in any way benefit; a majority of chances are against cure, but it is the only method of treatment which affords any hope whatever, and it is a method which is fairly safe.

## CHAPTER III.

### **TREPHINING FOR IMBECILITY DUE TO MICRO- CEPHALUS.**

Clinical Types of Microcephalic Children: (1) Paralytic Cases; (2) Imbeciles; (3) Cases of Sensory Defect. The Occurrence of Epilepsy in these Children. The Pathology of these Clinical Types. The Operation of Craniotomy and its Results. Table of Cases. Report of Personal Cases. Conclusions.

THE medical treatment of imbecility occurring in childhood is so hopeless that the recent proposal to invoke the aid of surgery in these cases has excited much interest. The public, as well as the medical profession, is anxious to learn how far success may be looked for from craniotomy, and to obtain facts upon which to decide the question of operative treatment. To neurologists the subject is of immediate importance, for they must be responsible for advising or opposing this method of treatment.

Craniotomy, or the operation of producing an opening in the skull of some extent, with the object of relieving pressure on the brain, or in some unknown manner of stimulating its development, has been proposed and performed in a number of cases.

#### *Clinical Types of Different Kinds.*

These cases present certain clinical features, and may easily be divided into three general groups: First,

cases of hemiplegia with or without athetosis. Secondly, cases of mental defects of various grades. Thirdly, cases of sensory defect of different types. Epileptiform seizures of petit mal or of grand mal type occur frequently in patients who may be assigned to any one of these groups, and may be the particular symptom in regard to which advice is sought. The subject, therefore, includes the question of trephining in organic epilepsy in childhood.

I. Infantile cerebral hemiplegia has been studied so carefully of late, and so much has been written upon it, that no elaborate description of the first class of cases is needed. The symptoms are the sudden development of a unilateral paralysis after a series of convulsions attended by high fever and its attendant discomforts, and a period of unconsciousness of varying duration; then a gradual improvement in the paralysis after the active manifestations of the onset have subsided; and, finally, a stationary condition, in which the face is but slightly affected in its voluntary or automatic movements; the speech is usually regained, if it had been lost; the arm is quite seriously paralyzed, the fingers being stiff and awkward, and sometimes being in constant slow involuntary motion (athetosis); the leg is held rather rigid, so that the child limps in walking and sometimes has a club-foot. There are, of course, on the one hand light cases in which the symptoms finally amount merely to clumsiness in the fingers. There are, on the other hand, severe cases in which a double hemiplegia has

occurred, both halves of the body being equally affected, and in which both arms are useless and both legs so stiff, so closely adducted, and so helpless that walking is impossible. These latter are cases in which all the symptoms date from birth, the birth palsies of Gowers. In all cases the paralyzed limbs are found to be affected in their growth and development, so that they are smaller, colder, stiffer, and weaker than the others; the reflexes are exaggerated, but the electrical reactions are not qualitatively changed and the sensation is normal. This condition remains through life as a permanent defect, and although the division of contracted muscles or tendons and the application of ingenious apparatus may correct deformities and make the paralyzed parts fairly useful, and although the application of electricity to the muscles chiefly affected may increase their nutrition and thus prevent contractures which come from the unbalanced strain between the various muscles, yet any great degree of improvement is impossible. In more than one-half of these cases epileptic attacks are of frequent occurrence.

These cases are so common that it seems needless to cite illustrative examples. In the well-known monographs of Osler and of Sachs on the "Cerebral Palsies of Children," the most complete description of the varieties of the affection is to be found. In the history of one of my cases, operated upon by Dr. McBurney—which is given later in this chapter—the ordinary course of the symptoms may be studied.

The chief clinical facts of importance in such cases are the time and character of the onset, the degree of spontaneous recovery, and the question whether the epilepsy is of so severe a type as to be dangerous.

The cases which date from birth must be divided into those in which there has been evidence of traumatism during labor, and those in which there was nothing about the delivery sufficiently unusual to awaken the suspicion of trauma. In the former class it may be stated confidently that cerebral hemorrhage, usually meningeal, is the cause of the symptoms. In the latter class it is probable that an intra-uterine encephalitis, or some unknown cause, has prevented the foetal brain from developing. I know of no positive means of differentiating these two sets of cases. The cases which have developed suddenly after birth are cases in which the ordinary causes of hemiplegia in adults have been acting, and, as Ashby has shown, must be traced either to encephalitis, hemorrhage, or embolism, or disease of the vessels. The degree of spontaneous recovery in any case can be pretty well determined by an examination at the end of the second year. It is evident that a complete cure never occurs.

The fits in organic epilepsy are more likely to be frequent and severe than in idiopathic epilepsy. I have one patient who has had as many as twenty convulsions daily for weeks at a time. These fits do not destroy life, but of course render life a burden, and almost any means for their relief is justifiable. When,

however, they are infrequent they may be benefited to some degree by the use of bromides.

II. The second class of cases presents mental defects rather than physical symptoms. The child may be slow in learning to talk, may seem unable to fix its attention upon anything continuously, may be exceedingly active, in constant motion—the activity being, however, aimless; may throw things about, or tear things up, or put everything into its mouth; may be very difficult to manage because of its inability to retain and combine impressions with sufficient power to reason upon them; and may, therefore, be incapable of appreciating the meaning of punishment, if this be inflicted. Such children may have good powers of perception, may recognize persons and objects, show pleasure at bright colors, or music, or caresses, but fail to show evidence of thought in the sense of reasoning power, judgment, or self-control. Some patients constantly drool at the mouth, cannot be taught cleanly habits, and are manifestly imbecile. Other patients are quite bright in many directions, may even be precocious, show talents in music, or drawing, or fondness for mathematics, designing, languages; yet are apparently unable to appreciate moral ideas, cannot be taught to tell the truth, are cruel and bad, will not control any of their impulses, and so are the distress and despair of parents and teachers. It is those mental qualities which are the product of the highest evolution which have failed to develop in this class of cases. The final result is that they have to be taken

care of all their lives, either at home or by attendants, being incapable of supporting themselves or directing their conduct. Many of them have epilepsy. One or two examples may be cited.

G. M., now 21 years of age, has the appearance and manner of a boy of fourteen. His head is small and narrow; forehead retreating; face small and expression stupid. He has always been a feeble-minded boy, never able to study long or to learn anything difficult, so that he is about on the level of a boy of ten in his education; and now, as he is becoming to some extent sensible of his defects, he is very moody, quiet, and retiring. He has always been hard to manage and prone to outbursts of temper, and in the past five years this irritability is increasing. He has also peculiar attacks. In an attack he is very restless, wanders about in an aimless way, hides or destroys anything he can lay his hands upon, and becomes much excited, angry, and even abusive and violent if opposed. Such attacks last for three or four hours, during which it is necessary to watch him. After the attack is over he has no recollection of what has occurred or of what he has done. He has many symptoms of neurasthenia, probably due in part to self-abuse. He has no paralysis or defect of sensory power. He is able to read, write, play on the violin, and sketch, but cannot be employed upon anything for any length of time, and therefore is a burden to his family.

I have three cases now under observation of children aged between three and five, who are apparently bright and capable of hearing and seeing properly, but who show no evidence of any desire or ability to learn to talk. They make crowing sounds of no special meaning, but any distinct articulation is never made, and attempts to teach them seem unavailing. All

three are restless, active children, easily attracted by interesting things, but incapable of fixing the attention long on anything. They are usually in constant motion, running about, working with the hands, and cannot be quieted long. They appear to understand perfectly what is said to them, will do various things at command, notice music and noises, yet are as mute as though perfectly deaf. They present a fair degree of intelligence, though two of them are still unable to be taught to make any sign of desire to urinate, and hence are dirty. Yet to watch these children at play at home, one would not suspect any mental weakness, and were it not for the speechlessness the parents would not have suspected any defect. None have epilepsy as yet.

III. The third class of cases is less common than the two preceding, and is likely to escape observation unless carefully investigated. The patients belonging to this class present no motor or mental defects, though they may be the subjects of epilepsy. They do have defects of sensory perception. It is probable that many cases of deaf-mutism belong to this class. Rheinhardt has described a case in which permanent deafness was due to manifest defects in the temporal convolutions of both sides. Dr. Donaldson has noticed a marked deficiency of development in the temporal and occipital convolutions of Laura Bridgman, who was both deaf and blind. The following case presents so many interesting features that I give the history in full:



The girl, who is now fourteen years of age, has suffered all her life from frequent attacks of petit mal and occasional attacks of grand mal, usually preceded by an epigastric aura, never by a visual aura, and her convulsions are general, never unilateral, in character. She has had from two to six attacks of petit mal daily, and grand mal attacks once a week, though at present, after three years of treatment by bromides, she has but three or four attacks of petit mal every week, and has had no grand mal attacks for two years. Her case, therefore, presents the features of an ordinary epilepsy.

But upon investigation it was found that she had a slight divergent squint and a left bilateral homonymous hemianopsia, the visual fields in the eyes being much diminished, not exactly symmetrically, and the field of vision extending ten degrees beyond the fixation point in both eyes, while its periphery was slightly contracted even in the clear field. This condition had never been discovered until the child was eleven years of age, although from her infancy her mother had noticed that she habitually held her head toward the left side and looked at objects with her head turned somewhat to the left, as she does now. An examination by Dr. Webster for the purpose of correcting the squint led to the discovery of the partial blindness. The child is quite sure that she has always seen as she does now, that she has never been able to see objects approaching her from the left side. This she supposed to be natural. This fact is of some interest, as it confirms what has been stated before, that hemianopsia may remain undetected for years, or if noticed by a patient is supposed to be a blindness in the eye whose visual field is chiefly contracted.

When a cause for this symptom was sought, it was ascertained from the mother that the child had been delivered with much difficulty, that the labor was prolonged, that the head was greatly misshapen at birth, and had a large caput succedaneum over the posterior part. When

the child's head was inspected, it was found that over the right occipital region there was a very perceptible flattening of the skull, so that the vertical parting of her hair was uniformly deflected to the right. The difference between the two sides was easily noticeable on looking down upon the head from above, or by the aid of touch. It seems reasonable to suppose that this little girl has a defective development of the right occipital lobe of the brain, and that this involves the cortex and also the subcortical tract, since Wilbrand has shown with much reason that a purely cortical lesion produces symmetrical defects in the visual field, while subcortical lesions produce asymmetrical defects. The pupils respond to light thrown upon the blind field of the retina, hence the lesion is not in the optic tract. There has never been any hemianæsthesia or hemiplegia, hence the lesion is not in the thalamus or near the internal capsule.

Peterson and Fisher have shown that cerebral atrophy in infants in the motor area is followed by an asymmetrical development of the skull, the depression in the skull lying over the atrophic part of the brain. Here there is present such a depression, or rather lack of convexity, over the occipital lobe to whose deficient development the symptom of blindness points.

When, therefore, this patient presented herself for treatment for epilepsy, it became evident that she belonged to the class of cases in which the epilepsy was due to the organic disease or defect in the brain.

It is interesting to note that a certain improvement in her condition—a marked diminution in the number of fits—has occurred under the influence of bromide; but this has also been noticed in cases of epilepsy with hemiplegia of infantile origin.

The important question to decide in this case is in regard to the possibility of any surgical interference. The history certainly points to the occurrence of great

congestion of the head during delivery, and the brain injury may reasonably be ascribed to a hemorrhage upon or in the occipital lobe. Such a hemorrhage compressing the lobe would prevent its growth, would finally be absorbed, leaving probably only a connective-tissue plaque or membrane. Now, it is known that brain-growth proceeds until the age of fourteen or thereabouts, and the question arises whether removal of this plaque would allow this brain to develop. It is hardly supposed that vision would be improved, but might not the epilepsy be benefited? As in the cases of hemiplegia and of mental defect, the question becomes a pressing one, involving the future of the individual.

This case is not a unique one. Moeli has recently published (*Arch. für Psych.*, XXII., 2) three cases of hemianopsia due to defective development of the occipital lobe with porencephalus or great hydrocephalus, found in adults, one at least of whom had epilepsy. In all the affection must have dated from infancy. In none of these would an operation have been feasible; in fact, in all secondary degeneration had developed even into the optic tracts. Henschen records two cases of infantile hemiplegia in which hemianopsia was found ("Pathol. des Gehirns," cases 32, 33); and Freund (*Wien. med. Woch.*, 1888, No. 32) also records two such cases. It is probable that the symptom has escaped detection in some cases of infantile hemiplegia from lack of examination.

It is evident, then, that three separable types of

clinical cases of cerebral disease exist, any one of which may be accompanied by epilepsy. It is of course possible that one case may present the symptoms of all the various types, and in fact there are many patients who present both mental defects, hemiplegia and sensory defects, as in a patient to be described later, on whom an operation was performed. One of these varying sets of symptoms, however, is usually more prominent than others, and hence it is hardly necessary to establish a fourth type including all such anomalous cases.

When a patient belonging to one of these clinical types is presented to the neurologist and the question is asked, Can surgical treatment benefit him? it is evident that a serious problem is opened. In these cases the disease is at a standstill and does not threaten life; surgical treatment is not free from danger, and the brain is still capable of great development. Can such development be aided by an operation? In many cases the epileptic attacks are of such frequent occurrence that any risk might well be taken if they could be surely stopped.

Any solution of the problem of operative treatment must be based upon two considerations: first, the pathology of the cases; secondly, the results of experience when such operations have been done.

#### *Pathological Conditions Present.*

Records of the pathological condition found in all the three classes of cases described are now accessible, col-

lections of cases with autopsies having been made by numerous writers.

The lesions found are various in type, in origin, and in situation, but a careful study elicits two facts: First, that the difference in the clinical types is due to the varying situation of the lesion rather than to its

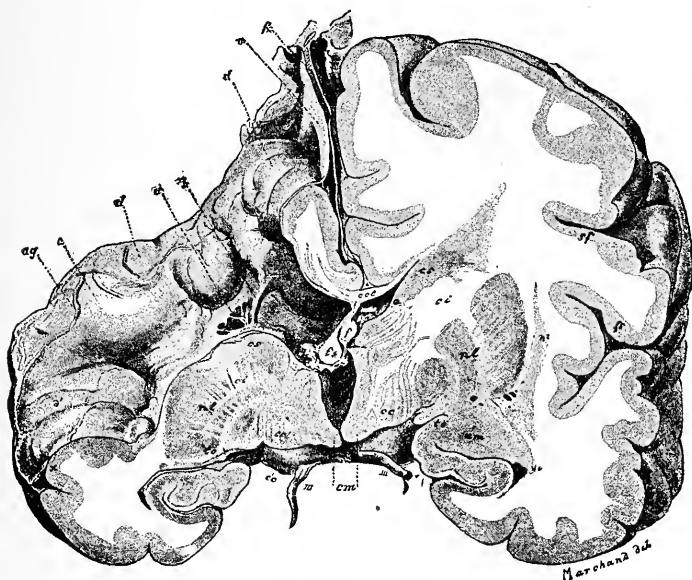


FIG. 38.—A Frontal Section through a Porencephalic Brain. The left hemisphere is normal. The right hemisphere is atrophied *in toto*, and has a cavity in the motor region which extends downward into the ventricle. The basal ganglia are atrophied. This condition is always congenital.—Shattenberg.

varying nature. Secondly, that the various processes of disease have, as a fairly uniform result, a condition of atrophy with sclerosis of the brain, which we may term sclerotic atrophy.

1. In the clinical cases of our first type the sclerotic atrophy involves the motor area of the brain, *i.e.*, the

central convolutions bordering the fissure of Rolando and the cortex of their immediate vicinity, and involves also the motor tract arising from this part of the cortex, and usually the basal ganglia as well. In the clinical cases of our second type the sclerotic atro-

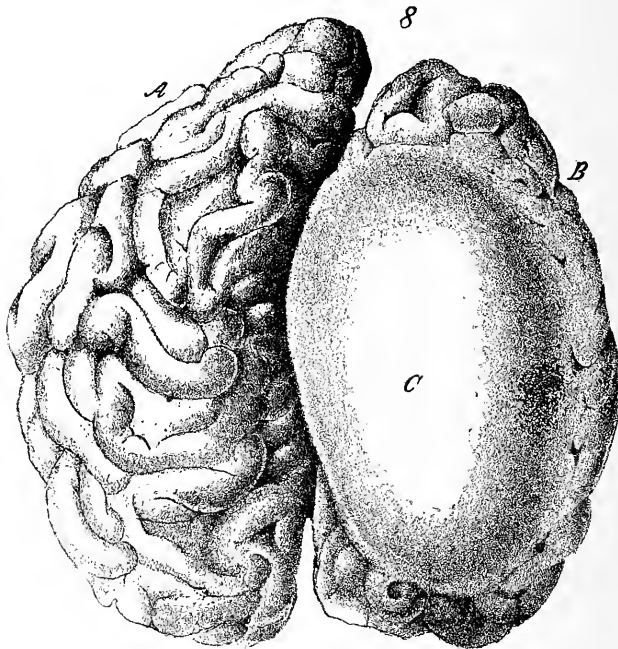


FIG. 39.—Superior Surface of a Brain of a Congenital Imbecile who had Hemiplegia and Epilepsy. The entire right hemisphere is atrophied. *C* is the arachnoid, which was thickened and formed the wall of a cystic cavity in the hemisphere.—Ferraro.

phy involves the anterior portion of the brain, and sometimes the entire hemisphere to a greater or less extent. In the clinical cases of our third type the sclerotic atrophy involves the posterior and lateral parts of the hemispheres. It is not surprising that

the variation in the situation should produce varying symptoms, in view of the facts of the localization of brain-functions now known. That there should be a limitation of the sclerotic atrophy to certain lobes or regions—to the frontal, or central, or occipital, or

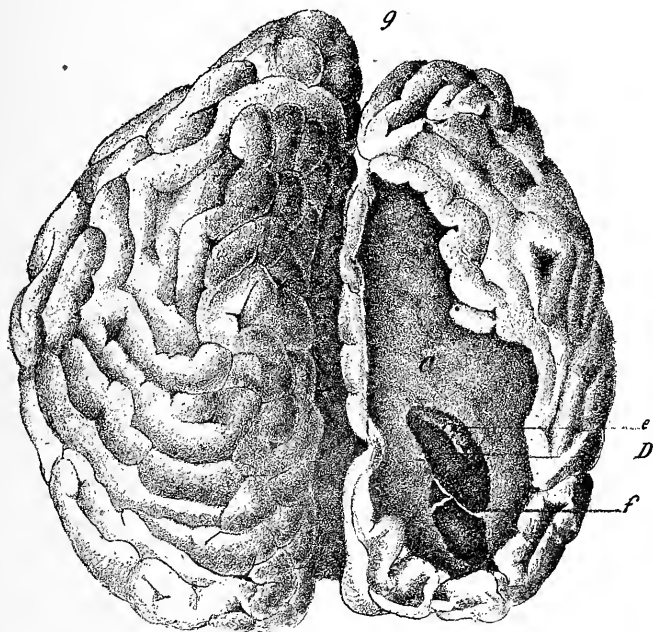


FIG. 40.—Superior Surface of the Brain of a Congenital Imbecile. The arachnoid being removed the porencephalic cavity is displayed. The cortex is wholly defective over the upper frontal and parietal lobes and the cavity in the hemisphere opens into the lateral ventricle at *D*, in which the choroid plexus, *e*, is seen.—Ferraro.

parieto-temporal regions—in various cases has led to the hypothesis that the origin of the disease lay in some interference with the blood-supply of the part, since it has often been evident that the atrophy was limited to the region nourished by blood reaching it

through one arterial trunk. And this hypothesis has been supposed to explain the pathogenesis of these cases. Yet its weak point is the fact that at the autopsies the vessels usually show no evidences of disease or of plugging, and the infrequency of vascular lesions in infancy cannot be denied. Schultze is doubtless right in this matter in saying that the pathogenesis of these defects is as yet quite obscure.

2. It has been stated that the various processes of disease have, as a uniform result, a condition of sclerotic atrophy.

This fact is borne out by the following *résumé* of results in 343 cases:<sup>1</sup>

*Porencephalus*, a localized atrophy or agenesis, leaving a cavity in the cerebral hemisphere, which may be deep enough to open into the ventricle, 132 cases.

Fig. 38 shows this condition. The right hemisphere is smaller than the left, and has a funnel-shaped cavity leading directly downward from the side of the cortex into the lateral ventricle.<sup>2</sup>

Figs 39 and 40 also show a condition of porencephalus, the drawings being made before and after the removal of the pia mater. The right hemisphere is seen to be atrophied *in toto*, and the arachnoid is so thickened as to form an opaque wall of a cyst. On

<sup>1</sup> This number of cases has been gathered from the records of Kundrat, Audry, Wallenburg, Osler, Wilmarth, Feer, Henoch, Hirt, Fowler, Schultze, Sachs, Richardière, Bourneville, Fisher, and from the American and foreign journals of the past three years, duplicates being sought and excluded.

<sup>2</sup> This case is described by Shattenberg in Ziegler's "Beiträge zur Path. Anat.," vol. v., p. 123, 1889.



removal of the pia the brain cortex was found to be defective in large part and the cavity opened into the lateral ventricle.<sup>1</sup>

*Sclerotic atrophy*, an atrophic condition of the brain with an increase of connective tissue and disappearance of the nervous elements; affecting both hemispheres, or one only, or a part of one only; or limited to small areas in various parts, 97 cases.

This condition is well shown in Figs. 41 and 42. They are photographs of a brain kindly put at my disposal by Dr. E. D. Fisher. The patient was a girl aged 19 at her death, who had been an imbecile and hemiplegic since birth and was subject to epilepsy. The condition was described by Dr. Fisher before the American Neurological Association in 1888, and this brain came from Case XXV. in his collection.

*Maldevelopment* and apparent atrophic condition of the minute structures of the hemisphere, chiefly cortical, the cells resembling those of a new-born child, but with no apparent gross defects in the brain, 32 cases.

*Atrophy*, consequent upon the condition of softening produced by embolism or thrombosis, and limited in extent to certain arterial districts of the brain, 23 cases.

*Meningo-encephalitis*, a condition shown by thickening and adhesion between the pia and the brain, with destruction of the cerebral cells and atrophy of the cortex, 21 cases.

<sup>1</sup>This case is described by Ferraro in *Revista Inter. d. Med. e Chir.*, Aug., 1886.

*Cysts* lying on the brain and producing atrophy by pressure, or associated with atrophy due to the original lesion of which the cyst remains as a trace, 14 cases.

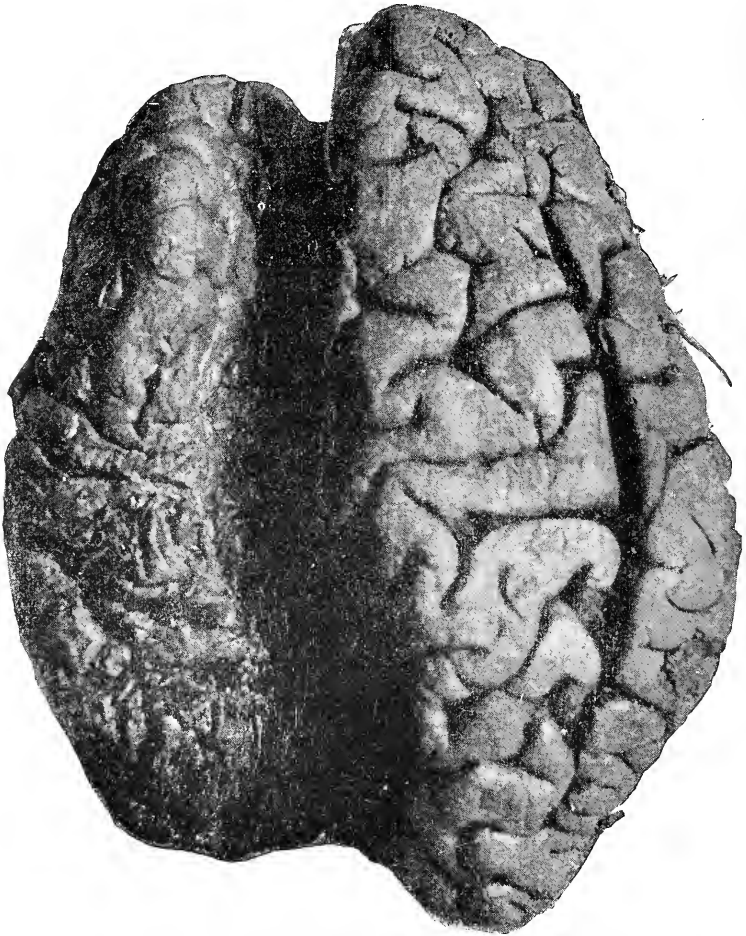


FIG. 41.—The Superior Surface of the Brain from a Case of Sclerotic Atrophy of the Left Hemisphere. The entire hemisphere is atrophic, but the frontal convolutions are less affected than the others.

*Hæmorrhage* on, or in, the brain, as shown by the remains of a clot, or by hæmatin staining of a cyst, of the pia, or of the sclerotic tissue, 18 cases.

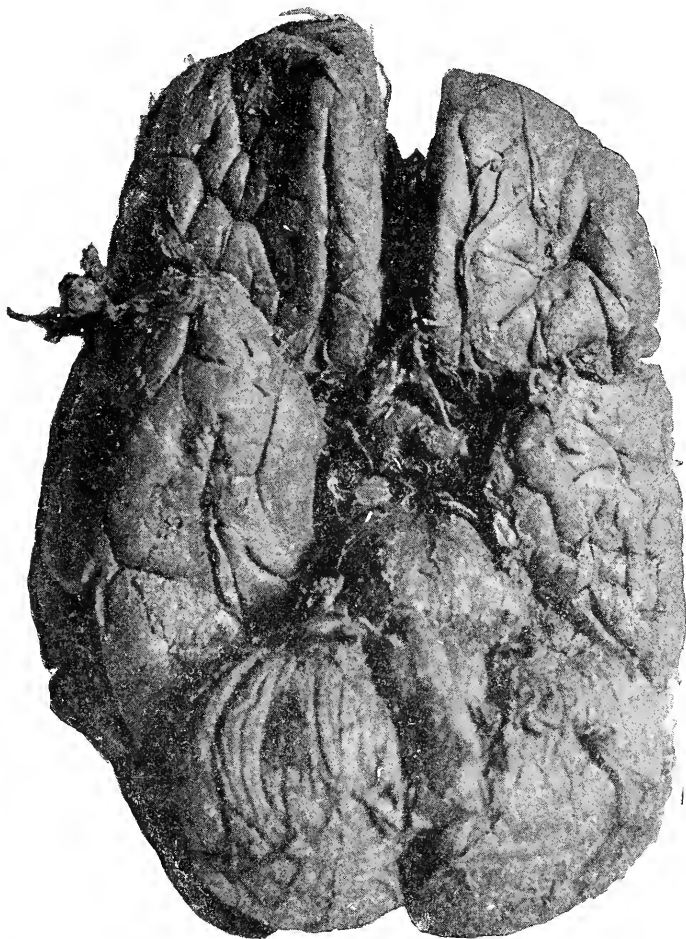


FIG. 42.—The Inferior Surface of the Brain from a Case of Sclerotic Atrophy of the Left Hemisphere. The frontal lobe is not greatly affected. The left temporal lobe is very much smaller than the right one. The right hemisphere of the cerebellum is atrophic. The left pyramid of the medulla is smaller than the right one.

*Hydrocephalus* with extreme dilatation of the ventricles, so that the brain tissue is reduced to a mere wall about the cavity, 5 cases.

Unilateral hydrocephalus, 1 case.

These are the conditions found at death in cases presenting the clinical features just studied. It is evident that they have this in common, namely, a condition of atrophy of the brain. The origin of this

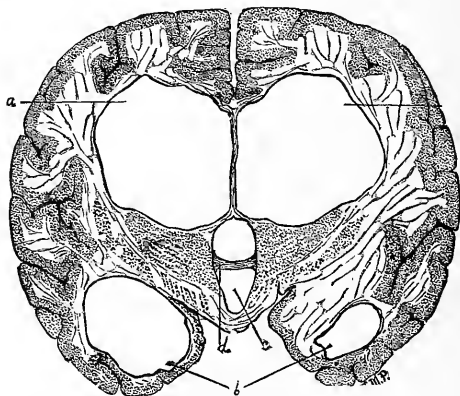


FIG. 43.—Distention of the Ventricles in a Case of Hydrocephalus; a frontal section being made through both hemispheres at the posterior part of the optic thalamus. *aa*, Lateral ventricles; *b*, descending horns of the lateral ventricles; *c*, third ventricle; *d*, middle commissure.—Delafield and Prudden.

atrophy is not always clear. In some cases it is clearly congenital and due to a maldevelopment of the embryo. In other cases it is clearly traceable to injuries at birth. Again, in other cases it must be ascribed to affections of various kinds, such as inflammations of the membranes, or of the brain substance, or vascular lesions and their consequences, such as occur in adults.

It is not always possible, in a given case, to deter-

mine clinically the origin of the disease. For the absence of a history of trauma at delivery does not exclude necessarily a congenital lesion. And the existence of certain symptoms in acquired cases does not always enable one to determine between an inflammatory process and a vascular lesion. Thus fever of long duration and great severity is as likely to occur in hemorrhage or embolism as in meningo-encephalitis in infants.

Nor are authorities by any means agreed as to the nature of the original pathological process of which the atrophy is the result. Wallenburg found evidences of embolism in 7 cases and of hemorrhage in 5 cases. Osler ascribes these causes to 16 cases in his collection. Ashby describes thrombosis in 3 cases, one of them due to syphilitic endarteritis, a very rare disease in infancy. McNutt found meningeal hemorrhage in 12 cases. Gowers ascribes some of the birth palsies to thromboses of the venous sinuses. Kundrat has recently affirmed that a laceration of the veins entering the sinus is a sufficient cause for hemorrhages during delivery.

Henoch, Oliver, Sachs, Hirt, and others, have described a condition of meningo-encephalitis as present in these cases, and Wallenburg considered this the primary condition in 14 cases of his collection. Strümpell's theory of an inflammation limited to the gray cortex has been discarded from lack of evidence. Thus it is evident that diseased states of the blood-vessels, their rupture or their plugging, or inflamma-

tory conditions of the meninges or brain, may be the primary conditions in many cases of sclerotic atrophy and of porencephalus; conditions which vary very widely and which it is often impossible, clinically, to distinguish from each other. It is also evident that in quite a proportion of cases the origin of the atrophy must be a maldevelopment, whose real reason is wholly obscure.

From this review it is apparent that many of the conditions are of such a nature as to be wholly unaffected by an operative interference. A porencephalic cavity, filled with cerebro-spinal fluid, is not likely to be benefited by any enlargement of the intra-cranial space, or by the abstraction of the fluid. In several cases operated upon the withdrawal of this fluid has been followed by sudden collapse and death.<sup>1</sup> On the other hand, there are conditions, such as maldevelopment of the cortex without gross lesion, in which it is possible that anything which may stimulate latent powers of growth, or may remove those influences which interfere with development, might result in improvement. It is to be remembered that the brain is capable of growth and development until the age of twenty, if not longer, and granting that a stimulus to its growth may be given during childhood, that the arrest of development in many cases might perhaps have been prevented.

<sup>1</sup> Cases of Bullard: Boston Medical and Surgical Journal, February 16th, 1888. Hammond: New York Medical Journal, August 12th, 1890.

The study of the pathological condition, therefore, does not absolutely contra-indicate the operative interference, although it makes it clear that the lesion in the majority of the cases is one which cannot be improved by any means. If we admit that porencephalus, atrophy from vascular lesion, meningo-encephalitis, and hydrocephalus are incurable, and that hemorrhages cannot be diagnosticated early enough to warrant the removal of the clot before it has caused atrophy from pressure, we have 193 cases out of 343 in which operation would have been futile. This leaves 150 cases of sclerotic atrophy, maldevelopment of the cortex, and cysts, in which it is barely possible that an operation, if it relieved pressure or stimulated brain-growth, might have had some effect. It is only by the latter hypothesis that the apparent improvement in certain cases can be explained.

The unfortunate fact remains that it is impossible to ascertain the actual pathological condition present without an exploratory operation, as no clinical facts are at our disposal to enable a pathological diagnosis to be made.

A suggestion is here offered incidentally, that when operation is undertaken the surgeon, before opening the dura, should, by manipulation or by exploration with a hypodermic needle, ascertain if possible whether a cavity in the brain exists beneath the opening in the skull, and if so avoid opening the dura lest the evacuation of this cavity result in death.

*The Results of Experience.*

Let us review secondly the results of the experience of surgeons in the treatment of these cases by operation.

The operation of craniotomy has been done by many surgeons during the past three years, and the results have been reported by several of them, notably by Lannelongue, Keen, Bullard, Oppenheim, Frank, Hammond, Horsley, Agnew, and Park. Many other operators have reported single cases.<sup>1</sup>

The accompanying table of thirty-four cases gives the name of the operators, the journal in which the report is given, the age of the patient, the symptoms for which operation was done, and the result, with the time which had elapsed before the result was reported. Lannelongue's cases are not included in the list. He stated at the French Congress of Surgery in Paris, in April, 1891, that he had operated twenty-five times with but one fatal result, and remarked in general terms that the patients—who were chiefly microcephalic infants or epileptic children—improved after the operation. Lannelongue's method of operation was to make a V or U shaped groove through the skull on one side, thus hoping to relieve intracranial pressure. As more precise facts are needed, these cases are excluded from the table.

<sup>1</sup> For a discussion of the methods and dangers, Dr. Keen's able paper in the American Journal of the Medical Sciences, June, 1891, may be consulted.



TABLE I.—CASES OF CRANIOTOMY IN CHILDREN.

Reporter.	Condition for which Operation was Performed.	Age (Years).	Result.	Time of Report after Operation.
Bradford and Bullard: Boston Surgical and Medical Journal, February, 1888.	Hemiplegia; imbecility.	4½	Death from shock in twenty hours. Porencephalus.	
Frank: American Journal of the Medical Sciences, July, 1890.	Double hemiplegia; imbecility.	6	Death from shock in three days.	
Bartlett: Hahnemann Monthly, May, 1890.	Hemiplegia; imbecility; epilepsy.	16	Recovery from operation.	10 days.
Oppenheim: Deutsche Medicinische Wochenschrift, May, 1890.	Hemiplegia; epilepsy.	12	Paralysis improved, fits less frequent.	2 mos.
Hammond: New York Medical Journal, August, 1890.	Hemiplegia; imbecility; epilepsy.	19	Death from shock in five days. Porencephalus found	
Trimble: Medical News, January, 1891.	Idiot; had never walked; microcephalus.	3	Some improvement.	1 mo.
Wyeth: New York Medical Record, February, 1891.	Imbecility; microcephalus.	11 mo.	Very great improvement.	2 yrs.
Anger: Progrès Médical, April, 1891.	Imbecility; microcephalus; epilepsy	8	Improvement.	
Maunoury: Progrès Médical, April, 1891.	Microcephalus; epilepsy; idiocy.	2	Death in twenty hours from shock	
Maunoury: Progrès Médical, April, 1891.	Double hemiplegia; athetosis; epilepsy; idiocy.	4	Improved for three months, then all symptoms returned.	5 mos.
Heurtaux: Progrès Médical, April, 1891.	Microcephalus; epilepsy.	5½ mo.	Death from exhaustion in five weeks.	
Keen: American Journal of the Medical Sciences, June, 1891.	Imbecility; microcephalus; epilepsy	4½	No marked improvement. Second operation three months later; no change.	5 mos.
Keen: Loc. cit.	Imbecility; microcephalus.	1½	No improvement. Second operation three months later; no change.	5 mos.
Keen: Loc. cit.	Imbecility; microcephalus.	1½	Death from shock in one hour.	
Gerster and Sachs, reported by Keen: Loc. cit.	Imbecility; microcephalus; epilepsy	4½	Death from shock in three hours.	
McClintock, reported by Keen: Loc. cit.	Idiocy; hemiplegia; blindness.	3½	Improved. "Paralysis almost disappeared."	1 mo.

TABLE I.—CASES OF CRANIOTOMY IN CHILDREN.—*Continued.*

Reporter.	Condition for which Operation was Performed.	Age (Years).	Result.	Time of Report after Operation.
Horsley: British Medical Journal, September, 1891.	Idiocy; microcephalus.	3	Some improvement.	
Horsley: Loc. cit.	Imbecility; microcephalus; epilepsy.	7	Death from fever on second day; brain normal.	
Willard, reported by Agnew: University Medical Magazine, October, 1891.	Imbecility; atetosis.	5	Death on third day from scarlet fever.	
Morrison, reported by Agnew: Loc. cit.	Imbecility.	2½	Improved.	
Hammond: Medical News, October, 1891.	Aphasia; traumatism; epilepsy.	3	Cure of aphasia and of epilepsy.	2 yrs.
Hammond: Loc. cit.	Hemiplegia; traumatism; epilepsy at eight years of age.	38	Death in fifty days from exhaustion.	
Fisher: Medical News, November, 1891.	Insanity; epilepsy; trauma at two years of age.	30	Fits at first fewer; later, no improvement.	2 mos.
McBurney and Starr: Medical Record, January, 1892.	Hemiplegia; epilepsy.	6	Improvement very marked.	9 mos.
Hartley and Starr: Medical Record, January, 1892.	Imbecility; epilepsy; hemiplegia; aphasia.	7	Improvement in paralysis and aphasia; fits, same.	6 mos.
Preugmeber: Neurol. Central, January, 1892, p. 294.	Imbecility.		Improvement.	3 mos.
Park: Medical News, December, 1892.	Imbecility.	3½	Great improvement.	1½ yrs.
Park: Medical News, December, 1892.	Imbecility; microcephalus.	4	No change.	1½ yrs.
Park: Medical News, December, 1892.	Imbecility; microcephalus.	18	Death in twelve weeks.	
Park: Medical News, December, 1892.	Epilepsy; imbecility.	15	Death from shock.	
Park: Medical News, December, 1892.	Epilepsy; imbecility; microcephalus.	9	Great improvement.	1 year.
Park: Medical News, December, 1892.	Epilepsy; imbecility.	12	No fits for three months.	
Park: Medical News, December, 1892.	Imbecility.	14 mo.	No improvement.	6 mos.
Bennie: Kansas City Medical Index, xiii., 125.	Microcephalus; imbecility.	10 mo.	Death from shock.	

It will be noticed that of 34 cases 14 died. This demonstrates that the operation of trephining is a more serious one in childhood than in adult life. Death has been due in 10 cases to shock from sudden evacuation of cerebro-spinal fluid, or from the severity and length of the operation, and under these circumstances it has occurred within a few hours or days of the operation. In 2 cases it has been due to exhaustion, and has not taken place within a month of the operation. This is a much greater mortality than occurred in Lanne-longue's experience.

Two criticisms must be offered upon the reports of this class of operations. First, they are considered too exclusively from a surgical standpoint, and recovery from the operation may often be misconstrued as recovery from the original condition. Secondly, they are reported too soon after the operation to warrant any very positive statements regarding its permanent effects.<sup>1</sup> In some cases the paralysis has been markedly relieved. In some cases the epileptic attacks have been said to be diminished in frequency and severity, or have been modified in character; but when the undoubted fact is admitted that any operation may modify the course of epilepsy,<sup>2</sup> such statements must be subjected to the test of long observation. It will be noticed that Maunoury reports an improvement for three months followed by return of

<sup>1</sup> See also criticism by Bourneville, Arch. de Neurol., 1892, No. 71.

<sup>2</sup> See Dr. J. William White on the supposed curative effects of operations *per se*: Annals of Surgery, August and September, 1891

the symptoms. In some cases a marked improvement in the mental condition has been reported, but here it is to be remembered that education and training will do much, and have been attempted perhaps more thoroughly after than before the operation. It is very desirable, therefore, that the medical reports in such cases should be more complete.

As a contribution to this subject the three following cases are reported :

CASE XIV. *Hemiplegia, epilepsy, mental weakness—  
Trepining—Improvement.*

E. H., now 8 years of age, was born without difficulty, and was a healthy baby until 5 months, when she was suddenly seized with general convulsions attended by high fever and followed by left hemiplegia. For three weeks the temperature varied from 100° F. to 105° F., and convulsions recurred from time to time, the child being unconscious almost all the time and being kept alive with difficulty. Then a gradual recovery began which had continued till the 6th year, when I saw her. She was still markedly hemiplegic on the left side, the face was noticeably affected when she made voluntary grimaces; the arm was moved fairly well, but the hand was useless and the fingers were in constant slow motion of flexion and extension, this athetosis being much increased by any effort with the other hand; the leg was moved well, though she dragged the foot a little in walking, and the ankle was quite rigid but not deformed, there being a tendency to talipes equinus. The paralyzed limbs were smaller than the others, but sensation was normal and electrical reactions were but slightly less than on the other side, there being no qualitative change of reaction. Ever since the onset of the hemiplegia she had been subject to attacks of an epileptic character. She had numerous slight attacks daily, lasting

a few seconds, in which she seemed alarmed, ran to and grasped some one, saying she felt sick. Since the age of 5 she has had severe attacks, chiefly at night, in which she cries out and has a short general convulsion, usually more marked on the left side, without biting the tongue or passage of urine. After such attacks she sometimes sleeps, sometimes goes on playing. In the past six months she had also had two very severe attacks of unilateral convulsions, there being a series in each attack. In these the spasm was first limited to the left face, the eyes turning to the left; then to face and arm, then to face, arm, and leg, extending in this order, and finally the entire left half of the body was invaded in each spasm. Each spasm lasted about six minutes, the series lasting an hour and a half, and she was unconscious throughout. After these two attacks she was quite weak for a day or two, and the hemiplegia was more marked and the athetosis was perceptibly less.

She had been petted much, and her parents think this is one cause of her being very fretful, irritable, hard to manage, and difficult to teach. The fact is that the child was deficient in the power of self-control and of voluntary attention, though her perceptions were keen and her mind active. All her sensory powers were perfect.

The increase in the number and severity of the epileptic attacks, and the realization of the mental deficiency of this little girl, led the parents to desire an operation; and with the distinct understanding that no positive result could be assured, Dr. McBurney trephined, at Roosevelt Hospital, on February 10th, 1891, at my request. A portion of skull about two by three inches was removed over the middle third of the motor portion of the right hemisphere. This point was selected by reason of the paralysis being more marked in the left arm and hand than elsewhere, because the athetosis was confined to these parts, and because the unilateral convulsion had affected these parts chiefly. The bone and dura were normal; the pulsation

of the dura, seen on exposure, was normal, and the sensation to touch made it evident that there was no cavity with fluid beneath the dura. The dura was therefore divided, and the brain tissue exposed. The fissure of Rolando and the anterior and posterior central convolutions were recognized. The brain appeared to be perfectly normal. There was no evidence of the previous occurrence of a hemorrhage, or of meningo-encephalitis, and no

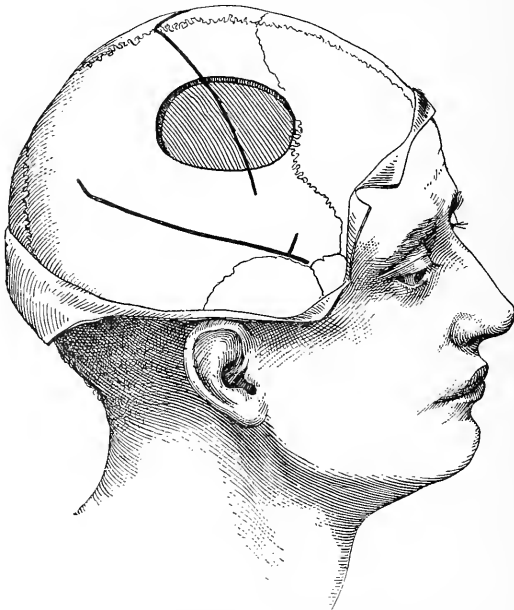

FIG. 44.—Diagram of the Situation of the Opening in the Skull in Case XIV.

trace of atrophy. The dura was then sutured, the bone was not replaced, the wound was closed and healed promptly, and in two weeks the child was at home again. For one month after the operation the hemiplegia was more marked, and the athetosis much less; then the paresis began to improve and the athetosis returned, and two years after the operation the hemiplegia may be said to be markedly improved, but the athetosis continues. The

severe epileptic fits with a cry which occurred nightly, and the Jacksonian fits of which she had had two series in the six months prior to the operation, have not recurred. The petit mal attacks continued for two months after the operation, and then began to diminish in frequency. The daily record shows the contrast between March and September. In March she was having two or three attacks daily. In September she had fourteen attacks only, having had none at all during the first twelve days of the month. The parents believe that the mental condition of the child is markedly better, and that she is more capable of concentrating her attention. She has a more intelligent facial expression than formerly, but I am of the opinion that such mental improvement as has occurred is owing to more special and intelligent instruction and management than she had prior to the operation, and to the progress of natural development.

During the past two years she has had three peculiar attacks in which she has suddenly become alarmed, fretful, and appeared to be suffering. At these times the face has been flushed, and the scalp over the opening in the skull bulged perceptibly. She has not lost consciousness and has had no fit, but subsequently has appeared to be very weak, and for several minutes quite unable to move, and for an hour after has complained of tingling sensations in the hand. Whether the opening in the skull has prevented a sudden cerebral congestion from irritating the brain and thus prevented a fit, may be regarded as an open question. That some marked change occurs in the intra-cranial pressure is proven by the marked bulging on each occasion.

CASE XV. *Imbecility, epilepsy, hemiplegia—Trephining—Improvement.*

L. B., now 8½ years of age, was born prematurely, and was raised with difficulty. Her mother died of phthisis. At the age of 5 months she began to have convulsions, which had continued up till the time I first saw her, in

April, 1891. She was then having twenty fits in a day, each lasting from two to five minutes. At one time she had gone a month without a fit under bromide treatment. The girl had always been an imbecile, had failed to develop properly, and appeared like a child of four years. She was very microcephalic, all the measurements being much below the normal, but the skull was not asymmetrical. She had learned to walk and to talk, but suddenly, in November, 1890, after a fit was found to be aphasic and hemiplegic on the right side. The aphasia was complete when I saw her, having persisted for five months. She understood what was said to her, obeyed commands, but said nothing. The hemiplegia had improved, but her right hand was useless and in a state of athetoid movement. It was less sensitive than the left hand. Her head was in constant rotary motion. Examination showed a right bilateral hemianopsia. The aunt had noticed an increase in the mental dulness, and said that the child was too stupid to cry.

While the appearance and the actions pointed to a condition of imbecility due to microcephalus, it was thought that the sudden onset of hemiplegia and aphasia, with hemianopsia, indicated either the occurrence of a hemorrhage or beginning tubercular meningitis. With a view to the possibility of removing a clot, the child was sent to Roosevelt Hospital, where, at my request, Dr. Hartley operated upon her on May 15th, 1891. A piece of bone, about two inches in diameter, was removed from the skull over the lower part of the motor area and Broca's convolution, and this opening was then enlarged upward and backward. There was no bulging of the dura and no evidence of increased cranial pressure. When the dura was divided the cortex of the posterior part of the third and second frontal convolutions and the lower half of the anterior central convolution were exposed to view and recognized. No clot was found, no evidence of meningi-



tis, and the brain presented a normal appearance. The wound was therefore closed, the bone being left out, and it healed promptly without any complication. For six weeks after the operation no change was apparent in the condition, and the fits continued as before, from six to twenty daily. Then a marked improvement began. At present, sixteen months after the operation, the child talks freely, names objects at once, can answer simple questions,

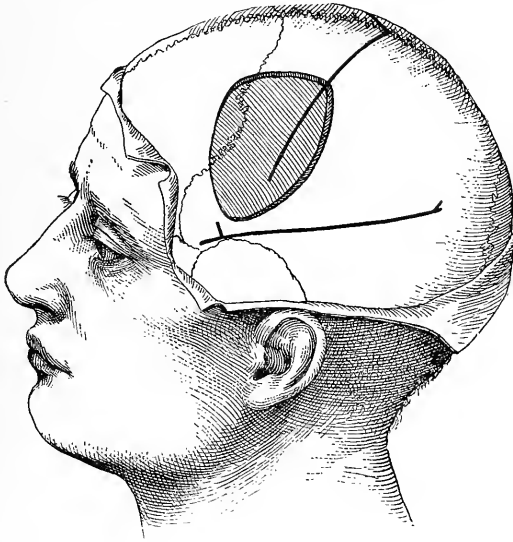


FIG. 45.—Diagram of the Opening in the Skull in Case XV.

and sing children's songs. The hemiplegia has disappeared entirely, but effort with the left hand produces associated motions in the right hand. All rotary movements of the head have ceased. Sensation seems keen in the right hand. There seems to be traces of right hemianopsia, but she is watchful of tests, though too stupid to give any accurate replies. She has been taught to keep herself clean, and is certainly more observant and obedient than formerly, though still imbecile. She is still having

fits, about six daily. They do not yield to bromide or to chloral. I am wholly unable to explain the very marked improvement which has followed the operation, especially as there was nothing accomplished by it at the time in the relief of local disease or of general pressure.

In both cases it is interesting to observe that no gross defect of brain substance, no marked atrophy was discovered, and if lesions were present in the brain, they must have been of microscopic character. Is it possible that there was in both cases an arrest of development rather than an actual lesion, and that the effect of the operation was to stimulate the growth of cerebral tissue?

CASE XVI. *Imbecility—Epilepsy—Microcephalus—Linear craniotomy on both sides—Improvement.*

A little girl of eleven was brought to me on account of attacks of petit mal which had developed within two years and had become so frequent as to occur every hour. Two such attacks occurred in my office, each lasting twenty seconds, consisting of a sudden dilatation of the pupils, relaxation of facial expression, turning of the eyes upward, falling backward of the head, and then recovery of balance just as she was about to fall. She was completely unconscious in the attack, had no warning of its onset, and no recollection of its occurrence. Slight stimulation of the surface anywhere—pinching, throwing water in the face seemed enough to arrest the attack, though loud sounds had no such effect. This child was well developed and very observant and active, but had no capacity for learning or for self-control. She had been trained with care, but could not read, and acted on every impulse. She was excitable, very quick in replies, impudent and saucy, delighting in doing everything which would annoy people, and it was impossible by punishment to effect any moral improvement. This defect of intelligence was associated by a very marked defect in the development of the forepart of her head. There appeared to have been a very early union of the coronal suture, so that

a decided depression existed in the skull over its situation, and a marked difference could be seen between the size of the frontal bone and the posterior part of the skull. It looked as if a cap had been applied over the entire frontal bone which had arrested its growth, while the rest of the skull had developed properly. The arch of the palate was high. In this case I advised an operation, which was undertaken by Dr. McBurney and performed during Decem-

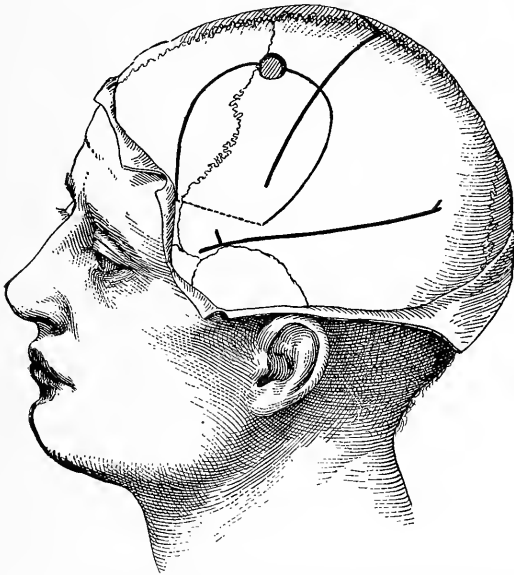


FIG. 46.—Diagram showing the Line of Incision through the Bone in Case XVI. The bony flap was elevated, being cracked across the dotted line.

ber, 1892. The object in view being to allow of growth of the frontal lobes, it was thought best to lift the bone away from the brain on both sides. The left side was first operated on and two weeks later the right side. Both sides were done in the same manner. A long semilunar incision was made in the scalp from the forehead near the temple backward to the mid-parietal region, its convexity being upward. A small trephine opening was made at

the summit of this incision, and with this as a centre a groove was chiselled in the bone, first downward and forward, then downward and backward. Thus an omega-shaped groove in the skull was cut. The bone was then gently pried up, the short limb of the omega between its ends being broken. Thus a bony flap with scalp attached was raised about an inch away from the dura. The dura was not opened. The wound was dressed so as not to make pressure on this flap. It healed by first intention, as did also the second wound on the other side. When the child went home the elevation of the two portions of bone was very perceptible.

Her attacks ceased entirely between the first and the second operation, but returned with their usual frequency after the second operation. Mentally she seems brighter and is beginning to learn.

CASE XVII. *Idiocy—Epilepsy—Hemiplegia—Trepthing—Death.*

A. H., aged 21, had been hemiplegic on the left side ever since birth, had never developed mentally, was a total idiot, unable to talk, dirty and drooling. Since the age of six months he had had frequent convulsions which began in the left hand. The parents insisted upon an operation, and Dr. Weir consented to make an exploratory operation at the New York Hospital, February 1st, 1892. The point selected for trephining was over the motor region of the arm on the right side. A large button of bone was removed and the opening enlarged with a rongeur. The dura did not pulsate and did not have as tense an appearance as usual. A hypodermic needle was thrust through it and did not encounter any resistance beneath, but could be freely moved about in a cavity. About a drachm of clear serous fluid entered the hypodermic syringe. It was evident that a porencephalic cavity lay beneath the dura, and as the opening of such a cavity was considered dangerous the wound was closed. During the following two days it was with much difficulty that

the patient was restrained. At last he succeeded in tearing off his bandages and died a few days later of meningitis. An autopsy was not allowed.

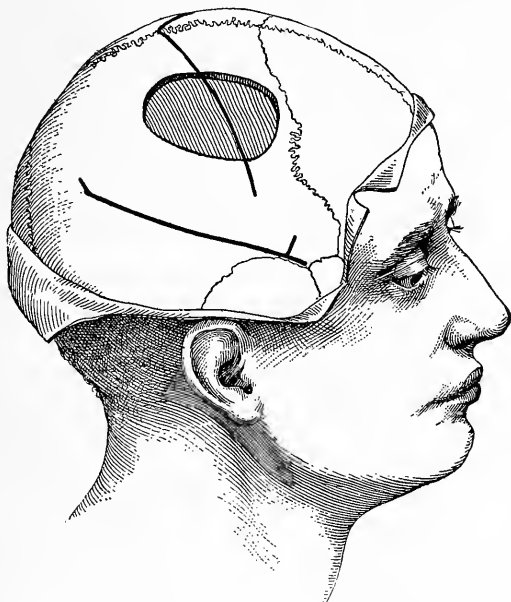


FIG. 47.—Diagram of the Opening in the Skull in Case XVII.

Dr. Rowell Park's experience with this new and radical procedure has been sufficiently varied, interesting, and important to justify the individual recital of his cases.<sup>1</sup>

(1) J. V., aged  $3\frac{1}{2}$  years, was referred to me by Dr. Crego. As a baby he was restless and "jerky," and when 9 months old had convulsions of the entire body. As he grew older he would sometimes fall in some of the attacks. These slowly assumed the conventional epileptic type, and by the time he was 3 years old, or in March,

<sup>1</sup> Medical News, Dec. 2d, 1892.

1891, were perfect examples of grand mal. They also increased in frequency and severity. At that time he began staggering in his gait, and his left leg grew weak. Soon after it showed relative decrease in length and size. His temper became violent and uncontrollable, his epileptic seizures more and more frequent, and during the twenty-four hours previous to the operation he had between thirty and forty distinct and severe seizures. Though he was by no means an imbecile, his mental development was retarded. His skull seemed relatively small for his age. On June 21st, 1891, I operated on him at the General Hospital. A long incision, one inch to the right of and parallel with the middle line, was made from the forehead to the occiput. With cutting bone-forceps I excised a strip of bone 2 cm. wide from the line of growth of hair in front nearly to the occipital protuberance behind. Then detaching the scalp for the purpose, I excised a narrow strip of bone over the fissure of Rolando on the right side down nearly to the temporal fossa. The wounds were closed without drainage. During the ensuing twenty-four hours shock was severe, and the child had several violent epileptic seizures. Since this first day he has never had another. His irascibility has subsided, his general health and intelligence have improved; he now runs, plays, acts, and talks just like other children of his age.

(2) Minnie R., aged 4 years, was referred to me by Dr. Putnam. This was a case of congenital microcephalus and imbecility. The parents were healthy and the family history was good, the previous children being sound. This girl had scarcely ever spoken a word, and manifested no more intelligence than an infant of three months. Her fontanel closed very early. She leads a vegetable sort of existence—without disturbance of function. Operation here seemed much less hopeful than in the previous case; it was, nevertheless, undertaken July 13th, 1891. An incision was made 3 cm. to the left of the middle line, from 4 cm. above the left superciliary region

to the occipital protuberance. A strip of bone was excised much nearer to the middle line. After removing it the scalp was pressed away on the left side and a strip excised over the Rolandic fissure. I then made an incision over the right Rolandic fissure and excised another strip of greater length, the three lines of defect having a common meeting-place. The central grooves were cut with forceps, the lateral grooves with a chisel. There was no great hemorrhage, and the wounds were closed without any provision for drainage. The child nearly collapsed after the operation, and for two days required constant attention. The after-results in this case have been practically *nil*. There has seemed to be a perceptible improvement in intelligence, and the child has appeared a little more alive to what is going on about her, and this is about all that can be said.

(3) W. K., aged 18 years, was referred to me by Dr. Crego. From an early age the patient's mental development has been very disappointing. He is physically large and well developed, but mentally shows scarcely more intelligence than a child of two or three years. At the age of about five he first showed epileptic manifestations. His seizures were then few and far between. They gradually increased in frequency, until now he has several in one day, but may possibly go a few days without any. His temper is usually good, but at times he is excessively wilful. The upper portion of his cranium is relatively small, though not conspicuously so. The muscles of his right side are somewhat atrophied. It seems that his epileptic fits have been somewhat more violent on the right side than on the left. His personal habits are good, as is also his family history. Dr. Crego and myself both thought that an extensive cranial opening might give relief, and the experiment was proposed and accepted by the father. Operation was done October 20th, 1891. A long incision was made to left of the middle line. When I endeavored to make a longitudinal division of the

skull, commencing with a common amputating saw, I found that the bone was very thick. I then applied a trephine over the motor area, and, through the opening thus made, with chisel and gouge-forceps removed a portion of bone, some 5 cm. in diameter, and in shape like a spherical triangle. Through a small opening in the dura I found that there were no adhesions, but that the arachnoid and pia were succulent and œdematous. I started to make a longitudinal excision of bone, but finding the same to be 1 cm. thick, desisted from this attempt and tried to make simply a large relief-opening. The wound was closed with catgut and an ice-bag applied outside the dressing. At 6 P.M. the boy was somewhat restless and had a fit. This condition became more marked, and by midnight, in spite of considerable morphine and other sedatives, he was convulsively restless and violent and required both a strait-jacket and chloroform. At 4 A.M. he died of exhaustion.

(4) J. M., aged 15 years, was healthy until he was three years old. Then his nurse used to frighten him, and he grew to be very nervous and timid. He soon began having fits every night, until he was 13 years old, when they occurred in the daytime also. Shortly after this he was having from thirty to forty fits every day. During one of these he fell and broke his elbow, which is now partially ankylosed. He also cut his forehead to the bone. For the last two years he has been lying most of the time helpless in bed and has had to be fed. His symptoms, mental and convulsive, seemed to occur in cycles of about three weeks each. During the first week of the three he would be noisy, in the second he would be weeping and wailing, and during the third apathetic and almost unconscious. He rarely spoke. All the children of this family were rachitic. November 2d, 1891, the boy was brought to my clinic in this third stage, and it seemed impossible to arouse him. He took mechanically most of what was put into his mouth. His bed



was constantly soiled. His arms, and sometimes his legs, were nearly always in the athetoid condition, and any little disturbance would bring on a mild seizure, during which his arms were drawn up over his head. There were no scars over his motor areas. November 7th, 1891, the operation was carried out at my clinic. A long incision was made to the left of the middle line, and after a first opening of the trephine a long strip of bone, 1 cm. wide and 13 cm. long, was removed just to the left of the longitudinal sinus. The operation had to be discontinued because of collapse. The patient stopped breathing, nearly died on the table, and was revived with great difficulty. The wound was closed as rapidly as possible. He seemed better the same evening, but next day the athetosis continued; he became uneasy and died, twenty-six hours after the operation, of shock.

(5) S. P., aged 9 years. This patient is of Russian-Jewish parentage, his father being an educated man and the other children healthy. He presents a defective skull-development, especially over the left frontal lobe; is imbecile and epileptic; has seizures coming on about every five days. His forehead slopes backward so as to give him somewhat the appearance of an Aztec child. Mentally he is an imbecile, mutters half a dozen words, staggers about the room, but in disposition is good-natured and even confiding. He was operated upon November 14th, 1891, at my clinic. In this instance I varied the ordinary procedure in that I laid up a V-shaped frontal flap, its apex reaching nearly to the vertex of the skull, its extremities extending nearly to the external angular processes. Then a small trephine was applied on each side of the middle line; the opening thus made was connected across the longitudinal sinus, and then two strips of bone were excised in a direction parallel to the scalp-incisions, by which considerable spring was given to the frontal bone and the fragments of others attached to it. The operation proceeded without incident, and the first

dressing was not made until eight days later, when perfect union was found. The immediate effects in this case were not very pronounced; the seizures, however, became less frequent and less severe, and when the boy left the hospital a few weeks later he had lost his staggering gait, and his various actions and attempted speech showed much more fixedness of purpose than was previously the case. But at the end of a year the results in his case have to me been astounding. He has had no fit for three months, and within a week or two was again exhibited at my clinic. He came up to me and publicly asked in clear and distinct tones whether he could go to school. I held some conversation with him before my class, in order to show that he was capable of rational thought and rational and even accurate conversation. In addition to this he has developed physically, and his face now has a really intelligent expression, whereas a year ago it was expressionless.

(6) C. S., aged 12 years, of Warren, Pa., was sent to me by Dr. Baker. This child was also an imbecile, speaking but few words, being at times irascible and having at times frequent epileptic seizures. There was partial paresis of the left arm, although she used it more or less. In her case there was great asymmetry, there being a great depression over the right side. She was operated on the same day as the previous case at a special clinic given for these two cases, and a strip of bone about 1 cm. wide was excised to the right of the middle line, extending well backward and forward into the frontal bone. The dura was not opened. At the first dressing, one week later, perfect union of the wound was found, and a light dressing only was applied. A few hours later she got restless and tore this off, and then picked the wound open so that it gaped for its whole distance. It was immediately re-dressed after disinfection with hydrogen dioxide, but healed the second time by the slower process of granulation. During the few weeks of her stay

in the hospital she improved a little. A letter from Dr. Baker, dated October 25th, 1892, nearly a year later, states that "she is no better now than she was before operation. For the first three months after operation there was a marked lessening in the number of paroxysms, but for the last three months the convulsions have been both severe and frequent, she having several daily. She is in much the same condition mentally that she was before operation."

### *Conclusions.*

From this review of the clinical types of cerebral atrophy in childhood, of the pathological conditions producing these types, and of the results of surgical treatment by craniotomy, the following conclusions may be drawn:

1. Hemiplegia, sensory defects, and imbecility occurring with or without epilepsy in children are chronic diseases, incurable by medical treatment. Any means which may be legitimately used to save the individual from a life of invalidism, and to take the burden of his care from the family, is to be employed.

2. The pathological conditions producing these symptoms may be either gross defects and atrophies of the brain, or an arrest of development in the cerebral cells, without any change which is apparent to the naked eye.

3. It is at present impossible to determine absolutely the pathological condition present in any given case, without an exploratory operation.

4. Such operations are not without danger, but if caution is used in opening the dura, and if the opera-

tion is made as short as possible, the dangers are avoided.

5. When manifest atrophies are present the operation will not produce any result. When the condition is one of arrested development of cerebral tissue, it may prove of service. When clots, cysts, or tumors are found and removed, the chance of recovery is increased. When the skull is markedly microcephalic from early union of the sutures, the increased space given to the brain by the operation appears to stimulate its growth and development.

6. Epileptic attacks are frequently reduced in frequency and modified in character by craniotomy. When the opening of the skull remains covered only by the soft tissues, it appears to act as a safety-valve, allowing changes in the intra-cranial contents to occur without producing pressure upon the brain.

7. Hemiplegia, aphasia, athetosis, and sensory defects have been relieved by operation, and in a number of cases the mental condition has been greatly improved.

## CHAPTER IV.

### TREPHINING FOR CEREBRAL HEMORRHAGE.

Records of Cases of Clots Removed from the Brain. Report of Personal and Selected Cases. The Symptoms of Traumatic Cerebral Hemorrhage. The Differential Diagnosis Between Intra-Dural and Extra-Dural Hemorrhage. Operations for Non-Traumatic Hemorrhage.

IN the remarkable paper which Macewen read before the British Association in 1888, he described three cases in which he had removed clots from the surface of the brain, having been guided in all these operations by symptoms which indicated an affection of the motor area of the cortex.

The first of these cases was one of paralysis in the left half of the face and left arm, in which the clot was found lying over the lower third of the motor area. The operation in this case was done in 1879. In 1883 two similar operations were successfully performed: the first for the relief of paralysis of the arm; the second for the relief of paralysis of arm and leg. All three cases had developed symptoms subsequently to an injury, all three were suffering from general symptoms of compression, and all three recovered completely after the removal of the clot.

Between that time and the present about thirty cases have been reported of successful attempts

to remove clots from the brain. The majority of these have been cases of hemorrhage developing within a few hours after the occurrence of an injury to the head. A few of them have been cases of spontaneous intracranial hemorrhage without external injury.

### *Traumatic Hemorrhage.*

In cases recorded by Ball and Schneider penetrating wounds inflicted by a knife in the left temple gave rise to gradually increasing symptoms of cerebral compression with the development of total aphasia and slight right-sided paralysis. In both these cases the exposure of the dura by trephining the skull revealed it to be pulseless and deeply stained by blood, and its division revealed the existence of a large clot, black and tarry, which was easily removed in both cases. The patients recovered completely the use of speech, but in Schneider's case the slight facial paralysis remained even at the end of six months.

Ball's case is as follows: <sup>1</sup>

F. B., æt. 26, admitted September 1st, 1887, had been struck on the head with a penknife ten days before coming under observation. Since the accident he had found difficulty in using the right words—for instance, he said he had a “man” in the side of his head, when he meant “pain.” He did not appear to be able to understand everything which was said to him and he was unable to read and to write at dictation. Upon examination a small scab was found adherent to the scalp, over the squamous portion of the left temporal bone; this, when detached,

<sup>1</sup> Dublin Journal, 1888, vol. 86, p. 243.

showed a cicatrix, apparently extending deeply through the temporal muscle, but the wound was quite healed. He was unable to name correctly articles which were shown to him, while in speaking he constantly used wrong words or parts of words. There was no paralysis whatsoever to be detected of any of the voluntary muscles when he came under my observation. Five days after his admission his symptoms had so much increased that it was determined to operate. A flap was turned down, including a portion of the temporal muscle and containing in its centre the cicatrix; this disclosed a wound of the squamous portion of the temporal bone of a size and shape likely to be produced by the small blade of an ordinary penknife. A medium-sized trephine was now applied, and a circle cut out, containing in its centre the cut in the bone; this was attended with some difficulty, as the lower part of the circumference was exceedingly thin, while the upper portion was tolerably thick; the piece was, however, removed without injury to the dura mater by the trephine. It was found that the knife had perforated the dura mater and brain. The wound in the dura mater was enlarged, in doing which the large posterior branch of the middle meningeal artery was divided, and gave some little difficulty to control. A sinus forceps was gently passed along the brain wound and the blades separated, when a dark-colored blood-clot presented and was gradually extruded by the internal brain pressure. Some more fragments of clot were removed by the sinus forceps and by a stream of weak perchloride of mercury solution from a syringe. A drainage tube having been introduced, the flap was replaced and held in position by deep sutures. On the evening of the same day the patient was much more rational. Next morning he was again more aphasic, and it was found that the drain had become blocked. Upon freeing it a considerable quantity of broken-down blood-clot was removed, and his power of speech improved. He made an uninterrupted recovery.

Schneider (*Archiv für klinische Chirurgie*, Bd. XXXIV., Heft 3) publishes the following history:

The patient was a young man, 18 years old, who was stabbed with a knife in his left temple, and who had, almost immediately, paralysis of the right side of the face and of the right arm and leg. Four days afterward he was brought into the hospital in Königsberg. He then had a small, almost healed wound over the third frontal convolution. He was perfectly conscious and could answer by signs, although he could not speak a word. As the hemiplegia increased without febrile symptoms, Schneider attributed it to an accumulating extravasation of blood and operated for its relief on the ninth day after the injury. He trephined the skull at the seat of the wound, opened the dura, removed a small clot, found the first branch of the middle cerebral artery spurting in the substance of the brain, seized it with forceps and ligated it with catgut. The wound was then cleansed, the opening in the dura was sutured with fine catgut, the soft parts covering the skull were also sutured, a drainage tube was inserted, and a Lister bandage was applied. The wound healed by first intention. On the third day after the operation the patient began to articulate, and in four weeks he spoke perfectly. Part of the hemiplegia disappeared more rapidly, the leg and arm recovering in eight days; but the facial paralysis was not wholly gone after a lapse of six months.

In cases recorded by Owen,<sup>1</sup> Walker,<sup>2</sup> Winkler,<sup>3</sup> Homans,<sup>4</sup> Allingham,<sup>5</sup> and Croft,<sup>6</sup> cerebral symptoms of the nature of paralysis developed within a few

<sup>1</sup> Owen: *Brit. Med. Jour.*, Oct. 13th, 1888.

<sup>2</sup> Walker: *Med. and Surg. Reporter*, 1890.

<sup>3</sup> Winkler: *Brit. Med. Jour.*, Aug. 22d, 1891.

<sup>4</sup> Homans: *Bost. Med. and Surg. Jour.*, June, 1890.

<sup>5</sup> Allingham: *Brit. Med. Jour.*, Apr. 20th, 1889.

<sup>6</sup> Croft: *Lancet*, Jan. 10th, 1889.



hours of a severe injury attended in two of the cases by fracture of the skull. In these cases the surgical condition indicated trephining, and in all of them the necessity of relieving cerebral compression and of arresting the increasing paralysis led to the opening of the dura and to the extraction of clots which were found. In all of these cases the symptoms gradually subsided and the patients made a good recovery not only from the operation but also from the cerebral symptoms.

In cases recorded by Duret,<sup>1</sup> Brewer and Carson,<sup>2</sup> Mouisset,<sup>3</sup> and Armstrong,<sup>4</sup> the cerebral symptoms had developed after injuries, but had come on slowly and had not been associated with any fracture of the skull. In these cases an operation was not performed until several weeks subsequently to the injury. In all of them the operation was guided by the symptoms of paralysis or of aphasia, and in all of them the clot was found, removed, and the patient recovered.

A somewhat similar case is the following, which was published by Dr. McBurney and myself two years ago:<sup>5</sup>

CASE XVIII. *Traumatic hemorrhage from a vein of the pia mater—Compression of Broca's convolution and of the sensori-motor area of the cortex—Aphasia—Partial right hemiplegia and hemianesthesia—Trepining—Removal of clot—Recovery.*

*History.*—A physician, aged 40, was thrown from his carriage on August 17th, 1889. He was slightly stunned

<sup>1</sup> Duret: La Semaine Médicale, Apr., 1891.

<sup>2</sup> Brewer and Carson: Amer. Jour. Med. Sci., Feb., 1892.

<sup>3</sup> Mouisset: Lyon Médical, 1889, p. 204.

<sup>4</sup> Armstrong: Jour. Amer. Med. Assoc., 1891.

<sup>5</sup> Brain, Part LV., p. 254

by the fall, but had no wound, and was able to help his wife, who appeared to be injured, to reach home. For several hours he seemed to be suffering merely from bruises, and was able during the afternoon to converse with a patient and to administer a hypodermic injection. In the course of the evening, however, he became delirious, then stupid, and for the following three days he lay in a semi-comatose condition. On the morning after the injury he was found to be completely hemiplegic on the right side and aphasic. When, after a week, his consciousness had fully returned, it appeared that the aphasia was purely motor, as he could understand what was said to him and could read. The hemiplegia was attended by a partial anæsthesia, the paralyzed limbs felt numb, were less sensitive to touch and to pain, but acutely sensitive to cold and to heat. In this condition he remained until December, when he was brought to New York and admitted to Roosevelt Hospital, where he was seen by us.

*Examination.*—The patient, a large man, was unable to say anything, even “yes” or “no,” the vowel sounds being the only sounds produced by effort. He evidently understood questions, and attempted to reply by gestures and by trying to write with his left hand. It was noticed, however, that he was mentally dull, so that the result of tests of muscular sense were not satisfactory, though he could be tested for tactile and pain senses, which were found to be impaired on the paralyzed side. He was emotionally unstable, laughing too readily and at times appearing to be much depressed. Ophthalmoscopical appearances were normal. Sight and hearing were normal. The right hemiplegia was partial. He could turn his eyes in all directions, but could not turn his head to the right. His left pupil was one-third larger than the right pupil, but both reacted normally. His face was slightly flat but not paralyzed, and his tongue protruded straight. His arm was almost totally paralyzed, the only motion possible being a slight abduction at the shoulder. His leg

could be moved a little at the hip and knee, and when held up by two persons he could drag the leg forward a little, but could not stand alone. The hand was flexed and pronated, the leg was extended; both were very rigid; and all the deep reflexes were greatly exaggerated, so that wrist and finger clonus, as well as patella and ankle clonus, were easily produced. He controlled his sphincters perfectly. There were no scars upon the head.

*Diagnosis.*—It seemed probable that as a result of the fall there had been a rupture of a small vessel, from which very slow hemorrhage had taken place; the vessel was thought to be a vein rather than an artery, because of the very slow development of the symptoms. The situation of the clot was thought to be upon the surface and not within the left hemisphere, and it was located upon the posterior part of the third frontal convolution and over the anterior central convolution in its middle third, as shown in the diagram. A flat clot in such a situation might fail too compress the face area, and could produce an absolutely total motor aphasia; while a sub-cortical or capsular clot could hardly produce total permanent motor aphasia and paralysis of the arm without producing paralysis of the face and tongue. On the strength of this diagnosis it was thought best to operate.

*Operation.*—On December 13th, 1889, Dr. McBurney trephined the skull. The trephine was applied at a point one inch and seven-eighths behind and seven-eighths of an inch above the external angular process of the frontal bone, and the opening was then enlarged by the rongeur forceps upward and backward, the dura being laid bare over an ovale area three by two inches. The dura did not pulsate. On opening the dura the pia was found to be very œdematous and discolored, and the surface of the brain was separated from the dura by a space of half an inch in depth and did not pulsate. The clot was seen lying beneath the pia upon the posterior part of the third frontal convolution, and extending over the an-

terior central convolution in a thin layer (marked in lines on Fig. 49) into the fissure of Rolando, which was filled with a larger clot lying in the situation shown in the diagram, and extending downward so as to fill up and distend greatly the *cul-de-sac* at the lower end of the fissure. The clot had not covered the lower third of the anterior central convolution and had not reached the upper quarter of the fissure of Rolando. The brain, at a dis-

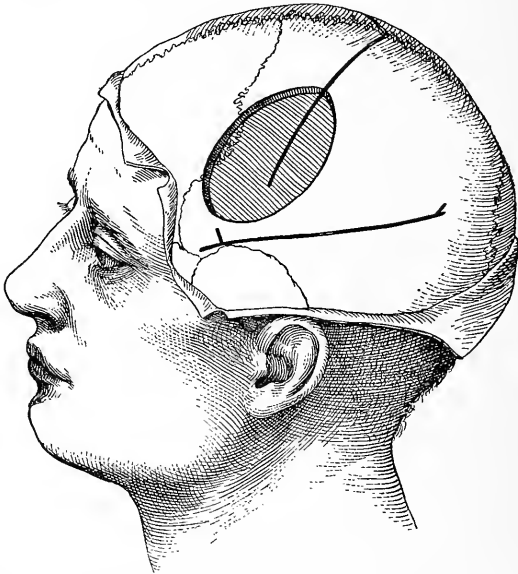


FIG. 48.—Diagram to show the Opening in the Skull in Case XVIII.

tance of an inch about it, appeared to be healthy and pulsated, but the parts of the cortex on which the clot lay were pulseless and stained a yellowish-red. After the pia had been incised the clot was removed little by little by fine sponges—at least a drachm of partly organized clot being taken out of the fissure of Rolando. The retraction of the brain from the skull was even more evident when the operation was complete. The operation was done under strict aseptic precautions, and was not followed by

any rise of temperature. The wound was dressed in the open method, being packed with gauze and drainage tubes being inserted. On renewing the dressings three days subsequently to the operation it was found that the entire surface of the brain was pulsating normally, and that the brain surface presented a normal color and appearance. After a week the drainage tubes were removed, and after three weeks the wound had entirely healed, the level of the scalp at the bottom of the cavity being an inch below the normal level.

*Result.*—On the evening of the day of operation the

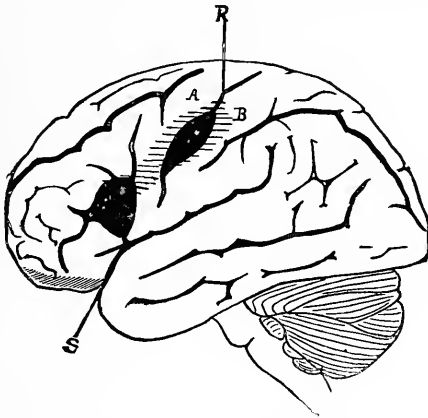


FIG. 49.—Diagram of the Left Hemisphere of the Brain, showing the Situation of the Clot in Case XVIII.

patient said yes and no for the first time since the injury, and since that time his recovery of speech and of power has been progressive. After a few days it was noticed that he was much more intelligent and no longer emotional. Power in his leg began to increase very soon, and two months after the operation he was able to walk with a cane. The return of speech was slow and continuous, and it appeared as if he were learning a new language. He repeated words after another until he had learned them. He talked in monosyllables for the first three months,

then he began to put two words together, and then used short sentences of three or four words. At the present time, three years after the operation, he is practising medicine in his native town, is able to walk without a cane, can name at once any object shown him, but in talking uses only a few words at a time, not speaking fluently, writes with his left hand, and were it not for the loss of power in the right hand might be considered fairly well. The paralysis of the right hand remains, and with it a marked diminution of tactile and pain senses, two points being felt as one when 2 cm. apart on the tips of the fingers. The muscular and temperature senses are perfect. He can move the arm and forearm in all directions with much force and can supinate the hand, but movements below the wrist are very slight, the fingers being flexed and rigid. The reflexes are much less exaggerated than before the operation, clonus not being elicited excepting at the ankle; the head can be turned in any direction, and the pupils are equal.

Stanley Boyd reports the following case in the Clinical Society's Transactions for 1892, p. 157:

M. J. L., male, 40, fell from a horse March 31st, 1891, was stunned, but walked upstairs and went to bed; was dazed; had swelling over left side of head, but no scalp wound. Had some pain in head for two weeks, when he was able to get up and go to work. On June 18th headache began again and right hand became clumsy. June 22d he was dull, confused, silly, and memory was bad, had paralysis of right hand and right leg was weak. The right hemiplegia increased and he became comatose and had fever.

He was trephined on June 28th, 1892, on the left side over the arm centre. On dividing the dura a cyst was seen, and when incised, four ounces dark red clear fluid escaped. This was drained. He was delirious for nine days, but gradually improved and was discharged from

the hospital August 15th quite well. He had remained in perfect health up to May, 1892, when the report was made.

The cases cited are sufficient to demonstrate the possibility of trephining for cerebral hemorrhage.<sup>1</sup> In traumatic cases where there is a history of punctured wound, or of a fracture of the skull, or of a severe fall upon the head, the development of symptoms of compression together with local symptoms of unilateral paralysis leaves little doubt in regard to the diagnosis. Hemorrhage upon the surface of the brain subsequently to injuries is usually due to a rupture of one of the veins in the pia mater; the hemorrhage occurs slowly, the clot spreading itself out beneath the pia or upon it in a broad thin layer; the blood settles in the depths of the fissures separating their sides, producing pressure upon the brain adjacent and beneath it. Such pressure developing gradually is sometimes sufficiently irritating to give rise to spasms or localized convulsions, and it is usually enough to arrest the functions of the cortex and produce paralysis if the clot lies in the motor region, or aphasia if it lies in the aphasic regions, or hemianopsia if it lies in the visual area. The gradual onset of these symptoms is a strong indication of the occurrence of a surface hemorrhage. The general symptoms of compression of the brain must be associated with these local symp-

<sup>1</sup> Lamphear has trephined for cerebral hemorrhage. The history is, however, too imperfect and the report made too soon after the operation to warrant its reproduction here. See Amer. Jour. of Surg. and Gyn., Jan., 1892.

toms in order to establish the diagnosis. Such symptoms are a condition of stupor which gradually deepens into coma with stertorous breathing, a slow and sometimes irregular pulse, a rise of temperature to  $101^{\circ}$  to  $103^{\circ}$ . Suppression of urine and polyuria have both been observed, and an appearance of albumen or sugar in the urine is not infrequent; vomiting occurs if the patients are not deeply comatose. Irregularity of the pupils with dilatation on the side of compression has been noticed.

*Extra-Dural vs. Intra-Dural Hemorrhage.*

In any case of injury of the head, either with or without a fracture of the cranial bones, followed at once by marked cerebral symptoms, the question will arise whether the hemorrhage which is probably causing the symptoms is extra-dural or intra-dural. This question it is often very difficult and sometimes impossible to decide. Extra-dural hemorrhage is almost uniformly from the middle meningeal artery, but intra-dural hemorrhage may occur at any part of the brain surface. The question will only have to be decided, then, in those cases which present symptoms of paralysis—for hemorrhage from the middle meningeal causes pressure whose greatest intensity is over the central convolutions, and quite uniformly produces hemiplegia. The symptoms of middle meningeal hemorrhage have been most completely analyzed and described by Jacobson in Guy's Hospital Reports for 1886, the conclusions being based on a study of 78



cases. Jacobson calls attention to the fact that the violence causing a rupture of the middle meningeal artery is often slight and insufficient to produce a fracture. He mentions the following symptoms of such a hemorrhage in the order of their value:

There is usually an interval of lucidity or consciousness between the concussion and the appearance of pressure symptoms, such as somnolence, stupor, and coma. This interval may be only an hour, but it may be even ten days. A long interval would be much less likely to occur in intra-dural hemorrhage.

Hemiplegia occurs on the side opposite to the injury, face, arm, and leg being usually affected, but the leg to a much less degree than the arm, and never alone. This is easily understood when it is remembered that the leg centres lying near the vertex will not be greatly compressed by a clot in the region of the middle meningeal artery (Fig. 50). There is no particular reason why an intra-dural clot should not involve the leg as well as the arm or should not affect it alone. Convulsions rarely precede the onset of the hemiplegia in extra-dural hemorrhage, but are not infrequent in intra-dural hemorrhage, especially if that lacerates the brain tissue. The pulse is slow and hard, but toward the close of life becomes very rapid in extra-dural clots. In intra-dural clots it is more likely to be rapid.

In both conditions slow, embarrassed, stertorous breathing and a rise of temperature may occur.

Vomiting is more frequent in extra- than in intra-dural hemorrhage. Changes in the pupils are re-

garded as an important symptom. Dilated pupils point to cerebral pressure, and the pupil on the side of the pressure is large and often fails to react to light. Jacobson holds that the inequality is less marked in

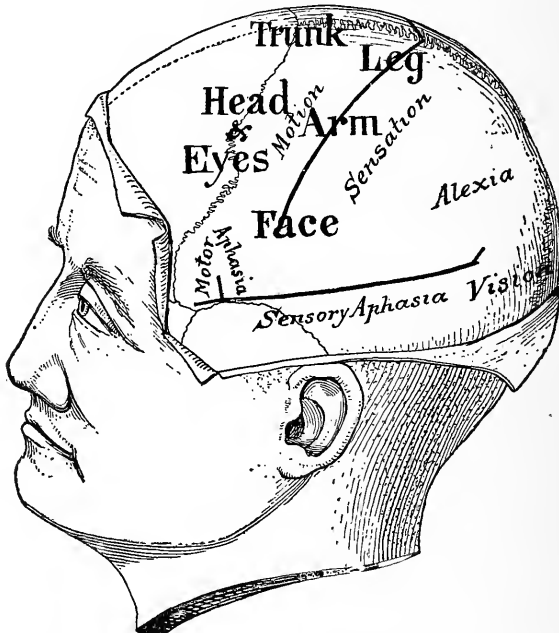


FIG. 50.—Diagram of the Left Side of the Head to show the Situation of the Functional Areas of the Brain and their Relation to the Fissures of Rolando and Sylvius. The symptoms produced by extra- or intra-dural clots will depend on the situation of the clot.

intra-dural hemorrhage, but this statement is open to doubt.

A unilateral impairment of sensation on the side of the paralysis is found to indicate an extension of the clot backward; while the development of aphasia when the clot is on the left side indicates an extension for-

ward. The same would be true in intra-dural hemorrhage, though there aphasia would be more likely to occur alone without hemiplegia. This is easily evident by reference to Fig. 50.

Disorders of the control of the sphincters and automatic movements are the last symptoms to be mentioned by Jacobson.

It is evident from this review that it may be exceedingly difficult to differentiate extra- from intra-dural hemorrhage. If, however, a diagnosis of a hemorrhage compressing the convexity of the brain is made, and it is evident that the case is becoming serious, it is usually advisable to trephine, and if the clot is not found outside the dura to seek it within.

There are some cases of traumatism of the head which are followed by general signs of compression, but in which there are no local symptoms such as paralysis or loss of sensation or aphasia to afford a guide to the surgeon. Where such local symptoms fail and where the original injury has left so little trace as not to point the way to an operation, trephining is venturesome, for the chances are by no means good of finding the clot.

When such local and general symptoms of compression develop, it is safe and proper before undertaking an operation to watch the patient for at least a week, being ready, however, to act promptly if the situation becomes alarming. The delay in the removal of the clot is not likely to do any permanent injury, and it is not at all impossible for the hemorrhage to cease

spontaneously or for a small clot to be completely absorbed. Thus, in a case recently under my observation, the patient, who had a severe fall without apparent cranial injury, lay for three days in a state of coma with left hemiplegia, then recovered consciousness, but for the following three days was entirely unable to speak, though able to understand what was said to him, and had continual rhythmical movements of a restless character in his right limbs, but nevertheless appeared to be gradually improving in his general symptoms. The left hemiplegia indicated a clot upon the right hemisphere, and the right-sided movements with aphasia indicated a clot upon the left hemisphere.<sup>1</sup> Operation was postponed from day to day as his symptoms gradually diminished in their intensity and severity, and it was finally abandoned. He made a good recovery and at the end of two months was out and about, perfectly able to talk and to control the movement of all his limbs. In a case of this character it is probable that small clots were absorbed from both hemispheres, leaving little or no apparent effects.

#### *Non-Traumatic Hemorrhage.*

In very few cases has trephining for the removal of clots been performed when the hemorrhage was not of traumatic origin.

<sup>1</sup> Dunn, Jour. Amer. Med. Assoc., 1886, p. 75, has recorded a case in which regularly recurring rhythmical movements of the left side of the body were produced by a large, thin surface clot on the right hemisphere.

Lucas Championnière<sup>1</sup> describes the case of a man who after a sudden stroke of apoplexy remained paralyzed upon the right side, the right arm being the limb which was chiefly affected and which was contracted, the right leg sharing in the paralysis but not being so severely involved. This patient had developed epilepsy subsequently to his stroke of apoplexy and his attacks were largely in the paralyzed limbs. He was trephined over the middle of the motor area, and an encysted clot was found lying just in front of the fissure of Rolando in the middle third of the anterior central convolution, and was removed. The next day the hand was no longer contracted, and when he was allowed to get up out of bed after the healing of the wound, he was found to be able to walk with more ease. One slight convulsion occurred two months after the operation, but at the time of the report of the case, six months after the operation, the paralysis had nearly passed away and no more convulsions had occurred.

Michaux<sup>2</sup> also reports a case of spontaneous hemorrhage, not traumatic in origin and successfully located and removed. This patient was suddenly taken with an apoplectic attack, his right arm and leg being completely paralyzed; the left face was also affected, he became comatose and had convulsions for three days and was evidently moribund. When Michaux operated, three trephine openings were made over the fis-

<sup>1</sup> Brit. Med. Jour., May 17th, 1890.

<sup>2</sup> La Semaine Méd., Apr. 1st, 1891.

sure of Rolando upon the left side and several ounces of clotted blood were removed. He gradually recovered consciousness, and at the time of the report, five months after the operation, he had practically recovered, though there was still a perceptible weakness in his right arm and he had some difficulty with his speech.

In the following case, which I saw with Dr. R. F. Weir, the operation was undertaken without a positive diagnosis, but with the hope of finding a clot. The history shows the result:

CASE XIX. *Opening the skull for removal of a clot.—  
Area of softening found.*

F. J. E., male, aged 40, had general convulsions in April, 1891, without known cause. This was followed by a slight degree of motor aphasia. Three days later he had a second fit, after which he was almost completely aphasic and had a slight paralysis of his right face and right arm. The paralysis gradually increased, so that by the end of a week his right leg was also slightly paretic. From that time until the present he has had a partial right hemiplegia with motor aphasia and agraphia. He has had repeated convulsions ever since he was first taken ill; the convulsions always begin by a tingling in the right hand and arm. Ophthalmoscopic examination showed the left optic disc rather pale and the vessels smaller than on the right side. The man had not suffered from headache or any general symptoms of brain tumor, but a loud bruit was heard over the left temporo-parietal region.

The diagnosis in this case was somewhat obscure. It was thought possible that the original trouble might have been a hemorrhage on the cortex, and that an operation might remove an old clot and thus relieve both the paralysis and the convulsions, but the existence of the bruit led

to the suspicion of an aneurism of the middle cerebral artery lying within the fissure of Sylvius. The operation was therefore an exploratory one and was so stated to the patient.

*Operation.*—On October 28th, 1892, Dr. Weir opened the skull at the New York Hospital, using Horsley's rotary electrical saw and removing a square piece of bone about two and one-half inches in each direction. A thin metallic

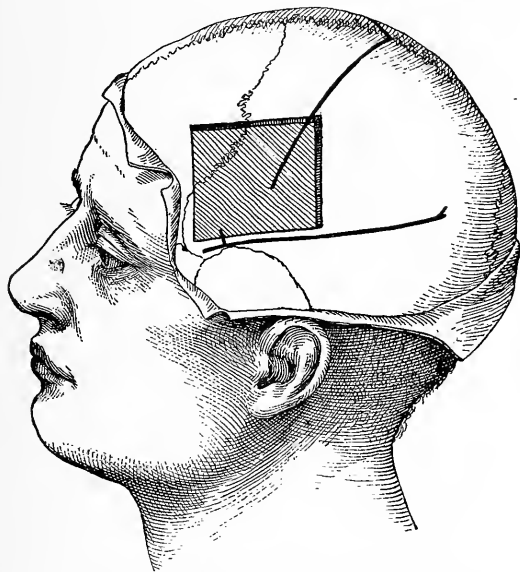


FIG. 51.—Diagram of the Opening in the Skull in Case XIX.

flat instrument, devised by Dr. Weir for the purpose, was passed through a small trephine opening and separated the dura from the bone, at the same time acting to protect the dura from the edge of the saw as it was carried along the various lines of incision. The operation of opening the skull in this manner was found to be more rapid than that of ordinary trephining. When the dura was divided and laid back the pia was found to be exceedingly cedematous; when by pressure the serum had left the pia it was evi-

dent that the brain in the region of the third frontal convolution and the lower half of the anterior central convolution had an abnormal appearance; it was shrunken, flat on the surface, and yellow; it was soft to the touch; there was no clot over it, and there was no aneurism. It was evident that the condition present was one of cerebral softening, probably due to thrombosis; it was also evident that nothing could be done to remedy this condition; the wound was therefore closed, the plate of bone being replaced. This plate of bone had to be removed after two weeks, as it had not united to the skull; subsequently the scalp wound healed kindly and the patient was discharged from the hospital, unimproved, at the end of a month; during that month he had two fits in the hospital.

In this case, therefore, the operation was entirely unsuccessful and the diagnosis of probable cerebral hemorrhage was incorrect. The case illustrates the difficulties attendant upon the diagnosis of cortical hemorrhage and also the safety of an exploratory operation, even when such an operation is very extensive.

Non-traumatic hemorrhages in the brain are very seldom open to an operation. The very large majority of sudden apoplexies are due to hemorrhages within the substance of the brain, or to embolism or thrombosis of large arteries. It is very rarely possible at the bedside to make an accurate diagnosis between cerebral hemorrhage and thrombosis or embolism, and in spite of the many points of differential diagnosis laid down in the books the question is always an open one in the presence of any patient. There are a few cases in which the history seems to point clearly to a surface



and not to a central clot. It is to be remembered that the motor centres in the cortex occupy a large area, and a clot forming upon the surface has its maximum of intensity over a small area, and therefore such a clot produces a greater paralysis in the one limb than in the others; and as it increases in size the paralysis extends from the point of greatest intensity to other parts of the body rather slowly. Such paralysis is usually attended by some disturbance of tactile sensation, and this is greater in the limb chiefly paralyzed than in the other limbs. A spastic contracture appears very soon after the onset of the paralysis in the limb most intensely involved, and a progressive aphasia either of motor or of sensory kind is almost inevitable if the clot lies upon the left hemisphere of the brain. The stupor is deeper and more continuous in a surface hemorrhage than in others, and if the brain cortex is lacerated by a clot, unilateral spasms may follow the apoplexy.

In a few cases of apoplexy such a history will point the way to surgical interference, but it must be confessed that in all cases of spontaneous hemorrhage in the brain surgical interference is purely exploratory. The period has not yet come, and it is questionable whether it ever will come, when the diagnosis of a surface clot can be made with such precision as to warrant immediate trephining in apoplexy.

When a hemorrhage has occurred within the cerebral hemisphere, lacerating the tracts and destroying tissue, operation is out of the question; for tissue once

destroyed in the brain is not repaired by nature, and an attempt to remove a deep clot would result in the production by the surgeon of further laceration and serious hemorrhage. No one who has had any experience in controlling the hemorrhage which arises from incision of the pia and cortex would advise deep incisions into the brain.

## CHAPTER V.

### TREPHINING FOR ABSCESS OF THE BRAIN.

The Surgical Treatment of Brain Abscess. The Varieties of Brain Abscess. (1) Traumatic Abscesses. Surgical Indications for Trephining, General and Local. Report of Cases. (2) Abscesses Secondary to Ear Disease. Symptoms. Differential Diagnosis between Abscess, Meningitis, and Sinus Thrombosis. The Situation for Trephining after Ear Disease. Illustrative Cases. Conclusions.

ABSCESSSES of the brain had been opened and drained by surgeons for many years prior to the beginning of modern brain surgery. It had long been known that abscesses of the brain develop subsequently to cranial wounds and fractures, and where these fractures were compound and comminuted it not infrequently happened that an abscess would present at the external wound and be opened and drained by the surgeon. Sometimes exploratory incisions were made when such an abscess was suspected.

Dupuytren and Detmold opened deep abscesses in the brain prior to 1850, and surgical journals contain many records of a similar nature from that time to the present. Many interesting facts bearing upon the doctrine of localization of brain functions may be gathered from the history of these surgical cases. Thus Hitzig records<sup>1</sup> a traumatic brain abscess accu-

<sup>1</sup> Arch. für Psych., iii.

rately limited to the lower third of the anterior central convolution and producing facial and hypoglossal paralysis, which occurred in a wounded French prisoner in the year 1871. This was before Hitzig had made his experiments on the cortex of the brain which first located the motor centres. As we look back over many of these histories of surgical treatment of abscess, and study the character of the symptoms which were observed by the operating surgeon, these cases afford an interesting proof of the theory of localization. At the time they were treated, however, this theory was unknown, and the bearing of the facts observed upon the cerebral functions passed unnoticed. It is evident, therefore, that although the facts of localization throw much light upon the diagnosis of abscess of the brain, explain symptoms which were formerly obscure, and point more precisely to the seat of the disease than the mere traumatism, yet trephining for abscess is an achievement of surgery which antedates the present era.

#### *The Causes of Brain Abscess.*

Abscess of the brain develops usually under one of two conditions: (1) as the result of injury to the head with or without fracture, and (2) as a sequel of otitis media and suppurative processes in the orbit and nasal cavity. It is true that a few abscesses develop in the brain as a result of metastasis from gangrene of the lungs, from typhoid fever, from pyæmia, and from general tuberculosis, but these secondary abscesses are

so rare and so manifestly removed from surgical treatment that we may disregard them.<sup>1</sup>

*Pathological Appearances.*

An abscess in the brain may present one of two very distinct and separate pathological appearances. It may be, first, a collection of pus within an irregular cavity without any distinct wall, but surrounded by a more or less pulpy broken-down and hemorrhagic area of brain tissue. The pus is usually green or brown and fetid. Such abscesses advance with great rapidity and rapidly lead to a fatal termination. This is clearly different from yellow softening of the brain, which is the result of necrosis following embolism and thrombosis; though yellow softening was for a time confounded by pathologists with brain abscess. Such an abscess requires prompt surgical treatment.

The second form under which abscess presents itself is a collection of pus inclosed in a thick connective-tissue capsule lying within the white matter of the brain and quite distinct from the brain tissue. This form occasionally shows a tendency to progress rapidly, but usually it lies in the brain like a foreign body and does not increase in size. Such an encapsulated abscess may remain in the brain for many years, may give rise to no symptoms whatever, and

<sup>1</sup> In Sajou's Annual from 1888 to 1892 inclusive there are records of 55 abscesses of the brain which have been operated upon. Of these 28 occurred after injuries, 24 after ear disease, and 3 after typhoid fever; 34 recovered, 21 died. Agnew in 1891 collected records of 18 abscesses of the brain, all of which had terminated fatally.

may be a surprise to the pathologist at the autopsy. It is undoubtedly the sequel of an acute abscess which for some unknown reason has ceased to progress. Nature provides for the disposal of the pus by shutting it up within a thick wall, and if it lies as it usually does in the temporo-sphenoidal or frontal lobes of the brain or in one hemisphere of the cerebellum, regions, as we have already seen, whose function is unknown, no symptoms will be produced. Such a patient lives, however, in constant peril, and many sudden deaths of unexplained nature are due to the sudden rupture of such an abscess into the ventricle or upon the surface.

Occasionally some unknown cause starts up a series of cerebral symptoms in the person who has carried such an abscess in his head for years, and then this abscess increases in size and surgical aid may be required. The existence of a thick wall does not preclude the possibility that an abscess is in process of rapid extension.

It thus appears that the surgeon may be called upon to trephine in brain abscess under two very dissimilar conditions: (1) after a recent injury when cerebral symptoms appear early and progress rapidly, (2) in a patient with serious cerebral symptoms of an obscure character developing years after an injury or after an acute or chronic inflammation in the eye, nose, or ear.

*Abscess following Injury.*

In the first class of cases the surgeon will be guided partly by the site of the original injury, partly by the evident development of serious symptoms of brain compression following upon that injury, and partly by the facts shown by the local symptoms developed.

In some cases the symptoms of abscess after an injury are clear. Thus in the well-known case of Fenger,<sup>1</sup> where an abscess developed after a pistol-shot wound in the eye and the lodgment of the bullet in the frontal lobe, the exploration of the wound led to the discovery of the abscess, which was apparently evacuated and healed. Some months later while going about the patient suddenly fainted, and subsequently developed serious cerebral symptoms. Fenger trephined the frontal bone, found an abscess two and one-half inches deep in the frontal lobe, and drained it successfully. The patient made a good recovery.

In other cases there are local symptoms in addition to the purely surgical indications to guide the surgeon.

Thus Elcan<sup>2</sup> relates the case of a little boy who suffered from a compound comminuted fracture of the left frontal bone from which brain matter was expressed. After a few days hemiplegia and aphasia developed and the boy became comatose. The fracture was laid bare and the bone elevated and portions removed. A hernia cerebri ensued and the symptoms

<sup>1</sup> Amer. Jour. Med. Sci., July, 1884.

<sup>2</sup> Amer. Jour. Med. Sci., April, 1880.

of aphasia and hemiplegia remained, though his consciousness was clear. Four days later the wound was again examined, and during its manipulation eight ounces of pus were suddenly evacuated from an abscess which unexpectedly broke. Subsequently the aphasia and paralysis subsided, the wound healed, and the boy recovered.

Stimson<sup>1</sup> opened and drained an abscess in the posterior central convolution in the wrist centre about six weeks after the occurrence of a fracture above the right ear. The patient had recovered from the fracture, but had remained in a state of dull listlessness with severe and constant headache and a constant temperature of about 99°. From the time of the injury the left wrist and fingers had been paralyzed. In this case then the fracture, the cerebral symptoms, and the beautifully localized paralysis occurring in the left wrist all pointed to a cerebral abscess lying in the middle of the motor region of the right hemisphere. It is not surprising to-day that the abscess should have been found in this region, though in 1880, when Stimson operated, the facts of localization were so new as to make the operation almost an experiment.

Janeway<sup>2</sup> has reported a case of abscess of the right occipital lobe following a blow on the left side of the head, in which two months after the injury trephining was done by Bryant. The patient had recovered from the injury but had suffered for some weeks from

<sup>1</sup> Archives of Medicine, April, 1881.

<sup>2</sup> Jour. Ment. and Nerv. Dis., 1886, p. 226.



headache, numbness, and weakness of the left arm and leg, which gradually increased, and from great mental dulness and apathy. When admitted to Bellevue he was somnolent, had temperature of 100°, pulse 106, left hemiplegia and left hemianopsia with choked discs and severe headache. He was trephined first over the parietal lobe of the right side, and then at the point of injury on the left side, but nothing was found by puncture of the brain. At the autopsy the abscess was discovered in the right occipital lobe. In this case it was impossible to determine whether the hemianopsia preceded or followed the hemiplegia, and some reliance was placed upon the surgical injury as a guide, though it was evidently on the side opposite to the hemisphere really affected. Had it been certain that the hemianopsia was the first local symptom to develop, the trephining would have been done over the occipital lobe and the abscess would have been found.

Wernicke and Hahn<sup>1</sup> have successfully located and drained an occipital abscess, being led to the diagnosis by the existence of hemianopsia.

The following case illustrates the history of traumatic abscess of the brain.

CASE XX. *Traumatic abscess of the Brain. Trephining—Death.*

I saw with Dr. Poore at St. Mary's Hospital, in 1888, a little girl who soon after a fall on the left parietal bone with wound of the scalp developed cerebral symp-

<sup>1</sup> Wernicke: Virchow's Arch., Bd. 87, 5, 335.

toms. For two weeks these appeared to be chiefly of a general nature; then she developed right hemiplegia with much loss of sensation in the paralyzed limbs, and though too young and stupid to answer questions, it seemed that there was also a right hemianopsia. These symptoms increased in degree and the stupor passed into coma. The child was then trephined by Dr. Poore; the middle of the parietal bone being selected just posterior to the fissure of

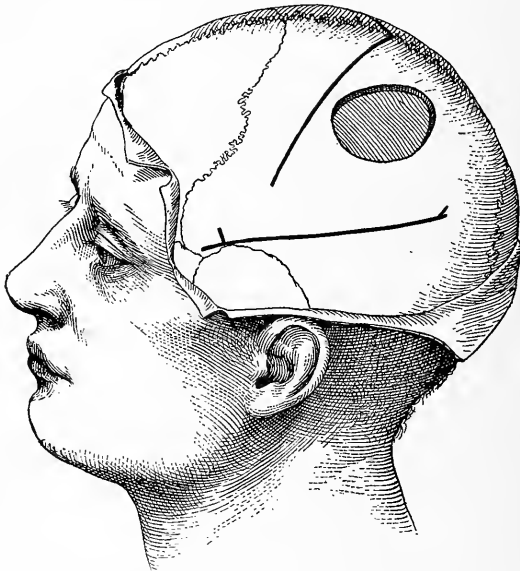


FIG. 52.—The Situation of the Trephine Opening in Case XX.

Rolando. On exposing the brain there was no evidence of meningitis, and the cortex appeared to be normal though feeling somewhat soft to the touch. As the child showed signs of shock the operation was not carried further and the wound was closed. The child lived two weeks and then died. The autopsy showed the existence of an enormous abscess occupying the entire parietal and occipital lobes and extending downward into the temporal lobe in the white matter at least an inch below the cortex, and

containing eight ounces of thick green pus contained in a capsule nearly one-fourth of an inch in thickness. This capsule would doubtless have been pressed inward and not punctured by a needle, had aspiration been attempted and the pus was too thick to have been drawn into any syringe.

The appearance of the brain containing this abscess is shown in Fig. 53.

It would be easy to cite many cases of this nature

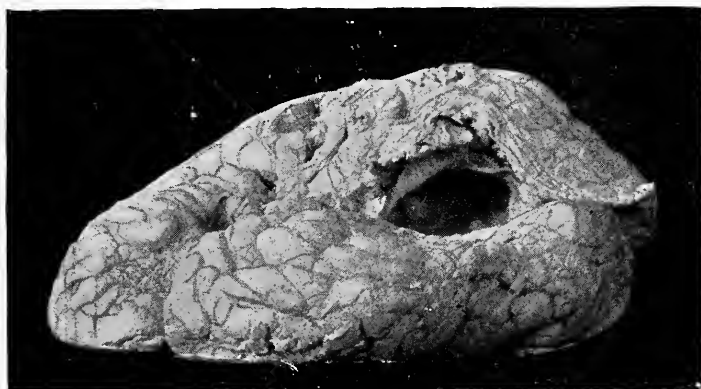

FIG. 53.—Photograph of the Left Hemisphere of the Brain (Case XX.) Containing an Abscess. The cavity of the abscess is seen to lie in the parietal lobe extending forward under the motor region and backward into the occipital lobes. The capsule of the abscess is also visible at the opening.

where surgical indications and medical symptoms both point to an immediate injury and a growing abscess in the brain. In these cases the modern surgeon is led to the diagnosis as much by his knowledge of surgery as by his knowledge of localization. From the medical standpoint, these cases require no further comment.

*Abscess following Ear Disease.*

Another class of abscesses, either acute in their onset or of long standing, are those which develop in connection with or subsequent to otitis media. These abscesses form as the result of direct infection carried to the brain from the middle ear.

Körner<sup>1</sup> has shown that they occur with much greater frequency on the right side. Barr<sup>2</sup> in a collection of 76 such abscesses found 55 in the temporo-sphenoidal lobe, 13 in one cerebellar hemisphere, 2 in the pons, and 1 in the crus. Poulsen<sup>3</sup> tabulates 13 abscesses, of which 9 were in the temporal lobe and 4 in the cerebellum.

There are no local symptoms produced by abscesses in the temporo-sphenoidal lobe that we can recognize unless the abscess grows to such a point as to invade the second or first temporal convolution on the left side, when sensory aphasia develops. There are no local symptoms produced by abscess in one hemisphere of the cerebellum unless the abscess grows to the point of invading the middle lobe or the peduncle upon the base, when staggering begins. Thus it is evident that in a very large majority of the cases of brain abscess developing after ear disease the diagnosis must be based entirely upon general cerebral symptoms and not upon any local signs. These general symptoms

<sup>1</sup> Zeitschr. f. Ohrenheilk., Bd. xvi., p. 212.

<sup>2</sup> Brit. Med. Jour., 1887, i., 723.

<sup>3</sup> Arch. of Otol., July, 1892, p. 346.

in the order of their importance are: (1) headache, usually general, occasionally worse on the side of the abscess; (2) mental irritability and mental dulness with slowness of thought, imperfect attention and memory, and occasionally delirium; (3) prostration, stupor, and appearance of illness wholly out of the proportion to the other symptoms; (4) temperature occasionally subnormal, showing little variation, rarely high and usually about  $99^{\circ}$ , and a pulse which is slow and sometimes intermittent; (5) tenderness of the head to percussion, and an elevation of temperature over the side of the head on which the abscess lies; (6) chilly sensations and even an occasional chill; (7) disorder of the entire digestive system, nausea, vomiting, and constipation; (8) facial paralysis of the peripheral type on the side affected. (9) Optic neuritis may appear but is not a constant or even a frequent symptom. Consciousness is usually preserved, but the patient appears stupid, and as the abscess increases the stupor may deepen into coma and general convulsions not infrequently occur.

When such cerebral symptoms develop either after acute otitis media or subsequently to an old, long-standing, chronic otitis media (the latter is more often the case), the question to decide is whether the patient is suffering from cerebral abscess, or from meningitis, or from thrombosis of the lateral sinus. The relative frequency of these three conditions after chronic otitis media is about the same. Thus in 36 cases recorded by Poulsen of cerebral complications of ear disease,

there were 13 cases of abscess, 12 of sinus thrombosis, 10 of meningitis, and 1 of hemorrhagic meningitis.

In meningitis there is usually a more rapid onset and progress of the symptoms than in brain abscess. In meningitis the headache is associated with hyperæsthesia to sound and light and touch all over the body, symptoms usually absent in cerebral abscess. In meningitis the temperature is high and the pulse is rapid, irregular, and intermittent. In meningitis there are occasional spasms and convulsions; strabismus appears and trismus is common; and pain and rigidity along the neck are complained of as the disease advances. Thus there are numerous points which distinguish the two diseases from one another.

Sinus thrombosis has also numerous points of differentiation from cerebral abscess. High fever with pyæmic variations in its range and frequent chills; a very rapid pulse, swelling and œdema over the mastoid process and œdema of the neck, swelling along the jugular vein, which stands out like a hard cord in the neck, exophthalmos and even swelling of the conjunctiva, and marked venous stasis in the vessels of the scalp, are all symptoms not observed in cerebral abscess, but characteristic of sinus thrombosis. Choked disc appears early in the course of the case, while it is often wanting in cerebral abscess.

Thus it is usually possible to differentiate cerebral abscess from the only two other cerebral complications of chronic or acute ear disease—and what is true of

abscess after ear disease is also true of abscess after disease of the nose or orbit.

It is thus evident that cerebral abscess produces marked general cerebral symptoms. If to these the local symptoms of aphasia or of cerebellar staggering are added, or if the general pressure of the abscess affects the function of the motor and sensory region, causing hemiplegia and hemianæsthesia of the opposite side, the situation of the abscess may be estimated with sufficient certainty to guide the surgeon in his search. Even when the situation is uncertain, it is his duty to explore. For cerebral abscess is a hopeless condition portending certain death, and some risk may be taken in an attempt to save the patient.

The best spot for trephining is one and three-fourths of an inch above and one and one-fourth of an inch behind the external auditory meatus, since at this point the temporo-sphenoidal lobe will be reached with greatest ease.<sup>1</sup> An attempt has been made by some aurists to approach the brain through the mastoid cells, but this seems to me to be very bad practice, as the thickness of the bone is great, the position is too low to reach the brain, there is danger of entering the lateral sinus, and it is impossible to lay bare a large region of the brain. We have seen already that large openings in the skull are preferable to small ones, as they are less liable to be followed by hernia cerebri, and give the surgeon plenty of room, and

<sup>1</sup> See Birmingham : Dublin Jour. Med. Sci., Feb., 1891.

they are specially desirable in trephining for cerebral abscess near the base of the brain, for it may be necessary to explore the brain in these cases with a large aspirating needle and subsequently to drain the abscess if it is found.

Ballance,<sup>1</sup> in an admirable article on the operation of trephining for the removal of pyæmic thrombi from the lateral sinus, gives a figure which I here reproduce and which shows the relations of the external meatus to the brain, to the lateral sinus, and to the cerebellum; and the best positions for trephining to reach the various parts (Fig. 54).

It occasionally happens that abscesses developing after ear disease are so superficial that there is a marked tenderness of the scalp and bone over them, but, as a rule, abscesses lie very deep within the white matter of the brain, and to be reached and emptied the brain must be incised. Horsley has invented an exploring instrument for this purpose which is very useful—a cylindrical speculum, long and pointed, and so divided that its sides can be separated gently after it has been thrust into the brain. Even with this instrument the wall of the abscess may be pushed onward and not perforated. The pus is entirely too thick to be withdrawn by an ordinary hypodermic syringe. When the abscess has been evacuated it must be washed out and drained. It usually heals slowly, and constant care is necessary to prevent the occurrence of a secondary meningitis.

<sup>1</sup> Lancet, May 17th, 1890.



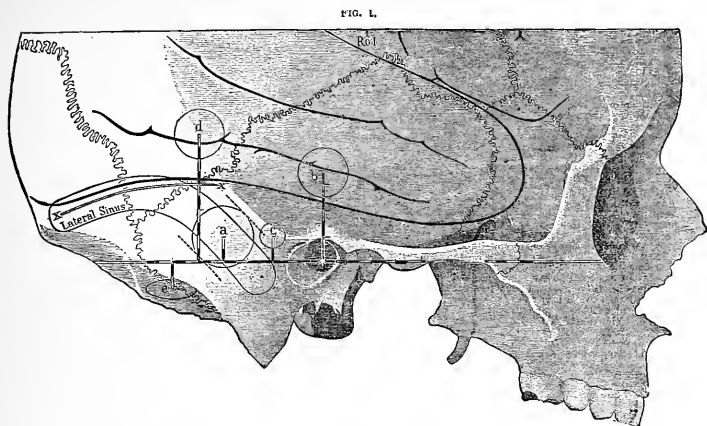


FIG. 54.—Lateral Aspect of a Small Adult Skull (Ballance). The illustration shows the relations of the lateral sinus to the outer wall of the cranial cavity and the position of the trephine opening (*a*) which should be made when it is deemed necessary to expose it. The base line (Reid's) passes through the middle of the external auditory meatus and touches the lower margin of the orbit; it is marked out in eighths of an inch, as are also the perpendicular lines drawn from it. The measurements are made along the base line from the middle of the bony meatus. The drawing also shows the convolutions of the temporo-sphenoidal lobe, the Sylvian fissure, and the position of the lower end of the furrow of Rolando (Rol.). *xx* indicates the site of the tentorium as far as it is in relation to the external boundary of the skull. The anterior *x* shows the point where the tentorium leaves the side of the skull and is attached to the superior border of the petrous bone. *a*, Trephine opening to expose sinus, five-eighths of an inch in diameter, its centre being one inch behind and a quarter of an inch above the middle of the bony meatus. This opening can easily be enlarged upward and backward and downward and forward (see the dotted lines) by suitable angular cutting bone forceps. It is always well to extend it forward, so as to open up the mastoid antrum (*c*) and the gutter of the carious bone (if there be one) which leads from the antrum, tympanum, or meatus down to the bony groove. The position of the trephine openings which must be made for the relief of inflammatory intra-cranial affections secondary to disease of the ear other than for sinus pyæmia have been added to the drawing for the sake of contrast and completeness. They are as follows: *b*, Trephine opening to explore the anterior surface of the petrous bone, the roof of the tympanum, and the petro-squamous fissure, half an inch in diameter, its centre being situated a short inch (seven-eighths of an inch) vertically above the middle of the meatus. At the lower margin of this trephine hole a probe can be insinuated between the dura and bone and made to search the whole of the anterior surface of the petrous. *c*, Trephine opening for exposing the mastoid antrum, a quarter of an inch in diameter, and half an inch behind and a quarter of an inch above the centre of the meatus; or a quarter of an inch above the centre of the meatus and a quarter of an inch behind its posterior border. The trephine should be directed inward and slightly downward and forward. When a superficial disc of bone has been removed it is well to repeat the operation with the gouge. A larger trephine may with advantage be employed, especially in adults. *d*, Trephine opening for temporo-sphenoidal abscess, half an inch in diameter. Situation recommended by Barker, one inch and a quarter behind and one inch and a quarter above centre of meatus. The needle of the aspirator is to be directed at first

inward and a little downward and forward. Birmingham prefers one and three-fourths of an inch above in order to avoid the lateral sinus. *e*, Trephine opening for cerebellar abscess half an inch in diameter and one inch and a half behind and a quarter of an inch below the centre of the meatus. Birmingham prefers two inches behind and one inch below to avoid the occipital artery. The anterior border of the trephine should just be under cover of the posterior border of the mastoid process. The drawing shows that a trephine hole made in this situation is far away from the lateral sinus, and that the trocar and canula of the aspirator, if directed forward, inward, and upward, would hit an abscess occupying the anterior part of the lateral lobe of the cerebellum, which is the usual site of collections of pus in this part of the brain.

### *Cases of Abscess of the Brain Successfully Opened.*

Stimson has reported the following interesting case:

M. D., aged 39, took cold and developed an acute otitis media with discharge of pus from the left ear in December, 1890. A month later he was admitted to the New York Hospital suffering from the chronic ear discharge and from severe pain in the left side of the head. He had had a convulsion two days before his admission and had been in a semi-comatose condition with intervals of restlessness and delirium since. On admission there was tenderness on pressure over the mastoid process but no redness or œdema. Pupils were normal; temperature 102°. He remained in a semi-comatose state for six days, growing worse, and then Dr. Stimson operated. A curved incision was begun behind the base of the mastoid process and carried forward and upward, passing close to the ear for about four inches; the flap was reflected, the bone exposed, and an opening three-fourths of an inch in diameter made through it with a chisel above and slightly behind the external auditory meatus in the posterior part of the squamous portion of the temporal bone. An incision through the dura gave exit to about three ounces of pus. The finger passed freely upward and backward. It was thought that an abscess had formed between the meninges and not in the substance of the brain, and that it had especially compressed the posterior part of the temporal lobe

in its inferior and outer surfaces. A drainage tube was inserted and the wound closed.

A few hours afterward his mental condition had improved and pain was less. The improvement was progressive and the wound healed six weeks after the operation.

Meanwhile his cerebral functions presented interesting features. During the first fortnight he seemed intelligent, but unable to comprehend his surroundings; he would listen intently when addressed and answer inarticulately, occasionally uttering a word that could be understood but which was usually unrelated to the question. It was not until the second week that he could name objects. He still failed to recognize faces at the end of the fourth week and was still unable to read. A month after the operation he began to remember things, and then little by little the recollection of the past and of his illness returned; but he had no memory of his admission to the hospital or of his first month's stay. He spoke of the difficulty he had had in calling things by their right names, and said the difficulty still persisted although it was very much less. He also had difficulty in reading. He could write his name rapidly. There was no paralysis but his walk was feeble. He eventually recovered entirely.—*N. Y. Med. Jour.*, May 30th, 1891.

The following case, which is described by Von Bergmann,<sup>1</sup> offers a good illustration of the history of an abscess secondary to ear disease:

The patient had suffered from time to time during fifteen years from a purulent discharge from the ear, with occasional earache. The pain suddenly became more severe than usual and he began to have attacks of vertigo; in the course of a few days his appetite failed; he began to feel sick and to have chills and fever at night. At the same time headache became very severe and kept him awake at

<sup>1</sup> "Die Chirur. Behandl. d. Hirnkrankh.," p. 59.

night; this headache was general, but more intense upon the right side, which was also tender to percussion. When admitted to the hospital, a few days after these acute symptoms had begun, he gave the impression of being a very sick man; was apathetic and stupid, and answered questions with difficulty and slowly; his skin was slightly yellowish and his tongue thickly coated; his temperature was  $99^{\circ}$  and pulse only 50; there was a slight difference in the power and sensation of the extremities, his left arm and leg being somewhat weaker and less sensitive than the right ones. There was an occasional twitching in the right side of the face; the pupils were equal and reacted promptly; the right ear was filled with granulations and was discharging pus; the hearing was much diminished. The mastoid process was not swollen or tender, but percussion above the ear over the temporal lobe was very painful.

The symptoms mentioned increased in intensity during the following week; his pain became greater and his mental condition more stupid. Von Bergmann then trephined above the ear, exposing a space 3 cm. square. The dura pulsated, and when it was divided the brain bulged into the wound. Incision into the brain did not at first reveal the abscess, but the third incision directed somewhat forward gave exit to 30 c.c. of fetid green pus. Exploration by the finger showed the abscess cavity with a thick wall. This was washed out with iodoform ether and drained by a tube 4 cm. long; the tube was surrounded by layers of iodoform gauze which protected the brain and membranes from contact with the pus, and the wound was thoroughly washed out before being dressed.

The pulse rose from 50 to 88 as soon as the pus was discharged; a daily change of dressing with a progressive closing of the abscess followed, so that on the ninth day the drainage tube was shortened, and by the end of the sixth week the wound had entirely healed. From that time for a year following the patient was in perfect health.

Another case is the following by Barker:<sup>1</sup>

Male, aged 33. Previous trouble in right middle ear, and epileptic attacks when young. In 1886 weakness and coldness in right leg; subsequently severe headache; tenderness over mastoid and right occipital regions. January 23d, 1887, two epileptic spasms within an hour; right side of body convulsed; subsequently unsteady gait, staggering to the left, and contraction of right pupil. January 25th, mastoid trephined in usual way; no pus found. Later, became semi-comatose, with paresis of left arm, and right pupil dilated. Diagnosis: Suppuration over or in arm and face centres of right side. February 3d, 1887, operation. Trephine applied over fissure of Rolando; dura bulging; serum found at depth of an inch and a quarter; when an inch and a quarter behind external meatus, pus found at considerable depth, and nearly half an ounce removed; abscess cavity drained by rubber tube, after which as much more pus escaped. Serious collapse of patient; reaction finally established. Patient soon convalesced, made nearly complete recovery.

Von Bergmann records seven other successful cases of operation for brain abscess quite similar in their history to his own.<sup>2</sup> Other cases have been successfully treated by Truckenbrod, Poulsen, Mayo, Pritchard, Cheyne, Paget, and others, and the records of the past three years show that a considerable percentage of cerebral abscesses secondary to ear disease, which have been accurately diagnosed, have been reached by the surgeons and emptied. Inasmuch as this disease had been uniformly fatal

<sup>1</sup> Brit. Med. Jour., 1888, April 14th.

<sup>2</sup> These cases are by Schede (1), Barker (2), Greenfield, Macewen (2), Horsley.

before the treatment by trephining was introduced, success in its treatment must be reckoned as among the brilliant results of modern brain surgery.

Abscess secondary to disease of the nasal cavity is less common than after disease of the ear. It is usually frontal in situation and produces no distinctly localizing symptoms.

Park<sup>1</sup> has recently reported a case of abscess developing in the frontal lobes after the removal of a polyp from the nose.

The patient developed general cerebral symptoms about four weeks after the operation and became unconscious. In the comatose condition there were no localizing symptoms whatever, and it was from inference rather than from any safer guide that Park decided to explore the frontal lobe. He raised a frontal flap and trephined above the orbit on the side from which the polyp had been removed. Exploration with a needle finally revealed an abscess cavity from which 12 c.c. of pus was evacuated. The cavity was drained with rubber tubing and the wound was closed and dressed. The patient died the following day. An autopsy showed the existence of a second abscess in the other frontal lobe corresponding in situation to the abscess opened.

### *Conclusions.*

Whenever severe cerebral symptoms develop rapidly after an injury to the head which has broken the scalp, or after an operation upon the nose, orbit, or ear, or during the progress or subsequently to an otitis media or chronic nasal discharge, an abscess of the brain

<sup>1</sup> Med. News, Dec. 3d, 1892.

must be thought of. If other conditions can be excluded, and if the situation of the abscess can be determined either by a study of the local symptoms or by a knowledge of the cause producing it, an operation should be undertaken at once. The earlier the surgeon is called in the better the chance of the patient. The opening in the skull should be large enough to allow of free exploration of the brain and to secure free subsequent drainage. The drainage should be kept up until the abscess cavity closes from the bottom. Every endeavor should be made to prevent the pus from coming in contact with the membranes. The wound should be dressed frequently and kept clean. The general condition of the patient should be attended to, so that every opportunity for recovery may be afforded.

## CHAPTER VI.

### TREPHINING FOR TUMOR OF THE BRAIN.

The Frequency and Varieties of Tumors in the Brain. Analysis of Six Hundred Tumors. Tumors in Children Contrasted with Tumors in Adults. The Diagnosis of the Nature of the Tumor. The Diagnosis of the Situation of the Tumor. The Percentage of Brain Tumors Open to Operation. The Results of Operation for Brain Tumors. Analysis of Ninety-seven Cases. I. Cerebral Tumors. Selected American Cases. Personal Case. Tumor of Frontal Lobes. II. Cerebellar Tumors. Diagnosis. Difficulties of Operation. Three Personal Cases. Table of all Brain Tumors Operated upon. Conclusions.

UNTIL a recent date the interest in a case of tumor of the brain appeared to end with the diagnosis, for prognosis was hopeless and treatment except in tumors of syphilitic origin was useless.

But with the advance in the power to diagnosticate the nature and exact position of tumors came the possibility of turning that power to a practical use. And the marvellous development of aseptic surgery opened the way to achievements in the removal of brain tumors more brilliant than in any other field. The work of Macewen, Durante, Horsley, Weir, Keen, and Park, and the later successes of Von Bergmann, Czerny, Lucas Championnière, Troissier, McBurney, Deaver Gerster, and others, have placed upon a sure and permanent basis the surgery of the brain. And in no department of this field of surgery have the re-



sults been more striking and successful than in the excision of new growths.

These facts have lent a new interest to the study of brain tumors. It is essential to investigate their frequency, their varieties, their various situations, their structure, and their diagnosis, and thus to reach some estimate of the prospects of success in their treatment by the trephine.

*The Frequency and Varieties of Tumors of the Brain.*

Authorities agree that brain tumors occur with about equal frequency in childhood and in adult life. Gowers states that one-third of the cases occur in persons below the age of twenty, so that it would seem that children were somewhat more liable than adults to this disease. In the list of organic nervous diseases of childhood cerebral tumor stands high, being only exceeded in frequency by meningitis, infantile spinal paralysis, and cerebral hemorrhage. In adult life it does not hold as conspicuous a place, being mentioned after cerebral hemorrhage, embolism, and thrombosis, and being less frequent than locomotor ataxia and than paretic dementia.

Some years ago I made a collection of 300 cases of brain tumor in children and youths, deriving the cases from Bernhardt's and Steffan's collections and from the journals published prior to 1888. The table then prepared is here reproduced, as it demonstrates the varieties and most common situation of these tumors in childhood.

To afford some information with regard to the points of difference between tumors in childhood and in adult life, I have now prepared a second table containing 300 tumors occurring in persons above the age of twenty. These have been collected from Bernhardt's tables; from my own collection of American cases of cortical lesion; from Bramwell's book, and from the critical digests by Bernhardt in Virchow's *Jahresbericht* from the years 1888 to 1892 inclusive.

TABLE II.—BRAIN TUMORS IN CHILDREN AND ADULTS.

Situation.	Tuber- culous.		Glioma- tous.		Sarco- matous.		Glio-sar- comatous.		Cystic.		Carcino- matous.		Gumma- tous.		Not Stated.		Total.	
I. Cerebral axis:																		
1. Basal ganglia and lateral ventricles.....	14	3	3	9	5	8	...	...	1	1	1	2	..	1	3	5	27	34
2. Corpora quadrigemina and crura cerebri....	16	1	1	2	3	2	..	5	..	..	1	2	..	..	1	7	21	14
3. Pons.....	19	11	10	..	5	1	2	1	1	..	..	2	..	3	1	..	38	17
4. Medulla.....	2	..	..	1	..	..	..	..	..	..	2	..	..	..	1	..	6	2
5. Base.....	..	3	..	2	1	3	2	1	1	1	..	..	..	..	4	1	8	9
6. Fourth ventricle.....	1	..	1	..	1	1	..	..	..	..	1	2	..	..	1	1	5	4
II. Cerebellum.....	47	8	15	8	10	13	1	6	9	..	3	..	..	11	10	96	45	
III. Multiple tumors.....	34	4	..	2	3	5	..	..	2	..	2	1	3	3	1	43	17	
IV. Cortex cerebri.....	13	9	6	19	1	46	..	8	..	1	19	..	13	..	12	21	127	
V. Centrum ovale.....	6	2	1	11	5	7	1	4	15	..	1	3	1	..	5	4	35	51
	152	41	37	54	34	86	5	25	30	2	10	33	2	20	30	41	300	300

The first columns are children's tumors; the second columns adults' tumors.

It will be noticed in comparing these tables that the relative frequency of the different varieties of tumors differs in children and adults, tubercular tumors preponderating in childhood, but being relatively infrequent in adult life.

Glioma and sarcoma appear to be about equally frequent in childhood, but in adults sarcoma is more frequent than any other tumor, glioma being the next in frequency. Carcinoma, as would naturally be ex-

pected, is more frequent in adults than in children, so also is gumma.

It is rather singular that so few gummata have been recorded in literature. It is my impression, derived from clinical observation, that gumma is the most frequent form of brain tumor occurring in adults. Rumpff in his book upon "Syphilis of the Nervous System" has been able to collect a very large number of gummata of the brain and has described this class of cases fully. That gumma may be absorbed by specific treatment is a fact which the majority of syphilographers hold and which my own experience confirms; it is, however, denied by Horsley, who recommends operation for gumma as well as for other tumors. It seems to me that the infrequency with which gummata are recorded in literature as having killed the patient would indicate that, though these tumors may be frequent in occurrence, they are susceptible to medical treatment and do not prove as fatal as other tumors do.

Cystic tumors of the brain may arise either in connection with glioma or glio-sarcoma or independently as the result of parasitic infection. Hydatid cysts, echinococcus, and cysticercus are very much more frequently met with in the German and Australian records than in English or American journals. Küchenmeister, in an article on this subject, has collected 88 cases, but I have not included them in the table, as they would give an appearance of undue frequency of this disease, which would mislead. In America a cerebral cyst of

parasitic origin is a curiosity, and but few cases are to be found in our journals. Cysts which are merely the result of preceding softening or hemorrhage are not to be reckoned among tumors, as they do not produce symptoms of tumor.

Primary carcinoma of the brain is a great rarity. Among the cases tabulated are four which invaded the brain secondarily, after beginning in the retina of one eye, a not infrequent form of the disease in childhood; the remainder being secondary to carcinoma elsewhere in the body.

In comparing this list of the relative frequency of the various forms of tumors with smaller lists, I find that the relative frequency is about the same in all lists; and therefore I think that this may be considered fairly reliable, though statistics are always to be looked at with care.

The diagnosis of the kind of tumor present is always a matter of probability in any case; and hence such a list has a certain diagnostic value. It will, of course, occur to any one in the presence of a child with brain tumor to inquire carefully into any history of hereditary tendency to tubercular disease, and to examine carefully for other evidence of tuberculosis, such as enlarged glands, scrofulous joint disease and phthisis, chronic diarrhoea, etc. Occasionally the tubercular tumor has been found, after death, to be the only manifestation of infection, but this is not the rule. Tubercular tumors are so frequently multiple that the occurrence of local symptoms pointing to

more than one tumor will also point to tubercular tumors. The determination of the question as to the existence of tubercular disease is of the greatest importance, in view of the possibility of surgical interference. Supposing that a brain tumor is diagnosed and is located in a place accessible by trephining: if it is thought to be tubercular is an operation justifiable? Such an operation may prolong life, but the disease may reappear in the brain or elsewhere. The operation is certainly attended by greater danger than in a non-tubercular person. Yet the existence of tuberculosis does not prevent the surgeon from attacking tubercular joints or tubercular testicle. Should it prevent his attacking a brain tumor? Von Bergmann<sup>1</sup> thinks that it should, affirming that it is impossible to remove the cheesy masses from the soft brain coverings and tissue with the thoroughness that is possible in dealing with bones. He claims that the operation will be incomplete, and that a relapse is then certain. In support of this view is the fact that a tubercular tumor of the brain was recently removed at St. Luke's Hospital in this city by Dr. B. Farquhar Curtis from a patient of Dr. J. A. Booth, but within three months it had recurred. English surgeons have taken a different view, and have removed successfully several tubercular tumors completely without relapse. But further experience is certainly necessary before any rule can be laid down in the matter. The greatest drawback met with in

<sup>1</sup> "Chirurg. Behandl. d. Hirnkrankheiten," p. 58.

dealing with tubercular tumors by surgical measures is the possibility of the presence of more than one tumor, the failure to detect and remove more than one, and the consequent need of a second operation when the second tumor develops sufficiently to give rise to special symptoms.

If there is no probability in a case of tumor that tubercular disease is present, the diagnosis of the kind of tumor present is difficult.

Carcinoma of the brain, though in a few cases primary, is usually secondary to carcinoma elsewhere. Should such a tumor be found in the body, especially if it should be found in the orbit and in connection with the retina, the diagnosis of the nature of the cerebral tumor can be made. Otherwise it cannot be thought probable. To remove a secondary cancer in the brain when the primary cancer remained would hardly be undertaken by any good surgeon.

Gumma is the form of tumor most likely to develop in adults, but unless there is a distinct history of acquired syphilis with other syphilitic manifestations, and unless nocturnal headache and insomnia are present, the diagnosis will be uncertain. The test of specific treatment should be applied in every case. Horsley limits the duration of medical treatment to six weeks. I would urge that unless the tumor is far advanced a more thorough trial be given. If no result in the amelioration of symptoms is obtained in three months it is probable that further treatment will avail nothing.

Cysts in the brain of parasitic origin form very slowly, never destroy but always displace the brain tissue, and rarely, if ever, give rise to localized symptoms. In a case of brain tumor in which the symptoms are all general and not local the possibility of cyst should not be overlooked, and the child's history should be investigated in regard to any exposure to infection, the presence of tapeworm or of hydatid tumors elsewhere. There is no reason why such cysts should not be removed.

The remaining varieties of tumor—glioma, sarcoma, or glio-sarcoma—cannot be absolutely differentiated from each other. Occasionally sarcomata in other regions of the body may lead to the suspicion that there is one in the brain, but secondary sarcomata are relatively rare in the brain. Hence this point of diagnosis is not to be relied upon. Glioma and sarcoma may be equally slow in growth, may produce very marked symptoms or none at all, and do not differ markedly in their selection of situations in which to develop. Bramwell believes that glioma starts in the white matter and invades the gray matter. Ziegler affirms the contrary, and the cases here cited certainly confirm the statement of the German pathologist; but from a disputed pathological question no diagnostic conclusions can be drawn. Nor does the mode of origin throw any light upon the differentiation of sarcoma and glioma, for both result from blows and falls upon the head with equal frequency.

There is but one fact which may make a differen-

tiation possible, viz., that glioma is usually very vascular, much more so than any other tumor. A tumor which is vascular varies very much in its size, being, as it were, erectile. Variations in size within the brain are impossible, but the corresponding condition to erection in such tumors is an increase of intracranial pressure. Variations of intracranial pressure manifest themselves, subjectively, by varying intensity of symptoms, and by the possibility of modifying symptoms by means of agents which affect the blood pressure, and objectively by the state of venous congestion of the retina. Furthermore, in glioma, hemorrhages within or near the tumor sometimes occur, giving rise to symptoms of apoplexy. Therefore, in a case of tumor, great and sudden changes of intensity in the symptoms, accompanied by visible changes of circulation in the retina, and affected in one way or another by such measures as hot baths, cold douches to the spine, hot mustard baths to the feet, or free watery purgation, will indicate a vascular tumor, probably a glioma. And this diagnosis will be reinforced by the occurrence of attacks apoplectic in character in the course of the case. And yet there are cases of glioma in which the tumor is quite hard and encapsulated, and in which these symptoms will be wanting.

But there is a practical application of these points of diagnosis regarding the vascularity of the tumor in view of surgical interference. The form of tumor most suitable for removal is the hard, encapsulated, non-vascular tumor. That is the usual form of sar-



coma, and is occasionally the form of glio-sarcoma but not of glioma. A case, therefore, is much more suitable for operation in which no vascular symptoms, such as those mentioned, are present, whether it be sarcoma or glioma. And, *vice versa*, a tumor showing marked vascular symptoms will not be a favorable one for operation, no matter what its variety or position.

Passing now from the consideration of the varieties of brain tumor and their differentiation, let us look at *the situation of the tumor*.

#### *The Situation of Brain Tumors.*

It is evident from Table II. that all parts of the brain may be invaded by tumor, but that certain parts are invaded with special frequency both in childhood and in adult life. These parts are the cerebral axis and the cerebellum in children and the cortex in adults. By the cerebral axis is meant that part of the brain which includes the basal ganglia and internal capsule; the corpora quadrigemina and crura cerebri; the pons and the medulla oblongata (Fig. 55); and which lies upon the cranial floor and is therefore invaded by tumors lying upon the base of the brain. Of the 600 tumors collected, 185 were in the cerebral axis. The diagnosis of such tumors is not difficult, as they usually give rise to very numerous local symptoms, chiefly those of involvement of the cranial nerves. It is not my purpose to discuss these here: they may be found in all the recent articles upon the local diagnosis of cerebral disease. The point of interest is that no case

of tumor of the cerebral axis can be reached by the surgeon. The situation of the parts is such that a tumor in them is not near enough to the convex sur-

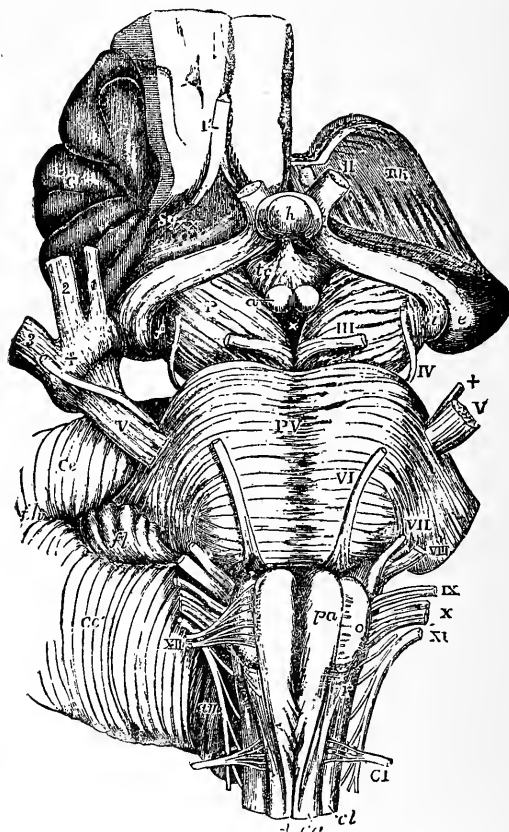


FIG. 55.—The Cerebral Axis, Basal Ganglia, Crura, Pons, and Medulla, with the Cranial Nerves.—Allan Thompson.

face of the skull to be accessible (see Fig. 56). And therefore, in estimating the number of the cerebral tumors in this collection which might have been the

subject of surgical treatment, this class, constituting one-third of the number, must be at once excluded.

Coming next to tumors of the cerebellum, we find

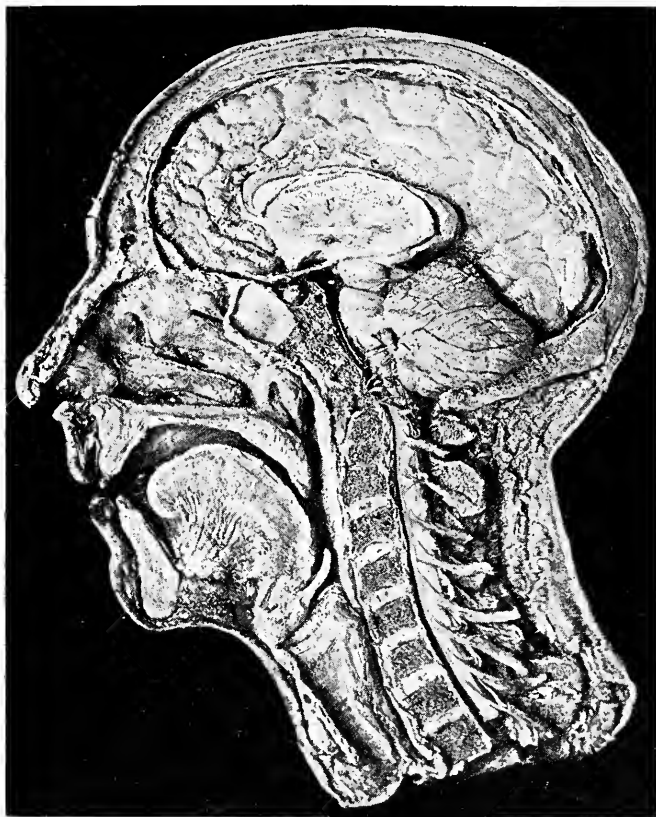


FIG. 56.—Photograph (Fraser) of a Dissection showing the Situation of the basal ganglia, cerebellum, pons, medulla, and spinal cord, and their relation to the other parts. The entire cortex of the left hemisphere has been removed so as to expose the basal ganglia and the left cerebellar hemisphere.

that they number 141. They are twice as common in children as in adults. Thus in a collection of American cases of cerebral tumor without regard to

age which I have made, I find that of 45 cerebral tumors 3 occurred below the age of nineteen, while of 29 cerebellar tumors 11 occurred below the age of nineteen. It is, therefore, evident that children are especially liable to develop cerebellar tumors. The results of attempts at the removal of cerebellar tumors will be carefully considered further on in this chapter, but it may be stated here that they are most difficult to reach or to remove.

Multiple tumors form the next class in the table, 60 in number, and these must be at once dismissed as outside the field of operation at the present time. It may be remarked in passing that where numerous local symptoms are present in a case which cannot be explained by a single lesion, the diagnosis of multiple tumor is justifiable.

The remaining classes are tumors of the cortex and tumors of the centrum ovale, not deep enough below the cortex to involve the basal ganglia, 56 in number in children and 178 in number in adults. Both these classes of tumors can be reached by the surgeon. There are no especial indications for their detection and removal in children as distinguished from adults, hence they may be considered together.

As to the differentiation of cortical from subcortical tumors, that is still impossible, tumors near the cortex giving rise to the same symptoms as cortical tumors. Let us now look at the situation of these tumors in the various parts of the accessible cortex, so far as the histories enable one to classify them.

TABLE III.—TUMORS OPEN TO OPERATION.

Cortex and Centrum Ovale.	Tubercle.	Glioma.	Sarcoma.	Glio-Sarc.	Cyst.	Carcinoma.	Gumma.	Not Stated.
Frontal . . . . .	9	9	13	6	4	5	4	9
Central . . . . .	12	11	22	1	..	3	7	6
Parietal . . . . .	2	3	3	..	1	2	..	..
Occipital . . . . .	3	2	4	..	..	5	..	1
Temp. sphen..	1	1	8	1	..	3	2	1
	—	—	—	—	—	—	—	—
	27	26	50	8	5	18	13	17

Of this total of 164 tumors near enough to the surface of the brain to have been reached by the surgeon<sup>1</sup> there were 46 in which an operation was clearly indicated from the general and local symptoms, and there were 37 in which had the attempt been made the operation would probably have been successful. Thus out of 600 tumors 37 could have been removed, *i.e.*, about 6 per cent.

It would require too much space to give in detail the history of each of these cases and to discuss the reasons for and against an operation. Suffice it to say that this conclusion is reached by a study of the local symptoms which during life would have given distinct evidence of the situation of the disease, and by a consideration of the pathological condition found at the autopsy which demonstrated whether the removal of the growth during life could have been accomplished.

Many tumors in this collection could have been diagnosed and located, but could not have been removed had the attempt been made. Others could have been removed, but the symptoms did not point

<sup>1</sup> The remaining 70 were inaccessible.

with sufficient distinctness to the situation to give an adequate guide to the surgeon. The majority of the removable tumors were encapsulated sarcomata lying on the cortex in the central region and giving rise to spasms and to paralysis. Three of the occipital tumors producing hemianopsia and five of the frontal tumors causing aphasia might have been removed. The large majority of the gliomata and of glio-sarcomata were infiltrated in the brain substance to such an extent as either to have escaped detection at an operation or to have been impossible of excision. The same is true of the carcinomata. Many of the tubercular tumors were multiple, and when one might have been reached the others would have eluded diagnosis.

There were several cases of tumors within the brain either in the optic thalamus or in one lateral ventricle, which demonstrate how both diagnosis and operation might fail. In these cases the symptoms might easily have led to a diagnosis of cortical tumors in the motor area, but had an operation been undertaken no tumor would have been found. Such cases should serve as a warning. They teach that under the most careful examination diagnosis is never absolutely accurate, and that many operations must necessarily be exploratory. This latter fact, however, is familiar to surgeons, and need not prevent the progress of cerebral surgery.

It may be remembered that in a review of 100 tumors in the museum of Guy's Hospital, Dr. Hale White found 10 which might have been removed safely. His

percentage, 10 per cent, is larger than my percentage—6 per cent including tubercular tumors. Mills and Lloyd found 10 cases in their collection of 100 which could have been operated upon. Knapp found but 2 cases in his collection of 40 cases, and he estimates that 7 per cent of the 485 cases tabulated by Bernhardt could have been removed. Dana states that 5 cases in 29 under his observation could have been removed. If we add these together the result is 7 per cent for operation.<sup>1</sup>

This conclusion appears to be very unfavorable to surgical interference in brain tumors. It is to be remembered, however, that in many cases the patients were only observed in a late stage of the tumor, when it had grown to such a size that early local symptoms were obscured, as they are likely to be, by later symptoms. And it is also to be remembered that at present the observation of nervous symptoms is more careful and accurate than in former years, and that many cases now come under observation at an earlier stage than formerly, so that the diagnosis can be made before the tumor has made much progress.

Turning now from these theoretical considerations, let us see what have been the results of experience in the removal of brain tumors.

#### *Analysis of Operations for Removal of Tumors.*

The number of cases of tumor of the brain in which surgical relief has been attempted up to the present

<sup>1</sup> See also Knapp: "Intracranial Growths."

time, so far as I have been able to find them in current literature, and including my own cases, is 97:<sup>1</sup> 81 of these were tumors of the cerebral hemispheres; 16 of them were tumors of the cerebellum. The results of these cases are stated in the table given below:

TABLE IV.—TABLE OF RESULTS OF OPERATION FOR BRAIN TUMOR.

	Cerebral.	Cerebellar.	Total.
Total number of cases operated upon.....	81	16	97
Cases in which tumor was not found.....	26	9	35
Cases in which tumor was found but not removed.....	1	2	3
Cases in which tumor was removed and patient recovered.....	39	3	42
Cases in which tumor was removed and patient died.....	15	2	17

It will be seen that the percentage of recoveries after the successful localization and removal of the tumor is 46 per cent. Considering how recently the facts of localization have been determined and how novel is the surgical procedure of operation upon the brain, this large percentage of successful results is both interesting and encouraging. It makes it imperative that every case in which a tumor of the brain is suspected should be studied with increased care, and that

<sup>1</sup> The literature is extensive. Recent important articles are as follows: Weir and Seguin, *Amer. Jour. of Med. Sci.*, July, August, and September, 1888. Keen, *Amer. Jour. of Med. Sci.*, November, 1888. Park, "Surgery of the Brain," *Transactions of the Association of Amer. Physicians and Surgeons*, 1889. Von Bergmann, "Die Chirurgische Behandlung von Hirnkrankheiten," 1889. P. C. Knapp, "Intracranial Growths," 1891; the last contains tables of all cases up to June, 1891. Theodore Diller, the *Pittsburgh Medical Review*, Oct., 1892. Articles in *Virchow's Jahresbericht* and in *Sajous' Annual*.



the question of operation should be thoroughly considered.

It seems best to distinguish broadly between tumors of the cerebral hemispheres and tumors of the cerebellum. The diagnosis between these two conditions is perfectly easy, and the risk of operation in the two conditions is so different as to demand their separate consideration.

*First. Cerebral Tumors.*

As shown in the table, 81 tumors of the cerebral hemispheres have been treated surgically.

In 54 cases out of these 81 the tumor has been successfully located and removed from the brain. Thirty-nine of the patients recovered, 15 died.

Of these 54 tumors 43 have been removed from the motor (central) region of the brain. It is in this region that the location of a tumor can be most easily determined and in which few mistakes of diagnosis have been made. The occurrence of spasms or of paralysis limited to one limb, or extending from one to the others in a definite order, is diagnostic. In one of my own cases the motor symptoms were certainly of the greatest service in determining the location of the tumor. So too in a case reported by Erb in July, 1892, in the *Deutsche Zeitschrift für Nervenheilkunde*. This case deserves mention on account of its unique history.

The patient was a male and had suffered from the general symptoms of brain tumor, viz., headache, vertigo, vomiting, and optic neuritis, for some months. The de-

velopment of occasional spasms followed by paralysis in the left arm and leg indicated the central convolutions of the right hemisphere as the probable position of the tumor. Czerny operated in November, 1890, and found the tumor to be an infiltrated glio-sarcoma, and removed a part of it, its complete extirpation being impossible. The patient recovered from the operation, was very much improved for eight months, and then began to suffer again from the old symptoms. In November, 1891, his condition had become so bad that it was thought best to repeat the operation. The tumor was found to have grown again, and again a large part of it was removed. Again improvement was very striking, but at the date of the report, July, 1892, a third operation upon this man was in contemplation, the symptoms having again appeared.

It is evident that in such a case where the complete extirpation of the growth cannot be attained, ultimate success cannot be expected. Yet this case demonstrates the possibility of relieving the serious symptoms and of prolonging life in a disease formerly considered incurable. The operation may be compared to that of removal of cancer of the breast, which prolongs life even at the risk of recurrence.

The location of the tumor in the remaining 23 cases was as follows: in the frontal region in 5, in the parietal region in 1, in the occipital region in 2. In the remainder the location was not exactly stated in the history. Occipital tumors can be so easily diagnosed by the existence of hemianopsia that it seems singular that but two have been removed. Parietal tumors give rise to sensory symptoms associated with motor symptoms, and when in the left hemisphere

they also produce symptoms of sensory aphasia of the variety known as word-blindness or alexia. It must be confessed, however, that the diagnosis of tumors in this location is much less certain than that of tumors in the motor zone. Tumors in the left temporal lobe also produce sensory aphasia of the variety of word-deafness. Mental changes and secondary motor symptoms occur in tumors of the frontal region. They will be more fully discussed in connection with one of the cases here recorded.

In 25 cases the operation was unsuccessful because the tumor was not found by the surgeon at the point at which it was supposed to lie, or because the operation was undertaken for the relief of the symptoms caused by intracranial pressure and not with a view to the removal of the tumor (8 cases). In some of these cases the local symptoms were clearly insufficient to indicate the position of the tumor, and a cautious neurologist would not have advised an attempt to find it. In other cases the local symptoms were well marked and the diagnosis seemed clear, yet the tumor really lay at such a depth as to be inaccessible, or was so infiltrated in the brain as to make its removal impossible. These cases must necessarily be counted as failures in the estimation of the percentage of success. Yet exploratory operation is not to be condemned, for we are dealing here with a hopeless disease, and it is proper to make an attempt to save the patient even though that seem to be desperate.

It is evident, therefore, that tumors have been suc-

cessfully diagnosticated and removed from almost all parts of the convexity of the cerebral hemispheres.

It is impossible either to satisfactorily diagnosticate or to remove tumors lying on the median or basal surfaces of the cerebral hemispheres, and no attempt at such removal has been made.

It is impossible to give any detailed history of all of these cases. I select a few American cases in which the diagnosis was clear both as to the nature of the disease and as to its location, and in all of which the tumor was found at the operation.

#### *Selected Cases of Brain Tumors Removed.*

HIRSCHFELDER and MORSE.—M., 33, in August, 1884, began to have pain in back of head and vertigo. Later he noticed dimness of vision and stiffness and weakness of left leg, then of left arm with occasional epileptic attacks and twitching of left side of face and left leg.

When seen in February, 1886, he had frequent spasms of the left side, beginning in the arm, and a condition of left hemiplegia with loss of muscular sense in the left arm and anæsthesia of left face and general symptoms of brain tumor.

Diagnosis was a tumor in middle part of posterior central convolution.

Trephined February 15th, 1886, by Dr. Morse. Bone thin. Dura found tense and white; when dura was divided brain bulged. The brain appeared to be hemorrhagic and gliomatous. The growth,  $2\frac{1}{2}$  c.c. in size, was excised in part, it being difficult to separate it entirely from the healthy brain tissue. It was a glioma.

Patient recovered from the shock of operation, but the paresis of the left side remained. The discharges from the wound became septic. The brain about the tumor was

much softened. He died on February 23d.—*Pacific Med. Jour.*, April, 1886.

BIRDSALL and WEIR.—M., aged 44. Paretic symptoms in limbs of right side, with diplopia, nausea, headache, etc.; later, hemianopsia and neuro-retinitis. Diagnosis of tumor in cuneus. This diagnosis was fortified by further observation, and symptoms of inco-ordination explained by its pressure on the cerebellum. Operation, March 9th, 1887, by Dr. Weir. On opening skull, dura did not pulsate, but was of dark color; incision; appearance of tumor of reddish color, covered with vascular connective tissue; enucleation of same after its incision, and removal in two parts; hemorrhage troublesome. Tumor found to be spindle-celled sarcoma; greatest circumference, eight inches and a half; weight, 140 grammes. Five hours later, patient in collapse from secondary hemorrhage; infusion of salt solution; bleeding continued. Death nine hours after operation.—*Med. News*, April 16th, 1887, p. 423.

SEGUIN and WEIR.—M., aged 39. Spasms of right side and neck. In 1886 fell one day unconscious; epileptic attacks preceded by aura in right hand and arm and right side of face. Diagnosis of tumor in left motor area. Operation, November 17th, 1887, by Weir. Dura protruded slightly; appeared normal; extensively incised; brain seemed to protrude; yielded deep resistance on palpation. Tumor, size of an almond, discovered at depth of an inch, not encapsulated, apparently infiltrating surrounding brain tissue. It was lifted out with a Volkmann spoon. A small fragment, which had separated in process of loosening, was also separately removed. No hemorrhage from brain; wound drained and irrigated; discs of bone with several fragments replaced over the dura. Tumor found to be sarcoma, principally of round cells. Patient recovered; several months later was in good general condition; better as regards paresis of face and hands; speech much improved. Five months later,

no recurrence of growth.—*Am. Jour. of the Med. Sciences*, July, 1888, p. 225.

Three years later this growth recurred and the patient died.

KEEN.—M., aged 26. Fell from a window when 3 years old, his head striking on a brick. A superficial wound was made, and no trouble was experienced until he was 23, when epilepsy developed, associated with aphasia and paralysis of the right arm and leg. Later there was recovery from much of this disturbance. Operation, December 15th, 1887. Keen removed a considerable area of bone and uncovered a tumor nearly three inches in length in its long axis. During the operation great trouble was experienced from hemorrhage, which was checked partly by hot water. Patient did well. For several hours on the third day symptoms of brain pressure were observed, and this was attributed to the presence of a large clot of greater size than the original tumor. This was removed by careful washing and all went well for ten days: then pressure symptoms were again observed. There was also some diarrhœa and a temperature of  $104\frac{1}{2}^{\circ}$ . The presence of pus was suspected and the wound reopened. No pus was found and a certain amount of hernia cerebri supervened. It was inferred that the unfavorable symptoms were largely due to the diarrhœa, and two or three other similar attacks made this still more apparent. The hernia was finally overcome, partly by skin grafting. The wound was drained by bichloride gauze for eight weeks. It healed perfectly, but with a concave shape instead of convex. Four months later he was quite well, but had had one epileptic attack.—*Amer. Jour. Med. Sci.*, Oct., 1888.

“As to the final results of the case reported in the *American Journal* in 1888, the man is still living, in Lancaster, Pa. He has occasional epileptic fits, not nearly so often nor so severe as formerly, and he has had an interval as long as a year or thereabouts between

his attacks. His eyesight has improved to a certain extent, but not very much. His mental condition is, I think, a little better, but nothing of any moment. He has no headaches and locomotion is good."—Letter from Dr. Keen, Jan. 23d, 1893.

KNAPP and BRADFORD.—M., 32, had a blow on the head in 1868, followed the next day by convulsions. He was perfectly well until 1886, when he began to suffer from nausea, vomiting, and headache. In March, 1887, he had a spasm with extension and abduction of the left arm. About the same time there was loss of power in the left arm and leg and numbness of the left hand with increased reflexes and contracture. Optic neuritis then developed, and the convulsions continued and the paralysis increased. The convulsions usually began with a sensory aura in the left hand and a clonic spasm of the left wrist extending to the elbow. Sometimes the convulsion became general with loss of consciousness. In January, 1888, headache had become so severe that he had to give up work, memory began to fail, and speech became slow. In November, 1888, Knapp found impairment of motion of eyes to the left, left hemiplegia with contractures, and hemianæsthesia most marked in the arm. Convulsions which were observed began in various parts of the arm. Trephined Dec. 28th, 1888, by Dr. Bradford, over the middle third of the anterior-central convolution. Tubercular tumor 4 by 3 centimetres, weighing 35 grammes, was removed from the middle third of the two central convolutions on the right side. The patient died of shock in about an hour after.—*Bost. Med. and Surg. Jour.*, April 4th, 1890.

CHURCH and FRANK.—M., 39, began to suffer from convulsions in July, 1888, which continued until his operation. Each began with pain and spasm in the right index finger, partially involving the rest of the hand and passing up the arm. The extremity presented a flexed attitude and rapid clonic movement; when the body was reached consciousness was lost and the patient would fall,

and the convulsion would become general and be followed by sleep. By January, 1889, the right hand had become continuously painful<sup>1</sup> and weak; he had become mentally dull and hemiplegic on the right side. He had constant severe frontal headache, tenderness to percussion on the left side of the head, but had no optic neuritis. He was trephined May 21st, 1889, over the middle third of the motor area on the left side. A small node was seen in the anterior part of the opening, and when a full exposure had been made a thickened, cicatricial-looking mass was found as large as a bone from which radiated filamentous processes. This was dissected away, causing a decortication of the brain over an area one and one-half of an inch in diameter. The wound was closed and drained and healed. During the following month his condition was stationary, the fits not recurring, but twitching of the arm being frequent. A rise of temperature then led to a reopening of the wound. The trephine buttons were found to be dead, and the cavity in the brain was full of thick pus which was washed out. After this his condition improved. The wound healed, he recovered, and at the end of six months was in fair health. He was then having convulsions once in ten days; had slight paresis in the right hand and arm, but was able to be about.—*Amer. Jour. Med. Sci.*, July, 1890.

“This case was under observation until July, 1892. He had so far improved that the attacks were two and sometimes three times as far apart. The pain in leg and arm was entirely gone. He was strong and had gained greatly in flesh. I do not expect, however, that he will ever be further improved, or be able to earn an independent livelihood.”—Letter from Dr. Frank, Jan. 30th, 1893.

THOMAS and BARTLETT.—Female; spasms beginning in fingers of left hand associated with numbness, advancing up the arm, occurred at intervals from January, 1887, to

<sup>1</sup> This is one of the few cases on record of “central pain,” such as has been described by Edinger.



March, 1889. After that the attacks became more frequent and extended to the left leg, and occasionally to the face, both arm and leg remaining paretic after the attack. These attacks continued until June, 1889. Headache was a constant symptom, but there was no optic neuritis. Diagnosis, a tumor in middle third of central convolutions. Operation June 13th, 1889. On removal of the bone a pointed conical projection of bone three-eighths of an inch long was found projecting into the brain through the dura. Under this a large tumor was found, to which the dura was adherent, measuring  $3\frac{1}{2}$  by  $2\frac{1}{2}$  by  $1\frac{1}{2}$  inches. This was removed. The convolutions under it were flattened and softened. Two days later left hemiplegia developed, the patient became comatose and died. The autopsy showed the cavity filled by a clot and the adjacent brain much softened.—*Hahnemannian Monthly*, May, 1890.

BREMER and CARSON.—M., 23, was well until 1887, when he began to suffer from spasms in the left arm which extended to the neck and later, as they increased in frequency, to the left leg. This condition was followed by spastic contraction with frequent spasms in the left foot and in the muscles of the left side of the neck, which later extended to the left arm, and the rigidity was attended by some weakness. Vomiting, insomnia, and great nervousness had developed by 1889, when he first came under Dr. Bremer's observation. There was slight beginning optic neuritis. The entire left side was paretic and the limbs were contracted, but could by effort be straightened. Every voluntary movement was opposed by simultaneous contractions of the antagonist. There was no anæsthesia. Spasms in the left side occurred frequently, beginning in the neck. The local symptoms of slowly increasing severity indicated a tumor in the right motor area at the centres for platysma and wrist in the post-central convolution. Near this spot an old scar was found. He was trephined by Dr. Carson, March 26th, 1890, over the site of the scar. The dura bulged but did not pulsate. On

exposing the brain it presented a reddish-brown appearance with torpid vessels, and the tumor could be outlined on three sides. It was very pliable, about the size of a walnut, and was removed with a spoon. The tumor was a cavernous angioma. The cavity was drained and the wound dressed, and in a week the scalp had healed. The improvement after the operation was progressive. There was no return of the spasms, and the paralysis, which was somewhat more intense after the operation, gradually improved. Anæsthesia of the hand and arm was found after the operation and had remained up to the time of the report.—*Amer. Jour. Med. Sci.*, Sept., 1890.

“Although there was no return of the distinct spastic seizures resembling the Jacksonian type after the operation, for the whole time that the patient remained under our observation at the Mullanphy Hospital (about sixteen months) the general improvement, *i.e.*, the relaxation of the diffuse spasticity of nearly the whole muscular system, lasted only between three and four months, the general stiffness of the muscles reappearing and increasing as time wore on. At his own request he was transferred to a city institution, where his condition seems to have progressively grown worse, and where he died about a year later. The chief findings at the autopsy were: General miliary tuberculosis of the bowels; left kidney contracted. The brain was examined by Dr. Carson and myself. It showed the following pathological features: Right hemisphere (the one operated upon) was somewhat flattened at its upper margin, the dura firmly adherent to the brain substance below. On making a frontal section through the brain at the site of the operation, a subcortical cavity was found at a depth of about an inch beneath the adherent dura and corresponding approximately to the middle third of the Rolandic region. This cavity was irregular in its outlines, about the size of a hickory nut. The surrounding brain substance was in a more or less softened condition and the whole brain was

œdematous. The cavity corresponded to the place where the spongy cavernous mass was scraped out at the operation. The presumable pathological process which took place after the operation seems to have been at first the formation of a blood cyst, which, after the manner of the apoplectic cysts, changed into one containing lymph. The emptiness of the cavity is explained, perhaps, by the thorough draining which the whole system underwent in consequence of the excessive diarrhœa. The principal lesson taught by the case is the fact established by other observers, that subcortical tumors (or their equivalents, cysts, *e.g.*) are apt to give rise to tonic spasms.

“The bone button, which had been replaced after Macewen’s method, was found to have formed a solid bony union with the edge of the trephine hole, rendering the vault of the skull practically intact. The completeness of the surgical success in this particular has no doubt militated against a better and more lasting result of the operation. For had the button not been replaced, leaving only the scalp to protect the injured brain, this more elastic and yielding cover would have mitigated the pressure from below. A second operation, tapping for instance or scraping out of the presumable post-operative blood cyst, would also have been facilitated.”—Letter from Dr. Bremer, February 4th, 1893.

WOOD and AGNEW.—In his address before the American Surgical Association in September, 1891, Agnew reported briefly that he had operated in a case of H. C. Wood in which a cyst occupying the cuneus was exposed and emptied, but that the patient died in thirty-six hours after the operation, and at the autopsy a large sarcoma was found in the temporo-sphenoidal lobe, which had offered no localizing symptoms previous to the operation.

The following case of my own is given in full because it illustrates the general symptomatology of brain tumor and the local guides to the surgeon:

CASE XXI. *Sarcoma of the left frontal lobe—Mental and motor symptoms—Successful localization and removal—Subsequent death.*

C. S., aged 40, a farmer by occupation, of good family history and of good general health until this illness (with the exception of specific disease acquired at the age of 22, but without subsequent manifestations), was suddenly seized with a convulsion in December, 1890, while driving a cart. He remembers a sudden feeling of dizziness and distress and then a turning of his head forcibly to the right side; he has no recollection of what followed, but learned that he had been found upon the road, had been picked up and carried home, where he remained unconscious for two hours and a half; he is not sure whether he had a general convulsion. On recovering consciousness he found his right side, including face, arm, and leg, slightly weak, and noticed some difficulty in talking; this condition gradually subsided, so that in two weeks he was able to go back to his work, and felt in his usual health. This is the only convulsion or sudden attack of any kind which occurred during his entire illness.

But it is from this attack that his illness dates. The various symptoms which subsequently developed were very gradual in their onset, so that it is quite impossible to fix any dates for particular symptoms. During the six months from January, 1891, to July, 1891, he suffered occasionally from headache and nausea, and in July began to notice that his sight was growing dim and that the headaches were becoming more and more frequent and intense. Between July, 1891, and January, 1892, the pain became localized over the forehead and top of the head on the left side; it was not particularly worse at night, but at times was very severe. During this period he noticed a progressive dulness of thought, general hebetude, an aversion to work which was unnatural to him, and a slowness of mental activity which he described as increasing stupidity; and increasing difficulty in the use of lan-

guage, so that it took him longer to express his ideas, there being, however, no difficulty in articulation and no lack of words.

He also noticed by the close of the year that his right side had become a little weaker than his left side; that his hand was slightly awkward and that his leg felt a little heavy. The symptom, however, which caused him most distress was his gradually increasing dimness of vision, and it was on account of this that he came to New York from his home in Alabama. He was seen at the New York Eye and Ear Infirmary by Dr. Derby, who discovered a well-marked condition of optic neuritis in both eyes, more marked in the left eye: V. O. D. =  $\frac{20}{L}$ , V. O. S. =  $\frac{20}{xx}$ . In right eye upper and inner quadrant of visual field wanting. Dr. Derby referred him to the Nervous Department of the Vanderbilt Clinic for confirmation of his diagnosis of cerebral tumor and also for treatment.

When I first saw him at the clinic on January 14th, 1892, the following symptoms were present: severe and constant *frontal headache*, located over the top of the head and more especially over the left side, about at the upper third of the coronal suture, and at this area, over a space about three inches in diameter, there was considerable *tenderness to percussion*. There was no vertigo on rising or on change of position. There was a state of *partial blindness* due to the very well-marked condition of *optic neuritis* and decidedly worse in the left eye.

There was a condition of *mental dulness* which was noticeable, and which he himself and a friend who accompanied him insisted was wholly unnatural. This dulness consisted in a slowness of thought, which made him appear very stupid. It took him some time to appreciate the meaning of questions, and it was an effort to answer them. This effort was not due to any actual disturbance of speech, any loss of words, or any difficulty in pronunciation, though he complained that he could not talk as fluently or rapidly as heretofore. The condition was, therefore, in

no sense an aphasic one, but could only be spoken of as a slowness in mental processes. His comprehension was good and his conclusions were correct when he had time to think, but rapid mental action was impossible, and if insisted upon he became confused and would say he could not think. Hence he distrusted his own mental power, and said that he did not think that his judgment was as good as formerly. He was disinclined to occupy himself in any way, and sat in a listless manner saying nothing for hours at a time. He would often sleep in the daytime, though at night his sleep was often broken by his pain. It was not easy for him to hold his attention to any subject continuously for any length of time. His mental state might be termed a dull listlessness, and gave the impression that he was a sick man.

Careful examination detected the existence of a *slight right hemiplegia*; his face was slightly flattened and slow in motion on the right side; his hand was somewhat awkward and clumsy, the power being 140 by the dynamometer, that on the left being 160. He dragged the toe slightly in walking, though his gait was not noticeable. He had great exaggeration of the knee jerks and marked ankle clonus. He complained of a feeling of numbness, both in the hand and foot, but there was no objective anæsthesia.

*Diagnosis.*—From these symptoms a diagnosis was reached of a brain tumor. The situation of the tumor was not easily determined. The slight right hemiplegia indicated that it was in the left hemisphere of the brain, near to but not within the motor region. The hemiplegia had appeared long after the other symptoms, hence it was evident that the motor zone had been reached only when the tumor had become large. The position of the headache and of the tenderness to percussion over the frontal region, and the existence of the mental symptoms described, appeared to indicate the frontal lobe as the probable situation. This was confirmed by the absence of anæsthesia

or of hemianopsia or of sensory aphasia, all of which conditions would have been likely to have been present in a tumor situated near to but behind the motor zone, in the parietal region. The mental symptoms were considered of very great importance in the diagnosis of a frontal lobe lesion.

A study of 23 cases of disease of the frontal lobes of the brain, made by me in 1884, showed that decided mental disturbance occurred in one-half of the cases.<sup>1</sup>

At that time the following conclusions were reached: "The form of mental disturbance in lesions of the frontal region does not conform to any type of insanity. It is rather to be described as a loss of self-control and a consequent change of character. The mind exercises a constant inhibitory influence upon all action, physical and mental, from the simple restraint upon the lower reflexes, such as the action of the sphincters, to the higher control over the complex reflexes, such as emotional impulses and their manifestation in speech and expression. This action of control implies a recognition of the import of an act in connection with other acts; in a word, it involves judgment and reason, the highest mental qualities. By inhibiting all but one set of impulses it enables one to fix the attention upon a subject and to hold it there. It seems probable that the processes involved in judgment and reason have for their physical basis the frontal lobes; if so, the total destruction of these lobes would reduce man to the state of an idiot, their partial destruction would be manifested by errors of judgment and reason of a striking character. One of the first manifestations would be a lack of that self-control which is the constant accompaniment of mental action, and which would be shown by an inability to fix the attention, to follow a continuous train of thought, or to conduct intellectual processes. It is this very symptom that was present in one-half of the cases

<sup>1</sup> Starr: "Cortical Lesions of the Brain," *Am. Jour. of Med. Sci.*, April, 1884.

collected. It occurred in all forms of lesion; from injury by foreign bodies, from destruction by abscess, from compression and softening, due to the presence of tumors, and therefore cannot be ascribed to any one form of disease. It did not occur in lesions of other parts of the brain here cited. But its presence in such a large number of these cases warrants the suggestion that in cases of suspected lesion of the frontal lobe the mental condition of the patient, as shown by his acts of judgment and reason, should be carefully examined, and a change of character or behavior accurately noted."

Ferrier, in his Croonian lectures, 1890, again called attention to the occurrence of such mental symptoms in connection with diseases of the frontal lobes.

Welt (*Alienist and Neurologist*, April, 1890) concluded from a study of eight cases under his observation that changes in character and disposition are characteristic of lesions in the frontal lobes. He says they may be the only symptoms present.

W. Gilman Thompson (*Medical News*, May, 1890) has described changes in temperament and alterations in the intellectual sphere occurring in three cases of tumor of the frontal lobes under his observation.

Schoenthal has also recorded a case diagnosticated as hysteria on account of the mental peculiarities and lack of self-control, in which a large tumor of the frontal lobe was found after death.

Griffith and Sheldon (*Jour. of Mental Science*, 1890, p. 223), in reporting a case of tumor invading the median surface and base of both frontal lobes in which mental symptoms were absent, call attention to the fact that mental symptoms occur chiefly when the cortex of the convexity of the frontal lobes is invaded, and this statement is borne out by my own collection of cases before alluded to.

The review of these cases, therefore, pointed to the conclusion that mental symptoms are likely to be produced by a tumor in the frontal region.



The diagnosis of the nature of the tumor was somewhat difficult. The existence of specific disease pointed to gumma and made it seem proper to try the effect of specific treatment; he was, therefore, put on inunctions of mercury and increasing doses of iodide of potassium, which was carried to the point of three hundred grains a day. This treatment was pursued without much apparent change in his condition. He then escaped from my observation for months, but returned about the 1st of June to the clinic.

It was then found that his headache was still severe, was still localized in the left side of the forehead. It was found that his sight was much worse, so that he was nearly blind in the right eye and could not read letters with the left eye. His hemiplegia was more marked; his face was flatter on the right side, his arm and hand more clumsy, and there was a decided dragging of the right foot. He complained that his right leg was getting stiffer all the time and that it felt dead. He said that he had recently been having twitching in the right leg as often as two or three times a day. He also said that at times his hand became clinched without his power to resist it, but he denied the existence of any clonic spasms. He had had some difficulty in micturition during the past months, it being impossible for him to control his bladder perfectly, the urine flowing unexpectedly. His speech was slower, and there was a noticeable tendency to the malposition of words in sentences, which, however, he noticed himself and corrected; he would often say "no" for "yes" and *vice versa*. His mental activity was evidently much weaker than it had been five months before.

Under these circumstances it seemed evident that specific treatment had failed of effect, and he was induced to enter Roosevelt Hospital and submit to an operation.

*Operation.*—The operation was performed by Dr. McBurney on June 23d, 1891. Ether anæsthesia. A semi-elliptical incision was made in the scalp, outlining

an area which measured about three inches in either direction, the attached base of the flap being below. The centre of the flap coincided with a point an inch and a half anterior to the fissure of Rolando opposite the junction of its upper and middle thirds.

The tumor was believed to occupy the posterior part of the second frontal convolution, just anterior to its junction with the anterior central convolution. The hemorrhage

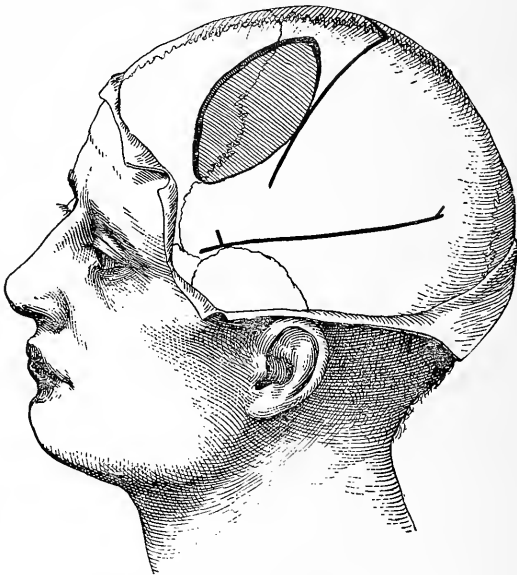


FIG. 57.—The Opening in the Skull in Case XXI.

caused by this incision was excessive, certainly treble the usual amount, and required a large number of pressure forceps and ligatures for its control. A button of bone one inch in diameter was then removed with the trephine from the centre of the area exposed by turning down the flap. This opening was enlarged with rongeur forceps downward and forward until it measured two inches by one and three-quarters (Fig. 57).

The dura appeared to be thickened and was unnaturally

pale, but pulsation seemed normal and no bleeding was noted. Profuse hemorrhage occurred from the veins of the diploë, and no little difficulty was met within its management. The largest of these veins were occluded only by plugging their orifices firmly with small bits of sponge.

The dura mater was then incised near the edge of the opening in the bone and turned down as a flap. It was quite adherent to the surface of brain beneath it, which



FIG. 58.—Photograph of a Sarcoma Removed from the Frontal Lobe. Case XXI.  
The measure above the tumor is divided into centimetres.

was uniformly dark in color and very vascular. At the first inspection the surface seemed to be that of a much-congested ordinary cortical substance. It was, however, firmer in consistency than was normal, and a good-sized section was removed with the knife, and it was then clear that the whole area exposed was tumor tissue. At the end of the section removed a distinct capsule was met with, and following this with finger and blunt scissors, it was not difficult to completely enucleate the large tumor,

which extended in every direction beyond the edges of the opening already made in the skull.

The tumor (Fig. 58) was oval in shape, measuring three and one-half by one and three-quarter inches. It was completely inclosed by a capsule, and after its removal a large cavity in the cortex remained. This cavity bled profusely at every point, the hemorrhage requiring for its control complete packing with iodoform gauze. The flap of integument was partially replaced and sutured at the sides only, a large loose antiseptic dressing being applied over all.

Loss of blood and shock produced a marked effect upon the patient's general condition before the close of the operation, and both rectal and hypodermic stimulation were actively applied, and after the patient's removal to bed he was given constant attention and every effort was made to improve his condition. After a large intravenous infusion of normal salt solution temporary marked improvement was noted, but the pulse soon failed again and death occurred about midnight, eight hours after operation.

The exact situation occupied by the tumor was as follows: It involved the posterior part of the second frontal convolution, the adjacent portion of the first frontal and the upper half of the anterior central convolutions. The entire anterior central convolution must have been compressed to some degree, and indirect pressure must have been exerted upon the third frontal convolution below the tumor. The situation of the tumor corresponded, therefore, very accurately to the diagnosis made before the operation, but the size of the mass was much greater than had been anticipated. After hardening in Müller's fluid and alcohol it displaced fifty cubic centimetres of water, weighed four grammes, and measured two and one-half by two by one and three-quarter inches. The tumor was carefully examined by Dr. Eugene Hodenpyl, and was reported by him to be a true sarcoma, consisting of a large number of delicate blood-vessels and rather large, irregu-

lar, but not branching, cells closely packed together with very little intercellular substance.

An earlier operation, when the tumor was much smaller and the vascularity of the tissues much less, would very probably have been successful. It was proposed to the patient in February, four months before it was done. The delay, which he insisted upon, was more readily submitted to because of his specific history, which induced us to give him the benefit of the doubt and to try anti-syphilitic treatment. If Horsley's dictum had been accepted, namely, that gumma is not curable by medicine and should be operated for (a dictum, however, which the experience of others in several cases does not support), an earlier operation would perhaps have been undertaken. The size of a brain tumor has undoubtedly much to do with determining the amount of shock resulting from its removal.

*Summary.*—In this case the diagnosis of the tumor of the brain was made from the general symptoms, headache, optic neuritis, and tenderness to percussion of the head, and from the local symptoms, mental dullness, slowness of speech, slight right hemiplegia with subjective numbness and occasional twitching in the paralyzed limbs. The situation of the tumor was determined by the slow onset of the hemiplegia, by the very marked mental symptoms, and by the location of the tenderness upon the head. Attention has already been called to the value of the mental symptoms in the localization of the tumor, and no further comment upon them is necessary. This is the first case, however, in which operative interference has been so distinctly directed by the existence of mental symptoms.

*Secondly. Cerebellar Tumors.*

As shown in Table IV. (p. 216), 16 cerebellar tumors have been operated upon. In 9 cases the tumor was not found. In 2 cases it was found, but could not be removed. In 3 cases it was removed and the patient recovered. In 2 cases it was removed and the patient died.

The diagnosis of cerebellar tumor is not difficult. The general symptoms of brain tumor are fully and rapidly developed, viz., headache; mental disturbance, irritability, and apathy; vertigo; vomiting; optic neuritis, with or without blindness, and possibly general convulsions. These present themselves in rapid succession because the situation of the tumor beneath the tentorium cerebelli is such as to obstruct the venous flow from the venæ Galeni and the free interchange of fluid between and through the ventricles, and to produce both general hydrocephalus and a stretching of the dura mater which are supposed to cause many of the general symptoms of brain tumor. It may be remarked that while headache is almost invariably present in cerebellar tumor and is often referred to the back of the head, it may be felt at any part of the head, and is as frequently frontal or temporal as it is occipital. In many of the tumors here collected the headache was entirely frontal. The pain does not indicate, therefore, the seat of the tumor. Tenderness to percussion over the occiput is, however, a valuable sign of cerebellar disease.

But, in addition to the general symptoms of tumor, there are local symptoms of great value. These are vertigo and cerebellar ataxia, or the staggering gait. The patient feels himself falling, staggers in walking, and often staggers toward one side with remarkable constancy. The occurrence of staggering indicates that the middle lobe of the cerebellum is either the seat of the tumor or is encroached upon by a tumor in the hemispheres. If it occurs quite early in relation to the general symptoms, it is the middle lobe in which the tumor began. If it occurs late, after many months of suffering, the tumor has started in one hemisphere, given rise to general symptoms, and has at last reached the middle lobe and produced the local symptom. The question at once arises, In which hemisphere has it begun? And here we are often in the dark. Patients are said to stagger, in walking, away from the side on which the tumor lies. An analysis of 20 cases in which staggering to one side was a prominent and constant symptom shows that in 16 cases the patient staggered away from the side of the lesion and in 4 cases toward the side of the lesion. No definite conclusion as to the side of the lesion can be drawn from the direction of the staggering. If there is no tendency toward one side in walking, there may be a tendency to fall forward or backward. As yet, no assertion is possible as to the significance of this symptom, as it is impossible during life to determine whether it is due to irritation or destruction of tissue.

When these symptoms fail it is sometimes possible to determine which hemisphere is invaded by the tumor, by observing on which side cranial nerve symptoms, such as strabismus, facial or lingual anæsthesia or paresis, deafness, or retraction of the head, appear. They usually come first on the side of the tumor, as this, by its presence, crowds the cerebellum down upon the base of the brain and presses on the nerves, or pushes it to one side and stretches the nerves. Paralysis of one fourth nerve, though difficult to detect, is a valuable symptom, as it always occurs on the side of the tumor.

By compressing one side of the pons or medulla a tumor may cause paresis or numbness, or increased reflexes in the opposite arm and leg, and these symptoms may aid the diagnosis.

The diagnosis being made, the question of operation arises: Can tumors of the cerebellum be removed? The cerebellum presents but one of its three surfaces to the skull, and there is, as yet, no means of determining whether a tumor is near that surface or not. Any operation must, therefore, be primarily exploratory.

In case a tumor is seen upon the exposed surface, it may be removed. But great care should be observed in the manipulations about the cerebellar hemispheres in order that the medulla may not be compressed, or the pneumogastric nerves torn or stretched in the process.

The figure (Fig. 56, page 211) shows how deep the



cerebellum lies in the skull and how impossible it is to reach its upper surface or its anterior lower surface. It is not surprising, therefore, that the difficulty of thorough exploration of the cerebellum has prevented the discovery of tumors in this part of the brain.

The following cases of cerebellar tumor, which have been diagnosed by me and operated upon by Dr. McBurney, illustrate the symptomatology of the disease and the difficulties of operation.

CASE XXII. *Fibro-sarcoma of the cerebellum and pons Varolii—Staggering away from the side of the tumor—Operation—Death.*

Male, aged 30, was under my observation from January, 1890, until December, 1891, when he died. He was referred to the Nervous Department of the Vanderbilt Clinic by Dr. Weeks. When first seen he was suffering from severe frontal and occipital headache; from vertigo, which was much increased by moving the head suddenly or by lying down; from tinnitus aurium; from numbness in the left side of the face and in the mouth; and from a very continuous feeling of drowsiness and dulness. These symptoms had developed gradually during the preceding three years; and within a year he had also noticed double vision and a gradually increasing blindness. His friends said that his speech had become slow and thick.

Examination showed a large, very dull, stupid man, with prominent eyes, the left one deviating outward, dilated pupils and marked nystagmus on lateral movement of the eyes. Dr. Weeks had found well-marked choked discs and a diminution of the visual fields. There was some slowness of speech which was accounted for by his mental dulness, there being no evidence either of aphasia or of paralysis of the tongue. There was no disturbance

of sensation or of motion or of reflex action, and there was no ataxia in his gait. The existence of headache, vertigo, tinnitus aurium, nystagmus, diplopia, and choked discs established the diagnosis of a cerebral tumor, but no conclusion regarding its localization could be reached. That the tumor was not a gumma was admitted, as he denied all specific infection, yet he was put upon mercury and iodide of potassium on the supposition that he might have acquired the disease without his knowledge.

During the year 1890 the symptoms continued and gradually increased in intensity, so that by the 1st of October he had become quite blind, with well-marked optic atrophy; and also deaf in the left ear, in which ear the tinnitus aurium had been intense. By this time also local symptoms had developed which gave an indication of the site of the tumor. There was a considerable degree of staggering in walking with a tendency to fall forward and toward the right, and a marked tendency to turn toward the right in walking. In addition there was some weakness in his right hand, the dynamometer registering only 39 while it registered 60 in the left hand. There was no ataxia or disturbance of sensation in the limbs. There was no apparent difference in the power in the legs, but the knee jerk was exaggerated on the right side and a slight clonus was obtained on the right foot.

The staggering was of the kind observed in cerebellar disease; a gait like that of a drunken man, without falling but with every appearance that the balance was uncertain. The tendency to turn and to fall to the right was noticed on every occasion on which he was tested.

*Diagnosis.*—The staggering indicated that the disease was located in the cerebellum, and its direction to the right, while not considered sufficiently diagnostic to decide absolutely the question regarding which side was involved, was thought to point strongly to the left side. This supposition seemed to be confirmed by a study of the other symptoms. The patient had complained early in

the disease of pain and numbness in the left half of the face, though at no time did examination show any anæsthesia. He had also had much tinnitus in the left ear which had been followed by progressive deafness. His headache, which had at first been frontal, was later referred with much constancy to the left occipital region, and in speaking of it he habitually put his hand back of his left ear. The weakness of the right hand and the exaggeration of the spinal reflexes on the right side; taken in connection with left cranial nerve palsies, appeared to indicate some pressure on the left side of the pons and medulla.

Thus the staggering to the right, the left cranial nerve palsies, and the right hemiplegia all pointed to a lesion in the left side of the posterior cranial fossa.

The diagnosis was, therefore, made of a tumor on the left side of the cerebellum. The negative result of specific treatment indicated that it was not a gumma, and the very slow progress of the case indicated that it must be a slowly forming tumor, probably sarcoma, as such tumors are more common than any other kind.

During the following year, from October, 1890, to November, 1891, the patient was seen occasionally, being apparently in a stationary condition. Finally, he was induced to enter the Roosevelt Hospital for operation. And then he was quite willing to submit, though knowing the dangers, because his life was a burden, for he was blind and partly deaf and suffering from severe headache, vertigo on any movement, and such exaggerated staggering that he could not go about. A careful examination in the hospital on December 1st, 1891, confirmed the existence of all the symptoms hitherto mentioned, but failed to elicit others.

*Operation by Dr. McBurney on December 3d, 1891.*—Ether anæsthesia. A vertical tongue-shaped flap was marked out with the knife over the left half of the occipital bone. The upper free convex border of this flap corresponded nearly to the superior curved line of this bone. The attached base was on the back of the neck about op-

posite the second cervical vertebra. The incision was carried down to the periosteum and all the coverings were removed in one flap. Experiments on the cadaver had satisfied the operator that the safest and most convenient method of entering the cerebellar fossa was by the use of the chisel and mallet. This method was adopted here, and an opening about one and a half inch in diameter was made through the thin bone, care being taken to be far enough away from the large venous sinuses. The dura mater was not diseased, but bulged very strongly through the opening in the skull in such a manner as to at once suggest intracranial pressure. Protrusion of cerebellar tissue was still more marked after the dura had been turned back as a flap from over its surface. Otherwise, however, the surface of the cerebellum was normal in appearance and palpation failed to give evidence of the existence of tumor. It was found to be quite easy to introduce the finger for some distance into the skull on all sides of the cerebellar hemisphere, to thus examine a large part of its surface, and to distinctly palpate the lateral and vertical sinuses. But nowhere could the existence of a tumor be demonstrated. So much protrusion of cerebellar tissue existed that it was necessary, in order to close the opening in the skull at all satisfactorily, to shave off the excess, which was done with the less compunction as even the gentle manipulations practised had somewhat injured the delicate surface convolutions. Hemorrhage throughout the operation was very moderate and easily managed. The flaps of dura mater and overlying soft parts were then replaced, fastened in all deeper parts with catgut, the skin wound being sewed completely with silk. A wet bichloride gauze dressing was applied over all and the patient was removed to bed in excellent condition.

Convalescence was perfectly satisfactory, and on December 9th, six days after the operation, the temperature being 90° and the pulse 100, the dressing was changed for the first time. Primary union was found throughout the

whole extent of the wound, and all sutures were removed.

During the following night the patient fell out of bed, and immediate examination revealed the presence of a large blood-clot beneath the skin flap. No other injury seemed to have resulted from the fall, but at 5 P.M. on December 10th a chill occurred followed by a temperature of 103°.

Difficulty in swallowing was then noted, and although at the end of two days the temperature fell to 99°, stupor gradually increased and involuntary evacuations of rectum and bladder began. The wound remained aseptic throughout, but the stupor deepened into coma and the patient died on December 15th with a temperature of 105°.

The autopsy showed the presence of a tumor, a gliosarcoma, whose limits were quite distinct from the cerebellar tissue, though it was not encapsulated.

It lay on the base and compressed the left hemisphere of the cerebellum and especially its anterior inferior (ventrocephalad) surface, and also pressed upon the left half of the pons Varolii at its lateral part. The left crus was slightly indented by the tumor, and the fifth nerve had been flattened out by it without being so pressed upon as to be degenerated. The auditory and facial nerves were also compressed by the lower part of the tumor.

The situation of the tumor was such as to have made it absolutely impossible to have reached it by operation, unless indeed the certainty of the situation of the tumor had been so complete as to justify full section of the cerebellum. It was almost identical in situation and appearance with a tumor reported by Wollenberg in the *Arch. für Psych.*, XXI., p. 791.

#### CASE XXIII. *Ghoma of the cerebellum—Characteristic staggering—Operation—Death.*

A little girl of 7 years of age had suffered for a year from severe headache all over the head, but chiefly in the forehead, from severe vomiting and from gradually ad-

vancing blindness, due to a progressive optic neuritis. For three months before she was seen it had been difficult for her to walk, on account of a tendency to stagger and on account of dizziness which was undoubtedly due in part to nystagmus, which was observed early in the history. The staggering was very marked, so that during the last month she could not walk without aid. She did not appear to stagger in any one direction constantly, but there was some tendency to fall backward and slightly to the left. She complained at times of earache in the right ear, but there was no evidence of cranial nerve palsy or of hemiplegia.

*The diagnosis* of cerebellar tumor in this case was quite evident, but the only clew to the position of the tumor was the tendency to stagger backward and to the left. It was thought probable that the tumor was in the vermiform lobe of the cerebellum, more likely upon the right than upon the left side. The absence of cranial nerve symptoms showed that it was not near the base. The operation was, therefore, undertaken.

*Operation.*—The operation was done by Dr. McBurney on December 29th, 1891. Ether narcosis. A horseshoe-shaped incision with the convexity upward was made over the right half of the occipital bone. The upper part of the incision lay a little above the superior curved line of the bone, and the flap which was then turned down included all of the soft fissures excepting the periosteum. The base of the flap was left attached to the upper part of the neck.

With chisel and mallet a considerable plate of bone was removed from over the centre of the cerebellar fossa, and the opening was then enlarged with rongeur forceps as much as was safe, having due regard for the venous sinuses. The dura obtruded forcibly but otherwise appeared normal. A large flap of dura was then cut and laid back, revealing only normal cerebellar convolutions. Examination of the sides and under surface of the cerebellum gave no information. A probe was then passed some distance,

about one and one-half inch into the brain substance, but no abnormal resistance was encountered.

An aspirating-needle introduced about one-half inch from the median line and parallel with the base of the skull entered a cyst from which two drachms of clear serous fluid was withdrawn.

A second introduction of the needle failed to detect the cyst and it was deemed unwise to make further exploration. The flaps were then replaced, being stitched deeply with catgut and superficially with silk. Hemorrhage during the operation was not troublesome, but before its close the patient showed the effects of shock. She rallied well, however, after rectal stimulation, and on the day following operation seemed about as well as on the day before it, at intervals complaining of headache only. Two days later complaint was made of pain in the ears; the wound was dressed and found to be aseptic. The temperature since operation had remained normal.

On January 4th, six days after operation, vomiting occurred repeatedly, the pulse became weak, stimulation had no effect, and the patient died suddenly in a convulsion at midnight.

The autopsy revealed a large glio-sarcoma, two and one-half by two by one inch, which occupied the vermiform lobe of the cerebellum and extended into both hemispheres, chiefly into the right one. It lay just under the superior surface of the cerebellar cortex, but it nowhere reached the surface of the cerebellum. It projected downward, compressing the fourth ventricle. Its consistency was about that of the cerebellum, and in its centre was a cyst which had been evacuated by the operation.

CASE XXIV. *Glioma of the cerebellum—Staggering to the left—Right cranial nerve palsies—Operation—Successful removal of the tumor.*

W. W., aged 10, of good family history, had been in perfect health until October, 1892, when he began to suffer

from headaches in the forehead, usually worse at night. These annoyed him occasionally during October and November, and he then began to suffer from occasional vertigo and from attacks of very intense headache associated with vomiting and occurring every third and fourth night. It was also noticed that he was becoming rather dull mentally and very irritable. These symptoms remained during December and to them was added the symptom of occasional uncertainty in gait so that he would fall while running. In the early part of January, 1893, he noticed some dimness of vision, and this was found by Dr. Kipp, of Newark, who examined him on January 21st, to be due to a well-marked condition of optic neuritis. At that time he was able to read large print without much difficulty; but within a month he had become almost totally blind. During February the headaches, usually nocturnal, increased in severity; were always associated with vomiting and vertigo, and he began to have ringing in the left ear and some deafness in the right ear; his gait was noticed to be very unsteady; his eyes were noticed to be prominent and to be in constant oscillation, and mental dulness became intense.

He was referred to me by Dr. William Pierson, of Orange, N. J., on March 12th, 1893, with the preceding history.

Examination showed a fairly nourished but pale little boy, with large head, rather prominent forehead, protruding eyes which were in constant lateral oscillation and with which he could see nothing. At rest there was a manifest tendency of the right eye to turn inward, but he could look in either direction without apparent paralysis of the ocular muscles. All ocular movement was attended by marked nystagmus. Very extensive optic neuritis was found in both eyes; smell was lost in the left nostril; there was no apparent paralysis or anæsthesia in any part of the body or face, but upon forced effort with the hands a slight facial paresis on the right side was noticeable, and



he was unable to whistle on account of inability to close the right half of the mouth. His hearing was decidedly defective in the right ear, both to nerve conduction with a tuning-fork and to the watch. His reflexes were diminished in both knees. His gait was distinctly of a staggering kind, and numerous tests revealed a marked tendency to stagger toward the left side. He described his headaches as being agonizing and referred them entirely to the frontal region; the skull was slightly tender to percussion over the vertex. The headache was much increased by a recumbent posture, so that for many nights he had sat up all night.

*Diagnosis.*—The headache, vomiting, vertigo, mental dulness, and optic neuritis indicated clearly that the boy had a tumor of the brain. The cerebellar gait indicated its location in the cerebellum. The tendency to stagger to the left side, together with the deafness in the right ear and a slight weakness of the right side of the face and right abducens muscle, indicated that the tumor was upon the right side of the cerebellum and near to the base. An operation was therefore recommended.

*Operation.*—On March 15th Dr. McBurney operated at the Roosevelt Hospital in the presence of Dr. Pierson and Dr. Kipp. The occipital bone was exposed upon the right side by a horseshoe-shaped incision, and an opening was made in the bone below the superior curved line one and one-half by one and five-eighths inches in size. The opening was made by chiselling and by enlarging the opening by the rongeur. There was no adhesion of the bone to the dura. The dura was seen to be very blue, over two-thirds of the region exposed. On dividing the dura a cyst containing about a drachm of yellowish-green fluid lying upon the surface of the cerebellum was opened. When the dura was laid back and the wall of this cyst removed it was evident that a tumor was present, lying upon and in the cerebellum and extending toward the median line beyond the area exposed. It being impossible

to get at this tumor through the small opening made on account of the extreme bulging of the cerebellum, a portion of the cerebellar tissue was cut off and thus access was gained to the tumor. The tumor was soft gray and very friable, having the consistence of jelly and being very vascular in structure. In attempting to remove it a cyst within it was ruptured and about a drachm of clear yellow fluid flowed out. By the aid of a sharp spoon the tumor was scraped out from within the cerebellum. After all accessible tumor tissue was removed, the cavity remaining in the cerebellum was an inch and seven-eighths in depth by about an inch in the other directions and admitted freely the finger of the operator. There was no distinct wall or capsule to the tumor, but as far as possible all tumor tissue was taken away, leaving clear cerebellar tissue about it. Hemorrhage was arrested by pressure by sponges introduced into the cavity, and when it was reduced to slight oozing the cavity was allowed to fill with blood and a rubber tissue drain was introduced. The wound was then closed, the dura and scalp being stitched with catgut ligatures and the skin united by silk. The entire operation was completed within an hour, but the shock was considerable and the boy required repeated stimulations before being removed from the table.

He rallied well, however, and the next day was very comfortable. He had no headache, had not vomited, the nystagmus had ceased, and he had no trace of the facial paralysis. His knee jerks were higher than before the operation. His mind was clear. During the following week he continued to improve.<sup>1</sup>

In the following tables<sup>2</sup> all cases of brain tumor thus far operated upon are tabulated. The first table

<sup>1</sup> This case was added while this work was in press. The final result will be published later.

<sup>2</sup> This list is made up from Knapp's list and from a search through the current journals from January, 1891, to January, 1893. (r, recovered; d, died.)

contains a list of the tumors found at the operation, their situation, and the result. The second table contains a list of the cases operated upon in which the tumor was not found at the operation, but was discovered at the autopsy.

TABLE V.—TUMORS SUCCESSFULLY REMOVED.

*Frontal.*

Durante, . . . .	Lancet, Oct. 1, 1887, . . . .	r
Macewen, . . . .	Brit. Med. Jour., Aug. 11, 1888, . . . .	r
Barton, . . . .	Annals of Surgery, January, 1889, . . . .	d
Booth and Curtis, . . . .	Trans. N. Y. Neurol. Jour., December, 1892 (recurrence), . . . .	r
Starr and McBurney, . . . .	Amer. Jour. Med. Sci., April, 1893, . . . .	d

*Occipital.*

Birdsall and Weir, . . . .	Phil. Med. News, April 16, 1887, . . . .	r
----------------------------	--	---

*Central.*

Macewen, . . . .	Lancet, May 16, 1885, . . . .	r
Bennett and Godlee, . . . .	Med. Chir. Trans., 1885, lxxviii., 243, . . . .	d
Hirschfelder and Morse, . . . .	Pacific Med. Jour., April, 1886, . . . .	d
Horsley, . . . .	Brit. Med. Jour., April 23, 1887, 3 cases (1 recurrence), . . . .	r
Macewen, . . . .	Lancet, Aug. 11, 1888, 3 cases, . . . .	r
Seguin and Weir, . . . .	Amer. Jour. Med. Sci., July, 1888 (recurrence), . . . .	r
Keen, . . . .	Amer. Jour. Med. Sci., Oct., 1888, . . . .	r
Lucas Championnière, . . . .	Jour. de Méd. et de Chir., 1888, 298, . . . .	r
Ballet and Pean, . . . .	Bull. Soc. Anat. de Paris, May, 1888, . . . .	r
Fitzgerald, . . . .	Sajous' Annual, vol. ii., 1888, p. 36, . . . .	r
Rannie, . . . .	Brit. Med. Jour., May 19, 1888, . . . .	r
Fischer, . . . .	Verhand. Deut. Gesell. Chir., 1888, p. 42 (recurrence and died), . . . .	r
Thomas and Bartlett, . . . .	Trans. Amer. Inst. Homœop., 1889, 464, . . . .	d
Limont and Page, . . . .	Brit. Med. Jour., Oct. 26, 1889 (recurrence), . . . .	r
Parker, . . . .	Brit. Med. Jour., Nov. 30, 1889, . . . .	r
Mercauton and Combe, . . . .	Rev. Méd. de la Suisse Rom., August, 1889 (unknown result).	
Von Bergmann, . . . .	Chirurg. Behand. d. Hirnk., 1889, p. 137, d	d

TABLE V.—TUMORS SUCCESSFULLY REMOVED.—*Continued.*

<i>Central.</i>	
Clarke, . . . . .	Lancet, March, 1890, . . . . . d
Knapp and Bradford, . . . . .	Bost. Med. and Surg. Jour., April, 1890, d
Church and Franke, . . . . .	Amer. Jour. Med. Sci., July, 1890 (recur- rence), . . . . . r
Oppenheim & Koehler, . . . . .	Berl. klin. Woch., July, 1890 (recurrence), r
Graham and Chubbe, . . . . .	Aust. Med. Jour., July, 1890, . . . . . d
Dunin, . . . . .	Neurol. Central., August, 1890, . . . . . r
Lampiasi, . . . . .	La Psychiatria, 1890, 261, . . . . . r
Bremer and Carson, . . . . .	Amer. Jour. Med. Sci., September, 1890, r
Castro, . . . . .	Neurol. Central., Oct. 15, 1890, . . . . . d
Reynier, . . . . .	La Sem. Méd., April, 1891, . . . . . r
Doyen, . . . . .	La Sem. Méd., April, 1891, . . . . . r
Jeannel, . . . . .	La Sem. Méd., April, 1891, . . . . . r
Anderson, . . . . .	Brit. Med. Jour., Mar. 14, 1891, . . . . . r
Pean, . . . . .	La Trib. Méd., June, 1892, . . . . . r
Hitzig, . . . . .	Berl. klin. Woch., July, 1892, . . . . . r
Hitzig, . . . . .	Berl. klin. Woch., July, 1892 (recurrence), r
Erb, . . . . .	Deut. Zeit. Nervenheilk., July, 1890 (re- currence), . . . . . r
Poirier, . . . . .	Rev. de Chir., xii., 412, . . . . . r
Braman, . . . . .	La Sem. Méd., December, 1892, 2 cases, r
Potempski, . . . . .	Annals Surgery, December, 1892, . . . . . r
Llobet, . . . . .	Rev. de Chir., November, 1892, . . . . . r
Stieglitz, . . . . .	N. Y. Med. Jour., January, 1893, . . . . . r

*Region Not Stated.*

Horsley, . . . . .	Brit. Med. Jour., Dec. 9, 1890; 4 cases, 3 died, . . . . . d
Verco, . . . . .	Trans. Intercol. Med. Cong., 1889, ii., 377, d

*Cerebellum.*

Horsley, . . . . .	Brit. Med. Jour., April 23, 1887, . . . . . d
May, . . . . .	Lancet, April 16, 1887, . . . . . d
Suckling, . . . . .	Lancet, Oct. 1, 1887, . . . . . d
Maunsell, . . . . .	New Zealand Med. Jour., 1889, ii., 151, . . . . . r
Starr and McBurney, . . . . .	Case XXIV., page 247, . . . . . r

TABLE VI.—TUMORS TREPHINED FOR BUT NOT FOUND.

*Frontal.*

Dana and Pitcher, . . . . .	N. Y. Med. Rec., Feb. 9, 1889.
Eskridge, . . . . .	Knapp, "Intracranial Growths," ix., 24.

TABLE VI.—TUMORS TREPHINED FOR BUT NOT FOUND.—*Continued.*

*Temporal.*

- Fraser, . . . . . Lancet, Feb. 27, 1886.  
 Wood and Agnew, . . . . . Univ. Med. Mag., April, 1889.

*Parietal.*

- Putnam and Beach, . . . . . Bost. Med. and Surg. Jour., April, 1890.  
 Stoker and Nugent, . . . . . Dublin Jour. Med. Sci., October, 1890.  
 Twynam, . . . . . Aust. Med. Gaz., May, 1892.

*Central.*

- Sands, . . . . . Phil. Med. News, April, 1883.  
 Sciamanna, . . . . . Bull. de R. Accad. Med. di Roma, 1885,  
 xi., 75.  
 Hammond, . . . . . Jour. Nerv. and Ment. Dis., June, 1887.  
 Ross and Heath, . . . . . Lancet, April 7, 1888.  
 Seguin, . . . . . Bost. Med. and Surg. Jour., Feb. 5, 1891.  
 Morse, . . . . . Pacific Med. Jour., Feb., 1891.  
 Dobson, . . . . . Lancet, May 14, 1892.  
 Gray, . . . . . Brain, 1892, lxi.

*Pons.*

- Keectley, . . . . . Lancet, Sept. 21, 1889.

*Basal Ganglia.*

- Kerr, . . . . . Occid. Med. Times, February, 1890.  
 Mitchell Clarke, . . . . . Brit. Med. Jour., June 13, 1891.

*Region Not Stated.*

- Horsley, . . . . . Brit. Med. Jour., Dec. 6, 1890, 6 cases.  
 Seguin, . . . . . Bost. Med. and Surg. Jour., Feb. 5, 1890.  
 Chisholm, . . . . . Aust. Med. Gaz., May, 1892.

*Cerebellum.*

- Maudsley and Fitzgerald, . . Lond. Med. Recorder, June, 1890.  
 Amidon and Weir, . . . . . Annals of Surgery, June, 1887.  
 Wyman, . . . . . Phil. Med. News, February, 1890.  
 Springthorpe and Fitzgerald, . Aust. Med. Jour., November, 1891.  
 Lampiasi, . . . . . Wien. med. Wochen., May, 1887.  
 Bullard and Bradford, . . . . Bost. Med. and Surg. Jour., April, 1890.  
 Knapp and Bradford, . . . . . Knapp's Case XXIX.  
 Potempski, . . . . . Annals of Surgery, December, 1892.  
 Stewart, . . . . . Amer. Jour. Med. Sci., Nov., 1892.  
 Starr and McBurney, . . . . . Amer. Jour. Med. Sci., April, 1893.  
 Starr and McBurney, . . . . . Amer. Jour. Med. Sci., April, 1893.

*Conclusions.*

In any case which presents the general symptoms of brain tumor and in which during the progress of the disease such local symptoms appear as indicate that the situation of the tumor is in or near the cortex of the convexity of the brain, the operation of trephining is indicated.

This operation is not to be undertaken hastily in any case, as it is important to try the effect of anti-syphilitic treatment in those patients who may have had syphilis, and to watch for other symptoms or for signs of multiple tumors in patients who may have tuberculosis. But if mercury and iodide of potassium fail to relieve the patient within three months, or if during that time the symptoms rapidly increase, the operation is not to be postponed.

The chances of success are greatest in hard encapsulated sarcomata and fibromata, and in these cases the history will show little variability in the symptoms during the progress of the disease. These tumors are usually on the surface and are easily removed. The chances of success are worth taking in glio-sarcomata and in soft infiltrating gliomata with or without cysts, as life may be prolonged by the operation and as several operations may be done successively if the tumor recurs. Such cases usually show much variability in the symptoms, as the tumors are vascular. The dangers are greater in their removal; partly from hemorrhage, partly from inability to excise them entirely

without great loss of brain tissue and consequent shock. It is not to be forgotten that these tumors are liable to recur. The chances of success are fairly good in cysts of the brain, provided the wall of the cyst is excised or the healing of the cyst from adhesion of its walls can be secured by permanent drainage. To empty a cyst and close the wound merely invites a refilling with fluid and is useless.

Secondary carcinoma and sarcoma are not favorable for operation, as the chances of their recurrence are great and the endurance of the patient is impaired by the primary disease.

## CHAPTER VII.

### **TREPHINING FOR HYDROCEPHALUS AND FOR THE RELIEF OF INTRACRANIAL PRESSURE.**

Hydrocephalus. Tapping the Lateral Ventricles. Keen's Cases. Robson's Cases. Broca's Cases. General Conclusions. Methods of Operation. Trephining to Relieve Intracranial Pressure.

THERE are certain cases of disease within the cranial cavity which are attended by a distention of the lateral ventricles with serous fluid. The exact pathology of acute congenital hydrocephalus is not understood, but secondary acquired hydrocephalus may be due to an inflammation of the lining membrane of the ventricle, to tubercular meningitis, or to venous stasis produced by pressure upon the veins of Galen. Tumors situated in the corpora quadrigemina, or in the crus cerebri, or in the middle lobe of the cerebellum, which produce pressure upon these veins are commonly attended by a great effusion of serum into the lateral ventricles. Distention of the ventricles is not necessarily associated with œdema of the pia mater of the convexity.

It is perfectly easy to recognize the existence of hydrocephalus occurring within the first three years of life by the characteristic distention of the head, and the imperfect or delayed closure of the fontanelles and sutures. When in later life the bones are so firmly



united as to resist any intracranial distending force the symptoms of an accumulation of fluid are very similar to those of brain tumor, viz., headache, optic neuritis, vertigo, vomiting, slow pulse, strabismus, and mental apathy. In the latter case it can never be decided clinically what is the cause of the symptoms, whether a brain tumor rapidly growing and of large size, or an accumulation of fluid in the ventricles of large amount, associated perhaps with a very small tumor. But in any case it is a natural conclusion that the only possible relief for the patient is to be obtained either by arresting the accumulation of fluid or else by letting it out. The object of medical treatment by purgation, by mercurials, and by iodide of potassium in such cases is to arrest the secretion of fluid, and this rarely if ever succeeds. The surgical treatment by opening the skull and giving exit to the fluid is really the only one which promises much relief.

For many years hydrocephalus has been treated in children by tapping the ventricle through the anterior fontanelle with an aspirating needle or by trocar and canula. The operation has been recorded as far back as 1667, it being said that Dean Swift, when a baby, was tapped in this manner. The usual method pursued has been to introduce the needle through the anterior fontanelle at one of its lateral corners, to press the needle or trocar deeply into the brain, and thus reach the anterior horn of the ventricle through its roof. This procedure is still practised, and several successful cases were reported as late as 1891 by

Tordoff,<sup>1</sup> Illingworth,<sup>2</sup> Unverricht<sup>3</sup> and Vinke.<sup>4</sup> The procedure is not one without danger and many deaths have been recorded. Thus Lawson<sup>5</sup> and Smythe<sup>6</sup> lost patients upon whom they had operated, by a slipping of the canula and laceration of the brain. There is a lack of precision in this method of treating hydrocephalus which condemns it in the eyes of many surgeons.

The operation of trephining the skull and making an opening into the lateral ventricle, inserting a tube and establishing a permanent drainage, was suggested by Wernicke in 1881, and again by Zenner in 1886, and again by Keen in 1888.<sup>7</sup> Von Bergmann, unbeknown to Dr. Keen, had attempted to tap a ventricle by opening into the anterior horn in July, 1887; he had succeeded in reaching the ventricle, but the case proved fatal on the fifth day. The first operation performed in this country was done by Dr. Keen on January 11th, 1889.<sup>8</sup> The patient was a boy 4 years of age, who had acute hydrocephalus and was rapidly developing blindness. It was supposed that the hydrocephalus was due to a tumor of the cerebellum pressing upon the strait sinus, a suspicion subsequently confirmed by autopsy. Keen was led to under-

<sup>1</sup> Brit. Med. Jour., Apr. 18th, 1891.

<sup>2</sup> Brit. Med. Jour., Apr. 4th, 1891.

<sup>3</sup> St. Petersburg med. Wochens., Oct. 5th, 1891.

<sup>4</sup> Weekly Med. Review, St. Louis, Feb. 28th, 1891.

<sup>5</sup> Brit. Med. Jour., Mar. 21st, 1891.

<sup>6</sup> Brit. Med. Jour., Mar. 28th, 1891.

<sup>7</sup> Med. News, Dec. 1st, 1888.

<sup>8</sup> Med. News, Sept. 20th, 1890.

take the operation of tapping the ventricle and thus relieve the condition of intracranial pressure by the fact that in a previous case, where he had made an exploratory trephining for supposed abscess in the temporo-sphenoidal lobe and had introduced a drainage tube, the autopsy had shown that the presence of this drainage tube had not produced any inflammation of the brain. The operation upon the boy was made by trephining at a spot one and one-fourth inch above and one and one-fourth inch behind the left auditory meatus, and by puncturing the brain with a hollow needle which was directed toward a point two and one-half inches above the opposite meatus. At a depth of about one and three-fourths inch, resistance to the passage of this needle suddenly ceased, and the cerebro-spinal fluid began to escape; three double horsehairs were then passed into the ventricle and the tube was withdrawn. The drainage thus established was kept up for fourteen days, when the horsehairs were replaced by a rubber drainage tube. On the twenty-eighth day after the operation, the symptoms returning, a corresponding operation was performed upon the right side and the drainage tube was passed directly into the right ventricle. On the thirty-second day the ventricles were washed out from side to side with a warm boric acid solution, eight ounces being run in, and two ounces only escaping. The child was very restless at the beginning of this procedure, but as it was done he said that "it felt good." Irrigation was continued subsequently at intervals,

never producing any ill effects, but the child died on the forty-fifth day. The autopsy showed a sarcoma in the cerebellum and a distention of the ventricles with fluid; the sinus through which the rubber tubes had passed was not surrounded by an inflammatory zone. Though the brain had been punctured in many directions at the operation in the attempt to find the tumor, no trace remained of these punctures at the time of the autopsy.

Keen's second patient was a boy  $3\frac{1}{2}$  years of age, who had been a subject of hydrocephalus since the age of 4 months. He was an imbecile and epileptic. On March 5th, 1889, the left ventricle was tapped in the same manner as in the previous case, and drainage by horse-hairs was established. Four days afterward a drainage tube was inserted in place of the horsehairs, an opening on the opposite side being made. As the escape of fluid then appeared to be too free the tubes were plugged up. Then convulsions began, and it was concluded that too much fluid had escaped, so warm water was allowed to run into the ventricle when the spasms ceased; eight times the convulsions returned and each time were they arrested by the introduction of an ounce of warm fluid. The child then died. The autopsy showed great hydrocephalic distention but no inflammation about the tubes.

Keen's third case was one of tubercular meningitis with unilateral acute hydrocephalus of the left ventricle. The foramen of Monro was closed and the unilateral distention had produced right hemiplegia. The

left ventricle was tapped through the arm centre and fluid evacuated, but the child died about four hours later.

In his article recording these cases Keen refers to two cases reported to him by letter by Mayo Robson. These cases were as follows:

A girl 10 years old, without preceding illness, began to have pain in the left ear and was feverish, December 19th, 1888. In three days a discharge followed, which gradually lessened, but was still present a month later when admitted to the hospital. There had been also rigidity of the neck and twitching of the right angle of the mouth. No vomiting; slight mental disturbance. On admission to the hospital January 19th, 1889, temp. was  $105^{\circ}$ ; she complained of pain in the left side of the head; there was paresis of the right arm and leg, which gradually developed into complete hemiplegia and aphasia. Optic discs inflamed. Robson trephined February 7th, 1889, over the arm centre; the dura was found healthy. On exposing the brain it did not pulsate, and seemed to be compressed. An exploring needle was passed deeply in various directions in the hope of reaching pus, but failing to find any the needle was pushed into the lateral ventricle and a half ounce of clear fluid was drawn off. After this pulsation returned in the brain. The wound was closed, no drainage being employed. On the next day there was slight power in the arm, soon after in the leg, and on the third day she could answer simple questions. Within a month the hemiplegia was gone, and six months later she was perfectly well.

This case cannot be called one of draining the ventricle, but merely of an accidental tapping in despair at failing to find an abscess. I have cited it as it has

given rise to a discussion regarding priority in the operation.<sup>1</sup>

Robson's second case was one of an infant suffering from rapidly increasing hydrocephalus following treatment of spina bifida by Morton's injection. The skull was trephined an inch in front of the fissure of Rolando over the second frontal convolution. The dura was opened, and the needle of an exploring syringe was inserted into the ventricle, which was reached an inch from the cerebral surface. By means of Lister's sinus forceps a rubber drain was inserted, following the needle as a guide. The drainage was so free as to wet the dressings freely, and after it the patient seemed much relieved. The drainage soon became less free, and on the third day the child died in convulsions. The post-mortem showed that the brain had shrunk so much that the end of the tube was lying between the dura and the brain.

In the *Revue de Chirurgie* for January, 1891, Broca gives a translation of Keen's article just cited and describes two cases of tapping the ventricle, one by himself and one by Thiriar of Brussels.

Broca's patient was a boy of 4 years of age, who had suffered from hydrocephalus and was an imbecile, and who had a contracture of the right arm which had followed a series of convulsions. The trephining was done at the point indicated by Keen, three centimetres above and three centimetres behind the left auditory meatus. It was noticed that there was no pulsation of the dura or of the brain when this was exposed. Broca punctured the ventricle with a trocar and canula

<sup>1</sup> Brit. Med. Jour., Feb. 2d, etc., 1891.

and evacuated sixty grammes of fluid; he introduced a drainage tube through the canula and allowed it to drain into the gauze dressings, which were changed every day or two. Pulsation returned in the brain after the operation. On the sixteenth day a very marked improvement was noticed in the child, the contracture in the right arm having disappeared. The amount of fluid drained away became progressively less, and on the fiftieth day after the operation the wound had entirely healed, and the child was discharged from the hospital very much better physically and mentally. This is the first successful case on record.

The case of Thiriar was one of epilepsy and hydrocephalus with very great exophthalmos and nystagmus. Drainage was established and the ventricle washed out. The exophthalmos and nystagmus entirely disappeared, but several days later the child died in convulsions.

From a review of these cases it is evident that trephining in hydrocephalus with drainage of the lateral ventricle is a possible and fairly safe operation, and when the hydrocephalus is not secondary to some incurable affection, the operation may be attended by a cure as in Broca's case. It is never possible to determine absolutely in the presence of a case of hydrocephalus, whether the distention of the ventricle is primary or secondary. In every case, therefore, trephining should be done, for if the disease is primary it may be cured, and if the disease is secondary the

patient will die and the operation will not necessarily hasten the fatal termination.

A few cases of rupture of the lateral ventricle, of abscesses and hemorrhages rupturing into the lateral ventricle have been gathered by Keen in his paper upon the surgery of the lateral ventricles, but in conditions of this character it is impossible to make a diagnosis sufficiently early to attempt trephining, and where trephining has been done in such cases the actual condition has not been diagnosticated before the operation. It is true that these cases do not all die, and Keen has shown that when they have been operated upon a few have recovered, but surgery of this character is not to be commended, being venture-some and not based upon accurate diagnosis.

The operation for reaching the ventricle and draining it, according to Keen's directions, seems to be a simple one. The trephine opening is to be small, one inch in diameter, and to be made one and one-fourth inch above and one and one-fourth inch behind the external auditory meatus, and the direction of the puncture of the brain, which is best made with trocar and canula, should be toward a point two inches above the opposite auditory meatus. Birmingham has shown that at this point there is some danger of opening into the lateral sinus, and recommends placing the trephine one-half inch higher. The drainage should be kept up by a large bundle of horsehairs, as drainage by a tube gives exit to the fluid at too rapid a rate. If the drainage is not free, Keen recommends that a



similar operation be done upon the opposite side and the ventricle be irrigated with a warm boric acid solution.

The nearness of the descending horns of the lateral ventricles to the surface when the ventricles are distended with fluid is well shown in Fig. 59.

This operation is necessarily one of very limited application, and when it is considered that its result is

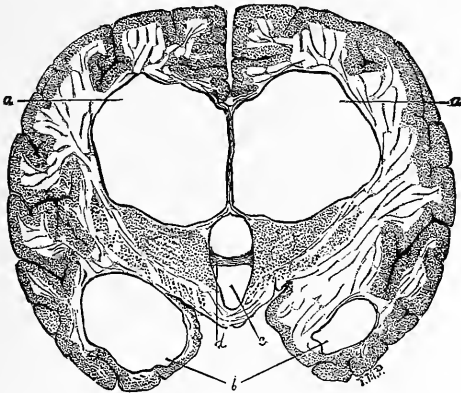


FIG. 59.—Dilatation of the Lateral Ventricles in Hydrocephalus.—Delafield and Prudden.

to relieve symptoms rather than to remove a pathological condition, it becomes evident that it is not an attractive one either to physician or surgeon.

Trephining has been done in a number of cases of brain tumor with a view of relieving the general intracranial pressure when the situation of the tumor was unknown but the symptoms were exceedingly severe. Horsley reported at the Berlin Congress six cases of "exposure of cerebral tumor for the relief of

pressure symptoms with recovery and immediate union in all." As he also reported the number of cases of cerebral tumor which he had removed (8), it is to be supposed that in these cases no tumor was found. Mills, Knapp and Bradford, and others have noticed a relief of the symptoms in cases of brain tumor which had been trephined even though the tumor was not removed. Trephining in this case is, of course, merely palliative, and yet it may prolong life for several months and hence may be employed. It seems to be best in such cases to tap the ventricles, since these are usually distended with fluid. If this is done, Keen's method already described should be the one adopted.

## CHAPTER VIII.

### TREPHINING FOR INSANITY.

Traumatic Insanity in Relation to Insanity in General. Report of Cases Operated Upon. Trephining in General Paresis. Uselessness of the Operation.

WHILE it is perfectly evident to any one familiar with mental disease that trephining has no place as a method of treatment in general, yet there are a few cases upon record in which the symptoms of mental derangement have developed immediately after a serious injury to the head with or without depressed fracture of the skull. The percentage of cases of insanity traceable to traumatism is small. Kiernan<sup>1</sup> states that 45 cases in 2,200 cases under his care were traumatic. Hays<sup>2</sup> found 61 cases in 2,500 under his observation; two per cent is therefore a fair estimate. In these cases the apparent connection between the injury and the development of the mental symptoms is so clear as to leave little doubt that the insanity is due to the trauma. Under these circumstances trephining has been thought of and has been successfully practised as a method of treatment of the mental disease.

Dr. Carlos F. MacDonald reported such a case as

<sup>1</sup> Jour. Nerv. and Med. Dis., July, 1881.

<sup>2</sup> Amer. Lancet, November, 1891.

long ago as 1886,<sup>1</sup> and collected other cases of the same character which had been recorded prior to that time (see page 65).

Frank and Church have reported<sup>2</sup> a case of a young woman who developed delirium immediately after a severe injury to the head. She became constantly worse and finally was so unmanageable as to require asylum restraint. She suffered from the ordinary symptoms of mania, which became chronic and went on to complete dementia. She was destructive at times, noisy, but for the most part sat idly silent and stupid. This condition remained from April, 1884, until February, 1889, when she was admitted to St. Elizabeth's Hospital, Chicago, and carefully examined by Prof. Brower.

The diagnosis was "that the insanity was caused by the injury, because of the absence of any other possible cause and the immediate connection between the two; that the injury need not have produced fracture or depression of the skull to have resulted in insanity; that the depression of the skull found might be congenital, but its situation over the right parietal region made it possible that it might be the cause of the insanity; that this possibility justified exploratory trephining, and that the danger of the operation was so slight that it should not weigh against the possible benefit." In accordance with this opinion Dr. Frank trephined, removing a large portion of bone about two

<sup>1</sup> Amer. Jour. Med. Sci., July, 1886.

<sup>2</sup> Amer. Jour. Med. Sci., July, 1890.

inches in each direction from the anterior part of the right parietal bone. On dividing the dura a considerable amount of cerebro-spinal fluid gushed out. No gross lesion of the dura or brain was found. The wound was closed after the buttons of bone had been replaced. During the following six months the improvement of the patient was very striking, though her mental powers were still very feeble, but in February, 1890, she was readmitted to the hospital in about the same condition as a year before. The second operation was performed March 24th, 1890, at the same location as the first. The buttons of bone were found to have united with the skull, but the small fragments which had been replaced had been absorbed. A large section of bone was removed, the dura and brain were again explored without finding anything, and the wound was closed, this time without replacing the bone. A month later the patient manifested a considerable degree of intelligence, memory, and appreciation of her condition and surroundings; she showed natural emotion when told of a slight illness of her father, and read a letter without difficulty. She presented a great contrast to the condition which had been manifest before the operation. This improvement had continued up to the time of the report, one month after the second operation was performed.

While this case cannot be regarded as a marked success, the report having been made too soon to warrant any general conclusion, it gives evidence that the

course of a dementia following trauma may be influenced by trephining.

Dr. Keen reports the following case: A male, aged 44, after a fall from horse developed delusional insanity. He heard imaginary voices and these led to delusion. These delusions led in July, 1890, to an attempt at suicide; the imaginary voice told him that he was about to be killed by some one pursuing him, and another voice said, "Don't let them kill you, but do it yourself." Accordingly he procured a revolver and shot himself, but recovered from the wound. For several months later his delusions continued and hallucinations of sight were also present. In October, 1890, he complained of constant headache, especially in the right parietal region which was the seat of the injury, and he heard voices constantly. He had no delusions of persecution and was quiet and docile; there were no physical symptoms of brain disease.

Dr. Keen trephined October 17th, 1890, over the depressed bone. The scalp was adherent to the skull, the bone was rather thin, the dura was adherent to the bone, there were no adhesions to the pia, and the brain appeared normal. He made an uneventful recovery and was up two weeks after the operation. The pain in his head was very much less, and he did not hear voices nor did he have any delusions after the operation. Six weeks later he was considered by his wife and employer much more rational than he had been, and was able to do light work. The improvement was not, however, permanent, and four

months later he was reported in about the same condition as before the operation.

The number of cases thus far trephined for traumatic insanity is too small and the operation has been performed at a period too far removed from the trauma to warrant any definite conclusion as to the propriety of this form of treatment. But it seems probable that in appropriate cases, where the derangement begins soon after the trauma and where an injury of the skull is evident, an early trephining may cut short the mental disease and prevent its going on to a condition of chronic dementia.

The mental symptoms which are likely to develop after injury of the head are those of mania or of dementia, other forms being rarely recorded. There is no reason to conclude that insanity not traumatic in origin is amenable to surgical treatment, and Burckhart's proposal made at the Berlin International Medical Congress, to trephine in chronic cases and make incisions at random into the brain, deserved the severe censure which it met with.

Trephining has been proposed as a form of treatment of general paresis, and it has been performed in several cases under the direction of Batty Tuke and Claye Shaw in England, and by Wagner in this country.<sup>1</sup> In some of these cases it has failed to produce

<sup>1</sup> Claye Shaw: *Brit. Med. Jour.*, Nov. 16th, 1889. Revington: *Brit. Med. Jour.*, Nov. 23d, 1889. T. Batty Tuke: *Brit. Med. Jour.*, Jan. 4th, 1890. R. Percy Smith: *Brit. Med. Jour.*, Jan. 4th, 1890. Claye Shaw: *Brit. Med. Jour.*, Sept. 12th, 1891. St. Bartholomew Hosp. Rep., 1892. Wagner: *Amer. Jour. Insanity*, July, 1890.

any effect; in other cases there has been a slight temporary improvement, such as may occur spontaneously in any case of general paresis at any time. No permanent results have been obtained, and the consensus of opinion at the British Medical Association at its meeting in 1891, when the subject was fully discussed, seems to have been against this method of treatment in general paresis. The plea was made for the operation that it would relieve the condition of intracranial pressure and give exit to fluid which is usually found upon the convexity of the brain in states of dementia. The reply made to this was that the state of fluid exudation was secondary to the lesion in progress in the brain, and that the trephining in no way affected the actual disease, which was the primary cause of the symptoms. It seems to me that in general paresis, a disease which has an organic lesion, a diffuse chronic meningo-encephalitis, it is impossible for the operation of trephining to do any good whatever. Even should it act as a palliative treatment, it is not to be encouraged, for it is very questionable whether there is any gain in prolonging life in such a hopeless and progressive form of mental derangement.



## CHAPTER IX.

### TREPHINING FOR HEADACHE, AND OTHER CONDITIONS.

HORSLEY and WEIR have performed the operation of trephining in two cases of localized headache of traumatic origin with success. The patients had both developed the headache subsequently to a blow without any fracture of the skull, and every form of treatment had been employed in vain before the aid of the surgeon was sought. In both cases the pain was a strictly local one, not of the nature of ordinary headache. In Horsley's case there was found an enlarged Pacchionian body eroding the dura and skull. In Weir's case the mere removal of a button of bone relieved the pain. Such cases are certainly rare, and it is evident that no special consideration need be given to trephining as a form of treatment for headache.

It has been suggested that in cases of meningitis it might be possible to make two or more openings in the skull and wash out the pus from the meninges; this idea having been suggested by the successful surgical treatment of peritonitis. Any one, however, who is familiar with the surgery of the brain will realize that trephining does not give access to any great extent of the meningeal surface, and any one who is

familiar with pathology will realize the impossibility of removing pus from the interstices of the cerebral membranes.

Trephining for the treatment of thrombosis of the lateral sinus occurring in connection with middle ear disease has been proposed. Those who are interested may consult the article by Ballance in the *Lancet* for May 17th and 24th, 1890.

Trephining for the removal of bullets and foreign bodies from the brain is a purely surgical subject and is treated in the text-books upon surgery.

## CHAPTER X.

### THE OPERATION OF TREPHINING.

THIS book would be incomplete did it not contain a chapter upon the technique of opening the skull.

I have seen this operation performed so many times in such different ways, by different surgeons, that I am quite familiar with it. But in the preparation of this chapter I have made use of articles by Park, by Horsley, by Von Bergmann, by Weir, and by Keen.<sup>1</sup> I have to thank Dr. McBurney for reading this chapter and for many valuable suggestions in its preparation.

It is an absolute requisite of success in cerebral operations that every detail of aseptic surgery should be carried out to perfection. It is useless to make elaborate preparations, to sterilize instruments, and to apply antiseptic solutions to the hands, if in the midst of the operation the surgeon stops for a moment to

<sup>1</sup> Horsley : *Brit. Medical Journal*, October 10th, 1886, and April 23d, 1887. *Transactions Berlin Internat. Med. Congress*, 1890.

Park : "Surgery of the Brain," *N. Y. Medical Journal*, November, 1888.

Von Bergmann : "Die Chirurgische Behandlung der Hirnkrankheiten," 1891.

Keen : "Surgery of the Brain," "Reference Handbook of the Medical Sciences," vol. viii., 1888, and "American System of Surgery," 1892.

Weir : *American Journal of the Medical Sciences*, July, 1888.

Macewen : *Brit. Med. Jour.*, Aug. 11th, 1888.

adjust his septic eyeglass, or to blow his nose on a septic handkerchief without subsequently washing his hands again, or receives an instrument from the hands of assistant or nurse which have not been specially prepared for the operation. By covering his hand with a wet aseptic towel, the surgeon can safely handle anything which he desires. When aseptic measures are carried out in perfect detail, the rapidity of healing after these operations upon the brain is something marvellous. Thus, in an extensive operation by Dr. McBurney where the incision in the scalp measured seven inches, and the division of the skull along a line measured six inches, and the entire bony flap was broken away, exposing an area of the dura several square inches in extent, the wound was entirely healed within a week of the time of operation. And in the majority of the cases which have been here given in detail, a favorable and immediate healing was secured. It is to be understood, therefore, that in these operations the patient is to be properly prepared and the scalp made aseptic; that the hands of the operator and his assistants shall all be prepared; that the field of operation shall be surrounded over a wide area with sterilized towels either wet or dry (preferably wet), and frequently renewed; that every instrument, sponge, towel, etc., shall have been rendered aseptic, either by subjection to boiling heat in a steam sterilizer or by being soaked in a strong antiseptic solution, such as carbolic acid 1:50 or bichloride 1:1000.

*The Preparation of the Patient.*—The patient's head is to be entirely shaven twenty-four hours before the operation and carefully washed with soft soap, being scrubbed with a nail-brush, then washed again with warm water, and then again with sulphuric ether, each successive drying being done with an aseptic towel sterilized by heat. The head is then to be enveloped in a corrosive-sublimate gauze dressing which is applied moist, having been soaked in a solution of bichloride, 1:2000, and bandaged with aseptic bandages. Stronger solutions may cause eczema of the scalp. This bandage is to be left on until the operation is begun. The preparatory treatment by a purgative and the selection of a time for operation several hours after a meal are not to be neglected. It is best to suspend the administration of bromides for a week before any operation.

*The choice of an anæsthetic* may be left open to the surgeon, but I can verify the statement that the hemorrhage from the cerebral vessels is much less intense when chloroform rather than ether is used. Horsley has suggested the hypodermic injection of morphine, one-sixth of a grain, prior to the operation. Keen has recommended ergot, two to four drachms. The object of both is to produce a contracting influence upon the cerebral vessels. I have seen morphine act efficiently in this respect.

*The marking off upon the scalp* of the fissures of Rolando and Sylvius requires some time and should in my opinion be done before the anæsthetic is admin-

istered. These lines, after being carefully laid down, should be marked upon the scalp with iodine. A light touch at a series of points with the Paquelin cautery, after the anæsthetic is administered, fixes the lines. It is also well to puncture the scalp at three points with a sharp instrument, an awl or gouge, and thus mark the bone along the line which it is most important to regard; so that when the scalp is retracted the position of the guiding line, whether it be the fissure of Rolando or the fissure of Sylvius, shall be clearly evident upon the bone. This I think is important, as it is difficult to replace the scalp in the exact position after it has been dissected up, and the markings of the scalp may be somewhat obliterated by the solutions used in cleaning it after the lines have been laid down. It is also well to make a mark on the skull through the scalp with a sharp instrument at the exact point at which the centre of the trephine is to be placed before the scalp is divided. After the anæsthetic is administered the scalp is to be again carefully washed with (1) soft soap and hot water with the nail-brush, (2) with sulphuric ether, (3) with absolute alcohol, (4) with a solution of corrosive sublimate, 1:1000.

The application of a rubber band around the scalp just above the eyebrows for the purpose of compressing the vessels and preventing hemorrhage on the principle of the Esmarch bandage, which I suggested to Weir in 1887, is a failure. It cannot be applied with sufficiently even pressure to compress the arte-

ries; it merely exerts pressure upon the veins and increases venous hemorrhage; it should be abandoned. Weir's device of passing four long needles at right angles to one another through the scalp, thus making pressure on all the vessels leading into the flap, is far better. It is of great service both during and after the operation to have the patient's head on a level above the body, and a semi-sitting posture is the one in which hemorrhage is the least. It is not to be forgotten that when chloroform is used as an anæsthetic this position is attended by danger.

*The incision in the scalp* should be of horseshoe shape, base downward, or so directed as to secure the best nutrition and sufficiently large to allow of the easy enlargement of the bone opening in case it should be necessary to enlarge this to twice the size anticipated. The chief hemorrhage during the operation comes from this incision in the scalp, yet nothing is to be gained by making the incision little by little, inasmuch as the edges of the incision must be easily accessible in order to reach the bleeding vessels. The better way appears to be to make the incision in three-fourths of its expected length with the first sweep of the knife, to have the scalp compressed by sponges or sterilized gauze in the hands of assistants as fast as the cut is made, and then to catch the vessels one by one with forceps as the sponges are lifted. Several varieties of forceps are in use for this purpose; either the blunt dog-tooth forceps of McBurney or the broad T-shaped end forceps of Gerster may be employed;

the latter grasp a portion of the scalp nearly an inch in breadth and hold it firmly for a time: a series of these may be applied along the incision, and then one by one they may be removed and the vessels caught with a single-tooth forceps and tied. When the bleeding is arrested from the original incision it may be extended at both ends to its intended size, the vessels near being successively caught and ligated.

In dissecting up the scalp *the periosteum should be left* upon the bone and not dissected up with it.

Surgeons differ as to the best method of *making an opening through the skull*, but all agree that whatever opening is made should be at least one and one-half inch in diameter, and many prefer the opening at least two inches in diameter. Such openings may be made by trephining at one spot with a trephine one and one-fourth inch in diameter and enlarging the opening with a rongeur, or by making two trephine openings an inch in diameter and cutting away with a rongeur the bridge of bone between, or by chiselling with gouge and mallet through the skull, or lastly by the use of the rotary saw run by an electric motor.

If the trephine is used care should be taken not to wound the dura when nearly through the skull. In using the rongeur the instrument of Horsley with its jaw at an angle with the shank is far more convenient than a straight instrument. If the gouge is used great care must be exerted to prevent its slipping and cutting the dura. The concussion produced by hammering is an objection to the use of the gouge or chisel



urged by some American surgeons. But this objection is not sustained by Dr. McBurney's experience. German surgeons prefer this method. If the gouge is used the opening in the skull may be made of  $\Omega$  shape and the plate of bone be then gently pried up, the attached part being broken but not separated. The electric motor with a rotary saw is a satisfactory instrument for cutting the bone. In order to use it safely a trephine opening must first be made, the dura must be carefully separated from the bone by a thin flat metal instrument, and the instrument must be held in place to protect the dura, and be pushed forward in advance of the saw as this is used. The difficulty of directing this flat instrument through the trephine hole, and the danger of sawing into the dura and brain if it is not properly placed, are great. It requires much practice and skill to handle the electric saw safely, and to an observer the danger of sawing through into the dura and brain seems to be great unless the metal plate between skull and dura is very firmly held and accurately adjusted. Yet the labor of trephining is so great and so wearisome that any mechanical electric motor would appear to be preferable to the hand, and as Horsley's apparatus can be so adjusted as to revolve the trephine, it seems as if the first two-thirds of the trephining can be safely done with it, the last third being done by hand so that touch shall guide the degree of pressure made upon the trephine. It is of course in a hospital only that the electric motor can be used.

The question of *replacing the piece of bone* that has been removed is an open one. If a single button of bone is removed, or if two buttons and the bridge between them are taken out, it is possible to replace them and to secure bony union. It is also possible to replace the large plate removed by the Horsley saw. But of late when larger openings are made by gnawing away the bone about the original trephine opening the bone is rarely replaced. If it is to be replaced it should be kept at a temperature of 99° by being wrapped in warm damp gauze wet with a corrosive sublimate solution, 1:2000, or in a sterilized salt solution, and kept in a warming box or in a jar immersed in warm water. It is also possible to preserve the small pieces of bone and to cut up the larger piece and replace them all by strewing them over the dura. It should be remembered, however, that such pieces of bone, no matter how carefully taken care of in the interim, may necrose after replacement. To avoid this accident McBurney never replaces a piece which has been entirely separated, and for the same reason he prefers lifting a plate of bone which is never entirely detached, and so never entirely cut off from a source of nutrition.

There is sometimes considerable *hemorrhage from the diploë*, and occasionally a vein or a large canal in the diploë will bleed profusely. Pressure with sponge at the bleeding spot usually stops this. If it persists Horsley's wax may be used, which consists of wax seven parts, oil two parts, carbolic acid one part.

This may not be sufficient to arrest hemorrhage from a large vein, and then a small plug of decalcified bone or of aseptic sponge may be forced into the opening. The two tables may be forcibly crushed together by a heavy forceps and thus the bleeding from the diploë stopped.

*The division of the dura* is made by the point of a curved bistoury, or an ordinary scalpel. A fine tenaculum then seizes the dura and draws it up from the brain surface, and into the small incision a curved blunt scissors blade can be inserted and the dura freely divided. The dura should be divided about one-fourth inch from the edge of the bony opening and the incision should be horse-shoe in shape. The dura can then be reflected downward leaving the brain exposed. It should be lifted carefully away from the brain, for very frequently close adhesions exist which cannot be roughly torn without incurring great risk of opening one or more large veins of the pia mater. If arteries are found passing over the dura they should be ligatured before the dura is divided. This is best done by Keen's small, curved needle attached to a handle, similar to an aneurism needle but very minute. A curved Hagedorn needle may be used. This can be passed around the vessel through the dura and a ligature threaded into it and drawn backward, thus surrounding the vessel. The same needle can be used in sewing up the dura at the end of the operation, the ordinary curved surgical needles being too large. Hemorrhage from little vessels of the dura is best ar-

rested by a light touch with the cautery if pressure is insufficient.

*The brain* is now exposed—covered by pia mater, whose numerous vessels are easily torn at the least rough manipulation. If it is necessary to dissect off portions of the pia—in removing scar tissues or tumors—or if it is necessary to incise the brain for the excision of cysts or tumors, *hemorrhage* may give some trouble. It can usually be arrested by continued pressure with sponge or with aseptic gauze. During the time that this pressure is being maintained, ligatures may be applied to bleeding vessels of the scalp, or the wound may be cleaned and new towels applied; thus no time is wasted. If pressure alone is not enough to stop hemorrhage from the pia a clamp or forceps may be applied for a time, and if it continues when this is removed the vessel may be tied with very fine catgut. As a last resort the Paquelin cautery may be employed, but it is less useful in the vessels of the pia than in those of the dura. Pressure alone is usually sufficient to arrest hemorrhage from the brain substance itself, though a cautery may be needed. It is impossible to tie the little brain arteries and veins. Solutions of antipyrine 1:40, or of cocaine 1:100, have been used as styptics by Keen and Park.

*Exploration of the Brain* may be made by palpation, and this is exceedingly satisfactory, for the degree of resistance to pressure may be contrasted at various points and the fluctuation of a deep cyst or the hardness of a solid tumor can be easily noticed.

If necessary a probe may be thrust into the brain or a hypodermic needle may be introduced quite freely and without danger, as Spitzka has shown. Incisions into the brain are not dangerous, but if they are made the knife should be passed down through the summit of a convolution, as then hemorrhage is less free than when the side of the convolution or the brain at the bottom of a sulcus is incised. When it is remembered that large portions of brain tissue have been destroyed by accidents (*e.g.*, in the crow-bar case and in the linch-pin case) without fatal results, less fear will be felt on wounding the brain. Yet it is to be also remembered that certain parts of the cortex have important functions—such as the speech areas or the motor areas—and all needless incision or excision should be avoided.

If there is much œdema of the pia, a few small incisions in it followed by pressure will evacuate the fluid.

If a clot is found it may be wiped away by fine sponges or, if organized, picked out with fine forceps, care being taken not to tear the pial veins.

If a tumor lies upon the surface, and is surrounded by a distinct capsule, it can be enucleated with the blunt point of curved scissors or with the finger without cutting. If it infiltrates the brain tissue and so has no distinct capsule, it should be cut out with the knife. The sharp spoon does not do good work in the brain. If the tumor lies below the surface, the brain tissue lying over it must first be incised and then enu-

cleation or dissection of the tumor from its bed may be done, the overlying substance being held away with flat retractors. If a cyst exists, it may be when superficial completely excised, or its superficial surface wall may be cut away and the remainder packed and healed by granulation. If the cyst lies deeper, it may be freely incised and packed, or a small incision for drainage may be made, and continuous drainage kept up by introducing a folded strip of rubber tissue through the incision.

The same device may be resorted to in draining an abscess.

After the removal of large tumors or cysts, or after the excision of large scars from the brain, a depression of the surface or a deep cavity may remain which if left to itself inevitably fills with blood. This may be avoided by packing such a cavity lightly with iodoform gauze, which at subsequent dressings may be removed little by little. It is well to use a single strip of gauze, otherwise the number of pieces used may not be accurately counted or remembered and one piece may never be removed. A tampon of folded aseptic gauze may be used in place of the iodoform packing.

If the operator has confidence in his methods, he might in some suitable cases, where bleeding was not active, practise the ideal method by allowing the cavity to fill with blood, and so get healing with organization of blood clot. One or more openings must be left in the suture line to allow of the escape of superfluous blood.

A very marked bulging of the brain tissue through the opening in the dura mater sometimes occurs at the time of the operation, or subsequently to it, as a hernia cerebri. It has been found that the smaller the opening in the dura the more likely this is to occur. If the bulging tissue be held back by a flat spatula while the stitches are put in the dura and a continuous suture be used, and then the edges of the dura be rapidly drawn together as the spatula is removed, the bulging will be slowly reduced. If this is impossible the bulging brain may be sliced off or wiped away with a sponge. Hernia cerebri developing after the operation is rare when asepsis is perfect.

*In case a sinus or a large vein is opened* and hemorrhage becomes alarming the wound may be packed with iodoform gauze with safety, or the wound in the sinus having been closed with a pressure forceps, the forceps may be left in place for a day or two supported by the dressings. Sewing up a bleeding sinus is difficult, but has been done successfully.

The *closing of the wound* should be preceded by a thorough irrigation with simple sterilized salt solution, one per cent, or with corrosive sublimate, 1:5000. A small drain of a folded bit of rubber tissue should be left in the most dependent part of the wound. The dura should be stitched with catgut except where the drain passes through it. The scalp is then to be stitched with silk. The head is to be washed with antiseptic solution. The wound is then to be covered with rubber tissue. It is to be covered

with aseptic gauze and this with many layers of cotton, and the whole held in place by a large bandage covering the entire head and held under the jaw.

In some cases there may be no necessity for a drain, in which case the entire dressing need not be changed for a week, when everything may be found to have united by first intention.

In other cases the drain may be removed on the third day and a second dressing applied—removal of which may be found to show a healed wound.

Damming up of blood giving rise to pressure symptoms, or the extreme oozing of cerebro-spinal fluid, or the development of a temperature with evidence of infection, necessitate an immediate inspection of the wound by the removal of dressings, and proper care upon general surgical principles.

THE END.



# INDEX.

- ABSCCESS of the brain, 179  
capsule in, 182  
cases of, 183  
cases operated upon, 183, 184,  
194, 195  
causes of, 180  
diagnosis of, 188, 189  
differentiation from meningitis, 190  
from sinus thrombosis, 190  
following ear disease, 188  
fevers, 180  
injury of the skull, 183  
pathology of, 181  
position for trephining in, 193  
symptoms of, 189  
trephining for, 182  
varieties of, 180
- Agnew*, 181, 227, 253  
*Agraphia*, 6  
*Alexia*, 6  
*Amidon*, 253  
Anæsthetic in trephining, 277  
*Anderson*, 252  
*Anger*, 137  
Aphasia, 6, 23, 42, 45, 48, 145,  
158, 160, 162, 174, 183, 188, 214,  
219, 228, 261  
Apoplexy, trephining in, 176  
Arm, motor area of, 3  
spasm in, 20  
*Ashby*, 117, 133  
Association tracts in the brain,  
10
- Atrophy of the brain, 125, 129  
Auditory area of the brain, 6  
speech, 7
- Ball*, 158  
*Ballet*, 251  
*Barker*, 197  
*Barr*, 188  
*Barton*, 251  
*Bartlett*, 137, 224, 251  
Basal ganglia, 11  
Base of the brain, 11  
tumors of, 210  
*Beach*, 252  
*Bennett*, 251  
*Bennie*, 137  
*Von Bergmann*, 195, 205, 251, 275  
*Bernhardt*, 215  
*Birdsall*, 221, 251  
*Birmingham*, 194, 264  
Birth palsy, 116  
Blindness, 121, 229, 246, 248  
Bone, lesions after injury, 69  
replacing after trephining,  
282  
*Booth*, 205, 251  
*Boyd*, 166  
*Bradford*, 137, 223, 252, 253  
Brain, bulging of, after trephining, 287  
changes in, in epilepsy, 73  
exploration of the, 284  
wounds of the, 76  
*Bramwell*, 207  
*Braman*, 252  
*Bremer*, 225, 252

- Briddon*, 41  
*Broca*, 262  
*Brower*, 268  
*Bryant*, 62, 184  
*Bullard*, 137, 253
- CARCINOMA of the brain, 202, 204, 206  
*Carson*, 225, 252  
*Castro*, 252  
 Centrum ovale, 10  
 Cerebellum, 11  
   abscess of the, 188  
   tumors of the, 238  
   cases operated on, 241-253  
   staggering in, 239  
   symptoms of, 238
- Cerebral abscess, see Abscess, 179  
 diseases, 1  
 functions, 3  
 hemorrhage, see Hemorrhage, 131  
 tumor, see Tumor, 200
- Championnière*, 173, 251  
*Charcot*, 21  
*Chisholm*, 253  
 Choked disc, 189, 190, 217, 238, 257  
*Chubbe*, 252  
*Church*, 55, 223, 252, 268  
*Clarke*, 252, 253  
*Clay Shaw*, 271  
 Clinical types of microcephalus, 114  
*Coen*, 76  
*Combe*, 251  
 Compression of the brain, 167  
 Congenital defects of the brain, 128  
 Consciousness after hemorrhage, 169  
 Corpora quadrigemina, 11  
   striata, 11  
 Cortical areas, 3
- Cranial nerves, symptoms of injury to, 240  
 Cranio-cerebral topography, 15  
 Craniotomy for microcephalus, 114, 136  
   table of cases of, 137  
*Crura cerebri*, 11  
*Cunningham*, 15  
*Curtis, B. F.*, 205, 251  
 Cysts in the brain, 74, 130, 203, 207, 284  
*Czerny*, 218
- Dana*, 215, 252  
 Danger of trephining in epilepsy, 27  
 Deaf-mutism, 120  
 Deafness in brain disease, 7, 240  
*Deaver*, 55  
 Dementia, 268, 271  
*Derby*, 229  
*Detmold*, 179  
*Diller*, 57  
 Direction of staggering as a local symptom, 239  
*Dobson*, 253  
*Donaldson*, 120  
*Doyen*, 252  
 Drainage of lateral ventricles, 256  
*Dunin*, 252  
*Dupuytren*, 179  
*Durante*, 251  
 Dura, changes in, in epilepsy, 70  
   treatment of, after trephining, 283
- Elcan*, 183  
 Epilepsy, trephining for, 19  
   aphasic attacks, 23  
   cases open to trephining, 24  
   cases trephined, 29-69  
   causes of, 25  
   following injury, 261  
   idiopathic, 19, 117

- Epilepsy in microcephalic children, 124  
 in tumor of the brain, 217  
 Jacksonian, 20  
 lesions of, 68, 75, 78-112  
 pathology of, 68-112  
 psychical attacks, 23, 65  
 reflex, 68  
 results of trephining for, 112  
 sensory attacks, 22  
 traumatic, 25  
 varieties of, 19  
 with insanity, 65, 267
- Erb*, 217, 252  
*Eskridge*, 252
- Excision of cortex, 27
- Extra-dural hemorrhage, 168
- Eyes, motor area of, 3
- FACE, motor area of, 3
- Facts of localization, 3
- Fenger*, 183  
*Ferraro*, 126  
*Ferrier*, 21, 232  
*Fischer*, 251  
*Fisher, E. D.*, 62, 63, 64, 122, 129, 138
- Fissures of the brain, 3, 15
- Fitzgerald*, 251, 253
- Fracture of the skull, 69
- Frank*, 55, 133, 137, 252, 268  
*Fraser*, 253  
*Freund*, 123
- Frontal lobe, functions of, 8  
 lesions of, 219, 231
- Functions of cerebellum, 11  
 of cortex, 4
- Gerster*, 59, 60, 61, 62, 137, 279
- Glioma, 202, 207, 245, 247
- Glio-sarcoma, 207
- Godlee*, 251  
*Gowers*, 116, 133  
*Gray*, 253  
*Griffith*, 232
- Gumma, 203, 206
- Hahn*, 185
- Hallucinations, 22
- Hammond*, 137, 138, 253  
*Hartley*, 48, 138, 144  
*Hays*, 267
- Headache, trephining for, 273
- Head, injury of, as cause of abscess 183  
 of epilepsy, 26, 121  
 of hemorrhage, 158  
 of insanity, 267  
 motor area of, 3
- Heath*, 253
- Hemianopsia, 7, 121, 123, 167, 214, 218
- Hemiplegia in children, 115
- Hemorrhage, 131  
 cases of, 158, 161, 166  
 extra-dural vs. intra-dural, 168  
 from the brain after trephining, 284  
 from the diploë, 282  
 from the pia, 283  
 intra-cerebral, 176  
 non-traumatic, 172  
 traumatic, 123, 158, 167  
 trephining for, 131, 157
- Henschen*, 7, 123  
*Heurtaux*, 137  
*Hirschfelder*, 220, 251  
*Hitzig*, 179, 252  
*Hodenpyl*, 236  
*Horsley*, 5, 76, 136, 138, 203, 206, 237, 251, 252, 265, 273, 275, 280, 281, 282
- Hydrocephalus, 132, 256  
 cases of, 259  
 diagnosis of, 257  
 draining ventricles in, 258  
 trephining for, 256
- IMBECILITY, 114

- Incision in scalp in trephining, 279
- Infantile hemiplegia, 115
- Insanity, 267
  - cases open to operation, 267
  - cases trephined, 268
  - dementia, 268
  - paresis, 271
  - traumatic, 267
  - trephining for, 267
- Internal capsule, 11
- Intra-dural hemorrhage, 168
- Jackson, Hughlings*, 19, 20
- Jacksonian epilepsy, 20
- Jacobson*, 168
- Janeway*, 183
- Jeannel*, 252
- Kelly*, 64, 65
- Keen*, 55, 56, 57, 136, 137, 222, 251, 258, 260, 270, 275, 283, 284
- Keetley*, 253
- Kerr*, 253
- Kiernan*, 267
- Knapp*, 58, 59, 215, 223, 252, 253
- Koehler*, 252
- Koerner*, 188
- Kuchenmeister*, 203
- Kundrat*, 133
- Lampiasi*, 252, 253
- Lannelongue*, 136
- Leg, motor area of, 3
- Llobet*, 252
- Lloyd*, 55, 215
- Limont*, 251
- Localization of brainfunctions, 3
- MacDonald, C. F.*, 65, 267
- Macewen*, 157, 251
- Maudsley*, 253
- Maunoury*, 137
- Maunsell*, 252
- May*, 252
- Mal-development of brain, 124
- Marking the scalp before trephining, 177
- McBurney*, 30, 32, 33, 35, 39, 44, 45, 50, 52, 53, 68, 138, 141, 147, 163, 233, 243, 246, 249, 251, 252, 253, 275, 279, 282
- McClintock*, 137
- McNutt*, 133
- Medulla, 11
- Meningeal hemorrhage, 117
- Meningitis, 72, 273
- Meningo-encephalitis, 117, 129, 271
- Mental defects in frontal lesion, 219, 231
  - in microcephalus, 118
  - faculties, 9
- Mercauton*, 252
- Michaux*, 173
- Microcephalus, 114
  - cases of, trephined, 137
  - clinical types of, 114
  - conclusions regarding trephining for, 155
  - epilepsy with, 115, 117
  - imbecility from, 118
  - paralysis from, 115
  - pathology of, 124
  - results of trephining for, 139
  - sensory defects with, 120
- Microscopic lesions in epilepsy, 79, 83, 102
- Middle meningeal artery, 169
- Mills*, 215
- Moeli*, 123
- Morrison*, 57, 138
- Morse*, 253
- Motor aphasia, see Aphasia
  - area of brain, 3
  - tract in brain, 9
- NEURITIS optica in abscess of brain, 189, 190

- Neuritis in hydrocephalus, 257  
 in sinus thrombosis, 190  
 in tumor of brain, 204, 206,  
 212, 217, 238
- Neuroglia, changes in, in epi-  
 lepsy, 99-106
- Nothnagel*, 21
- Nugent*, 253
- OCULO-MOTOR paralysis, 209
- Opening the skull, methods of,  
 280
- Oppenheim*, 137, 252
- Operation of trephining, 275
- Optic neuritis, see Neuritis op-  
 tica
- Optic thalamus, 11, 214
- Organic epilepsy, 20
- Osler*, 116, 128, 133
- Page*, 251
- Paralysis from brain disease, 3  
 of cranial nerves, 209
- Paresis, trephining for, 271
- Park*, 66, 138, 149, 153, 275, 284
- Parker*, 251
- Pathology of abscess of the brain,  
 181  
 brain diseases, 79  
 cerebral atrophy, 126  
 cerebral sclerosis, 124  
 epilepsy, 25, 68  
 hydrocephalus, 256  
 insanity, 272  
 microcephalus, 256  
 porencephalus, 128  
 tumors of the brain, 208  
 wounds in the brain, 76
- Pean*, 251, 252
- Petiole, changes in, 69  
 treatment of, 280
- Peterson*, 122
- Pia mater, changes in, 70, 71  
 treatment of, 280
- Pitcher*, 252
- Poirier*, 252
- Pons Varolii, 11  
 tumors of, 209
- Poore*, 46, 185
- Porencephalus, 125
- Post*, 58, 59
- Potemski*, 252, 253
- Poulson*, 188, 189
- Preparation of head for trephin-  
 ing, 277
- Preugmeber*, 138
- Projection tracts in the brain, 9
- Psychical epilepsy, 23
- Punctured wounds of the brain,  
 158, 285
- Pupils in cerebral compression,  
 170
- Putnam*, 253
- Rannie*, 251
- Reid*, 16
- Relation of fissures and sutures,  
 13  
 of skull and brain, 12
- Replacing bone after trephining,  
 282
- Results of trephining in abscess  
 of brain, 181  
 in epilepsy, 28, 54, 67,  
 112  
 in hemorrhage, 167, 171  
 in hydrocephalus, 263  
 in insanity, 271  
 in microcephalus, 137,  
 155  
 in tumor of brain, 216
- Retinal carcinoma, 214
- Reynier*, 252
- Rheinhardt*, 120
- Robson*, *Mayo*, 261, 262
- Roland*, 21
- Rolando, fissure of, 16
- Ross*, 253
- Rumpff*, 203
- Sachs*, 59, 60, 61, 62, 116, 133, 137

*Sands*, 253  
 Sarcoma of brain, 202, 207  
 Scalp, incision in, 279  
     wounds of, 68  
 Scars in brain, 76  
     in scalp, 68  
*Sciamanna*, 253  
*Shattenberg*, 125  
*Schneider*, 160  
*Schoenthal*, 232  
*Schultze*, 128  
 Sclerosis of brain, 125  
*Seguin*, 221, 251, 253  
 Sensory aphasia, see Aphasia  
     areas of cortex, 3  
     aura in epilepsy, 22  
     defects in imbeciles, 120  
     epileptic attacks, 22  
*Shaw*, 58  
*Sheldon*, 232  
 Sight area of cortex, 6  
 Sinus, thrombosis of lateral, 190  
     treatment of, in trephining,  
     287  
 Skull, fractures of, 69  
     relation to brain, 12  
 Smell area of cortex, 8  
 Sound area of cortex, 7  
 Spasms localized, 22  
     order of extension of, 21  
 Specific treatment in tumor, 254  
 Speech areas of cortex, 3  
*Spitzka*, 285  
*Springthorpe*, 253  
 Staggering, as a symptom, 239  
*Starr*, 21, 138, 231, 251, 252  
 Statistics of trephining, see Re-  
     sults  
*Stewart*, 253  
*Stieglitz*, 252  
*Stimson*, 184, 194  
*Stoker*, 253  
*Strumpell*, 133  
*Suckling*, 252  
 Sylvius, fissure of, 17

TABLE of cases of craniotomy,  
     137  
     of tumors of the brain, 202  
         open to operation, 213  
         operated upon success-  
         fully, 251  
         operated upon unsuccess-  
         fully, 252  
 Taste, area of, in cortex, 8  
*Thiriar*, 263  
*Thomas*, 224, 251  
*Thompson*, 232  
 Thrombosis of lateral sinus, 190  
     trephining for, 190, 274  
     of veins of pia, 133  
 Topography, cranio-cerebral, 15  
 Tracts within the brain, 10  
 Trauma as a cause of abscess,  
     180  
     epilepsy, 25  
     hemorrhage, 160  
     insanity, 267  
 Trephining for abscess of the  
     brain, 180  
     clots on the brain, 170  
     epilepsy, 13, 19  
     headache, 273  
     hemorrhage, 157  
     hydrocephalus, 132, 256  
     imbecility, 114  
     intracranial pressure,  
     256  
     insanity, 267  
     meningitis, 274  
     tumors, 200, 265  
     methods of, 280  
     operation of, 276  
     personal cases of, 29-54,  
         140-149, 161, 174, 185,  
         228-250  
     statistics of, see Statistics  
     technique of, 276  
*Trinble*, 137  
 Trunk, motor area of, 4  
 Tubercular tumors, 202, 204, 205

- Tumors of the brain, 200  
 analysis of operations for, 216  
 analysis of 600 cases, 202  
 cases open to operation, 209  
 cases operated upon, 220-250  
 cerebellar, 238  
 cerebral, 217  
 conclusions regarding operation for, 254  
 cortical, 217  
 diagnosis of, 204, 206, 212, 238  
 frequency of, 201  
 hemorrhages in, 208  
 in adults, 201, 212  
 in centrum ovale, 212  
 in cerebellum, 211, 238  
 in cerebral axis, 209  
 in cerebral cortex, 212  
 in children, 201, 211  
 multiple, 204  
 per cent of cases operable, 213, 214  
 situation of, 209  
 structure of, 208  
 symptoms of, 208, 212, 238  
 tables of cases of, see Tables  
 varieties of, 201  
*Twynam*, 253
- UNCINATE gyrus, 8
- Van Gieson*, 72, 78-111  
 Varieties of abscess, 180  
 aphasia, 6  
 epilepsy, 19  
 tumor, 201
- Verco*, 252  
 Visual area of brain, 6, 7  
 tract in brain, 9
- Wagner*, 271  
*Weeks*, 241  
*Weir*, 38, 148, 174, 221, 251, 253, 273, 275  
*Welt*, 232  
*Wernicke*, 258  
*White, Hale*, 214  
*Wilbrand*, 122  
*Willard*, 138  
*Wollenburg*, 245  
*Wood*, 227  
*Woolsey*, 63  
 Wounds of the brain, 76  
*Wyeth*, 137  
*Wyman*, 253
- Zenner*, 258  
*Ziegler*, 76







~~11/27~~

PR 11 1902

DV 20 1902

/ 26 1906



