



UC-NRLF



SB 174 231



EX LIBRIS





Digitized by the Internet Archive
in 2007 with funding from
Microsoft Corporation



Handwritten text, possibly a signature or date, at the top left of the page.

Handwritten text, possibly a signature or date, oriented diagonally in the upper right quadrant.

CLINICAL EXAMINATION OF THE
BLOOD AND ITS TECHNIQUE.



CLINICAL EXAMINATION OF THE BLOOD AND ITS TECHNIQUE.

A MANUAL FOR STUDENTS AND
PRACTITIONERS.

BY

PROFESSOR A. PAPPENHEIM,
Berlin.

TRANSLATED AND ADAPTED FROM THE GERMAN BY

R. DONALDSON,

M.A., M.B., Ch.B., F.R.C.S. Ed., D.P.H.

*Pathologist Royal Berks Hospital, Reading, Etc.; Late Assistant
Pathologist Royal Infirmary, Bristol, and Demonstrator of
Pathology, Universities of Bristol and Sheffield.*



BRISTOL: JOHN WRIGHT AND SONS LTD.
LONDON: SIMPKIN, MARSHALL, HAMILTON, KENT & CO. LTD.
TORONTO: MACMILLAN COMPANY OF CANADA, LTD.

1914

RE 114
P. 7

LIBRARY

TO THE
LIBRARY

JOHN WRIGHT AND SONS LTD.,
PRINTERS AND PUBLISHERS, BRISTOL

TO THE
LIBRARY

TRANSLATOR'S PREFACE.

THE clinical examination of the blood should be carried out as a routine much more frequently than is generally the case in practice. Indeed, while every other system is carefully gone over time and again, the blood is often thought of only as a last resort by the practitioner. Even then the technique employed is not all that might be desired, and the significance of what is found is not always properly understood.

In order to aid the practitioner, therefore, Professor Pappenheim has written this small book, which he expressly wishes to be regarded merely as a *guide* to the clinical examination of the blood.

A simple technique is described, and the main facts that every one ought to be familiar with are brought together in a condensed form, while everything of a controversial nature is omitted. The English edition has been enriched by the insertion of a few illustrations showing Professor Pappenheim's apparatus and the chief cell forms likely to be met with.

The cell types have been taken from his "Atlas der menschlichen Blutzellen," a book which contains a wealth of illustration and material. Since the German edition made its appearance, Professor Pappenheim has altered his technique, and the description given of this has been based on reprints which Professor Pappenheim kindly sent me, so that the book might be completely up to date.

ROBERT DONALDSON.

READING,

May, 1914.

PREFACE TO THE GERMAN EDITION.

THIS small book first appeared as a chapter in Carl Neuberg's "Handbuch der Ausscheidungen und Körperflüssigkeiten," published by Julius Springer in 1911. It was written with the idea of furnishing a very elementary guide to the most important and essential methods of blood examination regarded from the standpoint of the chemist and of the pharmacist. Soon after its appearance, however, I received numerous requests to publish the chapter in book form. As a matter of fact no small text-book of this kind had hitherto been published. Moreover, a chapter, dealing almost entirely with microscopy and cytology, seemed to a certain extent out of place in what was otherwise essentially a treatise on Chemical Physiology. The subject-matter of this chapter, in fact, belongs to quite a different category from the rest of the contents. For these reasons the publisher resolved to comply with the requests for a separate issue.

This little book differs from all others that treat of the blood in so far as it deals only with what is absolutely essential and of first import-

ance in clinical methods of blood examination. All less important, and all merely chemical or physical methods of examination have been purposely omitted; such, for example, as alkalinity, specific gravity, volumetry, dried residue, coagulation time, viscosity, etc.

Further, of the three cardinal lines of blood-investigation (*viz.*, staining, counting of cells, and hæmoglobin-estimation), only those methods have been described which have been definitely proved of value. All padding with less useful methods has been purposely omitted.

Coupled with the description of methods, the respective features of normal blood have been briefly discussed.

In addition, the most important facts in the semiology, necessary for a proper understanding of pathological conditions, have been dealt with.

In order to appreciate correctly the cytomorphological appearances, a series of good illustrations should be consulted.

A. PAPPENHEIM.

WANGEROOGE,
August, 1911.

CONTENTS.

CHAPTER I.—THE BLOOD FILM.

METHOD AND TECHNIQUE OF STAINING	I
MICROSCOPIC EXAMINATION OF THE STAINED BLOOD FILM	6
SEMIOLOGY AND DIFFERENTIAL DIAGNOSIS OF THE MOST IMPORTANT BLOOD CHANGES AS SEEN IN STAINED FILMS	27

CHAPTER II.—HÆMOCYTOLOGY: OR THE ENUMERATION OF THE BLOOD CORPUSCLES.

METHOD AND TECHNIQUE	43
RELATIVE PROPORTION OF CELLS IN NORMAL BLOOD .	56
PATHOLOGICAL VARIATIONS IN NUMBER, AND THEIR DIAGNOSTIC SIGNIFICANCE	56

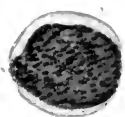CHAPTER III.—HÆMOGLOBINOMETRY: OR THE ESTIMATION OF HÆMOGLOBIN.

METHOD AND TECHNIQUE	66
SEMIOLOGY	69
THE COLOUR INDEX	71

PLATE I.

- 1-4.—Lymphoidocytes.
- 5-7.—Leucoblasts—basophilic cytoplasm with scanty azur substance.
- 8.—Microleucoblast with slightly oxyphilic cytoplasm.
- 9.—Myelocyte.
- 10.—Metamyelocyte.
- 11.—Neutrophil (polymorphonuclear).
- 12-13.—Eosinophils (with bisegmented nucleus).
- 14-16. Mast-cells. Note small rim of cytoplasm and coarse basophil granules.
- 17-21.—Typical lymphocytes. Note narrow rim of cytoplasm with a few azur points.
- 22-30.—Older forms of lymphocyte.
- 31-34.—Typical large monocytes with fine azur points. No neutrophil or other true granules present. Compare with leucoblast, which has a nucleus like that of a myelocyte and possesses coarse or myeloid azur points.

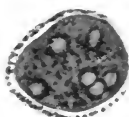
PLATE I




1



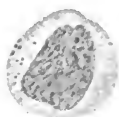
2



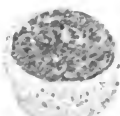
3



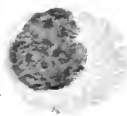
4




5



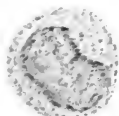6



7



8



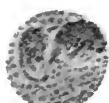
9



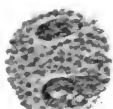
10



11



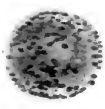
12



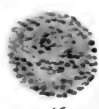
13



14



15



16



17



18




19



20




21



22



23



24



25

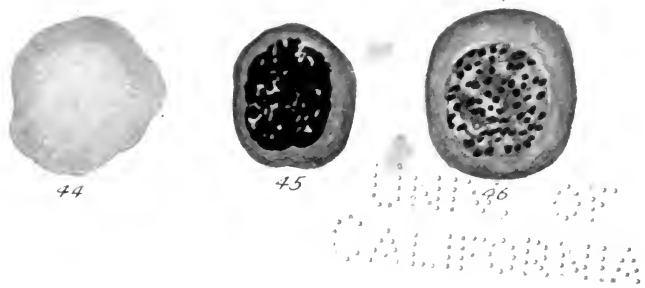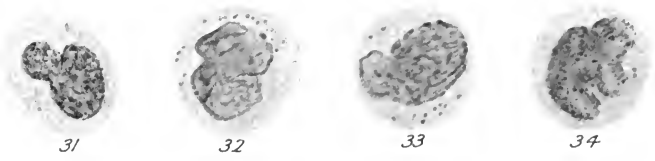
20 2000



PLATE II.

- 35.—Microcyte.
- 36.—Dwarf normoblast—microblast.
- 37.—Erythrocyte (orthochromatic).
- 38.—Erythrocyte (polychromatophilic with basophil points).
- 39.—Erythrocyte showing punctate basophilia.
- 40.—Erythrocyte showing a "Jolly" body.
- 41-43.—Normoblasts.
- 44.—Gigantocyte.
- 45.—Megaloblast (polychromatic).
- 46.—Gigantoblast.

PLATE II



1000

THE CLINICAL EXAMINATION OF THE BLOOD.

CHAPTER I.

THE BLOOD FILM.

METHOD AND TECHNIQUE OF STAINING.

THE microscopic examination of stained blood films implies a knowledge of three preliminary steps, viz. :—(1) *How to spread the film* ; (2) *How to fix the film* ; (3) *How to stain the film*.

I.—HOW TO MAKE A BLOOD SMEAR.

On Slides.—To make a blood film on an ordinary slide, proceed as follows: A medium-sized drop of blood, drawn as a rule from the finger, is removed on one end of a clean slide. The latter, with the drop of blood uppermost, is then laid on a firm flat surface. Next, a second perfectly clean slide is placed with the narrow edge touching the first slide, and just in front of the drop of blood, so as to form with the first slide an acute angle (not more than 45°). The drop of blood now lies in the acute angle formed by the two

slides, i.e., between the edge of the inclined slide and the end of the horizontal one. Since the second slide is placed just in front of and touching the drop of blood, it follows that the drop will spread out along the narrow edge of the second slide in the angle between the two. The inclined slide is then drawn firmly and evenly along the surface of the horizontal slide to its opposite extremity. In this way the drop of blood is drawn out over the slide in the form of a thin smear. All crushing and undue pressure can thus be avoided.

On Cover Glasses.—For this purpose, a pair of simple forceps such as Ehrlich's, without the catch, is necessary. The inner surface of the blades is smooth and flat. A series of cover-glasses, well cleansed in alcohol and ether, are lifted by means of the forceps and laid out near the patient on a sheet of clean white note-paper. A cover-slip is then taken up with the forceps and brought in contact with the drop of blood as it issues from the finger. This cover-slip is now allowed to fall on to a second cover-glass, in such a way that one-half of one cover-glass coincides with the opposite half of the other. The drop of blood then spreads out between the two by capillarity, so that one-half of each cover-glass is covered. When this has been accomplished, the projecting edge of one of the cover-glasses is seized with the forceps, and the two cover-slips, still stuck together, are lifted up. They are then transferred to the left hand and the forceps laid down. The

projecting edge of the other cover-slip is next seized in the fingers of the right hand, and the two are drawn gently apart. All forcible separation must be avoided.

II, III.—FIXING AND STAINING.

The only method which we employ is the so-called May-Giemsa stain, as modified by Pappenheim.* By it fixing and staining are carried out in two stages as follows. Since the stain, which is dissolved in methyl-alcohol, only acts as such in a watery solution,

* As this stain is panchromatic, all others are rendered unnecessary (such as hæmatoxylin-eosin, Jenner's methylene blue-eosin, May-Grünwald's methylene-blue-eosin, Pappenheim's or Ehrlich's triacid, and Pappenheim's methylene-green pyronin).

The stains in previous use failed to bring out all the detail, were misleading in so far as they gave false impressions of genetic relationships, and did not permit the various kinds of cell now known, to be distinguished. Our method, on the other hand, brings out clearly all that has hitherto been known of the morphology of blood-cells, while at the same time it combines all the merits of previous stains without any of their drawbacks. Hence it may be regarded as a universal stain. It is true that, by this method, the neutrophil granules do not come out as sharply or distinctly as with the triacid stain, nor are the eosinophil granules so brilliant as with Jenner's stain. On the other hand, our stain reveals an entirely new azurophil substance, hitherto unknown. The nuclei are as well defined as if stained by the hæmatoxylin method, and much better than by any of the older aniline dyes. The basophil cytoplasm, which does not stain by the triacid, comes out as beautifully as by Jenner's or by the methyl-green-pyronin method.

we use the alcoholic solution proper merely for the purpose of fixing. The film is first fixed simply by immersion in this solution. The actual staining is not effected till water has been added, i.e., the alcoholic solution is converted into an alcoholic-aqueous one.

Two stain mixtures are necessary, which can be readily purchased and kept in stock. They are (a) May-Grünwald's eosin-methylene blue dissolved in methyl alcohol (acid eosin and basic methylene blue), and (b) Giemsa's glycerin-alcoholic solution of the Romanowsky stain (containing eosin, methylene blue, and methylenazur), known in the trade as Giemsa's "new formula."

The film is stained first with the May-Grünwald stain and then with the Giemsa. As the Giemsa solution is sold in a concentrated form, it must be freshly diluted each time before use by the addition of water. When about to use the stain, 15 drops of Giemsa's "new formula" are added to 10 c.c. of distilled water. The stain is measured by means of a pipette graduated in cubic centimetres, while the water is measured in a small measure-glass and then poured into a test tube.

The actual staining is carried out as follows :—

Fix the dry film by immersing it in an alcoholic solution of May-Grünwald's stain* for 3 minutes.

*The cover-glasses are held in Cornet's forceps and covered with the solution. Slides are laid horizontally in a flat dish and are flooded with the solution.

Stain in the same solution after the addition of an equal quantity of water for 1 minute.

Pour off the excess and, without washing, stain with the freshly prepared Giemsa solution* for 15 minutes.

Thoroughly wash.

Dry ; but not over the flame, otherwise the azur stain is destroyed.

Mount in neutral Canada balsam or Dammar varnish.

This combines the merits of Giemsa's modification of Romanowsky with the beauty of the May-Grünwald stain, without any of the disadvantages of the latter, such as bad definition of nuclear detail, and absence of azurophilia.

Nuclear structures and remains of nuclei are stained reddish-violet.

The protoplasm of the lymphoid cells takes on a beautiful light-blue colour.

The azur substance of the lymphocytes and the chromatin of the malarial parasite are a bright purplish-red.

The azur substance of the myeloid cells, as well as the granular centre of the blood platelets, tend to be violet-brown.

Neutral granules are ill-defined and washed-out looking, varying in colour from brown to brownish-red.

Eosinophil granules are deep brick-red or brown.

* Cover-glasses are laid out on a flat dish and the solution is poured over them. The slides remain in the same place as above mentioned.

Mast granules show ultramarine with a shade of violet.

Red blood corpuscles appear a beautiful coppery-red.

Polychromatic forms are tinted lilac with a preponderance of blue.

The punctate basophilia of the erythrocytes appears a deep cobalt-blue.

By this method of staining, azurophil material appears purple-red in colour, chromatin reddish-violet, and basic protoplasm blue.

THE MICROSCOPIC EXAMINATION OF THE STAINED BLOOD-FILM.

I. NORMAL BLOOD.

The following morphological elements are met with in normal blood :—(1) *Red blood corpuscles or erythrocytes* ; (2) *Blood platelets* ; (3) *Colourless corpuscles or leucocytes*.

1. **The Red Blood Corpuscles** are round, homogeneous discs of uniform size and devoid of structure. They stain diffusely a dull orange-red with the acid element of the dye (eosin).

2. **The Blood Platelets** occur singly or in clumps, and are the smallest fragments of protoplasm which give the same staining reaction as the cytoplasm of the lymphoid leucocytes. Thus they stain a faint light-blue with the basic part of the dye, and at the same time they exhibit an azur-red substance in their interior.

3. **Leucocytes.**—The following types of leucocyte may be distinguished.

(a). **MONONUCLEAR LYMPHOID CELLS**, devoid of true granules—"agranulocytes,"—with basic (blue) protoplasm. Not infrequently this latter exhibits a coarse or fine purplish-red (lymphatic) azur-substance in varying amount. These mononuclears are further subdivided into two classes, viz. :—(i) Small lymphocytes ; (ii) Large monocytes.

(i). *Small Lymphocytes.*—These are small cells provided with a small nucleus round which, as a rule, there is a narrow or medium-sized rim of cytoplasm. This latter is rarely abundant. The nucleus is more or less round in shape, but may be flattened or notched at one side. It stains deeply, and frequently contains a nucleolus. With its coarse-grained and deeply tinted nuclear network it generally fills the larger part of the cytoplasm.

(ii). *The Large Monocytes.*—These are large cells*

* Normally in the blood of children these cells are also found consisting of a narrow rim of cytoplasm surrounding a round nucleus which contains a nucleolus. These are early immature forms, and are called large lymphocytes or macrolymphocytes. In the intermediate stages of their development, the large lymphocytes may possess nuclei which contain no nucleolus and whose cytoplasm is abundant, while the monocytes possess nucleoli and have only a narrow rim of cytoplasm. These cells, which represent intermediate stages in the course of their ontogenetic development, must sometimes be regarded therefore as large lymphocytes, and sometimes as monocytes, according to their predominant characteristics.

with a big nucleus, which is indented or may show an irregular contour. The nuclear network looks as if it were washed out in places, and appears relatively pale in colour. As a rule, a nucleolus is not present. The nucleus is surrounded by a more or less abundant rim of protoplasm, which is generally faintly basophil.

(b). POLYNUCLEAR LEUCOCYTES WITH TRUE GRANULES whose cytoplasm is more or less markedly oxyphil (red). These possess a complicated, segmented or polymerized nuclear outline. They are subdivided as follows :—

(i). *Neutrophil ε-Leucocytes*.—These contain fine granules which are densely packed together in a cell-body which has a definite oxyphil reaction. The granules take on a violet or reddish tint.

(ii). *Eosinophil α-Leucocytes*.—They possess large and uniformly round granules, deeply oxyphil (brownish-red) embedded in cytoplasm feebly oxyphil in reaction.

(iii). *Mast Cells*.—These are characterized by the presence of coarse, irregular basophil (bluish-violet) granules in a small and almost colourless cell-body.

The relative percentage of the different kinds of leucocyte in an adult is normally as follows :—

Lymphocytes	..	20-22%	} 22-28%
Monocytes	..	2- 6%	
Neutrophils	..	70-75%	} 72-80%
Eosinophils	..	2- 4%	
Mast Cells	..	0- 1%	

In the child, the non-granular lymphocytes are increased at the expense of the polynuclear leucocytes.

II. PATHOLOGICAL BLOOD.

THE RED BLOOD CORPUSCLES.

Morphological changes are met with exclusively in conditions of anæmia (invasion of the blood by the parasite of malaria always excepted), and consequently may be looked upon as evidence of the presence of an anæmic syndrome. The majority of anæmias—those of most importance clinically—depend on a hæmolytic intoxication caused by venom or by a living virus. Later, this is coupled with a regenerative reaction on the part of the erythroblastic apparatus of the bone-marrow. Accordingly the morphological changes occurring in erythrocytes fall into two groups, viz.: (1) *Degenerative* (hæmolytic); (2) *Regenerative* (characterized by the presence of young cells). The latest arrivals, viz., the young cell forms, may, on reaching the blood, at once undergo the same toxic degeneration. Hence, not only may degenerated cells and young forms be found side by side in one and the same blood, but not infrequently evidence of both may exist together within one and the same cell (degeneration of the immature forms).*

* To these combined types belong, for example, poikilocytes showing polychromasia or punctate basophilia, poikilocytes with nuclear remains, etc.

Degenerate forms alone are met with, not only in the so-called aplastic anæmias where active regeneration is taking place, but also in anæmias regarded clinically as pseudo-aplastic.

Regeneration forms are absent entirely from these cases.

I. DEGENERATION FORMS.

Size and Shape.—Red blood corpuscles of normal shape show variations in size—*anisocytosis*. Thus, alongside abnormally large cells—*Macrocytes*—may be found unusually small ones—*Microcytes*. The intermediate forms, of normal size, are called *Normocytes*.

The various sizes of red blood corpuscle may exhibit irregularity of shape, called *poikilocytosis* and *schistocytosis* (e.g., they may be club-shaped, pear-shaped, or may appear simply in the form of débris, etc.).

The Hæmoglobin Content.—The individual erythrocytes may be abnormally deficient in Hb, hence the term: *hypochromasia* of the cells. They stain at best a very pale rose tint. There is generally partial or total absence of Hb from the centre of the erythrocyte, the concavity of which is increased. The remains of the Hb are confined to a narrow strip at the periphery of the cell. According to circumstances this remnant may show a normal, but more likely a diminished, intensity of staining—*chlorotic anochromasia*.*

* It is still a matter of doubt whether chlorosis of the erythrocytes is due to a primary hypoplasia of the Hb, or is the result of a secondary degeneration.

In the so-called chloro-anæmia, degenerate forms may also be present.

On the other hand, the pallor may be diffused throughout the erythrocyte—anæmic hypochromasia, seen, for example, in the simple forms of secondary anæmia.

Again, the erythrocytes may show an abnormally high *hæmoglobin-content*—*hyperchromasia* of the cells, observed, for instance, in pernicious anæmia. Degeneration and malformation of individual erythrocytes are directly due to the damage sustained by these cells, thus leading to anæmia and oligocythæmia.

Poikilocytosis, when present, is always associated with anisocytosis, though the latter may exist without an attendant poikilocytosis. Hypochromasia and hyperchromasia of the cells may be met with here and there in what are otherwise well-formed normocytes in cases of anæmia and anisocytosis. Generally, however, alteration in colour is associated with degeneration and malformation of the cells. Further, in general isocytosis and in failing anæmia, even these microscopic colour changes may be absent. On the other hand, the presence of anisocytosis and poikilocytosis is always associated with a certain degree of hypo- or hyperchromasia. Hence anisocytes and poikilocytes may be either hypochromatic, as in the secondary and symptomatic anæmias, or hyperchromatic, as in the so-called pernicious type of secondary anæmia.

Degeneration and abnormality of form are always associated with hypo- or hyperchromasia, either of which is an invariable sign of the presence of abnormal cell forms. On the other hand, partial anochromasia is seen in cells of normal shape (e.g., in simple chlorosis), as well as in cells of abnormal shape (e.g., in chloro-anæmia). In other words, chlorosis of the individual cells is seen on microscopic examination only in erythrocytes of normal size and shape. In rare cases, however, macrocytes, microcytes, and poikilocytes may also be present (e.g., in chloro-anæmia).

2. EARLY FORMS AND THE SIGNS OF IMMATURITY.

(a). The erythrocytes still possess a reddish-violet nucleus or the (violet) reddish vestiges of one.

Nucleated erythrocytes are called *Erythroblasts*. These possess a round nucleus showing a kind of radial structure, the "Radkern" or radial nucleus. They are of two kinds, viz., Megaloblasts and Normoblasts.

Nucleated normocytes are called *Normoblasts* and, in the earlier stages of their development, possess a darkly-staining round nucleus with a coarse reticulum arranged more or less radially (the "Radkern").*

* As the nucleus grows older, it becomes pycnotic, owing to shrinkage, thickening of its chromatin, and disappearance of its parachromatin.

Larger or smaller nucleated erythrocytes with similar nuclear characteristics must be classed as normoblasts.

Nucleated macrocytes are termed *Megaloblasts*, and possess a feebly-staining nucleus containing a delicate narrow meshwork arranged in radial fashion.

Smaller forms with a similar nucleus are also met with. Megaloblasts are usually oligochromatic (and slightly polychromatic), while normoblasts are mostly orthochromatic.

Normoblasts are found in all varieties of anæmia but not in simple chlorosis. Megaloblasts are only seen in the more severe toxic forms, where the regenerative powers of the bone-marrow are taxed to their utmost. This occurs, not only in the hyperchromatic pernicious anæmias, but also in the simple secondary forms.

Nuclear vestiges consist of small, round basophil bodies. They are generally single, owing to their having originated by chromatolysis from pycnotic nuclei. Less frequently there are several, in which case they have arisen through karyorrhexis of the early radial nucleus. As a rule, they are devoid of structure, and generally give the violet-red reaction of chromatin.

The former—the so-called “Jolly bodies”—are found in all forms of anæmia, the latter only in the severe toxic varieties (myelopathic). They are the intermediate stage, preceding complete disappear

ance of the nucleus, and denote the transition from erythroblast to erythrocyte.*

(b). The cytoplasm of the red blood corpuscles is partially basophil (blue)—owing to the presence of remains of the basophil spongioplasm of the original progenitor of the erythroblast. This parent form was a lymphoid cell entirely devoid of hæmoglobin. These basophil vestiges indicate a stage immediately preceding the complete disappearance of the basophil cytoplasm in the course of development from the original lymphoid parent cells with their basic protoplasm (hæmoblasts, proerythroblasts, or erythrogonia) to the fully formed product, viz., the orthochromatic erythroblasts and erythrocytes con-

* Intermediate between the cell with multiple nuclear remains (resulting from karyorrhexis) and the erythroblast with its intact nucleus, comes the cell with a young nucleus. The latter shows bud-like projections from its wall, which give it a rosette-like appearance.

In the same way, pycnosis is a condition intermediate between the fully-formed nucleus and the so-called "Jolly" body. A cell with nuclear remains must therefore be regarded as intermediate between the cell whose nucleus is intact and that from which the nucleus has completely disappeared.

The so-called "Jolly" body must therefore be looked upon as an intermediate stage occurring in the normal process, which ends in complete disappearance of the nucleus. This is accomplished by a peripheral melting away, and by chromatolysis of the adult pycnotic nucleus. Multiple nuclear remains, on the other hand, are the product of the pathological disappearance of the nucleus. This metamorphosis is effected by a process of karyorrhexis.

taining nothing but hæmoglobin and devoid of all basic protoplasm.

The protoplasm of red blood corpuscles may show a more or less well-marked diffuse, basophilic stain (polychromasia). This is seen in nucleated and in non-nucleated, in normal and abnormal red blood corpuscles. Even punctate basophilia may be present. It is generally found where there is more or less deficiency in the hæmoglobin content of the red blood corpuscles attacked, since the space reserved for hæmoglobin is taken up by basic protoplasm.* Polychromasia is one of the simplest signs of anæmia. It appears after the slightest stimulus sufficient to cause regeneration has been applied to the erythroblastic apparatus of the bone-marrow. To a certain extent it is still within physiological limits. It may occur quite independently as the one and only symptom present, and then only in a few cells and not very well marked. In such a case, where no other symptoms of anæmia are present, it merely signifies an increased output of red blood corpuscles after destruction has occurred as a result of hæmorrhage (e.g., in menstruation). As such, this may be observed especially in the blood of young persons. Of course, in the severest forms of anæmia it is present in a marked degree along with other signs.

* In regeneration, poverty in Hb is indicated by polychromasia.

In degeneration of the orthochromatic erythrocytes, poverty in Hb is indicated by hypochromasia.

The cytoplasm of the red blood corpuscles may show coarse or delicate punctate basophilia (bluish stain).* This consists of a number of circumscribed granules, round, oval, or rod-shaped, scattered throughout the cell. It may be present both in erythrocytes and in erythroblasts—megaloblasts as well as in normoblasts. It may be observed where the nucleus is intact, or where there is only a single vestige of nucleus left; also in the rare cases where there are more than one vestige, and lastly in polychromatic forms.

In other words, punctate basophilia appears not only in orthochromatic red blood corpuscles, but may be combined with polychromasia. Along with other signs it is met with in the different types of toxic anæmia, and also in chloro-anæmia.† In every case it is evidence of pathological regeneration. It is one, and practically almost the only, sign present in cases of chronic lead poisoning, proof that the bone-marrow is being stimulated to activity, and is then a sign of definite pathognomonic value.

(c). Signs of immaturity of nucleus and cytoplasm may likewise exist together in one and the same cell. For example, red blood corpuscles with a nucleus, or

* This must be distinguished from multiple nuclear remains, which are reddish in colour.

† By the term chloro-anæmia we understand a combination of the signs of anæmia with simple chlorosis of the red blood-cells.

Chloroleukæmia, on the other hand, means a leukæmic chloromatosis.

with the remains of one, may also contain traces of a diffuse or punctate basic protoplasm (i.e., polychromatic cells or erythroblasts with punctate basophilia, polychromatic "Jolly bodies," etc.).

The appearance in the blood of immature erythrocytes indicates an effort at regeneration on the part of the bone marrow. This is met with as a result of a pre-existing anæmia. The signs of pathological regeneration occurring in the course of toxogenetic anæmias are as follows: megaloblasts, erythroblasts with bud-like processes projecting from the nuclear wall, erythrocytes with multiple nuclear remains, and erythrocytes with punctate basophilia. In simple anæmias the signs of normal regeneration alone are met with, while in the toxic anæmias there is evidence both of normal and of pathological regeneration. This latter means that abnormal or pathological forms occur in the blood during the process of regeneration. It is a regenerative impulse in a pathological direction. It is found where the process of regeneration is modified by these very toxic influences which, in the first instance, have provoked regeneration. Care must be taken to distinguish it from conditions where degeneration of form or of hæmoglobin is combined with signs of immaturity of regeneration. These latter belong to quite another category, and point to incomplete regeneration, whether occurring in normal or pathological blood (e.g., poikilocytes with Jolly's nuclear remains).

We have now seen that the following combinations may be encountered :—

- (i). Degeneration and regeneration.
- (ii). Degeneration of shape and of hæmoglobin.
- (iii). Immaturity, as evidenced by the presence of nucleus or of nuclear remains ; and by the existence of diffuse or multiple vestiges of basic cytoplasm.

In each case where complications are met with, it is necessary to institute a careful cytological analysis. For example, in a hypochromatic poikilocyte showing punctate basophilia and multiple nuclear remains, we are dealing with a cell where degeneration of the hæmoglobin is combined with degeneration of a pathological or abnormal shape. In other words, we are dealing with pathological signs of immaturity both of nucleus and of cytoplasm.

THE BLOOD PLATELETS.

These bodies are increased both in number and size, especially in cases of chlorosis, where they exist along with other signs.

On the other hand, they are very scarce, or may be absent altogether, in pernicious anæmia.

PATHOLOGICAL VARIETIES OF LEUCOCYTES.

IMMATURE FORMS.

Very occasionally immature forms may appear in the course of an ordinary leucocytosis (more rarely in a lymphocytosis). They are always present,

however, in myelocythæmia, and in lymphocythæmia.

The parent cells of the small lymphocytes and the forerunners of the monocytes are called *Lymphoblastic Macrolymphocytes* or *Large Lymphocytes*. Except in children, their presence in the blood denotes acute or chronic lymphatic leucocythæmia. They look like overgrown lymphocytes, which present exactly the same characters as the small variety. This applies especially to the presence of the azur substance and to the character of the nucleus. The only point of difference is their size : they are larger in all respects.

From the adult form—the large monocyte—they can be distinguished by a more complete rotundity of nucleus, and generally by the presence of one or two indistinct nucleoli.

In like manner the fully-formed polymorphonuclear leucocytes are preceded in the course of development by various immature cells. And here we must remember to distinguish the early ontogenetic forms of the cells present in normal blood from their phylogenetic precursors. Both immature varieties, viz., their immediate ontogenetic and their phylogenetic precursors, are always present in the blood in cases of myelogenous leukæmia. In simple leucocytosis, on the other hand, more particularly in the severer forms, only the ontogenetic precursors are present.

(a). The ontogenetic antecedents of the various

kinds of granular polymorphs are the respective myelocytes.

A *myelocyte* is a granular cell with oxyphil cytoplasm similar to that seen in the polymorphonuclear leucocyte. It is the exact counterpart of the latter, except that it has a single nucleus which is more or less rounded or simply indented. In structure, the nucleus shows a coarse reticulum of well-differentiated chromatin and parachromatin.

Metamyelocyte is the name given to that type of cell which is intermediate in development between the above-named myelocyte and the polymorphonuclear leucocyte of normal blood. In this granular cell the nucleus is distinctly indented, and not infrequently appears somewhat slender like that of the polymorph, but it has not yet attained to the full measure of its complexity. The nucleus is only twisted into a sort of bow and ribbon shape, but the lobes have no connecting threads, and are not yet split up into polymeric segments.

Developmentally speaking, the metamyelocyte is the immediate morphological precursor of the polymorphonuclear leucocyte, and as such may enter the circulation in the milder cases of leucocytic stimulation.

The polymorphonuclear leucocyte is therefore only a grown-up myelocyte which has matured, grown older, and become capable of functioning.

(b). The phylogenetic antecedents of the granular leucocytes are the natural precursors of the myelo-

cytes, i.e., they are to a certain extent immature myelocytes.

The lymphoid myelocyte or *Leucoblast* proper is a feebly basophil lymphoid cell with the nucleus of a myelocyte but devoid of neutrophil or of eosinophil granules. They possess, however, an azurophil substance such as we have seen is found both in the normal and pathological varieties of lymphoid cells. They are non-granular myelocytes with basic protoplasm.

This leucoblast with its large and indented nucleus is a sort of pathological monocyte, and can seldom be distinguished from the macrolymphocyte or from the monocyte of normal blood. The distinguishing features are more especially the absence of nucleoli from the nucleus of the myelocyte (see above under "a"), and, when present, azur substance much richer, and frequently coarser and darker, than that seen in the macrolymphocyte.

Since the monocyte is also undoubtedly devoid of any nucleolus, the leucoblast can only be distinguished from it by the peculiar myelocyte-like structure of its nucleus, and by the presence of coarse (myeloid) azur-material. Further, the cytoplasm often shows a slight tendency to be feebly oxyphil (i.e., the protoplasm has a slight lilac tint). Intermediate between the leucoblast (or non-granular myelocyte) and the granular myelocyte with its oxyphil protoplasm, stands the *promyelocyte* (neutrophil or eosinophil). This, to a certain extent, is a

myelocyte, with this difference, that its cytoplasm is still basophil. In a way it may be regarded as a granular leucoblast. The most typical example of this variety of cell is seen in the eosinophil series, for instance, in cases of myelocythæmia, where it is seen to perfection. Forms corresponding to the mast cells do not exist.

In the neutrophil promyelocyte the immature "ε-" granules are difficult to distinguish clearly. In the neutrophil series the promyelocyte may be represented as a leucoblast with amphochromatophil cytoplasm, i.e., still partly basophil, but becoming oxyphil. (See above, under "Polychromasia of Erythrocytes," p. 15).

It may be distinguished from the polychromatic erythroblast by the fact that the latter possesses the radial nucleus and the bluish-red protoplasm characteristic of the erythroblast. The neutrophil promyelocyte, on the other hand, possesses a myelocyte nucleus and cytoplasm in which the basic element can be more clearly made out than the oxyphil.

(c). Finally, the most aboriginal type of myeloid cell met with in the course of development is found in cases of myeloid leukæmia. This is a basophil, non-granular, lymphoid cell which we look upon as the common, undifferentiated parent of lymphocytes and leucocytes alike. This has been called the *Large Lymphocyte* or, better, the

Lymphoidocyte.—This type of cell is often markedly

basophil and beset with a (myeloid) azur substance. The structure of its nucleus is *sui generis*, in that it is characterized by an exceedingly fine reticulum (leptochromatic), and frequently contains several (as many as four) sharply defined nucleoli with basic protoplasm.

This peculiarity of structure enables the cell to be distinguished from the large lymphocyte as well as from the leucoblast and the monocyte. Further, in macrolymphocytes, monocytes, and leucoblasts, the nucleus always stains deeply in comparison with the more or less feebly basophilic cytoplasm with its well-defined spongioplasm.

In the case of the lymphoidocyte the nucleus as a rule is relatively pale compared with the surrounding zone of more or less strongly basophilic cytoplasm. This zone is usually narrow, or of medium breadth, but in rare cases it may be very broad. The latter is more rarely met with, and only occurs in the older forms.*

Of course, between the lymphoidocyte and the

* The metamyelocyte is the next stage in the further ontogenetic evolution of the myelocyte, and the immediate forerunner of the polymorphonuclear leucocyte.

The promyelocyte is the cell coming immediately before the myelocyte in the course of phylogenetic development from the leucoblast.

The promyelocyte, therefore, occupies a position intermediate between the leucoblast and the myelocyte, the metamyelocyte between the myelocyte and the polymorphonuclear leucocyte.

fully developed leucoblast there are cells which show all stages of genetic transition. While it gradually passes through the various intermediate phases to become the feebly basophilic leucoblast, the nucleus and cell-body bear a certain superficial resemblance to that of the small and large lymphocyte. This consists in a marked tendency towards rotundity on the part of the nucleus, together, frequently, with the presence of a fairly large number of nucleoli. It is these cells which are present in the acute myeloid leukæmias, often to the exclusion of nearly all other kinds, hence called parent-cell leukæmias or the myeloblastic leukæmias of the Dualists.

Just as the macrolymphocyte is the mother of the small lymphocyte, so the large lymphoidocytes give rise to a daughter strain. These are small pathological lymphocytes formed in the bone-marrow (myelolymphocytes) remarkably similar indeed to the normal lymphatic lymphocytes.

This kind of cell may be regarded as the type of Sternberg's so-called leucosarcoma cells found in certain varieties of leukæmia. These latter, however, as later investigation has proved, are not always sarcomatous in nature. Microlymphoidocytes, however, possess the leptochromatic nucleus peculiar to the lymphoidocyte. While the lymphocytes stain deeply, and are pachychromatic, the nucleus of the leucoblast, and more especially that of the micro-leucoblast, shows, like that of the lymphocytes, an incipient alteration which is to end in a differentiation

of the nuclear structure into chromatin and parachromatin.

Rieder's type of cell includes large and small lymphoidocytes as well as microlymphoidocytes with an atypical polymorph-like nucleus (pathological age forms). They are found especially in acute, and occasionally in sarcoma-like, myelocythæmia. In the latter case they represent a special type of leucosarcomatous cell. They indicate a very acute disturbance of the process of cell proliferation, which here consists in mere cell increase without any differentiation whatever. The nucleus alone becomes fully formed, while the cell remains immature. Indeed, it oversteps the normal limits of polymorphism characteristic of the normal cell.

In consequence, therefore, of a constitutional disturbance of cell development, and owing to a want of balance between the natural stimulus to development and that producing this type of cell, the nucleus reaches a state of ontogenetic maturity too quickly for the cytoplasm to keep pace with it. Hence there is no corresponding phylogenetic maturation, and they fail to become differentiated into functioning cells.

DEGENERATION FORMS.

By this designation we mean more especially the so-called irritation cells or plasma cells.

Apart altogether from degenerate types proper (such as the Klein-Gumprecht shadow nuclei seen in

macrolymphocytes and lymphoidocytes in all acute leukæmias), they include the products resulting from the metamorphosis which the various large and small lymphoid cells undergo in normal and pathological blood (especially the small and large lymphocytes, leucoblasts, lymphoidocytes, and monocytes). They are characterized by very pronounced basophilia of the cell body, which is always devoid of azurophil material. The protoplasm frequently contains very minute vacuoles, presumably fat-containing. According to the derivation of the cell in question, the nucleus may be of the lymphocyte, the leucoblast, or the lymphoidocyte variety.

A leucocytosis composed of specific plasma cells is never met with. Indeed, such cells are not generally seen till after the parent cells have made their appearance in the blood. The laws governing their appearance, however, are not yet fully understood. Such cells may be found in various inflammatory conditions, including granulomatous affections of the hæmopoietic apparatus.

Since they make their appearance in the course of a leukæmic leucocytosis (more especially in one of the lymphoidocyte variety), where they may be present in large numbers, it would seem to suggest an inflammatory cause for the leukæmias in question.

Symptomatology.
**SEMIOLOGY AND DIFFERENTIAL
 DIAGNOSIS OF THE MOST IMPORTANT
 BLOOD CHANGES* AS SEEN IN
 STAINED FILMS.**

**1.—THE MICROSCOPIC CHANGES OBSERVED IN
 THE RED BLOOD CELLS.**

If we exclude invasion of the corpuscles by the malarial parasite, such changes occur solely in the secondary anæmias, the result of an affection of the erythroblastic apparatus.

Apart from a diminution in numbers (*oligocythæmia*), and a reduction in the absolute amount of hæmoglobin (*oligochromæmia*), there is an alteration in the morphology of the individual cell. Various departures from the normal both in size and shape are invariably met with, such for example as anisocytosis and poikilocytosis. Whereas in chlorosis the only change in the erythrocytes is a specific reduction in hæmoglobin, in the anæmias proper (simple secondary, or pernicious secondary) there are, in addition, the above-named morphological changes. Moreover, in these anæmias we frequently, though by no means invariably, meet with, in addition to the morphological changes, various immature forms. These indicate an attempt at regeneration on the part of the erythroblastic apparatus.

* Changes in the cell count, and in the absolute Hb content (which must be determined by methods other than histological), take the form of diminution in the anæmias, but of increase in polycythæmia.

R.B.C. increase or Excess

The signs of immaturity are retention of the nucleus (erythroblastosis), polychromatophilia, and punctate basophilia of the normocytes, the degenerate macrocytes, the poikilocytes, and the erythroblasts.

The presence in the blood of the early forms already mentioned, indicates increased functional activity on the part of the bone-marrow. Their absence, on the other hand, does not mean the reverse. In other words, the absence of these early forms does not constitute an aplastic anæmia, although obviously the so-called aplastic forms of simple and pernicious anæmias may be further subdivided into simple secondary (hypochromatic) and pernicious secondary (hyperchromatic); also into primary hæmopathic (which is equivalent to secondary myelopathic), and into primary myelopathic forms. In the simple anæmias, the individual erythrocytes, anisocytes, and ultimately the poikilocytes, show hypochromasia of the cells.

In morbid and in irritative conditions of the bone-marrow consequent on a primary blood lesion, early forms make their appearance in the circulation. These include all kinds of erythroblasts (normo- and megaloblasts). The latter, however, are found only in the anæmias of toxic origin, e.g., in the secondary toxic anæmias.

Pernicious anæmia presents a characteristic blood-picture, consisting of hyperchromasia of the normal and abnormal types of erythrocyte. In the same film may be seen all phases of incomplete cell develop-

ment, especially normoblasts and megaloblasts. The appearance of the latter in the blood negatives a simple post-hæmorrhagic anæmia, but does not contraindicate a simple anæmia of toxic origin. It indicates rather the existence of a morbid or toxic condition of the bone-marrow, but is no evidence of the presence of pernicious anæmia (hyperchromatic). Conversely, their absence from the blood does not imply that it is not a case of pernicious anæmia. Thus in reactionary pernicious anæmia which is not of the aplastic type, erythroblasts in general and megaloblasts in particular may be absent exactly as in the so-called aplastic anæmia. Poikilocytes are found in simple as well as in pernicious anæmia, though only in the more severe forms of the former. Thus, so far as the red blood corpuscles are concerned, *the* sign of pernicious anæmia is hyperchromasia of the degenerated anisocytes. The blood-film in pernicious anæmia can only be distinguished from that of simple anæmia by the presence of hyperchromasia.

In chlorosis, the individual red blood corpuscles are of normal size, with a central circumscribed area from which the hæmoglobin has more or less disappeared (anochromasia). Frequently there are also present in chlorosis signs of degeneration (anisocytosis, poikilocytosis) or of regeneration (polychromasia, punctate basophilia) (chloro-anæmia).

In lead poisoning, not uncommonly the only sign of blood disturbance is a regenerative one, viz., punctate basophilia together with polychromasia.

Presumably this indicates not so much the presence of a reactionary regeneration, seeing that other evidence of degeneration is absent, as the result of a primary stimulus applied to the bone-marrow similar to what is observed in the blood during the exhibition of arsenic or mercury.

Polychromasia, the simplest and best known form indicative of immaturity, may be met with in various types of anæmic regeneration. When present alone, without any other blood change, it is the first indication of regeneration occurring after the simplest hæmorrhage, such as menorrhœa. It points to a merely functional irritation of the erythroblastic apparatus, without necessarily implying the existence of a pronounced anæmia.

SUMMARY.

Chlorosis is characterized by a specific anochromasia affecting the centre of the erythrocyte, frequently also by an increase in size and in number of the blood platelets, and by a leucocytosis.

referred HB
Simple Secondary Anæmia is characterized by the presence of ^{microcytosis} anisocytosis, accompanied by hypochromasia. In the more severe forms there is also a hypochromatic poikilocytosis. More or less polychromasia is always present. In the reactionary cases, punctate basophilia and normoblasts may also be encountered; while in the toxic forms (not the post-hæmorrhagic, but those associated with toxic hæmorrhages), megaloblasts may be found, indicating

pathological repair. That is to say, there is present a morbid condition of the bone-marrow toxic in origin.

The absence of erythroblasts from the blood does not indicate definitely a condition of aplasia of the bone-marrow.

As a rule, the blood-platelets are increased in number and in size, and not infrequently there is an absolute neutrophil leucocytosis.

Chloro-anæmia is a combination of chlorosis with simple anæmia.

Pernicious Anæmia.*—Here the red blood corpuscles show hyperchromasia and anisocytosis, and in more severe cases poikilocytosis and schistocytosis as well. In the reactionary cases, all kinds of early cell forms, especially megaloblasts, may be seen. Their absence from the blood does not contraindicate pernicious anæmia, nor does it point definitely to the aplastic form.

There is also, especially in the obscure disease described by Biermer—"Biermer's disease,"—an absence of blood platelets, and a relative lymphocytosis with a normal leucocyte count.

2.—CHANGES IN THE LEUCOCYTES.

These include variation in number both relative and absolute, and in quality (e.g., atypical cells in the

* E.g., in *Bothriocephalus* anæmia, von Jaksch's anæmia of children, and in acute leukanæmia. Pernicious anæmia in the more limited sense is only the cryptogenetic Biermer's disease.

shape of early forms), and indicate a lesion of the lymphatic as well as of the medullary leucoblastic apparatus. They result from some irritative interference with function, of a toxic character, leading to metaplasia or hyperplasia. The blood conditions which fall to be considered here are as follows :—

Secondary leucocytosis and lymphocytosis, indicative of irritation of the hæmopoietic apparatus. Such may be of a secondary or reactionary character, due to irritation, of a chemiotactic nature, or it may be due to a primary irritation (i.e., is a direct toxic metaplasia) of the leucoblastic tissue. The former is an active, the latter a passive, leucocytosis.

Lymphatic and myelogenous leukæmias, which indicate a primary idiopathic hyperplasia of the lympho- and leuco-poietic apparatus respectively.

The leukæmias due to hyperplasia, and the leucocytoses resulting from a toxic metaplasia, are of a passive nature, i.e., are repulsion-leucocytoses. Functional leucocytosis and lymphocytosis due to chemiotaxis are of an active or reactionary character. Generally, however, active functional leucocytosis is associated with some cause leading to metaplasia.* An increase in number is the commonest

* Acute leukæmias due to an infection ought perhaps rather to be classed among the metaplastic leucocytoses than among the actual hyperplastic leukæmias. At the same time, transition forms might exist between toxic metaplasia on the one hand and metahyperplasia on the other, that is to say, hyperplasia combined with toxic metaplasia, whence the name hypermetaplasia.

sign of the presence of a simple leucocytosis or of a leukæmia.

But irritative conditions due to interference with function, as well as leukæmic changes in the blood-forming apparatus, may exist without any increase in the leucocyte count (e.g., the leucopenic type of leucocytosis, the aleukæmic or subleukæmic form of leukæmia).

Hence it follows that the crucial sign of the presence of one or other of these conditions must be sought for in the *qualitative* nature of the cell present.

In both affections, early types of cell have been found in the blood. The occasional appearance of early forms is thus the essential criterion of a simple or of a leukæmic leucocytosis. There is this difference, however, in the simple leucocytoses: early forms *may* appear in the blood, whereas in leukæmias they are always and of necessity present. Hence it comes about that in leucocytoses, when early forms are present at all, they are generally more or less scarce, and are then only the immediate ontogenetic precursors of the mature polymorphonuclear leucocyte. In the lymphocytoses, the early forms are usually lymphocytes with a large amount of cytoplasm. In the former, i.e., the leucocytoses, metamyelocytes and sometimes myelocytes may be present. In the latter, lymphocytes may appear which are practically all nucleus, with very scanty surrounding cytoplasm.

In the leukæmias, large numbers of early forms appear in the blood from the first. Not only are the

immediate ontogenetic precursors invariably present, but also their phylogenetic prototypes. Hence, in the myelogenous leukæmias, not only are promyelocytes and leucoblasts seen, but also the immature parent cell-forms, the lymphoidocytes, which are present to a greater or less extent. Not infrequently numerous mononucleated mast cells are present, well as erythroblasts (more seldom megakaryocytes).

In the lymphatic leukæmias we find lymphoblastic macrolymphocytes and occasional parent lymphoidocytes. The following are the essential points of difference, therefore, between the simple leucocytoses on the one hand and the typical leukæmias on the other.

The former, in the more restricted sense, are invariably characterized by one type of cell, while typical leukæmias are of the mixed-cell variety. In the former, the mature blood-cells predominate, and along with them their immediate ontogenetic precursors.

In myelogenous leukæmia, on the other hand, we find both the granular and the non-granular forms of their immature phylogenetic precursors. These predominate over the normal mature cells. Most characteristic of all, however, is the presence of undifferentiated parent cells. In simple lymphocytosis, only these early forms, characterized by small body and large nucleus, appear when regeneration is going on. In lymphatic leukæmia, however, the

parent macrolymphocytes always make their appearance in the circulation. The more acute the leukæmia, the more do the immature phylogenetic forms tend to predominate over the early ontogenetic varieties ; in other words, the lymphoid progenitors tend to replace the later granular cell-types.

The semiological difference between leucocytosis and leukæmia in general may be inferred from the following. In the leucocytoses during the period of regeneration, the stimulus which, by chemiotaxis, induces this regeneration, always acts upon the immediate immature precursors of the mature and functionally active cells in the hæmopoietic tissue.

In the leukæmias, on the other hand, the main incidence of the stimulus is from the first borne by the parent cells. As a result of this impulse to hyperplasia, the most immature, undifferentiated cells appear and find their way into the general circulation. Compared with the normal, there is a greater absolute increase in the amount of metaplasia (from the undifferentiated parent form to the mature cell capable of functioning). Relatively, however, to the increase in hyperplasia, there is a diminution in metaplasia. The more acute the condition of myeloid leukæmia, the greater is the hyperplasia of lymphoid cells over the more differentiated transition forms ; in other words, the greater is the excess of non-granular over granular forms (leucocytes). Similarly, in the acute lymphæmias

there is a corresponding increase of macrolymphocytes over small lymphocytes.

There is this further point of difference, never observed in the leucocytoses, namely, that various atypical forms of cell are met with. These indicate imperfect differentiation, owing to a breakdown in the ontogenetic process of cell development. Thus we find in myelogenous leukæmias dwarf polynuclear leucocytes and dwarf mast cells, or giant polymorphs, non-granular oxyphil polymorphs, non-granular basophil polymorphs (i.e., leucoblasts with a polymorph nucleus), and polymorphonuclear lymphoidocytes, or, as they are sometimes called, Rieder's cells. Further mitoses are frequently observed in the leukæmias, but never in the leucocytoses. Occasionally, in the so-called atypical leukæmias, mast cells and even eosinophils may be absent, proving that these latter cells are not an essential feature of myelogenous leukæmia. Atypical leukæmias, therefore, of a neutrophil character may be met with.* In still more acute cases there may be an entire absence of neutrophil cells, so that only the non-granular lymphoid leucoblasts and lymphoidocytes remain. On hæmatological grounds alone such cases can scarcely, if at all, be distinguished from acute lympholeukæmias, especially from the parent-celled variety with its macrolymphocytes and lymphoplastic cells.

* They are distinguished from neutrophil leucocytoses of a metaplastic character, and of toxic origin, by the presence of lymphoidocytes, which in the latter are always absent.

Above all, in addition to amitotic cell division occurring in lymphatic leukæmias, the Rieder type of lymphocyte (polymorph lymphocyte) may be seen. The latter, however, differs somewhat from the Rieder cells met with in myelogenous leukæmia. Lymphatic leukæmia is often accompanied by a myelocytosis, i.e., a leucocytosis of a myeloid type due to irritation. Moreover, in acute atypical myelogenous leukæmias there is frequently present a toxic hyperchromatic anæmia. When present, the appearance of neutrophil promyelocyte forms in myelogenous leukæmia may be regarded as a fairly reliable means of distinguishing between acute lymphatic leukæmia on the one hand, and acute myelogenous leukæmia of the parent-cell type on the other. These cells, phylogenetically immature, are never observed in a lymphatic leukæmia accompanied by an irritation leucocytosis. This is due to the fact that the leucocytosis scarcely ever goes beyond the myelocyte stage. Hence a functional myelocytosis may accompany a hyperplastic lymphocytosis (lymphatic leukæmia), while a hyperplastic leukæmia of the lymphoidocyte type may also accompany an increase in promyelocytes and their entry into the blood.*

* In lymphæmia the myelocytes take their origin from myeloid tissue which has been stimulated merely to produce leucocytes.

The promyelocytes in myelæmia owe their origin to hyperplasia of the leukæmic myeloid tissue.

SUMMARY.

Leucocytes.—Functional leucocytosis induced by chemiotaxis is characterized by an increase in number of the normal polymorphonuclear leucocytes or of the lymphocytes, and later, during the period of regeneration, by the occasional appearance of their immediate ontogenetic precursors. The presence of these latter, even when there is no leucocytosis, or even where there is a diminished leucocyte count (leucopenia) merely indicates the existence of some irritation of the leucocytic function. It is frequently met with in simple toxic and hyperchromatic anæmias.

Irritation or Stimulation Leucocytosis is characterized by the presence of leucoblasts, plasma cells, and myelocytes. It is frequently also associated with anæmia due to a wasting of the bone-marrow (repulsion erythroblastosis).

Leucocytosis of Toxic Origin Characterized by Metaplasia.—This is frequently conjoined with a chemiotactic leucocytosis and toxic anæmia. Leucoblasts, promyelocytes, and myelocytes are present.

Leukæmias.—The most important and, at the same time, most invariable sign is the appearance of the immature precursors of the leucocytes and lymphocytes, more especially of the leucoblasts and macrolymphocytes, and in fact all the intermediate stages right back to the parent (aboriginal) forms. This is the essential distinguishing feature. All other signs may be absent, although as a general rule they

are present in most cases. Such other signs include an increased cell count, the appearance of atypical cells, and, in myelogenous leukæmia, the presence of mixed cells. These latter resemble the cells in the normal bone-marrow* and show all stages of phylogenetic and ontogenetic cell development.

In pure cases of lymphatic leukæmia, on the other hand, the blood picture shows a monotonously uniform collection of lymphocytes. Just as there are atypical myelogenous leukæmias minus mast cells and eosinophils, i.e., leukæmias of a uniformly neutrophil rather than of a mixed-cell type, composed sometimes entirely of purely lymphoid cells (accompanied frequently by an excess of the older stages of normal and pathological lymphoid cells), so on the other hand atypical lymphatic leukæmias may, to a certain extent, co-exist with leucocytosis and myelocytosis.

The character of the blood in myelogenous leukæmia varies considerably in individual cases.

In typical cases of the chronic myelogenous variety, the mixed cells above referred to include all kinds

* Just as in lymphatic leukæmia, so in cases of acute atypical neutrophil leukæmia and in leukæmias characterized by the presence of one type of cell only, e.g., the lymphoidocyte, the blood reflects the actual qualitative changes in the cells composing the bone-marrow, that is to say, in the blood-forming tissue. In typical myelogenous leukæmia, on the other hand, there is only a quantitative change in the cell composition of the bone-marrow as compared with the normal.

of granular cells, together with lymphoid myelogenous cells. In other words, all varieties of granulocyte are present, together with their ontogenetic and phylogenetic antecedents, which are derived in the first instance from lymphoid cells. Generally speaking, however, there is a preponderance of the granular type of cell over the lymphoid variety.

Lymphoidocytes and leucoblasts are seen in all stages of metaplasia, from the lymphoid type to the more differentiated granulocyte.

In typical acute leukæmias, the prevailing type of cell is the lymphoidocyte or parent cell (the so-called myeloblastic leukæmia of the Dualists).

Between the two extreme types of leukæmia above mentioned there are various transitional and intermediate forms, hence called atypical leukæmias.*

Thus, the mixed-cell type of myelogenous leukæmia may assume an acute character. In the same way, too, the small-celled type of lymphatic leukæmia may occasionally assume a neutral character. For instance, in the acute form of myelogenous leukæmia, we find not only an older form of lymphoidocyte and

* What are simply leukæmoid blood changes partly leucocytic in character, are the result of a simple functional or metaplastic stimulus. This latter attracts one kind of cell only in the blood-forming apparatus, that apparatus being normal, or having undergone metamorphosis into another normal type. This is in direct contrast to the atypical leukæmias, where the blood picture is the counterpart of an atypical condition of the blood-forming tissue such as is met with in hyperplasia.

leucoblast present, characterized simply by an indented nucleus, but also polymorphonuclear granulocytes with basophil cytoplasm, or, in other words, polymorphonuclear leucoblasts and promyelocytes. These indicate that the nucleus has already undergone complete ontogenetic development, while the phylogenetic differentiation of the cytoplasm has not kept pace with it. In addition to the above, the Rieder type of lymphoidocyte* may be present as a consequence of interference with the process of cell development. Moreover, there is a relative increase in the number of lymphoidocytes and leucoblasts, so that they far outnumber the granulocytes. In other cases, the polymorphonuclear granulocytes disappear before the mononuclear granulocytes. Mast cells alone, or mast cells plus eosinophils, are absent in other cases. The result is a partially neutral type of leukæmia. Lastly, as mentioned above, leukæmias of the lymphoidocyte variety may occur with or without Rieder types. As a rule, in myelæmia there is an absolute increase of mature polymorphs as compared with the normal. Relatively, however, there is a preponderance of their granular and non-granular mononuclear predecessors. In the acute atypical leukæmias, the polynuclear leucocytes are entirely absent, or at least are very considerably diminished in relation to the normal, while the immature lymphoid cells preponderate over the immature mononuclear granulocytes.

* See page 25.

Hyperplasia, the mere proliferative increase in cells, overshadows the further stages of differential development into cells capable of functioning. Further, just as leucocytosis or lymphocytosis may accompany the simple or pernicious types of secondary anæmia, so the various kinds of leukæmia are often complicated by the presence of simple or pernicious secondary anæmias. To this syndrome is given the name *Leukanæmia*. In direct contrast to this is the so-called von Jaksch form of splenic anæmia seen in children (anæmia splenica infantum pseudoleukæmica). This is not a variety of hyperplastic pseudoleukæmia conjoined with hæmolytic anæmia, but is an anæmia of the hyperchromatic, pernicious, megaloblastic type, associated with myeloid metaplasia of the spleen due to inflammatory changes of a toxic nature. In other words, it is a metaplastic leucocytosis of a leukæmic character originating in the spleen.

CHAPTER II.

HÆMOCYTOTOMETRY :
OR THE ENUMERATION OF THE
BLOOD CORPUSCLES.

THE determination of the blood-count is frequently of the utmost significance in diagnosis. We have to determine :—

1. *The absolute number—*

(a). <i>Of red blood corpuscles</i>	}	<i>in 1 c.mm. of blood.</i>
(b). <i>Of white „ „</i>		
2. *The ratio of red to white cells.*
3. *The percentage relation of the various types of leucocyte to each other both in normal and in pathological conditions.*

METHOD AND TECHNIQUE.

TO DETERMINE THE ABSOLUTE NUMBER OF CELLS.

For this purpose two Thoma-Zeiss pipettes are required, one for the red blood corpuscles and another for the leucocytes. A Bürker's counting-chamber, preferably provided with Türck's ruling, is also necessary, as well as two separate diluting fluids, one for the red cells and the other for the whites. For this purpose I myself use and recommend normal physiological salt solution, to which a few drops of

methyl violet or neutral red have been added in order to render the leucocytes conspicuous, so that they may not be counted among the red cells by mistake.

For the white blood-cells I use a .5 per cent solution of acetic acid, tinted with a few drops of methyl green or vesuvin. The acid destroys the red blood corpuscles but conserves the white cells, whose nuclei are rendered conspicuous by the stain employed.

Both mixing pipettes are capillary in their action, and so graduated as to permit of making various dilutions. The graduated capillary tube opens out at the top into a bulb or chamber, in which the blood is mixed with the diluting fluid.

In actual practice the drop of blood is sucked up to a certain mark on the graduated capillary tube. Any blood clinging to the point of the pipette is then wiped away, and the diluting fluid is next drawn up into the chamber till it rises to a certain mark figured above the bulb.

In order to distinguish at a glance the two pipettes, it may serve to remember that the pipette for the white corpuscles bears the figure 11 above the bulb, while that for the reds is marked with the number 101. Otherwise the two pipettes bear a superficial resemblance to one another. Both are graduated capillary tubes on which the figures .5 and 1 are marked. The pipette for the white cells, however, is of wider bore than that for the red. It requires a larger drop of blood, and allows only of a dilution of 1 in 10 if drawn up to the mark

1, or of 1 in 20 if drawn up to the mark .5. In consequence of the much greater number of red blood corpuscles in one unit of space as compared with the white cells, the former require a correspondingly greater dilution in order to be estimated by the same standard as the whites.

The narrower-bore pipette used in estimating the red blood corpuscles allows therefore of dilutions up to 1 in 100 when blood has been drawn up to the mark 1, and to 1 in 200 when blood has been drawn up to the mark .5. The numbers 11 and 101 show the point to which the diluting fluid must be drawn, in order to make the above dilutions. For instance, 11 indicates 1 part of blood and 10 of diluting fluid, while 101 indicates 1 part of blood plus 100 parts of diluent. This means that in the former the unit of blood drawn up to the mark 1 has been diluted 10 times, whereas in the latter it has been diluted 100 times. Hence, if blood be drawn up merely to the mark .5 in the first case it will be diluted 20 times, whereas in the second case it will be diluted 200 times.

Bürker's counting-chamber is so constructed that it contains two counting-surfaces separated from each other by a horizontal channel, and each of these has the same ruling. Consequently these two fields can be used for making control counts of the same specimen of blood. A simultaneous use of one field for estimating the number of red cells, and the other for the white corpuscles, cannot be recommended,

owing to the danger of an accidental mingling of the two drops.

The method of procedure is as follows :—

On the clean dry chamber (which is on the principle of a hollowed-out slide—the original Thoma's chamber) the cover-glass is first laid. Next, after thorough mixing in the pipette, a drop of the diluted blood is allowed to enter from one side or the other into the chamber, where it spreads out.

Türk's ruling* consists of lines crossing each other at right angles, whereby squares are mapped out. In the centre there is thus a field divided up into 16 large squares by triple horizontal and vertical lines. Each of these large squares is again subdivided into 16 small squares by single horizontal and vertical lines. At the four corners of the field are found large squares similar to the first, bounded at the edge by double parallel lines. These squares are not subdivided further. The central field, consisting of large squares subdivided into smaller ones, is reserved for the enumeration of the red blood corpuscles.

The more sparsely distributed white cells should be counted on the large corner squares which are not subdivided.

The next step consists in determining the average number of red blood corpuscles or of leucocytes in

* Bürker's ruling is preferable for general use; his counting-chamber can, however, be obtained, if desired, with the original Thoma ruling.

one small square. This is found by counting over carefully as large a series of small squares as possible. From this we can calculate the number of cells in 1 c.mm. of blood.

The average number of cells in a small square, multiplied by the degree of dilution (10 or 20 in the case of leucocytes, 100 or 200 in the case of erythrocytes) and by a constant factor, viz., 4000 (the so-called chamber-index), gives us the total number of red and white cells respectively in 1 c.mm. of blood. The enumeration is best carried out using a medium magnification and with a half-closed diaphragm, lowered condenser, and concave mirror. An endeavour should always be made to count as many squares as possible (small ones in making the red count, large ones in estimating the white cells). From this the average number per square may be calculated.

To determine the number per c.mm., the following universal formula is equally suitable for reds and for whites. It is based on the average number of cells in one small square.

$$\frac{\text{Number of cells counted} \times \text{degree of dilution} \times \text{chamber-index (4,000)}}{\text{Number of small squares counted}}$$

If, instead of counting the number of cells per small square we count the number per large square as in the leucocyte determination, since 1 large square is equivalent to 16 small ones, in the above formula

the denominator will be the "number of large squares counted $\times 16$."

Let N = the total number of cells counted in a series of large squares.

M = the degree of dilution.

C = the chamber-index.

X = the number of large squares counted.

$c = 16$, i.e., the number of small squares which make up one large square, i.e., a constant.

Then the number of red or white blood cells in 1 c.mm. of blood will be as follows:—

$$\frac{N}{X \times c} \times M \times C.$$

But $C = 4000$ and $c = 16$

\therefore the formula may be represented—

$$\frac{N \times M \times 4000}{X \times 16}$$

Since $4000 : 16 \left(\frac{C}{c} \right) = 250 \left(= \frac{1000}{4} \right)$

we can estimate the number of white cells in 1 c.mm. of blood by eliminating the constant 16, so as to obtain the average number per large square.

This may be represented by the formula—

$$\frac{N \times M}{X} \times 250.$$

For convenience sake, however, it is found that there is no need to go to the trouble of first determining the average number per large or small square respec-

tively by a preliminary calculation and then of multiplying the number thus obtained in the manner shown above: it is simpler and more convenient to reduce all these calculations to one step, so simplifying the formula. Since a considerable number of large squares, each equal to 16 small ones, should be counted, it is obviously advisable to count through a number of large squares, divisible by 4.

Four large squares may be taken as the minimum number to be of any service. If one is simply in the habit of never counting more than 4 large squares, then X is always equal to 4. The above formula will then be reduced to the following terms:—

$$\frac{N \times M \times 1000}{16}$$

In enumerating the red cells when the dilution is 1 in 200, if 100 small squares are counted (i.e., 6 large and 4 small squares), we need only multiply the number counted (N) by 8000. Thus the number of red cells per c.mm. = $N \times 8000$. It might be added that, in determining the number of red blood corpuscles, a dilution of 1 in 200 should be used; for the whites a dilution of 1 in 10. In estimating the number of red cells in the rare cases of polycythæmia, still higher dilutions, however, must be used. Thus, if we suck up the blood to the mark .4 we get a dilution of 1 in 250, if only to .2 the dilution is 1 in 500.

For the enumeration of red blood corpuscles in

the higher degrees of anæmia a dilution of 1 in 100 only should be used.

Similarly, the enumeration of the white cells in leukæmic blood is to be carried out by using dilutions of 20 or under (blood to the mark $\cdot 4 = 1$ in 25, or to the mark $\cdot 2 = 1$ in 50).

NEW METHOD OF HÆMOCYTOMETRY RECOMMENDED.

[Since the above was written, Professor Pappenheim has published a description of new apparatus devised by him for collecting blood and for enumerating the cell elements. He regards this apparatus as simpler and more accurate than any other, and accordingly now recommends its use in place of that described above in the text. He has now abandoned all other methods.

PIPETTES.—With the above-mentioned pipettes it is not always easy without practice to suck up fluid accurately to the desired mark. The rubber tubing

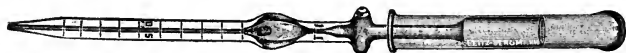

Fig. 1.—Pipette.

is apt to perish, and it is further objectionable on hygienic grounds. These defects are remedied in his new form of pipette, which is constructed as follows (*Fig. 1*).

A narrow glass tube or cap, closed at one end, is slid over the upper part or neck of the pipette.

This glass cap is so ground that it fits accurately round the pipette, thus forming what is practically an air-tight junction.

This can be slid up or down, and constitutes the suction apparatus.

The almost perfect vacuum which can thus be produced was not found to work satisfactorily in practice.

It was difficult to expel the last drops of fluid, and the rate of suction was too rapid and abrupt. Accordingly the closed top-end of the cap was made of slightly wider calibre, so as not to grasp the pipette so tightly.

Hence, when the cap is pushed home, a tiny cushion of air remains. The vacuum produced by withdrawing the cap is therefore rendered an imperfect one.

The difficulties above referred to were thus got over. Now, however, owing to this imperfect vacuum, the mixing bulb of the erythrocyte pipette could not be filled by one effort of suction. Pappenheim overcame this difficulty by adopting Portman's device.

This consists in the addition to the pipette of a second small ampulla placed further up the stem of the pipette beyond the mixing-bulb. It is provided with lateral openings through which air may enter or escape.

In drawing up fluid into the pipette, these lateral openings are closed by the fingers, while the cap,

which had previously been pushed down to its full extent, is slid upwards.

When the existing vacuum has been satisfied, before all the required amount of fluid has been drawn in, the fingers are removed from the lateral openings in the upper ampulla. This allows the cap to be pushed well down again over the pipette without disturbing in the process the level of fluid in the latter. The lateral openings are again closed, and suction is resumed by sliding the cap upwards as before.




Fig. 2.—Counting-slide.

The presence of the lateral openings also allows the cap to be removed for shaking purposes if desired. Prof. Pappenheim, however, effects the mixing by grasping the pipette near each end, and turning it to and fro between the fingers.

COUNTING-CHAMBER.—As already indicated, Prof. Pappenheim recommends the Bürker form of counting-chamber in preference to any other. As

accurate apposition of the cover-glass (proved by the presence of Newton's rings) is difficult, and can only be obtained by careful manipulation, he prefers the use of clamps in order to maintain equable pressure. These grasp the cover-glass and slide, the latter being grooved on its under surface to receive the lower limbs of the clamp (*Fig. 2*).

The cover-glass is placed in position and clamped, after which the fluid is allowed to run in between the cover-slip and the central counting-surfaces.

Of the many methods of ruling, Prof. Pappenheim recommended till recently that of Türk as described




Fig. 3.—Counting-field

above. In all these methods, however, he recognized defects, chief among which is the liability to confusion owing to the crossing of so many different lines. He has now obviated this objection by adapting to the Bürker chamber Goriaew's method of ruling, which he has modified in some degree.

The counting-field is marked off in a series of squares, certain of which are again subdivided into sixteen smaller ones (*Fig. 3*).

The squares thus further subdivided are so arranged that they are separated from each other on every side by the breadth of two squares of similar size but without smaller subdivisions. There are four rows, each containing four of the subdivided squares, and each row is separated from the other by the breadth of two undivided squares. There will therefore be $4 \times 4 = 16$ squares, each of which is subdivided into sixteen smaller ones. These squares are used in the enumeration of the red blood corpuscles. Since each of these squares is separated from its neighbour by the breadth of two undivided squares, it follows that there must be 4×9 or $3 \times 12 = 36$ squares not subdivided further. On these the leucocytes are counted. In dealing with leukæmic blood all the squares must be counted.

The whole apparatus is here illustrated, and can be obtained from the firm of E. Leitz.—R. D.]

THE DIFFERENTIAL COUNTING OF LEUCOCYTES.

For this a stained blood film is necessary. The procedure is as follows. The name of each type of cell found in normal blood, as well as the names of the various pathological cells likely to be met with, are written down on a sheet of paper, each name heading a separate vertical column. As each field is counted, the number of each separate type of cell found is entered in the column under its proper heading.

The relative percentage of one to the other is now easily estimated.

First of all, each vertical column is added up, thus giving the total number of each type of cell present. Then the total number of all leucocytes counted is found by adding together the sums of all the vertical columns, i.e., by adding together the various sums contained in the horizontal column at the bottom of the vertical ones.

Let S = the total number of all cells present.

N = the number of cells in one vertical column,
i.e., cells of one type.

X = the required percentage of this particular kind of cell.

The value of X will be found by means of a simple proportion sum:—

$$S : N = 100 : X.$$

In order to find the value of X we need only multiply N by 100 and divide by S :—

$$\frac{N \times 100}{S}$$

To obtain a correct value for X , as large a number of fields as possible should be counted, that is to say, the largest possible number of cells should be counted. Let us suppose that we count a total number of 500 ($S = 500$), the percentage (X) of any one type of cell will be found by multiplying the number (N) of cells of the type in question by 2 and dividing the product by 10. This is obtained by the following formula:—

$$X = \frac{N \times 100}{500} = \frac{N \times 100 \times 2}{500 \times 2} = \frac{2N}{10}$$

THE RELATIVE PROPORTION OF CELLS FOUND IN NORMAL BLOOD.

1. In the adult male the red cells (R) amount to 5 millions per c.mm.; in the female the amount varies from 4 to 5 millions.

2. The leucocytes (W) amount at most to between 5000 and 10,000. Anything over 10,000 is pathological. The higher counts within physiological limits are generally found during digestion.

3. The normal ratio, therefore, W : R must be somewhere between 1 : 500 and 1 : 1000 (i.e., must be .002 and .001).

4. The relative percentage of the various types of normal leucocyte to each other is as follows:—

Small and large lymphocytes	..	20-22	per cent
Mononuclears	2- 6	,,
Polymorphonuclear neutrophils		70-75	,,
,,	eosinophils	2- 6	,,
,,	mast cells	0- 1	,,

PATHOLOGICAL VARIATIONS IN NUMBER, AND THEIR DIAGNOSTIC SIGNIFICANCE.

VARIATIONS IN THE NUMBER OF RED BLOOD CORPUSCLES.

An abnormal increase in the absolute number is called *polycythæmia*. It is the cardinal sign in cases of plethora or idiopathic polycythæmia, especially in the so-called myelopathic polycythæmia accompanied

by splenomegaly (erythræmia or Vaquez' disease) and also in Gaisbock's hypertonic type. There is also a local or regional erythrocytosis in swellings confined to the extremities. Lastly, a temporary erythræmia may be met with in the blood at high altitudes where the barometric pressure is low, in general congestive processes, and in congenital cyanosis, etc.

Diminution in the number of red blood corpuscles, or oligocythæmia as it is called, is the cardinal feature of every anæmia, together with an absolute oligochromæmia as determined by hæmoglobin estimation.

CHANGES IN THE WHITE COUNT.

1. In the absolute number. Increase in the absolute number—*hyperleucocytosis*—is, when present, one of the most frequent and striking signs of a simple secondary functional leucocytosis. Such a condition is present in constitutional intoxications such as cancer, and in general organismal infections (sepsis, appendicitis, etc.), which act on the hæmopoietic system.

Further, although not the most essential, it is nevertheless the most important sign, from a practical point of view, met with in leukæmic conditions, where a still higher degree of leucocytosis may be reached.

An absolute hyperleucocytosis, however, is not the most essential sign of the presence of a leucocytic irritation or of a leukæmic hyperplasia of the hæmopoietic system. This sign may even be absent where a lesion of the hæmopoietic system exists. Hence,

if present, this sign is only of passing interest, and merely affords proof that the lesion in question has led to a quantitative blood change.

Not infrequently, leucocytic and leukæmic lesions (as recognized by the qualitative changes in the blood) may exist side by side with very insignificant alterations in number. Such quantitative changes may be absent altogether, or there may even be a diminution in the leucocyte count, as in the leucopenia of typhoid and in aleukæmic pseudoleukæmia. Even when hyperleucocytosis is present, a differential diagnosis between these two conditions cannot always be made with certainty merely on the strength of a blood count, as there is an extraordinarily high leucocytosis on the one hand and a relatively small blood count on the other. They are to be distinguished from one another rather by the quality of the blood cells. For instance, in simple leucocytosis it is always one particular type of mature cell that is increased, e.g., leucocytes, lymphocytes, or monocytes. Occasionally, their immediate precursors may also appear in the blood. On the other hand, both in lymphatic and myelogenous leukæmia the most essential and constant characteristic is the presence of the whole series of atypical progenitors of the mature cell, including even the original parent cells. Mature leucocytes and lymphocytes may, in fact, be absent even in acute cases.

When there is a diminution in the absolute number the condition is called *hypoleucocytosis* or *leucopenia*.

This is found, for instance, especially in typhoid and in measles, and is of value as a means of distinguishing these from perityphlitis and Rôtheln.

It is not diametrically opposed to hyperleucocytosis even when it appears from the first as a leucopenia, e.g., in typhoid. It ought rather to be regarded as differing in degree only, since high degrees of leucocytosis, or leucocytosis of long standing, may merge into leucopenia. When this occurs, especially if accompanied by the presence of early forms in the blood, it indicates commencing exhaustion of the overtaxed bone-marrow.

2. Variations in the Relative Percentages.—A hyperleucocytosis may consist in a simultaneous increase of the various types of cell present in normal blood, with the addition, in pathological lesions, of their progenitors.

This is the case in mixed-cell myelogenous leukaemia. In the functional leucocytoses, on the other hand, there is an increase in one type of cell only. This may lead to an absolute hyperleucocytosis, provided the other cells remain unaffected. The increase in one type of cell, however, may be merely relative, and take place at the expense of the others.

There is a certain antagonism in function between neutrophils and their lymphoid progenitors on the one hand, and lymphocytes and eosinophils on the other. Hence, owing to a selective attraction for one kind of cell, a direct or indirect repulsion of the other types will take place. These latter will then diminish

more rapidly in proportion or relatively, as a result of this negative chemiotaxis.

Thus it comes about that in cases of partial relative leucocytosis, a normal count, or even a leucopenia, may be observed if we take the total number of leucocytes present into consideration.

In this way a relative lymphocytosis is very often encountered, along with a relative neutropenia and a general leucopenia (leucopenic lymphocytosis), e.g., in Banti's disease, Biemer's disease, typhoid,* measles,† etc.

A RELATIVE NEUTROPHILIA OR NEUTROPHIL POLYNUCLEOSIS is the most important type of leucocytosis provoked by an irritant. In addition to that occurring during the digestion of albumins, it is found in the majority of general intoxications, bacterial infections (especially in granulomatous conditions of the lymphatic glands), and after the exhibition of adrenalin. Under the title of secondary concomitant leucocytosis it is met with in all kinds of anæmias and cachexias as a result of morbid products circulating in the blood and producing a leucocytosis by irritation—an irritation leucocytosis. It is met with in the majority of ordinary functional leucocytoses. In other words, the greater number of

* It is of importance in the differential diagnosis of this condition from appendicitis and epidemic cerebrospinal meningitis.

† Of value in the differential diagnosis between measles on the one hand and scarlet fever and Rôtheln on the other.

functional leucocytoses are characterized by a partial relative increase in the number of neutrophil cells.

Frequently, but by no means invariably, these latter overstep the normal limits and lead to an increase in the absolute number.

Thus it comes about that an absolute hyperleucocytosis always goes hand in hand with a relative increase in the neutrophil cells owing to the existence of a special attraction for the latter. Of course, it is also possible for a relative increase in neutrophils to co-exist with a normal or diminished absolute count. The latter is just as much the result of the same neutrophil-provoking stimulus as is an absolute neutrophil hyperleucocytosis itself, and, as such, has exactly the same significance. It is only to be distinguished from the latter (i.e., from an absolute increase in neutrophils) by the fact that it occurs only in occasional cases.

To put the matter in another way, it is to a certain extent an accident to find an absolute hyperleucocytosis of neutrophils (i.e., a relative neutrophilia with hyperleucocytosis is equivalent to hyperleucocytosis, the result of an increase in the neutrophil elements).

A corresponding lesion may exist, not only without any quantitative or qualitative change in the blood cells, as compared with the normal, but there may even be an absolute leucopenia although there is a co-existing relative increase in the neutrophils. In affections of the blood, the most essential proof of

the existence of a neutrophil-provoking stimulus is relative neutrophilia, which may occur when the leucocytes have undergone an absolute increase, i.e., in hyperleucocytosis as well as when there is a general leucopenia. Increase or diminution of the absolute cell count is therefore only of secondary importance in diagnosing the presence of an irritation inducing a neutrophil increase. Neutrophil leucopenia, i.e., relative increase in neutrophils with an absolute leucopenia, is only one particular type of neutrophil leucocytosis.

The presence of an irritant capable of inducing an increase in the neutrophil variety of cell may, therefore, be inferred from the following :—

(a). *Quantitative blood changes* : (i) Absolute neutro-leucocytosis (with relative increase in neutrophils) ; (ii) Relative neutrophilia alone.

(b). *Qualitative changes*, such as the appearance in the circulation of their ontogenetic predecessors, e.g., myelocytes and metamyelocytes.

Thus, the most constant and essential sign always present in the three varieties is a relative neutrophilia as in (a-ii), i.e., with or without absolute leucocytosis. An absolute leucocytosis as in (a-i) is generally, but not necessarily, present. The presence of early forms is similarly found only in cases where a process of regeneration happens to be going on.

The chemiotactic leucocytoses are as a rule characterized only by an increase in one particular

type of cell.* A relative neutrophilia with or without reduction in the absolute count develops at the expense of the lymphocytes and eosinophils. In other words, it is accompanied by a lymphopenia and an eosinopenia. The relative diminution in such cases is, therefore, indirectly produced and is without significance.† It does not bear the same relation to absolute leucopenia that a relative leucocytosis does to an absolute one. At the same time a relative cell increase is met with as one of the phenomena in absolute leucopenia. The latter, too, is generally merely the occasional concomitant of a relative increase. Absolute leucopenia has therefore nothing to do directly with a relative reduction in number.

A simultaneous increase of all the granular cell elements is seen only in typical mixed-cell leukæmias.

A RELATIVE EOSINOPHILIA simply expresses the condition of eosinophil leucocytosis. The eosinophils never appear to be increased in number to such an extent as to lead to an absolute leucocytosis. Further,

* The laws governing this double chemiotaxis (e.g., for lymphocytes and eosinophils) are unknown up to the present.

† The laws which govern direct negative attraction, i.e., repulsion (chinin, lactic acid, aggressins, etc.), such as is actually seen in cases of measles and typhoid especially, are still in doubt. In this respect we may mention that, in addition to functional repulsion from the blood as well as from the tissues, mere impairment of cell output, of cell formation, or of cell development, may be met with, as well as combinations of these.

eosinophilia has not hitherto been observed in cases of absolute leucopenia. It is met with in asthma (both during and apart from the attacks), in conditions of vagus irritation, such as mucous colitis, and the exudative diathesis generally, and in helminthiasis of various kinds, as for example, in that due to *cysticercus*, *echinococcus*, and *distoma*, but not in that due to *ascaris* or to tape-worm. In this latter type of case it is of value as a means of differential diagnosis from tuberculous meningitis and typhoid.

Partial lymphocytosis is found in cases where stimuli of various kinds are at work to cause hypertrophy of the lymphatic apparatus. It is also seen in poisoning by pilocarpine and during the process of fat-digestion.

In the functional lymphocytoses, the ontogenetic precursors of the lymphocyte are met with during the period of regeneration. These are cells which have merely a small rim of cytoplasm, and are therefore nearly all nucleus.

In cases of hypertrophic lymphadenitis, lymphocytosis is generally characterized by the presence of parent lymphocytes. Further, an absolute and relative increase in lymphocytes is found in cases of lymphosarcoma, where occasionally the blood assumes a leukæmic character. It is present also in tuberculous and syphilitic lesions affecting the mucous membranes, whereas in corresponding affections of the lymphatic glands neutrophilia is the rule. It may be combined with a vagotropic eosinophilia.

In cases of pernicious anæmia,* Banti's disease, and typhoid, we sometimes find a relative lymphocytosis, frequently associated with a direct relative neutropenia which may merge into absolute leucopenia (i.e., leucopenic relative lymphocytosis).

MONOCYTOSIS frequently accompanies lymphocytosis (e.g., in Banti's disease) and the rarer cases of polynucleosis. In the latter case they are really the myelogenous leucoblastic monocytes met with in leucocytoses caused by an irritant. In malaria and in certain other protozoal infections like variola, monocytosis alone appears even more frequently. Lastly, in children, monocytes are present normally in larger numbers.

* Here it is not a question of true lymphocytes, but of microleucoblasts.

CHAPTER III.

HÆMOGLOBINOMETRY :
OR THE ESTIMATION OF HÆMOGLOBIN.

METHOD AND TECHNIQUE.

THE method of most importance in blood examination is the estimation of the hæmoglobin.

The apparatus best suited for the consulting-room and in cases where very accurate precision is not essential, is Sahli's hæmometer (an improved Gower's hæmoglobinometer). The principle of the Gower's apparatus is as follows: A definite amount of blood taken from a normal individual, and laked with a known quantity of distilled water, is preserved in a small sealed tube. A second tube, open at one end, is so graduated from 10 to 100 that the same amount of blood diluted in exactly the same way and showing the same tint stands at the mark 100. The normal is therefore 100.

A blood of half the depth of colour, which therefore contains only half the amount of hæmoglobin contained in normal blood, will only require to be diluted up to the mark 50 in order to match the tint in the comparison tube.

As the hæmoglobin solution deteriorates in the

light, the tint will not keep. Sahli's apparatus, therefore, contains, instead of natural hæmoglobin, a hæmin solution. To make this up, a decinormal solution of HCl is required, and can be easily had from any chemist. The method of procedure is as follows. Before drawing the blood, some of the $\frac{N}{10}$ HCl is run in up to the mark 10 by means of a fine pipette.* Then blood is drawn up to the mark on the capillary pipette provided with Sahli's apparatus.

The outside and the point of this pipette must now be cleansed of any blood adhering to it. The pipette is then inserted into the graduated tube, and the contents of the pipette are carefully blown out into the $\frac{N}{10}$ HCl contained in the bottom of the tube.

The pipette is then rinsed by repeatedly drawing up into it some of the mixture and blowing it out again, care being taken to avoid the formation of bubbles.

The blood immediately turns a brownish tint owing to the formation of hæmatin chloride. This hæmin solution is next diluted by adding distilled water, by means of a second capillary pipette, up to a point when the tint of the comparison tube has just been matched.

The hæmoglobin value is then read off directly from the graduated tube as so much per cent. The

* Best of all, thin-walled pipettes, graduated in cubic millimetres.

normal hæmoglobin value of an adult male is 100 per cent; in females it is about 90 per cent, but before menstruation it may be slightly higher.

ESTIMATION OF HÆMOGLOBIN—NEW METHOD RECOMMENDED.

[Since writing the above, Professor Pappenheim informs me that he has adopted a new method of estimating the amount of hæmoglobin which he now recommends in place of the Sahli described above. While the latter is sufficiently accurate for general practice, and is easily manipulated, it has certain defects.

First of all it takes up time, for after mixing the blood and HCl, ten minutes must elapse in order to allow the full depth of colour to form.

Thereafter, the further dilution with water must be made drop by drop till the desired tint is obtained.

Secondly, this drop-method, together with the small content of the tube, is apt to lead to errors in estimation.

These are obviated by the new apparatus which he now advocates.

Like the Sahli method it is a colorimetric one. The same quantity of blood is taken with the same kind of pipette, and this is converted into hæmin by the addition of HCl as before.

This quantity now remains a constant which is not further diluted, thus differing from the Sahli method.

The standard solution is contained in a wedge-shaped glass vessel, and therefore shows all gradations in depth of colour between the two ends. This wedge is placed alongside the sample of blood to be examined, and, being movable, can be shifted upwards or downwards till it matches the depth of colour in the blood sample.

Apart from the time necessary for the hæmin to realize its full depth of colour, the comparison takes only about three minutes.

The instrument is known as the Autenrieth-Koenigsberger Hæmolorimeter.—R. D.]

SEMIOLOGY.

An increase in hæmoglobin beyond the normal, *Pleiochromæmia* as it is called, is found, as one would expect, in various conditions where the red cells are increased in number. In such conditions the individual erythrocytes have a normal Hb content, i.e., are *normochromatic*. More rarely they are *hypochromatic*, but *never hyperchromatic*. General pleiochromæmia is thus quite independent of hyperchromasia of the individual erythrocytes. Absolute pleiochromæmia, therefore, depends only on an increase in the number of erythrocytes, i.e., on polycythæmia.

A diminution or general *Oligochromæmia* is the cardinal sign of all anæmic conditions, in the broadest sense of the term. It may be the result of an oligocythæmia (the morphological evidence of which is

degenerative anisocytosis, poikilocytosis, and scistocytosis), but it does not necessarily follow.

It is seen not only where the individual cells show hypochromasia, but also where hyperchromasia is present, and even in anochromasia as in chlorosis. Oligochromæmia is thus completely independent of hypochromasia. The simple estimation of hæmoglobin, without reference to any other data, can furnish no information concerning the kind or character of the oligochromæmia in question. Apart altogether from a microscopic examination of the film, the number of red blood corpuscles must also be known. For instance, in chlorosis, or green-sickness as it is called, there is an absolute deficiency in Hb—an oligochromæmia while the count remains normal. The individual erythrocytes are, however, too pale and do not stain well.

On the other hand, in the anæmias proper, oligochromæmia is always associated with oligocythæmia, of which it is merely the result. Oligocythæmia, so far as it is concerned, is represented microscopically by the presence of various degenerate malformed cells (such as anisocytes and poikilocytes).

Hence, taking all the signs together, so far as they are met with in the erythrocyte element of the blood, we find the following:—

In Chlorosis.—Oligochromæmia plus normocythæmia (i.e., a normal number of erythrocytes) plus chlorosis of the individual erythrocytes as determined microscopically ; in other words, general

oligochromæmia plus normocythæmia composed of well-formed but chlorotic erythrocytes.

In the Anæmias.—Oligochromæmia due to oligocythæmia of malformed hypochromatic or hyperchromatic anisocytes; in other words, oligochromæmia plus oligocythæmia plus anisocytosis, the cells of which may show under the microscope either hypochromasia or hyperchromasia.

It follows that, for purposes of differential diagnosis, an oligochromæmia plus normocythæmia, where the cells are of normal shape, indicate chlorosis. If however, along with oligochromæmia, we find oligocythæmia plus degenerated malformed cells, the case is one of the varieties of true anæmia. For purposes of differential diagnosis, therefore, between chlorosis and true anæmia, the crucial sign is not oligochromæmia, but the presence or absence of oligocythæmia. In chloro-anæmia, chlorosis is combined with anæmia. The diagnosis in this case can only be made after microscopic examination.

THE COLOUR INDEX.

The relationship of the Hb value to the number of erythrocytes present is called the Hb index or the colour index. The index for normal blood is 1. This number is arrived at by multiplying the ratio between the normal Hb value and the normal number of erythrocytes by 50,000.

Thus $\frac{100 \times 50,000}{5,000,000} = 1$, i.e., the numerator—the hæmoglobin value—is multiplied by 50,000.

The pathological index must be either greater or less than 1. It is got by multiplying by 50,000 the value obtained from the ratio between the Hb and the number of erythrocytes, or, for convenience sake, by multiplying by 100,000 and dividing the product by 2.

Thus we obtain the following formula :—

$$\text{Normal} \left\{ \frac{\text{Hb}}{\text{erythrocytes}} \right\} = 1, \left\{ \frac{\text{Hb}}{\text{erythrocytes}} \right\} \text{found} = ?$$

$$\text{i.e., normal} \left\{ \frac{\text{Hb}}{\text{er}} \right\} : 1 = \left\{ \frac{\text{Hb}}{\text{er}} \right\} \text{found} : X$$

$$\text{i.e.,} \frac{100}{5,000,000} : 1 = \left\{ \frac{\text{Hb}}{\text{er}} \right\} \text{found} : X$$

$$\therefore X = \left\{ \frac{\text{Hb}}{\text{er}} \right\} \text{found} \times \frac{5,000,000}{100}$$

$$= \left\{ \frac{\text{Hb}}{\text{er}} \right\} \text{found} \times 50,000$$

$$= \left\{ \frac{\text{Hb}}{\text{er}} \right\} \text{found} \times \frac{100,000}{2}$$

Example :—

In a case of anæmia the Hb is found to be 55 per cent, while the number of erythrocytes equals 2 millions. The colour index for $\frac{55}{2,000,000}$ is calculated as follows :—

$$\frac{55}{2,000,000} \times \frac{100,000}{2} = \frac{27.5}{20} = \frac{2.75}{2} = 1.375$$

i.e., an index greater than 1.

SEMIOLOGICAL.

Two main varieties of anæmia are distinguished, according to their pathogenesis. Anæmia may result from loss of blood, from destruction of blood, or from damage to the blood; less frequently from diminished blood-formation on the part of the bone-marrow (myelopathic anæmia). In the first case it is mainly an occasional occurrence, and is then secondary to regeneration on the part of the blood (secondary regenerative myelopathy). In the second case it is the result of an increased secondary destruction of the blood-cells, especially affecting the hypoplastic, immature red cells of low vitality.

In the same way, two different kinds of anæmia may be distinguished from a symptomatic point of view, according as the hæmoglobin diminishes more rapidly than the erythrocyte count or, vice versa, according as the number of erythrocytes drops more rapidly than the Hb. In the first case the colour index is less than 1, in the latter it is greater than 1. It is easy to understand that in the first case, for the hæmoglobin to undergo a greater diminution than the number of cells, the loss in the latter must be more quickly made good than that of the Hb, for the newly-formed erythrocytes are still poor in Hb (i.e., show polychromasia).

Further, in the second case, where the number of cells decreases more quickly than the Hb, the latter, even when free in the plasma, must be relatively more resistant than the lipoids of the stroma (Ehrlich)

or those set free in the course of erythrolysis. Again, it is suggested that where the index is greater than 1, in the process of regeneration by reversion to the embryonic method of blood-formation, the Hb should be, relatively at least, more rapidly restored, owing to the presence of a special variety of hyperchromatic cell abnormally rich in Hb, when compared with the reduction in the cell-count as a result of erythrolysis.

The theory put forward to explain the first type of anæmia may be the true one. The other two theories urged, however, are not sufficient to explain the facts observed in the second type.

There is no doubt that these two different types of blood, differing in their semiology, do not correspond to two varieties of anæmia which differ in their pathogenesis (hæmopoietic and myelopathic). The blood picture of the first is not the equivalent of that found in hæmopathic forms of anæmia. It is much more likely that they are both merely the expression of two different kinds of hæmopathic anæmia (simple hypochromatic and pernicious hyperchromatic).

The hyperchromatic anæmias are not synonymous with the primary myelopathic varieties. It is true that the former may also be of myelopathic origin, but it is not a *sine qua non*. Similarly, the hypochromatic anæmias may also be of myelopathic origin, and vice versa, the myelopathic anæmias are generally hypochromatic, i.e., have a diminished colour index.

The evidence of pernicious anæmia rests on hyper-

chromasia alone (i.e., on a high colour-index) as determined by the microscope, not on myelopathy from the pathogenic point of view.

Toxic myelopathy brings about increased formation of red blood-cells and leads to the entry into the blood of megaloblasts, which, however, are not specific proof of the presence of pernicious anæmia. Hence the latter may also be found in simple hypochromatic anæmia. The myelopathic anæmias are, therefore, for the most part hypochromatic, while the hæmopathic anæmias are either hypochromatic or hyperchromatic.

The simple hypochromatic anæmias are both hæmopathic and myelopathic, while the hyperchromatic anæmias are a special form of anæmia and are always of the hæmopathic type. Thus, the two varieties of hæmopathic anæmia are distinguished from one another, according as their index is greater or less than 1.

In many conditions of theoretical and practical interest, such as polycythæmia and chlorosis, the Hb index is of special diagnostic importance (semiological and pathogenetic) for the proper understanding of anæmias. In all anæmias, both in those due to diminished blood formation and in those caused by increased blood destruction, the numerator and the denominator are diminished as compared with the normal.

This simultaneous reduction in both, however, is by no means uniformly proportional, for, if so, the

index would always remain equivalent to 1. As a matter of fact, it is sometimes the numerator (the Hb) and sometimes the denominator (the cell count) that is reduced relatively more than the other, according to the particular kind of anæmia in question.

In the first case the result is a fraction, i.e., is less than 1. In the second it is an improper fraction, i.e., is greater than 1.

In the first case there is both an absolute and a relative diminution in the Hb (oligochromæmia). In the second there is merely an absolute diminution in the total Hb content, with a relative pleiochromæmia.

The colour index, especially when it is pathological, is by no means evidence merely of anæmia. It serves another purpose, for it is of value in the differential diagnosis of anæmias, and, for this purpose, we recognize a diminished and an increased index respectively. Thus, apart altogether from the anæmias proper, there is also a diminished index in polycythæmia and in chlorosis. A diminished index, especially if there is no other sign present, cannot be regarded as a sign of anæmia, whereas an increased colour index is.

Oligochromæmic normocythæmia is present in chlorosis where there is a diminished index, but between the number of normocytes (denominator) and the oligochromæmia (numerator) there is no direct causal connection.

On the other hand, the colour index in anæmia

proper, whether diminished or increased, always depends on an oligochromæmia, the latter being the result of oligocythæmia.

A diminished index in anæmia accompanies and is the result of an absolute oligocythæmic oligochromæmia together with a relative oligochromæmia. As such, it is the direct functional reflex of hypochromasia of the cell as seen under the microscope.

On the other hand, an increased index in anæmia is the general semiological expression of an absolute oligocythæmic oligochromæmia together with relative pleiochromæmia, and as such is the functional reflex of the hyperchromasia seen in the cells under the microscope.

Hypochromatic anæmias accordingly mean the same thing as anæmias with lowered colour index, while hyperchromatic anæmias correspond to anæmias with increased colour index. Hence, in the hypochromatic type of anæmia the index is less than 1, i.e., a fraction whose numerator is smaller than the denominator.

In the so-called simple secondary anæmias (hæmopathic and myelopathic) the Hb is increased in greater proportion than the blood-count.

In the second class, embracing anæmias which are really only hæmopathic, the index is greater than 1. They include the specific pernicious or hyperchromatic anæmias. These latter are not myelopathic merely, but are really also hæmopathic, and may be so even *ab initio*. In any case they may be regarded

as mixed types of anæmia which are simultaneously hæmotoxic and myelotoxic* in origin. Further, the myelopathic anæmias are not always characterized by an index greater than 1, and vice versa, an index greater than 1 points to a form of anæmia which is hyperchromatic on microscopical examination of the cells. In other words, a high index has its histological counterpart in cell hyperchromasia. As a high index in anæmia is only one manifestation of a general anæmic oligochromæmia† (not of pleiochromæmia) resulting from oligocythæmia, and as the latter has its microscopic counterpart in the degenerative malformations (anisocytosis, poikilocytosis, schizocytosis), so a high index in anæmia indicates malformed cells which microscopically are hyperchromatic. At all events, hyperchromatic anæmia in a symptomatological sense does not coincide with myelopathic anæmia in a pathological sense. Hence, a diminished index by itself is not an indication of anæmia, but only when associated with oligocythæmia. Further, a low colour index in anæmias is found in the simple hæmopathic and in the myelopathic varieties. On the other hand, not every diminished colour index indicates a hæmopathic

* In myelotoxic anæmias, megaloblasts make their appearance.

† Polycythæmia is accompanied by general pleiochromæmia, where the index is generally equal to 1, rarely less than 1, and never greater than 1. In the above condition, however, there is a microscopic hyperchromasia.

anæmia, nor is every hæmopathic anæmia characterized by a diminished index. An increased index, however, is always a sign of anæmia (oligocythæmic in character), and as such indicates a hyperchromatic form of hæmopathic anæmia.

Hence, we find a diminished colour index in chlorosis, myelopathic anæmia, simple hæmopathic anæmia showing hypochromasia, and even in polycythæmia.

On the other hand, an increased colour index is a sign only of hæmopathic anæmia, hyperchromatic in character.

A diminished index, whether occurring in anæmia or not, is generally the indirect result of a general oligochromæmia, and is the direct expression of relative hypochromasia of the cells as seen from the histological point of view. An increased index is always found in anæmia, and accompanies oligocythæmia, and, as such, indicates a relative hyperchromasia regarded histologically.

Not every diminished colour index indicates oligochromæmia.

Not every diminished colour index indicates oligocythæmia.

Not every diminished colour index indicates anæmia.

Not every oligochromæmic index is less than 1.

Not every oligochromæmic index indicates anæmia.

Not every oligocythæmic index is less than 1.

A polycythæmic and pleiochromæmic index may

be a diminished one. Every oligocythæmic index is an index of anæmia, and vice versa.

Not every index of anæmia is less than 1.

Not every oligochromæmic index has its histological counterpart in hypochromasia.

Not every oligocythæmic index has its microscopic counterpart in hypochromasia.

Every increased index is always merely an index of anæmia, and is consequently oligocythæmic.

Every increased index in anæmia has its counterpart microscopically in hyperchromasia of the cells.

Every index in anæmia, whether increased or diminished, is always oligocythæmic.

If we consider together the whole group of evidence furnished by the erythrocytes, viz., the type of cell, its Hb content, the number of cells, and the total Hb content, we find :—

In Chlorosis : Oligochromæmia, normocythæmia, an index less than 1, normally shaped cells with a partial (central) anochromasia (chlorotic normal cells).

In Simple Secondary Anæmia of Hæmopathic Origin : Oligochromæmia, an index less than 1, malformed cells showing diffuse hypochromasia (hypochromatic malformed cells).

In Pernicious Hyperchromatic Anæmia of Hæmopathic Origin : Oligochromæmia, oligocythæmia, an index greater than 1, malformed cells with hyperchromasia (hyperchromatic malformed cells).

Or, in other words :—

Chlorosis : = Oligochromæmic normocythæmia with an index less than 1 owing to anochromasia.

Anæmia : = Oligochromæmic oligocythæmia, which may be (1) Simple anæmia, with an index less than 1 owing to hypochromasia ; or (2) Pernicious anæmia, with an index greater than 1, owing to hyperchromasia.

Hence an index higher than 1 always means hyperchromasia of the cells, while an index less than 1 indicates hypochromasia, or chlorotic anochromasia.

SUMMARY.

General Pleiochromæmia always depends on an increased number of red cells and never merely on a cell hyperchromasia, where the cell count is normal, i.e., it depends on polycythæmia.

General Oligochromæmia is not necessarily associated with oligocythæmia, but is found in anæmia and chlorosis. Only the oligochromæmia seen in anæmia results from oligocythæmia, that is to say, is oligocythæmic. In chlorosis it depends on partial anochromasia of normally-formed erythrocytes which are present in normal numbers. In anæmias it depends on oligocythæmia, where there are hyperchromatic or hypochromatic anisocytes and poikilocytes, and never solely on hypochromasia of normally-formed cells present in normal numbers.

Absolute Oligocythæmia (*per se*, together with oligochromæmia) always indicates anæmia, of which

it is the cardinal sign. Anæmia is accordingly an oligocythæmic oligochromæmia.

This oligocythæmia (always anæmic) is an accompaniment of malformed cells (anisocytes and poikilocytes), which are its morphological basis. *In simple hypochromatic anæmia* an absolute oligocythæmia and a relative oligochromæmia occur together with hypochromasia of the cells, i.e., the index is less than 1.

In the Pernicious Hyperchromatic Anæmias, absolute oligocythæmic oligochromæmia and relative pleiochromæmia co-exist with hyperchromasia of the cells, histologically speaking, i.e., the colour index is greater than 1. Absolute oligochromæmia may or may not mean anæmia. It may be associated with an index greater or less than 1, and, histologically, with ano-, hypo-, or hyper-chromasia of the cells.

Absolute oligocythæmic (i.e., anæmic) oligochromæmia may co-exist with an index greater or less than 1, with relative oligochromæmia, or pleiochromæmia, and with hypo- and hyper-chromasia of malformed cells as seen histologically.

Relative oligochromæmia in cases of general oligocythæmic (anæmic) oligochromæmia is represented by a diminished anæmic index. Relative pleiochromæmia has nothing to do with absolute pleiochromæmia, but is always merely one sign of anæmia. Hence it is associated with absolute oligocythæmic oligochromæmia, and is represented by an increased index.

The key to simple chlorotic normal-celled oligochromæmia is chlorosis of the cells.

The key to anæmic oligocythæmia is the degenerate malformed erythrocyte.

The key to a lowered anæmic index in oligocythæmic oligochromæmia is the hypochromatic malformed cell.

The key to an increased anæmic index in oligocythæmic oligochromæmia is the hyperchromatic malformed cell.

INDEX.

	PAGE		PAGE
ADRENALIN, relative neutrophilia		Biermer's disease, blood picture in	31
caused by	60	Blood, normal elements in ..	6
Aggressins	63	Bone-marrow, 15, 16, 17, 24, 28, 29,	
Agranulocytes	7	30, 31, 39, 59	
Amitotic cell division	37	Bürker's ruling	46
Amphochromatophil	22	— counting-chamber 43, 45, 52, 53	
Anæmia, 10, 11, 13, 15, 17, 27, 60,			
70, 71, 73, 75, 76, 77		CACHEXIAS	60
— aplastic	10, 28, 29	Cancer	57
— bothriocephalus	31	Cells, irritation-	25
— chloro-	11, 12, 16, 29, 71	— plasma	25, 26
— hæmopathic	74, 75, 77, 78, 79	Cell-type, Rieder's, 25, 36, 37, 41	
— hæmopoietic	74	Cerebrospinal meningitis	60
— hyperchromatic, 28, 29, 38, 42,		Chemiotaxis	60, 63
74, 75, 77, 78, 79		Chloro-anæmia, 11, 12, 16, 29, 71	
— hypochromatic, 28, 74, 75, 77, 82		Chloro-leukæmia	16
— myelopathic, 28, 73, 74, 75, 77,		Chlorosis, 10, 12, 13, 16, 18, 27, 70,	
78, 79		71, 75, 76, 79, 80, 81, 83	
— pernicious secondary, 11, 13, 18,		— blood-picture in	29, 30
27, 28, 29, 31, 42, 65, 74, 75,		— blood-platelets in	18, 30
77, 80, 81, 82		— microscopic changes in	27
— pseudo-	10	Chromatolysis	13
— reactionary pernicious non-		Chronic lead-poisoning	16
aplastic	29	Congenital cyanosis	57
— secondary	11, 27	Colour-index, 71, 72, 75, 76, 77, 79,	
— simple secondary, 13, 28, 29, 42,		80	
77, 80, 81		Corpuscles —	
— splenic of v. Jaksch	31, 42	— cytoplasm of	16
— toxic 16, 17, 28, 29, 30, 38		— degeneration forms of	10, 18
— — hyperchromatic	37	— early forms of	12
Anisocytes, 28, 29, 70, 71, 81, 82		— hæmoglobin content of	10
Anisocytosis, 10, 11, 27, 29, 70, 71,		— immature in simple leuco-	
78		cytosis	19
Anochromasia, 10, 12, 29, 30, 70, 80,		— immaturity of, 12, 16, 17, 18, 28	
81, 82		— normal	6
Appendicitis, leucocytes in, 57, 60		— ontogenetic precursors of	19
Arsenic	30	— orthochromatic	16
Ascaris infection, leucocytes in 64		— pathological forms of	17
Asthma, eosinophilia in	64	— phylogenetic precursors of	19
Autenrieth-Königsberger appar-		— polychromasia of	22
atus	69	— variations in number of	56
Azur substance 3, 19, 21, 26		Counting-chamber, Bürker's, 43, 45,	
— — myeloid	23	52, 53	
Bacterial infections	60	— Pappenheim's modification of 53	
Banti's disease, leucocytes in, 60, 65		Counting, differential	54
Basophilia, punctate, 9, 15, 16, 17,		Cysticercus infection, leucocytes	
18, 26, 28, 29, 30		in	64
Biermer's disease	60	Cytoplasm, immaturity of	18
		— amphochromatophil	22

	PAGE		PAGE
DEGENERATION of hæmoglobin,	17, 18	Hæmopoietic apparatus, granu-	
Diathesis, exudative	64	lomatous affections of .. .	26
Difference between leucocytoses		— — irritation of	32
and leukæmias .. 34, 35, 58		Hæmorrhages, toxic	30
— — lymphatic and myelo-		Helminthiasis, eosinophilia in ..	64
genous leukæmias res-		Hyperchromasia, 11, 12, 28, 69, 70,	
pectively	37	71, 74, 77, 78, 79, 80, 81, 82	
Diffuse basic protoplasm	17	Hyperleucocytosis .. 57, 59, 61, 62	
Digestion of albumin, neutro-		Hypermetaplasia	32
philia in	60	Hypertrophic lymphadenitis .. .	64
— fats	64	Hypochromasia, 10, 11, 12, 15, 28,	
Diluting fluid for red cells	43	29, 30, 70, 71, 77, 79, 80, 81, 82	
— — for white cells	44	Hypoleucocytosis	58
Distoma infection, leucocytes in	64		
Dualists	24, 40	IMMATURE red cells, 12, 16, 17, 19, 28	
ECHINOCOCCUS infection, leuco-		— leucocytes	18
cytes in	64	Immaturity of cell, pathological	
Ehrlich	2, 31, 73	sign of	18
Eosinopenia	63	Index, colour	71, 77
Eosinophil, 8, 22, 36, 39, 41, 59, 63		— — in differential diagnosis of	
Eosinophilia	63, 64	anæmias	76
Erythræmia	57	— — normal	71
Erythroblastic apparatus .. 27, 30		— — oligochromæmic	79, 80
Erythroblastosis	28, 38	— — oligocythæmic	79, 80
Erythroblasts, 12, 14, 16, 17, 22, 28,		— — pathological	72, 75
29, 31		— — pleiochromæmic	79
Erythrocyte, 14, 15, 16, 17, 28, 69		— — polycythæmic	79
— immature	17	Infections, bacterial	60
— in chlorosis	70, 71	Intoxications	57, 60
— morphological changes in .. .	9	Irritation cells	25
— polychromasia of, 9, 15, 16, 22,		— leucocytosis	37, 38, 60
29, 30, 73		— neutrophilia	62
Erythrogonia	14	Isocytosis	11
Erythrolysis	74	VON JAKSCH'S anæmia	31, 42
FAT digestion	64	Jenner's stain	3
GAISBOCK'S type of cell	57	Jolly-bodies	13, 14, 17
Giemsa's stain	4, 5	KARYORRHESIS	13, 14
Goriaew's ruling, Pappenheim's		Klein-Gumprecht shadow nuclei	25
modification of	53	LEAD-POISONING, chronic	16
Gower's hæmoglobinometer	66	— blood picture in	29
Granulocyte	40, 41	Leptochromatic nucleus	23
HÆMATIN chloride	67	Leucoblast 21, 22, 23, 24, 26,	
Hæmin	67, 69	33, 38, 40, 41	
Hæmoblasts	14	— non-granular lymphoid	36
Hæmocolorimeter, Autenrieth-		Leucocytes	7, 38, 58, 62
Königsberger's	69	— degeneration forms	25
Hæmoglobin content	10, 69	— dwarf polynuclear	36
— — degeneration of	17, 18	— eosinophil 8, 22, 36, 39, 41, 59, 63	
— — in chlorosis	70	— giant polynuclear	36
— — hyperchromatic anæmias .. .	75	— immature forms	18
— — hypochromatic anæmias .. .	75	— non-granular basophil	36
— — hypoplasia of	10	— non-granular oxyphil	36
— — normal value of	68	— pathological varieties of .. 18, 31	
Hæmoglobinometer	66	— percentage of	8, 55, 57, 59
Hæmometer, Sahli's	66, 67	— polynuclear 8, 19, 20, 23, 38, 41	
Hæmopathic anæmia, primary .. .	28	Leucocytosis, simple 18, 19, 26,	
		30, 33, 35, 36, 39, 59, 60	
		— absolute	62, 63

	PAGE		PAGE
Leucocytosis, active	32	Lymphoid mononuclear cells,	
— chemiotactic	62	hyperplasia of	35
— eosinophil	63	— — — immature	41
— functional 32, 38, 59, 60, 61, 64		— — — myelocyte	21, 40
— hyperplastic	37	— — — parent form	14, 35
— immature red cells in	19	Lymphoidocyte 22, 23, 25, 26,	
— irritation	37, 38, 60, 65	33, 34, 36, 39, 40, 41	
— leucopenic type of	33	— nucleus of	23, 24
— leukæmic	26, 33, 57	— polymorphonuclear	36
— metaplastic	32, 42	Lymphopenia	63
— neutrophil	62	Lymphopoietic apparatus, hyper-	
— passive	32	plasia of	32
— relative	63	Lymphosarcoma	64
— repulsion	32	MACROCYTES	12, 13, 28
— secondary	32, 57	Macrolymphocytes 7, 21, 23,	
— — concomitant	60	24, 26, 35, 36, 38	
— toxic	32	— lymphoblastic	19, 34
Leucopenia	38, 58, 59, 60	Malaria	65
— absolute	61, 62, 63, 64	Malarial parasite	27
— neutrophil	62	Mast cells	8, 36, 39, 41
Leucopoietic apparatus, hyper-		— — dwarf	36
plasia of	32	— — in leukæmia	34
Leucosarcoma cells of Sternberg	24	May-Giemsa stain, Pappen-	
Leukæmia, 24, 26, 32, 33, 35,		heim's modification of	3
38, 40, 42		May-Grünwald's stain	3, 4, 5
— acute lympho-	36	Measles, leucocytes in	60, 63
— aleukæmic	33	Megakaryocytes	34
— atypical	36, 37, 40, 41	Megaloblasts 12, 13, 16, 17,	
— hyperplastic	32, 37	28, 29, 30, 74, 75, 78	
— lymphoidocyte	31	Meningitis, cerebrospinal	60
— mixed-cell	63	— tuberculous	64
— myeloblastic	24, 40	Menorrhœa	30
— myelogenous 19, 32, 33, 36,		Menstruation	15, 68
37, 39, 40, 58, 59		Mercury	30
— myeloid 22, 24, 35, 39, 40		Metamyelocyte 20, 23, 33, 62	
— neutral type of	31	Microcytes	10, 12
— neutrophil	39	Microleucoblast	24, 65
— parent cell	24	Microlymphoidocyte	24
Leukanæmia	31, 42	Mitoses in leucocytoses	36
Lymphadenitis, hypertrophic	64	— in leukæmias	36
Lymphæmia	35, 37	Monocytes 19, 21, 23, 26, 58, 65	
Lymphatic glands, granulo-		Monocytosis	65
matous	60, 64	Mononuclear lymphoid cell 7,	
— leucocythæmia 19, 32, 34,		22, 26, 39	
37, 39, 40, 58		Mucous colitis, eosinophilia in	64
Lymphoblastic macrolympho-		— membranes, syphilis of	64
cytes	19, 34	— — tubercle of	64
Lymphocytes 33, 38, 39, 58,		Myelæmia	37, 41
59, 63, 65		Myelocytes 20, 21, 22, 23,	
— large	7, 19, 26	33, 37, 38, 62	
— parent forms of	19, 24, 64	Myelocythæmia 19, 28, 25, 34, 79	
— pathological	24	Myelocytosis	37, 39
— polymorph	37	Myeloid azur substance	21
— small	7, 24, 26, 36	— leukæmia	22, 24
Lymphocytosis 18, 32, 33, 34, 42		Myelolympocytes	24
— absolute	64	Myelopathy, toxic	75
— leucopenic	60	— secondary regenerative	73
— partial	64	Myelotoxic	78
— relative	60, 64, 65	NEUTROPENIA	60, 65
Lymphoid mononuclear cells 7,			
22, 26, 39			

	PAGE		PAGE
Neutrophil leucocytes ..	8, 61	Polynuclear leucocytes, onto-	
— promyelocyte ..	22	genetic antecedents of	20, 33
— series ..	22	— — phylogenetic antecedents	
Neutrophilia ..	60, 61, 62, 63, 64	of ..	20
Normoblasts ..	12, 16, 28, 29, 30	Polynucleosis, relative ..	60, 65
Normocytes ..	10, 11, 28, 69, 76	Portman's device ..	51
Normocythæmia ..	70, 71, 76, 80, 81	Proerythroblasts ..	14
Nuclear vestiges ..	13, 14	Promyelocyte ..	21, 22, 23, 33, 37, 38
— multiple remains ..	17, 18	Protozoal infections ..	65
Nuclei, Klein-Gumprecht shadow	25	Pseudo-leukæmia ..	42
Nucleoli of lymphoidocyte ..	23	— aleukæmic ..	58
Nucleus, radial ..	12, 13	Punctate basophilia ..	9, 15, 16, 17, 18, 26, 28, 29, 30
— leptochromatic of lymphoido-		Pycnosis ..	14
cytes ..	23, 24	Pycnotic ..	13
— immaturity of ..	18		
		RADIAL nucleus ..	12, 13, 22
OLIGOCHROMÆMIA ..	27, 57, 69, 70, 71, 76, 77, 78, 79, 80, 81, 82, 83	Radkern ..	12
Oligochromatic ..	13	Regeneration of cells, signs of	
Oligocythæmia ..	11, 27, 57, 69, 70, 71, 77, 78, 79, 80, 81, 82, 83	normal ..	17
Ontogenetic antecedents of poly-		— pathological ..	16, 17
morphs ..	20	Rieder's cell type ..	25, 36, 37, 41
Orthochromatic ..	13, 14, 15, 16	Romanowsky stain ..	4, 5
		Rötheln, leucocytes in ..	59, 60
PACHYCHROMATIC ..	24	Ruling, Bürker's ..	53
Pappenheim's ruling ..	53	— Goriaew's ..	53
— stain ..	3	— Pappenheim's ..	53
Parasite, malarial ..	27	— Türck's ..	46, 53
Parent cell leukæmias ..	24		
— lymphocytes ..	19, 24, 64	SAHLI's hæmometer ..	66
Percentage of leucocytes ..	8, 55, 57, 59	Scarlet fever, leucocytes in ..	60
Perityphilitis ..	59	Schistocytosis ..	10, 70, 78
Pernicious anæmia ..	11, 13, 18, 27, 28, 29, 31, 42, 65, 74, 75, 77, 80, 81, 82	Sepsis ..	57
— — blood picture in ..	28, 31	Signs of immaturity of cell ..	18
— — platelets in ..	18	Splenic anæmia of v. Jaksch ..	31, 42
Pilocarpine poisoning ..	64	Splénomegaly ..	56
Pipettes, Thoma-Zeiss ..	43, 44	Spongioplasm ..	14
— Pappenheim's ..	50, 51	Stain, Jenner's ..	3
Plasma cells ..	27, 26	— May-Giemsa's ..	3
Platelets ..	6, 18, 30	— May-Grünwald's ..	3, 4, 5
Pleiochromæmia ..	69, 76, 77, 78, 81, 82, 83	— Pappenheim's ..	3
Poikilocytes ..	9, 18, 28, 29, 70, 81, 82	Stained cells, appearance of ..	5, 6
Poikilocytosis ..	10, 11, 12, 17, 27, 29, 30, 70, 78	Staining technique ..	4, 5
Poisoning, chronic lead ..	16	Sternberg's leucosarcoma cells ..	24
Polychromasia ..	9, 15, 16, 22, 29, 30, 73	Syphilis of mucous membranes ..	64
Polychromatic ..	13, 16, 17, 22		
Polychromatophilia ..	28	TAPE-WORM infection, leuco-	
Polycythæmia ..	27, 56, 69, 75, 76, 78, 79, 81	cytes in ..	64
Polynuclear leucocytes ..	8, 19, 20, 23, 38, 41	Technique of staining ..	4, 5
		Transition forms of leucocyte ..	32
		Tuberculous lesions of mucous	
		membranes ..	64
		— meningitis ..	64
		Türck's method of ruling ..	46, 53
		Typhoid, leucopenia in ..	58, 59, 60, 63, 64
		— relative lymphocytosis in ..	65
		VARIOLA ..	65
		Vaquez' disease ..	57
		Vestiges, nuclear ..	13, 14, 17, 18

Large 8vo, Fully Illustrated in Black and White, and Colours
21/- net.

THE BIOLOGY OF THE BLOOD-CELLS

WITH A

Glossary of Hæmatological Terms.

FOR THE USE OF PRACTITIONERS OF MEDICINE.

By O. C. GRUNER, M.D. Lond.,

Author of "Studies in Puncture-fluids"; "A Code-system for the Hospital Pathologist to the Royal Victoria Hosp. and to the Maternity Hosp., Montreal; Assistant Professor of Pathology, McGill University, Montreal, etc.; Late Clinical Pathologist, General Infirmary, Leeds.

With 23 Full-page Plates (7 being beautifully Coloured) and many Illustrations (some Coloured) in the Text.

CONTENTS.

Introduction.—I. The Primordial Blood-Cell.—II. The Red Blood-Cell. III. The Lymphocyte.—IV. The Large Mononuclear Leucocyte.—V.—The Neutrophile Leucocyte.—VI.—Certain Phlogocytes. VII.—The Cytoplasmic Phenomena of Blood-Forming Tissues. Abbreviations employed.—References to the Literature.—Glossary of Hæmatological Terms.—General Index —Index of Diseases referred to.—Index of Animals referred to.—Index of Authors referred to.

EARLY PRESS NOTICES.

"Is well worth study by those who would acquire a knowledge of the existing opinions in a most difficult field. Fully illustrated and contains many diagrams and schemes of methods of blood formation."—*Lancet*.

"This volume is indeed the apotheosis of the blood-cell, for never in the history of medicine, probably, has it been accorded so much attention all at once. It embodies not only all we know about the blood-cell, but a vast amount which we did not know. . . Profusely illustrated by drawings, micro-photographs, and coloured plates. A really excellent idea of the subject. . . The remarkably complete glossary is a very useful feature which cannot fail greatly to assist the reader. . . Altogether an epoch-marking contribution to the study of the blood-cells."—*Med. Press & Circ.*


"It contains a huge store of information displayed to the best advantage by author and publisher, and well illustrated. We regard this as one of the best text-books on the subject, midway between those which are elementary and those which are so advanced as to be of value only to research students."—*Hospital*.

"We can highly recommend the work, not only to those who make the study of the blood their special province, but to those whose interests in biology lead them to cogitate on the problems of cell development."—*Universal Med. Record*.


"This is a most beautifully printed and bound volume, and contains some of the best hæmatological plates we have seen for many days. . . Teems with full descriptions of microscopic cell appearances, and as far as possible the origin, life history, and fate of all recognized cells is fully gone into."—*London Hosp. Gaz.*

BRISTOL: JOHN WRIGHT & SONS LTD.

LONDON: SIMPKIN, MARSHALL, HAMILTON, KENT & CO. LTD.







THIS BOOK IS DUE ON THE LAST DATE
STAMPED BELOW

AN INITIAL FINE OF 25 CENTS
WILL BE ASSESSED FOR FAILURE TO RETURN
THIS BOOK ON THE DATE DUE. THE PENALTY
WILL INCREASE TO 50 CENTS ON THE FOURTH
DAY AND TO \$1.00 ON THE SEVENTH DAY
OVERDUE.

BIOLOGY LIBRARY

SEP 17 1932

MAY 19 1934

MAR 15 1935

JUL 16 1935

MAY 1 1937

APR 10 1942

OCT 19 1951

OCT 7 1951

OCT 25 1952

OCT 25 1952

NOV 1 1952

APR 22 1960

Burner

JAN 30 1968

JAN 30 1968 12

FEB 20 1968

RUNKLE

MAR 4 1968

FEB 22 1968 9

0

2

MOLOS
LIBRARY

411526

RB145-

P27

UNIVERSITY OF CALIFORNIA LIBRARY

ANATOMY DEPARTMENT

