





THE LIBRARY
OF
THE UNIVERSITY
OF CALIFORNIA
LOS ANGELES

GIFT OF

Robert Huebert

Robt Hubert
Diplomist of
Miss G. H. G. 47

To O. C. J. A. Library
From Robert Hubert

Digitized by the Internet Archive
in 2007 with funding from
Microsoft Corporation

CLINICAL SURGERY
BY CASE HISTORIES

VOL. II

CLINICAL SURGERY

BY

CASE HISTORIES

BY

ARTHUR E. HERTZLER, M.D., Ph.D., F.A.C.S.

PROFESSOR OF SURGERY IN THE UNIVERSITY OF KANSAS; SURGEON TO THE
HALSTEAD HOSPITAL, HALSTEAD, KANSAS, AND TO ST. LUKE'S
AND TO ST. MARY'S HOSPITALS, KANSAS CITY, MO.

VOL. II

DISEASES OF THE ABDOMINAL AND
GENITOURINARY ORGANS

*WITH ONE HUNDRED NINETY-NINE ORIGINAL
ILLUSTRATIONS*

ST. LOUIS

C. V. MOSBY COMPANY

1921

COPYRIGHT, 1921, BY C. V. MOSBY COMPANY
(All rights reserved)

Press of
C. V. Mosby Company
St. Louis, U. S. A.

Biomedical
Library

W0

16

H445c

1721

v. 2

CONTENTS

VOL. II

CHAPTER XI

	PAGE
SEVERE ABDOMINAL CRISES	547
Upper Abdomen, 547; Lower Abdomen, 577; General Abdomen, 593.	

CHAPTER XII

SEVERE INTERMITTENT PAIN	613
Epigastrie, 613; Hepatic, 621; Renal, 642; Appendiceal, 650; Suprapubic, 669.	

CHAPTER XIII

ABDOMINAL DISTRESS	679
Epigastrie, 679; Hepatic, 690; Renal, 705; Ileocecal, 710; Suprapubic, 719.	

CHAPTER XIV

NUTRITIONAL DISTURBANCE	729
With Pain, 729; Without Pain, 743; Loss of Weight, 759; Jaundice, 767; Hematemesis, 778.	

CHAPTER XV

TUMORS OF THE ABDOMEN	788
Epigastrie, 788; Hepatic, 805; Renal, 818; Inguinal, 829; Suprapubic, 841.	

CHAPTER XVI

DISTURBANCES OF UTERINE FUNCTION	870
Menstrual Pain, 870; Hemorrhage, 891; Postmenopause Hemorrhage, 925.	

CHAPTER XVII

DISEASES OF THE ABDOMINAL WALL	942
Tumors in the Region of the Abdominal Ring, 942; Tumors of the Abdominal Wall Proper, Including Fistula, 955; Inflammatory Infections Involving the Abdominal Wall, 962.	

CHAPTER XVIII

	PAGE
BLADDER	974
Bladder Irritation, 974; Hematuria, 992; Obstruction, 1003	

CHAPTER XIX

RECTUM	1023
Hemorrhage and Pain, 1023; Fistula, 1039; Perianal Diseases, 1044	

CHAPTER XX

EXTERNAL GENITALS	1053
Affections of the Vulvar Region, 1053; Diseases of the Penis, 1068; Diseases of the Scrotum and Its Contents, 1075.	

ILLUSTRATIONS

FIG.	PAGE
285. Fat necrosis in the upper part of the omentum from a case of necrosis of the pancreas	550
286. Fat necrosis of the omentum in a case of acute pancreatitis	551
287. A necrotic pancreas nodule on the left and one nearly normal on the right	551
288. Subdiaphragmatic abscess containing gas	552
289. Subdiaphragmatic abscess drained after the pleural space had been obliterated by packing it a week with gauze	553
290. Schematic drawing of a neglected case of perforated ulcer	555
291. Schematic presentation of the direction of escape of duodenal contents over the watershed provided by the great omentum	560
292. Ulcerating duodenum in which perforation was prevented by the formation of omental adhesions	564
293. Loops of collapsed intestine lie below an opening in the mesentery through which they have slipped	568
294. Gallstones removed from the intestine following death from intestinal obstruction	570
295. Head of the pancreas in acute pancreatic necrosis	572
296. The two puckered openings in the gut are surrounded by granulation tissue	575
297. Emaciation due to intestinal fistulae and sepsis	576
298. Meckel's diverticulum with its tip adhering to the mesentery, showing the loop through which the intestinal coils had slipped	579
299. Drainage of subdiaphragmatic abscess below the costal margin	582
300. Perforating hemorrhagic myoma of the uterus	587
301. Fetus and blood clots from an extrauterine pregnancy	592
302. (A) Appearance of the diverticulum after it was restored to its normal position. (B) Diagram of the position of the diverticulum when it was causing the obstruction	597
303. Enterolith formed of pawpaw seeds	600
304. Small abscess within the gut wall covered with plastic exudate	606
305. Appendix in an advanced stage of necrosis	611
306. Appendix after it had been shelled out of the muscle coat	624
307. Strawberry gall bladder	629
308. The appendix located lateral to the ascending colon is surrounded by indurated tissue in which there was a small abscess	639
309. Chronic inflammation of the gall bladder	641
310. Hyperplasia of the mucosa of the gall bladder	641
311. Stones removed from the left kidney	643

FIG.	PAGE
312. Kidney stone filling the pelvis of the kidney	645
313. Shaded area indicates the extent of the adhesions	653
314. Acute miliary tuberculosis of the ileocecal region, young man aged nineteen	656
315. Enterolith protruding after the wall of the gut was cut	657
316. Acute necrosis of the appendix	659
317. An Acutely inflamed appendix entirely surrounded by the indurated omentum	661
318. Periappendiceal abscess from bubo	667
319. Papillary cystoma of the ovaries	670
320. Loop of small intestine adherent to malignant gut causing closure of the lumen	673
321. Carcinoma of the pelvic colon producing stenosis of the gut	673
322. Localized periappendiceal abscess	677
323. Hernia of the linea alba	681
324. Enormous dilatation of the common duct due to a stone	684
325. Gall bladder with corrugations of the mucosa	692
326. Dilatation of the vessels in the hepatocolic ligament in a patient who had had many attacks of cholecystitis, but at the time of operation was free from symptoms	699
327. Fistulous gall bladder containing a stone in the cystic duct	702
328. Carcinoma of the cervix	704
329. So-called carcinoma of the appendix	707
330. Luteal cyst of the ovary	708
331. Hemorrhagic ovary	709
332. Ovarian cyst with hemorrhage	709
333. Abscess within the broad ligament drained through the vagina	719
334. Interstitial myoma of the uterus	721
335. Luteal cyst of the ovary	724
336. Broad ligament abscess	726
337. Abscess situated far laterally in the broad ligament drained by an in- cision above Poupart's ligament	727
338. Hernia of the linea alba	731
339. Esophagus and stomach showing site of stricture, the greatly dilated esophagus and the marked dilatation of the cardiac end of the stomach	745
340. Interior of the esophagus showing the atheromatous degeneration of the mucosa	746
341. Slide of an atheromatous plaque of the preceding	747
342. X-ray picture of the filling defect in sarcoma of the ileocecal junction	750
343. Sarcoma of the ileocecal junction	752
344. Sarcoma of the ileocecal region	753
345. Esophageal dilatation due to a cicatrix of the cardia	756
346. Carcinoma of the esophagus	766
347. Stone from common duct	776

FIG.	PAGE
348. Large broad ligament abscess pointing both in the vagina and over Poupert's ligament	785
349. Bilateral broad ligament abscess	786
350. Adenocarcinoma of the stomach	789
351. Diagrammatic presentation of a supposed pancreatic cyst	792
352. Polycystic disease of the lesser omentum	794
353. Cross section of a polycystic tumor of the lesser omentum showing the numerous smooth-walled cysts	795
354. Slide of Fig. 353	796
355. Ulcerating carcinoma of the stomach	798
356. Pseudocyst of the pancreas	802
357. Malignant cystoma of the ovary	804
358. Ovarian cyst with twisted pedicle filled with blood clot	807
359. Enlarged thick-walled gall bladder	817
360. Rhabdomyosarcoma of the right kidney	819
361. Rhabdomyosarcoma of the right kidney	820
362. Dilated veins in the abdominal wall due to obstruction of the venous return	821
363. Aneurysm of the left renal artery	823
364. Hypernephrosis showing the dilated pelvis and thin cortex of kidney remaining	825
365. Hypernephroma of the kidney	827
366. Hypernephroma of the kidney	828
367. Pendulous fibrosarcoma of the external surface of the stomach	830
368. Fibrosarcoma of the stomach	831
369. Carcinoma of the cecum with lymph gland involvement	833
370. Pelvic hematoma	835
371. Colloid degeneration of a myoma of the uterus	840
372. Schematic presentation of a subperitoneal postoperative hematoma	841
373. Myxedema before treatment	843
374. Patient after ten days' treatment with thyroid extract	843
375. Before onset of the disease	843
376. Myoma of the uterus with an infected focus in its interior	846
377. Schematic differentiation between an enlargement of the uterus due (A) to a pregnancy and (B) to tumor	848
378. Hemorrhagic myoma which simulated pregnancy	849
379. Fibrosarcoma of the ovary	862
380. Perithelioma of the ovary	864
381. Hemorrhagic myoma	866
382. Adenocarcinoma of the ovary	868
383. Endocervicitis with mucus discharge	871
384. Early carcinoma of the rectum	873
385. Huge fallopian tubes possibly tuberculous in nature	875
386. (A) Beginning malignancy in adenomyoma of the uterus. (B) Metastasis in the ovary	881

FIG.	PAGE
387. (A) Metastatic malignant adenoma of the ovary. (B) Adenocarcinoma of the fundus	881
388. Papillary cystadenoma of the ovary	883
389. Pedunculated myoma protruding into a hematometrium	886
390. Technic for removal of pedunculated myoma of the uterus	888
391. Diagram showing relation of the tumor to the uterus in the preceding figure	889
392. Pedunculated myoma of the uterus	889
393. Technic for resection of a persistent corpus luteum	891
394. Carcinoma of the vagina	895
395. Polypoid degeneration of the cervical mucosa	896
396. Carcinoma of the cervix	898
397. Carcinoma of the cervix	901
398. Carcinoma of the cervix after myomectomy	903
399. Fungus carcinoma of the uterus	904
400. Adenomyoma of the uterus	905
401. Hyperplastic endometrium in adenomyoma of the uterus	906
402. Adenomyoma of the uterus	908
403A. Myosarcoma of the uterus	909
403B. Myosarcoma of the uterus	910
404. Pedunculated intrauterine myoma	912
405. Technic of vaginal hysterotomy	913
406. Myosarcoma of the fundus of the uterus	915
407. Myoma of the uterus showing lymph sinuses, some of which are filled with blood clot	917
408. Fundus carcinoma of the uterus	919
409. Fundus carcinoma of the uterus	920
410. Carcinoma of the fundus of the uterus	922
411. Retained placenta resembling deciduoma maligna	924
412. Small mucus polyp of the endometrium	925
413. Carcinoma of the body of the uterus	928
414. Carcinoma of the body of the uterus	929
415. Carcinoma of the fundus of the uterus	932
416. Beginning carcinoma of the fundus	933
417. Carcinoma of the body of the uterus	935
418. Temperature curve during the period of parotid suppuration	936
419. Granulomatous endometrium in a case of pyometrium	939
420. Lipoma of the femoral ring	943
421. Femoral hernia masked by lipoma	943
422. Cyst of the canal of Nuck	945
423. Abscess in a lipoma of the femoral ring	947
424. Inguinal hernia masked by lipoma	949
425. Femoral and interstitial hernias	951
426. Schematic presentation of the traction produced by the deposition of fat about the umbilicus	952

FIG.	PAGE
427. Diagrammatic presentation of a cross section of the abdominal wall in the region of a beginning umbilical hernia	953
428. Bald-headed endothelioma of the abdominal wall	957
429. Accessory mammary gland in male	958
430. Fibrosarcoma of the inguinal region	959
431. Bald-headed sarcoma	960
432. Spindle-celled sarcoma of the groin	961
433. Necrosis of a loop of ileum in a case of strangulated femoral hernia	963
434. Torsion of the great omentum	965
435. X-ray of sinuses filled with bismuth paste	972
436. Large stone in pelvis of kidney	976
437. Two large bladder stones	978
438. Papillary cystadenoma of the ovary	980
439. Early tuberculosis of the kidney	993
440. Carcinoma of the base of the bladder	996
441. Papilloma at base of bladder	998
442. Hypernephroma of the kidney	1002
443. Bar across the base of the bladder after prostatectomy	1004
444. Sarcoma of the posterior wall of the bladder	1005
445. Diverticulum of the bladder everted showing the structure of the lining wall	1008
446. Diverticulum of the bladder	1018
447. Keloid of the prostatic capsule after prostatectomy	1020
448. Diagrammatic presentation of stricture of the rectum	1024
449. Deep ulcerous carcinoma of the rectum	1027
450. Catheter with a silk suture protruding out of the suprapubic wound	1028
451. Carcinoma of the rectum	1034
452. Carcinoma of the rectum beginning just above the sphincter	1036
453. Fungating carcinoma of the anus	1038
454. Tuberculous pararectal fistula	1043
455. Tuberculosis of the pararectal tissue	1044
456. Tuberculous ulcer of the anal margin	1046
457. Condyloma of the anal region	1048
458. Condyloma of the anal region	1048
459. Strangulated hemorrhoid	1050
460. Prolapse of the rectum in a child	1051
461. Carcinoma of the vulva	1054
462. Hernia in the perineum	1055
463. Carcinoma of the clitoris	1056
464. Submucous myoma protruding from the vagina	1058
465. Supravaginal amputation of the uterus when inverted by a tumor	1058
466. Pedunculated tumor of the uterus	1060
467. Cyst of the vagina	1063
468. Esthiomene	1064
469. Slide from Fig. 468	1065
470. Lipoma of the labium majus	1067

FIG.	PAGE
471. Lipoma of the labium majus after excision	1067
472. Diagrammatic presentation of epispadias	1068
473. Chronic induration of the penis	1070
474. Chronic induration of the penis	1070
475. "Washboard" prepuce	1071
476. Cauliflower carcinoma of the glans	1073
477. Squamous-celled carcinoma of glans	1074
478. Benign papillomas of the prepuce	1075
479. Hematocele removed for mixed tumor of the testicle	1076
480. Sloughing testicle after operation for retained testis	1078
481. Mixed tumor of the testicle	1080
482. Mixed tumor of the testicle	1082
483. Mixed tumor of the testicle	1083

CLINICAL SURGERY

BY CASE HISTORIES

VOL. II

CHAPTER XI

SEVERE ABDOMINAL CRISES

Under this head are included those conditions which if unaided by surgical means are prone to end in death. They include intra-abdominal hemorrhages, perforations into the unprotected peritoneal cavity and obstructions to the gut current or conditions that impair the integrity of its walls. This group of diseases demands immediate action and does not admit of detailed study but must be attacked on the basis of the intuition of the surgeon, backed by experience in similar conditions.

These conditions must be distinguished from painful affections that are in themselves important but do not tend to destroy life.

UPPER ABDOMEN

Crises arising in the upper abdomen have to do with perforations of the stomach and duodenum and necroses of the pancreas. Rarely a necrosis of the wall of the gall bladder may result in an immediately serious condition. The diagnosis of perforation is dependent on a sudden atrocious pain in the pyloric region sometimes antedated by mild symptoms of gastric disorder. The cardinal symptoms of pancreatic disease are pain, collapse, distention and rapid pulse.

This group must be differentiated from the spasmodic affections in the upper abdomen, notably gall bladder and renal colics. The notable difference in these is that there is no collapse in propor-

tion to the severity of the pain and when they have existed for some time there is less tendency to general disturbances; notably those of the pulse and temperature. Often history can be of help.

CASE 1.—A farmer aged fifty was visited because of some affection of the upper abdomen.

History.—His illness began two months ago. He had been working hard all day on the farm but complaining a little of a feeling of fullness across the epigastrium. He ate a hearty supper and that night about 10:30 he was seized with a sudden and very severe epigastric pain. This was accompanied by vomiting and followed by distention and extreme abdominal rigidity. The physician who was called at that time said that his pulse was about 120 and his temperature normal. A surgeon was called, who made a diagnosis of intestinal obstruction. He was removed to a hospital that night and operated on the next morning. The vomiting had stopped some time during the night, but the rigidity and distention remained at the time of the operation. At operation a right rectus incision was made. It was said that an obstruction was found at the hepatic flexure of the colon. The character of the obstruction or the method of its relief could not be ascertained. The appendix was then removed and the wound closed without drainage. The patient was relieved for the time being but one and a half weeks after the operation and while still in bed at the hospital he had an attack much like the one he had the day before he was brought in for operation. The pain, as before, was across the epigastric region and was accompanied by vomiting, distention and rigidity. The pulse rate and temperature could not be ascertained. The pain was attributed to gas and treated as such. It gradually passed away in twenty-four hours.

The wound healed, but the patient did not improve. He became emaciated and weak, and took on a lemon-yellow color. A diagnosis of pulmonary tuberculosis was made while still in the hospital. It was claimed that organisms were found in the sputum. Four weeks after operation the patient was carried home on a stretcher, and he has been in bed since that time. His physical condition did not improve, and he has gradually grown weaker. Three weeks after he came home he was seen again by the operating surgeon who examined the blood and made a diagnosis of pernicious anemia. The hemoglobin was reported as 65 and the red

count as 1,500,000 with microcytes, poikilocytes and nucleated red cells.

Yesterday, three weeks after his return from the hospital, he had an attack of acute abdominal pain with some rigidity, but no vomiting. His temperature was 102° and the pulse 110 the attending physician says.

Examination.—The patient is emaciated, weak, approaching collapse. He has a temperature of 101.5° and a pulse around 100, very weak, scarcely palpable. The respiration is not markedly accelerated but labored. There is very little abdominal rigidity, but he complains of pain in the upper abdomen. Examination of the chest shows flatness and bronchial breathing over the whole lower right lobe of the lung. No flatness but crepitant rales over the lower left lobe. Blood examination at this time showed a hemoglobin of 60 per cent (Tallquist), a red count of 2,100,000 with the red cells normal and a white count of 6,000.

Diagnosis.—A vigorous farmer after eating a hearty meal had severe epigastric pain with a rapid pulse and distention but without fever. One thinks of perforation of an ulcer or pancreatitis. There is no history of gastric disturbance and the pain remained localized in the epigastric region. A perforated ulcer would have caused pain down along the right side unless indeed it had become localized. The operation excludes this. An account is given of an obstruction at the hepatic flexure. The onset is wholly unlike an obstruction in this region. Had the surgeon had a definite obstruction to deal with he would scarcely have bothered about an innocent appendix. We may conclude, therefore, that he was not clear in his own mind as to the presence of obstruction. The finding of tubercle bacilli does not require serious consideration. No mention was made of epigastric exploration at the time of the operation. There remains a consideration of pancreatitis. The progressive emaciation is in line with this, as is the anemia. The present examination indicates a secondary and not a pernicious anemia. His primary affection was probably a pancreatitis. The present state of the lungs, flatness and bronchial breathing on the right side and crepitant rales on the left suggests a hypostatic pneumonia. The state of the circulation and the general enfeebled condition are quite in harmony with the physical findings.

Treatment.—Stimulants were suggested.

After-course.—He died the next day.

Autopsy.—Only the abdomen was examined. Adhesions of the omentum were found along the under surface of the operative scar.

The omentum and mesentery were found studded with raised yellowish patches of various sizes, the largest about the size of a finger nail (Fig. 285). These were taken to be fat necroses. The intestines, including the hepatic flexure of the colon, were normal in appearance. There were no stones in the gall bladder. The pan-

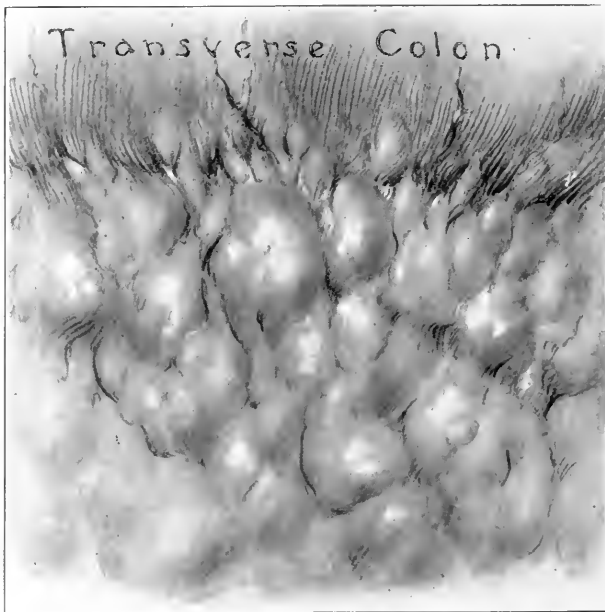

Fig. 285.—Fat necrosis in the upper part of the omentum from a case of necrosis of the pancreas. The white necrotic areas are set into the unchanged fat of the great omentum like tiles in a floor.

creas was mottled in appearance, but the larger pancreatic ducts were all stained with bile. The slide showed fat necrosis of the mesentery (Fig. 286). Many of the fat cells near the periphery of the necrotic area showed round-celled infiltration indicating that the necrosis had existed for some time. The pancreas itself showed islands of old necrosis (Fig. 287).

Comment.—It is important in operating for a grave abdominal crisis to search until a lesion is found capable of producing the

symptoms present whether the hypothetical lesion is found or not. This search is much facilitated if the operator has clearly in mind

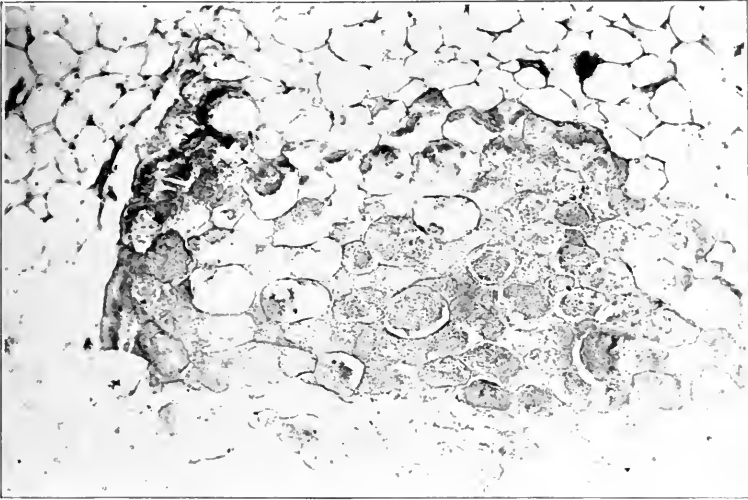


Fig. 286—Fat necrosis of the omentum in a case of acute pancreatitis. Note the opaque degeneration of the fat cells. Some of these have moderate cellular infiltrations about them.

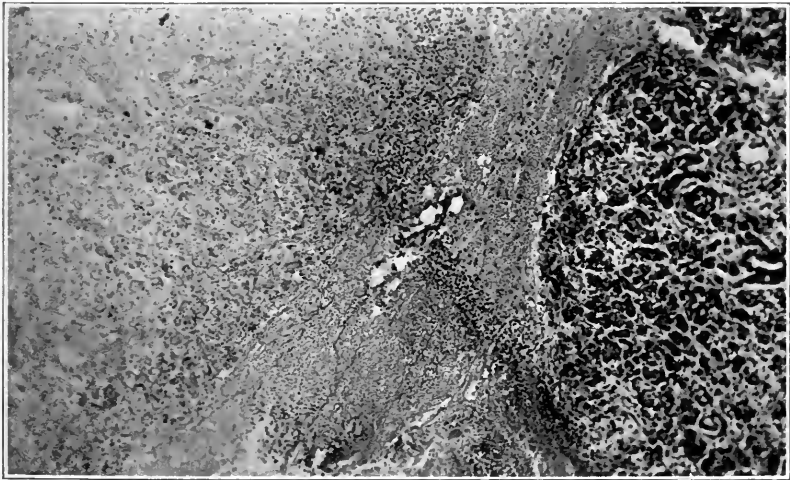


Fig. 287.—A necrotic pancreas nodule on the left and one nearly normal on the right.

all the conditions that might be responsible for a condition such as he has in hand.

CASE 2.—I was asked to see a boy aged four because of pus in the right side.

History.—The child has a markedly distended abdomen which is not tender. The patient has been sick five weeks. An adequate history of the onset is not obtainable. There was fever and digestive disturbance.

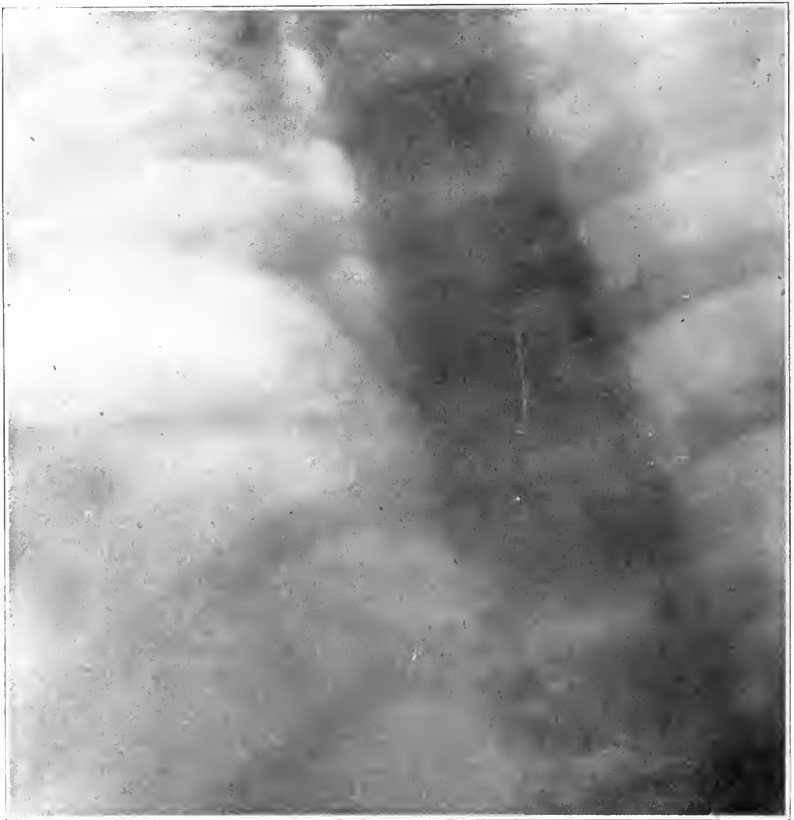

Fig. 288.—Subdiaphragmatic abscess containing gas.

Examination.—The liver is palpable below the costal margin, about two inches breadth. The dullness extends to the fourth rib. Above this is tympany. The x-ray shows a light shadow with a marked oval curve above (Fig. 288). This extends to the third rib. The leucocytosis is high, around 20,000, and the temperature ranges from 101-103°.

Diagnosis.—Because of the increased area of liver dullness, the leucocytosis and fever, the diagnosis of an abscess in the region of the liver advanced by his physician was accepted. The question at issue was what was the relation it bore to the diaphragm. Because it extended so high, to the third rib, it was my opinion that it was above the diaphragm, that is, that it was an empyema. My consultant insisted it was subdiaphragmatic. Above or below the diaphragm it seemed best to drain transpleurally. If it is pleural, the problem will be easily solved. If it is subdiaphragmatic, it will best be drained transpleurally.

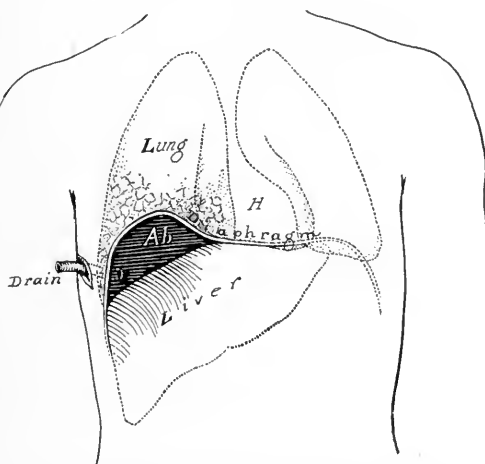


Fig. 289.—Subdiaphragmatic abscess drained transpleurally after the pleural space had been obliterated by packing it a week with gauze.

Treatment.—A rib was resected and the pleural cavity was found free from pus, but the bulging abscess was felt beneath the diaphragm. A pack was placed against the diaphragm in order that a walled-off tract might form between the abscess and the external wall. After four days the pack was removed and the abscess opened (Fig. 289). Much gas and foul smelling pus escaped. A rubber tube was placed in the abscess.

Pathology.—A pure culture of colon bacilli was obtained.

After-course.—The child died in twenty-four hours.

Comment.—The oval curve of the shadow in the plate should have made the diagnosis early. It seemed to me that the diaphragm could not be forced so high. In empyema confined between the lung and

diaphragm the border of the lung must needs be fixed, which it was not. In empyema there would most likely be some involvement of the lung adjacent to the pleura involved, which there was not. The child died evidently from a too early opening of the abscess before the pleura had had time to effectually wall off a tract. It was recognized that four days was too short a time to be sure that much walling off had occurred, but the drainage of the abscess seemed to my consultant to be urgently necessary. The patient was becoming rapidly more distended and he began to vomit. In draining a sub-diaphragmatic abscess transpleurally, as in draining a lung abscess, it is necessary that a walled-off tract be secured before the abscess is drained. If this precaution is not taken a suppurative pleuritis is almost certain to result. The light area seen in the x-ray plate at the dome of the diaphragm was obviously due to the pressure of gas.

CASE 3.—I was called to see a farmer aged fifty-six because of severe abdominal pain.

History.—The patient has not complained of gastric symptoms, other than occasional distention and eructation. Two days ago while driving a team about 5:30 P. M. he had a severe pain in the upper abdomen. He finished his journey, unhitched his team, and went to the house and lay down on the sofa. The pain increased in intensity and he called a physician some six hours later. The attendant found him with a pulse of 86 and a temperature of 100°. There was marked muscular rigidity along the whole length of the rectus. The chief point of tenderness was located three inches to the right of the umbilicus. The following day the pain extended across the lower abdomen and became much more intense and he began to become distended.

Examination.—Now two days after the onset of the disease he has a sensitive and distended abdomen. The temperature is 100.2°, the pulse 136, small and thready in character, and there is marked distention. The tenderness is marked, particularly across the lower abdomen. By placing him on the right side, a large amount of fluid can be demonstrated by percussion. The features are pinched, the extremities cooling.

Diagnosis.—The fact that he states that the onset was at 5:30 at once suggests a perforation. The beginning of the pain at the right upper abdomen, the extension downward and finally the invasion of

the whole pelvis is confirmatory of this suspicion. The demonstration of free fluid likewise is quite in harmony with this view. The perforation of an appendix lying high and lateral to the colon as his physician suggests is unlikely, because appendices lying in this position do not blow out. It is only appendices lying at the pelvic brim that perforate with these hyperacute phenomena. Obviously the man is moribund.

Treatment.—An incision was made over the right rectus between the costal border and umbilicus. A considerable amount of fluid escaped. When this field was cleared a perforation of the pyloric end of the stomach was found. By raising up the abdominal wall a large

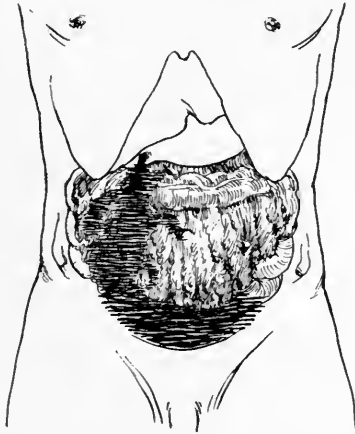


Fig. 290.—Schematic drawing of a neglected case of perforated ulcer showing the accumulation of the fluid in the pelvis.

quantity of fluid could be seen occupying the lower abdomen and pelvis. The amount of fluid was so great that the omentum was floated toward the left side (Fig. 290).

After-course.—The patient died in twenty-four hours.

Comment.—There were no protective adhesions about the perforation and it is a question why the initial pain was not so great as usually is the case in such large free openings. Possibly there was little to escape, for the patient had taken nothing into his stomach for five and a half hours. The fluid found in the abdomen was a peritoneal exudate and not fluid that had escaped from the stomach.

CASE 4.—A farmer aged fifty-four was brought to the hospital because of a severe abdominal pain.

History.—At 5:30 in the evening he was attacked by a severe pain in the region of the umbilicus. He took some liniment to relieve the pain. He vomited. He then took some whiskey and vomited again. His physician, who arrived at eight o'clock, gave him four quarters of morphine before the pain subsided sufficiently to make it possible to remove him to the hospital. At this time his temperature was 97° and the pulse 90. His physician says the upper abdomen was rigid while the lower was only moderately so. During the night the greatest pain was complained of in the hepatic region and in the back. He received two more quarters of morphine during the night. He passed urine once during the night. It was not attended by pain. His wife states that he has had some digestive disturbance during the recent past and has taken some tablets for it.

Examination.—The patient's appearance is that of acute distress. His temperature is 98° , pulse 80, full, just a little quick. The respiration is 48. The region of the gall bladder is tender and rigid and he seeks to halt the examiner by the interposition of his hands. The lungs are negative save for a few large bubbling rales at the level of the angle of the left scapula behind. The lower abdomen is but little tender, but there is dullness over the pelvis. It moves on change of position. There is no tenderness in the back.

Diagnosis.—The sudden onset of severe pain located in the beginning, at the umbilicus, later concentrating in the hepatic triangle, in an individual the subject of chronic indigestion, suggests a perforated ulcer. Against this assumption was the first appearance of pain at or below the umbilicus and the absence of deep tenderness and rigidity over the ascending colon. The initial pain in ulcer is usually over the site of the escaping fluid. He is a moderately thin man and the attack came on before supper, both points counting against a pancreatic necrosis. Besides, the pulse was slow, whereas in pancreatic disease, it is usually rapid from the beginning. Gall bladder colic was ruled out because of the very intensity of the pain associated with a subnormal temperature. He has vomited only after taking the liniment and whiskey, and the tympany was not marked, hence intestinal obstruction was not seriously considered. Taking all things into account, a grave abdominal crisis demanding immediate operation was diagnosticated. A perforated ulcer seemed the probable diagnosis.

Treatment.—An incision was made through the right rectus muscle, the midpoint of the incision being on the level of the umbilicus. As soon as the abdomen was opened a quantity of blood-stained serum escaped. Ulcer was therefore excluded. The transverse colon appeared blue-black and a mesenteric thrombosis was suspected. Close inspection showed this suspicion to be unfounded. The hand was passed into the pelvis and a mass of distended intestines was found here which could not be dislodged. The incision was enlarged downward when the fingers could be hooked under a band and by making traction the whole mass was brought out of the wound. A blackened area of gut was delivered, having as its midpoint a blackened and erectile Meckel's diverticulum. The diverticulum was adherent to the mesentery and a half dozen loops of gut had slipped through the loop so formed. After an interval the gut did not change color, therefore, the necrotic loop was fastened within the incision and a rubber tube placed in the proximal loop of gut.

After-course.—The patient rallied well after the operation, but died the following day.

Comment.—The cause of the crisis was not correctly diagnosed, but the fact that immediate operation was demanded was correctly recognized. That was the essential point. The uncertainty of the diagnosis was recognized and the incision so placed that it could be easily lengthened in the direction of the offending area. In such cases even when it is recognized that the gut is hopelessly lost, it is best to open the gut. Immediate attempt at anastomosis, while inviting, usually ends in disaster either from shock or from secondary perforation because the gut has become necrotic beyond the region of resection from extension of the thrombosis in the mesenteric vessels. Why the pain was referred to the upper abdomen does not appear quite clear. The distended loops lay in the true pelvis, putting the mesentery on the stretch. It is this tension on the mesenteric root, likely, that determined the location of the pain. The presence of a fluid exudate in the pelvis was not taken sufficiently into account. Fluid in the pelvis in the absence of pain along the ascending colon should have located the lesion independent of the upper abdomen. While the upper abdomen was sensitive to pressure, there was no evidence of reaction sufficient to account for the symptoms. However, listening to boiling instruments is not conducive to accurate thinking.

CASE 5.—A farmer aged thirty-six was brought to the hospital because of severe abdominal pains.

History.—At six o'clock, while unhitching his team, he was seized with sudden severe abdominal pain. He fell to the ground and was carried into the house. He vomited once at this time. A doctor was called, who refused temporary treatment, but hurried him to the hospital. On arrival at the hospital he was given $\frac{1}{4}$ grain of morphine. The patient had an attack of severe epigastric pain eighteen years ago. He was in bed two weeks at that time and he has had stomach symptoms ever since. The distress is worse in spring and fall. About three hours after meals he has a burning in the epigastrium, with nausea, but no vomiting. This pain is relieved by eating. The attacks last for two months or more and then they gradually disappear. Recently for a number of weeks he has had a return of the above symptoms. Two days before the present attack the symptoms were exaggerated. There was little pain, but shaking while driving on a wagon made him feel bad. He worked right along.

Examination.—The pulse is slow, there is no fever, but there is a board-like rigidity over the entire abdomen. There is very severe pain all over the abdomen which is not relieved by morphine gr. $\frac{1}{4}$.

Diagnosis.—The very severe pain coming on at a time so definite that the patient is able to recall the act he was performing when he was struck down spells only one thing—perforation. The previous long history of serious epigastric disorder is interesting and confirmatory evidence.

Treatment.—Operation was performed six hours after the attack began. A perforated gastric ulcer the size of the end of a lead pencil on the anterior surface of the stomach was found. There was an induration about it the size of a dollar. The perforation was sewed up and the abdomen drained.

After-course.—The patient made an uneventful recovery and with the aid of antacid treatment has remained free from his former symptoms, until two years after the operation. He now has renewed trouble with his stomach. Antacids and diet control the pain, but when the treatment is discontinued, the difficulty returns.

Comment.—The history of this case is classic. The diagnosis was promptly made by his physician, and he very properly refused palliative treatment until immediate operation was agreed upon and

preparations for the departure to the hospital begun. These are emergencies and it is the attendant's duty to point out the need of immediate operation at his command. With an overwhelming pain in the abdomen it is much easier for the patient to perceive the need than after he has been eased by morphine. Such strategy is wholly in the interest of the patient. With the persistence of the symptoms at the present time it is my opinion that operative treatment of the ulcer should be undertaken.

CASE 6.—I was called to see a jeweler aged twenty-eight because of severe abdominal pain.

History.—At 5:30 at the close of a Sunday evening meal the patient was seized by a sharp, lancinating pain in the epigastrium, just to the right of the median line. This pain was described as excruciating. After existing at its greatest intensity for some ten minutes, it began to subside somewhat. When I saw him at the end of twenty minutes he lay on the couch, trousers open, shirt drawn up, vainly holding a hot-water bottle to his right side. This position was chosen because the weight of the bottle was too great to be borne over the site of the most intense pain. His respirations were superficial and cautious. He began to moan loudly and lament that the awful pains were approaching again. The increased pain was marked by a horrified expression of the face and a beady brow. His general attitude was that of an agonizing serpentine movement with a general spasticity of the muscles. Every manifestation of human suffering both physical and mental found expression here in the most emphatic degree. It well deserved the French term "brutal." He has had some epigastric distress for some months, and three weeks before the attack he got an antacid mixture from his doctor which gave him some relief.

Examination.—The small, rapid pulse, the cold, beaded brow, and the history of preceding gastric hyperacidity left no question as to the diagnosis. The site of initial pain, well to the right of the median line, made the probable site of the lesion to be the duodenum. He was taken to the hospital and transported directly to the operating room.

Treatment.—Laparotomy was done. The incision was made at the lateral border of the rectus above the level of the umbilicus. The moment the peritoneum was opened, a flaky whey-like fluid escaped. This fluid contained a few flocculi like clabbered milk. A

fine stream of this flowed over the omentum directly to the pelvis (Fig. 291). When this was sponged away the opening in the duodenum appeared in the wound. The opening about 5 mm. in diameter occupied the center of an indurated area the size of half a dollar. The thickness of the indurated area seemed to be 5 to 6 mm. Because of the indurated, fragile condition of the gut wall about the opening, closure was imperfect. The sutures were re-enforced by a tag of omentum. Drainage was placed about the wound. Since the escape of fluid was slight, no deeper drains were placed.

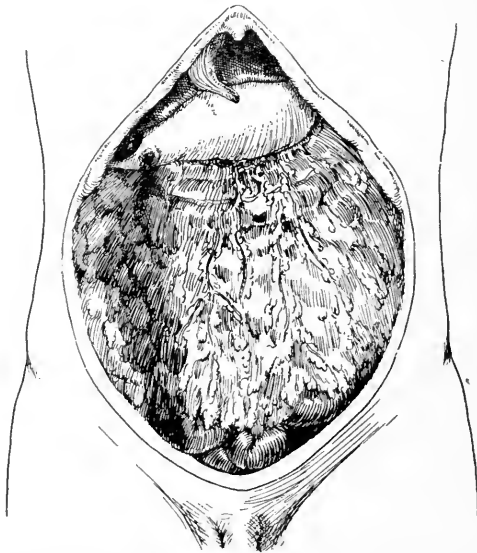


Fig. 291.—Schematic presentation of the direction of escape of duodenal contents over the watershed provided by the great omentum.

After-course.—There was considerable pain in the epigastrium for a few days, but the recovery was uneventful. He was placed on ulcer treatment and general improvement was rapid. For six months or more he had attacks of hyperacidity and had to have antacids. For some two years now he has been free from pain.

Comment.—This is the only patient I have ever seen in the throes of the first pains from perforation. It did much to impress on me the importance of the history of intense pain, and to appreciate how diabolical a peritoneal irritation may be. This early pain

must be due to the irritation of the peritoneal nerve endings by the action of the acid fluid from the gut. It can not be due to inflammation, for at the time of operation none of the phenomena of inflammation had been initiated, and when the fluid had been removed, the intense pains did not return though the phenomena of inflammation about the drain obviously increased and gave rise to pains of its own, but they were of a different character and of a lesser intensity than those which marked the onset of the disease. The fragile nature of the gut wall at the site of the ulcer made reinforcement by means of the omentum imperative. It is an open question as to whether or not a gastroenterostomy should have been done at once. Deaver advocates this measure as a routine procedure, and when it is necessary to greatly narrow the lumen of the gut in order to close the perforation, this means of reestablishing the circulation may be the only way out. As a routine procedure it can hardly be commended for the great omentum furnishes a means of protection of the peritoneum of the intestines, and if this organ is lifted to make anastomosis possible, this protection is largely negated. The mere existence of an ulcer can not be regarded as a routine indication for gastroenterostomy. Narrowing of the lumen alone can present such an indication. Deaver's experience merely proves that a great surgeon can do almost anything within the abdomen under almost any condition and meet but a small mortality. For the great bulk of lesser lights, more conservative measures are in order. The work of Deaver should excite our admiration, even our astonishment, but it should not excite our emulation.

CASE 7.—A clerk aged forty was brought to the hospital because of abdominal pain and distention.

History.—For the past eighteen years the patient has had gastric trouble. This took the form of an epigastric distress, coming on one or two hours after each meal. Only distress was felt in the epigastrium, but straight through to the back she felt a sharp, severe pain. This distress and pain were relieved by food, alkalies, and often even by a drink of water. She was often nauseated during these spells, but she never did vomit. The pain was made worse by sour foods. She often was troubled with "heart burn" and acid eructations. The attacks of pain after eating would last from six weeks to three months and then she would have a

free interval of several months. It was so during the eighteen years. Hard work during an attack always made the attacks worse, in fact hard work would often start the gastric trouble while a vacation sometimes made it disappear. She has been obstinately constipated during the eighteen years. The attacks continued so up to two weeks preceding the trouble that brought her into the hospital. For the last two weeks the old gastric distress which she has had for so long has been especially severe. The epigastric distress and pain in the back have been coming on a short time after eating and lasting until the next meal was taken. She has been very much nauseated after meals, but has not vomited.

Three days ago she ate a lunch about 1 P. M. and returned to work in the store. She had a great deal of epigastric distress that afternoon. About 4 o'clock she was just thinking of going out to get something to eat in the hope that it would relieve the distress, when she felt a sudden, sharp pain in the right epigastric region. This was immediately followed by severe pain straight through to the back and down in the lower abdomen in the bladder region. She staggered backward into a chair. She felt very weak and felt as though she could not get her breath. The pain became general all over the abdomen, but she did not vomit. She sat in a chair doubled over forward. A doctor was called, who took her home in his car. She could not straighten up on account of the pain. The doctor said her heart action was very weak and gave her strophanthus tr. by mouth (dose not known). This was about 5:30 P. M. This medicine apparently started her to vomiting. She vomited once then and once about 5:45. The vomitus looked like recently eaten food and contained no visible blood. At 6 P. M. the patient had a pulse of 80, of good force, and a temperature of 98°. She had general abdominal pain and soreness to pressure anywhere in the abdomen. Toward morning the pain settled in the epigastrium and right side of the abdomen. It extended across the epigastrium and down the right side of the abdomen, but not to the groin. It remained so until her entrance into the hospital three days after the attack. In the time between the onset of the attack and entering the hospital she had not eaten anything and her bowels had not moved, thought her physician had given her quantities of purges. Her pulse had run from 80 to 90, and the temperature from subnormal in the beginning to 100°. The abdomen gradually became distended.

Examination.—The patient is a thin, anemic-looking woman appearing to be about 40 years of age. She looks acutely ill. Her color is sallow and the facial expression is one of anxiety. The heart and lungs are negative. The abdomen is considerably distended and tympanitic. There is no palpable mass and no dullness in the flanks. There is tenderness to pressure all over the abdomen, but this is especially marked in the right epigastric region and down the right side of the abdomen about on a level with the iliac crest. The pelvis was not examined. The reflexes were all somewhat exaggerated; no Babinski.

Diagnosis.—The history of long endured gastric disease, indicating hyperacidity or ulcer, the sudden advent of pain, the vomiting, the pain in the subhepatic region and along the right lateral walls makes the perforation of a peptic ulcer certain. Gallstone colics sometimes first appear after years of hyperacidity due to referred irritation from the gall bladder. Gallstone colics are not attended by collapse. Renal colics, too, may at first refer their pain to the subhepatic region. There is usually pain in the back and down the ureter. In neither gall bladder disease nor renal colic is there board-like rigidity as there is in perforated ulcer. Pericholecystitis may produce rigidity, but it does not come on at once, neither is it as intense as in ulcer. That she is alive three days after being treated with purges indicates the perforation is slight, incomplete, or well walled off. Inspection only can show which it is.

Treatment.—Incision was made in the epigastric region in the right rectus just below the costal margin. The pyloric end of the stomach and the duodenum were found walled off by adhesions. A tongue of omentum was attached to the pyloric end of the stomach (Fig. 292). Some of the adhesions were recent, as much newly formed fibrin was found. The walled-off portion contained a somewhat cloudy, pale, serous exudate which did not contain any demonstrable gastric contents. The exact site of the perforation seemed to be at the site of the omental adhesion. The adhesions were disturbed as little as possible. A rubber tube and gauze drain were inserted and the abdomen partly closed.

After-course.—The pulse was 130 when the patient was taken from the operating room. This gradually became less rapid. She suffered very little if any from shock. There was no postoperative

vomiting, and the patient complained very little of nausea. The second day the temperature went to 101° , pulse 100. No nausea or vomiting. General abdominal pain and distention were relieved by gas enemata. The first food was given on the fourth day after operation, a milk diet only was allowed. The gauze drain was removed from the wound. A large amount of greenish-yellow drain-

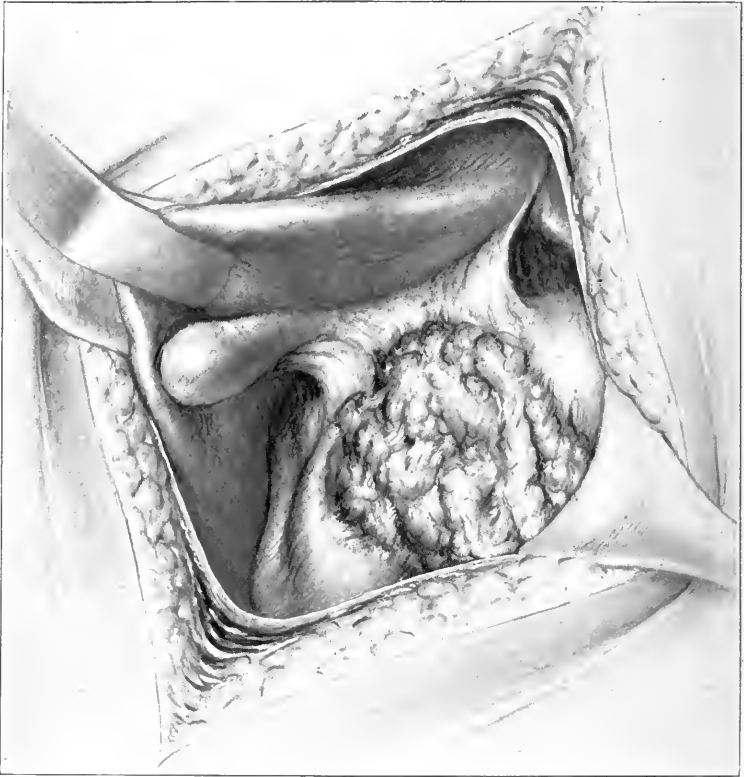


Fig. 292.—Ulcerating duodenum in which perforation was prevented by the formation of omental adhesions.

age followed the removal of the gauze. The drainage had a distinct acid reaction. It was not tested for digestive ferments. The patient felt well except for soreness in epigastrium and right side. The rubber drain was removed three days later, there was much yellowish drainage. On the ninth day the patient was given soft,

nonirritating food. The drainage continued quite free and the patient complained of pain in the right upper abdomen. The drainage grew less in amount, the pain gradually lessened, and by the eighteenth postoperative day the drainage had practically ceased. All abdominal pain and soreness was gone. The patient was put on a Sippy gastric ulcer treatment. In spite of the large amount of heavy magnesia taken daily, the patient was somewhat constipated and had abdominal distention which had to be relieved by enemas. Otherwise the patient felt fine and continued to gain in strength and at the time of dismissal, five weeks after entering the hospital, the wound was entirely healed except for the drainage opening which was crusted over. The patient had been free from abdominal pain for two weeks.

Comment.—In a case so clear as this, in which the opening is obviously closed by nature's efforts it becomes a matter of grave concern if one should allow her handiwork to remain unmolested or whether one should destroy this effort and apply therapeutics of his own. To have done so would have much prolonged the operation in a patient always frail and now reduced by three days of suffering and starvation. The adhesion bore every evidence of efficiency, consequently it was allowed to remain.

CASE 8.—A merchant of thirty-six came to the hospital because of persistent vomiting.

History.—Three or four months ago he began to have pain in the epigastrium. The pains at first were gnawing, but recently they have become darting in character. The pains at first were general in the upper abdomen but now they are more localized in the pyloric region. The digestion and appetite at first were unimpaired and there was no loss of weight. A month ago vomiting set in and loss of weight has been rapid, he having lost some twenty pounds in this interval. In the last week he has vomited nearly everything he has eaten and there is marked loss of strength in consequence. There has been no blood in the vomitus or in the stool. The bowel movements were but little constipated until the last few weeks, the constipation now is due, his doctor thinks, to the small amount of food retained. He had previously had good health without digestive disturbance of any sort.

Examination.—The patient is weak, is near collapse, the pulse 120, small and weak. He is emaciated and gives the appearance

of acute starvation. In the pyloric region there is a tumor the size of a lemon,—dense, fairly smooth, but somewhat nodulated at its upper pole. It is not movable in any direction. There is marked tympany due apparently to dilatation of the stomach and small intestines. Because of the extreme condition, no attempt at detailed analysis seems warranted.

Diagnosis.—The location and character of the tumor with the evident pyloric obstruction makes the diagnosis of carcinoma reasonably certain despite the early age of the patient, since there were no symptoms indicating an ulcer or inflammatory lesion. Furthermore neither of these conditions should have produced such a prominent tumor. An extragastric tumor should not cause such pronounced vomiting. Its density and nodular surface is typical of carcinoma. The probability, because of the fixity, is that it can not be removed. Yet starvation is imminent unless some sort of relief is obtained. A gastroenterostomy, therefore, it seems should be attempted.

Treatment.—After the abdomen was opened a tumor the size of a small fist occupied the transverse colon just below the pylorus. It was a dense nodular mass. The upper border of this tumor had infiltrated the second part of the duodenum obstructing its lumen. The lumen of the colon was partly but apparently not completely obstructed. The colon was adherent to the posterior parietal wall, therefore, an anterior gastroenterostomy was done. It appeared that a colostomy would soon be necessary, but this was left to be done at a later date under local anesthesia. The release of the obstruction to the outlet of the stomach seemed to be the one important need. When the lesion was first exposed, I was under the impression that the duodenum was the primary seat and that an ulcer lay at the base.

After-course.—The patient rallied from the operation—but vomited a moderate amount of blood during the first twenty-four hours. Subsequently he was able to retain fluids, but in spite of this he died on the third day, apparently from progressive weakness.

Comment.—The error in diagnosis was made because of the preponderance of gastric symptoms and because of the size and location of the tumor. Carcinoma of the colon was not considered. The site is unusual and usually neighboring structures are not involved so early. The operation was a poor, hopeless attempt. It would

have been better to have closed the abdomen without making any attempt at operative relief.

CASE 9.—A widow aged fifty-four was brought to the hospital because of abdominal pain and vomiting.

History.—The patient has always enjoyed good health. Twenty hours ago she had a sudden abdominal pain followed by vomiting. This subsided after an anodyne, but her abdomen began to distend. Enemas were given without result. There were spasmodic attacks of moderate pain despite the morphine given.

Examination.—The patient appears much older than the age given. Her face is serene and she appears an interested spectator of the activities surrounding her. There is moderate distention of the abdomen which is everywhere tympanitic. The walls are tense from distention, but nowhere is there rigidity, and only just below the umbilicus is there tenderness and even here it is not very marked. The nurse was able to introduce but little more than a pint of soap suds solution. Waves of peristalsis are seen at intervals beginning just to the left and above the umbilicus and travel downward and to the right. The pulse is 78, temperature 98.2, respiration 20.

Diagnosis.—The initial pain followed by vomiting and progressive tympany suggests some accident which produced an occlusion of the bowels. The failure of the enema to produce results strengthens this supposition. The absence of vomiting in the presence of a considerable distention and the small amount of enema retained suggests a low obstruction. A volvulus of the sigmoid would account for it. A sudden infection producing an adhesion or a bowel paralysis may produce a like picture. Usually a disturbance in pulse and temperature would be produced, but these may be absent. Chronic causes such as tumor or fecal impaction do not begin with pain, but may develop it later when tympany becomes pronounced.

Treatment.—Exploratory laparotomy. As soon as the abdomen was opened, loops of distended gut were encountered. By pushing them aside collapsed loops were found, by lifting on these a loop of moderately distended gut came into sight. It was easily discerned that the obstruction was due to the slipping of loops of gut through an opening in the mesentery (Fig. 293). By enlarging this opening, the imprisoned loops were easily loosened. The opening was then closed by suture.

After-course.—Recovery was undisturbed.

Comment.—The diagnosis of obstruction was not certain. The patient's condition was but little disturbed. If there had been a perforation with no reaction, early operation in the face of the absence of reaction was urgently demanded. In obstruction operation, when performed before the pulse becomes rapid and before there is vomiting, is a safe procedure. By following this plan there are few regrets, though occasionally one may operate needlessly. This is particularly true of flabby old women. In them the onset is

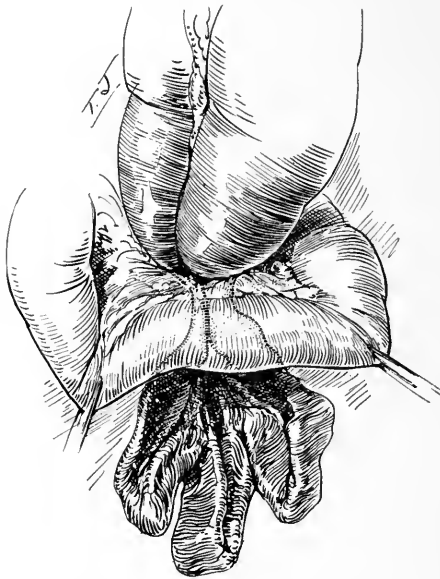


Fig. 293.—Loops of collapsed intestine lie below an opening in the mesentery through which they have slipped.

not so definite. If their pain is as acute they do not express it. Possibly the flabby state of their whole musculature is incapable of producing so much pain as in the case of husky young males.

CASE 10.—I was called to see a matron of fifty-six because of obstruction of the bowels.

History.—For some years previous to this trouble the patient has had pain at irregular intervals in the right upper quadrant of the abdomen. I saw her six years ago in one of these attacks. There was then severe pain in the upper right abdomen which re-

quired morphine for relief. Following a period of lesser pain in the hepatic region, she developed a smooth globular sensitive tumor in the hepatic triangle. This subsided after a few months. She had a similar attack a month ago which persisted more or less until the beginning of the present trouble. She had fever in the earlier period of the attack. After ten days the temperature was not determined. Six days ago she began to vomit at intervals with a few hours intermission. Two days ago she had severe pain and distention became marked and vomiting has been persistent since that time. It was announced by the attending physician that the patient had been much easier for the past four or five hours. The patient had ceased to vomit and she has no pain. He believed the crisis had passed though she had passed neither stool nor flatus.

Examination.—The patient lies indifferent, almost stuporous, but replies intelligently to questions put to her. The abdomen is moderately distended, not markedly tender. The chief site of tenderness is in the hepatic triangle. Pulse 120, temperature 100°, respiration 36.

Diagnosis.—Previous knowledge of the patient makes it possible to start with the premise that she has gallstones. Obviously there has been something superadded. There evidently is an intestinal obstruction; whether due to adhesions about the gall bladder itself or to a stone which has ulcerated into the gut is problematic. Most likely it is the latter. In cholecystitis there may be violent vomiting with distention which may suggest a grave abdominal crisis, but such events should not last a week, and above all, should not bring the patient to impending dissolution. That there is a surgical lesion is apparent. That she is a surgical patient was not nearly so obvious. My assistant (Wuttke) made an observation worth remembering: "When in a case of intestinal obstruction, a patient seems better without the passage of stool or gas, he is worse." It was obvious here that the seeming betterment in the past few hours, which her physician hailed as a good omen, was a precursor of disaster. Paresis of the intestinal walls has obviously supervened. The soft running pulse and quickening respiration confirmed this.

Treatment.—Stimulants.

After-course.—The patient died in four hours with a progressive enfeebling circulation.

Autopsy.—The small intestines in the upper abdomen were blue-green covered with a grayish exudate. They were but moderately distended. The mesenteric vessels supplying the proximal four feet of the jejunum were everywhere filled with a clot. About 20 inches from the duodenojejunal angle was a gallstone somewhat larger than a hulled walnut (Fig. 294). It could not be moved about in the gut because of the infiltrated, thickened state of the wall. The gall bladder was adherent to the duodenum and there was an opening uniting the two which showed a necrosis of all the layers with hemorrhagic infiltration of the mucosa.

Comment.—The autopsy findings raise the question as to whether or not we have to do with a mesenteric thrombosis, possibly due



Fig. 294.—Gallstones removed from the intestine following death from intestinal obstruction.

to the ulcerous process, the foreign body being but an incident, or whether the stone was an active participant in the production of the symptoms. The progressive character of the symptoms in the beginning indicate that it was the stone which made the disturbance and that the mesenteric thrombosis was a secondary factor coming on, likely, from the history, two days before. The necrotic state of the gut wall made it easy to understand why pain and peristalsis had ceased. The size of stone which is able to pass is dependent on factors other than mere volume. Smaller stones than this may cause obstruction and larger ones may pass. Ulceration with subsequent thrombosis with consequent laming of the gut wall is capable of causing obstruction with a relatively small

stone. The primary inflammation of the gall bladder is transmitted to the surrounding gut, which, in becoming attached, loses its power of peristalsis. The loss of the power of peristalsis at a time when peristalsis should be active no doubt adds to the mechanical difficulties. The reaction due to the adhesion no doubt tends mechanically to narrow the lumen of the gut.

CASE 11.—A matron of thirty-four called medical aid because of severe abdominal pain.

History.—For many years the patient has been treated by various members of the hospital staff for recurring attacks of pain in the upper abdomen. The pains were located in the right upper quadrant and radiated to the right shoulder blade. She was jaundiced at several different times. A diagnosis of gallstones was made and operation advised. The last attack was particularly severe. This morning her husband found her lying on the floor vomiting and suffering intense pain.

Examination.—There is marked tenderness over the whole epigastric area and there is marked rigidity. The vomitus is clear and contains flakes of mucus. The temperature is 102°, pulse 80, respiration 26. The patient seems much collapsed.

Diagnosis.—It is obvious that the scene has changed. In the previous attacks the pains were confined to the right side. Now they extend across the whole upper abdomen. The rigidity and sensitiveness indicates peritoneal irritation. One thinks first of all of an accident to the previously diseased gall bladder, or that the previous diagnosis was wrong and an ulcer existed instead which has now ruptured. The general constitutional effect is that of some such grave accident or perforation but there is too much involvement in the left side to permit a diagnosis of either a grave accident to the gall bladder or perforated ulcer. Necrosis or perforation of the gall bladder are usually preceded by premonitory signs. This patient has been free from pain since the last gall bladder attack three months ago. An ulcer lying in the middle of the curvatures of the stomach or which ruptures into the lesser peritoneal cavity may give rise to such symptoms, particularly if there is a partial walling off by adhesions before rupture. The onset resembles pancreatic hemorrhage except that the pulse is slow and there is little abdominal tympany.

Treatment.—She was given a preliminary injection of morphine.

After-course.—Vomiting continued and on the third day became dark brown with greenish streaks. She vomited from two to eight ounces at short intervals. The temperature remained about 102°, the pulse between 70 and 80. Repeated enemas failed to produce more than a few scybala. Abdominal distention became progressively worse. She died three days after the onset under the general symptom of weakness.

Autopsy.—The peritoneum is everywhere smooth and glistening, but there is a small amount of bloody serum between the coils of the intestines. There are numerous, small, white opaque patches in the omentum and mesentery. The pancreas is large, soft, and portions of it appear as a black, bloody mass shimmering through

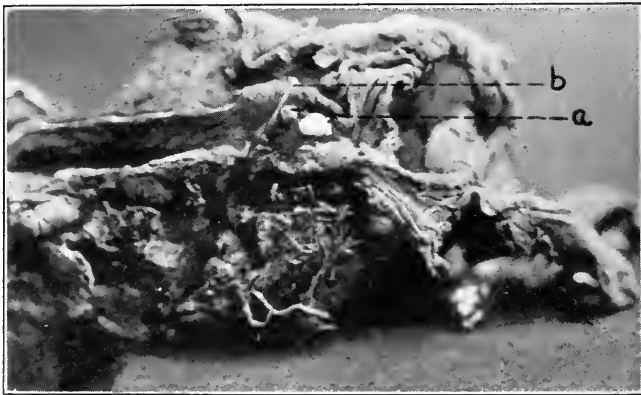

Fig. 295.—Head of the pancreas in acute pancreatic necrosis. *A*, stone in the pancreatic duct; *B*, edge of the duct retracted.

the peritoneum. On section the greater part of the gland is necrotic except a small part near the head drained by the duct of Santorini. The interlobular spaces are filled with black blood. The gall bladder is of average size and contains many stones. The stones were small and closely packed together. The orifice of the cystic duct was blocked by a stone 1 cm. in diameter. The common duct was free from stones, save for two at the papilla of Vater. One stone lay in the diverticulum between the duodenal opening and the orifice of the duct of Wirsung blocking the orifice of the papilla of Vater and converting the common duct and the duct of Wirsung into one continuous closed channel (Fig. 295). The stone was 0.4 cm.

in diameter. The common bile duct was greatly distended with bile. The duct of Wirsung also was distended and its orifice at the diverticulum was widely open and the terminal portion was bile stained. The remaining organs were without notable change, save that the spleen was large and tense. The slides show the usual picture of pancreatic necrosis.

Comment.—The associate who attended this patient was unfamiliar with the clinical picture of acute necrosis of the pancreas. A finer example of the truth of the observation of Fitz can hardly be imagined. "The onset of sudden and severe pain in the epigastrium associated with low fever, weak pulse, constipation, collapse and persistent vomiting, occurring apparently without cause in a patient previously in good health except for an occasional attack of gastric disorder." In the majority of cases the pulse is rapid as well as weak while in this case it was slow. Usually the distention becomes marked early in the course of the disease. This case presents as its chief point of interest the lodgment of a stone in the papilla in such a way as to convert the common bile duct and the chief pancreatic duct into one continuous channel fully confirming Opie's opinion that the entrance of bile into the pancreatic ducts is an important factor in the production of pancreatic necrosis.

CASE 12.—A farmer aged twenty was brought to the hospital because of persistent vomiting.

History.—Past history negative. Seven years ago he began to have attacks of severe general abdominal pain practically always accompanied by vomiting. He does not know whether he had fever or not. When the attacks subsided he was left with general abdominal soreness, the soreness persisting in the right side longer than in the left. He had these attacks at intervals of a very few months, but there was one period of two years in the seven when he was free from attacks. His last attack was five days ago when he was suddenly taken with severe epigastric cramps. Four or five hours later he began to vomit. The cramps subsided in five or six hours, but a soreness across the upper abdomen persisted until two days ago when he was relieved by an enema. His bowels have not moved without an enema since the onset of the trouble. He passed considerable flatus with one of the injections. He vomited some blood, about two teaspoonfuls he thinks, at one time. He has not vomited blood at any other time. In the last two days the pain

and soreness have subsided almost entirely, but the vomiting has persisted. Everything is vomited now. He has vomited once only a small amount from 1:30 A. M. to 8:30 A. M. today, however.

Examination.—The patient is sparsely built but fairly well nourished. Head and neck negative. Lung expansion good, equal on both sides, normal resonance over both lungs. No rales or increased fremitus. Lower end of sternum deeply sunken. Heart not enlarged, no murmurs. Dullness from midsternal line to 7 cm. to left. Apex beat in 5th interspace. Abdomen distended, no evidence of peristalsis, distention not extreme. Tympanitis to percussion. No palpable masses in abdomen; abdominal organs not palpable. Some tenderness to pressure all over the abdomen, but the greatest tenderness is just below the umbilicus and towards the right side. W.b.c. 9,800; R.b.c. 5,824,000. Hg. 70.

Diagnosis.—The history of repeated attacks of pain during the past seven years suggests an inflammatory lesion or some congenital rest producing recurrent occlusion. The latter seems the most likely, for there is no evidence of there ever having been any fever. At any rate an obstruction exists now. The persistency of vomiting after the cessation of pain indicates impending paralysis of the gut wall. There is not yet a break in the pulse rate, hence prospect from operation is fairly good despite the five days that have intervened since the onset.

Treatment.—Removal of two adhesive bands extending from the ascending colon to the omentum under which the small intestine was imprisoned. Drainage of the dilated intestine was done in order to rid the patient of the enormous accumulation and to facilitate the return of the coils to the abdominal cavity. The small intestines were found dark red in color and dilated larger than a normal large intestine. The abdominal cavity was filled with a straw-colored fluid and contained flakes and strings of fibrin. Two bands of adhesions of the omentum to the small intestine were found. A loop of intestine around these adhesions caused the obstruction. The cecum was examined and the appendix had apparently sloughed away at a previous attack. The intestines could not be replaced after removal of the obstruction so the contents were allowed to drain through a puncture of the intestine. A rubber drain was sutured through the abdominal wall. Pulse 100 and fairly good at the close of the operation.

After-course.—The patient vomited at intervals a greenish-black fluid, for the first five days following operation. Temperature ranged from 98° to 100.5°, pulse 90 to 110. Continuous proctoclysis was given and no food by mouth until the sixth day when a small amount of broth was allowed. There was much oozing through several places in the line of incision. Two days later the suture line opened its entire length. Drainage was profuse. At the lower end of the wound was seen a mass of necrotic tissue that looked like a loop of intestine. This necrotic tissue sloughed away at the

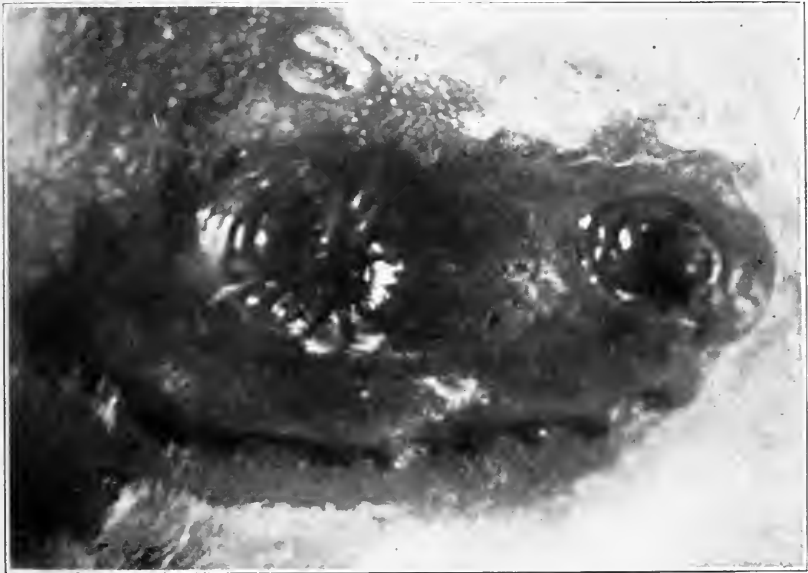

Fig. 296.—The two puckered openings in the gut are surrounded by granulation tissue.

upper end of wound, exposing the whole diameter of the intestine (Fig. 296) which was discharging its contents of partially digested food. At the end of two weeks the patient said he felt well and had a good appetite. Some food seemed to be passing through the intestinal tract as the nightly enema showed feces. There was no tendency of the wound to heal. Fistulas discharged a great deal. Condition seemed to remain about the same for several days. At the end of four weeks the wound was drawn as closely together as possible with adhesive straps. Small hemorrhagic spots appeared

in the skin on chest and abdomen and the patient was rapidly losing weight. No good results seem to come from strapping the wound, the skin became very irritated and the adhesive straps were discontinued. Four weeks after the operation a large drainage tube was inserted into the intestine with the idea of carrying the food past the fistulous opening. This failed by the tube becoming plugged with the contents. The patient became very weak and for some time he had spells in which his mind was not at all clear. Artificial feeding with peptonized foods through the fistulas was tried and proctoclysis resumed, but the patient continued to grow weaker and the periods of delirium increased in frequency. He developed a purulent discharge from the left ear. Death came from exhaus-

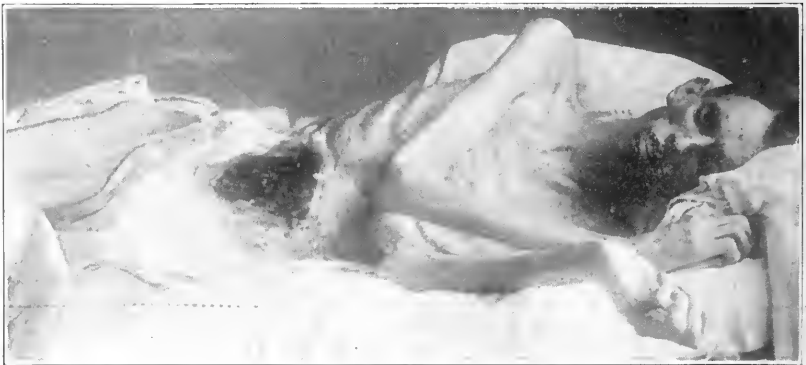


Fig. 297.—Emaciation due to intestinal fistulæ and sepsis.

tion at the end of seven weeks after operation. Emaciation was extreme (Fig. 297).

Postmortem.—Abdominal wall very thin, no omentum observed, intestines all matted down and connected to each other by adhesion bands. At upper end of abdomen on left of midline, stomach and omentum adhered to parietal peritoneum, forming a small pocket containing about 20 c.c. of pus, thick, yellow, and offensive. Intestines hard to loosen from each other because of adhesions. Many of the coils extending and matted down in pelvis, occasional small, necrotic, pus-like areas of adhesions scattered throughout. Appendix about 7 cm. long entirely retrocecal—distal end tapering. Duodenum for about 4 inches beyond pylorus distended with gas and

fluid. Stomach containing gas and fluid. First opening of intestine (operative) to abdominal wall is about 5 feet below pylorus, second about 1 foot below this. Intestines inside appear quite normal, external peritoneal surface everywhere ragged, dull appearance. Liver rather large, on section little blood, hepatic lobules rather distinct. Spleen about 12 x 7 x 2 cm., somewhat enlarged. On section little blood. Kidneys both apparently normal, very little fatty capsule. On section cortex 5 mm. thick, medulla normal, also pelvis.

Comment.—The interest in this case centers in the starvation apparently from the opening into the gut so near the stomach. At least it so appeared before the autopsy. The drainage opening was made about five feet from the duodenum. The gut was so much distended that when it burst out of the opening into the abdominal wall the peritoneum split. The drainage opening was made at this point instead of seeking a point more distal. After the autopsy it appeared as though death really was due to sepsis rather than starvation. The petechial hemorrhages should have emphasized the importance of sepsis. These spots were recognized as dependent on a septicemia but all this was deemed of secondary importance to the indifferent nutrition. The adhesions were so extensive that even had we known all the autopsy revealed, further operating would have been of little avail. Nevertheless, in operating for obstruction in the upper abdomen a point as far as possible from the duodenum should be selected for the formation of an enterostomy wound.

LOWER ABDOMEN

Severe crises in the lower abdomen have to do with perforation of the appendix and interruptions of tubal pregnancies, ruptures of preexisting abscesses, intestinal obstructions and irritations transmitted from elsewhere. Crises in this region, save in some cases of obstruction are seldom immediately dangerous and the indications for surgical operations are rarely absolute. When intestinal obstruction is due to a lesion in the lower abdomen the symptoms are usually referred to the upper abdomen or the pain is generalized. The general tendency in crises in the lower abdomen, is to act too quickly for very frequently the disease is less dangerous than the operator.

CASE 1.—A laborer aged seventeen was brought in because of acute abdominal pain and retention.

History.—For several years he has had abdominal pains at intervals. These attacks lasted from a few to fifteen minutes. He vomited several times, which relieved the pain. For the last three months the pains have been more frequent and more severe. They often come on after he has begun to eat, interrupting his meal. Forty-eight hours ago, while turning a heavy windlass, he was seized with a sudden pain, so acute was it that he was compelled to seek medical aid at once. The pain was continuous with periods of exacerbation. Morphine was required to relieve the pain. Twelve hours later, when he had been unable to urinate and distention of the lower abdomen took place, an attempt to catheterize him was made but failed. A trocar was introduced suprapubically and a quantity of fluid was drawn off. His physician believed that this was urine obtained from the free peritoneal cavity and he accordingly diagnosed a ruptured urinary bladder. This puncture was repeated at two additional occasions. Within the past six hours, however, he passed several ounces of urine spontaneously. Twenty-four hours ago the pulse was 80, temperature 98°. He has not vomited since the beginning of the attack, but the pain persists, though of less intensity.

Examination.—The patient's features are expressive of extreme pain and impending collapse. The pulse is 120, of good quality. The entire abdomen is board hard and tender all over, though not extremely so. He indicates the whole lower abdomen as the site of his greatest pain. The extreme upper ends of the recti muscles are perceptibly less tense than the lower portions. The extreme pain he suffers makes a satisfactory examination impossible.

Diagnosis.—The recurrent pain indicates a disease antedating the present attack. The pain coming on after the meal has been partly eaten suggests an ulcer of the stomach. The appearance of the present acute symptoms while doing heavy labor is in harmony with this view. A single initial emesis likewise points the same way. The pain is in the region of and below the navel. A ruptured duodenal ulcer should have the site of greatest pain near the costal arch. There should be some rise of temperature within twenty-four hours of the attack. The retention may have been due to the escape of stomach contents to the pelvis producing a reflex spasm of the bladder neck. A ruptured appendix is a possibility, though

the history is not that of a perforation of that organ. The recurrent attacks complained of were too frequent for appendicular colic, and they are not attended by after-soreness; yet this is a possibility. The frequent pains were not those of intestinal obstruction, particularly the advent of pain during the meal does not seem to fit with the theory of intestinal obstruction. An acute abdominal crisis is present, and since the chief pain was located below the umbilicus and the most marked rigidity is here, a suprapubic incision seems advisable. If there is a perforated duodenal ulcer, the suprapubic opening will be needed for the drain, for this,

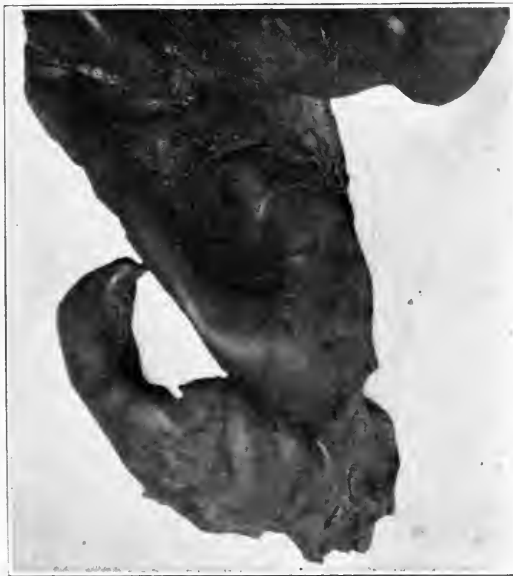

Fig. 298.—Meckel's diverticulum with its tip adhering to the mesentery, showing the loop through which the intestinal coils had slipped.

no doubt, is the site of the greatest conflict, irrespective of its source.

Treatment.—A 4 inch suprapubic incision was made. Coils of black gut presented. An investigation of the mesentery showed extensive thrombosis. The history precluding primary thrombosis, a further search was made. To the right of the conglomerate mass the gut was collapsed and of normal color. A rapid search proximally from the ileocecal valve showed a mass the size of a thumb compressing the gut (Fig. 298). This arose from the gut and was

attached to the mesentery. It was evident that we had to deal with a Meckel's diverticulum. The necrotic mass was lifted out of the wound, clamps placed on healthy gut and the whole resected. The severed ends were fastened outside of the abdomen and the remainder of the wound partly closed. Two gauze drains were placed about the ends and a double rubber drain into the pelvis.

Pathology.—The severed loops are blue-black in color. The lumen is filled with hemorrhagic exudate. The mesenteric veins are filled with blood clots. There are two small puncture openings in the wall of the gut from which bloody fluid was seen to escape during the operation. The slides show total necrosis of the gut wall with beginning loosening of some of the gland cells.

After-course.—The patient stood the operation without notable shock and the general condition continued favorable for the first twelve hours. Following this the pulse became more rapid and he died eight hours later.

Comment.—Intestinal obstruction by a Meckel's diverticulum should have been diagnosticated. It is the recurrent pain below the navel preceding a disaster that is characteristic of diverticulum trouble. This is particularly true when the recurrent pains extend over several years. The fact that he had pain during the meal is what misled me. Even the fact that the initial pain of the last attack was low and that the muscles of the upper abdomen were not wholly rigid was not sufficient to correct the delusion. The fact that the pains extended over several years in a seventeen-year-old husky boy should have made ulcer unlikely. However, an acute condition was promptly diagnosed and the incision was rightly placed and the lesion located promptly. This is all that concerned the patient. A more exact diagnosis would have been a matter of personal satisfaction and academic interest.

CASE 2.—A student aged seventeen was brought to the hospital because of chill and high fever following an operation for appendicitis.

History.—The patient was operated on two weeks ago for acute suppurative appendicitis. The wound still contains a drain. The appendix was normally located and contained pus. It was ruptured during removal. His progress until two days ago seemed favorable. At this time he began to have generalized abdominal pain most marked over the whole right side. In the evening he had a chill and

the temperature went to 104° following it. The operative wound was explored, but nothing to account for the exacerbation was found.

Examination.—The patient seems seriously sick. The abdomen is moderately distended but nowhere sensitive save near the appendix operation wound. There is some pain on deep breathing. The respirations are 32 per minute and superficial. The lung examination save for the increase in rate is negative. Pressure over the lower costal margin causes acute pain as does deep breathing combined with deep hepatic palpation. The area of liver dullness is not increased and the lower border of the lung is movable. There is no sensitiveness in the region of the kidney. The urine is negative. W.b.c. 22,000; 92 per cent polynuclear leucocytes.

Diagnosis.—Chill with rapid respiration following a surgical operation suggests pneumonia. The pain in the right side may well be compatible with a pneumonia involving the diaphragm. The lung signs are, however, negative. A metastatic lung abscess may be present. Metastatic abscess within the liver may produce such symptoms, but this accident is often attended by early jaundice. The pain caused by pressure over the lower rib border indicates an involvement of the diaphragm and liver. The onset is unusually stormy for an invasion of this region. Usually the liver dullness is extended upward in this affection but being early it may be assumed there has not yet been time for a fluid accumulation to take place. Should the abscess be intrahepatic, exploration may be a valuable first step in its drainage. At any rate the infection is pronounced and the lower costal and the subhepatic region alone give positive findings and an exploration of this region seems warranted.

Treatment.—An incision was made along the costal border from the outer border of the rectus to the anterior edge of the quadriceps muscle. Between the liver and diaphragm a quantity of seropurulent fluid was found. This was drained by tube and gauze wicks.

After-course.—Improvement was prompt. After a week he again got a rising temperature. Exploring the wound more deeply an encapsulated abscess was found. This was drained and improvement again followed. A third time the temperature rose and exploration again disclosed a pocket of pus. This time the entire subdiaphragmatic area as far as the falciform ligament was drained (Fig. 299). Following this no further disturbance took place. He was operated on some years later for a hernia in the site of the appendix operation. The liver was found not to be attached to the diaphragm.

Comment.—In draining a subdiaphragmatic abscess it is well to drain the entire space as far as the falciform ligament at the first sitting. The capacity of the liver to form adhesions to the diaphragm is very limited, and the abscess is likely to spread over the entire surface sooner or later. A generous packing of this space is followed by less pain than the placing of a few drains only.

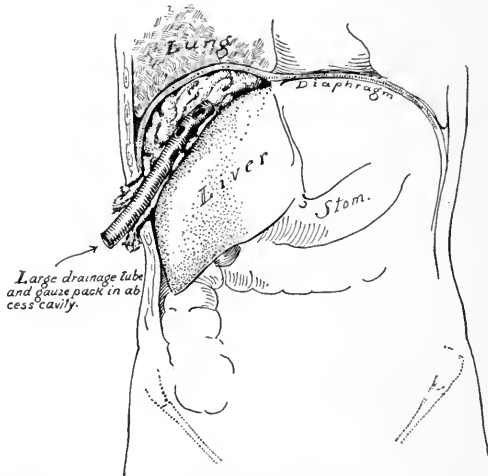


Fig. 299.—Drainage of subdiaphragmatic abscess below the costal margin.

CASE 3.—I was called to see a widow aged forty-six who was suffering with severe abdominal pain.

History.—The patient has three children, the youngest being fourteen years of age. The patient had had what her physician regarded as typical gallstone attacks. These were painful attacks in which the chief pain was located in the epigastrium and to the right of the median line. Six years ago she had a severe hemorrhage from the stomach. Since that time she has been reasonably free from epigastric disturbance, there being merely slight discomfort recurring at long intervals. Menstruation has been irregular during the past year. For a year, particularly during the past few months, she has noticed an increase in the size of her abdomen so that she has had repeatedly to enlarge the girth of her clothes. Five days ago at 2 A. M. she had severe abdominal pains not located in any particular region, but most intense at the lower portion. Since that time there has not been any severe pain, but soreness particularly

in the lower abdomen with bladder irritability. The menses came on after the severe pain above mentioned. She vomited once the second day after the severe pain and again on the day following. Bile only was vomited. The temperature during this period was around 99 degrees and the pulse less than a hundred. She had taken considerable fluid during the past several days and seemed in other ways well on the road to recovery. At 11 A. M. today she was struck with sudden excruciating pain which half a grain of morphine failed to relieve. Morphine has been repeated several times in the five hours now intervened, but she has continued to complain bitterly of the pain. In the past two hours she has vomited large amounts of greenish-yellow fluids.

Examination.—The patient is so restless, because of the pain, that an adequate physical examination can not be made. The abdomen is distended, contains free fluid, is everywhere moderately rigid and below the umbilicus, particularly on the right side, there seems to be a definite tumor outline. The constant movements of the patient prevent a satisfactory examination, however. The uterus is fixed, the culdesac is bulging, particularly on the right side, and there is a definite resistance on this side. The resistance is increased by firm pressure above the pubes. There seems to be a mass filling the pelvis and protruding over the pubes. The patient has a thick abdominal wall and the outlines can not be made out with certainty. The pulse is 120, temperature 99.4, respiration 36.

Diagnosis.—The prevailing symptoms point to trouble in the lower abdomen. The great pain points to intense irritation of a large area of peritoneum. The girth of the patient has been increasing noticeably during the past year according to the patient's statement, indicating the possible existence of an abdominal tumor. The uterus is fixed and there is resistance above the pubes. Sudden pain in a soft pelvic tumor suggests ovarian cyst with twisted pedicle. This is substantiated by the fixed uterus and by the appearance of menstruation at the beginning of the attack. There have been no marked upper abdominal symptoms for six years. From the history of hematemesis one is disposed to believe there has been an ulcer. The physician in attendance believes she has had gallstone attacks and the account he gives of the attacks makes it likely that he is correct. Neither ulcer nor gall bladder trouble seem to account for the dominating trouble in the lower abdomen.

Appendicitis also was considered, but there was no account warranting one in locating the trouble in this region. The pelvic symptoms did not seem to measure up with an affection of the appendix. A tentative diagnosis of an ovarian cyst with twisted pedicle was made.

Treatment.—Exploration was agreed to. As the patient was being anesthetized she began to vomit large amounts of yellowish green fluid. The anesthetist, an inexperienced man, was warned of the danger. In the act of vomiting she suddenly ceased to breathe. A gauze sponge passed deeply in the trachea brought up a quantity of bile-stained mucus. Death was probably due to the aspiration of stomach contents.

Autopsy.—A partial autopsy was permitted. The abdomen contained much straw-colored, cloudy fluid. The much thickened omentum lay in the pelvis. The walls of the intestines including the cecum and sigmoid were very much thickened, forming a conglomerate mass which filled the pelvis and extended over the rim of the true pelvis. The omentum over the ascending colon was similarly affected. The small intestines in the upper abdomen under the great omentum were distended but not thickened or inflamed. In front of the pyloric end of the stomach was an indurated ulcer as large as a watch, in the center of which was a perforation admitting the tip of the finger. This ulcer was partially covered by the adherent transverse colon. It appears that the entire ulcerated area had been covered by fresh adhesions, but recently had given way at one point.

Comment.—Evidently the first pain at 2 A. M. five days ago was caused by a small perforation, which being partly protected by adhesions, permitted the escape of a small amount of stomach contents. This having occurred at 2 A. M. the stomach contained little else than acid stomach contents. This fluid gravitating down the watershed of the great omentum to the pelvis, wrought its chief havoc in the lower abdomen, producing a conglomerate mass consisting of intestines and omentum. These are what I felt on examination. At 11 A. M. of the day of observation, evidently the larger perforation took place, throwing a large amount of stomach contents into the peritoneal cavity, causing the excruciating pains above mentioned. I have never seen such severe pains except in perforated gastric or duodenal ulcer, but I imagined it might be caused by an

inflamed cyst wall becoming simultaneously necrotic and irritating the peritoneum over a large area. I pictured in my mind a partial twist five days ago and a complete twist when the patient was visited. This case shows once again that a patient with ulcer symptoms who has sudden atrocious pain has a perforation. It takes all the adjectives indicating the superlative degree of human suffering, hitched tandem, to express the agonies caused by a perforating ulcer. When such a pain is present, an ulcer had best be diagnosticated.

CASE 4.—A matron aged fifty-six was brought to the hospital because of severe abdominal pain.

History.—The patient is the mother of five children. She passed the menopause nine years ago. Two years previous to this time she had been examined by me because of frequency of urination, constipation, and general pelvic discomfort. The urine contained some pus cells. A firm tumor attached to the uterus filled the pelvis. Its removal was recommended but the advice was not heeded. Two days before entering the hospital she had a sudden abdominal pain during the night. When examined by her doctor some hours later she had a temperature of 103.5° and a pulse of 140. Morphine was given for the pain and she was brought to the hospital.

Examination.—Her temperature now is 102° and the pulse 120. The face is pale and anxious and the abdomen tender. Fluid can be made out in the flanks. The leucocyte count is 12,000. There is pronounced abdominal tympany. The abdomen is very flaccid and muscular rigidity is not marked but a reflex contraction takes place whenever the right upper pole of the tumor is palpated. The tumor occupies the region above the pubes and appears to be about the size of an adult head. Combined examination shows a globular tumor riding on the pelvic brim. The cervix is continuous with the tumor. So far as can be made out the tumor is semifluctuating, though because of the tenderness its consistency can not be made out with certainty.

Diagnosis.—Knowing that the patient has a myoma and considering the onset of the stormy symptoms, temperature and rapid pulse, a septic infection of the myoma seems most likely.

If it were an infection, its escape beyond the tumor seems probable because there is fluid in the abdomen and evident tenderness, and an operation under an extremely grave prognosis seems the best course.

The other possibilities are that there was an intramyomatous hemorrhage or that the previous diagnosis was wrong and that an ovarian cyst is present, the pedicle of which has become twisted.

Operation.— A large congested myoma was delivered. At its upper right pole was an opening through the uterine shell in which was a hemorrhagic mass the size of a small lemon. There was a quart or



Fig. 300.—Perforating hemorrhagic myoma of the uterus. The area of perforation is shown in the left upper quadrant of the tumor.

two of hemorrhagic fluid in the free peritoneal cavity which was sponged out. The peritoneum was everywhere intensely congested and the guts markedly dilated. Because of experience in a previous case a pan-hysterectomy was done.

Pathology.—On section of the tumor, a large hemorrhagic mass surrounded by a shell of uterine tissue intact except at the upper right pole above noted was found (Fig. 300). Sections of the tu-

mor show thickened vessel walls. The hemorrhagic areas show fibrin network with abundant red corpuscles and a few small round cells. In much of the tumor the myomatous tissue remains intact being merely discolored by the infiltration.

After-course.—The wound healed without trouble though the patient was slow in recovering her strength. A year later the patient returned with a large scar hernia. This she chose to retain.

Comment.—The fact that the temperature rapidly subsided should have indicated that it was toxic and not infectious in origin. Faith in my previous diagnosis of myoma should have been strong enough to have precluded the consideration of a ovarian cyst with twisted pedicle. The occurrence of a hernia throughout the extent of the wound without there having been any obvious infection following the operation shows the influence of the hemorrhagic exudate from the tumor in preventing the normal course in wound healing. This acts by preventing the organization of the fibrin in the new wound into fibrous tissue. This influence is seen in the interior of all of these hemorrhagic myomas.

CASE 5.—I was called to see a married woman aged fifty-six because of severe abdominal pain and vomiting.

History.—The patient has never been pregnant. She has had flooding at intervals in late years. She is not certain when she passed the menopause, since she has been free from flow for long intervals for some years. She has had no flow for several years. She had been examined a number of years ago and was told she had a pelvic tumor. The tumor, the patient asserts, has become much larger in the past two weeks. She has been incapacitated now ten days with intense abdominal pain, vomiting and distention. She has had fever and rapid pulse.

Examination.—The lower abdomen was occupied by a tumor generally tender, but the outline could be well made out. No muscular rigidity. The tumor was dense and continuous with the cervix. No fluid could be demonstrated in the peritoneal cavity. Temperature 101°, pulse 120, respiration 24.

Diagnosis.—The presence of a large, hard tumor continuous with the uterus makes the diagnosis of myoma easy. The present storm, because of the general disturbance and the tenderness of the alleged sudden enlargement, most likely is due to a hemorrhage into its substance. Its removal is in order.

Treatment.—The patient was examined in her country home. She was advised to go to the hospital for operation. She promised to do so within the week.

After-course.—Five days after the examination while she was preparing to go to the hospital she was seized with a sudden severe pain and collapsed at once. Her physician found her pale and pulseless “like a ruptured extrauterine pregnancy.” Stimulants were administered but she died in eight hours. Autopsy showed a hemorrhagic myoma which had necrosed through the uterine wall. A considerable amount of bloody fluid was free in the peritoneal cavity. There was no evidence of infection and the amount of blood lost was not sufficient to have in itself caused death. The assumption, therefore, must be that death was due to shock, or in other words to the absorption of the toxic blood escaping from the degenerated myoma.

Comments.—The outcome of this case is of interest from a pathologic rather than in a clinical sense. The reason the blood in these myomas does not coagulate must be due to the absence of those elements which institute coagulation since the blood in the general circulatory system coagulates normally. This absence of coagulability must be due to the slowly developing degenerative changes common to a greater or less degree to many myomas. That blood in other situations which does not coagulate is prone to cause constitutional symptoms is seen, for instance, in subcutaneous hemorrhages after blunt trauma and in extrauterine hemorrhage.

CASE 6.—A matron of thirty-one was brought to the hospital because of severe abdominal pain and collapse.

History.—When first seen by her physician a week ago the patient was in bed and said that she had just started to flow after having missed her menstrual periods for the two preceding months. She complained of some pelvic cramps, especially on the right side. She had no rise of temperature but the pulse was 100. A diagnosis of threatened abortion was made and no pelvic examination was made. The patient was kept in bed and given codeine by mouth. In twenty-four hours the flow stopped and the pain subsided. During the week following the patient was not seen by her physician, but it was reported that at times she had pain in different parts of the abdomen but principally in the pelvis.

Four hours ago she got out of bed to go to the toilet when she was seized with a sudden acute abdominal pain from which she fainted.

When seen by her physician two hours later she was still prostrate where she fell. Her face and lips were pale to the extreme and she was pulseless at the wrist. She complained of great thirst. Her pulse counted by stethoscope was 160. The abdomen was quite rigid. The pain was not very severe, was mostly on the right side. A diagnosis of ruptured tubal pregnancy was made and the patient taken to the hospital. She gave a history of having had a uterine suspension thirteen years ago before the birth of any of her children. She has three living children, the eldest eight and the youngest three. Her menses have always been regular and painless.

Examination.—By the time the patient reached the hospital the pulse had become perceptible at the wrist (taken four hours after the acute attack) and was 150. The abdomen was rigid and there was dullness above the pubes. The extremities were cold.

Diagnosis.—The diagnosis is undoubtedly a ruptured tubal pregnancy. A tubal abortion would not likely produce such a profound shock. Hemorrhage evidently has ceased and she is on her way to recovery from the shock. Any other diagnosis is hardly possible. A ruptured ovarian cyst sometimes produces a profound shock, but not so great as this and there is the history of missed menstrual periods. A necrotic appendix sometimes produces severe pain, but never such pallor or air hunger.

Treatment.—She had been given stimulants of caffeine before she came to the hospital. She was given a fourth grain of morphine, and hot-water bottles were applied. She took so much water by mouth that none was given in any other way. The patient's condition was gradually improved during the week following. The pulse came down to 120 and was fairly good. A laparotomy was done. The pelvis was found to be filled with much dark blackish fluid blood and many large clots. A right-sided ruptured tubal pregnancy was found and removed. The body of a two months' fetus protruded through the ruptured tube. Nothing else was done. The patient left the operating table in good condition. Pulse 138 and good quality. Proctoclysis was started and heat applied to the extremities.

Pathology.—The distal end of the tube was filled with a clot distending it. At the site of rupture the villi had penetrated deeply into the tube facilitating rupture at that point. Fatal hemorrhage is less apt to occur if this is the case than when wide rupture takes place the result of greatly increased intratubal pressure.

After-course.—The pulse gradually improved and came down to the 80's during the following week. Recovery was uneventful.

Comment.—To have operated when she was first brought to the hospital would most certainly have resulted fatally. Usually tubal ruptures bleed to death before medical aid can be summoned. Tubal abortions rarely bleed to death. The ideal method is to discover them and operate before rupture. Once the pregnancy has terminated, the surgeon's chief function is to operate after it is safe and expedite recovery by removing the fetus and the blood clots. It is rarely a life-saving procedure. Much mischief has no doubt been done by precipitous and ill-advised operations for extrauterine abortions. The general impression seems to be that unless the attendant operates at once, regardless of his qualifications or the environment, he is derelict in his duty. Procrastination loses patients, but bad operating loses more. It must be determined whether the state of the patient is due to shock or hemorrhage. If it is due to shock, a good operator in a good environment had best stand to; if due to loss of blood, he must choose the hazardous risk and operate. Determination of the amount of free fluid in the abdomen is the best guide. Because of the state of the capillary circulation, blood counts and hemoglobin estimates are useless.

CASE 7.—A matron aged thirty-five was brought to the hospital because of severe abdominal pains.

History.—The patient has been married fifteen years. A year and a half after marriage she had an abortion at five months. Two years later she had a normal labor, and two years later had another abortion at five months. Seven years ago her last child was born. The menses have been regular since that time until the onset of present illness. Her last regular menstruation began March 24. She is positive conception occurred March 28. April 6 she had a sudden sharp, severe pain in the rectum. This pain was so severe that she had to go to bed and summon medical aid. She has had more or less pain at times ever since then. It is always worse when bowels move. On April 28 the patient passed some clots per vaginam. A slight pink flow which was not like menstrual blood followed, lasting until May 8. On this day there was a sudden severe pain in the lower abdomen and rectum. She vomited several times and felt very faint, but was never unconscious. She was kept under the influence of morphine all day. At 7:50 the same day she was

curetted by her home physician, who said he removed a six week fetus that had been dead two weeks. The uterus was packed for thirty-six to forty hours. During this time vomiting was continuous, but ceased as soon as the pack was removed. There has been no hemorrhage since pack was removed, now two weeks ago. There is still pain but not so severe as before the operation.

Examination.—The cervix is behind the symphysis pubis and is soft and patulous. Uterus is enlarged, tender, turned sharply to the right, and is fixed. There is a mass to the left of the uterus filling half of the pelvis, pressing the culdesac down in the vault of the vagina. The mass is dense, resilient and any pressure on it causes pain. Abdominal palpation elicits tenderness in the right lower abdomen from McBurney's point to the pubes. There is no muscular rigidity.

Diagnosis.—The sudden severe pain deep in the pelvis accompanied by irritation of the rectum with nausea and collapse spells on the face of it a disturbance of an extrauterine pregnancy. There are a number of interesting factors which enter. The patient is certain that the fruitful coitus took place just nine days before the onset of the illness. It is my experience that when a woman is so sure of the exact date on which conception took place, it most certainly did not take place on that date and that it is none of the surgeon's business why she fixed this date. The fact that there were two distinct attacks of pain indicates that there are two stages in the process. This stamps the lesion as a tubal abortion. The fact that the uterine flow followed some weeks after the first onset indicates that the first dislodgment was only partial. The second attack was much more severe and was probably attended by the expulsion of a fetus from the tube. We are confronted by the fact that her physician stated that he secured a six weeks' fetus as the reward of his curettage. Pregnancies have been reported both intrauterine and intratubal, but physicians also sometimes remove imaginary fetuses. The pelvic mass fixes the uterus and is painful to the touch. This might lead one to suppose that the mass is caused by an inflammatory exudate the result of the curettage. The peculiar resistance and resilience is characteristic of a blood clot and does not have the more suffused feel of an inflammatory exudate. Furthermore there is no fever and a leucocyte count of 10,000, just what one would expect in a blood clot. There-

fore, a diagnosis of a left tubal abortion seems justified. It is not certain that abortion is complete. There may be a possibility that a renewed attack of pain may occur. The later the date of pregnancy the more serious is tubal abortion. From the feel of the mass in the pelvis it is likely that abortion is complete and that the patient is safe from renewed attacks. However, the patient is in good condition and operation is safe and will expedite recovery.



Fig. 301.—Fetus and blood clots from an extrauterine pregnancy.

Treatment.—The culdesac is filled with blood clots. There is a fetus $2\frac{1}{2}$ inches long lying free in the clots. The tube is thickened and the fimbriated end is ragged. The right tube is normal. The left tube and ovary were removed.

Pathology.—The blood clots seem old and partly organized. The fimbriated end of the tube is split as if it had been torn when the tubal abortion occurred. The clots immediately about the fetus

seem partly organized (Fig. 301) as if this part of the hemorrhage had occurred at the first attack and that the whole mass was extruded at the last and more severe attack.

After-course.—Recovery was uneventful and she has remained well since.

Comment.—It is quite usual to find patients with extrauterine pregnancy who have been curetted. This always adds to the responsibility of the surgeon. Generally speaking, when a tubal abortion is complete as indicated by a period of quiescence and a curettement has been done it is well to defer operation long enough to determine whether or not the curettement may have produced an infection. Should the surgeon operate under such conditions without such precautions, he makes himself responsible for the acts committed during the curettement.

Generalized abdominal pains that do not tend to become localized, as is made evident by local tenderness and muscle rigidity or produce constitutional disturbances, are usually due to intestinal obstruction. Hemorrhage from visceral rupture or injury to the spinal nerves may do so. Vomiting is a valuable but late sign of intestinal obstruction and stercoraceous vomiting is the bridge between the clinical manifestation and the autopsy findings.

GENERAL ABDOMEN

CASE 1.—A farmer aged 26 came to the hospital because of a post-operative hernia.

History.—About seven years ago he had an attack of typhoid fever complicated by intestinal perforation. He was operated at his home and the hole in the intestine closed. The sutures gave way and the abdominal wound gaped open. It healed by granulation and was four months in closing up. A weak place was left in the abdominal wall which bulged when lifting and often gave some pain. Has worn a bandage over it ever since it first appeared.

Examination.—There is a scar four inches long over the right rectus. It bulges perceptibly when he attempts to raise his head and trunk from the table. When he is lax, the tips of four fingers can be placed in an opening between the two parts of the muscle.

Diagnosis.—His diagnosis of postoperative hernia is evidently correct. His belief that it can be repaired is likewise correct.

Treatment.—The hernia was reopened. The omentum was adherent to the medial and upper borders of the hernial opening. These were tied off and the edges inverted. The appendix came into the wound. It was a large, long appendix and looked slightly inflamed, therefore it was removed.

After-course.—Healing was uneventful and he returned home in two weeks. After being home only three days he was awakened at 3 o'clock in the morning with a severe cramping pain in the left side of the abdomen. Heat was applied which seemed to relieve him for a short time, but the pains soon became worse than before. They were paroxysmal in character, quieting down for a few minutes and then returning again. Vomiting began about one hour after the onset of the pain and continued up to the time of readmission, two days after the onset of the pain. He has taken practically nothing by mouth since the onset of the attack. Several enemas were given during the past two days. Part of these were expelled and part retained. Turpentine stupes were repeatedly tried, but with no relief. The abdomen became distended and hard early in the attack and has remained so. Last night he was given morphine gr. $\frac{1}{4}$ and slept all night. This morning the pain and vomiting returned worse than before. He was therefore brought back to the hospital.

The patient lies on his back and is bathed in perspiration. The face is anxious and the patient complains constantly of great pain in the left side of the abdomen. Pulse 120, temperature 99.5° . The abdomen is distended and rigid, particularly over the left rectus. The sensitiveness is most marked over the left lower quadrant. A diagnosis of intestinal obstruction was made. Because of the sudden onset and the remittent character of the pain, the early appearance and persistent character of the distention with the absence of fever and increase of leucocytes, the diagnosis of intestinal obstruction was made. A laparotomy was immediately done. A loop of small intestine $1\frac{1}{2}$ feet in length was found which had slipped through a hole in the great omentum, the band of omentum tightly constricting the intestine. They were much distended and of a dark red color. The omental vessels were filled with thrombi. The peritoneal cavity contained much serosanguineous fluid. The intestines were released a portion of the omentum removed and the wound closed without drainage.

After-course.—As soon as the patient awakened from the anesthetic he said his pains were gone. The subsequent recovery was rapid and uneventful and he has remained well.

Comment.—Evidently an opening was made in the omentum or one already present was overlooked at the time of the repair of the hernia. In cases of omental adhesions at hernial openings, that part proximal to the point of adhesion is usually exceedingly thin and a hole may be inadvertently made in it unless great care is exercised. They should always be sought for, and if found, carefully repaired.

CASE 2.—A school boy aged nineteen was brought to the hospital because of vomiting and abdominal pain.

History.—Two years ago the patient had a severe attack of abdominal cramps. He attributed it to eating raisins. The attending physician at his first visit found nothing, but an examination made a day later revealed a tumor immediately below the umbilicus. This was supposed by his physician to be a mass of raisins, and he manipulated it with his fingers in order to break up the lump. The cramps subsided and flatus and stool passed on the next day. The patient was free from any complaint from that time until four days ago when he became chilly and nauseated while loading a wagon. The two days following he felt much improved. On the third day he ate a hearty breakfast and later a ham sandwich, and took a small drink of whiskey, to which he was not accustomed. He immediately began to have cramps and walked about to lessen the pain. After a few hours he vomited freely. The pains increased during the afternoon and he rolled about from pain. A doctor was summoned. Morphine was administered hypodermically and was repeated the following day. Many enemata were employed during the following days, but pain and vomiting continued. During this period the physician was able to palpate a tumor to the right of the median line. On Friday the enema brought away a piece of the meat eaten on the Sunday previous. This gave some relief and a little supper was eaten. Thirty-six hours ago he began to have more pain and has vomited persistently since. He has had two hypodermics of $\frac{1}{4}$ grain of morphine during the day.

Examination.—The abdomen is but little sensitive and there is no rigidity. There is moderate distention; no dullness in either flank;

the tongue is dry and coated and there is evidence of impending collapse. The pulse is 144, temperature 97°, respiration 24.

Diagnosis.—The recurrent attacks of pain with obstipation suggest a recurrent partial obstruction. The history of palpable tumor which disappeared suggested transient intussusception as a possible cause. The duration of a week without collapse indicated that the obstruction was not complete until within the past day or two. The absence of stercoraceous vomiting suggests that the obstruction must be near the ileocecal valve. The location of the alleged tumor is in harmony with this assumption. The absence of tenderness excludes peritonitis unless the repeated injections of morphine mask the symptoms. An intussusception at the ileocecal valve seems the best diagnosis. At any rate immediate action is demanded.

Treatment.—The abdomen was opened in the right semilunar line below the level of the umbilicus. When the peritoneum was opened, about a quart of straw-colored fluid escaped. The intestinal coils appearing in the incision were injected and much distended. The ileocecal portion of the intestine was at once sought and was found lying over the kidney. It presented a tumor. When the tumor was drawn into the wound, it was seen to be an intussusception through the ileocecal valve, about twelve inches long, with a distinct tumor at its upper extremity. The tumor was thought to be a polyp which had produced the inversion of the gut. When the intussusception was reduced by traction and pressure on the tumor, a dimple remained over the base of the supposed polyp (Fig. 302, *B*). This made it obvious that the tumor mass was an inverted Meckel's diverticulum, with a thickened apex. By careful pressure the diverticulum was restored to its former position (Fig. 302, *A*). The diverticulum was nearly the diameter of the gut from which it sprang and was about two and a half inches long. The mass in its apex was about the size of a hulled walnut. The diverticulum was clamped just below the solid mass and a mattress suture passed the ileal side of the clamp. The clamp was removed and the gut severed, the edge being cauterized with carbolic acid and iodine. This raw end was then inverted into the lumen of the gut. The contracture of the walls of the intestine after the suture line had been inverted resulted in narrowing the lumen of the gut more than had been intended. No evil resulted, however, as the lumen remaining was the size of a finger, but looked small in contrast

to the adjoining dilated gut. The cecum was replaced and the loop of ileum containing the stump of the diverticulum was pulled

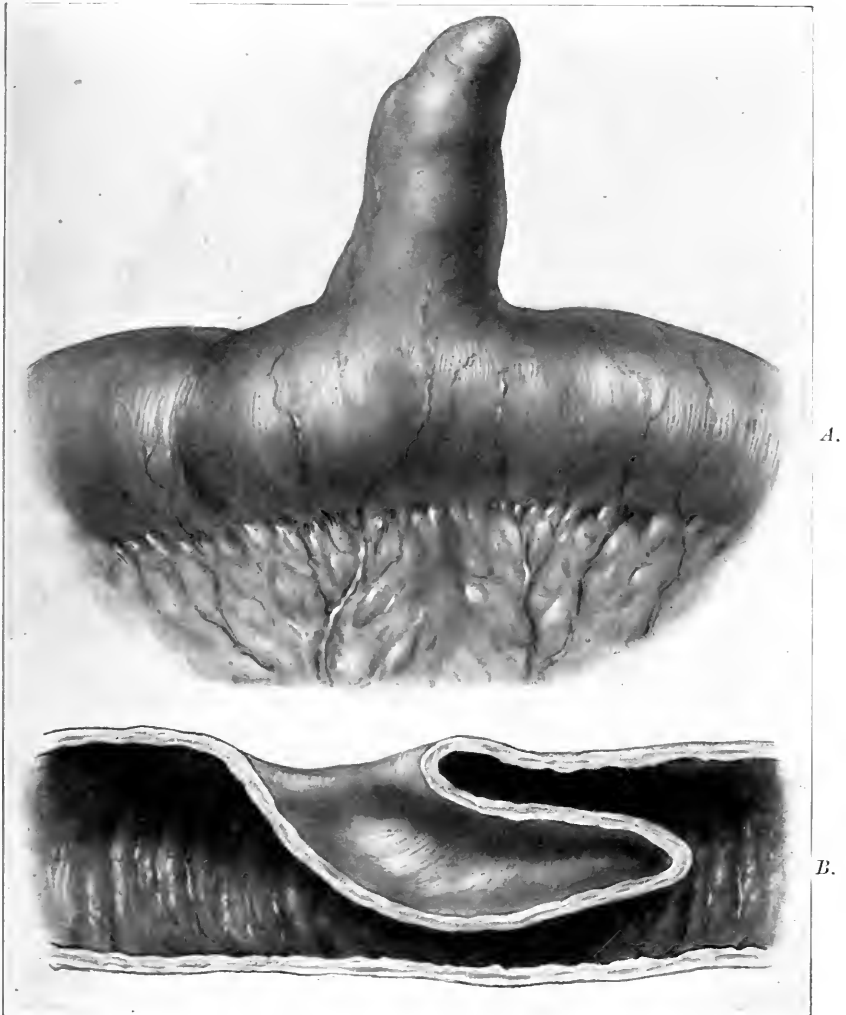


Fig. 302.—*A.* Appearance of the diverticulum after it was restored to its normal position.
B. Diagram of the position of the diverticulum when it was causing the obstruction.

over above and distal to the cecum. An inch stab drain opening was made in the abdominal wall just above the crest of the ileum. A

small, flat gauze pack was placed over the ileum and a drainage tube below it. The original incision was closed completely.

Pathology.—The part removed consisted of a mass about the size of a hulled walnut, with a flange of diverticular wall below it in which the muscular and mucous coats could be readily made out. On section the mass was seen to be composed in part of blood clot, giving the appearance of a submucous accumulation of blood of some days' duration. At the apex of the tumor immediately beneath the peritoneum was a cap 3 or 4 mm. thick, which was pearly white and resembled when cut the section of a skin papilloma. Microscopic examination showed the submucous thickening was due to an old blood clot. Toward the opening of the diverticulum the mucosa was normal, but at the apex it was continuous with the white thickened cap. The latter proved to be composed of glandular tissue arranged in two distinct layers; an inner, made up of Brunner's glands somewhat irregularly disposed; and an outer, which resembled the benign adenomas so often found in the intestines. This arrangement suggested strongly the aberrant masses of pancreatic tissue, which have often been reported present in Meckel's diverticulum, and particularly the case in which Küttner observed both Brunner's glands and aberrant pancreatic tissue. The fact that in our case some of the misshapen Brunner's glands terminated in the adenomatous portion, raises the question whether the so-called pancreatic tissue may not in reality have been aberrant intestinal glands.

After-course.—Following the operation the patient awoke quickly, and at 6 P. M. his chart showed pulse, 132; temperature 101°; respiration, 28. He attempted to vomit and his stomach was emptied by lavage of a large amount of greenish fluid. Flatus was expelled late in the evening following an enema. There were emesis and repeated gastric lavages in the days following. On Tuesday, the third day, there was free bowel movement, with much flatus, and the patient complained of hunger. On the fifth day, Friday, the chart showed pulse 92; temperature 99.2°; respiration 24. Saturday: pulse 78; temperature 99.4°; respiration 24. On the seventh day: pulse 68; temperature 98.4°; respiration 20. During the first two days there was a profuse drainage of cloudy serum from the drainage opening; this became reduced at the end of the second day, and the drains were removed. The skin of the entire central

incision opened on the sixth day, and a considerable amount of pus was expelled. Healing was complete in three weeks. He has remained well since.

Comment.—The recurrent attacks of obstructions, particularly in children, should suggest strangulation by some fetal remain. Invagination of a diverticulum is less common than looping about an adventitial band. The fluid exuded because of the strangulation of the gut, though itself free from bacteria, was likely the cause of the failure of the wound to heal. The development of a scar hernia was to be expected, but did not occur.

CASE 3.—A farmer aged twenty-six was brought to the hospital because of an acute abdominal pain.

History.—Thirty-six hours ago the patient was seized with severe pain in the right lower quadrant of the abdomen. It was not preceded by nausea. The temperature when taken by his physician an hour or two later was subnormal. He was given a hypodermic injection but was only partly relieved. After a few hours the pains became more intense and he was nauseated. The hypodermics had been repeated six times by the time he reached the hospital. On entering the hospital he still had severe pains and clamored loudly for relief. He had no previous attacks of a similar nature neither had he ever suffered from stomach disturbances. He had passed neither stool nor flatus since the beginning of the pain.

Examination.—The patient is restless and requests that he receive relief at once. His restlessness makes examination unsatisfactory. The abdomen is much distended, everywhere tympanitic but nowhere markedly sensitive to pressure. Deep pressure in the ileocecal region is responded to by expressions of active resistance. The temperature is 99°, pulse 120, respiration 32. A blood count was not made because of the apparent urgency of the need of treatment.

Diagnosis.—A sudden pain with subnormal temperature usually indicates an accident not primarily inflammatory, usually a perforation or obstruction. The very sudden onset suggested a perforation but the initial pain was lower than that usually seen in gastric or duodenal perforation. There was no history of previous stomach disease. A sudden perforation of an appendix was suggested by the location. The obstruction might be accounted for by an inflammatory paralysis. The pronounced tympany particularly at a distance

from the site of initial pain suggested an obstruction. A more definite diagnosis was not attempted.

Treatment.—An incision was made along the right semilunar line which had its midpoint at the level of the umbilicus. A large amount of cloudy serum escaped when the peritoneum was opened. The cecum was collapsed as was the terminal portion of the ileum. Many widely distended loops of small gut forced their way into the field of operation, while these preliminary surveys were being made. At the junction of the collapsed and distended portions was a mass the size of an unhulled walnut. The gall bladder region was free from adhesions. The mass was free from attachment to the gut wall hence must be a foreign body. An incision over it



Fig. 303.—Enterolith formed of pawpaw seeds.

along the convex surface was made and the foreign body extracted. The cut was closed by a Czerny-Lembert suture. A stab drain was made in the flank and the original wound closed completely.

Pathology.—The mass removed was a rounded lump with here and there unimportant irregularities (Fig. 303). The surface is covered by calcareous flakes. From the lightness it obviously is not solidly calcareous. A section shows that the bulk of the tumor is made up of a conglomerate of pawpaw seeds with a thin calcareous covering.

After-course.—The patient recovered from the immediate effects of the operation but after a week he had renewed evidences of

obstruction. Exploration showed a mass of closely adherent intestinal coils with thick, indurated walls. An attempt to separate all of them seemed futile and to resect the whole mass was obviously out of the question. A proximal distended loop was drained in the hope of reaching a point above the obstruction. This was partly successful, but he died in three days. The autopsy showed a mass of closely adherent intestinal loops, the obstruction being due to the close attachment with the added edematous thickening of the gut walls. A slide of the gut wall showed edema and fibrinous exudate.

Comment.—This case presents a number of factors of fundamental importance. It was formerly held that intestinal stones when lighter than water were derived from the gall bladder and when heavier were primarily of the gut lumen. This stone had as nucleus seeds of fruit. In many of the recorded cases this has been the case. Why this foreign body caused such a sudden stoppage of the lumen is not quite clear. It must have taxed the lumen for a considerable period. A reactive change in the gut wall may have been responsible. The irritation with the formation of a large exudate still able to undergo coagulation furnished an ideal field for the formation of extensive and persistent adhesions. This state is the common cause of postoperative adhesions. So far as could be determined, the patient had eaten freely of pawpaws six weeks or two months before. This is ample time for a calcareous deposit to form, as we know from the study of foreign bodies in the bladder. Each season, however, he was in the habit of eating this fruit, and we can not be sure but that these seeds represented fruits of previous seasons.

CASE 4.—A farmer aged thirty-six came to the hospital because of pain in the lower abdomen.

History.—The patient has had good health until the present attack which began two days ago. He thinks he ate something at dinner that disagreed with his stomach. He had general abdominal pain all the afternoon. He took castor oil to relieve it, but he vomited at once after taking the oil. The symptoms were the same the next day, but the patient did not go to bed. At the end of twenty-four hours he noticed a localized tenderness over the appendix in the right lower part of the abdomen which caused him to suspect the nature of his trouble and he presented himself for examination.

Examination.—There was distinct tenderness over the appendiceal region with rigidity of the right rectus muscle. Temperature 100.6°, pulse 110.

Diagnosis.—Acute appendicitis. The attack was wholly typical.

Treatment.—Appendectomy with drainage was done. A small gauze drain was placed medial to the cecum.

Pathology.—The appendix was large, blue black with a partial rupture near its base.

After-course.—The wound closed in three weeks and the patient was free from disturbance for four months.

Re-entry and Second Operation.—After a hard day's work the patient ate a heavy supper, felt perfectly well until about 10 P. M. At this time he had general abdominal pain and vomited once. These symptoms grew worse and he called a doctor who at once brought him to the hospital. It was then about 2:30 A. M. Morphine gr. $\frac{1}{4}$ was given before he was started on the journey.

Examination.—Pulse is slow and regular, there is no rise of temperature. There is abdominal tenderness at a well localized point to the left of umbilicus with some rigidity. He vomits whenever anything is taken. The pain is very severe and is more on the left side than on the right. Urine negative. He was relieved for a time by the morphine, but after a few hours the symptoms began to return with increasing severity.

Diagnosis.—Severe abdominal pain without rise of temperature or increase in pulse rate in one who has recently been operated on for a suppurative lesion always suggests obstruction from bands or adhesions at the site of the previous operation. The persistent tendency to vomit strengthens this assumption. The increasing tympany must be interpreted in the same light.

Treatment.—Laparotomy was done at noon. The probability was that the obstruction was near the site of the appendectomy scar, but since the chief pain has been located at the left of the umbilicus, it seemed wisest to make a midline incision. As soon as the peritoneum was opened a blood-stained fluid escaped. A band extending from the cecum to a v-shaped transverse colon had a loop of gut thrown over it. This band was removed. A loop of gut proximal to the site of obstruction had become adherent to the ascending colon. In liberating it the peritoneal surface was injured. This area was carefully repaired with silk. The intestines were distended. The abdomen was closed without drainage.

Pathology.—The band which caused the obstruction is as large as a slate pencil. It is covered with a layer of endothelial cells. The body of it is made up of parallel bundles of fibrous tissue interspersed by many blood vessels.

After-course.—The patient did well following the operation so that he seemed recovered by the end of the week. During this time, however, the patient had several times complained of a pain that would come on for a few minutes then leave when he felt something like gas pass through the intestines where his old pain used to be. This in no sense disturbed his well-being.

Third Attack.—Eight days after the operation he was taken with an attack like the first one. The pain was very severe and there was vomiting. There was a definitely localized tenderness to the right and above the umbilicus. The pain rapidly grew worse.

Examination.—The patient seemed markedly collapsed, the features were drawn, and the face wore an extremely anxious expression, not approached in either of his preceding attacks. There was sensitiveness and rigidity to the right and above the umbilicus.

Diagnosis.—The point of tenderness is over the site of the adhesion found at the first operation. Because of the thickness of the gut wall found at that time, showing a universal tendency to the formation of a plastic exudate, it must be considered likely that adhesions have formed which are responsible for the renewed trouble. This is confirmed by the slight attacks of pain noted at intervals during his convalescence from the operation for obstruction. Some disaster obviously must have been added to it to produce the marked change in the general appearance of the patient.

Treatment.—An operation was performed at once. The incision was made through the right rectus over the site of maximum tenderness. Adhesions were found. Loops of small intestine were adherent to each other and to the omentum. It was noted that the intestines making up the mass were unusually blue as compared to neighboring coils. Because of the involved arrangement of these coils and the unfavorable condition of the patient the adhesions were molested only enough to permit the selection of the proximal loop. A rubber tube was inserted into the intestine at a point well above the conglutinated coils. The stomach was washed before the patient left the table.

After-course.—The patient was much shocked following the operation and it was two days before the pulse became easily detectable

at the wrist. He rallied considerably, but despite frequent washing of the stomach, he vomited frequently. The pulse became markedly full, wave-like, and about 120 to the minute. At the fourth day, save for the increased amount of the vomitus, he seemed better. The pulse became small and running, and at ten in the evening the extremities began to cool. At 2:30 A. M. he asked for an orangeade, but before it could be prepared he suddenly died.

Autopsy.—The loops of gut that had made up the conglomerate mass were found to have loosed themselves for the most part. A hard firm clot occupied the mesenteric vein which drained the discolored loops of gut.

Comment.—The original attack of appendicitis was classical. The cause of the obstruction was a band extending from the cecum to the colon. The formation of this adhesion was fostered by the drain that was placed medial to the cecum at the time of the appendix operation. The operation for obstruction was done early, but notwithstanding this, there was evidence of a pronounced tendency to the formation of the plastic exudate. The extension of this process to the vein must be looked upon as the cause of the mesenteric thrombosis which formed the basis of the final disaster. The presence of a thrombosis was not recognized at the time of the operation. Had it been a resection or even a delivery of the affected loops it would have been a hazardous undertaking and in the light of the pronounced depression following what little was done would most certainly have terminated fatally. This case shows the similarity between the initial symptoms of obstruction and mesenteric thrombosis. Marked was the added degree of systemic disturbance in the latter, expressive no doubt of the absorption of toxins from the injured tissues.

CASE 5.—A boy aged four years was brought to the hospital because of a strangulated hernia.

History.—The patient has had a tumor in the right inguinal region at intervals since he was eighteen months old. At that time it came down and strangulated and had to be replaced under ether anesthesia. In March, 1917, six months ago, it again strangulated and was replaced without anesthesia. On the morning of October 5, 1917, it strangulated again and could not be replaced under ether. Patient came into the hospital at 8:30 P. M. The tumor was soft, slightly tender to the touch, but the patient appeared comfort-

able, was without temperature, and not vomiting. During the night the tumor became hard and the patient vomited twice. In the morning it was larger and harder.

Examination.—The lad's face looks pinched and he is restless. In the right inguinal region is a tumor as large as the end of the thumb. It is fairly firm to the touch and its manipulation causes pain. The testicles are in the scrotum.

Diagnosis.—The location of the tumor corresponds to the inguinal canal. The history of the preexistence of the hernia may be regarded as accurate. The only problem to be considered is that of irreducibility or strangulation, since quite frequently in children a hernia remains for a time irreducible and after a time it returns into the abdomen without aid. On the other hand strangulation in children is rare. In this case the patient has vomited and his features seem drawn and he is restless and the reaction shows a disturbance in the circulation of the gut.

Treatment.—Operation showed a strangulated loop of intestine of a very dark red color. A peristaltic wave could be made to traverse the strangulated portion and there was no constriction ring cutting the muscle layer. The viability of the gut therefore, was doubtful. Inasmuch as the patient is a child, it was deemed best to return it to the abdominal cavity. The loop was, therefore, replaced and the hernia repaired.

After-course.—For a number of days following the operation the abdomen was greatly distended and tympanitic and the patient vomited occasionally. No food was given. Water was given per rectum. The temperature and pulse were never high. After six days the tympanites gradually disappeared and improvement followed. He went home October 20, fifteen days after operation.

October 22, after being home but two days he became tympanitic to a marked degree. At intervals he had pain in the abdomen which was always accompanied by a very marked intestinal peristalsis. He became some better the next day, but October 26 was more tympanitic again. He vomited several times. On the next day vomiting continued and became of a fecal odor. Tympanites and peristalsis were marked and he was returned to the hospital.

Operation October 28.—On opening the belly two loops of intestine were found permanently adhered to the strangulated loop, forming a partial stenosis (Fig. 304). These were dissected off and the

strangulated loop sutured into the abdominal incision and a fistula formed. A catheter was inserted into the lumen of the intestine. Flatus and some brownish fluid immediately drained off. Improvement began immediately.

On November 5 he complained of severe abdominal pain. That night he passed bloody urine. No casts were found and the daily output was not decreased. On the night of November 6 he passed a small gravel. On November 7 the urine was practically free from blood.

November 19—intestinal fistula closed, peristalsis increased and became visible. Pain became intense and he vomited once. The fis-

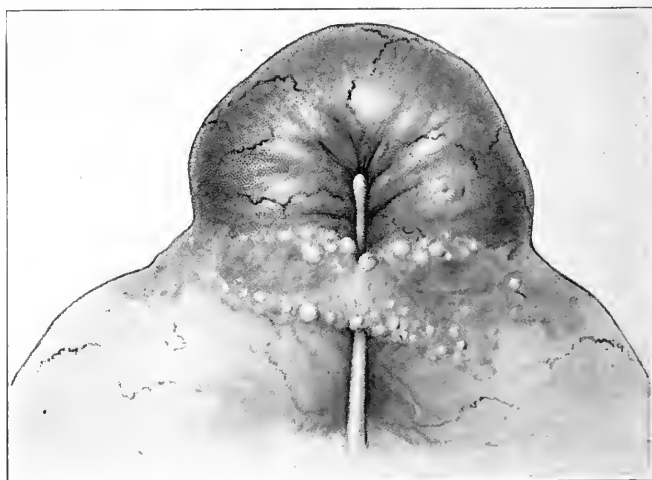


Fig. 304.—Small abscess within the gut wall covered with plastic exudate. A probe has partly separated this exudate. From a case of irreducible inguinal hernia.

tula was opened with a pointed hemostat, and gas and feces were at once expelled. The patient was relieved but remained very toxic. A catheter was introduced and the bowels were washed out. The patient became comfortable at once. He was now dismissed with both ends of the loop projecting from the abdominal scar. After recuperating several weeks he returned to the hospital and a Murphy circumcision clamp was placed one blade in each loop. In ten days this had separated by pressure necrosis and an opening between the two loops resulted. After this the opening in the abdominal wall nearly closed. The fistula being lined

with gut mucosa, the cuff had to be separated and turned back before closure could take place. This was done and the opening closed permanently. Since then he has occasionally had bellyache but he is developing normally.

Comment.—In this instance the gut was too much strangulated to make its return into the abdominal cavity safe. While the gut did not perforate, it was so badly injured that protective adhesions formed about producing obstructive strangulation. The only alternative would have been section of the formation of fistula. Since a fistula had to be done later it would have been better to have done it at once. The formation of a fistula is always safer than immediate anastomosis. It is interesting to speculate now as to the ultimate fate of the loop of gut now attached to the abdominal wall. A loop of gut is less apt to fall about this and produce strangulation than if a small strand were present. In as much as strands often exist in the abdomen without resulting in mischief, it seems best to allow conditions to exist as they now are rather than loosen the loop as a prophylactic measure. To loosen it would require a resection—a procedure not altogether without danger.

CASE 6.—I was called to see a farmer aged forty-four who was suffering from an acute abdominal distention.

History.—Two days ago he was attacked by severe pain in the epigastrium. There was no griping, but when most intense the pain radiated all over the abdomen. In the evening he vomited. His physician found him in great pain and gave him a fourth of a grain of morphine. His temperature was then 98 degrees and his pulse 70 per minute. One day ago his pulse was 84 and his temperature 100.2. He then had severe pain in the ileocecal region and was rigid chiefly in this region. In the evening the pain was most intense on the left side and the rigidity was equal to that on the right side. He now had frequent urination and complained of marked stinging and pounding in the glans penis during the act. He has had intense thirst during the day, but all fluids had been withheld. He has previously had good health.

Examination.—The patient lies in bed with the thighs flexed and his hands to either side of the trunk. His expression is one of deep alert thought, free from pallor or pinching of the features. When he was approached for examination, his hands met those of

the examiner as if to ward off danger. The abdomen is moderately distended, the muscles are fixed and the respiration is preeminently thoracic. There is general rigidity, marked along the whole of the right rectus and the lower half of the left. He complains everywhere of pain, particularly above Poupart's ligament on the right side. He will not permit percussion except over the left upper quadrant, and it is markedly tympanitic here. His tongue is red, small, not dry, or yet normally moist. There is a marked absence of saliva in the mouth. The pulse is 120, hard, and there is just a suggestion of a running pulse. The temperature in the mouth is 98; that of the axilla was 100.2. He had taken nothing by the mouth for many hours.

Diagnosis.—The triad of pain, rigidity and vomiting appeared early here, at first diffuse, it later became localized in the right iliac fossa. It remained localized here but for a short time, then proceeded across to the left side, as evidenced by the bladder irritation and the pain in the left side. The low temperature and gradually ascending pulse indicates an advancing sepsis. The lower mouth than axillary temperature indicates a change in the whole digestive apparatus. The process in two days spread across the lower abdomen involving both fossæ and the true pelvis. From the degree of pain it is evident that a considerable degree of reaction is present. The diagnosis therefore must include an unlimited peritonitis starting from the appendix and now involving the whole lower half of the abdomen without any evidence of a tendency to walling off. The differentiation between appendicitis and perforated ulcer in this case is easy. The initial pain while severe did not have the awful intensity which characterizes perforations which lead to a generalized peritonitis in two days. Ulcers sometimes perforate without the intense pain usually characteristic, but in these cases there is a more or less perfect walling off and the lower abdominal cavity is not affected. After a day or two one may have the right and lower abdomen chiefly involved as in this case, but in those the initial symptoms are more severe. Naming the disease is less difficult than determining the course to pursue. To open and drain will hasten absorption, perhaps lessen the resistance against a spreading of the infection. Considering the unfavorable surroundings in which he is placed, conservative treatment was decided on.

Treatment.—Salt water by rectum and morphine hypodermically to control the pain and secure quiet. Nothing by mouth.

After-course.—Much to my surprise he recovered. I removed his appendix three months later. There was evidence of a perforation near the base of the appendix.

Comment.—When there is evidence of spreading peritonitis from a perforation with marked tympany, operation does little good, in fact it seems rather to hasten than to slow the progress of the disease. This is particularly true in patients of his age. In young adults the tendency to limit the process is much greater. Once cases have reached this stage, in patients in middle life, operation is futile and a conservative course seems to offer more than operation.

CASE 7.—A baby girl aged five months was brought to the hospital because of a bloody stool.

History.—At 10 o'clock yesterday morning her mother noticed when she awoke that she seemed very pale and seemed to be sick. Shortly afterward she began straining to stool and began screaming. The bowels moved during the morning previous to this. At 1:20 A. M. today she passed blood by the rectum which the mother estimated at several ounces. At 6 A. M. she passed a considerable amount of bloody slime. During the day she passed the same material eight times. At 8 P. M. she vomited clotted milk and a few hours after vomited some greenish fluid. She has refused to nurse since the vomiting occurred. This morning her doctor suspected there was a tumor in the midabdomen. At another visit a few hours later the presence of a tumor was unmistakable. He started for the hospital without delay.

Examination.—The child is well developed and well nourished. There is no evidence of collapse. The abdomen is normally rounded. Above and to the left of the navel a prominence is visible as though an object the size of a walnut were lifting up the abdominal wall. On palpation the abdomen is everywhere soft. The tumor mass is easily palpable and is felt to project downward and to the left and can be followed until it disappears into the pelvis.

Diagnosis.—This is a classical picture of intussusception. The bloody stool, symptoms of obstruction and tumor make the diagnosis unmistakable.

Treatment.—An incision just to the right of the median line was made. A sausage-like mass an inch in diameter extended from above

the umbilicus in a curve to the left and downward as far as the bottom of the true pelvis. A loop of ileum disappeared into the end of the tumor mass. Traction on this loop failed to dislodge the gut, therefore the lower end of the tumor mass was grasped and its contents "milked" toward its proximal end. By this means the contents were made to escape. As the contents began to emerge it became evident that the cecum had become inverted into the transverse and descending colon. When reduction had become nearly complete the cecum could not become everted without combined pressure on tumor and traction on the gut. The appendix much inflamed appeared and by gently separating the adhesions, the entire cecum became unfolded. After reduction the appendix and the segment of the cecum below the valve alone were indurated; the ileum was free from induration.

After-course.—The baby continued to vomit for some hours after operation. Enemas were expelled and a hypodermoclysis was given. After this recovery was rapid.

Comment.—Obviously the cecum and appendix became inverted and traveled up the ascending colon, carrying the ileum with it. Whether inflammation preceded or followed this inversion is not known. The induration was of that solid, fragile type that ordinarily requires more than the time which elapsed since the symptoms began, in which to develop.

CASE 8.—A farmer aged thirty-two was brought to the hospital because of pain in the chest and abdomen.

History.—Thirty-six hours ago the patient had a violent chill. He soon developed a pain below the tip of his right shoulder blade. When his physician examined him he had a temperature of 104° and a respiration of 34. By that time there was pronounced abdominal pain, most marked on the right side. He was brought at once to the hospital. He has had some abdominal pain in times past but never any spells that incapacitated him.

Examination.—The patient on entrance has temperature 103.6° , respiration 30, pulse 110. There is no dullness in the lung but some crepitant rales at the base of the right lung. There is some pain on deep respiration. The abdomen is tympanitic, generally sensitive, but most marked on the right side. There is some rigidity of the right rectus in the ileocecal region. There is no expectoration. W.b.c.11,800; 90 per cent polymorphonuclears.

Diagnosis.—The sudden onset with chill and high fever certainly suggested a beginning pneumonia. In the intervening time dullness should have appeared in such a husky man, but there are but a few crackling rales to indicate any lung trouble. The abdominal distention is such as to make the determination difficult, but the pain is too diffuse to be a referred pain from a diaphragmatic pleurisy, which taken together with the probable lower right rectus rigidity indicates an appendicitis. Besides, the physician,

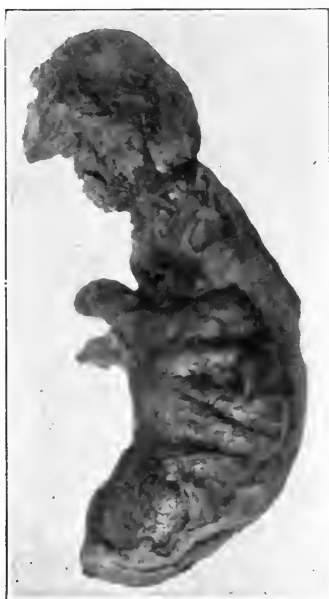

Fig. 305.—Appendix in an advanced stage of necrosis.

a very wide awake practitioner, evidently is convinced of the surgical character of the attack or he would not have sent the patient to the hospital. It seems wisest to see.

Treatment.—A large grayish-black appendix was found at operation. The wall was fragile and smeary. The base was ligated without any attempt at inversion.

Pathology.—The entire appendix had undergone necrosis (Fig. 305).

After-course.—A fecal fistula formed and a rather extensive infection of the wound followed. Healing took place without further treatment. A hernia developed and was repaired a year later.

Comment.—The cause of the chill is not apparent. If the entire process originated in the appendix, there must have been a bacteremia with some involvement of the lung. There was no complicating pneumonia. The cases of appendicitis which I have seen in which there was an initial chill were all cases of gangrene of the appendix. In such cases prompt operation is imperative.

CHAPTER XII

SEVERE INTERMITTENT PAIN

Under this head may be included those cases which either menace the life of the patient, and may require surgical aid to intercept them, either in the individual attack or to prevent a future attack, or the condition is of such a nature that they must be differentiated from the severe cases already discussed. This group includes lesions which require the immediate earnest attention of the surgeon, but which usually permit a degree of careful study.

EPIGASTRIC

Epigastric pains are sometimes due to ulcer, sometimes to impending perforation, less often to visceral crises and pancreatic affections. Most commonly the epigastric pains are due to disturbances referred from other regions, notably the gall bladder, kidney, and appendix. Cardiac disease and the associated visceral congestions and tabes mesenterica must not be forgotten.

CASE 1.—A retired farmer aged sixty-eight came to the hospital because of digestive disturbance and loss of weight.

History.—Since three months he has suffered from loss of appetite and epigastric distress and distention. This distress was not particularly influenced by the small amount of food he was able to take. He had lost some twenty or thirty pounds. He had never had marked epigastric pain but for some years had been subject to brief spells of loss of appetite. So far as he knows he has never had chills or fever. Three months ago he became jaundiced. This jaundice has gradually increased.

Examination.—The patient is sallow, the abdomen is flat but there is epigastric tympany. The muscles in the upper abdomen are tense and pressure produces discomfort, but no actual pain. The discomfort is not located at any definite point. There was no opportunity to make a gastric analysis. The urine contains much bile and the stool is clay colored.

Diagnosis.—The loss of weight with gastric disturbance in an old man suggests carcinoma in the absence of definite symptoms. This is particularly true when the onset is sudden and the decline rapid. The gradually progressive jaundice suggests an involvement of the pancreas and with it the common duct, either primarily or secondarily. The history seems to leave but little doubt as to malignancy, but the patient does not seem as feeble as the history of the case would seem to indicate; therefore, an exploration may be suggested.

Treatment.—Under local anesthesia a gall bladder the size of a finger with very thick walls was discovered. The common duct was thick but no stones could be felt, neither were any enlarged glands to be found. There must be a stone in the duct, however. A drain was kept in the gall bladder for four months.

After-course.—He began to improve rapidly and soon regained his weight. Now ten years later he is still in fair health but he has a slight recurrence of his former trouble. These attacks come on without known cause.

Comment.—The course precludes the existence of carcinoma and a definite answer as to the cause remains obscure. The other most obvious cause is a cholecystitis with or without stones. The previous slight attacks and the subsequent mild disturbance strengthens this belief. Why such relief should have come from simple drainage is a mystery not yet solved. The most reasonable explanation is that there was a duct stone and that it escaped into the gut.

CASE 2.—A farmer aged fifty-six came because of stomach trouble and loss of weight.

History.—He has always lead a vigorous business life and had enjoyed good health until the beginning of his present trouble. Last September he began to suffer general abdominal distress, loss of appetite and loss of weight. There were with it long periods of insomnia. He has a report from a stomach specialist who diagnoses carcinoma and advises operation. Aside from a reduced acid content the report does not look impressive. The patient regards this report as final and expresses a desire to go to the hospital at once "and have it out."

Examination.—Examination shows a supple skin, the tongue is clean and the abdomen is nowhere sensitive or rigid. It presents merely the emptiness of fasting. The patient seems extremely nervous, but not depressed or irritable.

Diagnosis.—The physical signs were not those of carcinoma. I learned on further questioning that his wife had died three months before and that his disability dated from that time. It is not unusual to find nutritional disturbance and actual digestive disorders following emotional disturbances. This may result in total anacidity. These cases are unattended by pain and they are sleepless from nervousness, while a carcinomatous patient loses sleep only because of pain. It may be put down as a general rule that if a patient loses sleep because of apprehension he does not have what he thinks he has. If a patient who thinks he has cancer does not sleep, it is important to know why he does not sleep. If because of pain, cancer is indicated, if because of "nervousness" he likely has not cancer. Even the neurotic may complain of pain, but he locates it in the cardiac or sternal region and it is likely to be most marked in the fore part of the night, while the organic disease causes most trouble in the after part of the night.

Treatment.—I directed his son to take the patient to a hotel and order a porterhouse steak for him, to take him to see the sights each day and repeat the porterhouse steak. He was given potassium bromide 20 grains four times a day. He was ordered to return in five days. At the end of this time and as soon as he hove in sight he exclaimed "Set some high furniture in the room and watch me step over it." The treatment was continued.

After-course.—The patient rapidly regained his weight and has remained well now many years.

Comment.—Young specialists who have seen much of chemistry and little of human nature are apt to get the surgeon into an embarrassing position. It is particularly true in complaints of the stomach. Laboratory diagnosis in gastric complaints is of less importance than a carefully obtained history.

CASE 3.—A merchant aged fifty-two came because of pain in the stomach.

History.—The patient's father died of a tumor of the stomach and a brother has been operated on for gastric ulcer. The patient had malaria at intervals from the age of one year to eleven years while living in southern Illinois. Typhoid at fourteen and twenty-three. Last attack was followed by severe night sweats for several months. About twenty years ago he had some stomach trouble which lasted about five years. He had a continual severe soreness in the stomach

which was not aggravated by meals. He took medicine given him by doctors and from this time up to four or five years ago he was very well. He was in a motor car accident eight years ago and suffered what he says was a dislocation of the cervical vertebræ. This was reduced. He has been troubled with hemorrhoids as long as he can remember. For the last four or five years he has noticed a fullness in the stomach after eating even a small amount of food. There was no real pain. Last September 4th, at one o'clock P. M. immediately after a meal he was seized with severe pain in the stomach, which was not relieved even by hypodermic of morphine. Since that time he has had pain after eating solid food. He has vomited but once after eating, and the vomitus consisted of rice and milk with no sign of blood or discoloration. He says the stomach fills with gas after each meal and pain begins in from 30 to 60 minutes after, but his greatest pain is at night. His bowels have been irregular, tending to constipation, but there has been diarrhea at intervals recently. His appetite is poor. No tarry stools. He has lost sixteen pounds in weight during the past three months.

Examination.—The patient looks thin and depressed and all movements show a bodily weariness. The abdomen is flat, retracted, rigid in its upper portion and there is sensitiveness in the epigastric region and to the right of it. The x-ray shows a normal motility and emptying time. The gastric analysis shows an absence of free hydrochloric acid and a trace of lactic acid. The benzadine reaction is positive for blood, and microscopic examination shows many red cells and many yeast cells. The feces are positive to the benzadine and Meyers tests. The blood examination showed a general anemia. The urine was without interest.

Diagnosis.—The general appearance of the patient suggests carcinoma. His statement that at one o'clock on September 4th he had a severe pain, looks like an impending perforation. His symptoms have increased markedly in severity since that time. If a partial rupture occurred, his marked trouble now may be due to perigastric adhesions resulting from it. The pain comes on in one-half to one hour which suggests ulcer. If there is malignancy, it must have become implanted on an ulcer. Because of the uncertain diagnosis an exploration seems warranted for if it is cancer, there may be a prospect of a cure.

Treatment.—An indurated mass was found at the pylorus which was thought to be nonmalignant. The induration lay just below the pylorus beneath the meson and gave the impression of a perigastric mass. Its density was equal to that of a carcinoma, but its relation made it appear as a perigastric induration, probably excited by an impending perforation of an ulcer. A simple posterior gastroenterostomy was done.

After-course.—A few days after operation the patient started to vomit large quantities of bile. This continued without abatement and interfered with giving of nourishment to such an extent that the incision was reopened in order to determine whether an obstruction was present. The tissues around the gastroenterostomy wound were found so indurated as to block this opening and perhaps the intestines. A drainage tube was placed in the stomach and gut in the hope of preventing so much absorption. The patient died on the tenth day.

Comment.—Notwithstanding the mass about the pylorus the opening was patent and a gastroenterostomy was not needed. The indurated mass I feel certain would have disappeared with ulcer treatment. We knew from the x-ray that the stomach was emptying, therefore the only indication for operation was to remove a malignant growth if one were present. I forgot the evidence the x-ray furnished. I have a number of times encountered the post-operative complications here encountered. It is due to a tremendous thickening of all the coats of the walls of both the intestine and stomach. The slide in such cases shows an enormous edema with some cellular infiltration but the preponderant bulk is an edema or a fibrinous exudate. The cause of it I do not know. I have been able to produce an imitation of it by injecting gastric fluid into the gut walls of animals. It is possible that the contact of the gastric fluid with the new wound is responsible for it. Silk sutures seem to further it, perhaps because the permanency of them seems to induct the acid into the interior of the gut wall. If this be true, catgut would be better, for in a few days it disappears. This unpleasant complication evidently has not occurred to any one else. At least the literature is silent. The futile attempt to lessen the trouble by drainage was about as effective as yelling at a runaway horse—it but expedites what we can not control.

CASE 4.—A farmer aged forty-one came because of pain in the epigastrium, the left side and back.

History.—His father is well at sixty-four, the mother died of convulsions at forty-five after an illness of some years. Two brothers and one sister are living. One brother died in infancy. The patient married seventeen years ago and has two children, both in good health, two dead, the cause of death being diarrhea, and measles and pneumonia, respectively. His wife is in fairly good health; no pregnancies for nine years; no miscarriages. He denies all venereal diseases. When he was twenty years of age he fell eighteen feet from a tree and struck on his neck and shoulders. He retained consciousness but could not get up, and had to be carried home. Paralysis was complete below the neck. He could move his head and neck but not his arms, body or legs. In a week or two slight movements of toes and hands began to return. Gradual improvement followed, but he was in bed for four weeks. After being up a few days he learned to walk again, but for two months more he dragged the left foot. Later he was able to walk apparently as well as before the injury. There were some contractions of both hands, the left worse than the right at first. Passive motion was used all the time. The right hand was strapped to a board for three months to prevent contracture. Now he can not straighten second, third, and fourth fingers of the right hand. He had obstinate constipation with the paralysis and following it for some time.

His present trouble began one and one-half years ago with slight pain in the epigastrium. There was no relation to meals and it was not affected by eating. This gradually grew worse. He was treated by his physician with little relief. The pain extended to the left under the ribs and to the back and somewhat to the right, but not so severe at this point. Pain became very severe, sometimes occurring in attacks but very seldom leaving altogether. He often had to be given hypodermics for pain. He received three hypodermics a week for two weeks before operation. There was no nausea or vomiting but some constipation. A surgeon diagnosed gall bladder disease and operated on him four months ago. He said he found a "knuckle" on the gall bladder but no stones. The gall bladder was removed and the incision was closed without drainage. The patient was in the hospital sixteen days. After he went home, he felt well for five weeks; then the symptoms returned and were just the same as before the operation. Three

months after this while drilling in the field the patient became dizzy and fell unconscious from the drill he was riding. He regained consciousness in ten or fifteen minutes but felt weak and dizzy and went to the house. Pain soon started in the epigastrium and became severe. A doctor was called who gave a hypodermic injection. He has had these same pains, often in severe attacks, ever since. He is never really free from pain for long at a time. He gets relief from the attacks best by lying on the floor with legs drawn up, especially the left leg. He averages two hypodermics a week for pain. The attacks often last several hours. No pain elsewhere. No fever, no headache, and no urinary trouble.

Examination.—Heart and lungs negative, abdomen negative. Eyes react to light but doubtful if they are as brisk as normal. There is evidence of injury to the spines of vertebræ of the 7th cervical and 1st dorsal. Reflexes, patellar and Achilles, markedly increased on both sides. Deep reflexes in arms also brisk. There is contraction of 2nd, 3rd, and 4th fingers of right hand. Wassermann, blood negative, spinal fluid is positive.

Diagnosis.—The injury twenty years ago left the spinal process of two vertebræ displaced laterally. The rapid recovery of the lesion indicates that the disability must have been due to a hemorrhage. The long free interval bespeaks perfect recovery. The pains now sharp and intense as they are indicate irritation of the sensory roots. They are typically lancinating, girdle-like. The increased reflexes indicate a compression of the cord. The feebly positive cord Wassermann is an excuse for antisiphilitic treatment only because the pains are so typically lancinating. The x-ray of the spine showed nothing capable of compressing the cord.

Treatment.—He received the regulation salvarsan treatment.

After-course.—His symptoms responded promptly but in a year he returned with renewed symptoms. Further treatment caused them to disappear again and he has now been free from pain for three years.

Comment.—The symptoms indicate a cord syphilis rather than an incipient tabes. If the symptoms were due to delayed results from the injury they should not have disappeared after specific treatment.

Case 5.—A school boy aged seventeen came to the hospital because of pain in the stomach.

History.—Eight months ago he began to have pains in the stomach, especially before meals. The x-ray showed a narrowing of

the outlet of the stomach he was told. A laparotomy was done by a young operator and a tumor of the stomach demonstrated. This being too big a job evidently, he allowed the tumor to remain unmolested and removed the appendix through a separate incision. The patient has grown gradually worse during the past four months and now is in constant pain located in the stomach region. He is relieved by vomiting residual food. He now has severe pain reaching to the left scapula. Distention has become progressively worse. He has lost 20 pounds in weight. For the past four days emesis has failed to secure results and distention has increased.

Examination.—The tongue is white and serrated. The abdomen is greatly distended but not sensitive. Despite the distention, there is a palpable mass in the epigastrium. X-ray examination showed an hour-glass stomach with pyloric obstruction. W.b.c. 7,700. R.b.c. 5,500,000.

Diagnosis.—The epigastric pain worse before meals and relieved by food suggests a hyperacidity. The reference of the pain to the back and the x-ray findings showing a narrowing of the outlet, suggest an ulcer. The mass palpable probably is an indurated area about an ulcer without abscess formation since there is no leucocytosis or fever. The marked distention must be due to involvement of the surrounding guts by this mass. The immediate requirement is relief from the marked distention.

Treatment.—A midline incision was made. An irregular mass the size of a small fist occupied the greater curvature of the stomach and mesocolon and involved the transverse colon as well. The colon was completely occluded. The mass was adherent to the duodenum but there were no glands palpable. The distention of the small intestines and the proximal end of the colon was enormous. Because of the age of the patient a diagnosis of carcinoma was made with reluctance. There was a small subperitoneal nodule, oblong in shape, on the surface of the stomach at some distance from the mass. This was believed to be carcinomatous and it was excised for examination. The mass being inoperable, an artificial anus was made in the cecum.

Pathology.—The nodule removed showed typical carcinoma.

After-course.—There was relief from the abdominal distention, but the general condition did not improve. The advice of another surgeon was sought who because of the age of the patient denied the

possibility of malignancy. He did a relaparotomy which was followed by a constant oozing until the patient died two days after operation.

Comment.—The symptoms in this case were intermittent and were relieved by eating. Subsequently they became constant and loss of weight began. This is typical for the implantation of carcinoma on an ulcer. At operation the history and character of the mass inclined me to a diagnosis of infiltrative perigastritis from ulcer until the small subperitoneal nodule above mentioned was sighted. When in doubt of the nature of a lesion, it is of importance to search for such nodules. Their gross appearance is characteristic. They are subperitoneal, oblong, flat. They differ from tubercles in being flatter and less rounded. They have the appearance of being lymph borne.

HEPATIC

The common cause of pain in the hepatic region is, of course, gall bladder disease, usually stone or inflammations, generally both. Not infrequently there are typical attacks without stone and but minimal anatomic changes. These may recur even after the gall bladder has been removed. Pain in the hepatic region may be due to diaphragmatic pleurisy and to sudden loss of cardiac compensation. Kidney crises may be referred to this region and an appendix lying high up may simulate hepatic colic and cholecystitis.

CASE 1.—A farmer aged sixty-two came to the hospital because of pain in the abdomen.

History.—Five months ago his trouble began with a sudden pain in the right side. There has been constant pain since. Now the pain radiates upward in the region of the right nipple, to the back and to the left side under the short ribs. There has never been any jaundice. His appetite became poor at the onset of the pain and he has lost 40 pounds in four months.

Examination.—The patient is a large, portly man bearing evidence that he has been a powerful man. There is evident emaciation, the trouser band is half a foot too large: mute evidence of loss of weight during the lifetime of the trousers in spite of the still generous abdomen. There is deep tenderness over the upper end of the right rectus, and there is well-marked muscle rigidity. There are 12,000 leucocytes. The temperature and pulse are not disturbed.

Diagnosis.—The sudden onset, the peculiar radiation of the pain, the marked local tenderness and muscular rigidity make it seem likely that there is a gall bladder infection. The loss of weight is unusual and the radiation of the pain to the left costal margin makes one suspicious of carcinoma. The sudden severe pain speaks for gallstones. The leucocytosis might be produced either by an infected gall bladder or a carcinoma. Since relief would be likely if the gall bladder be at fault, operation seems warranted.

Treatment.—Exploratory operation was undertaken. A hard nodular mass as large as an apple occupied the pyloric region and the lesser curvature. There was a packet of glands above the stomach and one below in the region of the head of the pancreas. The gall bladder was free.

After-course.—The progress downward, apparently accelerated by the confinement in bed, was rapid, and he died in three months.

Comment.—I have repeatedly had patients with gastric cancer name the day on which their symptoms began. What accident to the tumor marks the advent of these phenomena is not known. Surely the tumor must have attained a considerable size before these symptoms appear, for I have operated on patients within a month after such sudden onset and found large tumors. It is my opinion that the onset is caused by a breaking down of masses of tumor tissue, perhaps attended by more or less loss of blood. Whether or not such ulcerative processes expose nerves to irritation is not known, but it is the ulcerous carcinomas that are attended by such sudden advent of symptoms. What caused the acute pain in this case was not apparent unless there was a hemorrhage in some part of the tumor.

CASE 2.—A farmer aged twenty-nine came for consultation because of epigastric pain.

History.—Ten days ago the patient had severe pain in the upper part of the abdomen and was unconscious for a time. There was no vomiting or fever. The severe pain left rather suddenly but there has been some soreness since then. Since that attack the appetite has been good. For several years he has had epigastric pains but he does not know whether it is worse after eating. He has had spells similar to the above before, but not so severe and not attended by loss of consciousness. Bowel movements usually are regular, sometimes he has diarrhea, and sometimes he is consti-

pated. Following the above attacks, he was better for a year, but has now been sick all summer. He feels pressure in the epigastrium which extends to the back in the midline. Sometimes the pains are more severe in the back than in front. Sometimes when the pains are very severe he is relieved by vomiting. He thinks the pain comes on soon after eating.

Feb. 20, 1916: The patient has had severe pains chiefly in the epigastrium, but the chief point of tenderness is along the right costal border.

Feb. 26, 1916: One attack this week lasting the whole afternoon. No vomiting, appetite not so good. Half hour after meals the pains begin with lesser pain at night.

April 1, 1916: He had severe pain yesterday, lasting all day and most of the night. He thinks he was yellow after the pain. The pains now extend through to the back and sometimes they are worse in the back than in the region of the stomach.

March 17, 1918: He has been fairly free from pain, but had a slight spell two months ago. He feels pain in the back when he first gets up in the morning. His pain is increased when jarred in a wagon. It now bears no relation to meal times. During the past few days he has had pain lower down in the right side and the tenderness has extended lower than in previous attacks. He had some fever but no vomiting.

Examination.—During the previous attacks his pain has been most pronounced in the region of the gall-bladder. Now he has distinct tenderness over the right side of the right rectus and there is marked rigidity. There is marked deep tenderness. The urine was negative and the x-ray showed no stone.

Diagnosis.—Because of the relation to the time of maximum pain and the distribution, he was thought to have an ulcer despite negative laboratory findings. The severe pain with loss of consciousness was thought to be an impending perforation. He was treated for four years with antacids and diet under the impression that he had an ulcer. He usually improved under the treatment, but would relapse in spite of treatment. The site of the tenderness and the radiation to the right along the short ribs suggested a duodenal involvement. Later the pain in the back was located lower down and finally was exaggerated by being jolted over the roads. This suggested a kidney trouble, but the urine showed nothing and the x-ray was negative. His last attack was distinctly appendiceal.

Treatment.—A long indurated appendix lay lateral to the cecum and colon extending to beneath the gall-bladder. The stomach and duodenum were explored but no sign of trouble past or present was discovered. The base of the appendix was friable and an area of the cecum the size of a quarter had to be inverted because of the friability of the tissue in the immediate vicinity of the appendix stump. The appendix was adherent to the lateral wall of the colon. The

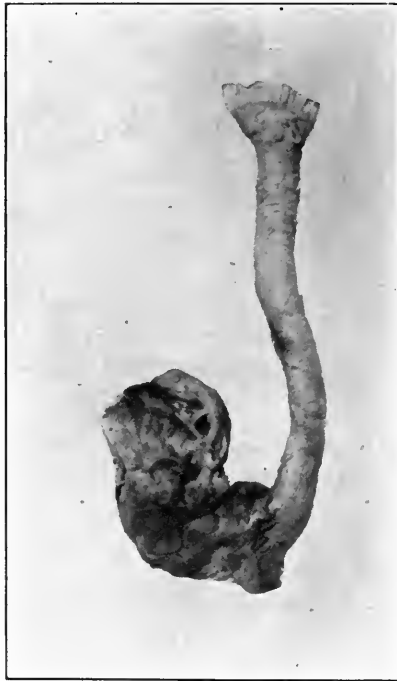

Fig. 306.—Appendix after it had been shelled out of the muscle coat. The clubbed extremity represents the tip with its indurated walls covered with a plastic exudate.

curved tip was much indurated. The remainder was shelled from the muscular coat (Fig. 306). Closure without drainage.

Pathology.—The appendix shows extensive recent induration and connective tissue proliferation of an earlier inflammation. The terminal three centimeters were much thickened by a partly organized exudate.

After-course.—He had a temperature of 101° the day following the operation and it remained near this level for a week and then permanently subsided with the drainage of a subcutaneous abscess. He was troubled with gas pains during the first few days following the operation. These were treated with starvation, stupes and a colon tube. After a few days he was given magnesia and bismuth.

Comment.—From the appearance of the specimen I am disposed to think there must have been a perforation at the very tip when he had his severe attack of pain four years ago. In those cases in which epigastric pains precede a frank appendix attack there has always been a chronic duration. The reason for these symptoms I believe is that there is a low grade proliferative process inside the peritoneum. This process keeps the nerves of the appendix more or less in a state of irritation with the consequent disturbance in the stomach. When finally the infection reaches the surface of the appendix and a periappendicitis is produced, the typical appendicitis symptoms result. I believe one should diagnose these cases early when the pains radiate around the short ribs when the other signs point to ulcer. In a young male gallstones are unlikely. Closer questioning in his native tongue indicates that what he meant by stating that he became unconscious was that he felt weak as though he would collapse.

CASE 3.—A farmer's wife aged forty-one came to the hospital because of pain in the right side.

History.—Her present trouble began a year ago with pain in the right side. The attacks began with a severe pain under the short ribs just below the right breast. They are very severe, requiring hypodermics for their relief. They cause nausea but she has vomited only once. The pain passes around the right border of the ribs margin and extends to the right shoulder blade. This severe pain lasts from one to one and one-half hours and is followed by a great tenderness under the right side under the short ribs. Sometimes the pain starts in the pit of the stomach. The attacks came on three weeks apart at first but kept coming closer together until now they come every few days and there is a constant tenderness. She has had fever up to 100° several times during these attacks. She was jaundiced once when she had had no pain of any kind for some weeks. She is troubled with gas a great deal since the beginning of these pains and bloats after every attack. The appetite is not

good but the bowels are regular. She gets up once a night to urinate. There is much sediment in the urine. She has no pain on urination except at intervals when she has some burning. Her weight remains about stationary. The menses have been irregular for a year, coming on at three-, seven- and nine-week intervals. There is always a good deal of cramping. She used to have very severe occipital and parietal headaches. They were very severe up to the last few months when they have subsided somewhat. She has two children living and well, the youngest seven years of age. She has always been well, with the exception of the severe headaches at the menstrual periods which began soon after puberty. They are very severe over the right eye and over the top head. She is often nauseated at these times. Her mother had severe headaches which disappeared when she passed the menopause. She passed some small stones from the bladder eight years ago. The description of the attacks and of the materials passed is unsatisfactory.

Examination.—The patient is of the adipose type. The skin is clear, without jaundice. There is tenderness to pressure over the gall bladder region and along the right subcostal margin, as well as over the appendix and right and left iliac regions. It is difficult to determine the relative intensity of superficial and deep palpation, though there seems to be a definite deep tenderness over the gall bladder region particularly in deep inspiration. The perineum is lacerated to the second degree. The cervix has a deep stellate laceration without erosion. The fundus is in position and is somewhat enlarged.

Diagnosis.—The patient has been treated for her headaches with cannabis indica in the out-patient department, for several years, without any very definite results. The impression was gained that they are migrainous in character, a supposition corroborated by the fact that her mother had similar headaches. The patient is very stout and the dysmenorrhea suggests a premature ovarian atrophy. The physical findings seem insufficient to account for them because of the absence of erosions, the usual accompaniment when uterine disturbances are responsible for headaches. The attacks of subcostal pain of sufficient degree to require morphine for their relief, extending to the right subscapular region attended by a slight rise in temperature and followed by definite subcostal soreness seemed to incriminate the gall bladder. The intermittent character suggested

stone rather than simple inflammation. The fact that there is a history of having passed gravel causes one to hesitate before making this diagnosis, though the urine and x-ray examination do not suggest stone. The stoutness of the patient makes the x-ray examination less certain than is ordinarily the case. Ureteral catheterization was considered, but the clinical history did not seem to warrant this additional traumatism. Because of the increasing suffering of the patient, a diagnosis of gallstones was made to serve as a basis of treatment.

Treatment.—The gall bladder seemed normal inside and out, but it was drained and the appendix was removed. The appendix seemed normal but it was attached laterally to the cecum in a way to suggest a past inflammation. The common duct seemed normal in size and pliability and could be palpated throughout its extent. The pylorus of the stomach was examined and was found normal.

After-course.—The patient made an entirely normal recovery. She suffered from no pain after the first few days. The drainage had always the appearance of normal bile. Since dismissal from the hospital she has remained free from pain, but the headaches and menstrual disorders continue as before.

Comment.—The type of patient, the history of the attacks and the physical findings seemed typical of gallstones, yet exploration failed to show anything abnormal. The removal of the appendix and the drainage of the gall bladder were done in the hope that changes too minute to admit of gross detection might have taken place. Possibly the appendix had something to do with the attacks. A stone in the kidney or other renal disease may have been a cause, though the presence of jaundice at one time hardly fits in with an uncomplicated renal disease. The attack of jaundice at a time when the patient was having pain might have been accepted as a sufficient cause for exploring the common duct, but the actual presence of jaundice was not sufficiently established to warrant this hazard, particularly since the anesthetist was relatively new at his work. On the whole this case must be marked up as unfinished business.

CASE 4.—Attacks of pain in the right side brought this man of sixty-three to the hospital.

History.—He has been troubled for two years with periodic attacks of pain which start under the right short ribs and is also felt in the epigastrium. He has vomited only three times with the

attacks. He has not had any fever of which he knows. At first the attacks were every few months but they are getting closer together until the last few weeks he has had them every few days. During the last few weeks he has had a constant tenderness under the right costal margin. His attacks usually last about an hour and then gradually wear off. His worst attack was in Colorado a year ago. It lasted two hours and he vomited continually. Opiates were given twice, but they did not stop the pain. He became deeply jaundiced after this attack and the urine was highly colored. He did not notice the character of the stools. This was the only time he noticed a jaundice. He has had no stomach symptoms in the interval between attacks. He is always constipated. There is no urinary disturbance.

Examination.—The patient is a portly, thick-necked individual. His blood pressure is 140-90. He is pale and anemic looking. The blood picture is that of a mild general anemia. Head, neck, heart, and lungs negative. The abdomen is very sensitive to pressure along right margin of the ribs and epigastrium. No mass is felt.

Diagnosis.—The history is typical of gall bladder colic with a cholecystitis during the last few weeks. The fact that he had no disturbance between the attacks suggests that there was no cholecystitis during the earlier period of his disease. This may be of importance in deciding the type of operation to be performed.

Treatment.—The gall bladder was found to show much evidence of acute inflammation. The omentum was attached all over the gall bladder. It was filled with grass green fluid and many flocculi. It contained one large stone the size of a hickory nut down at the cystic duct and many smaller ones above it. These were removed and a large rubber drain inserted in the gall bladder. Because of his general appearance it seemed best to play safe and do a simple drainage.

After-course.—For about ten days after operation the drainage from the gall bladder was a dark blackish green. This gradually changed after ten days to a normal yellowish-green color. The post-operative course was normal. The wound healed by primary union with the exception of the drainage opening. His temperature never went over 100.5° or pulse over 90. The drainage was maintained three weeks because of the pronounced inflammation. A week after he returned home he had an acute pain similar to his former at-

tacks. His family physician called another surgeon who reestablished drainage, and a month later removed the gall bladder.

Comment.—Obviously the duet was not yet patent and the gall bladder filled up and caused pain. I hoped I had circumvented just this thing by maintaining drainage three weeks. This evidently was not adequate. Had I removed the gall bladder I might have avoided the unpleasant sequence. I do not like to remove inflamed gall bladders from portly old men whose antecedents I do not know.

CASE 5.—A matron of forty-one came to the hospital because of pain in the pit of the stomach and back.

History.—For several years she has had periodic pain in the pit



Fig. 307.—Strawberry gall bladder.

of the stomach and back. There is soreness and indigestion between the attacks. Solid food disagrees, but the attacks are not related

to the meals. The attacks come on without warning and last an hour or so. She has to go to bed and has had to have hypodermics on several occasions for the relief of pain. She feels tired and worn out, and there is a constant aching under the right shoulder blade. Dieting used to help but it does not now. She now has a constant fullness and queer feeling high in the epigastrium. She has had six severe attacks during the past year, one a month ago and one five days ago. She now has a marked soreness under the short ribs on the right side. She has no fever with her attacks and is never jaundiced. She has never had rugged health. She has one child seventeen years old and has had no miscarriages. She had dysmenorrhea before pregnancy.

Examination.—There is marked tenderness over the hepatic region which is increased on deep respiration. Other examinations are negative save a pronounced laceration of the cervix.

Diagnosis.—This is a classic history of gallstones, well told. With such a history stones are rarely wanting.

Treatment.—The gall bladder was thickened, moderately distended, and contains many small stones. Therefore, the gall bladder was removed.

Pathology.—Many of the gallstones were friable, others very small. The gall bladder itself was studded with fine elevations, giving a perfect imitation of a strawberry (Fig. 307). The slide shows the glands prominent and pronounced about the vessel walls and in the submucosa.

After-course.—She was troubled with cystitis for some months following operation. She was given potassium citrate for this and gradually improved. Otherwise she was well.

Comment.—This case is remarkable because it is so typical; scarcely anything is lacking.

CASE 6.—A matron of thirty-five came to the hospital because of pain in the upper part of the abdomen.

History.—Her present trouble started five years ago during the first pregnancy. She had a sharp pain under the right costal margin which was not colicky in character and did not double her up and was not followed by jaundice, but she did have pain which extended straight through to the back at that time. It lasted for about six weeks and disappeared before the termination of pregnancy.

She had no pain then for two years. Then pains began again in the epigastrium which she describes as grinding. They would last for several weeks and then she would be free for from four to eight weeks. Since last April 1 the pain has been almost constant. In the epigastrium and under the right costal margin the pain is not constant, but under the inner margin of the right scapula it is, and it gets worse towards evening. It is more a feeling of soreness than real pain. She says that breakfast seems to relieve the pain in the epigastrium, but that following a hearty meal the pain and gaseous distention is much worse. She never vomits, and has no acid eructations, the appetite is good, bowels are regular, weight remains constant. The patient had measles in childhood and tonsillitis one year ago. She has been subject to severe headaches as long as she can remember. When between sixteen and seventeen years of age, she had a spell of unconsciousness which she said lasted three days. The right arm and leg were partially paralyzed when she regained consciousness, but she quickly recovered.

Examination.—The patient is extremely nervous, complaining of pain wherever touched, but soon settles down when pressure is maintained. The site of spontaneous pain is not more sensitive to pressure than other parts of the abdomen. The uterus is in position, no special tenderness. She has large hemorrhoids which bleed on examination. The urine is negative, the Hg. is 80 points, an Ewald meal gives total acidity 42 points, free HCl 13 points, and combined 29 points, and no blood. The nervous system shows no changes. The pharyngeal reflexes are absent.

Diagnosis.—The patient does not tell her story consistently and the tale told various members of the staff does not tally. She probably has had a nervous hyperacidity, possibly ulcer. The type of pain is not that characteristic of gall bladder disease. The fact that it came on during pregnancy suggests this possibility, however. She is extremely nervous, in fact typically neurasthenic. The paralysis she describes as having occurred during her seventeenth year was undoubtedly hysterical. The only lesion capable of objective demonstration was the hemorrhoids.

Treatment.—Inasmuch as the hemorrhoids demanded treatment, the removal of these was done in order that we might retain the patient for further observation.

After-course.—She improved considerably during her stay in the hospital, but after she returned home she was soon as bad as before. Another surgeon explored the gall bladder a few months later but found nothing. Her condition remains unchanged.

Comment.—It is difficult to determine to what extent such nervous conditions are based on organic lesions, particularly of the genital tract, and how much on functional nervous conditions. Even when there is some obvious lesion of the genital tract its correction must be undertaken with much circumspection, in neurotic persons, lest the operation be made the object of renewed nervous manifestation and the activities of the surgeon be made the subject of unfavorable comment. This is particularly true of patients who are not able to repeat their story, when the history is taken by different doctors at different times. In such cases it is often advantageous to have the history retaken by one who knows nothing of the patient or of the previous history. They sometimes dilate on their story to an illuminating degree when they believe they have a credulous examiner.

CASE 7.—A farmer aged fifty-one came because of abdominal pain.

History.—His general health was good until a year ago. Since then he has had much headache but no severe illness. The pain in the head has always been worse on the right side. Hemorrhoids operated on fifteen years ago and again two years ago by a rectal specialist. He had pleurisy twelve years ago. No chronic cough or pleurisy recently. His chief complaint now is a burning in the stomach and at times a bloating. No vomiting. At intervals there is a distinct pain in the region of the gall bladder which radiates to the back, which his physician describes as being typical of biliary colics. The patient describes the pains as continuous, dragging, and gnawing. He has never had a hypodermic for his pain. While describing his stomach symptoms he complains of pain in the right leg, in the tibia and also in the hip. Pain in the hip is not increased by walking; burning in right foot and leg. Pain in shoulders, pains would frequently shift from one place to another. These pains often make him nervous and irritable. He adds also that he has had domestic trouble twelve years.

Diagnosis.—On the assurance of his physician, the diagnosis of gall-bladder trouble was accepted. While he describes a fairly typical

attack of gall bladder colic he at once augments his account by irrelevant symptoms.

Treatment.—Nothing was found in the abdomen, but the gall bladder was drained.

After-course.—The patient was not influenced in any way. He declared himself cured but at once started to relate a long train of symptoms. Curiously enough he is satisfied that the operation was of great benefit to him. He becomes progressively more neurasthenic.

Comment.—I should have known better than to operate on this patient. While describing his supposed gall bladder symptoms he switched at once to vague scattered pains. If a patient has actually had gall bladder colic he keeps his mind on the subject and does not allow it to wander after minor symptoms. His volunteering the fact that he had had domestic trouble for many years should have deterred me. Digestive troubles may be both the cause and result of domestic infelicity, but the condition is not remediable by surgical means, at least not by drainage of the gall bladder.

CASE 8.—A housewife of thirty-three came to the hospital because of attacks of pain in the abdomen and in the bladder.

History.—Her trouble began four years ago with pain over the hip bone extending to the bladder. There was bloody urine for a few days following the attack and during the height of the pain she was unable to empty the bladder at all. There has been no recurrence of these attacks. She now has pain low in the back and there is a constant feeling of heaviness and some soreness under the right costal margin. She has had sudden severe attacks of cramping pain beginning along the right costal margin and extending across the abdomen to the left side. They often come on as frequently as one or two a week and sometimes remain away a month. Of late they are becoming more severe and require morphine to stop them. During this time she is nauseated but does not vomit. Stomach symptoms between attacks are mainly those of bloating and heaviness, if certain foods like cabbage are taken. Appetite is fair, bowels regular most of the time. She has had five children, the youngest two years of age. She has had no miscarriages. Menstruation started at twelve years of age, is regular, and lasts three days. The thighs and legs ache at the beginning of the flow but no great degree of pain. No discharge between periods. When the

pains in the side come near the menstrual time the flow begins a few days early.

Examination.—The patient has marked tenderness over the gall bladder, the uterus is retroverted so that the cervix impinges on the bladder. There is a second degree perineal laceration.

Diagnosis.—The beginning of this patient's complaints sound very much like a renal colic, but no trace of stone can be found and the urine was normal.

Treatment.—A number of gallstones were removed and the gall bladder was drained. The perineum also was repaired and a suspension of the uterus was done.

After-course.—Recovery was uneventful.

Comment.—I have several times been led to make a provisional diagnosis of renal colic when pain radiating to the bladder with blood in the urine was present, only to fail to demonstrate a renal disease and to be confronted later by typical gallstone attacks. The relation is not clear. The disposition of the advent of the menstrual flow to be expected when the gall bladder colic comes near the time for the flow is of interest. Gall bladder colics are prone to come at the conclusion of labor. This association in this case seemed to warrant a correction of the pelvic topography though there were no other symptoms to urge it.

CASE 9.—A school girl of seventeen came to the hospital because of abdominal cramps.

History.—Her general health has always been good. She has not had typhoid, but had severe tonsillitis at 11 years of age, which ended in a discharging right ear. One year and a half ago she had a sudden severe pain in the epigastrium, lasting one hour. When the pain in the epigastrium was most severe, she vomited and was somewhat relieved. She had another attack six months later which lasted two hours. After the attack she had a little pain accompanied by local tenderness in the region of the gall bladder. Another attack two months later ended in a series of light attacks which lasted for two or three months. In the intervals she felt sick at times and frequently had gas on the stomach. At this time she had a severe attack with vomiting which lasted 18 hours. There was some jaundice. She had another severe attack in the latter part of July, one week before entering the hospital. This attack also started with gas on the stomach and pain in the region of the gall bladder, but this time the pain radiated toward the back under the right shoulder blade.

Examination.—The examination is negative except for deep tenderness over the gall bladder, most marked at the height of inspiration.

Diagnosis.—As the attacks recurred, they became more typical of gall bladder disease. The age of the patient and the relief from vomiting suggested ulcer. The jaundice was not incompatible with this theory. The deep tenderness was most pronounced over the gall bladder and the direction of radiation spoke strongly for gallstones, hence this opinion was rendered.

Treatment.—Cholecystectomy with drainage was done. The gall bladder contained four stones.

After-course.—The recovery was uneventful and she has remained well.

Comment.—Probably in more cases than we suspect the gallstones are present early in life. Many patients who present gallstones in later life have epigastric pains early in life and many of them have distinct histories of septic infection.

CASE 10.—A matron of sixty came because of cramping pains in the upper abdomen with jaundice.

History.—The patient's illness began fifteen years ago when she first noticed a heaviness in the stomach after eating and a great accumulation of gas in the stomach and bowels. Two or three times each year she has had severe attacks of cramping pain in the pit of the stomach and along the rib border which doubled her up. These were always followed by jaundice. Two weeks ago she had one of these attacks and is now extremely jaundiced. She has had much tenderness over the gall bladder most of the time during the last year. She has been very constipated the last fifteen or twenty years. She has frequency of urination, especially at night, and a burning in the bladder region.

Examination.—Physical examination shows the patient deeply jaundiced, the sclera deeply tinted. There is marked tenderness to pressure over the whole epigastric and right subcostal regions. The urine contains much bile.

Diagnosis.—The pain preceding the appearance of jaundice many years, and the absence of chills suggests that the common duct obstruction may be due to inflammation rather than stone. The tenderness in the hepatic triangle indicates a cholecystitis. The deep state of jaundice would make a duct drainage hazardous. A simple gall bladder

drainage seems the operation of choice. If the jaundice is due to inflammation, this may subside if the causative factors are removed.

Treatment.—The gall bladder was drained and four stones were removed. Common duct was not examined at this time because of extensive adhesions about it. I did not care to invite hemorrhage by breaking them up. Because of the intense jaundice, a simple drainage was done.

After-course.—The patient drained profusely for a month and the jaundice cleared up. Four months later there was still a sinus. Exploration located a small stone in the gall bladder. After this was removed the sinus closed and she had no further trouble. Jaundice never reappeared after it once cleared up. She has remained well now many years.

Comment.—The patient was advised that after the jaundice cleared up a second operation should be done in order to explore the common duct. She feels too well to submit to this. Inflammatory occlusion with jaundice which occurs with cholecystitis may entirely recover when the inflammation subsides. In such cases the jaundice comes on some times after the acute onset, occurring only after the gall bladder inflammation has reached some degree. When the jaundice is due to stone, it begins with the onset of pain and is intense from the start. The prompt exploration of the common duct in such cases as this is theoretically correct but the course here followed makes for a lower mortality, particularly in the hands of the beginner. In many cases time proves that duct exploration was not necessary. So it proved in this case.

CASE 11.—A matron of forty-three came to the hospital because of epigastric pain.

History.—One child, menses always painful. Well otherwise until four years ago when she had a cramp in right side extending toward the pit of the stomach and backwards to below the shoulder blade lasting twelve hours. After a week the attack was renewed. These attacks were repeated several times during the past four years. In the attack-free interval she suffered much from epigastric pain and gas. These pains bore no relation to mealtime and were not influenced by the taking of food. These epigastric pains have been increasing in the past year. Recently these pains have been attended by vomiting. Vomiting at first gave some relief, but recently it has had no influence. There was jaundice following an attack three months ago and there was bile in the urine for a month.

Examination.—She is a plump woman presenting the general appearance of good health. There is pain over the hepatic region on deep pressure which radiates toward the epigastrium. There is greater resistance over the right than over the left rectus muscle. Gastric analysis shows no blood.

Diagnosis.—The attacks of pain were typical of gallstone colic. The continued epigastric disturbance, vomiting without relief, jaundice without other evidence of common duct obstruction point to a chronic inflammation of the gall tract likely with stone. Ulcer does not have such a typical radiation to the scapular region and vomiting should give temporary relief from pain. The absence of blood also favored the diagnosis of gall bladder disease.

Treatment.—A large number of gallstones were removed. The gall bladder was thickened but the common duct seemed free. Drainage.

Pathology.—The gall bladder was thickened, apparently due to an edema. The slide showed some round-celled infiltration but no changes in the glands.

After-course.—A normal recovery from the operation followed. There was complete relief from the attacks of pain and from the digestive disturbance. Four years later the patient again complained of epigastric distress. There were no colicky pains. There was greater loss of appetite than in the previous trouble. Treatment failed to secure any relief. A cholecystitis was diagnosed in spite of a beginning jaundice. The removal of the gall bladder seemed indicated. Before the patient could resolve to undergo operation there was loss of flesh and a hard nodular mass was discovered in the region of the gall bladder. A diagnosis of carcinoma of the gall bladder was made and operation was refused. Lancing pains radiating to the epigastrium and back appeared. The mass increased in size steadily, jaundice deepened, and emaciation grew apace. The patient died from exhaustion five years after cholecystotomy.

Comment.—There was no evidence of malignant change at the time of the operation. With the history of cholecystitis the gall bladder should have been removed. This might have prevented the occurrence of the carcinoma. As a preventive against carcinoma, cholecystotomy can hardly be recommended as a general proposition, for carcinoma is of rarer occurrence than the increased mortality of the cholecystectomy over cholecystotomy. This is true of the operation

in the hands of the average operator but with the expert the prevention of malignancy is a matter worthy of consideration.

CASE 12.—Pain in the upper abdomen brought a business man of fifty-two to the hospital.

History.—Six years ago this patient was operated upon at this hospital for the cure of inguinal hernia and two years ago for the removal of his prostate. Both these operations were for typical affections of their type and the recovery was without incident. The present trouble has manifested itself in slight degree for several years. Two years ago, while he was in the mountains recuperating from his prostatic operation he was attacked by a severe pain in the right upper quadrant of his abdomen. He vomited several times and after the relief of pain by opiates he had to lie abed a week because of soreness in the upper abdomen. He had had similar though less severe attacks some years before. He was attended by an able internist in a western city who diagnosed gall stones and advised operation. He has had several slight spells in the intervening time. Recently while at a summer resort he had a similar attack which was again diagnosed gallstones by his attendant. There has been no jaundice.

Examination.—It is now three weeks after the last attack above noted took place. He has lost some twenty pounds in weight and has a considerable general anemia, having 2,800,000 reds and 75 per cent Hg. The whites are 7,700. There is deep tenderness over the gall bladder region extending well outside the lateral border of the right rectus. No tumor can be palpated. There is deep tenderness in the flank. This is aggravated by deep respiration. No pain is caused by pressure over the epigastrium or along the ascending colon. The urine contains a trace of albumin, but his blood pressure is only 145.

Diagnosis.—The history of the attacks he had had, particularly the last one, seems typical of cholecystitis, especially of the type in which large, crumbly stones are found. There never has been any reason to suspect a kidney lesion during the frequent examinations that have been made in his previous sojourns in the hospital. There has never been any pain in the ileocecal region. It is suspicious that there should be so much peritonitis in the early days of the attacks. The deep tenderness in the flank likewise causes one

to hesitate but both these conditions may be associated with cholecystitis if the gall bladder be large and pendulous.

Treatment.—An incision was made along the lateral border of the right rectus muscle extending from the costal margin to below the level of the umbilicus. The gall bladder and duodenal region were free from any disease. Lateral to the hepatic region, reaching

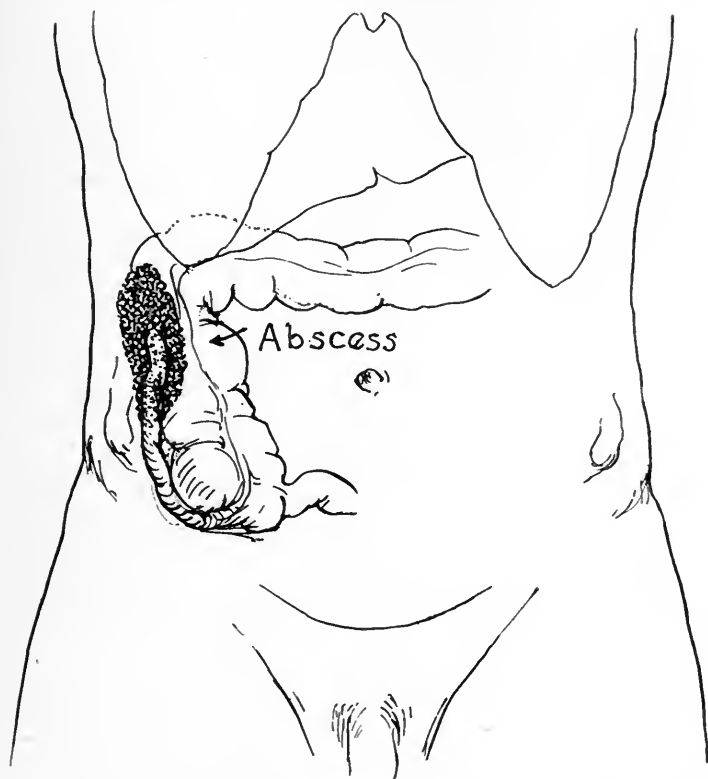


Fig. 308.—The appendix located lateral to the ascending colon is surrounded by indurated tissue in which there was a small abscess.

quite to the liver, was an appendix as large as a finger and four inches long. The tissues about it were deeply infiltrated and in the greater part of its length it was covered by fragile adhesions. When it was lifted from its bed, a small abscess was found lying between it and the colon. (Fig. 308.) The original incision was closed completely after a stab drain had been made in the flank.

Pathology.—The appendix was made up for the most part of edematous tissue infiltrated with round cells.

After-course.—The wound drained for six weeks and there was some subcutaneous infection of the primary incision. Despite the free discharge of pus, the pulse and temperature did not greatly exceed the normal. The patient seemed to recover from the operation completely, but within a year he began manifesting the Stokes-Adams syndrome and died in one of the attacks some six months after the appearance of the first one.

Comment.—The tenderness more laterally than the usual seat of pain and the ability to cause pain by deep pressure over the kidney region caused me to consider the kidney as the possible source of the pain, but the appendix as the offending organ was not seriously considered. Cardiac affections as sequence to chronic infections are by no means rare and constitute one of the chief secondary indications for the eradication of local foci.

CASE 13.—A matron of forty-one came to the hospital because of severe pain in the upper right quadrant.

History.—Eleven years ago, following childbirth, she had a severe pain in the region indicated. It was very severe and cramp-like but did not radiate and was not followed by soreness. After repeated attacks over a period of two years gallstones were diagnosed and operation performed. No stones were found, but the gall bladder was filled with a black, ropy substance the operator reported. Drainage was left in three weeks. She was free from pain four years. For the past five years she has suffered an increasingly severe attack of pain of the same character. For the past year and a half these pains have radiated to the right shoulder and the past several attacks have been followed by soreness under the ribs. Her health otherwise has been good.

Examination.—The patient is well nourished and bears no evidence of the suffering she relates. There is tenderness and a sense of resistance in the hepatic triangle. Otherwise examination is negative. There is no jaundice and the urine is free from bile.

Diagnosis.—Relief following previous drainage of the gall bladder indicates that this was the source of pain. The return of the pain may be accepted as a recrudescence of the disease. The attacks now

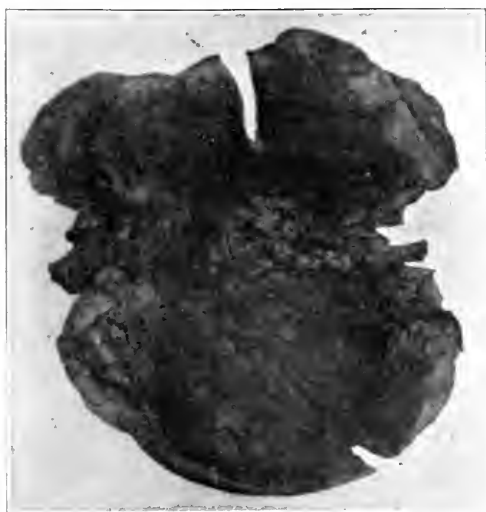

Fig. 309.—Chronic inflammation of the gall bladder. The mucosa is thickened and in part defective.

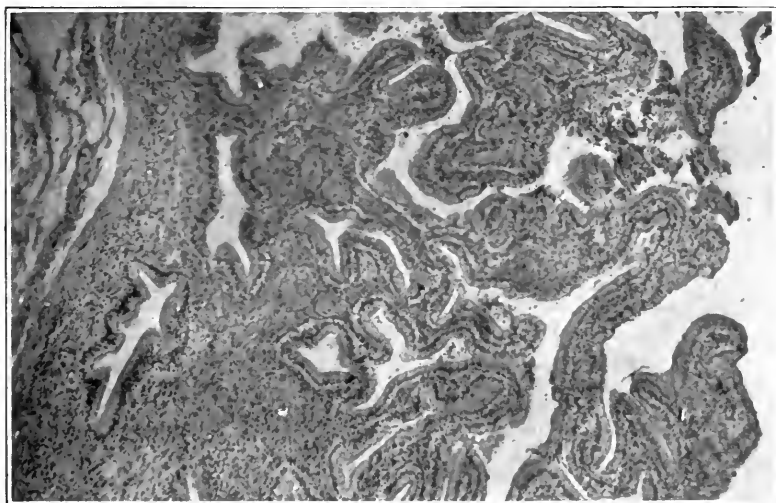


Fig. 310.—Hyperplasia of the mucosa of the gall bladder.

radiate to the scapula and are followed by local soreness, both factors indicating that there now is a stone present and a pericholecystitis. There is no evidence of duct stone.

Treatment.—The gall bladder is attached to the abdominal wound, the result of the previous drainage. The colon is attached to the gall bladder, the result of a recent inflammation. The gall bladder contains a single stone the size of a walnut. The gall bladder is edematous and much thickened. It was removed.

Pathology.—The stone is irregular and the surface seals off on slight pressure. The gall bladder besides the edema is corrugated (Fig. 309) and there is a marked proliferation of the gland suggesting malignancy at first glance (Fig. 310), but closer examination shows it to be a simple hypertrophy.

After-course.—Recovery was delayed by suppuration of the wound, but since it has healed, the patient has been free from complaint.

Comment.—In this case cramps and black, ropy mucus antedated the development of stone. True to rule when there was no stone the pain did not radiate and there was no local soreness, while when stone was present, radiation and local tenderness were both present. This case again shows that a gall bladder with a definite history of a trouble had best be removed.

RENAL

The classical cause of kidney crises is, of course, stone. There may be crises which disappear never to return again due probably to acute congestion. Renal colic may be referred to the epigastric region, but not higher, and the common direction is downward to the genital organs and bladder. Spondylitis may cause pain in the loin and the pain may be referred to the bladder and genital organs but not to the glans. Pain may occur in tumor, tuberculosis and in nephritis.

CASE 1.—A farmer aged forty-six came to the hospital because of pain in the left loin.

History.—Twenty-five years ago he first had a sharp cutting pain below the short ribs on the left side. This extended downward to the left testicle. While this attack was on, he passed small amounts of urine at frequent intervals. The attack lasted several hours. He did not notice any blood in the urine. Following that attack he had similar ones at intervals of a month to a year. During the past year the attacks come every three or four weeks and in the intervals between attacks he has a dull pain beneath the ribs. This pain is made worse by jolting and sometimes it starts an acute at-

tack. During the past year he has vomited with the acute attacks. He has much gas in the bowels during the acute stage, which adds to his pain. He has had some dribbling after urination, but no retention.

Examination.—Save for tenderness, 4 cm. to the left and 2 cm. above the umbilicus and in the lumbar region, examination is negative. The prostate is somewhat enlarged but it is smooth. The

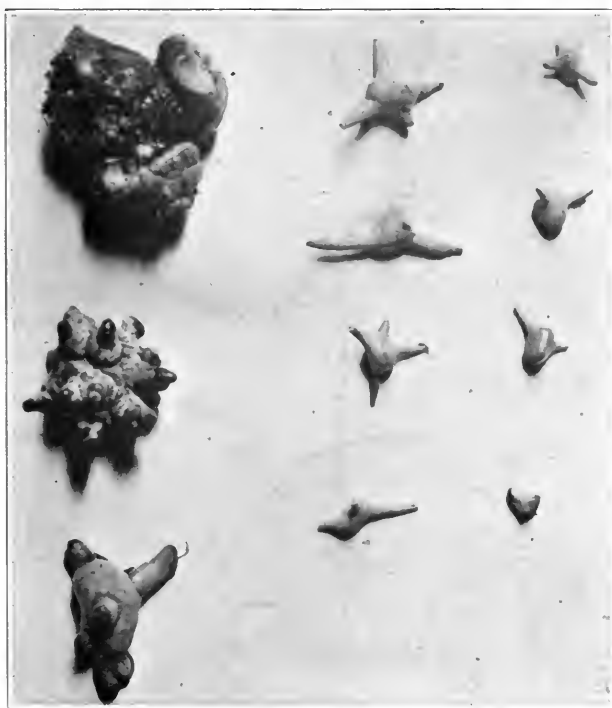


Fig. 311.—Stones removed from the left kidney.

x-ray shows a trilateral shadow in the region of the left kidney. A confirmatory plate showed an additional smaller shadow lateral to the main one. The urine contains no blood, but all of five examinations showed many crystals and two of them showed pus. Those which contained pus were alkaline in reaction.

Diagnosis.—The finding of a definite shadow in both plates makes the diagnosis of stone in the kidney certain when taken along with the long and definite history.

Treatment.—The kidney was large and the pelvis dilated to hold several ounces. The large stone (Fig. 311) shown on the x-ray lay in the pelvis. A smaller one was embedded in one of the calices. Many smaller ones were scattered throughout the kidney. About a dozen were removed. The presence of the dilated pelvis together with the many small stones made it appear wise to remove the kidney lest some of the small stones be overlooked.

Pathology.—The kidney showed some chronic interstitial changes and some cloudy swelling. The character of the stones is well shown in the illustration.

After-course.—Recovery was uneventful. He passed a normal amount of urine at once after the operation and seemed in no wise the worse off for the loss of his kidney.

Comment.—This case is unusual in the number and shape of the stones removed. The question of a justification of the removal of a kidney for stone is a vital one. Many good surgeons have done it, but it has always appeared to me to be poor surgery. I feel more convinced of it now than ever before.

CASE 2.—A farmer aged forty came because of pain in his left side.

History.—The patient had rheumatism for two weeks two years ago. One sister died of pulmonary tuberculosis. Patient's present illness began gradually four or five years ago with pain in the back and left loin. This pain grew gradually worse and soon it was nearly constantly present. Later spells of vomiting and general abdominal pain began. He was constipated at these times. Three years ago he was operated on in one of these attacks and he was told a kink in the bowel was corrected. The appendix was removed, and umbilical rupture was repaired at the same time. After the operation he felt well for about three months, when his old trouble returned. Then pain was most severe in the left lumbar region and in the abdomen usually two inches below and to the left of the navel. Sometimes the pains extended over the entire abdomen. The attacks of pain were often so severe that he would have to be carried home. The pain becomes less severe if he lies down and keeps quiet with external heat applied.

Examination.—There is deep tenderness in the left renal triangle. The urine shows some red cells and a goodly number of white ones. The x-ray shows a large stone in the left kidney (Fig. 312).

Diagnosis.—The x-ray makes the diagnosis. There is room for speculation as to the findings at the previous operation. A midline incision was made extending from the umbilicus to the pubes. This indicates that the appendix was not the original object of attack. An umbilical hernia was not mentioned before the operation. To say the least, such a hernia is unusual in a husky young male. Consider-

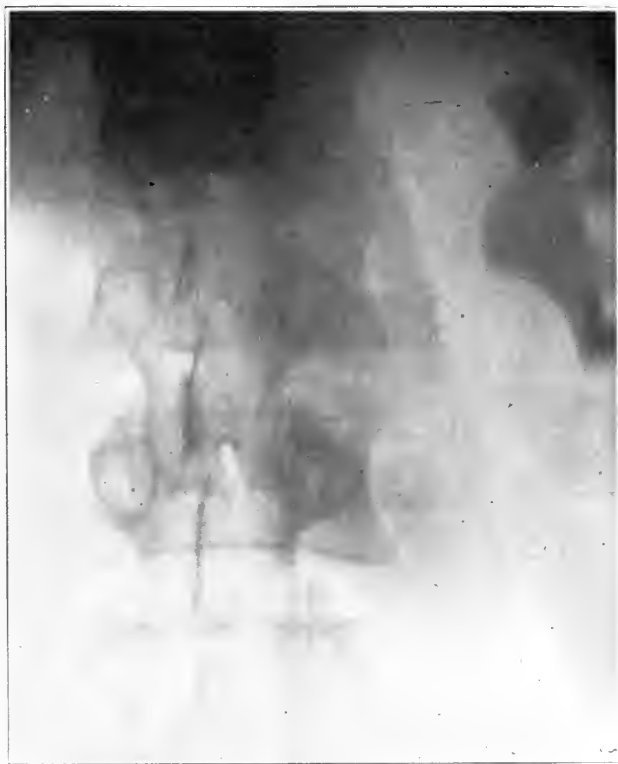

Fig. 312.—Kidney stone filling the pelvis of the kidney.

ing all these factors, it seems likely the operator was misled by the general abdominal pain.

Treatment.—A left nephrolithotomy was done.

After-course.—The wound healed in three weeks and save for bladder irritation which existed for some months he has been well. He was given five grains each of salol and boric acid for this blad-

der irritation. After this he was well for two years when he returned with renewed symptoms. The x-ray showed another stone. This was removed as before. It was exceedingly fragile and was much broken up in extraction. He was advised to drink only boiled water after this operation. He remained free from pain nine months when he returned with renewed pains and a stone was again demonstrated with the x-ray. He was advised to have a nephrectomy done. He hesitates to consent to this and I can not urge it. If he will bear the pains until he forms a firm hard stone its removal may be justified.

Comment.—The majority of patients on whom I have operated for kidney stone have been previously operated on for some condition of the gastrointestinal tract. The profession seems to be slow in learning that pain arising in the kidney may radiate or be transmitted to, almost any region of the body, but that pain arising in some disease of the gastrointestinal tract can not be transmitted to the kidney region. Pain from kinks happily have about ceased to be heard from except from a few extra-credulous persons. Once a stone has been removed, a patient should drink only distilled water or if this is not available the water should at least be boiled. If there is one recurrence, there are apt to be more following a second nephrolithotomy. Obviously a nephrectomy will stop this tendency, but if the patient exhibits such a stone-building capacity he is apt to develop one in the remaining kidney. In such an event, obviously, the surgeon is in a very embarrassing position. In my experience, young stones, particularly those that are fractured in removal, are particularly apt to be followed by recurrence. Likely fragments are left which form foci for new stones. The surgeon does well, in my opinion, to open the kidney wide enough to permit removal of the stone without fracturing it. A kidney stone should never be grasped with forceps unless it be a large, hard one lying free in the pelvis of the kidney. A stone is never so large as to justify nephrectomy. A stone found in a pus pocket does not indicate nephrectomy but prolonged drainage.

Case 3.—A housewife aged thirty-two came to the hospital with a complaint of attacks of pain in her back passing around to the bladder.

History.—For eight years the patient has had a soreness in the left lumbar region. Up until last May, 1919, it was only a soreness. At

that time she had suddenly a severe pain in the lumbar region which passed around the ribs and radiated down to the bladder. The pain came in paroxysms and was severe and cutting. The attack was accompanied by vomiting and a constant desire to urinate. The urine was scanty but she never noticed that it was bloody. She had no fever. The attack lasted an hour and ceased gradually. Since that time she has had many similar attacks. She has never gone three weeks without one, and they have come as often as every three days. They are all exactly alike, except differing in severity, and some stopped suddenly while others tapered off. The attacks have been getting worse ever since her miscarriage four months ago. Her last attack was one week ago. A week ago she had a severe pain start in the left groin just inside the anterior superior spine of the ileum. This pain passed into the bladder. It did not make her vomit but nauseated her. It made her urinate frequently, but nothing like the pain on the other side did. She has had several attacks of this pain every day since. The attacks last a few hours. All her attacks have been stopped by hypodermics of morphine. Her appetite is good. Digestion fair. Bowels regular. She has headache in temples and occipital region frequently. No cough. In 1914 she had an attack of pain in the right side accompanied by nausea, vomiting, and temperature. A diagnosis of appendicitis was made. The side was sore for three to four days. The attack had no relation to menstrual period. A year ago she had influenza. Since that time her menses have been irregular. They were regular previous to that time. She had a miscarriage four months ago. Has had three children; oldest aged eight years, is living; second died at two years of age of enteritis, the third one, born two years ago, lived only four hours after birth. She has always had severe cramps with menses and has to go to bed. The pain is most severe a day before the flow and right after. The pains have been worse since an attack of influenza a year ago. Cramps more severe and flow is offensive.

Examination.—Patient is well nourished, is pale but does not look acutely ill. Pupils equal, regular, and react to light and accommodation. No ptosis or nystagmus. Teeth good. Tonsils moderately large. Thyroid palpable. Lungs normal. Heart negative. Abdomen soft, no rigidity or distention. Point of extreme tenderness just above a line running from umbilicus to anterior superior spine on

right side. Much tenderness in right flank. Point of tenderness over left kidney both anteriorly and posteriorly. Some tenderness over right kidney. Perineum lacerated, second degree. Cervix bilaterally lacerated, thick mucopurulent discharge from cervix; fundus of uterus retroflexed and bound down on the left side of the pelvis. Tenderness on both sides of uterus. Extremely tender to left. X-ray examination of urinary tract negative. No shadows seen. Blood count, W.b.c. 11,400. Urine 1.004, negative.

Diagnosis.—The early attacks were typical of kidney colic. The later ones indicated a pelvic lesion. Pelvic infections may cause pains simulating a kidney colic but a kidney stone colic can not imitate pelvic disease. The physical findings indicate tubal infection. The presence of a moderate leucocytosis indicates a mildly active state.

Treatment.—Double salpingectomy. Anterior fixation of the uterus. The uterus and tubes were bound posteriorly by plastic adhesions which looked recent. Tubes were filled with pus, but the fimbriated ends were not closed. Both ovaries were partially destroyed by the abscess, but a portion of each was allowed to remain. The appendix was not examined.

After-course.—There was no postoperative shock, no vomiting. Temperature 99.6° , pulse 108 evening of first day. The following three days the temperature gradually rose, reaching 101° the fourth postoperative day, after which it gradually subsided and she felt well. A week after operation the lower end of the wound looked red and swollen, a small amount of pus was evacuated. Subsequent course uneventful. At the end of second week the patient passed a long mulberry calculus from the bladder. She had no attacks simulating renal crisis while in the hospital.

Comment.—Evidently both conditions were present. After the acutely inflamed tubes were removed, the patient seemed relieved of her trouble. The passing of the ureteral stone, therefore, came as a complete surprise. The stone was of such a size and character that its presence should have shown in the x-ray plate.

Case 4.—A lady aged twenty-five came to the hospital because of pain in the left side and back.

History.—She has a pain which appears in the back, at irregular intervals in the left side and extends to the back. It does not radiate

and is never cramp-like in character. It sometimes lasts from a day or two, to a week. When they last so long, it is more of a soreness than an acute pain. Pain has been present nearly constantly during the past three weeks. For the first time, a week or so ago, the pain radiated into the groin while she was passing urine. She has never noticed blood in the urine, and riding in a vehicle did not seem to make it worse until just recently. Working now makes it worse. She thinks the side swells when the pain is most severe. She gets up three times during the night to urinate. She has passed some blood in the stool. Her father now has a kidney stone and a sister died from an operation for the removal of one.

Examination.—There is marked tenderness below the twelfth rib behind. Pressure in front also causes pain to be felt behind. The urine shows much epithelium and leucocytes, but no red cells in any of several examinations. There is some albumin. The x-ray shows a shadow in the region of the kidney. Hg. 60; R.b.c. 3,800,000; W.b.c. 12,000.

Diagnosis.—The shadow on the plate makes the diagnosis. The sense of a tumor she feels when the pains are severe suggests a hydronephrosis. This may account for a failure of blood to appear in the urine.

Treatment.—The kidney was delivered with difficulty because of a hydronephrosis the size of two fists. When this was opened, a small stone was found in the beginning of the ureter. The redundant hydronephrotic sac was resected and sutured with twenty-day chromic catgut.

After-course.—The recovery proceeded uneventfully until the sixteenth day, when she had an elevation of temperature to 102°. Urine was draining from the wound. Two days later a quantity of pus escaped from the wound and she was at once relieved. She has been well since.

Comment.—The patient's sense of tumor at the height of the pain was correct. The hydronephrosis was formed chiefly by a bulging of the anterior wall. This made resection easy, and the prospect of ultimate results good. The farther the beginning of the ureter is from the kidney, the more difficult it is to reconstruct a pelvis that will empty itself. This patient's general condition was not good, and a nephrotomy was to be avoided at all hazards.

APPENDICEAL

The all important disease of this region is of course appendicitis. Other affections may occur, notably tuberculosis and tumors.

Case 1.—A young farmer came to the hospital because of pain in the lower abdomen following traumatism.

History.—Ten days ago the patient was thrown against the horn of a saddle, striking the lower abdomen. Pain came on the next day and gradually increased for several days. Two days ago he lifted a calf into a wagon and the pain became worse at once. There has been no nausea or vomiting and no bladder trouble. The temperature has ranged around 101 degrees since he has been under medical observation, now three days. Aside from gas at times, he has had no previous abdominal disturbance.

Examination.—There is sensitiveness and rigidity in the region of the appendix. The abdomen is moderately distended, but without general sensitiveness. The inguinal ring admits the tip of the finger but there is no protrusion. The temperature is 101°, pulse 84, respiration 20.

Diagnosis.—There is evidently some acute inflammatory process having its seat in the ileocecal region. Were it not for the history of definite trauma, one would make a diagnosis of appendicitis without hesitation. Being thrown against a saddle horn by a bucking horse is no gentle manipulation and is quite capable of producing a lesion of a hollow viscus. He does not know just the point of impact of the saddle horn, being too busy at the time trying to keep in anatomic contact with the pony, to conduct any topographic anatomic studies, and following there was general soreness without a localized contusion. Pain came on the day following the injury and gradually increased until two days ago when he had a sudden sharp pain following heavy lifting. It is possible that the injury so bruised an area of gut wall that it necrosed and a perforation followed a week later. The symptoms since that time have not been severe enough, however, for a free perforation, but a previous adhesion may have formed. The physical findings do not seem to be extensive enough for such a condition. An appendicitis may be present either causatively related or independent of the trauma. The uncertainties of the condition warrant exploration. The temperature precludes an uncomplicated hernia, and, besides, there is nothing in the inguinal canal. The temperature, pain and rigidity indicate an acute process.

Treatment.—The appendix was removed through a right rectus incision; the appendix was long and hung over the brim of the pelvis.

Pathology.—The appendix was brownish black, considerably indurated but without gross perforation. There was considerable exudate, but there was no part which showed changes indicative of trauma.

After-course.—There was some superficial infection of the wound but he has remained without a hernia.

Comment.—In order that trauma shall be considered as a causative agent, the injury must be such that the contusion may reach the site of the appendix and that the symptoms shall begin within 48 hours after the receipt of the injury. This case seems to meet both requirements. The position of the appendix was such that it would have been exposed to a trauma. This question is apt to come up in cases in which indemnity is claimed from accident insurance.

Case 2.—A child aged seven was brought to the hospital because of abdominal distention and obstipation.

History.—Ten days ago she complained somewhat of sore throat but played about as usual. The two days following she complained of feeling bad without definite pain. Six days ago she complained of pain in the abdomen. At this time rubbing the painful area gave relief. The pain was most pronounced at the level of, and to the right of the navel. The physician in charge diagnosed appendicitis. She coughed a little but raised nothing. In the three days following, the abdomen became distended and laxatives produced no bowel movements and seemed to increase the tympany. Intestinal obstruction was feared and she was brought to the hospital. The child has always had good health never having had either bowel or lung diseases.

Examination.—The patient lies in a semistupor. The abdomen is soft everywhere, not tympanitic, and not retracted. Deep pressure on the right side brings forth a slight protest. The respiration is 38, the pulse 110, and the temperature 101°. The breath sounds are distinct over both lungs in front, somewhat diminished in the back above, and the bases of both lungs are flat and there is an absence of breath sounds. The patient protests vigorously when the right side of the chest is percussed. Gentle pressure over the short ribs causes pain. There are many subcrepitant and medium-sized rales over the bases of the lungs, more marked on the right.

Diagnosis.—The fact that the abdominal pain was relieved by rubbing is sufficient to exclude the peritoneum as the site of its origin. The patient's mentality was in a state of hebetude, quite the opposite to what obtains in peritoneal inflammations. The absence of muscular rigidity is another important negative point for peritoneal pain. The attendant had not examined the lungs, hence the duration of lung changes is not known. Evidently the associated involvement of the diaphragmatic pleura is the cause of the abdominal pain. This occurred during the influenza epidemic and the lung changes likely were those common to that disease.

Treatment.—The lung condition was treated expectantly.

After-course.—The patient gradually recovered in the course of two weeks.

Comment.—The vast majority of cases in which I am called to operate for appendicitis in children have pneumonia instead of appendicitis. When a child complains of pain in the abdomen, this is too often accepted as topographically correct. There may be tenderness over the abdomen, but quite often slight pressure brings relief. Very early pressure may be acceptable in peritonitis when the pain is due to spasm, but when peritonitis begins, pressure is no longer acceptable. Muscular rigidity is absent in pneumonia. This may be difficult to determine if the child cries, but if it can be examined when asleep, the muscle is not rigid. Even in a crying child, if gentle pressure is made on several points of the abdomen at the same time when it draws its breath, less relaxation will be noted if there is an area of appendicitis (peritonitis). A muscle, when it guards an inflammatory lesion, never sleeps, but maintains its rigidity while the patient slumbers. Lung findings generally clear up all doubt, but early the lung findings may be obscure. Possibly hyperresonance with increased breath sounds is the only clue. The lesion is a diaphragmatic pleurisy, and when localized, lung findings may be absent; sometimes pressure over the ribs at the site of the attachment may elicit pain on the affected side. In rare instances a lung lesion may coexist with an appendicitis. Then the diagnosis is very confusing.

Case 3.—A minister aged forty came because of abdominal pain.

History.—The patient had an acute abdominal affection six weeks ago which began with pain and vomiting. The pain was diffuse and very severe, so severe that he became quite collapsed. It did

not at any time localize. Abdominal distention was pronounced and continued so for several weeks. He still has considerable trouble with gas and distention. He had fever for two weeks, but it was never over 102° , the pulse was as high as 140. His physician made a diagnosis of appendicitis and advised that the organ be removed in order to prevent a recurrence of an attack. He is obstinately constipated.

Examination.—The patient looks sick. He is evidently anemic and

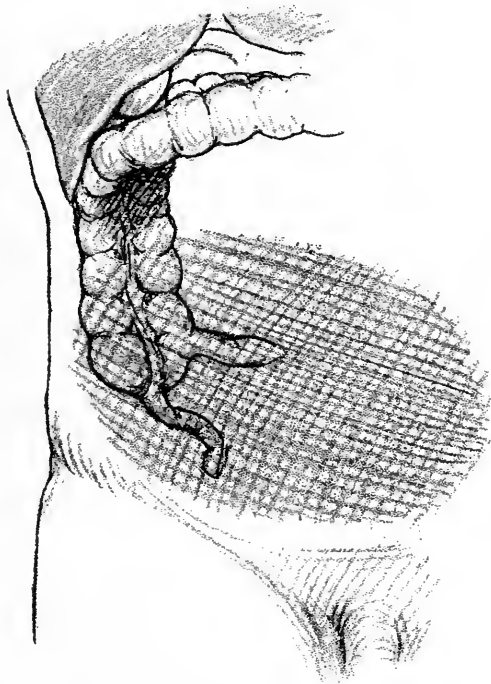


Fig. 313.—Shaded area indicates the extent of adhesions.

undernourished. The abdomen is rounded and generally tympanic, particularly at the lower portion. There is no fluid demonstrable, no sensitiveness, and no rigidity. General examination is negative as are the blood and urine examinations.

Diagnosis.—From the history it seems fair to assume that the attending physician was correct in ascribing the disturbance to an affection of the appendix. The only argument in favor of this

diagnosis is that it is the most frequent cause of acute abdominal affections. There was no localized pain at any time. Any of the rarer causes of infection may as well have been active. A partial leak from an ulcer may have caused it, despite there is no history of previous epigastric distress. The preponderance of tympany in the lower abdomen argues against this. Occasionally an acute seminal vesiculitis gives rise to such a history, but the seminal vesicles are not involved. The continued impairment of health is not explained by any of the findings. There is no abscess that is being absorbed, at least it gives no evidence in the pulse and temperature. The presence of tympany indicates that the intestinal walls have not yet fully recovered from the inflammation they had undergone. It seems best, therefore, to attack the problem on the theory of the most probable cause—appendicitis.

Treatment.—A right rectus incision was made. It was seen that there were still extensive adhesions between intestinal coils throughout a wide area (Fig. 313). The cecum was covered with omentum and adherent intestinal coils. After much difficulty the cecum was loosened but careful search failed to disclose an appendix. By following a strand of tissue downward from the cecal band a nodule the size of a bean was found 3 inches from the cecum. This was believed to be the remains of the appendix. It was removed. Considerable bleeding was caused by the separation of the adhesions and the gut was torn in one place and had to be sutured.

Pathology.—The small object removed proved to be the terminal half of the appendix.

After-course.—The patient was much shocked following the operation but recovered fully. He remained in fair health for ten years although he never regained his former vigor. He was easily subjected to colds and had an irregular and indefinite cough. Ten years after the operation the cough became much worse and he had rales over both lungs without dullness but with some dyspnea. There was irregular fever and a pulse of increased rate and soft. The blood count was not changed. He returned home and after some months suffered some acute lung trouble and died. His physician diagnosed pneumonia.

Comment.—After a severe abdominal infection a secondary operation should not have been done so early. At least three months are required for the reaction to subside and for the adhesions to

loosen as much as they will. After severe attacks of appendicitis, especially those which began with severe pain and were followed by evidence of a diffuse inflammation, it is questionable whether removal of the appendix is necessary. Once the appendix has perforated, a spontaneous cure results. In this case operation six weeks after the beginning of the acute attack was particularly ill-advised. There was no evidence of a localized affection that surgery could relieve. The patient was in no condition for a young surgeon to make a joy ride among his abdominal viscera. As I recall this case I am reminded of the ubiquitous young man with a new automobile and with no place to go. The obvious thing in either case is to do nothing. Neither the stump of the appendix nor the adhesions were responsible for his continued ill health and it is quite possible that he had a metastatic lung infection. Small foci there may cause prolonged ill health without giving evidence of any definite sort. Even if this be assumed, no direct connection could be traced between such an infection and the final termination in lung disease. The last illness resembled an acute miliary tuberculosis, and it is indeed possible that a post-infection may have had an influence on the development of such a disease. An empyema or lung abscess not infrequently ends as an acute tuberculosis.

Case 4.—A schoolboy aged nineteen presents himself because of pain in the lower abdomen.

History.—His father died of tuberculosis and a sister now has tuberculosis of the spine. The patient has had fair health. Six months ago he was in bed ten days with a slight attack of pneumonia. Two months later he had an attack of pain in the right lower quadrant of the abdomen. He remained in bed for a few days and the soreness subsided soon after. Recently he has felt a return of the soreness, but no severe pain, no nausea or rise of temperature.

Examination.—Negative except for deep tenderness in the region of the appendix. The area of tenderness is as large as a hand and seems quite pronounced in spite of the lack of muscular rigidity. The laboratory examinations are all without interest. He looks pale and distressed as though he had lost weight, but he does not show any blood changes.

Diagnosis.—The trouble which kept him in bed six months ago is not clear. A study of his record made at another hospital indicates

an indefinite pulmonary affection. The attack two months ago has all the earmarks of a mild acute appendicitis. The cause of so wide an area of tenderness without muscular rigidity is not apparent. The removal of the appendix seems advisable.

Treatment.—When the cecum was exposed, it was seen to be covered closely with submiliary tubercles. These covered the last

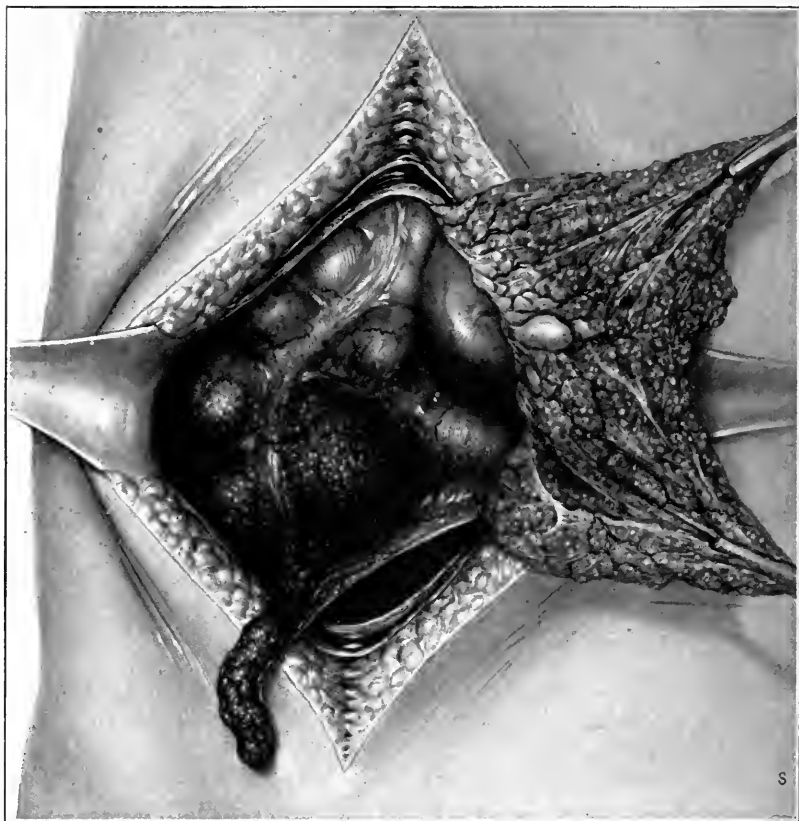

Fig. 314.—Acute miliary tuberculosis of the ileocecal region, young man aged nineteen. The great omentum is being drawn out of the wound. Save for a number of mesenteric lymph glands, the entire disease is exposed to view.

six inches of the ileum and a portion of the omentum. The remainder of the omentum was free (Fig. 314). All the affected omentum and the appendix were removed.

Pathology.—The tissue removed showed typical miliary and submiliary tubercles. There was no caseation in any of them.

After-course.—Recovery from the operation was uneventful except for a low temperature, slow pulse, and a diffuse weak apex beat. He returned for examination in fifteen months and seemed to be perfectly well and shows a marked gain in weight.

Comment.—The persistence of the pain in the abdomen, its diffuse extent and the history should have led to a correct diagnosis, even though physical findings failed to show any lesion of the lungs. The fact that he was in a hospital ten days because of an undiagnosed lung attack was in itself extremely suggestive. At the time of the supposed attack of appendicitis two months ago he probably received the first dissemination of bacilli in the cecum and appendix.

Case 5.—A gentleman of leisure came to the hospital because of pain in the abdomen.

History.—Two days ago he began to have pain in the lower part of his abdomen more pronounced in his right side. It was not attended by vomiting or nausea. He gives a history of previous attacks of pain, one many years ago which was attended by vomit-



Fig. 315.—Enterolith protruding after the wall of the gut was cut.

ing and fever and pain in the right side which lasted a week or two. More recent attacks were not attended by nausea and likely not by fever.

Examination.—There is tenderness on deep pressure and some rigidity in the ileocecal region. The pulse is 84, the temperature 99. In other respects he seemed without interest.

Diagnosis.—The local tenderness and muscular rigidity seemed sufficient to warrant a diagnosis of a mild appendicitis.

Treatment.—The abdomen was opened by a right rectus incision. An indurated mass the size of the finger ending in a clubbed extremity was at once palpated. This was readily determined to be the appendix with much thickened walls and hard and clubbed end of indetermined nature.

Pathology.—The clubbed extremity is due to the presence of a stone. When the wall over it was cut retraction of the circular fibers forced it from the lumen of the appendix (Fig. 315). The gut wall was thickened and showed only moderate round-celled infiltration. There was some periappendicitis. The surface of the mass was covered with calcareous material. The interior was in part made up of flaky material resembling oat chaff.

After-course.—Recovery has been complete. The digestion has been remarkably improved.

Comment.—There are a number of cases recorded in which stones found in the gut have begun in the appendix. What the central material may have been is problematical. Being a theologian, he more than likely had at some time or other indulged in foods calculated to combat constipation.

Case 6.—A farmer aged twenty-four came to the hospital because of pain in the abdomen.

History.—The patient complains of recurrent pain in the right side. He has had "indigestion" for six or seven years. He often has pains in the stomach in the morning, and sometimes vomits. His appetite is good and the bowels are regular. He has had numerous attacks of tonsillitis, the last three weeks ago. The patient has had pain in the right side frequently, six or seven times in the last year. He has soreness in the right side for two or three days, which then subsides. Sometimes it is accompanied by diarrhea, sometimes not. No urinary disturbance. The last attack of this character occurred two months ago. Four days ago while he was still not feeling very well, because of the attack of tonsillitis, he became very warm, and drank a great deal of water before dinner. He ate a little dinner, but vomited it fifteen minutes later. The following afternoon he had a diarrhea but no abdominal pain.

The following morning he had pain in the right lower abdomen, but ate a little dinner. He felt badly all afternoon and the pain continued, although he was up and about his work. He slept well during the following night and had no bowel movements. The following day he had a formed stool but the pain continued all day, and got much worse toward night. The pain became very severe and he vomited six times during the night. At the time of entering the hospital the next morning he still was nauseated and complained of pain in the right lower abdomen.

Examination.—There is marked rigidity of both recti below the umbilicus and very definite tenderness over the ileocecal region. The pulse is 88, temperature 100.4°, respiration 24, W.b.c. 17,000.

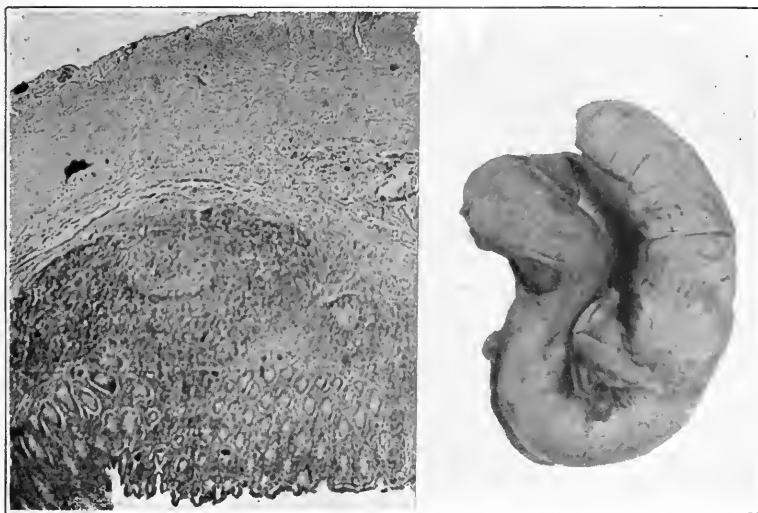

Fig. 316.—Acute necrosis of the appendix. *A*, microscopic. *B*, gross.

Diagnosis.—The gradual onset following a tonsillitis first with nausea and vomiting for three days before a definite localized pain began indicates a progressive endo-appendicitis with a toxic peri-appendicitis following. The low temperature and slow pulse indicate but little suppuration. One sometimes sees low temperature and slow pulse in gangrenous appendices but these begin with sudden severe pain.

Treatment.—Appendectomy. A muscle-splitting operation was done because from the history and physical findings it was not anticipated that drainage would be necessary.

Pathology.—The appendix is red, kinked upon itself, and is covered with a plastic exudate which attaches the folds of the loop of the appendix to each other (Fig. 316A). There is intense injection of the vessels and edema of the entire vessel wall. The microscopic changes are confined to proliferation of the endothelial cells in the lymph nodules, likely the product of previous attacks, and round-celled infiltration from this one (Fig. 316B). There are few changes in the muscle and subserous layers save the edema. The infective processes therefore played their game in the submucosa and the irritation of the outer layers was caused by toxic products and not by the invasion of bacteria. The irritation of the parietal peritoneum, which gave rise to the muscular rigidity, is due to the irritation of the toxic periappendicitis.

After-course.—The temperature went up to 101° for three days following the operation then rapidly descended to normal. At the end of the fifth day the temperature rose to 102.5° and remained so two days. A subcutaneous abscess was drained following which the temperature returned to normal. The pulse did not go above 70.

Comment.—Exudates at a distance from seats of bacterial activity may keep up a temperature for some days following the removal of the focus, just as a blood clot may keep up a temperature though entirely aseptic. These may be viewed as protein reactions. Frequently in such cases the reaction must be differentiated from subcutaneous suppurations due not to an infection from below but from the skin, for these infections present staphylococcus epidermidis albus which are not found about the appendix. Of course subcutaneous abscesses may occur from infections of the appendix, but the two can usually be distinguished on clinical grounds alone. Whenever the skin is irritated by abdominal exudates it is a signal for the staphylococcus epidermidis albus to get busy. Drainage of the skin wound for a few days following the operation may obviate this complication. In this case the first rise of temperature evidently was due to the toxic absorption, the last rise to the subcutaneous infection.

Case 7.—A banker aged forty-eight was brought to the hospital because of severe abdominal pain.

History.—Two weeks ago while walking he was seized with pain under the tip of the sternum, which grew steadily worse and radiated to the right costal margin. The pain was severe, cramp-like,

and lancinating in character. By morning a doctor had to be called. The patient's temperature was 102.4° . The next day the pain was less but he never has been entirely free from pain since the onset. He was able to be about the house, but unable to attend to any business. He has had no previous attacks of abdominal pain. There was no pain in the back with the present attack.

Examination.—Two weeks after the onset there was a mass in the ileocecal region the size of a lemon. There was some muscular rigidity and marked deep tenderness. There was neither tenderness nor rigidity in the hepatic region. The white count was 12,000.

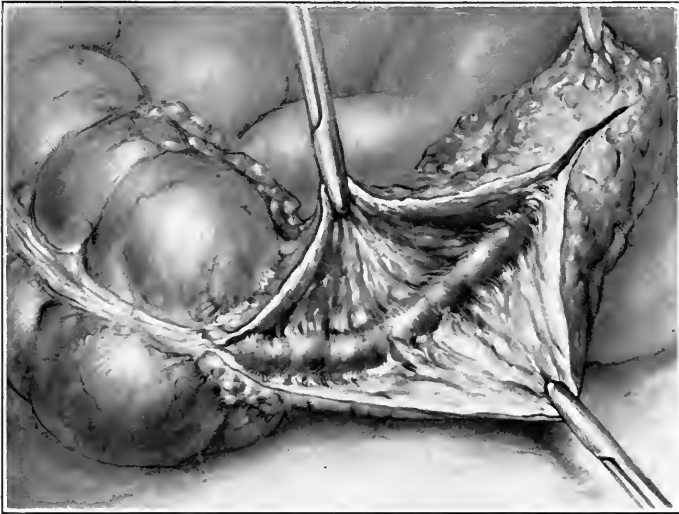


Fig. 317.—An acutely inflamed appendix entirely surrounded by the indurated omentum. The omentum was severed, allowing the appendix to show.

Diagnosis.—The onset was quite like a gallstone attack, but the pain was less intense. He did not send for his doctor until the next morning. In gallstone attacks relief is usually summoned at once. The mass in the side lies in the region of the appendix but the fundus of the gall bladder not infrequently attaches here and may simulate an appendicitis. While it is most likely an appendicitis, it is wise to so place the incision that either region may be attacked.

Treatment.—The great omentum was wound about a much thickened appendix (Fig. 317). It lay over the pelvic brim. The omental mass was removed along with the appendix.

Pathology.—The appendix was hyperplastic, the process evidently having existed longer than the case history reads.

After-course.—Aside from some skin infection, recovery was prompt.

Comment.—Differentiation between gall bladder and appendix attacks is not easy always. It is unusual for a normally located appendix to give pain along the costal margin, as in this case.

Case 8.—A farmer aged thirty-five came to the hospital because of pain in the lower abdomen.

History.—The patient's trouble began a week ago with epigastric pain with vomiting. After a day he was practically free from pain and worked during the day; he came to the hospital on the eighth day. His physician found no muscular rigidity at the time of onset but some deep tenderness. The temperature was 99 and the pulse 80. Since that time there is a gradually increasing tenderness and the pulse and temperature have kept pace.

Examination.—Abdomen is soft everywhere except above the anterior superior spine. There is a mass the size of a turkey's egg, tender to pressure and well circumscribed. The chief point of tenderness lies lateral to the main mass. The temperature is 102°, pulse 90, respiration 19.

Diagnosis.—Epigastric pain with vomiting and with subsequent deep pain in the ileocecal region without muscular rigidity indicates an affection of the appendix which does not reach the parietal peritoneum, either because it is retrocecal or lateral to the cecum. The localized mass indicates a periappendiceal abscess well walled off. The well-defined tumor with gradually ascending temperature and pulse indicates that the infection has escaped its original confines and has become a spreading process demanding relief.

Treatment.—Incision above the spine extending 1½ inches each way. I split the fibers of the external rectus and cut the fibers of the internal rectus. The parietal peritoneum was free from the mass. Some pus was escaping from below the cecum. An abdominal pad was placed over the cecum and one downward toward the pelvic brim, walling off the free peritoneal cavity. The appendix lay under the head of the cecum. After loosening the adhesions, it was found lying parallel with the incision. The appendix was soft, semifluid and of a greenish-gray color. It was ligated and cut off without any attempt to cover the stump. Several ounces of pus

were contained in the abscess about the appendix, the abscess being covered by the cecum and the tip of the great omentum. There was no reaction on the part of the peritoneum of the small gut or of the omentum beyond the tip actually involved in the walling off of the appendix. I noted this with apprehension. A large tube was placed in the pelvis and gauze drains both above and median to the head of the cecum. The abdominal wound was partly closed with silkworm gut suture.

Pathology.—Appendix is soft, semifluid and tears at the slightest grab of the forceps, but is less fragile near its base where it was ligated and cut.

After-course.—The patient reacted well, but a spreading peritonitis began at once and the patient died of a generalized peritonitis on the seventh day.

Comment.—The early history of pain corresponds to the period of beginning necrosis. The period free from pain indicates that the appendix was too dead to feel pain and the surrounding tissue had not yet reacted. The gradually increasing pain represents the period of reaction of the surrounding peritoneum. The return of the temperature represents the period of pus formation. The flaccid muscle wall in the presence of a distinct temperature showed the abscess to be walled off and free from the parietal peritoneum. Being walled off with a constantly ascending pulse and temperature indicated that the abscess was enlarging and unless drained would likely continue to enlarge until it ruptured spontaneously. The fact that the appendix had literally melted down made it evident that virulent bacteria likely were loosed, and to combat this, liberal drainage was used. It is possible that if an opening had been made into the abscess and simple drainage employed, without an attempt at the removal of the appendix, the issue might have been different. Transperitoneal drainage of an abscess is always a precarious proposition. Had I known what I know now, I should have done so. Had the abdominal wall been adherent to the inflammatory mass, I should have done so as a matter of principle.

Case 9.—A farmer was brought to the hospital because of pain in the abdomen.

History.—He has had several attacks of abdominal pain with nausea in years past. Seven days ago he had a more severe attack with nausea, fever and distinct pain in the right iliac fossa. The fever reached

the height of 102.5° but subsided by the third day, but pain persisted and he remained in bed. Operation advised by his physician was refused. Yesterday the pain became more severe and extended farther toward the median line and the fever reached 102.5 again and the pulse 108. He now expressed a willingness to undergo operation.

Examination.—The patient lies with the thighs drawn up; he seems apprehensive yet stoical. The abdomen is flat and moderately hard, particularly in the lower part. He makes no comment during the course of examination but admits pronounced pain when he is asked.

Diagnosis.—The history of repeated attacks together with the physical findings admit of no doubt as to the seat of the disease. The late recrudescence of pain and temperature make it clear that a localized appendiceal abscess has crept into the pelvis. His general attitude indicates a spreading condition. The flatness and hardness of the abdomen indicates an induration of the walls of the gut in the region of the infection. Such organs are not capable of further defense because they can not dilate and form barriers and their indurated areas do not admit of renewed formation of exudate and new adhesions. Therefore, help, if there be any, must come from outside.

Treatment.—The appendix is removed from its indurated environment with some difficulty. There is some pus about the appendix without a definite abscess, but there is a large amount of floccular exudate free in the pelvis. There seems to be no walling off toward the left. The intestinal walls are thickened, nonadherent, and are not responding to the renewed stimulus.

Pathology.—The lower portion of the appendix opposite the meson presents a necrotic area the size of a bean. A leak occurs at this place. This seems to be the source of the renewed infection rather than the extension of the periappendiceal abscess. It is interesting to note that just at this place there were no adhesions, indicating that this area was necrotic early in the disease, preventing adhesions at this point, and that a leak occurred as soon as the dead area became separated.

After-course.—The patient died on the second day from a generalized peritonitis.

Comment.—Secondary recrudescence of symptoms with a distinctly walled off abscess results from the giving way of the wall at some

point. In the flat, hard abdomen there is usually a creeping along of the infection between partly adherent coils of gut. The disease here is progressive. The secondary perforation from a necrotic area, as in this case, is unusual so long after the beginning of the disease.

Case 10.—A farmer aged forty came to the hospital seeking relief from abdominal pain.

History.—The patient has had epigastric distention and distress for two years. He has had several attacks in which the pains were severe under the short ribs and epigastrium and extended to the right shoulder. The last attack of this sort was six months ago. There has never been any jaundice. Six days ago he had renewed pain with a pronounced aggravation of the digestive disturbance. Two days after this an area of localized pain presented above the superior spine extending nearly to the level of the umbilicus. The bowels have been loose for ten or twelve years until the present attack, during which there has been no movement.

Examination.—The abdomen was everywhere soft except over the point of maximum pain where a definite moderately sensitive tumor mass the size of a walnut could be felt. The muscles between this mass and the liver border were soft, nonresistant to pressure. The tumor mass did not move on pressure or with respiration.

Diagnosis.—The early history of diarrhea, epigastric distress with periodic distinct pain with radiation to the right shoulder suggested gall bladder disease. It was not until the mass appeared that the affection could be definitely separated from the gall bladder. Even with this evidence gall bladder disease could not be put wholly out of mind for elongated, pedunculated gall bladders sometimes present low down and if they become adherent become independent of the movements of the liver. Because of the firm character of the tumor and the absence of muscular rigidity, a diagnosis of a subacute indurative appendicitis lying lateral to the cecum could be made. With the acceptance of such a diagnosis the possibility of an associated gall bladder disease must be kept in mind and the incision so made that the upper abdomen can be explored. When there is likely to be an abscess the fear of spread of infection negates this desideratum.

Treatment.—An oblique incision just anterior to the quadratus muscle exposed the mass. The appendix, as thick as the little finger, lay lateral to the cecum and was embedded in a complete new

membrane. This covering was incised and the appendix enucleated. The whole wall of the cecum was thickened so that inversion was not possible. Hence flaps were made of the peritoneal covering of the base of the appendix and the mucosa alone ligated. The serosa flaps as well as the new membrane which had covered the appendix were coapted with a running catgut suture. The abdomen was closed without drainage.

Pathology.—The walls of the appendix were much thickened owing to an extensive plasma cell infiltration. The mucosa was markedly thinned and the lymph follicles reduced in size.

After-course.—Recovery was uneventful save for a stitch abscess in the skin. The digestive disturbance including the chronic diarrhea has disappeared. It is by no means certain, however, that the gall bladder is unaffected, for chronic diarrhea with subcostal pain radiating to the shoulder suggests gall bladder disturbance. Possibly the great induration of the cecum may have been responsible indirectly for the symptoms. At any rate the patient has been well several years and does not share the apprehension of his surgeon.

Comment.—When the appendix is responsible for chronic gastric disturbance there is usually marked thickening of the walls. In the absence of such thickening the appendix should be assumed to be the cause of the digestive disturbance only after the most painstaking examination of the stomach and gall bladder. In such cases if conditions are favorable and the operator experienced, the removal of the gall bladder is advisable, particularly in women.

Case 11.—A hardware merchant aged thirty-two came to the hospital because of a painful swelling in the right groin.

History.—The patient is stated to be a prominent business man of exemplary habits. Two weeks ago a pain developed in the right groin which made walking difficult. It came on suddenly while working with a stalled car. When seen by his doctor the following day, he had temperature 101°, pulse 90, and was tender in the region of McBurney's point. He had no previous attack. During the past ten days the temperature has fluctuated between 100° and 102°. Several days ago a tumor appeared, and his physician made the diagnosis of irreducible inguinal hernia.

Examination.—The patient has an apprehensive look but is of good color. Two inches above the midpoint of Poupart's ligament he in-

dicates the seat of his trouble. He holds the thigh moderately flexed. At the point indicated is a deep mass quite tender to the touch. It extends from this point to the region of the external ring and is a sausage-shaped swelling, the largest part of which is at the level of the termination of the canal. (Fig. 318.) So far as he knows he has had no hernia. There is no definite rectus rigidity, but the apprehensiveness of the patient makes a careful examination impossible.

Diagnosis.—The mass is obviously inflammatory and because of the duration of the fever and its tendency to increase, the process likely has reached a suppurative stage. There is obviously irritation of the ileopsoas muscle. The inguinal canal appears to be the site of the mass in the groin. There is no muscular rigidity

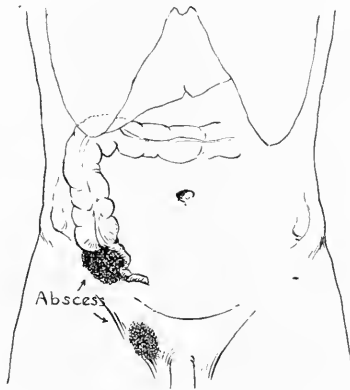


Fig. 318.—Periappendiceal abscess from bubo.

which would exclude a low lying appendicitis. An irreducible hernia is not likely because the tumor was not present at the beginning and was of gradual onset. An inguinal suppuration was therefore diagnosed.

Treatment.—As soon as the rectus fascia was severed a small amount of pus was encountered apparently about the vas deferens. The right testicle was brought into view and presented a small area of epididymitis. The revised diagnosis was a retroperitoneal abscess extending from a subacute epididymitis. The inguinal canal was now more freely opened and an abscess lying between the peritoneum and the psoas muscle was discovered. The deep abscess was drained at the lateral end of the incision and the lower abscess at

the medial end and the remainder of the incision was closed with a figure-of-eight silkworm gut suture. It was hoped in this way to avoid a hernia.

After-course.—The drains were removed in a week. Up to date, now seven years after operation, a hernia has not developed, so it is safe to say none will appear.

Comment.—Had the epididymis been carefully examined before operation it would not have been necessary to make a diagnosis that required revision. The patient seemed excessively modest, supporting the bed sheet with his hands during the course of the examination lest he be unduly exposed. I should have known that excessive modesty usually has more than the genitals to conceal. The history of a sudden onset likely was a fiction.

Case 12.—A farmer aged thirty-two came because of pain in the abdomen.

History.—The patient complained of pain in the right iliac fossa for some days and for the past two days has had some rise of temperature, 100° to 102° according to his physician. The pain is increased by flexing the thigh. He had no radiating pain, neither was there nausea or vomiting. There has been no previous attacks. He has always been well and has not previously consulted a physician in many years.

Examination.—The patient lies in bed with the right thigh slightly flexed and rotated outwards. His pulse is 85 and temperature 102.5° . The abdomen is soft, nowhere tympanitic and there is no rigidity. On deep pressure below McBurney's point there is marked tenderness. The right inguinal lymph glands are enlarged and tender. There is no tenderness in the lumbar region. The white count is 17,000.

Diagnosis.—The obvious diagnosis was appendicitis, as his physician had surmised. However, the absence of muscular rigidity in the presence of marked deep tenderness made such a diagnosis questionable. The gradual onset of soreness was not that common for appendicitis, and the leucocyte count was too high for the degree of abdominal disturbance. The history as to other pain being unsatisfactory, I set out to explore. I found a large right testicle, evidently an acute epididymitis. There was a point of fluctuation. I concluded, therefore, that the abdominal pain was due to an infection of the lymph node situated in the iliac fossa near the external iliac veins below the crossing of the ureter.

Treatment.—A drainage of the epididymal abscess was done.

Pathology.—The pus which escaped was thick, dirty, greenish white. The bacteria present were not identified.

After-course.—The testicular and abdominal pain rapidly subsided. There had been no recurrence when last heard from some three years after.

Comment.—Whenever there is deep abdominal tenderness without muscular rigidity, the lesion likely does not involve the peritoneum. The disease then is likely to be extraperitoneal, a retrocecal appendix, and endoappendicitis and endosalpingitis, or an inflammation so far distant from the anterior parietal peritoneum that it is not excited to reaction. Sometimes in a gangrenous appendix there is no rigidity because the dead tissue does not excite the peritoneum to reaction. Here the history of sudden severe pain is nearly always to be elicited. The nature of the testicular trouble was undoubtedly gonorrhoeal. No questions were asked, but it may be taken for granted that had his testicular trouble been acquired through legitimate channels, its presence would have been announced in the anamnesis. I have found that patients are always grateful if one does not discuss problems which both understand equally well.

SUPRAPUBIC

The acute lesions in the pelvis are most commonly due to inflammations of the tubes or a deeply lying appendix. Any affection capable of irritating the peritoneum may simulate these.

CASE 1.—A matron of thirty-two came to the hospital because of pain in the lower abdomen.

History.—The patient has had pain over her bladder for nine months. She has had some uneasiness before that time, but it never amounted to actual pain. The pain has been a dull heavy pain but recently has been more severe. On several occasions an anodyne was required. In the past two months she has had to get up at night to urinate. She is becoming more constipated each month. The menses are regular and last from four to six days. Her menses began at sixteen and have always been painful. She has been married eight years but has never been pregnant. She has never had any vaginal discharge.

Examination.—The patient is tall, thin, of the intellectual sort, and her general expression is that of good health. The abdomen, save for some rigidity just above the pubes and some sensitiveness, is negative. The pelvic examination shows a mass filling the pelvis, completely anchoring the uterus. She complains somewhat of pain during the examinations. The laboratory examinations show nothing of interest.

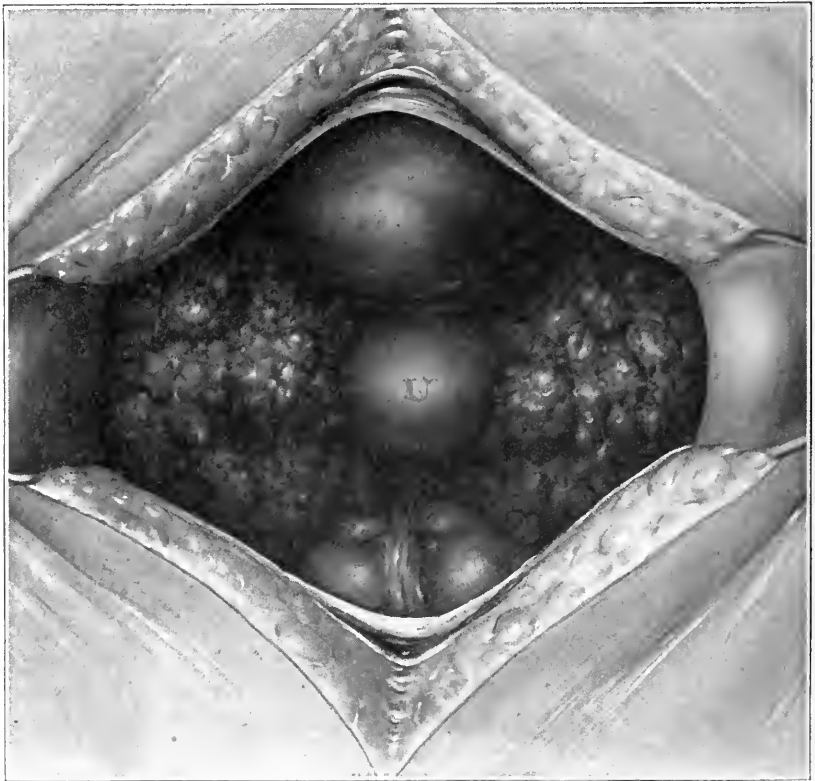


Fig. 319.—Papillary cystoma of the ovaries.

Diagnosis.—The large mass in the pelvis comes as a surprise after the mild history. One thinks first of pus tubes. The patient's bearing indicates that she is telling the truth. The masses are more elastic than indurated tubes, giving the feel more of cystic tumor, but no definite outline of tumor can be made out. There is no fluid in the abdomen to suggest malignancy. Her condition is becoming progressively more pronounced and relief is demanded.

Treatment.—After the abdomen was opened, cauliflower masses were seen to fill the space about the pelvic organs, evidently papillary carcinomas of the ovary (Fig. 319). The peritoneum of the pelvis, and to a lesser extent the gut walls, were studded with minute tumors. The masses and as many of the nodules as could readily be reached were removed.

Pathology.—The tissue removed presents the usual picture of a serous ovarian tumor that has become malignant.

After-course.—Recovery from the operation was uneventful. She has been free from trouble now eight years.

Comment.—It is a curious oncological fact that a permanent cure is possible in these tumors even after metastases in the peritoneum have formed. Relieved of the major mass the system is said to be able successfully to combat the remaining nodules. The explanation seems to be that the nodules are formed of cells mechanically detached from the tumor mass and have become encapsulated by the peritoneum. They are therefore dead masses which the peritoneum has interred. They do not represent developing metastases that regress. In no other way can this phenomena be fitted into the general scheme of tumor growth and development. Slides made of these little nodules bear this out.

Case 2.—A merchant aged fifty-five came to the hospital for relief of a fistula in the right side.

History.—Six months ago he had an attack of acute abdominal pain lasting about three hours. It was located in the lower abdomen. He did not vomit. He does not know whether there was any rise of temperature. He was unable to secure a bowel movement though several enemas were given. After some hours the trouble subsided and he had no further trouble for a month. The bowels moved without trouble or pain. At the end of a month he had another attack exactly duplicating the first in every detail. It failed to subside and after eleven days an opening was made into the bowels on his right side. Relief followed the operation. Six days later he again passed feces through natural passages with the aid of enemas. Some stool still escapes from the opening in the side and he wants to be rid of the opening. His general health has improved since the opening in the side was made and he has nearly regained his normal weight. There never has been blood in the stool.

Examination.—If he has regained his normal health as he states, he was before far from being a well man. He is sallow, looks haggard, and the skin is inelastic and hangs in folds. In the ileocecal region is an opening large enough to admit the tip of a finger; much feces is escaping from this. The skin about it is much excoriated. Rectal examination shows a hard mass in the culdesac just beyond the reach of the finger.

Diagnosis.—An obstruction recurrent and that opened again spontaneously following a colostomy can not have been wholly organic. If due to a temporary compression as in slipping through a diverticulum, the relief should be complete. The conclusion seems warranted that the situation must be represented by a half and half condition; that is, an organic state partly narrowing the lumen making the temporary occlusion by foreign substances more easily possible. Rectal palpation indicates that this is most likely a malignancy of the sigmoid, though a perisigmoiditis from a diverticulitis can not be excluded. His general appearance indicates malignancy.

Treatment.—A left rectus incision was made. A hard elongated mass occupies a loop of sigmoid and extends to within several inches of the floor of the culdesac. To the right of this mass a loop of ileum is adherent. This loop is firmly adherent and its walls are thickened, giving the impression that the malignancy has invaded its walls. Therefore a loop of ileum was resected and since it was found that the distal limb was severed too close to the ileocecal valve to admit of a lateral anastomosis and the whole ascending colon was involved in dense adhesions, the proximal limb was anastomosed to the descending colon. The tumor was cut close to the bottom of the culdesac, and a permanent artificial anus made after the redundant sigmoid had been removed. A gauze drain was conducted down to the pubis.

Pathology.—It was found that the loop of ileum was adherent to the tumorous gut only by inflammatory adhesions and might have been separated (Fig. 320). The tumor involving this side of the gut had ulcerated, leaving but a thin wall between it and the loop of ileus. The adhesion was, therefore, an anticipatory one. The opposite wall was as thick as the finger and showed an involvement for about three inches (Fig. 321). In structure it was an adenocarcinoma.

After-course.—There was much pus from the pelvic floor. Feces escaped at once from the stump of colon and the primary colostomy

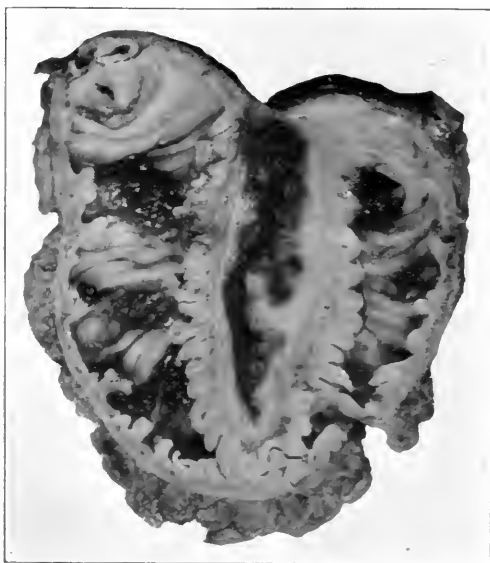

Fig. 320.—Loop of small intestine adherent to malignant gut causing closure of the lumen.

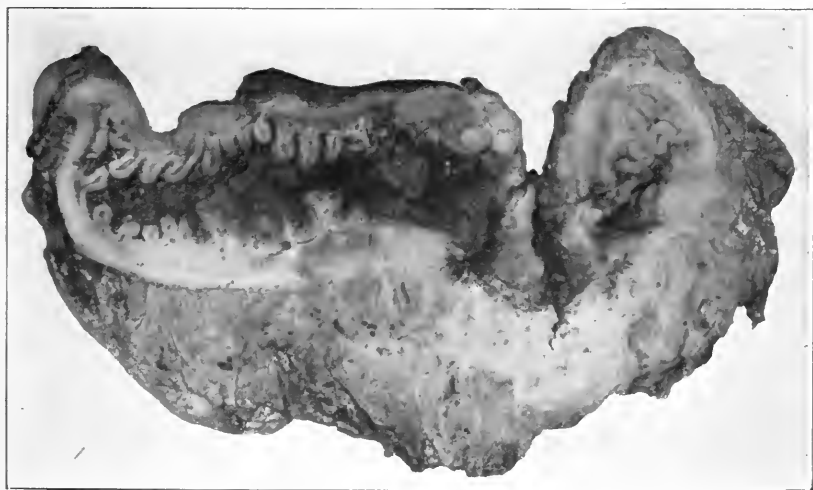


Fig. 321.—Carcinoma of the pelvic colon producing stenosis of the gut.

wound closed spontaneously. He was annoyed much by a persistent singultus. The wound from which the pelvic drain had protruded was very slow to heal. After he had been at home some months he had a spell of vomiting and distention following a dietary adventure. He never recovered fully from this and following it he had difficulty in securing a passage through his new anus. He returned after he had lost much weight and strength. Exploration showed that the gut wall about the ileocolic anastomosis was so thickened that the lumen was nearly occluded. Loops of ileum in the pelvis near the site of the preliminary gauze drain were matted together. The result of this conglomerate mass was to materially lessen the available lumen. He died of exhaustion soon after.

Comment.—A loop of gut attached to a malignancy most likely is not itself involved in the malignant growth and it should not be so regarded until definitely proved so. A gauze drain is a poor thing to place near a lot of guts not the site of a preexisting infection. The amount of irritation produced is more extensive and more lasting than when a suppuration has preceded the advent of the gauze. Many things, if anticipated strongly enough, are apt to happen. Infections belong to this category.

CASE 3.—A married woman of twenty-one was brought to the hospital because of acute pains low in the abdomen.

History.—The patient has been married eighteen months. The menses have always been regular since the age of thirteen years. She has passed her menstrual period about twenty days. Last night she had a sudden stabbing pain in the right side just above and to the right of the pubic bone. The temperature when first taken was 97° and the pulse 90. There was no marked collapse, no menstrual flow, and no rectal tenesmus. She had a similar attack in July.

Examination.—Two days after the onset the patient looks comfortable, the pulse is 90 and the temperature 101°. There is marked rigidity of the lower right rectus and tenderness over the brim of the true pelvis. Vaginal examination shows a uterus slightly enlarged and softened, slightly sensitive to lateral movement. There is some tenderness but no bulging in the right culdesac. The tubes are not palpable.

Diagnosis.—The delayed menstruation and the slight enlargement of the uterus speaks strongly in favor of a pregnancy. The history of a previous attack, the unilateral muscular rigidity, the sensi-

tive but empty culdesac speak strongly for an acute appendicitis. The blood count of 11,000 is a figure in harmony with either acute appendicitis or tubal rupture. The history of stabbing pain is suggestive of tubal pregnancy and the temperature 101° with a pulse of 90 is even more so. She may have had a previous attack of appendicitis and still this may be a tubal rupture. The patient's condition is favorable and the safer plan seems to be exploration.

Treatment.—Appendectomy. The appendix hung over the rim of the pelvis. The pelvic organs were not notably involved. The uterus was enlarged and soft, obviously pregnant.

Pathology.—The appendix was much thickened and pronouncedly erectile.

After-course.—Recovery was uneventful.

Comment.—When there is marked local reaction in an appendix extending into the pelvis, a mass may be formed beside the uterus. This mass is more confined, more edematous than when there is a hemorrhage in the culdesac from a ruptured extrauterine pregnancy, but when there is a moderate hemorrhage, the characteristic bilateral bulging of the culdesac is lacking. In such instances the leucocyte count may be of value. If they number more than 15,000 a suppuration is present for the leucocytosis of the hematoma of extrauterine hemorrhage rarely exceeds 13,000. In this case the tenderness was more acute than is normally the case in hemorrhage. Her designation of the pain as stabbing seems to have been due to the fact that persistent inquiry as to the character of the pain had been made by her physician. The subsequent questioning produced a less dramatic story. The history of previous attack was of great aid in arriving at a diagnosis.

CASE 4.—A waitress aged twenty-six came to the hospital because of periodic pain in the right side.

History.—She has had several attacks of pain in the right side in the last year or two. The pain at the first attack was very severe, after that was dull, and now is gradually becoming worse. She gets some relief from a hot-water bottle. The pain seems related somewhat to the menstrual period. Pain radiates down in the pelvis and down into the hip bone. This pain was first noticed about three years ago or one year before the last baby was born. She also complained of headaches which some time ago were occipital though now mostly frontal in type. She has had a small goiter for

the last three years. There is some choking sensation at times. Appetite and sleep are good. The bowels are constipated. She has had four pregnancies; one seven years ago, the second died at three months, the third was a miscarriage at three months, the fourth resulted in a normal child. Her menses began at seventeen, were regular and without much pain until first baby was born. Since then they are irregular and painful. She has been separated from her husband sixteen months.

Examination.—There is a small, uniform goiter, slightly more marked on the right side. Abdomen is sensitive over both lower quadrants. The right ovary is the size of an egg and when it slips from beneath the hand she complains of acute pain. The uterus is in position and the cervix is lacerated. The left tube is enlarged and adherent to surrounding structures. The left ovary is soft and enlarged. Perineum lax, probably a second degree laceration.

Diagnosis.—The location of the pain in the pubes radiating to the hip indicates that it is of ovarian origin. The sudden onset would suggest a pyosalpinx and the findings on the left side bear out this suggestion. However, she has had pregnancies since the onset of the pains and there are no adhesions about the right ovary which is apparently the chief offender. The sudden onset, together with the continued soreness, worse at the menstrual period and relieved by the hot-water bottle, suggests a hemorrhage into the ovary. The physical findings are in accord with such a suggestion.

Treatment.—The ovaries and tubes were found adherent to each other and to their broad ligaments. Both tubes were closed at the fimbriated extremities, swollen, thickened, but contained no pus. They were removed. There was a large hemorrhagic cyst the size of a hen's egg in the right ovary. This was removed.

Pathology.—The tubes show a thickening of the walls with much round-celled infiltration. The ovary is composed of a large blood clot with a thin layer of cortical substance remaining.

After-course.—The recovery was complete and permanent.

Comment.—The time of the development of the tubal inflammation is not clear. It must have developed after the last pregnancy. There is no history of there having been any increase in the leucorrhœa at any time. It is significant, however, that she was divorced sixteen months ago. It is quite possible that a foreign gonococcus completed

the domestic triangle. At any rate the histopathology indicates such a pathogenesis.

CASE 5.—A farmer lad was brought to the hospital because of an acute abdominal pain.

History.—Ten days ago he was seized by an acute pain in the abdomen. It was general at first, but after a few hours it localized in the right side. He had fever and he vomited twice. The soreness has nearly disappeared, but he still feels it when he walks. He had frequent urination for a number of days but that too has subsided. He is now free from pain and has had no fever for a week.

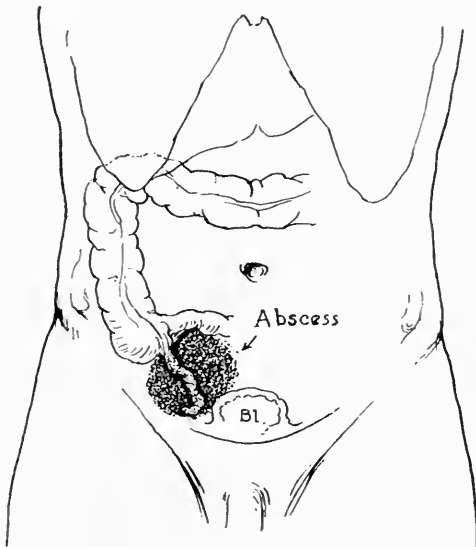


Fig. 322.—Localized periappendiceal abscess.

Examination.—There is slight tenderness over the ileocecal region and there is slight rigidity. There is a painful mass back to the bladder demonstrable on rectal examination (Fig. 322). There are 15,000 leucocytes.

Diagnosis.—The bladder irritation early in the attack together with the painful mass now palpable makes it certain that the offending appendix hangs into the pelvis. From the subsidence of the symptoms it is evident that the process is well walled off, but that there is still an active process going on is evidenced by the leucocyte count.

Treatment.—The patient was advised to wait a month before submitting to operation. Circumstances were such, however, that he desired to get it over with. A right rectus incision was made. The appendix at its base and the cecum were free. The end of the appendix lay embedded in a mass of adhesions in the floor of the pelvis (Fig. 322). It was carefully dissected out. There was about a dram of free pus about the tip of the appendix and a good deal of bleeding was caused by the enucleation. A drain was placed in the infected area.

After-course.—Despite the drain he developed a violent peritonitis and it looked as though he would die. He recovered after a month and has had no trouble of any sort now in fifteen years.

Comment.—This patient should not have been operated on at that time. The surrounding peritonium had regressed from its preliminary state of reaction and was unprepared to control the infection. On the other hand, the bacteria were still in a relatively virulent state. It was too late, therefore, for an early operation (because the preliminary hyperemia had subsided) and too early for a late operation (because the bacteria were still virulent). Most likely the abscess present would have been absorbed. If not, an ascending temperature would have announced the development of an important abscess. In that event, drainage in front of the peritoneum would have been sufficient, or it could have been drained into the rectum. There is an unwarranted prejudice against drainage into the rectum. Nature does it this way and gets away with it. When an abscess can be felt by rectal examination this is the easiest and safest way to drain it. Usually a single puncture is sufficient. I have never attempted to introduce a drain. Why surgeons should feel free to drain through the vagina and eschew the rectum is difficult to understand. The bacterial content is not so different and an appendiceal abscess is usually able to match flora with either.

CHAPTER XIII

ABDOMINAL DISTRESS

The simple complaint of abdominal distress is the most indefinite of the entire phraseology of disease. It may signify a too liberal diet, or an incipient malignancy, or any malady between these wide extremes. It indicates nothing more than that it will require a careful analysis of the patient in order to arrive at a diagnosis.

EPIGASTRIC

Epigastric distress usually implies some disturbance with the function of digestion, whether this be due to referred causes or to changes in structure. The search for possible referred causes and the analysis of the functions of the stomach must be invoked. Most commonly overlooked are the constitutional diseases and no patient may be convicted of having a stomach disease who has not been put on trial for evidence of general disease.

CASE 1.—A farmer aged sixty-four came to the hospital because of pain, abdominal distention, and obstinate constipation.

History.—For ten years he has had attacks of abdominal flatulence. These attacks have grown worse in the past four years. He has had attacks of pain in the midabdomen which radiate to the lower abdomen. The pains have never been so severe as to require an anodyne. They were never influenced by eating and bore no relation to meal time. Two days before being brought to the hospital he had a severe attack, and in spite of pills and salts, the bowels did not move. There was marked pain extending to the lower abdomen. The abdomen was distended and everywhere sensitive. Since being in the hospital he has improved on diet and the bowels moved with oxgall and now move with mineral oil only. His appetite has become better and there has been marked general improvement. He has had a gradually increasing difficulty in urination. He gets up six to eight times a night. Sometimes there is some pain and difficulty in starting the flow. He has had hemorrhoids which sometimes cause pain but little or no

bleeding. His pulse on entrance was 80, temperature 96° , respiration 18. Since then there has been a variation, pulse 60 to 96, temperature 96° to 100.2° , respiration 18. His former weight was 140, a year ago it was 120, now it is 119.

Examination.—The patient is a small man who carries his age badly. There is evidence of emaciation. One would think from his appearance that it was recent. The abdomen is flat, sensitive, and rigid, particularly the upper part. In the midline, halfway between the umbilicus and the sternum, is a soft lobulated tumor which is unattached to the skin but is intimately connected with the fascia. There are small mucocutaneous hemorrhoids. The prostate is large, smooth, but rather firm. The blood pressure is 110-70. Urine is without interest.

Diagnosis.—The general appearance is that of one suffering from carcinoma. The long duration makes that questionable. He has lost but two pounds in a year and in the three weeks he has been under treatment he has improved so much that a malignancy is unlikely. His appetite has become good and he relishes his food and his bowels now move with the aid of only a little mineral oil. The obstinate constipation, the general collapse, and the distention suggested pancreatic disease. However, the disease has been too constant for any acute disease of the pancreas. The pulse was only 75 to 90 which is not so fast as that usually observed in pancreatitis. Yet now that he has improved his pulse has dropped to 60. He has had a temperature as high as 100.2° which indicates a reaction of some sort. The small tumor of the midline is obviously a hernia of the linea alba. These often produce marked disturbance of the digestion, often marked pain. A rise of temperature and pulse is not a part of the symptoms usually produced by it. The prostate annoys him but there is nothing in the urine to indicate anything capable of producing a constitutional disturbance; as much may be said of the hemorrhoids. In view of the prominence of the hernia and the lack of any other definite source of trouble one seems warranted in removing this possible source and at the same time searching for other lesions.

Treatment.—The hernia was isolated under local anesthesia. As it was raised up, a distinct pedicle the size of a pencil was attached at either pole, evidently the round ligament of the liver (Fig. 323). A hard nodule the size of a grain of corn was found in the great

omentum just below the transverse colon. A hard nodular mass was then found along the lesser curvature of the stomach. Glands were palpable along the vertebral column on the right side. The midportion of the pancreas was hard, board-like, with nodulations.

Pathology.—The tumor removed is composed wholly of fatty tissue. The nodule removed from the great omentum is irregular in outline, very dense and on section is lobulated and greyish white in color. Pin point areas can not be distinguished. The slide shows the entire area to be composed of round cells with very sparse intercellular tissue.

After-course.—He recovered from the operation and to date has constantly improved.

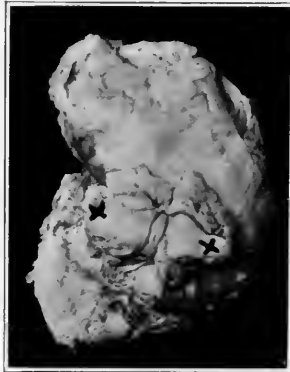


Fig. 323.—Hernia of the linea alba. The ends of the round ligament of the liver involved in the hernia are indicated by X.

Comment.—Both diagnoses were wrong. A differentiation between hernia linea alba and carcinoma was gone into but the now obvious ulcer was not considered. Yet the long duration of the marked complaint, four years, and the loss of weight should have suggested ulcer. In view of the history of an acute abdominal attack before he was brought to the hospital, together with the increased pulse rate relative to the temperature, with the subsequent rise of temperature might have meant an impending perforation. At the time of operation it was thought the hard pancreas was secondary to the supposed carcinoma of the stomach. The nodule removed from the omentum bears every evidence of being an area of fat necrosis which has become infiltrated with round cells. If so, then the pancreatic trouble obviously developed in an individual who already had

a stomach ulcer and a hernia linea alba. A somewhat complicated picture, one must admit, yet one capable of logical analysis had the history been properly interpreted.

CASE 2.—A married woman of thirty-two came for consultation because of pain in the stomach.

History.—The patient was married four years ago and has never been pregnant. Her trouble started seven or eight years ago. She had pain in the epigastrium, which was present practically all the time but was more of a soreness than real pain. It approached a real pain after eating. She would often fast on this account and was free from pain during that time. Vomiting occurred at irregular intervals, with no seeming relation to meals. There never was blood in the vomitus, but just watery fluid. She has always had a dragging, weak feeling in the lumbar region, especially when on the feet a great deal, and she is dizzy when she stoops. Her stomach trouble is worse at menstruation and she is nervous at these times. She flows three or four days and has some pain in the beginning. She becomes restive when details are sought relative to the pelvic troubles at the beginning of her complaint.

Examination.—The stomach empties very rapidly showing no abnormalities. The uterus is retroverted and fixed toward the left side. There is resistance on each side of the uterus but no mass can be made out.

Diagnosis.—The patient gives a history which corresponds with gastric ulcer. The fact that the symptoms are worse at the menstrual period does not necessarily associate the stomach trouble with pelvic disease. On the other hand pelvic symptoms often are associated with hyperacidity and a chain of symptoms closely resembling ulcer. If the pelvic trouble is relieved the gastric symptoms may disappear. The nature of the pelvic trouble can not be made out. The fact that her composure was disturbed when she feared she would be questioned gives a possible clew. Whenever a married woman becomes restive when possible pelvic disease is hinted at I suspect she may have had some trouble before marriage. Often they relieve the situation by hypothecating a previous marriage. At any rate the uterus is fixed in retroversion.

Treatment.—There was a bilateral chronic salpingitis, both tubes were firmly bound down. The uterus was brought forward and the tubes removed. The appendix seemed normal.

After-course.—Healing was prompt. She gradually improved and after the first year had little complaint save for slight pain at the beginning of menstruation.

Comment.—In neurotic women with pelvic and gastric symptoms it is extremely difficult to differentiate between them. In fact the nervous state may result from both and any sort of treatment may be of no avail. If there is actual anatomic disease in the pelvis it may be corrected. Often one can determine the rest by trying alternately ulcer and neuropathic treatment. Often gastric disturbances due to pelvic disorders are relieved by rest in bed and diet. They recur when the patient is again on her feet. Too much dependence, therefore, must not be placed on the diagnostic value of ulcer treatment. In this case most likely the trouble was due to the salpingitis.

CASE 3.—A matron aged fifty-six entered the hospital because of epigastric cramps and jaundice.

History.—The patient has had repeated attacks of typical gallstone colic extending over a period of ten years. During the first few years they were not followed by jaundice but during recent years they are attended by jaundice lasting from three weeks to two months. Her last attack occurred three months ago and was followed by jaundice which has lasted to date. She has lost 30 pounds in weight, but during the past three weeks she has gained a few pounds and she has a better appetite and feels stronger. The jaundice varies in intensity.

Examination.—All that remains of the last attack is deep tenderness over the hepatic region and a moderate jaundice. The pulse is 60, the blood pressure 190—90. The urine contains a trace of albumin and a few casts but the specific gravity is 1.021.

Diagnosis.—The typical colics preceding the jaundice suggest bladder stones, while the prompt appearance of jaundice with the attacks suggests a common duct stone. The long duration of the jaundice likewise suggests a stone rather than an inflammatory occlusion. On the other hand, malignancy is unlikely, for she has gained a little weight. A gain of even a few pounds is very uncommon in malignancy; besides the jaundice varies in intensity. This last fact is strongly suggestive of a ball-valve stone. The long duration of the jaundice suggests that the obstruction is maintained by the simple ball-valve mechanism. If this is so, less can be expected by waiting

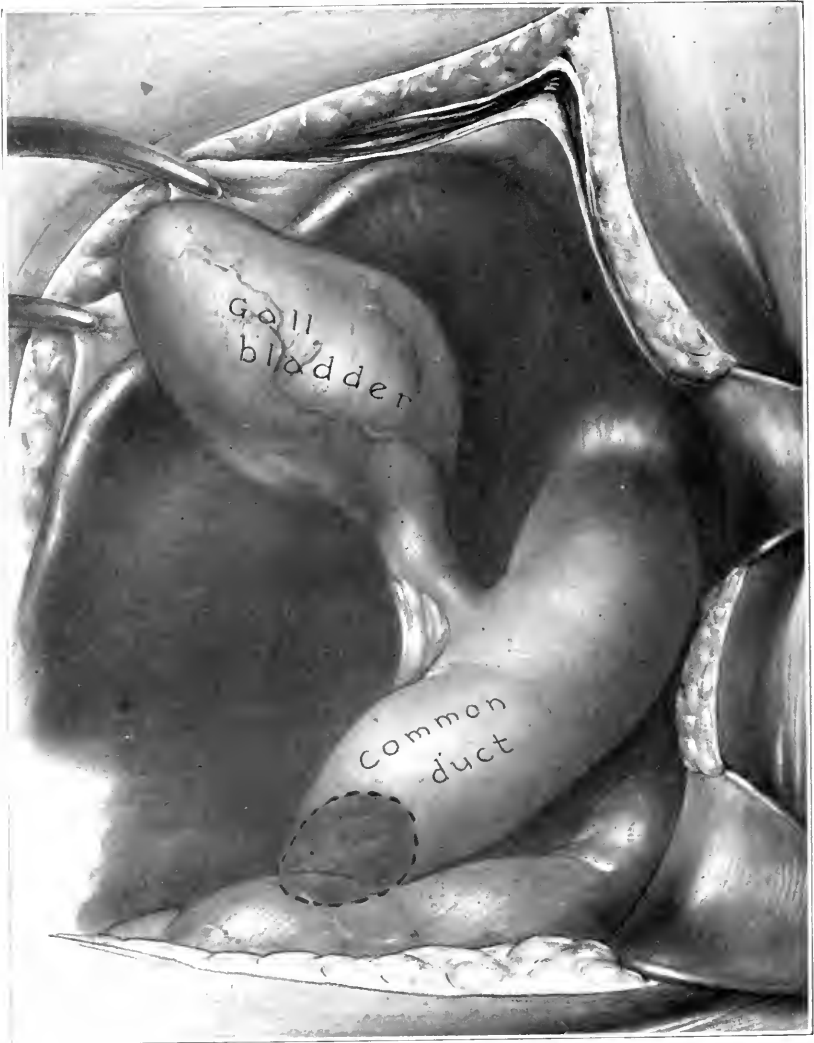

Fig. 324.—Enormous dilatation of the common duct due to a stone.

than if an inflammatory thickening played a part. Since the patient is now gaining a little, operation seems not all too hazardous.

Treatment.—When the abdomen was opened there appeared in the bottom of the wound a huge sausage-shaped body which at first appeared to be the colon (Fig. 324), but it lacked indentations and was deep blue in color. Exploration proved it to terminate in the duo-

denum and liver, respectively, and to receive the cystic duct. A large quantity of bile escaped when it was cut into and a stone as large as a hickory nut was extracted. The gall bladder itself contained no stones and was not molested.

After-course.—The patient has remained free from symptoms referable to the hepatic region, but has since suffered a cerebral hemorrhage.

Comment.—The interest in this case centers in the huge dilatation of the common hepatic duct. Despite the typical gall bladder colics there were no stones in the gall bladder. We may assume that this stone was at first in the gall bladder and escaped into the common duct. There is the additional evidence that the gall bladder was dilated. Had the stone been in the common duct from the beginning, the gall bladder should have been contracted according to an ancient and respected, though obsolete, theory. This is a logical explanation and is in harmony with the anatomic findings. However, the cystic duct was small and bore evidence of having given passage to a stone. The old saw of the contracted gall bladder being indicative of common duct stone is not in harmony with modern experience. A contracted gall bladder means a more or less ancient hyperplastic cholecystitis, stone or no stone, in the common duct or elsewhere.

CASE 4.—A housewife of sixty came to the hospital because of pain in the upper abdomen.

History.—Thirteen years ago she had an attack of severe pain in the right side and in the epigastric region. A doctor was called and gave her a hypodermic injection. She had a number of attacks after this, which were always worse in winter. Five years ago an attack was attended by jaundice. Recently she has vomited a number of times and is seldom free from pain. There is no pain in the back. She has had six children and has always been well except for attacks above recorded.

Examination.—Her general condition is negative. The abdomen is soft and flabby. There is deep tenderness over the gall bladder and over the epigastrium. Pressure in this region causes pain under the costal margin on the left side. Pressure directly over the left side causes no pain.

Diagnosis.—The definite initial attack thirteen years ago requiring morphine, the jaundice attending the attack five years ago and the deep tenderness over the hepatic region, and the age and general habitus of the patient seem to make the diagnosis of gallstones certain.

Treatment.—Laparotomy showed a large saddle ulcer on the lesser curvature extending well over the pylorus. The gall bladder was free from disease. The pylorus was not obstructed and there was no dilatation of the stomach. Hence the abdomen was closed and an ulcer treatment begun.

After-course.—The patient improved under treatment and save for bronchitis passed the next five years in comparative comfort. After this the digestive disturbance became aggravated but remained stationary for a time, then the symptoms became much increased. Emaciation set in and she died in five months from the time of the beginning of the last illness, having in the meantime developed a hard nodular tumor in the pyloric region.

Comment.—When pressure over the hepatic duodenal region causes pain on the left side of the abdomen, the lesion is most certainly gastric. I had not learned this point at the time the patient was examined. The jaundice most likely was caused by the ulcer. Evidently this is one instance in which carcinoma developed on an ulcer. The question arises whether or not the development of carcinoma would have been prevented had I excised the ulcer. Probably not. She might have died from the operation. The mortality from excision of ulcers in my hands is greater than the danger of transference of benign into malignant ulcers.

CASE 5.—A wagon manufacturer aged fifty-four sought relief from abdominal pain.

History.—For three or four months he has had general abdominal discomfort, chiefly in the region of the umbilicus, with eructations of gas. It is most pronounced at 2 to 3 o'clock A. M. He has lost 15 pounds in the last three months. The appetite has been good until just recently, when he vomited once. His father died of carcinoma, his grandfather with stomach tumor, and his grandmother of gastric hemorrhage.

Examination.—The red count is 5,000,000, white blood count 4,000, hemoglobin 70 per cent. The gastric analysis shows a reduced acidity. The patient appears apprehensive and even more anemic than his hemoglobin showed. There is moderate abdominal tympany and general soreness over the epigastric triangle. On deep palpation a mass can be felt in the region of the pylorus. There is no retention of food as measured by the raisin test meal.

Diagnosis.—The chief disturbance being in the early morning hours suggests ulcer, but the pain is not that of ulcer neither is the meal sequence in harmony with such a suggestion. Ulcer is attended by loss of weight only when there is serious disturbance with the food intake. The presence of a palpable mass is unusual in ulcer and its presence together with the general appearance speak strongly for malignancy. A carcinoma that has advanced to a stage of a palpable mass is rarely operable. There is no indication here for a palliative operation and the only excuse for exploration is the hope that the condition is still operable.

Treatment.—Exploratory laparotomy was undertaken. The pyloric region and the lesser curvature were involved in a thick nodular tumor covering the entire circumference of the gut near the pylorus. The regional lymph glands were enlarged and very hard.

After-course.—Despite the extent of the disease, the patient began to improve at once after the operation and regained his normal weight. He engaged actively in business for a year. At the end of this time the old symptoms returned with increased intensity and the decline was rapid, death occurring in about three months. Vomiting persisted for the last month of his life.

Comment.—Such marked improvement after simple incision is unusual, though briefer cessations are not so uncommon. The reason for such occurrences is not known, neither can such be predicted from findings at the operation. The cause of such improvement is unknown.

CASE 6.—A farmer aged fifty-six came to the hospital because of pain in the stomach.

History.—The patient had never had digestive disturbance before the onset of the present trouble. Beginning two years ago he has had periodic attacks of epigastric pain. He says they came on at no regular periods and did not seem to be closely related to meals. They were sometimes worse when the stomach was empty and sometimes worse just after eating. They were always relieved by soda. For the past year he has had but little trouble. The present attack began about two weeks ago. It is worse than any of the previous attacks. He has vomited about every other day one or more times since the attack began. He has never noticed blood. He has lost fifteen pounds in two weeks; his appetite is poor and the bowels are very constipated. There have been no urinary symptoms and he has never been jaundiced.

Examination.—The patient's statement is the only evidence of his plight. There is no anemia, the abdomen is soft, and no points of tenderness can be discovered. The x-ray shows a normal emptying time and there are no filling defects.

Diagnosis.—A provisional diagnosis of gastric ulcer was made and the patient advised to stay in the hospital. The fact that he had an attack two years ago confirms the ulcer hypothesis. If he has carcinoma now it must have been implanted on an ulcer. If he has carcinoma, operation has little to offer. The patient wished to go home, and the following prescription was given; Magnes. oxid. Pond. oz. ss, Bismuth subnitrate oz. ss, Soda Bicarb, oz. iii, half teaspoonful after meals and repeat in two hours.

After-course.—He improved on this treatment and rapidly regained his weight. He is still well four years later.

Comment.—This case represents a type of old men's stomach trouble. I do not presume an ulcer was cured. Either he had none or has it yet. In such cases one can follow one of three courses; operate, find no ulcer, remove an appendix or gall bladder and ascribe the cure to this, or find some dilated vessels and call it an ulcer, do a gastroenterostomy and ascribe the cure to that; or give him antacids or regulate his diet and confess you do not understand the condition. I have tried each in turn. One may argue that by removing the gall bladder or appendix the recurrence is prevented, that this cure is permanent while the antacid cure is only temporary or may be so. If one follows these cases many years this is not always, even usually, borne out. One is obliged to ascribe recrudescence to adhesions or something else. I have observed this fact in those who have been operated on by surgeons of the highest skill. I have rarely seen patients return with a carcinoma. The gastric analysis of these cases varies, sometimes there is much acid, sometimes it is diminished, there may even be none.

CASE 7.—A farmer of fifty-six came to the hospital because of pain in his stomach.

History.—Fourteen months ago he began without known cause to have diarrhea. There was much mucus in the stool and the movements were attended by cramping pain. There has been no blood in the stools. The pains were at first low in the abdomen but now are located in the upper abdomen. The symptoms improved at first under treatment but soon returned with increased intensity. His

usual weight has been 130 but now is 107, most of this loss of weight has occurred in the last three months. At the present time pain is nearly constant and opiates are required to control it and despite them sleep is much interfered with. Recently vomiting has set in. There never has been any jaundice.

Examination.—The patient is sallow and has the worried look of a constant sufferer. The abdomen is flat and the walls are rigid. On palpation a hard, nodular mass the size of an orange is felt to the right of the median line in the hepatic triangle. The mass is fixed to the surrounding tissue. Inflation of the colon causes it to distend below this mass. Inflation of the stomach causes this organ to distend to the left of the mass. The examination of the colon and sigmoid is negative.

Diagnosis.—The onset with diarrhea and tenesmus with the loss of weight would suggest malignancy in the large bowel. The ultimate spontaneous disappearance of this symptom in a measure relieves this suspicion. The appearance of vomiting points to the stomach. The distention of the colon below the mass and the dilatation of the stomach together with the typical site of the tumor fixes the growth near the pylorus. The size of the tumor would speak against its location on the large gut since the tumors in this situation are usually annular and do not attain a large size. The subsequent absence of constipation likewise speaks against a tumor in this situation. The cause of the early diarrhea and tenesmus likely was reflex possibly when the periphery of the colon was first involved in the growth of the tumor.

Treatment.—None. The tumor likely was inoperable and the patient did not care to consider exploration with the possible gastroenterostomy.

After-course.—Vomiting increased and the patient died in about two months from starvation.

Comment.—Usually when the initial symptoms of carcinoma have to do with carcinoma of the stomach one has not long to wait before the gastric preponderance declares itself. The characteristic of the colon symptoms secondary to carcinoma of the stomach in such cases is a sudden onset. When colon symptoms are due to disease of the colon itself, the onset is gradual.

HEPATIC

The common cause of discomfort in the hepatic triangle is a disturbed gall bladder, either from simple inflammation or "quiescent" gallstones. Yet evidence of organic changes should always be sought. Cardiac and lung diseases are prone to cause distress in this region. Organs in the lower abdomen not infrequently find the hepatic triangle a sympathetic sounding board.

CASE 1.—A matron of fifty-six came to the hospital because of digestive disturbance, loss of weight, and heart trouble.

History.—Menopause six months ago. Since then she has had a weak heart and periods of fainty feeling. She had jaundice four years ago which lasted six months. She lost 30 pounds during this period and has not regained her normal weight of 170 pounds. The chief complaint now is that she has no appetite and much of the time feels half nauseated. This is associated with shortness of breath and an irritable heart. This tendency is aggravated by any indiscretion in diet or overeating. She had some trouble with her heart eight years ago after taking a quantity of aspirin for headache. She never has had any trouble in lying down. Too much excitement tends to bring on the heart trouble. There never has been any actual pain in the region of the heart. Recently she has had a good deal of pain under the right shoulder blade and some under the right breast but never any tenderness. There has never been any bladder trouble but she gets up one or more times every night.

Examination.—Large, well-nourished woman with a slight waxy pallor. Blood pressure 200, pulse 70; there is a sharp click at the second aortic sound and there is some extension of the transverse diameter of the heart. The abdomen is soft and flaccid. There is slight but definite tenderness over the gall bladder region. The urine and blood examinations are without interest.

Diagnosis.—The attack of jaundice, the stomach disturbance, and the pain under the shoulder blades and under the breast indicated a gall bladder disturbance. The persistence of the symptoms without colic indicated inflammation rather than stone. This inflammation must have been severe at one time in order to produce jaundice. However, not infrequently a stone when fixed to the walls of the gall bladder produces prolonged irritation without colic. The results in the two conditions are the same.

Treatment.—The gall bladder is distended and of a deep blue color. It empties partly on pressure and no stone is palpable. The gall bladder was removed.

Pathology.—There are no obvious macroscopic changes in the gall bladder save a general granular appearance of the surface of the mucosa but no thickening of its walls. The slide shows round cells sparsely distributed throughout the mucosa and some hyaline degeneration of connective tissue nearest the glands.

After-course.—The relief from all the symptoms was prompt and complete. Six months later she had regained her weight and had no more heart attacks. She has remained well since.

Comment.—This is a typical case of chronic cholecystitis, so-called, in which a chain of symptoms is removed, yet the tissue shows so little change when studied in the laboratory that the manner in which the changes are brought about is not clear. There must be a certain degree of irritation exerted on the nerves supplying the gall bladder that they exert a deleterious effect on the surrounding organs. When the history points to the gall bladder as the source of irritation, if no stones are found its removal is more necessary than if stone is found. Drainage of the gall bladder is merely a subterfuge.

CASE 2.—A housewife aged forty-six came to the hospital because of repeated attacks of pain in the region of the liver.

History.—She has had repeated attacks of severe pain in the region of the liver during the last eight years. At first they came on about once in three months. They were relieved by hypodermic injections. Following an attack five years ago she had pain in her side for a month. During the past year she has had frequent light attacks, the last one a week ago. She has lost some 40 pounds in weight. She has had much digestive disturbance and backache and some bladder irritation.

Examination.—The patient is a small apprehensive woman who shows the effect of toil. The abdomen is lax, permitting palpation of the abdominal contents in an exceptional degree. There is deep tenderness in the hepatic triangle. The uterus is retroflexed, large, somewhat sensitive and the cervix is eroded. The perineum is lacerated to the second degree and there is a pronounced cystocele and rectocele. The urine is 1.010, contains pus cells.

Diagnosis.—The diagnosis of gallstones may be made with a degree of certainty from the history. Likely the attack of jaundice five

years ago was due to an inflammation and not to a common duct stone. The gall bladder trouble probably accounts for the loss in weight. Obviously the pelvic lesions should likewise be repaired, but considering the general condition of the patient, operation on the gall bladder will be quite enough for one sitting.

Treatment.—The gall bladder was found large and very long and

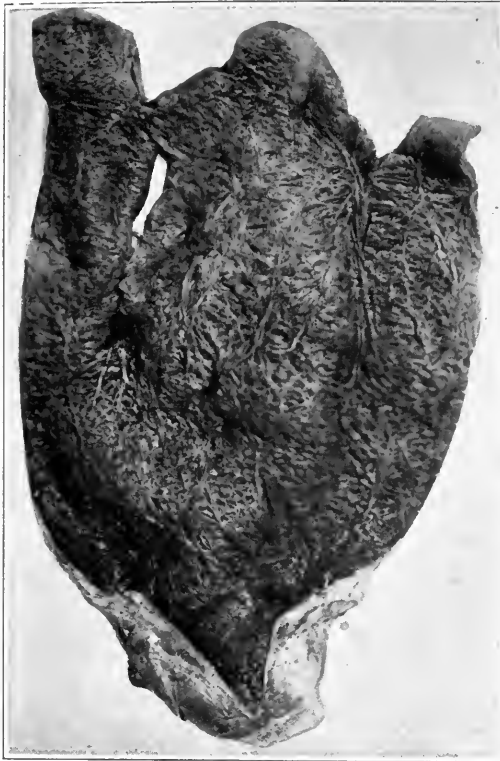


Fig. 325.—Gall bladder with corrugations of the mucosa. There is a stone in the cystic duct.

contained a quantity of stones. The easily accessible ones were removed, but one was firmly fixed in the cystic duct. The interior of the gall bladder was much congested and contained some strands of fibrin. It was deemed best, therefore, to remove it. This was exceedingly easy because of the laxity of the abdominal walls and the emaciated state of the patient.

Pathology.—The interior of the gall bladder shows an unusual degree of corrugation (Fig. 325). Long bands of fibrin are attached to the papillary projections of the mucosa. The wall is thick and firm. The slide shows extensive round-celled infiltration and some loss of substance of the mucosa.

After-course.—The patient waked up from the anesthesia promptly but the pulse was small and rapid. She took much fluid by mouth and received salt solution by the large bowel. The pulse became smaller and more rapid and on the third day her tongue became dry, she became delirious and died a day later. During the period following the operation she passed only eight ounces of urine which contained a little albumin and a few casts. The autopsy showed nothing abnormal in the field of operation, and save for some cloudy swelling of the kidneys, some fatty degeneration of the liver and hypostatic pneumonia, there were no findings.

Comment.—The findings were not those of a nephritis. Most likely death was caused by an acidosis, whatever that is. Patients who have become much emaciated from unknown causes are apt to die when operated on; it makes no difference how the operation is done. Perhaps a simple drainage would have been better surgery, but I have seen patients die in just the same way after simple drainage. Such patients should be put to bed and kept there until their nutrition improves. Whenever a patient has become emaciated from an unknown cause or from a cause not directly removable by the operation, the surgeon will save himself embarrassment by deferring operation. Chemical tests of the blood and urine for acetone will not give him a clue before operation or help him out once the process is started. Such tests are fine science, but a degree of perfection to the point where the studies are capable of materially helping the surgeon has not yet been reached.

CASE 3.—A housewife of thirty-eight entered the hospital because of cramping pains in the upper abdomen.

History.—The patient has had four spells of severe pain under the short ribs on the right side. These pains begin in the back under the shoulder blade and extend to the front, then across to the left side, and finally they settle over the right side. There is tenderness for a week or two following the attack. She had her last one two weeks ago. It lasted twelve hours and she still has abdominal tenderness.

Her general health is good. She has had ten children, the youngest two years old. There are no menstrual disturbances.

Examination.—The patient is markedly tender over the gall bladder and there is some muscular rigidity. The uterus is in position, is movable, and there is a slight laceration of the cervix with erosion.

Diagnosis.—The location of the pain followed by tenderness gives the typical picture of gallstones. There is evidently a cholecystitis following the attacks as expressed by the tenderness, but since they only follow the attack, the removal of the cause should break the chain. Simple drainage appears the operation of choice.

Treatment.—Cholecystectomy with the removal of three large gall stones was done. The gall bladder is free from adhesions, there is no thickening of the gall bladder or apparent change.

After-course.—Recovery was uneventful and she remained well for a year, when she returned complaining of epigastric distention after eating, pain under the right shoulder blade, dizziness and constipation. She now complains of pain at menstruation. The onset is painful and after flowing a few days the flow ceases and then starts again with renewed pain. Her epigastric troubles are markedly worse at the menstrual periods. She was given antacids. She returned in a month complaining of shortness of breath and pains extending to her heels. She is constipated and passed some blood from the bowel during the week. She has frequent urination, particularly during the periods, sometimes passing urine as often as three times in an hour. She has pain in the intermenstrual period like that she usually has at the menstrual period with augmentation of the epigastric distress. The patient now has a large and sensitive uterus. The cervical erosion is more pronounced. Her symptoms were relieved by taking hyoseyamus and bromides for three months. The epigastric symptoms likewise were relieved. The perineum and cervix were repaired and the hemorrhoids removed. She was freed from her symptoms.

Comment.—When this patient returned after a year complaining of epigastric distress, I felt sure she had a recrudescence of the gall bladder condition. It was not until her second visit that the pelvic symptoms came to the fore. Uterine antispasmodics were given as a test and seemed to give the desired relief. Operation made this permanent. After the last operation she admitted that the pelvic symptoms had troubled her before and that she minimized them in

order not to detract attention from the main trouble, the cramps. When questioned about the alleged pain under the shoulder blade she stated she probably was mistaken, that she so feared its recurrence that she included it in her complaints. In suspected recurrences in any well defined disease that has been remedied it is often of importance to re-examine the whole picture lest what appears to be a recurrence may be an antecedent or a wholly disassociated disease.

CASE 4.—A matron aged thirty-four came to the hospital because of pain in the upper abdomen and nervousness.

History.—The patient had two children aged six and eight years. No miscarriages. She has not been well for several years. She has had some pain in the right side under the short ribs, but it has never been severe enough to compel her to call a doctor. Her worst attack was a month ago. Sometimes the pains come on as often as two or three a week. She has vomited but once, but is often nauseated. When the pain is most severe, there is a griping, but at other times there is only a fullness in the gall bladder region. She has some gas but the appetite is good, and digestion is not affected by the pain. The patient has also a raised place in the right groin. It is not painful, but makes her feel weak. Menses are slight and come on too soon. She has now menstruated three times in forty-five days. She has always had some leucorrhœa. She has been nervous several years, subject to hot flashes, and palpitation.

Examination.—Pulse is 100, full, bounding. The apex beat is diffuse but there is no tremor, goiter, or eye symptoms. She is nervous and the epinephrine reaction suggests hyperthyroidism. There is tenderness over the gall bladder. The uterus is retroverted, and right ovary is behind the uterus and is very sensitive. Perineum is lacerated to the second degree.

Diagnosis.—Because of the nervous state and the obvious pelvic disturbance, a repair of these is important for the preservation of the nervous equilibrium. The symptoms referred to the upper abdomen seem strongly indicative of gallstones. These may be a subject for exploration.

Treatment.—The perineum was repaired, the round ligaments pliated and one gallstone removed and the gall bladder drained.

After-course.—She was unusually distressed by gas after the operation. After this was expelled the improvement was rapid. Four months after operation she had a sharp pain in the region of the

gall bladder during the menstrual period, but not at other times. There is no pelvic distress during the menstruation and she now goes the regular length of time. The general nervous state has improved markedly and the symptoms referable to the upper abdomen have been absent for several years.

Comment.—It was my impression that the one attack of subcostal pain indicated that the gall bladder should have been removed. From later developments it is possible that the attack was due to reactive processes which had not yet subsided after the operation. This was a hope rather than a prediction but events seem to have warranted it. The raised place in the right side, of which the patient spoke, evidently was a muscle contraction indicative of protection of a painful ovary.

CASE 5.—A matron of forty-nine entered the hospital because of abdominal pain.

History.—The patient complains of recurrent pain in the hepatic region and epigastric distention. For a dozen years she has had periodic epigastric pains which radiate to the side along the costal margin to the back under the shoulder blade. She has never been jaundiced. Between the spells she feels quite well save that in recent years she has had severe indigestion. She has one child twenty-four years old. She has menstrual pain during the first few days.

Examination.—She is a small, slight woman, with flaccid abdominal walls. There is distinct deep tenderness in the hepatic region. Below the costal arch is an ovoid tumor which glides freely between the hands in bimanual palpation and can be fixed between the hands and prevented from moving with the liver.

Diagnosis.—The history and the tenderness indicates gallstones. The mass which glides under the costal margin is regarded as a movable kidney. It seems surprisingly superficial but the thin, flaccid abdominal walls seem to account for this.

Treatment.—Resorcin bismuth mixture. Advised operation.

After-course.—After continued attacks for a year the patient consulted a surgeon who made a diagnosis of ovarian cyst and operated under this diagnosis. When the abdomen was opened no cyst was found but both ovaries were removed anyway. She continued to have pain and became weaker. I examined her again and found a globular tumor the size of a goose egg lying in the ileocecal region. The kidney could be palpated above it. The tumor could be pushed

to the midline and up under the liver. The diagnosis now was cystic gall bladder. After the abdomen was opened, this was found to be correct. When the gall bladder was delivered, it reached nearly to Poupart's ligament and contained about a quart of clear mucid fluid. A single stone lay in the cystic duct. Cholecystectomy was done. She died some years later of carcinoma of the stomach.

Comment.—Had I been more careful at the first examination I could no doubt have felt the kidney independent of the tumor. The failure of the previous operator to find the "ovarian cyst" after the abdomen was opened is explained by the fact that he operated in the Trendelenburg position and the tumor gravitated up under the liver.

CASE 6.—A matron of thirty-five came in with the complaint of pain in the shoulder and in the region of the liver.

History.—The patient has two children, the youngest twelve years of age. Menstruation is regular and lasts four or five days. She had an appendectomy and cervical repair seven years ago. She now complains of pain in the right shoulder and neck so severe that she can not do her work. The pain is worse at the menses, at which time the arm aches all the way to the fingers. These pains are worse in damp weather. She has pain under the right short ribs as well as back at times, which extend back under the shoulder blade. These pains are never severe. She has some pain before and after menstruation, none during the flow.

Examination.—The uterus is in position. It is somewhat sensitive on bimanual examination. X-ray of the right kidney region is negative. The cervix is extensively eroded. There is pronounced deep tenderness over the gall bladder. The 10th intercostal nerve is sensitive along its course.

Diagnosis.—The pain in the neck and the backache are reflex from the cervical erosion. The constant soreness under the shoulder and the occasional pains under the costal margin may be of the same origin, though the deep pain in the hepatic triangle is suggestive of gall bladder disease.

Treatment.—The gall bladder was found adherent to the great omentum which was separated from it with some difficulty. The gall bladder contained stones which were removed and a drain inserted. The cervix and perineum were repaired.

After-course.—Combinations of pelvic and gall bladder symptoms are frequently encountered and their separation may be difficult.

In this instance there is nothing in the history to indicate when sufficient reaction took place about the gall bladder to invite omental adhesions. The patient had eclampsia during her last confinement and since gall bladder troubles are prone to light up at such times, the adhesions may have taken place then without exciting attention and the reaction resulting may have been masked by the graver malady.

CASE 7.—A professional man aged forty-two came because of pain in the right upper abdomen.

History.—He has had several attacks of cramping in the upper abdomen. They lasted a few hours or less, and after a period of soreness, would subside. The present attack began four days ago with severe pain. This has persisted until the present time. He has had fever from the beginning and it still persists.

Examination.—There is marked sensitiveness in the hepatic triangle. The whole area is marked by muscular rigidity. The remainder of the abdomen is free from pain and rigidity. Pulse 90, temperature 102°, respiration 22.

Diagnosis.—This evidently is an acute cholecystitis and pericholecystitis. Evidently his previous attacks were colic without noteworthy inflammation. Likely, therefore, there are stones present. The attack probably will subside, but having persisted four days, grave changes may be taking place. At any rate he is suffering acute pain, and being a professional man, this is a matter of great importance. At least a drainage seems demanded, possibly a removal of the gall bladder. The details of this must be determined at operation.

Treatment.—After the gall bladder was exposed, it was found that it was wholly surrounded by adhesions, leaving but its summit exposed (Fig. 326). In view of this fact it seemed best to do a simple drainage rather than run the risks involved in a removal of the gall bladder. The gall bladder was, therefore, opened, and a quantity of stones with dark bile above and whitish pus at the bottom was found. A drainage tube was inserted and a small gauze drain was placed about it.

After-course.—He got up on the fourth day and in a week or so went about his business. He remained well for seven years, when he began to have pains again. At first they were not severe, but subsequent attacks became more pronounced. One attack lasted a week and he suggested a removal of the gall bladder. This was under-

taken. The gall bladder was of medium size, the walls thickened but there was not a sign of the adhesions present at the first operation. The common duct likewise was large, hard and thick. The anesthetic was given in an abominable fashion and I feared to open the common duct under such conditions and a simple cholecystectomy was done. The pains continued and five days later he passed a stone per anus. Following this he was completely relieved and has remained so.

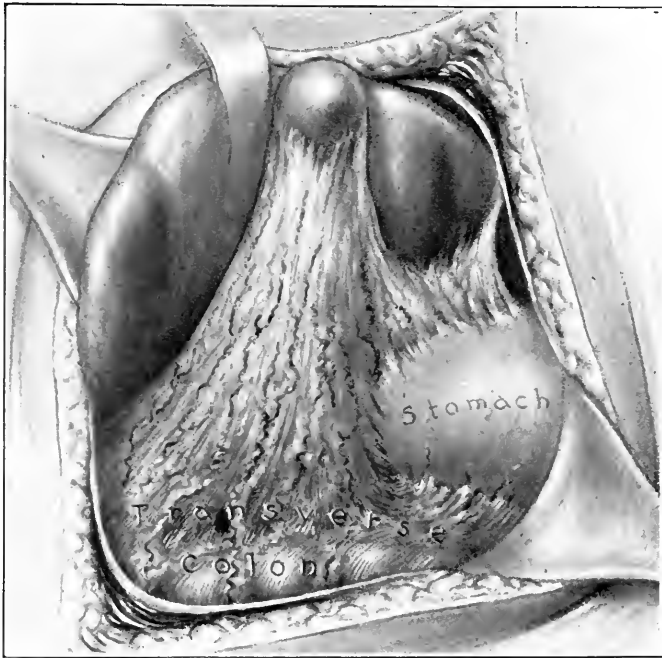


Fig. 326.—Dilatation of the vessels in the hepatocolic ligament in a patient who had had many attacks of cholecystitis, but at the time of operation was free from symptoms.

Comment.—There is a question as to what should have been done at the first operation. Undoubtedly the safest plan was chosen. To have removed the gall bladder then would not have insured against leaving a stone in the common duct. To open the duct in the face of pronounced infection is to invite a cholangitis. The time of the second operation was ill chosen. It should have been done earlier, when the first recurrence was noted. Even with a good anesthetic the opening of the common duct would have increased the risk, but leaving

it untouched was poor surgery and was so recognized. That the stone passed spontaneously was a fortuitous circumstance and came to relieve a bad situation. Had it not done so, a third operation would have been demanded before a final cure could have been expected. When operations are done in the acute stage and adhesions can be separated without producing too much bleeding, and the common duct can be readily palpated and declared free from stone, then the removal of the gall bladder is the ideal procedure. If the duct is thick, the only way one can be sure it does not harbor a stone is to open and explore it. When jaundice is present, this is a hazardous procedure, and in such cases simple drainage alone is permissible.

CASE 8.—A housewife of fifty-two came to the hospital because of pain in the abdomen and indigestion.

History.—The patient had typhoid fever twenty-six years ago. Her general health has never been good since that time. She has always been constipated and her appetite is always poor. She had attacks of pain in the right side under the short ribs at intervals for twenty years. They were often associated with vomiting. During the past few years she has had only two or three attacks a year. They were so severe that a doctor had to be called. She has not been jaundiced in any of these attacks. Two weeks ago she had her last attack. There was pain in the right side and in the back under the shoulder blade and she was "sick all over." She had fever for some days and has felt weak ever since.

Examination.—The patient is weak and emaciated—with a sallow complexion. She has temperature 100, pulse 80, respiration 22. There is marked tenderness in the hepatic triangle and some rigidity. Urine 1.008, a trace of albumin, no casts.

Diagnosis.—The history of gall bladder infection from the time of the typhoid fever stands out with unusual clearness. The generally impaired health speaks for a continued infection. The acute attacks of pain suggest a stone. There has been no jaundice and no chills. The slight fever observed from time to time is quite compatible with an infection associated with gallstones. The general impairment of the health of the patient suggests a continued intoxication. In such instances a removal of the gall bladder is indicated, whether stones are present or not. Whether or not the operation shall be done now or wait a fever-free period must be decided. There seems but little prospect of a much more favorable time, and since it is more

convenient to do the operation at once, it shall be done. There is no evidence pointing to a common duct stone.

Treatment.—A mass of adhesions exist between the liver, duodenum, and colon. Though the separation was carefully conducted, the duodenum was opened into. The opening was closed at once. Great difficulty was experienced in finding the gall bladder. It was finally found as an object as thick as a finger and about two inches long. There was a stone in the bottom of it. The common duct was not opened, though its walls were so thick that palpation was of little value. The gall bladder was removed. The cystic duct was much thickened down to the common duct. A drain was placed to the site of operation.

Pathology.—The nub of gall bladder obtained had very much thickened walls so that scarcely any cavity remained except below where a stone as large as a hazelnut lay. The walls were made up of dense fibrous tissue with much round-celled infiltration. The epithelial lining was reduced to patches of low epithelium.

After-course.—A duodenal fistula formed which closed after seven weeks. Fortunately the opening was small. She gradually gained in health and after a year was in good health, better than for many years.

Comment.—The common duct was not explored because the operation already was severe, due to the extent and character of the adhesions. There was good reason from the history to feel that the duct was free from stone, though the conditions were such that no trustworthy information could be gained from palpation. Since the cystic duct was thickened down to the common duct it seemed likely that the thickening of the common duct was a continuation from above. If such were the case, with the removal of the source of infection the thickening should subside. From the findings at operation it is a bit surprising that such acute exacerbations should have appeared so late in the stage of development.

CASE 9.—A school teacher aged fifty-two came to the hospital for relief from a discharging fistula of the abdominal wall.

History.—A year ago the patient had an attack of abdominal pain which was diagnosed appendicitis and an operation was performed. When the incision was made, the appendix was found normal, but there was an abscess of the gall bladder, the surgeon explained. The gall bladder was drained through the appendix incision. A fistula

has remained ever since the operation. It requires about two dressings a day because of the escape of a pale green fluid. When the fistula closes, pain begins, which is relieved when it opens again. The drainage is nonirritating to the skin.

Examination.—There is a fistula leading to the gall bladder region. At the bottom of this the probe impinges on a stone.

Diagnosis.—Fistula of the gall bladder with an impacted stone in the cystic duct.



Fig. 327.—Fistulous gall bladder containing a stone in the cystic duct.

Treatment.—The mouth of the fistulous opening was circumscribed and the contracted gall bladder freed from above downward. At the lower part of the cystic duct a stone as large as a hazelnut was found. The cholecystectomy was completed.

Pathology.—A stone the size of a marble lay deep in the gall bladder (Fig. 327). The gall bladder wall is thickened and microscopic

examination shows a considerable round-cell infiltration of the wall with a colloid degeneration of the submucosa.

After-course.—Recovery was prompt and complete.

Comment.—The operator who did the first operation was of limited experience and he did well to limit his efforts to simple drainage. This relieved the patient from her immediate trouble. Had he been an expert operator he would have done well to have removed the gall bladder, since there were no adhesions to make such a procedure extra hazardous.

CASE 10.—A matron of forty-two came because of pain in her right side.

History.—The patient began menstruating at the age of thirteen; periods were always regular, not painful. She has had three children, the second child dying soon after birth. The others are living and well, the youngest being eleven years old. The patient's father died of hemorrhage of the stomach, at the age of seventy-three; her mother, with congestion of the stomach at the age of seventy-eight; and a sister, with a tumor of the uterus. Thirteen years ago, while working, the patient was seized with severe cramp-like pain in the epigastrium. The pain soon spread over the entire abdomen. She said it felt as though something had burst in the right side. The attack lasted about two days, though she was not confined to bed. Since then the attacks have recurred two to three times a year and last from one to five days. The pain is always in the right upper quadrant of the abdomen, with tenderness two fingers below the right costal margin and three fingers from the median line. The pain also radiates to the inferior angle of the right scapula. The present attack began seven days ago following a two weeks' siege of la grippe. The cramp-like pain came on suddenly, was more intense over the region of the gall bladder, and radiated to the inferior angle of the right scapula. There was vomiting when anything was taken by mouth, the vomitus was greenish-yellow in color but contained no blood. Two to three hypodermic injections daily were required to control the pain. Menstruation is painless and regular, lasting usually five days. There has been a tendency to an increased flow during the past six months.

Examination.—The patient is poorly nourished. Lungs negative; heart irregular in rate and rhythm, apex visible at the fifth inter-

space. Two inches to the left of the midsternal line there is a loud systolic murmur replacing the second sound, and ending in a loud first sound, best heard at the apex. There is slight tenderness over the gall bladder and also over McBurney's point. She has had clay colored stools during the last week. The perineum is lax and there is a marked cystocele. The cervix is eroded, presenting a mass the size of a small hickory nut at the posterior part of the cervical canal (Fig. 328). It is fairly sharply defined from the surrounding tissue but it bleeds readily when touched. The urine is cloudy, contains some albumin, but no casts.

Diagnosis.—The various elements that go to make up this symptom-complex are simple enough, but their association makes them of interest. There is evidently a mitral stenosis. The gall bladder

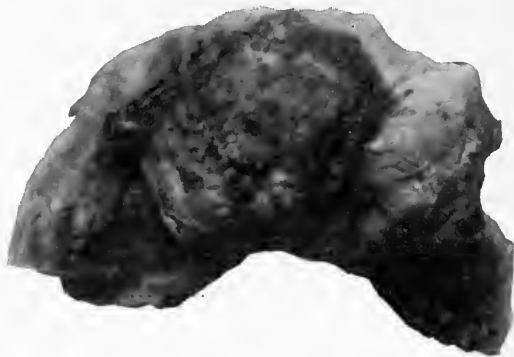


Fig. 328.—Carcinoma of the cervix.

attacks likewise are typical enough. Sometimes heart disorders are characterized by pain in the hepatic region. These do not extend over such a long period of years and there are usually other evidences of decompensation. Hepatic pain due to cardiac disturbances does not require such large doses of morphine for its relief. The accidental discovery of the cervical tumor is of especial interest. The location of the tumor in one quadrant of the cervix makes it suspicious. Its density and tendency to bleed is sufficiently characteristic of carcinoma.

Treatment.—Despite the discomfort of the gall bladder condition the cervical disease was regarded as the more important. Therefore the cap of the vagina, the basis of the broad ligament and the entire cervix were removed. Because of the patient's poor general con-

dition and the heart lesion, the operation was done under local anesthesia.

Pathology.—Section shows an early adenocarcinoma.

After-course.—The recovery from the operation was satisfactory. Two months after the first operation the gall bladder was relieved of a number of stones, likewise under local anesthesia. After the recovery from these operations, there was considerable improvement in the general health. She is still in good health five years after operation.

Comment.—Had I to operate on this cervix now, I should do it under spinal instead of local anesthesia. This case shows the advantage to be gained by a thorough general examination.

RENAL

Simple distress in the renal region is prone to be due to circulatory disturbance in the kidney itself or referred pains from the germinal glands. Static disturbances in the spine and its attached structures often are at the bottom of such disturbances.

CASE 1.—A professional man aged thirty-five came because of pain in the right upper abdomen.

History.—Eighteen years ago the patient was kicked in the abdomen in a football game. He was unconscious twelve hours but was able to be about the next day. He has never been well since. During the next two years he had attacks of obstruction at intervals. He was operated on by a competent surgeon who found "mesenteric hernia" and removed the appendix. During the next twelve years he had stomach symptoms, some sourness, with pain and soreness in the right upper abdomen. He finally became incapacitated and went to a distinguished diagnostician who diagnosed neurasthenia. He was later explored by a distinguished surgeon who found a very large cecum and ascending colon with adhesions. The adhesions were removed. Improvement followed this procedure. It did not last, however, and a year and a half later the ascending colon, a fourth of the transverse colon, and ten inches of ileum were resected. He had a stormy convalescence having a fever of 102° to 103° for two weeks with pain in the hepatic triangle, and rusty sputum and a leucocytosis of 23,000. A clear effusion developed in the chest. Later a phlebitis of the left leg developed. After a time he improved and did pretty well for a year. During the

past year he has again had attacks of pain in the hepatic triangle. It comes on sometimes once a month, sometimes two or three times a month. It seems to come on after exhaustion and lasts several days. It comes on gradually with pain and vomiting. The bowels are regular during these attacks but there is some dizziness. He began a course of rest six months ago with forced feeding. He has gained 30 pounds since then. He was able to work for a time but had to take a protracted rest recently. His chief complaint now is pain in the gall bladder region with hyperacidity and eructations.

Examination.—The patient is obviously on a high nervous tension, but seems well nourished. Physical examination is negative save for extensive abdominal scars the result of his numerous operations. There is possibly a slight general sensitiveness and a little tympany. The x-ray shows a delay of the barium current in the colon and the descending colon is much contracted.

Diagnosis.—Symptoms of obstruction which are associated with hyperacidity are usually spastic in character and when these symptoms coexist there is usually a preformed nervous substratum back of it. Unfortunately when these cases are once operated on, adhesions often form which give a real organic basis for subsequent complaints. The multitude of complications after the last operation seems to have left no trace. The fact that he has been in fair health at intervals but suddenly becomes exhausted indicates a nervous disturbance rather than an organic disease. The best guide to such nervous spastic states is usually a hurrying of the barium meal through the stomach and small intestines only to linger in the large bowel. In such cases operation is never indicated.

Treatment.—He was placed on hyoseyamus and bromides in sufficient doses to control nervousness and insure reasonable sleep.

After-course.—He began to improve at once and has continued in good health.

Comment.—It is a mistake to operate on such patients. The nervous exhaustion is but increased by the burden of the operation. Happily these extensive operations on the colon are now things of the past.

CASE 2.—A school girl of fifteen came because of pain in the right side.

History.—Her general health has always been good save that she has had three attacks of pain in the right side at intervals of six

months. The last, two months ago, was associated with local tenderness, fever, and vomiting.

Examination.—Nothing abnormal could be discovered on examination.

Diagnosis.—The diagnosis of appendicitis made by her physician had to be accepted from the history.

Treatment.—Appendectomy.

Pathology.—The appendix feels hard at its lower extremity. On section it is solid below near the tip but further up contains a lumen. The microscopic picture shows many groups of epithelial cells scattered throughout the mucosa and submucosa. (Fig. 329.)

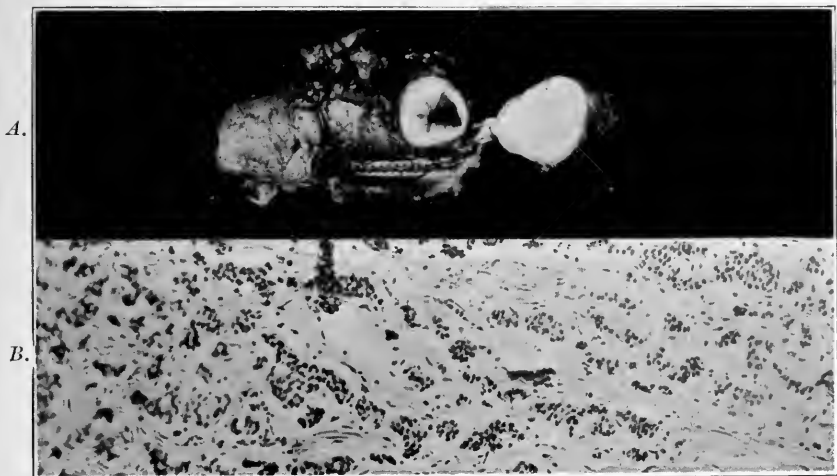


Fig. 329.—So-called carcinoma of the appendix. *A*, gross. *B*, microscopic.

Comment.—This is a typical so-called carcinoma of the appendix. It bears no clinical or anatomic relation to carcinoma. One sees the counterpart in the tips of Meckel's diverticula and it should be regarded as congenital peculiarities and not as proliferating cell processes tending to destroy life, as carcinomas do.

CASE 3.—A matron aged thirty-seven came because of pain just inside the anterior superior spine of the ilium.

History.—Her present trouble began about three years ago. The first two years she had attacks of pain in the right side at intervals of six weeks to two months. This was not severe and she did nothing

for it. It lasted a day or two and was gone. During the last year they have come on every two or three weeks and were very severe. They sometimes came on very suddenly and radiated to the vulva. The spasm would last 10 to 15 minutes and then develop into a dull pain which lasted for several days. She never vomited with the pain but felt slightly nauseated at times. She thinks she has some fever. The pain was made worse by lifting, and was worse before the menstrual period. The pain was not accompanied by urinary symptoms. Appetite good. She is always very constipated and has headache occasionally. She used to have much cramping pain at the

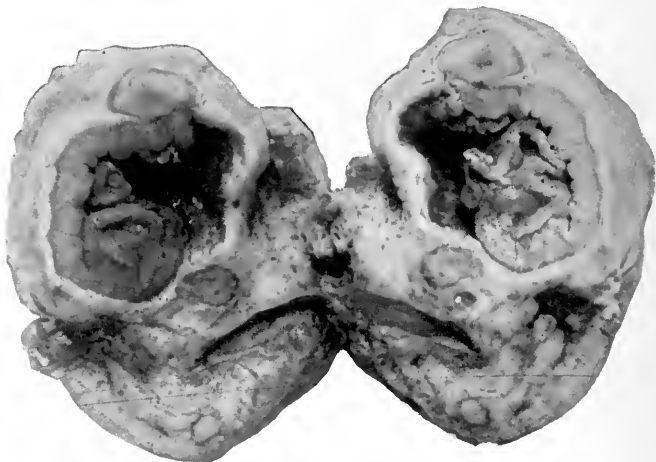

Fig. 330.—Luteal cyst of the ovary.

menstrual periods but these have been less during the past year. She has never been pregnant.

Examination.—The heart, lungs, and abdomen are negative. The uterus is slightly retroverted. There is a mass the size of a small orange to the right of the uterus. The mass and the uterus are independently movable. The mass is firm, elastic, somewhat irregular, and not sensitive to pressure.

Diagnosis.—The history sounds like appendicular colic during the first two years, but during the past year were evidently ovarian, a supposition confirmed by finding a tumor beside the uterus. The fact that they are now worse before the menstrual period and worse on lifting indicates the same thing. The tumor is firm but not solid,

which together with its form would suggest a dermoid but it is causing too much pain to be a dermoid. If it is a dermoid, there must be secondary changes. It is too large to be an ovarian hematoma.

Treatment.—Resection of the cyst of the right ovary the size of an orange. Resection of hematoma of left ovary size of a walnut. The appendix was small, hard, white in appearance, and was removed.

Pathology.—The section of the right ovary (Fig. 330) shows a thick-

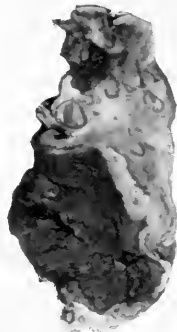


Fig. 331.—Hemorrhagic ovary.




Fig. 332.—Ovarian cyst with hemorrhage.

ened cortex with a large cyst in the center. The cyst contains a whitish mass lining it, which has retracted from a part of the wall. The slide shows this to be a luteal wall. The left shows a hematoma the size of a walnut (Fig. 331) with a portion of the medullary portion of the ovary at one pole, and a recent hematoma between this pole and the larger and older hematoma (Fig. 332). The appendix is sclerotic, the mucous membrane having almost entirely disappeared.

After-course.—She was much improved but has ovarian pains at times.

Comment.—The question is the relation of the appendix to the attacks earlier in the complaint. One might suppose that the changes took place earlier in the attack and were responsible for them. However, we know nothing about the genesis of these uniformly sclerosed appendices. The ovaries show sufficient changes to account for the symptoms complained of. The alleged conservative surgery of ovarian resection is usually greater meddlesomeness but in cases like this in which there are definite pathologic changes resection is the only means of removing the disease and retaining the menstrual function. Likely sclerotic changes in the remaining portions of the ovaries are responsible for her occasional pelvic pains.

ILEOCECAL

The common cause of continuous distress in the inguinal and ileocecal regions is ovarian in origin, much less commonly to disease of the appendix. Tumors and low grade infections in the broad ligament not infrequently are the exciting factors.

Case 1.—A housewife aged thirty-seven sought relief from pain in the lower abdomen.

History.—She has never been real strong; she had a nervous breakdown thirteen years ago. She had earache as a child, and a discharge followed. The right ear still discharges at intervals. Her menses began at 11, regular, free flow, five-day type. Used to have dysmenorrhea but has none now. Was married at twenty-three; has never been pregnant. She has a little leucorrhœa sometimes before periods but not sufficient to wear a pad for it. Some backache for years, not worse at periods.

The present trouble came on with attacks of pain in the right side low down, lasting several days, at intervals of a month or six weeks or longer. They bear no relation to the periods. They are now occurring further apart but are more severe than formerly. She has about one attack a year now, but they last several weeks. With the pain in the right side she has gas and bloating. She does not know whether she has fever or not, but she has to go to bed. There are some urinary symptoms, notably difficulty in voiding with burning at times. Sometimes she has palpitation. The last spell began six

weeks ago. The family doctor diagnosticated appendicitis and advised operation.

Examination.—There is sensitiveness over the sixth space and some over the lower abdomen. There is no muscular rigidity. The pelvis is filled by a hard nodular mass apparently attached to the uterus. Uterus feels as though it were pushed against the pubes. There is a nodule above the left border of the pelvis the size of an egg, apparently attached to main tumor.

Treatment.—A mass the size of a double fist occupying the fundus of the uterus was found, also a nodule the size of a hen's egg in the left cornua of the uterus. A supravaginal hysterectomy was done.

After-course.—Recovery was entirely uneventful. The abdominal wound healed by first intention and the patient made a good recovery. On dismissal the abdominal wound was entirely healed. Vaginal examination showed the stump of the cervix down low against the anterior vaginal wall. Some thickening and tenderness on each side of the cervical stump in the broad ligaments. Cervical stump rather fixed. She gradually improved and has remained well.

Comment.—There evidently had been considerable exudation about the field of operation. This delays recovery but does not prevent it. Her complaints were obviously due to the growing tumor. Had her physician examined her pelvic organs he would not have thought of the appendix. He did urge the need of a pelvic examination, but the patient refused to submit.

Case 2.—A lady aged thirty-three, a bookkeeper, came to the hospital because of pain in the right side.

History.—Ten years ago she had a sudden pain in the right side low down with some bladder irritation. Within a few days the right breast became very painful and sensitive and it was enlarged. At the end of a week the pain extended to the left side of the pelvis and a few days following this the left breast enlarged and became sensitive as the right had done. At this time she began to have a discharge from the vagina. She has had more or less leucorrhœa since that time. Six years ago she had nausea and pain in the stomach and some fever. This continued several weeks and the doctor called it walking typhoid. Two months ago she was seized with pain in the stomach and vomited at intervals for three days. She could not eat, and ptomain poisoning was diagnosticated. She was in bed a week. Two weeks ago there was a renewal of this attack and in

addition she had a pain in the right side above the hip bone. She was unable to straighten her leg. She had a severe pain in the back just below the ribs, which was more severe than the pain in the abdomen. She had frequent urination and the urine was highly colored. Her doctor reported a temperature up to 103° . She has lost 10 pounds in weight and has not slept well, though she is not nervous. She had various diseases of childhood and has had from one to three attacks of tonsillitis every winter. Her menses are regular, are painful the first two days, and last three or four days.

Examination.—Save for deep tenderness in the lower abdomen, more marked on the right side than on the left, the physical examination is negative. The urine contains a few leucocytes. There was no blood on a number of examinations. W.b.c. 5,200, Hg. and R.b.c. normal.

Diagnosis.—Recurrent epigastric pains with nausea and vomiting suggest appendicitis. This suspicion is strengthened by the recent localization of pain in the right inguinal region. At the first attack, too, there was pain low down first on the right then on the left side. This may be interpreted as having been an infection of the pelvis from an overhanging appendix which gradually crept across the pelvis. She had a vaginal discharge following the pelvic irritation. A rural lass of thirteen would not likely have an ascending infection. This charitable view is substantiated by the fact that the leucorrhœa followed the pelvic inflammation. Had the infection been of extraneous origin, the leucorrhœa would have preceded the pelvic irritation. The recent pain in the region of the right kidney likely is due to a ureteritis. That the inflammation about the appendix extends deeply is shown by the unusual degree of involvement of the psoas muscles. The absence of fever and leucocytosis indicates that the infection has subsided or that it is fully encapsulated.

Treatment.—Since there was an early history of involvement of both sides of the pelvis a midline incision was made. The omentum and several loops of intestine were adherent to the tubes. The right tube and a tongue of omentum were attached to the appendix at its tip. The base of the appendix was firmly attached to the parietal peritoneum just above the brim of the pelvis. The appendix was removed and the adhesions separated.

Pathology.—The appendix showed an extensive sclerosis near its base with more recent edema and round-celled infiltration in its more distal parts.

After-course.—The recovery was uneventful until the ninth day, when she had a severe pain in the right renal region. This was so great as to require an anodyne. She had a trace of albumin and a considerable number of red cells in the urine. These elements lessened and in a few days disappeared, never to return. The close proximity of the appendix to the ureter requiring violent separation may have accounted for this pain. There were no bacteria in the urine.

Comment.—Obviously this patient had an early attack of appendicitis which extended across the pelvis producing adhesions which endured. The subsequent attacks were confined to the appendix and its immediate environs. Many adhesions discovered later in life, and too often ascribed to unholy sources, find their origin in a past appendicitis. One is convinced of this if he systematically explores the pelvis in appendix operations done on girls and young women.

Case 3.—A housewife aged thirty-two came to the hospital seeking relief from pain in the left side and backache.

History.—Her trouble began with the birth of her last child, seven years ago, when she was badly lacerated. The lacerations were not repaired then, but were repaired five years ago. The trouble began with a numbness which started in the left hand and passed over the body. The hands and feet got very cold and she vomited a slimy mucus and has continued to have spells up to the present time. After the attack is over, she gets a dull, steady pain low down in the left side of the abdomen. These spells always come on from one to three days before the period and continue until stopped by hypodermics or sedative medication. The pain sometimes stops with the period but often stays for two or three weeks. This experience is repeated every month. She says she has only about 10 good days between the periods. When the trouble began the spells did not come every month, but they have come regularly for the past eighteen months. She can do no work without getting a backache. She has frequency of urination with small amounts of urine and uncomfortable feeling without actual pain. The frequency is most marked at night. After her monthly nervous spells, the frequency is much worse. She has three living children and has had four miscarriages. Her appetite is good but the bowels are habitually constipated. She has very little headache. Very little discharge between periods.

Examination.—There is abdominal tenderness to pressure over both iliac regions and over the bladder. The perineum is lax, the uterus is in position and movable. Left ovary is the size of an egg and is sensitive; the right ovary is not palpable. There are three large hemorrhoids.

Diagnosis.—The physical findings do not account for her multitudinous pains, neither does the appearance and attitude of the husband account for it. A small fibroma near the horn may be present. The most obvious cause is the large and sensitive ovary. The prospect for relief rests on the assumption that the ovary is the cause, or that something will be found to account for it, or finally if there is an important neurotic element that this can be controlled by after management.

Treatment.—The three hemorrhoids were removed. The left cystic ovary, about three times normal size, was removed. The veins of the pampiniform plexus were varicosed and were ligated and resected. There was no tumor of the uterus.

Pathology.—The ovary was polycystic.

After-course.—She complained much of pain for some months but with sedatives and general encouragement she is now free from complaints and most likely free from suffering.

Comment.—It is still not clear how much the operation and how much the general treatment had to do with restoring the patient's equilibrium. The pampiniform plexus was removed and with it I hope the nerves supplying the uterus. This may have been a factor. Symptoms usually due to pampiniform varicocele, namely heavy dragging especially when on the feet, was lacking here. The ovary must have been the chief cause. This is the more easily acceptable since the complaints are sometimes duplicated in males who have had unskillful operations done on their cords—a condition denominated "irritable testis" by Sir Astley Cooper. Patients with complaints not in harmony with the anatomic findings must be followed after they leave the hospital.

Case 4.—A matron aged thirty-seven came complaining of pains in the left groin, bloating, and frequent urination.

History.—The patient has one child twelve years old. She had dysmenorrhea as a girl; at sixteen had an attack of anemia lasting six months. About five years ago she began to have pain in the left groin. At first it came on at intervals of two or three weeks

and lasted two or three days only, but in the last six months it has been nearly constant. During the past three years she has had a severe pain in the back. This pain is below the small of the back and is steady. When she is on her feet much during the day her ankles become puffy. It disappears during the night. She has severe pains in the back of the head and some in the temples. These come on at intervals of a few days to several weeks. She becomes nauseated in these attacks and sometimes vomits. She has bloating at times, but her appetite is good and she suffers no notable indigestion. She is obstinately constipated. Urination is frequent, small in amount, and causes burning. Three years ago she had a severe attack of epigastric pain with vomiting, which lasted an hour. She describes the pain as agonizing. The next day she passed several stones, about the size of grape seeds, per rectum.

Examination.—There is tenderness in the left groin, none elsewhere over the abdomen. The hepatic region is not tender. The perineum is lax, the cervix lacerated and the fundus retroflexed. There is a mass to the right of the fundus. The urine, save for a pronounced acidity and high specific gravity, is normal.

Diagnosis.—This patient seems to fulfill all the requirements for entrance into the "pelvic case" league. The backache, and groin pain sometimes extending down the legs, and the headaches, all point to the same thing. The cause of the intense groin pains probably indicates some special trouble with the left ovary. The epigastric pain described has all the earmarks of a gallstone colic. The statement that she passed several stones the size of grape seeds may have been aided by the excitement of anticipation. The bladder irritation is probably a part of the pelvic congestion as are also the leg pains and evening edema.

Treatment.—A trachelorrhaphy was done. The mass lying to the right of the uterus proved to be due to an adhesion between the appendix and ovary. The appendix was removed. A large solitary stone was found in the gall bladder. The stone was held in the grasp of the gall bladder, causing the whole to look like a segment of a snake which has recently swallowed a bird.

After-course.—Recovery was uninterrupted. The final result can not yet be determined.

Comment.—Such cases are common among the simple folk, who labor hard and do not dissipate. The difficulty in management is

that the repair of the tangible organic lesions is but a small part of the treatment that should be applied. Usually they have borne a lot of children and often the condition is aggravated by marital excesses or by measures used to prevent conception. The pain down the legs and the swelling, usually limited to the region above the ankles, are all but phenomena referred from the congested organs in the pelvis. Such cases must be followed after they leave the hospital.

Case 5.—A retired farmer aged 70 years came to the hospital because of pain in the lower abdomen and obstipation.

History.—The patient's past history is negative. His present trouble began about two months ago when he was taken rather suddenly with a griping pain in the lower abdomen. He felt as though the bowels wished to move. They did move a little and then suddenly shut off. The griping then began worse than before and was accompanied by vomiting. The local doctor gave him an enema, got his bowels to act, and he felt relieved. His bowels then moved fairly well after that and he felt all right. Since that time he has never had an exactly similar spell, but he has had to take cathartics all the time or he becomes constipated, and when the bowels stopped acting he could only get them started again with great difficulty after three or four days. During all this time he felt generally bad all over and had some griping in the lower abdomen. His general health is good. His appetite is very poor. He sleeps well. His urine is slow in starting but he says it has always been so. He passes a normal stream. There is no pain or burning or frequency. He has no headaches or dizziness. He has lost 40 pounds in the last two months. He has never been jaundiced.

He has had a great deal of trouble with his stomach since his trouble began. The food has never tasted good. He has eructations of a sour substance. He has no pain after eating. In the last two months he has had several vomiting spells. The quantity has been large and he thinks it was caused by too much food. The vomitus is green. Never contains any blood.

Examination.—Blood pressure 160-70. No marked degree of arteriosclerosis, no discoloration of the skin. Marked areus senilis, scar in front of right pupil. Chest markedly emphysematous. Heart outline hard to determine on account of hyperresonance due to emphysema. Apex beat not discoverable, no murmurs, tones faint.

Hyperresonance over both lungs. No areas of dullness or rales. No abdominal masses palpable. Some tenderness to deep pressure in right iliac region. Nothing palpable by digital rectal examination. Hb. 70, W.b.c. 8,600; R.b.c. 4,880,000.

X-ray findings, first plate shows stomach shadow with stomach normally filled and normal pylorus and duodenal cap; two hours later stomach completely empty and barium all in small intestine. Twenty-two hours after first plate barium is shown in the cecum, transverse and descending colon. The shadow is seen in the descending colon down to the left iliac region where it abruptly breaks off as though a mass filled the lumen. Plate 4, taken after a barium enema, shows the rectum and part of the sigmoid partially filled with barium which cuts off abruptly in the left iliac region. There is a large loop of the sigmoid filled with barium below the obstruction.

Diagnosis.—Carcinoma of sigmoid colon.

Treatment.—The abdomen was opened under local anesthesia and the obstruction located in the sigmoid colon. It was adherent to the peritoneum on the side and was adherent to a loop of small gut. The adhesions were both cut loose and the raw spot in the gut covered. A perforation in the colon was left. There was a long loop of sigmoid rather mobile below the tumor. A large loop containing the tumor was pulled up into the abdominal wound and sutured to the peritoneum all around. The loop of sigmoid was then covered with moist dressings.

After-course.—There was no postoperative shock. Pulse 96, respiration 22, temperature 99.5°, the evening of first day. There was severe pain in the region of the wound. No abdominal distention. Vomited but once. On the second day the patient vomited twice and suffered much from gaseous distention of the abdomen. This was relieved by use of the colon tube. There was some leakage around the hemostats which were closing the bowel perforation. Temperature 99.6°, pulse 100. On the fourth postoperative day the wound was dressed. There was considerable dark fecal discharge through the intestinal perforation, but it had not contaminated the wound to any great extent. Temperature was 98, pulse 76, strong and regular.

Five days after the first operation, the carcinoma was resected and an end-to-end anastomosis of the sigmoid made. A rubber tube was inserted in the sigmoid and pushed up above the anasto-

mosis. The mass of intestines containing the anastomosis and drainage tube were left adherent in the abdominal opening just as they were before the operation. Vaseline gauze packs were inserted around between the intestines and abdominal wall.

After-course.—Second day after operation the wound was dressed. Gauze separating edges of wound from gut was contaminated with feces. These were removed and replaced. As there already was a fecal fistula, the rubber drain in the gut was removed. Temperature 99°, pulse 84 to 90. The patient continued in good condition, temperature ranging from normal to 99.6°. All of the bowel contents passed through opening in the gut, nothing passing by rectum. The wound had granulated in a great deal by the fourth week after operation, but it had not closed the opening in the bowel.

Third Operation.—Four weeks after second operation a third one was performed to close the openings in the gut, the one in the sigmoid in which the rubber drain had been and the one made by cutting through some of the anastomosis sutures. Their edges were everted, the skin and fascia along the edges of the wound were dissected up and closed over the sigmoid. Tension sutures tied over small rubber tubes were used in pulling the skin and fascia together.

After-course.—No apparent shock followed the operation. Temperature subnormal and pulse 84 the evening of the day of operation. The second day the temperature went to 101.2°, pulse 110. The sutures holding and wound not draining. The third postoperative day the upper and lower end of the incision opened a little and fecal drainage came through. This continued almost three weeks. The first normal bowel movement occurred the third week after the third operation. On dismissal, ten weeks after admission to the hospital, the wound was almost entirely healed. Small sinus at each end of the incision was still draining a small amount of feces. The patient had a natural normal bowel movement each day, pulse and temperature were normal and there was no abdominal pain.

Comment.—By doing a two step operation under local anesthesia one is able to work with perfect safety to the patient. This method is only applicable when the tumor is located in a portion of the gut which is sufficiently mobile to permit its dislocation outside of the abdomen.

SUPRAPUBIC

Distress in the suprapubic region demands a search for menstrual disorders, pelvic tumors, bladder disturbances and less often, renal diseases.

Case 1.—A widow aged thirty-six came to the hospital because of pain in the left side.

History.—One child four years old. Four weeks ago she was everted for reasons unknown, she being a widow. For ten days following the operation she was comfortable and began to go about the house. At this time sudden pain developed in the left side of the pelvis, with chill, temperature of 103° and a pulse of 140. The tem-

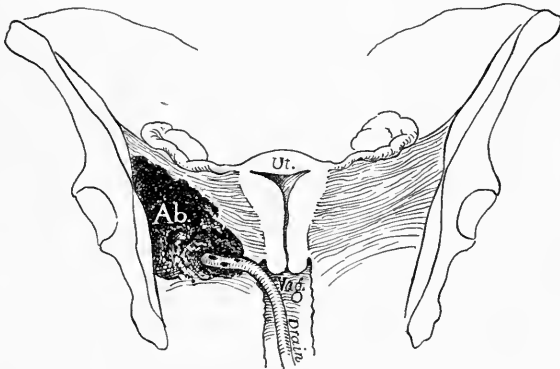


Fig. 333.—Abscess within the broad ligament drained through the vagina.

perature has subsided, but there is still pain in the left pelvis. There is some pain on defecation and there was slight bladder irritation in the beginning. She has had no chill following the initial one, but is very sensitive to changes in temperature when the bed clothes are lifted.

Examination.—The patient is pale and the cheeks are somewhat sunken, but the face is not expressive of suffering. The pulse is 130. The lower abdomen is tender, particularly on the left side and the left rectus is rigid in the lower fourth. The perineum is lax, the cervix low, and the uterus large and retroverted. It is not movable and an attempt to move it causes acute pain. To the left of the uterus in the base of the broad ligament is a mass the size of a goose egg. It is hard, not movable, and but moderately painful.

The mass seems to be just above the vault of the vagina. Nothing is palpable above the pubes.

Diagnosis.—The sudden onset of pain and fever following intra-uterine manipulation brands it as an infection extending from the uterine cavity. In these cases the site of infection is usually within the connective tissue of the broad ligament. That there is some peritoneal involvement is indicated by the rectus rigidity and pain. The mass is low down, which precludes tubal infection or infection of the pampiniform veins.

Treatment.—Expectant, with local douches not too frequently repeated so that the general strength may not be reduced by them.

After-course.—After this treatment had been continued fever and leucocytosis increased. The mass had not reduced, on the contrary, seemed semifluctuating. A drainage tube was, therefore, introduced into it (Fig. 333). (The artist has reversed the slide.) After a number of weeks of drainage, recovery was complete.

Comment.—In pus accumulations following interrupted pregnancies extraperitoneal drainage should be done whenever possible. The more virulent forms of bacteria are usually found in these abscesses.

Case 2.—A matron aged fifty comes because of general abdominal pains most marked in the epigastrium.

History.—The patient has had four children, the youngest being twelve years old. She has had no miscarriages. The menses are still regular every three weeks and she flows profusely a week or longer. Her trouble began about two years ago with pain which was very indefinite as to locality. More recently the pains have been most marked in the pit of the stomach. She refers to them as biting pains. They are not influenced by the taking of food. All the pains are worse at night. All these troubles have increased lately. She now has palpitation which is noticed especially upon lying down at night. The appetite is fair, but the bowels are very constipated. She gets up sometimes at night to urinate. Just recently she has had pain in the left side of the abdomen which is felt through to the back. There is pain under the right costal margin. She has never been jaundiced. She has had several attacks of sudden pain in the epigastrium which lasts only about five minutes. This is attended by much bloating and palpitation of the heart. She has a rupture on the right side which comes down but has never been strangulated. A truss has not been worn. There is puffiness of the hands and feet, most marked in the morning. She has lost twenty pounds in a year and a half.

Examination.—The heart and lungs are normal. The right kidney is easily palpable. There is no sensitiveness in the hepatic triangle. The inguinal canal is wide and a soft mass comes to the labium on coughing. The uterus is retroverted and the size of a fist with a moderately distinct bosselation at the right cornu. The hemoglobin is 50 per cent.

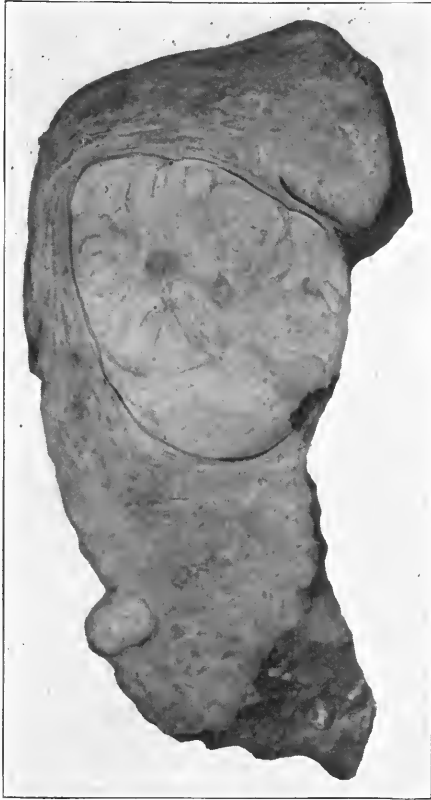

Fig. 334.—Interstitial myoma of the uterus.

Diagnosis.—There is a question whether or not the uterine trouble is responsible for all her symptoms or whether there is not some separate trouble in the upper abdomen. The fact that there is a distinct bosselation in the uterus makes it seem likely that this intramural tumor exciting the uterine fibers to contraction is responsible for all her pains. The pains have increased as the uterine trouble

increased. She speaks calmly of the extent of the flow but her marked anemia indicates that it must be excessive or that there is some added cause responsible for the anemia. There is no evidence of such and the anemia apparently is a secondary one. An unretained hernia sometimes causes marked epigastric disturbance, but in this case there seems to be no added disturbance in the epigastrium when the hernia protrudes. The symptoms in the upper abdomen are not definite enough to warrant one in diagnosing a definite disease in this region. The diagnosis of myoma of the uterus is made. At any rate the uterus is the source of the bleeding which is the real menace. The upper abdomen can be explored at the same time.

Treatment.—A supravaginal hysterectomy and a repair of the hernia was done. There was no evidence of gastric disease and there were no gallstones. The hernia was an inguinal one extending well into the base of the labium major. The sac at the time of operation was empty.

Pathology.—There is a myoma the size of a green walnut in the right cornu. It is a pure fibroma and is encapsulated by a thick layer of uterine tissue (Fig. 334). The tumor protrudes into the uterine cavity. Near the inner os the mucosa is thickened. This is evidently the source of the uterine hemorrhage. The endometrium shows an increase in the stroma cells.

After-course.—Save for a prolapsus of the vagina the patient has been well.

Comment.—The most difficult factor in myomas is to judge how nearly a given tumor may come to explaining all of the patient's symptoms. The interstitial ones are often responsible for the presence of pain in the pelvis or upper abdomen. The test may sometimes be made by means of bromides. Large doses of this drug will calm a uterine pain, while it is likely to make organic diseases of the upper abdomen worse. The uterine condition likely was responsible for the upper abdominal pain. The hernial sac was empty. Had there been a part of the omentum adherent in the sac, one might have preferred to ascribe the upper abdominal symptoms to that.

Case 3.—A married woman of twenty-seven years comes with the complaint of pain in the lower abdomen.

History.—The patient has had repeated attacks of pelvic pain, which have recurred at intervals during the seven years of her married life. The first attack began at the end of her first menstrual

period after her marriage. She had a sudden severe pain in the lower abdomen accompanied by frequent and painful urination. She had a high fever which lasted several weeks. She has never felt well since. The menses have been irregular, prolonged, and painful. Some bladder irritation has remained and she is now constipated. The bowels were normal before the advent of this trouble. The present attack began several months ago and has continued until the present time. She now has less pain than in the beginning, but when much on her feet, the pain is much increased. She has no children. She has been much troubled with leucorrhœa since her marriage.

Examination.—The patient is much emaciated and is evidently septic. The uterus is fixed and there is a dense mass in the right side of the pelvis. Nowhere is there evidence of softening. She has a count of 12,000 leucocytes and her temperature varies from 97.6° to 101°, pulse 90 to 110.

Diagnosis.—The patient had a gonorrhœal infection soon after marriage. The frequently recurring attacks indicate a severe infection and the prolonged course of this attack indicates a mixed infection. The presence of leucocytosis, fever, and rapid pulse indicates an active infection with a virulent organism. There is no point of softening which should make vaginal drainage definite of results. In such a mass without a guide one may open into a gut with a resulting fistula, a very embarrassing complication. Watchful waiting has its dangers since she is becoming more emaciated as time goes on. It seems best to accept the risk of a radical operation. The patient is destitute and can not avail herself of prolonged efficient general care.

Treatment.—A laparotomy was done. The adhesions were very extensive and much hemorrhage was encountered which was controlled with difficulty. The left side showed a typical subacute pus tube, while the right side had a pus tube and a thick-walled cystic tumor not quite as large as a goose egg. The pelvis was drained suprapubically with two large gauze drains and by a rubber drain through the vagina.

Pathology.—The cyst was lined with a mass resembling sheep's skin (Fig. 335). The section shows it to be composed of luteal cells. The pus contained streptococci.

After-course.—There was intense local infection which continued to drain for several weeks. As soon as she was able she was moved

to the country. She improved for a time but retained a discharging suprapubic sinus. She consulted a local surgeon who explored the wound and found a piece of gauze. He presented this to the husband as exhibit A. The general condition of the patient was not improved by either procedure. Following the operation of the surgeon she rapidly declined and died six weeks later.

Comment.—Drainage of the infected area through the vagina would have been the safer treatment. Even if one merely opens the culdesac the depletion hastens the process of resolution and often an abscess

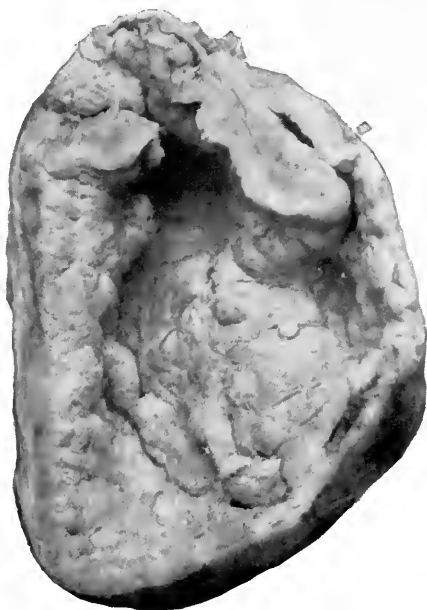

Fig. 335.—Luteal cyst of the ovary.

previously hidden may reveal itself or rupture spontaneously. The pus tubes which have a variety of bacteria and are characterized by frequent exacerbations with never a complete remission are unsatisfactory at best. With local drainage they often drag over years. If a radical operation is done, death may come from the operation itself or from secondary foci. In this case the after-care was entrusted to the family doctor. He removed the drains and inserted others from time to time. Whether the gauze which appeared as exhibit A was one of the original drains, one of those reintroduced as drains,

or if a gauze pad was left during operation could not be determined. A gauze drain should be left until it has served its purpose. Once removed, it should be left out.

Case 4.—A matron aged thirty-six sought relief from dragging pain in the right side and thigh.

History.—The patient's trouble started eleven years ago at the birth of the first baby. She was badly lacerated and the perineum was repaired at once, but the cervix was not. She says that the perineum broke down and the repair did no good. She had an eclamptic attack six hours after the birth of the first baby. She had no trouble at the birth of the second baby two years ago. Her chief complaint now is a dragging in the left side of the pelvis and a stinging pain extending down the left thigh. She has little appetite and is very nervous. She has a profuse vaginal discharge just before the period, which is scanty and lasts three days. She has pain in the temples, top head, and at the base of the neck.

Examination.—The uterus is large, retroverted but movable. The cervix is not lacerated, but the perineum is torn to the sphincter.

Diagnosis.—The large tender uterus without laceration, and the slight flow indicate that the chief trouble lies in the body of the uterus. The location of the headache, the pain in the pelvis, and nervousness are typical of metritis.

Treatment.—The ovary was large and lay in the culdesac. The pampiniform plexus was enormously dilated. The uterus was fixed in place and the pampiniform plexus ligated and cut. The perineum was repaired.

After-course.—Following the operation she had frequent urination and some irritability of the bladder. It was never pronounced. She has pain in the stomach before meal time which was relieved by eating, but eating did not appease her hunger. She was given antacids for this. The bowels became regular soon after the operation. Some leucorrhœa continued for some time and the rectum was irritable for a time several months after operation. At the end of a year she had but little leucorrhœa, she has but slight headache just before menstruation. The bladder irritation has disappeared and she sleeps well.

Comment.—This case shows very well the need for following up these patients so that their recovery may be aided by medical means and to a degree by moral suasion. Tonics and sedatives as may be

required may be necessary for a long time. Three months after operation she was quite sure she had not been benefited in the least by operation. She is the beautiful wife of an affluent and doting husband, a combination designed to delay recovery. The first result of replacing the uterus is often a bladder disturbance and that likely was the explanation in this case, though hemorrhage into the broad ligament after operation for varicocele of the broad ligament can not be excluded, but the advent was not sudden enough to be well accounted for on this explanation.

Case 5.—A matron of forty-one was brought to the hospital because of pain in the lower right side of the abdomen.

History.—She has three children, aged fifteen, thirteen and seven years, and had two abortions before the birth of the last child.

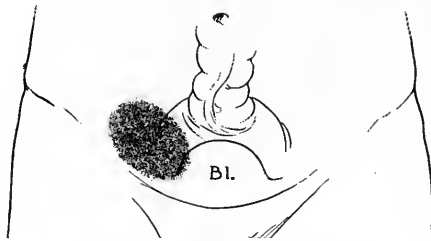


Fig. 336.—Broad ligament abscess.

These were self-induced. She began last Wednesday with soreness across the lower abdomen, chiefly on the right side, low down. The pains at first were intermittent and reached the maximum twenty-four hours after the onset. The last menses was three weeks before the onset of the pain and she flowed three or four days. She had some pain in the right side during menstruation. When she was first married she had attacks in which there was soreness throughout the abdomen. During the present attack when observed she had a temperature of 101° or 102° .

Examination.—There is tenderness over the lower abdomen, particularly on the right side. There is a mass the size of an orange in the right broad ligament high up (Fig. 336). It is fixed and boggy, and pressure on it causes pain.

Diagnosis.—The onset of the temperature following menses indicates a tubal infection. An appendix or a twisted cyst could not be

excluded. The shape of the mass was not that of a cyst and the onset was not that of appendicitis.

Treatment.—Exploratory incision. The mass is formed by a thick tube and adherent guts. The tube wall was thickened and there is pus about the tube. The left tube is not affected. The tube was removed and a drainage tube was introduced.

Pathology.—The tubal wall was infiltrated but the lumen contained no pus. The pus contained an unidentified coccus.

After-course.—The drainage lessened and the temperature was soon reduced to nearly normal. At the end of three weeks there was a sharp rise of temperature and a mass was found over the body of the ischium. This was drained from above extraperitoneally. The disturbance subsided, and following a secondary infec-

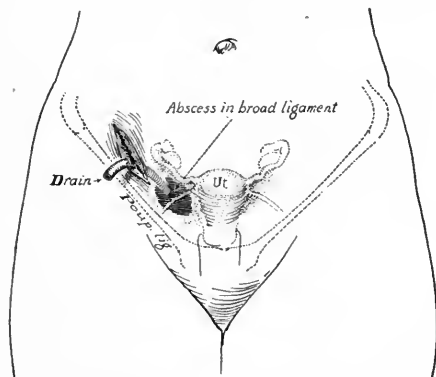


Fig. 337.—Abscess situated far laterally in the broad ligament drained by an incision above Poupart's ligament. (Drawing modified from Cullen.)

tion in the abdominal wall recovery was complete. She remained in good health for six months and the second attack began. During menstruation she had a rise of temperature and felt badly, but after the menses she felt better again. General ill feeling and rise of temperature came on at the next succeeding period and she had a temperature of 102°. The left side became extremely tender. A mass was formed in the left side and she was drained by another surgeon. The pus was said to have contained gonococci. She has had two other attacks requiring drainage. Following this she had another attack during which another surgeon attempted a radical operation and she died of peritonitis.

Comment.—There was a history of abdominal pain soon after marriage, which is suspicious. She had three births at term, however,

following this. The gonococci may have lived in the urethra of the husband rather than in the tubes. However, having admitted two induced abortions, there may have been such preceding this attack. The course has been distinctly that of infection by a pus coccus rather than a gonococcus. The infection evidently was intraligamentous, the tube being involved secondarily only. This should have been so identified and the ligament drained extraperitoneally as presented in Fig. 337. Had the exact condition been recognized, expectancy, for a time at least, would have been the wiser procedure. A radical operation in such cases is always a dangerous procedure.

CHAPTER XIV

NUTRITIONAL DISTURBANCE

When a patient loses weight he is sick. Loss of weight may be due to extraabdominal causes even if there is an associated intraabdominal disease.

WITH PAIN

When there is obvious disturbance of nutrition together with pain within the abdomen the possibility of malignancy must be the chief concern. Pain itself may disturb nutrition, by lessening the amount of food taken, when there are no lesions directly affecting the digestive tract itself. The relation of the two is of prime importance.

CASE 1.—A laborer aged thirty-four came to the hospital because of a pain in his right side.

History.—The present illness began four months ago with attacks of abdominal pain and some pain in the back. At first the attacks came on every week or so, but now they come on more often and he has been vomiting in the last few attacks. Now there is pain and soreness in the right side in the ileocecal region and it seems to go from front to back. There has been frequent urination with the attacks for the last month. One week ago he had a sudden pain in the epigastrium followed by vomiting. In a few hours the pain became fixed in the right lower region of the abdomen. He was in bed three days. When he did get up, he could hardly walk for the pain in the right side. He has had much pain in the back the last few days. In a few of the attacks he has felt hot as though he had a fever.

Examination.—Temperature 97.8°, pulse 58, respiration 20. There is no rigidity. There is tenderness over the whole right half of the abdomen. Urine 1.008, no albumin or other foreign elements.

Diagnosis.—The epigastric pain which finally settles in the ileocecal region seems indicative of appendicitis.

Treatment.—The appendix was removed.

Pathology.—There was apparently some round-celled infiltration in the submucosa. There were not enough changes to account for the symptoms complained of a week ago.

After-course.—The temperature after operation did not rise above 99.6°, pulse 58 to 70. The patient left the hospital two weeks after operation having run an entirely uneventful course.

Three months later he returned with a complaint of stomach trouble. He gave a history, which was not elicited at the first consultation, of stomach trouble extending over a period of ten years. The attack would last a few weeks, then pass away. He would have epigastric pain two or three hours after meals; then the time of appearance of pain grew shorter and finally came on immediately after meals. At first eating would relieve the pain. After going home from the hospital, following his operation for appendicitis, the pain did not subside but was continuous. The worst pain was on the right side under the ribs and going from front to back. There were frequent attacks of vomiting. The vomitus had a sour taste. His appetite was good. Stomach analysis showed free HCl 35 per cent, combined acidity 20 per cent, total acidity 55 per cent, and a trace of blood. An exploratory operation was done. A retroperitoneal sarcoma was found. He died two months later.

Comment.—Evidently his trouble from the beginning was due to his tumor. The history was too indefinite to have warranted such a diagnosis of appendicitis, but when one hears of epigastric pain which later “settles” in the ileocecal region, it is hard to think further.

CASE 2.—A farmer aged fifty-six came because of pain in the stomach and loss of weight.

History.—For twelve years the patient has had severe digestive disturbance. All foods distressed him, apparently without rhyme or reason. Foods that he seemed to tolerate for some months suddenly seemed to cause distress and he had to work out a new diet list. He frequently vomited, but without any rule relative to meal-time or food eaten. The pain was never intensely severe, but frequently compelled him to lie down. He has lost some thirty pounds in weight.

Examination.—The patient does not appear emaciated and there is no evidence of nutritional disturbance. Laboratory examination is without interest. There is a hernia of the linea alba three fingerbreadths below the ensiform cartilage (Fig. 338). It is not evident on inspection but is easily palpable. There is some abdominal tympany, but no sensitiveness.

Diagnosis.—The long duration of the illness and his apparent excellent general state excludes any grave disease. The duration is too long for even an ulcer. Obviously the stomach suffers from its environment. The hernia of the linea alba comes as a welcome object upon which to fix the blame.

Treatment.—The hernia was repaired under local anesthesia.

After-course.—The recovery was prompt and lasting.

Comment.—The careful search for hernias of the linea alba should always be made in all cases of chronic indigestion, particularly if the nutritional disturbances do not correspond with the degree of the complaint. I have seen patients lose as much as 50 pounds, but

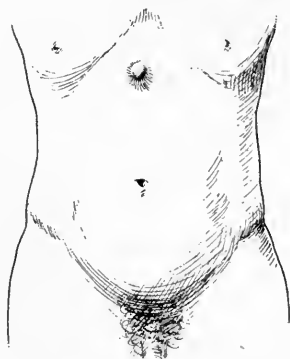


Fig. 338.—Hernia of the linea alba.

even with this loss there was no evidence of secondary anemia. The findings of a hernia should not end the search, however, for these patients sometimes have other diseases.

CASE 3.—A mechanic aged forty-eight came because of distress in the stomach and loss of weight.

History.—He began to lose weight and strength three months ago. He has lost 40 pounds in these three months and has been obliged to give up work. He has never had any digestive disorders before. He is troubled with a sense of fullness which is made neither better nor worse by eating. He has a sense of fainting sometimes. There has never been actual pain or vomiting. He does not have aversion to any particular article of diet. He has been examined by a well-known stomach specialist whose report shows a near absence of hydrochloric acid, makes the diagnosis of carcinoma,

and advises immediate operation. He is pessimistic and uncommunicative as to his symptoms, and contradictory replies were made when asked about his pain. He states that he slept enough, but his wife was of the opinion that he slept very little, and a man's wife generally knows better than he himself how much he sleeps. Therefore it is safe to say that this man did not sleep.

Diagnosis.—The gradual loss of weight and sleeplessness were the outstanding features. He believed the gastroenterologist was correct in his diagnosis, but was reluctant to consent to an exploratory operation, though urged to do so by his son who was a physician. He is merely an apathetic being ruled neither by fear nor hope. When a man is responsive to neither of these emotions, he hasn't any organic disease. Therefore, I asked him to be seated in my office where I could observe him unknown to himself. For twenty minutes he gazed fixedly into space. At the end of this time I put my hand on his shoulder and said, "Old top, tell me about it." With a startled look, he said that no one but himself suspected the cause of his trouble, that a trusted brother had cheated him out of his property. He did not want his own family to find it out.

Treatment.—I advised him to leave his environment for a period of months. In addition bromides with nux vomica were given regularly. He was advised to eat anything that looked good, particularly cheese and iron wedges.

After-course.—He returned in four months having regained his weight. He has worked at his trade some ten years now, without any impairment of health.

Comment.—When depression accompanies cancer it is accompanied by fear. Depression with indifference does not associate with organic disease, at least not within the realm of the operating surgeon.

CASE 4.—A housewife aged forty-four came to the hospital because of digestive disturbance and loss of weight.

History.—When about twenty-four years old she had digestive disturbance for several years. She had epigastric pain relieved by vomiting, sometimes by taking food. Never vomited any blood. The pain was localized in the pit of the stomach, but sometimes it extended through to the back, particularly when severe. For a number of years following the birth of her only child eighteen years ago she had pelvic trouble, and wore a pessary with some re-

lief for a number of years. Four months ago she began to have epigastric pains again, some nausea, but no vomiting. She lost her appetite and began to lose weight rapidly, having lost some thirty pounds in the four months since the trouble began.

Examination.—The patient looks worn but not cachectic. The abdomen is somewhat rigid in the upper part and there is a general sensitiveness. There is nearly an entire absence of hydrochloric acid after an Ewald meal. The blood picture was not materially changed.

Diagnosis.—Because of the marked epigastric disturbance and loss of weight, together with the change of the gastric secretions, a diagnosis of carcinoma of the stomach was made. The history seemed to indicate that the patient had had a gastric ulcer twenty years before and this was looked on as the basis for the present complaint.

Operation.—The stomach is free from any lesion. The gall bladder is as large as a hen's egg and is completely filled by a single gallstone. The wall of the gall bladder is firmly fixed to the stone. Hence a cholecystectomy was done.

Pathology.—The stone was composed of a dirty, brick-colored, brittle mass, to the surface of which the wall of the gall bladder was intimately united. There was an entire loss of mucosa and but the fibrous layer remained.

After-course.—Recovery was uneventful and the digestive disturbance disappeared and her former weight was restored. She remained well for ten years, but now suffers from diabetes.

Comment.—There had never been a typical gall bladder attack. At the time of operation the bladder wall was incompetent to react either by contraction or inflammation. What brought about the sudden gastric disturbance I am unable to say. There is no clue to the duration of the gallstone. Whether this had any relation to her trouble in early life is a speculation.

Case 5.—A retired farmer aged sixty came to the hospital because of stomach trouble.

History.—The patient's general health has always been good, save that he had typhoid at twenty-one. He smoked a great many cigarettes every day until 1895. He then quit for twelve years. His usual weight was 190 pounds, at forty years of age he gained 50 pounds in three years, reaching a weight of 250. He then got short of breath, but was not incapacitated. As far back as he can remem-

ber he has had to get up once each night to urinate. He has smoked two or three cigars a day until his present illness. A year and a half ago his appetite became poor, his food did not digest and he had diarrhea for several months, but no vomiting. He went to Texas last winter, where he improved. After four months he began to feel worse again. The diarrhea recurred, he could not eat, and he became very weak. At this time spots appeared on his wrists. He has no pain to speak of, but there is numbness in his fingers and toes.

Examination.—The patient is very pale, but not particularly emaciated, the tongue is smooth, glazed and pale. There is a systolic murmur and some emphysema. The abdomen is soft, flat, and flabby. There is some edema of the scrotum and there are a number of purpuric spots on each wrist. Red blood count 1,200,000; Hg. 35 to 40 per cent Tallquist; the smear shows poikilocytosis and anocytosis.

Diagnosis.—Though this man was sent in with a diagnosis of carcinoma of the stomach, he clearly is suffering from pernicious anemia, though the digestive disturbances have dominated. In some instances when the digestive symptoms are pronounced early in the disease before the blood picture becomes typical, the anemia may be regarded as secondary to the gastric symptoms. Therefore, there was some cause for the early confusion in the diagnosis. When such symptoms are great, malaise in proportion to the loss of weight, diarrhea, purpuric spots and possibly a history of remissions should have caused his physician to suspect pernicious anemia. The fact that he recuperated while in Texas should have been enough to exclude malignancy.

Treatment.—Cacodylate of soda hypodermically.

After-course.—The patient returned home and died after a few months.

Comment.—I once did an autopsy on a body in which a very good surgeon had done a gastroenterostomy. None of the signs of pernicious anemia were lacking, though the blood picture indicated a secondary anemia. I also once did an autopsy in a case in which the author of a book on hematology had made the diagnosis of pernicious anemia. There was a carcinoma of the cardia.

CASE 6.—A widow of fifty-six came because of epigastric distress and loss of weight.

History.—The patient has had stomach trouble for thirty years. Ten years ago she had several hemorrhages. She had pains in the re-

gion of the stomach at this time, which was relieved by taking food. These pains ceased after the hemorrhages started. Two years ago the pains began again, and one year ago she had several hemorrhages which compelled her to remain in bed for a number of months. She has free intervals from pain, lasting four or five days. The pains are most apt to occur in the afternoons and at night between midnight and three in the morning. Recently she has vomited her food, but no blood. She now takes two to three grains of morphine for the pain. She weighs 76 pounds. Her regular weight is 110 pounds.

Examination.—Abdominal examination is negative save for some muscular rigidity in the hepatic region. Stomach analysis fails to show blood. The x-ray shows a considerable portion of the test mass after seven hours.

Diagnosis.—Pyloric stenosis from peptic ulcer. The history of pain relieved by eating, its occurrence in the early morning hours, the vomiting of blood with the subsequent vomiting of food, and the x-ray findings are distinctive.

Treatment.—Gastroenterostomy. A mass occupies the pyloric region, reducing the lumen of that gut to the size of a lead pencil.

After-course.—The recovery was rapid and in a year had just exactly doubled her weight. Her appetite is good, and she eats everything.

Comment.—The pronounced increase in weight is interesting, and shows well the benefits of gastroenterostomy when it is really indicated.

CASE 7.—A matron of forty-nine came to the hospital because of digestive disturbance.

History.—The patient has had fair health. Menopause occurred thirteen years ago. She has been disturbed for a number of years by indigestion, backache, and dragging pain in the pelvis when much on her feet. Present complaint began four months ago. It began with a chill followed by a rise of temperature of 104° . For some days following it would be below normal in the morning and reach a high degree at night. Following the onset of the fever she had pain in the stomach and right breast which extended to the back below the shoulder blade. Soon after the onset she was yellow and had intense itching of the skin. This lasted several weeks and subsided quite rapidly. The urine at times looked bloody. Since the disappearance of the jaundice she has been weak, and while the

appetite has been good, she has not increased in strength. She has lost about 20 pounds in weight. She has not been jaundiced since the beginning of the attack.

Examination.—Heart and lungs are normal. A mass appears in the right upper quadrant which slips beneath the fingers on deep respiration, similar mass palpable to the left but less plainly. These evidently are the kidneys. There is deep tenderness over the gall bladder region, no muscular rigidity, no tumor palpable and the liver is not enlarged. There is some jaundice apparent in the sclera and the skin is sallow and inelastic. There is a trace of bile in the urine.

Diagnosis.—Chill, jaundice and subhepatic pain indicates infection of the hepatic ducts, likely obstruction from stone. The pain in the chest in the beginning likely was a referred pain, since there was pain in the back at the lower angle of the scapula present at the same time.

Treatment.—The gall bladder was the size of a thumb, no stones were palpable, but the walls seemed thickened. The common duct was thickened to the size of a finger. No stone was palpable. The pancreas was not changed. The common duct was opened and explored. The little finger was barely admitted. No stone was felt. A probe detected a foreign body below the reach of the finger, evidently within the wall of the duodenum. This portion of the gut, therefore, was mobilized according to the method of Kocher. This accomplished, a stone the size of a hazelnut kernel could be palpated. The duct was opened over the stone, which made its extraction easy. After it had been removed, the papilla was seen to be widely open, making an opening which communicated with the interior of the gut. The opening into the duct was carefully closed. The gall bladder was removed. Drainage was placed down near the duct.

Pathology.—The gall bladder wall was much thickened. The slide showed edematous fibrous tissue with abundant round-celled infiltration.

After-course.—The after-course was uneventful until the fourth day when the temperature began to rise and the pulse became rapid. The patient died on the tenth day of paraduodenal sepsis.

Comment.—This history is typical of duct stone. The fact that there was no stone palpable, of course, did not make me hesitate

to open into the duct. The history and the thickened duct left only the question of size and location of the stone to be determined. With the stone located in the duodenal portion of the common duct, the raising up of the gut was anatomically the logical procedure, but physiologically it was foolhardy. By so opening an area of loose fibrous tissue, it was exposed to the infection of the duodenum. The gut here having no peritoneal covering does not readily unite, and being poor in blood supply, can offer but little resistance. The better way would have been to remove the stone by the transduodenal route. By this route no connective tissue space would have been opened and a surface of the gut covered by peritoneum would have been available for suture, insuring union. Should bacteria have escaped, as is almost unavoidable, the peritoneal surface would have been much better able to care for it than the loose retroperitoneal tissue.

CASE 8.—A man aged sixty came to the hospital because of epigastric disturbance and loss of weight.

History.—This patient had typhoid fever at twenty-seven. He has never had any stomach trouble even during the many years he was a traveling salesman, eating and sleeping when and where he could. His present illness dates back to one year ago. The first thing noted was epigastric soreness and pressure and a feeling of fatigue constantly present. There is not a real pain, but a soreness. It is present almost all of the time. It gets worse almost immediately upon eating. A large drink of water gives a sensation of increasing pressure. He eats almost everything and no particular foods aggravate or relieve it. He has never taken anything to relieve it. The soreness extends around the rib margin on the right side and is often felt in the back. He never vomits after eating and is never nauseated. Bowels are obstinately constipated, would go three or four days without a bowel movement if he did not take cathartic. Never noticed blood in the stool, or tarry stools. His appetite has always been good. He has trouble starting the urine, there being a dribbling at first. He seldom arises at night to urinate. Has lost about 26 pounds of weight in the last year.

Examination.—The abdomen is soft and compressible without tenderness save in the upper abdomen and here at no definite point. There is not the resistance of a carcinoma or of a gallstone attack.

The motility is normal and the emptying time not delayed. Laboratory findings were negative.

Diagnosis.—The history of a rather definite beginning digestive disorder with a distinct loss in weight, and especially the marked loss of strength, suggested carcinoma. The disposition of the pain to radiate around the right costal margin suggested gall bladder disease. The prostate is moderately enlarged, smooth, and not tender. Exploration alone seems likely to give a definite diagnosis.

Treatment.—No disease of the stomach was found. The gall bladder was thickened and of a deep blue color. It was drained.

After-course.—The gall bladder drained for three weeks and the opening promptly healed after the drainage was removed. He was much improved and regained his former weight. He returned two years later complaining of soreness across the epigastrium and in the region of the gall bladder. There has been pain in the back during the past week. He has difficulty in retaining his urine and gets up several times a night. His bowels are regular and the urine is negative. He improved on antacids. He returned again in six months with renewed epigastric distress and more pronounced difficulty in retaining his urine. He retains his normal weight. He reappears from time to time and is relieved by the same means.

Comment.—This is rather a typical case of cholecystitis without stone. The temporary improvement from drainage with disposition to recurrence is characteristic. A cholecystectomy should have been done. This shows again that a patient with gall bladder symptoms without stone should have his gall bladder removed. He has with it a gradually enlarging prostate. As time goes on he likely will change from incontinence to retention and the catheter or prostatectomy.

CASE 9.—A matron aged sixty entered the hospital because of **epigastric disturbance and indigestion.**

History.—Beginning ten years ago the patient had gas and eructations after meals. Seven years ago she had an attack of acute epigastric pain which radiated along the right costal margin. She was completely prostrated for an hour or two, but after that the trouble was all gone without leaving any tenderness. She had several attacks during the few years following, but they ceased four years ago, but her present symptoms appeared. She now has epigastric disturbances and causes herself to vomit in order to relieve

the epigastric distress. The material produced is watery, very sour, and contains mucus, but no blood and no undigested food. Her appetite is poor and the bowels constipated.

Examination.—There is some deep tenderness over the gall bladder region, but otherwise the examination is negative.

Diagnosis.—The severe epigastric pain radiating along the costal margin and after a period of exhaustion ending in a sense of complete well-being is typical of gall bladder colic without infection. Later there is evidence of cholecystitis but no colic. Cases with such a history—typical cramps followed by cholecystitis or digestive disturbances—are candidates for removal rather than drainage of the gall bladder.

Treatment.—The gall bladder contains many stones and the cystic duct and the common duct were thickened. The common duct was explored and the cystic duct ligated near the common duct and the gall bladder removed in the usual way. A simple tube was placed in the common duct opening.

Pathology.—The gall bladder walls are thickened and show the usual cellular changes.

After-course.—She recovered from the operation but after a month complained of epigastric burning. This increased in the succeeding month, at the end of which time jaundice appeared. This increased until it became very intense. Four months later she was operated by a surgeon in a distant city who reports that the terminal portion of the common duct seemed completely obliterated and he united the hepatic duct to the duodenum. At this time a marked nephritis developed and she died.

Comment.—Evidently the common duct was not injured by the ligature or jaundice would have appeared at once. Besides, the artery and cystic duct were ligated separately so that the exact structures ligated could be seen. Perhaps an inflammation set up which caused the obliteration of the duct said to be present. I have never encountered such a condition and am unable to visualize a pathologic process that could bring it about. I have overlooked stones, and have removed quite a few left by other operators which produced jaundice, but never have I seen an obliteration of the duct. Whether the exploration of the common duct had anything to do with it, I do not know.

CASE 10.—A lumberman aged seventy came because of epigastric disturbance and loss of weight.

History.—Except for rheumatism, he has always enjoyed good health. Two months ago he awoke one morning at 3 A. M. with a gnawing pain in the epigastrium. He was chilled for an hour, and a fever of 103° followed. He drank a large amount of warm water and vomited freely. He felt better after this. After a few days he ate a heavy New England boiled dinner, but soon vomited everything he had eaten. Observing some dietary discretion, he gradually improved, but in ten days the attack was renewed more severe than the first. The chills and fever abated, but he grew weak, vomiting at times, and he had some chilliness. He lost some 40 pounds. He was able to be up at short intervals only. The bowels move with laxatives.

Examination.—The patient presents the hulk of a once large powerful man. The tongue is heavily coated. There is a marked jaundice, the stool is clay colored and the urine contains much bile and a few casts. There is no abdominal distention or rigidity anywhere. His heart is widely dilated and intermittent and there was some aortic regurgitation. The pulse is slow and full.

Diagnosis.—The great loss of weight at once suggests malignancy, but the rise of temperature has no place in carcinoma. Furthermore, when a carcinomatous patient once vomits, he never again attacks a New England boiled dinner. The subsequent jaundice is of too sudden origin to belong to a malignancy. On the other hand, the fever and vomiting and jaundice correspond to a common duct obstruction. The physical findings give little evidence. There is no evidence of gall bladder stone, but the usual association of the two makes it wise to predict their concomitant existence. The lack of sensitiveness over the hepatic triangle makes it questionable whether there is any stone in the gall bladder, or, if so, that the stones are embedded, since there has been no colic. Pancreatic disease can be excluded because of the slow pulse and absence of distention. The patient is as easily diagnosed as his disease. The loss in weight finds expression in an enfeebled circulatory system. The initial chill suggests an infection which endangers the patient from an ascending infection whether he be operated on or not. If an attempt be made to drain the common duct, to the danger of sending the ascending infection on its way must be added the danger of the operation itself, notably hemor-

rhage, either immediately following the operation or secondary hemorrhage a week or more later. The less one can do and yet rid the patient of his intoxication, the better.

Treatment.—Drainage of the gall bladder under local anesthesia was advised, but rejected. He desired a general anesthetic which I feared to use.

After-course.—After trying a "cure" for three weeks he was operated upon by another surgeon who removed a number of stones, none, I understand, from the common duct. He died a few days after the operation.

Comment.—The problem as to what treatment to advise may well give us pause. A once overfed man who has become feeble and emaciated is an undesirable risk at best. A large, vigorous body, always well fed, droops quickly when deprived of the daily nourishment. Impending feebleness was marked by feeble, distant, diffuse apex beat. I am reluctant to give such patients a general anesthetic. By draining the gall bladder under local anesthesia and securing a drainage I had hoped to render him bile-free and thus secure a favorable condition for a curative operation. Aside from the immediate danger from the operation, there are other considerations. It has been my misfortune to see patients with this association of symptoms develop an ascending cholecystitis following a radical operation such as opening the common duct or removing the gall bladder. I have not had this misfortune when I confined my efforts to the timid act of draining the gall bladder under local anesthesia.

CASE 11.—A widow aged forty-four came because of pain in the stomach, eructation of gas, and general weakness.

History.—Her trouble began two years ago. She first had a feeling of heat in the epigastrium running up under the sternum and followed by vomiting. She says she has had slight attacks for a period of twenty-five years, but they only lasted a short time each summer until two years ago when they became persistent. A year ago she began to have severe pains in the stomach after eating. They began immediately after eating or even before the meal was finished. She does not vomit often, but when she does, it is slimy, never dark colored, and it usually relieves the stomach. Up to two years ago she weighed 165 pounds. She now weighs about 115. Almost every meal is followed by pain. She has a great deal of gas in the stomach, chiefly in the afternoon and evening. She has grown very

weak in the last two years. Appetite very poor. Bowels very much constipated. She had her last period two years ago but now every two or three weeks she has a yellowish vaginal discharge. She has had ten children, the youngest five years old.

Examination.—The patient is obviously much emaciated. The abdomen is soft, except in the epigastric triangle where the muscles are rigid and she complains of sensitiveness on pressure. There is no tumor palpable. The x-ray shows no filling defects and the emptying time is little if at all delayed. There is some delay in the excursion through the colon. There is some pain in the right renal triangle.

Diagnosis.—The pain immediately after eating, relieved by vomiting, suggests an ulcer. The great loss of weight without pyloric obstruction makes it likely that the ulcer is cancerous. Slimy vomitus without obstruction usually means malignancy. If such is the case, it may be early enough to make operative removal possible. The urinary findings suggest a possible pyelitis.

Treatment.—The patient refused operation. Urinary antiseptics and antacids with diet were prescribed.

After-course.—She returned four months later stating that she felt much better. It was discovered, however, that she had lost an additional 15 pounds despite the fact that she felt better. The examination failed to show any new findings. She was advised to submit to exploration or nothing. She returned in two years and stated that she had tried internal treatment elsewhere, and receiving no benefit, she submitted to operation. A competent surgeon declared an inoperable malignancy to be present. Examination at this time showed a nodular mass in the midline. She had lost still an additional 15 pounds in weight, weighing 85 pounds, just half her normal weight.

Comment.—It is possible that at the time she was first examined she was just developing a malignancy on a preexisting ulcer. I have never yet to my knowledge succeeded in curing a definite carcinoma of the stomach. A number from whom I have removed tumors believed to be malignant have remained well after operation, but after reexamination in the light of greater experience I doubt whether any of them were really malignant. This patient seemed to be in an early stage, possibly she might have been cured. Possibly she might have consented to operation, had she not been given antacids which apparently gave her some relief.

WITHOUT PAIN

When there is marked disturbances of nutrition without pain, the surgeon meets his most difficult task. Here, more than in any other field, he must lean on his colleagues, for the condition implies a physiologic disturbance, without an anatomic basis in the surgical sense. History is often of little help and unless the surgeon is able to demonstrate a definite anatomic lesion, as a tumor, he will do well to retire in favor of the internist. The attempt to hypothecate a diagnosis from the history leads to much needless "exploration."

CASE 1.—A farmer aged fifty-eight came to the hospital because he had vomited blood.

History.—He never had any stomach trouble until the present attack began, which was two months ago. After feeling slightly nauseated all day he vomited his supper. He did not notice the character of the vomitus. He was still nauseated when he went to bed. He vomited again during the night and this time he noticed that there was blood in the vomitus. He vomited blood at intervals all night, clots as large as walnuts being expelled. Since this attack he has not vomited, but has had an aching pain in the region of the stomach, which comes on periodically and has no reference to meals. He has lost about 30 pounds since February and his appetite has been rather poor. He has an aversion to meats.

Examination.—The skin is inelastic and sallow, general evidence of loss of weight. The lower part of the abdomen is soft, but above the umbilicus the muscles are somewhat fixed and there is a tenderness on deep pressure. Because of the recent hemorrhage no gastric analysis was made. There are 11,800 leucocytes. There is no tumor or splenic enlargement and no fluid in the abdomen.

Diagnosis.—There being no evidence of hepatic cirrhosis, some sort of ulcer must be responsible. Since he was well up to the time of the hematemesis, ulcer would seem most likely. His color is not that of secondary anemia but of cachexia. The loss of weight likewise suggests malignancy as does the dislike for meats. The location of malignant growth which bleeds early before there are general symptoms is likely to be located at the cardia. There has been no difficulty in swallowing so that there is no tangible evidence in fixing the location.

Treatment.—He was given antacids and ulcer diet.

After-course.—Emaciation and weakness progressed, and when he came back for examination, a nodular mass could be felt in the epigastrium. He died in three months.

Comment.—The interest in this case lies in the fact that the first symptom of which the patient took cognizance was hematemesis, though there had been a growing aversion to meats before this time. The question is as to what should have been the line of treatment at his first examination. If a patient has lost weight from a carcinoma without there being obstruction, the patient can rarely be operated successfully. As a matter of fact, the operative cure of gastric cancer is pretty much a delusion. The cases cured are usually indurated ulcers. This has been my experience.

CASE 2.—A retired farmer aged eighty-three came to the hospital because of difficulty in swallowing.

History.—He has had trouble in swallowing for several years. It is only during the past few months that the difficulty has been pronounced. He complains that the difficulty is in swallowing, but that once it is down, it stays there. Recently he has been having severe headaches, and for ten days there has been marked swelling of the hands and feet. His general health has always been good; he has never had any digestive disturbances.

Examination.—He is an emaciated man with swollen hands and feet, with puffy face, and apprehensive look. His abdomen is retracted and hard. The apex is wide out of its position and diffuse, the pulse feeble but excited. The aortic second sound is accentuated. The urine contains both albumin and sugar and many pus cells. The x-ray shows the esophagus enormously dilated, a long fine line separating it from the stomach.

Diagnosis.—The x-ray shows the constriction to be at the cardia while from the history one would have expected it to be high up. The general state, edema, severe headaches, and urinary findings show him to be but little removed from a uremic state.

Treatment.—Expectant. His general condition did not seem to admit of a gastrostomy even under local anesthesia.

After-course.—He died of starvation after three weeks.

Autopsy.—There was a narrow constriction 3 inches long between the esophagus and stomach (Fig. 339). There were no metastases or

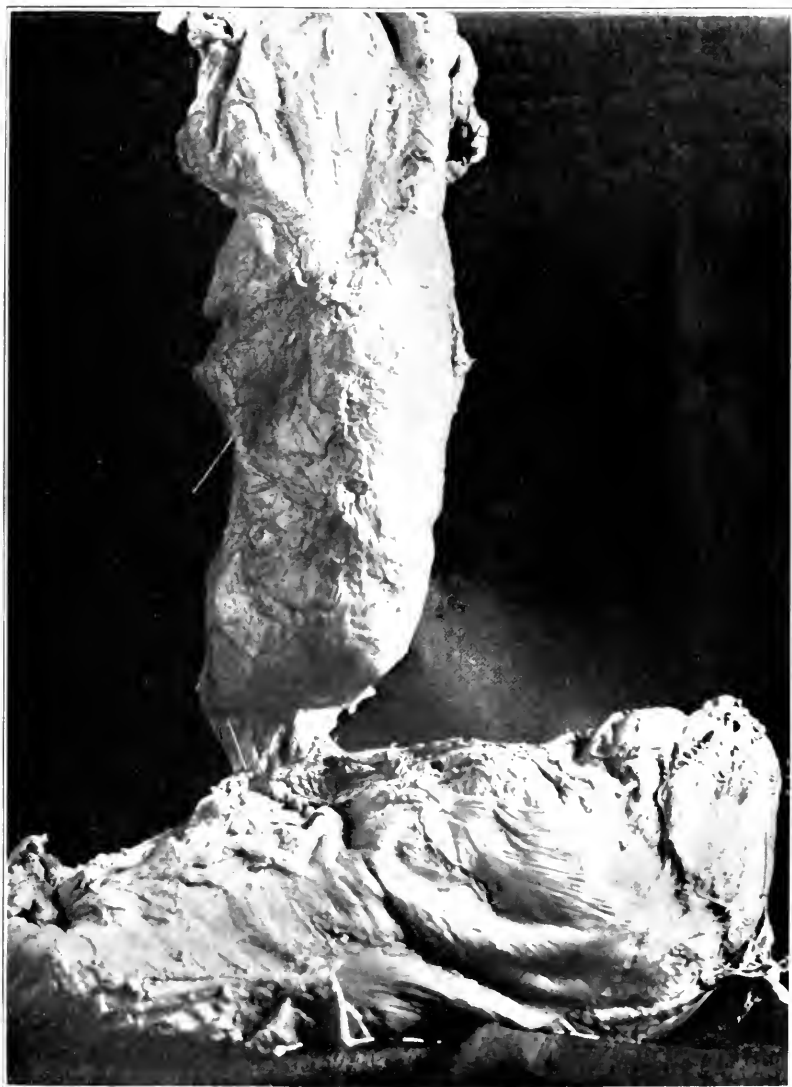

Fig. 339.—Esophagus and stomach showing site of stricture, the greatly dilated esophagus and the marked dilatation of the cardiac end of the stomach.

any invasion into the surrounding tissue. The area of constriction was not hard but leathery. When the esophagus and stomach were opened, no new growth was found at the point of constriction, but



Fig. 340.—Interior of the esophagus showing the atheromatous degeneration of the mucosa.

the mucosa is corrugated longitudinally. The mucosa of the esophagus was studded with yellowish-white plaques slightly raised above the surface (Fig. 340). The slide shows them to be made up of

desquamating cells which do not stain (Fig. 341). There is no reaction in the submucosa or the muscularis. The stomach is thin and the mucosa atrophied. The kidneys showed but little change, save the cortex of the left one was markedly thinned in some areas. Other organs showed no changes.

Comment.—He should have had a gastrostomy for which he begged, even in the face of the hazardous risk. From the findings of the autopsy it is impossible to determine the duration of the esophageal dilatation. The history of some dysphagia for two years is not definite, and it is only the last few months that the trouble

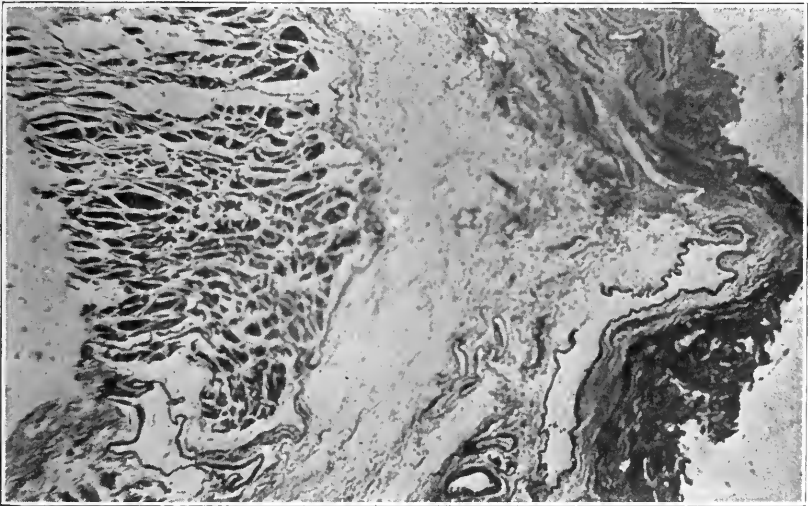


Fig. 341.—Slide of an atheromatous plaque of the preceding. The piling up of the structureless cells are shown at the left of the cut.

seemed to be definite. Considering the age of the patient and the general findings, no disease other than carcinoma was seriously considered. If time is a factor, evidently the dilatation must have existed for a long time. The plaques are supposed to be formed from prolonged irritation from retained contents, and since these are not found in dilatation from ordinary causes, the duration in this case must have been great. Likely other factors than long duration play a part. There was no history of any trouble in early life.

CASE 3.—I was called to see a farmer of fifty-eight because of difficulty in swallowing.

History.—He has always had good health, until four months ago when he noticed that he had difficulty in swallowing. Until then he was not conscious of any impairment in health. At first the dysphagia was periodic and he seemed to be free in the interval. Later it was constantly present for solids, while fluids passed unhindered. He discovered at this time that the spells when food apparently swallowed would regurgitate increased in frequency and became greater in amount. He now began to lose weight rapidly. For the last week he has been able to swallow but little food and even water was regurgitated.

Examination.—The patient was collapsed rather than emaciated. There were no physical signs and only the acetone breath corroborated the all too definite history of acute starvation. Because of the clear indication, the esophagus was not sounded.

Diagnosis.—The gradually progressive difficulty in swallowing makes the presence of a carcinoma in the region of the cardia certain. The chief indication is to secure a means of feeding him.

Treatment.—Gastrostomy by the Frank method under local anesthesia was done. The operation was done at a private home and our armamentarium failed to include a scalpel. The entire operation was done with a pair of scissors “gastrostomy without a knife” as my assistant facetiously remarked.

Pathology.—He presented a hard, annular ring at the terminal end of the esophagus. It seemed to occlude the opening entirely.

After-course.—The patient did not improve greatly following the operation, and he died in twelve weeks of gradually increasing inanition.

Comment.—The intermittent obstruction in the beginning of the disease may be accounted for by spasm attending the ulcerous process. The gradual tightening of the ring made the intermittent process organic and permanent. I have noticed that when starvation is allowed to proceed to an extreme degree response to increased nutrition is not prompt.

CASE 4.—A merchant aged thirty-three came to the hospital because of a mass in the lower right side of the abdomen, and a general feeling of weakness.

History.—The patient has felt perfectly well until nine months ago, at which time he commenced to have slight feeling of discomfort

and fullness in the epigastrium. This distress usually came on one to two hours after eating and lasted for about thirty minutes. Belching seemed to relieve the distress. Vegetables, except potatoes, seemed to increase the trouble; no other foods seemed to have this effect. During the first two months of his illness he had three severe vomiting attacks after eating heavy meals, but has had no nausea or vomiting since. Later the distress in epigastric region seemed to improve, but he began to have a feeling of fullness and distress in the lower part of his abdomen which has gradually grown worse since the onset. This distress generally comes on two to four hours after eating and comes by periodic attacks, lasting only from a few seconds to three or four minutes. During these attacks there are rolling movements and rumbling in the region above noted. The bowels usually move twice each day. For the past week the bowels have been loose, moving three times each day. He has noticed no blood, mucus or dark discoloration of the stools. Three months ago he felt a small mass which was not tender in the right lower part of the abdomen in front of the hip bone. His doctor diagnosed a hernia and advised its repair. Since this time it has gradually increased. Since the onset of his sickness he has gradually become weaker and has lost 16 pounds during the nine months. There is no urinary frequency. Last December he began having rather frequent night sweats, not profuse, but marked. He would sweat while sleeping in a cold room. He had them up to three days ago. He has never had any fever that he was aware of, no cough. Other than the present trouble the patient has had good health save for several attacks of tonsillitis. He had scarlet fever at thirteen years of age. No history of tuberculosis. He has been married three months.

Examination.—General appearance indicates a loss of weight. He is tall and looks emaciated. The skin is pale but mucous surfaces are red. Does not look acutely ill. Pupils equal and react to light and accommodation. Teeth good. Tonsils small. Thyroid not palpable. Chest rather long and of the flat type and gives the appearance of some atrophy of the scapular muscles. There is no muscle spasticity, and the expansion is fairly good on both sides. Right apex posteriorly not quite so resonant as left. Resonance

over rest of the chest is normal. There is bronchovascular breathing with accentuation of the expiratory sound over the right apex, but no rales. The spoken and whispered voice are a little more

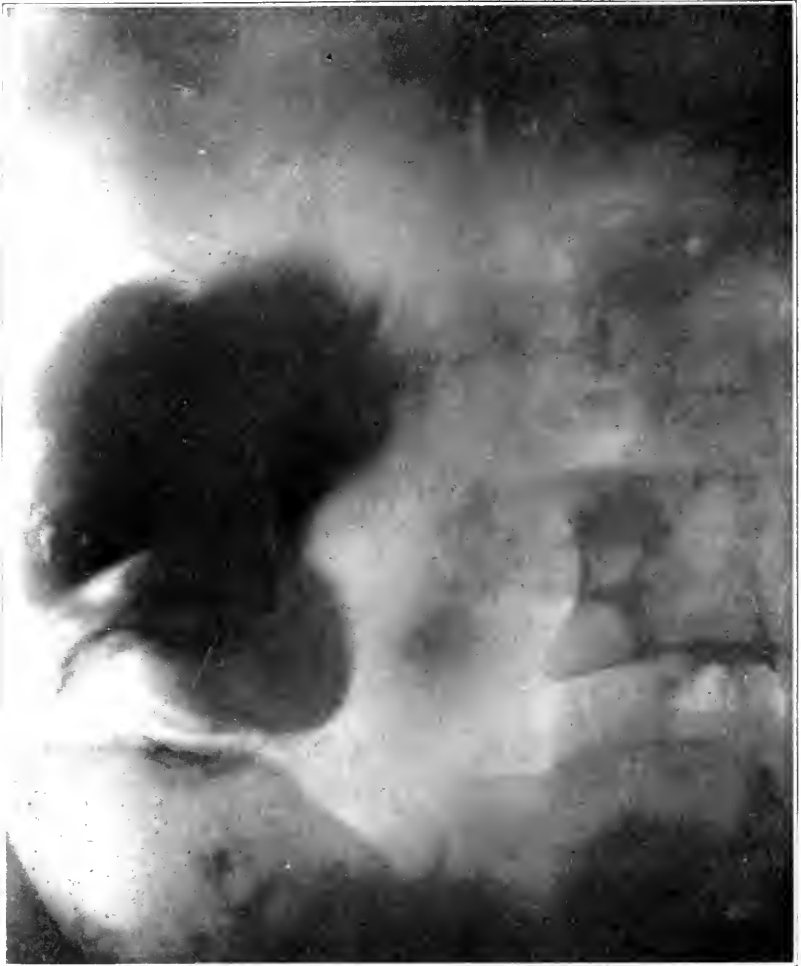

Fig. 342.—X-ray picture of the filling defect in sarcoma of the ileocecal junction. The bulbous enlargement below is a cast of the lumen of the tumor. The fine line joining it below represents the narrowed portion of the tumor.

marked over the right apex. The heart is not enlarged and there are no murmurs, thrills, or friction rub. Apex beat in 5th interspace. Heart dullness extends from right sternal border to 8 cm. to left

of left sternal border. The abdomen is slightly distended, but there is no visible paristalsis. In the right lower quadrant of the abdomen there is a rounded protrusion. It feels about the size of a baseball. It is smooth in outline with low bosselations. It may be moved around to a limited degree in any direction. It moves slightly with change of position. It is tender to rather firm pressure. There is no venous enlargement in the skin over it. Rectal examination is negative. External genitals negative. W.b.c. 8,800; R.b.c. 4,554,000; Hg. 85. Urine negative.

X-ray of gastrointestinal tract. Plate A. 8:50 A. M. Five minutes after taking barium meal stomach is filled, no distinct pyloric opening or duodenal cap. No filling defect. Plate B. 2:45 P. M. Stomach is empty. Barium in small intestines and a rather large mass in the cecal region, but there is an appearance of a filling in the lower end of the cecum (Fig. 342). There is a fine line of barium which approaches the cecal mass in a curved line from the lateral side. Plate C. 8 P. M. Barium out of cecum, all in descending colon and rectum. Plate D. 8 A. M. Barium practically all in sigmoid and rectum but there is a small amount in the cecal region which shows as a narrow line far lateralward.

Diagnosis.—The onset suggested a gastric lesion. Without cause the scenes shifted to the iliac region. When such a change occurs, one thinks of an appendiceal lesion as the primary factor. Indurated gut walls and an adherent omentum sometimes form tumors of considerable size and this must be kept in mind as one of the possibilities. Usually such tumors are more fixed and sensitive. The slowness of the process, together with the build of the patient and his suspicious right apex, suggest an ileocecal tuberculosis. These two are usually more fixed than this mass is. Its large size and mobility resembles more closely a sarcoma than anything else. Sarcomas do not cause narrowing of the lumen, however, and this point alone is sufficient to exclude this disorder. The mass has the firm consistency of a carcinoma and the lumen is narrowed as in carcinoma, but these are usually not so large in so short a time and the patient is only thirty-three years of age. However, carcinomas, when they do occur in young persons, are apt to grow rapidly and to form large tumors. Tuberculosis fits best with his general physical state, carcinoma with the physical appearance of the tumor itself, and induration about a subacutely inflamed appendix

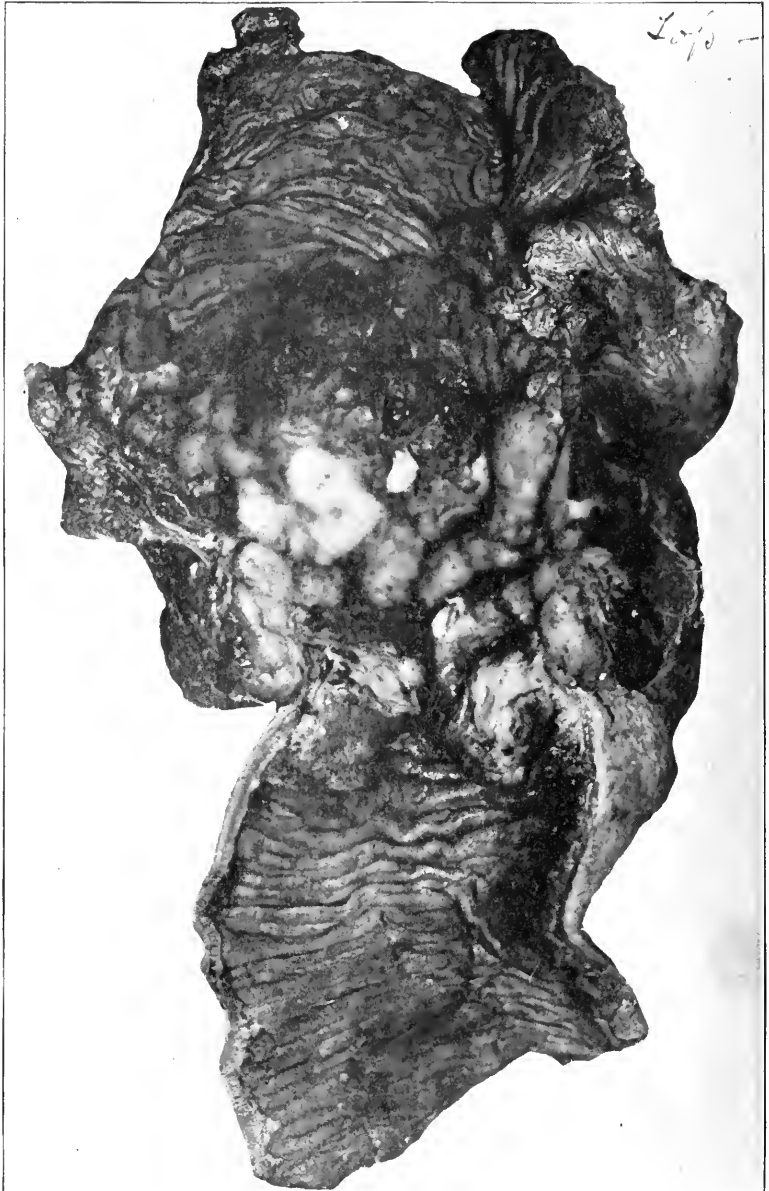


Fig. 343.—Sarcoma of the ileocecal junction.

accounts best for the introductory epigastric disturbances. At any rate, the patient needs to be rid of it and we shall see what we shall see.

Treatment.—A long right rectus incision disclosed a large, annular tumor involving the lower end of the cecum. The sigmoid colon was adherent to the mesial surface of the tumor at this point. The terminal ileum was distended to above the size of a normal colon. There were enlarged lymph nodes in the meson in the region of the tumor. The whole mass was resected, taking about ten inches of ileum and half of the ascending colon going above into the normal

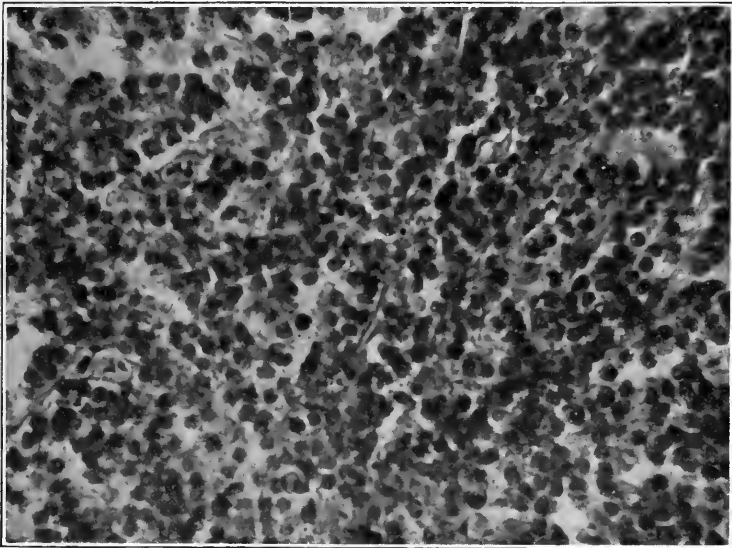


Fig. 344.—Sarcoma of the ileocecal region.

cecum. A lateral anastomosis was done. The wound was completely closed, but a rubber and gauze drain were put in a new opening through the flank.

Pathology.—The specimen is irregularly globular in form and measures 4 x 4½ inches. The much dilated ileum enters the lower border and the remains of the colon emerge from its upper border (Fig. 343). There is an irregular channel in the center measuring two inches in diameter except at the lower end where it is pronouncedly narrowed by bosselated outgrowths from the main tumor.

The upper termination also is surrounded by a collar of projecting tumor but the lumen is not narrowed by it. The cut surface is pinkish white near the border and whitish pink near the lumen. The mass is everywhere firm to the touch. The slides show a general cellular formation of small mononuclear cells interspersed by a limited amount of connective tissue (Fig. 344). The lymph nodes in addition show a few large lymphoid cells. The lymph glands show the same structure as the primary tumor.

After-course.—The patient stood the operation well. He went back to his room with a pulse of 120 of good force. Six hundred c.c. of normal saline was given by hypodermoclysis. At 6 P. M. there was no evidence of shock, no nausea or vomiting. Temperature 100°, pulse 88, good and regular. General condition of the patient good. The second postoperative day found the patient in good condition, temperature 100.2°, pulse 84. Small amount of abdominal pain. Some pain in the back. No gastric disturbance. Following this, recovery was uneventful.

Comment.—The peculiarities of growth made this apparently an exception to the rule that sarcomas of the gut do not cause narrowing of the lumen. In view of the history, together with the type of tumor it seems fair to assume that the disease was originally an indurative appendicitis and that the cells once a part of a sluggish inflammation went on to malignant development. The borderline between certain chronic inflammations, characterized by enormous round-celled infiltration, and sarcoma is exceedingly close.

CASE 5.—A farmer aged thirty-two came to the hospital because of vomiting after taking either solids or liquids.

History.—At the age of six the patient got some lye in his mouth. His parents did not think it got past his throat. They are not very certain as to the amount taken. Six years ago he suddenly began vomiting every time he ate or drank. He would vomit only a portion of the food or drink. The vomiting never occurred during a meal but always followed immediately after. He noticed from the first that with each meal he had to take a great quantity of water in order to make swallowing easy. At first he took three glasses of water with his meals and this amount gradually increased until two weeks ago it required six glasses. The vomitus was always just the food or drink that he had recently taken. There was never any blood in the vomitus. During the first few months of his trouble

he would get a hiccough whenever he swallowed food. This was relieved by drinking much water. He never had any pain. He weighed 145 pounds when the trouble commenced. He began to lose weight almost immediately, going to 118 pounds. He held this until the last two weeks. He now weighs 97 pounds. A year after the trouble began he had a tonsillectomy done, thinking it would give relief, but without results. On Feb. 3, 1920, he contracted influenza. He did not have a very serious attack. Temperature has been normal now about eight days. Immediately after his fever went down, he began to vomit every time he took anything by mouth. There is no pain or distress accompanying the vomiting. He vomited water as well as solid food. He was much weakened by the influenza and has not gained any strength since. Hunger has never been great. He does not think he is any weaker than when he first recovered from influenza. He has no cough, shortness of breath or swelling of the feet. His bowels have not moved without an enema since Feb. 3, 1920.

Examination.—Patient is emaciated and has the appearance and action of being sick and weak. Head and neck negative. Chest is sunken above and below clavicle, equal on both sides. Normal resonance over both lungs. No rales or increased vocal fremitus. Heart not enlarged. No murmurs or friction rubs. Dullness from midsternal line to $7\frac{1}{2}$ em. to left. Apex beat in 5th interspace. Abdomen scaphoid; no palpable masses, no area of tenderness. Abdominal organs not palpable. Reflexes all exaggerated. No Babinski.

X-ray plate taken of the esophagus immediately after the patient took xii ounces of barium mixture (all he could take) showed an enormously dilated esophagus, the barium stopping at the cardia. The cardiac end of the shadow tapered to a point. Plate of the stomach region taken immediately after the above showed no barium in the stomach. Eighteen hours later more barium was given and after vomiting three hours, another plate was taken of the stomach. This showed only a trace of barium in the stomach. Plate taken six hours after the second barium meal showed most of the barium in esophagus, a little in stomach and small intestine. It also shows the barium given the day before in the cecum and ascending colon. (Fig. 345).

Diagnosis.—Cicatricial stenosis of cardia.

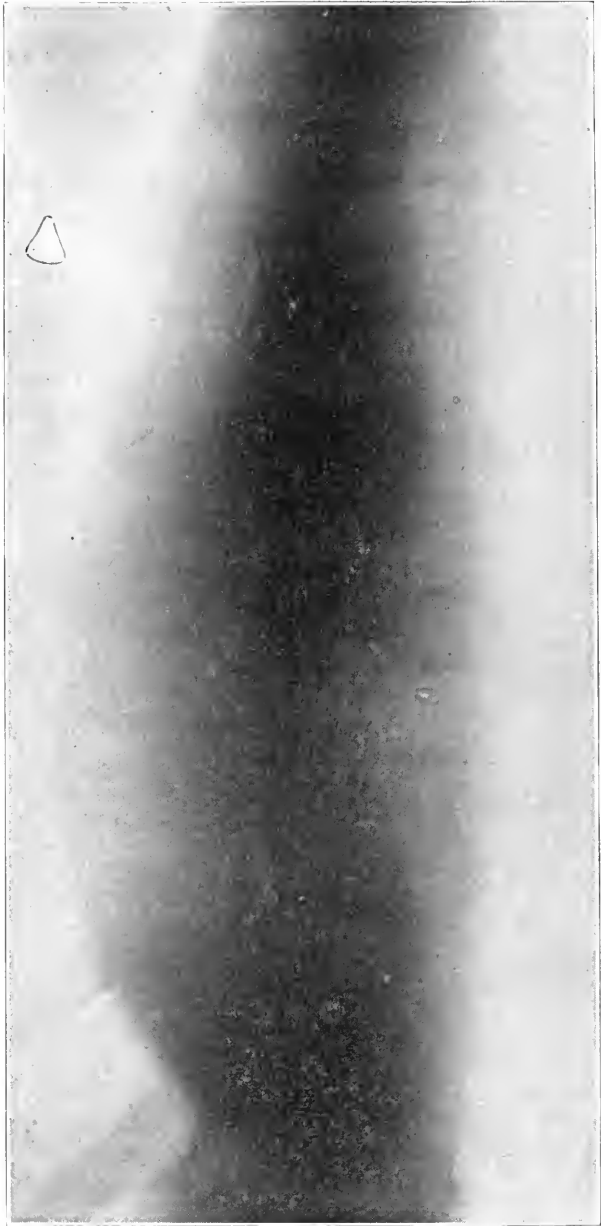

Fig. 345.—Esophageal dilatation due to a cicatrix at the cardia.

Treatment.—Feb. 22, 1920: Complains of much pain in left ear, no rise of temperature. Piece of impacted wax filling entire canal removed. Pain relieved by hot olive oil in ear and hot-water bottle to outside. Tympanum inflamed but not bulging.

Feb. 23, 1920: Plummer esophageal dilator inserted with smallest tip. Followed by stomach tube which entered the stomach. Swallowing ability not much improved.

Feb. 24, 1920, 1 P. M.: Patient complained of much pain in side. Temperature 100, abdomen sunken. Complains of pain in right lower abdomen. No tenderness, no rigidity, cecum palpable. Patient's mouth very dry. He thinks the pain is due to having had no bowel movement. Hot-water bottle to side. Plummer esophageal dilator inserted. Could not be positive it went into stomach. Patient felt so weak and pulses became so rapid that this was not followed by stomach tube. Temperature up to 101.6° after insertion of dilator. Pulse 80. There is tenderness over left mastoid. Ice cap applied.

Feb. 25, 1920: Patient feels better. Tenderness over mastoid gone. Still vomits after eating. Vomitus stained pink as with fresh blood. Dilator with smallest tip inserted and followed by stomach tube. Lavage given. Temperature went to 101°, pulse 96.

Feb. 26, 1920, 11 A. M.: Temperature normal. Had vomited while taking breakfast. Dilator passed with next to smallest tip. Followed by stomach tube. Stomach lavage of sodium bicarbonate given. Some water left in stomach. One glass of milk with two beaten eggs given through stomach tube. No vomiting after lavage until 3:50 P. M. Fluid watery and mucus blood stained. Temperature two hours later up to 100°. Complains of pain in right side along costal margin. Lungs show a little decreased resonance and a few rales in lower right lobes.

Feb. 27, 1920: Pain along costal margin on right side. Dilator inserted in esophagus. It caused emesis of a great deal of food previously taken. Had had no breakfast. Examination of lungs shows a marked dullness to percussion over lower right lobe with tubular breathing over this area.

Pneumonia involving lower right lobe. In the evening the temperature was 102°, pulse 96. Pain in right lower chest much better. Patient feels better.

Feb. 28, 1920: Lungs examined. Tubular breathing in right lower lobe gone, somewhat more resonant to percussion. Tubular

breathing changed to faintly heard breath sounds and rales. Higher up inside the right scapula is an area of dullness with distinct tubular breathing. Left lung normal. Patient still has some pain in the right chest, but feels better generally. Has vomited less today on taking food and water.

Feb. 29, 1920: Temperature 99.2° in the evening. Has been no higher today. Can take water in small amounts and keep it down.

March 1, 1920, 10 A. M.: Stomach tube passed but would not enter the stomach until a dilator had been previously introduced. Eight ounces of water, sixteen ounces of milk and two raw eggs were put into the stomach through tube. The milk and eggs were retained all day. There was general abdominal pain all day; temperature subnormal. Lungs clearing up.

March 2, 1920: Dilator and stomach tube passed. Two eggs and two glasses of milk left in stomach.

March 3, 1920: Tried to pass dilator with next to smallest tip but was unable to get it into stomach. Stomach tube also failed to enter stomach. Used smallest tip on dilator and it entered, after which stomach tube entered. Two eggs and sixteen ounces of milk left in stomach.

March 4, 1920: Dilator used, using all the tips successively, from smallest to the largest. Stomach tube then introduced and milk, sixteen ounces with two eggs and water left in the stomach.

March 5, 1920: All sized dilator tips put through esophagus. Stomach tube introduced and usual milk and eggs given. Patient has been drinking milk at intervals all day and retains it. Is able to get liquids into stomach but not solids.

March 6, 1920: Dilator largest size used. Eggs and milk with two ounces of sugar given through stomach tube.

Same treatment the three days following. Always kept down food given by gavage, but vomited solids taken at meal time.

After-course.—His condition remained good and then there has been a rapid restoration of weight. He still has at times some difficulty in swallowing, and the barium meal shows that there is a wide dilatation of the esophagus persisting.

Comment.—It is likely that the dilatation of the esophagus will persist and that the use of a sound will be necessary from time to time to maintain the patulency of the cardiac orifice. The history of the taking of lye in childhood is the only factor which makes a differentiation from spasmodic stricture possible.

LOSS OF WEIGHT

Nutritional disturbances usually imply loss of weight. Digestive complaints, however, are borne without any loss of weight. When no loss of weight is present the disturbance is physiologic and does not involve anatomic change. Since no anatomic change is present they are usually not surgical.

CASE 1.—A retired merchant aged seventy-one comes complaining of nausea and loss of strength.

History.—He has not been well for a year. Before that time he had bleeding piles for a number of years. The first symptom was sickness of the stomach. Sudden movements increase the nausea. He has no appetite but eats well when once started, and there is no disturbance from it. He vomits occasionally, several times a little blood. He is up part of the time but is kept in bed most of the time by his weakness. He weighs 140, this being nearly his normal weight. His feet have been swelling, particularly after being up for some time.

Examination.—The face is puffy, the skin yellow, inelastic, the pulse is 80, but soft. The tongue is moist and coated, and the edge is taken up by a pronounced angioma. The abdomen is soft and flabby, nowhere is there sensitiveness. He has an appetite for pickles and eats cheese with impunity. Urine 1.011, negative. Hg 40, R.b.c. 2,000,000, poikilocytosis and anicocytosis, no nucleated reds.

Diagnosis.—The progressive weakness, the blood findings, the absence of loss of weight, all speak for pernicious anemia. The soft heart sounds, the flabby abdomen, the relatively good digestion, all speak against carcinoma. The vomiting of blood might be ascribed to either carcinoma or pernicious anemia. The history is not clear. There may have been no blood. The several observers disagree.

Treatment.—He was given arsenic. He improved somewhat on this, going to 60 per cent Hg and R.b.c. 3,000,000.

After-course.—With the improved blood state the hemorrhoids again became troublesome, causing a considerable loss of blood. These were ligated. Following this he improved rapidly and apparently regained his health. He has remained so three years.

Comment.—This was apparently a grave secondary anemia. Two important factors were overlooked in the diagnosis; no nucleated red cells were found and the color index was not materially altered, being neither raised as in pernicious anemia nor lowered as in secondary

anemia. The improvement has persisted too long to ascribe it to a free interval in pernicious anemia. These are ticklish jobs for the surgeon. Pernicious patients are disposed to bleed and not infrequently a trivial operation is followed in a few days by the death of the patient. I have seen this disaster follow the pulling of a tooth, a gastroenterostomy under the impression that a vomiting of blood was from an ulcer, and once from ligation of supposititious hemorrhoids—all these happily in the hands of colleagues.

CASE 2.—A widow of forty-seven came to the hospital because of persistent vomiting.

History.—She began twelve weeks ago to have pain in the epigastrium. This pain was dull, heavy in character. It was not transmitted. It was made somewhat worse by taking food. It remained the same all day and at night it was not so severe. The abdomen bloated a great deal at times after this pain came on. The pain disappeared in four weeks and she has not had it since. The first vomiting spell came on five weeks after the onset of the pain. This usually followed the ingestion of food. There was no regularity about the vomiting. She would often go several days without it. The vomitus is sour. It looks like liquid stool quite often, but it never has a fecal odor and it is often a clear acid water. The vomiting is getting more pronounced. It is especially bad the last few days. She now vomits everything she eats. Previous to this attack of stomach trouble she had felt very well. The only previous gastric trouble she has ever had was gas after eating; this was several years ago. Her appetite continued good up to three weeks of the beginning of the trouble. Even now she can eat except for the fear of bloating and vomiting afterward. The bowels have been constipated ever since the trouble began. She has lost about 25 pounds of weight in the last three months. She has no other trouble and has always been well.

Examination.—She is a small, very emaciated woman but does not have the appearance of being severely ill. The abdomen is scaphoid. The stomach is filled with gas and its outline can be plainly seen through the abdominal wall. It extends to just below the umbilicus. Peristaltic waves can be readily seen traveling toward the pylorus; often three distinct waves can be seen at one time. There are no points of tenderness. In the right of the median line a little

above the umbilicus is a distinctly palpable tumor. It is freely movable.

Diagnosis.—The presence of a palpable tumor, rapid emaciation, and vomiting suggest a pyloric tumor. The location of the tumor is in harmony with this hypothesis. Whether or not it is an indurated ulcer or a carcinoma can not be determined. The rather definite onset twelve weeks ago is strongly suggestive of malignancy. The past history presents nothing but periods of slight flatulence—certainly not enough to diagnose ulcer. At any rate there is pyloric obstruction and relief is urgently needed. If it is a malignant tumor, as seems most likely, its mobility suggests there may be a possibility of a radical removal.

Treatment.—An incision was made in the midline above the umbilicus. The mass was readily found and delivered. It was a tumor extending from the lesser curvature of the stomach past the pylorus. It was hard and indurated and at the pyloric end there was considerable edema. There were no enlarged lymph nodes. A gastroenterostomy was done posteriorly. The condition of the patient made a resection of the mass an unjustifiable risk.

After-course.—The patient suffered considerably from shock immediately following the operation. The pulse went to 135 and was very weak. Adrenalin chloride m.x was given by hypo and a sodium bicarbonate proctoclysis was started. She made a good recovery from the shock and suffered very little thereafter. She was kept on liquid diet nine days. During this time she suffered a little from gas and nausea and vomiting a little on several successive days. The vomitus was always small in amount and never showed that there was much retention or hemorrhage. After taking soft solids the nausea and vomiting became less, but both would reappear every time she was given a cathartic. These were discontinued and enemas used. She improved markedly in the next few months following, gaining a weight she had never attained before. She refused to return for radical removal of the mass.

Comment.—She was right in refusing to return for removal. The removal of carcinoma of the stomach is a discouraging task. All of my own "cures" were either plain ulcers or conditions in which a positive diagnosis could not be made. The certain cases of malignancy are either all dead or too recent to permit judgment to be passed.

CASE 3.—An insurance agent aged forty came to the hospital because of pain in the stomach, and vomiting.

History.—His trouble began eight years ago. At first he was sick after eating and had to vomit. At that time he worked on a farm but had to give this up on account of his trouble. He had his appendix removed four years ago, but derived no benefit from the operation. He has been obstinately constipated for a number of years. He now sometimes has vomiting spells in which he throws up a green bile. Sometimes he can not retain food, vomiting the food without bile. He lives on toast and eggs. The food he vomits is fresh food, never food eaten a long time before. He sometimes has some pain in the morning. It is more of a gouging feeling than one of real pain. He has taken antacids prescribed by his family doctor. His stomach trouble was helped by this but a pain came in his back opposite his previous stomach pain. After taking this medicine for a time the old gnawing pain returned and he began to vomit again. A few nights ago he had a severe stabbing pain which required a hypodermic injection for its relief. Since then he has been much collapsed, being too weak to walk more than a short distance.

Examination.—He has a sallow putty-like skin. The skin is inelastic and there seems to be just enough of it to encase his body. The abdomen is flat, without tympany and without sensitiveness except over the epigastric region which seems sensitive to superficial rather than deep pressure. It is reported that the bismuth meal is still largely retained after seven hours. General examination is without interest.

Diagnosis.—The long history of pain with vomiting after eating followed by vomiting of food and the long retained bismuth meal indicate an ulcer with subsequent contraction. The severe pain at night suggests that an ulcer is still present. The pain so severe as to require a hypodermic is out of place but the patient is hyperesthetic and his doctor unduly sympathetic. The vomiting at once after food indicates an active ulcer rather than a vomiting due to the pyloric stenosis. The relation may be due to a pyloric stenosis. This seems to be so because he obtained temporary relief from antacids. His condition evidently is getting worse and operation is justified.

Treatment.—The stomach is not dilated, neither is there an ulcer.

An area of dilated veins medial to the pylorus was regarded as evidence of an ulcer within. A posterior gastroenterostomy was done.

After-course.—The operative recovery was without incident. While in bed he had a severe abdominal pain. It was clearly lancing in character and morphine was given. It was noticed that his pupils were unequal and reacted to light not at all. No reflexes could be elicited. A neurologist confirmed the diagnosis of tabes.

Comment.—The prolonged history was misleading. It was afterward learned that a previous examination had shown a normal motility and emptying time. This not being in harmony with his doctor's findings it was ignored in the report given me. It was an error to belittle the intensity of his night attack of pain. It was also an error to do a gastroenterostomy in the absence of definite evidence of pyloric obstruction. The findings of a petechial area in the walls of the stomach is poor salvage when one needs a real ulcer to justify his operative activities.

Case 4.—A matron of thirty-eight came because of distress in the lower abdomen.

History.—The patient complains of nausea, obstinate constipation, and pelvic fullness. She has had three children, the youngest of which is five years of age. She had an abortion at two months nineteen years ago and miscarriage at five months thirteen years ago. Her periods have usually been regular. She had a severe pain in the right side three years ago. Since then she has had pains in this side at the period. Six months ago she had a severe uterine flow for three weeks. Since then she has been regular lasting a week or more with pain in the right side. Her last period was a month before the attack. It was scant and lasted only a few days. Eight weeks ago she had a sudden severe pain in the right side. It seemed as if everything would fall out. There was rectal tenesmus and she passed urine frequently with much pain. A physician gave five doses of morphine. The pulse was rapid and at the time there was half a degree of fever. She had morphine for two weeks. After this time the pain subsided. Nausea, obstinate constipation, and pelvic distress continued. She vomits much of the food taken.

Examination.—Despite the two months of alleged nausea and vomiting the patient is well nourished and save for acetonuria presents

no evidence of starvation. Chest and upper abdomen are negative. There is marked tenderness above and to the right of the pubes. There is marked muscular rigidity here. Bimanual examination shows the uterus pushed to the left by a boggy mass to the right of the uterus. This is markedly tender but no fluctuation could be made out. The uterus is fixed, and attempts to move it cause pain. The mass is high up opposite the cornu of the uterus. The culdesac is somewhat thickened but presents no masses. The temperature since she is in the hospital varies from 97° to 100°, the pulse from 90 to 110.

Diagnosis.—The sudden severe pain coming on at the time menstruation was due, after a previously atypical menstruation, at once suggests tubal abortion. The pain was severe, the pulse rapid with little temperature disturbance. The persistent pain requiring or at least receiving morphine for two weeks is longer than the usual duration of tubal abortion pains last. After two months there is muscular rigidity and tenderness to deep pressure. The absence of the mass in the pelvis usually formed by a blood clot is absent though the sensations complained of lead one to expect it. The boggy mass high up feels like an unruptured tube but it is unusually sensitive. The whole picture seems best to fit a partial tubal rupture probably in the broad ligament.

Treatment.—The somewhat thickened cord passes over a rounded mass the size of an orange. In seeking to determine the outline of this it ruptured at its base allowing a cupful of pus to escape. The pus is thick, greenish-white, of sickening odor. The sac of the abscess was easily shelled out and removed. The sigmoid was adherent to the left side of the uterus covering the ovary and tube on this side. The right tube was attached to the bottom of the culdesac by a clubbed extremity. All these structures were allowed to remain attached.

Pathology.—The wall of the sac is made up of a homogeneous whitish tissue and is lined by a corrugated membrane.

Comment.—Subsequent inquiry revealed that there had been no temperature observations in the early course of the disease. After two weeks when she came into the hands of the second physician the temperature ranged a little above normal. Pain from irritation of the blood clot often persists for weeks. In these cases there is a mass going to the bottom of the culdesac. I explained the per-

sistence of pain in a mass situated high up as being due to a clot surrounding a probable ruptured tube. This is where the error occurred. Whether a luteal cyst first became infected at the beginning of the attack or whether there has been an abscess before and it partly ruptured at this time I do not know. I suspect she had a mild tubal trouble since three years ago and at the time of the present attack a luteal cyst became infected. If this is true there must have been some escape from the tube for there no doubt was some general pelvic peritonitis.

CASE 5.—A matron of thirty-four came to the hospital because of vomiting.

History.—She has had fairly good health until six months ago when she suddenly began to have stomach trouble, with vomiting. There has not been much pain but there has been much gas. She has lost some weight, the husband estimates the amount at fifteen pounds. Recently she vomits as soon as food is eaten, there being almost immediate regurgitation. She never has noticed any blood.

Examination.—She is tall, thin and narrow chested, but appears well nourished. Her Hg is 80 per cent with 4,000,000 reds and 6,600 whites. The urine is negative. Physical examination is negative. The stomach tube stops when the cardia is reached. A 20 F. bougie passes after a little manipulation. After being allowed to remain in position a few minutes it comes out easily. The x-ray showed a dilated esophagus, with a pointing like a cigar of the esophageal barium mass. A wide interval separates this from the mass contained in the stomach. (Fig. 346.)

Diagnosis.—The sudden onset, the good general nutrition after six months, and the absence of any positive signs pointing to organic disease warrants a diagnosis of functional stricture. The fact that the bougie comes out easily after being in place for a time confirmed this. The feel of dense resistance as it is passed, however, gives one a feeling of apprehension.

Treatment.—Attempts were made to increase the size of bogie passed but without result. Atropine was given but still without result. The patient lost little weight, but only liquid nourishment could be taken.

After-course.—Treatment being without result, attempts were made to find an organic cause. Rather suddenly an ascites developed which gave one the impression of a tuberculous exudation.

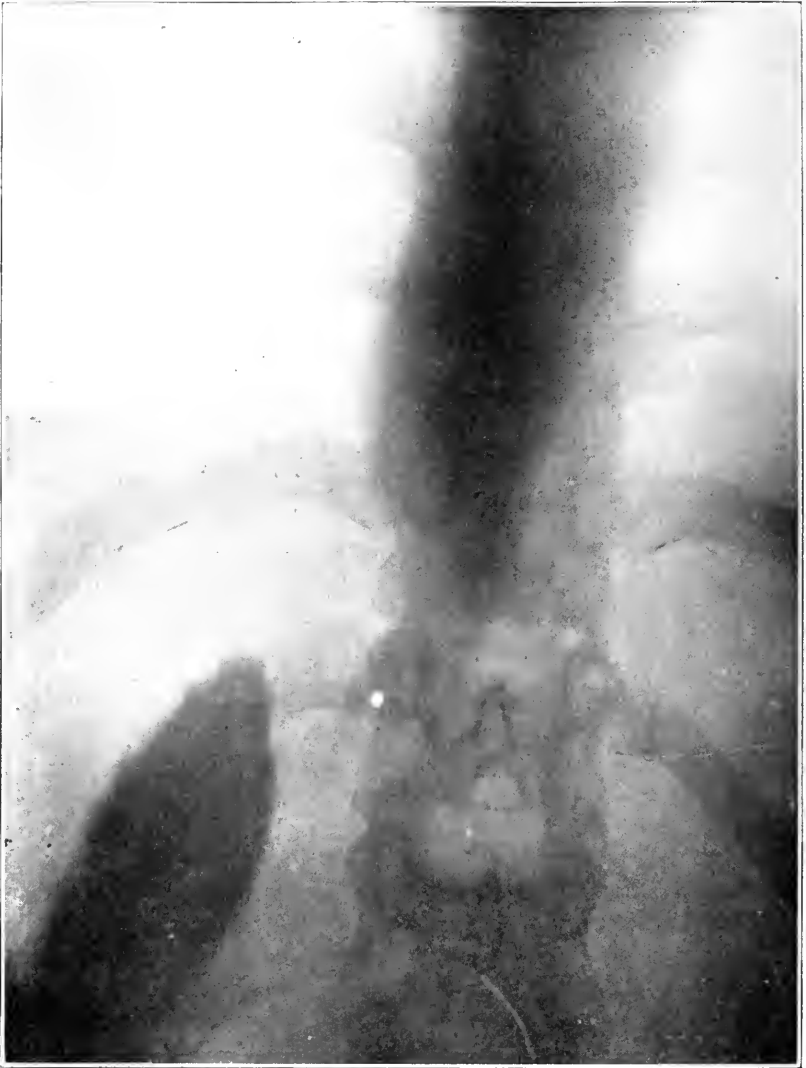

Fig. 346.—Carcinoma of the esophagus.

The abdomen was tapped and the fluid found to be 1022. The exudate must, therefore, come from a peritoneal irritation, though nothing was found on microscopic examination save a few lymphocytes. After aspiration a roughened mass could be felt within the

abdomen. It was suspected that the mass might be a tuberculous conglomerate of intestines or omentum. The esophageal narrowing could not be explained on such a basis, however. A Wassermann was made and the report was positive. Antisymphilitics were given without result. Gradually the esophageal stricture narrowed until fluids were expelled and the patient died of inanition. Autopsy showed carcinoma of the cardia and multiple carcinosis of the peritoneum.

Comment.—It was disconcerting to have such a sudden onset in so young a person. The Wassermann was misleading even if correct. The need for a gastroenterostomy did not appear until the mass appeared in the epigastrium and it was then deemed to be too late.

JAUNDICE

Jaundice with bile in the urine usually implies occlusion of the common duct either due to stone or new growth. In diagnosis the important points are to determine its actual presence, if they must be obtained from the history, whether continuous and progressive, as in malignancy, or interrupted, as in stone and inflammation.

CASE 1.—A matron of thirty-seven was brought to the hospital because of intense jaundice.

History.—The patient has had four children, the youngest three weeks old. During the last labor she had five eclamptic convulsions. These ceased after delivery. On the third postpuerperal day she had a violent pain in the right upper abdomen. Following this she became intensely jaundiced.

Examination.—The patient is intensely jaundiced. There is deep tenderness in the hepatic triangle and the lower border of the liver is palpable. The urine is 1.020 sp.gr., contains albumin and many casts and much epithelium and bile.

Diagnosis.—The nephritis is what one would expect after puerperal eclampsia. The jaundice causes one to think of a possible yellow atrophy of the liver, but the history of onset with pain is reassuring, and besides, gallstone manifestations in the puerperal period are vastly more common. The palpable edge of the liver likewise is comforting as is the deep tenderness. The relation of the jaundice to the nephritis can not be determined because careful urine analyses are lacking. Since jaundice in itself may produce

a nephritis or at least bring to the fore an existing one it seems highly desirable that the kidneys be relieved of the additional burden. Since a general anesthetic would add to the burden of the kidney, this seems best avoided.

Treatment.—The gall bladder was drained under local anesthesia.

After-course.—The jaundice rapidly cleared. The urine cleared slowly and not for six months was it deemed safe to give an anesthetic for the purpose of freeing the common duct of its stone. She recovered from this operation also and now six years later has no evidence of kidney disease and no disturbance of the gall bladder.

Comment.—The drainage of the gall bladder no doubt did much good by relieving the kidneys of the additional burden of eliminating the bile. The duct was not opened at this time because of the fear of after-hemorrhage. The second operation was not undertaken under local anesthesia because, having once operated in this region, adhesions most likely would be present that would make the operation difficult.

CASE 2.—A matron of sixty entered the hospital because of jaundice and progressive weakness.

History.—For six months she has been feeling weak without pain or known cause and for three months has been becoming progressively more yellow. The bowels have been growing more sluggish. There has been no pain. The patient said she could hear the stones rattle when she turned from side to side.

Examination.—The patient is intensely yellow and shows signs of emaciation. She has a tumor the size of a fetal head to the right of the rectus at the level of the umbilicus. It is smooth, firm and elastic. The edge of the liver can be felt above the tumor. It moves with the liver in respiration and can not be moved independently of the liver but is movable from side to side. It can not be made to recede under the ribs or present in the flanks. The colon lies lateral to it.

Diagnosis.—The association of the tumor with jaundice stamps the tumor as being derived from or involving the gall tract. This supposition is confirmed by its movement with the liver and not independent of it. On inspection one would think from the location that the tumor was renal, but the inability to make it appear in the flank excluded this supposition. The nature of the obstruction is not apparent. The patient believes she can feel stones when

she turns in bed. Such things are on record. The progressive emaciation and loss of strength antedating a slowly developing jaundice speak strongly for malignancy, however. Since the gall bladder is so enormously dilated the cystic duct must be involved or invaded. If this is the case a drainage of the gall bladder will give no relief, for if the cystic duct is obstructed by the stone it can not get out of a drainage opening into the gall bladder. But the reasoning may be wrong, hence exploration seems advisable.

Treatment.—An incision over the height of the tumor was made under local anesthesia. The tumor was aspirated and an opening made, when many stones were found. These were removed and the edge of the opening stitched into the abdominal incision. The anterior superior spine could be palpated when the finger was in the gall bladder. The gall bladder is much thickened, but a definite tumor could not be felt, either in the gall bladder or elsewhere. A section of the gall bladder was removed for examination.

Pathology.—Slides made from the diagnostic section removed showed typical carcinoma.

After-course.—Bile did not drain. The patient lived, however, eight months after the operation.

Comment.—The presence of jaundice was the welcome clue in this case. Without it the low position of the tumor and the large size would have made a tumor of other origin very probable. The fact that it could not be made to appear in the loin would have been the only point to differentiate it from a kidney tumor. The presence of a carcinomatous infiltration of the wall makes it likely that the tumor was primary in the gall bladder. Had the patient not been so enfeebled, a cholecystectomy would have been indicated. I have learned that she improved markedly for a few months after operation. The fact that jaundice continued makes it likely that the common duct likewise was involved and consequently inoperable.

CASE 3.—A merchant aged thirty-four requested a consultation because he had an intense jaundice.

History.—Three weeks ago he became feverish and had nausea which he regarded as due to an indigestion. He says he could feel a lump in his stomach just below the ribs. Any food he ate caused distress. After several days he noticed that the urine was very dark red in color. On disrobing he noticed that his skin was yellow. His family physician after a week or more called in a consultant. Bile was

reported in the urine, but the blood was negative to all tests including the Wassermann. A diagnosis of obstructive jaundice was made and operation advised. There has been no pain at any time. Nothing in the past history was indicative of any definite etiology.

Examination.—The patient is intensely jaundiced. The skin does not indicate any loss of weight. The abdominal walls are lax but not flabby. The urine is heavily loaded with bile, the stools clay-colored. There was a resistance deep in the hepatic triangle, but a definite tumor can not be made out. The edge of the liver is palpable, rounded and a soft protuberance can be indistinctly felt in the region of the gall bladder. Whether it is a part of the liver or a separate mass can not be determined.

Diagnosis.—The rather sudden onset with feverishness and digestive disturbance without pain in a young man speaks strongly for catarrhal jaundice. This is substantiated by the palpable liver and the distended gall bladder if such there be. A duct stone in a young man is uncommon and jaundice is usually preceded by some other evidence of stone and the gall bladder is not palpable. A neoplastic obstruction comes on more gradually, some little time being required before complete obstruction is reached.

Treatment.—He had been taking sodium phosphate and he was allowed to continue. He had some bismuth for the nausea.

After-course.—The nausea improved but the jaundice continued. He had lost some 30 pounds in weight and for a month he continued to lose though his appetite improved. The jaundice deepened. The skin took on a greenish hue and the stools became entirely bile-free. This status continued to eight and finally ten weeks. The duration seemed too long and the jaundice too intense for a catarrhal jaundice. Yet nothing appeared to point to any more definite diagnosis. The internists urged operation but there seemed no clear indication and in the presence of such an intense jaundice operation would not be without danger. At the height of the perplexity he began to have a good appetite and to gain in weight despite the fact that the jaundice had not cleared up. This gain in weight and the improvement was sufficient to exclude malignancy, for once patients go down from jaundice due to a malignant growth they never come up again. After he had regained half his lost weight the jaundice began to disappear. At this time he developed a troublesome cough and he had many large and medium sized rales

in both sides of his chest without any consolidation. At this stage, now three months after the onset of his disease, his family physician returned and developed from the history that the patient had had a chancre fourteen years before. A second Wassermann was made and a 4-plus was found. He was given salvarsan and rapid improvement followed.

Comment.—Evidently a syphilitic mass compressed the common duct. The sudden onset was unusual and the negative Wassermann was confusing. What, if anything, in the picture that would have warranted a persistent search for syphilis does not appear. The Wassermann reaction determinations were made by men of vast experience. Such experiences make agnostics. Jaundice from other causes, as duct stone, or positive carcinoma, not infrequently gives a positive Wassermann reaction even in the absence of syphilis. The long duration and the intensity of the jaundice should have prompted an abandonment of the catarrhal theory and a renewed search for a cause of obstruction. The diagnosis was in fact regarded as unsatisfactory and was returned only for the want of a better one. The return of the appetite and the gain in weight at a time when he was given a series of rounds of calomel was significant, but the importance of this escaped both the internist and myself. There was the negative Wassermann! Whether or not one would have been justified in operating, as I was requested to do, can be answered in the negative. It might have led to earlier diagnosis and might have lessened the disturbance from jaundice, but it would have added an element of risk. Besides, it is not pleasant to open the abdomen and find a syphilitic lesion, as I know from experience. It is still more unpleasant to open an abdomen and mistake the identity of such a lesion, as I also know. Internists should consider the sensibilities of the surgeon to a slight degree before they urge interference in wholly obscure cases. There are ways of determining the temperature of the bath besides throwing the baby in.

CASE 4.—A matron was brought to the hospital because of extreme jaundice.

History.—The patient has three children, the youngest eighteen months old. When she was eighteen years old she had severe pain in the region of the stomach with vomiting. The pains were confined to the epigastric region and did not radiate to the back. The

first attack came on in the night and lasted several hours. She felt badly for a few days following but she had no pain. She was free from pains for several years when another attack occurred with vomiting of mucus and bile but no blood. After the birth of her first child, five years ago, she had much backache, which was partly relieved by a pessary. The last attack of pain occurred five weeks ago. This extended along the right costal margin and was not completely relieved by vomiting. Following this jaundice appeared for the first time.

Examination.—The patient is much emaciated. There is pronounced jaundice. The pulse is 46, the temperature subnormal. The liver is not palpable and there is no tenderness over the gall bladder. The stool is clay colored. The urine is strongly acid and contains much bile. It contains no albumin but a few granular casts.

Diagnosis.—The earlier attacks could not be distinguished from ulcer, but the last attack radiating as it did, together with the jaundice, seemed to implicate the biliary tract as the primary seat of the disease. The great emaciation suggested catarrhal jaundice. My observation has been that patients lose weight more rapidly in catarrhal jaundice than in obstruction from stone.

Treatment.—The gastroduodenal region was free from disease. There were no stones in the gall bladder. The common duct was dilated and opened. There was a free passage into the duodenum.

After-course.—The patient has been free from any symptoms relative to the biliary tract now ten years. She has been, however, a chronic invalid more or less. She has had her cervix and perineum repaired. She is still thin, nervous, and undernourished.

Comment.—From the appearance of the common duct I was of the opinion at that time that there was a duct stone that had but recently escaped through the papilla into the abdomen. It may have been so, but the probabilities are that it was a catarrhal jaundice. At any rate, opening into the common duct in a patient intensely jaundiced surely was tempting the wrath of the gods.

CASE 5.—A widow aged seventy-five came to the hospital because of jaundice and weakness.

History.—She has had six children, all living and well. She has had jaundice at intervals for ten years. The first spell came on after an attack of dysentery which lasted many months. She had

some pain, but not very severe. A year ago during a spell of jaundice her speech began to be muddled. She was delirious part of the time and after recovery had some amnesia. She was able to write, but would repeat phrases often. Since then she has been able to transact business most of the time. She used to have pain in right shoulder blade but none lately. She never had chills but had fever at intervals, mostly when there was jaundice. She has had trouble with gas at times. Four months ago she had another attack of her speech trouble and was a little befuddled for a few days before, but there was no paralysis and no jaundice. She now has pain in the region of the umbilicus. It is not very severe but keeps her awake. She has pain in the front part of her thighs. Her usual weight was 221 but she now weighs 175.

Examination.—The abdomen is not sensitive except in the right upper quadrant on superficial examination and some resistance and marked sensitiveness on deep pressure. The reflexes are a little exaggerated but sensation is normal. Her heart is a little dilated to left, apex a little diffuse, sounds a little muffled. Laboratory findings are negative save a slight general anemia and bile in the urine.

Diagnosis.—The history of dysentery preceding the first attack of jaundice might suggest a metastatic abscess, but apparently the jaundice came simultaneously with the dysentery. Most likely the gall bladder was the cause of the diarrhea. The so-called dysenteric attack seems to have been nothing more than a diarrhea. There was neither mucus, blood, nor tenesmus. The history indicates a common duct involvement without stone in the bladder. Evidently she has had two cerebral hemorrhages. The amnesic attacks seemed to be associated with the onset of the jaundice. It was suggested that relief from the jaundice might prevent recurrence of the cerebral trouble. I refused operation, but after six weeks the patient returned somewhat improved and renewed her request for operation. I was reminded of the popular song, "Who Is Looney Now?"

Treatment.—A drainage of the gall bladder under local anesthesia was done.

After-course.—The wound drained freely for a week, when she had a renewed cerebral hemorrhage and died.

Comment.—The prospect of securing any noteworthy relief was very remote and the operation was done under a grave prognosis. Trying to do anything in a surgical way to prevent cerebral complications of any sort is chasing a rainbow of a pale blue sort, corner side down.

CASE 6.—A matron of fifty-nine came because of jaundice.

History.—About 25 or 27 years ago the patient began having attacks of acute epigastric pain with abdominal rigidity and vomiting. These were relieved only by opiates. In some attacks she was slightly jaundiced and with others she was not. About a year ago her trouble was diagnosed gallstones and carcinoma of the stomach, and she was operated on. No carcinoma of the stomach was found, but the gall bladder was found to be full of stones, and a cholecystectomy was done. Two weeks after the operation while she was still in bed she had an attack of acute epigastric pain with vomiting and muscle rigidity. She did not become jaundiced with this attack although the attack was just like the ones she had previous to the operation. She had these attacks one after another, often every day for a month at a time. During this last winter she became jaundiced and with every attack since would become yellow and clear up between the attacks. She had these attacks at different times up to four months ago when they ceased and did not reappear until this last one. During this free interval her skin cleared up and she ate everything without discomfort. The present attack began ten days ago. She was first nauseated and vomited and the pain started shortly afterwards. The pain was cramp-like and extended across the epigastric region. She has had an attack or two every day since. The jaundice has gradually deepened. At the time of her operation she weighed about 140 pounds. She started to gain four months ago and weighed 160 pounds before the present attack. She had never noticed whether or not the stools were putty-colored.

Examination.—The patient is intensely yellow and has marked tenderness over the hepatic triangle. The urine contains much bile and the stools are clay colored. The temperature is normal, and the pulse ranges at about 100. There is a long, transverse abdominal scar.

Diagnosis.—Common duct obstruction, probably by a stone. This seems probable since she had many attacks of jaundice and from the

history of the operation the common duct was not drained. The intermittent character of the jaundice indicated a stone, near the termination of the common duct capable of acting like a ball valve. Had she not had her gall bladder removed, a simple drainage as a temporary expedient should be seriously considered. Nothing but a drainage of the common duct will be of avail, however, since she has already had her gall bladder removed, and this in view of the fact that she was operated on by a surgeon who, in spite of the history, did not explore the duct, makes one apprehensive of the presence of many adhesions and in consequence an extra formidable operation must be anticipated.

Treatment.—Expectant treatment was followed—sodium phosphate and laxatives.

After-course.—The patient ran a septic temperature from the time she entered the hospital and had from one to two attacks of severe epigastric pain with rigidity which were relieved only by opiates. The jaundice gradually deepened. She vomited during the attacks very often. After ten days the temperature suddenly dropped to normal and remained so and the attacks of pain ceased. The jaundice gradually cleared up, and the patient was dismissed ten days later to go home and recuperate before any operative procedure should be attempted.

The patient returned in three weeks, the jaundice completely gone and the general conditions vastly improved. The operation was now undertaken. A transverse incision was made along the scar of her previous operation. On entering the abdomen all the abdominal viscera in that region were found densely matted together by adhesions. The transverse colon actually was adherent between the edge of the liver and the anterior abdominal wall. After breaking up dense adhesions about the common duct, it was exposed. The duct was carefully palpated throughout its length, but no stone could be felt. The duct itself was the size of the little finger with very dense walls. The duct was opened midway in order that the interior could be better explored. When opened the duct admitted the little finger. A stone was now palpable at the terminal end of the duct. Failing to extract it through the duct, it was removed transduodenally. The opening through the wall of the duodenum was carefully closed with silk. A T-tube was placed in the duct and a gauze drain passed to the bottom of Morrison's pouch.

Pathology.—The stone was a brittle one and was as large as a hickory nut (Fig. 347).

After-course.—A part of the gauze drain was removed on the fourth day, and the remainder on the sixth day. Up to this time there has been very little drainage through the T-tube. There has been a great deal of bile drained through the rubber drain and around the T-tube. On the seventh day there was $\bar{5}$ viii drainage through the T-tube. On the eighth day the drainage looks fecal in character and smells so. The T-tube was removed. The skin around the incision was much irritated. On the eleventh day the rubber drain was removed. The skin was excoriated by duodenal drainage. On the thirteenth day the drainage was much decreased and consisted mostly of bile. Therefore, it is concluded that the duodenal contents came from the opening in the common duct



Fig. 347.—Stone from common duct.

and not from a duodenal fistula coming from the place where the stone was removed from the duodenum. On the twenty-first day the patient went home feeling very well. The wound was healed with the exception of the place where the drainage tube had been. There was still a little drainage of bile. No duodenal drainage occurred. Since then she has been perfectly well.

Comment.—It is my opinion that this was a good job. A logical interpretation of the history indicated that there was a stone in the common duct. It seems incredible, however, that a stone of this size should not have been palpable. The explanation is found in the presence of the pronounced induration of the walls. The difficulties to be encountered by judging the skill of the operator were properly estimated, waiting for an interval of freedom from jaundice before operating was good judgment. Had I waited

longer, the induration would have disappeared and the stone could have been palpated and most likely have been removed through the opening in the duct. Months are required for such ducts to become normal and from her history a renewed attack was to be feared before this would take place. The transduodenal extraction brought with it the danger of a fistula, a distressing and dangerous complication. For a time it seemed that just this had occurred but the rapid closure of the wound makes this unlikely.

CASE 7.—A retired merchant aged seventy-five came because of jaundice and loss of weight.

History.—The patient was always well until three months ago, when he felt sick at the stomach. In six weeks he became jaundiced and the stools became clay colored at first, but later some color returned to the stools without any lessening of the jaundice. At the beginning of the jaundice there was some diarrhea and a certain degree of looseness continued amounting to two or three semi-fluid stools per day. Now he has an aversion to food but the small amount he is able to force down does not cause any great degree of distress. There is intense itching of the skin. Were it not for this, he thinks he would sleep well. He has lost much in weight.

Examination.—He is a large man, who shows evidence of marked emaciation, the skin is loose and inelastic and everywhere shows scratch marks. All exposed surfaces are intensely jaundiced. The upper abdomen is prominent, somewhat tympanitic, but without rigidity. A globular mass the size of an apple is easily palpable in the hepatic triangle. It is smooth, elastic and moves with respiration.

Diagnosis.—Malignant disease of the pyloric region, secondary dilatation of the gall bladder. The rather sudden onset of the jaundice speaks of carcinoma of the pylorus rather than of the pancreas, though the complete occlusion of the common duct is quite in accord with a primary affection of the pancreas.

Treatment.—General expectant treatment with Carlsbad salts and calomine carbolic solution for the skin in the following proportion: Carbolic acid, ʒ iss, Zinc Oxide, Calomine, Starch āā ʒ ii; Glycerine, ʒ i; Aq. ad ʒ xvi.

Subsequent Course.—The lotion above mentioned produced some relief from the intense itching and for a time his nausea was lessened.

After a month he had a large hematemesis, followed in ten days by another and he died in a few days.

Discussion.—The occurrence of the vomiting of blood speaks for the primary lesion being gastric rather than pancreatic. Relief from the jaundice and consequently from the itching may sometimes be secured by a cholecystostomy when the jaundice is due to the obstruction low in the common duct. When the onset is sudden and the primary lesion is gastric this is less likely to be the case than when the onset is slow and progressive before there is much gastric disturbance, indicating a primary affection of the stomach. When the gall bladder is so widely distended the operation is very simply performed under local anesthesia without marked inconvenience to the patient, and when urged to do so I frequently do it, though experience has shown that it more often fails than succeeds.

HEMATEMESIS

When nutritional disturbances are associated with loss of blood it means cancer or ulcer; if the loss of weight is marked it is likely the former.

CASE 1.—I was called to see a married woman aged thirty-four because of a continued fever following childbirth.

History.—She had her fifth child five weeks ago. At the fifth day postpartum she began to have fever. Two days following she had an eruption which the family doctor diagnosed smallpox. The fever continued after the eruption disappeared. A surgeon was called but found nothing of a surgical nature that could be made responsible for the fever. The fever has remained the same since the last consultation two weeks ago. It varies from 100° to 102.5° and the pulse from 90 to 110, the respiration about 20. She has no appetite but suffers no pain.

Examination.—The patient does not seem seriously sick, but is pale and anemic. The lungs show no abnormalities. The abdomen is soft and there are no points of sensitiveness. The uterus shows a normal rate of involution, is in position and is movable. To the right of the uterus continuous with the body of the ischium is a mass nearly as large as an egg. It is very hard and is not sensitive to pressure. The left side is unaffected.

Diagnosis.—Though there are no positive lung findings, a fever which continues for weeks postpartum keeps the lungs under suspicion so long as the fever lasts. The mass in the pelvis is sufficient to account for her difficulties, however. Since it is firm, the prospect for its ultimate resolution is good. The patient must be warned that subsequent abscess formation may take place.

Treatment.—Expectant.

After-course.—The patient improved for a time and the temperature ceased to be taken. After some months she began to have a rise of temperature again and this had persisted some three weeks at the time of the second visit. At this time, four months after the first visit, there was a marked tumefaction above and to the right of the symphysis pubis. It was sensitive to pressure and gave a sense of fluctuation. Bimanual examination showed that the mass extended nearly to the uterus but did not come to the floor of the pelvis. An incision was made from the pubic eminence parallel with Poupart's ligament for 3 inches. An incision made here caused a large quantity of pus to escape. A gauze drain was placed into the bottom of the wound. Healing took place in a month and she has had no further trouble.

Comment.—The dense mass noticed at the first examination was an infiltration of the cellular tissue of that region. This condition is pathognomonic of such cases. It resembles an exostosis when first palpated, so hard it is.

CASE 2.—A housewife aged forty-nine came with a complaint of pain in the lower abdomen and progressive loss of strength.

History.—Eight years ago she began to have attacks of severe pain in the epigastric region. They were so severe that a doctor had to be called. She usually vomited, which brought some relief. In some of the attacks she had some epigastric soreness. These attacks came on every two to six months. The last attack was three months ago. After this one she had fever for several weeks and had a pronounced soreness in the epigastrium and along the costal margin. Two weeks after the beginning of the attack she became jaundiced. This has continued to increase in severity to the present time. Her appetite is indifferent and she bloats easily. The patient has two children aged eleven and seven years, respectively. She flows two or three days every three weeks. She has had pain in the sacral region worse at the menstrual period.

She had some soreness and pain in the region of the stomach. The pains were sometimes relieved and were sometimes made worse by eating. This has troubled her but little for a number of years. She has had pain under the left shoulder blade for many years.

Examination.—The patient is well nourished but is intensely jaundiced. There is sensitiveness in the hepatic region and a tumor is palpable even in quiet respiration. It is hard but relatively smooth and is tender. There is a pronounced retroflexion and a moderate perineal laceration. The urine contains much bile, some albumin and a few casts.

Diagnosis.—The advent of jaundice following repeated attacks of epigastric pains with the subscapular pains leaves but little doubt but that there is trouble in the gall tract. The palpable tumor is evidently of the gall bladder. In spite of its great hardness, its smooth surface and the acute manner of its onset stamps it as inflammatory. There have been no chills, but the persistence of the trouble makes it seem likely that there is a stone in the common duct. The presence of an inflammatory tumor, most likely with adhesions and infection, completes the picture. The sacral pains likely were due to the retroflexion and the epigastric disturbance likely was the first expression of developing gallstones.

Treatment.—The tumor felt on palpation is a mass of thickened omentum which entirely envelops the gall bladder. The shrunken gall bladder was found by exploring the extensive omental adhesions. These were separated sufficiently to expose the fundus of the gall bladder only. This was incised and a quantity of gall stones removed, most of them brittle. There was some pus in the gall bladder. A drain was placed in the gall bladder.

After-course.—The jaundice cleared up within a few weeks and the patient regained her strength. She was advised to return after a few weeks for a common duct drainage.

Second Operation.—There were a few adhesions remaining about the gall bladder. The common duct was readily opened. It was free from stones. The hepatic duct was dilated. The ducts were drained with a tube and the gall bladder removed. She died in two days, without any cause being apparent except a suppression of urine.

Comment.—Evidently the obstruction was due to an inflammatory thickening of the common duct or else the stone had escaped before the second operation. The latter is not probable because the common duct was not dilated as it would have been had the obstruction been due to a recent stone. The operation was not difficult and the resources of the patient were not taxed. As in so many of these cases, the kidneys were made vulnerable by the prolonged jaundice. Had the second operation been omitted, the patient likely would have remained well. There seems to be no certain way of telling in such cases whether there is a common duct stone present or not except to look in and see. To do this requires a dangerous operation. That a shrunken gall bladder is a sign of common duct stone I do not believe. This alone can come from a proliferative inflammation of its walls. If no inflammation exists, the gall bladder does not shrink even if there is a stone in the common duct. It might have been better to have removed the gall bladder at the first operation. I hesitate to break up extensive adhesions when the patient has been jaundiced for a long time.

CASE 3.—A farmer sixty-eight sought consultation because of loss of appetite and strength.

History.—His health has always been good until the advent of the present trouble. For three months he has been losing appetite. There has been no vomiting, but recently he has had some difficulty in swallowing solid foods. He has lost 20 pounds in weight.

Examination.—He is a powerful man, but the skin is loose, non-elastic, and the abdomen flat. There is no tenderness anywhere. The tongue is large, foul, indented, and covered with a heavy fur. Red blood count 3,600,000, white blood count 11,800, Hg 70. Stomach tube stops suddenly 36 cm. from incisor teeth.

Diagnosis.—This presents the classic picture of a well advanced carcinoma of the cardia which has already advanced to the stage of occlusion of the esophagus. The tube was hardly needed to prove its presence. Attended by loss of weight, a moderate general anemia with a slight leucocytosis is sufficient to exclude cicatricial or spasmodic stricture of the esophagus.

Treatment.—The occlusion was not great enough to exclude the taking of all foods, hence a careful dilatation by means of bougies was done in order to put off as long as possible the inevitable gas-

trostomy. Following this treatment deglutition became quite free and treatment was discontinued.

After-course.—A month after the soundings were discontinued the patient began again to experience greater difficulty in swallowing. Gastrostomy was advised, but the patient desired that the sounds be tried again. While the argument was going on, the patient vomited a pint and a half of blood. Following this he was able to swallow more freely and he gained strength again. Vomiting of blood recurred at intervals and he died from hematemesis eight months after he was first examined.

Comment.—The improvement in swallowing following the hemorrhage was due, no doubt, to the breaking down of the tumor. Had I sounded the esophagus just prior to the hemorrhage it would have set the effort in a bad light. Possibly the earlier soundings contributed to its occurrence. Though at the time there was good authority for attempting to keep the esophagus patent by direct mechanical means, I never again repeated the attempt, fearing hemorrhage might be caused by it or occur simultaneously with it. Gastrostomy is safer and surer and does not invite a catastrophe.

CASE 4.—A retired farmer aged sixty-five came because of loss of appetite.

History.—He has never had an illness of any moment until now. This trouble began two months ago. After eating a hearty meal he says that he suddenly lost his appetite, and with the exception of one day, he has not been able to relish food since. He never has had any pain in the region of the stomach. He vomited a small amount at the onset of the trouble but has not vomited since. He has lost twenty pounds in weight and feels weak. He feels nauseated at the sight of food, particularly meats.

Examination.—The patient seems weak and gives one the impression of having lost more in weight than his statement indicates. Hg 85, R.b.c. 4,500,000; W.b.c. 4,500. The urine is negative. There is no free hydrochloric acid, also no lactic. The abdomen is soft and there is no sensitiveness.

Diagnosis.—The sudden onset of loss of appetite with loss of weight and anacidity strongly suggests beginning carcinoma, though there is nothing in the physical examination to support this view, save the lack of acid.

Treatment.—Exploration. An old scar near the pylorus was found, not appreciably narrowing the lumen, however. Nevertheless a gastric enterostomy was done.

After-course.—The patient gained rapidly but showed distinct nervousness requiring bromides. He has weak spells and loses his appetite at times but quickly recovers under the use of bromides.

Comment.—Whether the heavy meal he speaks of gave him an acute gastritis or whether there was some underlying nervous state it is impossible to say. Since he improves under nerve sedatives he probably has some trouble all his own which he has not seen fit to confide. At any rate there is no evidence that the operation had any thing to do with his recovery.

CASE 5.—A farmer aged thirty came because of pain in the right loin.

History.—Four months ago he developed a number of boils on his arms. A few days after these appeared he began to feel tired and weak. He developed a diarrhea which lasted four days. Following this he had a high fever. Because of this he was taken to a hospital where he remained eight weeks. During this entire time he had a general abdominal soreness most marked on the right side. During a part of this time he had night sweats regularly. The last two weeks of his stay in the hospital he had a severe bladder irritation which was attended by frequent and painful urination. He had to be catheterized several times. At the end of this time an abscess was opened beside his rectum. When this was done his bladder trouble ceased. Following this he developed pain in the lower right side of his abdomen. He was unable to straighten his right leg. A swelling now appeared in his back above the hip bone. He had a severe cough for a time but none now. There was no pain or expectoration. His bowels move without aid. His appetite is poor and he has lost much weight.

Examination.—The patient is pale and emaciated. He lies heavily in bed with the right thigh semiflexed. The chest expansion is poor but the two sides are equal. There is some prolongation of the respiratory sound over the right side. At the base there is diminished breathing and slight dullness. There is a faint systolic murmur at the apex which is not transmitted. The abdomen is generally distended and there is tenderness on deep pressure. This is marked in the right groin. The inguinal lymph glands on

the right side are enlarged. There is sensitiveness in the right lumbar region. The movements in the hip joint are free, except extension is limited. An attempt to force extension causes pain in the right groin. The blood pressure is 100-70. R.b.c. 3,000,000; W.b.c. 8,000 to 10,000; Hg 30; pulse 80, temperature 97°, respiration 22. Urine contained a few pus cells.

Diagnosis.—The flexed thigh indicates irritation of the iliopsoas muscle. The general dullness of the right side of the abdomen suggests a collection of pus. The relatively low leucocyte count is accounted for because of the long existence of the trouble. There is no evidence as to the findings in his previous trip to a hospital, but the diagnosis of typhoid fever was made. The sudden onset after the development of boils suggests a metastatic origin, particularly since the lungs seem likewise to have been infected, though this may have come secondary to the abdominal infection. The findings are those seen following a retrocecal appendix, though abscesses from this source usually cause a greater degree of disturbance. Its bulging in the groin seems now to suggest a perinephritic origin, but this phase seems to have been of late development, while it should have been primary if of renal origin. The general findings are those of a retroperitoneal abscess due to an appendix.

Treatment.—An incision was made above the crest of the ilium. An abscess was found extending from above the kidney to Poupart's ligament and into the pelvis to the base of the bladder. In this entire extent it seems to have elevated the peritoneum. A rubber drain was placed into the pelvis and the large cavity packed loosely with gauze.

Pathology.—The pus is yellowish in color and contains a Gram-positive coccus which could not be more closely identified.

After-course.—Relief of pain followed the opening of the abscess and after a day the temperature remained normal. In a week the leg could be fully extended.

Comment.—It is difficult to account for the genesis of this abscess. There is no history that would indicate its origin from any lesion of the gut tract. Retroperitoneal abscesses follow suppurations in other parts of the body not at all infrequently and it may perhaps not be too far fetched to assume that the infection reaches the retroperitoneal lymph glands by way of the lymphatic ducts.

Case 6.—A matron of thirty-six was brought to the hospital because of weakness following labor.

History.—Mother of six children. Following labor she had a protracted fever and an eruption. After six weeks the fever continued in a low form. There was some malaise but the general condition remained fair.

Examination.—The uterus was not fixed firmly and was in position being large, corresponding to one which has not undergone normal involution. At the lateral extremity of the broad ligament there was a dense indurated area of almost bony hardness. This mass seemed fixed to the body of the ischium as though it were a tumor going out from the bone itself. (Fig. 348).

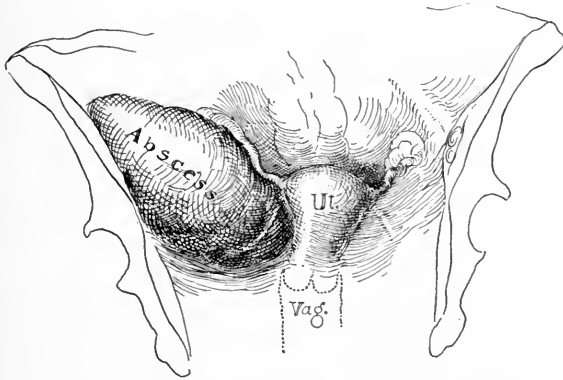


Fig. 348.—Large broad ligament abscess pointing both in the vagina and over Poupart's ligament.

Diagnosis.—Postpartum infection in the broad ligament.

Treatment.—Expectant. General measures to promote nutrition.

Subsequent Course.—Condition remained the same for a number of months. At the expiration of this time a mass appeared to the right of the pubes and temperature began to ascend. Bimanual examination showed a mass lying lateral to the bladder pointing to the surface above the medial termination of Poupart's ligament. Fluctuation could be made out. The mass was incised above Poupart's under local anesthesia without removing the patient from the bed. Recovery was rapid following this drainage.

Comment.—The question of the propriety of vaginal drainage might be raised. When an abscess has one collapsible wall it

makes little difference at which pole the incision is made. If conditions had been favorable this route would have been selected. Under the circumstances the site selected was at once more convenient to incise and the drainage opening was more easily cared for than if a vaginal opening had been made.

Case 7.—A matron of forty-six was brought to the hospital because of fever following childbirth.

History.—Abortion at third month, eurette. A low fever continued following an initial temperature of moderate degree—maximum 102.5. Her general condition became much impaired and she was confined to her bed except for short intervals each day.

Examination.—She showed the physical characters and general disposition of a prolonged septic process. There was some general

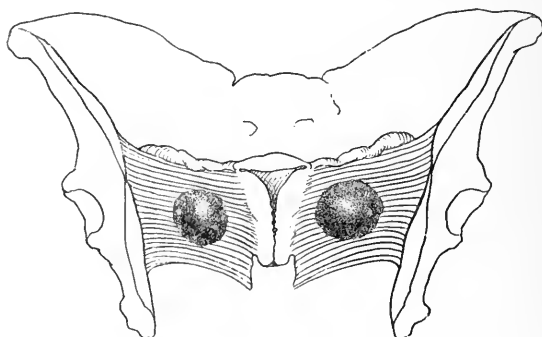


Fig. 349.—Bilateral broad ligament abscess.

tenderness over the pubes. The uterus was fixed and there was induration in the base of each broad ligament. (Fig. 349.) Nothing could be felt by the abdominal hand.

Diagnosis.—Streptococci infection in the base of the broad ligament.

Treatment.—Incision into the indurated areas, packed with gauze.

Pathology.—The tissue was dense and edematous. No pus pockets could be found in either broad ligament. The culdesae was carefully avoided.

After-course.—After some days the pockets occupied by the gauze began to exude a small amount of pus. The patient began to gradually improve and recovered completely in about four months.

It seemed likely that incision into the indurated areas hastens recovery by depleting the tissue. Not infrequently following such an incision, after the opening has closed, localized abscesses form. These generally are mixed infections. It seems quite likely that the mixed infection excites the tissues to reaction, which the streptococci do not and this reaction by forming a frank abscess accomplishes the destruction of the persistent streptococci.

CHAPTER XV

TUMORS OF THE ABDOMEN

Tumors of the abdomen imply surgical activity in all save the pregnant uterus. The chief concern lies first in determining its point of origin and then its character. Usually where the first is determined the second also can be determined.

EPIGASTRIC

Tumors of this region are usually developed from the stomach, less often from the pancreas and retroperitoneal tissue, rarely from the liver.

CASE 1.—A school teacher aged fifty-three came to the hospital complaining of dull aching in epigastrium and a movable tumor in the region of the umbilicus.

History.—A little more than a year ago he began having a dull heavy pain in the epigastrium after eating. He did not vomit and the pain was not sharp. He began to lose weight. A year ago his doctor was able to palpate a tumor in the abdomen just over the umbilicus. The type of tumor was not diagnosed. He was operated and nothing was done with the tumor, the abdomen being left as it was. He was told that the whole abdomen was filled with masses. He gained 12 pounds in the two months following operation, having previously lost 25. He began having the same epigastric distress almost immediately after operation and this has steadily grown worse. He lost his appetite. He now produces vomiting every night by putting his finger in his throat and relieves the distress for the night. He never vomits any other way. Never noticed any bloody or coffee ground vomitus. He has lost 32 pounds of his original weight, weighing now just 100 pounds. He never has any real pain. He was never subject to stomach trouble prior to about 14 months ago. He has never been jaundiced. He does not remember childhood diseases. Has always been well until this trouble began.

His mother died of cancer of stomach. One brother died in the late 50's of an undiagnosed stomach trouble.

Examination.—The patient looks older than his given age. He is extremely emaciated and has a cachectic appearance. He looks

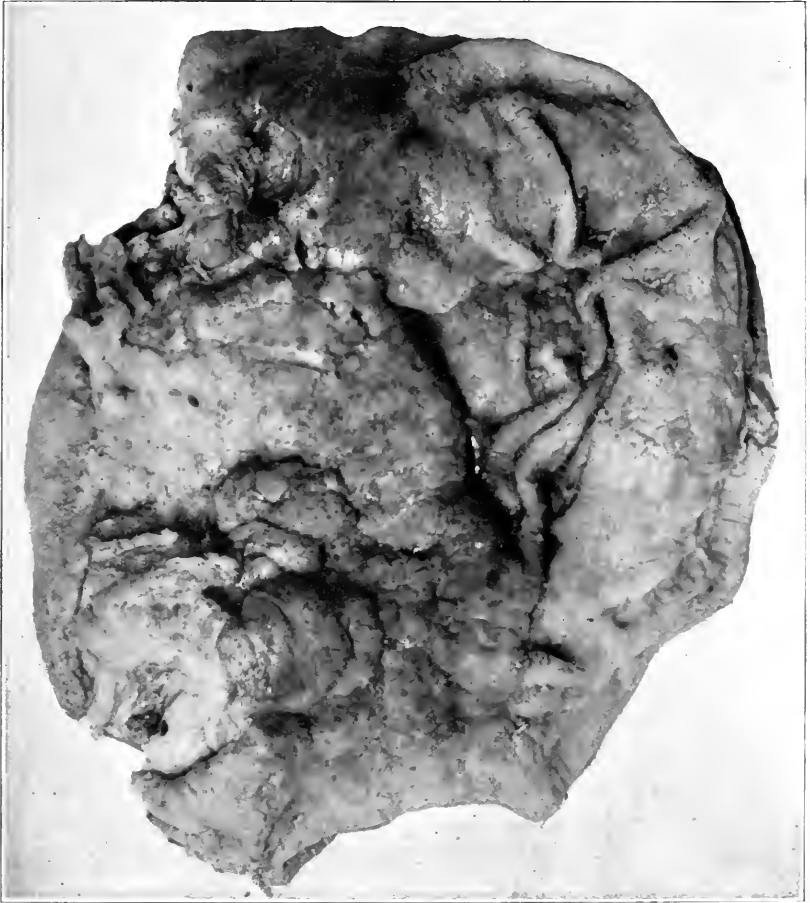


Fig. 350.—Adenocarcinoma of the stomach.

to be acutely ill. Head and neck negative. Chest flat, lower end of sternum shrunken, ribs prominent. Expansion fairly good, equal on both sides. Normal resonance throughout. No rales, no increased fremitus. Heart not enlarged, no murmur or friction rubs.

Dullness extends from midsternal line to $7\frac{1}{2}$ cm. to left. Apex beat in 5th interspace.

Abdomen scaphoid; walls extremely thin and hard. Liver and spleen not palpable. Left kidney palpable, not tender. Mass palpable just to right of umbilicus, circular, flat and hard. Feels about 4 inches across. It can be pushed around almost anywhere in upper half of abdomen.

X-ray taken five minutes after barium meal shows an absence of pyloric opening and duodenal cap and a distinct filling defect in pyloric end of stomach. Stomach extremely large, extending almost to the pelvic brim. Another picture taken six hours later shows a retention of almost half the barium meal in the stomach.

Diagnosis.—Carcinoma of the stomach.

Treatment.—Pylorectomy under local anesthesia with removal of the pyloric tumor. Gastrojejunostomy. On opening the abdomen a tumor was found in the pyloric end of the stomach. This had a rounded flat outline.

Pathology.—The tumor projects above the surrounding mucosa of the stomach like a cauliflower. (Fig. 350.) Herein is the explanation of its slow growth. This type of growth, common in the rectum, is unusual in the stomach.

After-course.—There was some postoperative shock. Temperature dropped to 96, pulse became very weak for a few hours but did not change in rate. Patient showed rather marked pallor. Did not perspire or change in respiration rate. No vomiting and no complaint of pain. Temperature remained subnormal the week following operation. He took soft food on the fifth day. The sutures were removed the ninth day. The wound was healed except for a small draining sinus at lower end of wound. On the tenth day the patient sat up in a chair. He continued to make an uneventful recovery and was dismissed in three weeks after the operation. He had gained 10 pounds, was taking general diet and had no gastric discomfort.

Comment.—It is strange that this tumor remained operable so long after the preliminary exploration. The extreme mobility was the factor that led to the conclusion that it was still operable.

CASE 2.—A carpenter aged forty-six came because of pain and tumor in the region of his stomach.

History.—He has enjoyed uniform good health until the beginning of the present trouble a year and a half ago. At that time

while at work he was struck violently in the pit of the stomach by a scantling which had slid from a considerable height. It knocked his breath out, but after half an hour he was able to walk to his home. After lying about for a few days he returned to work, and after a week the soreness disappeared. He never regained his former vigor, however. Several months later he noted he was losing weight. This has continued until the present time. His former weight was 190, now it is 146. Four months ago he noticed a tumor developing in the pit of his stomach. He has had a sense of fullness and some sensitiveness on pressure, but no actual pain. His appetite has been indifferent for some time past, and he has had loose stools at times.

Examination.—He is a large-boned man who evidently once was powerful, but he looks weary and worried. Mouth and lungs are normal. The abdomen is somewhat distended but soft and flabby. Below the ensiform cartilage is a tumor the size of a large grape fruit. It is tense, elastic, evidently cystic. Quite firm pressure can be applied before it elicits his interest. It seems smooth and globular. It can not be moved about either by manipulation or change in position. It can be tilted somewhat, but the base is not movable. There is a slight general anemia. The stools are negative.

Diagnosis.—Injury of a pronounced nature, followed by the development of a cystic tumor and attended by emaciation is pathognomonic of pancreatic cyst. It is a matter of academic interest to determine the relation it bears to the surrounding organs, notably the stomach and transverse colon. By inflating first the stomach and then the colon the tumor is proved to lie down between the two (Fig. 351A). The removal of as much as possible of the cyst wall, the attachment of the wall remaining to the edge of the incision in the abdominal wall seems to be the procedure indicated.

Treatment.—The tumor was exposed through a mid-line incision. The omentum, studded with many tubercles appeared. In going through this, coils of intestines were found to be matted over the cyst. By separating these, a cavity containing near a quart of fluid was encountered. There was no cyst. The fluid was imprisoned by extensive adhesions of coils of thickened intestines. The walls of these were covered with fibrinous exudates. Adjoining coils, not directly concerned in the formation of the cavity, were studded with

tubercles. A section of the omentum containing a number of tubercles was removed for further study. The fluid was mopped out and the abdomen closed.

Pathology.—The tissue removed showed typical tubercles with some small cascated centers.

After-course.—The patient gained some twenty pounds in weight in the months following the operation. Following this he began

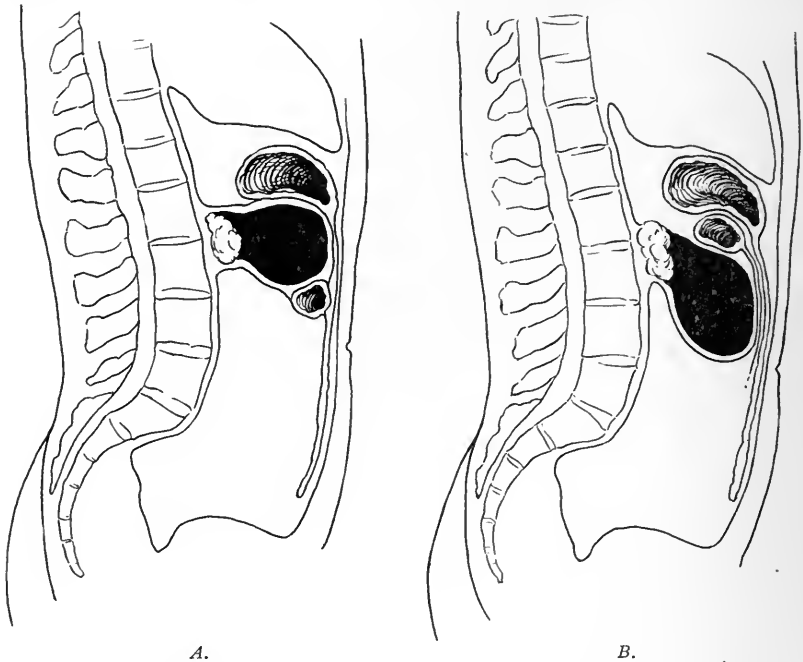


Fig. 351.—Diagrammatic presentation of a supposed pancreatic cyst. *A.* As it was supposed to be before operation. *B.* As it was found to be at operation.

again to decline and it was reported he died of lung tuberculosis, the lesion being first demonstrated in the right apex.

Comment.—The cyst was therefore a sacculated tuberculous exudate. The trauma likely afforded a favorable nidus for an infection already in the body, though the examination failed to reveal its presence. The perfunctory examination one usually makes when he has his eye on the surgical lesion is not calculated to discover incipient apical tuberculosis. This sacculated peritonitis was so

well defined and its situation so typical for pancreatic cyst that even the discovery of a lung lesion would hardly have restrained me from diagnosing a pancreatic cyst since the triad of symptoms, severe trauma, development of cyst, and emaciation, supposedly pathognomonic of that lesion, were so clearly pronounced. It may be noted finally that at operation the cyst lay below the transverse colon (Fig. 351-B) and not between it and the stomach as the physical examination had indicated. Had the x-ray been available, a barium meal and enema would have furnished a less fallible means of topographic determination.

CASE 3.—A matron aged twenty-nine came because of pain on each side of the navel.

History.—A year and a half ago she noticed pain in the right side below the navel. Soon after this she had pain in the other side. Following this the pain ascended until now it is most pronounced on the level of the navel. There has never been any acute pain, fever or vomiting. The soreness has been increasing. Exertion increases the pain and sometimes she is free from pain for a considerable interval. It has been continuous for the past two months. Eight months ago she felt a hardness above the navel, and two weeks ago her physician pronounced it a tumor. Her general health is good. She has two children, aged five and three years old. She has some eructations of gas, but no other stomach trouble.

Examination.—A tumor occupies the midline of the abdomen extending from the epigastrium to below the umbilicus. It extends lower on the right side than on the left. The surface is hard and seems intimately associated with the abdominal wall. It seems to be fixed to the abdominal wall. Firm pressure causes pain. The x-ray shows that the stomach is pressed upon, causing a constriction in its middle and dislocating the whole organ to the left side. Pelvic examination shows a stellate laceration of the cervix, and a high position of the uterus. Hg 80; R.b.c. 4,200,000; W.b.c. 12,000.

Diagnosis.—The impression the mass gives on first examination is a conglomeration of intestines which have become attached to the stomach wall. Localized hyperplastic tuberculosis gives this feel, but should not displace the stomach outward. She does not look tuberculous and there are no findings that warrant such an assumption. A pancreatic cyst might displace the stomach so, but

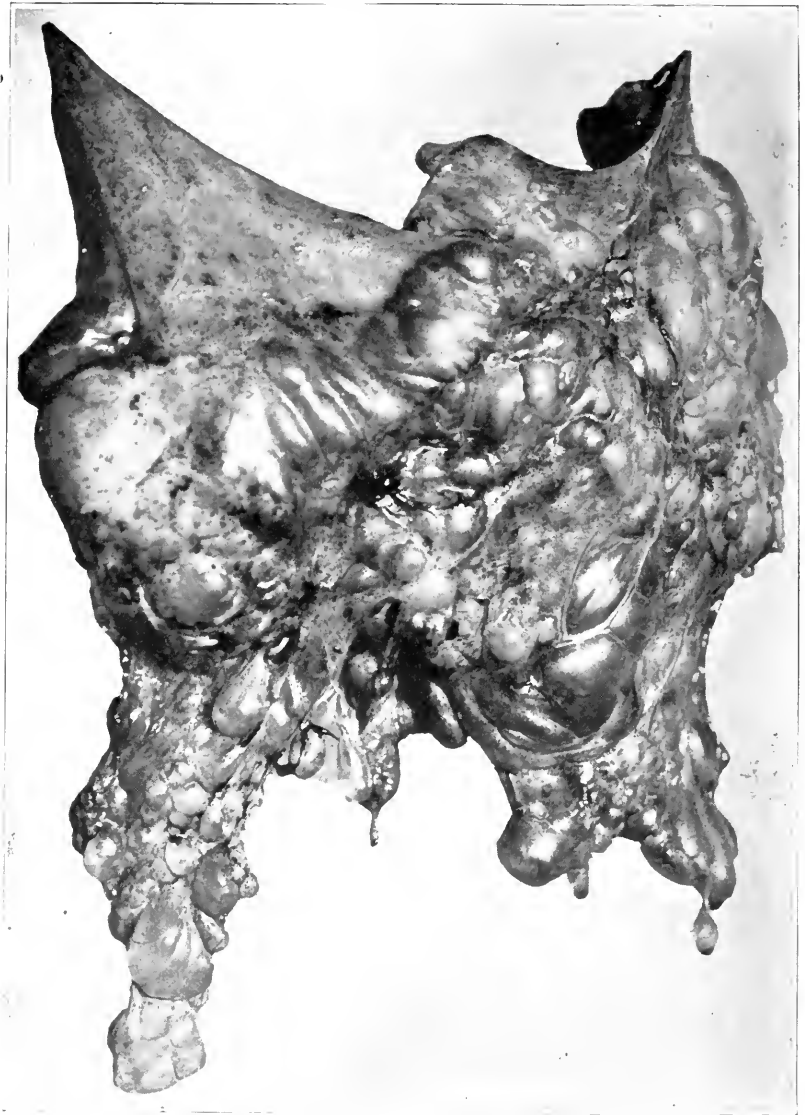


Fig. 352.—Polycystic disease of the lesser omentum.

there is no history of injury, and there is no loss of weight. The mass extends too low for a tumor of the lesser peritoneal cavity. It extends too high for an omental tumor, and is not movable

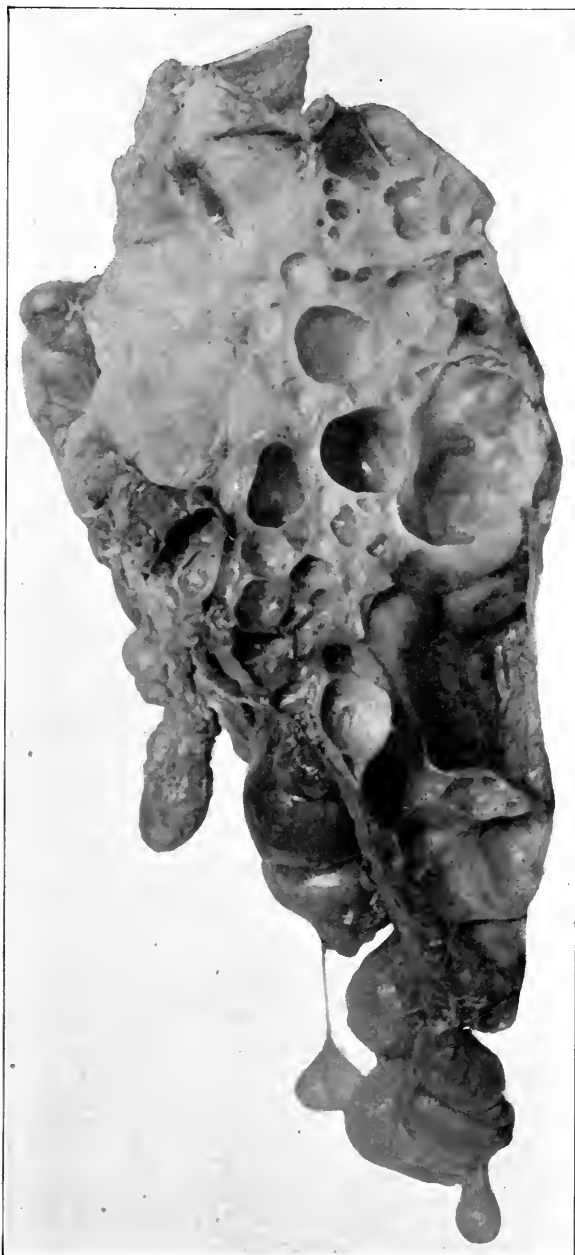

Fig. 353.—Cross section of a polycystic tumor of the lesser omentum showing the numerous smooth-walled cysts.

enough. It resembles somewhat the feel of a desmoid but it crosses the midline which a desmoid should not do. Its density and fixity seem best to fit in with a chronic proliferative process within the abdominal wall.

Treatment.—A midline incision showed the abdominal wall to be free. Beneath it was a polycystic mass lying wholly within the lesser omentum. It had inverted the lesser omentum so that a part of the tumor lay over and hung below the transverse colon. Lobules extended downward and lateralward toward each groin. The mass was removed and the lesser omentum reformed by the unaffected portions.

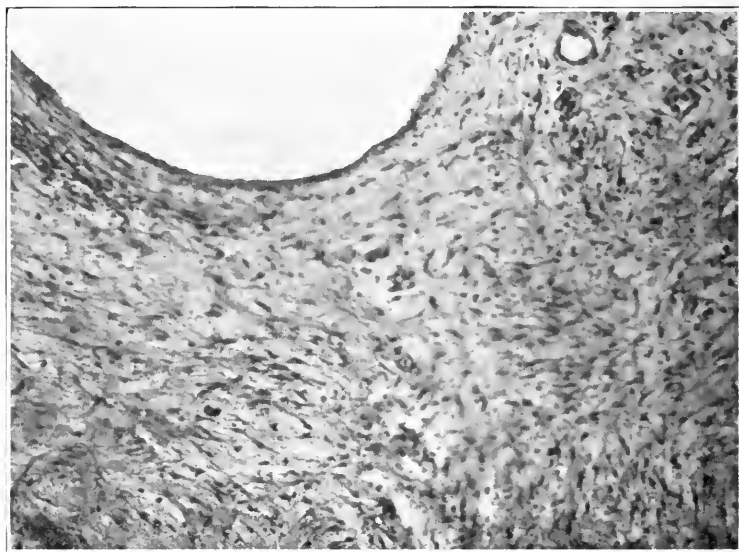


Fig. 354.—Slide of Fig. 353. The cysts are lined with endothelium while the solid portion is made up of loose connective tissue.

Pathology.—The tumor consists of a conglomerate mass of cyst six inches in breadth and nearly as long in the vertical diameter (Fig. 352). On section the cysts are seen to vary from microscopic size to the size of an unhulled walnut (Fig. 353). The contents is clear fluid. The slide shows the cyst walls to be lined with flat endothelial-like cells. The tissue between the cysts is poor in cells of spindleform or stellate shape, while the intercellular tissue is fibrinous or structureless. It resembles the tissue of certain slowly growing fibrosarcomas of the ovary or retroperitoneal tumors (Fig. 354).

After-course.—Recovery was prompt and uneventful. She still complains of a pulling in the pit of the stomach after a full meal.

Comment.—After seeing the tumor, it is easy to see how perfectly it accounts for the symptoms. However, polycystic tumors in this situation are exceedingly rare and exist only as pathologic reports. It is astonishing that the tumor felt so superficial despite the fact it had no attachment with the abdominal wall and was cystic. It occurred to me after seeing the tumor that a solid tumor of the abdominal wall was a ridiculous assumption, for it could not have displaced the stomach, but I had never felt anything so firm and immovable save a desmoid. It was wholly outside of my previous experience, and any diagnosis was better than none.

CASE 4.—A farmer aged fifty-six came because of sharp pains in the region of the stomach.

History.—The patient had grip four months ago. Since that time he has not been well. Fifteen or twenty years ago he had spells of diarrhea which were cured by "pain killer." He now has a sense of pressure in the pit of the stomach with cutting pain under the short ribs on each side. The appetite has been good but he has had so much gas following eating that he has limited his diet. He lost 15 pounds in the last few years, the most of it during this attack. When the pain is severe in the left side of the epigastrium it extends to the back under the tip of the shoulder blade. He has never vomited. During the past two weeks the appetite is decreasing.

Examination.—The patient is thin, seems worried and emaciated and appears as though he had lost more than fifteen pounds. There is rigidity in the epigastrium and there is on deep respiration a tumor palpable in the midline above the umbilicus. W.b.c. 10,800; R.b.c. 4,700,000. The stomach contents give a strongly positive reaction for lactic acid, but HCl is absent.

Diagnosis.—The rather rapid onset with the general appearance of the patient is strongly suggestive of carcinoma. The peculiar board-like rigidity of the upper ends of the recti muscles suggests the same thing, as does the presence of lactic acid and the absence of HCl. The presence of a tumor makes the diagnosis highly probable. There is no evidence of metastasis and operative removal may be possible.

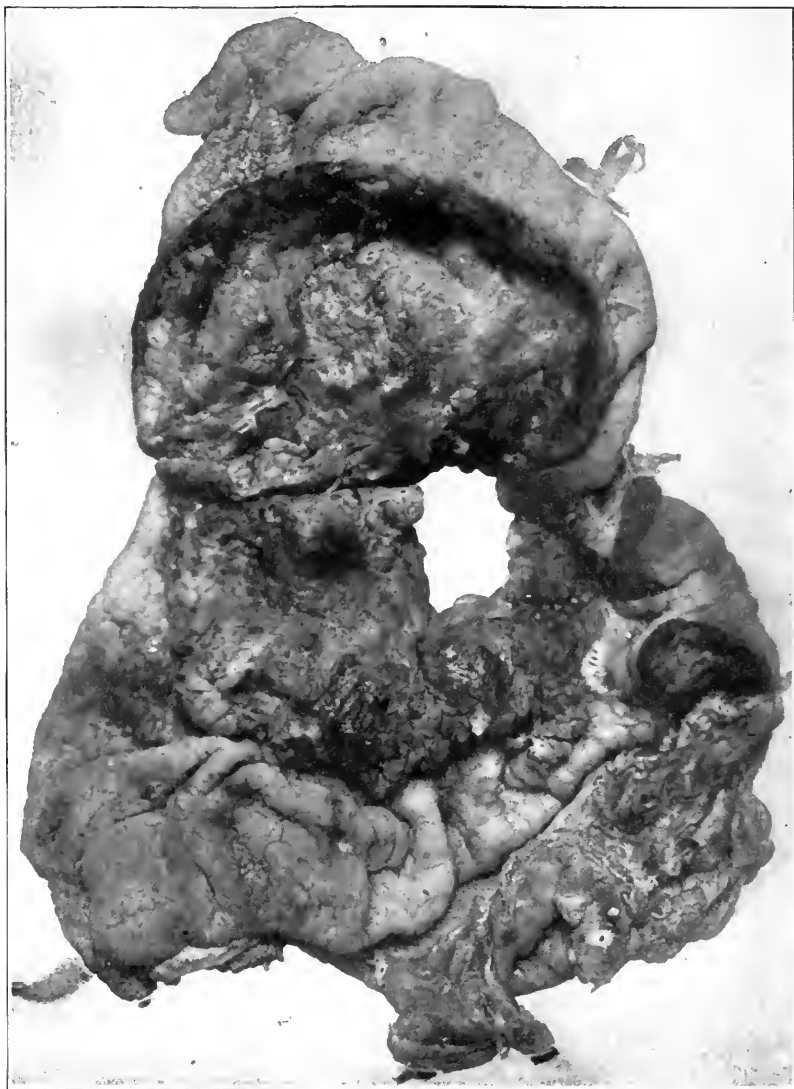


Fig. 355.—Ulcerating carcinoma of the stomach.

Treatment.—After the stomach was exposed an area of induration as large as the palm of the hand was found along the greater curvature and anterior surface. The stomach was movable and there were no palpable glands. Resection was done by the second Billroth method.

Pathology.—There is a large, indurated ulcer with a smooth base and sharply defined border with overhanging edges (Fig. 355). The border is bosselated and dense. The slide shows a typical carcinoma rather sharply circumscribed against the surrounding normal tissue.

After-course.—He progressed favorably for a week. During the second week he complained of epigastric distress. He had no actual pain and he took a fair amount of nourishment. He stated there was a feeling as of a foreign body which should be removed. At the end of the second week while sitting in a chair he drank grape juice which he at once vomited. He immediately became dyspneic, with a respiration of 48, with cyanosis, and died soon after. The autopsy showed induration in the walls of all the guts concerned in the operation. There was no peritonitis. The anastomosis opening was patent. The walls were edematous with much round-celled infiltration. There were no areas of abscess formation. There was a lung embolism.

Comment.—So far as the type of tumor was concerned, a cure might have been hoped for in this case. The unfavorable state of the area of operation likely accounted for the formation of the thrombus and the act of vomiting probably dislodged it. I have repeatedly noticed the marked induration of the gut walls in patients on whom a gastroenterostomy was done. It produces a board-like state of the gut wall. The cause of it is not apparent. Either other surgeons do not have this misfortune, or, like myself, are baffled by it.

CASE 5.—A housewife aged fifty-six came to the hospital seeking relief from pain in the epigastrium and left upper quadrant of the abdomen.

History.—The patient felt well until five months ago when her strength began to decline and she felt a heaviness in the epigastrium after meals. Her doctor told her she had influenza. About a month later she began to have pain in the left of her stomach and along the left side of the abdomen. She had some pain in the lower chest. A little later she began to have a continuous dull pain in the stomach which at times would be cramp-like in character and very severe. Eating did not affect it much either way, although at first eating seemed to relieve it a little but later to aggravate it. Two weeks ago she began vomiting. There was con-

siderable blood in the vomitus. She has been vomiting 5 or 6 times a day since. She brings up a sour substance and bloats a great deal. She has gradually become jaundiced the last two weeks and it is increasing. Her appetite is very poor and her bowels extremely constipated. She has lost 20 pounds since the beginning of her trouble.

Examination.—Her sclera are icteric and the skin is jaundiced. There is a tumor in the epigastrium the size of two fists. The x-ray findings are very indefinite and of no value. The patient can not swallow the smallest amount of bismuth without vomiting and the pyloric region can not be demonstrated. Hence it can not be determined whether the mass in the epigastrium is in the gall bladder. The condition is evidently utterly beyond relief. The attending physician is sure the tumor is a distended gall bladder and the patient and her friends desire an exploration.

Treatment.—An exploratory laparotomy was done. A carcinoma involving the pylorus was found. Metastases had taken place in the liver and the surrounding structures were infiltrated.

After-course.—The general weakness of the patient increased, the vomiting was persistent and frequent and the patient died two weeks later.

Comment.—It is a mistake for the surgeon to operate in such cases just because he is urged to do so. Even if he states that the only responsibility he assumes is that of technic when the inevitable result comes it is charged against surgery. Any man who has a disposition to cut and sew on order should be a tailor.

CASE 6.—A housewife of fifty came to the hospital for relief of an abdominal tumor.

History.—Six years ago she was operated on for gallstones. For five years previous to this operation she had had gallstone colic and gastric disturbances. She had noticed slight if any jaundice and had never noticed putty-colored stools. She passed 7 stones in the feces that she knows of during the five years. Those taken at operation were small but numerous. About ten or twelve days after operation she had a severe attack of pain across the epigastric region accompanied with distention and a rapid pulse. At the same time she had a pain in the left kidney region. Some pain remained in these places for three months and then stopped for the most part and she was comparatively free from pain for two years. About that time she noticed an epigastric tumor. It was

much smaller than now and remained stationary up to six months ago, when she noticed that it was growing larger. As it grew, the pains in the back and epigastrium increased in severity. About four years ago it was discovered that she had sugar in the urine. She has a large amount at the present time. She had no loss of weight, or excessive thirst, and the amount of urine voided was not greatly increased. Three weeks ago she had a sudden attack of severe pain in the left side of the back and in the epigastric region. She did not vomit or have rise of temperature. The attack recurred every day since. She has never had any urinary or gastric disturbance, since her gallstone operation and the pain in the back did not radiate to the bladder region. Her appetite has been good up to two weeks ago. Since then she has had none, and the bowels have been rather constipated. She has lost 40 pounds during the last year. She has one child living, twenty-seven years old. She menstruates about every five weeks. Four years ago she had three severe uterine hemorrhages and had to be packed. Aside from this and previous to her gallstone attacks she had had good health.

Examination.—The patient is sallow and weak and shows the loss of weight of which she speaks. The heart and lungs are negative. In the epigastric region in the midline and to the left is a smooth, tense, globular tumor the size of a fetal head. It is immobile on respiration, and is immovable to manual effort. It is slightly sensitive to firm pressure. A barium meal shows it to occupy the lesser peritoneal cavity. (Fig. 356.)

Diagnosis.—A severe epigastric pain attended by abdominal distention and a rapid pulse following a gallstone operation suggests a pancreatic affection. The development of an abdominal tumor in the situation in which this one is located confirms the suspicion. Its form and contour, with the attendant glycosuria confirms it. It but remains to determine whether it is a true or pseudo cyst.

Treatment.—The cyst was exposed under local anesthetic. The wall was thick and it was freed as far as possible and the fluid contents withdrawn. As much as possible of the cyst wall was removed, the border of that remaining was sewn to the edges of the incision and the cavity packed.

Pathology.—The fluid was slightly clouded and did not digest starches or albumin. The wall was made up of fibrous tissue with sparse nuclei, but an epithelial lining could not be demonstrated.

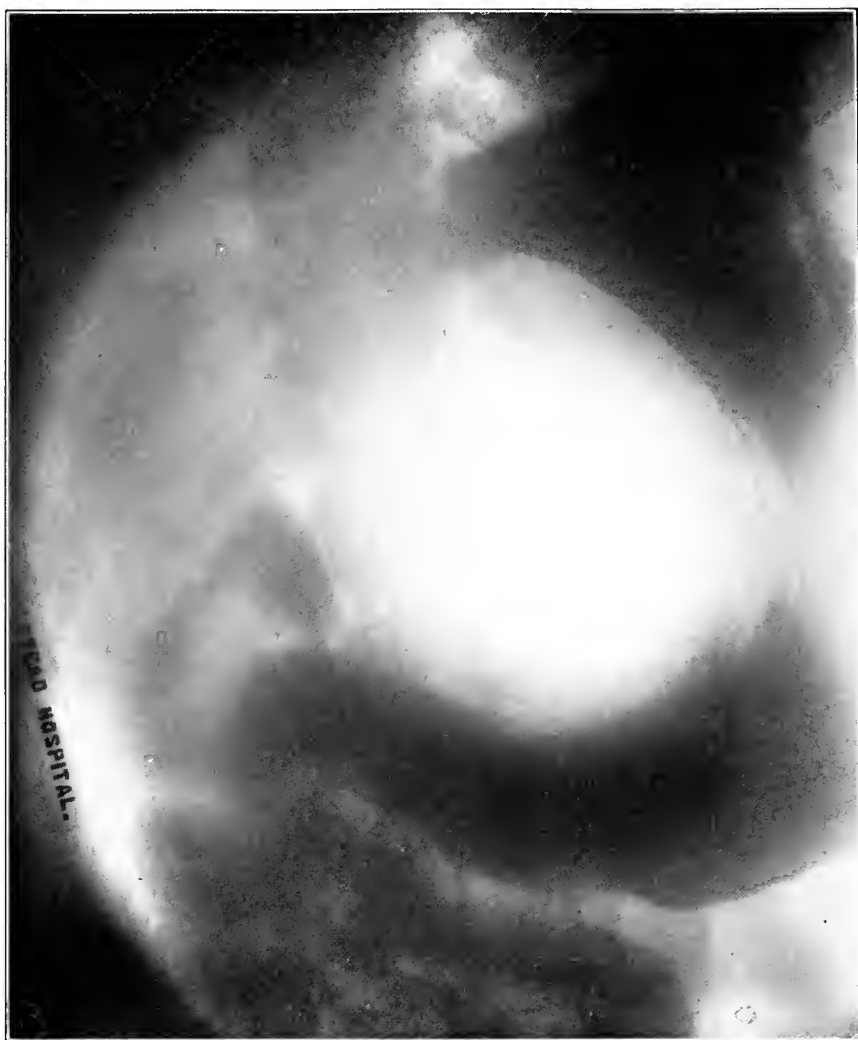

Fig. 356.—Pseudocyst of the pancreas. The stomach filled with barium appears as a dark shadow at the left of the cyst.

After-course.—On the fourth day following operation the patient began to show signs of acidosis. She was drowsy and had an acetone breath. The urine showed a strong positive test for diacetic acid and one drop of urine reduced Haine's solution. Twenty-four hours later the patient was in coma, but could be roused and took

water by mouth in large quantities. She was starved, given water per rectum and by mouth and given sodium bicarbonate as much as 200 grains a day. Four days later she began to rouse, and by the next day came out of the coma. She seemed to improve for several days, but a week later the symptoms of acidosis became more pronounced again. The previous treatment was used again with spiritus frumenti (that was some years ago) added as a stimulant, but the coma gradually deepened and in two days she died.

Comment.—In the presence of glycosuria it is important to avoid a general anesthetic. No doubt a more protracted treatment of the glycosuria should have been instituted before operation was attempted. I so little feared acidosis when operating under local anesthesia that I did not deem it necessary. What occurred following the operation for gallstones to excite the pancreatic affection can not be deduced from the evidence at hand. It may be categorically assumed, however, that the patency of the pancreatic duct was in some way interfered with. It was likely a mistake to starve the patient in such a state. A more liberal diet might have been less disastrous. In impending acidosis in surgical cases I have found large amounts of codeine the best agent.

CASE 7.—A matron aged fifty came because of a lump in the lower abdomen.

History.—The patient has had nine children. The menses stopped six months ago but two weeks ago she had a free flow for a week after being examined by a physician. For two years she has noticed a lump in the lower abdomen. As it grew in size, pain in the lumbar region developed with frequent and painful urination.

Examination.—In the right lower quadrant of the abdomen is a tumor the size of a grape fruit. It is hard, nodular, free at its median surface, but fixed at the brim of the pelvis. The fundus of the uterus can not be defined from the mass. The inguinal glands are free and the vessels in the skin of the abdomen are not dilated.

Diagnosis.—The appearance of a flooding six months after the menopause spells malignancy of some sort. A tumor that is still growing two years after the menopause is likewise likely malignant. The tumor is hard and bosselated and the uterus seems to be continuous with it. If the tumor is a malignant myoma, it should have developed more rapidly and the menopause would hardly have been established. When a malignant myoma becomes at-

tached, it is in the floor of the pelvis and not at its rim. Nevertheless, the hard bosselated mass it seems to be indicates that it can be nothing else than a myoma. Ovarian cystomas that have become malignant usually show softer areas.

Treatment.—The uterus was of normal size. The tumor felt was of the right ovary. It was attached to the peritoneum of the brim of the pelvis. It neither was attached to the abdominal wall nor to the peritoneum in the culdesac. It was removed but the peritoneal involvement could not be removed.

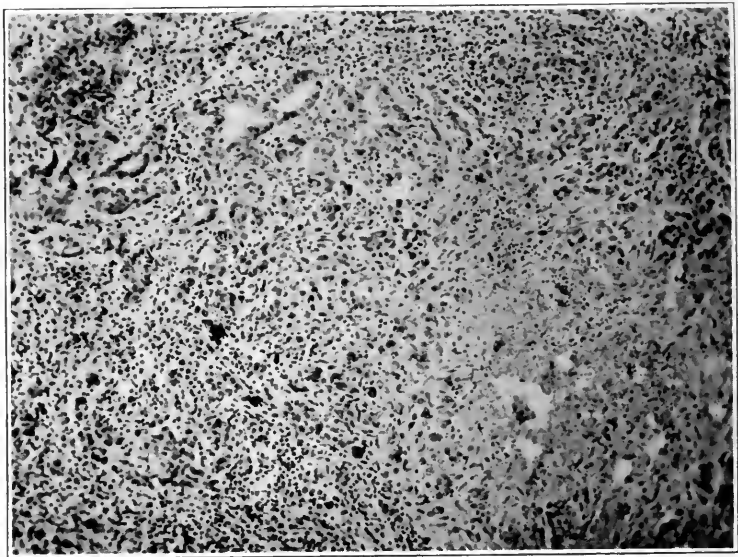


Fig. 357.—Malignant cystoma of the ovary.

Pathology.—The tumor was solid save near the lateral border where it had attachment to the peritoneum. Here there were papillary projections which had extended to the peritoneum in the culdesac. The slide shows solid and glandular epithelial tissue (Fig. 357). Therefore it is a malignant cystoma.

After-course.—The patient was considerably shocked and had much pain at the point where the tumor was attached, immediately after operation. When last heard from a year after operation, she had had no recurrence but it will inevitably return.

Comment.—Papillary cystomas are semimalignant but once they form solid tumors, as in this case, the prognosis is bad. The attach-

ment of the tumor did not involve the pelvic peritoneum to a sufficient depth to cause a damming back of the blood, and the tumor, not being attached to the abdominal wall, did not cause vascular dilatation by direct irritation. Therefore, there were no signs to indicate, positively, inoperability. When one has once exposed the field of operation it is as well to remove as much as can be removed. In this case a thin layer alone remained. Whenever a malignant tumor is forcibly separated from a peritoneal tumor, shock is likely to be very marked. There is no means of prevention.

HEPATIC

The liver is usually responsible for tumors in this region; the gall bladder if cystic, often too, if nodular. Irregular enlargement of the liver may appear as bosselated masses. Teratoid tumors are rarities.

Case 1.—A housewife aged thirty-two came to the hospital because of pain in the right side and lower part of the abdomen.

History.—Her trouble began early in her last pregnancy which terminated in a normal delivery eight weeks ago. She had bearing down pains in the right side of the abdomen extending along the hip bone towards the bladder. She had a severe pain the size of a dollar in her back. During the pregnancy she had several attacks of sudden severe pains accompanied by vomiting. She had to have hypodermics for the control of pain. After the baby was born she noticed a mass in the right side below the short ribs. She also had a severe backache and a dragging down sensation, particularly when she was on her feet. When she turns on her left side the mass sags toward the middle of the abdomen and causes severe pain. Her appetite is good, she is obstinately constipated, but has no bladder trouble.

Examination.—The patient has a sallow complexion but seems well nourished. The abdomen is rounded and distended. Palpation shows a rounded tumor extending from the costal margin to the crest of the ileum. It does not move on respiration and can not be made to appear in the flank. Neither is there sensitiveness in the renal triangle. When she is turned on the left side the tumor does not move but she thinks it does. It is not tender on pressure and is smooth and elastic. The uterus is high and to the left, lying on the pelvic brim. The fundus seems to disappear in the tumor.

The uterus can not be drawn down or pushed to the left. The urine contains a few leucocytes. Hg 60 per cent; W.b.c. 11,000; R.b.c. 4,000,000.

Diagnosis.—The fact that the uterus is drawn upward and to the right indicates that it is attached to the tumor. The tumor is smooth and elastic, evidently cystic. The fact that she had severe pains with nausea during pregnancy indicates that it became fixed in this high position at a time when it was raised upward by the growing uterus. It is too soft, smooth and nonelastic to be a pedunculated myoma of the uterus or a solid tumor of the ovary. It does not appear in the flank as it would if it were a hypernephroma or a hydronephrosis, though the localized pain in the lumbar region suggests the possibility of a renal origin. An inflammatory lesion of the gut tract would not produce an abscess of this size of so long duration. An abscess in this situation would produce a profound sepsis. The W.b.c. of 11,000 indicates a mild absorption as of extravasated blood. A cystic tumor of the upper abdomen might have secured attachment to the fundus during pregnancy and have retained this attachment after labor. However, the pain in the beginning was low in the right side and extended upwards. Therefore, it can not be primarily of upper abdominal origin. Furthermore, nothing occurs in that region that attains this size and consistence.

Treatment.—A right rectus incision was made. When the peritoneum was approached there was found to be a marked properitoneal edema. After the peritoneum was opened it was found firmly adherent to the tumor. This separated, the tumor was found firmly adherent to the under surface of the liver, and its nature being still doubtful, I feared to separate it. The omentum was adherent to the medial surface of the tumor. Following the tumor to the pelvis, a twisted pedicle was found to connect it with the horn of the uterus. The appendix was adherent at the point of torsion. The pedicle was severed and the appendix removed. The tumor could then be shelled out from below upwards. The firmest point of attachment was to the lower surface of the liver. The veins of the pampiniform plexus were filled with clots. There was also a hematosalpinx.

Pathology.—The tumor was 6 x 5 x 4 inches in size. On section after being hardened the interior was found to be a large blood clot (Fig. 358). The wall is that of a multilocular ovarian cyst.

After-course.—Recovery was uneventful and permanent.

Comment.—Her sallow complexion and the leucocyte count were exactly that likely to be caused by the absorption of a blood clot.



Fig. 358.—Ovarian cyst with twisted pedicle filled with blood clot.

No doubt the tumor secured its attachment to the under surface of the liver during pregnancy. Since she had several attacks of severe pain requiring morphine during pregnancy it is impossible to say

just in which one of the attacks the twist occurred, possibly partly in each. Perhaps the twist occurred in one and the hemorrhage at another time. At the time of the pain, the question of appendicitis or a hematogenous infection of the kidney would have been an important one. Ruling out the kidney by the urinary findings, operation would have been safer than to wait. The pain in the lumbar region may have been due to involvement of the kidney by the irritating cyst. There is no knowledge as to the state of the urine at that time.

CASE 2.—A laboring man aged thirty-three entered Bell Hospital because of pain in his side and back.

History.—His trouble started gradually about fifteen months ago. The first thing he noticed was that he had a chill every night for twenty nights. These were quite severe and following the chill he perspired freely. The chills came on usually about 8 or 9 o'clock. He felt stiff and tired in the morning following these chills but he continued to work. He had pain in the stomach and right side following these chills and he had to stay in bed two days on several occasions. He was nauseated but never vomited. He had a sharp shooting pain at the end of inspiration. He improved somewhat and went to work again and has worked up to the present time, but he has been nearly constantly in pain. Recently he has become quite stiff in the back and quite short of breath. He has no cough but has had fever ever since the trouble started and has lost 20 pounds in weight. Nocturia 2 to 3 times. No edema. For the past week he has had some pain in right leg. Preceding the present illness he had never been sick in bed since childhood. He has never had gonorrhoea, but had a sore on his penis two years ago, but it lasted only three or four days.

Examination.—The patient is well built and has evidently been a strong man. He has the appearance of suffering pain. The right pupil is larger than the left, both are irregular and react but little to light. Postauricular and epitrochlear glands are palpable. There is a slight bulging of the lower part of the right side of the chest. The bulging becomes more marked with deep inspiration. This bulging on palpation proves to be an irregular globular elastic mass, semifluctuating in character. The liver dullness reaches the 4th interspace, but the lower lung border is movable. The percussion note is clear and there are no rales. The

lower border of the liver is not palpable. The heart is normal, but its rate is increased. The abdomen is moderately distended and somewhat rigid particularly on the right half. There is no definite soreness but pressure increases the resistance. There is flatness in the right half and a faint percussion note can be made out. There is some bulging in front of the quadriceps muscle, none over the kidney. The area of maximum tenderness is over the outer border of the right rectus. It seems as though one could feel indefinitely sausage shaped coils beneath the abdominal wall on the left side. The dull area does not shift on change of position. The R.b.c. is 12,000. There is albumin and casts and a good deal of pus in the urine from both kidneys. There is some swelling of the right groin at the lower border of Scarpa's triangle. The legs are not swollen. The reflexes can not be demonstrated. The x-ray of the spine shows nothing.

Diagnosis.—The gradual onset of pain in the abdomen with emaciation resulting in the accumulation of fluid filling the right side of the abdomen suggests tuberculosis of the peritoneum. The rounded masses on the left side probably are coils of jejunum thickened by a tuberculous process. The failure of the fluid accumulation to move, it seems likely, is due to a sacculation because of hyperplastic tuberculosis. The exudate is of too long a duration and too widespread to make a perirenal abscess likely, and the leucocytosis is not high enough. The x-ray seems to exclude a tuberculosis of the spine. The fact that the liver is displaced upwards suggests an intraperitoneal exudate which is lifting the liver. A sacculated peritoneal tuberculosis of the right half of the body seems the best diagnosis.

Treatment.—A right rectus incision was made. The peritoneal cavity was free from fluid, the omentum and intestinal coils were unaffected. The thickened coils it was supposed that we felt were not in evidence. Beginning at the midline was a bulging, fluctuating mass which lost itself behind the liver above and extended down into the iliac fossæ. It showed no evidence of acute infection. The colon rode on its surface apparently unobstructed, but its vessels were much enlarged. The incision was closed and sealed with collodion. An incision was made from the midline of the twelfth rib downwards and inwards. The endoabdominal fascia bulged and where this was opened great quantities of yellowish

odorless pus rolled out. In this were many white flakes, some of which were as large as a bite of beefsteak. The cavity extended from behind the liver over to well in front of the spinal column, down to Poupart's ligament and into the pelvis as far as the mid-line. The wall was smooth for the most part. A portion of the kidney was found in fragments. The capsule of the kidney could be made out. At the lower portion of this was an opening admitting two fingers.

Pathology.—A great variety of organisms were demonstrated in the pus. A section of the kidney fragments showed areas of degeneration and round-celled infiltration but no positive evidence of tuberculosis.

After-course.—The wound closed rapidly down to a small sinus. This persisted and he is reported to have died nine months later of progressive weakness and cough.

Comment.—Though no positive evidence of tuberculosis could be demonstrated, the flake-like character of the pus suggested its presence. Likely it was a tuberculosis which later became complicated by a secondary infection. The almost complete obliteration of the huge cavity should have been followed by a degree of physical recuperation greater than that which actually took place. The opposite kidney evidently also was affected. After the recovery from the operation the urine of the remaining kidney should have been searched more persistently for tubercle bacilli. All that is known is that there were no marked urinary disturbances during the terminal period of his illness.

CASE 3.—A farmer's daughter aged nineteen came because of painful urination.

History.—Aside from a dysmenorrhea which confines her to bed during the first day, the patient has always had good health. Two and a half years ago she fell from a wagon, striking the right side of her back on a hard object. She was not confined to bed at the time but about one month later she began to have pain in the lumbar region, which was dull, aching in character, coming on periodically and aggravated by walking. This was accompanied by painful micturition, burning in character, being worse at the end of the act. The urine was cloudy, but no blood was noticed. The above condition has grown steadily worse and during the past month she has been entirely incapacitated. The patient is unable to lie down

and has slept very little. Micturition is very frequent and only a few drops of urine are passed at a time. The pain is localized in the region of the bladder and does not radiate. It is sharp, stabbing, and sometimes cramp-like in character.

Examination.—The lower abdomen is rigid and there is suprapubic tenderness. There is no pain in the groin. The region of the kidney is tender on deep palpation and on bimanual palpation a definite tumor which does not glide under the fingers can be made out. No difference in the skin in the two sides is discernible on direct palpation, but when a large fold is picked up, that over the affected side is felt to be thicker than that of the unaffected side. This shows that there is a deep inflammatory process. The cystoscopic examination aside from a purulent urine escaping from the right ureter, is negative, save for a general cystitis. No tubercle bacilli were found in the urine. The white count is 10,800.

Diagnosis.—The subjective symptoms suggested stone in the bladder, but the history and the physical findings indicate an infection due likely to rupture or severe contusion of the kidney at the time of the accident. Most likely there was but a severe contusion which resulted in a pyelitis. Had there been a rupture with subsequent infection the course likely would have been much more stormy. No examination of the urine was made at the time of the accident. Therefore the degree of injury is not known. At the present time evidently there is a pyelitis. There is no evidence of tuberculosis, but this can not be ruled out with certainty. Cystoscopy confirms this. The deep edema in the kidney region indicates that there is a perirenal induration. The low leucocyte count makes it doubtful whether there is actual abscess formation or not. Perirenal abscess usually gives a high white count. An ancient one, however, may give a normal count. At any rate the bladder affection does not account for her complaint and the kidney must be investigated.

Treatment.—The kidney was exposed and found to be surrounded by an infiltrated capsule, but there was no free pus. The kidney gave evidence of a subcapsular rupture, or at least a contusion, because there was a scar extending from the pelvis over the lower pole. The pelvis was tense with pus. A drain was placed through the substance of the kidney into the pelvis.

After-course.—Drainage brought an amelioration of the symptoms, but when last heard from, the sinus in the back had not completely healed, neither had the bladder irritation completely disappeared.

Comment.—In such a case, in a patient in such good condition, it would have been better to have removed the kidney. I believed by the plan followed I would be able to save the kidney. The cause for the reference of the pain to the bladder was due to transmitted pain from the pyelitis rather than from the moderate grade of cystitis present. In such cases one hesitates to do a nephrectomy without knowing the state of the other kidney. To pass a catheter through an infected bladder to the supposedly healthy kidney is like striking a match to see whether it will burn so that in case of need one will be assured of well tried material.

CASE 3.—A farmer of fifty-seven came because of a mass and pain under the short ribs on the right side.

History.—His present trouble began about three years ago with an attack of pain under the short ribs on the right side anteriorly. The attacks were not severe, they lasted a few hours and then stopped, leaving him sensitive under the costal margin for a week. He did not vomit or have any fever that he knows of. He took a course of olive oil and saline cathartics and was free from the attacks for a year. They then started again. They came on acutely, were very severe, and were accompanied by vomiting and fever of usually above 2 degrees. The spells left him acutely sensitive under the right costal margin and he has never been able to lie on that side at night on account of it. His last attack came on two weeks ago while hard at work on the farm. Eight months ago during one of these acute attacks a mass appeared in the right side just under the short ribs and has remained. His general health otherwise is good, except that he has had some burning on urination for about two or three years. He has never been jaundiced and has lost little or no weight.

Examination.—He is a large man, weighing about 220, of vigorous bearing and ruddy complexion. There is a palpable mass under the right costal margin in the gall bladder region. This does not move about on change of position. It seems to move slightly with respiration. It is definitely sensitive. There is no sensitiveness in the renal triangle and the urine is negative. The prostate is moderately enlarged.

Diagnosis.—The history of feverless attacks of rather severe pain in the hepatic triangle is suggestive of gall-bladder colic. The mass is indicative of a pericholecystitis and its failure to move but slightly on deep respiration indicates that the mass has become adherent to the anterior abdominal wall.

Treatment.—An incision was made in the gall bladder region. A mass of adhesions of colon and omentum were found just below the liver, this being the mass palpated on examination. They were separated in the expectation of finding the gall bladder beneath. On the contrary, the adhesions surrounded a subacutely inflamed appendix. The gall bladder was found to be normal and lay medial to the inflamed mass. The appendix was removed and the wound closed without drainage.

After-course.—The patient left the operating table in good condition and ran a normal course for about 24 hours. At the end of this time he became distended and began to vomit. The attacks of vomiting increased in frequency. The vomitus consisted of small amounts of brownish black fluid and it was regurgitated every few minutes. The distention also increased and the patient had attacks of singultus which were very exhausting. The temperature was just under 101° and the pulse 70. The patient was in no great pain. Stupes and colon tube helped get rid of some gas but afforded very little relief. A stomach tube was then passed; about two quarts of blackish-brown fluid was obtained. Gastric lavage was used with soda bicarbonate solution until the solution became clear. Much relief from vomiting and singultus was immediately experienced.

The following day vomiting began again, not so severe as before, but he was much distended. Lavage with soda bicarbonate was again given. About a quart of black fluid was syphoned off. The next day vomiting again set in, but not nearly so much as before, and there was still much distention. Gastric lavage was repeated, but no fluid syphoned off from the stomach. From this day on the symptoms began to clear up, and the patient made an uneventful recovery. During the latter part of his convalescence he developed some bladder irritation and some pus appeared in the urine. He was given salol and boric acid, 5 grains of each, every four hours, and the condition rapidly cleared up. He has remained well.

Comment.—Usually when an appendix lies lateral to the colon and makes symptoms in the gall bladder region there is sensitive-

ness in the renal triangle just anterior to the edge of the quadratus lumborum muscle. Likely there was such in the earlier attacks, but at the time of observation the appendix was so completely walled off that the parietal peritoneum was not irritated at this point. The nature of the pathologic process was correctly recognized, but the organ at fault was mistaken. It is of more importance to correctly evaluate the symptomatology in terms of pathologic anatomy than it is to name the organ from which the process originated. Evidently there was a postoperative introgastric hemorrhage causing distention of the stomach. The stomach likely projected the contents out of the stomach tube as soon as it was introduced indicating that the tonus of the stomach wall was not impaired. Therefore, it was not a true postoperative gastric dilatation. Had it been a true dilatation lavage should have been repeated at least every six hours. It would have been well perhaps to have used irrigations of hotter water than was used. The cause of the introgastric hemorrhage may be best attributed to the traumatism inflicted on the great omentum in separating the rather firm adhesions. It would have been better to have ligated proximal to the point of adhesion and to have removed that portion of the omentum involved in the adhesions.

CASE 4.—I was called to see a woman of twenty because of a tumor of the abdomen.

History.—For several years she has had frequent urination with some pain. She began menstruating at 14, has been regular since, but has had to lie abed the first day because of cramping pains. The urine, according to her doctor, has constantly contained pus during the period of his observation, now six months. During this period he has noted a tumor in the right side below the costal margin. This has varied in size from time to time. Its disappearance was followed by the discharge of large amounts of urine. He never searched for bacteria and never made a leucocyte count.

Examination.—The patient is well nourished and gives no evidence of suffering. There is a tumor in the right upper abdomen disappearing under the costal margin. It extends downward to the level of the umbilicus. It does not move on respiration. It is markedly sensitive to light pressure, less so to firm pressure. The urine is 1.004, free from foreign elements except an occasional leucocyte and squamous epithelial cells.

Diagnosis.—The patient is evidently neurotic. The history of recurrent tumor of the upper abdomen would suggest a hydronephrosis. The feel is not that of a hydronephrosis, being sensitive to pressure, and it can not be pressed into the flank. The urine is the thin urine of a neurotic, but is sometimes observed in pyelitis and hydronephrosis. This seems the best diagnosis.

Treatment.—As the patient went under the anesthetic the tumor disappeared. The abdomen could be palpated but nothing could be found. The physician in charge believed the diagnosis of phantom tumor was an impeachment of his intelligence. A right rectus incision was made but the abdominal contents were normal.

After-course.—The tumor was not present for three weeks after the operation. The family doctor incautiously told the mother that the patient's troubles were imaginary. The patient was vigorously upbraided by her mother. The tumor promptly reappeared. The patient married two years later and has since borne four children and has had good health now more than fifteen years.

Comment.—I have since seen phantom tumors aplenty, but have never again cut into one. There is one sign of phantom tumor not commonly mentioned. Its upper or lower limit is always at one of the inscriptions tendinae of the rectus muscle. The confines are sharply marked at the inscription. The tumor also always ends in a fairly tense muscle above. The tumor is due to a segmental contraction of the rectus muscle and the associated portion of the lateral abdominal muscles. When the patient goes under the anesthetic these portions of the abdominal muscles not involved in the tumor loose the tension first, making it possible to follow the relaxation of the muscles directly involved in the tumor.

CASE 5.—A matron aged fifty-four came to the hospital because of pain in the right side of the abdomen.

History.—Ten days ago she began to have a distress across the upper part of the abdomen, most marked in the pit of the stomach. There was no actual pain but a feeling of discomfort. There was neither nausea nor vomiting. Three days later a severe steady pain extending entirely across the abdomen, most marked in the region of the navel developed. She did not vomit until given medicine by her doctor. She continued to vomit every day after this. The vomitus was always greenish with a strong bile taste. Two days ago the pains became more intense in the right side. They

have remained there since. At the present time there is a pronounced soreness but no sharp pains. A cathartic and an enema are required to move the bowels. She never has had a similar attack. One year ago she had a spell of colic lasting three hours attended by vomiting. It was not followed by any soreness. She has had some bloating since then, but her appetite has been uniformly good.

Examination.—She is a plump, well preserved woman apparently not desperately sick, yet very uncomfortable and apprehensive of worse things to come. The abdomen is everywhere resistant, being most marked on the right side. There is marked tenderness between the costal margin and the crest of the ilium. Careful palpation demonstrates a tumor of those dimensions. The point of most pronounced tenderness is at the right rectus border on the level with the umbilicus. The mass does not move with respiration. She has some pain in the back in the region of the tenth rib. This is increased by pressure on the mass in front. The tumor can not be made to appear in the renal triangle. The urine shows a few leucocytes, W.b.c. 12,800.

Diagnosis.—An attack of colic a year ago in a woman of this type and weight suggests a gall bladder attack. The present attack is in harmony with that supposition, being a cholecystitis and not a colic. Usually a colic is the immediate forerunner of a cholecystitis. That is lacking here. The pain in the back made worse by pressure is in harmony with such a supposition. There is no fullness or edema in the renal region as there would be if it were a perinephritis, and the urine does not comport with such a supposition. An appendix lying lateral to the ascending colon would not make such a tumor, particularly not without showing pronounced septic symptoms. The condition likely is a gall bladder. She has markedly improved in the past two days but is still sick. It seems an act of prudence to allow her still further to improve before proceeding to operation.

Treatment.—Ten days later an incision was made along the right semilunar line. A blue-black cyst appeared which extended from near the crest of the ilium to under the rib border. The lower pole was delivered after separating the adhesions. It was followed to the liver and proved to be the gall bladder. It was cystic and no stone could be palpated. An incision was made and a large quan-

tity of liquid blood escaped. At the bottom two huge stones and two smaller ones were found. The gall bladder was removed. A drain was placed.

Pathology.—The two large stones each measured $2\frac{1}{2}$ inches long by




Fig. 359.—Enlarged thick walled gall bladder. (Reduced one-half.)

2 inches in diameter. The smaller ones are the size of a hickory nut. The wall of the gall bladder is necrotic and about 8 mm. thick (Fig. 359). The slide shows marked hemorrhagic infiltration. The epithelium is exfoliated for the most part.

After-course.—Recovery was uneventful.

Comment.—It seems strange that such huge stones could be carried without causing more distress. Had I known that the gall bladder was blue-black I should not have dared to wait a week before operating. In another week it might have perforated. There is no certainty of this for it is known ovarian cysts infiltrated to this extent recover their nutrition. This is particularly likely to occur if they have temporary aid by adhesions with neighboring organs. This gall bladder had this and likely would have weathered the storm unaided because there was no virulent infection present. The adhesions of the gall bladder were such as to make it stationary on deep respiration, thus obliterating one of the cardinal signs of enlargement of this organ.

RENAL

The renal region besides harboring tumors derived from the kidney may contain those from the gall bladder and perirenal space as well as wanderers from other regions of the abdomen.

CASE 1.—A child aged fifteen months was brought to the hospital because of a tumor in the right side.

History.—The child was normal in every way as an infant. Six months ago the mother noticed a tumor in the right side. The child seemed perfectly well otherwise.

Examination.—On the right side of the abdomen bulging from under the costal margin is a globular mass the size of a fist. It is easily palpable in the flank when pressed upon in front. It is smooth, dense, and pressure upon it does not inconvenience the child.

Diagnosis.—Nearly all tumors in this region in young children are some form of mixed tumor. The only diagnostic point of interest is whether or not it is a tumor of the kidney at all, for tumors in this region, not associated with the kidney, are by no means rare. The distinction is not possible clinically and even during the course of the operation the surgeon may be so preoccupied with other things that this detail of determining if it represents the kidney or not escapes his attention, and he puts the question to the pathologist.

Treatment.—The tumor was removed without difficulty (Fig. 360).

Pathology.—The structure was that of the usual mixed tumor, but was characterized by large bundles of perfectly striated muscle fibers, therefore it is a rhabdomyosarcoma (Fig. 361).

After-course.—The child recovered well from the operation, but died after a few months of an enterocolitis.

Comment.—Young children bear the removal of these large tumors very well and a considerable proportion remain free, at least for many years.

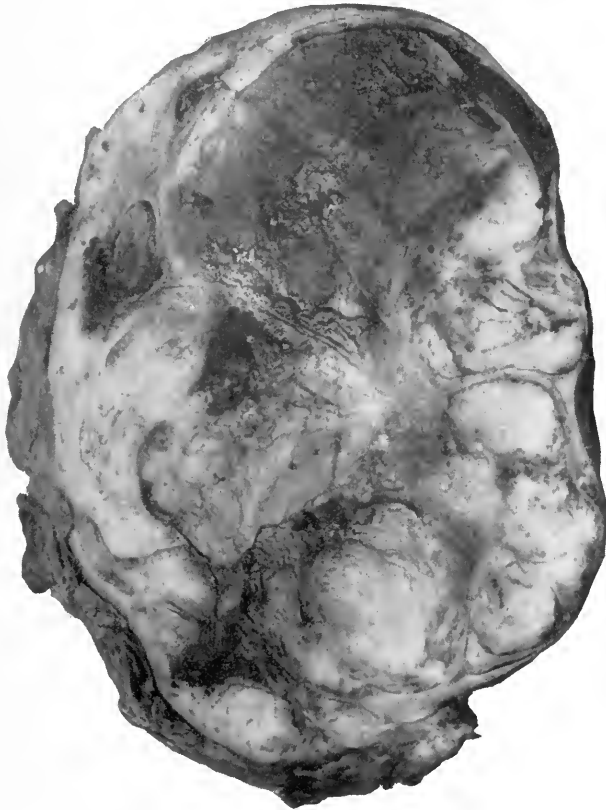

Fig. 360.—Rhabdomyosarcoma of the right kidney.

CASE 2.—A retired gentleman aged sixty-eight came for consultation because of a tumor in the right side of the abdomen.

History.—He has always had good health until 9 years ago. Since that time he has had pain in the chest which several times has extended down the left arm. In several of these attacks the pain has been very severe, so that he felt his life would be crushed out.

In the interval his general health has been good. Six months ago, however, he noticed that his general health was not so good. His appetite has become less and he has felt weaker. There has been some difficulty in urinating and at intervals he has noted some blood in the urine. He has had some pain in the right flank extending downward and forward but never to the bladder or testicle.

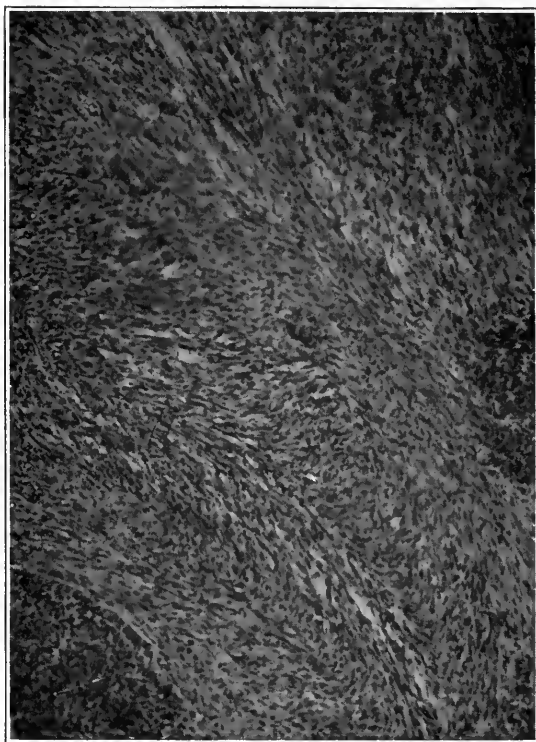


Fig. 361.—Rhabdomyosarcoma of the right kidney. The striated muscle fibers cannot be made to show in the photograph.

Examination.—The heart is generally enlarged, and the aortic sounds are exaggerated. The abdomen is prominent, particularly on the right side. The lower abdomen is marked by dilated veins extending upward toward the costal margin (Fig. 362). The abdomen for the most part is soft and flabby but the right upper quadrant is occupied by a firm roundish tumor. When pressed upon by

the anterior hand a bulging can be felt in the renal space and when the posterior hand makes pressure the mass can be felt to roll over toward the midline as far as the right border of the vertebral column. It moves slightly with respiration and is continuous with the lower dullness but at the medial border there is a deep angle of tympany between the liver and tumor. The prostate is but little enlarged and is smooth and not tender.

Diagnosis.—The physical findings indicate a tumor of the renal

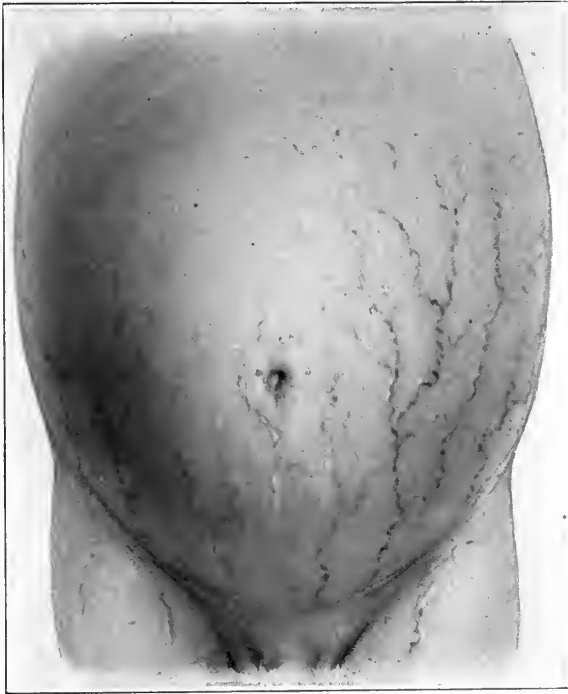

Fig. 362.—Dilated veins in the abdominal wall due to obstruction of the venous return. The artist wrongfully made the most prominent veins on the left side.

region. Other tumors of this region are excluded by the transient hematuria. Its large size makes a separation from it and the liver impossible. There is no evidence that the blood comes from the bladder.

Treatment.—None.

After-course.—He died rather suddenly three months later. The exact cause was not learned.

Comment.—The tumor itself was movable and while it was large and the operation would have been difficult, the technical hazards would not have forbidden the attempt. The proneness of hypernephroma to grow into the renal veins is well known and the presence of the dilated veins in the abdominal wall indicates that in this case not only the renal vein but the vena cava as well has become plugged by the tumor growth. Therefore, even though the growth might have been removed, the chief menace would have remained. Aside from this the manipulations of the operator might have dislodged a part of the intravascular growth with immediate disastrous results. The importance of the presence of dilated vessels in the abdominal walls over an intraabdominal tumor is not sufficiently recognized. I have seen surgeons cut down upon tumors despite this warning sign, only of course to be compelled to close the abdomen, or worse still, to attempt a removal of the tumor with more or less immediate disastrous results.

CASE 3.—A matron aged fifty-six came because of pain in the left side of the abdomen.

History.—The patient has always had good health and has three healthy children. Four years ago she began to have pain in the left lower abdomen. At first these were merely annoying but later they became so severe that she had to lie down. Being much on her feet seemed to increase the pain. When asked to locate the pain she applied the palm of her hand across her abdomen from the splenic region to the pubes.

Examination.—The patient is a large, strong woman with a slight general anemia. To the left of the median line just above the level of the umbilicus is a tumor the size of a goose egg. The aorta is palpable and the pulsations are unusually strong and can be followed well down the course of the external iliac arteries. The tumor seems to be independent of the aorta, but it pulsates with equal vigor. There is an area the breadth of two fingers where the pulsation of the tumor ends and that of the aorta begins. There is a trace of albumin in the urine and a few casts. The Wassermann reaction was strongly positive.

Diagnosis.—A pulsating tumor separate from the aorta in direct line with the renal artery suggested the rare renal aneurysm. Since there seemed to be a portion of the renal artery between the aneurysm and the aorta, it seemed that the tumor might be operable.

Treatment.—When the tumor was cut down upon, a tumor as outlined in the cut was exposed. What remained of the kidney sat as a cap on the outer upper part of the aneurysm. The external iliae arteries were markedly dilated, the left forming a short loop upward. At the narrowed portion of the tumor where it approached the aorta there was a calcareous plaque as wide as a dime and as long as a quarter. This formed a calcareous wall and it seemed useless to attempt to ligate through such tissue, so the operation was abandoned (Fig. 363).

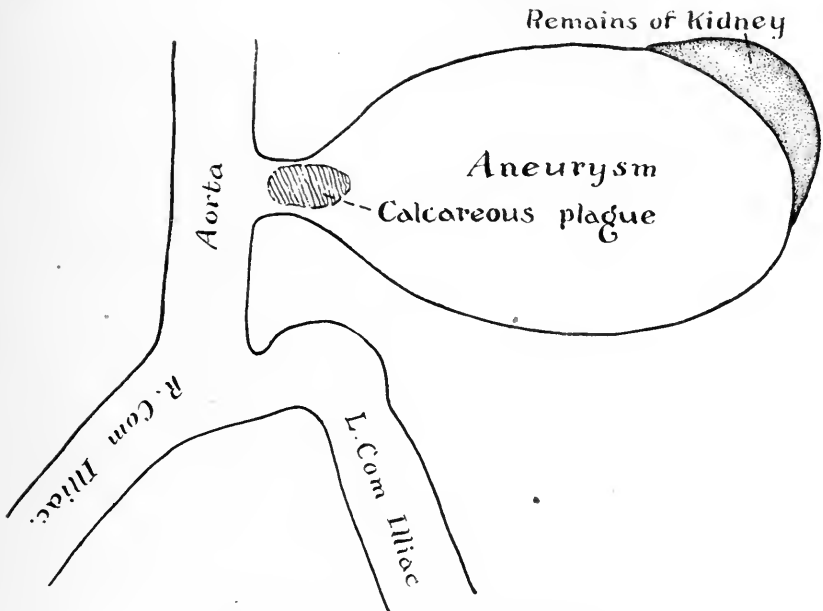


Fig. 363.—Aneurysm of the left renal artery.

After-course.—She was placed on antisyphilitic treatment which was followed by a marked amelioration of the pain and improvement of her general well being, but the tumor remains as before.

Comment.—This would have been an ideal case to try out the wire method, but the material was not at hand. The case is interesting from a diagnostic point of view because of its rarity. This in fact furnished the only element of doubt. The iliae arteries were markedly dilated and the left made a peculiar hump upward which gave the feel of a secondary pulsating tumor.

CASE 4.—A housewife aged forty-six came to the hospital because of a tumor in the left side.

History.—The patient noticed a tumor in the left side about four years ago. It has grown steadily since. Up to four months ago it gave no trouble at all and she felt strong and well. Since that time she has had severe pain in the left side of the abdomen. This comes on at no special time and is not affected by anything. It usually gets some better if she lies down. The pain is often almost unbearable and radiates to the left shoulder and head. She also has had a pain during the last six weeks under the right costal margin. It comes on at no special time and is not affected by eating. She is not troubled with general malaise and weakness. The appetite is not so good as formerly and the bowels are constipated. She gets up once each night to pass urine, usually, but sometimes has spells of marked bladder irritation. There is no shortness of breath on exertion but her feet swell towards evening at times. She has seven children living, and one, aged one year, died of pneumonia. Youngest living child ten years old. No miscarriages. Menstruation regular, somewhat painful, lasts four to five days.

Examination.—Patient fairly well nourished but appears anemic. The skin is slightly yellow tinged. Heart and lungs negative. A large abdominal tumor, situated on the left side, is apparent by palpation. It extends to the level of the umbilicus and within an inch of the rectus margin. This tumor is hard and smooth and has several irregularities along its inner border. By pressing on the tumor abdominally it can be felt from the back below the 12th rib. She has a pronounced cystocele. Hg 65 Tallquist; W.b.c. 377,000; 40 per cent polynuclears; large lymphocytes, 10 per cent; small lymphocytes, 15 per cent; Path. myelocytes, 35 per cent; R.b.c. 2,400,000. The urine contains many pus cells and some albumin.

Diagnosis.—The blood picture at once makes the diagnosis of myelogenous leucemia. The physical findings suggested a kidney tumor as much as the spleen because it could be made to appear so prominently in the renal triangle.

Treatment.—The patient returned home and her physician gave her arsenic.

After-course.—She died eight months later.

Comment.—In this case the blood examination was all important.

CASE 5.—A housewife aged fifty-six came because of a tumor in her left side.

History.—The patient had a severe sick spell sixteen years ago. She does not know its nature, but she was in bed all summer. There was pronounced digestive disturbance but there was no definite pain anywhere. Her weight was reduced to 85 pounds. After she

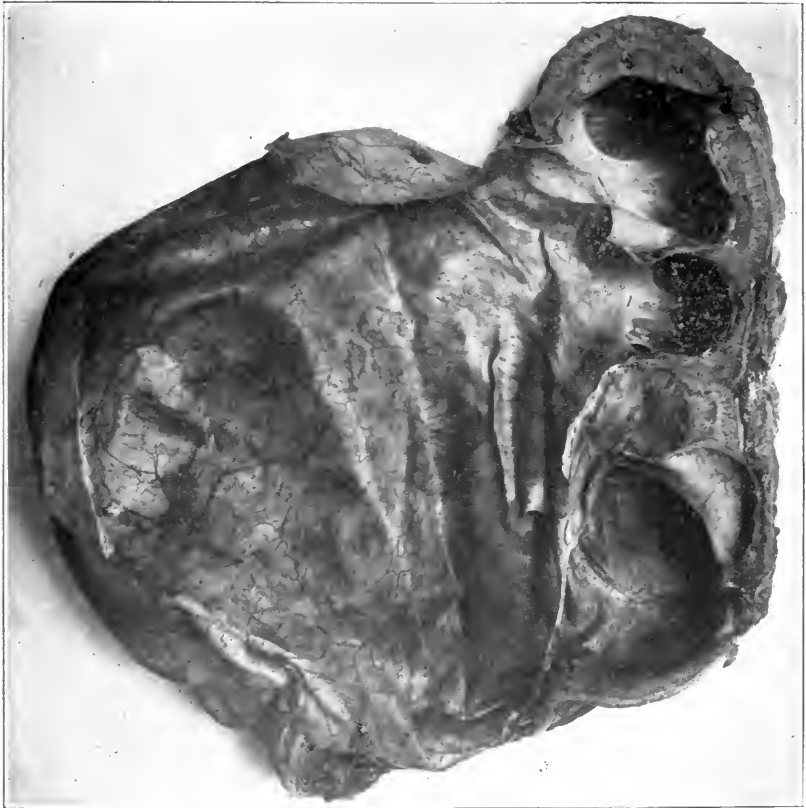

Fig. 364.—Hypernephrosis showing the dilated pelvis and thin cortex of kidney remaining.

recovered it was discovered that she had a tumor in the left side below the costal border. This tumor would disappear and then after a lapse of some time, would reappear. Five years ago she was sick of an unnamed disease several months. Since then the tumor has been constantly present. She has some digestive disturbance but

now weighs 100 pounds. Her stomach is sensitive to many foods and she thinks the tumor causes it by pressing on the stomach.

Examination.—A globular tumor occupies the space between the lateral border of the left rectus, the short ribs above, and the crest of the ilium below. On palpation it is fluctuant, slightly movable, and pressure upon it causes bulging in the renal region. The urine is negative. There is a general anemia. No urine flows from the left ureter.

Diagnosis.—The presence of a fluctuating tumor in this region is most likely a hypernephrosis. This assumption is made certain by the absence of the flow of urine from the orifice of this side.

Treatment.—The tumor was removed transperitoneally and the patient promptly recovered.

Pathology.—The tumor is the size of an adult head. A portion of the cortex of the kidney was well preserved and capable of performing some function. The pelvis was dilated to a thin parchment-like sack (Fig. 364). The ureter is occluded at the point of insertion into the dilated pelvis.

After-course.—The patient improved greatly in strength and weight and her stomach symptoms much improved, though she never ceased to have some digestive disturbance. She died of lobar pneumonia four years after operation.

Comment.—The nature of the process which gave rise to the occlusion of the ureter is not clear. Such a tumor is no real menace and likely disturbs because of its size. There was some renal substance left and had an internal plastic been done some function would no doubt have been performed. Since evidently she had relied on her right kidney for years a speedy termination of the operation was deemed more important than the preservation of the small amount of renal substance the affected kidney represented. The reconstruction of a pelvis from such an enormous sac is not altogether a simple bit of surgery and the functioning of the product is not always ideal.

CASE 6.—A widow aged sixty-two came to the hospital for relief of a tumor in her right side.

History.—The patient has felt somewhat weakened and shaky for six months. Three months ago she accidentally found a tumor in the right side. It has not been sore or painful and she has been able to go around without pain or inconvenience. There has



Fig. 365.—Hypernephroma of the kidney.

never been any blood in the urine. She passed the menopause ten years ago and has had no discharge since. She is obstinately constipated but not more so than usual and she has no pain when the bowels move. She has had some palpitation.

Examination.—A tumor the size of a fetal head occupies the right upper quadrant of the abdomen. The mass can be palpated from the renal triangle from behind. It can be made to disappear partly under the liver. It moves with respiration but it does not move with the whole respiratory act, but begins after the liver has already partly descended. When the patient turns on

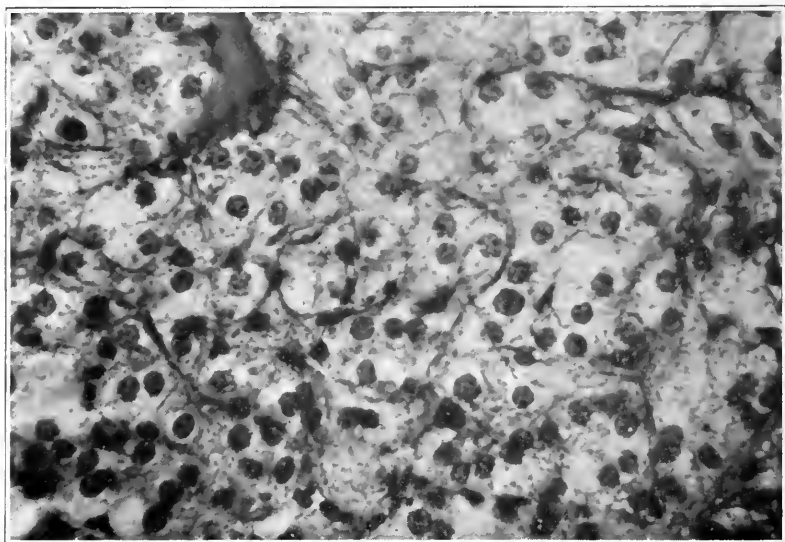


Fig. 366.—Hypernephroma of the kidney.

her left side the tumor falls toward that side. The urine is normal. The blood pressure is 160-120.

Diagnosis.—The fact that it can be easily palpated from the renal triangle makes it seem likely that it has its primary seat in the kidney. That it is not connected with the liver is evident from the fact that it does not begin its descent when the liver begins. There never have been any urinary symptoms, which makes an infective tumor unlikely, and its firm consistence excludes a cystic tumor. The slight irregularity of the surface likewise speaks for a solid expansile tumor. The law of probability suggests a hyper-

nephroma. This is supported by the fact that a carcinoma is seldom so large, and mixed tumors are products of early life. This tumor is more mobile than retroperitoneal tumors derived from the fibrous or fatty tissues.

Treatment.—A nephrectomy was done through a semilunar line incision.

Pathology.—The upper pole of the kidney is occupied by a large solid mass with here and there a cystic tumor (Fig. 365). It is fairly well encapsulated against the tumor. The renal vessels are not involved. The surface of the growth is grayish in color with yellowish areas. The tumor is made up of large cells with vacuolated protoplasm. The cells are arranged in columns or rows as in the cortex of the adrenals (Fig. 366).

After-course.—Healing was prompt. After a few months a small abscess formed in the scar.

Comment.—The insidious, painless onset with a great degree of encapsulation indicates a mild degree of malignancy. Inasmuch as the renal pelvis was not involved or invaded, there were no urinary disturbances. It was encapsulated against the large renal vessels, hence extension by this avenue is not likely. Whether these tumors are “hypernephromas” or not is open to question. Be this as it may, the term expresses a clinical entity surgeons have learned to understand and controversial matters may be left to the pathologists.

INGUINAL

Tumors found in the ileocecal region are usually inflammatory, granulomatous or neoplastic. These need to be distinguished from abscesses either without the abdomen or in the retroperitoneal tissue.

CASE 1.—A grocery man aged forty-eight came to the hospital because of pain in the right side of the abdomen.

History.—Two weeks ago he began having pain in the right lower part of the abdomen. The pain was most severe when he attempted to walk. A moderate degree of nausea was present, but no vomiting. He had some rise of temperature. Pain was continuous until four days ago. Since that time he has no pain when he is perfectly quiet. Pain returns if he walks or moves about. His general health has always been good. He has had no bowel movement for three days.

Examination.—The patient is thin and shows loss of weight. There is no abdominal distention and no rigidity of the abdominal wall. To the right and below the umbilicus is a tumor as large as the palm of the hand. The point of maximum tenderness is exactly over the classical McBurney's point. The mass is not movable, is sensitive to

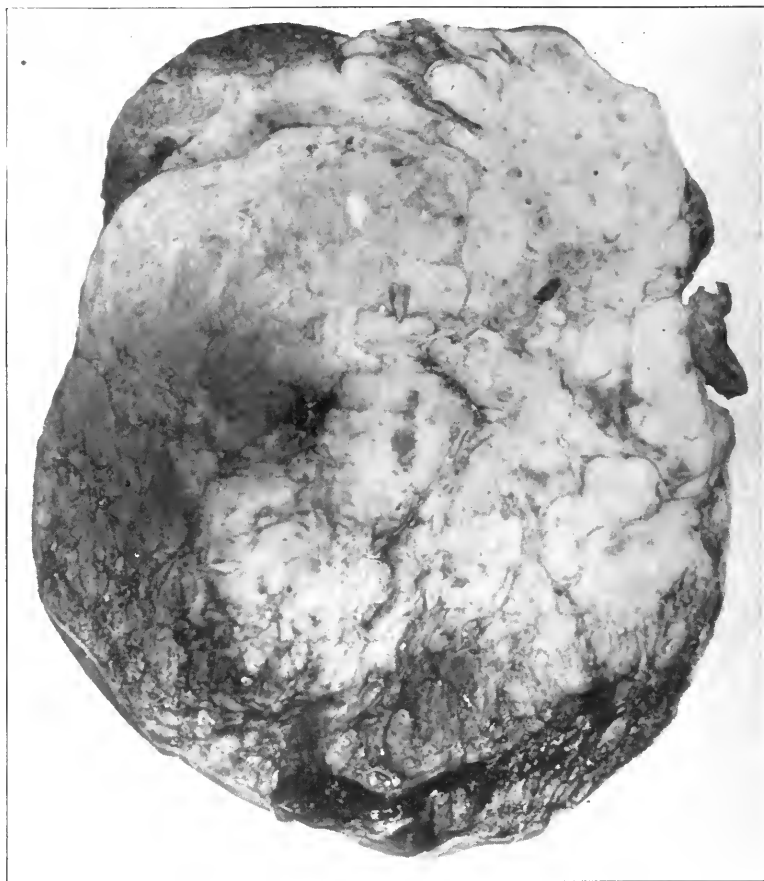

Fig. 367.—Pendulous fibrosarcoma of the external surface of the stomach.

the touch, but there is no surrounding muscular rigidity. It does not move with a change of position. He has 17,400 leucocytes, 86 per cent are polymuclears. The urine has a trace of albumin and a few casts and an occasional red cell.

Diagnosis.—The history and location of pain suggests an appendicitis. The point of maximum tenderness at the time of observation bears this out. The tumefaction is surprisingly well defined for an inflammatory mass. However, omental adhesions about an appendix when not attached to the anterior abdominal wall give such findings. Since it seems to be of recent origin, this is the only available explanation. The increase in leucocytosis suggests the likelihood of a deeply seated abscess pretty well encapsulated.

Treatment.—A right rectus incision disloses a tumor as large as the palm of the hand attached to the lower border of the stomach

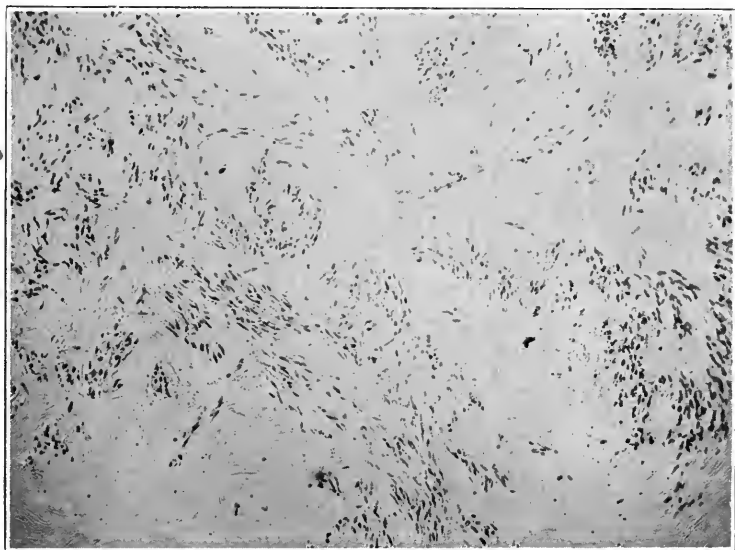


Fig. 368.—Fibrosarcoma of the stomach.

near the pylorus by a pedicle an inch wide and half as thick. At its lower outer pole is an area of attachment as big as a finger, apparently of recent origin. The pedicles were severed at the stomach and abdominal walls, respectively.

Pathology.—The tumor measures 8 x 5 x 2 cm. It is dense to the feel and its surface is slightly corrugated. Its color is mottled by varying shades of red and gray. The cut surface bears out this color scheme. The slide shows a spindle-celled, fibrous structure. (Figs. 367 and 368.)

After-course.—The recovery was prompt and to date permanent.

Comment.—The tumor obviously was of long duration, its anlage probably congenital. From the appearance of the attachment it is likely that owing to a partly twisted pedicle the lower portion obtained an attachment to the anterior parietal wall producing at once the pain and local tenderness. The leucocytosis can be explained on the ground of irritation of the whole tumor mass.

CASE 2.—A merchant aged forty-two came to the hospital because of pain in the right flank and loss of weight.

History.—Nine months ago he noticed a pain in the right side when he stooped over. At this time he had the pain only when he was working. He never had any sudden acute attacks of pain, neither did he ever vomit, feel nauseated, nor have fever. About two months ago he began to have pain clear across the lower abdomen in addition to the one in the right side. This pain in the lower abdomen seems to be present usually just before the passage of gas, and is relieved as soon as the gas is passed. The pain in the right side is now almost constantly present. It is a dull, heavy pain. Eating seems to affect the pain very little if any at all. The bowels have been constipated of late. The taking of purgatives does not seem to increase the pain. There are no urinary symptoms. The appetite is good, and there is no digestive disturbance. He has lost 20 pounds in weight in the last six months but feels pretty good except for the pain in the side and abdomen.

Examination.—Patient has the appearance of a normal healthy individual, and does not bear evidence of having lost weight. There is a small movable tumor in the right side half way between the right costal margin and ilium. It is freely movable on change of position and somewhat tender to pressure. It is hard and somewhat lobulated.

Diagnosis.—The history of progressively increasing pain with the appearance later of obstructive symptoms is suggestive of carcinoma or tuberculosis. The findings of a dense bosselated mass makes the former of these two possibilities the likely one. Sarcoma can be ruled out for these tumors do not produce obstruction. A low grade of inflammation sometimes produces a tumor with symptoms of narrowing of the lumen of the gut, but these are usually not movable and are not so dense as this one. This is a possibility that can be excluded after the mass is in hand.

Treatment.—A right rectus incision was made. The mass was found to be white, hard, and nodular. The appendix was large and hard, but not nodular. As far as could be determined, there were no metastases in the mesenteric lymph nodes except just medial to the mass. The mass with the cecum, appendix and a couple of inches of the ileum were resected. A lateral anastomosis made

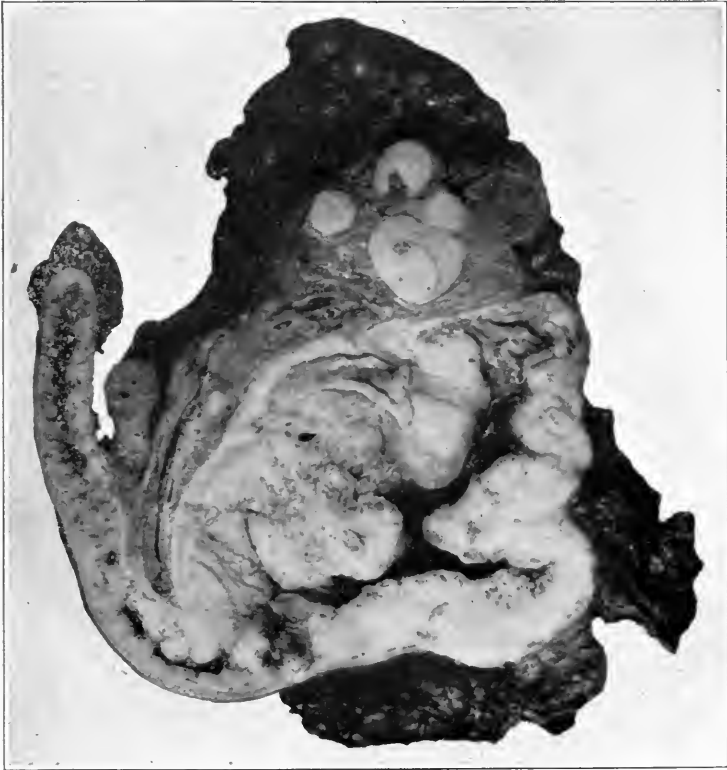

Fig. 369.—Carcinoma of the cecum with lymph gland involvement. The larger lymph gland shows necrotic center.

between the ileum and ascending colon. One gauze drain was inserted in the right flank through a separate incision.

Pathology.—The mass is 6 cm. in diameter and irregularly lobulated. It occupies chiefly the ileocecal junction which it narrows to the size of a lead pencil. The lumen of the cecum is reduced to a narrow slit (Fig. 369) and the appendix is thickened. Just outside

of the cecal wall are a number of lymph glands which show fine white points within them. The larger of them shows a necrotic area the size of a pea. The slide shows a typical adenocarcinoma.

After-course.—There was very little postoperative shock. The pulse did not go over 100 immediately following the operation. The temperature went as high as 102° by the fifth postoperative day, but then came down rapidly. There was a little vomiting every day which stopped when food and fluid were withheld and proctoeclysis given. There was considerable pus drainage from the flank wound. Food was withheld for a week. On the tenth day a cathartic was given by mouth followed by bowel movement the next day. On the twelfth day the main incision line was swollen. It was separated by hemostats and drained of a large amount of foul-smelling pus. The temperature immediately dropped to normal and remained so until dismissal on the twenty-fifth day. When the patient left the hospital the flank wound was entirely healed. The incision still drained a little pus through a small sinus. The temperature and pulse were normal. The patient was on a general diet and was feeling fine. The bowels move normally without a cathartic.

Comment.—There are glands affected about the cecum and while carcinoma of the cecum usually offers a relatively good prognosis, this makes it likely the growth will appear in the retroperitoneal lymph glands. Once lymph glands become involved in any malignant tumor prospects of a cure are not good.

CASE 3.—A married woman aged twenty-four was brought because of a tumor low in the abdomen.

History.—This patient passed a normal puerperium two and a half years ago. Three months ago she went through her second confinement. The labor was prolonged and difficult. She remained weak for a number of weeks and had much bladder irritation and was obstinately constipated. A month after labor she was examined by a surgeon who discovered a tumor in the pelvis and advised operation.

Examination.—The patient is pale and lies with the left thigh flexed on the abdomen. She declares she can not extend it. Abdominal palpation shows a tumor in the left iliac fossa reaching within two or three inches of the crest of the ilium and disappearing in the pelvis. Bimanual palpation shows the tumor to extend to the

base of the broad ligament and pushes the uterus to the right (Fig. 370). The uterus is not firmly fixed and the bottom of the culdesac is free. The tumor presses on the bladder, but does not irritate its walls. The tumor is but slightly movable in the pelvis and is quite firmly fixed over the brim of the pelvis. It is firm, elastic, and firm pressure and manipulation causes pain. The Hg is 75, with 12,000 leucocytes.

Diagnosis.—Obviously a tumor of such a size did not exist at the time of delivery or the birth of the child would not have been possible. The history is that the birth was difficult; this may be accounted for by the presence of a smaller tumor which has since grown. Such a tumor must have been a fibroid or an ovarian cyst. This evidently is neither, for it clearly lies in the fold of the broad

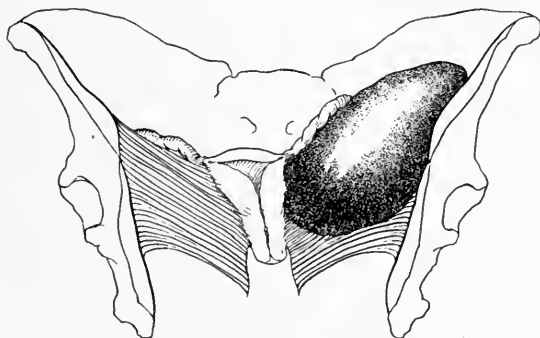


Fig. 370.—Pelvic hematoma.

ligament, and following this escapes to the iliac fossa extraperitoneally. No solid tumor could have done this. Obviously, therefore, the material of this tumor must have reached this situation when in the fluid state. It is solid now. There is but one fluid capable of doing this, namely, blood. We have, therefore, a blood clot located within the broad ligament and extending into the iliac fossa, irritating the psoas muscle, hence the thigh contraction. An inflammatory exudate may assume this form. If it were an acute suppuration, the reaction would be greater than in this case; and if chronic, more dense. Blood clot has a feeling all its own, dense, elastic, not simulated by any other material.

Treatment.—Rest in bed was advised until the contraction of the thigh subsides then as much exercise as she feels like taking.

After-course.—The patient was requested to appear for examination in three months. When she presented herself, very slight thickening only remained in the base of the broad ligament. The uterus was freely movable and but little pain was caused. The bladder irritation had disappeared and the bowels moved with mild laxatives. She had regained her normal strength.

Comment.—Had this been a malignant tumor as my predecessor assumed, it would have been utterly inoperable. Blood clots regularly require from two to three months to become absorbed. The activity of the therapeutics may be inversely proportional to the intelligence of the patient. These clots should be watched. Occasionally they become infected and must then be drained through the vagina or in some instances extraperitoneally above Poupert's ligament.

CASE 4.—A school boy aged fourteen came to the hospital because of a painful tumor in his side.

History.—For three years at intervals of several months, he has had attacks of abdominal pain sometimes attended by nausea but never by vomiting. The pains were cramp-like in character and lasted only a few hours and were followed by no tenderness. Some weeks ago he noticed a swelling in the right side above the hip bone. He had had no pain and he does not recall when he had the last attack of pain. The condition was diagnosed a hernia by an osteopath who administered treatments. Following this he had pains.

Examination.—A tumor the size of a small apple is located above and medial to the anterior superior spine. It is not movable and is sensitive to the touch. It seems quite superficial and the abdominal wall can not be moved over it. Temperature 101°, pulse 90.

Diagnosis.—The history of repeated colics with the appearance of a mass suggests at first thought an obstructive rather than an inflammatory lesion. Carcinoma in a lad is rare and would not extend over three years. Tuberculosis would not present such an intermittent history. The present sensation on palpation suggests an inflammatory lesion because of its relation to the abdominal wall and to the sensitiveness and fever. Whatever may have been the initial lesion an infection now exists.

Treatment.—A quantity of pus was drained. A smooth walled cavity the size of an egg containing an enterolith was found. No attempt was made to find the appendix.

After-course.—The opening healed in three weeks.

Comment.—Evidently the lad developed an enterolith and at intervals the appendix made fruitless attempts to expel it. Probably it escaped from the lumen of the appendix by gradually necrosing its walls. Adhesions had anticipated this process and a thoroughly walled off cavity resulted. The cure will be permanent, the appendix having been eliminated by the necrotic process. Unless a hernia develops as a result of the drainage, he will not require any further operations.

CASE 5.—A farmer aged forty-five came to the hospital because of pain and a lump in the right groin.

History.—He has had pain in his right groin for the past six months. He had some tenderness on two occasions preceded by spontaneous pain lasting for several days. During the past few weeks the pain has been constant. He has felt weak but has continued with his work. He has felt feverish at times. The bowels have moved regularly. Previously to the onset of this trouble he had a chronic digestive disorder characterized by burning both before and after eating.

Examination.—The patient is a long, lean, rawboned man who gives no evidence of having undergone suffering or disease. A nodulated mass the size of an egg lies internal to the anterior superior spine. It is dense, bosselated, and but little movable. It is sensitive on deep pressure. The abdominal wall becomes tense over it when pressure is made. There seems to be an indefinite mass projecting from the tumor to the epigastrium but the more or less voluntary retraction of the muscles makes a satisfactory examination impossible. Pulse 74, temperature 98.4°, respiration 16. The urine is negative. W.b.c. 11,000; R.b.c. 4,000,000. Polynuclears 72; large mononuclears 12; small mononuclears 16; Hg 80.

Diagnosis.—The history of disability extending over six months with two periods of exacerbation suggests an inflammation of the appendix without complete resolution. However, such a long duration would be very unusual without progressive improvement. Such a long duration could be counted on only if there was a chronic nonsuppurative inflammation of the great omentum. In six months that should have been more acute. The hard nodular feel is that of malignancy, but usually carcinomas early are more movable and less sensitive. The prolongation of the mass toward the epigastrium

suggests an omental affection. Extension in this direction in carcinoma so early and before obstruction appears would be unusual. The leucocyte count, both the absolute and the relative, might occur either in malignancy or induration of the omentum. If it is omental, time should remedy it; if malignant, early operation is urgent. On the other hand if there is an actual induration extending from the ileocecal region toward the epigastrium which is malignant in character, operation is wholly useless. Since the diagnosis is not certain, exploration may be advised.

Treatment.—An incision was made along the anterior border of the right rectus. A nodular mass was situated at the ileocecal junction which was free from the great omentum. From this in the retroperitoneal tissue extending to the epigastrium was a hard nodular mass, evidently malignant lymph glands. This mass seemed movable. Resection with lateral anastomosis of the severed ileum to the remains of the ascending colon was done. The renal vessels and the cava were exposed in the enucleation.

Pathology.—The tumor had narrowed the ileocecal orifice so that the tip of the little finger could hardly be forced through it. The retroperitoneal mass was composed of a conglomerate of lymph glands. The slides showed typical carcinoma.

After-course.—There was a moderate degree of shock, the pulse varying between 110 and 120 during the first twelve hours, but then came down to 90. On the second day he began to vomit quantities of greenish fluid. Gastric lavage was done a number of times and he became comfortable. He progressed favorably the succeeding days, but on the seventh day he began to hiccough. This was followed by brownish-green vomitus in large amounts. Lavage was again done and the gauze drain was removed. The condition remained unchanged, the temperature began to descend, and he died on the tenth day with subnormal temperature. The autopsy showed a gangrene of the terminal foot or more of the small gut with extensive thrombosis of the mesenteric vessels. There was no leak and no evidence of peritonitis.

Comment.—After the fact of retroperitoneal metastasis was established, the abdomen should have been closed. Once the field of operation is exposed most surgeons find it hard to desist if the operation is technically possible even if there is no prospect of actual cure. This was such a case. Obviously the thrombosis took

place some days after operation or separation of the necrotic portions of the gut would have occurred. Death was due likely to toxic absorption.

CASE 6.—A matron aged thirty-five was brought to the hospital because of a tumor in the lower abdomen following an operation for myoma of the uterus.

History.—For several years the patient has been suffering from the usual symptoms of myoma. This tumor, which was the size of a fetal head, was removed by supravaginal hysterectomy by a competent surgeon (Fig. 371). The tumor on section showed extensive colloid degeneration. Recovery was uneventful from the anesthetic and the immediate effects of the operation. In twelve hours the patient began to complain of bladder irritation and tenesmus was added in the two days following. This continued unabated for several weeks. There was moderate rise of temperature and increase of the pulse rate. At the end of three weeks she was examined by her surgeon and a mass was found to fill the pelvis. After consultation the diagnosis of sarcoma was made and an unfavorable prognosis rendered. The same state continued for two or three weeks until the time she presented herself for examination.

Examination.—The patient seems well nourished, without signs of anemia, but very apprehensive and scarcely able to walk with support. The abdominal walls seem firm, neither rigid or flaccid. Bimanual examination shows a firm tumor 3 x 5 inches lying transverse to the long axis of the pelvis (Fig. 372). It seems smooth in outline but firmly fixed in the tissue, lies close upon the bladder, and seems to surround the rectum.

Diagnosis.—The onset of bladder irritation soon after the operation, with the fever, speaks for a blood clot. The physical findings correspond to this, being identical with that after tubal abortion. Sarcoma does sometimes follow myomectomy with frightful rapidity, but never so quickly as this, and only follows hemorrhagic myomas and not colloid degeneration as in this one. Sarcomatous recurrences are soft, semifluctuating masses much softer than a blood clot, and the course is progressive.

Treatment.—None.

After-course.—After the patient was told the condition was an innocent one and would clear up in a few months she lost her apprehen-

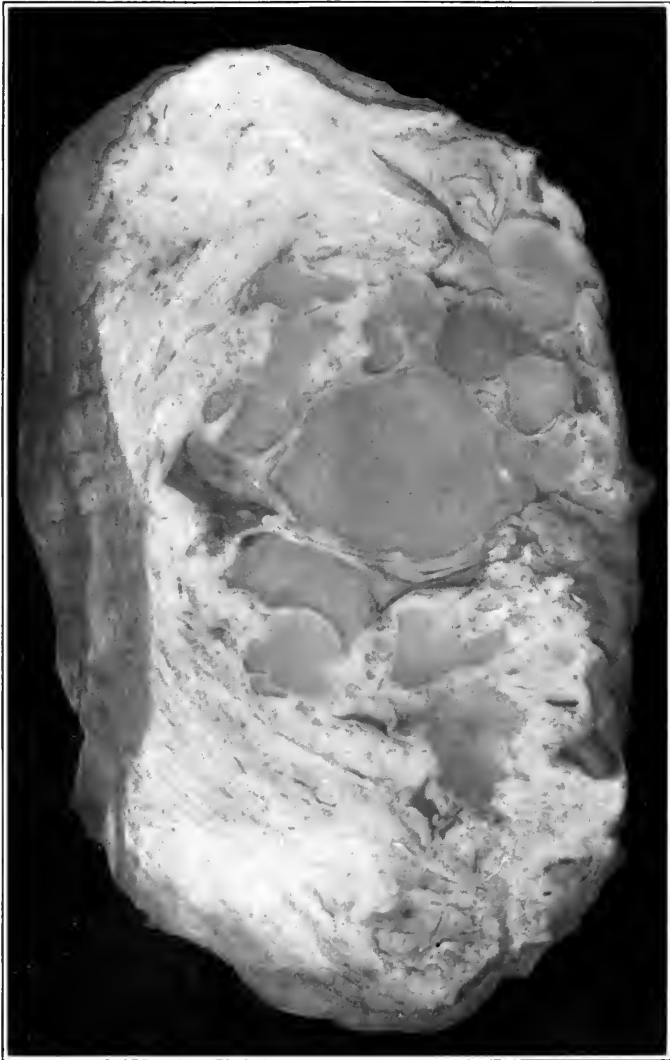


Fig. 371.—Colloid degeneration of a myoma of the uterus.

sive appearance and left the office with a stride far too vigorous to permit her escort to render assistance. In three months the entire mass had disappeared and the pelvis has remained free from any disturbance.

Comment.—Hematomas following operation are far more common than is generally appreciated. They give rise to a low degree of temperature, ranging usually from 99.5° to 102° with a leucocytosis of about 12,000. This disturbance is often ascribed to a low degree

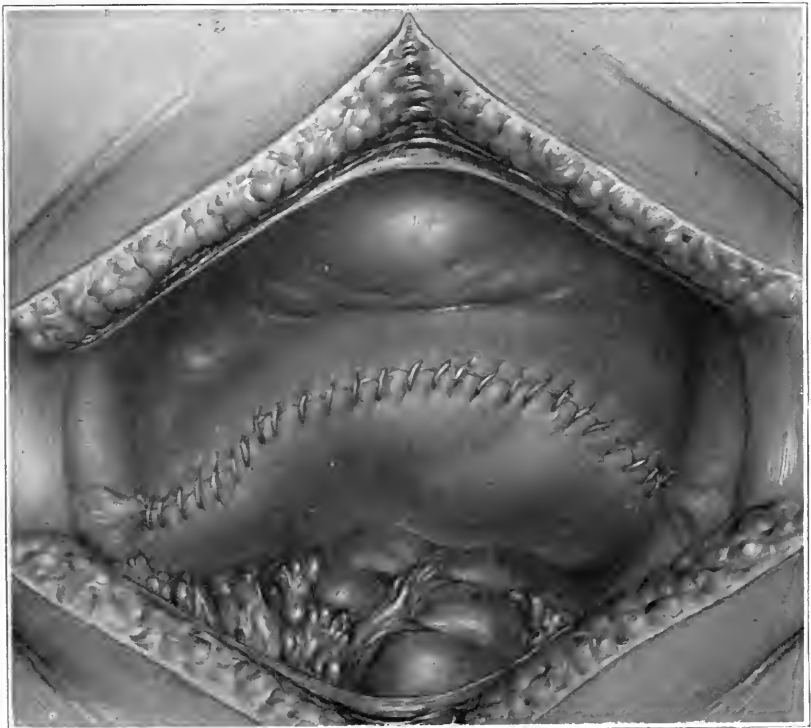


Fig. 372.—Schematic presentation of a subperitoneal postoperative hematoma.

of infection. The onset is usually more prompt after operation than in the case of low grades of infection. After pelvic operations their presence can easily be detected by palpation.

SUPRAPUBIC

Tumors in this region may be the pregnant uterus or a distended bladder. Once these two possibilities are excluded the diagnostic problems are simple. The uterine tumors are myomas, the ovaries either cystic, sarcomatous, or carcinomas.

CASE 1.—A farmer's wife aged twenty-six came to the hospital because of an increasing size of her abdomen.

History.—The patient says that for several years she has been getting larger across the abdomen. She consulted a surgeon a year and a half ago who diagnosed an ovarian cyst and at operation not finding one he removed both ovaries as a prophylactic measure. She has continued to grow larger since the operation. The patient has much trouble in keeping herself warm, but is not conscious of any other defect. She states she is over weight, but does not know how much. In fact she seems to have rather a hazy notion as to why she is seeking medical advice other than that she is growing so large. She has two children, the youngest three years old. She has had no menstruation since the operation a year and a half ago.

Examination.—The patient walks with an elephantine gait, sits down with great deliberation, and answers questions deliberately with a drawling voice. The features are heavy, the thick fatty pads about the neck are at once apparent (Fig. 373). The skin is markedly dry and rough. The legs are thickened, elastic rather than edematous. Her abdomen is as large as a seven months pregnancy. Fluid is demonstrable and the percussion note gives the impression of a confined fluid with a loose sac. Vaginal examination shows some bulging in the culdesac, but the uterus is small, movable, and evidently atrophic. The thyroid is not palpable. The examination is made difficult by the thick pads of fat in the neck. The urine contains some albumin, but no casts.

Diagnosis.—The heavy padded features, the deliberate gait, and the dry skin is enough to establish the diagnosis of myxedema. If the abdomen alone had been examined, it would have been quite easy to confuse the condition with a parovarian cyst.

Treatment.—She was given 5 grains of thyroid extract three times a day.

After-course.—She lost 16 pounds in ten days and her general appearance changed markedly (Fig. 374). The ascites had entirely disappeared at the end of this time. She regained her normal health and appearance in a few months, and has continued well now sixteen years, but she still takes 5 grains of thyroid extract a day.

Comment.—The fact that the ascites led an experienced operator to diagnosticate an abdominal cyst is sufficient excuse for including



Fig. 373.—Myxedema before treatment.



Fig. 374.—Patient after ten days' treatment with thyroid extract.



Fig. 375.—Before onset of the disease.

this case here. The patient favored me with a photograph of herself taken just before the onset of the trouble (Fig. 375). Comparison of these give an unusually good presentation of the marked change in features this disease produced and also the marked specificity of thyroid therapy.

CASE 2.—A farmer's wife aged forty-six was brought to the hospital because of severe pain in the lower abdomen.

History.—The present trouble started with sudden pain in the right and left iliac region. The pain was steady and quite severe. She felt sick and weak all over but was not nauseated and did not vomit. In twenty-four hours the pain settled down in the pelvis reaching all the way across. There seemed to be a soreness in both hip bones. The temperature was not taken during the attack. The attack was not related to the menstrual period. After the acute pain passed off she had soreness in the pelvis and hip bones for about a week. She has had five or six attacks during the past six months. They are getting more severe. The last one from which she is now recovering has lasted a week. The bowels are fairly regular now but during the summer months she was troubled with a severe diarrhea and passed blood with the stool. She is troubled with a purulent watery irritating vaginal discharge all the time. She has been troubled with frequency of urination both day and night all winter. She says that it feels as though something were pressing on the bladder. There is burning sometimes. Appetite good, but she sleeps poorly. She is very nervous all the time. She is troubled a great deal with occipital and frontal headaches. One year ago she had a severe uterine hemorrhage and again nine months ago. Both came just after a period. They were very severe for twenty-four hours. Her periods have been irregular for a year and a half, the last being six weeks ago. She has four children, youngest fifteen years old. All the labors were normal. She had asthma as a child and had a growth removed from the cervix thirteen years ago.

Examination.—There is marked tenderness to pressure over the right iliac region. A smooth, hard, rounded mass is felt just over the pubes. There is a second degree laceration of the perineum. The uterus is the size of two fists. The fundus is felt in anterior flexion and a smooth, hard, rounded mass lies to the left of it. A nodule the size of an egg lies to the right of the midline. This is

very dense. The cervix moves when the tumor moves. The whole mass, cervix plus tumor, is movable with but slight pain on manipulation.

Diagnosis.—A pain in the pelvis coming on suddenly, subsiding after several weeks leaving a definitely circumscribed tumor behind after the subsidence of symptoms usually indicates the presence of an ovarian cyst with twisted pedicle. This is made still more likely when such attacks are repeated. The tumor here is very dense to the touch and there is a smaller one to the right which is unquestionably a myoma. Another common cause for recurrent pelvic pain, with a residual tumor, is myoma with pus tubes. Besides the patient had a small tumor removed thirteen years ago. The tubes undergo periodic inflammation, then subside again. Usually the recurrences do not follow each other so closely as here and the period of defervescence is longer. Nevertheless the tumor mass is exceedingly hard and there is an associated small hard tumor. The surface of the tumor is smoother than is usual when pus tubes complicate fibroids. There should be masses beside the uterus if we had to do with pus tubes. Another possible source of irritation is within the uterus and tumor itself. This would fit in with all the findings, but is relatively an uncommon disease, not associated with pregnancy. In this case several attacks came on just at the termination of a menstrual period. Therefore, the diagnosis is most likely to be an infected myoma producing a pelvic peritonitis; the next most likely possibility, an ovarian cyst or dermoid with a twisted pedicle together with small myomas of the uterus.

Treatment.—On opening the abdomen all the coils of intestines occupying the pelvis were found adherent to each other by a thin translucent membrane of extreme delicacy. These loops were adherent to one another and many of them were adherent to the surface of a tumor which filled the pelvis. The tumor when dislocated proved to be a multilocular myoma of the uterus. A mass the size of a fist was found in the middle of the fundus and one the size of an egg was found in the anterior wall near the right horn. Both tubes and ovaries were bound up in the mass of delicate adhesions which covered not only the tumor, but broad ligaments anteriorly and posteriorly. The tubes were not thickened. The adhesions separated rather easily, leaving few shreds with very little hemor-

rhage; when separated they disappeared. The coils of intestines were separated from the tumor, broad ligaments, ovaries, and tubes, and most of the coils separated from one another. The cecum and sigmoid were but little involved in the adhesions. A supravaginal hysterectomy was then done, taking the left tube and ovary. In suturing through the top of the cervix a pocket of pus was

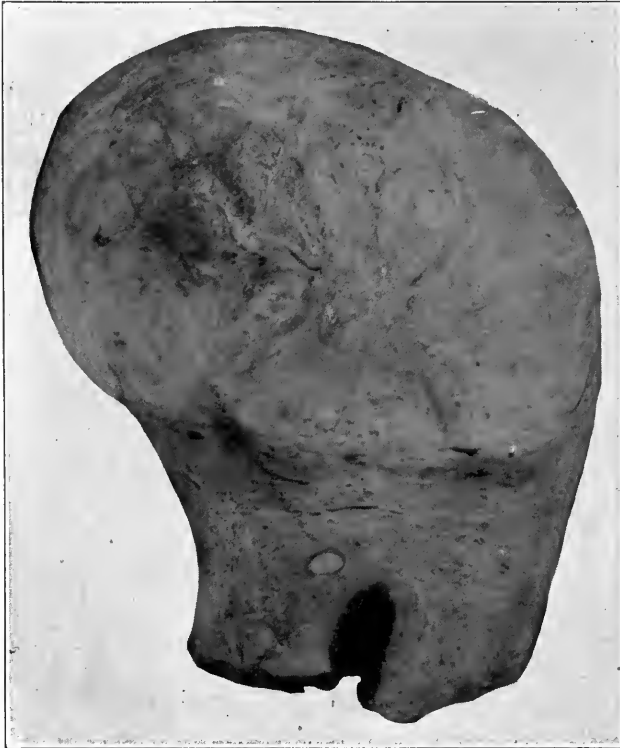

Fig. 376.—Myoma of the uterus with an infected focus in its interior.

opened. This was removed by reamputation lower down, the remaining ovary was removed, and the operation finished in the usual way.

Pathology.—Both ovaries were normal, the tubes but little involved. The uterine cavity was dilated, due apparently to a stricture at the internal os (Fig. 376), possibly the result of the removal of the tumor thirteen years before. The uterine walls were much thickened. The interior of the larger tumor showed a smooth

walled cavity which did not communicate with the interior of the uterus. The walls collapsed after the contents escaped. It contained no epithelial lining. The tumor tissue about the cavity was abundantly filled with round cells. The uterine mucosa was low, containing few glands.

After-course.—The patient suffered some from shock after the operation. The pulse went to about 115 and the temperature the next couple of days was 99.6°. She suffered considerably from gaseous distention which was relieved by enemata and stupes. About seven days after the operation she was given a cathartic, Pulv. Glys. Comp. dr. 2. She began to vomit shortly afterwards and kept it up every hour or two for three days. It was stopped by withdrawing everything by mouth and giving soda bicarbonate solution by proctoclysis, and by using gastric lavage. After the vomiting ceased, recovery proceeded uninterruptedly, except that she complained of soreness across the lower abdomen until within a few days of leaving the hospital. She ran a rapid pulse, usually from 90-100, most of the time in the hospital. Final recovery was complete.

Comment.—It is a matter of speculation as to how the interior of the tumor became infected; most likely by way of the uterus since there were no dense intestinal adhesions about it. Furthermore, evidently the tumor discharged into the cavity of the uterus from time to time. When the tumor emptied itself, the peritoneal surface ceased to be irritating, and the pelvic pain quickly subsided. The delicate but extensive adhesions indicated a slight irritation not attended by bacterial invasion.

CASE 3.—A matron of forty-six came to the hospital because of hemorrhage and a tumor.

History.—The patient is the mother of five children, the youngest of whom is twelve years old. She has had no miscarriages. For a year she has noticed a gradual lengthening of the menstrual flow. Before this time she was conscious of the presence of a tumor. It has gradually enlarged. Three weeks ago she had a severe hemorrhage with considerable pain in the lower abdomen. Since then the tumor has grown rapidly. She thinks she has lost some weight.

Examination.—The patient is well nourished, not anemic. She has a tumor in the midline extending up to the umbilicus. It is smooth, globular, semifluctuating and it moves freely from side to side but only slightly vertically. It does not vary in consist-

eny while under the pressure of the examining fingers. The patient answers questions clearly and definitely, yet her attitude is such that it appears to me the statements might not be reliable. The cervix is hard, the supravaginal portion not softened, but seems to extend into the tumor. The vaginal mucosa is not blue and there are no breast changes.

Diagnosis.—The entirely negative signs as to pregnancy, the history of duration of more than a year, the persistent menstruation seemed to rule out pregnancy, for any except one who has cut down on a pregnant uterus. For him there always is a question mark as tall as Uriah Heap. The direct attachment of the cervix to the tumor seemed to favor a soft myoma rather than an ovarian cyst.

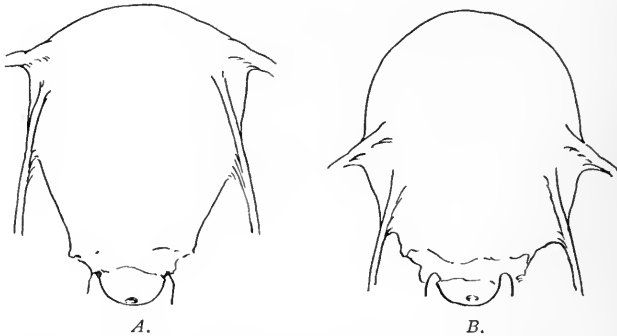


Fig. 377.—Schematic differentiation between an enlargement of the uterus due (A) to a pregnancy and (B) to tumor.

Treatment.—When the abdomen was opened a large, deep reddish blue tumor presented itself in the wound. It was perfectly symmetrical, a round ligament and tube attached to either side at exactly corresponding heights. The tumor was freely fluctuating and by practicing ballottement a roundish tumor could be made out in the depth. These were tense moments. I observed that the tubes and ovaries were attached at some distance from the summit of the tumor, as they must do if there were a pregnant uterus (Fig. 377). To make sure, I cautiously cut into the tumor. I went through a layer of deep red muscle tissue, then suddenly a small amount of clear serum escaped and out came a reddish mass which I at once took to be placenta. Close examination proved the mass to be a blood clot. It occurred to me that her discomfort three weeks



Fig. 378.—Hemorrhagic myoma which simulated pregnancy.

before might have been due to a hemorrhage into the placenta. Further investigation disclosed an area of colloid material. I knew then that I had to do with a myoma which had undergone colloid degeneration and in which a secondary hemorrhage had occurred. A supravaginal amputation was done.

Pathology.—Even after having demonstrated the nature of the tumor my assistants were very unpopular with me while I retired alone to cut open the tumor. It was a colloid myoma with secondary hemorrhage. In the center of the tumor (Fig. 378) was an area the size of a small fist which for some reason had not undergone degeneration and when the uterus was tapped the finger gave the sensation of a deeply lying head. The structure was that of a hemorrhagic myoma.

After-course.—The patient recovered more quickly than the surgeon.

Comment.—Conscience doth make cowards of us all. The patient was a widow, and as the examination was completed inquired whether the tumor might be a pregnancy. I did not know she was a widow, owing to an error of the admitting clerk, else I should not have placed any confidence in the statement of the duration of the tumor, nor of the date of the excessive flow, having once been placed in an embarrassing situation by accepting such statements. I had traveled a considerable distance to a strange environment. Under normal conditions I should have waited to see how rapidly the tumor would grow. I have often wondered what would have been the result had I found a pregnancy after cutting a hole in the uterus. It probably would have healed. Had a miscarriage followed, the suture line would most certainly have given way. This is the only instance I have ever seen in which the rule that only in pregnancy the round ligaments are attached symmetrically to each horn of the uterus (Fig. 377 B) did not hold. The explanation is that the tumor was primarily intramural located near the internal os. As it grew both cornua were carried on its summit.

CASE 4.—A housewife aged sixty-one entered the hospital because of a mass in the abdomen, pain in the hips and lower abdomen, and frequency of urination.

History.—She had had no children and was never pregnant. The menses started at thirteen, lasting three to four days. Had a severe attack of typhoid fever a few months after menses started

which stopped the periods and they did not reappear until she was seventeen years old. At the age of twenty-eight she had a tumor removed from the vagina, a pedunculated fibroid it was called. The menses stopped four months following this operation. She passed the menopause at forty-five. She was always regular before that time but flowed scantily for only one day since the attack of typhoid fever and the subsequent return of the menses at seventeen. She has never had any vaginal discharge between periods. The attack of typhoid fever at thirteen was complicated by a thrombophlebitis of the left leg which kept her in bed four months. The fibroid which was removed from the vagina at twenty-eight protruded from the vagina. It was about the size of an egg with a pedicle the size of the little finger she was told by her doctor. She said she knew of the existence of the tumor five years before its removal, although it protruded from the vagina only a few months prior to removal. Five years ago she had a tumor the size of a hazelnut growing around the bone outside of the left incisor removed. It was removed by electric cautery. She had pneumonia a year ago. The present trouble began about sixteen months ago. She noticed a lump in the left lower abdomen. There were no symptoms at that time. It grew steadily and a year later gave pain for the first time. It was in the nature of a soreness and heaviness, always worse when on her feet a great deal, and was relieved by lying down.

She has pain in the hips and lower abdomen. It does not radiate. The bladder symptoms began eight months ago. The greatest disturbance is during the last half of the night and the forenoon. She gets up eight to ten times at night and can not control urine well when she first gets up in the morning. There is a burning on urination. She has lost 15 to 20 pounds in weight in the past two years, the bowels have been very constipated, especially during the last six months. Sleep fair at first part of night but very poor after that on account of the frequency of urination.

Examination.—A nodular tumor the size of a fetal head is felt above the symphysis. One large nodule projects to the left, another projecting down to the right towards Poupart's ligament. The tumor mass is rather firmly fixed, tender to pressure, and has an elastic feel. The superficial veins on both sides of the lower abdomen and upper part of both thighs are enlarged and promi-

ment. There is a small oval tumor mass in left inguinal region, about 2 inches in length, somewhat lobulated and elastic. It can not be made to disappear. Vaginal examination shows the whole pelvis filled with a dense hard mass. It seems to be slightly movable, but can not be pushed out of the pelvis. Blood Hg 80 per cent, W.b.c. 9,500; R.b.c. 3,800,000. Differential count, polynuclears 38 per cent. L.l 10 per cent, S.l. 52 per cent. The urine is without interest save that it contains many pus cells.

Diagnosis.—The fixed tumor together with the dilated veins in the lower abdomen and the thighs disclose it to be a malignant tumor and inoperable. Sarcoma is suggested by the size of the tumor and by the fact that she had a pedunculated tumor removed many years ago. That she menstruated but a day rather precludes a submucous myoma. It is rare that myomatous tumors cause trouble so late after the menopause. The late malignancies are nearly always epithelial in origin. This mass is in places too soft for an epithelial tumor. Sometimes ovarian cysts showing malignancy appear late in life and retain in places a cystic or colloid character and may give a pseudofluctuating or elastic feel. This tumor, however, has the peculiar feel of a rapidly growing sarcoma. There is a type of sarcoma springing from small submucous tumors which late in life show malignancy. So far as the patient is concerned the exact diagnosis is of no interest. Despite the dilated veins the tumor feels as though it might be elevated out of the pelvis by an operation. It seems worthy of trial.

Treatment.—After the tumor was exposed by incision it could be rolled out of the pelvis save for a nodule the size of an orange situated on the right side just below the pelvic brim. This portion was firmly fixed to the vessel walls and had to be abandoned.

Pathology.—The tumor mass was made up of a brittle, friable mass which could be torn asunder by the fingers. In several places cysts the size of an egg containing clear fluid, were found. The slide showed carcinoma evidently of ovarian origin.

After-course.—The trouble rapidly returned and she died four months later.

Comment.—Pelvic tumors, particularly those springing up long after the menopause, are all malignant, and when they once fill the pelvis, are nearly always inoperable. When there is marked dilatation of the lower veins of the abdomen they most certainly

are inoperable. Usually the vessel wall is invaded and if a too rash attempt is made to remove it, a large vein may be injured and the patient caused to bleed to death under the surgeon's eye. Whenever one attempts to go against the obvious fact, disaster follows.

CASE 5.—A matron aged thirty-five came because of a mass in the abdomen, pain in the right and left iliac region, and pain and vomiting after meals.

History.—Four years ago she noticed a mass just below the navel. She had no symptoms of any kind and gave it no further thought. She did not notice that the mass was growing until a few weeks ago although she says that she has had to wear larger corsets the last few years than formerly. Two months ago she had a normal menstrual period, the flow stopping in three days. She then began to have an epigastric pain and a sensation as of bloating. The pain was constant and when she took food she vomited. The local doctor ordered turpentine stupes, after the use of which the flow started again. He then ordered hot lysol vaginal douches. After these were given she began to have severe pain in both iliac regions; this started suddenly and has continued since. She has had pain in the stomach and groins and there has been a bloody discharge from the vagina since then. The blood is now mixed with a yellowish, purulent discharge. The stomach disturbance is now her chief complaint. She feels bloated and she has pain and often vomiting soon after eating. In the last three days she has had a pain in the right side under the short ribs and under the right shoulder blade. For the last three days she has had a severe pain on urination but she has no frequency and does not get up at night. She is extremely constipated. She has no headaches. Her menses have always been regular, the flow lasting four to five days without pain, but has been very profuse the first two or three days during the last nine months. She has no children and has never been pregnant.

Examination.—The general appearance is that of good health. The abdomen is large, having the appearance of a seven-month pregnancy. Palpation shows a mass in the abdomen extending from above the pubes to a handbreadth above the umbilicus. It extends a little higher on the right than on the left. It is rounded in form and smooth in outline. It feels hard to the touch, does not fluctuate, and is nowhere tender on pressure. Pelvic examination showed cervix lacerated, perineum intact. A large, smooth, hard

rounded mass fills the entire pelvis. It appears to be attached to the uterine fundus. There is marked tenderness on the left side of the pelvis. White blood count 12,500, 65 per cent polynuclears.

Diagnosis.—The tumor likely has not grown rapidly for she has noticed that she had constantly to loosen her clothes, the surest sign of increasing girth. The beginning was associated with menstrual disturbance, the flow having stopped and then started again. She had severe pain in the iliac regions, which, while coincident with the giving of lysol douches, probably had nothing to do with them. The stomach trouble came on with these conditions and likely is reflex because it was not present before. The density of the tumor, its slow growth, and its obvious connection with the uterus indicates that it is a myoma. Some change obviously has taken place. If it were in the uterus itself, the reaction would be greater. The local examination shows the chief point of tenderness to the left of the uterus. Since pus tubes are frequently associated with large myoma, such a condition may confidently be expected here. The reaction is not such as to constitute a contra-indication to immediate operation. The blood count corroborates this opinion inasmuch as the polynuclear count is low.

Treatment.—The uterus is made up of a myoma as large as an adult head. It is adherent to almost everything in its environment by quite recent adhesions. On the left side was a large tuboovarian abscess, on the right side there is a cystic ovary with hemorrhage into the cyst. The uterus was removed by supravaginal amputation.

Pathology.—The mass as large as an adult head is made up of a single large tumor and several smaller ones the size of a lemon. The section shows numerous small cavities filled with a clear fluid. The face is pale pink, showing a distinctly fibrous arrangement. The slide shows regions with deeply staining cells. They are arranged in parallel bundles and the nuclei are arranged in a parallel fashion. The ovaries are polycystic and the one has a hematoma the size of a walnut.

After-course.—There were no immediate postoperative complications. Two days after operation she developed a cough, raising considerable phlegm. The principal discomfort was from the pull on the operative wound. Examination of the lungs was negative. Respiration and temperature were not increased. The cough subsided and the patient made an uneventful recovery.

Comment.—When tumors are alleged to have suddenly increased in size sarcoma is usually suspected and seldom present. Usually there is some complication in the tumor itself or in its adnexa. The inflamed tumor evidently, like a sore thumb, seems many times larger than its recent state, though the actual increase in size is not great. A sarcomatous uterus does not increase as rapidly as an inflamed one seems to the patient to have increased. Generally speaking, the organism in the pus in salpingitis associated with myomas is not very violent. In fact, often bacteria can not be found and in yet more none can be grown. In abscess within the substance of a myoma the bacteria are numerous and virulent until long after the beginning of the trouble.

CASE 6.—A matron aged forty-nine came to the hospital complaining of acute abdominal pain with gradual enlargement.

History.—Her menses stopped ten months ago without any attendant disturbance. She has noticed a gradual enlargement of the abdomen for seven months. Since that time she has had several attacks of acute abdominal pain which came on rather suddenly. They were of a cramping, colicky nature, and very severe. They have come on once a month on the average. Once she fainted from the pain. The last attack, three weeks ago, was the worst. This was the only one that was attended by vomiting. She has had no fever with any of the attacks. Following the attacks she becomes very much distended. Her general health is excellent. She sleeps well and her appetite is good, but she is extremely constipated. She has a goiter which she noticed first six years ago. She has two children, the youngest twenty-five years of age. She was operated on for hemorrhoids a year ago.

Examination.—She has a small goiter of the left lobe of the thyroid. There are no symptoms of intoxication. There is a fluctuating tumor in the lower abdomen reaching almost to the umbilicus. The perineum is torn to the second degree and the cervix is bilaterally lacerated. There is a large, rounded tumor filling the culdesac. The cervix is hard and the body of the uterus seems to lie over the bladder. Owing to the presence of the tumor over the pubes this can not be confirmed by bimanual examination. The tumor in the culdesac is semifluctuating but seems somewhat firm. There are no blood changes.

Diagnosis.—The sudden cessation of menstruation with the appearance of a tumor three months later suggests pregnancy, but there are no signs. The cervix is hard and the unchanged uterus seems palpable continuous with it. However, one can not be sure unless the uterus can be demonstrated by bimanual examination. This point could have been demonstrated by fixing a tenaculum and making traction, or by the archaic method of passing a sound. The advent of sudden severe pain might mean some accident of pregnancy, particularly if it were extrauterine. However, the first attack of pain came on after she had noticed a tumor above the pubes which would be very unlikely in an extrauterine pregnancy. An abdominal pregnancy might be suspected had the tumor appeared after the severe pain. If there were an extrauterine pregnancy the uterus should show some changes. These can not be demonstrated. The tumor fills the culdesac and, though semifluctuating, it seems too hard to be a simple cyst. The advent of severe pains suggests the possibility of an ovarian cyst with twisted pedicle resulting in inflammation in the culdesac with thickening. In such a case one would expect the uterus to be pushed to the opposite side. An ovarian cyst with twisted pedicle should have been attended by fever and symptoms of abdominal inflammation. The fainting might have been due to a hemorrhage into a cyst and the resistance in the culdesac might have been due to this if an inflammation of the wall had followed. The best diagnosis seems to be an ovarian cyst which has undergone some sort of accident.

Treatment.—A serous ovarian cyst the size of an adult head was found on the right side. In one side lying in the culdesac was a hard mass the size of the fist. The larger of the cysts was drained to facilitate removal. After removal the smaller compartment was found to be a papillary cyst adenoma. The sigmoid colon was adherent to the cyst. On the other side was a cyst the size of the first in which papillary cystadenomatous development had started. There were several small papillary growths on the outside of this tumor which were attached to the upper part of the pelvis. This with the tube was also removed.

After-course.—Immediately on recovery from the anesthetic the right eye was noticed to be much inflamed and the patient complained of it more than of the wound. An ulcer of the cornea on the right side was located just in front of the pupil. The eye was

kept bandaged, washed with boric acid solution and treated with yellow oxide and atropine ointment. Healing of the ulcer began immediately and was complete when the patient left the hospital. No scar could be seen. The operative wound caused very little postoperative trouble and the recovery was normal as far as this was concerned. On dismissal the eye was healed but the patient says there is sometimes a little blurred vision on that side. She has remained free from any pelvic trouble.

Comment.—The eye trouble probably was due to an ether burn. From the operative findings the cause of the attacks of preoperative pain were not definitely determined. The sigmoid was adherent to the adenomatous part of the right cyst. Some accident must have occurred to bring this about. There were some extracystic papillomas on the left side which were capable of producing an irritation. Possibly these represent a cyst which ruptured, leaving the papillary portion exposed. None of these should be capable of producing a pain great enough to cause fainting. Possibly there was a temporary twist of the pedicle which untwisted again. There is a question whether such an event can happen, though clinicians hypotheate it.

CASE 7.—A married woman of thirty-six came because of pain in the lower quadrant of the abdomen.

History.—The patient began to have pain in the left lower quadrant of the abdomen about four months ago. Other than hemorrhoids the patient has never had any illness. Her menstrual periods began at seventeen and have been regular, with scanty flow and dysmenorrhea. There has been sacral backache for years but very little headache. She has had no children and has never been pregnant. Four months ago the present illness began with pain and tenderness in the left lower abdomen. The pain would sometimes remit, but the tenderness was always present. The sacral backache became much more severe. Very often vomiting attacks would occur. The pain would radiate downward to the left thigh, also upward toward the costal margin. When the pain was severe, there would be painful urination. There was no leucorrhea, no history of rise of temperature.

Examination.—A smooth firm tumor mass can be felt in the abdomen extending a handbreadth above the symphysis and toward the left. It is large enough to be noticed on careful inspection of the

abdomen. By vaginal examination a smooth, firm tumor mass is found entirely filling the culdesac. It can not be moved about and is semiclastic on bimanual palpation. There seems to be a nodule low behind the uterus and attached to it. The large tumor is not closely attached to the uterus. Urine is negative; temperature 98, pulse 64.

Diagnosis.—The growth of the main tumor has been fairly rapid according to the patient's statement, which makes one think of an ovarian cyst. The physical examination is not incompatible with this notion. Myomas sometimes, when edematous or cystic, give the same physical characteristics, and when hemorrhage occurs in them there may be a rapid increase in size, and sometimes when a tumor comes suddenly to lie above the pelvic brim the patient believes a rapid growth has taken place. Furthermore, the patient has never been pregnant and has had dysmenorrhea, which speaks for myoma. Since she did not begin menstruating until seventeen years old, it must be assumed that there was some congenital defect, and the dysmenorrhea may be ascribed to this. The nodule behind the uterus furthermore is undoubtedly a myoma, and this may account for the more recent increase in pelvic pain. The dominant feature in the case seems to be the rapid growth of the larger tumor and the diagnosis of ovarian cyst is ventured.

Treatment.—A large ovarian cyst and a small uterine myoma were removed.

Pathology.—The tumor was a serous cystoma.

After-course.—The recovery from the operation was uneventful and the symptoms have disappeared.

Comment.—Ovarian cysts when uncomplicated do not cause pain. When pain exists usually there is a twisted pedicle or they have become malignant, or there may be some other condition responsible for the pain. In this case it was most likely the myoma that caused the pain.

CASE 8.—A matron of forty-nine came because of an abdominal tumor.

History.—The patient has had eight children, the youngest twelve years of age, and no miscarriages. She has repeated typical gall stone attacks. Her menses have been delayed from one to three weeks for several years and for the past year and a half she has had none. During the time her menses were irregular she was

examined and told she had a tumor and was advised to have an operation. She was not told the nature of the tumor. The patient volunteers that she is not pregnant, for having gone through eight previous pregnancies she feels qualified to speak. Her general health is excellent and she has gained 20 pounds in weight during the past six months.

Examination.—There is a tumor reaching well above the promontory. The cervix is soft and seems to be continuous with the tumor presenting above the pubes. The supravaginal portion of the cervix is not appreciably softened. It is not movable and is sensitive on bimanual examination. The tumor is smooth, semifluctuating and is pyriform in shape. There are no breast signs. No heart tones or souffle can be heard over the tumor.

Diagnosis.—The year and a half of amenorrhea seems an argument against pregnancy. She had been examined by her family doctor prior to the cessation of menstruation and a tumor was found. The tumor is pyriform and semifluctuating and the cervix is soft, very ominous positive findings, and, too, the vaginal mucosa is cyanotic. Amenorrhea sometimes exists for long periods in tumors of the ovary and this tumor is of a size to just about represent the normal rate of growth of an ovarian cyst. It is possible that the tumor is an ovarian cyst which is causing an amenorrhea or she may have passed the menopause and have incidentally an ovarian cyst. However, there is a pyriform tumor and a soft cervix. That much is certain; all the other factors are more or less speculation. Then, too, the patient is so certain that she is not pregnant, which is the best possible evidence that she fears that she is. At any rate, she is not suffering, and is in no danger and a period of waiting will do no harm.

Treatment.—Delay in order to wait developments was advised.

After-course.—A child at term was born four months later. She was operated on three years later and a number of gallstones were removed. The pelvic organs were examined at this time and no tumor was found.

Comment.—It is unusual for pregnancy to occur so long after menstruation. Evidently ovulation may continue for a period after menstruation has ceased. It has been my experience in several instances to have a patient state that her physician had found a tumor, at a time too long antedating the examination to make possible a preg-

nancy if the statement were true, who nevertheless were pregnant. In several such instances inquiry addressed to the physician failed to confirm such a report. At any rate when it comes to a question of pregnancy, one positive or even one suspicious sign is worth more than all the history that can be tabulated.

CASE 9.—A matron aged forty-six came because of discomfort in the pelvis.

History.—This patient related without questioning that she was the mother of nine children, that the youngest was fifteen months old and that she now had not menstruated for four months. She asserted with positiveness that she was not pregnant because the sensations now were entirely different than in pregnancy. She had no other complaint.

Examination.—There is a round semifluctuant tumor apparently connected with the uterus. The cervix has a stellate laceration and is neither soft nor hard.

Diagnosis.—A woman always regular who stops menstruating suddenly when in good health very likely is pregnant.

Treatment.—Delay was advised.

After-course.—She returned in eighteen months with an enormously distended abdomen. An ovarian cyst which held ten gallons of fluid was removed. She has remained well since.

Comment.—The examination was cursory and useless. Dependence was placed on a general proposition that absence of menstruation meant pregnancy. When a woman who has had many children says that she is or is not pregnant, her word should be weighed with due respect and her diagnosis disregarded with extreme caution. The statements of such women are not colored as are those of women who do not or have not regarded the function of motherhood with acclaim. An old soldier knows the roar of cannon, it is said.

CASE 10.—Housewife aged thirty came to the hospital because of pain in the bladder region, along both sides anteriorly and across hips posteriorly.

History.—Periods regular, five to six days, flows severely first three days. Pain not any worse at the periods. Backache worse at the periods. Never pregnant.

Never sick excepting tonsillitis, measles, and mumps. All these in childhood.

Present trouble started with the bladder pain fifteen months ago. It has been getting worse but has been especially severe the last six weeks. This pain is constant. It is much worse when the urine passes. She has had spells of great frequency of urination, four to five times at night and often in the daytime. No urethral pain. Always a soreness across the lower abdomen.

The pains in the sides, extending from down in the pelvis half way to the rib margin began a year ago and are getting worse. The backache started six months ago. Very little headache. Appetite good, bowels always constipated.

Some leucorrhœa between periods. No blood. She has a dragging sensation in the pelvis when on her feet a great deal.

Examination.—Patient has the appearance of excellent health. Head and neck negative. Heart not enlarged, apex beat in 5th interspace. Soft blowing systolic murmur at the apex. Lungs negative.

Mass in the pelvis reaching almost to umbilicus. Hard, somewhat tender. No fluctuation. No pelvic examination was made.

Diagnosis.—Uterine fibroid.

Treatment.—April 26, 1919. On opening the belly a cauliflower-like mass was found on the left side entirely replacing the ovary. On the right side replacing the ovary was a cyst the size of a baby's head. This was thick walled, and on being opened its whole inner surface was found covered with cauliflower-like growths. The large cyst was firmly adherent posteriorly and separated with difficulty. The tubes, broad ligaments and peritoneum were very edematous. Both masses and the tubes were removed.

Pathology.—Papillary cystadenomas of both ovaries.

After-course.—The patient made a perfectly normal recovery. The temperature and pulse were not affected by the operation to any abnormal extent and the postoperative shock was nil. The abdominal wound healed by primary union and the patient only complained of pain in both iliac regions for a time.

Comment.—The irritation of the bladder and the referred pains were wholly unlike myoma symptoms. This error could have resulted only from incomplete examination.

CASE 11.—A married woman of thirty-five came to the hospital because of pain and a tumor above the pubes.

History.—Her trouble dates back to one year ago when she began to have pain in her thighs and feet. It has gradually grown worse

and now the pain is constant. It is felt low in the back part of the pelvis and goes down the legs to the feet. It is much worse when the patient is obliged to stand a great deal and do hard work. She has noticed a fullness in the bladder region for a year and for the past two months she has noticed a tumor in the lower part of the abdomen. Her menses began at fourteen and have always been regular and painless. They last four or five days. She has six children living and well and no miscarriages.

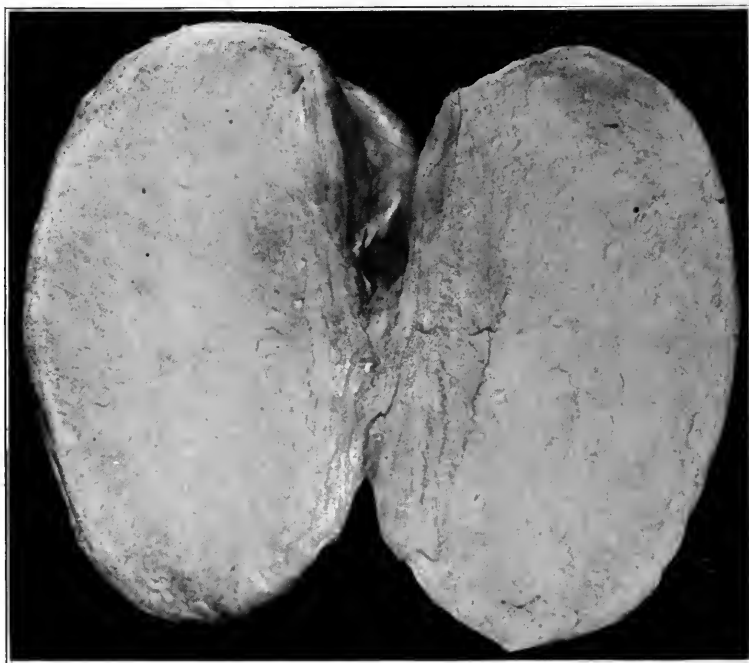


Fig. 379.—Fibrosarcoma of the ovary.

Examination.—An ovoid tumor is found protruding above the pubes and extends to the culdesac. It is freely movable, smooth, firm, and not tender to pressure.

Diagnosis.—The ovoid shape at once suggests a dermoid, but it is firmer than dermoids usually are. Solid tumors of the ovary are usually more globular but this has the dense, elastic, smooth feel of fibrosarcoma of the ovary. It is not attached to the uterus. At any rate it requires removal.

Treatment.—The right ovary is represented by a large solid pedunculated tumor. It was removed.

Pathology.—The tumor is oblong, smooth, and fairly firm. The cut surface in some parts is wavy with connective tissue fibers and at others it is homogeneous and glistening. The slide shows a sparse connective tissue containing spindle cells and some groups of round cells. (Fig. 379.)

After-course.—Recovery was uneventful.

Comment.—These tumors are of slow growth and if removed early do not tend to recur. Neglected they not infrequently invade the surrounding connective tissue.

CASE 12.—A school girl of nineteen was brought to the hospital because of amenorrhea and abdominal tumor.

The patient has always had good health. She began menstruating at thirteen and has always been regular and free from pain. Five months ago she ceased to menstruate and a globular tumor appeared above the pubes. The finger of scorn was pointed at her, a conclusion to which the mother acquiesced despite the vigorous protests of the patient.

Examination.—A globular mass can be felt above the pubes. It is movable laterally and is entirely painless. Examination under ether showed an intact hymen, a firm, normal colored cervix, and a dense tumor crowding the uterus to the left. There was no bluing of the vaginal mucosa and no breast changes.

Diagnosis.—The most common solid tumors of the ovary in young girls are endotheliomas or fibrosarcomas. This tumor is firm, elastic and is oblong in shape corresponding to the usual shape of such tumors. There are no signs of pregnancy. The presence of amenorrhea is unaccounted for. The menses failed to appear at the time the tumor was first noted above the pubes. It must have existed a considerable time to have attained a size too large to permit it to occupy the pelvis. The only two events occurring at this time to account for the amenorrhea is the dislocation of the tumor and the false accusation of a sensitive and sensible girl. The grief probably was a more important factor than the change in position of the tumor.

Treatment.—A solid tumor somewhat larger than a child's head was removed from the right broad ligament. It evidently represented the ovary.



Fig. 380.—Perithelioma of the ovary.

Pathology.—The tumor was partly solid and partly cystic (Fig. 380). The solid parts are typical perithelioma and the cystic parts contain a thin clear fluid. The tumor was distinctly oblong, suggesting a dermoid before it was cut into. Nothing to substantiate the suspicion was found.

After-course.—The menses were resumed three months after operation and remained normal.

Comment.—The sudden cessation of menstruation in the presence of an ovarian tumor is unusual, but by no means unknown. The type of tumor also is unusual but there is no evidence that there is any relation between the structure and the amenorrhea.

CASE 13.—A matron of fifty-three came to the hospital because of a tumor in the abdomen and general weakness.

History.—The patient is the mother of seven children, the youngest twenty years old. Her menstruation has always been regular until three months ago. She flows seven days, always profusely. She urinates several times a night but has no other evidence of bladder irritation. The bowel movements are variable, usually constipated, but move with laxatives without trouble. She has had for the past few months some pelvic discomfort. Two weeks ago the abdomen suddenly began to enlarge and she thinks a tumor appeared overnight. Since that time she has had no appetite and feels generally exhausted.

Examination.—The region above the pubes is occupied by a rounded tumor riding on the pelvic brim. It is smooth, soft, semifluctuating, and does not change in density. It is slightly movable from side to side. Vaginal examination shows a smooth, rounded mass which when rocked, by bimanual examination, carries the uterus with it. The cervix shows an old laceration and is hard. It is reddened and congested.

Diagnosis.—The form of the tumor and the history of its sudden appearance suggest that it is a tumor previously intrapelvic which has come to ride above the promontory because of its increased size. Tumors that do this are myomas and ovarian cysts. The sudden appearance in the abdomen when accompanied by constitutional symptoms are due, if myomas, to edema or hemorrhage, if ovarian cysts, to some disturbance of nutrition, usually a twisted pedicle. In this case there was no peritoneal irritation which would have been present were it the latter. On the contrary the abdominal

museles offered no resistance to the palpating finger, though firm pressure caused moderate pain. The consistency both on abdominal and combined examination was semifluctuating. Ovarian cysts which suffer disturbed circulation are more dense than those not so affected. The density did not vary and was greater than a pregnant uterus. The size likewise was greater than a uterus which has recently come to occupy an abdominal position, though pregnant



Fig. 381.—Hemorrhagic myoma.

uteri which have been confined to the pelvis by impaction or by adhesion may not come to reach the abdomen until they are larger than is usually the case. The age of the patient argued against pregnancy, but she had been regular until three months ago. The long continuation of the menses suggests myoma, particularly as they had been increasing in duration during recent years. The diagnosis because of the general malaise and loss of appetite seemed

to favor a myoma which had undergone some accident, most likely hemorrhage.

Treatment.—A laparotomy was done. A large uniform tumor the size of an adult head, semifluctuating and bluish-red in color, represented the uterus. The first look made me fear a pregnancy. Following the course of the tubes and round ligament they were noted to end in the sides of the tumor about midway of the tumor. If it had been a pregnant uterus they would have ended near the upper pole. Furthermore, the tumor was globular and not pear-shaped as is a pregnant uterus. Therefore, a supravaginal amputation was done and the operation delayed while the tumor was cut into for further information.

Pathology.—When cut into much blood flowed from the tumor and its size was reduced. A shell of uterine tissue, a centimeter in thickness surrounded a deep red semisolid mass (Fig. 381). The capsule everywhere seemed complete and the portion near the cervix seemed free. The primary tumor was a typical hemorrhagic myoma. Throughout it were areas of fibrin network with many large mononuclear cells within the meshes. Other areas showed the same fibrin network with unchanging cells within its meshes.

After-course.—The operative recovery was uneventful. In a week the patient was walking in the corridors and went home at the end of ten days.

At the end of six weeks it was reported to me that the wound had broken open and a tumor had reappeared. This was interpreted as being evidence of a late infection with opening of an abscess. Another report at the end of eight weeks from the time of operation stated that the patient was growing weaker and that there was bladder disturbance. On examination two days later a soft, granular mass the size of an orange was found occupying the site of the incision and the whole pelvis was filled with a soft, boggy mass. A diagnosis of small round-celled sarcoma was made. The patient died six weeks later. At autopsy the pelvis was filled with the hemorrhagic mass and the tumor over the site of the incision had increased to half the size of a fetal head.

The tissue obtained showed cells like those in the tumor tissue. Nowhere did the interstitial tissue take the fibrin stain but took only the picric acid of the Van Giesen stain.

Comment.—These frightfully rapidly recurring tumors seem to occur only when hemorrhagic myomas become malignant. I have seen one other run an identical course.

CASE 14.—A matron aged thirty-two came to the hospital because of a fullness above the bladder.

History.—The patient has had three children. She has had fair health until some three or four months ago when she began to have



Fig. 382.—Adenocarcinoma of the ovary.

a sense of fullness in the pelvis and frequent urination. Her physician discovered a pelvic tumor.

Examination.—The patient has a bosselated mass filling the pelvis. The right and left parts move independently of each other. The left

part is palpable above the pubes. The bosselations are indefinitely fluctuating.

Diagnosis.—The density of the tumors suggested cysts.

Treatment.—When the tumor masses were exposed some of the nodules were found dense while others were cystic. Wide exsision was therefore done.

Pathology.—The solid portions were granular, the solid portion obviously extending from the walls of the cyst toward the interior. Solid nodules and small cysts were often intermingled. On section the solid parts were seen to be epithelial, being formed of papillary outgrowths in some parts, and solid epithelial masses in others. (Fig. 382.)

After-course.—In two years there were recurrences solidly fixed in the walls of the pelvis. The patient died three years after the operation.

Comment.—The hope of cure in these cases is a delusion. They seem to come out clean, but recurrences take place with sickening regularity. Papillary tumors are much more hopeful of a cure.

CHAPTER XVI

DISTURBANCES OF UTERINE FUNCTION

The disturbances of uterine function are as protean as the complaints of women. Whenever a woman complains, disturbances of the uterus must be sought for and affirmed as excluded. The functional and psychic factors also must be determined, affirmed or excluded by careful examination.

MENSTRUAL PAIN

Painful menstruation in adolescents and the mature unmarried are enigmas. The cause in many, likely in most of them, is due to endocrine disturbance. In the parous there is commonly a tumor or the results of childbearing, particularly lacerations, displacements, and inflammations. In the first group the less the surgeon does the better. In the latter, careful search for an anatomic defect is required.

CASE 1.—A matron of thirty-three comes because of leucorrhœa and backache.

History.—The patient has three living children and has had one miscarriage at seven months five years ago. She has no dysmenorrhœa and is regular, the flow lasting generally three or four days. She has had a pronounced leucorrhœa for two or three years. She complains of a continuous backache in the small of the back and over the sacrum. Sometimes there is pain on the tophead particularly when she is much on her feet. Recently she has become pronouncedly nervous so that at times she can not sleep well. She passes her urine more frequently than formerly and sometimes gets up at night. Sometimes there is burning after urination. She sometimes feels bloated and has burning in the region of the stomach.

Examination.—The patient presents a well-formed physique giving little cause to anticipate her statement that she is nervous. There is marked epigastric tympany and pronounced diastasis

of the recti muscles. The perineum is lacerated to the second degree. Both the anterior and posterior vaginal walls can be seen in the vulva. The cervix is low, eroded, and the body of the uterus is large, boggy, and retroflexed. There is some tenderness on bimanual examination. The urine shows a greater number of pus cells than normal, but otherwise is negative. The erosion of the cervix is typical. The os is surrounded by reddened tissue which appears to have undergone proliferation. The border between the normal and abnormal, however, is sharply defined and

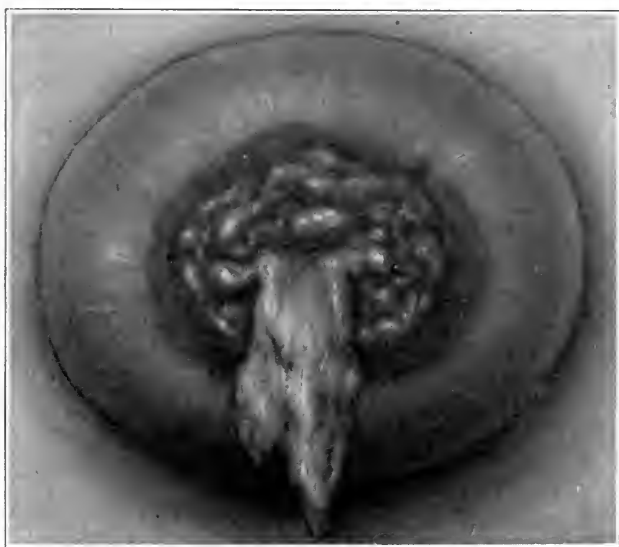


Fig. 383.—Endocervicitis with mucus discharge.

the entire periphery of the cervix is equally involved (Fig. 383). There are small nodules palpable in the depth. Rather rough palpation does not cause bleeding.

Diagnosis.—The location of the backache, the occipital and vertex headache, the leucorrhœa and the epigastric disturbance all lead us to anticipate a cervical erosion associated with a large and boggy uterus. The bladder trouble is symptomatic of the sagging uterus. The constipation is due to splanchnic inhibition rather than to direct pressure on the gut. We must conclude this for constipation as frequently attends an inflamed uterus that occupies the nor-

mal position as it does those in retroflexion. The deep nodules noted on palpation are seen to be located outside the reddened area and when stuck with a needle permit the escape of a thick, glairy mucus.

Treatment.—The eroded portion of the cervix areas was resected and the perineum repaired. The uterus was replaced and a Gilliam done. The diastasis was repaired by a wide lateral overlapping of the rectus fascias.

After-course.—The recovery was prompt and the symptoms effectually relieved.

Comment.—This is the type of cases that the old gynecologists relieved, but did not cure, by local treatment. When there are pronounced headaches, particularly in the occiput and vertex, it is important to resect the eroded area, particularly if the glandular secretion is active. This is even more important when there is no obvious laceration, as in this case, than when there is a laceration. In fact often in laceration the reddened surface may be due to a displacement or rather a dislocation of the columnar epithelium of the cervical canal rather than a reactive proliferation. Displacement aggravates these conditions by disturbing the venous return. If there is excessive menstrual flow a curettage may be of use, but when there is no metrorrhagia a curettement is worse than useless.

CASE 2.—A matron aged forty-three came because of painful and excessive menstruation.

History.—For the past several years she has had excessive menstruation with some pain low in the back. There has been pronounced leucorrhœa following menstruation. She formerly flowed three or four days but now flows six or more. She has severe occipital pains preceding menstruation. She has been constipated many years which state has become aggravated recently and she has some pain before the bowels move. She has had six children, the youngest of whom is seven years old. There have been no miscarriages. Her general health has always been fair.

Examination.—The patient is tall and angular and appears fatigued and older than the age given, but not cachectic or anemic. She has a small goiter on the right side. There is a systolic murmur heard best at the apex and is transmitted to the axilla, but is heard along the left border of the sternum. There is slight enlarge-

ment of the heart in all diameters. The perineum is lacerated to the second degree. The cervix is large, lacerated, and presents angry surfaces to view. There is an abundant glairy discharge.

Diagnosis.—The pronounced cervical erosion accounts for her com-

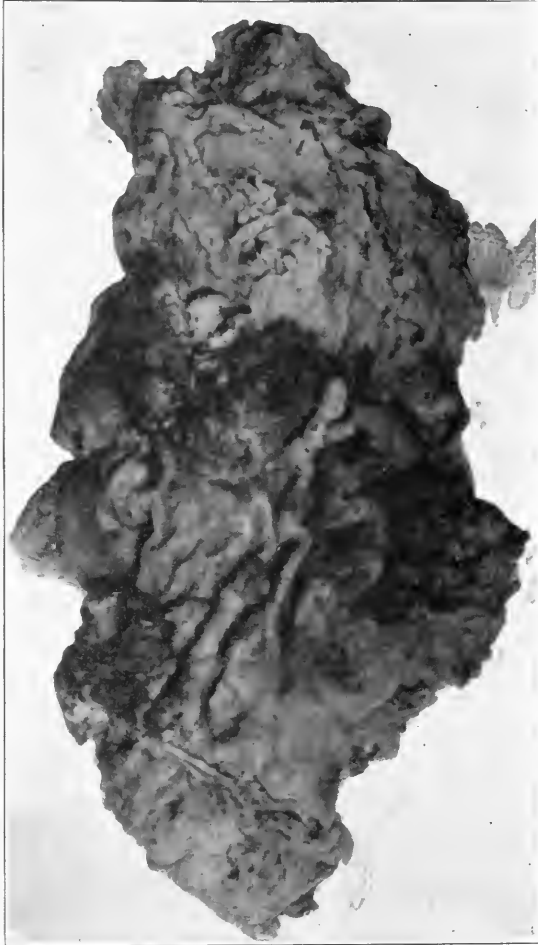

Fig. 384.—Early carcinoma of the rectum.

plaints. The occipital headaches are typically of pelvic origin. The removal of the offending portion with a perineal repair should remedy the difficulty.

Treatment.—A Schroeder amputation of the cervix and a perineorrhaphy was done. In casually examining the rectum after the completion of the above, a carcinoma of the rectum was found. It was 2 or 3 cm. in diameter and was located behind the cervix (Fig. 384.) Since there were fresh wounds in the vagina it was deemed best to allow them to heal. Two weeks later the carcinoma was removed through the perineum, the gut being attached to the preserved external sphincter.

Pathology.—The rectal growth was typically an early cancer. It measured about 2 cm. in diameter and invaded only the submucous tissue. The muscle layer contained some round-celled infiltration, but no tumor nests.

After-course.—The patient recovered normally from both operations. She reported at intervals during the succeeding years and nothing unfavorable was found. She had good control of her bowels unless the stool was very thin. There was noted a tendency of the anal scar to contract and this was gently dilated several times and once the scar was incised. Six years after the primary operation she had a more marked stoppage. Two weeks ago she had complete stoppage with severe cramps in the lower bowels and she had a severe headache and became nervous. Recently she has had shortness of breath and palpitation. The scar was incised freely and the rectal mucosa were united to the skin in the depth of the incision. Since then there has been no recurrence of the stricture.

Comment.—This tumor is unique in that it was accidentally discovered before it had given any symptoms whatever. The patient apparently is permanently relieved.

CASE 3.—A stenographer aged twenty-six came because of pelvic pain and irregular menstruation.

History.—She began menstruating at eighteen and had pain from the start. She came at first only several times a year, then for several years she was quite regular but in the past two years the periods have come every six to eight weeks. The flow is scanty and lasts but two or three days. She has a good deal of pain during the first day and frequently stays abed. Her general health is not good without being able to cite any particular disturbance. Chief of the complaints are uncertain sleep and general malaise.

Examination.—The patient is tall and slender and distinctly of the intellectual type. The lungs and heart show nothing abnormal.

The whole abdomen is sensitive. In the suprapubic region is a tumor the size of a small fist. It is oblong and extends over the brim of the true pelvis. It is slightly mobile and can be made partly to disappear in the true pelvis. It is smooth and firm and pressure upon it causes but little discomfort. Under anesthesia the hymen is found intact. The tumor above mentioned seems attached to the uterus, at least pressure on it causes the uterus to de-

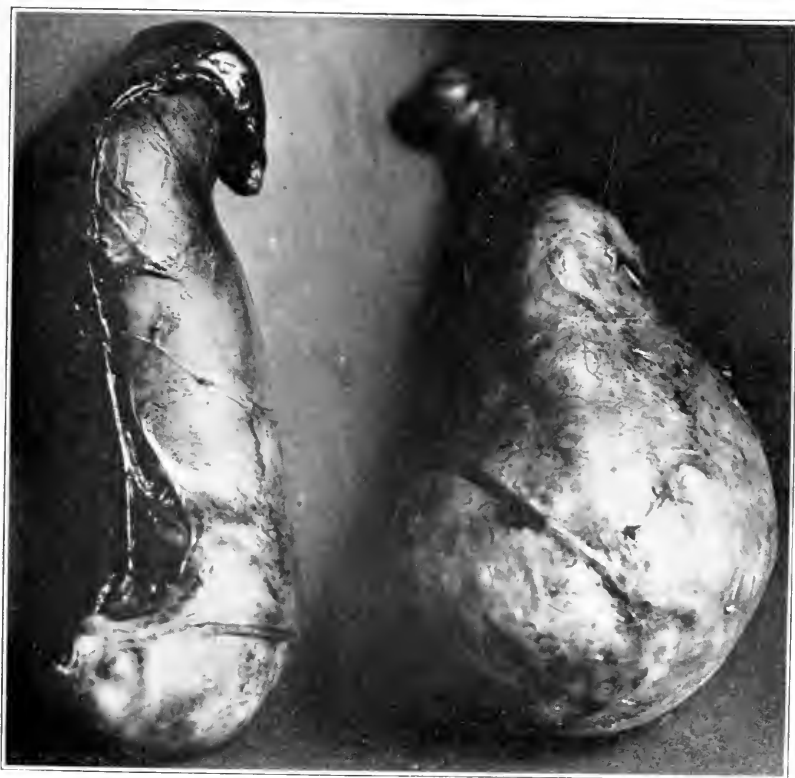


Fig. 385.—Huge fallopian tubes possibly tuberculous in nature.

scend and move to the left. Behind and to the left is another tumor the size of a small fist. It is smooth and can not be raised up. It is less firm than the other, but is not fluctuating. Blood and urine show nothing of interest.

Diagnosis.—The tumor on the right side extends up too high for anything other than a myoma riding on the fundus of the uterus.

That on the left side lies in the culdesac or in the broad ligament. Neither tumor seems quite as firm as myomas usually do, and the diagnosis must rest partly on exclusion. There is no evidence that the endometrium is encroached on. Therefore most likely a myomectomy with preservation of most or all of the uterus will be possible.

Treatment.—After the abdomen was opened the tumors were found to be enormously distended tubes. The left was kinked upon itself and was attached to the horn of the uterus. The right was firmly attached to the upper surface of the broad ligament. The tubes were removed leaving the ovaries and uterus. A good deal of hemorrhage was encountered coming from broad surfaces. The anesthetic was incomplete, which made the problem doubly difficult.

Pathology.—The right tube was 10 inches long and measured 4 inches in circumference. It was of nearly uniform diameter throughout its length (Fig. 385). The left tube measured 8 inches in length and 9 inches in circumference at its widest point. It was exactly pear shaped, the uterine end being small resembling the stem of a pear. The consistence was firm without resilience. On section the wall was found to be thin, not more than 3 mm. and smooth within. The contents were dry and cheesy, of a gray-white color, resembling the contents of a firm wen. The slide made from the wall showed it to be fibrous with few muscle fibers. A lining epithelium could not be demonstrated.

After-course.—The patient bore the operation well, but vomited persistently from the start. On the third day the vomiting persisted despite frequent washing of the stomach, and the abdomen became much distended. Examination showed a hard mass in the culdesac. Its nature was suspected, and an incision through the wall of the vagina brought forth a sponge. She improved for a day, then began to vomit more violently than before. She became distended and died on the sixth day. The autopsy showed the end of the omentum firmly adherent to the uterus and left broad ligament, Under it was imprisoned a loop of the small gut.

Comment.—The sponge nurse reported the count correct before the abdomen was closed. This was many years ago, and I have never since put any dependence on any one's statement as to the presence or absence of sponges. If neither operator nor assistant ever lets go of a sponge while it is in the abdomen, a sponge will never be

lost, for either the operator or his assistant would be missed should he disappear. Had a laparotomy been done to recover the lost sponge instead of a vaginal section, the omental adhesion would have been discovered and disaster averted. The nature of the tubal trouble is obscure. Where all the cheesy material came from I do not know. A few similar, but less extensive cases, have been recorded in the literature as tuberculous. There was nothing in the walls of the tube to warrant such a diagnosis. The patient was of such a type, but further than this there was no evidence. One may take his choice of diagnosing it such or declaring it of an unknown nature. The range of one's misinformation is ever greater than the protean manifestation of tuberculosis. Therefore nothing is gained by forcing such a diagnosis.

CASE 4.—A matron of thirty-three came because of pain in the right groin and leucorrhœa.

History.—Her general health was good until six years ago, a few months before marriage, when she began to have a profuse leucorrhœa. At first it was very profuse, but after being treated with suppositories it improved. She had one child five years ago. Delivery was normal; since then the leucorrhœa has not been so severe. During the past few years when she is much on her feet she has pain in her right side just above the hip bone and in the right shoulder. She has headache much of the time, most marked in the frontal region. No urinary symptoms. Appetite good. Sleeps very well. Very little backache. Menses regular now, four-day type. There is still pronounced leucorrhœa. Her menses began at seventeen and were irregular at first. She had much pain at the periods, it was cramp-like and compelled her to go to bed. In the interval she had pain in the right hip and often in the thighs. This was most marked when she was much on her feet.

Examination.—The patient is tall and slight of build. She is of the intellectual type and desires relief because her present state makes her inefficient. The abdomen is hyperæsthetic in the lower quadrants. There are no distinct points of tenderness save a general sensitiveness. The perineum is lacerated and lax. The cervix is lacerated, eroded, and presents some cystic degeneration. The uterus is big, boggy, and markedly sensitive to bimanual examination. The right ovary is as large as an egg and pronouncedly tender.

Diagnosis.—The patient did not menstruate until she was seventeen years old, which together with her general physique indicates a somatic system below par. The profuse leucorrhœa coming on suddenly a few months before marriage causes one a certain degree of apprehension. However, she became pregnant three months after marriage, an unlikely occurrence if the leucorrhœa had been due to an indiscretion and the gonococcus. Furthermore, she is of the type in which emotional disturbance of an unfamiliar sort is most apt to produce a congestive leucorrhœa. The chief complaint now, the groin pain and pain in the back, has a sufficient excuse in the lax perineum and the low hanging cervix. The leucorrhœa now may well be accounted for by the cervical erosion. The headache, being frontal, lacks the peculiar evidence of a pelvic relation of the more common vertex or occipital headache, and it must be questioned if the general enfeeblement or a latent eye strain may now be an intermediary link. The objective lesions demand repair, but the large and sensitive ovary, probably responsible for some of her antenuptial ills, must be regarded as a still existent menace to health. If she is to be brought to a satisfactory state of health, a long existent lesion must be found. Such ovaries must be included in the projected treatment. Even if this was the cause of the ills of girlhood its removal now, together with the repair of the obstetric lesions, the prognosis must still be guarded. Her subsequent health will be dependent on a fortunate environment, both economic and domestic. If she shall be able to remain within her strength in both these directions a satisfactory state may be attained and maintained.

Treatment.—Amputation of the cervix, perineorrhaphy, appendectomy and right oophorectomy was done.

Pathology.—The cervix on section shows extensive cystic degeneration. The slide shows much round-celled infiltration about the cervical glands. The ovary measures 5 x 3 cm., is hard and polycystic. The slide shows the capsule to be much thickened and the interstitial tissue shows much hyaline degeneration. The medulla is composed of a large number of vessels with very thick walls which show extensive hyaline degeneration.

After-course.—Operative recovery was uneventful and she has been generally much improved and gained some 20 pounds in weight.

Comment.—The bogginess of the uterus likely will lessen, but the remaining ovary may undergo cystic changes. In that event no other operative treatment can be undertaken, for a cystic ovary is vastly better than none.

CASE 5.—A matron of thirty-four came because of pelvic distress following abortion.

History.—Her general health has always been good. She has four living children, has had two premature births at seven months, eleven and five years ago. The youngest living child is six years old. She had a miscarriage, at two months, nine months ago. She was in bed three weeks at that time, and had fever. She has been in bed much of the time since then. When she is on her feet she has a dragging feeling with a pronounced pain low in the pelvis on the left side. This pain is much lessened as soon as she lies down. The menses have been fairly regular and last a week. She had a marked leucorrhœa soon after the abortion, but it is less now. The appetite is poor and the sleep variable.

Examination.—There is general abdominal sensitiveness. The perineum is lacerated to the second degree, there is a bilateral laceration of the cervix with much erosion. The body of the uterus is large, is in position and is sensitive to bimanual pressure. Blood and urine negative.

Diagnosis.—The history of two premature labors, followed by a normal one followed by an abortion at two months five years later indicates a chronic disease of the endometrium. The pronouncedly acute onset of her symptoms following this abortion, attended by fever, indicates an actual inflammatory trouble in the endometrium. The two premature labors suggest the possible presence of syphilis. She bore a healthy child after these premature labors, however, and her blood count is normal, viz., Hg 90 per cent; W.b.c. 7,000; R.b.c. 5,050,000. If in such a case I received a report of a positive Wassermann, I would not believe it. The pelvic distress is due evidently to congestion of the pelvic organs as indicated by the large, soft cervix. The perineum gives poor support which adds to her discomfort. The lacerated cervix adds to the congestion. Such a definite history of onset after an abortion suggests strongly that there may be retained products though usually when that is the case there is a more definite metrorrhagia. At any rate exploration seems justified.

Treatment.—Curettage. Repair of the cervix and perineum.

Pathology.—The material obtained by the curettage shows a hyperplastic endometrium with large round interstitial cells evidently decidual cells.

After-course.—Recovery was prompt and lasting.

Comment.—This is the one condition in which a curettage is really indicated, for there remains after the abortion decidual rests which act as constant irritants to the endometrium. A uterus that has contributed four living children and has become so much diseased had best be sterilized.

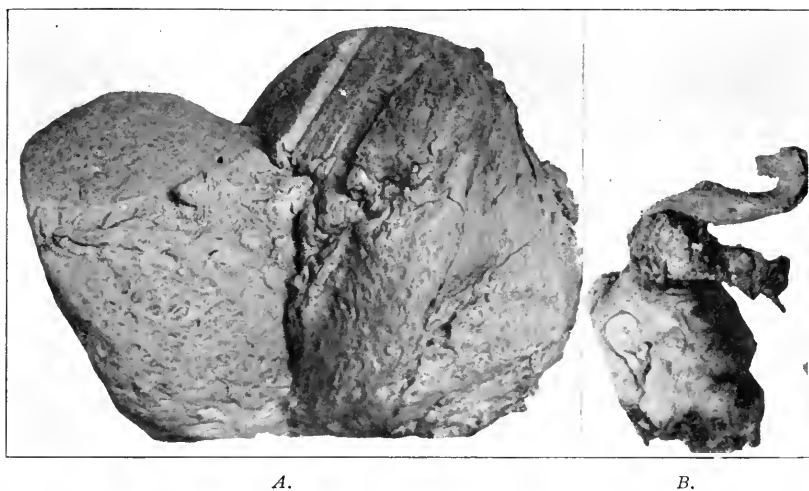
CASE 6.—A married woman aged forty-two came because of pelvic pain.

History.—The patient has never been pregnant. She has had dysmenorrhea many years. The flow is erratic, sometimes lasting a few days only, sometimes as long as twenty-one days. There is usually much exhaustion attending menstruation. She had no flow from June to November, then none again until January. During the past six months she has flowed several times. She has had several attacks of sciatica, sleeps badly, and is irritable generally.

Examination.—The patient does not exhibit evidence of irritability. General examination is negative. The uterus is as large as a fist, the bulk of enlargement being to the left and backward. The uterus is not fully movable and indefinite resistance is felt on either side of the uterus. The os is wide and a small soft polyp can be felt protruding from it.

Diagnosis.—The long history of menstrual irregularity, the sterility, the general increase in size of the uterus seems to make the diagnosis of adenomyoma reasonably certain. The periods of amenorrhea speak against malignancy, since if a malignant process were present, the flow should progressively increase instead of lessen. The increased pelvic distress which was urging her to operation was unexplained unless an increased hypersensibility made her more responsive to ailments long existent or that tubal trouble has been superimposed.

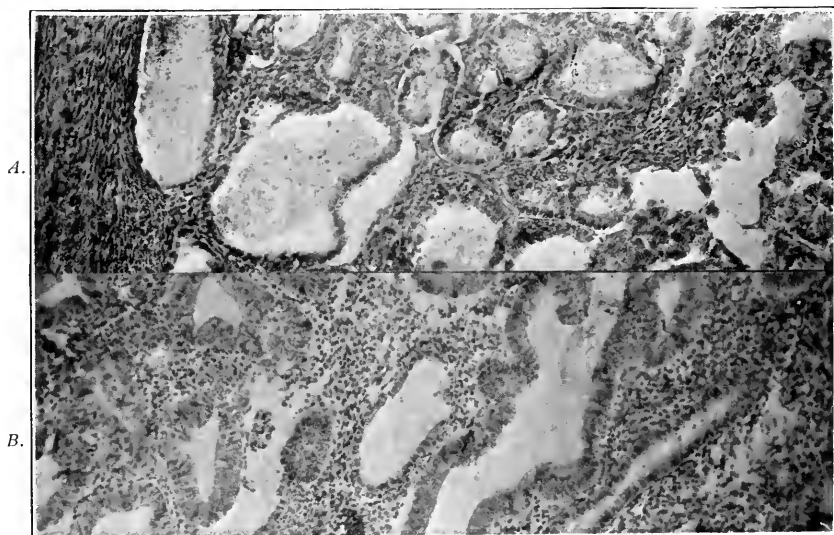
Treatment.—After the abdomen was opened a papillary tumor was discovered in each ovary. These growths were half the size of a normal ovary and were implanted upon the ovary, not arising from it. Therefore, the ovaries and tubes, together with the uterus, were removed, for it was obvious the ovarian tumors were extensions from the uterus.



A.

B.

Fig. 386—A. Beginning malignancy in adenomyoma of the uterus. B. Metastasis in the ovary.



A.

B.

Fig. 387.—A. Metastatic malignant adenoma of the ovary. B. Adenocarcinoma of the fundus.

Pathology.—The uterus was as large as a croquet ball. The uterine cavity was small but the endometrium was thickened and corrugated. (Fig. 386A.) The wall of the uterus was uniformly thickened.

The endometrium of the fundus was converted into a malignant adenoma (Fig. 387A). This, aside from the metastasis on the ovary (Fig. 386B) constituted the exclusive pathologic changes. The papilloma of the ovary was similar to the endometrium in structure (Fig. 387B).

After-course.—An intense infection followed both in the broad ligaments and in the subcutaneous tissue of the abdominal wall. A staphylococcus and an undetermined bacillus were recovered from the pus. In ten days the patient began to exhibit a delirium. It was noticed at this time that the right parotid gland was swollen, to be followed in three days by an enlargement of the other. A nurse employed in that part of the house had become affected with mumps and a consultant considered this a possible source of the parotid trouble. In a few days fluctuation was present, however, and the glands were drained. There was a general improvement following this and after a long period the patient recovered. As yet no reappearance of the malignant disease has occurred.

Comment.—The only two parotid suppurations I have had have both been in patients with malignant papillomas of the ovaries complicating carcinoma of the fundus. This patient was operated on after an infected gall bladder in another patient had been drained. The same organism was found in both cases. Obviously there was direct transportation of the infection.

CASE 7.—A matron of forty-six came because of apprehension that all was not right with her pelvic organs.

History.—The patient could recall no abnormality in her sexual life until recently when she had a sense of fullness in the pelvis with frequent urination and occasionally dull pain during the last three or four months. She had missed two periods and desired to know whether she had become pregnant or was entering the menopause.

Examination.—The uterus lay to the left of the median line and the right pelvic cavity was occupied by a tumor as large as a cocoon. It was oblong and soft, boggy, and rather fluctuating. The cervix was not softened and I was quite sure I could feel a distinct separation between the tumor and the uterus. In order to make certain, however, a tenaculum was attached to the cervix and an assistant made traction on this while I controlled the tumor by

bimanual examination. The uterus moved freely while the tumor was fixed by the hands.

Diagnosis.—A semisolid tumor of the ovary was diagnosticated. Because of its semisolid consistency and its oblong shape, a dermoid was suspected.

Treatment.—The ovary is as large as the operator's fist. After being cut into an extensive papillary formation was seen inside it. The tube being thickened and abnormally attached to the tumor, it was removed along with the tumor. The patient having missed two

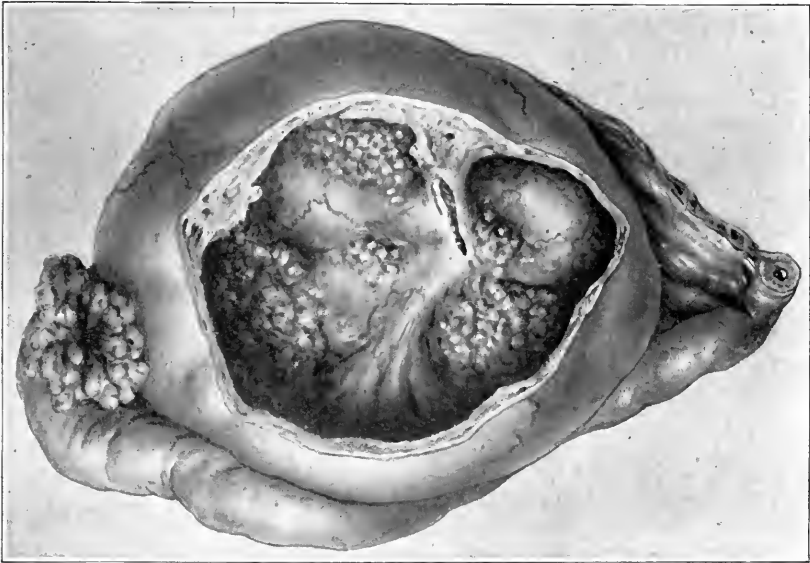


Fig. 388.—Papillary cystadenoma of the ovary.

periods and being forty-six years of age and taking into account the likelihood of the other ovary undergoing a like change also, it was removed.

Pathology.—The section of the tumor shows thick, fragile walls from which papillary projections have sprung (Fig. 388). The fluid contained was serous. The slide shows the papillary portion of the tumor is due to active proliferation about the base. At no point was the wall invaded. The cyst wall had the structure of a pseudomyxoma. The other ovary showed no signs of degeneration.

After-course.—There has been no evidence of a return of the trouble and she is well six years after the operation.

Comment.—This tumor differs from the usual papillary cystomas in being unilateral and in the thickness of the wall. When these tumors become malignant they fill the cyst with a solid mass and by invading the wall of the cyst reach the surrounding tissue instead of destroying the cyst wall by erosion and extension of the papillary processes themselves. The papillary tumors are nearly always bilateral, yet removing the other ovary on suspicion is a dangerous practice and is indefensible except when the patient is at or beyond the menopause. In case the associated ovary is allowed to remain in such cases it should be observed from time to time in order that any change may be detected early.

CASE 8.—A matron aged twenty-five came because of painful menstruation.

History.—The patient had excellent health until her only child was born two and a half years ago. She had a miscarriage at three months two years ago. Since then her menses have been irregular, with pain which is most severe just before the period. The headaches are more severe when menstruation is delayed. The pain is most severe in the top of the head. Recently she flows a few days, stops a day, then flows a few days again. The last few periods she has had pain in the region of the heart.

Examination.—The uterus is in position but the cervix is eroded. There is a sensitive mass in the left broad ligament.

Diagnosis.—The fact that her menstrual periods were normal before the birth of the child makes it possible to fix a point of origin. That she miscarried six months later indicates an abnormal endometrium at that time if the abortion was spontaneous, and most certainly since then if it was induced. The intermittent flow with headache and referred pains points to local disturbances in the uterus. The intermittent flow indicates the difficulty to be in the mucosa either as a primary affection or secondary to circulatory disturbance within the muscle itself. The mass at the side of the uterus suggests that the endometrium is not alone at fault. The mass beside the uterus feels like an inflammatory exudate. It is not likely it has existed since the abortion two years ago. It may represent terminal changes. It may be the judgment is erroneous. Bearing a close relation with the abortion it seems justi-

fied to explore the interior of the uterus with a curette. The eroded cervix indicates an irritating discharge and not a laceration.

Treatment.—Curetment. Iodine was used inside the uterus both before and after the curettage was done.

Pathology.—The products of the curettage showed a so-called hyperplastic endometrium which is equivalent to saying that for some reason the endometrium did not reduce or retrogress after menstruation, as it normally does. There were no decidua remains demonstrable.

After-course.—Improvement followed at once and she was freed from the intermittent flow though she retained some pelvic soreness. At any rate she has borne several children since.

Comment.—Whenever there is apparent a causal relation of the menstrual disturbance to some obstetric accident it is justifiable to explore the uterus. The touch of the curette should indicate to the operator whether or not the endometrium is hyperplastic, or whether there are nodulations as of retained placenta or decidua. If none exists, it is quite useless, to say the least, to denude the uterus.

CASE 9.—A matron aged forty-six was sent to me because of painful menstruation and passage of blood through the bladder.

History.—The patient has had dysmenorrhea for a number of years. Four years ago she was operated on and the lower portion of the uterus removed. Following this some months she had more pain than ever and she noticed that she passed blood from her bladder at those times. The pain is now intense for several days during the menstrual flow. Except for a feeling of exhaustion due to the pain she is in good health.

Examination.—The site of the former cervix is represented by a mass of scar tissue. No cervical canal can be made out. The body of the uterus is as large as a croquet ball, is smooth and dense elastic and not painful on pressure. The cystoscope shows a small opening half an inch above the trigone. The bladder wall is unaffected.

Diagnosis.—Obviously the traumatism inflicted by the cervical amputation effectually closed off the cervical canal and at the same time injured the bladder wall. The size of the uterine body suggests an adenofibroma because of its size and symmetry. The closure of the opening between the uterine cavity will demand the reestab-

ishment of the cervical canal and the loosening of the bladder wall from the uterus in order that the hole in the former may be closed. Because of the size of the uterus its removal may be demanded. It seems best to attack this by the vaginal route.

Treatment.—In attempting to separate the bladder wall from the scarred remains of the cervix a gush of blood was encountered. In palpating through the opening a cavity deeper than the finger could reach was discovered. At the depth of this a pedunculated




Fig. 389.—Pedunculated myoma protruding into a hematometrium.

tumor could be felt but the base could not be reached. This made it evident that the uterus was too large for easy removal through the vagina without morselement, hence this route was abandoned and the hysterectomy was completed through an abdominal incision. The hole in the bladder was located and closed by superimposed plication. A permanent catheter was placed in the bladder.

Pathology.—The body of the uterus is composed of a shell from the fundus of which a pedunculated fibroma the size of a hen's egg pro-

jects (Fig. 389). In structure this is composed of fibrous tissue covered by a thinned mucosa.

After-course.—Recovery was uneventful.

Comment.—The thickness of the abdominal wall and the tenseness under which the fluid was held prevented me from recognizing the uterine enlargement as hematomatous. In fact the opening into the bladder so absorbed attention that the nature of the uterine enlargement was given only fleeting attention. Being unable to determine the nature of the polypoid tumor at the base, I feared it might have malignant tendencies. Otherwise the proper formation of a cervical opening with removal of the tumor would have been all that was required.

CASE 10.—A married woman aged thirty-four came to the hospital because of painful menstruation.

History.—The patient's menstrual history is unimportant save for dysmenorrhea which has increased in severity during the past year. The flow has increased considerably in duration recently. She formerly flowed three to four days, but now she flows double that time. She has been married twelve years, but has never conceived. She is more concerned because of her sterility than the discomfort she experiences.

Examination.—The uterus is displaced to the left and the cervix points to the tuberosity of the sacrum. The fundus seems to lie in the culdesac. The right side of the pelvis is filled with a hard bosselated tumor which is not fixed but which is painful when an attempt is made to lift it out of the pelvis.

Diagnosis.—Its density and form and its unilateral attachment stamp it as a myoma. Its position to the right and the failure to spontaneously rise or to permit elevation suggest that it is confined to the right broad ligament.

Treatment.—The tumor is not associated with the broad ligament but is attached by a fairly broad base to the fundus of the uterus. A cuff is made of the peritoneum covering its pedicle and the vessels supplying the tumor are isolated and ligated separately (Fig. 390-A). All hemorrhage is controlled before the peritoneal flaps are brought together by Lembert sutures (Fig. 390-B). This technic is used in order to avoid placing deep sutures for the control of bleeding.

Pathology.—The tumor is a dense one formed chiefly of fibrous tissue.

After-course.—The patient bore a living child fifteen months after the operation.

Comment.—The situation and character of the tumor was not such as to in itself render the patient sterile. It must have been the dis-

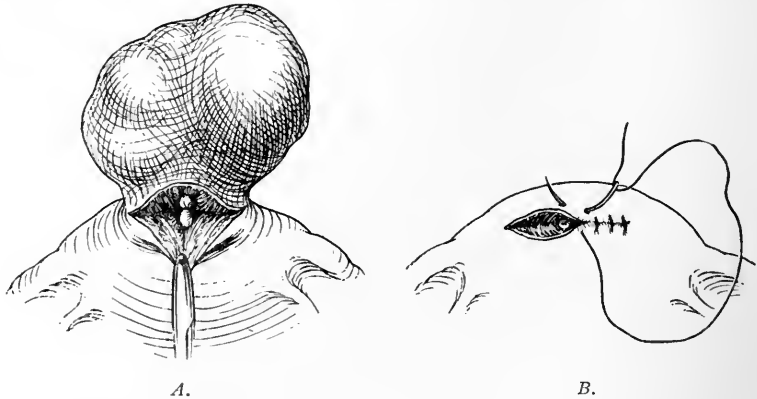


Fig. 390.—Technic for removal of pedunculated myoma of the uterus.

placement caused by it that brought about that state. This hypothesis makes it necessary to assume a very long duration of the tumor near its present size. The great density of the tumor makes this assumption tenable. This patient is one of the few in my experience who have borne children after a conservative myomectomy.

CASE 11.—A married woman aged thirty-six came because of painful menstruation and obstinate constipation.

History.—The patient has had no children, but one abortion fourteen years ago and one six months ago. The menses are regular, the flow slight, lasting one-half to three days. The menses have always been painful. She has obstinate constipation, never has a bowel movement without medicine or an enema or both. She has attacks of palpitation and precordial distress.

Examination.—A smooth, round tumor fills the pelvis, pressing the uterus against the pubes. Traction on the cervix seems to move the uterus independently from the tumor mass. It lies directly behind the uterus. The apex beat is diffuse without murmurs and the rate is 90.

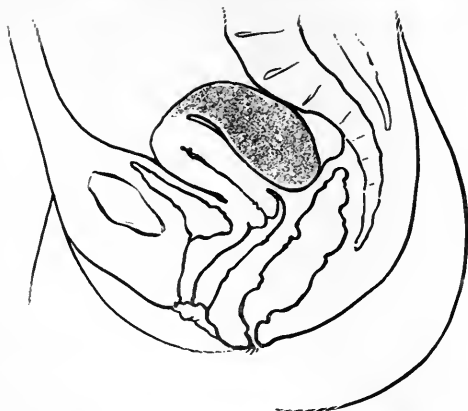

Fig. 391.—Diagram showing relation of the tumor to the uterus in the preceding figure.

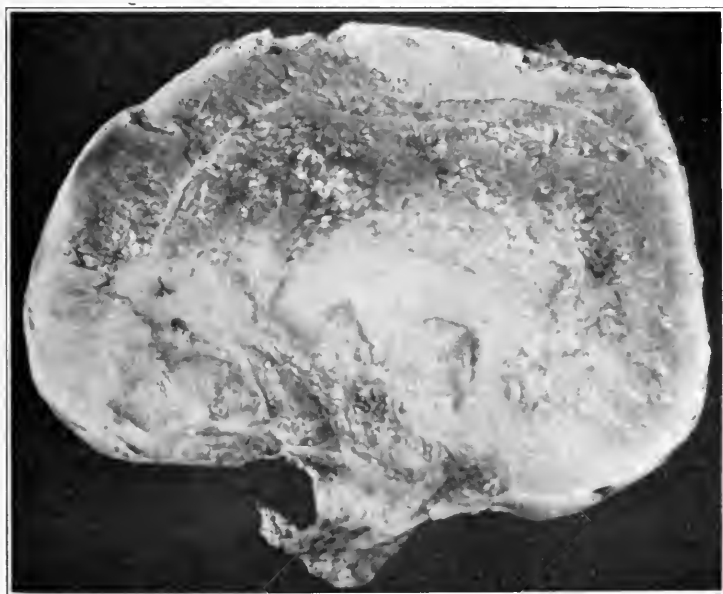

Fig. 392.—Pedunculated myoma of the uterus.

Diagnosis.—A solid tumor in the pelvis probably going out from the right ovary since the uterus seems to move independently of it. These tumors in women of this age are usually fibrosarcomas.

Treatment.—The tumor was attached to the fundus only by a long narrow pedicle (Fig. 391). The pedicle was divided and the tumor only was removed.

Pathology.—The tumor shows extensive colloid degeneration (Fig. 392), evidence perhaps that the narrow pedicle did not supply a sufficient nutrition to enable it to retain its integrity.

After-course.—Recovery was complete. The menses became less painful and the cardiac irregularity disappeared.

Comment.—Had the tumor been ovarian the uterus would most likely have been displaced in the opposite direction to a greater extent than was the case. The relation of myomas to cardiopathies is probably not direct through an intoxication from increase in muscle tissue in the body as once thought. Nevertheless, cardiac irregularities sometimes disappear when the myomas are removed.

CASE 12.—A married woman aged thirty came to the hospital because of amenorrhœa.

History.—The patient has neither borne children nor miscarried. Menstruation has always been irregular and painful. She has repeatedly missed her periods for several months together and she has not menstruated at all during the last nine months. She has pain in the right side, particularly when much on her feet and at uncertain intervals a rather intense pain in the sacral region.

Examination.—The uterus is in position, movable but somewhat sensitive on bimanual examination. The right ovary lies deep in the culdesac, is somewhat enlarged and very sensitive to the touch.

Diagnosis.—The patient desires to have children and to be rid of the pelvic pain which is particularly distressing on Saturday nights, her husband being a traveling salesman. The patient is a picture of perfect physical womanhood, and her husband having established an alibi by having children by a previous marriage, it was deemed permissible to explore, and at least anchor the truant ovary.

Treatment.—The right ovary was twice its normal size and contained no less than eight corpora lutea varying in size from a corpus luteum of pregnancy to that of a pea. There were several small ones in the left ovary. These bodies were resected and the defect repaired. A wedge-shaped section was removed. A running buried suture was placed to control the hemorrhage and then a second layer to coapt the cut edges (Fig. 393).

Pathology.—The structure of the corpora lutea did not differ from those of normal history. In one of them there was a cavity containing fluid, giving the appearance of a beginning luteal cyst. The tu-

nie of the ovary was not thickened. The uterus was in no wise changed.

After-course.—The patient began menstruating some three months later and has continued to menstruate regularly, with slight deviations, for ten years. Her desire to bear children has not been fulfilled.

Comment.—I have seen several corpora lutea present on several occasions but never to the number and size exhibited in this case. The results indicate that their presence had to do with the sustained

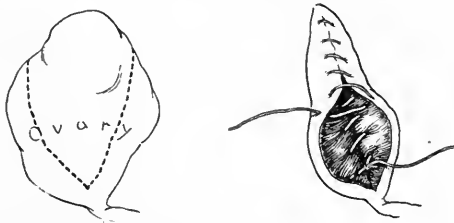


Fig. 393.—Technic for resection of a persistent corpus luteum.

amenorrhœa. Why they failed to undergo the usual retrograde changes did not appear from the study of their structure. The observation of this case causes me to wonder whether the corpus luteum of pregnancy may have the function of restraining the uterus from undergoing the periodic bleeding which has become its habit. This is one of the rare instances in which resection of the ovary seemed to do some good. Generally it is meddling surgery done on organs the pathology of which we are wholly ignorant. If one must resect, the operation should be executed with as much care as one would use in operating on an eye.

HEMORRHAGE

Accidents of gestation and conditions resulting from it and tumors encroaching on the endometrium are the innocent causes. Malignancies must be considered in every case. Last, but not least, constitutional diseases, notably pernicious anemia, may be the cause of bleeding.

CASE 1.—A married woman aged thirty-eight entered the hospital complaining of nervousness, headache and uterine hemorrhage.

History.—The patient was always well as a child and young woman. She has had three children, all living and well, the youngest of whom

is fifteen years old. Ten years ago she had amenorrhea for seven months. Retroversion was diagnosed at that time and the uterus was replaced bimanually, knee-chest positions and hot douches used and the flow started and continued for three weeks and then became regular, according to her physician. The patient had no notable illnesses until four years ago when she began to be troubled with headache, located chiefly in the back of the head and occurring usually, but not exclusively at night. Since that time she has been very nervous and excitable. At that time she presented herself at this hospital for examination, and a diagnosis of hyperthyroidism was made and she received medicinal treatment with some improvement. She had choking spells at that time but she herself noticed no enlargement until a year ago. During the past year the nervousness has increased markedly and is now more distressing than at any previous time. Six months ago she had influenza at the time for her period and the menses did not appear. At the time for her next period she had cramps, but did not flow. Her doctor started the flow, so he said, by tipping the displaced uterus into position. She then flowed for ten days, stopped three days and then started again and has been flowing most of the time since. Some days there is very little flow and on others the flow is profuse with clots. During the last two days she has been troubled with cramps and backache every day when she is on her feet. She sleeps but little because of nervousness. The appetite is good but the bowels are constipated. She has frequency of urination when she has nervous spells, otherwise she has no urinary symptoms.

Examination.—There is an enlargement of right lobe of thyroid which is smooth and moderately firm. It does not pulsate. There are no eye signs and but little tremor. The pulse is 90. The perineum is lacerated to the second degree and the cervix has a bilateral laceration with some eversion. There is a bloody discharge from the cervix. The uterus is in position, normal in size, and but little tender.

Diagnosis.—The history of the goiter as compared with the present symptoms indicates that there is a regression of the toxic symptoms. The nervousness and sleeplessness are the chief symptoms which might be referred to this cause. The chief factor now to be considered obviously is the uterine hemorrhage. Ten years ago she had a period of amenorrhea lasting seven months which it is al-

leged was relieved by the replacing of a retroversion. The present illness was initiated by a similar train. The intermission of the menstrual periods during some illness is not unusual but in influenza there is a tendency to hemorrhages. The flow begins before the usual time or the normal flow is prolonged. The failure of the menses to appear can not be ascribed therefore to the attack of influenza. The most obvious cause for amenorrhœa is pregnancy. The manual replacement, if we can accept the statement at full value, can not be regarded as having anything to do with the reappearance of the menses. Since the uterus is now in position, it is fair to infer that there has at no time been a displacement. The manual replacement may have been designedly done with a probe. The flow started at once and has continued more or less constantly since that time. The cramps have been most severe during the past few days and following this a lessening of the flow. This indicates that some factor responsible for the hemorrhage may have been expelled. A hyperplastic endometritis or a polyp should have been initiated by a gradual increase in flow, certainly not by missing a period. A long period of sterility, however, suggests some uterine trouble. Since both conditions are possible, the diagnosis, therefore, is hyperplastic endometritis or incomplete abortion.

Treatment.—Palpation with the curette failed to produce evidence of incomplete abortion, hence it was decided to explore the interior of the uterus. The vaginal mucosa was separated from around the cervix. The bladder was dissected up and the cervix and fundus split longitudinally. The mucosa over an area of 1.5 cm. was much hypertrophied, therefore, this area and the cornu of the uterus containing the fallopian tubes were resected. The two halves of what remained of the uterus were brought together with chromic 20-day gut and the vaginal mucosa sutured to the cervix. A perineorrhaphy was done.

After-course.—Uneventful. There was considerable bloody discharge from the uterus for a few days. This discharge decreased, but some was still present when the patient left the hospital.

Pathology.—The area noted at the operation on inspection proved to be sharply defined from the uterine muscle except at one point. At this point a pea-sized area seems to be invaded by glandular structures. This area on section shows a prolongation of the uterine glands but these show no malignant tendencies. At a distance from

the area above discussed the mucosa shows a cluster of well-defined chorionic villi.

Comment.—From the foregoing it is evident therefore that we had to do with an abortion. Whether or not the area above discussed might have become the starting point for a malignant growth can not be stated, but in view of the other findings it is a source of satisfaction to contemplate this possibility. The hemorrhage was due to an abortion, probably induced, whether intentional or not, and the hyperplastic area was an accidental finding. The correction of the uterine difficulty may have a salutary effect on the goiter. It is in the by-products that the justification for the operation must be sought.

CASE 2.—A married woman aged forty-two was brought to the hospital because of vaginal hemorrhage.

History.—The patient has two children, the youngest eleven years old. Two years ago the patient began having vaginal discharge. She noticed soon after that when she used the douche pain was caused and sometimes bleeding resulted. Later spontaneous pain of an indefinite burning character began. Her menses were regular and lasted four or five days, but there was a bloody discharge at intervals throughout the intermenstrual period. She had frequent painful micturitions and she was obstinately constipated, enemas being required to secure a bowel movement. Recently the patient has had constant severe pain and she has been taking anodynes to relieve it.

Examination.—The patient is extremely irritable and nervous, and gives the impression of a neurotic. She insists on having a general anesthetic before an examination be attempted. This given, the entire vulvar area from the earuncles up to the base of the clitoris on either side is seen to be ulcerated. Below a rectocele bulges between what is left of the labia minora. The entire vaginal surface is replaced by an ulcerating, bleeding granulous mass. The posterior wall is involved to within two inches of the vulvar margin and extends to the posterior vault but does not involve the cervix. The anterior wall is involved throughout its extent, but does not involve the cervix. The rectovaginal wall is much thickened, as is the anterior wall. (Fig. 394.)

Diagnosis.—Syncytiomas, by retrograde metastasis, sometimes produce fungating bleeding masses in the vagina, but these are more

lobulated, softer, and run a more rapid course. Tuberculosis is softer, tends to leave undermined edges and does not bleed so readily nor does it cover so wide an area. Syphilis maintains a uniform outline with soft bases and overhanging edges.

Treatment.—Morphine ad libitum.

After-course.—The patient lived three months. A rectovaginal fistula formed some weeks prior to her death.

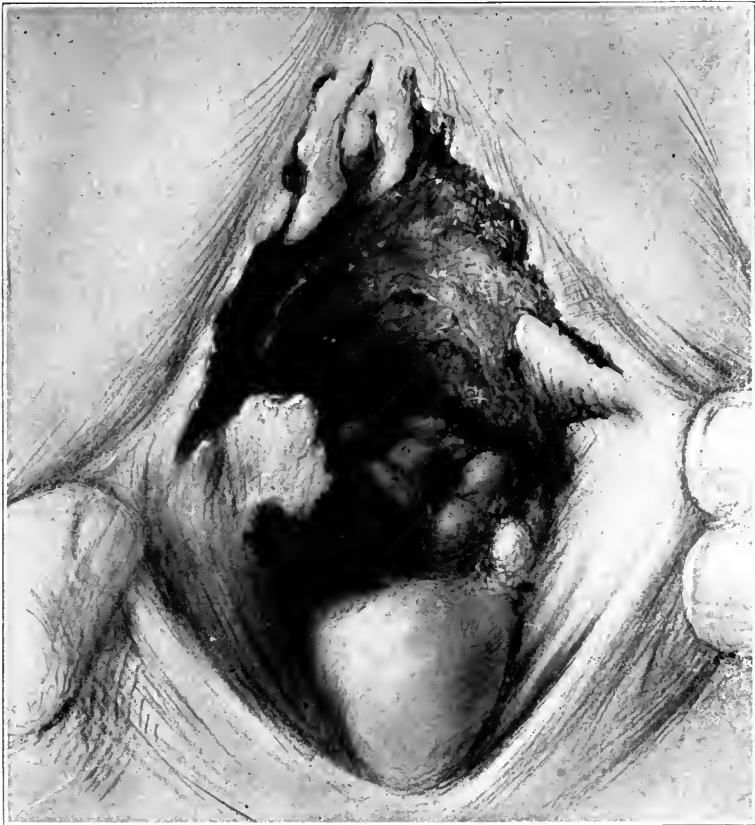

Fig. 394.—Carcinoma of the vagina.

Comment.—When vaginal carcinomas are seen early, a vigorous curettage followed by acetone gives surprisingly good results. This treatment is preferable to the cautery because a complete destruction of the tissue forming openings into one of the neighboring hollow viscera is less apt to occur.

CASE 3.—A matron aged forty-two came because of a bloody vaginal discharge between periods.

History.—Her menses have always been irregular and for the past year she has been flowing every two or three weeks, and there has been a profuse vaginal discharge at times between periods. Three months ago this intermenstrual discharge became tinged with blood. She has two children, ten and six years of age. Fourteen years ago she had a severe attack of pain in the bladder which kept her in bed for five weeks.

Examination.—The cervix is eroded and bleeds on touch. The mucosa of the cervix is soft and thin and the dividing line between squamous and columnar epithelial surfaces is sharp (Fig. 395). The uterus is of normal size and is freely movable.

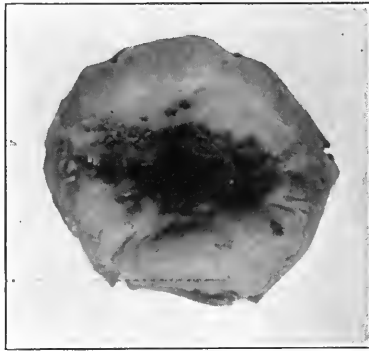


Fig. 395.—Polypoid degeneration of the cervical mucosa.

Diagnosis.—The only factor of significance is the tendency of the mucosa to bleed. It is soft and shows no proliferation, however. The bleeding is the only factor which might suggest malignancy. The size of the uterus and the character of the discharge precludes fundus carcinoma. As a matter of precaution cervical amputation seems warranted.

Treatment.—A pyramid-shaped portion of the cervix was removed with the electric cautery. The cervical canal was dilated and the interior of the uterine canal palpated with a curette.

Pathology.—The cross-section shows the mucosa to be of normal thickness and the slide fails to show any epithelial displacement. Four separate areas were examined.

After-course.—The wound healed and the trouble seemed to be effectually eradicated. After six months she had a little colored discharge again. The cervical canal was explored, but nothing found. Iodine-carbolic acid was applied. After a month bloody discharge was again noticed. The same treatment was repeated. She remained free for a number of months. Then a little blood appeared again. Inspection now disclosed a polyp as large as a slate pencil and half an inch long having its attachment just within the inner os. This was cauterized thoroughly. After this all discharge bloody and otherwise ceased.

Comment.—Likely this diminutive polyp was pressed against the wall of the cervix by the dilator so that it was overlooked at the time of the cervical amputation. I can not be sure whether the blood noticed at the time of the vaginal examination came from the mucosa of the cervix or whether it came from the polyp and overflowed the mucosa. I am disposed to believe the whole trouble was due to the little polyp and that the amputation of the cervix was unnecessary. Small comfort may be obtained from the fact that this removal will prevent a possible cancer.

CASE 4.—A matron aged forty-six came to the hospital because of a bloody vaginal discharge.

History.—The patient has had three children, the youngest twenty-one years old, and no miscarriages. Ever since the birth of her last child the periods have come every three weeks instead of four as before that time. The flow has always been free and lasts about one week. She has had a great deal of headache, but very little backache. The patient's present illness began gradually about three years ago. A vaginal discharge was first noted. It was whitish at first but later became yellowish and thick. For the last six months the discharge has been bloody. She now has constant pain in the lower abdomen, but it is worse sometimes than at others. It now radiates to the back. Menses are regular every three weeks and her pains are somewhat worse at those times. The appetite is variable. At the present time it is not very good. She is obstinately constipated. There is burning and pain on urination. She weighs 120 pounds now, though her usual weight is 130. She does not feel sick but the bloody discharge makes her feel apprehensive.

Examination.—The left side of the cervix is occupied by a fungoid mass which bleeds easily (Fig. 396). To the feel it is soft and velvety and the outlines of the eroded area are sharply defined and somewhat undermined. The right side of the vault is free but the left side is retracted and has pulled the cervix to that side. The fixation seems inflammatory rather than neoplastic.

Diagnosis.—The sharp border and the soft feel suggests tuberculosis, though the readiness to bleed makes me feel that it may be carcinoma. The fixation of the cervix to the left also suggests carcinoma. The fixation of the uterus to the left makes radical operation impossible if it is carcinoma and needless if it is not. It seems best, therefore, to excise the cervix with the cauterly and to destroy as much as possible of the broad ligament by the same means.

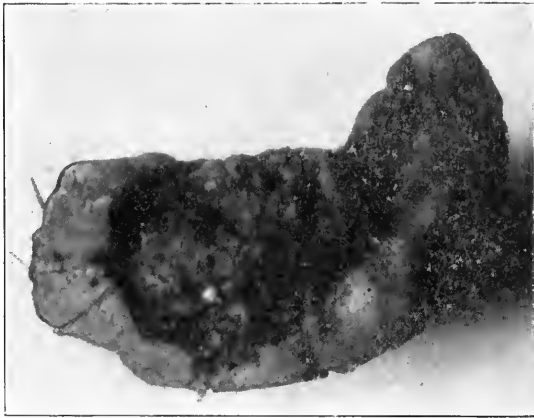

Fig. 396.—Carcinoma of the cervix.

Treatment.—Excision of the cervix with the electric cauterly under local anesthesia was done. An hour was spent in the process.

Pathology.—The eroded area is made up of fine papillae, like a small bladder tumor, but here and there are nests extending more deeply into the cervical tissue establishing it as a malignancy.

After-course.—The condition was reviewed three months later and a small suspicious area on the left side of the scar was cauterized. There has been no reappearance in six months.

Comment.—The feel of this erosion was wholly unlike any I have ever felt and having never observed a tuberculosis of the cervix, I presumed this might be one. I have since seen two other carcinomas of

the cervix like this one. They seem to be less malignant than the common form, though I have no doubt the final result will be the same. I have never cured a carcinoma of the cervix.

CASE 5.—A married woman aged thirty-four came to the hospital because of a vaginal discharge.

History.—She had a child six years ago which lived only three days. Though weak and nervous since then, she has had no special complaint until the onset of the present trouble. Beginning three months ago she had a continuous pain in the bladder region and a vaginal discharge. She was examined at this hospital at that time and the following note made: "There is a marked erosion of the cervix. It is soft, does not bleed on touch and there is a sharp dividing line between the erosion and the unaffected part. Operation advised." She was treated locally for this for some months by her family physician. Following this she became pregnant and all during her pregnancy she had a copious mucous discharge which became bloody as the time of labor approached. After the birth of the baby the discharge very suddenly increased and has continued to increase up to the present time. She has been very weak since delivery six months ago.

Examination.—There is a large cauliflower mass occupying the cervix. It fills the whole vault of the vagina. It is hard and friable and bleeds profusely on manipulation. The cervix is fixed to the right and resistance is felt in the right broad ligament.

Diagnosis.—The cauliflower form, the density and tendency to bleed leaves no doubt as to the malignant character of the growth. The fixation to the right and the resistance in the broad ligament indicate that radical operation is not possible.

Treatment.—The carcinoma was removed with a cautery knife.

Pathology.—The tumor is a squamous-celled papillary carcinoma.

After-course.—The patient was asked to return after three months. She did not return for a year. There was a circumscribed growth in the scar in the right side of the vault when she did return. This mass was excised with a cautery and two treatments of radium applied. The pain was in no wise abated, there being most likely other secondary growths. She continued to grow weaker and died eight months after the second operation.

Comment.—At the time of the first examination the appearance was that of a simple laceration. If this was such, did the malig-

nancy develop during pregnancy or very rapidly following this? When seen three months after labor the mass was large and cauliflower-like. If it had attained this size before labor it would have proved a serious impediment to delivery. It is fair to assume therefore that at least a considerable part of the growth took place after labor. Besides, the obstetrician noted nothing during the labor. Possibly a removal of the erosion when first discovered would have prevented subsequent trouble. This is the only instance where I examined a condition which was, or later proved to be, carcinoma. From the subsequent course of development I am inclined to think that it really was a simple erosion when first examined.

CASE 6.—A widow aged sixty-four came because of a bloody discharge.

History.—The patient has a son aged thirty-two, her only conception. During her menstrual life she flowed four days every three weeks without pain other than a dull backache. She passed the menopause at fifty-two without notable disturbance. She was free from discharge for six or seven years. About three years ago she began to have occasional discharges which a year ago became bloody. She consulted her family doctor who made a diagnosis of erosion and applied iodine. Despite this treatment, the discharge became more bloody. Otherwise her health is good.

Examination.—The general examination is without interest. The vault of the vagina is taken up by a superficial ulcer, the center of which contains an opening, the remains of the cervical canal. The edge of the ulcer is irregular and the base fine, granular, hard and bleeds readily on touch. The uterus is small and firmly fixed to the right.

Diagnosis.—The growth obviously is a carcinoma. The firm fixation to the right stamps it as incurable and virtually inoperable. This superficial type responds well to cauterization. Prolonged freedom sometimes follows this plan of treatment. The patient requests an attempt at operative removal and asks that any risk be taken to secure the uttermost chance at a cure. She states she understands what she is requesting.

Treatment.—A cuff was made by the vaginal route circumscribing the ulcer with a good half inch of healthy vaginal mucosa. The edges of the cuff so made were sewn together. The operation was completed by the abdominal route. There was a mass to the right

of the uterus that firmly fixed it. The ureter was identified at the side of the pelvis and followed it to the growth. An attempt to separate it from the growth was unsuccessful and the terminal 10 cm. was cut off. The ureter was ligated with silk. No attempt was made to unite it with any hollow viscus. The left ureter was separated without trouble. A wide dissection of the parauterine tissue followed. The abdominal wound was closed with through and through silkworm and catgut for the skin.



Fig. 397.—Carcinoma of the cervix.

Pathology.—The section shows but little invasion of the deep portions of the cervix. The relation of the proliferating epithelium to the underlying tissue resembled closely that of a basal-celled carcinoma. It is only at the right side that any extensive invasion has taken place. (Fig. 397.)

After-course.—The earlier days of the convalescence were without note. On the fifth day the physician under whose charge she

was, removed the sutures. That night the whole wound opened and many loops of small intestine caught in the dressing. The wound was resutured with through and through catgut and no further trouble ensued. The right kidney remained with its ureter ligated with silk. Usually it is said such kidneys atrophy and give no further trouble. She had much pain in the side and desired that it be removed. This was done and she was relieved. When last heard from seven years after operation, she was in perfect health. She derived as much joy apparently in her triumph over the adverse opinion of her surgeon as over the disease itself.

Comment.—It is quite remarkable how many things one may do that ought to remain undone, and yet secure favorable results. Evidently the disease had been many years in developing and was of low malignancy.

CASE 7.—A housewife of thirty-six came to the hospital because of irregular menstruation.

History.—The patient has had six children, the youngest six years old. She has had irregular menstruation since the birth of the last child. During the past six months she has had a flow much of the time. Three months ago she consulted a surgeon who diagnosed fibroids and is said to have removed one the size of a goose egg. She recovered from the operation but she still had as much bloody discharge as before the operation. This has continued to the present time.

Examination.—She has a recent scar over the pubes. The cervix is large and eroded (Fig. 398). The erosion is hard, papilliform and bleeds readily on touch. The cervix moves freely. Evidently a supravaginal amputation was done.

Diagnosis.—The hardness of the erosion and its tendency to bleed stamps it as unquestionably malignant. Evidently a myomatous uterus was removed, the operator having overlooked the more important condition of the cervix.

Treatment.—The stump of the cervix was removed through the vagina.

Pathology.—It is a squamous-celled carcinoma. It has an additional interest in that the cancer mass extends along the entire length of the cervix, being apparently one of those cases in which the squamous cells extend far up the cervical canal.

After-course.—The recovery was uneventful and she was free from a recurrence a year after. Since then she has not been heard from.

Comment.—It is fortunate that the condition of the cervix was found so soon after the myomectomy. Otherwise, this case might have gone down in history as an instance in which a carcinoma developed in the cervix after a supravaginal amputation and conse-



Fig. 398.—Carcinoma of the cervix after myomectomy.

quently serve as an argument in favor of a panhysterectomy in myoma. Obviously a myoma of the fundus is not a guarantee against carcinoma of the cervix. Evidently the surgeon after finding a possible course of the hemorrhage in the myoma failed to search for other causes.

CASE 8.—A matron aged forty-eight entered the hospital because of prolonged menstrual period.

History.—The patient has had four children, the youngest of whom is twelve years old. She has always had good health. She has noticed in the last six months that the menstruation has been prolonged and that there is a sense of heaviness in the pelvis at the periods, which she had not previously experienced. Being a person of intelligence, she desires to know the significance of these phenomena.

Examination.—The perineum is lacerated to the first degree, the uterus is in place, movable, a little large and sensitive. The cervix is large, nodular, and hard (Fig. 399) the nodules presenting a smooth elastic feel like a glandular endocervicitis rather than the hard graty feel of carcinoma. The glandules are more extensive than one sees in endocervicitis. The examination produces quite extensive bleeding.

Diagnosis.—The friability as expressed in bleeding from the ordinary manipulations of the examination indicates malignancy. The regular smooth rounded nodules are unusual and their density is not that usually observed in carcinoma, yet the increase in size of the cervix and its disposition to bleed can be explained on no other basis.

Treatment.—The vaginal mucosa was deflected from below and the operation then finished from above.

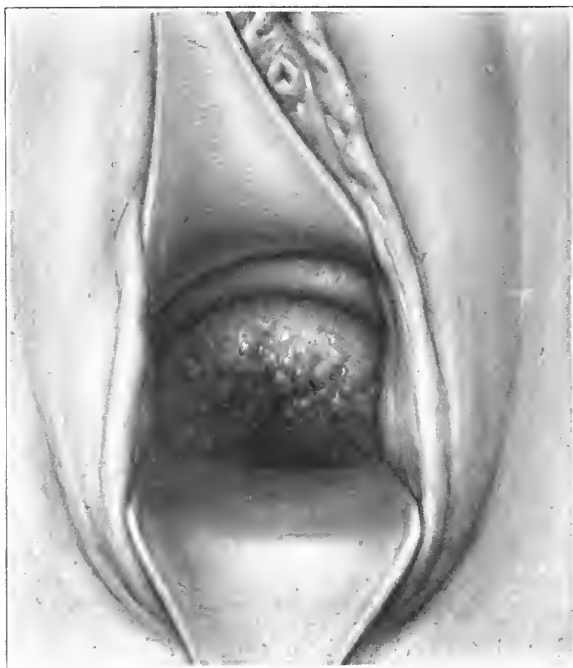

Fig. 399.—Fungus carcinoma of the uterus.

Pathology.—The section shows an extension of the growth through the cervical canal, apparently having its origin in this situation. The slide shows the growth to be a carcinoma.

After-course.—The recovery from the operation was uneventful. It has been but a year since the operation and there is as yet no evidence of recurrence.

Comment.—It was probably the hyperemia produced by the growing tumor that caused the increased duration of the flow and the

general pelvic pain. The prolongation of flow was that of congestion rather than that of a breaking down tumor. This would indicate that the process has been developing more than the nine months she has experienced these symptoms. From the arrangement of the nodules and their wide distribution it is likely that she had a bilateral laceration with erosion or possibly a "congested erosion" before the tumors developed. Usually the carcinomas developing from the glands are more friable than the squamous type. The gross appearance of this growth was that of an enormous congenital erosion.

CASE 9.—A matron of forty-three sought consultation because of a prolonged menstrual flow.

History.—Her menstruations were very painful until the birth of her first child. Since then she has had little pain. She has



Fig. 400.—Adenomyoma of the uterus.

had five children and has had four miscarriages since the last child was born. Menstruation had been regular, until the beginning of the present trouble, and lasted five or six days. Her present trouble began three years ago when she noticed her regular periods getting longer and that they were coming more closely together. After two years of this irregularity the flow became nearly continuous, there being only periods of from 3 to 6 days when there was no flow. During the last three months she has had a tired feeling and has had an ache in the lower abdomen. Her appetite is good but as the bowels do not act very freely she takes cathar-

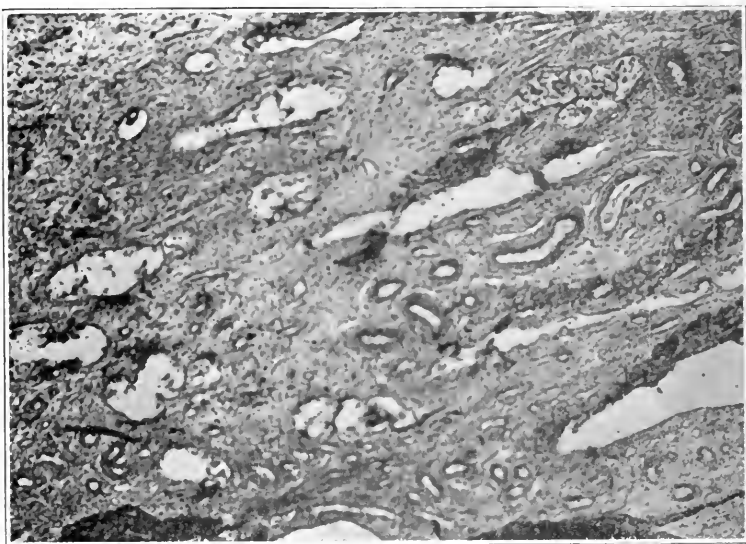

Fig. 401.—Hyperplastic endometrium in adenomyoma of the uterus.

ties. Her gall bladder was drained and the appendix removed three years ago when perineal lacerations also were repaired.

Examination.—The cervix is irregularly lacerated and the uterus is enlarged and nodular.

Diagnosis.—The gradual lengthening of the menstrual flow as the menopause is approached usually indicates a hyperplasia of the endometrium, particularly if attended by marked enlargement of the uterus. This enlargement of the uterus is usually due to an adenomyomatous condition, though often the glandular element may not be demonstrable. The clinical picture in each is the same.

Therefore the diagnosis may read adenomyoma of the uterus with hyperplasia of the endometrium.

Treatment.—Supravaginal amputation.

Pathology.—The wall of the uterus is much thickened (Fig. 400) and the endometrium likewise is irregularly thickened (Fig. 401). At one point the endometrium forms a polyp two centimeters long. The structure of this polyp is of interest. The interstitial cells are much increased and an ugly look is imparted to the field. The process is quite innocent, however, though I have known microscopists to call these sarcomatous.

After-course.—Recovery was uneventful and the patient remains well.

Comment.—The whole history of this case is in harmony. I have noted in a number of instances that patients with adenomyomas had a dysmenorrhea before bearing children. The frequent abortions in later years indicate a disturbance in the endometrium which did not find expression as a metrorrhagia until later. There is no treatment which avails anything in these cases except the removal of the uterus.

CASE 10.—A housewife aged forty-nine came to the hospital for relief from excessive and painful menstruation.

History.—A year ago she noticed that her menstruations which formerly had lasted only five days and were but little painful were increasing in length and painfulness. The duration has gradually increased until the flow is now continuous and profuse. She has some headaches, the bowels are constipated, and she has a sense of pressure on the bladder which causes frequent urination. She has had four children and three miscarriages.

Examination.—The patient is pale but otherwise rugged. The uterus is three times the normal size, hard, smooth, and movable. The cervix is hard and smooth.

Diagnosis.—The profuse flow together with the enlarged symmetrical uterus indicates an adenomyoma. It is unusual only in the short duration of the history. The repeated abortions following four normal deliveries suggest an earlier beginning than the history would indicate.

Pathology.—The uterus when cut open shows uniformly thick walls with a relatively thin endometrium. The vessel walls show an exten-

sive endometritis. There was a small polyp near the right tubal ostium. (Fig. 402.)

After-course.—She had a mild phlebitis of the right thigh which kept up a temperature. Only the superficial veins were involved, apparently the result of the intrapelvic cutting. There was no swelling of the leg or involvement of the deep veins of the thigh. After recovering from this complication she remained well.




Fig. 402.—Adenomyoma of the uterus.

Comment.—This type of tumor, far from uncommon, presents one of the most satisfactory objects for operative relief. Often they have a much hypertrophied endometrium which gives the impression of malignancy, but the muscle wall is not invaded and supra-vaginal amputation produces a permanent cure.

CASE 11.—A matron aged forty-three came to the hospital because of uterine hemorrhage.

History.—She has had two children but no miscarriages. She was well until two years ago when she began to be annoyed by pressure on the bladder and frequent urination. She began at the same time to flow more freely than formerly. Usually the flow

lasted a week. The last period lasted two weeks and was profuse. She had a pain in the lower abdomen and in the back. These pains were particularly severe at the last period. For some months she has noticed a tumor in the lower abdomen. Since the tumor appeared she has had less bladder trouble.

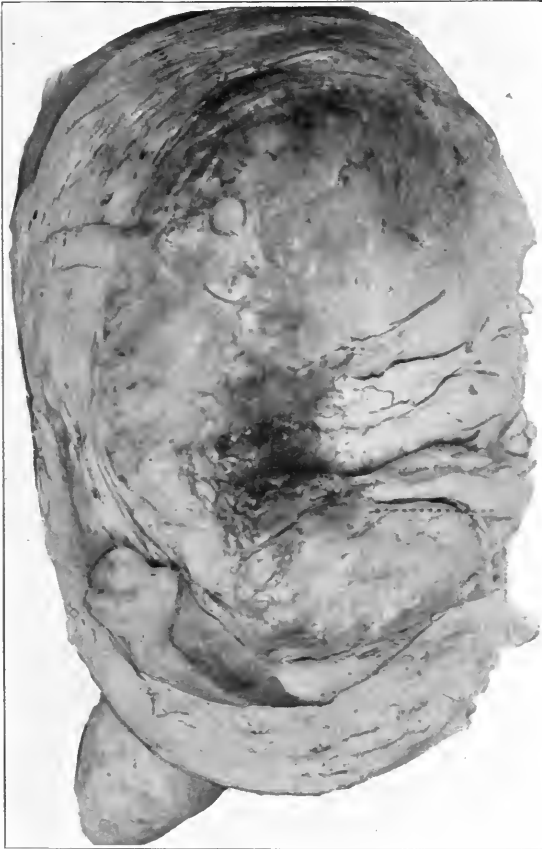


Fig. 403-A.—Myosarcoma of the uterus.

Examination.—There is a globular, fairly dense tumor the size of a five-month pregnancy. On bimanual examination it is found to be connected with the cervix. It moves freely in all directions. The cervix is free from disease.

Diagnosis.—The bladder trouble obviously was due to pressure

since this disturbance ceased when the tumor rose out of the pelvis. The tumor being globular, solitary, and not very hard, some type of degeneration probably is present in the interior of a myoma. The increase in the menstrual flow and increased pain at the last period suggests that it may be hemorrhagic.

Treatment.—After the tumor was delivered, the uterus was found to be globular, perfectly symmetrical, soft and elastic in consistency. Therefore the broad ligaments were removed as freely as convenient and the amputation was made through the vaginal junction.

Pathology.—On section the uterus is pink and homogeneous and

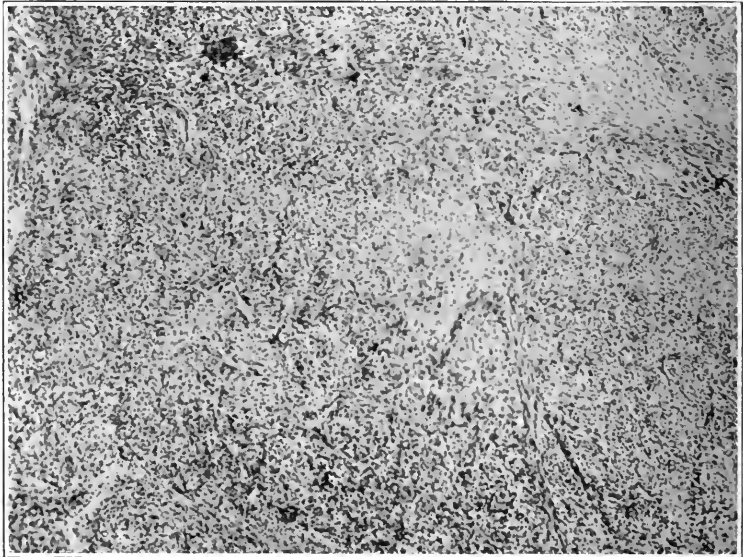

Fig. 403-B.—Myosarcoma of the uterus.

shows a hemorrhagic area the size of a walnut in its center (Fig. 403-A). The left ovary has a cyst and a hematoma. A large number of cysts from pin head to pea size are found in the endometrium. Other portions of the cut surface show areas of colloidal degeneration. The slide of certain areas shows simple colloidal degeneration. Adjoining areas are cellular, being formed of large cells with deeply staining nuclei and abundant cytoplasm (Fig. 403-B). This can not definitely be diagnosed as sarcoma but considering the hemorrhagic exudate and the character of the cells it must be regarded as a borderland condition.

After-course.—One year and a half has elapsed since the operation, not time enough to determine whether there will be a recurrence. If it really is a sarcoma, it will recur. Sarcomas usually recur early and freedom for this length of time is a very favorable indication.

Comment.—In solitary soft globular tumors, particularly if of rapid growth, as wide an operation as possible should be done. To anticipate any degenerative change eases the conscience of the surgeon, but if they are really sarcoma, recurrence will take place whether a panhysterectomy or a simple supravaginal hysterectomy has been done.

CASE 12.—A matron aged thirty-seven came because of prolonged menstruation.

History.—The patient is the mother of three children, the youngest being ten years of age. Her menstruation had always been normal, of five day duration, until the beginning of the present trouble four years ago. She noticed that the periods were lengthening, lasting a week or ten days instead of the usual five. Some periods the flow was particularly strong. Three weeks ago she had a very severe flooding requiring special measures to control it. She never had any pain and aside from the loss of blood she has nothing to complain of.

Examination.—The physical examination shows nothing abnormal, despite the patient's account of alarming hemorrhage. The blood count shows nothing abnormal. The uterus is in position, freely movable, the ligaments are somewhat lax and there is some tenderness on bimanual pressure. The cervix shows nothing abnormal.

Diagnosis.—The single symptom of hemorrhage from the uterus in a woman in the middle of the child-bearing period, after ten years sterility indicates some anatomic change in the endometrium or of the body of the uterus. In such cases retention of some product of conception is not to be expected. Placental rests sometimes cause hemorrhages a year or two later, but hardly after so long a period. Endovascular causes of hemorrhages are more common near or after the menopause, but may occur in women even younger than this patient, however. On the whole, we must anticipate in this case a polypoid degeneration of the endometrium or pedunculated fibroid.

Treatment.—The curette might remove some structure that would permit a diagnosis, but a cure in such cases is not secured by this instrument. Hence it was concluded to inspect the interior of the uterus, locate the offending part, remove it and preserve the remainder. Accordingly the bladder was lifted from the uterus as in the first step of vaginal hysterectomy and then the uterus was split in the anterior median line. Above the internal os a polypoid

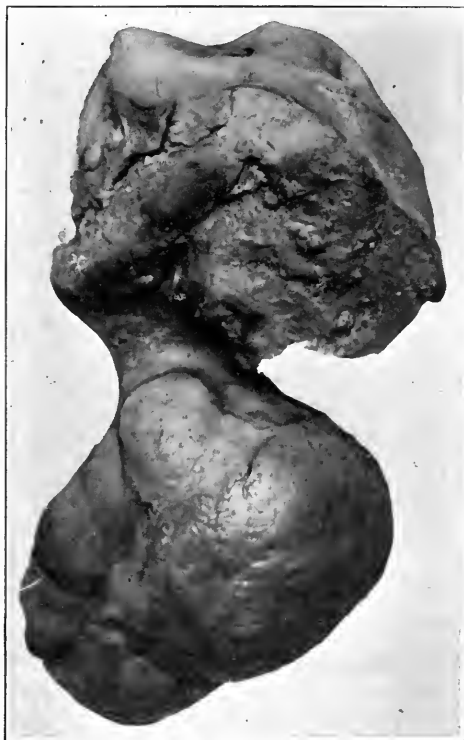

Fig. 404.—Pedunculated intrauterine myoma.

fibrous mass was encountered (Fig. 404). The entire uterus had to be split before its site of attachment at the fundus could be inspected. In order to secure its base, it was circumscribed, the portion of the fundus giving attachment to it being removed along with the tumor. The uterus was then closed, beginning at the highest point and terminating at the point of beginning in the cervix. (Fig. 405.)

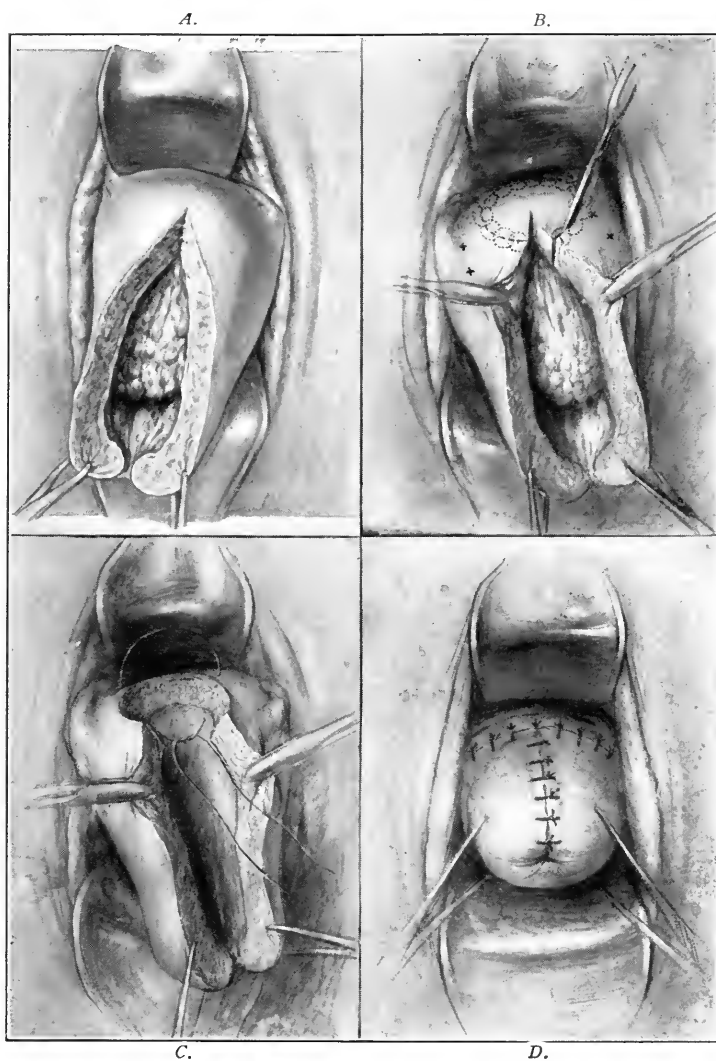


Fig. 405.—Technic of vaginal hysterotomy. *A.* The anterior wall of the uterus is split open, showing the polypus attached at the fundus. *B.* The base of the tumor is being circumscribed with a knife. *C.* The defect left after the removal of the tumor is being closed with sutures. *D.* The incisions in the anterior wall and in the vagina have been closed with sutures.

Pathology.—The tumor was made up of fibrous tissue covered with a very much attenuated mucosa.

After-course.—The patient ran a low temperature for two weeks, but recovered without other incidence. She returned to her normal

menstruation without excessive flow and regained her former health. A year and a half after the operation I had a letter from her physician stating that the patient was pregnant and expressing a desire to know the extent of the operation and asked to know my opinion as to the advisability of terminating the pregnancy. Having neither experience nor knowledge to guide me, I concluded that so much mutilation as I had inflicted would hardly leave a uterus capable of bearing a child. Abortion therefore was advised. This was done and the patient did not conceive again. The patient passed through the menopause without disturbance some three years ago, eight years after operation.

Comment.—This is the first patient on whom I did a diagnostic and therapeutic hysterotomy through the vagina. She is the only one who subsequently became pregnant, for in subsequent operations of this kind I have always taken the precaution to resect the tubes. In patients during the menstruating period of life this is the most rational procedure. By this means the surgeon is able to make a certain diagnosis and employ conservative therapeutic measures. It should not be employed unless the disturbance is of sufficient gravity to warrant one in terminating the fecundity of the patient. The operation makes some demands on the technical skill of the operator and the large wound connected with the vagina is apt to undergo a low grade of infection sufficient to keep up a low temperature longer than after most operations. Out of many dozens of these operations I have never had one proceed beyond a stage of annoyance. The patients during this temperature have good appetites and experience a sense of well being, but the nurse is apt to inquire why the temperature does not come to normal.

CASE 13.—A housewife of thirty-six came to the hospital because of profuse hemorrhages.

History.—The patient has had several children, the last about ten years ago. She was well until four months ago when she began to flood. She has had no pain at any time.

Examination.—The uterus is uniformly enlarged and dense, moves freely, and is not painful.

Diagnosis.—The uniformly enlarged bleeding uterus seemed to be clearly an adenomyoma. It was too dense to harbor a fetus and too uniformly enlarged to be a simple myoma.

Treatment.—Supravaginal amputation.

Pathology.—After the uterus was split open it was seen not to be an adenomyoma but a pedunculated tumor with a base proportionately broader than most intrauterine pedunculated tumors (Fig. 406). It seemed to be made up of fiber bundles arranged more or less parallel to each other and continuous with the muscle bundles of the

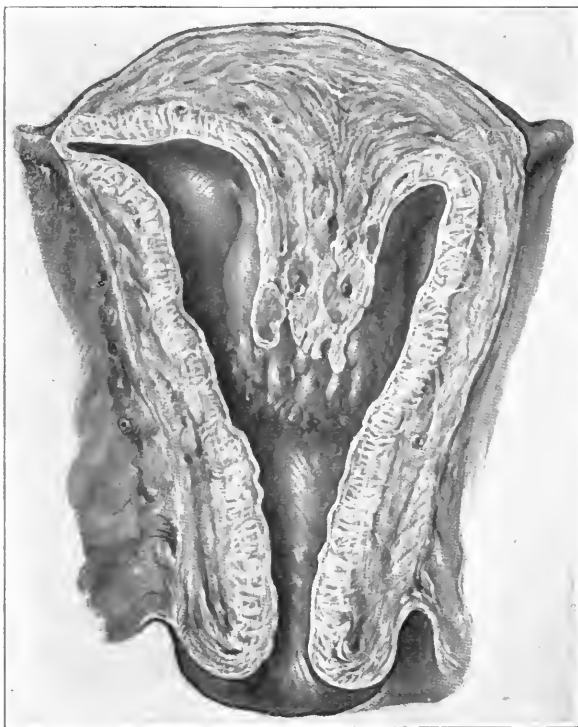


Fig. 406.—Myosarcoma of the fundus of the uterus.

uterine wall. The section showed these to be composed of spindle cells generally uniform in size, with occasionally a few with much broader nuclei and less cytoplasm. These worried me, but did not prevent me from giving a good prognosis as to cure.

After-course.—The patient returned a year and a half later with a tumor filling the pelvis. She died a few months later. The recurrence was a sarcoma.

Comment.—The broad base of the tumor and the large cells seen on microscopic examination should have excited me to caution of speech. This operation was done before I formed the habit of opening the uterus at the operating table when in doubt as to the cause of a hemorrhage serious enough to suggest a hysterectomy. Had I done so, I should have removed the entire uterus if the light had dawned.

CASE 14.—A matron aged forty-seven was brought to the hospital because of bleeding from the uterus.

History.—Soon after the birth of the last child, eight years ago, the patient noted an increase in the menstrual flow. Three years ago it became so severe that she had to remain in bed during the height of the flow. The flow at this time lasted from ten to thirteen days. She was curetted at this time without result. A year following she had renewed hemorrhages and a physician discovered a tumor. With these hemorrhages there was a discharge of large amounts of watery fluid after which the tumor would grow smaller and the hemorrhage would lessen for a few months. She has grown weaker as the hemorrhages continued. A month ago she had a furious hemorrhage which caused her to nearly faint. She had severe pain at the time which she had never had before. There was much soreness of the abdomen for two weeks following. She thinks there was some fever.

Examination.—She is still flowing at the time of coming to the hospital. The patient is moderately well nourished but she has a lemon-yellow color and the mucosae are white. The abdomen is flat, soft and flabby. A smooth tumor can be felt over the pubes being about the size of the head of a newborn child. The cervix is free and is continuous with the mass filling the pelvis. The tumor is movable. There is still blood escaping from the cervix. The urine is negative. The Hg is 30 per cent; R.b.c. 1,500,000; there is no evidence of pernicious anemia, a possibility the color of the patient suggests.

Diagnosis.—The history of hemorrhages and the form and consistency of the tumor left no doubt as to the diagnosis of myoma. The absence of signs of pernicious anemia makes it likely that the anemia is secondary to the hemorrhage. The severe pain she had a month ago suggests the possibility of some secondary change within the tumor. With a hemoglobin of 30 per cent she is not a desirable

risk. Since she has been bleeding profusely for a number of years it is likely that she has been anemic for some time. This is corroborated by the statement of her husband that she has had much the same color for a number of years. Patients long anemic bear operation better than those in whom the anemia is acute. Furthermore, the chronically anemic build up less rapidly than the acutely anemic. It seems best here, therefore, to operate with only a brief general treatment, lest renewed hemorrhage occur.

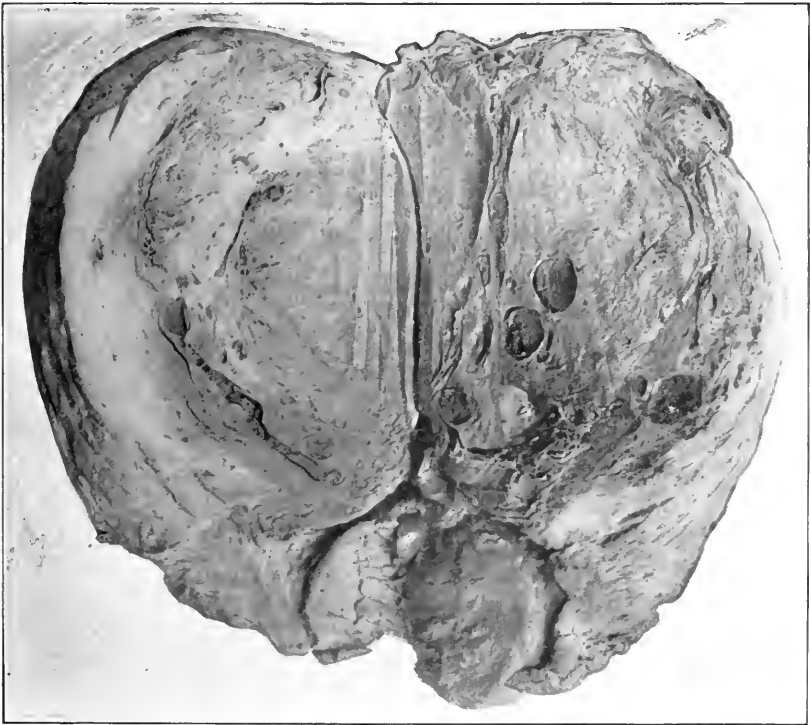

Fig. 407.—Myoma of the uterus showing lymph sinuses, some of which are filled with blood clot.

Treatment.—Owing to the impoverished condition of the patient's blood the uterus was packed with gauze soaked in terechloride of iron, and arsenic was given. After a week, a supravaginal amputation was done.

Pathology.—The myoma lay just beneath the mucosa, which accounted for the tendency to bleed. There were a number of cyst-

like sinuses which may have discharged into the uterus and produced the escape of watery fluid above mentioned. A hemorrhage had taken place in a number of these sinuses and a considerable portion of the tumor was somewhat infiltrated with blood (Fig. 407). This hemorrhage probably took place a month ago at the time she had the pain in the lower abdomen.

After-course.—The recovery was uneventful and the blood soon reached its normal state. She has remained well.

Comment.—In case of extreme anemia with hemorrhage of the uterus it is well to remember that the bleeding may be due to a pernicious anemia whether a uterine lesion be present or not. In such a case a careful blood study as well as actual observation as to the amount of blood lost may be necessary to determine whether the anemia be primary or secondary. Excessive uterine hemorrhage is by no means a rare, sometimes even the earliest, sign of pernicious anemia. This is sometimes true of women long past the menopause.

CASE 15.—A matron of sixty-five came to the hospital because of hemorrhage and a mass projecting from the vagina.

History.—She passed the menopause at fifty-two and for five years following had no vaginal discharge of any sort. About eight years ago she began to have uterine hemorrhages. Some blood appeared every two to four weeks. Sometimes the blood was bright red and sometimes only a bloody mucus. The amount was small at times and sometimes there were sudden gushes. At the present time she flows some every day. There was no pain until three months ago. Since then there has been a dull heavy pain in the pelvis with some sharp shooting pains downward toward the vulva. There has been a mass protruding from the vulva for the past six weeks. Since that time she has had pain in the neck of the bladder and she has increased frequency of urination especially at night. Her general health is good. She was eurettered some months ago without any improvement whatever resulting.

Examination.—The patient is a large fleshy woman without evidence of loss of weight or suffering. The anterior vaginal wall appears in the vulva but there is no tumor apparent. A mucobloody discharge fills the vagina. The uterus is as large as a cocoonut. Its surface is irregularly bosselated. It is movable, somewhat irregular in outline, and sensitive to firm pressure. Bp.140-80; the urine is 1.011 but free from abnormalities.

Diagnosis.—Freedom from any flow for five years, then a reappearance with an enlarged uterus suggests at once a carcinoma of the body of the uterus. The duration of this for eight years without notable change until three months ago marks this as unusual if it is a carcinoma. The recent appearance of a dull pain with lancinating pains at intervals, however, is quite in harmony with the




Fig. 408.—Fundus carcinoma of the uterus.

theory of invading malignancy. A slowly proliferating endometrium that developed malignant tendencies very slowly may be hypothesized. This can be accepted if the bosselations are accepted as small fibroids. If they are malignant nodules, as the lancinating pains would suggest, then the present excellent state of the patient

is difficult to understand. At any rate the uterus is movable and is bleeding. The uterus seems too large to remove by the vaginal route, so a laparotomy seems indicated.

Treatment.—After the uterus was exposed it was found studded with small fibroids from the size of a hazelnut to that of a hickory nut. The body was hard and gave no evidence of being invaded by malignant nodules. Because of the depth of the operative field and the fixation of the broad ligaments, clamps were left on the uterine artery rather than consume time in ligating them.

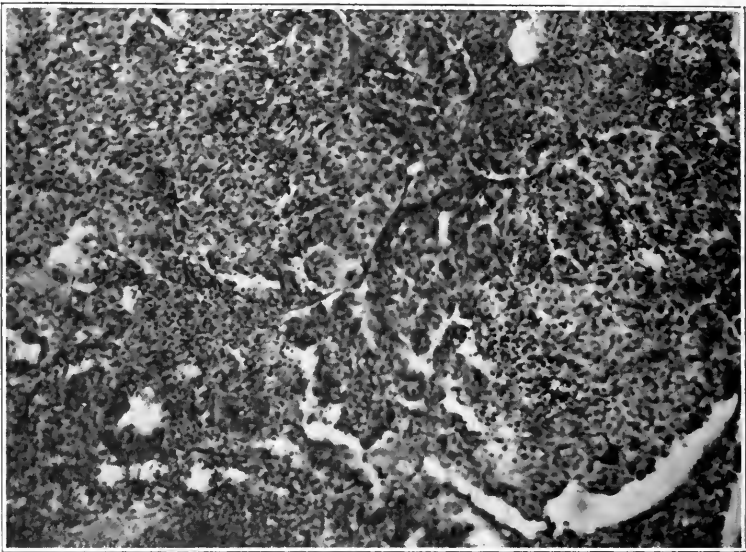


Fig. 409.—Fundus carcinoma of the uterus.

Pathology.—The uterus is firm and carries numerous calcified fibroids. The interior presents an ulcerated appearance without much thickening of the mucosa (Fig. 408), but it is definitely malignant (Fig. 409).

After-course.—Recovery was uneventful. The clamps were removed on the third day. She continues well.

Comment.—Evidently the hemorrhage was for years due to a proliferative endometritis rather than a malignancy. The fact that the nodules were palpable through so thick an abdominal wall should have identified them as fibromas, for the low bosselations

of malignancy would not have been palpable at all. In discussing with the patient the character of the alleged lancinating pains it appears she has in mind throbbing pains which were translated into lancinating pains by a too enthusiastic clinical recorder.

CASE 16.—A housewife aged forty-four came because of painful and excessive menstrual flow.

History.—Her periods have always been regular, flowing four or five days without pain. Since the birth of her three children, the last eleven years ago, she has flowed every twenty-three days, but without pain, and the duration of the flow was not increased. She had one miscarriage nine years ago. Two years ago the flow became more prolonged and later became painful. For the most of this time she has flowed seven to ten days each twenty-three days. The last period was particularly painful and she has now been flowing for a month. She now has pain in both groins. For some years she had pain in the back of her head. She has had goiter fourteen years, but it has caused no trouble.

Examination.—The patient has an enlargement of the right lobe of the thyroid as large as an orange. The uterus is in position, is somewhat large, fairly firm and is movable. The cervix is soft, eroded, and bleeds on touch. The urine contains much pus and many bacteria. Pulse 60, Bp. 160-90.

Diagnosis.—The goiter evidently has nothing to do with her present complaints. The beginning of excessive flow nine years after the miscarriage suggests some disturbance in the endometrium. The uterus is not large enough to suggest an adenomyoma. The erosion is soft, and regular, and while it does not in itself show malignancy, it does indicate a congestion of the uterus as a whole. Besides, even if the cervix were malignant, it would not occasion the pain and metrorrhagia of which the patient complains. The problem is to determine the state of the interior of the uterus. There is but one sure way of finding out and that is to look and see.

Treatment.—The uterus was split up its anterior surface after lifting off the vagina. When the interior of the body was exposed, it was found that the endometrium was thickened, felt granular and bled easily. A hysterectomy was done. In separating the uterus from the bladder an opening was made into the latter. The hole was closed with chromic sutures and a permanent catheter was placed in.

Pathology.—The wall is thick, fairly firm, and many of the vessels are prominent. The mucosa is as above noted. The slide shows an adenocarcinoma at the fundus. There is no sign of malignancy at the cervix. (Fig. 410.)



Fig. 410.—Carcinoma of the fundus of the uterus.

After-course.—The catheter was allowed to remain a week. There was no trouble from the accident. There has been no recurrence.

Comment.—In such cases the eurette is a useless instrument. While enough mucosa could have been secured to make possible a microscopic

diagnosis, a second operation would have been required. Besides, the slide is not so sure a means of diagnosis as is the organ *in situ* when exposed by the surgeon's knife. A vaginal hysterectomy as done here is preferable to an abdominal operation. The vaginal route makes it possible to view the entire interior of the uterus which the abdominal operation does not. The injury to the bladder in this case was pure awkwardness and does not militate against the operation. In younger women with dysmenorrhea or metrorrhagia coming after childbirth or abortion the uterus should be explored with a curette. After the child-bearing period is passed the curette ceases to be a legitimate instrument.

CASE 17.—A married woman aged thirty-seven came to the hospital because of bleeding from the uterus.

History.—She has seven children living, one abortion at five months a year ago. Has always had menstrual disturbance. Has had several attacks of inflammatory rheumatism. She has epigastric pain and is short of breath often on lying down. She has had some vesical disturbance for some years and a polyp was removed from the urethra at this hospital some years ago. She now has headache, especially in the forehead and occiput. She has severe backache and pain in the lower abdomen, both of which are worse at the menstrual period which is prolonged two weeks sometimes. The flow is often clotted. There is constant leucorrhœa. Appetite not good. She now has been flowing four weeks.

Examination.—The patient has a pronounced mitral regurgitation with evidence of disturbed compensation. The uterus is enlarged, the size of a four-month pregnancy. The cervix is hard, lacerated, especially in the right side. The cervix is pendulous and a boggy mass may be felt within the uterus. The uterus is lightly packed and a three-month mummified fetus was expelled the following day. Following this the uterus was still large and the flow continued.

Diagnosis.—Obviously the expulsion of the fetus was not the whole affair or else there is a retained membrane. There was flooding for a year and it is remarkable that a pregnancy should have occurred. Likely there was some disturbance resulting from the abortion a year ago for the profuse bleeding began at that time. It seems best to find out.

Treatment.—The uterus being too large to make a vaginal hysterectomy convenient, it was opened from above. The lumen contained a

mass as big as an egg. It looked like a deciduoma, and a hysterectomy was done.

Pathology.—The uterus is double the normal size. There is no sharp line of division between the uterine wall and mass. The mass itself is a mottled grayish red mass soft and fragile. It has the appearance of a deciduoma (Fig. 411) but the slide fails to show anything but placental tissue with some fibrinoid connective tissue.

After-course.—Recovery was uneventful.



Fig. 411.—Retained placenta resembling deciduoma maligna.

Comment.—On further questioning it was discovered that at the time of the alleged miscarriage a year ago she had pains and flooded. Since she continued to flow afterwards and the uterus did not grow she concluded she had miscarried at, as she estimated, five months. At the time the history was taken her statement that she miscarried at five months was accepted at its face value. Had the details been gone into, an exact diagnosis might have been made and the proper treatment instituted—curettage. The fetus expelled while in the hospital evidently had lain dormant a year. Details in a history are sometimes tremendously important.

POSTMENOPAUSE HEMORRHAGE

There is but one cause for postmenopausal hemorrhage; malignant disease. Once a woman has passed the menopause, and bleeds again only the most conclusive negative evidence warrants one in excluding malignancy.

CASE 1.—A widow of fifty-six came because of a bloody discharge from the vagina.

History.—The patient passed the menopause nine years ago without incident and remained free from any discharge until six months ago. Since that time she has had a bloody discharge at irregular in-

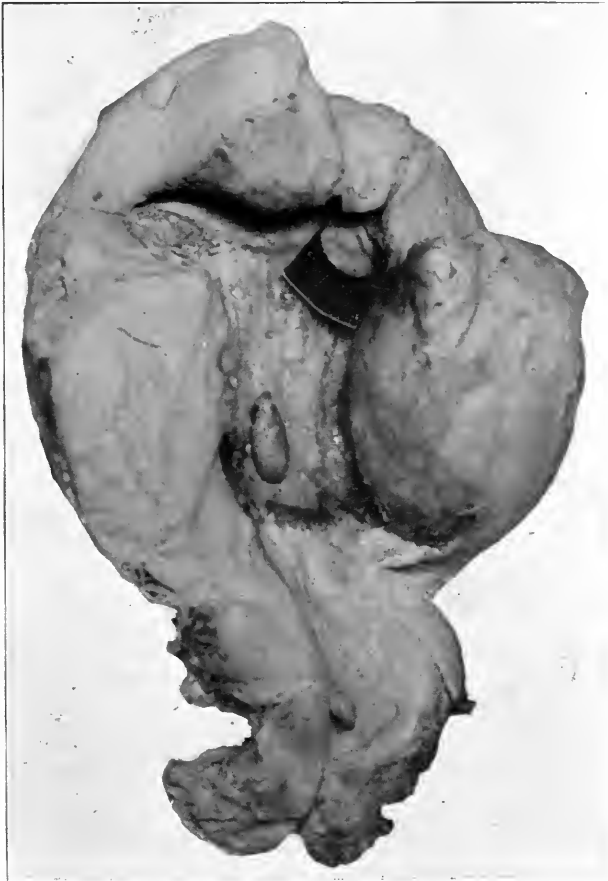

Fig. 412.—Small mucus polyp of the endometrium.

tervals. Save for the apprehension caused by this discharge she has nothing to complain of. She has had four children, the menstruation was normal in amount and painless until the menopause.

Examination.—The patient's general appearance confirms her estimate of general bodily health. The uterus is slightly larger than in the child-bearing age, the fundus is movable, very slightly irregular. Because of the fat abdominal walls the density can not be made out. The cervix is smooth and small.

Diagnosis.—A uterus that has remained quiescent for nine years and then bleeds must be suspected of harboring a malignant process. The large size of the fundus confirms this.

Treatment.—A vaginal hysterectomy was done. During the course of the operation several small intramural fibroids could be made out.

Pathology.—When the uterus was split open, instead of a malignant process, three diminutive polyps were seen, one in the cervix, one at a midpoint, and one at the fundus (Fig. 412). They are soft and easily compressible. The slide shows a few atrophied glands. The vessels are much thickened.

After-course.—She has remained well.

Comment.—The removal of the polyps would have cured the patient. The large size of the fundus was due to the small fibroids. In order to make an exact diagnosis it was necessary to inspect the interior of the uterus. In women during the child-bearing age exploration can best be made by elevating the bladder and splitting the uterus. In women past the menopause the broad ligaments are so fibrous that it is exceedingly difficult, much more so than is a hysterectomy. Under such conditions a vaginal hysterectomy presents the simplest way of determining why a uterus bleeds after once being quiescent for years. When such a state exists the best place to discuss etiology is in the laboratory.

CASE 2.—A matron aged fifty-four came because of vaginal hemorrhage.

History.—The patient has had three children and one miscarriage before the birth of the last child sixteen years ago. She passed the menopause five years ago without incident. After the menopause she remained free from any vaginal discharge until one year ago when she had a sudden profuse hemorrhage. She has had four other hemorrhages, the last two weeks ago. These hemorrhages were all so severe that active measures, such as stypticin and pack-

ing were required for their control according to her physician. She has some dyspnea on exertion.

Examination.—The patient is very fleshy and shows but little if any signs of anemia. The cervix is low, dilated, presenting within the os a friable mass the size of a walnut. The fundus is in the hollow of the sacrum the size of a two or three months pregnancy. The mobility of the uterus can not be determined. The apex beat is near the anterior axillary line, intermits occasionally, and the sounds are faint.

Diagnosis.—The discovery of the large fundus and the mass within the unchanged os are sufficient to make the diagnosis of malignancy certain. The question of operability is another matter. The uterus is large and seems fixed. The patient has evidence of a fatty heart and is dyspneic on exertion. Considering the gravity of the disease the risk of the anesthetic seems justified. If the uterus is fixed it likely is inflammatory, for fundus carcinomas seldom fix the uterus to a degree which makes its removal impossible. Because of the uncertainties of technical operability and her excessive adiposity, the vaginal route seems preferable. By this route if the tumor is inoperable it is easier to back out than when an abdominal incision has been made.

Treatment.—The culdesac was opened and the fundus was found free from adhesions. The cervix was circumscribed and the uterine arteries ligated and cut. The fundus was too large to deliver and the broad ligaments too inelastic to permit the exposure of the upper part. These were clamped, therefore, and the uterus removed. The upper part of the broad ligament still was not readily accessible, so the clamps were left *in situ*.

Pathology.—The entire interior of the uterus was filled with a friable fungoid mass (Fig. 413). On section some parts showed typical malignant adenoma, other parts carcinoma.

After-course.—The forceps were removed the second day and the gauze pack on the fourth. Recovery was uneventful.

Comment.—Fundus carcinoma of even this extent gives a fairly good prognosis because they do not invade the loose tissue of the broad ligament. Vaginal hysterectomy is more quickly done and is less likely to cause infection. By leaving the clamps on the broad ligaments the operating time is much reduced. The broad ligaments in these old patients are friable and if too much traction is made on



Fig. 413.—Carcinoma of the body of the uterus.

them in the effort to place a ligature about them they may pull off and provide much embarrassment for the operator. In some such cases, in which ether anesthesia was much feared, I have done this operation under spinal anesthesia. If there is much trouble in delivering the fundus, traction pain may be produced.

CASE 3.—A matron aged fifty-three came because of hemorrhage from the uterus.

History.—The patient passed her menopause six years ago. She remained free from trouble for three years. At that time she had some irritating vaginal discharge which at times was blood streaked. She was examined at this hospital and the uterus was found to be

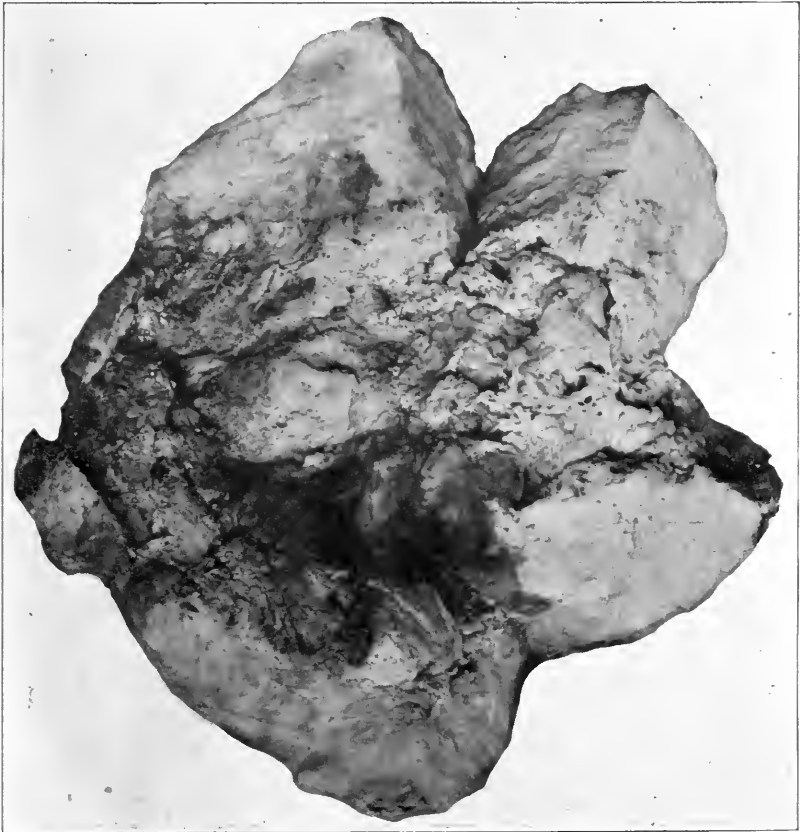

Fig. 414.—Carcinoma of the body of the uterus.

small, atrophic, and pointing slightly to the left. She returned a year and a half later with much the same story. She had a granular vaginitis due apparently to the irritating uterine discharge. She was given an anesthetic and the uterus explored. It was an inch and a half deep and the curette obtained only a little atrophic

endometrium. It was regarded as a bleeding from an endarteritis. She had more or less discharge during the next year and a half, rarely a little blood. She returns now because of more pronounced symptoms. Recently there have been pronounced hemorrhages, lasting five weeks at one time. For the past few months she has had pain in the left groin and in the left hip. The pain is now severe especially at night so that it interferes with her sleep. There is pain on urination. The vaginal discharge has been more profuse but never has had an offensive odor. She has always had good health. She has never been pregnant.

Examination.—The patient is a vigorous, well-preserved woman, but with the evidence of a general anemia. There is a deep tenderness in the region of the gall bladder. The cervix is eroded and granular and bleeds on touch. Blood is flowing from the cervix. The uterus is nearly as large as a fetal head. Low bosselations can be felt on the top and anterior surface. There are no extensions into the broad ligament and the whole seems movable. During the first days in the hospital the temperature varied between 97° and 99.8° . There is a moderate general anemia. The urine was negative save for many pus cells and occasional red cells.

Diagnosis.—Naming the disease offers no difficulty. The understanding as to how and why the marked change has come about during the past year and a half, is another matter; whether a malignancy in the diminutive uterus was overlooked; or whether the whole process has developed since that time; or whether an extension occurred from some neighboring structure. It hitherto has been my belief that, if a uterus was atrophic, fundus carcinoma was thereby excluded, and if hemorrhage existed, a vascular disorder could be diagnosticated. One thing only is clear, a carcinoma of the fundus of rapid growth is present.

Treatment.—A panhysterectomy by laparotomy was done. The disease does not seem to have involved other structures.

Pathology.—The uterus is as large as a croquet ball. When pressed upon it feels soft and squashy (Fig. 414). When cut open the interior is found to be filled with a soft, brittle mass surrounded by shell of uterine muscle. All topographic evidence of endometrium is lost. The slides show an adenocarcinoma.

After-course.—In three months she returned with complaint of frequent urination and dysentery, tenesmus and pain at stool. Ex-

amination showed a mass involving the perirectal tissue and the remains of the anterior vaginal wall. When examined three weeks later the mass had materially increased and movements of the bowels were obtained with difficulty. She soon died of exhaustion.

Comment.—I have never seen any other epithelial tumor grow so rapidly. I have seen sarcomas implanted on hemorrhagic myomas duplicate this for rapidity of growth but never a tumor derived from epithelial cells. The question is whether or not the curette in the presence of vessels with degenerated walls could have duplicated the condition found in hemorrhagic myomas. The vessel changes are the same and the environment is similar, but that epithelial cells are capable of such rapid development was new to me. One thing only is certain; a uterus once past the menopause that bleeds again is not a matter for hair splitting diagnosis. It should be removed.

CASE 4.—A woman aged sixty-two entered the hospital because of bloody vaginal discharge and uneasiness in the pelvis.

History.—The patient has had three children, no abortions. The menopause occurred ten years ago and she was entirely free from any vaginal discharge until several months ago when she noticed a slight bloody discharge and some sense of uneasiness in the pelvis. There was no actual pain. The hemorrhage ceases spontaneously, only to reappear after a week or two.

Examination.—The uterus is low in the pelvis, slightly larger than a postmenopausal uterus. There are no nodules but definite limitation of mobility. There is some general sensitiveness. The patient looks sick and has lost a little in weight.

Diagnosis.—The slight hemorrhage after ten years of freedom indicates some pathologic process, either an endarteritis or a malignancy. The size of the uterus would indicate the less grave lesion. The apparent fixity is without significance after the menopause for the muscle tissue in the broad ligament disappears and the fibrous tissue loses its elasticity, the uterus becoming fixed between fibrous bands. The general disturbance in health is significant.

Treatment.—An abdominal panhysterectomy was done.

Pathology.—A small fungoid mass occupies the fundus of the uterus (Fig. 415), not otherwise markedly enlarged.

After-course.—Recovery was uneventful, and there has been no recurrence after several years.

Comment.—This patient had informed herself of the significance of the appearance of a bloody vaginal discharge after the menopause and presented herself for treatment, making early hysterectomy pos-

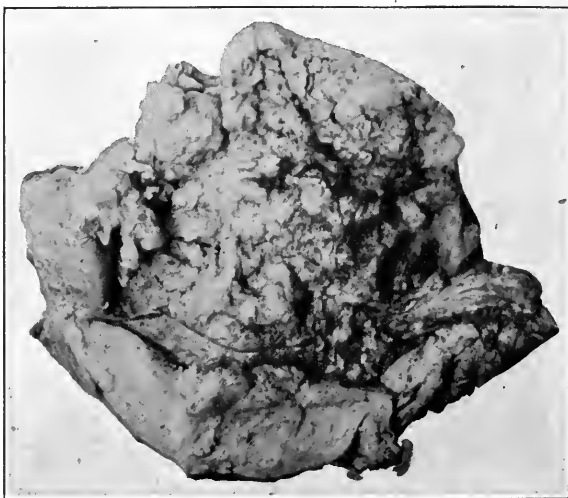


Fig. 415.—Carcinoma of the fundus of the uterus.

sible. It is unusual to see so small a uterus the site of a fundus carcinoma.

CASE 5.—A matron of fifty-six came for consultation because of hemorrhage.

History.—Her menstruation began at the age of fourteen years and was regular from the beginning, lasting from four to six days. She has had four children, the youngest twenty-four years old. The menopause occurred seven years ago without noteworthy disturbance. Two years and three months ago the patient had a blood discharge from the vagina which came with a gush. There were large clots in the discharge. She was much weakened by the loss of blood. Since this first attack there has been a more or less steady whitish yellow discharge which is generally streaked with blood. There has been no severe hemorrhage since the first onset. Since July she has had pain in the hips and lumbar region. The pain is worse in the right side low down in the pelvis. Her general condition has remained normal.

Examination.—The general condition is unaffected. The uterus is in position and is movable and the surface is smooth. There is a general uniform enlargement without nodulation of any sort. The consistency is dense but elastic. The cervix is small, and hard. Hg 70 per cent; R.b.e. 2,212,000; W.b.e. 8,200. The urine contains a considerable number of leucocytes and a trace of albumin.

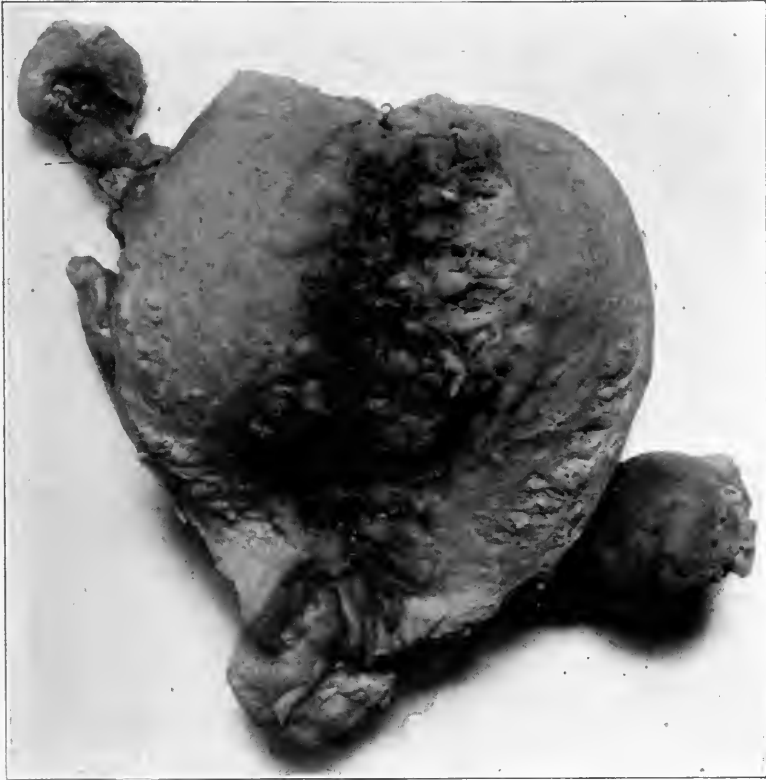

Fig. 416.—Beginning carcinoma of the fundus.

Diagnosis.—The general feel is that of an adenomyoma. Her premenopausal history does not bear this out. However, not all adenomyomas bleed. The present symptoms indicate a destructive process in the endometrium.

Treatment.—An abdominal panhysterectomy was done.

Pathology.—The fundus was large, thick-walled, and the mucosa is replaced by a dense friable mass of reddish gray color (Fig. 416).

The walls of the uterus are 2 to 5 cm. thick. The slide shows an adenocarcinoma but there is little disposition of the glands to invade the muscle wall. Likely an adenomyoma preceded the present state.

After-course.—Recovery was uneventful and the patient remains well, now three years after operation, and it is fair to predict that she will remain so.

Comment.—The thick uterine wall indicates that the patient had an adenomyoma before the advent of the present trouble. This case is peculiar in that cases of malignancy implanted on adenomyomas usually do not give a period of amenorrhea, but a prolongation of the menstrual period which gradually emerges into the hemorrhage of the malignant process. Obviously the process was a slowly growing one and it had advanced to a considerable degree before the initial hemorrhage took place. Evidently a vessel of some importance ruptured at that time. Had the bleeding been due to a general erosion of the affected area, bleeding would have taken place more constant since that time. The course of these lesions is relatively benign.

CASE 6.—A unmarried lady aged sixty-five came to the hospital because of hemorrhage.

History.—The patient passed the menopause ten years ago. Her present trouble began a year and a half ago. She had some pain much like that formerly accompanying the menstrual period. It would be present for several days in succession and absent for several days. The pain has been increasing in intensity but still not present every day. Four months ago the discharge from the vagina began. On some days the flow looked like pure blood and on others it was serosanguineous. The discharge has never been offensive. Her weight decreased thirty pounds in five months. Her appetite is good and she sleeps well. The bowels are not very regular.

Examination.—The patient is a well preserved woman for her age. The uterus is as large as a parous one, in position and movable. There is a polyp as large as a lead pencil protruding from the cervix. It is attached near the inner os and gives evidence of having recently bled, there being an eroded area covered with a clot on the surface. Otherwise she is well.

Diagnosis.—The polyp is vascular and, bearing evidence of recent hemorrhage, seems sufficient to explain the bleeding. The polyp is attached in the canal of the cervix near the internal os.

Treatment.—The uterine canal was dilated sufficient to give access to the base of the polyp. It was then destroyed with the cautery.

Pathology.—The tumor presents the usual structure of a glandular polyp.

After-course.—After the removal of the polyp the pain decreased and the discharge stopped. Her general condition improved and she gained some in weight. Two months later the discharge re-

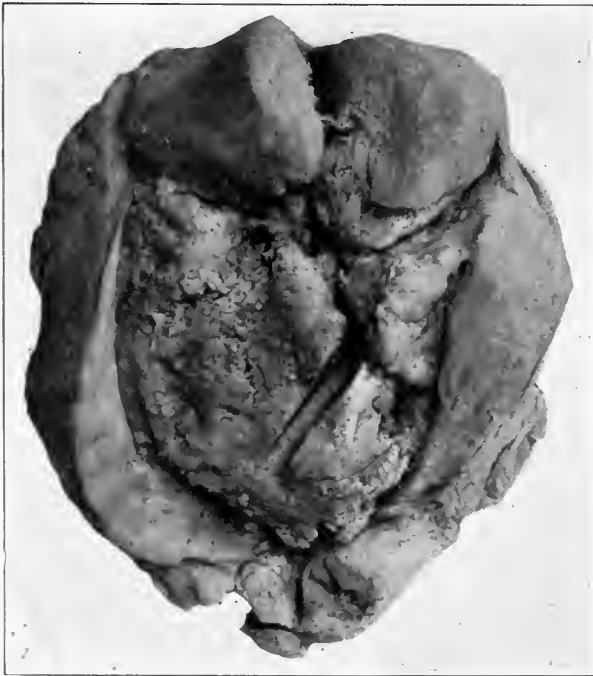


Fig. 417.—Carcinoma of the body of the uterus.

appeared and in addition to the recurrence of her old pain she now complained of pain in the right groin. Reexamination showed the cervix free from disease, but the fundus rather larger than before. The diagnosis now was of course carcinoma of the body of the uterus. Therefore, hysterectomy was performed. There were metastases along the tubes, but none other were discovered. The interior of the uterus was made up of a large amount of friable tissue (Fig. 417) which the slide shows to be carcinoma, in part

necrotic. The postoperative course was without incident until the tenth day when she had a violent chill. No cause for it could be discovered, but she was stuporous and lost her appetite. On the eighteenth day both parotids became swollen and hard. The temperature became irregular (Fig 418). Delirium set in on the twenty-first day, and she died without regaining consciousness on the twenty-fourth day.

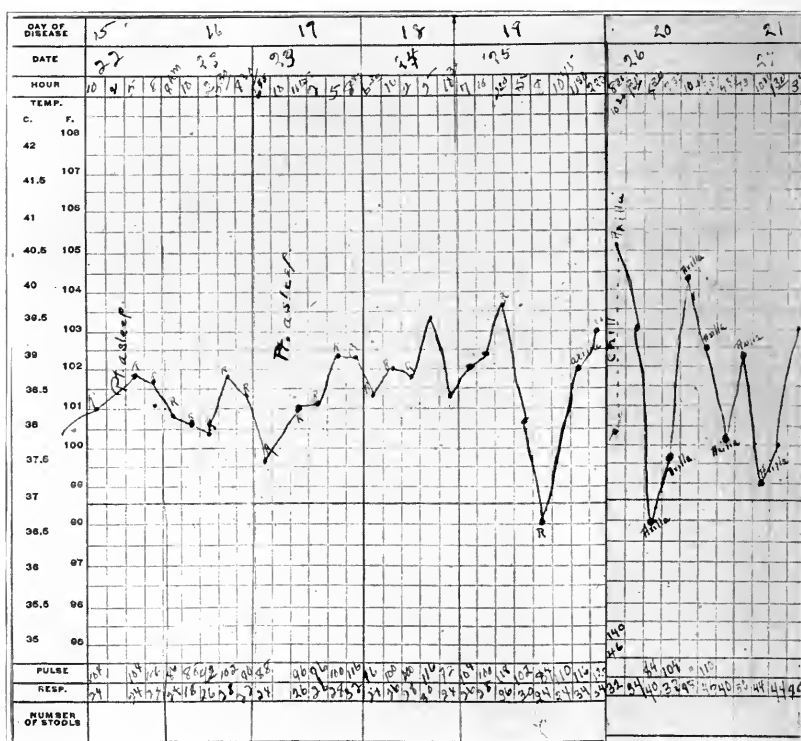


Fig. 418.—Temperature curve during the period of parotid suppuration.

Comment.—This case shows the result of superficial thinking, to put it in a charitable way. When a woman starts to bleed after a period of amenorrhea lasting ten years, with a uterus as large or larger than that normal to the child-bearing age, it can mean only carcinoma of the body of the uterus. The finding of the little polyp of the cervix offset all previous knowledge and experience. Why she should have had temporary improvement is as

mysterious as why improvement follows some of our other therapeutic endeavors. What the association may have been between this disease and the infection of the parotids I do not know. The only other like affection of the parotids I have seen occurred also in a case with carcinoma of the body of the uterus and metastases in the tubes and ovaries.

CASE 7.—A widow aged fifty-eight came because of a bloody vaginal discharge.

History.—The patient has had three children, the last thirty years ago. She passed the menopause at thirty-eight. She was lacerated with the first child and had a pelvic inflammation following. Following this, intercourse was always painful. She never had excessive flowing except for a short period following the birth of her second child. For a year or more she has had a bloody discharge from the vagina at times. She has much pain in the right side of the pelvis but this is relieved following the periodic discharge of pus. The discharge for the past few months is so constant that she wears a napkin. She had urethral trouble eight years ago and had a growth cauterized. She improved following this, but she still gets up several times a night. She has some pain in the tophead and epigastric burning at times.

Examination.—The patient is slight in build and anemic in appearance. Her hands show a moderate arthritis deformans. No other joints are appreciably affected, though she has occasional pains in various joints. The heart is not affected. The perineum is lax and shows the old laceration. The os is hard and smooth. The uterus is retroflexed, fixed and its outline can not be definitely made out. The fundus seems to widen from a narrow supravaginal portion. There is an offensive uterine discharge, yellowish white in color and containing a variety of organisms.

Diagnosis.—A uterus that has long been dormant which begins to discharge a bloody fluid is nearly always the site of a malignant tumor. The cervix here is free and the body is not large as when a carcinoma of the body is present. The flow of pus from the cervix is unlike the discharge from a malignant uterus. The diagnosis seems to be covered by the designation of the condition present, namely, a pyometrium.

Treatment.—The attempt to explore the interior of the uterus met with difficulty, for no instrument could be made to enter the uterus.

After some effort a Kelly forceps was passed, followed by a complete dilatation by larger instruments. As soon as the small forceps entered the uterus, there was a gush of foul smelling pus, amounting to several ounces. After the pus had escaped the interior of the uterus was swabbed with iodine and the interior explored with a curette. Nothing but a small amount of granulation tissue was obtained. A gauze pack was left in the uterus for twenty-four hours.

After-course.—The patient went home in a week and has not had a recurrence of her trouble after five years.

Comment.—I really only intended the above treatment to be preliminary to a hysterectomy when local and general conditions should become favorable. The subsequent course has made further treatment unnecessary. It is interesting to note that following the drainage of the uterus the arthritis subsided.

CASE 8.—A housewife aged sixty-four came for consultation because of vaginal discharge.

History.—About four months ago the patient noticed a whitish discharge from the vagina of considerable amount, tinged with a little blood. Vaginal douches were prescribed by her physician. These lessened the amount of discharge for a time. In one month there was an increase in the amount again and she consulted another physician who diagnosed a possible carcinoma of the uterus and advised operation. The patient has borne four children, the oldest is forty-eight, youngest forty-two. She had two miscarriages both at two months following the birth of her last child. Her general health has always been good. She passed the menopause without disturbance twelve years ago. There has been no flow of any kind since that time until the present illness. Her appetite is not very good but she sleeps very well. She has some fullness over the lower abdomen and some slight pain under the short ribs on either side.

Examination.—The patient does not look acutely ill and seems to be fairly well nourished. The abdomen is somewhat distended and there is a tympanitic note over the entire abdominal viscera. There is some tenderness over the abdomen especially in the right and left lower quadrant. No masses can be felt. There is a whitish discharge from the cervix, opening speculum caused pain. On palpation the upper end of the vagina seems constricted, barely admitting entrance of two fingers. The uterus can be felt on bi-

manual examination to be as large as an orange. It seems smooth and fairly soft. Adnexa negative. No tenderness in the culdesac. W.b.c. 9,600; R.b.c. 4,832,000; Hg 80. The urine is without note.

Diagnosis.—To find the uterus so large twelve years after the menopause indicates unequivocally carcinoma of the fundus.

Treatment.—Vaginal hysterectomy was done. The uterus was pulled down with difficulty. The fundus was half again as large

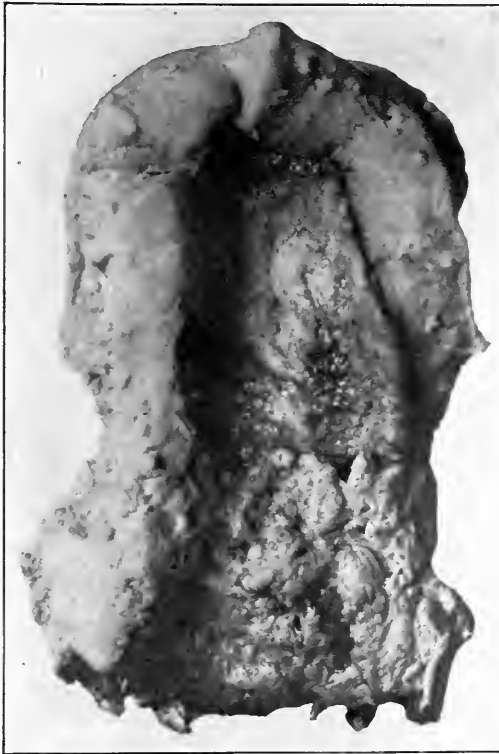

Fig. 419.—Granulomatous endometrium in a case of pyometrium.

as a parous uterus. When the uterine canal was opened into it was found to contain pus. There was a stenosis just outside the inner os. There was a growth in the cervical canal resembling carcinoma along the cervicofundal line. Gauze pack left in pelvis. Eight hemostats left on blood vessels.

Pathology.—The interior of the uterus is lined with a soft nodular material (Fig. 419). What was regarded as a possible malignancy

at operation proves now to be too soft. The slide confirms the granulomatous character of the tissue.

After-course.—The patient did not suffer from surgical shock but was extremely nauseated and vomited several times following the operation. The temperature the first day 99, pulse 90. The after-course was very little disturbed, the highest temperature was 101, pulse 90, of good quality. The gauze packs and hemostats were removed the fourth day. The patient continued to improve and was dismissed on the nineteenth postoperative day, feeling well. Vaginal tract drawing together at upper end, still a small amount of discharge. She has remained well.

Comment.—The smoothness and softness of the fundus should have given a clue to the correct diagnosis. The bloody discharge is unusual in pyometrium and likely the diagnosis was subconsciously made before the diagnosis was undertaken. A dilatation and curettage would have cured the patient.

CASE 9.—A matron aged thirty-four came because of prolapse of the uterus.

History.—The patient has four children and had one miscarriage at three months eight years ago. She has had a prolapse since the birth of the first child twelve years ago, but it is much worse since the birth of the last child five months ago. She has a burning pain in the left side. The general health is good but for some years she has been nervous and has had difficulty in going to sleep. She is most nervous just before menstruation. The flow is regular and lasts four or five days.

Examination.—The patient is a slightly built woman with a worn apprehensive look. The general examination is without note. The perineum is lacerated to the second degree and the cervix is lacerated and lies just within the introitus. The fundus lies on the rectum, is large, movable and sensitive to pressure.

Diagnosis.—The patient ascribes all her troubles to the displaced uterus, and, as a matter of fact, if a displacement is capable of producing trouble, then surely there is justification in her opinion. That there is need for correction is clear. Having four children and having had one miscarriage it seems justifiable to make certain of correcting the difficulty by doing a ventrofixation. She seems below par and though there is no definite premarital complaint she is of the type that does not recover fully.

Treatment.—The perineum and cervix were repaired and then the uterus drawn through a Pfannenstiel incision. The upper portion of the fundus was excised and the remainder of the fundus fixed in the fascia.

After-course.—The wound healed without event but when she began to menstruate blood forced its way through the scar. For a period of months she passed a part of the menstrual flow through the abdominal sinus. She was relieved of her symptoms otherwise. In order to relieve the complication, the sinus was excised down into the cavity of the uterus and several deep sutures placed in the remainder of the body of the uterus. This relieved the condition. She returned after eight years complaining of inability to sleep, pain in the back of the neck and constant nervousness. The menses are regular, last four days, are painless, and are not attended by an exacerbation of the nervous phenomena. The uterus was fixed in position, the fundus firmly fixed in the fascia but the lower portion freely movable. The bladder did not sag. There was no physical reason for her nervousness. She had nursed a member of her own family through a long illness and her increased nervousness followed this period of strenuous physical exertion and mental apprehension.

Comment.—Ventral fixation is the most effective way of remedying a prolapse. If the insertions of the tubes are not resected in the course of the operation they must be obliterated so that pregnancy can not take place. I had one other patient that discharged menstrual blood through such a sinus. In both instances the cervical canal seemed to be perfectly free, and there was no reason why the blood should force itself upward. When it is necessary to open the uterine canal in such cases the fascia after being fixed into the fundus should be fastened together above. In this patient the pelvic condition was only a contributory cause to her general ailment. The care of the sick relative brought on the same train of symptoms that the pelvic disturbance did. In such cases the patient as well as the disease must be treated.

CHAPTER XVII

DISEASES OF THE ABDOMINAL WALL

Diseases of the abdominal wall are numerous and aside from curiosities are of minor importance. Many intraabdominal diseases simulate affections of the parietes, consequently the relationship must be determined.

TUMORS IN THE REGION OF THE ABDOMINAL RING

Usually when a tumor is discovered in the region of an abdominal ring a hernia is at once diagnosticated. Inflammatory affections and tumors may occur independent of hernias or may complicate them. When a hernia is demonstrated the possible existence of other affections must be remembered.

CASE 1.—A widow aged fifty-six came because of a tumor in her groin which causes pain when she is on her feet.

History.—The patient has had frequent attacks of gallstone colic according to her physician and periodic attacks of bronchitis with persistent cough. This trouble has nothing to do with the attacks in her groin according to her. For some years she has had a lump in her groin which never fully disappears. She has no trouble when lying down. When on her feet, particularly when doing work which requires standing, she has much pain and is often compelled to lie down.

Examination.—The patient presents physical evidence that she is correct in the diagnosis of the accessory disease. In her right groin is a tumor the size of a turkey egg (Fig. 420). It lies below Poupart's ligament but partly overrides it. It is but little movable and obviously terminated in the foramen. It can not be reduced but attempts at reduction do not cause distress.

Diagnosis.—Its location is that of femoral hernia. Its consistency and irreducibility suggests an irreducible femoral hernia. Against a lipoma is the story of increased pain when long on her feet and the relief afforded by assuming the recumbent position. Occasion-

ally an imprisoned omental hernia is attended by jaundice and periodic colic attacks which are relieved by the repair of the hernia. Its repair seems indicated.

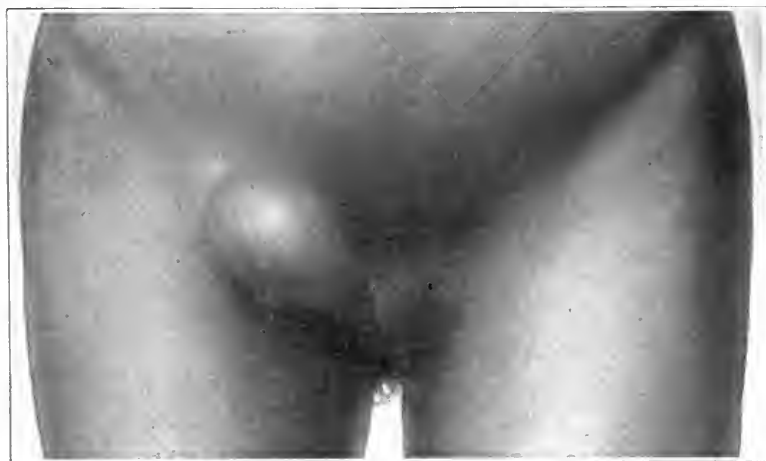

Fig. 420.—Lipoma of the femoral ring.

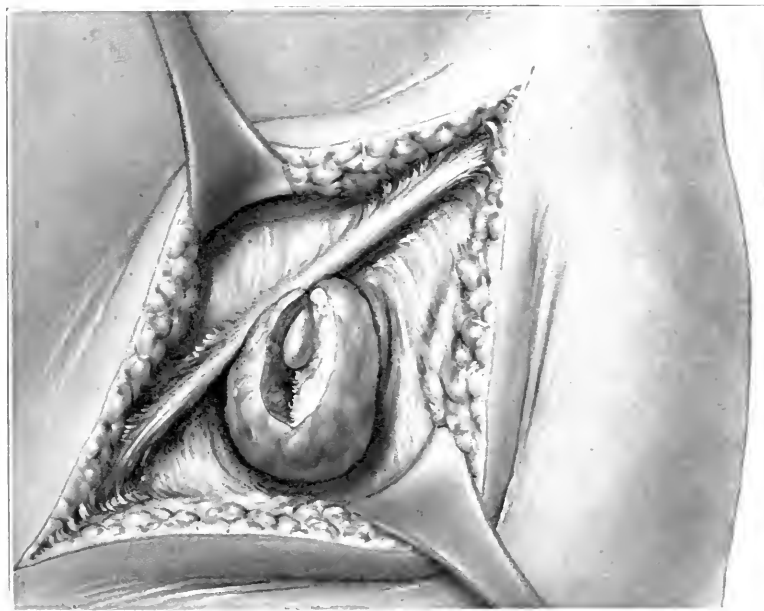


Fig. 421.—Femoral hernia masked by lipoma.

Treatment.—The tumor was exposed under local anesthesia. It proved to be a mass of fatty tissue in the center of which was a small peritoneal sac (Fig. 421). This was ligated and the mass removed.

Pathology.—The tissue removed is a pure lipoma containing in it a small peritoneal sac.

After-course.—Healing was uneventful. The patient was allowed to get up on the tenth day. As soon as she was on her feet she exclaimed to the nurse that she had her trouble just as before. An examination in the standing position revealed an interstitial inguinal hernia. The tumor we removed she declared had been there many years and had never caused any trouble. The patient lived many years with her inguinal hernia. She had many attacks of typical gallstone colics. Later she developed a diabetes, had several attacks of cerebral hemorrhage, and finally died in diabetic coma.

Comment.—Had she been examined in the standing position or had the inguinal canal been examined during the operation the oversight would not have occurred. If femoral hernias are operated on through the inguinal canal such oversights are not possible. It seemed during the operation that the pulling of the lipoma on the peritoneal sac fully explained her pains when she was much on her feet. As an example of logic it was very good, but the conclusions were fallacious. This case shows the far-reaching results of error. She refused to have the inguinal hernia repaired because of the failure of the first operation to secure relief from her trouble. She refused to have the gall bladder removed for the same reason. The diabetes likely resulted because of the persistence of the gall bladder trouble, and as a result of the diabetes she died—albeit at the advanced age of seventy-eight years.

CASE 2.—A seamstress aged forty-three came to the hospital because of a mass in the left groin.

History.—About six years ago the patient noticed a small mass in the left groin. This has gradually grown to about the size of a walnut. It is not reducible by pressure. It does not disappear or change in size on lying down. It causes no symptoms that she is aware of, is never painful or even tender. It feels the same whether she is on her feet a great deal or whether she sits in a chair all day to work. She has been very nervous the last few years and her physician attributed it to the tumor which he diagnosed hernia, not specifying what type. She has no bladder dis-

turbance of any kind. Her appetite is good, but her bowels are inclined to be constipated. She has no shortness of breath, or swelling of the face or extremities. No palpitation of the heart. Her menses are regular, flows four to five days, rather scanty, no pain. Has never been married. She had the usual diseases of childhood, not sick since but for many years she has had more or less difficulty breathing through her nose. She catches cold very easily and the left side of the nasal passage is occluded very easily.

Examination.—The patient is emaciated but looks to be in fair health. She looks older than the age given. Pupils equal, regular, react to light and accommodation; no exophthalmos, ptosis or

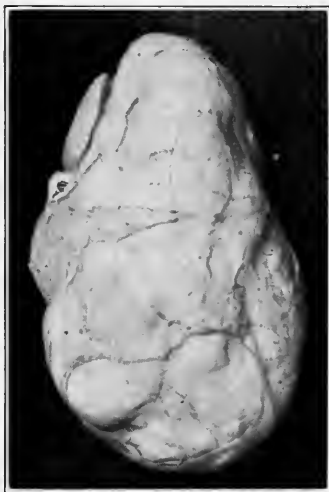

Fig. 422.—Cyst of the canal of Nuck.

nystagmus. There is a large exostosis on the left side of the nasal septum. It is wedge-shaped extending back about $1\frac{1}{2}$ cm. The lower turbinates on both sides are swollen and congested. Teeth are in good repair. The chest negative, the abdomen scaphoid, no palpable areas of tenderness. There is a mass the size of a walnut below Poupart's ligament just outside the external ring and extends down into the labia majora. It is movable, feels cystic, and it can not be reduced.

Diagnosis.—The mass is evidently cystic. It occupies the terminal area of the round ligament and must, therefore, represent the

canal of Nuck. Its contents are too evidently fluid to admit the question of irreducible omental hernia and it does not lie in the region of the femoral canal. The tumor is evidently innocent and its removal can not influence the general symptoms of which she complains. However, she is determined upon its removal and doing so may give her some mental comfort. The nasal obstruction obviously requires correction and this it may be hoped will aid her general well-being.

Treatment.—A cyst the size of a hen's egg lay just outside the left external inguinal ring and was continuous with the round ligament. It was removed. The cyst was egg-shaped (Fig. 422) and was filled with a clear straw-colored fluid. The cyst wall is composed of a fibrous capsule lined by endothelial cells.

After-course.—The recovery was normal, entirely uneventful. The wound healed by primary union and caused no disturbance of any kind. Ten days after the first operation the nasal exostosis on left side was resected. Recovery uneventful. On dismissal two weeks after the first operation the inguinal wound was entirely healed. Left nasal passage well open.

Comment.—Lesions of small clinical significance in persons who are nervous should receive dignified and respectful consideration. Persons without outside interests are apt to magnify small defects and ailments. A small wart to the spinster is of more social importance than the ninth son of a prolific mother and the belittling of it is more apt to produce resentment.

CASE 3.—A housewife aged seventy-nine was brought to the hospital because of a mass in the right groin and pain in the right groin and over the lower abdomen.

History.—For many years she has had a small lump in the right groin. Several times in the last few years she has had sudden attacks of vomiting lasting from a few hours to a day, for which there was no apparent cause. Three days before entering the hospital she took a cathartic and that evening she complained of a pain in the region of her hernia. She ate some supper and vomited once soon afterward. She has not vomited since. The pain in the region of the hernia became worse and she had general abdominal pain. The pain was quite severe. The next day her daughter, who is a trained nurse, noticed the mass was considerably enlarged and was tender to pressure. She developed a fever of 100 and had some

abdominal distention which was relieved by enemas. The above condition remained constant up to the time of entrance into the hospital. Her general health has always been good save for a pneumonia twenty-two years ago and again four years ago.

Examination.—The patient is well nourished and does not look acutely ill. The abdomen is markedly distended and tympanitic. There is no abdominal tumor or area of tenderness. In the right groin is a mass oval in shape extending below Poupart's ligament which is the size of a small egg. It feels extremely hard and is very tender to pressure.

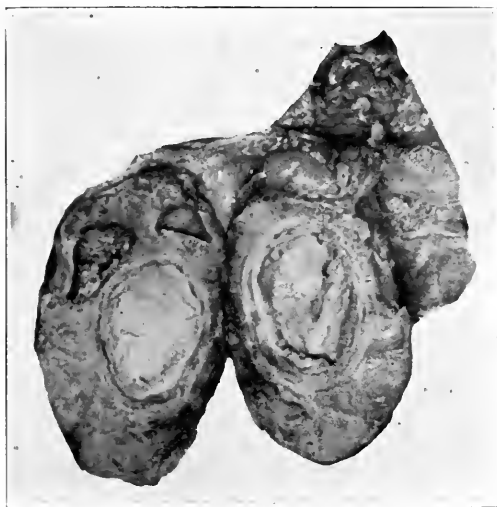

Fig. 423.—Abscess in a lipoma of the femoral ring.

Diagnosis.—Right strangulated femoral hernia.

Treatment.—Repair of right-sided strangulated femoral hernia. In addition a tumor the size of a hen's egg was removed. It appeared like a mass of omentum permanently adherent in sae.

Pathology.—On cutting into the mass a pocket of pus the size of a hazelnut was found (Fig. 423). This pus yielded on culture a Gram-negative coccus and a bacillus. Surrounding this was a lipomatous mass much infiltrated with leucocytes.

After-course.—The patient complained very little of pain, temperature not above 99.6°, pulse 88 for two days. On the third post-

operative day the patient seemed irrational, tried to remove dressings from the wound and to get out of bed. The temperature was normal and there was no abdominal distention or pain. This disturbance was only temporary, the patient became normal the following day and made an uneventful recovery. There was no swelling or tenderness over scar when patient was dismissed nine days after operation.

Comment.—Apparently the lipoma had existed many years. The partial obstruction probably yielded the bacteria that caused the infection.

CASE 4.—A married woman aged thirty-five came because of pain in the right groin.

History.—Three years ago the patient began having pain above and to the right of the pubis extending as far out as the hip bone. It was most pronounced at the menstrual period. She had a badly lacerated perineum with some prolapse of the uterus and a slight laceration of the cervix. The pains were regarded as of ovarian origin and her laceration and displacement were repaired but the pain in the side returned after she began to be about on her feet again. She felt better in general but the original pain persisted. She returned in two years complaining of a tumor in her groin which she had not noticed before. She stated that some months before the appearance of the tumor she had relief from her old pain.

Examination.—There is a protuberant mass above and to the right of the mons extending over the lower end of Poupart's ligament. When lying down this disappears and an opening can be felt.

Diagnosis.—It is very obviously a right inguinal hernia.

Treatment.—A herniotomy was done. A tag of omentum was firmly attached to the bottom of the sac. When this was pulled upon it proved to be the infundibulo-pelvic ligament. It so pulled upon the ovary that a plastic had to be made of the peritoneum in order to allow the ovary to recede from the internal ring.

After-course.—The hernia is cured and the pains are gone.

Comment.—The pain complained of was regarded as of ovarian origin. Most likely there was traction on the ovary by the sac and pain was thereby caused. At any rate a hernia was not suspected until the patient exhibited her tumor. It has been my experience that women suffer more pain in inguinal hernias than

men do. I have learned, in operating on inguinal hernias in women, to determine the location of the ovary and if it is near the hernial opening to so loosen the peritoneum that the ovary may recede to somewhere near its normal position. I have found the ovary high in so many cases of inguinal hernias that I have come to believe there is some developmental connection between the high position of the ovary and the persistence of the peritoneal tube in the inguinal canal. Conversely, when doing operations within the pelvis and the ovary is found near the pelvic brim without obvious cause, it is well to inspect the internal ring for a possible hernia.

CASE 5.—A business man aged thirty-two came because of pain and tumor of the groin.

History.—For about nine months he has noticed a dragging pain in his right groin. It is particularly pronounced after strenuous

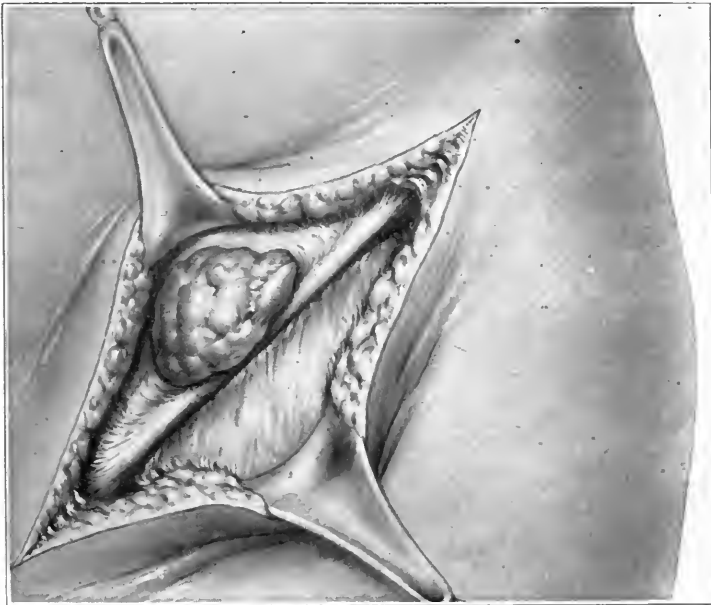


Fig. 424.—Inguinal hernia masked by lipoma.

exercise. There has never been fever or nausea. Ten days ago he was examined by his family doctor who found a small tumor and diagnosticated hernia and advised its repair. His general health is excellent.

Examination.—The general appearance of the patient is that of perfect health. Above Poupart's ligament is a small enlargement which is not painful neither is it reducible. The external ring easily admits a joint of a finger which receives a distinct pulse when the patient coughs.

Diagnosis.—An enlargement within the inguinal canal which gives impulse on coughing must be an incomplete hernia. It is irreducible yet causes but little inconvenience and must therefore be omental.

Treatment.—When the inguinal canal was opened, a fatty mass the size of an egg appeared (Fig. 424). It separated readily from the cord and could be followed with suspicious ease down to the internal ring. A search at the pedicle disclosed a teat of peritoneum the size of a sharpened end of a lead pencil and had to be opened into before it could be positively identified as a peritoneal sac. It was ligated and the tumor removed.

Pathology.—The mass removed was a typical lipoma.

After-course.—He was relieved of his symptoms.

Comment.—This tumor must have attained some size before his troubles began. The small sac seemed to be due to traction by the lipoma. It is not at all uncommon to find lipomas alongside of hernial sacs, but usually they are relatively small in comparison to the size of the hernial sacs. The diagnosis of irreducible omental hernia was unnecessary. Early hernias do not have fixed omental contents. On the contrary, a dragging pain coming on early is particularly suggestive of a lipoma. Besides this young man was disposed to be rotund. These individuals are particularly likely to have lipomas.

CASE 6.—A merchant aged thirty-six came because of discomfort from a lump in his groin.

History.—For a number of years he has noticed a lump in his groin. It causes considerable discomfort at times but disappears when he lies down. For some months he has had some pain higher up in the groin and believes he is developing another hernia. His general health is good.

Examination.—The patient is a large, powerful man. When he stands a bulging appears over the external ring and a bulging higher in the groin (Fig. 425). Both these give an impulse on coughing and can be easily reduced when he lies down.

Diagnosis.—The lower mass is evidently an indirect inguinal hernia. Most likely the upper one is a hernia which escapes from the internal ring and then passes upward and outward between the abdominal muscles.

Treatment.—An incision was made parallel to and just above Poupart's ligament. The inguinal canal was opened and no sac found about the cord. The femoral ring was explored and a shallow pocket admitting the terminal phalanx was present. The sac could be made to ascend over Poupart's ligament. The mouth of the opening was unusually broad. The sac was pulled upward by making traction above Poupart's ligament. The cord was searched for a sac near the internal ring but none found. The peritoneum was

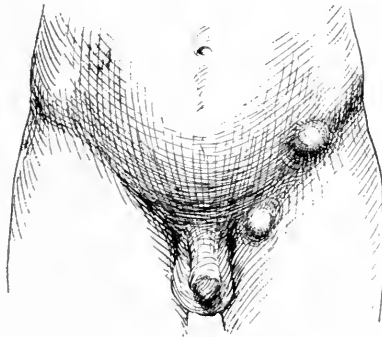


Fig. 425.—Femoral and interstitial hernias.

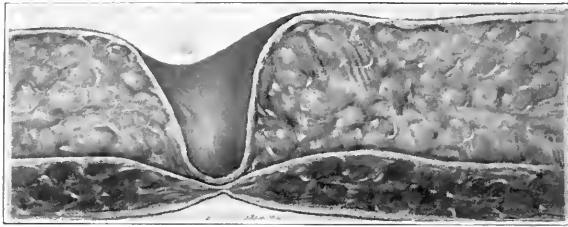
opened and above the entrance of the cord was a pouch lying between the external and internal oblique muscles. It was as though nature had done a Kocher operation—and had not done it well. This sac was ligated and removed.

After-course.—Healing was uninterrupted and there has been no recurrence, now seven years.

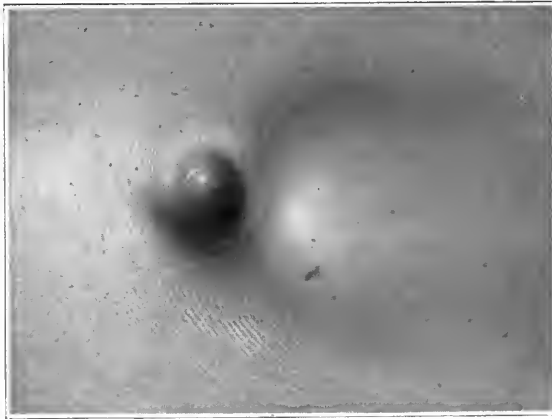
Comment.—A femoral hernia in a young man is not common and an interstitial hernia likewise is uncommon. I came near overlooking the upper hernia despite the patient's protest that he felt a distinct bulging. He could not produce it by coughing, however, during the operation (operating under local anesthesia). Care in studying the lower one should have made its nature apparent.

CASE 7.—A housewife aged fifty-five entered the hospital because of pain in the lower half of abdomen when lifting and the sense of falling out of the pelvic contents.

History.—The patient has two living children, two died in infancy. No miscarriages. She reached the menopause four years ago and has had no flow of any kind since that time. She complains of dragging down pain of dull aching character in whole lower half



A.



B.

Fig. 426.—Schematic presentation of the traction produced by the deposition of fat about the umbilicus. *A.* Cross section. *B.* As viewed from surface.

of the abdomen. This pain is worse when she moves around or tries to lift anything. It has bothered her for about two years. She also had dull aching pain in left lumbar region during the same period. Two years ago she noticed a sense of fullness in the region of the navel. This has gradually grown worse. For one year she has had difficulty in holding her urine and gets up two to three

times each night to urinate. She also has pain on urination and afterwards. The bowels move regularly but she has to strain considerably during defecation. She had severe laceration during the birth of her first child. At times she gets bloated considerably. She has swelling of her feet at times, especially if she is on her feet much. She has considerable shortness of breath when going upstairs.

Examination.—She is a large, obese woman. Blood pressure 175-80. Head, neck, and lungs negative. The heart is not enlarged and there are no murmurs but the second aortic sound is accented. There is a bulging at the umbilicus, especially on coughing.

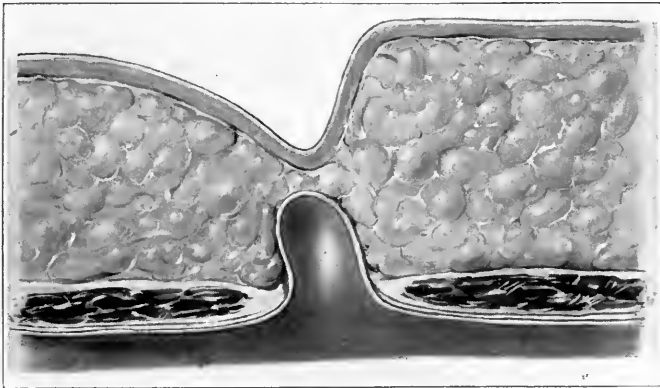


Fig. 427.—Diagrammatic presentation of a cross section of the abdominal wall in the region of a beginning umbilical hernia. The increased layer of fat between the superficial fascia and the recti muscles seems capable of producing traction on the umbilicus, thereby inverting it and thus inviting a hernia.

The umbilicus is deep and a finger placed therein perceives an impulse when she coughs. There is laceration of the perineum with extensive relaxation and a rectocele. There is an equally prominent cystocele and a urethral caruncle as large as a bean. The cervix is just within the introitus when she is in the recumbent posture. The urine is 1.012, contains much pus with albumin corresponding, but no casts or blood.

Diagnosis.—There is obviously an umbilical hernia. A lacerated perineum, a cystocele and rectocele and a urethral caruncle. The prolapse is sufficient to account for the discomfort in the lower abdomen. The urethral caruncle, as well as the cystocele, each

might well account for the vesical irritation. The albumin is nearly all removed by filtering out of pus cells, and since there is an absence of formed elements in the urine it seems safe to assume that the albumin present is due to the presence of pus. The umbilical hernia does not seem to add much to the list of complaints. Inasmuch as an abdominal fixation is required, its repair may be added.

Treatment.—The urethral caruncle was resected. The perineum was repaired, and this, together with the abdominal fixation, was depended upon to hold up the bladder. The fixation was made through a vertical incision. This incision was extended upwards through the fat to the umbilicus. A cup-like depression was formed which admitted the terminal phalanx of the thumb (Fig. 427). It was empty. It was excised and the defect closed by lateral overlapping.

After-course.—There was a normal postoperative recovery. At dismissal there was considerable induration in the scar line which was sensitive to pressure. The perineum was entirely healed and formed a good support for the bladder.

Comment.—This seemed to present the earlier stages of an umbilical hernia. The traction of the fatty layer seems capable of producing traction on the umbilicus producing a pit (Fig. 426). This is no doubt aided by the increased abdominal contents but there is no evidence to show that the intraabdominal pressure is increased in fat individuals. The relaxation of the abdominal walls seems to go apace with the increase in bulk of the intraabdominal organs due to the deposition of fat. The difficulty in reintroducing the abdominal contents into the abdomen when closing the incision in the abdomen of fat folks seems to be due to the solid character of the contents rather than increase of pressure. Increase of pressure during muscle contraction depends on the power and toxicity of the muscles. If intraabdominal pressure were the important factors in the production of umbilical hernia, the athlete, and not the fat, leisurely matron, should be most commonly afflicted. Most assuredly pinning the shoulders of an opponent to the mat increases the intraabdominal pressure more than the calling for a second helping of cheese. Once omentum gains entrance in an umbilical hernia the irritation attaches it and then evidently an increased deposition of fat adds to the bulk of the omentum imprisoned in the umbilical ring. At any rate those afflicted with an excess of adiposity are the most likely victims of umbilical hernia.

TUMORS OF THE ABDOMINAL WALL PROPER, INCLUDING FISTULA

The abdominal wall harbors desmoids and certain types of sarcomas. Slowly developing inflammatory affections both in the wall and beneath it may simulate tumors.

CASE 1.—This patient aged fifty-one came because of prolapse of the uterus.

History.—The patient has always had dysmenorrhea. She married at twenty and has had five children. She noticed a prolapsus after the birth of her last baby. She has always had headaches and backaches which were more pronounced at her periods. These have been much worse since the last baby was born, sixteen years ago. She has always been constipated. The menses stopped one and a half years ago. Since then her headaches and backaches have been better, but are still present. She has worn a pessary for prolapse with some relief. Last August she had a sudden attack of abdominal pain in the right lower abdomen. She was in bed three weeks. The trouble was diagnosed appendicitis by her physician. When she got up she felt a lump in the abdominal wall at the site of the pain. Six months later she had pain again in the same region and the spot looked inflamed. During March the patient felt pretty well.

Examination.—To the right of the median line, above the anterior superior spine she has a tumor 1 x 2 inches in size. The mass is still palpable when the abdominal muscles are put on tension and can be lifted with the abdominal wall. There is a moderate recto- and cystocele. The uterus is retroverted and the cervix presents in the introitus. The pelvic condition requires no comment. The tumor in the abdominal wall is dense elastic, is free from the muscle walls, yet it is not encapsulated. It has the relation to environment and consistency of a desmoid, though the onset suggested an inflammatory origin.

Treatment.—Fixation of the uterus and perineorrhaphy, together with excision of the abdominal wall tumor was done. The mass was not encapsulated and fused gradually with the surrounding tissue. In removing it a part of the external oblique muscle had to be sacrificed. One could not be certain that all the affected tissue was being removed.

Pathology.—The tumor is very hard to the touch and fairly grates when cut. The cut surface is pearly and presents irregular wavy lines. The slide shows the edge to be intimately attached to the external rectus muscle. The fibrous bundles present intimate interdigitations into the muscle bundles. There are a small number of small and medium sized cells with ovoid nuclei. It is evidently a dermoid.

After-course.—Healing was uneventful. After four years there is no disability save a slight bulging where a portion of the external oblique was removed with the tumor.

Comment.—The origin of desmoids shows many of the features of a subchronic inflammation simulating certain types of woody phlegmons and may very well, it seems to me, represent an organizing stage of such a process representing a midstage between inflammation and sarcoma.

CASE 2.—A married woman aged thirty-six came because of curious tumors at the edge of her arm pits.

History.—Since puberty she has been annoyed by swellings at the anterior edge of the arm pits. She first noticed them at the beginning of menstruation and at a previous labor they secreted milk for a time and afterwards became painful. After this labor the same process was repeated, but instead of subsiding, the right one became red and excessively sensitive to touch.

Examination.—At the anterior border of the right axilla, partly overhanging the edge of that muscle, is a flat mass carrying on the surface perfect little nipples with glandules of Montgomery and all. It is indurated and contains a small softened area. On the left side is a similar one but it is not inflamed.

Diagnosis.—The history and appearance is typical of accessory mammae and the location is the most common for this anomaly. The right one evidently contains an abscess.

Treatment.—The softened area was incised and drained. It contained a dram of pus.

After-course.—Healing took place in a week.

Comment.—There was no inflammatory disturbance of the normally situated mamma. The source of the infection above described was not determined. It must have taken place through its own little nipple.

CASE 3.—A maiden lady of thirty-four came because of a tumor on her right side.

History.—The patient has had a tumor on her side for some twelve years. It has never caused any pain but recently it has become larger and comes in contact with her elbow when engaged in the gentle art of hoeing potatoes. The corset has nothing to do with the irritation of this tumor for the simple reason that she has never worn one. Her general health has always been good.

Examination.—The tumor is the size of a base ball. The summit is covered by a thinned skin which is reddish brown in color. Half

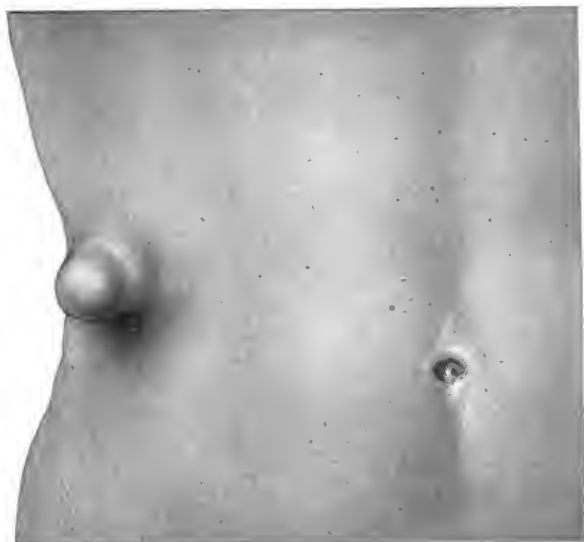


Fig. 428.—Bald-headed endothelioma of the abdominal wall.

way down the side of the tumor this skin abruptly terminates in the normal skin of the abdomen. (Fig. 428.) On palpation this thinned skin is felt to be intimately attached to the tumor, while the normal skin is not attached, but glides freely over the tumor. The tumor itself is dense elastic and is wholly insensitive to any manipulation. The whole mass moves on the deep fascia.

Diagnosis.—This is a representative of a type of tumor apparently not clearly defined in the literature. It is characterized by the thinned skin on the surface, slow growth and apparent encapsula-

tion. Because of the peculiarity of the skin covering the surface, I have called them "bald-headed" sarcomas.

Treatment.—An elliptical incision was made half an inch below the junction of the thinned and normal skin. The capsule of the tumor was freely excised along with the tumor.

Pathology.—On section this tumor was pearly pinkish, showing areas of fine granulations. On section it was made up of strands of spindle cells for the most part, but certain areas were made up of a network of epithelioid cells giving the general structure of an endothelioma. The majority of these tumors are made up of either endothelioid or spindle cells.

After-course.—The tumor did not return.

Comment.—The apparent encapsulation of these tumors leads to their being simply shelled out. When so operated on, they invariably recur. They must be removed widely, capsule and all.

CASE 4.—A professional man aged forty-eight came because of a tumor above Poupart's ligament.

History.—Has had a tumor above his hip bone ever since he can

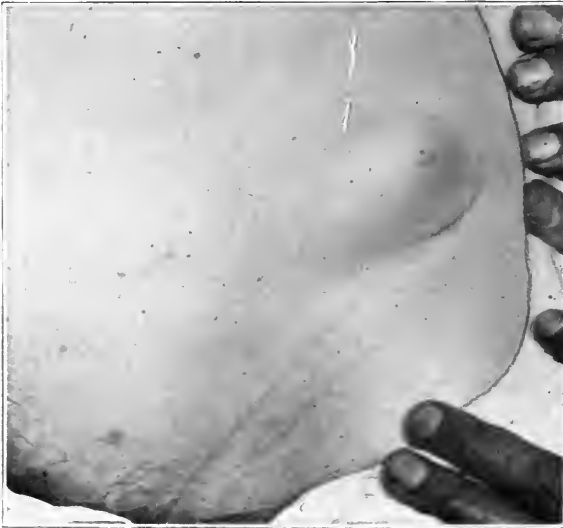

Fig. 429.—Accessory mammary gland in male.

remember. It has caused no trouble, but since his mind has been attracted to tumor possibilities because of malignancy in other members of the family, he desires to know its nature.

Examination.—A tumor 5x7 cm. is located directly above the anterior superior spine (Fig. 429). It is 2 cm. thick and is mounted by a small conical projection. A pigmented area surrounds this, about the periphery of which are large glands. The tumor mass is made up of soft fatty tissue with smaller, firmer nodules scattered here and there in its substance.

Diagnosis.—The size and shape of this tumor is identical with that of a mammary gland just beginning to show signs of puberty.

Treatment.—None.

Comment.—The interest in these conditions is solely one of diagnosis, since none of those yet observed has been the seat of a pathologic process.

CASE 5.—A woman of forty-two came to the hospital because of a tumor in her groin.

History.—Three years ago she noticed a lump in her groin. It was as large as a walnut when she first discovered it. It caused

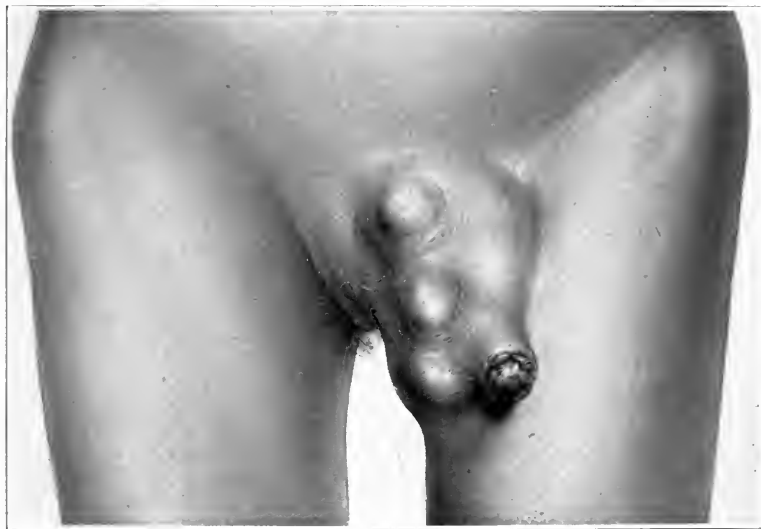

Fig. 430.—Fibrosarcoma of the inguinal region.

no pain and she did not consult her physician until it had attained the size of an orange. He removed it by injecting a local anesthetic and shelling it out. She was free from disturbance for nine months when she noticed another tumor in the same site. It has grown in

the past year and a half to its present size. Three weeks ago the skin over the end of it became ulcerated and a bloody fluid has escaped from it. Her general health has been good.

Examination.—An irregular tumor the size of a fist hangs from the iliopubic region (Fig. 430). It is attached at its base but the bulk of it can be moved from side to side. The greater portion of the tumor is firm elastic. The ulcerated nodule is soft, and pressure on it

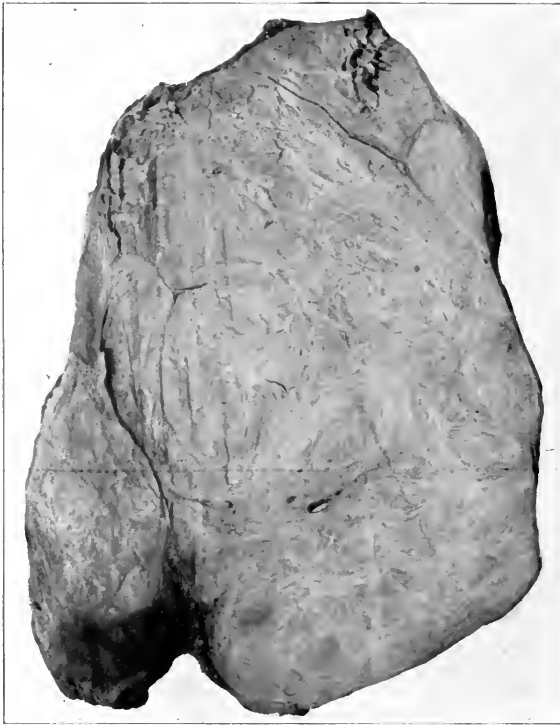


Fig. 431.—Bald-headed sarcoma.

causes the escape of a black fluid. There are no lymph glands palpable in this region or elsewhere.

Diagnosis.—The history of a relatively encapsulated tumor in this region which has recurred after removal is indicative of a type of sarcoma indigenous to this region. The tendency of the surface to ulcerate is characteristic.

Treatment.—A wide dissection was made exposing the deep fascia in the entire region. A sliding flap was required to fill the defect. Drainage was used in the lower angle of the wound.

Pathology.—On section the tumor is whitish pink and a wavy fibrous arrangement can be made out (Fig. 431). Near the ulcerated area the tissue is degenerated and there has been a hemorrhage. The slide shows a fibro-sarcoma (Fig. 432).

After-course.—The patient has been free from recurrence for two years.

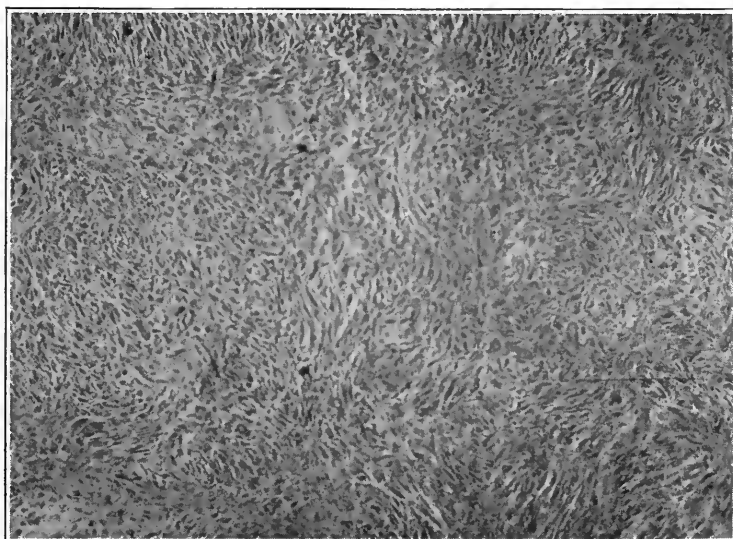


Fig. 432.—Spindle-celled sarcoma of the groin.

Comment.—These tumors are by no means uncommon, and it is the common experience that some operators shell them out with inevitable recurrence. Complete reoperation sometimes secures permanent results, but usually recurrence follows. On the other hand, if their importance is appreciated and an initial wide dissection as here indicated is made; permanent relief may confidently be expected. There is no tumor that recurs in the groin that may properly be “shelled out.”

INFLAMMATORY INFECTIONS INVOLVING THE ABDOMINAL WALL

Infections involving the abdominal wall are usually the product of disease beneath seeking exit. Their interpretation implies usually a search of the more important affections.

CASE 1.—A widow of sixty-eight was brought to the hospital because of a strangulated hernia.

History.—She has had a femoral hernia for many years. It has been strangulated a number of times, but she has always been able to have it reduced by her physician. Ten days ago it came down, but after trying for some time, it could not be reduced. It gave her no particular trouble and she allowed it to remain. Two days ago it became more painful and she vomited repeatedly on the morning of the day of entrance and the pain was much increased.

Examination.—The patient is a slight woman but seems to be in good general health. She gives no evidence of suffering or intoxication. There is a general moderate tympany but the abdomen is everywhere soft and without tenderness. There is a mass below Poupart's ligament on the left side. The skin is somewhat reddened and is sensitive to pressure.

Diagnosis.—The long duration of the imprisonment indicates that an irreducible condition rather than a strangulation existed until the past twenty-four hours. Events now indicate an infection or a necrosis which is irritating the surrounding tissues. The vomiting and tympany suggest an irritation of the gut wall rather than an obstruction of its lumen. At any rate intervention is indicated.

Treatment.—The lesion was exposed under local anesthesia. A loop of gut some four inches long was imprisoned in the femoral ring. When first exposed, it appeared blue black (Fig. 433). When released, the circulation soon became established so that it became brownish pink. Pressure blanched it but the color at once returned. A ring a quarter of an inch wide did not show this restoration. It seemed so narrow that some reinforcing Lembert sutures were employed to cover it. The gut was then returned to the abdomen and a drain placed through the ring into the abdomen. Should a leak occur it seemed likely the worst that might happen would be a fecal fistula.

After-course.—The operation did not inconvenience her. She seemed comfortable for a day or two, but after this time she developed a temperature which ascended as high as 103.5° . She seemed perfectly comfortable and her appetite remained good. There was a local suppuration and the temperature was ascribed to this. The temperature continued and she showed evidence of sepsis. This condition progressed and she died on the eighth day. Examination showed a generalized infection involving some loops of gut and the adjoining tissue. There was no evident leak in the gut. Ob-

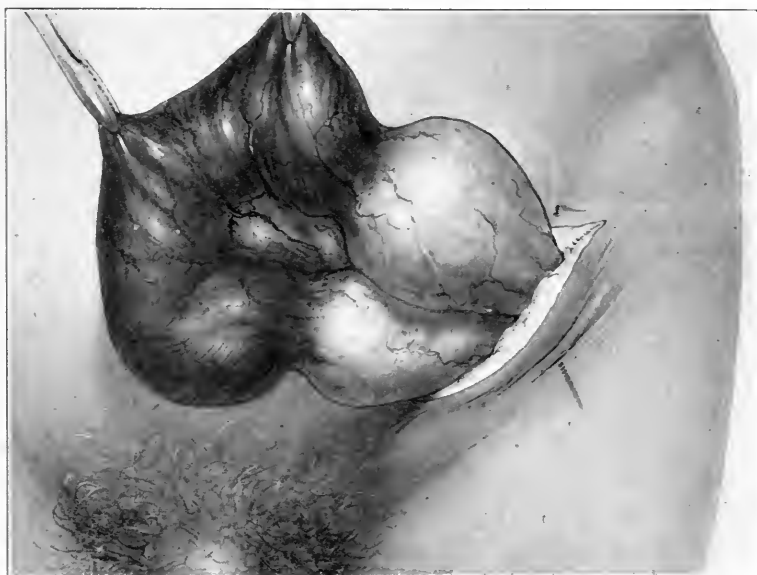


Fig. 433.—Necrosis of a loop of ileum in a case of strangulated femoral hernia.

viously there was a generalized infection by bacteria which escaped from the gut wall.

Comment.—It would have been best to have left the loop of gut entirely outside the wound. A fecal fistula likely would have been formed but this could have been dealt with at the proper time. Immediate resection would have been technically easy, but the mortality following this procedure is too high to make it the operation of choice. Where the gut is not viable the establishment of a fecal fistula with subsequent resection gives a less mortality than

immediate resection. The method employed in this case was the worst of all. Unless the circulation in an impaired gut is returned promptly the jeopardized loop should be fixed outside the wound.

CASE 2.—A merchant aged forty was brought to the hospital because of a strangulated hernia.

History.—The patient has had a hernia since boyhood. For many years it was retained by a truss but in recent years it has been indifferently held and much of the time he has abandoned the truss entirely. Ten days ago his hernia remained out and became very painful. Attempts at reduction failed. No symptoms of obstruction developed but the area became more painful and he developed fever. He has had a severe nephritis for a number of years and his surgeon feared to give him a general anesthetic, but since the condition is increasing in severity, operation under local anesthesia seems imperative.

Examination.—The patient is a slight person, as indicated by her presents a puffy face and slightly swollen ankles, despite a ten-day incumbency in bed. The apex is in the anterior axillary line, diffuse but faint. The left scrotum including the inguinal region is swollen and edematous. The affected area is sensitive to pressure. The induration extends a handbreadth above Poupart's ligament and medial to the anterior superior spine. The urine contains albumin and casts. Pulse 110, temperature 102.5°.

Diagnosis.—The history of old hernia, recently neglected, and now inflamed and painful, suggests thrombosed, irreducible omental hernia. It requires operation and even under local anesthesia presents a problem of some gravity.

Treatment.—An incision under local anesthesia was made from the midpoint of the scrotum to near the anterior superior spine. The root of the scrotum and the perineum was infiltrated in order to block the long perineal nerves as it was anticipated that the omentum would be adherent in the scrotum. When the hernial contents were exposed it was found to consist of a blue-black mass. This mass extended throughout the inguinal canal. It was dislodged and withdrawn through the internal abdominal ring. Within the abdomen was a twist in the omentum above which the omentum was normal save the vessels were much dilated (Fig. 434). It was ligated through the normal portion. The remainder was removed. The enormous wound was closed at its upper and lower portions, but the midportion was packed.

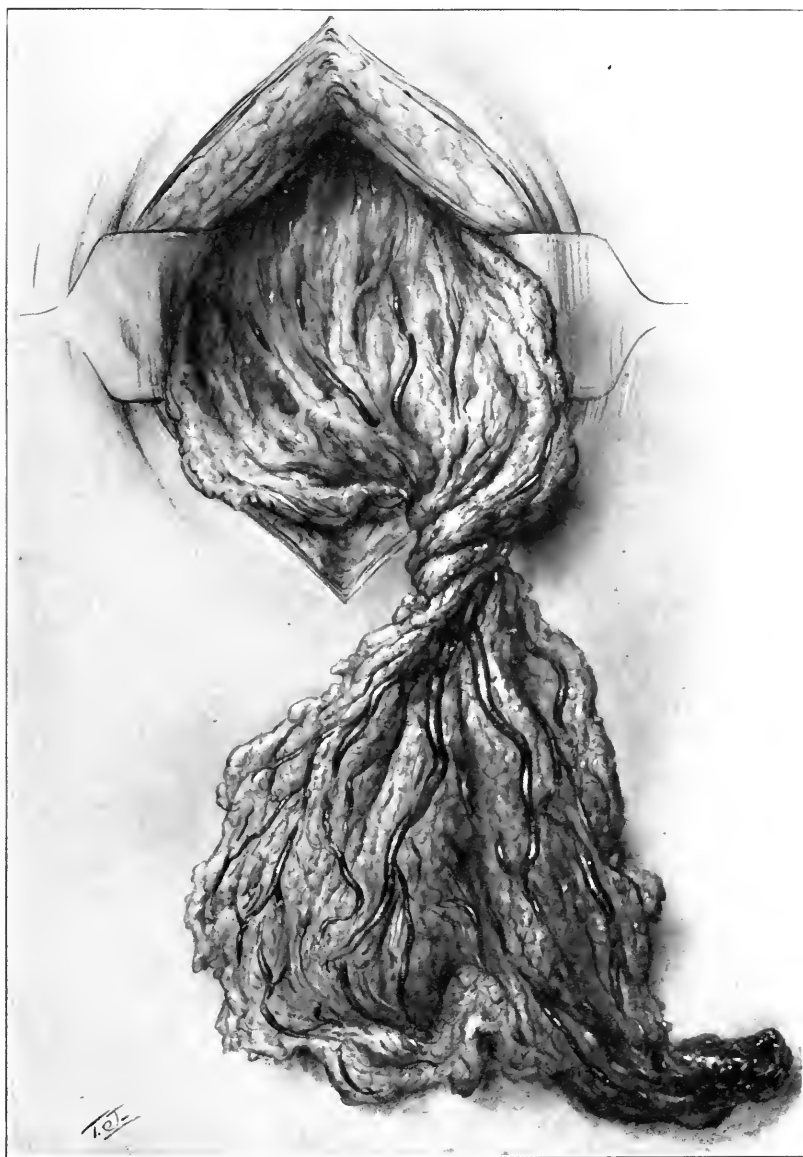


Fig. 434.—Torsion of the great omentum. The portion below the twist was black and dense while that above was unchanged save for the marked dilatation of the veins.

Pathology.—The twist of the omentum consisted of a complete turn below which the vessels were completely thrombosed. The thrombosis seemed to be complete. The interstitial tissue was indurated with a hemorrhagic exudate.

After-course.—There was some suppuration in the wound and healing was not complete for three months. He lived a year and a half before succumbing to his nephritis.

Comment.—The mass palpable within the abdomen above Poupart's ligament should have suggested a twist in the omentum. A simple strangulated omentum would not have made a mass extending so high in the abdomen. The prolonged rest in bed occasioned by the suppurating wound together with the loss of weight it entailed was likely an assistance in alleviating the nephritis.

CASE 3.—A matron aged fifty-six was brought to the hospital because of a fecal fistula following a strangulated femoral hernia.

History.—The patient has had a femoral hernia for several years. Two years ago it became strangulated but was reduced by her physician. Six weeks ago it became strangulated again and her physician, failing to reduce it, called a surgeon. The surgeon operated at once and finding the gut black, withdrew the loop from the wound and fastened it there. Two days later, the gut remaining black, he opened it, producing a fecal fistula. The gut contents have drained from this opening since that time. Her general condition now is satisfactory, but she desires to be rid of the fecal discharge.

Examination.—The patient seems in good health. From an opening in the groin two ends of the gut protrude from which intestinal contents are escaping. The skin about the opening is much excoriated.

Diagnosis.—The condition is easily ascertained at a glance. The plan of procedure alone requires solution. It seems best to open the abdomen away from the infected wound, secure a lateral anastomosis and then remove the terminal ends of the gut from above downward. In this way it will not be necessary to invade the infected area except in the final stage of the operation.

Treatment.—The area about the exposed ends of the gut was disinfected as well as possible and then covered with a formalin pack. A towel was then sutured over this. The noninvolved skin above Poupart's ligament was then sterilized with alcohol and

iodine and an incision made. The terminal ends of the gut were identified within the abdomen; these were clamped 10 inches from where they were imprisoned in the femoral ring. These were severed and the ends turned outside the abdomen. The ends within the abdomen were united by a side to side anastomosis and dropped into the abdomen. The ends outside of the abdomen were pulled down, as far as Poupart's ligament. The abdomen above was then closed. Poupart's ligament was then cut across and the terminal ends of the guts removed together with the tissues to which they were attached. The ends of Poupart's ligaments were then fastened to each other and to the fascia beneath. The wound below was closed in part and in part packed with gauze.

After-course.—The wound above closed by primary union. That below Poupart's ligament suppurated somewhat, but was closed by secondary suture in two weeks. She left the hospital in four weeks with the wound completely healed. I removed a bladder stone from her four years later. The hernia wound was noted at that time to be perfectly firm.

Comment.—In strangulated hernia with necrotic gut, this plan of a two step operation is the procedure of choice. It invalidated the patient for several months but is quite free from mortality. I have practiced it repeatedly since this patient, with equally good results in all. It requires a certain degree of courage to refuse to do an immediate resection and anastomosis. Logical as immediate resection seems to be, it causes too great a mortality to warrant its general adoption.

CASE 4.—A married woman aged forty-eight entered the hospital because of occipital headache, going down the back of the neck.

History.—Her headaches began about fifteen years ago. They were not severe at first; they came on in the morning, she would be nauseated and by night be as well as ever. The headaches have become worse and their period longer. They now sometimes last a week. They are usually unilateral and are accompanied by nausea and often by vomiting. They are extremely severe. She rarely has had them when pregnant. She has them now every ten days to six weeks. Her menses are regular, last two to four days, flow scant. No pain or trouble at the time. Last period now on. Her appetite is fair, bowels regular except during the attacks of headache. No urinary symptoms. Does not get up nights. She has no cough or

shortness of breath on exertion. Has had some swelling of the feet when working hard all day. Weight is stationary now, weighs 102, she weighed 125 twenty-five years ago. She has had eight children, six living and well; two have died, one at three months of inanition and one at fifteen months of pneumonia. The youngest child is now five years old. She had pneumonia in childhood and had repeated attacks of tonsillitis when she was from eighteen to twenty-five years of age. Her father died of apoplexy. He had had sick headache at short intervals lasting part of one day for many years. Two sisters have headaches of the same character. Her mother died at seventy-seven from cancer of stomach and liver.

Examination.—The patient is poorly nourished and appears much older than the age given. She does not look acutely ill. The pupils are equal, regular and react to light and accommodation. The thyroid is palpable, as are the lymph nodes in side and back of the neck. The chest is flat and the sternum sunken, but the lung expansion is good and equal on both sides. The heart dullness extends from midsternal line to 7.5 cm. to left. Apex beat in 5th interspace. Abdominal wall lax and flat. The cecum, descending colon, and left kidney are palpable. There is tenderness to pressure all over the epigastrium and some tenderness across lower abdomen. Perineum lacerated and lax. Cervix deeply bilaterally lacerated and extensively eroded. The uterus somewhat enlarged and rather tender. The fundus is in position, freely movable. W.b.c. 9,800; R. b.c. 4,802,000, Hg 75. Urine turbid, acid, 1.014, albumin present.

Diagnosis.—The patient has an endometritis, lacerated cervix and perineum. She desires to be relieved of her terrific headaches at any cost. The only clue as to their etiology is the fact that she did not have them during her numerous pregnancies. This together with the fact that migrainous headaches often disappear with the advent of menopause suggests the only hope of relief. The uterus is large, the periods regular, which does not give any evidence of an impending menopause. The laceration is pronounced, the erosions extensive and angry. This condition is a menace and the temptation to rid her of this by hysterectomy is great, doubly so because of the hope that the cessation of the menses will relieve her of the headaches. The patient earnestly desires the operation if it presents any hope whatever of any such a happy sequel.

Treatment.—A vaginal hysterectomy was done.

Pathology.—The uterus is above normal size, cervix deeply lacerated and eroded. The right ovary is almost destroyed by a cyst. The uterine wall is somewhat sclerotic and the interstitial cells of the endometrium much increased. There is extensive degeneration of the cervix.

After-course.—There was some postoperative shock. The patient perspired freely, was nauseated, vomited frequently and felt weak. The temperature was 96.5° , pulse 102, and weak the entire first day. The nausea and vomiting continued in all for three days at intervals. There was much pain low in the abdomen. On the fifth day the vaginal discharge changed from a red to a dark, almost black color and was very offensive. The temperature was 101° , the pulse 70. A vaginal examination with speculum showed a slough at the upper end of the vaginal tract and a large quantity of black foul-smelling discharge. The black offensive discharge continued and the patient gained strength very slowly. On the fourteenth postoperative day the temperature went to 102° and the patient complained of severe pain in the left inguinal region. There were no positive findings except a tenderness and rigidity on the left side low down. The discharge changed from black to grayish and was very profuse. The next day the temperature dropped to 101° and the patient felt better. The discharge was still profuse and of a greenish color. Temperature the next few days again went higher, up to 101.8° . Patient complained of but little pain, but felt weak and listless. On the twenty-eighth postoperative day the temperature again went to 103° , pulse 113. The patient had complained for several days of a pain in the left lumbar region coming around over the crest of the ilium to the left iliac region. Urinalysis showed an acid urine with much pus. W.b.c. 13,400. The temperature continued high for the next two weeks, usually 103° in the afternoon. The patient complained of pain in left lumbar region radiating around along the crest of the ilium anteriorly. Urine showed much pus and an occasional granular cast. The skin above the crest of the ilium as high as the twelfth rib became edematous and the whole area sensitive. The indurated area was incised and a quantity of pus escaped. The lower part of the abscess in this region communicated with a larger one in the pelvis. A drainage tube was placed in the pelvis from the lumbar incision. The temperature then dropped, and rapid improvement took place.

Comment.—The interest in this case centers in the postoperative complication and the interest is heightened because the abscess was so long unopened. This permitted the line of least resistance in these abscesses to be clearly demonstrated. The pain above Poupart's ligament indicated its development and an opening here would have cut short the process. In this stage an opening here would have been preferable to an attempt to open into the culdesac because of the danger of wounding important tissues. The old advice to always open abscesses at the lowest point may well be ignored when one or more walls of the abscess are movable. The disposition of these burrowing abscesses to glide along the iliac fossa often causes it to be mistaken for a disease of the bone, and once it arrives in the region of the kidney, it may well be mistaken for a perirenal abscess, all the more so since such abscesses are usually attended by pus in the urine, and not uncommonly a dysuria. Usually the history of an antecedent pelvic disorder aids the diagnosis, or an early pain above Poupart's ligament sets the observer aright. In true perirenal abscess there is a bulging in the renal triangle in front and less disposition to spread downward. Low grade perirenal infections, however, may burrow in various directions, particularly downward.

CASE 5.—A housewife aged fifty came to the hospital because of an abscess in left hip of several days' duration.

History.—Five years ago the patient had an abscess on the left side above the hip bone margin following an abdominal operation performed a year earlier. She has had small abscesses and discharging sinuses on the left side and back for the past five years. The last abscess developed three days ago. It has not discharged as yet. Older abscesses have been discharging at times. There has never been any bone discharged. The abscesses have all opened spontaneously. Sometimes there was pus or watery fluid discharged for several weeks at a time. Her general health has been fairly good except for the abscesses in the past five years. She had typhoid fever twenty years ago and was in bed seven weeks. She formerly had sick headaches with nausea and vomiting with her menses. Her menopause occurred six years ago and she has had no flow since. She has been married twenty-nine years but was never pregnant. Six years ago she was operated for adhesions; she had pain in the abdomen, loss of weight. The diagnosis was made by x-ray. She has

no urinary disturbance, no shortness of breath, no cough. The appetite is good, she sleeps well, and there is no loss of weight.

Examination.—The patient seems fairly vigorous with fair nutrition. She looks much older than the age given. The skin is soft and elastic. There is a median thyroid felt, soft, enlarged, not nodular. Chest symmetrical, respirations free and equal. Heart somewhat enlarged to left, 10 cm. out. Heart sounds clear. There is a large, red, swollen, fluctuating area 10 x 6 cm. over the crest of the ilium; the skin is smooth, tense, and hot. Several discharging sinuses are seen on the side of her back and above the crest of the ilium. There is definite tenderness over the lateral border of the sacrum on the left side. There is a marked spasm of the abdominal muscles in the right upper quadrant, and the liver is palpable. Operative scar left rectus below umbilicus about 5 cm. long. W.b.c. 17,800; R.b.c. 4,336,000; Hg 70 per cent. The x-ray shows no necrotic bone anywhere in pelvis, hip joint or lower spine.

Diagnosis.—The history of the trouble for which she was operated six years ago is difficult to get. She describes the trouble as a continuous pain in the left lower quadrant of the abdomen which at times became generalized over the whole abdomen. The pain in the left lower quadrant was also felt in the back. She thinks she had fever. She was cystoscoped and a ureteral catheterization was done and many x-ray plates taken previous to operation. Following this she had fever, frequent urination, and increased pain. These continued until the abscesses formed. Obviously the indication is to drain the abscess present. After this has been done it may be possible to trace the source of infection by means of a bismuth paste injection.

Treatment.—The abscess over the crest of the ilium was opened. Much pus was discharged. Two draining sinuses followed into this abscess cavity and through and through drainage from incision in abscess cavity out through the two sinuses was established.

Pathology.—Smears show leucocytes, no bacteria seen. Culture of pus showed no growth in twenty-four hours.

After-course.—After the abscess over the crest of the left ilium was opened, the patient's temperature dropped and she became comfortable. The acute inflammation subsided very rapidly. All the sinuses drained a thin yellow pus continuously. None of them closed up. The wounds made at operation healed out, but all left sinuses.

The patient ran some temperature all the time, varying from 99° to 101°. After the drainage had lessened the sinuses were injected with Beck's paste, it being put in under considerable pressure. The

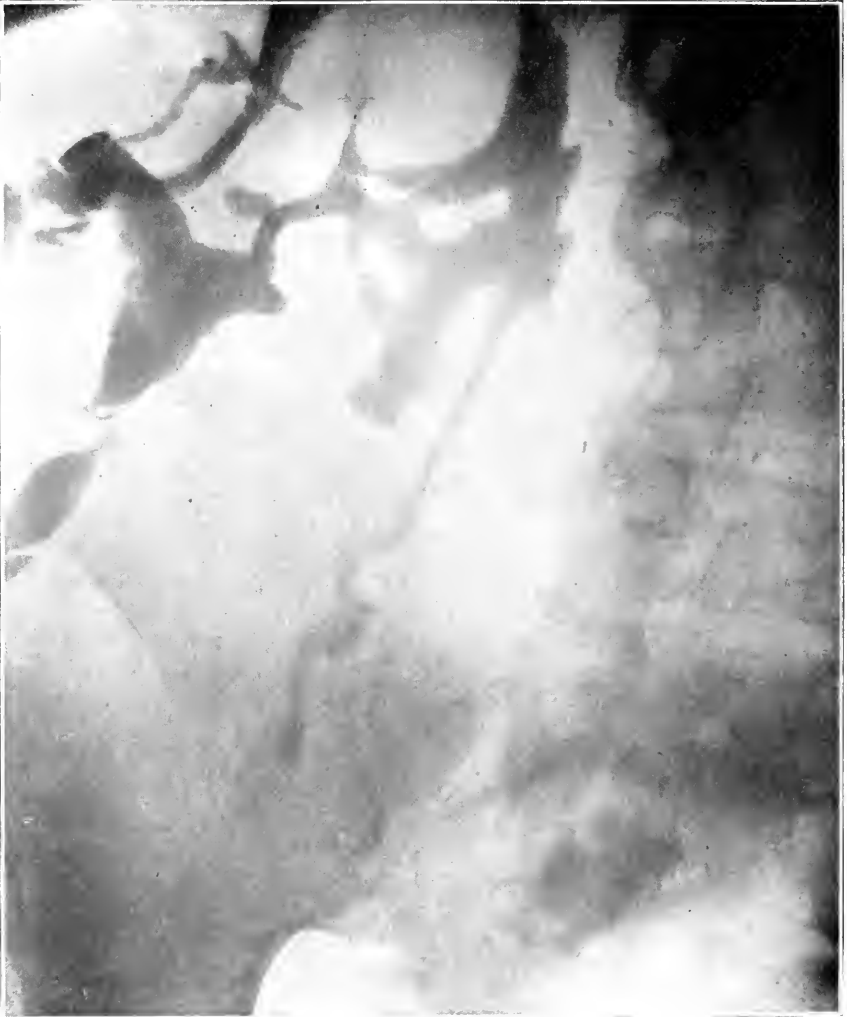

Fig. 435.—X-ray of sinuses filled with bismuth paste.

injection caused her considerable pain. After the bismuth injection, the x-ray showed a veritable network of sinuses in the soft tissues

about the crest of the ilium (Fig. 435). From these, three passed upward and ended exactly in the kidney region. One went down from the kidney region to about as far on the left sacroiliac joint. At dismissal the sinuses were discharging pus and pieces of Beck's paste. The temperature had been normal for eight days, pulse not above 80. The patient was examined four months later. She had had an acute illness with cough. There was a marked tuberculosis of the left apex.

Comment.—It was not possible to determine what was found at the operation six years ago. Usually when surgeons are noncommunicative after operation it is fair to assume they are busy thinking. It is clear that following the catheterization and operation she had a considerable and persistent fever. Since there was no wound infection it likely came from an infected kidney. The sinuses as shown by the Bismuth paste, extended to the kidney region. Likely the burrowing began there. The presence now of a lung tuberculosis raises the question of a possible tuberculous lesion of the kidney augmented by an infection by the urethral catheter. The extent of the burrowing and the length of time required for an opening to form indicate a low degree of infection. It was the intention to investigate the kidney, but the presence of a lung complication precludes that.

CHAPTER XVIII

BLADDER

Affections of the bladder have to do chiefly with irritation within it or to its inability to empty—not infrequently the two form a vicious circle. After the condition of the bladder is determined the general condition of the patient must be determined.

BLADDER IRRITATION

The bladder may be irritated from processes outside the bladder as well as those within. The presence of painful urination does not necessarily incriminate the bladder. Diseases of the bladder wall itself in fact are among the least common of the causes of urinary complaints. The presumption is, therefore, that in a case of urinary irritation the trouble is not one affecting primarily the bladder wall.

CASE 1.—A merchant aged twenty-eight was brought to the hospital because of pain in the rectum and bladder disturbance.

History.—Three weeks ago he began to have bladder irritation. The bladder was irrigated a number of times without relief. On the contrary, urinating has become more painful. Now he is unable to pass his urine spontaneously. He has had fever from the beginning. Pain in the pelvis has grown progressively worse and he is unable to say whether the pain is in the bladder or rectum. He knows of no cause for his trouble.

Examination.—A smooth, rounded tumor is felt above the pubes which is evidently the bladder. The catheter enters without difficulty, and more than a quart of urine flows out. Save for a few pus cells, it is negative. The prostate is normal in size. To the left side and anterior to it is a boggy swelling which is very painful to the touch. W.b.c. 22,000.

Diagnosis.—The condition of the urine indicates that the trouble is extravescical. The presence of the sensitive mass and the increased leucocyte count indicates an abscess lateral to the rectum, therefore perivesical.

Treatment.—An incision was made lateral to the anus and a large pus cavity was drained.

After-course.—Relief was immediate and the hole filled in in three weeks.

Comment.—The source of the infection is not known. Complete and apparently permanent healing took place. This would hardly be expected if the infection had come from the bowel. It is interesting to note that despite a normal urine his bladder was irrigated by his physician and it is of equal interest to know that the bladder remained normal in spite of the irrigation. Evidently the doctor's technic was better than his judgment.

CASE 2.—A farmer aged thirty came because of pain in his side.

History.—The patient's health was good as a boy. He had measles and mumps, but no serious illness. Nine years ago he had pain in the right loin which extended around in front toward the bladder. There was a recurrence of this with fever and vomiting and his appendix was removed. He felt feverish but does not know whether or not fever was present. He does not know the state of the appendix. He was free from pain for several years. Five years ago he began to have a pain in the right chest which extended from the shoulder blade to the front. He was in a hospital eight weeks with this pain. He developed fever, shortness of breath, and a little cough. The doctor called it typhoid fever. When the patient left the hospital he was no better than when he entered. He had a little non-productive cough, but it got better when the patient was up and around. Two weeks after this fluid was discovered in the right chest and one pint of fluid was removed. Aspiration was tried seven or eight times later but no fluid was obtained. Gradually pain, shortness of breath and fever left, and the appetite improved. Eighteen months ago he had a rather severe pain in the left lumbar region. It lasted two weeks and he had a little fever, but no urinary trouble at this time. The pain gradually ceased and there has been very little trouble until eight months ago, when severe pain in the same place set in and has been continuous since. For some months he has had pain and burning on urination. Sometimes "white chunks" are found in the urine. He passes urine only five or six times a day. He has passed no blood and does not know whether or not he has any fever. He caught cold three weeks ago and has coughed some since.

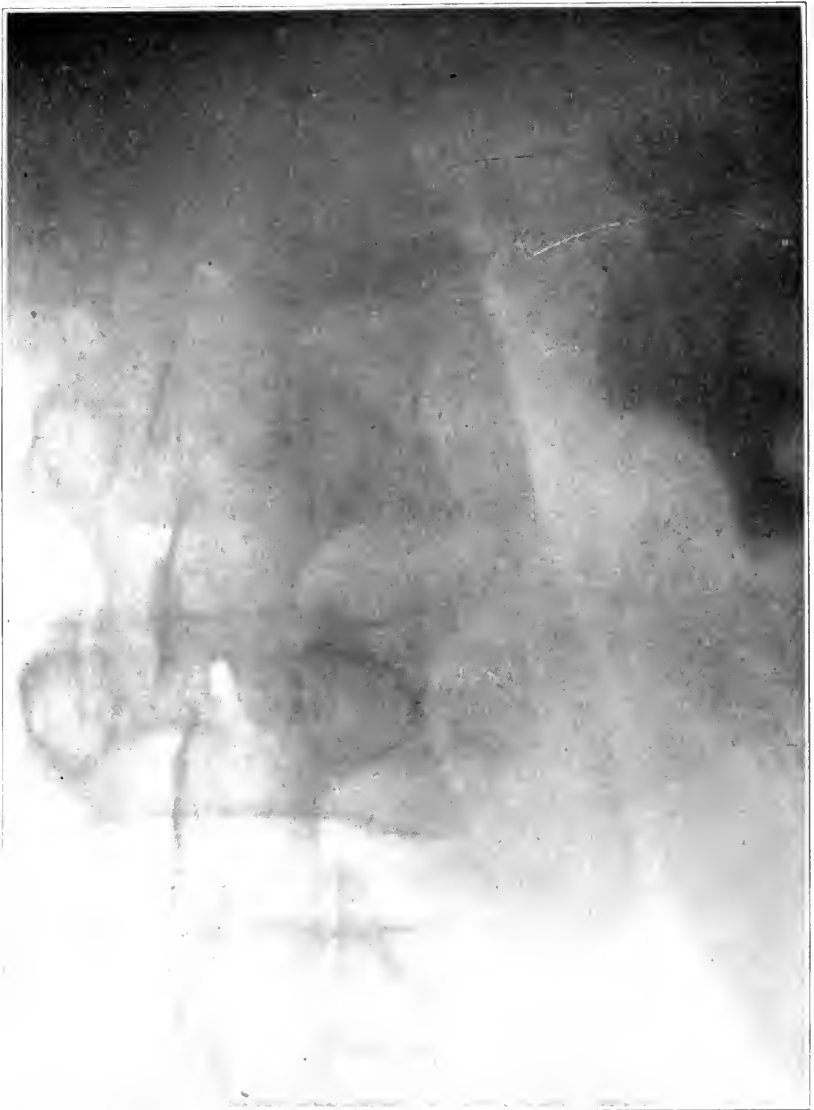

Fig. 436.—Large stone in pelvis of kidney.

Examination.—The right chest is much reduced in size and the respiratory excursions are feeble. The breath sounds are faint. The left lung is hyperresonant but no rales. There is some tender-

ness on pressure over the left kidney, both in front and in the back. The urine contains many leucocytes and a few red cells. The x-ray shows a large irregular shadow in the region of the left kidney. (Fig. 436.)

Diagnosis.—The cause of the pain in the left side is made plain by the x-ray picture. The shadow follows accurately the outline of the pelvis and calices. The determination of the past condition offers greater difficulty. There evidently was a pleurisy of unknown character, which caused fibrosis and contracture. After the withdrawal of the fluid, dullness must have remained or the numerous fruitless attempts at aspiration would not have been made. This was probably nonpurulent or an infection of low virulence, since healing spontaneously of purulent exudations is uncommon. The nature of the pain for which the appendix was removed is not clear. The site and character of the pain corresponded to a urethral calculus, but the removal of the appendix was attended by relief from symptoms. If a stone, it must have passed spontaneously. We may conclude that both those affections are things of the past and we have but to deal with the stone in the left kidney. The urine does not indicate any great degree of infection and the trouble amounts to the presence of a foreign body only.

Treatment.—The stone was removed without difficulty. Because of the large size of the stone, a complete bisection of the kidney was required. Hemorrhage was controlled by making traction on the kidney and gently twisting its pedicle.

After-course.—On the fourth day following operation a pneumonia developed in the left lung, from which he died on the tenth day.

Comment.—Possibly his statement of acute cough was not sufficiently heeded. There were no objective signs of lung trouble and the administration of the anesthesia was proceeded with. This may have formed the starting point for the postoperative pneumonia. The function of one lung being impaired made the involvement of the other of much greater consequence. Large stones may sometimes with advantage be removed through an incision in the pelvis. When there are so many branches as in this case, fragments are apt to be left behind if removal is attempted in this way.

CASE 3.—A retired railway engineer of sixty-seven came because of painful urination.

History.—The patient says he noticed frequency of urination at first about eighteen years ago. A few years later he had difficulty in passing urine. When it did pass he was compelled to strain, which produced great pain in the bladder region. Difficulty, frequency, and pain have progressively increased and he has seldom been without pain. He has had no symptoms other than the above. He has a double inguinal hernia. Now he has to press up on the perineum with the hand in order to urinate. Often he has to urinate every half hour at night, but not so often in daytime. The chief pain is in the glans and over the pubes.

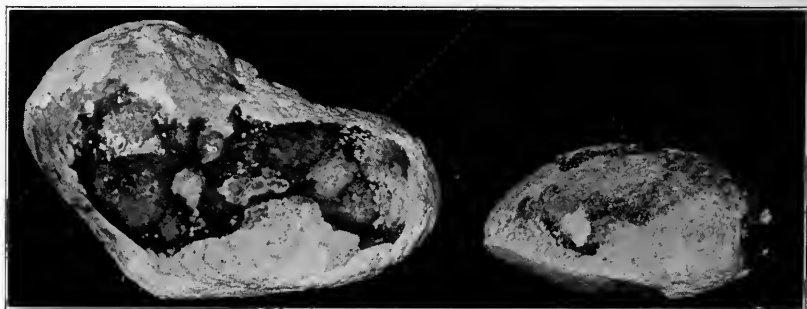


Fig. 437.—Two large bladder stones.

Examination.—The prostate is moderately enlarged, smooth, and elastic. There is considerable tenderness. The urine contains some pus.

Diagnosis.—The enlargement of the prostate, the dysuria, the nocturnal frequency seemed to make the diagnosis of enlarged prostate evident.

Treatment.—When the knife was plunged into the bladder wall it struck against a stone. After the bladder was sufficiently opened to permit exploration, two large stones were discovered. One was large as a turkey egg, the other as large as a bantam egg (Fig. 437). After they were removed, the prostate was found but moderately enlarged and no obstruction existed. It was noted that the prostate was pressed flat where the stone lay against it. A suprapubic drain was put in.

After-course.—After the suprapubic wound healed he could not pass his urine. The catheter passed without hindrance but the urine

would not flow when the catheter was not in place. Thereupon a permanent catheter was put in for two weeks after which urination became spontaneous and progressively freer. The bladder was irritable many months but this has gradually disappeared.

Comment.—The suprapubic pain and the referred pain to the glans as well as the relief of the obstruction by pressing on the perineum pointed to stone and should have stimulated to further study. The relatively slight complaint of pain threw me off my guard. The obstruction to urination caused by the flattened prostate is also a matter of interest. Likely the pressing downward of the base of the bladder caused by pressure of the stone receded and aided in restoring spontaneous micturition. When obstruction followed removal of the stone, I proposed the removal of the prostate. From this he demurred, since he felt so much relief.

CASE 4.—A matron aged thirty came to the hospital for bladder trouble.

History.—Fifteen months ago she began to have frequent and painful urination. It has been increasing in severity since then and has been particularly bad during the past six weeks. The pain is now constant but is much more severe when the urine passes. The site of the most severe pain is across the lower abdomen. There is little pain at the outlet of the bladder. She gets up four or five times at night and during the day time she passes urine very frequently. For the past six months the pain in the abdomen extends upward and now reaches to the rib margin. The appetite is good, constipation obstinate. She has some leucorrhœa between periods. It is never bloody. When much on her feet she has the sensation of weight in her pelvis.

Examination.—The general appearance is that of good health. The lower abdomen is occupied by a mass which reaches nearly to the umbilicus. It is hard, smooth and slightly sensitive to touch. The abdominal skin veins are not prominent. The pelvis is filled with a mass fixed to the uterus and forming lobulations to either side of it. General examination is negative.

Diagnosis.—The bladder history is that of pressure. The pain is abdominal rather than vesical though the pain is increased during urination. The smoothness and density of the tumor is that of a myoma. Though there is no history of acute inflammation, there is too much pain for a simple fibroid. The increased tenderness

in the culdesac and the disposition of the pain to increase as the tumor grows larger suggests a pyosalpinx as a complication of the myoma. Though the tumor seems fixed in the pelvis the absence of dilated veins in the skin speaks against a fixation from malignancy. Whatever the condition, therefore, it is capable of operative removal.

Treatment.—After the abdomen was opened a cauliflower mass was found filling the left side of the pelvis and a large, thick-walled




Fig. 438.—Papillary cystadenoma of the ovary.

cyst filled the other and projected above the pelvic brim. The cauliflower mass was firmly adherent to the floor of the pelvis. Both masses and tubes were removed. No visible parts of the tumor were left behind.

Pathology.—The cyst when opened was found to be lined with an irregular cauliflower mass (Fig. 438). This was dense and brittle to the touch.

After-course.—Operative recovery was uneventful and she has remained well at least two years.

Comment.—Whenever one is not sure about the diagnosis of a myoma it most likely is something else. A myoma after it raises out of the pelvis usually has a quiescent period. When they just begin to raise out of the pelvis and are complicated by inflamed tubes they do produce just the symptoms found here. In papillary cyst adenomas once the wall breaks and the papules are exposed to the peritoneum there usually is a serous exudate into the peritoneal cavity of an amount sufficient for clinical demonstration. There was none in this case. The essential thing, that the condition was technically operable, was correct. Though these conditions are semi-malignant, a cure may confidently be expected because the peritoneum was nowhere injured. The fact that there was no exudate likewise is a favorable sign.

CASE 5.—A farmer aged fifty-six came to the hospital for relief from a foreign body in the bladder.

History.—His general health has always been good. He is the father of four children. He states that three weeks ago he passed a grain of corn down his urethra and it escaped into his bladder. He has since had some irritation on urination and some precordial pain.

Examination.—No physical findings that would indicate a cause for the precordial pain and it may be regarded as a manifestation of the same neuropathic condition which induced him to introduce the foreign body into the bladder. His statements as to the introduction of the bladder are manifest by the presence of many leucocytes and a few red cells in the urine.

Diagnosis.—The urinary findings above noted warrant the acceptance of the patient's own diagnosis.

Treatment.—Perineal cystotomy. Drainage for a day. A stone the size of a small hickory nut was extracted with forceps.

Pathology.—In the center of this stone was the grain of corn.

After-course.—The patient was up and about in three days and down town on the fourth. The recovery was uninterrupted and complete.

Comment.—The chief interest lies in the fact that a stone of this size developed in three weeks. It is unusual also for a man of a family to perform such stunts. The passing of foreign bodies into the bladder is usually the work of single persons. Ordinarily I should be loath to accept a patient's statement that he had passed a foreign body into the bladder, for persons of this class are apt to

be the possessors of vivid imaginations, but this patient's brother, a physician of good judgment, urged its acceptance. Hence a cystoscopy was not done.

CASE 6.—A farmer aged twenty-seven came to the hospital because of severe pain in the left back and side.

History.—His general health never has been good. He had throat trouble as a boy and had pneumonia three times. He had pain in the left side in childhood. In the past eight years he has had several attacks a year of sour stomach which terminated in severe pain in the left side. The attacks would last from two to five days and before they terminated would cause pain toward the bladder and over the hip. Hypodermics were usually required. Riding seemed at times to bring on an attack. He thinks there has been blood in the urine. He has had to be catheterized several times during the attacks, but during the intervals of freedom, urination has been painless and unhindered. The last attack was two weeks ago; it lasted two days and recurred after only one week of freedom. During this attack some small gravel the size of bird shot was found. He has not recovered as usual from this spell and has had a temperature of 102° at one time. During this attack his doctor found a mass in the left abdomen.

Examination.—He is a large, fleshy young man, and aside from distinct tenderness over the kidney in front and along the ureter, physical examination was negative. His urine is 1.015 and is otherwise entirely negative. W.b.c. 6,500. The x-ray failed to show any stone.

Diagnosis.—The attacks of pain are obviously renal. The location of the pain and bloody urine made this plain. The temperature suggested an infection. The entirely negative urine showed at once that the ureter was occluded and that the opposite kidney was capable of carrying on the function. Having passed gravel, it seemed most likely that still another was obstructing the ureter. The failure of the x-ray to show it did not preclude its existence. The inability to pass urine during the attacks may have been due to a reflex spasm but more likely was due to the hypodermics which were given to relieve pain. The temperature and the marked local pain suggests a suppuration.

Treatment.—An incision was made down to the kidney which was found markedly distended, being as large as a grapefruit. It was

not palpable before operation because of the fat abdominal wall. The kidney was incised and a huge amount of cloudy urine escaped. Drainage was introduced. A month later failing to secure an opening through the ureter, the kidney was removed. After removal a small stone was found embedded in the constriction at the beginning of the ureter.

After-course.—The patient recovered rapidly from the operation and though he had some bladder irritation during the first months following operation, he made a good eventual recovery.

Comment.—Under ordinary circumstances the stone should have been discovered and removed. Because of the stoutness of the individual, which made the wound very deep and which caused the patient to take the anesthetic badly, it did not seem warranted to prolong the operation. Failure to enter the ureter by retrograde catheterization caused me to believe there was a cicatricial narrowing at the outlet of the pelvis. The kidney had been distended so long that the cortical portion had been nearly destroyed. It seemed hardly worth a prolonged effort to save it. The question arose as to whether a nephrectomy should be done at the primary operation. Patients who have recently suffered severe pain to the point of collapse bear operations badly and it seemed wise to secure relief from pain and allow him to recuperate and to allow an interval for the discovery of the cause and possibly its elimination and thus probably save the kidney. The statement of the patient that he had passed gravel was not certain proof that he had done so.

CASE 7.—A housewife aged fifty-four came to the hospital because of painful urination.

History.—There is no tuberculosis in the family, though one brother has a chronic cough. The patient was well until she was nineteen years old when she had whooping cough. Since that time she has coughed more or less and catches cold easily. She has four children and has had one miscarriage. Menopause three years ago. Two years ago she began to have frequent urination with pain and burning. She lost from 101 to 74 pounds since then. Eight months after the trouble in the bladder began she began to have pain in the abdomen to the left of the umbilicus and in the back. This pain has been severe in the last four months. Six months ago she vomited frequently for a period of a month or two. At this time she discovered a lump in the side. Though the lump increased

in size the vomiting ceased. She has never had chills and does not think she has had much fever. She has never seen blood in the urine, but it has often been milky, especially after standing.

Examination.—The patient is a slight person, as indicated by her weight, but outside of the very obvious tumor the patient showed no other lesion. The tumor occupies the splenic region and is the size of a large orange. It is movable and when pressed upon is easily palpable in the renal space. The mass is not tender. The urine is cloudy, neutral, and the specific gravity is 1.005. The microscopic examination shows many pus cells, but no casts. The bladder is hyperemic, no ulceration but the left ureteral orifice is crater formed while the right is normal.

Diagnosis.—The tumor can be none other than one attached to or formed by the kidney. The pus in the urine as well as the physical findings indicates as much. The onset three years ago with pain and vomiting following later suggests that the rather rapid enlargement of the kidney tends to nausea and vomiting. There was no chill and no notable fever which counts against a pus microbe infection. The appearance of the urethral opening speaks definitely for tuberculosis.

Treatment.—The kidney when exposed was large and extensively degenerated and the ureter was as thick as a finger and as hard. The diagnosis of tuberculosis is thereby confirmed. The kidney and ureter as far as over the brim of the pelvis was removed.

After-course.—The patient improved markedly, but there still remains some bladder irritation which is troublesome at times.

Comment.—There is a question how much time should be spent on refinements in diagnosis in such cases. That the left kidney was hopelessly damaged was very probable from the clinical signs. In old tuberculosis kidney tubercle bacilli are not always easy to find and the finding of acid-fast bacilli is often misleading. The guinea pig test is the only method that is wholly reliable, but in cases where action is demanded, the time requirement is forbidding. The state of this kidney had already proved that the opposite kidney was capable of performing the renal function for the body. The elimination tests bear somewhat on the strength of the patient, when the annoyance of prolonged catheterization is taken into account. In patients in whom a longer period for observation is permitted and where the diagnosis is less obvious, the finer re-

finements are desirable. Useful tests are not always applicable because of other considerations. I was once called to see a man with a pyonephrosis as large as a child's head. The patient was septic, with a high temperature. The physician desired that the opposite kidney should be examined by color test to determine its function. While the usual technic was being applied it appeared that the patient's resistance was being sorely tried, so I hastily prepared his side, slipped in a large tube in front of the quadratus and by the time the patient was pronounced operable, the operation had been done and the operator was dressed and ready to go down town. Valuable as other tests may be, the advisability of using a urethral catheter when there is an infected bladder seems questionable.

CASE 8.—A farmer aged seventy-two came to the hospital because of painful urination.

History.—After the usual prostate history, the patient had his prostate removed nine months ago by suprapubic route by a good operator. His wound healed after six weeks, but the bladder trouble continued. Recently he has had tenesmus of an extreme degree.

Examination.—The urine contains much pus, some red cells, but no casts. A sound introduced into the urethra impinges against a hard object which prevents the sound from entering the bladder. Rectal examination shows a rounded mass the general size and form of a prostate but very hard. It is very sensitive to pressure.

Diagnosis.—A mass of such a size nine months after the removal of a prostate suggests a possible recurrence. This mass is too well defined and is too sensitive to admit of such a diagnosis. The sound comes to a sudden stop but without a click indicative of stone and the body against which it impinges is somewhat elastic. Were it not that the operator is competent I would suspect that but the middle lobe if any had been removed. Stone is suspected, but in the absence of an x-ray, it can not be proved or excluded. The obstruction to the sound is not that of a stone. Despite the fact that every possibility can be logically excluded, the fact remains that the man has something that annoys him. An attempt must be made to exclude this geographically as well as logically.

Treatment.—After the bladder was opened, a calcareous mass the size of an egg occupied the position formerly occupied by the prostate. When an attempt to dislodge the stone with forceps was made, it was found that the mass was made up of a gauze tampon

infiltrated with calcareous material. After the mass was removed, it was found that a portion of the capsule had formed a shelf over the mass and there remained a bridge across the bladder. A V-shaped piece was cut from this.

After-course.—When last heard from months later there was still some pyuria and tenesmus.

Comment.—When tenesmus develops after a prostatectomy, there is nearly always a stone and no delay should be allowed in solving the problem. The x-ray usually shows the stone. The reason the sound did not detect the stone was that the portion of the tampon occupying the apex of the prostatic cavity was not infiltrated so that the sound impinged against the gauze.

CASE 9.—A farmer aged thirty-nine came to the hospital because of pain in the bladder.

History.—In November, 1917, he began to feel a general malaise with no other special symptoms. In December he began to notice frequency of urination by day and had to get up several times a night to urinate, something he had never done before. About the last of January, 1918, he began to have some pain across the lower abdomen and a short time after the urine started it would suddenly stop and he would have a severe pain in the neck of the bladder. He would jump up and down hard on his feet and the urine would sometimes start again. For awhile he noticed no blood, but in a few weeks the urine began to get very bloody and has continued so. The burning and pain has become steadily worse. Bowels have been constipated ever since the trouble started. Perfectly well otherwise. Has lost 15 pounds since November. Has never had any previous sickness.

Examination.—The x-ray showed a shadow in the bladder the size of a walnut. Urinalysis, bloody sediment, 1.030, albumin, and blood present. Pus cells present. The history in itself is so typical that the x-ray is needed merely to determine its size. The amount of albumin corresponds with the amount of blood in the urine. There being no casts, it is safe to say that the kidneys are unaffected.

Treatment.—The stone was removed suprapubically. The incision was closed about a drainage tube half an inch across.

After-course.—The bladder was irrigated with sterile boric acid solution from time to time and flaky particles were removed. The tube was removed after three days.

The patient was dismissed on the twelfth day with the suprapubic wound not quite closed. He was passing urine by urethra and draining some above. This opening closed soon after and he has remained well.

Comment.—The bladder was not markedly inflamed. A primary closure of the bladder (with catgut) would have shortened the stay in the hospital. A permanent catheter would have been required for a week.

CASE 10.—A widower of fifty-three came to the hospital because of painful urination.

History.—Three years ago he got up one chilly morning and discovered he could not pass his urine. He was catheterized twice during the day and once the day following. After this time he could urinate spontaneously. He had much pain for ten days but after that he had none. He continued with no trouble save frequency of urination until a year ago. For the past year he has had intense burning on urination, particularly after the completion of the act. He has some pain in the bladder at other times as well as during the past few months. Sometimes after the flow starts it stops suddenly attended by severe pain. To avoid this he now uses a catheter. The urine has been cloudy for a year. He has lost weight but his general health is good.

Examination.—There is a mass the size of a croquet ball to the right of the median line above the pubes. It is smooth and fluctuating. Pressure on it causes him to have a desire to urinate. The prostate is moderately enlarged, smooth, and but little sensitive to pressure. The x-ray shows a stone nearly as big as an egg.

Diagnosis.—Evidently he has a bladder stone. The reason for the location of the fundus of the bladder to the right of the median line is not clear. The failure to empty the bladder is evidently due to the presence of the stone. Obviously the removal of the stone is important.

Treatment.—A suprapubic incision was made and the distended sac opened into; a quantity of cloudy fluid escaped. No stone was found neither could the urethral opening be palpated. Toward the midline an opening was found which just admitted the end of the finger. (Fig. 441). In this cavity the stone was felt. The opening was enlarged anteriorly and the stone extracted. A large suprapubic drain was placed.

After-course.—It required five weeks for the suprapubic wound to heal, but since then he has had no difficulty.

Comment.—Obviously the sac was a distended diverticulum and in enlarging the communicating opening, I opened into the bladder. After making the diagnosis, my plan was to extract the stone and to attack the diverticulum at a second sitting. By enlarging the communicating opening, apparently the trouble was cured. On the other hand it is possible the diverticulum was an innocent complication and had he not developed the stone he would have had no trouble. On the contrary the diverticulum may have been the initial factor responsible for the development of the stone. At any rate, despite the fact that he already has sixteen children he has married again.

CASE 11.—A matron aged forty came to the hospital because of pain in the bladder.

History.—Three years ago, after a period of obstinate constipation with abdominal distention, she developed a persistent pain in the bladder. With this there was a sense of dragging down low in the back. When she urinated she had a bearing down pain but she could not be sure whether it was in the bladder or rectum. She had frequent urination both day and night. There was some blood in the urine at one time a year ago. After some weeks she grew better but had other attacks. The last one came on ten weeks ago. A year ago and again six months ago she was cystoscoped and had the ureters catheterized. A diagnosis of tuberculosis was made and the bladder was irrigated. She got much relief after six weeks. She has had a persistent vaginal discharge. She has four living children ranging in age from seventeen to five years. She had an abortion at two months, before the first child was born. Her menses come on every three to six weeks. She has no pain. She flows profusely three days and then less for two days.

Examination.—She has diastasis of the recti muscles and marked tenderness on deep pressure over the pubis. The kidneys are both palpable, are not enlarged, or tender. The perineum is lax, the cervix is low, bilaterally lacerated, extensive cystic degeneration and erosion. The fundus is in the culdesac, is large and boggy and sensitive to pressure. It is immovable. The urine is cloudy, contains much pus and some red cells. The bladder shows much congestion and a bulbous edema. There are no ulcers.

Diagnosis.—The nature of the initial pain and the difficulty of locating it either in the bladder or rectum suggests a uterine origin of the trouble. The irregularity of the menstruation shows at least an associated endometritis. The profuse discharge suggests the presence of cervical inflammation. The appearance of the interior of the bladder indicates an extravescical origin of the trouble. The persistent irrigation to which the bladder was subjected likely accounts for the large amount of pus. At any rate a definite surgical lesion of the uterus exists and demands treatment irrespective of the question of renal tuberculosis.

Treatment.—The cervix was amputated and the perineum repaired. The fundus was resected and fixed into the rectus fascia. The uterus was large, very fragile, and boggy.

Pathology.—The tissue removed from the cervix shows extensive cystic degeneration.

After-course.—The bladder pains rapidly improved after the operation and at the time of dismissal from the hospital were much improved. In the succeeding months they subsided save for an occasional spell of irritation. The pus likewise subsided.

Comment.—Most of the bladder troubles in women who have borne children are extravescical. The fact that this patient has a pronounced pelvic disease should have placed suspicion on this organ as the source of the difficulty. At most a cystoscopic examination which showed no definite bladder lesion should have directed attention from the bladder. An early correction of the uterine trouble no doubt would have cut down the duration of the disease. Many persistent bladder troubles are engendered by a too persistent use of the cystoscope in the hands of the inexperienced. Pyelitis not infrequently follows ureteral catheterization.

CASE 12.—A farmer aged twenty-five came to the hospital because of painful urination.

History.—Four years ago he began to notice pain on micturition, and the urine looked creamy at times. Later pain in the right side set in, lasting from half an hour to two or three days. The pains were so severe on several occasions that a doctor had to be called. The pain was most intense in the back below the short ribs and it extended to his right testicle. During the height of his attacks he passed urine frequently, but at one time he was unable to pass his urine and had to be catheterized. Six months ago he passed

a stone the size of a small pea. He was sick in bed two weeks after this severe attack and passed much pus. This continued until the present time. He developed a fever at that time which has continued to date.

Examination.—He has a temperature of 103° , a leucocytosis of 18,500 and a pulse of 115. A large mass is felt in the right lumbar region, it is not sensitive but is semifluctuating. The mass is palpable in front of the quadratus lumborum muscle and can be made to bulge the renal triangle. The skin in the renal region is edematous as can be demonstrated by catching a fold between the thumb and fingers and then making comparison with the unaffected side. The urine shows abundant pus and many casts.

Diagnosis.—The finding of a mass in the kidney region, together with the history and the urinary findings warranted the diagnosis of pyelonephritis with perinephritic abscess.

Treatment.—The abscess was incised and a pint or more of pus escaped. The kidney showed softened areas and these were incised and a drain inserted into the pelvis of the kidney. No stone could be found.

After-course.—Fluid could be passed through the kidney into the bladder, but an abundant discharge of urine and pus continued through the incision in the loin. The patient never gained sufficient strength to warrant an attempt at nephrectomy.

Comment.—In case of pyelonephritis with perirenal abscess it is a question whether it is best to take the full risk and do a nephrectomy at once. If drainage is done and a degree of healing is secured, secondary nephrectomy is apt to be attended by grave risks not only from the operation itself, but from danger of injury to the duodenum. In this instance it is not clear just why the patient died. There was continued albumin and casts. Whether these were from the drained kidney or from the opposite kidney could not be determined. He died from exhaustion without any signs of suspension of kidney involvement. An infected kidney is capable of surprising restitution if all the foci of infection are drained.

CASE 13.—A farmer aged seventy-eight entered the hospital complaining of frequent urination and pain in the back and constipation.

History.—His health has always been good until the onset of frequent urination and difficulty in voiding about three years ago.

When moving about he was unable to control urine. He passes very small amounts at each urination; while he has better control of his bladder lately, the pain is getting worse. He has severe pain on urination and for five to ten minutes after. He gets up about eight times each night. The urine is always cloudy and often contains blood. He has been having pain of a dull aching character in his back for the past three years; this has been relieved somewhat lately. He takes a laxative every day. There has been some swelling of his feet. Recently he has had difficulty on urination and has had to be catheterized several times.

Examination.—The x-ray of the bladder is negative for stone. The prostate is enlarged and nodular, particularly on the right side. The urine contains much pus.

Diagnosis.—The increased frequency of urination when on his feet suggests stone but the x-ray fails to disclose one. The nodulations in the prostate are not cancer hard but any nodulations are suggestive of malignancy. The disposition to bleed is in harmony with this. Considering his age and general condition, attempt at radical removal does not seem warranted.

Treatment.—The patient was put on urinary antiseptics and the bladder irrigated daily with potassium permanganate solution. The pain on urination disappeared almost immediately. The frequency persisted. The urine when he was dismissed showed many pus cells and red cells but his general condition was much improved.

After-course.—The difficulty soon returned more intense than ever. Urination became exceedingly painful. A permanent suprapubic drain was decided on. When the bladder was opened a stone as large as a bantam egg was found. This was removed and the patient recovered. He had a hemiplegia while in the hospital.

Comment.—After the stone was found the x-ray plates were re-examined and the faint outlines of the stone could be made out behind the pubic bone. A cystoscopy would readily have discovered the stone, but after the x-ray failed to indicate stone it was deemed certain that the nodulations were the clue to diagnosis. I might have known that when carcinoma is the cause of the trouble improvement by rest in bed with irrigation is not so marked as it was in this case.

HEMATURIA

Hemorrhages from the bladder may be caused by tumors, irritation, as by a foreign body or by an ulcer. Hemorrhages from above are due to like causes. Inspection differentiates the lesion within the bladder, but those from the kidney must be arrived at by inference or accessory evidence.

CASE 1.—A lad of thirteen was brought because of painful urination.

History.—The patient has had painful urination for nine months. He gets up three or four times a night and goes frequently during the day. The pain is never severe. His doctor has found pus in the urine from time to time during this interval. His appetite has not been good and he tires easily, but he has continued in school. When three years old he had a lame hip which was diagnosed and treated as tuberculous and he was kept in a splint for two years. The leg finally healed, but has become shorter than the other.

Examination.—The patient is pale and thin. The left leg has two inches of shortening and the head of the femur lies above the acetabulum. There is some contraction of the adductors and iliopsoas muscles. Evidently the diagnosis of tuberculosis was correct. The urine is straw colored, cloudy and neutral in reaction. It contains many pus cells, no casts. The filtered urine still shows a trace of albumin. The x-ray showed no stone. There is some sensitiveness in the right renal triangle. The cystoscope shows an injected bladder but without ulcers. Clear urine is ejected out of the left ureteral orifice but from the right it is cloudy. A few acid-fast bacilli were found in the centrifuged and concentrated specimen.

Diagnosis.—The fact that he once had tuberculosis suggests a possible diagnosis. The finding of acid-fast bacilli confirms it. The sensitiveness of the right renal region and the elimination of this side and the absence of both these abnormal factors in the other points to the right kidney as the chief offender. The probable localization in this one kidney seems to make it a favorable case for nephrectomy.

Treatment.—The right kidney was removed. The kidney was congested and there were a number of small white points on the surface. The ureter was as big as a lead pencil and was hard. This was followed over the pelvic brim when it became much smaller and soft.

Pathology.—The kidney showed a few areas of round-celled infiltration without definite caseous areas or giant cells (Fig. 439). The ureter, however, shows the typical lesions of tuberculosis.

After-course.—The lad improved and rapidly took on weight. When examined eight years later he was in fair health and had no complaint save that he sometimes had to get up to urinate.

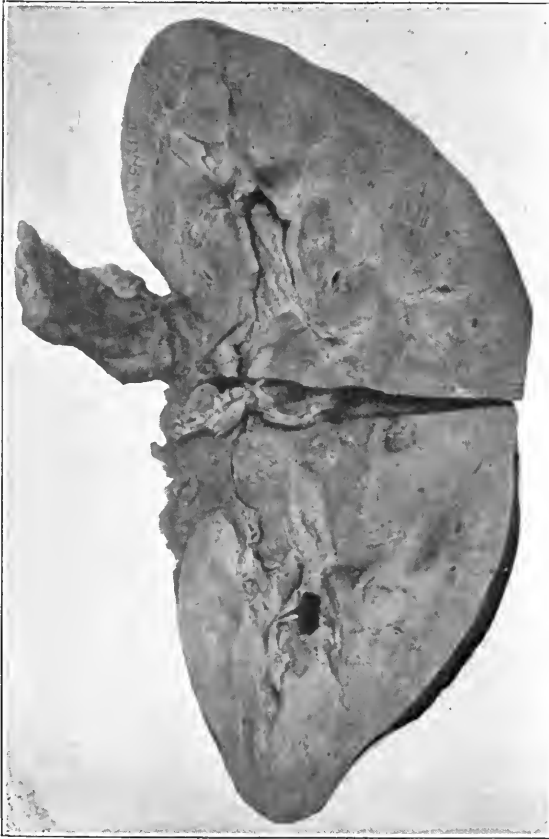


Fig. 439.—Early tuberculosis of the kidney.

Comment.—It may be questioned if a ureteral catheterization should have been done. I feared then, as I fear now, to pass a catheter through a bladder through a pool of infected urine to a supposedly normal kidney. The evidence here presented was enough to furnish a logical plan of procedure. The real error was in re-

moving the kidney at all. When it was found to be but little affected it should have been put back. The thickened ureter was a menace, but the menace likely was not lessened by mussing it up and removing it. The complete removal of a tuberculosis by a surgical operation is probably an iridescent dream. The removal of a part will help the system to eradicate the remainder, if in the eradication infection is not liberated and new foci formed. The operative removal of impaired organs essential to life and even to the pursuit of happiness should be approached with thought and circumspection. The removal of tuberculous lymph glands has been found to be too dangerous and it has taught also to what a degree the disease may heal under favorable conditions.

CASE 2.—A matron of fifty came because of pain in the left side and blood in the urine.

History.—For several years she has had pain in her back, more pronounced on the left side. During the period of fifteen to twenty-two years ago she had three spells of pain in left side of her back under the short ribs, which came around to front and ran down the thigh. She vomited at each of these attacks. The last attack was in the right side. She has had no urinary symptoms. Ten days ago while at work she had frequent urination; some burning and vesical tenesmus. During this time the urine was red with blood and some clots. This cleared up in a few days and four days later she began work again. The following few days she felt cold at times and once had a chill after going to bed. Blood again appeared in the urine. This was followed by some fever, and the next day she had a hard chill which lasted thirty minutes. She had pain in back and more or less all over the body, and the following day she was nauseated and vomited. Since that time she has felt better.

Examination.—The patient presents a fairly vigorous appearance without evident anemia or the appearance of suffering. The x-ray of the kidney region was negative. Cystoscopy and functional kidney tests were without interest. The urine was strongly acid, the sp. gr. 1.011, albumin positive, sugar negative, blood positive with Meyers, and some red cells and many leucocytes but no casts on microscopic examination. A second examination showed sp.gr. 1.008. The temperature was 100°, pulse 98 on entrance. Three days later both were normal.

Diagnosis.—This attack seems like those she had fifteen and twenty-two years ago. Pain in the region of the kidney with hematuria. The long duration precludes a tumor and makes tuberculosis unlikely. The x-ray does not show a stone. Some 25 per cent of ureteral stones are not shown by the x-ray, but the presence of such is unlikely because the pain is not intense enough for stone and the amount of blood lost too great. To explain conditions such as this a diagnosis of essential hematuria must be had or confess ignorance of the condition.

Treatment.—The patient was given a dram of potassium citrate a day.

After-course.—The patient became free from symptoms in a week and has remained so.

Comment.—In order to satisfy the requirements of exact diagnosis a ureteral catheterization should have been made in order to search for a stone too small to show in the x-ray. We know that the amount of blood is too great to come from an injury to the ureter and hence must come from the kidney. A kidney badly enough diseased to bleed is susceptible enough to be liable to be infected by catheterization. I have seen more disaster follow catheterization than I can find in the literature. This makes it likely that some urologists are suppressing interesting information. Such observations convince me that ureteral catheterization should not be done without a clear and definite reason, just as one would trephine or open a knee joint save that the latter are the safer procedures. Reverting to the cause of hematuria, it is a pity that the congested kidneys once described by Harrison have been forgotten.

CASE 3.—A retired farmer aged sixty-four came to the hospital because of blood in the urine and painful urination.

History.—This patient had had obstruction to the outflow at intervals for some years before he noticed that his urine was bloody. The flow continued to be interfered with at times after the appearance of blood. There was no pain at first but recently there has been much tenesmus and at times complete retention for twelve hours, then the flow would start again. Recently the pain has become so intense that opiates were required. He had lost some twenty pounds in weight.

Examination.—The prostate was but slightly enlarged and was smooth and elastic. There was no stone on x-ray examination and a soft catheter passed almost unhindered. The cystoscope impinged

against a mass but because of the bloody bladder contents a view of it could not be obtained. The bladder was freely irrigated and then several ounces of adrenalin solution fifteen minims to the ounce and after 10 minutes an air dilating cystoscope was passed. A large multilobulated mass was seen to be situated above the trigone. It oc-

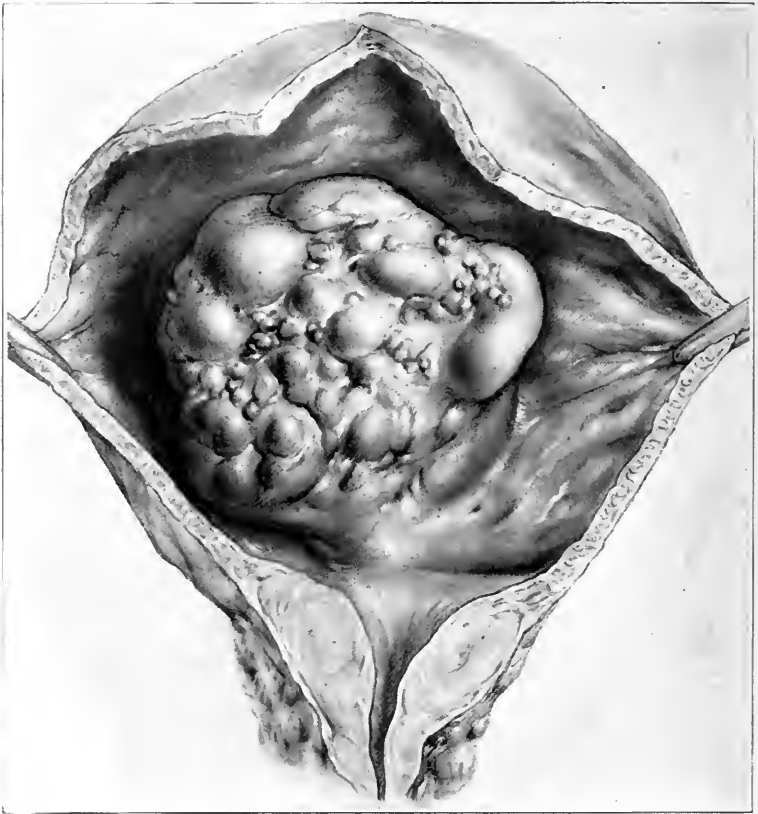


Fig. 440.—Carcinoma of the base of the bladder.

cupied a broad base. Many small papilli-like nodules were situated between the large bosselations. The remainder of the bladder wall was congested, but free from tumor infiltration. The tumor mass even with the mental picture obtained through the cystoscope could not be palpated by rectal examination.

Diagnosis.—Because the catheter passed readily and because the prostate was smooth and elastic it may be assumed that this is not at fault. However, there were periods of dysuria several years ago which requires the assumption that the prostate was at fault or that the tumor was of several years' duration. The form of the tumor suggests a primary cauliflower tumor which would most certainly have given rise to hemorrhage. The patient was not disposed to observe his condition carefully and the urine was not examined. It is quite possible, therefore, that there may have been hematuria present. If the tumor has been present several years it would seem futile to attempt radical removal. Since, however, there seems no great degree of infiltration of the bladder wall and the ureteral orifices are free, operative removal is not excluded. Since his dysuria has passed beyond the point of tolerance, some sort of relief must be sought.

Treatment.—After the bladder was opened a large dense bosselated mass was discovered. It had a broad base which encroached and included the right ureteral orifice. (Fig. 440.) The base was deeply infiltrating and because of this no attempt at removal was made. Instead a cupped permanent catheter was put in place.

Pathology.—A bit of tissue removed presented spindle form cells radiating from a common center.

After-course.—The patient lived nine months, dying from progressive weakness, though during the last few months he had much pain in the pelvis.

Comment.—A bold, or an enthusiastic, or an inexperienced operator might be justified in attempting the removal of such a tumor for it appeared to be technically operable. Unless a broad-based bladder tumor can be removed completely, it had best be left alone for attempts at removal or cauterization but tend to hasten its growth. When a tumor of this sort becomes large enough to produce obstruction, a suprapubic drainage is the best treatment. The suprapubic drain can be made water tight, making it possible for the patient to get about. These suprapubic drains are much more satisfactory than a perineal drain or a vesicovaginal fistula in females practiced by some surgeons. In such cases as this where obstruction long antedates hematuria the surgeon is apt to assume that the trouble is due to the prostate. Whether all prostatias should be subjected to cystoscopic examination may be a debated

question but when there is hematuria there can be but little doubt as to the need of it. However, since prostates are now removed by almost all surgeons by the suprapubic route, the need is less urgent, for should a bladder tumor be encountered it may be attacked or left alone as the case may be and the patient is no worse off than if the surgeon had proceeded with full knowledge of the presence of the tumor, however much it may chagrin the surgeon. When perirenal prostatectomy is done and the tumor then discovered, it is quite another matter.

CASE 4.—A young physician came because of hematuria.

History.—The patient has been having bladder hemorrhages at intervals for a number of months. The hemorrhage is moderate in

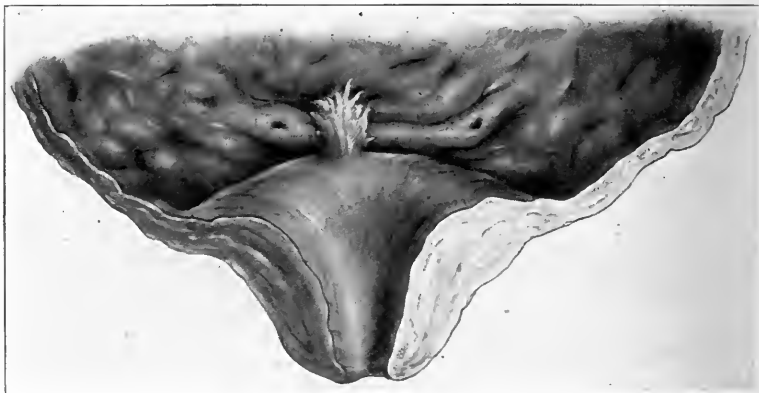


Fig. 441.—Papilloma at base of bladder.

amount and is unattended by pain. Save for the bloody urine he considers himself normal.

Examination.—The cystoscope shows a small papilloma (Fig. 441) the stalks of which wave like a fern in a breeze. The base is very narrow and the bladder wall is unchanged.

Diagnosis.—Benign papilloma. Such a diagnosis is possible only after having observed the patient many years. The thinness of the stalks, the narrowness of the pedicle and the unchanged state of the bladder wall immediately surrounding the stalk speak for its benign character.

Treatment.—Removal of the tumor with forceps and cauterization of the base with the Paquelin's cautery was done. The tissue was

destroyed for $\frac{1}{2}$ cm. about the tumor and through the mucosa into the muscle coat.

Pathology.—The bits of tumor remaining showed villi covered with a single layer of cells.

After-course.—He has remained free from recurrence now fifteen years.

Comment.—To treat such tumors through a cystoscope is not justified. Complete destruction of the base of the tumor is demanded in all cases. These tumors, like papillary tumors of the ovaries, are always semimalignant and can be cured only when thoroughly removed in the beginning of their growth.

CASE 5.—Farmer aged sixty-one came to the hospital complaining of attacks of pain in left lumbar region, coming around in the front above the ilium and passing down to the bladder.

History.—The present trouble started ten years ago. At that time he had a sudden attack of pain in the left lumbar region radiating around to the front just above the iliac bone and passing down to the bladder. Never felt in testicle as he remembers. It was accompanied by a constant desire to urinate and a burning sensation in the urethra. He did not vomit and did not have over a degree of temperature. From that time until two weeks ago he had two more attacks. These were exactly like the first. A few weeks ago he was suddenly taken ill with an exactly similar attack, except that he thought the pain started just above the ilium and passed back to the lumbar region and down to the bladder. The next day he had exactly the same kind of an attack. He had none then for four days when he had another. Since then he has had attacks of greater or less severity about every day and has remained in bed all the time. He can not say as to the length of an attack because they were all stopped by an opiate. He says it took a great deal to stop them. Appetite good, general health always good except for the above acute attacks. Has been rather constipated the last few years. Hardly ever gets up at night to urinate. Has no burning or pain on urination and passes it freely. Never any pain in the bladder region except when the acute attacks are on.

Examination.—The patient does not look acutely ill but he is unable to walk because of pain in the left side. There is marked tenderness on pressure in the region of the left kidney. Two sets of x-ray plates were taken, after proper preliminary treatment, but no shadows

were found. The urine was cloudy, contained some pus cells and many phosphate crystals in all of many examinations. The leucocyte count varied between 7,000 and 14,000. Temperature 99.5-100. There were some red cells in one examination.

Diagnosis.—The repeated attacks of pain typically located indicated stone in the ureter and this is probably the correct diagnosis, notwithstanding our inability to demonstrate one by the x-ray. The small amount of red cells speaks strongly for stone. On the other hand, 14,000 is too large a number to be accounted for from a simple urethral stone. If this count is correct the possibility of abscess must be considered. This is unlikely or the temperature would go higher.

Treatment.—He was placed in bed and given urinary antiseptics.

After-course.—He improved rapidly and was free from disturbance in a few days. He did not desire further treatment. He returned home and was free from pain for a year then he had a similar attack on the right side. He had to have hypodermies for their relief. He vomited during one attack of pain. There is some general abdominal distention and there is tenderness on pressure in the general direction of the ureter. The urine is cloudy and contains a considerable number of red and white blood corpuscles. The x-ray shows a shadow in the region of the right ureter near the bladder.

Comment.—Nine out of ten ureteral stones pass unaided. Whether or not in cases of renal colic we should proceed to a scientific examination or await the spontaneous passage of the stone is a question that must be answered. In cases where the colic is typical and the x-ray shows no stone I believe in watchful waiting. When there is stone repeated pictures should be taken in order to determine whether the stone moves or not. If the attacks are recurrent and there is no change in position, one should proceed with its removal. If there is persistent pus in the urine, the stone should be removed. If there is stone in the kidney it should be removed. Ureteral catheterization should be looked on as a major operation. Much damage has been done by promiscuous resort to this all too fascinating a procedure.

CASE 6.—A retired farmer aged eighty-three came to the hospital because of painful urination.

History.—The patient had a bladder operation eight years ago for a growth in the bladder. He was entirely relieved of his symptoms following the operation except for occasional spells of painful urination, until in the past summer. At this time he commenced to

have frequent and painful urination and passed only a small amount each time. He says his symptoms are somewhat similar to symptoms he had before his first operation. At the present time he sometimes has overflow of urine, and can not always control it. At other times he has almost complete stoppage of urinary flow and thought he would have to be catheterized, although this has not been necessary. He was catheterized for three months preceding his other operation. He has been passing blood and pus in his urine which has been worse the past three weeks. Lately severe dull aching pain in bladder region has developed. It is worse on urination. He has lost some weight recently.

Examination.—Well preserved man, muscles rather flabby and shows some evidence of loss of weight. Skin cool, dry. No abnormal discolorations. Head and face negative. No cardiac enlargement; systolic murmur at apex not transmitted to axilla. Some abdominal distention, no palpable masses; some tenderness on deep pressure in pubic region. Liver and spleen not enlarged. Slight enlargement felt in prostate region by rectal examination and there is distinct tenderness on pressure. Extremities and reflexes negative. Blood pressure 130-75. Urine 1.020, cloudy, alkaline, albumin present, blood present, white and red blood cells. Hg 85; W.b.c. 8,000; R.b.c. 4,600,000. X-ray shows shadow in the bladder region a little to the right of the midline.

Diagnosis.—Bladder stone.

Treatment.—The bladder was opened suprapubically. No bladder stone was found, but a large papilloma was found in the base of the bladder. An attempt at resection was made and the base where it was removed was cauterized with the electric cautery. The bladder was drained.

After-course.—There was no postoperative shock. The gauze drain was removed on the second postoperative day; its removal was followed by some bright red staining of the urine. Nausea developed the fourth day and gastric lavage was given. The bladder was irrigated daily with boric acid solution, removing large amounts of debris, blood clots, and the return fluid was stained a bright red. There was little attempt at wound healing; the nausea continued, the pulse became weak and irregular and the patient failed rapidly, death resulted 20 days after operation from ascending kidney infection.

CASE 7.—A matron of sixty-four came for consultation because of painful and frequent urination and loss of strength.

History.—For a year or more she has had an irritable bladder. There has been blood in the urine on several occasions. She has had some dull pain in her right side for some four months. Her son, a physician, has noted that she has had an irregular temperature varying from below normal to 102° . He has found microscopic blood in the urine on numerous occasions. Just recently he discovered a tumor in the right kidney.

Examination.—The patient is tall, thin and anemic. The abdomen

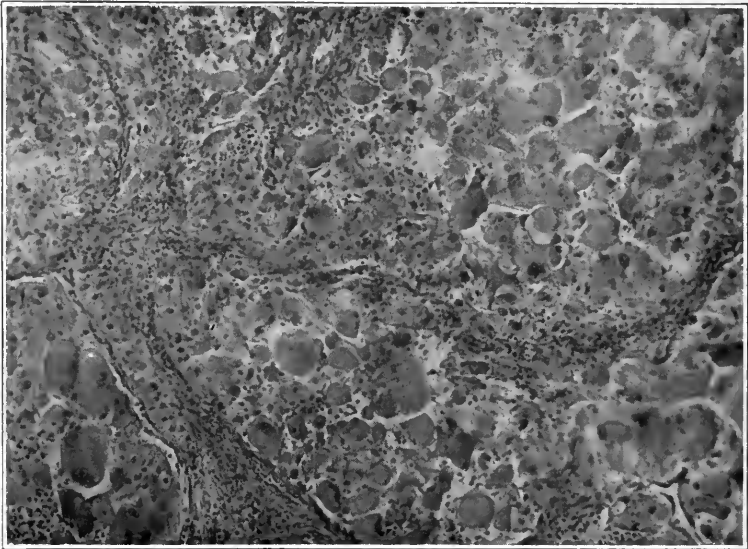


Fig. 442.—Hypernephroma of the kidney.

is soft and flabby. In the right renal region is a tumor three times the size of a normal kidney. It moves on respiration and is firm and nodular. It is not sensitive to pressure. The urine contains a small number of red cells and many leucocytes. Two acid-fast bacilli were found after prolonged search—in the twentieth stained slide to be exact.

Diagnosis.—The build of the patient, the irregular temperature and the acid-fast bacilli seem to warrant the diagnosis of tuberculosis. The tumor seems too large and firm for tuberculosis, it may be noted. At any rate removal seems indicated.

Treatment.—After the tumor was exposed it was seen to be a hypernephroma.

Pathology.—The slide shows a typical hypernephroma (Fig. 442).

After-course.—The wound healed slowly and a sinus persisted a long time, likely due to a ligature of silk which was used to ligate the vessels.

Comment.—The baffling thing was the low irregular temperature. I have not noted it in any other patient with hypernephroma. The finding of acid-fast bacilli completed the deception.

OBSTRUCTION

Obstruction to the outflow of the urine is usually due to an enlarged prostate. A prostate may cause obstruction without being enlarged and central nervous lesions may cause retention with or without enlargement of the prostate.

CASE 1.—A retired farmer aged sixty-one comes because of difficulty in urination following prostatectomy.

History.—The patient had the usual history of enlarged prostate. He was operated on two years ago and a very large smooth prostate was removed by the suprapubic route. The prostate was very large, bulging into the bladder so that it overhung the urethral orifices. The incision was made through the mucosa over the top of the prostate. After the gland had been removed a large pocket remained. This was packed with gauze for two days. The abdominal wound closed in four weeks and he was free from disturbances for six months. After this he began to have difficulty again.

Examination.—A 26 F. soft rubber catheter passes without much difficulty, and five ounces of residual urine was obtained. It contains a few pus cells, but no other abnormal constituents. The x-ray failed to show a stone.

Diagnosis.—There being no stone, it was concluded that a portion of a lobe was left behind. The mind naturally travels along lines it has traversed before. It was supposed that the contracting scar had drawn the offending mass before the urethral orifice.

Treatment.—The bladder was opened again, but instead of a portion of prostate which I had hypothesized, there was a ridge passing from side to side in front of the urethral orifice (Fig. 443). This could be pushed upward and the opening into the urethra readily palpated. This bar was cut across with the cautery, after which it retracted away from the opening.

After-course.—After two and a half years there has been no recurrence.

Comment.—Apparently too much of the mucosa covering the large prostate had been left behind. Since the above experience I have removed a part of the bladder mucosa covering large prostates. I believe in such cases the capsule could be pushed into the hole remaining after the removal of the prostate rather than to put the gauze into the hole, thus holding the flap up. The difficulty comes in making the gauze stay in place if it is placed on top of the flap.

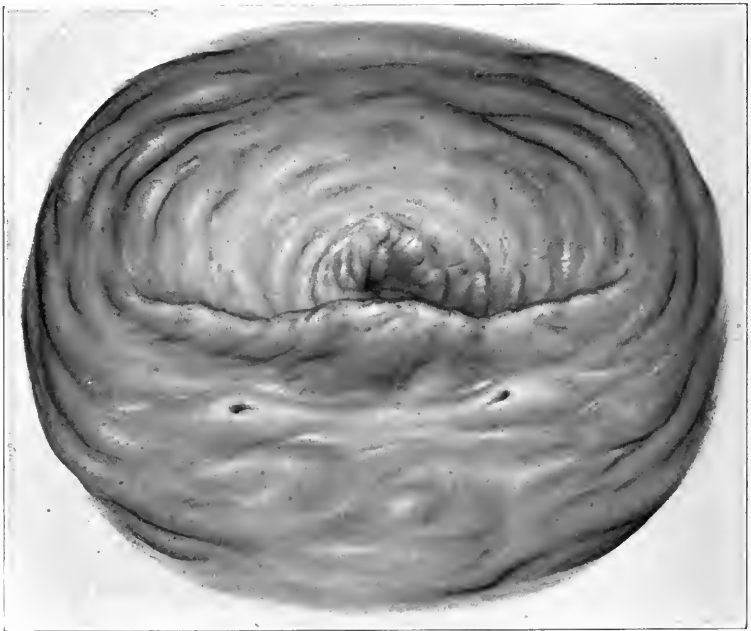


Fig. 443.—Bar across the base of the bladder after prostatectomy.

If there is not much bleeding it does not make much difference where the gauze stays. If the suture is left long it can be cut in two days and the pack removed. Suturing the gauze in place or suturing the flap itself in place requires a larger abdominal incision than is ordinarily required, which in general is to be avoided. I have in several instances threaded each end of a silkworm gut with a straight needle and passed each of these through the perineum tying the ends over a gauze pad at the base of the scrotum. This is

effective but usually unnecessarily elaborate, but when firm packing is required it is a valuable means. It is most likely to be required in small fibrous prostates where one is obliged to cut out the obstructing tissue.

CASE 2.—A school boy aged fourteen was brought because of bladder trouble.

History.—The patient has had a progressive bladder disturbance lasting now four months. At first he was annoyed only by frequent

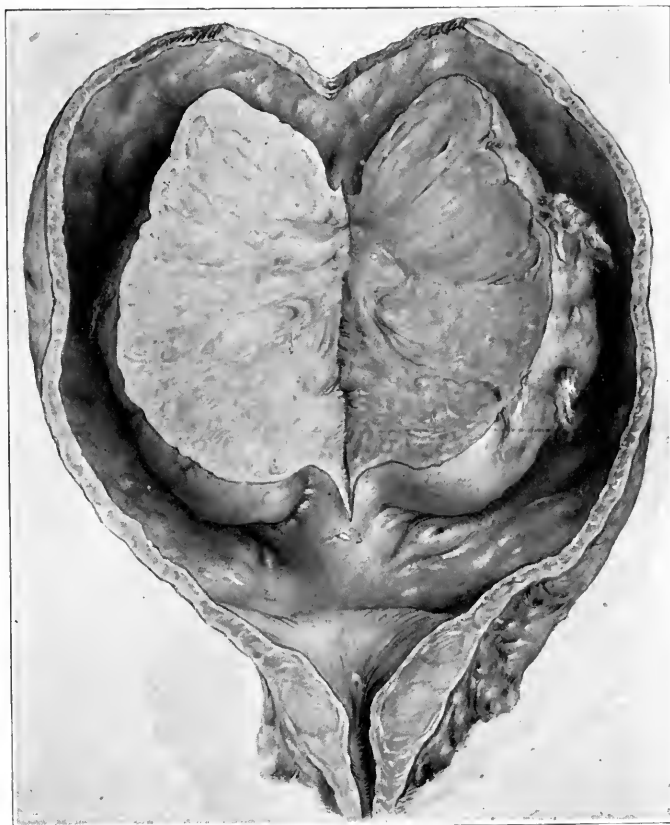


Fig. 444.—Sarcoma of the posterior wall of the bladder.

urination without pain. Later pain developed with a constant desire to urinate. There was no cause assigned and there was no antecedent disease that might have affected the urinary apparatus.

Examination.—Aside from a look of distress, the lad seems quite normal. Suprapubic palpation excites apprehension but no pain. Bimanual palpation shows a tumor in the midline of the pelvis the size and shape of a goose egg. It is tense elastic in consistency. Manipulation causes some pain. He explains it as a sense of urgent desire to urinate. The urine showed many leucocytes but no blood.

Diagnosis.—The patient's age and the size of the tumor suggested sarcoma. Epithelial tumors large enough to be palpated bimanually are quite rare and practically unknown in patients of this age. They are attended by pain and hemorrhage. The absence of pain, and its elasticity, excluded stone. A stone so large as this would have a longer time for its formation.

Treatment.—General measures only were advised.

Pathology.—At autopsy a tumor quite filling the bladder was found (Fig. 444). It did not involve the ureteral orifices and admitted of removal without destroying the entire thickness of the bladder wall. On section it was uniform, being grayish pink, and on microscopic examination it was found to be a spindle-celled sarcoma. In structure it resembled the retroperitoneal sarcomas save that it was more cellular than is the rule in these tumors.

Comment.—This is the only sarcoma of the bladder I have met with. As viewed at autopsy, its enucleation would seem to have been possible. That relief could have been had for any length of time is unlikely.

CASE 3.—A farmer aged forty-eight came because of difficulty in passing his urine.

History.—During the past fifteen years his urine has not passed as freely as it should, and for four years there has been actual trouble in passing the stream. About this time he noticed that he was passing quantities of mucus with the urine. Riding horseback and doing heavy work always increased the amount of mucus. During the past year he has had serious difficulty in passing the urine at times, and there was a severe burning along the urethra attending the act when it did start. Even during this time he had periods of several weeks free from disturbance. He has noticed that the act of defecation often gave relief and helped him to get the stream started. Seven weeks ago he had acute retention. He was catheterized without difficulty by his doctor, but the next day there was great difficulty in passing the catheter. Following these two catheterizations he was able to pass his urine with a fair degree

of comfort. Four days ago he had another retention and has been catheterized two or three days since that time. He has been taking 45 grains of urotropin per day for three weeks according to his physician. An attempt to catheterize a second time failed.

Examination.—The general examination is negative save some sensitiveness in the suprapubic region. There is some flatness here but no tumor can be made out. The prostate is not enlarged, the seminal vessels can not be palpated, but there is a bulging mass the size of an orange above the prostate bulging into the rectum. A catheterized specimen of urine shows acid reaction, specific gravity 1.026, albumin in moderate amount and blood and pus.

Diagnosis.—The difficulty in urination beginning so long ago in the presence of a normal sized prostate suggests a chronic inflammation. This may be brought about by encysted stone though there is no history of pain such as usually attends a stone. The failure to pass the catheter sometimes and the ease with which it is passed at others indicate a false pocket or some obstructive object. Since the catheter can not now be passed the cystoscope is useless, and a suprapubic opening offers the best means out of the difficulty.

Treatment.—A suprapubic opening was made. The prostate was not enlarged and the beginning of the urethra was not obstructed. At the base of the bladder was an opening large enough to admit the tip of the finger. It led into a cavity the bottom of which can not be reached by the finger. This is evidently an opening into a diverticulum. A large amount of urine loaded with mucopus escaped from this opening. Following the operation the patient was comfortable. The temperature rose to 101.5° for a day then came down again. A week later the base of the bladder was exposed through an enlarged suprapubic wound. The opening lay just behind the trigone. The index finger could be forced through the opening, but the bottom of the diverticulum could not be reached. The mucosa of the diverticulum half an inch below the opening was seized with forceps and pulled into the opening. A point more deeply down was then grasped by a second forceps and this point pulled into the wound. By repeating this maneuver the entire diverticulum was inverted into the bladder. The left ureter lay in the point of juncture of the diverticulum and bladder, and despite care was cut into. The diverticulum was cut off at the restricted neck and the defect in the bladder so remaining was closed with catgut. The bladder was drained with a large rubber drain through the suprapubic opening.

Pathology.—The diverticulum after removal contained 6 or 8 ounces. The wall was fairly smooth but with some irregularities of surface (Fig. 445). The wall was 3 or 4 mm. thick.

After-course.—The progress was uninterrupted for a week, when he began to be troubled with hiccough and the pulse rose to 110-120. During the next few days abdominal distention began. This increased despite stupes and enemas and the hiccoughs increased de-



Fig. 445.—Diverticulum of the bladder everted showing the structure of the lining wall.

spite gastric lavage. On the twelfth day he vomited. Hypodermoclysis gave no relief and the pulse rose to 140, the temperature to 102. He became delirious and died.

Autopsy.—There was a paravesical abscess holding several ounces of pus. The veins in this region contained septic thrombi. Neither the peritoneum nor the parenchymatous organs showed any changes to account for the hiccough or distention.

Comment.—The history of difficulty lasting over fifteen years with the passage of much mucus should have led straight to the diagnosis of diverticulum. Even the discovery of a boggy indefinite mass above the prostate failed to bring clarity in the mental picture. The need for relief was more impelling than an exact diagnosis was self-evident. Greater effort should have been made to sterilize the diverticulum before the operation was attempted. This might have averted the death from sepsis. The attempt to close the top of so deep a hole which from the very nature of things must be or become infected, was poor surgery, though this is the technic usually employed. I should now drain such a large cavity through the peritoneum, even placing a tube to the bottom of it so as to admit frequent drainage would be an improvement. Precedent rather than good surgical principles was followed.

CASE 4.—A boy aged five was brought to the hospital because of dribbling of the urine.

History.—The child has always had dribbling of the urine. He never has passed a stream. He never has complained of pain, but he never plays; sits about all day. He weighs only 35 pounds but usually has a fair appetite. The bladder was irrigated several times a week over a period of several months, because there was pus in the urine, but no improvement followed.

Examination.—The child is thin and listless and observes the manipulations of the examiner in an indifferent sort of way. He prefers to lie on his back with the thighs slightly abducted and flexed. The lower abdomen seems prominent; on palpation it shows a cystic tumor. Pressure on this hastens the dripping of the urine. The urine is 1.006, contains a trace of albumin and a number of mobile bacilli and many pus cells. Hg is 60; W.b.c. 10,000. The catheter passes easily without hindrance. The interior of the bladder is smooth, shows some injection and some purulent debris at the base. An obstruction can not be found.

Diagnosis.—The history of dribbling during childhood in the absence of any nerve lesion suggests a partial obstruction existent since infancy. The obstruction can not be located. A genitourinary specialist is equally unsuccessful. A diagnosis of chronic retention of childhood was made.

Treatment.—Since no obstruction can be found he was given urinary antiseptics until further information can be obtained.

After-course.—The patient died in ten days of diphtheria.

Autopsy.—The bladder was very large and smooth walled. Just distal to the veru montanum was a fold of mucosa resembling very much the valve of a vein. It allowed an object to enter freely toward the bladder but unfolded and obstructed the passage of any object which sought to pass from the bladder. There was no thickening anywhere or any evidence of inflammation.

Comment.—This affection is not so very uncommon. I have seen three of them, the other two in girls. I did not succeed in relieving any of them, and they all died of intercurrent affections. Could the obstruction be located its removal would be quite feasible. Usually it is in the beginning of the urethra. Its discovery in girls at least would seem to be a simple problem, but it is not.

CASE 5.—A retired physician aged seventy-five came because of difficulty in urination and indigestion.

History.—The patient has had trouble for six years in passing his urine. He has had pain and tenesmus at intervals, and used a catheter for some time two years ago. He had some blood in the urine at this time but none since. Now he gets on fairly well for considerable periods of time, when suddenly he will have tenesmus and stoppage of the urine. After a time the urine flows almost unhindered again. He has noticed that he has difficulty when he becomes chilled, particularly when circumstances have compelled him to use an outdoor closet. He gets relief by remaining in bed warmly covered. He has indigestion with much gas at times and is then very constipated. This condition is much aggravated when he has trouble with his bladder, but it is present at other times as well. His general health has always been good.

Examination.—The general appearance is that of an individual in good health at least ten years younger than his actual age. His blood pressure is 140-90, and the heart outline is normal. The lungs show nothing more than a moderate emphysema. He has a double inguinal hernia. The urine is 1.018, free from abnormalities. The catheter passes readily without causing pain. The prostate is uniformly enlarged without a notable enlargement of the middle lobe. The residual urine is less than an ounce. The prostate is smooth and of moderate size.

Diagnosis.—The presence of blood in prostatic enlargement is always suggestive of malignancy. Since in this instance it followed cathe-

terization and none has appeared in two years, malignancy may be excluded. Because of the advent of retention under conditions of chilling the cause may be ascribed to congestion. The absence of a middle lobe and the negligible residual, harmonizes with this theory. The digestive disturbance is of minor importance and apparently is dependent largely on his dietary. It has remained stationary, consequently likely is neither ulcer nor carcinoma.

Treatment.—He was directed to wear woolen underwear the year around. Measures were advised looking to the correction of his digestive disturbance and constipation (heavy magnesia, bismuth subnitrate and sodium bicarbonate) and he was given five grains each of salol and borie acid four times a day whenever there was any sign of urinary disturbance.

After-course.—He improved in every way promptly on this advice and has kept himself comfortable now six years. During the past year he has had some trouble in controlling his urine, evidence of continued enlargement of the lateral lobe.

Comment.—When prostatics have intermittent trouble only, comfort may generally be secured by attention to the conditions as above indicated, antecedent to the onset of the urinary trouble. These are usually digestive, or due to disregard of sudden changes of temperature. Had this man's trouble been persistent with a residual urine or with infected bladder, I should have operated. These conservative measures are particularly advisable in old men with nothing to do except to regulate the weather while awaiting an apoplexy or a sudden terminal pneumonia. The indications for operation in enlarged prostates are rather the sequelæ present or threatened than the enlarged prostate itself. That must be regarded as incident to advancing years and its consequences to the individual must be evaluated in each instance.

CASE 6.—A merchant aged thirty-eight came because of difficulty in urination.

History.—Four years ago following a gradually developing stricture he acquired a perineal urinary fistula after having a painful affection of the scrotum for three weeks. Since then he has urinated partly through the natural channel, and partly through the fistula. He had his gonorrhœa eight years before.

Examination.—The fistula admits a fine probe but the urethra is not passable for a filiform.

Diagnosis.—The extent of the stricture can not be determined since the stricture can not be passed.

Treatment.—A sound is passed to the stricture and the point cut down upon. The scarred urethra is followed for a cm. when the urethra again becomes widened, wider than normal as a matter of fact, readily admitting the finger into the bladder. The strictured portion of the urethra was excised and the severed ends loosened for 2 cm. and brought in apposition. A No. 22 catheter was passed and an end-to-end anastomosis was made about it. The catheter was fastened in place with a No. 2 pyoktanin catgut suture. The soft parts were then closed about the urethra without drainage.

After-course.—The catheter came away in seven days, it being released by the absorption of the catgut suture. There was some incontinence for a few days after the catheter was removed, but this soon disappeared. A sound was passed at intervals of a week for several months. After ten years the stricture has not re-formed.

Comment.—This method secures the most speedy result. In some 10 per cent primary healing is not secured and a perineal fistula develops. This heals spontaneously after three or four weeks. The method has the advantage of getting rid of the scar tissue. When the strictured area is very long, more than an inch, the method can not be employed. The urethra may be separated from the surrounding tissue for a centimeter without endangering its nutrition. When primary healing does not take place secondary hemorrhage may follow, as I have seen in two cases, both of which were easily controlled by secondary suture.

CASE 7.—A retired miner aged seventy-six came to the hospital because of difficulty in urination.

History.—The patient has had difficulty in urination for a number of years. He first noticed that he was compelled to get up eight or ten times at night to urinate. During the last year he has had difficulty in starting the stream and the urine only dribbled away when he did get it started. This condition has grown progressively worse during the last year, and two days ago he had a complete retention of urine and has had to be catheterized since.

Examination.—The patient is a decrepit old man who shows the effect of the use of alcohol. He has a double inguinal hernia, the right one coming clear down into the scrotum, the external ring is so large that scarcely any resistance is offered. The left extends into

the base of the scrotum only. The patient has a distended bladder which when catheterized proves to be the extent of three pints. The urine is cloudy, contains many pus cells but no blood. The specific gravity is 1.011, it is neutral in reaction and contains some albumin and a few casts. The prostate is large, smooth and plastic. The apex beat is near the anterior axillary line. The heart tones are indistinct. The pulse is easily depressible, irregular in rate and volume.

Treatment.—A suprapubic prostatectomy was done, the operation being completed in one step under local anesthesia. The prostate was large and quite hard to shell out. Considerable hemorrhage attended, and two gauze packs were placed in the prostatic capsule, and the bladder was drained with a large rubber drainage tube.

After-course.—After six days the silkworm sutures in the skin cut through and the wound gapped widely with a bulging of the peritoneum between the recti when the patient coughed. The wound was drawn together with adhesive strips, but the patient complained so bitterly of pain that they were taken off. His respirations became rapid at the end of the first week, and a dullness at the base of the lung developed. Later medium-sized rales were heard in the axilla. His temperature varied from 97.5° to 100° . He was given ammonium chloride internally and in inhalations. His lung trouble gradually cleared up. At the end of sixty days when the patient was about ready to leave the hospital, he complained of earache and a renewed temperature of from 99° to 99.6° occurred. Phenol in glycerine was dropped into the ear. There seemed to be no bulging of the ear drum though it was opaque and scarred. Two days following this the drum ruptured, discharging a small amount of pus, and the temperature dropped to normal. The patient states that he has had attacks of earache with discharge at intervals since childhood. During the next two weeks he had periodic attacks of pain and rise of temperature. There was no evidence of mastoid involvement. The patient was sent home on the seventy-eighth day with a perforation in the drum membrane and a small sinus above the pubis which drained urine occasionally when he exerted himself.

Comment.—This decrepit old man had consumed much "scotch" in his day and was unsuited for an operation completed in one sitting. Drainage for two weeks with a building up of his circulation would have given better results. The first evidence of an impending hypostatic pneumonia was seen in a mild delirium ob-

served by the night nurse. This naturally caused the suspicion of kidney involvement, either of uremia or multiple infection. Sometimes some days elapse before a positive diagnosis can be arrived at. Sometimes several conditions coexist, as multiple abscesses of the kidneys with a terminal hypostasis. The most important safeguards against such accidents are careful attention to the circulation, cardiac tonics, and the avoidance of the recumbent position. This case represents a stupendous amount of labor to secure for a derelict a few additional years of comfort.

CASE 8.—A farmer aged sixty-two was brought to the hospital because of pain on urination.

History.—For years he had to get up five or six times a night to pass urine. A year ago he suddenly had pain in passing urine. He has headache at intervals and usually vomits before he gets relief. He was operated on seven months ago, the prostate being removed by the transvesical route by an operator who assured the patient that he had done hundreds. The operation was very difficult the operator told him and the conclusion was arrived at that because of this it was malignant. The urine flowed freely for a few weeks, then obstructive symptoms began again. Now he has constant pain and passes the urine with difficulty. He had a sore testicle following the operation and it is still enlarged and sore.

Examination.—The patient's face bears the expression of a constant sufferer. His knees are flexed and his hands go involuntarily to his hip, evidently a sort of habit movement, but nevertheless a sure evidence of real and prolonged suffering. A broad, deep puckered scar marks the region about the pubes. The region of the prostate on rectal palpation is marked by a hard scar, but no enlargement or nodules can be made out. The urine contains pus but no red cells. A sound comes to an abrupt stop when the prostatic region is reached.

Diagnosis.—The statement of the operator that he had done hundreds is a sure indication that it was his first case. This is further indicated by the fact that he found the job difficult and concluded that the gland must be malignant. This, together with the early return of obstruction, indicates an incompetent operation. The possible presence of malignancy can not be ignored, but obstruction to a recurrent tumor would not take place in three weeks while obstruction

due to an incomplete operation would be expected to appear at about this time.

Treatment.—A nodule the size of a hickory nut was removed from the right side. The scar from the left side had drawn this over the outlet of the bladder producing an obstruction.

Pathology.—The nodule removed was not malignant.

After-course.—He had a free flow of urine following the operation but when last heard of, still had some pain with frequency of urination and some pus in the urine.

Comment.—Early renewed obstruction indicates the remains of a part of the prostate. I could have quoted cases in which I myself had overlooked a portion of a lobe, but it is more in keeping with professional practice to detail another man's shortcomings. Leaving a part of the gland is apt to occur unless the operator has an accurate knowledge of the size of the gland before he begins. It is particularly apt to occur when the operator does not use a finger of the left hand as a guide.

CASE 9.—A retired farmer aged sixty-two came to the hospital because of dribbling of urine.

History.—The patient had had some trouble in passing urine several years ago but none recently. He now complains that he is unable to retain his urine or that he must urinate at frequent intervals when he can pass only small amounts. For some months he has noticed a tumor in the lower abdomen. He consulted his physician who advised consultation. His general health has always been good until the past few months. Now he is weak, tires easily, has lost his appetite and thinks he has lost considerable weight.

Examination.—The patient presents a globular tumor above the pubes and reaching to the umbilicus. It is fluctuating and elastic. This disappears on passing the catheter. The catheterization is accomplished with some difficulty. The prostate is large, smooth, and resilient. The urine is acid, 1.008, albumin positive, and contains much pus. There is a moderate general anemia. The nervous system is normal.

Diagnosis.—The history of dysuria followed by the incontinence of retention indicates a gradually encroaching prostate. This is verified on palpation by the enlarged prostate, and the resistance the catheter meets. We may diagnose, therefore, hypertrophy of the prostate, retention cystitis, likely pyelitis. In prostates with pale

urine of low specific gravity it is very difficult to gauge the condition of the kidneys. If the urine is acid often the release of the pressure quickly restores the state of the urine. If alkaline, the difficulty may be increased.

Treatment.—Suprapubic drainage was done and in a week the prostate was removed, both operations being done under local anesthesia.

Pathology.—The prostate was characterized by unusual gland proliferation, but no definite area of malignancy was found.

After-course.—Following the placing of the suprapubic drain the urine remained unusually bloody, though there was no excessive bleeding at the time of the operation and palpation of the prostate at that time did not reveal any signs of malignancy. It was four days before the urine ceased to be bloody, and even after that it was bloody at intervals. This fact gave the suspicion of malignancy though it could not be determined whether the blood came from the prostate or from the suprapubic wound. After the prostatectomy the urine ceased to be bloody after the second day. On the seventh day after the prostatectomy the patient complained of being cold, and examination showed that he was having a considerable bladder hemorrhage. He was given pituitrin 1 c.c. and adrenalin m x. The pulse became very weak but not rapid. Twenty-one days after the prostatectomy the patient had another severe hemorrhage. He received 2 c.c. of pituitrin and 1/6 grain of morphine. The suprapubic wound had all but healed and blood escaped chiefly through the natural channel. Following this he slowly improved. The urine remained somewhat cloudy, but it always flowed freely with good control.

Comment.—In this patient there was a twofold reason for doing a preliminary drainage; the chronically distended bladder and the infected urine. When either condition exists drainage should be done. This patient was unusual, in that he had a considerable hemorrhage so late in the course of the convalescence. In cases of malignancy there is more disposition to bleed after the operation, but save for this, there is no reason for suspecting it. There is a further reason for hemorrhage. It is not known how long he had a distended bladder. Patients who have become anemic from a chronically distended bladder bleed profusely and stand operation badly. I once lost a patient on the third day from hemorrhage who had

become anemic from long distention. The degree of anemia and the coagulation time of the blood gave some index as to the degree of the risk.

CASE 10.—A farmer aged sixty-seven came to the hospital because of difficult urination and dyspnea.

History.—The patient says that serious trouble began about one year ago but that frequency of urination began some years earlier. He has intense scalding sensations which are most pronounced just before the urine starts to flow. After urination the urethra feels raw for some time. Sometimes he has difficulty in getting the urine started. He often noticed blood in the urine during the past year. He has passed urine ten to fifteen times a night during the last few months. During the day if he remained quiet he did not pass it so often. His bowels are regular and his appetite remained good up to the last couple of months. He has lost from 20 to 30 pounds in weight during the past year. For some months he has been troubled with a persistent cough with expectoration. There is dyspnea at times so that he can not lie down. He was treated by a distinguished urologist for a month by irrigations. He was told that there was a diverticulum of the bladder and that because of his general condition he could not be operated on.

Examination.—The patient is emaciated and decrepit, and exertion brings on dyspnea and cough. The respiration is labored and there is bluing of the lips and fingers. The lungs are emphysematous and there are many medium-sized and large bubbling rales. About the bases of the lungs are many fine crepitant rales. The apex beat is diffuse and not easily made out. The rhythm of the pulse is irregular and the volume inconstant. The prostate is enlarged and tender but smooth and not hard. Urinalysis shows specific gravity 1.022, albumin present, no sugar, much pus, and many red cells.

Diagnosis.—The bladder condition having been provided us by a written report from the urologist, we had only to call the condition of the lungs. Obviously a bronchitis, at least in part capillary, is present. This precludes any operative interference which would make a dorsal decubitus necessary.

Treatment.—He was, therefore, treated by inhalations of benzoin and ammonium chloride. Later on strophanthus was added. In three weeks the lung condition had cleared up notably and a suprapubic cystotomy was done. No diverticulum could be found. Three weeks

later the prostate was removed, both operations being done under local anesthesia.

After-course.—The patient made an uneventful recovery, going home in ten weeks with the suprapubic drainage stopped and the urine passing freely per urethra with good control. His general health is improving slowly, with still pus and albumin in his urine. This condition has persisted to date. The urine flows freely and a catheter

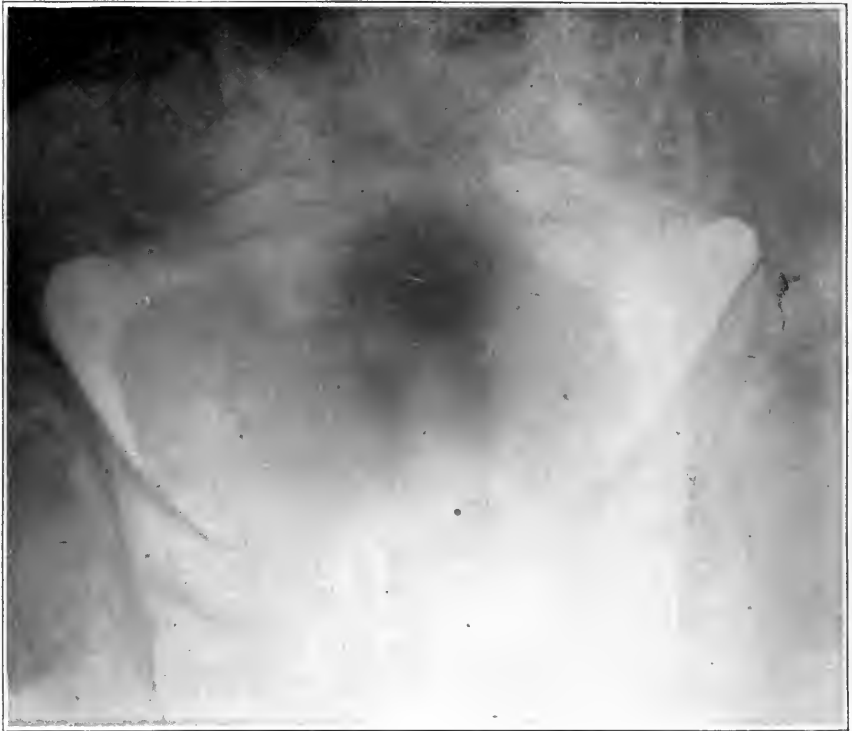

Fig. 446.—Diverticulum of the bladder.

passes readily. He has pain in the hips and sacrum and has the feeling as though the bladder were not empty. The amount of urine he passes varies greatly. Often when he has emptied his bladder he has the feeling as though it were full and often is then able to pass a considerable additional amount of urine.

Comment.—This patient seemed in such an extremely unfavorable condition that it seemed useless to attempt relief. By a judicious

combination of internal medicine and surgery he has evidently been given a new lease on life. The persistence of his bladder trouble, the feeling as though the bladder were not emptied probably indicates that the urologist was correct in diagnosing a diverticulum and that it was overlooked at operation and it was demonstrated by the x-ray (Fig. 446). One would not have dared to attack the diverticulum at that time. Now that his general condition seems to warrant it, such an operation may be undertaken. In such cases something may be learned from military tacticians—divide the enemy and beat them a part at a time.

CASE 11.—I was called to see a merchant aged fifty-four because of urinary retention following prostatectomy.

History.—His surgeon relates the following history. A year ago he came to the hospital because of urinary disturbance recently much exaggerated. The prostate was smooth, hard, and very large. A primary drainage was done, and ten days later the prostate was removed. The operation was difficult, much of the circumference of the prostate requiring sharp dissection for its removal. The wound drained five weeks. Six weeks after this it was noted that there was renewed difficulty in urination. This increased until the present time when he has considerable difficulty in urination and has a residual urine of three or four ounces. His general health has been fair save for a severe and persistent asthma which has compelled him to seek a change of climate from time to time.

Examination.—The site of the prostate is occupied by a very dense, hard mass longer than wide and ending in a pyramid form toward the urethra (Fig. 447). The abdominal scar is very much hypertrophied.

Diagnosis.—The mass obstructing the urethra evidently is newly formed scar tissue. It has the feel of a keloid, and the markedly hypertrophied state of the scar in the abdominal skin shows the individual is disposed to excessive scar tissue formation. If the obstruction were due to a bar, there would not be such a mass of dense tissue, but the findings would be that of complete absence of a prostatectomy. Furthermore the primary operation was done by a surgeon conversant with the precautions necessary to avoid such formation. If this is the true conception of the pathology its removal is apt to be followed by a reformation of a new scar if it plays true to the usual laws of keloids. The x-ray is often very ef-

fective in the removal of keloids, and while the nature of this ailment does not admit of the delay incident to x-ray treatment, once the sear is removed, its reformation may be prevented by the use of the x-ray.

Treatment.—After the bladder was opened under local anesthesia the bladder outlet was found to be surrounded by a dense wall of fibrous tissue and not by a simple bar as is usual in recurrent obstruction following prostatectomy. The tissue was too dense to permit infiltration with the novocaine solution, which made it necessary

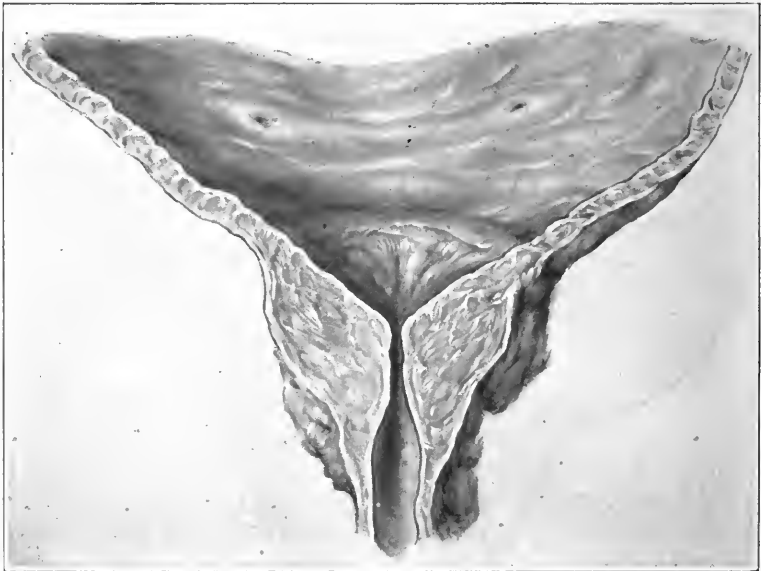


Fig. 447.—Keloid of the prostatic capsule after prostatectomy.

to infiltrate the soft parts surrounding. The tissue was so dense that the strength of the cutting instruments was tried to the utmost. After the sear tissue had been removed, a large catheter was passed, extending out of the meatus and to the suprapubic wound. The intravesical portion was armed with a silk string so that the catheter could be moved to and fro.

After-course.—The catheter was kept *in situ* five weeks. A week after the removal of the catheter the suprapubic wound had closed. He was repeatedly rayed during the healing of the wound. His sur-

geon reports that now two years after the operation he is able to void urine with a residual of a few drams. There is a firm scar at the prostatic site which seems to draw the bladder much more closely to the pubic bone than normal.

Comment.—This is an unusual cause for secondary constriction of the bladder outlet. It is very probable that the use of the x-ray deserves the credit for preventing a recurrence of the scar mass. There is no way to anticipate such a formation, or one might make prophylactic use of the ray after the primary operation.

CASE 12.—A banker aged fifty-five was brought to the hospital because of inability to empty his bladder.

History.—The patient has had some difficulty in passing urine for several years, but he never had to be catheterized. Suddenly, without warning, twenty-four hours ago he was unable to pass his urine. Attempts to catheterize by his physician failed. The cause of the retention could not be found in the history; venereal disease was denied and there had been no trauma.

Examination.—A rounded fluctuating tumor occupies the midline above the pubes. Pressure on it increases his already intense desire to urinate. Attempts at catheterization with several kinds of instruments all failed. The obstruction obviously is deep in the prostate. The prostate is small and hard.

Diagnosis.—The fact that the catheter passed to within the prostate excludes urethral stricture. The small size of the prostate does not exclude it as a possible source of obstruction. Some relief must be obtained at once, and incision is no more serious than a puncture. If the prostate proves to be the source of obstruction, the problem then arises whether a temporary drainage shall be done or the obstruction at once removed. This must be decided after the operative diagnosis is made.

Treatment.—After the interior of the bladder was exposed by suprapubic incision, the prostate was found to form an elastic roll across the trigone effectually shutting off the urethral opening. The urine was not infected and there was no evidence of cystitis. It was deemed best, therefore, to remove the prostate at once. Having had no notable previous disturbance and the patient being in excellent condition, this was deemed justifiable. Enucleation was not possible and the prostate had to be cut out with scissors. The loss of blood was considerable. It was controlled by a tampon.

Pathology.—The prostate consisted almost wholly of fibrous tissue, the glandular elements being very sparse.

After-course.—The suprapubic wound healed in three weeks and the retention was good. Within several months urination became painful and frequent and he passed some calcareous flakes. Irrigation helped some, but the trouble became worse. Therefore, fifteen months after the first operation the bladder was again opened and a large number of stones removed. Improvement occurred, but recovery was not complete. Therefore four months following the second operation the bladder was opened a third time and five stones were removed. Recovery promptly followed, but the x-ray showed a stone still remaining. This was overlooked at the time of operation. A year and a half after the third operation a number of stones were found and these again were removed. Inquiry into the geology of his locality disclosed that it is a limestone country and that the water was very hard. He was directed to drink only eistern or distilled water. There has been no further trouble.

Comment.—The formation of stones after prostatectomy occurs in a considerable percentage of cases, more often when gauze packs are used to control hemorrhage. The process in this case was invited by a rather ragged operation and by the fact that the water he drank was heavily charged with lime salts. Perhaps attention to his drinking water might have prevented the recurrences. These prostates are better removed by the perineal route because it can be accomplished without laceration of the bladder mucosa. These lacerated bits of bladder wall always invite the reformation of stones.

CHAPTER XIX

RECTUM

Rectal diseases are but few. They comprise anal affections, chiefly hemorrhoids and fissures, the granulomas and the more serious carcinomas.

HEMORRHAGE AND PAIN

These symptoms are often present in the mild as well as the more serious affections. This fact makes it imperative that when either of these symptoms exist manual demonstration of the lesion be made.

CASE 1.—A milliner aged thirty-two came to the hospital because of difficulty in defecation.

History.—Five years ago, without known cause, she began to experience difficulty in securing a bowel movement. Various remedies, together with injections, were used with diminishing results. She finally consulted a surgeon who diagnosed a stricture of the rectum and proceeded to do a dilatation under an anesthetic. She remained in the hospital two weeks and when she left she was given a rubber dilator and was instructed to use it twice a week. She got along very well for nine months, after which time she was unable to pass the dilator fully. After a time she discontinued its use. The difficulties increased after this time until a week ago, when she again entered this hospital. Dilatation was again attempted but was unsuccessful and she was advised that some other procedure would be required. She denies any venereal infection. She had no rectal discharge before the beginning of this trouble.

Examination.—The patient is a vigorous young woman whose appearance gives no evidence of the suffering she relates. The examining finger meets a resistance immediately above the external sphincter. A rubber catheter passes and the extent of the narrowing seems to be about four inches. The constriction seems to be firm. A bismuth meal shows a dilatation of the pelvic colon in the region above the cecum (Fig. 448). The blood count is not altered and the Wassermann reaction is reported negative.

Diagnosis.—The patient brings her own diagnosis which the examination confirms. The long duration and the extent of it excludes carcinoma. Having already been subjected to dilatation a more positive line of treatment seems necessary. This may consist in the removal of the constricted area or in an artificial anus. Incision is useless. The x-ray shows the extent to be not more than four inches, which makes a perineal resection feasible.

Treatment.—The sphincter was preserved and the offending portion of the gut was brought down and removed. The remaining stump of gut was attached to the sphincter and to the skin by a separate row of sutures. A large rubber tube was placed well up into the gut.

Pathology.—The specimen is five inches long and is as thick as a fork handle. When it is cut open a tortuous canal the size of a

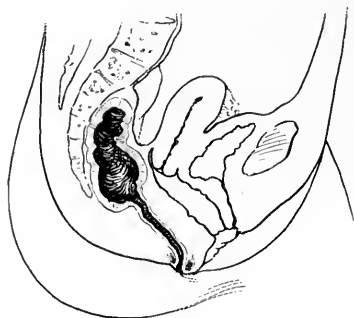

Fig. 448.—Diagrammatic presentation of stricture of the rectum.

lead pencil is found. The wall is thick and fibrous and grates under the knife. The slide shows only a solid mass of connective tissue composed of thick fibers and few very narrow cells. The structure is that of keloid. The submucosa was largely obliterated and the mucosa contains fewer than the normal number of glands and those that remain are misshapen and often defective.

After-course.—There was a tendency to constriction at the mucocutaneous junction and this had to be incised after about six months. Following this so long as the patient was under observation, about four years, she had no trouble. She had control of the bowels unless the stool was thin.

Comment.—In these long benign structures excision is the only satisfactory method of dealing with them. When longer than five

or six inches the perineal operation is not feasible and a permanent colostomy with excision of the diseased portion is the best way out. In this case as in many others there is no clue as to the etiology. There is no evidence that it was syphilitic, and tuberculosis certainly had nothing to do with it.

CASE 2.—A matron of fifty-three came to the hospital because of pressure and pain in the rectum.

History.—The patient has one child twenty-eight years old. Her menses stopped a year ago. She has not felt well for two years, and nine months ago she began to feel a pressure in the rectum. It throbs and aches, and bothers her particularly when she sits on a hard chair. There is pain in both groins at times. There has been no vaginal discharge and she has no bladder trouble. She had radium treatment six months ago, but just where the radium was applied is not clear and she has had treatment for her piles at intervals.

Examination.—The cervix is deeply lacerated. The uterus is large and nearly fills the pelvis. There is tenderness on pressure and the mass seems to be fixed. There are small marginal hemorrhoids.

Diagnosis.—The pelvic mass with the pronounced and progressive disturbance of the rectum suggests, because of the groin pains, a myoma undergoing secondary changes of a reactive rather than a neoplastic character. Infection would be early transmitted in the inguinal glands if the inflammation involved the floor of the pelvis. The disturbance on sitting on a hard surface suggests a perirectal inflammation. An inoperable malignant tumor had been diagnosed by an able diagnostician which makes it probable that there was evidence available that is not apparent now.

Treatment.—Instead of the myoma being as large as was supposed from physical examination, it proved to be about the size of a lemon, but there was a double infiltrative salpingitis on both sides. This made up the bulk of the mass felt. Both tubes and the uterus were removed.

Pathology.—An infiltrative salpingitis and a simple myoma.

After-course.—So far so good.

Comment.—Myoma not infrequently is accompanied by a salpingitis of low degree. The bulk of the tubal infiltration is added to that of myoma and gives an exaggerated notion of the size of the tumor. I have made this error many times. Whenever a myoma is not distinctly outlined a tubal trouble should be suspected. Peri-

neal tenderness and infiltration of the lymph glands aid materially in the diagnosis. When a myoma actually suppurates the constitutional symptoms are considerable and usually there is an associated tubal inflammation. When a myoma has undergone malignant changes, a considerable induration of the pelvic connective tissue, which is difficult to distinguish from reactive changes, results. These tumor changes are less common than the salpingitis and one ought to think of the common ailment first. In this case my regard for my friend's opinion caused me to ignore the obvious.

CASE 3.—A retired business man aged seventy-one came to the hospital because of bloody stools.

History.—For several years the patient has had some pain in the rectum when the stool was hard. During this time the stools were often very dark. One year ago mucus and blood appeared in the stool. His physicians at this time informed him that he had hemorrhoids and a malignant growth in the rectum. They tried to remove them by cauterization with a hot iron every third day for three months. The discharge did not cease but on the contrary it became worse. They then removed the hemorrhoids and since that time there has been a complete loss of sphincteric control and the discharge of blood and mucus is continous. There has been no urinary trouble. His health has always been good.

Examination.—There is an ulcerated area with high rolled up edges beginning two inches above the internal sphincter and extending up about two and one-half inches. The prostate does not seem notably enlarged, but the growth seems attached to it. Otherwise it seems free.

Diagnosis.—The disease is unquestionably carcinoma. Its close attachment to the prostate suggests an invasion of that organ. This point can be determined only after exposure of the parts. If attached only to the prostate and seminal vesicles, the disease is at least technically operable. The patient's excellent general condition warrants an attempt.

Treatment.—The resection of the rectum was proceeded with under local anesthesia. After the prostate was reached it was found attached to the growth and was removed along with the tumor. The prostate with the urethra was cut off flush with the neck of the bladder. After the rectum had been cared for, an attempt to find the opening into the bladder failed and a large tube was placed at the

neck of the bladder and a pack placed about it. The patient was becoming restless and the search was not prolonged. I presumed the urine would find its way to the tube.

Pathology.—Typical adenocarcinoma. Fig. 449.)

After-course.—My expectation that the urine would find its way out of the normal opening was doomed to disappointment and I had to put in a suprapubic drain. Three weeks after the rectal wound had



Fig. 449.—Deep ulcerous carcinoma of the rectum.

partly healed I attempted a retrograde catheterization, but could find no opening. I looked in with a cystoscope and there was none. I waited four weeks longer until the perineal wound had entirely healed and then passed a nubbed sound through the urethra until the bladder wall was reached. Through the suprapubic wound the end of the sound was cut down upon and the sound passed into the bladder. A silk string was looped over the sound and fastened to the eye end of a soft rubber catheter. The sound was then removed and the

catheter pulled after it. A silk loop was attached to the bell end of the catheter remaining in the bladder (Fig. 450). The catheter was allowed to remain in position three weeks. Now, three and a half years after the operation there is no recurrence of the carcinoma, and he passes his urine without hindrance and he has good control over his bladder and of the rectum when the stool is not loose.

Comment.—This case is of interest because of the prolonged free-

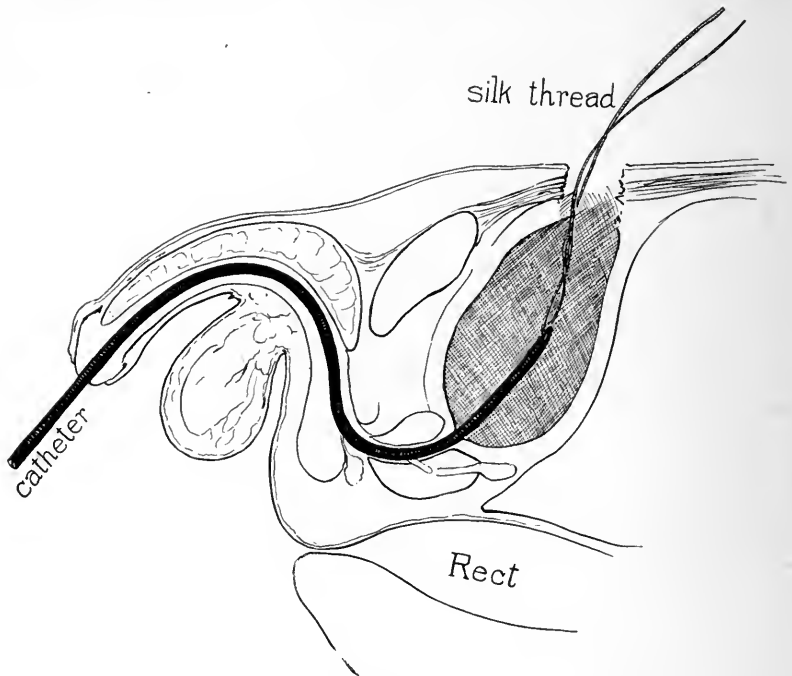


Fig. 450.—Catheter with a silk suture protruding out of the suprapubic wound remains.

dom from recurrence after the removal of the prostate along with the malignant gut. It does not seem possible that there should be difficulty in finding the opening into the bladder after the removal of the prostate. It seems even more surprising that the distended bladder did not force the opening. Likely in the ligation of vessels in the course of the rectal amputation the hole in the bladder was closed and dislocated. Possibly it was fortunate that the urine was kept from the fresh wound of the rectum. This accident might possibly be imitated with advantage when such extensive operations are required.

CASE 4.—A farmer aged sixty-six came to the hospital because of passage of blood and a brownish mucus from the rectum.

History.—About six months ago he noticed a little blood on the outside of the stool. He paid little attention to it, thinking it was caused by bleeding hemorrhoids. About a month later there was a brownish mucous discharge together with bright blood. The discharge has gradually become worse. Now he often has a movement consisting of thin brownish mucus alone. He has one to two movements consisting of feces and five to six consisting of the brownish mucus in each twenty-four hours. He has had no pain. In the last four months he noticed that the stool was long and ribbon like, as though it had come through a small lumen. He has control of the stool, but the discharge of mucus is hard to control. There is no loss of weight. The appetite is good and he sleeps well. There is no urinary disturbance. He had had neuralgia of both sides of the face starting a year ago and lasting until a month or more ago. One week ago he had a sort of cerebral hemorrhage. The whole left side including the face was affected. This lasted two to three hours. There was speech difficulty for a day. He had a similar attack about two years ago which lasted only a few minutes.

Examination.—Patient is a large robust man, ruddy complexion, looks younger than his age. Teeth very poor, molars decayed. One decayed tooth root in lower left jaw. Tongue furred, breath bad. Pharynx negative. Pupils small, equal, slightly irregular, react to light and accommodation. Barrel-shaped chest. Heart tones faint, apex in 5th interspace. Left border of dullness 8 cm. to left. Right at left sternal line. Soft systolic murmur at apex transmitted to axilla and sternum. Lung expansion is good on both sides. There are no rales and there is hyperresonance. The prostate is large, rounded, smooth. An annular mass felt in the rectum about 4 inches up just above the prostate. The edges are raised, hard, and ragged. The lumen barely admits the finger. The examining finger is blood streaked.

Diagnosis.—The history together with the physical findings leave no doubt as to the nature of the disease. Diagnosing the patient is a more difficult matter. He evidently has had two cerebral hemorrhages, the last one within the last two weeks. A patient who has had cerebral hemorrhage with a relatively low blood pressure is

a poorer risk than one in a like condition with a high blood pressure.

Treatment.—The rectum was dissected out at its anal end and pulled down and amputated above the carcinoma. The carcinoma was five inches above the anus, annular in type, and ulcerating. The peritoneal cavity was broken into in dissecting out the sigmoid. The end of the sigmoid was sutured into the skin. The space posterior to the sigmoid was packed with gauze and a tube put in the gut. Three hemostats were left on the mesenteric vessels to be removed later.

After-course.—There was no shock apparent and no postoperative vomiting. Highest pulse rate the first day of operation was 85 and the temperature 100°. A free bloody fluid drained the first day. The second day the patient suffered greatly. The pain extended entirely up in the abdomen. Temperature 100.2 and pulse 80. He passed only one ounce of urine in the first 48 hours after operation. There was a drainage of a fluid tinged with bright blood. This appears to be urine. No doubt the bladder was entered in dissecting out the sigmoid. The fourth day after operation he complained of abdominal pain after having a fairly comfortable day previous. Urine was draining entirely from the wound. He took much water. Examination of wound showed rectal mucosa still down in place. There was nausea at intervals throughout the day. The following day he vomited several times, a green colored watery emesis. Temperature normal, pulse 56 to 64. During the afternoon his arm jerked for ten minutes. Later in the evening his left arm and the left side of his face jerked spasmodically. On the sixth day a part of the gauze pack was removed. The urine drainage did not flow from the wound. The patient had several attacks of clonic convulsions of the left arm and left side of the face. He vomited almost all the water taken. The bladder became distended in the evening and on catheterization 15 ounces of urine were removed. It contained much albumin and many casts. The following day the remaining gauze pack was removed. The rectal tube loosened and came out. The patient had a better day, did not vomit, but had several spells of the clonic convulsions involving the left arm and left side of the face, but they were not so severe as the previous day. The patient became delirious on the ninth day. The convulsions continued to occur several times during the day, in-

volved the left arm and left side of the face. The temperature which has been subnormal the previous day went to 100.5° and pulse 100. The delirium continued and the patient died the tenth postoperative day. It seemed certain that sepsis was the cause of death, although the patient had cerebral hemorrhages. The extent of involvement was small, hardly enough to cause death.

Comment.—It is a question whether the fluid draining from the wound was urine. The culdesac was opened during the operation and the drainage was likely peritoneal exudate. The withdrawing of 15 ounces of urine on the sixth day precludes a perforated bladder. Furthermore, if the bladder had been entered during the operation the fact likely would have been noted. It seems quite likely that the actual cause of death was due to uremia.

CASE 5.—A man aged sixty-seven came to the hospital because of a growth in the rectum, hemorrhage, and loss of weight.

History.—The patient has had bowel trouble for three months. At first he had constipation, but the bowels are now loose, moving five to six times a day and two to three times at night. He has an aching feeling in the rectum. The blood is more constant now than at first. Mucus is present in the bowel movement. A year ago he weighed 152 pounds, now but 131. His appetite is good. One week ago he had some trouble passing urine, but he did not use a catheter. He has some pain on urinating now, but it passes freely. His general health has always been good.

Examination.—The patient is of slender, wiry build, and appears to have lost weight. His skin is loose and inelastic. The chest is emphysematous, the heart without moment, and the urine 1.010 to 1.012, but without abnormal elements. There is an annular constriction three inches above the sphincter. It just admits the examining finger. The constricting ring is about as thick as a finger. The gut with the ring is movable on the surrounding tissue. The constriction is hard and granular and the trauma causes a slight hemorrhage. The prostate is very large, but elastic and smooth.

Diagnosis.—The physical examination reveals nothing of moment, but the patient has a forbidding look. He is apprehensive of the operation. He is the type of patient prone to develop acidosis. The growth is definitely malignant and it is of a papillary type. The gut is movable and the tumor in a relatively early stage. Operation,

therefore, can be urged with good grace. Local anesthesia seems to be the least objectionable.

Treatment.—In order to accommodate the physician and friends the operation was done on the day of entrance to the hospital. The anus was circumscribed by an incision and the lumen of the gut closed. The gut to well above the tumor was mobilized, drawn down and cut off, the free edge sutured to the external sphincter and skin. About six inches of the rectum were removed. Gauze drains were placed on either side of the rectum. The operation was done under local anesthesia.

Pathology.—The tumor was a typical fungating annular carcinoma. The perirectal tissues were not invaded.

After-course.—There was considerable postoperative shock, but the patient rallied well. His chief complaint the first few days was of discomfort in the bladder. He was unable to void urine and had to be catheterized. On the third day his temperature went to 101°, pulse 102; subsided to 99.6°, pulse 92 on the sixth day. On the sixth day he complained of cramping pain in the right leg. There was some swelling in the thigh. This swelling continued to increase and the leg became sensitive, red, and edematous. No fluctuation could be made out. The leucocyte count was 38,200, mostly polymorphonuclears. On the sixth day after the swelling appeared in the thigh an incision was made along the inner side of the right thigh and a small amount of thin watery pus was evacuated. Another incision was made above Poupart's ligament on the right side extraperitoneally, but no pus was encountered. Two days later the patient died. Examination of the pus showed pure smear of short-chained streptococci.

Comment.—The tumor was so favorably situated for a simple operation that an adequate preparation was not made. The patient's resistance was not as great as anticipated. Such a tumor operated on under local anesthesia was looked on as not more than an inconvenience. It was a rude surprise when he was much shocked. The pulse remained slow but the temperature dropped to 96 and the pulse remained weak. After the temperature rose the pulse became more rapid. Though there was no extensive preparation, the operation was clearly done, the gut was not torn into and the surrounding tissues were not contaminated by gut contents. Nevertheless, he got a violent streptococcic infection. I have had this same

thing happen after the most elaborate preparation. Though such preparation may not do much toward sterilizing the field, it is fine salve when things go wrong. This was obviously a phlebitis. While the pus examined showed the offending organism to be a short-chained streptococcus the leucocyte count was much higher than is usually seen in the infections by this organism. Possibly other organisms were present and were overlooked or were confined to other regions than that incised. The gauze drain used was plain gauze. Possibly an impregnated gauze might have done more to prevent infection. Of such gauzes iodoform is unquestionably the most efficient, and bismuth gauze the least objectionable. The latter likely does little to prevent infection other than by aiding in the sealing up of tissue spaces.

CASE 6.—A physician aged seventy-five called me because of difficulty in passing urine and bloody stools.

History.—The patient has had rectal trouble two years. For many years preceding this he had difficulty in urination, but not severe enough to require special treatment. It was held measurably in check with urinary sedatives. When the rectal trouble began he regarded it as due to irritation from the prostate because it manifested itself in pain at stool and the passage of mucus both with and without stool. When the passage of blood with tenesmus was added to his troubles, he consulted a surgeon. A carcinoma of the rectum was diagnosed and pronounced inoperable. He resigned himself to his fate, and, besides the remedies he previously employed, he added opium suppositories for the relief of tenesmus. A year after this time the constriction of the rectum became so great that bowel movements were obtained with such difficulty that he felt compelled to seek more vigorous medical advice. Save for a progressively increasing dyspnea he feels reasonably well.

Examination.—The patient is a large, portly, worn-out physician, who typifies the old family doctor who served all but himself, and who in spite of his too long service had to drag his heavy infirmities about to visit lesser ones that he might secure his daily mite. There is a constriction which begins two and a half inches above the anus. The lumen is so small that it does not admit the finger, which makes it impossible to determine how high up the bowel it extends. The attempt to force the finger through the constriction produces a considerable hemorrhage. The prostate is large, smooth,

and presents a soft bosselation on the right side. The rectal mass impinges against the enlarged prostate but does not seem to be attached to it. He has a marked arteriosclerosis and blood pressure constantly above 200. His apex is in the mammary line and the sounds are indistinct.

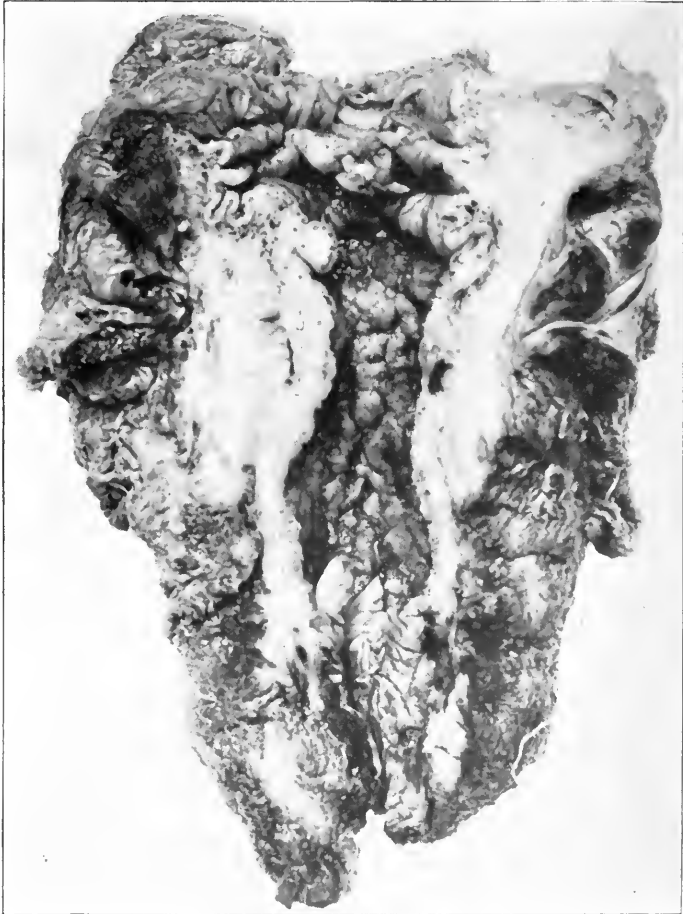


Fig. 451.—Carcinoma of the rectum.

Diagnosis.—The dense constricting mass in the rectum is typical of carcinoma. The question of operability can not be definitely determined because the lumen remaining does not permit the finger to reach above it so that its mobility can be established. There is

no evidence of metastasis and none of the pains complained of can be ascribed to secondary nodules. His general appearance does not suggest cachexia. A preliminary laparotomy in order to determine the operability would be desirable, but his adiposity and dyspnea, evidently cardiac, make a general anesthetic undesirable. The patient elects an attempt at the perineal operation under local anesthesia.

Treatment.—The rectum and tumor were carefully isolated under local anesthesia. He was given ether *rausch* while the mass was withdrawn out of the pelvis. The operation was then completed with the local anesthetic.

Pathology.—The tumor was an annular affair deeply infiltrating the walls of the gut and into the perirectal tissue about. It began about one inch from the anus and involved more than four inches of its extent (Fig. 451). As the gut was being withdrawn it had the dense tubular feel of a benign stricture. The slide shows an abundant connective tissue proliferation with a few epithelial cells—a veritable scirrhus of the rectum.

After-course.—Healing was prompt and after a few weeks he had less bladder trouble than he had had in years. The end of the gut tore away from its anchorage to the skin at the end of a week and retracted some two inches. Nevertheless, a good anal canal formed in five weeks. He attended his practice for a year following recovery from the operation, when he became hemiplegic and died without regaining consciousness.

Comment.—In very corpulent patients the combined operation is difficult to perform, the after-treatment because of the inevitable infection of the abundant fat is troublesome and the management of the artificial anus a source of constant annoyance. Therefore, when at all possible, I prefer to bring the bowel out below. Nor do I believe there is occasion for worry if one is not able to secure enough bowel that the end, after the tumor is cut off, does not withdraw itself within what is left of the anal skin after tension is taken off of it. If there is tension when the gut is sewn to the skin the stitches will surely pull out and the gut will retract, leaving a granulating channel between the skin and the end of the gut. I have had this happen many times and it has ceased to worry me. The very fact that much scar tissue forms in this region is often salutary. This forms a support and patients usually have fecal continence when the stool is at all formed, a condition that is by no

means always true when the gut remains well attached to the skin. True these fibrous channels may require attention at times for several years, but once the sear has fully formed they remain in *statu quo* without further attention.

CASE 7.—A widow of sixty-eight came to the hospital because of tenesmus and bloody stool.

History.—For the past nine months she has had pain on defecation. The stool has contained much mucus and recently some blood. In

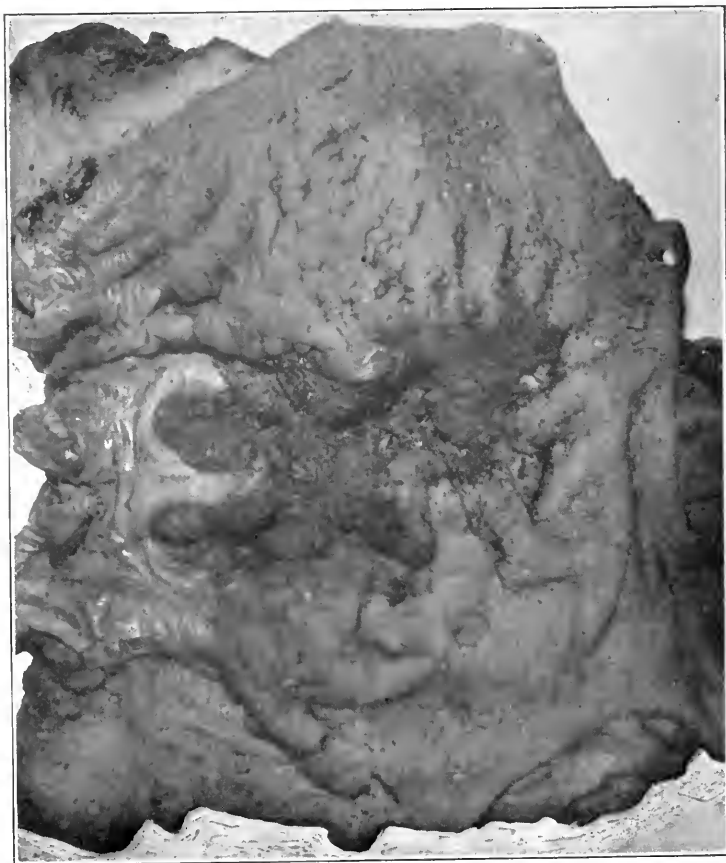

Fig. 452.—Carcinoma of the rectum beginning just above the sphincter.

the past two months the pain has increased markedly. She has always been constipated, but the bowels move readily with a laxative.

Examination.—The patient is tall and very thin, but save for a barrel chest, her general condition is without note. Just above the sphincter at the posterior quadrant of the rectum is an ulcerous area an inch wide and twice as long. It is deep red, hard and granular to the touch, and it bleeds readily on manipulation. At the anal extremity it ends abruptly at the cutaneous border. At the remainder of the periphery it ends irregularly sending here and there nodules into the otherwise unaffected mucosa (Fig. 452). The deeper structures of the gut do not seem to be affected. The urine is 1.008 and contains a few casts. There was no albumin in several tests.

Diagnosis.—The density, the tendency to bleed, and the character of its border suggests carcinoma. The superficial character and its granular base look like tuberculosis, an impression dispelled by the evidence obtained by palpation. The low situation and the lack of invasion of the deeper tissues make it an ideal case for perineal amputation.

Treatment.—The offending portion was resected under local anesthesia. The sphincter was removed along with the gut. After the gut was loosened it was turned on its axis before being sutured to the cutaneous border, the idea being to partly close the lumen of the bowel and thus aid in its control.

Pathology.—The glands were invading the muscular layer of the gut but nowhere did it extend beyond.

After-course.—Healing occurred quickly. She could control the bowels when the stool was hard. She died six years later of apoplexy.

Comment.—The appearance of this condition was strikingly like that of tuberculosis and the microscope alone could give the final decision.

CASE 8.—A retired blacksmith came for consultation because of frequent bowel movements.

History.—The patient has had excellent health until the past few years when he began to have scanty urine and sometimes a little trouble in starting the flow. He has never had to be catheterized. About a year ago he noticed streaks of blood in the stool. This has gradually increased. Later bowels move at frequent intervals. He has had no pain to speak of. He has been treated for piles by his family physician for the past seven months.

Examination.—A large fungoid mass can be felt in the rectum. The examining finger easily reaches the topmost border. It is hard

and nodular and bleeds on manipulation. The prostate is moderately large but is smooth.

Diagnosis.—The fungiform, hard, bleeding mass can be nothing other than a carcinoma. Its tendency to form a cauliflower mass indicates a relatively favorable prognosis and its low situation makes it readily accessible through a perineal incision.

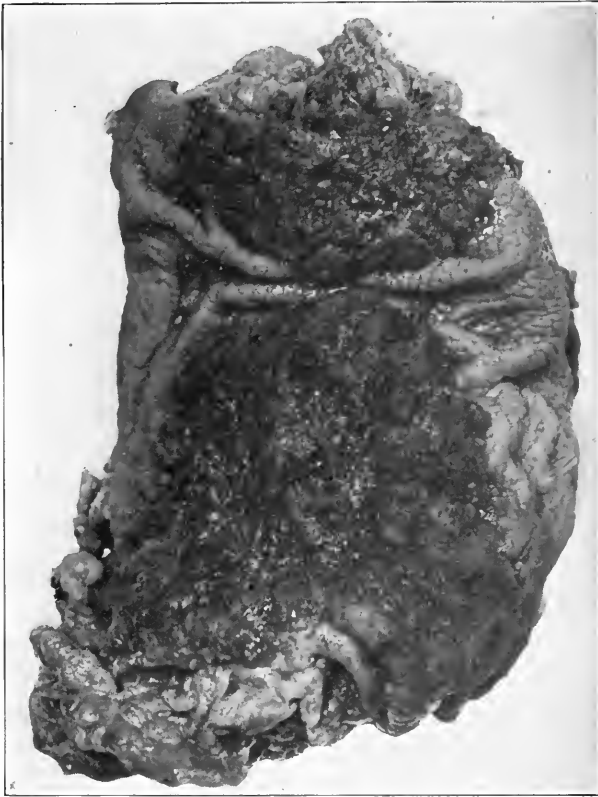

Fig. 453.—Fungating carcinoma of the anus.

Treatment.—The tumor was removed from below under local anesthesia. The external sphincter was preserved.

Pathology.—The tumor is typically everted adenocarcinoma (Fig. 453).

After-course.—The patient had retention of urine for one or two days following the operation. He had to be catheterized, which

resulted in a moderate cystitis. There was considerable infection in the field of operation which caused a partial loosening of the end of the gut from its anchorage in the external sphincter and skin. On leaving the hospital he still had some trouble in passing urine at times. After healing was complete, however, he was free from any trouble. There was a cicatricial narrowing of the anal opening a few months after operation. This had to be incised on three different occasions before a permanent efficient canal was established. He has no incontinence unless the stool is thin. He has remained free from recurrence many years and has had no trouble on urination.

Comment.—Fungating carcinomas of the rectum, if done at all early, give a uniformly good prognosis.

FISTULA

Perianal fistulas are due to perirectal abscesses, abscesses draining from a distance, as in broad ligament infections or bone disease and to tubercular processes in the soft parts. Vestigial rests while usually pointing in the midline behind the anus may point in other directions.

CASE 1.—A matron aged twenty-seven came to the hospital because of feces passing through the vagina.

History.—The trouble dates back six years ago when the patient was delivered of her first child. Delivery was by forceps after the patient had been in labor fifteen hours with the head of the child visible for ten hours, according to the patient's story. She was repaired immediately after the delivery, but she noticed that feces were passing through the vagina three or four days after the sutures were applied. Three months after delivery an unsuccessful attempt was made to repair the fistula.

Examination.—There is an opening from the vagina into the rectum which admits the end of a finger. It is situated just above the external anal sphincter.

Diagnosis.—A recto-vaginal fistula is obvious.

Treatment.—The rectum was loosened from the sphincter and vagina to a point an inch above the fistula. The gut was drawn down so that the opening through the rectal wall lay outside the sphincter. The gut distal to the fistula was then removed and the

gut sutured to the sphincter and to the skin about the anus. The opening in the vagina was pared and sutured.

After-course.—The sutures promptly pulled out and the end of the gut pulled above the opening into the vagina and the fistula recurred larger than before. I at once loosened the rectum about its entire circumference and brought down the whole gut as one would do in removing a low lying carcinoma of the rectum. The whole circumference was sutured to the anal margin. The gut stayed sutured and the fistula was healed.

Comment.—The important point in the performance of this operation is that the entire circumference of the gut must be loosened. If only one segment is loosened, the sutures regularly tear out. I learned this from repairing rectovesical or rectourethral fistulas following perineal prostatectomy, but I forgot it again before doing this operation.

CASE 2.—A farmer aged twenty-three came because of a fistula near his tail bone.

History.—A year and a half ago, while pulling on a post he lost his hold and sat down violently on a block of wood. Six months later pain and tenderness with swelling developed over the tail bone. It began to discharge and after a month or so it ceased. Ten months later, pain, tenderness, swelling as big as at first appeared, but after discharging for some time, it again healed. It soon reopened and has discharged constantly since. His general health has always been good.

Examination.—There is an opening in the midline over the coccyx. From this opening a sinus extends downward in the midline to near the anal sphincter. No sinus can be found leading upwards over the sacrum or into the pelvis.

Diagnosis.—A recurrent abscess formation following a trauma to the perineal region suggests ischiorectal abscess. However, the injury was sustained in March and the abscess did not form until October. Ischiorectal abscesses from trauma are usually due to mixed infection from the gut tract and develop violently soon after the receipt of the trauma. Furthermore, they do not usually discharge in the midline over the sacrum, though they may do so. Hence a diagnosis of sacral dermoid was made.

Operation.—A grooved director was placed in the fistulous tract and the whole of the affected area excised *en bloc*. Extending up-

wards from the opening was a tiny sinus not discovered at the time of the examination, lined with epidermoidal tissue bearing hair. A small drain was placed in the wound about midway.

After-course.—There was some infection of the wound but healing was nearly complete in two weeks. He remained well for nearly a year, when an opening reappeared two inches higher than the original opening. A sinus passed to the right of the median line but did not reach the bone. On dissecting out this tract a small bit of skin bearing four hairs was discovered. Following this recovery was permanent, now 13 years.

Comment.—These affections, though congenital in origin, as a rule do not become troublesome until early adult life. They seldom produce serious trouble. Their chief interest lies in the fact that the skin-bearing tract may extend much further than is at first apparent, and unless the entire tract is removed, recurrence will most surely follow. Here a miss is as good as a mile. Most cases require excision from the base of the sacrum to the sphincter and all the tissue as deep as the periosteum requires removal. When they are complicated by extension into the hollow of the sacrum difficulty in removing them without removal of a part of the sacrum is encountered.

CASE 3.—A farmer's boy of eighteen came to the hospital because of a discharging sinus near his anus.

History.—On January 18, 1917, the patient fell from a scaffold on an upright timber, a portion of the wood piercing the skin to the right of the anus. An abscess formed and was opened several days later. Pus discharged and a portion of the clothing came out with the pus. Early in February he again had severe pain in the perineum with swelling and fever. The doctor, probing in the old wound, opened into an abscess higher up, which was much larger than the first. He was then taken to the hospital and the abscess widely opened. He remained four days. The wound continued to drain and did not heal. It closed occasionally and then he had severe pain until it opened again. Pus decreased but a sinus remained. April 13 he went to some "rectal specialists" who opened up the sinus, put in a tube and irrigated every few days. May 24 they started to inject the sinus with bismuth paste. They injected this many times, the last being on the ninth of July. A week later he came here.

Examination.—A sinus exists on the right of the anus and extends upward some four inches.

Diagnosis.—When a large abscess exists on one side of the rectum usually the opposite side of the rectum also is affected. Therefore a bilateral infection was diagnosed in this case.

Treatment.—The sinus was opened up and a large pocket of pus found posterior to the rectum. No communication with the rectum was found. The cavity was found filled with Beek's paste. Another opening was made in the cavity to the left of the sinus and the Beek's paste was everted out of it also with a gallstone spoon. The cavity was found to be very large and extended up to the promontory of the sacrum. Two large rubber drains were put in on either side of the anus, together with two gauze drains. The gauze drains were left for three days and the rubber drains a week.

After-course.—The wounds narrowed down to a small sinus. A year after there was still a small opening which exuded a few drops of clear fluid at intervals.

Comment.—In the case of an open wound it is difficult to say whether there ever has been a communication with the rectum. The pus had burrowed throughout the pararectal connective tissue.

CASE 4.—An electrician aged thirty came for consultation because of a fistula in the buttocks.

History.—The patient is a thin, spare man, but apparently in good general health. Recently he has had some pain in the right anus and some weeks ago a discharging sinus developed.

Examination.—A cursory examination disclosed a discharging sinus two inches to the right of the anus. At the time of the examination I did not note that the opening instead of being scarred and puckered like the usual perineal sear, was wide open, craterform, exactly like the ureteral orifice in tuberculosis of the kidney.

Diagnosis.—Having failed to note the peculiarities above noted, I diagnosed fistula in ano.

Treatment.—In infiltrating the affected tract with novocain I noted that the tissues were everywhere softer than usual in fistulæ and I was unable to follow the main tract by the touch of the needle. I passed a grooved director into the opening and found not a sinus, but an undermined area (indicated by the dotted line in Fig. 454). I opened into this tract and found a granular area which made its

tuberculous nature clear enough. Notwithstanding the discovery of the nature of the disease, having started to dissect out the diseased area, dissect it out I did.

Pathology.—Many tubercles with typical giant cells were found. (Fig. 455.)

After-course.—The large wound left by the dissection was closed

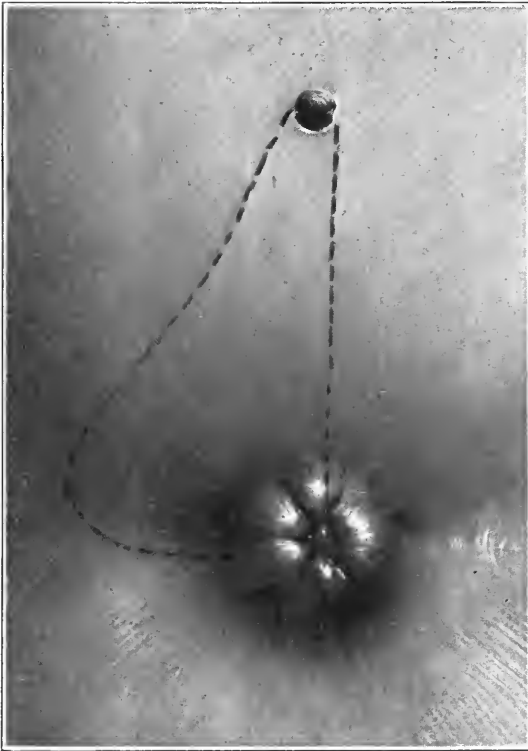

Fig. 454.—Tuberculous pararectal fistula.

in part by suture, but it did not remain so and a large granulating wound formed which required many months before it closed.

Comment.—Having discovered the tuberculous nature of the trouble, I should have split the affected area open and applied the caustic instead of making a fresh wound. But not being forewarned, I was not forearmed, and hence no caustic was at hand.

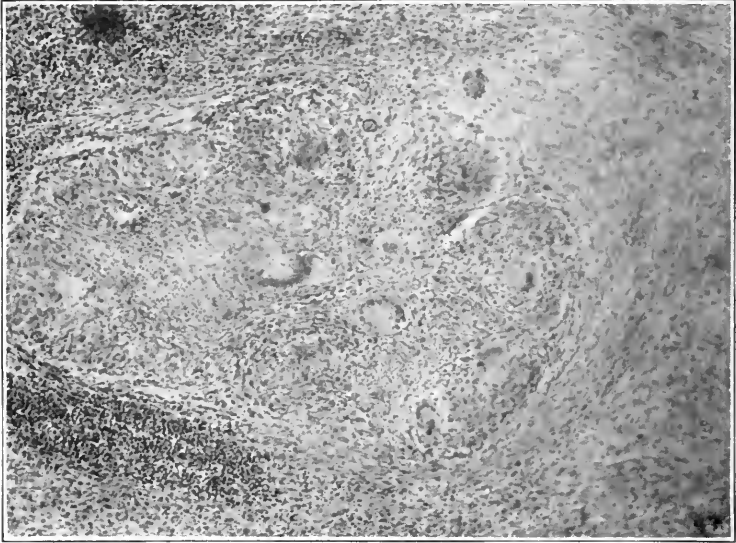

Fig. 455.—Tuberculosis of the pararectal tissue.

PERIANAL DISEASES

Ulcerous lesions may result from irritating bowel discharges, usually specific in character. Papillary tumors are frequently, but not always, due to venereal infection. Melanotic tumors at the anal margin are not common, but may resemble cutaneous hemorrhoids or prolapse of the bowel.

CASE 1.—An unmarried woman aged eighteen entered the hospital because of a fistula following an operation for appendicitis.

History.—The patient had tonsillitis in childhood and typhoid fever a year ago. On November 23 she had a sudden severe pain in the right side with nausea and no vomiting. For two weeks she was in bed with severe nausea and pain in the right side at intervals. She was told she had no fever. No distention of the abdomen was present. Patient was operated December 6, and the wound closed without drainage. The appendix was found to be adherent, but no pus present. She suffered from the operative shock on the table. On the third day following operation she developed a temperature and had localized swelling in the region of the operative wound. The next day the abdominal swelling was general and the pain severe. Vomiting began at this time. The

next day the abdomen was opened and a rubber drain inserted. No drainage followed. On the next day they put in a gauze drain, but still no drainage followed. The temperature, rapid pulse, distention and vomiting continued and another tube was inserted. The condition continued to increase in severity until eleven days after operation. She then began to improve, and on the twelfth day a fecal fistula started, which is still discharging.

Examination.—The patient is emaciated but not anemic. She has an opening in the center of a scar in the right iliac region, from which pus and intestinal contents are oozing. A probe passes inward and upward for a distance of three inches.

Diagnosis.—Obviously a fecal fistula is present. The probable site of the opening is conjectural. The statement that there was no pus present at the time of operation makes it likely that infection was due to the technic and not to the disease. The attempts at drainage make it likely that the fistula is the result of these efforts. Therefore the particular region of the gut affected must be determined at operation.

Treatment.—The opening was circumscribed by the incision and the fistula closed with a forceps. The fistula was then resected down to its attachment to the gut. It was found to communicate with a loop of small intestine. The fistula was ligated close to the gut and the stump invaginated. The wound was closed completely and a drainage opening was made in the flank.

After-course.—There was subcutaneous infection for a week but otherwise healing was complete. The patient has remained well.

Comment.—The history of this case shows the results obtained by the occasional operator. The repeated attempts at drainage indicate a planless procedure. These fistulas once they form should be allowed to thoroughly heal out before their excision is attempted. After they contract to a fibrous cord an aseptic operation can be done.

CASE 2.—A school boy aged eighteen came because of an ulcer of the anus.

History.—Two years ago he began to have a painful affection of the anus. It was treated for some months with salves and suppositories but the trouble increased. A fistula formed and a surgeon was consulted. The fistulous tract was cut across. This refused to heal and has continued to spread until the present time. It causes a continuous discharge but is only moderately painful. The

lad has always had fair health and has had no sickness save some of the minor affections of childhood. Save for a maternal aunt there has been no lung trouble in the family.

Examination.—The patient is slight of build, long and narrow chested. General examination discovers nothing of interest. At the left of the anal margin is an ulcer extending half an inch over the skin surface and about the same distance over the mucous surface (Fig. 456). The edge is slightly undermined but shows at some points a beginning at healing. At other points the margin is

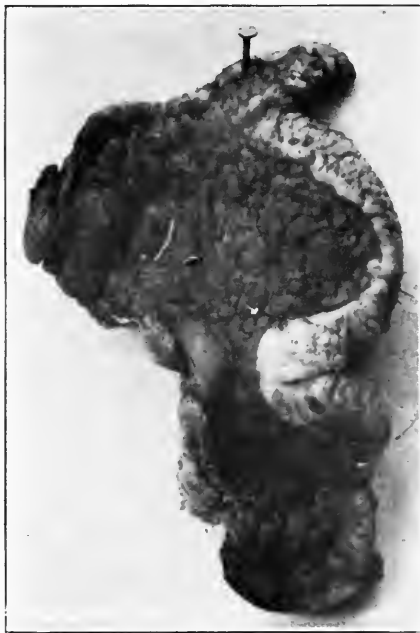

Fig. 456.—Tuberculous ulcer of the anal margin.

more elevated and of a brown color. The base of the ulcer is soft and granular and some pressure is required to produce bleeding. The upper border passes almost imperceptibly into the normal mucosa above.

Diagnosis.—The soft character of the base of the ulcer and the undermined but somewhat thickened border suggests tuberculosis. Carcinoma of the mucocutaneous border does not occur. The base would be harder and the border less evenly undermined and not indurated.

While the boy is slight, no evidence of preexisting tuberculosis can be discovered. He does not know much of his early life. Excision seems the treatment most suited to the condition.

Treatment.—The ulcerous area was excised with a healthy margin. The denuded area was closed by sutures.

Pathology.—Typical tubercles were found in abundance.

After-course.—A number of the sutures failed to hold, but the defect healed over in about three months and he has remained well.

Comment.—The cautery likely would have been a better treatment than excision. At least dissemination would be less likely to occur after the use of this agent than after excision. However, in this case healing took place. Carcinomas at the mucocutaneous junction have been reported. Many years ago I saw a distinguished surgeon remove an ulcerous lesion in this situation which he pronounced to be carcinoma. I obtained a piece of it surreptitiously as it passed on its journey to the incinerator. This proved to be tuberculosis. Unless diagnosed by the microscope the reports of carcinoma in this situation should be regarded with caution. Fistulous tracts lined with granulation tissue should be regarded with suspicion and carefully excised.

CASE 3.—A boy aged two was brought because of a warty growth about the anus.

History.—Six months ago a warty growth was first noticed near the anus. This was followed by others until in two months the anus was completely encircled by them. The child cries while stooling sometimes and he refuses to sit flat on both buttocks. When injured the warts bleed. He was treated for a month by a dermatologist who applied a powder which caused the child pain and stimulated the growth to renewed activity. The child, as well as his parents, has always been in the best of general health.

Examination.—The patient is a vigorous little lad presenting the picture of general good health. Surrounding the anus is a cauliflower-like growth (Fig. 457) which completely excludes the orifice from view. When the mass is parted the anal mucosa can be seen to be unaffected. The growth is firm to the touch. When the growth is viewed from the side the base can be seen to be formed by stalks with healthy skin between.

Diagnosis.—The narrow stalks with the healthy skin between indicate that the lesion is nonspecific. This is confirmed by the excellent physical condition of the child.

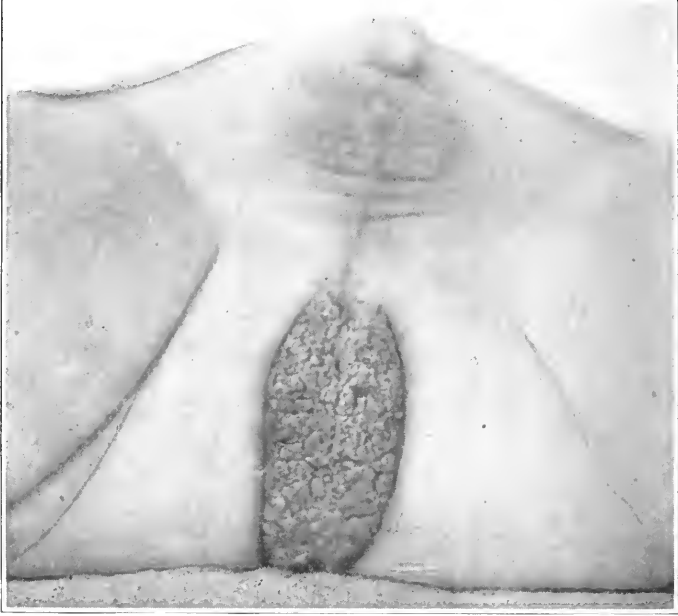


Fig. 457.—Condyloma of the anal region.

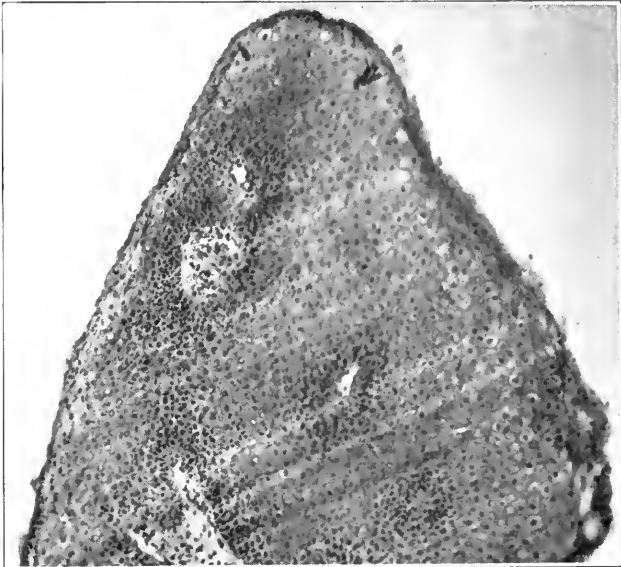


Fig. 458.—Condyloma of the anal region.

Treatment.—The growth was snipped off with the scissors and the bleeding points canterized with the platinum loop.

Pathology.—The slide shows the masses to be composed of epithelial cells, palely staining for the most part, with stalks of vessels bearing connective tissue between them (Fig. 458).

After-course.—Healing was uneventful. He has remained well.

Comment.—There was nothing in the previous state of the child to give any clue to the causation of this condition. The important of different character or of different sources may produce in character. When it comes to indicating the difference between the syphilitic and the nonsyphilitic one soon gets in a quandary. The anatomic difference is not convincing and the histologic pictures are identical. It appears as though the easiest way out of the difficulty would be to speak of condylomas of the syphilitic instead of syphilitic condylomas, implying thereby that condylomas of the syphilitic are not necessarily of specific origin. Likely irritants of different character or of different sources may produce the lesion.

CASE 4.—A physician aged fifty-four came because of prolapsed hemorrhoids.

History.—The patient has had some trouble with hemorrhoids for a number of years and for a year or more they have occasionally protruded, but were readily replaced by manual pressure. Two days ago following an attack of diarrhea they came down and were too painful and large to replace.

Examination.—Three large egg-shaped masses surround the anal opening (Fig. 459). They are tense, blue-black in color, and overhang somewhat the surrounding cutaneous margin. The skin surrounding their base likewise is inflamed.

Diagnosis.—The diagnosis is easily that of hemorrhoids. The intense reaction is obviously due to thrombosis within the vessels. The surrounding inflammation likewise is due to the irritation of the blood clot. The condition presents essentially the factors of a septic inflammation. The condition is such, however, that necrosis of the surface is imminent and then infection will most certainly take place. Since the veins contain clots it will be desirable to ligate them proximal to the clots if possible, lest the manipulation cause an embolus.

Treatment.—The site of attachment of each mass was isolated, deeply transfixed, and doubly ligated, and then cut off and the stumps replaced. Two opium suppositories were placed above them.

Pathology.—The masses are made up for the most part of edematous fibrous tissue. The veins are thrombosed and there is considerable perivascular exudation of leucocytes. The central factor in the pathology is the venous thrombosis.

After-course.—Immediate and permanent relief from pain followed. It required a week before he was able to be about, however.

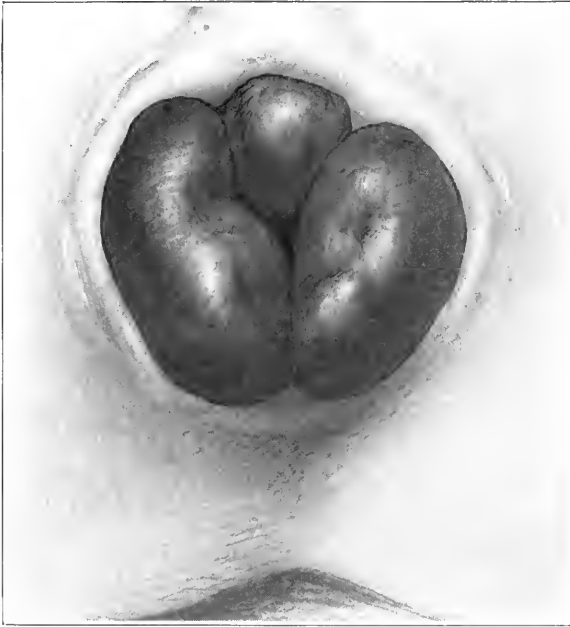

Fig. 459.—Strangulated hemorrhoid.

Comment.—Since the dominant lesion in these tumors is a venous thrombosis, a ligation as deeply in the mucosa of the rectum as possible seems rational. The minimum of manipulation likewise seems desirable. The patient being a physician desires to bear testimony to the fact that this is a very painful affection and worthy the prompt and careful attention of surgeons and should not be greeted with levity, even in corpulent persons.

CASE 5.—A child of four was brought to me because of prolapse of the bowel.

History.—The patient has been obstinately constipated since a small child. She has had much colic and is bloated much of the time. The appetite is poor and fitful. At the age of a year and a half the mother noted that the rectum everted whenever the child had a stool. At first the protruding portion gradually replaced itself spontaneously. As the disease progressed, manual replacement had to be

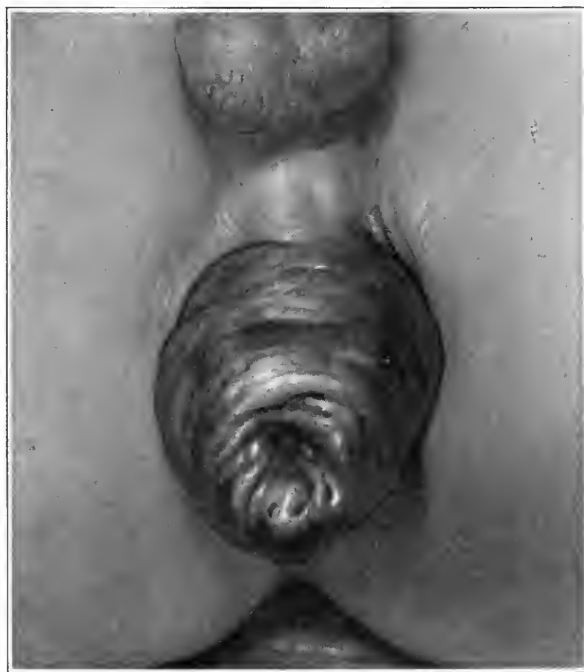

Fig. 460.—Prolapse of the rectum in a child.

resorted to. Bleeding rarely occurs now since the mother has learned to manipulate the protruding part.

Examination.—After the child has stooled, fully two and a half inches of the rectum protrudes (Fig. 460) and the mother exhibits the art of replacement. When the parts have returned the sphincter contracts well over it so that nothing abnormal is noticed. The child is anemic and exhibits signs of rickets. The abdomen is prominent and everywhere tympanitic.

Diagnosis.—Prolapse of the rectum is evident and there is good sphincteric control. The child has in addition an intelligent mother willing to follow medical advice.

Treatment.—Nothing was done directly with the offending gut. The patient's diet was regulated and she was given antacids and laxatives. She was also given strychnine at intervals. By these means the general health improved but the anal trouble showed no improvement for a year and a half, by the end of three years the trouble had wholly disappeared.

After-course.—She is now a perfectly normal university student. She has not required a laxative for many years.

Comment.—This treatment gives better ultimate results than operative measures but obviously it can be applied only to treatment of children of intelligent mothers. This treatment is of course applicable to children below par. I have had no success with it in husky children, though I must add the husky children I have tried it on were the offspring of mothers of lower intelligence.

CHAPTER XX

EXTERNAL GENITALS

Affections of the external genitalia while of many varieties but few of them offer any difficulty in diagnosis.

AFFECTIONS OF THE VULVAR REGION

Carcinoma and tuberculosis are the common ulcerous lesions, but the rarer esthcomine must not be forgotten. Cysts, lipomas, and hernial protrusions furnish the common tumorous affections.

CASE 1.—A widow aged thirty-six came to the hospital because of a tumor of the vulva.

History.—A year and a half ago she had a wart-like tumor of the right side of the vulva. This was cauterized with an acid by her physician and healing was complete after about a month. Some nine months later she began to have a tumor in the opposite side which was soon followed by a tumor in the groin. Later another tumor developed on the side of the original tumor but above it. All these grew rapidly and two or three months ago they ulcerated. Since then they have remained so. She has no pain but the continual discharge irritates and prevents sleep and recently she has lost her appetite.

Examination.—At the lower end of the right labium is a scar which confirms her statement that the original lesion healed. The labia now form large ulcerous tumor masses (Fig. 461) which are hard but fragile and bleed readily on touch. The left groin presents a large ulcerous mass equal to that of the vulva. The whole mass seems movable on the underlying fascia.

Diagnosis.—The growth is of course malignant. The fact that the original growth was wart-like and healed after cauterization and that these masses seem to move on the underlying tissue gives slight hope that something radical may be done. The rapid growth, however, makes the wisdom of such a course very dubious. It may at least remove the ulcerous mass for a time.

Treatment.—The labia with the tumors were removed and the inguinal region was completely dissected out. It was found that at

one point just medial to the large vessels the growth extended deeply in and could not all be removed. The wound was partly closed by suture and the patient turned over to the x-ray department.

Pathology.—The growth is a carcinoma.

After-course.—The large wound healed for the most part but at the point where the growth extended deeply it refused to heal even under the most rigorous treatment. Extension took place in this direction and she died six months later.

Comment.—Everting tumors in this region sometimes show good results from radical treatment. Had not deep extension already

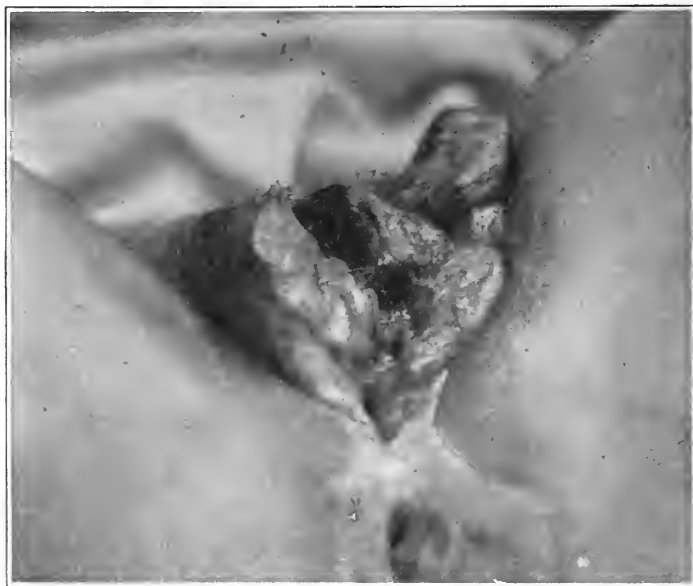

Fig. 461.—Carcinoma of the vulva.

taken place, temporary favorable results might have been obtained in this case. This extension could not be detected until the operation was well under way.

CASE 2.—A matron aged fifty-four came to the hospital because of a protrusion from the vulva.

History.—The patient is the mother of a number of children. She has always enjoyed good health and except for a protrusion from the vulva she has no complaints to offer. There has been little bladder disturbance.

Examination.—Anticipating from the history a uterine prolapse, I was astonished to find an enormous rectocele which quite overhung the anus. The cervix was but little low and there was no cystocele at all. The perineum was lacerated well into but not through the external sphincter. The mass could be replaced by a little effort but the sensation received in doing so was new to me.

Diagnosis.—Huge rectocele.

Treatment.—At the operation when the mass was pushed into the vagina and the vaginal wall lifted up from in front of the sphincters, I encountered not rectal wall but a sac containing clear fluid. The fluid was not under tension but I thought it must be a vaginal cyst, but what it should be doing in that situation was not clear to me. I decided to look in. An ounce of straw-colored fluid escaped and

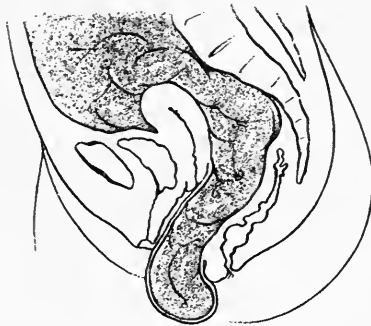

Fig. 462.—Hernia in the perineum.

much to my astonishment a loop of small gut presented at the opening (Fig. 462). The vaginal wall was now separated from the wall of the sac and then the sac separated from the rectal wall. The redundant vaginal wall resulted and then the edges of the vaginal wall were united to each other and to the rectal wall by one sweeping suture. A perineal repair completed the operation.

After-course.—Recovery was uneventful.

Comment.—The question is whether this represents a stretching of the culdesac because of a weakened vaginal wall, or an instance in which the culdesac extends down farther than the normal. The latter was the case, for the vaginal wall below the cervix presented no thinning and it is at this point where the relaxation must have begun if the whole tract had developed after the laceration. Besides, the mesentery of the intestine was enormously long.

CASE 3.—A widow of fifty-two came because of an ulcer on her privates.

History.—For the past nine months she has noticed an ulcer above the opening of the bladder. At first it caused annoyance only from contact with the clothing. Recently she has had pain even when carefully protected. She has had some irritation of the bladder for some years requiring her to get up four or five times a night.

Examination.—Just above the clitoris is an irregular ulcer 2 cm. in diameter (Fig. 463). It obscures the clitoris but does not extend to the meatus. It is freely movable over the underlying structures. It is hard to the touch and bleeds when manipulated. The inguinal glands are not involved.

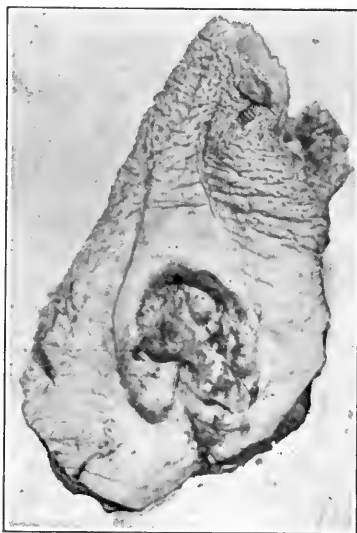


Fig. 463.—Carcinoma of the clitoris.

Diagnosis.—The density and tendency to bleed marks it as a malignant growth. It is free from important structures and its removal should be easy.

Treatment.—Under local anesthesia the inguinal glands were blocked out and a wide area about the growth extending to the meatus was removed.

Pathology.—The growth involves both the hood and the glans of the clitoris. It is impossible to determine from which structure it originated. The slide shows it to be a squamous-celled carcinoma.

After-course.—There has been no recurrence.

Comment.—These are unusual growths. If the prognosis is analogous to those of the male prototype, the prognosis should be good. Probably the removal of the inguinal glands was unnecessary but the operation as performed is theoretically correct.

CASE 4.—A married woman of thirty-four was brought to the hospital because of hemorrhage.

History.—The patient has been married twelve years but has never conceived. Menstruation had always been regular, though painful, until four years ago when they began to be prolonged. The flow seemed to be normal for four or five days, then a dribbling followed for a week or ten days. About two months ago she had a severe hemorrhage that caused her to go to bed. She has been weak since and has been in bed most of the time. For the past two weeks she has had fever and headache and a fetid brown vaginal discharge has been present for this time.

Examination.—The patient's pulse is 120, temperature 101.6, respiration 24. The blood count shows R.b.c. 2,400,000; W.b.c. 4,000; Hg 60 per cent. There is some suprapubic tenderness. The vagina is completely filled by a tumor nearly as large as a fetal head (Fig. 464). The finger can be passed anteriorly between the tumor and the pubic arch and the cervix palpated. The tumor on inspection is mottled brown and black.

Diagnosis.—Pedunculated fibroid in the act of extrusion.

Treatment.—When the perineum was retracted it was evident that a mechanical problem was present. A friend suggested the use of an obstetric forceps. These were applied and the tumor extracted. After it was withdrawn and hung in the vulva it looked very much like a child's occiput smeared heavily with meconium (Fig. 465-B). The cervix could be felt encircling the pedicle of the tumor (Fig. 465-A). While making traction on the tumor to determine the attachment of the pedicle it was discovered that the uterus could be inverted through the widely dilated cervix. This was accomplished and the fundus of the uterus removed along with the tumor (dotted line B, Fig. 2). After the cut surface of the uterus had been sewn and the stump allowed to retract it looked to be a very pretty job. It was noted then that the perineum had been lacerated to the first obstetric degree in the act of extraction. This was closed by two sutures.

Pathology.—The tumor consisted of a very hard myoma. It was necrotic throughout and contained several cavities filled with greenish

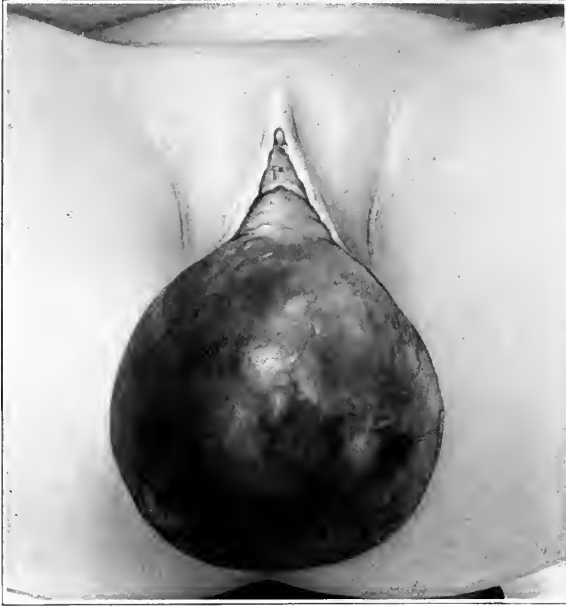

Fig. 464.—Submucous myoma protruding from the vagina.

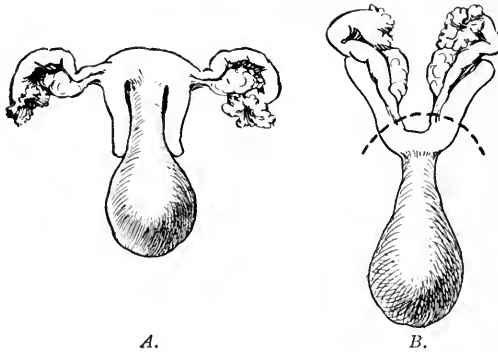


Fig. 465.—Supravaginal amputation of the uterus when inverted by a tumor.

fluid. The degeneration therefore affected the entire tumor and not the surface only.

After-course.—The first few days following the operation found the patient very comfortable and in a cheerful mood. The temperature remained slightly subnormal and the pulse low. The only unfavorable sign was a complete lack of appetite, even a positive anorexia and the patient appeared pale, even waxen. These phenomena excited my interest but not my apprehension. On the fifth day the nurse called my attention to the bad condition of the perineal wound. Much to my amazement the whole perineum was gangrenous. Any effort to alleviate the condition was without result and the patient died on the eighth day.

Comment.—I have pondered on this case now nearly a score of years. The anemia before the operation and the pallor evidently was not due to the loss of blood, as I thought, but to the poisoning from the tumor. I did not once suspect during the period after the operation that the gangrenous process might extend to the laceration. Morecellement instead of removing the tumor intact probably would have obviated the disaster.

CASE 5.—A matron aged thirty-seven came to the hospital because of a tumor protruding from the vulva.

History.—The patient has had five children and one miscarriage five years ago. She has always had leucorrhœa and dysmenorrhœa. Two months ago she had a severe pain in the small of the back. Soon after she noticed that when she had a bowel movement a tumor mass would come from the vagina. Her periods have been regular since the birth of the last child until nine weeks ago. Since then she has had no menstrual flow. She has had some bleeding since but it is irregular and much less than a normal flow. She is tired and weak and thinks she has lost some weight. Her appetite is good, she sleeps well and she has no abdominal pain or urinary disturbance.

Examination.—There is a pedunculated tumor the size of a small egg and about three inches long in the vagina with its pedicle extending into the uterus (Fig. 466-A). The uterus is as large as a three-month pregnancy and the fundus extends to the right. It is fairly firm, the cervix is not markedly softened, neither is the supravaginal portion thinned.

Diagnosis.—The tumor in the vagina is obviously a fibroid polyp which has become extruded from the uterine cavity. The alleged amenorrhœa may be accounted for by the size of the uterus but its con-

sistency does not suggest pregnancy. It is likely that the size of the uterus is due to tumor development with associated edema from irritation from the protruding mass. At any rate the tumor must be taken away.

Treatment.—The mass was withdrawn out of the vulva and the

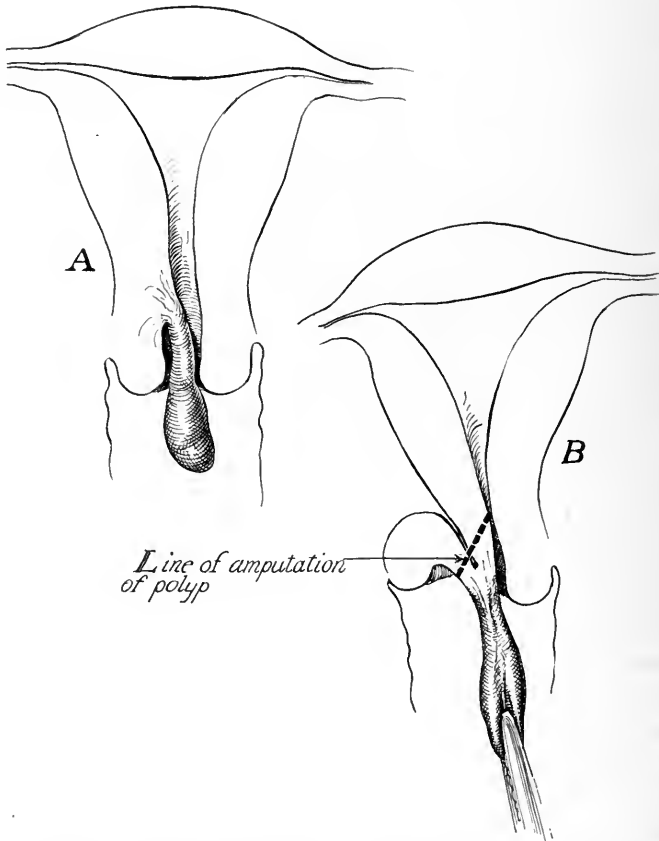


Fig. 466.—Pedunculated tumor of the uterus. A. Relation of the pedicle to the wall of the uterus before traction was made. B. After traction was applied.

pedicle cut across at the level of the internal os (Fig. 466-B). When the pedicle was examined it was found that the entire thickness of the uterine wall has been cut through. It now became necessary to explore the interior of the uterus. It was in fact inhabited and the uterus was cleaned.

Pathology.—The tumor was a simple fibrous polyp.

After-course.—An infection in the broad ligament occurred and she had a large indurated mass to the left and behind the uterus for many months. It ultimately cleared up completely.

Comment.—One can not be too careful in removing the pedunculated masses. Were it not for the fact that these tumors often come in rather young women a hysterectomy would be the operation of choice. These tumors are always infected, often gangrenous, factors which add hazard to such an operation. It seems curious that pregnancy could take place in spite of such an obstruction. Had the uterus not been pregnant inversion from traction would not have taken place. The tumor was attached at the inner os, and even had conditions been fully understood a subsequent emptying of the uterus could not have been avoided.

CASE 6.—A matron aged fifty-seven came to the hospital because of a general loss of strength and prolapse of the uterus.

History.—Four years ago while walking she had a feeling as if something popped within her. Since then she has had a prolapse of the uterus. She has had a bulging of the vagina and an irritation of the bladder. Since that time she has been troubled with obstinate constipation. She has noted, too, a general impairment of health. The general indisposition has been greatly augmented in the past four or five months, and in the past two weeks she has “gone all to pieces.” She has had three children, the last twenty-seven years ago, when she suffered a complete laceration.

Examination.—The patient presents the appearance of one much exhausted but of good nutrition. General examination fails to disclose anything of importance. There is a large varicocele and the cervix protrudes out of the vulva. There is a complete laceration of the perineum. The urine showed no abnormalities.

Diagnosis.—The physical examination makes the anatomic problems evident enough. Why she shows such a decline in recent months does not appear. She ascribes it unhesitatingly to the annoyance of the prolapse, and, in the absence of any tangible evidence to the contrary, this view is accepted.

Treatment.—The uterus is drawn up through a transverse suprapubic incision, a portion is excised and the stump fastened into the fascia.

Pathology.—The tissue removed shows the usual involutinal changes.

After-course.—The patient made a normal recovery for the first week. At the end of this time she became weaker and restless and complained of headache. The breath had a marked odor of acetone but none could be demonstrated in the urine. The urine varies from 1.015 to 1.020 sp. gr., contained a trace of albumin, and many hyaline and granular casts. The total acidity 35-40. The headache increased to unconsciousness on the twentieth day after the operation and she died. It was suggested there might be some spinal complication. The puncture gave no light. The blood sugar was negative.

Comment.—The preoperative nutritional state was not sufficiently studied. Here an elimination test would have been valuable as well as the total output for several days. The rapid decline of the patient could not be explained on the ground of the prolapse of the uterus.

CASE 7.—A matron of thirty-two came because of a protrusion into the vagina.

History.—This patient has two children and so far as the genital organs are concerned has no complaint other than the fact that she has a tumor protruding into the vagina the nature of which she does not understand. When she lies down she thinks the tumor recedes.

Examination.—A smooth “ovoid mass” is visible in the introitus (Fig. 467). It is elastic and seems to recede under pressure, but does not entirely disappear. It is semifluctuating and not boggy. The genitalia are normal.

Diagnosis.—The consistency and form suggest a vaginal cyst, but it seems to recede more than a cyst should do, besides it becomes more tense when the patient coughs. Therefore a perineal hernia must be held to be a possibility. Having never seen a vaginal hernia, the wish possibly was father of the thought.

Treatment.—The vaginal mucosa was lifted off from the sac which was filled with yellow fluid. When the sac was opened it was found to be a closed sac, therefore a cyst. It extended upward farther than the finger could reach until the vaginal wall was pulled down, whereupon the top of the sac could be palpated by the finger and proved to end as a blind sac. Its removal was accomplished without difficulty.

Pathology.—The sac was lined with a low cuboidal epithelium that could not certainly be differentiated from endothelium that had been much contracted.

After-course.—So far as the local condition is concerned, the patient has remained well.

Comment.—Other vaginal cysts I have seen were not so long as this, hence could be circumscribed by the palpating finger and thereby positively identified. The great length of this was dependent on its development from a more complete embryonal remnant than is the

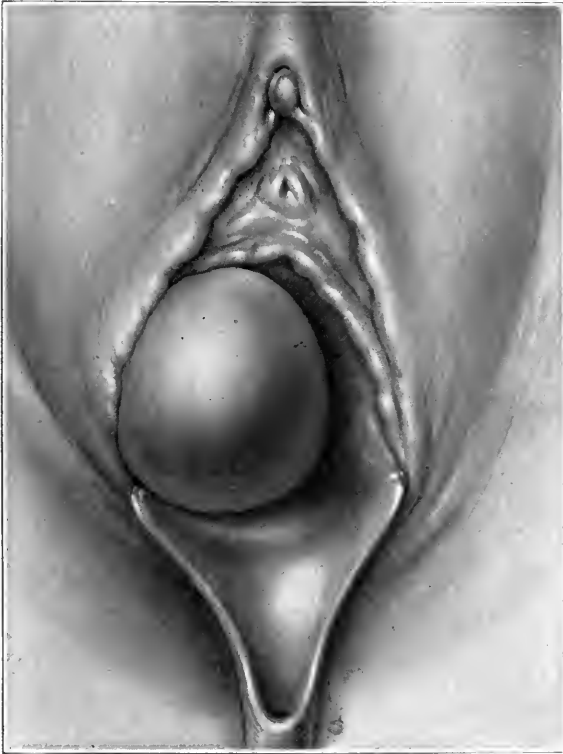

Fig. 467.—Cyst of the vagina.

ease in most instances. I was in error in supposing this might be a perineal hernia for a hernia of this character would appear between the vagina and rectum and not lateral to the vagina, where this tumor was located. It corresponds more to the position of a pudendal hernia, but instead of projecting into the labium it protruded into the vagina.

CASE 8.—A female aged thirty-five came to the hospital because of ulceration of the vulva.

History.—The patient gives her occupation as that of a cook, but is unable to give a very definite account as to where and when she plied this noble art. She states that she has been married but is

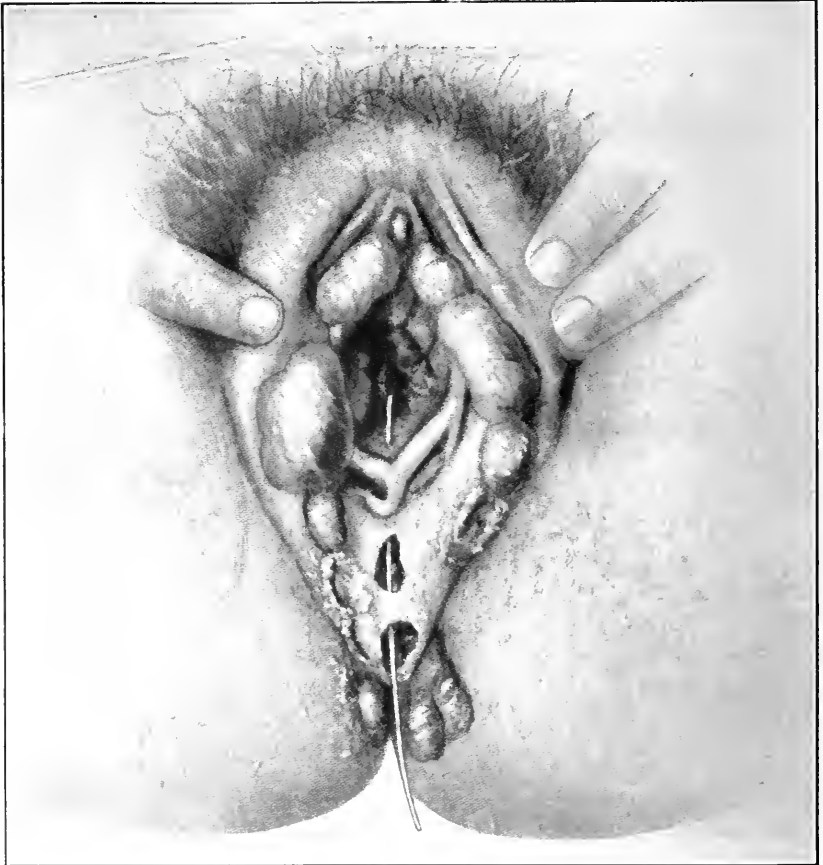


Fig. 468.—Esthiomene.

childless. She has had a vaginal discharge fifteen years. For five years she has had ulcers produced by the discharge. These ulcers were repeatedly cauterized with chemicals and dusted with powders. She obtained no benefit from any of them. Her general

health has become much impaired during the past year and she is unable to sleep because of the local pain.

Examination.—The patient is pale and appears older than the age given. The examination was negative save for the vulvar lesion. Here there was an extensive erosion involving the lower portion of the labia and extending into the vagina. The border of the ulcerous area is overhanging for the most part. It is dense to the touch but does not bleed. In some regions the healing process seems to be going on (Fig. 468).

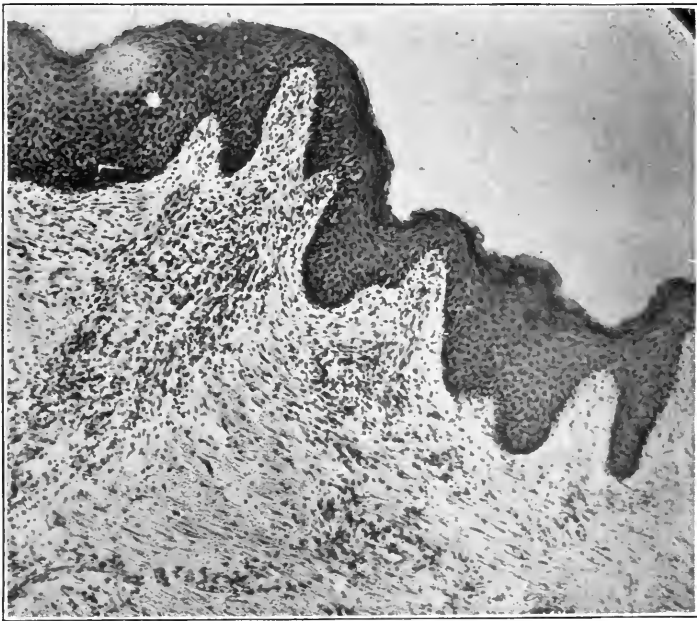

Fig. 469.—Slide from Fig. 468.

Diagnosis.—The diagnosis is made at a glance—esthiomene. The slow course, the dense surface, the tendency to heal as well as to spread in a person whose social status is not a pleasant theme for discussion, are pathognomic. Occasionally carcinoma runs a slow course and even tends to heal, but the cancer nests may be demonstrated about the border and they do not form the dense scar-like masses as in these cases. Tuberculosis makes an undermined border, but the border does not pile up and the affection is confined to young persons.

Treatment.—The more prominent masses were excised and the remainder cauterized with the actual cautery.

After-course.—She improved somewhat while under observation, but was soon lost track of.

Pathology.—The section shows an abundance of connective tissue with many plasma cells. Some of the vessels show a markedly thickened wall. The covering epithelium is somewhat thickened (Fig. 469).

Comment.—This affection is usually seen in prostitutes and is incurable. Some regard the disease as syphilitic in character. The usual changes above mentioned lend a little weight to this hypothesis. That some of these patients give a positive Wassermann is proof positive in the mind of some that the disease is specific in nature. Inasmuch as these patients are usually prostitutes it would be more remarkable if they had not a positive Wassermann than if they had. At any rate antisiphilitic remedies do not modify the course of the disease.

CASE 9.—A girl of sixteen was brought to the hospital because of a tumor of the labium majus.

History.—This patient's mother says this tumor was first noticed a year ago. It occasioned no inconvenience except a slight interception of the stream of urine.

Examination.—A tumor the size of a chicken egg occupies the lower part of the labium majus, displacing the minor inward (Fig. 470). On examination it is soft, semifluctuating. It is not connected with the deeper structures.

Diagnosis.—The soft semifluctuating nature of the tumor at first suggests the more common cyst. Careful palpation shows the mass to extend more deeply than a cyst would and the deeper portions were faintly lobulated. It must, therefore, be a lipoma. These tumors usually extend deeply and have a deep troublesome blood supply. Local anesthesia is not well suited in such a tumor, in a sensitive, nervous patient, hence she shall have ether.

Treatment.—The tumor was excised without moment. It extended in a wedge form deeply into the tissue (Fig. 471). A number of troublesome vessels were found in the depth.

After-course.—Recovery was prompt.

Comment.—Lipomas in this region are not rare and the chief interest in them centers in what they are not.

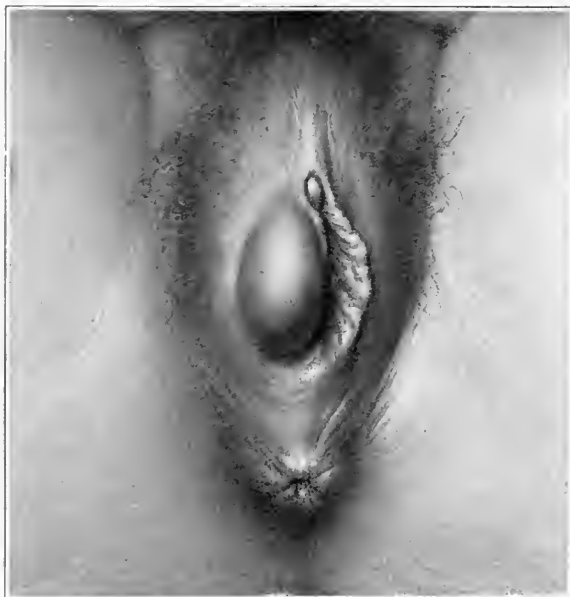

Fig. 470.—Lipoma of the labium majus.




Fig. 471.—Lipoma of the labium majus after excision.

DISEASES OF THE PENIS

The common disease of the penis is carcinoma. When in an old man there is a balanitis with phimosis, a malignant ulceration is very apt to be present. Acute inflammatory indurations and chronic indurations are the common diseases of the shaft.

CASE 1.—A school boy aged sixteen was brought to the hospital because of a deformity of his penis.

History.—The lad relates that ever since he began to have erections he has noted that the organ curved upward more than those of other lads. This was but slightly marked until he passed puberty. Since then it has been annoying at times.

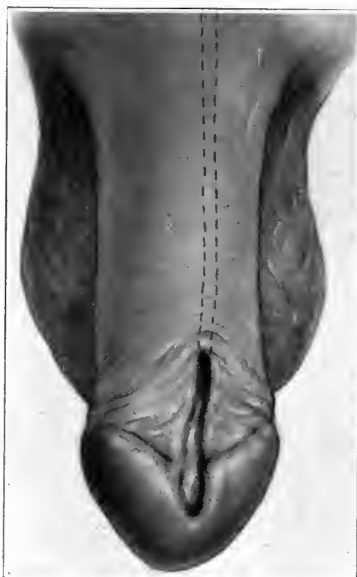


Fig. 472.—Diagrammatic presentation of epispadias.

Examination.—When flaccid the organ presents nothing unusual as to size and form. The foreskin is absent above the glans and hangs below like a hound's chop. In the middle of the glans is a groove which ends in a fossa half an inch from the glans. It looks like a partial degree of hypospadias. The fossa at the end of the groove easily admits an ordinary probe to well up over the pubic bone (Fig. 472). The pubic bone is partly defective, the ramus being rep-

resented by a reduced area the sides forming a notch like a buck horn rifle sight. The urethra is normal and in the right place. When erected, the organ curved over the abdomen giving a correct imitation of a friendly pug dog's tail.

Diagnosis.—This is evidently an epispadias.

Treatment.—The accessory canal was dissected out as far as over the pubic bone to the space of Retzius.

Pathology.—The canal removed was as large as a rye straw and was lined by stratified squamous epithelium.

After-course.—The symptoms complained of were relieved.

Comment.—This case is interesting because it is the faint representation which in the extreme degree represents an extrophy of the bladder and separation of the pubic bones.

CASE 2.—A merchant aged fifty-eight came because of disturbance on erection.

History.—Two months ago he first noticed an excessive upward curving when he had an erection. There was no pain, save a little burning back of the glans at times, when the organ was in a flaccid state. Gradually there has developed an excessive pain during erection, in addition to the excessive bending first noticed. He has enjoyed uniform good health.

Examination.—The patient is a hale, vigorous man. Aside from his peculiar complaint there is no suggestion of disease. Beginning half an inch proximal to the glans and extending upward for a distance of two inches is a hard cartilage-like mass a third of an inch broad and equally thick (Fig. 473). It seems to be T-shape or triangular form with the apex of the triangle directed downwards. It is hard, almost cartilaginous in consistency, and is all but painless even on firm pressure. Examination otherwise is negative.

Diagnosis.—The picture presented is typical of chronic induration of the penis. Nothing resembles it. Gumma sometimes forms a firm mass but it is not so indolent and the form is more egg-shaped. Chronic inflammatory indurations occur in the corpus spongiosum and are sensitive to pressure. The prognosis is as easy to state as the diagnosis.

Treatment.—The patient was told that no treatment would be of avail.

Pathology.—The slide shows heavy indistinct bundles of connective tissue sparsely interspersed by connective tissue cells with deeply staining nuclei (Fig. 474).

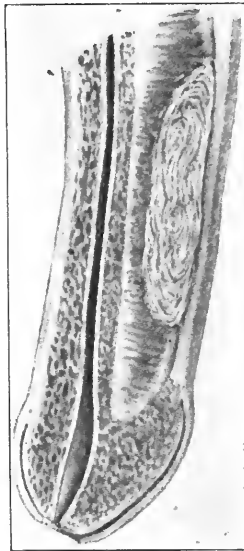


Fig 473.—Chronic induration of the penis.

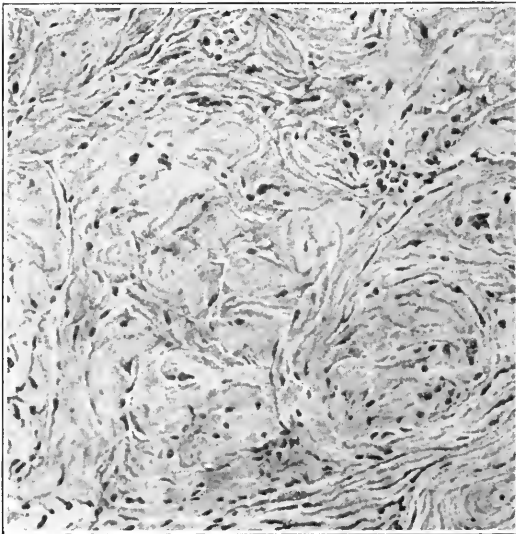


Fig. 474.—Chronic induration of the penis.

After-course.—In the eight years intervening there has been no change and he is quite resigned to his fate. He remained psychically potent, but impotent wholly because of the mechanical difficulties.

Comment.—These patients are sometimes possessed by a suicidal melancholy. Therefore it seems best not to consign them to utter despair. It has been reported that x-ray has cured a few cases. Since they closely resemble keloids in histological structure one would feel disposed to hope for some results from this means. Operation has uniformly failed in my hands. There has been no reformation of a perceptible growth but the primary mass seems to have been so extensive that the portion remaining, after as extensive dissection as possible has been done, is such that no improvement can be noted.

CASE 3.—A farmer aged fifty-six came because of difficulty in passing his urine.

History.—He has always had a long prepuce which he has never been able to retract. It never caused any trouble save that from time to time during the past fifteen years it would become inflamed and cause pain for a few weeks and then gradually subside again. During the periods of inflammation the opening sometimes became so small that the stream of urine was very much reduced. During

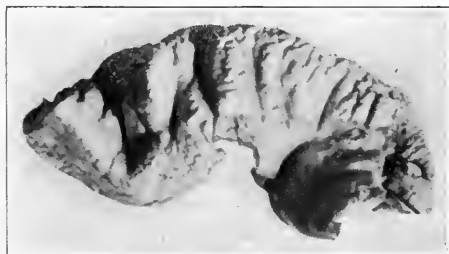


Fig. 475.—“Washboard” prepuce.

the past year this narrowing has been permanent. Now at times the stream is so small that some effort is required to complete the act. His general health has always been good.

Examination.—The prepuce extends an inch beyond the glans. It is hard and leathery. It can be drawn forward and the glans palpated behind it. The glans seems smooth. The prepuce is not sensitive. The opening between the folds of the prepuce admits a probe. There are no glands palpable in the groins.

Diagnosis.—The glans can be palpated and the smoothness of it excludes malignancy of that organ. The prepuce is too elastic to suggest malignancy, but this does not exclude undue epithelial proliferation in some part of it. Inspection of the interior alone can settle all doubt. Obviously removal is demanded.

Treatment.—A circumcision was done.

Pathology.—When the prepuce was spread out no evidence of new growth was discovered. The interior surface was corrugated and gave the feel of dense edema (Fig. 475). The slide showed proliferation of the subdermal layers. The cells are mostly spheroidal interspersed with fibre bundles and much structureless intercellular substance. The structure was that of an elephantiasis.

After-course.—He has remained well.

Comment.—Likely from the irritation, the connective tissue became inflamed, obliterating the lymph vessels. This would account for the elephantiasis-like appearance on microscopic examination.

CASE 4.—The patient aged fifty-three came because of a growth on his penis.

History.—His trouble began six years ago when he fell through the floor of a hay rack, crushing the head of his penis. A year later he noticed a small growth on the glans. It was called a wart by a local doctor and excised. It began to grow immediately. It was then burned by caustics at intervals for six or eight months, but it continued to grow.

Examination.—The growth now involved the whole head of the penis. The growth has a cauliflower-like appearance (Fig. 476-A). There are no metastatic lymph nodes anywhere.

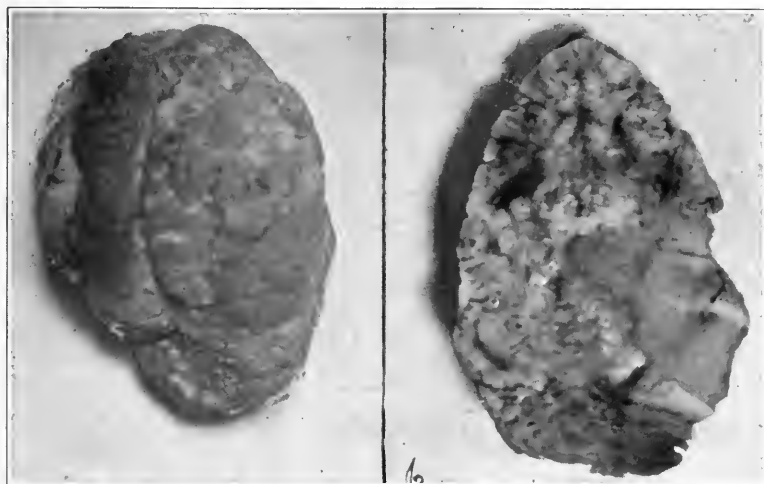
Diagnosis.—The persistent return when destroyed, the cauliflower-like form, its density and tendency to bleed stamp it as a carcinoma. The absence of any discoverable evidence of metastasis warrants operative interference.

Treatment.—Both inguinal regions were completely blocked out under local anesthesia, removing the fat and contained glands. The incisions were prolonged meeting each other at the base of the penis. An incision was made along the dorsum and the lymphatics were removed. When within half an inch of the growth the organ was circumscribed and a flap deflected. The shaft was then severed by a circular incision down to the urethra. This was cut half

an inch longer than the corpora cavernosa and was attached to the skin.

Pathology.—The section of the specimen shows a mass of grayish mottled tissue nearly an inch in thickness (Fig. 476-B). The slide showed typical squamous-celled carcinoma.

After-course.—Healing was uneventful, so far he is free from recurrence, now three years.



A. B.
Fig. 476.—Cauliflower carcinoma of the glans.

Comment.—This case shows the folly of tinkering with the unknown. It also shows the relatively good nature of these growths. After six years of maltreatment there were still no metastases. My experience is that most of the tumors of this organ are relatively little malignant, and unless there is evidence of metastasis, an attempt at cure is warranted no matter how unpromising the local lesion.

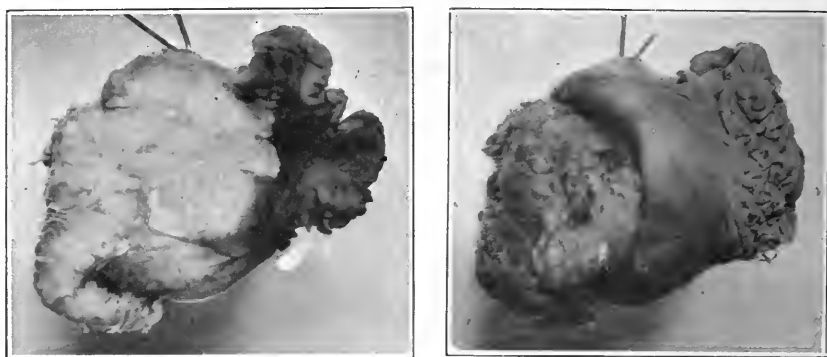
CASE 5.—A retired druggist aged sixty-one came because of pain in the end of his penis.

History.—He says he has had phimosis ever since he can remember. Recently he has had a sense of discomfort and occasionally twinges of pain. Otherwise he is well.

Examination.—The prepuce covers the glans but despite this covering the organ can be felt to be firm and nodular. There are no palpable inguinal lymph nodes.

Diagnosis.—The density and irregularity of the glans together with irritation and occasional pain suggests a beginning malignancy. The prepuce should be split, and if closer inspection confirms the suspicion of malignancy, amputation should be proceeded with.

Treatment.—After the prepuce was split besides the irregularity already noted, fine pinpoint cancer nests could be made out (Fig. 477-A). An amputation with block dissection of the inguinal lymph glands was done at once.



A. B.
Fig. 477.—Squamous-celled carcinoma of glans.

Pathology.—When the glans was cut in two it was seen to be replaced by an epithelial mass (Fig. 477-B). The slide showed it to be squamous-celled carcinoma.

After-course.—Recovery was prompt and he has been free for ten years.

Comment.—Carcinoma of the penis gives a relatively good prognosis. This is particularly true of the slowly growing types.

CASE 6.—A hospital interne desires to know the nature of a ring of papillomas above his glans.

History.—Some weeks ago he discovered a row of small wart-like excrescences above his glans. He knows of no cause and does not suffer.

Examination.—Just above the glans on the lining of the prepuce is a tandem line of small, soft dry papillary projections (Fig. 478). There is no moisture and no induration.

Diagnosis.—Their soft, dry reactionless character distinguishes them from the more vulgar variety.

Treatment.—They were trimmed off and a circumcision added.

Pathology.—The slide shows soft epithelial warts.

After-course.—The healing was uninterrupted but he developed a traumatism syphilophobia.

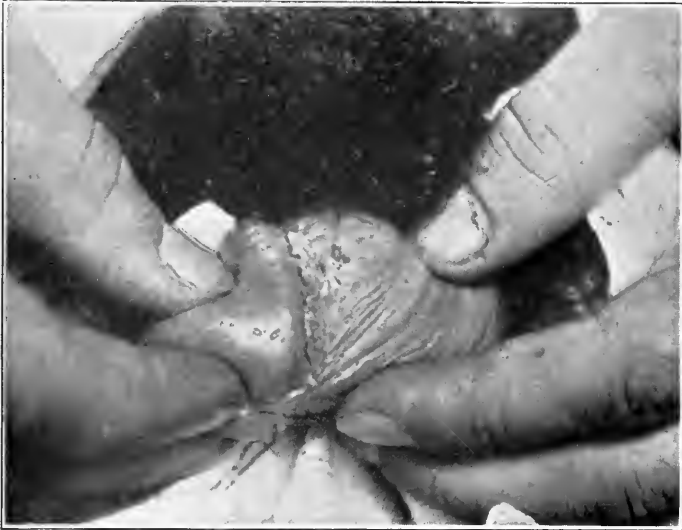

Fig. 478.—Benign papillomas of the prepuce.

Comment.—It might have been better to have disregarded these growths entirely. He could have seen then that there were no sequelæ to be expected.

DISEASES OF THE SCROTUM AND ITS CONTENTS

Testicular tumors are usually mixed tumors. Testicular enlargements are usually syphilitic and epididymal affections either tuberculous or gonorrhœal, but may be syphilitic; Hematomas may simulate solid tumors. Serous accumulations are easily detected.

CASE 1.—A farmer aged forty-two came because of a tumor of the testicle.

History.—A year ago he was thrown against a saddle horn and sustained an injury to his left testicle. It was swollen and painful for a time and then subsided but subsequently began to enlarge again. Three months ago he injured it again. Since then it has

enlarged rapidly. His physician tapped it a few weeks ago but obtained only blood. He diagnosed sarcoma and advised castration.

Examination.—The organ is as large as a goose egg, smooth, and firm to the touch and not sensitive. It is opaque on transillumination.

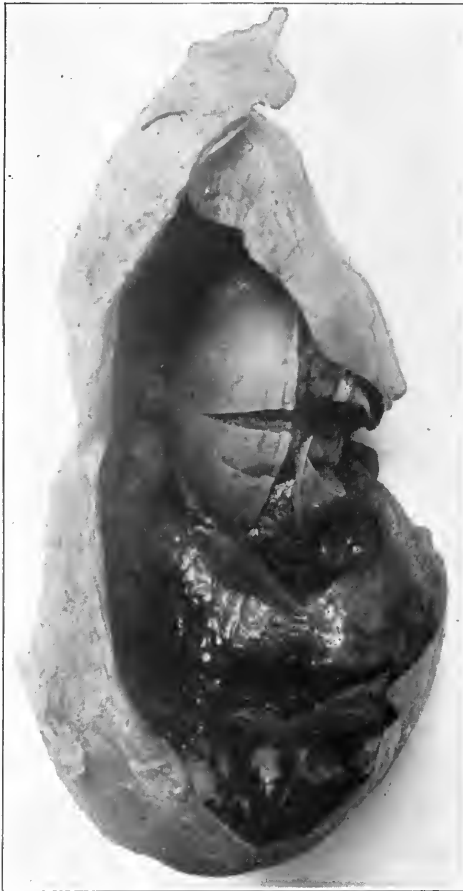

Fig. 479.—Hematocele removed for mixed tumor of the testicle.

Diagnosis.—The history of rapid growth following trauma seems pathognomonic of mixed tumor. Castration seems good advice.

Treatment.—The cord was traced as high as possible in the inguinal canal and then severed. The organ was then removed from above downward.

Pathology.—When the tumor was split open it was found to consist of a normal testicle and a mass of old blood clots. (Fig. 479.)

After-course.—The patient suffered less than the surgeon.

Comment.—Evidently the progressive increase in size was due to progressive hemorrhages. Pain following hemorrhage is usually more intense than this man seems to have suffered. Exploratory incision should of course have been done before castration was proceeded with.

CASE 2.—A farmer aged twenty-four came to the hospital because of a painful mass in the left groin.

History.—He first noticed a mass in the left groin 12 years ago. It disappeared when he lay down. Two years ago it became painful and on several occasions he has had to lie on his back with his hips elevated in order to make it disappear. He has worn a truss for a year. Several days ago a general anesthetic was given in order to reduce it.

Examination.—The left inguinal region is exceedingly sensitive to touch. The index finger can be passed through the external ring and receives an impulse on coughing. The right inguinal canal is occupied by a smooth round body. An impulse is transmitted on coughing. The right side of the scrotum is empty.

Diagnosis.—Obviously there is a left inguinal hernia and a right undescended testicle. Inasmuch as an operation is necessary to operate on the left side it seems expedient to repair the right side also.

Treatment.—The left side contained a sac extending well into the scrotum. The right side likewise had an open sac. The typical operation was done. The right testicle was brought down into the scrotum and anchored. The cord seemed unusually short, and difficulty was experienced in getting the testicle into the scrotum.

After-course.—The wound healed without disturbance, but he had severe pain in the transplanted testicle for the first week. After he had been home a few days the transplanted testicle began to be more painful again and the region occupied by it swelled. Three days ago the skin in this area broke leaving a grayish mass below. Since the sloughing began the pain has been somewhat less. Lateral to the root of the penis is an ulcer the size of a quarter. There is a soft blue gray mass protruding through the opening (Fig. 480). Below this is a smaller one about the size of the end of a lead pencil. The skin about is red and indurated. Very obviously the grayish mass was the recovered testicle for the tubules could

be made out in the macerated mass. The testicle was removed and healing was uneventful.

Comment.—Obviously the circulation was destroyed in transplanting the testicle either by injury to the vessels or by making too

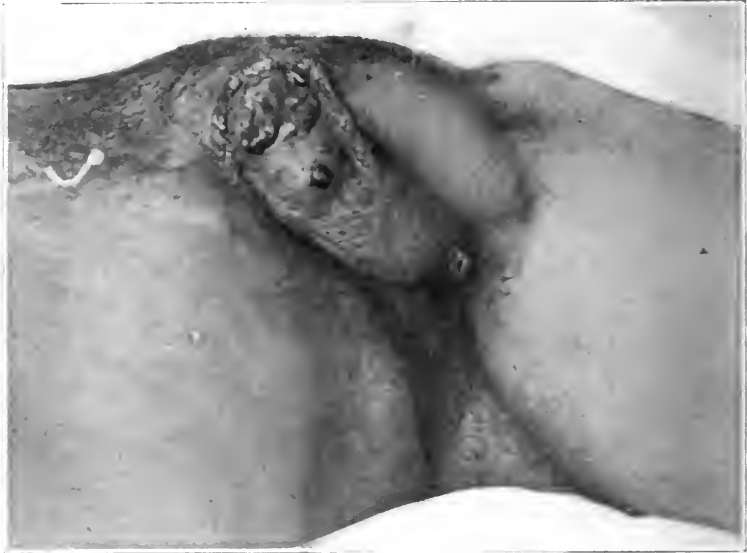

Fig. 480.—Sloughing testicle after operation for retained testis.

much tension on the cord. This is the only time I have ever known this accident to occur. When there is one normal testicle in the scrotum the patient is better served by removing the displaced organ.

CASE 3.—A farmer aged sixty-four was brought to the hospital because of pain in his left testicle.

History.—The patient complains of pain in the left testicle. He dates his trouble from the time two months ago when he had an operation for varicocele. The operation was done by a quack by the subcutaneous mass ligation plan. Since that time the left testicle and cord have been very painful, so painful in fact as to destroy all desire for food and to prevent his sleeping.

Examination.—The spermatic cord is very painful to touch, but despite the patient's protests, one can make out a marked thickening of the cord at the site of operation. At examination he seemed nervous and unreasonable. Otherwise he seemed well.

Diagnosis.—Following unskilled operations on the cord one not infrequently sees conditions quite parallel to Cooper's "irritable testis." Men not otherwise neurotic become so. The patient's physician assured me the patient's mentality was entirely normal before the operation, and I believed it.

Treatment.—Orchidectomy.

After-course.—The first night after operation the patient tried to commit suicide by striking himself in the head with a drinking glass. A few days later he tried to jump from the window. Between these attempts he was apparently normal. He went home on the tenth day still having delusions of persecution.

Comment.—The point of interest in this case was that I believed his mentality was normal before the original operation for varicocele and that I could cure his head by castration. A man who seeks an operation for varicocele at the age of sixty-four is crazy and is not a subject for any operation. The patient's son admitted when confronted with the facts, that the patient had imagined for some time, beginning soon after the operation for varicocele, that he had lost huge sums of money and that he was being pursued by enemies. He also admitted that he did not appear entirely normal for months before the operation. It is possible that the operation for varicocele may have precipitated the more pronounced mental manifestation.

CASE 4.—A farmer aged thirty-six came because of an enlarged testicle.

History.—The patient's general health has always been good. Three or four years ago he noticed an enlargement of the right testicle. It has gradually become larger until now he desires to have it removed because of its size. It has enlarged more rapidly in the past few months. Recently some backache and sensation of pulling and weight from the size of the scrotum has been noted.

Examination.—The right side of the scrotum is filled with an ovoid tumor, firm, eight inches in length and three and one-half in diameter. It does not transmit light.

Diagnosis.—Though it is perfectly uniform its huge size and slow uniform growth excludes syphilitic disease. The large size is found only in mixed tumors. Though there is no evidence of metastasis, the recent increase in size with evidence of distress makes it likely that secondary processes are active. The patient is told that he can be freed from the external mass but that return is inevitable.

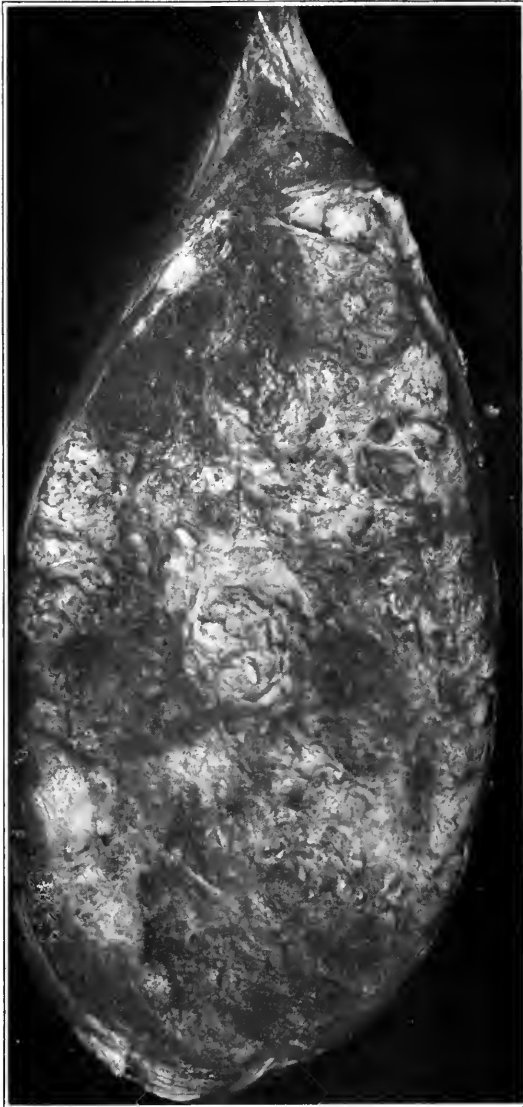


Fig. 481.—Mixed tumor of the testicle.

Treatment.—Right orchidectomy was done. The cord was followed into the abdominal cavity but no attempt was made to remove the retroperitoneal lymph glands.

Pathology.—On section the tumor mass showed broken down areas (Fig. 481). The islands of preserved tissue show ovoid cells of varying size, therefore a mixed tumor.

After-course.—He returned in four months with a number of retroperitoneal nodules as large as apples, as he was told there might be before he was operated on.

Comment.—Theoretically it is proper to remove the retroperitoneal lymph glands. The inguinal glands of course need not be removed. However, I have never seen the most extensive operations ward off the disease, and tiring of these useless extensive operations, I have confined my efforts to resection of the tumor and cord under local anesthesia.

CASE 5.—A farmer aged seventy-two entered the hospital because of a tumor of the scrotum.

History.—Five years ago he noticed some enlargement of the right testicle. It did not pain and he paid no attention to it. This enlargement gradually developed but caused very little pain at any time. Six months ago he noticed the left testicle begin to enlarge and gradually grow to the present time. It caused no trouble until ten days ago when he had a rather sudden retention of urine. The urine was drawn with a rubber catheter for a week but in the last three days he has been passing it normally. His general health is good. Appetite good, bowels regular. Gets up twice a night to urinate.

Examination.—The right testicle is about the size of an orange and does not transmit light. The scrotal veins are markedly dilated. The left testicle is the size of the fist and transmits light. The veins on this side are enlarged. The prostate about normal size.

Diagnosis.—The right testicle is firm and elastic, but does not transmit light. The most common solid tumors of the testicle are the mixed tumors. A syphilitic orchitis would not have been so long in developing and would have retained the form of the testicle. This one is slightly bosselated at some points. The left side is elastic and transmits light and may therefore be regarded as a hydrocele. There are no evident metastases in the retroperitoneal space and it seems justified to give the old man temporary relief by removing the offending enlargements.

Treatment.—The tumor of the right testicle was resected, taking as much of the spermatic cord as possible. The sac of hydrocele was dissected from the left testicle.

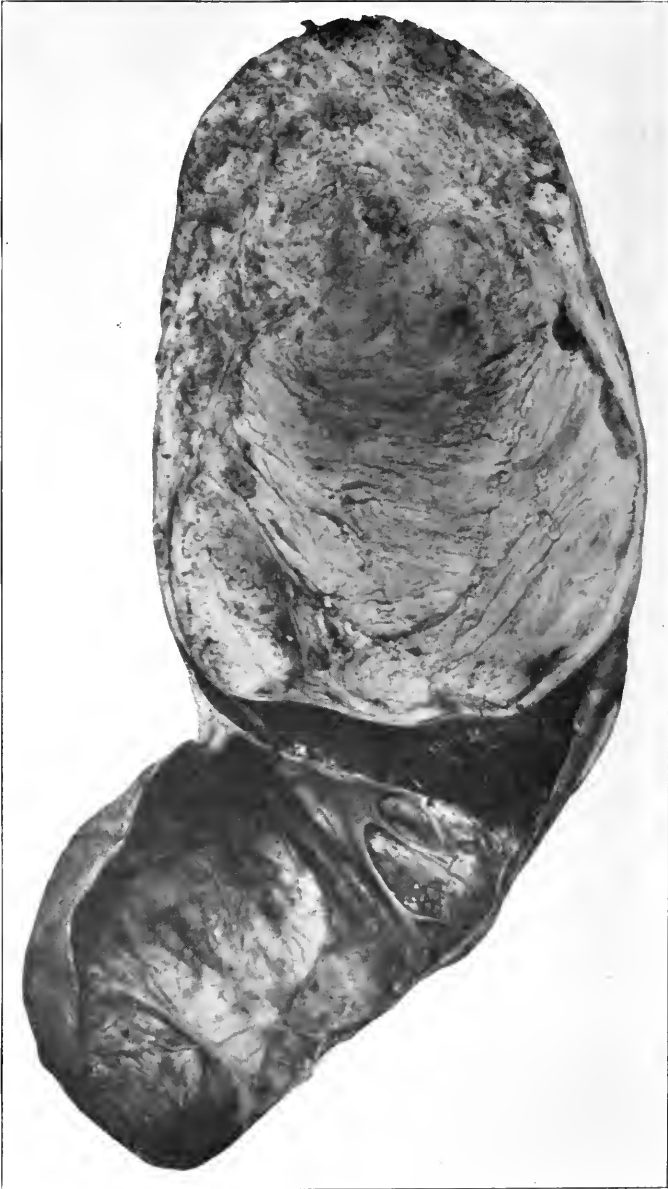

Fig. 482.—Mixed tumor of the testicle.

Pathology.—The section showed a mottled reddish-gray surface with some areas of hemorrhagic infarction (Fig. 482). The slide shows it to be made up chiefly of large cells with much protoplasm (Fig. 483). It may be accepted as a mixed tumor.

After-course.—Both incisions became infected and drained a great deal of pus. They cleared up very slowly and were not completely healed at dismissal, draining a little pus every day. The patient insisted on going home and agreed to come back once a week for

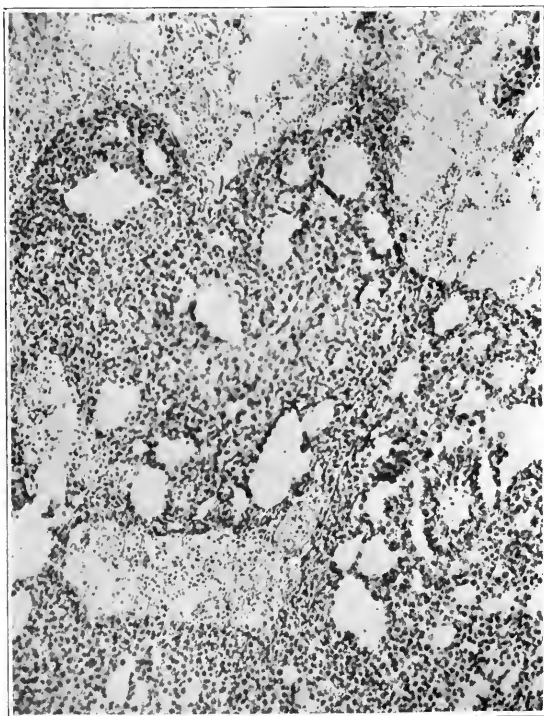


Fig. 483.—Mixed tumor of the testicle.

dressing and observation. This he did not do, but no doubt retroperitoneal metastases occurred.

Comment.—Either these patients have come at a time when metastasis was imminent or else operation but stimulates such a process. They come with histories dating back two, three, five or even more years. When operated on they have invariably died within a year or two.

INDEX

A

- Abdomen, enlargement of, due to
 myxedema, ii, 842
 general, ii, 593
 lower, ii, 577
 pain in upper, ii, 630
 perforated ulcer in, ii, 555
 tumors of, ii, 788
 upper, ii, 547
- Abdominal crises, ii, 547
 severe, ii, 547
 distention, ii, 607, 679
 and obstipation, ii, 651
 due to carcinoma, ii, 620
 distress, ii, 679
 due to abscess at right of uterus,
 ii, 764
 fistula, ii, 701
 pain, acute, ii, 599, 855
 and collapse, ii, 588
 and distention, ii, 561
 due to acute epididymitis, ii, 668
 due to adherent diverticulum, ii,
 556, 557
 due to gall bladder colic, ii, 632
 due to gallstones, ii, 634
 due to intestines slipping through
 hole in mesentery, ii, 567
 due to myoma of uterus, ii, 586
 due to nodular mass in pyloric
 region, ii, 622
 due to pancreatic necrosis, ii, 571
 due to perforated ulcer, ii, 554
 following traumatism, ii, 650
 tumor, ii, 800, 858
 amenorrhœa, ii, 863
 wall, bald-headed endothelioma of,
 ii, 957
 desmoid of, ii, 955
 diseases of, ii, 942
 inflammatory infections involving,
 ii, 962
 tumors of, ii, 955
 veins dilated due to obstruction
 of venous return, ii, 821
- Aberrant thyroid at angle of jaw, i,
 172
- Abortion, pelvic distress following, ii,
 879
- Abscess about appendix, ii, 662
 around kidney and bladder, ii, 784
 at right of uterus, causing abdom-
 inal distress, ii, 764
 broad ligament, ii, 726
 chronic, of breast, simulating car-
 cinoma, i, 322
 following appendectomy, ii, 660
 following tuberculosis of rib, i, 379
 lipoma of femoral ring, ii, 947
 lung, i, 285
 following pneumonia, i, 288
 of axilla, i, 376
 of broad ligament, ii, 786
 following labor, ii, 785
 of hard palate, i, 141
 of hip, ii, 970
 of lung, i, 281
 of neck due to infection from mouth,
 i, 190
 of symphysis pubis, ii, 779
 pararectal, ii, 1042
 paravesical, ii, 1008
 pelvic, following vaginal hysterec-
 tomy, ii, 969
 periappendiceal, ii, 677
 from bubo, ii, 667
 perirectal causing bladder disturb-
 ances, ii, 974
 perirenal, ii, 990
 retroperitoneal, ii, 784
 subdiaphragmatic, containing gas,
 ii, 552
 subdiaphragmatic following appen-
 dicitis operation, ii, 581
 surrounding displaced appendix, ii,
 638
 tuboovarian, ii, 854
 within broad ligament drained
 through vagina, ii, 719
 within the gut wall, ii, 606
- Accessory sinuses, diseases of, i, 96
 mammae, ii, 956
 mammary gland in the male, ii, 958
- Actinomyces of jaw, i, 133, 136
- Adenocarcinoma of breast, i, 358
 of intestine, ii, 672
 of ovary, ii, 868
 of stomach, ii, 788
 of uterus, ii, 930

- Adenoma, fetal, i, 230
of thyroid, i, 236
- Adenomatous thyroid, i, 222
- Adenomyoma of uterus, ii, 905, 908
beginning malignancy in, ii, 881
- Adhesions among intestinal coils due to
peritonitis, ii, 845
complicating appendicitis, ii, 653
following appendicitis, ii, 712
postoperative, ii, 603
preventing perforation of gastric ulcer, ii, 563
surrounding gall bladder, ii, 698
liver, duodenum, and colon, ii, 701
- After-course of surgical diseases, i, 26
- Alcohol injection in trifacial neuritis, i, 70
- Alveolar abscess, chronic, simulating a wen, i, 82
border, epulis involving, i, 155
granuloma of, i, 151
process, suppuration of, i, 107
- Amenorrhea, ii, 890
and abdominal tumor, ii, 863
associated with goiter, i, 246
- Amputation neuroma, i, 463
under spinal anesthesia, i, 524
- Anemia, pernicious, ii, 734
- Anesthetic for removal of angioma, i, 38
- Aneurysm, arteriovenous, of arm, i, 388
false, of popliteal artery, i, 485
in mediastinum, i, 260
of femoral artery, i, 460
of the renal artery, ii, 823
syphilitic, i, 271
- Angina, Vincent's, i, 196
- Angioma after removal, i, 38
of hand, i, 419
of lip, i, 113
of temple, in infant, i, 29
- Ankle, bony ankylosis of, i, 546
chondroma of, i, 525
melanoblastoma of, i, 532
tuberculosis of, i, 513
ulcer of, i, 512
- Ankylosis of ankle and shoulder following otitis media, i, 546
of knee joint, i, 492
- Antrum, carcinoma of the, i, 104
osteosarcoma of, i, 110
sarcoma of, i, 108
- Anus, condyloma of, ii, 1048
discharging sinus near, ii, 1041
fungating carcinoma of, ii, 1038
tuberculous ulcer, ii, 1046
- Anus—Cont'd.
ulcer of, ii, 1045
wart growth about, ii, 1047
- Aorta, syphilitic aneurysm, i, 271
- Appendiceal pain, ii, 650
- Appendicitis, ii, 601, 611, 623, 650, 659, 665, 712, 729
adhesions complicating, ii, 653
and indurated omentum, ii, 661
chill and fever following operation, ii, 580
complicated by abscess, ii, 662
fistula following, ii, 1044
kidney stone following, ii, 975
pneumonia simulating, in children, ii, 652
simulating gall bladder infection, ii, 813
tubal pregnancy, ii, 675
- Appendix adherent to ovary, ii, 715
attached to cecum, ii, 627
carcinoma of, ii, 707
in advanced stage of necrosis, ii, 611
in hernia, ii, 594
indurated, lying beneath gall bladder, ii, 624
located lateral to ascending colon, ii, 639
necrosis of, ii, 659
stone in, ii, 658
- Appetite, loss of, ii, 781
and digestive disturbance due to hyperthyroidism, i, 120
- Arm, arteriovenous aneurysm of, i, 388
edema of, from recurrent carcinoma of breast, i, 385
melanosarcoma of, i, 396
mixed-celled sarcoma, i, 390
multiple lipofibrosis of, i, 394
neurolipoma of, i, 393
osteomyelitis, acute suppurative, i, 375
osteosarcoma of, i, 392
pits, tumors at edge of, ii, 956
sporotrichosis of, i, 403
tumor of, i, 387, 396
ulcers on, i, 402
- Arteriosclerosis, i, 535
- Arthritis, infective, of hip joint, i, 437
- Astragalus, chondroma of the, i, 525
- Atheromatous degeneration of mucosa of esophagus, ii, 746
- Axilla, abscess of, i, 376
tuberculosis of, i, 377
- Axillary region, cancer of, i, 319
tumor in case of breast carcinoma, i, 317

B

- Bald-headed endothelioma of abdominal wall, ii, 957
 sarcoma of the ilio-pubic region, ii, 960
- Bar across base of bladder following prostatectomy, ii, 1004
- Basal-celled carcinoma of alæ of nose, i, 84
 epitheliomas beginning as warty growths, i, 86
 of the temple, i, 85
- Benign epithelioma of cheek, i, 88
 papilloma of bladder, ii, 998
 tumors of mediastinum, i, 260
- Birth mark, i, 32
- Bladder and bowels, inability to control in case of spina bifida, i, 307
 bar at base of, following prostatectomy, ii, 1004
 blood passing through, ii, 885
 carcinoma of, ii, 996
 diseases, ii, 974
 diverticulum of, ii, 1007, 1008, 1017
 foreign body in, ii, 981
 fullness above, due to ovarian tumor, ii, 868
 hemorrhage following prostatectomy, ii, 1016
 irritation, ii, 677, 725, 974
 due to tuberculosis of the kidney, ii, 984
 due to uterine lesion, ii, 989
 obstruction of, ii, 1003
 pain around, ii, 646
 pain in, ii, 633, 988
 papilloma at base of, ii, 998
 diagnosed bladder stone, ii, 1001
 sarcoma of, ii, 1005
 stone, ii, 648, 978, 981, 985, 986, 987, 991
 papilloma of bladder simulating, ii, 1001
 recurrent, due to drinking water in limestone country, ii, 1022
 trouble due to pressure of tumor of ovary, ii, 979
 uterus retroverted and impinging upon, ii, 634
- Bleeding from uterus, ii, 916, 923
- Broad ligament abscess, ii, 719
- Blood, passage of, through bladder, ii, 885
 vomiting of, ii, 743
- Bloody discharge between periods, ii, 896
 stool, ii, 609, 1026
 vaginal discharge, ii, 931
 due to carcinoma, ii, 897
- Blue spot on lip, i, 112
- Bony deformity from infected arthritis of knee, i, 491
- Bowel movements, frequent, ii, 1037
 obstruction of, ii, 568, 705
- Brain abscess following mastoiditis, i, 54
 cyst, i, 61
 effect of chloroform poisoning on, i, 47
 diseases, i, 46
 tumor, slide of, i, 63
- Breast, adenocarcinoma of, i, 358
 affections in relation to pelvic disorders, i, 366
 bone, painful swelling on, i, 273
 pain under, i, 271
 ulcer over, i, 315
 cancerous ulcer following operation for carcinoma, i, 331
 carcinoma, i, 311, 318, 336, 368
 in interstitial mastitis, i, 348
 metastatic, i, 316
 chronic abscess simulating carcinoma, i, 322
 colloid carcinoma of, i, 313
 cyst in an interstitial mastitis, i, 359
 cyst of, i, 362, 364
 cystic, i, 360
 carcinoma, i, 369
 sarcoma of, i, 355
 tumors of, i, 358
 desmoid of, i, 330
 diffuse affections of, i, 339
 diseases of, i, 310
 encapsulated tumors of, i, 350
 fibroadenoma, intracanalicular, i, 352
 interstitial mastitis, i, 340, 342, 344
 with malignant area, i, 346
 mixed tumor of, i, 351
 operation under local anesthesia because of heart disease, i, 319
 painful, due to premature menopause, i, 339
 recurrent nodule in, i, 314
 small duct carcinoma of, i, 311
 tumor in relation to tumor on back of head, i, 39
 tumor of, i, 342
 ulcerated area over, i, 332

- Bronchopneumonia, empyema following, i, 283
- Bronchus, pin in, ii, 284
- Broad ligament abscess, ii, 786
following labor, ii, 785
- Bruise of hip, i, 430
- Bubo, periappendiceal abscess from, ii, 667
- Bursitis of shoulder, i, 372
- Bursitis peroneus tendon, i, 529
- Buttocks, fistula in, ii, 1042
- C
- Calcareous deposit in wall of cyst complicating club foot, i, 528
mass in bladder, ii, 985
- Calcified thyroid gland attached to trachea, i, 204
- Calf, diseases of, i, 496
lymphangioma of, i, 509
muscles, Volkmann's contraction, i, 516
sarcoma, bald-headed, i, 505
tumor of, i, 505
- Cancer (*see* carcinoma)
- Cancer quack plaster, necrosis from, i, 35
- Cancerous ulcer of breast following operation for carcinoma, i, 331
- Capillary-venous angioma of lip, i, 113
- Carcinoma at ileocecal junction, ii, 838
en cuirasse, i, 326
in interstitial mastitis, i, 348
metastatic, about brachial tree, i, 280
of breast, i, 316
of antrum, i, 104
of anus, fungating, ii, 1038
of appendix, ii, 707
of bladder, ii, 996
of breast, i, 311, 318, 368
and axillary region, i, 319
edema of arm from recurrent, i, 385
encapsulated, i, 356
metastasis from, i, 328
recurrent, i, 337
scar after plaster treatment of, i, 333
skin over, i, 326
skin, recurrence in, i, 321
of cardia, ii, 781
of cecum, ii, 833
of cervix, ii, 704, 898, 901
after myomectomy, ii, 903
of cheek, i, 90
of clitoris, ii, 1056
- Carcinoma—Cont'd.
of esophagus, ii, 765
of floor of mouth, i, 131
of fundus of uterus, ii, 922
of gall bladder, ii, 769
following cholecystotomy, ii, 637
of hand, i, 422
of humerus, metastatic, i, 386
of lip, i, 119, 120
of mediastinum, i, 266
of neck, i, 180
of nipple, i, 324
of nose, i, 84
of ovarian origin, ii, 852
of pelvic colon, ii, 673
of penis, ii, 1072, 1073
of pylorus, ii, 777
involving liver and surrounding tissue, ii, 800
of rectum, ii, 873, 1027, 1030, 1031, 1034, 1036
of scalp from breast tumor, i, 39
of stomach, ii, 620, 689, 742, 743, 761, 782
differentiation from pernicious anemia, ii, 734
gall bladder disease simulating, ii, 733
of thigh developed in scar, i, 452
of tongue, i, 128, 166
of uterus, ii, 927, 929, 932, 933, 935
fungus, ii, 904, 919
of vagina, ii, 895, 899, 900
of vulva, ii, 1054
recurrence, i, 91
squamous-celled, of neck, i, 169, 185
systemic metastasis following, i, 371
ulcerating, of stomach, ii, 798
- Cardia, cicatricial stenosis of, ii, 755
constriction at, ii, 744
- Catarrhal jaundice, ii, 772
- Cauliflower carcinoma of the glans, ii, 1073
growth of cheek, i, 93
- Cavernous hemangioma of the temporal region, i, 32
- Cecum, acute miliary tuberculosis, ii, 656
carcinoma of, ii, 833
- Cell degeneration and exfoliation in exophthalmic goiter, i, 247
- Cellular fibrous tissue of goiter, i, 201
- Cerebral hemorrhage, ii, 685
hemorrhages following rectal carcinoma, ii, 1031
- Cervical carcinoma following myomectomy, ii, 903

- Cervical—Cont'd.
 erosion, ii, 697, 871, 873
 lymph gland, cystic carcinoma of, i, 167
 glands, enlargement of, i, 269
 mucosa, polypoid degeneration of, ii, 896
 spina bifida, i, 292
 Cervix, carcinoma of, ii, 704, 898, 901
 erosion of, ii, 877, 879, 884
 polyp of, ii, 934
 Charcot's hip, i, 444
 Check, benign cystic epithelioma of, i, 88
 carcinoma of, i, 90
 cauliflower growth of, i, 93
 tumor of, i, 80, 86
 due to carcinoma of antrum, i, 104
 ulcers of, i, 84
 wen of, i, 81
 Chest and spine, diseases of, i, 256
 empyema following bronchopneumonia, i, 282
 pain in, i, 282
 Childbirth, fever following, ii, 786
 Chill and fever following appendicitis operation, ii, 580
 Chloroform poisoning, i, 46
 Cholecystectomy, with drainage, ii, 635
 Cholecystitis, ii, 614, 628, 694, 698, 738, 739
 attacks simulating, ii, 638
 Cholesteatoma, i, 97
 Chondroma of ankle, i, 525
 of the astragalus, i, 525
 Chronic induration of penis, ii, 1069
 spondylitis, i, 299, 304
 Cicatricial stenosis of the cardia, ii, 755
 Cicatrization of area excised in carcinoma, i, 94
 Clitoris, carcinoma of, ii, 1056
 Club foot, cyst complicating, i, 527
 Colloid goiter, i, 198
 degeneration of myoma of the uterus, ii, 840
 toxic goiter, i, 253
 Colloidal carcinoma of breast, i, 313
 Colon, carcinoma of, ii, 673
 tumor of, ii, 566
 Condyloma of anal region, ii, 1048
 Congenital goiter, i, 211
 tumors, i, 30
 Congestion of pelvic organs, ii, 879
 Constipation, ii, 679
 and frequent urination, ii, 990
 obstinate, and painful menstruation, ii, 888
 Constriction at cardia resulting in starvation, ii, 744
 Convulsions in case of brain abscess, i, 55
 Corn on sole of foot, i, 541
 plantar, i, 542
 Corpus luteum, persistent, ii, 891
 Cough and expectoration due to lung abscess, i, 280
 Cough due to lung abscess, i, 285
 produced by enlarged thyroid, i, 202
 with recurrent tumor, i, 179
 Coughing due to goiter, i, 258
 Coxitis, senile, i, 438
 Coxa vara, i, 432
 Cramping pains in upper abdomen, ii, 693
 Cranial contents, diseases of, i, 46
 diseases, angioma of temple in infant, i, 29
 cavernous hemangioma of the temporal region, i, 32
 hemangioma, i, 31
 Cranium, diseases of, i, 28
 Cystadenoma of the ovary, papillary, ii, 980
 Cyst complicating club foot, i, 527
 dentigerous, i, 144
 gill cleft, i, 182
 in interstitial mastitis, i, 359
 luteal, of ovary, ii, 708
 of brain, i, 61
 of breast, i, 362, 364
 with discharging sinus, i, 326
 of canal of Nuck, ii, 945
 of gall bladder, ii, 697
 of neck, i, 181
 of ovary, ii, 969
 of pancreas, ii, 791
 of vagina, ii, 1063
 ovarian, ii, 723, 807, 852, 910
 simulating pregnancy, ii, 860
 thyroglossal, i, 124
 tuberculous, ii, 792
 Cystic breast, i, 360
 carcinoma of breast, i, 369
 of cervical lymph gland, i, 167
 degeneration of cervix, ii, 878
 diseases of the neck, i, 181
 lymphangioma of leg, i, 510
 sarcoma of breast, i, 355
 tumors of breast, i, 358
 Cystitis, ii, 811
 Cystoma, malignant, of ovary, ii, 804
 of uterus, ii, 858
 papillary, of ovaries, ii, 670
 Cystocele, ii, 704, 824

D

- Deciduoma maligna, retained placenta resembling, ii, 924
- Deformity of penis, ii, 1068
- Degenerated toxic goiter, i, 243
- Degeneration of kidney, ii, 810
of liver in delayed chloroform poisoning, i, 49
- Delirium due to thyroid intoxication, i, 212
following injury to skull, i, 53
- Dentigerous cyst of lower jaw, i, 144
- Dermoid cyst of neck, i, 188
of mediastinum, i, 262
- Desmoid, abdominal, ii, 955
of pectoral region, i, 329
- Diabetes insipidus, goiter in a case of, i, 207
- Diagnosis in surgical cases, i, 3
of patient, as well as disease, i, 22
of surgical diseases, i, 21
- Diagnostic laboratory, relation of surgeon to, i, 17
- Diarrhea and vomiting in carcinoma of the stomach, ii, 689
- Diffuse affections of the breast, i, 339
- Digestive disturbance and loss of weight, ii, 613, 732
due to appendicitis, ii, 665
due to hyperthyroidism, i, 220
due to stone in duodenum, ii, 736
- Dilated veins in abdominal wall due to obstruction of venous return, ii, 821
- Discharging sinus near anus, ii, 1041
- Disease, surgical, general principles underlying, i, 1
- Diseases of abdominal wall, ii, 942
of accessory sinuses, i, 96
of breast, i, 310
of calf, i, 496
of chest and spine, i, 256
of cranial contents, i, 46
of cranium and contents, i, 28
of elbow and forearm region, i, 387
of external genitals, ii, 1053
of face and accessory sinuses, i, 65
of foot, i, 517
of hand, i, 413
of hip, i, 430
of jaw, i, 112, 132
of knee, i, 474
of lips, i, 112
of lower extremities, i, 430
of lungs, i, 274
of mediastinum, i, 256

Diseases—Cont'd.

- of mouth and jaws, i, 112
of neck, i, 156
of penis, ii, 1068
of perianal region, ii, 1044
of rectum, ii, 1023
of scrotum and its contents, ii, 1075
of shoulder, i, 372
of spine, i, 291
of thigh, i, 452
of thyroid gland, i, 198
of tongue, i, 121
of upper extremity, i, 372
of wrist, i, 400
past history of, i, 11
- Disturbance of nutrition, ii, 729
- Diverticulum of bladder, ii, 1007, 1008, 1017
- Draining lung abscess, i, 288
- Dribbling of urine, ii, 1009
- Duodenal fistula, ii, 701
stone, ii, 736
- Duodenum, perforating ulcer of, ii, 559
- Dupuytren's contraction, i, 423
- Dysmenorrhea, ii, 885
- Dysphagia, ii, 744, 748
in case of thyroiditis, i, 208
- Dyspnea and difficult urination, ii, 1017
caused by goiter, i, 203
due to intratracheal thyroid, i, 204
- Dysentery complicating jaundice, ii, 773

E

- Ear, tumor of, i, 87
warty epithelioma of, i, 87
- Edema of arm from recurrent carcinoma of breast, i, 385
- Elbow, diseases of, i, 387
sarcoma of, i, 395
- Electric cautery, for lip tumors, i, 113
in nerve operation, i, 67
- Elephantiasis of prepuce, ii, 1072
- Emaciation due to intestinal fistulæ, ii, 576
operative risk in cases of, ii, 693
- Embolism of foot, i, 524
- Empyema, i, 260, 278, 282
due to foreign body, i, 285
- Encapsulated carcinoma of the breast, i, 356
tumors of breast, i, 350
- Enchondroma of finger, i, 416
- Endocarditis, symptoms of hyperthyroidism simulating, i, 242
- Endocervicitis with mucus discharge, ii, 871

- Endometrium, hyperplastic, ii, 885, 906
 mucous polyp of, ii, 925
- Endothelial lymph glands in case of Hodgkin's disease, i, 161
- Endothelioma of abdominal wall, bald-headed, ii, 957
- Enlarged testicle, ii, 1079
- Enlargement of the nose, i, 79
 of the prostate, ii, 1010, 1013
 of the thyroid gland, i, 198
- Enterolith, ii, 657, 836
 formed of pawpaw seeds, ii, 599
- Epididymitis, ii, 668
- Epigastric cramps, ii, 683
 distress, ii, 694
 and loss of weight, ii, 734, 737
 disturbance, ii, 738
 fullness and pain, ii, 548
 pains, ii, 613, 618, 622, 636, 679, 799
 due to syphilis, ii, 619
 due to perforating ulcer of duodenum, ii, 559
 with vomiting, ii, 662
 tumors, ii, 788
- Epigastrium, pain in, ii, 720
- Epispadias, ii, 1068
- Epithelial proliferation of ducts in tumor of breast, i, 353
- Epitheliomas, basal-celled, of the temple, i, 85
 benign, of cheek, i, 88
 warty, i, 87
- Epulis of jaw, i, 148, 149, 152, 154
 of upper jaw, i, 147
- Erosion of cervix, ii, 871, 877
- Errors in diagnosis, i, 21
- Erysipelas following removal of tumor, i, 177
 of the face, i, 75
- Esophageal dilatation, ii, 744
 due to cicatrix at cardia, ii, 756
- Esophagus, atheromatous degeneration of mucosa, ii, 746
 carcinoma of, ii, 765
 hard ring occluding opening, ii, 748
 occlusion of, by carcinoma, ii, 781
- Esthiomene, ii, 1064
- Examination in surgical diseases, i, 13
- Exophthalmic goiter, i, 226, 228, 246, 250
 cell degeneration and exfoliation in, i, 247
 temperature curve in fatal case of, i, 249
- Exophthalmos, i, 214
- Exostoses, odontoid, of lower jaws, i, 138
- Exostosis in spondylitis, i, 301
 of head of femur, i, 433
 of lower jaw, i, 137
 sublingual, i, 543
- External genitals, diseases of, ii, 1053
- Extrauterine pregnancy, ii, 591
- Exudates at distance from bacterial activities, ii, 660
- Eye, tumor, displacing, i, 102
- Eyeball, displacement of, due to cholesteatoma, i, 97
- F
- Face, diseases of, i, 65
 erysipelas of, i, 75
 painful affections of, i, 65
 tumors of, i, 78
 ulcer of, i, 89
- Facial expression in exophthalmic goiter, i, 251
- Fallopian tubes, huge, tuberculous, ii, 875
- False aneurysm of the popliteal artery, i, 485
- Family, history in relation to surgical diseases, i, 12
- Fat embolism following fracture of femur, i, 51
 necrosis of omentum in necrosis of pancreas, i, 550
- Faecal fistula, ii, 1045
 following strangulated femoral hernia, ii, 966
- Femoral and interstitial hernia, ii, 951
 artery, aneurysm of, i, 460
 hernia, ii, 942, 947, 963
 ring, ii, 947
- Femur, exostosis on head of, i, 434
 fracture of neck of, i, 447
 head of, from senile coxitis, i, 440
 fracture of, malunion, i, 467
 neck of, i, 442, 443
 fractured, i, 464
 impacted fracture of neck of, i, 445
 lateral displacement of fragments, i, 469
 osteomyelitis of, i, 473
 osteosarcoma of, i, 488
 sarcoma of, i, 451
- Fetal adenoma, i, 230
- Fever and delirium accompanying thyroid intoxication, i, 212
 following childbirth, ii, 786
- Fibroadenoma, intracanalicular, of breast, i, 352
- Fibroids, intramural, ii, 926

- Fibroliposarcoma of popliteal space, i, 476
- Fibrosarcoma of ovary, ii, 862
of inguinal region, ii, 959
pendulous, of stomach, ii, 830
- Fibrous goiter, i, 200
- Finger, enchondroma of, i, 416
granuloma of, i, 418
tumor of, i, 415
- Fingers, stiffness of, i, 426
- Fistula, duodenal, ii, 701
fecal, ii, 1045
following femoral hernia, ii, 967
 appendicitis operation, ii, 1044
in buttocks, ii, 1042
intestinal, ii, 574, 576
near tail bone, ii, 1040
of abdominal wall, ii, 701, 955
of right side, ii, 671
rectal, ii, 1039
rectovaginal, ii, 1039
tuberculous pararectal, ii, 1043
urinary, ii, 1012
- Fistulous gall bladder containing stone
 in cystic duct, ii, 702
- Flooding after menopause, ii, 803
- Fontanelle, hemangioma of, i, 31
- Foot, blackening of, i, 521
bursitis peroneus tendon, i, 529
corn on sole of, i, 541
diffuse dry gangrene of, i, 518
diseases of, i, 517
gangrene of, i, 521
Kohler's disease, i, 543, 544
localized dry gangrene of, i, 520
melanoblastoma of, i, 532, 535, 539
ulcer of, i, 534, 538
 and tumor of groin, i, 537
- Forearm region, diseases of, i, 387
lymphangioma of, i, 413
tuberculosis of, i, 401
tumor of, i, 412
ulcer of, i, 397
united fracture of, i, 388
- Forehead, sloughing ulcer of, i, 34
tumor of, i, 36, 42
- Foreign body in bladder, ii, 981
- Fracture of femur, malunion of, i, 467
of forearm, i, 425
 disabled hand due to, i, 424
 united, i, 388
of hip, i, 441
of humerus, i, 384
of temporoparietal region, i, 59
of thigh, i, 50
- Fractured femur, i, 464
patella, i, 494
- Frontal sinus enlarged, i, 97
 mucocele of, i, 103
 osteoma of, i, 99, 101
- Fundus, carcinoma of the uterus, ii, 919
- Fungating carcinoma of the anus, ii, 1038
- Fungus carcinoma of the uterus, ii, 904
- G
- Galactoecele, i, 367
- Gall bladder adherent to omentum, ii, 697
 adhesions surrounding, ii, 698
 carcinoma of, ii, 637, 769
 chronic inflammation of, ii, 641
 colic, ii, 628, 632, 684, 739
 cyst, ii, 697
 drainage, ii, 628, 636
 under local anesthesia, ii, 741
 drained, ii, 633
 and appendix removed, ii, 627
 fistulous, ii, 702
 infection, appendicitis simulating,
 ii, 813
 inflammation of, ii, 691
 strawberry, ii, 629
 thickened, ii, 614
 thickening of wall of, ii, 816
 with corrugation of the mucosa, ii,
 692
- Gallstone, ii, 635, 683, 691, 695, 702,
704, 715, 740, 774, 816
 causing digestive disturbance, ii, 733
 in common duct, ii, 683
 in cystic duct, ii, 697
 operation followed by pancreatic
 pseudocyst, ii, 801
 simulating carcinoma of stomach, ii,
 733
 ulcer of pylorus simulating, ii, 685
- Gallstones, ii, 630, 634, 635, 636, 694,
697, 739, 780
 causing intestinal obstruction, ii, 569
 findings typical of, ii, 627
 following pregnancy, ii, 859
- Gangrene, diffuse, dry, of foot, i, 518
localized dry, of foot, i, 520
of foot, i, 521, 524
- Gas eructation, ii, 741
- Gastric cancer, ii, 622
 hemorrhage following appendectomy,
 ii, 813
 ulcer, ii, 562, 583, 682, 688
 perforated, ii, 558
- Gastroenterostomy, ii, 617
- General abdomen, ii, 593

- Genitals, external, diseases of, ii, 1053
 Giant-celled sarcoma, i, 153
 Gill cleft cyst, i, 182
 Gland acini, normal, i, 361
 Glandular thyroid, i, 227, 230
 Glycosuria, general anesthesia to be avoided, ii, 803
 Goiter (*see also* Hyperthyroidism), i, 219, 257
 and uterine dysfunction, ii, 921
 colloid, i, 198
 toxic, i, 253
 congenital, i, 211
 cough caused by, i, 202
 degenerated toxic, i, 243
 dyspnea and nervousness due to, i, 235
 exophthalmic, i, 214, 226, 246, 250
 fibrous, i, 200
 in diabetes insipidus, i, 207
 in relation to uterine disturbance, ii, 892
 pregnancy in relation to, i, 213
 recurrence in left lobe after right lobectomy, i, 225
 thymus nodule in, i, 253
 toxic, i, 223
 Goiters, wandering, i, 240
 Gonococcus infection, ii, 727
 Gonorrhœal infection, ii, 723
 Granuloma of alveolar border, i, 151
 of finger, i, 418
 of wrist, i, 408
 Granulomatous endometrium in pyometrium, ii, 939
 Grief, stomach disturbance due to, ii, 614
 Groin, cyst of, ii, 945
 spindle-celled sarcoma of, ii, 961
 Gumma, mediastinal, i, 273
 of tongue, i, 123
 Gunmas of knee, i, 481
 Gums, hypertrophy, i, 139
 swelling of, i, 140
 tumor of, i, 148, 151
 Gut, malignant, ii, 672
- H
- Hand, angioma of, i, 419
 carcinoma of, i, 422
 disabled, due to fracture, i, 424
 Dupuytren's contraction, i, 423
 infected, i, 428
 swelling of, i, 400
 tuberculosis of, i, 400
 ulcerative lesion of, i, 421
 diseases of, i, 413
- Head, tumor, of, i, 43
 Headache complicating epigastric pain, ii, 626
 due to pelvic disorder, ii, 967
 inability to speak and partial paralysis, i, 60
 Heart trouble in ovary and thyroid disease, i, 241
 Hemangioma of cranium, in infant, i, 31
 of great fontanelle, i, 31
 of lip, i, 115
 of temple in infant, i, 30
 Hematemesis, ii, 743, 759, 778
 following occlusion of esophagus, ii, 782
 Hematocele removed for mixed tumor of testicle, ii, 1076
 Hematoma following breast operation, i, 363
 operation for myoma of the uterus, ii, 839
 of ovary, ii, 709
 of wrist, i, 405
 pelvic, ii, 835
 postoperative, ii, 841
 Hematometrium, pedunculated myoma protruding through, ii, 886
 Hematuria, ii, 820, 992, 998
 treated with potassium citrate, ii, 995
 Hemiplegia due to syphilitic thrombosis, i, 57
 Hemorrhage and pain in rectum, ii, 1023
 and tumor, uterine, ii, 847
 gastric following appendectomy, ii, 813
 meningeal, following fracture of femur, i, 52
 postmenopause, ii, 925
 of bladder following prostatectomy, ii, 1016
 uterine, ii, 891, 908, 912, 929
 profuse, ii, 914
 vaginal, ii, 894, 926, 932, 934, 937, 938, 1057
 Hemorrhagic cyst of ovary, ii, 676
 myoma, ii, 866
 simulating pregnancy, ii, 848
 ovary, ii, 709
 Hemorrhoid, strangulated, ii, 1050
 Hemorrhoids, ii, 631, 714, 759, 1025
 prolapsed, ii, 1049
 Hepatic pain, ii, 690
 region, pain in, ii, 621
 tumor, ii, 805

- Hepatocolic ligament, dilated vessels
of, ii, 699
- Hernia, appendix in, ii, 594
femoral, ii, 942, 947
and interstitial, ii, 951
fecal fistula of, ii, 966
strangulated, ii, 963
in the perineum, ii, 1055
inguinal, ii, 666, 948, 949
of linea alba, ii, 681, 730
omental, ii, 964
postoperative, ii, 593
strangulated, ii, 604, 962
umbilical, ii, 953
- Hip, Charcot's, i, 444
coxa vara, i, 432
diseases of, i, 430
fracture of, i, 441
infective arthritis at joint, i, 437
pain in, due to exostosis on head of
femur, i, 433
due to sarcoma, i, 449
sciatica, i, 448
senile coxitis, i, 438
- History, essentials to record in, i, 6
family, i, 12
interpretation of patient's statements
when taking, i, 9
of past diseases, i, 11
of present diseases, i, 8
site of pain, i, 10
study of symptoms, i, 10
use patient's own words in recording,
i, 10
- Hodgkin's disease, i, 159, 161, 162
differentiation from lymphosarcoma,
i, 158
gland, degenerated, i, 162
- Humerus, fracture of, i, 382
metastatic carcinoma of, i, 386
multiple myeloma of, i, 465
- Hydronephrosis, ii, 649
phantom tumor simulating, ii, 815
- Hydrops of subgluteal bursa, i, 431
- Hygroma of wrist, i, 406
- Hyoseyamus and bromides for epigas-
tric distress, postoperative,
ii, 694
- Hyperacidity, ii, 706
- Hypernephroma, ii, 828, 1002
- Hypernephrosis, ii, 825
- Hyperplasia of mucosa of the gall blad-
der, ii, 641
- Hyperplastic endometrium, ii, 885
in adenomyoma of uterus, ii, 906
- Hyperthyroidism, digestive disturbances
due to, i, 220
- Hyperthyroidism—Cont'd.
nausea and vomiting probably due to,
i, 216
nervousness in, i, 219
palpitation and nervousness in, i,
242
symptoms confused with endocarditis,
i, 242
toxic, i, 216
- Hypertrophy of gums, i, 139
- Hysterotomy, vaginal, technic, ii, 913
- I
- Ileocecal junction, carcinoma of, ii, 838
sarcoma of, ii, 750
pain, ii, 710
- Impacted fracture of femur, i, 445, 447
- Indigestion, ii, 658, 700, 738
and difficulty in urination, ii, 1010
- Indurated appendix, ii, 624
- Induration, chronic, of penis, ii, 1069
- Infant, ulcer on back, i, 293
- Infected hand, i, 428
- Infection of floor of mouth due to
sialolith, i, 194
of neck, i, 192
streptococic, following operation for
rectal carcinoma, ii, 1032
- Infective arthritis at hip joint, i, 437
- Inflammation of gall bladder, ii, 641
of tongue, i, 121
- Inflammatory diseases of neck, i, 189
infections involving abdominal wall,
ii, 962
- Infraorbital foramen, tenderness over,
i, 78
- Inguinal cyst, ii, 946
hernia, ii, 666, 948, 1010
double, ii, 1012
masked by lipoma, ii, 949
region, fibrosarcoma of, ii, 959
tumors, ii, 829
- Injuries in operations, i, 24
- Injury of knee, i, 493
- Intermittent pain, severe, ii, 613
- Interstitial and femoral hernia, ii, 951
breast with malignant area, i, 346
mastitis, i, 342, 344
carcinoma in, i, 348
cyst in, i, 359
with cyst formation, i, 367
proliferation, i, 340
myoma of the uterus, ii, 721
- Intestinal adhesions, ii, 654
carcinoma, ii, 833
fistula, ii, 574, 576

Intestinal—Cont'd.

- obstruction due to enterolith, ii, 600
- due to gallstone, ii, 569
- due to Meckel's diverticulum, ii, 597
- following appendicitis operation, ii, 602
- sepsis, ii, 575
- tumor, ii, 672
- Intestine, abscess within, ii, 606
- collapse of, through loop formed by Meckel's diverticulum, ii, 578
- Intestines, collapse of loops of through mesentery, ii, 567
- Intratracheal thyroid, i, 205
- Intramural fibroids, ii, 926
- Intussusception, ii, 609
- Irritated melanoma of the shoulder, i, 290
- Irritation of the bladder, ii, 974

J

- Jaundice, ii, 613, 627, 635, 637, 683, 690, 740, 767
- and loss of weight, ii, 777
- and progressive weakness, ii, 768
- catarrhal, ii, 772
- complicated by dysentery, ii, 773
- complicating nephritis, ii, 767
- caused by carcinoma of gall bladder, ii, 769
- due to syphilitic mass obstructing gall bladder, ii, 770
- following gallstone removal, ii, 774
- Jaw, actinomycosis of, i, 133, 136
- dentigerous cyst, i, 144
- diseases of the, i, 132
- epulis of, i, 147, 148, 149, 152, 154
- exostosis of, i, 137
- odontoid exostoses of, i, 138
- periodical swelling of, i, 195
- ranula of, i, 183
- sarcoma of, i, 150
- swelling, i, 170
- thickening of, i, 144
- tumor of, i, 147, 149, 154, 168
- upper, swelling of, i, 106
- tumor of, i, 107

K

- Keloid of prostatic capsule following prostatectomy, ii, 1020
- Keratosis of lip, i, 116
- Kidney, abscess around, ii, 784
- degeneration, ii, 810

Kidney—Cont'd.

- hydronephrosis, ii, 649
- hypernephroma, ii, 828, 1002
- hydronephrosis, ii, 825
- pyelitis, ii, 811
- pyelonephritis, ii, 990
- rhabdomyosarcoma of, ii, 818, 820
- stone, ii, 645, 975
- in ureter, ii, 983
- stones, ii, 643
- recurrence of, ii, 646
- tuberculosis of, ii, 810, 984, 992
- tumor, ii, 818
- Knee, arthritis of, i, 491
- discharging sinus above, i, 472
- diseases of, i, 474
- false aneurysm of popliteal artery, i, 485
- gummas of, i, 481
- injury of, i, 493
- joint affection due to trauma, i, 482
- myxosarcoma of, i, 478
- osteosarcoma of, i, 488
- rheumatism of, i, 491
- sarcoma of, i, 506
- stiff, i, 482
- swelling of, i, 475
- tuberculosis of, i, 486
- ulcers of, i, 481
- Kohler's disease, i, 544
- Krause operation for relief of pain in face and jaw, i, 66

L

- Labium majus, tumor of, ii, 1066
- Laboratory examinations in relation to surgical diseases, i, 17
- Leg, fibroliposarcoma of, i, 476
- Marjolin's ulcer, i, 503
- neurofibroma of, i, 514
- tumor of, i, 476
- ulcer of, i, 498
- following typhoid fever, i, 498
- ulcerated, i, 500
- varicose ulcers of, i, 497, 501
- Leucemia myelogenous, ii, 824
- Leucoplakia, i, 142
- benign, i, 143
- undergoing malignancy, i, 143
- Leucorrhoea and baekache, ii, 870
- and pain in groin, ii, 877
- Linea alba, hernia of, ii, 681
- Lip, blue spot on, i, 112
- capillary venous angioma of, i, 113
- carcinoma of, i, 119, 120
- diseases of the, i, 112

- Lip—Cont'd.
 hemangioma of, i, 115
 keratosis of, i, 116
 lower, scaling of, i, 116
 lymphangioma of, i, 114
 thick, i, 114, 115
 trachina of, i, 117
 tumor of, i, 113
 ulcer of, i, 118, 119
- Lipofibrosis of arm, multiple, i, 394
- Lipoma masking inguinal hernia, ii, 949
 of femoral ring, ii, 943, 947
 of the labium majus, ii, 1066
 of the shoulder, i, 380
 of the thyroid, i, 212
- Lipomas of, thymus, i, 260
- Liver, degeneration of, in delayed chloroform poisoning, i, 47, 49
- Loin, pain in, ii, 642
 right, ii, 783
- Loss of weight from nutritional disturbances, ii, 759
- Lower abdomen, ii, 577
 extremities, diseases of, i, 430
- Lung abscess, i, 280, 281, 285
 due to foreign body, i, 285
 following pneumonia, i, 288
 in pregnancy, i, 274-276
 infection following appendix operation, ii, 655
 puerperal, i, 274-276
- Lungs, diseases of, i, 274
- Luteal cyst of ovary, ii, 708, 724
- Lymph glands from case of Hodgkin's disease, i, 161
 of neck, tuberculous, i, 164
- Lymphangioma of calf, i, 509
 of forearm, i, 413
 of the tongue, i, 122
- Lymphangioma of lip, i, 114
- Lymphangitis carcinomatosa, i, 338
- Lymphatic glands of axilla, infected, i, 378
 metastases, i, 44
 tumors of the neck, i, 156
- Lymphosarcoma of mediastinum, i, 263, 269
 of neck, i, 157, 158
 of submaxillary lymph gland, i, 170
- M
- Malignancy in intestines, ii, 672
- Malignant adenoma of uterus, ii, 882, 927
 area in cystic carcinoma, i, 370
 in interstitial breast, i, 346
 in interstitial mastitis, i, 367
- Malignant—Cont'd.
 cystoma of the ovary, ii, 804
 diseases, operating on, i, 23
 tumors of mediastinum, i, 260
- Mammæ, accessory, ii, 956
- Mammary cyst with papillary projections, i, 365
 gland, accessory, ii, 958
- Marjolin's ulcer, i, 399, 503
- Mastoid operation, pain following, i, 54
- Mastoiditis, brain abscess following, i, 54
- Meckel's diverticulum adherent to mesentery, ii, 579
 inverted, ii, 596
 necrotic, as cause of abdominal pain, ii, 557
- Mediastinal gumma, i, 273
- Mediastinum, carcinoma of, i, 266
 dermoid of, i, 262
 diseases of, i, 256
 lymphosarcoma of, i, 263, 269
 malignant tumors, i, 260
 metastatic sarcoma of, i, 267
- Melanoblastoma, i, 455
 of foot, i, 533, 535, 539
 of thigh, i, 454, 455, 456
 of toe, i, 531
- Melanoma, irritated, i, 290
 of shoulder, metastasis from, i, 289
 of the thumb, i, 415
- Melanosarcoma of forearm, i, 396
- Melanotic metastasis, i, 289
- Meningitis following drainage of brain abscess, i, 53
- Meningocele, i, 292
- Menopause, premature, painful breast in case of, i, 340
- Mesenteric hernia, ii, 705
- Menstrual pain, ii, 870
 period, prolonged, ii, 903
- Menstruation, excessive, ii, 921
 and painful, ii, 872
 irregular, ii, 874, 902
 and hyperthyroidism, i, 219
 painful, ii, 884, 907
 and obstinate constipation, ii, 888
 prolonged, ii, 911
- Metastases, distant, schirrus breast cancers give rise to, i, 40
- Metastatic breast carcinoma, i, 316
 carcinoma in brachial tree, i, 280
 of humerus, i, 386
 of the mediastinum, i, 266
 sarcoma of mediastinum, i, 267
- Microscopy in relation to surgery, i, 20

- Miliary tuberculosis of the ileocecal region, ii, 656
- Milk leg, i, 502
- Mixed-celled sarcoma of arm, i, 390
- Mixed tumor of breast, i, 354
of parotid, i, 176
of parotid, recurrent, i, 178
- Mouth and jaws, diseases of, i, 112
carcinoma in floor of, i, 131
ulcer at angle of, i, 117
ulceration of roof of, i, 145
- Mucocele of frontal sinus, i, 103
- Mucous polyp of endometrium, ii, 925
- Multilocular myoma of uterus, ii, 845
- Multiple lipofibrosis of arm, i, 394
- Myelogenous leucemia, ii, 824
- Myeloma, multiple, of the humerus, i, 465
- Myocardial degeneration in thyroid and ovary disease, i, 241
- Myoma causing rectal pain, ii, 1025
causing stomach trouble, ii, 854
hemorrhagic, ii, 848, 866
infected, producing peritonitis, ii, 845
of uterus, ii, 887, 917
colloid degeneration of, ii, 840
perforating hemorrhagic, ii, 587
tumor following, ii, 839
pedunculated intrauterine, ii, 912
of uterus, ii, 889
protruding into hematometrium, ii, 886
submucous, protruding from vagina, ii, 1058
- Myomectomy, cervical carcinoma of, ii, 903
- Myosarcoma of fundus of uterus, ii, 915
of uterus, ii, 909
- Myositis ossificans traumatica, i, 458
- Myxedema, ii, 842
- Myxoma, i, 109
- Myxosarcoma of knee, i, 478
of sciatic nerve, i, 479
- N
- Nailing of fracture, i, 384
- Nausea and vomiting due to hyperthyroidism, i, 216
- Neck, abscess of, due to infection from mouth, i, 190
carcinoma of, i, 180
cyst of, i, 181
cystic carcinoma of, i, 166
diseases of, i, 181
- Neck—Cont'd.
dermoid cyst of, i, 188
diseases of, i, 156
Hodgkin's disease, i, 159, 161
infection of, i, 192
inflammatory affection of, i, 193
diseases of, i, 189
lymphatic tumors of, i, 156
lymphosarcoma of, i, 157, 158
nonlymphatic tumors of, i, 172
recurrent tumors of, i, 159
squamous-celled carcinoma of, i, 184
swelling of, i, 208, 210
caused by third molar, i, 191
tuberculous lymph glands of, i, 164
tumor of, i, 157, 160, 162, 164, 176, 184, 204
wen of, i, 187
woody phlegmon of, i, 192
- Necrosis of appendix, ii, 659
of loop of ileum in strangulated femoral hernia, ii, 963
of pancreas, ii, 550, 572
result of cancer quack's plaster, i, 35
- Necrotic appendix, ii, 611
bone following mastoiditis, i, 54
bone removed from chronic osteomyelitis, i, 471
Meckel's diverticulum, ii, 557
- Nephrectomy advisable in recurrence of kidney stone, ii, 646
- Nephritis complicated by jaundice, ii, 767
death from, ii, 739
- Nervousness and weakness due to exophthalmic goiter, i, 226
due to pelvic lesions, ii, 695
in goiter, i, 252
in hyperthyroidism, i, 219
- Neuralgia, i, 66
of head and face, i, 67
of right side of face, i, 67, 68, 69, 71, 74
of great occipital nerve, i, 78
trigeminal, i, 68
- Neurasthenia, ii, 631
- Neurofibroma of leg, i, 514
of superficial peroneal nerve, i, 515
- Neurolipoma of arm, i, 393
- Neuroma, amputation, i, 463
- Nipple, carcinoma of, i, 324
- Nodule in Hodgkin's disease, i, 159
- Nonencapsulated tumors of the breast, i, 310
- Nonlymphatic tumors of neck, i, 172
- Nonsuppurating thyroiditis, i, 234

- Nontoxic disease of the thyroid gland, i, 198
- Nose, basal-celled carcinoma of the, i, 84
 enlargement of, i, 79
 ulcer about, i, 83
- Nutritional disturbance, ii, 729
 causing loss of weight, i, 759
 due to linea alba, ii, 731
 without pain, ii, 743
- O
- Obstinate constipation, and painful menstruation, ii, 888
- Obstipation, ii, 651, 716
- Obstruction of bowels, ii, 568, 705
 of urine, ii, 1003
- Odontoid exostoses of lower jaw, i, 138
- Omental adhesions surrounding gall bladder, ii, 780
 hernia, ii, 964
- Omentum and intestine adherent to tubes, ii, 712
 indurated, ii, 661
 polycystic tumor of, ii, 794
 torsion of, ii, 965
- Operations, time required for, i, 24
- Operative injury, i, 24
 risk in emaciation, ii, 693
 risk must be less than that of disease, i, 22
- Orbit, tumor of, i, 96
- Ossifying spondylitis, i, 298
- Osteoma of frontal sinus, i, 99
- Osteomyelitis, acute suppurative, of arm, i, 375
 chronic, necrotic bone removed from, i, 471
 of femur, i, 473
- Osteosarcoma, i, 459
 of antrum, i, 110
 of arm, i, 392
 of frontal sinus, i, 101
 of knee, i, 488
- Ovarian carcinoma, ii, 852
 cyst, ii, 697, 723, 852, 858, 969
 and hematoma, ii, 910
 serous, ii, 856
 simulating pregnancy, ii, 860
 with hemorrhage, ii, 709
 with twisted pedicle filled with blood clots, ii, 807
- papillary cystadenoma causing bladder symptoms, ii, 980
- tumors, ii, 880
- Ovaries and tubes, adherent, ii, 676
 papillary cystadenomas of, ii, 861
 cystoma of, ii, 670
- Ovary, adenocarcinoma of, ii, 868
 adherent to appendix, ii, 715
 fibrosarcoma of, ii, 862
 hemorrhagic cyst of, ii, 676
 luteal cyst of, ii, 708
 malignant cystoma of, ii, 804
 papillary cystadenoma of, ii, 883
 perithelioma of, ii, 864
 polycystic, ii, 714, 754, 878
 removal of infected, in case of myocardial weakness, i, 241
 tumor of, in young girl, ii, 863
- P
- Pain accompanying nutritional disturbance, ii, 729
 appendiceal, ii, 650
 epigastric, ii, 679
 hepatic, ii, 690
 in back, i, 297, 299
 relief of, following removal of tonsils, i, 303, 306
 of head, i, 76
 in chest, i, 282
 in end of penis, ii, 1073
 in epigastrium, ii, 618
 in face and jaws relieved by Krause operation, i, 66
 in head and face, i, 67
 in hepatic region, ii, 621
 in ileocecal region, ii, 710
 in loin, ii, 642
 menstrual, ii, 870
 renal, ii, 705
 suprapubic, ii, 669, 719
- Painful affections of the face, i, 65
 menstruation, ii, 907
 testicle, ii, 1078
 urination, ii, 810, 978, 983, 985, 987, 989, 992, 995, 1000
- Palate, epulis of, i, 155
 hard, abscess of, i, 141
 syphilitic ulceration of, i, 146
 ulcer of, i, 142
- Palpitation due to thyroid intoxication, i, 232
 in thyrotoxication, i, 239
- Pancreas, fat necrosis in omentum in necrosis of, ii, 550
- Pancreatic cyst, ii, 791
 necrosis, ii, 572
 pseudocyst, ii, 801
- Pancreatitis following appendix operation, ii, 548

- Papillary cystadenoma of the ovary, ii, 980
 cystadenomas of ovaries, ii, 861
 cystadenomatous growth in pelvis, ii, 856
 cystadenomyoma of ovary, ii, 883
 cystoma of the ovaries, ii, 670
 formation in exophthalmic goiter, i, 247
 tumors of the ovary, ii, 880
- Papilloma of bladder, ii, 998
 giving symptoms of stone, ii, 1001
- Papillomas of prepuce, ii, 1074
- Pararectal abscess, ii, 1042
 fistula, tuberculous, ii, 1043
- Paravesical abscess, ii, 1008
- Parotid gland, swelling of, i, 195
 recurrent mixed tumor, i, 178
 suppuration, ii, 936
- Past diseases, history of, i, 11
- Patella, fractured, i, 494
- Patient's general condition, consideration of, in surgery, i, 2
- Pathologic findings compared with clinical, i, 26
 in surgical diseases, i, 25
- Pathologist and surgeon, cooperation, i, 19
- Pedunculated intrauterine myoma, ii, 912
 myoma of uterus, ii, 889
 protruding into hematometrium, ii, 886
 tumor of the uterus, ii, 1060
- Pelvic abscess following vaginal hysterectomy, ii, 969
 cystadenoma, ii, 856
 distress following abortion, ii, 879
 hematoma, ii, 835
 lesion in relation to hyperthyroidism, i, 216
 causing epigastric distress, ii, 694
 complicating gallstone, ii, 695
 organs, congestion of, ii, 879
 tumor, ii, 852
- Penis carcinoma of, ii, 1072, 1073
 chronic induration of, ii, 1069
 deformity of, ii, 1068
 diseases of, ii, 1068
 pain in end of, ii, 1073
- Peptic ulcer, ii, 735
- Perforated gastric ulcer, ii, 558
 ulcer of abdomen, ii, 555
- Perforating hemorrhagic myoma of the uterus, ii, 587
- Perianal diseases, ii, 1044
- Periappendiceal abscess from bubo, ii, 667
 localized, ii, 677
- Periappendicitis, ii, 658
- Pericholecystitis, ii, 698
- Perigastric ulcer, ii, 617
- Perinephritic abscess, ii, 990
- Perineum, hernia in, ii, 1055
- Periostitis due to syphilis, i, 274
- Peripheral resection for neuralgia, i, 72
- Perirectal abscess causing bladder disturbances, ii, 975
- Perisigmoiditis, ii, 672
- Perithelioma, cell arrangement suggesting, i, 45
 of the ovary in young girl, ii, 864
- Peritonitis, ii, 608, 727
 due to infected myoma, ii, 845
 following appendectomy, ii, 663
 general, following appendectomy, ii, 664
- Periungual melanoma of thumb, i, 414
- Perivascular degeneration in delayed chloroform poisoning, i, 50
- Pernicious anemia, ii, 734, 759
 simulating carcinoma symptoms, ii, 734
- Persistent nervousness in hyperthyroidism, i, 219
 vomiting, ii, 565, 573, 760
 in goiter and pregnancy, i, 214
- Petechial hemorrhage and perivascular degeneration as result of chloroform poisoning, i, 48
- Phantom tumor of abdomen, ii, 815
- Phlegmon, woody, i, 135
- Physical examinations in surgical diseases, i, 13
 findings and history should correspond, i, 15
- Pin in bronchus, i, 284
- Pins, steel, in treatment of patella fracture, i, 495
- Placenta retained resembling deciduoma maligna, ii, 924
- Plantar corn, i, 542
- Pleurisy, ii, 977
- Pneumonia, complication following, i, 287
 impending hypostatic, ii, 1013
 in children, simulating appendicitis, ii, 652
- Poise of surgeon under difficulties, i, 24
- Poisoning, chloroform, i, 46
- Polycystic disease of omentum, ii, 794
 ovary, ii, 714, 854, 878

- Polyp, cervical, ii, 934
 nasal, i, 107
 uterine, ii, 926
- Polypoid degeneration of cervical mucosa, ii, 896
- Postmenopause hemorrhage, ii, 925
- Postoperative hernia, ii, 593
- Postpartum hematemesis, ii, 778
- Postpuerperal jaundice, ii, 767
 painful menstruation, ii, 884
- Pregnancy, extrauterine, ii, 591
 in relation to toxic goiter, i, 213
 lung abscess complicating, i, 274-276
 ruptured tubal, ii, 589
 simulated by ovarian cyst, ii, 860
 simulating tumor, ii, 859
 termination of, in a case of thyrotoxicosis, i, 214
 thyrointoxication in, i, 238
- Prepuce, elephantiasis of, ii, 1072
 papillomas of, ii, 1074
 washboard, ii, 1071
- Pressure and pain in the rectum, ii, 1025
- Prognosis in surgical diseases, determining from diagnosis, i, 22
- Prolapse of the uterus, ii, 940, 955, 1061
 of rectum, ii, 1051
- Prolapsed hemorrhoids, ii, 1049
- Prolapsus of the vagina, ii, 722
- Prostate, carcinoma of, ii, 1026
 enlarged, ii, 680, 978, 1010, 1013, 1016
 causing incontinence of urine, ii, 738
 forming roll across trigone shutting off urethra, ii, 1021
 incompletely removed, ii, 1015
 gland proliferation in, ii, 1016
 removal by transvesical route, complications following, ii, 1014
- Prostatectomy, bar across bladder following, ii, 1004
 keloid of prostatic capsule following, ii, 1020
 urinary retention following, ii, 1019
- Prostatic capsule, keloid of, following prostatectomy, ii, 1020
 enlargement complicating carcinoma of rectum, ii, 1034
- Protrusion from the vulva, ii, 1054
- Psammoma of the dura, producing tumor in parietal region, i, 62
- Pseudocyst of the pancreas, ii, 801
- Pubic bone, sarcoma of, i, 450
- Puerperal lung infection, i, 274-276
- Pus in right side, ii, 552
- Pyelitis, ii, 742, 811
- Pyelonephritis with perinephritic abscess, ii, 990
- Pyloric stenosis from peptic ulcer, ii, 735
 ulcer, ii, 735
- Pylorus, carcinoma of, ii, 800
 tumor of, ii, 687
 ulcer of, ii, 686
- Pyometrium, ii, 937
 granulomatous endometrium in case of, ii, 939
- Pyosalpinx, ii, 676
- Q
- Quinine urea hydrochloride solution injected for occipital neuralgia, i, 78
- R
- Ranula bulging beneath angle of jaw, i, 183
 sublingual, i, 129
- Rapid heart in thyroiditis, i, 228
- Rectal and bladder pain, ii, 974
 carcinoma, ii, 1031, 1034
 above sphincter, ii, 1036
 diseases, ii, 1023
 fistula, ii, 1039
 hemorrhage, ii, 1023
 pain due to myoma, ii, 1025
 stricture causing difficult defecation, ii, 1023
- Rectovaginal fistula, ii, 1039
- Rectum, blood and mucus from, ii, 1029
 carcinoma, of, ii, 873, 1027, 1030
 pressure and pain in, ii, 1025
 prolapse of, ii, 1051
- Recurrent carcinoma, i, 337
 nodule in breast, i, 314
 pain in upper part of abdomen, i, 313
 tumors of neck, i, 159
- Renal aneurysm, ii, 823
 colic, ii, 642
 pain, ii, 642, 705
 tumors, ii, 818
- Respiration, difficult, i, 265
- Responsibility of surgeon, i, 5
- Retained testicle, ii, 1077
- Retroperitoneal abscess, ii, 784
 metastasis from carcinoma of ileocecal orifice, ii, 838
 sarcoma, ii, 730
- Retrosternal dermoid, i, 262

- Rhabdomyosarcoma of kidney, ii, 813, 820
- Rheumatism of right knee, i, 491
 tonsil removal for relief of, i, 475
- Rhinophyma, i, 79
- Rib, tuberculosis of, i, 380
- Roentgen treatment of basal-celled epitheliomas, i, 85
- Routine procedure, essential to every surgeon, i, 5
- S
- Sacral spina bifida, i, 295
- Salpingectomy, ii, 648
- Salpingitis, bilateral chronic, ii, 682
 causing rectal pain, ii, 1025
- Sarcoma, bald-headed, of calf, i, 505
 of iliopubic region, ii, 960
 cystic, of breast, i, 355
 giant-celled, i, 148, 150, 153
 involving pubis, ischium and head of femur, i, 451
 metastatic, of mediastinum, i, 267
 mixed-celled, of arm, i, 390
 of antrum, i, 108
 of bladder, ii, 1005
 of elbow, i, 395
 of ileocecal junction, ii, 750
 of jaw, i, 150
 of knee, i, 506
 of pubic bone, i, 450
 of scalp, i, 44
 of tibia, i, 507
 retroperitoneal, ii, 730
- Scalp carcinoma from breast tumor, i, 39
 sarcoma, i, 44
 wound, suppurative, i, 53
- Scar after treatment of carcinoma of breast by plaster, i, 330
 carcinoma of thigh developed in, i, 452
- Sciatic nerve, myxosarcoma of, i, 479
- Sciatica, i, 448
- Scirrhus of the rectum, ii, 1035
- Scrotum, diseases of, ii, 1075
 tumor of, ii, 1081
- Senile coxitis, i, 438
- Serous ovarian cyst, ii, 856
- Severe intermittent pain, ii, 613
- Shortness of breath due to toxic thyroid, i, 223
- Shoulder, fibrous ankylosis of, i, 546
 bursitis of, i, 372
 diseases of, i, 372
 imperfect motion of arm following fall on, i, 381
- Shoulder—Cont'd.
 lipoma of, i, 380
 pain, reflex from cervical erosion, ii, 697
 tuberculosis of, i, 374
 tumor of, i, 380
- Sialolith producing infection of floor of mouth, i, 194
- Sigmoid colon, carcinoma of, ii, 717
- Sinus, abdominal, menstrual flow through, ii, 941
 above knee, i, 472
 discharging, near anus, ii, 1041
 frontal osteoma of, i, 99
 in left side due to trauma, i, 277
 lined with epidermoidal tissue bearing hair near sacrum, ii, 1041
 of thigh, i, 470
- Sinuses, diseases of, i, 96
 filled with bismuth paste, ii, 972
 following abscess over crest of ilium, ii, 971
- Skull, enlargement of, over eye, i, 98
- Skin over a rapidly developing carcinoma, i, 336
 recurrence in carcinoma of the breast, i, 321
- Sloughing testicle, ii, 1077
- Sore throat and swelling of jaw, i, 196
- Spina bifida, i, 294
 of cervical region, i, 292
 of sacral region, i, 295
 perforating ulcer of heel, i, 308
- Spinal anesthesia, amputation under, i, 525
 cord in chronic spondylitis, i, 302
- Spine, diseases of, i, 256, 291
 metastasis in, from breast carcinoma, i, 328
- Spindle-celled melanoblastoma of foot, i, 533
 sarcoma of the groin, ii, 961
- Spondylitis, i, 298; ii, 642
 chronic, i, 299, 301
 involving cervical vertebræ, i, 297
 ossifying, i, 298
- Sponse left in abdomen, ii, 876
- Sporotrichosis of arm, i, 403
- Sputum from a case of lung abscess, i, 286
- Squamous-celled carcinoma of cervix, ii, 902
 carcinoma of glans, ii, 1074
 of neck, i, 169
 papillary carcinoma, ii, 899
- Starvation due to dysphagia, ii, 748

- Stenosis, cicatricial, of the cardia, ii, 755
- Stiffness of fingers, i, 426
- Stomach, adenocarcinoma of, ii, 788
- carcinoma of, ii, 620, 689, 742, 782, 797
- causing nutritional disturbances, ii, 761
- distress and loss of weight due to worry, ii, 731
- disturbances due to tabes, ii, 763
- pain and loss of weight, ii, 730, 741
- pain and vomiting, ii, 762
- pain in, ii, 615
- pain in, due to gallstone, ii, 629
- pendulous fibrosarcoma of, ii, 830
- trouble, i, 289
- and loss of weight, ii, 614
- due to grief, ii, 614
- Stone in bladder, ii, 648, 978, 981, 985, 986, 991
- in diverticulum causing painful urination, ii, 987
- in duct causing jaundice, ii, 775
- in duodenum, ii, 736
- in kidney, ii, 643, 645, 975, 983
- in pancreas, ii, 572
- kidney, in ureter, ii, 983
- Stones in the ureter, ii, 1000
- Strangulated hemorrhoid, ii, 1050
- hernia, ii, 604
- Strawberry gall bladder, ii, 629
- Streptococic infection of broad ligament, ii, 786
- Stricture of the rectum, ii, 1024
- of the urethra, ii, 1012
- Stump of thigh, pain in, i, 463
- Subdiaphragmatic abscess, ii, 581
- abscess containing gas, ii, 552
- Subgluteal bursa, hydrops, i, 431
- Submaxillary gland, mixed tumor of, i, 174, 179
- lymphosarcoma of, i, 170
- Sublingual ranula, i, 129
- exostosis, i, 543
- Superior maxilla, prominence of, i, 104
- Suprapubic pain, ii, 669, 719
- tumor, ii, 841
- Supravaginal amputation of the uterus, ii, 1058
- Suppuration of the thyroid, i, 210
- Surgeon, ideal, i, 4
- Surgeon's responsibility, i, 5
- Surgery, microscopy in relation to, i, 20
- pathologist in, i, 19
- Wassermann reaction in relation to, i, 17
- Surgical disease, general principles underlying, i, 1
- diseases, after-course, i, 26
- diagnosis, i, 3, 21
- examination, i, 13
- history taking, i, 6
- laboratory examinations, i, 17
- pathologic findings in, i, 25
- physical examinations in, i, 13
- diseases, treatment, i, 23
- problems, classified, i, 2
- Swallowing, difficulty, ii, 744
- Swelling above eye, i, 101
- of face and difficulty in opening mouth, i, 134
- of gums, i, 140
- of knee, i, 475
- of neck, i, 208, 210
- and inability to open mouth, i, 191
- Symptoms studied from history, i, 10
- Syphilis causing epigastric pain, ii, 618
- of tongue, i, 123
- Syphilitic aortic aneurysm, i, 271
- mass obstructing gall bladder, ii, 770
- peritonitis, i, 274
- thrombosis, i, 57
- ulceration of the forehead, i, 40
- of the palate, i, 146
- Systematic metastasis following carcinoma of breast, i, 371

T

- Tabes, causing stomach disturbance, ii, 763
- Teeth, extraction of, case of needless, i, 67
- Technic of alcohol injection for trifacial neuritis, i, 70
- Temperature chart in fatal case of exophthalmic goiter, i, 249
- Temple, angioma of, i, 29
- Temporal region, cavernous hemangioma of, i, 32
- Temporoparietal region, fracture of, i, 59
- Tenesmus and bloody stool, ii, 1036
- Testicle, enlarged, ii, 1079
- mixed tumor of, ii, 1079, 1081
- painful, ii, 1078
- tumor of, ii, 1075
- Testis, retained, ii, 1077
- Thick lip, i, 114, 115
- Thickened gums, i, 139
- Thickening of jaw, i, 144
- Thigh, aneurysm of femoral artery, i, 460
- diseases of, i, 452

- Thigh—Cont'd.
 fracture of, i, 50
 melanoblastoma of, i, 454, 455, 456
 myositis ossificans traumatica, i, 458
 pain in stump of, i, 463
 sinus of, i, 470
 tumor of, i, 453
- Thumb, melanoma of, i, 415
 nail, ulceration of, i, 413
 periungual melanoma of, i, 414
- Thymus, displacement of, i, 255
 nodule, i, 253
- Thyroglossal cyst, i, 124
 duct, i, 185
- Thyroid, aberrant, at angle of jaw, i, 172
- Thyroid, adenoma of, i, 236
 adenomatous, i, 222
 extract in treatment of myxedema, ii, 842
 fetal adenoma in, i, 230
 gland, diseases of, i, 198
 toxic diseases of, i, 212
 glandular, i, 227, 230
 intoxication, i, 232
 and pregnancy, persistent vomiting in, i, 214
 fever and delirium, i, 212
 intratracheal, i, 205
 lipoma of, i, 212
 nontoxic disease of, i, 198
 suppuration of, i, 210
 toxic, i, 223
- Thyroiditis, i, 208, 228
 nonsuppurating, i, 234
- Thyroidintoxication complicating pregnancy, i, 238
 palpitation in, i, 239
- Thyrotoxicosis, i, 214
- Tibia, sarcoma of, i, 507
- Toe, melanoblastoma of, i, 531
 sore, i, 530
- Tongue, carcinoma of, i, 128, 166
 carcinoma under, i, 121
 diseases of, i, 121
 gumma of, i, 123
 inflammation of, i, 121
 lymphangioma of, i, 122
 sublingual ranula, i, 129
 syphilis of, i, 123
 thyroglossal duct, i, 185
 tuberculosis of, i, 126, 127
 tumor of, i, 123, 124
 tumor under, i, 129
 ulcer of, i, 126, 128
- Tonsils, infected, as cause of rheumatism, i, 476
- Tonsils—Cont'd.
 relief of pain in back following removal, i, 303, 305
- Toxic diseases of the thyroid gland, i, 212
 fetal adenoma, i, 222
 goiter, i, 243
 thyroid, i, 223
- Trachea, compression of, by goiter, i, 203
 recurrence of tumor in, i, 206
- Trachina of lip, i, 117
- Transplantation of a pedicled skin into thoracic cavity in empyema, i, 279
- Traumatism, abdominal pain following, ii, 650
- Treatment of surgical diseases, i, 23
- Trifacial neuritis, i, 70
- Trigeminal neuralgia, i, 68
- Tubal pregnancy, appendicitis simulating, ii, 674
 ruptured, ii, 589
- Tubes adherent to intestine and omentum, ii, 712
 and ovaries, adherent, ii, 676
 fallopian, enlarged, ii, 875
- Tuboovarian abscess, ii, 854
- Tuberculosis and carcinoma of tongue, diagnosis, i, 127
 of ankle, i, 513
 of axilla, i, 377
 of forearm, i, 389, 401
 of iliocecal region, ii, 656
 of knee, i, 486
 of kidney, ii, 810, 984, 992
 hypernephroma simulating, ii, 1003
 of mediastinum, i, 260
 of pararectal tissue, ii, 1044
 of rib, abscess following, i, 379
 of shoulder, dry, i, 374
 of tendon sheath, i, 400
 of tongue, i, 126, 127
 of ureter, ii, 992
 of wrist joint, i, 411
- Tuberculous and syphilitic ulceration, differentiation, i, 41
 cyst of pancreas, ii, 792
 lymph glands of neck, i, 164
 pararectal fistula, ii, 1043
 ulcer of anal margin, ii, 1046
- Tumor, abdominal, ii, 800, 858
 adherent to liver and uterus, ii, 806
 above Poupart's ligament, ii, 985
 and pregnancy, differentiation between, ii, 848
 displacing eye, i, 102

Tumor—Cont'd.

- hepatic, ii, 805
- in right groin, ii, 837
- in parietal region, psammoma producing, i, 62
- in stomach region, ii, 790
- in vagina, ii, 918
- low in abdomen, ii, 835
- mixed, of breast, i, 351
- mixed, of testicle, ii, 1079, 1081
- of abdomen following operation for myoma of uterus, ii, 839
- of arm, i, 396
- of breast, i, 342
 - in male, i, 353
- of cheek, i, 80
- of colon, ii, 566
- of face, i, 82
- of forearm, i, 387, 412
- of forehead, i, 36, 42
- of groin and ulcer of foot, i, 537
- of gums, i, 148, 151
- of head, i, 43
- of jaw, i, 147, 149, 154, 168
- of kidney, ii, 818
- of knee, i, 478
- of labium majus, ii, 1066
- of leg, i, 476
- of lip, i, 113
- of lumbosacral region, i, 295
- of neck, i, 157, 160, 162, 164, 176, 184
- of orbit, i, 96
- of ovary causing bladder symptoms, ii, 979
- of parotid, mixed, i, 176
- of pyloric region, ii, 687
- of stomach, ii, 761
- of shoulder, i, 380
- of submaxillary gland, i, 173
 - mixed, i, 174
- of scrotum, ii, 1081
- of testicle, ii, 1075
- of thigh, i, 452, 453
- of tongue, i, 123, 124
- of upper jaw, i, 107
- of uterus, enlarged fallopian tubes simulating, ii, 875
- of vulva, ii, 1053
- of wrist, i, 405
- pelvic, ii, 852
- phantom, ii, 815
- polycystic, ii, 795
- protruding from vulva, ii, 1059
- recurrence in trachea, i, 206
- under tongue, i, 129

- Tumors at edge of arm pits, ii, 956
 - cystic, of breast, i, 358
 - inguinal, ii, 829
 - in region of abdominal ring, ii, 942
 - lymphatic, of the neck, i, 156
 - nonencapsulated, of breast, i, 310
 - of abdomen, ii, 788
 - of abdominal wall proper, including fistula, ii, 955
 - of arm, multiple, i, 393
 - of breast, encapsulated, i, 350
 - of epigastric region, ii, 788
 - of face, i, 78
 - of neck, nonlymphatic, i, 172
 - of renal region, ii, 818
 - of suprapubic region, ii, 841

U

- Ulcer about nose, i, 83
 - at angle of mouth, i, 117
 - gastric, ii, 583, 688
 - in breast in operative scar, i, 330
 - Marjolin's, i, 399
 - of ankle, i, 512, 532
 - of anus, ii, 1045
 - of face, i, 89
 - of foot, i, 534, 538
 - of forearm, i, 397
 - of genitals, ii, 1056
 - of heel, perforating, in spina bifida, i, 308
 - of leg, following typhoid fever, i, 498
 - of lip, i, 118, 119
 - of palate, i, 142
 - of pylorus, ii, 686
 - of tongue, i, 126, 128
 - of vagina, ii, 900
 - on back of infant, i, 293
 - over breast bone, i, 315
 - peptic, ii, 735
 - perforated gastric, ii, 558
 - in abdomen, ii, 555
 - perforating, of duodenum, ii, 559
 - perigastric, ii, 617
 - varicose, of leg, i, 497
- Ulcerated area over right breast, i, 332
 - leg, i, 500
- Ulcerating carcinoma of the stomach, ii, 797
 - duodenum perforation prevented by adhesions, ii, 563, 564
- Ulceration of alveolar border, i, 132
 - of forehead, syphilitic, i, 40
 - of roof of mouth, i, 145

- Ulceration—Cont'd.
 of thumb nail, i, 413
 of vulva, ii, 1064
- Ulcerative lesion of hand, i, 421
- Ulcerous carcinoma of the rectum, ii, 1027
- Ulcers of knee, i, 481
 of arm, i, 402
 varicose, of leg, i, 501
- Umbilical hernia, ii, 953
- Umbilicus, fat about, producing hernia, ii, 952
 pain around, ii, 793
- Unconsciousness following fall, diagnosed apoplexy, i, 58
- Upper abdomen, ii, 547
 extremity, diseases of the, i, 372
- Uremic coma, death from, following fall, i, 58
- Ureter constricted by kidney stone in, ii, 983
 tuberculosis of, ii, 992
- Ureteral catheterization, danger of, ii, 988
- Ureteral stones, ii, 1000
- Urethra obstructed by deformed prostate, ii, 1021
- Urethral obstruction causing dribbling of urine, ii, 1009
 stricture, ii, 1012
- Urinary fistula, ii, 1011
 obstruction, ii, 1003
 retention, following prostatectomy, ii, 1019
- Urination, difficult, ii, 1006
 difficult, and indigestion, ii, 1010
 due to diseased prepuce, ii, 1071
 frequency of, ii, 850
 frequent, and constipation, ii, 990
 painful, ii, 810, 978, 983, 985, 987, 989, 992, 995, 1000
- Urine, dribbling of, ii, 1009
 hematuria, ii, 992
 incontinence, ii, 737
- Uterine fibroid, ii, 861
 function disturbances, ii, 870
 hemorrhage, ii, 891, 908
 mass causing ileocecal pain, ii, 711
 mass protruding from vulva, ii, 1059
- Uterus, adenocarcinoma of, ii, 930
 adenomyoma of, ii, 881, 905, 908
 and liver adherent to tumor, ii, 806
 bleeding from, ii, 916
 carcinoma of, ii, 922, 927, 929, 932, 933, 935
- Uterus—Cont'd.
 cystic degeneration of cervix, as:
 cause of bladder irritation, ii, 989
- eystoma of, ii, 858
 differentiation between tumor and:
 pregnancy, ii, 848
 fixed, ii, 725
 fundus, carcinoma, of, ii, 919
 fungus carcinoma of, ii, 904
 hemorrhage of, ii, 929
 hemorrhagic myoma of, ii, 850, 866
 interstitial myoma of, ii, 721
 malignant adenoma of, ii, 927
 mass near, complicating appendicitis, ii, 674
 myoma of, ii, 887, 917
 with infected focus, ii, 846
 myosarcoma of, ii, 909
 myosarcoma of fundus of, ii, 915
 pedunculated myoma of, ii, 886, 889
 pedunculated tumor of, ii, 1060
 polyps of, ii, 926
 prolapse of, ii, 940, 1061
 complicating abdominal wall tumor, ii, 955
 pyometrium, ii, 937
 retroverted, ii, 682
 causing bladder symptoms, ii, 634
 supravaginal amputation of, ii, 1058.

V

- Vagina, carcinoma of, ii, 895, 900
 cyst of, ii, 1063
 mass in, ii, 918
 submucous myoma protruding from, ii, 1058
- Vaginal carcinoma, ii, 899
 discharge, bloody, ii, 931
 hemorrhage, ii, 894, 926, 932, 934, 937, 938, 1057
 hysterotomy, ii, 913
 prolapse, ii, 722
- Vaginorectal fistula, ii, 1039
- Varicocele, ii, 1061
 varicose ulcer of leg, i, 497, 501
 vein on lip, i, 113
- Ventral fixation of uterus, ii, 941
- Vincent's angina, i, 196
- Volkman's contraction, i, 516
- Vomiting after solids or liquids, ii, 754
 and abdominal pain, ii, 595, 853
 and diarrhea in carcinoma of the stomach, ii, 688
 and stomach pain, ii, 762
 blood, ii, 743

- Vomiting—Cont'd.
 caused by carcinoma of the esophagus, ii, 765
 due to collapse of intestines through hole in mesentery, ii, 567
 in goiter cases, i, 240
 persistent, i, 565, 573, 760
- Vulva, carcinoma of the, ii, 1054
 esthiomene of, ii, 1064
 lipoma of, ii, 1066
 tumor of, ii, 1053
 ulceration of, ii, 1064
- Vulvar region, affections of, ii, 1053
- W
- Wandering goiters, i, 240
 Warty growth about anus, ii, 1047
 Warty growths, basal-celled epitheliomas beginning as, i, 86
 Washboard prepuce, ii, 1071
 Wassermann reaction in relation to surgery, i, 17
- Water containing lime salts, cause of bladder stones, ii, 1022
- Wen of cheek, i, 81
 of neck, i, 187
- Wisdom tooth causing inflammatory swelling of neck, i, 191
 malerupted, causing swelling of neck, i, 195
- Woody phlegmon, i, 135
 of neck, i, 192
- Worry as cause of stomach distress and loss of weight, ii, 732
- Wrist, diseases of, i, 400
 granuloma of, i, 408
 hematoma of, i, 405
 hygroma of, i, 406
 joint, tuberculosis of, i, 411
 tumor of, i, 405
- X
- X-ray burn, i, 34
 treatment of lymphangioma of lip, i, 114



UNIVERSITY OF CALIFORNIA LIBRARY
Los Angeles

This book is DUE on the last date stamped below.

Form L9-50m-11,'50 (2554)444

THE LIBRARY

UC SOUTHERN REGIONAL LIBRARY FACILITY



A 000 374 083 4

0
445c
121
-2

