



2027



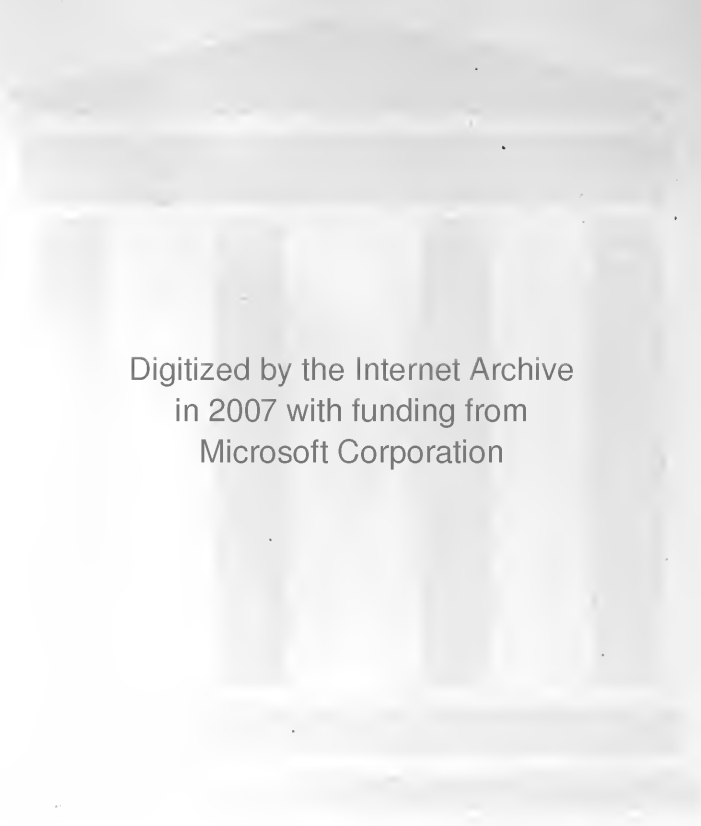THE LIBRARY
OF
THE UNIVERSITY
OF CALIFORNIA
LOS ANGELES

GIFT OF

SAN FRANCISCO
COUNTY MEDICAL SOCIETY

SAN FRANCISCO COUNTY
MEDICAL SOCIETY
LIBRARY

Digitized by Google



Digitized by the Internet Archive
in 2007 with funding from
Microsoft Corporation

RECEIVED
MAY 10 1954
LIBRARY OF CONGRESS

1905
1906
1907
1908
1909
1910
1911
1912
1913
1914
1915
1916
1917
1918
1919
1920
1921
1922
1923
1924
1925
1926
1927
1928
1929
1930
1931
1932
1933
1934
1935
1936
1937
1938
1939
1940
1941
1942
1943
1944
1945
1946
1947
1948
1949
1950
1951
1952
1953
1954
1955
1956
1957
1958
1959
1960
1961
1962
1963
1964
1965
1966
1967
1968
1969
1970
1971
1972
1973
1974
1975
1976
1977
1978
1979
1980
1981
1982
1983
1984
1985
1986
1987
1988
1989
1990
1991
1992
1993
1994
1995
1996
1997
1998
1999
2000
2001
2002
2003
2004
2005
2006
2007
2008
2009
2010
2011
2012
2013
2014
2015
2016
2017
2018
2019
2020
2021
2022
2023
2024
2025

2027

THE COLLECTED WORKS

of

CHRISTIAN FENGER, M.D.

1840 — 1902

ILLUSTRATED

VOLUME II

PHILADELPHIA AND LONDON

W. B. SAUNDERS COMPANY

1912

Copyright, 1912, by W. B. Saunders Company

PRINTED IN AMERICA

W0

7

F356c

1912

v.2

RENAL CALCULUS*

THE third specimen is a stone from the pelvis of a kidney.

The patient, Mrs. P., aged thirty, from Dakota, had always been healthy, with the exception of chronic indigestion, for which she had been under medical treatment off and on for years, until a year ago last March, when she noticed intermittent pains in the right side, soon followed by a whitish sediment in the urine. She gradually lost strength and flesh, and the attacks of pain, often running down the right leg, became more frequent and more severe.

On admission to Emergency Hospital she looked exceedingly pale and emaciated; a swelling 7 inches long and 4 inches broad was found in the right side of the abdomen, extending from 1 inch to the right of the umbilicus outward and backward into the region of the kidney. The tumor was somewhat tender to the touch, indistinctly fluctuating, and slightly movable below and separated from the liver. An exploratory puncture in the lumbar region disclosed the presence of stone and brought out pus. Pulse, 100; temperature, 101° F. On January 21st I made nephrotomy by lumbar incision. When the surface of the kidney was reached, fluctuation was distinctly felt through a thin layer of kidney tissue. This was divided by Paquelin's cautery, and a pint and a half of fetid pus evacuated. Digital exploration revealed three stones the size of a hazelnut, and a large one, 2½ inches long, with projections corresponding to the calices of the kidney, slightly movable, but still so firmly embedded that it was necessary to divide it by crushing. In attempting to remove the pieces it was still found difficult to dislodge the projections into the calices without tearing through the thin layer of cortical tissue. For fear of breaking through the surface of the kidney into the peritoneal cavity it was found necessary to enlarge the opening on the convex side of the kidney to about 1½ inches so as to bring out the fragments without too dangerous manipulation. The irregular cavity was washed out with boric acid through two large drainage-tubes.

In the course of five weeks the suppuration diminished, temperature became almost normal, the patient improved in general health, and toward the end of April had gained 35 pounds in weight. There still remained, however, a purulent discharge through the drainage-tube around which the wound had contracted considerably, and there was still some pus in the urine. On the supposition that either the drainage was insufficient or that some portion of the stone still remained the fistula into the kidney was reopened on May 9th. In the cavity, now much contracted, a small amount of gravel was found, and in the upper part of the kidney an abscess cavity the size of a walnut, apparently not connected with the pelvis. No stone was found here. Drainage and packing with iodoform gauze. Since that time the discharge has diminished, but a fistula still remains; the urine has become clear, but still contains a small amount of pus.

* Jour. Amer. Med. Assoc., 1889, vol. xii, p. 905. Chic. Med. Soc., May 6, 1889.

TUBERCULOSIS OF BONES AND JOINTS*

History.—The tuberculosis of bones and joints form anatomically and clinically a unit, because the tuberculosis of the bones usually extends to the joints, and derives from the affections of the latter the main clinical features.

Our knowledge of this branch of tuberculosis is only twenty years old, commencing at the time when Karl Küster called attention to the frequent occurrence of miliary tubercles in the fungous granulations of the disease then known as white swelling. Soon afterward Friedländer, Hueter, and especially Volkmann and König, not only verified Küster's statements, but carefully studied anatomically, clinically, and experimentally this form of local tuberculosis. This naturally attracted the universal attention of the profession, so that an extensive literature of the subject quickly sprang up—so quickly, indeed, that even before Koch's discovery of the *Bacillus tuberculosis* in 1881 the tuberculosis of bones and joints was already well established as a distinct form of disease. So much was this the case that Volkmann, at the German Surgical Congress in 1885, was able to state that all cases of the hitherto so-called *paidarthrocacis*, *spina ventosa*, *tumor albus*, fungous and strumous arthritis, etc., belonged to tuberculosis.

Etiology.—Tuberculosis of bones and joints is evidently always a secondary invasion; that is, the place of primary invasion of the bacillus must be elsewhere in the body, and one or more depots must exist in the lungs or lymph-glands before so deep-seated localities as the bones and joints can be invaded. When, therefore, authors speak of primary tuberculosis of the bones and joints, it is only a clinical term, and means that clinical examination, or even the autopsy, fails to reveal the place of invasion—the primary depots. As a clinical distinction, its importance lies in the fact that if tuberculosis is practically localized to a joint, the patient's life is not in danger from deposits in other organs, and the total removal might prove efficient to extinguish the disease.

In this sense a primary, or, to use the more correct expression, a localized, articular and osseous tuberculosis is, according to Kümmer, found in about 40 per cent. of the cases. In the remaining 60 per cent. depots are found at the same time in other organs of the body. The lungs come first, with 25 per cent.; other joints, 10 per cent.; bones, 10 per cent.; glands, 10 per cent.; peritoneum, 3 per cent.; pleura, 2 per cent.

The presence of the bacillus of tuberculosis in a body is the *condition*

* Jour. Amer. Med. Assoc., 1889, vol. xiii, p. 587. Read before Chicago Med. Society.

sine qua non, and may be aided by other etiologic elements, the most important of which is traumatism. Max Schüller proved experimentally in animals infected with tuberculosis, for instance, through the respiratory tract, that a slight traumatism to a joint would determine the localization of the *Bacillus tuberculosis* by way of the circulation, to the place of traumatism, and that a tuberculous synovitis or panarthritus would follow.

Clinically, the tuberculosis of joints has been traced in 56 per cent. of the cases to traumatism, by a direct blow to a joint, distortion, or over-exertion. It is characteristic that the traumatism is always slight; a severe trauma, causing intra-articular fracture, is very rarely followed by tuberculosis.

As a general characteristic of the articular and osseous tuberculosis, it must be stated that it belongs to the benignant chronic forms of disease; that is, it lasts for years and years, has a tendency to spontaneous recovery, little tendency to generalization, and, consequently, to the destruction of life, as compared with the acute forms of tuberculosis of the internal organs, or even the experimental inoculated tuberculosis.

An explanation of this clinical fact is given by Baumgarten, who distinguishes between three forms of miliary tubercles:

1. The lymphoid-celled tubercle, Virchow's small-celled tubercle, which is rich in bacilli, extremely malignant, and is found in tuberculosis *miliaris acutissima*, for instance, in the lungs.

2. The mixed tubercle of lymphoid cells and epithelioid cells, which contains fewer bacilli, is less benignant, and is found in the more chronic forms of general miliary tuberculosis.

3. The epithelioid and giant-celled tubercle, with no lymphoid cells, containing comparatively few bacilli, more benignant, and found in the benign forms of localized tuberculosis, joints, bones, lupus, and lymph-glands.

That this benignancy of the tubercle can be dependent upon lessened vitality in the tubercle bacillus has been proved experimentally by the inoculation of artificially weakened cultures, which were seen to produce localized tuberculosis in the nearest lymph-glands only, with no generalization (Baumgarten). Kümmer found heredity as an element in 37 per cent. of the cases.

Anatomy.—Tuberculosis has a distinct predilection for the medullary tissue of the bones; thus it is correct to speak of the tuberculous osteomyelitis as a first effect of the arrest of bacilli in some place of the medulla. The anatomic condition of the vessels in this tissue, thin walls, slight contractility, and sluggish circulation favor the implantation on the vessel-wall in the same way as pus-microbes are localized in acute osteomyelitis.

Embolism from foci in the lungs opening into the pulmonary veins may cause a tuberculous infarction of the bone. The interesting experiments of Müller, who injected pus from a tuberculous abscess into the nutrient artery of the long bones of goats and rabbits, have proved that this is a possible origin of local osteotuberculosis.

The seat of the tuberculosis in bones is usually in the cancellous substance of the epiphysis of the long bones, the short and flat bones, and, very seldom, the medulla of the shafts. The only exceptions to this are the shafts of the phalanges of the fingers and toes, and the metacarpal and metatarsal bones in children, where the tuberculous osteomyelitis gives rise to the well-known spina ventosa of the old authors.

The frequency of the localization in the different bones of the body is given by Schmallfuss, as follows:

BILLROTH.	JAFFE.	PER CENT.	SCHMALLFUSS.	PER CENT.
Vertebra	Vertebra	26.0	Knee	23.0
Knee	Foot	21.0	Foot	19.0
Cranium	Hip	13.0	Hip	16.0
Face	Knee	10.0	Elbow	9.0
Hip	Hand	9.0	Hand	8.0
Sternum-ribs	Elbow	4.0	Vertebra	7.5
Foot	Pelvis	3.0	Tibia	4.0
Elbow	Cranium	3.0	Cranium	4.0
Pelvis			Pelvis	3.6
Tibia and fibula	Sternum, clavicle, and ribs	3.0	Sternum, etc.	3.6
Femur	Shoulder	2.0	Femur	1.9
Shoulder	Femur	1.0	Shoulder	1.5
Humerus	Tibia	1.0	Ulna	1.4
Ulna	Fibula	1.0	Humerus	1.0
Radius	Humerus	1.0	Radius	0.7
Scapula	Scapula	0.6	Fibula	0.5
	Ulna	0.6	Patella	0.1

The gross appearances of the osteotuberculosis as it is found in the articular extremities of the long bones are well described by König under the three following forms: (1) The granulating focus; (2) the tubercular necrosis, and (3) the tuberculous infarct—the diffuse tuberculous osteomyelitis.

1. *The granulating focus* is found as single or multiple, round or cylindrical cavities, from the size of a millet-seed to that of a pea or hazelnut, and contains either grayish-red, soft, living granulation tissue, or, if coagulation necrosis has taken place, yellowish-gray, cheesy matter or liquid tuberculous pus. Fine spicules of bone may be felt with the finger, or, when smaller, seen with the microscope in the contents.

The granulation tissue contains epithelioid and giant-celled tubercles and bacilli. The wall of the cavity is either soft, when rarefying osteomyelitis has taken place, significant of destruction and extension; or sclerotic, when an osteoplastic osteomyelitis surrounds the focus, showing a tendency to localization and cicatrization. As little as this form of osteomyelitis has in common with the usual form of acute osteomyelitis due to pus-microbes, with its extensive area of inflammation and large sequestra, still it may be difficult to distinguish it from the more rare form of subacute multiple osteomyelitis of the epiphysis, in which multiple foci of similar form are found. But the infectious osteomyelitis has thin

yellow pus and flabby granulations without tubercles, and the pus contains pus-microbes.

2. *The Tubercular Necrosis*.—When the area of the tuberculous osteomyelitis is larger than a hazelnut, the bone is usually not absorbed, but remains as a sequestrum in the cavity. This sequestrum is sometimes osteosclerotic, sometimes osteoporotic, sometimes like the surrounding bone, according to the character of the osteomyelitis previous to the interruption of nutrition. It is yellowish-white or grayish-red, according to the contents of the Haversian canals or medullary spaces of dead or living tuberculous tissue. It may be separated from the wall of the cavity by a layer of tuberculous granulation tissue, dry cheesy matter, or tuberculous pus. If separated by a layer of granulation tissue, this may be so thin that the sequestrum fits the cavity exactly, and, if its shape is irregular, fits in so immovably that it takes a good deal of force to pry it out by the gouge and chisel.

3. *The tuberculous infarct* has the characteristic conic shape of infarcts in other parts of the body, with the apex in a proximal and the base in a distal direction. It represents the territory of an artery and suggests embolism. Large infarcts, then, must require either a larger embolus, or, in addition to the embolus, arterial thrombosis, from the place of arrest of the embolus. Their seat is usually a little inside of the cortical substance of the bone; thus, they may be overlooked if the bone is not sawed through. If, as in the specimen here presented, the base takes in the articular surface of the joint, this surface will be ground off and polished, signifying instantaneous death of the infarct at the time of the embolism.

The line of demarcation forms slowly as a furrow surrounding the dead area, the central portion of which may remain in connection with the living bone for a long time,—a year or more,—even in a joint apparently on the way to recovery.

The smallest sequestrum, in the dry forms of tuberculosis with a tendency to cicatrization, may heal in or be embedded in the non-tuberculous cicatricial tissue, remaining after the tuberculosis has come to an end and incomplete recovery taken place, without perceptibly disturbing the function.

The fate of the osteotuberculous foci varies according to the activity of the microbe and the size of the focus. The smaller granulation foci in the dry forms of tuberculosis may result in either complete recovery by removal of the tuberculous elements by absorption and filling up the cavity with cicatricial tissue, or in incomplete recovery, in which part of the focus is transformed into cicatricial tissue, in part of which dormant bacilli remain. These are apt to be revived under favorable circumstances, of which a fresh culture fluid from a traumatism is the only one known. In the joints, however, this is a very common occurrence, as we shall see later on. This accounts for the local relapses so frequent in tuberculosis as to make a permanent recovery almost impossible.

Small sequestra may, as stated above, disappear by absorption, or be included in the cicatricial tissue. Large sequestra will, of course, neither

be absorbed nor be included in a cicatrix. Moreover, they furnish an inexhaustible depot of bacilli and keep up the local tuberculosis on its progressive way to further destruction.

We have hitherto considered the osteotuberculosis at its place of origin in the bone, where it is of comparatively little importance, since so long as it is confined to the bone it gives rise to little or no functional disturbance. We shall now follow it on its extension beyond the bone, and then distinguish between its extension to the periosteum and the soft tissues, on the one hand, and to the joints, on the other. It is not until the tuberculosis has extended to one of the places named that its symptoms become manifest and the grave consequences to the patient's welfare takes place.

1. *Extension to the Periosteum Outside of the Joints.*—It is characteristic of tuberculosis that the periosteum, on the whole, is rarely affected to any great extent. We do not find, as in acute osteomyelitis, a diffuse infiltration of the periosteum and the formation of extensive masses of bone. Tuberculosis of the periosteum is localized in the joint in the same way as in tubercular osteomyelitis, and the place of perforation limited to a small area surrounded by normal periosteum, with little or no thickening or enlargement of the bone affected. When the dry, granulating form of tuberculosis reaches the periosteum, a small, soft, elastic, limited granulation tumor forms, first under the periosteum, then outside of it. It is characterized by slow growth, comparatively little pain, slight tenderness, and a tendency to remain stationary for a long time. It is different with the soft suppurating tuberculosis, which, although it also breaks through the periosteum in a limited space, acts in an entirely different way as soon as it has reached the paraperiosteal loose connective-tissue spaces. Here it has a tendency to extend rapidly and to form large abscesses—the so-called cold abscesses, traveling, like all other abscesses in connective tissues, in the direction of least resistance. On its way from the deep paraperiosteal tissues out toward the skin it forms large or small abscess cavities, and finally breaks through to the surface, after having transformed the skin into tuberculous tissue, which sometimes presents the appearance of lupus at the place of perforation. No conclusion can be drawn from the size or acuteness of the abscess as to the extent of the osteotuberculosis. A large abscess may come from a small focus in the bone, and vice versâ.

The question has arisen whether the rapid formation of tuberculous abscesses is not the consequence of a mixed infection from autoinfection of pus-microbes. It must be said that such autoinfection is rare, as the pus in these abscesses is found on microscopic examination and culture in culture substances, not only not to contain pus-microbes, but its inoculation in the camera anterior of the eye, or the abdominal cavity of animals, produces an unmixed tuberculous invasion and no suppuration.

Diffuse Tuberculous Osteomyelitis.—This form is rare. On the cut surface of the bone we find large, irregular, often multiple areas and islands, with no tendency to definition, of a yellowish-white infiltration, containing small multiple foci of liquid pus. Here is no tendency to

limitation or the formation of sequestra, but rather a tendency to spread indefinitely and to invade even the medullary tissue of the shafts. This form has, in common with the acute diffuse osteomyelitis, that it will spread through the Haversian canals diffusely to the periosteum and cause a diffuse plastic periostitis with irregular, diffuse masses of bone formed on the outside of the cortical substance. Consequently it resembles, in its clinical features, acute osteomyelitis. Locally and generally, it is a severe form; locally, it forms an extensive tuberculous depot, from which abscesses may form indefinitely; generally, patients with this form are exposed to the dangers of a fatal general tuberculosis if the whole depot is not removed in time. In operating it is important to recognize this form, since it requires more radical measures—either amputation or very extensive excision. As a rule, the mere removal of the periosteal tuberculous masses and the diseased medullary tissue is insufficient, and the whole continuity of the bone must be taken away, as in the specimen here presented. Fortunately, this form is extremely rare.

Tuberculous Abscess.—In addition to what has already been stated about the tuberculous abscess, I shall here briefly call attention to the main characteristics of its wall, which is formed of a thinner or thicker layer of tuberculous granulation tissue thickly studded with the characteristic miliary tubercles of the benignant type, with relatively few bacilli. This tuberculous pyogenetic membrane, as it was called by the old authors, is only very loosely connected with the surrounding tissues and organs, in the spaces between which it is located. So loose is the connection that, when the abscess is opened, the whole membrane can be wiped off the wall with a sponge, or, when more firmly attached, easily removed with a sharp spoon, leaving the walls so healthy as readily to unite by first intention when brought together; hence the modern treatment of these abscesses by incision of the whole length, removal of the wall, and reunion. In rare instances, however, a fascia—for instance, the fascia lata of the femur—may be diffusely infiltrated, even to such a degree as to cause diffuse necrosis, presenting the appearance of diffuse phlegmonous inflammation. In such cases careful removal, by the knife and scissors, of the whole area involved is required.

At this place I will call attention to the latest step in the conservative treatment of large tuberculous abscesses, especially the large psoas abscesses from tuberculosis of the vertebral column from Pott's disease. It is well known that the opening of these abscesses in preantiseptic times was almost always followed by a fatal septic infection from without. The modern opening and drainage under antiseptic precautions, so much praised in the beginning, has been proved not to be without danger, inasmuch as, in many cases, late infection has taken place when, after months, the inclosed fistulous openings have been guarded with less stringency in the application of antiseptic dressings.

Thus, two years ago, Bruns, in Tübingen, proposed a return to the older subcutaneous method, namely, aspiration; but, in addition to this, injection into the emptied abscess cavity of a 10 per cent. iodoform

emulsion in equal parts of glycerin and alcohol, this procedure to be repeated every four to six weeks. Usually, after three or four aspirations the formation of pus in the abscess cavity ceases, the fever stops, and the patient regains health and strength. No iodoform poisoning from this treatment has yet been reported.

2. *Extension into the Joints.*—The osteotuberculous foci in the epiphyses of the long bones are situated so near the surface of the joint that, when they come to the surface, in an overwhelming majority of the cases they will be inside of the articular cavity; the bacilli of tuberculosis are consequently poured into the joint, and a tuberculous synovitis or arthritis is the result.

Tuberculosis of joints is by far the most common joint disease—so much so that König states that, in the surgical clinics, the surgeon will have 100 cases of tuberculosis of the joints to deal with to one of the other classes of inflammation, such as gonorrhœal, syphilitic, septic, osteomyelitic, rheumatic, or the metastatic inflammations subsequent to acute infectious disease. Although the statement may seem to the general practitioner to be carried to the extreme, still the authority of König is sufficient warrant for the statement that tuberculosis as a cause of joint disease far exceeds all others, and that the tubercular arthritides are the every-day cases of the surgeon.

We distinguish, as to origin, between primary synovial and primary osteal tuberculosis of the joints. Max Schüller stated, as a result of experiments, that a slight injury to a joint in a person who had bacilli floating in his blood would determine localization, commonly in the form of a synovial tuberculosis. It may be said here that, as to the relative frequency of the two forms, it has been shown that the primary osteal tuberculosis occurs two or three times as often as the primary synovial. As far as the course and development of the articular tuberculosis is concerned, the difference in origin makes little or no difference—so little, indeed, that we are unable to make a differential diagnosis, even from the symptoms.

As to the primary osteal tuberculosis of the joints, we have already seen that an osteotuberculous infarct is located in the joint from its very beginning, while the smaller granulation foci open into the joint secondarily. When located close to the articular cartilage, this must be destroyed before the joint is invaded, the cartilage forming a barrier which may sometimes prove sufficient to resist invasion. A small, dry granulation focus may heal up before perforation takes place.

When located at the surface of the joint, where the bone is not covered with articular cartilage, the thin periosteum and the serous membrane covering it are more easily opened through. An important complication is when an osteotuberculous focus is placed right at the insertion of the capsule of the joint. It may then open in and outside of the joint simultaneously, or the one or the other, the saving of the joint depending upon the few lines of difference. When the tubercle bacillus invades a joint and tuberculosis of the joint ensues, all the constituent parts of the joint will be successively affected, namely, the synovial

membrane, parasynovial tissue, ligaments, and perisynovial tissues, the articular cartilage, and, finally, the articular surface of the bone.

It is a question whether so light a form of inflammation as a simple synovitis, whatever that may be, as mentioned by Kümmer, can set in as an effect of either ptomains alone, from a near focus, or from extremely weakened tubercle bacilli. A simple serous synovitis of entirely benignant character, if it exist, is of extremely rare occurrence.

Commonly, the presence of the tubercle bacillus in the joint produces one of the following forms: (1) A pannous hyperplastic synovitis. (2) A tuberous hyperplastic synovitis or papillomatous plastic synovitis. (3) A granular or fungous hyperplastic synovitis (Hueter). (4) The tuberculous articular empyema (König).

1. *The Pannous Hyperplastic Synovitis (Hueter).*—The synovial membrane is moderately thickened. From the border of the cartilage a thin vascular layer of granulation tissue creeps in over the surface of the latter—so much so as sometimes to cover the larger part of the surface and unite with the cartilage, which gradually becomes transformed into connective tissue. The tubercles are usually not visible to the naked eye.

2. *The Tuberous Plastic Synovitis, or Circumscribed Nodular Tuberculosis of the Synovial Membrane.*—The tubercular fibroma is characterized by the development of a subserous tumor the size of a walnut or larger, protruding into the joint and filling, for example, the suprapatellar recess of the knee-joint, with simple synovitis or pannous synovitis in the rest of the cavity. Such a local tuberculosis is amenable to extirpation of the tuberculous tumor followed by recovery. The papillomatous plastic synovitis is a diffuse form of hyperplastic tuberculosis, and, as shown in the specimen, we find the whole inner surface of the synovial membrane covered with sessile or pedunculated papillomatous growths, small and rather uniform in size, some of which may become detached and constitute the so-called “rice bodies.”

3. *Diffuse Granulating Synovial Tuberculosis.*—Here the synovial membrane is considerably thickened, hyperemic, with or without visible tubercles, always accompanied by invasion of the para-articular tissue and the ligaments of the joint. Thus is formed the thick, edematous mass of tissue, usually of a gelatinous appearance, in which coagulation necrosis will cause, in the more dry forms, islands of cheesy matter; in the more liquid forms, islands of pus, that is, small multiple abscesses.

Any of the above-named forms of synovitis may give rise to the exudation of serous or serofibrinous fluid in the joint—the tuberculous hydrops of König. A considerable hydrops is most commonly associated with a diffuse synovial tuberculosis, with little thickening of the capsule. Less commonly it is found in the tuberous and papillomatous synovitis; most rarely in the fungous or granulating synovitis. The fluid is clear in the lighter forms; slightly milky from migratory corpuscles, or mixed with shreds of fibrin in the severer forms. So-called rice corpuscles may be found and derived either from islands of fibrin or from loosened papillomata. Their presence indicates tuberculosis (Reidel).

4. *Empyema Articulationis Tuberculosisum—Cold Abscess of the Joint (König).*—The inside of the capsule is covered with loosely adherent tuberculous membrane similar to that in tuberculous abscesses, so loosely connected with the capsule as to permit of its being scraped off. The remaining synovial membrane is diffusely infiltrated with miliary tubercles, but only slightly thickened, if at all, because of the non-invasion of the parasynovial tissues.

The articular cartilage plays, as a rule, only a passive part in tuberculosis of the joint, as its fate is destruction or absorption. The cartilage covering a large sequestrum dies off and is mechanically detached from the bone in smaller or larger pieces. An osteotuberculous focus, when reaching the cartilage, will cause gradual local absorption, and a local, usually round defect, through which red granulation tissue or cheesy matter protrudes. The surrounding cartilage may be entirely normal and efficient for the function of the joint. A primary synovial tuberculosis has a tendency to develop most intensely in the region of the capsule at the circumference of the articular cartilage. From here it has an easier way down into the vascular bone than into the non-vascular cartilage, and extends down between the bone and the cartilage as a tuberculous osteomyelitis, creating a layer of tuberculous granulation tissue that will detach the cartilage from the bone. Local hyperplastic foci in this granulation tissue may perforate the cartilage in many places, just the same as a primary osteotuberculous focus, so that the cartilage presents the appearance of a sieve. Finally, either the whole cartilage or shreds of it are found loose in the cavity of the joint.

In the pannous synovitis and the dry forms of fungous synovitis an apparently direct transformation of cartilage into connective tissue takes place.

The articular surfaces of the bone, after the disappearance of the cartilage, present the following appearance: In the dry form, a layer of not very vascular connective tissue covers the surface and connects it with the opposite similarly transformed surface. In the more moist and suppurating forms a layer of miliary tuberculous tissue covers the bone with visible yellow miliary tubercles, extending usually only a short distance down from the surface. Thus the whole head of the femur, the acetabulum, etc., is gradually destroyed.

SYMPTOMS

1. *Tuberculous hydrops*, as we have stated, is common in diffuse synovial tuberculosis with little swelling of the capsule, also in papillomatous diffuse synovitis or local tuberous synovitis, but is seldom found in the granulating fungous synovitis. It is characterized by the usual symptoms of a painless intra-articular accumulation of fluid, which usually reaccumulates when removed, and sooner or later the tuberculosis going on shows some thickening of the capsule after removal of the fluid.

The prognosis is relatively good because there is little tendency to destruction of the joint or to suppuration. Some cases recover after

puncture and rest. Rice bodies, when present, can be felt to give a peculiar friction sound when moved from one point of the joint to another. The joint remains for a long time in relatively good function, which ceases only when, later on, thickening of the capsule and destruction of the joint set in. A tubercular fibroma can be felt after the aspiration of the joint as a sessile, more or less movable tumor, simulating floating cartilage. Simple arthrotomy and extirpation may prove effectual. The tuberculous hydrops is never accompanied by fever. As above stated, the lighter forms may recover by aspiration and immobilization. More obstinate forms require opening of the joint, excision of the local tumors if found, a partial excision of portions of the capsule, with iodoformization and drainage. König has opened the knee-joint on both sides of the patella, excised large slices of the capsule, and seen perfect recovery. However, the result is always uncertain, and the tuberculosis may, in spite of initial, more conservative treatment, go on to the severe and more destructive forms, and require more radical operative measures.

2. *Fungous Arthritis—Granulating Synovial Tuberculosis, White Swelling, Tumor Albus.*—This is by far the most common form of tuberculosis of the joints, whether primary osteal or primary synovial. No symptoms enable us to make a distinct diagnosis between a primary osteal and a primary synovial tuberculosis of the joint, but, as we stated in the discussion of tuberculosis of the bones, the primary osteal form is the most common. In the knee the proportion of the primary osteal to the primary synovial form is 3 to 1; in the hip, 4 to 1; in the elbow, 4 to 1 (König). As to age, the proportion in children below fifteen is 2 to 1; above fifteen, 3 to 1. If it were possible to know that a large osteo-tuberculous focus was to be found in a given case of articular tuberculosis, this knowledge would determine an immediate operation, and no time would be lost by conservative treatment. But, unfortunately, as yet the diagnosis is almost impossible.

The fungous arthritis is much more frequent in the lower than in the upper extremities. According to Albrecht, out of 325 cases of which he gives the statistics, 91 were found in the joints of the upper extremity, and 234 in those of the lower extremity. The granulating synovitis or fungous arthritis presents a great variety of clinical forms, according to the acuteness of the onset and the course, slowness or rapidity of destruction, and extent of the infiltration of the synovial tissues. It is especially the degree of periarticular infiltration, its almost entire absence or presence, in abundance, that makes the clinical distinction between the dry and soft forms so characteristic that Volkmann has called attention to the former as a distinct class of cases.

(1) *The dry granulating tuberculosis, the atrophic form, plastic synovitis (Kümmer), caries sicca of Volkmann*, so common in the shoulder-joint, is characterized by the tendency of the tuberculous tissue to cicatrization, and slight tendency to extensive destruction of cartilage and bone. Absence of invasion of para-articular tissues results in only a slight or in no swelling in the region of the joint, which may even be found atrophic, as in the shoulder-joint from atrophy of the muscles, or

in the hip-joint in young individuals (König); more rarely in the knee. In the shoulder-joint there may be considerable atrophy, and still so much mobility that the disease may simulate a neurosis resulting in atrophy of the muscles of the joint. A careful examination in narcosis, revealing restriction of mobility from cicatricial contraction of the tuberculous capsule, will enable us to make an early diagnosis, which is confirmed later on when para-articular abscesses form. In a majority of cases, however, this form has a tendency to come to an end without the formation of abscesses, terminating simply in a more or less restricted mobility of the joint. Dry caries of the shoulder-joint is found not infrequently in young women (König).

(2) *Fungous arthritis, tumor albus, synovitis fungosa sive granulosa*, is probably the most common of all the forms of articular tuberculosis. It is characterized by the softer condition of the tuberculous granulation tissue, with tendency to destructive invasion of all the elements of the joint, coagulation necrosis, and liquefaction. The invasion of the para-articular tissues causes considerable swelling in the region of the joint, giving to the latter the characteristic spindle shape so frequently found in the knee-, elbow-, and ankle-joints, the swelling being so much the more apparent when atrophy of the muscles above and below has taken place. Extension of the infiltration from the para-articular tissues out toward the subcutaneous tissues finally causes the swollen joint to be covered with a whitish, immovable, dense skin, giving the joint the appearance from which the time-honored name of white swelling is derived. In the beginning of the disease a slight degree of hydrops is found in a few cases; most often the cavity of the joint contains no fluid, or not a sufficient amount to be recognized by palpation.

Later in the disease liquefaction in the islands of coagulation necrosis, and in the islands of soft granulation tissue, gives rise to the presence of tuberculous pus. This may be found as small foci in the soft granulating capsule, small abscesses inside the granulation tissue, or as pus from the cavity of the joint. At this stage of the disease, especially in the softer form of tuberculosis, the peri-articular abscess is formed. Most commonly a local destruction of the tuberculous capsule facilitates the invasion of the peri-articular intermuscular spaces by the tuberculous pus already contained in the joint; and a more or less rapid increase in size of the abscess cavity in the direction of least resistance causes the formation of more or less distant abscess cavities, which, of course, always lead into the cavity of the joint. More rarely, peri-articular abscesses form directly from an osteal focus by the extension of a mass of tuberculous granulation tissue, extending through the capsule out into the peri-articular tissue, as a primary mass of solid granulation tissue in which liquefaction takes place secondarily. A peri-articular abscess originating in this way may attain the same size as that previously mentioned, but, owing to its original form, a local osteotuberculous focus is of less prognostic importance, inasmuch as it does not necessarily indicate suppurative destruction of the cavity of the joint. This latter form of abscess may be opened and evacuated and may then close up, with or

without the removal of the osteotuberculous focus, and still leave the joint in a more or less unimpaired condition; while, on the other hand, the peri-articular abscess communicating directly with the destroyed joint cavity has no tendency to come to a close, but leaves fistulous openings which keep open permanently, and only too often, when not protected by antiseptic dressings, sooner or later furnish a place of invasion for pus-microbes, adding acute suppuration or sepsis to the tuberculosis, and giving rise to a rapid increase in the destruction of the articular surface.

A fungous arthritis, when limited to a single joint, will rarely cause any rise in temperature. High temperature is always indicative of a mixed infection with pus-microbes, or, what is very rarely met with, general acute tuberculosis. By far the most common is the mixed infection which comes from without, the pus-microbes entering the open and unprotected peri-articular abscess. It is very exceptional that auto-infection, that is, invasion of a closed tuberculous joint by floating pus-microbes from a distant place of invasion, takes place. A slight rise in temperature, remittent or intermittent, however, commonly accompanies the formation of tubercular peri-articular abscesses. A temperature of 100° to 101° F. in the evening, with normal morning temperature, is indicative of this complication, and this, as first pointed out by König, is an important diagnostic symptom.

Contractions, lateral deviations, or other abnormal positions of the articular surfaces usually signify destruction of the articular ligaments and articular surfaces. They are thus not seen in the articular hydrops or the lighter forms of synovial tuberculosis, while we find them in tumor albus, or the destructive forms of para-arthritis. König very properly uses the term "Destructions-Contractur" (contraction by destruction) for these displacements, in preference to the usual term of spontaneous dislocations, and employs the latter expression to signify the condition when, through muscular contraction or a slight injury to the joint, whose strengthening ligaments are destroyed, a sudden, very painful, and often considerable displacement takes place. This is especially common in the hip-joint. The clinical importance of any of these displacements lies in the fact that they signify a certain amount of destruction of the joint, thus often indicating surgical interference.

Pain as a symptom accompanying tuberculosis of the joint, although always present, is of extremely variable intensity; two patients with an apparently similar degree or form of tuberculosis in the knee-joint may differ so much, as far as pain is concerned, that the one may be able to walk almost without pain, while in the other the slightest movement will cause intense suffering. Although the intensity of the pain does not give any absolutely certain information as to the extent of destruction of the joint, it may be said that, in general, the more acute destructive forms of tuberculosis are the more painful, and, further, that intense pain on movement may mean large intra-articular osteal foci and extensive intra-articular destruction, while slight pain would indicate that the articular cartilage was as yet comparatively intact. A sudden attack of intense

pain sometimes means that perforation of an osteal focus into the yet intact joint cavity has taken place. It is of more practical importance when we find a local painful spot on the articular extremity of the bone, especially when it is outside of the usual line of the swollen and tender capsule. Inasmuch as this may indicate an osteal focus if the tender spot shows some localized softness or swelling, it is of even more significance in this direction, and indicates a local operation which may save an as yet comparatively intact joint.

(3) *Cold abscess*, the *pyarthrous tuberculosis*, is rare. Its most typical form is found in diffuse miliary tuberculosis, and a less typical form, that is, less fluid in the joint, in the soft forms of granulating tuberculosis. The onset is usually acute, often with considerable pain, accompanied by fever, so as even to simulate suppurative synovitis. There is a tendency to destruction of the capsule and the early formation of large peri-articular and intermuscular abscesses. The symptoms of general acute tuberculosis are likely to set in sooner or later.

DIAGNOSIS

As a rule, there is no difficulty in the diagnosis of tuberculosis of the joints when the history, course, and symptoms of the disease are taken into consideration, as above stated; but, as König justly remarks, it is well to remember that an articular tuberculosis, even of the large joints, is practically a local disease, and has for a long time little or no influence on the general health of the patient. Thus we may find patients apparently strong and healthy looking suffering from articular tuberculosis.

The hydrops tuberculosis is distinguished from a "common articular hydrops," whatever that may mean, traumatic, for instance, by its persistency and tendency to relapse as soon as the joint is put to use again. Flocculi of fibrin or rice bodies indicate tuberculosis.

The tubercular fibromata might be mistaken for lipoma arborescens or gummata. The diagnosis of the latter will be cleared up by anti-specific treatment, which should always be tried in cases of doubt.

Cold abscess is distinguished from the suppurating synovitis by less pain, some swelling of the capsule, and the frequent presence of tuberculosis in other organs.

The fungous synovitis or panarthritís rarely causes any difficulties in diagnosis. The elastic swelling, comparatively painless abscesses, or fistulous openings with fungous granulation tissue protruding are characteristic. It can be distinguished from acute multiple osteomyelitis of the articular surfaces by its slow and comparatively painless onset, and the slight tendency to ankylosis as compared with the latter.

The caries sicca of Volkmann, or dry cicatricial atrophic tuberculosis, especially as found in the shoulder-joint, might be mistaken for a neurosis with atrophy of the muscles covering the joint. An examination in narcosis will reveal some loss of mobility in the tuberculosis as compared with the absolutely free mobility in neurosis. Exact measurement may reveal some shortening, that is, articular destruction in the tuberculosis.

PROGNOSIS

It is almost impossible, in any given case of articular tuberculosis, to state the future fate of the joint, inasmuch as the course of the tuberculosis is in the highest degree atypical. König states that all forms and cases of tuberculosis of bones and joints are capable of spontaneous recovery, with more or less loss of function; but it may be stated, as a general rule, that the softer and more acute the tuberculosis, the larger the osteal foci, the earlier the suppuration, and the less careful the early treatment, the graver is the prognosis. An apparent recovery is always uncertain as to its duration, inasmuch as relapse or rekindling of the tuberculosis is likely to take place at any time. The articular tuberculosis usually extends over many years, especially the fungous pan-arthritis. The caries sicca may, according to König, come to an end in two or three years with some loss of mobility. Lighter forms of synovial tuberculosis or articular hydrops may disappear with proper treatment in a much shorter time.

As to the question when it can be said that recovery or disappearance of the tuberculosis has taken place, we may be guided by complete disappearance of the pain and swelling, and by the painlessness of what mobility has been left in the joint. As has been stated before, complete ankylosis is rare, but when it takes place, it gives this advantage, that the pain disappears, even when the tuberculous foci are left in the capsule or the bones.

As to the prognosis in different ages, it may be said in general that children will more easily recover even from a severe articular tuberculosis than adults—a fact that permits of more extensive conservatism in the treatment of tuberculosis in early age. This is an important fact, as the articular ends, as is well known, play an important part in the growth of the extremities, and destructive operations in children are apt to leave useless limbs from lack of growth.

The danger to life from articular tuberculosis presents the following points for consideration:

1. Sepsis, a secondary invasion of the pus-microbes into the joint and peri-articular abscesses, is not uncommon. The pus-microbes invade, not by auto-infection, but through careless or rather non-antiseptic treatment of spontaneous or artificial openings, leading to peri-articular abscesses. It may thus be said that although, practically, this complication is not an uncommon one, it can be prevented by careful, systematic, antiseptic treatment. The difficulty is that the fistulous openings into tuberculous joints remain open for months and years, attendants and patients grow careless in course of time, and late septic invasion takes place.

2. General tuberculosis, acute or chronic, is much graver, since it is impossible to prevent it. In the course of years a number of patients succumb to this complication. Billroth states that in sixteen years 27 per cent. were lost in this way. König, from a table of 117 operations for

tuberculosis, found that after four years 16 per cent. had died from general tuberculosis.

3. It has recently been pointed out by various authors, especially König, Wartmann, and Albrecht, that operations on tuberculous joints may cause immediate infection—the so-called operation tuberculosis. This complication is not very common; König, in his extensive experience, has seen only 16 cases, and Wartmann, from a collection of excisions amounting to 837 cases with 225 deaths, found only 26 cases of operation tuberculosis. It sets in, as König describes it, seven to ten days after an operation, which may be aseptic and heal by first intention, either as acute tuberculosis of the lungs or tuberculous meningitis, terminating in death three to four weeks after the operation. Sometimes, in cases where the operation is followed by suppuration and secondary operations become necessary, it follows these.

4. A number of patients in the course of years succumb to amyloid degeneration of the spleen, the liver, and especially the kidneys, with its accompanying dropsy, which takes away some of the survivors.

I shall say nothing as to the treatment of the articular tuberculosis, inasmuch as this question belongs to special surgery, and would be altogether too extensive to be taken up in the time allotted by this Society to the discussion of the question of tuberculosis.

However, before leaving the field of tuberculosis I want to call the attention of the Society to a comparatively rare localization of the tubercle bacillus, and to an affection that has only recently been recognized as such, namely—

TENDON TUBERCULOSIS

Tendon tuberculosis is a necessary appendix of tuberculosis of the joints. I do not mean tuberculosis of the tendons, where the tuberculosis creeps out along the tendons from a tuberculous joint, as you find it around the tendo Achillis from the ankle-joint, or the flexor tendons of the arm from a tuberculous wrist-joint; but I mean primary tendon tuberculosis, which is on an equal footing with any other primary synovial tuberculosis. The subject of tendon tuberculosis is a new one. French authors, more than thirty years ago, called attention to a so-called fungous tendon synovitis, describing it, as far as gross appearances go, very well, but, of course, they did not come to an understanding about its pathology any more than about that of the so-called synovitis of the joints. Nothing was done until 1875, when Volkmann* gave a masterly description of the tendon tuberculosis, but without recognizing it as a tuberculosis. Then came Riedel, König's assistant, who showed that the rice bodies so commonly found in the so-called fibrinous hydrops of the tendon-sheaths, or hygromata of the flexor tendons of the hand, always indicate a synovial tuberculosis.

I wish to say only a few words about the pathology of this form of tuberculosis, because, as far as it needs treatment, it is a synovial tuber-

* Beiträge z. Chir.

culosis—a fungous synovitis. It is a tuberculosis with an enormous development of tuberculous tissue in the sheath of the tendon and on the tendon itself. In the sheath of the tendon it forms a layer of from one to four lines in thickness, of the usual well-known gelatinous tuberculous tissue. On the tendon it forms a similar layer, usually smaller, and with that important anatomic feature that this granulation tissue creeps down between the bundles of the tendon and separates them until finally it makes a perfect brush out of them; then atrophy of these separate bundles of the tendon takes place and the tendon ruptures—a spontaneous rupture in the same sense as a spontaneous fracture, that is, that with a very slight movement the tendon tears. If left alone, this tendon tuberculosis has the same fate as tuberculosis of the same character in other parts of the body; it goes on to liquefaction of the tubercles and the surrounding tissue, and pus—if we may so call it, tuberculous pus without the pus-microbes—forms. This abscess is opened or breaks spontaneously, leaving tuberculous fistulas with no tendency to heal, just the same as fistulas leading into tuberculous joints. The same fate as with all other tuberculous tissue will be the result of the opening, namely, that if septic invasion from without takes place, that is, if the tuberculosis is not removed at that time or antiseptic precautions taken, then sepsis sets in and finds a congenial soil in the tuberculous tissue, an excellent culture soil for the common pus-microbe, just the same as in tuberculous abscess from Pott's disease, or tuberculosis of the vertebral column, in which the opening is, in the large majority of cases, the beginning of the end. Tendon tuberculosis most commonly attacks the flexor tendons of the hand; then we have the so-called hygroma of the hand, with its swelling in the palm and above. These are undoubtedly always tuberculous; further, we find isolated tendon tuberculosis in the extensor tendons of the hand, more rarely in the tendons of the lower extremity, as the patellar ligaments, of which I have seen one case.

I wish to present a patient tonight who has kindly consented to come down and show his hand. The history is as follows:

John Harrington, laborer, aged thirty-five. Family history good. The present trouble commenced about three years ago, when the patient noticed a slight painless swelling on the dorsum of his hand. A watery fluid collected, which was removed, but collected again; the increased swelling gave rise to severe pain and inability to flex the fingers. After a few months the swelling broke spontaneously, and there was a seropurulent discharge. This discharge continued for about two years, the swelling increasing slightly, until October 27, 1888, when the patient came to my clinic at the College of Physicians and Surgeons.

Examination revealed a swelling about 5 inches long in the median line of the dorsum of the hand, extending from about $1\frac{1}{2}$ inches from the metacarpophalangeal articulation to beyond the wrist-joint.

Diagnosis.—Tendon tuberculosis of the extensor tendons of the hand. An incision was made, extending from within $\frac{1}{2}$ inch of the metacarpophalangeal articulation, 7 inches up the forearm in the median line, over the swelling. The incision was made down to the muscles and tendons, and a quantity of rice bodies removed; these were also found inclosed in the sheaths of each of the tendons when opened. The sheaths of the extensor

tendons were removed, and each and every tendon was thoroughly scraped to remove the tuberculous material. The extensor tendon of the thumb was divided, it being impossible to separate the tuberculous tissue without this. The tendon was united to one of the other extensor tendons. The integument was sutured with silk, and the hand and forearm dressed antiseptically. One week after the operation the wound had united, and the sutures were removed and the hand dressed. Two weeks after the operation there was good union. Four weeks after the operation flexion and extension of the fingers were regained. There was no sign of return of the disease.

When this man came for operation, one of the tendons—the short extensor of the thumb—was destroyed; the others could be separated from the tuberculous tissue. This dissection of the tendons from the tuberculous tissue takes a long time. It has to be done with the utmost care, because the tuberculous tissue that runs down between the fibers of the tendons is adherent; there is no short way of rubbing it off the tendons—it must be dissected off carefully, particle by particle, and then the whole sheath of the tendon dissected off with scissors and forceps, just as carefully as in the joints, particle by particle, and this law holds good in all operations for tuberculosis. Then come the difficulties of dressing. It has been found that in dressing with drainage-tubes, antiseptic washes, etc., the results are not so good as if the wound is left to heal by the organization of an aseptic clot, as Lister called it. But this healing without drainage implies that the wound shall be filled with blood. No exact union of the wound is made, but a couple of spaces are left between the sutures, so that the surface blood can get out. Schede recommends this method, having found that the connective tissue formed in the nidus of the clot was more pliant than the connective tissue formed when there was drainage. That method was used in this case, and the consequence is that much more extension than before is possible. This patient also shows a tuberculosis of a metacarpophalangeal joint.

The prognosis as to the future functions of the tendons depends upon perfect asepsis (if there is not perfect asepsis, then the result is lost); supuration must not take place after the operation. It further makes a great difference as to the future function of the hand whether the tuberculosis is on the dorsal or on the palmar side. On the palmar side of the hand, where we have to open from the palm up to the middle of the forearm, the palmar ligament may be divided and reunited with sutures, and it may be necessary to do this so as to dissect out the wall of the common tendon-sheath. Tuberculosis in the palm of the hand gives much less satisfactory results after operation for removal of the tuberculous sheath from the tendon than on the dorsal side of the hand. Another point is that when the tuberculosis has reached the upper end of the tendons, it creeps up the muscles not only in the loose connective tissue, but up between the bundles of the muscular fibers. This we can recognize with the naked eye by the color and consistence of the muscle. The invaded muscle becomes hard and grayish, and is not shining, as the normal muscle tissue. Of course, all this tissue has to be cut away carefully, because it is one of the modern improvements of our technic in operating for tuberculosis that every part of the diseased tissue is

carefully removed from the joints by scissors and forceps, so as to leave, if possible, no tuberculous tissue at all. This makes a very different operation from the one where the bones are sawed off from the joints, for instance, and the abscess drained, no care being taken either of the walls of the abscess or the cartilage, the consequence being that the tuberculosis very often grows right out again and there is greater liability to sepsis setting in. These operations are long and tedious, but if perfect asepsis is secured, we may expect the results to be locally permanent. Tendon tuberculosis is a rare disease; it exists only in 1 or 2 per cent. of the cases in the statistics of tuberculosis.

OPERATIVE TREATMENT OF CARCINOMA OF THE RECTUM*

THE results of palliative and operative treatment cannot very well be compared, because each one serves its own limited field of usefulness. The palliative operations will be used where total extirpation of the carcinomatous tissue is either impossible or too dangerous to the life of the patient. Total extirpation should be resorted to whenever there is a possibility of removing all the diseased tissue without taking the life of the patient.

We will first discuss the palliative operations, which all have the intention of doing away with symptoms of stenosis.

1. Linear rectotomy, as devised by Nélaton and extensively practised, especially in France, by Verneuil, Trélat, and others, consists in division of the posterior wall of the rectum for carcinoma in the median line backward to the coccyx, and is done with either the knife or the cautery, the cautery giving more security against hemorrhage and sepsis. The effect of the operation is often a very beneficial one in reducing the frequent painful passages to few and painless ones. As to its dangers, Verneuil estimates the mortality from the operation at about 5 per cent., and he states that the suffering from incontinence is small. This operation can be made use of only in low carcinomata, where the finger can reach the upper border of the tumor, and the peritoneal cavity is in no danger of being opened. In regard to this matter, Esmarch states that in the majority of the cases of carcinoma low down total extirpation is not only possible, but easy, and consequently ought to be preferred. It should be limited to cases where the wall of the bladder, the prostate gland, the uterus, or the fornix of the vagina have been invaded by carcinoma, making total extirpation inadvisable.

2. Opening into the rectum from the ischio-rectal fossa above the carcinoma, as devised by Marshall, is practically making a posterior artificial anus above the carcinoma. Spontaneous fistulous openings in this place had taught Marshall that relief from stenosis symptoms took place. This operation, however, has never been resorted to to any extent.

3. Cureting of the carcinoma with the sharp spoon and cauterization of the scraped surface with Paquelin's cautery is another method. The cureting was devised by Simon, and the cauterization of the cureted surface by Küster, who has practised this method of late extensively. He advocates the method very strongly, saying that it affords great

* Med. and Surg. Reporter, 1890, vol. xliii, p. 311.

relief in inoperable cases. Of from 25 to 30 patients, only 2 died from peritonitis, and Küster estimates the mortality from the operation at about 8 per cent. Many of his patients lived more than a year, and in a comfortable condition. Küster has for years never performed colotomy in low carcinomata. The operation just described is applicable only to tumors low down in the rectum, because in the carcinomata above the line of the peritoneum surgeons always run the risk of opening into the peritoneal cavity. Esmarch has seen cicatrization of a large carcinoma take place after this operation, but still calls attention to the dangers of hemorrhage and collapse following this method.

4. Lumbar colotomy, as devised by Amussat and Callisen, has been extensively practised by English surgeons, but is now rapidly losing ground and being replaced by the more modern modifications of inguinal colotomy. The mortality from the old statistics was high—between 30 and 40 per cent. This mortality has decreased considerably of late, so as to enable Cripps to report 14 cases without a death. There are certain objections to the method, sufficient to prevent its future use. Prominent among those objections is the difficulty of finding the colon and opening into it at a place not covered by the peritoneum. The descending colon frequently has a mesentery, and it often necessitates great distention to find sufficient space to open into the bowel without opening the peritoneal cavity. The wound is always a deep one, and the artificial anus is in an inconvenient place for cleaning away the feces, except in patients who are unable to get out of bed. It is impossible to prevent part of the fecal matter from passing down to the carcinoma and causing the usual irritative effect on the ulcerated surface, and, consequently, it does not relieve the pain and tenesmus. The advocates of the operation, such as Henry Morris, claim for lumbar colotomy a wider application, as, for instance, in carcinoma of the sigmoid flexure or lower portion of the descending colon, where inguinal colotomy would give no relief. Knies' modification of inguinal colotomy is practicable on the transverse colon as well as on the cecum and ascending colon, thus making this claim of advantage somewhat doubtful.

5. Inguinal colotomy, as devised by Littré, or laparocolotomy, is rapidly gaining favor. The mortality of the operation was in early times (Batt and Van Erkelen) even higher than in lumbar colotomy, being from 46 to 53 per cent. This was the consequence of opening into the peritoneal cavity without antiseptic precautions. The introduction of antiseptic methods here, as in all other intra-abdominal operations, reduced the mortality to the neighborhood of 5 per cent. König reports 20 cases with only 1 death from peritonitis; Cripps, 26 cases with only 1 death.

The attempts to perfect inguinal colotomy had in view, besides guarding against infection of the peritoneal cavity, to effect complete evacuation of the feces in the place of the artificial anus, so as to prevent any fecal matter from passing down into the carcinoma, thus preventing irritation and painful tenesmus, and, furthermore, to facilitate the

washing out of the carcinomatous bowel from above. Closure of the lower bowel, as devised by Madelung, was thus abandoned, and Knies' method, as modified by Maydl, is the one nowadays mostly adapted to fulfil all the indications. When it can be performed in two stages, it must be considered almost without danger from peritonitis, and its advantages, as stated by König, are the following: The operation is done openly, mostly outside of the peritoneal cavity; no fecal matter can pass over the carcinoma, and this can be easily irrigated and kept clean.

6. The radical operation, that is, the total extirpation of carcinoma, should always be done when it is possible to remove all the diseased tissue without too great danger to the life of the patient. It is the only hope of a radical cure, and a number of permanent recoveries are on record. In the earliest period only low carcinomata were operated upon, as the dangers to life became almost insurmountable. Modern modifications, especially the sacral method of Kraske, has greatly reduced the dangers for the high carcinomata. The removal of part of the sacrum or its osteoplastic—that is, temporary—resection, as devised by Hochenegg, gives ample space for the removal of carcinomata even above the rectum and in the lower portion of the sigmoid flexure. Nevertheless, it cannot be disputed that a considerable amount of preliminary operating in the high or sacral operation causes additional danger from hemorrhage, collapse, and peritonitis in patients already reduced in vitality by the disease. If we want to consider the danger of the radical operation for carcinomata from a statistical point of view, we meet with a difficulty yet in the literature that the authors did not distinguish sharply enough between high and low operations.

In comparing the low and high operations, we find that the enormous mortality before Volkmann's time, of over 70 per cent., has come down to 36 per cent. By comparing statistics from the literature in 1887, I have collected 272 cases, with a mortality of 22 per cent. In the hands of other operators, however, after that time the mortality has been lowered considerably. Thus König gives us a mortality of his operations, for the last six years, of 16 per cent., and von Bergmann gives us a series of 46 operations, with only 3 or 4 deaths; Cripps, 30 operations, with 2 deaths; Hochenegg, 12 operations (from Albert's clinic), with no deaths; Bardenheuer, 13 cases, with 2 deaths. It may be reasonable to conclude that the mortality of today, with proper selection of cases, may be estimated at between 10 and 15 per cent.

As to the number of radical cures, it is impossible, from the literature, to give an estimate, but I should expect a radical cure in about 10 per cent. of the patients that survived the operation.

As to the functional disturbance, comparatively little is known, from the fact that little mention is made of the patient's condition in after years. König takes a rather gloomy view of the condition of those patients, and states that the functional results after the high operation are better than those after the low operation. Of 21 patients, he considers 15 in an unsatisfactory state; always unclean except when

constipated; and only 6 had tolerably good power of retaining the feces. Von Bergmann takes a brighter view of the condition of such patients, and so do most other authors—so much so that the functional condition of the patient is not permitted to interfere with the choice of operation between palliative and radical when there is a possibility of saving the life of the patient with the latter method.

OVARIOTOMY DURING PREGNANCY*

It would seem strange to bring this important subject before the Society with only one case as an illustration. I do not pretend to bring forward anything new or anything of my own in this connection, but merely desire to present to the Society the thoughts and reflections that I experienced after looking over the literature on the subject. This has been the more interesting to me because of the radical changes in the views as to the choice of treatment of this condition which have taken place within the last ten years.

CASE.—Mrs. G. E., thirty years of age, primipara. Health always good up to the time of this sickness; she had never been treated for any uterine disease. First menstruated at fourteen. Until the nineteenth year she was occasionally troubled with frequent and profuse menstruation. From the nineteenth to the twentieth year the menstrual flow was regular, but scanty. After the twentieth year it again became normal, and continued so until the time of last menstruation, May 21, 1890.

She was married in 1886, at the age of twenty-five, and was well from that time until pregnancy, with the exception of some attacks of pain in the lower part of the abdomen, radiating from the lumbar to the inguinal regions. The pain would come on suddenly, had no connection with menstruation, would last from fifteen minutes to half an hour, and would be followed for several days by tenderness over the lower part of the abdomen. She generally felt chilly during these attacks, but had neither fever nor vomiting. She has had five attacks in all: the first one five years ago, the second a few days later, the third a month later, the fourth a year after the third, and the last attack during January, 1890. Dr. Hartman, her family physician, to whom I am indebted for the information as to her previous history, considered these attacks to be ovarian colic. She consulted Dr. Hartman on July 26, 1890, when she complained of failing health, general weakness, loss of appetite and flesh, having lost 16 pounds within five weeks. She further complained of pain and considerable tenderness in the left inguinal region, and had not menstruated since May 21st.

On bimanual examination the uterus was found slightly enlarged, mobile, and pushed over to the left side by a tumor which partially filled the pelvis minor. It did not appear to be firmly adherent to the uterus. An upper portion of the tumor projected above the brim of the pelvis in the right lower part of the hypogastric region. It appeared movable. The surface, although smooth, was not uniform in appearance, inasmuch as the portion in the large pelvis appeared to be solid, while the portion felt through the vagina was elastic and appeared to fluctuate. Dr. Hartman made a diagnosis of dermoid cyst, and this diagnosis was confirmed by the examination October 24, 1890. The gravid uterus was now found projecting in the hypogastric region, the size of the uterus of the fourth month. Auscultation revealed uterine bruit, but no fetal heart-sounds. The tumor had also increased in size, and on examination was found almost to fill the pelvis minor. The wall was in some parts hard and nodular. The upper part could now be felt only indistinctly, as it was covered by the gravid uterus. The patient had not felt any fetal movements, but had had frequent shooting pains in the mammae, which as yet were not enlarged or changed in appearance. Her general health had improved during the summer.

* Read before the Chicago Gynecological Society, May 22, 1891. *Amer. Jour. Obst.*, 1891, vol. xxiv, p. 1097.

October 24th I examined the patient in consultation with Drs. Hartman and Lee, and confirmed the diagnosis of dermoid cyst in the small pelvis on the right side of the uterus, and pregnancy of the fourth month. The ovarian tumor was immovably fixed in the small pelvis, and the vaginal portion of the uterus could now be felt high up to the left side and apparently movable against the tumor.

In consultation held as to what course to pursue it was thought likely that this ovarian cyst, which almost filled and was incarcerated in the small pelvis, might be a dangerous complication to the delivery, or might rupture later on in the course of pregnancy. After considering the choice between the induction of premature labor and subsequent ovariectomy, on the one hand, and ovariectomy during pregnancy, on the other hand, the latter was decided upon, and the patient taken to the Emergency Hospital and prepared for laparotomy in the usual manner.

October 30th, in the presence of the doctors from the Polyclinic and some of my students from the college, and assisted by Drs. Bernauer, Lee, and Hartman, the anesthetic being administered by Dr. Rosa Engert, the operation was performed as follows:

An incision was made in the median line from the symphysis pubis to the umbilicus, the pyriformis muscle transversely divided, and the parietal peritoneum sutured to the skin. The gravid uterus presented through the abdominal wound, and the tumor could be felt deep down and behind the uterus, but was inaccessible until the incision had been prolonged above the umbilicus to midway between the latter and the ensiform cartilage.

On introduction of the left hand into the abdominal cavity a cyst could now be felt, of the size of a small child's head, the lower part of the tumor filling the small pelvis to the right of and behind the uterus, an upper portion projecting up into the pelvis major. The cyst was so firmly incarcerated in the small pelvis that it could not be removed so as to bring it up into the wound. As I expected to find a dermoid cyst, I did not want to empty its contents in order to facilitate its removal. Therefore I enlarged the abdominal incision still a little further upward, and everted the gravid uterus out through the wound. The uterus was wrapped in warm aseptic cloths soaked in sterilized water, and was held on the side of the abdominal cavity and to its left side by Dr. Bernauer.

I now introduced the left hand down into the small pelvis behind the cyst, and lifted it up and out through the abdominal wound. It was found to have a smooth surface and to be non-adherent. After having packed the abdominal cavity around the pedicle, the cyst was removed entire. It was somewhat difficult to ligate the broad ligament, as the pedicle was short, especially in the upper part of the broad ligament, which was unfolded and filled by the gravid uterus. The pedicle was transfixed and then dropped, without, as I usually do, dividing it on the clamp by Paquelin's cautery, because the pedicle was too short to permit the application of the clamp. After dropping the pedicle the cloths around the uterus were removed, and, after turning the patient on the side, a pitcher of sterilized water was poured over the uterus, which, after the removal of the large flat sponges, was replaced. It was somewhat difficult to push the uterus back through the wound, the borders of which had to be tightly drawn during its replacement. Several small, subserous ecchymoses had formed on the surface of the uterus during its stay outside. Small sponges on sponge-holders, pushed down behind the uterus, showed the abdominal cavity to be free from blood and serous fluid. The abdominal wound was then united with alternate deep and superficial sutures; no drainage.

At the end of the operation, which lasted an hour and a quarter, the patient was in natural condition; pulse, 90, strong; no symptoms of collapse.

The second evening after the operation temperature rose to 100.8° F.; pulse, to 96. During the rest of the first week after the operation the morning temperature did not reach 99° F., the evening temperature being about 99° F. During the second week morning temperature was normal, the evening temperature about 99° F. From the beginning of the third week the temperature remained normal.

During the first two weeks the only important symptom was occasional severe par-

oxymsal pain, simulating uterine contractions; it could, however, be controlled by repeated hypodermic injections of $\frac{1}{4}$ grain of morphin. This pain made me fear impending abortion, but it gradually decreased, and entirely ceased at the beginning of the third week.

On the fifth day the dressings were changed and the wound found to be perfectly dry and aseptic. The patient was sitting up at the end of the third week.

The subsequent course of the pregnancy was entirely normal, and on February 19, 1891, the patient fell in labor, which lasted fifteen hours, the child being delivered by forceps. The child was fully developed, at full term, and weighed six pounds. The convalescence after delivery was not attended by fever, but was somewhat tedious. The patient had only a small quantity of milk, and so after three weeks artificial alimentation was tried, but proved injurious to the child. A wet-nurse was then procured, after which the child recovered and is now doing well. The mother regained her strength slowly but fully; she suffered for a time, however, from looseness of the bowels and indigestion.

In the cicatrix at the line of incision and at the point of insertion of the sutures a remarkable degree of pigmentation took place. Dr. Hartman stated that the entire cicatrix became deeply pigmented—in fact, almost black. The patient herself declared that this pigmentation did not begin to appear until after labor (?). It reached the maximum degree of color after delivery, from which time it began to fade, and at the end of nine weeks had almost disappeared, leaving only a light-brown cicatrix.

The tumor was a dermoid cyst with the usual characteristics of such tumors. At the time of removal it was about the size of a child's head at term; it now appears considerably smaller on account of the shrinking of the cyst-wall in the alcohol. The outer surface is smooth, free from adhesions, but uneven; in some places thin, in others consisting of hard, nodular tumors from $\frac{1}{4}$ inch to 1 inch in diameter. One portion of it forms a solid mass the size of a small hen's-egg, which consists of whitish, solid tissue, and includes a cyst the size of a walnut, densely packed with brownish hair. On the inner wall of the larger cyst, which is smooth in its upper portion, may be seen, down near the large tumor, a number of smaller cysts from the size of a pea to that of a hazelnut. In some places the cyst-wall is quite thin and transparent, indicating the liability of rupture upon manipulation or by pressure during delivery.

Remarks.—Ovarian tumors, which are at all times a source of danger, are still more so when complicating pregnancy, as the two conditions, when in combination, mutually influence each other, to the detriment of both mother and child. The ovarian tumor is subject to acceleration of growth, to more rapid development, during pregnancy. The gravid uterus is liable to cause torsion of the pedicle by changing the form and position of the latter, or by circulatory disturbances in the pedicle, resulting in gangrene or perforation of the cyst. When situated in the pelvis minor, an ovarian tumor is especially liable to become an obstacle to the delivery of the child, and to cause difficult and consequently dangerous labor, which may result fatally to both mother and child.

In discussing the measures for the prevention of these dangers, we will first consider the fate of the mother and child when the pregnancy is left to run its course. The dangers to the mother, as gathered from the statistics, are the following: Litzmann has collected 54 cases, with 24 maternal deaths; Jetter, 215 deliveries in 165 mothers, with 64 deaths; Playfair, 57 deliveries, with 23 deaths; Braxton Hicks, 6 deliveries, with no deaths; Rogers, 5 deliveries, with no deaths; Spencer Wells, 11 deliveries, with 1 death; Fritsch, 4 deliveries, with 1 death. In all, 355 deliveries are reported, with 113 maternal deaths, or a maternal mortality of about 32 per cent.

The mortality to the children from either abortion or premature labor, according to Engström, is much greater. In a series of 216 cases a mortality is reported of 48 per cent.

The proliferating cystoma is the form of cyst most commonly observed. These cysts are frequently located outside of the small pelvis, and are often overlooked during pregnancy. They rapidly increase in size, and may cause overdistention of the abdomen and severe pressure symptoms from the organs of the abdomen and thorax, necessitating speedy relief. In such cases the treatment by puncture comes in question. As these cysts are located outside of the small pelvis, they are not liable to prove a serious impediment to delivery. Thus it would seem that small dermoid cysts located in the pelvis minor constitute the gravest complication of ovarian tumors with pregnancy.

Dermoid cysts are common. Jetter found 37 dermoid cysts in 165 cases. They are often small, and thus remain in the pelvis, are easily diagnosed by vaginal examination, and, therefore, as Olshausen states, are seldom overlooked. These are the tumors which most frequently prove a serious difficulty at the time of delivery, when immovably incarcerated in the pelvis minor.

Puncture of the dermoid cyst is dangerous, as its contents are more poisonous than those of most of the other ovarian tumors, but puncture becomes unavoidable at the time of delivery when the cyst cannot be pushed out of the way up into the abdominal cavity. The usual location of dermoid cysts in the pelvis minor makes liable the occurrence of spontaneous rupture during delivery, with consequent septic peritonitis resulting partially from infection from the contents of the cyst and partially from mixed infection through the puerperal wounds.

Treatment.—While, outside of pregnancy, prompt extirpation of an ovarian tumor is always indicated, widely different measures have been advocated for the treatment of ovarian tumor when complicated with pregnancy.

1. Induction of abortion and premature labor has been recommended by Barnes, but in most cases this sacrifices the child and is not without danger to the mother. In 5 cases cited by Olshausen 2 mothers died. As ovariectomy necessarily must follow, this method of treatment exposes the mother to the dangers of two serious operations.

2. Puncture of the cyst to relieve the symptoms and so permit natural labor to be undisturbed. This procedure, like the preceding one, is, of course, only temporary, and resorted to with a view to awaiting the earliest opportunity for ovariectomy. Puncture of the ovarian tumor may relieve the dyspnea and prevent abortion. It is not more dangerous in pregnancy than under ordinary circumstances, but the puncture of ovarian tumors in general is attended by a mortality of 19 per cent. Cohn states that 1 out of every 6 ovarian cysts is malignant; therefore puncture might cause rapid diffusion of the malignant tumor in the peritoneal cavity—malignant peritonitis. The more rapid growth of ovarian tumors during pregnancy is apt to cause refilling of the cyst after puncture, and thus necessitate repeated punctures, which, of course,

will increase the danger to the mother. Cohnstein states that of 6 mothers in whom puncture had to be repeated 3 or more times during pregnancy, 5, or 83 per cent., died within a short time after delivery from exhaustion. Puncture does not predispose to the interruption of pregnancy in more than 18 per cent. of the cases.

The difficulty in differential diagnosis between an ovarian tumor and the gravid uterus is apt to lead to puncture of the latter. Olshausen states that in 7 cases the uterus was mistaken for an ovarian tumor and punctured. The operator then made a Cesarean section, sutured the uterus, and closed up the abdomen. This was done in 5 cases with success; in 2 cases the puncture terminated fatally.

3. During the last few years a third method of treatment of ovarian tumors during pregnancy has come into the field, namely, ovariectomy during pregnancy. This operation is comparatively new, as in 1877, according to Olshausen, only 14 cases were on record. In the next year over 40 cases were on record, and now this method of treatment bids fair to become a regularly established procedure. Although ovariectomy in the pregnant woman was at first performed with a good deal of apprehension, it has been seen from the very beginning that the dangers were highly overrated, and that the mortality for mother and child has been decreased by this operation far beyond our expectations. In 1886 Olshausen collected 82 cases with only 8 deaths; but he points out that individual operators had a much lower mortality, as out of 36 cases operated upon by Lawson Tait, Spencer Wells, and Schroeder, only 1 mother died.

Engström, in 1890, reported a series of 48 cases with only 2 maternal deaths, or a mortality of 4.2 per cent., as follows: Schroeder, 12 cases, no deaths; Lawson Tait, 11 cases, 1 death; Spencer Wells, 10 cases, 1 death; Olshausen, 8 cases, no deaths; and Engström, 7 cases with no deaths.

I consider the mortality of the operation today to be below 5 per cent.; therefore ovariectomy during pregnancy is not any more dangerous than this operation in the non-pregnant condition.

The fate of the child is influenced by this operation to a like favorable degree. According to Olshausen, abortion follows ovariectomy in only 20 per cent. of the cases; hence 80 per cent. of the children were born at full term. When we compare this with the mortality to the children of 48 per cent. with non-interference, we see that by ovariectomy 28 per cent. of the children are saved.

It is generally thought, and probably it is true, that the earlier in pregnancy an ovariectomy is performed, the more favorable is the result. Wilson states that ovariectomy becomes less favorable after the fifth month, because, as Schroeder has pointed out, the operation becomes more difficult by shortening of the pedicle, on account of the unfolding and filling-in of the broad ligament to which the tumor belongs by the gravid uterus. Late in pregnancy the size of the uterus naturally makes the operation difficult by decreasing the available operating space in the abdominal cavity. This sometimes necessitates the inconvenient lateral operation to gain access to the ovarian tumor. The vascularity of the

tumor and pedicle late in pregnancy always increases the difficulty of the operation. But in such cases the facts have proved a surprise to our expectations. Olshausen reports 21 cases operated upon after the fourth month, with only 2 deaths. Pippingsköld reports an operation made after the commencement of labor which resulted successfully. Stratz reports 14 operations performed by Schroeder, with no maternal deaths, and with 12 living children, and formulates the answer to the question whether ovariectomy should always be performed during pregnancy, that it should be done as soon as the diagnosis is made, because:

1. Ovariectomy is inevitable, and its prognosis is not aggravated by the presence of pregnancy.
2. Delivery in childbed without the tumor has a much better prognosis than when the tumor exists.
3. One out of 6 tumors is malignant, contraindicating puncture.
4. Prognosis for children is much better.

He formulates the following conclusion: "The complication of ovarian tumor with pregnancy indicates ovariectomy."

In the discussion which followed the reading of this paper Veit and Löhlein protested against laying down absolute rules, and suggested that it might be well to individualize. Schroeder, however, fully supported Stratz's recommendation always to operate.

Final Remarks.—Small tumors in the pelvis minor are especially dangerous to the child and mother, as has been well illustrated in a case published by Lomer, in which, in a secundipara twenty-one years of age, who had an ovarian tumor the size of a child's head in the small pelvis, after rupture of the bag of waters extraction by the foot was tried in vain. Prolapse of the umbilical cord and death of the child resulted, followed next day by version in narcosis, during which the child's head was torn off and the patient died from collapse in three hours.

In another case, published by Nölting, a small ovarian tumor in the pelvis made delivery difficult in the following way: Forceps were first applied in vain; puncture of the tumor evacuated only a small amount of blood. The child died, and was extracted only after perforation, and still with difficulty, as the tumor came down so far in Douglas' fossa that prolapse of the rectum took place. The patient died of peritonitis after four days. The autopsy showed a double twist of the pedicle, with rupture of the cyst.

Instances of this kind, on the one hand, and the low mortality of ovariectomy during pregnancy, on the other, would tend to lead to the conclusion that in small ovarian tumors located in the small pelvis and diagnosed during pregnancy immediate ovariectomy is the safest procedure.

BIBLIOGRAPHY

- Olshausen: Die Krankheiten der Ovarien, p. 129.
 Stratz: "Ueber der Complication der Tumoren und Gravidität," Zeitschr. f. Geburts- und Gynäk., 1889, vol. xii, p. 262.
 Engström: Annales de Gynécologie, 1890, vol. xxxiv, p. 241.
 Cohnstein: Volkmann's Sammlung klinischer Vorträge, No. 59.
 Lomer: Centralbl. f. Gynäk., 1890, vol. xiv.
 Nölting: *Ibid.*

A CASE OF ELEPHANTIASIS OF THE SCROTUM, WITH REMARKS ON ITS OPERATIVE TREATMENT*

ELEPHANTIASIS of the scrotum is so rarely met with outside of the tropics that to us it has little more than a theoretic interest. At the same time our relations with the surrounding tropical countries where the disease is endemic are sufficiently intimate now, and are increasing to such an extent that it is very possible that cases of this disease may be met with here among immigrants from these countries, as, for instance, Barbados, Samoa, and China.

J. E., twenty-three years of age, German, was admitted to the German Hospital, Chicago, in January, 1891. He was born in Strassburg, of German parents, both of whom are in good health. He has three brothers and four sisters, all in good health. When he was six years old he came with his parents to Chicago, and a few years later moved to a farm at Rose Hill, one of the suburbs of that city. With the exception of the usual diseases of childhood, and a rather severe attack of typhoid fever three years ago, from which he recovered perfectly, he has always been healthy.

His present ailment, the elephantiasis, commenced eight years ago, without any apparent cause, as a slight enlargement of the scrotum, followed later on by thickening of the prepuce. The enlargement increased gradually and uniformly, with no intermission. There was never any pain nor symptoms of inflammation,—that is, erysipelatoid attacks in the enlarged scrotum,—according to his statement. About four years ago he suffered for some time from frequent micturition and urinary tenesmus, which, after a while, subsided. Two years ago, without any cause, so far as he knew, he had swelling and pain in the inguinal glands on both sides, above and below Poupart's ligament, accompanied by pain, and followed in a short time by suppuration. This terminated in two or three abscesses on each side, which were permitted to open spontaneously, and, after discharging for some time, the opening definitely closed.

Several years ago he was obliged to have trousers especially made on account of the scrotal tumor. In spite of the size and weight of the tumor, however, he has been able to work as driver of a wagon for a railroad company with satisfaction up to this time.

On examination he was found to be robust, well nourished, of healthy appearance and color. Thoracic and abdominal organs normal. Muscular strength and development normal (Fig. 53). The scrotum was enlarged and formed a tumor weighing 22 pounds, extending down an inch below the knees. The skin was nodular, here and there covered with scales and crusts of dried epithelium. The nodular prominences were somewhat harder than the remainder of the skin. The tumor was of a uniform firm, leathery consistence. Pressure with the fingers did not leave any indentation, as in edema. The skin was thickened so that it could not be lifted up in a fold. On the anterior upper surface of the tumor was seen a second round tumor, about the size of a fist, on the right side of which was a vertical furrow 2 inches long, through which a probe could be passed upward into the tumor a distance of 4 inches. This was the opening of the prepuce, through which

* Amer. Jour. Med. Sci., 1891, vol. cii, p. 352.

the patient urinated, the urine dribbling down over the large tumor. The skin over this enlarged prepuce was hard and nodulated, as was the skin of the scrotum. There were no hairs on the scrotum. The pubic hair was sparsely developed. At the junction of the scrotum with the pubic region the skin was softer and not nodulated, but still somewhat thickened and immovable, as if edematous.

This part of the tumor formed a sort of pedicle 6 inches wide and 3 or 4 inches thick. Neither the testicles nor the penis could be made out.

The inguinal glands on both sides were enlarged to the size of a small walnut, as were also the glands in Scarpa's triangle. On the right side three cicatricial depressions—scars after the old abscesses—could be seen, one below and two above Poupart's ligament; and on the left side two similar scars. There was no enlargement of the deeper glands along the external iliac vessels.

The skin at the upper part of the inside of the thigh and the corresponding skin of the outer part of the tumor was the seat of intertrigo, the surface denuded, red, and moist, partially covered with a whitish, fetid smegma. This surface inflammation caused the

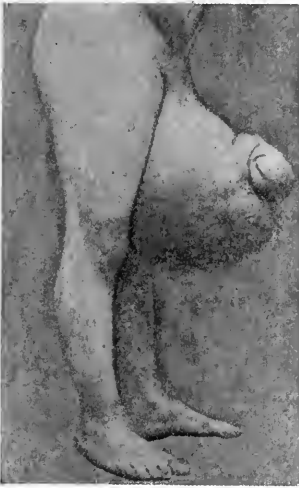

Fig. 53.

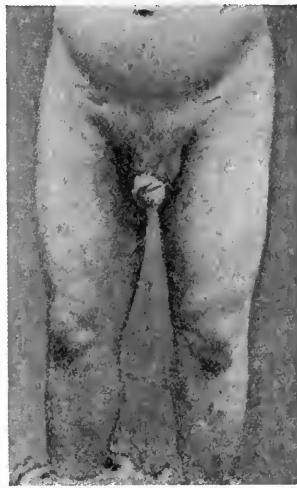


Fig. 54.

patient no pain, itching, or other inconvenience. There were no enlarged lymph-glands in any other part of the body, and no edema of the lower limbs, on which, as well as elsewhere on the body, the skin was perfectly normal.

Urine normal. Repeated examinations of the blood at different times of the day and night showed no filaria and nothing abnormal. Appetite good, bowels regular. His mental condition was somewhat abnormal; he was melancholy and morose, did not want to talk with any one, was not very willing to answer questions, but otherwise appeared to be sufficiently intelligent.

For two weeks previous to the operation antiseptic dressings were applied and local treatment directed to the excoriated surface between the thigh and scrotum, so as to heal the superficial inflammation of the skin at this point and as a further preparation for the operation.

On the day previous to the operation the patient was given a sublimate bath, and on the morning of the operation the tumor was held up in an elevated position for an hour in order to deplete the vessels of blood.

The patient was anesthetized, and the tumor held up by two assistants, and a Turner's clamp, which I had had made to secure bloodless operating, applied over the uppermost part of the pedicle, a careful examination having first been made for inguinal hernia, which showed that no such complication existed.

A grooved director was now introduced into the sinus of the prepuce leading to the glans penis, and the overlying wall of skin divided upon it until the glans penis was exposed about 3 inches above the peripheral opening.

Flaps of skin were now cut as follows: The anterior surface was divided into three equal parts and three semilunar flaps cut, the median being a little larger than the two lateral flaps—each lateral flap being about 2 inches long and 2 inches broad, the median flap of the same breadth but $2\frac{1}{2}$ inches long. The two lateral flaps were intended to cover the testicles, the median flap to cover the penis. A single posterior flap was then cut through the skin, about 2 inches long and 6 inches broad; that is, the whole width of the posterior surface of the neck of the tumor. The cutaneous flaps were then dissected up to the clamp. The penis was next dissected out of the tumor, leaving about 1 inch of preputial mucous membrane all around the glans. The skin in this region was somewhat thickened and edematous, but reasonably movable and pliable. The left testicle was now sought for and found without much difficulty, the tunica vaginalis communis being surrounded by a looser layer of somewhat edematous tissue, which permitted the isolation of the testicle covered with the tunica vaginalis communis, and the spermatic cord, which was then dissected up to the clamp. The right testicle was now isolated in the same way.

Both testicles and the penis, together with the three anterior flaps, were held up toward the abdomen over the upper arm of the clamp, covered with carbolyzed gauze, and the neck of the tumor was ablated by a series of cuts. After dividing each portion, all visible vessels were ligated, including a number of veins 2 to 3 lines in diameter.

When the ablation of the tumor had been finally completed and all visible vessels ligated, the clamp was loosened a little at one end, whereupon a number of bleeding vessels appeared, which were taken up and ligated one by one. In all, more than 60 ligatures to large and small vessels were applied. All bleeding-points in each portion cut were ligated before the next portion was divided.

The clamp was then removed, and the hemorrhage having entirely ceased, the wound was irrigated with 2.5 per cent. solution of carbolic acid and the flaps united in the following way:

The two lateral flaps were united to the lateral portion of the posterior flap over each of the testicles, and the median anterior flap and the middle portion of the posterior flap made to cover the penis by stitching the lower end to the prepuce above the glans penis. The glans penis was uncovered, and although there was no tension in the covering of the body of the penis when not in a state of erection, I should in a future case like to make the median anterior flap and the middle portion of the posterior flap about an inch longer, because the skin and the prepuce were here somewhat thickened and stiff, and thus not so mobile and flexible as in the normal condition.

Three short drainage-tubes, one for the penis and one for each testicle, were inserted and stitched to the border of the wound, and a dry iodoform dressing applied.

The wounds healed without suppuration, pain, or rise in temperature. After a week the drainage-tubes were removed, and in four weeks the granulating surfaces at the point of insertion of the drainage-tube and at one side of the penis, where the union between the skin and prepuce had reopened a little, were entirely healed over. As will be seen from a photograph taken six weeks after the operation (see Fig. 54), the shape of the external genitals is comparatively normal, and the following condition is now present:

The glans penis is plainly visible, protruding below the scrotum. On the left side the skin of the penis is normal; on the right, above the glans penis, there is an edematous fold which is rapidly decreasing in size and becoming softer. The left half of the scrotum is of almost natural shape and size; the right half not so much so, but both testicles can

easily be palpated in the normal position, behind the penis. The skin at the root of the penis in the pubic region is a little thicker than normal, and is still a little more voluminous than normal, but nearly approximates the natural shape. Both inguinal regions are somewhat enlarged on account of the swelling of the subjacent lymph-glands, as will be seen in Fig. 54, where the depressions due to the somewhat retracted scars over the openings from the glandular abscesses of two years ago are plainly visible.

Urination normal. As to the sexual function, I know nothing at present. His mental condition is widely different as compared with his condition prior to the operation. Instead of his former morose and non-communicative behavior, he shows now a bright and smiling countenance, and, without being invited to do so, states that his present condition is one of great happiness as compared with the period before the operation.

Microscopic examination of the structure of the tumor from the skin downward shows thickening of the epidermis and papillary layer, but the epithelial cells are of normal shape and size. There is no line of demarcation between the cutis and the subcutaneous tissue, the entire tumor consisting of a wide, semisolid, elastic mass of tissue, which shows under the microscope the following characteristics:

Large areas of thick bundles of non-fibrillar connective tissue, the bundles in some locations running parallel to each other, and in other places interwoven and cut obliquely or transversely. Between the bundles may be seen occasional and rare connective-tissue corpuscles of normal size and shape. The vessels, arteries as well as veins, but especially veins, show an enormous thickening of the walls, the smaller veins having walls five to ten times the normal thickness. This thickening is mainly an enlargement of the external coat, the endothelium not participating at all in the thickening of the wall. In the perivascular spaces are seen here and there conglomerations of leukocytes; in other places no young cells are to be seen at all. Islands of young granulation tissue, consisting of embryonal cells densely packed together and having the same appearance as the cells in ordinary young granulation tissue, are spread all over the connective tissue. These islands differ greatly in size. I was unable to find anywhere enlarged lymph-spaces or lymphatics, but am inclined to believe that some of the islands occupied by embryonal cells, in which no blood-vessels could be seen, are lymph-vessels or lymph-spaces in a state of plastic inflammation.

Elephantiasis of the scrotum (*elephantiasis arabum*) is anatomically identical with elephantiasis of other parts of the body, whether affecting the scrotum, prepuce, labia majora, or the lower extremities. We find in all cases, irrespective of the etiology, an increase in all the constituent elements of the skin and subcutaneous tissue, with the exception of the hair and the glands. Thus we find thickened epidermis and inter-papillary spaces of the epithelium, enlarged papillæ, and connective tissue of the cutis. The enlargement here and in the subcutaneous tissue is due to a universal formation of new connective tissue. This new formation of connective tissue in the vessel-wall, chiefly in the external coat, produces the characteristic thickening of the vessels to five or ten times their normal size. It also produces a thickening of the nerves by a similar increase of interstitial tissue between the nerve-bundles.

We find in the lymphatics in the later stages of elephantiasis, as in the case reported, no very characteristic dilatation. It is different in the earlier stage of elephantiasis of the scrotum,—the so-called “lymph scrotum,”—where the tissue is still soft and edematous. Here we find lymph-vessels and lymph-spaces dilated, sometimes to such an extent

that, when situated at the surface of the skin, they may form thin-walled, transparent bullæ on the surface of the tumor, which may burst and empty a clear or milky lymphatic fluid, which sometimes escapes in great quantity and may cause a temporary decrease in the size of the tumor.

The condition of the lymph-glands is important. It is common to find, as in the above case, a considerable enlargement of the glands, an inflammatory enlargement, which, when due to invasion of pus-microbes from an abraded surface on the scrotal tumor, may terminate in suppuration.

The etiology of elephantiasis is still shrouded in mystery; this is especially true in the non-parasitic forms of the disease. Etiologically, there is a great difference between the elephantiasis found in tropical countries and the variety of the disease seen in temperate and cold regions. In tropical countries the disease is uniformly ascribed to a parasite belonging to the class of nematodes, namely, the *Filaria Bancrofti*.^{*} This filaria, a thin, white worm, 3 to 4 inches in length and as thick as a human hair, is found in the lymph-vessels of the area of the elephantiasis. Here it deposits its thousands of eggs, out of each of which is developed an embryonal worm small enough to pass through the capillaries. This worm is periodically found in the blood of patients suffering from this disease, and is the so-called *Filaria sanguinis hominis*. It is supposed that the mature animal, as well as the ova and embryos, may cause, on the one hand, by accumulation in the lymph-vessels and glands, stoppage of the lymph-current, and consequent edema in the corresponding distal territory; and, on the other hand, by chemical products of their excretions, they may cause inflammation of the lymph-vessels, a plastic lymphangitis, which naturally would tend to further obstruct the lymph circulation. This may, perhaps, account for the repeated attacks of erysipelatoid inflammation in the territory of the elephantiasis.

This parasite, also, whose life history and relation to elephantiasis have been studied so carefully by Wucherer in Brazil, Lewis in Calcutta, and especially by Manson, father and son, and Myers in Amoy, and whose method of entering the human body has been studied by the last-named authors and by my friend of former years, Prospero Sonsino, of Egypt, is commonly found in our Gulf States, as has been shown in an excellent paper by Mastin, of Mobile, and confirmed by Matas, of New Orleans, and others.

It is natural, then, to find elephantiasis a common, and in some places an endemic, disease in tropical countries, to which the filaria of Bancroft is geographically limited. In some localities, as, for instance, Samoa, the disease is so common that, according to Turner, 50 per cent. of the adult population will, sooner or later in life, have the disease. The filaria and elephantiasis have probably been imported into islands

^{*} B. Scheube: "Die Filaria-Krankheit," Volkmann's Sammlung klin. Vorträge, 1883, No. 232.

comparatively near our coast by coolies from China, as, for instance, Barbados, where the disease has become endemic.

But the *Filaria Bancrofti* is not the only cause of elephantiasis, for sporadic cases of this disease in the scrotum, as well as in the lower extremities, are found in temperate and cold countries where the filaria does not exist, and are found in patients, as in the case here reported, who have never been in places where they could have been exposed to the invasion of the parasite. As would naturally be expected, the parasite is never found in these patients. Cases of this kind have been reported in England by Fergusson, in France by Velpeau, in Germany by Graefe, in Switzerland by Bircher, and also by other observers.

Clinically and anatomically, there seems to be no difference between the elephantiasis of the tropics due to the filaria, and the elephantiasis in the temperate zone where no filaria is found. The changes in the lymphatic system, erysipelatoid inflammations in the lymph-spaces of the skin, and swelling of the lymph-glands, are characteristic of both classes of the disease. This swelling of the lymph-glands does not necessarily mean obliteration of the lymph-current, as stated by Kocher in his excellent monograph on Diseases of the Male Genital Organs,* for in a case of elephantiasis published by Bryk, the enlarged lymph-glands were permeable and the lymph-vessels dilated, even as far as the thoracic duct. Swelling of the lymph-glands, according to Kocher, often precedes the development of elephantiasis, and is supposed to play an important part in the etiology of the disease, both within and outside of the tropics. But it is entirely unknown why so common an affection as enlargement of the lymph-glands should result in elephantiasis in such exceedingly exceptional instances as we find to be the case.

Symptoms.—Elephantiasis of the scrotum is usually of a softer consistence than when the disease exists in the legs, but the swelling increases more rapidly. Soft and edematous at first, the so-called lymph-scrotum, it gradually becomes harder. The unequal thickening of the epidermis causes the surface, which was originally smooth, to become nodular and irregularly corrugated. The increase is not uniform, but intermittent, following the repeated inflammatory attacks. These attacks are characterized by redness and swelling, but are attended by very little pain, the skin over the tumor being to a greater or less extent anesthetic. Atrophy of the sebaceous glands and hair-bulbs is followed by falling out of the hair. Here and there scales of thickened epidermis and crusts of dried secretion from abraded surfaces or from ruptured dilated lymph-vessels cover smaller or larger areas over the tumor.

By the increase in the size of the tumor the testicles are buried, so that after a while their location cannot be detected except when hydrocele coexists. The increase in size of the prepuce, together with the increase in the skin of the scrotum, makes the penis disappear, the skin being drawn downward and forward in front of the glans, forming a sinus, sometimes several inches long, leading up to the urethra, sur-

* Theodor Kocher: "Die Krankheiten der männlichen Geschlechtsorgane," Deutsche Chirurgie, von Billroth und Luecke, 1887.

rounded by a separate tumor like a smaller appendix on the anterior surface of the large tumor. A deep furrow is usually seen on the end or on one of the sides of the transformed prepuce, which forms the entrance to the urinary sinus through which the urine dribbles down during micturition over the tumor, which probably helps in the causation of the maceration of the epidermis and the surface inflammation.

As the elephantiasis is, on the whole, painless, the chief inconvenience to the patient is caused by its weight. Tumors of 30 to 50 pounds in weight are commonly seen, and a tumor weighing 100 pounds has exceptionally been observed. This, however, does not influence the general health of the patient, who is, as a rule, as in the case cited above, able to do manual labor, notwithstanding the presence of the large tumor.

The *prognosis* is good, and it is only in exceptional cases that danger arises from septic inflammation on the surface of the tumor, with gangrenous destruction of a portion of the inflamed area and resultant general sepsis.

Treatment.—Elevation of the tumor, compression, warm, moist applications, local mercurial inunctions, in connection with the internal use of the iodids, iron, chlorate of potassium, and bichlorid of mercury, have proved successful in exceptional cases only, and then in the earlier stages alone.

Non-radical treatment is, of course, of far more importance in elephantiasis of the lower extremities, where amputation should be deferred as long as possible, than in elephantiasis of the scrotum, where early operation is so much the more admissible, as no mutilation of the genital organs is caused by it.

The dangers of the operation in elephantiasis of the scrotum are hemorrhage and sepsis. For this reason, in former times, partial excisions and operations with the *écraseur* or galvanocautery were resorted to, but these procedures have now become entirely obsolete.

The prognosis of the operation, which in preantiseptic times was comparatively grave, has gradually lost its dangers. Thus we see, from Kocher's statistics, an early mortality of 27 per cent. in 61 cases reported by Fayrer; of 9.5 per cent. in 21 cases reported by Ballingall; of 5 per cent. in 161 cases reported by Esdaile; of 33 per cent. in 61 cases reported by Manson; and more recently 1.5 per cent. in 138 cases reported by Turner. The better prognosis of the operation in Turner's cases is due to a sepsis as well as to the great improvement in the technic of the operation. Therefore, in the case above reported, I adhered strictly to the method of operating as laid down by Turner. Hemostasis is made absolute by the use of Turner's clamp, which has been already mentioned.

Perfect covering of the penis and testicles is secured by the flaps as devised by Turner and described in my operation, thereby avoiding sepsis from non-union of a large wound surface, as in the older operations, in which, for fear of hemorrhage, the tumor was cut off trans-

versely, or in which sometimes the penis and testicles were removed with the tumor and the large wound surface left to heal by granulation.

The bloodless operation, by means of the clamp or elastic constriction, gives the operator time carefully to dissect out the penis, testicles, and spermatic cord, and to open and radically operate upon hydrocele, if present. The clamp is preferable to an elastic constrictor, because the latter is, as stated by Kocher, very liable to slip off during the separation of the tumor, while the clamp can be gradually loosened one end at a time, admitting ligation of the smaller vessels step by step. This makes the operation with the clamp, notwithstanding the numerous and very large vessels, almost entirely bloodless.

The removal of the penis and testicles can in all probability be always avoided by Turner's operation, and should at least be always attempted, although Esdaile regards it as dangerous not to remove these organs in tumors which weigh more than 50 pounds. In 2 cases reported by Lloyd, tumors of 65 and 61 pounds in weight, respectively, were successfully removed, with preservation of the penis and testicles. In these operations soft twisted ropes were used as constrictors and the flaps made according to the method of Turner.

The preservation of the penis and testicles is the more important because the genital functions remain undisturbed in the case of patients suffering from elephantiasis.

THE OPERATIVE TREATMENT OF EXTRA-UTERINE PREGNANCY AT OR NEAR TERM, WITH REPORT OF A CASE*

It is not my intention in this paper to give an exhaustive exposé of all the details and the questions that arise in late extra-uterine pregnancy, but merely in connection with a case of this kind, which terminated fatally, to describe the thoughts and reflections that presented themselves to me in connection with the case.

I shall, then, first describe the case, the different methods of operation and their prognoses, and, later, review the more important points in the management of such cases from my own experience and from the literature as far as I have been able to obtain it.

CASE.—Mrs. C., thirty-four years of age, married thirteen years. Healthy as a child; first menstruated at the age of fourteen; always regular; three days' duration; for the past ten years two days only; never very abundant. A slight leukorrhœa for a few days following menstruation. Married at twenty-one; a year later, after a normal pregnancy, was delivered of a female child who lived only ten days. Labor was difficult, but forceps were not used. Slight laceration of perineum. She was in labor from midnight until half-past ten the next morning. She had puerperal fever and pelvic cellulitis, which confined her to bed for three months. She had a slow convalescence, not being well until three months later. Menstruation returned five months after the birth of the child, and since that time, about ten years ago, has been always regular. She has occasionally had slight leukorrhœa, but otherwise has had no symptoms of disease of the genital organs excepting sterility.

She had her last normal menstruation March 20, 1890. Two or three weeks later, in April, she felt sick, wanted to eat, but after eating would often feel nauseated. May 15th, at noon, she suddenly felt a severe pain through the anterior part of the abdomen and the rectum, followed by vomiting. These symptoms lasted for ten days, during which time she was obliged to stay in bed. No fever, no symptoms of hemorrhage. The symptoms then disappeared, and after three weeks she resumed her work of teaching school. She was well until July, when a sudden attack of pain, which came on at night while she was in bed, necessitated her keeping quiet for a few days. After this time pain would often come on during the night, extending from the abdomen down to the knee, more severe in the right leg. August 5th she had a sudden, severe attack of pain and vomiting, which kept her in bed for two weeks and necessitated her stay at home for two weeks longer. During this time her temperature was normal.

Between the fifth and the tenth of August, while in bed with this apparent attack of peritonitis, she first felt fetal movements, faint at first, later stronger. These continued to be felt until December 29th. Uterine hemorrhage with passage of a decidual membrane was never observed. During September, October, and November she was able to be up and about attending to her work in school, but almost every evening she would have pain

* Jour. Amer. Med. Assoc., 1891, vol. xvi, p. 879.

in the abdomen, which would be aggravated on change of position and would prevent her from sleeping in the early part of the night. In the second week of December the abdominal pain increased and also came on during the day, so that for fear the pain would come on, she did not dare go out of the house.

December 31st spurious labor set in, with severe pain in the left side of the abdomen, increasing toward night, which lasted for two days. At this time fetal movements ceased. She remained in bed three weeks, during which time the abdomen commenced to decrease in size. February 10, 1891, six weeks after the death of the child, there was a sudden recurrence of the abdominal pain, with vomiting and rise of pulse and temperature.

February 11th I made an examination. The patient was in bed, somewhat pale; pulse, 100; temperature, 100° F. She had been suffering from pain and vomiting for two days, but at this time the vomiting had ceased. The mammary glands were large, areolæ pigmented, and abundance of milk coming from the nipples on pressure. The abdomen was enlarged to about the size of pregnancy at term, but more prominent on the left side, with an area of dull percussion up to the body of the ninth rib, while on the right side it did not extend to within 2 inches of the lower border of the ribs. Tympanitic percussion in the epigastric and both lumbar regions; dull percussion over the umbilical, hypogastric, and inguinal regions.

Through the abdominal wall could be felt a harder, round portion of the tumor to the right of and above the umbilicus—the fetal head. Over the remainder of the tumor no distinct fetal parts could be felt. In the territory below a line extending from the border of the right ribs downward and inward, to midway between the umbilicus and symphysis pubis, and from here to the outer third of the left Poupart's ligament, a distinct placental souffle could be heard, most pronounced in the right hypogastrium.

On vaginal examination the vaginal portion of the uterus was shown to be somewhat flaccid, standing high up and directed forward against the symphysis pubis. The posterior lacuna was pushed downward into the vagina by a doughy, immovable tumor, probably the placenta, as no fetal parts could be felt. The patient complained of frequent micturition—that she was obliged to pass water every hour except when asleep. The urine was normal in quantity and color, and contained neither pus, sugar, nor albumin.

I resolved to wait for the cessation of the placental circulation, as might be indicated by the placental souffle, keeping the patient in bed and under symptomatic treatment.

February 10th: Area of placental souffle diminished about one-half.

February 22d: No placental souffle could be heard. The patient was removed to the Emergency Hospital for operation, which was fixed for a week after her arrival there.

February 25th: Diarrhea set in, with slightly bloody stools, the passages soon becoming chocolate-colored. On microscopic examination no pus-cells were found, but fecal matter, fine granular matter, and blood-corpuscles. Pulse and temperature increasing.

February 28th: Pulse, 110; temperature, 103° F. She had several passages of a dark, reddish-brown color. Concluding from this that perforation of the sac into the bowel had taken place, and consequently that sepsis had commenced to appear in the sac, operation at once became necessary.

March 1st: Operation. In the presence of the doctors from the Chicago Policlinic, Dr. Bellinger, of Council Bluffs, Iowa; assisted by Drs. Bernauer, Hall, and Brohm. Chloroform given by Dr. Rosa Engert. Percussion at this time over the entire tumor was tympanitic where it had formerly been dull, showing the presence of air in the fetal sac from perforation of the intestines.

An incision was made in the linea alba, 7 inches long, from a point midway between the symphysis pubis and umbilicus, to 3 inches above the umbilicus. The parietal peritoneum was loosely adherent to the wall of the sac downward; above was the free peritoneal cavity. The sac was here covered with omentum containing a large number of dilated vessels, some of the veins two or three lines in diameter, while most of the adipose tissue of the omentum had disappeared. The parietal peritoneum was united by sutures

to the skin. As the adhesions between the parietal peritoneum and the omentum were incomplete, I separated the remaining adhesions with the hand, and packed large sponges into the peritoneal cavity all around the incision, or rather around the territory where the opening of the sac was to be made.

On account of the numerous and large vessels, double ligation of which would have taken too long, I opened the sac with a Paquelin cautery knife. This was used only at red heat. There was considerable hemorrhage from the omentum, necessitating numerous ligatures. On opening into the sac there was an escape of fetid air, and later on a discharge of a thin, grayish, fetid fluid of fecal odor. During this time the patient was turned on the side and the wound flushed with warm sterilized water.

The incision was now prolonged 6 inches. The child presented with the back and left shoulder in the wound. The left arm was first drawn out, but as it was found impossible to deliver the head, the arm was replaced and the left leg drawn out, then the right leg, and thus the child was delivered. After incising the tympanic abdomen, which collapsed after the escape of the gases, extraction was now easy without violence to the wall of the sac. The umbilical cord was tied 2 inches from the placenta, at the lower border of the wound. The fetal cavity contained fetid, chocolate-colored fluid and smegma. The patient was now turned on the side, and warm sterilized water poured in from a pitcher to flush the cavity until it became reasonably clean, the water being mopped off with large sponges. The large placenta entirely filled the small pelvis and the right iliac fossa up over the surface of the transverse colon. The uterus could not be seen, as it was covered by placenta. The cord was attached down near the symphysis pubis, was of a whitish-gray color, and macerated on the surface, showing no signs of circulation. The fetal surface of the placenta was smooth and bluish-gray, looking as if the circulation had ceased.

An attempt to cleanse the inside of the sac by means of soft sponges on long artery forceps, the borders of the sac being held apart by the hand, was immediately followed by a sudden gush of bright red arterial blood from the borders of the placenta, which necessitated immediate packing of the cavity with large pieces of gauze. The deepest part of the sac was in the left iliac fossa, where, to the left of the placenta, the distinct contour of loops of large intestine, probably the descending colon and sigmoid flexure, were distinctly seen. They were felt to be covered with a layer of tissue so thin as to indicate that no sac-wall existed. No perforation into the bowel could be seen at any point, and no escape of gases from the bowel into the sac was noticed, but the contents of the sac had a distinctly fecal odor. A thorough search for the opening into the intestine was not made, as even the slightest manipulation caused copious hemorrhage from the borders of the placenta.

The large sponges were now removed from the peritoneal cavity, which was then cleansed by means of smaller sponges on long forceps, and the borders of the sac united to the skin by sutures. Strips of iodoform gauze, for capillary drainage, were introduced between the sutures at six different places to a depth of about 2 inches between the sac and the abdominal wall. One strip at the right upper border of the wound was introduced 4 inches up under the liver. A handful of a mixture of equal parts of salicylic and tannic acids was strewn over the inner wall of the sac, and the whole cavity packed loosely with sterilized gauze impregnated with the same powder, of which 4 ounces in all was used. The wound of incision into the sac was left open, and over the packing an antiseptic dressing was applied.

The child was a normally developed male at full term, in a state of commencing maceration. The epidermis was covered with smegma, and in many places was loosened from the corium, which presented a brownish-red, discolored surface.

At the end of the operation, which lasted an hour and a half, the pulse was 150 and reasonably strong; color natural. Half an hour after the operation, pulse 120. 7 P. M.: Temperature, 100° F.; pulse, 120; no vomiting; the patient has some pain in the sac and the wound; skin moist, expression natural. She has slept for a short time and does not complain much.

March 2d: No vomiting; has slept a little and taken some boiled milk; pulse, 120; temperature, 101° F. The outer dressing, which contained a great amount of thin, grayish fluid of fecal odor, was changed.

March 3d: A very little discharge in the dressings. Pulse, 110; temperature, 101° F. She takes liquid nourishment and has a moderate amount of pain, which can be controlled by morphin.

March 5th: Two stools of a chocolate-colored fluid containing many small clots of blood. Very little secretion from the dressings.

March 6th: Three copious evacuations of a bloody fluid containing several clots as large as a hen's egg.

March 7th: Last night and this morning several large coagula and liquid blood passed through the rectum. The patient is pale and extremely anemic; conjunctiva pale, exsanguinated; pulse, 130, weak; temperature, 99.5° F. The patient is fully conscious, and complains of extreme weakness. Skin of extremities and face cold. Injection of 16 ounces of slightly alkaline, saccharated saline solution into the cephalic vein. In the evening, pulse, 120, stronger, and the extremities warm after the application of hot-water bottles.

March 8th: During the night there was another hemorrhage from the bowel, after which the patient became semiconscious, dozing most of the time, and complaining but little. Extremities and face cold. Pulse, 150, weak; temperature, 98° F. Died at midnight.

March 9th: Autopsy, ten hours after death. No blood in the dressings or in the cavity of the sac. The packing of the cavity is almost dry. The cavity of the sac has diminished to one-quarter the size at the time of operation, partly by retraction of the walls, partly by filling in. After removal of the gauze the placenta was found in place on the posterior wall of the sac.

The autopsy revealed an opening at the upper insertion of the placenta, between the sac and the transverse colon. This opening was so covered by the border of the placenta as to make the blood pass down into the bowels, and not out into the sac. The sac was of very different thickness in its different portions. On the anterior surface it was about $\frac{1}{4}$ inch thick, corresponding to the surface where the fetus was covered with omentum, and consisted, in fact, of the thickened omentum. The remainder of the fetal cavity was entirely surrounded by loops of intestines,—small intestine and colon,—and here the sac-wall was extremely thin, in some places cobweb like, in other places slightly thicker, and everywhere more or less intimately adherent to the wall of the intestine. These adhesions were the result of a plastic peritonitis commencing at the time of the primary rupture into the peritoneal cavity, and extending as the fetus increased in size.

The placenta extended from the posterior surface of the uterus, entirely filling Douglas' fossa, more than 6 inches upward to the transverse colon. The placental area of the sac was very thin in some places—so much so that it tore into shreds on even so slight a manipulation as that required for the removal of the intestines en masse during the autopsy.

Summary of History.—We find, in a patient thirty-four years old, who had had one child, child-bed being followed by pelvic cellulitis, and who was then sterile for eleven years, an extra-uterine pregnancy characterized by the following course:

In the eighth week after last menstruation probable rupture of a tubal pregnancy, indicated by sudden pain and vomiting; that is, symptoms of peritonitis lasting for ten days. In the sixteenth week a similar attack, less severe. In the nineteenth week another severe attack of peritonitic symptoms, keeping the patient in bed for one month. In the

fifth month she felt life. In the second week of the ninth month a moderate attack of peritonitis. At the end of the ninth month spurious labor and death of the child, indicated by cessation of fetal movements. In the fifth week after the death of the child the placental souffle began to diminish, and two weeks later it had ceased entirely. Six weeks after the death of the child another severe attack attended with peritonitic symptoms. In the eighth week perforation of the sac into transverse colon. At the beginning of ninth week operation; death six days later from hemorrhage through the bowel.

Remarks.—This case undoubtedly belongs to a class of cases consisting of an original tubal pregnancy which secondarily becomes an abdominal pregnancy with the placenta and fetus located in the abdominal cavity. In the great majority of cases where a tubal pregnancy ruptures at the end of the second or in the third month the fetus dies and disappears, and if the patient survives the hemorrhage, both fetus and placenta are removed by absorption. In a small proportion of cases after this rupture the development of the fetus is continued, and the placenta, still partially connected with the old site in the tube, keeps on growing and implants itself on the walls of the peritoneal cavity, from the small pelvis upward on the anterior, posterior, or lateral abdominal wall. When the rupture has given rise to no symptoms of hemorrhage, a plastic peritonitis takes place, which quickly forms a barrier between the territory occupied by the fetus and placenta and the remainder of the peritoneal cavity. The product of this plastic peritonitis is probably first a fibrinous exudate, later on organized into connective tissue which forms the so-called sac. This probably does not differ in any respect from the connective-tissue layer found in the wall of any other localized or, as it is called, encapsulated peritoneal exudate.

As the growth of the fetus and placenta continues, more and more space is required, rupture of the sac occurs into a new territory of peritoneal cavity up to this time intact, and this territory is again limited by a plastic peritonitis resulting in an enlargement of the sac sufficient for the needs of its contents for some time. This procedure gives rise to symptoms of peritonitis, acute in its onset, but which gradually subside. In certain forms of purulent peritonitis we find a similar method of intermittent extension giving rise to successive attacks of peritonitis with free intervals between the attacks.

This mode of development makes it natural that the sac should vary in thickness and resistance in different parts. Thus we would expect to find it thicker in the space between two intestinal loops or between a loop of intestine and one of the viscera, than on the convexity of the wall of these organs. The greatest thickness of the sac will be found, as in this case, where the omentum has participated in its formation. This would naturally occur on the anterior surface of the fetal sac. The thinnest portion of the sac-wall will be found on the convexity of the loops of intestine, and this is the place where rupture into the intestine takes place, either spontaneously or during attempts at extirpation of the sac.

In extra-uterine pregnancy, where a uniformly thick sac-wall is found,

it is natural to suppose that rupture of the tube has not taken place, but rather a uniform dilatation. These are probably the cases in which one layer of the wall of the sac is composed of organic muscular fibers, and in such cases total extirpation of the sac is possible.

Entire absence of the sac, the fetus lying in the free peritoneal cavity, between intestines which are not matted together with adhesions, is a rare occurrence. Such cases have, however, been described by King, Lawson Tait, and Goetsch. In the case of Lawson Tait the intestines protruded immediately after the extraction of the fetus through an opening made in the posterior culdesac of the vagina. In the case of Goetsch, at the time of laparotomy, a full-grown child was found free among the intestines, but yet, strange as it may seem, fresh and not decomposed, although laparotomy was not performed until two years and a half after the spurious labor.

Symptoms.—I shall not enter into a consideration of all the symptoms of extra-uterine pregnancy, because these are to be found in the text-books. There are, however, two symptoms in this case to which I wish to call attention, mainly on account of their prognostic significance; first, the repeated attacks of peritoneal irritation, and, second, the final symptom of perforation into the bowels—the bloody diarrhea.

We notice in this case repeated severe attacks of symptoms of peritonitis—so severe as to keep the patient in bed sometimes for a month at a time, and characterized by intense abdominal pain, vomiting, and occasionally tympanites. These attacks necessarily caused progressive loss of strength and emaciation, and thus the patient's condition became gradually less and less favorable for operation. In this class of cases early operation, irrespective of the condition of the child or of the placenta, would be likely to give a better prognosis for the mother.

The final catastrophe, perforation of the sac into the intestines, bladder, or vagina, is characterized by a discharge of the liquid contents of the fetal sac, liquor amnii or pus, usually mixed with blood. Perforation into the intestinal tract is by far the most common, as the intestinal wall furnishes only slight resistance, and as a large area of the fetal sac must necessarily be formed of loops of intestine. Diarrhea, usually bloody, is the first symptom, rapidly followed by symptoms of sepsis due to microbial invasion of the sac. Rapid pulse and high temperature commence within twenty-four hours of the rupture. An especially characteristic symptom, and one well marked in this case and caused by the entrance of gases from the intestinal tract into the sac, is tympanitic percussion over the area where formerly dull percussion was found. This symptom is, of course, absolutely pathognomonic of rupture into the bowel.

Rupture into the bowel is a common occurrence, as out of 132 cases collected by Hecker, cited by Bandl, the fetus was eliminated through the rectum in 28 instances, with recovery of the mother. It is not too much to assume that this condition was present in at least a corresponding proportion of the 44 cases in which the mother died without an operation having been performed, as sepsis must invariably follow the perforation.

Prognosis.—The prognosis is always grave, varying in the older statistics between a mortality of 42 and 88 per cent.—Hecker, 42 per cent.; Kiwisch, 82 per cent.; Henning, 88 per cent.

Operative Treatment.—Asepsis in operating has recently given a mighty impulse toward the amelioration of the prognosis of this grave condition, and the successful results as regards saving the lives of the mothers has made the operations for extra-uterine pregnancy to be counted by hundreds during the last four or five years, while formerly they were only sporadic occurrences.

The greatest success is accomplished by the operation in the early months of pregnancy, but it must be acknowledged that operations at or near term are at present not nearly so dangerous as they were in former years. A strict line of distinction must be drawn between the operations in the beginning, and those toward the end, of extra-uterine pregnancy. The two conditions, although only different stages of the same anomaly, present such vitally different anatomic conditions, chiefly on account of the difference in the size of the territory and the difficulty of the operation, that comparison is impossible. The early operation is technically no more difficult than the extirpation of the normal non-adherent uterine appendages; the operation toward the end of pregnancy, however, by which we mean the total removal of the ovum and its contents, is always formidable, and often technically an absolute impossibility.

Early in pregnancy, whether before or after rupture of the tube, which is almost always the primary seat of extra-uterine pregnancy, the operation presents no technical difficulties. The adhesions are slight or not present, for the tumor rarely exceeds the size of an orange or a large fist. Hemorrhage is easily controlled by ligation of the vessels of the broad ligament, which can always be found without difficulty. The prognosis of the operation is always good if the mother is in good condition; that is, is not exsanguinated by copious intra-abdominal hemorrhage from a previous rupture of the tube.

The operation in the latter half or at the end of pregnancy is usually formidable. The extirpation of a sac which often fills the greater part of the abdominal cavity, with adhesions to innumerable loops of intestines, the walls of the sac varying in thickness and consistence from that of tissue-paper to a $\frac{1}{4}$ inch, together with the danger of hemorrhage from a full-grown placenta, which may be divided by the incision into the sac, or if not divided, may even, by slight detachment at its border, cause a gush of blood which would fill the sac in a minute; such conditions put to a most severe test the presence of mind of even the most experienced operator.

In considering the operation in the latter half of extra-uterine pregnancy we distinguish between laparotomy with living child—the so-called primary laparotomy—and laparotomy after the death of the child—the so-called secondary laparotomy. This distinction has no technical, but only a prognostic, value for the child and mother.

From another point of view, we distinguish between the radical operation, removal of the whole of the fetal sac with its contents, child

and placenta, and the non-radical operation, or incision of the sac, a linear opening into the sac large enough for the delivery of the child, and the union of the borders of this incision with the opening in the abdominal wall. As regards this latter operation, we make a further distinction between the operations where the placenta is removed at the operation and those in which it is left to come away spontaneously later on, or, as in very rare instances, to remain in the peritoneal cavity, where it partially disappears by absorption, or may be transformed into a mass of cicatricial tissue, as has been observed by Goetsch and Braithwaite, on the outer wall of the uterus.

It is evident, from what has been already stated, that the radical operation is technically the most difficult one, for, on account of the nature of the so-called sac, its total removal is usually difficult and very often impossible. Thus the choice between incision and extirpation would require very serious consideration in the individual case, and the surgeon will often find himself in a very serious dilemma in this regard.

Thus, in a number of instances extirpation of the sac has been commenced, but after the operation has been partially performed the extirpation had to be abandoned on account of the impossibility of proceeding further. In such cases a part of the wall has been extirpated and part united with the abdominal wound; in other instances the connection of the sac with the uterus has made it necessary to amputate the latter, in order to accomplish the total removal of the sac. The advantage of the total removal of the sac, even if it involve so serious a complication as abdominal supravaginal amputation of the uterus, lies in the control of hemorrhage by ligation of the uterine arteries, and in the greater security against sepsis or intoxication from a non-removed sac and placenta.

The prognosis of the operation, as given by the statistics from the literature up to date, shows a remarkable decrease in mortality in the last five years. Primary laparotomy was attended by a very great mortality up to the end of 1886. Thus, Werth reports 8 cases with 7 deaths—a mortality of 85 per cent.; Litzmann, 10 cases with 9 deaths—90 per cent.; Harris, 30 cases with 25 deaths, 83 per cent. From 1887 to 1890 inclusive we find reported by Leopold Meyer 17 cases with 5 deaths—a mortality of 30 per cent. This may be fairly considered as the present mortality of primary laparotomy for this condition.

Up to 1886 the mortality of secondary laparotomy was, as Litzmann states, to a great extent dependent upon the presence or absence of placental circulation. The operations before cessation of placental circulation had a high mortality. In 10 cases in which the operation was done within the first five weeks after the death of the fetus there were 8 deaths—a mortality of 80 per cent.; while later operations, from six weeks to a year after death of the fetus, had a much less mortality; Litzmann reports 23 cases with 6 deaths—a mortality of 26 per cent., and Werth, 25 cases with 8 deaths—a mortality of 32 per cent. This great difference in the mortality led Litzmann to advise against operation immediately after the death of the fetus, and to advocate delay until after cessation of the placental circulation.

For the last four years the statistics of secondary laparotomy show a

still better prognosis. Leopold Meyer reports 72 cases with 12 deaths—a mortality of only 18 per cent. As far as can be observed, the secondary laparotomies during the last four years have not been performed with strict regard to the cessation of placental circulation. It is likely, however, that Litzmann's advice has caused many operators to postpone the operation as long as possible.

The prognosis of extirpation as compared with incision, so far as the statistics of the last four years enable us to judge of this question, shows very little difference in the mortality of the two operations. Thirty-six cases of extirpation, or the radical operation, have been reported, with 6 deaths—a mortality of 16.7 per cent.; and 64 cases of incision, or the non-radical operation, with 12 deaths—a mortality of 18.7 per cent. Four cases were reported in 1890 of partial extirpation, that is, cases in which extirpation was attempted, but could not be completed on account of the impossibility of freeing the sac, with 2 deaths—a mortality of 50 per cent. It will thus be seen, from the statistics, that incision has been performed nearly twice as often as extirpation.

In the non-radical operation, incision, the question has been raised as to what should be done about the placenta—whether it should be removed or left *in situ*. The attempt to remove it had its justification in the desire to obviate the danger of sepsis or intoxication from the considerable amount of dead tissue of the decomposing placenta. The danger of removing the placenta at the time of operation is on account of the difficulty or impossibility of controlling the hemorrhage from the site of the placenta. It has been proposed that those who perform the radical operation should control the hemorrhage in one of the following three ways:

1. By previous ligation of the spermatic and uterine arteries before removal of the placenta.
2. By ligation *en masse* of the bleeding parts of the placental territory of the sac after the removal of the placenta.
3. By pressure from packing the sac full of sterilized gauze impregnated either with iodoform or with a mixture of salicylic and tannic acids.

Ligation of the spermatic and uterine arteries can be done only in cases where the broad ligaments are accessible. This is probably of comparatively rare occurrence, as in most cases in which the sacs are not well defined the broad ligaments and uterus are hidden below the placenta.

Ligation *en masse* of the placental territory of the sac is extremely difficult and often impossible, partly because of the enormous hemorrhage from this territory, and partly because of the danger of injury to the intestines if in close proximity to the bleeding placental site.

Pressure by packing the sac with gauze is unreliable, as we have to deal with a cavity which has no firm walls against which to make pressure.

The statistics for the last four years show 12 cases in which the placenta was removed, with 4 deaths—a mortality of 33 per cent.; and 29 cases in which the placenta was left undisturbed, with 5 deaths—a mortality of 17 per cent. Thus we may conclude that it is at the present

time safer to leave the placenta intact, as was done in the majority of cases, or, at any rate, to limit the attempt to remove the placenta to those specially favorable cases where the afferent vessels can be found and secured before its removal.

Final Remarks.—The most important points to consider in 'extra-uterine pregnancy advanced beyond four months are:

1. When shall we operate?
2. What operation shall be done?

The question of the time for operation cannot be solved merely by looking at the mortality from the statistics. The fate of the child I shall leave entirely out of consideration, as I believe that very few operators of today agree with Lawson Tait in weighing the life of the child against that of the mother.

The maternal mortality, as seen in the statistics, shows, as stated above, a great difference between primary and secondary laparotomy—a difference of 12 per cent. in favor of the latter. Notwithstanding this, a number of modern operators are inclined to give up the secondary operation and operate as early as the diagnosis is made, irrespective of the child or of the placental circulation.

Certain operators, such as Olshausen, Lawson Tait, Thornton, Werth, Lusk, Wilson, Doran, Hart, Martin, and others, advocate operating as early as possible. To explain this, notwithstanding the apparently greater safety of the late operation, there must be a fallacy in the conclusions drawn from the statistics. This fallacy is the following: A number of patients, especially those having recurrent attacks of peritonitis, will die either from peritonitis or from perforation and sepsis before the time for the late operation has arrived. If these cases of speedy death after rupture were included in the statistics of the mortality of the secondary operation, its percentage would be materially increased.

During extra-uterine pregnancy the mother is in danger all the time from rupture with hemorrhage and sepsis. It is impossible to know when this will occur, and it has often been observed, as it was in my case, that rupture has taken place during the time of waiting, before the day set for the operation.

Rupture is always followed by sepsis, and an operation of necessity in the case of a septic patient has, of course, a bad prognosis. Sometimes, even, death will come so suddenly that it would have been impossible to perform an operation, as in an instance mentioned by Harris, in which the patient died half an hour after perforation had taken place.

It remains true that a number of extra-uterine pregnancies go through to full term without rupture or even after term for months or years. It also remains true that the longer after the death of the fetus the operation is performed, the less is the mortality. But it is impossible to foresee in a given case whether or not the patient will escape rupture and sepsis, hence the conclusion to operate as early as possible as a prophylactic measure. As early as possible means as early as the diagnosis is made, and this I consider to be the standpoint of today in this regard.

If the future repeats the history of the past, we may confidently

expect that the prognosis of the early operation will be still better than heretofore. Future clinical observations should enable us to make a differential diagnosis between two distinct classes of cases: the one, those in which perforating peritonitis does not take place and the patient is in no danger at any period before or after term; the other, those in which the patient is exposed to the dangers of perforation and sepsis at any time. When this stage of progress has been reached, the late operation may again have a legitimate field.

The question of the choice between extirpation and incision is much more difficult. The almost equal mortality from these operations, as shown above in the statistics, helps us very little in this respect, as it does not indicate, by any means, an equal choice between the two procedures.

The radical operation, desirable as it is, as far as control of sepsis and hemorrhage is concerned, can be done only in a limited number of cases where the sac is so uniformly strong and the adhesions so favorably arranged as to make this operation possible. In a large number of cases incision would have to be done as a matter of dire necessity in cases in which the condition of the sac and extensive, short adhesions, especially to the intestines, have made extirpation impossible.

The choice between the two operations is much more difficult after the sac has been opened and the child delivered, for it is often impossible to determine whether an attempted extirpation can be finished or not. The unfinished operation—the so-called partial extirpation—has a mortality of 50 per cent.

A difficult radical operation will tax the skill of the most experienced operator to its utmost, and the attempt to loosen the sac from the intestines has in several instances resulted in multiple intestinal wounds, followed by death from shock and hemorrhage, and this result may follow too bold an attempt in this direction even during the operation. Slight manipulations of the sac have often caused so formidable and sudden a hemorrhage from the placenta that further operating has been rendered well-nigh impossible.

The future will have to decide whether rapid removal of the placenta and hemostasis after its removal can be advocated as a justifiable and safe procedure.

The non-radical operation has the advantage of being easy of performance, of requiring only a slight amount of operating, and of taking but little time. Thus it would seem natural that this operation should be preferred by less experienced operators in all cases.

The placenta should not be removed in the operation of incision excepting in those very late cases where it has been already detached and lies loose in the sac.

BIBLIOGRAPHY

Ernst Herman: *Obstetrical Transactions*, 1887, vol. xxix.

Leopold Meyer: *Gynäkologische og Obstetristiske Meddelelser udgivne of Prof. F. Howitz*, vol. vii.

Ibid.: vol. viii.

Bandl: *Deutsche Chirurgie*, 1886.

Harris: *Amer. Jour. Med. Sci.*, 1888, vol. lxxxvi, p. 430.

A NEW OPERATION FOR HARELIP*

IN all forms of harelip (*labium leporinum*), whether single or bilateral, whether partial or total, whether combined with cleft intermaxillary bone or not, we find not an excess, but rather a defect, of labial tissue, mucous membrane, prolabium, and skin. The two portions of the upper lip, when brought together, are too small to form a lip of normal shape; it would require the interposition of a triangular piece of lip with apex toward the nose and base toward the border of the lip to obtain at once a lip of normal shape. The tissue defect is greatest in the skin, less manifest in the mucous membrane and prolabium; still, in the majority of cases of complete harelip the defects in these tissues also may be considerable.

It would thus seem natural to select a method of operating by which no tissue should be lost. In all the older methods the so-called "freshening" of the surfaces to be united requires the removal of at least a part of the prolabium, in some more, in others less, at the best, as in the method of Nélaton for small harelip, a displacement downward, to form a projection which must either disappear by retraction and atrophy, or be removed, if present in excess, by a secondary operation.

About five years ago I was led to consider this question in a case of double harelip with rather defective lateral portions, in which I operated after the old method, and suppuration with consequent non-union took place. At the next attempt at union the increased defect of tissue made union still more difficult than at the first operation. I therefore concluded to operate in my next case without the removal of any tissue, so as to have, at least, not lost anything in this respect if suppuration and non-union should make one or more later operations necessary. When I commenced to operate in this way I found it necessary to apply a separate row of sutures to the prolabium before bringing the edges of the skin together, thus closing the wound toward the mouth, and I soon found this to be a protection against infection.

I have since that time never had any reason to abandon this method for any of the older methods.

OPERATION FOR UNILATERAL HARELIP

1. *Incision.*—The incision is made at the border of the skin and prolabium, 4 to 6 mm., or 2 to 3 lines deep, care being taken to guard against opening through the mucous membrane into the mouth.

It is necessary to draw the lip down in order to procure sufficient

* Jour. Amer. Med. Assoc., 1891, vol. xvii, p. 176.

tension for the knife to divide the tissues; this traction causes anemia of the border of the lip, making the line between the white skin and red prolabium indistinct. It is necessary to be careful to have the incision precisely in this line, because a small margin of prolabial tissue left with skin will, as I have seen in one case, leave a red brim along the line of union, necessitating a secondary operation for cosmetic reasons (Fig. 55).

The length of the incision downward and outward depends upon the shape of the two portions of the separated lip. It is unnecessary, at the beginning of the operation, to estimate the length correctly, as the incision can be prolonged later on, after some of the sutures have been applied and tied, according to the requirements of the shape of the lip when united.

2. *Sutures of the Prolabium.*—Interrupted sutures of fine silk are applied or inserted from the mucous surface so as to place the knot of the suture in the mouth, the first suture close to the top of the triangle, as shown in Fig. 56. The ends of

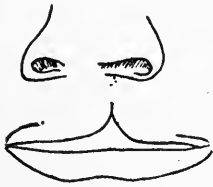

Fig. 55.

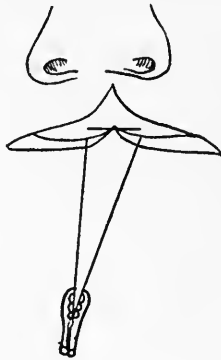


Fig. 56.

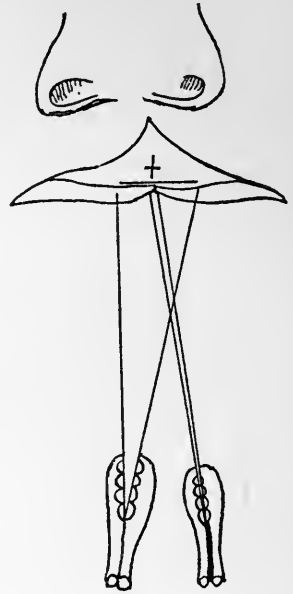

Fig. 57.

the sutures are left long and held together with an artery forceps which is left hanging down. The succeeding sutures are applied in a similar manner, at a distance of from 3 to 5 mm. from each other, in a number corresponding to the extent of the line of prolabium to be united. These prolabial sutures should include the mucous membrane and submucous tissue only, or as little tissue as will suffice to keep the prolabial edges together. There must be no tension whatever at the line of union; if tension exists from shortness of the labial flaps, it must be overcome by the tension sutures, which will be described later.

When apparently a sufficient number of these sutures have been applied, they are tied from above downward, or from the nose to the prolabium, the upper or nasal suture first, the forceps being held up toward the forehead. The united line must be long enough to give sufficient length to the lip, and permit the lowest point of union to be a little lower down (toward the lower lip) than the sides of the lip and the corners of

the mouth. The wound to be united is now closed against the mouth—is made a subcutaneous wound.

3. *Sutures of the Skin.*—(1) *Tension Sutures.*—According to the size of the defect, one or two tension sutures become necessary. I have entirely discarded the figure-of-8 suture with harelip pins, and also the button and shot sutures, and always employ an interrupted suture, using silk a little heavier than that used for the coaptation sutures of the prolabium and skin. In ordinary cases of single harelip one tension suture is sufficient. This suture enters the skin at a distance of $\frac{1}{4}$ to $\frac{1}{2}$

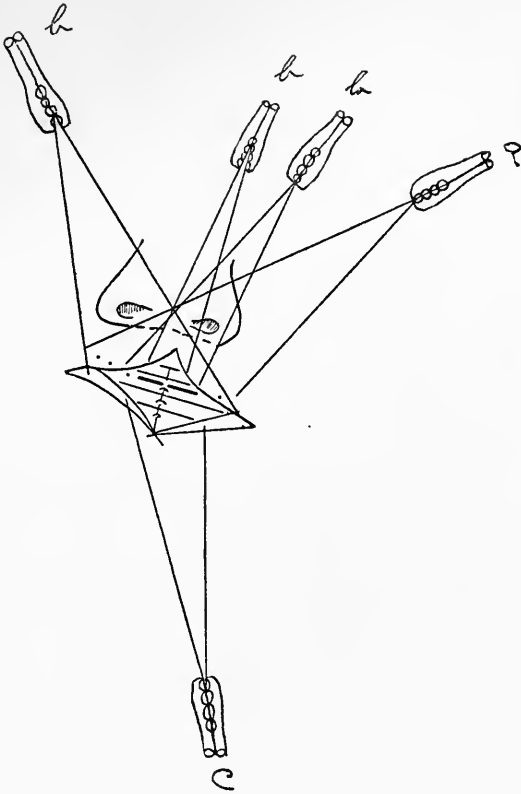


Fig. 58.

inch from the cutaneous margin of the wound, and is passed deeply down into the tissue of the lip. Care is taken not to have it pass through to the mouth, but to have it take in about two-thirds of the tissue of the lip, as shown in Fig. 58, *a*. This tension suture should be placed at or near a point where the margins of the wound are the greatest distance from each other—that is, near to the prolabium of the undivided portion of the lip. The tension suture is left with long ends held by artery forceps, and should not be tied until all the cutaneous coaptation sutures have been inserted.

(2) *Coaptation Sutures.*—These sutures (Fig. 58, *b, b, b*), for which common silk twist (which may be bought in a dry-goods store, and disinfected in the usual manner by boiling it from fifteen to thirty minutes in a 5 per cent. solution of carbolic acid) is used, are applied from above downward, or from the nasal angle of the wound to the prolabium, at a distance of 3 to 5 mm. Three to five sutures are usually required. The lowest suture (Fig. 58, *c*) is passed through the ununited borders of the prolabium.

The wound is now carefully cleansed by small aseptic sponges, and is finally touched with a sponge wrung out of 2.5 per cent. of carbolic acid, or 1:2000 sublimate solution.

If any hemorrhage is present, it can be stopped by continued pressure with an aseptic sponge for a few minutes; if the hemorrhage is slight, it will cease upon tying the sutures.

The closure of the sutures should begin with the tension suture, so as to prevent the coaptation sutures from tearing through, as they would be liable to do if tied before all tension was done away with.

If, in drawing the sutures together, it is found that the middle of the lip does not come down low enough, or that there is still an indentation in the prolabium at the line of incision, it is advisable to prolong the cutaneoprolabial incision a little on one or both sides, as the shape of the lip may require, and then apply an additional cutaneous coaptation suture.

When the cutaneous sutures are tied, the united wound should present the appearance shown in Fig. 59.

4. *Dressing of the Wound.*—After careful cleansing of the line of the wound with saturated solution of boric acid a layer of finely powdered boric acid is dusted on, and a cotton-collodion dressing applied. When I began to use this method, I plugged the nostril with borated cotton, but on account of its inconvenience to the patient, I have now discontinued this practice. I do not use iodoform-cotton or iodoform-collodion dressing for fear of iodoform poisoning; I prefer to have the nurse or mother dust finely powdered boric acid into the nostril every three or four hours during the day.

A single or double strip of rubber adhesive plaster, extending from ear to ear, is applied over the collodion dressing in such a manner as to draw the two cheeks somewhat together, for the purpose of immobilizing the cheeks and lips when the child cries or nurses.

The dressing may be changed once a day, or every two or three days, if it remains dry. If, however, the dressing becomes soaked by nasal secretion or milk when the child is nursed, it should be changed according to the necessity of the individual case.

5. *Removal of Sutures.*—The cutaneous coaptation sutures are removed after a week; the tension suture is allowed to remain two to four days longer if it has not been loosened by pressure atrophy or pressure necrosis of its canal. After removal of the sutures the borated cotton-collodion dressing and adhesive straps are reapplied, to be continued

until the suture canals have entirely healed, which takes place toward the end of the second or third week.

At the junction of the two lateral corners of the wound there often remains, after the suturing, a small quadrangular ununited space 1 to 2 mm. in diameter, where it may have been impossible to approximate the edges of the wound (Fig. 59). A very fine suture may help to close this little defect. If, as is often the case, this little suture cuts through, the small defect heals by aseptic granulation, requiring only very little more time than the primary union of the remainder of the wound. It leaves at most a small cicatrix in the line of union at the border of the skin and prolabium, and does not result in permanent disfigurement.

The prolabial sutures will sometimes cut through and peel off if the process of healing goes on undisturbed, or some of the sutures may remain and be removed after the end of the second or third week, at a time

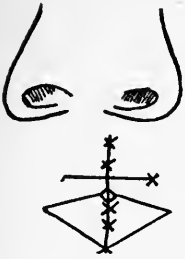

Fig. 59.

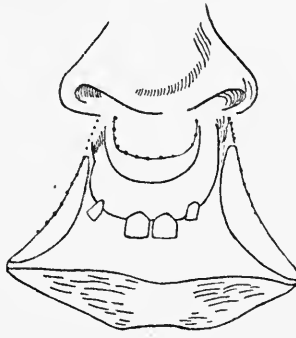


Fig. 60.

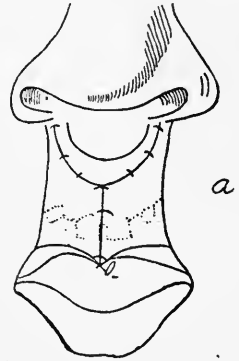


Fig. 61.

when union is strong enough to tolerate the manipulations necessary for their removal.

OPERATION FOR DOUBLE AND COMPLICATED HARELIP

The operation for double and complicated harelip (as represented in Figs. 60 to 63) is performed on the same general principles, namely:

1. *Incision.*—The incision along the cutaneoprolabial border should be of sufficient length to cover the space of defect. A second incision should be made along the cutaneoprolabial border of the median peninsula of labial tissue below the nasal septum, if this peninsula is so situated as to be available for use in the formation of the lip. (See Fig. 60.)

2. *Suture of the Prolabium.*—The prolabial sutures are applied as just described for the unilateral harelip, to be tied on the oral surface of the wound. The sutures should be first inserted on both sides of the nasal peninsula until this is wholly covered, and until both lateral halves of the prolabium come together at the median point of its lower border (Fig. 61, a). When this point is reached, these two rows of sutures are tied.

The lateral prolabial borders are now united in the median line as low

down or as far out as required to give to the lip the necessary length, as described in the operation for single harelip. These labial sutures are tied in the mouth usually without any tension, because the prolabium, when loosened from the skin and retroverted, furnishes a flap of sufficient size and elasticity to permit of ready approximation.

It is important, as before stated, that the linear incision should not penetrate into the mouth. When, as is often the case when the cleft extends through the nostril or nasal cavity, there is a lack of prolabium near to and in the nostril, and the prolabial sutures cannot be applied high up, it is usually possible, by careful dissection and separation of the mucous membrane at the oral fornix of the lateral half of the upper lip,

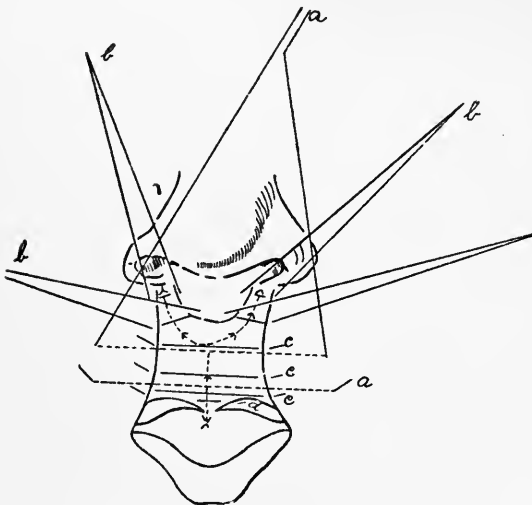


Fig. 62.

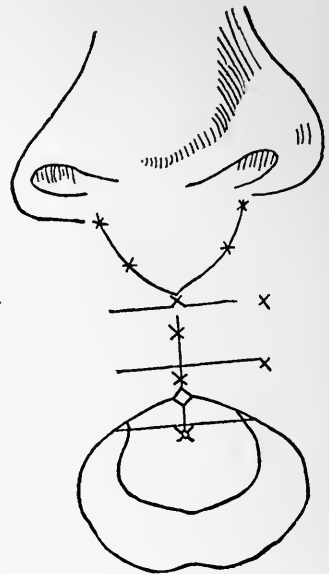


Fig. 63.

to displace the mucous membrane to some extent laterally, so that the uppermost suture may be applied reasonably high up toward the nostril.

When the prolabial sutures have been tied, the wound presents the appearance represented in Fig. 61.

3. *Sutures of the Skin.*—Tension and coaptation sutures are now applied as follows (see Fig. 62):

(1) *Tension Sutures.*—For these sutures somewhat heavier silk should be employed. The upper suture should be inserted at the lower border of the nasal peninsula, the lower one near the lower border of the lip. They should be passed in and out at a distance of $\frac{1}{4}$ to $\frac{1}{2}$ inch of the border of the skin, and should include one-half or a little more than one-half of the thickness of the lip (Fig. 62, a). The ends should be held by artery forceps, and should not be tied until all the skin sutures have been applied.

(2) *Coaptation Sutures.*—The coaptation sutures (Fig. 62, *b, c*) are now inserted from above downward. The first two or three sutures (Fig. 62, *b*) are inserted on both sides, between the lateral skin-flap and the skin of the peninsula, until this is united to the side flap throughout its entire circumference. The lateral flaps, uniting in the median line just below the nasal peninsula, form the upper portion of a Y-shaped line of union. Then the lower portion of the wound is united by two or three sutures (Fig. 62, *c*), and a lower fourth suture (Fig. 62, *d*) is inserted through the two halves of the prolabium.

After thorough cleansing and disinfection of the wound the sutures should be tied—first the tension and then the coaptation sutures (Fig. 61).

4. *Dressing of the Wound.*—The wound should be dressed with borated cotton collodion, or in older patients with iodoform collodion. The nostrils, especially in older patients, should be loosely packed with borated or iodoform cotton. Over this two straps of adhesive plaster should be applied. In older patients a strip of iodoform gauze should be laid in the mouth along the line of union of the prolabium. In new-born children the nostrils need not be packed with cotton, and no iodoform gauze should be used, but these localities should be frequently dusted with finely powdered boric acid. The dressing should be changed according to the amount of discharge—never more than once daily.

5. *Removal of Sutures.*—The coaptation sutures of the skin may be removed at the end of the first week; the tension sutures, according to the amount of tension remaining, usually late in the second week; finally, what may remain of the prolabial sutures should be removed still later, when the union is so solid that the upper lip is able to tolerate manipulation.

It is immaterial how narrow the new upper lip may appear to be immediately after the operation. König remarks, in speaking on plastic operations on the lips,—cheiloplastic operations following the extirpation of labial carcinomata,—that the shape of the mouth, however deformed it may appear on account of unequal size of the lower and upper lip in the first weeks after the operation, in the course of some months becomes more normal—surprisingly so when a sufficient time—from three to six months—has elapsed.

The all-important feature of the operation is to make the upper lip long enough in a sagittal direction, and to have exact union of the lower portion of the prolabium.

Apparatus to draw the cheeks together for the sake of immobilization or to diminish tension I have, up to this time, found superfluous.

CONCLUSIONS

The two main points in this harelip operation are the incision and the prolabial sutures.

1. The incision—a linear incision—is similar to that made in the operation for laceration of the perineum as proposed by Lawson Tait,

and by him termed "flap-splitting." As stated above, this possesses the advantage of not sacrificing any tissue of the parts already more or less defective; on the other hand, repeated denudations, made necessary by unsuccessful attempts at union, would tend to make the lateral portions of the lip smaller and smaller. Furthermore, the linear incision, by loosening the everted prolabium (which is readily converted into mucous membrane by the simple change of position into the oral cavity), furnishes so much tissue for the posterior surface of the lip that union of the prolabial borders is easy, even before any tension sutures have been applied.

2. The prolabial sutures should be accurately applied. Fine curved needles should be used, the sutures made of fine silk. Interrupted sutures should be employed in sufficient number and at such intervals as to furnish exact union. These sutures close the wound against the mouth, and make the wound, so to speak, cutaneous instead of visceral, and thereby prevent infection from the ever-present multitude of microbes in the mouth. I believe that this suture will prove to be a potent factor in securing uniform results by preventing suppuration and non-union of the wound.

3. The cosmetic results have been all I could desire. If a slight indentation at the line of union of the prolabium has existed immediately after the operation, it has generally disappeared after a few months, provided the lip has been made long enough at the time of the operation.

4. I think that this method is applicable in all cases, and should take the place of all the numerous older methods of operating.

THE VAGINAL OPERATION IN EXTRA-UTERINE PREGNANCY*

Introduction.—Having been invited by the president of the Chicago Gynecological Society to take part in the discussion upon the question of the treatment of extra-uterine pregnancy at or near term, and having for my associates in the discussion the president himself and Professor Parkes, I have chosen, as the part of the entire subject for my consideration, the vaginal operation, elytrotomy, as applied to extra-uterine pregnancy. I have made this choice because, three years ago, I met with a case of this kind and resorted to the vaginal method of operation, as at that time I considered it to be the one indicated under the circumstances. I shall first relate the case, and afterward bring the question of this method of operating, as it now presents itself to me, before the Society for consideration and discussion.

I am very much indebted to Dr. William Mackie, of Milwaukee, Wisconsin, for the notes of the following case, as well as for his extremely able management of the after-treatment. Dangerous and troublesome as this always is, I consider the success due only to his unremitting care and attention. The case was operated upon in Milwaukee during the absence in Europe of Dr. Senn, who, on his departure, requested me to operate on the patient.

J. X., twenty-eight years of age, unmarried, had a single intercourse (her voluntary statement) in March, 1886. A month later she experienced dragging pains in the right iliac region. She menstruated regularly until June, 1886, after which menstruation ceased until November 25th. In June she first noticed an enlargement on the right side of the abdomen, which gradually increased in size, the increase being unaccompanied by pain. In November some hemorrhage appeared, which she supposed to be her regular menstruation. It was not periodic, however, as a slight hemorrhagic discharge persisted until the following March. The amount of hemorrhage varied, usually increasing after exercise.

In November, 1886, she first consulted a physician, who diagnosed a fibrocystic tumor and advised her to enter a hospital. She entered St. Mary's Hospital, Milwaukee, and was under treatment there until the end of January, 1887. During this time the vaginal discharge resisted all treatment, but the tumor did not increase in size. If there was any change, it seemed rather to decrease.

On January 31, 1887, she was admitted to the Milwaukee Hospital. On examination her condition was found to be as follows: A tumor occupied the abdomen, which, on inspection, appeared to be most prominent to the left of the median line. On palpation the outlines of the fetus could be distinctly felt through the abdominal parietes. The head of the fetus lay in the left iliac fossa, and the body was inclined upward obliquely to the

* Read before the Chicago Gynecological Society, December 19, 1890. Amer. Jour. Obst., 1891, vol. xxiv, p. 418.

right. On vaginal examination the uterus was found displaced upward and to the right. Douglas' fossa and the posterior lacuna were pressed downward into the vagina, most prominently on the left side, where, through the thin, distended walls, the fetal head could be felt and the posterior fontanel distinctly made out. Auscultation failed to detect any fetal heart-sound, but the placental souffle could be heard over the abdomen, most distinctly at a point 3 inches below the level of the umbilicus and a little to the left of the median line.

The patient had no idea that she was pregnant, and denied, or would not admit, ever having felt any fetal movements. In this respect the patient's statement may be considered perfectly reliable.

About the end of February she had an attack of chicken-pox. On March 2d the vaginal discharge ceased, and on March 6th the placental souffle was inaudible.

On March 13, 1887, the external genitals having been shaved and thoroughly disinfected, antiseptic injections having been applied to disinfect the vagina, liquid diet and cathartics having been given for several days, together with an enema on the morning of operation, with the able assistance of Dr. Mackie, and in the presence of the members of the German Medical Society of Milwaukee,* I operated in the following manner:†

The patient was anesthetized and placed in the lithotomy position. After a median incision through the perineum to enlarge the field of operation, the vagina was distended by Simon's retractors, the left index-finger in the rectum marking out the extent to which the tumor was covered by the rectal wall, and a transverse incision made in the posterior lacuna above this point by the knife of a Paquelin cautery. Upon entering the cavity a moderate amount of almost clear, serosanguinolent fluid escaped, and the head of the fetus presented in the opening. The opening was dilated transversely as far as it was deemed safe, but it was soon ascertained that it would be impossible to deliver the fetus through an opening of this size. I therefore performed craniotomy, and, after emptying the brain-substance, introduced a biconcave cranioclast and extracted the head, guided by two fingers of the left hand, slowly and with some difficulty, it being necessary to cut away with bone scissors portions of the cranial bones as they presented in the opening. The delivery of the remainder of the body was comparatively easy.

The umbilical cord was ligated as a precautionary measure, pulsation being absent. The fetal sac was thoroughly irrigated with boric-acid solution. Gentle digital exploration of the sac showed that the placenta was attached high up in the left iliac fossa, that it was apparently of normal size and still adherent all over.

Two large rubber drainage-tubes, $\frac{3}{4}$ inch in diameter, were introduced into the cavity and surrounded by a packing of sterilized gauze thickly dusted over with salicylic acid to which had been added some tannic acid. The vagina was also filled with this packing. The drainage-tubes extended to the introitus vaginae, over which a large antiseptic gauze and salicylated cotton dressing was applied.

At the close of the operation the patient was somewhat collapsed, but toward evening she rallied. Pulse, 160 and feeble; temperature, 100.5° F.

March 14th to 16th: Temperature from 99° to 102.5° F.; pulse, 108 to 120. March 16th the gauze tampon was removed from the vagina and cyst. The discharge had then become fetid. The rubber drains were replaced by glass drainage-tubes. Evening temperature, 103° F. After one hour of irrigation with saturated solution of boric acid, ordered by Dr. Mackie, the temperature fell one degree. A similar irrigation was repeated every three or four hours. On March 17th the discharge was very fetid and sanguinolent, and contained many shreds of broken-down tissue.

* Verein Deutscher Aertze aus Milwaukee.

† Dr. Bayard Holmes, of Chicago, accompanied me with some culture substances, with a view to the investigation of the existence of microbes in the fetal sac and the organs of the fetus. A report of these very careful and valuable investigations was read about two years ago by Dr. Holmes before this Society.

March 18th: Discharge coffee-colored, containing much placental débris. Evening temperature, 102° F.; pulse, 134. Alternate hourly irrigation with boric acid and 2.5 per cent. carbolic acid solution ordered.

March 19th: The urine was cloudy and of a greenish hue, indicating the presence of carbolic acid. After this a 2 per cent. solution of acetate of aluminium was substituted for the irrigations with carbolic acid solution. On digital exploration Dr. Mackie found that most of the placenta was still firmly adherent.

March 24th (cleventh day): Morning temperature normal. A small portion of the placenta came away with the irrigating fluid.

March 30th (seventeenth day): The placenta was found to be free at the margins, and Dr. Mackie broke it up with the finger and completely removed it. The placenta, as removed, consisted of edematous connective tissue containing numerous calcareous particles. Many of the blood-vessels were also undergoing calcareous degeneration. On the following day (the eighteenth) all the fetid odor had disappeared from the discharge, and a week later the patient was allowed to get out of bed.

On May 25th menstruation reappeared. July 14th the patient was discharged from the hospital. On vaginal examination the uterus was found to be of normal size, but firmly adherent to the left side of the pelvis.

The child was a fully developed fetus at term, and presented no further signs of decomposition than local desquamation of the epidermis and a slightly grayish color of the skin, indicating beginning aseptic maceration. It was still in many places covered with smegma. All the organs were apparently of normal development. It had no odor whatever, and, as Dr. Holmes' bacteriologic investigations proved, was in a perfectly aseptic condition.

The later fate of the patient Dr. Mackie has kindly ascertained for me, and reported as follows: About the end of April, 1887, during the convalescence after the operation, symptoms of commencing pulmonary tuberculosis—an apex catarrh—were discovered by Dr. Mackie. The disease progressed gradually into pulmonary consumption, of which the patient died a year ago—that is, two and a half years after the operation.

Remarks.—As to the duration of pregnancy before the operation in this case, it must have varied between ten and twelve months. If we take the single coitus as the point of departure, the period would be twelve months; if we take the last regular menstruation, it would be ten months. As no fetal heart-sound was heard at any time, it is impossible to ascertain the exact time of the death of the fetus. The indications of development of the fetus to full term, however, would make it likely that death occurred in the eighth or ninth month.

At the time when I first saw the patient, in January, 1887, the symptoms were not urgent, and I consequently considered that I had the choice of the time in operation. In this regard I resolved to follow the advice of Litzmann, namely, to postpone operating in cases where the child is dead, and where, consequently, the life of the child does not have to be taken into consideration, until a time when we may be sure of the cessation of placental circulation. As to this question, it was necessary to take into consideration how long after the death of the fetus we might expect the placental circulation to continue. Werth gives this time as ten to twelve weeks; Litzmann, as five to six months. Schroeder saw a case in which there was hemorrhage from the placenta in an operation performed nine weeks after the death of the fetus.

As in my case it was impossible to know the exact time of the death of the fetus, and as there was a symptom present—namely, the placental soufflé—which I considered indicative of placental circulation, I resolved to wait until this bruit had ceased and operate a week later. As seen from the history, there was a slight hemorrhage at the time of the spontaneous detachment of the placenta. The placental circulation, as indicated by the soufflé, lasted for at least five weeks after the death of the fetus. The operation was thus performed one week after the supposed cessation of fetal circulation, at a period when as yet no symptoms of fermentative intoxication or sepsis had appeared.

There is one other feature in the symptoms of the case to which I wish to call attention—the fact that the patient was a young primipara. It is usually stated that we most commonly meet with extra-uterine pregnancy either in old primiparæ, or in multiparæ where a long period of sterility has elapsed after the birth of the last child—five to ten years or more. The patients then unexpectedly recognize the symptoms of pregnancy from the experience of former years, or find the symptoms of the present condition so different that they hardly believe in the possibility of pregnancy. The difficulty of an early diagnosis is naturally much greater in primiparæ.

I will briefly mention in this place another case of extra-uterine pregnancy in a young primipara which I have recently seen:

Mrs. R. S., of Chicago, twenty-six years of age, always in good health. She menstruated first at thirteen, was always regular, and continued so after her marriage, four years ago. She had never been pregnant. In February, 1890, menstruation ceased. About the middle of March she had an attack of pain low down in the pelvis which lasted a few days. In April a similar attack of pain in the region of Douglas' fossa (involuntary statement by the patient during exploration) was accompanied by the passage of what she considered to be a clot of blood, by pain and vomiting, which confined her to bed for a week. In May she went into the country. At this time the abdomen had already commenced to enlarge. In June she had a severe attack of abdominal pain and vomiting which confined her to her bed and room for several weeks. After this time the abdomen grew larger and fetal movements were felt almost daily. In September an almost constant bloody discharge occurred from the uterus. In November normal labor was expected, and by the end of the month labor pains came on, but ceased after about a week. Examination in narcosis revealed a condition which led to the diagnosis of extra-uterine pregnancy, and expectant treatment was advised.

I was called in by the patient to verify the diagnosis and found the following condition: Patient healthy, well nourished, with pigmented areolæ in the well-developed mammae; colostrum could be pressed out of both nipples. The abdomen was ununiformly enlarged, a round prominence being seen below and to the right of the umbilicus, extending from this point downward and to the left, filling both iliac fossæ, the left iliac fossa being much less prominent than the right umbilical region. The linea alba was dark brown from pigmentation.

The tumor was semisolid, elastic, non-fluctuating. No fetal heart-sound could be heard, but a distinct placental bruit or soufflé could be heard in a round area, 4 inches in diameter, from 1 inch below the umbilicus toward the symphysis, the larger half of the area being situated to the left of the median line. No bruit was heard over the remainder of the tumor.

Vaginal exploration showed the vaginal walls to be soft, the vaginal portion of the uterus high up, pushed forward behind and somewhat to the left of the symphysis, soft and voluminous. The fetal head could be felt in Douglas' culdesac as a solid round tumor, not very deep down in the pelvis, and somewhat movable when pressure was made with the other hand over the abdomen. The patient states that from the time of the examination under anesthesia, five weeks ago, fetal movements ceased entirely and the abdominal tumor noticeably decreased in size.

Diagnosis.—Extra-uterine pregnancy; death of child five weeks ago; absorption of amniotic fluid. Position of child: Head in left iliac fossa, face toward the sacrum; dorsal side of child toward the abdominal wall; breech in right iliac fossa, near the umbilicus, below and to the right of the latter. Placenta attached to anterior abdominal wall below the umbilicus. Pulse, 80; evening temperature, 100° F. I advised, as the placental circulation was yet present, as evidenced by the distinct souffle, and as the child was dead, to wait until the cessation of placental circulation before abdominal section, unless, in the mean time, alarming symptoms should occur.

The course of the case first reported after the operation was by no means peaceful, as symptoms of severe sepsis, from which the patient barely escaped with her life, made recovery uncertain for some time and necessitated energetic antiseptic irrigation to such an extent as to make the after-treatment an exceedingly trying task.

I call especial attention to this point, as I consider it one of the great drawbacks inherent to the vaginal operation.

Remarks.—In the following remarks I shall endeavor to review, as far as the literature at my disposal enables me, the question of the indications for, and the advisability of, the vaginal operation in extra-uterine pregnancy, and its relation to laparotomy for the same condition.

1. *Anatomic Conditions Calling for or Making Possible the Vaginal Operation.*—The vaginal operation is to be considered only when the sac or fetus is located so deeply in the recto-uterine fossa that it pushes the walls of this region downward so as to form a prominent tumor in the posterior wall of the vagina. Further, as stated by Herman, through this vaginal wall, made thin by pressure atrophy, the head of the fetus, which can be recognized by the sutures and fontanelles, the breech or the feet should be felt, so as to make extraction possible without turning. If the softness of the protruding tumor in this place makes it likely that the placenta is here attached and placed between the vaginal wall and the fetus, the vaginal operation should not be done because of the danger of hemorrhage when the incision is made through the placenta.

2. *Frequency of this Location of the Fetal Sac.*—It is generally stated to be a rare occurrence. If we look at nature's way of expelling an extra-uterine fetus, or the spontaneous evacuation when left to take its course, we might be deceived. An extra-uterine fetal sac, when the seat of supuration,—that is, when it has become an abscess,—will travel on its way to spontaneous opening in the direction of least resistance. The intestinal wall is the place of least resistance; thus, elimination through the rectum is common.

Hecker (Bandl) found the fetus expelled through the rectum in 28 out of 132—that is, in 20 per cent. of extra-uterine pregnancies. This frequency, however, does not indicate that the sac was always located deep down in Douglas' fossa, as the opening into the intestinal canal

might be located high up above the rectum in almost any part of the tract.

It is safer to draw conclusions from the frequency of spontaneous opening into the vagina or from the number of vaginal operations on record. The frequency of vaginal operations is given by Hecker as 3 out of 26; by T. Gaillard Thomas, as 3 out of 30; that is, respectively, in 12 and 10 per cent. of the cases.

Spontaneous evacuation through the vagina is rare. Ernest Herman, in his most excellent and scholarly paper on the subject of vaginal operation, read in the Obstetrical Society of London in 1887, was able to collect from the literature only 4 cases (Schmitt, Santini, Charleton, and Lusk). To this may be added a case reported by Werth, making, up to date, 5 cases in all.

An abscess cavity low down in Douglas' fossa is likely to open into the rectum, as is so well known from hematoceles and peri-uterine abscesses. Perforations low down in the rectum have been recently reported by Tuttle, of New York, and Autoriello, of Naples, in which the fetal sac could easily be explored and treated through the opening in the rectum immediately above the anus.

From the above considerations we may conclude that, in about 10 per cent. of the cases of extra-uterine pregnancy, the location is so low down as to make the vaginal operation possible.

3. *Prognosis of the Vaginal Operation.*—About fifty years ago Campbell stated that elytrotomy gave a better prognosis for the mother than laparotomy. In 9 cases of vaginal operation there were 5 living mothers and 4 living children, a maternal mortality of 44 per cent. At this time laparotomy with living or recently dead children had a maternal mortality of 100 per cent., as in the 9 cases cited by Campbell all the mothers died.

We shall now consider for a moment the respective mortality of the two operations as they have developed from that time until now. Laparotomy, with a mortality of 100 per cent. in 1841 (Campbell), will be shown to have progressively a much better prognosis the nearer we come to the present time. In 1880 Litzmann gave a series of 43 cases, with 23 maternal deaths—a mortality of 53 per cent. His statistics in detail are: Ten laparotomies with living children, 9 deaths, or 90 per cent.; 33 laparotomies with dead children, of which 10 were performed one to five weeks after the death of the child, with 8 deaths, or 80 per cent., and 23 performed from six weeks to a year after the death of the child, with only 6 deaths, or 26 per cent.

The low mortality of the last series caused Litzmann to advise earnestly against operation late in pregnancy, after the death of the child, until a sufficient time had elapsed to insure cessation of the placental circulation, provided that no urgent symptoms, suppuration or peritonitis, made immediate action imperative.

In 1889 Leopold Meyer, of Copenhagen, in his most excellent annual compilation and summary, collected from the literature the operations of the previous year (1888)—24 laparotomies, with 8 maternal deaths, or

33 per cent. The same author, in his summary in 1890, gives the laparotomies for 1889 as 35, with 6 maternal deaths; that is, a mortality from all laparotomies late in pregnancy of only 17 per cent.

It will thus be seen that laparotomy for extra-uterine pregnancy at or near term, irrespective of the condition of the placenta and child, has had the enormous decrease in maternal mortality from about 100 per cent. in 1841 to 17 per cent. in 1889. This is in conformity with the modern prognosis of laparotomy for other causes, and is, of course, due almost entirely to asepsis in the operation and after-treatment, to better technic, and to clearer indications for the operation.

If we look for similar progress in the prognosis of the vaginal operation, we will find a vast difference between the latter and laparotomy. In 1887 Herman collected from the entire literature 12 operations in which the child was developed to full term, with 7 maternal deaths, or 58 per cent.* To these 12 cases I have added one published by Godson and my own case, in both of which the mother recovered. This makes in all 14 cases, with 7 deaths, a mortality of 50 per cent., in cases uncomplicated by any perforation of the fetal sac.

In cases in which spontaneous perforation had taken place into the vagina or rectum, and this condition necessitated immediate vaginal operation, the prognosis, as might be expected, was aggravated by septic invasion into the sac. In 4 cases collected by Herman 3 mothers died. In a case reported by Charles, in which perforation into the intestines had taken place, the mother also died. This makes a total of 5 cases, with 4 maternal deaths, a mortality of 80 per cent.

We will, in conclusion, exclude the last-named class of cases from the comparative prognosis between the vaginal operation and laparotomy.

It will thus be seen that the vaginal operation, even at this date, has a mortality of nearly 50 per cent.; laparotomy, a mortality of 17 per cent. These statistics speak strongly in favor of the substitution of laparotomy for the vaginal operation in all cases.

4. *Dangers of the Vaginal Operation.*—(1) *Hemorrhage.*—In operating through the vagina for any disease in the pelvic organs there is always considerable difficulty in controlling hemorrhage, because the field of operation is narrow, and it is difficult, or even impossible, to secure bleeding vessels if they cannot be brought down into easy reach near the introitus of the vagina.

In extra-uterine pregnancy, where the placenta is the source of hemorrhage, it is entirely out of reach in the vaginal operation, and any attempt at local arrest of hemorrhage is, therefore, impossible. Severe hemorrhage was noted in 4 out of the 14 cases, and was the immediate cause of death in 2 cases (Rupin and Lawson Tait). In 3 cases the placenta was removed during the operation (Lawson Tait, Bandl, Mathiesen). In one case (Rupin) the placenta was left intact. In the remaining 10 cases there was only slight or unimportant hemorrhage.

* I eliminate from this consideration the cases in which the fetus had died at or before six months, as the delivery of a small fetus is easier, and consequently less dangerous, than that of a full-grown child.

In 9 of these cases the placenta was not touched, and in 1 of these (Chauvenet) it never came away. In the tenth case (Agnew) it lay loose in the cavity and was readily extracted.

Thus it is advisable, in the vaginal operation, that the placenta should be left as far as possible undisturbed, to come away by spontaneous detachment, as Litzmann has advised in the abdominal operation.

Hemorrhage from the placenta is, as we should expect, often seen when the vaginal operation has been performed in the early stages of pregnancy. From Herman's statistics we find 3 vaginal operations before rupture of the sac (Thomas, Harrison, O'Hara), with 2 recoveries and 1 death. In 1 of these cases (Thomas) severe hemorrhage was brought on by traction on the cord. In O'Hara's case the placenta was divided by an incision and peeled out without much hemorrhage.

In 4 operations soon after rupture of the sac (Simpson, Lewers, Goelet, —cited from Herman,—Bernays), with 4 recoveries, there was severe hemorrhage in 2 cases (Simpson and Lewers). In the latter case an attempt was made to remove the placenta ten days after the operation, which brought on severe hemorrhage. In 2 of these 4 cases the placenta was removed without hemorrhage.

(2) *Retention of the placenta* is likely to cause intoxication from decomposition. It is, therefore, important to know when we may expect the placenta to come away. In the cases recorded the placenta came away on the second day in 1 case (Hancock), on the sixth day in 1 case (Godson), on the sixteenth day in 1 case (Herman), and on the seventeenth day in 1 case—my own. In the 2 latter cases the decomposing placenta caused considerable intoxication and fetid discharge, the fetor ceasing promptly after the spontaneous removal of the placenta.

(3) *Delivery of the child through the vaginal opening* is often difficult, and sometimes impossible, in cases near, at, or after, full term. To the 14 cases cited we must add 3 cases in Herman's series in which spontaneous opening had taken place, and deduct the cases of Lusk, Edis, Caignan, and Rupin, because the fetus died in these cases at about the sixth month and was easily extracted—making a total of 13 cases with full-grown children to be considered, as follows:

(a) *Delivery was impossible* in 2 cases, and the patients died with the children in the sacs (Smith). Charleton turned, but was unable to deliver, the child.

(b) *Craniotomy or cephalotripsy* was necessary in 4 cases (Norman, Herman, Godson, and my own), with 2 recoveries and 2 deaths (in Godson's case the thorax was also perforated).

(c) *Delivery by turning* is especially dangerous in extra-uterine pregnancy, as the sac-walls are so thin that they will almost always rupture during the manipulations. In the 2 cases reported (Santini and Bandl) both mothers died.

(d) *Forceps delivery*. Three cases are reported (King, Hancock, and Mathiesen), all of which recovered.

(e) *Delivery by simple extraction*. In only 3 cases was delivery by extraction easy: Chauvenet's, whose patient lived; Lawson Tait's,

whose patient died from hemorrhage; and Agnew's, whose patient is reported to have died from poisoning by potassium permanganate.

It will thus be seen that the delivery of the child developed to full term, through a vaginal incision, was easy in only 3 cases, and that more or less difficulty was present in 11 cases. The difficulty of delivery would be a strong argument against the vaginal operation, especially against turning, which is probably always fatal, as Herman has pointed out. We should agree with Herman's seventh conclusion, that if the child cannot be delivered by the vagina without being turned,—that is, when the head, breech, or feet do not present,—vaginal section is absolutely contraindicated.

(4) *Sepsis*.—It is probably absolutely impossible to keep a fetal sac which communicates with the vagina free from sepsis by any surgical precautions as yet known. Drainage, combined with packing with gauze impregnated by iodoform or salicylic acid, or a mixture of salicylic and tannic acid (Werth), has proved utterly insufficient to secure an aseptic course. Although sepsis was not mentioned in all the cases of unruptured sac, we find that in 5 (Hancock, Mathiesen, Godson, Herman, and my own) of the 7 cases which recovered frequent daily or even hourly irrigations with antiseptic fluids, such as Condy's fluid, iodine water, carbolic acid solution, and boric acid, were resorted to, thus indicating strongly that a more or less grave sepsis was present.

In the 7 cases of death there were 2 from peritonitis (Bandl and Norman); 2 from sepsis (Edis and Caignan); and in the remaining 3 cases in which death occurred from hemorrhage or poisoning sepsis is, of course, not excluded.

In the rare instances where there is no sac and the fetus consequently lies freely movable among the intestines,—as in King's case, which recovered, and in which the intestines protruded on the third day; and in Lawson Tait's case, which died from hemorrhage, and in which the intestines protruded immediately after extraction of the fetus,—it is possible that we would meet with similarly favorable circumstances for the immediate closure of the abdominal cavity as we find after vaginal extirpation of the uterus, when a simple iodoform gauze drain is sufficient to procure an aseptic course from the immediate closure of the abdominal cavity. This, however, is a rare condition, and in a great majority of cases we have to deal with the fetal sac, which must necessarily be infected through the vaginal opening, and the patient thereby exposed to an intoxication or sepsis which is beyond control and the outcome of which is at least uncertain.

5. *Vaginal Operation for Suppurating Fetal Cavities*.—When the fetal sac has been transformed by suppuration into an abscess cavity, and disintegration of the soft parts of the fetus has partially or entirely destroyed them, leaving finally only the bones, the conditions are much more favorable, and the treatment has the same indications and prognosis as in abscess cavities in the small pelvis of any other origin.

In 11 cases cited by Herman there were 9 recoveries and only 2 deaths. In this class of cases the vaginal operation is strongly indicated,

and is preferable to laparotomy. Where the abscess presents in the posterior culdesac there is, comparatively speaking, no difficulty in delivering through a small vaginal opening, and no danger of infection to the peritoneal cavity, which might easily be exposed to sepsis by a laparotomy for this condition.

Vaginal operation early in pregnancy, although not included in the consideration of this discussion, I shall mention in a very few words. It is today uniformly condemned by all authorities. Herman has collected 6 cases, to which may be added a case reported by Bernays, making 7 in all. Three of these were operated upon before rupture of the fetal sac, with 2 recoveries and 1 death; and 4 operated upon at the time of, or soon after, rupture, all of which recovered. Although the mortality in these cases was only 14 per cent., dangerous symptoms of sepsis, requiring frequent antiseptic irrigation, were present in 5 of the 7 cases (Thomas, Harrison, O'Hara, Goelet, and Bernays), in 1 of which (O'Hara's) fatal peritonitis occurred.

However, a retro-uterine hemocele may have had its origin in the rupture of a fetal sac, and a vaginal incision has in a few cases revealed a small fetus as the proof of such an origin. In an instance of this kind in which a thorough diagnosis cannot be made the vaginal incision is to be regarded as being made for a retro-uterine hemocele rather than for an extra-uterine pregnancy.

In all cases where a diagnosis of extra-uterine gestation early in pregnancy can be made before the time of rupture of the sac, the vaginal operation should never be resorted to, inasmuch as total extirpation of the fetal sac and tube cannot be accomplished by vaginal incision. When the diagnosis is made after rupture of the sac and operation becomes necessary, the vaginal operation is also out of the question, for the following two reasons: The seat of hemorrhage, the ruptured Fallopian tube, cannot be reached and treated properly, nor can the accumulated blood in the abdominal cavity be properly evacuated. Thus hemorrhage and sepsis cannot be guarded against. Abdominal section is in such cases the only rational and safe way of operating, as all the necessary indications can be complied with by this method.

To return to the subject of tonight, "The Anatomy and Treatment of Extra-uterine Pregnancy at or Near Term," I desire to present, in regard to the vaginal operation, the following—

CONCLUSIONS

1. In cases where the fetal cavity is still aseptic, the vaginal operation exposes the patient to danger of sepsis in the fetal sac, which cannot be guarded against. Abdominal section gives far better means of protection against septic infection.

2. Hemorrhage from the placenta cannot be controlled by the vaginal operation. By abdominal section, on the other hand, ligation of the internal spermatic and uterine arteries, as devised by Olshausen, might in some cases be accomplished as a means of checking hemorrhage from

the site of a removed placenta, in the territory supplied by these vessels. Abdominal section further permits of ligation en masse of the bleeding portions when the placenta has been divided at the place of incision.

3. Delivery of the child at full term is usually difficult, and thus dangerous to the mother, by the vaginal operation, but easy by the abdominal operation.

4. If the fate of the child is to be considered, the vaginal operation must be abandoned and replaced by abdominal section.

5. When suppuration has set in, in an extra-uterine pregnancy presenting low down in the small pelvis, and the placental circulation has ceased, the vaginal operation may be considered in comparison with the abdominal operation.

6. The vaginal operation is strongly indicated in old suppurating fetal sacs, with disintegrated fetus presenting in the vagina.

Final Remarks.—The vaginal operation is condemned by a number of modern authors, among whom may be mentioned Werth, Olshausen, Lawson Tait, Thornton, and others. At the Gynecological Congress at Freiburg in June, 1889, Olshausen condemned the vaginal operation, as well as drainage into the vagina after laparotomy in such cases.

As an advocate of the vaginal operation Landau stands isolated. He stated that he had performed 13 vaginal operations and lost only 1 mother. As his cases have not been published in detail, this material is not available for consideration here, and can have no influence on the conclusions above stated.

BIBLIOGRAPHY

Bandl: Deutsche Chirurgie, 1886.

Hecker: P. 70.

T. Gaillard Thomas: Medical Record, 1882, vol. xxii, p. 740.

Ernest Herman: Obstetrical Transactions, 1887, vol. xxix, p. 429.

Campbell: Ueber die Schwangerschaft ausserhalb der Gebärmutter. Aus dem englischen übersetzt von Ecker, 1841.

Werth (Kiel): Beiträge zur Anatomie und zur operativen Behandlung der Extrauterin-schwangerschaft, 1887.

Werth and Veit: "Transactions of Gynecological Congress in Freiburg." Arch. f. Gynäk., 1889, vol. xxxv, p. 511.

Tuttle: Medical Record, 1887, vol. xxxv, p. 78.

Autoriello: Wien. klin. Wochenschr., 1889, p. 127.

Litzmann: "Zur Feststellung der Indication für die Gastrotomie bei Schwangerschaft ausserhalb der Gebärmutter," Arch. f. Gynäk., 1880, vol. xvi, p. 323.

Leopold Meyer: Gynäkologiske og Obstetristiske Meddelelser udgivne af Prof. F. Howitz, vol. vii; vol. viii.

C. Gosdon: "Case of Extra-uterine Fetation," Obstetrical Transactions, 1887, vol. xxix, p. 499.

Charles: Centralbl. f. Gynäk., 1887, vol. x, p. 165.

Bernays: "History of Two Cases of Extra-uterine Pregnancy," Annals of Gynecology, January, 1888, vol. i, p. 151.

SURGICAL CLINIC OF CHRISTIAN FENGER, M.D.*

BY T. A. DAVIS, M.D.

CASE I.—*Oxalate Calculus in Pelvis of Left Kidney*.—Patient male, thirty-four years old. Lived in Wisconsin for thirty-one years. He is next to the youngest in a family of ten, eight of whom are alive and healthy. Two died at an early age from typhoid fever. Father died at the age of seventy-two, cause not known. Mother died of heart disease at the age of fifty.

Previous Health.—During infancy was cross and irritable. When a child, had measles and typhoid fever. Since he has been able to remember he has suffered pain, at intervals, in the region of the left kidney, varying in intensity and duration. Sometimes he would be entirely free from pain for a period of three months, while at other times he would suffer daily; in other words, these attacks would come on at varying intervals of from one day to three months. The intensity of the pain also varied. At times he has been unable to walk from his place of business to his home, while at other times he has been able to drive a delivery wagon over car-tracks without bringing on the pain. Riding across street-car tracks during an attack of pain would aggravate it.

He was addicted to the use of liquor when suffering great pain, drinking at times as much as 20 glasses of whisky a day during an attack.

He would also resort to pressure with his hand, or, if lying down, would use some article about the size of a rolling-pin, and by either of these means could ameliorate his suffering.

He began medical treatment when ten years of age, and has been under treatment more or less since that time.

The diagnosis of "spinal neuralgia" was given to his disease some years ago by a physician, and each succeeding physician consulted concurred, and prescribed the usual analgesic medicines. The patient went under Dr. T. A. Davis' care, when his urine was submitted to careful microscopic examination. Out of 12 specimens, 2 revealed the presence of a few blood-corpuscles. The urine examined was voided always during an attack of pain, and with the specimens in which blood appeared there was a history of very violent attacks of pain. Not enough blood at any time was passed to discolor the urine nor to give rise to chemical or heat indication of albumin. Dr. Davis made the diagnosis of renal calculus.

Present Illness.—Pain in side occurs at irregular intervals, sometimes twice a day, but may be only once in two weeks or more. Attacks last from one to twenty-four hours. They are very severe, and are always in the left side and at the same point. He is often sick and vomits from the pain. The pain does not radiate. During the last six or seven years the attacks have been growing worse and more frequent. Now, heavy lifting will sometimes bring them on. Patient knows nothing about the condition of his urine previous to three months ago, when Dr. Davis found blood during an attack of pain. On

* College of Physicians and Surgeons, Chicago, January 3, 1893. Chicago Clin. Rev., 1893, vol. i, p. 376.

examination we find very slight tenderness on pressure in the left lumbar region, none at all on the right side. Patient is well nourished and has a good color. No swelling can be found by palpation in the region of the kidney.

The pain is the same at night as in the daytime. There is no disease of the back nor of any of the internal organs.

The trouble is probably in the left kidney. On palpation there is some pain. If we put one hand on abdomen, just below the ribs, and the other behind at the angle of the twelfth rib, we should feel, by pressure, the lower third of the kidney if it is enlarged. Here we cannot find the kidney.

The trouble is probably due to a stone in the pelvis of the left kidney or in its calices.

Remarks.—Nephrotomy—opening into the kidney for examination, etc.

Nephrolithotomy—the removing of a stone—should be performed when the kidney containing the stone is healthy.

Nephrectomy—the removing of the kidney—when there is much disease of the kidney, far-advanced, destructive pyelitis, etc.

Stone in the kidney may vary in size from that of a fine sand to a large stone, or several smaller ones. It is common to find several of the shape of the calices of the kidney. These are the phosphatic stones. In 50 per cent. of all cases there is more than one stone. These stones are of the same concretions as the stones which form in the bladder.

In acid urine: the urates, oxalates, and cystin.

In alkaline urine: the phosphates.

The urates and oxalates are found in the healthy kidney; the phosphates do not form until sepsis has occurred and the urine has become alkaline. We may have a stone of the oxalates and urates mixed, and this we expect to find in this case today. Infection comes from without by the use of a catheter, etc. If there are stones of urates or oxalates first and then infection takes place, they become covered with phosphates.

The oxalate stones in the kidney have the same fine, sharp points as those in the bladder, and thus give rise to much pain and blood in the urine.

The stone may be situated in the pelvis or in the cavities of the kidney, or in both. A stone that forms in the calyx is usually adherent to the wall of the calyx.

Stones are most common in the upper and lower parts of the kidney. When a stone partially or wholly stops up the opening of a calyx, the calyx dilates, but its opening does not. It keeps its original size. The left and right kidneys are affected in about the same ratio, and in men about as often as in women.

Calculi occur in both kidneys in about 15 per cent. of all cases, so the prognosis for surgical operation is good. In case of stone, the tissue of the kidney is normal so long as there is no sepsis and no obstruction. A stone in a calyx can obstruct only that calyx. A third of a kidney, bearing a stone, has been removed, and the remainder of the kidney left, with a good result, by Kümmell. If there is a large stone in the pelvis, there may be no obstruction, as the urine may run down at the sides of it.

Small stones in the pelvis, which are too large to pass the ureter, cause

obstruction, dilatation, and distention above them. During the passage of a stone through the ureter we have renal colic. A small stone may partly stop the flow of urine and produce some dilatation above the point of lodgment. If there is obstruction, the pelvis gets larger and the kidney tissue becomes thinner and thinner, and later there is usually infection, with its destructive inflammation.

Before infection the stone does not cause much trouble; there may be simple irritation and simple pyelonephritis, with thickening of the walls of the pelvis and sclerosis, resulting in strangulation of the glomeruli and uriniferous tubules, and a final transformation of the kidney into a mass of connective tissue.

If there is no obstruction, the stone may be surrounded by a capsule, and that may be all that is left of the kidney, and still no symptoms may have been noticed. Hydronephrosis very rarely exists as such for any length of time, as the kidney usually becomes infected. Infection outside of the kidney—perinephritis—often takes place. If there is no infection, there is simply a plastic inflammation; if septic, it is suppurative.

Symptoms of stone in the kidney are not at all characteristic, and so there are often errors in diagnosis. In one class of cases there are no symptoms; in another, very little pain; in another, the stone has been in a calyx and passes down into the pelvis suddenly and stops, causing severe pain; in another, there are much pain and hematuria recurring; and in still another recurrence of the pain is occasioned by jolting. In some cases the patients bend toward one side to ease the pain, and by so doing develop scoliosis. This is always lumbar.

Pain from a stone, tumor, or any renal trouble may radiate to the other kidney, the ureter, bladder, or testicle. The testicle may be sensitive to pressure and be drawn up. The urethra may be hyperesthetic.

We can never be certain of finding a stone, but in cases like this one we are justified in operating, on account of the increasing pain and the presence of blood in the urine.

The exploratory incision for diagnosis is not very dangerous—considerably less than 10 per cent.

Examination with a sound shows no stone in the bladder nor any obstruction in the urethra.

We will perform the lumbar operation. The incision will be made from the angle of the twelfth rib downward and forward to a point an inch above the crest of the ilium, and from here down to a point an inch above Poupart's ligament. How far down we shall go depends upon the amount of room required. When we come to the convex surface of the kidney we will loosen it up, and if it is high up, pull it down. Then feel all over the organ to find a hard place (a stone) or a limited soft place (a dilated calyx). If the stone is in the pelvis of the kidney it is easy to feel. Most operators open the kidney on the convex surface instead of through the pelvis, as wounds in the pelvis are said to heal badly. Again, it is easier to explore the whole of the kidney through an opening

in its convex surface. This is important, for we must be sure to remove all the stones.

Next to palpation, explore for the stone by passing a needle into different parts. Should a large stone be found, it may be necessary to divide it before removing. Large stones are phosphatic, and the acid urine in this case precludes the possibility of such.

Operation.—Incision was made as described. Kidney found somewhat enlarged. Palpation elicited neither hard nor soft regions in body of kidney. Something like a stone felt in pelvis. The aspirating needle was introduced twice into upper and middle portions of the kidney without coming in contact with any stone, and on aspiration fluid blood was withdrawn. A long plastic pin was introduced into lower third and a stone was found.

Paquelin's cautery was used to cut into the kidney, and still the hemorrhage was very profuse. A large, irregular, black stone, with sharp points, was removed with the forceps.

Remarks.—An oxalate stone which was located in the pelvis of kidney, with two points extending into the calices. These two calices of the kidney are much dilated, and but one stone is found. The oxalate of lime stones are rather common.

We now find, after removing the stone, even by cutting through the kidney with Paquelin's cautery, that the hemorrhage is very profuse, and that compression by means of gauze packed into the wound for a few moments does not stop it. By inspection we see that in the cortex proper the action of Paquelin has stopped the hemorrhage there, but deeper down among the pyramids we find many spurting vessels of considerable size. These are the arteriæ proprie renales, which lie between the bases of the pyramids and the cortical arches. Their calibers are so large and the arterial pressure is so great that coagula formed by means of the cautery are immediately swept away. We will apply an iodoform gauze tampon sufficiently deep to cover the whole surface of the wound, but not into the pelvis of the kidney, and allow it to remain for two or three days. The space surrounding the kidney, made by pressing away the adipose tissue capsule, will also be packed with iodoform gauze, which will be removed and a rubber drainage-tube inserted in two or three days, and at the same time the muscles will be sutured. A heavy antiseptic dressing will now be applied, and the patient will be kept on his right side to prevent much urine from passing out into the dressing: at the same time it will lessen blood-pressure in the left kidney and the wound, and put the patient in the most comfortable position.

Subsequent history uneventful. Patient suffered very little. Urine was slightly bloody for thirty-six hours. On the third day the gauze packing was removed, muscles and skin sutured, and rubber drains inserted.

January 16, 1893: Patient is up and about the house. Wound perfectly healed and urine normal.

Analysis of the stone, which weighed 7 grams, showed its composition to be of oxalates and urates.

CASE II.—Talipes Equinovarus.—This young lady, now twenty-four years old, has suffered from the deformity of her left foot as long as she can remember. She has used club-foot shoes with braces, off and on, for years, with the object of correcting the deformity, but, as you see, with little or no effect. When she walks on the foot the heel and sole of the foot do not touch the floor, but she rests on the outer border and nearest dorsal surface, about in the region of the base of the fifth metatarsal bone and anterior half of the cuboid bone. The concave plantar surface is turned inward and slightly upward and backward.

In comparing the left, deformed, with the right, normal, foot, we find the following differences:

1. The left foot is shorter than the right, but most so along the inner side. The measurements are as follows:

Inner side of left foot,	7½ inches.
“ “ right “	10½ “
Outer border of left foot,	7 “
“ “ right “	7½ “

2. On the inner border and the plantar surface we see a deep groove perpendicular to the long axis of the foot, nearly corresponding to the location of Chopart's joint. This groove is, according to the statement of Adams, pathognomonic of the congenital club-foot, in contradistinction to the acquired or paralytic form, where the groove does not exist.

3. The internal malleolus cannot be seen as a prominence. There is rather a depression in the place, where it can be felt, and it is, as you see, situated much more anteriorly as compared with the external malleolus than in the healthy foot.

4. The body of the talus and the external malleolus form this large convex prominence on the outer side of the dorsum of the foot. The covering skin is thick from the pressure against the ill-fitting club-foot shoe, but in more extreme cases this point may come in contact with the floor, when walking on it would cause the skin to become calloused. The deformed position of this club-foot is a combination of the following, namely: plantar flexion, adduction, and supination. We find not only an excess, especially of the adduction and supination, but also that the foot is retained in these positions, so that it is impossible to move it over into the corresponding opposite ones, namely, dorsal flexion, abduction, and pronation. Rotation of the foot in the position named causes, in the course of time, by growth of the foot, very important changes in the shape of the tarsal bones. The most important of these are the following:

1. Plantar flexion. The articular cartilage on the anterior third of the upper surface of the body of the talus, as it is not in use, disappears, and a surface of cartilage forms on the posterior surface, now articulating with the tibia. The posterior half of the body of the talus does not keep pace in growth with the anterior half, probably because it has to bear the constant pressure from the tibia; thus the talus in club-foot is flattened posteriorly.

2. Adduction, although normally not belonging to the upper talus joint, causes the body of the talus to depart from its normal position. Its sharp borders, from sliding against the articular surfaces of the tibia and the external malleolus, are rounded off, so that the joint, instead of being a hinge-joint, becomes more and more a sort of ball-and-socket joint. The result is loss of firmness in movements, even after the bones are brought back into a normal position.

3. Supination tends to change the form and position of Chopart's joint. It is not only the moving and change of direction of the articular surfaces, but also a change in shape of the tarsal bones in general, that result from the above-named false positions, and it is easy to understand that the more pronounced these changes are, as in old, neglected cases, the greater will be the difficulties in obtaining a good result from the correction of the deformity. The soft parts of the foot are changed correspondingly. There is shortening of the plantar fascia and plantar muscles to the hallux, as well as of the deep ligaments, especially along the inner, tibial border of the foot.

In answer to what causes the congenital club-foot, it has been proved by Bessel Hagen that the older theories of Eschricht and Huter are probably not longer tenable. It was thought that club-foot was an exaggeration and retention of the position of supination of the foot, said to be found normally in the fetus.

Bessel Hagen has pointed out that a fetus of 30 mm. has its foot ex-

tended; when 40 mm. long, slightly dorsal flexed; when 100 mm. long, the foot is in dorsal flexion at a right angle, but no position of supination is seen until late in the pregnancy. At this period, especially when the liquor amnii is not abundant and the fetus has little room for movement, the feet resting against the inside of the globular uterus will naturally be held in a position of supination. Club-foot has been found early in fetal life before the normal time of supination. On the other hand, club-foot is found commonly in children with spina bifida, cleft-palate, and allied congenital deformities; as for these, the cause is generally recognized to be amniotic adhesions. It is likely that similar disturbances in fetal developments cause club-foot.

Treatment.—A bloody operation is necessary only in neglected cases of club-foot in adults. Children rarely need operations, especially when early treatment—and the treatment can never be commenced too early—is resorted to.

It is only in exceptional and severe cases that operation is required until after the age of ten years.

Our patient, being an adult and having a rather severe and neglected club-foot, an operation is made necessary.

I shall not discuss the orthopedic treatment for the lighter forms and for infants, but point out the best plan when we have to choose between the different operations that come into question in such cases.

The operations I will name according to their increased gravity as follows:

1. Tenotomy, subcutaneous or open.
2. Open division of soft parts alone or of joints or bone—Phelps' operation.
3. Osteotomies of the scaphoid bone, or tibia and fibula above the ankle, or of the head of the talus.
4. Enucleation of the astragalus alone or together with other of the talus or of a wedge of the talus or a wedge of the tarsus, irrespective of bones and joints.

Of these operations, I always begin with the least severe and see how much effect is to be gained, first, by tenotomy, next by Phelps' operation, and finally, when correction is not yet obtained, I proceed to osteotomy or cuneiform resection in the part of the tarsus where I find the most resistance, irrespective of the bones and joints. In the majority of cases I have found that tenotomy and Phelps' operation carried into Chopart's joint was sufficient to effect the needed correction. However, you will remember the boy of twelve from last spring, where a cuneiform excision of the neck of the talus had to be added, giving the good functional result, shown here in the clinic six months later, now about six weeks ago.

The patient anesthetized and the foot disinfected, I shall first make tenotomy on the tendo Achillis. The tenotome is inserted flat on the tibial side of the tendon, close to and passing along its anterior surface; now I turn the edge and point toward the tendon and divide it while the foot is held in dorsal flexion, with my thumb as a guide to avoid cutting

through the covering skin. The divided ends of the tendon now separate about half an inch and we see that not sufficient dorsal flexion is obtained.

The reason for this is the following: In many old contractures it is not only the tendon that is shortened, but also its sheath and the surrounding tissues, especially the fascia. To divide these without injury to the nerves and vessels, I prefer the open method to the subsequent one; therefore, I now make a longitudinal incision over the tendon, have the borders of the wound held out by retractors, and divide the tense bands and strings of tissue as I see and feel them down to the upper talus joint and through the capsule if necessary.

By forcible dorsal flexion of the foot I am now able to bring it into a position exceeding a right angle, thus enabling the patient to rest the heel on the floor. The next step will now be Phelps' operation. I make an incision perpendicular to the tibial border of the foot, from before the malleolus internus down over the head of the talus into the sole of the foot. It divides the skin, fascia, tendon of the tibialis anticus, the adductor and flexor brevis of the hallux, and some of the flexor brevis communis down to the tarsus. I now try if forcible abduction and pronation will correct the position of the foot—even as forcible as to rupture opposing ligaments. As you see, I apply almost as much strength as I can. The position of the foot is not yet sufficiently corrected. I will, therefore, have to divide the inner border of the tarsus. The incision now enters Chopart's joint, and the tarsus gives way some more. Forcible correction again tried, brings the foot into the designed position. As you now see, the foot can be brought into and held without any pressure in pronation, abduction and dorsal flexion exceeding a right angle. This position is slightly overcorrected, that is, a position slightly in excess of the middle position between the former plantar flexion, supination, and adduction and this opposite one.

Any further operation on the tarsus is here not needed. We shall now disinfect the wound with 1 : 5000 bichlorid solution. The wound over the tendo Achillis is united by sutures.

The wound from Phelps operation is left open—as you see, there is a distance of $1\frac{1}{2}$ inches between the borders of the skin. It is covered with disinfected protective, and, filled with an aseptic coagulum, is left to heal under an antiseptic dressing. A rather voluminous dressing of iodoform gauze covers the foot, including the toes, and extends up to the knee. Outside of this comes a layer of borated cotton, over which a plaster-of-Paris cast is applied. The foot shall be held carefully in position until the plaster has begun to set.

The foot or leg shall be placed in the bed in an elevated position.

If we have procured asepsis in the operation, the wound will close in five or six weeks.

A careful orthopedic after-treatment, consisting of massage, electricity, and a well-fitting club-foot shoe, is required to obtain as good a functional result as the anatomic correction of the foot will permit. The operation is only a step in the treatment of club-foot.

CASE III.—Married woman; age twenty-one years. One year ago began to have pain in the lower part of right forearm, followed by swelling.

Present condition of swelling: Hard, tender, and situated along the radius. Lower half of radius is enlarged; movements of wrist and forearm and elbow not impeded, or but very little so; consequently the disease is limited to the bone and the joints are not affected. The swelling has gradually enlarged and has been painful since first noticed. There are no enlarged glands.

Remarks.—Diseases which may occur in medullary cavity:

1. Osteomyelitis—pyogenic or tuberculous.
2. Tumors—osteosarcoma most common.

3. Syphilis, which might cause, in the first place, periostitis, more rarely osteomyelitis.

Acute diffuse osteomyelitis begins suddenly with intense pain and high fever. The suppurating process rapidly progresses, extending through the cortical substance, periosteum, and into the subcutaneous tissue, where an abscess forms and soon opens spontaneously, leaving a suppurating track leading into the diseased bone.

In the subacute and chronic forms of osteomyelitis there are slight pain and temperature. They are often mistaken for rheumatism. Although the destruction of bone takes place and abscesses and sequestra form, the destructive process is often confined within the bone or is very slow to extend without the confines of the periosteum.

Syphilis, in the periosteal form, enlarges bone and there is no cavity, no pus, no sequestra.

Tuberculosis of the medullary cavity of long bones is as rare as it is frequent in the epiphyses, and there it is attended with pain and swelling of the joint, which are absent in this case.

Operation.—Incision is made through the soft tissues over the inner aspect of the swelling down to the resisting enlarged bone. We will next remove the hard cortical substance by means of a chisel. The gouge removes soft flexible masses of bone and sequestra, which speak against tuberculosis and for sarcoma. Another sequestrum is removed, having the characteristics of tuberculosis, surrounded by yellowish-white, cheesy matter, covered with a gelatinous mass. After more scooping out of coagulation necrosed tissue we come to a cavity filled with whitish, cheesy matter. This looks like tuberculosis, or endosteal or medullary syphilis, as osteomyelitis from pyogenic origin extends its destructive process to the thickened periosteum, and consequently the cavity would extend to that structure. It is impossible to make a positive diagnosis even at this stage of the proceeding; we will, therefore, refer some of this tissue to the microscopist, and in the mean time put the patient upon inunctions of mercury and the iodids and mercury internally.

I have now removed apparently all the diseased bone, and, after burning over the walls of the cavity with Paquelin's cautery, washing it with tincture of iodine and iodoform and ether, will treat the condition as that of a benign affection, by adopting the treatment which will result in the most rapid closure of the cavity and restoration of the function of the limb.

We will now fill the cavity with decalcified bone chips and then remove the Esmarch bandage and allow blood to complete the filling process. We will make some compression of the wound now with antiseptic gauze.

As we are out of rubber protective, we will close the wound by suture, and then apply a voluminous dressing and plaster cast, which will remain on for weeks if there should occur no indication for change of dressing. In the mean time all attention will be given to determine the proper diagnosis.

CASE IV.—*Tuberculosis of Deep Cervical Lymph-glands.*—Patient, woman; twenty-five years old. Has noticed a knotty feeling in cords of neck for three months. Has had no pain nor inconvenience from the disease as yet.

Examination.—Find many nodular swellings along the anterior border of the sternocleidomastoid, quite deeply seated, and also an extension of the group along the course of the cephalic vein. The deep lymph-glands are involved.

This patient has a nasopharyngitis, or a chronic nasopharyngeal catarrh, which, although not tuberculous, necessarily has made a tria for invasion for the bacilli of tubercu-

losis, which have passed down through the lymph-channels and lodged in the glands, in a short time to produce their destructive inflammation. This disease passes on from gland to gland through the lymph system, and is a local disease until it reaches the blood-current and is sent all over the body.

The average duration of life in these cases, where the local tuberculosis of the cervical lymph-glands is allowed to continue uninterfered with, is five years; hence the importance of early operation while the disease is still localized and a radical cure can be expected.

This patient will return in another week for operation. In the mean time thorough preparation will be made by shaving neck and applying wet antiseptic dressing for two days prior to operation.

CASE V.—George Baker, age, seven years. Recently recovered from typhoid fever. Temperature now, 99° F. Complains of pain in lower region of spine, over sacrum. There is tenderness on pressure, but no swelling.

Diagnosis.—Osteomyelitis of sacrum or lower lumbar vertebræ, following typhoid fever. Cause, pus-microbes and perhaps typhoid microbes.

Patient's father will not permit of an anesthetic being given, so we cannot proceed with an examination. No case. Discharged.

CASE VI.—*Congenital Inguinal Hernia.*—Child; age, ten months. The sac contains omentum and bowel.

Treatment.—1. Truss. 2. Operative.

The skin may be so sensitive or irritable that a truss cannot be used, in which case it is imperative to operate. Operation mortality about 1 per cent.—a little more than that in children on account of the difficulty in keeping the wound aseptic, on account of its close proximity to the natural orifice, the anus.

If competent nursing can be had, the mortality need be no greater in children than in adults.

No operation but the radical should be performed.

The operation for congenital hernia is more difficult than in the acquired on account of the sac, which, being continuous with the tunica vaginalis testis, requires great care in its dissection so as not to injure the cord. In this case the truss must first be tried, and if it fails, then have the radical operation.

REMARKS ON APPENDICITIS, WITH REPORTS OF CASES*

I SHALL not attempt to go through this vast subject in detail, as the literature during the last ten years has increased to an enormous extent, but I will limit myself to a sketch of the latest investigations on the subject and the controversial points brought up by the modern surgical treatment of the disease.

PATHOLOGY

Appendix.—Inflammation of the mucosa is in all probability most often caused by extension from a catarrhal inflammation of the cecum, because fecal concretions are found in less than one-half (39 per cent.—Ranvers) of the cases of perforation, and because foreign bodies and ulcers are only exceptionally seen. Thus we may say, with Iversen and Küm-mel, that the cause of the initial catarrh of the appendix is unknown. The swelling of the mucosa leads to stenosis at the narrowest point,—at Gerlach's valve,—and the products of hypersecretion are retained in the appendix. Septic material from the contents invades the wall either through intact epithelium, which is most common, or through a loss of substance by ulceration (Senn, Höhg).

Microscopic examination of the wall of the appendix reveals evidences of septic lymphangitis, swelling of the mucosa and the solitary glands, and filling of the paravascular spaces in the muscularis and subserosa by leukocytes (Senn, Iversen). In the subserosa diffused islands of leukocytes (Iversen) or miliary microscopic abscesses are seen, as in my Case XIII.

The lymphangitis and diffuse inflammation are more pronounced in the subperitoneal tissue than in the muscular coat; this explains why plastic peritonitis is an almost constant consequence, and accounts for the adhesions in which the appendix is afterward found buried.

This catarrhal inflammation may subside (Iversen), the opening into the appendix again become patent, and, after one or more attacks, permanent recovery with a normal appendix take place. A transparent veil of fine adhesions binding the appendix to its surroundings alone remains as an evidence of the appendicitis of years ago (my Case XV). More often, perhaps, a partial or total obliteration of the lumen of the appendix remains (Ranvers; my Cases III and XIII).

Virulent acute septic inflammation is often caused by fecal concretions. It takes the form of diffused phlegmonous inflammation, termina-

* Gynecological Society of Chicago, March 17, 1893. Amer. Jour. Obst., 1893, vol. xxviii, p. 116.

ting in gangrene or necrosis of usually a small portion of the wall, but rarely of the entire appendix up to the cecum, as in Case I. When the dead tissue is separated, we have a perforation corresponding in size to the necrotic territory. The fecal concretions remain in the appendix or fall out* into the peritoneal cavity, or the whole or a part of the appendix is separated and floating in the fecal peritonitic exudate.

A localized annular necrosis is seen in Fig. 72, Case XIV, close to the cecum, with mucosa and muscularis absent, and with a small perforation in the serosa leading into a small cavity communicating with the cecum.

Perforative inflammation of the appendix is common behind a stricture (Kümmel), and multiple small openings are often found in appendices removed because of chronic or intermittent appendicitis.

Perforation of the appendix almost always occurs in the more severe cases. In 87 cases reported by Weir 84 perforations were observed, and in only 3 cases was the wall intact. In the milder cases, which terminate in resolution, the wall is not perforated (Lange). In mild localized cases of intermittent appendicitis, however, perforation frequently exists. A small opening and a slow process of perforation do not necessarily lead to a serious attack.

Location of the Diseased Appendix.—It is important for diagnosis as well as for operation to know where the appendix is most often found. The interesting investigations of Bryant show that the appendix was found, in the 144 cases he tabulated, behind the cecum in 32 cases; on the medial side of the cecum in 34 cases; below and on the medial side of the cecum in 28 cases; below and down toward the pelvis minor in 21 cases; straight down in the iliac fossa in 5 cases; outward and on the outer side of the cecum, at different heights, in 2, 3, and 4 cases; and on the medial side of the cecum, high up toward the liver, in 1 case.

It will be seen that McBurney's point, about which there has been so much debate lately, corresponds very well with the location of the appendix, and consequently with the center of the disease, in 66, if not in 115, of the 144 cases reported. Consequently, although McBurney's point is not an absolute guide, it is, nevertheless, of value in the majority of cases.

The location of the perityphlitic abscess will, therefore, be, as Lange has pointed out, in one of the following places: (1) Around the cecum in the iliac fossa, above the outer half of Poupart's ligament, and upon the anterior wall of the abdomen; (2) on the mesial side of the cecum; (3) rarely in the small pelvis; (4) on the outer lateral side of the cecum, extending up into the lumbar or renal regions.

The inflammation may extend to the surroundings of the appendix in two directions: first, to the peritoneal cavity; and, second, to the retroperitoneal tissues.

(1) *Extension to the Peritoneal Cavity.*—Peritonitis, whether caused by a mere lymphangitis or by a perforation and fecal extravasation, may cease or become limited at any point from the immediate neighborhood

* See Fig. 64, Case II, p. 603.

of the diseased appendix to the entire peritoneal cavity. The causes for limitation, many of which are unknown, I shall pass by, with the exception of the anatomic conditions which influence the limitation of a spreading peritonitis, as pointed out by Mikulicz. He points out that certain natural barriers aid in the localization of the inflammation. The transverse colon and large omentum divide the abdomen into supra-omental and infra-omental spaces. The infra-omental space is again divided obliquely by the mesentery of the small intestine into supra-mesenteric and infra-mesenteric portions. The supra-omental space is divided by the liver into a subphrenic and an infrahepatic portion. All the barriers are located transversely and thus oppose extension in a vertical direction. The transverse colon and omentum protect the larger median part of the abdomen only. On the lateral sides of the ascending and descending colon there are no barriers to prevent extension in a vertical direction. The barriers are active in limiting extension from below upward only, while from above downward septic fluid will sink, by gravitation, unopposed, to the bottom of the small pelvis. These anatomic facts and points correspond as well to the clinical experience as to the extension of peritonitis from a focus anywhere in the peritoneal cavity.

(2) *Extension to the Retroperitoneal Tissue or Space.*—Körte has called attention to the extension of septic inflammation through the mesenteriolum of the appendix. Experiments upon the cadaver—namely, injection of a colored fluid through a cannula pushed from the lumen of the appendix into the mesenteriolum—showed that the fluid would penetrate into or between the two folds of the mesenteriolum, then into the retroperitoneal tissue in the iliac fossa, from there upward into the perirenal tissue, and finally up behind the liver. It is well known that abscesses are often located in these places, sometimes simultaneously in more than one, and not infrequently the only communication between the abscesses is through a narrow canal.

GENERAL COURSE AND PROGNOSIS OF APPENDICITIS

At the present day, when surgery, or rather surgeons, are on the verge of claiming appendicitis almost to the exclusion of the claims of internal medicine, it is important to remember that, on the whole, appendicitis is a benignant disease with a good prognosis, and that in the great majority of cases surgical interference is not called for. Taking it for granted that perityphlitis originates from the appendix in the great majority of cases,—Einhorn, from postmortem material of Bollinger's in Munich, found the appendix diseased in 91 per cent. and the cecum in only 9 per cent.,—we are practically justified in applying the clinical statistics in this respect to appendicitis.

The mortality in general of appendicitis is only about 5 per cent. Pepper stated that 20 cases to 1 are permanently cured without operation. Ranvers collected from the reports of the Prussian army 2000 cases, with 96 per cent. of cures without operation; and from four years'

service in the Charité Hospital in Berlin, 54 cases with 3 deaths, or 94.5 per cent. of cures. I. Vollert gives the statistics for seven and three-quarter years at Nothnagel's clinic in Vienna as 65 cases with 3 deaths, or 95.4 per cent. of cures; 34 were cured, 25 improved, 2 not cured, 1 was sent to the surgical clinic, and 3 died. Fürbringer reports a mortality of 10 per cent.

The condition of the appendix in cases in which one or more attacks of appendicitis have terminated in permanent cure has been investigated by Ranvers. He examined by autopsy 13 cases, and found in almost every case complete obliteration of the entire appendix. The appendix was buried in adhesions down to the cecum. The cecal serosa was thickened, adherent to the wall of the pelvis, but not to loops of intestine. In the obliterated appendix he found only once a small fecal concretion surrounded by a capsule of cicatricial tissue. Ranvers said that it was impossible to state whether or not perforation had existed in these cases, but that from the detailed pathologic conditions he regarded it as highly probable that perforation had taken place.

Lange attempts to explain the discrepancy between our home literature and these facts by stating that the surgeon sees only the severe cases; that the most severe cases of appendicitis are not treated in the hospitals, but die at home; and that severe cases of appendicitis are probably more common in America than in Europe, on account of the different mode of life, diet, etc.

The facts mentioned above seem to me to put an end to any absolute claim of surgery upon appendicitis.

CLINICAL FORMS OF APPENDICITIS

1. Diffuse peritonitis.
 - (a) Acute sepsis.
 - (b) Acute diffuse suppurative peritonitis.
 - (c) Subacute progressive peritonitis (Mikulicz).
2. Localized suppurative peritonitis—perityphlitic abscess.
3. Recurring chronic appendicitis and peri-appendicitis.
4. Adhesive appendicular peritonitis with localized non-suppurative peri-appendicitis—Keen's mild form.
5. Late consequences following appendicitis: chronic abscess, bands, adhesions, intestinal obstruction, pain.

I shall consider these forms in the order named, with the exception of adhesive non-suppurative appendicitis, which has no relation to surgery.

1. *Diffuse Peritonitis*.—I have operated in this form of appendicitis in the following eleven cases, only one of which recovered:

CASE I.—*Diffuse gangrene of appendix; commencing diffuse peritonitis; extirpation of appendix three days after symptoms of appendicitis had appeared, and twenty-nine hours after symptoms of diffuse peritonitis had set in; recovery.*

Mrs. H., thirty-five years of age. Previous health good. December 28, 1889, had a chill, followed by moderate fever. December 29th, fever. December 30th was up and around the house. December 31st was attacked with pain in the left iliac region and

vomited all night. January 1, 1890, acute pain over entire abdomen, which was later localized to the right iliac region. At noon, January 2d, the patient had a chill followed by collapse. At 7.30 P. M. her temperature was 104° F., pulse, 150. After consultation with Dr. Denslow Lewis, who kindly assisted at the operation, I extirpated the appendix in the following manner:

A lateral longitudinal incision was made. The small intestine was red and injected. The cecum could not be brought out of the wound. The appendix was surrounded by fetid, purulent, bloody fluid, was non-adherent, gangrenous, grayish, discolored to close to the cecum, and contained two fecal concretions. No perforation of the wall had taken place. The appendix was now ligated and extirpated. An attempt was made to cover the wound with the wall of the cecum and with the red, thickened mesenteriolum. This was partially successful. The abdominal cavity was washed out with sterilized water, gauze and glass drains introduced. The drains were taken out on the third day, and all the stitches removed on the eighth day. Convalescence was slow, but the patient finally recovered.

CASE II.—Localized gangrene of appendix; perforation; fecal stone; diffuse peritonitis; extirpation of appendix; death after twelve hours.

October 8, 1892, I was called in consultation with Drs. Johnson and Billings to see Mr. S. The patient, a lumber merchant forty-six years of age, had previously been healthy. On October 5th he went to Grand Rapids. While there he walked about a good deal and ate some grapes. On October 6th he returned to Chicago and was attacked by pain in the abdomen and vomiting. The next day Dr. Johnson was called to see the patient. Temperature, 102° F.; pulse, 96, strong. There were pain and tenderness localized in the right iliac fossa. The bowels had not moved for several days. Morphine and salines were given. On October 8th, at noon, he was attacked by sudden, acute pain in the lower part of the abdomen. Vomiting, clammy perspiration, collapse; pulse, 120.

Consultation at 4 P. M. The patient was in bed; pulse, 120, weak; temperature, 101° F. He complained of pain on coughing. The abdomen was tense, tympanitic, hard. The tympanites rendered the liver dulness uncertain. A dull area the size of the palm of the hand was found over the cecal region. The characteristic facies peritonitica was not present; the patient was not cold; the right leg could be moved without pain, and the abdomen was not very tender. At 6 o'clock the collapse was greater; pulse, 150; temperature, 100° F.; no pain; patient subjectively better.

Operation at 6.30 P. M. Lateral incision 6 to 7 inches in length. The abdominal walls were very thick on account of the corpulence of the patient. On opening the peritoneal cavity, a little thin, grayish, fecal fluid escaped. The omentum and intestine were congested. Exudate on borders of small intestine. The appendix was found deep down, and could with difficulty be brought into the wound. A fecal concretion was squeezed

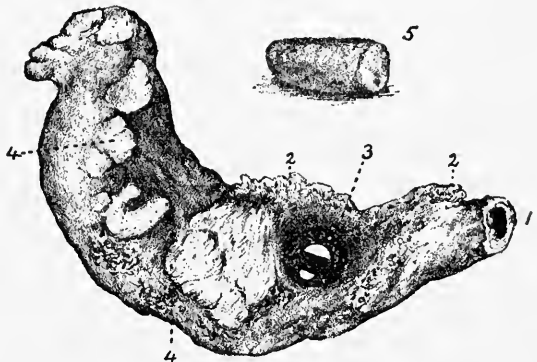


Fig. 64.—Case II. Appendix, 11 cm. long; 1, Cecal end; 2, 2, mesenteriolum appendicis; 3, perforation opening surrounded by area of gangrene, where wall of intestine is as thin as paper, dark brown, and discolored; in center are two openings from the perforation in the mesenteric attachment of the appendix out through both sides of the mesentery; 4, 4, swollen, red epiploic appendices along both sides of the appendix; 5, fecal concretion.

out of the appendix, whose mesenterium was thick and rigid. The appendix was ligated after tying the mesenterium, which could not be ligated in portions on account of the thickness of the abdominal walls and the impossibility of getting sufficient room for the procedure even after transverse division of the rectus muscle. The abdomen was flushed out with warm sterilized water, a gauze and three glass drains introduced, and the wound united. At the end of the operation the patient was pulseless.

At 11.30 the patient had no pain, felt well, and joked with his friends. Temperature, 101°; pulse, 130. An hour later the pulse was 136 and extremely weak. At 2 A. M. temperature 102° F.; pulse, 134. The pulse became weaker and could not be counted. Just before his death, at 6.30 A. M., he vomited a large quantity of black matter resembling coffee-grounds.

Autopsy showed diffuse plastic peritonitis. In the iliac fossa a teaspoonful of brown, gangrenous-looking fluid was found. (See Fig. 64.)

CASE III.—*Non-perforative appendicitis; two grape-seeds taken from appendix; old obliteration of distal half of appendix; extirpation of appendix; diffuse hemorrhagic peritonitis; death after thirty-six hours.*

Mrs. F. H. J., thirty-five years of age; father living; mother died from vesical cancer; married twelve years; never pregnant; has been under the care of an eminent gynecologist for dyspareunia and sterility. November 5, 1892, while patient was in New York, she ate grapes and swallowed the seeds. Two days later she had pain in the right iliac region external to the ascending colon. November 12th she had pain which was controlled by opium, which, however, caused nausea and vomiting. November 19th examination in consultation with Dr. Ryan, of Springfield, Ill. No tympanites; slight, hardly perceptible fullness over cecum; tenderness on deep pressure over cecum; no appetite; has obtained sleep and relief from pain only by the use of opiates for the past week. The bowels had been moved every day or two by Hunyadi

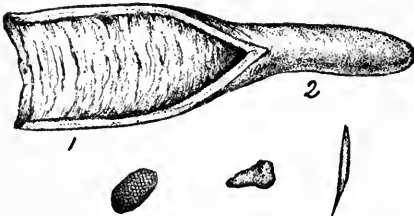


Fig. 65.—Case III. Appendix, 5 cm. long: 1, Cecal half dilated; contains fluid feces, two grape-seeds, one fecal concretion the size of a split-pea, and the husk of an oat. Mucosa not ulcerated, but swollen and reddish. 2, Distal half of appendix obliterated. Microscopic examination shows epithelium everywhere present. Mucosa thickened and shows a mass of embryonal cells and enlarged solitary follicles, with small empty spaces in the center, possibly representing miliary abscesses in these little lymph-glands. In muscularis paravascular infiltration with leukocytes, and in the subserous tissue in some places diffuse infiltration, in others paravascular infiltration, but much more extensive than in the muscularis.

water or Epsom salts, but she experienced neither relief nor increase of pain after bowels moved. There has never been any swelling in the region of the appendix, but only tenderness. For the past week the temperature has ranged from 99.5° to 100° F., the pulse from 90 to 120. Tympanites was first noticed on November 18th.

The patient did not have the facies peritonitica. Diffuse tympanites; liver and spleen pushed up. Increased abdominal tension. No tumor; no dullness. Greatest tenderness on pressure between anterior-superior iliac spine and umbilicus. Vaginal and rectal examination negative.

Operation November 19th, assisted by Drs. Ryan, Townsend, Dresser, and Bernauer. Lateral incision 5 inches long to the ligamentum Fallopii. The peritoneum was united to the skin. The omentum was red and velvety. The cecum on its under side was red, injected, velvety, not shining; no fibrinous, whitish exudate, but on lifting up omentum an ounce or two of thin, bloody, odorless fluid welled out. On lifting up the cecum more of this fluid gushed out. The ileum was also distended and red, the appendix buried in or adherent to loops of small intestine and the right Fallopian tube, which was normal. The adhesions were recent and were easily separated, upon which more of the thin red fluid

welled up. The appendix with the cecum was lifted out of the wound. Free fecal circulation in the cecal half of the appendix, in which air and fecal matter could be felt to move. The distal half of the appendix was obliterated. (See Fig. 65.)

The mesenteriolum was now ligated in portions and the appendix close to the cecum ligated en masse. After careful packing of the abdominal cavity with sponges the appendix was divided by scissors and the cecum emptied in order to diminish the enormous dilatation, which seemed to threaten rupture on manipulation. When the cecum was empty the stump of the appendix was ligated en masse, the mucous membrane removed, and the walls of the appendix stitched together. The cecum was folded in over the stump of the appendix by means of Lembert's sutures, but with great difficulty, because of the friability of the intestinal wall. The omentum could not be drawn down as a covering. The adjacent loops of the ileum were bathed in red fluid, but there was no yellow, fibrinous exudate. In the triangular space between a lower loop of the ileum, near the ileocecal valve, and two other loops of intestine parallel and in contact with it, there was a ridge of reddish, fibrinous exudate resembling that found in dry diffuse peritonitis, except that it was reddish and not white. This indicated a somewhat dry hemorrhagic peritonitis, with exudate around the appendix and on the lateral side of cecum and ascending colon.

The patient was now turned a little on the right side and the cavity flushed with warm sterilized water. The sponges were removed and the abdominal cavity cleansed with sponges on long forceps passed down into Douglas' fossa and up external to the ascending colon. The wound was then closed, gauze packing and a glass drain introduced, and dressings applied. The operation lasted one hour.

5 P. M.: Patient speaks rationally; not restless; pulse, 120; no pain; no facies peritonitica. 10 P. M.: Wound dressed; no fluid in tube; pulse, 120; temperature, 103.5° F. Patient died thirty-six hours after the operation.

CASE IV.—A boy, aged six; had acute appendicitis for three days. No distinct tumor could be made out. On the fourth day, as the symptoms were increasing, laparotomy was performed. Feculent pus was found around the cecum. The appendix was accessible. The wound was disinfected and drained. The patient died on the following day.

CASE V.—Man, thirty-five years of age; kindly referred to me by Dr. Potter, of Atlantic, Iowa. He was suffering from appendicitis and diffuse peritonitis. I made a lateral laparotomy in the second week of the disease, washed out abdomen with sterilized water, and drained. The patient died on the following day.

CASE VI.—*Acute perforative appendicitis; spreading purulent peritonitis; lateral laparotomy; death after twelve hours.*

Mrs. A., thirty-five years of age; was seen by me in consultation with Dr. Henrotin August 19, 1891. She had been suffering for four days with peritonitis accompanied by vomiting and pain in right side of abdomen. There was some tympanites, but no tumor. The following day I made a lateral laparotomy. The incision extended upward over the cecum from 1 inch above Poupart's ligament a distance of 4 inches, later increased to 6 inches along the right rectus muscle. Fetid pus was found along the outer side of the cecum and up as far as the liver. Upon separating the transverse colon from the lower surface of the liver another cavity, not connected with the first, was found, which contained 4 or 5 ounces of pus. The abdomen was flushed with sterilized water, gauze and glass drains introduced, and the wound closed and dressed in the usual manner. The patient died in less than twelve hours after the operation.

At the autopsy Dr. Henrotin found a perforation of the appendix and an accumulation of pus between the liver and the stomach, which had not been found at the time of the operation.

CASE VII.—*Limited appendicitis for two months; sudden onset of peritonitis ten days prior to operation; remission after two days; exacerbation three days later; large exudate apparently localized in right iliac and lumbar regions; oblique lateral laparotomy; counter-opening in lumbar region; appendix not removed; death after forty hours.*

Miss A. A., twenty years of age. Family history good. Patient had always been healthy until August, 1891, when she had an attack of pain and soreness in the right iliac region. Until October 15th, however, notwithstanding the pain, she attended to her ordinary duties. On that day she had a sudden increase in the pain, with vomiting, and was obliged to go to bed. She was better for a few days, then had another increase of pain, which extended from the right iliac fossa up along the outer side of the colon into the post-renal region.

I saw the patient, in consultation with Dr. Bradley, on October 24th. She was pale, did not have the characteristic facies peritonitica. Pulse, 108; temperature, 101° F. She had vomited once in the last twenty-four hours. There was a hard swelling over the cecum, extending from Poupart's ligament up along the iliac border 2 inches into the lumbar region, where, high up between the twelfth rib and the spinal column, there was a point very painful on pressure. The right lumbar region was larger than the left.

Operation October 25th. The patient was not collapsed. Pulse, 100, strong; temperature, 100° F. On the introduction of an aspirator needle into the lumbar region below the twelfth rib fetid fecal pus was found at a depth of less than 1 inch. A curvilinear incision, 3 inches long, was now made over the seat of the dullness and tumor, extending from 1 inch from the anterior-superior iliac spine upward and backward. Upon division of the abdominal muscles and separation of the peritoneum from the pelvic wall there was an escape of about half a pint of fetid fecal pus and a large slough of loose, dead, gangrenous tissue from a large cavity which extended up along the colon. The appendix could neither be seen nor felt. A counteropening was made on the point of a dressing forceps, in the postrenal region close to the twelfth rib, and a large drainage-tube passed through. The patient died forty hours after the operation. No autopsy could be obtained.

CASE VIII.—Woman, thirty-five years of age; had an abscess, apparently localized, exterior to cecum, with high fever and vomiting. At the request of Dr. Schirmer, of this city, I operated, making a curvilinear incision. The distended cecum was emptied by incision and the abscess cavity drained. The patient died in twenty-four hours.

CASE IX.—Man, forty-five years of age; was seen by me in consultation with Dr. Gudden, of Oshkosh. He had been ill two weeks and had apparently a localized accumulation. The symptoms increased slowly, and so a curvilinear lumbar incision was made, through which feculent pus was evacuated. The cavity was irrigated and drained. From the time of operation symptoms of general peritonitis became more pronounced, and the patient died in about twenty-four hours.

CASE X.—Man, about sixty years of age, a patient of Dr. Bluthardt, of Chicago. I operated, in the second week of the disease, for a localized swelling in left iliac region. Upon incision over the tumor a large cavity was opened, which extended over into the right iliac region near the cecum, where a counteropening was made and the cavity washed out and drained. The patient died.

CASE XI.—*Perforating appendicitis; gradual onset of symptoms of appendicitis; operation on sixth day; diffuse dry peritonitis; no fecal extravasation; extirpation of appendix; death after three days.*

Miss M. E. R., forty years of age. Previously healthy excepting constipation. Menstruation always regular. March 21, 1893, she was in Joliet and drove home, a drive of two hours; she felt tired, but was otherwise well. The next day she had a headache in the

morning, but was not confined to bed. In the afternoon she had pain in the right iliac region; she took an enema, the passage from which was attended by considerable pain. March 23d the pain still continued, and she was obliged to lie down a portion of the day. Next day Dr. Brennon was called in. The patient's temperature was 101° F.; pulse, 100; no tympanites, no vomiting, but she felt nauseated, and there was tenderness on pressure in the right iliac region. March 25th she was in the same condition, but had some tympanites in the right iliac fossa. Enema was twice administered with no effect. The pain was continuous, but not so severe as the initial paroxysm. No vomiting, but regurgitation and spitting. Temperature, 101° F.; pulse, 100.

March 26th patient began to vomit in the afternoon, and the tympanites increased. She had two enemata, attended by no pain, but considerable pain whenever she was not under the influence of morphin. No flatus passed except during or after enemata. March 27th vomiting of bilious matter, increased to once every two hours. Temperature, 98.6° F.; pulse, 120; increased tympanites. Two enemata were given. The patient slept for an hour at a time. She had pain when she moved in bed. March 28th she had vomited at 2 and 9 A. M., just after an enema. I saw the patient at 3 P. M. On examination I found her thin; no facies peritonitica; mouth dry from morphin; tongue coated; temperature, 100.2° F.; pulse, 120. She vomited all she took; complained of no pain when under the influence of morphin. Urine normal. The abdomen was moderately tympanitic; only slight tenderness on pressure, as I could press my fingers down 2 inches without causing much pain. No area of dullness could be found, no swelling nor tumor, and only a slight elastic resistance in right iliac region. Vaginal and rectal examination negative. Patient stated that she felt less uncomfortable, but weaker, than on the previous day. She had never had a similar attack of sickness. Diagnosis, appendicitis, with spreading peritonitis or intestinal obstruction located in right inguinal region.



Fig. 66.—Case XI.

Operation March 28, 1893. A median incision was made 3 inches below the umbilicus. The peritoneum was very slightly injected. A dry, fibrinous exudate was found on the intertangential lines of the loops of small intestine, which were moderately dilated. The peritoneum was now united to the skin. Not a drop of liquid exudate could be found upon the intestines or in Douglas' fossa. No odor was perceptible. Diagnosis, diffuse dry peritonitis. The appendix could not be found until the wound had been extended up to the umbilicus; it could then be felt against, and slightly adherent to, the posterior outer wall of the cecum. The adhesions were easily broken up and the cecum and appendix brought into view. A large perforation opening was found in the middle of the dorsum of the appendix. (See Fig. 66.) A transverse incision was now made perpendicular to the first incision, in the direction of the right anterior-superior iliac spine.

No liquid exudate could be found around the cecum and appendix nor in the right iliac fossa. Upon loosening the appendix there was slight hemorrhage, but the fluid was odorless. The mesenteriolum was now ligated in three portions; this procedure was rendered difficult by the immobility of the cecum. The appendix was ligated and removed. By careful handling there was no escape of fecal matter or of the contents of the appendix. The appendix was found to contain no stone, but only a little fecal matter. The stump was now cauterized with 95 per cent. carbolic acid, and a glass drain and gauze packing applied around the cecum and appendix. The longitudinal wound was united with sutures, but the outer half of the transverse incision was left open. The usual dressings were applied. Two days later the patient was in good spirits; wound dressed; very little fluid in drainage-tube; no odor; wound looked well. She died the next day.

Remarks.—Among these cases we find all the forms represented, from

diffuse peritoneal sepsis down to the more chronic forms. We follow Mikulicz's classification into the following three forms:

(a) Acute sepsis with no exudate, and only slight injection of the peritoneum, which is glistening and apparently normal.

(b) Less acute septic peritonitis with dry, fibrinous exudate, but no fluid in the peritoneal cavity.

(c) Diffuse peritonitis with liquid exudate, bloody or seropurulent; odorless when perforation of the appendix has not occurred, fetid or feculent when perforation has taken place.

It is evident that surgery is powerless against the dry forms of peritonitis; it is only in those rare cases in which there is a liquid exudate to remove or wash out that surgery can be of use. The majority of these cases occur where fecal concretions cause a large perforation with fecal extravasation; but in a small number of cases, those of septic lymphangitis in a non-perforated appendix, a diffuse peritonitis results, in which operation is of no avail (as in Case III).

The mortality following operation for this form of the disease is uniformly high. Mikulicz reports 11 cases with 2 recoveries, and Sonnenburg 9 cases with no recoveries. Of the 11 cases reported by me, only 1 recovered.

As to the time for operating, almost all operators agree that the earliest possible time should be chosen; but, as Lange remarks, "we cannot make the diagnosis early enough to save life by laparotomy, that is, by removal of the appendix. It would seem to require a toxic antidote not yet discovered rather than laparotomy to effect a cure."

It is just as impossible to designate a certain period from the inception of the disease—as, for instance, one to three days—in which operation should of necessity be done, because a number of the fatal cases commence slowly and the symptoms increase gradually. Such symptoms as pulse and temperature furnish an entirely inadequate guide.

As far as I have observed, more importance should be attached to other symptoms, such as vomiting, tympanites, and a steady increase of the symptoms of peritonitis in the period in which, in benignant cases, we would expect a standstill or a decrease in symptoms.

In some cases the surgeon declines to operate. Körte did this in 3 cases in which he considered the patient unable to endure the operation.

Lange also advises against operating in the first violent onset of the disease, when the patient is depressed from the sudden septic intoxication, but prefers to wait until he has had time to recuperate somewhat—perhaps on the fifth or sixth day—and then operate. Lange believes that by this method he has saved some patients.

As the acute sepsis and diffuse peritonitis not infrequently occur secondarily, in cases which begin with mild symptoms, as a result of perforation of the appendix or rupture of an abscess into the general peritoneal cavity, and as it is impossible in any given case to foresee this event, I usually give the advice to have all preparations made for laparotomy at short notice. Whenever it is possible I have the patient taken

to the hospital for this purpose. The fact that the majority of patients recover without operation is immaterial in this connection.

The operation itself has for its object the removal of the appendix, if possible, and the evacuation of the exudate. Disinfection can hardly be thought of in the peritoneal cavity.

For the removal of the appendix the lateral incision over the cecum is preferable; for removal of exudate, median incision, or both combined, is the method of choice. In rare instances we meet with the form of peritonitis described by Mikulicz under the name of "spreading fibrino-purulent peritonitis," which has so slow a course as to permit of successive incision into separate collections of exudate. In one case he made five incisions in one month and saved his patient. Careful watching of the local symptoms of spreading peritonitis, and cautious evacuation of the collection without disturbing surrounding fresh adhesions, are deemed by Mikulicz essential to success.

2. *Localized Purulent Appendicitis—Perityphlitic Abscess.*—This form is characterized by its localization and by plastic peritonitis around a smaller or larger area surrounding the appendix. I am unable to enumerate cases of this class, as notes have been taken of special cases only. I meet with 4 or 5 cases a year on the average, and they all terminate in recovery. As the free peritoneal cavity is not opened, the operation is nothing more than an oncotomy, or opening of an abscess.

The circumscribed collection of exudate—the perityphlitic abscess—is difficult to characterize as a separate class of cases, because the limiting wall is at first simply a fibrinous exudate, which later on is gradually transformed into connective tissue. The barrier between the septic focus and the free peritoneal cavity is consequently extremely variable as to firmness and resistance. Furthermore, we are unable, even when we have the exudate before our eyes, to distinguish between a benignant, limiting fibrinous exudate and the dry, fibrinous exudate of diffuse dry peritonitis. Furthermore, we meet with a combination of a liquid exudate around the appendix and fibrinous exudate further off; and in such cases it is impossible to see during the operation whether or not limitation has taken place—in other words, it is impossible to say where the perityphlitic abscess terminates or the diffuse peritonitis commences. The symptoms and the time from the onset of the disease are not reliable as guides in this direction.

On account of these reasons the diversity of opinion about early and late operating, and about the method of operating, has arisen—that is, whether the abscess shall be evacuated by carefully avoiding the disturbance of the adhesions, or whether the diseased appendix shall be removed irrespective of opening into the free peritoneal cavity.

The typical well-defined and well-protected perityphlitic abscess leaves little doubt in this direction. It will be opened where it is most easily accessible. Its location can be reasonably well understood from the anatomic considerations above alluded to. The great majority of perityphlitic abscesses are reached by a curvilinear incision over the

cecum, more or less close to the ilium and Poupart's ligament. A smaller number are reached by a lumbar incision.

When the abscess is situated in the small pelvis and is accessible through the rectum, aspiration or puncture and drainage may be tried from this point. A boy, ten years of age, a patient of Dr. Lewis, of Dubuque, Iowa, presented in the second week of appendicitis a perirectal abscess. By means of an aspirator more than half a pint of feculent pus was removed, and the patient made a speedy and lasting recovery.

Lange reports 5 cases in which he opened and drained abscesses through the rectum. In 2 of these cases this procedure was sufficient, but in the other 3 rectal incision was combined with incision in the usual place.

In rare cases we find the abscesses most easily accessible in the umbilical region. In one case, a boy of sixteen, a patient of Dr. Schirmer, of this city, I made the incision in the umbilical region, where, in a localized swelling, pus was found by Dr. Schirmer by means of the hypodermic needle. Incision and drainage led to permanent recovery.

The abscess was opened in my Case X by an incision in the left iliac region.

When a tumor or swelling is felt in the region of the cecum, the question arises whether or not pus is present, or whether the tumor is due to non-liquid exudate. To determine this by a probatory aspiration is a very much disputed point. Surgeons, as a rule, condemn the proceeding as of little value and dangerous. Physicians, on the other hand, from their experience in alleviating tympanites, consider aspiration with a fine needle as not at all dangerous. The minute wound through the intestine does not permit the exit of even liquid feces. Ranvers goes so far as to believe that aspiration of part of the pus, even as little as 5 gm., is likely to promote absorption of the remainder.

Incision and drainage of perityphlitic abscesses in 119 cases collected by Noyes up to 1882 gave a mortality of 16 per cent. The modern method of operating, inaugurated by Willard Parker,—namely, early operation in appendicitis,—has led to the now much-debated question of the advisability of early operation. The question of when to operate is also very important and very much debated. The good results from the so-called early operation have brought this question prominently to the front. The mortality from the early operation is not great. Weir had a death in 35 operations; McBurney 1 in 24; Sonnenburg none in 34, in what he calls simple cases; Murphy 2 in 12; Bull 2 in 17; Kraft and Dealna have each 8 operations with no deaths.

Prognosis of the Early Operation.—Here come the questions: What is early operating? and When should the operation be done? There is little or no dissent to the advice not to operate at the first acute onset of symptoms, but to wait until these symptoms subside—usually on the second day or a few days later (Vollert). Ranvers advises that the operation be made if the tumor increases slowly in the first eight days, with or without fever. Treves will not operate until after the fifth or sixth

day, or even later. Morton gives the advice not to operate later than the third day if no improvement has taken place since the acute onset of the disease, and says that no surgeon will regret having operated early. Lange holds that, in the majority of cases, we can incise the abscess at the end of the first or the beginning of the second week without danger, and Thomas Bryan states that in the majority of cases it is the wisest course to delay operation.

Appendicitis is so atypical in its course and presents so infinite a variety of clinical features that a certain time in hours or days cannot be a guide to determine operation (Lange). Joseph Price justly remarks that early operation is not measured by the duration of the disease, but by the time of the duration of severe symptoms.

In the early operation for an as yet localized appendicitis the important question now arises whether the pus should be evacuated by an extraperitoneal incision or by opening through the free peritoneal cavity. The extraperitoneal incision is without doubt preferable, and the oblique incision close to the ilium will, in the majority of cases, permit the evacuation without entering the free peritoneal cavity.

Edebohls, after incision through the abdominal wall, entered the free peritoneal cavity, and, finding the abscess more laterally situated, he closed the abdominal wound and incised the abscess inside of the protecting adhesions. Lange, on entering the free peritoneal cavity, found the abscess covered with omentum. He stitched this to the abdominal wall and then opened the abscess through the omentum. Sonnenburg invented his operation in two sections for the same purpose of avoiding evacuation through the free peritoneal cavity.

On the other hand, the cases are steadily accumulating in which collections of pus are opened and drained successfully through the free peritoneal cavity. It seems probable that free incision and packing with iodoform gauze—the Mikulicz drain—have decreased the danger from infection very materially.

The next important consideration is, What shall be done with the appendix? Shall it be removed under all circumstances, or shall it be left when not easily accessible? While in acute suppurative peritonitis the appendix is the main source of infection to be feared, and is, therefore, almost always removed, the case is different in the localized collections in the abscesses where the evacuation of the pus is the main object.

The fear of relapse from a diseased appendix left *in situ* is small, as relapses are not, on the whole, common. On this account, in a typical case of abscess, no attention is paid to the appendix.

The cases subjected to early operation, however, occupy the middle ground between the typical abscesses and the acute cases, and therefore in early operating the removal of the appendix is growing more and more in favor. Furthermore, the earlier the operation is done, the easier it is to remove the appendix, unless adhesions from former attacks are present.

Sonnenburg advises almost always to extirpate the appendix, even if the peritoneal cavity has to be opened for this purpose. He leaves the appendix only in exceptional cases, where it is so firmly buried in

old adhesions that its removal would cause an undue prolongation of the operation and materially increase the danger of shock. Morton holds that the appendix should be left only in a small, constantly decreasing number of cases, and for the same reasons as Sonnenburg gave. The majority of more conservative surgeons lay less stress on the removal of the appendix, and limit the cases of removal to those in which the appendix readily presents in the wound and can be easily removed.

The appendix, when found, is treated in the following manner: Although Treves has freed the appendix from its adhesions and left it *in situ*, and although Lawson Tait has opened and drained the appendix, its removal is nowadays universally practised. When buried in adhesions it is loosened by the finger, its mesenteriolum ligated in sections, and the freed appendix is then ligated and cut off close to the cecum. The stump of the appendix is disinfected, and, if possible, inverted or pushed in between two folds of the cecal wall, and retained in this position by uniting the folds over it by means of seromuscular sutures. If a portion of the mesenteriolum is available, it is sutured to the cecum over the stump of the appendix. Suturing is often difficult because of the friability of the inflamed peritoneum, on account of which the sutures are liable to tear through and not hold.

Fecal fistula from the ligature cutting through the appendix is very rare, but occasionally this suture will keep a fistula open for months. To avoid this mischance Morton advises that the ends of the ligature be left long enough to hang out of the wound, so that the ligature may be pulled out when it has cut through the appendix. In some cases the appendix has sloughed off close to the cecum, leaving an opening into the latter, which should be closed by Czerny-Lembert sutures.

The removal of the appendix can be effected most easily through a lateral straight or oblique incision over the middle of the cecum. It is difficult and almost impossible to gain access to the appendix from the curvilinear incision close to the ilium. The nearer the incision is to the ilium, the less liable, says Bryant, is it to be followed by hernia.

It is advisable, in operating for perityphlitis, to arrange beforehand whether the appendix is to be extirpated or the abscess to be evacuated. If the appendix is to be extirpated, make a lateral laparotomy incision, go through the free peritoneal cavity down on the cecum to the appendix. First open and clean out the abscess cavity. If the aim be to evacuate the abscess, make an incision over it wherever found, with a view to the avoidance of the free peritoneal cavity, and make no attempt to find the appendix. In the majority of late operations I consider this the operation of choice.

3. *Relapsing or Intermittent Appendicitis.*

CASE XII.—*Chronic appendicitis with exacerbations; four attacks in eight months; pain in the intervals; extirpation of non-perforated appendix; small chronic abscess around apex of appendix on external surface of cecum; recovery.*

E. L. H., age seven, Family history good. She had whooping-cough at the age of two and scarlet fever when five and one-half years old, but recovered perfectly. From birth she had trouble with her stomach, occasional loss of appetite, vomiting, and evening

headache. These attacks followed hard play, and usually lasted for a day or two. The bowels were always regular. In October, 1889, she fell off a tricycle and was in bed for two days. Headache was the principal symptom. In January, 1890, she had another "bilious" attack, with vomiting and fever.

Present illness dates from June, 1890, when she had another so-called bilious attack, but this was accompanied by pain in the ileocecal region and tenderness. The attack lasted three days, and was so slight that a physician was not called. Three months later she had a similar attack, with vomiting and violent ileocecal pain. In less than twenty-four hours tympanites set in; temperature, 103.5° F. A diagnosis of acute typhlitis was made, and the patient kept in bed under the influence of morphin for three weeks. She was then allowed to get up, but walking caused vomiting and headache. She remained in bed or on a couch until January 5, 1891. January 6th she had a sudden collapse, from which she recovered in two hours, but continued to run down. In February she had

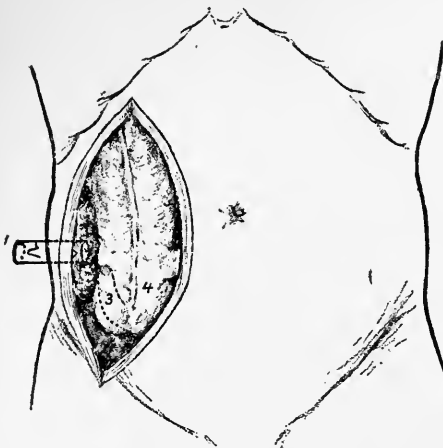


Fig. 67.

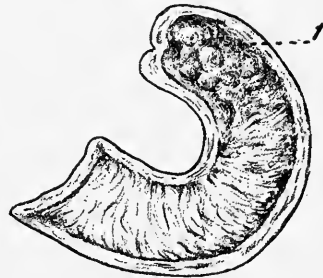


Fig. 68.

Fig. 67.—Case XII. 1, Drainage-tube; 2, pericecal abscess; 3, appendix; 4, cecum.

Fig. 68.—Appendix, 33 mm. long, 10 mm. in diameter. Not enlarged; contained no fecal matter, but a little mucus. Mucous membrane apparently thickened, but otherwise normal, except at point 1, near the end of the appendix, where the mucosa was irregularly nodulated and red, looking like tuberculous infiltration, but no perforation, and outer wall of appendix looks normal. Microscopic examination: Section through nodulated mucosa at 1 shows epithelium and tubular glands normal, solitary follicles enlarged; in the submucosa, muscular and subperitoneal tissues, small-celled, paravascular infiltration. Section through middle of appendix shows similar condition, but more pronounced, and in addition irregular spaces in the center of the solitary follicles—possibly miliary abscesses.

another collapse, which lasted three hours. At this time the physician in charge thought he detected a tumor. Since August, 1890, the child has never been free from pain in the ileocecal region. The bowels have been constipated during the entire time, but her appetite has always been good. In January and February, 1891, she passed a great deal of mucus from the bowel, but never passed pus or blood.

She was brought to me in March, 1891. At this time she was emaciated, pale, had tenderness in ileocecal region; urine, lungs, and heart normal.

Operation March 15, 1891. A perpendicular incision 6 inches long was made on the right side over the cecum, and the peritoneum united to the skin. The cecum was bound down so that it could not be lifted out of the wound. The appendix could not be seen, and the cecum was covered with apparently smooth peritoneum. By pushing the anterior against the posterior wall of the cecum a hard mass 1½ inches long could be felt on the outer side of and behind the cecum. The parietal peritoneum was divided in order to avoid tearing into the cecum. Upon dissecting down toward the indurated territory a small

abscess the size of a hazelnut was opened, and half an ounce of yellow, odorless pus escaped. The abscess wall was scraped, and a ring-shaped body, the appendix, could then be felt fixed to the posterior wall of the cecum by short, old connective-tissue adhesions. By careful dissection I succeeded in separating the appendix from the wall of the cecum without opening into the latter. The appendix was then ligated and cut off. The stump of the appendix was buried by pushing it in toward the lumen of the cecum and joining the peritoneum of the cecal wall over it with buried sutures.

The peritoneal cavity was cleansed with sponges and the cecum covered with a corner of omentum, fixing it around the cecum by silk sutures in order to guard against diffuse peritonitis in case the appendix should reopen. A rubber drain and a strip of iodoform gauze were passed down through the wound and brought out through a counteropening in the lumbar region near the place of the abscess. (See Fig. 67.)

The wound was closed by separate suturing of the peritoneum, abdominal muscles, fascia between muscles and skin, in order to avoid ventral hernia. Strips of iodoform gauze were passed through the lower corner of wound. The gauze strips were removed on the third day. Recovery. The appendix lay with its apex, which was curved like a worm, in the abscess cavity; the remainder was buried in adhesions, lay close to the wall of the cecum, and required very careful dissection for its removal.

The appendix was $1\frac{1}{4}$ inches long and $\frac{1}{3}$ inch in diameter. It was not enlarged, and contained no fecal concretion nor body, but only a little non-fecal mucus. The mucous membrane was somewhat thickened, but was otherwise normal, excepting near the apex, where it was irregularly nodulated, red, and inflamed, resembling a tuberculous infiltration or ulcerated surface. There was no perforation, and the outer wall of the appendix was normal in appearance. (See Fig. 68.)

Microscopic Examination.—A section made through the nodulated mucosa at the apex showed that the epithelium and glands were normal. The solitary follicles were enlarged, and in the submucous, muscular, and subperitoneal tissues there was small-celled, perivascular infiltration—chronic lymphangitis.

Section through the appendix at its middle showed the same condition more pronounced, and, in addition, irregular spaces in the center of the lymph-glands, solitary follicles—probably miliary abscesses.

CASE XIII.—*Chronic appendicitis for eighteen months; constant pain, with slight exacerbations and palpable swelling when constipated; removal of perforated appendix, which communicated with cecum through a small abscess cavity; partial resection of wall of cecum; recovery.*

P. L. G., forty-four years of age, married; was kindly referred to me by Dr. Winterbotham. Personal and family history good. In April, 1890, he first suffered from pain in the right inguinal region, with fever; no swelling; constipation. He was in bed a week, and since that time he has always complained of pain, more severe when he is constipated. At such times a tumor often appears in the right inguinal region, which disappears when the bowels move.

September 26, 1891, examination. The patient was pale, but looked healthy. In the right inguinal region, below the middle point of a line drawn from the umbilicus to the anterior superior iliac spine, was a tender, somewhat movable tumor, 2 or 3 inches long and $\frac{1}{2}$ inch in diameter.

Operation September 28th. A longitudinal incision, 10 cm. in length, was made along the outer border of the rectus muscle over McBurney's point. The muscular band on the cecum could then be seen, and the tumor felt through the parietal peritoneum. The peritoneum was opened and united with the wound in the skin. At the lower inner end of the cecum was a hard, nodular mass which was adherent to the ileum and cecum and was covered with a mass of omentum. This was ligated in two portions and divided, and, after separation, the hard mass was found to be convolutions of the appendix. The

apex of the appendix was not dilated, but was considerably thickened for $\frac{3}{4}$ inch. The middle portion was dilated and ampulliform. The short, firm adhesions to the ileum were loosened and cut with scissors slowly and with difficulty, leaving an area of the ileum 1 inch

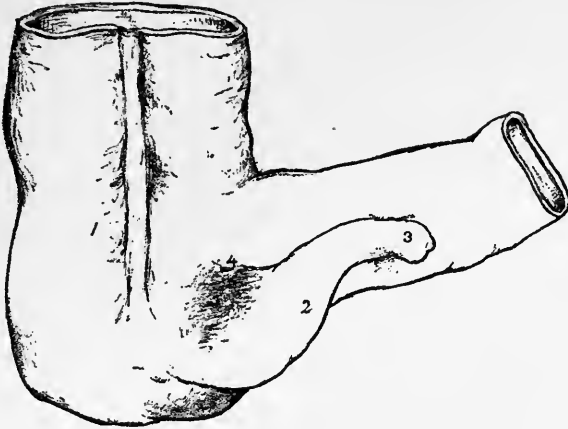


Fig. 69.—Case XIII. 1, Cecum; 2, appendix; 3, its apex adherent to cicatrix in wall of ileum; 4, wall of small abscess cavity between the dilated portion of the appendix and the perforation opening into the cecum.

in diameter denuded of its serous coat. In the center of this area was a hard nodule, probably a closed perforation opening into the ileum. (See Figs. 69 and 70.)

Isolation of the ampulliform portion of the appendix was next to impossible. During the attempts at separation some pus escaped. The ileum was washed with sterilized water and all the pus squeezed out from the appendix. Continued attempts at isolation of the appendix revealed a small cavity from which pus escaped, opening into the cecum and appendix, and located immediately above the cecal end of the latter.

The appendix was now amputated $\frac{1}{2}$ cm. from the cecum; its lumen was patent, but no fecal matter escaped on pressure of cecum. At the point of perforation in the cecum was a thickened mass the size of a hazelnut, which made me believe that a tuberculous ulcer, with thickening of the wall of the cecum, surrounded the opening. I therefore resected this indurated place in the cecal wall. A small amount of mucus and fecal matter escaped, and dark-red folds of mucous membrane protruded.

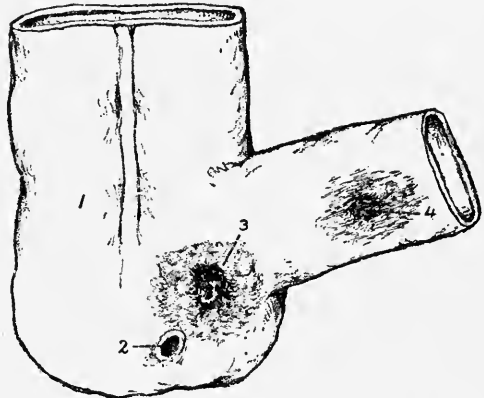


Fig. 70.—Case XIII. 1, Cecum; 2, stump of the appendix; 3, perforation opening from abscess cavity into the cecum; 4, cicatrix on the ileum, probably a closed perforation opening.

On the introduction of a finger into the cecum it was found that no ulcer existed, but red, injected, swollen folds of mucous membrane surrounded the opening between the appendix and the cecum. A piece of the cecal wall, $\frac{3}{4}$ inch in diameter, was removed. The wound in the cecum was united with a triple row of sutures: first, mucous sutures; second, Lembert's seromuscular sutures; and third, serous sutures to bury the Lembert sutures. It

would have been impossible to unite the opening in the cecum without resection of the indurated portion of the wall. At the place at which the ileum was adherent to the appendix there was a thickened band, showing a red cicatrix in the center, but no perforation, although no serous surface was left. It was thought inadvisable to invert this territory by means of Lembert sutures, as the patency of the gut would have been endangered, and it was, therefore, covered with an omental flap (Senn). The omentum was also drawn over the wound in the cecum and fixed in position in both these places with fine silk sutures.

The territory was flooded with sterilized water several times during the operation, which occupied about two hours. The intestine was now repositied, the toilet of the peritoneum made, iodoform gauze and glass drains introduced, the wound closed, and the usual dressings applied.

At close of the operation the patient was not collapsed; pulse 90, strong.

The stitches were removed after two weeks, the glass drain removed on the eighth day, and the gauze taken out little by little at each dressing until in five weeks all had been removed. The patient had no pain.

The appendix was $2\frac{1}{2}$ inches long; the apex had thickened walls and narrow lumen for 1 inch—that is, the portion which was adherent to the ileum; the proximal portion, $1\frac{1}{2}$ inches in length, was dilated, and the wall two or three times as thick as that of a normal appendix. (See Fig. 71.)

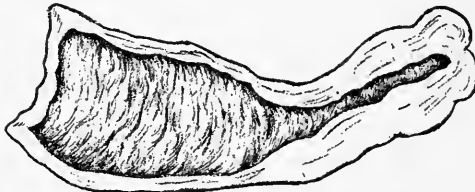


Fig. 71.—Case XIII. Appendix, 65 mm. long. At apex, wall much thickened for 3 cm. with narrow lumen; the proximal portion, $3\frac{1}{2}$ cm. long, is dilated. Wall doubly as thick as normal. Microscopic examination: Thickened distal end shows epithelium and tubular glands present. Mucosa thickened and solitary follicles enlarged, with spaces in center. Diffuse small-celled infiltration through muscularis, lymphangitis; and in the subserosa, besides lymphangitis, multiple miliary abscesses. Proximal end, which was dilated and filled with pus and opened into the abscess communicating with cecum, wall is thinner, but presented the same microscopic appearances as in the thickened apex.

Microscopic examination of the distal end showed the mucosa to be thickened; epithelium present; Lieberkühn's glands normal; large solitary follicles with abscess in center. There were lymphangitis and diffuse small-celled infiltration through the muscular, and multiple miliary abscesses in the subserous, coat.

The dilated proximal end of the appendix, which was filled with pus and opened into the abscess communicating with the cecum, had a thinner wall, but presented a microscopic appearance similar to that of the distal end.

CASE XIV.—*Relapsing appendicitis; operation between sixth and seventh attacks; base of appendix transformed into abscess cavity communicating with cecum where the wall of the appendix was absent from previous gangrene; second abscess in anterior wall of cecum $1\frac{1}{2}$ inches above base of appendix; openings into cecum sutured; death from sepsis after two weeks.*

Mrs. C., forty-nine years of age. She had had six attacks of appendicitis, gradually increasing in severity, the last one on January 30, 1892, at which time I saw her in consultation with Dr. Pierce. She had fever, swelling the size of an orange, and tenderness in the right iliac region, or rather in the region of the appendix, between the umbilicus and the anterior superior iliac spine. I advised her to wait until the attack was over.

She came to my office March 1st. At this time there was little if any tenderness, but by deep pressure I thought I could make out a longitudinal tumor the size of a thumb, slightly movable transversely. This I thought might be an enlarged appendix surrounded by cicatricial tissue.

After the usual preparation I operated upon her on March 16th. A vertical incision 4 inches long was made over the cecum. The peritoneum was divided and united with the skin. Sponges were introduced to keep the small intestines out of the field of operation. In the lower end of the wound the anterior wall of the cecum was found to be adherent to the parietal peritoneum, or rather to a hard mass of tissue between the cecum and the anterior wall. Close to this an oval body, which was supposed to be the appendix, could be felt.

The incision was now prolonged downward 2 inches near to Poupart's ligament, in order to gain space sufficient to isolate the appendix, whose apex and mesenterium for a distance of $1\frac{3}{4}$ inches were free. At its base the appendix was embedded in a mass of cicatricial tissue the size of a walnut, which was adherent to the anterior abdominal wall. In the attempt to separate this tissue from the parietal peritoneum a small abscess cavity in the mass of adhesions or cicatricial tissue surrounding the base of the appendix was opened and a little thin, yellow pus escaped. The appendix could not be followed to the wall of the cecum, but was lost in a mass of soft granulation tissue on the wall of the abscess cavity close to the cecum. At this point the mucosa and muscularis ceased abruptly, the result of sloughing. (See Fig. 72.)

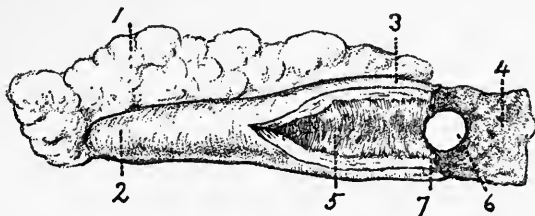


Fig. 72.—Case XIV. Appendix, $3\frac{1}{2}$ cm. long, from apex to point where wall ceases, and 1 cm. of abscess cavity with perforation and absence of wall between this point and wall of cecum: 1, Mesentery, adipose tissue; 2, obliterated distal end of appendix, $1\frac{1}{2}$ cm. long; wall here looks normal; 3, open portion of appendix, 2 cm. long; 4, abscess wall, granulation surface 1 cm. long where wall of appendix is absent; 5, mucous membrane in non-obliterated portion of appendix looks normal; 6, perforation opening; 7, line where wall of appendix disappears, representing the line of demarcation of circular gangrene of wall of appendix. Microscopic examination of wall of appendix shows lymphangitis and miliary abscesses in subperitoneal tissue. Mucosa in middle portion thickened, but has epithelium and tubular glands.

The mesenterium, which was normal, was ligated close to the appendix and the appendix removed. The abscess wall was scraped off from the cecum around the entrance to the appendix. About $\frac{1}{2}$ square inch of the abscess wall was adherent to the abdominal wall. The entrance of the appendix into the cecum was now scraped and cut off on a plane with the wall of the cecum. A probe was passed easily 2 inches down into the cecum, but no gas escaped.

The entrance of the appendix into the cecum was then closed by sutures through the mucous and muscular coats, Czerny-Lembert sutures, and covered by the mesenterium of the appendix fixed by sutures.

One and one-half inches above this abscess, on the anterior, outer, lateral surface of the cecum, or the beginning of the ascending colon, another mass of cicatricial tissue the size of a hazelnut was found between the intestines and the abdominal wall. This was excised from the abdominal wall—that is, the transversalis fascia was excised with it. It was impossible to separate this mass from the wall of the cecum. In the center of the mass were found islands of thick, yellow, inspissated pus, one of which extended into the wall of the cecum. This was the point of perforation of the abscess into the cecum, and was surrounded by firm cicatricial tissue. This inspissated pus focus was removed, and with it the corresponding portion of the cecal wall, which left a wound $\frac{1}{2}$ inch long in the cecum, from which normal mucous membrane protruded.

The wound in the cecum was closed by Czerny fine silk sutures through the mucous and muscular coats, then a continuous row of Lembert sutures, and finally an outer row of

serous sutures. The sutured wound was $1\frac{1}{2}$ inches long, and was continuous with the sutures of the entrance of the appendix and with those of the lower abscess.

The cecum now presented the following appearance: On its anterior outer surface there was a line of sutures $2\frac{1}{2}$ inches long, extending from the apex up to 1 inch above the ileum. The cecum was somewhat narrowed, but was still almost $1\frac{1}{2}$ inches in diameter. The ileum was almost empty. The line of suture passed 1 inch to the left of the entrance of the ileum, in order to avoid the ileocecal valve. At the upper end of the line of sutures—that is, the upper abscess—the ascending colon was of normal caliber. Gas now was seen to pass freely from the ileum into the cecum and ascending colon, and the passage was thus shown to be free. The abdomen was now cleansed, the cecum mopped off with bichlorid solution on gauze; no irrigation. The peritoneum was separately sutured. It was difficult to bring the edges of the wound together, on account of the loss of substance in the site of the two abscesses.

A gauze drain was placed upon the sutured cecum and passed out through the wound. The rectus fascia was united with buried sutures. A gauze drain was introduced into the upper end of the wound, and the external wound closed by step sutures down to the gauze drain.

On the second day the temperature began to rise; no symptoms of peritonitis, but symptoms of increasing sepsis necessitated the reopening of the wound on the third day. Septic inflammation, with purulent and fibrinous exudate, was found in the abdominal wound and on the cecum below. The sutures in the cecum did not open at all, as evidences of fecal fistula never were found. Opening and disinfecting the septic wound was of no avail. On the fourth day the patient became delirious, and died two weeks later. No autopsy was permitted.

Remarks.—As a separate clinical form of appendicitis, with special indications for, and method of, operating, recurrent appendicitis has come into prominence since 1889, when Treves first operated for this condition. At this time more than 40 operations of this kind are on record (Kümmel).

This form derives its name from its clinical feature of recurrent attacks with free intervals. The frequency of the attacks varies from two or three a year to one a month, or even more frequently. In the cases with frequent attacks there are usually some pain and inconvenience during the free interval. The attacks may be so slight and the local disturbance so constant that such cases are better spoken of as cases of chronic appendicitis or perityphlitis, with slight exacerbation of the symptoms occurring very frequently, every week, for instance, or, as in Case XIII, every time the patient became constipated.

The pathology of this form is different in extent only from that of the other two forms. We find in and around the appendix all the pathologic conditions above described—the catarrhal endo-appendicitis, with or without ulcers, perforations, fecal concretions, lymphangitis and perilymphangitis, periappendicitic abscess, and perforation openings into the cecum.

Iversen has called especial attention to stenosis as a cause of the recurrent attacks. A stenosis at the cecal orifice or at Gerlach's valve may cause dilatation of the entire appendix (Senn, Högh). Stenosis in other parts of the appendix, the middle, for instance, may cause dilatation of the distal portion. Strictures are frequent—in 5 out of 8 cases

(Kümmel). Perforation is very common, single or multiple openings often situated just behind the stricture, or, more rarely, in the territory of a fecal concretion. Perforation was reported in 6 out of 8 cases. The perforation opening leads out into a small abscess cavity, which again may open into the cecum, or else there is no abscess cavity but a direct communication between the two in this place, united by adhesions. Small abscesses may not communicate either with the cecum or appendix, but may be in close proximity to both of them, or may be located in the very wall of the cecum, as in my Case XIII. Miliary microscopic abscesses may occur in the subserosa of the appendix, as in my Case XII.

A closed perforation opening into the cecum is seen as a localized thickening of the wall of the cecum, with retraction and folding of the mucous membrane. Stenosis or stricture of the cecum is rare. It has been seen by Kümmel and Lange. Ulcers are also of rare occurrence.

Prognosis.—Spontaneous recovery after several attacks is not uncommon (Pepper, Bryant, Lange); hence the advice of some surgeons not to be too hasty in operating in all cases. But it must be borne in mind that the more frequent the attacks, and the less free the intervals or the nearer the disease approaches to chronic appendicitis with exacerbations, the more urgently is operative interference indicated. Spontaneous recovery takes a long time—in 3 cases reported by Leiden, from six months to a year. In one of Körte's cases the patient was in bed for nine months. The operation, when successful, gives perfect recovery in a month or two.

The prognosis of the operation is, on the whole, very favorable. Eleven cases were operated upon prior to March, 1891, and were reported by Iversen. All of these recovered (Treves, Senn, Högh, Kümmel, Malthe, Teale, Iversen). Kümmel lately reported 12 operations in which he did not lose a patient. But, difficult as the operation sometimes is, fatal cases are occasionally met with. In 1 of my 3 cases the patient died. Lange also alludes to the loss of one patient, operator unknown. I should consider the mortality of the operation as about 5 per cent.

Operation.—Most operators agree that the operation should be performed during the free interval between the attacks. The only dissentient opinion in this matter was expressed by Morton, who advises to wait for the next attack, which may not come, on the ground that the operation in the interval may be made difficult and dangerous by dense adhesions around the appendix.

The plan of operating in intermittent appendicitis is simple—namely, removal of the diseased appendix. Simple loosening of the adhesions (Treves) or opening and draining of the appendix (Lawson Tait) are deemed insufficient.

The necessity of the removal of the appendix is well illustrated in a case reported by Lange, who, during a laparotomy, found a narrow, retracted cecum, on which he made the Heineke-Mikulicz operation to relieve the constriction. He did not remove the appendix. The operation had no apparent effect upon the symptoms. At a later laparotomy

the appendix, which contained a fecal concretion, was extirpated, and the patient recovered completely. On the other hand, there are cases in which the symptoms are caused by a small abscess, after the removal of which the patient is cured, even if the appendix is not removed, as in a case reported by Lange.

The operation may be very easy or extremely difficult. It is easy in catarrhal appendicitis with no adhesions (Senn's case), but this case was exceptional. Usually the removal of the appendix is more or less difficult, and is complicated by adhesions, abscesses, perforations into the cecum, etc. In rare instances it is extremely difficult and dangerous. In one of Kümme's cases, in which stenosis of the cecum was found, he was obliged to resort to resection and implantation of the ileum into the ascending colon. Morton speaks of several instances in which some of the best operators have been obliged to abandon the operation in the interval because the appendix could not be found.

The technic of the operation is simple as to its general plan, but variable and difficult in detail. A direct perpendicular or oblique incision should be made over the cecum and into the peritoneal cavity. The adherent omentum on the anterior abdominal wall is carefully removed from the cecum. The appendix is now sought for; it is usually felt as a small tumor around or behind the cecum. The loosening of the appendix with the finger-nail or instruments must be done with the utmost care to avoid injuring the wall of the cecum. When the appendix has been loosened throughout its entire extent, the mesenterium, if not torn during the previous manipulations, is ligated in portions. The freed appendix is now ligated, cut off, and invaginated. The stump may, after disinfection, be inverted and buried between two folds of the cecum, or the mesenterium may be used as a covering. The territory may, in addition, be covered by an omental flap. Some operators regard the last-named precautions as of little importance.

Openings into the cecum should be united by Czerny-Lembert sutures. This procedure may sometimes have to be preceded by resection of the thickened cecal wall. Through the resection opening the cecum may be explored with the finger for ulcers and strictures, which can then receive the proper consideration and treatment.

Drainage will be necessary in the majority of the cases, and it is exceptional that a case of catarrhal appendicitis without adhesions is met with in which drainage could be dispensed with. Senn and Högh had each a case of this kind. Drainage is usually effected by gauze or drainage-tubes, or a combination of the two. The abdominal wound is usually united by step sutures down to the point of drainage, in order to avoid hernia. Iversen and others advocate the employment of Trendelenburg's position.

On the whole, it may be said that the removal of the appendix in the free interval of intermittent and in chronic appendicitis is satisfactory, and, although sometimes very difficult, is in general a comparatively safe operation.

5. Post-appendicitic Conditions, or Late Consequences Following Appendicitis.—This condition is illustrated by the following two cases:

CASE XV.—*Chronic perityphlitic abscess of four years' standing, reaching from the kidney down to 4 inches below Poupart's ligament; several compartments communicating with narrow tracts; walls ½ inch thick, and dilatation of subcutaneous veins and hardness of swelling simulating malignant tumor; after removal of two fecal stones, definite closure of cavity.*

J. E. H., farmer, age thirty-two, was admitted to Emergency Hospital, in my service, June 27, 1892. Family history good. Previous health good. Present illness dated from the autumn of 1888, when he was suddenly seized, while working in the harvest field, with acute pain in the right side of the abdomen. A year ago he had another sudden attack of pain in right iliac region, and a month later an abscess, which was incised, with escape of fetid pus, and left a fistula in the right lumbar region which still remains open. At present the discharge through the fistula is free for two weeks and the tumor decreases; then the discharge lessens and the swelling increases in size.

Examination.—The patient was strong, fairly well nourished, pale; heart, lungs, and urine normal. In the right iliac region there was a hard tumor extending from the false ribs down to Poupart's ligament, a distance of $4\frac{1}{2}$ inches, and which entirely filled the lumbar region from the twelfth rib to the crest of the ilium, and extended forward to the outer border of the rectus muscle. It was 6 inches in transverse diameter, and took in the outer half of Poupart's ligament; at its medial border at this point the external iliac artery could be felt. The swelling was hard, like wood, with no soft places, no fluctuation, no tenderness on pressure. In the lumbar region it was covered by dilated veins, resembling in this regard a malignant tumor. In the upper part of the lumbar region, 1 inch below the twelfth rib, close to the lumbodorsalis and erector spinæ muscles, there was a fistulous opening forming a crater-shaped depression surrounded by nodules of cicatrized granulations, in the center of which a minute opening could be seen through which a common probe could be passed. The probe passed in transversely toward the median line for 4 or 5 inches and could not be moved about in any cavity.

Diagnosis.—Appendiceal abscess. The abscess was located on the outer side of the colon, and extended along the lateral aspect of the cecum, then ascending toward the liver.

Operation.—The patient was placed on the left side in the position for lumbar nephrotomy. The incision was made through the fistulous opening from the upper corner of Petit's triangle downward and forward toward the crest of the ilium. When the internal oblique muscle had been cut through, a layer of hard, white, fibrous connective tissue, $\frac{1}{2}$ inch thick, was reached. This was divided first in the region of the fistula, in order to permit digital exploration, which revealed a flat space lying between the anterior abdominal wall and the cecum and ascending colon. The abdominal wall and the cicatricial tissue were now divided down to the crest of the ilium. The cavity was 3 inches long and lined with a layer of flabby, grayish, red granulation tissue, which was removed with the sharp spoon. This cavity extended down to the anterior-superior spine of the ilium. On the posterior wall of the cavity, near the iliac crest, a sinus was found which led down in the iliac fossa close to the bone, which was not denuded, and through which a probe could be passed down to the outer half of Poupart's ligament.

The fibrous wall, $\frac{1}{4}$ inch in thickness, between the two cavities, was now divided with a knife close to the crest of the ilium. The wall was probably the transversalis fascia or the transversalis muscle. The division was continued downward to the outer half of Poupart's ligament, about 1 inch external to the pulsating iliac artery.

The sinus was denuded of its flabby granulation-tissue layer. At its lower end an extension was found, through which a probe passed easily downward and inward, 4 inches below Poupart's ligament, along the femoral vessels. Careful curetting of the sinus wall below Poupart's ligament revealed granulation tissue.

The upper portion of the cavity extended upward under the twelfth and eleventh ribs, and inward to the lower surface of the liver, 3 inches above and internal to the lower border of the twelfth rib. The sinus wall was curetted for a distance of 4 inches toward the vertebral column.

While the cavity was being irrigated a smooth, hard, ovate fecal stone or concretion, 1 inch long and $\frac{1}{4}$ inch in diameter, and having a fecal odor, was washed out.

The wound and cavities were treated in the following manner: A drain $\frac{1}{4}$ inch in diameter was passed down into the sinus leading to the femur for a distance of 4 or 5 inches. A second drainage-tube was passed up behind or below the ribs toward the liver. The remainder of the cavity was packed with iodoform gauze, over which a bridge of skin and abdominal muscles was drawn together at the upper anterior extremity of the crest of the ilium, leaving the upper and lower ends of the wound open for packing. He recovered after two months. A month later another fecal stone was washed out, and in another month the cavity closed.

CASE XVI.—Constriction of ascending colon by a ring in the adherent omentum after appendicitis and peritonitis ten years before; appendix adherent; median laparotomy with additional transverse incision; division of omentum; extirpation of appendix; recovery.

Mrs. M., thirty-four years of age, no children, was referred to me by Dr. Burwash in September, 1892. Ten years ago she had an attack of appendicitis and was in the hospital for eighteen weeks. Two years later she had another attack, and after this an attack every year. In March, 1892, she consulted Dr. Burwash for the pain. He made a diagnosis of constriction of the colon following an old appendicitis. She has been constipated ever since she had appendicitis, and the bowels now move only when physic is taken. If the bowels do not move for two days, the patient has pain in the right hypochondrium and cecal region, and when the bowel is empty, she experiences a burning sensation in the right half of the abdomen. She has employed large enemata for four years, without relief save the temporary respite when the warm water is injected. She has a feeling of pressure in the cecum when she eats, when she bends down, and when she rises up again.

The trouble seems to be increasing year by year. The patient has taken 11 Ayer's pills, then large enemata, to effect evacuation of old, hard scybala. If she neglects the bowels for five or six days, she has ptomain intoxication.

Diagnosis.—Contracture of cecum, or peritonic bands around cecum after appendicitis.

Operation November 29, 1892. The patient's bowels were empty; neither tumor nor appendix could be felt. A median incision 7 inches in length was made from 4 inches below the umbilicus to 2 inches above. The peritoneum was united to the skin. The omentum presented in the wound, also loops of small intestine with adherent omental shreds, and above this the transverse colon and stomach; the latter was reddish and injected, but normal. The omentum was adherent to the right border of the abdominal cavity and covered the cecum and ascending colon. In order to get space for operating it was necessary to make a transverse incision $3\frac{1}{2}$ inches long, extending from the first incision at a point 1 inch below the umbilicus outward to near the anterior-superior iliac spine. This exposed the entire right half of the abdominal cavity to view. In the upper portion of the exposed area, below the stomach, which was held up by a flat sponge, could be seen the transverse colon, from the left to near the right upper corner, where it disappeared in an opening or ring in the omentum. The omentum was drawn over the cecum and ascending colon to the abdominal wall in front of them, and adherent to the wall throughout its entire length down to the middle of Poupart's ligament. The cecum and ascending colon could not be seen, nor could the adherent omentum covering them be dislodged.

At the upper border of the omentum, where it passed from the transverse colon over the ascending colon to the right abdominal wall, there was a ring, 1 inch in diameter, having an upper free border. It was a band, or rather a cord, of omentum extending from the abdominal wall to the ascending mesocolon. The ring easily admitted one finger. The surface of the intestine was not adherent to the ring. The finger could be easily passed down through the ring into a space in the free peritoneal cavity between the posterior surface of the adherent omentum and the ascending colon and cecum.

The omentum was lifted on the finger and ligated in portions for a distance of 4 inches over the ascending colon and cecum. The omentum was divided in portions between double ligatures, from the colon near the upper end down to the middle of Poupart's ligament below the cecum. The medial portion, or border of the omentum, was attached to loops of small intestine.

After division of the omentum the normal ascending colon could be seen. The cecum was normal on its anterior surface, and quite movable. On turning the cecum to the medial side it was seen that the appendix was stretched out over the posterior and up on the outer border of the cecum, and bound to it with, or buried in, adhesions so thin that the appendix was plainly to be seen throughout its entire extent.

The appendix was 7 cm. long and flattened, but was otherwise normal. I resolved to loosen and remove it, as it was not obliterated (Behring), and as it was buried in adhesions, the results of the former attacks of perityphlitis mentioned in the history.

The appendix was removed. The mesenterium was found to be folded against the cecum and buried in the adhesions. The appendix was loosened from the cecum by blunt dissection; it was most firmly adherent at its distal end. The appendix was now ligated close to its entrance into the cecum, the mucosa cut out on the distal side of the ligature, the stump disinfected with strong carbolic acid, and the peritoneum united over the end of the stump.

The stump of the appendix was buried by means of Lembert sutures passed through the cecum and its mesentery.

The intestine was now freely movable. The right half of the abdominal cavity was irrigated with sterilized water.

The wound was now closed in the usual way, and a Mikulicz drain passed down to the site of the appendix through the lateral corner of the transverse incision. The wounds were dressed. The operation lasted for one and one-half hours. At its close the patient's pulse was 110.

The patient remained in the hospital for eight weeks. The wound closed in six weeks. The bowels move more easily since the operation, but the burning sensation still remains.

BIBLIOGRAPHY

1. Körte, W.: "Ueber chirurgische Behandlung der Perityphlitis," Berlin. klin. Wochenschr., 1891, vol. xxviii, p. 637.
2. Iversen, Axel: "Einige Bemerkungen über Appendicitis und deren Behandlung," Deut. med. Wochenschr., 1891, vol. xvii, p. 425.
3. Treves: "Relapsing Typhlitis Treated by Operation," Lancet, 1888, vol. i, p. 322.
4. Senn: "A Plea in Favor of Early Laparotomy for Catarrhal and Ulcerative Appendicitis," Jour. Amer. Med. Assoc., 1889, vol. xiii, p. 630.
5. Renvers: "Zur Pathologie und Therapie der Perityphlitis," Deut. med. Wochenschr., 1891, vol. xvii, p. 177.
6. Sonnenburg: "Operation in Two Sections," *ibid.*, 1889, vol. xv.
7. Mikulicz: "Weitere Erfahrungen über die operative Behandlung der perforativen Peritonitis," Langenbeck's Arch. f. klin. Chir., 1889, vol. xxxix, p. 756.
8. Sonnenburg: "Neuere Erfahrungen bei der chirurgischen Behandlung der Perityphlitis," Deut. med. Wochenschr., 1893, vol. xix, p. 62.
9. Lange, F.: "Ueber Perityphlitis," New Yorker med. Wochenschr., 1891, vol. iii, p. 89.
10. Bryant, J. D.: "The Gross Anatomy of the Vermiform Appendix," Annals of Surgery, February, 1893, vol. xvii, p. 164.
11. Kümmel: "Weitere Erfahrungen über die operative Heilung der recidivirenden Perityphlitis," Langenbeck's Arch. f. klin. Chir., 1892, vol. xliii, p. 466.
12. Keen, W. W.: "Four Operations for Appendicitis, Three Recoveries, One Death from a Very Small Concealed Abscess," Times and Register, 1891, vol. xxiii, p. 306.
13. Price, Joseph: "Report of Cases of Appendicitis," *ibid.*, p. 308.
14. Morton, T. S. K.: "The Operative Treatment of Appendicitis," *ibid.*, p. 312.
15. Pepper, William: "Discussion on Appendicitis," *ibid.*, p. 316.
16. Vollert, J.: "Resultate der Behandlung der Perityphlitis auf der ersten medicinischen Klinik in Wien, und über die Indicationen der operativen Behandlung der Perityphlitis," Deut. med. Wochenschr., 1891, vol. xvii, p. 988.
17. Kammerer, F.: Zur chirurgischen Therapie der Perityphlitis.

TOTAL EXTIRPATION OF THE VAGINA FOR CARCINOMA*

PRIMARY carcinoma of the vagina is so rarely seen that it has been customary of late to publish every case met with in detail. It is desirable that this should be done also for other reasons. The prognosis of the disease is particularly grave; the operative treatment has been developed only of late, and is thus as yet *sub judice*. Thus I concluded, in connection with a case I have met with, to present a brief review of the subject.

Synopsis.—Primary vaginal carcinoma of four to six months' standing. Large tumor on posterior and left wall. Multiple smaller tumors all over the remainder of the vagina. Extension to the surface of the vaginal portion of the uterus. Total extirpation of the vagina and removal of vaginal portion. Recovery from the operation. Relapse in loco two and a half months later. Nephritis. Sent home as incurable.

History.—Mrs. C., of Cedar Falls, Iowa, sixty years old. A grandfather died of cancer of the tongue, an aunt had cancer of the breast. She has 6 children; the youngest son is now eighteen years old. After the first child, thirty years ago, descent of the uterus followed, never causing any serious inconvenience. She has always been a strong and very active woman. Menopause came fifteen years ago, at the age of forty-five, accompanied with irregular hemorrhages which soon ceased entirely. She was perfectly healthy in the following years. The present illness began six months ago, in August, 1891. At this time she fell from a hammock, striking on the gluteal region, and suffered severe pain; but she could walk, was not confined to bed, and the pain soon disappeared. Two months later she noticed a purulent, odorless discharge from the vagina, which, after some weeks, showed streaks of blood. In October, 1891, she first noticed some pains in the pelvis when she had been on her feet for an unusually long time or taken a long walk; in ordinary daily life she would never feel any pain. Her appetite has been good until a few weeks ago, when she became alarmed about her condition. Bowels were regular, and she has had no symptoms from the bladder until a few weeks ago, when occasionally more frequent urinating was noticed, but not accompanied by pain. The husband thinks that she has lost some in weight and grown pale in the last two months. She herself thinks that she has not emaciated any. A week ago she went to her family physician, who made a careful examination, declared her disease to be of a serious nature, and advised her to consult a specialist in Chicago. The digital examination of the vagina was followed by some hemorrhage and pain, and traveling twenty-four hours in a sleeping-car aggravated these symptoms enough to prevent her from sleeping on the train.

I examined Mrs. C. on January 30, 1892. I found her a strongly built woman, moderately well nourished, rather pale, although she had lost no blood to account for this; her expression was nervous and anxious. Heart, lungs, abdominal organs, urine, pulse, and temperature were normal.

Vaginal examination revealed a large, hard, nodulated tumor on the posterior and

* Amer. Jour. Obst., 1893, vol. xxvii, p. 218.

left vaginal wall. It began $\frac{1}{2}$ inch from the introitus, extended upward $2\frac{1}{2}$ inches; its transverse diameter was $2\frac{1}{2}$ to 3 inches; its borders elevated and hard, the surface uneven, partly ragged, with crevices giving it a cauliflower appearance. From the posterior and left lateral wall of the vagina it extended up into and filled the posterior lacunæ and left lateral fornix. Its apparent thickness was $\frac{1}{2}$ to $\frac{3}{4}$ inch. Above this tumor no distinct vaginal portion of the uterus could be felt (she was an old woman with small, senile atrophic uterus), but the external os was found $\frac{1}{2}$ inch above the upper border of the tumor. The place of the vaginal portion felt uneven, as if not covered with smooth mucous membrane, but like an ulcerated or excoriated surface. Close to the borders of the large tumor were a number of flat, rather smooth, roundish nodules or plaques, $\frac{1}{2}$ to 1 inch in diameter, occupying the right vaginal wall, the right fornix, and anterior vaginal wall, all around the place of the vaginal portion of the uterus. The wall of the vagina between these tumors and the surface of the vaginal portion was not smooth, but velvety or warty, rough, uneven, most so nearest to the tumors, gradually becoming smooth out toward the labia minora and in the region of the urethra. The anterior upper triangle of the vagina—that is, the urethral protuberance—felt smooth, and was the only portion of the vagina that was normal.

Combined Rectal and Vaginal Examination.—The tumor on the posterior vaginal wall was $\frac{3}{4}$ inch thick all over; the wall of the rectum was smooth, soft, and movable against the posterior surface of the tumor. Above the upper border of the tumor was felt the small, freely movable uterus; the lateral ligaments were apparently not thickened and were free from nodules. However, on the left side, where the tumor reaches highest up, there appeared to be somewhat less mobility of tumor and uterus than on the right side. There was no infiltration of the perirectal or inguinal lymph-glands.

Diagnosis.—Diffuse malignant tumor (carcinoma or sarcoma) of the whole vagina, extending to the vaginal portion of the uterus; doubtful extension to the left broad ligament.

Plan of Operation.—If, in narcosis, extension to left broad ligament is found, sacral operation for total removal of uterus and vagina; if no extension to broad ligament, total extirpation of the vagina and amputation of the lower cervix from the perineum. Preparation for the operation as usual for vaginal extirpation of the uterus.

Operation on February 8, 1892, in the presence of the physicians of the Chicago Polyclinic, assisted by Dr. Gudden, of Oshkosh, Drs. Bernauer, Waters, Brougham, and others. Ether narcosis. Examination in narcosis showed condition as stated above, but I found both lateral ligaments freely movable and not infiltrated; uterus small and movable, slightly drawn to the left from shortening of the left fornix vaginae. The uterorectal ligaments and anterior rectal wall were found apparently normal and freely movable. I thus decided on extirpation of the vagina by perineal incision.

The patient being in the lithotomy position, the vagina, held open by Sims' speculum, was found narrow; therefore I divided the left side of the perineum, as is usually done in the vaginal extirpation of the uterus. The surface of the large tumor was scraped off with a sharp spoon, and whitish, friable, medullary masses of tumor tissue removed. This was followed by irrigation with 2.5 per cent. carbolic acid and rubbing off the vaginal wall with carbolized gauze sponges. A transverse incision (see dotted line in Fig. 73, 8), 3 or 4 inches long, was made in the perineum between the anus and the vulva, between the two tubera ischii. The posterior vaginal wall was separated from the anterior wall of the rectum. Dissection with blunt instruments, scalpel handle, and scissors, ligating vessels when divided, was made to a depth of 3 or 4 inches until above the upper border of the large tumor. The wall of the rectum was in some places denuded almost to the mucous membrane. The dissection was made, guided by the left index-finger in the rectum, and the posterior vaginal wall grasped by forceps and held upward by an assistant.

Lateral incisions (Fig. 73, 9) were now made on each side of the vagina from the transverse incision upward, along the introitus, into the labia minora. The left and right

vaginal walls were dissected off with blunt instruments, as above stated, up to the lateral fornix or lower border of the broad ligaments. The vaginal portion of the uterus was now grasped with American bullet forceps, so as to move, pull down, to the right or left, the cervix, to bring into view the paracervical tissues, and facilitate step ligation of the paracervical tissue or the lower portion of the lateral ligaments,—as in the vaginal extirpation of the uterus,—from the lateral border of the lacunæ upward and inward until the wall of the neck was reached. Before taking in a new amount of tissue to ligate en masse it was carefully ascertained, by touch with the finger, that the tissue to be ligated was not hard and infiltrated, and that it was some distance off from the tumor or nodules.

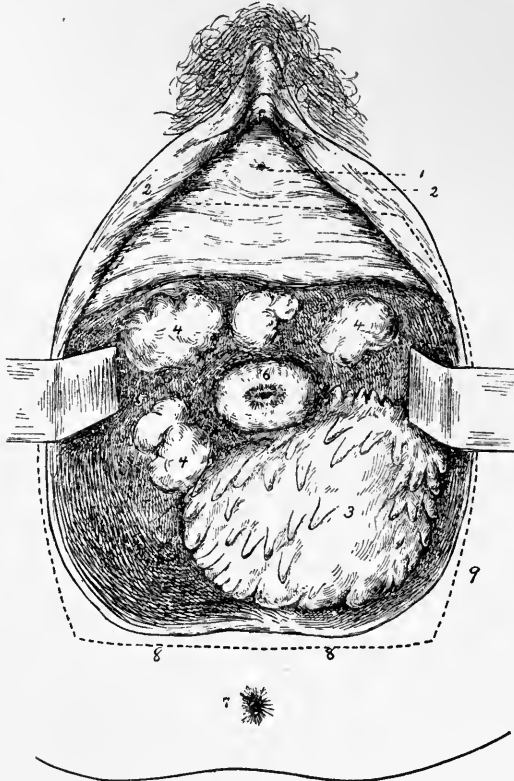


Fig. 73.—1, External orifice of the urethra; 2, labia minora; 3, large tumor on the posterior and left vaginal wall; 4, smaller flat tumors; 5, excoriated mucosa between the tumors; 6, the vaginal portion of the uterus with excoriated mucosa; 7, anus; 8, perineal incision; 9, perivaginal incisions.

In this manner the vaginal wall was loosened in both lateral and posterior lacunæ until close to the vaginal portion of the uterus, and cut off from the posterior lip and sides. The vagina was now attached to the anterior lip and posterior wall of the bladder and the urethra only. With a catheter in the bladder as a guide, a semicircular incision was made through the vaginal wall close to the anterior lip of the vaginal portion of the uterus. The vagina was dissected off or separated from the posterior wall of the bladder with blunt instruments, beginning at the right lacuna, working up toward the urethra and to the left, the vaginal portion of the uterus being pulled strongly down toward the perineum, and the already loosened walls of the vagina being held or pulled upward against the symphysis pubis. This separation of the anterior vaginal wall was continued until the terri-

tory occupied by the flat tumors and the velvety, uneven mucosa was passed, and normal, smooth vaginal wall was reached. After cutting off the anterior vaginal wall in the region of the urethra, and after removal of the vagina, there remained only a small anterior triangle of vaginal wall covering the urethra and extending out to the anterior half of the labia minora. (See Fig. 73.) To get still further away from suspicious velvety vaginal mucosa, the posterior portion of the triangle was denuded of its mucosa, and immovable submucous tissue, removing it by scissors in strips, as in the old operations for lacerated perineum, and going as deeply as possible without opening the urethra, guided by the catheter. Careful palpation of the wound surface failed to detect any infiltrated places or lymph-glands anywhere.

As the mucosa on the vaginal portion was diseased, and possibly this surface affection extended up into the mucosa of the cervix, supravaginal amputation of the cervix, or rather Schröder's operation, had to be the final step in the total extirpation of the vagina; cureting of the uterus and disinfection of the cavity with tincture of iodine and iodoform. After bilateral incisions about 1 inch in length and separating the halves of the cervix, it was seen that the cervical mucosa was healthy from $\frac{1}{4}$ inch above the external os. The vaginal portion was cut off with the wall of the cervical canal to 1 inch above the os, and the cervical wound surfaces folded on themselves by two sutures for each of them, to stop hemorrhage. Inspection of the wound and final arrest of hemorrhage by a few ligatures were followed by a cleaning with gauze sponges moistened in 2.5 per cent. solution of carbolic acid. No union of wound surfaces was attempted, except that the middle portion of the perineal incision was drawn together for about 1 inch in the median line; this was made to bring the anal opening out of almost direct contact with the perivaginal wound surface. The place of the vagina was loosely packed with sterilized iodoform gauze, and a voluminous antiseptic external dressing held by a T-bandage.

Remarks.—Hemorrhage during the operation was easily controlled and inconsiderable. During the extirpation of the vaginal wall in the right posterior fornix I made an opening into the peritoneal cavity $\frac{1}{2}$ inch in diameter, through which omentum protruded. It was at the time closed by a mass ligature.

The operation lasted one and one-half hours. Toward the end of the operation the pulse became 120 and weak, necessitating subcutaneous injections of camphorated oil and digitalis. I considered it dangerous to do any more operating then, and gave up the intended vaginoplastic operation; to cover the wound with paravaginal mucous membrane and skin would have required at least one-half hour's time.

Course after the Operation.—In five weeks she was able to sit up and had regained the same strength as before the operation. Irritation of the bladder, frequent micturition without any abnormal condition of urine, followed in the third week; later on the urine contained albumin and a few casts, probably indicating amyloid nephritis.

March 23d, forty-four days after the operation, I wanted to make the vaginoplastic operation. She was anesthetized and placed in the lithotomy position. A narrow, funnel-shaped, granulating cavity leads up toward the uterus; in the upper portion it was so narrow as scarcely to permit the tip of my finger to pass. The granulation surface was apparently normal, and was scraped off with a sharp spoon. After disinfecting irrigation I tried to dilate laterally, with blunt instruments, out toward the tubera ischii. In so doing I made a tear through the thin

posterior wall, opening into Douglas' fossa, from which a flap of omentum immediately prolapsed. The opening, about 1 inch in diameter, was loosely packed with iodoform gauze after replacing the omentum. I desisted from the plastic operation, as this is always followed by some suppuration, and packed the vagina with iodoform gauze. She was kept in bed for three weeks.

April 20th she had been out of bed for a week and thought that she was gaining strength. However, she looked pale and cachectic. Albumin and casts in the urine indicated chronic nephritis.

Now, seventy-two days after the extirpation of the vagina, examination reveals the following condition: Vulva normal; entrance to the vagina narrow; slight odorless secretion; no pain; a finger passes in 2 inches; at a height of $1\frac{1}{2}$ inches is a constricting ring, through which the end of the index-finger narrowly passes into a larger space, the bottom of which can be felt, but the uterus cannot be distinctly made out.

Rectal examination shows a nodule the size of a hazelnut on the anterior wall of the rectum, $1\frac{1}{2}$ inches above the sphincter ani. About 1 inch higher up, in the left broad ligament, is a diffused, hard thickening

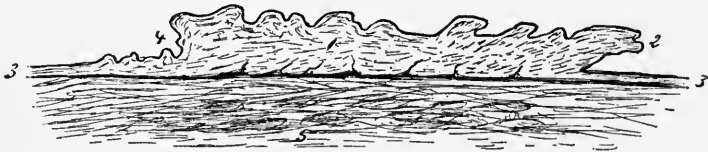

Fig. 74.—Section through the large tumor and post-vaginal tissue; 1, The large tumor; 2, its borders overlapping the surrounding vaginal wall; 3, vaginal wall; 4, papillomatous or wart-like thickening of the vaginal mucosa near the large tumor; 5, the post-vaginal connective and adipose tissue.

and a movable nodule the size of an almond. Thus there was relapse of the carcinoma *in loco* in these two places. I did not consider her a fit subject for further attempts at a radical operation, especially on account of the nephritis, and she left for her home.

Description of the Specimen (See Figs. 73, 74, and 75).—1. The large tumor on the posterior and lateral wall, extending from the vulva to near the vaginal portion of the uterus, is $2\frac{3}{4}$ inches long, $2\frac{3}{4}$ inches broad, and $\frac{1}{2}$ inch thick. Its surface is irregular, ragged (from scraping with the sharp spoon), in some places papillomatous. Its borders are elevated, or even overlapping the surrounding vaginal mucosa (Fig. 74, 2). The rectal surface is apparently free from infiltration in the loose connective tissue and adjoining tissue that covers it.

2. The smaller, flat, sessile, round, nodulated tumors on the right wall, right fornix, and anterior wall of the vagina appear like conglomerations of 3 to 5 smaller tumors. There are 4 such conglomerate tumors (Fig. 73, 4). They are whitish or red, rather smooth on the slightly elevated surfaces, as if covered with a distended, not ulcerated, mucosa.

3. The vaginal wall between the tumors and on the vaginal portion is uneven, velvety or warty, as the surface of a mole or flat wart on the skin, or like the surface of the skin in ichthyosis. (See Fig. 74, 4.) In

other places it is excoriated, looking like the finely ragged bottom of a tuberculous ulcer. (See Fig. 73, 5.)

Microscopic Examination.—1. Large tumor. Transverse section shows no epithelium; irregular nests and islands of large pavement-shaped epithelial cells with large nuclei, oval, round, or irregular; no *Stachel-* or *Riffzellen*; no cancrioid pearls. The carcinoma islands extend down into the muscularis, where they become smaller and are surrounded by a zone of granulation tissue. In the deeper layers of the muscularis there are no carcinoma nests, but all the way through there is an interstitial infiltration with embryonal cells or leukocytes, especially in the perivascular spaces. This infiltration extends beyond the muscularis into the paravaginal connective and adipose tissue.

2. The flat tumors are mostly covered with a thin layer of epithelium,

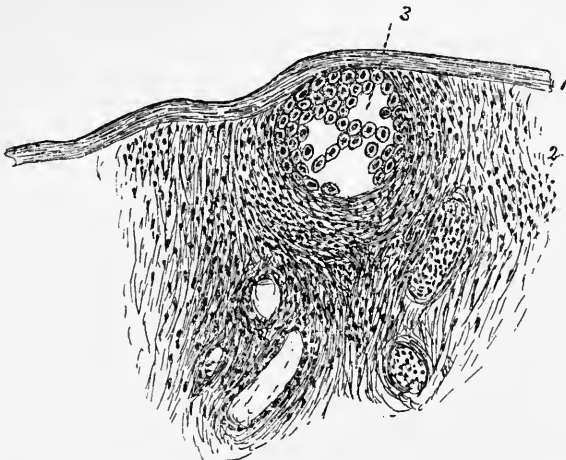


Fig. 75.—Microscopic section from the vaginal portion of the cervix: 1, Thin layer of pavement-celled epithelial covering; 2, mucous membrane, in which, close to the surface, lies 3, a small carcinoma island.

under which is a layer of carcinoma tissue; the islands of this are mostly longitudinal and arranged perpendicularly from the surface down to the muscularis. In the latter are, here and there, smaller, round carcinoma nests embedded in granulation tissue, but, on the whole, the line between tumor and subjacent tissue is well defined, showing little tendency to rapid invasion of the surrounding tissues. Through the whole wall is a considerable interstitial infiltration with leukocytes.

3. The vaginal portion. (See Fig. 75.) A thin layer of pavement-celled epithelium is found in some places, but mostly there is no epithelium, and the mucosa is naked, with an irregular surface from which the mucous glands with their cylindric epithelium extend down. There is no proliferation of the epithelial cells in the glands. In a number of sections I find in one only a small but typical round nest of pavement-shaped epithelial cells immediately below the epithelium (a carcinoma island). (See Fig. 75, 3.) The muscular wall of the vaginal portion shows some perivascular interstitial infiltration with

leukocytes, especially near to the mucosa, but not nearly so prominent as in the vagina.

Remarks.—The tumor is a large-celled, pavement-celled carcinoma. The tumor territories are rather well defined, which might indicate relative benignancy from little tendency to diffusion. On the other hand, the diffused interstitial infiltration of the surrounding tissue with leukocytes, a lymphangitis, possibly from infection through the denuded vaginal wall, signifies malignancy, as it favors rapid extension through invasion of the lymphangitic areas by carcinoma-cells. We see this condition in some cases of carcinoma of the breast, where a not well-defined redness and a slight swelling of the surrounding skin indicate a lymphangitis, often, but not always, mixed carcinomatous and septic. This condition is so ominous as absolutely to contraindicate operating in the great majority of cases. The diffused velvety or excoriated appearance of the vaginal wall signifies not merely a surface inflammation, but also extension of the carcinoma to, or implantation of the carcinoma-cells in, parts of the surface distant from the visible tumors. (See Fig. 75, 3.) The whole of such a wall or surface surrounding a carcinoma must consequently be removed.

PRIMARY CARCINOMA OF THE VAGINA

Definition.—Carcinoma of the vagina is common enough if we count the carcinomata which originate in the cervix or vaginal portion and secondarily extend down into the vagina. Of a primary carcinoma of the vagina we must require that it originates in the vaginal wall proper. It may extend to the vaginal portion secondarily; and it may be difficult in a late extensive case to trace the place of primary origin, especially in the diffused, infiltrating forms when the tumor extends up into the cervical canal. Such cases should not be counted as primary vaginal carcinomata.

Forms.—As in the sarcomata, so we find two forms of vaginal carcinoma: the localized, papillary, so-called canceroid, and the diffused, scirrhous, or medullary carcinoma. The localized carcinoma, or canceroid, forms well-defined, circumscribed, flat, sessile, or more globular prominent tumors in the mucous membrane proper, or rather in the surface of the mucosa, often with raised or overlapping borders, with a papillary, lobulated, cauliflower-like surface, often covered with cockscomb-like protuberances.

The diffused, infiltrating carcinoma transforms the vaginal wall into a stiff, narrowed tube. It has a smooth surface before epithelial necrosis takes place. Its seat is essentially in the deeper parts of the mucous membrane and submucous tissue. It has no elevated or well-defined borders, but forms a diffused thickening of the vaginal wall.

Frequency.—Vaginal carcinoma is a rare disease. Küstner* could collect from the literature in 1875 only 24 cases, to which Preuschen,†

* Küstner: Arch. f. Gyn., 1875, vol. ix, p. 279.

† Preuschen: Real-Encyclopädie der gesammten Heilkunde, v. Eulenberg, 1883, vol. xiv, p. 368.

in 1883, added 9, making in all 33. If we count the 19 cases of West,*—about which Preuschen and Küstner say that it is doubtful if all of them were primary vaginal carcinomata,—and add 1 case from Meyer,† one from Teuffel,‡ 1 from Menzel,§ 1 from Grammaticati,|| and my case, we get a total of 57 cases. The scarcity of vaginal carcinoma is the more remarkable when contrasted with the frequency of carcinoma of the uterus. As an example, it has been calculated that not less than 5000 to 25,000 women died of uterine carcinoma in England during a period of fourteen years—from 1847 to 1861¶ (Simpson, Schröder, Preuschen). One-third of the carcinomata in women are located in the uterus (Schröder); of 441 carcinomata in both sexes, 113 were uterine (E. Wagner).

Etiology.—1. *Gravity and childbirth* undoubtedly exert a potent influence on the origin of carcinoma of the uterus. Gusserow has calculated, for 450 women suffering from uterine carcinoma, 5.19 as the average number of children for each. Küstner found, for 24 women with vaginal carcinoma, an average of only 2.8. Preuschen seeks the explanation of this difference in the fact that the vagina takes no active part in gestation as compared with the uterus, and, further, that the traumatism to the uterus during childbirth is much greater than to the vagina proper. Laceration of the cervix or vaginal portion is almost physiologic, while partial ruptures of the vagina, excluding the perineum as belonging to the vulva, are rarely found—according to Winckel, in 1.5 per cent. of births.

2. *Pessaries.*—Continued traumatism from pessaries, perhaps ill-fitting, sometimes forgotten in the vagina and left for many months or years, will occasionally determine the location of a vaginal carcinoma. Morgagni (Preuschen) saw two almond-shaped indurations in the vagina caused by a pessary. Hegar** found, in a woman of fifty-six who died later with general carcinosis of the abdominal organs, two partly ulcerated carcinoma nodules, corresponding to the places where a closed Hodge pessary pressed against the descending ramus of the pubic bones. Kaltenbach†† found, in a woman of thirty-five who had used a Hodge pessary for a long time, a carcinoma high up in the posterior fornix where the posterior arch of the pessary had pressed. Meyer‡‡ saw a woman of sixty who, for prolapse of the vagina, had used a Hodge pessary of celluloid and left it in continuously for over a year. A purulent secretion mixed with blood caused an examination to be made. Erosions were found on the posterior lip of the vaginal portion and on the posterior

* West: *Lehrbuch der Frauenkrankheiten*, 1870, p. 829; cited from Preuschen, *loc. cit.*

† Meyer: *Zeitschr. f. Geburtsh. u. Gyn.*, 1891, vol. xxii, p. 179.

‡ *Centralbl. f. Gyn.*, 1885, vol. ix, p. 345.

§ Menzel: *Ibid.*, p. 244.

|| Grammaticati: *Ibid.*, p. 243.

¶ Gusserow: "Ueber Carcinoma Uteri," *Volkmann's Samml. klin. Vorträge*, 1891, No. 18.

** *Operative Gynecology*, third edition, 1886, p. 183.

†† Kaltenbach: *Ibid.*

‡‡ Meyer: "Zur Etiologie des Scheidenkrebses," *Zeitschr. f. Geburtsh. u. Gyn.*, 1891, vol. xxii, p. 179.

vaginal wall. They healed in a few weeks, and later the pessary was reintroduced. Six months afterward the discharge returned, and there was now found, $1\frac{1}{2}$ inches behind the posterior lip, a flat red tumor, 1 inch in diameter, filling the posterior fornix, elevated 5 to 6 mm. above the vaginal surface, soft, lobulated, with beginning ulceration on the surface. Another smaller tumor of the same character was seen lower down on the middle third of the posterior vaginal wall, in the place where the tumor in the fornix lay in contact with it. Microscopic examination showed the tumor to be carcinoma. At the attempted local extirpation it was found that the upper large tumor extended both to the vaginal portion and the cervix and to the posterior parametrium; thus vaginal extirpation of the uterus was combined with removal of the diseased part of the vagina.

In favor of the probability that pessaries may cause carcinoma are some observations reported by Küstner, who saw a thickened border of epithelium, and even small warty excrescences, surrounding the places of pressure atrophy caused by pessaries, and these places were sometimes very obstinate in healing.

Prolapse of the uterus and vagina does not seem to predispose to the disease. Cohabitation is in this respect uncertain. Three of Küstner's nulliparous patients were not married. As to age, the vaginal carcinoma is most common in the fourth decennium; next comes the sixth, and then the fifth and third. One case was in a child nine years old, one between five and ten, one between ten and twenty. The uterine carcinoma has its greatest frequency in the fifth decennium, followed by the fourth and sixth; consequently the most common period is about ten years earlier for the vaginal than for the uterine carcinoma.

Heredity was noted in 2 cases. Baldwin's* patient stated that her father and grandfather had died from cancer. My patient had a grandfather and an aunt affected with carcinoma, respectively, of the tongue and of the mammary gland.

The seat of the carcinoma is, in the great majority of cases, the posterior vaginal wall. It was so found in 10 of Küstner's 27 cases, in 10 of Preuschen's 11 cases, in Teuffel's, Grammaticati's, Menzel's, Meyer's, and my case, or in 25 out of 39 cases. In 2 cases it occupied the lateral wall, and in 2 cases, of which the one of West is doubtful, while Baldwin's patient had a carcinoma the size of a walnut near the urethra, the anterior wall. In several of the cases of large, apparently circular tumors there was found a narrow rim of healthy vaginal wall extending from the anterior lip of the vaginal portion to the introitus vaginae, proving that the place of origin was the posterior wall (Küstner). Preuschen sees the cause of this predilection in the relation between the posterior vaginal wall and the vaginal portion with the os. An enlarged vaginal portion rests and moves against the posterior wall, where the secretions from the uterus are, so to say, rubbed into the mucous membrane constantly during movements of the body or contraction of the abdominal

* Baldwin: Philadelphia Medical Times, 1870, p. 15.

muscles, especially where the uterine ligaments and vaginal wall have lost some of their tonus.

Symptoms.—Hemorrhage, purulent discharge, and pains are almost invariably found. Hemorrhage is an early symptom (Preuschen). Küstner states that hemorrhage is present in 8 out of 12 cases. It is often caused by cohabitation, and a small tumor may be made to bleed easily in this way, as smaller papillomatous excrescences are often very vascular when carcinomatous. Difficult defecation in a constipated patient will sometimes start the hemorrhage. A discharge of purulent or watery secretion not tinged with blood, from the ulcerated surface, is more rare; it was present in 2 of Preuschen's 12 cases. More common is a purulent secretion with streaks of blood, the quantity of which is increased by coitus, exploration, or defecation. Pain was regarded as an early symptom by West. Küstner found pain absent in one-half the cases. In 1 case painful coitus was the only symptom. It is often not until late in the disease that pain becomes a prominent symptom. It is then often aggravated by defecation, which causes pressure upon and protrusion of the posterior vaginal wall, where, as we saw, the oldest and often ulcerated portion of the tumor is found. Invasion of the bladder causes urinary tenesmus and frequent urination. A dull pain deep down in the pelvis and a feeling of pressure downward come on late in the disease.

Course.—The vaginal carcinoma shows a tendency to early necrosis and rapid extension locally, as well as to adjacent organs, first to the lymph-glands in the paracervical connective tissue, and later to the inguinal glands when the disease extends down near the vulva. The rectum and bladder are invaded later on, fistulas form, and the vagina forms finally a large cavity, in which feces and urine pass over the ulcerated surface, and the horrible condition so well known in cases of cervical carcinoma makes the patient an object of pity. Diffuse carcinosis of the peritoneum is more common than metastases in distant organs.

Diagnosis.—When the symptoms have called for a digital examination of the vagina, it is usually easy to diagnose a malignant tumor. But as the sarcoma presents nearly the same appearance as the carcinoma, a differential diagnosis between the two can be made only by microscopic examination. It is of the utmost importance to regard any erosion caused by a pessary with suspicion, especially if it is surrounded by thickened or papillary, uneven epithelium, and if it persists in spite of removal of the pessary and ordinary antiseptic treatment.

Treatment.—Complication of gravidity with carcinoma. Diffused or annular carcinoma usually causes so much retraction of the vagina as to prevent delivery. Roulston tried to dilate the carcinomatous vagina with sponge tents when the labor pains had already commenced. It required three days of dilatation before a finger could be passed through the stricture and feel the normal os. The patient died nineteen days later, not delivered, and the autopsy revealed a dead but normally developed child at full term. Cesarean section would, as Preuschen

remarks, probably have saved the child and possibly prolonged the life of the mother. An isolated tumor on the posterior vaginal wall, even a voluminous one, may, especially in a multipara with lax vaginal wall, as in Bailly's case, be pushed out of the vagina before the child's head, and retreat back again into its old place after delivery. When the carcinoma is diagnosed before the time of delivery it should, according to Schröder's advice, be extirpated during the pregnancy, if it cannot be easily pushed out of the vagina by the child's head.

Induced labor at the fifth month was resorted to in a case reported by Küstner. A considerable quantity of carcinomatous tissue was first removed by curet, followed by carbolized injections. No reaction ensued. Eight days later labor was induced by an elastic catheter in the uterus; spontaneous expulsion of a dead child. Septicemia followed and caused death on the seventh day.

Martin succeeded in dilating a carcinomatous vagina sufficiently to permit of extraction of the child by forceps. After delivery of the placenta, and after contraction of the uterus had taken place, he shelled out the tumor at its base. The patient recovered, and the place of the carcinoma healed over, but general carcinosis caused death after one year. In this case the carcinoma was not a diffused one, as there was a free space on the anterior vaginal wall two finger-breadths in diameter.

Radical removal of a vaginal carcinoma should always be attempted if practicable. It has been performed a number of times in cases of circumscribed tumors, but only once in a diffused carcinoma, by Schröder, in addition to, or before, the case operated on by me.

Circumscribed carcinomatous tumors have been removed by the galvanocaustic loop. Spiegelberg and Grünwald recommend the method. Grünwald's patient was operated on for a secondary tumor on the posterior vaginal wall—a relapse after a primary carcinoma of the cervix which had been amputated six months before. Toward the end of the operation a severe hemorrhage occurred and proved fatal in six minutes, before it was possible even to ascertain the source. The autopsy showed that the anterior branch of the hypogastric artery, half the size of a goose-quill, had been divided obliquely.

Excision of circumscribed tumors by knife was practised by Schröder in 3 cases of carcinoma on the posterior vaginal wall, as follows: Incision in healthy vaginal wall incircling the tumor, and through the whole thickness of the wall, was followed by dissection from above downward, thus removing the carcinoma from the subjacent tissues. In one of the cases the posterior lip of the cervix was also removed. An opening into Douglas' fossa was closed by a ligature. One case died from sepsis, 2 others recovered. The vaginal defect is, if possible, drawn together by sutures, and a drainage-tube inserted behind the vagina. If the vaginal wound is so large as not to permit of union by sutures, then the hemorrhage is stopped by ligatures or thermocautery and the wound packed with iodoform gauze.

The operations in the rectovaginal septum should be guided by two

fingers of the left hand in the rectum, and it is thus possible to feel that no carcinoma nodules are left.

Operation for diffused carcinoma was first performed by Schröder.* In an elderly woman with a carcinoma that extended over a large portion of the vagina he removed the whole of the vagina and the cervix, operating from below upward, dissecting out the vagina like the finger of a glove. The wound surface was cauterized with a Paquelin burner, and an iodoform gauze tampon inserted. The patient recovered from the operation, but relapse *in loco* speedily followed.

Removal of the vaginal carcinoma, combined with total extirpation of the uterus, was done by Meyer in his case related above. This procedure was indicated by extension of the carcinoma to the cervix.

If the lateral parametrium is invaded and the infiltration extends up into the lower portion of the broad ligament, we would have, if we concluded to attempt removal at all, to resort to total extirpation of vagina and uterus by the sacral method.

The prognosis of the operation by knife, even in the most extensive cases, is good, as far as the immediate results are concerned. Asepsis, drainage, and packing with iodoform gauze proved efficient to insure relative asepsis and recovery from the operation in Schröder's, Meyer's, and my own case.

As to permanent cure, the prognosis is exceedingly grave. Breisky, in 1886, stated that all operative attempts had proved futile, and it may be said that no observations since then have proved that there are exceptions to this sinister rule.

A local relapse, a continuance of growth, is often reported, coming on very rapidly. In Martin's first case a local tumor was felt twenty-seven days, in my case seventy-two days, after the operation. But in other cases, if not a radical cure, at least temporary comfort and prolongation of life have been seen. Menzel's patient was well for one year and three months, when a relapse of the purulent discharge was reported, and makes a relapse probable. The remaining cases have been reported too short a time after the operation to permit of any conclusions as to the future fate of the patients.

The future of operations for vaginal carcinoma will depend upon early diagnosis and extensive operating. As Breisky states, only very few cases have as yet come to be operated on at a period when there was any chance for removal. It is to be hoped and expected that when we operate away off from the tumor, as Kaltenbach advises, irrespective of rectum and bladder, defects of which can be made to heal by careful suturing, better results and some radical cures may be recorded for carcinoma in the vagina as well as in other parts of the body.

* Schröder: Handbuch der Krank. d. weibl. Sexualorgane, sixth edition, 1884.

DEMONSTRATION OF SPECIMENS FROM OPERATIONS ON THE KIDNEY, WITH PRESENTATION OF PATIENTS*

I DESIRE tonight to demonstrate some specimens, gathered in the course of years from surgery of the kidney, and to present before the Society certain patients upon whom I have operated. I shall not attempt any systematic treatment of the subject of surgery of the kidney, but have grouped together specimens taken from patients upon whom I have operated. A short synopsis only of the histories, sufficient to illustrate the specimens, will be given here, as a detailed report of the cases will be published in connection with special papers on the different subjects at a future time.

We will consider, first, carcinoma of the kidney; second, stones of the kidney, and third, stones in and stenosis of the ureter.

I. CARCINOMA OF THE KIDNEY

CASE I.—(With presentation of specimen.) J. P. B., miner, aged forty. Six years previous to the operation he suffered from vague pains in the back and attacks of general malaise. Four years later he jumped from a rock to the ground, a distance of about 10 feet. This was followed by copious hematuria, which continued for eight days; intermittent attacks of hematuria of greater or less severity occurred from this time until three months before the operation, when the hematuria became continuous. The patient had also had pain in the left lumbar region ever since the first attack of hematuria.

Physical examination negative; no tumor; no increased dullness on percussion. The patient was anemic and weak. Amount of urine in twenty-four hours, from 11 to 24 ounces. On one occasion a shred of tissue was found, which on microscopic examination was found to contain medium-sized oval and spindle-shaped cells with oval nuclei.

Diagnosis.—Incipient sarcoma.

Operation.—On April 24, 1888, lumbar nephrectomy was performed. The patient rallied well from the operation, but in twenty-four hours symptoms of uremia appeared, he became comatose and cyanotic, with normal temperature and rapid pulse, and died on the third day after the operation. At the autopsy the right kidney was found to be normal in shape and size; microscopic examination showed a slight cloudy swelling. The left kidney, which is here presented, shows a tumor the size of an orange, with part of the capsule adherent to it, situated in the middle of the kidney, leaving the upper and lower extremities free. There is a conic projection of the tumor down in the pelvis which resembles a mountain, and on the top of this mountain is a little ulcer. This is the place of the hemorrhage. It is strange, however, that the hemorrhage should have existed for more than two years and the ulcer still remain so small.

* Chicago Medical Society, February 6, 1893. Chicago Med. Recorder, 1893, vol. iv, p. 155.

CASE II.—With presentation of patient and specimen. V. L., tailor, twenty-seven years old. Previous health good, with the exception of polyarticular rheumatism at age of eighteen. His father had undergone an operation for carcinoma of the lip, which resulted in cure.

In June, 1890, he suffered from hematuria, which persisted for two weeks and was followed by intermittent attacks of weakness. The hematuria was accompanied by pain in the left hypochondrium, in the region of the infundibulum, or pelvic end of the ureter.

Physical Examination.—The patient was anemic. Neither a tumor nor the lower end of the kidney could be felt. The urine was acid and contained a moderate quantity of blood. A diagnosis was made of nephrolithiasis or tumor, and exploratory incision recommended.

Operation November 27, 1890. An exploratory lumbar incision was made, which revealed a tumor the size of an egg in the middle of the kidney. After ascertaining by an exploratory incision over the right kidney that it was of normal size and appearance, left lumbar nephrectomy was performed. The patient made a good recovery. He remained eleven weeks in the hospital. The fistula closed after six months. A small temporary abscess formed a year later. In the first year after the operation the patient gained 15 pounds in weight, and he is now in perfect health.

The tumor, which I here present, is round, two inches in diameter, situated on the anterior surface of the middle of the left kidney. It has a conic prolongation three-quarters of an inch in height projecting into the pelvis. On the apex of this cone there is a small ulcer or abrasion which was the source of the hematuria. Upon microscopic examination the tumor was found to be a tubular carcinoma with cubic and cylindric cells. No capsule surrounded the tumor, but the kidney tissue was partly infiltrated and partly pushed aside, which would signify a reasonable degree of limitation.

Remarks.—1. Early diagnosis is impossible when the tumor is situated in the upper portion, or even in the middle of the kidney, and when the lower third of the kidney is not changed in size or shape. When a tumor is so large that it can be felt by bimanual palpation the disease is, as a rule, of relatively long standing. In my experience it is exceptional to be able to palpate the lower third of a kidney of normal size and in normal location.

2. Hematuria is a symptom of the utmost importance when it occurs early, but it is absent in one-fourth of the carcinomata and one-half of the sarcomata in adults, and in three-fourths of both carcinomata and sarcomata in children. It is an early symptom if the tumor at an early stage of the disease extends into the pelvis, and necrosis of the covering mucosa takes place. The importance of early hematuria lies in the possibility of extirpating the kidney before the tumor is so large as to be felt by palpation, and on early operation depends the prognosis as to permanent cure. The hematuria is independent of movements, as walking, jolting, horseback riding, etc., and in this respect it differs from the hematuria of renal calculus. In those early cases in which no tumor can be felt, however, it will be often impossible to make a differential diagnosis until, in the progress of the operation, a tumor is found which extends the operation from an exploratory incision into a nephrectomy.

3. Pain as a symptom is not characteristic of tumors of the kidney, in contradistinction to renal calculus or pyonephrosis.

4. Lumbar exploratory incision for exploration of the other kidney

I consider preferable to abdominal nephrectomy, which has been advocated in cases of this kind. While the latter operation permits satisfactory palpation of the kidney and ureter, I consider lumbar incision, as practised in Case II, less grave, and perfectly sufficient to obtain the necessary information.

5. The prognosis of nephrectomy for malignant tumors is grave. In 1888 Tuffier reported a mortality of 65 per cent. Chevallier collected all the cases to be obtained from the literature a year later, and announced the mortality as 62.5 per cent. Radical cure is very rare. Tuffier, in 1892, stated that the cures on record were only sporadic. Terrillon, Israel, Küster, and Sigrist report radical cures.

Tuffier insists that the patient must be well for six years after the operation before a radical cure can be considered certain, as the disease may last for six to ten years. Israel considers three years a sufficient time for radical cure. Czerny lost one patient from relapse two years after nephrectomy. In this case the relapse must have commenced long before that time.

This gloomy outlook is brightened by the recent report from Israel, who has had quite an extensive experience and whose results have been better than those of any previous operator. He reports 11 nephrectomies for malignant tumor, with a mortality of 2, or 18 per cent. Of the 9 who recovered, 2 died from relapses, 1 after six, the other after thirteen, months. Seven are now alive and well. Two of these may be considered as radical cures, as five and one-half and four years respectively have elapsed since the operation. This gives a percentage of radical cures of 18 per cent. The other 5 have been operated upon too recently to be considered cured. Israel is right in stating that on early diagnosis and early extirpation depends the possibility of radical cure. The earliest diagnosis is that in the renowned case of Israel, in which he palpated a carcinoma the size of a cherry and extirpated the kidney, with radical cure. I do not know of any case in which a relapse has occurred later than the time which has elapsed since the operation in my second case, namely, two and one-half years.

2. STONES OF THE KIDNEY

Stones of the kidney are composed of uric acid, urates, oxalate of lime, phosphates, and of mixtures of these. They may be classified as aseptic and septic stones. Aseptic stones in an aseptic kidney with aseptic urine constitute one class, and septic stones in a suppurating kidney with alkaline urine the other class. In the first class the stone is the important, or rather the only, feature, while in the second the stone is secondary in importance to the sepsis or suppuration in the pelvis and the kidney.

Morris, who was the first to operate for stone in an aseptic kidney, has termed the operation nephrolithotomy, in contradistinction to nephrotomy, by which term he designates the operation on the septic kidney. I consider this a good distinction, and think that it will be

adopted in the literature, because these two operations are entirely different both clinically and in their results.

(a) NEPHROLITHOTOMY

I present here three stones from aseptic kidneys, which are composed of a small nucleus of urates, surrounded by layers of oxalate of lime. Cross-sections of these stones are often very beautiful, resembling agate. They are very hard. The surface is usually of a chocolate color, and is covered with little, sharp, projecting points.

CASE I.—(With presentation of patient.) H. J. G., aged twenty-six. He has had severe pain in the left lumbar region for eighteen years—so severe at times that to relieve it he would lower the left shoulder and bend to the left. As a result of this a scoliosis has taken place, with torsion in the lumbar region simulating a tumor. Several years ago he consulted me for pain and occasional hematuria.

Operation September 16, 1891. No stone could be found on exploration with the needle, but on digital exploration the stone which I here present was found in a dilated calyx in the upper third of the kidney. It corresponds in shape to the location in which it was found, and presents a groove corresponding to the sharp border of the entrance to the dilated calyx, and which separates an upper portion located in the calyx from a lower portion which extends down into the pelvis.

During the operation the hemorrhage was so serious that I contemplated intravenous injection. Fortunately, this procedure was not necessary. The patient made a good recovery and is now entirely well.

CASE II.—M. M., aged thirty-four. The patient had suffered from severe pain in the right lumbar region for at least twenty-six years. At times the pain was so excruciating as to make him unfit for work. He also suffered from hematuria, and some pus was found in the urine.

Operation August 25, 1892. The pelvis and calices were found to be moderately dilated. The hemorrhage was considerable. The large, rugged stone here presented was found in the infundibulum. Four smaller stones composed of oxalate of lime surrounding coagula of blood were found on digital exploration in a dilated calyx having a rather narrow neck, and which was located in the lower third of the kidney. These smaller stones could not have been found by exploration with a steel sound. Careful digital exploration was required to find them. Exploration of the ureter showed that it was not obstructed. The patient had a fistula which closed after four months, and he made a good recovery. The intensity of the pain which this patient suffered may be explained by the sharp points, like pin-points, on the surface of the stone.

CASE III.—G. N., aged thirty-five. The patient had suffered from pain in the left lumbar region for at least thirty-one years. The pain was so severe as, at times, to disable him for work and to force him to drink large quantities of whisky. Slight hematuria. Dr. Thomas A. Davis, who kindly asked me to operate on this patient, had found blood on several occasions upon microscopic examination of the urine.

Operation December 3, 1892. A large stone with a conic lower end was found in the infundibulum. Little if any dilatation of the pelvis and calices was present. No other stones could be found upon digital exploration. The hemorrhage from the kidney was so alarming as to preclude the possibility of exploring the ureter, and to necessitate packing the pelvis and wound in the kidney with aseptic gauze.

Microscopic examination of the kidney tissue showed that it was almost normal.

Only one very small patch of interstitial infiltration around a glomerulus in the midst of healthy kidney tissue was found. The wound closed in four weeks.

(b) NEPHROTOMY

CASE IV.—The patient was a man from thirty-five to forty years of age, who suffered from cystitis, pyelitis, and pyonephrosis. Upon operation the 144 small, round, and flat uric-acid and urate stones, often faceted, here presented, were found. The removal of these stones did not help the patient materially. This shows that in such cases the stone is often of secondary importance while the sepsis and inflammation remain.

CASE V.—A man from twenty to thirty years old. Upon operation the large phosphatic stone here presented was found, which filled almost the entire pelvis of the kidney. The patient died from uremia. The autopsy showed that the other kidney contained a stone of equal size.

(c) NEPHRECTOMY

CASE VI.—J. D., miner, aged twenty-three, suffered a traumatic rupture of the kidney, caused by a fall of rock which struck him in the right lumbar region. This injury was followed by a perinephritic abscess which left a fistula.

Operation February 2, 1892. The kidney was found to be atrophied and suppurating; therefore nephrectomy was performed. In a perinephritic cavity the stone here presented was found. It is composed of oxalate of lime around a uric-acid nucleus. The broken surface seen in the specimen proves that the stone was crushed at the time of the injury and forced out through the rupture in the kidney. Microscopic examination of the kidney showed diffuse suppurative nephritis. The patient recovered.

Remarks.—Newman has collected 42 cases of nephrolithotomy with no deaths; McCosh, 18 cases with 1 death; Legueu, 43 cases with 3 deaths; Tuffier, 43 cases with 3 deaths; this gives a mortality of 6 per cent. In these operations nephrolithotomy was performed and the kidney incised on the convex border. The result is different when the pelvis contains a stone and the operator does not wish to make an incision in the kidney and so incises the pelvis. Twelve such cases are on record, with a mortality of 16 per cent. as compared with 6 per cent., mortality following incision through the convex border of the kidney.

The material at our disposal is not yet large enough to draw conclusions from, but it would seem better to open on the convex surface of the kidney. Nephrolithotomy with a mortality of 6 per cent. has left only 3 per cent. of fistulas. Pyelotomy, as incision through the pelvis might be called, on the contrary, has a mortality of 16 per cent. and has left 29 per cent. of permanent fistulas. This would seem to show that a pelvic wound will not heal so readily as a wound through the kidney.

One hundred and fourteen cases of nephrotomy, or operations on the septic kidney, are reported by Tuffier, with a mortality of 33 per cent., and with permanent fistulas in 34 per cent. This high rate of mortality is in the main due to the septic condition of the kidney.

The second alternative in cases of nephrolithiasis is nephrectomy. When the stone is removed by this operation there is, of course, no fistula.

If the patient survive the operation, he is cured. Tuffier reports 67 cases of lumbar nephrectomy with a mortality of 39 per cent., and 16 cases of abdominal nephrectomy with a mortality of 37 per cent.

The statistics of nephrectomy give a mortality of 38 per cent. as compared with 33 per cent., the mortality from nephrotomy, consequently we must regard nephrotomy as the operation of choice.

In operations on the kidneys the question of hemorrhage is important. In former times I used the Paquelin cautery, but now I use the knife first and tear through afterward, and find that the hemorrhage is no greater than when I used the Paquelin cautery. Hemorrhage may be controlled by packing with iodoform gauze or by suture (Tuffier). The wound in the aseptic kidney can, as a rule, be sutured.

In operating for stone in the kidney the introduction of an exploring needle through the convex surface of the kidney is uncertain and unsatisfactory. The exploration of the kidney with the steel sound is also unsatisfactory, because while one stone may be found, smaller stones may be left in the calices, and these are the more dangerous, because they are about the size to pass into and occlude the ureter. Tuffier reports 20 errors in 114 cases, in 9 of which an existing stone was not found, and in 11 a stone was removed, but others were left in the kidney. This incomplete extraction resulted in prolonged drainage and in 34 per cent. of fistulas which necessitated secondary operation.

Nine of the 38 deaths reported by Tuffier occurred as a result of stone in the other kidney existing at the time of operation.

The only way to avoid leaving stones in the kidney is to make the opening large enough for digital exploration. The kidney should always be incised near the center, so that the finger-tip can explore the entire kidney. If the entrance to a calyx is not large enough to admit the finger, it should be broken through, so that the operator may be sure that no stone has been left. The ureter must also be examined so as to be sure that it is patent from kidney to bladder.

3. SURGERY OF THE URETER

CASE I.—*Stones in the ureter.*

E. V. C., aged thirty-five. In December, 1890, the patient had the initial attack of renal colic. Six months later came a second attack. The attacks then became more frequent until he suffered almost constant pain. There was no hematuria. No tumor could be detected, nor could the kidney be made out by palpation. Diagnosis, nephrolithiasis.

Operation March 27, 1892: nephrolithotomy. The pelvis of the kidney was found to be somewhat dilated; no stone could be found on intrarenal digital exploration. A probe from the wound in the kidney would not pass down the ureter. An examination of the ureter by palpation, after enlarging the lumbar wound, disclosed a stone in the ureter $1\frac{1}{2}$ inches below the infundibulum. A longitudinal incision $\frac{3}{4}$ inch long was made in the ureter, and the stone, which I here present, removed. The groove on the stone was caused by a needle which was pushed into the ureter in the endeavor to dislodge the stone and force it up into the pelvis. A second smaller stone was felt above and removed. A No. 9 French scale flexible bougie could now be passed down into the bladder.

The incision was not united by sutures. On the first day urine passed down into the

bladder. After the third day no urine was found in the dressings. The wound or fistula closed in a month.

Tuffier has collected 17 cases of operation for stone in the ureter, with 3 deaths and 3 resultant fistulas. Stones in the upper portion of the ureter have been operated for in 9 cases, in 4 of which the stone was removed by pushing it up into the pelvis, and then incising the pelvis, that is, pyelotomy. One death resulted from nephritis, and the other 3 patients recovered, 2 with permanent fistulas. In one case nephrolithotomy was performed, the stone pushed up and removed through the wound in the kidney. This patient recovered. Longitudinal ureterotomy was done in 4 cases, which were all cured, leaving one fistula.

Exploratory Ureterotomy for Stone.—Exploration of the kidney and ureter by means of ureterotomy, for the purpose of clearing up diagnosis, may be made without detriment to the patient, as will be seen from the following case:

CASE II.—*Exploratory operation on right kidney and ureter for stone.*

M. R., aged twenty-eight.

Diagnosis.—Stone in an aseptic kidney.

Operation September 15, 1892. Lumbar incision. Palpation and examination with needle negative. The kidney was incised by the Paquelin cautery. Profuse hemorrhage followed, and I could not find my way into the pelvis. The pelvis, which was normal in size, was not accessible from below after lifting up the kidney. The ureter was now incised, and a probe passed down into the bladder and up into the pelvis and calices, but no stone could be found. The wound in the ureter was closed by silk sutures passed through the muscular and external coats of the ureter. One drain was passed into the kidney and another down to the wound in the ureter. For two days after the operation no urine escaped into the dressings. For eighteen days thereafter the dressings were saturated with urine. From the fifth to the seventh day blood was found in the urine. The fistula closed in fifty days.

CASE III.—*Stricture of ureter, with presentation of patient. Valvular stricture or stenosis of pelvic orifice of ureter in a somewhat floating kidney.*

Mrs. H., twenty-eight years of age, eight years ago had the first attack of intermittent hydronephrosis; the tumor disappeared in two weeks. She had a second attack after childbirth, which lasted eight days. Attacks occurred at intervals of one or two months until two years ago, when they became more frequent, occurring every two weeks. During the last year she has had an attack every week. On March 11, 1892, during an attack of pain, a tumor could be felt in the region of the left kidney. Five days later no tumor could be found. During and immediately after the disappearance of the tumors the urine was milky from pus.

Diagnosis.—Intermittent pyonephrosis; stenosis in pelvis or ureter, possibly from stone. Advised nephrotomy and exploration of ureter.

Operation May 31, 1892. Nephrotomy in the interval between attacks. I desired to operate during an attack, but evacuation took place the night preceding the operation. Before the kidney was reached the spleen, which was somewhat movable, had to be pushed up out of the way. On palpation, no stone could be felt in the kidney or the pelvis; the latter felt like an empty sac. An incision was then made through the convex surface of the kidney. On digital exploration some dilatation of the pelvis and calices was present, but no stone could be found. Catheterization of the ureter was impossible. The pelvis was now opened from its posterior surface. This revealed a valvular opening from the pelvis into the ureter. The valve was divided transversely, and the ends of the incision united by a suture. A bougie was inserted through the wound in the kidney and brought down into the ureter and retained there for two days. The wound in the pelvis was united by

sutures. The floating kidney was secured by nephrorrhaphy, the wound in the kidney drained, and the usual dressings applied. The patient recovered without fistula, and up to the present time has had no return of the pyonephrosis.

CASE IV.—Traumatic stricture of ureter close to its entrance into the pelvis of the kidney. Intermittent hydronephrosis.

The patient was a man forty-seven years of age. Thirty-four years ago, in jumping from a horse to the ground, on account of miscalculation of distance he sustained an injury by a violent jerk, his feet not touching the ground, while his hands still retained hold of the hames. He was in bed a month at this time, and after ten years the hydronephrosis developed which eventually compelled him to come under my care. A year after the first attack he had four or five attacks a year, lasting two or three days and then subsiding rapidly, being followed by pus in the urine. I examined the patient on November 12, 1892, and found a tumor in the left kidney, and made a diagnosis of nephrolithiasis in the pelvis or infundibulum, or pyonephrosis from stone or obstruction in the ureter.

Operation November 26, 1892. No tumor could at this time be felt. I made a lumbar nephrotomy, and found the kidney sacculated, but could find no stone in the pelvis or calices. The ureteral entrance could not be found through the wound in the kidney. The dilated pelvis was now incised on its posterior wall, but still the opening of the ureter could neither be seen nor felt. The ureter was now isolated. Its upper end for $\frac{1}{2}$ inch was found to be embedded in cicatricial tissue. Lower down, though small in caliber, the ureter was normal. A longitudinal incision 1 cm. long was now made in the ureter just below the cicatrix. The sound could now be passed easily down into the bladder, but when passed upward, its progress was stopped by a stricture situated immediately below the pelvis. The stricture was 1 cm. long, and the ureter below it was somewhat narrowed, not in one place, but diffusely throughout its extent. The stricture was then incised up into the pelvis. A plastic operation was now made similar to that of Heineke-Mikulicz for stenosis of the pylorus; that is, the ureter was united to the pelvis on that principle. The pelvic wound was united by sutures. No bougie was left in the ureter. A drainage-tube was passed into the pelvis through the wound in the kidney. The usual external drainage was employed and the wound united. The patient left the hospital in six weeks with the wound perfectly healed. The urine at this time contained no pus visible to the naked eye. On microscopic examination a few isolated pus-cells could be found in the sediment.

Remarks.—In all cases of pyonephrosis we may expect to find some obstruction to the flow of urine in the renal pelvis, the ureter, the bladder, or the urethra. If the obstruction is external to the ureteral opening in the bladder, the pyonephrosis is double; if on one side, the obstruction must be in the ureter or the pelvis of the kidney.

Lumbar nephrotomy for pyonephrosis has a mortality of 23.3 per cent. and primary lumbar nephrectomy a mortality of 34 per cent. (Tuffier). Secondary nephrectomy must be made to close the fistula after some time has passed, but this should not be delayed until amyloid nephritis of the other kidney has set in. The mortality from this operation is low—5.9 per cent. If we add the 5.9 per cent. mortality from secondary nephrectomy to the 23.3 per cent. mortality from primary nephrotomy, the total of 29.2 per cent. is still 7.8 per cent. less than the mortality from primary nephrectomy, which is 37 per cent., and 4.8 per cent. less than the mortality from primary lumbar nephrectomy, which is 34 per cent. Consequently, in pyonephrosis, nephrotomy is the operation of choice (Tuffier).

The disadvantage of nephrotomy as compared with nephrectomy for pyonephrosis is that a fistula remains in 45 per cent. of the cases. This means that after a time a secondary nephrectomy must be made. Fistulas remained in 34 per cent. of the cases of calculous pyelitis and in 54 per cent. of the cases of non-calculous pyelitis. The smaller number of fistulas in calculous pyelitis is to be accounted for by the fact that in a certain number of these cases the stone prevents the passage of urine, and with the removal of the stone the obstruction is removed. Where there is no stone, simple nephrotomy will leave the impediment in all cases. If in both calculous and non-calculous pyonephrosis we can re-establish the permeability of the ureter, we may expect materially to diminish the percentage of permanent fistulas.

Tuffier, in the discussion of pyonephrosis in his excellent monograph on surgery of the urinary organs, which appeared in vol. vii of Duplay and Reclus' *Traité de Chirurgie* in May, 1892, remarks: "It would be interesting to know the condition of the ureter, the strictures, bands, valve-formations that transform an open pyelonephritis into a temporarily closed hydro- or pyonephrosis. As yet these investigations for the intermittent pyonephrosis have not been made."

THE OPERATION FOR PYONEPHROSIS

The operation for pyonephrosis should be nephrotomy, followed by exploration of the ureter from the kidney or pelvis to the bladder, and, if necessary, by a plastic operation for valves or stricture in the ureter.

A differential diagnosis is impossible before the kidney is incised. It is often impossible to determine beforehand whether a stone is or is not present; the number of stones; whether the stones are located in calices, the pelvis, or ureter, or whether or not the obstruction is caused by a valve, band, or stricture of the ureter. It is also impossible to know beforehand the condition of the kidney tissue, whether it is totally destroyed, filled with multiple abscesses, or if a greater or less amount of functionally valuable tissue is present.

The operation for pyonephrosis must in a great number of the cases be exploratory, and the urinary passages should be thoroughly explored for stones, tumors, tuberculosis, stenosis, etc., from the kidney to the bladder. That this exploration can be done successfully in case of valve-formation at the pelvic orifice of the ureter or in case of stricture near this region has been shown in the case reports above given.

I propose the following plan of operation, which I have followed out in a number of cases:

1. Lumbar incision, oblique, from the corner of the twelfth rib and erector spinæ muscle downward and forward toward the ilium.
2. Palpation of the kidney after detachment of the adipose capsule and palpation of the pelvis.
3. Exploration of kidney by needle to detect stone is unreliable.
4. Excision of a piece of kidney tissue for microscopic examination.
5. The incision should be longitudinal, on the convex border of the

kidney, and $1\frac{1}{2}$ to 2 inches in length, and may be made by the Paquelin cautery or the knife. If possible, I make the incision guided by an aspirator needle which has been introduced into the dilated pelvis to explore for pus. Without such a guide it may be very difficult to find the way into the non-dilated pelvis, as was shown in Case II, exploratory ureterotomy.

6. Exploration through the renal wound by a curved steel urethral sound, to detect stones in the pelvis and calices, is also unreliable. In 9 cases an existing stone was not found, and in 11 cases one or more stones were extracted, but stones still left in the kidney, that is, incomplete extraction. This resulted in 34 per cent. of permanent fistulas which required later another operation for their closure.

7. Digital exploration of the pelvis and calices I consider the most satisfactory method, and the one that will best secure against incomplete extraction of stones. A narrow entrance to a dilated calyx can be dilated or ruptured by the finger.

8. Exploration of the ureter as to its permeability should be done from the renal wound by a long flexible silver probe (a uterine probe) or an elastic bougie, either olive pointed or not. If the bougie passes into the bladder, the examination is at an end.

9. The size of bougie that will pass through a healthy ureter is from No. 9 to No. 12, French scale.

10. If the pelvic orifice of the ureter cannot be found from the renal wound, it should be sought for by opening the pelvis—pyelotomy—or by incising the ureter—ureterotomy.

11. Pyelotomy. A longitudinal incision, $\frac{1}{2}$ inch to 1 inch long, in the posterior wall of the pelvis can be made while the kidney is lifted upward against the twelfth rib. This procedure is easy if the pelvis is dilated, but may be impossible if the pelvis is of normal size.

(a) Extraction of a stone in the infundibulum through an incision in the pelvis is advised against by Tuffier on the ground that pyelotomy increases the danger of the operation, and that union of the wound in the pelvis is difficult. My experience in this regard is not in accord with Tuffier's statement.

(b) The pelvic wound should be united by extramucous sutures.

12. Ureterotomy. A longitudinal incision from $\frac{1}{2}$ cm. to 2 cm. in length is sufficient for the extraction of a stone which cannot be dislodged upward into the pelvis, and for exploration of the ureter if the pelvis is not dilated, and consequently not easily accessible.

The wound in the ureter may be closed with extramucous sutures or may be left open. In either case the wound will close without causing stenosis of the canal. A ureteral fistula is not to be expected if the ureter is open between the wound and the bladder.

13. A valve or valvular stricture at the pelvic orifice of the ureter is usually caused by lateral insertion of the ureter in a dilated pelvis. A plastic operation upon the valve, in order to secure free passage of urine from the pelvis into the bladder, can be performed through the incision in the the pelvis, as shown in Case III.

Küster performed a similar operation on a valve, but finding a stricture lower down in the ureter, he proceeded to resect the upper strictured portion of the ureter, and united the cut end of the ureter below the stricture with the pelvis.

14. A stricture in the ureter, if not too long, can be treated by a plastic operation on the plan of the Heineke-Mikulicz operation for stenosis of the pylorus, longitudinal division of the stricture, and transverse union of the longitudinal wound.

This method of operating for ureteral stricture seems to me preferable to resection of the strictured part of the ureter (Küster's operation), for the following reasons:

(a) It is a more economic operation, and preferable when the elongation of the ureter is not sufficient to permit the two cut ends of the ureter, after excision of the stricture, to come in contact without stretching.

(b) It is easier to secure union of a ureter which has been incompletely divided in a transverse direction. Tuffier's experiments on dogs gave the following results: Six cases of transverse ureterotomy all failed; 4 cases of longitudinal ureterotomy were followed by a successful result in 2 cases.

15. Resection of the upper end of the ureter and implantation of the distal end into the pelvis has been performed in an important and interesting case by Küster, and the result was a brilliant success. His method was to split and unfold the end of the ureter, and to implant it into the opened pelvis, to which it was united with sutures.

In a similar case of stricture in the upper end of the ureter, especially if the ureter were not elongated or the kidney movable, I should prefer the plastic operation already described, as it is easier of technic, and as it proved successful in my case of traumatic stricture in the ureter below the pelvic orifice.

16. The ureter is accessible through an extraperitoneal incision, a continuation of the oblique incision for lumbar nephrotomy, from the twelfth rib down along and 1 inch anterior to the ilium and along Poupart's ligament to about its middle. This incision gives access to the upper three-fourths of the ureter and down to within $1\frac{1}{2}$ inches or 2 inches above the bladder.

The vesical and lower pelvic portions of the ureter may be reached, as Cabot, of Boston, has pointed out, by means of the sacral operation or Kraske's method, modified by osteoplastic temporary resection of the os sacrum. In woman, the vesical portion of the urethra is accessible through the vagina.

The vesical orifice of the ureter may be reached from within the bladder by suprapubic cystotomy in man or by dilatation of the urethra or suprapubic or vaginal cystotomy in woman.

In conclusion, I wish to cite literally the remarks made by Küster at the conclusion of his communication to the German Surgical Congress, because I fully agree with Küster and think that his remarks apply well to my proposals of this evening. Küster says:

“Gentlemen: When I bring this case before you, it is not to present to you a curious operation or a curiosity in the line of operating. The value of the observation appears to me to lie in the fact that it shows a method by which it may be possible to avoid the mutilating and dangerous operation of nephrectomy in cases of pyonephrosis where and when we do not know that the other kidney is perfectly healthy.”

I would add—and a means to save or avoid some instances of permanent fistulas following nephrotomy for pyonephrosis or hydro-nephrosis.*

* When I commenced to investigate the question of stenosis of the ureter and its possible operative treatment, I did not know that Küster had commenced work in the same direction. The first publication of Küster's case which reached me was his report before the Twenty-first German Surgical Congress, June 8 to 11, 1892, which appeared in the *Centralblatt für die gesammte Medicin* for August 13, 1892.

My first operation for stenosis was performed at a clinic and described in a clinical lecture given on May 31, 1892, at the Emergency Hospital, Chicago, for the Chicago Polyclinic.

HYPERPLASTIC SALPINGITIS AND ITS OPERATIVE TREATMENT BY DRAINAGE*

SUPPURATIVE inflammation of the Fallopian tubes was, until the beginning of the last decad, not studied in its details either as to etiology or as to pathologic anatomy. The typical pyosalpinx—a closed, dilated tube filled with pus, effecting rupture into the peritoneal cavity and peritonitis, or extension to the surrounding organs, and local pelvic inflammation, with or without abscess formation—was then regarded as a common form of the disease.

A. Martin first called attention to the fact that in some cases of salpingitis there was no dilated tube filled with pus, but a thickened wall surrounding a normal or narrow lumen in which only a slight amount of secretion was contained. We owe to Martin, to a great extent, through work by himself and his pupils, the detailed knowledge of today of the pathologic anatomy of suppurative salpingitis. Kaltenbach, in 1885, described a case of gonorrhoeal salpingitis, with stenosis of the canal and consecutive hypertrophy of the muscularis. The patient had suffered from attacks of excruciating pain preceding menstruation; she would roll on the floor and cry out loud—would scream like a maniac. The right extirpated tube was as thick as a finger and rigid; the fimbriated end was closed, and the narrow canal contained only a little blood. The thickness of the wall was due to an enormous hypertrophy of the muscular coat. Kaltenbach explained this muscular hyperplasia as a result of overwork of the muscular coat of the tube in trying to evacuate the contents into the uterus through the stenosed portion of the tube. Kaltenbach had expected to find a typical pyosalpinx, and was surprised to find no dilatation of the lumen of the tube.

Orthmann, in an excellent paper on the pathology of the tubes, using the material from A. Martin's private clinics, and A. Martin, in a paper read in Berlin in 1886, state that thickening of the wall of the tube is commonly found in chronic salpingitis, and is due to a diffused granulated infiltration of the whole wall of the tube; rarely to hypertrophy of the muscular coat.

From an anatomic point of view Martin made a distinction between catarrhal, interstitial, and follicular salpingitis.

In endosalpingitis catarrhalis the mucous membrane is thickened by small-celled infiltration below the undestroyed epithelium.

* Med. Record, 1893, vol. xliii, p. 678.

In interstitial salpingitis the whole wall is the seat of the infiltration; the tube is hard and stiff, and thick as a lead-pencil or a finger.

In follicular salpingitis the tube is elongated, tortuous, not dilated, and contains a small amount of mostly serous, often bloody, fluid. The wall of the tube is thickened sometimes to $1\frac{1}{2}$ or 2 cm., is rigid, and does not collapse when the tube is cut across. The thickening of the tube is due to small-celled infiltration and young connective tissue that separates the muscle-bundles and contains dilated vessels which are either empty or filled with blood, sometimes to such an extent as to rupture and cause small ecchymoses. In the wall are also to be found small abscesses and cystic spaces. A plastic peritonitis unites the tube with all its surroundings, intestines, uterus, and walls of pelvis, and makes the convolutions of the contorted tube adhere to each other so as to form a tubal tumor, as it is often termed. This tumor is from the size of a hen's egg to that of a fist, and consists of the convolutions of the diseased tube united into one mass, in which the canal runs as a labyrinth which is hard to unravel even on a careful postmortem dissection. The lumen may be locally narrowed so as to admit only a hair and may be surrounded by dilated round spaces.

I will first describe a typical case of this kind, treated in the usual manner by extirpation:

CASE I.—Synopsis.—Gonorrheal infection eleven years ago; symptoms of salpingitis over ten years ago, increasing in severity; considerable aggravation for the last year and a half. Extirpation of the left tubal tumor by laparotomy; recovery.

History.—Mrs. A. F. A., of Chicago, twenty-nine years of age, married, does her own housework. She has been married nine years, has no children, and has had no miscarriages. Menstruation commenced at the age of thirteen and was regular until sixteen, when it disappeared for a time after bathing in the lake. During this time she had diphtheria and was sick in bed for five weeks. At the age of eighteen she was exposed to gonorrheal infection and a purulent discharge from the vagina followed, which remained for years. An attack of typhoid fever was followed by weakness for one year. After her marriage, at twenty, menstruation became copious, and was accompanied by intense pain in the back and hips. One year and a half before her marriage, while lifting a heavy trunk, she felt a sudden pain in the left inguinal region, followed by chills and fever, confining her to bed for two months. After this there would be some pain in the left lower abdomen now and then, sometimes extending over to the right side, and she never since has regained her full health. During the last ten years the pain would occasionally increase so as to force her to stay in bed for some days about once every two months. In the fall of 1890 a more severe attack of pelvic cellulitis came on, with chills and fever, pain, tenderness, swelling of the lower part of the abdomen, and frequent painful micturition. She was in bed for six weeks, but remained disabled from persisting pains, weakness, and nervousness. In May, 1891, a similar attack kept her in bed for two weeks. Her family physician, Dr. Otto, of Chicago, finding a tumor to the left of the uterus, sent her to me for operation in June, 1891.

On examination I found the patient somewhat pale, moderately well nourished, with the organs of the thorax and upper abdomen normal. No fever. There was pain in the pelvis minor, chiefly on the left side, aggravated by walking or being on the feet much, which incapacitated her for domestic work.

Examination of the abdomen revealed tenderness above the symphysis, most pronounced to the left, where a tumor was felt. Vaginal examination showed the uterus dis-

placed somewhat to the right by a tumor the size of an orange; it was even on the surface, hard, not fluctuating anywhere, located in the left broad ligament high up, and connected with the left side of the uterus, so as to permit of only slight mobility between them. There had never been any discharge of pus from the rectum, and rectal examination showed no softer points on the posterior surface of the tumor. Puncture by a fine aspirator needle through the vagina brought from high up about a teaspoonful of pus, and was followed by fever for twenty-four hours.

The diagnosis was pyosalpinx gonorrhœica buried in pelvic exudate, and extirpation, or rather exploratory abdominal section, was advised.

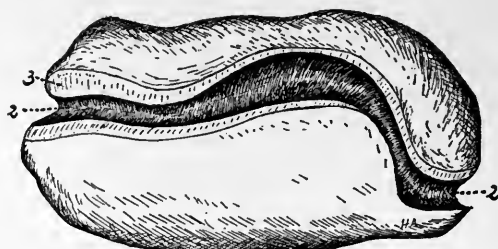


Fig. 76.—The tube: 2, 2, Tubal canal; 3, thick wall.

Operation June 22, 1891, in the Emergency Hospital. A median incision was made, from the symphysis to near the umbilicus, and a transverse division of the rectus muscle was made low down. I found a tumor the size of an orange, covered with omentum, after detachment of which enucleation was effected with some difficulty by the fingers. The tumor finally came out as a mass, no pedicle was found, and a number of vessels had to be ligated subsequently. The right ovary and tube were found to be apparently healthy, and were not removed. It was impossible to cover the rather extensive bed from which the tumor was enucleated with folds of peritoneum from the broad ligaments; therefore drainage with iodoform gauze surrounding a glass tube was employed.

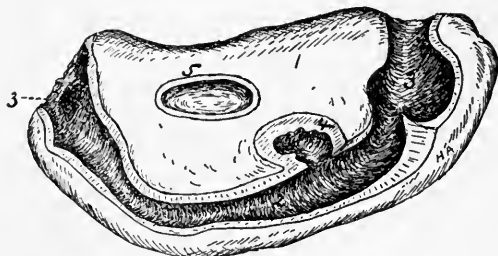


Fig. 77.—The tube: 1, The surface; 2 and 3, the lumen; 4, dilatation of lumen; 5, tear in removal.

For three days after the operation there was slight elevation of temperature to 101.5° F. and some vomiting, but at the end of the third day the symptoms subsided. The day following the operation the patient asked for beer, which she kept down, and she took from one to three pints of beer a day during the first week, while milk, tea, and other liquids were vomited. The glass drain was removed on the fourth day, and the gauze drain on the twelfth day, and she left the hospital five weeks after the operation.

Her present condition now, one year later, is perfectly satisfactory, as shown by an examination on August 19, 1892. She gained some 20 pounds in weight in the two months succeeding the operation, and has retained that weight since. Menstruation reappeared

in the third month, and has been regular and painless ever since. Sometimes she feels slight pains low down in the pelvis, but these are only transitory. She can be on her feet

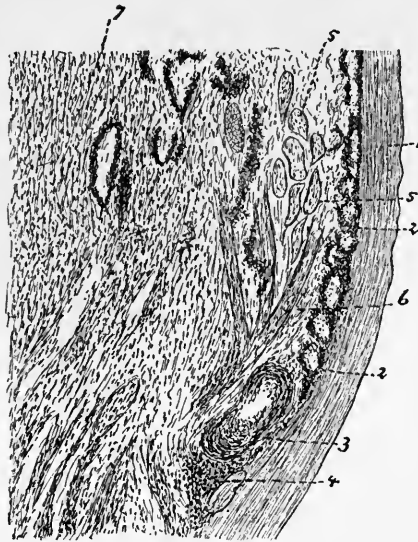


Fig. 78.—1, Thick peritoneum; 2, 2, lymphoid cells; 3 and 4, chronic phlebitis and periphlebitis; 5, 5, dilated vessels; 6 and 7, tubal wall.

all day and do her housework, except the washing. Cohabitation is only occasionally accompanied by slight pain, and in general she thinks that her health is better now than it was even before her marriage.

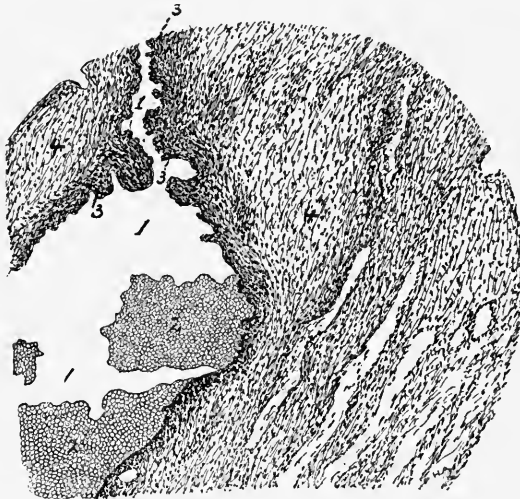


Fig. 79.—1, 1, Cavity filled with pus or mucus; 2, coagulum; 3, embryonal tissue in wall; 4, tubal wall.

Description of Specimens.—For gross appearances see Figs. 76 and 77. The extirpated tube forms a globular tumor the size of an orange, one side convex, the other

more flattened. On the convex side and along the borders are seen longitudinal ridges the thickness of a finger, forming a bas-relief on the surface, running in curves interwoven with

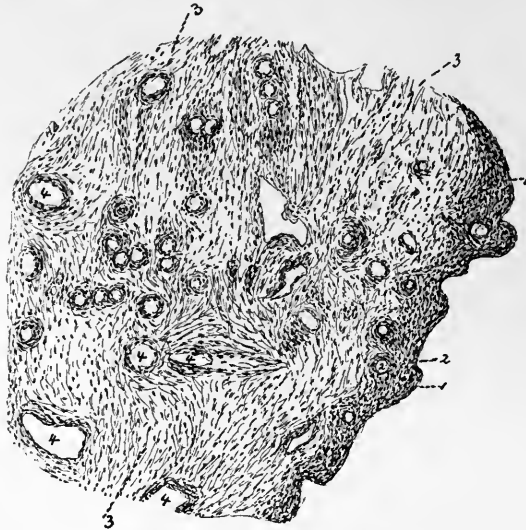


Fig. 80.—1, 1, and 2, Round-cell infiltration in wall; 3, 3, 3, tissue of wall; 4, 4, 4, 4, vascular spaces.

one another. These are the convolutions of the elongated, thickened, and contracted tube, which have been united by connective tissue into one globular tumor. Incision along the top of the ridges shows the thickened wall of the tube, and leads into the open, not much

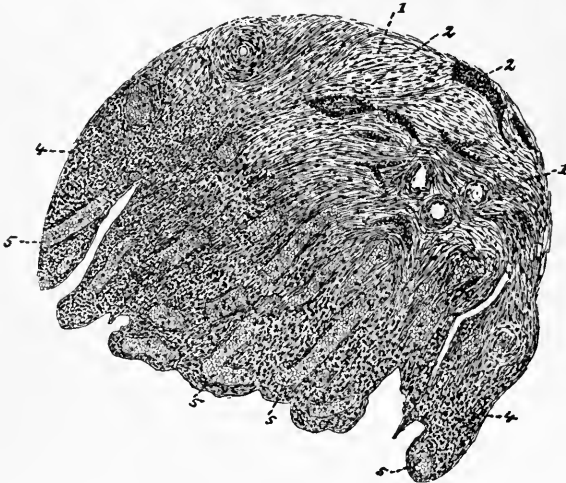


Fig. 81.—1, 1, and 2, 2, Tissue of tubal wall with islands of infiltration (2); 4, 4, cellular infiltration; 5, 5, 5, 5, mucosa with epithelium and with dilated capillaries.

dilated, canal that remains patulous when opened into longitudinally or divided transversely, on account of the rigid condition of the thickened wall. The canal contains a slight amount, less than a teaspoonful, of pus or mucopus. The tumor is not of uniform

caliber, but with round spaces alternating with narrower spaces, especially on the convexity of the curves of the convolutions. The abdominal end of the tube is closed and buried in the mass of the tumor. The ovary I could not find. The uterine portion of the tube is dilated and presents as a round opening on the flat surface of the tumor, where it has been torn across during the enucleation. The thickness of the wall of the tube varies from 3 mm. to 1.5 cm.

Microscopic Examination (Figs. 78, 79, 80, and 81).—The peritoneal portion shows thickened peritoneum in the shape of a layer of old fibrillary connective tissue. Below this, in the subperitoneal tissue, are numerous lymph-spaces partly filled with, but all of them surrounded by, a layer of granulation cells or lymphoid cells. This shows a chronic subperitoneal lymphangitis. After this comes a layer of young connective tissue rich in cells, with thickened vessels and small-celled infiltration in many of the perivascular spaces (chronic periphlebitis). Below this thickened peritoneum and subperitoneal tissue the muscularis is seen. It is not particularly hypertrophic, neither are the muscular bundles separated by layers of young connective tissue to any appreciable extent. In the wall inside of the muscularis is an irregular cavity filled with pus or mucous matter, as seen in the coagulum adherent to its wall. The wall consists of a layer of embryonal tissue with the cells so numerous as to permit almost no stroma to be seen between them. I am uncertain whether this cavity is an abscess in the wall of the tube or an occluded space of the irregular lateral sinuosities of the lumen, on the mucosa of which the epithelium has been destroyed. Both of these conditions—miliary abscess and occluded spaces—are found in the walls of such tubes (Martin). The submucosa is the next stratum, and consists of a very thick, uniform mass of young connective tissue with spindle-shaped cells. It is rich in small and large vessels, the walls of which, arteries as well as veins, are thickened. The vessels are not dilated, but in a number of perivascular spaces are seen groups of leukocytes, showing that inflammation is going on, or at least a formative process tending to increase of the hyperplasia of the wall. The inner and last layer is the mucous membrane, or what is left of it. The epithelium has disappeared and the mucosa appears like a heavy layer of embryonal tissue packed with leukocytes or lymphoid cells. A considerable number of large, thin-walled vessels, probably dilated capillaries, filled or distended with blood, give the tissue an almost angiomatous appearance. In some places the dilated vessels have ruptured, and islands of extravasated blood are found. Between the dilated and filled vessels numerous empty capillaries are also seen. There is an enormous vascularity in this innermost layer of the tubal wall.

This specimen represents an average form of chronic salpingitis. The whole wall of the tube is thickened in the majority of cases. Orthmann found it to be so in all of his 8 cases of "salpingitis purulenta." But he also found it in at least 8 of his 9 cases of "salpingitis catarrhalis." Looking carefully over the detailed description of Orthmann's 9 cases of salpingitis catarrhalis and the following 8 cases of salpingitis purulenta, I am unable to see any difference in the anatomy of the diseased tubes, and I do not understand how he differentiates between the two forms. In both classes of cases we find the thickened tube either straight and not elongated, or elongated and convoluted, the convolutions uniting to form a tubal tumor.

A. Freund has probably given the best explanation of the fact that the tube in some cases takes on the straight and in others the convoluted form. In his beautiful investigations of the development of the Fallopian tubes in intra-uterine and after-life he found not infrequently an arrest of development on one or both sides in adult females. He found

the tube as follows: A short, narrow, uterine portion, followed by two to four convolutions, which were sometimes spirally contorted so as to form a number of multiple loops, like the old post horn. This is the shape of the tube normally found in the fetus and new-born child, and when found in the adult, signifies that the tube has been arrested at an early stage of development as far as the change in shape is concerned. Freund points out that a tube of this shape is less liable to empty its contents than a normal straight one. This condition consequently predisposes to retention of secretion, and makes the tube, when injected with gonococci or pus-microbes, less apt to pass through an attack of inflammation spontaneously.

It is natural to suppose that a tube of the shape described by Freund, when infected, would easily be transformed into a tubal tumor, as was the one described in my case.

N. Savinoff has described a well-marked case of a thickened, non-contorted tube. He names the disease "salpingitis chronica productiva vegetans." This name, although somewhat long, is a correct one, but it does not apply to a singular or rare form of salpingitis, as his case does not differ from the common chronic salpingitis as described by Martin, Kaltenbach, Orthmann, Cornil and Terrillon (salpingitis purulenta), Gottschalk, and others. Boldt, in a short and excellent paper on the pathology of the tubes, uses the term interstitial salpingitis, as first proposed by Martin. Orthmann attempts to make a rigid distinction between salpingitis purulenta and pyosalpinx. The pyosalpinx is a dilated tube filled with pus, and requires for its existence closure of the ostium abdominis or a stenosis somewhere in the canal. He regards pyosalpinx as the first stage of a purulent salpingitis where the mucous membrane is destroyed by pressure and the remainder of the tubal wall thickened. I have extirpated more than once a typical pyosalpinx where the epithelium was well preserved and the wall of the dilated tube little if at all thickened.

It seems to make little if any difference whether the pyosalpinx is due to infection with the gonococcus or with the pus-microbe. In Orthmann's 8 cases of salpingitis purulenta the origin was found to be gonorrhoea in 3 cases and puerperal infection in 3 cases, and there was no particular difference in the pathologic anatomy of these tubes.

In the treatment of salpingitis it must be borne in mind that the majority of cases recover under conservative measures—rest, antiphlogosis, and so on. Martin states that in his series of 287 cases, over four-fifths recovered without operation. But the minority of obstinate cases that have proved refractory to conservative treatment require operation.

Abdominal extirpation of the diseased tube, as inaugurated by Lawson Tait, is today in the hands of the profession all over the world. The removal of a pyosalpinx or a tubal tumor is sometimes easy, but often difficult, and in some cases absolutely impossible. The difficulty and consequent danger depend mainly upon the relation between the tube and the intestines. Adhesions to the sigmoid flexure or to loops of small intestine may be so extensive as to render it impossible to loosen the

intestine without rupture of its wall. Perforation of the pus cavity into the bowel and a communication between them, characterized by periodic evacuation of pus through the rectum, is another danger, and is, in my opinion, so grave as to contraindicate abdominal extirpation. It is probably more often a peritubal abscess than a perforated dilated tube that opens into the bowel.

A peritubal abscess, with the thickened tube adherent to or embedded in its wall, has been removed *in toto* with the diseased tube in a number of Martin's cases.* Martin says that, "verhängnisvoll," the cases with extensive intestinal adhesions or perforation into the intestine are severe or difficult. In 3 out of 12 deaths from a series of 61 operations this complication was found. Martin regards the danger of infecting the peritoneal cavity with pus from a tube ruptured during extirpation as less than the danger from extensive adhesions to the intestines. Leopold, who in 1886 operated on 5 cases with 3 deaths, met with a case where, after the removal of the right appendages, he found it impossible to remove those on the left side. He fears, besides the infection from the tube, hemorrhage from the severed adhesions. Martin, at the Congress in Copenhagen, stated that he had met with cases where extirpation was impossible, and considered the operation more grave than the removal of ovarian tumors.

It is of little practical value to consider the mortality of removal of diseased tubes by laparotomy, because of the above-mentioned difference in the cases.

Westermarck gives a mortality of 8 per cent. from 489 operations reported by 8 operators. Gusserow had 1 death in 31 cases; Wylie, 2 deaths in 14 cases, both of which were in a series of 8 cases of pyosalpinx; Rosthorn, 2 deaths in 40 cases—the cause of death in both cases was overlooked injuries to the intestine during the extirpation; Martin had 12 deaths in 61 operations, in 3 of which, as above stated, intestinal complications were present; Boldt, 8 deaths in 112 cases; Kummel, 1 death in 10 cases; Pozzi, 1 death in 26 cases; Keith, no deaths in 33 cases; Leopold, 3 deaths in 5 cases.

It is easily seen that the mortality varies with the character of the cases operated upon, and that the most skillful operator will have a higher mortality when he happens to meet the more severe cases, and when removal is effected in spite of the difficulties in the given case. To draw the line where removal should be abandoned as too dangerous is a clinical problem for which no rule can be laid down.

What can be done or has been done in the cases that have been abandoned as impossible? Martin advises that the opened sac be closed after drainage is established down into the vagina. This method of operating is applicable only to the cases where a pus-containing cavity, dilated tube, or abscess exists. As above stated, there is no such cavity in many cases. Drainage of the tube through an opening in the vagina is proposed by Mundé as the primary operation to be attempted when the tube is accessible from below. Mundé states as follows: "I have

* Orthmann, Cases XII, XV, and others.

had a number of these cases, and by persistence and perseverance have succeeded in curing them, although the drainage-tube had to be worn for a number of months."

This operation is applicable only to cases where a cavity filled with pus is present. It will be impossible to enter from the vagina the comparatively narrow canal of a tubal tumor in a hyperplastic salpingitis.

Drainage of a non-dilated tube can be obtained from the abdomen with beneficial results, as is shown in the following case:

CASE II.—Synopsis.—Gonorrheal infection two years ago; nine months ago increase in endometritis; seven months ago pelvic cellulitis terminating in abscess, aspiration through the vagina; three months ago opening of abscess into the bowel; periodic evacuation of pus per anum; abscess inaccessible from the vagina. Laparotomy; no pus found; operation in two tempos; opening and drainage of the non-dilated tube; recovery.

History.—Mrs. A. W., of Sheboygan, Wis., entered the German Hospital November 12, 1891. She is twenty-eight years of age, married eight years. No hereditary disease in her family; both parents are alive; she has 10 brothers and sisters, all in good health. As a child she had measles and scarlatina, otherwise she was always healthy. Menstruation commenced at the age of fifteen, and was always regular. She was married when nineteen years of age, has 3 children healthy—seven, six, and three years of age. Her husband had gonorrhoea two years ago, and transmitted it to his wife, who suffered from the usual symptoms of an acute attack of the disease. Nine months ago, in February 1891, there came on an increased purulent discharge from the vagina. It would lessen after menstruation, which continued to be regular as to time and quantity, and was never accompanied by any unusual amount of pain. Seven months ago, in April, 1891, she was taken with chills, fever, and pain in the left hypogastric region and had to go to bed. Three days later a profuse discharge of pus from the vagina came on, as she states, suddenly, and then the fever decreased somewhat, but the pain and tenderness forced her to stay in bed. After a few weeks the fever again increased, she became emaciated, and the lower part of the abdomen became swollen and hard. About the end of May a physician opened an abscess through the vagina without an anesthetic, and evacuated over one quart of pus mixed with blood. Toward the end of June she got out of bed and was around for about two weeks. The pain, however, returned and made her go to bed for days at a time off and on. The growth in the lower abdomen had disappeared when the abscess was opened, but when the pain returned she again felt a tumor in the left hypogastrium, smaller at first, but later increasing in size to that of a coconut. In August, 1891, she began to notice periodic evacuations of pus through the rectum, followed by a decrease in the pain and in the size of the tumor. In September and October she passed most of the time in bed. The abscess would discharge through the bowel two or three times a week. The swelling increased to the size of a child's head, and the pain became more intense toward the end of two or three days, then during the night the pain would disappear, the swelling decrease, and in the following evacuation of the bowels a noticeable quantity of pus could always be found. She never noticed any difference in the fever at such times. This condition continued until the time I first saw her.

Present Condition.—She is rather emaciated, the muscles of the extremities being flabby; face pale; pulse, 100; temperature, 99° F. in the evening, normal in the morning. Heart and lungs normal. The urine contains no albumin or sugar. Examination of the abdomen reveals a tumor in the left hypogastric region, which extends from the symphysis pubis upward for 3 inches, and from the median line 4 inches outward into the iliac region. The tumor is round, hard, apparently solid, slightly tender on pressure, and has a smooth, non-nodulated surface.

The vaginal portion of the uterus is pushed to the right side, but is at a normal dis-

tance from the introitus. On the left side of the vaginal portion, and high up, is felt a hard, immovable mass, filling the upper portion of the small pelvis. The upper part of the neck and the body of the uterus cannot be felt as distinctly separated from the tumor, and the uterus is immovable in all directions. Bimanual palpation reveals no fluctuation or softer portions of the tumor, and immobility, or only a very indistinct mobility of the whole mass.

Rectal examination reveals the hard, non-nodulated tumor behind and to the left of the uterus, high up in Douglas' fossa. No signs of a perforation opening can be found between the rectum and the tumor, which is only moderately tender to pressure on its lower surface. Neither ovaries nor tubes can be felt.

Diagnosis.—Pyosalpinx on the left side, and probably an abscess in the left broad ligament communicating with the intestine above the rectum.

Plan of Operating.—I wished to drain the abscess cavity. This was inaccessible from the vagina, as it was situated high up behind the uterus; it could probably be reached from above the symphysis without opening into the peritoneal cavity. If there was a free peritoneal cavity anterior to the abscess, I wanted to open in two tempos. I did not intend to extirpate the tube at this time, on account of the communication with the bowel, but I intended to close the abscess by drainage, and then, if needed, later on, when inflammation had subsided, to remove the offending appendages. I further waited for a day when the abscess cavity might be expected to be distended by pus, in order to make it more easy to find by an aspirator syringe the place of the abscess where the opening should be made.

Operation November 17, 1891. First tempo: Laparotomy. Assisted by Drs. Goldspohn and Bernauer. An incision nearly 5 inches long was made at the left lateral border of the rectus. The free peritoneal cavity was found, and after the introduction of a sponge the parietal peritoneum was stitched to the skin.

Exploration of Tumor.—On its anterior aspect was found a bluish, transparent, thin-walled cyst, the size of a hen's egg. This was opened, and clear serous fluid evacuated; the thin cyst-wall contained vessels, and was smooth on both the outer and inner surface. A smaller cyst, the size of a hazelnut, with transparent walls, showed through its wall a whitish precipitate that moved in the clear cyst fluid upon change in the position of the cyst. This was ligated at its base and removed. Thus I reached the surface of the solid tumor, but scarcely a square inch above the larger cyst was accessible. The remainder was covered with adherent loops of intestine as follows: Upward loops of small intestine were firmly adherent to and covered the tumor; down toward the symphysis the sigmoid flexure was distended over the tumor from side to side, and so short and diffused were the adhesions that the intestine was immovable—almost stretched out over the tumor. The left side of the tumor was, in a similar way, covered with the upper portion of the sigmoid flexure; the remainder of the anterior aspect of the tumor was covered with adherent omentum. By separating this from around the base of the large cyst, a space of 2 square inches of the surface of the tumor was uncovered. The surface of the tumor was apparently solid, showing no softer places designating abscess wall; it was uneven, and showed convolutions in relief over the surface. The tumor consisted of rather hard and resistant tubal convolutions, the thickness of a finger, grown together into one mass large enough to fill the whole pelvis minor. It was impossible to distinguish the uterus or right tube and ovary in the mass.

Puncture with an aspirator syringe with long needle in six different directions and places gave no pus, but only blood. As I was unable to find any abscess cavity, I resolved to make another attempt, at the second stage of the operation, in two tempos, and if no abscess cavity was reached, to open into the cavity of the tube and drain it. Stitching of the peritoneum to the surface of the tumor had to be done by loosening flaps of parietal peritoneum from the anterior abdominal wall, as the surface of the tube could not be brought readily into contact with it. I use this flap operation whenever a deep-seated surface, as, for example, a small or contracted gall-bladder, has to be isolated from the

general peritoneal cavity for an opening in two tempos. A surface of 2 square inches was prepared in this manner by stitching the peritoneal flaps to its periphery. A place on the top of the most central ridge or knuckle was marked out by a silk suture left long, as the place where I would open into the cavity of the tube. I have found it convenient, in the operation in two stages, whether for peri-uterine abscess or for opening into a gall-bladder or any other cavity or organ, to mark out the exact place for the intended incision, or, as I mostly use the opening with Paquelin's cautery-knife, by a silk suture left long. If the excluded space is small, it may be exceedingly difficult to find it at the second stage of the operation, four to eight days later, when, after removal of the iodoform gauze, the whole wound is a uniform red granulating surface, and thus the anatomic landmarks have disappeared, at any rate as far as color of the organs or tissues is concerned. The final steps consisted of union of the superfluous portions of the abdominal wound, packing with iodoform gauze in several places, hiding the guiding suture between them, and the application of an antiseptic dressing.

The operation was entirely unsatisfactory. Enuclation of the tubal tumor was hardly possible with the adherent condition of intestine described above, and was not tried on account of the communication with the intestine.* No pus was found, no abscess cavity or dilated tube to drain, but only the knuckles of thickened tubal convolutions were seen. It might have been preferable to do vaginal extirpation or morcellement of the uterus (Péan) to evacuate pus from within or around the tube.

Opening into the pyosalpinx on the seventh day, November 24th. The patient was anesthetized and the gauze removed from the wound. The wall of the emptied cyst formed a red, granulating mass the thickness of a finger, above which was the guide suture on top of the ridge of the convolution of the tube running from the right and upward down to the left. Exploration with the syringe and long needle did not bring out pus. Incision with the Paquelin cautery-knife, $\frac{3}{4}$ to 1 inch long, was made at the place of the guide suture in the direction of the tubal convolution. At a depth of 6 or 8 mm. was found a narrow cavity from which came a few drops of odorless, yellowish, thick mucus. A probe inserted into the opening passed upward and to the right 2 inches in a narrow tract, and a similar distance in the opposite direction down toward the symphysis pubis. A small rubber drainage-tube, 4 mm. in diameter, was the largest that could pass, even after dilatation with a long forceps. Two drains were inserted 2 inches in each direction into the tube. Dry antiseptic dressing was placed over a packing of iodoform gauze.

Remarks.—I intended to drain the tube in the hope of closing the communication with the bowel; but on opening the tube, it was found that it did not communicate with the intestinal tract, as the contents were odorless. A peritubal abscess cavity could not be opened, because it was not found.

The after-treatment consisted only in changing the dressings and washing the wound; no washing out through the drains was done, as they entered no cavity.

In January, after a gradual improvement locally and in general health, the patient began to sit up. The wound closed about the middle of January, 1892, eight weeks after the operation.

February 12, 1892: The abdominal wound is closed, except a fine fistulous opening at the upper border, from which a little pus comes out once in a while. Pressure on the abdomen causes no pain whatever, and no tumor or swelling can be reached even by deep pressure on and below the promontorium. Vaginal exploration shows the uterus somewhat movable up and down, and the cervix and body can be felt to be somewhat enlarged when held between the fingers of the two hands during bimanual exploration. Rectal exploration reveals some adhesions posteriorly, but the uterus can be moved more than

* Veit: "Über Durchbruch von Pyosalpinx nach aussen," *Zeitschr. f. Geb. u. Gynäkol.*, 1889, vol. xvi, p. 318.

$\frac{1}{2}$ inch. The left uterosacral ligament is shorter and more rigid than the right, and the left half of the posterior culdesac is shorter and more rigid. On account of rigidity and adhesions the ovaries and tubes cannot be felt distinctly; but I can get the fingers of the right hand above the symphysis, and the fingers of the left hand in the rectum and vagina, near enough together to insure that there can be no abscess or considerable tumor between them.

February 18th: She has gained 14 pounds in weight, walks about all day without pain, and has regained her strength. The appetite is good. For the last two months there has been no evacuation of pus from the rectum and no peritoneal swelling at the seat of the tube.

Abdominal examination shows that the tumor has disappeared, so that the hand above the symphysis can pass deep down into the small pelvis without feeling any hardness or tumor.

The vaginal portion is in nearly normal position; the uterus is movable 1 inch; the right broad ligament movable and normal; the left broad ligament is thicker and less movable, and high up there is felt a nodular, hard tumor, the tube the size of a walnut; it is painless on pressure and on moving the uterus.

The patient left for her home with the advice to have the appendages removed if any symptoms in the future should call for surgical interference.

August 15th: She is as yet in perfect health.

Conclusions.—In conclusion I will state that it is not my intention to propose drainage of an infected Fallopian tube as a substitute for its removal. When Mundé proposes to drain the Fallopian tube from the vagina as a conservative measure, to avoid the more dangerous operation of laparotomy, it is doubtful whether his cases prove that drainage of the Fallopian tube is effective or not, as it is impossible, by opening through the vagina, to see or know whether the tube or a peritubal abscess has been opened into. But it is possible that in some of the cases the cavity of the tube was drained, which would tend to prove that this measure is effective in abating the salpingitis as well as the surrounding pelvic inflammation. To drain a tube with the view of restoring its activity or usefulness is a measure for the advocacy of which no data as yet exist. But the case mentioned above, together with Mundé's experience, makes it probable that drainage of an infected tube may be effective in bringing the inflammation to an end. In cases of impossible or difficult extirpation, and when the tube or a peritubal cavity communicates with the intestinal canal, which latter condition is regarded by T. Veit as an absolute contraindication for removal, I believe that drainage of the tube, if the latter be not accessible from the vagina, should be resorted to by abdominal section.

The operation in two tempos for such cases is also advocated by Winter as exceedingly safe; no pus need enter the peritoneal cavity; the tubal convolutions can be distinctly seen, and the place for opening into the tube may be marked out by a guide suture. When drainage of the tube has brought about cessation of the parasalpingitis and closure of the abscess communicating with the bowel, and the uterus is again movable, we have more favorable conditions for extirpation of the offending tube when this operation becomes necessary.

LITERATURE

- A. Martin: "Ueber Tubenerkrankung," *Zeitschr. f. Geburtsh. u. Gynäk.*, 1886, vol. xiii, p. 298.
- N. Savinoff: "Ein Fall von Salpingitis Chronica Productiva Vegetans," *Arch. f. Gynäk.*, 1889, vol. xxxiv, p. 237.
- Paul F. Mundé: "The Conservative Treatment of Salpingitis," *Amer. Jour. Obstet.*, 1892, vol. xxvi, p. 1.
- Gottschalk: "Verhandlungen der Gesellschaft für Geburtshilfe und Gynäkologie zu Berlin," *Zeitschr. f. Geburtsh. und Gynäk.*, 1892, vol. xxiv, p. 139.
- Boldt: *New York Medical Record*, 1890, vol. xxxvii, p. 545.
- Kümmel: *Centralbl. f. Gynäk.*, 1890, vol. xiv, p. 752.
- Winter: "Pyosalpinx Durchbruch im Rectum," *Zeitschr. f. Geburtsh. u. Gynäk.*, 1891, vol. xxi, p. 210.
- Rosthorn: *Arch. f. Gynäk.*, 1890, vol. xxxvii, p. 327.
- Guetsch: *Centralbl. f. Gynäk.*, 1884, vol. viii.
- A. Martin: Report from International Medical Congress in Copenhagen.
- Leopold: "Ueber Salpingotomie," *Centralbl. f. Gynäk.*, 1886, vol. x.
- Kaltenbach: "Ueber Tubenstenose mit secundärer Hypertrophie des Muscularis," *Arch. f. Gynäk.*, 1885, vol. xxvii, p. 317.
- Keith: *Edinburgh Medical Journal*, 1887, vol. xxxii, p. 811.
- Boldt: "Interstitial Salpingitis," *Amer. Jour. Obstet.*, 1888, vol. xxi, p. 122.
- A. Freund: *Volkmann's Sammlung klinischer Vorträge*, 1888, No. 323, p. 2321.
- Gusserow: *Arch. f. Gynäk.*, 1888, vol. xxxii, p. 165.
- Westermark: *Nordiskt Medicinskt Archiv*, 1888, vol. xix, p. 1.
- Orthmann: "Beiträge zur normalen Histologie und zur Pathologie der Tuben," *Virchow's Arch. f. Pathol. u. Anat., etc.*, 1887, vol. cviii, p. 165.
- Wylie: *New York Medical Record*, 1885, vol. xxvii, p. 161.
- Pozzi: *Bulletin de Chirurgie*, 1890, vol. xxi, p. 774.
- Kümmel: *Centralbl. f. Gynäk.*, 1892, vol. xvi, p. 752.
- Menge: *Zeitschr. f. Geburtsh. u. Gynäk.*, 1891, vol. xxi, p. 117.

SURGERY OF THE URETER*

ANATOMY

THE ureter is a cylindric muscular canal, in the living subject probably contracted to some extent, with a rather uniform diameter of 3 to 4 mm. throughout its entire extent from the pelvis of the kidney to the bladder. It varies in length from 11 to 13½ inches according to Henle;^{28†} 10 to 12 inches according to Tanquary,⁶⁹ cited by Van Hook,⁹⁷ and Tanquary states that it never exceeds 15 inches.

Its course is straight or slightly curved as it passes down from the kidney, and its direction is somewhat oblique toward the median line. The curve described is sigmoid; above the small pelvis the slight convexity is toward the median line, while the pelvic portion is more strongly curved,—almost the arc of a circle (Tanquary), with its convexity directed toward the lateral wall of the pelvis,—until it finally reaches the neck of the bladder, the wall of which it penetrates so obliquely that it runs for ½ or ¾ inch between the muscular and mucous coats (Cabot⁹). In the male it crosses the vas deferens on the posterior wall of the bladder; in woman it crosses the cervix and enters the bladder at a point midway between the meatus urinarius and the cervix.

The canal is not absolutely uniform in caliber throughout its entire course; Hallé²⁷ and Tanquary have pointed out that in normal subjects it is narrowed in three places, namely: (a) At a point between 1½ and 2½ inches from the pelvis of the kidney; (b) at the junction of the pelvic and vesical portions; and (c) at the place where it crosses the iliac artery, found in three out of five subjects. These localities correspond with the places where small stones from the kidney have been found to be arrested.

In the same connection it is well to remember the variations in the upper end of the ureter, as pointed out by Hyrtl.²⁹ In the first variety there is no pelvis, but the ureter divides into two branches without dilatation at the point of division, each branch having a caliber a little larger than that of the ureter. In the second variety there is a pelvis—that is, a funnel-shaped dilatation at the point of division. The upper portion is the smaller, and terminates in three short calices; the lower and more voluminous portion terminates in four or five calices. In the third variety there is only half a pelvis; that is, the lower branch

* A short résumé, made by request of the President of the American Surgical Association, to introduce the discussion on this subject at the annual meeting of the association, May, 1894. Trans. Amer. Surg. Assoc., 1894.

† See bibliography at the end of article.

divides and is funnel shaped, forming a narrow pelvis which terminates in one, two, or three short calices; while the upper is not dilated, and extends to the upper portion of the kidney as a continuation of the ureter. The ureter not uncommonly divides far below the kidney, between the kidney and the bladder; sometimes there is no division at all, and two separate ureters enter the bladder.

There is one variation in the point of entrance of the ureters into the bladder which is of especial practical importance, namely, those cases, few in number, in which the ureter, instead of entering the bladder high up or low down, posterior to the sphincter of the urethra, opens into the latter at or near its external orifice or even into the vagina (Secheyron⁶⁵). This anomaly causes a congenital partial incontinence of urine, for the relief of which successful operation has been performed.

In passing down from the large to the small pelvis the left ureter lies between the vertebra and the psoas muscle, while on the right side, on account of the vena cava inferior, the ureter is situated a little more laterally.

The relation of the ureter to the peritoneum is an important consideration in the surgical anatomy of the ureter. This was first carefully studied by Cabot, who pointed out that in the extraperitoneal operations, especially in fat subjects, it is extremely difficult to find and recognize the ureter in the deep wound, unless guided, for instance, by the presence of a stone. The ureter is adherent to the peritoneum, and always follows it when it is stripped up from the parts behind. This fact has occasionally been mentioned before by Crampton,¹³ Twynam, and others, but the condition was not studied until Cabot made microscopic sections of the ureter and peritoneum, and demonstrated that the ureter is bound to the under surface of the peritoneum by fibrous bands.

Cabot further pointed out that the relation of the ureter to that part of the peritoneum which is adherent to the spine is rather constant, the ureter being situated just external to the line of adhesion. Therefore when the operator has stripped up the peritoneum and reached this point, he will find the ureter on the stripped-up peritoneum a little external to it. On the left side the distance from the line of adhesion to the ureter is from $\frac{1}{2}$ inch to 1 inch, while on the right side the distance is somewhat greater, owing to the outward displacement of the ureter by the interposition of the vena cava inferior between it and the spine.

As a guide in the palpation of the ureter on the living subject in examining for stone, dilatation, or extravasation consequent upon rupture, the following landmarks are given by Tourneur⁷⁰ (cited from Tuffier⁷³): The course of the abdominal portion of the ureter in the large pelvis corresponds to a vertical line erected upon a point at the junction of the internal and middle thirds of Poupart's ligament. Tourneur considers its direction vertical from the border of the kidney down to the small pelvis, over the brim of which it passes $4\frac{1}{2}$ cm. from the median line. The exact location of this point is the intersection of a horizontal line drawn between the anterior-superior iliac spines and a vertical line passing through the pubic spine. At this point, under favorable cir-

cumstances, a dilated or tender ureter may be felt by gentle, steady pressure backward upon the abdominal wall until the resistant brim of the pelvis is reached.

The vesical portion of the ureter can be palpated in man through the rectum. Guyon²³ has called attention to the exquisite sensitiveness of this portion of the ureter upon rectal exploration in cases of stone, even when located high up. In woman vaginal examination permits the palpation of the ureter to an extent of 2 or even 3 inches, as it runs in the broad ligament in close relation to the upper wall of the vagina (Cabot).

SURGICAL ANATOMY

Access to the ureter, which is most often required for the removal of stones, is gained by two different routes: the transperitoneal and the extraperitoneal.

By means of a median or lateral abdominal incision the entire course of the ureter can be reached with comparative ease, but intraperitoneal operations upon a ureter wherein the urine is not absolutely aseptic should not be undertaken if an extraperitoneal operation is possible, on account of the danger of peritonitis. This is well illustrated by the transperitoneal ureterolithotomy performed by Cullingworth,¹⁴ whose patient died from peritonitis.

On the other hand, abdominal examination for diagnostic purposes, to locate a stone or a para-ureteral urinary infiltration following rupture, has been of value when followed by extraperitoneal operation, as evidenced in the cases of stone operated upon by Hall²⁶ and Arbuthnot Lane,⁴¹ and in the cases of rupture reported by Page⁴⁶ and Allingham.²

Extraperitoneal access to the ureter is technically much more difficult because of the depth of the wound; but, as by it the danger of peritonitis is avoided, it is, on the whole, preferable. The upper two-thirds of the ureter, that is, the abdominal portion and the portion which extends over the brim of the pelvis, can be reached by a continuation of the ordinary oblique incision for lumbar nephrotomy from the twelfth rib down along and 1 inch anterior to the ilium, and along Poupart's ligament to about its middle.

Cabot thinks that it would be possible, in a very thin subject with lax abdominal walls or in children (Twynam), to gain access to the ureter down to within an inch or two of its entrance into the bladder by extraperitoneal incision, but, on account of the depth of the wound in this place, operation would be difficult.

The lower pelvic portion of the ureter can be reached by the sacral operation, an incision lateral to the sacrum, as proposed by Delbet¹⁶ or, better, by Kraske's operation, or the osteoplastic resection of the sacrum, as proposed by Cabot, who made investigations on the cadaver and found ample space for careful inspection and operation.

In women the pelvic portion of the ureter can be reached through the vagina. Ureteral fistulas opening into the cervix and vagina have been operated upon, and stones in this portion of the ureter have been re-

moved by Emmet,¹⁹ when situated low down, close to the vesical orifice, and by Cabot, when located higher up, in the broad ligament, close to the cervix uteri.

INJURIES TO THE URETER

Accidental wounds, of which Tuffier found only 5 cases in the literature, 3 incised or punctured wounds, and 2 gunshot wounds, have not as yet been treated by direct ureteral surgery, as these cases date back to a time when such a procedure had not been thought of. If positive diagnosis can be made (and intermittent discharge of small quantities of urine at the time might make the diagnosis positive), and if the external wound is extraperitoneal, there is no reason why the ureter should not be cut down upon and the wound treated by one of the methods now at our disposal.

Subcutaneous wounds or ruptures of the ureter have been carefully studied by Herbert Page, who collected 10 cases from the literature, to which he added 1 of his own. Five additional cases have been reported by Le Dentu,¹⁷ making 16 in all. In these cases the traumatism was caused either by a direct blow on the abdomen, such as the kick of a horse (Pye-Smith, Chaput), by a blow in the region of the kidney (Soller), by a blow from the handle of a wheelbarrow (Allingham), by being run over by a wagon (Page, Barker, Godlee, Bardenheuer), by traumatism from overstretching (my case), or by violent displacement of the kidney and pelvis, whereby the ureter was ruptured in the upper portion (Le Dentu).

It is uncertain whether, by these injuries, the ureter is crushed against the transverse process of the first lumbar vertebra, as Tuffier thinks, or is so stretched from the kidney as to rupture in its upper portion, as in my case. Both methods are possible. The fact remains, however, that most of the ruptures are found above the small pelvis.

Early diagnosis is often difficult, if not impossible, because of the uncertainty of the symptoms. Slight transient hematuria, which might easily be overlooked, was noted in only 3 cases (Barker, Allingham, and Page). Copious hematuria, as reported in Hicks' case, indicates rupture of the kidney rather than of the ureter. Hematuria may be entirely absent, as in Godlee's case.

If no injuries to other organs complicate the ureteral rupture, there are no grave symptoms in the beginning.

The next important symptom, swelling from the accumulation of urine around the place of rupture, is not seen until some time after the receipt of the injury—seven days (Allingham); two weeks (Chaput); two to three weeks (Godlee, Page, Barker, Hicks); thirty-nine days (Croft); seven weeks (Stanley), or several weeks (Cabot). The swelling is usually accompanied by pain, is localized, round, oblong, or sausage-shaped, following the course of the canal, and is palpable from the abdomen.

The surgical treatment has never yet been directed in an early stage to the ureter itself, but has consisted in puncture, single (Joel), once

repeated (Hicks), or five times repeated (Stanley), all of which were successful; or incision and drainage either through the abdominal cavity (Chaput, Page) or through the lumbar region (Allingham).

In most of the cases septic infection of the kidney took place through the resultant fistula, and secondary nephrectomy was necessary in order to save the patient's life (Godlee, Page, Barker, Chaput, and Bardenheuer). In other cases wherein the collection was not even opened and the patients survived, the kidney remaining, obliteration of the ureter (Haviland) or strictures ensued (Pye-Smith, Soller, and my case).

As before mentioned, suture of the ruptured ureter has not yet been attempted, but, as Page points out, it might possibly be done, although it will probably be difficult to find the rupture, and this so much the more as an early diagnosis is rarely made. It is ordinarily not until some weeks later, when the swelling from urinary infiltration sets in, that operation is resorted to. Whether or not the ureter can be found in this cavity, which usually contains infected urine, and the rupture successfully dealt with, is as yet an open question.

OPERATIONS ON THE URETERS FOR STONE

Stones in the ureter are most commonly arrested in the upper portion, and with about equal frequency in the middle and vesical portions. They are removed by different methods, according to their location.

(a) *Removal Through the Bladder.*—Stones have been removed by dilatation of the female urethra by Emmet, Berg,⁶ Richmond, Czerny, and Sanger; by suprapubic cystotomy in 2 cases (Tuffier). Ureteral stones often protrude into the bladder, and can be recognized by the sound. The mucous membrane covering them may have to be divided, but the stones are usually extracted without difficulty. The wound in the vesical end of the ureter is usually left open, but is sometimes sutured, as in the case reported by Berg. Stones in this location, so far as operative procedure is concerned, should be classed among stones in the bladder.

When the stones are located a little higher up, but not accessible from the bladder, they may be reached from the vagina or rectum by—

(b) *Ureterotomy Through the Rectum.*—Ceci¹¹ removed successfully a stone from the ureter by incision through the rectum.

(c) *Ureterotomy Through the Vagina.*—Removal of stone by means of vaginal ureterotomy has been performed by Emmet and Cabot.

EMMET'S¹⁹ CASE.—Female. Click having been elicited by the sound, ureteral stone was suspected. On backward pressure with larger sound stone could be felt through vagina and rectum. Stone cut down upon through vaginal wall by scissors. Opening enlarged forward toward the neck of the bladder, "this being the only safe direction to avoid entering the peritoneal cavity." Opening closed with interrupted sutures. Good recovery.

CABOT'S¹⁰ CASE.—Woman, aged thirty-nine years. Attacks of renal colic for sixteen years, often followed by passage of stones. Left pyonephrosis felt as distinct tumor. Vaginal examination revealed a small, hard mass in the left broad ligament, close to cervix

uteri. Sound in bladder could not be brought within $\frac{1}{2}$ inch of mass. Ureterotomy and removal of stone through the vagina. Evacuation of 10 to 12 ounces of pus. Tumor in region of kidney disappeared. Ureterovaginal fistula remained for four months, with small amount of pus. The author concludes that the kidney was destroyed, so far as secreting tissue is concerned.

(d) *Extraperitoneal ureterotomy* has been performed in 5 cases by Twynam, Cabot, Ralfe and Godlee, Kirkham, and myself.

TWYNAM'S⁷⁵ CASE.—Boy, aged eight years. Left renal pain; hematuria. Laparotomy for diagnosis revealed stone in right ureter, just below brim of pelvis. Laparotomy wound closed. Three weeks later extraperitoneal incision in right iliac region. Ureterotomy, removal of stone, ureterorrhaphy, drainage; recovery. Long ends of sutures brought out of wound.

CABOT'S⁹ CASE.—Man, aged forty years; seven or eight sharp attacks of pain, referable to left side of abdomen above middle of Poupart's ligament. During three months before operation sensitive spot on back, midway between crest of ilium and twelfth rib. Diagnosis, stone in ureter; lumbar incision, ureterotomy, removal of calculus 2 inches below kidney. Wound in ureter not sutured. Recovery.

RALFE AND GODLEE'S⁵⁶ CASE.—Woman, twenty-six years of age. Nephritic colic persistent on left side; lumbar nephrotomy; no stone in kidney. Exploration revealed stone in left ureter, 2 inches below kidney. Longitudinal ureterotomy; removal of stone. Subsequent right renal colic; lumbar nephrotomy; no stone in kidney or ureter. Subsequent passage of gravel and small stone per urethram. Recovery.

KIRKHAM'S³⁷ CASE.—Man, aged fifty-eight years. Right renal colic, followed by pain on left side and anuria. Diagnosis, destruction of right kidney by previous attack. Left kidney now affected. Exploratory left lumbar incision. Palpation of kidney negative. Stone in ureter $\frac{1}{2}$ inch above crossing of external iliac artery. Ureterotomy, removal of stone, no sutures; drainage. Recovery.

FENGER'S²⁰ CASE.—Man, aged thirty-five years. Increasing attacks of renal colic for two years; no hematuria; no tumor. Diagnosis, nephrolithiasis; lumbar nephrolithotomy; no stone in kidney. Palpation showed two stones in ureter, $1\frac{1}{2}$ inches below kidney; longitudinal ureterotomy; no sutures. Recovery.

(e) *Intraperitoneal ureterotomy* has been performed in 2 cases by Cullingworth and Arbuthnot Lane:

CULLINGWORTH'S¹⁴ CASE.—Woman, aged thirty years; right renal colic. Vaginal examination showed hard masses to right and left of uterus. Diagnosis, right pyonephrosis and independent ovarian disease; laparotomy; right ureter dilated. Stone immediately above bladder; ureterotomy; removal of stone; escape of pus; ureterorrhaphy, with interrupted silk sutures; glass drain in abdomen. Death from peritonitis in eighty hours. Autopsy revealed right and left pyonephrosis. Sutures in ureter held.

ARBUTHNOT LANE'S⁴¹ CASE.—Woman, aged twenty-three years. Left renal colic for twenty years; hematuria; pyuria; laparotomy; pelvis of left kidney dilated; no stone; ureteral opening could not be found; eight months later laparotomy; stone in pelvic portion of ureter forced up to crest of ilium; abdominal ureterotomy; removal of stone; ureterorrhaphy with continuous silk suture. No leakage. Recovery.

Diagnosis as to the location of the stone was made before operation only in the cases in which the stone was afterward removed through the rectum or vagina (Ceci, Emmet, Cabot). When the stones are located higher up, it is, as a rule, impossible to make a positive diagnosis. In the small pelvis diagnosis may possibly be made by vaginal examination, but in Cullingworth's case he mistook the stones for diseased ovaries, and positive diagnosis was not made until the abdomen had been opened.

If the stone is located still higher up, diagnosis of location is well-nigh impossible. Cabot made the diagnosis of stone in the ureter, but could not locate it until after lumbar incision had been made.

The location of the stone in the ureter has not been determined until exploratory incision, either extraperitoneal or intraperitoneal, has been made. When the stone has been found in this way, its removal has been accomplished either by pushing it up into the pelvis and extracting it through the opening in the pelvis or kidney, or by longitudinal ureterotomy.

It is often impossible to push the stone up into the pelvis, because of the local dilatation of the ureter—the nest, as Le Dentu calls it; but some operators, such as Israel, von Bergmann in 2 cases, Hall, and Tuffier have succeeded in accomplishing this. I once tried unsuccessfully to push a stone into the pelvis by a needle passed through the wall of the ureter. I do not consider this procedure important if the ureter can be reached by an extraperitoneal incision.

The difficulty in dislodging the stone is well illustrated in the case reported by Hall, who succeeded only by manipulations with one hand in the abdomen.

HALL'S²⁶ CASE.—Woman, aged thirty-six years, had had recurrent attacks of renal colic for four years. Pain in region of left kidney, which could be palpated between the hands. Examination caused no hematuria. No stone could be felt. Diagnosis: Stone in kidney or ureter. Dr. Hall was unwilling to make lumbar incision on uncertain diagnosis, and advised exploratory laparotomy. Examination under narcosis revealed a small tumor in the region of the left kidney; this was the dilated ureter above the stone. Abdominal section. Stone could now be felt about 3 inches below the kidney. Diagnosis, impacted stone in ureter. Lumbar incision for removal of stone. Stone difficult to dislodge; finally accomplished by hand in abdomen; incision on convex surface of kidney; invagination of sac consisting of dilated ureter and pelvis; extraction of stone. Recovery.

The dislodgment and removal of the stone was easy in the case reported by Tuffier.

TUFFIER'S⁷³ CASE.—Renal colic for nine years, finally with constant pain. Right kidney enlarged. Nephrolithotomy. Examination revealed no stone. Examination of ureter showed hard, ovoid body, 3 cm. long, located where ureter crossed the promontory. Stone movable; it was pushed up into pelvis of the kidney. Incision of convex surface of kidney. Extraction of stone. Suture of kidney and lumbar wound. No drainage. Healing by first intention.

Longitudinal ureterotomy has thus been done in 5 cases through an extraperitoneal incision, all of which were successful, and in 2 cases

through the abdomen, 1 case being successful, and 1 patient died from peritonitis.

The treatment of the wound is different in the extraperitoneal and intraperitoneal operations. In the intraperitoneal operations the immediate absolute closure of the ureter is of vital necessity; as the urine above a stone is almost always infectious, the question of accurate suturing is one of great importance. In the extraperitoneal operation, where the infected urine can be drained out effectually until the wound closes, the question of suturing is of little import. In his transperitoneal operation Arbuthnot Lane used a continuous silk suture with perfect success. In Cullingworth's intraperitoneal operation he employed interrupted silk sutures, and postmortem examination revealed no leakage from the wound in the ureter.

In an extraperitoneal operation Twynam applied interrupted silk sutures, the long ends of which were brought out through the wound. As might be expected, these sutures did not hold.

In some of the extraperitoneal operations no sutures were used, but drainage was employed, and the wound closed in Kirkham's case in forty days; in my case of stone, in a month; in my case of exploratory longitudinal ureterotomy, in fifty days, and in Cabot's case the wound also closed without disturbance.

Whenever practicable, the stone should be removed through a lumbar incision rather than through the abdomen. Stones located low down in the small pelvis, which cannot be pushed up within the reach of an extraperitoneal incision like that for ligation of the iliac artery, might be reached by a sacral operation, although no case of this kind is as yet on record.

Laparotomy for the purpose of diagnosing the location of the stone has been of value in several instances. In Arbuthnot Lane's case the stone was thus located after exploratory lumbar incision had failed. In this case, however, it might have been possible, by opening the kidney or ureter and exploring from above, to locate the stone through the lumbar incision. In Hall's case the stone was located through a median abdominal incision and removed through a lumbar incision into the kidney. As in this case it had already been determined which ureter was the seat of the stone, the laparotomy might have been omitted.

In Twynam's case, however, the exploratory laparotomy was absolutely necessary, since the symptoms pointed to stone in the left ureter, which was healthy, while the stone was found in the right ureter, and was removed three weeks later by an extraperitoneal ureterotomy.

OPERATIONS FOR THE RELIEF OF VALVE FORMATION

As valve formation always causes an intermittent or a permanent impediment to the flow of urine, the pelvis of the kidney is in a state of hydronephrosis or pyonephrosis. The so-called sac is accessible through the peritoneal cavity or by an extraperitoneal operation through the lumbar region. The first attempt after Simon's⁶⁷ to operate on the valve

was made in 1890 by Trendelenburg,⁷¹ who opened the anterior wall of a large hydronephrotic sac by lateral laparotomy, saw the ureteral opening on the side of the sac, divided the ureter down to the lower part of the sac, to the inner wall of which he sutured the divided borders of the ureter. The ureteral opening was thus displaced from the side to the bottom of the sac, in order to keep the ureter patent. The result of this operation is uncertain, as the patient died from ileus.

In 1891 Küster,³⁹ in his celebrated case of resection of the ureter and implantation of the distal end into the pelvis, opened the hydronephrotic

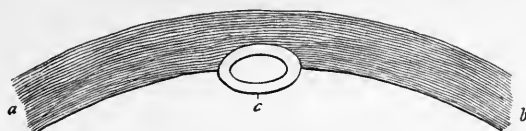


Fig. 82.—Küster's intended operation on the valve: *a, b*, Wall of sac; *c*, transverse section of ureter (same as Trendelenburg's).

sac from the lumbar region, found the ureteral opening, and divided it through its course in the sac-wall, with the intention of stitching the divided border to the inner wall of the sac, as Trendelenburg had done. (See Figs. 82 and 83.) Before finishing this operation, however, he explored the ureter and found a stricture which caused him to abandon the operation for valve formation and to resect the stricture.

The third, and first successful, attempt at operating for valve formation was made by me May 31, 1892.

FENGER'S²¹ CASE.—Woman, aged twenty-eight years. Valvular stricture or stenosis of pelvic orifice of ureter in a somewhat floating kidney. Intermittent hydronephrosis for

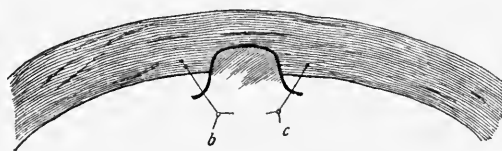


Fig. 83.—Küster's intended operation on the valve: *b, c*. The ureter divided on its anterior surface. Near *b* and *c* are sutures uniting the borders of the divided ureter and the walls of the sac.

eight years, with more and more frequently recurring attacks, until one a week. Nephrotomy between attacks. No stone could be found in the pelvis. Pelvic orifice of ureter could not be found through the opening in the kidney. Incision of pelvis, whereupon valvular opening of ureter could be seen. Plastic operation on valve; bougie left in ureter for two days; pelvic wound sutured; fixation of floating kidney; recovery without fistula (Fig. 84).

The second successful operation was performed on August 14, 1893, by Herman Mynter, of Buffalo.

MYNTER'S⁴² CASE.—Man, aged twenty-five years. Valvular stricture of pelvic orifice of ureter, intermittent hydronephrosis for twelve years. Periodic attacks of pain every two or three months in right lumbar region. Diagnosis, right renal calculus, pro-

ducing occlusion of ureter. Exploratory nephrotomy. No stone found. Ureter permeable, with valve formation at pelvic orifice. Plastic operation on valve. Gauze drain. Recovery without fistula.

The operation for valve formation can be best done by the extra-peritoneal lumbar incision. The dilated pelvis or hydronephrotic sac is easily found and opened by a longitudinal incision. The opening of the ureter into the sac should be looked for, but cannot always be found,

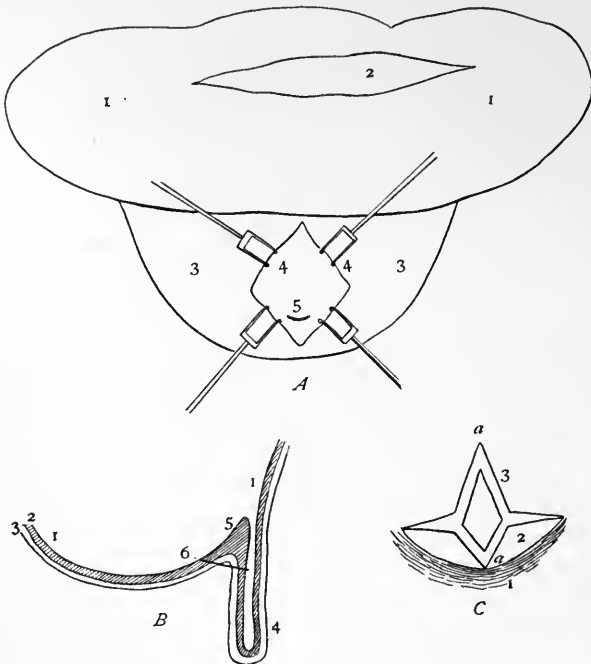


Fig. 84.—Illustrating operation for valve formation.

A, Kidney and dilated pelvis: 1, 1, Kidney; 2, opening on its convex surface after nephrotomy; 3, 3, dilated pelvis; 4, 4, with opening on its posterior surface from pelviotomy; 5, opening of the ureter into the pelvis—a small transverse crescent-shaped slit.

B, Dilated pelvis and ureter, showing valve formation: 1, 1, Pelvis; 2, mucous membrane; 3, muscular and external coat; 4, ureter; 5, valve; 6, line of the incision dividing valve.

C, Valve seen from the pelvis and divided, to illustrate the plastic operation: 1, Inner wall of pelvis above the ureteral opening; 2, ureteral opening; 3, the divided valve; a and a, the corners of incision, to be united by a suture.

as in some cases it is very narrow. In such cases it may be located by incising the ureter below the sac and passing a probe upward toward the pelvis. The valve or inner wall of the ureter running in the sac is now divided longitudinally from the opening in the sac, and the resultant wound treated in one of the three following ways:

(a) By turning the flaps out and uniting them to the inner walls of the sac by sutures (Trendelenburg, Küster).

(b) By drawing the corners of the longitudinal incision together with one suture, transforming the longitudinal into a transverse wound, as in my operation, or—

(c) By uniting the wound longitudinally with numerous fine silk sutures, "taking in the two outer coats of the ureter and sac and avoiding the mucous membrane" (Mynter).

COMPRESSION OF THE URETER FOR DIAGNOSIS OF KIDNEY AFFECTIONS

This has been done in order to collect urine from each ureter separately. It has been attempted from the rectum by Weir⁷⁹ and Sands.⁶² Tuchmann⁷² has compressed the ureter from the bladder by an instrument resembling a lithotrite, between the jaws of which the ureter was caught. Silbermann⁶⁶ attempted to compress the ureter from the bladder by a balloon which, after introduction, was filled with mercury and was expected in this manner to make compression. All these attempts were, however, abandoned, and gave way to catheterization.

CATHETERIZATION OF THE URETER

Catheterization of the ureter has reached a state of practical usefulness, as indicated by Simon,⁶⁷ only in women, on account of the ease of access to the vesical opening of the ureter in the female. Pawlik⁴⁸ was the first to put this procedure in extensive practice. He has employed it since 1881. Pawlik was followed by Newman,⁴⁴ and the method has now been made reasonably practical, chiefly through the arduous work of Howard Kelly,³⁴ who introduces a Pawlik catheter through Simon's speculum, guided by a head-mirror.

Strictures of the ureter and accumulations of urine above strictures have been successfully treated in this way by Pawlik and Kelly.

Kelly³⁵ made a diagnosis of stricture low down in the left ureter by catheterization. The patient was catheterized about six times at intervals of ten to twelve days, each catheterization being followed by marked exacerbation of the pain for a few days. The consequence, however, of the repeated catheterization was marked relief for several months. The symptoms finally returned, the ureter was opened from the vagina, and a small calculus removed from the ureteral orifice.

Pawlik⁴⁸ mentions a case of pyonephrosis from Billroth's clinic in which he introduced through the ureter from the bladder a long elastic catheter with a metal point, which passed through a stenosis of the ureter up into a cavity above. The patient had an abdominal fistula, the result of a previous nephrotomy, and a probe passed through this fistula would touch the metal tip of the ureteral catheter. On attempting to withdraw the catheter the tip was caught in the stenosis and broken off, and Dr. von Hacker removed it through the abdominal fistula.

Pawlik,⁴⁹ cited by Albarran and Lluria,¹ reports 2 cases of pyonephrosis in which this method was employed. In 1 case cure was effected after 30 successive soundings of the ureter; in the other, the ureter was impermeable and nephrotomy had to be made.

The treatment of tuberculosis of the bladder has been assisted by permanent catheterization of the ureters by Guyon,²⁴ cited by Albarran

and Lluria,¹ who burned the tuberculous ulcers with the Paquelin cautery, packed with iodoform gauze, and was able to leave the ureteral catheters in for nine days.

As regards leaving the catheter permanently in the ureter, Pawlik mentions a case of ureterovaginal fistula in which a catheter was left in for seven days. Force was required to remove it, and it was found to be incrustated with salts.

Weil,⁷⁸ in a case of ureterovaginal fistula caused by a pessary, was enabled to stop the flow of urine by leaving a tube in the ureter for six days, when pain in the region of the kidney necessitated its removal.

A catheter left in the ureter for some time is apt to cause inflammation of the ureter, just as we find permanent urethral catheterization followed by inflammation of the urethra.

Poirier⁵³ cautions against leaving a catheter in the ureter. He mentions a case of Segond's of exstrophy of the bladder wherein catheterization caused pyelonephritis, and a case of his own in the service of Tillaux, in which, thirty-six hours after catheterization of the ureter, obstruction occurred, which caused an attack of renal colic. He also cited the experience of Sinitzin, who was never able to allow a sound to remain for more than four hours, and concludes that the harmlessness of the procedure is not altogether beyond question.

Catheterization of the ureters in man is difficult and uncertain of accomplishment. Perez⁵¹ concludes that it is of no importance, as it can be done only by epicystotomy. Poirier,⁵² however, has succeeded in introducing a catheter with the aid of the Nitze-Leiter cystoscope; but other attempts in this direction have not as yet brought practical results. It cannot be denied that catheterization through epicystotomy possesses some practical value. In one instance catheterization of the ureter to the healthy kidney in a case of left pyonephrosis in which granular casts were found in the urine deterred Iversen³⁰ from performing nephrectomy.

Keen,³³ in a case of hematuria and suspected tumor of the bladder, made an epicystotomy, but found no tumor. As he was unable to determine from which of the ureteral openings bloody urine was evacuated, he introduced a catheter through each ureter and collected the urine separately, as a result of which he ascertained that the hemorrhage was from the left kidney.

It is to be hoped that by means of the cystoscope, or in some other way, catheterization of the ureter in man may be made more practical.

OPERATIONS FOR STRICTURE OF THE URETER

It is probable that only strictures situated in the upper abdominal portion of the ureter are accessible for operative interference. Such strictures have been dealt with in three ways:

1. *Dilatation by bougie* (as reported by Alsberg).

ALSBERG'S³ CASE.—Lumbar nephrotomy in a case of left hydronephrosis. For ten days all urine passed through fistula, from which it was concluded that the other kidney

was defective in function. Ureter successfully dilated from wound by thin bougies. After several days urine passed through bladder. Some months later fistula closed. Hydro-nephrosis did not reappear.

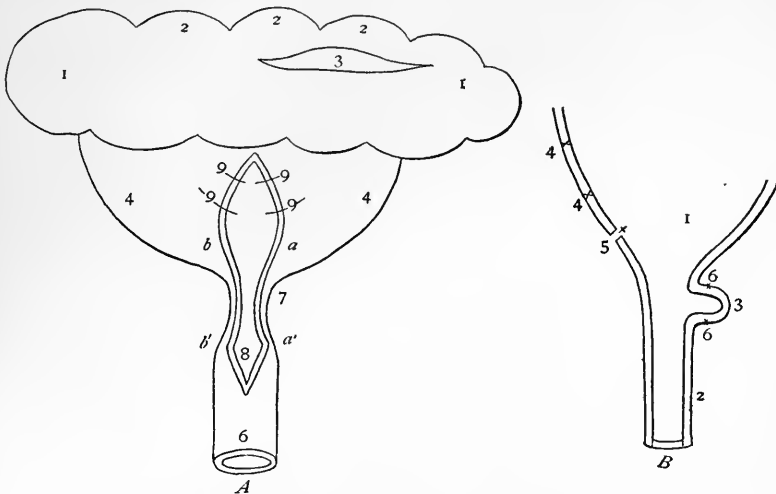


Fig. 85.—Illustrating operation for stricture of ureter.

A, Sacculated kidney, dilated pelvis, ureter with stricture at its upper end: 1, 1, Kidney; 2, 2, 2, sacs corresponding to dilated calices; 3, nephrotomy; 4, 4, dilated pelvis; 5, opening in posterior surface of pelvis, pelviotomy wound; 6, ureter below stricture; 7, stricture in upper end of ureter; 8, opening in ureter below stricture, extending up through the stricture into the pelvis; 9, 9, 9, 9, sutures closing the upper half of the wound in the pelvis; *a*, *a'*, and *b*, *b'*, points of incision in ureter and pelvis to be united by sutures after folding the ureter upon itself at the place of stricture.
B, Pelvis and ureter after union by sutures: 1, Pelvis; 2, ureter; 3, fold of ureter at place of stricture; 4, 4, sutures of wound in pelvis; 5, place of sutures between points *a*, *a'* and *b* and *b'*; 6, 6, additional sutures, as many as needed, to close the borders of the fold formed by approximation of *a* to *a'* and *b* to *b'*.

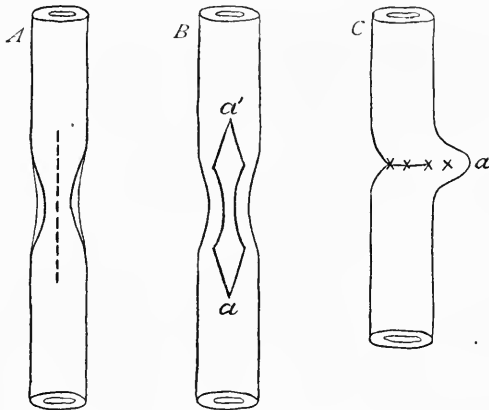


Fig. 86.—My plan of operating for ureteral stricture on extraperitoneal surface of ureter: *A*, Ureter showing stricture and line of incision. *B*, Opening through the stricture extending into the proximal and distal portions of the ureter. The extreme ends of the incision *a* and *a'* to be united. *C*, Ureter after suturing; *a*, The bend at the site of the stricture.

2. *Longitudinal incision* (as practised by me). When the stricture is not too extensive, it is divided longitudinally after opening the ureter above or below. The upper and lower ends of the longitudinal wound

are then brought together by folding the ureter upon itself. The remainder of the wound is united by sutures through the outer and middle coats, thus transforming the longitudinal into a transverse wound. (See Figs. 85 and 86.)

FENGER'S²¹ CASE.—Traumatic stricture of ureter close to entrance into pelvis of kidney, intermittent pyonephrosis for twenty-four years; increased frequency of attacks. Nephrotomy; no stone in sacculated kidney; ureteral entrance could not be found. Longitudinal ureterotomy revealed stricture at upper end of ureter; longitudinal division of stricture and plastic operation on ureter. Recovery without fistula.

3. *Resection of the ureter and implantation of the distal end into the pelvis, as practised by Küster in the following case (see Figs. 87 and 88):*



Fig. 87.—*a*, Upper end of ureter (*a*, *b*) running in the wall of the sac; *c*, slit in upper end of ureter.

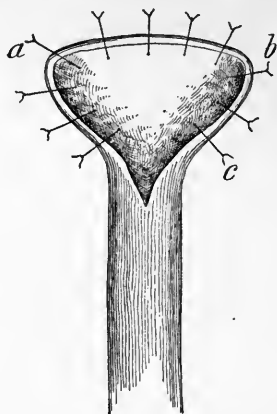


Fig. 88.—Küster's operation for implantation of the ureter into the sac (pelvis). The divided end of the ureter unfolded, and in the extent of *a*, *b*, *c*, sutured to the wall of the sac.

KÜSTER'S³⁹ CASE.—Boy, aged eleven years. Two years previously, left hydronephrosis. Braun made lumbar nephrotomy, which was followed by vesical anuria and lumbar fistula. Two years later dilatation of fistula and digital exploration of dilated pelvis. Catheterization of ureter from pelvis impossible. Septic pyelitis followed operation. Two months later patency of ureter secured in following manner: Lumbar extraperitoneal incision; ureter could not be found; incision of dilated pelvis revealed the ureter. On attempting to introduce probe into ureter, stricture was encountered. Transverse division of ureter below stricture and at pelvic entrance. Union of ureter to pelvis by dividing upper end of ureter, unfolding divided end, and suturing it to opening in sac. Remainder of wound closed by catgut sutures. Urine passed through fistula for four months, when fistula was closed. Recovery.

WOUNDS OF THE URETER

(*a*) *Longitudinal wounds of the ureter* have already been considered in the discussion of the operations for stone. An intraperitoneal longitudinal wound should be carefully united with extramucous sutures. In addition to the suture Van Hook⁷⁷ makes a suggestion which appears valuable in cases where the incised ureter is covered with peritoneum;

namely, to slide a fold of peritoneum from both sides over the sutured wound and unite the peritoneum over it. If no peritoneum can be used, an omental graft may be employed.

(b) *Transverse wounds of the ureter* are much more difficult to treat satisfactorily, as there is a tendency to retraction and gaping of the wound, and as, if direct suturing is resorted to, there is always a tendency to stenosis, even if the sutures do not tear out.

Van Hook proposes, in incomplete transverse wounds, to transform the transverse into a rhomboid shaped longitudinal wound by opening longitudinally upward and downward from the transverse wound and cutting off the four corners, thus creating a condition similar to that produced when a stricture of the ureter is opened longitudinally. The rhomboid wound may then be united transversely by folding the ureter upon itself in the manner proposed by me in the operation for stricture.

This operation will probably be safe in extraperitoneal wounds. If, however, the wound opens into the peritoneal cavity, it is not certain that covering with a fold of peritoneum would be sufficient. It might be safer to divide the ureter completely and then resort to Van Hook's method of lateral implantation. The first method has not yet been tried for intraperitoneal wounds; the latter has been tried with good results.

Attempts to unite complete transverse wounds of the ureter have, as a rule, failed in experiments upon animals and in operations on the human subject. In Tuffier's⁷⁴ experiments on dogs, death from peritonitis usually followed, and when union took place, there was so much cicatricial constriction as to cause stenosis.

In the only case in which direct union has been attempted in the human subject the result was also unsatisfactory. This case was reported by Schopf:⁶⁴

SCHOPF'S CASE.—During laparotomy for the extirpation of an intraligamentous ovarian cyst he divided the ureter near the brim of the pelvis. Having secured the divided ends by artery forceps, he united the ureter by eight silk sutures, which did not pass through the mucosa, and which probably invaginated the borders of the transverse wound. The patient made an uneventful recovery, but died seven weeks later from tuberculosis. The autopsy showed that the right ureter, at the place where it crosses the psoas muscle, was embedded in cicatricial tissue, and a cicatrix existed in the entire circumference of union.

The operator was dissatisfied with this result, and proposes in the next case to unite the transverse wound over a ureteral catheter brought out through the urethra and left in place during the healing of the wound, to prevent leakage and also stenosis.

Van Hook's method of invagination or uretero-ureterostomy, as Kelly calls it, is an important step forward in this direction, as it has proved on animals and on man sufficient to prevent leakage and also stenosis (see Figs. 89, 90, and 91). His method is as follows:

1. Ligate the lower portion of the tube $\frac{1}{8}$ or $\frac{1}{4}$ inch from the free end. Silk or catgut may be used. Make, with fine, sharp-pointed

scissors, a longitudinal incision twice as long as the diameter of the ureter in the wall of the lower end, $\frac{1}{4}$ inch below the ligature.

2. Make an incision with the scissors in the upper portion of the

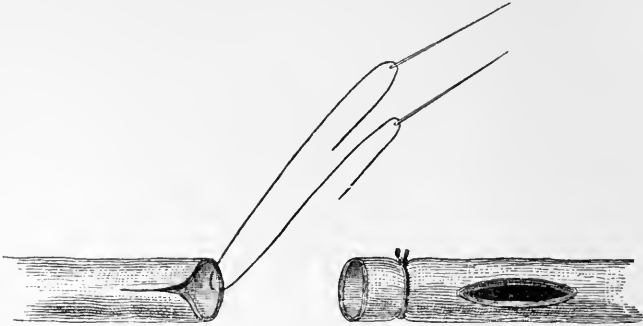


Fig. 89.—The needles have been introduced into the wall of the renal portion of the ureter. The end of the vesical portion of the tube has been ligated, and a slit made in its wall.

ureter, beginning at the open end of the duct and carrying it up $\frac{1}{4}$ inch. This incision insures the patency of the tube.

3. Pass two very small cambric sewing needles armed with one

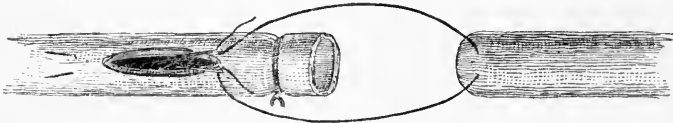


Fig. 90.—The needles carrying the traction suture attached to the renal portion of the ureter have been passed into the slit in the wall of the vesical portion, carried down a short distance, and pushed out through the wall.

thread of sterilized catgut through the wall of the upper end of the ureter, $\frac{1}{8}$ inch from the extremity, from within outward, the needles being from $\frac{1}{16}$ to $\frac{1}{8}$ inch apart, and equidistant from the end of the duct.

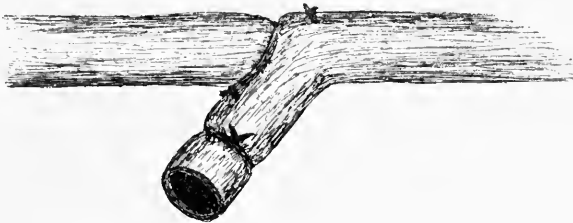


Fig. 91.—Uretero-ureterostomy (Van Hook's method). By means of the traction suture the renal portion of the ureter has been implanted into the vesical portion. The ends of the traction suture have been tied together.

It will be seen that the loop of the catgut between the needles firmly grasps the upper end of the ureter.

4. These needles are now carried through the slit in the side of the lower end of the ureter, into and down the tube for $\frac{1}{2}$ inch, where they are pushed through the wall of the duct side by side.

5. It will now be seen that the traction upon this catgut loop passing

through the wall of the ureter will draw the upper fragment of the duct into the lower portion. This being done, the ends of the loop are tied together securely, and, as the catgut will be absorbed in a few days, calculi do not form to obstruct the passage of the urine.

6. The ureter is now enveloped carefully with peritoneum, as already described in other operations, provided an intraperitoneal operation has been done.

Bloodgood⁷ has repeated Van Hook's experiments, with equally




Fig. 92.—Bloodgood: Uretero-ureteral anastomosis (experimental). Ureter anastomosed, traction sutures tied, and two fixation sutures in place ready to be tied.

satisfactory results. In addition to Van Hook's procedure, Bloodgood applied two sutures through the external coats only, as an additional security against leakage. His drawing of the united ureter (see Figs. 92 and 93) shows not only no narrowing of the caliber at the point of union, but even a little diverticulum of the canal.

A most important and interesting proof of the value of this method

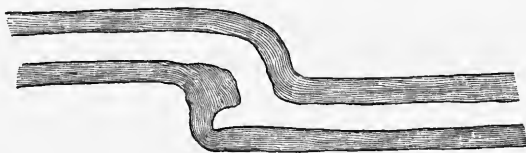


Fig. 93.—Longitudinal section of ureter showing new lumen and diverticulum.

has been furnished by Kelly³⁶ in the first operation of this kind on the human subject. This important case was the following:

KELLY'S CASE.—Woman, aged twenty-five years. During hysteromyomectomy the right ureter was accidentally ligated and transversely divided. Uretero-ureteral anastomosis by ligating lower end close to cut surface and making a slit 1 cm. long in its anterior wall, $\frac{1}{2}$ cm. below ligature. Invagination of upper into lower portion of ureter. Edges of slit sutured to the intussuscepted ureter; iodoform gauze drainage. Patient passed urine voluntarily on second day. Union by first intention. Recovery.

DIVISION OF URETER WITH LOSS OF SUBSTANCE

Division of ureter, with loss of substance so considerable as to make reunion of the two ends impossible, requires different operative procedures, namely, implantation into the bladder, into the bowel, or upon the skin.

(a) *Implantation of Ureter into the Bladder.*—When the upper end of the divided ureter is long enough to reach the bladder, implantation into this organ is preferable to all other procedures, as the danger of subsequent infection of the ureter and kidney is thereby avoided.

The experiments of Paoli and Busachi⁴⁷ in 1888 upon dogs were suc-

cessful. Their method consisted in splitting the distal end of the ureter and uniting it by sutures to an incision in the bladder.

1. *Extraperitoneal implantation of the ureter into the bladder* has been made in one case by Baumm.⁵ The patient had a double ureter on the right side, one ending at the mouth of the urethra, and causing partial incontinence of urine. Baumm made a suprapubic operation, cut an opening through the bottom of the bladder, and connected it with the proximal end of the accessory ureter, the distal end of which was ligated. The author himself does not recommend this operation, which he chose because the patient was a virgin, as he considers it, under ordinary circumstances, unnecessarily severe. He considers the operation through the vagina preferable.

2. *Intraperitoneal Implantation of Ureter into Bladder.*—In February, 1893, Novaro⁴⁵ operated successfully by the Paoli-Busachi method in the following case:

NOVARO'S CASE.—The patient had had vaginal hysterectomy performed for carcinoma extending into the broad ligament. The operation was followed by ureterovaginal fistula. Two months later laparotomy in Trendelenburg's position was made, the ureter dissected out from the vagina, divided for 1 cm., unfolded, and united by sutures to an incision in the bladder $1\frac{1}{2}$ cm. long, situated two fingerbreadths above the normal point of insertion. Gauze drainage out through the abdominal wound. For several days the gauze was impregnated with urine, showing leakage at the point of union. This was only temporary, however, and ten days after the operation the function of the urinary organs was normal and remained so.

In the two following cases of implantation into the bladder the operators acted upon Van Hook's suggestion of uretero-ureterostomy, and the effect of the operation in each case was complete, as undoubtedly no leakage of urine took place:

KRUG'S³⁸ CASE (kindly communicated to me by Dr. Krug).—"The case was operated on in Philadelphia. The patient was a colored woman, about thirty years of age, who had suffered from a fibroid for over six years. During most of this time she had been subjected to electric treatment. When I saw her on the morning of the operation, I found her very much emaciated, with a poor pulse. The tumor filled the entire pelvis and extended to about the umbilicus. On opening the abdomen universal adhesions were found. After having removed the greater part of the omentum, I commenced by tying off the tube and ovary on the left side. The next ligature was placed around the round ligament and the excess of the broad ligament on that side. Although I expected to meet with some difficulty in shelling out the tumor, which was entirely intraligamentous, and, therefore, paid particular attention to the ureter, I found that in cutting off the round ligament I had cut off the left ureter in front of the tumor. The tumor had evidently grown intraligamentous, unfolding the two sheets of the broad ligament, lifting up the ureter, and the injury was done at a place where I felt absolutely secure. Putting clamp forceps on the proximal and distal ends respectively, I finished the operation, which was an extremely difficult one. Finding, then, that I could reach the bladder without putting too much tension on the proximal end of the ureter, I decided to graft the ureter into the bladder. An incision being made into the bladder, the ureter was treated in a manner similar to that employed by Dr. Van Hook in invaginating the cut ends of the ureter. In sewing up the incision in the bladder, care was taken to prevent leakage without constricting the lumen of the ureter. Several tiers of running sutures were made, and all the available peritoneum used to build

up a solid wall around the ureter. A permanent catheter was introduced into the bladder, which remained for four days. For two days more the patient was catheterized every four hours. A normal amount of urine was passed right after the operation. There was no rise of temperature nor any other untoward symptom. The patient left the hospital about four weeks after the operation; she is now doing hard work and feeling splendidly."

PENROSE'S⁵⁰ CASE.—Woman, aged forty years. Carcinoma of cervix uteri involving left broad ligament and about 1 inch of ureter involved therein. No obstruction of ureter. After removal of uterus, excision of 1 inch of ureter, distal end of ureter was ligated, and proximal portion implanted into the bladder after Van Hook's method. Abdomen closed without drainage. Good recovery.

The perfect success of this operation in these cases would seem to indicate that Paoli and Busachi may be right in proposing the application of this operation to uretero-uterine and ureterovaginal fistulas. If this operation is as safe and certain as the above cases indicate, and if the future function of the implanted ureter remains undisturbed, this method would seem to be superior to the older plastic operations through the vagina, which are difficult in technic, uncertain in results, and sometimes fail entirely.

Operations for Uretero-uterine and Ureterovaginal Fistulas.—The prevention of the incontinence of urine caused by these infirmities is accomplished in three ways:

(1) Plastic operations with a view to displace the fistula from the vagina or cervix into the bladder.

(2) Colpocleisis.

(3) Nephrectomy, the operation of last resort.

The plastic operations known by the names of their originators—Simon, Landau, Bandl, Schede, and Pozzi—who have brought them to their present state of perfection, I shall not detail here, but merely recall the main steps in the development of the operations.

Simon,⁶⁸ through a vesicovaginal fistula, artificial if not preëxistent, opened the proximal end of the ureter from the bladder for some distance, cauterized the divided borders until cicatrization had taken place, thus securing against reclosure, and finally closed the vesicovaginal fistula.

Landau⁴⁰ passed a catheter into the ureter through the vesicovaginal fistula, bringing the distal end of the catheter out through the urethra, and, by immediately closing the vesicovaginal fistula, invaginated the opening of the ureter into the bladder.

Bandl⁴ employed a combination of the methods of Simon and Landau.

Schede⁶³ inverted the ureteral opening into the bladder, together with a zone of the surrounding mucous membrane, with the intention of preventing subsequent cicatricial stenosis.

Pozzi⁵⁵ employed with advantage a method by splitting similar to that devised by Gerdy for vesicovaginal fistula.

These plastic operations are often difficult in technic, repeated attempts at closure have frequently to be made, and in some cases inflammation of the ureters and kidneys has resulted. The operations on uretero-uterine and ureterocervical fistulas are especially difficult. The operations are, however, rather more taxing to the patience of the operator

and patient than dangerous to life. They have always been attempted before the indirect methods of obliteration have been resorted to.

Colpocleisis, proposed by Vidal du Cassis and Simon, and first practised by Hahn,²⁵ consists in closure of the vagina on the distal side of a vesicovaginal fistula, and possesses the disadvantages that the latter may contract and that marital relations are made impossible, excepting in the cases wherein partial colpocleisis, as devised by Kaltenbach,³² can be made.

Nephrectomy, the operation of last resort, really means the abandonment of the struggle with the fistula. It has been necessitated in some instances by infection of the kidney, and although not very fatal, as in 14 cases on record only 1 patient died, it is applicable only to cases where the other kidney is healthy.

The operative results as collected by Nebe⁴³ in 1890, and Iversen³¹ in 1892, were as follows: Of 14 uretero-uterine and ureterocervical fistulas, all following childbirth, 8 were operated upon—1 with hysterocleisis (Duclout); 1 colpocleisis (Hahn), both relatively successful. The remaining 6 cases (Zweifel, Crede, Fritsch, Netzel, Traub, and Iversen) were unsuccessful and nephrectomy had to be made. It will thus be seen that direct displacement of the ureter into the bladder was not found applicable to this class of cases.

Of ureterovaginal fistulas, 32 cases were collected by Nebe, 5 by Iversen, 1 by Arie Geyl, 1 by Pozzi, and 1 by Hergott (cited by Pozzi)—a total of 40 cases, of which 10 were secondary to operations or pelvic abscesses, 28 followed childbirth, and in 2 the cause was unknown. Of these 40, 24 were operated upon as follows: Plastic invagination into the bladder through the vagina was successful in 10 cases (Bandl 2, Lannelongue, Geyl, Parvin, Schede, Solowjeff, Schauta, Pozzi, and Hergott), colpocleisis was performed in 5 cases (Gusserow 2, Kehrer, Schede, and Kaltenbach, partial), and nephrectomy in 5 cases (Schede, Gusserow, Czerny, Heilbrunn, and Fritsch). In the remaining 4 cases attempts at operating were abandoned as unsuccessful.

In the 10 cases which did not follow childbirth 5 followed vaginal hysterectomy, 3 pelvic abscess, and 2 operations on vesicovaginal fistula. Two were cured by direct closure (Nicoladoni, Emmet), 3 by colpocleisis (Kaltenbach 2, Hempel), in 3 nephrectomy was performed (Stark, Böckel, Bardenheuer, whose patient died); the remaining 2 cases, both following pelvic abscess (Emmet), were not operated upon.

It will thus be seen that in 34 cases of ureteral fistula this condition was remedied by plastic operations in 11 cases, by colpocleisis in 7, hysterocleisis in 1, and nephrectomy in 15.

Taking into consideration the fact that in almost all, if not all, the cases the kidney in question was healthy from the beginning, it seems to be a reproach against our present methods of treatment that in 44 per cent. the kidney should have been sacrificed.

A pyelonephritis in its early stage is amenable to cure, as has been shown experimentally by Rovsing,⁶⁰ and Geyl²² may be right in calling attention to the possibility that a non-advanced stage of pyelonephritis

may disappear when the distal end of the ureter is implanted into the bladder.

The successful implantations of the ureter into the bladder by Novaro, Krug, Penrose, and Baumm lead us to believe it possible in these cases to save the kidneys, which would otherwise be sacrificed.

The congenital abnormal opening of the end of the ureter outside of the bladder, in the urethra or the vagina, causing partial incontinence of urine, is naturally treated in the same way as ureterovaginal fistulas, by vaginal, suprapubic, or abdominal implantation into the bladder.

The vaginal implantation, as probably the safest method, was chosen by Davenport¹⁵ in the following case:

DAVENPORT'S CASE.—Woman, aged twenty-nine years; incontinence of urine from early childhood, due to malposition of the ureter. Incontinence increased by menstruation and pregnancy. One ureter was found in the vesicovaginal septum running forward, its orifice being close to the external orifice of the urethra. Operation for displacement of ureter and implantation of its orifice into the bladder. Recovery.

Bois (d'Auvillac)⁸ reports the following case:

BOIS' CASE.—Congenital incontinence of urine, although the bladder acted regularly. Fine canal in left wall of urethra from which urine continually dribbled. A probe at this point passed into the left ureter. Operation: Division with tenotome of wall between ureter and bladder, and opening kept open by bougies. The closure of the peripheral end of ureter was postponed on account of pregnancy.

(b) *Implantation of the Ureter into the Bowel.*—Implantation into the small intestine, colon, and rectum has been studied experimentally by Rosenberg, Novaro, Morestin, Tuffier, Gluck and Zeller, Harvey Reed, Van Hook, and others. The technical difficulties of this procedure have been fairly well overcome, but there seems to be a serious objection to this plan of implantation on account of the liability to infection of the ureter and kidney by intestinal microbes, and also because of some tendency to constriction at the place of implantation. Van Hook found both these conditions present as early as ten days after the operation. Reed⁵⁷ found acute nephritis in one dog killed twenty-four hours after the operation, but in another similar case the kidney was apparently healthy.

In man the implantation suggested by Roux was tried unsuccessfully by Simon, but successfully, according to Rosenberg,⁵⁹ by Chaput in 2 cases. Chaput¹² has recently published the following case:

CHAPUT'S CASE.—In a case of ureterovaginal fistula following vaginal extirpation of the uterus he implanted the ureter into the colon. He made a laparotomy, divided the peritoneum on the posterior wall, isolated the ureter, divided it transversely, and fixed its renal end into the colon by a double row of step sutures. The vesical end of the ureter was ligated. The patient recovered, and was well satisfied with her condition. She was obliged to void mixed urine and feces three or four times a day. Five months after the operation there were no signs of infection of the kidney.

Van Hook condemns the operation very strongly on account of the liability to infection, and he is undoubtedly right. The bowel, therefore, should never be chosen when it is possible to implant the ureter into the

bladder. If this is impossible on account of defect in the ureter, it is still an open question whether or not implantation into the colon should be tried before resorting to implantation on the skin in the lumbar region or the abdominal wall, or nephrectomy.

(c) *Implantation of the Ureter on the Skin.*—Le Dentu¹⁸ was the first to implant the ureter on the skin for anuria in a case of absolute impermeability from cancer in the small pelvis. The symptoms were relieved, but the patient died thirteen days later from cancerous cachexia. This case, however, established the operation as an effective procedure to be employed in combating anuria due to incurable mechanical causes, as it at least prolonged life.

Pozzi,⁵⁴ in the removal of a retroperitoneal parovarian cyst by laparotomy, divided the ureter at about its middle. The upper end was dissected out for 5 or 6 cm., and implanted into the skin in the lumbar region through a buttonhole opening. The distal portion of the ureter was sutured to the lower end of the abdominal wound. The patient recovered from the operation, and three months later nephrectomy was resorted to, which was followed by recovery. Microscopic examination of the kidney showed that it was healthy, with the exception of a few small islands of interstitial nephritis. No septic invasion had taken place, as no micro-organisms were found.

The integrity of the kidney in this case, after so long a period of exposure through the open ureter, is remarkable, and, according to Albarran, due to the antiseptic precautions in the after-treatment. This case was one in which uretero-ureterostomy might have been performed with advantage.

Losses of substance of the ureter too extensive to permit of uretero-ureterostomy, or located too high up to permit of implantation of the upper end into the bladder, will require either implantation on the skin or into the bowel. As both of these methods are objectionable on account of the liability to infection sooner or later, and the consequent necessity of nephrectomy, operative procedures to effect a connection with the bladder have been proposed by Rydygier and Van Hook from dissections on the cadaver.

Rydygier⁶¹ proposes to implant the two ends of the ureter on the abdominal wall, and, by plastic operation, to make a channel of skin between them, to make good the loss of substance of the ureter.

Van Hook proposes, by plastic operation on the bladder, to create a diverticulum long enough to meet the upper end of the ureter.

In both of these methods it is proposed to place the newly formed channels in the abdominal wall. Theoretically, these methods appear feasible, but they have not as yet been practised in animals or the human subject.

Reichel⁵⁸ reports the following unique case of ureter in an inguinal hernia:

REICHEL'S CASE.—Boy, aged nine and one-half years; movable right inguinoscrotal hernia for four and one-half years. Herniotomy revealed small sac containing a little water. Behind this was another tortuous sac adherent to its surroundings. This was the ureter. Incision of sac. Palpation revealed a canal narrow down to the bladder, but

dilated up to the kidney; hydronephrosis. Extraperitoneal nephrectomy seven days later. Recovery.

CONCLUSIONS

Accidental wounds and subcutaneous ruptures of the ureter have not as yet been objects of direct surgical procedure upon the ureter at the seat of lesion. It will be advisable, however, when, and as soon as the diagnosis can be made, or when lumbar opening of a peri-ureteral cavity containing extravasated urine is made, to look for the seat of rupture, and, if practicable, to restore the continuity of the canal.

Catheterization of the ureters from the bladder for purposes of diagnosis of diseases of the kidneys has given valuable information affecting the decision for or against operation on the kidney. The procedure is reasonably practicable in the female by the methods developed by Simon, Pawlik, and Kelly.

In man catheterization is practicable only through epicystotomy. The danger of this operation is steadily decreasing. The old mortality, which varied from 27 to 20 per cent., has been reduced in the more recent series of operations (Utzmann⁷⁶). Albert has had 20 cases, with 1 death; Assandelft, 102 cases, with 2 deaths; Utzmann, 9 cases, with 1 death; Bergman, 10 cases; von Itersen, 12 cases; Trendelenburg, 6 cases; and Antal, 8 cases, all without a death. Therefore, this procedure is justifiable in selected cases.

Catheterization of the ureter from the bladder as a curative measure for the evacuation of hydronephrosis or pyonephrosis has occasionally been performed successfully (Pawlik). It is more difficult and more uncertain than nephrotomy, and the attempt to find and remedy the stenosis of the ureter from the pelvis of the kidney.

Dilatation of strictures of the ureter by elastic bougies or catheters has been tried from the bladder by Kelly with temporary success, and from the pelvis of the kidney by Alsberg successfully; consequently this procedure is of use in isolated cases.

Permanent catheterization of the ureter from the bladder, a fistula, or an implanted ureter is often tolerated only for a limited time, and must be employed with caution for fear of causing ureteritis.

Ureterolithotomy, longitudinal incision over a stone for its removal, is a safe operation by the extraperitoneal method. The wound heals without stenosis. In extraperitoneal operations suturing is unnecessary, drainage down to the wound being sufficient.

Intraperitoneal ureterotomy should be done only when access outside of the peritoneal cavity is impossible, and it should be completed by careful suturing, covering with a peritoneal or omental flap, and drainage.

Opening of the peritoneal cavity to locate the seat of the stone may occasionally be necessary, but when the diagnosis is once made, ureterotomy for the removal of the stone should be done through an extraperitoneal incision and the abdomen closed.

In valve formation or stricture of the ureter causing pyonephrosis or hydronephrosis or a permanent renal fistula, nephrotomy should be

followed by exploration of the ureter in its entire course from the kidney to the bladder.

Exploration of the ureter as to its permeability should be done from the renal wound by a long, flexible silver probe (a uterine probe) or an elastic bougie, either olive-pointed or not. If the bougie passes into the bladder, the examination is at an end. The size of bougie that will pass through a healthy ureter is from No. 9 to 12, French scale.

If the pelvic orifice of the ureter cannot be found from the renal wound, it should be sought for by opening the pelvis (pyelotomy) or by incising the ureter (ureterotomy).

A longitudinal incision, $\frac{1}{2}$ inch to 1 inch long, in the posterior wall of the pelvis, can be made while the kidney is lifted upward against the twelfth rib. This procedure is easy if the pelvis is dilated, but may be impossible if the pelvis is of normal size.

Operation for valve formation should be done through the wound in the pelvis. If the opening cannot be seen or found from the pelvis, ureterotomy should be performed immediately below the pelvis; a small incision should be made in the ureter, and a probe passed up into the pelvis. The valve should be split longitudinally, and the incised borders so treated as to prevent reformation of the valve.

A stricture in the ureter, if not too extensive, can be treated by a plastic operation on the plan of the Heineke-Mikulicz operation for stenosis of the pylorus, namely, longitudinal division of the stricture and transverse union of the longitudinal wound. This method of operating for ureteral stricture seems to me preferable to resection of the strictured part of the ureter (Küster's operation), for the following reason: It is a more economic operation, and preferable when the elongation of the ureter is not sufficient to permit the two cut ends of the ureter after excision of the stricture, not only to come in contact, but even to permit of closure and invagination without stretching.

Resection of the upper end of the ureter and implantation of the distal end into the pelvis may be useful in rupture or division or stricture of the upper end of the ureter, as described by Küster.

In a similar case of stricture in the upper end of the ureter, especially if the ureter were not elongated or the kidney movable, I should prefer the plastic operation proposed by me, as it is easier of technic, and as it proved successful in my case of traumatic stricture in the ureter below the pelvic orifice.

The ureter is accessible through an extraperitoneal incision, a continuation of the oblique incision for lumbar nephrotomy, from the twelfth rib down along and 1 inch anterior to the ilium and along Poupart's ligament to about its middle. This incision gives access to the upper three-fourths of the ureter and down to within 2 or 3 inches above the bladder.

The vesical and lower pelvic portions of the ureter may be reached, as Cabot has pointed out, by means of the sacral operation, or Kraske's method, modified by osteoplastic temporary resection of the sacrum. In woman the vesical portion of the ureter is accessible through the vagina.

The vesical orifice of the ureter may be reached from within the bladder by suprapubic cystotomy in man, and by dilatation of the urethra or suprapubic or vaginal cystotomy in woman.

Uretero-uterine fistulas can be treated satisfactorily by plastic closure of the vagina or by nephrectomy. Implantation of the ureter into the bladder is, under favorable circumstances, the operation of the future for this condition.

Ureterovaginal fistulas and congenital urethral or vaginal terminations of the ureter should be treated by vaginal plastic operation for displacement of the proximal end of the ureter into the bladder. If these attempts fail, and the kidney is not infected, extraperitoneal or transperitoneal implantation into the bladder should be done, and, finally, as a last resort, nephrectomy.

Complete transverse wounds in the continuity of the ureter should be treated by uretero-ureterostomy after Van Hook's method of lateral implantation, if possible.

Complete transverse wounds of the upper end of the ureter should be treated by implantation of the ureter into the pelvis of the kidney, as devised by Küster.

Complete transverse wounds of the ureter near the bladder should be treated by implantation into that viscus either by splitting the ureter or by invagination.

Loss of substance of the ureter too extensive to permit of uretero-ureterostomy, or too high up to permit of implantations into the bladder, may be treated by implantation on the skin or into the bowel.

Implantation into the bowel is objectionable on account of the infection which is almost certain to follow sooner or later.

Implantation into the rectum should not be resorted to when implantation into the bladder is possible.

Implantation on the skin in the lumbar region or the abdominal wall may have to be followed by secondary nephrectomy, which, however, is much less dangerous than the primary operation.

BIBLIOGRAPHY

1. Albarran and Lluria: *Compt. rend. de la Soc. de Biol.*, 1891, vol. iii, pp. 543 and 587.
2. Allingham: *Brit. Med. Jour.*, 1891, vol. i, p. 699.
3. Alsborg: *Verhandl. der Deut. Gesellschaft f. Chir.*, XXI. Congress, 1892, p. 43.
4. Bandl: *Wien. med. Wochenschr.*, 1877, vol. xxviii.
5. Baumm: *Centralb. f. Gynäk.*, 1892, vol. xv, p. 336.
6. Berg, J.: *Hygiea*, 1889, vol. li, p. 144.
7. Bloodgood: *Annals of Surgery*, 1894, vol. xix, p. 77.
8. Bois (d'Auvillac): *Bull. et Mém. de la Soc. de Chir. de Paris*, 1893, vol. xix, p. 371.
9. Cabot, A. T.: *Amer. Jour. Med. Sci.*, 1892, vol. ciii, p. 43.
10. *Ibid.*: *Boston Med. and Surg. Jour.*, 1890, vol. cxxiii, p. 247.
11. Ceci: *La Riforma Médica*, 1887.
12. Chaput: *Bull. et Mém. de la Soc. de Chir. de Paris*, 1893, vol. xix, p. 309.
13. Crampton, Sir P.: *Medico-Chirurgical Transactions*, vol. xvi, p. 162; cited from Page.
14. Cullingworth, C. J.: *Trans. London Path. Soc.*, 1885, vol. xxxvi, p. 278.
15. Davenport, T. H.: *Boston Med. and Surg. Jour.*, 1890, vol. cxxiii.
16. Delbet: *Annales des Maladies des Organes Génito-Urinaires*, 1891, vol. ix, p. 246.
17. Le Dentu, A.: *Affections Chirurgicales des Reins des Urètres et des Capsules Sur-rénales*, Paris, 1889.

18. *Ibid.*: Congrès Français de Chirurgie, 1889, p. 533.
19. Emmet, T. A.: Principles and Practice of Gynecology, 1884.
20. Fenger, C.: Chicago Medical Recorder, 1893, vol. iv, p. 155.
21. *Ibid.*: Jour. Amer. Med. Assoc., 1894, vol. xxii, p. 335
22. Geyl, Arie: Volkmann's Sammlung klin. Vorträge, 1892, No. 37, p. 311.
23. Guyon: Cited from Tuffier, *op. cit.*, p. 520.
24. *Ibid.*: Cited by Albarran and Lurria.
25. Hahn: Berlin. klin. Wochenschr., 1879, vol. xvi, p. 397.
26. Hall, R. B.: Medical Record, New York, 1890, vol. xxxviii, p. 430.
27. Hallé, N.: "Urétérite et Pyélite," Thèse de Paris, 1887.
28. Henle, J.: Handbuch der Eingeweidelehre des Menschen, Braunschweig, 1873, p. 335.
29. Hyrtl: Cited from Henle's Handbuch der systematischen Anatomie.
30. Iversen: Centralbl. f. Chir., 1888, vol. xv, p. 281.
31. *Ibid.*: Nordiskt Mediciniskt Arkiv, 1892, vol. ii, p. 1.
32. Kaltenbach: Cited from Iversen.
33. Keen, W. W.: Medical News, Philadelphia, 1891, vol. lviii, p. 431.
34. Kelly, H. A.: Amer. Jour. Obstet., 1892, vol. xv, p. 768.
35. *Ibid.*: Johns Hopkins Hosp. Reports, 1892, vol. ii, p. 235.
36. *Ibid.*: Annals of Surgery, January, 1894, vol. xix, p. 70.
37. Kirkham, F. W.: Lancet, 1889, vol. i, p. 525.
38. Krug, Florian: Unpublished.
39. Küster, Th.: Arch. f. klin. Chir., 1892, vol. xlvi, p. 850.
40. Landau: Arch. f. Gynäk., 1878, vol. ix.
41. Lane, W. Arbuthnot: Lancet, 1890, vol. ii, p. 967.
42. Mynter, H.: Annals of Surgery, 1893, vol. xviii, p. 658.
43. Nebe: "Ueber Harnleiterscheidenfisteln," Inaug. Diss., Halle, 1890.
44. Newman: Glasgow Medical Journal, 1885, vol. xxiii, p. 433.
45. Novaro (published by Bottini): Centralbl. f. Chir., 1893, vol. xx, p. 596.
46. Page, H.: Annals of Surgery, 1894, vol. xix, p. 513.
47. Paoli and Busachi: Annales des Maladies des Organes Génito-Urinaires, 1888, vol. vi, p. 553.
48. Pawlik: "Ueber der Harnleitersondirung," Arch. f. klin. Chir., 1886, vol. xxxiii, p. 717.
49. *Ibid.*: Cited by Albarran and Lurria.
50. Penrose, C. B.: Medical News, Philadelphia, 1894, vol. lxiv, p. 470.
51. Perez: "Exploration des Uréteres," Thèse de Paris, No. 302.
52. Poirier: Cited from Le Dentu.
53. *Ibid.*: Discussion of Albarran and Lurria's paper.
54. Pozzi, S.: Congrès Français de Chirurgie, 1891, p. 606.
55. *Ibid.*: Medical and Surgical Gynecology, 1891, vol. ii, p. 328.
56. Ralfs and Godlee: Clinical Society of London, February 22, 1889; cited from Cabot.
57. Reed, R. H.: Annals of Surgery, 1892, vol. xv, p. 601.
58. Reichel, P.: Verhandl. der Deut. Gesellschaft f. Chir., 1892, vol. ii, p. 68.
59. Rosenberg: Virchow's Archiv, vol. cxxxii, p. 158.
60. Rovsing, Th.: Om. Blaerebetaendelsesernes Aetiologi Pathogenese og Bchandling, Copenhagen, 1889.
61. Rydygier, L.: "Ureteroplasty," Oest.-Ungarisches Centralbl. f. med. Wissenschaft, 1892.
62. Sands: Cited from Le Dentu.
63. Schede: Centralbl. f. Gynäk., 1881, vol. v.
64. Schopf, F.: *Ibid.*, 1887.
65. Secheyron, L.: Archives de Tocologie, 1889, p. 254.
66. Silbermann: Cited from Le Dentu.
67. Simon: Chirurgie der Nieren, vol. ii, Stuttgart, 1876.
68. *Ibid.*: Wien. med. Wochenschr., 1876.
69. Tanquary, W. M.: Cited by Van Hook.
70. Tournay: "De l'Urétérite et de la Périurétérite," Thèse de Paris, 1886.
71. Trendelenburg, F.: Volkmann's Sammlung klin. Vorträge, 1890, No. 355, p. 3378.
72. Tuchmann: Virchow-Hirsch Jahresbericht, 1874, vol. ii, p. 282.
73. Tuffier, Th.: "Appareil Urinaire," Duplay et Réclus' Traité de Chirurgie, vol. vii, Paris, 1892.
74. *Ibid.*: Études Expérimentales sur la Chirurgie du Rein, Paris, 1889, p. 165.
75. Twynam: Transactions Clinical Society of London, 1890, vol. xxiii.
76. Ultzmann, R.: "Die Krankheiten der Harnblase," Deutsche Chirurgie, Lieferung 52, p. 290.
77. Van Hook, W.: Jour. Amer. Med. Assoc., 1893, vol. xx, p. 225.
78. Weil: Centralbl. f. Gynäk., 1893, vol. xvii, p. 14.
79. Weir: Cited from Le Dentu.

OPERATION FOR THE RELIEF OF VALVE-FORMATION AND STRICTURE OF THE URETER IN HYDRONEPHROSIS OR PYONEPHROSIS*

IN all cases of pyonephrosis we may expect to find some obstruction to the flow of urine in the renal pelvis, the ureter, the bladder, or the urethra. If the obstruction is external to the ureteral opening in the bladder, the pyonephrosis is double; if on one side, the obstruction must be in the ureter or the pelvis of the kidney.

Lumbar nephrotomy for pyonephrosis has a mortality of 23.3 per cent., and primary lumbar nephrectomy a mortality of 34 per cent. (Tuffier).¹ Secondary nephrectomy must be made to close the fistula after some time has passed, but this should not be delayed until amyloid nephritis of the other kidney has set in. The mortality from this operation is low—5.9 per cent. If we add the 5.9 per cent. mortality from secondary nephrectomy to the 23.3 per cent. mortality from primary nephrotomy, the total of 29.2 per cent. is still 7.8 per cent. less than the mortality from primary abdominal nephrectomy, which is 37 per cent., and 4.8 per cent. less than the mortality from primary lumbar nephrectomy, which is 34 per cent. Consequently, in pyonephrosis nephrotomy is the operation of choice (Tuffier).

The disadvantage of nephrotomy as compared with nephrectomy for pyonephrosis is that a fistula remains in 45 per cent. of the cases. This means that after a time a secondary nephrectomy must be made. Fistulas remained in 34 per cent. of the cases of calculous pyelitis and in 54 per cent. of the cases of non-calculous pyelitis. The smaller number of fistulas in calculous pyelitis is to be accounted for by the fact that in a certain number of these cases the stone prevents the passage of urine, and with the removal of the stone the obstruction is removed. Where there is no stone, simple nephrotomy will leave the impediment in all cases. If in both calculous and non-calculous pyonephrosis we can reestablish the permeability of the ureter, we may expect materially to diminish the percentage of permanent fistulas.

Tuffier, in the discussion of pyonephrosis, in his excellent monograph on Surgery of the Urinary Organs, remarks: "It would be interesting to know the condition of the ureter, the strictures, bands, valve formations, that transform an open pyelonephritis into a temporarily closed hydronephrosis or pyonephrosis. As yet these investigations for the intermittent pyonephrosis have not been made."

* Jour. Amer. Med. Assoc., 1895, vol. xxii, p. 335.

VALVE FORMATION AND BENDING AT THE PELVIC ORIFICE OF THE URETER

Valve formation and oblique insertion of the ureter were first noticed in a case reported by Glass² and cited by Rayer.³ A girl was born with right hydronephrosis and died at the age of twenty-three. At autopsy three gallons of liquid were found in the sac. On the interior surface of the sac the orifice of the ureter was seen to be as large as a goose-quill. The ureter passed obliquely for 12 inches between the membranes of the sac, and was patent the entire distance to the bladder. On account of the non-obstruction of the ureter, Rayer considers this the most remarkable case on record.

Rayer observed a case of double hydronephrosis in which the ureters were also patent, which he attributes to congenital malformation. The patient was a boy of seventeen, who had been sickly all his life and had had pain for seven years in the region of the left kidney. A tumor was found, and the diagnosis made of left hydronephrosis. He died from septic infection of the sacs. At autopsy the left ureter was found patent, the upper portion situated in the wall of the sac, with an opening almost similar to a valve in a vein. Water passed easily from below upward, but not down from the sac into the ureter. There was a smaller hydronephrosis in the right kidney. The right ureter was dilated to the size of a lead-pencil from the bladder up to the sac. At the upper end it was retracted, and when water was injected from below, it entered the sac through an opening the size of the lacrimal punctum.

Virchow, in discussing hydronephrosis, remarks: "The cases are extraordinary in which hydronephrosis exists with the ureter patent. I have examined such cases several times, and have found in each case a valvular obstruction caused by folding of the wall, due to oblique origin of the ureter from the renal pelvis."

Simon⁵ gives a full and comprehensive description of this condition. The ureter does not enter the pelvis of the kidney at its lowest point with a funnel-shaped opening, but enters it at the side, at an acute angle, and often even runs for a variable distance in the wall of the pelvis. In two similar observed cases the ureter ran, not in the wall proper, but between the wall and the peritoneal covering for 7 to 10 cm. In contradistinction to the previous authors, who thought that valve formation was the cause of the hydronephrosis and therefore congenital, Simon believes that the hydronephrosis in its beginning causes the valve formation, and consequently that valve formation is not a congenital affection. He has examined a specimen in which a stone was found in the ureter 5 cm. from the pelvic orifice, in a case of hydronephrosis the size of a child's head, and with valve formation in the upper end of the ureter. He believes that temporary obstruction from any cause may produce sufficient asymmetric dilatation of the pelvis to give rise to oblique insertion and valve formation, which, when it once exists, even if the primary cause of obstruction disappear, may remain as a permanent obstruction of greater or less degree to the passage of urine. He

considers valve formation in hydronephrosis very common, as he found it in 11 out of 18 reported cases.

The mechanical aspect of valve formation in the causation of intermittent hydronephrosis was studied by Krakauer,⁶ who made experiments designed to explain the fact that spontaneous evacuation of urine is sometimes seen in hydronephrosis due to this cause. Acting upon the proposal of Simon, Krakauer produced an imitation of the hydronephrosis due to valve formation in the following manner: He caused to be made a rubber balloon having a capacity of 150 c.c. with a tube which ran for several centimeters in the wall before opening at an acute angle into the side of the balloon. When the balloon was filled to distention, he observed that the first 50 c.c. were evacuated rapidly, the second 50 c.c. less rapidly, and the remainder still less readily. From this experiment Krakauer concluded that a higher pressure in the balloon, equivalent to an overfilling of the distended pelvis, is capable of overcoming a greater hindrance or impediment in the tube of exit, the ureter, than is a lower pressure. Applying this fact to the obliquely inserted ureter in the dilated renal pelvis, he concludes that partial filling of the dilated pelvis will close the valve of entrance and permit no evacuation through the ureter; further accumulation of urine and overdistention of the dilated pelvis will overcome the obstacle, and the urine will be evacuated through the ureter. This fact explains the intermittent hydronephrosis observed in Case 1.

Landau⁷ states that intermittent hydronephrosis, where there is no gross pathologic impediment to the passage of urine, is not so rare as might be judged from the infrequency of reports of this condition in the literature. He has seen 4 cases, all women aged from thirty to sixty years. In one case infection pyonephrosis and perinephritis took place, which necessitated nephrotomy.

The etiology of this condition was given by Landau as—(a) Bending; (b) torsion; (c) oblique insertion of the ureter. These conditions caused stagnation of urine in the pelvis of the kidney, dilatation of the pelvis, and then compression of the upper part of the ureter by the distended pelvis. These pathologic conditions of the ureter are in many cases caused by floating kidney. Direct traction upon the ureter has also been reported as the cause of hydronephrosis in certain cases of prolapse of the uterus.

The amount of secreting kidney substance left is very variable; more of it is to be found in the smaller tumors, but even in large tumors secreting kidney substance may be spread out over a large surface. In one of Simon's cases he could feel the calices from the tenth rib to the crest of the ilium.

The ureter is small on account of atrophy from non-use. Its upper portion, which passes up through or in the wall of the pelvis, is stenosed from pressure of the sac. Its opening into the pelvis is a narrow, crescentic slit, sometimes only a line in length, and often difficult to find on the specimen (Simon).

Spontaneous cure with *restitutio ad integrum* is impossible, because

more or less kidney substance must necessarily be destroyed by the dilatation; but a condition almost identical with recovery is seen when the obstacle to the passage of urine disappears spontaneously, as, for instance, when a stone passes away. This is possible only, however, when no secondary valve formation has taken place (Simon).

TREATMENT

Nephrectomy.—In large hydronephroses, often mistaken for ovarian tumors, nephrectomy or rather extirpation is exceedingly difficult, as hydronephrosis is a retroperitoneal tumor, and as in the course of the extirpation the mesocolon must be divided. At the time of Simon's report the mortality was absolute; in 2 cases where total extirpation was made, and in 4 cases in which it was tried and given up as impossible, all the patients died.

Puncture and aspiration are only palliative measures, and in only 1 out of 11 cases collected by Simon was there even temporary improvement.

Nephrotomy.—An abdominal opening into the sac of a hydronephrosis cannot be done without first procuring adhesions to the wall, either by leaving the cannula in or by Recamier's cauterization. The patients died either from the operation or later from infection through the fistulas, with the exception of 2 out of the 8, 1 of whom (Spencer Wells' case) recovered accidentally by passing of stones. In the other case (Simon's) a fistula remained. Spencer Wells's case was as follows: "A woman of fifty had had intermittent attacks of pain in the region of the right kidney for seventeen years. Having made a diagnosis of intermittent pyonephrosis and finding a large tumor with indistinct outlines on May 19, 1865, he evacuated, by puncture through the abdomen with a fine trocar, 2 to 3 pints of pus. Eight days later he reopened the wound and dilated with a laminaria tent to evacuate the accumulated fluid. One month after the first puncture, on June 20th, two uric-acid calculi the size and shape of a broad bean passed, followed by relief. After a few weeks the tumor disappeared, and the patient was well for the fifteen remaining years of her life."

Obliteration of Sac after Nephrotomy.—The difficulty, we might almost say impossibility, of curing hydronephrosis without reëstablishing the passage through the ureter is well illustrated by one of Simon's cases. A man of twenty-two had a hydronephrosis of sixteen years' standing, for which 5 abdominal aspirations had been made in seven years. A large abdominal incision was made after double puncture to get adhesions. Unsuccessful attempts were made to obliterate the sac by cauterization of the sac-wall and its kidney substance. Partial extirpation of the secreting kidney substance was abandoned on account of hemorrhage. After this the daily secretion diminished one-fourth, but 150 c.c. were still secreted. He then attempted to open up the ureter from the pelvis, without success, in the following manner: He filled the sac with milk, but none passed down into the bladder. He therefore con-

cluded to open the pelvic ostium of the ureter, or dilate it if valve formation was present. He enlarged the abdominal wound until the opening would admit the hand, and then searched all over with artificial light and probes, but in vain. A year later the patient's condition was satisfactory as to general health, but 150 to 180 c.c. of fluid containing 0.7 per cent. to 1.1 per cent. of urea was passed daily.

Simon, therefore, came to the conclusion that it is probably impossible to obliterate the sac of a hydronephrosis as long as secreting kidney substance remains.

Reestablishment of the passage through the ureter would give the best results in the treatment of hydronephrosis and pyonephrosis, even if no *restitutio ad integrum* of the kidney is possible (Simon). Spencer Wells' case has proved that a condition may result in which the patient may be restored to perfect health. If it should be possible to reopen the ureter, the same good results may be expected as in Spencer Wells' case.

There are two ways in which the ureter might be opened: from the bladder or from the pelvis of the kidney.

1. *Catheterization of the Ureter from the Bladder.*—This is considered by Simon as the more natural and easy way in women. He succeeded in finding the ureter in 15 out of 17 cases. He therefore proposes in this way to empty the contents of a hydronephrosis or pyonephrosis, but he has never put the method into practice.

The catheterization proposed by Simon was taken up by Pawlik,⁹ who constructed his ureteral sound, later improved by Howard Kelly.¹⁰ The catheterization of the ureters in women has thus been made practicable, but for the purpose of overcoming stenosis, or the cure of pyonephrosis or hydronephrosis, little or nothing has been accomplished.

Pawlik mentions a case from Billroth's clinic of pyonephrosis in which he introduced, through the ureter from the bladder, a long elastic catheter with a metal point, which passed through a stenosis of the ureter up into a cavity above. From previous nephrotomy the patient had an abdominal fistula, a probe passed through which would touch the metal tip of the ureteral catheter. On attempting to withdraw the catheter the tip was caught in the stenosis and broken off. Dr. von Hacker removed it through the abdominal fistula.

Pawlik,¹¹ cited by Albarran,¹² has two reports of cases of hydronephrosis in which his method was used. In 1 case (observation 6) cure was accomplished after 30 successive soundings of the ureter. In the other (observation 10) the ureter was impermeable and nephrotomy had to be resorted to. As regards leaving the catheter permanently in the ureter, Pawlik mentions a case of ureterovaginal fistula in which a catheter was left in for seven days. Force was necessary to remove it, and it was found incrustated with salts.

2. *Catheterization of the Ureter from the Pelvis of the Kidney.*—Simon, after his unsuccessful trial in the case above cited, states that the opening in the pelvis must be large, in order to find the ureteral opening, and still, even if access is good, we will probably be able, only in exceptional cases, to sound the ureter and remove the obstruction, because in large

tumors there are valve formation and so small a pelvic ostium that it cannot be found in the large cavity, anatomic landmarks being absent, by inspection either with natural or artificial light. It would be only in exceptional cases, where the pelvic ostium is dilated or not too small, that it could be found and a probe inserted. If the pelvic ostium was found, a stenosis could be dilated with bougies or knives and the valve might be operated upon by cutting the inner wall away. Simon, however, never had occasion to bring these proposals into execution.

Landau recommends not nephrectomy, but rather abdominal nephrotomy, eventually followed by probing of the ureter and perhaps by high fixation of the hydronephrotic sac, nephropexy, so as to facilitate the exit of urine from the pelvis into the ureter. Landau, however, has not yet operated in this manner.

The valve formation can be remedied by a plastic operation after previous opening of the dilated pelvis following lumbar nephrotomy. It is natural to select the lumbar region for entering the pelvis because the operation is extraperitoneal, and consequently there is no danger of infecting the peritoneal cavity, and because the lumbar incision gives the readiest access to the upper portion of the ureter. If it is possible in this manner to reestablish the flow of urine, we can save for future function what active kidney tissue may be left, the danger of primary nephrectomy is avoided, and the patient may regain perfect health without urinary fistula. That this can be accomplished satisfactorily and promptly is illustrated by the following case:

CASE 1.—Synopsis.—Valvular stricture or stenosis of pelvic orifice of ureter in a somewhat floating kidney; intermittent hydronephrosis for eight years; more and more frequent attacks until finally one a week; nephrotomy in interval between attacks; no stone in pelvis; pelvic orifice of ureter could not be found through opening in kidney; incision of pelvis; valvular opening of ureter seen; plastic operation on valve; bougie left in ureter for two days; pelvic wound sutured; fixation of floating kidney; recovery without fistula.

Mrs. D. H. consulted me at my office February 22, 1892. She gave the following history: Age twenty-eight; family history good; previous health good; married eight years; two children living, one dead. Four months after marriage had an attack of pain in the region of the left kidney, with the formation of a tumor at the site of pain, immovable and tender on pressure. At the end of two weeks tumor and pain suddenly disappeared. Two or three days after the birth of her first child she had a similar attack, which lasted about eight days. She had intermittent attacks every month or two from that time until 1878. The attacks varied little in intensity, and persisted usually for about one week. In September, 1888, after the birth of the third child, she had a severe attack of pain in the region of the kidney, with frequent shooting pains along the course of the ureter and accompanied by a swelling, tender on pressure, and by difficult but painless micturition. This attack lasted for two or three weeks. Since that time she has had similar attacks every two weeks, which last on the average two days, and are always accompanied by difficult urination. The last attack, which occurred on February 8, 1892, lasted for a week. Since that time she has had no pain.

The patient began to menstruate at ten years of age, and has been regular until a year ago. Flow normal, but considerable dysmenorrhea. For the past year menstruation has been irregular,—every two to four weeks,—but the flow has been normal.

Present Condition.—The patient is somewhat emaciated, has a nervous, suffering ex-

pression, not pale, abdomen easy to palpate, heart and lungs normal. Temperature 99° F. Urine contains pus, but neither albumin nor sugar.

On March 11th, during an attack of pain, a tumor could be felt in the region of the left kidney, but five days later no tumor could be found. During and immediately after the disappearance of the tumor the urine was milky from pus. May 24th she had another attack which lasted two days. During the days of pain urine is scanty and dark colored.

Diagnosis.—Intermittent hydronephrosis; stenosis in pelvis of kidney or ureter, probably from stone. Advised nephrotomy; removal of stone from kidney or ureter without opening into ureter if possible. If necessary to open ureter, pass bougie from opening in kidney to bladder, and suture ureter over bougie.

Operation May 31st at the Emergency Hospital, in the presence of the doctors from the Polyclinic, and Drs. Waters, Bernauer, and Krost, the patient was anesthetized with ether and placed on the right side, with a pillow under the loin. No tumor could be felt. An incision 4 inches long was made, from the angle of the twelfth rib and the extensor dorsi muscle, obliquely downward and forward to the iliac crest above the anterior superior spine. It was necessary to divide the quadratus lumborum for 1½ inches below the rib in order to gain space for operating. The transversalis fascia was now divided. The retroperitoneal adipose tissue was scanty. Two tumors could now be felt—one close under the margin of the ribs was recognized as the spleen. Behind and below this could be felt the convex posterior border of the left kidney. During inspiration the spleen was pushed down upon the kidney, but it could be easily replaced. Dissection of the adipose capsule from the kidney was difficult, on account of a plastic perinephritis which had made the capsule tense and adherent to the kidney. The surface of the kidney was not smooth and glistening, but velvety from connective-tissue strips. By pressure over the anterior portion of the lumbar region of the abdomen the kidney was pushed into the wound and the adipose capsule dissected off by forceps and the finger, so as to permit palpation of the kidney between the thumb and index-finger. The kidney was rather small, 3½ inches long, 1½ inches broad, and 1½ inches thick. Neither hard nor soft spots could be felt. Palpation of the pelvis was accomplished by pushing the fingers of the left hand forward toward the hilum, holding the upper half of the kidney meanwhile between the thumb and index-finger of the right hand. The pelvis contained no fluid and no stone could be felt. Following down from the pelvis no ureter could be felt, nor could any hard spot or stone be discovered.

A long exploring needle was introduced through the convex surface of the kidney, at a point between the middle and lower thirds, in the direction of the pelvis, for a distance of 2 inches. An empty cavity was entered by the needle, in which no stone could be felt. The needle was next inserted into the upper half of the kidney, but neither fluid nor stone could be felt.

The pelvis was now opened through the kidney by means of the Paquelin cautery along the needle as a guide, in the middle third of the kidney. The hemorrhage was slight; no fluid escaped. The opening was dilated with forceps so as to permit palpation of the pelvis and calices with the left index-finger. The calices were dilated, but still the kidney substance was ½ inch thick. The pelvis was a large cavity extending to the lower border of the kidney, with a round, smooth, soft surface. No stone could be felt, nor was the ureteral entrance perceptible to the finger. Through a small opening, or over a ridge, the palpating finger could be passed into the upper part of the pelvis. The calices here were dilated, but no stone could be felt. Examination with a steel urethral sound gave similar negative results.

In order to find, if possible, a stone in the ureter, a small bent metal probe was passed into the pelvis, but the ureteral entrance could not be discovered. The dilated pelvis was now isolated and opened for ocular inspection, to determine the pelvic entrance to the ureter. The lower third of the kidney was lifted forward and drawn into the wound by means of a blunt retractor passed through the wound in the kidney, the posterior surface of

the pelvis isolated from the adipose tissue, and an incision $\frac{3}{4}$ inch to 1 inch in length made obliquely downward from about $\frac{1}{4}$ inch from the hilum of the kidney. The wall of the pelvis was 2 mm. thick. Neither fluid nor urine escaped. The borders of the wound were grasped and held open with forceps. The inner surface of the pelvis was now seen to be normal in color and appearance. At the lower posterior portion of its inner wall was seen a small, semicircular opening, 2 lines in length from above downward, and 3 lines in transverse diameter. The posterior border was convex; the anterior border, straight. A metal probe introduced through this opening passed easily down 7 or 8 inches into the bladder without encountering resistance, either from stricture or stone.

An olive-pointed bougie, No. 5 French, which was passed down, was tightly grasped by

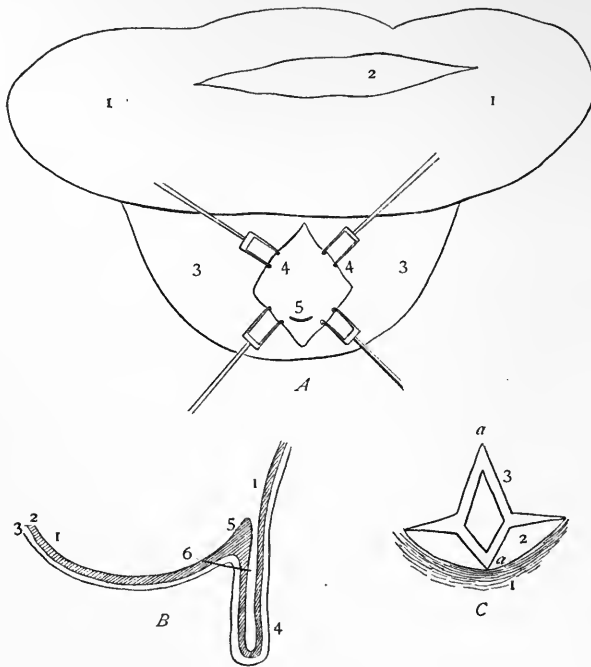


Fig. 94.—Illustrating operation for valve formation (Case 1).

A. Kidney and dilated pelvis: 1, Kidney; 2, opening on its convex surface after nephrotomy; 3, dilated pelvis; 4, with opening on its posterior surface from pelviotomy; 5, opening of the ureter into the pelvis, a small transverse, crescent-shaped slit.

B. Dilated pelvis and ureter, showing valve formation: 1, Pelvis; 2, mucous membrane; 3, muscular and external coat; 4, ureter; 5, valve; 6, line of incision dividing valve.

C. Valve seen from the pelvis, and divided to illustrate the plastic operation: 1, Inner wall of pelvis above the ureteral opening; 2, ureteral opening; 3, the divided valve; a and a', the corners of incision to be united by a suture.

the ureter. By lifting up the pelvis the ureter could now be palpated. The wall was thin, and seemed liable to rupture unless great care was exercised. The bougie was removed, and on again lifting the pelvis and inspecting the entrance into the ureter it was seen that the ureter came off not from the most dependent portion of the dilated pelvis, but from its posterior half or wall. Thus the anterior straight border of the ureteral entrance formed a valve or fold, resembling the valve in a vein, which would close against the posterior wall of the opening when the pelvis was filled with urine or fluid to a slight or medium degree. A greater degree of dilatation would push away the posterior wall of the pelvis and thus

reopen the entrance to the ureter. This accounted for the evacuation of urine containing pus after a period of occlusion of two days' duration.

To do away with this valve formation the following operation was performed on the plan of the Heineke-Mikulicz operation for stricture of the pylorus (Fig. 94): An incision $2\frac{1}{2}$ lines in length was made through the mucous membrane into the muscular wall or fold of the pelvis. The terminal points of the incision through the valve were now approximated by a fine silk suture, thereby changing the former vertical incision into a horizontal line. The entrance into the ureter was by this means made wider and more nearly circular.

A No. 11 French bougie was now passed through the opening in the pelvis down 5 inches into the ureter, and the upper end brought up through the pelvis and out of the wound in the kidney, to keep the opening into the ureter dilated during healing of the wound.

The incision in the pelvis was united by 10 fine silk interrupted sutures passed through the pelvic wall, but not including the mucosa. A piece of the cortical substance of the kidney was removed for microscopic examination.

The kidney was now replaced and fixed in normal position by two sutures passed through it, which anchored it to the transversalis fascia. The pelvis was drained by a rubber drainage-tube $\frac{1}{2}$ inch in diameter, inserted along the side of the bougie through the wound in the kidney into the pelvis. The drainage of the external wound was accomplished by the employment of a gauze drain on anterior surface of the kidney, one on posterior surface of kidney, one down along the ureter, and a rubber drainage-tube on posterior surface of pelvis, over the wound in the pelvis. The lower part of the abdominal wound was united by silk sutures, the upper half left open for drainage, and the usual dressings applied. The operation required two hours; at its close the patient was in good condition; pulse strong, 90; the operation was mechanically easy on account of the lax abdominal walls due to childbearing and the leanness of the patient.

The bougie was removed on the second day. The patient suffered considerable pain for four days; the pain along the course of the ureter persisted for two weeks. Four weeks after the operation the tube was removed and a smaller one introduced, which was taken out a week later. The discharge was excessive at first, but gradually decreased. Two weeks after operation she could lie on the left side without pain. The patient recovered without fistula, and up to the present time has had no return of the hydronephrosis.

A somewhat different method of operating on this valve has been suggested by Küster,¹³ but has not yet been tried. He reports a case in which he divided the valve longitudinally, as I did. He proposed to freshen each flap and unite it by sutures to the freshened inner wall of the sac. Küster was not able to carry out this plan because he found, in addition to the valve, a stricture in the ureter 2 cm. below the pelvis. This condition caused him to resect the upper 3 cm. of the ureter and unite the upper end of the distal portion to the pelvis by a plastic operation to which I shall refer later.

It appears to me that my method of operating upon the valve is simpler than Küster's: his requires at least two sutures, mine only one; the method, moreover, proved efficient in my case just reported.

STRICTURES IN THE UPPER PORTION OF THE URETER

It has been seen, in the description of valve formation, that stricture often forms in the portion of the ureter located in the wall of the dilated

pelvis; but this stricture is treated by the operation for valve formation, as described above. Independent strictures below the pelvis require different treatment. If such strictures are single and accessible, they can be operated upon with a view to reëstablishing the continuity of the canal.

Outside of observations at the postmortem table little attention has been called to the question of strictures of the ureter, because in the cases of hydronephrosis and pyonephrosis operated upon the kidney has been opened or extirpated, and no attention has been paid to the ureter. From the postmortem table we know that multiple strictures can be found as a result of chronic inflammation of the canal, as in the instance depicted by Hallé,¹⁴ mentioned by Tuffier, in which not less than three strictures were found, the canal between the strictures being dilated. It is doubtful if cases of this kind would be suitable for operation.

As a result of traumatism, limited strictures have been seen to be formed, as in the cases of Pye-Smith¹⁵ and Sollier.¹⁶ Pye-Smith reports the following case of stricture of the ureter and dilatation of the kidney, apparently of traumatic origin:

PYE-SMITH'S CASE.—August 16, 1871. Male, twenty-four; farrier. Never had stricture. Frequently been kicked in abdomen. Two years before kicked on left side, "under the short ribs," and passed blood with urine several days. In bed only three days. August 7th, diarrhea, swelling of abdomen, vomiting, pain in abdomen. No difficulty in passing water. Examination: Large tumor occupying left half of abdomen, smooth, deep fluctuation. Urine contained trace of albumin.

Diagnosis.—Probable vascular fibrocystic growth. August 22d tapped, and 6½ pints of a reddish fluid containing pus and blood-corpuscles flowed out. Tumor gradually filled and was again tapped. Patient improved and went home in October. He had return of the diarrhea and died October 14th.

Autopsy October 17th: Renal tumor firmly adherent to surroundings. Right kidney swollen; early parenchymatous nephritis. Bladder normal; ureter dilated 1½ inches, then contracted so as not to admit smallest probe. No impacted calculus; no sign of recent inflammation. Tumor; little renal tissue remained. Organ dilated into a series of communicating cysts containing yellow, puriform fluid; scarcely any blood. No trace of calculus; no cheesy material. No abnormal tissue. In one of the cavities vegetable fibers, apple-core, and fragment of clove were found; therefore opening must have existed during life, with communication with adherent bowel. Disease probably traumatic. Ureter probably injured. During two years following canal was gradually contracting and forming stricture; consequently, pelvis of kidney gradually expanded. Adhesion to colon determined diarrhea and suppuration, from which patient died.

Sollier's case was one of traumatic stricture of the ureter in a man of forty-five who, in 1870, sustained a traumatism by a kick from a horse in the left hypochondrium. The injury was followed by pain in the left side, gradually increasing for nine years, when symptoms of nephritis appeared and the patient died from uremia. At the autopsy it was found that the left kidney had been transformed into a number of cavities the size of nuts. The calices, pelvis, and upper portion of ureter were dilated. In the middle portion of the ureter was found a "cica-

tricial stenosis." Hypertrophy of the heart was found, which had already been diagnosed during the patient's life.

Little is also known as to the frequency of strictures, but it may possibly be concluded, from the frequency of permanent urinary fistulas following nephrotomy, that they are not of infrequent occurrence. Tuffier states that fistulas followed nephrotomy in 45 per cent. of the cases collected, and we are forced to believe that the permanency of the fistula is caused by imperviousness of the ureter either from valve formation or from stricture. How often this is caused by a stone lodged in the canal, and how often by a stricture without stone, we will not know until the ureter has been investigated by probing from above in a large number of nephrotomies. From the statistics collected by Tuffier, which show that nephrotomy for calculous pyelitis was followed by 34 per cent. of fistulas in 114 collected cases, and that nephrotomy for non-calculous pyelitis was followed by 57 per cent. of fistulas, we cannot draw any certain conclusions as to the frequency of stricture in non-calculous pyelitis as compared with the frequency of stones in the ureter; but it is likely that strictures are common.

As to the frequency with which strictures occur in different parts of the ureter, we have a statement from Tuffier to the effect that in 29 instances of congenital hydronephrosis a stricture was found in the upper end of the ureter in 15 cases, and at the lower end in 14. In Sollier's case of traumatic stricture it was located in the middle portion of the ureter.

The question of gaining access to different portions of the ureter in order to overcome obstruction has been solved as far as the removal of stones is concerned, by a number of operations already on record, as follows: The vesical end of the ureter has been reached from the bladder by Emmet, Richmond, and others; from the vagina, by Emmet and Cabot.

The pelvic portion of the ureter has been reached by extraperitoneal lumbar incision, and the stones removed either by pushing them up into the pelvis and pyelotomy in 4 cases (Tuffier), or by longitudinal incision of the ureter in 4 cases (Tuffier), and in my case published in Chicago Medical Recorder.

From the middle portion of the ureter stones have been removed in 4 cases (Tuffier) by longitudinal ureterotomy by the prolonged lumbar incision. There is no difficulty in gaining access to the upper two-thirds or three-fourths of the ureter by the oblique lumbar incision. It is different with the lower third or fourth of the ureter, which is located deep down in the pelvis, and is even held by Le Dentu to be inaccessible. But Cabot has justly pointed out that this portion of the ureter is also accessible without opening into the peritoneum by means of the sacral operation of Kraske, with removal of part of the sacrum or temporary resection of the latter.

As far as strictures are concerned, there have as yet been made only two attempts at operating, namely, by Küster and myself, and a successful result in both cases was reached by a somewhat different method.

Both were strictures in the upper part of the ureter close to the pelvis of the kidney.

Küster resorted to resection of the narrow portion of the ureter and united the distal portion to the pelvis of the kidney. His most remarkable and interesting case was as follows:

The patient was a boy eleven years of age. As a baby and until his fifth year he was sickly, but afterward was healthy. In June, 1889, spontaneous enlargement of the abdomen was noticed, accompanied by pain. This was diagnosed as left hydronephrosis. The urine was clear and sufficient in quantity, indicating open hydronephrosis. On June 23d Professor Braun made a lumbar nephrotomy, which was followed by vesical anuria, and the patient left the hospital with a fistula.

On May 25, 1891, the boy was seen by Küster. The fistula was permanent, and little or no urine came from the bladder. The fistula in the lumbar region was dilated and digital exploration of the pelvis made. Catheterization of the ureter from the dilated pelvis could not be effected. The operation was followed by septic pyelitis.

July 14, 1891, it was decided to attempt to make the ureter patent, which was accomplished by Küster in the following manner: A lumbar extraperitoneal incision was first made into the sac, but the ureter could not be found. The lower end of the sac, the dilated pelvis, was then incised, on the upper border of which was seen a layer of kidney substance the thickness of a thumb. The ureter could now be seen running several centimeters in or upon the posterior wall of the sac, and terminating in a slit in the pelvis. It was then intended to divide the pelvic wall of the ureter by pushing a probe-pointed knife down into the ureter from the pelvis to a point close to its exit from the sac, to spread out the divided walls and unite them to the wall of the sac, thus making a funnel-shaped opening into the ureter (see Fig. 95); but on attempting to introduce a fine probe into the ureter, a stricture was encountered 2 cm. below the pelvis. The ureter was, therefore, divided from above downward, as far as the stricture, through which a fine probe could now be passed.

As cure seemed impossible without removing the stricture, the ureter was transversely divided below the stricture and at the entrance to the sac. The ureter was now united to the pelvis by dividing the upper end of the ureter, unfolding the divided end, suturing it to the opening into the sac, and closing the remainder of the wound in the pelvis by catgut sutures.

The next day bloody urine escaped into the bladder, but ordinarily the urine passed out through the lumbar fistula. From this time more and more urine passed into the bladder, until, four months after the operation, as much as 100 c.c. passed in the twenty-four hours. The pelvis was now washed out for pyuria with 0.25 per cent. solution of nitrate of silver; this was followed by local and general improvement.

November 6, 1891, the fistula was closed by curetting, dilating, and closing the canal by step sutures. In the first twenty-four hours after the operation the patient passed 1300 c.c. of bloody urine from the bladder. He recovered, but with a lumbar hernia which had to be held in place with a bandage; the fistula remained closed. The boy is able to work and has excellent health. The urine contains a few pus-corpuscles and a small quantity of albumin.

Plastic operation on the stricture without resection of the ureter was practised by me in the following case:

CASE 2.—*Synopsis.*—*Traumatic stricture of ureter close to entrance into pelvis of the kidney; intermittent pyonephrosis of four years' standing; increased frequency of attacks; nephrotomy; no stone found in sacculated kidney; ureteral entrance could neither be found*

through wound in kidney nor through incised pelvis; longitudinal ureterotomy revealed stricture at upper end of ureter; longitudinal division of stricture and plastic operation on ureter; recovery without fistula in six weeks.

W. B., a farmer forty-seven years of age, came under my care November 12, 1892. Father died as a result of accident. Mother dead; cause unknown; one brother died of phthisis. Patient's health good up to age of thirteen. The present trouble dates back thirty-four years, when, as a boy of thirteen, in jumping from a horse to the ground, on account of miscalculation of distance he sustained a violent jerk, his feet not having touched the ground, while his hands still retained hold of the hames. This injury was immediately followed by a sharp, constant pain in the left side, which was mitigated by blistering, but he was obliged to remain in bed for a month. He suffered no inconvenience with the exception of slight soreness in the region of the left kidney, increased by hard work, until ten

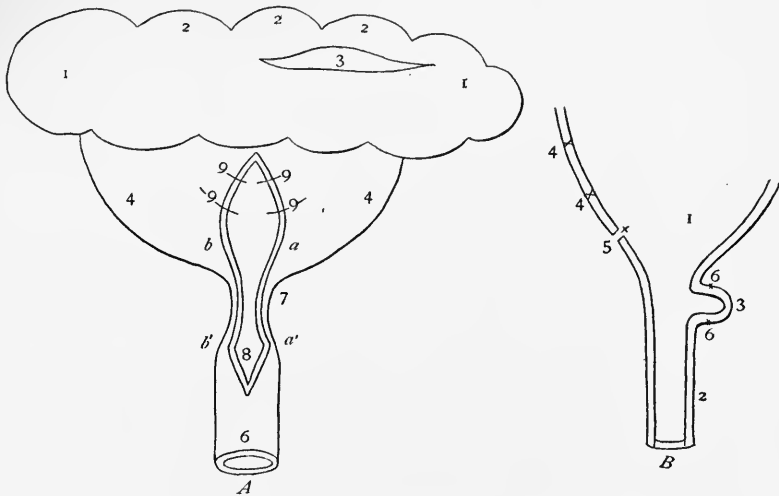


Fig. 95.—Illustrating operation for stricture of ureter (Case 2).

A, Sacculated kidney, dilated pelvis, ureter with stricture at its upper end: 1, Kidney; 2, sacs corresponding to dilated calices; 3, nephrotomy; 4, dilated pelvis; 5, opening in posterior surface of pelvis—pelviotomy wound; 6, ureter below stricture; 7, stricture in upper end of ureter; 8, opening in ureter below stricture, extending up through the stricture into the pelvis; 9, sutures closing the upper half of the wound in the pelvis; *a a'* and *b b'*, points of incision in ureter and pelvis to be united by sutures after folding the ureter upon itself at the place of stricture.

B, Pelvis and ureter after union by sutures: 1, Pelvis; 2, ureter; 3, fold of ureter at place of stricture; 4, sutures of wound in pelvis; 5, place of sutures between points *a-a'* and *b-b'*; 6, 6, additional sutures, as many as needed, to close borders of the fold formed by approximations of *a* to *a'* and *b* to *b'*.

years later, when, after overexertion, he had an attack of sharp pain in the left side; at this time he was in bed about a week. One year later he had a third attack, which followed free indulgence in liquor. This attack was attended by pain, soreness, and obstinate constipation. For the next ten or fifteen years he had four or five attacks a year, lasting from two to three days, and always after indulgence in liquor. During the last six years the attacks have apparently been caused by overexertion, with the exception of one attack a year ago, for which no cause could be assigned. The last attack occurred October 22, 1892. It was no more violent than previous attacks, but was of longer duration.

Examination November 12, 1892: Patient well nourished. In left hypochondrium could be found a tumor immovable, hard, and not nodular, which extended 2 inches below the ribs and to within 3 inches of the umbilicus. Temperature, 101° F.; urine contained a little pus.

Diagnosis.—Nephrolithiasis in the pelvis or infundibulum, or pyonephrosis from stone or obstruction in the ureter.

November 26th: For the past week there has been more pus in the urine, indicating that the contents of the pyonephrosis have been evacuated through the ureter. Examination in narcosis showed that the tumor had disappeared. Operation at the German Hospital. The patient was anesthetized with ether, and placed on the right side with a pillow under the loin. An incision was made from the angle of the twelfth rib 6 inches downward and forward, to within 1 inch above and anterior to the crest of the ilium. The muscles were strong. After division of the transversalis fascia and removal of a layer of adipose tissue, the adipose capsule of the kidney was exposed, which was so adherent to the surface of the kidney that when it was removed the fibrous capsule was stripped off also. The exposed surface of the kidney was not shining, but was red and velvety. It was nodulated, each nodule forming a flat prominence about 2 cm. in diameter. Each prominence was compressible and resembled a dilated calyx. The kidney was of normal size, about 9 cm. long, 4 cm. broad, and 3 cm. thick. In one place a cyst the size of a pea, with clear, yellowish contents, was seen. After excision of a piece of the kidney substance for microscopic examination the dilated cavity of pelvis and calices was opened, and a jet of urine tinged with pus came out over the wound. The incision along the convex border of the kidney was enlarged by the Paquelin cautery.

Digital exploration revealed that the globular protuberances were dilated calices which communicated with the pelvis, forming a common cavity. Some of the calices had openings large enough to admit the tip of the finger; others had openings which would admit a No. 10 urethral sound. No small abscesses could be seen on the surface of the kidney or in the incised substance. The protuberances now appeared to be collapsed, but a reasonable amount of kidney substance appeared to be present, especially in the lower part. The index-finger was passed through the wound in the kidney down into the pelvis, which was 7 cm. long and 4 cm. deep. The wall was smooth, and there was no stone or gravel. Neither by the palpating finger nor by the sound or probe could anything be discovered resembling an entrance to the ureter.

The kidney was therefore lifted up over the border of the twelfth rib, so that its anterior surface was directed upward and toward the median line, and its posterior surface backward and downward, thus exposing the posterior surface of the dilated ureteral half of the pelvis. A longitudinal incision, 1 inch long, was made in the pelvis, and the edges held apart with retractors. The pelvic mucosa looked red and inflamed, but no ureteral entrance could be seen or felt.

The external wound was now prolonged downward for $1\frac{1}{2}$ inches to within an inch of the anterior-superior spine of the ilium, to secure more operating space. The ureter could now be seen as a string or band, not dilated. Its upper end for $\frac{1}{2}$ inch was embedded in cicatricial tissue. A longitudinal incision, 1 cm. long, was made in the ureter $\frac{1}{2}$ or $\frac{3}{4}$ inch below the pelvic opening. A small metal probe introduced into the ureter through this incision passed downward freely for 6 inches. In passing it upward, however, a stricture was found just below the point of entrance of the ureter into the pelvis. The ureter was adherent to the surrounding adipose tissue at this point. The adhesions were separated by the handle of the scalpel, and the stricture opened by a longitudinal incision on the probe as a guide. The opened stricture was seen to be 1 cm. long. The remainder of the ureter was examined by a French bougie, which would pass down 4 or 5 inches, but would then be caught by the ureter. There was no stricture, but a diffuse atrophic narrowing of the ureter. A fine probe or a small bougie could, however, be passed without difficulty into the bladder.

The patency of the ureter was reestablished by uniting the wall of the ureter below the stricture to the pelvic wall, leaving the stricture as a loop, as shown in Fig. 96. This procedure was similar to the Heineke-Mikulicz operation upon the pylorus.

The upper part of the wound in the pelvis was closed by sutures. No bougie was left in the ureter. The wound was drained by a large tube passed into the wound in the kidney, 3 inches upward to the upper corner of the kidney. A smaller drain was passed down to the pelvis and ureter. Gauze strips were packed around the anterior and posterior surfaces of the kidney, and 3 inches down along the ureter. The divided muscles of the abdominal wall were then united, with the exception of the lower 3 inches, which was packed with gauze. The external wound was united by sutures and dressed in the usual way. The operation occupied two hours. The patient was weak at its close, pulse, 130; much pain along course of ureter. The next day he passed naturally water containing no blood. The wound was dressed daily, and the dressings were found to be saturated with 5 ounces of urine. The amount was determined by the difference in weight of the dressings on application and after removal. The patient steadily improved. The pain decreased, and the amount of urine in the dressings became progressively less. November 29th to 31st blood was found in the urine, which showed that the ureter was patent from the third day after the operation. December 19th half the tube was removed, and a day later the remainder was taken out.

January 5, 1893, the wound was closed. The patient was well and strong, suffered no pain, and could walk about all day. No tumor could be made out. Pressure in renal region was painless. The urine at this time was normal in quantity, 46 ounces, and upon microscopic examination of the sediment a few pus-cells could be seen. No trace of albumin could be found in the urine. The patient thinks he has gained flesh and is much better than before the operation.

November 14th, while the tumor was present and the temperature high, the quantity of urine for the twenty-four hours was 18 ounces. After the disappearance of the tumor on November 17th and 18th the temperature fell to normal, and the amount of urine increased to 34 ounces on November 19th and to 32 ounces on November 20th. On the evening of the day of operation the patient passed 18 ounces of urine; on November 27th, 26 ounces; on November 28th, 32 ounces, and from this time on the amount of urine passed averaged 30 ounces a day.

Reunion of a transversely divided ureter, first studied experimentally on dogs by Tuffier¹⁷ and others, was not successful until the method of invaginating the upper into the lower portion was devised by Poggi¹⁸ and Van Hook. It was first practised successfully in man by Kelly, who used Van Hook's method. Poggi found that, by invaginating the upper end into the lower, union would take place. He divided both ureters in dogs, dilated the lower end with a forceps, invaginated the upper end into the lower, and united with sutures. When the animals were killed fifteen days and three and one-half months later, respectively, he found union without stenosis at the point of operation.

Van Hook,¹⁹ in a preliminary contribution, has also succeeded in reuniting the completely divided ureter by a different method, which might be termed lateral implantation of the upper into the lower end after the closure of the end of the latter. In a very elaborate paper upon the surgery of the ureter²⁰ he gives the reasons why his method of lateral implantation is preferable to the simple invagination of Poggi. He believes that the ureter can sustain resection involving a considerable amount of tissue, since ureters measuring 10 inches while *in situ* will easily measure 12 to 14 inches when removed, and he further re-

marks that traction on the divided ends is probably admissible to a very considerable extent.

The first reunion of a completely divided ureter by uretero-ureteral anastomosis, or uretero-ureterostomy in the human subject, has recently been reported by Kelly.²¹ Eight years ago his attention was called to the danger of cutting a ureter during operation for an abdominal tumor which had displaced it. He now reports:

Mulatto, twenty-five years of age, who had a large uterine myoma. The uterus filled true and false pelvis and extended above umbilicus. Hysteromyomectomy was performed May 1, 1892. Ureter ligated and cut, supposing it to be an engorged vein. Ureter was four times its normal size by reason of pressure from the tumor (hydro-ureter). On removal of upper ligature 20 c.c. of clear urine escaped. Van Hook's plan tried, of tying

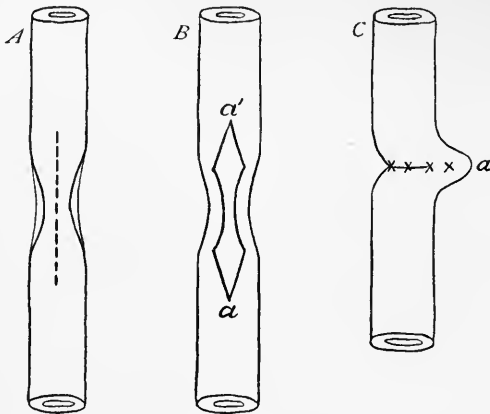


Fig. 96.—My plan of operating for ureteral stricture on extraperitoneal surface of ureter.

A, Ureter showing stricture and line of incision.
 B, Opening through the stricture extending into the proximal and distal portion of the ureter. The extreme ends of the incision *a* and *a'* to be united.
 C, Ureter after suturing: *a*, The bend at the site of the stricture.

lower end of divided ureter, making slit in ureter below ligature, and invaginating upper into lower end by means of silk traction sutures. Edges also sutured to intussuscepted portion by ten fine silk rectangular sutures passed through outer coat only. Gauze laid over anastomosed end, and brought out at lower angle of abdominal wound, to insure drainage. No urinary odor about dressings. Passed water second day. Discharged in six weeks. After Kelly's successful operation Bloodgood made an experiment upon the dog. He performed anastomosis of right ureter after section. Kidney and ureter were removed two and one-half months later. The kidney was found normal, ureter not dilated, caliber and mucous membrane restored without stricture.

CONCLUSIONS

1. Exploration of the ureter as to its permeability should be done from the renal wound by a long flexible silver probe (a uterine probe) or an elastic bougie, either olive pointed or not. If the bougie passes into the bladder, the examination is at an end. The size of bougie that will pass through a healthy ureter is from 9 to 12 French scale.

2. If the pelvic orifice of the ureter cannot be found from the renal wound, it should be sought for by opening the pelvis—pyelotomy—or by incising the ureter—ureterotomy.

3. A longitudinal incision, $\frac{1}{2}$ inch to 1 inch long, in the posterior wall of the pelvis, can be made while the kidney is lifted upward against the twelfth rib. This procedure is easy if the pelvis is dilated, but may be impossible if the pelvis is of normal size.

4. A stricture in the ureter, if not too extensive, can be treated by a plastic operation on the plan of the Heineke-Mikulicz operation for stenosis of the pylorus; namely, longitudinal division of the stricture and transverse union of the longitudinal wound (Fig. 96). This method of operating for ureteral stricture seems to me preferable to resection of the strictured part of the ureter (Küster's operation), for the following reason: It is a more economic operation, and preferable when the elongation of the ureter is not sufficient to permit the two cut ends of the ureter, after excision of the stricture, not only to come in contact, but even to permit of closure and invagination without stretching.

5. Resection of the upper end of the ureter and implantation of the distal end into the pelvis have been performed in an important and interesting case by Küster, and the result was a brilliant success. His method was to split and unfold the end of the ureter, and to implant it into the opened pelvis, to which it was united with sutures.

6. In a similar case of stricture in the upper end of the ureter, especially if the ureter were not elongated or the kidney movable, I should prefer the plastic operation already described, as it is easier of technic, and as it proved successful in my case of traumatic stricture in the ureter below the pelvic orifice.

7. The ureter is accessible through an extraperitoneal incision, a continuation of the oblique incision for lumbar nephrotomy, from the twelfth rib down along and 1 inch anterior to the ilium and along Poupart's ligament to about its middle. This incision gives access to the upper three-fourths of the ureter and down to within $1\frac{1}{2}$ or 2 inches above the bladder.

8. The vesical and lower pelvic portions of the ureter may be reached, as Cabot, of Boston, has pointed out, by means of the sacral operation, or Kraske's method, modified by osteoplastic temporary resection of the os sacrum. In woman, the vesical portion of the ureter is accessible through the vagina.

9. The vesical orifice of the ureter may be reached from within the bladder by suprapubic cystotomy in man, by dilatation of the urethra, or suprapubic or vaginal cystotomy in woman.

In conclusion, I wish to cite literally the remarks made by Küster at the conclusion of his communication to the German Surgical Congress, because I fully agree with Küster and think that his remarks apply well to my suggestions made above. Küster says:

"*Gentlemen:* When I bring this case before you, it is not to present to you a curious operation or a curiosity in the line of operating. The value of the observation appears to me to lie in the fact that it shows a

method by which it may be possible to avoid the mutilating and dangerous operation of nephrectomy in cases of pyonephrosis where and when we do not know that the other kidney is perfectly healthy."

I would add—and a means to save or avoid some instances of permanent fistulas following nephrotomy for pyonephrosis or hydronephrosis.

Note.—When I commenced to investigate the question of stenosis of the ureter and its possible operative treatment, I did not know that Küster had commenced work in the same direction. The first publication of Küster's case which reached me was his report before the Twenty-first German Surgical Congress, June 8 to 11, 1892, which appeared in the *Centralblatt für gesammte Medicin* for August 13, 1892.

My first operation for stenosis was performed at a clinic, and described in a clinical lecture given on May 31, 1892, at the Emergency Hospital, Chicago.

BIBLIOGRAPHY

1. "Appareil Urinaire," Duplay and Reclus' *Traite de Chirurgie*, 1892, vol. vii.
2. Glass: *Philosophical Trans.*, vol. xlv, cited by Rayer.
3. Rayer, P.: *Traité des Maladies des Reins*, 1839.
4. Virchow, R.: *Die krankhaften Geschwülste*, 1863, vol. i.
5. Simon: *Chirurgie der Nieren*, 1876, vol. ii.
6. Krakauer, A.: *Virchow-Hirsch's Jahresber.*, 1881, vol. ii, p. 207.
7. Landau, L.; "Ueber intermittirende Hydronephrose," *Berlin. klin. Wochenschr.*, 1888, vol. xxv, p. 941.
8. Wells, Spencer: *Ovarian and Uterine Tumors*, 1882, p. 129.
9. Pawlik: "Ueber die Harnleitersondirung beim Weibe," *Arch. f. klin. Chir.*, 1886, vol. xxxiii, p. 717.
10. Kelly, H. A.: "The Ureteral Catheter," *Amer. Jour. Obst.*, 1892, vol. xxvi, p. 768.
11. Pawlik, cited by Albarran.
12. Albarran: "Permanent Catheterization of the Ureters," *Comptes rendus de la Soc. de Biol.*, 1891, vol. iii, p. 543.
13. Küster: "Ein Fall von Resection des Ureter," *Arch. f. klin. Chir.*, 1892, Bd. xlv, p. 850.
14. Hallé: *Thèse de Paris*, 1887, cited by Tuffier.
15. Pye-Smith, P. H.: "Stricture of the Ureter and Dilatation of the Kidney, Apparently of Traumatic Origin," *Trans. Path. Soc. of London*, 1871-72, vol. xxiii, p. 159.
16. Sollier, T.: "Observation des Reins Kystiques," *Lyon Méd.*, 1880, vol. xxxv.
17. Tuffier, Th.: *Études experimentelles sur la chirurgie des reins*, 1889, p. 165.
18. Poggi: "Guérison immédiate des sections transversales des uréterès sans obliteration de leur cavité," *Riforma Medica*, 1887, vol. liii, liv.
19. Van Hook, W.: "Experimental Union of the Ureter after Transverse Division," *Jour. Amer. Med. Assoc.*, 1893, vol. xxi, p. 225.
20. Van Hook, W.: "The Surgery of the Ureters; a Clinical, Literary, and Experimental Research," *Jour. Amer. Med. Assoc.*, 1893, vol. xxi, p. 94.
21. Kelly, H. A.: "Ureteral Anastomosis, Uretero-ureterostomy," *Ann. Surg.*, 1894, vol. iv, p. 70.
22. Kelly, H. A.: p. 89. "The direct examination of the female bladder with elevated pelvis. The catheterization of the ureters under direct inspection, with and without elevation of the pelvis," *Amer. Jour. Obstet.*, 1894, vol. xxix, p. 1.

BENIGNANT TUMORS OF THE ILEUM*

BENIGNANT tumors of the intestinal tract are not uncommon, but they rarely develop to such a size or in such a location as to cause danger to life. While both benignant and malignant tumors are relatively common in certain portions of the intestinal tract, the small intestine is usually exempt, with the exception of the portion where the bile and pancreatic ducts enter the duodenum, in which localities carcinomata are quite common.

From the connective tissue and muscularis, tumors of the connective-tissue type develop; the sarcomata of the small intestine have been recently described by M. Baltzer,¹ who could find only 14 cases in the literature.

Benignant tumors—myomata, fibromata, lipomata, angiomyomata—are more common, but have attracted less attention, as they only exceptionally give rise to obstruction as such, more often to invagination. They consequently play only a secondary part in the causation of the grave symptoms attendant upon invagination.

Leichtenstern distinguishes between—(1) Fibromata, which originate in the submucosa and protrude in the lumen of the bowel as fibroid polypi, and which may cause obstruction or invagination. (2) Myomata, originating in the muscularis mucosæ, or intestinal muscularis, in some cases rich in vessels (angiomyomata), in other cases more fibrous; these latter protrude into the intestines as polypi, and give rise to the same disturbances as the first variety. (3) Submucous lipomata, which protrude as pedunculated polypi, often multiple, but which seldom attain such a size as to cause obstruction. (4) Mucous polypi, papillomatous or with a smooth surface.

As to the frequency of polypi of all the different varieties in the entire intestinal tract, Leichtenstern gives the following table:

Rectum.....	(estimate too low) 75
Colon.....	10
Cecum.....	4
Ileocecal valve.....	2
Lower portion of the ileum (usually found by causing invagination) ..	30
Jejunum.....	5
Duodenum.....	2

He states that they often give only indistinct symptoms, until in some cases obstruction is caused either by congestive swelling and rapid growth, or, more commonly, when situated in the lower ileum, by in-

* Chic. Clin. Rev., 1894, vol. iv, p. 107.

vagination. As the tumors are never large enough to be discovered by palpation, they are not diagnosed, with the exception of the polypi of the rectum, which are found on rectal examination.

Rokitansky,¹⁰ in speaking about connective-tissue tumors of the intestine, states that such tumors may develop from the subperitoneal tissue, or the muscularis may become pendulous toward the peritoneal cavity, and, by traction on the intestinal wall, form a pocket communicating with the lumen of the intestine. They may also, in rare instances, extend into the lumen of the intestine, and cause disturbance by reason of their size. Thus they may cause obstruction or intussusception, or if they press upon the bile-duct or pancreatic duct, may cause retention of the respective secretions.

Förster⁴ states that fibroid tumors in the intestinal tract are commonly myomata which develop in the submucous tissue and protrude into the lumen of the intestine. Such a tumor, in the case of a man of seventy, developed from the muscular coat of the intestine, he has described as follows: The tumor was round, 6 to 7 lines in diameter, originated from the muscularis of the ileum, the muscular fibers extending continuously into the tumor. The tumor protruded toward the peritoneal surface with its whole mass so that the lumen of the intestine was not narrowed. Microscopic examination showed the tumor to consist of organic muscle-fibers interwoven with a sparse stroma of connective tissue and a normal development of blood-vessels. The muscle-cells in the tumor were two or three times as large as those in the wall of the intestine, and the nuclei were correspondingly larger than those in normal muscle-fiber.

He remarks that such tumors might be of practical importance if they should develop to more considerable size or protrude into the lumen of the bowel, but neither in the literature nor in his experience had he found a single instance of this kind.

Virchow¹¹ states that myomata are rare, and, if we exclude uncertain observations, develop only into small tumors. He has found these tumors only in the small intestine. He describes a specimen from the Berlin Museum, of a tumor in the transverse portion of the duodenum, the size of a cherry-stone, clad with mucous membrane, which protruded into the lumen of the intestine, and which had undergone calcareous degeneration. Microscopic examination showed that the tumor was composed of connective tissue and muscle-fibers, and that it was connected with the muscularis of the intestine.

He also states that submucous lipomata are found in the stomach, jejunum, and colon. They may become pedunculated, and the large polypi of the jejunum are usually pedunculated lipomata which push the mucosa before them, and which often extend for an inch into the intestine. Innocent in themselves, they may give rise to intussusception, but Virchow does not state that they have ever caused occlusion by their size alone.

Huss⁵ reports a case of lipomata in the mucous membrane of the small intestine. The patient, a man forty-four years of age, had a dysentery a

year before, followed by chronic diarrhea, cachexia, and death, but had no symptoms of ileus. In the small intestine 12 polypi the size of a hazelnut were found protruding into the gut; chronic dysenteric ulcers were also found in the rectum and large intestine. The lipomata were not caused by the dysentery, nor did they cause any symptoms.

Klebs⁶ considers intestinal myomata rare, and states that their muscle-fibers are much larger than normal.

Böttcher³ has described a myomatous polypus of the ileum from the Dorpat Pathological Museum. The specimen consisted of a piece of intestine which showed an angular flexure with stenosis. In the angle was a tumor, $5\frac{1}{2}$ cm. long and 3 cm. in diameter, which protruded into and almost filled the lumen of the dilated intestine. The polypus was covered with normal mucous membrane. On transverse section three layers of the tumor could be distinguished; first, a whitish layer, $\frac{1}{2}$ cm. thick, consisting of thickened mucous membrane and containing dilated vessels in firm fibrous tissue. Next to this was seen a wavy band, 1 to $1\frac{1}{2}$ mm. in diameter, extending into the muscular coat and representing a thickened layer of intestinal muscularis. The main mass of the tumor consisted also of muscular fiber with a sparse amount of connective tissue, but a large number of vessels.

Böttcher believes that this myoma had grown into the lumen of the intestine in the following manner: By reason of its weight it pulled the peritoneal surface of the intestine inward, causing a funnel-shaped depression on the outside, and consequent agglutination of the peritoneal surfaces thus brought in contact with each other.

Wesener¹² thinks it likely that the myoma, as such, may be developed toward the mucous side of the intestine.

Perls⁹ states that leiomyomata are not very rare in the intestinal tract, but that they usually remain small—from the size of a cherry to that of a plum. Larger myomata are found only in the fundus of the stomach.

Birch-Hirschfeld² states that submucous pedunculated lipomata have been known to reach the size of an apple. If developed to this extent, they might cause stenosis directly or might be caught by the peristaltic movements of the intestine and cause invagination. Mucous polypi originate by chronic catarrhal inflammation, are often multiple, and may attain a large size. They are most commonly found in the lower part of the ileum, colon, and rectum.

Wesener,¹² to whom we are indebted for a careful and exhaustive review of the literature of the subject, found in the Pathological Museum of Giessen a round tumor of the duodenum the size of an apple. It was located in the posterior wall of the duodenum, 5 cm. above the entrance of the bile-duct, but the large mass of the tumor extended into the peritoneal cavity and protruded only slightly into the lumen of the intestine. Behind the tumor were the pancreatic and bile-ducts, which, however, were not compressed. On microscopic examination this tumor was found to be a myoma.

Wesener also found a myoma of the duodenum in the following case:

A man, fifty-five years of age, had suffered from gonorrhœal cystitis and chronic polyarthritis, and toward the end of his life presented indistinct symptoms of intestinal disturbance, constipation alternating with diarrhœa, and occasional attacks of copious vomiting which persisted for two or three days and then disappeared, to recur after a short time. The increasing emaciation for the last few months before the patient died caused the diagnosis of carcinoma of the stomach to be made, though neither tumor nor coffee-ground vomiting was observed. The autopsy showed a dilated stomach, together with dilatation of the pylorus and the upper portion of the duodenum, but no carcinoma. Fifteen centimeters below the pylorus a nodular tumor the size of a plum protruded into the intestine. On its apex was a depression with loss of substance, where the mucous membrane was wanting. The tumor in the duodenum was part of a larger tumor, the size of a fist, situated outside of the intestine, between the duodenum and the transverse colon, lying on the atrophied pancreas, to the head of which it was adherent. Microscopic examination showed the tumor to be a myoma which had originated in the circular fibers of the muscularis of the intestine without causing absolute obstruction. The tumor had evidently caused a certain degree of stenosis, as was shown by the dilatation of the duodenum and stomach above.

Pellizari⁸ reports the case of a young girl in whom a large round tumor presented in the ileocecal region. This tumor was supposed to be ovarian. It caused no symptoms at first, but later on pain, vomiting, constipation, and finally symptoms of ileus occurred. Sixteen days later a myoma, one pound in weight, was passed by the rectum, and the symptoms disappeared.

I am not aware that any benignant tumors of the small intestine have been operated upon, with the exception of polypi in cases of invagination, where they play only a secondary part in the obstruction.

I desire to report the following case as an instance in which the myoma itself caused obstruction, and in which the tumor was successfully removed by operation:

CASE.—Synopsis.—Chronic intestinal obstruction, with intermittent attacks of fecal vomiting, accompanied by paroxysmal pain and visible peristaltic contraction of isolated coils of intestine. No tumor felt. Exploratory abdominal incision in the interval between attacks. Sessile tumor of ileum. Longitudinal incision of intestine. Excision of tumor. Suture of intestinal wound. Recovery.

R. M., male, seventy-five years of age, consulted me May 16, 1893. Family history negative. General health always good until a year before, when he had occasional attacks of constipation unattended with vomiting. During the last five or six weeks bowels have moved but slightly and the stomach has refused food, or, after eating, he would feel a sensation of heaviness and become nauseated; in an hour or two after eating there was occasional vomiting of fecal matter. During the last two weeks he has vomited almost every day, first the stomach-contents, then the contents of the bowels. Paroxysmal pain in the abdomen, the paroxysms becoming more frequent. No pus or blood in the feces.

Examination.—Patient in bed, old, pale, decrepit, emaciated. Abdomen not

tympanitic, but when a paroxysm of pain occurred, I found that it was accompanied by peristaltic contraction of coils of intestine, which was plainly visible through the thin abdominal wall. The paroxysm lasted a few minutes. No tumor could be felt anywhere on the abdomen; no hernia existed. Rectal examination negative.

Diagnosis.—Chronic intestinal obstruction from carcinoma, probably in large intestine, high up in the sigmoid flexure, or in the left or right flexure of the colon.

The patient was advised to go to the hospital for operation. I proposed to make an exploratory median laparotomy. If an inoperable carcinoma of the colon was found, to make the Maydl colotomy in two stages; if operable, to perform the radical operation.

Operation on May 19th at the Emergency Hospital, in the presence of doctors

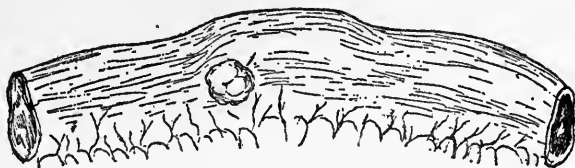


Fig. 97.—Myomyxofibroma of ileum.

from the Polyclinic, and assisted by Drs. Waters, Bernauer, and Livingston, I operated in the following manner:

During the two days preceding operation the patient had not vomited. On palpation in narcosis no tumor was felt. During the preparation of the field of operation a copious evacuation of the bowels occurred, due probably to the relaxation of the intestine in narcosis.

An incision 3 inches in length was made in the median line below the umbilicus, and the peritoneum sutured to the skin. The loops of small intestine which came into

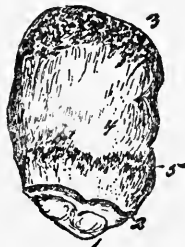

Fig. 98.—Cylindric tumor, 45 mm. long, 28 mm. in diameter, clad with mucosa: 1, Base; 5, proximal end of tumor in wall of ileum, as seen in Fig. 97; 2, border of mucous membrane covering tumor; 3, distal end of tumor, dark, discolored, mucosa yellow from imbibition of bile coloring-matter from feces, signifying necrosis of mucosa; 4, mucosa; Light red ecchymosis at 5.

view were neither injected nor dilated. Examination with the hand in the abdominal cavity revealed nothing abnormal in the rectum or colon. This made me think that perhaps a false diagnosis had been made, and that the patient's condition was merely due to chronic senile constipation.

Upon examination of the small intestine I now discovered a small round tumor, which felt like an intussusception, and pulled the loop in which it was contained out of the abdominal wound. The tumor was the size of a walnut; the intestinal wall over it was somewhat thickened and movable, but the tumor could not be dislodged. Attempts at dislodgment caused traction upon the base of the tumor, which was seen to be $1\frac{1}{2}$ cm. in diameter, covered with serosa, not the smooth muscularis, but a slightly

depressed, slightly lobulated surface. It was situated on the side of the loop, midway between the convex border and the mesenteric attachment, $\frac{1}{2}$ inch from the latter (Fig. 97).

The loop was now emptied to a distance of 5 inches on each side of the tumor, and a strip of iodoform gauze pushed through the mesentery and tied, to prevent feces from getting into the loop.

A longitudinal incision $1\frac{1}{2}$ inches long was now made over the tumor, in the middle line of the convex border of the loop, whereupon the tumor came out (Fig. 98). It was smooth, cylindric, rounded, 45 mm. long and 28 mm. in diameter, clad with mucosa, dark at the rounded end, and yellowish from imbibition of bile coloring-matter from feces. As the base or pedicle of the tumor, which was $1\frac{1}{2}$ cm. in diameter, extended beyond the line of incision, the latter was prolonged to the base, which was excised, leaving a transverse incision 1 inch in diameter.

The T-shaped intestinal wound was now united by step sutures—first a continuous silk suture from the distal end of the longitudinal to the transverse wound, and the transverse wound united by interrupted sutures passed through the mucosa only. Interrupted Lembert sutures were then introduced through the serosa and muscularis to bury the mucosa sutures, especial care being taken at the angles of the wound.

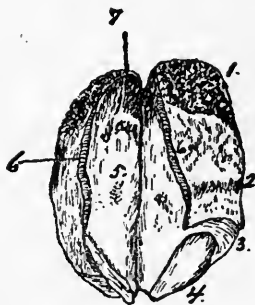


Fig. 99.—Tumor laid open: 1, Distal end; 2, normal mucosa on surface of tumor; 3, divided mucosa and muscularis at base of tumor; 4, tumor tissue at base covered with peritoneum; 5, cut surface of tumor, smooth, homogeneous, grayish-white, perfectly uniform, tough; 6, divided mucosa, immovable on tumor (no submucosa); 7, cut surface of distal end of tumor, dark brown from imbibition of blood (hematin).

Examination of the intestine as to its permeability for feces and gases now revealed an indentation on the side of the intestine opposite to the base of the incision, indicating that one of the mucosa sutures had caught the mucosa on the opposite side of the intestine. The sutures of the transverse wound were, therefore, loosened, and the opposite wall of the intestine freed by division of the offending suture. The transverse wound was then reunited by mucosa and seromuscular sutures as before, and the loop flushed with sterilized water.

The iodoform gauze strips which compressed the loop above and below were removed, and the permeability of the intestine as to feces and gases again tested. It was found that the intestine was entirely permeable at the place of operation, and that at the line of sutures the intestine was air-tight. The intestine was now flushed again with sterilized water.

An omental flap was then made by pulling down the omentum, which was followed by the transverse colon. The omentum was not quite long enough to go around the loop without some compression, but it was brought around and sutured to both sides of the mesentery.

The loop in the field of operation and the omental flap were now anchored by

sutures to the parietal peritoneum at the lower border of the wound, and an iodoform gauze drain laid down to the base of the loop. The remainder of the abdominal wound was then united in the usual manner.

The operation occupied about an hour and a half. At its close the patient was in good condition; pulse, 110, and strong. He made a good and uneventful recovery and is at this time, sixteen months later, well.

MACROSCOPIC EXAMINATION OF THE TUMOR

The tumor is 45 mm. long, 28 mm. broad, cylindrical, smooth. At its distal end it is dark brown, with spots of yellow from imbibition of bile coloring-matter from the feces. The surface here is clad with mucosa, necrosed as in typhoid ulcers, with red stripes from injection and ecchymosis. Over the remainder of the tumor the mucosa is normal. The base of the tumor, which is $1\frac{1}{2}$ cm. in diameter, is situated in the muscularis, from which it probably originated.

The cut surface of the tumor (Fig. 99) is smooth, gray, tough, moist—a fibromyoma. At the apex, which corresponds to the necrotic mucosa, it is dark red brown, from imbibition with blood or hematin.

MICROSCOPIC EXAMINATION OF THE TUMOR

Sections from the base at the place of the divided mucous membrane show:

1. The mucous membrane is of normal thickness and structure, with perfect tubular glands and a normal layer of lymphoid cells between them.

2. The muscularis mucosæ also extends over the whole surface of the tumor, and forms a layer of bundles of organic muscular fibers half as thick as the mucosa proper, consequently considerably hypertrophied; there is a sharp line of definition between this muscularis and the tumor tissue, and the elements of the one are not interwoven with those of the other.

3. The deep or circular layer of muscular fibers presents at the base of the tumor, the following conditions: At the free end of the base (Fig. 99) it is of normal thickness, and covered with a normal layer of the longitudinal muscularis; but at the corner where the tumor commences the fibers spread out in bundles separated by fibrous tissue—the tissue of the tumor. These bundles of the muscularis can be followed as long, radiating tracts deep into the tumor; they spread out like a fan, and their branches become gradually more slender until bundles of 4 to 10 muscular fibers form bands that finally are lost in the tissue of the tumor.

4. The longitudinal or outer layer of muscular fibers is present in normal condition as a continuous covering outside of the circular layers, and is covered with a normal layer of peritoneum.

The tissue of the tumor proper is a dense connective tissue with small connective-tissue cells, and has many vessels; the latter are empty and not dilated, almost all small subcapillaries; neither larger veins nor arteries are seen. In many places, as well between the bundles of the circular muscle-fibers above mentioned as in the tumor inside of them, are tracts of myxoma tissue with branched cells and fine fibrillated, rarely homogeneous, intercellular substance.

The anatomic character of the tumor would thus be designated as a mixed form of the connective-tissue type—a myomyxofibroma.

The tissue from which the tumor originated is the muscular coat of the intestine, not the external layer of longitudinal muscle-fibers, but the inner layer of circular muscle-fibers exclusively.

BIBLIOGRAPHY

1. Baltzer, M.: Arch. f. klin. Chir., 1891, vol. xlv, p. 717.
2. Birch-Hirschfeld, F. V.: Lehrbuch der pathologischen Anatomie, vol. ii, p. 585.
3. Böttcher: Archiv der Heilkunde, 1871, vol. xi, p. 125.
4. Förster: Virchow's Archiv, 1858, vol. xiii, p. 270.
5. Huss: Schmidt's Jahrbücher, 1847, vol. li, p. 171.
6. Klebs: Handbuch der pathologischen Anatomie, vol. i, p. 266.
7. Leichtenstern: von Ziemssen's Handbuch der speciellen Pathologie und Therapie.
8. Pellizari: Centralbl. f. Chir., 1875, vol. ii, p. 222.
9. Perls: Lehrbuch der pathologischen Anatomie und Pathogenese, 1877, S. 425.
10. Rokitsky: Lehrbuch der pathologischen Anatomie, vol. iii, p. 231.
11. Virchow, R.: Die krankhaften Geschwülste, vol. i, p. 382.
12. Wesener: Virchow's Archiv, 1894, vol. xciii, p. 377.

BASAL HERNIAS OF THE BRAIN*

WHILE the occipital and sincipital cerebral hernias form external visible tumors in the occipital and nasofrontal regions respectively, we find no external visible tumors in the basal hernias. As the sincipital hernias, however, leave the cranium in close proximity to the place of exit of the basal hernias, let us first review briefly the various forms of sincipital hernias:

1. The nasofrontal hernias leave the cranium between the frontal and nasal bones and form a tumor in the median line in the region of the glabella.

2. The naso-ethmoid hernias leave the cranium between the frontal and nasal bones on the one side, and the lateral mass or labyrinth, on the other, which is forced or displaced downward toward the nasal cavity. The tumor appears externally in the region of the border between the osseous and cartilaginous portions of the nose, hanging down toward the tip or the wing of the nose.

3. The naso-orbital hernias leave the cranium between the frontal, ethmoid, and lacrimal bones. In the region of the latter they enter the orbit, and present at or near the inner canthus of the eye.

All the above-named varieties present external visible tumors. The naso-ethmoid and naso-orbital varieties are probably not distinguishable from each other, as they leave the cranium at the same place, namely, the nasal notch of the frontal and the cribriform plate of the ethmoid bone. Furthermore, the same hernia may divide into two branches, of which the anterior passes downward and forward behind the nasal bone, to protrude in the face at the border of the osseous and cartilaginous part of the nose, and the posterior branch descends into the anterior and medial portion of the orbit, between the frontal, ethmoid, and lacrimal bones. There is always some defect of the bones in question at the point where the encephalocele leaves the cranium.

4. Basal hernias are, as already stated, distinguished from the other sincipital hernias by not causing a protruding tumor in the face. Heineke⁶ distinguishes between three forms of these hernias:

1. Cephalocele sphenopharyngea is the most common variety, and leaves the cranium through an opening between the body of the sphenoid bone and the ethmoid bone, or through one of these bones, to come down in the nasal or nasopharyngeal cavity. Extending from this point they may present in one of the nostrils, as in Czerny's case; in the nasopharyngeal cavity, as in the cases of Giraldès, Otto, and Klimentowsky,

* Amer. Jour. Med. Sci., 1895, vol. cix, p. 1.

cited from Larger,¹¹ and in my case, or come down into the mouth through a cleft-palate, as in the cases reported by Virchow, Lichtenberg, Klintosch, and Serres, also cited from Larger.

2. Cephalocele sphenoidal, which leaves the cranium through the superior orbital fissure, to enter the orbit behind the globe of the eye.

3. Cephalocele sphenomaxillaris, which, like the second form, leaves the cranium through the superior orbital fissure, but instead of remaining in the posterior part of the orbit, descends through the inferior orbital fissure into the sphenomaxillary fossa. The tumor presents, and can be felt in the mouth on the medial side of the ascending ramus of the inferior maxilla, and is visible on the outside of the face, on the cheek below the zygoma, in the same place where the retroramaxillary branches of retronasal fibroids present.

The two last-named hernias are exceedingly rare, and I have been unable to find all the varieties to which Heineke's classification refers. Larger mentions 3 instances of retro-orbital encephalocele referred to by Spring. In the case published by Walther the tumor descended through the superior orbital fissure and caused exophthalmos and destruction of the eye. Spring had seen 2 similar specimens in the museum at Bonn.

The first variety, the sphenopharyngeal, is less uncommon. I shall mention the more accurately described instances of this variety, as they present more of surgical interest than Heineke ascribed to them when he said: "Cephalocele basalis is of no surgical importance, as it has been found only in non-viable monsters (*nicht lebensfähigen Missbildungen*)."

Attempts at the removal of encephalocele by operation have been made by Lichtenberg, Czerny, and myself. Lichtenberg's patient died from the operation; Czerny's patient survived the operation, but died later from apparently independent causes; my patient made a definite recovery.

Lichtenberg¹² reports the case of a new-born girl in whom a large, reddish tumor, the size of a small fist, hung out of the mouth, covering the chin, with its base resting on the sternum. On more minute examination it was seen that the patient had a harelip situated nearly in the median line of the lip, and complicated with cleft-palate. The tumor was divided into two portions by a slight constriction in the middle, was elastic to the touch, and was attached by a pedicle which could be followed up to the right wall of the nasal cavity by opening the mouth, where it was continuous with the nasal mucosa. The patient died from the operation, and the autopsy demonstrated that the tumor was a cerebral hernia.

Klintosch¹⁰ gives a vague description of an infant in whom a tumor protruded in the mouth. The patient had a harelip and cleft-palate, some bones of the face were wanting, and the eyes were atrophied. In the sella turcica was an opening the size of a goose-quill, through which the neck of the hernia came down into the mouth, there to form

a tumor the size of a hazelnut. This contained the hypophysis, which was hollow and communicated directly with the ventricle.

Serres¹⁵ describes an infant in whom some portions of the brain, with their envelops, protruded from the cranium in the median line between the sphenoid and ethmoid bones. The tumor descended into the nasal fossa almost into the pharynx.

Giraldès,⁵ according to Dupuytren,³ observed an encephalocele which descended into the interior of the nose.

Otto,¹³ cited by Spring, states that he has seen, in the museum at Vienna, a cerebral tumor which had penetrated into the nasal cavity through the cribriform plate of the ethmoid.

Kelsch,⁸ according to Otto, has seen a case in which the hypophysis was situated in the sphenoid sinus.

Klimentowsky⁹ describes an encephalocele in a new-born child, in which the anterior portion of the two frontal lobes descended into the right side of the nasal cavity, as was verified by the autopsy.

Rippmann,¹⁴ cited by Meyer, found, in a fetus of twenty-three weeks, the head of which was double the normal size, and consequently hydrocephalic, a lobulated tumor having a pedicle 3 or 4 lines in thickness, which descended through a canal in the body of the sphenoid bone.

Virchow¹⁷ describes a specimen in the Berlin museum of hydrancephalocele palatina in a new-born child. (See Fig. 100.) From the open mouth protruded an irregular, nodulated tumor the size of a small apple. It was apparently adherent to the hard palate, but upon section it was seen that it

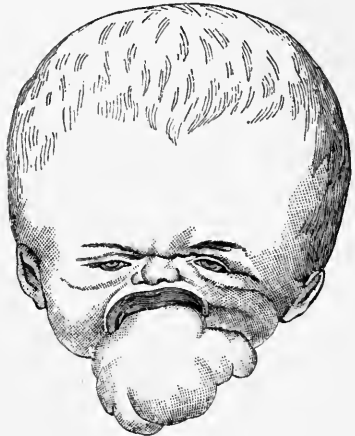

Fig. 100.

had pushed both the vomer and the hard palate forward and upward, and that it emerged from the cranial cavity through a broad opening immediately anterior to the sphenoid bone, and behind the still cartilaginous ethmoid. The anterior portion of the sphenoid was forced downward and backward, and the connection between it and the vomer interrupted by the tumor, so that the vomer was connected only with the ethmoid. The anterior portion of the sac contained a cavity lined with smooth dura mater, below and behind which were several irregular smaller cavities. In the upper portion of the tumor was brain substance which extended from this point up into the cerebral portion of the cranial cavity. The brain was pushed downward toward the base of the cranial cavity, and above it was a large cavity filled with fluid and surrounded by a thick membrane.

In addition to this more or less cursory discussion of cases from the older literature there has now appeared an accurate and excellent report

of a case by Meyer¹⁹ from Czerny's clinic. The case was one of congenital nasal polypus, and was brought to the Heidelberg clinic for operation. The child died six weeks later, and the diagnosis was made after postmortem microscopic examination.

The patient was a child three days old, well developed, weighing 5 or 6 pounds. The left ala nasi was broadened and pushed upward by a soft, elastic, compressible, pedunculated, transparent tumor the size of a hazelnut, half of which protruded through the opening of the nose, and was clad with smooth, yellowish-red mucous membrane, and covered with dried crusts of serous exudate. The tumor did not increase in size when the child cried; it was attached $1\frac{1}{2}$ cm. behind the free border of the septum. Upon incision of the tumor bloody serum escaped, and upon pressure puriform mucus was forced out.

On October 22, 1888, the left ala nasi was divided at its line of insertion and pushed upward. The pedicle was tied off by a double ligature and divided, and the tumor removed. The external wound was united, and an iodoform gauze-collodion dressing applied. This dressing was at first changed every day; later on, every two or three days. A serous discharge continued from the nose. The wound healed, and the child did well for a few weeks; then it suffered gradual loss of strength, and died six weeks after the operation from marasmus. There was no meningitis.

The autopsy revealed that the wound was healed. The left eye was located obliquely, so that the left inner canthus was 2 or 3 mm. deeper than the right. In the left nostril was a polypoid, grayish-red tumor, which extended nearly to the external opening. The fontanels were broad and large. The subarachnoid fluid was somewhat increased. The meninges in the right central fissure were opaque, and the left frontal lobe less prominent than the right, as if it had sunk back.

The left frontal lobe could not be lifted up from the frontal fossa, but was fixed by a flattened string or band 1 cm. in anteroposterior diameter, and clad with vascular meninges. The pedicle made its exit from the cranium through a longitudinal, oval, funnel-shaped opening, 1 cm. long and $\frac{1}{2}$ cm. broad, in the cribriform plate of the ethmoid bone. It was smooth, hard, the size of a goose-quill, descended into the posterior nares, and divided into two branches, one of which formed the polypus while the other was adherent to the posterior border of the hard palate. The nasal septum was deviated to the right side, and the middle meatus of the nose absent. The left nostril was much larger than the right.

Meyer remarks that it is possible that basal encephaloceles are more common than would appear from the literature, but that they have been mistaken for nasal polypi, which they resemble, and have not been recognized as hernias of the brain.

As a result of research in the literature on the diseases of the nose, for which I am indebted to the kindness of Dr. George Morgenthau, the 2 following cases have been found. (Abraham¹ demonstrated a case on February 1, 1889, before the West London Medico-Chirurgical Society):

The patient was a man, thirty-one years of age, who had a meningocele which occupied the greater part of the nose and originated beneath the nasal bones. After birth the tumor was relatively of the same size until 1883, when it became inflamed as a result of injury and was incised, whereupon blood and "water" escaped. The watery discharge continued for about a day, when the wound of incision closed. At the time of demon-

stration the tumor was $2\frac{1}{2}$ inches in length and diameter, and showed expansile pulsation, which was registered graphically and showed rapid systolic uprise and well-marked dirotic impulse. These phenomena were only slightly affected by respiration.

Tilleux¹⁶ reports the case of a man who, following the removal of a nasal polypus, commenced to suffer from a profuse watery discharge from the nose which persisted during the entire twenty-four hours, excepting when the patient was recumbent. When the head was bent forward, the discharge seemed to increase. The amount of discharge in the twenty-four hours was about 9 ounces. Upon analysis the fluid was found to be identical with arachnoid fluid. Tilleux, therefore, supposed that, in the extraction of the polypus, the cribriform plate of the ethmoid had been broken, and that the discharge occurred from the arachnoid cavity.

On March 16, 1891, I operated on a case of basal hydrencephalocele simulating nasal polypus, in which the compressibility of the tumor led me to suspect basal hernia before the operation, although I found it impossible to make a positive diagnosis until the polypus had been removed. I reported this case, and exhibited the specimen and patient before the Chicago Medical Society March 7, 1892. The case is as follows:

CASE.—Synopsis.—Symptoms of obstruction of nose from early childhood. Pedunculated polypus in left posterior nares, apparently somewhat compressible, pedicle located at root of nose. Suspicion of cerebral hernia. Attempt at positive diagnosis by aspiration of cerebrospinal fluid from polypus failed. Removal of polypus by écraseur, followed by free discharge of cerebrospinal fluid. Packing of left nostril with iodoform gauze preparatory to radical operation to close hollow pedicle. Osteoplastic resection of superior maxilla, as devised by von Langenbeck. Pedicle found, transfixed, and ligated. Recovery.

A. A., Swede, single, twenty-nine years of age, coachman, came to my clinic at the College of Physicians and Surgeons March 4, 1891. Parents living and healthy; none of his brothers or sisters died at birth or in early life; no cranial or cerebral deformities in the family. The patient has had the usual diseases of childhood, and has also had occasional headaches. Even when he was a boy he could not blow his nose satisfactorily; there was no discharge at all. Two years before he had difficulty in breathing through the nose, and consulted an advertising specialist, who claimed that he removed a growth from the nose. The operation was attended by slight hemorrhage, but no serous fluid escaped. He could breathe well for a few days, but the nostrils soon again became obstructed.

Upon examination at the clinic I found a tumor filling the post-nasal space above the soft palate. On palpation with the index-finger the tumor seemed somewhat compressible. As I thought the case might possibly be one of cerebral hernia containing fluid, I refused to operate, and told the patient to come to my office for further examination before deciding upon the method of treatment.

He came repeatedly to my office, and at each examination the tumor would, upon pressure, appear to decrease in size so that it could be pushed up into the left half of the posterior nares. It would remain small in size and in this location for a time, but within twenty-four hours would be as large and would occupy the same position as before. I could not see the tumor nor its pedicle from the nostril, but upon examination with the probe I thought I could trace the pedicle to the roof of the nose.

The suspicion of cerebral hernia made me consider the various operations for this condition. As ligation high up, near the base of the cranium, would be called for, the operation to gain access to this point would be somewhat grave. The choice of operations, therefore, lay between—(a) Temporary transverse resection of the nose at its root, as devised by Ollier and von Bruns; (b) temporary division of the hard palate close to the median line, as devised by Annandale; and (c) temporary resection of the upper maxilla, as devised by von Langenbeck.

As these operations preparatory to access are so grave, I did not wish to undertake any one of them on an uncertain diagnosis. On May 14th, therefore, I attempted to make the diagnosis certain by aspiration with the hypodermic syringe at my office. I palpated

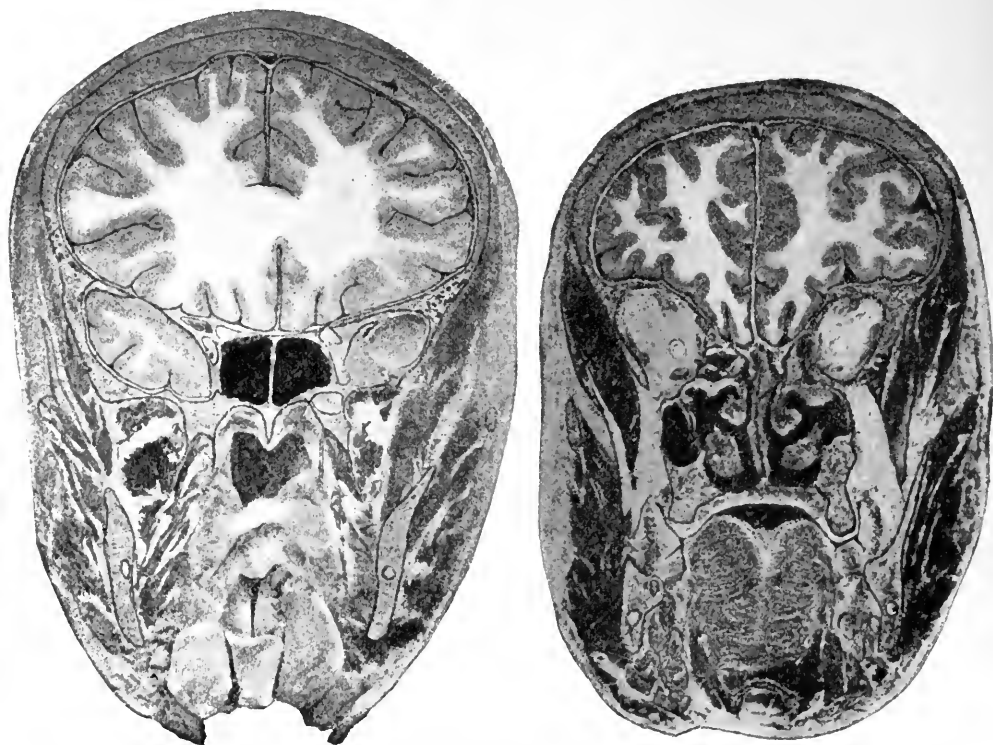


Fig. 101.—Showing the extent to which the cerebrum descends upon the cranial base (McEwen's Atlas of Head Sections, Series A, Plates 2 and 4).

the tumor with my left index-finger. It was in the usual position—above the soft palate, behind the posterior nares. Without compressing the tumor I pushed a hypodermic needle through the soft palate up into the tumor, and my assistant, Dr. Hall, withdrew the piston, but no fluid appeared. When this had been twice tried with negative results, I concluded that the tumor was an ordinary polypus and not a basal hernia, and proceeded to remove the growth in the usual way with the wire snare. The loop was introduced through the left nostril, carried over the tumor with the left index-finger, and tightened with the *écraseur* until resistance was encountered. I could now locate the tumor as being fixed to the roof of the nose between its middle and posterior thirds. I tightened the *écraseur* and divided the pedicle. After withdrawal of the snare slight hemorrhage oc-

curred, but neither coughing nor sneezing brought forth the tumor. The hemorrhage soon ceased, but was immediately followed by dripping of a clear watery fluid, of which I collected about a teaspoonful in a watchglass. This fluid, upon being boiled, showed the presence of a small amount of albumin, and upon the addition of nitrate of silver gave the characteristic white precipitate of chlorid of silver.

As I concluded that the fluid was cerebrospinal, and as I desired to examine the tumor to make the diagnosis positive, I made the patient vomit, and this brought forth the tumor, as shown in Fig. 102. The tumor when empty was of the size of a hazelnut, and consisted of two portions—a solid distal and a hollow proximal portion. The solid distal portion was spheric, 18 mm. broad and 13 mm. deep, was covered with smooth mucosa, resembling in color a fibrous polypus of the nose. The hollow proximal portion of the tumor, which was separated from the distal portion by a groove, was 15 mm. in all its diameters. At the point of division the cavity was 1.5 by 1 mm. in diameter, and had a wall 2 mm. thick, covered with smooth mucous membrane. The interior surface of the cavity was smooth, whitish, and showed distinctly dendritic vessels.

I now knew that I had to deal with a hollow pedicle of the diameter mentioned, which

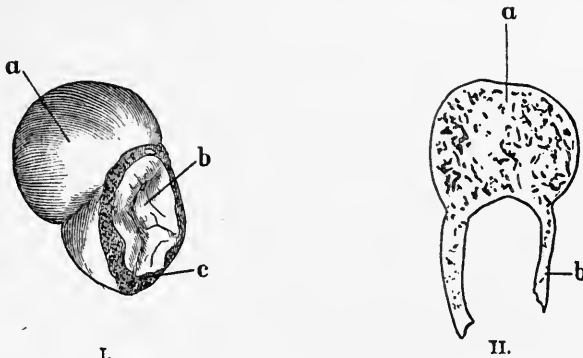


Fig. 102.—I, Tumor (natural size): *a*, Solid portion of tumor; *b*, cavity in pedicle of tumor; *c*, divided border of pedicle. II, Cross-section of tumor and hollow pedicle: *a*, Solid portion of tumor; *b*, wall of pedicle.

communicated with the cranial cavity and was probably in direct connection with one of the cerebral ventricles.

The left nostril was thoroughly cleansed with 1 : 1000 bichlorid solution, packed with iodoform gauze, and the patient immediately taken to the Emergency Hospital. He felt perfectly well, and when lying down nothing was noticeable, but when he sat up, with the head bent forward, a discharge of clear cerebrospinal fluid occurred from the left nostril.

The further plan of operation now came under consideration. The basis of this plan was to secure the pedicle for transfixion and ligation as close to its exit from the cranium as possible; that is, the nasal surface of the cribriform plate of the ethmoid bone. Taking into consideration the location of the pedicle, partly from what I had observed during the operation at my office and partly from our knowledge of the places of exit of basal hernias, I located the opening near the anterior border of the body of the sphenoid bone, about 2 cm. anterior to the border of the posterior nares.

I found, by investigation upon the cadaver, that in order to gain access to the place of exit of the hernia, not simply for the scraping or cutting off of a tumor, but to obtain sufficient space for manipulation—that is, to pass a needle through the pedicle for transfixion or ligation—neither temporary resection of the nasal bone nor Annandale's longitudinal division of the hard palate and separation of the divided portions would

give me the space required, but that the osteoplastic or temporary resection of the superior maxilla, as devised by von Langenbeck, would enable me to deal satisfactorily with the pedicle.

This operation was accordingly proposed and executed on March 16th, in the presence of the doctors from the Chicago Polyclinic, and with the assistance of Drs. Hall and Bernauer, in the following manner: The patient was anesthetized with chloroform and placed in Rose's position, the mouth held open by Heister's gag, and a loop of heavy silk passed through the tongue.

An incision was made from the internal canthus of the left eye along the infra-orbital border and outward over the malar bone to its junction with the frontal bone, then downward over the anterior portion of the zygomatic arch to its lower border, and from here forward along the lower border of the malar bone inward and upward to the upper border of the wing of the nose. The base of the flap thus formed was the skin between the ala of the nose and the internal canthus of the eye. The incision having been carried down to the bone, the masseter was divided at its origin on the lower border of the malar bone, and detached, with the periosteum from the bone, by a periosteal elevator. The elevator was pushed inward along the posterior surface of the superior maxilla through the sphenopalatine foramen, where it could be felt by the left index-finger, and the contents of the orbit loosened from the floor and the outer border for $\frac{3}{4}$ inch along the line of incision.

I now divided the zygomatic arch with bone-scissors, and introduced a metacarpal saw through the sphenopalatine foramen into the nose, with the cutting-edge upward, and divided the bony structures in the posterior wall of the antrum of Highmore, namely, the frontal process of the malar bone and the upper bone of the posterior surface of the body of the upper maxilla. Then, bringing the handle of the saw forward, I cut through the bony floor at the orbit or the upper wall of the antrum of Highmore to the posterior border of the frontal process of the superior maxilla. The saw was now withdrawn, and replaced in its first position through the sphenopalatine foramen, but with its edge directed downward and forward, and the lower half of the body of the maxilla divided on a line corresponding with the lower portion of the incision, from behind forward and finally upward, terminating in the pyriform aperture of the nose. The saw was not withdrawn, and the periosteal elevator passed into the sphenopalatine foramen and the divided portion of the upper maxilla, now attached only by its nasal process to the frontal and nasal bones, lifted out after fracture of this process.

This part of the operation was attended with considerable hemorrhage through the wound, the mouth, and the nose.

The resected portion attached to the skin-flap was now displaced upward on the patient's forehead, which exposed and made readily accessible the left half of the nasal cavity and the antrum of Highmore.

I now found without difficulty the pedicle of the tumor, 2 cm. long, 1 cm. broad, and flattened so as to be about 6 or 7 mm. in thickness. The distal end of the pedicle terminated in a ragged surface where the *écraseur* had cut through, and showed distinctly a smooth outer surface, a large cavity, and a smooth inner surface, with no redness, swelling, or other signs of inflammation.

The end of the pedicle was grasped by Kocher's artery forceps, and transfixion and double ligation close to the roof of the nose performed. The space for this purpose was not very abundant, and a very short needle was employed to pass a silk thread through the middle of the pedicle, at about $\frac{1}{2}$ cm. to 1 cm. from the cribriform plate of the ethmoid. The pedicle was thus ligated in halves, and, in addition, one of the ligatures was passed around the entire pedicle. The ends of the ligatures were cut short.

The pedicle was now enveloped in iodoform gauze, which was packed very carefully along the upper third of the nose. The resected portion of the superior maxilla was replaced, and the remainder of the nostrils packed with iodoform gauze. A separate pack-

ing of iodoform gauze filled the antrum of Highmore, and was brought out through the lower border of the wound, while the ends of the strips used in packing the nose were brought out through the left nostril. A drainage-tube was placed beside the gauze packing in the antrum, the rest of the wound united, and the usual dressing applied.

Notwithstanding the severe hemorrhage, the patient's pulse at the close of the operation was 88, and the temperature never exceeded 100.5° F., a point which it reached during the first week, but came down to normal in the second week. The pulse was 110 on the second and third evenings, 90 at other times, and was normal after the middle of the second week.

The patient was allowed to sit up after three weeks. In the fifth week two small pieces of bone were discharged from the drainage opening.

On June 1st, ten weeks after the operation, the wound was so nearly closed that collodion dressing could be applied over the fistula leading into the antrum, which remained open for about three months, but secreted little and did not interfere with the patient's work as coachman.



Fig. 103.




Fig. 104.

The accompanying photographs of the patient (Figs. 103 and 104) show a face of ordinarily intelligent expression, the left eye a little more open than the right, from division of some fibers of the seventh nerve distributed to the orbicularis palpebrarum. He can close the eye voluntarily. On the cheek is seen a fine linear cicatrix, which marks the line of incision for the osteoplastic resection; and at the lower border of the malar bone there is a depressed cicatrix, corresponding to the site of the drainage-tube into the antrum. The left ala of the nose is slightly flattened; this is the only indication of any asymmetry between the two halves of the face, and I am unable to state whether this flattening existed prior to the operation.

Besides this feature, there is one condition in the patient's face which has attracted my attention, and that is that the root of the nose is abnormally broad, and consequently the distance between the eyes is unusually great. The distance between the internal canthi of the

eyes is 45 mm., which is 10 to 12 mm. in excess of the normal distance. Upon measurement of adults I found this distance to vary between 30 and 34 mm., with an average of 32 mm. To this point I shall call attention later.

Microscopic examination of the hollow portion of the tumor shows the following layers in a section of its wall (Fig. 105):

The nasal surface shows—(a) A continuous layer of cylindric epithelium with papillæ. (b) A thick, rather homogeneous layer of connective tissue half the thickness of the epithelial layer. (c) A thick layer of firm fibrous tissue, with heavy connective-tissue bundles densely interwoven, and rather sparsely provided with medium-sized vessels.

This layer has the same structure as the periosteum and dura mater, and undoubtedly represents the continuation of these structures. (d) A layer of much finer connective-tissue fibers, much more vascular than the previous layer, showing numerous larger and smaller vessels, corresponding to the outer layer of the pia mater. (e) A layer of fine, fibrillated connective tissue, with scattered small nucleated cells, and yet comparatively rich in vessels, corresponding to the deeper layer of the pia mater and the beginning of the cortical substance of the brain. (f) A layer of gray cortical brain substance, characterized by fine fibrillated neuroglia tissue, in which there were no large vessels, but subcapillaries and capillaries only, as is evident from their rectangular branching in this substance, shown by the higher power (Fig. 106). Numerous ganglion-cells, partly small round-cells with large oval nuclei and distinct nucleoli, partly large multipolar ganglion-cells with large cell-bodies, large oval nuclei and nucleoli, could be seen, and two or three branches or poles could be traced for a distance out into the surrounding tissue. No distinct anastomosis between any two cells could, however, be seen. (g)

The cerebral wall of the sac is clad with a layer of flat endothelial cells, some of which, as

seen in the figure, are loosened, and appear as free, spindle-shaped cells with distinct nuclei.

The microscopic examination shows distinctly that the tumor was a cysto-encephalocoele, as we find under the covering membrane of the nose, first dura mater, then pia mater, than a layer of cortical brain substance surrounding a cavity clad with endothelium. Although no layer of white brain substance was present, there is no doubt that this cavity was a continuation of a ventricle—probably the third ventricle. Its regular shape and the fact of its being entirely surrounded by a layer of cortical brain substance make it distinctly different from the serous cavities which we find in hernias of the brain as well as of the

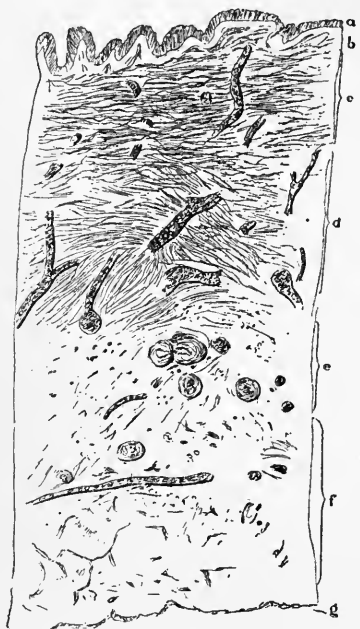

Fig. 105.—Section of wall of tumor. (For explanation see text.)

spinal cord, developed from, or an exaggeration of, the subarachnoid lymph-spaces.

It will probably always be difficult, if not impossible, to state at the outset whether a nasal polypus is or is not a hernia of the cerebrum. This is especially true in meningoceles and encephaloceles, in which the tumor is not compressible. In hydrencephaloceles the compressibility of the tumor, followed by return to its former size, as in my case, will lead us to suspect communication with the cranial cavity. Aspiration with the hypodermic needle when the tumor is not compressed may bring out cerebrospinal fluid and lead to a positive diagnosis. That this procedure was not successful in my case was due to the fact that the needle entered the peripheral solid portion of the tumor, and I believe that repeated attempts, through the nostrils, for instance, would eventually have resulted in the withdrawal of cerebrospinal fluid.

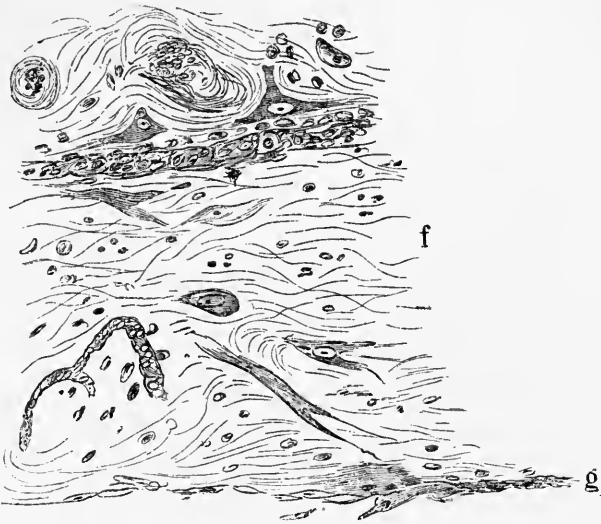

Fig. 106.—Cortical brain substance in tumor. For explanation see Fig. 105.

The location of the pedicle should also be considered; when it extends up toward the roof of the nose, in the region of the cribriform plate, we may suspect cerebral hernia, as this class of polypi is of necessity limited to this locality. Fig. 107 shows the points of exit of some of the recorded cerebral hernias.

As a point in diagnosis, my attention has been attracted to the distance between the eyes. It is possible that a basal cerebral hernia might cause a broadening of the root of the nose and a corresponding increase in the distance between the inner walls of the orbits, just as occurs in sincipital hernias. In my case the measurements show an increase in the interorbital distance of 1 cm., and this increase imparted to the face a certain expression which may be seen in the full-face photograph (Fig. 103).

As an analogue to this I have added a reproduction of a photograph of a case of cerebral hernia in the glabella reported by Volkmann¹⁸ (Fig. 108), in which it seems to me a similar expression is present.

Bruns² depicts a cerebral hernia at the root of the nose in which an increased distance between the eyes is apparent. I merely call attention to this symptom as a possible help in diagnosis, the value of which future observations must decide.

There is very little difference between cerebrospinal fluid (Hoppe-Seyler) and pure lymph (Hensen and Dähnhart). They contain respectively 98.7 and 98.6 per cent. of water, and 0.6 and 0.14 per cent. of albumin. There will probably be only slight difficulty in recognizing the cerebrospinal fluid when it escapes through the nose, as any secretion, even the most watery, through the nasal mucous membrane, will contain some mucin, and will consequently be more or less viscid. Furthermore, it may be confidently expected to contain at least as much, if not more, albumin than is found in the hydropic exudates of the serous cavities, where the pericardial fluid, for instance, contains 2.46 per cent. of albumin, or 15 times as much as is found in the cerebrospinal fluid.

While we must admit the correctness in general of Heineke's remark that most of the basal cerebral hernias possess no surgical interest, as they are found only in non-viable children, the case reported by Abraham and my own case show conclusively that patients with basal hernias may live to adult age, and my case demonstrates, in addition, that the development of the brain and mental faculties may be unimpaired, notwithstanding the cerebral hernia.

The treatment should be extirpation, even if the tumor is small and causes no other disturbance than that of a stationary nasal polypus; there will always be the danger of meningitis and death from accidental injury or surface inflammation. We would think, *a priori*, that the greatest danger would exist in case of hydrencephaloccles. A suppuration into the cavity would at once expose the entire ventricular system of the brain to infection, and it is well known

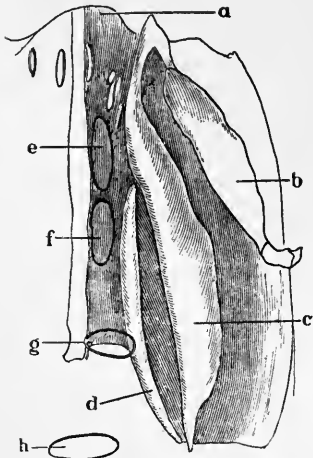


Fig. 107.—Places of exit for basal encephalocles (ethmoid bone seen from below): a, Cribriform plate; b, unciform process; c, inferior turbinate process; d, superior turbinate process; e, f, cases reported by Czerny, Serres, Spring, and Klimentowsky; g, cases reported by Heineke, Virchow, and Fenger; h, case reported by Ruppmann.

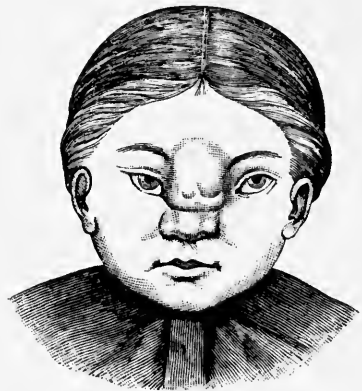

Fig. 108.

that when an abscess opens into the lateral ventricle, death follows in a short time.

The surgical treatment is comparatively simple so far as the size of the pedicle is concerned, because it is always small or narrow, seldom larger than a goose-quill, and consequently requires only simple ligation, which is best accomplished by transfixion.

The difficulty in operating lies in the inaccessibility of the pedicle at a point close to its exit from the cranium. The more posterior the point of exit, the greater the difficulty of the operation.

Various preparatory operations are required in the treatment of hernias whose pedicles are situated in different parts of the nose. Ligation and transfixion require much more operating space for manipulation than does simple division of the pedicle.

The anterior third of the nasal cavity can be reached, as in Czerny's case, by longitudinal division of one nostril, or by Ollier's method of temporary transverse osteoplastic resection of the nasal bones and septum at the root of the nose, or by Bruns' lateral osteoplastic resection of the nasal bones and septum.

If the pedicle is located in the anterior part of the middle third of the nose, Annandale's operation, which has already been mentioned, may give sufficient space for manipulation. If it is located in or just anterior to the posterior third of the nasal cavity, von Langenbeck's resection of the superior maxilla, as practised in my case, will be required. If, however, the pedicle should be found to be located in or behind the posterior nares, I am of the opinion that nothing short of total extirpation of the superior maxilla will furnish the space necessary for operating and it is a serious question whether a tumor in this location should be removed when its extirpation would entail so great a sacrifice.

BIBLIOGRAPHY

1. Abraham: Brit. Med. Jour., 1880, vol. i.
2. Bruns: Chirug. Atlas, Tübingen, 1860, Plate XII, Fig. 12.
3. Dupuytren: Leçons Cliniques.
4. Fenger: "Basal Hydrecephalocoele, Removal by Osteoplastic Resection of Superior Maxilla. Exhibition of Specimen and Patient," Chicago Medical Record, 1892, vol. xli, p. 157.
5. Giraldès: Leçons Cliniques, etc., 1869.
6. Heineke, W.: "Die chirurgischen Krankheiten des Kopfes," Billroth and Leucke's Deutsche Chirurgie, 1882, p. 224.
7. Huguenin: "Der chronische Hydrocephalus," Ziemssen's Handb. d. spec. Pathol. u. Ther., 1880.
8. Kelsch: Otto, cited by Spring from Larger.
9. Klimentowsky: Moskow. med. Zeit., 1868.
10. Cited by Larger.
11. Larger, R.: Arch. gen. de Médecine et de Chirurgie, 1877.
12. Lichtenberg: Cited by Larger and Huguenin.
13. Otto: Cited by Spring from Larger.
14. Rippmann: Cited from von Meyer.
15. Serres: Philos. Anat. ii, p. 92.
16. Tilleux: Traite de Anat. Topograph., 1878.
17. Virchow, R.: Die krankhaften Geschwülste, Berlin, vol. i, p. 188.
18. Volkmann: Beiträge zur Chirurgie, p. 261.
19. V. Meyer, E.: "Ueber eine basale Hirnhernie in der Gegend der Lamina Cribrosa," Virchow's Archiv, 1890, vol., exx, p. 309.

CASES OF HERNIA OF THE BLADDER MET WITH DURING OPERATIONS FOR INGUINAL AND FEMORAL HERNIA*

UNTIL the last decad hernias of the bladder were considered as of comparatively rare occurrence; but since the radical operation for hernia has been revived and has become so common as to be almost an every-day operation, the bladder has been met with quite frequently in the course of these operations. Although the bladder has been encountered in almost all forms of hernia, it is practically only the femoral and inguinal hernias that we have to deal with in this regard.

In 1891 Siegel²¹ collected 73 cases of hernia of the bladder, 48 of which were inguinal; since that time 13 more cases have been reported—3 by Roth,¹⁹ 2 by Walther²³ (published by Bourbon²), and 1 each by Postempski,¹⁷ Leszinsky,¹⁵ Guelliott,⁵ Israel¹⁰ (published by Feilchenfeldt), Thiriari,²² Reverdin,¹⁸ Kummer,¹² and Polaillon—to which I add my case. This makes in all 62 cases of inguinal hernia of the bladder. In 1893 Guépin⁶ collected 8 cases of femoral hernia of the bladder, 1 case being reported by each of the following operators: Levret, Habs,⁹ Güterbock,⁷ Cooper, Aue,¹ Schoonen,²⁰ and 2 by Lang.¹³ To these I add my 2 cases, making in all 10 femoral hernias of the bladder.

In the great majority of these cases the hernia was not suspected before operation. There has been so much difficulty in recognizing the bladder, even during operation, that in most of the cases the bladder was wounded before being discovered; on this account many of the writers on this subject during the last five or six years have paid especial attention to and have described very carefully all the essential characteristics of hernia of the bladder.

One of the chief points in vesical hernias is the relation of the hernial sac to the bladder, which again is identical with the relation of the peritoneum to the protruding part of the organ. This has been clearly yet briefly described by Dieffenbach in 1848 as follows: "Hernias of the bladder have sometimes a hernial sac, at other times none. If that part of the bladder which has a peritoneal covering prolapses, there is a hernial sac. If a part of the bladder uncovered by peritoneum protrudes, the sac is wanting. If a portion of the bladder on the borderline between the intraperitoneal and extraperitoneal surface comes out, then there is half a hernial sac." (That is, a hernial sac is present on half the prolapsed surface of the bladder, and on the other half the sac is absent.)

*Trans. Amer. Surg. Assoc., 1895, vol. xiii, p. 321.

The location of the hernia is invariably in the medial and lower part of the respective rings, inguinal as well as femoral; if an intestinal hernia is also present, its contents are situated above and to the external side of the vesical hernia.

I. We most frequently find the peritoneum of the sac covering only a portion of the prolapsed bladder; its upper anterior surface is clad with peritoneum, but the inferior medial portion is not. The sac, whether empty or filled, is ordinarily larger than the prolapsed portion of the bladder, which is found as a small mass at the neck of the sac only, on its inferior medial aspect.

II. Less frequently a complete sac is found; that is, the protruding bladder is entirely covered by peritoneum, as in my case of inguinal hernia.

CASE I.—Synopsis.—Left femoral hernia; no distinct symptoms of hernia of the bladder; radical operation; bladder not recognized and opened; bladder wound sutured and anchored to deep portion of wound; recovery without leakage.

Miss L. S., school-teacher, aged twenty-three years, was admitted to the German Hospital February 3, 1894. Family history negative. Aside from the ordinary diseases of childhood, she was healthy. At the age of fifteen she suffered from chlorosis, which persisted for four years. A year later she had uterine inflammation, and in August, 1893, a mild attack of scarlatina. Following this she had hysteric attacks, during which she cried and sobbed so much that she thought it might be the cause of the present disease. In October, 1893, she noticed a soft tumor in the left femoral region, which was somewhat tender and could not be reduced by pressure. A few weeks later she began to have pain in the tumor, which increased until it became almost intolerable. Patient says that even when a child she would have to be awakened during the night to pass water. As she grew older she was obliged to get up once or twice in the night. When she was excited, she would have to urinate more frequently. She never had any pain before, during, or after urination.

Upon examination I found an irreducible left femoral hernia the size of a walnut.

Operation February 5, 1894. An incision 3 inches in length was made below and parallel to Poupart's ligament, across the crural opening. Blunt dissection was then made down to the empty sac, which was doubly ligated and the end cut off. Reduction of the stump was impossible. A diffuse lipoma, or rather a conglomeration of adipose tissue, was found on the internal surface and dissected off. When this was cut off, another sac-like cavity was opened, through which a probe passed into the abdominal cavity. I believed this to be the sac of a properitoneal hernia, but as I found, after dissecting off more adipose tissue, another sac, I searched for the relation between them, and found that they all communicated and were folds of the abdominal parietal peritoneum, which was so loosely attached to the surrounding peritoneum that it simulated an independent hernial sac or diverticulum, but was in reality a portion of the first cavity, which was curiously folded upon itself.

Upon the dissection of more adipose tissue a third peritoneal sac was opened. Still deeper, on the internal surface in the medial portion of the ring, was an ovoid body, whitish, elastic, the size of an almond. Upon traction this could be pulled out an inch or more, but no neck could be seen, as the mass filled the entire ring. It looked like an ovary or the anterior surface of a small testicle, but manipulation with the fingers proved that it was a thin-walled, empty sac whose walls moved against each other. As I supposed this to be a fourth fold, I cut it open for about 2 inches. As its surface, although

whitish and smooth, presented a slightly different appearance from the peritoneal surface of an ordinary hernial sac, I suspected that it might be the bladder, and my suspicion proved correct, as a sound in the bladder met the finger-tip introduced through the opening in the supposed sac. No urine escaped, as the bladder had been emptied by catheter. The bladder wound was immediately united by a row of Lembert sutures of catgut, reinforced by another row. In the center a heavy silk suture was inserted, with the ends left long to anchor the bladder in the wound, and thereby render the abdomen safe against urinary infiltration. The opening into the peritoneal cavity was then united, the wound packed with iodoform gauze, a permanent soft catheter inserted in the bladder, and the usual dressings applied.

A week later the anchor suture was removed. The peritoneal wound was healed. Two weeks after the operation the permanent catheter was removed and the patient catheterized every three hours. There was at no time any leakage of urine through the wound, and the patient made a good recovery. She left the hospital after seven and a half weeks. In April, 1895, the urinary trouble was the same as before, but the pain in the region of the hernia has disappeared. She now wears an elastic pad.

Remarks.—Opening into the bladder may be avoided by constantly keeping the bladder in mind—(a) When the hernial sac, after its neck has been loosened, isolated, and ligated, does not pass up readily through the internal ring, but stops in the canal.

(b) When, after pushing the ligated neck of the sac up, the fibrous ring is not felt free all around, but a mass remains which fills the canal in its inferior medial or internal portion.

(c) When the sac cannot be readily isolated and the neck freed, but on one side resistance is met with by reason of adhesion to something in the paraperitoneal space. This adhesion is due to the fact, first, that the peritoneal covering of the neck of the bladder is adherent and cannot be stripped off sufficiently to form a neck; and, second, that the peritoneal surface of the bladder in hernia is not neck-shaped, but is a broad surface, or rather that the presence of the bladder with its broad back, clad with peritoneum which is adherent and thus immovable against the bladder-wall, does not permit the formation of a narrow neck for the sac; it forms folds simulating separate hernial sacs.

(d) When separate sacs are encountered, whether empty or filled, suspect that this is a traction phenomenon, and examine for bladder. In short, when there is irregularity or difficulty in isolating the neck or in getting a well-shaped narrow neck, be suspicious of the bladder. It is necessary to think of the bladder only to avoid opening into it, unless its wall is so thin that it is teased or torn open in dissecting off or removing paraperitoneal, or in this case paravesical, lipomata or islands or lumps of adipose tissue.

(e) In vesical hernia the usual treatment of the neck of the sac, as in the ordinary radical operation, namely, isolation, transfixion, and ligation, cannot be carried out, as the sac has no narrow neck. There is only a slit-shaped opening into the peritoneal cavity which must be closed by sutures.

(f) Be careful in removing or dissecting off lipomata, as the bladder is often thin walled.

CASE II.—*Synopsis.*—*Left femoral hernia of five years' standing; right femoral hernia of six months' standing; the left femoral hernia becoming gradually irreducible and painful; radical operation for the hernia on the left side; bladder recognized, demonstrated by passing urethral steel sound from the bladder out through the crural ring, and vesical hernia reduced.*

Mrs. M. M., aged fifty-one years, was admitted to Mercy Hospital February 10, 1894. Family history negative. Patient was well up to the birth of her last child, eight years ago, which was attended by lacerations of cervix and perineum. Soon after she was troubled with supposed stone in the bladder, but no operation was performed on bladder, cervix, or perineum. Five years ago she began to have soreness in the region of the left groin, and noticed a slight swelling in the left femoral region. This gradually increased in size until a year before she came under observation; since that time it has not increased. In the autumn of 1893 the patient noticed a tumor in the right femoral region, which was reduced by taxis. At the same time an attempt was made to reduce the tumor on the left side by taxis, but on coughing it became larger, and the patient experienced pain of a darting character. She has never worn a truss or support of any kind excepting an extemporized cloth pad.

Operation February 15, 1894. Upon examination in ether narcosis I found a left femoral hernia the size of a large hen's egg, situated below Poupart's ligament. The tumor feels like omentum. Percussion dull. The hernia was irreducible, but Dr. Morgan stated that he had partially reduced it four days before. An incision 4 inches long was made $\frac{1}{2}$ inch below and parallel to Poupart's ligament through the skin, subcutaneous tissue, and fascia. The sac-wall was thin and transparent, and I could see omentum through it. The sac was now opened, and no hernial fluid escaped; the omentum was reddish, thick, hard. The omentum was loosened from the inside of the sac, and three band-like adhesions between the omentum and neck of the sac divided. Still I could not reduce the omentum. I pulled out more omentum, but at the medial border of the ring I could not move the omentum nor get my fingers around it on account of adhesions. The internal ring was narrow, and at its inner lower border there was a mass that I could not reduce. I then partially divided Poupart's ligament upward so as to get at the adhesions, and divided the sac at its upper surface. In this enlarged opening I found that the adhesions were between the omentum and peritoneum on the posterior surface of the bladder. On pulling the adhesion out into view I found a sac or corner of the bladder filling the medial and lower aspect of the crural ring. The adherent omentum was loosened and the omentum was now freely movable. The thickened extrahernial omentum was divided into three portions, each of which was successively transfixed, ligated, and cut, and the ends replaced in the abdomen. I then attempted to isolate the neck of the empty sac for ligation and extirpation by grasping the borders of the opening in the sac with four artery forceps and holding them forward, whereupon I found a body or mass on the lower wall of the sac, which I suspected to be the bladder, because it adhered to the extraperitoneal surface of the sac, felt like a fold of the bladder, and because I thought I could see the contour of the upper convex border of the bladder through the peritoneal covering of the peripheral portion of the opened sac. To make sure, I introduced a male steel sound into the bladder through the urethra, and easily brought its tip out through the canal into the mass, thus easily demonstrating that this was a vesical hernia. The peritoneal opening was now united by suturing the peritoneum on the posterior surface of the bladder to the peritoneum of the abdominal wall by a continuous silk suture. The slit was transverse and 2 to $2\frac{1}{2}$ inches long. The hernia of the bladder was now reduced by pushing it into the abdominal cavity behind the crest of the pubes. The crural ring was closed after the method of Bassini. The corners of the external wound were now closed by deep sutures, the middle of the wound, a space $1\frac{1}{2}$ inches long, being packed with iodoform gauze. The usual dressings were applied. The patient made an uneventful recovery.

Remarks.—1. Vesical hernia might have been suspected from the previous symptoms referable to the bladder.

2. The fact that, in an operation two weeks previous, I had opened the bladder, put me on my guard and prevented a repetition of the accident.

3. During the operation I remarked, "When a hernia presents something unusual, a strange, irreducible extraperitoneal mass, the experienced operator thinks of the bladder and inserts a sound, bringing its tip up into the ring.

4. To avoid opening into the bladder, think of the bladder while operating.

CASE III.—Synopsis.—Strangulated left inguinal hernia; no vesical symptoms, although irreducible hernia had existed for many years; during operation, vesical hernia found behind incarcerated intestine, and recognized by a steel sound in the bladder; recovery.

V. F., an Italian, aged thirty years, bartender, was admitted to the German Hospital March 6, 1895, suffering from an incarcerated left inguinal hernia the size of a large orange. Efforts at reduction without anesthesia had been made without avail. The tumor was dull upon percussion, and the patient stated that it had been present for many years, but had always been irreducible.

The patient was immediately prepared for operation, etherized, and placed in the dorsal position. I attempted to reduce the hernia for about ten minutes, but was unsuccessful.

Operation. Incision 7 inches in length over the hernia. The distended hernial sac presented in the wound, was incised, and found to contain about 4 ounces of reddish-brown fluid. Cultures were made from this fluid, but with negative results. The hernial sac contained about 6 inches of small intestine. There was deep congestion of the vessels, but no signs of gangrene. The constricting portion of the ring was cut and the intestine replaced. In the upper medial part of the sac I found a flat, tongue-shaped tumor, $1\frac{1}{4}$ inches long, resembling a lipoma. A sound passed up into the apex of the bladder passed into this mass, and thus proved that it was a diverticulum. The vesical hernia was now replaced in the abdomen, and the internal ring nearly closed by sutures, which brought the fascia together. The wound was irrigated with warm boric-acid solution. I next united the fascia of the external oblique, and passed a thick strip of iodoform gauze subcutaneously down to the middle of the scrotum, where an incision was made and another heavy gauze drain passed up subcutaneously to a point a little above and internal to Poupart's ligament. Another heavy strand of gauze was packed in the middle of the wound and skin sutures applied. The hernia was direct, and had probably never been entirely reduced. The diverticulum of the bladder was first forced down, and became a predisposing cause for the intestinal hernia, which was forced down during an attack of coughing.

Remarks.—The strangulated loop of small intestine was congested, but viable, and, after being washed, returned to the abdomen. No omentum was found, but in the inner, medial, and lower aspect of the inguinal canal there was a small, lipoma-like mass extending like a tongue down into the lower posterior part of the hernial sac. I first thought of omentum, but it was smooth; then of a paraperitoneal lipoma, but it was flat, with a broad base; I also thought of the bladder, and, to find out the relation of the tumor to the bladder, I introduced a sound into the latter, and found that the tumor was hollow and empty, and

was a flat, empty diverticulum or prolongation of a corner of the bladder, resembling the cornu of a uterus bicornis.

The diverticulum was a smooth, yellow, tongue-shaped, flat mass, $1\frac{1}{4}$ inches long and 1 inch broad. When taken between the thumb and finger, it feels like an empty glove-finger, and its walls appear to be $\frac{1}{2}$ cm. to 1 cm. thick. A curved steel sound was passed into the bladder, but its end could not be brought up and out of the inguinal canal. The diverticulum could now be inverted $1\frac{1}{2}$ inches into the lumen of the bladder, and the end and curve of the sound could be easily made out. I could pass the diverticulum by pressing the corner of the bladder down over the end of the sound, so that the curved end of the sound was inside the diverticulum in its whole length for over 1 inch, and its tip was at the apex of the diverticulum.

I might have filled the bladder with water and made the diverticulum stand out of the inguinal canal like a thumb, for demonstration to the students, but for my own diagnosis this was not necessary.

I reduced the diverticulum; that is, I replaced it, pushing it into the abdomen behind the internal opening of the inguinal canal.

CASE IV.—Synopsis.—Left scrotal vesical hernia of fourteen years' standing, finally becoming irreducible and causing difficult micturition and transient hematuria and cystitis; operation refused.

D. C., dry-goods merchant, aged fifty-nine years, consulted me in May, 1895. Family history negative. Had ordinary children's diseases; no venereal disease. Patient is married and has six healthy children. The present trouble began in 1881, when he occasionally experienced severe pain in the inguinal region after walking, which persisted until he sat or lay down. Upon examination he found a tumor, the size of a hen's egg, in the left inguinal region. This could be forced back when he stood up, and disappeared spontaneously when he lay down. He consulted a physician, who diagnosed inguinal hernia and prescribed a truss. The truss gave relief until a year ago, when, upon coughing, he felt pain in the left inguinal region. About the same time he noticed that his urine was bloody, especially after he had walked. If he remained perfectly quiet, there was, as a rule, no blood in the urine. He had no pain referable to the bladder.

He consulted me and I prescribed for him, and after three or four weeks the hematuria disappeared and has not since returned.

About a year and a half ago the hernia commenced to increase in size and extended slowly down into the scrotum. The pain was very severe when he walked without his truss. In February, 1895, he ceased to wear the truss.

About five weeks ago the urinary difficulty became prominent. Just before urinating the tumor would become enlarged and tense, but would reduce in size and become soft after urination. He was obliged to urinate about every two hours; although there was still some swelling, he felt that the bladder was emptied at each urination.

At present the hernia increases in size prior to urination, and partly or entirely disappears after urination. The patient wears no truss, and, unless he walks too long,—an hour or more,—has no pain. When he stands too long, he has a sensation of weight in the scrotum, which passes away when he sits down. The hernia is irreducible, but otherwise the patient is in good health and does not want an operation.

III. The cases most rarely met with are those in which there is

no sac at all, the protruding portion of the bladder being entirely extra-peritoneal.

Symptoms.—The classic symptoms of hernia of the bladder, such as disturbance of urination, the patient having to press on the hernia to empty the bladder, or fluctuation, the hernial tumor increasing in size before urination, are met with only in very pronounced cases, where a large portion of the bladder enters the hernia. There is, of course, no difficulty in the diagnosis of cases of this kind.

In only a few of the cases encountered during operations for hernia vague subjective vesical symptoms had been observed, which caused suspicions of vesical hernia. In the majority of cases there are no vesical symptoms at all, since, when a vesical hernia is small, it gives no distinctive symptoms. A symptom of possible value is the pain and tenderness in the almost always irreducible hernia; but if this pain does not radiate downward in the direction of the bladder, it is of little value in distinguishing between the bladder and other contents of the hernia.

It is important to know the different aspects under which the bladder presents when unexpectedly encountered during the operation for hernia. In this connection the distribution of the adipose tissue surrounding the bladder is of interest. Sometimes there is no adipose tissue at all, and the bladder-wall then presents the well-known network of muscle-fibers. There is more frequently, however, a layer of adipose tissue surrounding the wall of the bladder. This adipose tissue may be a uniform, thin, smooth layer under the peritoneum, as in my third case, or a uniform layer covering the extraperitoneal portion of the bladder, or, as is most common, the adipose tissue forms irregular, smaller or larger, often multiple, lipomatous masses, such as are found everywhere near the peritoneum. In exceptional cases these lipomatous masses attain considerable size, but ordinarily they vary in size from a hazelnut to a walnut. Roux found an adipose mass, 6 to 7 cm. in diameter, not clad with peritoneum, and supposed it to be degenerated omentum. Lucas-Champonnière found an adipose mass below the hernial sac which he believed to be a second hernial sac. Monod¹⁶ found a large adipose mass, not resembling omentum, which was a lipoma covering the prolapsed corner of the bladder. Lanz¹³ found a mass the size of a pigeon's egg, looking like a subserous lipoma, on the posterior side of the hernial sac. Similar adipose masses were found in 11 out of the 27 cases tabulated by Lejars.¹⁴

In the cases where no lipomatous masses were found the bladder presented in various ways. Berger found a bluish-gray, dense nodule, the size of a hazelnut, adherent to the under surface of the sac. Lanz¹³ observed a bluish, transparent mass, 1 cm. long, resembling a duplication of the hernial sac. Walther found a voluminous cystic pouch coming out from the medial corner of the inguinal canal. Postempski¹⁷ describes a mass which looked like a thickened hernial sac, but upon dissection he saw the muscular fibers of the bladder, and Krönlein reports a case in which a similar appearance enabled him to make a diagnosis of hernia of the bladder.

In other cases, in the attempt to isolate the sac for ligation at the neck, there was found only a thickening of the neck on its inferior medial aspect, as in Boeckel's case, cited by Hedrich,⁸ in which this part of the sac was thick, soft, and flesh-like, and in which he recognized the muscle-fibers of the bladder and avoided opening it.

It will be seen that we cannot expect the diagnosis to be made before operating; in exceptional cases only, one or another vesical symptom leads to a suspicion of vesical hernia. But a suspicion is in itself an advantage, as it calls attention to the bladder, and merely thinking of the bladder during the radical operation for hernia may prevent the operator from wounding it. Thus, for instance, Boeckel, Lanz, and myself, after wounding the bladder in our first cases, avoided this accident in our subsequent cases by simply bearing the bladder in mind when some unusual appearance presented in the hernia.

We have two methods of positive diagnosis during operation: First, injection into the vesical hernia by filling it from the bladder; and, second, introduction of a sound through the extrahernial into the intrahernial portion of the bladder.

Injection of the intrahernial portion of the bladder is an excellent means of diagnosis when it succeeds. In most of the cases, however, the ring is so narrow that the fluid from the bladder does not enter the hernial portion. Monod¹⁶ suspected a hernia of the bladder before the operation, but injection proved negative at this time. Injection during the operation, when the conditions led the operator to think of the bladder, also proved negative until the ring had been divided, in Krönlein's, Boeckel's, and Monod's cases. Consequently filling the hernial portion of the bladder, to be proof positive, must be preceded by free division of the ring, and this can always be done safely in an upward direction.

A curved metal sound passed into the bladder, and from the bladder out into the hernial portion, has proved an excellent means of diagnosis in the cases operated upon by Roth,¹⁹ Kummer,¹² and myself. For this procedure, however, it is also necessary to have a wide ring or to divide the ring, as in Roth's and my own case. Sometimes the end of the sound can be passed out into or through the canal, as in my case of femoral hernia. If the sound cannot extend as far as this, a finger passed down through the widened ring will meet the tip of the sound in the bladder, and the hernial portion of the bladder, when made movable, can be pushed down over the sound, as in my case of inguinal hernia.

I can see no objection to dividing the ring sufficiently for the introduction of a finger for diagnostic purposes, since this division has, as a rule, to be made in order to enable the operator to reduce the prolapsed bladder, and since the divided ring can easily be reunited after reduction of the hernia. Lanz¹³ is hardly right when he argues against this procedure, which he calls laparoherniotomy, as a dangerous addition to the operation, and his argument is incomplete when it is remembered that in all operations for hernia we do not hesitate to divide the ring sufficiently for exploration and operation to secure a normal con-

dition of the reduced contents of the hernia, division of adherent omentum, or loosening of intestinal adhesions to the intraperitoneal portion of the ring.

Digital exploration through a wide or divided ring, as practised by Walthers, will also help in the diagnosis of hernia of the bladder when it is seen that a mass or sac found in the hernia leads down behind the symphysis toward the bladder, but is, of course, less positive than when combined with examination with the sound. But even examination with the sound has sometimes proved negative, as in Postempski's¹⁷ case, in which he recognized the muscular fibers of the bladder, introduced a sound, found that he could not pass it up into the suspected mass, concluded that his suspicion was unfounded, and opened into the bladder.

In large vesical hernias with typical symptoms the diagnosis is, of course, not very difficult, but such cases are comparatively rare, as in 65 operations collected by Siegel²¹ in which vesical hernia was found, diagnosis prior to operation was made in only 12 cases.

The bladder has been frequently wounded during the radical operation for hernia. Lejars,¹⁴ in 1893, collected 20 cases, in 15 of which the wound in the bladder was immediately recognized; in the remaining 5 cases the wound of the bladder was not recognized until later. Besides the cases of Israel, Berger, Guelliot, Aue, and Jungengel, cited by Lejars, there are on record the cases of Leszinsky¹⁵ and Habs,⁹ and Reverdin¹⁸ found, on microscopic examination of the sac by Zahn, that the sac was partly bladder. In these cases the diagnosis is either made when the urine shows in the dressings or when tenesmus and hematuria occur.

It is, of course, extremely difficult to make the diagnosis in cases of vesical hernia with no sac. Thus Aue, in a case of femoral hernia, found no peritoneal covering, and supposed the bladder to be the hernial sac. He then made an incision above Poupart's ligament into the abdominal cavity, and attempted to make digital exploration of the sac, but found no opening. Jungengel had a similar experience, in which he took the bladder for an empty sac, ligated it, and cut it off without seeing any other sac. He must have opened a fold of peritoneum, as when reopening of the wound became necessary two days later, on account of hematuria and tenesmus of the bladder, a large amount of blood was found in the peritoneal cavity.

The danger of wounding the bladder is not so great as would naturally be expected. Six patients out of the 20 cases of bladder wounds collected by Lejars¹⁴ died, but the cause of death was almost invariably independent of the wound of the bladder, such as strangulation of the intestine, hemorrhage, pneumonia, embolism, etc. In the majority of the cases in which the bladder is healthy the wound heals, usually after a temporary fistula has existed for a variable time—weeks or months. The fistula has also healed in cases in which the bladder was not recognized. When the bladder wound was recognized and sutured, a tem-

porary fistula usually formed; Lejars found primary union in only 2 out of 9 cases of primary suture.

The prognosis of femoral hernias, of which Guépin,⁶ in 1893, collected 8, and to which I have added 2, was as follows: With the exception of Livret's case, which was not operated upon, all were discovered accidentally during the operation. The bladder was opened in 5 cases—those of Habs, Güterbock, Lanz (first case), Aue, and my first case. It was not opened in Cooper's, Lanz's second case, Schoonen's, and my second case. The wound in the bladder healed without a fistula in Lanz's and in my case. A temporary fistula formed in the cases of Habs and Aue, and only one of the patients, namely, Güterbock's, died, not at all from the wound in the bladder, but from an entirely independent perforation of a diseased intestine.

Treatment.—Hernias of the bladder which have given symptoms sufficiently distinct for certain diagnosis have been treated by replacement when this was possible, by being left alone as not being imminently dangerous to life, or, finally, have been operated upon. Early operation, when the diagnosis can be made, is advocated, since the vesical hernia is likely in the course of time to cause cystitis, and finally ascending pyelitis and nephritis. Thus Justo¹¹ (cited by Lejars) operated upon a large vesical hernia in a case in which the patient had himself made the diagnosis from the difficulty in urination three weeks after symptoms of strangulation had disappeared by taxis. He excised the sacculated portion of the bladder, 6 cm. in length, and sutured the wound in the bladder, which was 8 or 9 cm. long.

In a great majority of cases, however, an operation on the bladder is not planned, as no diagnosis has been made. The question as to the treatment of the bladder accidentally met with during operations for hernia is twofold: First, how to treat the bladder when it is recognized and not yet opened, and, second, what to do when the bladder is accidentally opened.

When hernia of the bladder is recognized during operation the operator will, as a rule, avoid opening into the bladder and limit himself to replacement of the prolapsed portion within the abdomen. But here the question has been brought up, as, for instance, by Monod¹⁶ and Délagenière,³ whether it is not better to extirpate the prolapsed portion of the bladder, as it often forms a diverticulum with weakened muscular walls and covering lipomatous masses. They fear that a diverticulum of this kind may cause, by reason of incomplete evacuation, retention, cystitis, and even formation of calculi, and, as accidental wounds in healthy bladders have healed so readily, they consider extirpation of the hernia as possibly safer for the patient. It is not advisable to formulate a general rule in this respect, because most of the smaller vesical hernias do not have the shape of a diverticulum with a narrow neck, but when the hernia is loosened we find the bladder-wall at this point drawn out to some extent, but the communication at the base is usually broader than the middle of the prolapsed portion. Therefore, in the

majority of cases the prolapsed portion of the bladder when reduced will not be the seat of retention.

Extirpation of the vesical hernia will always prolong the operation, and inasmuch as primary union seldom takes place, it necessitates so much effective deep drainage of the bladder wound that it must of necessity interfere with the course of the modern radical operation. When the wound in the bladder has to be drained, the successive layers of the canal cannot be closed, as in Bassini's operation. Thus the result of the radical operation for hernia, namely, the prevention of relapse, is to some extent jeopardized. Furthermore, the necessity of either a permanent catheter in the bladder or, at all events, frequent catheterization, is a disagreeable and possibly dangerous element in the after-treatment, and, finally, the urinary fistula, although only temporary, takes weeks or months to close.

On the other hand, if the prolapsed bladder is reduced without opening, there is no interference with the typical short aseptic course of the radical operation for hernia. Monod,¹⁶ in his own case, having made the diagnosis during the operation, replaced the unopened bladder. Lanz¹³ also did this in his second case, but he deliberated upon the advisability of making the diagnosis positive by opening into the bladder. The other operators who have made the diagnosis during the operation before opening into the bladder have rejoiced at being able to replace the bladder without wounding it.

When the bladder has been opened, there is little controversy as to the treatment of the wound. A double or triple row of extra-mucous sutures should be applied. When the wall of the bladder at the border of the wound is torn or very thin, some of the operators have excised a portion of the lipomatous area, so as to be able to apply the sutures in a thicker and more nearly normal bladder-wall. This is a very rational procedure, inasmuch as experience has taught us that even careful primary suture of the bladder-wall does not always secure primary union, but that slight leakage follows in the majority of cases. It therefore seems advisable to do as I did in my first case, namely, to anchor the wound of the bladder by a temporary suture to the deepest part of the ring. If, as happened in my case, no leakage takes place, the anchoring suture has done no harm; if leakage takes place, it may lead the urine out through the wound and prevent it from entering the peritoneal cavity.

BIBLIOGRAPHY

1. Aue: *Centralbl. f. Chir.*, 1891, vol. xviii, p. 227.
2. Bourbon, Henri: *Thèse de Paris*, 1892.
3. Delagènière, H. (and C. Monod): "Contribution à l'étude de la cystocèle inguinale," *Revue de Chirurgie*, 1889, vol. ix, p. 701.
4. Diffenbach: *Operative Chirurgie*, 1848, vol. ii, p. 632.
5. Guelliot: *Revue de Chirurgie*, 1889, vol. xiii.
6. Guépin: "Cystocèle Crurale," *ibid.*, 1893, p. 646.
7. Güterbock: "Zur Kenntniss der Blasenhernien," *Deut. Zeitschr. f. Chir.*, 1891, vol. xxxii, p. 296.
8. Hedrich: *Gazette Médicale de Strasbourg*, 1890.
9. Habs, Rudolph: "Bericht über 200 Herniotomien," *Deut. Zeitschr. f. Chir.*, vol. xxxii.

10. Israel (Feilchenfeldt): Berlin. klin. Wochenschr., 1887, vol. xxiv, p. 40.
11. Justo: *Vide* No. 14.
12. Kummer: Revue Médicale de la Suisse Romande, 1892.
13. Lanz, Otto: "Ueber crurale Blasenhernie," Berlin. klin. Wochenschr., 1892, vol. xxix, p. 741.
14. Lejars: "Hernie inguinale simultanée de la trompe utérine et de la vessie. Les hernies de la trompe. Les Lésions opératoires de la vessie herniée," Revue de Chirurgie, 1893, vol. xiii, p. 12.
15. Leszinsky: Centralbl. f. Chir., 1891, vol. xviii, p. 448.
16. Monod, C., and H. Delagénère: *Vide* No. 3.
17. Postempski: La Riforma Medica, 1891.
18. Reverdin: Revue Médicale de la Suisse Romande, 1890, p. 698.
19. Roth: Virchow-Hirsch's Jahresbericht, 1892, vol. ii, p. 227.
20. Schoonen: Revue de Chirurgie, 1893, vol. xiii, p. 331.
21. Siegel, Ernst: Zur Casuistik der Blasenhernien, Inaugural Dissertation, Würzburg, 1891.
22. Thiriar: Virchow-Hirsch's Jahresbericht, 1891, vol. ii, p. 297.
p. 411.
23. Walther (operator): Virchow-Hirsch's Jahresbericht, 1892, vol. ii, p. 227.

CONSERVATIVE OPERATIVE TREATMENT OF SACCULATED KIDNEY—CYSTO- NEPHROSIS*

DILATATION of the urinary passages (cystonephrosis, Küster) above a stenosis or occlusion presents remarkable variations according to the character of the pathologic conditions which cause the retention of urine above it.

A sudden, complete, acute occlusion of a ureter, as shown by Cohnheim and others experimentally by ligation of the ureter in animals, is followed by only a temporary, medium degree of dilatation above, of the ureter, pelvis, and calices, often followed by absorption of the urine, atrophy of the kidney, and final transformation of the latter into a small mass of cicatricial tissue, with or without small cysts, from which a dilated, normal-sized, atrophic, or even obliterated ureter leads down to the original place of occlusion.

It requires a slowly developing, incomplete, or intermittent obstruction for the development of a permanent dilatation of the kidney, a hydronephrosis containing an aseptic fluid, or a pyonephrosis containing an infected fluid—pus.

Incomplete obstructions caused by pressure on the ureter from without by many different pathologic conditions, or by obstruction within from stones, valves, or strictures, do not come within the scope of this paper.

Obstruction by bending and valve formation at the pelvic end of the ureter, or oblique insertion of the latter on or in a dilated pelvis, has been studied carefully by Simon,† and since his time by many investigators, Tuffier, Landau, Terrier, Fenger, and others, so that this condition is comparatively well understood at the present time, and the surgical means of treatment in a fair way of development.‡

Obstruction above the ureter—that is, in or above the pelvis of the kidney, with the exception of those cases in which stones in the pelvis or calices cause retention and dilatation above—has not been studied, and little attention has been paid to this condition, in all probability because the kidney in these cases has been removed, either by primary nephrectomy or, when a permanent urinary fistula has followed nephrotomy, by secondary nephrectomy at an earlier or later period.

The dawning conservatism in the surgery of the kidney has naturally

* *Annals of Surgery*, 1896, vol. xxxiii, p. 637.

† Simon: *Chirurgie der Nieren*, 1876, vol. ii.

‡ Fenger: *Jour. Amer. Med. Assoc.*, 1894, vol. xxii, p. 335.

led to the attempt to save all the "noble tissue of the kidney," as Tuffier terms it, that may still be of use to the organism. It is consequently important to study these obstructions in detail, with the hope that we may be able to recognize and, perhaps, find means to remedy the stenosis, instead of sacrificing the organ.

I have found that a non-calculous obstruction may take place in or rather above the pelvis, in a similar manner to that which occurs at the pelvic end of the ureter, and for this reason I shall call attention to some points in the pathology of the latter condition.

Valve formation at the pelvic end of the ureter is always combined with bending or oblique insertion of the ureter in the dilated pelvis, and often with stenosis or stricture of that portion of the ureter which is located in or on the pelvic wall.

I shall first consider the bending or oblique insertion of a non-stenosed ureter. How does this condition develop?

Cohnheim* regards it as a congenital anomaly—"Bildungsfehler."

Landau† and Terrier believe that the bending is originally caused by descent of a movable kidney. Landau has seen, on the cadaver, that the ureter bends at its pelvic orifice when the kidney is pulled down, because the ureter at this point is held against the posterior abdominal wall by strong connective tissue and does not follow the moving kidney. He further states that hydronephrosis with patent ureter is more frequently seen in women and on the right side, consequently, under the circumstances, most favorable for a preëxisting movable kidney.

Tuffier‡ was the first to establish conclusively, by a series of beautiful experiments and by careful clinical observations, the exact causal relation between floating kidney and cystonephrosis. He found that when a kidney was made movable, bending of the ureter would take place in more than one-half of the cases, usually a few centimeters below the pelvis, the bend being either angular or sigmoid; this would give rise to gradual obstruction and dilatation above the bend. The cystonephrosis is at first remittent as long as the bend can be straightened, but later on, as shown in the clinical observations, becomes permanent.

The results of these experiments correspond so well with the clinical manifestations of intermittent hydronephrosis that Tuffier considers nephrorrhaphy sufficient to establish a cure in the majority of these cases. This opinion is based upon nine operations, all of which were successful. In all these cases the kidney was movable.

Simon§ believes that temporary obstruction from any cause may produce sufficient asymmetric dilatation of the renal pelvis to give rise to twisting of the kidney on its longitudinal axis, leading to bending, oblique insertion, and valve formation.

* Cohnheim: Allgemeine Pathologie, vol. ii, p. 403.

† Landau: Berlin. klin. Wochenschr., 1888, vol. xxv, p. 366.

‡ It is self-evident that nephrorrhaphy can be useful only when the bending and valve formation caused by the mobility of the kidney are not complicated by stenosis, and it may be difficult to be sure of this condition without opening the pelvis or ureter.

§ Simon: *Op. cit.*

Küster* considers the primary cause to be pyelitis; the inflammation causes swelling of the mucous membrane in the ureter and pelvis, the swelling causing relative stenosis and increased pressure from the urine above. This pressure causes prolapse, invagination, or folding of the movable mucosa, at or above the pelvic orifice, down against or into the narrower ureter, and thus produces an effective, even if only temporary, obstruction.

Israel,† reported by Rosenstein, takes issue with Küster, and states that oblique insertion and valve formation are often found in perfectly aseptic hydronephroses where pyelitis has not previously existed (Landau and others).

All the opinions which have been cited above undoubtedly have their legitimate place and part in the causation of cystonephrosis.

I think that Simon is correct in laying greatest stress upon the asymmetric dilatation of the pelvis caused by temporary obstruction of whatever origin. Thus a temporary pyelitis (Küster) may lead to a moderate pyonephrosis, which is made permanent and progressive by subsequent valve formation. Furthermore, a movable kidney (Tuffier, Landau, and Terrier) may lead to bending of the ureter, causing a temporary obstruction, followed by asymmetric dilatation of the pelvis and oblique insertion, and this condition subsequently leads to a progressive aseptic hydronephrosis.

My reason for considering the asymmetric dilatation caused by slight temporary obstruction as the main factor in the development of valve formation is that I have found that temporary obstruction causing valve formation above the pelvis was followed in a case of pyelitis by a septic cystonephrosis (pyonephrosis), and that in another case, after compression of a ureter from without by a perityphlitic exudate, an aseptic cystonephrosis (hydronephrosis) followed.

I will illustrate the asymmetric dilatation above referred to by the following figure (Fig. 109), which shows unilateral, asymmetric dilatation of a canal or tube. The dotted lines a^1 to a^5 represent the increasing dilatation of one side of the wall of the ureter, b . Pressure from the contents in the dilated portion will act upon the wall of the tube at d , and will press the upper free end c over against the opposite wall at e^1 . Thus it is evident that, upon a certain degree of pressure from fluid in the dilated space, this unilateral dilatation will result in closure of the tube.

The fact that the ureter is ordinarily a narrower tube than the pelvis is immaterial—it even may facilitate the oblique insertion from unilateral dilatation of the pelvis.

In considering occlusion above the pelvis, it is well to remember the variations in the upper end of the ureter, as pointed out by Hyrtl.‡ In the first variety there is no pelvis, but the ureter divides into two

* Küster: "Ueber die Sackniere—Cystonephrosis," Deut. med. Wochenschr., 1888, vol. xiv, p. 369.

† Israel: Berlin. klin. Wochenschr., 1888, vol. xxv, p. 941.

‡ Hyrtl, cited from Henle's Handbuch der systematischen Anatomie.

branches without dilatation at the point of division, each branch having a caliber a little larger than that of the ureter. In the second variety there is a pelvis—that is, a funnel-shaped dilatation at the point of division. The upper portion is the smaller, and terminates in three short calices; the lower and more voluminous portion terminates in four or five calices. In the third variety there is only half a pelvis—that is, the lower branch divides and is funnel-shaped, forming a narrow pelvis which terminates in one, two, or three short calices, while the upper is not dilated and extends to the upper portion of the kidney as a continuation of the ureter. The ureter not uncommonly divides far below the kidney, between the kidney and the bladder; sometimes there is no division at all, and two separate ureters enter the bladder.

Unilateral dilatation and valve formation may take place in any canal in the body,—biliary passages, esophagus, intestinal tract,—and inasmuch as not only each branch of the ureter, but also the neck of each of the calices, is a canal, any of these may become the seat of this anomaly. If one of the two main branches of the ureter becomes the seat, retention occurs in the corresponding territory—that is, in the upper or lower half of the kidney. As the branch to the upper portion of the kidney runs in a straight direction, while the branch to the lower portion goes off at a right angle, the latter portion will probably be more liable to this condition, and, in fact, in both of my cases and in Rayer's obstruction from stone and Israel's—4 cases in all—the lower branch was involved. I have not seen or found in the literature any instance of this anomaly in the upper branch. When, on the other hand, the unilateral dilatation begins at the neck of a single calyx, the retention will be limited to the territory of this calyx. It will thus be seen that valve formation takes place independent of any rotatory movement of a dilating kidney (Simon), and that unilateral dilatation is the only condition necessary to this development.

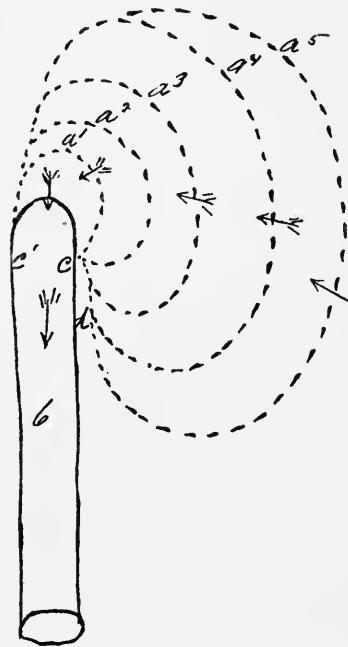


Fig. 109.—Causation of asymmetric dilatation of a canal or tube (diagrammatic).

While valve formation and retention in one of the branches of the ureter are probably very rare,—as partial or local hydronephrosis is very rare, 7 cases only,—valve formation and retention at the neck of a single calyx are, I believe, relatively common.

In Rayer's Atlas* a number of kidneys with this condition are illus-

* Rayer, P.: *Traité des Maladies des Reins*, Paris, 1837.

trated, and in my case of pyonephrosis I found not less than three calices in this condition.

Fig. 110 illustrates schematically unilateral dilatation and valve formation, at *a*, in the lower branch of the ureter, where the free end of the valve at *a* is pushed over to *a*¹, and dilatation of a single calyx at *b*, where the end of the valve at *b* is pushed over to *b*¹, causing occlusion.

Dilatation of one-half of the kidney, local or partial cystonephrosis, may thus be caused by gradual occlusion of the lower branch of the ureter in the hilus of the kidney (Rayer, 1 case; Israel, 1 case; Fenger, 2 cases), or it may be caused by occlusion of one of the divisions of an

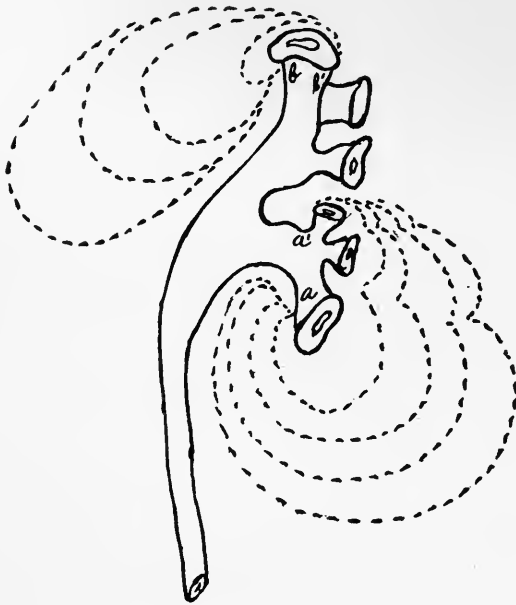


Fig. 110.—Development of unilateral dilatation and valve formation of the lower branch of the ureter and of a calyx (diagrammatic).

anomalous double ureter, as in 2 cases described by Heller* and in 1 described by Valter.†

The first case on record of valve formation in the lower branch of a ureter causing hydronephrosis was observed by me in 1872, when I was prosector in the Communchospital in Copenhagen.‡

The patient was a man of twenty who had, in August, 1872, an attack of perityphlitis, or what is now known as appendicitis, followed several months later by a fluctuating swelling, the size of an orange, in the region of the right kidney. This dilatation was

* Heller: Deut. Arch. f. klin. Med., 1869, vol. v, p. 267; *ibid.*, vol. vi, p. 276.

† Valter, cited from Heller.

‡ Fenger: "Om den partielle Hydronefrose, oplyst ved et Sygdomstilfælde," Nordiskt Medicinskt Arkiv, 1872, Bd. v.

intermittent, as it would disappear suddenly and reappear a few weeks later. Besides this tumor, another swelling gradually developed above and below Poupart's ligament, and hectic fever set in. When the patient entered the hospital, two distinct fluctuating swellings were discovered, one up under the liver and the other in the iliac fossa, in contact with each other, but with a distinct groove between them.

Exploratory aspiration of the upper tumor evacuated 2000 c.c. of urine, which had a specific gravity of 1007, contained 0.4 per cent. of urea and no uric acid. The upper tumor disappeared after puncture. Five days later the lower tumor was aspirated and 500 c.c. of fetid pus evacuated. The patient died two weeks later of pyemia.

The autopsy revealed septic infarctions and abscesses in both lungs, a large perityphlitic abscess around the cecum and lower ileum, extending through the iliac fossa

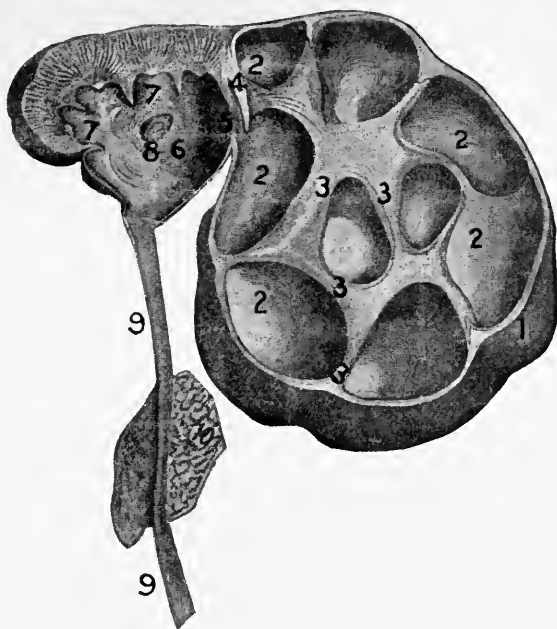


Fig. 111.—Vertical section through a right hydronephrosis with valve formation, and through kidney and ureter (one-half normal size): 1, Hydronephrotic sac; 2, cavities of dilated calices surrounded by—3, semilunar partition walls, one of which forms 4, the valve which covers from below and closes 5, the opening up into 6, the somewhat dilated upper branch of the ureter—that is, the pelvis of the upper two-thirds of the kidney; 7, calices; 8, entrance to a calyx from the pelvis; 9, ureter somewhat narrowed or compressed in its course through 10, the perityphlitic abscess.

down upon the femur. The patient consequently died from pyemia, following what would now be called appendicitis. The left kidney, ureter, and the bladder were normal.

The right ureter passed through the perityphlitic abscess and was somewhat narrowed in this territory, but still admitted a grooved director. Pressure on the upper half of the kidney and the somewhat dilated pelvis caused urine to pass without difficulty down through the ureter. Pressure, however, on the hydronephrotic sac of the lower half of the kidney did not result in the passage of a drop of fluid. The ureter above the perityphlitic abscess was slightly dilated, and led up to a pelvis dilated to the size of a hen's egg. This pelvis belonged to the upper two-thirds of the kidney. In this part of the kidney the kidney tissue was slightly compressed, as the papillae were somewhat flattened and the pyramids shorter and broader than normal, while the cortical substance was

of normal thickness. The kidney tissue in this locality was healthy, with the exception of two septic infarctions the size of peas.

The lower third of the kidney was occupied by a large hydronephrotic tumor, a thin-walled multilocular sac the size of a child's head, which contained 750 c.c. of light-yellow, clear fluid. On its posterior wall was the puncture-opening surrounded by ecchymoses, and close to this point was a fresh coagulum the size of a walnut. The upper, posterior portion of the sac, which was in connection with the kidney, showed a round opening, 1 cm. in diameter, leading up into the pelvis of the upper two-thirds of the kidney. This opening was covered by a valve 5 cm. broad and $1\frac{1}{2}$ cm. high, which hung over the opening like an upper eyelid, and closed it when the sac was filled with fluid. When, on the other hand, fluid was injected into the pelvis through the ureter, it opened the valve and opened and filled the hydronephrotic sac. The valve was semilunar, and was formed by the partition wall between two calices. The inner wall of the sac was smooth, and showed an inner layer of atrophic kidney tissue $\frac{1}{2}$ to 1 mm. in thickness, in which only a few uriniferous tubules and glomeruli were visible upon microscopic examination. The outer layer was 2 to 3 mm. thick, and was composed of firm connective tissue.

It is evident that the valve formation in this case, which was located in the lower branch of the ureter, had for its primary cause the incomplete and temporary compression of the ureter by the perityphlitic abscess. This led to moderate dilatation of the ureter and of both of its branches. The valve formation in the lower branch then followed as a secondary effect, and this gave rise to a gradually increasing intermittent hydronephrosis of the corresponding lower third of the kidney. This hydronephrosis remained uninfected despite the pyemia, because there was no preëxisting infection of the mucosa of the urinary tract.

That an entirely similar valve formation may take place from temporary obstruction caused by pyelitis, which may lead to a similar partial cystonephrosis, but, as we would naturally expect, with infection of the contents and consequent formation of a pyonephrosis, is well illustrated in the following case, in which valve formation occurred in all the three places which I have pointed out above as the seat of this condition, namely, the ureteral end of the pelvis, one of the two branches of the ureter (in this case again the lower branch), and at the necks of the calices, in one of which the occlusion was complete.

CASE I.—*Synopsis.*—*Gonorrhea, May 29, 1893, followed by posterior urethritis. Renal colic on right side, November 7th. Tumor in right kidney, November 20th. No colic from December 7th to March 4, 1894. Colic from March 8th to 11th; large tumor; high fever. Lumbar nephrotomy March 11th. Three weeks later, about 250 small, round stones, the size of shot, passed through the fistula; complete obstruction of ureter from right kidney for eight days. Ureter then open for ten days, proved by injection of pyoktanin. March 30th, ureter again closed; lumbar renal fistula discharges 30 ounces in the twenty-four hours. September 16th, operation for oblique implantation and stricture of pelvic end of ureter; persistence of urinary fistula secreting 25 ounces in twenty-four hours. January 22, 1895, sudden attack of colic from pyelitis in left kidney, lasting for two weeks. April 13th, operation for sacculated right kidney; bisection of kidney. During the summer of 1895 one-eighth of the urine passed through ureter, seven-eighths through the lumbar fistula. August 17th, operation for reunion of bisected kidney. September 17th, three-fourths of the urine passed into the bladder. November 30, 1895, fistula closed. Fistula reopened January 5, 1896, and finally closed January 15th.*

Mr. D'O. H., a medical student, twenty-one years of age, consulted me on June

22, 1894. Family history negative; no tuberculosis in family. Patient had the ordinary diseases of childhood.

On May 29, 1893, he contracted gonorrhea, which ran a somewhat typical course. A month later, as a result of excessive exercise, intemperance, and neglect, he suffered intense pain of a spasmodic character at the neck of the bladder on micturition. This was diagnosed as inflammation of the neck of the bladder, and persisted until August. From this time on there was no pain in the bladder or on micturition, but a slight discharge from the urethra continued until November 10th.

On November 7th, while in Philadelphia pursuing his studies, he had a sudden severe attack of right renal colic which lasted seven hours. Examination of the urine at this time revealed marked hematuria, a thick, reddish sediment, and a large amount of pus. Four days later he was removed to Presbyterian Hospital, where he remained under treatment for four weeks, during which time he had recurrent attacks of renal colic lasting from three to ten hours every other day. The hematuria disappeared after five days, but the urine contained large amounts of pus, varying from $\frac{1}{2}$ ounce to 2 ounces to the pint of urine, phosphates in abundance, no uric acid, no casts, no sugar.

November 20th the patient consulted Professor Martin, who could detect no marked tumor in the region of the kidney, but considered that there was probably a calculus impacted in the ureter and advised patient to go home, rest, and adhere strictly to diet and flushing. At this time he was emaciated, anemic, and had sustained a diminution in weight from 148 to 130 pounds.

The patient then returned to his home in Milwaukee and placed himself under the care of Dr. I. Mendel. Under enforced rest and rigid diet the pus in the urine slightly decreased during the next four weeks. He then had a severe diarrhea which persisted for six weeks, whereby his weight was reduced to 120 pounds, and he was in a wretched condition of body and mind.

On February 1, 1894, he returned to Philadelphia and entered the Presbyterian Hospital, in the service of Drs. Musser and Martin. He steadily improved, gained in strength and weight, but the pus in the urine increased in amount.

March 8th he had a severe attack of renal colic, which persisted for three days. The patient suffered intense pain; temperature, 101° to 104° F.; pulse, 110 to 140; had a large, hard tumor on the right side.

On March 11th Dr. Martin made a lumbar nephrotomy, with the idea of removing the kidney if it should prove to be tuberculous, and of securing drainage through the fistula if tuberculosis did not exist. The operation occupied twelve minutes. The lower two-thirds of the kidney was found to be dilated, and the large sac contained about two pints of urine and pus. The upper third of the kidney contained good secreting tissue. No calculi were found; no tuberculosis. The patient's condition did not warrant prolonged manipulation or search for the ureter.

For the first eight days no urine passed from the right kidney to the bladder, but for ten days thereafter the right ureter was patent, as was proved by the presence of pyoktanin, which had been injected into the fistula, in urine passed by way of the bladder. The ureter then closed, and its patency could not be reestablished. Three weeks after the operation a large number of small, well-formed calculi, about the size of No. 6 shot, aggregating about 250, were passed through the fistula. The patient wore a silver urinal and passed about 30 ounces of urine through the bladder in the twenty-four hours.

On June 22d the patient came to Chicago, and in August I examined him, and he entered Passavant Memorial Hospital preparatory to operation for obstruction of the right ureter, presumably from calculus at the pelvic orifice.

First Operation.—September 17th I operated in the following manner: Ether was administered by Dr. S. C. Stanton. The granulation tissue at the fistulous opening was removed with the sharp spoon. An incision was then made in the lumbar region through

the fistula downward and forward through the skin, fascia, abdominal muscles, quadratus lumborum, and transversalis fascia. The perirenal fat which presented in the wound was separated by forceps from the anterior and inferior surface of the kidney, which was thus laid bare. The incision was prolonged downward 2 inches. The surface of the kidney was normal in color; the kidney enlarged and lobulated. The adhesions were slight and were easily broken up. The pelvis was now laid bare and found to be dilated. Search for the ureter was now made, and it was recognized below its pelvic origin. The pulsation of the renal artery could be felt in front of the ureter. The ureter was now exposed for about $1\frac{1}{2}$ inches from the pelvis. An aspirator needle was introduced into the dilated pelvis of the kidney, and thin, bloody fluid withdrawn. The pelvis was now opened on its posterior surface, the contained fluid evacuated, the wound thoroughly flushed with warm, sterilized water, and sponged dry.

A futile attempt was made to locate the pelvic orifice of the ureter from the pelvis. A small depression, however, was noticed, which was later shown to indicate the point of entrance.

A longitudinal incision was now made in the ureter, about 1 inch from the pelvis, below the stricture; a flexible sound introduced through this incision passed easily down into the bladder. The lower portion of the ureter was somewhat contracted from disuse. A silver uterine probe was next introduced through the incision and passed upward; the location of the stricture was thus found to be at the point where the ureter emerges to form the pelvis. With considerable difficulty a fine silver probe could now be pushed through the stricture into the pelvis. With the probe as a director a longitudinal incision was now made through the stenosed portion of the ureter between the two openings. The upper and lower borders of the wound were brought together by silk sutures, thus folding the ureter upon the pelvis, as described in a previous article.

The small, longitudinal opening in the ureter was left unsutured.

Before closing the wound in the pelvis an incision was made through the convex outer border of the kidney into the dilated calices, and the upper end of a flexible bougie, which had been previously passed down into the ureter through the opening in the pelvis, was passed up from the pelvis through the convex surface of the kidney and out of the lumbar wound, to remain twenty-four hours, and then be removed. A piece of kidney tissue was also removed for examination. Hemorrhage was controlled by the Paquelin cautery.

Early in the operation, while a digital exploration of the old sinus was being made, a small piece of rubber drainage-tube, left in at the time of the first operation and evidently forgotten, was removed.

The kidney was thoroughly explored for stones, but only one small calculus, 4 mm. in diameter, was found and removed.

Drainage-tubes were inserted in both openings on the convex surface of the kidney, and one in the bottom of the wound, the perirenal space, and around these gauze was loosely packed. The external wound was closed by uniting the transversalis and internal oblique, and then the external oblique muscle by interrupted silk sutures, and then the skin and superficial fascia by a continuous silk suture. Time of operation, two and one-quarter hours.

Microscopic examination of the piece of kidney tissue cut out through the entire thickness of the convex surface of the kidney to its inner surface shows the following: On the inner surface, nearest the calices, is a brim of young granulation tissue in which here and there a straight canal and a glomerulus are seen. This brim forms one-third of the thickness of the kidney wall, and terminates in a rather sharply defined line. The remaining two-thirds of the kidney wall from this point to the convex surface shows almost perfectly healthy kidney tissue.

The epithelium in the straight and convoluted tubules is everywhere present, and

almost normal. A somewhat granular appearance is present, which is probably due to the preparation of the specimen, as another specimen shows normal epithelium. The glomeruli are mostly normal, and only here and there is seen a small island of embryonal cells (interstitial nephritis). This would tend to show that at least two-thirds of the kidney tissue is available for secretory function, and this corresponds well with the 25 ounces of urine excreted in the twenty-four hours through the lumbar fistula.

The patient made a good recovery from the operation, but the fistula persisted, and all the urine from the right kidney passed out through the lumbar wound. He returned to his home in Milwaukee, but made monthly visits to Chicago for examination by me and urinalysis by Dr. C. W. Purdy. Marked improvement in the size of the kidney and in the quality of the urine occurred. From 25 to 30 ounces of urine were passed through the fistula in the twenty-four hours.

On November 30th the patient had gained 30 pounds in weight, had no pain, passed through the fistula 25 to 35 ounces of urine, and through the bladder 18 to 20 ounces of urine daily. Pus was present in the urine, but in small amount only. The patient's general health was excellent. He had an enormous appetite, and, as he said, "would not know anything was the matter were it not for the fistula."

January 22, 1895, the patient had a sudden attack of colic on the left side, accompanied by hematuria and pyuria. This was entirely unexpected, as the left kidney had up to this time been regarded as healthy. This new development, of course, rendered extirpation of the right kidney out of the question. This attack lasted for two weeks. The patient came immediately to Chicago, and reentered the hospital. The symptoms yielded to therapeutic measures, and the patient's condition materially improved.

On March 19th Dr. Purdy made the following analysis of urine from the right and left kidney:

Right Kidney.—Color, milky; specific gravity, 1010; reaction, slightly acid; quantity in twenty-four hours, 25 ounces; urea, $2\frac{1}{2}$ grams per ounce; total urea, $494\frac{1}{2}$ grams; albumin, 6 per cent. bulk measure; sugar, absent; casts, none; pus, 1 per cent. bulk measure; blood, none; bacteria, none.

Left Kidney.—Color, normal; specific gravity, 1020; reaction, strongly acid; quantity in twenty-four hours, 43 ounces; urea, $11\frac{1}{2}$ grams per ounce; albumin, trace; sugar, absent; casts, none; pus, small amount; blood, none; bacteria, none.

Remarks Prior to my Second Operation.—I had seen at the time of the previous operation that the condition was one of sacculated kidney, and had opened three or four of the sacs, which varied in size from a walnut to that of a hen's egg, from the surface of the kidney. These sacs I found to be filled with pus, and in one of them I discovered a small calculus.

I had opened the slightly dilated pelvis from behind in order to look into it, but could neither see nor find the pelvic orifice of the ureter. I could see a small depression, but, as there was a very narrow stenosis, could not pass a probe down into the ureter.

I had opened the ureter by a longitudinal incision 1 inch below the pelvis, and passed a probe through this incision up to the pelvis, finding at the entrance a narrow stenosis—almost a complete occlusion; the lumen at this point was from $\frac{1}{2}$ to 1 mm. in diameter.

I had performed my plastic operation for stenosis as described in the Journal of the American Medical Association, March 10, 1894. I had left the small longitudinal opening in the ureter to heal without suture.

I had brought out an elastic bougie passed into the ureter through the opening in the pelvis, and out through an opening in the convex surface of the kidney, and this bougie remained *in situ* for two days.

After the operation blood, pus, and injection fluid passed into the bladder for a short time only; later on all the urine passed out through the renal fistula.

The lack of success of the operation may have been caused by the failure to make a sufficiently large opening at the pelvic entrance of the ureter. This failure may have been due to cicatricial contraction around the upper end of the ureter from connective-tissue masses surrounding the seat of the former incision in the pelvis and the stricture of the ureter, or to the fact that the sutures did not hold, and the opened stenosis of the ureter, together with the incision into the ureter through the stricture, hung down after the sutures gave way, and by retraction of the cicatrix the stricture formed again, as the folding of the ureter upon the pelvis would then, of course, have been again undone.

A second cause might have been in the kidney itself. The arrangements of the sacs with narrow entrance openings (see Fig. 112, *a*), often not wide enough to allow the passage of a finger or a urethral sound, and, in addition, valvular arrangements of the separation walls between the sacs, such as I described more than twenty years ago in a case of partial hydronephrosis.*

This condition, if the ureter was patent, would permit the urine and pus from the kidney below the valve to pass through the fistula, and only the urine and pus above the valve to pass down into the bladder. (See Fig. 113.)

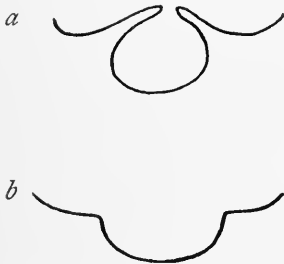


Fig. 112.—Shape of sac before and after division of partition wall (diagrammatic).

Plan of Operating.—In order to guard against insufficient communication between, and evacuation of, the sacs into the pelvis of the kidney, I proposed to open the narrow entrances to the sacs—that is, to transform the multilocular sacculated kidney into a unilocular sac with free evacuation into the pelvis of the kidney. This would have to be done from the convex surface of the kidney by opening the sacs one by one until all were transformed, so that a cross-section of each sac would show the opening of the sac to have a diameter equivalent to that of the sac at its center. In other words, to transform each sac into a hemisphere. (See Fig. 112, *b*.) This was especially necessary for the sacs situated in the lower third of the kidney, where, as I had previously found in an operation for stone in the kidney, the body of the sac is dependent from the lower end of the pelvis and the narrow entrance high up, the sac being flask-shaped. In the case referred to the sac contained stones small enough to pass out through the opening had the position of the sac allowed. The stones, however, remained in the

* Fenger: *Op. cit.*

sac because the patient was never inverted for any length of time. My plan was, therefore, to open all the dilated calices, even if it should prove necessary to bisect the kidney—that is, to divide it longitudinally into two halves down to or into the renal pelvis.

If the stenosis of the ureter at its pelvic orifice had reformed,—that is, if the stricture had contracted, or if valve formation from cicatricial, extra-ureteral contraction had taken place,—I proposed to repeat my former plastic operation for stricture or valve formation, or to resect the stricture and implant the unfolded upper end of the ureter in the pelvis by Küster's method.

The patient's symptoms for the previous six months appeared to me to indicate that the ureter was patent, although the patency might be imperfect, and that the localized hindrance to the exit of urine was in the kidney or the pelvis above the ureter.

Second Operation.—On April 13, 1895, I operated at the Passavant Memorial Hospital, in the presence of the doctors from the Polyclinic, and with the assistance of Drs. Brown, Brougham, and Bluthardt; Dr. Waters administered the ether. The patient was placed on the left side, with a cushion under the left loin. After the granulations around the fistula had been scraped off, an incision 5 inches long was made through the fistula and the old cicatrix down into the sacculated kidney. The kidney was loosened from the cicatrix and the abdominal muscles down along its posterior surface until the pelvis of the kidney was reached. I now searched for the ureter, but after half an hour or more was unable to find it. I therefore determined to first bisect the kidney down into the pelvis and search for the ureter from within the pelvis.

I now proceeded to bisect the kidney and operate upon the calices in the following manner: I first made a longitudinal incision from the opening at A, Fig. 113, downward and upward on the middle of the convex surface of the kidney. By so doing I opened a cavity whose wall was composed of friable kidney tissue, 3 or 4 mm. in thickness on the convexity of the sacs, and 8 to 10 mm. in thickness in the partition walls between the sacs, the wall becoming thinner again near the entrance to the sacs. This kidney tissue bled profusely, and there was abundant arterial hemorrhage from the vessels in the partition walls. The kidney tissue was seared, and the partition walls divided with the Paquelin cautery, which stopped the hemorrhage from the small vessels. The spurting from the larger arteries, however, was so violent that I was obliged to clamp with forceps and ligate many of the thicker partition walls step by step with catgut mass ligatures. The openings to some of the sacs were large, but others were so small as to permit the passage of my little finger-tip only.

After having thus divided partitions 1, 2, 3, 4, and 5, I believed that I had reached the pelvis, as I found a narrow opening at B, which I thought might lead down into the ureter; but I was unable to pass down either a silver probe or an elastic bougie. I now began a second search for the ureter from below the kidney. By blunt dissection I worked downward toward the outer wall of the renal pelvis and came upon the vermiform appendix extraperitoneally. The appendix was as thick as a lead-pencil. I finally found the ureter, and isolated it for 1 to 2 inches below the kidney. The pelvis was cone-shaped and was not much dilated. Upon making traction on the ureter I could detect no movement in what I had supposed from above to be the pelvis, nor could I pass a sound or bougie through the opening at B down into the ureter. This opening was so small that it would not permit the passage of the end of my little finger, but a probe passed down through it into a wider space below. I now dilated the opening with a large artery forceps until

I could pass my little finger down into the cavity, which was 1 inch deep in a medial direction and 2 inches long laterally and upward.

I then divided the partition walls on Kocher's sound with the Paquelin cautery and passed mass ligatures to control the hemorrhage from the arteries. The pelvis was now open. The wall was whitish, in contrast to the reddish wall of the calices. The mucous membrane on part of the wall was thickened and covered with small, flat, warty excrescences.

The opening into the ureter was visible, and the ureter patent. A silver probe and elastic bougies, Nos. 16 to 20, easily passed down into the bladder. This showed conclusively that the former operation for stricture of the ureter had been entirely successful so far as the reëstablishment of the patency of the ureter was concerned. I could now pass an olive-pointed bougie easily down into the ureter along the posterior and the two lateral walls of the pelvis, but on the anterior wall, corresponding to the band encountered in the previous operation, a transverse fold arrested the end of the bougie. Thus in order to make the entrance to the ureter still more funnel-shaped, I made a plastic operation—that is, incision with transverse union of the wound on the anterior and posterior borders of the ureteral opening. I now inserted an elastic bougie, No. 16, to remain for twenty-four hours.

After inserting a rubber drain surrounded by sterile gauze in the kidney I proceeded to close the wound. I partially sutured the wound on the convex surface of the kidney, leaving a large opening for drainage. I then packed gauze on the medial side below and on the lateral side of the kidney, united the divided muscles by buried catgut sutures, and finally united the external wound with silk.

Toward the end of the operation the pulse became weak, but was slow, and camphorated oil was twice injected.

The operation lasted two hours and a half. Considerable hemorrhage continued in spite of the Paquelin cautery and mass ligatures. In future, in a similar case, I should stop the hemorrhage by continuous suture of the wounds in the partition walls.

Four hours after the operation the patient was awake, the body warm, pulse 150, weak, nose cool.

Nine hours after the operation the patient was awake, could speak strongly and clearly, said he felt better and less weak than four hours previously. Pulse 150, weak, not much pain, excepting on vomiting, when he felt pain in the wound. Considerable bloody fluid soaked through the dressing onto the bed. The patient lay on his right side. I did not consider that he was losing too much blood, because the conjunctiva and lips were red, the feet cool, but he had only a sheet over them, and he was not restless. Whisky and milk were now injected into the rectum. The patient had not yet passed water. He had had a subcutaneous injection of strychnin. The shock was considerable and the hemorrhage profuse, the latter because the kidney tissue was healthy.

The cause of the passage of all or almost all of the urine through the fistula lay not in the ureter or the pelvis, but in the kidney itself, in the sacs with valvular arrangements of their partition walls and narrow openings into the sacs, and also in the valve formation in the lower branch of the ureter at B, Fig. 113. This caused much dilatation in the territory of the lower branch, due to valvular obstruction of this territory—namely,

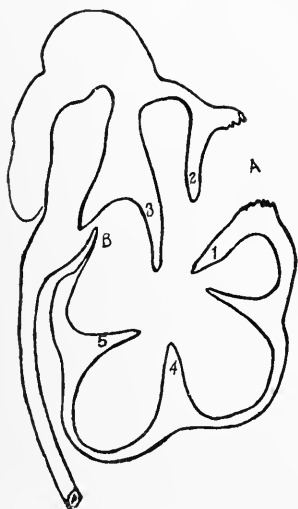


Fig. 113.—Sacculated kidney (Case I)
(diagrammatic).

the lower two-thirds of the kidney, while only slight dilatation of the territory of the upper branch was present, because this was dilated only from the stenosis in the ureter.

After-Treatment.—*April 14th:* The patient urinated once, passing 8 ounces of urine slightly colored with blood. Nausea still continued, and stimulant enemata were frequently repeated. The kidney was irrigated with boric-acid solution.

April 15th: During the night the patient experienced a strong desire to urinate, with a sensation along the ureter as if urine were passing into the bladder. He could not urinate, but 5 ounces of urine were withdrawn with a catheter. In the morning the patient passed 10 ounces of urine, and from this time on no bloody urine was passed. The dressings were saturated with slightly bloody urine. The permanent bougie was removed from the ureter, and one strip of gauze around the drainage-tube was removed.

April 16th: The patient complained of great soreness, and movements of the body were painful and difficult. All the gauze drains were removed; their removal was attended by excruciating pain. The wound was irrigated, and a light gauze packing introduced.

April 17th: Dressings saturated with urine and very offensive pus. The offensive discharge came entirely from the drainage-tube in the kidney. The wound was dressed again in the evening, and at this time and for the next two days the discharge of offensive pus was profuse.

April 20th: The discharge of pus was still profuse, but less offensive in odor. The drainage-tube in the pelvis and the stitches were removed. The patient felt stronger and the appetite increased.

The offensive odor emanating from the wound persisted until the time of the next operation, August 7th. The offensive odor and discharge were attributed to infection from the catgut sutures in the kidney.

Six weeks after the operation, in order to test the patency of the ureter, I introduced a small filiform elastic bougie through the lumbar fistula into the pelvis and down through the ureter into the bladder. This procedure I repeated every second or third day, allowing the sound to remain from half an hour to an hour, gradually increasing the size of the bougie until finally a No. 5 English olive-pointed bougie was used. After each dilatation, and sometimes from twenty-four to forty-eight hours thereafter, pus and urine passed through the ureter into the bladder. This systematic dilatation of the ureter was carried on for three months. At the end of this time about one-eighth of the urine from the right kidney passed down through the ureter and about seven-eighths was discharged from the lumbar wound and the sinuses which had formed along the line of incision in the lumbar region.

On August 7th Dr. Buffum examined a specimen of urine from the bladder, which was supposed to contain some of the urine from the right kidney, and made the following report:

Specific gravity, 1014; sediment, flocculent; albumin, trace; blood, a few red corpuscles; pus, large quantity; epithelium, a few columnar cells.

In a specimen of pus taken from the fistula at the same time Dr. Buffum found the *Bacillus pyocyaneus*. During this time the patient's condition was fairly good, considering his long residence in the hospital, the great discomfort and pain in the wound, and the depression incident upon the hot weather.

As there seemed little prospect of a change, I decided upon operating for the closure of the fistula by reunion of the bisected kidney, and for the division of any partition walls that might have been left at the time of the previous operation.

Third Operation.—On August 17th I operated in the following manner: The patient was anesthetized with A. C. E. mixture. The anesthesia was difficult, and the patient vomited during the operation. The granulations in the wall of the fistula were first scraped off, and an incision then made through the cicatrix into the kidney. Inspection

of the bisected kidney showed that three sacs containing pus and urine still remained. Two sacs were successively opened and divided with the Paquelin cautery, which was also employed to check the hemorrhage. Only one large vessel required ligation. A flexible bougie, No. 7 French, could now be passed down with some difficulty into the ureter.

In order to unite the bisected kidney the dense adhesions to the abdominal wall were separated. While thus isolating the organ a third sac was opened. This sac had evidently entirely closed, and the contained fluid was under considerable pressure, for when a small incision was made in its wall, a jet of pure urine spurted out, and foul-smelling pus afterward flowed slowly from the opening. After free division of the partition wall and thorough irrigation, the separation of the kidney from its adhesions was completed. The kidney was now united with fine catgut, with the exception of an opening $\frac{1}{2}$ cm. in diameter for an elastic bougie passed into the ureter to remain for twenty-four hours, and an opening for a small drainage-tube in the kidney.

The wound was closed and dressed in the usual manner. The operation lasted an hour and a half; the shock was severe. The patient had severe nausea, but no vomiting after the operation until the fourth day.

August 21st: Accumulation of mucus in the throat caused slight vomiting, which brought on a slight hemorrhage from the wound and caused the superficial stitches to tear out, and also, as I afterward discovered, caused the stitches on the convex surface of the kidney to tear out, leaving an anterior fistula which remained open until November 30th.

The gauze drain was removed at the time of the first dressing, and the bougie was withdrawn from the ureter at the same time. The wound was thoroughly irrigated with boric acid, as in the previous operation, and for the first two weeks and a half a considerable discharge of débris, urine, and offensive pus was brought out with the irrigating fluid. The offensive odor gradually decreased until, in the third week, it entirely disappeared. From this time on the irrigation showed a marked decrease in pus, and at the end of the fifth week the urine was apparently aseptic.

On September 17th, after many unsuccessful attempts to pass a bougie into the ureter, William Kessler succeeded in passing a No. 10 French with the greatest ease. The ureter was sounded every day thereafter, and as a result about three-fourths of the urine now passed down through the ureter into the bladder. The drainage-tube remaining in the pelvis was now withdrawn and the fistula allowed to close.

October 3d: No distention of the kidney could be felt upon pressure, but there was still a slight discharge of pus from the fistula. About seven-eighths of the urine at this time passed into the bladder. The patient's general health was good, and his condition much improved since the last operation. The quantity of urine discharged through the lumbar opening rapidly diminished, and on November 30th the wound and fistula closed.

From this time on the patient had excellent health until January 3, 1896, when, as a result of excessive drinking at Christmas time, he had a sudden violent attack of colicky pains in the region of the right kidney, with reflected pain down Poupart's ligament into the right testicle. The pain steadily continued for seven hours, when it became necessary to administer morphin hypodermically. At one point in the cicatrix there was extreme tenderness, which increased day by day until an abscess finally opened. The urine passed during the night of the attack appeared normal, but on the next morning it changed to a murky, dark chocolate color, with a marked fetid odor, and, upon examination was found to contain large quantities of pus. The urine showed these characteristics for a few days, there being sometimes 3 ounces of pus in 12 ounces of urine. After this time the pus decreased and the urine improved in character and color. On the second day after the attack the patient came to Chicago and consulted me. On the same night the abscess opened spontaneously, with great relief to him. A drainage-tube was inserted. The bladder was filled with boric-acid solution through the kidney opening, thus demon-

strating the patency of the ureter. From this time on the symptoms gradually decreased, the pus soon disappeared, and on January 15th the fistula finally closed. The patient has been perfectly well up to the present time, April 10th.

On April 22d I received the following report from the patient: "Since January 15th no interference or treatment of any kind, and even under pressure of constant work since February 1st I have never experienced better health or greater strength. Appetite excellent; sleep sound; physically stronger than ever; wound occasions not even the slightest inconvenience; kidney exhibits no symptoms of pain whatsoever, neither in rest nor during greatest exertion, such as running up or down four or five long flights of stairs. Right side feels as sound as left. I am careful of the existing hernia in the anterior and lower part of the incision on the right side. Weight, 155 pounds, stripped. Urinalysis made by Charles H. Miller shows the following: Quantity, 1700 c.c.; reaction, acid; clear; specific gravity, 1016; total solids, 48 grams; sugar, absent; albumin, 2 grams daily; blood and bile, absent; urea, 22.1 grams daily."

Remarks.—The course of the development of the stenosis in this case is quite clear. The ascending pyelitis in the right ureter caused moderate incomplete retention and unilateral dilatation of the pelvis, with valve formation and oblique insertion of the ureter. The inflammation in the pelvis caused the stricture in the upper end of the ureter, a condition which has been so often observed as a complication with valve formation in infected cases. On account of this condition further retention and moderate dilatation of the pelvis, or rather of both branches of the ureter, took place. Then followed unilateral dilatation and valve formation in the lower branch of the ureter, which resulted in local cystonephrosis (pyonephrosis) of the lower half or two-thirds of the kidney. During the development of this condition unilateral dilatation and valve formation of the necks of three or more calices took place, with absolute occlusion of one calyx.

General Plan of Operating for Cystonephrosis.—(a) The general plan of operating for pyonephrosis should first take into consideration the dangers from infection. Thus, opening and drainage of the dilated kidney should first be done to evacuate the pus, and then the pyelitis should be treated locally through the drainage-tube. I always make the nephrotomy from the lumbar region, as Küster advises, because this is so much safer than the transperitoneal operation.

It is ordinarily impossible at this time to find or remedy the obstruction unless renal calculi are present as the cause of retention. On account of the sepsis, a prolonged search for obstruction of the ureter other than stone cannot be borne by the patient.

(b) In cases of hydronephrosis, when the patient's condition will admit of a prolonged operation, it is usually impossible to find the orifice of the ureter in the large sac, and it is impossible to find the ureter outside of or below the sac, because the latter fills the large pelvis and covers the ureter. We must, therefore, wait for two or three months until the sac has retracted, or, in pyonephrosis, until the septic absorption has disappeared and the sac diminished in size, before further operating for the obstruction can be done.

If the obstructed kidney has still some secreting value, and if the

other kidney is diseased, nephrectomy becomes out of the question. While primary nephrectomy in pyonephrosis, according to Tuffier, has a mortality of 37 per cent., it has been found that in 40 per cent. of the fatal cases death resulted from disease of the other kidney. Although Israel* has made a successful nephrectomy on a patient whose other kidney was the seat of pyelitis, we must consider such a case as a rare exception which does not alter the rule not to extirpate a kidney whose fellow is not healthy. In the case just reported I considered nephrectomy absolutely out of the question after the attack of pyelitis and colic in the left kidney.

The importance of extirpation of a piece of kidney tissue during nephrotomy for microscopic examination is well illustrated in Case I. The specimen removed in this case showed large territories of almost perfectly healthy kidney tissue, with glomeruli and epithelium in the canals, with only a few islands of disseminated interstitial granulation tissue. It is likely that this nephritis stops during the local treatment of the pyelitis through the lumbar wound, and that what is left of the kidney tissue remains useful.

If some of the urine passes into the bladder, we would probably underestimate the secretory value of the kidney if we came to this conclusion, from the quantity of urine passed through the fistula alone, and here microscopic examination of the kidney tissue may be valuable.

As soon as the condition of the patient permits, search for the obstruction should be made. I have already discussed the operation for obstruction in the ureter in an earlier paper,† and shall detail a case later to illustrate conservative operation in hydronephrosis.

Operation for Obstruction Above the Ureter.—Up to this time no systematic operation planned beforehand has been made for this condition.

Küster‡ mentions in his paper that he attempts to transform the multilocular into a unilocular sac by breaking down the partition walls with the fingers, or by dividing them with a blunt-pointed knife introduced into the sac, evidently without the aid of the eye. This operation is probably sufficient for those cases of pyonephrosis in which little or no secreting kidney tissue remains, and in which obliteration of the sac is the object to be attained.

An entirely different operation, however, is required in those cases where considerable kidney tissue remains, and where the object is to restore to a useful kidney its normal function.

What is the reason that in some cases the obstruction causes dilatation of the pelvis and kidney, terminating in a unilocular sac, with little or no traces of calices, but only flat semilunar bands on the wall, and in other cases a sacculated kidney, with narrow necks or entrances to multiple dilated calices—that is, a system of narrow-necked sacs

* Israel: "Erfahrungen über Nierenchirurgie," Langenbeck's Arch. f. klin. Chir., 1894, vol. xlv, p. 344.

† Fenger: Operation for Valve Formation, *loc. cit.*

‡ Küster: *Loc. cit.*

surrounding a moderately dilated pelvis? The cause of this difference is not known, but it seems to me that dilatation of the calices into sacs with narrow necks is more common in cases of retention with early infection than in cases of retention infected later or not at all (hydro-nephrosis). The intensity of the infection—the inflammation—is apparently a potent factor. It may be that the inflammation causes thickening of the pelvis and necks of the calices where the mucosa is provided with a considerable layer of submucous connective tissue, and even with muscular layers capable of inflammatory thickening followed, if not by retraction, at least by resistance against dilatation. The papilla, meanwhile,—that is, the kidney tissue proper, the tissue of the pyramids with thin mucosa and no submucous tissue or muscularis,—does not form a sufficiently thick layer of inflammatory connective tissue to protect against dilatation. If this be correct, it explains the formation of a comparatively small pelvis and of largely dilated calices having narrow necks, formed by the papillary portion of the calyx.

An operation to restore the function of a sacculated kidney must have for its object the overcoming of the obstruction in the three places I have already described. Obstruction in the pelvic end of the ureter and in one or more calices is often found, while the local cystonephrosis is rarely encountered. Occlusion at the necks of the calices is probably met with a greater degree of frequency, proportionate to the relation between the number of the calices and the number of branches of the pelvis.

The operation must begin with bisection of the kidney from its convex surface down to the pelvis. The characteristic features of this operation, which I have termed "operation for sacculated kidney," in contradistinction to nephrotomy, are the treatment of the bisected kidney, the division of all partition walls between the dilated calices and the finding of all the calices, some of which may be very difficult to detect.

This operation must be done with full view of, and free access to, the inner surfaces of the bisected kidney. The hemorrhage varies considerably in proportion to the more or less normal condition of the kidney tissue. Hemorrhage is controlled by the Paquelin cautery, mass ligatures, or continuous suture along the divided partition walls, together with digital compression of the renal artery by an assistant. It will be impossible to find the calices, which often have a narrow entrance, to divide all the partition walls, to check the hemorrhage, to examine the pelvis, and to remedy folds or valve formation unless we have ready access to the whole interior of the organ with eyes, hands, and instruments.

During the after-treatment I consider it important to have free access to the ureter for the introduction of bougies every day or two when irrigation is made.

Finally, after months of local treatment, when the pyelitis has subsided and the ureter is patent, the bisected kidney should be reunited after the two halves have been loosened from the abdominal wall.

Catgut is probably preferable to silk as a suture material in this procedure. When the ureter is patent, when all the calices have been laid open and the two halves of the kidney have been reunited, the fistula will always close.

Scope of the Operation.—I am well aware that the operation for cystonephrosis proposed by me has a comparatively narrow field in the mass of cases of pyonephrosis or hydronephrosis. It is not intended that it should replace nephrectomy altogether, nor that it should be employed after nephrotomy in all cases. Each of these three operations has its own legitimate field.

(a) *Infected Cystonephrosis (Pyonephrosis).*—In infected sacculated kidney primary nephrectomy is rarely indicated, and in this respect I fully agree with Küster; but although nephrotomy, opening, and drainage is the operation of choice, and should be the first operation in the great majority of cases, we may encounter a kidney with multiple abscesses in the kidney substance,—surgical kidney,—in which case primary nephrectomy would be the only means of stopping a sepsis immediately dangerous to life.

1. *Primary nephrectomy* for pyonephrosis has a mortality, as given in the statistics of various observers, as follows: Tuffier reports 67 cases, with a mortality of 38 per cent.; Brodeur reports 58 deaths out of 128 cases, a mortality of 46.7 per cent.; von Bergmann reports 32 deaths in 73 cases, a mortality of 43.9 per cent.; and Israel, in 19 cases, reports a mortality of 21 per cent.

2. *Secondary nephrectomy*, whether performed early or late, may become an immediate necessity when nephrotomy is followed by persistence or increase of the septic symptoms from additional microbic invasion, leading to the same condition of multiple septic foci in the kidney substance proper.

Tuffier reports 24 cases of secondary nephrectomy with 2 deaths—a mortality of 5.9 per cent.; von Bergman reports a mortality of 9.3 per cent.; and Israel reports 4 cases with 3 deaths, a mortality of 75 per cent. The striking difference in the mortality-rate is undoubtedly due, in part at least, to the fallacy attendant upon statistics from a small number of cases.

3. *Nephrotomy.*—Franz Ris* states that general rules governing the choice between nephrectomy and nephrotomy in pyonephrosis cannot be formulated. It is necessary to individualize. Nephrectomy, he says, is rarely called for, but “nephrotomy in simple (non-tuberculous) pyonephrosis is to be defended also in the cases where the chances for life by extirpation are favorable.”

In a large number of cases nephrotomy effects a cure (Küster). The fistula closes, either because the ureter becomes patent from retraction of the sac and spontaneous disappearance of the oblique insertion and valve formation, or because a sac which has no secretory kidney tissue remaining shrinks and becomes obliterated like a drained abscess. Thus in all cases where nephrotomy is followed by cure—that is, in

* Ris: “Zur Nierenchirurgie,” P. Bruns' Beiträge, vol. vii, p. 164.

which urinary fistula does not persist, further operation is not called for.

The statistics of nephrotomy in pyonephrosis show a mortality, in the cases reported by Tuffier, of 33 per cent. in calculous, and of 23 per cent. in non-calculous, pyonephrosis; von Bergmann reports 22 deaths out of 72 cases, a mortality of 30.5 per cent.; Küster, 1 death out of 13 cases, a mortality of 7.7 per cent.; and Israel 2 deaths out of 13 cases, a mortality of 15.4 per cent.

How often further operation is called for, how many permanent fistulas remain, and how many kidneys secrete a sufficient quantity of urine to be of value to the patient I am unable to say, but the statistics of various observers show marked differences in these regards. Tuffier reports 34 per cent. of fistulas in calculous, and 57 per cent. in non-calculous, pyonephrosis; S. W. Gross reports 29.5 per cent.; Küster, 9 per cent.; and Israel reports 7 cases out of 13 in which fistula persisted, a percentage of 53.8. The same observer reports 2 out of 13 cases cured without fistula, or 15.4 per cent.

(b) *Non-Infected Cystonephrosis (Hydronephrosis)*.—The statistics of primary and secondary nephrectomy and of nephrotomy in hydronephrosis are as follows: Tuffier reports 26 cases of nephrectomy with 2 deaths, a mortality of 7.7 per cent. He reports a mortality of 31 per cent. for primary, and no mortality for secondary, nephrectomy. De Jong reports 5 deaths out of 15 cases of primary nephrectomy, a mortality of 33.3 per cent.; and S. W. Gross 8 deaths out of 21 cases, a mortality of 38.1 per cent.

Tuffier reports 32 cases of nephrotomy for hydronephrosis, with a mortality of 18 per cent.; Küster had 1 death in 5 cases, a mortality of 20 per cent. Tuffier reports 66 per cent. of fistulas, and Küster, 40 per cent.

Herczel,* in a report from Czerny's clinic, advises—"First, nephrotomy; later, if necessary, secondary nephrectomy."

It is likely, when the above plan is followed,—that is, when primary nephrectomy is made only when sepsis renders the operation imperative,—when secondary nephrectomy in cases of copious urinary fistula is abandoned in favor of the search for and operation for stenosis in the various places in which it occurs, that the cases in which it is possible to save the kidney, which has hitherto been accomplished only when absence of the other kidney made it imperative (Küster's case of resection of the upper end of the ureter and implantation in the pelvis), will be more common than we have hitherto expected, or than can be found in the literature of the past.

I will here give a few examples from the literature of similar cases in which, it seems to me, the kidney might have been saved had this method of procedure been adopted.

Rupprecht† reports a case of hydronephrosis in a girl of nine years. The patient had smallpox at the age of three, and the hydronephrosis

* Herczel: P. Bruns' Beiträge zur klin. Chir., vol. vi, p. 494.

† Rupprecht: Centralbl. f. Gynäk., 1885, vol. viii, p. 523.

developed four years later. Nephrotomy was performed by Dr. Meusner. There was a very considerable discharge of urine through the fistula, or, as the author expresses it, she was "flooded with urine all the time." In spite of the fistula and the slowly increasing albuminuria she felt well for years. Five years after the operation the patient died. The autopsy revealed general amyloid degeneration; the right kidney was embedded in a large cicatricial mass, and was adherent to the colon and liver. There was also cicatricial occlusion of the ureter at the place of its exit from the renal pelvis. This patient's life might have been saved had the operation for valve formation been performed in time.

Rupprecht also reports the case of a boy of five years who had a probably congenital, intermittent right hydronephrosis. Aspiration evacuated boric acid with which the bladder had been washed out. Later aspiration evacuated purulent urine, probably from infection from the bladder. Abdominal nephrectomy was performed. The removed kidney was 17 cm. long, 11 cm. wide, and 4 cm. thick, and weighed 530 grams. The pelvis contained purulent urine. There were valve formation and oblique insertion of the ureter, but the obstruction was not complete, as urine would pass down into the bladder upon pressure on the tumor. The patient made a good recovery from the nephrectomy and felt well for eight months,* although cystitis persisted. Sudden uremic coma and a swelling in the region of the left kidney now appeared, and the patient died two days later. The autopsy showed that the left kidney was not much changed. Three valvular folds of the mucosa of the ureter existed, which divided the ureter into four parts of widely different diameters. Regarding this case, Rupprecht remarks, "Puncture or nephrotomy might perhaps have prolonged life."

I think that nephrotomy of the right kidney and operation on the valve formations in the ureter might have permitted the patient to bear up, notwithstanding the attack in the left kidney, long enough to permit of nephrotomy and possibly operation on the valves in the ureter, which would have saved his life.

Valvular strictures of the ureter at some distance below the pelvis can be extirpated through a longitudinal incision in the ureter. I have done this successfully in a case which will shortly be published.

J. Israel† reports the case of a woman of twenty-one years, with intermittent right hydronephrosis, in which the tumor would disappear sometimes spontaneously, sometimes on pressure, as, for instance, during examination. After evacuation a somewhat enlarged, movable kidney could be felt. The urine at this time was "slightly catarrhal." The intermittent pain was relieved by an elastic bandage with pad. The patient felt better during pregnancy. In the course of ten years, as the pain persisted, as the tumor became more immovable and could not be emptied as completely as before, as hematuria and increasing pyuria, increase in size of the tumor, and permanent invalidism resulted, Israel decided to remove the kidney by lumbar nephrectomy. This was

* Rupprecht: *Centrabl. f. Gynäk.*, 1888, vol. xi, p. 235.

† J. Israel: *Op. cit.*, p. 553.

done and the patient recovered. The kidney "forms a large, nodular (gebuckelten) sac; in its lower two-thirds the sac-wall is as thin as paper. In the upper third a rather thick layer of kidney substance remains. The pelvis of the kidney is moderately dilated and heart-shaped. In the normal position of the kidney only a small portion of the liquid contents runs off, while the greater portion stagnates in the sacculated and dilated lower portion of the kidney. This is not evacuated until the kidney is turned up into an almost horizontal position with the pelvis directed downward."

This cystonephrosis resembled in every particular the condition in the autopsy, and in the case of local cystonephrosis described by me, and it seems probable that early conservative operation—that is, ten years previous—might have saved the kidney.

Rayer, in Plate XV, Fig. 2, of his atlas, illustrates a similar local hydronephrosis of the lower half of the left kidney in a case of nephrolithiasis.

As an instance of conservative operation for aseptic cystonephrosis (hydronephrosis), to prove that when the ureter is made patent the fistula closes or does not form, and, further, to illustrate the series of operations indicated, I report the following case:

CASE II.—Synopsis.—Aseptic remittent cystonephrosis in movable kidney of at least seven months' duration; intermittent hydronephrosis with evacuation of clear urine; pain; lumbar nephrotomy; ureter not to be found; packing, drainage; infection of sac. Two months later retraction of sac one-half; diminution of urine through fistula from 5 to 3 ounces daily. One month later sac considerably diminished in size. Operation for valve formation and oblique insertion of ureter at pelvic orifice. Closure of wound and fistula in forty days.

Mrs. C. L., aged twenty-eight years, was referred to me by Dr. G. E. Newell, of Burlington, Wis., early in August, 1894. The patient has been married four years, has one child three years of age. She was well until the birth of the child, at which time she was attended by a midwife, had a dry labor, and was much torn. For four weeks thereafter she had more or less severe pain, but at the end of this time had an attack of "inflammation of the bowels," with pain on either side of the pelvis, in the back, and down the thigh. She was in bed two weeks, but has complained more or less ever since.

In February, 1894, she first noticed a movable lump in the left side, which descended toward the pelvis when the patient was erect, and was then accompanied by pains in the lumbar region and slipped back toward the lumbar region when she lay down.

The tumor varies in size, and this variation is associated with urinary secretion. When the tumor is enlarging, a relatively small amount of urine is passed, and when it decreases in size, there is a very considerable increase in the amount of urine, and the urine is lighter colored and clearer than at other times.

Upon examination the tumor was felt in the left renal region, which, by ballottement, with one hand on the abdomen and the other in the lumbar region, was shown to be movable.

Operation.—On August 8, 1894, I operated in the following manner: I made an oblique lumbar incision, whereupon a lobulated, thin-walled, transparent tumor presented in the wound. Upon incision of the sac-wall a quart of clear, straw-colored fluid was evacuated. The inner wall of the sac was then inspected. It was smooth, whitish-gray in color, and resembled a serous membrane, but was more velvety. Five minutes after incision

and evacuation thousands of small ecchymoses appeared, and oozing commenced from the now blood-red inner surface of the sac.

Upon palpation the finger could not reach either the upper or the lower end of the sac, which was shaped like an hour-glass. (See Fig. 111.) The lower portion of the sac was round and larger than the fist, and its lower end extended down into the large pelvis. I could palpate the wall by pressure from outside of the abdominal wall with one hand in the sac, but could not find the ureteral opening. Upon inspection with direct light—sunlight—no ureter could be seen, and search for the ureteral opening with a probe was also negative. I therefore thought that the ureteral entrance was in the upper portion of the sac.

Between the upper and lower portions of the sac there was an isthmus $1\frac{1}{2}$ to $2\frac{1}{2}$ inches in diameter, circular, and with a sharp edge over which two or three fingers could be passed into the upper portion of the sac, but could not reach the medial or upper end. Through the anterior wall I could feel the spleen moving with respiratory movements. The posterior wall was in close proximity to the vertebral column, the anterior surface of which, together with the aorta, I could feel.

The incision opening in the lower portion of the sac was sutured to the skin, and the remainder of the wound united with buried sutures for the muscles and sutures for the skin. The hydronephrotic cavity was packed with borated gauze and two large drains introduced, one up and one down.

The secretion from the sac gradually decreased until only 4 or 5 ounces passed through the fistula in the twenty-four hours, and she was sent to her home for further treatment. The wound was dressed every day.

On October 1, 1894, Dr. Newell sent the patient back to me for examination on account of suspected infection of the sac. Upon inspection of the sac at this time with sunlight the wall was seen to be rose-red, velvety. The sac was somewhat retracted, and could be easily palpated all over its lower portion, but after careful search no ureter could be found. The isthmus was unchanged, I could not reach the upper or medial end of the upper portion of the sac, and a sound passed up for 6 inches. When two fingers were introduced through the isthmus into the upper portion of the sac, its walls closed upon the fingers with the respiratory movements, and the sac-walls came in contact with each other down to the isthmus, while the lower portion of the sac was distended with air.

The question of choice of operation now arose between an operation for reopening of the ureter and nephrectomy. I decided against the latter operation on account of the size of the sac. During the next five weeks the excretion of urine through the fistula diminished to 3 ounces.

On November 17th I operated to reopen the ureter. Palpation prior to operation showed the sac to be considerably diminished in size. I could palpate all over the surface of the lower portion of the sac, the isthmus, and the upper portion of the sac, the wall of which was smooth.

I made an incision over the lower portion of the sac, through the old cicatrix and the abdominal muscles. On the anterior and lateral outer wall at the lower end of the sac I found the ureter, which was normal in size. The ureter was now partially isolated, with the intention of incising it and passing a probe up through the incision into the sac, and thus determining the pelvic entrance of the ureter. On making traction on the isolated ureter outside of the sac, however, and inspection of the sac, I saw a nipple-shaped projection with a depression in its center. Through this depression a long flexible silver uterine probe passed into the ureter and down into the bladder without difficulty. Flexible bougies Nos. 4, 5, and 6 passed easily down into the bladder. This demonstrated that there was no stenosis or stricture of the ureter or ureteral opening into the pelvis, but that valve formation or occlusion by lateral implantation of the ureter on the antero-lateral wall of the lower sac existed.

I now operated on the ureter from within the sac in the following manner: A grooved director was inserted into the ureter and the sac-wall and ureter divided for $\frac{3}{4}$ inch to 1 inch. The opened ureter was recognized, unfolded, about 1 cm. broad, and its wall normal or perhaps a little thinner than normal. The divided sac-wall, which was separated from the ureter by loose, movable connective tissue, was resected all around, and the borders of the unfolded ureter sutured to the borders of the wall of the sac. Thus the free entrance of liquid from the sac into the ureter was positively secured.

The large opening in the sac, 2 inches in diameter, was now closed by sutures in the outer half of the wall, which did not take in the mucous membrane or the kidney tissue layer in the inner wall of the hydronephrotic sac. Only a small opening the size of a lead-pencil was left for drainage. The adhesions of the opening into the sac were first dissected off from the skin or from the border of the lumbar opening. Gauze was packed along the drainage-tube down to the opening in the sac, the abdominal wall united by buried and skin sutures, and the usual dressings applied.

November 18th: Much discharge of blood, severe pain, pulse 126, rapid; temperature 101° F.; urine thick and muddy, but contains no blood.

November 19th: Considerable discharge, consisting of blood with very little urine. No blood in the urine.

December 6th: Gradual improvement. The patient has little or no pain. Very little discharge through the drainage-tube, no pus in the sac, some discharge of pus from the extranephritic sinus. On irrigation, when the sac is filled with fluid, pain is felt along the course of the ureter to the bladder. The first urine passed after irrigation contains bubbles of air. A solution of pyoktanin was injected into the sac and the tube plugged. In less than an hour urine heavily stained with pyoktanin was passed.

December 16th: Tube was removed from the kidney and the opening packed with gauze; no pus; very little pain. At times the patient feels a fullness in the right side, but no tumor can be felt. She has soreness in the region of the erector spinæ muscles.

December 19th: Since the removal of the tube the discharge has been very slight, at times hardly staining the gauze. On removal of dressings it is usually found that the gauze has been forced out of the wound, and the opening into the sac is made with difficulty. On the introduction of a silver catheter no urine escapes from the sac. Boric-acid irrigations were made daily. One ounce of boiled milk was injected into the sac, and fifteen minutes later urine of milky whiteness was passed. One hour later urine of the same character was again passed.

December 20th: On inserting the catheter, which was difficult on account of the small size of the opening, half a teaspoonful of milky fluid, pus, or milk, or a mixture of the two, was evacuated.

December 21st: Irrigation stopped. Before operation, when the sac was irrigated, the patient would only notice distention. Since the operation she has felt, in addition to the distention, pain along the course of the ureter to the bladder.

December 22d: The patient has been menstruating for the last twenty-four hours, and complains of pain extending down along the course of the right ureter. There is tenderness on pressure in the right hypochondrium. When the patient lies on the left side a tumor, tender on pressure, can be felt on the right side just below the liver, which can be pushed upward and backward.

December 26th: Fistula closed. There has been no passage of air since the irrigations were discontinued. The patient passed 27 ounces of urine containing 70 pus-corpuscles to the field.

The renal fistula closed on the fortieth day after operation.

December 27th: Patient passed 26 ounces of urine containing no albumin, but a slight cloudy sediment. On microscopic examination 50 pus-corpuscles to the field were seen.

December 29th: Patient urinates 5 to 10 times in the twenty-four hours. The urine is acid and contains no albumin, but pus-corpuscles, about 10 or 20 in the field.

Remarks.—The ureter ran obliquely on the anterolateral wall of the sac for $1\frac{1}{2}$ inches. There was no stenosis of the slightly atrophic ureter. The ureteral opening could not be seen or found from the inside of the sac until the ureter below the sac had been laid bare, so that the place of entrance could be seen when traction was made on the ureter.

The sac retracted slightly in the first two months after the nephrotomy, but considerable retraction took place in the third month.

The practicability of lumbar nephrectomy seems to be increased after retraction of the hydronephrotic sac. In this case this could have been done three months after the operation, as the wall of the hydronephrotic sac was only loosely connected with the surrounding tissues or organs.

I think that nephrectomy might have been safely performed in this case, as the urine was normal, and as only about 3 ounces was secreted in the twenty-four hours from the fistula. I decided, however, to try opening the ureter to see if this procedure would prove efficacious in closing the lumbar urinary fistula.

The case conforms to the law that a lumbar renal fistula does not persist when the ureter is patent. Whether it is worth while to save a kidney with a daily excretion of only three ounces is a question not to be decided until future observations have taught us more about the subject than we know at present—namely, where to draw the line between a valuable and a valueless organ.

CONCLUSIONS

Conservative surgery in cystonephrosis demands a number of successive operations:

I. Hydronephrosis.—(1) Lumbar nephrotomy, followed by packing and aseptic drainage. If urinary fistula remains, after three months—

(2) Operation for the stenosis—namely, for (a) stricture of ureter, or (b) valve formation and oblique insertion. If the fistula still remains with the ureter patent, which occurs only when there is obstruction above the ureter—

(3) Operation for sacculated kidney as designed by me—namely, bisection of the kidney and division of the partition walls between sacs. When the entire territory of the sac is thus laid open and the ureter is patent, as demonstrated by free passage of bougies from the kidney to the bladder and by free passage of injected fluid, then—

(4) Closure of the fistula by reunion of the bisected kidney. This last operation may confidently be expected to be followed by disappearance of the fistula. It should not, however, be done until the pyelitis, if present, has been cured by thorough irrigation from the kidney to the bladder. Küster observed a case of nephrotomy in which the fistula closed spontaneously, with patent ureter, but the pyelitis persisted, giving an incomplete cure. I have seen, however, that when the fistula is closed before the pus has disappeared entirely from the urine, the pus

in the urine having remained unchanged in amount for a considerable time, the closure of the fistula acts as a curative measure and causes the pyelitis to cease. Is this beneficial effect on the kidney after closure of the fistula due to cessation of continued infection through the lumbar opening or to cessation of irritation of the drainage-tube, when the stenosis has been removed, as shown in my two cases reported in a former paper?

In unilocular hydronephrosis the operation for sacculated kidney is, of course, not required, and only nephrotomy, the operation for valve formation in the ureter, and that for closure of the kidney, are needed.

II. Pyonephrosis.—(1) Lumbar nephrotomy, followed by drainage and local treatment of the pyelonephritis. When the fistula persists, when considerable healthy urine passes through it, and the kidney has retracted to a reasonable degree—that is, in two or three months—

(2) Search for the obstruction and operation to remove it.

(a) Stricture of ureter and valve formation at its pelvic entrance. If this condition, with a ureter patent from pelvis to bladder, still does not prevent the passage of large quantities of urine through the lumbar fistula, obstruction above the pelvis should be suspected, and—

(b) Operation for sacculated kidney with bisection and division of the partition walls of the calices and of the branches of the ureter should be made. When the whole territory of secreting kidney tissue is thus in unimpeded connection with the bladder and still spontaneous closure does not take place, although the pyelitis is almost cured, the final step to effect closure of the fistula should be taken—namely,

(3) Closure of the bisected kidney, by loosening the adhesions of its two halves to the abdominal wall and by suturing the kidney substance together.

Nephrectomy, like amputation, is a short and summary way of dealing with the diseased organ or limb. The loss of a kidney, even if half its function remain, may be more dangerous to life than the loss of an arm or a leg. At the present day we would not think of sacrificing an extremity which might be of even partial use, but kidneys have been sacrificed by hundreds, as is shown by the number of cases of primary nephrectomy in cystonephrosis (pyonephrosis or hydronephrosis). It is impossible to estimate how many of these kidneys might have been saved by conservative operation.

Conservative operation to save a cystonephrotic kidney requires a hard struggle, many operations during a long period of time, and a great deal of energy and patience on the part of both patient and surgeon; but the case above detailed demonstrates that when this course of treatment has to be carried out because nephrectomy would mean death, a final success can be obtained and the patient be saved from the dangers of, and the social misery attendant upon, an abundantly secreting urinary fistula.

STONES IN THE COMMON DUCT AND THEIR SURGICAL TREATMENT

WITH REMARKS ON THE BALL-VALVE ACTION OF FLOATING
CHOLEDOCHUS STONES*

GALL-STONES in the common duct were found by Fiedler in only 2 out of 800 autopsies (Courvoisier). Schloth, in 343 cases of cholelithiasis, found stones in the common duct 9 times, that is, in 2.6 per cent. of the cases. Courvoisier found stones in the common duct in 10 out of 255 cases of cholelithiasis, or in 3.9 per cent. of the cases. Conradi found gall-stones in 2.6 per cent. of dead bodies; namely, 1.6 per cent. in men and 3.6 per cent. in women. In 97 cases of cholelithiasis he found stone in the gall-bladder alone in 82 cases, in the gall-bladder and common duct in 10 cases, and in the common duct alone in 5 cases; that is, he found stones in the common duct in nearly 15 per cent. of the cases of cholelithiasis.

As gall-stones, when located in the common duct, almost always give rise to serious disturbances, obstruction to the flow of bile and its consequences, while, when located in the gall-bladder or cystic duct, they cause little or no disturbance as long as no infection or inflammation occurs, it is obvious that, although the cases of choledochus stone are in the minority, varying from 2.6 per cent. to 15 per cent., this minority will make itself felt, partly from the gravity of the symptoms caused and partly from the dignity of the operation demanded for relief.

Operation for stone in the common duct is of comparatively recent origin. A number of different operative procedures have been employed and are yet under discussion. The symptoms of stone in the common duct, in contradistinction to those of stone in the gall-bladder and cystic duct, have not hitherto been sufficiently differentiated. The surgical anatomy and pathology of the common duct and its surroundings have received little attention, as this region of the body has become a field of operation only within the last five years. I have had the opportunity of observing 6 cases of stone in the common duct during the past year, in 5 of which I operated and in 2 obtained an autopsy. The material thus obtained I have used as a basis for the study of stones in the common duct, with especial reference to some points in the anatomy, symptoms, and operative treatment, which have either not been mentioned at all, or have received only slight attention in the brilliant and

* Amer. Jour. Med. Sci., 1896, vol. cxi, p. 125.

exhaustive monograph of Courvoisier. To this author we owe not only this monument in the pathology and surgery of the bile-ducts, but also choledochotomy, or, as he calls it, choledocholithotomy, the operation of choice for stones in the common duct.

I will first report the 6 cases in detail. When attempting to think over the plan of operation to be performed in a difficult or uncertain case, I have often derived great help from reading the reports in detail of similar cases. The greater the detail, the more valuable were they to me. The too common method of presenting a merely cursory report of a large number of cases is entirely valueless in this regard. For this reason I present in detail the reports of the following cases. The first case, in which no operation was performed, but in which an autopsy was made, furnished the material for the study of the pathologic anatomy and the mechanism of ball-valve action in choledochus stone. In order to avoid repetition the most essential points in relation to these two subjects have been embodied in the report of the autopsy in this case and in the remarks thereon. The remainder of the cases furnished the material for symptomatology and treatment.

CASE I.—Synopsis.—Two years ago first attack of colic, with icterus. Attacks more and more frequent, with slight remittent icterus. Remittent pain every two or three days for three weeks, followed by fever, icterus gravis, and death. Autopsy revealed one small floating stone in the dilated common duct.

Mrs. G. E., aged thirty-one years, was admitted to the German Hospital in the service of Dr. Hessert March 29, 1895. The mother of the patient died at the age of forty-two years from a trouble similar to that for which the patient entered the hospital. Nothing further of the family history of the patient could be ascertained.

As a child the patient was weakly; at the age of twelve years she began to menstruate; menstruation has always been regular and without pain. At about the age of eighteen years she began to have vomiting attacks at intervals of five or six weeks or less, especially after eating indigestible food. The vomitus consisted first of food, and later on of brownish slime. The emetic efforts were exceedingly violent, as though "she could vomit up the abdominal viscera."

The patient always appeared healthy, except after one of these attacks of vomiting, when she would lose in weight, but would afterward regain health and flesh rapidly. The attacks lasted one or two days, during which time she would vomit for perhaps five minutes at intervals of an hour. The vomitus was usually a brownish fluid. Each year there has been a slight increase of the symptoms, and the vomiting has been more severe and frequent.

In 1883 the patient married. She has had 7 children. Three or four days before her last confinement she had a very severe attack of vomiting, with intense pain in the lower part of the back and abdomen. Shortly after her confinement she had another attack of vomiting, accompanied by intense pain in the epigastric region. A few hours after this attack began the skin and the sclerotics were noticed for the first time to be icteric. This attack lasted for fourteen days, during which time the patient rapidly lost weight, losing altogether about 60 pounds. The attacks of vomiting finally recurred every two weeks. The pain in the abdomen, epigastric region, and back became constant, but the pain over the region of the gall-bladder occurred only every two or three days. On the day following each attack the skin was of a darker icteric hue.

In February, 1895, the patient undertook the water-cure, which resulted in slight

temporary improvement of her condition. About March 1st she was suddenly seized with severe pain in the "inguinal region" and lower lumbar region, accompanied by vomiting. The patient felt during this attack as if something had given way, whereupon the severe inguinal pain immediately ceased, but the pain in the back continued for several hours. Two days later she had another attack of pain which lasted for three weeks, with exacerbations of pain every two or three days in both hypochondriac regions. After March 17th the patient felt better, but every afternoon at about 4 o'clock she was seized with a chill and fever. Upon March 24th severe general headache began, which became constantly worse, until she lay in a stupor. Her condition became more grave, the stupor more profound, and she died on April 5th. For three days before she died there was no vomiting. The stools were very dark, greenish-brown, and without foul smell, but had a very peculiar moldy odor. The patient had exceedingly severe and almost constant pain, located over the left lobe and median line of the liver. The bowels moved twice during the three days before she died, and the urine was drawn off by catheter.

Autopsy by Dr. Haiselden. The subject was emaciated, the skin dark, and presented a somewhat bronzed appearance. The thoracic viscera were normal, with the exception of old adhesions in the apex of the right lung. The abdominal viscera were normal, with the exception of the kidneys, which contained small hemorrhagic infarcts, and the left ovary, which was small and atrophic, and contained a cyst the size of a butternut, filled with clear serous fluid. The brain, on section, showed a large quantity of fluid in the ventricles. The liver, gall-bladder, pancreas, and duodenum, which was ligated above and below the pancreas, were removed entire.

The liver was flabby and a dirty brown in color. Upon cross-section the surface was a dirty brownish-yellow; the tissue was soft and friable, so that the finger could be easily pushed into it (acute yellow atrophy).

The gall-bladder was empty, atrophied, and small, so that it did not extend to the incisura hepatis. When a glass tube was inserted into the gall-bladder and the latter inflated with air, the air filled first the gall-bladder, then passed down into the cystic duct, then into the common duct, and then entered and distended the duodenum. No stones could be felt in the gall-bladder or in the cystic duct.

In the common duct a small, round stone, 1 cm. in diameter, was felt; it was movable—that is, it could be pushed or dislodged with the finger from the duodenal end of the common duct into the hepatic duct. It could be pushed up into the hilus at 4 (Fig. 114); was more superficially located at 2 at the border of the duodenum; from this point it passed downward behind the duodenum to 1. The horizontal portion of the canal was 4 to $4\frac{1}{2}$ cm. long, and the oblique portion $4\frac{1}{2}$ to 5 cm. long. The lower portion of the duct was surrounded by pancreas tissue, and the stone was stopped at the lower end of the head of the pancreas on the middle of the posterior surface of the duodenum.

Remarks.—The cause of death was cholemia or icterus gravis. The opening from the common duct into the duodenum was not completely closed, as air could be inflated, and as the duodenum contained greenish fluid feces. The cystic duct was open to air-inflation, and the gall-bladder contained a dirty green fluid, together with yellowish-green gravel.

The stone acted as a "ball-valve" and caused icterus, when it lay close to the opening of the common duct into the duodenum, by stopping the passage of bile into the duodenum. The stone was freely movable in the common and hepatic ducts. The stone was not grasped tightly by the common duct, as Courvoisier states. The wall of the common and hepatic ducts was not thickened, but the ducts were considerably dilated. There was neither pus nor inflammation in or around the duct,

nor cholangitis. The stone was probably the cause of the emptiness and atrophy of the gall-bladder and of the cystic duct.

That the small gall-stone, 1 cm. in diameter, freely movable, floating or swimming in the ductus choledochus, cystic and hepatic ducts might have caused complete stoppage of the flow of bile by acting like the ball in a ball-valve was proved by the following experiment:

The duodenum was opened opposite the diverticulum of Vater, and the papilla, on which the opening from the duodenum into the diverticulum was found, was seen to be of normal size and shape, and the duodenal mucosa and wall in normal condition. A silver probe passed readily from the duodenum into the common duct, and when it was pushed

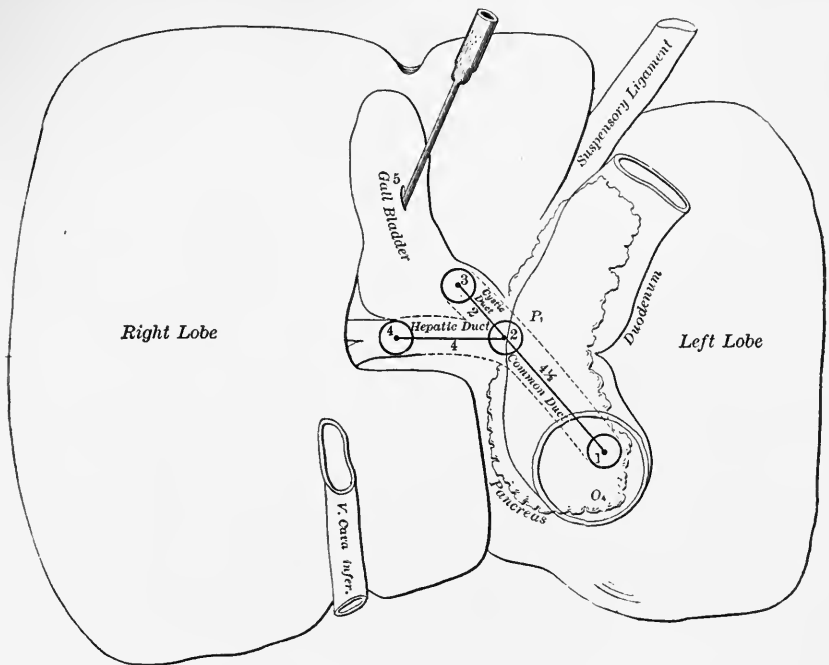


Fig. 114.—To show effects of injection of glycerin in gall-bladder.

down toward the end of the common duct, grated against the stone. A silver probe passed down from the gall-bladder into the common duct passed easily through the latter into the duodenum. It is comparatively easy to pass a probe through a dilated common duct, but it is not until search has been made by pushing and sliding the mucous membrane of the duodenum that the exit of the duct is found, because the dilated duct, just above the canal, through the wall of the duodenum, forms a pouch or pocket in which the probe is caught until the narrow exit is found. There was no stenosis of the duodenal opening of the common duct, but the common, cystic, and hepatic ducts were all dilated.

A cannula was now inserted in the gall-bladder (see Fig. 114), through which glycerin, which has about the same consistence as bile, was injected until first the gall-bladder, then the cystic, then the common, and finally the hepatic, ducts were filled and distended.

When the stone was now placed in any of the ducts or in any place with the exception of the lower end of the common duct, the glycerin would flow out in a continuous stream through the opening into the duodenum.

When the stone was made to slide down as far as it would pass into the common duct, namely, into the culdesac or pouch just above the duodenal opening (Fig. 115), the flow of glycerin into the duodenum ceased, and a further injection through the cannula into the gall-bladder

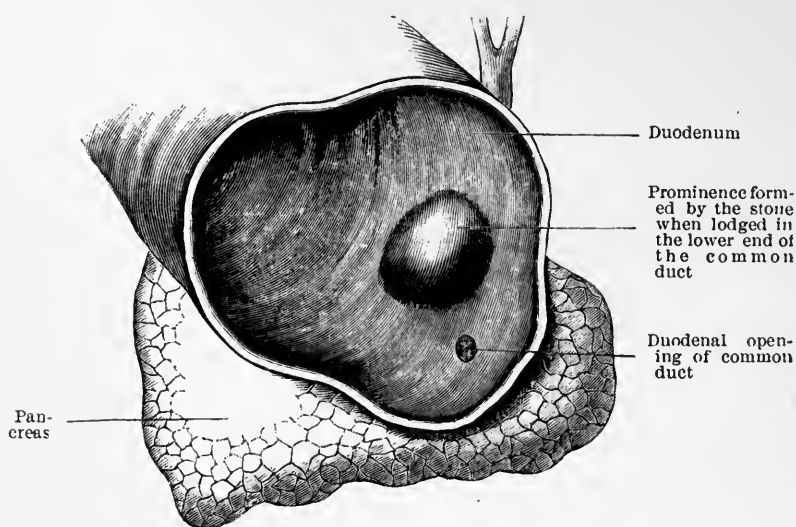


Fig. 115.

made the duct and the gall-bladder more tense and full, but not a drop of the glycerin entered the duodenum.

When I now dislodged the stone a little, pushing it up out of the pouch by pressing slightly on the prominence which it formed in the duodenum, $\frac{1}{2}$ cm. above the opening, the glycerin immediately began to flow into the duodenum. This flow would continue until I again pushed the stone back into its former position. I repeated this experiment a number of times, and always with the same result, namely, that the flow of glycerin would cease entirely as soon as the stone came down into the culdesac immediately behind the opening of the duct into the duodenum. I therefore considered that the "ball-valve" mechanism, as effected by the small round stone in the pouch at the lower end of the common duct, behind the normal duodenal end, was the sole cause of the stoppage of the flow of bile, of the retention of bile, and of the icterus.

Exact measurements of the distances which the stone could be moved in the respective ducts gave the following results, as shown in Fig. 114:

(a) *Common Duct*.—From the culdesac, the lowest point to which the stone could be forced, up to the junction of the hepatic and cystic ducts, was 4.5 cm.

(b) *Cystic Duct*.—The lower part of the cystic duct was 2 cm. long; that is, the stone could be pushed up into the duct to this distance. Its direction was in a line with the common duct, an oblique line directed from above anteriorly, and the right, downward, backward, and to the left, forming an angle of 45 degrees with the horizontal and vertical lines respectively.

(c) *Hepatic Duct*.—The stone could be moved in the hepatic duct a distance of 4 cm. in an almost horizontal direction from left to right. (See Fig. 114.) When the stone was lodged in the right end of the duct, or was pushed or made to slide as far to the right as possible, it disappeared from the surface down into the liver, so that only its upper or anterior surface could be felt, and even this was attended with considerable difficulty. The point at which it descended into the liver was 1 cm. to the left of the medial or left border of the right lobe (in the horizontal branch of the "H" in the hilus, 1 cm. from its right end). The hepatic duct, having a horizontal direction, thus formed an angle of about 45 degrees with the cystic duct, and an angle of about 135 degrees with the common duct.

The passage of bile back into the cystic duct and the gall-bladder was free when the entire system of gall-bladder and ducts was filled with glycerin, and when the stone was free in the middle of the common duct.

The ball-valve action of the stone in the cystic duct, whereby the filling of the gall-bladder with bile was prevented, was demonstrated in the following manner:

The gall-bladder was opened at 5, Fig. 114. The stone was made to slide up into the cystic duct until it lodged at 3. Glycerin mixed with white lead, so as to look milky white, was injected through a cannula inserted from the duodenum through the duodenal opening into the common duct for a distance of 1 to $1\frac{1}{2}$ inches. The common and hepatic ducts filled slowly until the place of lodgment of the stone in the cystic duct was reached, but here the fluid was stopped and did not pass up into the gall-bladder. When the stone was made to slide down into the common duct, the fluid flowed up into and out of the gall-bladder at 5. This experiment was repeated several times, with identical results; the stone acted as does the ball in the ball-valve, and prevented the passage of the fluid into the gall-bladder.

During this experiment, while the common duct was distended with the fluid, the hepatic duct also became distended, and the glycerin emulsion escaped from the cut surface of the right lobe, from the right border of which pieces had been removed for microscopic examination. This escape of the fluid from the distal branches of the bile-ducts of the liver proved that the larger hepatic ducts and the smaller bile-duct

were permeable. The prevention of regurgitation of bile from the common duct into the gall-bladder by ball-valve action of the stone in or near the cystic duct explains why the gall-bladder is found small and empty in cases of movable stone in the common duct. When the stone has been lodged in the cystic duct at 3, and the gall-bladder has been empty for a considerable time, possibly for months, the latter naturally retracts and loses its power of distention, its elasticity, so that it cannot be filled to its normal capacity, even if the passage becomes free later on by occasional dislodgment of the stone.

It is impossible to demonstrate the ball-valve action of a choledochus stone on animals or even in normal biliary passages. The proof of this action requires a system of biliary passages altered by the presence of a choledochus stone in the manner here described. The experiment undertaken with this specimen proved conclusively, and to the satisfaction and conviction of those present, the ball-valve action described above.

The bearing of the effect of this ball-valve action on the symptoms and course of cases of choledochus stone is obvious. Its action is dual:

(a) It causes intermittent attacks of retention of bile and icterus when the stone is lodged immediately above the duodenal opening of the common duct.

(b) It causes atrophy and shrinkage of the gall-bladder when the stone is lodged in or immediately below the cystic duct.

The ease with which a comparatively small stone is dislodged and floats around in the dilated canal, namely, the common, cystic, and hepatic ducts, is remarkable; it requires only a very slight touch with the finger or sound outside of the duct to push the stone from one place to another. As the stone has about the same specific gravity as the bile, it moves upon the slightest contraction of the wall or when currents of bile act upon its surface. Thus, movements of the body which cause movements of the liver, duodenum, or transverse colon may cause movements of the stone from one place to another.

The specific gravity of the human bile is 1.030. Although the choledochus stones, as, for instance, in 3 of my cases, float in the bile, they sink in water. The specific gravity of gall-stones thus lies between 1.000 and 1.030.

The direction of the large bile-ducts is almost horizontal when the body is erect. If the specific gravity of the stone plays any part in causing its dislodgment, it might be possible to dislodge it from its position behind the duodenal opening of the common duct, where it causes biliary colic and icterus. I, therefore, think it might be well to place the patient suffering from this condition for a time, but not constantly, on the right side or on the stomach.

Ball-valve action was observed by Courvoisier in the cystic duct in 2 cases of his own, and in 1 case of Socin's during operation for gall-stone, but neither Courvoisier nor any other author has, to my knowledge, observed this phenomenon in the common duct.

Courvoisier describes his observation as follows: "A peculiarly

strange condition is the following: The more or less round, spheric stone is situated in a dilated portion of the cystic duct in such a manner that it is not immovably grasped by the wall of the duct, but so that it can be moved or moves only a short distance in a proximal and distal direction. If we now make pressure on the fundus of the gall-bladder, its contents will press the stone firmly down into the duct, causing it to close the duct hermetically like a ball-valve, so that not a drop can pass out. The bile, however, from the hepatic duct [Why not from the common duct?—F.] can yet enter the gall-bladder as long as no great tension exists here. This peculiar condition, which plays a part in the genesis of certain ectasias of the gall-bladder, I have myself observed in 2 cases during cholecystectomy and also in an analogous case of Socin's."

Neither Courvoisier nor any other author seems to have observed the ball-valve action of floating stones in the common duct. While this condition in the cystic duct is comparatively rare and is of little practical importance, as it could cause dilatation of the gall-bladder only, I have reason to believe that the floating stone with ball-valve action is the condition ordinarily found in the common duct, and is of great practical importance, as it explains the causation of the remittent icterus and of the multiple slight attacks of icterus and colic. It has also a scientific importance, as it explains the atrophy of the gall-bladder, which takes place in the way I have described above.

CASE II.—First attack of biliary colic two years ago, followed by icterus; second attack October, 1894, followed by frequent lighter attacks; loss of weight—15 pounds in ten weeks; slight icterus; no tumor of gall-bladder; operation; adhesions to atrophic gall-bladder; cholecdochotomy; one stone, 2 cm. in diameter, removed; no leakage of bile; recovery; gained 50 pounds in three months.

Mrs. C. L., married, aged forty-two years, was admitted to the German Hospital January 3, 1895. Family history good; patient began to menstruate when sixteen years of age; has always been regular; flow has been excessive, and each period accompanied by backache and nausea; no leukorrhœa, no pain on urination. She was married when twenty years of age, has six living children, and has had two miscarriages, both of which occurred after the birth of the third child, and within one year of each other.

Twenty-two years ago the patient began to have pain in the epigastric region after eating food difficult of digestion, or after drinking cold water. For the ten years following she was obliged to be very careful in eating.

The present illness began in 1892, when a sudden attack of intense pain over the lower ribs on the right side and in the stomach occurred. The pain persisted for twenty-four hours and then subsided, only to return with greater severity. These attacks occurred at frequent intervals for three weeks, during which time the patient was confined to her bed. Her physician, Dr. Illingworth, attributed the attacks to gall-stones, and noticed that the patient was somewhat icteric. Since this time the patient has never felt entirely well; she frequently feels weak, and has severe backache and heaviness in the epigastric region, more marked after eating.

The next severe attack occurred October 8, 1894, when the patient had vertigo and pain in the right side, which gradually became more severe and was accompanied by vomiting. The pain began in the region of the gall-bladder, and soon extended to the epigastrium.

The bowels moved regularly, but the feces were grayish-black. Since that time the stools have been grayish and foul-smelling. Since the beginning of this attack the patient has had frequent recurrences of the pain, which would always begin on the right side, over the lower costal cartilages, and would soon radiate to the stomach. The attack lasted ordinarily from noon until 10 p. m., and was relieved by morphin. Her sleep has been much disturbed since the attack.

The patient did not notice any icterus until after the pain had commenced, when the skin became "as yellow as wax." There was also an intolerable itching of the skin. After this attack the patient remained in bed for about five weeks. For the two weeks following she had constant pain in the right hypochondriac region and stomach. On January 1, 1895, pain commenced in the back and the patient felt chilly. A few hours later she had very severe shooting pains in the right side and stomach, and these attacks recurred at frequent intervals for three days. On the fourth day she felt somewhat better, and was up and around, and the next day she entered the hospital, since which time she has had no pain.

The patient has a fair appetite when not in pain, the tongue is not usually coated, but at this time was slightly furred. She states she has lost 15 pounds in weight since October 15, 1894. Examination of urine showed no abnormality.

Upon examination the patient was found to be rather poorly nourished; the icterus was disappearing, but a slight trace of yellow remained in the conjunctiva. Upon percussion the liver was found to be of normal dimensions. On palpation the liver was felt below the border of the ribs for about $1\frac{1}{2}$ or 2 inches, but the border was not distinct. There was some tenderness upon pressure in the region of the gall-bladder, but no tumor nor hardness could be felt in this place. The urine was apparently normal; the last two stools were yellow from bile-coloring.

The patient was prepared for operation in the usual manner and anesthetized with ether. Upon palpation in narcosis I thought I could feel a rounded resistance in the region of the gall-bladder. With the assistance of Drs. Bernauer, Brown, and Haiselden, and in the presence of Drs. Illingworth, Hecht, and Goldspohn, I operated on January 5, 1895, in the following manner:

A lateral longitudinal incision was made, 10 cm. in length, along the outer border of the right rectus muscle, through the parietal peritoneum, whereupon I felt a rounded tumor which I thought to be the gall-bladder, but which proved to be the obtuse, rounded border of the quadrate lobe. The anterior border of the liver was rounded and not sharp. The liver was bluish, smooth, and on the upper surface of the convex right lobe there was a whitish, rounded spot, 3 mm. in diameter, not prominent upon the surface, and not hard. The incisuræ between the anterior and right lobes, and between the left and anterior lobes, were marked. In the grooves between the quadrate lobe and the right lobe—that is, the groove for the gall-bladder—no gall-bladder could be seen or felt, but the groove was filled with adhesions to the transverse colon.

By blunt separation and division between ligatures I now loosened the transverse colon, but still the gall-bladder did not come into view. The pyloric portion of the stomach was found to be adherent to the lower surface of the liver, and the liver was held up toward the ribs by the second and third fingers of an assistant.

Large, flat sponges were now packed in the abdomen around the field of operation, and the wound was held open by retractors. Upon loosening the adhesions of the pyloric portion of the stomach I found a small, empty gall-bladder, 4 cm. long and 1 cm. broad, whitish, extending from below the border of the liver 4 to 5 cm. backward to the hilus. The duodenum was pulled upward and to the left, away from the lower surface of the atrophied gall-bladder. Blunt dissection with the fingers and Kocher's sound finally permitted me to feel, partly through the duodenum and partly behind it, a nodular mass in the hilus of the liver, consisting of soft, almost immovable glands, and a hard, rounded, mov-

able mass, which was a large gall-stone, and a little nearer to the median line another semisolid mass, which was the head of the pancreas. As I was uncertain whether the whole mass was carcinoma or gall-stone, and in order to gain further operating space, the abdominal wound was prolonged downward and below the umbilicus, making an incision in all 12 to 15 cm. in length. The colon and omentum were now held down, the stomach held to the right, the liver pushed up, and the duodenum separated from the gall-bladder so that I could get a finger in behind the nodular mass. With the index and third fingers I could now push the mass out into the field of operation. I could not distinguish the hepatic artery, vena porta, or common duct, but I could see large, swollen glands the size of almonds. I now explored for the stone with a straight needle, the mass being held forward by my left third finger in the foramen of Winslow, and the stone held firmly in position against the wall of the common duct, whereupon the needle pushed against it gave forth a grating sound.

A longitudinal incision, 2 cm. long, was now made at the left border of the mass through the loose layer of the hepaticoduodenal ligament, the soft mass of glands and the whitish wall of the common duct, which was 2 mm. thick, to the surface of the stone. The stone, which was rounded, 2 cm. in diameter, finely nodular, and weighed 5 grams (see

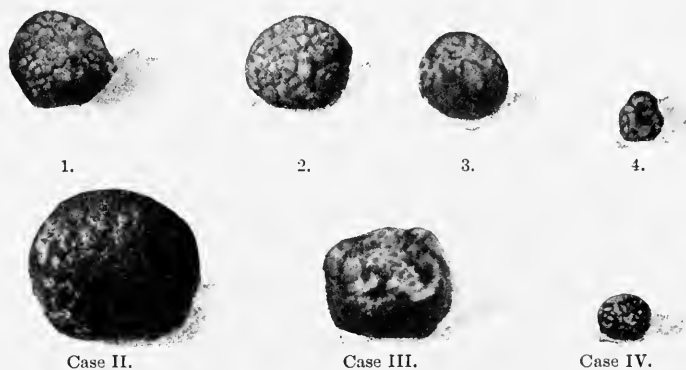


Fig. 116.—Calculi removed.

Fig. 116), was removed, and my finger then passed readily into the common duct, which had formed a pouch for the stone large enough to admit the finger. One or two drams of clear yellow bile escaped.

After thorough sponging the ductus choledochus was explored by a curved metal sound, which passed easily upward for 10 to 12 cm., but detected no other stones. I did not, however, succeed in passing the probe into the duodenum through the ductus choledochus, either downward or toward the median line. The wall of the ductus choledochus was thickened from hypertrophy of the muscularis, grayish-red, but not hard or friable. There was no carcinoma. The inner wall of the surface of the dilated ductus choledochus, where the stone was located, was whitish-red, the mucosa normal; neither carcinoma nor ulcer was found. The hilus glands surrounding the ducts were enlarged, soft, and reddish from inflammatory swelling.

As bile had already passed down into the bowel, as was seen from the biliary coloring of the last two stools, I desisted from further search for an opening into the duodenum, and proceeded to close the wound in the bile-duct by a double row of extra-mucosal silk sutures, as follows:

First, five sutures through the muscularis of the duct; second, five sutures through the glands and tissues of the hepaticoduodenal ligament. This second series of sutures

covered the deeper row. No bile escaped after the first row of sutures had been inserted. I now proceeded to close the field of operation. The bleeding points in the duodenum and elsewhere were first ligated, and a Mikulicz drain applied. A glass tube was inserted to the bottom of the wound, and iodoform gauze packed in over the sutured duct. The upper half of the abdominal wound over the ribs and the liver was united by step sutures: first, separate buried peritoneal sutures, and, second, cutaneous silk sutures, which included the skin, muscles, and sheath of the rectus. The lower border or end of the wound was united by three transperitoneal sutures. The middle of the wound was left open on account of the gauze and glass drain and the usual dressing applied. The operation lasted two and one-half hours.

Five hours after the operation the glass drain contained about $\frac{1}{2}$ dram of bloody fluid, which was removed with the dressing and a rubber tube inserted in its place. The gauze drain was not disturbed.

January 10th: Patient had a slight hemorrhage from the mouth and nose; the blood was bright red and was not preceded by cough.

January 13th: Dressing changed, considerable serous discharge, somewhat tinged with blood. Faint odor to be detected in the wound. Very little tenderness on pressure except over gauze drain, and some soreness along the stitches in the upper part of the wound.

January 15th: Rubber tube and part of the gauze drain removed.

January 16th: Wound redressed and more gauze removed from the abdomen.

January 17th: More gauze removed and also two stitches.

January 20th: Wound dressed and repacked, stitches removed.

February 3d: The granulations forced out the packing from the wound. The wound was closed until only a sinus about the diameter of the little finger remained. Patient complained of moderate, constant pain on the right side under the lower ribs upon deep inspiration.

February 9th: The sinus now is about 2 inches in depth, but is very narrow, with very little discharge.

March 10th: The sinus entirely closed.

April 10th: The patient has gained about 50 pounds in weight, looks very strong, and says she feels entirely well.

Remarks.—Hemorrhagic Diathesis.—Hemorrhage from the nose and mouth occurred on January 10th, five days after the operation, and on the eighth day the dressings were tinged with blood. The hemorrhagic diathesis is well known in icterus gravis, and is also found in the icterus from gall-stone. It is a grave complication, and Courvoisier found 58 cases, in most of which operation was not performed, and in which the hemorrhage was severe and often fatal. He collected 6 cases in which hemorrhage from the wound of operation in the gall-bladder had a fatal termination. He warns us to search the history of the patient and make careful examination all over the body in order to ascertain whether or not a predisposition to hemorrhage exists, either from the mucous membranes or in the subcutaneous tissues; and in case the patient presents this symptom, to abstain from operation, which is likely to prove fatal on account of the uncontrollable hemorrhage from the wound of operation or from other organs.

In some cases, however, in which no symptoms of hemorrhage pre-existed, the operation has been followed by fatal hemorrhage, not from the operation wound, but from other portions of the body. It seems

almost as if the operation brings into active existence a latent hemorrhagic condition. Mermann reports that Czerny lost 7 patients out of 43 upon whom he operated for diseases of the biliary tracts. Three of the 7 deaths were caused by cholemic secondary hemorrhage, which in 1 case occurred from the intestine, entirely independent of the wound of operation.

CASE III.—First attack of biliary colic five years ago; after third attack frequent slighter attacks of pain and icterus for four months; one year ago, fourth attack with icterus, followed by frequent slighter attacks at intervals of ten days; five months later cholecystotomy, with no relief; loss of weight, 50 pounds; slight icterus; mucous gall-bladder fistula; chole-dochotomy; removal of one stone, 1½ cm. in diameter; no leakage of bile; recovery; gained 20 pounds in three months.

Mrs. R., aged forty years, was admitted to the German Hospital February 10, 1895. Family history good; patient began menstruating at twelve years, always regular, no pain, moderate flow. At age of twenty years had an attack of acute gastro-enteritis, with vomiting and diarrhea, but without pain or icterus. She married at twenty-three years, and has had five children and one miscarriage, the latter probably due to a concurrent attack of measles.

Her present illness began suddenly about five years ago, with cramps in the stomach, accompanied by constipation and vomiting of green, slimy matter. The pain in the stomach lasted about two hours, and did not recur for about six months, when a second attack occurred, lasting two to three hours. Since that time she has had similar attacks at irregular intervals. Until 1892 there was no icterus. At this time the patient had attacks of pain in the region of the stomach and gall-bladder, occurring at very frequent intervals, and sometimes lasting all night. Icterus was present, which persisted for about four months, but afterward disappeared.

In the winter of 1893 the patient, who had been ill in the interim, had another attack, not so severe as the former ones, and without icterus, but the stools were gray. The patient was confined to her bed for about a week and then felt better, until April, 1894, when the attacks again recurred every three or four days, with pain in the region of the stomach and gall-bladder, but most severe in the lower dorsal region. About two days after each attack the urine was brown, the icterus intense, and the stools gray. The icterus varied in intensity with the severity of the pain. After a few weeks the attacks occurred only every ten days, but continued during the entire summer. In September, 1894, Dr. Wiener operated, making a right lateral incision, and removed one stone about the size of a hazelnut from the gall-bladder. Patient remained in bed for five weeks after the operation. She obtained no relief from the operation, and all the symptoms returned.

Present Condition.—Patient was anemic, rather poorly nourished; had lost about 50 pounds in weight in the last five months. The skin and sclerotics were slightly icteric, stools clay-colored, heart and lungs negative; pressure over the lower border of the liver and the median line caused considerable local pain and also pain in the back.

There was a longitudinal cicatrix 7 cm. long along the border of the rectus muscle over the gall-bladder, and a small fistulous opening from which a clear, viscid mucus exuded, a few drops at a time, which, upon examination, was shown to contain pus-corpuscles.

On February 21st I operated, with the assistance of Drs. Bernauer, Brown, Haiselden, and Gottschalk, in the presence of physicians from the Polyclinic. Ether was the anesthetic. The fistula, which was 5 cm. in depth, was scraped and closed with a silk continuous pouch suture. An incision was made around the fistulous opening, 1 cm. therefrom. The incision was then carried up above the border of the ribs and down through the old cicatrix. The peritoneal cavity was opened 5 cm. below the fistula, and, guided by the fin-

ger in the abdomen, the fistula was excised and left connected with the gall-bladder. The right lobe was an elongated corset-lobe. The transverse colon and pylorus were adherent to the gall-bladder and hilus. These adhesions were broken up, and palpation showed the gall-bladder to be contracted and empty, containing no stone, nor could a stone be felt below the gall-bladder in the cystic duct. The adhesions were now loosened from the anterior surface of the hepaticoduodenal ligament, and its free right border, the entrance to the foramen of Winslow, isolated so that the index-finger of the left hand could pass into the foramen along the posterior surface of the hepaticoduodenal ligament. Upon palpating the ligament of the liver down to the duodenum I could feel a movable, rounded stone the size of a hazelnut, which would slip away from my fingers up to and into the hilus of the liver. By passing the finger high up on the posterior surface of the hepaticoduodenal ligament I could feel the stone in the hilus and could move it down, forward, and to the median line as far as the border of the duodenum, and even a little behind its right border. The stone could move in the dilated ductus choledochus for 6 or 8 cm. I could fix the stone between the index-finger on the posterior surface of the hepaticoduodenal ligament and the thumb on its anterior surface, and push the stone against the wall of the ductus choledochus at the right free border of the hepaticoduodenal ligament. Upon pressing the stone against the wall of the duct in this place I could see the enlarged white stone shining through the dark-red peritoneal covering of the ligament. I could feel the hepatic artery across the median line, about 2 cm. from the free border of the ligament, and to the right of the hepatic artery I could see a bluish band running longitudinally in the ligament from the hilus of the liver to the left of the duodenum; this was probably a branch of the vena porta.

The abdomen was packed with large, flat sponges, one between the right lobe of the liver and the diaphragm, one over the pylorus and stomach, and one over the upper surface of the transverse colon and omentum.

Fixing the stone against the anterior surface of the hepaticoduodenal ligament close to the duodenum, 1 cm. from the entrance to the foramen of Winslow, I made a longitudinal incision, 1 to 2 cm. long, down to the surface of the stone which was then lifted out with a sharp spoon, as I wished to avoid crushing the stone; a moderate flow of light-yellow, transparent bile followed.

An assistant now held the liver up against the diaphragm with both hands, one on the right lobe and the gall-bladder, and the other on the left lobe. This hand also pushed the stomach upward and to the left. Another assistant held down the transverse colon with two fingers of the hand. Thus I obtained space for suturing the longitudinal wound in the duct. The duct was now explored by probe, elastic bougie, and finger. The probe and elastic bougie passed up 8 or 10 cm. into the hilus of the liver, and down 4 or 5 cm. behind, but not into the duodenum. The dilated duct easily admitted my little, third, or index-finger to a distance of 5 cm. upward into the hilus, where no stone could be felt, and 4 cm. downward behind the duodenum, into a pocket which ended blindly like the finger of a glove.

The wound in the ductus choledochus was closed by, first, a row of six mucosa sutures (the ends of which were left long) through the muscularis and mucosa, which was smooth and pale yellow from bile, and, second, an outer row of Lembert serosa sutures, $\frac{1}{2}$ cm. from the first row, taking in 2 to 4 mm. of the serosa. After six of these sutures had been inserted there was a flow of bile from the lower corner of the wound. The ends of the inner row of sutures were cut short, and four additional Lembert sutures applied, after which the flow of bile ceased, and I considered the canal hermetically closed.

The skin and abdominal wall over the fistula into the gall-bladder and down to the surface of the liver were now excised. The fistula was narrow; a silver probe was passed down 5 cm., but a bougie or elastic catheter, 2 mm. in diameter, could not be passed down until I had dilated with Lister's forceps. The catheter was left in and the border of the

fistula united to the skin. The toilet of the abdomen was performed as usual. The drainage consisted of, first, a Mikulicz drain of iodoform gauze surrounding a glass tube, over and upon the sutures of the ductus choledochus to the hilus of the liver; iodoform gauze was packed over the pylorus and down on the duodenum; second, an iodoform gauze strip along the gall-bladder or fistula, out of which a few drops of clear, transparent bile escaped.

The wound was now united by a row of silk sutures through the whole abdominal wall.

The operation occupied two hours; the patient was in good condition at its close; pulse, 110.

Five and one-half hours after the operation no fluid was found in the tube, which was, therefore, removed. The patient has no pain upon high percussion over the abdomen, but complains of pain in the stomach.

February 22d: The patient feels weak and passed gas by the anus; complains of pain in the wound; has vomited dark-green matter, the vomiting of which causes an intense burning in the throat and mouth.

February 28th: Wound dressed. Wound in good condition and apparently no bile. Packing removed and replaced.

March 3d: Wound dressed; a portion of the packing removed from the wound. Considerable sensitiveness on pressure over the lower part of the wound, apparently caused by a tight suture, which was removed. Pain ceased immediately after dressing.

March 8th: Stitches removed; considerable pain on pressure along lower border of wound. Small drainage-tube in the gall-bladder was removed and sinus packed. No bile on dressings.

March 12th: The icterus has almost entirely disappeared. Patient feeling well. All the gauze removed. The entire index-finger can be introduced into the wound leading to the duct. Very slight amount of discharge, consisting principally of blood, which followed the removal of the gauze packing.

April 20th: The patient has gained 7 pounds in weight since operation; is very much stronger. The sinus is small and closing in rapidly, and the discharge slight. The patient gained 20 pounds in weight in three months after the operation and is now in perfect health.

Remarks.—The opening of the ductus choledochus was 1 cm. above and to the right of the duodenum, and was 2 to 3 cm. long. When the stone was removed, it was found that the wall was not thickened, and clear yellow bile flowed out. The probe and elastic bougie could be passed upward in the hilus of the liver 10 cm., and down behind the duodenum 5 cm., but it may be that the bougie was flexed in the duct.

The ductus choledochus was so dilated that it would admit the little and even the third finger easily. The wall was smooth; no more stones could be felt. The finger could be passed 5 cm. up to the hilus without reaching the upper end. The finger passed downward behind the duodenum, entered a pocket 2 to 3 cm. deep, with a smooth wall, in which I could feel no stone, and through which neither finger, flexible sound, nor elastic bougie could be passed into the intestine—exactly the same conditions as in the previous case.

Six mucosal sutures were first inserted, and then ten seromuscular buried sutures, because of the clear, light-yellow bile which exuded all the time between the sutures first introduced.

A probe passed through the gall-bladder was arrested somewhere

in the cystic duct; it did not go down into the ductus choledochus. I could feel no more stones in the ductus choledochus, cystic duct, or the gall-bladder. At first nothing but a clear watery fluid passed out of the gall-bladder, but later there was a discharge of bile. A small drain was passed into the gall-bladder, the end of which was united to the skin. A Mikulicz drain was inserted down to the sutured wound in the ductus choledochus. The operation lasted two hours. I could see the yellow-spotted stone shining through the wall of the duct when pressed against it by two fingers behind the hepaticoduodenal ligament and the thumb on its anterior surface. The stone moved easily for 6 to 8 cm. in the ductus choledochus, from the hilus of the liver down to the pocket behind the duodenum. Sometimes it slipped up out of reach into the hilus of the liver, but could be brought down again by pushing the fingers behind the hepaticoduodenal ligament high up into the hilus of the liver. The stone could also be pushed down near the duodenum and to the right free border of the hepaticoduodenal ligament, the fingers being in the foramen of Winslow.

I thought that I could see the vena porta as a blue band about 1 cm. broad, and that I punctured it with the needle; but the bleeding stopped as soon as the sutures were tied. Hereafter, in operations of this character I shall employ fine, curved, round-pointed needles and fine silk. The ends of the inner sutures should be kept long in order to make traction on the wound when the outer sutures are introduced. Straight needles cannot be used, as the bottom of the wound is deep and the operating space narrow. The liver must be held up by both the index- and third fingers of an assistant.

It is not necessary to find the opening into the duodenum, and this is often impossible; it could not be found in either of my two cases. The icterus was intermittent, and there was no inflammation of the wall of the duct. The choledochus stone could be moved for 8 or 10 cm., and obstructed the flow of bile like a ball-valve.

CASE IV.—Biliary colic and icterus two years ago; frequent attacks of indigestion and pain in cardiac region for two years without icterus; then second severe attack with icterus; later very frequent slight attacks twice a week; fever; loss in weight—25 pounds in twelve days; slight icterus; no tumor in region of gall-bladder; operation; extensive adhesions over atrophied and empty gall-bladder; choledochotomy; removal of four stones; recovery; gained 40 pounds in forty days.

H. J. W., American; weight, 140 pounds; height, 5 feet 11 inches; married; occupation, dial-maker. Family history good; no trace of hereditary disease. For the past two years the patient has been working in the baking-room of the dial department of a watch factory, where the heat is so intense that it can be endured for a few minutes only, and the men are obliged to work in relays. For eight years previously he had worked in the dial department. Patient's habits are good, he lives a simple life, smokes an occasional cigar, and at rare intervals drinks a glass of beer. So far as he knows he has not been exposed to accidents or contagion in any form. With the exception of the ordinary illnesses of childhood, he has always been well until three years ago, when he had a very severe attack of typhoid fever, from which he recovered, however, without complications.

The present illness commenced in August, 1893, when the patient had a sudden

attack of pain in the region of the gall-bladder, accompanied by chills, fever, very intense pain, and marked jaundice. The jaundice gradually passed away, but from that time until February 5, 1895, he had frequent attacks of what he supposed to be indigestion or gastralgia, which were always sudden in onset, attended by severe pain, occasionally nausea, no vomiting, sometimes by chills and fever, and apparently independent of the food taken or the time of day. On February 5th, while at work, he was suddenly seized with severe pain in the region of the gall-bladder, chills, fever, but no vomiting. Within twenty-four hours intense jaundice appeared and marked constipation. He was seen by Dr. Webster on February 17th, and at that time, although enormous amounts of cathartics had been taken, his bowels had not moved for ten days. The jaundice was intense, the pain not severe, temperature, 101° F., tongue coated, a bad taste in the mouth, no vomiting, occasional sweats, urine limited in quantity and containing a large amount of bile. The patient lost about 25 pounds in weight in the twelve days intervening between the attack and the time he was seen by Dr. Webster, and averaged two attacks a week, which were preceded by a vague uneasiness, and were always accompanied by a chill, temperature as high as 102.5° F., pulse, 60, sweating, marked increase in the intensity of the jaundice, increase of bile in the urine, and very light stools. The pain persisted from a few minutes to an hour or more, was always quite severe, and the patient learned from experience that relief was more quickly obtained when he lay on his abdomen.

In the intervals between the attacks the jaundice faded, but did not disappear entirely; the urine became lighter in color, but always contained bile; the feces were darker. Itching of the skin was annoying and constant.

Present Condition.—Inspection shows a fairly nourished body. Jaundice well marked, though not so intense as at any time since February 5th; stools light colored, but very much darker than during or a day subsequent to the attacks. Urine normal in amount, specific gravity 1020; no albumin, sugar, or casts; urea, 0.017 per cent., strongly acid, and contains bile. Blood contains 78 per cent. hemoglobin; pulse in sitting posture, 60. Heart normal; respiratory system normal. Nervous system: The patient is cheerful and hopeful, although the characteristic despondency has been present, but without great melancholia, nausea, or severe manifestations of nervous perturbation. Digestive system: Tongue is less coated than previously, bad taste in the mouth, worse during attacks. Appetite: Can eat but simple, light food at intervals between attacks. Slight eructations, considerable nausea but very little vomiting, but none during the last few days. The bowels have moved under small doses of sodium phosphate. Patient has never had piles nor bloody stools. There is no enlargement of glands, the liver is normal in size, and there is no apparent enlargement of the gall-bladder.

On April 14th I operated at Mercy Hospital, in the presence of Drs. Morgan, Roler, Raymond, Webster, Billings, Andrews, Black, and Thiel. Upon inspection the patient was rather lean, skin of yellowish tint, but not exactly icteric; conjunctiva slightly yellowish. Ether was the anesthetic, and was given by Dr. Weir.

Operation.—A lateral longitudinal incision, 18 to 20 cm. in length, was made at the outer border of the right rectus muscle from above the border of the ribs to below the umbilicus. After packing with flat sponges the parietal peritoneum was sutured to the skin. Upon examination I found that the liver was drawn or extended more to the right than normal, so that the suspensory ligament of the liver and part of the left lobe presented in the middle of the lateral wound. The wall of the stomach presented below the liver; the groove for the gall-bladder was situated to the right of the wound, and could not be brought into view without extending the field of operation to the right, and therefore a transverse incision, 6 to 8 cm. in length, became necessary. I could now reach the groove for the gall-bladder—the incisura between the right and the anterior lobe. At this point was found a cord-like adhesive band, $1\frac{1}{2}$ cm. broad and 8 mm. thick, binding the liver to the abdominal wall, which was probably the cause of the abnormal position and retention of the liver. After double ligation and transfixion this band was cut.

The gall-bladder could not be seen, as the incisura was filled with omentum, the wall of the stomach, and the lesser curvature of its pyloric portion, which was at this point adherent to the liver and omentum.

The division of the omentum between double ligatures did not bring the gall-bladder into view, but exposed the transverse colon. The division of the ligamentum hepaticogastricum made it possible to push the stomach to the left, there to be retained by a flat sponge. The loosening of the colon by division of the ligamentum gastrocolicum finally brought the gall-bladder into view. It was empty, contracted, 2 cm. broad and 4 cm. long, and whitish. Upon blunt dissection backward with the finger and Kocher's sound, the hilus of the liver with the foramen of Winslow were laid bare, and also the bile-ducts and descending portion of the duodenum.

I could now feel a movable stone at this point, and could insert the index- and third fingers into the foramen of Winslow, behind the hepaticoduodenal ligament, and grasp between these two fingers and my thumb the vena porta and bile-ducts. With the fingers of my right hand I pushed the duodenum to the left, and could feel two movable stones which glided from right to left in the common duct with absolute ease and freedom. They could be dislodged to the left down behind the duodenum, and then could be pushed upward and to the right into the hilus of the liver. A slightly enlarged lymph-gland lay on the anterior surface of the common duct. The vena porta could not be seen. After packing with more sponges the first stone was now pushed down to the left and fixed in position against the anterior wall of the common duct, close to the right border of the duodenum. An incision, 1 cm. long, longitudinal to the axis of the common duct, was now made on the upper aspect of its anterior surface down to the stone, whose yellowish-white nodulated surfaces presented in the wound. Transparent, light-yellow bile flowed out of the incision, from which Dr. Black took cultures, but which he found to be sterile. A round stone (see Fig. 116, 1) was lifted and pressed out of the opening with the help of Kocher's sound, which was passed into the duct behind it. This stone was globular and 14 mm. in diameter. A second stone of the same size and shape was now removed; also a third stone, a little smaller—probably 12 mm. in diameter.

I now explored the common duct with my little finger, which passed down behind the duodenum 2 cm. into a smooth culdesac in which I could feel no stone. I then passed the finger upward for 2 cm., when it was grasped rather tightly by the walls of the duct, but here also no stone could be felt. A silver probe was now passed first downward, which did not enter the duodenum, and then upward for 8 cm., not into the gall-bladder, but into the hepatic duct. On withdrawing it I felt a grating as of a stone, and manipulation between the fingers of the contents of the hepaticoduodenal ligament brought forth a fourth stone, smaller than the preceding, globular, about 6 mm. in diameter.

An elastic, olive-pointed bougie, No. 10 American, was now passed into the common duct, first downward, when it entered the duodenum and could easily be passed down its entire length; then upward about 10 cm. into the liver, but not into the gall-bladder. The wall of the common duct was normal, but was rather thinner than usual.

The wound in the common duct was now sutured, first, by mucous membrane sutures; the mucosa was grayish white, soft, with longitudinal folds. It was held with forceps, three silk sutures applied, upon the knotting of which the flow of bile almost ceased; second, the seromuscular sutures, which took in 4 mm. of the outer layer of the wall with its covering layer of hepaticoduodenal ligament. Five sutures were first applied, but the flow of bile was rather increased than diminished, and bile was seen to come out of the needle-punctures. Two or three more sutures were applied obliquely and transversely to the others in the axis of the common duct, but even then the oozing of the bile did not completely stop. As I considered that when the pressure on the ducts and the liver, which was being held up with some difficulty by two assistants, was relieved, the flow of bile would stop, I resolved to close the wound.

Boric-acid gauze was packed in the hilus of the liver over the common duct, the six large abdominal sponges removed, and one large clean sponge spread over the abdominal contents behind the wound in the abdominal wall.

The abdominal wound was closed by suture of the divided muscles in the transverse wound with buried silk sutures, and then by heavy transperitoneal sutures through the entire wall to the skin.

A rubber drainage-tube, 1 cm. in diameter, was passed up to the wound in the common duct; borated gauze packed in above the surface of the tube on to the hilus of the liver and also below the surface of the tube, and the abdominal wound left open for 4 to 5 cm. The wound was then dressed in the usual way.

The operation lasted an hour and a half; the pulse became better and stronger during the latter part of the operation.

The next day the outside dressings were removed and were found to be thoroughly saturated with bile—probably 10 to 12 ounces—and renewed.

April 17th: The wound was again dressed. The deeper layers of the dressing were soaked with bile, but probably not more than 2 or 3 ounces. The wound looked well.

April 18th: The bowels moved spontaneously, the feces were ocher-brown in color.

April 20th: There was very little discharge of bile until the patient was turned on the right side, when the dressing became soaked in about half an hour with probably 3 or 4 ounces of a greenish-yellow fluid.

April 21st: When the patient was turned on the right side, the discharge again became profuse, and soon assumed a fermentative odor. When the wound was redressed, the discharge in the upper layers of the dressing had a sour, fermentative odor, but the dressings next to the wound were sweet, the discharge resembling warm, digesting milk, but was not of an intestinal character. The packing was now removed, and the wound found to be healthy, granulating condition. A little stitch-necrosis was present. The superficial stitches were removed, the wound washed with a saturated solution of boric acid, and repacked lightly.

April 22d: After an enema of magnesium sulphate the bowel movement was of a dark-greenish color.

April 23d: The wound was redressed; about half an ounce of discharge was found on the proximal dressing, very slightly sour in odor and chylous in appearance. The drainage-tube was removed and found plugged at the bottom with a mass of pressure necrosis material. The tube was not replaced. The wound was irrigated with warm saturated solution of boric acid and lightly repacked with borated gauze.

April 25th: The wound was redressed; about 3 ounces of discharge, of the same chylous appearance as before, but with a great admixture of bile, appeared on the dressing. Upon removal of the dressing 3 or 4 drams of odorless pure bile floated down on the surface. Streak and stab cultures were made from both the chylous-like discharge and from the bile, both of which were negative.

On April 28th Professor W. E. Morgan made the following report:

“The patient still discharges through the wound, and from the duct a quantity of the chylous-appearing fluid, and for the past two days a considerable quantity of bile also—2 to 3 ounces in twenty-four hours. As it occurred to me that the fluid might possibly be pancreatic in origin, I subjected some of it to a physiologic chemist for examination, and inclose his report. The discharge in question certainly comes from within the duct, and not from the surface of the wound, for I have been able at the last two dressings to watch its accumulation in the deepest part of the wound. At first it looks like a coarse emulsion of fat in water, then slowly separates into two layers, the deeper one milky in appearance, the upper one like clear bile. I would naturally think the oily portion would be lighter in specific gravity, but perhaps the admixture of mucus may make the deep layer heavier; it certainly is more adherent. The patient is doing well.”

Report of chemical examination of the discharge by Dr. Charles H. Miller:

"*Source*.—Liquids obtained by washing out the dressing.

"(A) *External Dressings*.—The dressings were colored green from the dried discharge, which had ascended highest from more perfect capillary attraction. On washing, obtained 350 c.c. green liquid, of neutral reaction, with a specific gravity of 1.016, which contains a considerable quantity of bile, traces of serum-albumin, and practically nothing else.

"(B) *Internal Dressings*.—The internal dressings, especially those used for packing the wound, yielded 200 c.c. of a yellowish-white, creamy liquid, of slightly acid reaction, due to lactic acid. Specific gravity, 1.023. On standing, this gave a heavy white precipitate containing pus-corpuscles (Donné's test). The supernatant liquid is strongly albuminous, and contains mainly serum-albumin with a small amount of peptone.

"Bile was present in small quantity; chlorids; phosphates, as salts of the alkali; urea, in minute traces only; fat, traces only; blood, in minute traces only (guaiac test); sugar was not present.

"The results of the approximate analysis would indicate that the liquid is a mixture of lymph and bile containing large numbers of pus-corpuscles. The examination was made twenty hours after the liquid was obtained. The trace of acidity is attributed to bacterial decomposition after removal from the body."

On November 9, 1895, I received the following report from Dr. Webster:

"In reply to your inquiry regarding my brother's health, I am pleased to write you that he gained 40 pounds in weight in forty days after leaving the hospital, and has not missed one hour's work since recovery."

Remarks.—The operating space was small, and the application of sutures in the common duct difficult. For this purpose small, rounded, curved needles are necessary. If the wall of the duct is thin or normal, it is not easy to close the duct hermetically.

The liver was normal in color, little if any enlarged, and its borders were not rounded. On the upper surface of the right lobe I could feel numerous (50 or more) small, superficial, hard or resistant nodules, from the size of a pin's head to that of a split-pea. They could be seen as slight prominences over the surface of the liver. The liver tissue was perhaps a trifle darker than normal, but neither whitish, yellowish, nor green. When I felt these nodules before I had found the stone in the common duct I feared they were malignant metastatic tumors in the liver, due to a primary tumor somewhere around the hilus; but their large number, uniformly small size and color, made me consider them peripheral dilatations of the small bile-ducts. This was made certain by finding stones in the common duct. The nodules were not distributed all over the liver—none could be found on the lower surface; they were limited to a territory the size of the palm of the hand on the convex surface of the right lobe, and each was almost in contact with the others. My belief is that a large branch of the hepatic duct had been occluded by a stone, possibly by the smaller one (No. 4), or a stone which I did not discover. It may thus be well, as was done in this case, to pass an elastic bougie or probe and attempt to dislodge a stone situated higher up in the larger ducts of the liver. The increased flow of bile toward the end of the operation, at the time of incision and suture of the common duct, may have been due to the successive evacuation of a distended and overburdened territory of peripheral bile-ducts,

and it is more than likely that the creamy fluid so abundantly discharged in the early part of the after-treatment was the contents of these dilated peripheral bile-ducts, which contained not bile, but an acholic serous fluid.

The peculiar nodulated condition found in the lower right half of the upper surface of the right lobe of the liver was due to dilatation of the distal ends of the bile-ducts. Courvoisier mentions one case in the literature in which the superficial branches of the bile-ducts presented a varicose appearance, and 4 cases in which the superficial terminal bile-ducts were transformed into small cysts the size of a cherry, protruding from the convex surface of the liver. It is natural that large quantities of bile should be evacuated even during the operation, after the opening of the common duct, and that the flow of bile should be considerable for several days thereafter. In such cases it might be advisable not to close the common duct entirely, so that evacuation of bile might be permitted through the wound.

Another remarkable phenomenon observed in this case was the discharge of large quantities of a milky fluid which did not contain bile-pigments, and which was characteristic of the acholic condition. Courvoisier found in the literature 10 cases of hydrops of the biliary ducts, which were filled with a watery, colorless, or slightly mucoid fluid which did not possess any of the characteristics of bile. In these 10 cases the entire system of the biliary tract, possibly with the exception of the gall-bladder, was filled with a hydropic fluid of this nature. In none of these 10 cases was the obstruction due to stone, but to tumors within or outside of the common duct, or to obliteration of the duct in one case. He explains the acholia by assuming that cessation of the secretion of bile may, under certain circumstances, be caused by high pressure on the liver-cells due to the stagnation of bile behind the obstruction. In this case the acholia was partial, and was caused by a stone, probably a small stone, which was at last removed and dislodged by introduction of the probe high up through the hepatic duct into one of its branches. This phenomenon is remarkable in both these respects, as it is the only observation of the kind on record.

As the patient has had no disturbing symptoms up to the present time,—eight months after the operation,—and as the acholic territory became entirely empty shortly after the operation, it is not likely that a stone which had not been removed could have caused the localized dilatation of the ducts, nor that the acholic fluid could have come from any other territory than that of the dilated ducts. Professor Morgan thought that the fluid might be pancreatic, from division of the pancreatic duct during the operation; but the incision in the common duct was nearly an inch from the pancreatic duct, and the fluid was shown to be non-pancreatic by the chemical examination made by Dr. Miller and reported above.

When it is impossible to close the common duct by suture so that no bile escapes, thorough drainage is important, namely, a rubber drain up to the sutured wound in the duct, carefully packing gauze around it,

not only in the hilus, but out toward the stomach to the left, toward the flexure of the colon to the right, and to the transverse colon downward. This packing should be done before the closure of the abdominal wall is commenced, while the liver is still being held up by the assistants, so that the nooks and corners to be packed may be clearly seen; a sufficiently large opening should also be left in the abdominal wound to allow free exit for the bile through the tube and packing.

CASE V.—Six attacks of biliary colic since December, 1894, the later ones followed by icterus; frequent short attacks of pain in epigastrium; slight icterus; loss of weight, 23 pounds; no tumor in region of gall-bladder; diagnosis, stone in common duct; operation; adhesions to gall-bladder; enlarged glands in hilus; no stone found; change of diagnosis to malignant tumor in head of pancreas; cholecystenterostomy with Murphy button; death on fourth day, probably from cholemia; autopsy, no malignant tumor; small gall-stone size of a cherry-stone found in diverticulum of Vater.

P. W., railroad clerk, aged twenty-five years, was admitted to Emergency Hospital May 18, 1895. Family history negative, with the exception of his paternal grandfather, who, in the course of an illness of three weeks, during which he was much jaundiced and had excruciating pain in the region of the liver, passed a number of gall-stones.

The patient had the ordinary diseases of childhood, and has had two attacks of gonorrhoea. He also had typhoid fever five years ago. He seldom drinks liquor, never to excess; uses tobacco sparingly; has a good appetite and no cough. Has never suffered from any accident; is generally constipated.

The present illness commenced in December, 1894, when he was awakened early one morning by a slight, dull aching pain in the epigastric region. The pain continued quite severe in character, notwithstanding a warm compress, for about nine hours, when it suddenly disappeared. This time he did not notice that he was jaundiced. The character of the pain in this attack was somewhat paroxysmal. Each paroxysm would last from ten to fifteen minutes, and would be followed by an interval of from half an hour to an hour and a half. The second attack occurred about the last of February, 1895. It commenced early one morning. The pain gradually increased in severity, and then suddenly disappeared, exactly as in the former attack. This attack lasted about twelve hours, but for six or seven days afterward he felt more or less ill and his appetite was poor. He did not notice any jaundice. The pain was localized in the epigastric region, in a territory about 3 inches in diameter. The third attack occurred on March 28th. In the morning of that day he had a disagreeable feeling, accompanied by fleeting pains in the epigastric region. In the afternoon he felt cold and chilly, but had no distinct chill. About 3.30 P. M. the pain began to increase rapidly in severity and soon became intense. After about fifteen minutes it suddenly disappeared. About two hours later he had another paroxysm, but not so severe as the first. This attack was not accompanied by jaundice. Three days later, while he was on his way home, he vomited three times on the train and perspired profusely. He had no pain, but had three very loose movements of the bowels. The next day he did not feel well, but had no pain.

The following day the fourth attack seized him and persisted for two hours and a half, but was not so severe as the former attack. During this attack he was not jaundiced, but his face was discolored. The day after this attack he was decidedly jaundiced, and the urine was very dark. He had painful attacks once or twice during the day. During the succeeding ten days he had an attack of pain every day, which lasted from half an hour to two hours, at the end of which time it would suddenly disappear. The jaundice was noticeable for about a week after its appearance. At the end of this period of ten days the pain continued in a less severe form for about five days. On April 19th he had a very severe attack which lasted about three hours, and for two weeks thereafter had less

severe attacks of pain each day. The pain was always included in a space in the epigastric region, about 3 inches in diameter.

During the two weeks preceding his admission to the hospital he had three attacks of pain. The first two were not severe, but the last attack, which occurred on May 14th, lasted for twelve hours. For the first four hours of this time it was not especially severe, but from this time on there was constant pain of varying intensity. He vomited three times during this attack, while the pain was at the maximum, and the vomiting was followed by a cessation of pain for about half an hour. He was distinctly jaundiced after this attack.

The character and intensity of the pain were varied by the patient's position. If he lay on either side or on his stomach, the pain was increased. When he would lie on the back, with the right thigh flexed to a right angle and the left leg drawn up and thrown across the right thigh, or with both thighs flexed as much as possible, or when he would sit up in bed and draw the knees up to the chin, the pain was less severe. The patient never tried to stand erect.

After the third attack the urine became very dark, and continued so for about ten days. After the next attack the duskiness of the urine continued for about five days. On May 14th it again became very dark, and has remained so up to the present time. On May 17th he had another slight attack, which lasted only two or three minutes. During the attacks of pain pressure of any kind was intolerable, and any noise or jarring in or around the room seemed to increase the pain; pressure during the free intervals, however, was not attended by pain.

The patient's usual weight is 165 pounds, but on April 15th he weighed only 142 pounds, a loss in weight of 23 pounds.

No stones have ever been found in the feces.

Diagnosis Before Operation.—As the patient had had six distinct attacks of gall-stone colic, increasing in severity and duration, and increasing also in frequency; as the pain was located in the epigastric region, and not in the region of the gall-bladder; as icterus of medium degree followed the later attacks; as marked emaciation (a loss in weight of 23 pounds) was present; and as there was an absence of tumor or pain in the region of the gall-bladder, I made a diagnosis of floating gall-stones in the common duct, feeling certain that this was a typical case, as all the characteristic symptoms were present. I therefore advised operation.

Operation.—After the usual preparations the operation was performed on May 10th. The patient was anesthetized by ether, an incision was made over the gall-bladder extending downward from the lower border of the costal arch to the level of the umbilicus, through the skin and superficial fascia. The rectus muscle was then separated by blunt dissection, and an opening made in the peritoneum, which was enlarged to the limits of the wound. The peritoneum was sutured to the skin, and the intestines protected by large flat sponges. The wound was now enlarged upward to the costal cartilages and downward to half an inch below the umbilicus. Extensive adhesions existed between the liver and the surrounding organs. These adhesions were loosened with considerable difficulty by blunt dissection or division between ligatures, and the common duct, artery, and vein could be felt by the examining finger passed through the foramen of Winslow. Careful palpation of the common and cystic ducts was negative, as no stones could be felt. The liver was then palpated, and hard, round nodules were found on its surface, which felt like dilated hepatic ducts. The head of the pancreas was enlarged, and I was inclined to attribute to this fact the symptom of jaundice due to pressure upon the common duct. Some enlarged lymphatic glands were found—one as large as a horse-chestnut. One of these glands was removed for examination. To determine the patency of the common duct, a flexible sound was passed down through an incision into the gall-bladder, through the cystic duct into the common duct, and finally into the duodenum.

I now made a diagnosis, which afterward proved to be erroneous, of malignant disease of the head of the pancreas. I therefore attached the gall-bladder to the jejunum by means of a medium-sized Murphy button. This procedure was attended with extreme difficulty on account of the small caliber of the atrophied gall-bladder. The abdomen was then thoroughly cleansed and two strips of gauze inserted, one above and the other below the point of anastomosis. The abdominal wound was closed with interrupted sutures, which were passed through the entire wall. One of these sutures was placed, but not tied. The ordinary dressings were now applied. The operation occupied two hours.

Twenty-four hours after the operation the temperature began to rise, and four days later reached 104° F., attended with vomiting, pain, a dry tongue, with no tympanites. The patient died on the fourth day.

Autopsy.—Upon opening the abdomen no diffused peritonitis was found; the gauze in the hilus was adherent to the surrounding intestines and stained with bile. There was no leakage from, or peritonitic exudate around, the cholecystenterostomy. The liver, together with the stomach, duodenum, pancreas, and a loop of jejunum at the site of the anastomosis, was removed entire.

The liver was of normal size and appearance; the atrophied gall-bladder was united with the jejunum by a perfectly tight agglutination at the place of anastomosis.

Careful palpation of the hepaticoduodenal ligament failed to detect any stone or dilatation of the common duct. The pancreas was normal on palpation, and its head did not now appear enlarged, nor were any nodules nor abnormally hard territories to be felt in it.

I now opened the duodenum by a longitudinal incision over the head of the pancreas, in order to examine the duodenal opening of the common duct. The inner surface of the duodenum appeared normal, and presented the usual transverse folds. On the inner surface of the posterior wall of the duodenum, at the point where it crossed the head of the pancreas, I could now see a small round polypus, 1 cm. in diameter, movable freely from side to side, but less movable in a vertical direction; it was covered with mucosa, and was attached to the duodenum posteriorly by a broad base. I supposed this to be a small submucous lipoma or fibroma, protruding like a polypus into the lumen of the intestine. Upon closer examination, however, I found, on its convex surface, near the upper end, the opening into the common duct. A sound passed easily from this opening into the duct, which appeared of about normal caliber. On passing the sound through the opening in the duodenal mucosa I felt a slight grating as from a stone at the location of the supposed polypus. I now made an incision from the opening downward through the mucosa covering the polypus, and found a gall-stone the size of a cherry-stone (see Fig. 116) in the supposed polypus, which was thus shown to be the diverticulum of Vater dilated downward so as to form a small pouch wherein the stone was contained. There was ample room over the stone to allow the passage of a bougie No. 14, French scale, in the common duct, as had been done during the operation. No other stones were found in the common duct, cystic duct, or gall-bladder.

Microscopic examination of the liver showed a slight degree of fat-infiltration of the liver-cells, most of which contained one or more oil-globules, not large enough, however, to fill the entire liver-cells, the contour of which could almost always be recognized. The branches of the hepatic vein at the center of the acini were somewhat dilated. The smallest bile-ducts could be seen to be not dilated and to have normal epithelium. Around the periacinous branches of the vena porta there was slight infiltration with leukocytes, but this did not extend from the paravascular spaces out into the acini between the rows of the liver-cells.

It was thus seen that a slight degree of beginning interstitial hepatitis and a medium or slight degree of fat infiltration were the only abnormal conditions to be found in the liver.

Remarks.—As I found the gall-bladder small, empty, and retracted, surrounded by the usual characteristic adhesions, I confidently expected to find a stone in the common duct, and was greatly surprised to find no stone upon palpation of the hepaticoduodenal ligament. The large lymph-glands in the ligament were soft; this might have been from inflammation, as in case of choledochus stones, but might also occur as a result of sarcoma. As I now found the head of the pancreas unusually large and firm, I changed my diagnosis, and thought of a tumor—a carcinoma or sarcoma—in the head of the pancreas, which had caused the intermittent paroxysms by compression of the common duct in its course through the head of the pancreas. I therefore opened the gall-bladder, first, to determine the patency of the common duct, and, second, to establish a cholecystenterostomy. As the flexible olive-pointed bougie passed easily down into the duodenum, I thought that no stone could be present, and that the bougie might have passed by a tumor in the head of the pancreas large enough to make compression of the common duct. I resolved upon cholecystenterostomy, because I expected the tumor in the head of the pancreas to increase in size and gradually to cause more compression.

The stone, covered with the soft wall of the diverticulum of Vater, was so small as to escape detection even after the duodenum was opened at the autopsy. If I had used a metallic instead of a flexible sound, I might possibly have detected the stone by the grating sensation at the location of the diverticulum of Vater. Had this been the case, I would have been able to remove the stone either from the ordinary incision in the common duct or from the duodenum, after incising the latter.

The small stone found in this case had a rather roughened, crystalline surface, with sharp, jagged points, or rather wavy ridges, like a fine saw. It imparted a feeling of grating or scratching when rubbed over the skin of the dorsum of the hand. It is possible that this stone would cause more destruction of epithelium and subsequent inflammation than the smooth stones found in Case IV.

The hard, swollen condition of the pancreas, and especially of the head of the pancreas, led me to believe during the operation that a malignant tumor existed which had caused the biliary obstruction, and this so much the more as I was unable to detect the small stone in the diverticulum of Vater. The autopsy demonstrated that the stone was present, and that no tumor of the pancreas existed; consequently the swelling or enlargement of the pancreas, which I felt during the operation, must have been of an inflammatory nature. This is in conformity with the considerable inflammatory swelling of the lymph-gland, the size of a small walnut, in the hepaticoduodenal ligament, on the anterior surface of the common duct. Although I had in other cases found swellings of the lymph-glands in this location as a symptom of the inflammation which probably caused the adhesion between the biliary tract from the gall-bladder to the end of the common duct, on the one hand, and all the movable adjacent organs,—the omentum, stomach, trans-

verse colon, abdominal wall, and duodenum,—on the other, I had not before observed any marked inflammatory swelling of the pancreas.

Similar observations have recently been reported by Riedel in a communication made before the Section on Surgery of the Convention of Naturalists in Lubeck on September 19, 1895. Riedel found inflammatory changes in the pancreas following gall-stone disease, which caused so considerable a swelling as to give the impression of a large pancreatic tumor. The author mentioned two cases in which these apparent tumors disappeared entirely, and a third case in which the autopsy demonstrated the simple inflammatory character of the tumefaction.

CASE VI.—Tuberculosis of knee and shoulder for which resections were made; last operation three years ago; two years ago, pain in epigastric region; May, 1895, pain over liver; July, 1895, pain in epigastric region, with icterus; August, 1895, third attack, medium degree of icterus, emaciation; loss of weight, 53 pounds in seven months; no tumor in region of gall-bladder; choledochotomy; two large stones and one small stone removed; cholecystotomy; one stone removed; recovery; gained 38 pounds in two months.

Miss A. E. D., aged twenty-four years, was admitted to Passavant Memorial Hospital October 5, 1895. Family history negative. Patient had the ordinary diseases of childhood; she began to menstruate at the age of sixteen years, and has always been regular. She was reared at the breast, and has never used cow's milk to any extent.

In 1887 I operated upon her first, making a resection of the right knee-joint on account of tuberculosis. A second operation was performed six months later. Six months after this I operated upon her for tuberculosis of the right shoulder-joint, and since that time I have twice operated upon the right shoulder, the last operation being performed three years ago.

Her present illness began in 1893, when she had severe epigastric pain of a dull, aching character. The pain persisted for about a week, but she remained in bed for a week after this. The pain was accompanied by vomiting attacks, which recurred twice a day. The patient thinks that she was given emetics, for the vomiting attacks always gave relief, which continued until she took solid food, when the pain would recur, to be relieved by another attack of vomiting. During the second week of this illness she had no attacks of vomiting. At this time she had no trouble with her bowels and was not jaundiced, although she thinks her skin was a little darker than usual after the attack. During the last two years she has had slight attacks of pain, which were usually followed by slight darkening of the skin.

In May, 1895, she had a severe attack, which began suddenly, with dull pain, increased on deep respiration, in the right side, in the region of the costal arch, over the liver. This pain continued until the latter part of June, but was not attended by vomiting. The pain then grew worse, and became so severe that on July 1st she was obliged to take to her bed. Two days later the attacks of vomiting recurred. She vomited continually for two weeks upon the slightest provocation—even the ingestion of a few drops of water would cause an attack. At this time vomiting gave no relief from the pain. The pain had now extended until the epigastric, hypochondriac, and lumbar regions were included, and these parts were sore and tender to the touch.

On July 6th she had jaundice for the first time, and this has persisted up to the present time. She improved slightly, so that she was able to be up and around about July 20th; but on August 5th she had a third and very severe attack, localized in the epigastric region, but without pain in the sides, except at the maximum of the attack. Forced

vomiting gave her immediate relief, and up to this time she always nauseates herself before she vomits. This third attack lasted for about two weeks. Since that time she has had occasional pain, but no continued attack. Solid food always causes or increases the pain. During the attacks there is great tenderness in the epigastrium, but this tenderness disappears with the pain.

There has been a marked diminution of weight. In February, 1895, she weighed 133 pounds; in October, seven months later, she weighed only 80 pounds, a loss of weight of 53 pounds.

Upon examination the patient was found to be very thin, her eyes surrounded by dark circles; the skin was a dark greenish-yellow, but not distinctly icteric. On account of her previous history and this bronzing of the skin I thought of Addison's disease, tuberculosis of the suprarenal capsules. The thoracic organs were normal, the abdomen flat, liver dullness normal, no tumor in the region of the gall-bladder. The borders of the liver could not be distinctly felt. There was no tumor in the epigastrium, and the aorta appeared normal. There was slight tenderness upon deep pressure in the median line midway between the xiphoid appendix and the umbilicus, but it was indistinct, and no swelling or resistance could be felt. Dr. Conley states that the patient says she has passed many gall-stones.

Operation.—On October 8th, assisted by Dr. Waters, who administered the ether, Drs. Brougham and Brown, and in the presence of Dr. Conley, I made a longitudinal incision, $1\frac{1}{2}$ inches to the left of the linea alba, in the outer third of the rectus abdominis muscle. The peritoneum was stitched to the skin from the border of the ribs to the umbilicus, and later on to 1 inch below this point. A flat sponge was inserted to push back the omentum. Exploration revealed the border of the liver and the end of the gall-bladder, the latter appearing as a whitish, empty, folded sac, the end of which protruded like the end of a finger. It was $1\frac{1}{2}$ cm. in diameter and firm to pressure, as if it were contracted around a small stone. This led me to believe that the lumen of the gall-bladder was obliterated behind a stone lodged in its distal end. The finger could be easily passed down to the neck of the gall-bladder and the cystic duct, and from here into the foramen of Winslow. The hepaticoduodenal ligament was palpated between the index-finger and thumb and two floating stones felt therein, which could be easily moved from the hilus down to the posterior surface of the duodenum.

The abdominal incision was prolonged to 1 inch below the umbilicus, making the incision in all 12 or 14 cm. in length, in order to gain operating space without the necessity of making a transverse incision. The sponge over the stomach was held to the left by the fingers of an assistant, the liver held up by the fingers of another assistant, and I had my left index-finger in the foramen of Winslow. The tip of the finger could be seen through the hepaticogastric ligament above the hepatic artery, which could be seen and its pulsations felt. One of the two stones was pressed against the anterior wall of the hepaticoduodenal ligament, whereupon I saw a blue strip or line above the stone, which I feared was the vena porta; but upon releasing the pressure I saw a branch passing downward from this vein, and therefore judged the blue line to be a branch of the vena porta dividing in the loose layer of the hepaticoduodenal ligament on the anterior wall of the left half of the dilated ductus choledochus. I now incised the duct over the stone below the upper horizontal branch and to the left of the descending branch, being guided by the stone, which showed through the wall of the duct, or rather gave the wall of the duct a whitish appearance. No enlarged lymph-glands were found. When the stone was reached, clear yellow bile escaped. The first stone was then squeezed out and the second stone brought into view and pushed out. I then easily inserted my little finger into the ductus choledochus for a distance of 2 inches behind the duodenum, where I felt a small stone, and up into the hilus of the liver, where I could feel no stones. By manipulation with the left third finger in the duodenal half of the duct and the right index-finger and thumb

on the duodenum and head of the pancreas I could push the small stone out on the end of the left third finger. I then attempted to bring the stone out into the incision in the common duct, but it would always slide off the finger. I then introduced a small sharp spoon-curet, but could not extract the stone with it. Finally, with the left third finger in the duct and the sharp spoon, I brought the stone out into the wound, where it broke into small pieces, which were removed in the form of débris.

A flexible bougie, No. 13 French, was now passed through the common duct into the duodenum, and another bougie up into the liver. A flexible silver probe passed down through the duct to the duodenum did not pass into the duodenum, but no stones could be felt, and when the probe was passed up into the liver, no stones could be felt.

The incision in the common duct was closed by five or six silk mucosa sutures and a continuous suture through the wound in the anterior layer of the hepaticoduodenal ligament. Notwithstanding the introduction of additional sutures, bile still oozed out. The field of operation in the common duct was now cleansed and packed with sterilized gauze. As the stone in the end of the gall-bladder was immovable, I now incised the wall of the gall-bladder over it. The wall was thick, and considerable hemorrhage followed the incision. The stone, which lay in a bed of mucosa which inclosed it snugly, was now removed, but broke into débris during this process. I introduced my little finger into the gall-bladder and found it empty, but so contracted as only just to permit my finger, 14 mm. in diameter, to pass down to the cystic duct, where no stone was felt.

A drainage-tube was now inserted into the gall-bladder and gauze packed in over the wound in the common duct, up between the liver and stomach, and above and below the drainage-tube, which was passed down to the incision in the ductus choledochus. The gall-bladder wound was now united to the upper end of the external wound, the lower part of which was closed. The union of the wound was then completed with the exception of the opening for drainage-tubes and gauze packing in the wound over the common duct.

The operation lasted an hour and a half. At its close the patient was in good condition with strong pulse. The operation was easy, as there were no adhesions. I feared tuberculosis, but found the peritoneum normal and no enlarged glands in the hilus of the liver. I also feared collapse from the cholemia, but the patient bore the operation well, and five hours afterward was in good condition; pulse 80, strong; no vomiting, and was anxious to see the stones which had been removed.

October 9th: The patient had a fairly good night; no vomiting. The dressings were removed and found to be soaked with bile coming mostly from the large tube leading to the common duct. She vomited a small quantity of bile three times during the day, and on the day following vomited considerable quantities of bile.

October 11th: She vomited several times very small quantities of bile.

October 12th: Wound was dressed, found to be perfectly clean; no bile was found in the dressings, but only a serous, odorless discharge.

October 13th: A portion of the gauze drain in the gall-bladder and of that passed down to the common duct was removed. The icterus appeared to be less, and the patient's general condition was much improved.

October 17th: All the gauze was removed from the gall-bladder wound; patient was continuously improving.

October 19th: The remainder of the gauze drain and also the drainage-tubes were removed. No bile in the dressings.

October 21st: Stitches removed, wound in good condition, and the discharge materially decreased.

December 17th: Wound healed and patient left hospital. She has gained 38 pounds in weight, looks well, feels well, has a splendid appetite, and feels no pain.

Anatomy.—In attempting to outline the field of operation for the

common duct and its topographic anatomy, it must be remembered that when operating we do not have a normal duct to deal with, but a duct more or less dilated. I, therefore, think it justifiable to use the specimen here presented as a paradigm, and the exact anatomic relations between the organs in the hilus of the liver in this specimen will hold good for the majority of the cases of this kind with which we have to deal. I have found this to be the case in 4 out of 5 cases in which I have operated, and think it safe to conclude that the conditions about to be described will be those generally found. I will describe the organs in the position in which the operations are made; the patient lying on the table in the dorsal position, and the anterior border of the liver held up by assistants, which makes its normally somewhat dependent position almost vertical; that is, the plane of the lower surface of the liver forms a right angle with the frontal plane of the body. Thus the vertical position is changed, when the patient is upright, to a horizontal position. This does not change the relations of right to left, but changes the anterior or horizontal direction to a vertical or upright one, and vice versâ. The vessels, bile-passages, and duodenum have been injected with colored paraffin.

The organs to be considered are located between the two folds of the hepaticoduodenal ligament. This extends from the transverse sulcus, called the hilus of the liver, downward, and consequently backward to the transverse colon, the duodenum, and the lesser curvature of the stomach, from right to left. Its right border is free and forms a free border between the posterior and anterior surface, being the free border of the entrance to the cavity of the lesser omentum, the anterior border of the so-called foramen of Winslow. The posterior surface is the anterior wall of the beginning of the lesser omental sac, and a finger introduced at this point will have the bile-ducts, vena porta, and hepatic artery on its anterior surface. The anterior surface of the ligament is covered with peritoneum from the large peritoneal cavity, continuous with the anterior surface of the greater omentum. When the index- and third fingers of the left hand are passed into the foramen of Winslow and the thumb laid on the anterior surface of the ligament, the organs in question will be between the ends of the fingers. The ligament is on the average 5 to 6 cm. long, 3 to 4 cm. broad; its direction, being the direction of the common duct, is oblique, and forms an angle of about 54 degrees with the frontal plane of the body.

Lymph-glands.—In the loose connective tissue below the anterior (lower) surface of the ligament are situated from two to four lymph-glands, usually somewhat enlarged; I have seen them as large as a walnut. The upper, anterior glands are situated on the vena porta; the lower, posterior ones, on the anterior surface of the common duct. In the connective tissue in this locality, and running in the direction of the common duct, there are three or more branches of the vena porta, 1 to 2 mm. in diameter, 3 to 4 cm. long, and two or three branches of the hepatic artery of the same length, and about 1 mm. in diameter.

Common Duct.—The common duct is 6 to 7 cm. long, runs in an

oblique direction, forming an angle of 45 degrees with the frontal plane of the body, and when it contains a stone or stones, is ordinarily dilated. It is thus 15 to 20 mm. in diameter, and may be divided into three portions, each 2 to 2½ cm. long.

The upper or anterior portion, nearest the hilus, begins at the junction of the cystic and hepatic ducts. Its upper half is partially covered with the main trunk of the vena porta, which gradually retreats from its anterior to its posterior surface, to disappear behind the common duct at about its middle.

The middle portion has no vena porta on its anterior surface, but the upper half of the lower or right border is overlapped by the retreating vena porta. At its upper or left border the hepatic artery passes behind it on its way to the hilus of the liver, and at this point gives off a branch which passes forward on the anterior surface of the common duct, where it divides into two branches, one of which runs upward and to the right to the cystic duct, the other downward and to the left on the anterior surface of the lower half of the common duct. This middle portion of the common duct, the anterior surface of which is not in relation with the vena porta, is the place of choice for the incision in choledocholithotomy, as at this point only small branches of the vena porta and hepatic artery, as already described, are met with—vessels too small to cause serious or uncontrollable hemorrhage. Its upper border, together with the right free border of the duodenum and the hepatic artery, forms a triangular space.

The third, lower, or posterior portion of the duct is almost entirely hidden by the duodenum, which covers its anterior surface and its entire upper border for 2 to 2½ cm., while only 1 to 1½ cm. of its lower border is covered by the intestine. This part of the duct lies partly in the head of the pancreas. Its lower end is, as a rule, dilated and forms a culdesac, usually a little smaller than the duct higher up, and at some place in this culdesac (the dilated diverticulum Vateri) the opening into the duodenum is situated. The possibility of passing a sound down into the intestine from the incised common duct depends upon the situation of the duodenal opening in this culdesac, and upon the direction of the canal through the wall of the duodenum. In some cases it is easy to pass a sound down, in others impossible, although the opening may allow free exit to bile (this may be due to valve formation or to the fact that the probe or bougie is caught in a fold). The head of the pancreas overlaps or comes down below the lower border of this portion of the duct for 1 cm. or more.

Vena Porta.—The vena porta commences behind the pancreas, runs as a trunk 18 mm. in diameter from left to right, slightly upward, first, behind the middle portion of the common duct; about its middle it emerges on the lower or right border of the duct, and runs from here upward and to the right for a distance of 3 to 3½ cm., when it divides into its hepatic branches. On its way it passes from the posterior surface around the lower border up on to the anterior surface of the upper portion of the duct, and covers the lower part of this, extending to or a

little upon the cystic duct. The terminal portion of the vena porta is situated on the anterior surface of, and consequently covers, the hepatic duct and its branches. Its termination is about 10 cm. above and to the right of the end of the cystic duct; in dividing, it gives off a main branch for the right lobe of the liver at an angle of about 110 degrees, which passes downward and to the right. This main branch is $1\frac{1}{2}$ cm. long and 10 to 12 mm. in diameter. From the place of division a branch for the quadrate lobe, 2 cm. long and 7 mm. in diameter, passes downward, backward, and a little to the left. At the left border and behind this branch is the bile-duct for this territory of the liver, which is 3 mm. in diameter. Behind the bend and the upper border of the branch to the right lobe the upper border of the right branch of the hepatic duct comes into view. At the place where the trunk of the vena porta curves around from the lower upon the anterior surface of the common duct it takes up three other branches which run along this surface.

Hepatic Artery.—From behind the pancreas the hepatic artery, with a trunk 3 mm. in diameter, passes from left to right into the hepaticoduodenal ligament, for a distance of 15 mm., from the right border of the duodenum horizontally to the right until it reaches the common duct; then on its posterior surface into the hilus of the liver. When it reaches the common duct it gives off a branch which passes forward to the anterior surface of the common duct. This branch soon divides into two or three smaller branches, one running upward and to the right for the upper part of the common duct and the cystic duct, the others downward and to the left to supply the middle and lower portions of the common duct.

Cystic Duct.—The cystic duct is about 4 cm. long; its lower half, which runs upward and to the right in the direction of the common duct, is 10 mm. in diameter, but gradually diminishes until its diameter is only 4 mm. Its upper portion runs vertically, forming an obtuse angle with the lower portion, the concavity being to the left. At its entrance into the gall-bladder in this specimen it is only 3 mm. in diameter. (In the specimen here described a round diverticulum, thin walled, 2 cm. in diameter, was found upon its upper vertical portion.) The upper or distal half of the cystic duct may be incised in a vertical direction for the removal of stone at any place in its extent without wounding the vena porta; the lower or proximal half should be incised for stone as far from its lower or right border as possible, so as to avoid wounding the vena porta.

Hepatic Duct and its Branches.—The hepatic duct goes off from the common duct at the same place as the cystic duct, and bends backward behind the latter and behind the vena porta and its branches. It is $2\frac{1}{2}$ to 3 cm. long, passes to the right, downward and backward, and then divides into the branches for the liver. The upper border of the upper anterior branch to the right lobe can be seen behind and over the border of the vena porta. The branch to the quadrate lobe can be seen to the left, behind the corresponding branch of the vena porta. The hepatic duct is thus situated behind, and is covered by the cystic duct and the

vena porta. A stone in this duct can therefore scarcely be felt from the anterior surface through these two organs, and when a floating stone is pushed or passes up here, it apparently disappears into the liver, and search and manipulation are required to bring it again down into the common duct.

Gall-bladder.—The gall-bladder, when distended, is pear-shaped, with its fundus toward the free border of the liver, which, in its normal condition, it never overlaps, so that it can never be felt when the condition of the patient is normal (Rheinstein). It is from 8 to 14 cm. long and 3 cm. in diameter. At the entrance to the cystic duct it narrows down to 3 mm. in diameter. When retracted and atrophic from inflammation or protracted emptiness and disuse, as in the specimen here described, it may shrink to a length of 4 cm. and to a diameter of $1\frac{1}{2}$ cm., or, as in Case V, to even smaller dimensions.

Remarks.—The descriptive anatomy, as detailed in the text- and hand-books, differs to a great extent from that just given, partly because of the pathologic condition of the specimen described—the dilatation of the common and hepatic ducts and the atrophy of the gall-bladder; but at the same time the position of the vena porta in its relation to the bile-ducts is so different from that given by Henle that I hardly think that the entire difference can be due to the pathologic condition. Henle says (p. 200): “The common duct is situated at the right free border of the hepaticoduodenal ligament, or at the free border which forms the fold at the entrance of the foramen of Winslow. The hepatic artery is situated on its left side close to it, and behind both lies the vena porta.”

These are entirely different relations between the upper part of the common duct, and particularly the hepatic duct, from those found by me, and would naturally lead to the conclusion that any of these ducts might be incised without risk of opening into the vena porta. From the relations described by me it will be seen that a stone in the hepatic duct cannot be cut down upon without passing through the vena porta, with the exception, perhaps, of a small place at the beginning of the duct and behind the cystic duct. In the upper half of the common duct it is unsafe to incise close to the free border of the hepaticoduodenal ligament, because the vena porta here may overlap the right or lower border of the common duct; and it is only the lower half of the common duct that lies close to the free border of the ligament, entirely covering the vena porta. Thus only the lower or right half of the common duct can be incised without danger of opening into the vena porta.

Pathology.—It has been the general belief that most of the chole-
dochus stones are formed in the gall-bladder and pass secondarily through the cystic duct down into the common duct. We also know that stones form in the hepatic branches, and, consequently, in all probability, also in the hepatic and common ducts. In 62 out of 150 cases one or more stones were found in the common duct alone. In the remaining 88 cases stones were found simultaneously in one or more of the biliary passages (Courvoisier).

The stones in the common duct are ordinarily from 1 to 2 cm. in di-

ameter; that is, they are on the average larger than the stones in the gall-bladder. In two-thirds of the cases only one stone has been found; in the remainder, from two to six, but seldom in large number. The shape is usually oval, more rarely globular or irregular.

The locality in the common duct where the stones are found (according to Courvoisier) is, in 67 per cent. of the cases, the lower or duodenal portion; in about 15 per cent., in the upper or hepatic portion; and in the remaining 18 per cent., in the middle portion. I think it is singular that Courvoisier devotes so little attention to floating stones. He says: "The stone was sometimes—in 5 cases only out of 150—found movable in both directions in its culdesac," but does not seem to appreciate that a stone might float through the entire common duct. As he makes his deductions from the literature, it is likely that other authors have overlooked the mobility of the stones in many cases and have simply noted the place where the stone was found, paying no attention whatever to the ease with which it could be moved; for instance, from the more narrow duodenal portion up into the wider upper territory of the common duct.

The natural and usual effect of a stone in the common duct is occlusion to the passage of bile and subsequent dilatation of the biliary passages in a proximal direction. Dilatation of the common duct was noted in 47 out of 200 cases. The duct was dilated from the size of the thumb up to 2 to 4 cm. in diameter. It was rarely—in 14 cases only—dilated to a large, cyst-like cavity. The hepatic duct and its intrahepatic branches were found dilated in 25 per cent. of the cases. While it was always believed previously that the gall-bladder would be found dilated in cases of obstruction from choledochus stones, Courvoisier found, in 1890, to his great surprise, that the gall-bladder was atrophic and more or less empty in 80 per cent. of the cases of choledochus stone and dilated in only 20 per cent. He explains this curious fact in the following manner: Supposing the stones are found in the gall-bladder and have secondarily emigrated to the common duct, they have caused, while in the gall-bladder, a chronic inflammation of its walls, terminating in retraction and atrophy. In support of this view he mentions cases in which local losses of substance or cicatricial territories indicated pre-existing gall-stones. But in many cases such traces of local injury are not found; the cystic duct is open and normal. The atrophy in these cases, hitherto incomprehensible, is easily explained by the ball-valve action of a floating choledochus stone at the distal end of the cystic duct, as described above. This atrophy of the gall-bladder is, as Courvoisier has rightly pointed out, so characteristic for choledochus stone that it is a valuable symptom in the differential diagnosis between stone and other causes of occlusion of the common duct.

Out of 35 operations for obstruction of the common duct collected by Courvoisier, 17 were on account of stone and 18 on account of non-calculous obstructions, strictures, tumors, obstructions within or outside of the duct, etc. In 4 of the 17 cases of stone the gall-bladder was dilated; in 13 it was atrophic. In the 18 cases of non-calculous obstruc-

tion the gall-bladder was dilated in 16, and in only 2 was there no ec-tasia.

The contents of the dilated biliary passages is ordinarily bile, either

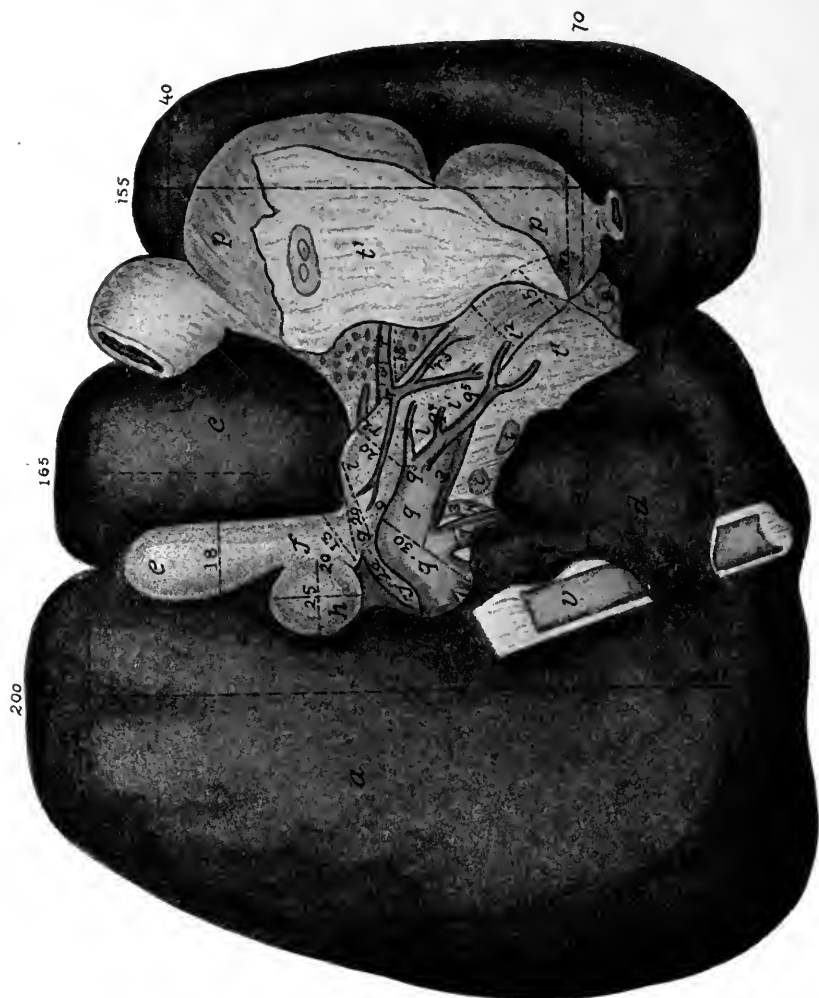

Fig. 117.—*a*, Right lobe; *b*, left lobe; *c*, quadrate lobe; *d*, lobus Spigelii; *e*, gall-bladder; *f*, upper vertical portion of cystic duct; *g*, lower oblique portion of cystic duct; *h*, diverticulum in upper portion of cystic duct; *i*, hepatic duct; *j*, branch of hepatic duct to right lobe; *k*, branch of hepatic duct to lobus Spigelii; *l*, common duct, upper portion; *l*¹, common duct, medial portion; *l*², common duct, lower portion; *m*, diverticulum of Vater; *p*, duodenum; *q*, vena porta; *q*¹, vena porta branch to right lobe; *q*², vena porta branch to lobus Spigelii; *q*³, vena porta branch taking up—*q*¹; *q*⁴ (smaller branches of vena porta from anterior surface of common duct located in hepatoduodenal ligament below its anterior peritoneal surface); *r*, trunk of hepatic artery; *r*¹, branch of hepatic artery to anterior surface of common duct, giving off *r*²; *r*², branch of hepatic and cystic ducts, and *r*³, branch of lower half of common duct; *s*, pancreas; *t*, lymph-glands in hepatoduodenal ligament; *u*, peritoneal surface of hepatoduodenal ligament divided and dissected off from vena porta and common duct; *u*¹, vena cava inferior.

normal, light yellow, or thickened and dark. Pus was found in only a minority of the cases; empyema of the gall-bladder in 8 cases; em-

pyema of the bile-ducts—that is, suppurative cholangitis—in 5 cases; and these conditions combined, in 5 out of a total of 18 cases. In 10 cases only the dilated biliary passages contained no bile, but either watery, colorless, or slightly mucoid fluid, bearing no resemblance to bile, a condition of acholia ascribed to pressure atrophy of the liver-cells, depriving them of the faculty of manufacturing bile. In all the 10 cases collected by Courvoisier not one case of gall-stone was found, but tumors in or outside of the duct, and in 1 case pyemia, were observed.

The relation of the icterus to “gall-stone disease,” or gall-stone in the different parts of the bile-passages, is as follows:

Stones in the gall-bladder cause no icterus (the so-called “gall-stone colic” is suppuration of the gall-bladder).

Stones in the cystic duct—

(a) In the upper proximal half cause no icterus.

(b) In the lower distal half may cause icterus from compression of the hepatic duct.

Stone in the common duct causes icterus by impaction, obstruction, or ball-valve action.

Stone in the hepatic duct causes icterus when impacted in a narrow duct.

Symptoms.—In the attempt to build up a special group of symptoms characteristic for stone in the common duct we are confronted with certain difficulties:

1. In nearly one-half of the cases stones are present not only in the common duct, but also in some other portions of the biliary passages.

2. Very few authors have attempted to separate the cases of choledochus stone, as a distinct group, from the general gall-stone group, but have given the symptoms of the entire class. Courvoisier was, I believe, one of the first to make a separate classification, and I agree with him that it is possible to differentiate choledochus stone as a distinct class by means of a somewhat characteristic group of symptoms:

1. *Gall-bladder.*—The condition of the gall-bladder, as has already been stated, furnishes valuable information. Atrophy, or at least absence of tumor, abscess, or local tenderness in this locality, is characteristic for uncomplicated choledochus stone (Courvoisier).

2. *Icterus.*—The most important, or, as Courvoisier avers, the cardinal, symptom in choledochus obstruction is icterus. It must be present when obstruction occurs. Multiple small stones may not obstruct the flow of bile, but larger stones will do so, either by occlusion of the lumen of the duct or by ball-valve action. Any one very small stone may, as in Case V, cause intermittent obstruction by ball-valve action.

The icterus is rarely continuous and equal in intensity for a long time, because a large stone is seldom permanently wedged in the duct. In cases of choledochus stone the icterus is ordinarily intermittent or remittent.

(a) *Intermittent Attacks of Icterus.*—A few attacks of relatively short

duration, separated by free intervals of months or years, are found in 25 per cent. of the cases of choledochus stone. This probably signifies passage of gall-stones into the duodenum. It is the classic gall-stone colic with icterus, and is consequently characteristic, not of a larger

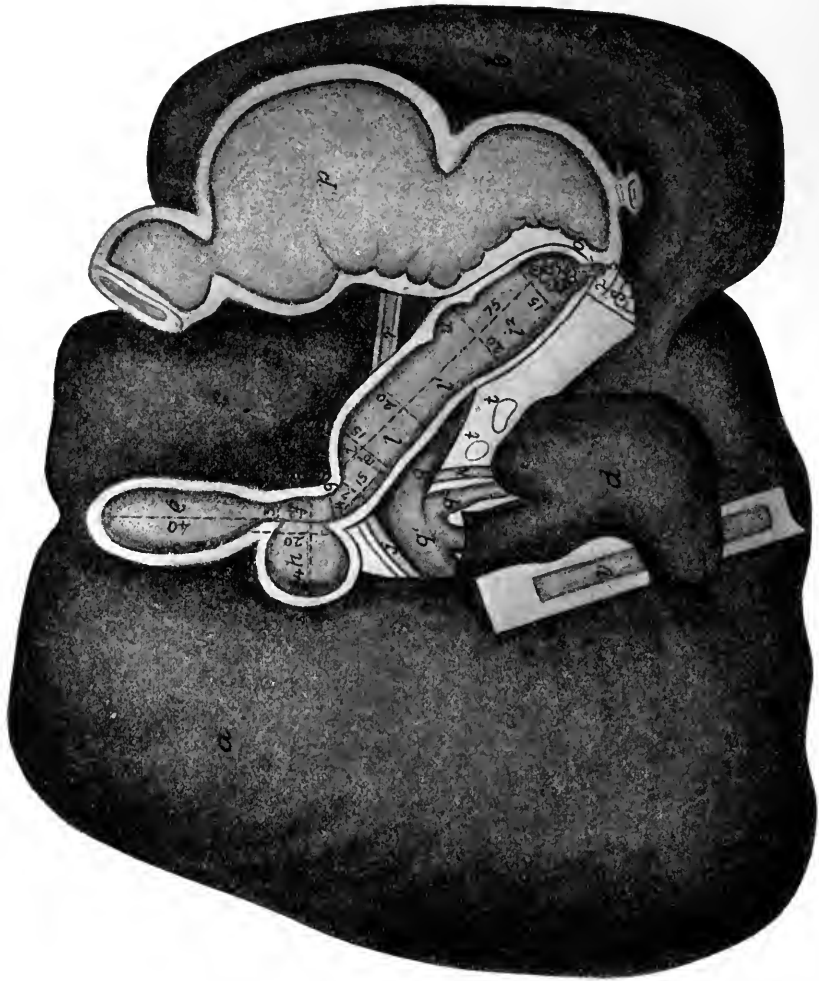


Fig. 118.—*a* Right lobe; *b*, left lobe; *c*, quadrate lobe; *d*, lobus Spigelii; *e*, gall-bladder; *f*, upper vertical portion of cystic duct; *g*, lower oblique portion of cystic duct; *h*, diverticulum in upper portion of cystic duct; *i*, hepatic duct; *j*, branch of hepatic duct to right lobe; *k*, branch of hepatic duct to lobus Spigelii; *l*, common duct, upper portion; *l'*, common duct, medial portion; *l''*, common duct, lower or duodenal portion; *m*, diverticulum of Vater; *n*, stone in diverticulum; *o*, duodenal opening of common duct; *p*, duodenum; *q*, vena porta; *q'*, vena porta branch to right lobe; *q''*, vena porta branch to lobus Spigelii; *r*, trunk of hepatic artery; *s*, pancreas; *t*, lymph-glands in hepaticoduodenal ligament; *u*, diverticulum in common duct; *v*, vena cava inferior.

stone remaining in the duct, but of smaller stones passing out. The occurrence of icterus with colic as a distinct, rare attack, occurring occasionally in the history of choledochus stone, speaks for gall-stone

disease in general, as compared with other causes of obstruction, such as tumor, compression, stenosis, etc.

(b) *Remittent icterus*, on the other hand, slight and, as we might say, incomplete attacks of icterus, occurring as often as once or twice a week, is characteristic of stone in the common duct, and, in my opinion, of floating choledochus stone. This remittance is such that the icterus varies in intensity. In the short interval between attacks of complete occlusion, with a day or two of clay-colored stools, followed by the presence of bile in the passages, the skin becomes less yellow, but another occlusion takes place before the icteric color has had time to disappear entirely.

In rare cases the icterus may temporarily disappear because of a longer interval between attacks, or because of a shorter period of occlusion—one day, for example. In such cases the icterus is incomplete, the skin may be yellowish, but the conjunctiva normal, with bile in the urine, and the interval may be sufficiently long to allow even this slight icterus to disappear temporarily.

Cruveilhier gives the following explanation of remittent icterus: During the attack of complete icterus with clay-colored stools the stone is tightly grasped by or wedged in the wall of the common duct, and complete occlusion occurs. Accumulation of bile on the proximal or liver side of the stone causes dilatation of the duct on this side; the wall is pressed away from the stone, some bile is thereby permitted to pass down, and a state of incomplete occlusion ensues, with bile-colored stools and decrease of the icterus. The distention of the duct on the proximal side of the stone subsides, the wall again contracts closely over the stone, and the preparation for another exacerbation is now complete.

Courvoisier found in the literature 12 cases of this form of remittent icterus in which autopsies were obtained; in 9 cases choledochus stone was found, and in 3 a tumor was found in the duct. He thinks that Cruveilhier is right, and considers his explanation "plausible" for the cases of tumor in the duct and for some cases of single or multiple large stone when immovably fixed or situated in a locally dilated portion of the duct. His explanation cannot, however, in my opinion be accepted for small stones, when a stone, for example, 1 cm. in diameter, is located in a duct 2 cm. in diameter, or when a stone is present which is movable or floating not only during the attack of icterus (as in my Case I), but also during the intervals between attacks (as in the cases in which I operated). In such cases—and I believe them to be vastly in the majority—the frequency of the attacks of incomplete icterus or the remittance of the icterus cannot be explained in any other way than by ball-valve action.

The exacerbation in the remittent icterus not infrequently follows a heavy meal. A distended stomach adherent to the hilus of the liver or the wall of the gall-bladder, as we so often find it in these cases, is likely so to displace the floating stone as to bring on an attack, by pushing the stone down into the culdesac in the duodenal end of the duct—the diverticulum of Vater.

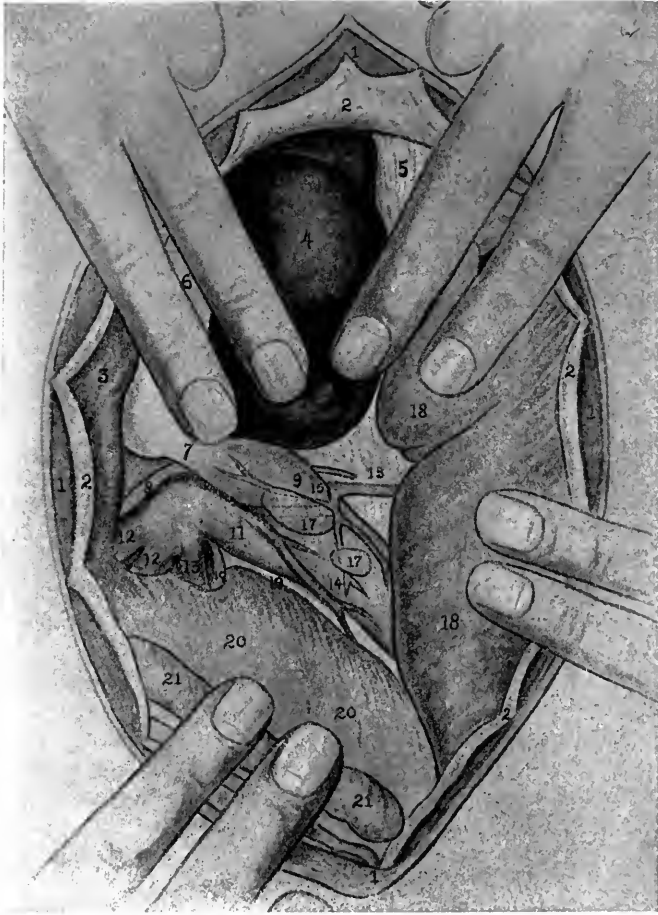


Fig. 110.—Field of operation: 1, Wound through abdominal wall; 2, parietal peritoneum sutured to skin; 3, right lobe of liver, lower surface; 4, quadrate lobe of liver; 5, suspensory ligament of liver; 6, gall-bladder; 7, cystic duct; 8, hepatic duct; 9, common duct; 10, branch of hepatic duct to lobus Spigelii; 11, trunk of vena porta; 12, branches of vena porta to right lobe; 13, branches of vena porta to lobus Spigelii; 14, small branch of vena porta in hepaticoduodenal ligament; 15, hepatic artery; 16, branches of hepatic artery to hepaticoduodenal ligament; 17, lymph-glands in hepaticoduodenal ligament; 18, duodenum; 19, entrance to foramen of Winslow; 20, hepaticocolic ligament; 21, transverse colon.

If Courvoisier's explanation is correct, the increased secretion of bile following a heavy meal would act in an opposite manner and would cause an existing attack to disappear by permitting some bile to pass by the obstructing stone.

I might even go so far as to say that the frequently repeated incomplete attacks of icterus—the remittent icterus—rather indicate choledochus stone and ball-valve action from a floating stone.

Is icterus present in cholelithiasis outside of the common and hepatic ducts? In stones of the gall-bladder, with or without inflammation, it is not present. If the stone enter the dilated cystic duct, it may, by its size or possibly by pericyclic inflammation, cause compression of the hepatic duct and icterus. This would explain those cases of stone in the gall-bladder in which icterus is present and removal of the stones by cholecystotomy effects a cure. In some cases the cystic duct might be large enough to permit the stones to float down into the common duct and back into the gall-bladder. Remittent icterus would, of course, be expected in such cases.

Continuous or remittent icterus persisting for years may be caused by stone or by non-calculous occlusion. If the icterus exists for two or more years without cachexia, it is probably due to stone, because a malignant tumor in the duct or duodenum would cause death in a shorter time. Lawson Tait states that intense icterus lasting for years speaks for stone in contradistinction to tumor. Courvoisier, from his investigation of the literature, arrives at a diametrically opposite conclusion. Intense and continuous icterus, on the whole, speaks for tumor; but Lawson Tait is correct in stating that icterus extending over a number of years is presumptive evidence of stone. This explanation will render possible the reconciliation of the opinions of both these authors.

3. *Colic*.—It is generally conceded that colic is a capital symptom of stone in the biliary passages. In 80 cases of obstruction from choledochus stones collected by Courvoisier he found colic in 51, or 63.7 per cent.; the symptom was not mentioned in 19, or 23.7 per cent.; and it was positively stated to be absent in 10, or 12.5 per cent. In 74 cases of obstruction from tumors colic was noted in only 9 cases, or 12.2 per cent., and was absent in 65, or 87.8 per cent. Thus it will be seen that colic speaks strongly for choledochus stone as the cause of occlusion, as opposed to tumors.

Preceding attacks of colic indicate choledochus stone which has passed into the duodenum. Courvoisier states that in 51 cases of choledochus stone colic stones were found in the feces in only 5 cases.

Colic is a natural companion to icterus of sudden onset, but continued attacks of colic and icterus speak for occlusion from stone in the common duct, either temporary, when the stone passes down into the duodenum, which is relatively rare; remittent, in floating choledochus stones, which is common; or, finally, permanent, when the stone is impacted and causes complete permanent occlusion, which is also rare.

4. *Localization of Pain*.—In the cases of stone in the common duct

the pain, according to my observation, is seldom localized in the region of the gall-bladder or in the right hypochondrium, unless concomitant inflammation of the gall-bladder, caused by stones in that viscus, is present. I found the pain located in the epigastrium in Cases II, III, and V; in III and V there was simultaneous pain in the region of the gall-bladder. The pain was located in both lumbar regions in Case VI; equally in both hypochondriac regions in Cases V and VI; and in the lower part of the back or lower dorsal region in Cases I, II, III, and VI. I consider this localization of pain outside of the gall-bladder as a characteristic symptom of floating choledochus stone.

5. *Remittent Pain.*—The frequent remittance of pain, either slow or sudden in onset, and suddenly disappearing, attended by a flow of bile, but with no stone in the feces, signifies a single stone or a few stones that do not pass through, but float in a dilated common duct. The attacks of colic or pain in the course of the disease become more and more frequent—from once or twice a month to once or twice a week, and in some cases even daily. In Case II the attack of pain lasted for ten hours; in Case V, from half an hour to two hours.

6. *Vomiting.*—Vomiting was present in Cases I, II, III, and V. In Case VI the patient experienced relief from vomiting—so much so that she was accustomed to produce vomiting in order to gain relief from the pain.

7. *Relief of Pain in Certain Positions.*—The pain is frequently relieved and the attack brought to an end by changes of position, which probably displace the floating stone, or by the maintenance of some one position. In Case IV the patient obtained relief by lying on the stomach; in Case VI, by inducing vomiting; in Case V, by flexing the thighs upon the abdomen.

8. *Loss of Weight.*—An important and characteristic symptom I have found to be the rapid and considerable loss of weight, which cannot be explained by fever, as fever is either absent or of only slight degree; by sepsis in the bile, as the bile may be aseptic, as in Case IV, or by the severity of the icterus, as icterus is frequently slight, and as the feces are intermittently or generally bile-colored. The loss of weight must, in my opinion, be attributed to intermittent, frequent ptomain intoxication,—that is, bile absorption,—as well as to disturbed digestion.

The loss of weight is characteristic and rapid, and after the operation the patient rapidly regains weight. In Case I the loss of weight was 60 pounds; in Case II the patient lost 15 pounds in ten weeks, but after the operation gained 50 pounds in three months; in Case III the patient lost 50 pounds, and after the operation gained 20 pounds in three months; in Case IV the patient lost 25 pounds in seventeen days, and after the operation gained 40 pounds in forty days; in Case V the patient lost 25 pounds; and in Case VI the patient lost 53 pounds, and since the operation has gained 38 pounds in weight. In Czerny's Case XX, reported by Mermann, the patient lost 36 pounds, and after the operation gained 40 pounds in nine months; in Case XXI the patient gained 4 pounds in

one month after the operation; and in Case XXII there was a loss of weight of 25 pounds.

9. *Fever*.—Intermittent or remittent biliary fever ordinarily follows or precedes the attacks of colic and icterus. It is not yet decided whether this rise in temperature is due to absorption of retained aseptic bile, or whether the microbic invasion from the intestine, which infects the bile, causes inflammation of the wall of the duct, thus making the fever septic. Charcot described an intermittent hepatic fever due to absorption of retained aseptic bile. Schüppel is inclined to believe that inflammation—that is, infection from microbes—is essential in the causation of fever. Courvoisier, after analyzing the cases collected from the literature, found fever in 25 per cent. of the cases of occlusion from stone, and only in 10 per cent. of the cases of occlusion due to other causes. In all these latter cases he found a well-defined microbic cause for the fever. He, therefore, accepts Schüppel's opinion in this regard. Acorimbini believes that the fever is caused by bacteria which enter the bile-passages from the duodenum or from the circulation. He states that the *Bacterium coli communis* is normally found in the bile-passages, and is a factor in the formation of gall-stones. The bacteria cause a desquamative angiocholitis (Dujardin-Beaumetz, Mosler, Naunyn), and the stone contains the colon bacillus throughout its mass. When the stone has formed, it causes abrasion of the epithelium of the ducts, and the microbes enter and cause inflammation of the wall, which leads to the plastic peritonitis which causes the formation of adhesions between the peritoneal surfaces of the ducts and the surrounding organs.

It seems to me, however, that we cannot positively deny the possibility of a rise in temperature due to the absorption of aseptic bile caused by sudden retention from obstruction due to stone. The fever, according to R. Schmitz, sometimes precedes the colic, and is consequently the earliest symptom of occlusion. If bacterial infection and inflammation of the wall of the ducts cause the fever, why should it cease with the removal of the obstruction? If infection of the bile contained in the biliary passages, the bile being the culture-medium for the bacteria contained in the stone, and if the ptomaines thereby produced, cause the fever by their absorption, why should the fever in some cases be the earliest symptom, even preceding the pain caused by the obstruction? Furthermore, would we not expect to find, in all cases of stone causing remittent attacks of fever, that the bile contained some of the microbes, even the most innocent—the colon bacillus? In my Case IV the bile from the common duct was sterile, and yet the attacks of retention were always accompanied by marked fever.

Operation.—Many operations have been employed for the removal of stone in the common duct.

Indirect lithotripsy—crushing—leaves débris, some of which may remain in a pouch in the duct, increase in size, and, as the stone is always a bacterial depot, may cause inflammation of the wall or even cholangitis.

Cholecystenterostomy—the formation of an anastomosis between

the gall-bladder and the jejunum—is possible only when the cystic duct is patent.

Choledochoduodenostomy is more generally applicable, but it does not remove the stone, and consequently does not remove the cause of septic inflammation, even if it removes the retention of bile and icterus. A patient of Körte's died from cholangitis caused by a choledochus stone, notwithstanding the existence of a duodenal fistula which permitted free egress to the bile.

Cholecystenterostomy is an operation of necessity when the obstruction cannot be found or removed. It is never an operation of choice, and will very rarely be called for in cases of choledochus stone.

Cholecystotomy—it is only in rare cases that a choledochus stone can be removed through the gall-bladder; namely, when the cystic duct is so dilated as to permit the passage of the stones back into the gall-bladder or of a forceps down to grasp or crush the stones. It is impossible, however, to be sure of removing all the multiple floating stones through the gall-bladder, as the exploration of the common duct through its lumen can be accomplished only very imperfectly by a sound or probe through the gall-bladder.

Perfect, thorough exploration of the common duct should be made by the finger, and should extend up into the hepatic duct, and this can be accomplished only by choledochotomy and exploration through the opening thus made.

The only remaining operation of choice which has a legitimate field, but is rarely called for, is the transduodenal incision over a stone in the dilated diverticulum of Vater. One case of this kind is reported by Pozzi and one by McBurney.

Internal choledochotomy, division of strictures in the common duct through an opening in the gall-bladder, a successful case of which Albé has reported, is rarely applicable, and is a dangerous procedure, as it is an operation in the dark, and there is grave danger of wounding the vena porta or the hepatic artery. My preference in such cases would be to make an external choledochotomy and then deal with the stricture.

Choledochotomy, the choledocholithotomy of Courvoisier, the excision of the gall-stone from the ductus choledochus, is the operation of choice which is most commonly indicated, and which effects the most complete cure. This operation was proposed by Langenbuch in 1884. Charles T. Parkes, of Chicago, also spoke of the operation in 1885, and proposed to leave the duct open and drain it by means of a rubber drainage-tube, or to close the opening in the duct by sutures. Kummel, in 1890, stated that several years before, about the time Langenbuch proposed the operation of cholecystectomy, he had a patient, a woman of forty years, in whom, after having extirpated the gall-bladder, he found a choledochus stone the size of a walnut in the dilated common duct. He incised the duct, removed the stone, and closed the opening with sutures. The operation was long and severe, and the patient died twenty hours after (Courvoisier).

Courvoisier was the first to perform choledocholithotomy. He had made the diagnosis of choledochus stone, and had planned the operation beforehand. He made the first operation on January 22, 1890; operated on a second patient February 18, 1890, and on a third on March 17, 1890, and all three of these operations were successful.

The remarkable success achieved by Courvoisier immediately secured for choledocholithotomy a place in the front rank of the operation for choledochus stone.

In 1892 Martig had already collected 27 cases, and in 1895 Mermann collected 17 additional, making a total of 44 cases of choledochotomy, with a mortality of 18 per cent.

Technic of Choledocholithotomy.—The operation is not always easy, and requires at the least one to two hours for its performance. The wound is necessarily deep, and the operating on the duct has to be done at the bottom of the wound. The liver is often swollen and hard, and adhesions are almost always present. Good light is absolutely essential (Mermann). I prefer daylight to artificial light. Skilled assistants are necessary, as the liver must be lifted and held up, preferably by the fingers of an assistant. I prefer this to the method proposed by Studsgaard, who had the liver held up by means of a loop of silk passed through the liver tissue near the border of the organ. (See Fig. 119.)

A. Incision.—An incision of ample length is required in order to secure operating space, and it is often necessary to supplement the longitudinal lateral incision with a transverse horizontal one (Czerny). The peritoneum should then be sutured to the skin.

B. Adhesions.—After the introduction of large flat sponges the adhesions between the gall-bladder, stomach, transverse colon, and the greater omentum, which are common, should be separated. These organs, together with the duodenum, are often adherent to the common duct. These adhesions are often band-like and comparatively easy to loosen, either by blunt dissection or by division between ligatures, but they necessarily prolong the operation. In some cases, fortunately rather rare, the duct is found buried in such extensive and firm masses of cicatricial tissue that it is impossible to isolate it or even to find the stone. Thus Körte reports 2 cases of attempted choledochotomy in which he was unable to isolate the common duct and could not find the stone. At the autopsy on the first case he found, but not until he had removed the liver from the body and laid it upon the table, a small stone in a parietal dilatation of the common duct. In the second case he tried at the autopsy, first, to find the stone through the wound of operation, but in vain, and it was not until the liver and surrounding organs had been removed and laid upon the table for dissection that he was able to find a stone the size of a bean in the common duct, which was firmly adherent to the surrounding organs.

C. Examination of the Gall-bladder.—After isolation of the gall-bladder from the adherent organs it is usually found to be small, atrophic, and empty; it may even be obliterated, but no reports of this condition are on record. Professor Frank Billings has, however, told me of two

cases, when he was present at the operation, in which this condition was found. In rare cases it is found to be dilated. A distended gall-bladder should be emptied by aspiration. When stones are found in the gall-bladder and in the common duct, the stones in the former must be removed by cholecystotomy. I think it sufficient to open the gall-bladder only when a stone can be felt through its wall. Czerny (Mermann) considers it necessary to incise the gall-bladder and examine it for stones, whether stones can be felt through its wall or not.

D. Isolation of the Common Duct.—After loosening the adhesions to the gall-bladder the cystic duct is exposed, and the attempt should now be made to lay bare the anterior surface of the hepaticoduodenal ligament. I have ordinarily found in this locality one or more enlarged lymph-glands. The ligament should now be laid bare downward and to the left until the right border of the duodenum is reached. The free right border of the hepaticoduodenal ligament should now be isolated, and the foramen of Winslow found. The index-finger of the left hand should now be passed upward and to the left in the foramen, whereupon the contents of the ligament, namely, the vena porta, the common duct, and the hepatic artery, may be palpated between the index-finger and thumb.

E. Palpation of the stone is made by searching the duct from behind the duodenum, at about its middle, upward and to the right as far as the hilus of the liver. A floating stone, if present, is felt at the duodenal end or elsewhere in the duct, and often slips away when the attempt is made to engage it between the finger and thumb. It is easy to find the stone again anywhere in the common duct, but when it slips up into the hepatic duct it disappears, and may require considerable manipulation to bring it down into the common duct again. Czerny, in Case XX (reported by Mermann), performed choledochotomy without finding a stone, but removed two stones from the gall-bladder by ideal cholecystotomy. In Case XLI biliary colic existed for one week five months prior to the operation. The icterus gradually decreased. The patient was emaciated, had lost 36 pounds in weight, and was sleepless. On three occasions small gall-stones were found in the feces. The patient was pronouncedly icteric, and the feces acholic. A median incision was made, and the gall-bladder found to be atrophied. During the loosening of adhesions to the greatly dilated hepatic and common ducts a sudden flow of bile occurred, and, as Mermann states, "consequently a tear or an opening in the common duct." The operator felt, through the walls, a stone, which was easily displaced and slipped or floated up under the liver. No stone could be found after exploration with the sharp spoon and the forceps, but only old, blackish-green coagula were brought out. (This, I think, was the crushed stone, as in my Case VI I encountered a small third stone, which I could feel with the tip of my finger in the wound, but could not dislodge into the wound by manipulation of the hepaticoduodenal ligament.) The operator searched for the choledochus stone for an hour, but could not find it. The ductus choledochus was sutured and

tamponed; on the second day the drain was removed. The operation lasted two hours; the patient was out of bed in three weeks, and in nine months after the operation had gained 40 pounds in weight. Mermann remarks: "Where did the stone that disappeared under the palpating finger, and could not be found, although searched for for an hour, go to? It is not clear; it was not found in the feces. It has probably not remained, as the patient recovered, and was well nine months after the operation. The stone was the size of a pea, and could hardly have passed into the gall-bladder, as the caliber of the cystic duct was not sufficient to permit this." My own idea is that the stone was either crushed during palpation between the thumb and finger or by the sharp spoon, and that the blackish-green coagula were simply the débris of the crushed stone.

The field of operation should now be surrounded by three, four, or five large flat sponges.

F. Fixation of the stone at the place of intended incision is made by grasping the stone between the finger and thumb, and holding or pushing it up against the anterior surface of the duct. When the stone is floating, and we are consequently able to select the point of incision into the duct, it should be moved to the anterior surface of the left or lower half of the duct close to the duodenum. When the stone is yellow, we can sometimes see it shining through the thin wall of the duct. In order to ascertain whether a stone or a tumor of the duct is present, a needle should be passed in, which will grate upon the stone.

G. The incision in the duct should be $1\frac{1}{2}$ to 3 cm. long, and in the direction of the axis of the duct, over the surface of the stone, which should present in the opening and should then be lifted out. The removal of the stone is ordinarily followed by a flow of bile, from which cultures should always be made. The place of incision in case of floating stone can be chosen, and should be, as I have already pointed out in the anatomy, in the duodenal portion of the duct, to avoid wounding the vena porta.

H. Exploration of the duct through the wound in it may be made with the finger; in the majority of cases the duct is sufficiently dilated to admit the little finger. It is my custom to explore in both directions: down behind the duodenum and up into the hepatic duct. By this means a small stone not felt upon external palpation of the hepaticoduodenal ligament may be discovered and extracted.

I. Extraction of Stones.—Stones of the common duct can usually be pushed up into the opening by manipulation and will then slide out, or they may be removed by forceps or lifted out by sliding a sharp spoon behind them, or may be crushed and the débris removed by the sharp spoon. I have had made for this purpose a sharp spoon with a long, flexible handle, which may be bent in any position for the removal of the stone from the duct.

J. Sounding the common and hepatic ducts for stone should be accomplished with a metal probe, which, upon touching the stone, imparts a grating sensation. For this purpose I employ a silver uterine probe.

A stone may also be dislodged by this means from the hepatic duct, as in my Case IV.

K. Probing to ascertain if the opening or passage down into the duodenum is free cannot always be accomplished, not because of an obstructing stone or stricture, but because the sound may meet a fold of mucosa in the dilated common duct. As bile passes after the removal of the stone, as we know from the remittance of the obstruction symptoms, any further attempt at opening the passage into the duodenum by means of the probe is unnecessary.

L. Closure of the wound in the common duct should be accomplished by a double row of sutures: an inner row through the muscular and external coats of the wall of the duct, but not penetrating the mucosa; and an outer row, including or taking in the peritoneum of the anterior wall of the hepaticoduodenal ligament. I usually leave the sutures long, in order to hold up the wound in the duct during the insertion of the following sutures. The insertion of sutures is easy when the wall of the duct is thickened, but difficult when the wall is thin, as the needle penetrates the mucosa and bile flows through the needle-punctures. The outer row of sutures may stop the flow of bile, but it is sometimes impossible to seal the wound hermetically, however carefully the sutures may be applied. In two of my cases no bile exuded from the wound, but in others, which terminated as favorably, there was a discharge of bile for a limited time—a much shorter time than obtained in the majority of my cases of ordinary cholecystotomy.

M. Drainage is accomplished by a rubber drainage-tube passed down to the wound in the duct, and gauze drains inserted one above and the other below the rubber drainage-tube. When the gall-bladder is opened, and instead of being closed is united to the abdominal wall, I drain the gall-bladder by a rubber drain only, and unite the abdominal wall below, so as to separate the drains in the gall-bladder and common duct.

CONCLUSIONS

1. In the great majority of cases of stone in the common duct the duct is dilated and the stone floats in it.
2. Choledochotomy is the operation of choice, and should be employed whenever applicable, as it is far superior to all other methods of operation.
3. Choledochotomy is applicable in the vast majority of cases of stone in the common duct; the cases demanding other operative procedures are rare.

BIBLIOGRAPHY

- Charcot: Cited by Courvoisier.
Conradi: "Cholelithiasis," Norsk Magazin for Laegevidenskaben, 1891, p. 1046.
Courvoisier, L. G.: Casuistisch-Statistische Beiträge zur Pathologie und Chirurgie der Gallenwege, Leipzig, 1890.
Cruveilhier: Cited by Courvoisier.
Czerny: Cited by Mermann.

Fiedler: Cited by Courvoisier.

Mermann, F.: "Beiträge zur Chirurgie der Gallenwegen," Bruns' Beiträge zur klinischen Chirurgie, 1895, vol. xiii, p. 319.

Rheinstein: Berlin. klin. Wochenschr., 1891, vol. xxix, p. 1328.

Schloth: Cited by Courvoisier.

Schüppel: Cited by Courvoisier.

Socin: Cited by Courvoisier.

Tait, Lawson: Cited by Courvoisier.

AN OPERATION FOR VALVULAR STRICTURE OF THE URETER *

IN cases of hydronephrosis or pyelitis with distention (pyonephrosis) it is not uncommon to find comparatively narrow or thin-walled, semi-lunar valves located transversely in the ureter. These open upward and have the same mechanical action as the valves in veins, and stop the passage of liquid through the ureter on its way from the kidney to the bladder. These valves are sometimes single and sometimes multiple, two or three in the same ureter. They have been depicted in Rayer's atlas,† and are not uncommonly mentioned in the descriptions of specimens in the literature. They cause a gradually increasing impediment to the flow of urine, and effect dilatation of the ureter above and usually near to the valve, so that a ureter with multiple valves will present as many dilatations and constrictions as there are valves. It is natural that if small stones form in the kidney, they should be arrested at the valves.

That such a valve can be successfully operated upon from within the ureter through a longitudinal incision in the latter is well illustrated in the following case:

CASE.—Synopsis.—In 1880, at the age of seventeen years, probably traumatic right floating kidney; remittent attacks of pain, reawakened after first pregnancy, in 1885, to disappear for eight years, returning in 1893, subsequent to miscarriage, to become intermittent or almost constant; pyonephrosis, with tumor in region of right kidney; pelviotomy August 6, 1895; removal of four stones from ureter above a valvular stricture: longitudinal ureterotomy over stricture; excision of stricture; plastic operation on ureter; wound in pelvis left open for bougie passed down into ureter; wound healed without fistula in six weeks; patient well in March, 1896, seven months later.

Mrs. G., aged thirty-two years, was referred to me by the courtesy of Dr. E. E. Simpson, and entered the German Hospital, in my service, August 1, 1895. The patient's family history was good. She had had the ordinary diseases of childhood, but was in other respects in excellent health until her seventeenth year. At this time, after jumping from a wagon to the ground, she at once experienced pain in the right side, immediately under the ribs, so severe that she fainted. She was not confined to her bed, and the pain was not constant, but after an intermission of several days intense pain, lasting from a few hours to several weeks, would recur. The pain was located in the right hypochondriac region. No blood was noticed in the urine or stools either immediately following the injury or subsequently.

Menstruation commenced at the age of eighteen years, and she was fairly regular and had comparatively little pain or discomfort. She married at twenty-one years; has two

* Amer. Jour. Med. Sci., 1896, vol. cxii, p. 657.

† Rayer: *Traité des Maladies des Reins*, Paris, 1837.

children. After the birth of the first child the pain in the side again became quite severe, but during her second pregnancy she complained of little pain. The second child was born three years after the birth of the first, after a tedious labor. On the third or fourth day she had a chill, followed by fever, and during the six weeks following had fever and intense pain in the back, the left half of the abdomen, and the joints in various parts of the body. During the first week after her confinement a large slough, 4 inches in length, extending from the anus upward over the sacrum, occurred. Five weeks later the gangrenous tissue was removed, but the wound did not heal for three months and a half. During the next four years the patient had three miscarriages. At the time of the last miscarriage, in 1893, the patient had the same pain that she had had fifteen years previously in the right hypochondriac region, ranging to the median line.

The patient was somewhat emaciated; heart and lungs normal; abdominal examination revealed an obscurely defined tumor in the right side of the abdomen, close to the umbilicus, 4 inches long by 3 inches wide, dull upon percussion. The tumor was readily movable to the median line, and backward to the normal position of the kidney, but attempts to move the tumor caused considerable pain. Vaginal examination showed that the uterus was somewhat enlarged but in normal position, and not freely movable. Pressure over ovaries caused only slight pain. The urine contained neither albumin nor sugar.

During the attacks of pain she urinates frequently, but passes only small quantities of urine. The pain always begins in the right lumbar region, and from here radiates to the epigastrium, anterior part of chest, right and left inguinal regions, and also sometimes into the leg. She has lost 40 pounds in weight during the last seven years.

Diagnosis.—Cystonephrosis of right movable kidney, probably due to stone in kidney or pelvis. Probably infected.

I therefore advised exploratory incision for drainage and possible removal of stones.

Operation.—On August 6th I operated in the following manner: The patient was anesthetized with ether and placed on the left side on a cushion. An incision was made between the twelfth rib and the rim of the pelvis, forward for about 9 inches from the border of the erector spinae muscle (Fig. 120).

The kidney was large, with but little perirenal fat, and was freely movable. Two small cysts presented on the convex surface of the kidney, about the size of a pea, which contained clear fluid. A part of the kidney tissue which included these cysts was removed for examination. After isolation of the pelvis, which I found to be somewhat dilated, but in which I could feel no stones, I laid bare the ureter and felt a nodular mass 2 inches below the pelvis. I then incised the pelvis longitudinally, and about an ounce of urine escaped, from which cultures were made. I could now insert my little finger down into the dilated ureter for 1 inch without feeling a stone, but upon manipulation of the ureter with

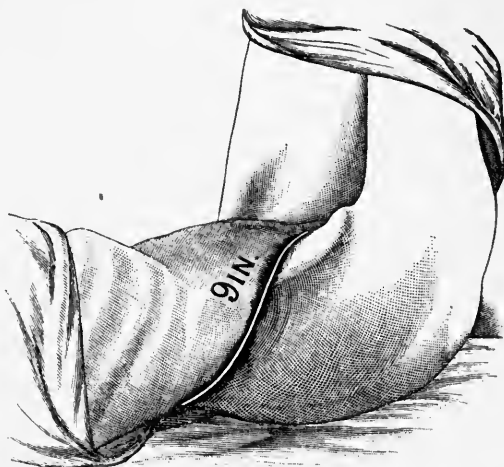

Fig. 120.—Line of incision when wound was nearly healed.

the other hand I was able to squeeze four stones up into the pelvis and remove them through the wound in the pelvis (Fig. 121). A sound passed down from the pelvis into the ureter was arrested $2\frac{1}{2}$ inches below the pelvis, at a point where a somewhat soft thickening was felt on palpation. A longitudinal incision was now made, $\frac{3}{8}$ inch long, into the ureter upon the end of the sound above, through and below a transverse valvular stricture. A probe inserted through the opening in the ureter below the stricture passed easily down into the bladder. By holding the longitudinal wound open and stretching this part of the ureter over the index-finger, I clipped off the valvular stricture (Fig. 122) from within the ureter with scissors, leaving the muscular and internal coats of the ureter intact. I now made my plastic operation on the ureter* and inserted a flexible bougie, No. 12, from the wound in the pelvis into the ureter. The wound in the pelvis was left open. Upon



Fig. 121.—Stones from ureter above stricture (natural size).

digital exploration of the calices through the wound in the pelvis I found the calices moderately dilated, and in one of them a small stone, which I removed. No other stones were found after careful examination. On this account I did not consider it necessary to incise the kidney on its convex surface. Rubber drainage-tubes were then inserted—one down to the wound in the ureter, and another to the pelvis of the kidney. These tubes were surrounded with gauze. The external wound was closed with heavy silk sutures.

The operation occupied two hours. At the close of the operation the patient was in good condition, pulse strong, respiration good. She vomited twice after the operation. In the evening she was catheterized, and 2 ounces of dark-brown urine withdrawn. She complained of severe pain in the wound. During the night she passed 4 ounces of urine, and toward morning the pain decreased.

Microscopic examination of the valve (Fig. 123) showed that this consisted of firm



Fig. 122.—Circular valve in the ureter (natural size).

fibrillary connective tissue, with normal distribution of vessels (*a*), no muscular fibers of the wall extending into it. The free border of the valve looking into the lumen of the ureter (*d*) was clad with stratified cylindrical and cuboid epithelium (*b*). The border of the valve was folded, and thus a cross-section through the bottom of a fold showed an island of cuboid epithelial cells (*c*).

August 7th: The patient vomited several times, complained of severe pain in the afternoon, and passed bloody urine. During the twenty-four hours she passed $16\frac{1}{2}$ ounces of urine. She complained of severe pain in the wound, but was otherwise bright and cheerful. Considerable discharge found in the dressings.

August 8th: The patient passed bloody urine throughout the day and complained of very severe pain.

* Fenger: Jour. Amer. Med. Assoc., 1894, vol. xxii, p. 335.

August 9th: The patient had but little pain during the day, and the nausea and vomiting ceased.

August 10th: The gauze was almost dry, indicating that the urine had passed along the bougie through the ureter.

August 11th: The patient was perspiring profusely for about half an hour in the evening, and a little later complained of severe pain.

August 12th: Thirty ounces of urine were passed in the twenty-four hours.

August 13th: The patient complains of severe pain. The bougie was removed, but the drainage-tube allowed to remain in place. In the afternoon she complained of severe pain.

August 15th: The patient complains of sharp pain in the bladder at the close of urination and also of pain in the wound.

August 20th: Condition of wound and patient excellent.

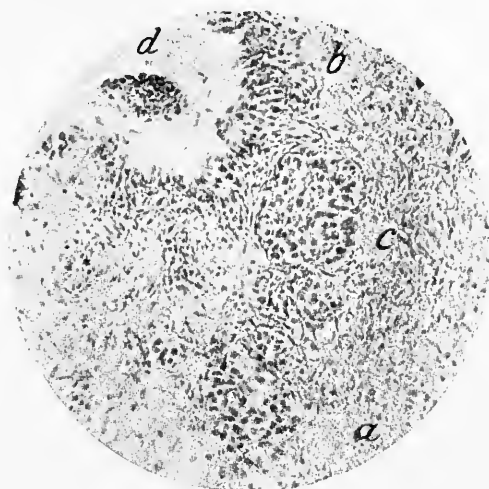


Fig. 123.—Microscopic section of valve.

August 26th: No urine in the dressing. Drainage-tube to the pelvis of the kidney removed and tube to the wound in ureter shortened.

September 1st: Drainage-tube removed.

September 8th: The patient sitting up. Feels strong, and is bright and cheerful.

September 20th: The patient left the hospital for her home. The wound was healed, with the exception of a narrow superficial granulating line.

On March 19, 1896, Dr. Simpson wrote me as follows: "Mrs. G. is doing remarkably well."

It will be seen that the operation for infected cystonephrosis in this case was not nephrotomy, as the convex surface of the kidney was not divided at all. Pelviotomy (opening of the pelvis) was made, partly for the removal of the stones squeezed up out of the ureter and partly for the exploration of the ureter and calices.

Exploration of the ureter with the sound led to the detection of the stricture, a valve, which was excised through a longitudinal opening in the ureter at its seat. I consider this operation preferable to excision

of the entire wall of the ureter and invagination after Van Hook's method, as it is followed by the least possible shortening of the canal. This point may be of importance if more than valvular stricture should have to be operated upon.

Exploration of the calices can be made just as well through an incision in a somewhat dilated pelvis when the latter is wide enough to permit exploration with the finger and sound. For additional security against leaving stones in hidden calices with narrow entrances it would be well to explore through the convex surface of the kidney with steel needles. When this is done in addition to digital exploration through the pelviotomy wound, I think there is as little risk of overlooking stones as exists when the convex surface of the kidney is divided. To avoid dividing the posterior surface of the kidney avoids hemorrhage, the operation on the pelvis of the kidney being entirely bloodless.

For the local treatment of pyelitis—that is, inflammation of the pelvis and calices—drainage through the wound in the pelvis will be sufficient, at least in ordinary cases of stones and valves in which, by removal of the cause, we may reasonably expect the pyelitis to come to an end.

RETENTION FROM DISPLACEMENT, BENDING, AND VALVE FORMATION (OBLIQUE INSER- TION) IN THE BILIARY TRACT*

IN the following paper I wish to call attention to a form of obstruction of the biliary passages which has as yet received comparatively little attention, partly because it is not very common, and partly because a minute study of the anatomic conditions is required to make us see the real character of the obstruction—namely, bending and valve formation in the biliary passages.

Schüppel, in his encyclopedic article on the Extrahepatic Bile-ducts, states that the hepatic duct originates from a right and left main branch, 5 mm. in diameter, which take up three or four smaller branches coming in from the longitudinal grooves in the hilus of the liver. The hepatic duct is 3 cm. long and 6 to 7 mm. in diameter.

The gall-bladder contains, on an average, 50 c.c. of bile; its fundus is in a line with the anterior border, and in contact with the hypochondrium corresponding with the cartilage of the eighth rib, at the place where the right parasternal line crosses the arch of the ribs.

The cystic duct is 4.8 cm. long, 4.5 mm. in diameter. At its place of origin from the neck of the gall-bladder it makes a considerable—almost an abrupt—bend. The shape of its lumen is peculiar and distinct from that of the other biliary passages in that, when it is distended with fluid, the duct does not present a uniform, smooth tube, but globular protuberances with furrows between, having a shape similar to a miniature colon; corresponding to the furrows there are found, on the inner side of the wall, semilunar valves, folds of the mucous membrane, the so-called Heister's valves, alternating on one and then on the other side of the canal at variable distances.

The axis of the canal of the cystic duct will thus be a rather curved or wavy line. It is evident that this condition will not only predispose to the arrest of gall-stones on their passage through the duct, but is also apt to favor occlusion by bending and valve-formation, as this condition is here, so to speak, preëxisting.

The common duct is 7 cm. long, and 6 or 7 mm. in diameter. In the hepaticoduodenal ligament it has the hepatic artery on its right and the vena porta on its inferior and posterior surface down to the cavity of the duodenum. Its relations to the head of the pancreas are as follows: (a) It is located in a groove on the posterior surface of the head

* Med. Stand., 1896, vol. xviii, p. 353.

of the pancreas in 15 out of 22 bodies (O. Wyss); or (b) it perforates the head of the pancreas; that is, it is surrounded by the tissue of the pancreas on all sides in 7 out of 22 cases. This anatomic condition is important inasmuch as a swelling of the pancreas will, in the first case, push the common duct out of the way without compressing it, and only very considerable enlargement of the pancreas can cause stenosis by pushing or bending of the duct; while in the second case compression leading to occlusion may easily take place where the duct passes through the head of the pancreas.

The intestinal portion of the common duct is 2.4 cm. long, 2 mm. in diameter, perforates the wall of the duodenum obliquely, first passing through the muscularis, then running for a while in the submucosa before it passes through the mucous membrane, which here forms the so-called *caruncula duodenalis major*, through which it enters the duodenum. While running in the submucosa of the duodenum it takes up the pancreatic duct at an acute angle 8 or 10 mm. before it enters the duodenal caruncle. The opening or canal through the latter is called the *porus biliaris*. This main trunk, 8 to 10 mm. in length, is the so-called *Vater's diverticulum*.

When we examine into the mechanism of occlusion of the bile-passages as given by Schüppel, we find it arranged as follows:

1. Obstruction from within. (a) Bodies that fill the lumen, gall-stones, parasites, *echinococcus*, *ascaris*, *Distomum hepaticum*. (b) Cicatricial strictures following local inflammations of the mucosa, causing or leading to either complete occlusion, that is, obliteration, or stricture formation. (c) Tumors within the bile-ducts—benignant or malignant.

2. Obstruction from without. Compression from masses of cicatricial tissue or adhesions, the result of chronic inflammation, peritonitis, or perihepatitis.

3. Finally, as has been especially stated by Niemeyer, deviations of the bile-ducts in the hilus from displacement caused by peritonitic adhesions between the hilus of the liver and the neighboring organs, colon, omentum, duodenum, stomach, abdominal wall. Virchow has pointed to similar conditions due to pregnancy and other causes.

I shall call attention at this time only to the last group. Virchow was probably the first definitely to call attention to retention from bending of the bile-ducts. He states that in women with corset-liver-lobe and with considerable atrophy of the liver tissue in a line with the pressure from the ribs he has seen, during pregnancy, that the lobe has been folded over against the right lobe of the liver, and when the line of atrophy is located high up near the hilus, the gall-bladder has followed it, and this bending of the gall-bladder has caused traction on the bile-ducts, displacement of their shape, and icterus.

Virchow saw a fatal case of severe icterus where the corset-liver-lobe was turned upward in a patient who was not pregnant, but because of adhesions between the gall-bladder and the colon which came up on the anterior surface of the liver, pulling the bile-ducts with it.

Courvoisier mentions bending of the cystic duct at its origin as a cause of obstruction of the gall-bladder. He further mentions that the permanency of a biliary fistula following cholecystostomy with normal bile-ducts may be due to traction on the gall-bladder and cystic duct in an abnormal direction (for instance, downward), causing a bend at the upper end of the ductus choledochus, so that the hepatic duct is in line with the cystic duct, resulting in all or most of the bile passing out through the fistula and little or none through the common duct.

Bending of the duodenal portion of the common duct, followed by unilateral dilatation above and valve formation, the same as in the urinary passages, has been observed and rightly interpreted by Konitzky. Seyffert, in a similar case of dilated common duct, speaks briefly of "ventilartige Verschluss," valve-like occlusion, but does not enter into any detailed consideration of the subject.

My views on the question, from what I have seen in the cases to be mentioned below, are the following:

Bending is most likely to take place at the beginning of the cystic duct and at the beginning of the duodenal portion of the common duct, because these are the places where there is a sudden change in the diameter of the passages. The bending may be caused either by elongation of the ducts or by traction from adhesions. The obstruction caused by the bending is here, as in the urinary passages, at the beginning incomplete, resulting in intermittent retention and consequently in intermittent attacks of the symptoms. The obstruction will be followed by retention and increased pressure above, resulting in dilatation or hypertrophy. Hypertrophy without dilatation I have seen in the gall-bladder; dilatation sometimes with and sometimes without hypertrophy, in the ducts.

Obstruction caused by valve formation will give rise to the same symptoms as obstruction from other causes, namely, recurrent attacks of biliary colic without icterus, if the obstruction is above the common duct; with icterus, if the passage of the bile into the intestine is prevented.

CASE I.—Bending of the cystic duct.—Synopsis.—Recurrent attacks of pain in region of gall-bladder for twenty years; no icterus. Tumor to be felt in region of gall-bladder. Cholecystectomy. Hypertrophied gall-bladder occluded by bend of cystic duct at its origin. Cystic duct otherwise normal. Extensive and firm adhesions between the entire biliary tract and surrounding organs. Recovery from operation. Four months later, relapse of attacks of pain.

Mrs. M. L., thirty-eight years of age, was admitted to Mercy Hospital in my service January 8, 1896. The patient's family history was good. She had had the ordinary diseases of childhood. She is married and has two children, aged respectively fifteen and thirteen. Twenty years ago the patient began to complain of severe pain in the umbilical region, occurring in attacks at intervals of one or two months, and the attacks lasting four or five days. Occasionally the attacks terminated with vomiting. The patient was never jaundiced, and never to her knowledge had clay-colored stools. Early in November, 1895, the attacks became more severe, and without free intervals between the attacks, constant soreness being present. The appetite failed, and the patient lost 10 pounds in

weight. About this time she noticed a tumor in the abdomen, just above and to the right of the umbilicus. The tumor moved with respiratory movements, and after palpation it almost disappeared. The urine was normal, but there was impaction of feces.

The diagnosis lay between carcinoma of the ventricle or transverse colon, inflammation in and around the gall-bladder, peritoneal tuberculosis, and fecal accumulation. Dr. Billings made the diagnosis of right movable kidney, and in addition a tumor, probably of the gall-bladder.

Operation.—On January 17, 1896, I operated in the following manner: The patient was anesthetized with ether. An incision was made along the outer border of the right rectus muscle. The gall-bladder presented in the wound, 1 inch below the border of the liver. It was hard on the sides, but there was fluctuation over the fundus. It was adherent to the transverse colon and pylorus and the lesser curvature and anterior wall of the stomach. The adhesions were so firm that it was necessary to peel off a layer of the wall of the gall-bladder in order to loosen the organ. From the feeling of the gall-bladder I suspected carcinoma, but no carcinomatous nodules could be found anywhere in the surrounding organs. The introduction of a hypodermic needle brought out no fluid, because the gall-bladder was afterward found to contain only a little bloody, gelatinous mucus, and a number of small, irregular, pigment concretions. I could detect no grating of the needle on stone, but Dr. Morgan noticed a grating which was probably produced by contact of the needle with one of the pigment concretions.

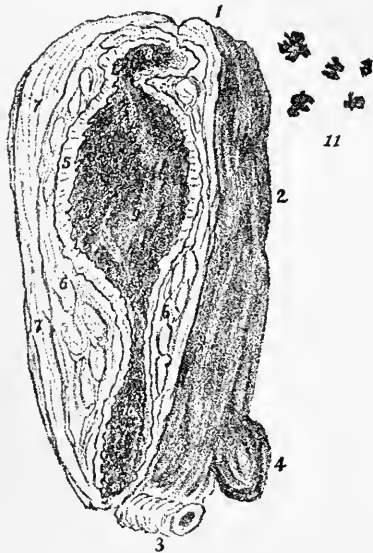

Fig. 124.—Gall-bladder: 1, Fundus; 2, corpus; 3, cystic duct; 4, lymph-gland; 5, mucosa, thickened and velvety, 1 to 2 mm. thick; 6, submucosa, 3, 5, 7 mm. thick; 7, muscularis, 3 to 5 mm. thick; 8, small cavity in fundus, 15 mm. wide, 5 mm. high, caused by constriction, separated from 9, large cavity in corpus, 25 mm. wide, 33 mm. long, separated by a stricture 15 mm. long from 10, cavity 15 mm. long, 15 mm. wide, entrance to cystic duct, whose opening is 1.5 mm. wide; 11, hard, irregular, bile-pigment concretions.

As shown by the figure (Fig. 124), there is a very considerable hypertrophy of the non-dilated gall-bladder, and the cavity is smaller than usual, and is partitioned off in three wide spaces with narrow necks between. It contained about a teaspoonful of reddish, gelatinous mucus, not bile-colored, in which were found a few irregular concretions of inspissated bile-pigment masses, not gall-stones.

Microscopic examination of the wall shows no distinct hypertrophy of the muscularis, but the wall consists of a mass of wavy connective tissue, sparsely provided with vessels. In the paravasculer spaces and lymph-spaces are granulation-tissue cells, here and there in larger groups, showing a chronic lymphangitis and periphlebitis, similar to the condition I have so often found in the chronic inflammations of the appendix, giving rise to attacks

of remittent appendicitis. Near the surface of the gall-bladder, in the place of the serosa, the accumulation of leukocytes is more dense. The inner wall is covered with a layer of mucous membrane, in which are a number of tubular glands, on the surface of which is cuboid and cylindrical epithelium.

On the outer wall of the gall-bladder, near the cystic duct, is a swollen lymph-gland the size of a hazelnut. The cystic duct goes off at a right, or rather at an acute, angle; its wall is normal, not thickened. Its lumen is 15 mm. wide, and is consequently, if anything, smaller than normal. A probe passes from the cystic duct easily into the gall-bladder, and at the entrance, at the angle of the bend, the wall forms a valve which has caused the occlusion.

On May 16th I received a letter from the patient in which she said she had been gaining steadily until a week previous, when she began to feel very much as she did before the operation. It therefore seems probable that a second operation will be necessary in this case.

Remarks.—The choice of operation in this case between leaving and removing the gall-bladder was easy, as the gall-bladder was evidently useless and was the seat of inflammation of long standing. The density of the adhesions of the surrounding organs to the whole tract of bile-ducts made any further loosening of the adhesions inexpedient; so much the more as I thought I had the right to expect that the symptoms would be relieved by division at this point, as the cystic duct was normal. The return of symptoms, as shown by the letter from the patient, seems to prove that it belongs to the same class as the 18 cases operated upon by Riedel, where the pain was caused by adhesions between otherwise normal bile-passages and the surrounding organs, and in this case it would seem as if separation of the adhesions from the remainder of the bile-ducts would be necessary in order to cause permanent cessation of the symptoms.

Riedel remarks: "But even when the stones have been passed by the bowel, the patient is not even then sure to be free from attacks of pain and digestive disturbance, as these symptoms can be caused by adhesions between neighboring organs and the gall-bladder, which may contain bile, but is oftentimes pulled into manifold shapes." He also states that, in addition to 120 cases of gall-stones operated upon in his surgical clinic, there were 18 patients who were operated upon on account of attacks of pain caused by adhesions alone. As long as these adhesions do not cause retention, as in the 18 cases mentioned, the patients retain their weight and strength, because there are no cholemia and no sepsis. If infection from retention in the gall-bladder has been the cause of the pericystitis, we may expect to find the remaining adhesions less dense and easier to separate.

The reason why, in this case, the symptoms should persist, while the remaining adhesions after the apparent removal of the cause should yet cause recurrent attacks of pain, is as yet unknown to us. As Riedel remarks: "Why is it that thousands of patients walk around with their adhesions without ever dreaming of their existence, and a few only have to suffer all the time from identical adhesions?"

CASE II.—*Bending of the duodenal portion of the common duct without dilatation above.*
 —*Synopsis.*—*Intermittent attacks of pain in right hypochondriac region, with vomiting and jaundice for eight years. Three or four months previous to the operation a gall-stone passed by the bowels. Since that time, increasing frequency of attacks. Operation between attacks. Icterus prescut. No gall-stones in biliary passages. Gall-bladder slightly thickened, but*

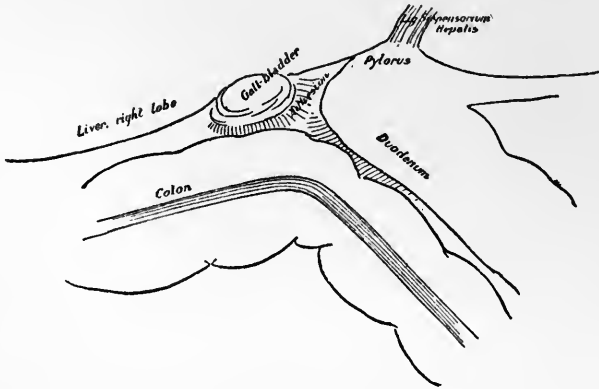


Fig. 125.—Gall-bladder adherent to fundus.

otherwise normal. Dilatation of cystic duct. Common duct not dilated. Extensive adhesions between duodenum and common duct and between descending and ascending portions of duodenum. Loosening of all adhesions. Cholecystostomy. Free passage of a flexible sound from gall-bladder down into duodenum. Recovery.

Mrs. A., twenty-eight years of age, was admitted into Mercy Hospital in my service

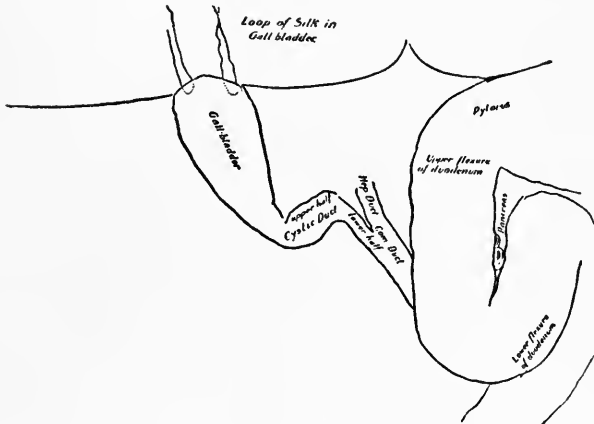


Fig. 126.—Bend in cystic duct.

April 20, 1896. The patient's family history was good. She had had the ordinary diseases of childhood, but until 1888 was very healthy. At this time, however, she began to have severe paroxysms of pain in the right hypochondriac region, radiating toward the right scapula, accompanied by nausea and vomiting and followed by jaundice, which would last for about a week. The stools were clay-colored, and there was great tenderness at the

right costal arch. The first attack lasted for a few hours only, and she felt well until three months later, when she had a similar attack. These attacks have since recurred at irregular intervals, which diminished gradually from three months until now they recur every two to four days.

Although the patient had carefully examined the stools for several years, she found a gall-stone for the first time in December or January last. She has lost rapidly in weight and strength since the attacks have recurred so frequently. Her appetite is good; the bowels are obstinately constipated, but the bowel movements are normal in appearance and color. During the attacks the patient gets relief only by assuming the knee-chest position.

Examination.—The patient's skin was slightly icteric, the conjunctivæ very slightly if at all abnormal; the abdomen was lax, as the patient had borne children; the border of the liver could be felt in normal position right below the costal arch, at the outer border of the rectus. An indistinct hardness could be felt at the border of the liver. There was slight tenderness over the gall-bladder and over the entire right half of the epigastric region.

Diagnosis.—Cholelithiasis obstruction from stones in the duct, one having passed four months ago. The symptoms were apparently typical; many slight attacks—two or three per week; the stone passed four months ago, which presented round surfaces and no facets, and the inflammation of the gall-bladder, which was retracted, but thickened with adhesions.

I advised cholelithotomy, and on April 24th, after the usual preparations, I operated in the following manner: The patient was prepared as usual. Dr. Letourneau administered the ether, and Drs. Morgan and Rankin assisted.

A lateral longitudinal incision was made from the ribs to the umbilicus, the peritoneum stitched to the skin, and 18 flat gauze sponges inserted. Upon palpation the fundus of the gall-bladder was found free in line with the border of the liver. The transverse colon was adherent to the body of the gall-bladder, close to the fundus (Fig. 125). The pyloric portion of the duodenum was adherent to the gall-bladder and the transverse colon. The adhesions were loosened, partly by cutting between the ligatures and partly by blunt dissection with the end of the finger and Kocher's sound, and the gall-bladder freed up to the neck. Below the neck could be seen a transverse swelling, the upper half of the cystic duct, which went off at a right angle, was 1 cm. broad and 2 to 3 cm. long, and on palpation was found to be empty—that is, it contained no stones. (See Fig. 126.)

The gall-bladder was empty, the wall slightly thickened. The duodenum was found to be pushed over so as to cover the hepaticoduodenal ligament, and was loosened by blunt dissection and pushing with the ends of the fingers so as to expose the territory of the common duct. When this had been laid bare for $1\frac{1}{2}$ or 2 inches, the finger passed up through the foramen of Winslow could feel no stone, but the pancreas was so swollen and nodular that I suspected cancer.

Upon palpation of the duodenal (anterior) surface of the pancreas through the duodenal wall neither stone nor movable polypus could be felt, but only the enlarged hard lobes of the pancreas. Along the common duct, on its free border, were two lymph-glands the size of a half hazelnut.

By stretching the common duct I could see it shining through the anterior wall of the ligament as a whitish band, 7 to 10 mm. broad, little if any dilated. I could also see the lower half of the cystic duct shining through, beginning at the bend, dilated, horizontal, upper half of the duct, and going down to the common duct at a right angle with the upper portion and in line with the common duct.

So far, the examination gave no explanation of the symptoms. Stenosis from the bend in the dilated and thickened cystic duct might cause pain in the region of the gall-bladder by reason of retention, but would not cause icterus, and besides this, the gall-bladder was empty. I thought of carcinoma in the head of the pancreas, but the pancreas

felt exactly as the inflamed pancreas feels in cases of gall-stone. I sought for stone in Vater's diverticulum, but could detect no hard, movable body through the duodenal wall.

The pancreas was not freely palpable on both sides of the duodenum because the left side of the pancreas near the head was covered with a loop of the duodenum—that is, the ascending portion.

The ascending portion of the duodenum was now loosened from the descending portion; the adhesions were soft and elastic, like a spider's web, and an inch or more below the nodular left border of the head of the pancreas was encountered.

I thought perhaps the traction on the duodenum from adhesions might cause pain and possibly icterus, and that by loosening the adhesions and freeing the ascending from the descending portion of the duodenum the attacks of pain might cease. When this had been done, I could grasp the head of the pancreas and the duodenum over it with the left index-finger and thumb, the index-finger being in the foramen of Winslow, and lift the head of the pancreas and the duodenum a little forward, and could palpate the entire duodenal surface of the head of the pancreas with the fingers of the right hand. I could detect no stone, but felt some harder, nodular portions, especially one shown in Fig. 126, between the two portions of the duodenum.

I then passed a long, fine sewing-needle through the side of the pancreas and the hard nodule into the head of the pancreas and its duodenal portion in the endeavor to discover a stone in Vater's diverticulum. The fine needle could do no harm, even if it went through the duodenum. However, after pushing the needle in different directions from a single point of insertion I could not detect any stone.

I concluded that no stone could be present except perhaps a small one in Vater's diverticulum, and that there was no carcinoma. The question as to the cause of the icterus and the measures to be taken to relieve the condition then arose.

I did not want to open either the duodenum or the common duct simply for exploration; I therefore resolved to open the gall-bladder, to attempt to explore the common duct from this point, and to relieve the icterus and cholemia for the time being by the establishment of a biliary fistula.

Sponges were packed entirely around the hilus of the liver, and two loops of heavy silk, $\frac{1}{2}$ inch apart, were inserted in the gall-bladder. The wall of the latter was thickened. The gall-bladder was now incised between the loops. Upon incision, neither bile, pus, nor other fluid escaped, but after a few minutes a little blood came out, from which cultures were taken, with negative results. Upon exploration with the little finger no stones were found in the gall-bladder, whose walls were smooth and velvety.

The common duct was now explored through the gall-bladder. A flexible, olive-pointed bougie was inserted in the wound in the gall-bladder, but was stopped at the bend in the cystic duct, which it could not pass. By lifting the liver and making traction upon the gall-bladder the bent upper half of the cystic duct could be straightened, and by manipulating the cystic duct with the index-finger (exactly as a finger in the rectum on the prostate gland can guide a catheter into the bladder) the end of the bougie was passed through the cystic into the common duct, and, by manipulating the duodenum and head of the pancreas, was finally passed down into the duodenum.

Digital exploration along the bougie in the gall-bladder, the cystic duct, the common duct, and for 3 or 4 inches in the duodenum, where it met the lower bend of the duodenum, failed to detect any stone.

I therefore concluded that no stone was present; that the bile-passages and the common duct were patent, and that the icterus had been due to bending or oblique insertion of the intestinal portion of the common duct, which was pulled to one side by the adhesions between the ascending and descending portions of the duodenum.

The cholecystostomy was completed by uniting the gall-bladder to the parietal peritoneum, but not to the skin, by 8 sutures, and packing the wound in the wall outside of the

opening in the gall-bladder, in which a rubber drainage-tube was inserted. A gauze drain was also passed down on the common duct and the duodenum. The operation required about two hours. The patient's progress was uneventful.

May 1st: The dressings were soaked with bile. The packing below the gall-bladder was removed, and the stitches tightened. The wound was clean.

May 4th: The stitches were removed; the wound had united perfectly. The dressings were saturated with bile. The packing around the tube was removed, and new packing inserted.

May 6th: Very little bile in the dressings.

May 8th: No bile in dressings, and icterus disappearing.

May 11th: Tube removed. Dressings slightly stained with bile. Light packing inserted and the stich tightened.

May 13th: Dressings stained with bile and wound closing.

May 17th: The patient has been out of bed for six days, has had no pain since operation; can walk about, is up all day, and can eat anything. The stools are normal. The dressings are slightly tinged with bile and serum. The skin and sclerotics are normal in color. Two weeks later biliary fistula finally closed.

Remarks.—Could the stone which had passed four months prior to the operation and had caused adhesions—that is, local plastic peritonitis on the surface of the biliary passages and the pancreas—have left adhesions uniting the ascending and descending portions of the duodenum over the head of the pancreas, producing a displacement sufficient to cause pain? This was possible. Could this condition also have caused recurrent retention of bile and icterus by deviation or displacement of the direction of the duodenal portion of the common duct or the papilla, or must there of necessity be a small stone in Vater's diverticulum to account for the icterus?

The plastic peritonitis on the left half of the head of the pancreas caused the here otherwise movable descending portion of the duodenum to adhere to its surface and become still more firmly fixed by additional adhesions to the ascending portion of the duodenum.

Could the immobilization of the duodenum have caused the difficult passage of ingesta and the duodenitis? Duodenitis would not give rise to such frequent attacks of pain. A mechanical cause for the frequent attacks would be much more likely, but in a former observation (Case V, Stones in the Common Duct) a small stone in Vater's diverticulum did not cause obstruction, but did cause the frequent attacks of pain, not by inflammation of the wall of the duct, but by some mechanical action.

The course of the disease in this case seems to be as follows: When the symptoms began, eight years ago, with biliary colic and icterus, a stone or stones, perhaps the one passed four months previous to the operation, became impacted in the cystic duct, causing dilatation and bending, as found during the operation and shown in Fig. 126. The inflammatory swelling around this dilated cystic duct caused compression of the hepatic duct or inflammation of the ducts sufficient to occasion icterus. The stone passed down into the common duct so short a time before its removal through the intestine that no permanent dilatation

of this duct resulted. During its passage through the common duct the usual plastic peritonitis, which extended to the pancreas, caused the free surfaces of the ascending and descending portions of the duodenum to become adherent to each other for 1 inch in the transverse diameter of the intestine. This adhesion in the exact line where the duodenal portion of the common duct is situated caused displacement (*Verlegung*) and the consequent continuance of the attacks of pain and icterus after the disappearance of the stone or stones.

Leichtenstern reports a similar case of frequently recurrent attacks of colic without passage of stones by the bowels, with chronic icterus. At the operation the gall-bladder was found to be totally atrophied. It was universally adherent to the surrounding organs, and contained a thimbleful of mucus. No stones were found here or in the cystic or common duct, after thorough separation of the adhesions. The icterus disappeared immediately after the operation, and perfect recovery followed. Leichtenstern remarks: "The pain and periodic attacks of colic, as well as the icterus, must have been caused by pulling and constriction from the adhesions."

The anxiety I experienced in this case in order to make sure that no stone existed anywhere in the biliary tract was not relieved by the passage of a flexible sound from the gall-bladder down into the duodenum,



Fig. 127.—Flexible metallic sound.

because a small stone, half hidden in a diverticulum, might escape notice, notwithstanding palpation along the sound.

As the rubber sound does not permit of feeling the click of a stone, I have had made a flexible metallic sound. (See Fig. 127.) I first had made a flexible metallic sound, 33 cm. long, olive pointed at both ends, and made of a steel spiral. In searching for stones in the cystic duct through the gall-bladder I found that the click of a gall-stone could be easily felt at any distance, but I also found that the flexibility of the sound would not allow it to pass the angles of a bent cystic duct. I therefore made the following modification: Through the hollow flexible metal sound I passed a soft metal (copper) stilet. This permits of giving the sound any shape or bend desired, which is retained as long as the stilet is in. I am thus enabled to pass the sound over the angle or bend, and by removal of the stilet the flexible sound can then be passed further on. I can thus feel the click of a stone low down in the common duct or in Vater's diverticulum, even of a small stone that would escape notice upon palpation along the sound through the wall of the duodenum.

I have recently had an opportunity to demonstrate the usefulness of this sound at a postmortem examination on a patient upon whom I

had made an exploratory laparotomy which had failed to detect any gall-stones, and who died a month later with symptoms of duodenal obstruction. A biliary calculus the size of a cherry-stone was found in the duodenal portion of the duct. The sound passed down from the gall-bladder, passed by the stone, and entered the duodenum without difficulty. On moving the sound up and down I could easily feel the grating of the stone against the side of the spiral sound.

CASE III.—Oblique insertion of the duodenal portion of the common duct, with dilatation above.—Synopsis.—Recurrent attacks of pain of varying intensity and at irregular intervals in the region of the liver for twenty-five years, sometimes followed by icterus, most severe in the spring and autumn. Probable diagnosis, stones in the common duct with probable cholecystitis. Operation during severe attack in January, 1896. No stones found, but chronic cholecystitis and extensive adhesions between the cystic and common ducts and surrounding organs. Extreme dilatation of the common duct, which presented a sac the size of a hen's egg. Cholecystotomy; no stones in the gall-bladder. Duodenum opened to explore diverticulum of Vater; no stones found; wound closed. Opening of common duct revealed no stones, but enormous cystic dilatation. Closure of wound in common duct. Opening in gall-bladder united to skin. Death after twenty-four hours. At autopsy: No bile in peritoneal cavity, no peritonitis. Duodenal portion of common duct of normal size and patent; at its upper portion bending and oblique insertion into the dilated common duct; dilatation of cystic and hepatic ducts.

Miss X, a teacher, thirty-three years of age, was sent to me for operation by Dr. Windrow, January 24, 1896. She was never well as a child, but was always dull, hypochondriacal, and morbidly retiring. She had an extremely violent temper, which, as she came to adult life, she was careful to keep under control. She had the first attack of pain in the region of the liver at the age of seven to eight. The attacks, which were sometimes followed by icterus, recurred, and she began early to use morphin to relieve the pain. During the more severe attacks she became intensely cold, and was obliged to use hot baths to overcome the cold and pain. She had consulted prominent medical men in Europe, but without relief. One physician diagnosed gall-stones and advised operation. During all this time she was treated with internal medicine, massage, and electricity, but did not improve.

Change of climate and work was advised for her, and she came to the United States in 1889. During her stay in the east she felt better at first, but later on the sea-coast did not seem to agree with her, and so in 1892 she came to Chicago. She seemed, on the whole, better after this, but had severe attacks in the spring and autumn. The attacks would last for ten days with one exacerbation daily, which usually occurred one hour later each day. The attacks would be brought on by mental excitement, anger, or irregularities in diet, such as too heavy a meal or too much wine or coffee. As she was aware of this, she put herself upon a well-regulated diet, and lived a quiet life, but still had difficulty in filling her position as a teacher.

Menstruation commenced at the age of twelve. It was always painless, and lasted three days. She had no leukorrhœa. She was habitually constipated, and sometimes her bowels would not move for several days. She used rhubarb as a laxative, and after it operated the movements were apparently normal. Occasionally the stools were clay colored. The urine was often dark after the attacks, was passed slowly and in small quantities. She was subject to severe headache, and became very nervous after work or when exhausted.

The attacks often commenced with sudden and violent pain, which forced her to lie down, undress, and apply hot compresses over the liver, and also required the hypodermic

use of morphin. Icterus was sometimes present during the attacks, with yellowish-green skin and yellow conjunctivæ.

During 1892 and 1893 she drank a good deal of Vichy water and applied cold water compresses over the liver at night, which seemed to help her for a time. During the summer of 1895 she was ill most of the time and had very frequent attacks. With the advent of 1896 she became worse. Her last attack occurred on January 13th; it was attended with violent pain, which was not relieved by morphin; icterus, temperature 103° F., extreme tenderness over the liver, and obstinate constipation. When the latter condition had been overcome by large doses of rhubarb, the stools were clay-colored. At the time of this last attack the patient was confined to her bed for two weeks in the hospital, where I was called to see her.

Upon examination the patient was not emaciated, was deeply icteric, the skin was dark greenish-yellow, and conjunctivæ icteric; temperature, 102° F.; pulse, 110. She had constant pain in the region of the gall-bladder, and the feces were clay colored. Examination of the abdomen showed that the hot fomentations for the pain had so burned

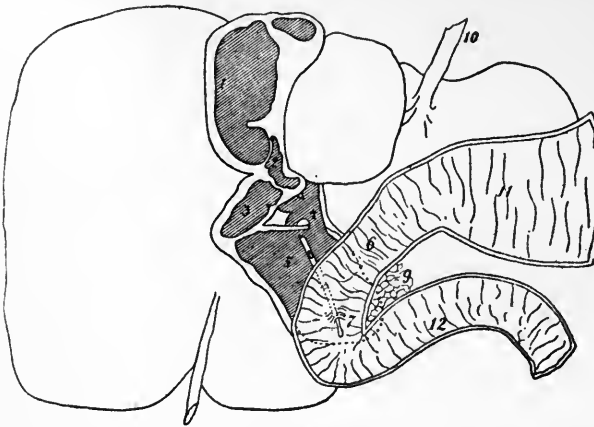


Fig. 128.—Bile-ducts filled with paraffin (one-third natural size): 1, Gall-bladder; 2, upper half of cystic duct; 3, lower half of cystic duct; 4, hepatic duct, somewhat dilated; 5, common duct dilated to a large sac extending downward and to the left, behind the descending portion of the duodenum, and even a little behind the ascending portion of the duodenum; 6, descending portion of duodenum; 7, biliary papilla; 8, probe passed through duodenal portion of common duct; 9, pancreas; 10, suspensory ligament of the liver; 11, stomach; 12, ascending portion of duodenum; 13, point at which non-dilated portion of common duct enters dilated portion of the duct.

the skin of the right half of the abdomen that several granulating surfaces were present. The liver was somewhat enlarged, extending 1½ inches below the costal arch. There were indistinct resistance in the region of the gall-bladder and tenderness on pressure.

The frequently recurrent attacks of pain and icterus, with comparatively short duration of the latter, made the diagnosis likely to be gall-stones in the common duct, together with probable stones in the gall-bladder, causing inflammation of the same. The patient was removed to the Passavant Memorial Hospital for operation.

Operation.—On January 26th I operated in the following manner: Ether, preceded by morphin, was administered by Dr. Waters. The abdomen was disinfected, the granulating skin surfaces scraped with a sharp spoon, and a piece of gauze sewed to the margin of the skin incision.

I now made a lateral longitudinal incision from the ribs to below the umbilicus. Considerable hemorrhage ensued from the vessels in the abdominal wall. The fat was an inch in thickness, and the posterior sheath of the rectus muscle tense. The peritoneum was sewed to the skin wound. The border of the liver and the gall-bladder presented in

the wound. The gall-bladder was of the same color as the liver, and, on a plane with its free border, felt like a mass of flesh or liver; it had the shape of a bent finger, and no fluctuation could be detected. There were no adhesions at the top of the gall-bladder, but the corpus was adherent to the pylorus, duodenum, and transverse colon. The adhesions between the gall-bladder and the pylorus, greater curvature of the stomach, and duodenum, which was covered by the fundus of the stomach, were separated to a depth of 2 or 3 inches, partially by division between ligatures and partially by blunt dissection. The pylorus and duodenum were thus loosened from the body of the gall-bladder, and the adhesions between the latter and the transverse colon separated by division between ligatures and blunt dissection. The duodenum could not be recognized until the ventriculum of the stomach had been separated from its anterior surface. Finally, I found the foramen of Winslow, and on introducing the finger into the lesser omental sac I found an elastic tumor the size of the small intestine between the duodenum and the hilus of the liver; this was the common duct dilated to a tumor 2 inches in diameter, with the duodenum adherent to and partially covering it. I could detect no stones; no enlargement of the pancreas could be felt, nor could any tumor be felt through the duodenum.

With a view to exploring the bile-ducts for gall-stones from within the gall-bladder was opened at the fundus by an incision $\frac{3}{4}$ inch long. The wall was 1 cm. thick, soft and bleeding, and mucus escaped, followed by bile. Upon digital exploration after incision I found the supposed tumor to be a thick partition wall encroaching upon the lumen of the gall-bladder from the knee-like bend (Fig. 128, 1), dividing off the smooth upper portion. The exploring finger entered the cavity in the fundus, below which was a narrow isthmus, and below this a larger cavity in the body of the gall-bladder. The walls were smooth and velvety, and no stones could be felt. No sound or probe, either metal or elastic, could be passed down into the cystic duct. The introduction of Murphy's button was impossible on account of the thickness of the wall, which was 1 cm. thick. Consequently cholecystenterostomy by this method was out of the question. In continuance of the search for stones in the duodenal portion of the duct I now opened the duodenum over the diverticulum of Vater. An assistant made digital compression of the duodenum above and below the point of incision. I made a longitudinal incision $\frac{1}{2}$ inch long in the duodenum over the head of the pancreas, which was followed by the escape of air-bubbles, bile, and mucus. Upon introduction of the finger in the incision no stone could be felt, nor could the opening of the bile-duct be discovered.

The next step in the operation was the opening and exploration of the common duct. With the finger in the foramen of Winslow an incision $\frac{3}{4}$ inch long was made in the common duct, through which bile exsaped. Digital exploration revealed a cavity the size of a hen's egg, with smooth walls, and which contained no stone. In the upper right portion of this cavity I could feel two openings, the anterior being the entrance to the cystic duct and the posterior the entrance to the hepatic duct. I could feel the division or place where the hepatic and cystic ducts united to form the common duct. The openings were 1 cm. or more in diameter at the upper right end of the cavity of the dilated common duct. The wall of the duct was white and firm, 2 mm. in diameter, slightly thickened, and the duct was considerably dilated. The probe or sound could not be passed down into the duodenum, nor could any stone be felt. The duodenum was so immovable that it was im-

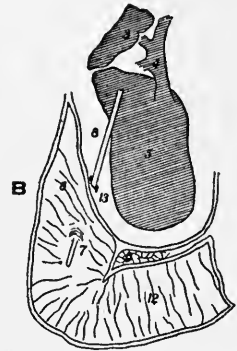


Fig. 129. — Showing oblique insertion of common duct. Duodenum covering common duct has been removed.

possible to bring it into apposition with the common duct for choledochoduodenostomy. I therefore closed the wound in the duodenum with Czerny-Lembert sutures.

As the operation had already lasted a considerable time,—about two hours and a half,—and as the patient was becoming weak, it was not deemed advisable to unite the common duct to the small intestine, and I therefore concluded to close the wound in the common duct and make a gall-bladder fistula to the skin to relieve the icterus. The wound in the common duct was now closed with a double row of sutures, and the opening in the gall-bladder sutured to the skin. A drainage-tube was inserted in the gall-bladder, with gauze above and below the gall-bladder, down to the wound in the common duct. Another drainage-tube was inserted down to the wound in the common duct, with gauze packing below it. The wound was then closed and dressed in the usual way. At the close of the operation the patient was weak; pulse, 120.

She never recovered from the collapse; in the course of a few hours her temperature began to rise, the pulse grew weaker, and she died, twenty-four hours after the operation.

Autopsy.—The condition of the peritoneum was normal; the intestines little, if any, distended; the ovaries, uterus, appendix, lungs, heart, and liver normal. The incision wound of the duodenum was agglutinated, and the gauze packing adherent to it. The wound in the common duct was firmly agglutinated, the duct greatly distended, and its walls very much thickened. The gall-bladder was enlarged and its walls thickened. The gauze was universally adherent to the field of operation. No stone could be found. The kidneys were not examined, but the pancreas, spleen, and stomach were normal; the latter was filled with a brownish fluid.

The body was markedly jaundiced and quite well nourished. The dressings and gauze were saturated with greenish-yellow bile. After removal of the gauze around the drain to the common duct no bile, pus, or serous fluid could be found; the surfaces were perfectly dry; there was no fluid of any kind in the peritoneal cavity, and the parietal and visceral peritoneum was glistening, smooth, and perfectly normal.

The following injection experiments were made to show the patency of the biliary tract:

1. Water was injected into the gall-bladder through the opening in the apex by a four-ounce hard-rubber syringe. The water filled the gall-bladder, but was stopped at the neck and did not enter the cystic duct. Fluid could pass up into the gall-bladder, but, by reason of the valve-like formation, nothing could pass down.

2. The nozzle of the syringe was now inserted into the common duct through a small opening made on its anterior surface above the sutured incision made during the operation. The common duct now became distended until it formed a large, round tumor, the size of a hen's egg or larger, extending downward and to the left behind the duodenum and upward to the hilus of the liver. As this sac became more tense the water entered the gall-bladder and flowed out through the opening in its apex, but even when this was held closed and more water was injected, not a drop passed from the common duct into the duodenum, showing complete obstruction when the common duct was distended.

After reopening the wound in the duodenum the opening in the diverticulum of Vater could easily be found, and the probe passed up through the duodenal portion into the common duct. Small quantities of water passed down along the probe into the duodenum.

As no stone could be found in the common duct or gall-bladder, it was evident that the obstruction to the flow of liquid was caused by valve formation or bending or oblique insertion between the gall-bladder and the cystic duct and between the common duct and its duodenal portion.

These obstructions were still further studied and illustrated by filling or injecting the biliary passages with paraffin, for the careful accomplishment of which I am indebted to Dr. Haiselden, my house surgeon in the German Hospital of Chicago.

Remarks.—No stone was present; the gall-bladder was hypertrophied by reason of a valve in the cystic duct; the common duct was dilated on account of a valve formation near the diverticulum of Vater. The operative indications under these circumstances were to open the duodenum and make a communication opening between the duodenum and the common duct. This can be done when the common duct is found to be dilated by first opening the common duct and making digital exploration, and then opening the duodenum, sewing the wall of the common duct to the wall of the duodenum, and closing the openings in the duodenum and common duct. In this case, as the patient had been two and a half or three hours under operation, I was unable to carry the operation beyond this point. If the duodenum is sufficiently movable to allow the openings to be brought together, choledochoduodenostomy could be made by suture or by the Murphy button.

Konitzky reports the case of a girl, twenty-one years of age, who was admitted to the Gynecological Clinic at Marburg October 24, 1887. She was healthy as a child, menstruated at sixteen. Menstruation was regular for a year, then ceased for two years and was irregular thereafter. She last menstruated June, 1887. At the age of fifteen she had general weakness, nose-bleed, and was ordinarily subject to headaches. In July, 1887, the headache increased, with loss of appetite, gradually increasing icterus, increasing weakness, and enlargement of the abdomen in the region of the liver. On examination strongly marked icterus was observed, and a tumor which included almost the entire right half of the abdomen and extended 10 cm. over on the left side. The tumor extended from the liver to the ilium. It was fluctuating and had no connection with the pelvic organs; the stools were clay colored and the urine contained bile. The diagnosis was made of echinococcus cyst of the liver, causing pressure on the bile-ducts. He operated on November 6, 1887. A longitudinal lateral incision was made, whereupon the cyst presented in the opening. Before the cyst was opened it was sutured to the parietal peritoneum. Upon incision the cyst-wall was found to be 2 mm. thick. A large amount of thin, greenish fluid was evacuated. The inner wall of the cyst was dark green. After evacuation the cyst-wall was united to the skin, and the usual dressings applied. Microscopic examination of the cyst-wall showed it to be connective tissue, and no traces of glands, epithelium, or muscles could be found. The condition of the patient was satisfactory immediately after operation. On the third day cough set in, with bloody sputum; on the sixth day she passed 510 c.c. of urine, and vomiting commenced. On the seventh day the pulse was 100 and weak, with severe vomiting and beginning collapse, and she died on the eighth day. The autopsy showed no peritonitis. The gall-bladder was atrophic, and the bile-ducts in the liver dilated. After opening the duodenum the duodenal papilla was found low down, and permitted the passage of a sound from the papilla into the cyst. The duodenal portion of the common duct was $2\frac{1}{2}$ cm. long, not dilated, but rather narrower than normal, but perfectly patent; was located on and entered the cyst on its lower left aspect or wall. It passed through the wall obliquely from behind forward. At the upper end of the cyst (the dilated common duct) was a dilated hepatic duct. The gall-bladder was contracted and narrow, the cystic duct, or at least its lower half, dilated, and about 2 cm. in diameter, and entered the cyst about 5 cm. away from the hepatic duct. The cyst then was a common duct dilated in its whole extent down to the duodenal portion. The pancreas was normal. The pancreatic duct did not unite with the duodenal end of the common duct, but passed into the duodenum separately and opened into the latter $\frac{1}{4}$ cm. above the papilla for the common duct.

The author thinks it possible that gall-stones may have been the primary cause of the

dilatation, but after their passage other causes must have come into play. As the autopsy showed a bend of the common duct at the point where it enters the wall of the intestine, he believes that this bend caused a valve-like occlusion, and calls attention to the analogous condition of valve formation in the upper end of the ureter, where it originates from the pelvis of the kidney. As the valve formation in the ureter is often incomplete at first, causing intermittent hydronephrosis and gradual dilatation commencing at the place of obstruction, so he thinks that a gradually increasing dilatation of the common duct above the duodenal portion took place in this case above the valve or bend.

He cites a similar case reported by Douglas in 1852, who found the following condition at the autopsy of a girl, seventeen years old, who had presented the symptoms of icterus, fever, and a painful tumor in the right hypochondrium. The common duct was dilated to a large sac containing half a gallon of fetid bile. The walls of the sac were thickened, and the openings of the hepatic and cystic ducts dilated so as to permit the passage of a finger. The gall-bladder and the portion of the cystic duct nearest the gall-bladder were not dilated, but there was considerable dilatation of the hepatic and bile-ducts. At the lower edge of the large sac, toward the duodenum, there was a small opening leading into a normal, undilated duodenal portion of the common duct, at the upper end of which a sort of valve was found.

Seyffert reports the case of a woman, twenty-three years of age, who had been married three years. One year later, after childbirth, icterus set in, which was permanent, with an interruption of three months. Six months later she had swelling of the abdomen and tenderness on pressure, and nine months later a sudden and violent attack of hepatic colic, which lasted a day and a half and was accompanied by hematemesis, vaginal hemorrhage, and some gastric disturbance; the urine was dark; she had pain in the lumbar and sacral regions, which was relieved by flexing the thighs upon the abdomen. An ovarian tumor was suspected. Examination showed tenderness over the liver, and in narcosis a normal sized, somewhat hardened gall-bladder was found in the normal location.

Below, and close to the right lobe of the liver, was a large round tumor the size of a child's head, soft, fluctuating, and extending from the border of the liver to 2 inches above the symphysis pubis. The fluctuation was indistinct, and there was clear percussion over the tumor. It was not connected with the genital organs. The urine contained a small amount of bile coloring-matter.

Diagnosis.—Cyst of the pancreas.

Operation.—On May 28, 1888, an incision 10 cm. long was made in the linea alba above the umbilicus, and the peritoneum sutured to the skin. The cyst was punctured, and a portion of its contents, which consisted of dark-green, ropy bile, evacuated; a piece of the wall of the cyst, which was about 5 mm. thick, was excised, and the cyst-wall sutured to the skin with mattress sutures. The cyst was now emptied and showed a smooth inner surface with no gall-stones or concretions. A drainage-tubewas inserted and dry dressings applied.

For several days after the operation the dressings were soaked with bloody bile; the stools were yellowish brown and covered with bile. The patient got on well until four weeks after the operation, when more blood appeared in the dressings, mixed with bile, and suddenly obstinate vomiting, with abdominal pain, dizziness, and increasing weakness, set in, and she died two days later, apparently without much pain, with symptoms of anemia.

Post-operative Diagnosis.—Cystic tumor in the right hypochondriac region containing bile.

The autopsy revealed a small, retracted, empty gall-bladder, which did not extend beyond the border of the right lobe of the liver; the liver was large, smooth, and grayish-green. The liver, stomach, pancreas, and duodenum were taken out together; the biliary papilla in the duodenum was found to be swollen and no bile passed on pressure. The

probe could be passed in for 5 cm. The duodenal portion of the common duct was cut open from the biliary papilla, and from this point up the duodenal portion of the common duct was normal, patent, and opened freely into the large cavity. A sound could be passed from the gall-bladder into the cystic duct, which was somewhat dilated and $2\frac{1}{2}$ cm. long, and from here into the cystic cavity. The hepatic duct also opened into the cystic cavity, consequently the latter was formed by the enormously dilated common duct, the cystic and hepatic ducts partaking in the dilatation. The cyst, when opened, presented a cavity the size of the fist; up toward the liver the surface was of a grayish-red color, the inner surface showing, even to the naked eye, the appearance of a dilated bile-duct. On microscopic examination the inner wall of the sac was found to be covered with typical cylindrical epithelium. In the neighborhood of the cystic duct the sac was of a greenish color; the lower portion of the sac, near the duodenal third of the common duct, was ulcerated, uneven, with necrotic strings and masses, and was covered with a soft, fresh coagulum the size of a walnut.

Postmortem Diagnosis.—Large cyst of the common duct; laparotomy; ulcerative destruction of the inner wall of the cyst, with hemorrhage; universal anemia.

Remarks.—The autopsy showed neither stones, strictures, valves, nor tumors in or outside the common duct. The ulcerated territory was probably caused by gall-stones that had disappeared, but no gall-stone could be found in the body or the feces. The lumen of the duodenal portion of the common duct was normal, patent, and passage was impeded only by swelling of the mucous membrane. The violent attacks of gall-stone colic, as given in the history, would speak for a preëxisting stone, but the anamnesis is imperfect, as the patient was in the clinic only two days before the operation, and the diagnosis of pancreatic cyst was made. The icterus, having persisted for almost a year and a half, was probably caused at first by catarrhal duodenitis. The attacks of pain, which lasted a day and a half, were thus probably caused by incarcerated gall-stones. The feces were ordinarily not clay colored, consequently the occlusion of the bile-ducts was not complete; the history also stated that feces were mostly normal. Subsequent to the operation the feces were always bile colored; there was consequently incomplete retention, as both urine and feces contained bile, and the author concludes that the valve-like occlusion of the common duct must have permitted the passage of some bile after emptying of the cyst. [The valve mechanism is not described or further mentioned by the author.—F.]

Why did the patient die, as the bile passed down into the duodenum after the operation, and as at first all the other grave symptoms disappeared? This was due to the necrotic inflammation of the sac and hemorrhage and subsequent fatty heart.

From the above cases it will be seen that bending and valve formation at the beginning of the duodenal portion of the common duct are followed by considerable, even enormous, dilatation of the latter. When the dilatation reaches an extreme degree, a cystic tumor is found below the liver.

Diagnosis has never yet been made before the operation or before the autopsy. The prognosis is apparently grave, as all the patients

operated upon have died. As to the plan of operation, we can conclude what to do only when it is possible to make a diagnosis during the operation. The choice of procedure will be between choledochoduodenostomy or choledoch-enterostomy, on the one hand, and choledoch-abdominal fistula, on the other. If the common duct is dilated to a large cavity, which presents like a cyst against the abdominal wall, choledochostomy might be preferred for temporary relief, and possible spontaneous disappearance of the pain when the sac is retracted. If the passage of bile into the intestines is not reëstablished spontaneously, choledoch-enterostomy might be attempted later on. In lesser degrees of dilatation of the common duct primary choledoch-enterostomy might be made, preferably into the duodenum.

In all cases of this kind it is impossible to make an exact diagnosis beforehand. There is no difference in the symptoms between obstruction from stone and obstruction from other causes, with the exception of malignant tumors. As calculous obstructions are by far the most commonly encountered, we naturally at first expect to find a stone, and it is not until during the operation that we are disappointed in this respect, and find that we have to look out for other conditions. It is natural, therefore, that this is the class of cases which causes the operator a great deal of mental anxiety during the operation in regard to making the choice of the different procedures at his disposal. How to relieve the patient from the symptoms must be decided then and there.

BIBLIOGRAPHY

- Courvoisier, L. G.: *Casuistisch-Statistische Beiträge zur Pathologie und Chirurgie der Gallenwege*, Leipzig, 1890.
- Douglas: Cited from Konitzky.
- Fenger: "Stones in the Common Duct and Their Surgical Treatment," *Amer. Jour. Med. Sci.*, 1896, vol. cxi, p. 125.
- Konitzky G.: "Ein Fall von hochgrädiger cystischer Erweiterung des Ductus Choledochus," *Inaugural Dissertation*, Marburg, 1888.
- Leichtenstern, O.: "Behandlung der Erkrankungen der Gallenwege innere Behandlungsweisen," *Handbuch der speciellen Therapie innerer Krankheiten*, vol. iv.
- Niemeyer, F.: *Lehrbuch der speciellen Pathologie und Therapie*, Berlin, 1863, vol. i, p. 671.
- Riedel, B.: *Chirurgische Behandlung der Gallensteinkrankheit*, vol. iv.
- Schueppel, O.: "Die Krankheiten der Gallenwege und Pfortader," *Ziemssen's Handbuch der speciellen Pathologie und Therapie*.
- Seyffert, R.: "Zur Pathologie der Gallengänge. Cyste der Ductus Choledochus operative behandelt," *Inaugural Dissertation*, Greifswald, 1888.
- Virchow, R.: *Die krankhaften Geschwülste*, vol. i.
- Virchow R.: *Gesammelte Abhandlungen*, p. 756.
- Idem.*: P. 777.
- Wyss, O.: "Zur Ätiologie des Stauungs-Icterus," *Virchow's Archiv*, 1866, vol. xxxvi, p. 454.

A CASE OF FATAL ACUTE DILATATION OF THE STOMACH FOLLOWING CHOLECYSTOTOMY*

WITH THE COLLABORATION OF WILLIAM HESSERT, M.D.

Mrs. M., referred by Dr. Webster, of Evanston.

Personal History.—Age, thirty-eight. Married; American; born in Texas; lived in Illinois last nine years; average weight, 145 pounds. Began to menstruate at fourteen, and the function was regular and not painful for three years. At seventeen her menses began to be more profuse, lasting seven days, and accompanied by pain, more severe on the right side. Married at twenty-one. First childbirth at twenty-two. Labor difficult and protracted—forceps. Menses after that less profuse and painful. Second child six years later. Labor easy and normal. Miscarriage some time after. For last six months menses are more scanty, lasting seven to nine days. Was under gynecologic treatment. Children are living and healthy.

Family History.—Mother died of puerperal fever at twenty-four; father of cholera at forty-two; maternal grandmother of intestinal obstruction; maternal grandfather of cholera or dysentery. Paternal grandmother died of pneumonia; paternal grandfather of gout at eighty-two. Sisters, none. Brothers: one died in infancy of pneumonia; two living—one is healthy, the other suffers with renal calculi. Maternal aunts and uncles living and healthy. Paternal aunts none; paternal uncle died at sixty-three years of carcinoma of the liver.

Previous Illness.—During early childhood had measles, whooping-cough, chicken-pox, and pleurisy. Facial erysipelas at seventeen. Curetment three years ago, following miscarriage.

Present Illness.—After a miscarriage at sixth week in 1894 a curetment was performed for excessive flowing. In the second night after the operation she was awakened by pain in epigastrium and left scapula. No pain in region of gall-bladder. Belched gas; pain constant and lancinating. The pain in region of scapula was not constant; attack lasted from 11 P. M. to 8 A. M. Was so narcotized with morphin that she does not know whether attack subsided gradually or suddenly. Since this time, up to the present, she has suffered with flatulency after eating, not benefited by treatment.

In February, 1895, while dressing for dinner she felt a sensation of weight and distention in region of gall-bladder, gradually extending into the epigastrium; was taken to bed in half an hour, the pain in epigastrium having greatly increased. Pain in region of gall-bladder was either absent or so slight, as compared with the epigastric pains, that it was not observed during latter part of attack. No radiation into scapula. Morphin was administered, after which she went to sleep; awakened without pain and felt as well as before the attack. The attack had lasted four hours.

In April, 1895, she had three attacks in one week. Between the second and third attacks she felt a constant heaviness and aching in region of gall-bladder. After the third attack she was so weakened and so nauseated by morphin that she was confined to the house for four weeks and recovered her strength very slowly. These attacks were all

* Clin. Rev., 1898, vol. vii, p. 261.

severe, coming on without special cause, and lasting four or five hours (she was dieting at the time). The pain was first in the region of the gall-bladder, traveling into the epigastrium, where it was most severe, and from there radiating into right scapular region. After the second attack she noticed that her urine was very dark and high colored, becoming lighter again in two or three days. Stools were of normal color. The physician at the time said she was sallow, but not jaundiced. In September, 1895, she had a similar attack, lasting two hours, which left suddenly without morphin; no physician. December, 1895, two slight attacks; cereal diet most of the time up to the present. Gained 20 pounds again in six months. March, 1896, slight attack. Threatened with attack subsequently, but on expelling gas from the stomach she felt easier. During the winter of 1896-97 her weight was 143 pounds; in April, 1897, 138 pounds; gradual loss of weight since.

April 24, 1897: Two attacks in one week, and between the attacks was said to have had influenza; temperature, 103.5° F., only lasting a few hours, and diarrhea lasting two days; color of stools dark. Urine was normal except for increased uric acid. First attack lasted only a short time.

Early in September, 1897, had a severe attack which was relieved by morphin. Since then she cannot take ordinary food, owing to distress in gastric and hepatic region, flatulence, or pain in scapula. Weight, 128 pounds; progressive loss of strength.

September 20, 1897: An attack of the usual type, which left her very weak and with gaseous distention of stomach after meals. Confined to house three weeks.

October 10, 1897: Three attacks in the week following. During the first one she had great pain in the region of the gall-bladder, which shifted on change of position.

October 13, 1897: Severe attack lasting three days; pain radiating around to right side from region of gall-bladder.

After all the attacks before mentioned there was no pain nor tenderness in the region of the gall-bladder. No tumor ever observed. No icterus at any time, nor clay-colored stools. No stones ever found in stools.

Physical Examination.—Skin dark and dry, but not jaundiced. Heart and lungs negative. Abdomen normally distended, not tender on palpation anywhere. Liver not enlarged, palpable in region of gall-bladder, the latter not being palpable. Spleen negative.

Urine, specific gravity, 1015; acid; no albumen nor sugar; bile, slightest trace. Microscopically, no epithelium, pus, or red corpuscles. Few bacteria. Few crystals of ammonium phosphate.

Operation November 2, 1897. Ether narcosis by Dr. Palmer. Operative assistants, Drs. Waters and Buford. Dr. Randall, of Galveston, Tex., was present.

Longitudinal incision in outer border of sheath of rectus, from one inch above border of false ribs to below the umbilicus. Peritoneum sutured to skin. Liver border extends 1½ to 2 inches below ribs. Gall-bladder small, whitish, thickened. No stone felt. No adhesions to gall-bladder nor to common duct; slight adhesions to cystic duct. Gall-bladder apparently rather empty, or contains only about a tablespoonful of fluid, which cannot be pressed down through common duct and does not get beyond middle of cystic duct, which is S-shaped, and at the point of obstruction a small stone, the size of a No. 6 shot, is felt, being apparently embedded in the tissues about the wall of duct, as it was immovable.

Exploration of common duct revealed no stones, no enlarged gland. No enlargement of pancreas.

Diagnosis.—Obliteration of cystic duct; small stone in wall of cystic duct. Probable retention and suppuration from stones in the gall-bladder.

The small stone was removed by incision of the cystic duct, the lumen of which was not opened; wound closed with two fine silk sutures.

I chose to do a cholecystotomy in preference to cholecystectomy, because the patient

was weak and some of her symptoms—pain, loss of strength and weight—would seem to be due to some undiscovered cause, as I could not account for them by the slight effects of inflammation about the gall-bladder—viz., no adhesions, no dilatation. I suspected some hidden disease in some other organ.

As the gall-bladder could easily be brought to the skin surface, I performed a cholecystotomy, as follows:

- I. Two loops of silk inserted into gall-bladder.
- II. Protective packing of gauze around it.
- III. Incision with scalpel brought out a fluid, not bile, but yellowish mucus, containing bilirubin gravel, about one teaspoonful in amount.
- IV. Gauze sponge passed into gall-bladder came out with three small, flat, irregular, yellow concretions adhering to it. Exploration with finger revealed no more stones. Gall-bladder narrow, just admits index-finger. Wall thick, fibrous; concentric atrophy beginning.
- V. Gall-bladder sutured to skin. Drainage-tube inserted in gall-bladder. Another tube and gauze drain down to the wound in cystic duct.
- VI. Suture of abdominal wound.

Duration of operation, one and one-half hours; pulse, 130, weak. After operation morphin, $\frac{1}{4}$ grain, with atropin injected and repeated in half an hour, as the first injection did not relieve the pain. Second injection followed by only slight relief; vomited several times, mostly bile. At 10 P. M. constant pain in lower end of wound on right side (proved by autopsy to be due to hemorrhage from stitch canal into peritoneal cavity). Seems anxious to try to do without morphin for fear of vomiting. Occasional hiccup causes intense pain in wound. Temperature, 98.6° F.; pulse, 90, fair strength. No discharge through dressing, no restlessness; vomited bile.

November 3d: Has had a bad day, temperature and pulse rising, the latter becoming quite weak. Constant nausea and some vomiting. Tongue moist; feeding by mouth almost entirely stopped, and nutrient enemata given. Morphin caused nausea, so chloral was administered per rectum, with some rest and sleep following. Dressed wound at midnight and found no bile in dressings nor in tube in gall-bladder, nor in the one draining the cystic duct.

November 4th: Has been somewhat better; pulse stronger and slower, less nausea and no vomiting since noon. Much pain in abdomen. Attempts at vomiting occasioned pain in wound. Champagne per os. Nutrient enemata every two or three hours. Tongue moist. Pulse 120 to 130, but stronger. Temperature, 101.6° F. Has begun to menstruate and has pain in pelvis. Has had strychnin, chloral, and digitalis.

November 5th: 10 A. M.: Has had little sleep, but does not complain of more pain. Since midnight has drunk a bottle of iced lithia water, with no distress in stomach. Is distressed by flatus and a desire to expel the enema. Says that abdomen feels as if distended by gases, but no flatus passed; tongue moist. Temperature, 99.3° F.; pulse, 130, fairly strong. 8 P. M.: Feeling fairly comfortable. A soap enema at 11 A. M. was followed by a large passage and much flatus, giving relief. Pulse, 120, strong and full; temperature, 100° F. Some hiccup, causing considerable pain in wound. No vomiting; no restlessness.

November 6th: 9 P. M.: Had some sleep during the night at intervals. Chloral by rectum at 1 A. M. Feels stronger. Pulse, 104, and of good strength; temperature, 99.8° F. Still has hiccup, which causes severe pain in side. At noon felt some nausea following a drink of beef-tea; stomach began to feel as if distended with gas, and at 3 P. M. vomited what had been taken, viz., beef-tea, kumiss, etc. Vomited several times after that; some bile in vomitus. Enema of water, glycerin, and turpentine, after which she felt somewhat better. General appearance much better toward evening. Enema followed by bowel movement.

November 7th: Had a little rest during the night, but vomited some. This morning is

much better than any day since the operation, so that her brother, a physician, took a train for his distant home. Pulse, 92, full and strong; temperature, 99.3° F. General expression better; no vomiting since early morning. Stomach feels better—nausea at intervals only; occasional hiccup. Dressed wound at 10.30 A. M.; no bile in dressings; loosened tube extending down to cystic duct. About the middle of the afternoon she began to complain of pain in the abdomen, *about 2 inches to the left and 1 or 2 inches below umbilicus*. The pain increased in intensity, and at the same time the vomiting returned, consisting of greenish fluid, coming up without any effort, viz., “mouth filling” or “projectile” in character. Constant nausea and occasional hiccup. Pulse became more rapid and smaller; at 10 P. M. pulse 120 and temperature 100.2° F. The bright expression of the morning is gone—now the features are haggard. At 10 P. M. reopened dressings. Two inches to left and $\frac{1}{2}$ inch below umbilicus I thought I felt a resistance. No *general* tympany, but in left epigastric region, and extending 2 inches below umbilicus, a soft, “cushion-like” protuberance was felt and seen. The lower third of abdomen *above* symphysis yet concave. No swelling nor pain in right half of abdomen. I thought that a sponge was left in the peritoneal cavity.

November 8th: 2 A. M.: Pulse, 115; temperature, 99° F. Vomiting. I considered—(1) Peritonitis and possible reopening of abdomen to remove a possible sponge or drain (!). (2) Acute dilatation of stomach. During the night patient slept for a few minutes at a time only, but did not feel much acute pain. Tenderness in left side. At 10 A. M. consultation with Dr. Favill. Pulse, 120; temperature, 100.2° F. Vomiting. Tympanites increased—whole left half of abdomen and also right suprapubic region convex. I felt now no resistance to left of navel. The tympanitic percussion extends high up over lower ribs. For the first time about one teaspoonful of bile was found in the dressings. I resolved that, before reopening wound or cutting down independently of old wound in left side of abdomen with a view of—(1) overcoming an intestinal obstruction or (2) removing sponge—to (1) wash out the stomach and (2) inject salt solution. At 11 A. M. stomach-pump introduced,—siphon,—brought out $1\frac{1}{2}$ quarts of green fluid. *All the tympany disappeared*; upper half of abdomen was concave above umbilicus, and slightly concave below. No resistance, no hardness felt now, no tenderness nor pain. Patient felt much relieved immediately, and the pulse became stronger. Infusion of normal saline solution under both mammae with an aspirator needle and fountain syringe. Later on enema and voluntary discharge of small amount of flatus.

The diagnosis of acute dilatation of stomach became almost certain, as the tympany and pain disappeared and the vomiting ceased after use of the stomach-tube.

Is the dilatation due to—(1) Edema and paralysis of stomach-wall, or (2) bending or kinking of pylorus from an overfilled, heavy stomach, or (3) stenosis of duodenum from gauze packing, pulling up of gall-bladder, or formation of bands of adhesions (as after anovariotomy an intestinal loop adhering to stump)?

In the evening patient was weaker and more exhausted than in the morning.

November 10th: No vomiting; no bile in dressings; no pain; no decubitus; some hiccup. Pulse, 120; temperature, 99° F. General condition worse. Abdomen on left side protuberant and tympanitic again. Convex above umbilicus and flat below. Tympanitic percussion from fifth rib anteriorly to 1 inch below umbilicus. Stomach-tube passed, and 44 ounces of green fluid evacuated; lavage with warm water brings out flocculi of green, amorphous matter. After the introduction of the tube five minutes' manipulation was required before the fluid contents began to flow out. After emptying the stomach the previously protruding and tympanitic area collapsed and left the abdomen flat again. No tenderness nor resistance anywhere. After the lavage 20 ounces of salt solution was injected into the loose cellular tissue beneath the mammae. After this there was marked improvement in the general condition. Pulse became slower and stronger. The patient felt relieved, and expressed herself as “so much better.” Later in the day a high rectal

euema of a solution of salts and glycerin was given, followed by much discharge of gas and large bowel movement. No nourishment by stomach; rectal feeding with brandy and milk. At 5 p. m. injected salt solution, which did not have the beneficial effect on the pulse as previously. Strychnin, $\frac{1}{30}$ grain, every three hours, began at 10 p. m. No bile in dressings. MIDNIGHT: Patient has been very restless during the evening, and is constantly wanting something done for her. Is becoming more and more restless; no change of position gives relief. Pulse 140 and weak. Expression of face haggard and worn; eyes sunken and bordered dark.

November 11th: 2 A. M.: Becoming worse—more restless; pulse, 154 and weak. Hypodermics of digitalis, 10 minims, every three hours. 4 A. M.: Slept for a half-hour. Pulse, 140. Dressed wound to relieve odor. No tympanites. 10 A. M.: Feeling somewhat stronger. Pulse, 130, quality somewhat better; temperature, 101.4° F. No pain; no tympany; no vomiting. Slept somewhat during forenoon. Hot olive oil rubbed over entire body. Elixir alimentaire, one teaspoonful, given by stomach every hour. Digitalis and strychnin continued. 2 P. M.: Pulse, 130; temperature, 101° F.; is quiet. 8 P. M.: Continues about the same. Pulse, 130; temperature, 101.4° F. No restlessness; is very weak, but does not feel as exhausted as last night. No tympanites. Stomach not washed out today.

November 12th, A. M.: Patient is gradually failing; pulse more rapid and very weak; extremities becoming cold. Complains of nothing except extreme weakness. *No nausea or vomiting.* Elixir alimentaire and malted milk given every hour or two by stomach. Remains conscious. A little tympanites has developed.

Toward evening became unconscious and quietly passed away at 7.30 p. m.

The following is revealed by an examination of the stomach-contents of November 10th: Amount, 44 ounces; color, grass green; consistence, thin fluid, stringy on dripping. Sediment after twenty-four hours' standing consisted of a few small flocculi, like curdled milk, of a grass-green color. Reaction, acid; specific gravity, 1007; filtrate, 1004; bile, large amount; albumin, large amount; sugar, none. Microscopically, the flocculi were amorphous, homogeneous, greenish masses. No red corpuscles; few leukocytes; many fat-globules; few columnar epithelia. No bacteria nor fungi.

Autopsy three hours after death; body not yet cold; no rigor mortis; eyes sunken; rubber drain in gall-bladder; tube and drain to cystic duct. No redness or swelling around stitches; sutures *in situ*. Abdomen opened from sternum to pubes. Panniculus adiposus 1.5 cm. thick; adipose tissue of normal yellow color. No edema or atrophy. On careful opening of peritoneal cavity no fluid, no adhesions, no fibrinous matter. The anterior wall of stomach fills the entire space from xiphoid process to umbilicus, and from right border of right rectus muscle 20 cm. to the left, and from umbilicus to fifth rib (21 cm.). Although not distended ad maximum, the stomach presents the appearance of a fat arm in flexion, the colossal upper arm being formed by the fundus and descending cardiac portion of the stomach, and the smaller forearm being formed by the pyloric (ascending) portion. The descending and ascending "arms" are in contact, forming almost one line. The surface of this enormous sac is smooth, grayish-white—not bluish (Riedel)—color normal, perhaps somewhat paler. Surface smooth and shining; if anything, somewhat dry. Cultures taken on blood-serum, agar, and glycerin-agar from the left side of stomach and abdominal wall and from the transverse colon and omentum.

The fundus fills out the whole left half of abdomen above umbilicus up to the fifth rib. Below the greater curvature lies the transverse colon, situated below the umbilicus transversely, of normal grayish-white color. Below the colon the omentum (of normal appearance) covers the intestines, not yet revealed. On the right border of the ascending pyloric half of the stomach is an uninterrupted layer of whitish yellow, adhesive exudate, gelatinous or fibrinous, with a perfectly dry surface, situated between stomach and anterior wall of abdomen. The exudate extends below stomach between hepatic flexure of colon

and abdominal wall, and below transverse colon between omentum and abdominal wall, down to 1 inch below the colon and to 1 inch below the lower end of operation wound. In this portion of the omentum is felt a swelling the size of a hen's egg, semifluctuating, and by loosening and stripping up the omentum from the abdominal wall 1 ounce of dark, liquid blood flowed out and ran down over the omentum into the pelvis. Cultures taken from the blood on agar and blood-serum (staphylococci). The blood came from the egg-shaped swelling that is now found to be a cavity 6 cm. by 5 cm. It is lined with fresh,

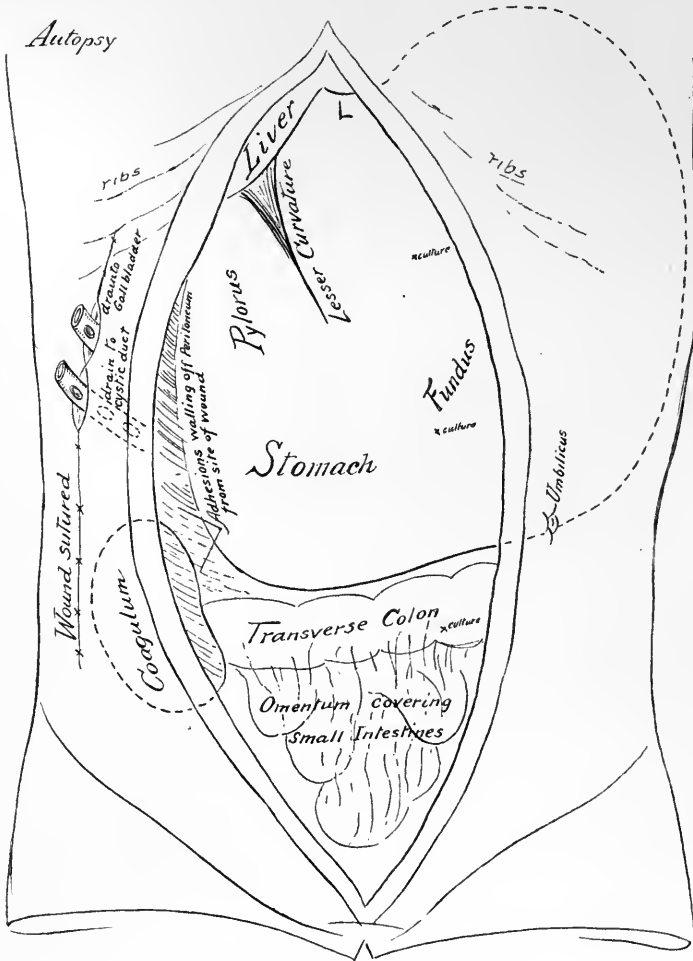


Fig. 130.—To show dilatation of stomach.

dark, soft coagula, adherent to omentum and anterior abdominal wall in region of lower inch of operation wound. (Bleeding from a stitch through branch of superior epigastric artery—the hemorrhage walled off by abdominal wall and omentum.) This corresponds to the region of pain felt by patient immediately after operation, and on first and second days following it in region of lower end of wound (pain disappeared on the third day).

In loosening the adhesions (fibrinous exudate) above the transverse colon between

the right border of pyloric half of stomach (ascending branch of "arm"), the walled-off cavity for drain (tube and gauze) down to cystic duct is opened. From this point a teaspoonful of pus exudes from around tube and gauze. Cultures made from the pus (*Staphylococcus aureus*).

[*Note*.—Pus always wells up when the gauze drains are removed; *e. g.*, from a gauze drain in suprapubic cystotomy. Here some pus had exuded from around lower drain and gall-bladder drain during dressing of wound, the same as when dressings were changed, but in small quantity—not more than around the drains in all gall-stone operations.]

Examination of abdomen below transverse colon was now made by lifting up the omentum from the small pelvis. On the small intestines filling lesser pelvis some blood had run down when the sac of blood described above was opened into (cultures). Small intestines empty and contracted—color and peritoneal covering normal. At the floor of pelvis there was no fluid—no exudate around uterus nor adnexa, the color of which was normal. A small fibroid in anterior aspect of cervix, size of hazelnut. Bladder half full of urine—normal. The sigmoid flexure and rectum were distended by gas, the peritoneal covering normal, only the color was somewhat more red than that of the transverse colon. (The distention and injection due to the nutritive enemata.)

The fibrinous adhesions between stomach and gall-bladder were loosened; the fundus of the gall-bladder, with its opening (cholecystotomy), was adherent all around and walled off from the peritoneal cavity. All the drains and sutures now removed, and the operation wound reopened. The wall of stomach was incised, and some gas, together with the green fluid noted above, escaped. Palpation of interior of stomach showed it to reach up to the fourth and fifth ribs. Digital examination of the pylorus and duodenum shows the former of sufficient size to admit three fingers, as was also the latter for 2 or 3 inches of its course. Below this dilated portion, where duodenum lay over the vertebral column, it was normal or so contracted as to admit one finger only.

Mucous membrane of stomach smooth, pale, of normal color. The wall of stomach was not thinner, but rather thicker, than one would expect of a stomach so enormously dilated. Examination of bile-ducts—no stones felt in or around gall-bladder nor in cystic duct; no bile in gall-bladder nor around wound in cystic duct; no stone nor anything abnormal was felt or seen. The lesser omental sac was opened after lifting up the stomach and found to be empty, and the peritoneum smooth and shining. Pancreas of normal appearance.

Liver of normal size, shape, and color, as were also the kidneys.

After lifting up the distended fundus the spleen was found of normal aspect throughout.

Postmortem was restricted to the abdomen by request of the family.

Résumé of Autopsy.—No peritonitis; no sponge left behind; peritoneal cavity safely walled off from field of operation, gall-bladder, and tract of drain down to cystic duct.

Extravasation of blood (hematoma) size of hen's egg, containing two or three ounces of blood partly coagulated, partly liquid, in region of lower end of operation wound, between it and the omentum, and walled off from the drainage tract down to cystic duct and from general peritoneal cavity.

Enormous dilatation of stomach and upper portion of duodenum.

Contraction of small intestines and colon ascendens, transversum, and descendens. Dilatation of sigmoid flexure and rectum.

Microscopic Examination.—Stomach: The cylindrical epithelial cells of mucosa surface are normal in shape, size, and structure. The glandular cells of peptic glands also perfect, and the central and parietal cells can readily be distinguished from each other. Pancreas of normal structure. Kidneys—cloudy swelling of epithelial cells in tubuli contorti. Liver—cells slightly cloudy and granular. Not a trace of fat in the liver-cells. Spleen normal.

Bacteriologic Examination.—(By Dr. E. J. Brougham, at the laboratory of the Passavant Hospital of Chicago.) Stomach contents (green fluid) contains *Staphylococcus albus*. Peritoneal cavity, from different points, sterile. Hematoma from bleeding stitch-hole—*Staphylococcus aureus* (probably contaminated during the autopsy). Pus along gauze drain—*Staphylococcus aureus*.

Henry Wald Bettman* reports an interesting case of acute dilatation of the stomach. The author considers that—(1) there is such a condition as acute dilatation of the stomach; (2) the disease is fairly uniform in its onset, course, and tendency to a rapid fatal termination; (3) treatment must be prompt and active, and some lives can be saved by early diagnosis and energetic treatment.

His case was a female, aged seventeen, Russian; well nourished. Admitted to hospital October 23, 1895. Sick two weeks prior to admission, with headache, anorexia, fever, general malaise, vomiting. Diagnosed typhoid fever, as she had enlarged spleen, temperature, 101° to 103° F.; diarrhea; roseolæ. Vomited much, and had to be catheterized. Diagnosis—typhoid and acute gastritis. Up to November 7th progress uneventful, save vomiting and delirium. Abdominal tenderness; fever gradually abated.

November 7th to 13th: Convalescing; hungry; took nourishment (ice-cream, soup, soft-boiled eggs) well.

November 13th: Vomited once, but felt well otherwise.

November 14th: Severe abdominal pain, nervous, delirious, vomited 8 times; food stopped; abdomen enlarged and tender.

November 15th: Restless until 10.30 p. m. Sudden collapse; temperature, 96.5° F.; was kept alive next day with the greatest difficulty. Pulseless, cold, vomited large amounts green, thin fluid. Cracked ice with a few drops of chloroform given. Sensorium dull. Bowels moved spontaneously; brown and watery. Withdrew 700 c.c. urine in twenty-four hours by catheter. Vomited about 20 times, about 150 c.c. each time.

November 17th: Vomiting unabated; light green fluid coming up in large quantities. Bowels moved three times spontaneously. Abdomen distended. Still collapsed, but conscious.

November 18th: Condition desperate, and gastric lavage done; thin tube easily passed, and large quantity of thin green fluid withdrawn. Improvement almost immediate; abdominal distention disappeared; sensorium clearer. Rectal feeding. No vomiting for eighteen hours after lavage. Bowels moved spontaneously, thin and brown.

Gastric lavage once or twice daily for three days. Rectal feeding only. Convalescence slow; vomited and remained weak, slightly delirious now and then.

November 21st: Retained iced tea and orange-juice.

November 22d: From this on improvement more rapid. Retained kumiss, butter-milk, and chicken broth, and strength slowly returned. Remained in hospital two months suffering with ulcers on legs where she had been injected. Since then her health has been perfect.

The author thinks there can be no doubt as to the diagnosis. The violent and increasing vomiting, collapse, distention of abdomen, and nature of vomitus are all characteristic; also the disappearance of the abdominal distention after lavage. The regular spontaneous movements of the bowels and the persistence of the liver dullness precluded the idea of a perforation, which was first suspected.

* Gaillard's Medical Journal, 1897, p. 78.

Author's conclusions:

1. During the course of convalescence from some acute or chronic disease the stomach may undergo rapid dilatation.

2. This condition is marked clinically by a sudden and violent onset; vomiting is violent and intractable; large quantities of fluid are ejected; the fluid is usually greenish, due to admixture of bile. The patient is reduced to a state of collapse or exhaustion which may prove fatal in a few days.

3. During the progress of the disease the abdomen becomes distended, the right hypochondrium remaining flatter. The bowels move spontaneously, and a splashing sensation may be elicited over the site of the distention. Sensorium usually cloudy.

4. If treatment is unsuccessful, the abdomen becomes more distended, vomiting ceases, and the patient dies of exhaustion.

5. Indications for treatment are: (a) Supportive measures. (b) Use of stomach-tube one or more times daily, as early in case as possible. (c) Rectal feeding. (d) No food by mouth until vomiting is nearly or quite controlled.

6. The treatment without lavage is unavailable, and the use of narcotics worse than useless.

Rosenheim* has also observed cases of mechanical insufficiency of the stomach occurring periodically in neurasthenic patients.

Ewald† states that very appreciable dilatation may occur in which the injurious effects are equalized by efficient compensation on the part of the absorptive and motor functions. Thus some individuals may for years have an abnormally large stomach which causes them little or no trouble, just as people live for years in ignorance of the existence of a valvular lesion, owing to perfect compensation of the heart muscle. But some day, suddenly, or in a surprisingly short time, all the symptoms of the dilatation appear. These are the cases in which the dilatation has apparently arisen acutely, and which are spoken of especially in the English literature.

Albutt,‡ in a paper on simple dilatation of the stomach, pointed out that simple gastrectasis, both acute and chronic, and independent of pyloric obstruction, was often overlooked, and indeed many physicians have been disposed to ignore it in an uncomplicated form. He urged the great importance of diagnosing the disease, whether it occur as a complication of febrile or debilitating illness or as a result of prolonged gastric derangement and as a malady to which infants, youths, and adults were liable. He held further that the dilatation was due rather to a diminished power of resistance on the part of the stomach-wall to the normal or slightly augmented intragastric pressure, than to a giving way of the stomach-wall, owing to largely increased pressure from within.

* Magenkrankheiten, 2. Aufl., p. 452.

† Diseases of the Stomach, p. 290.

‡ Lancet, 1887, vol. ii, p. 905.

J. B. Hunter* reports a case of acute dilatation of the stomach following laparotomy.

Female, married four years, never pregnant, age twenty-eight. Dysmenorrhea and pelvic bearing-down pains; right inguinal hernia; well nourished. Local treatment for endometritis and for prolapsed and painful ovaries without benefit. Tait's operation performed. Physical examination showed no organic disease and nothing unusual to direct attention to the stomach. Typical operation; catgut ligatures. After operation continued nausea and vomiting, and patient died on the ninth day from exhaustion. Autopsy showed the abdominal cavity, to within 3 inches of pubes, occupied by the dilated stomach, which contained one gallon of dark acid contents (color not noted). No obstruction of pylorus. Chronic inflammation of mucous membrane and marked atrophy of all the coats. Nothing noted in report as to presence or absence of peritoneal adhesions nor fresh exudate, nor whether or not the stomach was washed out.

H. Schultz, in an article entitled "Zur Casuistik der acuten Magenerweiterung"† says that dilatation of stomach should be of interest because it can be diagnosed with the ordinary physical methods of examination and without chemic analyses. The causation of the atonic paralytic condition of the muscularis may be:

1. General low condition of the vitality, as in the different anemias, cachexias, tuberculosis.

2. Infiltration of the muscularis by chronic gastritis, chronic venous engorgement.

3. Disturbance of innervation by diseases of the brain and spinal cord, mental diseases, hysteria and hypochondriasis.

Aside from the above, many authors (Andral, Magendie, Duplay, Skoda, Rosenbach) believe in a simple, primary, or essential weakness or paralysis of the stomach-wall. Schultz reports a case as follows:

November 28, 1889: Female; twenty-four; single. No previous illness. Four months ago was taken down with severe febrile disease lasting to date. The exact nature of the ailment could not be determined by the attending physicians. The diagnosis lay between typhoid and malaria.

Examination November 28th: Patient, previously well nourished, is now in a state of extreme emaciation; temperature, normal; pulse, 84, regular, weak; pains in feet, ankles, and knees. Feet in position of pes equinus; toes flexed; knees flexed; joints very painful on motion.

Heart and lungs negative. Abdomen very much retracted; no tenderness anywhere. Spleen negative. Bowels costive. Urine contains trace of albumin; no morphologic elements.

Put on liquid diet, baths, wine, stimulation.

December 13th: Improved, is stronger, and has some appetite. Can now eat scraped beef and potatoes without causing distress. No nausea or vomiting. Abdomen still retracted; no tenderness anywhere.

December 17th: Knees and ankles less painful, and can now be moved more easily. Massage and passive motion.

December 19th: During the night of the seventeenth was taken with sudden severe

* Boston Medical and Surgical Journal, vol. cxvii, p. 361.

† Jahrbücher der Hamburgischen Staats-Krankenanstalten, 1890, vol. ii, p. 145.

pains in gastric region. Suffered terribly, and morphin brought only slight relief. Yesterday vomited frequently large amounts of greenish fluid. This morning bulging of epigastrium (contour of the stomach); peristaltic movements can be elicited on handling. Liver dullness much diminished from below, and tympany all over site of left lobe. Great tenderness now in epigastrium. Had a spontaneous evacuation of the bowels. Treatment—nutrient enemata; stimulation; morphin.

December 20th: The distention in the epigastric region has increased and extended downward to midway between umbilicus and pubes. The abdomen above symphysis is retracted. Great tenderness over the distended area, which gives forth a deep tympanitic percussion-note; some dullness in the flanks. No peristaltic movements. Continued vomiting of bile-stained fluid.

Death from exhaustion the same evening, the condition having lasted three days.

Autopsy five hours later. On opening abdomen the dilated stomach is revealed occupying almost the entire cavity from xiphoid to pubes. At the site of the pylorus the dilated duodenum and pyloric half of the stomach join at an acute angle, the stomach forming the descending, the duodenum the ascending, limb. Duodenum in its lower third slightly stenosed, owing to dragging down of stomach. No peritoneal adhesions. Stomach contains large quantities of an acid, greenish fluid. Walls of stomach attenuated.

No stenosis of pylorus; rather dilatation admitting five finger-tips and involving upper portion of the duodenum. Echymoses in mucous membrane. No ulcers; no scars; no pigmented areas.

Spleen, liver, and kidneys normal.

Microscopic Examination.—Muscularis of stomach-wall very thin; fibers partly in granular degeneration; many fresh hemorrhages. The glands are distorted from their normal relative direction and position; gland-cells mostly intact. Some fresh echymoses and granular degeneration here and there.

[*Note.*—The author makes no mention of the use of the stomach-tube.]

Poensgen* believes that acute dilatation of the stomach may be due to definite structural changes or may appear without such, viz., functional.

Brinton,† in treating of acute paralytic dilatation of the stomach, says that sometimes, during convalescence from acute febrile diseases, the patient will suddenly be taken with violent abdominal pains associated with great tympany and tenderness of abdomen, and no reason present to suspect peritonitis. The patient may rapidly become exhausted and die. He has performed autopsies on such cases, and found the stomach enormously dilated and filling the entire abdomen. No mention of stomach-tube is made.

Acute dilatation of the stomach, according to Osler, is rarely seen, although it has been known to occur when large amounts of solid or liquid food are taken. Occasionally this leads to extreme paralytic dilatation, and Fagge has described two cases which came on in this way, one of which proved fatal.

Boas‡ states that cases of acute dilatation of the stomach are of the greatest rarity. He could find only two cases recorded in the literature,

* Die motorischen Vorrichtungen des menschlichen Magens und seine Störungen, Preisschrift, Strassburg, 1882, p. 96.

† Diseases of the Stomach.

‡ Deutsche med. Wochenschr., 1894, vol. xx, pp. 155 and 172.

viz., Kelynaek* and Schultz.† Both cases were cachectic individuals, the dilatation coming on without appreciable cause and ending fatally.

Boas cites a case as follows: Malc, aged twenty, previously healthy; never had any gastric disturbances previously.

December 10, 1893: Error in diet; ate too much fat roast goose, and was taken sick next day with anorexia and belching of gases; no nausea, vomiting, or diarrhea. After three days' diarrhea, nausea and vomiting of acid fluids of foul odor, finally exceeding in amount that taken into the stomach. Constipated now.

January 10th: Greater curvature of stomach; when the organ is moderately distended, reaches the breadth of 4 fingers below navel; when distended with gas, it reaches 2 inches further. Splashing and succussion can be elicited by agitation. No tenderness anywhere. Passage of stomach-tube brought out 300 c.c. of a thin liquid, containing particles of undigested matter from previous meals. The fluid contained sulphureted hydrogen; free hydrochloric acid in about normal amount. Microscopically, sarcinæ, bacteria, yeast, fat-crystals, muscle-fibers, starch-cells.

Stomach washed out regularly after that; 200 to 400 c.c. were evacuated at each time. The conditions improved immediately—no more vomiting nor sour eructations.

This is a case where an acute dyspepsia, arising in an individual previously healthy as to the stomach, was followed by an acute dilatation of the stomach. Analogous to the "acute overexertion of the heart" by O. Fräntzel, Boas would designate the above condition of the stomach as an "acute overexertion of the stomach."

Boas' prognosis, *quod restitutionem ad integrum*, is not very favorable; he thinks the tonus will never be quite restored to the normal. He thinks that an emetic administered at the onset of the illness would have prevented the development of the dilatation.

Albu,‡ in a communication, "Über acute tödtliche Magen-Dilatation," states that acute and chronic dilatation of the stomach differ essentially as to etiology. In the acute dilatation, stenosis of the pylorus takes no part, whereas it is important in the causation of the chronic dilatation. Acute dilatation, in contradistinction to the chronic, arises from an affection of the stomach-wall. Acute gastrectasia develops without there having been any previous diseases of the stomach. However, a diminished tonus of the stomach-wall of long duration is a predisposing factor. Albu, with Boas, accepts two forms of acute gastrectasia:

1. Dilatatio ex ingestis, viz., due to overeating. (Cases of Hilton Fagge, A. Fraenkel, Boas, and others.) This is not the type of extreme, rapidly progressive, fatal cases.

2. Dilatation from paralysis of stomach-wall of central nervous origin. (Cases of Gross, Köberlé, Hunter, Kelynaek, Schultz, A. Fraenkel.)

Albu's case is as follows:

Male, twenty-six years old, admitted to hospital May 20, 1895, with scarlet fever. Previously healthy. In the habit of overeating and overloading the stomach. For ten

* Medical Chronicle, 1892.

† Jahrbücher der Hamburgischen Staats-Krankenanstalten, 1890, vol. ii, p. 115.

‡ Deutsche med. Wochenschr., 1896, vol. xxii, p. 102.

days he ran a typical course of fever, with severe angina and some cardiac weakness. Temperature came down to normal, and he began to have some appetite.

May 31st: Began to vomit violently, without any ascertainable cause as to diet. Vomiting repeated and epigastric tenderness appeared.

June 1st: Still vomiting; getting weaker; sensorium cloudy. Vomitus is watery, with mucus and bile admixed. It was now evident that there was a great distention of the upper abdomen, especially to the left side. Fluctuation and succussion. Percussion elicits dullness over the protuberant area, and confluent with the dullness of liver, heart, and spleen. Greatest intensity in left hypochondrium.

Patient apathetic; great pain in stomach, no evacuation of bowels for two days. Pulse scarcely palpable; extremities cold. Vomiting ceased later in the day. Stomach-pump brought out large quantity of green, foul-smelling fluid. No improvement; delirium and death in the following night, in spite of constant stimulation.

Autopsy.—Parenchymatous myocarditis and nephritis. Gastritis parenchymatosa pigmentosa. Dilatatio permagna ventriculi; no pyloric stenosis; no scars from old ulcers.

As the pain and tenderness of the distended abdomen was so sudden and so great, the author considered the possibility of peritonitis, especially with the dullness in the lateral dependent portions of abdomen.

Two further points of importance were also noted, viz.: (1) Total absence of peristaltic movements and (2) cessation of vomiting when the dilatation is at its maximum. Finally, referring to the cerebral symptoms,—apathy, somnolence, delirium,—Albu would consider them due to the absorption of toxic substances from decomposition in the stomach, rather than to anemia of the brain.

The primary causation of the acute dilatation may be regarded as toxic, as following some acute infectious disease; and, indeed, paralyses of the most varied regions of the nervous system have been noted, *e. g.*, after typhoid, cholera, and puerperal fever. He quotes from Brinton, who considers the solar plexus and pneumogastric the nerves affected and paralyzed by the action of toxic substances upon them.

Engström* reports a case of intestinal paralysis following operation in the abdominal cavity:

Female, thirty-seven; ovariectomy right side. Sponged out large amounts of bloody ascites. After operation vomiting, soon fecal in character, meteorism, accelerated pulse, subnormal temperature. Sensorium clear. Stimulation. Lavage of stomach and intestines. Reopened abdomen and found no mechanical obstruction. One hour after death cultures taken from peritoneal cavity, which remained sterile. Ileum greatly distended; upper portion of duodenum and colon not distended.

Grundzach† reports a case of paralysis of stomach and intestines after laparotomy:

After operation for rupture of an extra-uterine pregnancy there developed, in the first three days, the symptoms of motor and secretory paralysis of the stomach, viz., great

* Nordiskt medicinsk Archiv, 1895.

† Ueber Lähmung des Magens und Darms, namentlich nach Laparotomie, Medycyna, 1895.

tympany in epigastrium, reaching to navel. Frequent vomiting of a fermenting fluid (absence of HCl, traces of lactic and acetic acids, yeast). Constipation and no flatus. Rapid, thready pulse, subnormal temperature, apathy. On the sixth day passed flatus and vomited 50 c.c. fluid, grass-green, containing free hydrochloric acid, but no yeast or lactic acid. Recovery uneventful after that. With reference to treatment: No nourishment—absolutely nothing by stomach, and instead nutrient enemata, lavage of stomach, ice-bag to abdomen, and sometimes faradism.

B. Riedel* after operation for gall-stone: In thirty-six or forty-eight hours the patient may begin to vomit; no rise in temperature. The upper half of abdomen becomes tympanic, then the lower abdomen is affected, even down to left Poupart's ligament or to symphysis. Vomiting continues; pulse rises and becomes softer—130 to 140 beats. Face becomes sunken; extremities cool. It is the picture of a foudroyant peritonitis—yet it is not peritonitis!

If the abdomen is opened, no trace of fibrous or inflammatory exudate is found, but, instead, the enormously dilated stomach. The cardiac half passes down horizontally toward the left Poupart's ligament; there it joins at an acute angle the ascending pyloric portion. The lesser omentum is stretched between. The condition is an acute dilatation of the stomach, coming on twenty-four to twenty-eight hours after operation in an individual whose stomach was, at the time of operation, seen to be normal.

Riedel had two cases; in both there existed adhesions—in one between liver and right end of lesser curvature; in the other a band of omentum passing over pylorus to lesser omentum. These adhesions may have predisposed to the dilatation, but it is certain that a previously healthy stomach may become, in twenty-four to forty-eight hours, dilated down to pubes, and it is immaterial whether due to the effects of separation of adhesions or to some obstruction in the pyloric region.

The vomiting is excited, first, by the fluids taken into the stomach soon after operation; but soon the amount vomited or removed by tube exceeds by far what has been taken per os. The fluid is thin, serous, containing dark coagula; these latter are structureless; red corpuscles whose pigment had diffused were also found.

To prevent vomiting, Reidel would give no fluids by mouth in the first twenty-four hours. If vomiting occurs, nevertheless, wash out the stomach and administer 0.01 gm. morphin hypodermically. The effect is marvelous—the vomiting ceases and the pulse becomes stronger. Lavage may be repeated three or four times daily. He thinks he could have saved his two cases had he resorted to these procedures; but, on the contrary, he thought there was infection, reopened the abdomen, found out his mistake, and then the patients *did* die of infection.

* Chirurgische Behandlung der Gallenstein Krankheit," Handbuch der speciellen Therapie der inneren Krankheiten, Penzoldt und Stintzing.

REMARKS ON SURGERY OF THE BILE-DUCTS*

CLINICALLY, it is impossible in all cases to separate the common duct from the rest of the bile-ducts. I shall point out some facts referring to the ducts in general and the gall-bladder, but, on the whole, limit my remarks to the surgery of the common duct.

Biliary colic is a symptom common to the whole biliary tract. First, as to the causation of pain, which we will consider irrespective of the presence or absence of icterus. There are three distinct factors operative in the causation of the pain, namely—(a) Incarceration; (b) inflammation; (c) retention.

Incarceration.—Contraction of the wall of the duct around the obstructing stone, or pressure of a stone too large for the duct against its wall, may cause the attack. The observation of Dr. Billings that a sound passed through a biliary fistula into the cystic duct caused pain in the right scapular region is highly instructive. It is said the narrower a duct through which a stone passes, the more violent the pain. Thus the cystic duct, which has the narrowest lumen, would be the seat of the most violent pain from incarceration of a stone, much more so than if the wider common duct were the seat of obstruction (Lawson Tait). Courvoisier, in his monograph,† shows that, of the 9 cases of gall-stones reported in the literature where death occurred during the paroxysm of violent biliary colic, there was a stone in the common duct in 6, a large stone in the gall-bladder in 1, stones in all parts of the biliary tract in 1, and no autopsy made in 1 case. It is doubtful, therefore, if the cystic duct is more to be dreaded in this respect than the rest of the biliary tract.

Inflammation of the wall of the duct in the region of the stone mechanically injures the epithelial surface and creates an atrium for infection. This is found in most instances of remittent attacks of inflammation (suppuration) of the gall-bladder—typical attacks of pain and fever at intervals of months. Can the inflammation, however, be the cause of the daily colic or pain occurring every few weeks? As Dr. Billings has pointed out, a small and non-obstructing stone in the diverticulum of Vater may be the cause of this colic. I made the same observation in Case V of my paper.‡ In this case the small stone lay

* Chicago Med. Recorder, 1898, vol. xiv, p. 309; discussion before the Chicago Medical Society.

† Casuistisch-Statistische Beiträge zur Pathologie und Chirurgie der Gallenwege, Leipzig, 1890.

‡ "Stones in the Common Duct and Their Surgical Treatment, With Remarks on the Ball-valve. Action of Floating Choledochus Stones," Amer. Jour. Med. Sci., 1896, vol. cxi, p. 125

loosely in Vater's diverticulum. This, I think, may be explained as follows: A daily or weekly exacerbation of an existing subacute inflammation takes place, analogous to a protracted nasal catarrh or laryngitis, which gets better and worse at intervals.

Retention of bile behind an obstructing (fixed or floating) stone or behind a valve or bend caused by adhesions is also found to cause biliary colic. It is probably the sudden obstruction only that causes an attack of colic, as none occurs in the cases of gradual obstruction—for example, following cancer of the duodenum or the pancreas near Vater's diverticulum. At the present stage of our knowledge it is not possible, in a given case of biliary colic, to diagnose, from the clinical symptoms, which of the three etiologic factors are operative. This may, however, be a possibility in the future.

Differential Diagnosis.—Dr. Herrick has mentioned the fact that acute disease of the bile-ducts sometimes simulates acute intestinal obstruction. A case of this kind is the following: I saw the patient, a woman of about forty, May 20, 1896, in consultation with Dr. Loevenson. She was suffering with all the symptoms of an acute intestinal obstruction, seemingly with peritonitis, and nothing to point to the biliary tract. She was taken to the German Hospital of Chicago for operation. I opened the tympanic abdomen in the median line, and found the peritoneum normal throughout, the intestines uniformly distended and nowhere obstructed. A distended gall-bladder was the only abnormality found. I closed the median incision and made a lateral one over the gall-bladder. The gall-bladder was considerably enlarged, tense, free from adhesions, and somewhat congested. Thinking that the condition of the gall-bladder might not be the cause of the obstruction, but that the latter might be dynamic and of unknown cause, I resolved upon a cholecystostomy in two stages. I selected this operation as the one which, if subsequent events showed it to have been superfluous, would be least harmful in its effects. The symptoms of absolute obstruction continued unabated after the first operation. After thirty-six hours I felt constrained to incise the gall-bladder. Pus escaped, and 140 good-sized gall-stones were evacuated. The symptoms of intestinal obstruction ceased immediately. She recovered with a fistula in which one year later a cylindric-celled carcinoma of the gall-bladder made its appearance.

Another point of interest in the diagnosis which has attracted my attention is the following: Does the shape of a given gall-stone, passed by the bowels, give us any clue by which we may locate its former seat in the biliary tract, or the place it occupied during the greater time of its period of formation, and, if so, where might we expect to find more stones?

(a) Stones with facets—pyramidal stones—I believe are ordinarily from the gall-bladder, as here the stones occur in groups.

(b) Stones with two parallel facets—barrel-shaped stones—are commonly from the ducts, where they lie in a single row.

(c) Spheric stones with no facets, when single, and either large or small, may occur anywhere, but when multiple, I believe they often come from a dilated common duct.

I will pass around stones in illustration of these views—stones from the common duct, Vater's diverticulum, and the gall-bladder. As an exception, however, in the following case all the biliary passages were filled with pyramidal stones.

CASE I.—Male. Age, thirty-two; first attack of biliary colic fifteen years ago; second, five years ago; colic with increasing frequency since; icterus; no tumor felt; operation; cystic, hepatic, and common ducts dilated and filled with stones; gall-bladder small, contained stones—choledochotomy; removal of stones; cholecystotomy—removal of stones. Recovery; no attacks of biliary colic since.

Remarks.—Duration of operation, two hours and twenty minutes. It was tedious and difficult to extract all the stones. Slight bleeding occurred from the wall of the duct, which stopped when sutures were tied. There was dilatation of hepatic half of common duct, of hepatic duct, and of lower half of cystic duct. No dilatation of duodenal half of common duct.

Sometimes large quantities of gravel are found behind a large obstructing stone. These may occur either as amorphous masses of bilirubin lime, and can be identified positively only by chemical tests, or as masses containing hundreds of well-formed minute stones, 1 to 3 mm. in diameter. With a low magnifying lens these stones can be recognized as biliary calculi, especially if the broken surface, with its characteristic radiation, is seen. The importance of identifying as gall-stones concretions passed with the feces is obvious, as thereby we have a positive clue in tracing the origin of vague symptoms.

I believe it is yet impossible clinically to differentiate diseases of the gall-tracts caused by stones from those caused by bending or valve formation of the ducts. This I have shown in a former paper.*

We may have either the frequently recurring short attacks of colic, as in floating stone in the common duct, or those monthly or semi-annual attacks of colic with inflammation, as with stones in the infected gall-bladder, or, finally, no colic at all, icterus, if present, being the only symptom pointing to the biliary tract.

Should the operation of cholecystotomy in two stages be abandoned?

Courvoisier's statistics showed the mortality to be the same, namely, 10 per cent., whether the operation was performed in one or two acts. We read and hear less and less of the two-stage operation being performed now. Many operators have given it up (F. Lange); others pronounce it a bad operation,† others resort to it only exceptionally, as Kehr,‡ in

* "Retention from Displacement, Bending, and Valve Formation—Oblique Insertion in Biliary Tract," *Medical Standard*, Chicago, 1896 and 1897, vol. xviii, p. 353; also *Trans. Amer. Surg. Assoc.*, 1896.

† Halsted: *Bulletin Johns Hopkins Hospital*, 1897, vol. viii.

‡ "Ein Rückblick auf 209 Gallensteinlaparotomien," *Langenbeck's Archiv*, 1896, vol. liii, p. 362.

3 out of 100 operations. Riedel is one of a few who holds to it with certain well-defined indications.*

The chief objection to the operation in two stages is that it does not allow of the removal of incarcerated stones from the neck of the gall-bladder or from the ducts. This makes the operation for gall-stones an imperfect one, necessitating, perhaps, a secondary operation to remove stones which cannot escape by way of the fistula.

Riedel's indication for the operation in two stages is the presence of a small, deep-seated gall-bladder, which cannot be brought out and sutured to the parietal peritoneum.

I do not feel like giving up this operation entirely, as it is safer against infection of the peritoneum than the operation in one stage. It protects as certainly and surely when we operate for a suppurating gall-bladder as when we operate for abscess of the liver or any other retroperitoneal collection of infective material. I never had a patient die from the effects of an operation in two stages; in one cholecystostomy in one stage, however, a fatal septic peritonitis followed. It seems to me that when the object of a cholecystostomy is not so much the removal of stones from the biliary tract as drainage of a septic gall-bladder (a temporary operation to avert the danger of rupture, perforation, and sepsis), the two-stage operation is preferable or the only rational one (Riedel).

If we have to operate during an acute attack of cholecystitis and find a small, deeply situated gall-bladder, to which all the surrounding organs, namely, duodenum, transverse colon, stomach, pylorus, etc., are adherent, or a gall-bladder that is entirely buried beneath succulent, edematous adhesions to other organs, I prefer to operate in two stages. In some of the most complicated cases—and the cases of disease of the bile-ducts that come to operation at the present time are generally more or less complicated, as 73 of Riedel's 120 cases were complicated—the local condition and condition of the patient may necessitate the two-stage operation as the wisest compromise, as the patient may not be able to bear an operation lasting one to three hours.

There is another reason, aside from safety, that induces me to operate in two stages in some of the most complicated cases; namely, the simple drainage of the gall-bladder not only relieves symptoms, but brings about a change in the pericystitis whereby the hard, edematous, infiltrated adhesions become soft and pliable and the organs again become movable. At a later operation, under these circumstances, the isolation of the bile-ducts without rupturing the gall-bladder or intestines becomes possible. We can then recognize the identity of the different structures, which is sometimes impossible in the acute active stage of the pericystitis.

There are many cases reported where the radical operation had to be abandoned, or where the patient died because the operation was too complicated or the intestines were opened into. I have in several cases of this kind been satisfied to be able to lay bare a square inch of the gall-

* Penzoldt and Stintzing's *Handbuch der speciellen Therapie, Chirurgie der Gallenwege*.

bladder surface for an operation in two stages. The majority of my cholecystostomies in two stages, although operations of necessity, have given permanent relief.

For the young surgeon who begins to operate on the biliary tract it is better to perform more cholecystostomies in two stages, even at the risk of making incomplete operations, than to venture too far into a more complete operation and lose the patient. With years of experience his operations will gradually become more and more complete.

Pericystitic Abscesses or Fistulas.—The greatest difficulties are encountered in the cases where pericystitic abscesses are located between the biliary and the intestinal tract, with fistulas between these hollow organs. A localized hard mass in the adhesions indicates the presence of an abscess. As an instance, I cite the following case of fistula into the pylorus:

CASE II.—Female. Age, thirty-five; married; first authentic attack of biliary colic one year ago; one or two attacks every month; no icterus at first; after eight months icterus and clay-colored stools. Operation; indurated mass uniting ducts and stomach; found to contain cavity filled with cheesy detritus and a sinus opening into stomach; fistulous opening in stomach sutured. Stone in common duct removed by choledochotomy. Cholecystostomy. No recurrence of biliary colic. Recovery.

In another instance a pericystitic abscess between the gall-bladder and the transverse colon terminated in a fecal fistula one month after a cholecystostomy in two stages. In this case the gall-bladder was buried among the adjacent intestines.

Would it have been better to have laid the bile-ducts bare and sutured the colon at the first operation? If this had been done, would the patient be alive today?

Displacement of the gall-bladder and of the entire liver I found in two cases due to very firm adhesions to the parietal wall. Lateral displacement will necessitate a transverse branch to the longitudinal incision. Displacement upward under the costal arch may require resection of the costal cartilages, as proposed by F. Lange.

An instance of this is the following case:

CASE III.—Male, age forty-seven. Biliary colic for ten years, at first without jaundice or clay-colored stools. August, 1897, severe biliary colic with jaundice and clay-colored stools. Operation: Liver and gall-bladder retracted high up under ribs, requiring resection of costal cartilages to bring gall-bladder into view. Very extensive adhesions everywhere; operation in two stages; gall-bladder with difficulty sutured to peritoneum; gall-bladder opened thirteen days later; stones escaped; fistula for some months; eventually recovered; no more colic.

In what cases should we operate and when are questions concerning which there exists a difference of opinion between internal medicine and surgery. Operation is now performed earlier in the disease than formerly, when only the most desperate cases sought surgical aid. The local conditions which tend to make operation difficult, if not im-

possible, are due to the recurrent attacks of infection and inflammation in and about the gall-bladder. In Kehr's 209 operations, 41 lasted more than two hours, 6 more than three hours, and 2 over four hours; in other words, 25 per cent. lasted over two hours. In the early operation less complications are liable to be encountered, and the operation is consequently shorter, and for this reason it should be advocated. It is questionable, however, if the cases that present the greatest difficulties during operation always present a history pointing to the same or, indeed, have a history that indicates early operation.

In cases with remittent attacks I prefer to operate in the interval of rest, as in appendicitis. I do so because I believe the adhesions are less rigid and edematous and the microbes less active in the free interval.

When stones are being passed with the feces, whether through a dilated Vater's diverticulum or through perforation, into the intestine, we naturally await the result and see if relief does not follow. This is evidenced by the following case:

CASE IV.—Male, age sixty; biliary colic for four years; icterus two years ago; stone found in the feces; recurrence at least once or twice every month; during last year attacks almost every week; sometimes very severe; icterus; late in December, 1896, severe biliary colic; each day stones were found in feces until there were six. Spontaneous recovery without operation. Has had no attacks since.

In choledocholithotomy it is important to find and remove all the stones, as a stone being left may necessitate a second operation. Kehr was unable to find all the stones in 5 out of 30 cases (16.6 per cent.). I was unable to find a small stone in Vater's diverticulum, and Küster, Terrier, Lauenstein, and Riedel, according to Kehr, each report one case. Where do these stones hide, even sometimes after they have once been felt at first? When they do not slip up into a dilated hepatic duct, where they may be felt with the finger or probe, I believe that they hide in diverticula in the wall of the ducts.

As an aid in detecting stones after the common duct has been opened, I devised my flexible metallic probe, made of spiral wire, as described in my paper of 1897.* Not only is a click felt when the probe strikes a biliary calculus, but, what I consider of much greater importance, should the point of the probe glide past a calculus, half hidden, we will say, in a diverticulum, we feel a grating sensation caused by contact of the stone and the uneven surface of the probe. I believe that I might have been thus able to feel a small stone in Vater's diverticulum, which would otherwise have remained undiscovered, and perhaps saved my patient.

The wound in the common duct is always closed with sutures; or, as Kehr terms it, the choledochotomy operation is always the ideal one. It is difficult to insert the sutures in the common duct, located, as it is, at the very bottom of the deep field of operation. I will pass around the hammer devised by Halsted to facilitate the introduction of the sutures.

* Medical Standard, 1897, vol. xviii, p. 353.

The prognosis of choledochotomy, as of operations on the ducts in general, is improving. In 1896 I estimated the mortality of the 44 cases then reported in the literature, and found it to be 18 per cent. I have operated on 7 cases with 1 death—14.3 per cent. In Kehr's 30 cases there was a mortality of 6.6 per cent. only; this is an exceptionally favorable record, that will probably not be obtained by the majority of operators, nor be improved by a larger series of cases.

Of the cases demanding operation on the biliary tract, which are easy and which are difficult of operation? It is notable that the two operators who have had the most extensive personal experience in this field of surgery should have such diverging opinions. Riedel has greater fear of the cystic duct than of the common duct. Kehr, however, performed 23 cystotomies without encountering complications or having a death, whereas he found his 30 choledochotomies mostly difficult and complicated. The explanation is that the number of operations is yet too small to avoid drawing erroneous conclusions.

In my opinion, the difficulty in operating on the ducts increases as we approach the duodenum, but conditions aside from the location of the disease must also be considered. Some of these are, for example, adhesions, fistulas, abscesses, bands and valve formation, retracted, inaccessible location of the gall-bladder, etc. The former may complicate the disease in any part of the tract to such an extent as to render the aspect of the case extremely grave and the operation highly dangerous, if not impossible.

I have no time for and dislike controversy. Before reading his paper, Dr. Bevan made known to me his intention of questioning the anatomic relations of the common duct and portal vein, as set forth in my paper on "The Treatment of Gall-stones." I endeavored to demonstrate to him that he was in error. As he still holds to his opinion, I feel it incumbent upon myself to set him and the matter aright. It is a serious accusation to state that I am mistaken in the anatomy by claiming that the portal vein comes up on the anterior surface of the common duct; especially so as I had brought out some points in the pathologic surgical anatomy of this region never before described. I cannot allow the suspicion of unreliability to rest upon any of my writings. In my paper I have illustrated and described the pathologic surgical anatomy of the field in operating on the common duct.

For the sake of clearness and comprehensiveness, as I stated in my preface, I decided to describe the relative position of the organs in question as they are observed with the patient in the horizontal position, as on an operating table.

The relation of the organs of the patient lying down, to the operator standing, has, therefore, changed 90 degrees from vertical to horizontal. Thus it follows that, for example, the anterior aspect of the common duct, with patient erect, becomes the upper surface when the patient is recumbent. Under the same conditions the upper surface becomes posterior, the posterior aspect becomes inferior, and the inferior becomes anterior when the patient is placed in a horizontal position. When I state,

therefore, that the vena porta emerging from behind is located, relative to the common duct, first on the posterior, then on the inferior, and finally on the anterior, surface, I refer to the relation in the horizontal position. In the upright position of the patient it would follow that the vein is first superior or above, then posterior, finally inferior or below, the common duct. I consider that the relations described with the patient horizontal are more comprehensible to the surgeon, as they are thus exposed by operation.

Dr. Bevan has evidently read my article carelessly if he doubts my statement that the portal vein in its terminal course is found located on the anterior (or inferior) surface of the right hepatic portion of the common duct.

Furthermore, the statement of Dr. Bevan that the specimens from which my plates were made were anomalous is equally erroneous. As I state in my paper, I have, in operating on patients with stones in a dilated common duct, found the relation of vein and ducts repeatedly and constantly just as it appears in the specimen and plate in question. My experience has upheld my opinion, that the description of the specimen was correct, and expresses the anatomic pathologic relations ordinarily met with in operating for stones in the common duct. I have further, through the kindness of Dr. William Hessert, procured a specimen of the normal organs with vessels and ducts injected with plaster-of-Paris and gelatin. This specimen also corroborates the correctness of my description as do the pathologic specimens which I now demonstrate. Owing to their treatment with formalin, they are somewhat shrunken.

The description attached to my plates contains exact measurements in millimeters of all parts. The figures are not schematic drawings, like those of Dr. Bevan, but are exact reproductions from nature of the organs involved. They are equal in correctness to photographs, but superior in comprehensiveness.

Dr. Bevan presents a specimen of a liver and bile-ducts with the latter, together with the vessels, dissected out and the vein empty. When the ducts and vessels are loosened from their surroundings, it is practically impossible to judge of their relative position, because they are then easily displaced. When the portal vein is empty, it is impossible to obtain even a remote idea as to its relation to the ducts; an empty vein is collapsed and appears like a strand of fascia or a band of connective tissue. In operating on the neck we are familiar with the great difference presented by a full or an empty internal jugular vein.

Consequently, inasmuch as Dr. Bevan's drawings are made evidently from specimens in which the portal vein was not injected, they must necessarily convey a false impression; they portray the organs and relations as taken from the cadaver, and not as seen in the living subject, as is the case with my description. Surgery does not deal with cadavers.

I would say, further, that it is well to consider the relation of the portal vein to the common duct while the left index-finger is passed into the foramen of Winslow.

In this manner the hepaticoduodenal ligament inclosing the common duct and portal vein is lifted upward (patient horizontal) or forward (patient erect). It is an advantage to study relations in this position because palpation of the ducts (common, cystic, and hepatic) is thus accomplished, and, furthermore, because incision of the common, cystic, or hepatic ducts is made with the finger in this location and the organs thus exposed. It facilitates orientation and tends to prevent injury to the portal vein. Finally, it is important, as neither by inspection nor palpation can the operator distinguish individually the vein from the ducts.

Dr. Bevan has made some 40 dissections, and presents us, as the result, a series of drawings of the bile-ducts and their surroundings. These drawings do not differ materially from the time-honored classic illustrations of this territory to be found in the anatomic atlases. They differ only in that they are less correct than the classic ones, inasmuch as they are entirely schematic and do not give any dimensions.

Some of the illustrations are evidently intended to show the pathologic anatomy of the bile-ducts. The doctor has in some of his charts inserted imaginary gall-stones in the normal ducts. This matter of developing pathologic anatomy at one's writing desk must lead necessarily to grave errors and absolutely erroneous conceptions.

A beginner in the surgery of the bile-ducts who, in a given case of stones in the gall-bladder or ducts, would rely upon Dr. Bevan's anatomic plates as guides in his operation would be much deceived and very much at sea. He would find the conditions in the case so entirely different from the normal anatomic conception that he would be at an utter loss to find his bearings.

Dr. Bevan seems to ignore the fact that surgical diagnosis and operating are based indirectly only on normal anatomy. Nobody will deny that a prospective surgeon must first acquaint himself with normal anatomy. But operations are not performed on the normal body or on normal organs. The second step in the development of the surgeon and operator is the study of pathologic anatomy. General pathology enlightens him relative to the different morbid processes of diseased organs. This knowledge is needed for an intelligent comprehension of the anomalous life processes in diseased organs. A surgeon might diagnose and do moderately good mechanical work on the plane of the ordinary artisan without much attention to pathology or pathologic physiology.

But pathologic anatomy, namely, the knowledge of the shape, size, relations, and so on of diseased organs, is absolutely essential to the good operating surgeon. The field of operation, its topographic pathologic anatomy, as I have, for example, described it in operating on the common duct, is often widely different from the same region in perfect health. The ducts may be dilated and tortuous; irregularly sacculated in places; diverticula may be present; these conditions necessarily change the relations of the parts concerned. For example, how would it aid the surgeon, operating on a fibroid in the broad ligament, to have before

him an illustration of a normal uterus and adnexa? The normal anatomic relations are entirely and absolutely distorted. If the surgeon has not studied the pathologic anatomy of uterine fibroids, he will be guided by normal anatomy alone, and will be utterly helpless when he comes to operate. Pathologic anatomy must first be studied at autopsies preparatory to work in the operating-room.

Next the pathologic anatomy must be studied during operations—at first in seeing others operate, and finally in operating one's self.

The variety of pathologic lesions met with during operations is so great that an extensive experience only will in time enable the operator to unravel the difficulties encountered among the diseased organs, with their abnormal relations and surroundings. Riedel justly remarks: "The surgeon who intends to operate for gall-stones must acquire an exact knowledge of the pathology (pathologic anatomy) of the disease, and then be familiar with all the operations proposed and performed by all the different operators." This remark of Riedel's may explain the fact, with which we are all familiar, that a very good anatomist often makes a very poor surgeon.

In conclusion a word relating to the phrasing of Dr. Bevan's criticisms of my paper. He "feels sorry" for me that he must "do his duty by the profession" by "correcting my erroneous anatomy," because my paper has been widely read and has attracted attention. This, with my previous reputation for reliability, might mislead those who read my paper, etc.

I need not suggest that such language is not used in the best scientific medical literature. Time and experience, however, may improve the tenor of the doctor's future writings.

The next question I wish to bring before the society concerns the history of choledochotomy or choledocholithotomy (Courvoisier). Most writers, including myself, assign the priority of this operation to Courvoisier, who performed his first operation January 22, 1890. Dr. Henry O. Marcy, of Boston, disputes the priority of Courvoisier, basing his claim on an operation performed October 26, 1889.*

In preparing my paper on the "Treatment of Gall-stones,"† in reviewing the history of choledochotomy I considered the case of Dr. Marcy not choledocholithotomy, but simply an operation on the gall-bladder or cystic duct for the removal of a stone. I therefore made no mention of it, as my paper treated of the surgery of the common duct only. In a letter to me Dr. Marcy still claimed priority, and reproached me for overlooking his paper and thus doing an injustice both to him and to American surgery and surgeons. In my answer to him I stated my reasons for not considering him in the question of choledochotomy, and expected the matter to be ended thereby. That Dr. Marcy, however, holds to his claim of priority is seen in a later publication, "Obstruction of the Common Bile-duct."‡ Dr. Alexander Hugh

* Jour. Amer. Med. Assoc., 1890, vol. xv, p. 887.

† Amer. Jour. Med. Sci., 1896, vol. exi, p. 125.

‡ Annals of Surgery, January, 1897, vol. xxv, p. 80.

Ferguson, in an article,* sustains the claim of Dr. Marcy. In order to settle the question of priority I will lay the facts in the case before the society tonight.

I consider the operation performed by Dr. Marcy on October 26, 1889, to have been an incision, either in the neck of the gall-bladder or perhaps in a dilated portion of the cystic duct, for removal of an impacted stone. I do not consider it possible that it was an incision of the common duct, for the following reasons:

In the first place, the first report of Dr. Marcy's case is very imperfect. For this reason alone I could have disregarded it in the bibliography of my paper. In sifting the literature for reports of cases bearing on a certain subject we must necessarily pass over those that are inaccurately reported, as no accurate opinion can be based upon them.

Dr. Marcy's first report of the case (*loc. cit.*), as well as a more extended later report of the same case (*loc. cit.*), shows that any operation on the common duct can be excluded.

His patient, a female, aged forty, suffered with attacks of biliary colic with icterus, diarrhea, and clay-colored stools. The abdomen being opened, the gall-bladder, "like a cystic growth, distended the lips of the wound." Gall-bladder sutured to peritoneum, incised, 10 ounces of bile, together with a calculus, evacuated. [Dilated gall-bladder.] With a probe he felt a stone deep down, "quite beyond the cystic duct." He does not specify by measurement how far he probed, and this is important. This statement of the probe passing "quite beyond the cystic duct" is not contained in his first report in 1890, but is found in his report of 1897 published after I had raised the question of priority. This stone could not be dislodged or crushed. The gall-bladder was washed out, the stitches between gall-bladder and peritoneum cut, and the wound packed with gauze. "After having somewhat forcibly drawn the gall-bladder through it (the wound), even this procedure did not enable us to seize and remove the calculus. I then divided the walls of the duct (paper of 1890) [of the common duct (paper of 1897)] with scissors, and everted its edges from over the roughened calculus, which was even then removed with difficulty. The thickened mucous membrane of the duct [what duct? Evidently, not common duct, but cystic duct] and bladder was joined by a fine, continuous tendon suture, and in a like manner the peritoneal edges were carefully adjusted, while over all a third layer of suturing was taken." A continuous para-serous stitch interfolded the edges; "the entire wound of the viscus measuring about 4 inches" [paper of 1890]. In the paper of 1897 it reads: "The wound through the duct and gall-bladder thus closed measured 4 inches." Abdominal wound closed without drainage; patient recovered. "The rough, mulberry-looking calculus, grape size, was the offending member, weighing when dried 59 grains."

* "Personal Observations on the Surgery of the Gall-bladder and Bile-ducts," Brit. Med. Jour., 1897, vol. ii.

To say nothing of the very significant changes made in the text of the second publication, and overlooking the lack of clearness and comprehensiveness in the description of the operation, it is evident that Dr. Marcy first incised the enlarged gall-bladder at its fundus. This incision was then later enlarged downward toward the neck of the gall-bladder or to the cystic duct for a distance of 4 inches.

A normal gall-bladder, containing from 1 to 3 ounces of contents, is about 4 inches long from the fundus to the cystic duct. A gall-bladder containing 10 ounces, and appearing "like a cystic growth distending the lips of the (abdominal) wound," is longer, we will say, at least, by 1 inch, making a total of 5 inches from fundus to neck. The normal cystic duct measures 2 inches in length. A continuous incision from the fundus of a normal gall-bladder to the beginning of the common duct would be $4 + 2 = 6$ inches. A continuous incision from the fundus of the dilated gall-bladder in Dr. Marcy's case down to the beginning of the cystic duct would be 5 inches, and to the beginning of the common duct would be 2 inches more, or at least 7 inches. It is evident, consequently, that Dr. Marcy, with his 4-inch incision, divided only the gall-bladder, the stone being lodged firmly in a sacculation in the wall of the gall-bladder, which occurs commonly. His 4-inch incision might have reached slightly into the cystic duct, although to accomplish this would have required an incision of 5 or 6 inches. It is a physical impossibility that Dr. Marcy's 4-inch incision reached the common duct. Before the second publication of 1897 I communicated to him by letter my disbelief in his claim. His persistency, however, in the matter of priority imposes upon me the thankless task of setting the matter right.

As to Dr. Bevan's incision, for which he claims superiority because—(1) it gives more room for operating, and (2) avoids the section of nerves and muscle-fibers, and is consequently less liable to be followed by hernia. The upper oblique branch of the incision divides the rectus muscle transversely, and the lower oblique arm divides two of the flat abdominal muscles and runs at right angles to the motor nerves. Consequently it divides as many nerves as is possible in this region.

The incision of Dr. Bevan is a compromise between the oblique incision parallel to the costal border and the longitudinal incision along the outer border of the sheath of the rectus muscle. It is not well chosen, as it divides about the greatest possible number of nerves and muscle-fibers.

I always make a longitudinal lateral incision through the outer third of the sheath of the rectus muscle. Occasionally only is it found necessary to extend a transverse lateral branch, as proposed by Czerny. This incision is preferable, as it divides the least number of nerves and muscle-fibers.

DISEASES OF THE URETER*

WITH THE COLLABORATION OF S. C. STANTON, M.D.

ANATOMY

THE ureter is a cylindric muscular canal, in the living subject probably contracted to some extent, with a rather uniform diameter of 3 to 4 mm. throughout its entire extent from the pelvis of the kidney to the bladder. It varies in length from 28 to 34 cm., according to Henle; 25 to 31 cm., according to Tanquary, cited by Van Hook; and Tanquary states that it never exceeds 38 cm. Luschka gives the length of the ureter as 27 cm., and Kelly states that it varies from 25 to 30 cm.

Its course is straight or slightly curved as it passes down from the kidney, and its direction is somewhat oblique toward the median line. The curve described is sigmoid; above the small pelvis the slight convexity is toward the median line, while the pelvic portion is more strongly curved—almost the arc of a circle (Tanquary), with its convexity directed toward the lateral wall of the pelvis until it finally reaches the neck of the bladder, the wall of which it penetrates so obliquely that it runs for $1\frac{1}{2}$ to 2 cm. between the muscular and mucous coats (Cabot). In the male it crosses the vas deferens on the posterior wall of the bladder; in woman it crosses the cervix and enters the bladder at a point midway between the meatus urinarius and the cervix.

Kelly gives a most valuable and minute description of the regional anatomy of the ureters. The ureter is divided into an abdominal and a pelvic portion by the bend over the common iliac artery about 3 cm. above the brim of the pelvis. The abdominal portion is 12 to 15 cm. long; the pelvic portion, 10 to 12 cm.

1. *Abdominal Portion.*—The abdominal portion may be divided into three parts—upper, lower, and middle. The upper is the most inaccessible portion for examination where it enters the pelvis of the kidney, as here it lies concealed by the ribs from 4 to $4\frac{1}{2}$ cm. from the median line, and at about the same distance posterior to the anterior plane of the vertebral column. The middle part lies from $2\frac{1}{2}$ to 3 cm. from the median line on the psoas muscle, and on a plane level with the anterior surface of the vertebral bodies. The ureter crosses the psoas obliquely until it reaches the common iliac artery at or just above its bifurcation, where it is about 3 cm. from the body of the sacrum. The course is thus obliquely downward and inward, with a slight inward convexity, and

* American Text-book of Genito-Urinary Diseases, Syphilis, and Diseases of the Skin, 1892, pp. 470-542.

with always a marked convexity forward, due to its course over the psoas. The ureters lie in the loose cellular tissue back of the peritoneum, partly under the cecum and the ascending colon on the right and the descending colon and sigmoid flexure on the left side. The abdominal portion of the ureter in its course over the psoas muscle is crossed by the ovarian or spermatic artery and vein, which descend into the pelvis along the outer border of the ureter. At the brim of the pelvis on the right side the ureter lies just behind the peritoneum, where it can be seen with the ovarian or spermatic vessels. The peritoneum can be incised at this point and the ureter laid bare. On the left side the relations of the ureter to the sigmoid flexure and the rectum depend upon the length of the mesosigmoid and the variable position over the brim at which the rectum enters the pelvis. Thus in one case the ureter may lie beneath the sigmoid vessels and in another directly behind the intestine. (If we try to expose the left ureter from the right side of the sigmoid mesentery, it is covered by the sigmoid vessels. If we try to expose it from the left surface of the sigmoid mesentery, it is directly below the peritoneum.) After traversing the psoas it crosses the common iliac artery obliquely above or at its bifurcation, and enters the pelvis minor. This is the third or lower part of the abdominal portion.

2. *Pelvic Portion.*—The pelvic portion of the ureter (see Figs. 131, 132) lies first to the inner side of the internal iliac artery. In woman it is again crossed by the ovarian vein and artery, which pass over its anterior surface and leave it at an acute angle just above the inner border of the iliopsoas. In man the spermatic vessels do not cross the ureter a second time on the way to the inguinal canal, but diverge more and more from it. The ureter now descends to the floor of the pelvis in a forward direction. In woman it is crossed by the uterine artery, which passes over its anterior or upper surface at a right angle on its way inward from the internal iliac to the neck of the uterus. The ureter here passes through the base of the broad ligament along the upper lateral vaginal wall, and finally curves in over the anterior vaginal wall, following its uppermost converging folds, and terminates in the bladder, where the two ureteral orifices are connected by the interureteral ligament.

Hallé and Tanquary have pointed out that in normal subjects the canal is narrowed in three places, namely—(a) at a point between 4 and 7 cm. from the pelvis of the kidney; (b) at the junction of the pelvic and vesical portions; and (c) at the place where it crosses the iliac artery, found in three out of five subjects. These localities correspond with the places where small stones from the kidney have been found to be arrested. The canal is not absolutely uniform in caliber throughout its entire course. When injected, it is not of uniform caliber, but is always dilated, spindle shaped in some places—so much so that the wider portions may be more than double the mean width of 6 mm. (Luschka).

The ureters are located in the retroperitoneal tissue, surrounded by a layer of loose fat in well-nourished individuals (Luschka).

The wall of the ureter, according to Luschka, is 1 mm. thick, and

consists of three layers: (a) External, consisting of connective tissue rich in plastic fibers; (b) a double layer of organic muscular fibers, namely, an external layer of circular fibers and a thicker internal layer of longitudinal fibers; (c) mucous membrane, easy to isolate from the muscular layer, rich in vessels, presenting longitudinal folds in the empty ureter, but perfectly smooth when the ureter is distended. Microscopic examination reveals neither papillæ nor glands. The epithelium is 0.05 mm. thick, and consists of nucleated cells of different shapes—

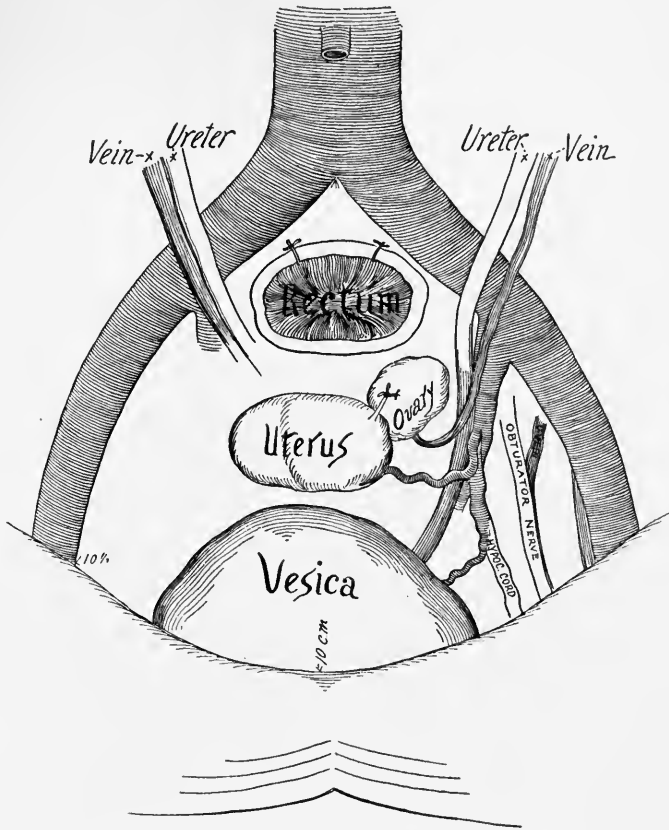


Fig. 131.—Pelvic portion of the ureter from below (Kelly).

namely, round and polygonal, cone-shaped and cylindric, so arranged as to fit into each other.

Margarucci made researches regarding the circulation in the ureter from injection of the vessels in dogs. He found that the ureter has an artery on each side coming from the renal artery and running along the wall of the ureter almost to the bladder. From these two main arteries the branches perforate the wall of the ureter to supply the mucosa. If the injection is made through the hypogastric artery, the vessels of

the bladder are filled, but the injection mass goes from the bladder up on the ureter for only a very short distance; consequently the ureter has its own vascular system from the renal artery, and has no important anastomoses with any of the arteries of the surrounding organs. This fact explains the possibility of isolating the ureter for a great distance without causing necrosis. Monari, as a result of injections on the cadaver, found that, besides the main ureteral arteries coming from the renal artery, important arterial branches also come from the spermatic

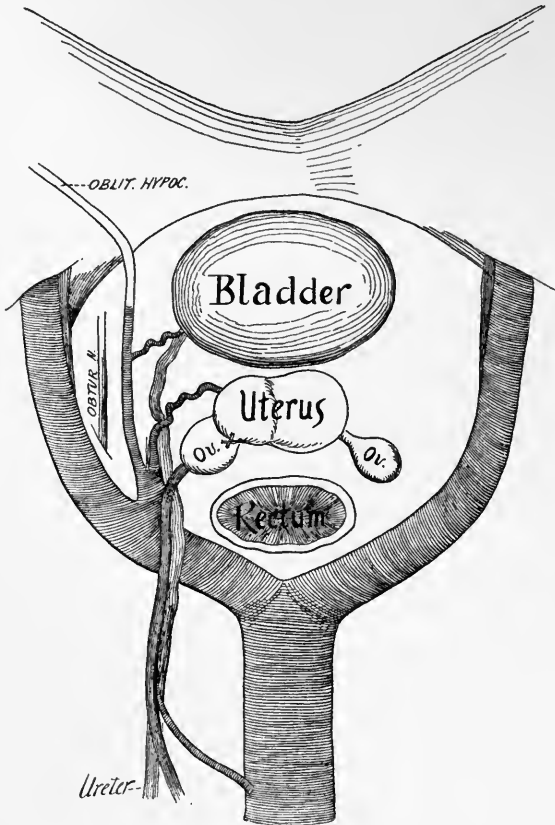


Fig. 132.—Pelvic portion of the ureter from above (Kelly).

arteries, and that the arteries from these two sources supplement each other, so that if, as seldom takes place, the branches of the renal arteries are small, the branch from the spermatic artery is extremely well developed. Branches from the vesical arteries extend only to the extreme lower end of the ureter. It is thus evident that the ureter has its own circulation, independent of the surrounding organs, which permits of extensive isolation without necrosis.

Glanteny gives an admirable description of the relations of the

ureters to the surrounding organs. He thus describes the pelvic portion of the ureter:

The *pelvic portion* consists of an upper parietal and fixed part and a lower visceral and more movable part.

The *parietal part* is covered with peritoneum where it crosses the iliac vessels, lying behind the ileum on the right side and the sigmoid flexure on the left, passes down over the pyramidalis and obturator internus muscles, from which it is separated by the pelvic fascia, and is here crossed by the obturator and umbilical arteries, branches from the hypogastric.

The *visceral part* leaves the lateral wall of the pelvis to pass toward the trigone of the bladder. In man it is crossed on the anterior surface by the vas deferens and deferent artery, and then lies close to the base of the seminal vesicle on its anterior surface, and enters the wall of the bladder above the prostate. It crosses the wall of the bladder obliquely, running in the wall for 2 cm.

The ureters open into the bladder near each upper corner of the vesical trigone, sometimes at the top of a little round prominence, sometimes on an oval prominence, sometimes in a depression. The distance between the two ureteral openings varies from 2 to 6 cm.

In passing down from the large to the small pelvis the left ureter lies between the vertebra and the psoas muscle, while on the right side, on account of the inferior vena cava, the ureter is situated a little more laterally.

SURGICAL ANATOMY.—The relation of the ureter to the peritoneum is an important consideration in the surgical anatomy of the ureter. This was first carefully studied by Cabot, who pointed out that in extra-peritoneal operations, especially in fat subjects, it is extremely difficult to find and recognize the ureter in the deep wound, unless guided, for instance, by the presence of a stone. The ureter is adherent to the peritoneum, and always follows it when it is stripped up from the parts behind. This fact has been occasionally mentioned before by Crampton, Twynam, and others, but the condition was not studied until Cabot made microscopic sections of the ureter and peritoneum, and demonstrated that the ureter is bound to the under surface of the peritoneum by fibrous bands.

Cabot further pointed out that the relation of the ureter to that part of the peritoneum which is adherent to the spine is rather constant, the ureter being situated just external to the line of adhesion. Therefore, when the operator has stripped up the peritoneum and reached this point, he will find the ureter on the stripped-up peritoneum a little external to it. On the left side the distance from the line of adhesion to the ureter is from 1 to 2 cm., while on the right side the distance is somewhat greater, owing to the outward displacement of the ureter by the interposition of the vena cava inferior between it and the spine.

Monari studied the question of the extent to which the ureter could be isolated from the surrounding connective tissue without necrosis on dogs, and found that isolation for 12 to 13 cm. did no harm, provided it

was carefully brought into contact again with the tissues from which it had been isolated, and at the same time when transperitoneal isolation was made covered with a flap of peritoneum. When these precautions were not taken, there was danger of necrosis of the wall of the ureter, as was proved by the following experiment: He isolated the ureter, and kept it away from the surrounding tissues by packing a layer of gauze around it. If isolated for a distance of only 6 cm., necrosis and extravasation of urine followed.

As a guide in the palpation of the ureter on the living subject in examination for stone, dilatation, or extravasation consequent upon rupture, the following landmarks are given by Tourneur, cited from Tuffier: The course of the abdominal portion of the ureter in the large pelvis corresponds to a vertical line erected upon a point at the junction of the internal and middle thirds of Poupart's ligament. Tourneur considers its direction vertical from the border of the kidney down to the small pelvis, over the brim of which it passes $4\frac{1}{2}$ cm. from the median line. The exact location of this point is the intersection of a horizontal line drawn between the anterior superior iliac spines and a vertical line passing through the pubic spine. At this point, under favorable circumstances, a dilated or tender ureter may be felt by gentle, steady pressure backward upon the abdominal wall until the resistant brim of the pelvis is reached.

The vesical portion of the ureter can be palpated in man through the rectum. Guyon has called attention to the exquisite sensitiveness of this portion of the ureter upon rectal exploration in cases of stone, even when located high up. In woman, vaginal examination permits the palpation of the ureter to an extent of 4 to 7 cm. as it runs in the broad ligament in close relation to the upper wall of the vagina (Cabot).

Access to the ureter is gained by two different routes, the transperitoneal and extraperitoneal.

By means of a median or lateral abdominal incision the entire course of the ureter can be reached with comparative ease, but intraperitoneal operations upon a ureter wherein the urine is not absolutely aseptic should not be undertaken if an extraperitoneal operation is possible, on account of the danger of peritonitis. This is well illustrated by the transperitoneal ureterolithotomy performed by Cullingworth, whose patient died from peritonitis.

On the other hand, abdominal examination for diagnostic purposes, to locate a stone, or a para-ureteral urinary infiltration following rupture, has been of value when followed by extraperitoneal operation, as evidenced in the cases of stone operated upon by Hall and Arbuthnot Lane, and in the cases of rupture reported by Page and Allingham.

Extraperitoneal access to the ureter is technically much more difficult because of the depth of the wound, but as by it the danger of peritonitis is avoided, it is, on the whole, preferable. The upper two-thirds of the ureter—that is, the abdominal portion and the portion which extends over the brim of the pelvis—can be reached by a continuation of the ordinary oblique incision for lumbar nephrotomy, from the twelfth

rib at the outer border of the erector spinæ, down along and 2 cm. anterior to the anterior superior spine of the ilium, and along Poupart's ligament to the outer border of the rectus.

The lumbar portion of the ureter is accessible through any of the varieties of the lumbar incision for access to the kidney. When the kidney is denuded from its adipose capsule, we search for the pelvis and the ureter below its posterior surface. Glantenay gives the advice to rotate the kidney a little around its pedicle by lifting the lower end of the kidney upward and outward, instead of pulling the whole organ into the wound. The ureter must be searched for by separating the loose adipose tissue which surrounds it, and, while it is easy to find a dilated or thickened ureter, it may be difficult to find a normal one.

Cabot thinks it would be possible, in a very thin subject with lax abdominal walls or in children (Twynam), to gain access to the ureter down to within an inch or two of its entrance into the bladder by extra-peritoneal incision, but on account of the depth of the wound in this place operation would be difficult.

The lower pelvic portion of the ureter can be reached by the sacral operation,—an incision lateral to the sacrum, as proposed by Delbet,—or, better, by Kraske's operation, or the osteoplastic resection of the sacrum, as proposed by Cabot, who made investigations on the cadaver and found ample space for careful inspection and operation. However, Reynier, in attempting to extirpate the lower pelvic portion of the ureter through a pararectal incision, found the prostate and seminal vesicles easily, but was unable to find the ureter.

The pelvic portion of the ureter may be reached by the rectal, vaginal, perineal, sacral, iliac, and hypogastric routes. Of these, only the sacral, iliac, and hypogastric really come into question. Glantenay believes that the sacral route may be preferable to the iliac in women, as it is easier to avoid the uterine artery, and as the conditions for drainage are good.

In women the lower pelvic portion of the ureter can be reached through the vagina. Ureteral fistulas opening into the cervix and vagina have been operated upon, and stones in this portion of the ureter have been removed by Emmet when situated low down, close to the vesical orifice, and by Cabot when located higher up in the broad ligament, close to the cervix uteri. Kelly has extirpated the lower pelvic portion of the ureter through a wound in the vaginal vault.

The vesical portion of the ureter can be reached by suprapubic cystotomy.

MALFORMATIONS AND ANOMALIES

It is well to remember the variations in the upper end of the ureter, as pointed out by Hyrtl. In the first variety there is no pelvis, but the ureter divides into two branches without dilatation at the point of division, each branch having a caliber a little larger than that of the ureter. In the second variety there is a pelvis—that is, a funnel-shaped dilatation at the point of division. The upper portion is the smaller,

and terminates in three short calices; the lower and more voluminous portion terminates in four or five calices. In the third variety there is only half a pelvis—that is, the lower branch divides and is funnel shaped, forming a narrow pelvis which terminates in one, two, or three short calices, while the upper is not dilated and extends to the upper portion of the kidney as a continuation of the ureter. The ureter not uncommonly divides far below the kidney, between the kidney and the bladder; sometimes there is no division at all, and two separate ureters enter the bladder.

There is one variation in the point of entrance of the ureters into the bladder which is of especial practical importance—namely, those cases, few in number, in which the ureter, instead of entering the bladder high up or low down, posterior to the sphincter of the urethra, opens into the latter at or near its external orifice, or even into the vagina (Secheyron). This anomaly causes a congenital partial incontinence of urine, for the relief of which operation has been performed with success.

The details of malformations and anomalies of the ureter have been studied by Carl Schwarz, who classifies abnormalities of the ureter as follows:

A. Double Ureter with Normal Termination.—Double ureter with normal termination is rather common (Weigert, 10 per cent.; Boström, 3 per cent.; Poirier, 4 per cent.). The ureters originate from separate pelves, and consequently double ureter means double pelvis. The double ureters either unite before they reach the bladder (incomplete duplication), or reach the bladder separately (complete duplication). The condition is unilateral or bilateral. By separate termination in the bladder the ureter from the upper part of the kidney will enter the bladder lower down than the ureter from the lower part. If one division of the double ureter is or becomes impermeable, atrophy or cystonephrosis of the corresponding territory of the kidney follows.

Visconti describes a case in which the right kidney was double the natural size and had a double ureter, and in which the left kidney was absent. He says that “when there is only one kidney, it is usually right-sided; the left kidney is absent.”

B. Abnormal Termination of the Ureter.—1. Open termination inside of the male genito-urinary organs. The ureter may terminate—

(a) In the bladder, with narrow opening in the territory of the sphincter vesicæ.

(b) In the urethra, always in the prostatic portion, behind or at the side of the caput gallinaginis, usually with a small opening. A small opening signifies stenosis, and is followed by dilatation above. No ureter was ever seen to terminate in man outside of the sphincter urethræ.

(c) In the seminal vesicle, ejaculatory duct, or vas deferens.

As the abnormal termination is almost always so arranged that the passage of the urine is not free, we find the consequences of chronic retention—namely, dilatation of the ureter and pelvis and cystonephrosis. The cystonephrosis is partial in cases of double ureter, and is always located in the upper portion of the kidney, as the ureter from this por-

tion is the one which has a termination outside of the bladder. When the ureter terminates in the seminal passages, there is usually a localized dilatation of the ureter on or in the wall of the bladder, where it forms a cystic tumor which protrudes into the bladder.

Of 23 cases of open termination inside of the male genito-urinary organs, 10 were of single and 13 of double ureter, which terminated 3 times in the bladder, 10 times in the urethra, and 10 times in the seminal passages.

2. Open termination in the female genito-urinary organs. The ureter may terminate—(a) In the urethra; (b) in the vagina; (c) in the vestibule; (d) in a persistent Gärtner's duct.

The ureter may enter the wall of the bladder in the normal place, but instead of opening in the bladder, may pass along in the wall until it finally opens in the urethra, or it may run along over the fornix for some distance before it enters the urethra. In cases of this kind, where no incontinence is found, and where, consequently, some part of the muscular apparatus acts as a sphincter for the ureter, there are always stenosis and dilatation above, either localized, forming a sac close to the bladder, or diffused through the whole territory. This is also sometimes found when the ureter terminates in the vagina and vulva. In 23 collected cases belonging to this class the termination was 5 times in the urethra, 6 times in the vagina, 11 times in the vulva, and once in a persistent Gärtner's duct.

3. Blind termination of the ureter. This usually congenital anomaly is found in single as well as in double ureters, and we have here to consider both the place and the manner of the blind termination, as well as its consequences. The ureter usually terminates in the wall of the bladder, but sometimes in the muscularis and sometimes in the submucosa. On examination of the bladder we find, instead of the ureteral orifice, a flat or rounded, cystic, thin-walled tumor which extends out over Lieutaud's triangle, and, when large enough, may compress the opening of the other ureter, and fill up and close the entrance to the urethra. If this local termination of the abnormal ureter does not protrude into the bladder, it forms a cystic tumor on the outer wall of the bladder, and may form a prominence in the anterior vaginal wall.

As to the consequence of the anomaly in this class of cases, we find local or total uniform sacculated dilatation of the ureter, local or total cystonephrosis, sometimes of enormous size, or we find a small, atrophic, non-dilated kidney. In cases in which the dilated ureter protrudes into the bladder and compresses the urethra or the opposite ureter there will be stasis and dilatation of the other ureter and kidney, and eccentric hypertrophy of the bladder. In 23 collected cases 15 were single and 8 double ureters, and in 5 cases death resulted from the consequences of the anomaly.

Orthmann narrates a case of "bifurcation" of the left ureter in a nullipara of twenty-seven years. The "second branch" terminated in a dilated culdesac, forming a tumor of the size of a hen's egg on the

anterior wall of the vagina, not communicating with the bladder. The tumor was extirpated.

4. Termination of the ureter in the rectum and cloaca (Schwarz). This anomaly was found only in non-viable fetuses and possesses no practical importance.

For explanation of the anomalies described above it is necessary to recall the embryologic development. The ureter originates as a process branching off from the lower end of the Wolffian duct, growing from this point up into the kidney, and opening, together with the Wolffian duct, into the urogenital sinus. By dilatation of the latter the two ducts separate, and the ureter comes to be located at a distance anterior to the Wolffian duct, which in man develops into the seminal passages, and in woman is obliterated or leaves a rudiment only—Gärtner's duct. If the ureter does not separate from the Wolffian duct, but remains a branch of the latter, the ureter will terminate in the seminal passages in man, and in woman in Gärtner's duct (one case on record). If the ureter separates from the Wolffian duct, but does not move up into its normal place on Lieutaud's triangle, we will have an abnormal termination low down in the prostatic portion of the urethra. If the ureter separates from the Wolffian duct without opening into a hollow organ, a blind termination results. If the ureter, instead of moving forward into the anterior portion of the cloaca, remains at its original location in the posterior portion, we find the termination of the ureter in the rectum. Double ureters originate either as a double branch from the Wolffian duct or as a single branch which later divides.

SYMPTOMS AND DIAGNOSIS.—It is almost impossible to make a diagnosis of an anomalous termination of a ureter in the bladder, seminal vesicles, ejaculatory ducts, and male urethra, unless, perhaps, by means of the cystoscope; and such a diagnosis has not yet been made. On the other hand, it is possible to recognize the abnormal termination of a ureter in the urogenital system of women, and the ureters with blind terminations. The first of these conditions is characterized by a certain form of incontinence when the ureter terminates on the distal side of the sphincter of the bladder. It is an incontinence—that is, an involuntary, steady dribbling of urine, interrupted at certain intervals by a voluntary discharge of urine; in other words, the urine from the kidney with the abnormal ureteral termination is discharged continually (incontinence), while the urine from the kidney with the normal ureteral termination is discharged voluntarily at the usual intervals. A careful examination of the genital organs reveals a small opening in the vulva, vagina, or urethra, from which the urine continually dribbles out. When a probe is passed into this minute opening it passes into a canal which does not communicate with the bladder. In three of the cases on record there was a saccular dilatation of the ureter, from the size of a pigeon's egg to that of a fist, a short distance above its termination. Such a sac might easily be mistaken for a second or double bladder.

The ureters with blind terminations may, if the lower end is dilated to a cyst or sac, be recognized by the protrusion of the sac into the bladder,

or even into the female urethra. Digital examination or exploration may reveal their presence. A one-sided hydronephrosis, corresponding to the occluded ureter, will aid in the diagnosis. As yet, however, a correct diagnosis has not been made, but the knowledge of the anomalies above described may make a diagnosis possible in the future.

TREATMENT.—The abnormal termination of open ureters in the urogenital apparatus in man will probably never be diagnosed, and consequently not be an object of treatment. The same may be said of open ureters terminating in the rectum, as this anomaly has been found only in non-viable fetuses. On the other hand, the abnormal termination of the ureter in the vulva, vagina, or urethra in woman has already often demanded surgical interference, with the object of curing the incontinence. The operation has for its object the direction of the abnormal ureter into the bladder as near as possible to the normal place, and the exclusion of the distal end of the ureter from the passage of urine.

The following methods have been used or proposed:

(1) **Epicystotomy**—implantation of the ureter in the posterior wall of the bladder and obliteration of the peripheral end. Tuffier performed epicystotomy and inserted a sound in the aberrant ureter, pushing its end so as to make it protrude into the bladder. From here he cut down upon it, making a longitudinal opening into the ureter. He then excised a piece of the peripheral stump, and cauterized the remainder with the Paquelin cautery. The upper end of the ureter was so well fixed in the bladder-wall that no further suturing was needed to secure it. Recovery.

Baum performed suprapubic cystotomy. In the bladder he found the two ureteral openings in their normal place. The third ureter was injected with water, and a dilatation the size of a pigeon's egg showed in the bladder below the opening for the right ureter. He made an incision intending to enucleate the third ureter, divide it transversely, and implant the central end into the bladder. This did not succeed, because the sacular dilatation was too large and thin walled and the hemorrhage considerable. He then cut out a piece of the sac to make a large round opening into the third ureter, and sutured the margins of the opening with silk. On the distal side of the sac he ligated the third ureter and brought the knot out into the vagina. He then closed the wound in the bladder with a double row of silk sutures. Healing followed in four weeks. Five and a half months later a stone came out; the patient had a ventral hernia. The evacuation of urine remained normal.

(2) **Excision of the distal end of the abnormal ureter**—vaginal implantation of the proximal end into the bladder. The vaginal implantation, as probably the safest method, was chosen by Davenport in the following case: Woman, aged twenty-nine years; incontinence of urine from early childhood, due to malposition of the ureter. Incontinence increased by menstruation and pregnancy. One ureter was found in the vesicovaginal septum, running forward, its orifice being close to the external orifice of the urethra. Operation for displacement of ureter and implantation of its orifice into the bladder. Recovery.

Baker isolated the peripheral end of the ureter from its termination in the vagina and implanted it into the bladder through an opening 1 inch from the neck of the bladder, suturing the vaginal mucous membrane over it. Recovery.

(3) Extraperitoneal isolation of the abnormal ureter and the bladder through a convex subpubic incision, and resection of the lower border of the symphysis. Through this wound the ureter is isolated and its central end implanted into the bladder. Colzi reports one successful case.

(4) Ureterocystostomy—a communication opening between the bladder and the dilated portion of the abnormal ureter. Wölfler effected this with apparent success by means of a special instrument analogous to or constructed on the plan of Dupuytren's enterotome.

Bois (d'Aurillac) reports the following case: Congenital incontinence of urine, although the bladder acted regularly. Fine canal in left wall of urethra, from which urine continually dribbled. A probe at this point passed into the left ureter. Division with tenotome of wall between ureter and bladder; opening kept open by bougies. Closure of the peripheral end of the ureter was postponed on account of pregnancy.

Criticism of the Methods.—Epicystotomy and implantation of the ureter in the posterior wall of the bladder, although successfully performed by Tuffier and Baumm, is a more grave operation than the vaginal implantation. The same may be said of the extraperitoneal implantation with partial resection of the symphysis, as successfully performed by Colzi. To make a direct communication opening between the dilated ureter and the bladder, as done by Wölfler and Bois, is technically difficult. Thus the operation from the vagina is probably the safest method, and should be first attempted. If unsuccessful, one of the other methods might be resorted to.

Operation for blind termination of the ureters, when this condition can be diagnosed and the saccular dilatation protruding into the bladder causes retention of urine by occluding the posterior opening of the urethra, should be made on the plan of making a large communication opening between the bladder and the sacculated ureter by excising a large portion of the wall of the sac. This may be done in woman through the dilated urethra; in man, by suprapubic cystotomy.

EXAMINATION

PALPATION.—1. Palpation through the vagina. Howard Kelly states that the ureter can be palpated through the anterior vaginal wall from its terminus in the bladder to the point where it passes beneath the broad ligament. It can be rolled in the loose connective tissue under the index-finger, or often bimanually between two fingers, or in advanced pregnancy on the head of the child, like a narrow tape or flattened cord without hardness. It must not be mistaken in this position for the obturator artery and nerve, or the upper border of the levator ani, or fibers of the obturator muscle, or the brim of the obturator for-

men. A diseased ureter, when nodular and thickened, is apt to be mistaken for a cellulitis or adherent ovary.

When the ureter, whether diseased or not, is pressed upon or manipulated by palpation, it is characteristic that the patient complains of an intense desire to urinate. One patient in whom Kelly persisted in making the examination was forced to urinate on his hand.

2. Palpation by the rectum. An enlarged ureter can be palpated up to the brim of the pelvis in both man and woman through the rectum. (Stones have been felt here.) In woman the finger is brought up behind the broad ligament, and the ureter can be followed from this point up

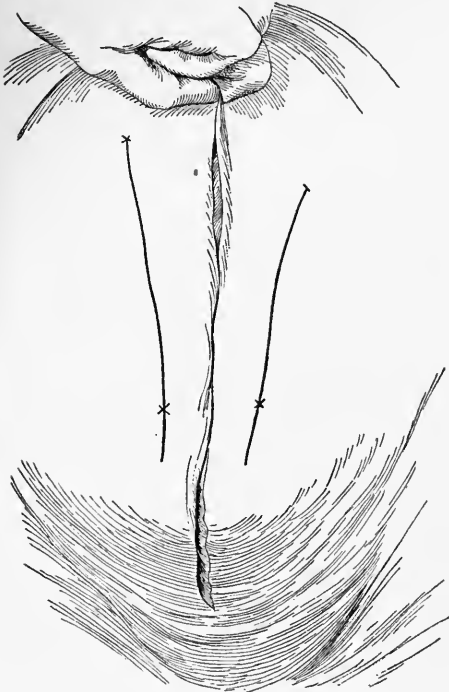

Fig. 133.—Course of ureters on skin of abdomen (Kelly).




Fig. 134.—Landmarks on the skin for the transit of ureters from abdomen into pelvis (Kelly).

over the posterior pelvic wall. As an aid in the palpation of a normal ureter from the vagina and rectum Kelly has introduced a ureteral catheter or bougie and carried it up over the brim of the pelvis, whereby the catheter can be felt and alterations in the caliber of the ureter readily detected.

Kelly's landmark for the upper portion of the pelvic ureter is the internal iliac artery, which can readily be felt per rectum. In some individuals the artery can be palpated up to the common iliac, close along the inner side of which the ureter, if diseased, can be felt. If nothing is felt, it is safe to conclude that the ureter is not enlarged.

3. Palpation through the anterior abdominal wall. From the abdominal wall the ureter can be felt for 5 or 6 cm. from the brim of the pelvis up toward the kidney. A normal ureter can be thus palpated when it contains a catheter, and a diseased ureter when thickened.

4. Abdominal palpation of the ureters by surface landmarks is less satisfactory than palpation from below. Kelly's method consists in locating the promontory of the sacrum by pressure through the abdominal wall, and from this point locating the place where the ureter enters the pelvis, namely, 3 to 3½ cm. external to and a little below the promontory. (See Figs. 133, 134.) Here the fingers recognize the location of the common iliac artery, and the ureter, which crosses it at this point, can be felt when enlarged and when the abdominal walls are thin. The patient complains of pain, and often of a desire to urinate, when the diseased ureter is touched.

5. Palpation of a thickened pelvic portion of a ureter after incising the vault of the vagina. Through this incision Kelly was able to follow the diseased ureter up to the posterior wall of the pelvis.

6. Palpation of the ureter through an abdominal incision. The ureter can be palpated directly by this means throughout the whole of the abdominal portion, and the upper 4 or 5 cm. of the pelvic portion for the detection of stones, tuberculosis, etc.

1. Various methods have been employed to determine disease of one kidney and presence or functional ability of the other:

Lawson Tait and Thornton: Exploratory laparotomy to determine existence, size, etc., of the other kidney in case of nephrectomy. This method is uncertain in fat persons (König).

Fenger: Lumbar exploratory incision for palpation of the other kidney during nephrectomy for malignant disease.

Czerny: Exposure of the ureter by lumbar incision on the diseased side, temporary closure of the ureter, cleansing of the bladder, examination of bladder urine from the other kidney.

Gluck: The same as Czerny, but he gives the patient iodid of potassium. If iodine is found in the urine, the other kidney is present.

Iverson: Suprapubic cystotomy and catheterization of the ureters.

Hegar: In woman laying bare the ureter through an incision in the anterior vaginal fornix and temporary ligation.

Emmet: In woman incision into the bladder from the vagina, and catheterization of the ureters through this opening.

Harrison: Opening the bladder by a perineal section, through which he sees the ureteral opening and introduces a catheter. This method has been practised on cadavers only.

Silbermann: Quicksilver balloon in the bladder to compress the ureter.

Tuchmann: Ureteral forceps shaped like a lithotrite, introduced through the bladder.

Hegar and Sängner: In woman feel the ridge of the ureter through the vaginal fornix and pass a threaded needle around it for temporary ligation.

Ebermann: Compression of the ureter between forceps, one blade in the rectum and the other in the bladder.

Weir: Compression of the ureter from the rectum against the bones of the pelvis.

Sands: Compression of the ureter by the finger in the rectum.

2. To determine the presence of stone or obstruction.

Exploration of the ureter by sound or bougie from the pelvis of the kidney after nephrotomy, pelviotomy, or longitudinal ureterotomy.

Exploration of the ureter from the bladder by ureteral sound or bougie.

CATHETERIZATION OF THE URETER.—1. *Direct Method.*—Catheterization of the ureter (see Fig. 135) has reached a state of practical usefulness by direct methods, but especially in woman, on account of the ease of access to the vesical opening of the ureter in the female. Pawlik was the first to put this procedure in extensive practice. He has employed it since 1881, using the knee-chest position without inspection of the bladder. Pawlik was followed by Newman, who employed an electric lamp through Simon's tubular speculum. The method has now been made practical chiefly through the arduous work of Howard Kelly in woman and Nitze, Casper, and others in man.

Strictures of the ureter and accumulations of urine above the strictures have been successfully treated in this way by Pawlik and Kelly. Kelly made a diagnosis of stricture low down in the left ureter by catheterization. The patient was catheterized about six times at intervals of ten to twelve days, each catheterization being followed by marked exacerbation of the pain for a few days. The consequence, however, of the repeated catheterizations was marked relief for several months. The symptoms finally returned, the ureter was opened from the vagina, and a small calculus removed from the ureteral orifice.

Pawlik mentions a case of pyonephrosis from Billroth's clinic in which he introduced into the ureter from the bladder a long elastic catheter with metal point, which passed through a stenosis of the ureter up into a cavity above. The patient had an abdominal fistula, the result of previous nephrotomy, and a probe passed through this fistula would touch the metal tip of the ureteral catheter. On attempting to with-

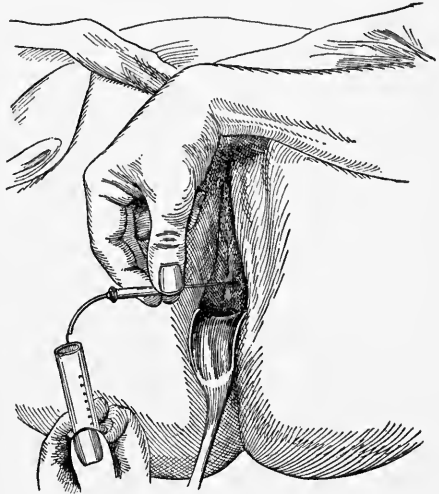


Fig. 135.—Catheterizing the ureters, one catheter (Kelly).

draw the catheter, the tip was caught in the stenosis and broken off, and von Hacker removed it through the abdominal fistula.

Pawlik, cited by Albarran and Lluria, reported 2 cases of pyonephrosis in which this method was employed. In one case cure was effected after 30 soundings of the ureter; in the other the ureter was impermeable and nephrotomy had to be performed.

The treatment of tuberculosis of the bladder has been assisted by permanent catheterization of the ureters by Guyon, cited by Albarran and Lluria, who burned the tuberculous ulcers with the Paquelin cautery,




Fig. 136.—Ureteral searcher.

packed with iodoform gauze, and was able to leave the ureteral catheters in place for nine days.

As regards leaving the catheter permanently in the ureter, Pawlik mentions a case of ureterovaginal fistula in which a catheter was left in for seven days. Force was required to remove it, and it was found to be incrustated with salts.

Weil, in a case of ureterovaginal fistula caused by a pessary, was enabled to stop the flow of urine by leaving a tube in the ureter for six days, when pain in the region of the kidney necessitated its removal.

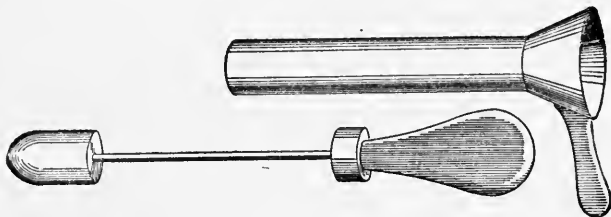


Fig. 137.—Speculum and obturator.

A catheter left in the ureter for some time is apt to cause inflammation of the ureter, just as we find permanent urethral catheterization followed by inflammation of the urethra.

Poirier cautions against leaving a catheter in the ureter. He mentions a case of Segond's of exstrophy of the bladder wherein catheterization caused pyelonephritis, and a case of his own, in the service of Tillaux, in which, thirty-six hours after catheterization of the ureter, obstruction occurred, causing an attack of renal colic. He also cites the experience of Sinitzin, who was never able to allow a sound to remain

for more than four hours, and concludes that the harmlessness of the procedure is not altogether beyond question.

Howard Kelly thus details his method of procedure in catheterization of the ureter in woman under direct inspection:

The following instruments are required for examination: A series of ureteral dilators, from 5 to 20 mm. in diameter; cylindric specula with obturators of the same caliber (Fig. 137); a common head-mirror and lamp; a long, delicate, mouse-tooth forceps; a suction apparatus for completely emptying the bladder; a ureteral searcher (Fig. 136); and a ureteral catheter without handle (Fig. 138).

The bladder is first emptied by the catheter. In order to determine the proper size of dilator to be used first, a calibrator can be pushed into the urethra and the corresponding dilator chosen. By introducing the dilators as they occur in the series the average female urethra can easily be dilated up to 12 mm. in diameter, with only a slight external rupture. Kelly has never seen a tear more than 3 mm. in length and 1 to 1½ mm. in depth, and he has not had to incise the meatus, as Simon did, to avoid extensive rupture. Kelly's metal dilators are double-ended, of a flattened, sigmoid shape, each end representing a single dilator in the series. The points are conic. On the flattened area in the middle of each dilator the diameter is marked in millimeters. This also affords a convenient grasp. As soon as a dilatation of 12 to 15 mm. is reached, a speculum of the same diameter is introduced and its obturator removed.

The hips of the patient are now elevated 20 to 40 cm. above the level of the table. The specula are 9½ cm. long, and each is provided with a conic mouth to assist in reflecting light into the bladder. The caliber is marked in millimeters on a little handle at the side of the speculum. Either artificial light or direct light from a window is sufficient for the head mirror. When the obturator is withdrawn and the pelvis sufficiently elevated, the bladder becomes distended with air.

The urine remaining in the bladder is withdrawn by the suction apparatus, and what little urine still remains is removed by absorbent cotton on the forceps. The posterior wall of the air-distended bladder is 2 to 5 cm. distant from the anterior wall, and presents a whitish background with a network of vessels. The veins are darker in color than

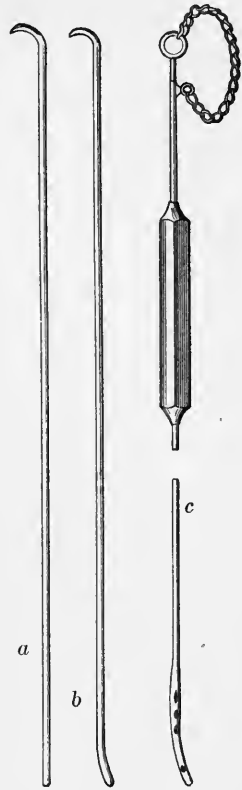


Fig. 138.—*a* and *b*, Ureteral catheters without handles, for direct catheterization through speculum; *c*, ureteral catheter with handle sufficiently reduced in size to allow speculum to be withdrawn after catheter is engaged in ureteral orifice.

the arteries. The larger vessels coming to the surface from the deeper vessels divide stellately and anastomose. By moving the speculum by its handle the entire wall is successively inspected. The interureteric ligament can be seen as a slightly elevated transverse fold, sometimes of a different color. By turning the speculum 30 degrees to one side or the other the ureteral orifice can be found, and the characteristic jets of urine, normal or pathologic, can be seen. The ureteral orifices and their surroundings are not constant in their appearance. Sometimes the orifice appears as a little dimple or little pit, or, in inflammatory cases, as a round hole on a cushioned eminence; at other times as a V with the



Fig. 139.—Left ureteral orifice exposed and searcher engaged (Kelly).

point directed outward. Again, it may be scarcely visible, appearing as a fine crack in the mucosa, and occasionally is so obscure as to be recognized only by the jet of urine or by a slight difference in the color of the mucosa. Rarely it has the form of a truncated cone with gently sloping sides. The bladder mucosa is usually a little deeper in color around the ureter. Upon direct inspection the ureteral orifice appears to lie nearer the urethra than one would anticipate.

As an aid in locating the ureteral orifice a point is marked on the speculum $5\frac{1}{2}$ cm. from its vesical end, and from this point two lines are drawn diverging at an angle of 60 degrees. The speculum is introduced

up to the point of the V, and turned to right or left until one side of the V is in line with the axis of the body. Then, by elevating the speculum until it touches the floor of the bladder, the ureteral orifice will usually be seen.

To determine the orifice of the ureter Kelly uses a searcher, a long, delicate probe with a bent handle, which is passed through the speculum into the suspected ureteral orifice, which, when found, permits the sound to pass up from 2 to 6 cm. The ureteral catheter is then passed. Kelly's ureteral catheters differ in shape from those of Pawlik in this respect, that they are straighter, and either have no handle or only a small one which will pass readily through a 10 mm. speculum. The catheter may be left in place some minutes or an hour or more. The urine which accumulates in the mean time in the bladder represents the discharge of the opposite kidney. Thus the urine of each kidney may be isolated by using only one catheter.

When the patient is placed in the genufacial posture, a higher degree of distention of the bladder takes place; the interureteric ligament is more sharply seen, but the ureters are not so plainly defined, as they are concealed by the outer extremities of the fold. The genufacial posture is indispensable in some inflammatory cases when the bladder will not balloon out in the ordinary posture.

The ureters can also be catheterized without distention of the bladder with air—that is, without elevation of the pelvis. To find the ureters requires, however, more experience. The speculum is introduced from $5\frac{1}{2}$ to 6 cm., and its outer end elevated until the base of the bladder appears, when it is turned 30 degrees to the right or left to find the ureteral orifice. To prevent the residual urine from obscuring the field the speculum is gently pressed against the mucous membrane. It is then only necessary to take up the urine with pledgets of cotton as it flows from the ureter into the speculum.

An anesthetic is not necessary for catheterization of the ureter unless the urethra is to be dilated to No. 14 or 15.

In nervous women it is often better to make a thorough examination first under anesthesia; subsequently a satisfactory illumination of the bladder can be made, and the ureters catheterized or local treatment applied through a No. 10 speculum without anesthesia. Anesthesia of the urethra can be effected by a pledget of cotton with 5 per cent. cocain solution inserted seven minutes beforehand.

The instruments ordinarily required are four specula—Nos. 8, 10, 12, and 14; dilators Nos. 7 to 16; a long, delicate, mouse-tooth forceps; a ureteral searcher; an aluminum applicator; and one ureteral catheter.

Catheterization of the ureters and introduction of bougies have proved of great value in abdominal hysterectomy for carcinoma of the cervix, and in hysteromyomectomy to avoid including the ureters in ligatures or cutting them, as the bougie will make it possible to feel and see the ureter during operation.

For use in the ureter Kelly has had constructed short (30 cm.) ureteral and long (50 cm.) renal catheters made of woven silk, and from

2 to 3 mm. in diameter. An oval eye is located 2 cm. from the conic end. Elastic bougies of the same size serve for diagnosis of blockades in the ureter, such as stone or stricture. A wire stilet stiffens the catheter during introduction and prevents it from coiling up in the bladder. The instruments are sterilized by boiling in pure water for two minutes, and are kept in sterile glass tubes.

By means of the renal catheter Kelly has been able to make the diagnosis of malignant tumor in the pelvis of a dilated kidney in a woman with a large tumor in the right side of the abdomen. He passed the renal catheter and evacuated 10 c.c. of urine and some black specks, which, upon microscopic examination, were found to be pieces of stone. As the large elastic tumor remained, he was enabled to make a diagnosis




Fig. 140.—Nitze's instrument in use.

of malignant tumor complicated with dilatation and some stone formation.

2. *Indirect Method.*—Only a few years ago Perez stated that catheterization of the ureters was of no importance, as it could be done only by epicystotomy. In one instance catheterization of the ureter up to the healthy kidney in a case of left pyonephrosis in which granular casts were found in the urine deterred Iversen from performing nephrectomy.

Keen, in a case of hematuria and suspected tumor of the bladder, performed epicystotomy, but found no tumor. As he was unable to determine from which of the ureteral openings the bloody urine was evacuated, he introduced a catheter through each ureter, and collected the urine separately, as a result of which he ascertained that the hemorrhage was from the left kidney. By means of the cystoscope invented

by Nitze and improved by him and by Oberländer, Otis, Brenner, and Casper, with attachments for the introduction of ureteral catheters, catheterization of the ureters by this method first became possible, and is now becoming more and more practicable.

Nitze employs the cystoscope, aided by elastic bougies or catheters, which can be introduced and left in the ureter after the cystoscope has been removed. His method possesses the further advantage that all instruments can be easily sterilized and that both ureters can be catheterized at one sitting.

He states that the tube must be curved at the end and situated on the upper side of the cystoscope in a removable tube, the curve of which coincides with the bent end of the cystoscope. The ureteral catheter is inserted with the cystoscopic view as a guide. The curved tube permits the introduction of a ureteral catheter even in patients with hypertrophy of the prostate.

Brenner in 1888 modified the Nitze-Leiter cystoscope by incorporating a small tube with the tube of the cystoscope at its lower part. (See Fig. 141.)

Brown employs the Brenner instrument with the modification of a




Fig. 141.—Brenner's ureter-cystoscope.

spring stilet with bent end, and succeeded, at Johns Hopkins Hospital, in catheterizing the ureter in man in the following two cases:

CASE 1.—Right renal colic in a man of nineteen years, following trauma four years previous, followed by occasional hematuria. May 12, 1894, catheterization of the ureters. The anterior Leiter cystoscope was passed and replaced with the Brenner instrument. The ureteral orifice was found, the ureteral catheter inserted, and 3 or 4 c.c. of urine collected from each ureter. The urine from the right ureter was cloudy and contained leukocytes; that from the left kidney was practically normal. He thereupon removed the right kidney, in one of the infundibula of which a calculus was found. The patient made a good recovery.

CASE 2.—Left renal colic with hematuria following trauma from lifting a heavy weight twenty-one years previous. The discharge of a calculus was followed by a cessation of symptoms. Four attacks of renal colic prior to 1886. Since that time constant dull pain in region of left kidney, greater behind than in front, and most intense at the brim of the pelvis. After dilatation of a urethral stricture catheterization of the ureters was done on November 21, 1894, under anesthesia, and 7 c.c. of urine withdrawn. The urine from the left kidney contained granular and hyaline casts, red blood-corpuscles, epithelial cells, many pus-corpuscles, a small amount of albumin, and calcium oxalate. The urine from the right kidney contained a trace of albumin, a few granular and hyaline casts, a few

red blood-corpuses and occasional leukocytes, and flat and tailed epithelial cells. Non-interference with the calculous left kidney was advised.

Brown considers an enlarged prostate an insuperable bar to catheterization of the male ureter.

A. B. Gaither employs an injection of 2 c.c. of 4 per cent. solution of cocain into the deep urethra, and 4 c.c. of the same into the bladder.

If the ureter is not easily found, it may be located by occasional jets of urine shooting across the window, or jets of blood in case of renal hematuria. The ureter may be inserted at such an angle as to render catheterization impossible. Raising or lowering the patient's legs or increasing or diminishing the fluid in the bladder may aid in finding the ureter. When the ureter is found, the stilet is withdrawn and the catheter must have a sharp enough bend to engage in the mouth of the ureter, otherwise it slips over it along the bladder-wall. The bend in the catheter is brought about by means of the stilet, which is kept in the catheter for two days and imparts to the latter a corresponding temporary bend. (Nitze's cannula on the cystoscope has the necessary bend and obviates the necessity of the spring stilet.)

When the catheter is pushed into the ureter, it can be seen running under the mucous membrane until it leaves the bladder-wall. It is essential for the finding of the ureters and introduction of the catheter that the bladder be capable of holding sufficient fluid (200 c.c.) to bring the mouths of the ureters into view. Ordinarily, it is possible, after several attempts, to catheterize the ureters, but the operator must necessarily be familiar with cystoscopic examination of the normal bladder, which requires considerable experience.

In chronic nephritis catheterization of the ureters may be of great value for the prognosis: namely, if disease is found to be in one kidney with the other normal or slightly involved, the prognosis is likely to be good, in spite of large quantities of albumin and casts, the patient living for years on the strength of the healthier kidney.

Max Nitze, in his interesting article on cystoscopic diagnosis of surgical diseases of the kidney by means of catheterization of the ureters, states that cystoscopy teaches us—

1. Whether the bladder is diseased or healthy.
2. If both kidneys or only one are acting.
3. It shows us the source of a hematuria from one or the other of the ureters. We see blood or bloody urine pass out with a jet from the ureteral opening on the diseased side, or sometimes a cylindric clot hanging out of the opening.
4. Pyuria from one or the other of the ureters if the quantity of pus is considerable.

This author mentions 5 cases of so-called essential bleeding from apparently healthy kidneys, in 4 of which extirpation of the kidney saved the lives of the patients. In 3 cases of malignant tumor of the kidney the cystoscope determined from which kidney the hemorrhage proceeded,

and, besides this, that the other kidney was present and excreted clear urine.

In pyuria the cystoscopic picture varies with the amount of pus. When little pus is present, it is seen to come out of the ureter as a darker shadow passing over the bottom of the bladder, or if the pus is abundant, a thick mass mixed with smaller and larger pieces of débris pours out of the ureteral opening. In one of his cases the pus was evacuated like a semisolid mass, making the impression as if it was pressed out of the ureter like sausage from a sausage-machine.

Lohnstein has made a comparative investigation as to the value of the cystoscopic instruments of Leiter, Otis, Casper, and Nitze-Oberländer. He prefers Casper's instrument, because the disturbing reflexes from the uneven wall of the bladder are less troublesome, since this instrument works with reflected light. Furthermore, this instrument permits the use of a smaller tube on account of the absence of the cooling apparatus, and finally the glow lamp is more easily replaced in this instrument than in any of the others. The details of the cystoscopic view with Casper's instrument appear sharply and clearly defined, so that even a minute exudate can be distinctly seen.

In January, 1895, Casper exhibited in the Berlin Medical Society his



Fig. 142.—Casper's ureter-cystoscope.

instrument (Fig. 142), with which he catheterized two men without anesthesia, general or local. Below the canal for the optical apparatus was a groove for the ureteral catheter, closed by a slide which could be removed after the introduction of the catheter, and the cystoscope then withdrawn, leaving the catheter *in situ*. This canal ends 6 mm. below the prism, and its end is so bent that the catheter comes out at an angle of 45 degrees in the direction of the vesical end of the ureter. The lamp is in the long axis of the instrument, as proposed by Lohnstein. With this instrument he catheterized the ureters in 21 men and 1 woman. One of the men had hypertrophy of the prostate.

It is necessary to have a clear view of the ureteral opening. After washing out, the bladder is filled with 150 to 200 c.c. of clear fluid. By slight movements of the end of the instrument in various directions it is possible so to localize the ureteral openings that the end of the catheter must pass in. When this is done, the cystoscope is so manipulated that the direction of the ureteral sound corresponds with that of the vesical portion of the ureter. After this manœuvre the catheter is carefully pushed in. In all but 2 cases he was able to insert the catheter without difficulty and without especial inconvenience to the patient. As soon as the catheter is in the vesical end of the ureter, the urine commences

to flow, usually at the rate of 8 to 10 c.c. in ten minutes. If with the catheter in this position fluid—for instance, boric-acid solution—is injected, colicky pains ensue, but if the catheter is pushed up into or nearly to the pelvis of the kidney, injection of small quantities of fluid causes no pain. The catheterization will not succeed in all cases: sometimes the openings are so small as to be scarcely visible; in other cases they are hidden by pathologic swollen folds of vesical mucous membrane or protruding ridges, making it impossible to see them. Such cases are, however, in the minority, and ordinarily the method is applicable and useful.

F. Mainzer states that, in Landau's clinic, the cystoscopes of Casper and Brenner are used for the catheterization of the ureters in woman. He says it is easier to find the ureteral openings with Casper's instrument, but more difficult to introduce the catheter, while the opposite obtains with Brenner's instrument.

Poirier, on injecting a ureter on the cadaver, found that the injected mass passed out through the renal vein. At first he thought this was due to rupture from violence. Later he found, on injecting anesthetized dogs, that he could inject one, two, or three 10 c.c. syringefuls of tepid water into the ureter. The kidney enlarged, and finally the water came out through the renal vein. He deduces that when a stone obliterates the ureter and the urine accumulates above, sufficient pressure may come to force the urine back into the renal vein. He advises that injection of medicaments into the ureter or renal pelvis shall be done without great force, to avoid forcing the liquid into the renal vein.

INJURIES AND WOUNDS OF THE URETER

SUBCUTANEOUS RUPTURES.—When these occur by violent direct injury, rupture of the ureter is apt to be accompanied by rupture of the other abdominal organs, the symptoms of which often dominate or mask those of the ureteral rupture. These injuries have been carefully studied by Herbert Page, who collected 10 cases from the literature, to which he added 1 of his own; 5 additional cases have been reported by Le Dentu, making 16 in all. In these cases the traumatism was caused by a direct blow on the abdomen, such as the kick of a horse (Pye-Smith, Chaput), by a blow in the region of the kidney (Soller), by a blow from the handle of a wheelbarrow (Allingham), by being run over by a wagon (Page, Barker, Godlee, Bardenheuer), by traumatism from overstretching (Fenger), or by violent displacement of the kidney and pelvis whereby the ureter was ruptured in the upper portion (Le Dentu).

It is uncertain whether by these injuries the ureter is crushed against the transverse process of the first lumbar vertebra, as Tuffier thinks, or is so stretched from the kidney as to rupture in its upper portion, as in Fenger's case. Both methods are possible. The fact remains, however, that most of the ruptures are found above the small pelvis.

Early *diagnosis* is often difficult, if not impossible, because of the

uncertainty of the symptoms. Slight transient hematuria, which might easily be overlooked, was noted in only 3 cases (Barker, Allingham, and Page). Copious hematuria, as reported in Hicks' case, indicates rupture of the kidney rather than of the ureter. Hematuria may be entirely absent, as in Godlee's case.

If no injuries to the other organs complicate the ureteral rupture, there are no grave symptoms in the beginning.

The next important symptom, swelling from the accumulation of urine around the place of rupture, is not seen until some time after the receipt of the injury—seven days (Allingham), two weeks (Chaput), two or three weeks (Godlee, Page, Barker, Hicks), thirty-nine days (Croft), seven weeks (Stanley), or several weeks (Cabot). The swelling is usually accompanied by pain, is localized, round, oblong, or sausage-shaped, following the course of the canal, and is palpable from the abdomen.

The *surgical treatment* has never yet been directed in an early stage to the ureter itself, but has consisted in puncture—single (Joel), once repeated (Hicks), or five times repeated (Stanley), all of which were successful—or incision and drainage, either through the abdominal cavity (Chaput, Page) or through the lumbar region (Allingham).

In most of the cases septic infection of the kidney took place through the resultant fistula, and secondary nephrectomy was necessary in order to save the patient's life (Godlee, Page, Barker, Chaput, and Bardenheuer). In other cases wherein the collection was not even opened and the patients survived, the kidney remaining, obliteration of the ureter (Havilland) or strictures ensued (Pye-Smith, Soller, Fenger).

As before mentioned, suture of the ruptured ureter has not yet been attempted, but, as Page points out, it might possibly be done, although it will probably be difficult to find the rupture; and this so much the more as an early diagnosis is rarely made. It is ordinarily not until some weeks later, when the swelling from urinary infiltration sets in, that operation is resorted to. Whether or not the ureter can be found in this cavity, which usually contains infected urine, and the rupture successfully dealt with, is as yet an open question.

OPEN WOUNDS of the ureter, of which Tuffier found only 5 cases in the literature,—3 incised or punctured wounds and 2 gunshot wounds,—have not as yet been treated by direct ureteral surgery, as these cases date back to a time when such a procedure had not been thought of. If positive diagnosis can be made (and intermittent discharge of small quantities of urine at the time might make the diagnosis positive), and if the external wound is extraperitoneal, there is no reason why the ureter should not be cut down upon and the wound treated by one of the methods now at our disposal.

Pozzi states that three injuries are possible:

1. Incomplete division.
2. Complete division without displacement of divided ends.
3. Loss of substance.

He suggests suture of the ends of the divided ureter.

Longitudinal wounds of the ureter will be considered in the discussion of the operation for stone. An extraperitoneal longitudinal wound should be carefully united with extramucous sutures. In addition to the suture Van Hook makes a suggestion which appears valuable in cases where the incised ureter is covered with peritoneum—namely, to slide a fold of peritoneum from both sides over the sutured wound and unite the peritoneum over it. If no peritoneum can be used, an omental graft may be employed.

Transverse wounds of the ureter are much more difficult to treat satisfactorily, as there is a tendency to retraction and gaping of the wound, and as, if direct suturing is resorted to, there is always a tendency to stenosis, even if the sutures do not tear out.

Reunion of a transversely divided ureter, first studied experimentally on dogs by Tuffier and others, was not successful until the method of invaginating the upper into the lower portion was devised by Poggi and Van Hook. It was first practised successfully in man by Kelly, who used Van Hook's method. Poggi divided both ureters in dogs, dilated the lower end with a forceps, invaginated the upper end into the lower, and united with sutures. When the animals were killed, fifteen days and three and a half months later, he found union without stenosis at the point of operation.

Van Hook has also succeeded in reuniting the completely divided ureter by a different method, which might be termed implantation of the upper into the lower end, after closure of the end of the latter. In a very elaborate paper upon the surgery of the ureter he gives the reason why his method of lateral implantation is preferable to the simple invagination of Poggi. He believes that the ureter can sustain resection involving a considerable amount of tissue, since ureters measuring 25 cm. while *in situ* will easily measure 30 to 35 cm. when removed, and he further remarks that elongation by traction on the divided ends is probably practicable to a very considerable extent.

Van Hook proposes in incomplete transverse wounds to transform the transverse into a rhomboid-shaped longitudinal wound by opening longitudinally upward and downward from the transverse wound and cutting off the four corners, thus creating a condition similar to that produced when a stricture of the ureter is opened longitudinally. The rhomboid wound may then be united transversely by folding the ureter upon itself in the manner proposed by Fenger in the operation for stricture.

This operation will probably be safe in extraperitoneal wounds. If, however, the wound opens into the peritoneal cavity, it is not certain that covering with a fold of peritoneum will be sufficient: it might be safer to divide the ureter completely, and then resort to Van Hook's method of lateral implantation.

Early attempts to unite complete transverse wounds of the ureter, as a rule, failed in experiments upon animals and in operations on the human subject. In Tuffier's experiments on dogs death from perito-

nititis usually followed, and when union took place there was so much cicatricial constriction as to cause stenosis.

In the first case in which direct union was attempted in the human subject the result was also unsatisfactory. This case was reported by Schopf.

Schopf's Case.—During laparotomy for the extirpation of an intraligamentous ovarian cyst he divided the ureter near the brim of the pelvis. Having secured the divided ends by artery forceps, he united

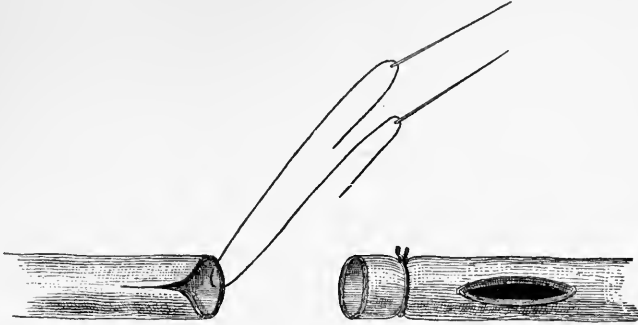


Fig. 143.—Uretero-ureterostomy (Van Hook's method). The needles have been introduced into the wall of the renal portion of the ureter. The end of the vesical portion of the tube has been ligated and a slit made in its wall.

the ureter by silk sutures, which did not pass through the mucosa and probably invaginated the borders of the transverse wound. The patient made an uneventful recovery, but died seven weeks later from tuberculosis. The autopsy showed that the right ureter at the place where it crosses the psoas muscle was embedded in cicatricial tissue, and that a cicatrix existed in the entire circumference of union.

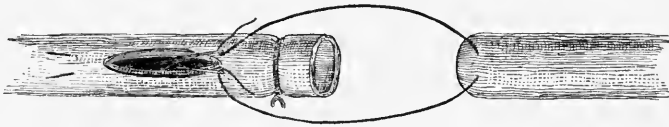


Fig. 144.—The needles carrying the traction suture attached to the renal portion of the ureter have been passed into the slit in the wall of the vesical portion, carried down a short distance, and pushed out through the wall.

Uretero-ureterostomy.—Van Hook's method of invagination (Figs. 143, 144)—or uretero-ureterostomy, as Kelly calls it—is an important step forward in this direction, as it has proved on animals and men sufficient to prevent leakage and also stenosis. He describes his method as follows:

“1. Ligate the lower portion of the tube from 3 to 6 mm. from the free end. Silk and catgut may be used. Make, with fine, sharp-pointed scissors, a longitudinal incision twice as long as the diameter of the ureter in the wall of the lower end, $\frac{1}{2}$ cm. below the ligation.

“2. Make an incision with the scissors in the upper portion of the

ureter, beginning at the open end of the duct and carrying it upward $\frac{1}{2}$ cm. This incision insures the patency of the tube.

"3. Pass two very small cambric sewing-needles, armed with one thread of sterilized catgut, through the wall of the upper end of the ureter, 3 mm. from the extremity, from within outward, the needles being from

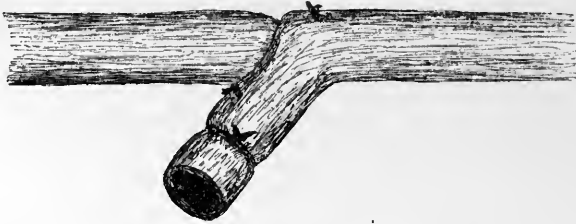


Fig. 145.—By means of the traction suture the renal portion of the ureter has been implanted into the vesical portion. The ends of the traction suture have been tied together.

2 to 4 mm. apart, and equidistant from the end of the duct. It will be seen that the loop of catgut between the needles firmly grasps the upper end of the ureter.

"4. These needles are now carried through the slit in the side of the



Fig. 146.—Ureter anastomosed; traction sutures tied, and two fixation sutures in place ready to be tied (Bloodgood).

lower end of the ureter into and down the tube for 1 cm., where they are pushed through the wall of the duct side by side.

"5. It will now be seen that the traction upon this catgut loop passing through the wall of the ureter will draw the upper fragment of

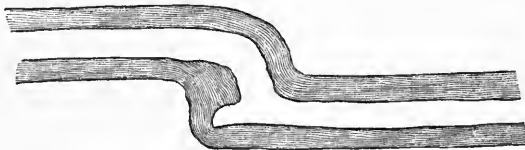


Fig. 147.—Longitudinal section of ureter, showing new lumen and diverticulum (Bloodgood).

the duct into the lower portion. This being done, the ends of the loop are tied together securely, and, as the catgut will be absorbed in a few days, calculi do not form to obstruct the passage of the urine.

"6. The ureter is now enveloped carefully with peritoneum, as already described in other operations, provided an intraperitoneal operation has been done."

Bloodgood has repeated Van Hook's experiments, with equally satisfactory results. In addition to Van Hook's procedure, Bloodgood applied two sutures through the external coats only as an additional security against leakage. His drawing of the united ureter shows not only no narrowing of the caliber at the point of union, but even a little diverticulum of the canal.

A most important and interesting proof of the value of this method has been furnished by Kelly in the first operation of this kind on the human subject. This important case was the following:

Kelly's Case.—Mulatto, twenty-five years of age, who had a large uterine myoma, filling both true and false pelvis, and extending above the umbilicus. Hysterectomy was performed May 1, 1892. The ureter was ligated and cut, supposing it to be an engorged vein. Ureter was four times its normal size by reason of pressure from the tumor (hydro-ureter). On removal of upper ligature 20 c.c. of clear urine escaped. Van Hook's plan tried, of tying lower end of divided ureter, making slit in ureter below ligature, and implanting upper into lower end by means of silk traction sutures. Edges also sutured to intussuscepted portion by 10 fine silk rectangular sutures passed through outer coat only. Gauze laid over anastomosed end and brought out at lower angle of abdominal wound to insure drainage. No urinary odor about the dressings. Passed urine second day. Discharged cured in six weeks.

B. McE. Emmet, in removing a tumor from the pelvis, divided the left dilated ureter at the level of the fifth lumbar vertebra. Although the upper end of the dilated ureter was wider than the lower, he succeeded in making a union by Van Hook's method, and the patient recovered. He used fine silk for the sutures.

Oblique End-to-end Uretero-ureteral Anastomosis.—J. Wesley Bovee reports the case of a woman of thirty-six who had received a blow on the right flank from a stone thrown by a boy, followed by an exudate in the pelvis to the right of the uterus. Abdominal section, performed April 30, 1896, showed a right tubo-ovarian abscess, during the extirpation of which the right ureter was included in the ligature of the ovarian vessels and cut off. The diagnosis was made by passing a sound through the lower end of the ureter down into the bladder, and after enucleation of the sac of the abscess an end-to-end anastomosis of the ureter was made in the following manner:

The ends of the ureter were cut obliquely, the lumen dilated for an inch, and the ends sutured together with fine silk. With a small round, straight needle a rectangular suture was inserted and tied, but not very tightly. Two interrupted sutures followed, and this alternation of rectangular and interrupted sutures was continued until the entire circumference of the ureter had been sutured. Over these sutures were inserted four or five interrupted sutures. None of them penetrated the mucous membrane of the ureter. The sutured ureter was covered by sewing the peritoneum over it. The abdominal wound was closed without drainage. For the first two days the urine was withdrawn by the catheter every six hours. The wound healed in two weeks, and the

patient left the hospital four weeks after the operation. Four months later the urine was normal. A month later a sound was passed freely into the right ureter, and no constriction could be found.

The author concludes that uretero-ureteral anastomosis should be done, preferably by lateral implantation (Van Hook's method) or by oblique end-to-end anastomosis (the author's method), although the transverse end-to-end method may be safely employed.

STONES IN THE URETER

It is a common occurrence that small renal stones pass down through the ureter, under the symptoms of renal colic, into the bladder, to be evacuated with the urine. But it is comparatively rare that a stone is retained in the ureter permanently. This takes place when the stone is too small to be retained in the renal pelvis and too large to pass entirely through the normal ureter, or when a small stone which would pass through a normal ureter is retained in a ureter with strictures, valves, or bends.

Stones in the ureter are usually small, round or oval, single or multiple. As an exception may be mentioned a stone in the St. George's Hospital Museum, 14 cm. long, which almost filled one of the ureters (Harrison).

Stones in the ureter are most commonly arrested in the upper portion, and with about equal frequency in the middle and vesical portions.

Uric-acid and oxalate-of-lime stones may be found in a non-infected urinary tract, while phosphatic calculi are found after infection has taken place. The ureter at the seat of the stone shows symptoms of chronic inflammation; the wall is thickened, or the ureter is dilated, and the stone may cause pressure atrophy and perforation. In the vesical portion of the ureter the dilated canal may protrude into the bladder, forming the so-called encysted stone of the bladder. Above the seat of the stone the ureter is often dilated, so that the stone can be pushed up into the pelvis of the kidney. In other cases, where there is only a local dilatation at the seat of the stone, this is not possible. The ureter below the stone is often smaller than normal, either from contraction due to chronic ureteritis or from disuse, when little or no urine passes down.

When once permanently located in the ureter, the stone may increase in size. So long as no infection has occurred the disturbance is merely mechanical, causing dilatation above, and at the most only a local aseptic inflammation at the seat of the stone.

Infection usually takes place, however, sooner or later, and, on the whole, it is more common to find pyonephrosis than simple aseptic dilatation.

SYMPTOMS.—These are pain, renal colic, intermittent cystonephrosis, or calculous anuria. In many cases the symptoms are not typical, and the beginning is often insidious, as the symptoms of renal colic may disappear when some urine passes down by the side of the arrested stone. The location of the arrested stone can usually not be diagnosed from the

symptoms, which are substantially the same whether a stone is arrested in the pelvis of the kidney or at any place in the ureter down to its vesical end. Dilatation of the ureter above the stone can very rarely be felt, and the stone itself has been felt in only one case near the middle portion of the ureter, while when located in the vesical portion it may be palpated through the vagina or rectum. When the end of the stone protrudes into the bladder it may be felt by a steel sound.

Location of pain in the ureter is of value only when fixed pain or tenderness remains in the same place after the intermittent attacks of renal colic have passed away. Guyon has called attention to the fact that excessive sensitiveness at the vesical orifice of the ureter upon rectal exploration may indicate stone in the ureter. Pain increased by walking or flexing the body is found both in stones in the pelvis and in the ureter. Abdominal palpation in the line of the ureter, as indicated in the anatomy, should be done by gentle, steady pressure until the fingers feel the resistance of the posterior abdominal wall; but this is of value only in thin subjects with lax abdominal walls. Rectal and vaginal palpation should be aided by pressure with the other hand above the symphysis pubis.

As to the course of stones in the ureter, it is well to remember that some cases present no symptoms whatever. Sometimes spontaneous expulsion takes place after several months; in other cases infection and calculous pyelonephritis come on after an interval free from symptoms following the original renal colic. Calculous anuria was found in about 50 per cent. of the cases operated upon (Tuffier), and oftentimes the bilateral obstruction comes on insidiously without any symptoms in the previous history to indicate the lesion of the opposite kidney.

DIAGNOSIS may be easy if the stone is located in the vesical end of the ureter, but it is usually difficult or impossible for stones in the middle or upper portion. The pain is not characteristic, as the same fixed pain is found in nephrolithiasis, pyelonephritis, and neurosis. Pain may be absent entirely, and in some cases no symptoms of stone in the ureter have been present until dilatation of the pelvis—cystonephrosis—develops. Stones in the middle or upper portion of the ureter cannot be diagnosed from stones in the pelvis or calices of the kidney.

As an aid in the diagnosis of renal calculi catheterization of the ureter has been done by Kelly in the two following cases:

1. Pyelitis; colon bacillus infection. Several black specks in the pelvis of the kidney were withdrawn by suction with the renal catheter. The specks were found to be uric-acid gravel. By nephrolithotomy a renal calculus was removed.

2. Small black pieces of stone were caught in the eye of a renal catheter in a case of pyonephrosis; the end of the catheter showed scratch-marks from the stone, and a diagnosis of renal calculus with pyonephrosis was made.

This procedure may also prove of value in the diagnosis of stones in the ureter.

TREATMENT consists in removal of the stones. This may be accomplished by different methods according to their location.

(a) *Removal Through the Bladder.*—Stones have been removed by dilatation of the female urethra by Emmet, Berg, Richmond, Czerny, and Sanger; by suprapubic cystotomy in 2 cases (Tuffier). Ureteral stones often protrude into the bladder and can be recognized by the sound. The mucous membrane covering them may have to be divided, but the stones are usually extracted without difficulty. The wound in the vesical end of the ureter is generally left open, but is sometimes sutured, as in the case reported by Berg. Stones in this location, so far as operative procedure is concerned, should be classed among stones in the bladder.

When stones are located a little higher up, but are not accessible from the bladder, they may be reached by—

(b) *Ureterotomy Through the Rectum.*—Ceci removed successfully a stone from the ureter by incision through the rectum.

(c) *Ureterotomy Through the Vagina.*—Removal of stone by means of vaginal ureterotomy has been performed by Emmet and Cabot.

Emmet's Case.—A click having been elicited by the sound, ureteral stone was suspected. On backward pressure with a larger sound a stone could be felt through the vagina and rectum. Stone cut down upon through vaginal wall by scissors. Opening enlarged forward toward the neck of the bladder, this being the only safe direction to avoid entering the peritoneal cavity. Opening closed with interrupted sutures. Good recovery.

Cabot's Case.—Woman, aged thirty-nine. Attacks of renal colic for sixteen years, often followed by passage of stones. Left pyonephrosis felt as a distinct tumor. Vaginal examination revealed small hard mass in left broad ligament close to cervix uteri. Sound in bladder could not be brought within $\frac{1}{2}$ inch of mass. Ureterotomy and removal of stone through vagina. Evacuation of 10 to 12 ounces of pus. Tumor in region of kidney disappeared. Ureterovaginal fistula remained for four months, with small amount of pus. The author concludes that the kidney was destroyed so far as secreting tissue was concerned.

(d) *Extraperitoneal ureterotomy* has been performed by Twynam, Cabot, Ralfe and Godlee, Kirkham, Morison, and Fenger.

Twynam's Case.—Boy, eight years. Left renal pain, hematuria. Laparotomy for diagnosis revealed stone in right ureter just below brim of pelvis. Laparotomy wound closed. Three weeks later extraperitoneal incision in right iliac region; ureterotomy, removal of stone, ureterorrhaphy, drainage; recovery. Long ends of sutures brought out of wound.

Cabot's Case.—Man, forty years. Seven or eight sharp attacks of pain, referable to left side of abdomen, above middle of Poupart's ligament, during three months before operation. Sensitive spot on back, midway between crest of ilium and twelfth rib. Diagnosis: stone in ureter. Lumbar incision; ureterotomy; removal of calculus 2 inches below kidney; wound in ureter not sutured; recovery.

Ralfe and Godlee's Case.—Woman, twenty-six years. Renal colic persistent on left side. Lumbar nephrotomy. No stone in kidney. Exploration revealed stone in left ureter, 2 inches below kidney. Longitudinal ureterotomy; removal of stone. Subsequent passage of gravel and small stone per urethram; recovery.

Kirkham's Case.—Man, fifty-eight years. Right renal colic, followed by pain on left side and anuria. Diagnosis: Destruction of right kidney by previous attack; left kidney now affected. Exploratory left lumbar incision. Palpation of kidney negative. Stone in ureter, $\frac{1}{2}$ inch above the point of crossing of external iliac artery. Ureterotomy; removal of stone; no sutures; drainage; recovery.

R. Morison's Cases.—1. In a case of anuria due to calculus in the right ureter Morison removed two stones from the right ureter close to the bladder by extraperitoneal ureterotomy, and closed the wound in the ureter with fine catgut. The patient died on the table. Autopsy showed dilated right ureter, sacculated right kidney with interstitial nephritis; left ureter occluded by stones. Left sacculated kidney contained no kidney tissue.

2. Man, thirty-one years. Occasional left renal colic, no hematuria. Lumbar incision; stone in ureter 3 inches below the kidney removed by ureterotomy. Wound in ureter left open; recovery.

Fenger's Case.—Man, thirty-five years. Increasing attacks of renal colic for two years. No hematuria; no tumor. Diagnosis: Nephrolithiasis. Lumbar nephrolithotomy. No stone in kidney. Palpation showed two stones in the ureter, $1\frac{1}{2}$ inches below kidney. Longitudinal ureterotomy; no sutures; recovery.

(e) *Intraperitoneal ureterotomy* has been performed by Cullingworth and Arbuthnot Lane.

Cullingworth's Case.—Woman, thirty years. Right renal colic; large pyonephrosis. Vaginal examination showed hard masses to the right and left of uterus. Diagnosis: Right pyonephrosis and independent ovarian disease. Laparotomy. Right ureter dilated. Stone immediately above bladder. Ureterotomy; removal of stone; escape of pus. Ureterorrhaphy, with interrupted silk sutures. Glass drain in abdomen. Death from peritonitis in eighty hours. Autopsy revealed right and left pyonephrosis. Sutures in ureter held.

Arbuthnot Lane's Case.—Woman, twenty-three years. Left renal colic for twenty years; hematuria; pyuria. Laparotomy. Pelvis of left kidney dilated. No stone. Ureteral opening could not be found. Eight months later laparotomy. Stone in pelvic portion of ureter forced up to crest of ilium. Abdominal ureterotomy; removal of stone. Ureterorrhaphy, with continuous silk suture; no leakage; recovery.

Diagnosis as to the location of the stone was made before operation only in the cases in which the stone was afterward removed through the rectum or vagina (Ceci, Emmet, Cabot). When the stones are located higher up, it is, as a rule, impossible to make a positive diagnosis. In the small pelvis diagnosis may possibly be made by vaginal examination but in Cullingworth's case he mistook the stones for diseased ovaries

and positive diagnosis was not made until the abdomen had been opened.

If the stone is located still higher up, diagnosis of location is well nigh impossible. Cabot made the diagnosis of stone in the ureter, but could not locate it until a lumbar incision had been made.

The location of the stone has not been determined until exploratory incision, either extraperitoneal or intraperitoneal, has been performed. When the stone has been found in this way, its removal has been accomplished either by pushing it up into the pelvis and extracting it through an opening in the pelvis or kidney, or by longitudinal ureterotomy.

It is often impossible to push the stone up into the pelvis because of the local dilatation of the ureter, the "nest," as Le Dentu calls it, but some operators, such as Israel, von Bergmann in 2 cases, Hall and Tuffier, have succeeded in accomplishing this. Fenger tried, unsuccessfully, to push a stone into the pelvis by a needle passed through the wall of the ureter. He does not consider this procedure important if the ureter can be reached by an extraperitoneal incision.

The difficulty in dislodging the stone is well illustrated in the case reported by Hall, who succeeded only after manipulations with one hand in the abdomen.

Hall's Case.—Woman, thirty-six years: had had recurrent attacks of renal colic for four years. No hematuria. Pain in region of left kidney, which could be palpated between the hands. Examination caused no hematuria. No stone could be felt. Dr. Hall was unwilling to make a lumbar incision on uncertain diagnosis, and advised exploratory laparotomy. Examination in narcosis revealed a small tumor in region of left kidney—the dilated ureter above the stone. Abdominal section. Stone could now be felt about 3 inches below the kidney. Lumbar incision for removal of stone. Stone difficult to dislodge, finally accomplished by hand in abdomen. Incision on convex surface of kidney; invagination of sac consisting of dilated ureter and pelvis. Extraction of stone; recovery.

The dislodgment and removal of the stone were easy in the case reported by Tuffier:

Tuffier's Case.—Renal colic for nine years, finally attended with constant pain. Right kidney enlarged. Nephrolithotomy. Examination revealed no stone. Examination of ureter showed hard, ovoid body, 3 cm. long, at place where ureter crossed the promontory. Stone movable, and was pushed up into pelvis of kidney. Incision of convex surface of kidney. Extraction of stone. Suture of kidney and lumbar wound. No drainage. Healing by first intention.

Longitudinal ureterotomy has thus been done in 7 cases through an extraperitoneal incision, 6 of which were successful, and 1 patient died; and in 2 cases through the abdomen 1 case was successful, and 1 patient died from peritonitis.

The treatment of the ureteral wound is different in the extraperitoneal and intraperitoneal operations. In the intraperitoneal operation immediate absolute closure of the ureter is of vital necessity: as the

urine above a stone is almost always infectious, the question of accurate suturing is one of great importance. In the extraperitoneal operation, where the infected urine can be drained out effectually until the wound closes, the question of suturing is of little importance.

In his transperitoneal operation Arbuthnot Lane used a continuous silk suture with perfect success. In Cullingworth's intraperitoneal operation he employed interrupted silk sutures, and postmortem examination revealed no leakage from the wound in the ureter.

In an extraperitoneal operation Twynam applied interrupted silk sutures, the long ends of which were brought out through the wound. As might be expected, the sutures did not hold.

In some of the extraperitoneal operations no sutures were used, but drainage was employed, and the wound closed in Kirkham's case in forty days; in Fenger's case, in a month; in Fenger's case of exploratory longitudinal ureterotomy, in fifty days; and in Cabot's case the wound also closed without disturbance.

Whenever practicable, the stone should be removed through a lumbar incision rather than through the abdomen. Stones located low down in the small pelvis, which cannot be pushed up within reach of an extraperitoneal incision, like that for ligation of the iliac artery, might be reached by a sacral operation, although no case of this kind is as yet on record.

Laparotomy for the purpose of diagnosing the location of the stone has been of value in several instances. In Arbuthnot Lane's case the stone was thus located after exploratory lumbar incision had failed. In this case, however, it might have been possible, by opening the kidney or ureter and exploring above, to locate the stone through a lumbar incision.

In Hall's case the stone was located through a median abdominal incision and removed through a lumbar nephrotomy. As in this case it had already been determined which ureter was the seat of the stone, the laparotomy might have been omitted.

In Twynam's case, however, exploratory laparotomy was absolutely necessary, since the symptoms pointed to stone in the left ureter, which was healthy, while the stone was found in the right ureter, and was removed three weeks later by an extraperitoneal ureterotomy.

The operative results for stone in the ureter are, on the whole, favorable. In 17 cases collected by Tuffier only 3 patients died, and in these cases the other kidney was diseased. In ordinary cases, in which a certain amount of healthy secreting kidney tissue remains, removal of stones from the ureter presents no more dangers than removal of stones from the kidney or its pelvis.

The question of gaining access to different portions of the ureter in order to overcome obstruction has been solved, so far as the removal of stones is concerned, by a number of operations already on record, as follows: The vesical end of the ureter has been reached from the bladder by Emmet, Richmond, and others; from the vagina, by Emmet and Cabot. The pelvic portion of the ureter has been reached by extra-

peritoneal lumbar incision, and the stones removed either by pushing them up into the pelvis and pyelotomy in 4 cases (Tuffier), or by longitudinal incision of the ureter in 4 cases (Tuffier), and by Fenger in 1 case.

From the middle portion of the ureter stones have been removed in 4 cases (Tuffier) by longitudinal ureterotomy by the prolonged lumbar incision. There is no difficulty in gaining access to the upper two-thirds or three-fourths of the ureter by the oblique lumbar incision. It is different with the lower third or fourth of the ureter, which is located deep down in the pelvis, and is even held by Le Dentu to be inaccessible. But Cabot has justly pointed out that this portion of the ureter is also accessible without opening into the peritoneum by means of the sacral operation of Kraske, with removal of part of the sacrum or temporary resection of the latter.

VALVE FORMATION, BENDS, AND STRICTURES

Valve formation and oblique insertion of the ureter were first noticed in the case reported by Glass and cited by Rayer. A girl was born with right hydronephrosis, and died at the age of twenty-three. At the autopsy three gallons of liquid were found in the sac. On the interior surface of the sac the orifice of the ureter was seen as large as a goose-quill. The ureter passed obliquely for 30 cm. between the membranes of the sac, and was patent the entire distance to the bladder. On account of the non-obstruction of the ureter Rayer considers this the most remarkable case on record.

Rayer observed a case of double hydronephrosis in which the ureters were also patent, which he attributed to congenital malformation. The patient was a boy of seventeen who had been sickly all his life, and had had pain for seven years in the region of the left kidney. A tumor was found, and the diagnosis made of left hydronephrosis. He died from septic infection of the sacs. At the autopsy the left ureter was found patent, the upper portion situated in the wall of the sac, with an opening almost similar to a valve in a vein. Water passed easily from below upward, but not down from the sac into the ureter. There was a small hydronephrosis in the right kidney. The right ureter was dilated to the size of a lead-pencil from the bladder up to the sac. At the upper end it was retracted, and when water was injected from below, it entered the sac through an opening the size of the lacrimal punctum.

Virchow, in discussing hydronephrosis, remarks: "The cases are extraordinary in which hydronephrosis exists with the ureter patent. I have examined such cases several times, and have found in each case a valvular obstruction caused by folding of the wall, due to oblique origin of the ureter from the renal pelvis."

Simon gives a full and comprehensive description of this condition. The ureter does not enter the pelvis of the kidney at its lowest point with a funnel-shaped opening, but enters it at the side at an acute angle, and often runs for a variable distance in the wall of the pelvis. In 2

similar cases observed the ureter ran, not in the wall proper, but between the wall and the peritoneal covering for 7 to 10 cm. In contradistinction to the previous authors, who thought that valve formation was the cause of hydronephrosis, and therefore congenital, Simon believes that the hydronephrosis in its beginning causes the valve formation, and consequently that valve formation is not a congenital affection. He has examined a specimen in which a stone was found in the ureter 5 cm. from the pelvic orifice in a case of hydronephrosis the size of a child's head, and with valve formation in the upper end of the ureter. He believes that temporary obstruction from any cause may produce sufficient asymmetric dilatation of the pelvis to give rise to oblique insertion and valve formation, which, when it once exists, even if the primary cause of obstruction disappear, may remain as a permanent obstruction of greater or less degree to the passage of urine. He considers valve formation in hydronephrosis very common, as he found it in 11 out of 18 reported cases.

The mechanical aspect of valve formation in the causation of intermittent hydronephrosis was studied by Krakauer, who made experiments designed to explain the fact that spontaneous evacuation of urine is sometimes seen in hydronephrosis due to this cause. Acting upon the proposal of Simon, Krakauer produced an imitation of the hydronephrosis due to valve formation in the following manner: He caused to be made a rubber balloon having a capacity of 150 c.c., with a tube which ran for several centimeters in the wall before opening at an acute angle into the side of the balloon. When the balloon was filled to distention, he observed that the first 50 c.c. were evacuated rapidly, the second 50 c.c. less rapidly, and the remainder still less readily. From this experiment Krakauer concluded that a higher pressure in the balloon, equivalent to an overfilling of the distended pelvis, is capable of overcoming a greater hindrance or impediment in the tube of exit—the ureter—than is a lower pressure. Applying this fact to the obliquely inserted ureter in the dilated renal pelvis, he concludes that partial filling of the dilated pelvis will close the valve entrance and permit no evacuation through the ureter; further accumulation of urine and overdistention of the dilated pelvis will overcome the obstacle, and the urine will be evacuated through the ureter. This fact explains intermittent cystonephrosis.

Tuffier has studied the mechanism and treatment of intermittent hydronephrosis as caused by movable kidney by a series of experiments, the first of which takes into consideration the mode of formation of the hydronephrosis. In the first experiment he made an artificial exstrophy of the bladder on a dog. A few days later he examined the function of the ureters, and found the same number of contractions, jets, and the same quality and quantity of urine on both sides. He then mobilized one kidney, and found, first, that the intervals between the jets grew larger and the quantity of urine one-third to one-fourth less, but the proportion of urea was unchanged. From the sixth to the eighth day the pelvis and ureter became distended above the bend, especially the pelvis.

As neither the pelvis nor the kidney has a muscular layer capable of

compensatory contraction, the hydronephrosis once established would continue. The first symptoms, then, are increased pressure of the urine in the pelvis and renal congestion. The distention later on leads to bending of the ureter at the border between the fixed and movable portion—namely, at the pelvis. It is usually in a line with the renal vessels that the bend is found after four weeks.

Secretion and absorption may take place above the bend. The organ may continue to secrete for a long time. Patients have been found to live for several years with one kidney only, and this kidney hydronephrotic (Wright, Küster). The kidney tissue may remain relatively healthy.

The same was observed in some of the experiments. A dog with intermittent hydronephrosis of forty-five days' standing lived after ligation of the other ureter, and microscopic examination of the hydronephrotic kidney tissue showed only interstitial edema and dilated collecting tubes, but a normal condition of the kidney tissue.

Convincing proof is also found by urinalysis. In the experiments the urine from the bladder—that is, from the other kidney—and the urine from the dilated kidney contained the same amount of urea. This was also found in some observations on man in the cases of Rogers, Rochet, and Weir, and in one case by Tuffier in the service of Tillaux.

The kidney showed various changes in shape: In 3 operations the kidney was increased in volume and horseshoe-shaped; in another it formed almost a complete circle. In another variety the kidney was elongated, flattened, and had the shape of the tongue of a dog (one of Tuffier's observations). Tuffier believes this change in shape is characteristic of the initial stage of hydronephrosis, and that if he had taken this into consideration, he would have observed more than 9 hydronephroses in his 45 nephropexies.

The physical phenomena in the beginning of hydronephrosis are as follows: The kidney is a secretory organ, but has the power to absorb liquids and salts. In a state of retention the kidney absorbs part of the liquid contained in the calices, pelvis, and collecting tubes. It is easy to prove this endosmotic action. There is only little absorption in the ureter, but rapid absorption in the calices and parenchyma in the normal condition; when there are retention and pressure, however, absorption becomes rapid. Tuffier injected 2 cg. of strychnin into the pelvis of the kidney of a dog. It produced no symptoms until the ureter was ligated. In spite of this absorption of liquid under pressure, in spite of this distention, the kidney tissue goes on secreting for a long time in the intermittent—that is, open—hydronephrosis.

On the other hand, when the hydronephrosis becomes closed and of long standing, the secretion of urea first diminishes, then stops, and the secreting kidney tissue gradually disappears.

Intermittent hydronephrosis has a double mechanism:

(a) The bend is movable. In the beginning it is easily straightened out when the kidney is brought into position. Even when the pelvis is much distended it can be straightened out by replacing the movable

kidney. This was proved in a case where the bend straightened out when the patient lay down. At the operation Tuffier found a large, fluctuating, horseshoe-shaped kidney, the pelvis much dilated, and the ureter normal. This condition was entirely cured by nephropexy.

(b) The kidney is immovable, and the bend is forced when the tension reaches a certain point. Tuffier found in an operation the following condition: the kidney was voluminous, but not very tense; the bend was visible, and the ureter empty below. Pressure on the kidney forced the liquid down through the bend.

Consequently, intermittence may be due to two mechanisms: (1) Straightening of the bend, and (2) a certain degree of pressure.

Tuffier considers that a causal relation between intermittent or permanent cystonephrosis and mobility of the kidney is shown by the following facts:

1. Cystonephrosis is more frequent in women—21 women to 5 men; Tuffier's 12 operations were all on women.

2. The seat of the hydronephrosis is on the right side in 21 out of 23 cases. This is in accord with the opinion of Landau, defended by Terrier and Baudoin, but Tuffier considers himself the first who has given anatomic proof of this by experiments and clinical observations. In his experiments on dogs he produced a bend in the ureter as follows: Through a lumbar opening he rendered the kidney movable and fixed the ureter in some cases, fixed the kidney in an abnormal position in others, and left the movable kidney and ureter without fixation in others. He had 4 negative results and 5 hydronephroses. The latter presented the following conditions: 2 or 3 cm. below the hilus there was a sharp bend of the ureter. The pelvis and kidney above were thin walled and distended, the more so the longer the condition had existed—from seven to fifty-five days. These hydronephroses were open—that is, a slight compression on the kidney caused the liquid to force its way through the bend. In these cases the kidney continued its function, as was proved by an experiment in which the opposite ureter was ligated, and the animal remained alive in spite of the intermittent cystonephrosis.

The simple mobilization of a healthy kidney is sufficient to cause a hydronephrosis, and this condition is due to bending of the ureter. When the kidney is lifted up the bend is straightened out, and there remains only the difference in diameter above and below to show the place of the former obstruction. The bend can consequently be straightened out with the utmost facility. The bend is formed by displacement of the upper movable portion of the ureter upon the lower immovable portion. Tuffier gives some very instructive plates showing the changes in kidneys and ureters of the animals experimented upon. Besides these experimental results, he has seen this bend of the ureter in two operations for hydronephrosis. In 1892, in a case of nephrectomy for cystonephrosis, he dissected out the ureter and found an S-shaped bend 4 cm. below the pelvis. He could not straighten it out completely. Pressure on the kidney forced the liquid down to the bend, and it required increased

pressure to force it through the bend. Here the bend was fixed, but in another case the bend could be straightened. In this case of intermittent hydronephrosis, which was cured by nephropexy, lumbar incision was made, the kidney isolated, but likewise the ureter for 10 cm. Two cm. below the pelvis was a bend with dilatation above. In freeing the bend the renal vessels were in the way. By lifting the kidney up in place the bend straightened out and the pelvis evacuated its contents into the bladder. The pelvis was as large as a mandarin orange.

A third clinical observation was in a woman with movable right kidney who had presented the following symptoms for several years: When she was up and around she had pain, a tumor could be felt, and she passed a small amount of urine. The symptoms disappeared when she lay down, which she was compelled to do for an hour twice a day. On examination Tuffier found the kidney so displaced that the hilus pointed upward. He performed nephropexy, and found the pelvis and kidney dilated, but the ureter not dilated. It was thus evident that in the upright position the ureter was bent on the pelvis, and that the bend disappeared in the horizontal position.

These observations correspond with the experiments, and further with the observations, of Clement Lucas, Israel, Monod, and Rochet. It is evident that the mobility of the kidney causes the bend, and this is important because it gives a clue to the treatment.

Nephropexy is advised by Tuffier in all hydronephroses not too voluminous, and is the method of choice in the great majority of intermittent hydronephroses. Tuffier reports 9 operations with 9 recoveries.

In our opinion the operation is effective only in beginning valve formation, and useless when stenosis is present, and it is often impossible to make a diagnosis without examination of the seat of obstruction from within. There must consequently be some uncertainty when nephropexy alone is made.

There is a marked difference in shape between the empty and the full dilated floating kidney. The full kidney is round and tense; the empty kidney is flat and flabby. The color is whitish. Little hemorrhage follows denudation or incision. The suture for fixation is passed through the parenchyma, but not into the pelvis.

Nephropexy, however, is not effective in very voluminous sacs, and when the drainage cannot take place through the ureter—that is, where the ureter is inserted too high up.

Landau states that intermittent hydronephrosis, where there is no gross pathologic impediment to the passage of urine, is not so rare as might be judged from the infrequency of reports of this condition in the literature.

The etiology of this condition was given by Landau as—(a) Bending; (b) torsion; (c) oblique insertion of the ureter. These conditions cause stagnation of the urine in the pelvis, dilatation of the pelvis, and then compression of the upper part of the ureter by the distended pelvis. These pathologic conditions of the ureter are in many cases caused by

floating kidney. Direct traction upon the ureter has also been reported as the cause of hydronephrosis in certain cases of prolapse of the uterus.

The amount of secreting substance left is very variable: more is found in the smaller tumors, but even in large tumors secreting kidney substance may be spread out over a large surface. In one of Simon's cases he could feel the calices from the tenth rib to the crest of the ilium.

The ureter is small on account of atrophy from disuse. Its upper portion, which passes up through or in the wall of the pelvis, may be stenosed from pressure of the sac or from inflammation. Its opening into the pelvis is a narrow, crescentic slit sometimes only 2 mm. in length, and often difficult to find.

Weigert describes an autopsy in a case of hydronephrosis: A vigorous man who had been treated in the hospital for chronic hemorrhagic nephritis finally died of uremia. Autopsy revealed right hydronephrosis the size of a child's head. A bend in the ureter 9 cm. below the kidney and 21 cm. above the bladder (the left ureter was normal and was 30 cm. long) had caused the hydronephrosis. The ureter below the bend was normal; above the bend it was dilated, first to 1 cm., and finally to 4 cm., in diameter. When the hydronephrotic sac was lifted up and the bend

straightened out, the clear fluid contained in the hydronephrosis could be squeezed down through the bend into the bladder. (See Fig. 148.) Weigert described this as a congenital anomaly. It is more likely that it was not congenital, but that the bend in the ureter was caused by the descent of a floating kidney, and that bending of the ureter at the end of its upper third caused the stenosis, which consequently was an acquired condition.

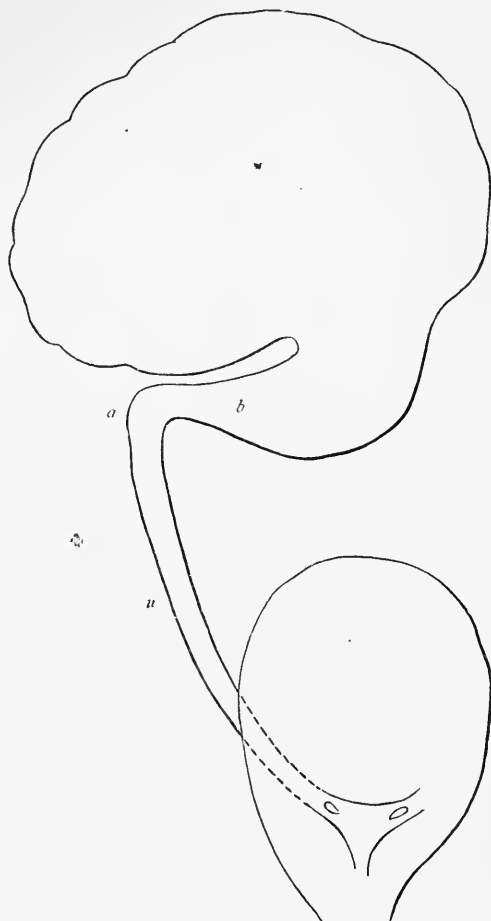


Fig. 148.—*u*, Right ureter; *a*, bend; *b*, dilated portion of ureter above bend (Weigert-Virchow).

Operations for the Relief of Valve Formation.—As valve formation always causes an intermittent or permanent impediment to the flow of urine, the pelvis of the kidney is in a state of hydronephrosis or pyonephrosis. The so-called sac is accessible through the peritoneal cavity or by an extraperitoneal operation through the lumbar region.

The first attempt to operate on the valve, after Simon's, which was unsuccessful, was made in 1890 by Trendelenburg, who opened the anterior wall of a large hydronephrotic sac by lateral laparotomy, saw the ureteral opening on the side of the sac, and divided the ureter down to the lower part of the sac, to the inner wall of which he sutured the divided borders of the ureter. The ureteral opening was thus displaced from the side to the bottom of the sac in order to keep the ureter patent. The result of this operation is uncertain, as the patient died from intestinal obstruction.

In 1891 Küster, in his celebrated case of resection of the ureter and implantation of the distal end into the pelvis, opened the hydronephrotic sac from the lumbar region, found the ureteral opening, and divided it through its course in the sac-wall, with the intention of stitching the divided border to the inner wall of the sac, as Trendelenburg had done. Before finishing this operation, however, he explored the ureter and found a stricture, which caused him to abandon the operation for valve formation and to resect the stricture.

The valve formation can be remedied by a plastic operation after previous opening of the dilated pelvis following lumbar nephrotomy. It is natural to select the lumbar region for entering the pelvis, because the operation is extraperitoneal, and consequently there is no danger of infecting the peritoneal cavity, and because the lumbar incision gives the readiest access to the upper portion of the ureter. If it is possible in this manner to reestablish the flow of urine, we can save for future function what active kidney tissue may be left, the danger of primary nephrectomy is avoided, and the patient may regain perfect health without urinary fistula. That this can be accomplished satisfactorily and promptly is illustrated by the following cases, the first of which, by Fenger in 1892, was the third attempt and the first successful operation for valve formation:

CASE 1.—Woman, twenty-eight years, with valvular stricture or stenosis of the pelvic orifice of the left ureter in a somewhat floating kidney, with intermittent infected cystonephrosis of eight years' standing. An incision 10 cm. long was made from the angle of the twelfth rib and the extensor dorsi muscle obliquely downward and forward to the iliac crest above the anterior superior spine. Palpation of the kidney revealed neither fluid nor stone.

Nephrotomy by means of the Paquelin cautery and dilatation of the opening with forceps, so as to permit digital palpation of the pelvis and calices. The calices were dilated, and the pelvis was a large cavity extending from the lower border of the kidney with a round, smooth, soft surface. No stone could be felt nor could the ureteral entrance be made out. Examination with a steel sound gave similar negative results. A small bent metal probe was now passed into the pelvis, but the ureteral entrance could not be discovered. The posterior surface of the pelvis was now opened, and the borders of the

wound grasped and held open with forceps for ocular inspection. The inner surface of the pelvis was seen to be normal in color and appearance. At the lower posterior portion of its inner wall was seen a small semicircular opening 4 mm. in length from above downward and 6 mm. in transverse diameter. The posterior border was convex, the anterior border straight. A metal probe introduced through this opening passed easily down into the bladder.

An olive-pointed bougie, No. 5 French, which was passed down, was tightly grasped by the ureter. By lifting up the pelvis the ureter could now be palpated. The wall was thin, and seemed liable to rupture unless great care was exercised. The bougie was removed, and on again lifting the pelvis and inspecting the entrance into the ureter, it was seen that the ureter came off, not from the most dependent portion of the dilated pelvis, but from its posterior half or wall. Thus the anterior straight border of the ureteral entrance formed a valve or fold resembling the valve in a vein, which would close against the posterior wall of the opening when the pelvis was filled with urine or fluid to a slight or medium degree. A greater degree of dilatation, by pushing away the posterior wall of the pelvis, would reopen the entrance to the ureter. This accounted for the evacuation of urine containing pus after a period of occlusion of two days' duration.

To do away with this valve formation the following operation was performed on the plan of the Heineke-Mikulicz operation for stricture of the pylorus (Fig. 149): An incision 5 mm. in length was made through the mucous membrane into the muscular wall or fold of the pelvis. The terminal points of the incision through the valve were now approximated by a fine silk suture, thereby changing the former vertical incision into a horizontal line. The entrance into the ureter was by this means made wider and more nearly circular.

A bougie, No. 11 French, was now passed through the opening in the pelvis 13 cm. down into the ureter, and the upper end brought up through the pelvis and out of the wound in the kidney, to keep the opening into the ureter dilated during healing of the wound. The incision in the pelvis was united by ten fine silk interrupted sutures passed through the pelvic wall, but not including the mucosa. The kidney was now replaced and fixed in normal position by nephropexy. The patient recovered without fistula and had no return of the cystonephrosis.

CASE 2 (Fenger).—A married woman, twenty-eight years of age, with aseptic remittent cystonephrosis in a movable kidney, of at least seven months' duration. On making a lumbar incision a thin-walled tumor presented in the wound, from which, upon opening of the sac-wall, a quart of clear, straw-colored fluid was evacuated. Upon palpation the finger could not reach either the upper or the lower end of the sac, which was shaped like an hour-glass. The lower portion of the sac was round and larger than the fist, and its lower end extended down into the large pelvis. The ureteral opening could not be found on palpation or inspection with sunlight; search for the ureteral opening with a probe was also negative. The incision opening in the lower portion of the sac was sutured to the skin and the remainder of the wound united. The hydronephrotic cavity was packed with borated gauze, and two large drains introduced, one up and one down. The secretion from the sac gradually decreased until only four or five ounces passed through the fistula in the twenty-four hours, and she was sent to her home for further treatment.

Two months later the patient was sent back on account of infection of the sac. Six months later operation to reopen the ureter. Palpation prior to operation showed the sac to be considerably diminished in size, but the entrance to the ureter could not be found from within the sac. Thus the ureter was searched for and taken up below and outside of the sac. Incision over the lower portion of the sac, where the ureter was found and isolated. On making traction on the ureter and inspection of the sac a nipple-shaped projection with a depression in its center was seen on the side of the sac. Through this

depression a long flexible silver probe passed into the ureter and down into the bladder without difficulty.

The ureter was now operated upon from within the sac in the following manner: A grooved director was inserted into the ureter, and the sac-wall, which was separated from the ureter by loose, movable connective tissue, was resected all around, and the borders of the unfolded ureter sutured to the borders of the wall of the sac. Thus free entrance of liquids from the sac into the ureter was positively secured. The large opening in the sac, 5 cm. in diameter, was now closed by sutures in the outer half of the wall, which did not take in the mucous membrane or the kidney tissue layer in the inner wall of the hydronephrotic sac. Only a small opening, the size of a lead-pencil, was left for

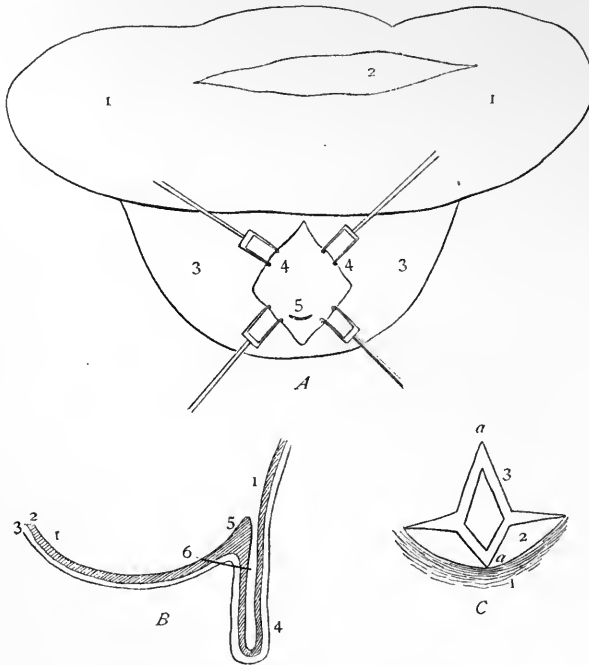


Fig. 149.—Illustrating operation for valve formation.

A, Kidney and dilated pelvis: 1, Kidney; 2, opening on its convex surface after nephrotomy; 3, dilated pelvis; 4, with opening on its posterior surface from pelviotomy; 5, opening of the ureter into the pelvis, a small transverse, crescent-shaped slit.

B, Dilated pelvis and ureter, showing valve formation: 1, Pelvis; 2, mucous membrane; 3, muscular and external coat; 4, ureter; 5, valve; 6, line of incision dividing valve.

C, Valve seen from the pelvis and divided to illustrate the plastic operation: 1, Inner wall of pelvis above the ureteral opening; 2, ureteral opening; 3, the divided valve; a and a', the corners of incision to be united by a suture.

drainage. The adhesions of the opening into the sac were first dissected off from the skin or from the border of the lumbar opening. Gauze was packed along the drainage-tube down to the opening in the sac, the abdominal wall united by buried and skin sutures, and the usual dressings applied. The renal fistula closed on the fortieth day after operation.

In this case a slightly atrophic ureter ran obliquely on the anterolateral wall of the sac for 3 cm. There was no stenosis. The ureteral opening could not be seen or found from the inside of the sac until the ureter below the sac had been laid bare, so that the place of entrance could be seen when traction was made on the ureter.

This case conforms to the law that a lumbar renal fistula does not persist when the ureter is patent. Whether it is worth while to save a kidney with a daily secretion of only three ounces is a question not to be decided until future observations have taught us more about the subject than we know at present—namely, where to draw the line between a valuable and a valueless organ.

A somewhat different method of operating on this valve has been suggested by Küster, but has not yet been tried. (See Fig. 150.) He reports a case in which he divided the valve longitudinally. He proposed to freshen each flap and unite it by sutures to the freshened inner wall of the sac. Küster was not able to carry out this plan, because he found, in addition to the valve, a stricture in the ureter 2 cm. below the pelvis. This condition caused him to resect the upper 3 cm. of the ureter and unite the upper end of the distal portion of the pelvis by a plastic operation.

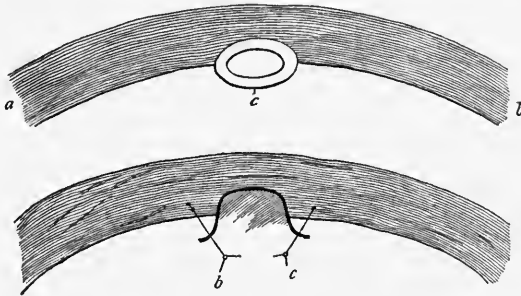


Fig. 150.—1, Küster's intended operation on the valve (same as Trendelenburg's): *a, b*, Wall of sac; *c*, transverse section of ureter. 2, *b, c*, The ureter divided on its anterior surface; near *b* and *c* are sutures uniting the borders of the divided ureter and the wall of the sac.

The second successful operation was performed on August 14, 1893, by Herman Mynter.

Mynter's Case.—Man, twenty-five years of age. Valvular stricture of pelvic orifice of ureter. Intermittent hydronephrosis for twelve years; periodic attacks of pain every two or three months in right lumbar region. Diagnosis: Right renal calculus producing occlusion of ureter. Exploratory nephrotomy. No stone found. Ureter permeable, but presented valve formation at pelvic orifice. Plastic operation on valve. Gauze drain; recovery without fistula.

The operation for valve formation can best be done by the extra-peritoneal lumbar incision. The dilated pelvis or hydronephrotic sac is easily found and opened by a longitudinal incision. The opening of the ureter into the sac should be looked for, but cannot always be found, as in some cases it is very narrow. In such cases it may be located by incising the ureter below the sac and passing a probe upward toward the pelvis. The valve or inner wall of the ureter, running in the sac, is now divided longitudinally from the opening in the sac, and the resultant wound treated in one of the three following ways:

(a) By turning the flaps out and uniting them to the inner wall of the sac by sutures (Trendelenburg, Küster).

(b) By drawing the corners of the longitudinal incision together with one suture, transforming the longitudinal into a transverse wound (Fenger).

(c) By uniting the wound longitudinally with numerous fine silk sutures, "taking in the outer two coats of the ureter and sac and avoiding the mucous membrane" (Mynter).

In one case Kelly emptied a large hydronephrosis by catheterizing the ureter. The patient had an obscure tumor the size of a quart measure on the right side of the abdomen. It was movable, elastic, and painless. He introduced the long renal catheter until a little fluid escaped, and then, by pressure on the tumor, emptied it completely, confirming the diagnosis of large hydronephrosis.

Strictures of the Upper Portion of the Ureter.—It has been seen in the description of valve formation that a stricture often forms in the portion of the ureter located in the wall of the dilated pelvis; but this stricture is treated by the operation for valve formation as described above. Independent strictures below the pelvis require different treatment. If such strictures are single and accessible, they can be operated upon with a view to reëstablishing the continuity of the canal.

Outside of observations at the postmortem table little attention has been called to the question of strictures of the ureter, because in the cases of cystonephrosis formerly operated upon the kidney was opened or extirpated and no attention was paid to the ureter.

From the postmortem table we know that multiple strictures can be found as a result of chronic inflammation of the canal, as in the instance depicted by Hallé, mentioned by Tuffier, in which not less than three strictures were found, the ureter between the strictures being dilated.

As a result of traumatism, limited strictures have been seen to be formed, as in the cases of Pye-Smith and Sollier. Pye-Smith reports the following case of stricture of the ureter and dilatation of the kidney, apparently of traumatic origin:

Pye-Smith's Case.—Male, twenty-four years of age; farrier. Never had stricture. Two years before kicked on left side "under short ribs," and passed blood with urine several days. In bed three days. No difficulty in passing water. On examination a large tumor was found occupying left half of abdomen. The urine contained a trace of albumin. August 22, 1871, the tumor was tapped, and 6½ pints of a reddish fluid containing pus and red blood-corpuscles evacuated. He died six weeks later. On autopsy the ureter was found to be dilated to a circumference of 4 cm., then contracted so as not to admit the smallest probe. No impacted calculus; no sign of recent inflammation. The disease was probably traumatic, and the ureter probably injured. During the two years following the canal was gradually contracting and forming stricture; consequently, the pelvis of the kidney gradually expanded.

Sollier's case was one of traumatic stricture of the ureter in a man of forty-five who in 1870 sustained a traumatism by a kick from a horse in the left hypochondrium. The injury was followed by pain in the left side, gradually increasing for nine years, when symptoms of nephritis appeared and the patient died from uremia. At the autopsy it

was found that the left kidney had been transformed into a number of "cavities the size of nuts." The calices, pelvis, and upper portion of the ureter were dilated. In the middle portion of the ureter was found a "cicatrical stenosis."

Little is also known as to the frequency of strictures, but it may possibly be concluded, from the frequency of permanent urinary fistulas following nephrotomy, that they are not of infrequent occurrence. Tuffier states that fistula followed nephrotomy in 45 per cent. of the cases collected, and we are forced to believe that the permanency of the fistula is caused by imperviousness of the ureter either from valve formation or from stricture. How often this is caused by a stone lodged in the canal, and how often by a stricture without stone, we will not know until the ureter has been investigated by probing from above in a large number of nephrotomies. From the statistics collected by Tuffier, which show that nephrotomy for calculous pyelitis was followed by 34 per cent. of fistulas in 114 cases, and that nephrotomy for non-calculous pyelitis was followed by 57 per cent. of fistulas, we cannot draw any certain conclusions as to the frequency of stricture in non-calculous pyelitis as compared with the frequency of stones in the ureter; but it is likely that strictures are common.

As to the frequency with which strictures occur in different parts of the ureter, we have a statement from Tuffier to the effect that in 29 instances of congenital hydronephrosis a stricture was found in the upper end in 15 cases and at the lower end in 14. In Sollier's case of traumatic stricture it was located in the middle portion of the ureter.

It is probable that only strictures situated in the upper abdominal portion of the ureter are accessible for operative interference. Such strictures have been dealt with by dilatation or operation.

Dilatation by bougies from above has been reported by Alsberg.

Alsberg's Case.—Lumbar nephrotomy in a case of left hydronephrosis. For ten days all urine passed through fistula, from which it was concluded that the other kidney was defective in function. Ureter successfully dilated from the wound by thin bougies. After several days urine passed through bladder. Some months later the fistula closed. The hydronephrosis did not reappear.

Dilatation from below has been practised by Kelly, who found in a case of pyuria from gonococcus infection the region about the left ureteral orifice puffy, red, and edematous, and also a stenosis in the vesical portion of the ureter, through which he finally succeeded in passing the catheter, whereupon 160 c.c. of purulent urine escaped.

Only 4 operations have as yet been performed for stricture—namely, 1 by Küster and 3 by Fenger,—and the successful results were reached in each case by a different method. All were strictures in the upper part of the ureter near the pelvis of the kidney. The methods employed were longitudinal ureterotomy through the stricture and transverse union (Fenger, 2 cases), resection of ureter and implantation of the distal end into the pelvis (Küster), and longitudinal ureterotomy, excision of stricture from within, and transverse union (Fenger).

Longitudinal Incision (Fenger).—When the stricture is not too extensive, it is divided longitudinally after opening the ureter above or below. The upper and lower ends of the longitudinal wound are then brought together by folding the ureter upon itself. The remainder of the wound is united by sutures through the outer and middle coats, thus transforming the longitudinal into a transverse wound.

CASE 1 (Fenger).—A farmer forty-seven years of age. At the age of thirteen, in jumping from a horse to the ground, he sustained a violent jerk on account of miscalculation of distance, his feet not having touched the ground, while his hands still retained hold of the hames. This injury was followed by sharp, constant pain in the left side, which obliged him to remain in bed for a month. He had no special inconvenience until ten years later, when, after overexertion, he had an attack of sharp pain in the left side; at this time he was in bed about a week. One year later he had a third attack, which was attended by pain and soreness and obstinate constipation. For the next ten or fifteen years he had four or five attacks a year, lasting from two to three days. The last attack occurred October 22, 1892.

The patient was well nourished. In the left hypochondrium could be found a tumor, immovable, hard, and not nodular, which extended 5 cm. below the ribs and to within 8 cm. of the umbilicus. The urine contains a little pus. Diagnosis: Nephrolithiasis in the infundibulum or pyonephrosis from stone or obstruction in the ureter.

November 26th: For the past week there has been more pus in the urine, indicating that the contents of the pyonephrosis have been evacuated through the ureter. Examination in narcosis showed that the tumor had disappeared. The patient was anesthetized with ether, and placed on the right side with a pillow under the loin. An incision was made from the angle of the twelfth rib, 15 cm. downward and forward, to within 2 cm. above and anterior to the crest of the ilium. The adipose capsule of the kidney was so adherent that when it was removed the fibrous capsule was stripped off also. The exposed surface of the kidney was not shining, but was red, velvety, and nodulated, each nodule forming a flat prominence about 2 cm. in diameter. Each prominence was compressible and resembled a dilated calyx. The kidney was of normal size. After excision of a piece of the kidney substance for microscopic examination the dilated cavity of pelvis and calices was opened, and a jet of urine tinged with pus came out over the wound.

Digital exploration revealed that the globular protuberances were dilated calices which communicated with the pelvis, forming a common cavity. A reasonable amount of kidney substance appeared to be present, especially in the lower part. The wall of the pelvis was smooth, and there was no stone or gravel. The entrance to the ureter could not be found. The kidney was therefore lifted up over the border of the twelfth rib. A longitudinal incision 2 cm. long was made in the exposed pelvis and the edges held apart with retractors. No ureteral entrance could be seen or felt.

The external wound was now prolonged downward for 4 cm. to within 2 cm. of the anterior superior spine of the ilium. The ureter could now be seen as a string or band, not dilated. Its upper end was embedded for 1 cm. in cicatricial tissue. A longitudinal incision 1 cm. long was made in the ureter, about 2 cm. below the pelvic opening. A metal probe introduced into the ureter through this incision passed easily into the bladder. In passing it upward, however, a stricture was found just below the point of entrance of the ureter into the pelvis. The ureter was adherent to the surrounding adipose tissue at this point. The adhesions were separated by the handle of the scalpel and the stricture opened by a longitudinal incision on the probe as a guide. The opened stricture was seen to be 1 cm. long. In the remainder of the ureter a diffuse atrophic narrowing had occurred.

The patency of the ureter was reëstablished by uniting the wall of the ureter below the stricture to the pelvic wall, leaving the stricture as a loop (Fig. 151).

The upper part of the wound in the pelvis was closed by sutures. No bougie was left in the ureter. The wound was drained by a large tube passed into the wound in the kidney, 7 cm. upward, to the upper corner of the kidney. A smaller drain was passed down to the pelvis and ureter. Gauze strips were packed around the anterior and posterior surfaces of the kidney and 7 cm. down along the ureter. The divided muscles of the abdominal wall were then united, with the exception of the lower 7 cm., which were packed with gauze. The external wound was united by sutures and dressed in the usual way. The operation occupied two hours. The patient was weak at its close. The next day he passed naturally urine containing no blood. The pain decreased and the amount of urine in the dressings became progressively less. November 29th to 31st blood was

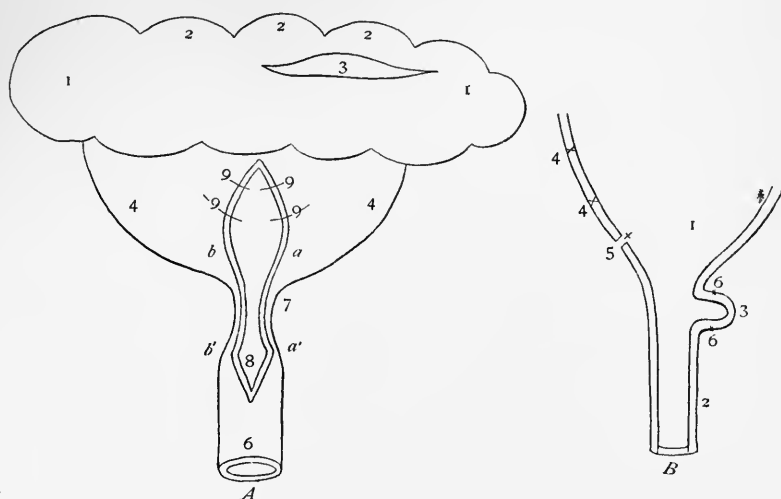


Fig. 151.—Illustrating operation for stricture of ureter.

A, Sacculated kidney, dilated pelvis, ureter with stricture at its upper end; 1, Kidney; 2, sacs corresponding to dilated calices; 3, nephrotomy; 4, dilated pelvis; 5, opening in posterior surface of pelviopelviotomy wound; 6, ureter below stricture; 7, stricture in upper end of ureter; 8, opening in ureter below stricture, extending up through the stricture into the pelvis; 9, sutures closing the upper half of the wound in the pelvis; *a*, *a'*, and *b*, *b'*, points of incision in ureter and pelvis to be united by sutures after folding the ureter upon itself at the place of stricture.

B, Pelvis and ureter after union by sutures: 1, Pelvis; 2, ureter; 3, fold of ureter at place of stricture; 4, sutures of wound in pelvis; 5, place of sutures between points *a*, *a'*, and *b*, *b'*; 6, 6, additional sutures, as many as needed to close borders of the fold formed by approximations of *a* to *a'* and *b* to *b'*.

found in the urine, which showed that the ureter was patent from the third day after the operation.

The wound was closed January 5, 1893. The patient was well and strong, suffered no pain, and could walk around all day. No tumor could be made out. Pressure in renal region was painless. The urine at this time was normal in quantity,—46 ounces,—and upon microscopic examination of the sediment only a few pus-cells could be seen. No trace of albumin could be found in the urine. The patient has gained flesh, and is much better than before the operation. Four years later he was accepted as a good risk by a life-insurance company.

CASE 2 (Fenger).—A man, twenty-one years of age. A year previous, in 1893, he had contracted gonorrhœa, which was followed by inflammation of the neck of the bladder. Three months later he had a sudden severe attack of right renal colic, which lasted seven hours. Examination of the urine at this time revealed marked hematuria and

pyuria. For four weeks he had recurrent attacks of renal colic, lasting from three to ten hours, every other day.

Under enforced rest and rigid diet the pus in the urine slightly decreased. On March 8, 1894, he had a severe attack of renal colic, which persisted for three days, and a large hard tumor could be felt on the right side.

Lumbar nephrotomy three days later. The lower two-thirds of the kidney was found to be dilated, and the large sac contained about two pints of urine and pus. The upper third of the kidney contained good secreting tissue. No calculi were found, no tuberculosis. The patient's condition did not warrant search for the ureter.

After the first eight days the right ureter was patent for ten days, as was proved by the presence in the bladder urine of pyoktanin, which had been injected into the fistula. The ureter then closed, and its patency could not be reestablished. Three weeks after the operation about 250 small, well-formed calculi about the size of No. 6 shot were passed through the fistula. The patient wore a silver urinal, and passed through the bladder about 30 ounces of urine in the twenty-four hours, and about the same through the fistula.

On September 17th operation for relieving occlusion of the ureter. The granulation tissue around the fistulous opening was removed with the sharp spoon. A lumbar incision was made through the fistula downward and forward and the kidney laid bare. The incision was prolonged downward 5 cm. The surface of the kidney was normal in color, the kidney enlarged and lobulated. The adhesions were slight and were easily broken up. The pelvis was found to be dilated. Search for the ureter was now made, and it was recognized below its pelvic origin, and exposed for about 4 cm. from the pelvis. An aspirator needle was introduced into the dilated pelvis of the kidney, and thin, bloody fluid withdrawn. The pelvis was now opened on its posterior surface. A futile attempt was made to locate the pelvic orifice of the ureter from the pelvis. A small depression, however, was noticed, which indicated the point of entrance.

A longitudinal incision was now made in the ureter, about 2 cm. from the pelvis, below the stricture; a flexible sound introduced through this incision passed easily down into the bladder. The lower portion of the ureter was somewhat contracted from disuse. A fine silver probe was next introduced through the incision and passed upward; the location of the stricture was thus found to be at the point where the ureter emerges to form the pelvis. With considerable difficulty the probe could be pushed through the stricture into the pelvis. With the probe as a director a longitudinal incision was now made through the stenosed portion of the ureter between the two openings. The upper and lower borders of the wound were brought together by silk sutures, thus folding the ureter upon the pelvis. The small longitudinal opening in the ureter was left unsutured.

Before closing the wound in the pelvis an incision was made through the convex outer border of the kidney into the dilated calices, and the upper end of a flexible bougie, which had been previously passed down into the ureter through the opening in the pelvis, was passed up from the pelvis through the convex surface of the kidney and out of the lumbar wound, to remain twenty-four hours and then be removed. A piece of kidney tissue was also removed for examination.

The patient made a good recovery, but the fistula persisted.

At an operation seven months later the cause of the persistent fistula was found to be valve formation at the upper end of the lower branch of the ureter, which prevented the urine from the lower half of the kidney from passing down into the pelvis. The pelvic end of the ureter was open, and permitted free passage of the urine from the upper half of the kidney into the bladder, thus demonstrating that the previous operation for stenosis of the ureter at its pelvic orifice had been effective.

Resection of the ureter and implantation of the distal end into the pelvis were done by Küster in the following case:

The patient was a boy eleven years of age, who had had a lumbar nephrotomy six months previous for open left hydronephrosis. The operation was followed by vesical anuria and permanent fistula. On May 25, 1891, the boy was seen by Küster. Two months later Küster reestablished the patency of the ureter by the following operation: A lumbar extraperitoneal incision was first made into the sac, but the ureter could not be found. The lower end of the sac—the dilated pelvis—was then incised, on the upper border of which was seen a layer of kidney substance the thickness of a thumb. The ureter could now be seen running several centimeters in or upon the posterior wall of the sac, and terminating in a slit in the pelvis. On attempting to introduce a fine probe into the ureter a stricture was encountered 2 cm. below the pelvis.

As a cure seemed impossible without removing the stricture, the ureter was transversely divided below the stricture and at the entrance to the sac. The ureter was now united to the pelvis by dividing the upper end of the ureter longitudinally, unfolding the divided end, suturing it to the opening into the sac, and closing the remainder of the wound in the pelvis by catgut sutures (Figs. 152, 153).



Fig. 152.—Küster's operation for implantation of the ureter into the sac (pelvis): *a*, Upper end of *a*; *b*, ureter running in the wall of the sac; *a, c*, slit in upper end of ureter.

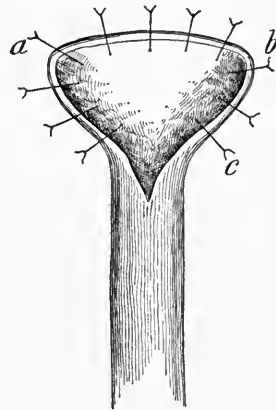


Fig. 153.—The divided end of the ureter unfolded, and in the extent of *a, b, c*, sutured to the wall of the sac (Küster).

The next day some bloody urine escaped into the bladder, but ordinarily the urine passed out through the lumbar fistula. From this time more and more urine passed into the bladder, until, four months after the operation, as much as 100 c.c. passed in the twenty-four hours.

Four months later the fistula was closed by curetting, dilating, and closing the canal by tier sutures. In the first twenty-four hours after this operation the patient passed 1300 c.c. of bloody urine from the bladder. He recovered, but with a lumbar hernia which had to be held in place with a bandage; the fistula remained closed. The boy was able to work and had excellent health. The urine contained a few pus-corpuseles and a small quantity of albumin.

Longitudinal Ureterotomy, Excision of Stricture from Within, and Transverse Union (Fenger).—A woman, thirty-two years of age. At the age of seventeen, after jumping from a wagon to the ground, she at once experienced pain in the right side, immediately under the ribs, so severe that she fainted. This was followed by intermittent attacks of pain in the right hypochondrium lasting from a few hours to several weeks.

After a miscarriage in 1893 the attacks increased. The patient was somewhat emaciated; abdominal examination revealed an obscurely defined tumor in the right side of the abdomen, close to the umbilicus, 10 cm. long and 7 cm. wide, which was dull upon percussion. The tumor was readily movable to the median line and backward to the normal position of the kidney, but attempts to move the tumor caused considerable pain. The urine contained neither albumin nor sugar. During the attacks of pain she urinated frequently, but passed only small quantities of urine.



Fig. 154.—Line of incision when wound was nearly healed.

Cystonephrosis of right movable kidney, probably due to stone in kidney or pelvis, and probably infected, was diagnosed, and exploratory incision for drainage and possible removal of stones advised.

On August 6, 1895, a lumbar incision was made (Fig. 154). The kidney was large, with but little perirenal fat, and was freely movable. After isolation of the dilated pelvis, in which no stones could be felt, the ureter was laid bare, whereupon a nodular mass was felt 5 cm. below the pelvis. The pelvis was then incised longitudinally and about an ounce of urine escaped. Upon manipulation of the ureter four stones were squeezed up into the pelvis and removed through the wound. A sound passed down from the pelvis into the ureter was arrested 6 cm. below the pelvis, at a point where a somewhat soft thickening was felt on palpation. A longitudinal incision 1 cm. long was now made into the ureter, through and below a transverse valvular stricture (Fig. 155). A probe inserted through the opening in the ureter below the stricture passed easily down into the bladder. By holding the longitudinal wound open and stretching this part of the ureter over the index-finger the valvular stricture was excised from within the ureter with scissors, leaving the muscular and external coats of the ureter intact. A plastic operation on the ureter was now performed—namely, longitudinal division of the stricture and transverse union of the longitudinal wound. (See Fig. 156.)



Fig. 155.—Circular valve in the ureter (natural size).

This method of operating for ureteral stricture is preferable to resection of the strictured part of the ureter (Küster's operation), for the following reason: It is a more eco-

nomie operation, and preferable when elongation of the ureter is not sufficient to permit the two cut ends of the ureter, after excision of the stricture, not only to come into contact, but even to permit of closure and invagination without stretching.

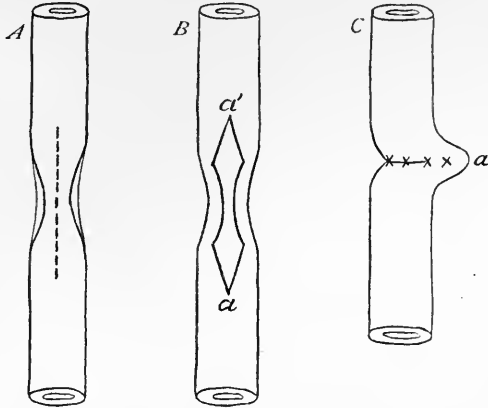


Fig. 156.—Fenger's plan of operating for ureteral stricture on extraperitoneal surface of ureter: (A) Ureter stricture and line of incision; (B) opening through the stricture extending into the proximal and distal portions of the ureter, the extreme ends of the incision *a* and *a'* to be united; (C) ureter after suturing; *a*, the bend at the site of the stricture.

A flexible bougie was passed from the wound in the pelvis into the ureter and left there. The wound in the pelvis was left open. The calices were moderately dilated, and in one of them a small stone was found and removed. Rubber drainage-tubes were in-

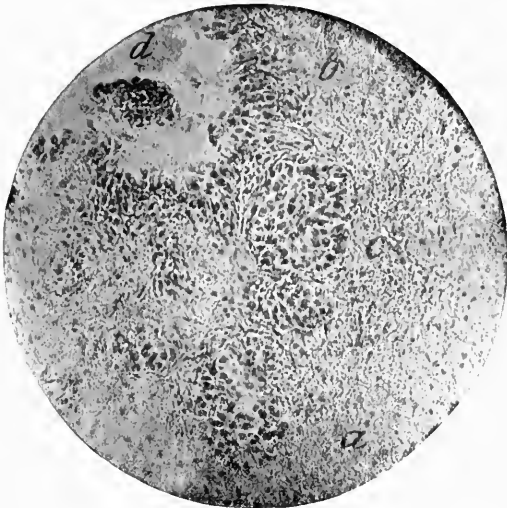


Fig. 157.—Microscopic section of valve: *a*, Firm fibrillary connective tissue, with normal distribution of vessels; *b*, stratified cylindric and cuboid epithelium, lining free border of valve; *c*, island of cuboid epithelial cells; *d*, lumen of ureter.

serted, one down to the wound in the ureter, and another to the pelvis of the kidney. These tubes were surrounded with gauze. The external wound was closed with heavy silk sutures.

Microscopic examination of the valve showed that it consisted of firm fibrillary connective tissue, with normal distribution of vessels, no muscular fibers of the wall extending into it (Fig. 157).

The free border of the valve looking into the lumen of the ureter was clad with stratified cylindric and cuboid epithelium. The border of the valve was folded, and thus a cross-section through the bottom of a fold showed an island of cuboid epithelial cells.

On the fourth day the gauze was almost dry, indicating that the urine had passed along the bougie through the ureter. On the sixth day the amount of urine passed was thirty ounces in twenty-four hours, and on the following day the bougie was removed from the ureter. Six weeks after the operation the fistula was closed and the patient left the hospital, and has since remained well.

Exploration of the ureter with the sound led to the detection of the stricture, a valve, which was excised through a longitudinal opening in the ureter at its seat. The author considers this operation preferable to excision of the entire wall of the ureter and invagination after Van Hook's method, as it is followed by the least possible shortening of the canal. This point may be of importance if more valvular strictures should have to be operated upon.

INFLAMMATION OF THE URETER

Ureteritis very rarely exists isolated, but almost always together with inflammations in the bladder or the pelvis of the kidney. It has the same causes as the inflammations of the bladder and the pelvis of the kidney—namely, as predisposing causes, arteriosclerosis, incomplete retention of urine in prostatic patients, and retention of urine in the ureter from obstructive causes in the small pelvis so common in women. The retention causes stagnation and gives the microbes time to develop, and the arteriosclerosis lowers the vitality of the epithelium, favoring infection. Congestion in the whole urinary tract by exposure to cold on the skin or paraplegia from diseases or injuries of the medulla may also cause retention and lower the vitality of the mucosa. Infection only rarely takes place as a metastasis from microbes in the circulation.

Infectious diseases and pyemia only exceptionally come into question as determining causes. Most often the microbes are brought in directly from without. In traumatism to the ureter and the kidney they may be brought in by an unclean catheter. In exceptional cases only an abscess in the small pelvis may communicate with the ureter or bladder and cause infection with pus-microbes or the colon bacillus. The stagnating urine behind a hypertrophied prostate or a stricture of the urethra is an excellent culture-soil for the microbes that invade from without. Gonorrhœa is followed by ascending infection in 2 to 3 per cent. of the cases only. Ascending infection following childbirth finds a ureter prepared by compression to receive infection from suppurating genitals and unclean catheters. Pelvic inflammations, pyosalpinx, or abscess of the broad ligament may also prepare the way, either by pressure on the ureter or by lymphangitis extending to the ureter wall (Hallé). The balsamic irritants cause transient aseptic inflammation only. The microbes that most commonly enter are the pus-microbes, the colon bacillus, and the gonococcus, the latter rarely alone, but usually preparing the way for one or several of the others. Albarran (cited by

Tuffier) found in 25 cases of pyelonephritis the colon bacillus alone in 16, streptococcus alone in 2, and mixed infection in 7 cases—namely, streptococcus, colon bacillus, micrococci, and other bacilli. The microbes from the bladder may ascend into the ureter from reflux of the urine

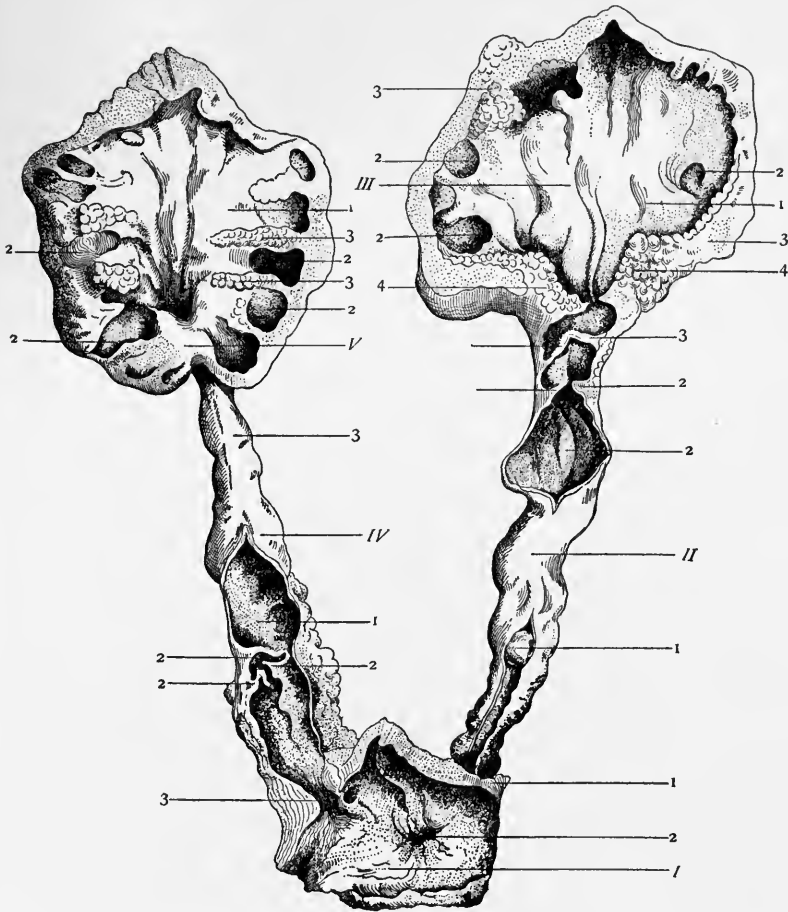


Fig. 153.—Double ureteropyelonephritis, with stricture and dilatation of the ureter (Musée Guyon, Specimens Nos. 158 and 159).

I, Part of the opened bladder: 1, Hypertrophic vesical wall; 2, vesical opening of left dilated ureter; 3, vesical opening of right ureter.

II, Left ureter opened and unfolded in its upper portion; split in its lower portion: 1, Stone arrested in lower third of canal; 2, lumen of dilated ureter, constricted by two valvular folds, 3, 3.

III, Left kidney opened on its convex border: 1, Cavity of dilated pelvis; 2, openings to dilated calices; 3, renal tissue; 4, fibrolipomatous deposits.

IV, Right ureter opened in its lower half: 1, Cavity of the canal; 2, imbricated valvular folds; 3, narrowed upper portion.

V, Right kidney opened on its convex border: 1, Cavity of pelvis; 2, calices; 3, fibrolipomatous septa.

during vesical contractions, from active locomotion of microbes or migration by diffusion, or antiperistaltic movements of the ureter.

Tuffier calls attention to the fact that in retention in the bladder with distention of the ureter the ureterovesical sphincter becomes insufficient,

facilitating regurgitation of infected urine from the bladder or diffusion of microbes up into the urine stagnating in a dilated ureter. Such urine, if it contains albumin, is an excellent culture-medium, especially where the vitality is lowered by arteriosclerosis or where painful cystitis causes frequent contractions of the bladder.

Infection through the circulation rarely attacks a ureter directly, but, having located in the kidney, from there secondarily may cause a descending infection of the ureter, which generally occupies the upper third of the canal only.

The inflamed ureter in acute cases, besides the usual signs of acute inflammation, may, according to Hallé, show multiple superficial ulcers in the mucosa. The deeper of these may result in consecutive stenosis.

The condition of the ureter presents two different aspects in the chronic forms. We distinguish between ureteritis with dilatation and ureteritis without dilatation, but with considerable thickening of the wall. The vesical opening of the ureter seldom undergoes change, with the exception that it may be insufficient. In patients with hypertrophy of the prostate Tuffier has found sclerosis of the orifice.

Ureteritis with Dilatation.—The ureter is enlarged and elongated from the size of a finger to that of an intestine; a circumference of 10 cm. has been seen. It is not uniform in caliber, but is often irregularly nodulated, showing dilated portions between multiple, sometimes very narrow, strictures. Secondary phosphatic stones often form, and are arrested at the seat of the narrow strictures. The wall is thickened and hard at the place of the strictures, thinned and transparent in the dilated portions. The mucosa is red and thickened, rarely ulcerated, and liquid injected passes down with difficulty. The strictures are usually located in the upper, middle, and lower portions of the ureter, at the neck of the pelvis, and 7 or 8 cm. above the bladder. The strictures are formed by thickening of the muscularis and are clad with mucosa often devoid of epithelium.

Ureteritis Without Dilatation.—The ureter is not elongated; its caliber is diminished, so that it forms a thick, straight, hard cord, with a thick wall of sclerosed fibrous or fibrolipomatous tissue, due to the chronic peri-ureteritis. The hardened cord can sometimes be felt upon abdominal palpation. The lumen is either uniform, or presents here and there local retractions. These strictures consist of sclerotic connective tissue with no hypertrophy of the muscularis. The mucous membrane is usually deprived of its epithelium; hence the tendency to obliteration when the kidney is removed and no pus or urine passes down.

SYMPTOMS.—The symptoms are the same as those of pyelonephritis, and it is very difficult to differentiate the symptoms of disease of the ureter from the concomitant disease of the pelvis and kidney above. Pain may be felt along the course of the ureter, dull persistent pain below the kidney, tenderness on pressure by rectal, vaginal, or abdominal palpation. The urine is uniformly whitish, often acid, and may contain more pus than would occur from a cystitis alone. Upon standing in a glass or test-tube there is a sediment of pus at the bottom, above

which the urine is thin and milky. But this is characteristic of pyelitis rather than of isolated ureteritis.

Crises of renal retention of urine form a most valuable symptom in the cases of multiple valves or strictures in the ureter, and signify, as Hallé has pointed out, the characteristic symptoms for temporary occlusion of a valve. If the disease is unilateral, the pus disappears suddenly from the urine, which remains clear for three or four micturitions, or even for a day or two. Following the pain of the crisis, the distention may be felt by abdominal palpation either as a swelling of the corresponding kidney or of the ureter at the brim of the pelvis. He advises that the bladder be left undisturbed, if possible, during these attacks of fever and pain. The swollen ureter may be felt as a tender cord through the rectum or the vagina, extending upward, backward, and outward in the direction of the ureter, but may be difficult to distinguish from a pyosalpinx or a tuberculous vas deferens. Upon abdominal palpation a nodulated, tender cord may rarely be felt.

An acute ureteritis may disappear with the cystitis or pyelitis that caused it. Even chronic cases may improve temporarily after successful treatment of prostatic hypertrophy or strictures. Recovery may take place by obliteration of the ureter if either the kidney is removed or is also obliterated. This is especially apt to take place in ureteritis without dilatation, while a dilated, suppurating ureter after nephrectomy is apt to continue to discharge pus and eventually to require ureterectomy.

DIAGNOSIS.—Cystoscopy and catheterization of the ureter are of immense value in the diagnosis, and may be the only ways in which a positive diagnosis can be made, especially in cases where other symptoms, except the flow of pus from the ureteral opening, are absent.

TREATMENT may be either preventive or curative. We must treat the urethral strictures, the cystitis, the prostatic hypertrophy, to prevent or reduce the inflammation of the ureter. Antiseptic internal remedies, salol, borax, etc., may have some if only temporary effect. Double pyelitis in old prostatic patients cannot be helped by direct surgical procedures, which, on the other hand, may be most effective when the disease is unilateral (Hallé).

Local treatment by means of catheterizing the ureter and intra-ureteral injections is a most effective and rational procedure, and we owe to Kelly the introduction of this treatment, which in his hands has proved eminently successful.

In the case of a woman with pain in the right kidney Kelly passed a renal catheter into the pelvis of the right kidney, but nothing flowed, The catheter was left in position, and was afterward, as nothing escaped, connected with an aspirator bottle, and 280 c.c. of thick yellow pus withdrawn. In several other cases he had a similar experience.

Ureteral and renal pyuria are treated, according to Kelly, by the new method in three ways: (1) Evacuating the pus; (2) washing out the inflamed ureter and pelvis; (3) dilating the stricture or removing the calculus.

The treatment begins with the evacuation of the pus, which establishes

the diagnosis, and now the catheter can be left *in situ* for drainage or reintroduced at intervals of from one to three or four days. Kelly prefers not to leave it in permanently. For washing out the ureter and the pelvis of the kidney he prefers bichlorid of mercury, 1:10,000, or boric acid, one-half saturated solution. The latter can be used all the time; the bichlorid at shorter or longer intervals, as shown by the effect.

The washing out can be done in one of two ways: first, on the siphon plan, in a manner similar to that employed for siphoning out the stomach, by elevating and lowering the funnel connected with the catheter by a long rubber tube. This method is preferable when the dilatation, and consequently the quantity of pus, are considerable. Second, the fluid can be injected with a small one- or two-ounce syringe. When the pus is too thick to flow, the injection of a watery fluid thins it and permits it to escape. If the kidney can be handled, manipulation will help to mix the pus with the fluid. If this is not done, the injected fluid may return without bringing the pus with it. Suction by means of the syringe may start the flow by clearing the catheter of clots which obstruct its lumen. After evacuating large accumulations from the kidney Kelly never injects more than two-thirds to three-fourths the amount taken out, to avoid renal colic. He has cured 3 cases by this treatment, and states that the improvement takes place in the following order: (1) The amount of pus diminishes; (2) the pus becomes thinner and more mixed with urine as the kidney begins to secrete; (3) the pus becomes scanty, the dilatation of the kidney diminishes and finally disappears, and cure takes place.

Thorikild Rovsing describes, under the name of "pseudomembranous pyelitis," an inflammation of the ureter accompanying nephrolithiasis, characterized by the passage of pseudomembranous bodies of various sizes up to that of an olive-stone, grayish, like boiled meat, round or olive-shaped masses, arranged in concentric layers, and containing a nucleus of gravel of urates. The author believes them to be coagula deposited around gravel and changed by the action of microbes in this peculiar manner. The microbes found in the author's two cases and in one reported by Lennander were the colon bacillus. These round and oval masses are found in great numbers, and occasionally occlude the ureter and give rise to attacks of renal colic. One of the patients refused operation, but in the other case he did a nephrectomy on the dilated suppurating kidney. The ureter was irrigated from the lumbar wound, bringing down into the bladder a great deal of pus and the masses described above. The upper end of the ureter was then closed by a ligature. In the course of the following two months similar bodies and pus appeared in the urine, and finally a stone, $2\frac{1}{2}$ cm. long, $1\frac{1}{2}$ cm. broad, and 1 cm. thick, was found in the vesical end of the ureter, and removed by suprapubic cystotomy. Perfect recovery followed.

TUBERCULOSIS OF THE URETER

Tuberculosis of the ureter may be descending or ascending. The ureter may be either dilated or stenosed. In the dilated ureter local retractions alternating with dilatations may be found, and tuberculous ulcers on the mucosa in the dilated territories. The ureter is more commonly not dilated, but is the seat of diffuse tubercular infiltration of the entire wall, so that the ureter is felt as a hard solid or nodular cord. The tuberculous infiltration of the mucous membrane may produce caseous masses, which may encroach upon or fill the lumen.

The ureter may be primarily obliterated, and no pus will be found in the urine. If the ureter is permeable, the kidney is not enlarged; while if the ureter is stenosed or obliterated, tuberculous cystonephrosis is found.

Tuffier saw a case of tuberculosis of the spine, the tuberculous abscess from which was in contact with the ureter. In this place the tuberculosis invaded the ureter, causing an ascending tuberculous ureteritis which obliterated the canal and extended to the kidney. In another case of tuberculosis he observed on one side a ureteritis obliterans extending the whole length of the canal, with dilatation of the kidney of this side; on the other side there was a ureteritis with dilatation, alternating with stenosis and tuberculous ulcers.

Edward von Meyer reports a case from Czerny's clinic. The patient was a girl of eighteen with right pyonephrosis. Tubercle bacilli were not found, although she had a tuberculous history. She was kept a long while in the hospital in order to ascertain, if possible, the condition of the other kidney; this was obtained accidentally by the injection of Koch's tuberculin. The general reaction was not violent, but locally the sensation of pressure in the region of the right kidney increased. "In a few hours after the injection the patient passed perfectly clear urine free from pus, in considerable quantity, of normal specific gravity, and containing no albumin." This experiment was repeated several times, and always with the same result. The diagnosis was made of tuberculosis of the pelvis of the kidney and part of the ureter; the tuberculin injection caused swelling and occlusion of the ureter. Tubercle bacilli were now found in the urine, probably from "disintegration of the tubercles." Czerny performed nephrectomy and found a kidney with multiple cheesy abscesses, the ureter thickened and embedded in cicatricial masses, so that its removal down to the pelvis minor was necessary.

N. Tirard reports a case of tubercular growth of the ureter in a boy of five who died from general tuberculosis. In the left ureter a hard nodule was found at the junction of the upper and middle thirds. The ureter was dilated above and constricted below. Force was required to pass a probe through this nodule. On slitting the ureter open it was found to be studded with small tubercles, and at the place of the nodular swelling the wall was surrounded by a ragged mass which consisted of

a caseous surface on which urates were deposited. There was no tuberculosis outside of the ureter, either in the bladder or the kidney.

Howard Kelly reports the case of a woman of twenty-five who had chronic pyuria. The ureteral catheter showed clear urine from the right kidney. In the left ureter resistance was met some distance up, and no fluid passed after waiting ten minutes. He succeeded in manipulating the catheter through an obstruction, when a continuous stream of purulent alkaline urine containing tubercle bacilli were evacuated. Thus the diagnosis of tuberculosis of the left kidney and ureter was made, and the patient cured by nephro-ureterectomy.

TUMORS OF THE URETER

Tumors of the ureter are rare, and consequently little is known about them. No primary tumor of the ureter is on record. A tumor from the kidney or its pelvis may extend down into the ureter, which has been seen in villous tumor of the pelvis. It has also been observed that a primary tumor of the pelvis may be implanted at a distance in the ureter in the shape of multiple polypi.

Ribbert reports the case of a four-year-old girl operated upon by Oscar Witzel. The child had a tumor which filled the right half of the abdomen. No history. The tumor and the upper 2 cm. of the ureter were extirpated, but large retroperitoneal tumors had to be left, and the patient died six days later. The autopsy showed a large right cystonephrotic sac, on which the flattened kidney lay. The cyst was consequently the dilated pelvis, the wall of which was transformed into a layer of tumor tissue 3 cm. thick. On the inside of the sac, in addition to flat prominences in the thick portions, there were seen polypoid tumors, especially from the site of the kidney—one as large as the fist with a pedicle the size of a finger, a second tumor a little smaller, with a broader base, and a considerable number of small, thin-pediced polypi.

The right ureter, as shown at the autopsy and described by Ribbert, was enormously dilated, tortuous, and tense. The dilatation was caused by numerous polypi of different sizes originating from the mucous membrane. They occurred in groups in the somewhat thickened wall. They were from several millimeters to several centimeters long, and some were as "large as a catheter." The larger ones were thickened in the middle; the smaller ones had a thin pedicle, terminating in a club-shaped end. Some of the polypi had no free end, but were reattached at a place where a second group of polypi originated. Three long and slim polypi originated 2 cm. above the vesical orifice of the ureter. The total number of polypi, not counting the very small ones, was twenty-two. The polypi were soft and mostly gelatinous and transparent, grayish-white in the thicker portions, with here and there hemorrhagic spots. The vesical opening of the ureter was normal. Upon microscopic examination the tumors were found to be striocellular myosarcomata.

In Rayer's Atlas, Plate XI, Fig. iv, are shown a kidney and ureter.

In the ureter, 2 inches below the pelvis, is a polypus 1 cm. long and $\frac{1}{2}$ cm. in diameter; in the pelvis are seen seven polypi about the same size and five smaller ones. The polypi were soft, spongy, and yellowish red.

A primary tumor of the bladder may extend to the vesical portion of the ureter, causing stenosis, as is so often found in malignant tumors in this region. A tumor may invade the ureter from without when located somewhere in its course, as was seen in J. H. Taggart's case of sarcoma of the ureter. Retroperitoneal sarcoma had invaded the right ureter, after totally surrounding the ureter from the kidney to the brim of the pelvis. In this territory the sarcoma also entirely surrounded the aorta and vena cava, and invaded the latter with a sarcomatous thrombus. The whole lower part of the ureter was transformed into a large solid cord, the sarcoma having invaded the wall down to the bladder, into which the sarcomatous wall of the ureter projected as a polypoid tumor.

An especial position, not strictly speaking among the tumors, is occupied by the psorospermial cysts which may be found in the ureter alone or in the renal pelvis and bladder also. Harrison states that obstruction from psorospermial cysts or mucous cysts of the ureter is very common in rabbits, but exceptional in man.

Rayer, in his Atlas, Plate LII, has depicted two cases of what he terms "vesicular eruption" of the ureter, pelvis, and bladder, which undoubtedly are psorospermial cysts. They form multiple small, globular, transparent protuberances, with the mucosa stretched over them, from the size of a pin to that of a buckshot. They may cause dilatation and obstruction, as in J. Jackson Clarke's case of psorospermial cysts of the left kidney and ureter and of the bladder, with hydronephrosis of the left kidney: A woman about sixty was admitted to St. Mary's Hospital, where she died soon afterward from cerebral apoplexy. In the dilated pelvis of the left kidney and the upper half of the ureter numerous cysts were seen, of a greenish-brown color and of the size of a hempseed. There was moderate hydronephrosis. There were also numerous small cysts at the neck of the bladder and at the vesical orifice of the ureters. He found psorosperms in the cysts.

In F. S. Eve's case of psorospermial cysts of both ureters they were found together with hematuria, but there was probably no connection between them. The patient, a woman of fifty-one, complained of frequent micturition with hematuria. The urine later became alkaline and the patient anemic. Fever set in, and the patient died two weeks later. The ureters were the seat of the psorospermial cysts, some of which had ruptured and left round openings in the mucous membrane. The author did not know whether or not the psorospermial cysts were the cause of the hematuria.

FISTULAS OF THE URETER

Fistulas of the ureter are either traumatic or spontaneous. A traumatic fistula is caused either by a complete rupture or a transverse wound, when retraction of the ends of the ureter renders reestablishment of the canal impossible. A spontaneous fistula may result from a per-

foration caused by a stone, by tuberculosis, or by cancer, but spontaneous fistulas are comparatively rare.

Each fistula has two openings and a canal. The external opening is either cutaneous, when it is located on the skin either of the inguinal region or the anterior abdominal wall; or visceral, when it opens into the uterus, vagina, or intestinal tract.

The canal is usually shorter in the visceral and longer in the cutaneous fistulas, and is often tortuous, with thick, indurated walls.

The internal or ureteral opening is frequently surrounded by a small cavity close to the divided ureter or the opening in the ureter above the stone or stricture.

The characteristic symptom is the flow of urine. The urine is either normal or contains pus if pyelitis exists or if a peri-ureteral abscess cavity is present. The flow of urine is continuous if the fistula is located in the upper portion of the ureter, but may be intermittent if located in the lower third and if the opening is small (Tuffier). The urine may remain clear, and infection may not take place for a long time in the cutaneous fistulas, but if the ureter opens into an abscess or into the uterus, intestine, or vagina, infection will cause ascending ureteritis and nephritis, often accompanied by dilatation from stenosis in some part of the fistula. The stenosis and retention will cause intermittent attacks of fever and pain.

COURSE AND TERMINATION.—The fistula, unless caused by operation, is persistent throughout the patient's life. Often he may be in relatively good health for a long time, but ascending infection is always liable to supervene, and the flow of urine is a constant source of misery.

DIAGNOSIS.—In making a diagnosis it must be determined whether the urine comes from the renal pelvis or ureter. In pelvic and renal fistulas the urine is usually purulent, as it comes from a suppurating pelvis or kidney, while in ureteral fistulas the kidney is often healthy, and the urine therefore normal.

To distinguish a ureteral from a vesicovaginal or vesico-uterine fistula colored fluid may be injected into the bladder, or a sound may be passed through the fistula into the bladder, to be felt by a sound passed through the urethra.

TREATMENT.—It is difficult, and probably impossible, to cure ureteral fistula without operation. Possibly permanent catheterization of the ureter may be of advantage in a few cases, but as yet no cures have been recorded. Fistulas above the vesical portion of the ureter have, as a rule, been cured only by nephrectomy; and, although this operation has given fairly satisfactory results, we should always seriously consider the possibility of saving the kidney by an attempt to reestablish the continuity of the ureter, either by uretero-ureterostomy or by operation for the stenosis of the ureter below the fistula. Persistence of a ureteral fistula is always due to occlusion or stricture of the distal or vesical portion of the canal. Thus we should attempt to determine the cause of the impermeability and overcome it by dilatation or operation. Nephrectomy of a useful kidney should be the operation of last resort.

Fistulas in women in or near the vesical portion of the ureter—the uretero-uterine or ureterovaginal fistulas—have been treated by colpoceleisis or by implantation into the rectum, but should preferably be treated by implantation into the bladder.

The cure of the incontinence of urine caused by uretero-uterine and ureterovaginal fistulas is accomplished in four ways: (a) Plastic operations with a view to displace the fistula from the vagina or cervix into the bladder. (b) Colpoceleisis. (c) Implantation of the ureter into the bladder. (d) Nephrectomy, the operation of last resort.

(a) *Plastic Operations*.—Simon, through an artificial if not pre-existent vesicovaginal fistula, opened the proximal end of the ureter from the bladder, cauterized the divided borders until cicatrization had taken place, thus securing against reclosure, and finally closed the vesicovaginal fistula.

Landau passed a catheter into the ureter through a vesicovaginal fistula, bringing the distal end of the catheter out through the urethra, and by immediately closing the vesicovaginal fistula, invaginated the ureteral opening into the bladder.

Bandl employed a combination of the methods of Simon and Landau.

Schede inverted the ureteral opening into the bladder, together with a zone of the surrounding vaginal mucous membrane, with the intention of preventing subsequent cicatricial stenosis.

Pozzi employed with advantage a method of splitting similar to that devised by Gerdy for vesicovaginal fistula.

These plastic operations are often difficult in technic. Repeated attempts at closure have frequently to be made, and in some cases inflammation of the ureter and kidney has resulted. The operations on uretero-uterine and ureterocervical fistulas are especially difficult. The operations are taxing to the patience of the operator and patient, rather than dangerous to life. They have always been attempted before direct methods of obliteration were resorted to.

(b) *Colpoceleisis*, proposed by Vidal du Cassis and Simon, and first practised by Hahn, consists in closure of the vagina on the distal side of a vesicovaginal fistula, and possesses the disadvantage that the latter may contract, and that marital relations are made impossible excepting in cases wherein partial colpoceleisis, as devised by Kaltenbach, can be done.

(c) *Implantation of the ureter into the bladder* for ureterovaginal fistula was performed in 1893 by Novaro. In February, 1893, he operated successfully by the Paoli-Busachi method in the following case: The patient had had vaginal hysterectomy performed for carcinoma extending into the broad ligament; the operation was followed by ureterovaginal fistula. Two months later laparotomy in Trendelenburg's position was performed, the ureter dissected out from the vagina, divided for 1 cm., unfolded, and united by sutures to an incision in the bladder $1\frac{1}{2}$ cm. long, situated two finger-breadths above the normal point of insertion. Gauze drainage out through the abdominal wound. For several days the gauze was impregnated with urine, showing leakage

at the point of union. This was only temporary, however, and ten days after the operation the function of the urinary organs became normal and remained so.

(d) *Nephrectomy*, the operation of last resort, really means the abandonment of the struggle with the fistula. It has been necessitated in some instances by infection of the kidney, and, although not very fatal, as in 14 cases on record only 1 patient died, it is applicable only to cases where the other kidney is healthy.

The operative results, as collected by Nebe in 1890 and Iversen in 1892, were as follows: Of 14 uretero-uterine and ureterocervical fistulas, all following childbirth, 8 were operated upon—1 with hysterocleisis (Duclout); 1 colpocleisis (Hahn), both relatively successful. The remaining 6 cases (Zweifel, Credé, Fritsch, Netzel, Traub, and Iversen) were unsuccessful, and nephrectomy had to be done. It will thus be seen that direct displacement of the ureter into the bladder was not found applicable to this class of cases.

Of ureterovaginal fistulas, 32 cases were collected by Nebe, 5 by Iversen, 1 reported by Arie Geyl, 1 by Pozzi, and 1 by Hergott (cited by Pozzi)—a total of 40 cases, of which 10 were secondary to operations or pelvic abscesses, 28 followed childbirth, and in 2 cases the cause was unknown. Of these 40, 24 were operated upon as follows: Plastic invagination into the bladder through the vagina was successful in 10 cases (Bandl 2; Lannelongue, Geyl, Parvin, Schede, Solowjeff, Schauta, Pozzi, and Hergott); colpocleisis was performed in 5 cases (Gusserow 2, Kehrer, Schede, and Kaltenbach, partial); and nephrectomy in 5 cases (Schede, Gusserow, Czerny, Heilbrunn, and Fritsch). In the remaining 4 cases attempts at operating were abandoned.

In the 10 cases which did not follow childbirth 5 followed vaginal hysterectomy, 3 pelvic abscess, and 2 operation on vesicovaginal fistula. Two were cured by direct closure (Nicoladoni, Emmet); 3 by colpocleisis (Kaltenbach 2, Hempel); in 3 nephrectomy was performed (Stark, Böckel, Bardenheuer, whose patient died). The remaining 2 cases, both following pelvic abscess (Emmet), were not operated upon.

It will thus be seen that in 34 cases of ureteral fistula this condition was remedied by plastic operation in 11 cases, by colpocleisis in 7, hysterocleisis in 1, and nephrectomy in 15.

The perfect success of implantation of the ureter into the bladder in Novaro's case, as well as in cases of wounds of the lower end of the ureter, would seem to indicate that Paoli and Busachi may be right in proposing the application of this operation to uretero-uterine and ureterovaginal fistulas. If the operation is as safe and certain as the cases now on record indicate, and if the future function of the implanted ureter remains undisturbed, this method would seem to be superior to the older plastic operations through the vagina, which are difficult in technic, uncertain in results, and sometimes fail entirely.

Taking into consideration the fact that in almost all, if not in all, of the cases the kidney in question was healthy from the beginning, it seems

to be a reproach against our present methods of treatment that in 44 per cent. of the cases the kidney should have been sacrificed.

URETERECTOMY

Ureterectomy has been done for tuberculosis or suppuration of the ureter where there was retention or evacuation of infectious contents, either into the bladder or through a persistent lumbar fistula.

Ureterectomy is termed primary when the ureter is removed simultaneously with the kidney; secondary when, after nephrectomy, the removal of the ureter of the same side becomes necessary.

Both primary and secondary nephrectomy may be either total or partial, and the operation may be performed by either the transperitoneal or extraperitoneal method.

Primary total ureterectomy was twice performed by Kelly in 1895. Primary partial ureterectomy was performed in February, 1891, by Tuffier, who removed 4 cm. of the ureter with the kidney; by Kelly in March, 1893, for tuberculosis; by Postnikow in February, 1894, who termed the operation nephro-ureterectomy, and removed the kidney and the ureter down to 2 cm. above the bladder; and in 1896 by Elliot, who removed the kidney and the abdominal portion of the ureter.

Secondary ureterectomy is done when, after removal of the kidney, the fistula from the diseased ureter does not close or persistent discharge into the bladder takes place. Secondary total ureterectomy was first performed by Reynier, who did a nephrectomy in April, 1892, and an extirpation of the ureter seven months later. Secondary partial ureterectomy was made by Poncet, who extirpated a tubercular kidney in February, 1891, and about three years afterward extirpated 7 to 8 cm. of the ureter.

Primary Total Extraperitoneal Nephro-ureterectomy.—CASE 1.—Kelly reports a left nephro-ureterectomy for tuberculosis of kidney and ureter in a woman of twenty-three who had suffered from childhood from incontinence of urine. She had had intermittent pain in the bladder for six years, and pain in the left kidney and pyuria for a year. Cystoscopic examination and catheterization showed the right kidney to be normal; the bladder normal, except the left ureter, which was found to furnish the pus and to be stenosed, probably from tuberculosis. Kelly determined, therefore, to extirpate the kidney, together with the entire ureter, and eventually to resect the diseased portion of the bladder-wall around the ureteral opening. The kidney and ureter down to the bladder were removed by an extraperitoneal operation in December, 1895, in the following manner: An oblique lumbar incision was made from the vertical muscles of the back down to an inch above the symphysis pubis. The tuberculous kidney was enucleated after clamping and tying the renal vessels, but was left connected with the ureter during the dissection of the latter. This dissection was continued down to the pelvic brim, the ureter being freed with the fingers and pulled downward with the

attached kidney. The lumbar portion of the wound was closed over a gauze drain before the dissection of the pelvic portion of the ureter was made. Through the lower part of the incision the round ligament was exposed and the deep epigastric vessels divided between ligatures. The peritoneum was loosened from the external iliac vessels, and the ureter dissected out down to the base of the broad ligament. The uterine vessels were here ligated by passing sutures around them, and divided where they cross the ureter, so as to expose the latter, which could then be loosened up to its intravesical portion at a point 5 cm. below the vaginal vault. The contents of the ureter were squeezed up toward the kidney and the ureter clamped 2 cm. above the bladder, and a ligature put around it close to the latter. The ureter was divided close to the clamp, and the kidney, with its ureter, 23 cm. long, lifted out. The vesical end of the ureter was sterilized with crude carbolic acid and dropped to the pelvic floor, whence a gauze drain was brought out through the lower end of the wound. The patient made an uninterrupted recovery.

CASE 2.—Kelly performed a similar operation on a woman of thirty with tuberculosis of the right kidney and ureter, with remittent attacks of colic and retention. Vaginal examination showed the ureter as a hard, tender cord, 1 cm. in diameter. Cystoscopic examination showed that the left kidney and ureter were normal, the bladder normal with the exception of a red, mammillated area around the right ureteral orifice, from which purulent urine was taken with the ureteral catheter. No tubercle bacilli were found in the urine.

In 1895 an oblique incision 16 cm. long was made from the posterior vertical muscles to the outer border of the right rectus muscle. The kidney was loosened, found to be the seat of extensive tuberculosis in its middle portion, and removed after first clamping the renal vessels and ligating them separately. At this moment the renal vein slipped out of the forceps, but was speedily caught and a ligature put around it by means of a needle. The kidney, still connected with the ureter, was pulled out of the wound, thus making the ureter tense, while the peritoneum was stripped off with the fingers down to the common iliac artery. From here the ureter in the small pelvis was isolated by introducing the whole hand in the wound to strip off the peritoneum from the small pelvis and ureter down to the broad ligament. At this point the ureter broke off, and was caught by a forceps and isolated for 2 cm. more. The ureter was then ligated just behind the broad ligament and cut off above the ligature. The lower portion of the ureter was caught through an incision in the vaginal vault and drawn down into the vagina, and held there while the abdominal wound was closed with a gauze drain inserted in its middle. The patient was then placed in the lithotomy position, and the lower end of the ureter extirpated through the vagina. During this dissection the friable ureter broke off twice, but was caught again, and finally cut off close to its entrance into the bladder-wall. The vaginal wound was left open and packed with iodoform gauze. Recovery was uneventful.

Primary Partial Extraperitoneal Ureterectomy.—Tuffier reports the case of a married woman, thirty years of age, who had suffered for six years from symptoms of right pyelitis with intermittent cystonephrosis. The left kidney was healthy. On February 22, 1891, he operated immediately after one of the periodic evacuations. Through a lumbar incision he came down upon the dilated kidney half full of liquid. In attempting to make a subcapsular nephrectomy, the thin-walled sac was ruptured and discharged its purulent contents; it consequently became necessary to remove the capsule with the kidney. During the isolation of the sac he exposed the abdominal portion of the ureter. This was the size of a pen-holder, and presented a sigmoid bend 4 cm. below the hilus of the kidney. When pressure was made upon the sac before rupture, the fluid would pass down and distend the ureter as far as the lower curve of the bend. Upon increased pressure the bend would straighten and the fluid would pass through. This manipulation demonstrated the cause of the intermittence of the cystonephrosis. The isolation was difficult because the partially filled, thin-walled sac was adherent to its surroundings. After isolation down to the ureter the pedicle was clamped with a curved forceps and the sac cut off. He thus gained space to ligate the vessels. The ureter was then ligated immediately below the sigmoid bend, and the upper portion removed.

The operation, which had lasted for an hour, was followed by considerable shock and complete anuria for more than twenty-four hours. The patient recovered without fistula, and regained her health with the exception of a slight cystitis.

Transperitoneal Primary Partial Nephro-ureterectomy.—On March 30, 1893, Kelly performed this operation for tuberculosis of the left kidney and ureter. The patient, who had been a stout and healthy girl, had become worn out and emaciated from tuberculosis of the left kidney and ureter, which caused frequent and extremely painful spasms of the bladder. Vaginal examination showed a thickening of the left ureter, which was felt as a tender, nodular cord, 1 cm. in diameter, and could be palpated up to the brim of the pelvis, and above this point could be traced by abdominal palpation as a well-marked line of tenderness. Catheterization of the ureters showed that the right ureter and kidney were normal. The catheter in the left ureter passed through a stricture, whereupon 90 c.c. of purulent alkaline urine containing tubercle bacilli were evacuated.

An incision was made through the left side of the abdomen parallel to the outer border of the rectus muscle. The viscera were displaced to the right, and the posterior peritoneum cut through on the outer side of the colon, which was drawn to the right to expose the ureter on the psoas muscle. The ureter was traced up to the cystic kidney, which was enucleated with difficulty on account of fibrous tissue which surrounded the hilus. After ligation of the vessels and removal of the kidney the large hard ureter was dissected from above downward to the pelvic brim. At about the middle of its course the ovarian vessels were tied. After freeing the ureter from the common iliac vessels its further detachment

became so difficult that it had to be tied and cut off 4 cm. below the pelvic brim on the floor of the pelvis. The abdominal portion and upper half of the pelvic portion of the ureter were thus removed. The mucosa of the ureter above the ligature was sterilized with the thermocautery and the wall sutured. From the bed of the ureter an opening was made outward through the lumbar region for drainage with a strip of gauze. The opening in the posterior peritoneum was not united, as the borders lay in apposition. The abdominal wound was closed without drainage. The lumbar drain was removed on the fifth day, and both wounds healed by primary union. The urine became clear, and the patient made an excellent recovery. About six weeks later Kelly attempted to remove the lower end of the ureter by a vaginal incision, but found it impossible, as it was surrounded by dense cicatricial tissue which bled profusely when incised. Three years later the patient was in excellent health, with but one of her old discomforts remaining—namely, frequency of micturition.

Primary Partial Transperitoneal Nephro-ureterectomy.—P. J. Postnikow, in a case of left hydronephrosis in a woman of fifty-five, on February 18, 1892, found by median laparotomy a dilated ureter connected with the hydronephrotic sac. The hydronephrotic kidney was opened, and stones found in the lower portion of the ureter. Thirteen stones were pushed up and removed through the wound, leaving a large one which could not be caught. The ureter was isolated down below the stone, and the kidney and ureter down to 2 cm. above the bladder removed. A lumbar opening was made, and a strip of iodoform gauze inserted down to the ligated lower end of the ureter, the peritoneum closed by sutures over the ureter, and the abdomen closed. The patient had severe shock and vomiting for four days. After this she improved rapidly, was out of bed in fourteen days, and two months afterward was in perfect health.

Primary Partial Extraperitoneal Nephro-ureterectomy.—J. W. Elliot reports the case of a woman of twenty-four who had a right nephrotomy in 1895 for suppuration. Wound closed in twenty-six days. On account of recurrent pain the wound was reopened and a urinary fistula remained. The amount of urea in the urine from the fistula was, on an average, 48 grains in twenty-four hours. On April 17th he removed the right kidney by extraperitoneal operation. The ureter was found to be dilated to the size "of a man's thumb"; the walls were thick and rigid. This ureteritis, with dilatation, extended to the brim of the pelvis. The ureter was extirpated down to this point, and the upper end of the pelvic portion closed by inversion and sutures. The specimen showed "ureteropyelonephritis; this was probably caused by a stone which had disappeared." The wound healed without fistula, and seven months later the patient was in perfect health.

Secondary Total Extraperitoneal Ureterectomy.—Paul Reynier had a patient, a man with pyonephrosis following typhoid fever. Lumbar incision April 27, 1892, revealed the "kidney transformed into a purulent cyst" and the ureter dilated to size of intestine. The kidney was extirpated, and the ureter sutured to lower angle of wound. Suppuration in

the dilated ureter continued, so as to cause a flow of pus partly through the lumbar fistula and partly through the ureter into the bladder, as seen by the cystoscope. The suppuration continued in spite of irrigation of ureter from the lumbar wound. Two or three months later a second operation was performed, consisting of dilatation of the lumbar wound and isolation of the ureter up to the "superior strait of the pelvis." The ureter was pulled out as far as possible and a ligature applied, and the ureter divided low down. During this manœuver the ureter ruptured and retracted into the small pelvis, and the operator was unable to find it. Thinking the ureter had been ruptured close to the bladder, he did a third operation eight days later, and tried to find it through a pararectal incision, as devised by Roux for extirpation of the seminal vesicles, but was unsuccessful, as two months later pus was still seen to enter the bladder through the ureteral orifice. A fourth operation was done for the total extirpation of the lower end of the ureter on November 14th, as follows:

The bladder was distended with boric-acid solution; Peterson's balloon inserted in the rectum; an extraperitoneal incision was made above and parallel to Poupart's ligament; the peritoneum was loosened from the iliac fossa, and blunt dissection made along the vas deferens until the iliac vessels were exposed, on top of which the ureter was found adherent to the peritoneum, its upper end obliterated, enlarged to the size of an intestine until just above the bladder, where the caliber became normal. The length of the dilated portion of the ureter was 12 cm. After having isolated it and scraped the mucous membrane with the sharp curet in its intravesical portion, he applied a ligature close to the bladder and extirpated the ureter above. The patient made a speedy and lasting recovery.

The author believes this to be the first total extirpation of the ureter, and concludes that in a certain number of cases it is not sufficient merely to remove the kidney and leave a dilated suppurating ureter, as persistent fistulas have been seen to follow nephrectomy, most commonly in tuberculosis, but also in non-tuberculous cases. He attributes the complaints of pain in the side so often stated to follow nephrectomy to the leaving of the ureter. In the author's case these pains persisted until the whole of the ureter was removed, and in cases of this kind a subsequent total ureterectomy is the only means of effecting a cure.

As to the method of operating, the author lays stress upon the inguinal incision and the route along the vas deferens as a guide to find the lower portion of the ureter in the small pelvis, either at the superior strait or lower down, where the vas deferens crosses the vessels. Peterson's balloon in the rectum will push up the bladder and make the vesical portion easier of access. This incision gives better access than the iliac incision of Twynam, and, being extraperitoneal, is preferable to the pararectal route, which does not give free access to the ureter.

Secondary Partial Extraperitoneal Ureterectomy.—Poncet reports the case of a woman of twenty-eight with tuberculosis of right kidney and ureter. On November 5, 1890, right nephrotomy was performed.

On February 28, 1891, the right kidney was extirpated. The patient was well, with the exception of a small fistula, for two years. Then she had pain in the course of the ureter and frequent micturition. In April, 1893, deep curetment of the fistula was done. On October 18, 1893, on account of the persistence of the fistula and pyuria, ureterectomy was performed. An incision was made from the fistula toward the anterior superior spine of the ilium, $1\frac{1}{2}$ cm. from it, and prolonged 5 or 6 cm. below. After division of the wall the peritoneum was pushed aside. Small openings were twice made in the peritoneum and sutured. When the iliac vessels were reached, two small lymph-glands, which were at first mistaken for the ureter, were removed. It was difficult to find the ureter, and the peritoneum was opened repeatedly. Finally, the ureter was found as a hard cord in the peritoneum which had been pushed aside. The ureter was now isolated upward and downward with great difficulty on account of adhesions. When the neighborhood of the bladder was reached, the ureter was caught by a hemostatic forceps, cut off above, isolated upward, removing a cord 7 or 8 cm. in length. It was obliterated in the upper portion for 1 cm. The large opening into the peritoneum was drained with iodoform gauze. The wound healed and the patient recovered after a catheterization cystitis. (This operation was probably not a total extirpation of the ureter, as the portion removed was only 7 to 8 cm. in length, and was probably not removed below the posterior surface of the broad ligament.)

Tuffier has studied the remote results of nephrectomy. A permanent fistula following nephrectomy is a rare complication. In 12 cases of Tuffier's there was no fistula, and in 73 operations collected from the literature there were 25 per cent. of definite fistulas, but it was not stated whether the operation was performed for tuberculosis or renal calculus. In reality, however, there is often prolonged, although not abundant, suppuration. Thus, suppuration continued in one of Tuffier's patients for ten months after lumbar nephrectomy. In 7 per cent. of the cases he has found temporary fistulas. The cause of the fistula is either perirenal sclerosis or ureteritis. The perirenal sclerosis forms a septic cavity with unyielding walls, like an empyema. Such a patient is operated on too late. The ureteritis should be treated by scraping the wall (?). It is only the ureteritis with dilatation—that is, with retention of pus—that is capable of causing a fistula, but even in this case, if there is sufficient drainage into the bladder, a cure may take place, but the suppuration goes on, and pus enters the bladder all the time.

If it is desired to extirpate the entire ureter with the kidney, Tuffier proposes the following procedure: Make a lumbar linear incision, commencing at the angle of the twelfth rib and the sacrolumbar muscle, down to the crest of the ilium, and then parallel to it, along it, and then down along Poupart's ligament to the upper orifice of the inguinal canal. Cut off the kidney, ligate the ureter, pull it out, and enucleate progressively from above down to the bladder. This is an exceptional operation, to be employed in cases of obliterations of the ureter only, and, as permanent fistulas are infrequent, it will be rarely indicated.

H. A. Kelly details the operation of nephro-ureterectomy as follows (see Figs. 159, 160, 161): Oblique lumbar incision from the sacrolumbar portion of the erector spinae downward and forward 2 cm. anterior to the anterior-superior spine of the ilium, and then obliquely downward to the terminal of the semilunar line, 2 cm. above the symphysis pubis. The perirenal fat is loosened from the kidney, and the latter brought out of the incision, drawing it down over the lower lip of the incision to expose the renal vessels, pelvis, and ureter. The kidney and pelvis are now examined to determine whether nephrectomy or a conservative operation is to be done. When tuberculosis is found, nephrectomy is done. The vessels are clamped by artery forceps 1 cm. from the kidney, after freeing them from the surrounding fat. The vessels are then ligated separately, if possible.

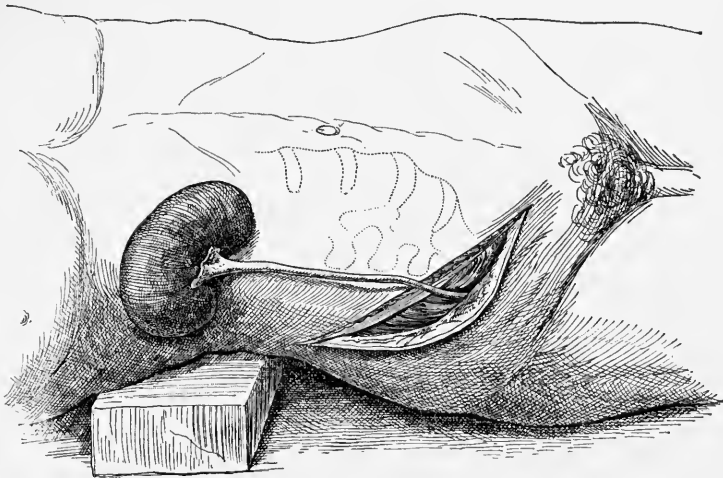


Fig. 159.—Extraperitoneal nephro-ureterectomy. Cadaver with kidney detached and entire ureter separated down to its vesical extremity through the incision shown in the cut, without opening the peritoneum at any point (Kelly).

If the ureter is found to be diseased, the kidney and entire ureter are now removed in the following manner: By pulling on the kidney and ureter the latter is made tense and dissected out from the surrounding loose connective tissue with the index- and middle fingers, pushing the colon and cecum to one side, and stripping off the loose connective tissue surrounding the ureter. This dissection is carried down to the brim of the pelvis, where the common iliac artery is felt. To free the ureter from this point down to the vaginal portion the entire hand is passed into the wound, at first between the peritoneum and the abdominal wall, then under the peritoneum of the pelvis major, and finally between the peritoneum and the walls of the pelvis minor. This blunt dissection is facilitated by pulling on the kidney and making the ureter tense. In this way the ureter is freed and followed to the broad ligament, where considerable resistance may be felt, and the ureter appears to pass

through an opening in the ligament, above which the pulsations of the uterine artery can be felt. At this point, about 6 cm. from the kidney, the abdominal end of the ureter is caught in forceps and held, and a stout silk ligature put around it and tied securely just behind the broad ligament. By pushing and working with the finger about 2 cm. more of the ureter is freed. The ureter is now cut off $\frac{1}{2}$ cm. above the ligature with a long pair of scissors introduced through the lumbar incision, guided by the hand introduced into the pelvis in the same way. Before cutting through the ureter the operator should take care to squeeze back its contents and keep the upper end tightly compressed until it is removed.

The next step is the removal of the lower end of the ureter. This is done either through a continuation of the original incision or through the

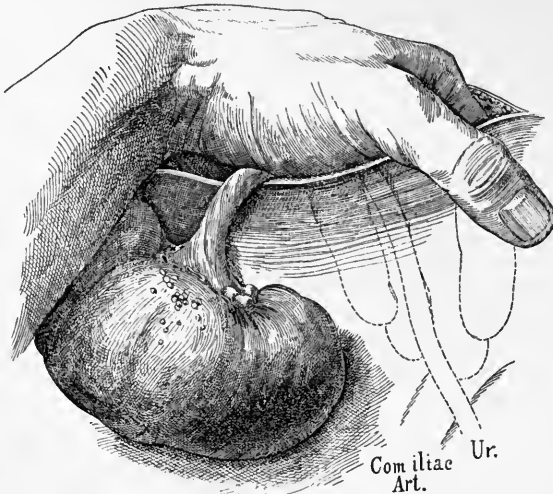

Fig. 160.—Renal vessels divided and ureter freed down to the brim of the pelvis. The object of this picture is to show the ease with which the entire abdominal portion of the ureter can be palpated through a horizontal incision, with only a part of the hand introduced (Kelly).

vagina. The vagina is thoroughly disinfected, and, with the patient lying on the opposite side, two fingers of the hand corresponding to the ureter to be removed are passed up to the vaginal vault, and the other hand introduced into the pelvis through the abdominal incision. The fingers of both hands can now be brought together with only vaginal tissue between them. An opening is made in the vaginal vault, the end of the ureter brought down into the vagina, clamped in a pair of forceps until the lumbar wound is closed, after which the vaginal end of the ureter is removed.

The steps in this operation are as follows: The opening in the vaginal vault is made by passing the entire hand through the lumbar wound down into the pelvis, and pressing the index- and middle fingers against the vaginal fornix, at the same time lifting up the uterine artery on the

index-finger so as to avoid the danger of cutting it. The end of the ureter lies between these fingers. The index- and middle fingers of the other hand are now introduced into the vagina and pressed up against the fingers of the hand in the abdomen, the palmar surfaces of both hands being turned upward. The opening in the vault necessary to draw the end of the ureter into the vagina is now made by an assistant, who introduces a pair of sharp-pointed scissors up to the vaginal vault along the fingers of the operator, and, guided by him, pushes the scissors through the thin septum. By spreading the blades of the scissors in withdrawing them the opening in the vault is enlarged to about 2 cm. This opening is located about 2 cm. to the side of the cervix. A pair of

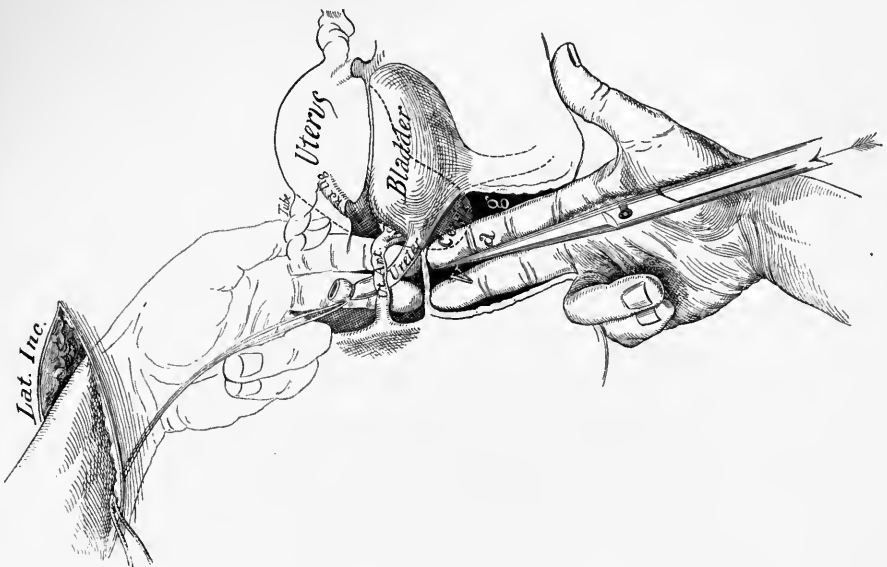


Fig. 161.—Opening the vaginal vault to bring the extremity of the right ureter through. The patient lies in the left semiprone posture, and the left hand is carried through the lumbar incision behind the peritoneum down to the right vaginal fornix; the uterine artery is held up on the index-finger. The right hand is introduced through the vagina to the vault. The assistant then pushes the scissors through the vault, guided by the operator (Kelly).

forceps is pushed through the opening to grasp the ligature attached to the ureter, and the ureter is drawn through into the vagina and held there during the closure of the lumbar incision. This is done in the usual manner, after thorough cleansing of the wound, by separate suturing of the muscles and fascia, and a gauze drain placed through the wound.

If the patient's condition permits, the last step in the operation—namely, the extirpation of the vesical end of the ureter—is now proceeded with. The patient is put in the lithotomy position, the end of the ureter and the opening in the vault exposed by retractors, and the corresponding side of the cervix caught by a bullet-forceps and drawn to the opposite side. By pulling on the forceps holding the ureter this is made tense,

while the operator cuts down through the vaginal vault, at first at the side between the anterior and lateral walls, and then, curving the incision forward under the base of the bladder, to a point $1\frac{1}{2}$ cm. from the vesical end of the ureter. The ureter should now be freed down to its vesical extremity, and here ligated and cut off. The wound in the vaginal vault is then closed by sutures, leaving space for a gauze drain, which is pushed up through the vault into the extensive connective-tissue space above, and left hanging down in the vagina.

That this operation is difficult it is needless to state. The wound is extensive; the freeing of the ureter in the pelvis minor has to be done guided by touch, and not aided by vision, and the ureter, especially when extensively diseased, is liable to break and cause trouble in finding the broken ends. In fact, the ureter broke off three times in one of Kelly's operations, and also in the operation of Reynier.

The three cases whose histories Kelly gives exhibit three different ways of removing the kidney with its ureter:

"First, transperitoneal—that is, through an incision through the abdominal wall opening the peritoneal cavity; this incision involves the necessity of a second incision through the peritoneum, covering the posterior abdominal and pelvic walls in order to get at the ureter.

"Second, retroperitoneal—the extirpation of the kidney and ureter through a long abdominal incision beginning in the loin, and extending downward and forward, and ending somewhere in the neighborhood of the symphysis pubis. By this method the peritoneum is detached from its cellular connection with the abdominal and pelvic walls, lifted up, and the ureter exposed without opening the peritoneal cavity.

"Third, retroperitoneal—by a short abdominal and a vaginal incision; by this procedure the kidney is detached and the ureter freed from all its connections through a short incision in the loin as far forward as the base of the broad ligament. The rest of the ureter is then pulled through an opening made in the vault of the vagina, and removed down to its vesical end by continuing the vaginal incision forward toward the neck of the bladder."

IMPLANTATION OF THE URETER

1. IMPLANTATION OF THE URETER INTO THE BLADDER.—When the upper end of the divided ureter is long enough to reach the bladder, implantation into this organ is preferable to all other procedures, as the danger of subsequent infection of the ureter and kidney is thereby avoided.

The experiments of Paoli and Busachi in 1888 upon dogs were successful. Their method consisted in splitting the distal end of the ureter and uniting it by sutures to an incision in the bladder.

The successful implantation of the ureter into the bladder by Novaro, Krug, Penrose, Baumm, and others leads us to believe it possible in these cases to save the kidney, which would otherwise be sacrificed.

The congenital abnormal opening of the end of the ureter outside of the bladder, in the urethra or the vagina, causing partial incontinence of urine, is naturally treated in the same way as ureterovaginal fistulas—by vaginal, suprapubic, or transperitoneal implantation into the bladder.

(a) *Extraperitoneal implantation of the ureter into the bladder* has been made by Baumm and Westermark.

Baumm's patient had a double ureter on the right side, one ending at the mouth of the urethra and causing partial incontinence of urine. Baumm performed a suprapubic operation, cut an opening through the bottom of the bladder, and connected it with the proximal end of the accessory ureter, the distal end of which was ligated. The author himself does not recommend this operation, which he chose because the patient was a virgin, as he considers it, under ordinary circumstances, unnecessarily severe. He considers the operation through the vagina preferable.

Westermark reports the case of a woman, forty-two years old, with carcinoma of the uterus, which he extirpated by the sacral method. The carcinoma had invaded the lower portion of the left ureter and the neighboring portion of the bladder. He then extirpated the lower end of the ureter and a portion of the bladder-wall 4 cm. in diameter. The wound in the bladder was united, and the ureter implanted in the corner of the bladder wound. Fine catgut sutures were applied through the muscularis of the bladder, not including the mucosa and the muscular layer of the wall of the ureter. By means of four such sutures the outer surface of the bladder-wall was folded over the ureter, making it pass obliquely into the bladder. Over this a new row of sutures was placed, folding in, over an additional piece of the ureter a little higher up, an additional layer of bladder-wall, on the principle of Witzel's operation for gastrostomy. The ureter healed without any leakage of urine. Six months later the patient was in perfect health.

(b) *Intraperitoneal Implantation of the Ureter into the Bladder.*—In February, 1893, Novaro operated successfully by the Paoli-Busachi method in a case of vaginal hysterectomy, followed by ureterovaginal fistula, which has been reported in the section on Fistulas.

In the two following cases of implantation into the bladder the operators acted upon Van Hook's suggestion of uretero-ureterostomy, and the effect of the operation in each case was complete, as undoubtedly no leakage of urine took place:

Krug reports the case of a colored woman, about thirty years of age, who had suffered from a fibroid for over six years. During most of this time she had been subjected to electric treatment. When he saw her on the morning of the operation he found her very much emaciated, with a poor pulse. The tumor filled the entire pelvis and extended above the umbilicus. On opening the abdomen universal adhesions were found. After having removed the greater part of the omentum, he commenced by tying off the tube and ovary on the left side. The next ligature was placed around the round ligament and the excess of broad ligament on that side. Although he expected to meet with some difficulty in shelling

out the tumor, which was entirely intraligamentous, and therefore paid particular attention to the ureter, he found that, in cutting off the round ligament, he had cut the left ureter in front of the tumor. The tumor had evidently grown intraligamentous, unfolding the two sheets of the broad ligament, lifting up the ureter, and the injury was done at a place where he felt absolutely secure. Putting clamp-forceps on the proximal and distal ends respectively, he finished the operation, which was an extremely difficult one. Finding then that he could reach the bladder without putting too much tension on the proximal end of the ureter, he decided to graft the ureter into the bladder. An incision being made into the bladder, the ureter was treated in a manner similar to that employed by Van Hook in invaginating the cut ends of the ureter. In sewing up the incision in the bladder care was taken to prevent leakage without constricting the lumen of the ureter. Several tiers of running sutures were made, and all available peritoneum used to build up a solid wall around the ureter. A permanent catheter was introduced into the bladder, which remained for four days. For two more days the patient was catheterized every four hours. A normal amount of urine was passed immediately after the operation. There was no rise of temperature nor any other untoward symptom. The patient left the hospital about four weeks after the operation; at last report she was doing hard work and feeling splendidly.

Penrose reports a case of a woman, forty years of age, with scirrhus carcinoma of the cervix uteri involving the left broad ligament and about 2 cm. of the ureter. He performed abdominal hysterectomy in July, 1893. The left ureter passed through a hard mass in the left broad ligament: 2 cm. of the ureter was excised, and the distal end ligated with silk. The peritoneum was sutured over the seat of operation, and the proximal end of the ureter implanted into the bladder, after Van Hook's method. The vagina was closed. The abdomen was closed without drainage. No disturbance of bladder or kidney followed. The patient left the hospital twenty days after the operation and made a good recovery.

In a case of vaginal hysterectomy for fibroma, followed by ureterovaginal fistula, Bazy performed laparotomy, and found the lower portion of the dilated ureter, which was buried and compressed in cicatricial tissue. The ureter was aspirated, loosened, and implanted into the bladder. The operator placed a permanent catheter in the bladder and one in the ureter for five days. Cystoscopic examination one month later showed the ureteral opening in the bladder to be patent, and that a preëxistent dilatation of the kidney had disappeared. Bazy termed this operation "ureterocystoneostomy."

The perfect success of the operation in these cases would seem to indicate that Paoli and Busachi may be right in proposing the application of this operation to uretero-uterine and ureterovaginal fistulas. If this operation is as safe and certain as the above cases indicate, and if the future function of the implanted ureter remains undisturbed, this method would seem to be superior to the older plastic operations through the

vagina, which are difficult in technic, uncertain in results, and sometimes fail entirely.

(c) *Vaginal implantation*, as probably the safest method, was chosen by Davenport in the following case: Woman, twenty-nine years. Incontinence of urine from early childhood, due to malposition of the ureter. Incontinence increased by menstruation and pregnancy. One ureter was found in the vesicovaginal septum, running forward, its orifice being close to the external orifice of the urethra. Operation for displacement of its orifice into the bladder; recovery.

2. **IMPLANTATION OF THE URETER INTO THE BOWEL.**—Implantation into the small intestine, colon, and rectum has been studied experimentally by Rosenberg, Novaro, Morestin, Tuffier, Gluck and Zellar, Harvey Reed, Van Hook, and others.

Morestin made experimental bilateral implantation of the ureter in the rectum on 10 dogs, all dying—6 from peritonitis and ascending renal infection, 2 from infection, and 2 from compression of the ureter. He also made unilateral implantation of the ureter in the rectum on 14 dogs, most of which died. He concludes that implantation of the ureter into the rectum is a grave operation, and that bilateral implantation is to be rejected.

Tuffier, in the discussion of Morestin's paper, stated that the absence of the ureteral sphincter facilitates ascending infection. If the vesical orifice of the ureter be implanted, it is better, but there is still liability to ascending infection.

Boari, after successful experiments on this point in dogs with a bobbin, refers to two cases in the human subject in which the method was successfully applied. The ureter is fastened around one end of the bobbin, which is then introduced into the bowel through a small longitudinal incision, which is afterward sewn up. In process of time union occurs and the bobbin is passed per anum. The drawings which illustrate the paper make the method easy to be understood.

In the first case (tuberculosis of the bladder) the button was passed per anum on the eighth day, and around its neck was seen the silk which had been fastened around its end to affix the ureter. The first urine was noticed sixteen to twenty-four hours after the operation, and henceforth, at intervals of two to three hours, about 200 to 300 c.c. In the second case (large vesicovaginal fistula with total destruction of the urethra) the button came away per anum on the twelfth day. In both cases Boari reports that the results were satisfactory.

The technical difficulties of implantation of the ureter into the bowel have been fairly well overcome, but there seems to be a serious objection to this plan of implantation on account of the liability to infection of the ureter and kidney by intestinal microbes, and also because of some tendency to constriction at the place of implantation. Van Hook found both these conditions present in dogs as early as ten days after the operation. Reed found acute nephritis in one dog killed twenty-four days after the operation, but in another similar case the kidney was apparently healthy.

In man the implantation suggested by Roux was tried unsuccessfully by Simon, but successfully, according to Rosenberg, by Chaput in two cases.

In a case of ureterovaginal fistula following vaginal extirpation of the uterus Chaput implanted the ureter into the colon. He performed laparotomy, divided the peritoneum on the posterior wall, isolated the ureter, divided it transversely, and fixed its renal end into the colon by a double row of step sutures. The vesical end of the ureter was ligated. The patient recovered and was well satisfied with her condition. She was obliged to void mixed urine and feces three or four times a day. Five months after the operation there were no signs of infection of the kidney.

Van Hook condemns the operation very strongly on account of the liability to infection, and he is undoubtedly right. The bowel, therefore, should never be chosen when it is possible to implant the ureter into the bladder. If this be impossible on account of defect in the ureter, it is still an open question whether or not implantation into the colon should be tried before resorting to implantation on the skin in the lumbar region or abdominal wall, or nephrectomy.

Maydl has proposed and executed an original and ingenious way of implanting both ureters with an island of the surrounding bladder-wall into the sigmoid flexure as a cure for exstrophy of the bladder. He thinks it possible that when the ureteral sphincter in the vesical wall is preserved, ascending infection may be avoided, and the results thus far obtained seem to justify his expectations.

He performed the operation in the case of a girl of twenty-two who had exstrophy of the bladder, with a double left and a single right ureter. He made an incision around the bladder so as to loosen it from the abdominal wall, beginning at the umbilical end, and at this point opening into the peritoneal cavity. He next excised from the lower portion of the bladder an oval island containing all three ureteral openings, the margin of the island being $1\frac{1}{2}$ cm. outside of the ureteral openings, care being taken not to open into the ureters. The ureters were now carefully dissected out after sounds had been introduced through the ureteral openings. The dissection was made guided partly by the sounds and partly by the fingers introduced into the peritoneal cavity from above. The island with the ureters was now freed from its surroundings, care being taken not to divide the vessels in connection with the ureters. The remainder of the bladder-wall was extirpated. The sigmoid flexure was then drawn out of the wound, emptied, compressed above and below, and a longitudinal incision made in its convex surface for implantation of the island with the ureters. This was accomplished first by a row of mucosa sutures, and this again covered by muscularis and serosa sutures. The bowel was then replaced in the abdomen and an iodoform gauze drain passed down to the place of implantation. The abdominal wall was united by step sutures down to the drain, and a permanent drainage-tube inserted in the rectum. The patient left the hospital in eighty-four days. One year later she was in excellent health; rectal micturition took place every six or eight hours. The patient was able to

do her work as a servant, and showed no symptoms of infection of the kidneys.

In another case, a girl of seven, there was rectal micturition only five or six times in the twenty-four hours.

Maydl has operated on 5 cases: 1 died in twelve hours, probably from protracted narcosis. He believes that the danger of infection is less in the sigmoid flexure than if implantation is made in the ileum, where the processes of decomposition are more active.

The contraindications for this operation are preëxisting nephritis or pyelitis.

3. IMPLANTATION OF ONE URETER INTO ITS FELLOW.—Monari divided the ureter close to the bladder in dogs, closed the vesical end with a silk suture, isolated the renal end sufficiently to permit it to pass through an incision in the mesentery of the sigmoid flexure, and united it with the ureter of the opposite side (Fig. 162). Union followed, and when the dog was killed four months later, a constriction was found at the place where the ureter passed through the opening in the mesentery, with consequent dilatation of the ureter above and of the pelvis, but at the place of anastomosis with the other ureter there was no narrowing of the lumen. He proposes to use this method on man in cases of abnormal exit of the ureter, in preference to implanting it in the bladder.

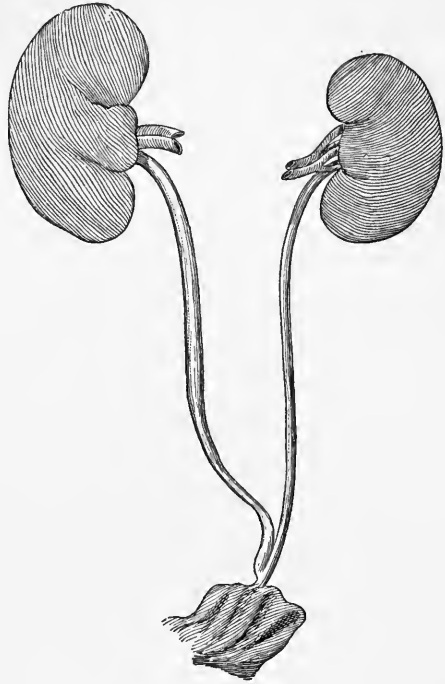


Fig. 162.—Monari's operation of implantation of one ureter into its fellow.

Implantation the bladder is probably preferable to the the method proposed by Monari, because it is easier of performance.

4. IMPLANTATION OF THE URETER ON THE SKIN.—Le Dentu was the first to implant the ureter on the skin for anuria in a case of absolute impermeability from cancer in the small pelvis. The symptoms were relieved, but the patient died thirteen days later from cancerous cachexia. This case, however, established the operation as an effective procedure, to be employed in combating anuria due to incurable mechanical causes, as it at least prolonged life.

Pozzi, in the removal of a retroperitoneal parovarian cyst by laparotomy, divided the ureter at about its middle. The upper end was dissected out for 4 or 6 cm., and implanted into the skin in the lumbar

region through a buttonhole opening. The distal portion of the ureter was sutured to the lower end of the abdominal wound. The patient recovered from the operation, and three months later nephrectomy was resorted to, which was followed by recovery. Microscopic examination of the kidney showed that it was healthy, with the exception of a few small islands of interstitial nephritis. No septic invasion had taken place, as no microorganisms were found. The integrity of the kidney in this case, after so long a period of exposure through the open ureter, is remarkable, and, according to Albarran, was due to the antiseptic precautions in the after-treatment. This case was one in which uretero-ureterostomy might have been performed with advantage.

Losses of substance of the ureter too extensive to permit of uretero-ureterostomy, or located too high up to permit of implantation of the upper end into the bladder, will require either implantation on the skin or into the bowel. As both of these methods are objectionable on account of the liability to infection sooner or later, and the consequent necessity of nephrectomy, operative procedures to effect a connection with the bladder have been proposed by Rydygier and Van Hook, based upon dissections on the cadaver.

Rydygier proposes to implant the two ends of the ureter on the abdominal wall, and by plastic operation to make a channel of skin between them to make good the loss of substance of the ureter.

Van Hook proposes, by plastic operation on the bladder, to create a diverticulum long enough to meet the upper end of the ureter.

In both of these methods it is proposed to place these newly formed channels in the abdominal wall. Theoretically, these methods appear feasible, but they have not as yet been practised on animals or on the human subject.

BIBLIOGRAPHY

- Albarran, G., and Lloria, H.: "Cathétérisme permanent des uretères," *Comptes rendus de la Société de Biologie*, 1891, vol. iii, p. 587.
- Allingham, Herbert W.: "A Case of Presumed Rupture of the Ureter from External Violence; Laparotomy; Cure," *Brit. Med. Jour.*, 1891, vol. i, p. 699.
- Alsberg: "Resection eines Harnleiters mit Krankenvorstellung. Discussion," *Verhandlungen der Deutschen Gesellschaft für Chirurgie*, XXI. Congres, 1892, p. 43.
- Baker, W. H.: "Malpositions of the Ureters," *New York Med. Jour.*, 1878, xxvi, p. 575. Bandl: *Wien. med. Wochenschr.*, 1877, vol. xxviii.
- Baum: "Operirter Fall von 3 Ureteren bei einem erwachsenen Mädchen," *Centralbl. f. Gynäkologie*, 1892, vol. xv, p. 336.
- Bazy: "De l'urctéro-cystonéostomie," *Annales des Mal. des Organes génito-urinaires*, 1893, vol. ii, p. 938.
- Berg, J.: *Hygeia*, 1889, vol. li, p. 144.
- Bloodgood, J. C.: "Anastomosis of the Right Ureter in a Dog," *Annals of Surgery*, 1894, vol. xix, p. 76.
- Boari, A.: "Manière facile et rapide d'aboucher les uretères sur l'intestin sans sutures A l'aide d'un bouton spécial," *Annales des Mal. des Organes génito-urinaires*, 1896, vol. xiv, p. 1.
- Bocchini: "Nuovo processo operativo del Prof. Novaro per la cura della fistola ureterovaginale," *Riforma Medica*, 1893.
- Bois (d'Aurillac): "Anomalie de l'uretère chez la femme," *Bull. et Mém. de la Société de Chirurgie de Paris*, 1893, vol. xix, p. 371.
- Bostrom: *Beiträge zur pathologischen Anatomie der Nieren*, Freiburg, 1884, vol. i.

- Bovee, J. Wesley: "Uretero-ureteral Anastomosis," *Annals of Surgery*, 1897, vol. xxii, p. 51.
- Braun, H.: "Über Nierenextirpation," *Deut. med. Wochenschr.*, 1881, vol. vii, p. 437.
- Brenner: "Katalog vom Instrumentenmacher Leiter," Vienna, 1887, p. 8.
- Brown, J.: "Catheterization of the Male Ureters," *Johns Hopkins Hosp. Bull.*, 1893, vol. iv, p. 73. "Catheterization of the Ureters in the Male," *ibid.*, 1895, vol. vi, p. 12.
- Cabot, A. T.: "Another Successful Case of Ureterolithotomy," *Boston Med. and Surg. Jour.*, 1890, vol. cxxiii, p. 613. "Observations upon the Anatomy and Surgery of the Ureter," *Amer. Jour. Med. Sci.*, 1892, vol. ciii, p. 43.
- Casper, L.: "Der Katheterismus der Ureteren," *Deut. med. Wochenschr.*, 1895, vol. xxi, p. 104.
- Ceci: *La Riforma Medica*, 1887, vol. liii.
- Chaput: "Fistule urétérovaginale guérie par l'abouchement de l'uretère dans le colon iliaque; Guérison," *Bull. et Mém. de la Société de Chirurgie de Paris*, 1893, vol. xix, p. 309.
- Clarke, J. Jackson: "A Case of Psorospermial Cysts of the Left Kidney and Ureter and of the Bladder, with Hydronephrosis of the Left Kidney," *Pathological Transactions*, 1892, vol. xliii, p. 94.
- Colzi, F.: "Contributo allo studio delle anomalie di degli ureteri," *Sperimentale*, 1895, vol. xlix, p. 37.
- Crampton, Sir P.: "A Case of Aneurysm of the External Iliac Artery in which a Ligature was Applied to the Common Iliac Artery," *Medico-Chirurgical Transactions*, 1830, vol. xvi, p. 162.
- Cullingworth, C. J.: "Impaction of a Large Calculus in Each Ureter Immediately Above the Vesical Orifice, Causing Dilatation of the Ureters and Abscesses in the Kidneys," *Pathological Transactions*, 1885, vol. xxxvi, p. 278.
- Czerny: Cited from H. Braun.
- Davenport, F. H.: "Incontinence of Urine Due to Malposition of the Ureter," *Boston Med. and Surg. Jour.*, 1890, vol. cxxiii, p. 420.
- Delbet: "D'une opération qui permet de découvrir la dernière portion de l'uretère," *Annales des Mal. des Organes génito-urinaires*, 1891, vol. I, p. 746.
- Ebermann: Cited by König-Maas, *Lehrbuch der Chirurgie*, 3. Auflage, Berlin, 1881.
- Elliot, J. W.: "Nephro-ureterectomy; Retroperitoneal Extirpation of a Kidney with its Ureter," *Boston Med. and Surg. Jour.*, 1897, vol. cxxxvi, p. 173.
- Emmet, B. McE.: "Injured Ureters in Abdominal Surgery," *Amer. Jour. of Obstetrics*, 1895, vol. xxxii, p. 449.
- Emmet, T. A.: Cited by Hunter, *Medical Record*, 1883, vol. xxiii, p. 386. *Principles and Practice of Gynecology*, 1884.
- Eve, F. S.: "A Case of Psorospermial Cysts of Both Ureters," *Pathological Transactions*, 1889, vol. xl, p. 444.
- Fenger, Christian: "An Operation for Valvular Stricture of the Ureter," *Amer. Jour. Med. Sci.*, 1896, vol. cvii, p. 667. "Conservative Operative Treatment of Sacculated Kidney—Cystonephrosis," *Annals of Surgery*, 1896, vol. xxiii, p. 637. "Demonstration of Specimens from Operations on the Kidney," *Chicago Medical Recorder*, 1893, vol. iv, p. 155. "Operations for the Relief of Valve Formation and Stricture of the Ureter in Hydronephrosis and Pyonephrosis," *Jour. Amer. Med. Assoc.*, 1894, vol. xviii, p. 335. "Surgery of the Ureter," *Annals of Surgery*, 1894, vol. xxii, p. 257.
- Gaither, A. B.: "Catheterization of the Ureters in the Male," *Jour. Cutaneous and Genito-urinary Diseases*, 1894, vol. xii, p. 491.
- Geyl, Arie: "Zur Therapie der Ureterfisteln," *Volkmann's Sammlung klinischer Vorträge*, No. 37 (*Gynäkologie*, No. 14), 1892, p. 311.
- Glantenay, L.: *Chirurgie de l'Uretère*, Paris, 1895.
- Glass: *Philosophical Transactions*, vol. xlv, cited by Rayer.
- Gluck: Cited from Nitze.
- Guyon: Cited by Albarran and Lloria. "Exploration urétérale," cited from Tuffier, "Appareil urinaire," p. 520.
- Hahn, E.: "Bericht über einzelne bemerkenswerthe Urinfisteln beim Weibe," *Berlin klin. Wochenschr.*, 1879, vol. xvii, p. 397.
- Hall, R. B.: "Report of a Case of Extirpation of a Calculus from the Ureter by the Combined Abdominal-lumbar Section," *Medical Record*, 1890, vol. xxxviii, p. 430.
- Hallé, N.: "Les maladies chirurgicales de l'uretère; son exploration," *Gaz. des Hôpitaux*, 1887, No. 112, p. 925. "Uréterites et pyérites," *Thèse de Paris*, 1887.
- Harrison, Reginald: "A Study on the Dead Subject Relative to Catheterism of the Ureters and Exploration of the Male Bladder," *Lancet*, 1884, vol. i, p. 198. "Diseases of the Kidneys and Ureters," *Twentieth Century Medicine*, vol. i, p. 193.

- Hegar: Cited by Sänger.
- Henle, J.: *Handbuch der Eingeweidlehre des Menschen*, Braunschweig, 1873, p. 335.
- Hyrtl: Cited from Henle's *Handbuch der systematischen Anatomie*.
- Iversen, A.: "Beitrag zur Katheterization der Ureteren bei dem Männe," *Centralbl. f. Chirurgie*, 1888, p. 281. "Über Ureterfisteln," *Nordiskt Medicinskt Arkiv*, 1892, vol. xxiv.
- Kaltenbach: Cited by Iversen, "Über Ureterfisteln."
- Keen, W. W.: "Five Cases of Suprapubic Cystotomy . . . one for Exploration, with Catheterism of the Ureters," *Medical News*, 1891, p. 431.
- Kelly, H. A.: "Catheterization of the Ureters," *Annals of Gynecology and Pediatrics*, 1893, vol. vi. p. 641. "Direct Examination of the Female Bladder with Elevated Pelvis. The Catheterization of the Ureters Under Direct Inspection With and Without Elevation of the Pelvis," *Amer. Jour. Obstetrics*, 1894, vol. xvii, p. 1. "Colpoureterotomy. Incision of the Ureter Through the Vagina for the Treatment of Ureteral Stricture," *Johns Hopkins Hosp. Bull.*, 1890-91, vol. ii, p. 235. "My Recent Ureteral Work," *Annals of Gynecology and Pediatrics*, 1893, vol. vii, p. 449. "Nephro-ureterectomy," *Johns Hopkins Hosp. Bull.*, 1896, vol. vii, p. 31. "Some Recent Important Advances in the Diagnosis and Treatment of Urinary Diseases in Women," *Pittsburgh Medical Review*, 1896, vol. x, p. 1. "The Ureteral Catheter," *Amer. Jour. Obstetrics*, 1892, vol. xxv, p. 768. "Ureteral Anastomosis; Uretero-ureterostomy," *Johns Hopkins Hosp. Bull.*, 1892, vol. iii.
- Kirkham, F. W.: "A Case of Suppression of Urine Treated by Removal of an Impacted Calculus from the Ureter by Operation," *Lancet*, 1889, vol. i, p. 525.
- Krakauer, A.: "Hydronephrosis," *Dissertation*, Berlin, 1881.
- Krug, Florian: Personal communication.
- Küster, Th.: "Ein Fall von Resection des Ureters," *Arch. f. klin. Chirurgie*, 1892, vol. xlv, p. 850.
- Landau, L.: "Ueber Entstehung, Erkenntniss und Behandlung der Harnleiterscheidenfisteln," *Arch. f. Gynäkologie*, 1876, vol. ix, p. 426. "Über intermittirende Hydronephrose," *Berlin. klin. Wochenschr.*, 1888, vol. xxv, p. 941.
- Lane, W. Arbuthnot: "Calculus Impacted in the Ureter for Twenty Years; Removal; Recovery," *Lancet*, 1890, vol. ii, p. 967.
- Le Dentu, A.: *Affections chirurgicales des Reins, des Uretères et des Capsules surrénales*, Paris, 1889. "Greffe de l'uretère entre les lèvres d'une incision du flanc, chez une femme atteinte d'anurie absolue," *Congrès français de Chirurgie*, 1889, p. 533.
- Lennander: "Om Njursten med två lyckligt opererade Fall," *Upsala-Läkareförenings Förhandlingar*, 1896, vol. ii, p. 56.
- Lohnstein: "Über die neueren Methoden der Urethroskopie," *Berlin. klin. Wochenschr.*, 1894, vol. xxxii, p. 1054.
- Luschka: *Die Anatomie des Menschen*, vol. ii, Tübingen, 1863.
- Mann, M. D.: "Inflammation of the Ureters in the Female," *Trans. Am. Gynec. Soc.*, 1894, vol. xvi, p. 224.
- Margarucci, O.: "Ricerche sulla circolazione propria de l'uretore," *Policlinico*, 1894, vol. xv, p. 321.
- Maydl: "Neue Beobachtungen von Ureterimplantation in die Flexura romana bei Ectopia Vesicae," *Wien. med. Wochenschr.*, 1896, vol. xlvii, p. 1241.
- V. Meyer, Edward: "Ein Beitrag zur Verwendung des Koch'schen Tuberkulins als diagnostischen Hilfsmittels," *Deut. med. Wochenschr.*, 1893, vol. xix, p. 200.
- Monari, U.: "Über Ureter-Anastomosen. Experimentelle Untersuchungen," *Brunsv. Beiträge zur klin. Chir.*, 1896, vol. xv, p. 720.
- Morestin, N.: "Greffe de l'uretère dans le rectum," *Mercredi médical*, 1892, p. 622.
- Morison, R.: "Two Cases of Ureterotomy for Removal of Calculi," *Lancet*, 1894, vol. ii, p. 1093.
- Morris, H.: "A Case of Congenital Dilatation of Both Ureters, Right Ureterotomy and Left Nephrotomy in a New-born Child; Remarks," *Lancet*, 1895, vol. i, p. 1435.
- Mynter, Herman: "Case of Acute Intermittent Hydronephrosis from Valvular Stricture of the Ureter," *Annals of Surgery*, 1893, vol. xviii, p. 658.
- Newman, D.: "Instruments for Catheterization and Compression of the Female Ureters; a Method of Inspecting the Female Bladder by Means of the Electric Light," *Glasgow Medical Journal*, 1885, vol. xxiii, p. 52.
- Nitze, Max: "Über kystopische Diagnostik chirurgischer Nierenerkrankungen mit besonderer Berücksichtigung des Harnleiter-Katheterismus," *Berlin. klin. Wochenschr.*, 1895, vol. xxxii, p. 350.
- Novaro: Published by Bocchini.

- Orthmann, G. G.: "Zur Kasuistik der überzähligen Harnleiter," *Centralbl. f. Gynäkologie*, 1893, vol. xviii, p. 137.
- Otis, W. K.: "Aëro-urethroscopy," *Jour. Amer. Med. Assoc.*, 1895, vol. xxii, p. 319.
- Page, Herbert W.: "On Traumatic Ruptures of the Ureter, with Report of a Case of Ruptured Ureter Followed by Nephrectomy in a Child," *Annals of Surgery*, 1894, vol. xix, p. 513.
- Paoli and Busachi: "La greffe des ureteres dans un point anormal de la vessie," *Annales des Mal. des Organes génito-urinaires*, 1888, vol. vi, p. 553.
- Pawlik, C.: "Über die Harnleitersondirung," *Arch. f. klin. Chir.*, 1886, vol. xxxiii, p. 717.
- Penrose, C. B.: "A Case of Abdominal Hysterectomy in which the Ureter was Resected and Implanted into the Bladder," *Medical News*, 1894, vol. lxiv, p. 470.
- Perez: "Exploration des uretères," *Thèse de Paris*, No. 302.
- Poggi: "Guérison immédiate des sections transversales des uretères sans oblitération de leur cavité," *Riforma Medica*, 1887, vol. liii.
- Poirier, P.: "Anatomie et physiologie des uretères," *Annales des Mal. des Organes génito-urinaires*, 1891, vol. ix, p. 745. "Cathétérisme permanent des uretères. Dérivation du cours de l'urine," *Compt. rend. de la Société de Biologie*, 1891, vol. iii, p. 570.
- Poncet: "Uretérectomie totale pour urétérite oblitérante, scléreuse, tuberculeuse, après ablation du rein droit remontant à 2 ans $\frac{1}{2}$ —Guérison," cited by Glantenay.
- Postnikow, P. J.: "Hydroureter cum Hydronephrosi. Nephrourectomia," *Arch. f. klin. Chirurgie*, 1895, vol. xlix, p. 675.
- Pozzi, S.: "Des blessures de l'uretère en cours de la laparotomie," *Annales des Mal. des Organes génito-urinaires*, 1891, vol. ix, p. 538. "Ureterovaginal Fistula," *Med. and Surg. Gynecology*, vol. ii, p. 328.
- Pye-Smith, P. H.: "Stricture of the Ureter and Dilatation of the Kidney, Apparently of Traumatic Origin," *Pathological Transactions*, 1871-72, vol. xxiii, p. 159.
- Ralfe, C. H., and Godlee, R. J.: "A Case of Suppression of Urine Caused by Impaction of Calculi in Both Ureters, Relieved by Operation," *Clinical Society of London's Transactions*, 1889, vol. xxii, p. 155.
- Rayer's Atlas: Plate 52; Plate 11, Fig. 4.
- Rayer, P.: *Traité des Maladies des reins*, Paris, 1839.
- Reed, R. Harvey: "Experimental Research on the Implantation of the Ureters into the Rectum," *Annals of Surgery*, 1892, vol. xvi, p. 193.
- Reichel, P.: "Über hernienartigen Vorfall eines Ureters durch den Leistenkanal," *Verhandlungen der Deutschen Gesellschaft für Chirurgie*, XXI. Congres, 1892, vol. ii, p. 68.
- Reynier, Paul: "Néphrectomie combinée avec l'uretérectomie totale," *Annales des Maladies des Organes génito-urinaires*, 1893, vol. xi, p. 233.
- Ribbert: "Über ein Myosarcoma striocellulare des Nierenbeckens und des Ureters," *Virchow's Archiv*, 1886, vol. cvi, p. 282.
- Rosenberg, S.: "Experimentelle Harnblasenplastik," *ibid.*, vol. cxxiii, p. 158.
- Rovsing, Thorkild: *Om Blaerebetaendelsesernes Aetiologi, Pathogenese og Behandling*, Copenhagen, 1889. "Pseudomembranös Pyelitis," *Hospitalstidende*, 1897, pp. 213 and 237.
- Rydygier, L.: "Ein Vorschlag zur Ureteroplastik," *Oesterreich-Ungarisches Centralbl. f. med. Wissenschaft*, 1892, p. 76.
- Sands: Cited from P. Müller's "Über künstlichen zeitweiligen Harnleiterverschluss," *Deut. med. Wochenschr.*, 1887, vol. xiii, p. 689.
- Sänger, M.: "Über Tastung der Harnleiter beim Weibe," *Arch. f. Gynäkologie*, 1886, vol. xxviii, p. 54.
- Schede, M.: "Die operative Behandlung der Harnleiterscheidenfistel," *Centralbl. f. Gynäkologie*, 1881, vol. v, p. 484.
- Schopf, F.: *Ibid.*, 1887, vol. xi.
- Schwarz, Carl: "Über abnorme Ausmündungen der Ureteren und deren chirurgische Behandlung (nebst Bemerkungen über die doppelte Harnblase)," *Brun's Beiträge zur klin. Chir.*, 1895, vol. xv, p. 159.
- Secheyron, L.: "Les abouchements anormaux de l'uretère dans le vagin à la vulve. Étude anatomique et clinique sur l'incontinence d'urine congénitale et considérations d'embryogénie sur une variété peu connue d'anomalie urétérale," *Archives de Tocologie*, 1889, pp. 254 and 335.
- Segond, P.: *Traité chirurgicale de l'Exstrophie de la Vessie*, 1890, G. Chamerot.
- Silbermann, O.: "Über eine neue Methode der temporären Harnleiterverschliessung und ihre diagnostische Verwerthung für die Krankheiten des uropoëtischen Systems," *Berlin. klin. Wochenschr.*, 1883, vol. xx, p. 518.
- Simon: *Chirurgie der Nieren*, Stuttgart, 1876, vol. ii. *Wien. med. Wochenschr.*, 1876, vol. ii.

- Sinitzin: Edited by Poirier.
- Sollier, T.: "Observation des reins Cystiques," Lyon médical, 1880.
- Tait, Lawson: Cited from Nitze.
- Tanquary, W. W.: Cited by Van Hook.
- Targett, J. H.: "Sarcoma of the Ureter," Trans. Lond. Path. Soc., 1892, vol. xliii, p. 92.
- Taufer, W.: "Beiträge zur Chirurgie der Ureteren und der Niere," Arch. f. Gynäkologie, 1894, vol. xlvii, p. 531.
- Thornton: Cited from Nitze.
- Tillaux: Cited by Poirier.
- Tirard, N.: "Tubercular Growths of the Ureter," Trans. Lond. Path. Soc., 1892, vol. xliii, p. 91.
- Tourneur: "De l'uretélite et de la périuretélite," Thèse de Paris, 1886.
- Trendelenburg, F.: "Über Blasenscheidenfisteloperationen und über Beckenhochlagerung bei Operationen in der Bauchhöhle," Volkmann's Sammlung klin. Vorträge, 1890, No. 355, p. 3378.
- Tuchmann: "Über künstlichen Verschluss einer Harnleitermündung," Deut. Zeitschr. f. Chir., 1875, vol. v, p. 62. Die Diagnose der Blasen- und Nierenkrankheiten, mittelst der Harnleiter Pincette, Berlin, 1887.
- Tuffier, Th.: "Appareil urinaire reins—uretères—vessie—capsules surrénales," Duplay et Reclus' Traité de Chirurgie, Paris, 1892, vol. vii. "Des résultats éloignés de la chirurgie rénale," Annales des Mal. des Organes génito-urinaires, vol. xi, p. 370. Études expérimentales sur la Chirurgie du Rein, Paris, 1889, p. 165. "Résultats éloignés de la néphrorrhaphie pour rein mobile," Congrès français de Chirurgie, 1891, p. 377.
- Twynam, George E.: "A Case of Calculus Impacted in the Ureter; Removal," Clinical Society of London's Transactions, 1890, vol. xxiii, p. 93.
- Ultzmann, R.: "Die Krankheiten der Harnblase," Deutsche Chirurgie.
- Van Hook, Weller: "Experimental Union of the Ureter after Transverse Division," Jour. Amer. Med. Assoc., 1893, vol. xx, p. 225. "The Surgery of the Ureters: A Clinical, Literary, and Experimental Research," *ibid.*, 1893, vol. xx, pp. 916 and 965.
- Vaughan: "A Case of Hydronephrosis From Obstruction of the Ureter; Nephrotomy; Prolonged Drainage of the Kidney," Jour. Cutan. and Genito-urinary Dis., 1894, vol. xii, p. 537.
- Virchow, R.: Die krankhaften Geschwülste, Berlin, 1863, vol. i.
- Visconti, A.: Atti della Associazione Medica Lombarda, 1892, p. 250.
- Weil, J.: "Ein Fall von isolirter Harnleiter-scheidenfistel, bewirkt durch einen Mayer'schen Ring," Wien. klin. Wochenschr., 1892, vol. v, p. 235.
- Weir, R. F.: "Compression of the Ureter," Medical Record, 1884, vol. xxiv, p. 385.
- Westermarck: "Ein Fall von Implantation des Ureters in der Blase," Centralbl. f. Gynäkologie, 1895, vol. xix, p. 184.
- Wiegert, C.: "Über einige Bildungsfehler der Ureteren," Virchow's Archiv, 1877, vol. lxx, p. 498.
- Witzel, O.: "Beiträge zur Chirurgie der Bauchorgane," Deut. Zeitschr. f. Chir., 1886, vol. xxiv, p. 337.

ENTEROPLASTIC OPERATION TO OVERCOME OR PREVENT STENOSIS, WITH ESPECIAL REF- ERENCE TO THE SPUR IN PRETERNATURAL ANUS *

THE principle of overcoming a stenosis of a canal by transverse union of a longitudinal incision, as applied by Heineke-Mikulicz on the pylorus and by me on the ureter, is applicable in any portion of the intestinal tract below the duodenum wherever the mechanical conditions will permit.

The longitudinal incision or opening should be made in the middle of the convex surface,—that is, equidistant from the two sides of the mesentery,—so as not to interrupt blood-supply by the division of large vessels in the intestinal wall. Free mobility of the loops of intestine and intact peritoneal covering are desirable conditions, but the latter is not absolutely necessary. In places where the intestine has no mesentery and where there is a limit to the infolding or bringing into apposition of the convex surface or the surface of the intestine opposite the mesentery, as the cecum, extraperitoneal border of the rectum, or flexures of the colon, there is a limit to the length of the longitudinal incision. In an organ so free and movable as the small intestine I see no reason why I could not unite the convex surface to an extent of 5 or 6 inches or more, if this would be desirable. In fact, I see no other limit than that of the length of the mesentery, the time required for suturing, and the length of the wound. It is evident that the length of the longitudinal wound should not be unnecessarily great.

When there is no mesentery, and consequently only slight mobility, for folding in or apposition of the convex free surface of the intestine, or where the mobility is diminished or lost by diffuse inseparable adhesions, there is, of course, a limitation to the application of this principle.

In one case of stenosis of the cecum from tuberculosis, with remittent attacks of pain from incomplete occlusion, in which I did not deem excision of the cecum advisable, I made this plastic operation, uniting transversely an incision of about 4 cm. in length. The operation gave partial relief only, and a fecal fistula resulted, which necessitated an ileocolic anastomosis, which was followed by relief of the symptoms of the stenosis and left the fistula secreting mucus, as a rule, with, very rarely, some fecal matter.

Tension in the united wound and lack of free fecal passage at the place of operation are, when the sutures are applied correctly, undoubt-

* Amer. Jour. Med. Sci., 1899, vol. cxvii, p. 431.

edly the main cause of non-success—that is, of spontaneous reopening of the sutured intestine.

This plastic operation, when applied to resection and circular suture, will enable us to avoid narrowing of the intestine by folding in of its wall at the place of suture (Fig. 163). If, for the sake of additional safety, it is deemed desirable to apply a second row of seromuscular sutures at a distance of 0.5 cm. from the first row, the advantage of having a larger amount of serous surface in contact is counterbalanced by the increase in size of the circular fold. The narrowing effect of a large fold can be overcome entirely by the plastic operation, because we can make the longitudinal division long enough to secure a circumference of any size desired.

The same principle is applicable when we wish to unite an intestine of small caliber end to end with one of large caliber. By longitudinal division of the smaller intestinal tube the line of union is easily made to correspond to that of the larger tube. If the lumen of the larger intestine is not deemed sufficiently wide to permit of so much folding in

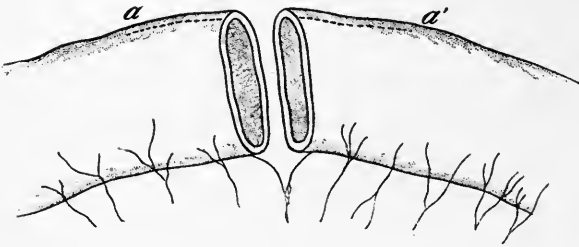


Fig. 163.—Suture of intestine so as to avoid narrowing.

as is required, a longitudinal division is also here resorted to, until at least as large a line of union as we deem desirable is secured.

In artificial anus, whether this be the result of a premeditated operation or of an accident, where the mucosa of the intestine is finally united to the skin, it is commonly observed that the so-called spur forms a more or less complete obstruction to fecal passage from the proximal into the distal portion of the intestine. The spur, so to speak, leads the bowel contents from the bowel out through the opening in the skin. The distal portion becomes small and retracted from non-use.

The spur is formed by a semicircular fold or group of folds located opposite to the opening through the abdominal wall at the place of the bend of the opened intestine. This semicircular fold may increase so as to extend entirely around the lumen of the intestine, thus becoming a circular fold, and is then located at the end of the proximal portion of the intestine, close to the opening in the skin, through which it may protrude as a prolapse of the mucosa or wall of the proximal bowel. When this spur is well developed, it may form, even when the intestine is loosened from the abdominal wall, an impediment to free fecal passage that frustrates simple transverse or longitudinal suture of the intestinal

opening, and consequently necessitates resection of the loop containing the spur.

As resection with subsequent circular suture is as yet an operation of some gravity, it would be an advantage to avoid resection and still overcome the stenosis and the influence of the spur with a simpler operation. That this can be done by application of the principle of the transverse union of a longitudinal wound I propose to show by the following case:

A. T., male, aged fourteen years, an American of German descent, entered the German-American Hospital for operation, in my service, on April 2, 1898.

Family History.—Father, mother, brothers, and two sisters living and healthy. One sister died of perityphlitic abscess. Grandparents, uncles, and aunts living and healthy, or cause of death unknown. Paternal grandfather died in old age of diphtheria. One paternal cousin had operation for appendicitis in 1894.

The patient's personal history was negative as regards disease or injury.

Present Illness.—On the evening of March 22, 1897, the patient was seized with acute pain in the abdomen below the level of the umbilicus; the pain was generalized, very severe from the first, and of a severe aching, griping character, and was accompanied by vomiting and diarrhea. He had elevation of temperature, but no chill until the following day. The pain lasted throughout the night, but in the morning it was not so severe and the patient walked about outdoors. At noon he had a chill and went to bed. Nausea and slight diarrhea were present. Severe abdominal pain in the lower half of the abdomen came on at 2 o'clock the next morning, and continued with remissions for two weeks, accompanied by daily elevation of temperature.

A physician was called on March 24, who made a diagnosis of appendicitis. On April 5 the perityphlitic abscess was opened in narcosis. Fecal matter, with pus, escaped from around the appendix at the time of operation.

From this time until April 2, 1898, when I operated, a fecal fistula had existed, which has discharged a varying amount of feces daily. For the first eight weeks after the operation from one-fourth to one-eighth of the feces passed through the fistula, and the remainder by the rectum. The rectal discharges were normal in color, and occurred once daily. At the end of eight weeks the fecal discharge through the fistula decreased rapidly, so that it amounted only to a moistening of the dressings three times a day with fecal matter. About this time the wound was explored for gauze, which was supposed to have gotten into the intestine. After this exploration there was an immediate increase in the amount of fecal discharge through the fistula, which continued up to the time of operation. He has usually had about four to six evacuations daily through the fistula, varying from a dram to three ounces, but ordinarily about one ounce. The feces were of normal color and soft, but not liquid. The amount of feces passed per rectum appears to be about the same as before the fistula was formed; the character is normal; the bowels are regular, and there is no tendency to diarrhea.

Relief from pain immediately followed the opening of the perityphlitic abscess and he has felt well ever since, with the exception of a few hours after the operation.

Operation April 2, 1898. After the usual preparation, liquid diet, and irrigation of the bowels through the fistula in another room, without using a rubber tube to push the spur

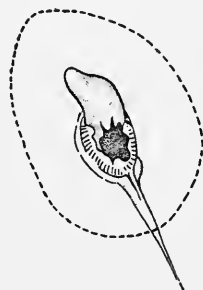


Fig. 164.—Prolapse of tongue-shaped mucosa. Opening passable for the little finger. Dotted line indicates incision for cutaneous flap.

back or down, he was brought to the operating-room. When he was put upon the table feces welled out. There were present at the operation the doctors from the Polyclinic. Drs. Haiselden and Buford assisted, and Dr. Gottschalk administered the ether.

The fistula was located in the right inguinal region, 1 to 1½ inches from Poupart's ligament, or from the anterior-superior spine of the ilium. The opening was 6 cm. in circumference, 2 cm. in diameter, and would admit the little finger. The mucosa of the intestine was united to the skin, that is, the fistula was labiate. The mucosa bled when

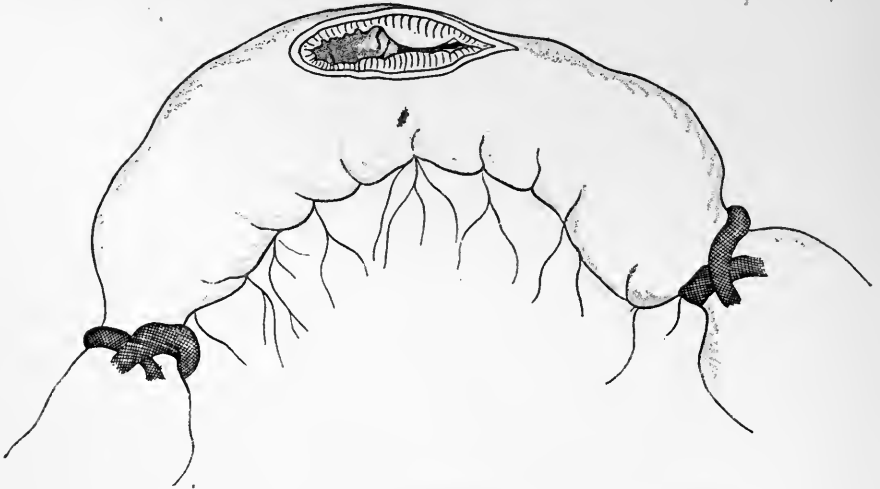


Fig. 165.—Proximal end of gut incised through prolapsed mucosa; spur seen on mesenteric side, within gut.

the finger was introduced. A tongue-shaped flap of mucosa, 1 cm. square, protrudes when he strains. It comes out of the upper, outer corner of the fistula, and can be easily replaced. The fistula is surrounded by excoriated skin for an inch or more.

The fistula was now circumsised, 1.5 cm. from its border, through the skin, subcutaneous tissue, and abdominal muscles, down to the transversalis fascia. This cir-

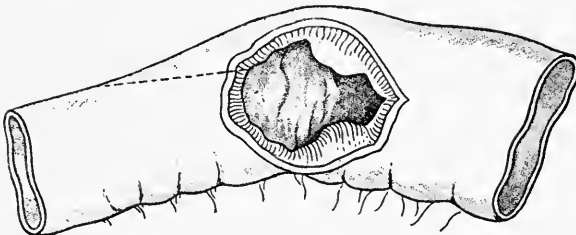


Fig. 166.—Wound in ileum held out, showing spur, viz., a counter-fold or group of folds of mucosa. Line of incision 1 inch down into distal (smaller) portion of ileum.

cular flap, like a collar, was loosened and closed tightly by a continuous silk suture, so that none of the intestinal contents could pass out.

The abdomen was then disinfected, and clean covers put on the table and the patient.

I now opened the peritoneal cavity, 1 inch medial to and above the fistula, using great care to avoid adherent intestine. The omentum met with at first was ligated in portions. The isolation of the loop with the fistula was relatively easy. It was found to be a loop

of small intestine, and was surrounded by gauze sponges, freed from adherent omentum and held aside out of the abdominal wound while search was being made for the cecum and the appendix. The wound was packed with several sponges, the parietal peritoneum united to the skin, the branches of the inferior epigastric artery ligated, and the incision prolonged up and down in the sheath of the rectus muscle.

The cecum was found to be free from adhesions, and the appendix was adherent to the cecum. The end of the appendix was dilated, fluctuating, and contained a fecal concretion.

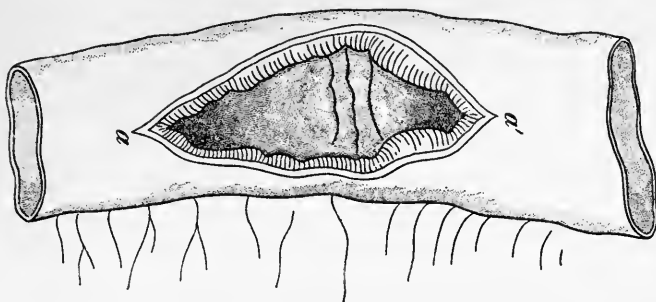


Fig. 167.—The whole of incision, viz., the longitudinal wound in the ileum at middle of convex (opposite to mesentery) border—1 inch up, 1 inch down; width of fistula, $\frac{1}{2}$ inch = 2 $\frac{1}{2}$ inches; a, Lower and a' upper corner to be united by a guide suture left long.

The appendix was amputated, and the stump buried under a musculo-serous circular flap.

I now proceeded to operate on the fecal fistula, which was found to be located 2 feet above the cecum. The loop of the ileum containing the fistula was pulled well out of the wound and surrounded by gauze. The loop was emptied and ligated by means of gauze strips, 2 to 3 inches on each side of the fistula. The adherent omentum was dis-

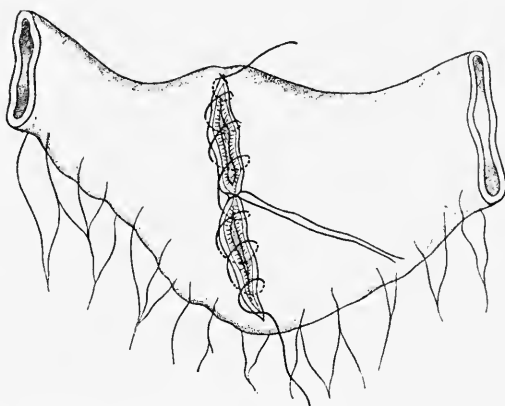


Fig. 168.—Continuous suture. Lies through whole thickness of wall, aided by the guide suture.

sected off from the intestine, which necessitated only a few ligatures. The abdominal-wall flap was then cut off from the border of the fistula.

The fistula appeared as a round or oval opening, $\frac{1}{2}$ to 1 inch in diameter, on the convex surface of the ileum, $\frac{1}{2}$ to $\frac{3}{4}$ inch from the mesenteric border on each side. The tongue-shaped flap of mucosa was found to be part of a circular fold hanging down from

the proximal border of the fistula, continuous with the spur, and forming with this a circular prolapsed and invaginated valve or flap.

It was evident that a simple union of the fistulous opening, either in a transverse or longitudinal direction, would not do away with the stenosis caused by this ring-shaped valve of the mucosa, and consequently would not remove the impediment to the passage of feces at this point, because this ring of mucosa would protrude into the lumen of the intestine and perhaps be the beginning of an invagination, or would, at times at least, impede fecal circulation.

I believe that the spur or circular valve, by causing a disturbance of fecal circulation, is the cause of the common failure of permanent closure of the fistula following simple suturing of the intestinal opening.

The fistula reappears in a week or two, and reopens because of the spur which remains.

I therefore decided to overcome the effect of the spur by the following plastic operation on the intestine:

1. A longitudinal incision at the convex border of the intestine, 1 inch in length in the proximal end of the intestine through the tongue-shaped valve, up into the normal intestinal wall above it.

2. A longitudinal incision, 1 inch long, into the distal or narrower portion of the

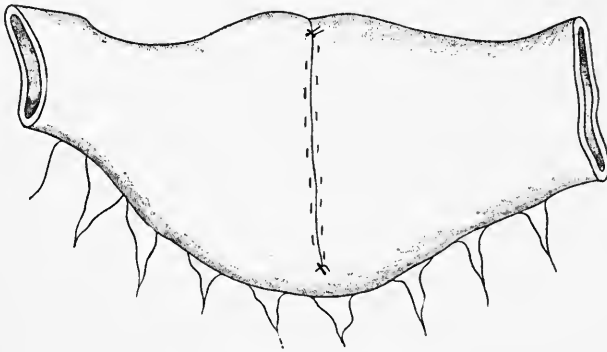


Fig. 169.—Seromuscularis continuous suture to bury the preceding suture.

intestine below the spur, thus making a longitudinal wound 2 inches in length, on the convex border of the intestine. As the original fistulous opening was 2 cm. in diameter, the wound would be about 3 inches in total length. Upon making the incision at the upper end of the wound I saw a Peyer's patch.

The spur formed a circular valve of two or three parallel folds of mucosa, $\frac{1}{2}$ inch broad, most pronounced on the mesenteric side, extending around the entire circumference of the intestine, but smaller on the convex border.

3. Transverse union of this longitudinal wound.

(a) Suture *a-a'* united the upper and lower corners and was left long for traction, dividing the wound into two transverse halves with the suture in the middle.

(b) A continuous silk suture through all the layers of the intestine (Fig. 168).

(c) A continuous serosa-muscularis suture, 1 cm. outside of the former.

(d) A second continuous serosa-muscularis suture to bury the former (Fig. 169).

4. Disinfection of the sutured loop with 1 : 1000 sublimate solution, and removal of the gauze ligatures around the loop of intestine.

5. Removal of the sponges and examination of the abdomen for hemorrhage.

6. Step sutures of the abdominal wall.

7. Gauze drain down to the appendix and over to the sutured loop of the ileum.

8. Injection of two quarts of physiologic saline solution into the rectum.

The operation lasted three hours and a half. At its close the patient's pulse was good; no shock.

7.30 P. M.: Gaseous distention of the abdomen. A little gas escaped after insertion of the rectal tube.

April 3: Patient had a small, dark-green, and very thin bowel movement. Throughout the day he had considerable trouble on account of gaseous distention, for which injections of warm water and peppermint were made, but little gas passed. Temperature, 97.4° to 100.2° F.; pulse, 120 to 130.

April 4: A small amount of gas passed after injection of peppermint water. During the day he vomited several times; dressings were changed; ½ ounce of bloody fluid, with some bright yellow pus, followed the removal of the packing. A drainage-tube was introduced. Temperature, 98.4° to 100° F.; pulse, 100 to 108. During the day he had two small bowel movements.

April 5: He passed considerable gas and had two dark-green, thin bowel movements. Temperature, 99.2° F.; pulse, 90.

April 6: Slept well last night. Temperature 99.6° F.; pulse, 76. The drainage-tube was removed, ½ inch cut off, and reinserted. Dressings were dry.

April 7: Temperature, 99.6° F.; pulse, 66. A large bowel movement followed the use of enemata.

April 8: Temperature, 99.4° F.; pulse, 56. Tube removed.

April 11: Temperature, 98.4° F.; pulse, 68. He has no pain. Eats and sleeps well.

April 24: Only a granulating surface remains. The function of the bowels is normal.

October: Patient remains well.

EVERSION OR TURNING INSIDE OUT OF THE SAC OF A CYSTONEPHROSIS AS AN AID IN OPERATING UPON THE RENAL END OF THE URETER AND UPON THE PARTITION WALLS BETWEEN DILATED CALICES *

I DESIRE to describe a new method of systematic search for the ureteral opening on the inside of a cystonephrotic sac; not by "bisection," as I have described in the case of infected partial cystonephrosis,† but by eversion of the cystonephrotic sac through an opening large enough to permit of turning the wall inside out. This eversion of the cystonephrotic sac, combined with methodic consecutive division of the partition walls one after another, enables us gradually to lay bare and turn out for ocular inspection the whole inner wall of the sac. This is also a sure way of finding the renal orifice of the ureter. The division of the partition walls transforms the multilocular into a unilocular cavity, and facilitates drainage of urine down the ureter into the bladder.

This method of eversion of the sac is new and superior to the method employed by Simon, and, later, by myself, of inspecting the inner wall of the sac *in situ* through the opening in its wall by means of specula and reflected sunlight or lamplight. This method also makes it much easier to find the ureteral orifice. I cannot see how the renal orifice of the ureter can escape being seen by this method. However, if it is nearly obliterated by stenosis from infection or inflammation, it might be impossible to see it, even under these circumstances, and it might, therefore, become necessary to lay the ureter bare from below and outside of the sac, open the ureter by a small longitudinal incision, and pass a fine probe up into the sac, as described by me in a former paper.‡

Another advantage of the method of eversion is the ease and promptness with which the ureteral orifice is brought into the field of operation. We do not need to wait three months or more for retraction of the sac and then bisect the kidney in order to find and operate on the ureteral entrance from within, but can accomplish all that is required in a single operation.

I do not, of course, know in what proportion of cases a cystonephrotic sac is so movable and so easy to handle that this eversion is feasible, but I think it likely that it would be the rule in cystonephrosis following or caused by a descended floating kidney, and would be the case as

* Am. Jour. Med. Sci., 1899, vol. cxviii, p. 48.

† Annals of Surgery, 1896, vol. xxiii, p. 637.

‡ Jour. Amer. Med. Assoc., 1894, vol. xxii, p. 335.

long as the cystonephrosis was aseptic—that is, not yet fixed to its surroundings by perinephritic inflammation from the infected contents of the sac.

The eversion proved in the following case to be a great help, and was probably the only means possible of finding and operating upon the renal orifice of the ureter:

CASE.—Miss C. W. was referred to me by Dr. J. V. Bacon for operation on February 21, 1898, and entered Passavant Memorial Hospital in my service. The patient was twenty-three years of age, American, single.

Family History.—Negative, with the exception that her father passed stones with the urine thirteen years ago.

Personal History.—Patient had the ordinary diseases of childhood, and, in addition, dysentery at the age of three years, and typhoid fever at the age of fourteen, complicated by hemorrhage from the bowels. At the ages of seven and twenty years she had attacks of jaundice, with nausea and vomiting, attended by slight elevation of temperature, but without pain in the epigastrium or the region of the gall-bladder. No clay-colored stools nor stones in the feces were observed. The second attack, in 1895, was characterized by a gradual onset of jaundice for a month, at which time she was most deeply jaundiced. This attack was attended by nausea and vomiting after all meals, and occasional nausea between meals. She was able to retain food by drinking lemon phosphate, obtaining in this way relief from the nausea. The jaundice and nausea continued until the spring of 1896. She lost some weight, but does not know how much. Since the spring of 1896 she has had no further nausea, jaundice, or other symptoms pointing to the biliary tract.

She had prolapse of the uterus at the age of fourteen, which continues to the present time. She gives no history of injury.

Present Illness.—In July, 1893, while at the World's Fair, the patient was seized with pain in the right mammary line, $1\frac{1}{2}$ inches below the costal arch. This pain came on very suddenly, was sharp, constant, and severe, and localized to an area the size of a silver dollar, and without radiations. Flexion of the right thigh caused the pain to increase in severity. She had no urinary disturbance at this time. Upon going to bed she found that while the pain lasted she could not lie on the left side, and that there was much tenderness on pressure over the painful territory, which did not alter upon change of posture from standing to lying down. There was no tenderness on pressure beyond the area of pain. After fifteen to thirty minutes in the recumbent posture she was entirely free from pain. During, before, or after the attack she does not think she had any chill or elevation of temperature. She perspired freely and felt faint during the attack.

For the two years following she had similar attacks, varying in frequency from one in seven to fourteen days to several a day. Very soon after the first attack she noticed that certain bodily movements, such as elevation of the right arm above the head, flexion of the trunk to the left, or any movement that produced extension of the muscles on the right side brought on the pain. Most of the time she was forced to sleep with the right thigh semiflexed. Extension apparently caused a feeling of tension on the right side of the abdomen, and was followed by an attack. She found that lying down for fifteen or twenty minutes would give her relief from the attacks. By going to bed in the beginning of the attacks she was able to abort them or cut short their duration.

During or preceding attacks she had no unusual desire to pass urine, but a month or two after the first attack she noticed that about the time the pain subsided, or a few minutes thereafter, she had a desire to urinate and passed from two to four ounces, a smaller quantity than she ordinarily passed when feeling well. The urine was never stained with blood, nor did it contain any foreign matter that attracted any attention. During these two years she lost considerably in weight and became very pale and thin. She was not so strong as before, although she continued her work as a saleswoman.

In the autumn of 1895 she first noticed a tumor in the right side, about 2 inches in diameter, not tender to pressure, and of firm consistence, located just beneath the tender area above referred to. The tumor seemed to make traction on this tender area, and she says it "felt as hard as a stone." It was at first spheric, barely noticeable when erect, and apparent only when the patient assumed a recumbent posture. She could not feel or see it at first when sitting or standing. The tumor was not noticeable at all times, but in about ten or fifteen minutes after she made some movement which would bring on an attack of pain she would notice the swelling, which would gradually enlarge.

From this time on, and during 1896, the tumor increased in size in all directions, but principally downward. By the end of the latter year the tumor extended from 1 inch below the costal arch in the mammary line about 3 inches downward. As the tumor increased in size the attacks became progressively less painful up to September, 1897. At that time the tumor extended from the costal arch to 1 or 2 inches above the crest of the ilium. She could now place her hand beneath the tumor and lift it up; she could also outline it all around except posteriorly.

In 1897 she noticed that the tumor was constantly present, but varied greatly in size.

She also observed that as time went on it required a longer time for the tumor to empty itself, and that it was more resistant. At such times it showed no tendency to decrease when she lay down, and it was necessary to use massage and pressure to bring this about. It usually required about three hours to accomplish this, and even then the contents of the tumor were not completely evacuated.

Throughout 1897, and until the present time, pressure upon the tumor causes her to have a desire to pass water, and she apparently evacuates the bladder; and, if pressure is continued, she has another evacuation in from fifteen to forty-five minutes, this being repeated until the tumor becomes collapsed.

At this time the tumor extends from the costal arch to the brim of the pelvis and Poupert's ligament, and from the median line in front to the scapular line posteriorly.

These boundaries are constant. The tumor varies in consistence, is fluctuating, and feels soft.

Its contour is regular, and it is not tender to pressure. For two months preceding the examination it has not been painful except in the original area of tenderness, where there is an almost constant feeling of soreness.

The tumor causes her no discomfort excepting when it is much distended; at such times she notices abdominal distention and a feeling of weight in the middle of the tumor. So far as she knows she has never passed blood or other foreign matter in the urine, but is said to have had intermittent slight albuminuria. She feels well at present.

Operation February 22, 1898, in the presence of the doctors from the Polyclinic, and assisted by Drs. Hessert, Buford, Waters, Doepfner, and Gillett, under ether narcosis I made cystoscopy with Kelly's instrument, the patient being in the knee-chest position. The bladder was normal; the left ureter could not be found; the right ureter was normal, and an elastic catheter was easily inserted 35 or 36 cm. No urine escaped, and the catheter could not be passed higher. I thought that this probably meant a bend in the ureter close to and below the pelvis of the kidney, or, rather, the cystonephrotic sac. As

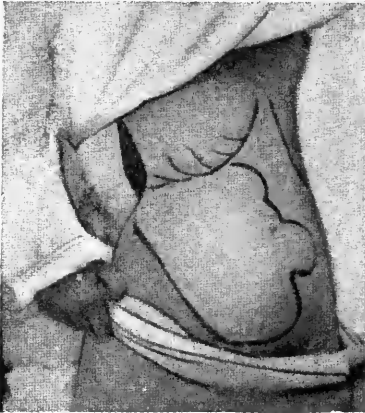

Fig. 170.—The tumor.

I could see no urine dribbling down when the elastic catheter was in the ureter, into which it had passed easily, I was afraid that I might have made a mistake, and therefore reintroduced Kelly's tube that I might see the catheter in the ureter. I then saw that the catheter was in the ureter, but that there was some bleeding at the ureteral orifice.

The patient was now turned on the left side, with a pillow under the left hip. An oblique incision, 10 to 12 cm. long, was made parallel to the twelfth rib from the erector spinæ. The latissimus dorsi was pulled aside or divided, and the quadratus lumborum divided. There was little perirenal fat. Respiratory movements could be observed through the transversalis fascia. The adipose capsule was a loose connective-tissue mass, containing little or no fat. It was so movable against the kidney that I took it to be the peritoneal cavity.

The surface of the kidney was globular and sacculated. It presented an elastic sac with a smooth, reddish or bluish-gray surface, resembling the color of kidney substance. In the wound a globular surface presented, 5 or 6 cm. in diameter. This was the top of the kidney located below the twelfth rib. It was consequently a floating kidney displaced downward. Below this surface was an annular depression corresponding to a partition wall of interpyramidal substance, and then a larger globular prominence below. Other less marked globular prominences corresponding to calices were felt in the abdomen toward the median line. The sacs averaged 6 to 8 cm. in diameter.

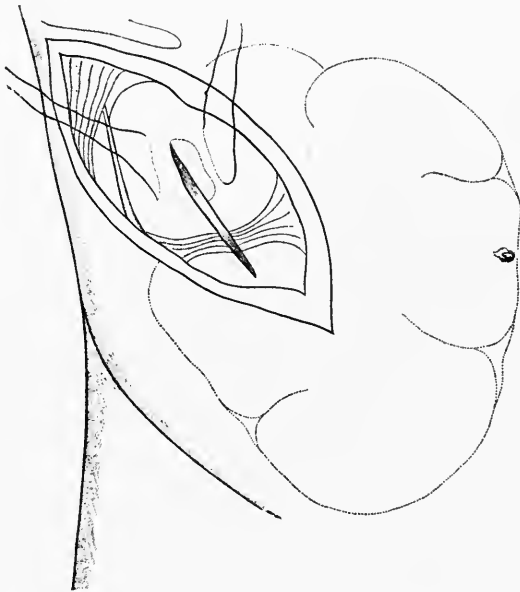


Fig. 171.—Exposure of sac.

After packing sterile gauze around the borders of the sac, the upper globular portion of the sac was fixed with two loops of heavy silk. A perfectly limpid, clear, thin, transparent, light yellow fluid spurting from the stitch-holes. Dr. Brougham made cultures from this fluid.

I now incised the sac for a distance of 2 cm. between the sutures. Hemorrhage followed the incision, which was so profuse that the yellowish, clear fluid became bloody. About a quart of the fluid was caught in a basin. The fluid was too transparent to contain any cells—that is, it was an aseptic cystonephrosis.

I now searched for the ureter inside of the sac. As the sac extended downward so as to fill the whole of the large pelvis, the ureter was not sought for outside of the sac. In another case I might, however, do this after having found the ureter inside and passed a catheter down.

The incision was now prolonged downward for a distance of 6 or 8 cm. The wall of the sac was 3 mm. thick. There was profuse hemorrhage from small vessels all over the wall, and from spurting arteries, especially at the location of the partition walls. I concluded that this vascularity was due to the presence of a good deal of secreting kidney substance. A small piece of this tissue was cut out for microscopic examination. The hemorrhage was stopped by the Paquelin cautery, but the spurting arteries in the partition walls began to bleed again after the territory had been manipulated later on in the operation. This required the reapplication of the cautery three or four times in the course of the operation.

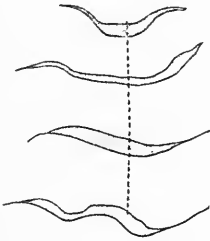


Fig. 172.—Four partition walls.

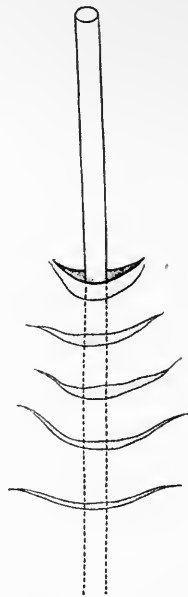


Fig. 173.—Catheter passed into ureter through sacs.

The inside of the cystonephrotic sac was sacculated; a narrow opening, $1\frac{1}{2}$ cm. in diameter, led into a sac 4 to 7 cm. in diameter; the inner surface was smooth, shining, reddish-white, and looked like a smooth mucous or serous surface. After an hour multiple small ecchymoses changed the surface to a spotted red, not a dark blood-red, exactly as I have seen in a normal bladder after opening and manipulation.

The nearest presenting opening into a calyx was now pulled out of the incision in the sac by hooking a finger into the calyx, and the partition wall was divided on a flat director with a Paquelin cautery. The division was bloodless, close to the thin borders of the opening into the sac, but the outer part of the partition walls, where they were 2 or 3 mm. thick, bled considerably, so that the divided arteries required repeated applications of the cautery.

I divided four partition walls to the extent of 2 or 3 cm., thus laying open four sacs. Three or four sacs had wide openings, and were not divided. During this consecutive

division of the partition walls the entire cystonephrotic sac was drawn out and turned inside out. This and the manipulation during the division of the partition walls were accomplished by hooking the index-finger into a sac through an opening or around the free border of a septum, and at the same time pushing in the wall of the sac from the outer surface of the cystonephrotic sac.

In this manner I gradually exposed for inspection the whole inner surface, and finally laid open to view a cavity, the pelvis or the pelvic portion of the sac, on which I found the entrance to the ureter as a semilunar, transverse fold, 5 to 7 mm. in diameter, below which I could see a row of larger folds, transverse, and located 1 cm. apart. A probe could be passed easily down 2 cm. into the ureter.

Examination of the Ureter.—A long metal sound was passed down 24 cm., as I supposed, into the bladder, but in order to make sure I passed a steel sound into




Fig. 174.

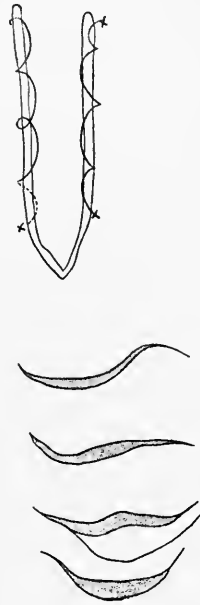

Fig. 175.

Figs. 174 and 175.—Suture of ureter to wall of the pelvis.

the bladder through the urethra. I could not feel the click, however; the sounds did not meet, nor could they be felt by Dr. Bacon's finger in the vagina. The sound in the bladder appeared to be separated from the probe in the ureter by a soft wall. As I thought the probe might be too short, I passed a long, flexible catheter down through the ureter, expecting to see it in the bladder through the Kelly speculum. I could feel the end of the flexible catheter from the vagina. I could feel it move, but the movement was not free, as it would have been had it been in the bladder. It felt rather as if it was in the wall of the bladder, but was arrested in the portion of the ureter which passes through the wall of the bladder. I could feel no stone at the end of the catheter, and with the speculum I could not see the catheter in the bladder. The flexible catheter was now withdrawn; the attempt at withdrawal met with resistance, as if the catheter were caught low down in the ureter near or in the bladder-wall.

I now operated for the relief of the valve formation from the lateral implantation of the ureter in the pelvis. The pelvis was made tense by a finger of the left hand in the nearest calyx, and a flexible bougie passed down and into the ureter, which was then divided, together with the covering sac-wall, with scissors for a distance of 2 cm. The wall of the pelvis was grayish, 1 to 1.5 mm. thick, with loose connective tissue connected with the ureter, and consequently movable over it. The wall of the ureter was much thinner, probably $\frac{1}{2}$ to $\frac{2}{3}$ mm. thick. The wall of the divided ureter was united with the divided wall of the pelvis by a continuous catgut suture.

A long, flexible catheter was passed down 24 cm. or more, when it met with a soft resistance, and when withdrawn was held at this point by something which it pulled upon when the attempt at withdrawal was made. This resistance was overcome with a sudden jerk low down in the ureter, above which place the catheter moved easily. Dr. Buford noticed that the withdrawal of the catheter was followed by a welling up of blood from the ureter, but I am not sure that this blood had not run down from the bleeding surfaces in the cystonephrotic sac.

A bougie was now passed down 20 cm. and left permanently in the ureter.

The everted cystonephrotic sac was inverted and replaced, after final stoppage of the hemorrhage from the partition walls with the Paquelin cautery.

The opening in the cystonephrotic sac was sutured to the skin by eight silk sutures.

After uniting the quadratus lumborum with a buried mattress suture, a part of the posterior and anterior borders of the wound was united.

A large rubber drain was passed inside of the cystonephrotic sac down to the bottom, and the sac was loosely packed with sterile gauze around the drain. Gauze drains were packed around the outside of the sac, between the latter and the abdominal wall.

The operation lasted two hours and a half; the loss of blood was slight. Toward the end of the operation the pulse became weaker, but not too frequent—100 or below. Hypodermatic injections of camphorated oil and strychnin were made.

Examination of the Fluid from the Tumor.—The tumor contained about 1200 c.c. of fluid, which was limpid and transparent, distinctly acid, and had a specific gravity of 1013. It contained 36 gm. of solids—about one-half the normal amount; 4.8 gm. of urea—about one-fifth the normal amount; 7.8 gm. of chlorid—one-half the normal amount. Phosphates, sugar, bile, and indican were absent and sulphates present.

After-treatment.—The first twenty-four hours after the operation the quantity of urine was much less than normal. This was followed by a rapid increase, which, on the third day, exceeded the normal amount, and on the sixth day amounted to 149 ounces. During this rapidly increasing secretion of urine the patient was extremely nervous and slept very little, although for the first few days, when the urine was fairly normal, the nervousness was not so marked. During this period of polyuria the patient drank large quantities of water both day and night, the quantity corresponding fairly well with the amount excreted. The patient constantly complained of thirst, and especially of dryness in the throat; no special symptoms referable to the kidney were observed, and the only inconvenience was the frequent desire to empty the bladder.

On the tenth day a solution of pyoktanin was injected into the kidney, the openings carefully closed, and the patient instructed to lie on the opposite side for one or two hours. The solution did not appear in the urine, however. A week later, before the daily irrigation, the patient passed $7\frac{1}{2}$ ounces of urine of normal color. Immediately after the irrigation, 12 ounces of perfectly clear fluid were withdrawn from the bladder. Pyoktanin was again used two and four days after the first employment, but still with negative results. The increased quantity of urine passed was not in any way dependent upon the filling up of the bladder by the boric-acid solution used for irrigating the wound, as there was no appreciable difference noticed in the quantity of urine passed within the same period before and after the irrigation. The ureter was demonstrated to be open only once,—

on the seventeenth day,—when the quantity of urine passed was about normal. As the restlessness and nervousness of the patient subsided the quantity of urine decreased, and the thirst and dryness of the throat gradually diminished.

The right kidney secreted from 3 to 11 ounces in the twenty-four hours, which was estimated by weighing the dressings when applied and when removed, the difference in weight of the dressings representing the amount of urine excreted.

The outcome of this case is not material, as the object of this report is only to show the feasibility of this method of operating.

DISEASES OF THE KIDNEY AMENABLE TO SURGICAL TREATMENT*

GENTLEMEN:

Before entering upon the consideration of the topic assigned to me, I desire to acknowledge my appreciation of the compliment paid in inviting me to speak before this association, and to express the pleasure that it gives me to appear before you on this occasion.

ORIGIN AND GROWTH OF SURGERY OF THE KIDNEY

The surgery of the kidney began thirty years ago, when, on August 2, 1869, Gustav Simon, of Heidelberg, removed a kidney by the lumbar method for an irreparable ureteral fistula. This operation demonstrated that a man could live in perfect health, if not perfect security, with only one kidney.

This new field of surgery developed rapidly, as may be seen from a review of the literature on this subject. If we take, for example, the *Virchow-Hirsch Jahresbericht*, and count the number of papers on surgery of the kidney therein noted, the count will not include all the papers written on this subject, but will give a relatively correct idea of the growth of the literature.

In the first decade, from 1869 to 1879, less than 20 articles appeared; in the next decade, from 1879 to 1889, about 300, or an average of 30 papers a year, while in the third decade, from 1889 to 1899, about 800 papers, or an average of 80 a year, appeared.

The latest field in surgery, that of surgery of the ureter, is, as might be expected, inseparably connected with the surgery of the kidney and of the urogenital organs.

The surgery of the ureter is represented in the literature during the last decade by 90 papers, 87 of which appeared between 1894 and 1899. Thus the surgery of the ureter is only about five years old in its recent development.

STAGES OF DEVELOPMENT OF SURGERY OF THE KIDNEY

PERIOD OF RADICALISM.—*Nephrectomy or Nephrotomy Through Diseased Kidney Tissue*.—The first decade of kidney surgery might be termed the period of nephrectomy or radical surgery, during which the loss of one kidney was not considered so much as was the speedy cure of the patient. Nephrotomy and nephrectomy were performed indiscriminately in sup-

* Read before the Ontario Medical Association, 1899. Chic. Clin. Rev., 1899, vol. xi, p. 77.

purating kidneys, with or without stone, nephrectomy in calculous kidneys without suppuration, and even for floating kidney with healthy secreting tissue, as done by Martin, of Berlin, in 1878.

PERIOD OF CONSERVATISM.—*Operation Through Healthy Kidney Tissue (Morris).*—At the beginning of the second decade the first steps in the direction of conservatism were taken, and instead of nephrectomy, less radical operations were made to remedy the disease without sacrifice of the “noble tissue of the kidney,” as Tuffier calls it. In 1881 Hahn made nephropexy or nephrorrhaphy for floating kidney, thus saving the healthy organ, which previously would have been removed.

The most important step, however, and one whose consequences have been most far reaching, covering the entire field of kidney surgery, we owe to Henry Morris, of London, who, on February 11, 1880, had the courage to operate through healthy kidney tissue and remove an oxalate-of-lime stone from an undistended, healthy-looking kidney, by an incision through the renal parenchyma.

No operator prior to this time had dared to encounter the hemorrhage which follows incision through healthy kidney substance. Thus stones had been removed only from suppurating and often distended kidneys, where the interstitial nephritis made the incision almost bloodless.

From this important operation of Morris dates the possibility of the development of conservatism which is pressing forward, fighting its way toward the goal of renal surgery, which is the preservation for the patient of all kidney tissue available for secretion.

Morris' operation has made it possible to save the kidney from the destructive influences of the stone; namely, suppuration and dilatation, which are finally bound to occur.

I consider Morris' operation on healthy kidney tissue of far greater importance, however, because, in addition to allowing resection of the kidney, it paves the way for the exploratory incision which now, in less than twenty years, has grown to be an operation of far-reaching diagnostic as well as therapeutic value.

In the third decade the latest step toward conservatism was made, namely, the surgery of the ureter. This somewhat limited field of surgery has, with the exception of ureterectomy for tuberculosis and septic pyelitis, no other object than to save the secreting kidney tissue above from disturbances from below, due to retention or infection.

In a review of this nature the time at my disposal will permit me to indicate only a few points in urinalysis and the present status of treatment of surgical diseases of the kidney.

Tuffier's experiments on dogs have demonstrated that the minimum amount of healthy kidney tissue necessary for life is 1.5 gm. for each kilogram of body weight. An adult man should have 300 gm. of kidney tissue; if his weight is 75 kilos, or 150 pounds, he needs only 75 to 112 gm. of the 300 gm. of kidney tissue; that is, he can spare two-thirds or three-fourths of the normal amount of kidney tissue before crossing the danger-line, and he may live in perfect or relative health for years

during the destruction of the kidneys until the last fourth is reached, when sudden uremia sets in.

When the amount of kidney tissue approaches the lowest limit, the quantity of urea diminishes, although the amount of urine may still be normal. It is, therefore, a matter of vital necessity to examine the urine for urea before operating.

Compensatory hypertrophy or regeneration of kidney tissue of the healthy kidney when its fellow has been removed or destroyed by disease has been studied experimentally by Tuffier. After extirpation of one kidney he removed, by successive partial operations, portions of the remaining kidney, aggregating in all the weight of the kidney first removed. From this he concludes that, as a quantity of kidney tissue equal to both kidneys was removed without disturbing the health of the animal, at least the necessary one-fourth of the kidney tissue must have been formed by regeneration or compensatory hypertrophy.

EXAMINATION OF THE URINE (BACTERIOLOGIC).—After thorough cleansing of the external genital organs and of the urethra, the bladder urine must be withdrawn by a sterile catheter lubricated with boiled olive-oil, and collected in sterile test-tubes. If there is doubt whether the pus or blood comes from a diseased bladder or from the kidneys, the bladder should be washed out and the urine collected directly from the ureter by means of a catheter left in the bladder. An aspiratory puncture with a fine needle above the symphysis, and removal of the urine through an aspirator syringe, as practised in Johns Hopkins Hospital, does away with the danger of infection by the catheter and protects against contamination of the bladder urine.

Examination of the collected urine must be made without delay, as the urine changes rapidly by decomposition. The reaction, whether acid, alkaline, or neutral, should be noted. Microscopic examination after sedimentation by means of the centrifuge may reveal red blood-corpuscles, white corpuscles, pus-cells, crystals, cylinders, and epithelial cells from the urinary tract, or, very rarely, abnormal cells from tumors. Chemical examination should be made for albumin, blood, and sugar. If the filtrated, purulent urine contains much albumin, disease of the kidney must be suspected, since the longer the pus-cells remain in the urine, the more of them will be dissolved.

Quantitative Examination for Urea.—After the patient has been on nitrogenous diet for some time, a sample from the twenty-four-hour urine should be examined, by Esbach's method, for example. The hypobromite solution should always be made fresh. As alkaline decomposition of urine diminishes the urea, the bladder should be washed out, so that acid urine may be voided, and the examination should be made as soon as possible after the urine has been passed.

If the quantity of urea is below normal, as is found in tumor, stone, and pyonephrosis, it may be concluded that the other kidney is not healthy, and consequently that operation is dangerous. As an aid in the differentiation between disease of the bladder and of the kidney, and to ascertain from which kidney the blood or pus is excreted, resort is

made to cystoscopy. Direct cystoscopy through a tube, the light being thrown into the bladder, previously distended with air, from a head-mirror, as practised by Kelly, is useful in women. Indirect cystoscopy is made by means of Nitze's cystoscope, in which an electric lamp in the bladder, previously filled with water, illuminates the bladder-wall.

To collect the urine separately from each ureter we resort to catheterization of the ureter by means of a long, fine, flexible ureteral catheter inserted by the aid of the cystoscope. An instrument devised by Harris for this purpose may be tried.

Direct examination of the kidney through an extraperitoneal (lumbar) incision is the last step in a positive diagnosis. When the surface of the kidney has been laid bare, we may palpate or aspirate, as in cystonephrosis and stone, or excise a piece of kidney tissue for microscopic examination, or we may bisect the organ longitudinally down into the pelvis in case of stones in the calices, stenosis, valve formation, or abscess. Division of the healthy kidney tissue, even in the median line, causes considerable hemorrhage, which may be controlled by compression of the renal vessels by the hand of an assistant, or an intestinal compressor, or directly by packing with gauze.

MOVABLE KIDNEY

An elastic abdominal supporter with a pad under the ribs, together with appropriate internal treatment, should always first be tried, as many patients obtain a sufficient degree of relief therefrom. If this treatment fails, the operation of nephrorrhaphy or nephropexy, which was first made by E. Hahn in 1881, should be performed. The operation is as follows: After lumbar incision and division of the capsule the kidney is laid bare, pushed up into its normal location, and the fibrous capsule, together with a layer of the cortical substance, united with the fascia and outer periosteum of the twelfth rib by three or more sutures. To avoid relapse, however, it is advisable to follow the suggestion of Tuffier, who, in addition to the sutures, dissects out a flap of the fibrous capsule 2 cm. broad and of the length of the kidney, and unites this flap with the borders of the divided muscles. Nephrorrhaphy has a mortality of about 1 to 1.125 per cent.; about 65 per cent. of permanent cures; in 10 per cent. improvement takes place, and relapses occur in 22 per cent. of the cases.

CONTUSION OF THE KIDNEY (SUBCUTANEOUS RUPTURE)

Absolute rest in bed for three weeks is essential to avoid the danger of secondary hemorrhage. Stimulants should be given during the period of shock and morphin for the pain. Local application of cold (ice-bag) is often employed, and Tuffier recommends compression of the costal-iliac space by a pad of cotton, held in place by a flannel bandage. The patient should be put on light, liquid diet. Ergot, acetate of lead, or other hemostatics may be employed. It is important to avoid the use

of the catheter, and absolutely essential to secure asepsis if the catheter must be used. Hemorrhage or infection may necessitate operative treatment. Hemorrhage from the larger vessels may be stopped by ligature or tampon, but if the whole kidney is found to be crushed, it should be removed. Infection may require evacuation of pus by nephrotomy, followed by drainage or nephrectomy if the greater part of the kidney tissue is destroyed, or if the kidney is the seat of multiple abscesses.

WOUNDS OF THE KIDNEY

Gunshot wounds should be sealed after thoroughly cleansing the skin, and the patient should be kept in bed for at least three weeks. If a large swelling and symptoms of anemia appear, the kidney should be laid bare and the hemorrhage stopped by ligature or tampon, or nephrectomy should be made if the renal vessels are injured. Incised wounds with external hemorrhage should be freely opened and the kidney examined. If the wound is aseptic, the kidney can be sutured; if infected, the hemorrhage should be stopped by packing and the wound united later on by secondary suture. If urine exudes, drainage is required. If infection of the accumulated blood and urine occurs, as indicated by onset of fever, pain, and increased lumbar swelling after eight or ten days, free incision (nephrotomy) or eventually nephrectomy must be made. The hematuria almost always stops spontaneously, but if it persists despite rest and ergot, and if copious, the patient's life has been saved by nephrectomy (in 5 out of 6 cases—Tuffier). If the bladder is filled with coagula, causing vesical retention, catheterization is usually resorted to, but this is difficult, as the clots often occlude the eye of the catheter. It is, therefore, better to use Bigelow's litholapaxy evacuator. If this procedure is unsuccessful, suprapubic puncture and aspiration of the urine and liquid blood may be of assistance during the few days required for the crumbling of the coagula. If aspiration is tried in vain, the bladder must be opened either by perineal section or, preferably perhaps, by epicystotomy.

NEPHROLITHIASIS

Medical treatment should always be resorted to after operation for removal of stone and when operation is deemed unnecessary or dangerous. In acid lithiasis with urate or oxalate stones, lithia water, from a pint to a quart a day, and half a teaspoonful of bicarbonate of soda with the meals, should be given for six weeks, to be repeated three or four times a year. The alkaline mineral waters, open-air exercise, regular diet, no abuse of alcoholics, will serve as an outline for treatment. In alkaline or phosphatic lithiasis the urine should be made acid by the use of boric acid in doses of 50 eg., or salol in $\frac{1}{3}$ gram doses three or four times a day. Three or four pints of cold boiled water should be taken daily by all patients.

Surgical Treatment.—The operations for nephrolithiasis are nephrolithotomy, pyelolithotomy, nephrotomy, and nephrectomy.

Nephrolithotomy, or removal of stones from a healthy, non-infected kidney, was first made by Morris in 1880. Through an oblique lumbar incision the kidney is isolated, brought out into the wound, and palpated in order to feel stones in the pelvis. The stones in the calices are sought for by puncture with an aspirator needle, and if found, are removed by an incision made with the needle as a guide. If retention exists, the pelvis is found by aspiration and the kidney opened on its convex surface on the needle as a guide. When the pelvis is opened, exploration is made with the finger or a metal sound. The stones are extracted after division if they are very large, but always with as little manipulation as possible. The hemorrhage from healthy kidney tissue is considerable, and must be controlled by compression of the vessels in the hilus or by local pressure with gauze sponges. The thermocautery may also be of use as a hemostatic measure in these cases.

The ureter is then examined with a metal probe to determine its permeability and to detect stones. The stones extracted should be carefully examined to determine whether pieces have been broken off and left in the kidney. If asepsis is certain, the wound in the kidney should be united by catgut sutures, by which hemostasis is assured. Primary union may take place.

Pyelolithotomy—if the stone is located in the pelvis near the ureter it may be removed through an incision in the posterior pelvic wall. This operation possesses the advantage that there is no hemorrhage, but has the disadvantage that stones are more easily overlooked, and that the operation is said to be more frequently followed by fistula (Rovsing).

Nephrotomy, or opening into a suppurating kidney to evacuate pus and remove stones if present. The kidney is opened at its most prominent point over one of the thin-walled sacs. Exploration is then made with the finger and steel sound for stone. This must be done carefully, as stones were either not found or as all stones were not removed in 16 per cent. of 114 cases reported by Tuffier. The thin, atrophic kidney wall does not bleed. The wound in the kidney is united to the skin, and the cavity packed and drained in order to overcome the pyelitis by local treatment.

Nephrectomy, which was formerly much in vogue, has been almost entirely abandoned. It possesses the advantage that if the patient survives, he is cured by a single operation, but the mortality is 38 per cent. as against 33 per cent. mortality for nephrotomy. For this reason many operators follow the advice of Guyon, first, to make nephrotomy and later on nephrectomy if demanded. This secondary nephrectomy, after the lapse of months or years, is a relatively safe operation.

Calculous Anuria.—When the only useful kidney is closed by stone, nephrotomy, as suggested by Thelen in 1882, should be done during the period of tolerance. Hot baths, careful massage of the ureter, electricity, and chloroform narcosis may be tried for a day or two. If the

patient is not operated upon, Tuffier and Legueu's statistics show that 28 per cent. recover by spontaneous expulsion, and that 72 per cent. die, while operation has saved 60 per cent.

PYONEPHROSIS AND PYELONEPHRITIS

Treat or cure the cystitis and overcome the causes of retention—stricture, enlarged prostate, abdominal tumors, etc.

Primary hematogenous pyelonephritis in a patient who has free passage of urine is amenable to internal treatment. The lines upon which the treatment is based are rest in bed, increased diuresis by drinking large quantities of water or milk, and bicarbonate of soda up to 30 gm. daily (Tuffier). Salol in doses as high as 3 gm. a day has been recommended, but is apt to cause poisoning (hemoglobinuria). Boric acid and the alkaline waters are safe agents to employ.

When the disease is unilateral or the sepsis acute, operative treatment is indicated. Nephrotomy is the operation of choice; lumbar incision, evacuation of the perinephritic abscess, incision of the kidney, evacuation of pus and stones, division of the partition walls in a multilocular cavity, irrigation, packing with sterile gauze, and drainage after suturing the kidney wound to the skin.

If the suppuration persists, secondary nephrectomy may be required. If a fistula remains and the kidney is worth saving, a secondary operation to reestablish the passage through the ureter is required. Primary nephrectomy should be made only when the kidney tissue is filled with multiple abscesses and acute sepsis demands the removal of the organ.

Weir, in an article on "The Surgical Treatment of Surgical Kidney," reports 71 cases of acute surgical kidney, ascending infection, 12 of which, or 17 per cent., were unilateral. Thus, if the condition of the patient permit, exploratory lumbar incision may be made on one or both sides and the kidney removed, if needed. He reports a case of gonorrhoeal cystitis in a man of twenty-five. During convalescence, acute septic infection of the right kidney occurred. On the eleventh day after the initial chill the patient had right renal pain. He was taken to the hospital, where a diagnosis of ileotyphus was made, and ice-bags applied for the pain. A swelling appeared in the region of the right kidney. On lumbar incision it was seen that the kidney was twice its normal size. No pus was evacuated on puncture. An incision 1 inch in depth revealed multiple miliary abscesses and ecchymoses. The kidney was, therefore, removed, and the patient recovered.

Nephrectomy should also be made in all cases where no active kidney tissue remains. As it is, however, usually impossible, during an operation, to determine the secretory value of a kidney, nephrotomy should always be first resorted to.

In operations for nephritis, as in all operations on the kidney, it is not permissible to employ poisonous antiseptics. Sterile water should be used and sterile gauze, not iodoform gauze, as has been so often recommended.

TUBERCULOSIS OF THE KIDNEY

Internal treatment has symptomatic value only. Operation may effect a cure which will last for years. Nephrectomy, total or partial, the latter being rarely applicable, is the operation of choice. It is applicable when the other kidney is healthy and when the patient's condition as regards tuberculosis in other organs permits. It has, however, been seen that tuberculosis in the bladder has improved after nephrectomy. The tuberculous ureter may be excised with the kidney if the patient's condition permits. Subcapsular nephrectomy with cureting of the adipose capsule has the advantage of being easy of execution, but has the disadvantage of not removing all the tuberculous foci.

Nephrotomy for evacuation, cureting, and local treatment are recommended by as high an authority as Guyon, to be followed by secondary nephrectomy when the patient's health is improved. Guyon gives the excellent advice on technic of the operation to suture the divided adipose capsule to the skin before opening into the tuberculous kidney, in order to avoid infection of the wound.

Nephrotomy as a curative operation is being abandoned, as not 1 of the 90 cases reported by Vigneron and Facklam was cured, and as the operative mortality was 12 or 13 per cent., making the mortality from the disease 33 to 38 per cent. On the other hand, of 88 primary nephrectomies reported by Facklam, 28.4 per cent. died, and 40.9 per cent. resulted in perfect cure; in 14 cases the patients lived from two to eight years after the operation. No operation should be made when the urea is diminished below one-third of the normal.

MALIGNANT TUMORS OF THE KIDNEY

Nephrectomy should be made by lumbar incision in case of the smaller tumors, but the transperitoneal operation will be required if the tumors are too large to be removed through a lumbar wound. The tumor is operable if it is limited to the kidney and if there are no metastases in the lymphatic glands. In many cases this cannot be determined before exploratory incision renders palpation of the organ possible. If it is found that enucleation cannot be completed in perfectly healthy tissue, the operation should be abandoned. The prognosis of the operation is grave; the operative mortality before 1890 was over 60 per cent., but has decreased in the last five years to 25 per cent. (Wagner). Radical cure is rare, but the instances are increasing in which a permanent good result is obtained. Israel reports 3 patients out of 11 operated upon who were in good health after three years. I have one case in which the patient is still in good health eight years after operation. Local relapses may come on later—after three years or more. Therefore Tuffier gives six years as the time which must elapse before the patient may be said to be permanently cured.

BENIGNANT TUMORS OF THE KIDNEY

Lipomata, adenomata, fibromata, angiomata, myomata, and combinations of these have been found in the kidney. In most cases the tumors are small, give rise to no symptoms, and are discovered accidentally on the postmortem table. Benignant tumors have been removed by nephrectomy in about 10 cases only; 2 of these were adenomata and 8 fibromata (Rovsing). Serous cysts about the size of a walnut, either solitary or multiple, should be recognized during operation and removed by resection.

Echinococcus cysts are found most commonly in men between the ages of twenty and forty—ordinarily, in one kidney only, and most often in the left. There is usually only one mother-cyst, which begins in the cortical substance, causes expansion and atrophy of the kidney tissue, and when large, may extend to the abdominal cavity, becoming adherent to the colon, liver, spleen, etc. Finally, after one or two years the cyst ruptures, fortunately most often into the pelvis of the kidney, and evacuates part of its contents through the ureter.

The symptoms are at first vague the tumor is globular and often movable. Rupture is marked by a sudden pain, followed by renal colic as the daughter-cysts pass down the ureter, and vesical tenesmus when they pass out into the urethra. The cysts are usually crushed during their passage from the kidney, and we find in the urine transparent gelatinous masses (the sac-walls) and a little blood. Microscopic examination reveals the characteristic hooklets and lamellated membranes of the sac. Later on infection occurs, which is attended by fever and emaciation, terminating fatally in most cases (23 out of 29 cases, Boeckel), spontaneous recovery being the exception.

Treatment.—The cysts should be opened by lumbar or transperitoneal incision, the contents evacuated, and drainage maintained until the cavity is closed. The opening in the cyst-wall must be united to the skin. Lumbar incision, if practicable, is to be preferred. If the transperitoneal route is chosen, the operation in two stages is preferable. Le Dentu treated 9 cases and Wagner 28 cases in this manner, and all the patients recovered; while out of 10 cases in which nephrectomy was performed, Wagner reports 3 deaths, and of 11 cases of puncture alone or puncture with injection of tincture of iodine, 3 were cured, 3 remained unimproved, and 5 died.

ANEURISM OF THE RENAL ARTERY

Rovsing reports that only 9 well-described cases of aneurism of the renal artery are to be found in the literature. The diagnosis was made in none of these cases until an exploratory operation or autopsy revealed the true character of the disease. If the aneurism is located on one of the large intrarenal branches, the swelling is central and causes distention of the kidney. If it is an aneurism of the trunk of the renal artery,

the tumor is located outside of the kidney in the hilus, and pushes the kidney aside without making any change in the shape of the organ.

The symptoms are a rapidly increasing, tense or elastic tumor, with a feeling of heaviness and pain which may radiate down to the testicle of the same side. Pulsation has not been noted in any of the cases. Diagnosis is practically impossible before an exploratory incision has been made. The possibility of aneurism should be considered when, subsequent to an injury in the region of the kidney, a tumor of considerable size develops rapidly, with no hematuria, especially in patients having arteriosclerosis or syphilis. The treatment is nephrectomy, after ligation of the renal vessels as close to their origin as possible. Two patients have been saved in this manner (Hochenegg, Hahn).

CYSTONEPHROSIS (HYDRONEPHROSIS; PYONEPHROSIS)

Dilatation of the urinary passages occurs above an obstruction to the free flow of urine. It begins immediately above the point of stenosis, and extends gradually backward toward the kidney. Thus, a stricture of the bulbous portion of the urethra causes, first, dilatation of the membranous urethra, next of the bladder, then of both ureters, and finally of the pelvis and calices. If the obstruction is in or below the bladder, the dilatation extends to both kidneys, while if the obstruction is located in the ureter or above it, the dilatation will be limited to the kidney of the affected side. If only one of the two branches of the ureter is occluded, a partial dilatation of the kidney takes place, which is limited to the corresponding half of the organ. Dilatation of the pelvis and calices above the ureter may be termed cystonephrosis. When no infection of the retained urine has taken place, it contains a watery fluid and is termed hydronephrosis. When infection has transformed the fluid into pus, we speak of pyonephrosis.

(a) *Remittent Cystonephrosis*.—The most formidable enemies to kidney tissue are retention and infection, and it is difficult to state which of the two is the more formidable. Retention, if incomplete,—that is, remittent,—may, I believe, be tolerated for a long time; if complete, it is rapidly destructive.

In movable kidney with paroxysms of pain we find, upon microscopic examination of apparently healthy kidney tissue, a glomerulonephritis or interstitial nephritis. I do not know whether or not this is caused by retention or venous congestion from torsion of the vessels in the hilus. Whatever the cause may be, the development of the nephritis and slow destruction of the glomeruli, and consequently of the secretory value of the kidney, furnishes a probable argument for operations for replacement of the kidney, for nephropexy, irrespective of and in addition to the symptomatic relief obtained by it.

Remittent or beginning retention—and all retention is, in its early stages, as a rule, remittent—is a condition in which we should always consider the possibility of saving kidney tissue by reestablishment of the free passage of the urine.

The obstruction may be located in the calices; in a branch of the ureter; in the bottom of the pelvis or origin of the ureter, or in the ureter.

Obstruction in the first two locations causes a local or partial cystonephrosis, and demands, for the relief of the condition, bisection of the kidney from its convex surface and division of the partition walls.

Stenosis at the exit of the ureter (valve formation, oblique implantation from unilateral dilatation) requires operations which vary in accordance with the absence or presence of stricture at the upper end of the ureter.

If there is no stricture at the upper end of the ureter, the valve formation may be overcome by a transpelvic operation (Fenger, Mynter, Trendelenburg, Küster).

If there is a stricture of the ureter at its exit from the pelvis, as may be expected in infected cases, we may resort to extrapelvic operation, plastic operation (Fenger), or resection (Küster).

I have twice made the extrapelvic plastic operation, which has also been done by Morris, Kelly, Maurice Richardson, and others. The operation consists in division of the stricture up into the pelvis and down into the ureter and transverse union of the longitudinal wound.

Resection of the strictured end of the ureter and implantation of its upper or divided end into the pelvis has been done by Küster.

If the stenosis or obstruction is located in the ureter, it must be dealt with according to the laws laid down for surgery of the ureter.

There is one drawback or difficulty in the way of the development of surgical treatment of renal retention when the obstruction is located in the kidney and pelvis (to a less extent in the ureter), namely, that the subject cannot be well studied by experiments on animals. We can produce a stricture of the ureter, but we cannot artificially produce valve formation and oblique implantation of the ureter in the pelvis, nor can we cause obstruction in a branch of the ureter or in the calices. Thus the best methods of operation and development of technic have to be studied and perfected by operation on the relatively rare cases met with in the human subject.

Are the results of these, so to speak, tentative, conservative operations permanent, or does relapse eventually occur?

In 4 of my cases no relapse occurred:

1. Woman: Valve formation, intrapelvic or transpelvic operation. No relapse six years later.

2. Man: Stricture of upper end of ureter, extrapelvic operation. No relapse six years later.

3. Man: Valve formation of lower branch of the ureter; extrapelvic operation; bisection of kidney; division of partition walls. No relapse after three years.

4. Woman: Excision of valve in ureter by my plastic operation. No relapse after three years.

In 3 cases relapse occurred:

1. Woman: Intrapelvic operation on valve formation without stricture. Relapse of stenosis, occlusion of pelvic orifice. Nephrectomy one year later.

2. Man: Operated on by another surgeon; later on by myself; operation was incomplete, failed, and nephrectomy was finally necessary.

3. Man: Stone in upper end of ureter removed by myself. One year later plastic operation on ureter by another surgeon; six months later I found complete occlusion of the ureter at site of second operation, and made another attempt at a plastic operation. Patient still under treatment.

Beginning cases of open, intermittent, non-infected cystonephrosis, when due to bending of the ureter in a floating kidney, may be treated by nephropexy, provided the bend is found to straighten out when the kidney is replaced. If no bend exists, the sac should be opened and the obstruction sought for by exploring the ureter from its pelvic origin down to the bladder. A valve or stricture may be remedied by a plastic operation, or a stone may be removed from the ureter. If it is thus possible to remove the cause, the kidney can be saved, and should be saved if secreting kidney tissue still remains.

Infected, remittent cystonephrosis (pyonephrosis) must necessarily be opened for drainage and examined as regards the removal of the obstruction, but here the question of removal of the kidney comes up, and if suppurative nephritis, with multiple abscesses in the kidney tissue, is found, nephrectomy should be done, but this is extremely rare.

(b) *Stable, permanent, non-infected cystonephrosis (hydronephrosis)* has been treated by puncture, incision, and extirpation (nephrectomy).

Rovsing has collected from the literature 92 operations for hydronephrosis, with the following results:

OPERATION.	RE- COVERY.	UNIM- PROVED.	DIED.	TOTAL NUMBER OF CASES.
Puncture with drainage	1	2	9	12
Nephrotomy	15	13	28
Transperitoneal primary nephrec- tomy	16	..	3	19
Transperitoneal secondary nephrec- tomy	7	..	3	10
Lumbar primary nephrectomy	18	..	2	20
Lumbar secondary nephrectomy . . .	3	3

It will be seen from this table that puncture, even with drainage, is insufficient, dangerous, and should be abandoned. Nephrectomy or total extirpation of the hydronephrotic sac has given the best results, and is the operation which should be employed in the majority of cases. Transperitoneal nephrectomy was most often performed in cases in which a large sac filled the abdomen, and a correct diagnosis was not made before the operation. If it is known that a hydronephrosis is present, the lumbar operation should probably always be done. If the hydronephrotic sac contains no secreting kidney tissue, as is the case in most of the very large hydronephroses, nephrectomy is indicated. A large sac which is practically valueless as to secretion and is clad with mucous membrane is very apt to become infected after nephrotomy and

drainage. It is almost impossible in such cases to prevent infection, and Rovsing's statistics show that, out of 28 cases of nephrotomy, 13 patients died. In most cases of large, stable hydronephrosis we find the other kidney sufficient for the urinary secretion. This is demonstrated by the fact that out of 52 cases of nephrectomy only 8 patients died.

In small recent stable hydronephroses, however, when kidney tissue can be recognized in the walls of the sac, and when remittent evacuation, found at first, has recently ceased, we may expect to find secreting kidney tissue that is worth saving. Here nephrotomy should be tried and the obstruction sought for. If the sac is too large to permit of finding the ureter, we may wait for a few months until it has retracted. During this time we must examine the quantity and quality of the urine excreted daily from the lumbar opening. If the quantity is considerable, the obstruction can be sought for and remedied by a secondary operation. If no urine is secreted, secondary nephrectomy should be done.

EXPLORATORY INCISION WITH INCISION OF PIECE OF KIDNEY TISSUE FOR MICROSCOPIC EXAMINATION

Exploratory incision, which is probably the most important consequence of Morris' operation on healthy kidney tissue, has been developed gradually by mistakes in diagnosis.

Kidneys which presented symptoms of pain, and even attacks of simulated renal colic or hematuria, or both of these conditions combined, were laid open under the diagnosis of stone or tumor, and none of these conditions was found. The kidney was explored more or less thoroughly by inspection, needle puncture division of capsule, division of capsule, division of cortical substance, and even by bisection, laying open the pelvis and calices.

As it was gradually recognized, according to Albarran, that this operation was without danger, and as almost all authors agreed in this regard, it was natural that it should be resorted to without hesitation. It was still more commonly practised because it was found that in many cases in which neither stone nor tumor was found, and in which no definable disease of the kidney could be made out without microscopic examination, which at this time was not made, the operation relieved the pain and hematuria and effected a symptomatic and often a permanent cure.

In the course of time, as exploratory incisions for pain and hematuria became more frequent, and as the kidneys were more closely observed, some slight pathologic conditions were often found to account for the symptoms as well as for the cure of certain of these cases by exploratory incision. Thus, Tiffany found a cicatrix in the upper lobe of the kidney; Barker, oxalate-of-lime crystals; Abbe, gravel in a calyx, and Lauenstein, dilatation of pelvis and consequently retention.

In cases of the so-called hemophilia of the kidney, for which, since the celebrated case of Senator, the kidney has five times been extirpated, Albarran believes that a careful microscopic examination would often demonstrate the presence of nephritis. In chronic nephritis we may

have unilateral hematuria, as in the infectious nephritis following la grippe.

To relieve the tension caused by pressure in some forms of albuminuria, probably due to non-surgical nephritis, Reginald Harrison advised, in 1896, exploratory operation with puncture or division of the albuminous capsule. With the same object in view, Le Dentu, as early as 1881, and Lambret, in 1897, found relief of symptoms due to division of the capsule along the convex border of the kidney by the knife or Paquelin cautery.

To make exploratory incision complete as to its diagnostic value, which may go hand in hand with and be as important as its therapeutic value, it is essential to excise a small piece of kidney tissue for microscopic examination. This has been my custom for years. It is often impossible, when we have the divided kidney in our hands, to make a correct diagnosis of the apparently healthy kidney tissue with the naked eye. This has been well demonstrated by a series of 7 cases operated upon by Oscar Bloch, 4 of which I will briefly mention:

CASE I.—Diagnosis before operation: Stone, slight pyelitis, movable kidney, or neoplasm.

Diagnosis during or after operation: Beginning diffuse sarcoma (malignant tumor).

Diagnosis after microscopic examination of excised renal tissue: Slight nephritis with microbes.

CASE II.—Right renal pains for eight years at intervals first of one month, later of a few days only.

Diagnosis before operation: Doubtful whether or not renal disease exists.

Diagnosis after nephrotomy and digital exploration of pelvis and calices: Chronic, adhesive perinephritis; uncertain renal disease.

Diagnosis after microscopic examination: Parenchymatous and interstitial nephritis.

One year later the patient was suffering no pain and was in perfect health.

CASE III.—Diagnosis before operation: Deep peritoneal or retroperitoneal abscess on right side.

Diagnosis after lumbar incision and evacuation of 1400 c.c. of pus: Uncertain as to location and nature of abscess.

Diagnosis after microscopic examination of piece of sac: Pyonephrosis (uriniferous canals and tubules found in wall of sac).

CASE IV.—Diagnosis before operation, but after puncture which evacuated old pus: Pyonephrosis of long standing, with closed ureter.

Diagnosis after operation. Chronic nephritis (yellowish cortical substance; indistinct border-line between cortex and pyramids).

Diagnosis after microscopic examination: Normal kidney.

The tumor in this case was a cyst of the spleen.

Albarran reports a case of a man of fifty-one who had had nephritic colic for a year, after which hematuria appeared. Upon cystoscopic examination blood was found to issue from the right kidney. Diagnosis: Stone or neoplasm (not tuberculosis).

Operation: Exploratory nephrotomy, kidney slightly enlarged, pelvis and calices somewhat dilated and flaccid. Opening through kidney into the pelvis; digital exploration found no stone, "but the finger

brings out some fragments resembling false membrane." A bougie introduced through the kidney passed down freely into the ureter. Wound and kidney closed by catgut sutures and healed by first intention.

Microscopic examination: The false membrane showed carcinoma. The kidney was removed thirty-one days later, and the patient recovered.

As regards the technic of exploratory incision, it may be said that the kidney should be exposed by a lumbar incision, the condition of the adipose and fibrous capsules noted, the kidney liberated in the usual manner for palpation and inspection, needle puncture if stone is suspected, the fibrous capsule divided longitudinally along the free border of the kidney as far as is deemed necessary by the operator.

Hemorrhage is controlled by digital compression of the hilus by an assistant or by a clamp. The cortical substance is divided by the knife or cautery, the knife being preferable, as it gives a natural view of the cut surface; if it is considered necessary, the division may be prolonged through the pyramids into the pelvis, which is then examined by digital exploration. If it is deemed necessary to expose the pelvis to ocular inspection, incision is prolonged through both poles, so that finally the kidney is completely bisected ("Sektionschnitt" of the Germans).

The hemorrhage, which usually recurs as soon as compression of the hilus vessels is released, is best stopped by reuniting the bisected kidney by deep and superficial sutures. In an aseptic kidney this can always be done; but when there is suppuration in the pelvis and calices and the kidney is, consequently, infected, it is wiser to stop the hemorrhage by packing with sterile gauze after only partial union of the bisected kidney.

There is no question that exploratory incision, bisection of the kidney, and microscopic examination of a piece of its tissue is the court of ultimate appeal in diagnosis. The question naturally arises, whether there is any danger following division of a healthy or only slightly diseased kidney. The danger of infection from without seems to be minimal with our present operative technic, and, in fact, so high an authority as Albarran does not hesitate to aver that the operation is devoid of danger ("*ne presente aucun danger*").

While I believe that the danger is minimal, still there are two cases on record, and these are, so far as I know, the only ones of the large number of exploratory incisions made which have presented a peculiarly dangerous consequence; namely, gangrene of the kidney tissue.

CASE I.—*Nephrolithotomy. Stone in pelvis. Primary suture of kidney. Hemorrhage eighth day. Local gangrene of kidney. Nephrectomy. Death.*

A. B., male, forty-four years of age, was admitted to the hospital in my service on May 25, 1893. Family history negative. Patient's general health was fair until the present trouble began, three years before. In August, 1890, after prolonged driving over rough roads, he was seized with severe pain in the right testicle, accompanied by vomiting. The pain gradually disappeared, and was entirely gone in about two days. Toward the close of the attack he felt slight pain in the region of the kidney. During the next two

years he had several attacks, usually occurring after severe or prolonged exercise. Following April, 1893, he had almost constant pain, localized in the region of the right kidney, the pain extending at times down the right leg as far as the foot. No apparent hematuria. Under the microscope the urine was found to contain some blood-corpuscles and pus-cells, but no albumin. The patient had lost about 25 pounds in weight during the last year.

Examination.—The patient looked reasonably healthy and well nourished, the color of his face being neither rosy nor extremely pale; no tumor can be felt; slight tenderness upon pressure in the lumbar region; no tenderness on rectal examination of the ureter.

Operation.—Under ether narcosis an incision was made, from $\frac{3}{4}$ inch below and parallel to the twelfth rib through the skin, latissimus dorsi, and abdominal muscles. After dividing the tendon of the transversalis, a mass of paraperitoneal adipose tissue the size of a goose-egg bulged out in the wound. After pressing this aside by piercing it with dissecting forceps, I reached the retroperitoneal thin fascia covering the adipose capsule of the kidney.

At first I could not feel the kidney, and as the operating space was small, I divided the quadratus lumborum transversely back to the extensor dorsi, and finally reached the lower end of the kidney.

The adipose capsule was thick, and so adherent in places that it was necessary to prolong the incision so as to insert the entire left hand. The kidney was then brought down into the wound, but nothing abnormal could be seen or felt on its surface, nor could any stones be felt in the pelvis.

Exploration from the convex surface of the kidney by a needle inserted upward, inward, and downward was negative as to stone, cavity, or urine. A piece of the cortex was excised for microscopic examination.

I next made an incision 2 inches long on the convex surface of the kidney; the incision was followed by considerable hemorrhage. It was so difficult to find the cavity of the pelvis that I lifted up the kidney, and there saw the ureter on the posterior surface, not dilated, and with no stones in its upper portion. I then succeeded in reaching the pelvis from the convex surface of the kidney. Examination of the pelvis with a steel urethral sound disclosed no stone, nor could any stone be found on digital examination, but I could feel grating after a flexible lead catheter had been passed in various directions in the lower end of the kidney.

I then extracted the stone, which was oval, flat, with a roughened, crystallized surface, and was 1.5 cm. in diameter and 0.5 cm. thick. No more stones could be found on exploration.

A flexible bougie was next introduced into the ureter, and passed down into the bladder without obstruction.

I now proceeded to close the wound in the kidney. The hemorrhage was so profuse that it was necessary to compress the lips of the kidney wound continuously, as every time the compression was removed the blood welled up. I then attempted, without success, to compress the vessels in the hilus. The hemorrhage was finally checked by the insertion of four deep sutures, and the closure of the kidney wound was completed by inserting two surface sutures. The adipose capsule was then drawn over the kidney and drains inserted down to the kidney surface. The divided muscles were next united in inverse order, and the skin sutured down to the point of insertion of the drainage-tube, and the usual dressings applied. The patient did well for six days, when hematuria and rise in temperature appeared. After this condition had increased for three days I reopened the lumbar wound and the wound in the kidney, and packed the latter down to the pelvis. This checked the hemorrhage, but the temperature continued to rise, and in two or three days reached 104° F. As a last resort I made nephrectomy. The operation occupied only a few minutes, but the patient died ten minutes later.

In the removed kidney was found a cuneiform, gangrenous infarction; about 1 cubic

inch of the kidney tissue was gangrenous and was beginning to separate, thus giving rise to the secondary hemorrhage.

In the second case the whole kidney was gangrenous and the patient survived.

CASE VII (Bloch).—Diagnosis before operation: Acute suppurative pyelonephritis of two months' standing, renal tumor, pyuria, fever, probably stone in kidney.

Operation: Nephrotomy; incision in kidney $2\frac{1}{2}$ inches long. No stone found on digital exploration of pelvis. Hemorrhage profuse, stopped by packing, but returned when packing was removed. A pack of gauze was, therefore, left in the kidney wound.

Microscopic examination of the excised tissue revealed infiltration of leukocytes, interstitial nephritis, and parenchymatous degeneration of the epithelium.

Two days after the operation the tampon was removed and serious hemorrhage followed, necessitating reopening of the outer wound. Ten days later gangrene of the whole kidney, which came away in shreds during the following two weeks, and the patient recovered.

In my case of gangrene the supposedly healthy kidney tissue was sutured closely. I attributed the gangrene to the deep sutures, and intended, in future cases, to abandon deep suturing and substitute packing. Now, however, as shown in Bloch's case, as gangrene may set in after either packing or suturing of slightly diseased kidney tissue, and as greatly diseased kidney tissue, as in pyonephrosis of all degrees, may be divided without gangrene, we may conclude that the cause of gangrene is unknown. These rare cases surely do not contraindicate exploratory operations on the kidney in general.

NARCOSIS

The position of the patient, who is placed on the left side with a pad under the costo-iliac space, causes some embarrassment of the respiratory movements of the thorax and some difficulty to the anesthetizer, because the face rests with one side on the table, thus making it difficult to watch the pupils and to manage the tongue.

As regards the choice of anesthetics as between ether and chloroform, after the use of both of which albuminuria and cylinders or cylindroids have sometimes been found in the urine, the investigations of Wood and others seem to favor the use of ether. Albuminuria followed the use of chloroform in 11.5 per cent. of the cases, and of ether in 6.9 per cent. Cylinders were found after the use of chloroform in 34.8 per cent., and after ether in 24.6 per cent., of the cases.

Repeated narcoses at intervals of a few days should be avoided. An examination in narcosis for diagnostic purposes should not be made, therefore, a few days before operation.

TREATMENT OF THE OPERATION WOUND

Solutions of sublimate and carbolic acid should never be used in these cases, as they have a destructive effect on the kidney tissue, causing albuminuria and hemoglobinuria respectively. When irrigation is

required, sterilized water, boric acid, or physiologic salt solution should be used. The avoidance of the use of iodoform either for dusting over the wound, or iodoform gauze for packing or dressing, is equally important. The experiments of Stubenrauch have proved that even small quantities of iodoform applied locally to kidney tissue cause extensive fatty and parenchymatous degeneration of the renal epithelial cells. In general iodoform intoxication similar extensive degeneration is found in both kidneys and liver. Fatal iodoform poisoning following nephrectomy has been reported by Israel and others. In these cases the wound cavity had been packed with iodoform gauze, and the autopsy showed fatty degeneration of the remaining kidney.

SURGERY OF THE KIDNEY

Anatomy.—The kidneys are situated in the deepest part of the abdominal cavity, behind the peritoneum.

The twelfth rib divides the kidney into an upper and a lower half. The inner border of the kidney rests on the outer border of the psoas muscle; the remainder of the kidney lies on the lumbar fascia, which covers the quadratus lumborum. The outer border of the kidney lies 2 or 3 cm. ($\frac{3}{4}$ to $1\frac{1}{4}$ inches) external to the quadratus lumborum (Fig. 176).

Anomalies.—*Absence of Kidney.*—One kidney may be absent, the anomaly occurring in 1 out of 4000 cases (Morris). Rovsing believes this estimate too large. Beumer collected from the literature between 1853 and 1870, 48 cases, in 44 of which the kidney was entirely absent, and in the remainder existed only as a rudiment. A number of fatal operations due to ignorance of this condition are on record.

Anomalies in Shape.—The union of the two kidneys, forming the “horseshoe-shaped kidney” or one of its varieties, is more easily detected before or during an operation, as the organ is located in the median line, on the anterior surface of the vertebral column.

Anomalies in Position.—A kidney may be located in the small pelvis, and here, in case of pyonephrosis, may be difficult to remove or to operate upon.

Physiology.—The normal quantity of urine in adult males is 1000 to 1500 c.c. (2.1 to 3.2 pints); in adult females, 900 to 1200 c.c. (1.9 to 2.5 pints). It has a specific gravity of 1.015 to 1.025, and 30 to 40 grams (463 to 617 grains) of urea are excreted in the twenty-four hours.

If the quantity of urea is decreased to one-third of the normal, the individual is near the danger-point, and the slightest surgical operation will cause a further decrease, followed by fatal uremia.

Tuffier's experiments on dogs have demonstrated that the minimum amount of healthy kidney tissue necessary for life is 1 to $1\frac{1}{2}$ grams (15 to 23 grains) for each kilogram (2.2 pounds) of body weight. An adult man should have 300 grams (9.6 ounces Troy) of kidney tissue; if his weight is 75 kilograms, or 150 pounds, he needs only 75 to 112 grams (2.4 to 3.6 ounces Troy) of the 300 grams of kidney tissue; that is, he can spare two-thirds or three-fourths of the normal amount of kidney tissue before crossing the danger-line; and he may live in perfect or relative health for years during the destruction of the kidneys, until the last fourth is reached and sudden uremia sets in.

When the amount of kidney tissue approaches the lowest limit, the quantity of urea diminishes, although the amount of urine may still be normal. It is, therefore, a matter of vital necessity to examine the urine for urea before operating.

*The International Text-book of Surgery, 1902, vol. ii, second edition, pp. 600-639.

Compensatory hypertrophy or regeneration of kidney tissue of a healthy kidney, when its fellow has been removed or destroyed by disease, has been studied experimentally by Tuffier. After extirpation of one kidney he removed by successive partial operations portions of the remaining kidney, aggregating in all the weight of the kidney first removed. From this he concludes that, as a quantity of kidney tissue equal to both kidneys was removed without disturbing the health of the animal, at least the necessary one-fourth of the kidney tissue must have been formed by regeneration of compensatory hypertrophy.

Examination and Diagnosis.—*Inspection* in the dorsal or knee-elbow position may reveal a swelling, which begins at the lateral border of the extensor dorsi communis and extends from under the border of the ribs obliquely downward toward the physis.

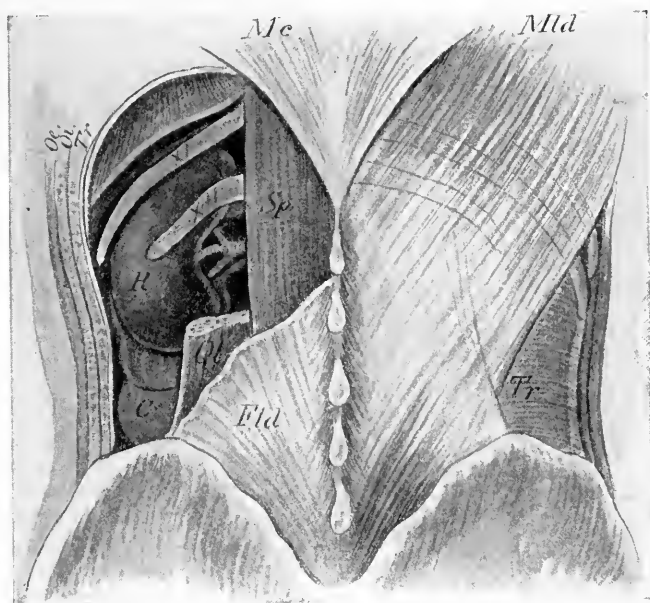


Fig. 176.—*Mc*, Trapezius; *Mld*, latissimus dorsi; *Sp*, sacrolumbalis; *Ol*, quadratus lumborum; *Oe*, obliquus externus; *Oi*, obliquus internus; *Tr*, transversalis; *Fld*, lumbodorsalis fascia; *R*, kidney; *C*, descending colon (from Esmarch and Kowalzig's Surgical Technic).

Palpation.—A normal kidney in normal position cannot be palpated; but if displaced or enlarged, it can be felt in the costo-iliac space by bimanual examination with the patient in either the dorsal position, the thorax elevated and the legs flexed, or in a half-sitting position, or else lying on the side opposite to the affected kidney. The enlarged kidney can be palpated between one hand in the lumbar region and the other hand on the abdomen, pushed gently up under the border of the ribs. In this position the kidney can usually be moved between the hands. Nareosis is often necessary for this manipulation.

The so-called *ballotement* (Guyon) is as follows: The one hand in

the lumbar region makes sudden, short, quick pushes from behind forward, tossing the kidney against the hand on the abdomen.

Abdominal Percussion.—As the colon usually passes over the anterior surface of the kidney, an area of tympanitic percussion, when found, is a proof that the location of the tumor is retroperitoneal, although in some cases the colon may be pushed aside, and the tumor will show dull percussion over its entire surface.

Percussion of the lumbar region is uncertain.

Direct palpation of the kidney, when it is necessary to establish its presence, has been made through an abdominal incision (Knowsley

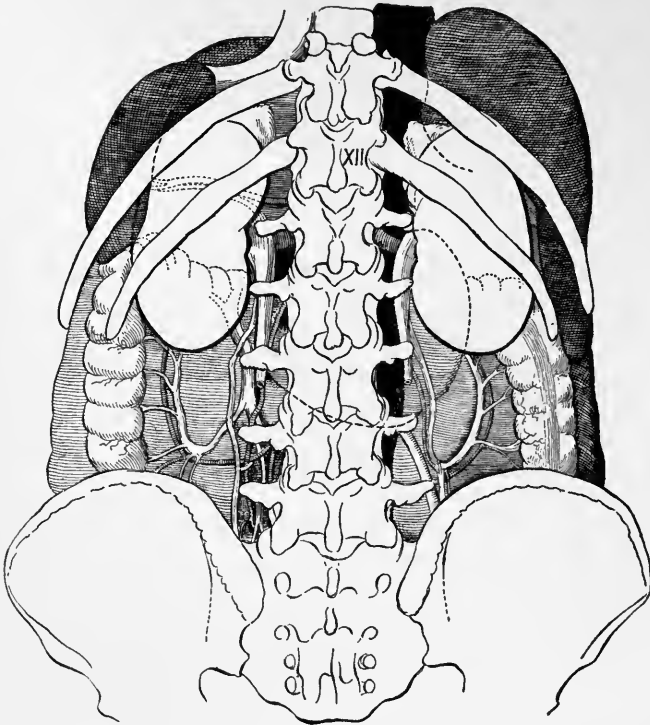


Fig. 177.—Relation of the kidneys as viewed through the lumbar wall. The two dark-shaded parts indicate the liver to the right, the spleen on the left; in front of the vertebral column the black tint represents the vena cava; the twelfth rib is longer than usual (after Farabeuf).

Thornton). This procedure is attended with risk of peritonitis. Palpation of the kidney through a lumbar (extraperitoneal) incision is not dangerous, and is a more satisfactory procedure.

Examination of Urine.—Examination of the collected urine must be made without delay, as the urine changes rapidly by decomposition. It should be noted whether the reaction is acid, alkaline, or neutral. Microscopic examination, after sedimentation, by means of the centrifuge, may reveal red blood-corpuscles, white corpuscles, pus-cells, crystals, cylinders, and epithelial cells from the urinary tract, or, very rarely,

abnormal cells from tumors. Chemical examination should be made for albumin, blood, and sugar. If the filtrated purulent urine contains much albumin, disease of the kidney must be suspected, since the longer the pus-cells remain in the urine, the more of them will be dissolved.

As an aid in the differentiation between disease of the bladder and of the kidney, and in order to ascertain from which kidney the blood or pus is excreted, resort is made to cystoscopy. Direct cystoscopy through a tube, the light being thrown into the bladder, previously distended with air, from a head-mirror, as practised by Kelly, is useful in women. Indirect cystoscopy is made by means of Nitze's cystoscope, in which an electric lamp illuminates the wall of the bladder previously filled with water. In suppurative renal diseases, as a general rule, it may be stated that lesions of the bladder-wall are most marked around the ureteral orifice corresponding to the diseased kidney.

To collect the urine separately from each ureter we resort to catheterization of the ureter by means of a long, fine, flexible, ureteral catheter, inserted by the aid of the cystoscope.

In contemplated operation upon one kidney the determination of the efficiency of the opposite one is of paramount importance. While there is no certain and accurate means of establishing this point, some indication of the physiologic activity of the kidney may be ascertained by means of cryoscopy and the methylene-blue test. In health the freezing-point of the blood is almost constant, being at or near -56° C. In renal insufficiency it varies between -58° C. and -60° C. But there are other conditions, such as abdominal tumors and uncompensated heart disease, which also alter the relations, and must, therefore, be taken into account. Cryoscopy gives more accurate information when it is applied to the separated urines. If the freezing-point of the urine on the side opposite to that of the diseased kidney shows a freezing-point of -9° C. or less, renal insufficiency is indicated, and the operation should not be done (Kümmell).

The methylene-blue test consists in injecting a solution of methylene-blue subcutaneously. If a healthy kidney is present, the blue coloration of the urine produced by the elimination of the dye should appear in the urine at the end of an hour, and should increase in intensity for several hours, when it should diminish and disappear after thirty-six to forty-eight hours.

Direct examination of the kidney through an extraperitoneal (lumbar) incision is the last step in a positive diagnosis. When the surface of the kidney has been laid bare, we may palpate or aspirate, as in cystonephrosis and stone, or excise a piece of kidney tissue for microscopic examination; or we may bisect the organ longitudinally down into the pelvis, as in case of stones in the calices, stenosis, valve formation, or abscess. As the blood-supply of the kidney is arranged in two planes, an anterior and a posterior, following the division of the arteries, and as the line of division is situated a little posterior to the median line of the kidney, the best incision is at this point. Such a cut will enter just anterior to the posterior pyramids, and will expose the whole

pelvis (Zondek and Brödel). Should there be much hemorrhage, it may be controlled by compression of the renal vessels with the fingers or by an intestinal compressor, or directly by packing with gauze.

Floating Kidney (*Ren Mobilis*).—When the fixation apparatus of the kidney becomes defective, the organ becomes movable and sinks downward and forward in the abdomen. This condition was found in 0.2 per cent. of autopsies by Ebstein, and in 2.2 per cent. of the patients by Skorchewsky. It is more common in women than in men: Lance-reaux gives the proportion as 55 women to 5 men. It is found four times as often on the right side as on the left, probably because the heavy liver pushes the right kidney out of place. Movable kidney is usually found in patients from twenty to forty years of age. It is said to be caused by atrophy of the adipose capsule, by repeated pregnancies,

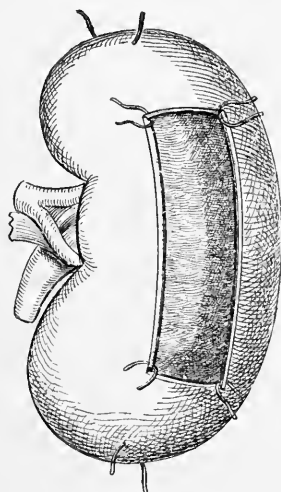


Fig. 178.—Tuffier's operation.

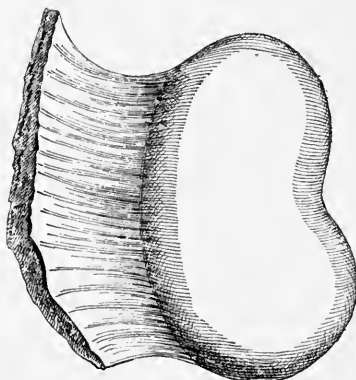


Fig. 179.—Result of Tuffier's operation.

by enteroptosis, when the displaced intestine makes traction on the kidney, and by pressure on the waist, due to the corset or skirt-string. It is seldom caused by traumatism. Enteroptosis is present in 29.5 per cent. of the cases of floating kidney (Godart-Danhieut). The downward displacement of the kidney may result in circulatory disturbances by reason of traction on the vessels, and in retention of urine, due to bending of the upper end of the ureter.

The *symptoms* of floating kidney are a falling or sinking sensation, or a feeling of heaviness in the side, and pain, either steady or paroxysmal, from torsion of the vessels or ureter. A fact of great diagnostic importance is the disappearance of the pain when the patient lies down and the kidney returns to its proper place. Digestive disturbances consequent upon the enteroptosis, neurasthenia, varices, and hemorrhoids are found in many cases. Floating kidney may sometimes lead

to Bright's disease, and Edebohls has shown that anchoring the kidney will cause a disappearance of casts in the urine.

The *diagnosis* is made by bimanual palpation, when a smooth, movable tumor, shaped like the kidney, is felt and can be easily pushed up in place. The tumor is in some cases painless; in other cases tender on pressure. It is of the size of the kidney, unless bending of the ureter has caused retention and dilatation of the pelvis and calices. The tumor may increase to double the size of the kidney during an attack of pain; that is, retention, or during menstruation.

The *prognosis* is good as to life, but spontaneous cure is not to be expected.

Treatment.—The treatment of floating kidney by means of abdominal supporters is sometimes successful as a palliative measure. It is useless to try to keep the kidney in place by means of a pad under the ribs, for the kidney will inevitably slip past it. The cases most amenable to treatment by the abdominal supporter are those complicated with enteroptosis. General tonic and systemic treatment should also be advised, in the hope of restoring the adipose tissue around the kidney, in which event a cure may sometimes follow. If this treatment fails, the operation of nephrorrhaphy or nephropexy, which was first made by E. Hahn in 1887, should be performed. The operation is as follows: After lumbar incision and division of the capsule, the kidney is laid bare, pushed up into its normal location, and the fibrous capsule, together with a layer of the cortical substance, united with the fascia and outer perosteum of the twelfth rib by three or more silk sutures. To avoid relapse, however, it is advisable to follow the suggestion of Tuffier, who, in addition to the sutures, dissects out a flap of the fibrous capsule 2 cm. broad and of the length of the kidney, and unites this flap with the borders of the divided muscles. Nephrorrhaphy has a mortality of about 1 per cent. to 1.8 per cent.; about 65 per cent. of permanent cures; in 10 per cent. of the cases improvement takes place, and relapses occur in 22 per cent. of the cases. Following the operation, pain is relieved in 90 per cent. of the cases (Morris), but dyspeptic and bowel symptoms are relieved in only 50 per cent. of the cases (Tuffier).

The Cure of Chronic Bright's Disease by Operation.—This has been brought forward by Edebohls. He noticed that nephropexy in cases in which chronic Bright's disease existed was followed by disappearance of casts and albumin, and the idea suggested itself to him that disturbance in circulation was the cause of the inflammatory derangement in the kidney. Sixteen cases of movable kidney associated with chronic Bright's disease were operated upon by him with the result that a cure followed in all, the duration of the cure being from six months to ten years. Acting upon this suggestion, further progress was made when Edebohls deliberately cut down upon the kidney, incised the capsule along the convex border, and stripped the capsule to the hilum of the kidney. The idea was to create a new blood-supply, by inflammatory anastomosis, between the raw kidney surface and the fatty capsule. While results cannot be stated, owing to the recent date

of the operations, it has been shown that immediate and rapid improvement has followed the operation; even patients far advanced in the disease, with cardiac hypertrophy and uremic symptoms, have been much benefited. Enough time, however, has not elapsed to enable one to give the operation its proper position in surgery.

Trauma of the Kidney.—**CONTUSION.**—Traumatic subcutaneous rupture of the kidney is caused by direct violence, either from a small body through the iliocostal space, as, for instance, a wagon-wheel, the kick of a horse, a fall against a rail or the edge of a table, etc.; or by a large body striking the abdomen with such force as to break the ribs or pelvic bones before reaching the well-protected kidney. The kidney is thus squeezed between the object and the twelfth rib or the transverse process of the first lumbar vertebra. The extent of the rupture may vary from a small, subcapsular tear to complete bursting of the organ. The rupture is ordinarily stellate and transverse, and extends through the capsule into the pelvis. The resultant hemorrhage may be limited to the kidney tissue and capsule, or the blood may flow down the ureter or may enter the abdominal cavity through a tear in the peritoneum. In case of a small rupture the blood is absorbed in a few weeks, leaving a cicatrix which shuts off the divided urinary tubules. This causes atrophy of the cortical portion of the obstructed canal; consequently the greater the number of the canals divided, the greater the loss of cortical substance. A completely ruptured kidney will shrink until it becomes a useless lump of connective tissue.

Symptoms.—Shock is common; but if persistent, is probably due to intraperitoneal hemorrhage or to injury to other abdominal organs. The pain in the kidney extends down along the ureter. Sometimes renal colic, due to coagula in the ureter, and attended by vomiting, is present. Hematuria is almost a constant symptom, being absent in only 8 per cent. of the cases, as when the rupture is cortical or when the ureter is crushed or obliterated. The hemorrhage usually ceases in from two to five days; it is rarely persistent or remittent, or so considerable as to cause anemia. Anuria, which is a grave complication, or oliguria, is common during the first forty-eight hours, and is then followed by polyuria. The tumor is small if the rupture is intrarenal; when perirenal, it is larger and more diffuse, and is due to an accumulation of blood and urine outside of the kidney. In aseptic cases there is a slight rise in temperature from 100° to 102° F. This gradually decreases after a few days. If infection takes place, as often occurs from an infected catheter, or, more rarely, from preëxisting cystitis or microbes in the circulation, chill and increasing temperature up to 104° F., with pain and pyuria, may supervene. This is a grave complication, and has a mortality of 47 per cent.

Prognosis.—If the rupture is limited to one kidney, the mortality is 22 per cent. (Rovsing); when complicated with fractures or injuries of other organs, the mortality is increased to 87 per cent. Primary hemorrhage caused death in 6 and secondary hemorrhage in 4 of 71 cases (Maas). Delbet collected 319 cases of contused kidney. In 225 of

these no surgical treatment was given; the mortality was 46.8 per cent. In 50 of the other cases some operation was performed—puncture, partial nephrectomy, or incision; there were 48 cures and 2 deaths. In the remaining 44 cases primary or secondary nephrectomy was done, with a mortality of 25 per cent.

Treatment.—The treatment should be purely symptomatic from the first. Absolute rest in bed for three weeks is essential to avoid the danger of secondary hemorrhage. Stimulants should be given during the period of shock, and morphin for the pain. Local application of cold (ice-bag) is often employed; and Tuffier recommends compression of the costo-iliac space by a pad of cotton held in place by a flannel bandage. The patient should be put on light liquid diet. Ergot, acetate of lead, or other hemostatics may be employed. It is important to avoid the use of the catheter; or, if the catheter must be used, it is absolutely essential to secure asepsis. Operation should not be performed unless indicated. Hematuria in itself is rarely an indication. But severe hemorrhage, especially if intraperitoneal, with extravasation of urine into the peritoneal cavity, is an urgent indication. If the kidney is found crushed, it should be removed. Hemorrhage from a large vessel may be stopped by ligature or tampon. Secondary interference is indicated by anuria, gradually increasing subperitoneal hemorrhage, and also by persistent hematuria; if hematuria comes on secondarily after a lapse of time during which it has temporarily ceased, operation may be seriously thought of. Infection may require evacuation of pus by nephrotomy, followed by drainage; or nephrectomy, if the greater part of the kidney tissue is destroyed or if the kidney is the seat of multiple abscesses.

WOUNDS OF THE KIDNEY.—Wounds of the kidney are rarely observed in time of peace. Punctured wounds by the stiletto or rapier are rare and heal readily. Incised wounds by the saber or knife are also rare, but gunshot wounds are more common. Hemorrhage is considerable only in incised wounds or when large vessels are divided; in punctured and gunshot wounds the hemorrhage is usually slight. An aseptic incised wound will heal in about seven days. Infection and extravasation of urine do not occur unless the pelvis has been opened. The blood-clot which fills the wound is absorbed in from two to seven days, and is replaced by granulation tissue. The amount of kidney tissue lost by atrophy depends upon the number of tubules divided. Thus, a longitudinal wound on the anterior or posterior surface of the kidney causes more atrophy than either a longitudinal wound along the convex border, which is attended by slight hemorrhage, or a transverse wound, which is followed by a greater hemorrhage. An incision parallel to the course of the uriniferous tubules divides the smallest possible number. Gunshot wounds heal readily and an aseptic bullet may become encapsulated and cause no disturbance. Infection leading to local or diffuse suppuration disturbs the process of healing, and the danger of sepsis makes the course protracted and serious.

Symptoms.—Shock is observed, especially in gunshot wounds. The

external wound may be in the lumbar region over the kidney or at a distance from it. The hemorrhage may be internal if large vessels are divided, or external and abundant, but is usually not fatal in incised wounds. Secondary hemorrhage is due to infection only. Urine exudes from the wound only when the pelvis has been opened, and when its passage through the wound is more easy than through the ureter. It was seen in 23 per cent. of gunshot wounds, and in only 3 per cent. of incised wounds. The *x*-ray may be of assistance in locating a bullet. Hemorrhage from gunshot wounds is generally retroperitoneal, and the resulting hematoma may be large (Keen). Pain may be absent from the outset; if it appears on the second or third day, it usually signifies peritonitis; if on the eighth to the tenth day, it means infection of a cavity containing blood and urine. Hematuria is a pathognomonic symptom, but is absent in 42 per cent. of the cases; it is common in gunshot wounds because the pelvis has been opened.

Complication with injuries to other organs, as, for instance, the lungs, liver, spleen, or intestines, must be carefully considered. The kidney may be found prolapsed into or outside of an incised wound; if viable, it should be disinfected and replaced. Infection of the extravasated blood and urine through the wound or from catheterization will cause pain, fever, and increase of the lumbar swelling, and calls for prompt evacuation and drainage. Peritonitis is common in gunshot wounds, and may also be caused by infection.

The *prognosis* is doubtful. A mortality of 60 per cent. for all cases is reduced to 31.5 per cent. in the uncomplicated wounds (Rovsing). Gunshot wounds are more grave, having a mortality of 42 per cent.; while incised and punctured wounds are attended by a mortality of only 26 per cent.

Treatment.—Gunshot wounds should be sealed after thoroughly cleansing the skin, and the patient should be kept in bed for at least three weeks. If a large swelling and symptoms of anemia appear, the kidney should be laid bare, and the hemorrhage stopped by ligature or tampon; or nephrectomy should be made if the renal vessels are injured. Incised wounds with external hemorrhage should be freely opened and the kidney examined. If the wound is aseptic, the kidney can be sutured; if infected, the hemorrhage should be stopped by packing, and the wound united later on by secondary suture. If urine exudes, drainage is required. If infection of the accumulated blood and urine occurs, as indicated by onset of fever, pain, and increased lumbar swelling after eight or ten days, free incision (nephrotomy) or, eventually, nephrectomy, must be made. The hematuria almost always stops spontaneously; but if it persists despite rest and ergot, and if copious, the patient's life may be saved by nephrectomy (in 5 out of 6 cases, Tuffier). If the bladder is filled with coagula, causing vesical retention, catheterization is usually resorted to; but this is difficult, as the clots usually occlude the eye of the catheter. It is better, therefore, to use Bigelow's litholapaxy evacuator. If this procedure is unsuccessful, suprapubic puncture and aspiration of the urine and liquid blood may be of assist-

ance for the few days required for the crumbling of the coagula. If aspiration is tried in vain, the bladder must be opened, either by perineal section or, preferably, perhaps, by epicystotomy.

Renal Calculus (*Nephrolithiasis*).—Stones are found in the parenchyma, the calices, and the pelvis of the kidney. The small concretions, sand, or gravel, which easily pass out with the urine, belong to the field of internal medicine; and it is not until the concretions become so large that they cannot pass out from the calices or pelvis that the aid of surgery is invoked.

In 50 per cent. of the cases only a single stone is found, and in the remaining half ordinarily 2 to 10, and occasionally many (200) small stones are found. The size varies in uric-acid and oxalate-of-lime stones from that of a hazelnut to that of a walnut; the phosphatic stones are much larger. The weight varies from 10 to 1000 grains. The shape of renal stones depends, as does the shape of vesical calculi, first on the form of the crystal. Thus, a uric-acid stone is oval, and an oxalate-of-lime stone spheric. The shape depends, in the second place, upon the shape of the cavity in which it is located. Thus, in the ureter we find cylindrical stones; in the ureteral portion of the pelvis, where the ureter divides into two branches, a Y- or heart-shaped stone; in a calyx, an hour-glass-shaped stone, part of which is in the calyx and part in the pelvis; and, finally, when a stone fills both pelvis and calices, it will be coral-shaped, having a stem corresponding to the pelvis and branches corresponding to the calices. The physical characteristics of stones vary with their composition. Thus, uric-acid and urate stones are yellow or reddish, hard, smooth, or finely granulated; oxalate-of-lime stones are chocolate-colored, hard, rough, and nodular, the color depending upon a covering of blood-pigment; the phosphatic stones are gray or white, soft and friable. We often find a nucleus of one substance surrounded by concentric layers of other substances.

Stones in the kidney are found at all ages, and with equal frequency, in both sexes. There is no difference as to frequency between the right and the left kidney. Fortunately, the disease is limited to one kidney in most cases. Dickinson found bilateral lithiasis in only 11 out of 59 cases.

The *cause* of stone-formation is not well understood. Urate stones seem to be hereditary and coexistent with uric arthritis throughout several generations. There are three theories as to their formation. The old theory is that an anomaly in metabolism causes the urine to deposit the elements of the stone around dead cells from a catarrhal inflammation of the mucosa (Ebstein). Galippe considers that they may be caused by microbes in the urine. Stones may also be formed around small blood-clots or other foreign bodies as nuclei. If the urine is acid, we find uric and oxalate calculi; if it is alkaline, phosphate and carbonate-of-lime stones are formed.

Pathologic Anatomy of the Calculous Kidney.—A stone may exist in the kidney for as many as thirty years and do no harm to the secreting tissue, provided it does not cause obstruction or infection. A stone in the pelvis at the ureteral orifice is liable to cause a variable degree of obstruction, retention of urine, and dilatation of the pelvis and calices, with gradual atrophy of the kidney substance from interstitial nephritis. Infection may occur by invasion of microbes, either from the bladder or, more commonly, from the circulation. The stone wounds the mucosa, microorganisms from the blood or kidney urine find a favorable culture-medium, and an inflammation of the pelvis—a pyelitis—results, which extends to the kidney tissue and causes its destruction. If retention and infection are combined, the kidney is more rapidly annihilated, abscesses form in its substance and extend to the perirenal tissue, resulting in perinephritic abscess. A dilated pelvis may contain a large stone, with smaller stones in the dilated calices; these form thin-walled,

globular prominences on the surface of the kidney, which is usually enlarged, and is thus transformed into a multilocular sac filled with purulent urine around the stones—the condition called by Küster *sacculated kidney* (Fig. 180).

Symptoms.—The main symptoms of nephrolithiasis are pain, attacks of renal colic, and hematuria. It is remarkable that even large or multiple stones may give rise to no symptoms at all. In autopsies in St. Bartholomew's Hospital Bruce Clark found 24 cases of nephrolithiasis,

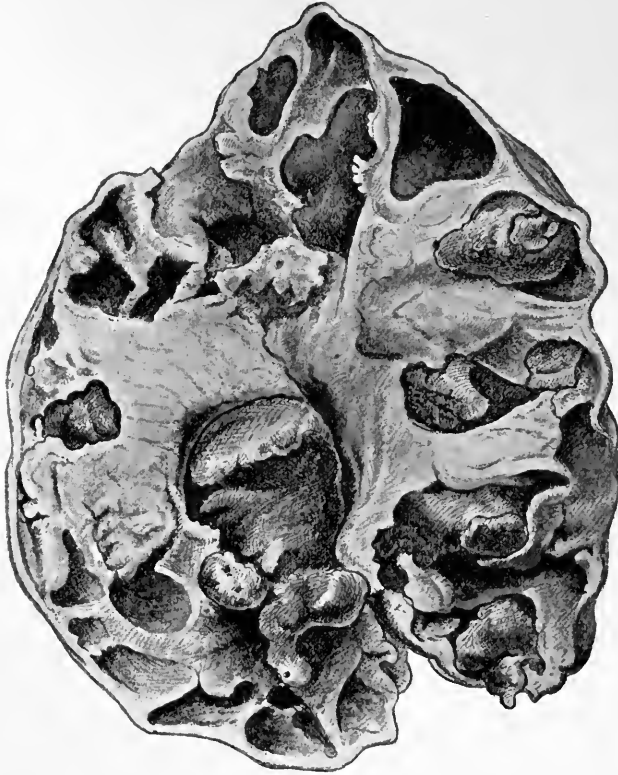

Fig. 180.—Multiple calculi in a sacculated kidney (Rovsing). Very large stone in pelvis; the whole kidney transformed into a number of cystic cavities filled with pus; each of the dilated calices contains a large stone; fibrous degeneration of kidney tissue ($\frac{3}{4}$ natural size); nephrectomy; recovery.

in all of which no symptoms had existed. In other cases there may be only slight lumbar pain or occasional attacks of renal colic during the patient's life. In a few cases sudden calculous anuria is the first manifestation. Pyuria is seen only when secondary infection has occurred. In the majority of non-infected cases, however, the following symptoms are marked:

1. *Pain in the Region of the Kidney.*—The pain may vary from a simple soreness to a tearing, biting pain. It is seldom continuous; often remittent. The attacks are brought on by exercise, or sometimes by

palpation. It may cause lateral lumbar scoliosis, from habitual bending of the back. It may radiate down into the inguinal region, or toward the abdomen, and by reflex action cause respectively vomiting and frequent painful micturition; or it may extend down the anterior side of the thigh and simulate crural neuralgia. The pain usually disappears at night or when the patient lies down.

2. *Hematuria* is almost constantly found, but the amount of blood is usually so slight as to be detected only by microscopic examination of the sediment after the urine has been centrifuged. It is increased by exercise and pressure.

3. *Physical Symptoms*.—The kidney cannot be made out by palpation unless it is dilated or displaced, in which case grating from multiple stones may in rare instances be observed.

4. *Renal Colic*.—The attacks of pain extending from the kidney down along the ureter are probably always due to painful contractions of the ureter, and would better be termed ureteral colic (Rovsing). This is caused in most instances by passage of a stone; rarely, of coagula or echinococcus cysts down the ureter.

The acute onset, the violence of the pain, tympanites, constipation, frequent micturition, perspiration, and relief upon pressure on the abdomen or flexion of the thighs characterize the attack, which may last from four to six hours to as many days, and ceases suddenly when the stone enters the bladder, or diminishes gradually, leaving a tender spot in the course of the ureter, if the stone is here arrested.

Diagnosis.—In tumors the hematuria is more abundant. In tuberculosis we must inoculate a guinea-pig if the bacillus cannot be found. It may be impossible to distinguish between stone and nephralgia or to determine whether or not an infected cystonephrosis contains stone. In the later case an exploratory lumbar incision is indicated, as it is not dangerous and is ordinarily the first step in a curative operation. The diagnosis of renal calculi by means of the *x*-ray has lately been much perfected. Leonard claims that less than 2 per cent. of the stones are missed in this way. Bevan and Abbe have had similar results. The uric-acid stones throw the least distinct shadow. Kelly's method of passing a wax-tipped bougie up into the renal pelvis may be of some advantage; scratching of the wax is indicative of stone.

Complications.—Infection causing pyelonephritis is especially common, and is the beginning of loss of health and strength. The microbes most commonly enter through the circulation, where the colon bacillus frequently exists; or more rarely we may have an ascending infection from below, due to the use of an unclean catheter. The colon bacillus is often tolerated for years without marked discomfort; while the pyogenic staphylococci and streptococci cause serious illness, with acute fever, rigors, pain, and all the dangers incident to sepsis.

Calculous Anuria.—Suppression of urine occurs when a stone suddenly obstructs the passage of urine from the only kidney in function. It occurs in bilateral lithiasis, in advanced disease, or, more rarely, when the other kidney is absent. The onset is sudden, occurring without

symptoms or during an attack of renal colic. Tuffier gives the course as follows: In cases of complete anuria there is a period of tolerance, when the patient feels quite well for five to eight days; this period is much longer if some urine is passed. This is followed by a period of intoxication, during which the patient becomes weak, has a dry tongue, hiccup, tympanites, subnormal temperature, contracted pupils, and edema around the malleoli. In 71 per cent. of the cases death occurs during the first three weeks; and in 28 per cent. spontaneous recovery takes place by reëstablishment of the passage of urine. Many lives have been saved by timely nephrotomy.

Prognosis.—The prognosis is desperate only in calculous anuria. It is serious in the septic cases, although the patient may live for years; and good in the non-infected cases, especially in those without dilatation. Permanent cures may occur after operation, but recurrence is possible, and Morris states that recurrence happens in 10 per cent. of the operated cases.

Medical Treatment.—Medical treatment should always be resorted to after operation for removal of stone, and in some cases in which operation is deemed unnecessary or dangerous. In acid lithiasis with urate or oxalate stones, lithia water, from a pint to a quart a day, and half a teaspoonful of sodium bicarbonate with the meals, should be given for six weeks, to be repeated three or four times a year. The alkaline mineral waters, open-air exercise, regulated diet, and sparing use of alcoholics will serve as an outline of the treatment. In alkaline or phosphatic lithiasis the urine should be made acid by the use of boric acid in doses of 50 eg. (7.7 grains) or salol in $\frac{1}{3}$ -gram (5.1 grains) doses three or four times a day. Three or four pints of cold boiled water should be taken daily by all patients.

Surgical Treatment.—The operations for nephrolithiasis are nephrolithotomy, pyelolithotomy, nephrotomy, and nephrectomy.

Nephrolithotomy.—Through an oblique lumbar incision the kidney is isolated, brought out into the wound, and palpated in order to feel stones in the pelvis. The stones in the calices are sought for by puncture with an aspirator needle, and if found, are removed by an incision made with the needle as a guide. If retention exists, the pelvis is found by aspiration, and the kidney opened on its convex surface on the needle as a guide. When the pelvis is opened, exploration is made with the finger or metal sound. The stones are extracted after division if they are very large, but always with as little manipulation as possible. The hemorrhage from healthy kidney tissue is considerable, and must be controlled by compression of the vessels in the hilus or by local pressure with gauze sponges. The thermocautery may also be of use as a hemostatic.

The ureter is then examined with a metal probe to determine its permeability and to detect stone. The stones extracted should be carefully examined to determine whether pieces have been broken off and left in the kidney. If asepsis is certain, the wound in the kidney

should be united by catgut sutures, by which hemostasis is assured. Primary union may take place.

Pyelolithotomy.—If the stone is located in the pelvis near the ureter, it may be removed through an incision in the posterior pelvic wall. This operation possesses the advantage that no hemorrhage is produced; but it has the disadvantage that stones are more easily overlooked; and the operation is said to be more frequently followed by fistula (Rovsing).

Nephrotomy is the operation of opening into a suppurating kidney to evacuate pus and remove stones, if present. The kidney is opened at its most prominent point over one of the thin-walled sacs. Exploration is then made with the finger and steel sound for stone. This must be done carefully, as stones are either not found or all the stones may not be removed, as was the case in 16 per cent. of 114 cases reported by Tuffier. The thin, atrophic kidney-wall does not bleed. The wound in the kidney is united to the skin and the cavity packed and drained, in order to overcome the pyelitis by local treatment.

Nephrectomy, which was formerly much in vogue, has been almost entirely abandoned. It possesses the advantage that if the patient survives he is cured by a single operation; but the mortality is 38 per cent., as against 33 per cent. mortality for nephrotomy. For this reason many operators follow the advice of Guyon, first to make nephrotomy, and, later on, nephrectomy, if demanded. This secondary nephrectomy, after the lapse of months or years, is a relatively safe operation.

Treatment of Calculous Anuria.—When the only useful kidney is closed by stone, nephrotomy, as suggested by Thelen in 1882, should be done during the period of tolerance. Hot baths, careful massage of the ureter, electricity, and chloroform narcosis may be tried for a day or two. If the patient is not operated upon, Tuffier and Legueu's statistics show that 28 per cent. recover by spontaneous expulsion, and that 72 per cent. die, while operation has saved 60 per cent.

Technic of Operations for Stone in the Kidney or Pelvis.—The patient is anesthetized with ether and placed on the well side, with a pillow under the costo-iliac space. An oblique incision is made, parallel to the twelfth rib, from the erector spinæ forward and downward through the skin, latissimus dorsi, the three flat abdominal muscles, the transversalis fascia, and the lateral portion of the quadratus lumborum muscle. The adipose capsule can then be seen to move with the respiration, and is divided. The surface of the kidney is denuded, and the organ isolated by blunt dissection, first on the posterior and then on the anterior surface, until the vessels and pelvis are reached. The kidney and pelvis are now palpated to detect the presence of dilated calices, abscesses, or stone. If a stone is felt in the pelvis and grating noticed when an aspirator needle is inserted, the stone may be removed.

Pelviotomy.—This consists in a longitudinal incision on the posterior surface of the pelvis. No hemorrhage follows this incision; while division of healthy kidney tissue is attended by a considerable loss of blood. When the stone is removed, exploration with the finger or steel urethral

sound should be made to detect the presence of stones in the calices. A flexible sound is inserted in the ureter to determine its patency. If there is no infection, the wound in the pelvis can be united, and the external wound closed around a gauze drain. If no stone is felt in the pelvis, we next resort to—

Nephrolithotomy.—Thorough exploration should be made with a thin aspirator needle inserted in different parts of the middle longitudinal line of the kidney. If a stone is felt, the needle should be left in place and the stone cut down upon, the needle being used as a guide. If no stone is detected, the pelvis should be opened from the convex surface of the kidney. It is difficult to find the pelvis in a normal kidney; but if there is a little dilatation, the pelvis may be made out by aspiration of urine or pus, the needle being left in as a guide for the knife. After the pelvis has been opened, the stones are sought for by the finger or steel sound, the narrow entrances to the dilated calices enlarged, and all concretions removed. In aseptic cases many operators close the incision in the kidney with sutures; this method possesses the advantage of stopping the hemorrhage. If infection exists, the kidney must be drained, and hemorrhage stopped by packing. Some authors (Morris and Tuffier) make a distinction between nephrolithotomy as an operation for the removal of stone from a healthy aseptic kidney, and nephrotomy for the operation for the removal of stone from a suppurating kidney.

Nephrotomy, or incision into a suppurating calculous kidney (Sackniere), is an easier operation, as the atrophic kidney tissue does not bleed and as the pelvis can easily be found. It is well to unite the wound in the kidney to the skin, in order to avoid perirenal infection. The kidney should then be packed and drained.

Nephrectomy is done in rare cases of acute or chronic infection, either because the kidney is valueless or is a dangerous source of infection by reason of multiple abscesses in the kidney substance. Only the second of these indications is vital in order to save the patient during acute sepsis, which is a very rare contingency. Many authors advocate nephrotomy as the normal procedure, because it is impossible to know the exact secretory value of the organ or whether the patient can survive its loss. It is better to leave the kidney, and if, later on, it is found to be valueless, to resort to secondary nephrectomy.

Suppurative Infective Inflammation of Kidney and Pelvis (*Pyonephrosis and Pyelonephritis*).—Infection of the upper urinary tract centers in the pelvis (pyelitis), but almost always extends above to the kidney (nephritis) and below to the ureter (ureteritis). The microbes which cause the infection require certain favorable conditions for their localization. Chief among these are decreased resistance of tissue elements and impeded evacuation of the urine, in which the microbes find a culture-medium, or a combination of both these conditions. The microbes enter either through the circulation or by ascent of the urinary passages from without.

Etiology.—Impediment to evacuation of the urine may be caused by any obstruction from the external orifice of the urethra to the calices,

such as stricture of the urethra, hypertrophy of the prostate, disease of the ureter causing stenosis, stone, or stricture, pressure from the gravid uterus or tumors, obstructions in the renal pelvis from stone or valve-formation, and obstruction in the calices. Decreased power of resistance of tissue elements may be due to arterial sclerosis or to paralysis consequent upon fracture of the spine. A combination of the factors named above is well illustrated by the pyelonephritis so commonly observed in connection with hypertrophy of the prostate.

The microbes enter from the circulation. Pyemia may cause a metastatic abscess in the kidney tissue, as in osteomyelitis; but more commonly a traumatism to the organ, as caused by rupture or stone, gives a favorable soil for the localization of microbes circulating in the blood. This statement has been corroborated by the experiments of Albarran.

The microbes invade from below. An unclean catheter may infect the bladder and cause cystitis. This is often unavoidable in hypertrophy of the prostate. The microbes ascend through the ureter, either in the urine or in the mucosa. Gonorrhœa rarely causes pyelitis (in about 3 per cent. of the cases only), and then it is probably due not to the gonococcus alone, but to mixed infection with pus-microbes.

Chemical substances, such as turpentine, cantharides, etc., will cause an aseptic and, consequently, transitory inflammation.

The microbes most commonly found are the Staphylococcus aureus, the colon bacillus, and the Streptococcus pyogenes; occasionally the pneumococcus and typhoid bacillus have been observed.

Pathologic Anatomy (Pyelitis, Nephritis).—The kidney and its pelvis are surrounded by a dense mass of fibrous and adipose tissue, because the microbes or their ptomains invade the adipose capsule and cause a chronic inflammation resulting in adhesions to all the surrounding organs—fasciæ, muscles, vena cava, and colon—making ordinary nephrectomy difficult. In such cases subcapsular nephrectomy (Ollier), shelling out the kidney and leaving the capsule, can be accomplished with little loss of blood. In pyelitis without dilatation we find in acute cases that the mucosa is swollen, red, ecchymosed, and covered with fibrinous deposits or sandy incrustations; in chronic cases the wall is thickened, and ulcers (flat defects) are seen in the grayish-red mucosa, covered with grayish-red detritus and gravel. In pyelitis with distention the pelvis and almost always the calices are dilated, so as to form a multilocular sac on which the thin wall of the kidney sits like a cap, the surface of which is nodulated from the globular, prominent dilated calices (Fig. 181).

The kidney tissue is sclerotic from interstitial nephritis. It may contain miliary abscesses, appearing as whitish points or stripes; or, as is seen in many cases of hypertrophy of the prostate, the large hyperemic kidney may appear normal, but microscopic examination reveals a diffused microbial interstitial nephritis.

Symptoms.—General Symptoms.—Acute cases are marked by rigor, fever (102° to 105.5° F.), vomiting, delirium, coma, and death; or by continued fever and emaciation if life lasts for many weeks. In chronic cases there is either no fever or the fever is slight (100° F.); but there are dyspepsi, loss of appetite, coated or clean tongue, aphthæ in the pharynx, flatulence, tympanites, diarrhea, mental depression and weakness, soft and irregular pulse. Toward the end there may be sub-delirium. This condition may last in light cases for months or years, and constitutes the so-called *urinary cachexia*. In children gastrointestinal symptoms are apt to be severe.

Local Symptoms.—If the kidney is not distended, no tumor can be felt. In cases of old men with chronic cystitis, polyuria is observed early. The patient passes from 2 to 4 quarts daily, containing a little albumin and a few cylinders besides the pus-corpuscles. The acid or

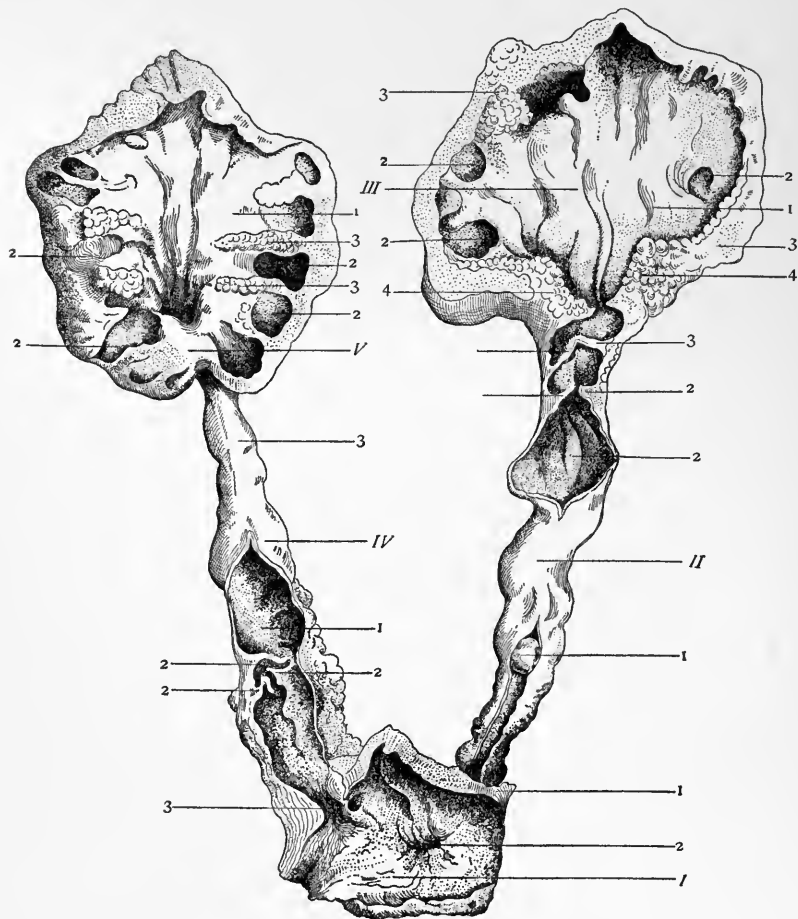


Fig. 181.—Double ureteropyelonephritis, with stricture and dilatation of the ureter (Musée Guyon, Specimens Nos. 158 and 159).

I. Part of the opened bladder: 1, Hypertrophic vesical wall; 2, vesical opening of left dilated ureter; 3, vesical opening of right ureter.

II. Left ureter opened and unfolded in its upper portion; split in its lower portion: 1, Stone arrested in lower third of canal; 2, lumen of dilated ureter, constricted by two valvular folds, 3, 3.

III. Left kidney opened on its convex border: 1, Cavity of dilated pelvis; 2, openings to dilated calices; 3, renal tissue; 4, fibrolipomatous deposits.

IV. Right ureter opened in its lower half: 1, Cavity of the canal; 2, imbricated valvular folds; 3, narrowed upper portion.

V. Right kidney opened on its convex border: 1, Cavity of pelvis; 2, calices; 3, fibrolipomatous septa.

neutral urine becomes alkaline. If the quantity of urine decreases to 500 or 600 c.c. (16 to 20 ounces), there is danger of uremia. The hematuria is ordinarily slight, but is sometimes abundant. The kidney may be tender on deep pressure, but spontaneous pain is uncommon.

Frequent micturition indicates cystitis. If retention is present, the distended kidney may be felt as a round, firm tumor, which may evacuate its purulent contents into the bladder from time to time, the evacuation being followed by temporary relief of the pain and fever. The urine, which was clear during the attack, will then be found purulent.

The *prognosis* is always serious, the more so if retention and infection are combined or the disease is bilateral. If only one kidney is affected, spontaneous cure or cure by operation makes the prognosis more favorable.

Diagnosis.—The differential diagnosis from cystitis, tuberculosis, typhoid fever, pyemia, acute septicemia, and tumors must be made. Further, whether one or both kidneys are diseased; if only one, it must be determined which is the affected kidney. In 61 deaths following operation for pyelitis the opposite kidney was found to be diseased in 56 per cent. (Tuffier). Cystoscopy and collection of the urine separately from each ureter, either by Harris's instrument or the ureteral catheter, may be required. In unilateral cases, ulcerations of the bladder-wall are most numerous around the ureteral orifice corresponding to the diseased kidney.

Treatment.—We must treat or cure the cystitis and overcome the causes of retention (stricture, enlarged prostate, abdominal tumors, etc.).

Primary pyelonephritis in a patient who has free passage of urine is amenable to internal treatment. The lines upon which the treatment is based are rest in bed, increased diuresis by drinking large quantities of water or milk, and sodium baborate up to 30 grams (7 or 8 grams) a day (Terrier). Salol, in doses as large as 3 grams (46 grains) three times a day, has been recommended, but is apt to cause poisoning (hemoglobinuria). Boric acid and the alkaline waters are safe agents to employ.

When the disease is unilateral or the sepsis acute, operative treatment is indicated. Nephrotomy is the operation of choice. The steps of the operation are lumbar incision, evacuation of the perinephritic abscess, incision of the kidney, evacuation of pus and stones, division of partition-walls in multilocular cavity, irrigation, packing with sterile gauze, and drainage after suturing the kidney wound to the skin.

Unilateral pyelonephritis, the result of strictured ureter, may sometimes be cured by dilating the stricture and washing out the renal pelvis with antiseptics. Israel investigated this subject and tried the treatment in 81 cases, but only 3.7 per cent. were cured. Amelioration of symptoms was common. The treatment is applicable only in those cases in which the pus is not too thick and when the ureter can be well dilated. But even if the ureteral stricture can be well dilated, retention of urine above the constriction has been known to persist, though the infection has been cured (Kelly).

If the suppuration persists, secondary nephrectomy may be required. If a fistula remains and the kidney is worth saving, a secondary operation to reestablish the passage through the ureter is required. Primary nephrectomy should be made only when the kidney tissue is filled with

multiple abscesses, and the organ must be removed to save a life imperiled by acute sepsis. Nephrectomy should also be made in all cases where no active kidney tissue remains. It is, however, usually impossible during an operation to determine the secretory value of a kidney; nephrotomy should, therefore, always be first attempted.

In operations for nephritis, as in all operations on the kidney, it is not permissible to employ poisonous antiseptics. Sterile water should be used and sterile gauze—not iodoform gauze, as has been so often recommended.

Tuberculosis of the Kidney.—*Etiology.*—Renal tuberculosis is rare, being found in only 2 per cent. of the cases of tuberculous patients (Heiberg, Morris). The tubercle bacillus ordinarily reaches the kidney through the medium of the circulation, but it may ascend from the ureter from below, from the seminal vesicles, prostate, or bladder. Occasionally a carious spinal abscess has been known to have been the source of origin of a renal tuberculosis, the infection in such instances having been through the capsule of the kidney. The influence of trauma has been well proved in many cases, and many patients will date their first symptoms from the time of receiving an injury in the lumbar region. In such cases, however, we may always suspect that the disease has existed in a latent form in the kidney for some time. Antecedent inflammatory affections are predisposing causes of tuberculosis, the germs finding in such conditions favorable soil for their growth. This is thought to be the case particularly in old gonorrhoeal inflammations, the tubercular disease in such patients starting in the bladder and traveling up to the kidney. Primary tuberculosis of the kidney in its strict sense probably never occurs, and there is always another focus elsewhere in the body. Such a focus may exist in the lung in the form of a cicatrized process, or it may be an old retroperitoneal or cervical lymph-gland which has undergone tubercular changes. Such instances of infection are occasionally met with at autopsy. In 3424 autopsies performed at the Massachusetts General and at the Boston City Hospitals during the last ten years there were 24 cases of renal tuberculosis of the caseous variety, and in not one of these was the kidney the only organ diseased by tubercular processes; in 4 of the cases the primary lesions were tuberculous retroperitoneal and cervical glands. This fact must necessarily render the prognosis after nephrectomy for tubercular disease always doubtful, and a patient who has had a nephrectomy for tubercular kidney can never consider himself safe. Recurrence of the disease has been known to occur in some other part of the body as late as eight years after the nephrectomy, the patient having been well in the mean time.

The disease is usually unilateral—in 216 out of 250 cases (Rovsing). This fact is important, as it makes surgical aid possible early in the disease. It is more common in the right than in the left kidney. In the course of time the other kidney may be attacked, the infection being either through the medium of the circulation or by extension along the urinary tract through the bladder. The disease is met with twice as

often in males as in females, because the genital tuberculosis is so common in the male. More women are operated upon (67 per cent.) by nephrectomy than men, and the reason is that advanced genital tuberculosis in the male renders many men unfit for operation. The disease is commonest between the ages of twenty and forty, quite as many cases occurring between twenty and thirty as between thirty and forty.

Pathologic Anatomy.—Diffuse miliary tuberculosis of both kidneys, like the same condition in other organs of the body, does not belong to surgery. Miliary tuberculosis of the kidney almost never occurs alone, and it is a part of miliary tuberculosis of other organs of the body. The only interest that miliary tuberculosis of the kidney has in a surgical sense is whether a miliary tuberculosis ever goes on to the production of the caseous type of the disease. It is highly probable that it never does, death taking place before this happens. The localized (hematogenous) tuberculosis begins in the cortical substance or in a calyx or papilla (Heiberg). The tuberculous nodule grows, liquefies in the center, and finally opens into the renal pelvis, which event is indicated by the presence of pus and blood in the urine; or it may open through the capsule, and if it does, a perinephritic abscess forms in the fibro-lipomatous pararenal tissue; this is of relatively infrequent occurrence.

When the disease has originated in the renal pelvis, tubercles are first formed, and later necrosis occurs. The mucosa, papillæ, and pyramids are transformed into a thick, grayish-white mass of tuberculous granulation tissue covered with pus and urine. The process gradually extends to the renal parenchyma, and the end-result is the same as in case the disease originates in the soft part of the kidney; gradual extension with abscess formation, necrosis, and softening occurs, until finally, if the capsule resists invasion, the whole kidney is transformed into a bag filled with pus, shreds of tissue, and grumous material; septa occasionally mark the site of the abscesses; the kidney is usually enlarged after the disease has existed some time. Extension downward occurs in time, and the ureter when attacked always becomes enlarged and can be felt as a hard cord through a lax abdomen. Vaginally, an enlarged ureter can always be felt, and this constitutes a valuable diagnostic sign. If the ureter becomes occluded by débris, and this is very apt to occur, or if it is stenosed by swelling of its wall, retention of urine is caused, and dilatation of the pelvis and calices ensue, resulting in enlargement, so that a tumor may be discovered by palpation (tuberculous cystonephrosis).

The relation between genital and urinary tuberculosis in the male is very close. The urinary tract is invaded in 56.6 per cent. of the cases in which genital tuberculosis exists (Villard); but in the female there is no such relation between the two systems. Tubercular endometritis or tubercular affections of the adnexæ are quite common in women, yet it is rare that the urinary tract is invaded in such cases.

Symptoms and Diagnosis.—The symptoms on the part of the kidney before the ureter and bladder have been infected are obscure and ill defined. There is reason to believe that the disease may be present

many months in the kidney without causing any symptoms whatever. If, however, the disease has started in one of the papillæ, we may sometimes observe an abundant hematuria of renal origin as the first symptom. The hematuria may last a day or two and then stop, to recur again at the end of a few weeks or months. Sometimes the urine is only slightly stained with blood, but usually the hemorrhage is copious and alarming. Such a hemorrhage is always to be taken with the greatest concern, and should lead at once to cystoscopic examination and catheterization of the ureters in order to determine the source of the bleeding. Inoculation of two guinea-pigs with the separated urines will sometimes clear up the diagnosis, the pig inoculated with the in-

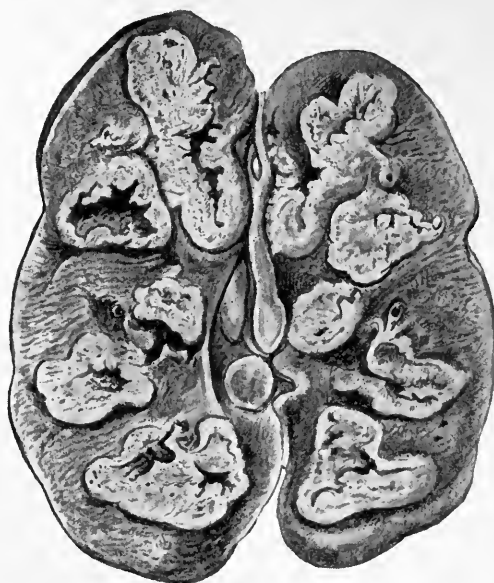


Fig. 182.—Tuberculous kidney (Rovsing).

fectured urine contracting the disease and exhibiting characteristic lesions at autopsy.

In the early stage of the disease we may sometimes observe slight pyuria with albumin and casts. Very exceptional symptoms on the part of the bladder first attract attention, without there being any demonstrable lesion in the bladder itself. Thus, pain in the neck of the bladder and frequent micturition may be the first evidence of a parenchymatous renal abscess, and that too before either pus or albumin have appeared in the urine. Pain in the affected organ may be entirely absent or may be so slight as to attract little attention. Fever and chills are usually absent. Pressure over the affected kidney sometimes causes resistance of the muscles lying over it, and this has diagnostic weight. Polyuria has been mentioned as a sign of early renal

tuberculosis. If the cystoscope is used and there is renal abscess in the kidney, the ureteral slit may be retracted further out than normal, and it may be more patulous than usual (Fenwick). The general health begins to suffer when the disease has lasted an appreciable length of time, though it is astonishing how well some of the patients preserve their health even with a diffusely suppurating kidney.

When the disease has invaded the ureter and bladder, the clinical picture is a tolerably clear one. But even here the renal symptoms are often overshadowed by the vesical ones, and may even be absent or so slight as to escape notice unless the patient is closely questioned. Slight renal pain may be complained of, or occasional uneasiness in the lumbar region. In other cases pain is a prominent symptom, and may take on the character of a true renal colic, the cause of which is the passage of a shred of necrotic tissue through the ureter. The renal pain is of a deep, boring character, and may be felt in the lumbar or hypochondriac region or in both. Exertion of any kind aggravates the pain. Of the vesical symptoms, frequent painful micturition is the most prominent and gives the most severe suffering. The patient always has the desire to micturate, and there is no ease night or day from the constant desire to empty the bladder. The pain is usually felt at the vesical neck, and it may radiate into different parts of the body. Tenesmus is always present. Incontinence is rare, even in the late stages of the disease, unless the vesical neck has been attacked, which is rare. Hematuria is, in vesical cases, quite a prominent symptom, the blood being observed at the end of micturition and not being more than a few drops; occasionally, however, if deep ulceration is present in the bladder, there may be a sharp hemorrhage, and then it is difficult to distinguish it from a renal hemorrhage; in such a case the cystoscope will locate the seat of the eroded artery.

Symptoms on the part of the kidney become more pronounced if the ureter becomes permanently occluded, as pyonephrosis with disintegration of the remaining renal tissue is much hastened thereby. The focal symptoms on the part of the kidney are increased pain in the renal region and tumor, which forms under the ribs; chills and fever may occur; there is now no difficulty in diagnosing blocked renal supuration. The pyuria coincidentally becomes lessened, and this is a diagnostic feature under these circumstances. The separated urines in a case of advanced renal tuberculosis show which kidney is diseased, and the examination of the urine gives some evidence of the amount of renal structure remaining intact. Cryoscopy is of more value in determining this than the chemical examination of the urine, though neither is infallible. Finding the bacilli establishes the diagnosis.

Cystoscopic examination shows the characteristic tubercular ulcers, with ragged edges and of excavated appearance. They are usually grouped about the affected urethral orifice, though they may be found in other parts of the bladder, particularly on the posterior wall above the trigone. They vary in size, but are usually of small diameter; if the disease has lasted any length of time, however, they may be of

considerable size and extent, and eventually the whole mucous membrane of the bladder is eroded and eaten away; the muscular tissue is seldom invaded.

The general health in a case of renal tuberculosis is gradually undermined by the effects of the progressive suppuration, and the nervous system suffers severely from the effects of the constant vesical irritation. The other vital organs gradually become impaired, and if tuberculosis is present elsewhere in the body, as it is almost sure to be, death is thereby hastened. A not uncommon termination of the disease is general miliary tuberculosis. Amyloid degeneration of the opposite kidney is sometimes a contributing cause of death. The duration of the disease untreated is from six months to two years. In some cases temporary arrest of the disease may take place, or even a definite cure by encapsulation has been observed.

Treatment.—Internal treatment has a symptomatic value only. Operation may effect a cure that may last for years or may even be permanent.

In the early stages of the disease, before much tissue has been involved, it is well to consider the possibility of cure by means of change of climate before resorting to nephrectomy. This measure may be productive of great good and may even result in cure, as it has in cases of tuberculosis elsewhere in the body, notably of the bladder (Desnos). While there may be some risk in adopting this line of treatment from the possibility of dissemination of the disease elsewhere in the body, the results have been so good in tuberculosis of other organs as to warrant its trial in the case of the kidney. The patient, while away from home, should be under the constant care of a competent physician. It is strongly advisable, even after nephrectomy, to recommend a change of climate, for convalescence is thereby favored.

Resection of the kidney should never be contemplated, as we can never be sure that the whole of the disease has been removed by this method of treatment. Pathologic examinations have confirmed this view (Pels-Leusden).

Total nephrectomy is the operation of choice. It is applicable when the opposite kidney is healthy, and it is not contraindicated by moderate pulmonary tuberculosis or by tuberculosis elsewhere in the body, provided the general health is of reasonable excellence. Tuberculosis of the bladder will, after nephrectomy, undergo a remarkable improvement; but the cure of the bladder is much hastened by local treatment with pure nitrate of silver. The latest statistics as regards the mortality after nephrectomy show an immediate operative mortality of 17.4 per cent. (Garceau). Patients usually do very well after nephrectomy, for a time at least. The percentage of promising cases, that is, of patients who do well up to a year from the time of operation, is as high as 58.6 per cent. But when we examine the histories of reported cases in which the cure has persisted two years or more after the operation, the percentage drops to 21 per cent. (Garceau). Patients who have

had nephrectomy done should take the utmost care of themselves in order to maintain their constitutions up to the highest possible pitch of vigor, for by this means only can they hope to keep down the disease which is lurking within them.

Nephrotomy alone should never be considered in the treatment of renal tuberculosis. The reported cures by this method of treatment are less than 1 per cent. Tubercular sinus almost invariably results, and it refuses to heal under any treatment. The patient's health gradually becomes undermined, and dissemination of tuberculosis elsewhere is the result. The only indication for nephrotomy is a large abscess, either perinephritic or pyonephrotic, which has produced a condition of general sepsis. Nephrectomy under these circumstances is very dangerous. Incision and drainage for a while allows the inflammatory deposit to subside, and meanwhile the patient recuperates. If nephrectomy is then performed, the results are most excellent. The immediate mortality of nephrectomy following nephrotomy is only 11.9 per cent., and the final results as regards cure are quite as good as after primary nephrectomy.

If the ureter is diseased, it should always be removed. The operative mortality of total nephro-ureterectomy is not greater than that of simple nephrectomy alone, provided the patient is in fair condition. Occasionally the ureter is only partially diseased, and then it is necessary to remove only the diseased portion.

If the diseased ureter is abandoned, further complication may be expected. Lumbar abscess under these conditions has been known to occur as late as two years after the nephrectomy (McCosh), and fistula is common. Besides this, there is the further danger of dissemination of the disease elsewhere.

TUMORS OF THE KIDNEY.—Malignant Tumors.—The differential diagnosis between carcinoma and sarcoma of the kidney was not made until about ten years ago; up to that time all cases were described as "cancer." The symptoms of carcinoma and sarcoma are so similar that they may be considered under the same head. Malignant tumors are more common in man than in woman, and occur in all ages. Sarcoma is more common in children; and carcinoma is more frequently met with between the ages of fifty and seventy. In 18 cases of carcinoma reported by Brodeur, 17 occurred in adults and only 1 in a child; in 27 cases of sarcoma, 15 adults and 10 children were affected; almost 80 per cent. of the sarcomata in children occur during the first four years of life, and some may even be congenital. Primary malignant disease is, of course, unilateral; when a tumor is found in both kidneys, therefore, one or both must be metastatic. The size varies from that of a hazelnut (Israel's case) to one-third the weight of the body (in a child). The tumor is either circumscribed or diffused. The circumscribed tumor extends from the kidney substance into a calyx or into the renal pelvis, where it may cause hematuria as long as the ureter is patent; or it may perforate into the renal vein and the vena cava, causing malignant thrombosis.

Histology.—Carcinomata are not so common as sarcomata, and are usually soft, large, nodular tumors; seldom small and hard. Microscopic examination shows the structure of the tubular carcinoma from proliferation of the epithelial cells of the urinary canals. Metastases occur later than in carcinomata in other parts of the body, but earlier than in renal sarcomata; and the metastatic carcinomata are usually located in the retro-peritoneal lymph-glands, the lungs, and the other kidney.

Sarcomata originate from the inside of the capsule or from the suprarenal bodies, or from aberrant islands of their tissue located in the kidney, or rarely from the perirenal tissue. Microscopic examination reveals round-cell, spindle-cell, or mixed sarcoma, endothelioma, and rarely rhabdomyoma or myxosarcoma. The sarcomata are usually nodular, grow gradually, and may attain an enormous size.

Symptoms.—There are often no symptoms for a long time during the so-called latent stage of the disease. Pain is often absent, is not characteristic, and is not influenced by movements or pressure. Attacks of renal colic are caused by coagula or pieces of tumor tissue obstructing the ureter. Shortness of breath may be due to the presence of a large tumor pushing the diaphragm upward. A palpable tumor coming down from under the ribs, covered by the colon, with a tympanitic area on its abdominal surface and palpable in the lumbar region, is found later in the disease in 96 per cent. of all cases. Hematuria is a most important symptom, but is absent in one-fourth of the carcinomata, in one-half of the sarcomata, and in three-fourths of the malignant tumors in children (Tuffier). It occurs when the tumor has entered the pelvis, is more profuse than in stone and tuberculosis, is observed, as a rule, in the beginning of the disease, may be steady for months or remittent, and may finally disappear entirely when the ureter is occluded by the tumor. Coagula may cause renal colic. Tumor elements may be found in the bloody urine. The quantity of urine is ordinarily normal. It is, however, sometimes increased, and less frequently decreased. Emaciation and cachexia are late symptoms in the disease, possibly because the kidney is an excretory organ, and therefore, evacuates the toxin with the urine (Rovsing). Varicocele on the affected side has been mentioned as an occasional sequence of renal tumor by Morris and Guyon.

Course and Prognosis.—If the patient's life is not saved by an operation, the time from the first appearance of symptoms until death is in most cases from one to four years; but in some cases the patient may live from ten to fifteen years (Roberts).

Diagnosis.—In early diagnosis lies the only hope of saving the patient's life by extirpation. In cases without hematuria the tumor is the first indication. In children a relatively small tumor can be palpated, because the subdiaphragmatic space is flat and small, the kidney less firmly fixed, and the abdominal wall relatively thin. In adults, when the tumor begins in the suprarenal capsule or the upper pole of the kidney, it may push the diaphragm upward and attain a considerable size before it can be felt below the borders of the ribs; it is then, as a rule, too late to hope for a permanent cure. In the cases attended by hematuria an early diagnosis can more easily be made. A copious,

sudden hematuria, initiated without trauma, pain, or other symptoms referable to the urinary organs, directs the attention to malignant tumor. In the diagnosis, tuberculosis, nephrolithiasis, hemophilia, enlargements of the spleen, ovarian tumors, and malignant growths of the large intestine must be excluded. If no tumor can be felt, cystoscopy or catheterization of the ureter must determine which of the kidneys is the source of the hemorrhage. If these measures fail, exploratory lumbar incision must be resorted to.

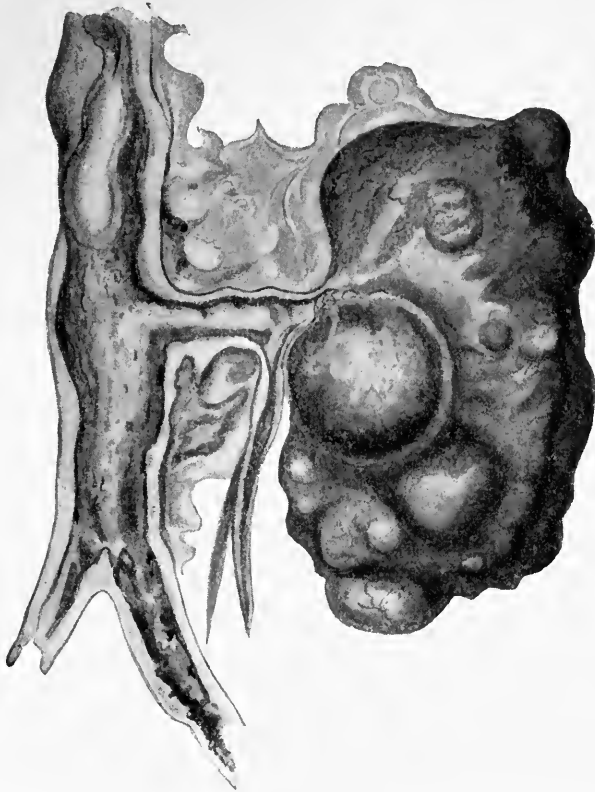


Fig. 183.—Sarcoma of the kidney extending into the vena cava and the spermatic vein from the renal vein (Rayer).

Treatment.—Nephrectomy should be made by lumbar incision in case of the smaller tumors; but the transperitoneal operation will be required if the tumors are too large to be removed through a lumbar wound. The tumor is operable if it is limited to the kidney, and if there are no metastases in the lymphatic glands. This, however, often cannot be determined before exploratory incision renders palpation of the organ possible. If it is found that enucleation cannot be completed in perfectly healthy tissue, the operation should be abandoned. The prognosis of the operation is grave. The operative mortality before

1890 was over 60 per cent., but has decreased in the last five years to 19 per cent. (Heresco). Radical cure is rare; but the instances are increasing in which a permanent good result is obtained. Israel reports 3 patients, out of 11 operated upon, who were in good health after three years. I have 1 case in which the patient is still in good health eight years after operation. Local relapses may come on later—after three years or more. Therefore, Tuffier gives six years as the time which must elapse before the patient may be said to be permanently cured.

Benignant Tumors.—Lipomata, adenomata, fibromata, angiomata, myomata, and combinations of these have been found in the kidney. In most cases the tumors are small, give rise to no symptoms, and are discovered accidentally on the postmortem table. Benignant tumors have been removed by nephrectomy in 10 cases only; 2 of these were adenomata and 8 fibromata (Rovsing). A villous tumor of a papilla of the kidney has been described by Fenwick. The chief symptom is persistent hematuria. The disease attacks young adults by preference, and yields only to surgical treatment. On operation an intensely red and vascular-looking papilla is seen, which should be removed with the curet; it is not apt to recur. Fenwick believes the condition to be due to a localized patch of interstitial nephritis impeding the circulation in the boundary layer of the pyramid, and thus preventing venous drainage of the papillary plexus. Microscopic examination shows extravasation of blood, congestion of vessels, and increase in cellular stroma. Serous cysts about the size of a walnut, either solitary or multiple, should be recognized during operation and removed by resection.

Echinococcus cysts are found most commonly in men, between the ages of twenty and forty; ordinarily in one kidney only, and most often in the left. There is usually only one mother-cyst, which begins in the cortical substance, causes expansion and atrophy of the kidney tissue, and when large may extend to the abdominal cavity, becoming adherent to the colon, liver, spleen, or other organs. Finally, after one or two years, the cyst ruptures, fortunately most often into the pelvis of the kidney, and evacuates parts of its contents through the ureter.

The *symptoms* are at first vague; the tumor is globular and often movable. When rupture takes place, it is marked by a sudden pain followed by renal colic as the daughter-cysts pass down the ureter, and by vesical tenesmus when they pass out into the urethra. The cysts are usually crushed during their passage from the kidney, and we find in the urine transparent gelatinous masses (the sac-walls) and a little blood. Microscopic examination reveals the characteristic hooklets and lamellated membranes of the sac. Later on, infection comes on, attended by fever and emaciation, terminating fatally in most cases (23 out of 29, Boeckel), spontaneous recovery being the exception.

Treatment.—The cysts should be opened by lumbar or transperitoneal incision, the contents evacuated, and drainage maintained until the cavity is closed. The opening in the cyst-wall must be united to the skin. Lumbar incision, if practicable, is to be preferred. If the transperitoneal route is chosen, the operation in two stages is preferable. Le Dentu treated 9 cases and Wagner 28 cases in this manner, and all the patients recovered; while out of 10 cases in which nephrectomy was performed Wagner reports 3 deaths; and of 11 cases of puncture alone or puncture with injection of tincture of iodine, 3 were cured, 3 remained unimproved, and 5 died.

Aneurism of the Renal Artery.—Keen reports that only 13 well-described cases of aneurism of the renal artery are to be found in the literature. The diagnosis was made in none of these cases until an exploratory operation or autopsy revealed the true character of the disease. If the aneurism is located in one of the large intrarenal branches, the swelling is central and causes distention of the kidney. If it is an aneurism of the trunk of the renal artery, the tumor is located outside of the kidney (in the hilus), and pushes the kidney aside without making any change in the shape of the organ.

The *symptoms* are a rapidly increasing, tense or elastic tumor, with a feeling of heaviness and pain, which may radiate down to the testicle of the same side. Pulsation has not been noted in any of the cases. Diagnosis is practically impossible before an exploratory incision has been made. The possibility of aneurism should be considered when, subsequent to an injury in the region of the kidney, a tumor of considerable size develops rapidly, with no hematuria, especially in patients having arteriosclerosis or syphilis.

The *treatment* is nephrectomy, after ligation of the renal vessels as close to their origin as possible. Three patients have been saved in this manner (Hocheneegg, Hahn, and Keen)

CYSTONEPHROSIS (*Hydronephrosis; Pyonephrosis*).—Dilatation of the urinary passages occurs above an obstruction to the free flow of urine. It begins immediately above the point of stenosis and extends gradually backward toward the kidney. Thus, a stricture of the bulbous portion of the urethra causes, first, dilatation of the membranous urethra, next of the bladder, then of both ureters, and finally of the pelvis and calices. If the obstruction is in or below the bladder, the dilatation extends to both kidneys; while if the obstruction is located in the ureter or above it, the dilatation will be limited to the kidney of the affected side. If only one of the two branches of the ureter is occluded, a partial dilatation of the kidney takes place, which is limited to the corresponding half of the organ. Dilatation of the pelvis and calices above the ureter may be termed *cystonephrosis*. When no infection of the retained urine has taken place, it contains a watery fluid, and is termed *hydronephrosis*. When infection has transformed the fluid into pus, we speak of *pyonephrosis*.

NON-INFECTED CYSTONEPHROSIS (*Hydronephrosis*).—We may classify hydronephrosis as follows:

1. *Congenital* hydronephrosis, when the stenosis is caused by intra-uterine disease.
2. *Acquired* hydronephrosis, when the retention of urine is caused by diseases late in life.

If the hindrance to the evacuation of urine is absolute, we have a *permanent* hydronephrosis; if the urine passes out at intervals, the condition is known as *intermittent* hydronephrosis.

Etiology and Pathogenesis.—Sudden, complete occlusion of the passage of urine, as exemplified experimentally by ligation of the ureter, is followed in most animals by atrophy without dilatation, and only exceptionally by hydronephrosis. In most instances in which a progressive hydronephrosis is developed the occlusion is also gradual and for a time incomplete.

Compression of the ureter by tumors is of common occurrence. Morris states that 90 per cent. of hydronephroses are caused by malig-

nant tumors in the small pelvis. When a carcinoma of the uterus extends into the broad ligaments, compression of the ureter and hydronephrosis result in one-half of the cases. Disease in the wall of the ureter, such as traumatic rupture, ureteritis, or tuberculosis, may lead to stricture. Bending of the ureter, due to floating kidney, is followed by incomplete obstruction, retention, and dilatation above the bend. When the dilatation of the renal pelvis is unilateral or not uniform, lateral implantation and valve formation of the ureter at its pelvic end give rise to retention and hydronephrosis. This condition is not uncommon. Finally, an obstruction within the canal of the ureter, such

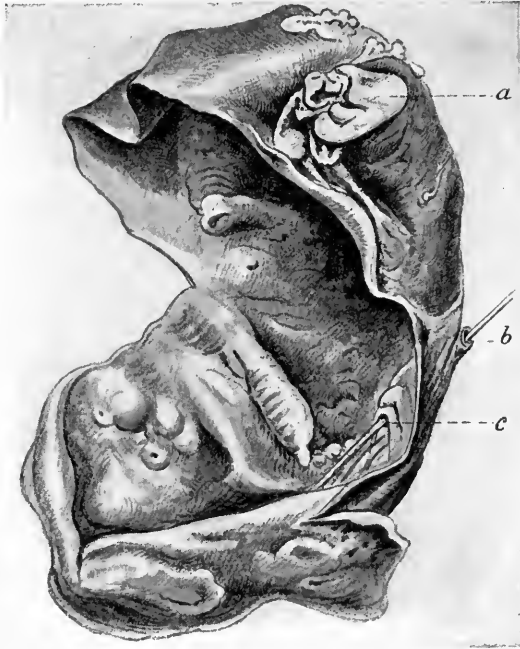

Fig. 184.—Right congenital hydronephrosis in a child nine months old. Extirpation; recovery (Rovsing).
a, Supracapsular sac; *b*, ureter; *c*, valvular obstruction at the pelvic end of ureter.

as a stone, a foreign body, or a blood-clot, may occasionally be the cause of hydronephrosis.

Congenital Hydronephrosis.—A congenital cause for hydronephrosis is found in one-third of all cases. The disease may be bilateral when the hindrance to the evacuation of urine is located in the prepuce or the urethra. Absence of the urethra or complete occlusion by a membrane at the external or internal orifice causes complete hydronephrosis. Phimosis or incomplete valve formation in the urethra causes incomplete hydronephrosis. In rare cases the cause is found to be bilateral obliteration of the ureter. Children affected with bilateral hydronephrosis die shortly after birth. Unilateral congenital hydronephrosis is compatible with life, as the other kidney is sufficient for the necessary function. This condition, therefore, is often not noticed until later in life, unless the sac at the time of

birth is so large as to cause an impediment to delivery. The obstruction is most often in the ureter; rarely in the bladder.

In some cases there is obliteration of the ureter; in others, compression of the ureter by anomalous renal arteries; torsion of the ureter is of rare occurrence. In most cases valve formation at the pelvic orifice of the ureter is found as a congenital anomaly which causes hydronephrosis. In some cases other disturbances in development, such as spina bifida, pes varus, cleft-palate, harelip, and imperforate anus, are found with the congenital hydronephrosis (Fig. 184).

In rare cases stenosis of the ureter at the pelvic or vesical orifice is seen. When the kidney has a double ureter, one portion patent and the other obliterated, a partial hydronephrosis or dilatation of the half of the kidney corresponding to the occluded ureter is seen.

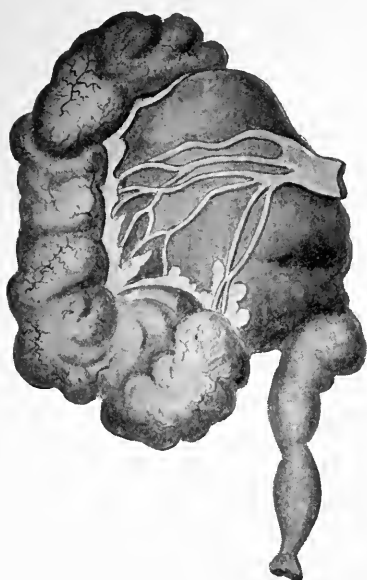


Fig. 185.—Hydronephrosis. First stage (Le Dentu).

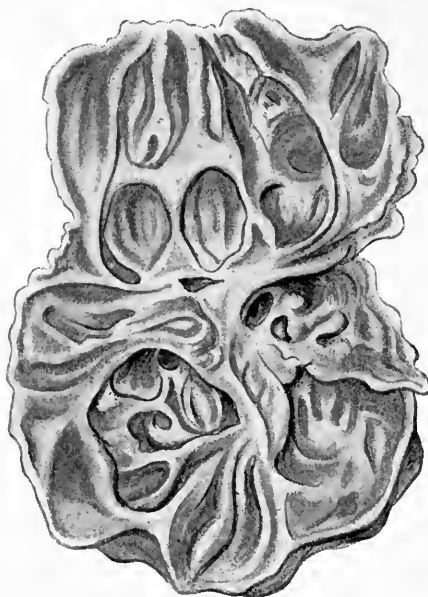


Fig. 186.—Hydronephrosis. Second stage (Rayer).

Acquired hydronephrosis is much more common, and may be permanent or intermittent. Permanent, unchangeable hydronephrosis was found by Morris 239 times in 3926 autopsies. External compression of the ureter by malignant tumors in the small pelvis is the cause of 90 per cent. of hydronephroses. Carcinoma of the uterus which has extended to the broad ligaments compresses the ureters, causing bilateral hydronephrosis and death from uremia. Pelvic cellulitis, hematocoele, retroflexions or lateroflexions of the uterus may also operate as causes. Other abdominal tumors, such as ovarian cystomata, uterine myomata, intestinal carcinomata, or sarcomata may cause hydronephrosis, but ordinarily on one side only.

Obstruction within the ureter is caused by stone (11 out of 22 cases, Roberts), or by stricture due to inflammation or trauma. In the upper

end of the ureter the injury is usually due to rupture; in the lower end to difficult delivery and the use of forceps.

Intermittent hydronephrosis exists when the urine retained in the sac is evacuated at intervals. This is often found in case of floating kidney (Landau). When the kidney is descended, the upper end of the ureter is bent, and this causes obstruction and retention above. When the kidney returns to its place, as is the case when the patient lies down, the bend or twist is straightened out, and the retained urine is evacuated; but in the course of time unilateral dilatation and valve-formation or fixation of the bend take place, evacuation becomes more difficult, and the hydronephrosis becomes stable.

Pathologic Anatomy.—The retained urine causes, first, dilatation of the pelvis and calices, with stasis, swelling of the kidney tissue, and multiple ecchymoses, followed later by edema, paleness, and atrophy beginning in the pyramids. The papillæ become flattened, and the pyramids and, later on, the cortical substance are gradually transformed into, or replaced by, connective tissue from interstitial infiltration, until finally a large multilocular sac is formed, in which globular cavities, separated by fibrous partition-walls or annular prominences corresponding to the calices and pyramid, alone remain. At first the kidney substance is extended like a cap over the dilated pelvis (Fig. 185); but later on no kidney substance can be seen on it in the wall of the large multilocular sac (Fig. 186).

The rapidity, however, with which the kidney tissue and, consequently, the secretion of urine disappear is very variable. Krause found a thin layer of kidney tissue, 36 cm. long by 13 cm. (14.3 by 5.3 inches) broad, spread out over the surface of the sac. It has been observed that when a hydronephrotic sac, even of enormous size, where a thin layer of kidney tissue could scarcely be recognized, has been opened and drained, a quantity of urine from 400 to 500 c.c. daily has been secreted. If, as in Küster's case, the other kidney is absent, life is dependent upon the hydronephrotic kidney alone. It is thus evident that the kidney substance may be spread out as a thin layer over a large surface without losing its secretory power.

The hydronephrotic sac gradually becomes adherent to the surrounding organs by chronic inflammation, so that its extirpation is rendered difficult. If the obstruction is located in the ureter, this organ is found to be dilated above the obstruction; normal or atrophied below, from disuse.

The sac contains, as a rule, a transparent fluid resembling thin urine. If active kidney tissue is present, the fluid contains a variable amount of urea or uric acid, but if all kidney substance has disappeared, the fluid is serous and contains albumin, but no urea or uric acid.

The *symptoms* are indistinct in the first stage of development. Pain is usually absent, and the hydronephrosis is detected only when the sac has attained a considerable size. The tumor in the renal region gradually extends from below the ribs downward into the lateral half of the abdomen, and is then often accidentally discovered by the patient. It subsequently extends downward toward the symphysis and inward to the median line, which it finally passes, until it fills the entire abdomen. The tumor is usually fluctuating, and may be felt to extend up behind the ribs and backward into the lumbar region. As the tumor is usually covered by ascending or descending colon, there is an area of clear percussion on the abdominal surface; but when the sac becomes very large,

the colon is pushed far over toward the healthy side, leaving the percussion dull over the corresponding half of the abdomen. Sometimes a firmer and somewhat nodular territory is felt, which corresponds to a considerable layer of kidney substance.

Pain is often absent, and is sometimes remittent, even in stable hydronephrosis, and may then be due to a sudden increase in the size of the tumor. In open or intermittent hydronephrosis attacks of pain and tenderness occur during the period of accumulation. The pain and tumor disappear upon evacuation of the sac, often during the night, simultaneously with the passage of an increased amount of urine. The patient is often aware that certain positions or manipulations of the tumor aid in the evacuation. The intervals between attacks vary from four to five days to a month or more.

Fever is absent in non-infected cystonephrosis; if fever is present, it signifies infection and consequent additional danger to the kidney as well as to the patient. Frequent micturition is sometimes observed.

The disease runs an indefinite course, and if unilateral and not infected, does not disturb the general health. Spontaneous cure is possible, but rare. It may take place, for instance, when a stone impacted in the ureter passes down into the bladder.

INFECTED CYSTONEPHROSIS (*Pyonephrosis*).—The contents of a hydronephrotic sac furnish an excellent culture-soil for the growth of microbes, and the low vitality of the sac-walls offers no resistance to them; therefore, when microbes once gain access to the cavity, they multiply with great rapidity. The sac-contents become purulent, the increased tension causes pain, and high fever, with rigors and all the other symptoms of acute sepsis, give warning of impending danger. If the pus is not promptly evacuated, sepsis will soon cause the death of a patient who has only one kidney to carry off the toxins, and this kidney is so overtaxed as to become the seat of a septic nephritis, which almost invariably terminates in fatal uremia. The suppuration of the sac may lead to perforation and rupture. If this takes place into the peritoneal cavity, a fatal peritonitis results. If it opens into the retroperitoneal space, a diffuse phlegmonous inflammation (perinephritic abscess) results. Although this disease is not always fatal, it is grave, and demands prompt surgical interference.

The *diagnosis* cannot be made until a tumor is felt. In small hydronephroses the location of a fluctuating tumor in the region of the kidney, extending up under the ribs and easily palpable in the lumbar region, will lead to a diagnosis. Large tumors which fill the entire abdomen simulate, and have often been mistaken for, ovarian or other abdominal cysts. If the sac is not tensely filled, it may simulate ascites. A small hydronephrosis on the right side may be mistaken for a distended gall-bladder; on the left side, for a cyst in the spleen.

Pyonephrosis presents the acute symptoms of infection, and in the more chronic cases the patients are cachectic and emaciated.

If we always consider the possibility of cystonephrosis, and on examination of the ureters find that one is occluded, the diagnosis is

reasonably certain. Aspiratory puncture and examination of the fluid are often uncertain, because in the large and old sacs none of the components of the urine exists. Puncture may be dangerous, because it may be followed by extravasation of the fluid around the sac.

Treatment.—Beginning cases of open, intermittent, non-infected cystonephrosis, when due to bending of the ureter in a floating kidney, may be treated by nephropexy, provided the bend is found to be straightened when the kidney is replaced. If no bend exists, the sac should be opened and the obstruction sought for by exploring the ureter from its pelvic origin down to the bladder. A valve or stricture may be remedied by a plastic operation, or a stone may be removed from the ureter. If it is thus possible to remove the cause, the kidney can be saved, and should be saved if secreting kidney tissue still remains.

Infected remittent cystonephrosis (pyonephrosis) must necessarily be opened for drainage, and examined as regards the removal of the obstruction; but here the question of removal of the kidney comes up, and if suppurative nephritis, with multiple abscesses in the kidney tissue, is found, nephrectomy should be done.

Stable, permanent, non-infected cystonephrosis (hydronephrosis) has been treated by puncture, incision, and extirpation (nephrectomy).

Rovsing has collected from the literature 92 operations for hydronephrosis, with the following results:

OPERATION.	RECOVERY.	UNIMPROVED.	DIED.	TOTAL NUMBER OF CASES.
Puncture with drainage	1	2	9	12
Nephrotomy	15	13	28
Transperitoneal primary nephrectomy . .	16	..	3	19
Transperitoneal secondary nephrectomy	7	..	3	10
Lumbar primary nephrectomy	18	..	2	20
Lumbar secondary nephrectomy	3	3

It will be seen from this table that puncture, even with drainage, is insufficient and dangerous, and should be abandoned. Nephrectomy, or total extirpation of the hydronephrotic sac, has given the best results, and is the operation which should be employed in the majority of cases, but one should be certain that obstruction is irremediable before resorting to nephrectomy. Transperitoneal nephrectomy was most often performed in cases in which a large sac filled the abdomen, and a correct diagnosis was not made before the operation. If it is known that a hydronephrosis is present, the lumbar operation should probably always be done. If the hydronephrotic sac contains no secreting kidney tissue, as is the case in most of the very large hydronephroses, nephrectomy is indicated. A large sac, which is practically valueless as to secretion, and is clad with mucous membrane, is very apt to become infected after nephrotomy and drainage. It is almost impossible in such cases to prevent infection; and Rovsing's statistics show that out of 28 cases of nephrotomy, 13 patients died. In most cases of large, stable hydronephrosis we find the other kidney sufficient for the urinary secretion. This is demonstrated by the fact that out of 52 cases of nephrectomy, only 8 patients died.

In small, recent, stable hydronephrosis, however, when kidney tissue can be recognized in the walls of the sac, and when remittent evacuation, present at first, has recently ceased, we may expect to find secreting kidney tissue that is worth saving. Here nephrotomy should be tried, and the obstruction sought for. If the sac is too large to permit of

finding the ureter, we may wait for a few months until it has retracted. During this time we must examine the quantity and quality of urine excreted daily. If the quantity is considerable, the obstruction can be sought for and remedied by a secondary operation. If no urine is secreted, secondary nephrectomy should be done.

OPERATIONS ON THE KIDNEY.—Narcosis.—The position of the patient, who lies on his side with a pillow under the costo-iliac space, causes some embarrassment of the respiratory movement of the thorax and some difficulty to the anesthetizer, because the face rests with one side on the table, thus making it difficult to watch the pupil and to manage the tongue. As to the choice of anesthetic: After the use of both ether and chloroform, albumin and cylinders or cylindroids are sometimes found in the urine. Investigations of Wood and others seem to favor the use of ether. Albuminuria followed the administration of chloroform in 11.5 per cent. of the cases, and of ether in 6.9 per cent. of the cases. Cylinders were found in 34.8 per cent. of the cases after chloroform, and in 24.6 per cent. of the cases after ether. Repeated narcoses at intervals of a few days should be avoided; thus, examination in narcosis for diagnostic purposes should not be made a short time before operation.

Treatment of the Operation Wound.—The antiseptic solutions of sublimate and carbolic acid should never be used, as both of these substances have a destructive effect on the kidney tissue, causing respectively albuminuria and hemoglobinuria. When irrigation is called for, boric-acid solution, sterilized water, or the physiologic salt solution should be used. It is also important to avoid the use of iodoform, either dusted over the wound or in the form of iodoform gauze for packing or dressing. The experiments of Stubenrauch have proved that even small quantities of iodoform applied locally on the kidney tissue caused extensive fatty and parenchymatous degeneration of the renal epithelial cells. General iodoform intoxication is attended by similar extensive degeneration in both kidneys and liver. Fatal iodoform poisoning following nephrectomy has been reported by Israel and others. In these cases the wound cavity had been packed with iodoform gauze, and the autopsy showed fatty degeneration of the remaining kidney.

Incision.—Access to the kidney is had either through the peritoneal cavity (the transperitoneal method) or through the lumbar region (the extraperitoneal method). The latter operation should always be performed, when practicable, in order to avoid the danger of peritonitis.

Transperitoneal Incision.—The patient is placed on the back, and the incision is made either in the median line or laterally at the outer border of the rectus muscle. The lateral incision gives better access to the kidney. The parietal peritoneum may be united to the skin by a few sutures. After digital examination of both kidneys and ureters the intestines are pressed over to the healthy side, held in place with gauze sponges, and the posterior peritoneum—that is, the mesocolon—is divided by a longitudinal incision corresponding to the anterior sur-

face of the kidney. The lateral layer of the mesocolon is usually divided; but if the colon is pushed outward by the tumor, it may be more convenient to divide the medial layer of the mesocolon. The anterior surface of the kidney is now laid bare to the hilus, then the lateral border, the upper and lower poles, and finally the posterior surface are exposed. This prepares the field for the operation on the kidney.

Drainage.—If the kidney is aseptic, the advice of Terrier may be followed, who closes off the wound from the peritoneal cavity by suturing the wound in the mesocolon to the parietal peritoneum or the skin, and packs the aseptic wound with a gauze drain. If the kidney is infected, it is preferable to make a counteropening in the lumbar region for drainage (Morris), and then either to close the wound in the mesocolon and the abdominal incision separately, without drainage through the abdominal wound, or to combine anterior and lumbar drainage.

Lumbar or Extraperitoneal Incision.—The patient is placed on the side, with a pillow in the costo-iliac space, so as to increase the distance between the costal border and the ilium.

The longitudinal or vertical incision of Simon, along the lateral border of the erector spinæ muscle, is 9 or 10 cm. ($3\frac{1}{2}$ or 4 inches) long, begins over the eleventh rib, and ends midway between the twelfth rib and the crest of the ilium. It divides the subcutaneous tissue, the latissimus dorsi muscle, and the lumbodorsalis fascia. Anterior to the quadratus lumborum is a fascia covering the adipose capsule of the kidney, and by blunt separation of this fascia the lower pole of the kidney is reached. The vertical incision gives little space for operating on the kidney, and has been superseded by the oblique incision.

Oblique Incision.—The oblique incision is made from the lateral border of the erector spinæ muscle below the twelfth rib, downward and forward, parallel to either the quadratus lumborum muscle or the linea semilunaris (Thornton, Guyon, and Tuffier) or the twelfth rib (Küster). The incision is 10 or 12 cm. (4 or $4\frac{3}{4}$ inches) long and divides the skin, latissimus dorsi muscle, possibly the quadratus lumborum, the external and internal oblique, and transversalis muscles. When the retroperitoneal adipose space is reached and the kidney has been palpated, the incision may be prolonged downward and forward to the outer border of the rectus abdominis muscle or to Poupart's ligament, by extraperitoneal division of the abdominal muscles as far as operative space is required. This incision gives ample operating space, and is applicable to most cases.

Combinations of the vertical and oblique incisions are employed by König, Bardleben, and others, and may be of use in special cases; or to the oblique incision, if required, may be added an incision at a right angle up toward the twelfth rib or down toward the crest of the ilium.

OPERATIONS ON THE KIDNEY include puncture, pyelotomy, nephrotomy, and nephrectomy.

Puncture with the trocar or hollow needle through the skin, for aspiration of fluid, has been done to confirm the diagnosis of a renal tumor. Transperitoneal puncture should never be made, on account

of the danger of infection of the peritoneal cavity by the contents of the kidney. Extraperitoneal puncture through the lumbar region is less dangerous, but it is uncertain, and is of little value either for diagnosis or for effecting a cure, as, for instance, in hydronephrosis. When, however, the kidney has been laid bare by an incision, puncture may be made with a thin needle to search for stone in the pelvis or calices, or fluid may be evacuated from a large sacculated kidney through a trocar or aspirator syringe, in order to facilitate the further steps of the operation. If a large sac contains pus, infection of the wound during the extirpation of the sac may thus be prevented.

Pyelotomy, or incision of the renal pelvis, may be done for removal of fluid or stones in the pelvis. After the kidney has been laid bare through a lumbar incision, the adipose capsule carefully separated from the posterior surface of the kidney and pelvis, and the organ lifted forward and out into the wound, a longitudinal incision may be made through the posterior wall of the pelvis. It is well to insert a loop of silk on each side in the border of the incision, which must be large enough to permit the introduction of the finger to explore for stone. Stones may be felt in the pelvis or in some of the dilated calices; or a stone may be so large that it will have to be divided before extraction. After removal of stones or evacuation of pus the question of drainage or closure of the wound must be considered. If a stone has been removed from an aseptic pelvis, the incision in the latter may be closed by a single or double row of extramucous sutures, on the principle of the Lembert sutures in the intestine. In most cases, however, there is doubt as to the aseptic condition of the pelvis, and a drainage-tube must be inserted.

Pyelotomy as a means of access to the pelvis has the advantage, as compared with division of the kidney substance, of being attended by little or no hemorrhage, and of causing no injury to the kidney-tissue. It possesses the disadvantage of giving no access to abscesses in the kidney substance and less freedom of access to the calices.

Many authors state that pyelotomy has the disadvantage of being almost always followed by a permanent lumbar urinary fistula. We must remember, however, that no ordinary fistula will be permanent if the ureter is patent. The condition of the ureter should always be ascertained by exploration with a bougie or sound, or by injection of fluid; and any obstruction, whether it be oblique insertion and valve-formation or stones or strictures in the ureter, should be relieved. This may be accomplished through the wound in the pelvis or by operations lower down in the course of the ureter. After this has been done and free passage of the urine into the bladder has been secured, there is no reason why a lumbar urinary fistula should follow pyelotomy more frequently than it follows an opening into the renal pelvis through the convex surface of the kidney (nephrotomy).

Nephrotomy.—Incision through the kidney tissue is made to evacuate pus from the kidney, calices, or pelvis; to remove stones; or, finally, to remedy obstructions in the kidney above the pelvis. The

gravity of the operation depends on the condition of the kidney tissue. A thick layer of normal kidney substance is extremely vascular, and its division gives rise to considerable and often enormous hemorrhage. When the kidney substance has been destroyed by interstitial nephritis from infection and suppuration, or when obstruction has caused dilatation of the calices (cystonephrosis), the vascularity is thereby lessened and the hemorrhage upon division is slight and unimportant.

Nephrotomy in Healthy Kidney Tissue (Nephrolithotomy; Bisection of Kidney).—The adipose capsule is separated by blunt dissection, and the kidney brought well out into the field of operation by pulling it down slowly and cautiously below the twelfth rib. Exploration for stone is then made by a solid steel needle or by the fine needle of an aspirator syringe. If the aspirator needle detects fluid, we know that it must be in a calyx or the pelvis, and the needle is therefore left in, to cut upon as a guide. Division of the healthy kidney tissue is accompanied by considerable hemorrhage. This cannot be stopped by hemostatic forceps or by ligatures, because they tear through the friable kidney tissue. We must, therefore, resort to compression of the pedicle of the kidney or to direct compression of the kidney wound. Compression of the pedicle of the kidney—that is, the renal artery and vein—can be made by digital compression between two fingers of an assistant, or by instruments. Tuffier uses for this purpose a Péan forceps with broad jaws, covered with rubber tubing, in order to avoid injury to the vessels and secondary thrombosis. Rovsing uses a compressor similar to those used on the intestines during resection of the bowels. Direct compression of the wound-surface is made by a tampon of dry sterile gauze, against which the wound-surfaces are held firmly together. After a few minutes the bleeding is considerably diminished. This method is applicable to the smaller incisions, one-fourth to one-third of the length of the kidney; but it is insufficient when the kidney is divided through its entire length, as in bisection, when compression of the pedicle cannot be dispensed with.

Exact suturing of the kidney wound by deep and superficial sutures furnishes a good and certain method of hemostasis.

Division of the kidney tissue is made by the knife, rarely by the Paquelin cautery. The incision should be made just posterior to the median line of the convex border; that is, longitudinally, straight into the pelvis, because here only the smallest vessels are found; and as the incision is parallel to the uriniferous canals, the smallest possible number is divided. Thus the minimum amount of hemorrhage and of atrophy of kidney tissue will follow. A single incision of the kidney is preferable to two incisions, one at each of the poles, as it gives the best access to the pelvis and calices. When the pelvis has thus been opened, stones are sought for by exploration with the finger or steel sound. The narrow entrances to enlarged calices must be dilated and all calices examined, as stones are here often left undetected. If the pelvis contains a large stone with branches extending into the calices, the necks of the calices may be divided to free the stone. A large stone

may be divided with a crushing forceps to facilitate removal. Ordinarily a flat sound or director can be passed around the corner of the stone to free it and lift it out. As a rule, however, the stones are small and easily removable.

The ureter should always be sought for at the bottom of the pelvis, and a probe or bougie passed down into the bladder to make certain that the ureter is patent, that no stones are arrested in it, and that no strictures or bends exist. If the pelvis is dilated, oblique insertion of the ureter may be expected. When these conditions have been remedied, permanent fistula will not follow.

The *treatment* of the wound in the kidney tissue depends upon the condition of the latter. If the kidney is aseptic, the wound is united by deep and superficial sutures, preferably of catgut (Figs. 187, 188).

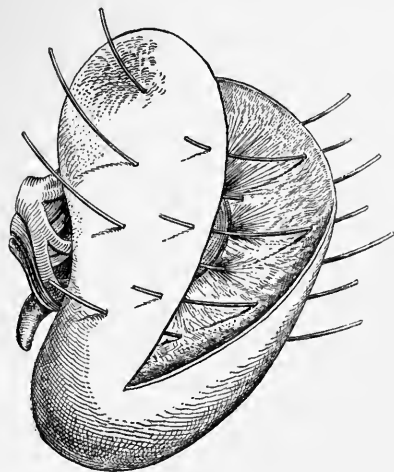


Fig. 187.—Bisection of kidney. Insertion of sutures (Tuffier).

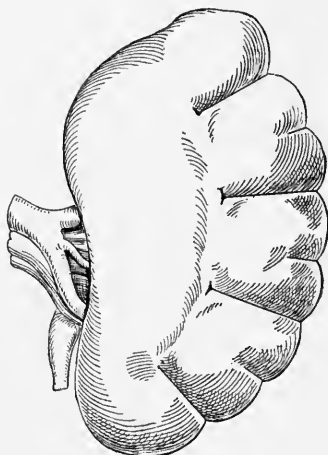


Fig. 188.—Bisection of kidney. Sutures tied (Tuffier).

The deep sutures of heavier catgut pass through the whole thickness of the kidney tissue, while the superficial sutures of finer catgut take in the capsule and a little of the cortical substance. The adipose capsule and the abdominal muscles are united by buried sutures. Drainage with gauze or a tube down to the kidney may or may not be made, depending entirely upon the operator's confidence in his asepsis. If the kidney is infected, or if infection is suspected, it is safer to drain either with a tube inserted down into the renal pelvis or by packing with aseptic gauze. The latter is preferable when hemostasis is not absolutely certain.

The after-course is usually aseptic, and primary healing in from two to three weeks is common. The urine is bloody from three to seven days. Fistulas rarely follow. In 43 cases collected by Tuffier there were 3 deaths, 2 fistulas, and 38 recoveries.

Nephrotomy in an Infected, Suppurating, Often Dilated Kidney (Nephrotomy Proper).—Lumbar nephrotomy is the operation of choice. The operation has for its object the evacuation of infected fluid (pus) or non-infected fluid in cystonephrosis, the removal of stones, if present, and the local treatment of the infected pelvis and calices. It is often an operation of necessity in a septic patient with high fever to remove the pus and put an end to the septic absorption. The adipose capsule is exposed through the oblique lumbar incision—and in septic cases it is transformed into a thick, fibrolipomatous mass adherent to the surface of the kidney. This is divided with the knife either on one of the bulging, fluctuating prominences, or along the convex surface by an incision 3 to 4 cm. ($1\frac{1}{4}$ to $1\frac{1}{2}$ inches) long, either made directly or on an aspirator-needle as a guide. If a large infected cystonephrosis containing a considerable quantity of pus is found, it is well to evacuate the pus through a trocar, and pull the sac out of the wound with forceps before incising it, in order to protect the outer wound against infection from the contained pus. A finger is now inserted into the pelvis, while the other hand makes compression on the abdomen, to push the kidney against the exploring finger, thus making it possible to palpate the whole interior of the kidney. Stones are carefully sought for by the finger or steel sound. If the entrances to dilated calices are narrow, they may be dilated by forceps or the finger. The object of the operator should be to transform a multilocular cavity, in which access to some of the dilated calices is difficult, into a single or unilocular cavity, in order to facilitate drainage.

If the patient's condition permits of more than the simple evacuation of pus and insertion of a drain, as it sometimes does in non-infected cystonephrosis and in some cases of bending and valve formation of the ureter, it is advisable to bisect the kidney by complete longitudinal division in the median line. By this means the pelvis and all the calices are exposed, and the division of partition-walls between dilated calices with narrow necks, for thorough exploration and evacuation of their contents, is made possible. It further permits the exploration of the ureter from the pelvis and operation on strictures or valve formations. Bisection is preferable to a shorter incision for the division of the narrow necks of calices, as larger vessels may be divided, which will necessitate ligation or searing with the Paquelin cautery.

The pockets in the dilated kidney and the pelvis are cleansed with sponges, in order to remove stringy pus from the walls, to which it may adhere, and also stones, gravel, and incrustations. Incomplete removal of stones was found by Tuffier to have taken place in 11.3 per cent. of 114 cases. This was caused by the difficulty of exploring a large sacculated kidney with multiple pockets.

The *treatment* of the kidney wound must be such as to secure free lumbar drainage for a time sufficient to cure the pyelitis. Thus, the borders of the renal wound are united to the skin. If the kidney has been bisected, the ends of the kidney wound may be united and the middle portion left open. The external wound is united at the upper

and lower extremities only, leaving open the middle portion, which has been sutured to the edges of the kidney wound.

Drainage of the kidney is made by packing the pelvis and calices with sterile gauze, which may be removed in a day or two and replaced by rubber drainage-tubes. Drainage of the lumbar wound is made by gauze strips or rubber tubes on the outer side of the kidney at its upper and lower poles.

A voluminous aseptic dressing is needed to take up the pus and urine from the kidney. The quantity of urine secreted from a kidney which is to all appearances useless or destroyed may be unexpectedly very large. If this be the case, it may be necessary to change the dressing once or several times daily.

The *prognosis* of lumbar nephrotomy depends upon the disease for which the operation has been made, and especially upon the condition of the other kidney. The operation, as such, has very little danger, and may be done very rapidly, as for simple evacuation of pus. The mortality in 259 cases collected by Tuffier was as follows: Pyonephrosis with and without stone, 23.3 per cent.; aseptic cystonephrosis, 18 per cent.; tuberculous pyelonephritis, 46.6 per cent.

Transperitoneal nephrotomy should be abandoned, as it is far more dangerous and never called for. Its mortality in pyonephrosis was 50 per cent.; and in hydronephrosis 20 per cent.

A permanent lumbar urinary fistula will remain if the passage through the ureter is not free. Of 220 cases of pyelonephrosis, fistulas remained in 43 per cent., and in aseptic cystonephrosis in 66 per cent. (Tuffier).

Nephrectomy.—Total removal of the kidney may be a relatively easy operation when the organ is not enlarged, and when it can easily be loosened from the surrounding tissues, as, for instance, in case of central tuberculosis or of a small malignant tumor. Commonly, however, the operation is difficult or dangerous when the kidney is considerably enlarged or is firmly adherent to the surrounding organs.

The operation is either transperitoneal or extraperitoneal; extraperitoneal or lumbar nephrectomy is the operation of choice.

Lumbar Nephrectomy.—An oblique incision is made from the outer border of the sacrolumbalis muscle, 1 inch below the twelfth rib, parallel to the rib downward and forward for about 12 cm. ($4\frac{3}{4}$ inches). Exploration by the finger or hand reveals the size and condition of the kidney. If there is not sufficient operating space, this incision is prolonged or another incision at an angle to the first is made. The kidney is now isolated, and either regular nephrectomy, subcapsular nephrectomy, or nephrectomy with morcellement may be done.

Regular nephrectomy is done when the kidney can be easily isolated without much danger of injury to the surrounding organs. The size of the kidney is not important in this connection, as the incision may be enlarged to obtain space for handling the organ. Isolation must be done by blunt dissection and with only moderate force. The hand must loosen the kidney down to the hilus, care being taken not to rupture peritoneum or intestines. Palpation of the pedicle will deter-

mine whether it is free and movable or stiff and infiltrated, or adherent to the vertebral column and the adjacent soft parts. If the kidney and pedicle are freely movable, the kidney is brought cautiously out of the wound, so that the pedicle may be inspected, and isolated ligation of the renal artery and vein is performed. This is accomplished as follows: A blunt aneurism needle, doubly threaded with strong catgut or silk, is inserted between the artery and vein; the thread is caught and divided, the aneurism needle removed, and each half of the pedicle ligated. The ends of the ligatures are cut short, so as to avoid the risk of slipping off of the ligature, which may occur by pulling on the ends if they are left long. As a matter of additional security, it is well to clamp the pedicle on the distal side of the ligature with a bent forceps, so that the pedicle may be drawn into view if there should be hemorrhage after the kidney has been cut away. The ureter should be doubly ligated and divided between ligatures. The ends of the lower ligature are left long, that the ureter may be pulled out and examined later on if extirpation is necessary, as in case of tuberculosis. The artery and vein are then divided 1 cm. (0.4 inch) distal to the ligature, and the kidney lifted out of the wound. It has been advised that a little wedge of kidney tissue be left on the pedicle, to secure against the slipping of the ligature. This is not wise, for in most cases in which nephrectomy is indicated harm might result; in malignant tumors relapse might be caused, and in septic cases suppuration of the wound might ensue. If thrombotic tumor-masses hinder manipulation of the pedicle for isolated ligation, the pedicle may be caught in a clamp with broad blades and the clamp-forceps left on for thirty-six or forty-eight hours. At the expiration of this time the forceps is cautiously removed by slowly opening the jaws of the forceps without making traction on it, and after a few minutes, if no hemorrhage follows, cautiously lifting the forceps out of the wound.

The great danger in nephrectomy lies in hemorrhage from the pedicle. Careful ligation should therefore be performed, and after the pedicle has been dropped, careful inspection should be made to see if there is any hemorrhage deep in the wound. If hemorrhage persists, trust should not be reposed in tamponade, which is ineffective, because there are no firm walls in the cavity against which pressure with gauze packing can be made; the wound must be revived and every bleeding point ligated.

Subcapsular Nephrectomy (Ollier).—When thick, hard, fibrous capsular masses surround the kidney and bind it to the peritoneum, diaphragm, colon, vena cava, or other organs in such a manner that its isolation would cause rupture of these organs, incision is made through the renal capsule to the kidney tissue. This is now loosened and peeled off by blunt dissection down to or into the pedicle, leaving the fibrous capsule. If possible, the pedicle is now ligated; if not, it is clamped by a forceps, which is left in place. This method is of use in chronic suppurative and tuberculous nephritis. After removal of the kidney the inside of the capsule should be cureted, to remove shreds

of kidney tissue or granulation tissue, and the cavity then packed. In case of malignant tumors, this, or in fact any, operation is useless.

Transperitoneal Nephrectomy.—The incision is median, in the linea alba, or lateral, at the outer border of the rectus muscle. The lateral incision gives better access to the kidney. The intestines are held aside with sterile gauze sponges, and palpation of both kidneys and, eventually, of both ureters, is made. The posterior peritoneum which covers the kidney is now divided on either the median or the lateral side of the colon, according to its location on the anterior surface of the kidney. The tumor is isolated by uncovering, first, its anterior surface down to the hilus, then its lateral border, next, the upper and lower poles, and finally the posterior surface. The vessels in the hilus are isolated from the ureter and ligated as described above. The ureter is then divided between two ligatures and the kidney lifted out.

Drainage and the treatment of the ureter are different in septic and aseptic cases. In septic cases the ureter, which may become a source of infection, should not be dropped into the wound cavity, but must be brought out to be united with the skin (Thornton), either in the lower corner of the abdominal incision or through a counteropening in the lumbar region (Morris).

Drainage of the wound cavity may be effected through the abdominal wound or through a counteropening in the lumbar region. In the first case the opening in the posterior peritoneum is sutured to the wound in the parietal peritoneum, excluding the peritoneal cavity from the wound cavity, which is then packed with gauze or has a tubular drain inserted into it. If lumbar drainage be preferred, a counteropening is made in the lumbar region for the insertion of a strip of gauze or a drainage-tube, over which the posterior peritoneal opening is then closed by a continuous suture. The abdominal incision can then be closed without drainage.

If the kidney is aseptic, drainage may be dispensed with and the ureter left in the wound. The perirenal or posterior peritoneal wound is closed by continuous suture, and finally the abdominal wound is united without drainage.

Accidents During Nephrectomy.—The pleural cavity may be opened if the incision is made too close to the twelfth rib. When this occurs, the opening should be rapidly plugged with a sponge and united by a continuous suture. The peritoneal cavity is often opened. If the tear is small, it is easily closed by a continuous or a purse-string suture. A large opening, with loss of substance, such as is made when part of the peritoneum is extirpated with the tumor, should be closed by suture, if possible; otherwise it should be packed with gauze. In aseptic cases there is little danger from opening into the peritoneum or pleura. Any opening into the colon, or even a denudation of its muscularis during isolation from the tumor, must be carefully closed or covered in by Czerny-Lembert sutures, and a drain inserted down to the place of suture.

Hemorrhage from the vessels of the hilus may result from cutting,

from rupture during isolation, or from slipping of the hemostatic forceps or the ligatures. Rapid digital compression in the hilus, and cutting away the kidney piece by piece or as a whole, may give access to the bleeding vessel. Rupture of the vena cava is rapidly fatal.

Symptoms Following Nephrectomy.—Shock is common, and is often caused by a diseased condition of the other kidney. The urinary secretion is diminished for two days; this is followed by progressive reestablishment of the secretion, which is normal on the seventh day if the other kidney is healthy.

Operative Results.—The mortality of nephrectomy has been given by Tuffier as follows: Primary nephrectomy, 371 cases, 36.8 per cent.; lumbar nephrectomy, 200 cases, 28.4 per cent.; transperitoneal nephrectomy, 161 cases, 44.1 per cent.

It is natural that the mortality should depend upon the disease for which the operation was done.

Lumbar nephrectomy had a mortality of 35 per cent. in 112 cases of suppurating kidney; of 23.7 per cent. in 21 cases of aseptic collection of fluid; of 24.2 per cent. in 21 cases of tumor; and of 28.2 per cent. in 46 cases of tuberculosis.

Abdominal transperitoneal nephrectomy had a mortality of 42.2 per cent. in 53 cases of suppurating kidney; of 32.4 per cent. in 49 cases of aseptic collections of fluid; of 59 per cent. in 66 cases of tumors; and of 36 per cent. in 11 cases of tuberculosis.

In 36 cases of secondary nephrectomy the mortality was 13.9 per cent. only, as follows: In 25 cases of suppurating kidney the mortality was 12 per cent.; in 3 cases of aseptic collections of fluid, none died; and in 8 cases of tuberculosis the mortality was 25 per cent.

Later statistics are more favorable. Thus the mortality of nephrectomy for tuberculosis has fallen to 17.4 per cent., and of nephrectomy following preliminary nephrotomy to 11.9 per cent. (Garceau).

TREATMENT OF TUBERCULOSIS OF THE PERITONEUM*

It is impossible to elucidate this question satisfactorily without giving a brief résumé of the entire subject, and this is not so easy as would appear at first. Borchgrevink¹ states that our knowledge of peritoneal tuberculosis dates back to the year 1825, in the time of Louis, when only sporadic cases of the disease were known, and when the diagnosis was made with great difficulty. This might be termed the first stage in the history of this disease.

The second stage was from 1825 to 1884, when tuberculosis of the peritoneum became better known and was more easily recognized. The relation between simple, non-tubercular, chronic peritonitis and tuberculosis proper excited considerable discussion. The simple peritonitis at that time terminated in recovery, while tuberculosis was said to be always fatal. Formerly, tuberculosis was considered as dangerous and fatal a disease as malignant tumor; but our views have undergone a radical change since that time.

The third stage of our knowledge regarding peritoneal tuberculosis began in 1884, when König proposed laparotomy for this condition. At that time the gravest apprehensions were entertained in regard to the disease, which was looked on as necessarily fatal, with but few exceptions, according to Hilton Fagge, who stated that children frequently recovered.

The treatment of the disease, which is the part of the subject assigned to me, comes within the last twenty-five years. The surgical treatment of tubercular peritonitis cannot be discussed without taking into consideration the gradual change which has taken place in our ideas of tuberculosis in general, but more particularly of tuberculosis of the peritoneum.

In 1884 König² read a paper in which he reported 4 cases of tuberculosis of the peritoneum, one or two of which had been diagnosed as ovarian tumors. In others there was a localized peritonitic exudate, which he advocated should be removed in the same way that an abscess is evacuated. König, who has done more toward increasing our knowledge of tuberculosis than any living man, and who would, naturally, be very cautious about drawing general conclusions from a few cases, said, at the end of his short paper: "May this short paper have the effect that we soon will know more about this disease, as the experience

*Annals of Surgery, 1901, vol. xxxiv, p. 771.

from these cases is so little in harmony with our old views on the subject of peritoneal tuberculosis."

König's experience in these 4 cases was very favorable, inasmuch as 3 patients recovered and only 1 died. From this time on surgeons began to operate for peritoneal tuberculosis to such an extent that in 1889 König published a second paper,³ in which he was able to collect from the literature and from his own cases 131 operations for this condition. Of this number, 120 were women and 11 men. He also reported the autopsy statistics of 107 cases, 89 of which were men and 18 women, showing an enormous difference as regards sex. This can be best explained by the fact that peritoneal tuberculosis is often found in the course of gynecologic operations for other conditions, and that it exists as a relatively common and not fatal complication.

The result of operation in these 131 cases was good, as 107 of the patients were in satisfactory condition when they left the hospital. Of these 107, 74 were cured and 33 improved. König, however, asks the question, "How long does this improvement last?"

König was the first to call a halt in the wholesale operating for tuberculosis of the joints in the early stages, with a view to saving patients from general tuberculosis. He said that patients should be traced for several years after operation for tuberculosis, and ascertained that after two years or more the recoveries, which had been recorded as from 60 to 70 per cent., were reduced to 25 per cent. so far as radical cure was concerned.

From a study of the 131 cases collected from the literature, he concluded that the most common procedure was a simple incision through the abdominal wall. In some of the cases the wound was closed as soon as tuberculosis was observed, while in others the treatment consisted very largely of evacuation of the fluid.

In a minority of cases solid tuberculous products, thickened omentum, or masses of exudate with conglomerated tubercles were removed.

König, however, still concludes that "we stand before an enigma. May we hope that diligent use of laparotomy and careful scientific observation will clear up this enigma?"

Teleky⁴ has summed up the whole question as to the value of the internal or non-operative treatment of tubercular peritonitis up to 1900, and from his excellent paper the following résumé is taken. The common local remedies employed were green soap and mercurial ointment. For the relief of intestinal troubles, pain, etc., enemata and opium were given, and warm-water applications, rest in bed, alternated with fresh-air treatment, hyperalimentation, etc., syrup of iodid, cod-liver oil, creasote, arsenic, painting the abdomen with tincture of iodine, and covering the abdomen with elastic collodion were recommended. Massage of the abdomen was advised by Thompson and Bouilly, and general roborative and dietetic treatment was recommended by all.

After 1884 an important change took place in our views with regard to peritoneal tuberculosis, when the introduction of laparotomy as a therapeutic measure materially changed the prognosis of the disease.

As regards prognosis, Nothnagel states that spontaneous cure may take place. Chaffee and Hilton Fagge say that spontaneous cures are common in children, and Nassauer avers that this is the case in adults also. Marfan thinks that there is a tendency to healing in many cases. Hegar saw 1 case in which, on the occasion of a later celiotomy, a preëxisting peritoneal tuberculosis had entirely disappeared.

Up to 1884 all the cases of tuberculosis of the peritoneum in which recovery had occurred were regarded as mistakes in diagnosis; that is, they were considered to be cases of non-tuberculous peritonitis. After the treatment by laparotomy had been inaugurated, almost all the authors during the next 14 years—up to 1889—reported recoveries in from 70 to 85 per cent. of the cases. The time of observation, however, was considered too short in all those series collected from the literature, because the operator made reports only a month or two after operation.

Von Winckel does not consider that a patient has recovered from the disease unless he has survived five years. Cellier reported 71 per cent. of recoveries in 287 cases shortly after operation, but after the patients had been observed for two years or more the percentage dwindled down to 25.

As regards anatomic recoveries, there is a limited number of cases on record with absolute disappearance of the tuberculosis that was found in the peritoneum at the time of operation.

The question arose as to the influence of operation on tuberculosis of the peritoneum, and this gave rise to a good deal of experimentation, of which the work of Gatti deserves especial mention. In the early stages, before the tubercles are fully developed, laparotomy has no effect. If caseation is present, laparotomy may check the tuberculous process, or cause encapsulation of the conglomerated tubercles, but the cheesy material is not resorbed.

All other forms of tuberculosis are retarded in development or brought to histologic healing by laparotomy.

Grazer says that we are not only justified, but that it is our duty, to try laparotomy in all cases of peritoneal tuberculosis, and Nothnagel deems it our duty to operate in most cases.

From a clinical standpoint, most authors distinguished three forms of tuberculosis:

1. The ulcerative or suppurative form.
2. The serous exudative form.
3. The adhesive form.

In the suppurative form cheesy matter predominates in the spaces between the intestines, and there are small cavities filled with liquefied cheesy matter or tuberculous pus—a condition corresponding to that found in tuberculous abscess in other parts of the body. König, in tuberculosis of the joints, calls this condition tubercular pyarthrosis. Why is the tubercular process in this cheesy form sometimes called ulcerative? Because there is greater destructive activity in the tuber-

cular process when pus is present than when there is only clear fluid. The ulcers perforate from the peritoneal side into the intestine, and we have spontaneous fecal tubercular abscess, followed by fecal fistula. The mixed infection, from communication with the interior of the bowel, makes the prognosis more grave. True, opposed to all other writers, believes that tuberculous abscess in the peritoneal cavity is the only indication for laparotomy, and that puncture is sufficient in the serous cases. Angyrany considers that the ulcerous forms demand laparotomy only when they are localized. Naumann says that laparotomy is the only hope in the ulcerous form. Jaffé advises against operation in the ulcerative form with multiple abscesses, because in breaking down adhesions to reach the cavity we must and will tear the friable bowel-wall.

In the form with serous exudate, Teleky states that the good effects of laparotomy cannot be disputed when the cases are considered as a whole. Jaffé, the most skeptical of the later writers, believes that the effect is only symptomatic, and leads eventually to the adhesive form of the disease, and this, in his opinion, is a step toward recovery. Monti, although skeptical, says that at times the effect of laparotomy is satisfactory. Many other writers speak more favorably of laparotomy in the cases of serous tuberculosis of the peritoneum. The percentage of recoveries, from the experience of all authors, averages 75 for both children and adults in this form of the disease. The prognosis is better after laparotomy in the serous form without adhesions, and less favorable in the cases with encapsulated exudate.

In the adhesive form of tuberculosis the opinions of authors as to the effect of laparotomy are diametrically opposite. Merkel says that operation is the only remedial measure to adopt. Condamin and Margarucci consider that the operation is strongly indicated. Thomas reports 66 per cent. of recoveries in these cases. In one of Condamin's cases, which terminated in cure, the peritoneal cavity was obliterated by extensive adhesions. Jordan advises, in such cases of complete obliteration of the peritoneal cavity, to make 2 or 3 incisions below or, better, above the umbilicus through the abdominal wall. In my opinion, this is the height of folly, because there is no peritoneal cavity to enter. Borei, Schmitz, and Israel are in favor of laparotomy. Thompson, Angyrany, and Naumann are less enthusiastic, and hold that laparotomy is indicated only when pain and symptoms of occlusion become manifest. It is doubtful whether we should operate for pain alone; but in cases of occlusion operation must be done, and this should not be confounded with, or considered in connection with, operative measures for peritoneal tuberculosis.

Monti says that this form is not suitable for laparotomy; Jaffé considers the operation useless and even dangerous, from the risk of injury to the bowel and of fecal fistula.

As to the effects of operation in the 3 forms of the disease, Teleky, from the literature, comes to the conclusion that in the ulcerative form an unfavorable operative prognosis must be given; that is, that opera-

tion is the last resort. In the miliary, serous, exudative form, operation is followed by the best results, and is probably always indicated.

In the adhesive form it is difficult to give definite indications for operation; but it is probable that operation is advisable when, after prolonged conservative treatment and observation, there is no tendency toward recovery. In such cases resort should be made to laparotomy because other therapeutic measures have proved ineffective. This conclusion seems to me to be on a par with the advice to cut, irrespective of consequences, in other incurable diseases, such as cancer, cirrhosis of the liver, Hodgkin's disease, exophthalmic goiter, etc. Different opinions prevail as to the period of the disease which should be selected for operation. Drackel, Schmitz, and Nothnagel say that we should operate before extensive caseation has taken place. Merkel would operate earlier. Gatti and Hildebrandt, from experiments on animals, would not operate early because too early operation has no influence on the tuberculosis.

The effect of laparotomy as a means of cure in many instances is only apparent, and in spite of seeming recovery, peritoneal tuberculosis gradually progresses. Some patients enjoy a period of comparative health for one or two years; that is, operation obviates mental and bodily misery for that length of time. In many such cases the first laparotomy was not effective; some of the patients, however, were cured by the second operation. One patient underwent four operations before an absolute cure was effected.

As a parallel, Teleky mentions laparotomy for sarcoma or carcinoma of the peritoneum in which operation has apparently exerted a beneficial effect.

Technic of the Operation.—Teleky, from the literature, gives the following technic of operation:

Vaginal laparotomy has been done only once by Condamin, but all others, as von Winckel, Martin, Hegar, are opposed to this procedure, as the opening is too small. Transabdominal laparotomy is the prevalent operation. The abdomen is first opened and the fluid evacuated (Merkel). The cavity is then dried by careful removal of all fluid with sterile sponges. Weak antiseptic solutions are used by von Winckel, and stronger antiseptic solutions by Hayem, Galvani, Westphal, Israel, Gustinelli, and others, for irrigation of the cavity. Iodoform powder is rubbed in by Diddens, Rendu, Noré, Jossierand, and Schmitz. Jaffé considers that rubbing with iodoform causes a beneficial injury of peritoneum, resulting in adhesions which further the cure.

The disposal of the primary focus, if located in the abdomen, has been considered in widely different ways by various authors. Quervain advises that it be removed; the removal of the appendages has also been advocated; Scheuer advises that a bowel with tuberculous ulcers be resected, while Schmitz is opposed to this course; von Winckel advises that the tubes be removed if this can be easily done, but other writers advise that the primary focus be left, as it is helped by the laparotomy. Others, Valenti, for instance, consider that laparotomy cures distant

foci, as, for instance, pulmonary tuberculosis, and Merkel believes that the operation improves it. On the other hand, Monti and Jaffé aver that laparotomy is often followed by rekindling of a latent tuberculosis in distant organs.

As regards closure of the abdominal wound, von Winckel considers drainage superfluous, and most authors close the wound without drainage, but Grazer inserts an iodoform gauze drain in the lower corner of the wound, and some operators pack the abdominal cavity with iodoform gauze.

Within the last year three excellent papers have appeared in which series of cases have been reported. One of these papers was by Herzfeld,⁵ with a report of cases from Körte's clinic; one by Frank,⁶ with cases from Czerny's clinic, and the third by Bottomley,⁷ who reported 28 cases from the Boston City Hospital. There is a great similarity in these reports. From Czerny's clinic 41 cases were reported, of which 26.8 per cent. recovered and remained well for three years, and 19.5 per cent. recovered for a shorter period than three years. Five patients recovered with complications, namely, relapse, hernia, and fistula; 4 were not cured; and 14 died, but only 3 of these from the operation itself.

By reason of the resistance offered by the peritoneum to ordinary pus-microbes the operation has the remarkably low mortality of from 1 to 2 per cent. Fecal fistula appeared in 6 out of the 19 cases of tuberculosis sicca. This demonstrates how easy it is to injure the intestine in the dry form of tuberculosis in an attempt to loosen the intestines to reach the semifluid exudate, and also how easily gauze drainage may aid the tuberculosis in perforating into the bowel, with a resultant fecal fistula.

Czerny advises extirpation of the tuberculous adnexa before tubercular peritonitis sets in. It is hard to conceive how a diagnosis could be made before that time; it would be largely accidental or purely guesswork. Tuberculosis of the peritoneum disappears in cases where the appendages are left. It seems feasible, however, in a limited number of cases, to remove the tuberculous appendix. When fecal fistula is present, the attempt to close it is a thankless task, and it is much better to let it alone. In 3 out of 4 cases Czerny failed to close fecal fistulas by suture. He reports 8 cases, 3 of which remained cured after three years, and 2, two years later. Three patients died in from two months to a year after operation. Czerny considers the results as not bad—that they are about as good as those obtained without operation.

Herzfeld concludes: "There is nothing left but to confess that we still stand before an enigma which, for the time being, cannot be cleared up."

In 1900 the best prognosis of operation for tuberculosis of the peritoneum was 40 to 50 per cent. of cures in the most favorable forms of the disease. In the ulcerative form the prognosis was grave, and these patients almost always died. When stenosis of the bowel complicates peritoneal tuberculosis, operation should be done, but cure is rare.

Frank reports 8 cases in which conservative treatment was employed. Three of these patients were well after three years and 2 were well two years later. Three died—1 in a few days, 1 after two months, and 1 after a year. Frank considers these results not bad, but regrets that neither reports nor statistics from the internal medicine clinics exist from which the fate of patients with tuberculosis of the peritoneum thus treated might be compared with the results in patients subjected to operation.

We must regard tuberculosis as a disease having a tendency toward spontaneous recovery. König and Hegar believe that this tendency to recover is aided by laparotomy; others are inclined to believe that it is due to the laparotomy itself. The conclusion has been reached that the recovery from tuberculosis is due to a combination of effects, such as a change in the circulation, a change in abdominal pressure, the beneficial influence of laparotomy, etc.

There is very little difference between the results reported by Bottomley and those of the other two. Bottomley reports a series of 28 cases of tuberculosis from the Boston City Hospital. He states that the disease is more commonly met with in women than in men, because, in all probability, laparotomy is performed more frequently on women. According to the reports of the Boston City Hospital, however, 14 men and 14 women were affected with the disease. In the 18 cases in which drainage was used, fecal fistula followed in 5. Drainage was instituted in 10 of the 11 fatal cases. There was no drainage in 11 of the 28 cases, and in only 1 of these was there a fatal result.

The mortality from the operation is practically *nil*, and, consequently, these patients do not die because of the operation. It is rare for sepsis to occur in a tuberculous peritoneum, and it is also rare for tuberculosis to develop in the drainage tract. Only 1 case of the latter has been observed by Nassauer.

Bottomley says that laparotomy may be done under local anesthesia in the case of patients weakened from tuberculosis of other organs, and in those in which the disease has reached an advanced stage.

As regards the immediate result, he says that there is always more or less improvement in the general or local condition of patients, 20 out of 28 of whom showed immediate improvement. Of these 20, 11 improved both locally and generally, while the remaining 9 improved as to their general, but very little as to their local, condition. In 4 of the cases followed by no improvement after operation the patients all died. Entire absence of pain and distention of the abdomen is uncommon, even in the most favorable cases, when discharged from the hospital three weeks after operation. In most of the cases operation was followed by reduction of the temperature, but this did not fall to normal, as most patients had some fever when they left the hospital. Finally, he says, apparently desperate cases have been restored to perfect health.

Kümmell, Richelot, Welch, Nassauer, Jordan, and Wunderlich have demonstrated anatomic cures.

The conclusions to be drawn in this regard up to and including the year 1900 are as follows: A cure may be expected in from 30 to 40 per cent. of the cases that heretofore were considered fatal. In the fatal cases the patients die in five or six months after operation; that is, about one-half of the patients die at the height of the peritonitis; the other half die within a year to two years. In the cases in which the patients do not recover from the operation, either locally or generally, no benefit is derived from the operative interference, and the prognosis is unfavorable.

After having plowed through this chaos, out of which it is next to impossible to extricate a ray of light, because reasoning is at a standstill, despite the enormous labor of a multitude of able and indefatigable workers in all countries, one cannot but feel inclined to look for a new departure. It is refreshing, at last, to find an author (Borchgrevink) who, after the most careful and painstaking labor with all the weapons of modern scientific investigation at his disposal, has the courage to tear down this whole artificial house of cards and make *tabula rasa* of the entire question.

How easy it is to be deceived when one tries to draw conclusions from his own limited experience, or from the few cases one meets with as a casual observer, I will give an example from my own practice:

About ten years ago I operated, for chronic intestinal obstruction, on a woman of about thirty. She was pale, but well nourished, and had a swelling in the region of the appendix and cecum, and daily attacks of painful contractions of loops of bowel in the right iliac region, which were visible on the abdomen during the attacks, which were often followed by vomiting. A diagnosis of stenosis in the cecal region was made, but operation revealed tuberculosis of the appendix and cecum, with considerable thickening and retraction of its wall, whereby its lumen was made too narrow for free passage of feces. Excision of the thickened wall of the cecum and transverse union of a longitudinal defect were thought efficient to establish a sufficiently free passage from the ileum down into the colon. At the time of operation the peritoneum was normal. Relief for a time followed, although a small fistula, generally mucous, but occasionally slightly fecal, remained. After a year and a half the symptoms of obstruction gradually returned, and the fistula became constantly fecal. Thereupon I planned to extirpate the cecum, if practicable, or otherwise to relieve the obstruction. When the abdomen was opened, I found diffuse miliary tuberculosis over the whole of the free peritoneal cavity. The cecum and lower portion of the ascending colon formed a solid mass 3 inches long and 2 inches in diameter, adherent to the iliac fossa and the lower end of the ileum so firmly that I deemed extirpation inadvisable when the tuberculosis of the peritoneal cavity was taken into consideration. Ileocolostomy was resorted to, uniting the nearest free loop of the lower ileum with the transverse colon. Both portions of bowel were thickly covered with gray miliary tubercles, but no fibrinous exudate, free fluid, nor caseous larger nodules were present, and the intestinal walls were not any more thickened than the presence of the tubercles would account for. An opening $2\frac{1}{2}$ inches long in both portions of the bowel was sutured in the usual manner. The fecal fistula leading to the cecum was left open.

In spite of the miliary tuberculosis, recovery from the operation was undisturbed, and the effect of the ileocolostomy was complete relief of the obstructive symptoms, which permitted the patient, a poor woman with a large family, to resume her household duties. The cecal fistula secreted a little mucus, with rarely a trace of fecal matter.

I have heard that the patient died about two years ago, after she had had five or six years of relief from the obstruction.

This led me to draw the conclusion that miliary tuberculosis on the serous covering of the intestines—tuberculosis of the peritoneum—was no contraindication to operation on the intestines; that an intestinal wall filled with miliary tubercles in the subserosa would permit of suturing and would unite almost as readily as a non-tuberculous wall.

If I had published his case, I should certainly have expressed the above conclusion as an opinion fortified by the case. How erroneous this conclusion would have been we can see from the accumulated experience and knowledge of tuberculosis of the peritoneum, where perforation of the bowel and fecal fistulas are seen in cases not operated on—in cases operated on by simple laparotomy, many of which had adhesions, and in the majority of cases of operation on the tuberculous bowel-wall.

Czerny reports a death in ten hours after resection of 9 cm. of bowel. Rotgans and Helmerich report suture of a tear in the bowel ruptured by loosening of adhesions in which the sutures did not hold. Korteweg reports a case in which the sutures cut through.

In a patient of my own, a doctor's wife, with multiple tubercular stenosis of the ileum and 8 or 10 strictures over ulcers, I did not make a resection, but a simple enterostomy above the most proximal stricture, but the patient died from shock in less than twenty-four hours.

Borchgrevink, in his excellent paper, has now brought the subject back on a rational basis by most scientific and careful observation of two almost equal series of cases of peritoneal tuberculosis, one of which was treated by laparotomy and the other without operation.

He has observed 22 cases treated by laparotomy and 18 cases treated without laparotomy. In addition to this, he has made a number of observations on so-called simple peritonitis, which he almost always was able to demonstrate to be tubercular.

Of these 22 cases of laparotomy, 11 patients had fever and in the other 11 it was absent; of these latter, 10 lived and 1 died. Of the 11 with fever, 8 died and 3 only were cured.

The forms of peritoneal tuberculosis without fever or with only slight fever usually run a favorable course, and laparotomy is unnecessary.

In progressive tuberculosis, or the ulcerative form, most of the patients die from the disease sooner or later, and therefore laparotomy has no influence on them. In the 11 cases reported with fever, laparotomy undoubtedly did harm in 9, and it is not proved that the operation was responsible for or aided in the improvement in the other 2 cases.

In general, Borchgrevink concludes, after careful observation of the patients operated on and of their condition before and after laparotomy, that if the operation did any good it was, to say the least, doubtful.

His conclusions from these cases are the following:

“That the laparotomy, in strong patients, in whom fever is absent

and their condition of good nutrition speaks for a spontaneous disappearance of the tuberculous process, is well tolerated.

"Laparotomy, however, in patniets with fever, when the tuberculosis has a progressive character, must diminish what slight power of resistance such a patient has remaining. This power of resistance may thus yield and death follow, or it may, by concurrence of fortunate circumstances, rebound, and the patient recover in spite of the operation.

"That form of peritoneal tuberculosis which exists without fever, or with only slight fever, runs in itself a favorable course. In such cases laparotomy is unnecessary. In progressive tuberculosis the operation is dangerous and should be abandoned."

Of the 22 cases which Borchgrevink reports, 8 were light, 6 moderately severe, and 8 severe. Fourteen of the patients, or 63.6 per cent., recovered, and 8 patients, or 36.4 per cent., died.

In 17 cases conservative treatment was employed. Of these, 14, or 82.3 per cent., recovered and were still well after two or three years, or were clinically cured and remained well for two or three years. Of the 3 patients who died, the death was due in one case to tubercular peritonitis, in a second to intestinal tuberculosis after six months, and in a third to measles after five months.

The question of the disappearance of fluid exudate after puncture as compared with the result after laparotomy shows 7 negative results out of 15 laparotomies, and 15 negative results out of 19 punctures. But in 11 of the latter the exudate was absorbed spontaneously later on.

The advantage of laparotomy over puncture as regards its effect on the exudate is probably more apparent than real. It seems likely that the termination of the progress of the tuberculous process is the main factor in the causation of improvement, and in one or the other of these conditions the method of evacuation of the exudate is immaterial.

The frightfully disappointing results of the energetic surgical treatment of peritoneal tuberculosis—cureting, excision of tuberculous tumors in the omentum, adhesions, and mesenteric glands—must teach us that nature cures tuberculosis of the peritoneum better than the surgeon.

Are there any cases of tuberculous peritonitis for which laparotomy is the only means of cure or in which laparotomy is the best method of treatment? Borchgrevink does not hesitate to state that even the "serous tuberculous peritonitis is a territory which surgery must hand back to the internal medicine clinic with thanks for the splendid opportunity which a misunderstanding gave to the profession, by means of laparotomy, to study tuberculosis in one of the large cavities of the body."

REFERENCES

1. O. Borchgrevink: *Klinische und experimentelle Beiträge zur Lehre von der Bauchfelltuberkulose*. Bibliotheca Medica, Stuttgart, 1901.
2. F. König: *Ueber diffuse peritoneale Tuberkulose und die durch solche hervorgerufenen*

Scheingeschwülste im Bauch, nebst Bemerkungen zur Prognose und Behandlung dieser Krankheit," Centralbl. f. Chirurgie, 1884, vol. xi, p. 81.

3. F. König: "Die peritoneale Tuberkulose und ihre Heilung durch den Bauchschnitt," *ibid.*, 1890, vol. xvii, p. 657.
4. L. Teleký: "Die Bauchfell-Tuberkulose und ihre Behandlung: Sammel-Referat, mit Berücksichtigung der Literatur der letzten vier Jahre," Centralbl. f. d. Grenzgebiete der Medicin und Chirurgie, 1899, Bd. ii.
5. J. Herzfeld: "Zur chirurgische Behandlung den tuberkulösen Bauchfellentzündung," Mittheilungen aus der Grenzgebieten der Medizin und Chirurgie, 1900, vol. v, p. 1884.
6. A. Frank: "Die Erfolge der operativen Behandlung der chronischen Bauchfelltuberkulose und verwandter Zustände," *ibid.*, 1900, vol. vi, p. 97.
7. J. F. Bottomley: "A Consideration of Twenty-eight Cases of Tuberculous Peritonitis at the Boston City Hospital, with Particular Reference to the Results of Operative Treatment," Boston City Hospital Report, 1900, p. 118.

A LOOP AROUND THE HYOID BONE AS AN AID IN NARCOSIS DURING CERTAIN OPERATIONS ON THE LOWER JAW AND IN THE MOUTH, AND IN AFTER-TREATMENT*

ABOUT ten years ago I lost a patient after extirpation of one-half of the inferior maxilla, including the whole of the middle portion of the bone, together with the muscles of the floor of the mouth, the operation being rendered necessary by carcinoma. The patient died suddenly during the following night. When seen in the evening, his condition was good; when seen at midnight by the nurse, he was awake and well and went to sleep; about an hour later the nurse found him dead. No other explanation for his death could be found than asphyxia from the sinking back of the tongue during sleep, the tongue and larynx being deprived of the muscles which connected them with the lower jaw.

As a result of this experience, after resection of one-half of the lower maxilla I have always allowed a loop of silver wire or silk, passed through the anterior portion of the divided bone, to remain, the ends being brought out through the dressing, so that the nurse or patient might pull on it if dyspnea should arise. This precaution is sufficient only when the muscles extending from the hyoid bone to the maxilla are intact on one side, and if it can be seen during the operation that the entrance to the larynx is made free by traction on the end of the bone left.

In case of removal of the floor of the mouth for malignant tumors, when all the muscles from the body of the inferior maxilla backward to the tongue and hyoid bone are removed, the tongue and larynx, with the epiglottis, have necessarily lost their attachment to the maxilla, and will sink backward against the posterior wall of the pharynx, causing occlusion of the entrance to the larynx and strangulation, especially during sleep.

During narcosis this difficulty is obviated to a great extent if the tongue can be pulled out of the mouth in a longitudinal direction. This cannot be accomplished when the jaws are closed and fixed, so that the mouth cannot be opened nor access gained to the tongue, as in operations for osseous ankylosis of the jaw.

Further, I have observed that in the Regnoli-Billroth operation,—that is, the operation for the removal of the floor of the mouth or tongue through a horseshoe-shaped incision below the maxilla,—when the

*Annals of Surgery, 1901, vol. xxxiii, p. 673.

tongue is pulled out of the inframaxillary opening, not in a longitudinal direction, at right angles to the posterior wall of the pharynx, but in a downward direction, where it forms an acute angle with the frontal plane,—under such conditions, when, during narcosis, there is difficulty in maintaining a free entrance to the larynx, this difficulty is best obviated by making traction on the hyoid bone by means of a sharp hook, as advised by Kappeler, or by a loop passed around the body of the bone,

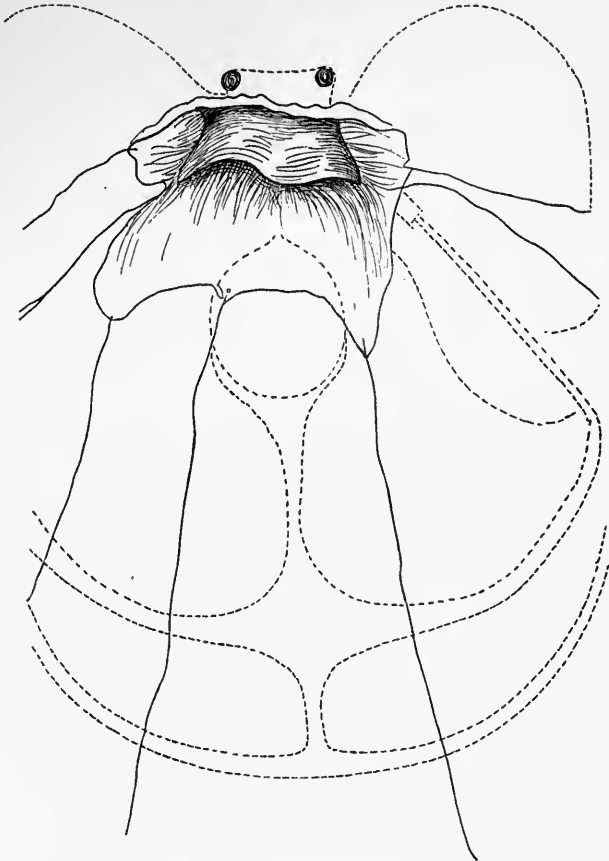


Fig. 189.—Head in horizontal position or on a small pillow.

which I have found to be more convenient, and which, after having used for several years in at least a dozen cases and found without danger, I recommend.

The value of this procedure has been demonstrated over and over again during prolonged operations, so that the students in the amphitheater could easily observe the change from labored and noisy respiration to free and noiseless respiration as soon as traction was made on the loop.

It is impossible for the assistant who gives the anesthetic to hold a sharp hook around the hyoid bone for a long time, possibly for hours, while he can manage a loop of silk passed around the hyoid bone just as easily as a loop passed through the tongue. The loop is not needed for an emergency; that is, for an attack of asphyxia during narcosis, where the sharp hook will be sufficient; but it is needed during the entire

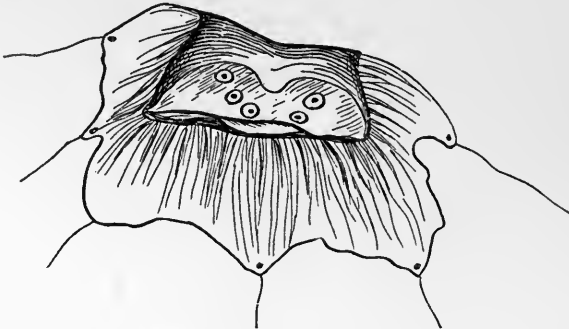

Fig. 190.—Head bent backward by lifting or pulling under the chin; mouth closed.

narcosis, because, as I have seen in these classes of cases, asphyxia supervenes the moment traction on the hyoid bone is released, and is followed by perfectly free respiration when traction is again made.

There is another reason why it is important that the space behind the larynx should not be half obstructed, but be perfectly free, with space to spare, if possible; namely, because it is impossible to keep the

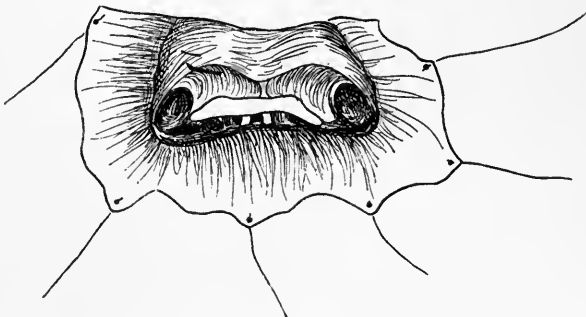

Fig. 191.—Tongue pulled out of the mouth.

pharynx perfectly free from the frothy mucus. If one-half of the entrance to the larynx be obstructed, the inferior half lying against the wall of the pharynx, there is no space for the mucus, and, therefore, it must be aspirated down into the larynx, and the air must pass through it and tend to bring it down. On the other hand, if the larynx is perfectly free, and if there is more room behind it than is actually necessary, there will be less aspiration of mucus, and possibly less bronchitis or bronchopneumonia, following the operation.

In discussing the measures against respiratory troubles caused by the tongue and the epiglottis during anesthesia, or, rather, while the anesthetic is being administered, Kappeler* stated, in 1880, that the following methods are employed:

1. Howard—elevation of the thorax to let the head and neck sink backward.
2. Lifting of the lower jaw, devised by an Englishman (Little?), introduced in Germany by von Esmarch, and first minutely described by Heiberg.
3. Pulling out the tongue with tongue forceps and lifting the epiglottis with the finger (Howard).

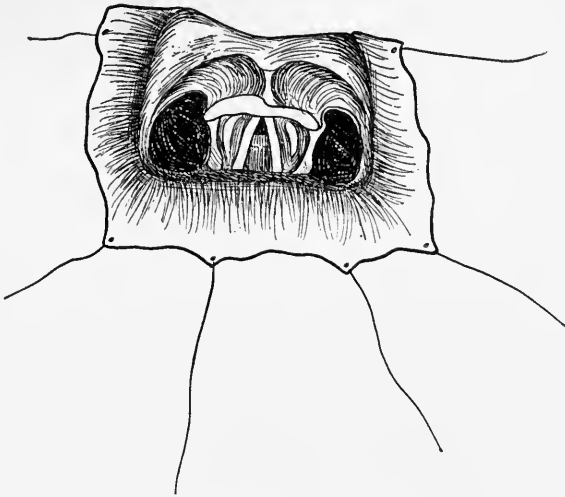


Fig. 102.—Lower jaw (inferior maxilla) lifted forward by pushing the posterior borders of the ascending rami upward when the patient is recumbent, or forward when the patient is in an upright position. If the tongue is pulled now while the jaw is lifted, the epiglottis is moved a little forward, almost to a line with the soft palate.

Although the manipulation of Howard, namely, elevation of the thorax, and the lifting of the jaw described by Heiberg, are, as a rule, sufficient during deep narcosis, they are not sufficiently effective during the initial stage of excitation, when there is a spastic retraction of the tongue and spasm of the muscles of the jaw, which often necessitate forcible opening of the mouth with a gag, pulling out of the tongue, and direct lifting of the epiglottis. In alcoholics, who present a protracted stage of excitation and vigorous, obstinate retraction of the tongue, he prefers to pass a loop of silk through the tongue and pull it out, with no more injury to the organ than occurs from the use of the tongue forceps.

In a foot-note on page 127 he mentions the hyoid bone briefly as follows:

* Kappeler: *Anæsthetica*, Deutsche Chirurgie, Billroth und Luecke.

"Recently I have succeeded in avoiding the rough manipulation necessary to separate the jaws during the tetanic closure of the mouth, by resorting to an easy and only slightly injurious method, namely, lifting of the hyoid bone forward. I passed a small, strong, pointed hook up behind the middle of the body of the hyoid bone and hooked it into the bone, which was then pulled forward. The tongue and epiglottis followed the hyoid bone in its forward movement, the epiglottis from traction on the hyo-epiglottic ligament.

"I observed without exception that the respiration became free when this manipulation was resorted to during asphyxia in chloroform narcosis, caused by closure of the entrance to the larynx."

To demonstrate the effectiveness of the different manipulations to allow free passage of air into the larynx, Kappeler made experiments on the cadaver, which I have verified and completed as shown by the accompanying cuts.

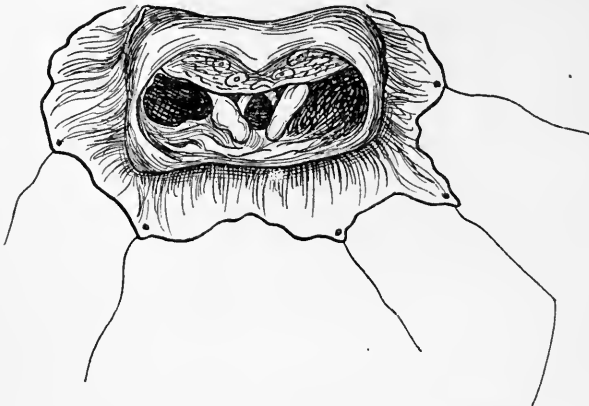


Fig. 193.—Hyoid bone pulled forward. Loop of silk around its body.

When the calvarium has been removed, as is usually done in post-mortem examinations, and the brain taken out, the whole basilar portion of the occipital bone and the body of the sphenoid as far as the posterior clinoid processes are removed with a chisel and the pharynx opened from above. A clear view can now be obtained of the upper (posterior) surface of the soft palate and the root of the tongue below it. If, in case of small skulls, the view into the pharynx is not sufficiently free, a portion of the posterior wall of the pharynx, the anterior arch of the atlas, and its odontoid process may be removed. The head is then placed in a horizontal position or on a small pillow, whereupon the soft palate can be seen lying against the posterior wall of the pharynx, either entirely so or separated from it by a narrow slit through which the upper ridge of the epiglottis may be seen (Fig. 189).

If the chin is now lifted up, the mouth being closed, the soft palate moves forward away from the wall of the pharynx, and we see the root

of the tongue and the upper border of the epiglottis; but its whole posterior surface still lies close to the posterior wall of the pharynx (Fig. 190).

If the tongue is now pulled forward out of the mouth in front of the teeth, it is seen that the posterior part of the tongue moves forward away from the epiglottis, and the median glosso-epiglottic ligaments come into view, while the epiglottis is either not moved at all or makes only a slight forward movement (Fig. 191).

If the lower jaw is now lifted forward by pushing the descending rami upward when the patient is recumbent, or forward when the patient is upright (Howard?), the epiglottis moves forward, so as to free the entire upper (anterior) half of the entrance to the larynx (Fig. 192).

It will thus be seen that this manipulation alone is much more effective than pulling out the tongue. If the tongue is now pulled for-

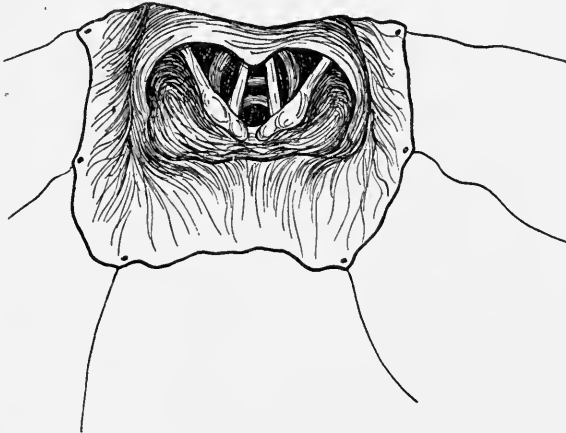


Fig. 194.—Hyoid bone pulled forward and tongue pulled forward.

ward while the jaw is lifted forward, the epiglottis is moved a little forward, but only very little, and not beyond the border of the soft palate.

If the hyoid bone is now pulled forward, either by the sharp hook of Kappeler or by the loop as devised by me, the mouth closed and the tongue untouched, the posterior (lower) half of the entrance to the larynx is made free, and the anterior (upper) half of the larynx is covered by the root of the tongue, which also covers the epiglottis (Fig. 193).

If, in addition to the pulling forward of the hyoid bone, traction is made on the tongue, the whole of the entrance to the larynx is made free. The tongue and epiglottis have disappeared forward under the soft palate. It is really the pulling forward of the hyoid bone that frees the entrance to the larynx from the wall of the pharynx, with room to spare (Fig. 194).

It will be seen from the plates that traction on the hyoid bone is far more effective than any other method, because this is the only manipula-

tion that makes the entire posterior commissure of the larynx with the arytenoid cartilages visible. This it accomplishes by lifting them from the posterior wall of the pharynx. It is, therefore, only by pulling the hyoid bone forward that the entire entrance to the larynx is made free.

Through a small longitudinal incision over the middle of the body of the hyoid bone it is easy, by means of an aneurism needle, to pass a loop of silk around the posterior surface of the body, up over the upper border, and out through the wound. A small pad of iodoform gauze is packed in the wound and the loop tied over it, the ends being left long enough to permit of manipulation by the operator or anesthetizer during the operation. At the close of the operation the loop is left in place and attached to a plaster-of-Paris cast loosely covering the dressing at the field of operation, with traction on the hyoid bone sufficient to prevent any sinking back of the larynx and epiglottis, and thus to keep the entrance to the larynx open even during sleep. I usually allow the loop to remain for three or four days, until the patient is able to breathe without difficulty, with the head and body in any position. It is needless to add that the small wound over the hyoid bone adds nothing to the gravity of the operation.

CONSERVATIVE OPERATIONS FOR RENAL RETENTION*

It is only in the last decad that this new branch of surgery has come into existence, and, as it is still young and not fully developed, the technic of the methods of operation is not yet well defined. The number of operations already performed, however,—and there are about 30 on record,—permit us to form an idea not only as to the justifiability of the object aimed at, namely, the salvation of a kidney doomed to removal, which may be considered as firmly established, but also as to the general direction in which the different methods of operating, which are already well grouped, must be developed for further perfection.

This subject has already been made accessible to the profession at large by the articles in the larger modern handbooks—in France, by Albarran¹ and Tuffier;² and in the English literature, by Henry Morris³ and Fenger.⁴

The field for this group of operations has thus far been limited to the kidney and the upper portion of the ureter, and it is this territory that has been the object for direct operative attacks in renal retention. This has naturally come to pass because it is accessible and the operations are reasonably safe and easy, and because the majority of the unilateral retentions are located in this region.

Unilateral obstruction to the flow of secreted urine may be located from the kidney downward.

- (a) In the neck of a calyx.
- (b) In one branch of the ureter.
- (c) At the exit of the ureter from the renal pelvis.
- (d) In the course of the ureter.

It will be seen, from the tabulated statement of cases, that the exit of the ureter from the renal pelvis is by far the most common location for the obstruction: 26 operations for obstruction in this locality are recorded, as against 1 in a branch of the ureter and 3 in the ureter below the pelvis.

There have been excluded from this consideration—

- (a) Nephrotomy and drainage.
- (b) Nephropexy, to correct and straighten out a bend in the upper end of the ureter caused by descent of the kidney.
- (c) Catheterization of the ureter from below to overcome retention from stricture or bending.

*Report presented to the Section on Urinary Surgery of the Thirteenth International Medical Congress, Paris, 1900, *Annals of Surgery*, 1901, vol. xxxiii, p. 369.

These procedures have been excluded, not because they do not deserve earnest consideration, as they are in some cases sufficient for cure, but because this paper must be limited to operations which directly attack the place of obstruction. I shall also leave out of consideration those cases of obstruction in which calculus is the cause of the retention, which is relieved by the removal of the stone.

I. OBSTRUCTION LOCATED IN THE KIDNEY, NAMELY, IN THE CALICES, OR IN ONE BRANCH OF THE URETER—PARTIAL CYSTONEPHROSIS

The operation to relieve this condition is bisection of the kidney and division of the partition walls between the sacs and the pelvis, thus making a unilocular out of a multilocular cavity or sac. If no obstruction be found at the exit of the pelvis or in the ureter, no further operation is required, as in removal of stones from the calices or pelvis of the kidney. If no stones are found, it is probable that there is obstruction below this point in one of the locations mentioned, and this must be overcome by one or another of the operations which have been devised for the relief of obstruction in these localities.

Hemorrhage from the division of voluminous partition walls may be overcome by the Paquelin cautery, ligation, or continuous suture.

Only one case of this variety has been recorded by Fenger (No. 9).⁵

II. OBSTRUCTION LOCATED AT THE EXIT OF THE URETER FROM THE RENAL PELVIS

This variety possesses naturally the greatest practical interest, as it is the most frequent site of non-calculous obstruction. Twenty-six of the operations collected were for obstruction at this point, and the methods of operation were quite varied. The condition found was either valve formation without stricture of the ureter, from unilateral dilatation of the pelvis and consequent oblique insertion of the ureter on the side of the dilated pelvis, rather than at its lowest point, or stricture of the ureter at its exit, with insertion either at the lowest part of the pelvis or on the side higher up.

The operations to reestablish free passage of the urine through the place of obstruction have varied with the existence or non-existence of stricture of the ureter, and with the point from which the valve formation is attacked, either from within, through an opening in the pelvis or the bisected kidney (transpelvic operation), or from without (extrapelvic operation).

Finally, the distorted shape of the pelvis has been made the object of operation—pyeloplication and capitonnage.

Transpelvic Operation on Valve, Section of Ureteropelvic Spur, Amelioration of Ureteral Orifice.—This is the oldest of the plastic operations in this locality, and was first done by Trendelenburg⁶ in 1886. Nine cases are on record, operated upon by Trendelenburg,⁷ Mynter,⁸ Bardenheuer,⁹ Fenger,⁵ Helferich,¹⁰ Israel,¹¹ Gerster,¹² and Fenger,¹³ in chronologic order.

Valve formation from oblique implantation of the ureter was first seen through the divided pelvis or kidney (cystonephrotic sac); it was natural, therefore, that the first attempts at widening the opening into the ureter should be made from inside the pelvis.

The valve formed by the oblique implantation of the ureter into the side of the dilated pelvis is seen through an incision in the dilated pelvis or through the bisected kidney, and the valve, that is, the wall of the pelvis and ureter in contact with each other, divided. This is done either by one incision sufficiently long to secure an amply wide opening into the ureter, or, better, to the bottom of the pelvis, or by multiple incisions of the valve (this was incised in three places by Gerster).

In all the cases the incision was closed transversely by sutures, one of which united the upper and lower ends of the incision, and others which united the divided walls of the ureter to those of the pelvis throughout the whole extent of the divided surface.

This operation was performed in 9 cases: 2 patients died, 1 from ileus (Trendelenburg, No. 1) and 1 from uremia in a case of bilateral disease (Helferich, No. 12). In 2 cases the operation was not successful; in 1, where obliteration of the ureter at the seat of operation followed (Fenger, No. 23), and 1 in which the operation was temporarily successful, as the ureter remained open for about one year, after which relapse occurred, the ureter closed, and a second operation became necessary (Gerster, No. 15).

In 5 cases the operation was successful (Fenger, No. 3; Mynter, No. 7; Bardenheuer, No. 8; Fenger, No. 9, and Israel, No. 14).

EXTRAPELVIC OPERATIONS

1. *Resection of Ureter and Reimplantation in Renal Pelvis—Uretero-pyeloneostomy (Küster).*—Six resections have been made by Küster,¹⁴ Van Hook,¹⁵ Bardenheuer,¹⁶ Bazy,¹⁷ Bazy,¹⁷ and Morris.¹⁸ A stricture in the upper end of the ureter led Küster to excise the strictured part of the ureter, although he had planned to make a transpelvic division of the valve. Resection and reimplantation proved successful in Küster's case (No. 2), Bardenheuer's (No. 6), and in 1 case of Bazy's (No. 17). Bazy's second patient, a case of calculous anuria (No. 18), died from sepsis—iodoform poisoning. In Van Hook's case (No. 5) the result was uncertain, as an extensive stricture in the ureter below necessitated immediate nephrectomy. In Morris' case (No. 22) the operation was planned, but the operator abandoned his plan and made an immediate nephrectomy, which he considered to be demanded by the extreme atrophy of the ureter.

It will thus be seen that resection and reimplantation of the ureter in the pelvis proved successful in 3 and was abandoned for nephrectomy in 2 cases. It was followed by death in 1 case from sepsis, a result that cannot be considered as attributable to the operation as such.

2. *Operation on Ureter and Pelvis at the Seat of the Valve or Stricture (Fenger).*—It was the same condition that obtained in Küster's case,

namely, a stricture in the pelvic end of the ureter, that caused Fenger to abandon an intended transpelvic operation and to resort to extrapelvic division of the ureter from below the stricture up into the pelvis, followed by transverse union of the longitudinal wound.

This operation has been performed in 11 cases, and none of the patients has died. In some of the cases there was stenosis of the pelvic end of the ureter, and in others the obstruction was caused solely by the oblique implantation of a normal ureter. In one case (Fenger, No. 20¹⁹) the operation was unsuccessful and was followed by nephrectomy. In the other 10 cases (Fenger, Nos. 4,²⁰ 9,²¹ 30,¹⁹ Albarran, Nos. 25,²² 26;²³ Bardenheuer, No. 16;²⁴ Richardson, No. 19;²⁵ Delbet, No. 24;²⁶ Kelly, No. 21;²⁷ Morris, No. 28³) the operation was followed by successful functional results. In one of Albarran's cases (No. 25)²² the operation was combined with partial excision of the dilated pelvis—capitonnage—to reestablish the normal shape of the pelvis.

In 1 case only (Bazy, No. 17) was the kidney approached through the peritoneal cavity by lateral laparotomy; in the other 10 cases extraperitoneal lumbar incision was made.

3. *Pyeloplication—Plastic Operation on the Renal Pelvis (Israel); Capitonnage (Albarran).*—In lateral implantation, when the ureteral orifice is of normal caliber, the passage of urine would be free were the ureter inserted at the lowest part of the pelvis, or if the normal shape of the pelvis were reestablished. This has been accomplished by the following operations on the pelvis:

(a) Shortening the excess of pelvic wall by folding it in toward the lumen of the pelvis, and uniting the folds by sutures (pyeloplication of Israel; pelvioplication of Albarran).

(b) Excision of part of the wall of the dilated pelvis and closure of the defect by sutures (capitonnage of Albarran).

In Israel's case (No. 13)¹¹ the operation sufficed to reestablish the flow of urine and effect a cure. In the case of Albarran (No. 26)²³ pelvioplication was made, and in case No. 25²² the same operator made a partial excision of the superabundant portion of the sac-wall with a portion of the kidney, but in both of these cases the operation was combined with extrapelvic operation on the valve.

Israel's case is the only one in which pyeloplication alone was effective in relieving the obstruction.

III. OBSTRUCTION LOCATED IN THE URETER

1. *Ureterolysorthosis (Rafin-Verrière).*—This operation, first performed by Rafin and reported by Verrière, consists in loosening the adhesions around a bend in the ureter. The upper end of the ureter below the renal pelvis is made impervious by a bend due to descent of a floating kidney. In Rafin's case the bend was double and S-shaped. The bend was buried in connective-tissue adhesions which prevented the straightening of the ureter. After division of these adhesions without opening the ureter it was straightened, and remained straight and per-

meable after the kidney had been replaced and retained by nephropexy. One successful case (No. 27) is reported by Rafin.

2. *Plastic Operation on the Ureter (Fenger).*—Longitudinal division of the strictured or obliterated ureter through the stricture into the normal ureter above and below it, followed by transverse union of the ureteral incision by folding the ureter upon itself, has been performed by Fenger in 2 cases, and was effective in both. In 1 (No. 11)²⁹ a valve was incised from the inside of the opened ureter at the point of occlusion; in the other (No. 29)¹⁹ complete occlusion of the ureter had followed a plastic operation on a stricture caused by a stone in the ureter. The second plastic operation through the then obliterated ureter was successful, notwithstanding that great tension was made on the ureter after folding and suture. This case demonstrated that an operation for reopening a closed ureter may be successful after an unsuccessful attempt has been made, and this justifies even repeated attempts to reestablish the patency of the ureter, and thereby save the kidney from removal.

CONCLUSIONS

1. *Choice of Operation.*—The choice of operation comes into question only in the cases of obstruction at the pelvic orifice of the ureter (unilateral implantation, with or without stricture of the ureter at this point), and lies between transpelvic plastic operation, extrapelvic incision and plastic operation, and pyeloplication.

Transpelvic plastic operation may be the operation of necessity in large cystonephrotic sacs, because of the difficulty in reaching the ureter outside of the pelvis. In 9 cases, 2 were followed by obliteration. In smaller sacs with moderate dilatation of the pelvis I consider extrapelvic plastic operation preferable to transpelvic plastic operation, and to resection and reimplantation of the ureter (ureteropyeloneostomy). Resection was practised in 6 cases. In 2 the operation was incomplete and was followed by nephrectomy. It was successful in 3 cases and functionally successful in 1 (Bazy, No. 18). One patient died from iodoform poisoning or sepsis. Thus it proved effective in all the 4 cases in which the operation was completed.

Extrapelvic plastic operation was chosen by most of the operators. It was performed 11 times, was successful in 10 cases, with good functional results, and was unsuccessful in 1 case. It would thus seem that this should be the operation of choice by reason of the results obtained, and because its technic is relatively simple.

2. *Danger to Life.*—The risk to life from this entire group of conservative operations for renal retention is small. Three of the 30 patients died, but in none of them was death due to the operation *per se*. In Trendelenburg's case the patient died from ileus, and both Helferich's and Bazy's patients had bilateral disease and could not have been saved by nephrectomy.

3. *Effect of the Operations.*—The results of the operations to reestablish evacuation of urine and thus save the kidney were as follows:

CHRONOLOGIC TABLE OF OPERATIONS FOR RENAL RETENTION

No.	OPERATOR.	DATE.	OPERATION.	RESULT.			
				Recovery.	Death.	Mucous Fistula.	Nephrectomy for Urinary Fistula.
1	Trendelenburg.	1886.	Transpelvic division of valve.
2	Küster.	July 14, 1891.	Resection of ureter. Implantation in pelvis. Ureteropyelonecstomy.	1	Ileus.
3	Fenger.	May 31, 1892.	Transpelvic plastic operation on valve.	1
4	Fenger.	Nov. 26, 1892.	Extrapelvic plastic operation. Stricture of upper end of ureter.	1
5	Van Hook.	1892.	Resection.	1
6	Bardenheuer.	March 24, 1893.	Resection. Ureteropyelonecstomy.	1	1
7	Mynter.	Aug. 14, 1893.	Transpelvic plastic operation.	1
8	Bardenheuer.	Jan. 28, 1894.	Transpelvic plastic operation.	1	1
9	Fenger.	Sept. 17, 1894.	Extrapelvic operation on valve at exit of pelvis.	1
10	Fenger.	Nov. 17, 1894.	Transpelvic plastic operation on valve.	1
9	Fenger.	April 13, 1895.	Bisection of kidney. Division of valve in lower branch of ureter.	1
11	Fenger.	Aug. 6, 1895.	Plastic operation on ureter. Excision of valve.	1
12	Helferich.	Nov. 13, 1895.	Extrapelvic plastic operation. Bilateral disease.	Uremia, ninth day.
13	Israel.	1896.	Pyeloplication.	1
14	Israel.	1896.	Transpelvic plastic operation on valve.	1
15	Gerster.	Feb. 6, 1896.	Transpelvic plastic operation on valve.	1	1
16	Bardenheuer.	Feb. 17, 1896.	Extrapelvic plastic operation.	1
17	Bazy.	July 27, 1896.	Resection. Ureteropyelonecstomy.	1
18	Bazy.	Oct. 13, 1896.	Resection. Ureteropyelonecstomy.	1
19	Richardson.	Nov. 11, 1896.	Extrapelvic operation.	1
20	Fenger.	1897.	Extrapelvic operation (unpublished).	1
21	Kelly.	1897.	Extrapelvic operation.	1
22	Morris.	1897.	Resection attempted.	1
23	Fenger.	Feb. 22, 1898.	Transpelvic operation on valve. Obliteration of ureter at place of operation.	1
24	Delbet.	1898.	Ureteropyelonecstomy.	1
25	Albarran.	1898.	Ureteropyelonecstomy.	1
26	Albarran.	1898.	Pyeloplication.	1

27	Albarran.	1898.	Extrapelvic plastic operation.	1
28	Rafin (Verrière).	Nov. 12, 1898.	Ureterolysorthosis.	1
29	Morris.	1898.	Extrapelvic plastic operation.	1
30	Fenger.	May 23, 1899.	Extrapelvic plastic operation on ureter (unpublished).	1
	Fenger.	July 9, 1899.	Extrapelvic plastic operation on pelvis and ureter (unpublished).	1	1

TABLE OF OPERATIONS FOR RENAL RETENTION

I. BRANCH OF URETER

CHRONOLOGIC. No.	OPERATOR.	DATE.	AGE. SEX.	DISEASE.	OPERATION.	RESULT.				BIBLIOGRAPHIC. No.
						Recovery.	Death.	Mucous Fistula.	Nephrec- tomy for Urinary Fistula.	
9	Fenger.	April 13, 1895.	22 M.	Gonorrhœa. Renal colic. Lumbar nephrotomy. Passage of stones through fistula. Intermittent ob- struction of ureter. Oper- ation for oblique implan- tation and stricture of pelvic end of ureter. Uri- nary fistula. Pyelitis. Sacculated kidney.	Incision through fistula and old cicatrix into sacculated kidney. Could not find entrance to ureter. Bisection of kidney and division of partition walls between calices. Ureter patent. Plastic operation on ureteral en- trance; incision with transverse union of wound. Four months later, reunion of bi- sected kidney. Five months later, fistula closed spontaneously.	1

II. URETER AND PELVIS FOR VALVE FORMATION OR OBLIQUE INSERTION, WITH OR WITHOUT STENOSIS OF UPPER END OF URETER

A. *Transpelvic Operation on Valve*

1	Trendelen- burg.	1886.	Large hydronephrosis.	Anterior wall of sac opened by lateral laparot- omy. Division of ureter to lower part of sac. Suture of divided borders of ureter to inner wall of sac. Displacement of ureteral opening to bottom of sac.	?	Ileus.	6
---	---------------------	-------	-------	-----------------------	--	---	--------	----	-------	---

TABLE OF OPERATIONS FOR RENAL RETENTION.—(Continued.)

CHRONOLOGIC No.	OPERATOR.	DATE.	AGE.	SEX.	DISEASE.	OPERATION.	RESULT.				BIBLIOGRAPHIC No.
							Recovery.	Death.	Mucous Fistula.	Nephrectomy for Urinary Fistula.	
3	Fenger.	May 31, 1892.	28	F.	Valvular stricture or stenosis of pelvic orifice of ureter in somewhat floating kidney. Intermittent hydronephrosis for eight years.	Nephrotomy in interval between attacks. No stone in pelvis. Pelvic orifice of ureter not found. Incision of pelvis. Valvular opening seen. Plastic operation on valve. Fixation of floating kidney.	1	7
7	Mynter.	Aug. 14, 1893.	25	M.	Intermittent hydronephrosis for twelve years.	Lumbar incision. Valve formation. Transpelvic operation on valve through incision one inch long, prolonged downward through valvular stricture.	1	8
8	Bardenheuer.	Jan. 28, 1894.	45	F.	Right pyonephrosis.	Bisection of kidney. Intrapelvic division of ureter and sac to bottom of sac. Union of ureter to sac.	1	1	9
10	Fenger.	Nov. 17, 1894.	28	F.	Large aseptic remittent cystonephrosis in movable kidney for seven months.	Lumbar nephrotomy. Drainage. Two months later, sac retracted one-half. Transpelvic operation on valve. Division of wall of ureter and pelvis to bottom. Suture.	1	5
12	Helferich.	Nov. 13, 1895.	25	F.	Intermittent left hydro-nephrosis or pyonephrosis.	Bisection of kidney. Division of ureter. Implantation in lower end of divided sac. Uræmia. Bilateral disease.	..	Ninth day.	10
14	Israel.	1896.	11	M.	Right intermittent hydro-nephrosis or pyonephrosis, colic, etc., for two years.	Lumbar incision. Kidney double ordinary size. Lateral implantation and bend at origin of ureter. Adhesions. Incision in posterior wall of pelvis. Valve divided with scissors, ureteral mucosa united to pelvic mucosa. No permanent catheter.	1	11

15	Gerster.	Feb. 6, 1896.	9	M.	Trauma, 1895, hematuria (rupture of kidney or ureter). Six months later, tumor in right hypochondrium. Large aseptic cystonephrosis. Oblique implantation and stricture of pelvic end of ureter.	1	12	
23	Fenger.	Feb. 22, 1898.	23	F.	Right intermittent hydro-nephrosis for five years.	13	
					Lumbar incision. Multilocular hydronephrosis. Incision of sac. Eversion of its inner side. Division of partition walls between dilated calices. Intrapelvic division of exit or valve of obliquely inserted ureter and corresponding wall of pelvis to bottom. Suture of ureter to pelvis. Fistula. Three months later extrapelvic plastic operation. Ureter completely obliterated. Valve in lower end of ureter persisting. Urinary fistula, 1899. Nephrectomy.					Obliteration of ureter at seat of operation.	
2	Küster.	July 14, 1891.	11	M.	Left open hydronephrosis. Lumbar nephrotomy. Vesical anuria and fistula. One year later, dilatation of fistula. Catheterization of ureter impossible. Septic pyelitis.					14	
					<i>B. Resection and Reimplantation of Ureter</i> Lumbar extraperitoneal incision. Ureter not found. Incision of dilated pelvis. Ureter in or on posterior dilated wall of sac. Division of pelvic wall of ureter prevented by stricture of ureter 2 cm. below pelvis. Division of ureter to stricture. Resection of ureter. Divided end of ureter unfolded and sutured to opening in sac. Four months later fistula closed by curetting, dilating, and closing canal by sutures.	1	1	15
5	Van Hook.	1899.	19	...	Infected cystonephrosis.	1	
					Nephrotomy. Urinary fistula. Oblique implantation, valve. Resection of ureter. Re-implantation in pelvis. Exploration of ureter below. Obliteration lower down for several inches. Nephrectomy.						

TABLE OF OPERATIONS FOR RENAL RETENTION.—(Continued.)

No. CHRONOLOGIC	OPERATOR.	DATE.	AGE. SEX.	DISEASE.	OPERATION.	RESULTS.				BIBLIOGRAPHIC No.
						Recovery.	Death.	Mucous Fistula.	Nephrec- tomy for Urinary Fistula.	
6	Bardenheuer.	May 24, 1893.	49 M.	Right cystonephrosis.	Lumbar operation. Unilateral oblique im- plantation for 5 cm. Resection of ureter. Implantation in deepest part of sac. Small fistula six months later.	1	1	16
17	Bazy.	July 27, 1896.	40 M.	Non-intermittent hydrone- phrosis.	Transperitoneal operation. Median incision. Ureter inserted at middle of sac. Resection of 4 cm. of ureter. Implantation in lower portion of sac. Resection of portion of pelvic sac. Catheter from ureter through pelvis and out through abdominal wound.	1	17
18	Bazy.	Oct. 13, 1896.	48 M.	Hematuria. No pain. Large right kidney calcu- lous anuria for three days.	Lumbar incision. Bilobate kidney. Stone and old coagulum in pelvis. Ureter very hard and di- lated. Resection and implantation. Death from infection. Operation a mechanical suc- cess.	..	Iodo- form poison- ing or sepsis.	17
22	H. Morris.	1897.	56 F.	Intermittent hydronephro- sis. Extrapelvic opera- tion unsatisfactory.	Kiister's operation. Uretoropyeloneostomy. Ureter thin and small. Operator not satis- fied. Nephrectomy.	1	18
4	Fenger.	Nov. 26, 1892.	47 M.	Traumatic stricture of ure- ter close to pelvis of kid- ney. Intermittent pyo- nephrosis for four years.	<i>C. Extrapelvic Operation on Valve and Stricture</i> Nephrotomy. Sacculated kidney. No stone found. Ureteral entrance not found. In- cision of pelvis. Longitudinal ureterotomy showed stricture. Longitudinal incision of stricture and plastic operation on ureter and pelvis.	1	20

9	Fenger.	Sept. 17, 1894.	21	M.	Gonorrhea. Renal colic. Lumbar nephrotomy. Passage of stones through fistula. Intermittent obstruction of ureter.	Operation for oblique implantation and stricture of pelvic end of ureter.	1	21
16	Bardenheuer.	Feb. 17, 1896.	32	F.	Intermittent hydronephrosis for five years. Movable kidney.	Incision from pelvis through spur into ureter below. Transverse union of longitudinal wound.	1	24
19	M. H. Richardson.	Nov. 11, 1896.	29	F.	Intermittent hydronephrosis for eight or ten years. Gall-stone suspected. Cystotomy. Gall-bladder normal, but retroperitoneal tumor in region of kidney.	Ureteroplasty. Lumbar incision. Ureter found inserted in inner convexity of dilated pelvis, collapsed and flattened. Lifting up kidney's straightened ureter. Change of pelvic outlet of ureter into funnel-shaped mouth. Ureteroplasty on principle of pyroplasty.	1	25
20	Fenger.	March, 1897.	38	F.	Remittent infected cystonephrosis in floating kidney. Renal stone passed per urethram. Stricture of ureter.	Extrapelvic operation. Kidney small. Pelvis dilated. Incision of pelvis. Stricture of ureter below exit. Division of stricture into pelvis. Pyelitis and cystitis persisted. One year later, nephrectomy.	1	19
21	Kelly.	1897 (?).	35	F.	Stricture of ureter. Hydronephrosis for five years. Close to pelvis. Probably calculus.	Stricture found close to pelvis. Strictured portion of ureter divided longitudinally and sutured transversely to pelvis.	1	27
24	Delbet.	1898.	33	F.	Intermittent hydronephrosis for fifteen years.	Lumbar incision, stenosis, and oblique insertion of ureter from pelvis through stricture (ureteropyelonecstomy).	1	26
25	Albarran.	1898.	22	F.	Left pyonephrosis. Nephrotomy. Permanent ureteral catheter.	Lumbar incision. Extrapelvic division of spur. Extirpation (capitonnage) of lower portion of sac. Suture of borders of ureter to pelvis.	1	22
26	Albarran.	1898.	22	F.	Hydronephrosis. Stricture and oblique insertion of ureter. Stone in pelvis. Nephrotomy. Removal of stone.	Extrapelvic operation. Ureter incised. Opening in ureter united to opening in lowest part of pelvis.	1	23
28	H. Morris.	1898.	29	F.	Stricture and valvular obstruction in upper end of ureter. Normal insertion.	Longitudinal ureterotomy. Division of stricture. Transverse union of ureter to pelvis.	1	3

TABLE OF OPERATIONS FOR RENAL RETENTION.—(Concluded.)

No CHRONOLOGIC	OPERATION.	DATE.	AGE. SEX.	DISEASE.	OPERATION.	RESULTS.				
						Recovery.	Death.	Mucous Fistula.	Nephrec- tomy for Urinary Fistula.	No. Biologic.
30	Fenger.	July 9, 1899.	14 F.	Intermittent infected hy- dronephrosis for ten years; left floating kid- ney.	Lumbar incision. Kidney large and elongated. Pelvis dilated. Oblique insertion of ureter, upper end bent. Incision of pelvis. Division of exit of ureter and pelvis. Transverse union.	1	1	19
13	Israël.	1896.	39 F.	Intermittent hydronephr- osis for six months. Pelvis dilated so that ureter originated from lateral side of wall. Ureter ran upward for 1.5 cm., then bent downward.	<i>D. Pyeloplasty</i> Incision of posterior wall of pelvis in direction of axis. No stone; no fold. Folding-in and suturing of medial side of pelvis (pyeloplica- tion). By similar folding-in of another part of pelvis, ureteral bend straightened. Neph- ropexy.	1	11
26	Albarran.	1898.	22 F.	Hydronephrosis. Stricture and oblique implantation of ureter. Stone in pelvis.	Nephrotomy. Removal of stone. Pelviopli- cation. Two months later, extrapelvic op- eration.	1	23
III. URETER										
A. <i>Ureterolysorthis</i>										
27	Rafin (Verrière).	Nov. 12, 1898.	32 F.	Left movable kidney, 1890. Intermittent left hydro- nephrosis, 1895. Nephro- pexy, April, 1896. Re- lief, then relapse.	Lumbar incision. Kidney small, lobulated. Pelvis dilated. Ureter had sigmoid bend and was inserted in lower part of pelvis. Adhe- sions separated, and sigmoid bend straight- ened. Nephropexy, November 12, 1899.	1	28

B. Plastic Operation

11	Fenger.	Aug. 6, 1895.	32	F.	Probable traumatic right floating kidney, 1880. Remittent attacks of pain, reawakened after pregnancy in 1885. Returned in 1893 after miscarriage. Pyonephrosis. Tumor in region of right kidney.	1	29
29	Fenger.	May 23, 1899.	25	M.	Large left pyonephrosis. Lumbar nephrotomy. Ureterotomy. Removal of stone, 1 inch long, from upper end of ureter, 1897. Lumbar urinary fistula. Fenger's plastic operation on strictured ureter, 1898, by Dr. Allport, of Chicago. Fistula persisted.	1	19
					Isolation of kidney. Bisection. Stricture 2 inches below pelvis. Ureter isolated and found completely obliterated for 1 cm. Longitudinal ureterotomy 1 inch through stricture. Transverse union. Considerable tension on ureter. Bougies from kidney into ureter below stricture. Reunion of bisected kidney. Lumbar urinary fistula closed, and remains closed. January, 1900, osteomyelitis of humerus.	2	

(a) Non-effective. The operation was non-effective in 5 cases, in 4 of which nephrectomy was performed (Van Hook, No. 5; Fenger, No. 20; Morris, No. 22; Fenger, No. 23), with no deaths. In 1 case (Gerster, No. 15) a urinary fistula returned.

(b) Functionally effective. The operation was functionally effective in 22 of the 30 cases; that is to say, 22 out of 30 kidneys, or 73 per cent., have been saved from nephrectomy. In a few of these cases a mucous fistula still remained at the time of publication, but an almost dry mucous fistula, leading probably to a suture or ligature, will close in time, and will never necessitate the removal of a kidney the urine from which passes into the bladder.

BIBLIOGRAPHY

1. Albarran, J.: "Maladies du Rein," *Traité de Chirurgie*, par Le Dentu et Delbet, 1892, vol. viii, p. 805.
2. Tuffier: "Appareil Urinaire," *Traité de Chirurgie*, par Duplay et Reclus, 1892, vol. vii.
3. Morris, Henry: "Hunterian Lectures on Surgery of the Kidney," *Brit. Med. Jour.*, 1898, vol. i, p. 809.
4. Fenger, C.: "Surgery of the Ureter," *American Text-book of Genito-urinary Diseases*, p. 470.
5. Fenger, C.: "Conservative Operative Treatment of Sacculated Kidney, Cystonephrosis," *Annals of Surgery*, 1896, vol. xxxiii, p. 637.
6. Trendelenburg, F.: *Volkmann's Sammlung klinischer Vorträge*, 1890, No. 335, p. 3378.
7. Fenger, C.: "Operations for the Relief of Valve Formation and Stricture of the Ureter in Hydro- or Pyonephrosis," *Jour. Amer. Med. Assoc.*, 1894, vol. xxii, p. 335.

8. Mynter, H.: "Case of Acute Intermittent Hydronephrosis from Valvular Stricture of the Ureter," *Annals of Surgery*, 1893, vol. xviii, p. 658.
9. Bardenheuer: "Zur konservativen Behandlung der Hydro-resp. Pyonephrose by Dr. K. Cramer," *Centralbl. f. Chirurgie*, 1894, vol. xxi, p. 1145.
10. Helferich: "Ein Beitrag zur Ureterchirurgie by Dr. Enderlen," *Deut. Zeitsch. f. Chirurgie*, 1896, vol. xxxiv, p. 323.
11. Israel, J.: "Ueber einige neue Erfahrungen auf dem Gebiete der Nierenchirurgie," *Deut. med. Wochenschr.*, 1896, vol. xxiii, p. 345.
12. Gerster, Arpad G.: "A Contribution to the Surgery of the Kidney and of the Ureter," *Amer. Jour. Med. Sci.*, 1897, vol. cxvii, p. 677.
13. Fenger, C.: "Eversion or Turning Inside Out of the Sac of a Cystonephrosis as an Aid in Operating upon the Renal End of the Ureter and upon the Partition Walls between Dilated Calices," *Amer. Jour. Med. Sci.*, 1899, vol. cxviii, p. 48.
14. Küster: "Ein Fall von Resection des Ureters," *Arch. f. klin. Chirurgie*, 1892, vol. xlv, p. 850.
15. Van Hook, W.: "The Surgery of the Ureters; a Clinical, Literary, and Experimental Research," *Jour. Amer. Med. Assoc.*, 1894, vol. xxi, pp. 911 and 965.
16. Bardenheuer: "Eine operative Behandlungsweise der hydronephrotischen Wanderniere, by Dr. K. Cramer, Assistant," *Centralbl. f. Chirurgie*, 1897, vol. xxiv, p. 586.
17. Bazy: "Contribution à l'étude de la chirurgie de l'uretèr-urétéro-pyélonéostomie," *Revue de Chirurgie*, 1897, p. 400.
18. Morris, Henry: *Loc. cit.*, p. 814.
19. Fenger, C.: Unpublished.
20. Fenger, C.: *Loc. cit.*, No. 7, p. 19.
21. Fenger, C.: *Loc. cit.*, No. 5, p. 12.
22. Albarran, J.: *La Presse Médicale*, 1898, vol. iii, p. 39.
23. Bardenheuer: *Loc. cit.*, No. 16, p. 586.
24. Richardson, M. H.: "A Successful Case of Ureteroplasty for Intermittent Hydronephrosis," *Trans. Amer. Surg. Assoc.*, 1897, vol. xv, p. 555.
25. Delbet: "Présentation d'un malade, urétéro-pyélo-néostomie," *La Presse Médicale*, 1898, vol. iii, p. 199.
26. Kelly, H. A., and Ramsey, O.: "De l'usage du cathetér rénal dans le diagnostic et le traitement des maladies des reins et des uretères," *Revue de Gynecologie et de Chirurgie Abdominale*, 1897, p. 834.
27. Verrière, A.: "Contribution a la chirurgie conservative dans le traitement des rétentions rénales—bassinets extrémité supérieure de l'uretère," *Thèse de Lyon*, 1899, p. 56.
28. Fenger, C.: "An Operation for Valvular Stricture of the Ureter," *Amer. Jour. Med. Sci.*, 1896, vol. cxvii, p. 667.

UNIVERSITY OF CALIFORNIA LIBRARY
Los Angeles

This book is DUE on the last date stamped below.

--	--	--

Form L9-10m-3,'48(A7920)444

THE LIBRARY
UNIVERSITY OF CALIFORNIA
LOS ANGELES

W0 Fenger -
7 The collected
F356c works of
1912 Christian
v.2 Fenger.

Biomedical

Library

UC SOUTHERN REGIONAL LIBRARY FACILITY



A 000 379 309 8

W0
7
F356c
1912
v.2
Biomedical
Library

