

R-226

LIBRARY

New York State Veterinary College
ITHACA, NEW YORK

SF	Schmeisser, Harry C
995	Leukaemia of the fowl: Spontaneous and
S342	experimental. 1915

Cornell University Library

SF 995.S34I

Leukaemia of the fowl:spontaneous and ex



3 1924 000 946 461

vet

JOHNS HOPKINS HOSPITAL REPORTS
MONOGRAPHS. NEW SERIES No. VIII.

**LEUKÆMIA OF THE FOWL:
SPONTANEOUS AND
EXPERIMENTAL**

BY
HARRY C. SCHMEISSER, M. D.
(From the Department of Pathology of The Johns Hopkins University)

Illustrated: 4 Plates

BALTIMORE
THE JOHNS HOPKINS PRESS
1915

[Copyright, 1915, by The Johns Hopkins Press]

SF
995
S34 l

N. Y. STATE VETERINARY COLLEGE
1897

for the use of the

ROSSELL P. FLOWER

FOUNDED BY

Flower Veterinary Library

THE

CORNELL UNIVERSITY

ROSSELL P. FLOWER


~~8~~
~~5~~
~~10~~

SF
995
5348

No. 5699

CONTENTS.

	PAGE
I. Review of the Literature.....	1
II. Studies on the Normal Fowl.....	9
1. External Appearance	9
2. Blood	9
3. Autopsy Protocol (gross).....	11
4. Microscopical Examination	13
III. A Case of Spontaneous Leukæmia.....	15
1. Blood	15
2. Autopsy Protocol (gross).....	16
3. Microscopical Examination	17
4. Summary	19
5. Conclusion	20
IV. Experimental Leukæmia	20
1. Preparation of Material, Methods of Injection, etc.....	20
2. Clinical History	21
3. The Blood	22
4. Autopsy Findings (gross and microscopical).....	24
5. Table: Weights of Body, Organs and Relation of Organs to Body at Autopsy.....	30
6. Summary	30
7. Conclusion	31
V. Conclusion	31



Cornell University
Library

The original of this book is in
the Cornell University Library.

There are no known copyright restrictions in
the United States on the use of the text.

<http://www.archive.org/details/cu31924000946461>

LEUKÆMIA OF THE FOWL: SPONTANEOUS AND EXPERIMENTAL. * †

By HARRY C. SCHMEISSER, M. D.

(From the Department of Pathology of The Johns Hopkins University.)

I. REVIEW OF THE LITERATURE.

The first publication was made by Moore¹ in 1895-1896, in which he reported observations upon an epizootic disease of fowls which he designated "infectious leukæmia." His studies were based upon cases obtained from five different outbreaks, and upon those artificially produced by means of the specific organism (*Bacterium sanguinarium*) isolated from the organs of these fowls. The descriptions of the spontaneous and experimental cases clearly show that he was not dealing with a true leukæmia of the fowl, but rather with an acute infectious disease, characterized by fever, diminution in the number of red blood cells, and increase in number of white blood cells, this increase being "restricted" to the polymorphonuclear leucocyte with the eosin staining spindles, *i. e.*, the phagocyte of the normal fowl's blood.

Butterfield,² in 1905, reported three cases of aleukæmic lymphadenoid tumors of the hen. His studies were limited to the livers of these animals. They correspond in every detail, both grossly and microscopically; were uniformly and strikingly enlarged (340, 420, 270 gm. respectively) and of a diffuse, light, cream, yellow color. Histologically, the liver tissue was extensively replaced by large oval or round, sometimes irregular, collections of cells. The intralobular capillaries were filled with the usual nucleated red blood cells. Most of the nodules of tumor cells were thought to be in connection with the portal spaces. The cells resembled in general the "large

* Submitted for publication, October, 1914.

† Dissertation submitted to the Board of University Studies of The Johns Hopkins University, in conformity with the requirements for the Degree of Doctor of Philosophy, 1914.

lymphocyte" of the hen's blood.* Allowing for flattening due to pressure, these cells were round or oval, with round or oval nuclei, mostly eccentric. The nuclear chromatin appeared granular or reticular. The nucleus was not infrequently pale and vesicular with one or more bright chromatin bodies. The cytoplasm was present as a narrow rim, non-granular, and basophilic. Mitoses were common. Between these cells was seen a delicate reticulum. In association with these tumor masses were quite large collections of eosinophilic cells, the majority showing a single, pale, round or oval, eccentric nucleus and a relatively abundant cytoplasm, filled with large, round, elongated, or spindle-shaped oxyphilic structures. They varied greatly in size and shape. The lymphocytes and eosinophiles were occasionally seen in the capillaries, but there was "certainly no definite increase within the blood-vessels." From the character of the cells, their relation to the portal spaces and absence of the lymphæmia, the condition was regarded by Butterfield as a proliferation of periportal lymphadenoid tissue, and thought by him to merit the designation "aleukæmic lymphadenoma."

Mohler had under observation five similar cases showing lymphæmia and the same lymphadenoid condition. Mohler's description of two of his cases, as presented by Butterfield, is as follows: The process showed a tendency to involve several organs. In one case the liver and spleen were the principal seats, the lungs and intestine were also involved. The liver was enlarged to twice the normal size, of very light color and mottled. Throughout its surface and within its parenchyma were whitish lymphomatous deposits of varying diameters. A section shows the liver tissue only partly obliterated as a result of a filling up of the interacinous capillaries with leucocytes. The spleen was about the size of an ordinary blue plum. Each lung contained a white spherical area, the size of a pea and composed of hyperplastic lymphoid tissue, infiltrating white cells. In the wall of the large intestine, involving the lymphadenoid tissue, were round, slightly raised nodules. In the second case the changes were most marked in the kidney and spleen. The liver, intestine and heart were also involved. The kidneys were three or four times the normal size and had macroscopically very much the same appearance as the liver in the first case. The myocardium contained some small, whitish

* Obviously the large mononuclear cell of the classification presented in this paper.

areas. Butterfield, in comparing the histological findings in Mohler's cases with his own, finds a convincing similarity between, or identity of, the infiltrating cells. In Mohler's cases, the infiltration was more diffuse and not so regularly arranged about the portal tissue. Above all, the white blood cells were markedly increased in all the blood-vessels, from the intraacinar capillaries to the largest veins. The predominating white cell was indistinguishable from the cells in the tumor masses of both these and Butterfield's cases. From the foregoing, Butterfield felt justified in granting "the existence of a leukæmic and aleukæmic lymphadenoid hyperplasia in hens."

Butterfield and Mohler deserve the credit of showing that leukæmia occurs in the fowl. Their studies were limited to post-mortem findings.

To Warthin,³ in 1907, we are indebted for the first complete study of this disease in fowls. He had the good fortune to secure a living animal, which he kept under observation for two and a half months before it died. During this time he had an opportunity of carefully studying the clinical course. The blood showed a great reduction in the total number of red blood cells. These varied greatly in size and shape, and contained less hæmoglobin than normal. The total number of white cells was greatly increased. Differential counts showed a striking increase of the "large lymphocyte" at the expense of the other cells of the normal blood. Numerous mononuclear forms of the eosinophiles, cells abnormal to the blood, were seen. From the blood changes Warthin felt justified in making a diagnosis of "lymphatic leukæmia of the large cell type." A careful autopsy revealed the following findings: The liver was greatly increased in size and was pale yellow in color. The spleen and kidneys were also enlarged; both showed numerous yellowish spots from pin-point to pin-head in size. In the hæmolymph nodes small yellowish nodules were found. The bone-marrow appeared as solid plugs, reddish-yellow and friable. The tissue changes were summarized as follows: (1) Tumor-like nodules and infiltrations of lymphoid cells in all the organs, particularly in the liver, spleen, kidneys, bone-marrow and hæmolymph nodes; (2) replacement of the normal white cells of the blood by cells of the large lymphocyte type, more or less atypical in character, but identical with cells in the tumor masses. From the findings, both in the blood and in the tissue, Warthin made the diagnosis of leukæmic lymphocytoma.

He likewise examined the material from two additional cases of lymphadenoid tumors of the fowl. One proved to be of the aleukæmic type, as described by Butterfield; the other was of the leukæmic form, as described above. The histological picture, apart from the increase of white cells in the blood-vessels in the one case, was identical in both cases and also with that in the cases given above (Butterfield's, Mohler's and Warthin's). From these cases Warthin concludes, therefore, that there occurs in the common fowl a condition of disseminated lymphocytoma, sometimes aleukæmic, at other times associated with an increase of the white cells of the blood, this increase consisting in the appearance of great numbers of cells of the large lymphocyte type and apparently identical with the lymphoid cells of the tumor nodules. He also regards the aleukæmic and leukæmic conditions as genetically related, if not actually one and the same process in different stages. Both conditions, he thinks, are in all respects analogous to the similar ones existing in man.

The preceding cases appear to be very similar to those reported by later investigators and designated by them as splenomedullary in type.

Kon⁴ in 1907, after the appearance of Warthin's article, reported what he considers a true case of leukæmic disease of the chicken. The gross and microscopical changes, which were studied and reported in great detail, are in general identical with those of the cases above. In addition, he found giant cells, though only a few, in the bone-marrow, and mitoses in the basophiles as well as in the eosinophiles in the kidneys. Because of the lack of smears, he determined the ratio W/R and made differential counts from sectioned blood-vessels of the liver. He found that the white cells, as compared with the reds, were greatly increased and that the large mononuclear was the predominating cell of the whites. Mitoses of this cell were observed. The evidence given, he thinks, is sufficient to consider this a case of true leukæmia. Because of the enormous swelling of the spleen and the plentiful occurrence of the characteristic cell in the pulp of the normal spleen and to a lesser degree in the normal bone-marrow, and in the absence of lymphatic swelling and the occurrence of this cell in the normal lymph tissue, it seems to him most likely that this is a case of true "splenic leukæmia."

Soshestrenski,⁵ in May, 1908, reported a case of spontaneous leukæmia of the fowl, very similar to the case described by Kon.

His study was limited to gross and microscopical findings at autopsy. The bone-marrow was omitted. The contents of the blood-vessels of the organs were found to be leukæmic. He designates the case also as "splenic leukæmia," but in so doing he calls attention to the fact that the process involves many of the other organs and appears to be only primary and most marked in the spleen. There was no enlargement of the lymph-glands.

With Ellermann and Bang,⁸⁷ in 1908, the subject takes on a different phase. Up to this time, the communications dealt entirely with the recording of spontaneous cases of leukæmia in the fowl. Ellermann and Bang were the first to successfully transmit the disease by experimental inoculations from a spontaneous case to other, healthy, fowls. In fact, they claim to have been the first to successfully produce the disease experimentally in any animal. They report the findings in two typical spontaneous cases giving identical pictures. The blood study during life was found to be practically the same as that of Warthin's case, with the exception that the large mononuclears frequently contained in their cytoplasm many granules, and thus represented cells which are not found in the normal blood—myelocytes. Small granules alternated with very large ones. The autopsy showed an enlarged spleen and liver, the latter with white dots and streaks. The bone-marrow was gray-red. The other organs presented nothing of interest. The microscopical changes were very similar to those of Warthin's case. The experimental leukæmia they transmitted to the third generation, producing a blood picture and organic findings identical with those of the spontaneous cases.

Pseudoleukæmia, which is characterized by the same organic lesions as are found in true leukæmia, but in which the blood picture is normal, they found to occur spontaneously among chickens. They received from the same flock, at the same time, a leukæmic and pseudoleukæmic animal. From the pseudoleukæmic animal, by inoculation, they produced a leukæmic animal, and conclude, therefore, that the leukæmia and pseudoleukæmia of chickens are etiologically identical.

Multiple sarcomatosis of the peritoneum occurs epidemically in the fowl. They consider this a manifestation of leukæmia, because by inoculation from such a case they produced an atypical leukæmia and carried this to the second generation.

They were successful in two out of five inoculations with a filtrate from an emulsion passed through a "Kerze aus Infusorierde" and

conclude, therefore, that a cell-free filtrate is effective and that the cause must be an organized virus.

In the same year, Ellermann and Bang⁸ reported that the blood of leukæmic fowls contained the virus. They also showed that among transmitted cases the disease may appear as a typical leukæmia or as a pseudoleukæmia, or only as an anæmia with changes in the bone-marrow. The injection of five animals with a Berkefeld filtrate resulted in one early leukæmia. The injected fowls were isolated and great care was exercised during the experiment.

The following year, 1909, Ellermann and Bang,¹⁰ reported the transmission of the disease into the sixth generation, and also an additional positive Berkefeld filtrate series. Because the disease can be produced by a cell-free filtrate, they conclude: (a) Leukemia must be an infectious disease; (b) it is to be placed among the diseases due to a filterable virus. They call attention to the fact that mitoses in the blood are pathological and always present in leukæmia.

Schridde,¹¹ in 1909, was the first to question whether, in leukæmia, we are really dealing with an infectious etiology. Basing his conclusions upon experimental work, he claims that chickens, injected with extracts of entirely normal organs, present the same changes as Ellermann and Bang have reported for leukæmia. He thinks that their findings are not leukæmic and that, therefore, there is no proof in favor of the infectious etiology of this disease.

Hirschfeld and Jacoby¹² in 1909, report a spontaneous case of leukæmia showing changes in the blood and organs which, they claim, agree entirely with the description of Ellermann and Bang. In a second case, the blood picture, although not typical, appeared to them leukæmic. At autopsy this fowl showed a typical chicken tuberculosis. They succeeded in transmitting this tuberculosis, in association with the apparently leukæmic blood picture, into the fourth generation. They did not know whether they were dealing with a combination of tuberculosis and leukæmia in the same animal, or with pure tuberculosis. An animal injected with a pure culture of the chicken tubercle bacillus developed a blood picture identical with that of the second spontaneous case. Therefore it seems highly probable that this case may have been one of pure tuberculosis. At any rate, it cannot be accepted as a definite and pure case of leukæmia.

The following year (1910) the same authors¹³ report the injection of fowls subcutaneously from their first spontaneous case. They

obtained no takes and their strain died out. From a leukæmic animal given to them by Ellermann and Bang, they transmitted the disease into the fifth generation, obtaining both leukæmic and pseudoleukæmic cases. In the blood, they found normoblasts and megaloblasts, *i. e.* small and large, round, nucleated, mostly polychromatophilic red blood cells. Although they state that the disease begins in the bone-marrow, they leave it an open question whether in the chicken one is dealing with a myeloid or a lymphoid leukæmia.

Burckhardt,³⁵ in 1910, advanced the theory, based upon investigations of his own on transmissible chicken leukæmia, that a particular leukæmic virus does not exist, and that in the so-called chicken leukæmia one is very probably dealing with a very chronic chicken tuberculosis. As proof, he claims that with a pure culture from such an animal (leukæmic) and also with older pure cultures of chicken tubercle bacilli, one can produce the same blood picture described by Ellermann and Bang for chicken leukæmia. The anatomical findings, he states, likewise correspond. Gratz³⁶ suggested that possibly in the culture of chicken tubercle bacilli from the leukæmic animal, there may have been cultivated, in addition to the tubercle virus, also the virus of leukæmia. Friedberger³⁶ considered this objection invalid, because, as he claimed, one could produce the leukæmic blood picture also by using old laboratory tubercle cultures.

Burckhardt,³⁶ in 1912, still adheres to his theory, but admits that he is unable ever to bring the blood into a leukæmic condition by inoculating with tubercle bacilli.

Hirschfeld and Jacoby³⁷ in the same year inform us that they presented to Burckhardt and Friedberger the chicken with which these investigators started their transmissions, and that on the day of delivery it showed a pronounced leukæmic blood picture. The animal, in addition, surely had tuberculosis, because all the transmitted leukæmic animals of the stock from which this animal originated had tuberculosis. They feel confident that in Burckhardt and Friedberger's stock the tuberculosis had crowded out the leukæmia, until finally only tuberculous and not leukæmic animals were obtained. They had a similar experience with the stock from which Burckhardt and Friedberger's animal originated.

Against the existence of an etiological relationship between tuberculosis and leukæmia, they present the following arguments: (1) The blood picture in tuberculosis is never to be confused with that of

leukæmia. It is characterized by a hyperleucocytosis due to the polymorphs. (Ellermann and Bang¹⁰ had also stated this fact at an earlier date.) (2) The organs of the tuberculous chickens were entirely free from the changes which Ellermann and Bang, and they themselves, found to be characteristic of leukæmia and which correspond entirely with leukæmic lesions in man. (3) By injections of organic emulsions obtained from spontaneous tuberculous chickens, or of pure cultures of chicken tubercle bacilli, they uniformly produced a typical tuberculous blood picture and organic changes, always without any signs of leukæmia.

Ellermann^{18, 19} in 1913 and 1914, in answer to the question whether this chicken disease is really leukæmia, shows that it has all the symptoms of human leukæmia. He meets Schridde's objection by the argument that this investigator's claim was limited to the blood picture, and in the absence of the characteristic organic changes, of which he makes no mention, his experiments are of no importance. The injection of an organic emulsion Ellermann never found to cause any change in the blood, provided the material was not virulent. Ellermann and Bang had previously produced the disease with Berkefeld filtrates in three different experiments. In this paper Ellermann reports two more successful series. All other investigators have had only negative results. Thus, Hirschfeld and Jacoby¹⁷ were unsuccessful in two experiments and Burckhardt¹⁶ in one.

Ellermann is convinced that the filtrate experiments prove the theory of infection, for all the cells were surely removed. He feels that the fact that the virus passed through a rather thick-walled Berkefeld filter demonstrates that it is an invisible filtrate virus. He clearly shows that the leukæmic virus can be separated from the virus of tuberculosis by filtration and that, therefore, the two diseases are distinct. Starting with an emulsion of spleen taken from an animal, both leukæmic and tuberculous, in which tubercle bacilli had been demonstrated, he passed this through a porcelain (Reichel) filter and with the filtrate he produced leukæmia with complete absence of tuberculosis in all the inoculated animals.

Ellermann finally states that both the spontaneous and the transmitted leukæmia occur in two types; (a) myeloid, (b) lymphatic. In the first the blood is characterized by the presence of numerous myelocytes and transitional cells, occurring in association with a pronounced myelosis (large deposits of myelocytes) in the organs. In the

second, the blood is characterized by a predominance of small and large lymphocytes (90 per cent of the total number) occurring in association with a pronounced lymphomatosis (numerous infiltrations with lymphoid cells) of the organs. Of interest is the fact that a myeloid type may occur in one generation and a lymphatic in the next, or that both types may occur in the same generation. The occurrence of both types in the same stock suggests very strongly that both forms of leukæmia in man are due to one and the same infection.

II. STUDIES ON THE NORMAL FOWL.

With the hope of making the findings in the leukæmic animals more clear, the following brief data of the normal fowl are presented. These are limited to those portions of the body which are involved in leukæmia. They are compiled from a large number of chickens.

EXTERNAL APPEARANCE.

Healthy, young, adult Plymouth Rock hen. Comb, featherless area about eyes, and wattles bright red. Conjunctivæ and buccal mucous membrane pink. Skin of body white with a faint yellow tint. Well nourished, sides of sternum covered with a thick pad of tissue, ribs not palpable. Average rectal temperature, 42 ° C.

BLOOD.

The blood for counting and smears was obtained from the vein under the wing, which always appears to be well filled. From a small needle puncture the blood flows under pressure, is thick, dark red and clots quickly.

Blood-count.—The nuclei-containing red blood cells of the fowl make it practically impossible to count the white blood cells by the usual direct method. After laking the former, one cannot differentiate between the nuclei of the two types of cells. It was therefore necessary to resort to the indirect method, *i. e.*, to determine the proportion of white to red cells from a stained smear, count the total number of cells, both whites and reds, by the direct method, and then calculate the total number of each present.

The red blood cells vary somewhat: lowest limit, 2,500,000; highest, 4,500,000; average, 3,000,000-4,000,000 per c. mm. White blood cells:

the extreme limits are between 20,000 and 80,000 per c. mm. Proportion of whites to reds, lowest limit, 1/40; average, 1/50-1/150.

Hæmoglobin (Sahli).—This shows considerable variation, lowest limit, 45 per cent; highest, 75 per cent; average, 60-70 per cent.

Blood Smears.—Wilson's stain was found to give the best results, especially when applied immediately after the smears were made.

Classification of blood cells (Fig. 1).

Erythrocyte.

1. Normocyte (*a*): Elliptical disk. Nucleus, same shape as cell, deep blue, slightly picnotic. Cytoplasm yellow and glassy. (Both cell and nucleus uniform in size, shape and staining).

Blood Platelet (b).

Length of normocyte, width less than that of normocyte. Nucleus round, purple, chromatin diffuse, diameter equal to width of its cell. Cytoplasm pale gray with vacuoles about nucleus, frequently containing small circumscribed red structures. May vary in size and shape.

Leucocytes.

1. Polymorphonuclear leucocyte with eosinophilic rods (*c*): Round, diameter about length of normocyte. Nucleus has two or more lobes, pale blue, chromatin diffuse. Cytoplasm colorless with bright red, spindle-shaped rods.

2. Polymorphonuclear leucocyte with eosinophilic granules (*d*): About the same in shape and size. Nucleus has two or more lobes, purple, slightly picnotic. Cytoplasm faintly blue with dull red granules.

3. Lymphocyte (*e, e'*): Round, diameter about width of normocyte. Nucleus round, purple, chromatin diffuse. Cytoplasm small in amount, to one side of nucleus, pale blue. Same cell may be slightly larger. Thus a division into the small (*e*) and large (*e'*) lymphocyte may be made.

4. Large mononuclear cell (*f*): Round or oval, diameter about length of normocyte (at times, more or less). Nucleus round, oval or slightly irregular, and larger, otherwise similar to nucleus of lymphocyte. Cytoplasm abundant, completely surrounds nucleus, pale blue. (A suggestion of fine granules.)

5. Mast cell (*g*): About same size and shape. Nucleus round or oval, very pale blue. Cytoplasm abundant, colorless, mostly to one side of nucleus with purple granules, some scattered over nucleus.

Differential Count, 300 Cells.

	Per cent.
Polymorphonuclear with eosinophilic rods.....	29.6
Polymorphonuclear with eosinophilic granules.....	4.3
Lymphocyte	42.3
Large mononuclear cell.....	19.4
Mast cell	2.2
Unclassified cells.....	2.2
	<hr/> 100.0

AUTOPSY PROTOCOL.

The following findings would correspond to those in a fowl of the average size and weight (1760 gm.) of the animals injected.

Subcutaneous Fat Abundant (Fig. 4). Thick muscle pad covering the skeleton (Fig. 4). Inner surface of skin slightly yellow.

Cervical Lymph-glands * (Figs. 3, a and b). Sometimes difficult to find. Present as two chains, each consisting of six to ten glands, one on each side of neck, lying upon the internal jugular vein, buried in fat, and extending from the middle of neck to base of heart. They are delicate, elliptical, flat, lobulated bodies, averaging 1 x .5 x .2 cm. The parenchymatous lobules are pink and separated from each other by narrow septa of fat. No other lymph-glands were found in the entire body.

Thyroids and Parathyroids.—Two of each gland. The thyroid, a dark red, translucent, spindle-shaped body, 1 x .4 x .4 cm., with just visible colloid-filled acini, separated by delicate gray septa. The parathyroid is attached to its lower pole. This is a small bluish-white sphere, 2 mm. in diameter. Thus, in pairs, they are found, one pair on each side of the body, just above the heart.

Peritoneal Cavity (Fig. 4).—An omentum composed entirely of fat, 1 cm. in thickness, takes its origin from the anterior surface and lower margin of the gizzard, extending over coils of intestine, etc., holding

* Kon⁴ considers these structures the thymus. He⁴ and Ellermann^{18 19} state that the fowl has no lymph-glands. Soshestrenski⁵ asserts their existence by stating that in his case they were not enlarged.

them against the posterior peritoneal wall. It is fastened to the parietal peritoneum, laterally, and at the pubis. The lower margins of the right and left lobes of the liver extend down between the sternum and omentum to within 3 cm. of the tip of the xiphoid.

Liver (Fig. 4).—The first organ which presents itself on removing the sternum. Right lobe measures $7.5 \times 4.5 \times 2$ cm.; left lobe, $6.5 \times 5 \times 2$ cm. Total weight 50 gm. or 2.8 per cent of body weight. Uniformly reddish brown with smooth and glistening surface, soft and friable. Lobule about pin-head in size, center darker than periphery; usually distinct, at times difficult to see. The cut surface shows small blood-vessels on cross and longitudinal section. The lobulation is less readily seen.

Spleen (Fig. 6).—Lies just behind the liver. Measures $2 \times 1.5 \times 1$ cm., weighs 1 gm., or .05 per cent of body weight. It is small, soft, reddish brown. Beneath its smooth and glistening capsule, may be seen bluish white Malpighian bodies, slightly larger than pin-points, at times indistinct. On section, the capsule appears very delicate; trabeculae are few, but usually definite, containing gaping blood-vessels. Malpighian bodies at times are prominent. Pulp does not rise above edge of capsule.

Heart.—Lies within a delicate, transparent pericardium, containing a small amount of clear serum. Myocardium is uniformly reddish brown.

Lungs.—Bright red and of a characteristic construction, consisting of a mass of entwined air tubules with large lumina and spongy walls, separated from each other by a small amount of vascular connective tissue. On section, this construction becomes more pronounced. The wall of each air tubule projects as a pale ridge, separated from its neighbor by a red linear depression, in which blood-vessels are common.

Gastro-intestinal Tract, Pancreas and Adrenals.—These are of little interest except that beneath the serosa of the lower half of the intestine are frequently seen pearly nodules, less than a pin-head in size.

Mesentery.—A delicate, cobweb-like membrane with some fat, but no demonstrable lymph-glands.

Kidneys.—Measure $6.5 \times 1.7 \times 1$ cm., and weigh together 12 gm., or 7 per cent of body weight. They are uniformly reddish brown with a slightly nodular surface.

Bone-marrow.—Taken from long bones of upper and middle third of leg. It is very soft, semifluid, bright red, mottled with yellow, *i. e.*,

rich in red blood cells and fat. Lower part of middle third frequently consists of a solid, yellow column of fat. The marrow cavity may be almost occluded by bony septa.

MICROSCOPICAL EXAMINATION.

Cervical Lymph-gland.—Section shows lobules of parenchyma, separated by fatty tissue. Each lobule is surrounded by a delicate fibrous capsule and contains a very fine reticulum, in which the lymphocyte is diffusely scattered. This is a small, round cell with a round, deeply staining, picnotic nucleus, usually incompletely surrounded by a narrow rim of pink cytoplasm. Sometimes red blood cells are associated with the lymphocyte, but mostly they are confined to and form the sole occupants of the numerous capillaries. They appear as elongated, yellowish-pink cells, with a solid black rod or dot for nucleus, according to whether this is seen in longitudinal or cross section. Scattered through the lobule are small, sharply outlined, hyaline structures, which Kon^{*} considered as corresponding to Hassall's corpuscles of the thymus.

Thyroid.—Consists of polyhedral acini, which vary in size, are lined with cubical epithelium and filled with granular colloid. They are separated from each other by a small amount of fibrous tissue, rich in blood capillaries. Sometimes accumulations of lymphocytes may be seen near the larger vessels.

Parathyroid.—Within its capsule is seen a prominent reticulum filled with closely packed cells, whose nucleus is round or oval, semivascular and larger than that of the lymphocyte.

Liver.—The lobule is difficult to limit. Periportal spaces are not easy to find. They consist of one or several arteries, a vein, one or several gall-ducts, and very little or practically no fibrous tissue, usually free from infiltrated cells, although lymphocytes may be present diffusely or in small follicles. The liver cells are arranged in trabeculæ, separated by capillaries. All blood-vessels and capillaries are filled exclusively with red blood cells.

Spleen.—The Malpighian bodies are indistinct, numerous, closely packed, composed of masses of lymphocytes surrounding very small arteries. Red blood cells are limited to the pulp, where they occur more or less in clusters, although one is unable to demonstrate sinuses or inclosures of any kind. The lymphocytes are also diffusely scattered throughout the pulp. Veins tend to be rich in lymphocytes and poor in red blood cells; the artery shows the opposite picture.

Lung.—Presents a characteristic structure, entirely different from that in the human lung. The tubules mentioned in the macroscopical description are seen in cross, oblique, or longitudinal section, forming large polyhedral units with wide walls composed of capillaries. The intercapillary air spaces communicate with each other and with a large central lumen. The latter is lined with a narrow band of smooth muscles surmounted by endothelium, frequently cuboidal. The inter-tubular fibrous tissue is small in amount, and contains large blood-vessels, whose branches extend into the capillary bed. These structures are closely packed with red blood cells. Only occasionally does one see a lymphocyte. The bronchi resemble those of the human lung. Follicles of lymphoid cells are frequently found in the submucosa or outside of the bronchi near arteries.

Bone-marrow.—A low-power picture is very similar to human resting marrow, *i. e.*, one sees a framework of fatty tissue inclosing nests of marrow cells. Arteries are filled solely with red blood cells. Venous spaces are difficult to determine..

Classification of Marrow Cells.—Very thin paraffin sections were stained with hæmatoxylin and eosin and studied under the oil-immersion lens. The same cells appear slightly different under these conditions than when seen in the Wilson smears of normal and leukæmic blood.

Erythrocytes.

1. Normocyte (*a*): Elongated, varying in shape, due to pressure. Nucleus a solid, black rod or dot (longitudinal or cross section). Cytoplasm yellowish-pink and glassy.

2. Normoblast (*b*): Round, diameter about width of normocyte. Nucleus round, uniformly black. Cytoplasm pink or faintly blue, and glassy. Frequently a narrow clear zone is seen about the nucleus.

3. Megaloblast (*b*): Same, larger, about length of a normocyte. Nucleus slightly picnotic.

Leucocytes.

1. Polymorphonuclear myelocyte with eosinophilic rods* (*c*): Round, Nucleus, two or more solid black lobes. Cytoplasm colorless with bright red, spindle-shaped rods.

* These are obviously the polymorphonuclear with eosinophilic rods, the polymorphonuclear with eosinophilic granules and the large mononuclear cell of the normal blood.

2. Polymorphonuclear myelocyte with eosinophilic granules * (b): Round, about same size. Nucleus has two or more slightly vesicular lobes. Cytoplasm colorless with bright red granules.

3. Mononuclear myelocyte with eosinophilic granules (a): Round, or oval, varying in size, mostly larger than 1 and 2. Nucleus round, oval, or horseshoe-shaped, eccentric, slightly or very vesicular. Cytoplasm colorless with bright red granules.

4. Large mononuclear myelocyte * (d): Round, slightly larger. Nucleus round, very vesicular, one or more nucleoli. Cytoplasm basophilic, moderate in amount.

Reticular Cell.—Branched. Nucleus elongated, vesicular, several nucleoli. Cytoplasm pink, giving off delicate fibers to form reticulum.

Lymphocytes, mast cells, platelets, mitoses of red and white cells were not seen. Letters in () = order of predominance.

Heart, Pancreas and Kidney: For all practical purposes similar to the human.

III. A CASE OF SPONTANEOUS LEUKÆMIA.

On October 31, 1912, a typical case of leukæmia of the fowl was brought to the pathological laboratory. The animal, a Plymouth Rock hen, had just been killed, and its body was still warm. Nothing is known of its clinical history. An abstract of the findings is here given.

BLOOD.

The study of the blood was limited to smears taken from the heart just after the animal had been received at the laboratory. They were stained by Wilson's method. A detailed description of the cells of leukæmic blood will be reserved for the experimental leukæmia where far better opportunities for careful study of the same were offered. Suffice it here simply to enumerate and briefly comment upon those cells which were present.

Blood Smears. There was an enormous increase in the white blood cells, the proportion of whites to reds being 1:1.3. The predominating cells were the large mononuclear and the mononuclear myelocyte with eosinophilic granules. The latter is abnormal to the blood,

* These are obviously the polymorphonuclear with eosinophilic rods, the polymorphonuclear with eosinophilic granules and the large mononuclear cell of the normal blood.

normal to the bone-marrow, and when extramedullary is typical of leukæmia. Lymphocytes and polymorphs were strikingly decreased. Of the latter those with red granules and the mast cell were rare. Mitoses of the large mononuclear were common. The red blood cells appeared to be poor in hæmoglobin and showed anisocytosis, poikilocytosis and polychromatophilia. These cytoplasmatic changes were usually associated with an increase in the size of the nucleus. Premature red blood cells, normoblasts and megaloblasts were present in large numbers.

Differential Count, 300 Cells.

	Per cent.
Polymorphonuclear with eosinophilic rods.....	8
Polymorphonuclear with eosinophilic granules.....	0
Lymphocyte	2
Large mononuclear cell.....	30
Mast cell	0
Monuclear myelocyte with eosinophilic granules.....	52
Unclassified cells.....	8
	<hr/>
	100

AUTOPSY PROTOCOL.

The animal was of medium size; the weight was not taken.

External Appearance.—Comb, featherless area about eyes, and wattles of an ash color. Buccal mucous membrane and conjunctivæ, very pale. Anterior chamber of left eye filled with an old blood-clot. Right eye normal. A moderately firm slightly nodular tumor, 3.7 x 2 x 1.5 cm., occupied the triangular space on the left side of head between the angle of the mouth, ear and angle of the lower jaw, extending below the ramus of the latter. Subcutaneous fat was practically absent. Emaciation was extreme and there was marked muscular atrophy. A second, slightly smaller tumor, 1.7 x 1 x 1 cm., was found just inside the ramus and below the orbit, apparently communicating over the ramus with the first growth and continuous below with a slightly larger, third mass.*

Cervical Lymph-glands.—Somewhat enlarged. Lobulation indistinct.

* A more detailed description and study of these tumors will be reserved for a future communication.

Peritoneal Cavity.—Omental fat entirely absent. Lower margins of right and left lobes of liver extended almost to the pubes, *i. e.*, far below xiphoid.

Liver.—Enormous. Dimensions and weight not taken. Its surface was extremely mottled. It was reddish brown and specked with innumerable gray or slightly yellow spots from a pin-point to a few millimeters in diameter, frequently closely packed to form irregular areas, the largest 1 cm. in diameter. In addition there were scattered gray or slightly yellow nodules, averaging about 2 mm. in diameter. Sectioned surface similar in appearance. The blood-vessels were surrounded by a gray zone.

Spleen.—Enormous. Dimensions and weight not taken. It was about the size of a small hen's egg. Diffusely gray.

Heart.—At the apex there were several gray spots, pin-point in size.

Kidneys.—Greatly enlarged. Both showed nodules, similar to those in liver.

Bone-marrow.—Abundant, gray, with absence of fat.

Thyroids, Parathyroids, Lungs, Gastro-intestinal Tract, Pancreas and Adrenals.—Apparently uninvolved.

MICROSCOPICAL EXAMINATION.

Cervical Lymph-glands.—The normal structure was somewhat changed. There was complete disappearance of the interlobular fat with approximation of the greatly swollen parenchymatous lobules. Here and there were intra- and inter-lobular foci of myeloid tissue. These frequently enclosed an artery or vein. There was also a more diffuse infiltration of the parenchyma by myeloid cells, filling capillaries, veins, arteries and in places breaking through the lobular capsule into the interlobular tissue. Of the infiltrating cells two predominated: (1) A large mononuclear, usually round, at times slightly polygonal due to pressure, with a single, round, oval, or indented, vesicular, at times multiple, nucleus with one or more nucleoli. Its cytoplasm was non-granular and slightly basophilic. (2) The mononuclear myelocyte with eosinophilic granules, described under normal bone-marrow. Mitoses of these two cells were quite common. Normoblasts and megaloblasts appeared to be present.

Liver.—Here the process was most extreme. Very little liver tissue remained. Everywhere were closely packed masses of myeloid cells from which the liver trabeculæ had completely disappeared. These

masses of cells surrounded blood-vessels, both arteries and veins, infiltrating the walls of the latter and filling the lumina of both. Within the vessels the white blood cells were present in about equal proportion with the red blood cells. Between these more focal accumulations the myeloid cells had infiltrated in a more diffuse manner between the liver columns, spreading them apart. It was usually difficult to demonstrate the capillary wall. Hepatic cells in these locations did not suffer so much. Some of the above-mentioned, circumscribed infiltrations showed a coarse sclerosis. The same infiltrating cells were present as in the cervical lymph-glands, with a prevalence of the large mononuclear, which was very rich in mitoses, and the mononuclear myelocyte with eosinophilic granules. The two types of polymorphonuclear cells and the premature red blood cells were present in fewer numbers.

Spleen.—Pulp diffusely infiltrated with closely packed leukæmic cells, which crowded the reticulum, distended the blood-vessels and separated and compressed the Malpighian bodies. The mononuclear myelocyte with eosinophilic granules, although present, was scarce. The large mononuclear, frequently showing mitoses, was the common cell.

Heart.—The intramuscular capillaries, were moderately distended with the large mononuclears and red blood cells, present in about equal proportion. The former had also infiltrated between the muscle fibers. The mononuclear myelocyte with eosinophilic granules was only occasionally seen, both within and without the blood-vessels.

Lungs.—The intertubular blood-vessels, their branches which extend into the capillary bed, and also the capillaries, were distended with leukæmic blood, in which the large mononuclear seemed to exceed the red blood cell. Mitoses were common. Infiltration of the tissue was limited to two foci of myeloid cells. The one was composed principally of the mononuclear myelocyte with eosinophilic granules and the large mononuclear. Mitoses, especially of the first cell, were seen. Both types of polymorphs were also present. The other focus was composed exclusively of premature red blood cells, normoblasts and megaloblasts showing mitoses.

Kidneys.—All the blood-vessels, from the largest to the capillaries of the glomerular tuft, were distended with the characteristic leukæmic blood. Throughout the section there was a diffuse infiltration of myeloid cells, especially between the convoluted tubules. Here and there were foci, in some of which the mononuclear myelocyte with

eosinophilic granules predominated, frequently showing mitoses; others seemed to be composed exclusively of the large mononuclear. Here mitoses were also common. In these foci the convoluted tubules had either been pushed aside or had atrophied.

Bone-marrow.—This was greatly changed. It consisted of a closely packed mass of white marrow cells, with complete atrophy of the fat and great rarity of normocytes. One or two small focal areas of sclerosis were present. The arteries were mostly empty. Some showed a little blood containing a few large mononuclears. Those marrow cells, which were present, both red and white, answered to their descriptions given under normal bone-marrow, with the exception of the large mononuclear myelocyte, which showed considerable variation in its nucleus. This was either single or multiple, round, oval, or horseshoe-shaped. The order of predominance had changed greatly. The large mononuclear myelocyte was present in far greater numbers than any other cell, and showed extensive mitoses. The normoblast and megaloblast with mitoses followed next in frequency; then the normocyte. Polymorphonuclear myelocytes, those with eosinophilic rods and those with eosinophilic granules, had disappeared entirely. Curious is the fact that the mononuclear myelocyte with eosinophilic granules could not be demonstrated with certainty. As in the normal marrow lymphocytes, mast cells and platelets were not seen.

Thyroids, Parathyroids, Pancreas and Adrenals.—These were not studied.

SUMMARY.

In summarizing the changes in the blood and organs, there was found:

1. *In the Blood.*—(a) A great increase in the total number of white blood cells. Although a total count was not made, this increase was evident from the appearance of the blood smears, and of the blood-vessels in sections. The actual proportion of white to red cells substantiated this fact. The differential count showed a marked increase of the large mononuclear cell at the expense of the other white blood cells of the normal blood. In addition, a true myelocyte appeared in the circulation. Mitoses of the large mononuclear were common. (b) A corresponding decrease in the total number of red blood cells. These showed a drop in hæmoglobin, variation in size and shape, basophilic staining of the cytoplasm, and swelling of their nuclei. Premature red cells, normoblasts and megaloblasts made their appearance.

2. *In the Organs.*—(a) A diffuse and circumscribed, at times nodular, infiltration of myeloid cells, in which the large mononuclear, and mononuclear myelocyte with eosinophilic granules predominated, although the other cells of the normal bone-marrow were at times present. This myelosis involved especially the liver, spleen, kidneys and bone-marrow, resulting in an extreme enlargement of the first three organs. Almost all of the remaining organs showed infiltrations, but to a less degree. (b) A change in the contents of the blood-vessels. The proportion of white to red cells was greatly increased. The predominating cells were the same as those of the infiltration.

CONCLUSION.

In conclusion, if we consider that the cells, characteristic of both leukæmic infiltrate and blood, were the same, and that under normal conditions the mononuclear myelocyte with eosinophilic granules occurs only in the bone-marrow and the large mononuclear only in the marrow and blood, it is evident from the summarized facts, that the above case must be considered a typical case of *myeloid leukæmia*.

IV. EXPERIMENTAL LEUKÆMIA.

With material from the above case, the disease was successfully transmitted into the fifth generation. A total of 105 animals were used in conducting many different kinds of experiments. Of this number, 22 in all have developed leukæmia. In four additional animals, a definite diagnosis could not be established, although the appearances were highly suggestive. The strain has now been running for more than 13 months.

This paper will be confined to a report of those series which deal with simple transmission of the disease by the injection of an organic emulsion.

Five of these series were conducted, each consisting of 5, 10 or 15 fowls. The percentage of positives per series varied from 20-40 per cent. Of the total number of 40 chickens injected, 13 became leukæmic, *i. e.* 32.5 per cent. In addition, a definite diagnosis could not be made in three, although the findings were very suggestive.

PREPARATION OF MATERIAL, METHODS OF INJECTION, ETC.

The material used for transmission was an emulsion of liver, and sometimes of spleen also. It was prepared by thoroughly macerating

pieces of the organ in a mortar, after the addition of .9 per cent normal salt solution. This was filtered through a single layer of fine linen or a small amount of raw cotton, thus removing the fibrous tissue sufficiently for intraperitoneal injection, although, when it was used intravenously, instant death frequently resulted. Hence it was found best to filter also through two layers of filter paper with the aid of a suction pump. This filtrate was found to be absolutely fiber-free, but still contained blood and parenchymatous cells. A 15 per cent emulsion gave the best results. The entire preceding process, as well as the following steps, were carried out aseptically.

The fowls were injected either intravenously or intraperitoneally with 10 cc. Both methods were sometimes combined, when a total of 20 cc. was administered. The vein selected for injection was the large one under the wing.

Animals used for transmission were young, adult hens of the same breed as the spontaneous case, and exemplified by the normal control.

CLINICAL HISTORY.

Incubation Period.—This is usually from five to six weeks. In rare cases, it may reach a maximum of 16 weeks.

Signs and Symptoms.—The onset is usually rather abrupt, preceded by no definite premonitory symptoms. The animal, which has previously appeared entirely normal, begins to show a slight but progressive, at times a sudden and intense, pallor of its comb, the featherless area about the eyes and the wattles. This is almost invariably associated with jaundice, which is likewise progressive and usually reaches an extreme grade. The combination of intense pallor and jaundice results in a characteristic, yellowish-pink color, which gives the fowl a ghastly appearance. The comb may be surprisingly red or extremely pale without jaundice. The animal emaciates rapidly and to an extreme degree. The actual loss in weight during the disease is striking and best illustrated by the following figures. No. 28, on the day of the onset of the disease, weighed 1484.5 gm. The duration of the disease was three weeks, four days. At death the weight was 897 gm. Therefore, there was a loss of 587.5 gm. in 25 days, or at rate of 23.5 gm. per day.

At first the bird acts entirely normally, or it may appear slightly ill. In a few days, however, it acts as if it were very sick, stops eating and drinking, and stands about with head retracted, eyes closed and tail drooping. It prefers to assume a squatting position. If made to move

it does so very slowly and carefully. Weakness becomes more and more marked, until on the last day it lies prostrated, with its head on the floor, wings drooping, eyes closed and at times is dyspnoëic.

Fever has never been observed.

Duration of the Disease.—This is most frequently from one to two weeks. One case exceptionally acute lasted only 33 hours. Two cases, three days. The longest course was four weeks, four days.

Prognosis.—Having once begun, the disease progresses steadily to a fatal issue. Only in one case out of 23 leukæmic animals did a spontaneous cure result.

BLOOD.

In Gross.—With the onset of anæmia, the vein under the wing collapses and the blood undergoes a change. It soon flows with the greatest ease and rapidity, resembles pale yellow water and shows no tendency to clot. The animal apparently would bleed to death from a pin-point wound, if the hæmorrhage were not artificially arrested.

Blood-count.—In most cases there is a progressive and extreme decrease in the total number of red blood cells. At onset the count may be but slightly below normal, 2,224,000, while just before death it, at times, reaches 630,000. More commonly, the lowest point ranges between 1,112,000 and 1,408,000 per c. mm. In one case, the count remained normal.

The count of white cells is invariably high, between 131,200 and 210,000 per c. mm.

Ratio of W/R = $1/3 - 1/9$.

Hæmoglobin.—This usually falls steadily and reaches a very low point. From slightly below normal, 40-50 per cent at onset, it frequently drops to 10-15 per cent just before death. In several cases it fell only to 23 per cent. In one case there was no change at all.

Blood Smears.—The morphology of the leukæmic blood is exceptionally interesting. In addition to the enormous increase in the number of white cells, all of the cellular elements show marked changes and many new forms make their appearance. Smears were stained by Wilson's method.

Classification of blood cells (Fig. 2).

Erythrocytes.

1. Normocyte: (a) Normal (a), except for variation in the amount of hemoglobin. (b) Showing anisocytosis, poikilocytosis and

polychromatophilia, mostly associated with a swelling of the nucleus and separation of its chromatin (*b*).

2. Normoblast (*c*): Round, diameter less than length of normal normocyte. Nucleus round, of same color or slightly purple, but larger and with more scattered chromatin than nucleus of normal normocyte. Cytoplasm greenish-blue and glassy. Frequently with clear zone about nucleus.

3. Megaloblast (*d*): Same, except diameter equal to or greater than length of normal normocyte.

4. Mitotic Cells (*e*): All stages, from monaster to complete division of nucleus. (a) Round or elliptical, diameter about length of normal normocyte. Dense, deep blue chromosomes, massed in center of cell. Cytoplasm greenish-blue and glassy. (b) Same, with two masses of chromosomes in opposite extremes of cell. (c) Same (at times with a slight constriction in the middle of the cell) with irregular, dense, deep blue or slightly purple chromatin masses in place of individual chromosomes. (d) Same, with two nuclei, similar in appearance to those of normoblast. (e) Same as normal normocyte with two nuclei, similar in appearance to those of normoblast, but only slightly larger than nucleus of normal normocyte. (a), (b), (c) and (d) may show polychromatic cytoplasm.

Blood Platelets (f).

1. Same as normal, except that cell and nucleus are both larger.
2. Larger than normal with two nuclei.

Leucocytes.

1. Polymorphonuclear leucocyte with eosinophilic rods (*g*): Same as in normal blood, at times possibly a little smaller.

2. Polymorphonuclear leucocyte with eosinophilic granules (*h*): Same as in normal blood, at times possibly a little smaller.

3. Lymphocyte (*i*): Same as in normal blood.

4. Large mononuclear cell: (a) As described in normal blood, with a little less cytoplasm. (b) Same size to one half times larger than (a), with both nucleus and cytoplasm paler (*j*). (a) and (b) cannot be separated absolutely. Every gradation. (c) Mitoses (*k*): All stages, from monaster to complete separation of nucleus. (a') Elliptical, diameter about one and a half length of normal normocyte. Dense, purple chromosomes centrally massed. Cytoplasm pale bluish-gray,

granular. (b') Same, with two masses of chromosomes in opposite extremes of the cell. (c') Same, with two purple nuclei. (d') Same, with three purple nuclei.

5. Mast Cell (*l*): As described in normal blood.

6. Mononuclear myelocyte with eosinophilic granules (*m*): Round or slightly elliptical, diameter about length of normal normocyte or longer. Nucleus, oval, pale blue with dense chromatin, eccentric. Cytoplasm colorless with small and large, bright red granules, some scattered over granules.

Cytoplasmatic Masses without Nuclei (*n*): Round or slightly oval; diameter varies, usually about width of normal normocyte. No nucleus. Cytoplasm grayish-blue, sometimes with vacuoles.

This, then, is the blood picture common to all the leukæmic cases. The order of predominance of the white cells is typical of leukæmia, differing from the normal, but agreeing with that of the spontaneous case. The large mononuclear is present, by far, in greatest numbers. The other cells of the normal blood are decreased. The polymorphonuclear with eosinophilic granules and the mast cell are very scarce. The mononuclear myelocyte with eosinophilic granules, although not as common as in the spontaneous case, can usually be demonstrated in every leukæmic animal.

The platelets are greatly increased in number.

Differential Count, 300 Cells.

	Per cent.
Polymorphonuclear with eosinophilic rods.....	6
Polymorphonuclear with eosinophilic granules.....	0
Lymphocyte	4
Large mononuclear cell.....	86
Mast cell	1
Mononuclear myelocyte with eosinophilic granules...	1
Unclassified cells	2
	<hr/>
	100

AUTOPSY FINDINGS.

The weight of the animal in every case was far below its weight before injection.* Two lowest weights, at autopsy, were 675 and 897 gm.

External Appearance.—The jaundice was found at times to involve the skin of the entire body.† The conjunctivæ and buccal mucous mem-

* Animals which remained negative invariably gained in weight.

† Probably this was more frequent but not recognized, except when very grave, because of the normal yellow tint of the skin.

branes were always very pale. The eyes, nose and mouth were never involved. There was extreme emaciation, and great scarcity or entire absence of subcutaneous fat. Muscular atrophy was usually marked, at times practically only the skeleton remained (Fig. 5).

Cervical Lymph-glands.—Macroscopically, these were usually uninvolved. In two cases they were definitely enlarged (Fig. 3, a and b), in the one very much so, measuring 1.5 x 8 x 4 cm. and 2 x 1 x .5 cm., respectively. They appeared uniformly gray. The lobules of the parenchyma were enlarged and the interlobular fat had disappeared. In a third case, they were of normal size and appearance, but showed several gray nodules, 1 mm. in diameter. Microscopically, those glands which appeared normal in gross were usually free from myeloid infiltration, although their blood-vessels contained leukæmic blood. The diffusely enlarged glands showed a marked swelling of their parenchyma, with complete atrophy of the interlobular fat. Myeloid cells, both the large mononuclear and the mononuclear myelocyte with eosinophilic granules, were scattered through the lobules. Foci, some composed entirely of the first, and others exclusively of the second, were localized principally in the interlobular connective tissue. They were rich in mitotic figures. The gray nodules seen in gross proved to be masses of proliferating myeloid cells. All the blood-vessels were filled with the characteristic blood.

Thyroids and Parathyroids.—These were grossly and microscopically uninvolved, with the exception of the blood-vessels, which were filled with leukæmic blood.

Peritoneal Cavity.—In every case the omental fat was greatly decreased. At best, it was present only in moderate amount. As a rule it was replaced by a thin yellow membrane. Ascites occurred in six out of 13 cases, at times in sufficient quantity to distend the abdomen. It was always associated with a sero-fibrinous mass, which covered not only the liver and most of the other abdominal viscera, but also spread over the outer surface of the pericardium.

With enlargement of the liver, the lower margins of its two lobes change their position in relation to the tip of the xiphoid. They descend to this landmark and frequently extend far beyond. With the exception of Nos. 31 and 70, every animal of the 13 had an enlarged liver (Table 1). The margins of the right and left lobes of the smallest of the enlarged livers were, respectively, 1 and 3 cm. above the xiphoid, while the margins of the largest liver extended 3.5 and 3 cm., respectively,

below it. In fact, the latter organ *in situ* (Fig. 5) was so enormous that it filled the entire peritoneal cavity and was the only viscus visible on entering the abdomen.

Liver.—As mentioned, the liver was greatly enlarged in 11 cases (Table 1), frequently enormous (Fig. 5). In the smallest of these the right lobe measured 9 x 4.5 x 3.8 cm.; the left lobe, 7 x 5 x 3.8 cm.; in the largest, right lobe 13.5 x 4.5 x 4 cm.; left lobe 12.5 x 4 x 3.5 cm. On comparing them with the normal, these dimensions are not very convincing, with the exception of the length of the lobes. As the organ enlarges, it becomes distorted, because the limited cross-diameter of the peritoneal cavity prevents its expansion in this direction and forces the lobes to follow the costal framework, posteriorly. The long diameters of the lobes are more reliable, because the organ can enlarge freely in this direction.

The weight of the liver is a more accurate indication of its size, especially when expressed in per cent of body weight, *i. e.*, the number of grams of weight of organ per 100 gm. of weight of the animal at death. Thus, the weights were found to range from 80-265 gm, *i. e.*, they were over five times the normal or 6.2-10.3 per cent of body-weight, an increase of 3.6+ times the normal (Table 1).

The external appearance of the liver may not differ much from the normal, but usually it is very characteristic (Fig. 5). It may appear diffusely gray, due to very closely packed subcapsular spots, pin-point to 2 mm. in diameter. These are usually more scattered and translucent, at times slightly yellow and opaque. They may fuse to form larger areas with a diameter of 0.5-1 cm., or they may be arranged in a delicate gray network. In addition, numerous gray or slightly yellow nodules, ranging from 2-0.5 cm. in diameter are often present. The whole gives the surface an extremely mottled appearance. Lobulation at times is visible, usually indistinct. The liver may be slightly firm or friable. The sectioned surface appears very similar to the external surface. Dots and lines often form gray borders along the blood-vessels. The latter also occupy the centers of some of the larger, circumscribed, gray areas. The perivascular connective tissue in rare instances is bile-stained. Microscopically, there is usually a diffuse infiltration of myeloid cells. They are closely packed within and without the intralobular capillaries. The liver trabeculae show fatty degeneration and atrophy. The large mononuclear, rich in mitotic figures, is by far the predominating cell.

The mononuclear myelocyte with eosinophilic granules is very scarce. Scattered through the section are also foci of large mononuclears, or of mononuclear myelocytes with eosinophilic granules. Some contain both types of cells. They abound in mitotic figures. The liver cells in these foci have entirely disappeared. The small, gray nodules consist of circumscribed masses of myeloid tissue, usually occupying the periportal spaces and composed of a central portion of large mononuclears surrounded by the mononuclear myelocyte with eosinophilic granules. In the blood-vessels and capillaries, the large mononuclear, at times, seems to greatly exceed the red blood cell in numbers.

Spleen.—Except in Nos. 31 and 70, the spleen in every case was enlarged (Table 1); usually very much (Fig. 6). The dimensions, in contrast to those of the liver, are of definite comparative value. The smallest of the enlarged organs measured $3 \times 2 \times 1.7$ cm., the largest $4 \times 3 \times 2.3$ cm., the latter being just twice the normal in every dimension.

The weights were strikingly increased. The lowest was 6 gm., the highest, 18 gm., *i. e.* 18 times the normal, or .6-1.6 per cent of the body weight, *i. e.*, 32 times the normal.

The surface of the spleen may look normal, be reddish brown and show beneath its capsule pin-point, gray Malpighian bodies. More frequently one sees scattered, gray or slightly yellow spots and nodules (Fig. 6), the first from 1-3 mm., and the largest of the second from 0.5-1 cm. in diameter. Again, the organ appears just diffusely gray. A section (Fig. 6) appears usually the same as the surface. When diffusely gray, the pulp is somewhat granular and bulges. Microscopically, the entire pulp may be diffusely infiltrated with the large mononuclear cell, separating and compressing the Malpighian bodies. In addition, circumscribed, closely packed masses of pure large mononuclears or mononuclear myelocytes with eosinophilic granules are scattered through the section. Again, the myelosis may be present only in foci, with practically no disturbance of the normal splenic structure. Mitoses are abundant wherever the large mononuclear occurs. The contents of the blood-vessels are the same as in the liver.

Heart.—As mentioned above, the external surface of the pericardium is frequently covered with a serofibrinous mass. The heart itself may be somewhat enlarged, otherwise it appears normal (Fig. 5). Microscopically also there is little to be seen besides a great excess of the large

mononuclear in the intramuscular capillaries, with an occasional small extravascular focus of infiltration, consisting of the same cell.

Lungs.—These are seldom involved. In two cases they were œdematous. In one, the tubular walls were wide and gray, occluding the lumina. On section, the latter case presented a similar but more marked picture. Microscopically the intertubular blood-vessels, their branches which extend into the capillary bed, and the capillaries themselves, are always filled with leukæmic blood. At times they are greatly distended. The white cells are always increased in number, and sometimes the blood seems to consist solely of closely packed, large mononuclears. Mitoses are everywhere abundant. Very rarely, a few mononuclear myelocytes with eosinophilic granules or large mononuclears are gathered in small masses in the intertubular connective tissue.

Gastro-intestinal Tract, Pancreas and Adrenals.—These in gross showed nothing of interest. No mesenteric lymph-glands were demonstrated. The pancreas, microscopically in no case showed any infiltration of its parenchyma proper, but in several there were numerous nests of myeloid cells in the interlobar fat tissue, usually surrounding one or more capillaries, and composed of the large mononuclear, eosinophilic myelocytes, both mononuclear and polymorphonuclear. Mitoses of both the mononuclears were frequent. The blood-vessels in the parenchyma and fatty tissue contained, as usual, the predominating large mononuclear.

The adrenals also reveal interesting findings histologically. It is quite common for the intertrabecular capillaries to be enormously distended with the characteristic leukæmic blood and for the myeloid cells to have infiltrated between the capillary wall and parenchymatous cells. These nests contain mostly the large mononuclear, but now and again they seem to be very rich in lymphocytes. The parenchyma has suffered greatly; its nuclei stain poorly and frequently its cells show disintegration.

Kidneys.—Of the 13 cases, the kidneys of five were enlarged. The smallest measured 7 x 1.5 x 1.2 cm., the largest 7.2 x 2.2 x 1.4 cm. The weight of both kidneys ranged from 12-26 gm., or 0.8-1.4 per cent of the body-weight. In one case the kidneys were extremely œdematous and weighed 32 gm. or 2 per cent of the body-weight.

The surface and section of the kidney may appear entirely normal, but usually one can see, below its capsule, scattered, gray pin-point dots,

delicate lines, or even one or two nodules, the largest 0.5 cm. in diameter. Again, they may appear diffusely gray. In the one case, they were large, succulent and translucent, due to œdema. Microscopically, the kidneys always show more or less distension of their blood-vessels and inter-tubular capillaries with the characteristic leukæmic blood, in which white blood cells, at times, seem even to exceed the normocytes, and in which the large mononuclear predominates. When capillary distension is moderate, the tubules appear normal; but at times they are so enormously over-filled as to cause extreme atrophy and degeneration of the tubular epithelium, resulting frequently in circumscribed areas devoid of any parenchyma. These areas tend to form a kind of zone about the larger blood-vessels. The glomeruli are surprisingly free. The walls and perivascular tissue of some of the vessels are infiltrated with actively generating myeloid cells, especially the large mononuclear.

Bone-marrow.—This is always involved, usually more or less characteristically, being increased in amount, moderately soft and red, mottled with countless gray dots to slightly larger areas, or it may be diffusely gray. In either case the fat is absent entirely and red blood cells are very scarce. The marrow may be involved as a whole or only in part. Now and again it has been converted into a uniformly gray, dry and slightly firm column, which bulges from the marrow cavity. In such cases it is obviously very rich in white cells, poor in red cells and fat. Microscopically, the normal structure of the marrow is greatly changed. The fatty tissue has completely disappeared and the marrow cells are closely packed in a solid mass, in which the normocyte is rather inconspicuous. The arteries in the center of the marrow are poor in blood. One or two contain a few normocytes and large mononuclears. The description of the red and white cells, which are present agrees with that given under normal marrow. Possibly the large mononuclear is more commonly polygonal, due to pressure. Mitoses of both the large mononuclear and the erythrocytes are common especially the first. The order of predominance has changed from the normal. The large mononuclear myelocyte is present by far in greatest numbers; the normoblast, megaloblast and mononuclear myelocyte with eosinophilic granules follow in about equal numbers; the normocyte comes last. Both types of polymorphonuclear cells, as well as the lymphocyte, mast cells and platelets were not seen at all. Mitoses of the mononuclear myelocyte with eosinophilic granules were not demonstrated.

TABLE 1.—EXPERIMENTAL LEUKÆMIA.

WEIGHTS, IN GRAMS OF BODY, ORGANS AND RELATION OF ORGANS TO BODY AT AUTOPSY.

Animal No.	Body.	Liver.	Liver to body %.	Spleen.	Spleen to body %.	Kidneys.	Kidneys to body %.
Normal	1760	50	2.8	1	0.05	12	0.7
1	1515	117	7.7	11	0.7	20	1.3
6	1200	124	10.3	15	1.2	10	0.8
12 ¹	95	15
14	1573	125	7.9	18	1.1	32 ²	2.0
15	1660	116	6.9	10	0.6	20	1.2
24 ³
28	897	85	9.6	6	0.7
30	1410	107	7.6	17	0.6
31	675	20	2.9	3	.4	5	0.7
53	265	12
57	1070	91	8.5	18	1.6	15	1.4
70 ⁴	65	4	26
103	1282	80	6.2	8	0.6	12	0.9

¹ Not weighed.² Very œdematous.³ Whole animal kept as a museum specimen. Illustrated, Fig. 5.⁴ Spontaneously cured. Not leukæmic at death.

SUMMARY.

In summarizing the essential points deduced by the simple transmission of leukæmia by the injection of an organic emulsion, we shall consider:

1. *Clinical History*.—After an incubation period, usually from five to six weeks, the fowl suddenly becomes pale, jaundiced, emaciates rapidly, loses weight and shows signs of extreme weakness, followed almost without exception by death in one to two weeks.

2. *Blood*.—(a) The total number of white blood cells is greatly increased, resulting in a proportion of one white to three red blood cells. The differential count shows a marked increase and predominance of the large mononuclear over the other white cells of the normal blood, which have decreased. The mononuclear myelocyte with eosinophilic granules is present in more or less numbers in practically every case. Besides the normal-appearing large mononuclear, one sees many larger, pale forms. In these cells, mitoses, in all stages, typical and atypical, are common. (b) The total number of red blood cells is correspondingly decreased, with a marked fall in the hæmoglobin. They present

variations in size, shape and staining, associated with swelling of the nucleus. Normoblasts, megaloblasts, with mitoses in all stages make their appearance. (c) There is an increase in the number of the blood platelets, associated with an increase both in the size of the cell and the nucleus. The cells frequently contain more than one nucleus. (d) The blood loses its power of clotting.

3. *Organic Findings.*—(a) There is a diffuse, focal, less frequently a nodular infiltration of marrow cells, in which the large mononuclear and mononuclear myelocyte with eosinophilic granules predominate. The foci may be limited to the large mononuclear or granular eosinophilic myelocytes, commonly the mononuclear, or may be composed of both types. Extensive mitoses testify to active proliferation. This myelosis affects most particularly the liver, spleen, kidneys and bone-marrow, causing a great increase in the size of the first three organs. Rarely, the cervical lymph-glands are also very much enlarged. Most of the remaining organs and neighboring tissues may contain infiltrations but not so extensive. (b) The relative proportion of white to red blood cells is greatly increased in the blood-vessels. The same cells predominate as in the infiltrations. (c) There are atrophic and degenerative changes of the parenchyma, general atrophy of the adipose tissue, ascites etc.

CONCLUSION.

The injection of an organic emulsion causes a picture of myeloid leukæmia in every respect similar to that of spontaneous leukæmia as it occurs in the fowl.

The chemical picture and changes produced in the blood and organs are analogous to those which occur in human leukæmia.

V. CONCLUSION.

1. The spontaneous occurrence of myeloid leukæmia of the fowl is confirmed.

2. Myeloid leukæmia in the fowl is transmissible by the intravenous or intraperitoneal injection of an organic emulsion. The latter is in confirmation of the work by Ellermann and Bang who, as I have stated, were the first to successfully transmit the disease. They were followed by Hirschfeld and Jacoby, whose successful transmissions, however, seem to be limited to a strain, which had its origin in a fowl presented to them by Ellermann and Bang. Burckhardt likewise transmitted the

disease, but here again the stock animal came from Hirschfeld and Jacoby, and therefore indirectly from Ellermann and Bang.

The above reported transmission is of special interest, because it originated from an animal entirely independent and far remote from those of the previous investigators.

LITERATURE OF LEUKÆMIA IN THE FOWL.

1. MOORE, V. A.: Infectious Leukæmia in Fowls—A Bacterial Disease Frequently Mistaken for Fowl Cholera. Twelfth and Thirteenth Annual Reports, Bureau of Animal Industry, U. S., 1895-1896, 185-205.
2. BUTTERFIELD, E. E.: Aleukæmic Lymphadenoid Tumors of the Hen. *Folia hæmat.*, 1905, II, 649-657.
3. WARTHIN, A. S.: Leukæmia of the Common Fowl. *Jour. Infect. Dis.*, 1907, IV, 369-381.
4. KON, J.: Ueber Leukämie beim Huhn. *Virchows Arch. f. path. Anat.*, 1907, CXC, 338-349.
5. SOSHESTRENSKI, N. A.: (Leukæmia of the Chicken.) *Uchen. zapiski Kazan. Vet. Inst.*, 1908, XXV, 215-222.
6. ELLERMANN, V., and BANG, O.: Experimentelle Leukämie bei Hühnern. *Vorläufige Mitteilung. Centralbl. f. Bakteriöl.*, 1908, Theil 1, Orig., XLVI, 4-5.
7. ——— Experimentelle Leukämie bei Hühnern. *Centralbl. f. Bakteriöl.*, 1908, Theil 1, Orig., XLVI, 595-609.
8. ——— Experimentelle Leukämie bei Hühnern. *Verhandl. d. d. path. Gesellsch.*, 1908, XII, 224-225.
9. ——— (Experimental Leukæmia in Fowls.) *Overs. v. d. k. Danske Vidensk. Selsk. Torh., Kbenk.*, 1908, 65-94; *ibid.*, 1909, p. 261.
10. ——— Experimentelle Leukämie bei Hühnern. *Ztschr. f. Hyg. u. Infektionskrankh.*, 1909, LXIII, 231-272.
11. SCHRIDDE: Gibt es eine infektiöse Aetiologie der Leukämie? *Deutsche med. Wehnschr.*, 1909, XXXV, 280.
12. HIRSCHFELD, H., and JACOBY, M.: Zur Kenntnis der übertragbaren Hühnerleukämie. *Berl. klin. Wehnschr.*, 1909, XLVI, 159-160.
13. ——— Uebertragbare Hühnerleukämie. *Berl. klin. Wehnschr.*, 1909, XLVI, 314.

14. HIRSCHFELD, H., and JACOBY, M.: Uebertragungsversuche mit Hühnerleukämie. *Ztschr. f. klin. Med.*, 1910, LXIX, 107-120.
15. BURCKHARDT, J. L.: (Bei der 82. Versammlung Deutscher Naturforscher und Aerzte zu Königsberg.) *Ztschr. f. Immunitätsforsch. u. exper. Therap.*, 1910, Theil 2, 810-811.
16. ——— Ueber das Blutbild bei Hühnertuberkulose und dessen Beziehungen zur sogenannten Hühnerleukämie, nebst Bemerkungen über das normale Hühnerblut. *Ztschr. f. Immunitätsforsch. u. exper. Therap.* 1912, XIV, 544-604.
17. HIRSCHFELD, H., and JACOBY, M.: Uebertragbare Hühnerleukämie und ihre Unabhängigkeit von der Hühnertuberculose. *Ztschr. f. klin. Med.*, 1912, LXXV, 501-505.
18. ELLERMANN, V: Undersøgelser over Hønseleukaemiens Virus. *Ugesk. f. Læger*, 1913, LXXV, 1685-1691.
19. ——— Untersuchungen über das Virus der Hühnerleukämie. *Ztschr. f. klin. Med.*, 1914, LXXIX, 43-48.

EXPLANATION OF FIGURES.

FIG. 1.—Normal blood of the fowl. Wilson's stain. Zeiss objective 1/12, eye-piece No. 3. Composite picture. (a) Normocytes. (b) Blood platelets. (c) Polymorphonuclear leucocyte with eosinophilic rods. (d) Polymorphonuclear leucocyte with eosinophilic granules. (e, e') Lymphocytes (small and large). (f) Large mononuclear cell. (g) Mast cell.

FIG. 2.—Leukæmic blood of the fowl. Wilson's stain. Zeiss objective 1/12, eye-piece No. 3. Composite picture. (a) Normal normocytes. (b) Normocytes showing anisocytosis, poikilocytosis, polychromatophilia, with swelling of nucleus and separation of its chromatin. (c) Normoblast. (d) Megaloblast. (e) Mitoses of erythrocytes; all stages from monaster to complete division of nucleus. (f) Blood platelets; both cell and nucleus increased in size; increase in size with two nuclei. (g) Polymorphonuclear leucocyte with eosinophilic rods. (h) Polymorphonuclear leucocyte with eosinophilic granules. (i) Lymphocyte. (j) Large mononuclear cell; same size and larger than normal with both nucleus and cytoplasm paler. (k) Mitoses of large mononuclear cell; all stages, from monaster to complete separation of nucleus. (l) Mast cell. (m) Mononuclear myelocyte with eosinophilic granules. (n) Cytoplasmatic masses without nuclei.

FIG. 3.—Cervical lymph-glands of the fowl; normal and leukæmic. Actual size and $\times 2$. Note the great increase in size; replacement of fat by the greatly swollen parenchymatous lobules.

FIG. 4.—Normal fowl with organs *in situ*. Weight, 1750 gm. Note the well-nourished condition of the body; the abundance of fat, subcutaneously,

in the neck, and in the omentum; the large muscles; size of heart and liver.

FIG. 5.—Leukæmic fowl with organs *in situ*. Weight, 1350 gm. Note great emaciation of body; almost entire absence of fat; atrophy of muscles; large heart; enormous liver with the characteristic myeloid infiltrations.

FIG. 6.—Spleen of the fowl; normal and leukæmic, actual size; surface and section. Note the enormous increase in size; in upper half of surface, circumscribed areas of myeloid infiltration; the swollen pulp and infiltrations on section.

DESCRIPTION OF PLATE I.

FIG. 1.—Normal blood of the fowl. Wilson's stain. Zeiss objective 1/12, eye-piece No. 3. Composite picture. (*a*) Normocytes. (*b*) Blood platelets. (*c*) Polymorphonuclear leucocyte with eosinophilic rods. (*d*) Polymorphonuclear leucocyte with eosinophilic granules. (*e. é*) Lymphocytes (small and large). (*f*) Large mononuclear cell. (*g*) Mast cell.

FIG. 2.—Leukæmic blood of the fowl. Wilson's stain. Zeiss objective 1/12, eye-piece No. 3. Composite picture. (*a*) Normal normocytes. (*b*) Normocytes showing anisocytosis, poikilocytosis, polychromatophilia, with swelling of nucleus and separation of its chromatin. (*c*) Normoblast. (*d*) Megaloblast. (*e*) Mitoses of erythrocytes, all stages from monaster to complete division of nucleus. (*f*) Blood platelets; both cell and nucleus increased in size; increase in size with two nuclei. (*g*) Polymorphonuclear leucocyte with eosinophilic rods. (*h*) Polymorphonuclear leucocyte with eosinophilic granules. (*i*) Lymphocyte. (*j*) Large mononuclear cell; same size and larger than normal with both nucleus and cytoplasm paler. (*k*) Mitoses of large mononuclear cell; all stages, from monaster to complete separation of nucleus. (*l*) Mast cell. (*m*) Mononuclear myelocyte with eosinophilic granules. (*n*) Cytoplasmic masses without nuclei.

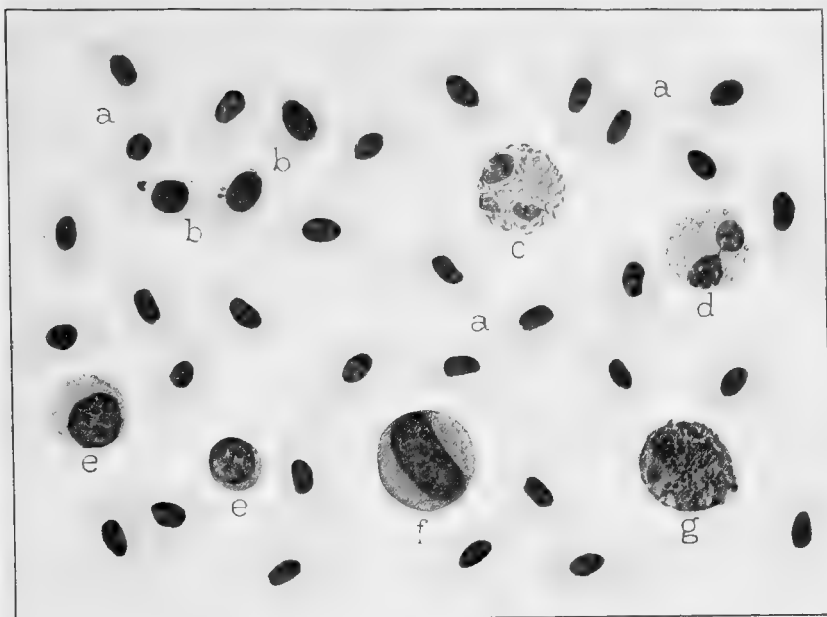


FIG. 1.

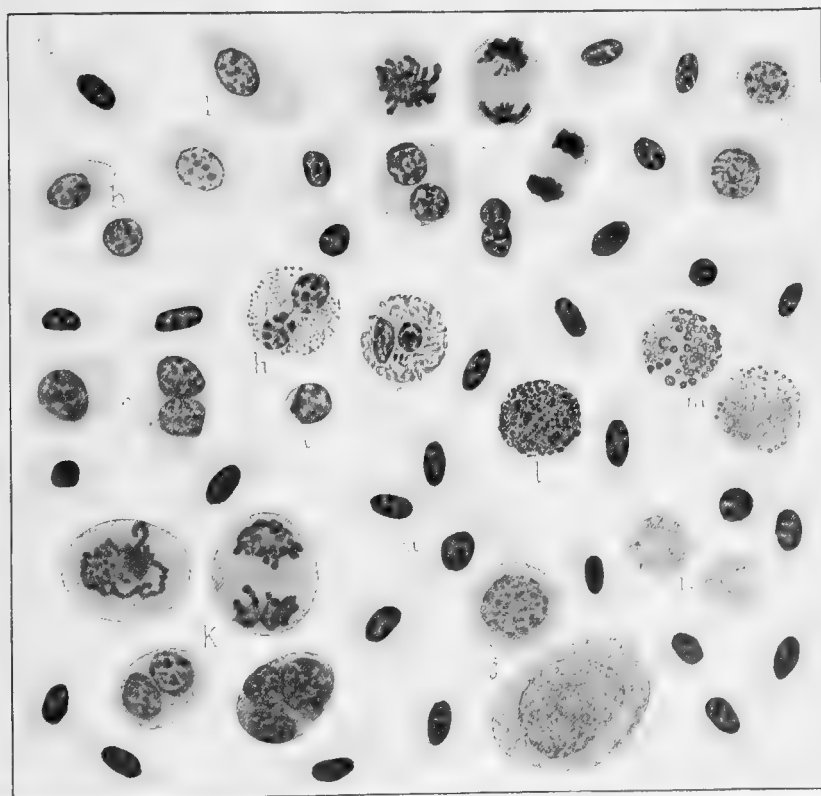


FIG. 2.

Dorothea Pennington fec.

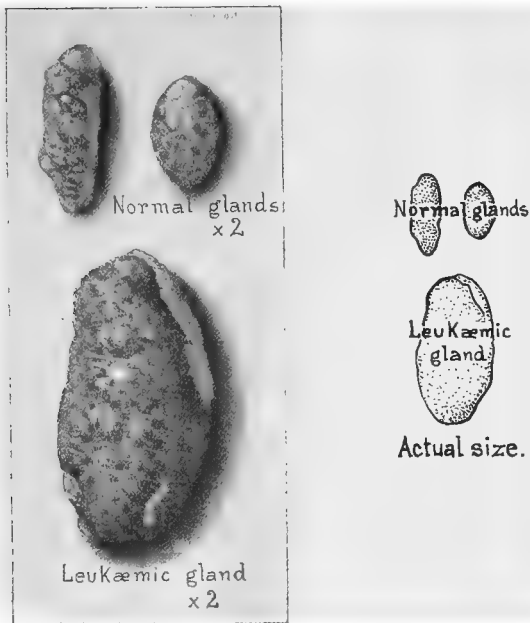


FIG. 3.—Cervical lymphglands of the fowl; normal and leukæmic. Actual size and $\times 2$. Note the great increase in size; replacement of fat by the greatly swollen parenchymatous lobules.




FIG. 6.—Spleen of the fowl; normal and leukæmic, actual size; surface and section. Note the enormous increase in size; in upper half of surface circumscribed areas of myeloid infiltration; the swollen pulp and infiltrations on section.

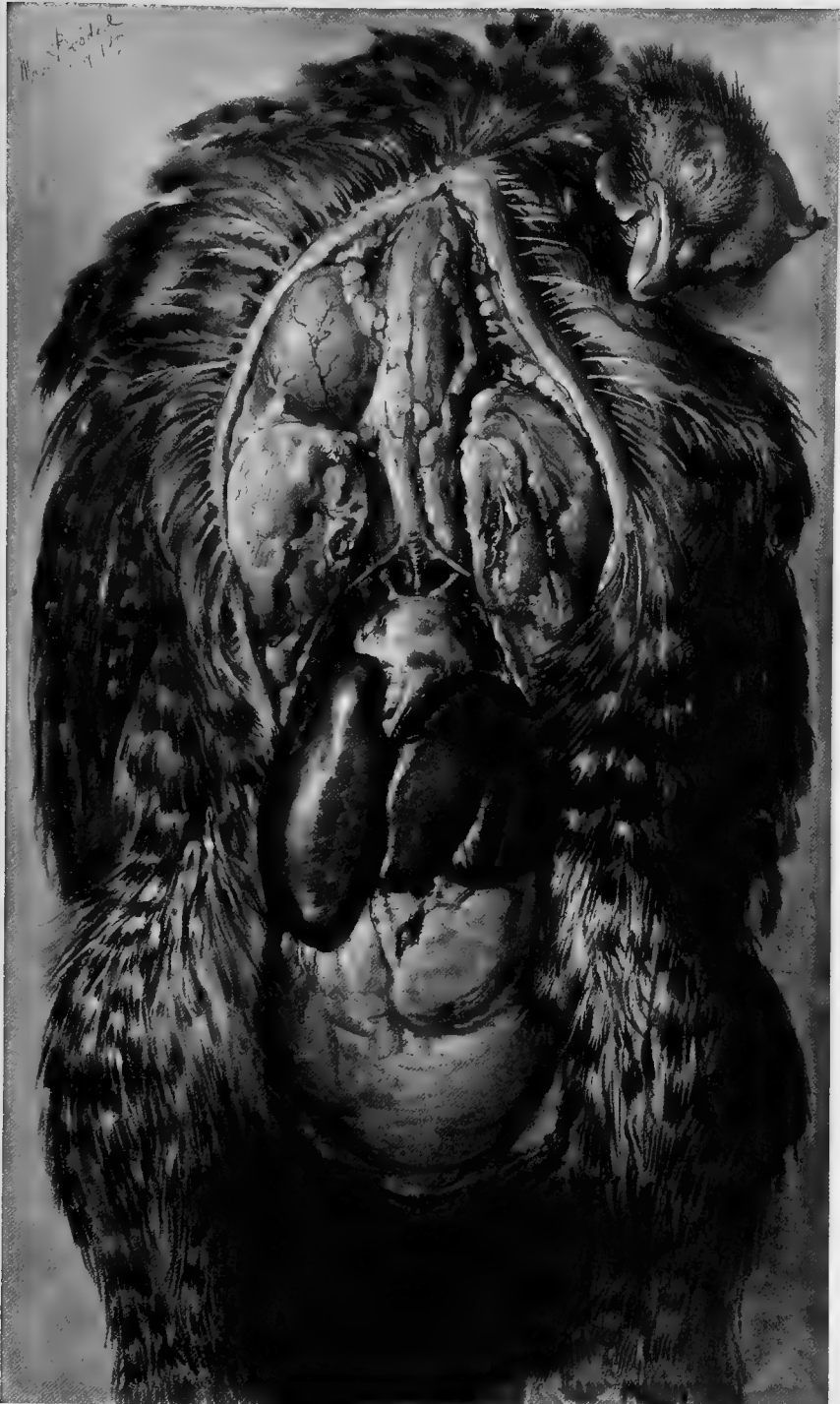


FIG. 4.—Normal fowl with organs *in situ*. Weight, 1750 gm. Note the well-nourished condition of the body; the abundance of fat, subcutaneously, in the neck, and in the omentum; the large muscles; size of heart and liver.

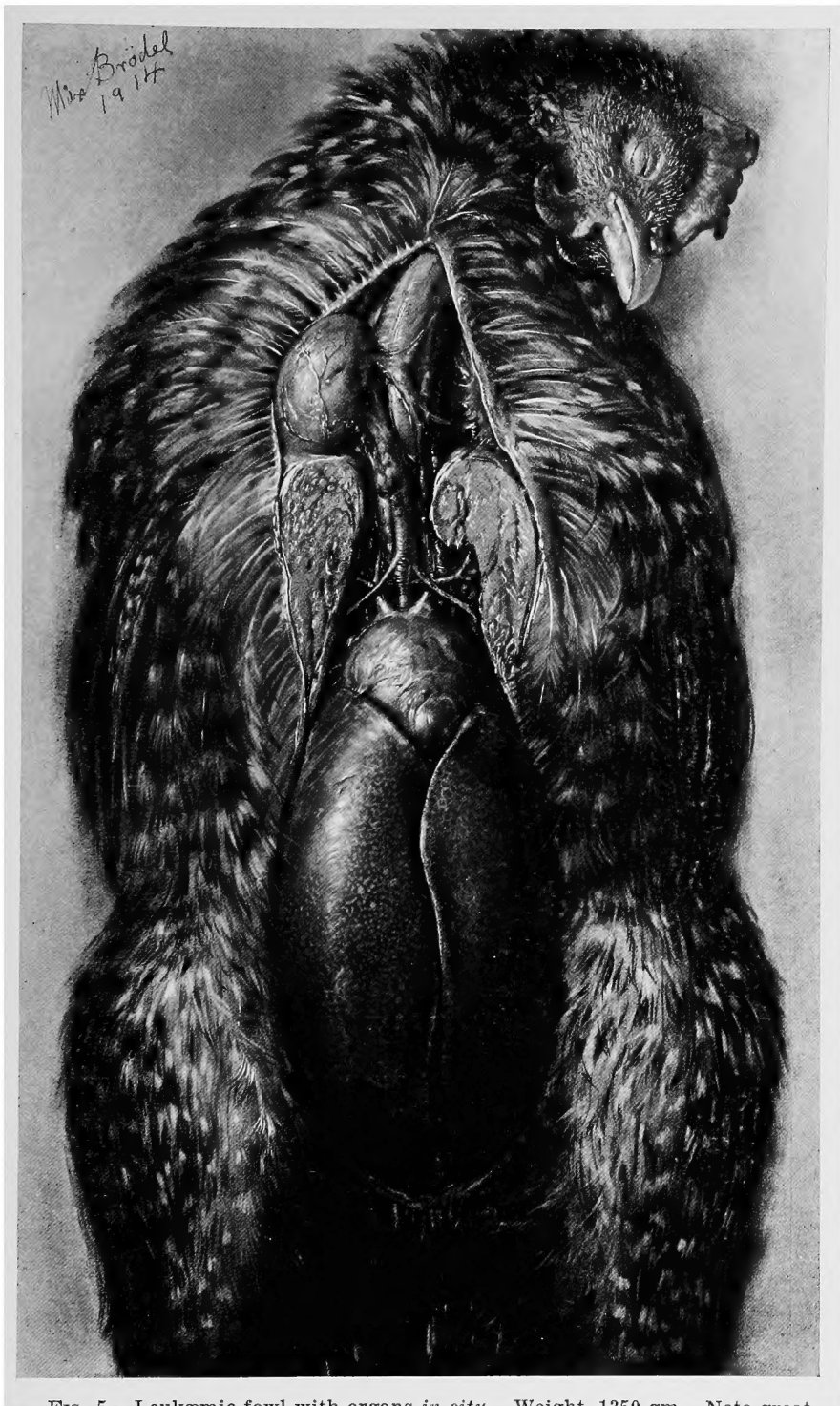


FIG. 5.—Leukæmic fowl with organs *in situ*. Weight, 1350 gm. Note great emaciation of body; almost entire absence of fat; atrophy of muscles; large heart; and enormous liver with the characteristic myeloid infiltrations.

