

LIBRARY
New York State Veterinary College
ITHACA, NEW YORK

SF
765
H79 Hopkins, Grant Sherman
A guide to the dissection of the blood
vessels and nerves of the pectoral and pelvic
limbs of the horse.

SF
765
H79

A GUIDE
TO THE
Dissection of the Blood Vessels
and Nerves
OF THE
PECTORAL AND PELVIC
LIMBS
OF
THE HORSE

BY

GRANT SHERMAN HOPKINS,
New York State Veterinary College at Cornell University,
ITHACA, N. Y.




THIS BOOK IS THE GIFT OF

DR G. S. HOPKINS

A GUIDE
TO THE
Dissection of the Blood Vessels
and Nerves
OF THE
PECTORAL AND PELVIC
LIMBS
OF
THE HORSE

BY
GRANT SHERMAN HOPKINS,
New York State Veterinary College at Cornell University,
ITHACA, N. Y.

COPYRIGHT 1914
BY GRANT SHERMAN HOPKINS



Cornell University Library

The original of this book is in
the Cornell University Library.

There are no known copyright restrictions in
the United States on the use of the text.

<http://www.archive.org/details/cu31924001090483>

PREFACE

Every teacher who has had experience with classes in Anatomy appreciates the difficulties that confront the student in his attempt to dissect any portion of the body with only his text-book of Descriptive Anatomy, for a guide. The present "Guide" has been prepared in the hope of assisting students in the dissection of the blood-vessels and nerves of the pectoral and pelvic limbs. A knowledge of the muscles is presupposed. In our experience, we have found it most desirable that, upon the completion of a part, the student should demonstrate his dissection to the instructor in charge. By no other means can the student be brought to realize more clearly the vast difference between studying and knowing the actual object itself and the mere memorizing the description of it as given in his text-book.

G. S. H.

Dissection of the Blood-Vessels and Nerves of the Arm or Pectoral Limb

Cut the skin along the median line from the xiphoid cartilage to a point 15 or 20 cm. cephalad of the presternum; also cut at a right angle to this along the middle of the proximal half of the antebrachium and reflect the skin from the pectoral muscles. Note the large vein (V. cephalica) and the small artery lying in the groove formed by the anterior superficial pectoral muscle and the adjoining border of the M. mastoido-humeralis. Transect the two superficial pectorals close to their sternal attachments. Now dissect up the cervical panniculus, transect it a short distance from its attachment to the sternum and turn it aside. Beneath this portion of the panniculus is a mass of fatty tissue in which are numerous lymph nodules—the **Prescapular** or **superficial cervercal lymph gland**. The full extent of this gland may be seen when the M. mastoido-humeralis is turned aside. Transect the mastoido-humeralis a little above (cephalad) the point of the shoulder and turn it aside sufficiently to expose the underlying prescapular portion of the anterior deep pectoral muscle and the prescapular lymph gland. Do not disturb unnecessarily the gland for beneath it are an artery and vein of some surgical importance. Trace the large vein (**V. cephalica**) and the small artery (a branch of the A. cervicalis inferior) that cross the anterior deep pectoral muscle in the groove between this muscle and the mastoido-humeralis, in so far as the vessels are at present accessible. Ligate and cut the vessels. Abduct the arm somewhat and identify the two deep pectoral muscles. Transect the latter muscles close to their attachment to the sternum. Abduct the arm a little and dissect between the deep pectoral muscles and the thoracic wall until the large **A.** and **V. Axillaris** are exposed. Carefully clean up the **V. Axillaris** noting meantime the lymph glands, **Posterior cervical** or **prepectoral**, that lie just cephalad or anterior to the V. Axillaris. Cut the vein in order clearly to expose the **A. Axillaris** which lies immediately dorsal to it. Clean up the A. Axillaris taking care not to cut any of its branches or the nerves that cross the ventral surface of the artery a short distance (4 to 6 cm.) from the first rib. Cut the artery close to the rib. Occasionally a large vein lies just anterior to the A. Axillaris; if so, this also should be cut.

A. cervicalis inferior arises from the **axillaris** nearly opposite the first rib. Near the ventral border of the M. scalenus it divides into two nearly equal branches—a **ventral** and a **dorsal branch**. The **ventral branch** crosses

the superficial surface of the anterior deep pectoral and then runs in the groove formed by this muscle and the mastoido-humeralis, as already seen, and terminates in the mastoido-humeralis. Small branches are supplied to the posterior cervical lymph glands, the cervical panniculus, the sterno-mandibularis, sterno-thyrohyoideus, anterior superficial pectoral and a small branch to the region of the presternum. The **dorsal branch** extends antero-dorsally along the anterior border of the anterior deep pectoral muscle. It passes beneath the prescapular lymph gland and between the muscles subscapulo-hyoideus and mastoido-humeralis to the latter of which it is principally distributed. It also gives off branches to the anterior deep pectoral muscle and to the posterior cervical and prescapular lymph glands.

The ventral portion of the M. scalenus intervenes between the axillary blood-vessels and the nerves that form the **brachial plexus**. The **brachial plexus** is formed by the ventral divisions of the 6th, 7th and 8th, cervical and the 1st and 2d thoracic nerves, as will be demonstrated later. Cut the dorsal branch of the **A. cervicalis inferior** and carefully remove the connective tissue that surrounds the large nerve trunks of the brachial plexus.

N. phrenicus or diaphragmatic nerve originates from the ventral divisions of the 6th and 7th cervical nerves; occasionally it receives a small branch from the 5th cervical also. The two or three radicals of the phrenic nerve extend obliquely across the superficial face of the M. scalenus and at its ventral border unite to form a single trunk, just as the nerve enters the thorax, or a short distance within the thoracic cavity. Dissect up from the surface of the scalenus the two or three radicals of the N. phrenicus. Immediately after crossing the A. cervicalis inferior the N. phrenicus receives a small communicating branch from the inferior cervical ganglion of the sympathetic nerve. The course of the phrenic nerve through the thoracic cavity to the diaphragm will be studied when the thoracic portion of the vagus and sympathetic nerves are traced.

Exposure of the brachial plexus and removal of the thoracic limb.

Expose as follows, the ventral divisions of the nerves that form the brachial plexus, viz., the 6th (not constant), 7th and 8th cervical and the 1st and 2d thoracic. Cut the **N. phrenicus** at the first rib. Remove a section of the ventral portion of the M. scalenus opposite the 6th, 7th, and 8th intervertebral foramina. Cut the skin and the Mm. panniculus and latissimus, some distance (30 to 50 cm.) posterior to the scapula; cut the skin and both portions of the trapezius close to the ligamentum nuchae;

also cut the serratus magnus, and rhomboideus close to their attachments to the scapula thus leaving the arm attached to the body only by the nerves of the brachial plexus. Before attempting to expose farther the ventral divisions of the 6th, if present, 7th and 8th cervical and the 1st and 2d thoracic nerves, first note on a skeleton the relation of the first two ribs to the 6th, 7th and 8th cervical and the 1st and 2d thoracic intervertebral foramina, through which the above mentioned nerves emerge from the spinal cord. Now place the arm in such a position that the whole of the thoracic portion of the M. serratus magnus is exposed. Carefully remove the small portion of the M. scalenus that lies dorsal to the brachial plexus taking care not to cut any of the nerves. The large nerve to the thoracic portion of the serratus magnus arises from the 7th and 8th cervicals (or from the 8th only) and extends posteriorly on the surface of the serratus magnus to which it is distributed. This nerve, more or less covered by connective tissue, may emerge from between the dorsal and ventral portions of the scalenus, or it may pass through the small dorsal portion of the muscle. After tracing the nerve, cut it 15 to 20 cm. from its origin. The ventral divisions of the 7th and 8th cervical nerves are readily exposed; the 1st and 2d thoracic nerves however, are covered by the ribs of which the first one must be cut in order to expose the nerves. Remove enough of the serratus magnus to expose the first rib. Cut the rib a little ventral to the **A. Axillaris**, also cut it close to the tuberosity of the rib and remove the detached portion. The **A. cervicalis inferior** should now be traced to its place of origin from the **A. Axillaris**. With a little care the ventral divisions of the first two thoracic nerves may be found and cut close to the intervertebral foramina; the 7th and 8th cervical nerves also should be cut close to the vertebrae and the arm removed.

Nn. pectorales. Before attempting to demonstrate the nerves to the pectoral muscles first carefully remove the connective tissue and fat from the nerves of the brachial plexus using for this purpose the forceps, the back of the scalpel, or some other non cutting instrument. The origin of the pectoral nerves vary somewhat in different individuals. The following disposition however, is common. The most cephalic or anterior of the pectoral nerves originates from the 7th and 8th cervicals and is distributed wholly to the anterior deep pectoral muscle (Pl. I, 27). The nerve enters the muscle a little dorsal to the cephalic vein where it crosses the anterior deep pectoral. A communicating branch between this nerve and the phrenic is quite commonly present. The nerves to the superficial pectoral muscles arise from the loop or arch formed by the **N. musculo-cutaneous** (Pl. I, 29) and the **N. medianus** (Pl. I, 32) immediately beneath the **A. axil-**

laris and from the brachial plexus, in common with the N. medianus (Pl. I, 30, 31). Carefully dissect up the overlying posterior portion or sternal extremity of the anterior deep pectoral and trace the nerves to their respective places of distribution in the superficial pectoral muscles. The two or more nerves to the posterior deep pectoral and the panniculus are readily found. They arise from the brachial plexus apparently in common with the Nn. medianus and ulnaris. The smaller and more anterior of the two nerves (in the present specimen) soon divides into three or four branches which enter the muscle near its humeral end along with the artery and vein supplied to the muscle. The larger and more posterior nerve also divides into several branches some of which are distributed to the posterior deep pectoral and some to the panniculus; note particularly the large branch which accompanies the large V. thoracica externa which runs along the dorsal margin of the posterior deep pectoral and is continued posteriorly in the panniculus.

A. suprascapularis arises from the **A. axillaris** near the anterior border of the tendon of the subscapularis, and close to the N. musculo-cutaneous where it crosses the A. axillaris. About one centimeter from its origin the A. suprascapularis divides into two branches, of which one is distributed to the subscapularis, anterior deep pectoral and the supraspinatus; the other branch is distributed to the anterior deep pectoral, supraspinatus, the shoulder joint, and the proximal tendon of the biceps. The artery is accompanied by the V. suprascapularis.

N. suprascapularis (Pl. I, 28; Pl. II, 21) originates from the 7th and 8th cervical nerves but principally from the 7th; occasionally some fibres originate from the 6th cervical nerve also. This large nerve passes between the adjacent borders of the supraspinatus and subscapularis. Carefully dissect the supraspinatus from the adjoining subscapularis, on one side of it, and the infraspinatus, on the other, and transect the muscle opposite the N. suprascapularis. Reflect the muscle sufficiently to expose the two or three large branches of the nerve to the supraspinatus, which branches are given off just as the nerve crosses the anterior border of the scapula. Trace the nerve across the supraspinus fossa and note its width, 1 to 2 cm. opposite the spine of the scapula. Just as the nerve enters the M. infraspinatus it divides into 5 or 6 branches, all of which are distributed to this muscle.

Nn. subscapulares (Pl. I, 47). There are usually two or more of these nerves. They pass directly to the M. subscapularis but before reaching it they divide into numerous branches which diverge somewhat like the rays of a fan.

The nerve to the *M. latissimus* arises from near the middle of the brachial plexus, most of its fibres coming from the 8th cervical (Pl. I, 48). It passes obliquely across the deep face of the *Mm. subscapularis* and *teres major* and is distributed wholly to the *latissimus*.

Nerves to the *M. teres major* (Pl. I, 7). There are from 1 to 3 small nerves supplied to this muscle. They arise from the **N. axillaris** or rather are branches of it, and pass directly to the muscle, close to its anterior border.

N. axillaris (Pl. I, 46) arises from the 7th and 8th cervical nerves. It passes through the triangular space formed by the *Mm. subscapularis*, *teres major*, and the *caput longum tricipitis*. To demonstrate the distribution of the nerve first remove the skin and the panniculus from the lateral or external surface of the scapular region. Dissect up the borders of the *M. deltoideus* and transect it about 15 to 18 cm. from its attachment to the deltoid tuberosity. Carefully reflect the humeral portion of the muscle in order to expose the **N. axillaris** which enters the deep face of the muscle directly opposite the above mentioned triangular space (Pl. II, 22). Beneath the muscle, the nerve divides into several branches which are distributed as follows: several branches enter the *deltoideus*; one large branch passes obliquely across the superficial surface of the *teres minor* (near its humeral end) to the anterior face of the *brachium* and enters the *mastoido-humeralis* several centimeters below (distal to) the point of the shoulder (Pl. I, 24); another large branch crosses the superficial surface of the *caput laterale tricipitis* or sometimes, is embedded in the substance of this muscle, and emerges from beneath the posterior border of the *M. deltoideus* at the level of the deltoid tuberosity where it becomes subcutaneous (Pl. II, 23); from here, this subcutaneous branch extends to the antero-internal aspect of the *antebrachium* where it breaks up into several cutaneous branches some of which extend nearly to the *carpus*. One branch of the **N. axillaris** is distributed to the *teres minor*. This branch may be readily demonstrated by transecting the muscle, a little proximal to the *N. axillaris*, and drawing aside the muscle. One or more branches are supplied to the *teres major*, one branch to the *subscapularis* and a very small filament to the *M. capsularis*. The branches to the *subscapularis* and the *capsularis* may arise from the main nerve trunk either separately or by a common branch.

Clean up the **V. axillaris** and the several veins from the pectoral, panniculus, and *latissimus* muscles also clean up the portion of the **V. subscapularis** that lies in the space between the *Mm. subscapularis* and *teres major*. Demonstrate the **axillary lymph gland** (Pl. I, 49), which lies on the tendon

of the *teres major* in the angle formed by the **Vv. subscapularis** and **brachialis**. Now slit the posterior superficial pectoral longitudinally near its middle. Turn aside the anterior portion of the muscle, together with the posterior deep pectoral, in order to expose the *Mm. coraco-brachialis* and the *biceps brachii*.

N. musculo-cutaneous (Pl. I, 29, 29¹) is a large nerve and originates from the 7th and 8th cervical nerves. Immediately after crossing the lateral face of the **A. axillaris** (Pl. I, 21) a large portion of the nerve joins the **N. medianus** by a large short branch that passes beneath the *A. axillaris* and with the *N. medianus* forms a loop around it. Occasionally this nerve loop is entirely wanting. From the loop thus formed, one or more branches are given off to the superficial pectoral muscles as already demonstrated. The larger portion of the **N. musculo-cutaneous** however, passes through the *M. coraco-brachialis* (Pl. I, 13, 29¹), the overlying portion of which should be cut just proximal to the nerve, and drawn aside. As the nerve enters the *coraco-brachialis* it supplies a branch to it. Trace the main nerve through the *coraco-brachialis* to its termination in the *biceps brachii* near to the proximal end of the fleshy portion of the muscle (Pl. I, 29¹). The connective tissue and aponeurosis covering the vessels and nerves on the medial face of the brachial region should now be removed. Note that here the vessels and nerves have the following relations, viz., the **N. medianus** lies most anteriorly and is followed in order by the **A. brachialis**, **V. brachialis**, **N. ulnaris**, and finally, in the proximal part of the brachium, the large **N. radialis**. Note also the small mass of lymph glands lying on the artery and vein near the distal third of the brachium (Pl. I, 49¹).

N. radialis (Pl. I, 40) lies posterior to the **Nn. medianus** and **ulnaris** and is the largest nerve of the brachial plexus. It originates from the 7th and 8th cervical and the 1st thoracic nerves, but principally from the 8th cervical and 1st thoracic. The nerve passes into the triangular space formed by the tendon of the *teres major* and *latissimus*, the *caput longum tricipitis* and the proximal end of the *brachialis*. An artery and vein also enter this space and should be left intact. As the **N. radialis** enters the above mentioned triangular space it gives off several branches which are distributed as follows: (a) one branch to the *tensor fasciae antebrachii* (Pl. I, 44). To demonstrate this branch, transect the *tensor fasciae antebrachii* near its distal third and turn the muscle aside but do not injure the nerve (a branch of the *N. ulnaris*) which runs along the anterior border (Pl. I, a), or sometimes crosses obliquely, the superficial surface of the distal half of the muscle. Sometimes a small communicating branch passes from

the N. ulnaris to this branch of the N. radialis supplied to the tensor fasciae antebrachii. (b) A large fasciculus composed of several branches, some of which recurve slightly around the tendon of the teres major and latissimus; all the branches of this fasciculus are distributed to the caput longum tricipitis (Pl. I, 41). (c) Branches to the caput laterale tricipitis, caput mediale tricipitis, and anconeus. Of these branches the small one to the caput mediale is readily found and traced to its muscle; the branches to the caput laterale and anconeus, however, are more or less completely hidden by the caput longum and caput laterale and often can be satisfactorily demonstrated only after the caput laterale has been dissected as follows: Turn aside the skin and the panniculus from the outer surface of the triceps. The posterior surface of the caput laterale may now be freely separated from the caput longum, but in dissecting up the anterior border of the muscle care should be taken not to cut the cutaneous nerve (a branch of the **N. radialis**) which emerges from beneath the muscle at, or close to, its anterior border (6 to 8 cm. distal to the cutaneous branch of the N. axillaris, or 8 to 10 cm. from the posterior edge of the M. deltoideus, Pl. II, c). Transect the caput laterale a little distal to its middle and freely reflect the distal portion of the muscle; the proximal portion of the muscle can be turned aside only a little distance as the nerve and blood-vessels to the muscle enter its deep or anterior face. Trace this nerve and also the cutaneous branch to their origin from the **N. radialis**. Now trace the main trunk of the **N. radialis** in its course along the musculo-spiral groove to the point where it passes beneath the M. extensor carpi radialis at its origin, near the proximal end of the external epicondyle of the humerus (Pl. II, 11, 25). Remove the skin of the antebrachium as far as to the carpus. Trace the cutaneous branches of the **N. axillaris** and the **N. radialis**, the former to the antero-internal side of the antebrachium and the latter to the antero-external side of the antebrachium. Both of these cutaneous branches may readily be traced to near the carpus. The M. extensor carpi radialis should now be dissected as follows: Transect it near the middle and freely turn aside the distal portion, but in turning aside the proximal part of the muscle care must be exercised to avoid cutting or breaking the nerves and blood-vessels that enter the deep face of the muscle (near the posterior border of the distal end of the M. brachialis). Now trace the **N. radialis** beneath the proximal portion of the extensor carpi radialis taking care not to cut the branches of this nerve, usually three in number, that enter the deep face of the muscle (Pl. II, d). The main nerve now passes beneath the extensor digitalis communis, near the origin of the muscle. Transect the extensor digitalis communis near the middle of the antebrachium and as the proximal portion is reflected avoid breaking the

blood-vessels and the two or three branches of the N. radialis supplied to the muscle (Pl. II, e). Beneath this muscle the N. radialis gives off a small branch to the extensor carpi obliquus (Pl. II, f); this branch lies directly upon the anterior-lateral face of the radius, at the side of the **A. radialis anterior**, and beneath the deep face of the extensor digitalis communis which must be turned aside sufficiently to expose the extensor carpi obliquus. Shortly before the N. radialis passes beneath the extensor digitalis lateralis, close to its origin, it gives off a small branch to this muscle (Pl. II, g). Slit open the aponeurotic sheath of the muscle and trace the branch some little distance. Now transect the muscle at the level of the N. radialis and trace the latter into the flexor carpi externus where the nerve terminates (Pl. II, h). It will be seen from the above that the **N. radialis** supplies the following muscles; the triceps (caput longum, laterale and mediale), the tensor fasciae antebrachii, the anconeus, the extensor carpi radialis, the extensor digitalis communis, the extensor digitalis lateralis, the extensor carpi obliquus, and the flexor carpi externus, and one or more cutaneous branches to the skin of the antebrachium.

Blood-vessels of the Brachial Region

The large V. axillaris and several of the vessels opening into it, viz., V. thoracico-dorsalis from the deep pectoral muscles; the V. suprascapularis, the V. thoracico-externa together with the branches from the latissimus and panniculus that communicate with the V. thoracico-externa a short distance from its termination, have already been exposed. Additional veins should be noted as they are uncovered in the further dissection.

A. axillaris (Pl. I, 21). Upon emerging from the thorax the **A. axillaris** crosses the tendon of origin of the coraco-brachialis and the insertion of the subscapularis, at the postero-internal side of the scapulo-humeral joint. From here the artery is continued by the **A. brachialis** (Pl. I, 23) which extends obliquely across the middle of the humerus to the antero-internal side of the distal third of the shaft of the bone where it divides into two terminal branches—the **A. radialis anterior** and the **A. radialis posterior**.

Branches of the A. axillaris,

A. cervicalis inferior.

A. suprascapularis.

A. subscapularis.

The **A. cervicalis inferior** and the **suprascapularis** have already been traced, pp. 5, 8. The large **A. subscapularis** (Pl. I, 22) arises from the

axillaris at the posterior border of the M. subscapularis. Before exposing the A. subscapularis first trace the branch, **A. thoracico-dorsalis**, that arises from the subscapularis 1 to 2 cm. from its origin (Pl. I, immediately below 22). This artery extends obliquely across the inner face of the teres major supplies small branches to it and to the axillary lymph gland and terminates in the latissimus and panniculus. Transect the M. teres major near the middle and turn it aside. Now trace the **A. subscapularis** between the Mm. subscapularis and teres major across the inner surface of the caput longum tricipitis to the posterior angle of the scapula. The **A. subscapularis** gives off the following branches:

(1) **A. thoracico-dorsalis** already dissected. See above.

(2) **A. circumflexa humeri posterior** arises 1 to 2 cm. peripheral to the A. thoracico-dorsalis. It accompanies the N. axillaris to the deep face of the M. deltoideus and is distributed to this muscle and also to the caput longum, the caput laterale, the brachialis, the teres minor and a small twig to the capsule of the scapulo-humeral joint.

(3) **A. circumflexa scapulae** arises from the **subscapularis** 5 to 8 cm. peripheral to the A. circumflexa humeri posterior and extends directly to the posterior border of the scapula; here it divides into two branches of which one passes to the outer and the other to the inner surface of the scapula. The outer branch crosses, at nearly a right angle, the outer face of the scapula, a little below the spine, and is distributed to the infra and supraspinati and the teres minor. The inner branch is distributed to the subscapularis. The general course of these vessels is indicated by the vascular grooves of the scapula. (See cleaned scapula.)

(4) **Rami musculares**. Numerous small branches of the A. subscapularis are supplied to the Mm. subscapularis and teres major. Two or more large branches of the **A. subscapularis** are given off to the caput longum, the tensor fasciae antebrachii, the infraspinatus and the deltoideus. The V. subscapularis accompanies the artery.

A. circumflexa humeri anterior arises from the **brachialis** 1 to 4 cm. peripheral to the subscapularis. It passes between the humerus and the M. coraco-brachialis, supplies a branch to this muscle and terminates in the biceps brachii and mastoido-humeralis. (The biceps may now be transected.) It gives off a branch which extends towards the scapulo-humeral joint and is distributed to the biceps brachii and its synovial tendon sheath. Occasionally the A. circumflexa humeri anterior is a small vessel supplying only the coraco-brachialis.

external flexors of the carpus and to the artery and vein. Five to eight centimeters from the carpus the nerve divides into two branches of which one pierces the aponeurosis and passes, subcutaneously, across the tendon of the flexor carpi externus and divides into numerous branches which extend obliquely to the antero-lateral face of the carpus and metacarpus (Pl. III, 25^r; Pl. II, 26). The other terminal branch of the **N. ulnaris** unites with a branch of the **N. medianus**, below the supracarpal arch, and thus forms the **N. volaris lateralis** (Pl. III, 26).

A. radialis anterior (Pl. II, 19) is the smaller of the two terminal branches of the **A. brachialis**. It passes obliquely downward and outward between the anterior face of the humerus and the Mm. biceps brachii and the brachialis. Transect the brachialis where it crosses the external surface of the tendon of the biceps. Beneath the brachialis and the extensor carpi radialis, the artery supplies branches to these muscles. Beneath the extensor digitalis communis the **A. radialis anterior** gives off two or three small branches to this muscle; it also sends a branch to the extensor digitalis lateralis and to the flexor carpi externus. The **A. radialis anterior** is continued as a small branch which extends along the antero-internal aspect of the radius to the carpus where it joins the rete carpi dorsalis.

A. radialis posterior (Pl. I, 26) is the direct continuation of the **A. brachialis** and is the larger of its two terminal branches. The artery crosses the antero-internal face of the humero-radial joint and is here covered by the skin, the aponeurosis and the posterior superficial pectoral muscle. Note that in this region the **N. medianus**, as it passes from the posterior to the anterior side of the artery and vein, lies superficially to the blood-vessels (Pl. I). A little below the humero-radial joint the **A. radialis posterior**, accompanied by the **N. medianus**, passes under the flexor carpi internus (Pl. I, 16) which should be transected and turned aside. Beneath this muscle it extends to the distal third of the shaft of the radius and is then continued by the large **A. digitalis communis** and the two **metacarpal arteries**.

Branches of the A. radialis posterior.

- (1) One or more small branches to the humero-radial joint.
- (2) **Muscular branches** to the flexor carpi internus and medius and to the flexor perforatus and perforans.
- (3) **A. interossea communis**, is a large branch that arises from the **radialis posterior** near the level of the radio-ulnar arch through which the **interossea communis** passes. In the interosseous space it gives off the nutrient artery of the radius. After passing through the interosseous space

the artery gives off one or more branches to the flexor carpi externus, anastomoses with the radialis anterior, and is continued along the antero-external face of the radius, beneath the common digital extensor, to the carpus where it anastomoses by a fine branch with the radialis anterior and also commonly joins the rete carpi dorsalis. Near the proximal third of the radius it gives off a small branch which runs along the extensor digitalis lateralis, supplies twigs to this muscle and to the extensor carpi obliquus. One or two centimeters distal to the **interossea communis** the A. radialis posterior may give off another branch nearly as large as the A. interossea communis. This second branch (in the present specimen) crosses at a right angle the posterior face of the radius then turns towards the carpus and is distributed by numerous branches to the flexor perforans and flexor perforatus.

N. medianus (Pl. I, 32) arises from the 8th cervical and 1st thoracic nerves. Immediately below the A. axillaris the nerve usually receives a large branch from the **N. musculo-cutaneous** thus forming with it a loop through which the artery passes (Pl. I). Near the middle of the brachium the **N. medianus** gives off a large branch which extends very obliquely beneath the biceps, rarely sending a small filament to it, and divides into two branches (Pl. I, 34, 35) of which one is distributed to the brachialis; the other branch winds very obliquely across the lateral face of the biceps, near the distal end, to the antero-internal face of the antebrachium where it divides into two principal branches which accompany the two respective subcutaneous veins, i.e. the cephalic and accessory veins, on the inner surface of the antebrachium (Pl. I, 34'). The vein should of course, be dissected along with the nerves. The larger of the two subcutaneous branches of the nerve may be traced to the middle of the metacarpus. The main trunk of the **N. medianus** and the artery and vein radialis posterior, after crossing the humero-radial joint, pass beneath the flexor carpi internus as already demonstrated (Pl. I, 16). Note very carefully the relation of the nerve, artery and vein to each other and to the posterior superficial pectoral muscle and to the internal tuberosity of the radius. Median neurectomy is performed in this region and also the pulse may here be readily felt. A little before the **N. medianus** passes beneath the flexor carpi internus it gives off two or three branches which are distributed as follows: One or two branches, to the flexor carpi internus (Pl. I, 36); a much larger branch which soon divides into two parts both of which are distributed to the humeral portion of the flexor perforans (Pl. I, 37); and finally a small nerve which also divides into two branches (Pl. I, 38) one of which extends into the radio-ulnar arch and is distributed principally to the periosteum; the

other branch extends along the posterior face of the radius to the radial head of the flexor perforans to which it is distributed. Continue the dissection of the **N. medianus** in its course beneath the flexor carpi internus. Near the distal third of the antebrachium the nerve (Pl. III, 24) divides into two terminal branches one of which unites with a branch of the **N. ulnaris** as already seen, and with it forms the **N. volaris lateralis** (Pl. III, 26); the other terminal branch of the **N. medianus** forms the **N. volaris medialis** (Pl. III, 27).

N. volaris lateralis, as already stated, is formed by the union of two branches, one from the **N. ulnaris** and the other from the **N. medianus**. The **N. volaris lateralis**, accompanied by a small artery (**A. metacarpea volaris lateralis**) and vein, crosses the carpus at the medial side of the pisiform bone, in a special channel in the carpal sheath. At the proximal end of the metacarpus the nerve gives off a large branch to the suspensory ligament; before tracing this branch however, follow the **N. volaris lateralis** as far as to the fetlock noting the branch of considerable size from the **N. volaris medialis** that joins it a little proximal to the distal end of the rudimentary metacarpal (Pl. III, 28). Transect the two flexor tendons near the middle of the metacarpus taking care not to injure the **N. volaris medialis** and the large artery and vein at the medial side of the tendons (Pl. III). Reflect the proximal portion of the tendons and carefully trace the branch from the **N. volaris lateralis** to the suspensory ligament to which it supplies more small branches and also two branches that accompany the respective two or arteries **metacarpea volaris medialis** and **lateralis**.

A. retis carpi volaris is a small vessel which arises from the **A. radialis posterior** near the distal third of the antebrachium and descends to the posterior surface of the carpus where it divides into several small branches which help to form the **rete carpi volare**.

A. metacarpea volaris lateralis. This is the smallest of the three branches that continue the **A. radialis posterior**. It arises from the lateral side of the **A. radialis posterior**, crosses the medial face of the pisiform bone, with the **N. volaris lateralis**, and continues to the proximal end of the metacarpus. Here it is connected with the **A. metacarpea volaris medialis** usually by two transverse branches, thus forming the **arcus volaris profundus**. The larger of the two transverse branches lies between the subcarpal or inferior check ligament of the perforans tendon and the suspensory ligament: the other transverse branch, not always present, lies between the suspensory ligament and the large metacarpal bone. Cut the suspensory ligament near the middle and draw it aside. Below the deep vascular

arch, the **A. metacarpa volaris lateralis** runs in a flexuous course on the posterior face of the large metacarpal bone, close to the lateral rudimentary metacarpal. Near the distal third of the metacarpus the artery unites with the **A. metacarpea volaris medialis** to form a short trunk which joins the **A. digitalis lateralis** close to the origin of the latter.

A. metacarpea volaris medialis (Pl. III, 17) arises from the **radialis posterior**, usually a little proximal to the metacarpea volaris lateralis, and is considerably larger than that artery. It passes across the postero-internal face of the carpus with the large vein of the same name, imbedded in the carpal sheath or posterior annular ligament. At the proximal end of the internal rudimentary metacarpal it is connected with the **A. metacarpea volaris lateralis**, usually, by two transverse branches (**arcus volaris profundus**) as mentioned above. It then continues in a flexuous course, on the posterior internal face of the large metacarpal, to near the distal third of the metacarpus where it unites with the **metacarpea volaris lateralis** to form a short common trunk which joins the **A. digitalis lateralis**. The nutrient artery of the large metacarpal bone is a branch of the metacarpea volaris medialis.

A. metacarpea dorsalis lateralis and **A. metacarpea dorsalis medialis** are two very small arteries that have a variable origin. Sometimes they arise from the **A. metacarpea volaris**, of the same side, at the level of the deep vascular arch. They extend anteriorly across the heads of the rudimentary metacarpals, descend in the grooves between the large and small metacarpal bones, and anastomose with the corresponding **A. metacarpea volaris**. Sometimes these two small arteries arise from the rete carpi dorsalis and in other cases, they arise in part from the rete carpi dorsalis and in part from the **A. metacarpea volaris lateralis** and the **A. metacarpea volaris medialis**.

A. digitalis communis (Pl. III, 18) is the largest and most direct continuation of the **A. radialis posterior**. It extends through the carpal canal at the medial side of the flexor tendons, in company with the **N. volaris medialis**. Slit open the carpal canal and trace the artery and the large metacarpal vein that, in the metacarpal region, accompanies the artery along the medial side of the flexor tendons to near the fetlock where the artery divides into the **A. digitalis lateralis** and the **A. digitalis medialis**. Remove the hoof or horn capsule.

N. volaris medialis (Pl. III, 27) is formed by one of the terminal branches of the **N. medianus**. It passes through the carpal canal in close company with

the large *A. digitalis communis* and both artery and nerve are in close relation with the flexor tendons. Note that near the middle of the metacarpus the nerve gives off a large branch which crosses very obliquely the posterior face of the flexor tendons and joins the *N. volaris lateralis* a little above the distal extremity of the rudimentary metacarpal (Pl. III, 28). At the level of the sesamoid bones of the fetlock, the nerve divides into two, sometimes three, branches, viz., an anterior, a middle, if present, and a posterior branch (Pl. III, 30, 31, 32). These branches are of very unequal size, the posterior being much the largest and the most important. This branch is the one that is cut in the operation of low neurectomy. The anterior branch descends in front of the vein and is distributed to the skin on the anterior face of the digit and to the coronary band or matrix. The middle branch is small and irregular; it descends between the artery and vein and is generally formed by the union of several small branches which cross over the artery before uniting. This branch terminates in the coronary band or matrix and the sensitive laminae. The posterior branch lies close behind the artery, except at the fetlock, where the nerve is more superficial than the artery. This posterior branch accompanies the digital artery and will be traced with it. It is distributed to the sensitive laminae, sole and frog.

A. digitalis lateralis and **A. digitalis medialis** are formed by the bifurcation of the **digitalis communis** near the distal third of the metacarpus. Each artery passes over the outer surface of the corresponding sesamoid bone at the fetlock, and descends parallel to the borders of the deep flexor tendon to the volar foramina of the third phalanx; in the semilunar canal of this bone the two arteries anastomose with each other. Expose the artery of one side, as follows: remove the lateral cartilage and the anterior or apical two-thirds of the plantar cushion; remove also, the portion of the deep flexor tendon that is exposed by the removal of the anterior part of the plantar cushion, i.e. the portion of tendon in relation to the navicular bone and the semilunar crest of the third phalanx. Each digital artery is accompanied by a vein and the two or three branches of the volar nerves. Proximal to the fetlock the artery lies deeply and is covered by the vein and nerve; at the fetlock the three structures lie at the same level, the vein being anterior and the large posterior branch of the nerve back of the artery. The anterior branch of the volar nerve crosses obliquely the digital artery and vein at, or a little below, the fetlock (Pl. III, 30). The vessels and nerves are crossed obliquely by a small ligamentous band extending from the ergot to the fascia at the side of the first interphalangeal or pastern joint (Pl. III, 13).

Branches of the *A. digitalis lateralis*.

(1) Numerous small branches to the ergot, joints, tendons and tendon sheaths.

(2) **A. phalangis primae**. (Artery of the first phalanx). This is a short trunk which arises at a right angle near the middle of the first phalanx and divides almost immediately into an **anterior** and a smaller **posterior** branch. The **anterior** branch divides into an ascending and a descending portion both of which are distributed on the anterior face of the first phalanx. A branch passes between the extensor tendon, which should be cut, and the first phalanx and anastomoses with the corresponding artery of the opposite side. The small **posterior** branch of the **A. phalangis primae** divides into several branches of which one passes between the infrasesamoidean ligaments and the first phalanx and anastomoses with the opposite artery; the other branches are distributed to the structures on the posterior face of the first phalanx.

(3) **A. toricae phalangis tertia** (artery of the plantar cushion) arises at a right angle from the **digitalis**, at the proximal border of the lateral cartilage. It extends postero-distally and is distributed to the plantar cushion and to the matrix of the frog.

(4) **A. dorsalis phalangis secundae** (dorsal or anterior artery of the second phalanx). This artery arises at a right angle from the **digitalis**, near the middle of the second phalanx, and under cover of the lateral cartilage. It extends anteriorly beneath the lateral cartilage and the extensor tendon and anastomoses with its fellow of the opposite side. Just as it passes beneath the extensor tendon it gives off a branch to the coronary band or matrix; it also supplies small branches to the tendon and to the joint capsule. A branch of the volar nerve accompanies the artery.

(5) **A. volaris phalangis secundae** (ventral or posterior artery of the second phalanx) is smaller than the preceding opposite to which it arises. It passes above the proximal border of the navicular bone and anastomoses with its fellow of the opposite side.

(6) **A. dorsalis phalangis tertiae** (dorsal artery of the third phalanx) arises from the **digitalis** at the inner or medial side of the wing of the third phalanx. In company with the posterior branch of the *N. volaris*, it passes through the notch (or foramen) of the wing of this bone and extends anteriorly in the vascular groove on the lateral surface of the bone. It gives off a posterior branch to the plantar cushion.

The branches of the *A. digitalis medialis* are the same as those of the *A. digitalis laterales*.

PLATE I

MEDIAL OR INNER VIEW OF THE PECTORAL LIMB

- 1, 1' Posterior superficial pectoral.
2. Anterior superficial pectoral.
3. Posterior deep pectoral.
4. Anterior deep pectoral.
5. M. supraspinatus.
6. M. subscapularis.
7. M. teres major.
8. M. latissimus dorsi.
9. M. panniculus.
- 9'. Aponeurotic tendon of panniculus.
- 10, 10'. Tensor fasciae antebrachii.
11. M. caput longum tricipitis.
12. M. caput mediale tricipitis.
13. M. coraco-brachialis.
14. M. biceps brachii.
15. Aponeurotic tendon-slip from biceps brachii.
16. M. flexor carpi internus.
17. M. flexor carpi medius.
- 17'. Ulnar head of flexor carpi medius.
18. Ulnar head of flexor perforans.
19. M. flexor perforatus.
20. M. flexor perforans.
21. A. axillaris.
22. A. subscapularis.
23. A. brachialis.
24. A. profunda brachii.
- 25, 25'. A. ulnaris.
26. A. radialis posterior.
VII, VIII, I, II, = 7th - 8th cervical and 1st and 2d thoracic nerves.
27. Nerve to anterior deep pectoral.
28. N. suprascapularis.
- 29, 29'. N. musculo-cutaneus.
- 30, 30'. Nn. to anterior and posterior superficial pectorals.
31. Nn. to posterior deep pectoral.
- 32, 32'. N. medianus.
33. Nerve filament to biceps brachii (very rarely present).
- 34, 34'. Cutaneous branch of N. medianus.
35. Branch of N. medianus to M. humeralis obliquus.
36. Branch to M. flexor carpi internus.
37. Branch to flexor perforans.
38. Small branch to radial head of flexor perforans and to the radio-ulnar arch.
- 39, 39'. N. ulnaris (a) cutaneous branch; (b) branch to M. flexor carpi medius; (c) branch to flexor perforatus; (d) branch to ulnar head of flexor perforans; (e) branch to ulnar head of flexor perforatus.
40. M. radialis.
41. Branch to caput longum tricipitis.
42. Branch to caput longum, laterale, mediale and anconeus.
43. Portion of N. radialis that continues along the spiral groove to the extensors of the metacarpus and phalanges.
44. Branch of N. radialis to the M. tensor fasciae antebrachii.
45. Nerve to the panniculus and posterior deep pectoral.
46. N. axillaris.
47. Nn. subscapulares.
48. Nerve to the M. latissimus dorsi.
49. Axillary lymph gland.
- 49' Lymph gland.

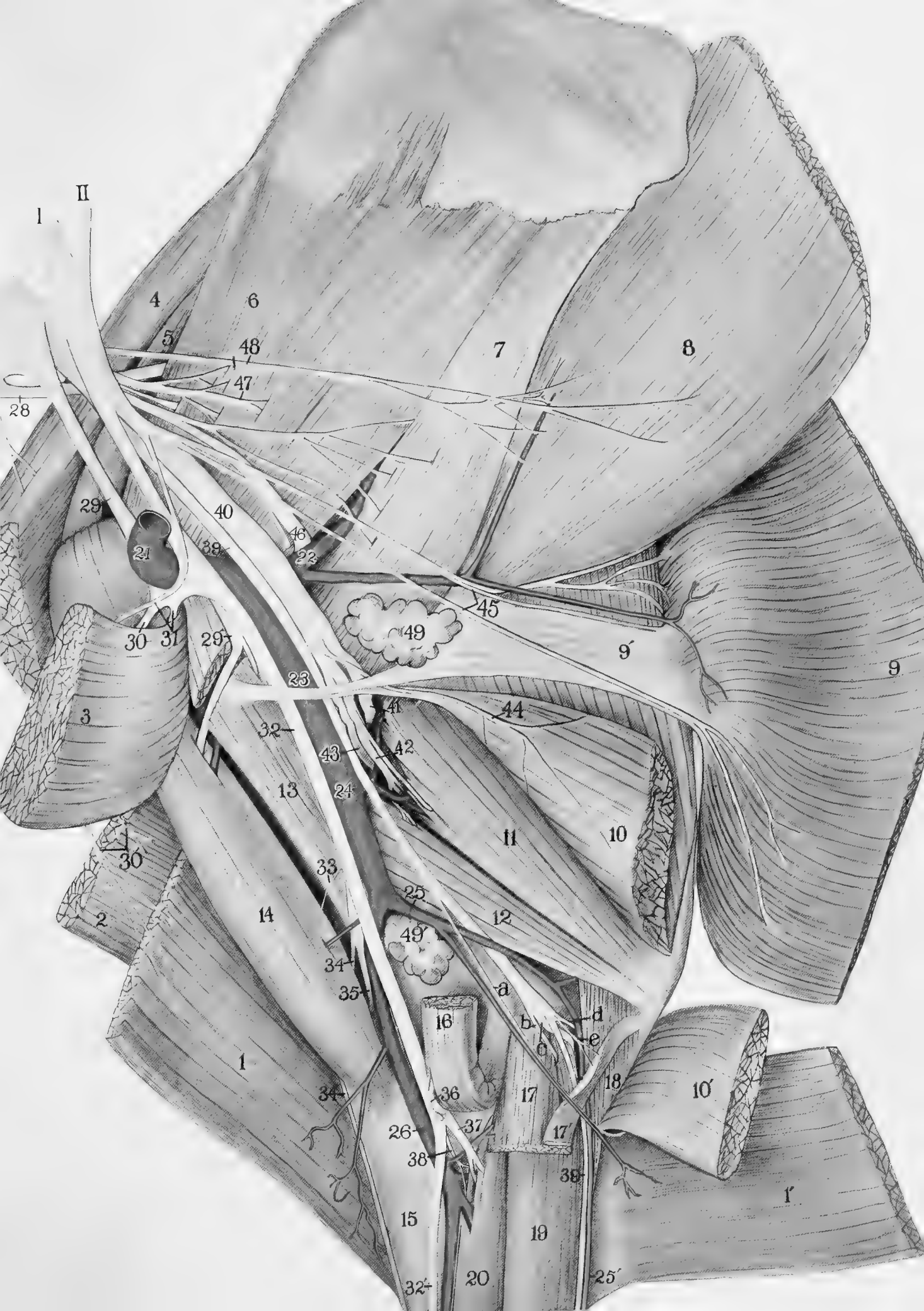


PLATE II

LATERAL OR EXTERNAL VIEW OF THE PECTORAL LIMB

1. *M. supraspinatus*.
- 2, 3, 3'. *M. deltoideus* (transected and turned aside).
4. *M. teres minor*.
5. *M. caput longum tricipitis*.
- 5'. *M. tensor fasciae antebrachii*.
- 6, 6'. *M. caput laterale tricipitis* (transected and the distal portion turned back).
7. *M. anconeus*.
8. *M. biceps brachii*.
9. *M. mastoideo-humeralis*.
10. *M. brachialis*.
- 11, 11'. *M. extensor carpi radialis* (transected and the distal portion turned aside).
12. *Radius*.
- 13, 13'. *M. extensor digitalis communis* (*extensor pedis*) a portion of the muscle has been removed.
14. *M. extensor carpi obliquus*.
15. Ulnar head of *M. flexor perforans*.
16. *M. flexor carpi externus*.
17. *M. extensor digitalis lateralis*.
18. *M. flexor perforans*.
- 19, 20. *A. radialis anterior*.
21. *N. suprascapularis*.
22. *N. axillaris*.
23. Cutaneous branch of *N. axillaris*.
24. Branch of *N. axillaris* to *M. mastoideo-humeralis*.
- 25, 25'. *N. radialis*.
 - a. a'. Branch of *N. radialis* to *caput laterale tricipitis*.
 - b. Branch to *M. anconeus*.
 - c. Cutaneous branch of *N. radialis*.
 - d. Branches of *N. radialis* to *M. extensor carpi radialis*.
 - e. Branches to *M. extensor digitalis communis*.
 - f. Branch to *M. extensor carpi obliquus*.
 - g. Branch to *M. extensor digitalis lateralis*.
 - h. Termination of *N. radialis* in the *M. flexor carpi externus*.
26. Cutaneous branches of *N. ulnaris*.

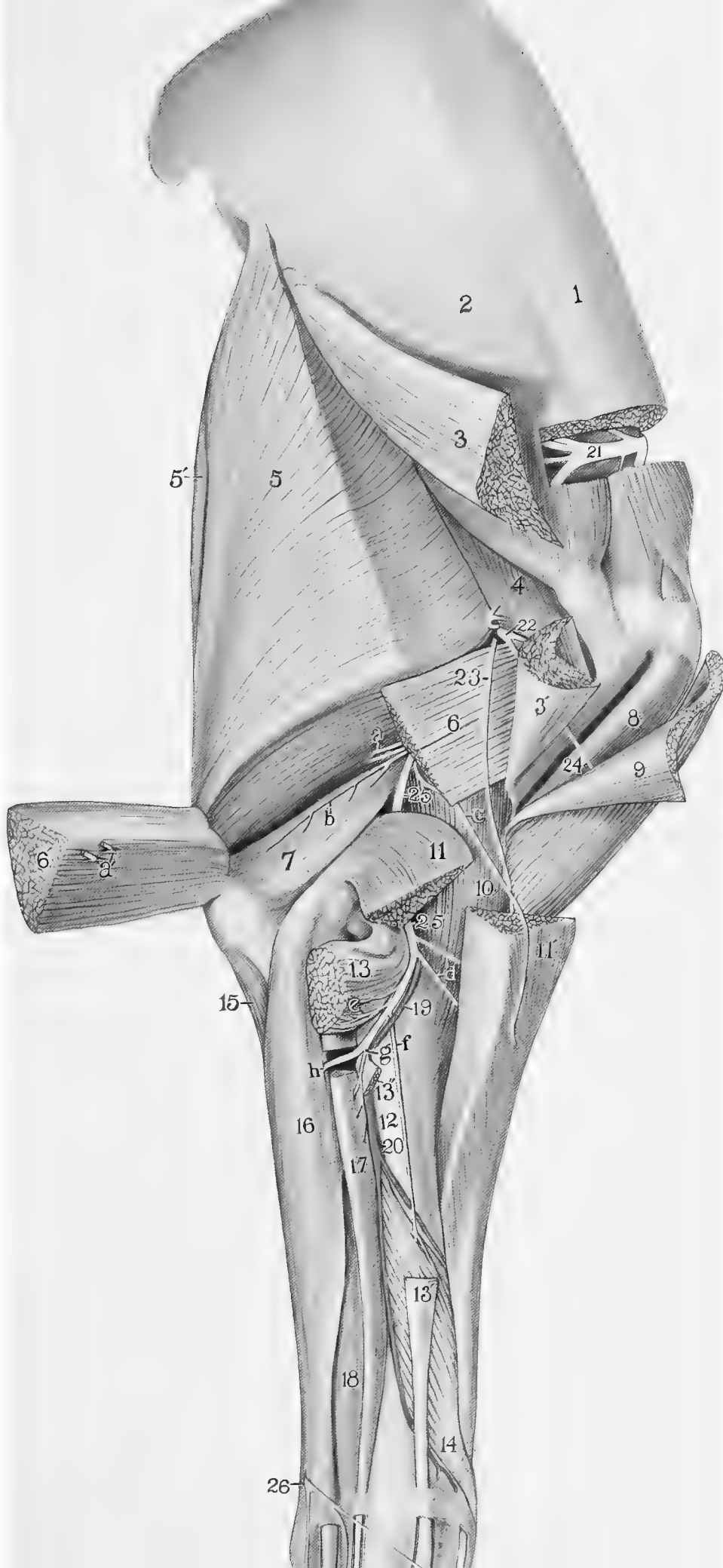
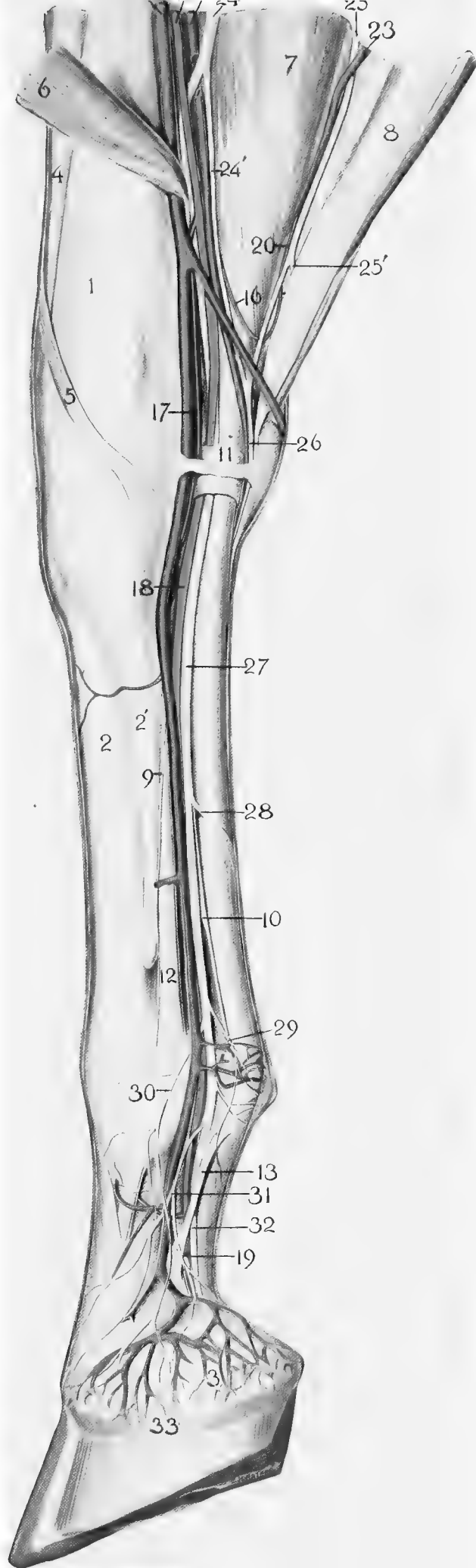


PLATE III
MEDIAL OR INNER VIEW

1. Radius.
- 2, 2'. Principal and medial metacarpal bones.
3. Lateral cartilage.
4. M. extensor carpi radialis.
5. M. extensor carpi obliquus.
6. M. flexor carpi internus.
7. M. flexor perforatus.
8. M. flexor carpi medius (turned aside).
9. M. interosseus medius.
10. M. lumbricalis medius.
11. Portion of carpal sheath or annular ligament.
12. Suspensory or suprasesamoid ligament.
13. Ligament of ergot.
14. Cut edge of antebrachial aponeurosis (not clearly shown in figure).
15. A. radialis posterior.
16. Supracarpal arch.
17. A. metacarpea volaris medialis.
18. A. digitalis communis.
19. A. digitalis medialis.
20. A. ulnaris.
- 21, 22. V. radialis posterior.
23. V. ulnaris.
24. N. medianus.
- 24'. Branch of N. medianus to the N. ulnaris.
25. N. ulnaris.
- 25'. Cutaneous branch of N. ulnaris.
26. N. volaris lateralis.
27. N. volaris medialis.
28. Anastomosing branch from N. volaris medialis to the N. volaris lateralis.
29. Small branch to region of ergot.
- 30, 31, 32. Anterior, middle and posterior branches of the N. volaris medialis.
33. Coronary band of matrix.



Dissection of the Blood-Vessels and Nerves of the Leg or Pelvic Limb

Remove the intestines and transect the body immediately caudal to the last pair of ribs. In the male, find the spermatic veins and the much smaller spermatic arteries near the **peritoneal** or **vaginal ring** through which they, together with the ductus deferens or spermatic duct, pass to the testes. Trace the right spermatic vein to the posterior vena cava, and the left one to the left renal vein (or to the posterior vena cava, close to the renal vein); also trace the spermatic arteries to their respective places of origin—the right spermatic artery, from the **A. mesenterica posterior** and the left one from the **aorta** a little cephalad of the preceding; sometimes both of these arteries arise from the aorta close to the **A. mesenterica posterior**. In the female the **utero-ovarian** arteries correspond to the spermatic arteries but are much shorter. Each artery passes in a tortuous manner between the two peritoneal layers of the anterior part of the broad ligament of the uterus and divides into two branches of which one is distributed to the ovary and the other to the cornu of the uterus. Clean up the aorta (and vena cava) taking care not to remove the **lumbar lymph glands** which lie near the place where the aorta divides into the **Aa. iliaca externa** and **interna**, (sometimes spoken of as the terminal branches of the aorta) (Pl. V, 30, 34). Note the size, number and location of the lumbar lymph glands. The posterior portion of the body should now be divided into halves by a sagittal section through the lumbar and sacral vertebrae, the pelvic symphysis and the pelvic organs. Identify each lumbar and sacra vertebra. Identify also the trunk of the sympathetic nerve which, in this region, lies on the ventro-lateral face of the bodies of the vertebrae and is covered by the aorta and the posterior vena cava (Pl. V, 45). This nerve trunk and its connections with each of the lumbar and sacral nerves, by the rami communicantes, should be noted as the dissection of the lumbo-sacral nerve plexus proceeds.

A. circumflexa iliaca (Pl. V, 29) usually arises from the **A. iliaca externa**, close to its origin, but sometimes directly from the aorta. It extends laterally across the ventral surface of the psoas muscles and divides into an anterior and a posterior branch shortly before it reaches the posterior border of the **M. transversus abdominis**. Transect the transversus abdominis near the middle of its fleshy portion and turn it aside. Note the location and size of the **external iliac lymph glands** (Pl. V, 64) which

are situated near the bifurcation of the *A. circumflexa iliaca*. Dissect up the peritoneum cephalad of the **peritoneal** or **vaginal ring** and note very carefully the relation of this ring and the spermatic cord, to the posterior edge of the *M. obliquus internus*. Do not confuse the *M. cremasteric externa* with the *obliquus internus*. Transect the *obliquus internus* a little dorsal to the peritoneal ring. Now trace the anterior branch of the *A. circumflexa iliaca*. At, or near, its origin it may give off one or two small branches to the *psoas magnus* and *iliacus*. About 5 cm. from its origin this anterior branch divides into two branches which are distributed to the *Mm. transversus*, *abdominis obliquus internus* and *obliquus externus*. The posterior branch of the **A. circumflexa iliaca**, 5 to 8 cm. from its origin, also divides into two branches of which one goes to the *obliquus internus* and the other, after perforating the abdominal wall near the external angle of the ilium, runs downward on the inner face of the *M. tensor fasciae latae*, about 5 cm. from its anterior border, and is distributed to the panniculus, the **precrural** or **subiliac lymph gland** and to the inner face of the *tensor fasciae latae*. To demonstrate this latter branch reflect the skin in the region of the flank and dissect between the abdominal wall and the inner face of the *tensor fasciae latae*. Find the artery (and vein) on the inner surface of the *tensor fasciae latae*, 5 to 8 cm. from its anterior border, and trace it in both directions.

Internal inguinal ring.

The internal inguinal ring should not be confused with the small peritoneal or vaginal ring of the male. The internal inguinal ring is from 10 to 12 cm. in length, measured from the prepubic tendon to the dorsal margin of the peritoneal ring. The anterior boundary of the internal inguinal ring is formed by the posterior edge of the *M. obliquus internus*; the posterior boundary is formed by the inguinal ligament. In the male the following structures pass through the inguinal canal, viz., the evaginated peritoneum of the spermatic cord, the ductus deferens or spermatic duct, the spermatic nerves, artery and vein and lymph vessels, the *A. pudenda externa* and the *M. cremasteric externa*. The skin in the region of the **external inguinal ring** should now be carefully turned aside in order to expose the superficial inguinal lymph gland, the external inguinal ring and the structures which pass through it. The **superficial inguinal lymph gland** forms a large mass, 8 to 10 cm. long, which lies anterior to the external inguinal ring. In the male the gland extends along the course of the *A. abdominalis subcutanea* on either side of the penis; in the female the gland is situated between the mammary gland and the abdominal wall. Now turn aside the portion of the *M. obliquus internus* that forms the anterior boundary of the **internal**

inguinal ring and note that the space (i.e. the inguinal canal) occupied by the spermatic cord is bounded posteriorly by the inguinal ligament and anteriorly, by the *M. obliquus internus*; note also that the length of the canal from the external inguinal ring to the level of the peritoneal ring, measured along the spermatic cord, is about 10 cm.

A. iliaca externa (Pl. V, 30) arises from the **aorta** at the level of the 5th lumbar vertebra and extends obliquely ventrally, at the side of the pelvic inlet, to the level of the anterior edge of the pubis where it is continued as the **A. femoralis**. Remove the overlying peritoneum and fascia. Note that the large *V. iliaca externa* is immediately posterior to the artery. The termination of the *A. iliaca externa* and the beginning of the *A. femoralis* is indicated by the **truncus pudendo-epigastricus** or prepubic artery.

Truncus pudendo-epigastricus or **prepubic artery** (Pl. V, 31) is only 6 to 8 cm. in length. It arises from the **A. iliaca externa** near the level of the anterior border of the pubis. The artery crosses the dorsal or free edge of the inguinal ligament and extends for a short distance along the abdominal or anterior face of the ligament to the internal inguinal ring where it divides into two branches—**A. epigastrica caudalis** or **posterior abdominal** and **A. pudenda externa** or **external pudic**.

(1) **A. epigastrica caudalis** (or posterior abdominal).

This branch of the pudendo-epigastric trunk extends cephalad along the lateral border of the *M. rectus abdominis* to which it is principally distributed; small twigs however, are also supplied to the *transversus abdominis* and the *obliquus internus*. The artery is accompanied by a vein.

(2) **A. pudenda externa** (or external pudic).

This artery and its branches may be readily exposed by dissecting, en masse, the sheath and penis from the abdominal wall as far back as to the external inguinal ring taking care not to cut the artery as it emerges from the ring at the postero-internal commissure.

The *A. pudenda externa* is from 4 to 6 cm. in length. Immediately after it passes through the external inguinal ring it divides into two branches—the **A. abdominalis subcutanea** and the **A. dorsalis penis**. Trace the former cephalad, along the side of the sheath, to which and to the superficial inguinal lymph gland it is distributed. The dorsal artery of the penis passes to the dorsum of that organ and terminates at the glans penis. It gives off collateral branches to the *corpus cavernosum* one of which usually passes posteriorly and anastomoses with a branch of the *A. obturatoria*. In the female the mammary artery takes the place of the dorsal artery of the penis. Note that the enormous venous plexus on the dorsal and lateral sides of the

penis, (or the mammary glands) is drained mainly by the large **V. pudenda externa** (Pl. V, 42), which lies in the subpubic groove of the pelvis.

A. pudenda interna (Pl. V, 37).

Care must be exercised in tracing this artery especially its distal half, not to injure its numerous small branches or the neighboring nerves; the adjoining veins however, may be cut if desired. The urocyst and all of the other pelvic organs should be turned dorsally. The **A. pudenda interna** arises from the **A. iliaca interna** near the origin of the latter vessel. It extends posteriorly across the lateral wall of the pelvic cavity, lying close to the dorsal border of the iliac portion of the M. obturator internus. Opposite the superior ischiatic spine the artery is covered by the M. retractor ani which should be transected and turned aside (Pl. V, 21 and 21'). Near the lesser sacro-sciatic foramen the artery either passes through the sacro-sciatic ligament i.e. from its inner to its outer surface, or is imbedded in the substance of the ligament. Trace the artery peripherally as far as can be done readily (to the posterior border of M. retractor ani) and then proceed as follows: make a circular cut in the skin of the anal region at a little distance, 4 to 6 cm., from the anal orific; also cut the large bundle of muscle fibres (recto coccygeal, Pl. V 23) that attaches the terminal part of the rectum to the coccygeal vertebrae. Cut also, the M. retractor penis (Pl. V, 22). Now carefully remove the connective tissue from the side of the anus until the artery and nerves are exposed. The main trunk of the artery terminates in the erectile tissue at the root of the penis.

Branches of the A. pudenda interna.

(1) **A. umbilicalis** (Pl. V, 39) arises from the **pudenda interna** 2 to 3 cm. from the origin of that vessel and passes directly to the urocyst. Before birth the A. umbilicalis is a very large vessel and carries the foetal blood to the placenta. After birth the vessel extends only to the urocyst and is very much smaller than in foetal life.

(2) **A. haemorrhoidalis media** (or vesico-prostatic). This small artery in the male, arises from the **pudenda interna** about 8 cm. from the origin of the latter (or about half way between the origin of the A. pudenda interna and the anterior edge of the M. retractor ani) and runs posteriorly. It supplies small twigs to the rectum, urocyst, prostate gland, and seminal vesicle. Near the ischial arch the A. pudenda interna gives off a small branch—**A. perinei**—which passes somewhat dorsally at the side of the anus which it supplies; the A. pudenda interna also gives off twigs to the M. bulbo-cavernosus and the skin of the perineum. In the female the corresponding artery is much larger and gives off the **A. uterina caudalis**. This

runs cephalad on the side of the vagina to which it gives branches and ramifies on the body of the uterus, anastomosing with the anterior and middle uterine arteries.

N. femoralis (Pl. V, 46, Pl. VII, 14) originates from the ventral divisions of the 3d, 4th, 5th and 6th lumbar nerves; very commonly however, the branch from the 6th lumbar nerve is wanting. Turn aside or remove the iliac fascia from the ventral surface of the sublumbar muscles. The proximal portion of the N. femoralis is covered by the M. psoas parvus. Transect this muscle a little caudal to the A. circumflexa iliaca and turn its distal portion toward the median plane. The large **N. femoralis** will now be seen to have the same general direction ventro-caudally, as the A. iliaca externa. Transect the psoas magnus at the same level as the psoas parvus; separate the two muscles from each other sufficiently to trace the N. femoralis to its respective places of origin from the 3d, 4th, 5th, and 6th, if present, lumbar nerves (Pl. V, III, IV, v). Near its origin the N. femoralis lies at about the same level as the A. iliaca externa. At the ventral border of the tendon of the psoas parvus where the nerve passes under the anterior end of the M. sartorius (Pl. V, 11), the nerve lies just anterior to the artery but is separated from it by the tendon of the psoas parvus which lies between the artery and the nerve (Pl. V, 8¹).

Branches of the N. femoralis.

The first branch of the N. femoralis is given off a little peripheral to the place of junction of the ventral divisions of the 3d, and 4th lumbar nerves. It is a small branch supplied to the psoas magnus. The next branch, much larger than the preceding, leaves the N. femoralis a little peripheral to the junction of the 4th and 5th lumbar nerves. This second branch extends laterally between the psoas magnus and the iliacus and divides into several branches which are distributed to the M. iliacus; one or more small filaments may go to the psoas magnus. The remaining portion of the N. femoralis may be exposed as follows: Cut the femoral aponeurosis near its attachment to the M. obliquus externus and remove it. With the fingers, principally, dissect between the muscles of the thigh and the posterior face of the inguinal ligament, leaving the ligament intact. Identify the M. sartorius and note its relation, together with that of the iliacus and the psoas magnus, to the inguinal ligament. Free the sartorius from its attachment to the iliac fascia. Dissect between the sartorius and the M. gracilis taking care not to injure the nerve and blood-vessels that emerge from between these two muscles near the middle of the thigh. Transect the sartorius near the middle of the thigh. Draw aside the

proximal portion of the muscle taking care not to cut the small nerve branches it receives from the **N. saphenus internus** (Pl. V, 47, 48) (a branch of the N. femoralis) which lies immediately beneath the proximal half of the sartorius; also do not disturb the **deep inguinal lymph gland** which lies in the interstice between the sartorius and the pectineus (Pl. V, 63). As the **N. femoralis** crosses the tendon of the psoas magnus it gives off the large branch just mentioned, **N. saphenus internus**, which runs beneath the sartorius for about one-half the length of the muscle, supplies small branches to it, as just stated. It then emerges with the A. and V. saphena interna, from between the adjacent borders of the sartorius and gracilis, near the middle of the thigh, where it breaks up into several large subcutaneous branches which are distributed to the inner and anterior faces of the thigh and leg. The longest of these branches accompanies the A. and V. saphena interna to the flexor side of the tarsus. Frequently the N. saphenus internus is divided into two parallel branches. After giving off the N. saphenus internus the main trunk of the N. femoralis, together with a large artery and vein, passes between the rectus femoris and the vastus internus into the quadriceps femoris group of muscles. Dissect between the vastus internus and the rectus femoris; transect the rectus femoris 10 to 15 cm. from its attachment to the patella and reflect the ends. The vastus internus also may be partially transected, if desired. Now trace the N. femoralis to its termination in the rectus femoris, vastus internus, vastus externus, and vastus intermedius. The small M. capsularis is not supplied by this nerve but by one of the gluteal nerves as mentioned later.

Exposure of the **A. iliaca interna**, the **A. sacralis lateralis** and the sacral nerves (Pl. V, 34, 35, 52, 54, 55, 56, 57, 60).

Turn the rectum and other pelvic organs ventrally and find the small nerves (Pl. V, 58) 2 to 4 in number, which lie between the peritoneum and the sacro-sciatic ligament and extend from the 2d, 3d, and 4th or from the 3d and 4th only, sacral nerves towards the lateral side of the pelvic organs where, in connection with branches of the sympathetic nerve, they form an intricate network of nerves known as the **hypogastric or pelvic plexus** (Pl. V, 51). (If put on the stretch these two or more small nerves will stand out as more or less tense bands.) Great care must be exercised in exposing the **A. (and V.) sacralis lateralis** and the sacral nerves, because of their intimate relation to each other and to the sacro-sciatic ligament. Cut the ligament along the ventral mid surface of the V. sacralis lateralis and carefully turn it from the vein. It will now be seen that the largest of the sacral nerves, **N. ischiadicus**, 5 to 8 cm. in width (Pl. V, 54), originates from the 5th and 6th lumbar and the 1st and 2d sacral nerves. This large

nerve trunk lies on the outer or lateral surface of the sacro-sciatic ligament and is not very liable to be mutilated. Two smaller nerves however, the **N. pudendus** (Pl. V, 57) and the **N. haemorrhoidalis** (Pl. V, 60) which originate from the 2d, 3d, and 4th or from the 3d and 4th, only, sacral nerves lie on the inner or pelvic surface of the sacro-sciatic ligament or else are imbedded in its substance. Each of these two nerves is from one-half to one centimeter in width but is so thin, and in color so closely resembles the ligament that it is liable to be overlooked and removed along with the ligament.

A. iliaca interna (Pl. V, 34) is a very large vessel and arises from the aorta close to the intervertebral disc between the 5th and 6th lumbar vertebrae. It runs under the wing or transverse process of the sacrum, then turns ventrally and extends along the pelvic surface of the shaft of the ilium to near the psoas tubercle of the ilium, where the vessel divides into its two terminal branches—the **A. circumflexa femoris lateralis** (iliaco-femoral artery) and the **A. obturatoria**. To demonstrate this, remove a portion of the overlying V. iliaca interna.

Branches of the A. iliaca interna.

(1) The last one of the six lumbar arteries arises from the dorsal side of the A. iliaca interna and passes into the spinal canal through the intervertebral foramen between the last lumbar vertebra and the sacrum.

(2) **A. pudenda interna** (Pl. V, 37), already described. See p. 30.

(3) **A. sacralis lateralis** (Pl. V, 35). Remove the overlying V. sacralis lateralis. The **A. sacralis lateralis** arises from the **iliaca interna** close to the lumbo-sacral articulation. It extends along the sacrum ventral to the sacral foramina and the nerves that emerge from them. At the third sacral vertebra the artery divides into two branches—**A. coccygeus lateralis** and the much larger **A. glutea posterior**. Trace the A. coccygeus lateralis some distance along the tail to which it is distributed. The dissection of the A. glutea posterior must be deferred until the gluteal nerves are dissected. See p. 38.

(4) **A. iliolumbalis** arises at a right angle from the lateral side of the **iliaca interna**, crosses the ventral surface of the ilium beneath or dorsal to the Mm. psoas magnus and iliacus to which it gives small branches. Transect the M. iliacus opposite the artery. Draw aside the iliacus and the psoas magnus and trace the artery to where it crosses the external border of the ilium a little behind the external angle. Its terminal branches which will be demonstrated later, enter the gluteus medius and the tensor fasciae latae.

(5) **A. glutea anterior** is the largest branch of the **iliaca interna**. It arises nearly opposite the iliolumbalis, passes through the greater sacrosciatic foramen and immediately enters the gluteal muscles by several branches. These branches cannot be demonstrated until the gluteal muscles have been dissected. Frequently one of the radicals of the N. obturatoria (from the 6th lumbar, Pl. VII, 16) crosses the ventral face of the A. glutea anterior, close to its origin from the iliaca interna.

(6) **A. circumflexa femoris lateralis** (iliaco-femoral artery) is one of the terminal branches of the **iliaca interna**. To expose the vessel, draw aside the distal portion of the psoas magnus; transect the iliacus and draw it aside. The artery crosses the shaft of the ilium a little dorsal to the insertion of the psoas parvus and enters the quadriceps femoris group of muscles between the rectus femoris and the vastus externus. It supplies branches to the psoas magnus and iliacus, rectus femoris, tensor fasciae latae, vastus externus and medius and the superficial and middle gluteal muscles. The artery is accompanied by two large veins.

(7) **A. obturatoria** (Pl. V, 38) is the inner terminal branch of the **A. iliaca interna**. It passes posteriorly on the inner or pelvic surface of the shaft of the ilium along the ventral border of the iliac portion of the M. obturator internus. The obturator vein and nerve accompany the artery. At the anterior border of the obturator foramen the artery, vein and nerve dip beneath the M. obturator internus (Pl. V, 18^t). Cut the overlying portion of this muscle close to its origin and turn it aside. In its course beneath the M. obturator internus the artery gives off small twigs to it; also a larger branch which passes through the obturator foramen and is supplied to the hip joint. At the very posterior part of the obturator foramen the obturator artery gives off a small branch which passes posteriorly on the dorsal surface of the ischium, to the ischial arch, where it anastomoses with a branch of the A. obturatorius that extends along the ventral face of the ischium; it also anastomoses by a small branch with the A. pudenda interna. The extrapelvic portion of the A. obturatoria is deeply covered by the muscles of the inner side of the thigh and can be only partially exposed at present. First dissect the M. gracilis, beginning at its posterior border; free it from the underlying muscles and at the same time transect it a little below its middle. Turn back the proximal portion of the muscle noting the blood-vessels and nerves that enter it. Now beginning at its posterior border, cut the muscle about two-thirds of the way across, close to its attachment to the pelvis, in order to expose clearly the origin of the adductor magnus. (The adductor magnus as here used includes the adductor parvus of some writers). Note the **deep inguinal lymph gland** 12 to 15 cm. in length, that lies in the space between the

sartorius and the pectineas (Pl. V, 63). Note the relation of this gland to the large artery (A. femoralis) beneath it and to the inguinal ligament. Dissect between the pectineus and the adductor magnus, on one side, and the deep inguinal lymph gland and the A. and V. femoralis, on the other. Transect the pectineus a little below its middle and draw aside the distal portion. Carefully remove any connective tissue or fat from the space between the pectineus and the adductor magnus and find the small nerves that enter each of these muscles. Dissect between the adductor magnus and the semimembranosus; transect the adductor magnus close to its pelvic attachment and draw up the muscle sufficiently to expose the M. obturator externus which is directly beneath the proximal portion of the adductor magnus. Find the **A. obturatoria** (and large vein) where it emerges from beneath the posterior border of the M. obturator externus, close to the ventral surface of the ischium. The posterior portion of the M. obturator externus must now be cut close to its origin and drawn aside in order to expose the A. obturatoria, after it passes through the obturator foramen. About 5 cm. from the posterior edge of the foramen the artery gives off a large branch which runs along the ventral surface of the ischium to the ischial arch where it divides into several branches, of which one goes to the crus penis close to its attachment to the ischium. The extrapelvic portion of the A. obturatoria also gives off a branch to the ventral surface and one to the dorsal surface of the penis. About 5 cm. peripheral to these two branches a much larger branch is given off to the semimembranosus. Further dissection of the obturator artery must be deferred until the overlying muscles have been dissected.

N. obturatorius (Pl. V, 49; Pl. VII, 16) originates from the 4th and 5th lumbar nerves; frequently however, it receives a branch from the 6th lumbar nerve. The nerve extends directly to the anterior part of the obturator foramen. It lies just beneath the peritoneum and for some distance accompanies the obturator artery and vein; the nerve and blood-vessels then diverge from each other, the nerve passing through the anterior part of the obturator foramen and the blood-vessels through the posterior part. Reflect the proximal portion of the M. gracilis and the large branch of the N. obturatoris that supplies it will be seen on the proximal portion of the muscle extending transversely toward its posterior border. Upon drawing aside the proximal portion of the M. pectineus the branches of the N. obturatorius to it and to the adductor magnus may be seen. Upon drawing the adductor magnus from the obturator externus the branch of the obturator nerve that passes through the M. obturator externus, near its anterior border, and enters the adductor magnus, may be seen.

Turn aside or remove a portion of the obturator externus and trace the respective branches supplied to it and to the adductor magnus, the gracilis, and pectineus to their respective places of origin from the obturator nerve. It will now be seen that N. obturatorius divides into two branches one of which is distributed to the gracilis and pectineus and the other to the adductor magnus and obturator externus.

N. pudendus (Pl. V, 57, 57¹) originates from the 2d and 3d sacral nerves, or in some cases from the 3d only. It extends posteriorly, at first on the inner or pelvic surface of the sacro-sciatic ligament, but gradually passes into the substance of the ligament. Near the lesser sciatic foramen the nerve crosses the lateral surface of the **A. pudenda interna**, (Pl. V, 37), and inclining inwards, turns around the ischial arch and gains the dorsal surface of the penis along which it continues as the **N. dorsalis penis**. Shortly before the nerve crosses the A. pudenda interna it gives off the **N. haemorrhoidalis medius**, or **perinaeo-anal** nerve (Pl. V. 57¹¹) which is distributed by numerous branches to the muscles of the urethra and penis, including the ischio-cavernosus muscle, and to the terminal portion of the rectum. The communicating branch of the **posterior ventral gluteal nerve** (Pl. V, 55) to the **N. pudendus** joins the latter at the place of origin of the **perinaeo-anal** nerve. In the female the N. pudendus is distributed to the labia, clitoris, and the constrictor muscles of the vulva and anus and to the perineum.

N. hemorrhoidalis (Pl. V, 60) is formed from the 3d and 4th sacral nerves or from the 4th only. It passes posteriorly on the inner or pelvic face of the sacro-sciatic ligament to the anal region where it divides into a number of branches which are distributed to the retractor and sphinctor muscles of the anus and to the skin of the perineal region.

A. profunda femoris arises either in common with the **truncus pudendo-epigastricus** (or prepubic) or a little peripheral to it. It passes caudo-ventrally between the pectineus and the terminal tendon of the iliacus and psoas magnus. Draw aside the pectineus and demonstrate the one or more small branches supplied to it. Beneath the adductor magnus the artery gives off a very large branch which is distributed to this muscle, and to the gracilis and the semimembranosus. It also supplies twigs to the deep inguinal lymph gland. The remaining portion of the A. profunda femoris is covered by muscles and cannot be traced at present. A large vein accompanies the artery.

A. femoris anterior (Pl. V, 32) arises from the **A. femoralis** about 2 cm. peripheral to the femoris profunda, from the opposite side of the A. femoralis. It passes

anteriorly and enters the precural group of muscles between the rectus femoris and vastus internus. It supplies branches to the iliacus and the quadriceps femoris muscles.

Exposure of the gluteal vessels and nerves.

Remove the skin from the gluteal and femoral regions. Dissect between the biceps femoris and the adjoining muscles, viz., the gluteus superficialis and vastus externus, anteriorly, and the semitendinosus, posteriorly. Also dissect between the semitendinosus and the semimembranosus. Transect the semitendinosus opposite the ischial tuberosity and draw aside the proximal portion just enough to expose the nerve and blood-vessels that enter it immediately dorsal to the ischial tuberosity (Pl. IV, 25). Transect the biceps femoris at the level of the external small trochanter and also at the level of the nerve, just exposed, to the semitendinosus, i.e. immediately dorsal to the ischial tuberosity. In this latter transection one of the large nerve branches to the biceps femoris will probably be cut; the other large nerve branch to this muscle lies more deeply and may be seen readily if the proximal portion of the muscle be drawn aside. Trace both of these large branches peripherally for some distance. Upon drawing aside the proximal portion of the biceps femoris it will be seen that the two or three large branches just mentioned (and the A. and V. glutea posterior) emerge from beneath the gluteus medius and are distributed to the biceps femoris and also one small branch to the posterior border of the gluteus superficialis (Pl. IV, 23). These large nerve branches cannot be traced at present to their place of origin from one of the posterior gluteal nerves. Now dissect between the tensor fasciae latae and the gluteus superficialis taking care not to cut the nerve or blood-vessels that emerge from beneath the anterior edge of the gluteus superficialis near its middle, and enter the adjoining borders of the tensor fasciae latae and the gluteus superficialis (Pl. IV, 22). Transect the gluteus superficialis a little proximal to the nerve just exposed, turn it aside somewhat, and note the small nerves and blood-vessels supplied to its anterior edge. The gluteus medius should now be transected a little proximal to the two above mentioned nerves that emerge from beneath the respective anterior and posterior borders of the muscle, i.e. the nerve to the tensor fasciae latae and the nerve to the biceps femoris (Pl. IV, 22, 23). The deep face of the gluteus medius is indicated by these two nerves and they should be kept in view while transecting the muscle; this may be done if while transecting it, the proximal portion of the muscle be freed largely from its attachment to the iliac fossa and the sacrum and turned back. Note the vein and artery—**A. iliolumbalis**—that cross the external border of the ilium from 5 to 8 cm. ventral to the

external angle of the ilium and are distributed to the gluteus medius and tensor fasciae latae. See p. 33.

A. glutea anterior. The distribution of the A. glutea anterior to the middle and deep gluteals may now be demonstrated. The artery will have been cut when the gluteus medius was turned back. Clean up the artery in so far as it can be traced. See p. 34.

A. glutea posterior or **ischiadicus** (continued, see p. 33). The distribution of the **A. glutea posterior** to the biceps femoris, the semitendinosus and, in this specimen, to the internal part of the gluteus superficialis, may now be demonstrated.

Nn. glutei. There are 5 or 6 of these nerves which are usually described as the anterior and posterior gluteal nerves.

Nn. glutei anterior. There are three or four nerves in this group. They pass through the great sciatic foramen and are distributed to the gluteal and other muscles as follows: one large nerve lying at the anterior side of the N. ischiadicus passes postero-laterally across the dorsal surface of the shaft of the ilium and between the middle and deep gluteal muscles and is distributed to the tensor fasciae latae and the gluteus superficialis as has been already demonstrated (Pl. IV, 22). Sometimes this nerve sends a small branch to the gluteus medius. A short distance from its origin it frequently gives one or more short branches to the gluteus profundus; a branch from this nerve is also sent to the M. capsularis. The other large anterior gluteal nerves have a very short course before entering the gluteus medius; they arise from the lateral side of the plexus but are so completely hidden from view by the great N. ischiadicus that they are liable to be overlooked. They accompany the A. glutea anterior through the great sciatic foramen and immediately enter the gluteus medius.

Nn. glutei posterior (Pl. V, 55, 56). There are two large nerves in this group, a dorsal or superior, and a ventral or inferior nerve, both of which apparently arise from the dorso-caudal side of the N. ischiadicus. The one first given off, the **posterior dorsal gluteal** (Pl. V, 56), really has its origin from the 6th lumbar and the 1st and 2d sacral nerves; only a few fibres however come from the 6th. The nerve extends posteriorly between the sacro-sciatic ligament and the gluteus medius and upon emerging from beneath the latter muscle it extends between this muscle and the biceps femoris to which it is distributed as has already been demonstrated (Pl. IV, 23). One small branch from this nerve is sometimes supplied to the gluteus

medius and one to the posterior edge of the gluteus superficialis. The second posterior gluteal nerve, **posterior ventral gluteal**, originates from the 1st and 2d sacral nerves but to a very slight extent however, from the 1st sacral. This nerve also passes posteriorly between the sacro-sciatic ligament and the M. gluteus medius. Eight or ten centimeters from its origin it divides into two branches of which one enters the semitendinosus immediately dorsal to the ischial tuberosity as already demonstrated (Pl. IV, 25). This branch of the posterior gluteal nerve gives off a filament that unites with the **N. pudendus** as already demonstrated. The other branch of the **posterior ventral gluteal** nerve emerges near the middle of the outer surface of the ischial tuberosity and may be seen between the biceps femoris and the semitendinosus, upon turning aside the latter muscle (Pl. IV, 25¹); it is distributed subcutaneously to the region just below the ischial tuberosity. In addition to the gluteal nerves already mentioned there is given off from the N. ischiadicus another small nerve which extends nearly parallel to the N. ischiadicus and is distributed to the M. gluteus profundus. Sometimes this small nerve originates from the gluteal nerve that supplies the tensor fasciae latae and the gluteus superficialis.

A. profunda femoris (continued).

Draw out the middle one of the three portions into which the biceps femoris has been cut and note the large **A. profunda femoris** (and veins) that enters the muscle a little above the level of the external small trochanter (Pl. IV). Cut the vessels, turn back this portion of the muscle as far as possible and trace the artery to its distribution in the biceps femoris principally; small twigs are supplied to the gluteus medius, the quadratus femoris and the adductor magnus.

A. obturatoria (continued).

Remove piecemeal a portion of the semimembranosus and trace the artery to this muscle; one or more branches go to the semitendinosus and one to the biceps femoris.

Nerves to the Mm. gemelli, obturator internus and quadratus femoris.

Place the specimen with the gluteal region uppermost, clean up the **N. ischiadicus** (Pl. IV, 26) and identify the following muscles—the gemelli, the tendon of the obturator internus and the quadratus femoris. The one or two small nerves that supply these muscles originate from the deep or internal face of the **N. ischiadicus** at nearly the same level as the posterior ventral gluteal nerve and lie between the N. ischiadicus and the sacro-sciatic ligament so that in order to see them the N. ischiadicus must be

drawn aside. Near the posterior border of the *M. gluteus profundus* the small nerve to the gemelli, etc., (in cases where only one nerve is present), gives off a small branch which passes through the lesser sciatic foramen into the pelvic cavity where it divides into two branches one of which extends anteriorly along the surface of the iliac portion of the *M. obturator internus* to which it is distributed; the other branch supplies the other head of the obturator internus (Pl. V, 50). The main nerve itself crosses the deep or internal face of the gemelli and the tendon of the obturator internus, supplies branches to the gemelli and may be seen again at the posterior border of this muscle where it enters the adjoining quadratus femoris (Pl. IV, 27). Demonstrate this by carefully separating the adjoining borders of the gemelli and quadratus femoris in order to expose the nerve. The gemelli and the tendon of the obturator internus may now be transected in order to expose completely the nerve and its branches as above mentioned.

N. ischiadicus (Pl. V, 54; Pl. IV, 26) arises from the 5th and 6th lumbar and the 1st and 2d sacral nerves; occasionally it receives a branch from the 3d sacral nerve. It passes through the great sacro-sciatic foramen and between the sacro-sciatic ligament and the *M. gluteus medius*, crosses a portion of the *gluteus profundus*, the gemelli and the tendon of the obturator internus and the quadratus femoris. Near the level of the gemelli the *N. ischiadicus* divides into two terminal branches—**peroneus communis** and **N. tibialis** (Pl. IV, 29, 34). (It should be kept in mind that the *N. ischiadicus* and its branches are named differently by different authors. The names here given are the names used in the more recent text books of anatomy and are the terms recommended by the various National Anatomical Societies.) In the femoral region the *Nn. peroneus communis* and *tibialis* are surrounded by the biceps femoris, the adductor magnus and the semimembranosus. Near the level of the gemelli there is given off, either from the *N. ischiadicus* or from the *N. tibialis*, a large fasciculus which extends somewhat posteriorly and supplies the biceps femoris, semitendinosus and semimembranosus (Pl. IV, 28). Demonstrate, by dissecting between the biceps femoris and the semitendinosus and between the semitendinosus and the semimembranosus. Transect the semitendinosus at the level of the 3d trochanter and trace the nerve branches to their respective muscles.

N. peroneus communis (Pl. IV, 29). The distal portion of the biceps femoris must now be turned aside, noting the blood-vessels, which must be cut, that enter the muscle and also the small nerve—**peroneal cutaneous** (Pl. IV, 30, 30¹)—a branch of the *N. peroneus communis*. This small

branch appears to go to the biceps femoris but in reality it passes through the muscle and is distributed subcutaneously to the external face of the tibial region. The large **N. peronaeus communis** is given off from the N. ischiadicus at the level of the gemelli muscle; it lies at the side of the **N. tibialis** until it reaches the M. gastrocnemius where it diverges from the N. tibialis and passes between the external head of this muscle and the biceps femoris (Pl. IV, 29). Beginning at the posterior border of the biceps femoris slit the tibial aponeurosis lengthwise the tibia and turn aside the aponeurosis and the distal end of the biceps femoris (Pl. IV, 10¹, 11¹). Now trace the **N. peronaeus communis** to the place where, between the M. peroneus (or lateral digital extensor) and the extensor pedis, it dips into the anterior tibial group of muscles. Shortly before the nerve enters these muscles it divides into two terminal branches—the **N. peronaeus superficialis** and the **N. peronaeus profundus** (Pl. IV, 32, 33). The **N. peronaeus superficialis** is much the smaller of the two and is for the most part subaponeurotic. Near its origin it gives off a muscular branch to the M. peroneus or lateral digital extensor (Pl. IV, 32¹). Trace the superficial or subaponeurotic portion of the nerve (Pl. IV, 32¹¹) to its place of distribution near the middle of the metatarsus. Note the relation of the nerve to the extensor pedis, peronaeus and to the tibial aponeurosis.

N. peronaeus profundus (Pl. IV, 33). Just as this nerve passes between the extensor pedis and peroneus it divides into several branches of which all but one are distributed to the extensor pedis and the tibialis anterior (Pl. VI, 34). Cut the extensor pedis below the middle of the tibia and draw it aside. The remaining branch of the **peronaeus profundus** lies deeply between the extensor pedis and the tibialis anterior (Pl. VI, 34¹). In tracing this branch to its termination in the digital region the tendons of the extensor pedis and peroneus may be cut near the middle of the metatarsus and drawn aside. As the nerve crosses the tarsus it gives off several small branches to this region and to the M. extensor digitalis brevis. At the tarsus the nerve divides into two main portions of which one accompanies the **A. metatarsea dorsalis** (lateralis) to the region of the fetlock (Pl. VI, 35); the other portion of the nerve extends obliquely across the anterior face of the large metatarsal bone and may be traced as far as the fetlock and often even beyond that joint.

N. saphenus externus arises from the N. tibialis at the level of the third trochanter (Pl. IV, 35; Pl. VI, 36). It extends along the postero-external part of the gastrocnemius, accompanied by a vein, to near the beginning of the tendo Achillis. At this point it occasionally receives a small

accessory branch from the **N. peronaeus communis** (Pl. VI, 31). The **N. saphenus externus** then gains the interval between the tendo Achillis and the M. perforans and extends the length of this space, immediately beneath the tibial aponeurosis, accompanied by the V. saphena externa. Trace the nerve to its subcutaneous distribution at the outer face of the tarsal and phalangeal regions (Pl. VI, 36).

Demonstrate the **popliteal lymph gland**, 6 cm. long by 2 cm. wide, in the space between the biceps femoris and semitendinosus immediately posterior to the gastrocnemius.

N. tibialis is the larger of the two terminal branches of the N. ischiadicus (Pl. IV, 34; Pl. VI, 29). It lies beneath the biceps femoris until it reaches the gastrocnemius. Just as it passes between the two heads of the gastrocnemius it gives off, anteriorly, a large fasciculus to the muscles on the posterior side of the tibia (Pl. VI). To demonstrate the branches of this fasciculus carefully dissect up the external head of the gastrocnemius and transect it a little below the middle of its fleshy portion taking care not to cut the flexor perforatus which is partially embedded in the gastrocnemius (Pl. VI, 11, 11', 12). The **Nn. saphenus externus** and **peronaeus communis** should also be left intact. The several branches of the fasciculus just mentioned should now be traced to their respective muscles, viz., one branch to the external head and one to the internal head of the gastrocnemius; a somewhat smaller branch to the flexor perforatus. Transect the perforatus a little below the nerve supplied to it and draw aside the proximal part of the muscle. Trace the remaining branches of the fasciculus to the popliteus and flexor perforans (Pl. VI). **The N. tibialis** passes between the two heads of the gastrocnemius and for a short distance runs along the posterior surface of the flexor perforatus; it then gradually crosses the inner face of this muscle and accompanied by a small artery, descends to the tarsus in the space at the inner side of the leg, between the tendo Achillis and the flexor perforans. Place the leg with its inner or medial surface uppermost and expose the N. tibialis in this part of its course taking care not to injure the one or more small arteries that accompany the nerve. At the tarsus the N. tibialis divides into two terminal branches—the **N. plantaris medialis** and the **N. plantaris lateralis**. Note very carefully the relation of the N. tibialis to the internal saphena vein and artery and to the tibial aponeurosis.

Nn. plantaris medialis and lateralis. These two nerves are the terminal branches of the **N. tibialis**. They follow the tendon of the flexor perforans through the tarsal sheath and, diverging somewhat from each other, descend

the metatarsal region on either side of the perforans tendon. Each nerve is accompanied by a slender artery (**A. metatarsea plantaris superficialis**) and by a vein. The **N. plantaris lateralis** gives off a branch of considerable size to the proximal portion of the suspensory ligament. Near the middle of the metatarsus, the **N. plantaris medialis** gives off a branch that runs obliquely across the posterior face of the flexor tendons and joins the **plantaris lateralis** a little above the distal end of the rudimentary metatarsal bone. At the fetlock each plantar nerve divides into two or three branches which are identical with those of the thoracic limb.

A. saphena. This small artery was noted when the N. saphenus internus (p. 32) was dissected. The artery arises from near the middle of the A. femoralis. It extends along the inner or medial face of the thigh and leg to near the tarsus where it anastomoses (usually) with a small recurrent branch of the A. tibialis posterior. The artery is accompanied by the large V. saphena.

A. femoralis. Turn aside the M. gracilis leaving intact the A. and V. saphena. Transect the semimembranosus a hand's breadth (10 cm.) from its attachment to the epicondyle of the femur and turn back the distal portion of the muscle. Now trace the A. femoralis from its origin at the level of the anterior border of the pubis to its termination just before it passes between the two heads of the gastrocnemius where it is continued by the **A. poplitea**. Note the muscles that are related to the artery, viz., the sartorius, pectineus, vastus internus and adductor magnus. Note also its relation to the deep inguinal lymph gland.

Branches of the **A. femoralis**.

- (1) **Pudendo-epigastricus** or **prepubic**, see p. 29.
- (2) **A. profunda femoris**, see p. 36.
- (3) **A. femoris anterior**, see p. 36.
- (4) **Rami musculares**, to the vastus internus, sartorius, gracilis, adductor magnus and semimembranosus.
- (5) **A. saphena**, see above.
- (6) **A. nutritia femoris** enters the nutrient foramen of the femur.
- (7) **A. genu** (articular branch). This small branch arises from the **A. femoralis** a little before the latter passes through the adductor magnus. It runs near the posterior border of the vastus internus to the inner or medial surface of the femoro-tibial joint where it ramifies. It also gives small twigs to the vastus internus and the adductor magnus.
- (8) **A. femoris caudalis** (or **A. femoris posterior**), is a large vessel which arises from the caudal or posterior face of the **A. femoralis**, just before the

latter passes between the two heads of the gastrocnemius. Two or three centimeters from its origin the A. femoris caudalis divides into two branches as may be seen upon turning aside the biceps femoris. (The external head of the gastrocnemius may be partially transected close to its origin from the femur.) One of the branches of the A. femoris caudalis passes upwards or proximally, a short distance (4 to 6 cm.) between the semimembranosus and the biceps femoris and is distributed principally to the latter muscle; it also gives off two branches, in this specimen, to the vastus externus. The other and larger branch of the **A. femoris caudalis** extends downward and backward close to the posterior margin of the internal head of the gastrocnemius and is distributed principally to the biceps femoris and semitendinosus; small branches are also supplied to the gastrocnemius and to the popliteal lymph gland. In the present specimen, about 1 cm. peripheral to the A. femoris caudalis a small artery arises which passes between the two heads of the gastrocnemius, immediately posterior to the flexor perforatus, gives small branches to that muscle and to the perforans and is continued as a slender vessel which accompanies the N. tibialis. It unites with a small recurrent branch of the A. tibialis posterior a short distance above the tarsus. In the present specimen, two additional arteries originate from the **A. poplitea** about 4 cm. peripheral to the A. femoris caudalis. The smaller of these two arteries goes to the external head of the gastrocnemius; the larger one is distributed to the distal portion of the biceps femoris and the vastus externus. The **A. poplitea** also gives off a small branch to the internal head of the gastrocnemius. All the above arteries are accompanied by veins.

A. poplitea is the direct continuation of the **A. femoralis**. It runs between the tibia and the Mm. popliteus and flexor perforans as far as to the proximal part of the tibio-fibular or interosseous space where it divides into the **A. tibialis posterior** and the **A. tibialis anterior**. Cut the M. popliteus a short distance from its origin on the external epicondyle of the femur and draw aside the muscle. Dissect between the M. peroneus and the flexor perforans. Insert the finger beneath the portion of the flexor perforans that originates from the external tuberosity of the tibia and the adjoining portion of the fibula and identify the tibio-fibular space (see skeleton). Taking care not to injure the underlying artery, cut the perforans close to the external tuberosity of the tibia and the adjoining portion of the fibula; draw back the muscle and demonstrate the **A. poplitea** as mentioned above. It gives off a branch that enters the intercondyloid space of the femur and supplies the femoro-tibial joint.

A. tibialis posterior is the smaller of the two terminal branches of the **A. poplitea**. Begin the dissection of this artery near its peripheral end, i.e. at

its S shaped curve on the medial side of the leg, anterior to the tuber calsis. Turn back or remove the covering aponeurosis taking care not to cut the A. and V. saphena, draw aside the small internal head of the flexor perforans (M. flexor digitalis longus or flexor accessorius) and trace the artery as far as possible, without cutting muscles, towards its origin. Now returning to the origin of the artery, draw aside, and at the same time cut the flexor perforans from its attachment to the posterior face of the tibia sufficiently to expose the artery.

Branches of the A. tibialis posterior.

- (1) **Rami musculares** to the Mm. popliteus and perforans.
- (2) **A. nutritia tibiae** enters the nutrient foramen of the tibia.
- (3) **A. tarsea lateralis** is a small branch which arises at the first flexure of the sigmoid portion of the **tibialis posterior**. It runs between the tibia and the flexor perforans and is distributed by several small branches to the tendon and the lateral surface of the tarsus.
- (4) **One or more small branches** from the convexity of the first curve of the sigmoid portion of the artery to the medial surface of the tarsus.
- (5) **A. tibialis recurrens** is a small artery which arises from the second convexity of the sigmoid curve of the **A. tibialis posterior**. It extends proximad along the N. tibialis and anastomoses with either the A. saphena or with a branch from the A. femoris caudalis that accompanies the N. tibialis.
- (6) A branch given off from the second convexity of the sigmoid curve passes between the tendo Achillis and the flexor perforans and is distributed to the tendon and the region of the tuber calsis. The **A. tibialis posterior** ends in two small terminal branches—the **A. plantaris medialis** and the **A. plantaris lateralis**.

A. tibialis anterior. Dissect between the M. peroneus and the tibialis anterior and draw aside the latter muscle. The **A. tibialis anterior** is the larger of the two terminal branches of the **A. poplitea**. It passes through the proximal part of the tibio-fibular arch and descends, with two large veins, on the antero-lateral face of the tibia beneath the M. tibialis anterior. At the tarsus the artery gives off the **A. tarsea perforans** which passes through the tarsal canal and anastomoses with the two plantar arteries or sometimes with only the **plantaris externus** to form the **arcus plantarus** or **plantar arch**. The trunk of the **A. tibialis anterior** is continued along the metatarsus as the **A. metatarsea dorsalis (lateralis)**. The **A. tibialis anterior** supplies branches to the Mm. extensor pedis, tibialis anterior, and several branches to the tarsal joint. Near its middle the A. tibialis anterior gives off a variable branch—**A. peronea**—which descends along the fibula

under the M. peroneus to which it supplies small branches; it also gives off a cutaneous branch.

A. plantaris medialis and A. plantaris lateralis.

These two small terminal branches of the **tibialis posterior** vary somewhat in different specimens. The following disposition however is common. Each plantar artery descends with the respective plantar nerves, on either side of the perforans tendon, to the proximal part of the metatarsus where, between the flexor tendon and the suspensory ligament, they unite with the **A. tarsea perforans** to form the **arcus plantaris** or **plantar arch**. The flexor tendons should be cut and turned aside. Sometimes the **A. plantaris medialis** does not join the plantar arch but is continued as the small satellite vessel of the N. plantaris medialis. Four **plantar metatarsal arteries** originate from the plantar arch. The two small superficial arteries, **metatarsea plantaris superficialis medialis** and **lateralis** accompany the plantar nerves on either side of the flexor tendons and unite with the **A. metatarsea dorsalis** or with the corresponding **digital arteries**. Sometimes, as mentioned above, one of the superficial plantar metatarsal arteries is the direct continuation of the A. plantaris medialis. Transect and draw aside the suspensory ligament.

The two deep plantar metatarsal arteries, **Aa. metatarsea plantaris profundus medialis** and **lateralis**, descend between the suspensory ligament and the corresponding rudimentary metatarsal bones and unite near the fetlock with the **A. metatarsea dorsalis**. Of the two deep metatarsal arteries the medial or internal one is much the larger and supplies the nutrient artery to the large metatarsal bone.

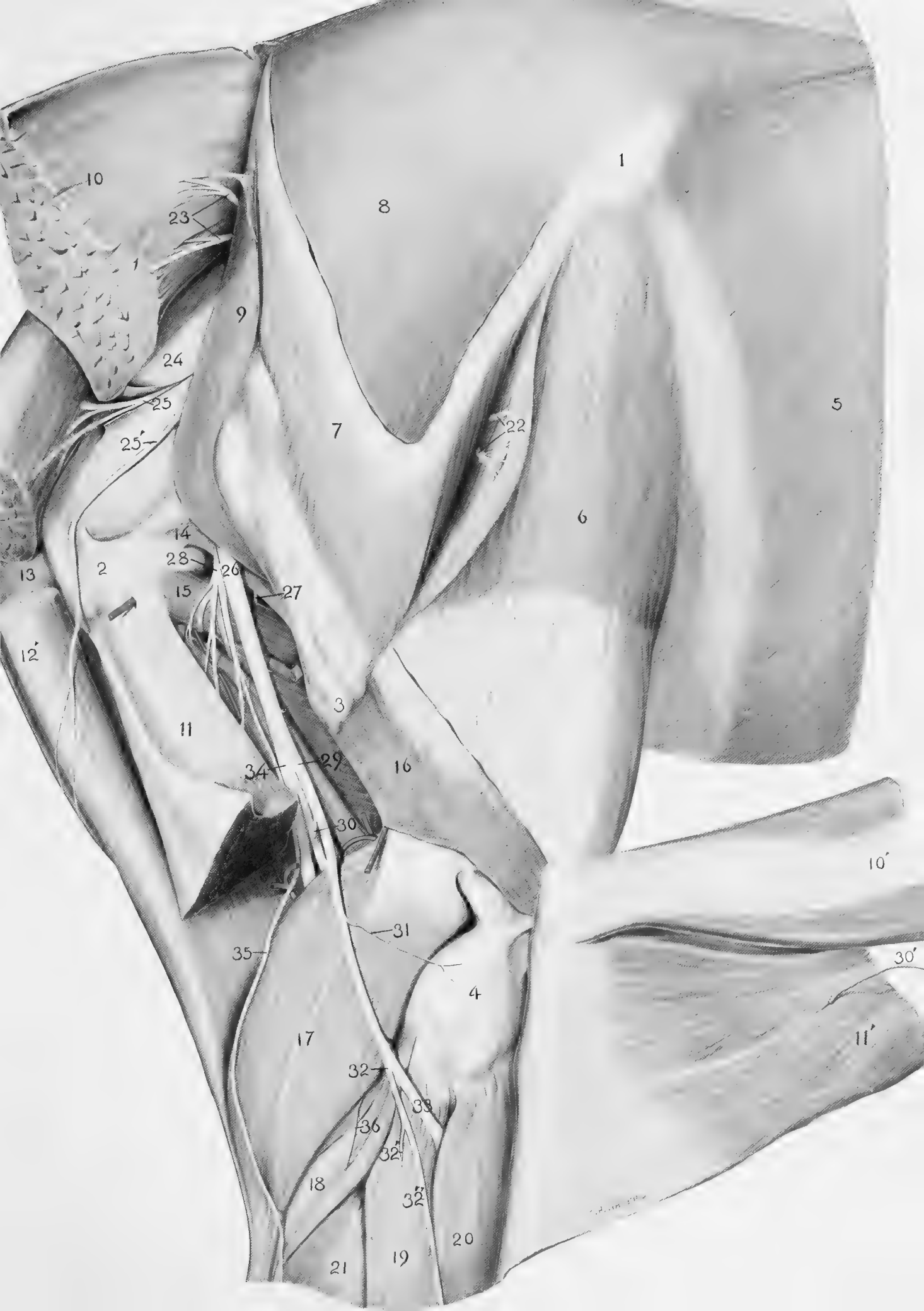A. tarsea perforans arises from the **A. tibialis anterior**, passes through the tarsal canal and unites with the plantar arteries or with the external one only, to form the plantar arch.

A. metatarsea dorsalis (lateralis) is the direct continuation of the **A. tibialis anterior**. It crosses the anterior surface of the tarsal joint and descends, at first, in the oblique vascular groove on the lateral face of the proximal part of the principal metatarsal bone and then in the groove formed by the principal and the lateral rudimentary metatarsal bones. Near the distal end of the rudimentary metatarsal the artery passes between the two bones and divides on the posterior face of the principal metatarsal, between the two divisions of the suspensory ligament, to form the **A. digitalis medialis** and the **A. digitalis lateralis**. These two arteries and their branches are similar to those of the thoracic limb.




PLATE IV
LATERAL SURFACE

1. External angle of ilium.
2. Tuber ischii.
3. External small or third trochanter.
4. Lateral epicondyle of femur.
5. M. obliquus abdominis externus.
6. M. tensor fasciae latae with posterior edge drawn aside.
7. M. gluteus superficialis; (the gluteal aponeurosis has been removed).
8. M. gluteus medius.
9. M. gluteus profundus (in part.)
- 10, 10', 11, 11'. M. biceps femoris.
- 12, 12'. M. semitendinosus.
13. M. semimembranosus.
14. Mm. gemelli.
15. M. quadratus femoris.
16. M. vastus externus.
17. M. gastrocnemius.
18. M. soleus.
19. M. peroneus or extensor digitalis lateralis.
20. M. extensor pedis or extensor digitalis longus.
21. M. flexor perforans.
22. One of the anterior gluteal nerves.
23. Gluteal nerve to M. biceps femoris.
24. Sacro-sciatic ligament.
- 25, 25'. Posterior ventral gluteal nerve.
26. N. ischiadicus.
27. Nerve to the Mm. gemelli, obturator internus and quadratus femoris.
28. Nerve fasciculus to the Mm. biceps femoris, semitendinosus and semimembranosus.
29. N. peronaeus communis.
- 30, 30'. N. peroneal cutaneous.
31. Small filament to the femoro-tibial joint.
32. N. peronaeus superficialis.
- 32'. Nerve branch to M. peroneus.
- 32''. Superficial or subcutaneous branch of N. peronaeus superficialis.
33. N. peronaeus profundus.
34. N. tibialis.
35. N. saphenus externus.
36. Nerve filament to M. soleus.



1

8

5

6

10

23

9

24

25

25'

7

22

14

2

28

26

15

27

13

12

11

3

34

29

16

30

10'

35

31

4

30'

17

32

33

36

32'

18

32''

20

21

19

11'

PLATE V
MEDIAL VIEW.

- 1-6. Lumbar vertebrae.
- 1'-5'. Sacral vertebrae.
- 1''-6''. Coccygeal vertebrae.
7. Pelvic symphysis.
- 8, 8'. M. psoas parvus.
9. M. psoas magnus.
10. M. iliacus.
- 11, 11'. M. sartorius.
12. M. obliquus abdominis internus.
13. M. transversus abdominis.
14. M. rectus femoris.
15. M. vastus internus.
16. M. gracilis.
17. Portion of prepubian tendon.
- 18, 18'. M. obturator internus.
19. M. sacro-coccygeus.
- 20, 20'. M. compressor coccygeus.
- 21, 21'. M. retractor ani.
22. M. retractor penis.
23. M. recto-coccygeus.
24. M. sphincter ani externus.
25. M. sphincter ani internus.
26. Sacro-sciatic ligament.
27. Aorta.
28. A. mesenterica posterior.
29. A. circumflexa iliaca.
30. A. iliaca (of right side).
- 30'. Cut end of left A. iliaca.
31. Truncus pudendo-epigastricus (prepubic artery).
32. A. femoris anterior.
33. A. femoralis.
34. A. iliaca interna.
35. A. sacralis lateralis.
36. A. glutea anterior.
37. A. pudenda interna.
38. A. obturatoria.
39. A. umbilicalis.
40. V. obturatoria.
41. V. femoralis.
42. Large vein in subpubic groove.
43. V. pudenda externa.
- XVIII. Last thoracic nerve. I-VI. Lumbar nerves.
I'-IV'. Sacral nerves.
44. Posterior mesenteric ganglion of the sympathetic nerve (just below 44).
45. Sympathetic nerve trunk.
- 46, 46'. N. femoralis.
47. N. saphenus internus.
48. Branch of N. saphenus internus to M. sartorius.
49. N. obturatorius.
50. Small nerve to the M. obturator internus.
51. Pelvic plexus.
52. Anterior gluteal nerve to the Mm. tensor fasciae latae and gluteus superficialis.
53. Nerve to the M. gluteus profundus.
54. N. ischiadicus.
55. Posterior ventral gluteal nerve.
56. Posterior dorsal gluteal nerve.
- 57, 57'. N. pudendus.
- 57''. N. dorsalis penis (of the left side) a continuation of the N. pudendus.
58. Small nerves to the pelvic plexus.
59. Branch of N. haemorrhoidalis to the M. retractor ani.
60. N. haemorrhoidalis.
61. Branch of N. haemorrhoidalis to the M. compressor coccygeus.
62. Nerve branch to rectum.
63. Deep inguinal lymph gland.
64. External iliac lymph glands.

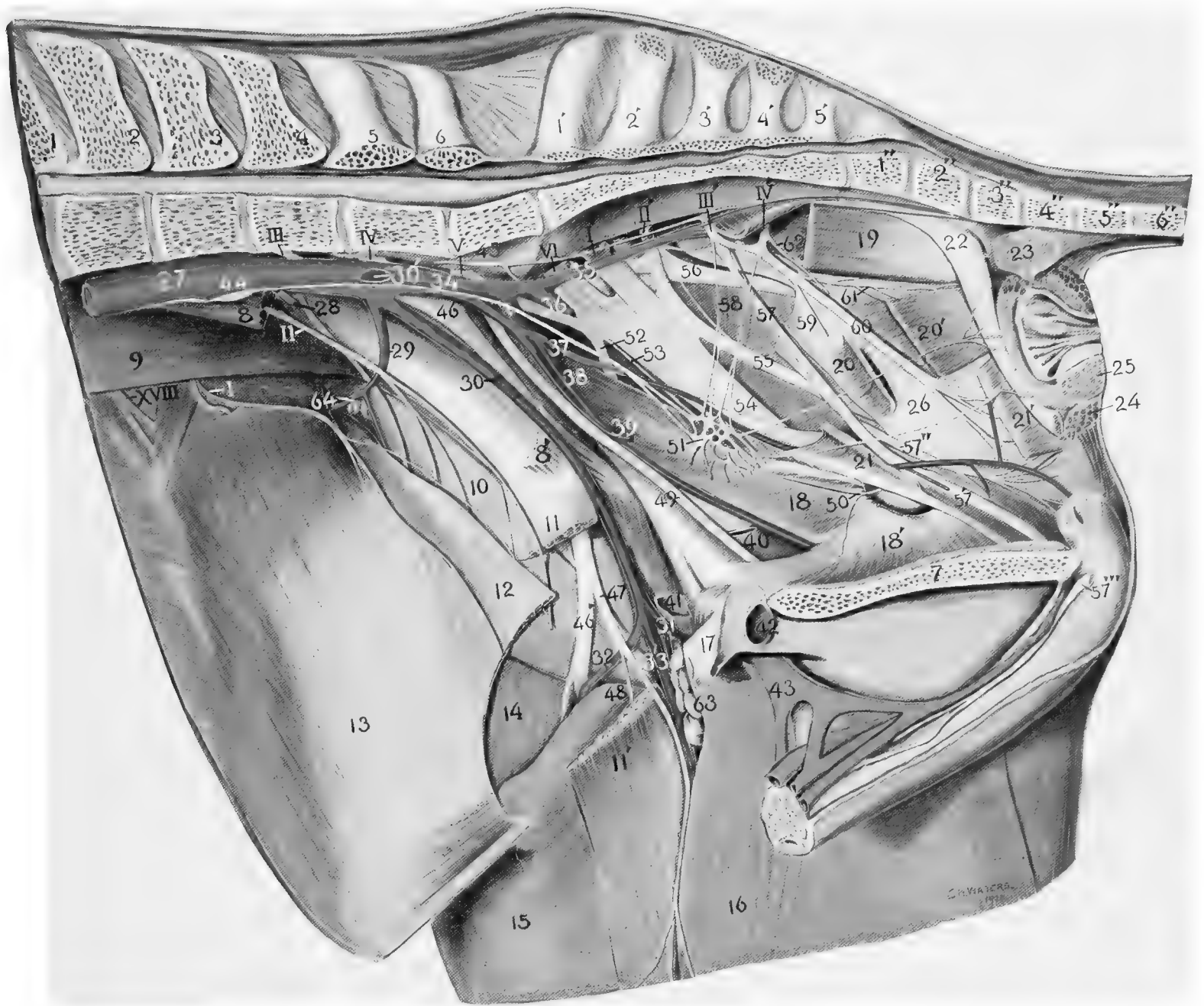


PLATE VI
LATERAL VIEW OF PELVIC LIMB

1. External small or third trochanter.
2. Lateral epicondyle of femur.
3. Os calcis.
4. Lateral rudimentary metatarsal.
- 4'. Principal metatarsal.
- 5, 5'. M. vastus externus.
6. M. adductor magnus.
7. M. semimembranosus.
8. M. semitendinosus.
- 9, 10. M. biceps femoris (turned aside).
- 11, 11'. Lateral or external head of M. gastrocnemius (transected and the distal portion turned aside).
- 11''. Medial or internal head of M. gastrocnemius.
12. M. flexor perforatus (a short section has been removed).
13. M. popliteus.
14. M. flexor digitalis longus.
15. M. soleus.
16. M. flexor perforans.
17. M. peroneus or extensor digitalis lateralis.
18. M. tibialis anterior.
19. M. extensor pedis or extensor digitalis longus.
20. M. extensor brevis.
21. M. interosseus lateralis.
22. M. lumbricalis lateralis.
- 23, 23', 23''. Tibial and metatarsal aponeurosis.
24. Suspensory or suprasesamoid ligament.
25. Ligament of ergot.
26. A. metatarsae dorsalis (lateralis).
27. A. digitalis lateralis.
28. V. digitalis lateralis.
29. N. tibialis.
30. N. peroneus communis.
31. Small branch from N. peroneus communis to N. saphenus externus.
- 32, 32'. N. peroneal cutaneous.
33. N. peroneus superficialis.
- 33', 33''. Muscular and cutaneous branches of N. peroneus superficialis.
- 34, 34'. N. peroneus profundus.
35. Branch of N. peroneus profundus accompanying the A, metatarsal dorsalis (lateralis).
- 36, 36'. N. saphenus externus.
37. N. plantaris lateralis.
38. Communicating branch for the N. plantaris medialis to the plantaris lateralis.
- 39, 40, 41. Anterior, middle and posterior branches of N. digitalis lateralis.
42. Portion of N. digitalis in the dorsal groove of third phalanx.

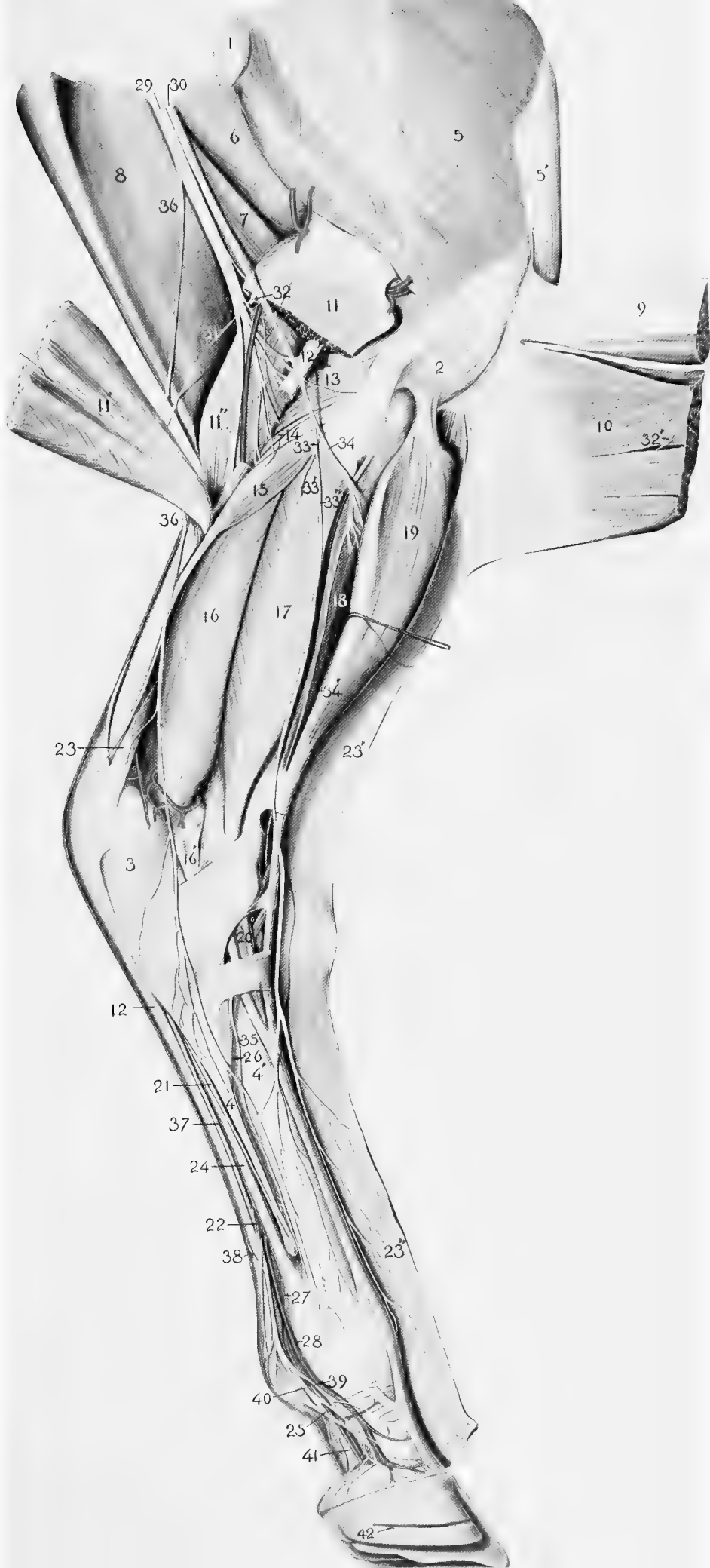


PLATE VII

DIAGRAM OF THE LUMBO-SACRAL NERVE PLEXUS

- 1-6. Lumbar vertebrae.
- 1'-5'. Sacral vertebrae.
- 1''-6'' Coccygeal vertebrae.
- I-VI. Ventral branches of lumbar nerves.
- I'-V'. Ventral branches of sacral nerves.
- I''-V'' Ventral branches of coccygeal nerves.
7. Gangliated nerve-trunk of the sympathetic nerve.
8. Ramus communicans.
9. N. ilio-hypogastricus.
10. N. ilio-inguinalis.
11. N. spermaticus externus.
12. N. cutaneous femoris lateralis.
13. Branch to M. psoas parvus.
14. N. femoralis.
15. Branch to M. iliacus.
16. N. obturatorius.
- 17-20. Nn. glutei anterior.
21. N. ischiadicus.
22. Posterior ventral gluteal nerve.
23. Posterior dorsal gluteal nerve.
24. N. pudendus.
25. Small nerves to the pelvic plexus.
26. Nerve to the M. retractor ani.
27. N. haemorrhoidalis.
- 28, 29. Fourth and fifth sacral nerves.
30. First coccygeal nerve.
31. Nerve trunk formed by branches of the coccygeal nerves.
- 32-36. Coccygeal nerves.

