


VERTEBRATE HISTOLOGY

GAGE AND KINGSBURY



*New York
State College of Agriculture
At Cornell University
Ithaca, N. Y.*

Library

Cornell University Library


QM 555.G13

Vertebrate histology; a guide for course



3 1924 003 122 326

mann



Cornell University Library

The original of this book is in
the Cornell University Library.

There are no known copyright restrictions in
the United States on the use of the text.

VERTEBRATE HISTOLOGY

A GUIDE FOR COURSE 2, DEPARTMENT OF MICROSCOPY, HISTOLOGY AND EMBRYOLOGY. CORNELL UNIVERSITY AND THE NEW YORK STATE VETERINARY COLLEGE

BY SIMÓN HENRY GAGE
PROFESSOR OF MICROSCOPY, HISTOLOGY
AND EMBRYOLOGY

AND

BENJAMIN FREEMAN KINGSBURY
ASSISTANT PROFESSOR OF MICROSCOPY
HISTOLOGY AND EMBRYOLOGY

COMSTOCK PUBLISHING COMPANY

ITHACA, NEW YORK

1899-1900

© 127,385

Copyright, 1899.

BY GAGE AND KINGSBURY.

CONTENTS.

	PAGE.
Literature, Equipment and Reagents.....	7-10
I. INTRODUCTORY	11
II. WEEKLY EXERCISES	13
Introductory and Technic	15
The Epithelial Tissues	18
The Connective and Supporting Tissues.....	22
The Blood and Lymph	30
The Muscular Tissues and the Muscular System	37
The Nervous Tissues and The Peripheral Nervous System.....	41
The Blood and Lymph Vascular System.....	45
The Digestive System.....	49
The Respiratory System.....	57
The Urinary Organs.....	60
The Genital Organs.....	63
The Skin and its Appendages.....	67
The Central Nervous System	74
The Organs of Special Sense.....	78
III. TECHNIC.....	
Isolation	82
Fixation	87
Sectioning, Free-hand and by	94
(a) The Paraffin Method	96
(b) The Collodion Method	99
(c) The Freezing Method	105
Staining and Mounting.....	106
Staining	111
Mounting	120
Sealing, Labeling, Cleaning Slides and Covers.....	123
Special Methods.....	127
Blood	127
Fine Injection	129
Bone and Tooth, (a) and (b).....	130
Nervous System	132
Silver Nitrate Impregnations.....	136
Formulas (additional)	137

PREFATORY NOTE.

• This guide is the outgrowth of the printed and mimeographed sheets furnished the students during the last few years in the course of Vertebrate Histology in Cornell University. The course is meant to be fairly comprehensive in order to meet the needs of the three groups of students who pursue it, viz. : students in the academic department, both graduate and undergraduate, whose aim is general culture and attainment of a sound basis for investigation in morphology and physiology; (2) Veterinary students; (3) Medical students. For the two latter, the course forms an integral part of their professional training, and is designed to furnish aid in the comprehension of gross anatomy, of physiology, and also as a foundation for the appreciation of the changes revealed by pathological histology.

It will be seen in looking through the guide that definite information is given or will be supplied during the course for each specimen studied, and that each student has opportunity and is required to carry on from the beginning all the processes necessary for preparing tissues and organs for study according to the great groups of methods, like the paraffin and the collodion methods, isolation, and the methods of study of living and fresh material. It is believed that this training in independent work is as important as the formal instruction in histology; for every investigator must, and every practitioner of either human or veterinary medicine, ought to be able to work out by himself some of the problems arising in his study or practice.

An effort has been made in this course to combine the excellencies of the three great methods of learning, viz. : (1) That of text-books and works of reference with recitations or quizzes; (2) that of the living teacher in lectures, and in personal instruction and supervision in the laboratory; (3) finally, and most important, that of personal contact with the truths of nature in actual work where knowledge is gained at first hand.

If this guide is looked over or used by teachers in other institutions, we shall deem it a favor if any errors of statement are pointed out to us, and if suggestions for improvement are made by those who have had much experience in conducting laboratory courses with definite objects in view.

SIMON HENRY GAGE,

BENJAMIN FREEMAN KINGSBURY.

SEPTEMBER, 1899.

LITERATURE, EQUIPMENT AND REAGENTS.

TEXT BOOK.

Text-Book of Normal Histology : including an account of the Development of the Tissues and of the Organs. By George A. Piersol, M. D. Fifth Ed. Lippincott Co., Phila.

REFERENCE BOOKS.

The following books and journals will be placed on the reference shelves in the laboratory, or will be referred to :

A. Anatomy and Histology.

Quain's Elements of Anatomy. Ed. by Schäfer & Thane. 1893.

Text-Book of Histology. By Dr. Philipp Stöhr. Trans. by Dr. A. Schaper.

Essentials of Histology. By A. Schäfer.

Text-Book of Histology. By Clarkson.

Manual of Histology. By S. Stricker. Translation. 1872.

Handbuch der Gewebelehre des Menschen. By A. Kölliker.

Lehrbuch der Histologie und Mikroskopische Technik. By Böhm and Davidoff. 1898.

Traite Technique d'Histologie. By L. Ranvier.

Anatomie du Système Nerveux de l'Homme. By A. van Gehuchten. 1897.

B. Physiology.

Text-Book of Physiology. By M. Foster.

An American Text-Book of Physiology. Edited by W. H. Howell.

Essentials of Physiological Chemistry. By Hamersten.

Text-Book of Physiology. By E. A. Schäfer. 1898.

C. Embryology.

Human Embryology. By Minot.

Text-Book of Embryology : Man and Mammals. By O. Hertwig. Trans. by Mark.

Vertebrate Embryology. By Marshall.

Quain's Anatomy : Part I, Vol. 1; Embryology.

D. Journals and Periodicals.

Volumes of the following may be referred to and in that case will be placed on the shelves :

Archiv für Mikroskopische Anatomie.
 Quarterly Journal of Microscopical Science.
 Journal of Anatomy and Physiology.
 Journal of Physiology.
 American Journal of Physiology.
 Journal of the Royal Microscopical Society.
 Anatomischer Anzeiger.
 Proceedings of the American Microscopical Society.
 Journal of Morphology.
 Journal of Applied Microscopy.

E. Technic.

In addition to Stöhr, Ranvier, and Böhm & Davidoff, consult:
 The Microtometist's Vade-mecum. By A. B. Lee.
 Methods of Pathological Histology. By A. C. von Kahlden.
 Practical Histology. By E. A. Schäfer.

 PERSONAL OUTFIT.

The student must supply himself with the following

1. Text-books.
 2. 25 quarto portfolios ($16\frac{1}{4} \times 10\frac{3}{4}$ in.).
 3. 100 sheets of paper, quarto size ($8 \times 10\frac{1}{2}$ in.), for laboratory drawings.
 4. 100 sheets of paper, ruled if preferred, quarto size ($8 \times 10\frac{1}{2}$), for descriptions, etc.
 5. One simple microscope (tripod magnifier).
 6. Two needle holders and No. 6 needles.
 7. Fine forceps, straight or curved.
 8. Dividers.
 9. One-half gross of slides; more will be needed later.
 10. Three slide boxes.
 11. Cover glasses; $\frac{1}{2}$ oz., No. 1, $\frac{3}{4}$ in. circles; $\frac{1}{2}$ oz., No. 1, $\frac{7}{8}$ in. circles; $\frac{1}{2}$ oz. oblongs, No. 1, 23×30 mm.
 12. One section razor (W. B. & E., Phila.).
 13. One or more scalpels.
-

EQUIPMENT OF THE PERSONAL LOCKER.

(Supplied by the Department.)

The personal locker contains the following, for which the student is responsible.

Xylene balsam, bottle.

$\frac{3}{4}\%$ collodion, bottle.

Albumin fixative (Mayer's), homeopathic vial.

Eosin, $\frac{1}{2}\%$ aqueous solution; bottle with pipette.

Hematoxylin, large shell vial.

Hematoxylin, bottle with pipette.

Clearer, carbol-xylene, large shell vial.

Clearer, carbol-xylene, bottle with pipette.

Picric alcohol, bottle.

Castor oil, homeopathic vial with brush.

Two Stender dishes for benzin and alcohol.

Carbon ink, bottle.

Pen and penholder.

Glass jar for slides.

Glass box for cleaning cover glasses.

Two small glass boxes for clean covers.

Five medium shell vials.

Three small shell vials.

Two watch glasses.

Box of lens paper.

Box of vaseline.

Centering card.

Thirty centimeter metric rule.

Two slide trays.

Two towels.

Three pipettes.

Five bottles for 95% alcohol, 67% alcohol, microfuchsin, normal salt solution and distilled water.

EQUIPMENT OF THE MICROSCOPE LOCKER.

Be careful not to put any of these in your personal locker, thereby causing inconvenience to others using the same locker. Do not leave them out on the table.

A compound microscope with $\frac{2}{3}$ in. (No. 3), $\frac{1}{8}$ in. (No. 7), and 1-12 in. oil immersion objective; nose piece; 1 in. (No. 3 or 4), and 2 in. (No. 1) ocular; iris and stop diaphragms; eye-shade.

Bottle of benzin for cleaning the immersion objective.

Bottle of homogeneous immersion oil.

Steel scale, marked in 1-5 mm.

Glass micrometer scale, ruled in 1-10 and 1-100 mm.

Slide of *Pleurosigma angulatum* (a diatom).

Slide showing letters in stairs.

GENERAL LABORATORY REAGENTS.

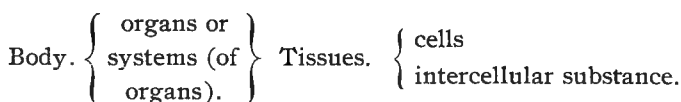
Distilled water.
Normal salt solution.
67% alcohol.
82% alcohol.
95% alcohol.
Cedar-wood oil (thickened).
Paraffine for infiltration.
Paraffine for imbedding.
Ether-alcohol.
1 ½% collodion (thin, for infiltrating).
6% collodion (thick, for infiltrating).
8% collodion (thick, for imbedding).
¾% collodion.
Chloroform.
Clarifier (castor-xylene).
Benzin.
Clearer (carbol-xylene).

SPECIAL LABORATORY REAGENTS.

These will be placed on the supply shelves when needed. There is included a wide range of stains, fixers and solutions.

INTRODUCTORY.

The animal body is made up of different "organs" having special functions. These may be either more or less independent anatomically, or they may be grouped together into systems. The organs of the body and the parts of the systems are composed of different *tissues*, which in turn consist of *cells* and special permanent products of the cells—*intercellular substance*. This analysis may be set forth diagrammatically as follows :



The fundamental tissues of the body are of four kinds :

- A. *Epithelial*. Cells only slightly modified structurally and arranged in layers or masses; intercellular substance (cement) small in amount and undifferentiated.
- B. *Connective and Supporting*. Cells insignificant in number, slightly modified structurally; intercellular substance predominant and variously modified.
- C. *Muscular*. Cells specialized in structure for the purpose of producing movement (i. e., for contracting in one direction).
- D. *Nervous*. Cells specialized in structure for the purpose of originating, transmitting, and transferring "nervous impulse."

In pursuing the study of Histology the following principles are believed to be the most advantageous:

1. The study of the different tissues should precede the study of the organs.
2. Every tissue and organ should be studied *fresh* as far as possible in order to have correct notions of the structural appearances unmodified by reagents.
3. Every tissue and organ should be studied *alive* as far as possible in order to see the function and thus associate function and structure.
4. Before the microscopic structure of an organ or part is studied the *gross anatomy* should be first thoroughly understood.

Gross preparations for reference should be 'at hand and constantly referred to while the microscopic study is carried on.

5. In the study of the tissues it should be remembered that, though at first distinct, in the adult body there is more or less mingling of the different tissues; but in this composite structure there is one tissue which from its predominance forms the characteristic feature of the structure. The epithelia are the simplest in this as in other respects. The different organs likewise are not isolated and independent units, but are thoroughly permeated by the parts of the vascular and peripheral nervous systems contained within them.

In this course the tissues and organs will be studied in the order below:

- | | | |
|------|---|---|
| FALL | } | 1. The Epithelia (including Endothelia). |
| | | 2. The Connecting and Supporting Tissues and the Skeletal System. |
| | | 3. Blood and Lymph; i. e., the fluids of the body and their corpuscles. |
| | | 4. The Muscular Tissues and the Muscular System. |
| | | 5. The Nervous Tissues and the Peripheral Nervous System. |

-
- | | | |
|--------|---|--|
| WINTER | } | 6. The Blood and Lymph Vascular Systems. |
| | | 7. The Digestive System. |
| | | 8. The Respiratory System. |
| | | 9. The Urinary Organs. |
| | | 10. The Genital Organs. |
| | | 11. The Skin and Its Appendages. |
| | | 12. The Central Nervous System. |
| | | 13. The Organs of Special Sense. |

During the fall term the principal aim will be to gain a knowledge of the kinds, structure and distribution of the different tissues and a working knowledge of general histological methods. During the winter term the minute anatomy of the different organs will be studied.

The connective and supporting and the muscular tissues are so closely associated with the organs and systems that they principally

compose that the tissue and system will be studied together. The peripheral nervous system, likewise, may best be studied with the nervous tissues.

METHOD OF LABORATORY WORK.

Laboratory work is arranged as weekly exercises, and each week's work is to be completed before the next succeeding is undertaken. Mounted preparations of the various tissues and organs taken up will be studied. These preparations may be divided into four groups: A, those owned by the department and *assigned for study*; B, those prepared by the department and simply to be mounted by the student; C, those in which the fixing, imbedding and sectioning are done by the department and the staining and mounting by the student; D, preparations made entirely by the student, i. e., fixed, imbedded, sectioned and stained; and E, demonstrations of preparations illustrating special features. With all specimens prepared or partially prepared by the department exact data will be posted on the bulletin board as to (a) the mode of fixation, (b) imbedding method, (c) thickness of the section, when known, (d) stains employed.

In the case of preparations belonging to class D the student is expected to keep a record of the different steps and times. Since there will be slides owned by the student (B, C, D) and by the department (A), care must be exercised in keeping them separate; those owned by the student on one slide tray, those of the department on the other.

To gain a working knowledge of histological technic each student will prepare from the beginning certain organs or tissues, i. e., fix, imbed, section, stain and mount, imbedding them by the paraffin and by the collodion methods.

LABORATORY REPORTS.

Reports upon each tissue or system are to be submitted when the work on that tissue or system is finished, the reports and the times they are due being posted on the bulletin board. These reports are to consist in part of drawings of the preparations studied, in part of descriptions and such discussions as may be specifically called for. In the drawings, name all the parts presented or at least recognized. Large figures are preferable to small ones. Colored

pencils, though not required, will be found helpful in making clear interpretations. The descriptions should be made out in accordance with the following scheme :

Descriptions for Laboratory Reports.

1. Name of the specimen.
2. Names of its principal parts.
- 3-4. Constituent elements or tissues of each of the main parts and the relation of the parts to one another.
5. Structures present in the specimen, but not recognized.
6. Distribution in the body.
7. Function of the organ and of its principal divisions.

RECITATIONS.

There will be a weekly recitation, or quiz, covering the ground of the lectures and the laboratory work. Its purpose is not only that of a weekly examination, but it is also intended to unify the work of the week, bring out the important features and clear up difficult points. Weekly references to the text-book covering the matter for which the student is held responsible will be posted, and under Points for Quiz are given the most important features of the work, which the student will be expected to know. In the weekly exercises following, these are left blank and should be filled out from the bulletins posted.

EXAMINATIONS.

There will be a written examination at the end of each term, covering the lectures and the laboratory work. In addition there will be a laboratory examination to test the students' ability to recognize the different tissues and organs. In the laboratory examination at the end of the fall term, he will be required to recognize the different *tissues* in the preparations given him. At the end of the winter term, the identification of *organs* will be expected of him. In addition, at intervals during the year, especially in the last half of the winter term, unlabeled slides will be assigned for study and report. Also unknown tissues may be given from which preparations are to be made and reported on subsequently as called for. These two methods will help the student in the recognition of the different organs and tissues, and also prepare him for the laboratory examinations.

INTRODUCTORY AND TECHNIC.

LABORATORY WORK FOR THE-----WEEK.

I. **Imbedding tissue.** Go to the delivery desk with two small shell vials filled with 82% alcohol from the supply shelf and get two pieces of tissue already fixed and hardened and now in 82% alcohol. One of these is to be imbedded according to the paraffine method and sectioned during the _____ week of the term. The other piece is to be stained *in toto* in paracarmine, imbedded in collodion, and sectioned during the _____ week of the term. By means of a ribbon pin attach to the cork of each bottle a label giving the name of the animal, the tissue or organ, the fixer employed, the method in which it is to be imbedded, and the date.

In order that you accomplish this successfully it is necessary for you to study carefully §§ 39-47 ; 50-60. Keep a record of the steps and the times of transfer to each fluid and present it as part of the laboratory report on _____ due _____. (See bulletin board).

II. **Fixation of tissue.** Fill two medium shell vials with picric-alcohol and go to the delivery desk for two pieces of *fresh* tissue, to be *fixed* and *hardened*, and *imbedded* according to (a) the paraffine method, and (b) the collodion method. Your name, together with the tissue you are to receive and the imbedding method to be employed is posted on the bulletin board.

Label the specimen, giving the name of the animal, the organ or part, the fixation method, imbedding method, and the date.

Keep a record of the steps in the process, and submit it as part of the report for the _____ week of the term.

In order that this work be successfully pursued, it is necessary to study carefully §§ 18-21 ; 25 ; 39-47 ; 50-60. Be sure that you understand the order of succession of the various steps and the reason for them, and follow directions absolutely. Fix in picric-alcohol 1-2 days, place in 67% alcohol 1-2 days, in 82% alcohol several days, changing the alcohol to fresh three or four times (§ 25). In this work, be as independent of assistance from the instructors as possible.

III. **Isolation.** From the stock bottle on the shelves, fill a small shell vial with Müller's fluid dissociator and go to the delivery desk for a small piece of trachea of cat (sheep or calf). Label it, naming the animal, tissue, and dissociator. Leave the tissue in the dissociator until you come at the second period (1-2 days) when the action of the dissociator will have been sufficient. For this work study carefully §§ 2-7.

At your second period, in accordance with the directions in §§ 5-7, (*a*) examine the isolated cells unstained, in dissociator; (*b*) stain a second preparation with methylgreen and eosin (§92, *b*), and mount in glycerin; (*c*) mount a third preparation of the ciliated cells in alum-carmine and eosin glycerin (§ 156).

IV. Label the bottles of clearer; fill and label the bottle for distilled water and those for 95% alcohol and normal salt solution; prepare and label in their respective bottles 110 c. c. of picro-fuchsin and 90 c. c. of 67% alcohol.

V. Make 4 shellac rings (cells) for $\frac{3}{4}$ in. cover glasses; prepare two for $\frac{7}{8}$ in. covers (§ 106).

VI. Read carefully §§ 1; 18-21; 64; 71-78.

Review what you have so far done on I, II, and III.

Study carefully §§ 64-70; 79; 100-112.

THE CELL AND THE TISSUES.

References :

Points for Quiz :

Laboratory Report :

Due :

I. **Ovarian Ova.** Starfish (*Asterias Forbesii*). Assigned for study. Picro-acetic fixation; paraffine; hematoxylin and eosin. Study, noting the nucleus (germinal vesicle), cell-body (vitellus), nucleolus, nuclear membrane, and structure of the nucleus and cell-body (spongioplasm and hyaloplasm). This prep-

aration affords a demonstration that young ova are single cells with nucleus and cell-body. Sketch one or more that show typically.

2. **Ovarian Ova.** *Amblystoma*. Demonstration. Study, recognizing in the young ova nucleus and cell-body. Compare with (1).

3. **Early blastula stage.** *Amblystoma*. Assigned for study. At this stage the fertilized ovum has divided up into a few cells, arranged in a single layer around a central cavity (blastocœle),—comparable to a simple epithelium. Make a sketch showing outlines of cells and, if possible, of nuclei.

4. **Late blastula stage.** *Amblystoma*. Assigned for study. The cells at this stage have greatly increased in number, are smaller, and the wall bounding the cavity is of several layers of cells,—comparable, therefore, with a stratified epithelium. Sketch, showing the outline of the egg, the outline of the cavity, and for a portion of the wall, the outlines of the cells and nuclei.

5. **Medullary plate stage.** *Amblystoma*. Assigned for study. At this stage *differentiation* is well advanced. The three germ layers are seen in the section; from the entoderm the notochord is forming; from the ectoderm, the central nervous system; the cavity is the alimentary canal (archenteron). Sketch the dorsal portion, and compare with the figure in the text-book.

THE EPITHELIAL TISSUES.

LABORATORY WORK FOR THE-----WEEK.

*References :**Points for Quiz :**Laboratory Report :**Due :*

Go to the delivery desk for slides assigned for study, 6, 10, 14, and 19.

Prepare a clean slide with albumen fixative (§ 67, *a*) and go to the delivery desk for 18, paraffine section; carry on according to §§ 67, *a*-70.

From the bottle on the delivery desk place a small drop of glycerin jelly on the center of a clean slide and go to the instructor for 9 and 16, already stained. Cover (§ 105).

Go to the delivery desk with a clean slide for 17, now in thin balsam. Mount in balsam (§109).

Go to the desk for 7; in glycerin; place a drop on the slide and cover it (§ 104).

Clean carefully and seal (§ 110) the preparations of ciliated cells from the trachea, made last week (8).

COLUMNAR EPITHELIUM.

6. **Small intestine.** Cat. Assigned for study. Transection. Flemming's fluid fixation (§ 24); paraffine (§ 42); safranin stain (§ 79); sections 10 μ .

Study the epithelium covering the villi, noting the two kinds of cells and the structure of each; the position and shape of the nucleus; the striated border; the relation of the epithelium to the underlying tissue. Find a place showing a surface section of the epithelium.

7. **Epithelial cells from the small intestine.**

Isolated in Müller's fluid dissociator (§ 4); now in alum-carmine and eosin glycerin (§ 156).

Place a small drop of the glycerin on a slide and cover with a cover-glass. Search the preparation to find (*a*) completely isolated cells, (*b*) cells adhering together in clusters and affording a surface view of the epithelium. Note as before the shape and structure of the cells and the shape and position of the nucleus. Try to find goblet cells.

CILIATED EPITHELIUM.

8. **Ciliated cells** from the trachea. Cat. Two preparations made last week.

Carefully clean around the cover glass and seal with shellac (§ 110). Study the preparations, searching for completely isolated cells and cells adhering in clusters. Note the shape of the cells, the structure and position of the nucleus, the cilia, the shape of the basal end. Compare the two slides, noting the identity of structure but different staining.

9. **Ciliated cells** from the trachea. Horse. Isolated in Müller's fluid dissociator; stained with _____, now in _____. Mount in glycerin jelly (§ 105). Study carefully, noting the shape of the cells, the shape and position of the nucleus, the length of the cilia. Compare with 8.

10. **Ciliated epithelium.** Section of the soft palate. Cat. Assigned for study.

The nasal side will show a so-called stratified ciliated epithelium. Observe the cilia covering the free ends of the cells; compare the, apparently, superficial cells bearing the cilia with the deeper cells. Examine 8 again to see if you can find any isolated cells of the deeper layer.

11. **Living ciliated cells.** Go to the desk with a slide for living ciliated cells from the oral epithelium of the frog. Place upon the slide in a drop of saliva or normal salt solution; cover. Study the activity of the ciliated cells, trying to ascertain the movements of the cilia. This may best be done in cells in which the ciliary movements have considerably slackened.

12. **Living ciliated cells.** From the trachea. Cat. Demonstration. Observe the ciliary movements, noting the rate and direction of the vibrations.

13. **Ciliated pavement epithelium.** From the peritoneal

epithelium of an Amphibian (*Necturus*, *Amblystoma*. Frog). Demonstration. Note the short cilia projecting up from the flattened cells of the peritoneal epithelium.

PAVEMENT EPITHELIUM.

14. **Peritoneal epithelium** (endothelium). Mesentery of cat. Assigned for study. The fresh mesentery was treated with a $\frac{1}{2}\%$ aqueous solution of silver nitrate, washed in water, exposed to sunlight until the cell-cement between the cells had blackened, washed in water, stained in hematoxylin to bring out the nuclei, dehydrated, cleared and mounted in balsam.

Study the preparation, noting the nuclei and cell-outline as indicated by the stained cell cement. Remember that the cells are flat and a single layer deep.

(13). **Ciliated pavement (peritoneal) epithelium.** Demonstration. See 13 above.

STRATIFIED EPITHELIUM.

(10). **Stratified epithelium.** Vertical section. Assigned for study. The oral side of the soft palate is covered with a stratified epithelium.

Note the shape of the cells and nuclei in the deeper layers and compare with the cells of the superficial layers, observing the gradual transition as you pass from the deepest to the superficial cells. Are intercellular bridges to be seen?

15. **Stratified epithelium; surface cells.** With the finger nail gently scrape the inside of your own cheek and mount the scrapings on a slide, adding a drop of normal salt solution if necessary. Examine the preparation, noting the shape and size of the epithelial scales, the shape and size of the nucleus. The surface of the cells may be marked by ridges where neighboring cells have overlapped. Can you find groups of two or more cells?

Compare with the superficial cells of 10 where you see them in section, or on edge.

16. **Stratified epithelium; deeper cells.** Isolated cells from the deeper layers of the epithelium of the lip.

Müller's fluid dissociator; stained with _____; now in _____

Mount in glycerin jelly. In studying this preparation find

cells in which the intercellular bridges (prickles) are well shown, noting as well the shape and size of the cells and their nuclei.

17. **Epidermis.** Human finger. Section slightly oblique with the surface. Fixed in _____; paraffine; sections _____ μ ; stained with hematoxylin; now in thin balsam. Mount in balsam.

This is an epithelium in which the scale-like superficial cells form a very thick layer and their nuclei disappear. In the cells of the deeper layers the nuclei are present. This preparation is to illustrate the intercellular bridges in a stratified epithelium and also to show the relation of the deepest cells to the connective tissue upon which the epithelium rests.

18. **Follicular epithelium.** Section of the ovary of a young cat. _____; paraffine; sections _____ μ .

Stain with hematoxylin 5 minutes, eosin 15-30 seconds. The ovary will contain eggs of various ages, covered with a follicular epithelium of a single layer of cells or many layers of cells, depending upon the maturity of the follicle. The follicular epithelium in the older follicles therefore is a stratified epithelium in which the cells are all cuboidal, rounded, or polyhedral. Search the preparation to find ova covered with such an epithelium and note that the cells are approximately alike, and not as in the ordinary stratified or squamous epithelium.

(10.) **Glandular epithelium.** Section of the soft palate. Assigned for study.

In the substance of the soft palate are contained numerous mucous glands, illustrating glandular epithelium. The tubules of the glands are made up of columnar cells with the nuclei in the bases; the epithelium in these glands is therefore a simple columnar epithelium.

19. **Germinal epithelium.** Section of the ovary of a kitten 2-3 weeks old. Hermann's fluid (§ 23); paraffine (§ 42); iron hematoxylin (§ 98); sections _____ μ .

The germinal epithelium is the cuboidal or low columnar epithelium upon the surface of the young ovary, from which the ova are developed. Examine the preparation, observing the surface epithelium, with here and there a much enlarged cell with a large round nucleus—a young ovum.

THE CONNECTIVE AND SUPPORTING TISSUES.

LABORATORY WORK FOR THE-----WEEK.

*References :**Points for Quiz :**Laboratory Report :**Due :*

Go to the delivery desk (*a*) for assigned slides, 20, 22, 27.

(*b*) With a slide prepared for a paraffine section (§ 67, a), 26.

(*c*) With clean slides for 28 and 30, already stained and in 95% alcohol ; clear and mount in balsam.

(*d*) With clean slides for 24 and 25, now in glycerin ; mount in glycerin jelly (§ 105).

(*e*) With a clean slide for 31 ; stain and mount as directed below.

(*f*) With a clean slide for 29 ; tease as directed below ; mount in glycerin jelly.

(*g*) With a clean slide for 21, a fresh preparation ; treat as directed below.

MUCOUS TISSUE.

20. **Mucous tissue.** From the umbilical cord of a fetal mammal. (Jelly of Wharton). Spread preparation. Assigned for study. Stained with hematoxylin and eosin.

In studying this preparation, note the shape of the cells and the anastomosis of their processes ; the general homogeneity of the intercellular substance. Compare with 22.

AREOLAR TISSUE.

21. **Areolar tissue** (subcutaneous). **Fresh preparation.** The instructor will make for you an artificial edema by injecting normal salt solution into the subcutaneous connective tissue of a kitten. This separates the constituents somewhat and enables one to get so thin a layer that the different elements can be easily made out.

Cut out a small piece with the scissors and spread it out in a thin layer on the slide, using a dry slide and new needles. Draw the edges away from the middle, and if they are dry enough they will stick to the slide and hold the film outspread. It will probably be necessary to absorb some of the liquid by means of lens paper before you can make the edges stick. Do not allow the middle to dry. Place on the middle a drop of normal salt solution and a cover-glass.

Examine the preparation carefully, recognizing (*a*) the white fibers, in wavy bundles; (*b*) the yellow elastic fibers, straight and single; if possible find a place where they anastomose (see, however, below); (*c*) the connective tissue cells; can you find more than one kind? (See 22).

Action of Reagents. Remove the cover glass and place upon the preparation a drop of 2% acetic acid. Note that it makes some of the fibers disappear, the white fibers, while others, the yellow elastic, are sharply brought out. It is now possible to observe the course, anastomosing and branching of the yellow fibres. Note also that the nuclei of the connective tissue cells are more sharply defined.

22. **Subcutaneous areolar tissue. Stained preparation.** Assigned for study. Tissue spread on the slide by means of needles, as in 21; stained with hematoxylin and erythrosin (or eosin) (§ 79).

Study the preparation carefully, recognizing again the white and yellow fibers and the cells, of which find if possible three kinds (text-book).

23. **Adipose tissue. Demonstration.** Spread preparation. Stained with hematoxylin and eosin (§ 79).

In this preparation of subcutaneous adipose tissue note (*a*) the lobular grouping of the fat cells, (*b*) the blood vessels and the relation of the fat cells to the capillary network, (*c*) the structure of the individual fat cells, the fat globule, the nucleus with the protoplasm surrounding it.

WHITE FIBROUS TISSUE.

24. **Tendon.** From the tail of a mouse. Tendons pulled out, spread out flat by means of a needle and stained 15-20 minutes

with Ehrlich's acid hematoxylin (§ 81), now in glycerin. Mount in glycerin jelly (§ 105).

To show the tendon cells (connective tissue cells). Note their arrangement in parallel rows between the tendon fibers, their shape in relation to each other, the position of the nucleus in the cell in relation to the nucleus of the contiguous cell. Consult also 26 for the true shape of the cells.

25. **Tendon.** From the tail of a mouse. Silvered to show negative images of the tendon cells (§ 147). The tendons were pulled out and treated for a few minutes with a solution of silver nitrate, washed in water, exposed to the light, washed in water; now in glycerin. Mount in glycerin-jelly. The places occupied by the cells are white, while the cement substance was colored brown by the silver nitrate on exposure to the light. Note the outlines of the cells and compare with the positive images of 24.

26. **Tendon.** Transection of tendon, biceps of a new-born puppy. Müller's fluid (§ 29); paraffin; sections μ .

Stain 30 minutes with hematoxylin, 15 seconds with picrofuchsin. Mount in balsam. Note the relation of tendon-cells and fibers as shown in transection and compare with 24 and 25. Note also the staining reactions of the white fibrous tissue with picrofuchsin in comparison with the transected muscle fibers (central), and the elastic tissue in 28.

27. **Cornea.** Cat. Assigned for study. Free-hand sections. The cornea silvered (§ 147), free-hand sections cut from the ental surface and mounted in glycerin jelly.

To show the negative images of the cells of dense connective tissue (*i. e.*, the cornea). Note the shape of the cell spaces, and the anastomosing of the processes; compare with the similar preparation showing the cell spaces in tendon, 25.

YELLOW ELASTIC TISSUE.

28. **Ligamentum nuchae.** Horse. Transection. ; paraffin; sections μ . Stained with hematoxylin and picrofuchsin, now in 95% alcohol. Clear and mount in balsam.

Note the yellow elastic fibers, their shape and size in transection, the white connective tissue in between them, and the nucleus

of an occasional connective tissue cell. What is the staining reaction with picrofuchsin? Compare with 26.

29. **Ligamentum nuchae.** Horse. Teased preparation. With your needles tease out very carefully a small piece of ligamentum nuchae obtained from the instructor. Remember that the course of the elastic fibers is longitudinal, and therefore tease by pulling the fibers to the side, trying to keep them parallel. Tease carefully and thoroughly. Mount in glycerin jelly.

Note the anastomosing and branching of the fibers; are transverse markings to be detected?

PIGMENT CELLS.

30. **Pigmented pia.** Sheep. From the frontal region of the brain. Now in 95% alcohol; no staining required. Clear and mount in balsam.

Note the shape and anastomosing of the pigment cells, the pigment granules, and the clear space occupied by the nucleus of the cell.

31. **Pigmented peritoneum.** *Necturus*. Picric alcohol; peritoneum removed and now in 82% alcohol. Stain with hematoxylin 10 minutes, eosin 15 seconds (§ 94). Mount in balsam. Since this preparation is not fixed to the slide, care must be taken in changing fluids (§ 65, a).

Note the shape, the nucleus, the pigment granules, and the state of expansion or contraction of the pigmented connective tissue cells. Does the preparation show cells well expanded and cells quite contracted?

CONNECTIVE AND SUPPORTING TISSUE.

LABORATORY WORK FOR THE-----WEEK.

*References :**Points for Quiz :**Laboratory Report :**Due :*

Go to the delivery desk (*a*) for 35, assigned for study ; (*b*) with a slide prepared for a paraffin section, 32 ; (*c*) with a clean slide for collodion sections, 37, 38, 39 ; fasten to the slide according to § 66 ; place in benzin.

While the above preparations are being carried on (§§ 68-70) go to the desk for 33 and 34, from which free-hand sections of the cartilage are to be cut, stained and mounted as directed below. Return the tissue to the desk when you have finished with it.

During the week you will make preparation 36, in accordance with the directions, §§ 133-134. Read them carefully in advance.

CARTILAGE.

32. **Embryonal cartilage.** . Transection of
 ; ; stained *in toto* (§ 74, c, § 86) in
 paracarmine ; paraffin ; sections μ . Mount in balsam (benzin,
 clearer, balsam).

The skull should be studied. It is at this stage cartilaginous, and the cartilage in an embryonic stage ; note the cells with their nuclei and cell-bodies ; the small amount of matrix deposited between them, and compare with adult cartilage in 33 and 38. What would be the structure of the cartilage at an earlier stage of development ?

33. **Hyalin cartilage.** *Necturus* (Amphibian). You will receive one of the following from which to cut free-hand sections of cartilage, (*a*) head of the humerus ; (*b*) head of the femur ; (*c*) a branchial arch ; (*d*) part of the hyoid arch ; (*e*) the pectoral arch ; (*f*) the pelvic arch.

Cut the sections very carefully and as thin as possible. Place 6-10 good sections in an alum solution ($\frac{1}{2}\%$) in a watch-glass for 5-10 minutes; place 3-4 sections on a slide in a drop of normal salt solution; cover and examine, studying the character of the cells and their nuclei, their grouping, the character of the matrix.

After the 5-10 minutes, drain off the alum solution from the sections in the watch-glass. Mount one-half of them directly in glycerin jelly; the remainder, stain in hematoxylin for 5-10 minutes, wash in water, and mount in glycerin jelly. These two preparations are to be studied in connection with the sections in normal salt solution, for the structure of hyalin cartilage.

(38). **Hyalin cartilage.** Mammal. For this, study 38, noting the structure of the cartilage, the grouping of the cells, their shape and arrangement, in the deeper portion and at the articular surface, and the corresponding difference in the density of the matrix. Compare with 33.

34. **Elastic cartilage.** From the ear of the ox (or horse). Picric alcohol fixation. Make free-hand sections, cutting them as thin as possible. Place three or four of the thinnest in water for 5 minutes, stain in hematoxylin 15 minutes, picrofuchsin 1-2 minutes; dehydrate, clear, and mount in balsam. Study carefully, noting the areas of hyalin matrix surrounding the cells and the reticulum of elastic tissue. Compare with sections of hyalin cartilage, 33, 38, and contrast with the ligamentum nuchae (28). Note again the different staining reaction of the elastic fibers of the cartilage and the white fibrous tissue surrounding the cartilage.

35. **Fibro-cartilage.** From the inter-vertebral disc. Assigned for study. ; ; stained with . There are shown the interlacing bundles of white fibrous tissue with the cartilage cells surrounded by hyalin matrix scattered through the tissue. Compare with the elastic cartilage, 34, and in this comparison recall the staining reaction of the white and the elastic fibers (26, 28).

BONE.

36. **Dry bone.** Homo. Transection of femur. To be ground down to a thin section and mounted in accordance with the special directions, §§ 133-134.

Study the preparation very carefully, recognizing (*a*) the Haversian systems, (*b*) the interstitial lamellae. In the Haversian systems, note the Haversian canal, the concentric lamellae of bone, the lacunae (cavities occupied during life by the bone cells), the canaliculi. Understand from the development of bone, the meaning of the concentric arrangement constituting an Haversian system. In the interstitial bone, observe the lacunae and canaliculi. What is the meaning of interstitial lamellae?

If desired, a tangential section of femur may be prepared to show the lacunae from another aspect, and thus gain a better idea of their real shape.

37. **Developing bone.** Longisection of the hand (or foot) of a fetal mammal. Fixed in _____; collodion; sections μ . Stain with hematoxylin _____ minutes; picrofuchsin _____ seconds.

This illustrates endochondral ossification (early stage) and the cartilaginous stage of the primary (endochondral) bones—in this case the phalanges and carpal (or tarsal) bones.

In at least one of the phalanges that is cut longitudinally the early stages of ossification may be seen. Study it carefully, noting the areolation of the cartilage, identifying if possible the osteoblasts and osteoclasts; if the section is in the right plane the ingrowth of periosteum may be seen. If the process of ossification is far enough advanced, note the formation of the primary marrow cavity and the lamellae of spongy bone. The later processes of ossification are shown in 28.

In addition the preparation illustrates: (*a*) true or diarthrodial articulations, (*b*) capsular ligaments, (*c*) muscle and tendon, and (*d*) developing hair.

38. **Developing bone.** Longitudinal section of the head of a long bone _____. Picric alcohol; decalcified in nitric acid decalcifier (§§ 131-132); collodion; sections μ . Stain in hematoxylin 30-45 minutes, picrofuchsin $\frac{1}{2}$ -1 minute. Mount in balsam.

This preparation will illustrate (*a*) the formation of endochondral bone, (*b*) the structure of the epiphyses and the longitudinal growth of a long bone. Recognize the following features: (1) the center of ossification of the epiphysis, (2) the center of ossification for the shaft, (3) the marrow, (4) the bone, (5) cartilage, (6) peri-

osteum. Study carefully the centers of ossification in the epiphysis and shaft, so as to understand the dissolution of the cartilage (degeneration of the cells, absorption of the matrix) and the deposit of bone. How is spongy bone converted into dense bone? Study the structure of the periosteum, recognizing the two layers; understand the part it plays in the processes of ossification. In addition, study the preparation for the structure of cartilage, articular cartilage, the general structure and articulation of a long bone.

39. **Transection of a long bone.** ; Picric alcohol; decalcified in nitric acid decalcifier (§ 131); collodion; sections μ . Stain in hematoxylin minutes, eosin seconds. Mount in balsam.

Study, noting (*a*) the marrow with its nutrient artery, (*b*) the structure of the bone, (*c*) the structure of the periosteum. Compare the structure of the decalcified bone with the dry preparation of bone, 36. Recognize the identity of structure in the two preparations so differently prepared.

BLOOD AND LYMPH.

LABORATORY WORK FOR THE-----WEEK.

*References :**Points for Quiz :**Laboratory Report .**Due :*

Go to the delivery desk with two clean slides for 45 and 46 now in balsam ; place a small drop of the balsam on the slide, and cover.

Obtain from the desk 48, spread on a cover-glass ; stain as directed below and mount in balsam.

To economize time, next prepare 42 and 43.

Obtain 47 at your second period.

HUMAN BLOOD.

40. **Fresh blood.** Flame a needle and after it is cool, prick the finger near the nail-bed (best) or the side of the finger ; wind a handkerchief around the base of the finger and press the finger with the other hand ; a drop of blood will be obtained. Or, you may disinfect the needle of a haemostath and with it obtain the blood more quickly and easily (§ 120). Touch a cover-glass to the large drop so obtained and place it upon a slide, blood side down. The drop of blood should be large enough to easily fill the space under a cover-glass. Seal the preparation at once with castor oil.

Study the corpuscles carefully, noting the form as determined by observing the face, profile and oblique views ; the corpuscles can be made to turn over by pressing gently on one edge of the cover-glass. Observe that most of the corpuscles are arranged in rolls or rouleaux. Here and there may be seen a leucocyte or white blood corpuscle.

41. **Action of reagents.** Obtain a large drop of blood as in 40 ; ascertain the effect upon fresh blood of four reagents as given below. Since this will take some time and needs fresh blood it may be necessary to prick the finger more than once.

(a) *Normal salt solution.* Place upon a clean slide a small drop of fresh blood and add to it a small drop of normal salt solu-

tion ; apply a cover glass. Is any change observable? If so, what? Is the fluid truly normal?

(b) *Distilled water.* Place upon a clean slide a drop of fresh blood and place beside it a small drop of distilled water ; cover. What is the effect of the water upon the corpuscles? Where the blood and water meet observe the changes ; find some corpuscles entirely in the water. What is the meaning of the change?

(c) *2 % salt solution.* Place a small drop of blood upon a slide, cover, and at the side of the cover glass place a drop of a 2% solution of common salt. What is the effect of the solution upon the corpuscles with which it comes in contact? Meaning?

(d) *2 % acetic acid.* Make another preparation of fresh blood and at the side of the cover glass place a drop of a 2% solution of acetic acid. Note the effect of the solution upon the red corpuscles and compare with the action of distilled water. What is the effect of the solution upon the white corpuscles? What is the meaning of these experiments in connection with the structure of the red corpuscles?

42. **Dry preparation.** With a piece of lens paper wet with 95% alcohol wipe off the finger at the point where it is intended to obtain blood ; prick the finger as in 40, and as directed in § 121, (1.), prepare six or more blood films upon clean covers ; allow two of them to dry and place the others in a watch glass of ether-alcohol for 43.

Allow the two films saved out to dry thoroughly, then warm gently and mount the best (or both) film side down upon a shellac ring prepared at some previous time (§ 103, a). Select a place where the film is thin and even to study the appearance of the dried corpuscles. Choose several corpuscles that are not distorted and with the ocular micrometer for which you determined the valuation measure their diameter in microns. Compare with the size given in the text-book.

43. **Stained preparations.** (§§ 121-123). Allow the preparations that were placed in ether-alcohol to fix for one hour or longer, remove them and allow them to dry for a few minutes, when they may be stained immediately or later (at your second period). Stain the blood films in two ways : (a) *with eosin and hematoxylin*

(§ 124) ; rinse in water and dry. Mount in balsam without clearing (§ 109), (b) with Ehrlich's triacid mixture (§ 125).

In the first preparations the red corpuscles will be red or pink, in the second yellow or orange. Compare with 42 as to shape and size.

44. **Blood-plates.** Demonstration. The tip of the finger was carefully cleaned with 95% alcohol, the finger pricked, a drop of 1% osmic acid was placed over the puncture and the blood squeezed out into the drop of osmic acid, which was transferred to a slide, covered, and sealed with castor oil.

Note the appearance and size of the blood-plates in comparison with the red corpuscles.

AMPHIBIAN BLOOD.

45. **Blood of Necturus.** A *Necturus* was pithed, the gills cut, and the drops of blood caught in a vial of 1% osmic acid. It was allowed to fix in this 1-2 hours, washed in water, changed several times, washed in 67% alcohol, stained several hours in paracarmine (§ 86), washed in 82% alcohol, 95% alcohol, absolute alcohol, xylene and xylene balsam. Cover a drop of the balsam containing the corpuscles.

Note the shape of the corpuscles, their nuclei, size as compared with human blood and frog's blood (42, 46).

46. **Blood of frog.** Prepared as was 45. Mount a drop of the balsam containing the corpuscles. Compare with 42, 45.

LAMPREY BLOOD.

47. Place a drop of the blood of the lamprey upon the center of a slide, apply a cover-glass, and seal with castor oil.

Study carefully the form of the red corpuscles and compare with human (mammalian) blood as to form and size. Do they arrange themselves in rouleaux? Observe the occurrence of leucocytes, their number and size.

Carefully wipe away the castor oil, lift the cover a little, and place under the edge a small drop of 2% acetic acid. What is the effect? Compare with the effect of acetic acid upon human blood.

What differences are there between the red corpuscles of mammalia, amphibia, and the lamprey?

DEVELOPING RED BLOOD CORPUSCLES.

48. Smear preparation of red marrow.

A drop of red marrow was spread upon a cover-glass as a thin film (§ 121); fixed in a saturated solution of mercuric chlorid (§ 26) 15 minutes or so, and placed in 67% alcohol. Rinse off the alcohol with distilled water and stain with Ehrlich's triacid mixture (§ 125) for 10-15 minutes, rinse with distilled water, dry and mount in balsam.

In this preparation find (*a*) marrow cells, medium sized cells with a large nucleus and scanty protoplasm, resembling leucocytes somewhat; (*b*) giant cells, with one or many nuclei; (*c*) cells with deeply staining nuclei and more or less hemoglobin in the cell body (stained orange),—erythroblasts; (*d*) finally, red blood corpuscles, non-nucleated. Find as many forms of erythroblasts as possible, and compare with the red corpuscles.

•

BLOOD AND LYMPH.

LABORATORY WORK FOR THE-----WEEK.

*References :**Points for Quiz :**Laboratory Report :**Due :*

Go to the delivery desk for 51; stain as directed below and mount in balsam. Next prepare 53. Make the remaining preparations in order.

LEUCOCYTES.

49. **Amoeboid movement.** Amphibian leucocytes. Place upon the slide a drop of frog's blood; apply a cover glass at once and seal the preparation with castor oil.

Search the preparation until a leucocyte is found undergoing amoeboid movement. Keep it under observation for some time, observing the changes of form and mode of progression. Make several sketches at intervals of 2-3 minutes showing the changes.

50. **Amoeboid movement.** Human leucocytes. Place a drop of fresh human blood upon a slide, cover quickly and seal with castor oil. Ten or fifteen minutes after the preparation was made examine it, find a leucocyte in amoeboid movement. Study it carefully and make several sketches at intervals, as in 49.

51. **Ingestion of foreign particles.** Leucocytes of rat. A solution containing particles of lampblack (§ 157) was injected into the abdominal cavity of a rat; the following day the rat was killed and smears were made of the abdominal lymph. Stain for 10 minutes with hematoxylin (§ 124). Mount in balsam.

Study the preparation, noting that the particles of lampblack have been taken up or ingested by the leucocytes of the lymph. Consider, in the light of 49 and 50, how this ingestion took place.

(43) **Forms of leucocytes.** Study the preparations 43, (a) and (b), searching carefully for different kinds of leucocytes. The following types will probably be found: (a) *small lymphocytes*,

small leucocytes with a large round nucleus and scanty protoplasm, (*b*) *large lymphocytes*, large leucocytes with a large, clear nucleus and rather scanty protoplasm, (*c*) *polymorphonuclear neutrophiles*, medium-sized leucocytes with irregular, horse-shoe shaped nucleus or several nuclei, the protoplasm granular, and (*d*) leucocytes with the nucleus irregular or in two or more parts, protoplasm containing large granules that stain intensely with eosin (or other acid staining principle), hence they are called '*eosinophiles*'. (*c*) will be most abundant, (*a*) and (*b*) less abundant, (*d*) least abundant. It is generally believed that (*a*), (*b*), (*c*), and (*d*) are stages in the growth of a leucocyte from youth to old age. Consult .

FIBRIN.

52. Upon a clean cover glass place a large drop of fresh human blood and cover it with another cover glass, taking care that the two covers are a little eccentric to each other. Place the two covers so prepared in a moist chamber (on the table) for 15 minutes or longer. Transfer the two covers to a slide, flood them with water and carefully separate them. Wash the film side of each very carefully with water by means of a pipette to remove the red corpuscles. Stain the film side with eosin or erythrosin for 5 minutes, drain off the stain and dry without washing. When dry mount the better of the two preparations upon a shellac ring film side down.

Observe the network of the fibrin coagulum adherent to the cover.

BLOOD CRYSTALS.

53. **Hemoglobin.** Place upon a slide a small drop of mammalian blood (rat, cat, or human); place beside it a small drop of a 10% aqueous solution of pyrogalllic acid; cover both drops with a cover-glass and seal carefully with castor oil. Label the slide so prepared with your name and place it upon the window sill. At the second period (*i. e.*, after one or two days), examine it for crystals of hemoglobin. These will be found near the line where the drops of blood and pyrogalllic acid met. Observe their color, shape and arrangement.

54. **Oxy-hemoglobin.** Blood of *Necturus*. Demonstration. A plentiful supply of *Necturus* blood was placed upon a slide, mixed

with a drop of 2% aq. sol. of chloral hydrate, and covered and sealed and allowed to stand for several days, when crystals of oxy-hemoglobin appeared. Note their shape and color.

55. **Hemin.** Place upon a slide a little powdered blood (from a dried blood clot or stain), and a few granules of common salt (sodium chlorid), grinding well together. Add two or three drops of glacial acetic acid and cover. Heat gently two or three times until the acid just boils, adding a fresh drop of the acid after each boiling. Allow it to cool, remove the cover and permit the matter on the slide and cover to dry. Examine both, dry and mount in balsam the one showing best the crystals of hemin. If there are rough lumps of blood in the preparation, they may, without injuring the preparation, be removed by scraping before mounting. A large number of hemin crystals will probably be found. Their shape and color are characteristic and afford one of the best tests of blood.

THE SPECTRA OF BLOOD.

56. A demonstration of the spectra of hemoglobin and oxy-hemoglobin will be given. Note the characteristic absorption bands of each and their points of occurrence in the spectrum and the differences between the spectra of hemoglobin and oxy-hemoglobin. It is advisable to read in some work on physics about the spectroscope and spectrum analysis; also microscopical methods, §§ 179-203.

THE MUSCULAR TISSUES : THE MUSCULAR SYSTEM.

LABORATORY WORK FOR THE-----WEEK.

*References :**Points for Quiz :**Laboratory Report :**Due :*

Go the delivery desk for (a) assigned slide, 69 ; (b) a paraffin section, 61 ; (c) a collodion section, 67 ; (d) 58 ; 68, now in glycerin ; mount as directed. (e) 57 is in thin balsam ; mount a drop of the balsam. (f) Obtain 63, 64 and 65 and prepare them as directed. (g) 60, 62 and 66 take in order.

NON-STRIATED, PLAIN OR SMOOTH MUSCLE.

57. **Muscle cells from the intestine.** Cat. Isolated. The muscular coats of the intestine were dissociated in nitric acid dissociator (§ 11), washed in water, the cells separated and stained with eosin, now in balsam. Place a drop upon a slide and apply a cover glass. Note the length of the muscle cells, the form and size of the nucleus in the center. Contraction nodes may also be found in the fibers (cells) ; study them. For the nucleus and striation study 59.

58. **Muscle cells from an artery.** Cow. The uterine artery was placed in nitric acid dissociator (§ 11), the muscular coats teased out to separate the cells. Stained in erythrosin, now in glycerin ; mount in glycerin jelly. Find good examples of isolated cells and study, comparing them with the cells in 57 as to relative length and width, and the form and size of the nucleus.

59. **Plain muscle cells.** Demonstration. This preparation is intended to show especially (a) the shape, size and position of the nucleus in the cells of plain muscle, and (b) the longitudinal striation of the muscle fiber. Compare 57 and 58, identifying in them the nucleus and, if possible, the longitudinal striation.

60. **Anatomy of muscular coats (intestine).** Cat. Obtain from the delivery desk a small piece of the intestine, that has been

macerated in nitric acid dissociator. Demonstrate the outer longitudinal and inner circular coats, observing the relative thickness of each. Tease out upon a slide the end of a piece of the longitudinal coat, fraying the end with a needle, and spreading it out like a fan; cover in a drop of water and examine. Observe the course of the fibers (cells) and their relation to each other. Compare with the longisection and transection in 61.

61. **Transection and longisection of plain muscle.** Cat. Transection of the intestine. Picric alcohol; paraffin; sections μ . Stain with hematoxylin 15 minutes, eosin $\frac{1}{2}$ minute. Mount in balsam.

The outer muscular coat will afford a transection of plain muscle, the inner coat a longisection. In the outer coat, note the variation in the size of the sections of different fibers; and the occurrence of nuclei in only a few; why is this? Compare the section of the inner coat with the appearance found in 60. Study well the general structural appearance of plain muscle in section; what are the staining reactions of muscle and connective tissue with picrofuchsin?

STRIATED MUSCLE.

62. **Fresh muscle fibers.** Frog. Tease out upon a slide in normal salt solution a small shred of the muscle from the leg of a frog. Apply a cover glass and examine.

Observe the semi-translucent appearance of the fresh muscle. With a $\frac{1}{8}$ objective study the individual fibers, noting the transverse striations. Here and there broken fibers may be found; examine the broken ends to detect the torn sarcolemma. Lift the cover and add a drop of 2% acetic acid, and note the effect upon the fibers in bringing out sharply the muscle nuclei.

63. **Stained muscle fibers.** Macerated in acetic acid and glycerin and stained with Ehrlich's hematoxylin (Sihler's method). Now in thin balsam. Carefully separate the individual fibers of the muscle, keeping them parallel with each other and tearing them as little as possible. Mount in balsam.

The transverse striations and the muscle nuclei will show with great clearness. Note also the difference in caliber of different fibers.

64. **Fibrillae.** (Longitudinal striations). Biceps of rabbit. Treated with $\frac{1}{10}\%$ platinum bichlorid 6-24 hours; now in 82% alcohol. Carefully tease apart with needles the fibers of a shred of muscle and stain 5 minutes with erythrosin; dehydrate and clear. On the slide in the clearer tease again, trying to split the individual fibers; you cannot tease too finely.

If the teasing is fine enough in many places the fibers will be separated into their component fibrillae. Observe this feature and the structure of the individual fibrillae, the alternate light and dark zones, lateral and transverse discs, the dark intermediate disc in the midst of the light disc, and possibly the light middle disc in the midst of the transverse disc. Ask the instructor to show you a longisection of striated muscle stained with iron hematoxylin, in which the discs are more sharply differentiated.

65. **Tendinous ends of muscle fibers.** Cat. Intercostal muscle, dissociated in nitric acid; now in 82% alcohol. With the needles gently separate the fibers of a small fascicle, taking care to have the ends of the fibers well separated. If this is successfully done, the continuity of fiber and tendon will be shown. Stain the preparation with picrofuchsin five minutes, wash with 67% alcohol, dehydrate, clear, and mount in balsam. The muscle fiber will be stained yellow or orange, the tendon fibers red. Note the shape of the end of the muscle fiber and its relation to the fibrous tissue of the tendon. Can you determine the relation of the sarcolemma at the end of the fiber?

66. **Anatomy of a skeletal muscle.** Obtain from the desk an entire muscle which has been macerated in 20% nitric acid. Dissect it carefully, determining the course and arrangement of the component muscle fascicles in relation to the tendons (if present) of origin and insertion. Are the fascicles parallel with the axis of the muscle? Is it a penniform or bipenniform muscle?

67. **Transection of a skeletal muscle.** Cat.
 ; collodion; sections μ . Stain with hematoxylin 15 minutes, picrofuchsin 30 seconds. Mount in balsam.

Observe the connective tissue sheath of the muscle, the epimysium, the transected muscle fascicles surrounded by the perimysium, the individual fibers held together by the endomysium; finally, in the transection of the fibers, note the punctate appearance of the

cut ends, due to the transected fibrillae, and the muscle nuclei entad of the sarcolemma. Can you recognize areas of Cohnheim? The transections of the fibers are of different sizes. This may or may not mean a difference in the caliber of the fibers. Why? Compare with 61. You may be shown transections stained with iron hematoxylin in which the fibrillae are better differentiated.

CARDIAC MUSCLE.

68. **Muscle cells.** Isolated in caustic potash dissociator (§ 14); now in glycerin. Place a small drop of the glycerin containing the cells upon the slide; cover carefully; seal with shellac.

Study the preparation, examining many cells and noting the shape, the position of the nucleus or nuclei, the trans-striations, the relation of the cells to each other, and their processes.

69. **Transection of myocardium.** Human auricle or ventricle. Assigned for study. Müller's fluid; paraffin; sections 10 μ . Stained with hematoxylin and picrofuchsin.

Observe the shape and relation of the cells, the muscle columns and fibrillae, and the position of the nucleus; compare with the transections of plain and striated muscle (61, 67). You may be shown transections and longisections of cardiac muscle stained with iron hematoxylin, in which the fibrillae and cross-striations are better shown.

THE NERVOUS TISSUES : THE PERIPHERAL NERVOUS SYSTEM.

LABORATORY WORK FOR THE-----WEEK.

References :

Points for Quiz :

Laboratory Report :

Due ;

Go to the delivery desk for (a) assigned slide, 73 ; (b) paraffin sections, 74, 75, 76, 77, 78 ; (c) 72, stained ; now in clearer ; tease as directed below and mount in balsam ; (d) 70 and 71 may be prepared while the paraffin sections are being carried through.

NERVE CELLS.

70. **From the myel (Spinal cord).** Calf. The myel was split lengthwise and placed in formaldehyde dissociator (§§ 8 and 9). Place a small piece of the grey matter upon a slide in a drop of $\frac{1}{10}\%$ eosin (§ 94), and proceed as directed in § 10.

Search the preparation carefully until you find a nerve cell with quite long processes (dendrites). Observe (a) the nucleus with its nucleolus, (b) the number, extent, and branching of the processes of the cell-body, (c) the structural appearance of the cell-body and its processes. Can you determine the identity of the neurite? If desired, you may be shown nerve-cells in section stained with methylene blue, for Nissl's corpuscles.

71. **From the cerebral cortex.** Cat. The hippocamp was cut up into pieces and placed in formaldehyde dissociator. Carefully prepare two or three preparations according to § 10. The best preparation may be retained as a permanent mount.

Examine the slide carefully, finding as many cells with long processes as possible. Compare with 70, recognizing the identity of structure of the cells, but observe that these cells are of a pyramidal form, with a long apical process and basal processes. Can you find the neurite springing from the base of the cell?

NERVE FIBERS.

72. **Myelinic (medullated) nerve fibers.** Cat. Isolated fibers from the sciatic nerve. Hardened in Müller's fluid 8-10 days; hardened in alcohols; dehydrated; in chloroform 1-2 days; 95% alcohol; 82% alcohol; water; stained in Delafield's hematoxylin 12-24 hours (§ 82); now in clearer. With needles tease out a small bundle of fibers, keeping them parallel if possible. Mount in balsam.

In studying this preparation, determine the axis cylinder, the myelinic sheath, the nodes of Ranvier, the internodes,—their length,—the nerve corpuscles (nuclei). Can you recognize the neurilemma? Does the preparation show medullary segments or a reticular structure of the myelinic sheath?

73. **Amyelinic nerve fibers.** Ox. Isolated fibers from the splenic nerve. Assigned for study. Dissociated in $\frac{1}{10}$ % osmic acid (§ 17); teased apart with needles.

Both myelinic and amyelinic fibers are present, and care must be exercised in distinguishing between delicate myelinic fibers and the amyelinic ones. When a good place is found, study the amyelinic fibers, noting, as compared with the myelinic nerve-fiber, the absence of the myelinic sheath and the greater number of nerve nuclei. Compare the myelinic fibers in this preparation with those in 72. The myelin of the sheath is retained and blackened in 73; in 72 it has been dissolved out.

PERIPHERAL NERVES.

74. **Sciatic nerve.** Cat. Transection; chrome-oxalic (§ 32); paraffin; sections μ . Stain with hematoxylin 15 minutes, picrofuchsin $\frac{1}{2}$ minute. Mount in balsam.

Study this preparation for (a) the structure of a nerve trunk, noting its component funiculi or bundles, surrounded by connective tissue sheaths, the perineurium, and bound together by the epineurium, while within the funiculi, the individual nerve fibers with the endoneurium; (b) the structure of myelinic nerve fibers in transection, showing the central axis-cylinder, surrounded by the myelinic sheath (the myelin dissolved out). Find a place where a nerve nucleus is cut. Compare with the transection of a muscle, recognizing the analogy in the relations of the connective tissue.

75. **Ulnar nerve.** . Transection. Hermann's fluid (§23); paraffin; sections μ . Stain for 2-3 minutes with picrofuchsin.

This will be a supplementary preparation to 74, since here the myelin is not dissolved out and is stained black by the osmic acid. Compare the two preparations, recognizing in this one the features enumerated above.

76. **Vagus and sympathetic.** Transection; Hermann's fluid (§ 23); paraffin. Stain 2-3 minutes with picrofuchsin.

There will also be included a transection of the carotid artery. Note the myelinic nerve fibers, with blackened myelinic sheaths in both nerves and in the vagus, the variation in their caliber. In addition, recognize if possible the transected amyelinic fibers by the absence of a myelinic sheath.

GANGLIA.

77. **Sympathetic ganglion.** Cat. Section of the semilunar ganglion. Zenker's fluid; paraffin; sections μ . Stain 1 hour with hematoxylin, picrofuchsin 30 seconds. Observe well the characteristic appearance of ganglion cells in section; their finer structure, indications of their processes; recall the structure of the nerve cells in 70 and 71, realizing the extent of the dendrites.

78. **Spinal ganglion.** Section of the ganglion upon the dorsal root of a spinal nerve. Flemming's fluid; paraffin; sections μ . Stain with hematoxylin 1 hour, picrofuchsin 30 seconds. Observe the characteristic appearance of a ganglion, the (apparently) round ganglion cells with their capsules; the nerve fibers; the connective tissue within the ganglion and forming a covering sheath. Compare with 77. What is the real form of the nerve cells in the two kinds of ganglia and their relation to the fibers?

PERIPHERAL NERVE ENDINGS.

79. **Motor end-plate.** From the muscle. Demonstration. The preparation will show the nerve fiber terminating in the end-plate with its nuclei and the branching axis-cylinder.

80. **Sensory.** Free nerve endings in

Demonstration. Stained by Golgi's rapid method.

Illustrates the branching and free termination of the axis-cylinder in an epithelium.

81. **Pacinian corpuscles.** Cat. From the mesentery.

Demonstration. Note the core (inner bulb) in which the axis-cylinder of the nerve fiber terminates and the concentric connective tissue lamellae of the capsules.

82. **Meissner's corpuscles.** From the human finger. Demonstration. There is shown a corpuscle in one of the papillae of the skin. Observe the form and structural appearance.

Examine 17 for transected corpuscles in the papillae of the skin. Personal preparations showing 81 and 82 will probably be obtained later. (149, 153).

THE BLOOD AND LYMPH VASCULAR SYSTEM.

LABORATORY WORK FOR THE----- WEEK.

*References :**Points for Quiz :**Laboratory Report :**Due .*

Obtain from the delivery desk (*a*) assigned slide, 85 ; (*b*) paraffin sections, 83, 84, 86, 92, 94 ; (*c*) collodion sections, 91, 95 ; (*d*) 93, already stained.

ARTERIES.

83. **Muscular artery.** Cow. Transection of the uterine artery. Zenker's fluid (§ 28) ; paraffin ; sections μ . Stain with hematoxylin 30 minutes, picrofuchsin 30 seconds.

In this preparation identify the three coats forming the walls of arteries and veins,—the intima, media and adventitia ; noting the relative thickness of each. In the intima, recognize the vascular epithelium, the internal elastic membrane, and the subepithelial connective tissue. In the media should be found, plain muscle cells, elastic bands and white connective tissue ; recall the staining reactions of picrofuchsin (used for this preparation) with muscle, white and elastic connective tissue. Are there longitudinal muscular bundles present ? Note the relative amounts of white and elastic tissue. In the adventitia, observe the relative amounts and arrangement of the white and yellow elastic fibers. Is an external elastic membrane present ?

84. **Elastic artery.** Transection of the carotid artery. ; paraffin ; sections μ . Stain with hematoxylin minutes, picrofuchsin seconds.

Compare this preparation with 83, recognizing the coats, their relative thickness and structure. Especially compare the media in the two preparations, noting the relative amounts of muscle and elastic tissue in each.

85. **Aorta.** Homo. Transection or longitudinal section of the aorta. Assigned for study. Picric alcohol ; paraffin ; stained with hematoxylin and picrofuchsin.

Study carefully in comparison with 83 and 84. Are internal or external elastic membranes present? What is the relative thickness of the coats and the relative amounts of muscle and elastic tissue in the media? Are *vasa vasorum* to be seen in the adventitia?

VEINS.

86. **Femoral vein** (and artery). Transection of the femoral artery and vein. ; paraffin ; sections μ . Stain with hematoxylin minutes, picrofuchsin seconds.

Identify the artery from your knowledge of its structure as gained from a study of 83, and compare with it the vein, observing the differences and resemblances in the following particulars: (*a*) the thickness of the wall, (*b*) its flaccidity, (*c*) the presence of blood in the lumen, (*d*) relative thickness of the coats, (*e*) relative amounts of white connective tissue, elastic tissue and muscle present. From a study of their structure, compare arteries and veins as to their elasticity and contractility.

CAPILLARIES.

87. **Vascular epithelium.** Demonstration of the vascular epithelium as seen in capillaries and arterioles. Silvered (§ 146).

Note the shape of the cells as outlined by the blackened cell-cement ; their relative size in the capillaries. Remember that the vascular epithelium is the structure common to all parts of the vascular system.

88. **Capillaries in striated muscle.** Demonstration. Free-hand longitudinal section of muscle that was injected with carmine gelatin mass (§ 127).

Study carefully the capillary network and its relation to the muscle fibers.

89. **Capillaries of plain muscle.** Rabbit. Demonstration. The blood vessels of the small intestine were injected with carmine gelatin mass (§ 127), the muscular coats stripped off, pieces of the longitudinal coat laid out flat. Balsam mount.

Note the distribution of the vessels in the muscular tissue, the shape of the capillary network, and compare it with 88.

90. **Capillaries of an organ.** Demonstration. Blood vessels injected with carmine gelatin mass; hardened in alcohol; collodion.

Note the capillary network and the great vascularity. The vascularity of the different organs will be considered subsequently with the organs themselves.

LYMPHATIC TISSUES.

91. **Peyer's patch.** Cat. Transection of the ileum. vom Rath's fluid; collodion; sections μ . Stain with hematoxylin 15 minutes, picrofuchsin 15 seconds.

The section passes through a Peyer's patch. In the villi and mucosa will be found diffuse adenoid (lymphatic) tissue. Peyer's patch is an aggregation of lymphatic nodules, "dense" lymphatic tissue. Note carefully the general structural appearance of adenoid tissue, the character of the lymph cells and their nuclei. Can you recognize the lymphoid reticulum? Does the preparation show the relation of the lymphatic tissue to the epithelium?

92. **Tonsil.** Dog. Section of the tonsil. Zenker's fluid; paraffin; sections μ . Stain the section with hematoxylin 30 minutes, picrofuchsin 30 seconds.

Study the preparation, recognizing that it is composed of adenoid tissue, consisting of nodules surrounded by diffuse adenoid tissue. Identify its structure with that of Peyer's patch. Note the relation of the lymphatic tissue to the overlying stratified epithelium of the oral cavity; is the epithelium destroyed or filled with lymph cells; are there any lymph cells upon the surface of the epithelium?

93. **Lymphatic gland.** Cat. Transection. vom Rath's fluid; stained *in toto* in paracarmine; collodion; sections μ . Mount directly.

Study the general structural appearance of the gland. Identify the following regions or parts: (a) the cortex, medulla and the hilum; (b) the lymphatic nodules (follicles) in the cortex; (c) the capsule and the trabeculae; can you find plain muscle in the cortex? (d) blood vessels. Compare the lymphatic gland with 91 and 92. Can you recognize the lymph sinuses bordering the trabe-

culae? Understand the relation of the afferent and efferent lymph vessels to the gland and the course of the lymph through it.

94. **Thymus.** Transection. ; paraffin ; sections μ . Stain with hematoxylin 15 minutes, picrofuchsin 30 seconds.

Compare this preparation carefully with 93, identifying as before, capsule, trabeculae, cortex and medulla, lymph follicles (nodules), and in addition, the lobular structure. Can you find corpuscles of Hassall ; what is their significance? Study the structural appearance of the organ so that you may distinguish it from 93 and 95. Study the microscopic appearance of the thymus.

95. **Spleen.** Dog. Transection. vom Rath's ; collodion ; sections μ . Stain with hematoxylin 15 minutes, picrofuchsin 30 seconds.

Examine the gross preparations of the spleen, observing carefully the structural appearance of natural and cut surfaces. Study the microscopic preparation, recognizing (*a*) the capsule and the trabeculae ; is plain muscle present in these? (*b*) the splenic pulp containing the Malpighian corpuscles (lymphatic follicles or nodules), and blood vessels. Examine the Malpighian corpuscles, noting their structure and the eccentric artery ; compare them with the lymphatic nodules in 93 and 94. For the supporting framework of the spleen, the capsule and trabeculae, examine the gross, macerated preparation. Study carefully the general structural appearance of the section of spleen, so that you may distinguish it from lymph gland or thymus. Again consult the gross section of spleen, identifying capsule and trabeculae, Malpighian corpuscles and splenic pulp. Understand the relation of the blood vessels to the Malpighian corpuscles and to the pulp.

THE DIGESTIVE SYSTEM.

LABORATORY WORK FOR THE-----WEEK.

*References :**Points for Quiz :**Laboratory Report :**Due .*

Go to the delivery desk for (a) assigned slide 100, (b) paraffin sections 103, 108, (c) collodion sections 96, 97, 101, 104, (d) 98, 99, 102, 105, 106, already stained and in clearer.

THE ORAL CAVITY.

(10). **Epithelium, glands.** Section of the soft palate, cat. Assigned for study (10). The oral side of the soft palate affords a demonstration of the stratified epithelium of the oral cavity ; study its appearance. In the substance of the soft palate are numerous mucous glands, which open upon the mucosa of the oral cavity. Serous glands are not present. Study their appearance and structure ; find if possible a duct leading to the surface. These would belong to the group of palatine glands ; others would be lingual, buccal or labial, according to their location.

96. **Developing tooth.** Early stage. Transection through the cephalic part of the head of an embryo long. ; collodion ; sections μ . Stain with hematoxylin and eosin.

Within the section will appear the two nasal cavities and below them the oral cavity, with the tongue projecting up from the floor of the mouth. On each side, opposite the developing lower and upper jaws, will be seen the dental ridge projecting from the epithelium of the oral cavity. One of the four sections of dental ridge will probably pass through a developing tooth, showing the cap-like enamel organ covering the papilla which forms the dentine and pulp of the adult tooth.

97. **Developing tooth**; later stage. Dog. Transection through the lower jaw of a new born puppy. Picric alcohol; decalcified (§ 131); collodion; sections μ . Stain with hematoxylin and picrofuchsin.

Be sure your section passes through a developing tooth. In this more mature tooth there should be recognized (*a*) the enamel organ with its three layers, (*b*) the enamel, (*c*) the dentine lined by the odontoblasts, and finally (*d*), the dental pulp, containing blood vessels.

98. **Tongue**. Rabbit. Transection. Müller's fluid; stained *in toto* (§ 74 c); collodion; sections μ .

Study the preparation, noting the surface epithelium with low papillae, in the body of the tongue, the mesal septum and the bundles of muscle in general running vertically, longitudinally and transversely; also nerves and blood vessels.

ESOPHAGUS.

99. **Esophagus**. Dog. Transection. ; sections μ . Stained *in toto*.

In this preparation, as well as in the succeeding regions of the digestive tract, identify the four coats—mucosa, submucosa, (inner and outer) muscular and serous coats. In the mucosa and submucosa observe the character of the lining epithelium, the mucous glands; find if possible a duct opening upon the lining epithelium; the muscularis mucosa; the character and direction of its fibers. In the muscular coats determine the character and direction of the muscle fibers. What differences are there in different animals in the muscular coats of the esophagus?

100. **Esophagus**. Homo or sheep. Assigned for study. Transection.

Compare with 99, recognizing the coats, the epithelium, muscularis mucosa, character and relation of the muscular fibers in the muscular coat. Are glands present?

STOMACH.

101. **Stomach**. Dog. Vertical section of the wall, cardiac end near the esophagus. ; collodion; section μ . Stain the sections with hematoxylin and eosin.

Identify as before the four coats, noting the character of the muscular tissue in the muscular coat, the number of layers recognizable in it and in the muscularis mucosae. In the submucosa observe the presence of blood vessels, both arteries and veins. In the mucosa are the tubular gastric glands opening, two or three together, into depressions of the surface epithelium. In these gland tubules recognize the two kinds of cells, chief and border cells; recall the function of each. Compare the surface epithelium of the stomach with that of the esophagus. If your preparation does not show well the gland tubules and their cells ask the instructor to show you one that does.

102. **Stomach.** Dog. Vertical section through the wall, pyloric end. ; stained *in toto* in paracarmine; collodion; sections μ .

Compare this preparation with 101, recognizing the coats and their structure and noting differences in the muscular coats, especially the increase in the thickness of the inner circular coat, and in the glands of the mucosa. Observe that the pyloric glands differ from the peptic (oxyntic) glands shown in 101 in (a) the absence of parietal cells, (b) the longer duct into which several tubules open. Recall the relative extent of the regions occupied by the two kinds of glands.

103. **Zymogen granules.** Calf. Vertical section through the mucosa of the cephalic end of the stomach (fourth stomach or abomasum). 1% osmic acid; paraffin; sections μ . No staining or Hcl. carmine (§ 87).

In the deeper part of the mucosa will be seen the gastric tubules, cut across in various directions and lengthwise. The ends of the cells forming the tubules—the chief cells—toward the lumen of the tubule will be seen crowded with granules of a yellowish brown color. These granules are the precursors of the ferment, or pepsinogen granules. Find a border cell and note that no such granules are contained in it.

SMALL INTESTINE.

104. **Duodenum.** Cat. Transection. Zenker's fluid; collodion; sections μ . Stain with hematoxylin and picrofuchsin.

In studying this preparation, observe that the coats recognizable in the esophagus and stomach, also form the intestine. Determine the character and direction of the fibers in the two layers of the muscular coat. Is a muscularis mucosa recognizable? In the mucosa, note the tubular crypts of Lieberkühn extending down into the mucosa, and the villi, tongue-like elevations of the mucosa. Study the character of the epithelium of the intestine, noting the striated border of the columnar cells and the goblet cells. Compare the epithelium covering the villi with that of the crypts of Lieberkühn. In the submucosa are the glands of Brunner with here and there a duct leading through the mucosa. What relation do they have to the pyloric glands? Study carefully the structure of a villus; (*a*) its covering epithelium, (*b*) the central core of diffuse adenoid tissue, (*c*) a strand of plain muscle; and in comparison, study 105, 106, and 6.

105. **Duodenum.** Rabbit. Injected with carmine gelatin mass (§ 127); now in clearer. Mount a piece of the mucosa, villi up.

The villi are rather short and leaf-like, flattened. Observe how the arteriole passes up to near the summit of the villus, there to break up into a cascade of capillaries that unite on the opposite side to form one or two venules.

106. **Ileum.** Rabbit. Transection. Injected with carmine gelatin mass (§ 127); alcohols; collodion; now in clearer; sections μ .

In the ileum the villi are longer and more filiform. Note the relations of the blood vessels in the villi and compare with 105.

107. **Ileum.** Rabbit. Demonstration. Blood vessels injected with carmine gelatin mass (red); the central lacteal is filled with Berlin blue gelatin mass (blue). Observe the position of the lacteal (lymph vessel) in the villus, its extent and size in comparison with the blood capillaries. By means of 6, 104, 106 and 107 a fairly complete idea may be formed of the structure of a villus; from your physiology recall the part played by the epithelium in absorption and what food stuffs pass into the lacteal and what are taken up by the blood vessels.

108. **Fat absorption.** Intestine of the frog. Flemming's fluid (§ 24); paraffin. The frog was fed with bacon 24 hours be-

fore it was killed, and the fat is being absorbed by the epithelial cells; the globules in the epithelium are blackened by the osmic acid of the Flemming's fluid. If desired the preparation may be stained with safranin (§§ 89, 99).

The intestine of the frog has no villi, the elevations of the mucosa shown in the transection are folds cut across. The epithelial cells covering the villi in mammals, however, have the same function in the absorption of fat (6).

(91). **Ileum.** Cat. Re-examine this preparation in the light of the knowledge gained of the structure of the intestine, noting the lymph follicles and their relation to the intestinal epithelium; the occurrence of lymph cells in and upon the epithelium. Identify also the coats and structures mentioned under 104, save, of course, Brunner's glands, which are limited to the cephalic part of the duodenum.

THE DIGESTIVE SYSTEM.

LABORATORY WORK FOR THE-----WEEK.

*References :**Points for Quiz :**Laboratory Report :**Due :*

Go to the delivery desk for (a) assigned slides, 110, 114, 118 ; (b) paraffin sections, 112, 113, 115 ; (c) collodion sections, 109, 116, 117 ; (d) sections already stained, 111.

LARGE INTESTINE.

109. **Colon.** Transection. Picric alcohol ; collodion ; sections μ . Stain with hematoxylin and picrofuchsin.

Compare with the sections of small intestine, noting identity of structure of the coats and their general structure and relations, differences in the absence of villi, greater number of crypts of Lieberkühn, increase in the relative number of goblet cells.

110. **Rectum.** Kitten. Transection. Assigned for study. ; collodion ; sections μ . Stained with

Compare this preparation with 109, observing especially the increased thickness of the muscular coats and the muscularis mucosae, and the looser connection of the mucosa with the muscular coat.

111. **Caecum.** Rabbit. Blood vessels injected with carmine gelatin mass ; now in clearer ; mount in balsam, rough side (mucosa) up. Note the capillary net work and its denser arrangement in small areas,—rudimentary villi.

SALIVARY GLANDS.

112. **Mucous type.** Submaxillary gland. Cat. Mercuric chlorid + 5% glacial acetic acid (§ 26) ; paraffin ; section μ . Stain with hematoxylin and picrofuchsin.

Study the section carefully, noting (a) the general structural appearance of the gland, its lobulation, (b) the component acini and

ducts, (*c*) the blood vessels and nerves (and ganglion), together with the connective tissue.

Study carefully the character of the cells composing the secreting acini, noting (*a*) the structure and staining reaction of the cell-body, (*b*) the position and structure of the nucleus. Can you find a place where duct and secreting portion are continuous? Recognize the presence of demilunes and note the character of the cells.

113. **Serous type.** Section of the parotid gland. Cat. Mercuric chlorid + 5% glacial acetic acid (§ 26); paraffin; sections μ . Stain with hematoxylin and picrofuchsin.

Study the section for the general structural appearance and lobulation, the secreting acini and ducts, blood vessels, nerves and connective tissue. Study the acini carefully, comparing them with the secreting acini in 112 as to the shape and size of the cells, the position and structure of the nucleus, and the structure and appearance of the cell bodies. What are the differences? Can you distinguish mucous and serous glands? Compare the glands you found in the esophagus and soft palate.

PANCREAS.

114. **Pancreas.** Horse. Assigned for study. Picro-formalin; paraffin; hematoxylin and eosin.

Examine the gross preparations for general appearance, lobulation, compactness, color, etc.

In studying the section analyze its structure in the same manner as 112 and 113, observing carefully its general structural appearance, the ducts and secreting acini (tubules), the structure and shape of the cells forming these, the position of the nucleus. Are areas of Langerhans present in the section? Compare the section with 113 as to (*a*) compactness, (*b*) shape of the secreting acini, (*c*) the lumen of the acini. Can you distinguish them?

115. **Zymogen granules.** Pancreas. Calf. 1% osmic acid (§ 22); paraffin; sections μ . No staining.

In the ends of the cells forming the secreting acini (tubules) observe the presence of light brown granules—trypsinogen granules, precursor of the ferment secreted by the gland. Compare 103.

116. **Injected pancreas.** Rabbit. Blood vessels injected with carmine gelatin mass; alcohols; collodion; stain lightly with hematoxylin. This preparation illustrates the vascularity of the

gland and the relation of the capillary network to the tubules of the acini of the gland.

LIVER.

117. **Liver.** Pig. Picric alcohol ; collodion ; sections μ . Stain with hematoxylin and picrofuchsin.

Study thoroughly the preparations illustrating the gross anatomy of the liver ; (*a*) position, (*b*) aspects, (*c*) lobes, (*d*) the longitudinal and transverse fissures, (*e*) the appearance of the liver substance as seen in section and the natural surface (covered by the connective tissue capsule), (*f*) the indistinct lobulation.

In studying the section of liver note the lobules separated by connective tissue septa. Within the lobules recognize the intra-lobular vein and the arrangement of the liver cells. In the inter-lobular connective tissue will be found inter-lobular veins, inter-lobular arteries, small bile ducts. Can you find intra-lobular blood capillaries passing off from the inter-lobular veins or entering the intra-lobular veins? Be sure you understand the course of the blood and the origin and relations of the different vessels. What is the relation of the liver cells to the blood capillaries and the bile capillaries? Note well the structural appearance of the liver so that you can distinguish it from other glands. The liver of the pig has a large amount of connective tissue between the lobules, separating them completely ; hence their distinctness.

118. **Liver.** Horse or Homo. Assigned for study. Potassium dichromate or Erlicki's fluid ; paraffin ; stained with hematoxylin and picrofuchsin.

Study carefully, identifying the parts and structures already recognized in 117 ; compare with that preparation, noting the incomplete isolation of the lobules, less inter-lobular connective tissue, etc. Again consult the gross preparations, examining them in the light of your present knowledge of the structure of the liver.

119. **Bile capillaries.** Liver of ox. Demonstration. The bile capillaries are gorged with bile, caused by physiological stasis of bile in Texas fever. Note the fineness of the capillary network and the relation of the capillaries to the cells.

120. **Glycogen.** Demonstration. Liver hardened in absolute alcohol ; paraffin ; sections stained with a solution of iodine ; mounted in iodine-gum arabic. The glycogen is stained a yellowish brown ; note its accumulation in one end of the cells (generally toward the intra-lobular vein). Consult

THE RESPIRATORY SYSTEM.

LABORATORY WORK FOR THE-----WEEK.

*References :**Points for Quiz :**Laboratory Report :**Due :*

Go to the delivery desk for (a) assigned slide, 121 ; (b) paraffin section, 128 ; (c) colodion sections, 122, 123 ; (d) sections ready to mount, 124, 126 ; (e) prepare 125.

(10) **Soft palate.** Cat. Assigned for study. The nasal side of the soft palate will afford a demonstration of the ciliated epithelium of the nasal fossae. This will be spoken of in your text book as a stratified ciliated epithelium. Compare it with the epithelium in the trachea.

LARYNX.

121. **Larynx.** . Assigned for study. Longisection. ; collodion ; sections μ . Hematoxylin and picrofuchsin. Understand what structures are shown in the section. Of the cartilages shown in the section, the first is the hyoid, the second the thyroid, followed by the cricoid and the rings of the trachea. Identify the true and false vocal cords and the ventricle of the larynx. Note the character of the epithelium in the different regions, *i. e.*, in the ventricle and upon the false and true vocal cords. Are glands present? Where are they located? Note also the structure of the mucous membrane and its variation in the different regions.

TRACHEA.

122. **Trachea.** Cat (young). Transection. Picric alcohol ; collodion ; sections μ . Stain with hematoxylin and picrofuchsin.

Identify the three coats of the trachea, (1) the mucous coat, (2) the submucous coat, (3) the fibrous coat with its incomplete

ring of cartilage, studying carefully the structure of each coat. Compare the lining epithelium with that in the ventricle of the larynx and upon the soft palate. Note especially the overlapping of the ends of the cartilaginous rings and the character of the epithelium in the fold of the mucosa caused thereby, and the relation of the muscle to the cartilage. In the last respect, compare with the relations in man and sheep, as demonstrated to you.

123. **Trachea.** Cat (old). Transection. Picric alcohol; collodion; sections μ . Stain with hematoxylin and picrofuchsin.

Recognize in this preparation exactly the same structures identified in 122 and compare the two preparations, especially as to the epithelium lining the fold where the cartilages overlap. This will illustrate how the original character of an epithelium is altered by changed conditions.

LUNG.

124. **Lung.** Transection (or longisection) of a lobe (in part). Picric alcohol; collodion; sections μ . Stained *in toto*.

Examine the gross preparations of lung, showing the lobes, and the appearance of lung tissue seen in surface view and in section. Is a further division of lobes into lobules recognizable? The section will illustrate the structure of normal lung.

The following features are to be noted: (*a*) the general structural appearance of lung tissue, (*b*) the structure of a bronchus or bronchiole, (*c*) the infundibula with air sacs opening into them, and (*d*), if possible, the transition of terminal bronchus or alveolar duct to infundibulum.

125. **Dried lung.** Cat. The fresh lung was inflated and dried. Prepare a slide with a rubber cell (§ 103, *b*), and mount within the cell two sections of lung cut free-hand, a surface section and a deep section, mounting the surface section pleural side up. Cover and seal (§ 103, *b*).

This preparation will illustrate well the infundibula and the compartments in their walls, the air sacs. It is possible that there may be a good natural injection of the blood capillaries (filled with blood,—yellow); if so, note the size of the capillaries and the denseness of the net-work.

126. **Lung.** . Injected with Berlin blue gelatin mass (§ 128); alcohols; collodion; sections μ . No staining.

Search the preparation to find places showing well the capillary net-work in the walls of the air sacs, and compare it with the natural injection, if present, in 125.

127. **Respiratory epithelium.** Cat. Demonstration. Free-hand section of silvered lung. The blackened cell cement outlines the cells lining the air sacs, of which recognize the two kinds, large flat cells with irregular outlines and small granular cells. Understand the significance of the two kinds.

THYROID.

128. **Thyroid.** Chrome-oxalic; paraffin; sections μ . Stain with hematoxylin and eosin. Consult the gross preparations for the position, shape (general), and color of the glands; their appearance superficially and in section. In the section there are to be noted, the shape, size, and structure of the acini; the colloid mass; the connective tissue dividing the gland into lobes and lobules; the blood vessels. Study well the epithelium in connection with the formation of the colloid mass. Can you recognize two kinds of cells? This is a ductless gland; in what way may the secretion be utilized by the body?

THE URINARY ORGANS.

LABORATORY WORK FOR THE-----WEEK.

*References :**Points for Quiz :**Laboratory Report :**Due .*

Obtain from the delivery desk (*a*) paraffin sections 129, 132, 133, (*b*) collodion sections 130, 134, 135, 136, 137, 138.

KIDNEY.

129. **Kidney.** Transection. Müller's fluid ; paraffin ; sections μ . Stain with hematoxylin and eosin.

Examine the gross preparations of kidney for (*a*) the form and color of the organ, (*b*) the unilobular (apparently) and multilobular kidney ; compare the kidney of the child with that of the adult, and with the kidney of the ox. In the transected and longisected organs, recognize if possible (*a*) the cortex (superficial zone) and (*b*) medulla, (*c*) the papillae. Some of the kidneys have one, others several papillae ; note in which animals each of these conditions occurs and correlate lobules and papillae.

In studying the section recognize the following regions : (*a*) cortex and (*b*) medulla ; in the cortex, medullary rays and labyrinth, and in the medulla, the pyramids and the columns of Bertini. Study carefully these four regions, identifying the structures that should be present in each. Understand the course the uriniferous tubule would pursue from its beginning (Bowman's capsule) to the opening of the collecting tubule into the pelvis of the kidney and the regions in which its successive parts are found. Again examine the longisected kidneys ; recognize the regions and note the structural appearance of each, for which you have the explanation in this preparation.

130. **Injected kidney.** Cat. Transection. Blood vessels injected with carmine gelatin mass ; collodion ; sections μ .

This preparation will illustrate the relations of the blood vessels within the kidney, and should be studied in connection with 129, which it supplements. Understand the regions in which the following occur and the courses they pursue: (*a*) the renal arteries, (*b*) "interlobular" arteries, (*c*) afferent arteries, (*d*) glomeruli, (*e*) efferent vessel, (*f*) capillaries, (*g*) interlobular veins, (*h*) renal veins, and (*i*) the arteriae and venae rectae. Identify them in the preparation.

131. **Bowman's capsule.** Cat. Demonstration. Injected kidney; paraffin; sections μ . Stained with hematoxylin and picric alcohol. The injection has caused a transudation of fluid into Bowman's capsule; this fluid has taken the hematoxylin stain, thus illustrating the relation of the glomerulus to Bowman's capsule and the beginning of the urinary tubule.

132. **Papilla of the kidney.** (*a*) Horse. Transection. paraffin; sections μ . Stain with hematoxylin and picrofuchsin. From your study of 129 and 130 identify the tubules and vessels shown in this section and note their grouping in relation to each other.

133. Same; (*b*) Homo. Müller's fluid; paraffin; sections μ . Stain with hematoxylin and eosin. Compare this with 132.

URETER.

134. **Ureter.** . Transection. Picric alcohol; colloidion; sections μ . Stain with hematoxylin and picrofuchsin.

In addition to the recognition of the three coats and the structure of each, note well (*a*) the character of the lining epithelium and compare it with the stratified squamous epithelium (10, 99), and (*b*) the direction of the muscular fibers in the two (or three) muscular layers, and compare with the condition in the digestive tract, *e. g.*, intestine. Compare the epithelium of the ureter with that of the pelvis of the kidney (129).

BLADDER.

135. **Bladder,—distended.** . ; colloidion; sections μ . Stain with hematoxylin and picrofuchsin.

Note the three coats, and their structure. Can you recognize three layers in the muscular coat? What is the course of the fiber

bundles? Recognize blood vessels, nerves (and ganglia?). Study well the epithelium and compare it with the epithelium of the ureter.

136. **Bladder,—collapsed.** ; collodion ; sections μ . Stain with hematoxylin and . This preparation is to be compared with 135 for (*a*) the epithelium, its differences in a distended and contracted condition, and (*b*) the layers of the muscular coat.

URETHRA.

137. **Urethra—female (and vagina).** Transection. collodion ; sections μ . Stain with hematoxylin and picrofuchsin.

Study the preparation carefully, noting the coats, the character of the lining epithelium, the layers composing the muscular coat, and the direction of the fibers ; compare with the condition in the ureter and bladder. Are glands present? Note the blood vessels of the mucosa.

138. **Urethra—male.** Transection. collodion ; sections μ . Stain with hematoxylin and picrofuchsin.

Compare this preparation with 137 and note differences. What is the character of the epithelium and therefore what part of the urethra is it? Are the muscular layers well defined?

GENITAL ORGANS : MALE.

LABORATORY WORK FOR THE-----WEEK.

*References :**Points for Quiz :**Laboratory Report :**Due :*

Obtain from the delivery desk, (a) paraffin sections, 141, 143 ; (b) collodion sections, 139, 140, 144. (c) 142, cover-glass preparation.

TESTICLE.

139. **Testis,** . Longisection ; collodion ; sections μ . Stain with hematoxylin and picrofuchsin.

The following parts should be recognized, (a) the testis, and (b) the epididymis ; in the testis, the three coats, the lobules of the testis, and, composing the lobules, the seminiferous tubules, straight tubules and rete testis ; in the epididymis, note its relation (as a mass) to the testis, the structure of the tubules, the character of the epithelium. Does the section include the globus major or minor or both ? Is the vas epididymis sectioned ? Can you determine the vas deferens ? In addition, note the blood vessels.

140. **Testis,** . Transection of the testis in the tunica vaginalis. ; collodion ; sections μ . Stain with hematoxylin and eosin.

Identify, as far as possible, the parts recognized in 139, and in addition, the tunica vaginalis with its two layers, and the mediastinum. Note the position occupied by the blood vessels. What is the cavity between the two layers of the tunica vaginalis and its lining epithelium ? Identify the vas deferens.

141. **Spermatogenesis.** Rat. Section of a part of the testis. ; paraffin ; sections μ . Stain with hematoxylin and acid fuchsin ($\frac{1}{4}$ % solution).

Examine different tubules and find if possible five different stages in the formation of the spermatozoa, remembering that the process

occurs from the outside toward the lumen of the seminiferous tubules, so that in the innermost layer would be found maturing (or mature) spermatozoa, in the outermost layer spermatogonia (parietal cells), and between spermatocytes (mother cells) and spermatids (daughter cells), which metamorphose into the spermatozoa. Find also the supporting cells (Sertoli cells) and observe their relation to the ripening spermatozoa.

142. **Spermatozoa.** Cat. Dried on the cover glass. No staining. Mount on a shellac ring (§ 103, *a*).

Recognize the three parts—head, middle-piece, and tail, noting the shape and relative length of each; compare with the spermatozoa found in the tubules and ducts (*vasa*) in 139, 141, noting the staining reactions of the parts.

VAS DEFERENS.

143. **Vas deferens.** ; paraffin; sections μ . Stain with hematoxylin and

Determine the number of the coats and their structure; the course of the fibers in the muscular layers and the character of the epithelium, and compare it with the epithelium found in the tubules of the epididymis.

PROSTATE GLAND.

144. **Prostate.** Transection of the gland and urethra. ; collodion; sections μ . Stain with hematoxylin and eosin.

Understand the relation of the gland to the bladder and the urethra. In the section, observe the relation of the gland mass to the urethra. Is a division into lobes indicated? Note the capsule and its structure, the acini and ducts forming the gland mass, together with connective tissue and plain muscle. Does the section include the prostatic sinus or the ejaculatory ducts (*vasa deferentia*)?

THE GENITAL ORGANS: FEMALE.

LABORATORY WORK FOR THE-----WEEK.

*References :**Points for Quiz :**Laboratory Report :**Due :*

Obtain from the delivery desk, (*a*) paraffin section, 147 ; (*b*) collodion sections, 145, 146, 148.

OVARY.

145. **Ovary.** ; collodion ; sections μ .
Stain with hematoxylin and eosin.

Examine the gross preparations for the shape, superficial appearance of the ovary and its relations to the ligaments and to the Fallopian tube. In the section, note the regions, roughly defined,—the cortex and medulla and the structural appearance of each. As composing the ovary, note (*a*) the covering tunica albuginea, (*b*) the ovarian stroma containing (*c*) Graafian follicles at various stages of maturity, together with (*d*) the blood vessels and nerves. Points to which attention is called are (*1*) the peculiar structure of the stroma of the ovary, (*2*) the large size of the veins, and (*3*) the structure of the mature Graafian follicle. In studying the Graafian follicle, recognize (*a*) the theca and its layers ; (*b*) the membrana granulosa surrounding the cavity of the follicle and bearing on one side an eminence containing the ovum,—the discus proligerus.

Study carefully the structure of the ovum and its parts, identifying it as a single cell, and comparing it with other cells. Understand how the ovum may escape from the ovary by the rupture of the Graafian follicle. Compare 1.

(19). **Ovary.** Cat, new-born (1-2 weeks). Assigned for study.

This preparation illustrates especially (*a*) the germinal epithelium, (*b*) the egg-nests or egg-tubes, and (*c*) early stages in the formation of Graafian follicles. Examine the germinal epithelium to find here and there the large sexual cells. Can you find inter-

mediate steps between them and the young ova? Remember the difference of opinion as to the origin of the follicle cells.

(18). **Ovary.** Cat (young). Preparation previously made (18).

In this will be found stages in the formation of the Graafian follicles. Note the layer of young ova under the tunica albuginea, Graafian follicles with one layer of follicle cells surrounding the ova, follicles with a several-layered follicular epithelium, and older follicles in which the cavity of the follicle has appeared.

146. **Corpus luteum.** Section of the ovary of a pregnant ; collodion ; sections μ . Stain with

In studying this preparation understand when and how the corpus luteum is developed. Note its structure, observing the polyhedral cells, the connective tissue, and the blood vessels. Is there any trace of the original cavity of the follicle?

FALLOPIAN TUBE.

147. **Fallopian tube.** ; paraffin ; sections μ . Stain with hematoxylin and picrofuchsin.

Identify the coats, noting their structure, the extensive folds of the mucosa, the character of the lining epithelium, the presence of a muscularis mucosae (?) the arrangement of the fibers in the muscular coat, the character and location of the blood vessels. Are all the cells of the epithelium ciliated?

UTERUS.

148. **Uterus.** Transection. ; collodion ; sections μ . Stain with hematoxylin and eosin.

The same coats are present as in 147, but note the differences, especially (*a*) the character of the lining epithelium, (*b*) the peculiar structure of the mucosa, (*c*) the glands contained in the mucosa, (*d*) the thickness of the innermost muscular layer and the direction of its fibers, (*e*) the veins.

VAGINA.

(137). **Vagina.** Transection. Preparation already made (137).

Recognize the three coats and study the structure of each, noting (*a*) the character of the lining epithelium, (*b*) the structure of the mucosa, (*c*) the course of the fibers of the muscular coat. Are ganglia recognizable in the muscularis or mucosa? Note the number and size of the blood vessels.

THE SKIN AND ITS APPENDAGES.

LABORATORY WORK FOR THE-----WEEK.

*References :**Points for Quiz :**Laboratory Report :**Due :*

Obtain from the delivery desk (*a*) assigned slides 152 and 154, (*b*) paraffin sections 150, 152, 157, 158 and 159, (*c*) collodion sections 149, 151, 156, (*d*) 153 will be sectioned in your presence during the week ; read §§ 61-63.

THE SKIN.

149. **Skin of palm or heel.** Homo. Vertical section ; collodion ; sections μ . Stain with hematoxylin and picrofuchsin.

Identify epidermis and corium ; in the former recognize the layers and study their structure ; are the layers of the corium distinguishable ? Search the preparation carefully for sweat glands ; corpuscles of Meissner may be present in the papillae of the corium. Are inter-cellular bridges shown in the stratum Malpighii ?

(17). **Skin of palm or heel.** Homo. Surface section (slightly oblique). Preparation already made (17). In this preparation note (*a*) the inter-cellular bridges of the cells of the Malpighian layer and the relation of the deepest cells next the corium to the connective tissue, (*b*) the transected papillae of the corium.

150. **Skin, general body surface.** Homo. Vertical section. ; paraffin ; sections μ . Stain with hematoxylin and picrofuchsin. Study this preparation carefully in comparison with 149, identifying the epidermis and corium, the layers composing them, and the relative development of each. Does the section show the presence of hairs ? Sweat glands ?

151. **Lip.** Homo. Transection. ; collodion ; sections μ . Stain with hematoxylin and picrofuchsin.

This preparation affords a demonstration of the transition of the epidermis of the skin to the epithelium of the oral mucosa. Note well the character of the epithelium upon the two sides of the lip, and the presence of hairs on the dermal side. Study the section also for the structure of the skin,—the layers, glands, etc. As illustrating the structure of the lip, note the striated muscle, connective tissue, nerves and blood vessels and their arrangement.

152. **Lip.** Horse or calf. Assigned for study. Transection. ; collodion ; sections μ . Stained with . Compare this preparation with 151, recognizing the features enumerated above. Note the greater development of the hair of the skin.

NAIL.

153. **Finger.** Child. Transection through the tip. ; frozen section (§ 61). Now in water. Stain with hydrochloric acid carmine minutes (§ 87), and counter-stain slightly with picric alcohol.

This preparation illustrates: (*a*) the structure of the nail, (*b*) the skin (of the finger). Note well the structure of the nail and the nail-bed with its longitudinal corrugations cut across; the relation of nail and nail-bed to the skin of the finger. In addition there are illustrated the structure of Pacinian corpuscles and sweat glands.

HAIR.

154. **Hair.** Homo. Assigned for study. Section of scalp, cutting the hairs at right angles. ; paraffin ; stained with hematoxylin, picrofuchsin, and methyl green.

Since the section cuts the hairs at right angles and the hairs are oblique to the surface, there appear transections of hairs at different levels. Study carefully the sections of hair, identifying the layers composing the hair and follicle at different levels, especially comparing sections through the mouth of the follicle, through the middle of the root, and through the hair bulb. Study the structure of the sebaceous glands, their relation to the hair follicle and the point at which they open.

155. **Hair.** Homo. Demonstration. Section of scalp, cut longitudinally with the hair showing the entire length. Note carefully the root of the hair, the follicle and its relation to the epidermis, the sebaceous glands and the hair muscle.

156. **Hair muscle.** (Arrector pili). Cat. Section of the skin from the dorsal side of the tail, cutting the hairs longitudinally. Picric alcohol ; collodion ; sections μ . Stain with hematoxylin and picrofuchsin.

This preparation will illustrate especially the hair muscles and their relation to the hair follicles. Study, noting their relation to the follicles and sebaceous glands ; their large size in this preparation. Understand their action in raising the hair. Compare 154, identifying in it the hair muscle.

MAMMARY GLAND.

157. **Mammary gland.** Cow. In lactation. ; paraffin ; sections μ . Stain with hematoxylin and eosin.

Observe carefully the general structural appearance of the gland, noting the lobulation and the secreting acini. Study carefully the epithelium forming the acini, noting the character of the cells and their appearance and indications of functional activity. Note also the secretion (if present) in the lumen of the acinus. Compare with 158 and 159.

158. **Mammary gland.** Cow. In lactation. 1% osmic acid (§ 22) ; paraffin ; sections μ . No staining.

This preparation supplements 157. The osmic acid blackens the fat globules which in 157 were dissolved out. Observe the number and size of the globules in the epithelial cells of the acini and in the secretion in the lumen of the acinus.

159. **Mammary gland.** Cow. Not in lactation ; paraffin ; sections μ . Stain with hematoxylin and eosin.

This section is to be compared with 157, the identity of structure noted, and the different appearance of the acini due to the resting condition of the cells.

THE CENTRAL NERVOUS SYSTEM.

LABORATORY WORK FOR THE-----WEEK.

*References :**Points for Quiz :**Laboratory Report :**Due :*

Go to the delivery desk for (*a*) paraffin section 160, (*b*) preparations already stained 161, 162, 164-168, (*c*) section 163 will be given you some time during the first period.

MYEL (SPINAL CORD).

160. **Cervical myel.** Transection. vom Rath's fluid; paraffin; sections μ . Stain with hematoxylin 2-3 hours, picric alcohol 30 seconds or longer.

Gross anatomy : Examine the preparations of myel, noting the three regions—cervical, thoracic and lumbar; the end of the segment of myel, observing the halves separated by the dorsal septum and the ventral fissure, the central gray matter, cinerea, and the superficial, ectal alba (white matter); the spinal nerves formed by the union of a dorsal and a ventral root, the former with an enlargement—the ganglion.

In the section recognize (*a*) the lateral halves, (*b*) the ventral fissure, (*c*) the dorsal septum, (*d*) the central cavity—myelocoele with its lining epithelium—endyma. In the cinerea note (*r*) the rough division into lateral masses connected by a commissure surrounding the myelocoele, (*z*) the dorsal and ventral cornua. In studying the structure of the cinerea note (*a*) the general structural appearance of the substantia spongiosa and substantia gelatinosa, (*b*) the size and character of the nerve cells in the ventral cornua, in the dorsal cornua, and intermediate region. Consider the significance of the large cells of the ventral cornu. In the alba, distinguish the dorsal columns and the roughly defined lateral

and ventral columns; remember the physiological tracts, indistinguishable in this preparation, that compose the alba. Are the points of exit of the dorsal and ventral roots of the spinal nerve shown in the section? if not, compare with 161 and 162.

161. **Thoracic myel.** Transection. ; stained *in toto* in ; collodion ; sections μ .

Compare this preparation with the above, 160, noting (*a*) the general shape of the myel in the thoracic region, (*b*) the size and shape of the cornua of the cinerea, (*c*) the number and size of the nerve cells in the parts of the cinerea, especially the cells in Clarke's column. Is a lateral horn well defined? Are issuing fibers of the dorsal or ventral roots shown in the section?

162. **Lumbar myel,** Transection. ; collodion ; stained *in toto* in ; collodion ; sections μ .

Compare with 160 and 161, noting differences in (*a*) the general shape of the myel, (*b*) the relative extent of the cinerea and the shape of the cornua, (*c*) the relative number and size of the nerve cells in the regions of the cinerea, (*d*) the obliquely coursing root bundles of the lumbar nerves, constituting the *cauda equina*.

163. **Myel.** Transection. Golgi's rapid method (§ 141) ; collodion ; sections μ . No further treatment ; now in clearer. Mount in balsam without a cover-glass.

In this preparation there will be outlined by a black precipitate, one or more large nerve cells and their dendrites, so that their extent and branching may be seen better than in 160, 161 or 162, with which comparison is to be made. In addition, there will probably be stained, neuroglia cells, and many neurites running in the cinerea.

THE (MEDULLA) OBLONGATA.

Gross anatomy. In connection with the study of the following sections, make a careful examination of the preparations of the brain. Ascertain the location of the oblongata in relation to the myel and the remainder of the brain. Upon the ventral aspect recognize (1) the pyramids with an indication of their decussation, (2) the olives (olivary bodies), (3) the pons, and (4) the cranial nerves springing from this portion,—the Vth to the XIIth. Upon the dorsal aspect with the membranous roof (metatela) removed, there should be noted, (*a*), the nuclei (enlargements) of the gracile

and cuneate funiculi, (*b*) the restiform body. Note the relation of the restiform body and the pons to the peduncles of the cerebellum. In examining the following sections, whenever one of these structures is mentioned, examine the gross preparations and ascertain the plane of the section.

164. **Decussation of the pyramids.** Cat. Transection of the oblongata at the level of the decussation of the pyramids.

3% and 5% potassium dichromate; collodion; Weigert's hematoxylin stain (§ 137); sections μ . Now in 95% alcohol. Clear and mount in balsam (alkaline).

Recall the positions in the myel occupied by the following tracts: (*1*) the crossed and direct pyramidal tracts, (*2*) the direct cerebellar, (*3*) the funiculi gracilis and cuneatus composing the dorsal column. In this section will be seen the decussation of the fibers that will constitute the crossed pyramidal tracts in the myel from their position on the ventral side (pyramids) to the lateral column of the myel. Recognize the dorsal and ventral columns, the substantia gelatinosa Rolandi, the nucleus gracilis. Laterad of the cap of gelatinosa Rolandi is the ascending (sensory) root of the Vth cranial nerve; ventrad of this, the fibers of the direct cerebellar tract.

165. **Decussation of the lemniscus.** Transection of the oblongata, through the nuclei gracilis and cuneatus and the pyramids (caudal part). Weigert's hematoxylin method (§ 137); now in 95% alcohol; sections μ . Clear and mount in alkaline balsam.

At this level, slightly cephalad of 153, the decussation of the pyramidal tracts has not yet begun, the gracile nucleus has enlarged and the cuneate nucleus has appeared. Recognize these features and, in addition, the decussation of fibers from these nuclei to form the lemniscus. Note the pyramids, the diminished funiculus gracilis (what has become of the fibers?); the dorsal cornu and substantia gelatinosa Rolandi; can you identify the ventral cornu? Note increased distinctness of the ascending root of the Vth and the direct cerebellar tract. The nuclei of the XIIth and Xth nerves and the fibers of the XIIth passing to their exit may also be seen. The section may be slightly cephalad or caudad of the level desired for this preparation; which is it?

166. Olives. Transection of the oblongata through the olives. Weigert's hematoxylin method. Sections μ . Now in alcohol. Clear and mount in alkaline balsam.

Identify in this section the tracts already recognized: (*a*) the pyramids, (*b*) the lemniscus, (*c*) the direct cerebellar tract, (*d*) ascending root of the Vth, and (*e*) the nucleus of the XIIth, (*f*) the cuneate nucleus (and tract). Has the gracile nucleus disappeared? Note the (dentate) olivary nuclei causing the prominences upon the lateral aspects of the oblongata (the olives). Are the fibers of the Xth or XIIth nerves shown? Note the extent of the cavity (metacoel); the membranous roof (metatela) has been removed.

167. Pons. Transection of the oblongata through the pons. Weigert's hematoxylin method; sections μ . Now in alcohol. Clear and mount in alkaline balsam.

Identify in the section (*a*) the pyramidal tracts, (*b*) the lemniscus, (*c*) the ascending root of the Vth, (*d*) the posterior longitudinal fasciculus. Does the section pass through the nuclei of the VIth, VIIth or VIIIth nerves? Are any of these nerves shown? What has become of the restiform body? Note well the fibers forming the mass of the pons, their decussation, relation to the medipeduncle of the cerebellum; the nuclei of the pons.

MESENCEPHAL.

Gross preparations. In the region cephalad of the cerebellum and pons,—the mesencephal, identify upon the dorsal aspect the pregemina and postgemina (corpora quadrigemina, anterior and posterior); upon the ventral aspect, the crura (cerebri) and the IIIId cranial nerve.

168. Crura and Gemina (Pre- or Post-). Transection through the mesencephal. Weigert's hematoxylin method; sections μ ; now in alcohol. Clear and mount in alkaline balsam.

In this section identify (*a*) the pyramidal tracts (the crura), (*b*) the fillet, (*c*) the posterior longitudinal fasciculus. Note also the central cavity (mesocoel) with the lining endyma, the central cinerea surrounding it, the nucleus of the IIIId nerve. Locate the following parts: (*1*) the crura, (*2*) the substantia nigra, (*3*) the tegmentum, (*4*) the prepeduncles of the cerebellum, or their decussation. Does the section include the red nucleus? Is the IIIId nerve shown?

THE CENTRAL NERVOUS SYSTEM.

LABORATORY WORK FOR THE-----WEEK.

*References :**Points for Quiz :**Laboratory Report :**Due :*

Go to the delivery desk for (a) assigned slide 177; (b) paraffin sections 172, 176; (c) sections already stained, 169, 170, 174, 175; (d) 171 and 173 will be given you during the first period.

CEREBELLUM.

Gross Preparations. Examine the gross preparations, noting (a) the parts of the cerebellum—the vermis, lateral hemispheres, and the flocculus, comparing man and the different animals shown; (b) the *lobes* of the cerebellum and the *folia*, their size and direction; (c) the three peduncles of the cerebellum by which it is connected with the rest of the brain and myel.

169. **Cerebellum.** Cat. Sagittal section of the vermis; vom Rath's fluid; stained *in toto* in paracarmine; collodion; sections μ .

Note the deep division into lobes and these into folia. As constituting the cerebellum, recognize (a) the central core of alba (fibers) extending into the lobes and folia, (b) the covering cinerea—cortex. Observe the layers of the cortex, the grouping of the cells of the granular layer, the size of the Purkinje cells, the relatively small number of cells in the molecular layer. Remember the real extent of the dendrites of the Purkinje cells, the destination of the neurites of the Purkinje cells and granules, and compare with 171.

170. **Cerebellum.** . Transection (in part); Weigert's hematoxylin method; collodion; sections μ ; now in 95% alcohol. Clear and mount in alkaline balsam.

This preparation will illustrate the ento-cinerea of the cerebellum—the nucleus dentatus and the nuclei of the roof, as well as the

commissural fibers of the cerebellum. Note the shape of the dentate nucleus and compare with the nucleus of the olive (166). Can you identify the fibers of the pre- and post-peduncles of the cerebellum? Compare with 169 for the general structure of the cerebellum.

171. **Cerebellum.** Cat (young). Golgi's rapid method (§141); collodion; sections μ , cutting the folia transversely.

This preparation will afford a demonstration of the extent of the dendrites of the Purkinje cells, the basket cells of the molecular layer, and possibly the dendrites and neurites of the granules of the granular layer, neuroglia cells, and nerve fibers.

CEREBRUM.

Gross anatomy. Consult the preparations, studying them carefully so that you may have clearly in mind (*a*) the relative size and position of the cerebrum, (*b*) that it consists of two halves connected with each other (principally) by a large commissure, the callosum, (*c*) the incision of its surface by deep depressions, fissures, dividing it into gyres, (*d*) the aspects of the cerebrum—dorsal, frontal, occipital, mesal, temporal. The cinerea of the cerebrum comprises (*r*) the superficial cortex and the hippocamp, (*2*) masses deeply situated, of which the most important are the caudatum, and lenticula, with which may be considered the closely associated thalamus and subthalamus. Examine the series of sections through the cerebrum, noting the cortex and the location of these masses of cinerea, their relation to each other and to the cavities of the diencephal and cerebrum.

172. **Cerebral cortex.** Cat. Transection of a portion at the dorso-mesal angle, including the callosum; 95% alcohol; paraffin; sections μ . Stain with hematoxylin (2–3 hours) and picrofuchsin.

The points to be noted are (*a*) the transected gyres with the septums of pia in the fissures, (*b*) the structure of the cortex upon the summit of a gyre and at the bottom of a fissure. Can you recognize the (four) ill-defined layers? Note the number, shape and size of the nerve cells, and compare with 71 and 173.

173. **Cerebral cortex.** Cat (young). Golgi's rapid method (§141); collodion; sections μ ; in clearer. Mount in balsam without a cover-glass.

This preparation will demonstrate the real form of the cells already seen in 172. Find good examples of the small pyramidal and large pyramidal cells, and note the extent of the apical process and the number and length of the dendrites arising from it and from the cell body. Trace the neurite as far as possible. Can you find collaterals arising from it? Find also good examples of well impregnated cells from the layer of polymorphous cells. Doubtless glia (spider) cells will also be stained. Compare preparation 172.

174. **Hippocamp.** Cat. Transection of the hippocamp and adjacent parts. Weigert's hematoxylin method; collodion; sections μ . Now in 95% alcohol. Clear and mount in balsam.

The parts to be recognized in this preparation are (1) the hippocampal gyre, (2) hippocampus, (3) dentate gyre, (4) fimbria, (5) the rima with the plexus, (6) the caudatum. Note the continuation of the cortex of the hippocampal gyre as the grey matter of the hippocamp and dentate gyre; observe the massing of large pyramidal cells in the hippocamp and the dense layer of small pyramidal cells in the dentate gyre, the continuation of the fimbria with the central (sub-cortical) alba. Recognize that the hippocamp is an infolding of the cortex.

175. **Caudatum, Lenticula, and Thalamus.** Transection through a hemicerebrum (or part) including these masses of cinerea (ento-cinerea). Weigert's hematoxylin method; sections μ . Now in alcohol. Clear and mount in alkaline balsam.

Locate in this preparation the cortex, the caudatum, lenticula, claustrum and thalamus; between the claustrum and the lenticula the external capsule; between the lenticula and thalamus (and caudatum) the internal capsule. The internal capsule is the continuation of the crusta (168); the subthalamic region is continuous with the tegmentum; the thalamus and subthalamus constitute the larger portion of the diencephal, intermediate between the mesencephal (168) and the cerebrum (prosencephal). Consult the transections of brain and the special references given.

176. **Olfactory bulbs.** Rabbit. Transection; vom Rath's fluid; paraffin; sections μ . Stain with hematoxylin (1 hour) and picrofuchsin.

Recognize the following layers: (1) the layer of olfactory nerve fibers, (2) the layer of glomerules, (3) the large nerve cells

(mitral cells), (4) the granular layer, (5) the olfactory tract, (6) the entocinerea, (7) the central cavity (rhinocoele) with its lining endyma. Understand the course of the olfactory impulse from the olfactory nerve fibers to the olfactory tract (leading to other parts of the brain). Remember that in the human brain there is no rhinocoele (in the adult).

ADRENAL BODY.

177. **Adrenal body.** Cat. Assigned for study. Chrome-oxalic ; paraffin. Stained with hematoxylin and picrofuchsin.

One of the "ductless" glands. In studying this preparation, note (*a*) the regions,—cortex and medulla, (*b*) the zones of the cortex and their structure, (*c*) the structure of the medulla and the number and character of the contained blood vessels. Other ductless glands studied by you are the thyroid (128), and the thymus (94). Note the diversity in structure and origin of these three glands.

It should be recognized that the inclusion of the adrenal body with the organs of the central nervous system is a matter of convenience rather than because it may logically be grouped with them. On an embryological basis, however, it might be placed in the peripheral nervous system. The thyroid (128), likewise, should only be grouped with the respiratory organs, in a classification the basis of which is embryology.

THE ORGANS OF SPECIAL SENSE.

LABORATORY WORK FOR THE-----WEEK.

*References :**Points for Quiz :**Laboratory Report :**Due :*

Obtain from the delivery desk, (*a*) paraffin sections, 178, 179, 180, 183, 185; (*b*) collodion sections, 181, 182, 184.

EYE.

178. **Eye.** Fig. Section through the anterior quarter of the eye-ball. Zenker's fluid; paraffin; sections μ . Stain with hematoxylin and picrofuchsin.

This section will include cornea, iris, ciliary body (muscle and processes), schlera, choroid and retina. Study well the structure of each of these parts, observing the relation of (*a*) schlera and cornea, (*b*) iris and choroid, (*c*) ciliary and sensory parts of the retina. Note also the canal of Schlemm, ciliary arteries, sphincter of the pupil. Is there any trace of the suspensory ligament of the lens?

179. **Eye.** Cat. Section through the posterior half showing the entrance of the optic nerve. Zenker's fluid; paraffin; sections μ . Stain with hematoxylin and picrofuchsin.

This preparation is to illustrate the structure of the three coats of the eye, the layers of the retina, and the relation of the optic nerve to the eye-ball, especially to the retina, and should be studied to afford demonstration of these points.

180. **Retina.** Fig. Vertical section. ; paraffin; sections μ . Stain with

In this section identify the layers of the retina already seen in 178; be sure you understand the real structure of the retina as revealed by other methods, and the meaning of the layers brought out by ordinary methods. Distinguish the rods and the cones; remember which side of the retina faces outward, i. e., is toward the other coats of the eye. What course would the sensory impulse pursue in order to reach the optic nerve?

(27). **Cornea.** Cat. Assigned for study. Silvered preparation. Again examine the preparation of cornea already studied, and in connection with the structure of the cornea (177) note the cell spaces and their relation to each other.

181. **Optic nerve.** Transection. vom Rath's fluid; collodion; sections μ . Stain with hematoxylin and picrofuchsin.

Note the connective tissue sheath and its relation to the sclera (178), the fibers in bundles. Compare the individual fibers with the fibers of the peripheral nerve given (74); what is the difference? Can you ascertain? Are the retinal vessels included?

182. **Eye-lids.** Transection. collodion; sections μ . Stain with hematoxylin and eosin.

In this section recognize (*a*) the dermal and conjunctival sides and the character of the epithelium of each, (*b*) the cilia (eyelashes), (*c*) the Meibomian gland and compare with the sebaceous glands of the hair follicle (154); (*d*) the orbicularis muscle. Can you find the glands of Moll?

183. **Lachrymal Gland.** ; ; sections μ . Stain with hematoxylin and eosin. Determine the type of gland, noting the secreting acini and the ducts; and compare with the salivary glands (112, 113).

THE NOSE.

184. **Nasal fossae.** Transection through the head and nose. ; decalcified (§ 131); collodion; sections μ . Stain with hematoxylin and picrofuchsin.

The preparation illustrates (*a*) the respiratory and olfactory (sensory) regions in the nasal fossae of this animal and their epithelium, (*b*) the nasal septum and the turbinal bones.

185. **Olfactory mucous membrane.** Guineapig. Transection of a part of the more dorsal turbinal bones. Flemming's fluid; stained *in toto*; paraffin; sections μ .

The general structure of the sensory epithelium is shown, the glands of Bowman, and the olfactory fibers in the mucosa. Can you distinguish the sustentacular and sensory cells in the epithelium?

THE ORGANS OF SPECIAL SENSE.

LABORATORY WORK FOR THE----- WEEK.

*References :**Points for Quiz :**Laboratory Report :**Due :*

Obtain from the delivery desk (a) paraffin sections 187, 188, (b) collodion section 186.

THE EAR.

186. Middle ear, inner ear, semi-circular canals.

 ; collodion ; sections μ . Stain with hematoxylin and eosin.

Study this preparation for (a) the mucosa of the tympanum and the character of the epithelium, (b) the bony labyrinth, membranous labyrinth, perilymphatic space of the inner ear. Does the section include one of the maculae or cristae of the membranous labyrinth? Is the utricle sectioned as well as the semicircular canals? Note carefully the structure and relations of the parts.

187. Cochlea. Guinea-pig. Longisection. Zenker's fluid ; decalcified (§131) ; paraffin ; sections μ . Stain with hematoxylin and eosin.

Study this preparation in connection with figures in your text book, identifying the parts and studying their structure. Is Reissner's membrane intact?

THE TASTE BUDS.

188. Papilla foliata. Rabbit. Longisection. Zenker's fluid ; paraffin ; sections μ . Stain with hematoxylin and eosin.

The taste buds will be found in the epithelium in the depressions or transverse fissures of the papilla. Examine them carefully, observing their form and structure, relation to the surface, and the gustatory hairs.

TECHNIC.

§ 1. Very few structures of the animal body can be examined microscopically without being first subjected to a preparatory treatment involving in most cases the employment of complicated methods. Increase in our knowledge of the finer structure of the body in the past has been accompanied and made possible by the improvements in the methods employed. Advance in the future, likewise, will be dependent on the application of a more exact technic. For those who aim to do work in practical histology and pathology, a mastery of the more important methods is indispensable; for the student of pathology, also, very desirable is the acquisition of skill in the application of simple methods which require neither expensive apparatus nor expenditure of time,—methods which, while they do not advance knowledge, serve to meet the needs of a rapid clinical diagnosis.

Of the multitudinous methods employed in microscopic work, only those are here given which are necessary for a general working knowledge in histology, or are used in this course. Animal tissues are bulky and unfitted for examination under high powers of the microscope; examination may be made possible in one of two ways,—the elements composing the structure may be separated from each other, or thin slices may be prepared. Furthermore, tissue may be examined in either of these ways, *fresh* (or alive), or after special chemical treatment. The technic of histology involves then :

- A. *Examining fresh*, by either B. or C. Advantageous or necessary when haste is required, or in examining the tissue alive.
- B. *Isolation or Dissociation*. Separating out the elements composing a tissue by (a) teasing or (b) treatment with reagents and teasing.
- C. *Cutting thin sections* of the tissue or organ.

For C. are generally necessary :

1. *Fixing* the tissue (§§ 18-38). *Hardening*.
2. *Sectioning* by one of the following methods :
 - (a) *Free-hand*, without an imbedding mass, or
 - (b) With an imbedding mass, as
 - (1) By the Paraffin method (§ 42), or
 - (2) By the Collodion method (§ 50), or
 - (3) By the Freezing method (§ 61).

ISOLATION.

§ 2. One of the simplest ways of examining the structure of a tissue is the separation from one another of the structural elements composing it, thus permitting its analysis. Likewise, for a correct conception of the forms of the cells and fibers of the various tissues of the body, one must see these elements isolated and thus be able to inspect them from all sides. It frequently occurs also that isolation is not quite complete and one can see in the clearest manner the relations of the cells or fibers to one another.

In the employment of this method the tissue may be taken fresh and isolation accomplished by teasing with needles or similar instruments ; or it may be treated with media which will serve to render teasing partially or entirely unnecessary. In such cases simply shaking or gently tapping the preparation will often suffice. In many instances it is desired to examine the tissue while the elements are still alive, as, for example, in the study of ciliated cells, and recourse must be had to some "normal," "indifferent" medium. Best of all is the medium with which they are bathed during life—in the case of tissue from the animal body, blood serum, the aqueous humor of the eye, liquor amnioticus, or, as an artificial substitute often more convenient if reagents are to be used subsequently, *normal salt solution*, being a $\frac{6}{10}-\frac{9}{10}\%$ solution of common salt (sodium chlorid) in distilled water.

The chemical agents or solutions for isolating are, in general, the same as those used for fixing and hardening. But the solutions are only about one-tenth as strong as for fixing and the action is very much weaker and requires from one or two hours to as many days. In the weak solution the cell cement or connective tissue is softened

so that cells and fibers may be separated from one another, and at the same time the cells are preserved. In other words, a weak fixing action is retained while the hardening action is reduced on dilution. The time required for the action of the dissociator varies inversely as the vehemence of the fixer and the density of the tissue, 2-3 hours to several days. In fixing and hardening, on the other hand, the cell cement, like the other parts of the tissue, is made firmer. It is better also to dilute the fixing agents with normal salt solution than merely with water.

§ 3. Of the many dissociators, the following may serve most of the needs of histology: (1) Müller's fluid dissociator; (2) formaldehyde dissociator; (3) nitric acid dissociator; (4) caustic potash dissociator; (5) Ranvier's one-third alcohol; (6) osmic acid ($\frac{1}{10}\%$).

§ 4. **Müller's fluid dissociator.** *Formula:* Müller's fluid, 1 part; normal salt solution, 9 parts (*i. e.*, potassium dichromate, 2.5 grams; sodium sulphate, 1 gram; sodium chlorid, 6 grams; water, 1,000 c.c.).

This is a good general dissociator for epithelia, including glands. Dilution decreases the hardening action of Müller's fluid as is shown especially on the cell-cement,—hence its dissociating action. Considerable latitude in time is allowed in the use of this dissociator; 12 hours being often sufficient, although a stay of several days in the dissociator usually does no harm.

§ 5. *Directions for use.* In the employment of this fluid for the isolation of epithelial cells, proceed as follows:

Place the tissue covered with the epithelium which it is desired to isolate in the dissociator in a shell vial or dish, where it may remain from 2-3 hours to 2-3 days; for the epithelium of the trachea, intestines, etc., the action is sufficient in 2-3 hours, although good preparations may be obtained after two days or more. For the stratified epithelia, like those of the skin, mouth, etc., it may require 1-3 days for the most satisfactory preparations. After the tissue has remained in the dissociator a sufficient time, scrape the epithelial surface gently with a scalpel and place the scrapings on a slide in a drop of the dissociator; cover and examine. If one proceeds after two hours or so, probably most of the cells will cling together, and

in the various clumps will appear cells on end showing the tops or bases, and other clumps will show the cells in profile.

Tap the cover gently with a needle-holder or other light object in order to separate the cells from each other more completely. Many fully isolated cells as well as cells in groups will be seen. Examine carefully.

§ 6. *Staining.* Scrape gently the epithelial surface in a fresh spot and place the scrapings on the slide in a drop of eosin (§ 94) or a mixture of *eosin and methylgreen* (§ 92). Mix well so that the stain can penetrate. If for temporary examination, cover immediately and examine as before.

§ 7. *Permanent preparations.* If a permanent mount is desired, (a) allow the above mixture to stand for 5–10 minutes; drain off the stain, collecting the fragments carefully at one side; add a *small* drop of glycerin or glycerin-jelly (§§ 104, 105); cover and examine, tapping the cover gently as before, if necessary, in order to separate the cells more thoroughly. Unstained preparations may be mounted in the same manner.

(b) The following method will also give satisfactory stained preparations. Place a small mass of cells in a drop of alum carmine and eosin glycerin (§ 156); cover and isolate the cells by tapping gently on the cover-glass as before. Clean and seal the preparation (§ 110).

If it is desired to make a permanent mount of a preparation already covered and examined, place a drop of glycerin at the edge of the cover, apply to the opposite side of the cover a piece of blotting paper or filter paper, and by absorbing the fluid—dissociator or stain—under the cover, cause the glycerin to flow under to take its place.

Seal the preparation (§ 110); it is usually better, however, to allow a glycerin or glycerin-jelly mount to stand for a day, being careful that it is not touched, and then seal.

§ 8. **Formaldehyde Dissociator.** *Formula:* 40% formaldehyde (formalin), 2 c. c.; normal salt solution, 1,000 c. c. (i. e., .08% sol. of formaldehyde in normal salt solution). This is a good general dissociator and as such may be employed instead of Müller's fluid dissociator. It is especially serviceable in the isolation of the nerve cells of the brain and spinal cord.

§ 9. *Directions for use.* Employ this fluid for the isolation of the nerve cells of the spinal cord and of the cerebral cortex, proceeding as follows :

Split the spinal cord along its median plane, separating thus the two halves, and place it in an abundance of the dissociating fluid. The cerebral cortex should be cut into small pieces by sections vertical to the surface. Allow it to remain in the dissociator from 2–24 hours ; for the best results a stay in the fluid of more than 24 hours is not so satisfactory ; although isolated cells are readily obtained their processes are broken off much nearer the cell body.

§ 10. Place a fragment of the cinerea of the spinal cord or the cortex of the cerebrum on a clean slide in a drop of $\frac{1}{100}$ % eosin in formaldehyde dissociator ; with the blade of a scalpel crush the tissue, grinding it thoroughly with a rotary movement, which will reduce it to small pieces. Gather the debris together, drain off the fluid, and add a drop of glycerin containing $\frac{1}{100}$ % of eosin. Cover and examine, tapping the cover sharply with the handle of the scalpel to shake out the processes of the cells and free them from surrounding matter. Examine, searching for cells with many and long processes. If a satisfactory preparation, seal according to § 110.

§ 11. **Nitric acid dissociator.*** *Formula :* Strong nitric acid, 20 c.c. ; water, 80 c.c. This fluid is employed in the isolation of muscle fibers, both striated and plain. The nitric acid acts upon the connective tissue surrounding the muscle fibers, softening and gelatinizing it so that the fibers may be quite easily separated from one another.

§ 12. *Directions for use.* Place in the nitric acid dissociator the fresh striated muscle, gland or organ containing the muscle,—(plain or striated,)—that it is desired to isolate. If it is the intention to work out the anatomy of the muscle or the relation of the muscular coats in an organ, the entire muscle or organ should be taken ; otherwise, portions will suffice. At the ordinary temperature of the laboratory the dissociating action will have been sufficient

* A more detailed discussion may be found in the original paper : “ Staining and Permanent Preservation of Histological Elements Isolated by means of Caustic Potash (KOH) or Nitric Acid (HNO₃),” by Simon H. and Mrs. Susanna Phelps Gage. *Proc. Am. Soc. of Microscopists.* 1889 : pp. 34–45.

in from 1 to 3 days; test at intervals with needles to ascertain whether the fascicles and fibers can be easily separated; or fragments may be shaken in a test tube or vial with water in order to separate the fibers.

When the dissociation is sufficient pour off the acid and wash the muscle gently but thoroughly with water. If the tissue is to be stained with hematoxylin or carmine, or kept for any length of time, drain off the water and add a half-saturated solution of alum. For permanent storage, pour off the alum solution and place successively in 67% and 82% alcohol.

For *temporary examination*, tease out a portion of the muscle in water, separating the fibers carefully by means of needles; cover and examine.

§ 13. *Permanent preparations.* (*a*) *unstained.* After teasing out with the needles drain off the water and add a small drop of glycerin or glycerin jelly; cover, and seal after first properly cleaning (§§ 110, 111). (*b*) *stained.* Either before or after the final teasing stain with picric alcohol, picrofuchsin (for relation of muscle fiber to tendon), or after the alum solution with hematoxylin or carmine. Wash away the staining fluid with water and mount (*a*) in glycerin or glycerin jelly (§ 104, 105), or (*b*) dehydrate, clear, and mount in balsam (§ 107+).

§ 14. **Caustic potash dissociator.*** *Formula:* Caustic potash, potassium hydroxid (in sticks), 35-40 grams; distilled water, 65 or 60 c.c. This solution will be used for the isolation of cardiac muscle cells, although it may be used for striated or plain muscular tissue, or as a general dissociator. It may also be employed for isolating the cells of hair, horn or nail, either full strength or diluted.

§ 15. *Directions for use.* Place in the fluid small pieces of the heart muscle of a fetal, new-born or young animal; after 10 or 15 minutes, the tissue should be tested with needles at intervals of about five minutes, so that the action may not be too prolonged; probably 15-30 minutes will suffice. As soon as the elements separate readily, pour off the caustic potash solution and add an abundance of 60% solution of potassium acetate (potassium acetate, 60 grams; distilled water, 40 c.c.). Take small fragments and tease them in this solution, or shake them in a vial, until the cells are separated from each other.

* See note on page 85.

For *temporary examination*, cover in a drop of the potassium acetate solution. For *permanent preparations*, drain off the potassium acetate solution and add a small drop of glycerin or glycerin-jelly.

Stained preparations. Pour off the potassium acetate solution and add a half saturated solution of alum, letting it remain for 24 hours or longer. Tease in water, stain with hematoxylin or carmine, wash away the stain with water, and add a drop of glycerin or glycerin-jelly. Cover and seal (§ 110).

If a large amount is desired, the tissue may be carried through the various steps in a vial.

§ 16. **Ranvier's one-third alcohol.** *Formula:* 95% alcohol, 1 part, water 2 parts. This is an excellent dissociating fluid for epithelia. An action of 24 hours is generally sufficient. A weaker solution is often advantageous.

§ 17. **Osmic acid.** A $\frac{1}{10}$ % solution of osmic acid is a valuable dissociator, especially serviceable in the isolation of nerve-fibers, myelinic and amyelinic, and when fat is present, since fat and the myelin of myelinic nerve-fibers are blackened by it. 12-24 hours generally affords sufficient time for it to act.

FIXATION.

§ 18. Living tissue, when allowed to die and remain undisturbed, gradually loses the structural features it had in life and undergoes disintegration and decay. A *fixer* is a fluid (or gas) into which the living, or at least very fresh, tissue is placed in order to preserve the structure of its elements as nearly as possible as in life.

The action of the fixer is a *chemical* action in which the living substance is coagulated (fixed) by the reagent, which in some cases forms a chemical union with the organic substance. The chemical action is generally attended with a more or less marked *mechanical* distortion, as shrinking or swelling, to obviate which chemicals of opposite tendencies are, in the best fixers, combined with each other in proportions intended to neutralize such effects. The chemicals of most service as fixers are (1) osmic acid, (2) platinic chlorid, (3) picric acid, (4) acetic acid, (5) chromic acid, (6) mercuric chlorid, (7) nitric acid, (8) ethyl (or methyl) alcohol; also, (9) potassium dichromate, (10) sodium sulphate, (11) copper sulphate. The last

three are not as strictly fixers as hardeners. The following solutions containing these salts, combined or uncombined, are used as fixers in this course : (1) Osmic acid, aqueous solution ; (2) Hermann's fluid ; (3) Flemming's fluid (stronger formula) ; (4) Picric alcohol ; (5) Mercuric chlorid, in aqueous solutions ; (6) Picro-aceto-sublimate (vom Rath's fluid) ; (7) Zenker's fluid ; (8) Müller's fluid ; (9) Erlicki's fluid ; (10) Potassium dichromate in aqueous solutions ; (11) Chrome-oxalic ; (12) Alcohol (absolute—67% strength) ; (13) Formaldedyde ; also, as embryological fixers, (14) Perenyi's fluid ; (15) Picro-sulphuric ; (16) Picro-nitric ; (17) Nitric acid.

§ 19. The following general rules should be regarded in the fixation of tissues and organs :

(1) The volume of fixing-fluid used should be large, exceeding the volume of the tissue at least thirty times. The less energetic the action of the fixer, the greater the amount of fluid to be employed. When the fluid becomes turbid, it should be changed to fresh at once.

(2) Fix only as small pieces of tissue as possible, or as practicable with the results in view. The block of tissue should not be more than 1 c.m. in any diameter, and, if possible, let one of the diameters be much shorter,—only one-fourth or one-half of a centimeter. This is desirable for the rapid and complete penetration of the fixer. Of course, in the case of entire organs, it may not be possible to comply with the conditions.

In addition to these two general principles, there are four points to be carefully considered, upon which the excellence in the results attained depends ; they are (*a*) the *fixer* chosen, (*b*) the *time* of fixation, (*c*) the *washing out* of the fixer, and (*d*) the subsequent *hardening* in alcohol.

(*a*) The choice of a fluid into which the tissue is placed should be made dependent on (1) a consideration of the degree of excellence of fixation that is desired or necessary,—whether, in other words, details of cell structure or the structure of the tissue in terms of cells, be sought ; (2) the penetrating power of the fixer and the size of the piece of tissue that it is necessary to have ; and (3) the stain that is desired subsequently, which is largely affected by the fixer employed. For example, Hermann's fluid is possibly the finest

fixer known, but its penetrating power is weak, and it gives good results only when very small pieces of tissue are taken ; furthermore, the number of stains that give good results after its employment is limited. On the other hand, such fluids as Müller's fluid or Erlicki's fluid should be avoided when the preservation of finer nuclear structures is desired. Within these limits, the fixer that will give the best results in a special case must be determined by experimentation, or the experiments and results of others accepted and their methods applied.

(b) The *time* a fixer is allowed to act must be considered in connection with the character of the fluid and the tissue. Often the exact limitation of time is a matter of secondary importance ; in other cases, however, its disregard affects the results seriously, and as a general rule, there is a minimum and a maximum time and between them an optimum time that should be adhered to.

(c) After the tissue has been in the fixing fluid a proper length of time, it is necessary that it be washed thoroughly to remove the fixer from it. This should be done by means of water or alcohol or both. In general, fixers containing salts insoluble in alcohol, or but slightly soluble, as osmic acid, chromic acid, potassium dichromate, etc., should be thoroughly washed in water. Fixers containing picric acid should always be removed by alcohol ; mercuric chlorid may be washed out by either water or alcohol.

Inadequate washing out of the fixer may either seriously affect the cutting quality of the tissue if it is to be subsequently imbedded, the ease with which it can be stained, or there may be formed precipitates in the tissue, giving illusory effects, distortions, or at least a dirty appearance to the preparation. Time in properly washing out a fixer is always well spent, as it is a matter for serious attention.

§ 20. *Resumé*. In brief, then : In fixing, take relatively large amounts of fluid and small pieces of tissue, choose the fixer well with a view to the tissue and the results desired, regulate the time carefully, and wash out thoroughly.

HARDENING.

§ 21. Each fixer has also more or less of a hardening action upon the tissue. Some fluids spoken of above as fixers are præeminently hardeners, such as Müller's fluid and Erlicki's fluid ; while

with others the hardening action is a minimum, e. g., aqueous solutions of picric acid. The hardening action of the fixer is generally supplemented by the subsequent use of alcohols of increasing strengths (50% to absolute), as well as in preparation for the paraffin and collodion methods of imbedding. In fact, with modern methods of imbedding excessive hardening of the tissue is not necessary and indeed often should be avoided as affecting the cutting quality of the tissue. Tissue after fixation has been completed may be stored in 82% or 95% alcohol, or (better) imbedded at once.

FIXERS.

‡ 22. **Osmic acid.** A very useful as well as expensive reagent and somewhat difficult to use. It is generally employed as a fixer in conjunction with other reagents, as in the mixtures below (‡‡ 23 and 24). When used alone as a fixer weak solutions are generally best— $\frac{1}{10}$ –1%. It penetrates slowly and it “over-fixes” cells very easily, obscuring detail and giving the parts a homogeneous, glassy appearance. Over-fixed cells cannot be stained, or with great difficulty. More or less blackening of the protoplasm also occurs. It will be used in this course chiefly to demonstrate fat, which is blackened by it, and the zymogen granules of pepsin and trypsin, which it preserves and browns slightly.

Fix small (about $\frac{1}{4}$ c. c.) pieces of tissue in 1% osmic acid for 6–12 hours, wash well in water (running or changed frequently) for 12–24 hours, and place in 67% and 82% alcohols. It is somewhat difficult to prevent pure osmic acid of this strength from over-fixing the tissue, and cell detail is generally lost, though the form of cells is well preserved.

‡ 23. **Hermann's fluid.** *Formula:* 1% aq. sol. platinic chlorid, 15 parts; 2% aq. sol. osmic acid, 4 parts; glacial acetic acid, 1 part; or you may take 10% aq. sol. platinic chlorid, 3 parts; 1% aq. sol. osmic acid, 16 parts; glacial acetic acid, 2 parts; water, 19 parts. This is generally recognized as the finest fixer known, and it is also the most expensive. The form and structure of cells are well preserved. It should only be employed, however, with very small pieces of tissue, and is to be used especially when cell structure is to be studied. Fat and the myelin of nerve fibers are stained black.

Fix in this 1–24 hours (or longer—days or weeks are used by some), wash well in water (running or frequently changed) 2–24 hours, and then place in 67% and 82% alcohols, 12–24 hours in each. In using this fluid, the smaller the pieces taken the better the fixation will be, and in order that it be possible to obtain a good stain afterwards tissue should not be over-fixed and the fixer should be thoroughly washed out. If there is a blackening of the tissue, or a precipitate in it, both may be removed by treatment of the sections on the slide with a 10–20% solution of hydrogen dioxid in 67% alcohol. Employ

after Hermann's fluid, as stains, Heidenhain's iron hematoxylin, Delafield's hematoxylin, safranin (as a red stain), or gentian violet (as a blue stain).

§ 24. Flemming's fluid (Chrome-aceto-osmic). *Formula*: 1% aq. sol. chromic acid, 15 parts; 2% aq. sol. osmic acid, 4 parts; glacial acetic acid, 1 part; or, 10 aq. sol. chromic acid, 3 parts; 1% osmic acid, 16 parts; glacial acetic acid 2 parts; water, 19 parts. This is a fine fixer and in most cases gives as good results as Hermann's, and is not as expensive. It browns tissue less, and while it blackens fat, does not blacken the myelin of myelinic nerve fibers as does Hermann's. It should be employed in general in the same cases and in the same way as Hermann's fluid.

Fix tissue 1-24 hours (or longer); wash well in running water 2-24 hours; place in 67% and 82% alcohols, 12-24 hours in each. Bleaching of the sections may be necessary, as with Hermann's fluid. Take only very small pieces of tissue. Employ the same stains as with Hermann's fluid.

§ 25. Picric alcohol. *Formula*: Distilled water, 250 c. c.; 95% alcohol, 250 c. c.; picric acid, 1 gram. A delicate fixer, penetrates well, and does not make the tissue brittle or tough. It may be used with most tissues and organs.

Allow it to act 1-3 days, changing to fresh each day if the bulk of tissue is large, transfer to 67% alcohol for 1-2 days, 82% alcohol several days, changing several times. If the paraffin method of imbedding is to be employed it is best to leave the tissue in 82% alcohol until no more or very little color comes away from it, as otherwise it affects the cutting quality of the tissue. Most staining methods may be employed. Staining is good, though not quite as brilliant as with mercuric chlorid fixers.

§ 26. Mercuric chlorid. One may employ (a) a saturated solution in water, or better, (b) a saturated solution in normal salt solution with 1-5% glacial acetic acid. Water will dissolve about 5%, normal salt solution about 12% of the mercuric chlorid. This is a good fixer, especially when the piece is small. It fixes as soon as it penetrates and is apt to make tissue brittle if it is left too long. Staining after it is brilliant. The larger percentage of acetic acid is, perhaps, to be preferred for most histological objects.

Fix the fresh tissue $\frac{1}{2}$ -24 hours according to the size of the piece. Remove to 67% alcohol for 1-2 days, 82% alcohol several days, changing often. The 82% alcohol should contain enough tincture of iodine to give it a yellow color, and fresh tincture added or (better) the alcohol changed when the yellow color of the iodine in the alcohol is lost. As long as the alcohol is decolorized, washing should be continued, since it is important that the mercuric chlorid be all removed from the tissue; otherwise precipitates will form in the preparation after it is mounted or before, and spoil the result. Wash out in alcohol thoroughly and carefully. Almost any stain may be employed after a mercuric chlorid fixation.

§ 27. Picro-aceto-sublimate. (vom Rath's fluid). *Formula*: Saturated aqueous solution of picric acid, 50 c.c.; saturated aqueous solution of mercuric chlorid, 50 c.c.; glacial acetic acid, 1 c.c. (1-5 c.c. according to the organ). This is quite a satisfactory fixer if care is taken in its employment, combining

to a certain extent the advantages of picric acid and mercuric chlorid. A stronger percentage of acetic acid (4 or 5%) is to be preferred with organs containing a large amount of connective tissue.

Fix the object for 1-24 hours; place in 67% alcohol for 1-2 days, 82% alcohol for several days, changing several times, whenever the alcohol has become colored yellow. The tissue should be left in the 82% alcohol until almost all the picric acid has been washed out and the alcohol no longer becomes colored, or but slightly. Tincture of iodine may be used as with mercuric chlorid tissue, but is not necessary. Stain as you like.

‡ 28. **Zenker's fluid.** *Formula:* Potassium dichromate, 2.5 gr.; sodium sulphate, 1 gram; mercuric chlorid, 5 gr.; water, 100 c. c.; and add before using, glacial acetic acid, 5 c. c. This is a fluid used quite generally of late. The potassium dichromate seems to check the brittleness that the mercuric chlorid would cause, otherwise its advantages and faults are those of mercuric chlorid; staining after it, however, is apt to be a little more difficult and not as brilliant as with mercuric chlorid fixation. Its penetration is surprisingly good.

Fix in Zenker's fluid 12-48 hours, wash well in water, running or frequently changed, 12-48 hours, to remove the dichromate; transfer to 67% alcohol for 1-2 days, 82% alcohol for several days, keeping in the dark while in the alcohol. To the 82% alcohol add a drop or so of tincture of iodine, adding fresh iodine or changing the alcohol when the color is lost. This should be continued as long as the iodinated alcohol is decolorized in order to avoid a precipitate of the mercuric chlorid in the tissue. Avoid, however, adding an excess of iodine, since it will affect the staining quality of the tissue. Stain as you wish.

‡ 29. **Müller's fluid.** *Formula:* Potassium dichromate, 2.5 grams; sodium sulphate, 1 gram; water, 100 c. c. This fluid is more of a hardener than a fixer; it should be avoided (as likewise Erlicki's fluid and potassium dichromate) when the preservation of nuclear structure is desired. Staining after its use is sometimes difficult. It is, however, useful for general work.

Place the object in an abundance of the fluid and harden for from 1-8 weeks, changing the fluid at first each day. In general, 10-14 days will be sufficient. Wash in running water for 24-48 hours or longer, remove to 67% alcohol for 1-2 days, 82% alcohol several days. Keep in the dark while in the alcohols, and change to fresh when the fluid is colored yellow. Tissue hardened in Müller's fluid cuts well, and it is useful in preparing sections of large organs, or organs with much connective tissue.

‡ 30. **Erlicki's fluid.** *Formula:* Potassium dichromate, 2.5 grams; copper sulphate, 1 gram; water, 100 c. c. This is quite similar to Müller's fluid in its action and results, save that its action is more rapid and stronger. Therefore, it had better be employed with smaller objects, and allowed to act only 2-14 days. Otherwise, employ like Müller's fluid.

‡ 31. **Potassium dichromate.** 2%, 3%, and 5% aqueous solutions.

This is quite similar to Müller's fluid in its action, and may be employed in the same cases. It is generally used for the central nervous system.

Harden in an abundance of the solution for 2-8 weeks, beginning with the 2% solution for 2-6 days, 3% solution 1-3 weeks, 5% solution 1-3 weeks. Wash out in running water 24-48 hours. Place in 67% and 82% alcohols several days, keeping in the dark meanwhile, changing when the alcohol is colored.

§ 32. **Chrome-oxalic (Graf).** *Formula:* 8% aqueous solution of oxalic acid, 4 parts; 95% alcohol, 3 parts; 1% chromic acid, 3 parts. Mix the solutions in the order given.

Fix tissue in the solution 1-6 hours, wash in running water $\frac{1}{2}$ -1 hour, and harden in 50%, 67%, and 82% alcohols.

This appears to be a good general fixer for many organs; it penetrates well, the tissue cuts well after this method of fixation, and the staining is sharp and strong.

§ 33. **Alcohol.** 95%, 67-70%, absolute alcohol. The employment of most of the fixers so far mentioned requires the expenditure of considerable time, rendering them inapplicable or unsuitable in many instances. 95% alcohol itself answers admirably for most histologic objects, fixing well, hardening and likewise dehydrating (§ 41) preparatory to imbedding in paraffin or colodion, affording thus a considerable economy of time. It is also most serviceable in pathological tissues where the presence of bacteria is suspected. In some instances 67% alcohol answers as well or better, while in other cases absolute (99%) alcohol should be employed. The addition of 5% glacial acetic acid increases the penetrating power and improves the cutting quality of objects containing much connective tissue.

Fix in 95% alcohol for 1-3 days, changing two or three times, after 3 or 4 and after 24 hours. The tissue will probably be found to be dehydrated and ready for the next step of the imbedding process (§ 44 or 52). Stain as you wish.

§ 34. **Formaldehyde.** Solutions of this chemical have been found to be good preservatives and hardeners and fairly good fixers. It penetrates rapidly, and preserves the natural transparency and pigmentation of the tissue, making it valuable for gross anatomy and museum purposes. As a fixer, an aqueous solution of 2-4% strength may be employed, or it may be used in conjunction with other chemicals, as picric acid, in *picro-formalin*, or chromic acid and acetic acid.

Fix 12-24 hours, remove to 67% alcohol for a day, 82% alcohol one to several days. Stain as you wish.

§ 35. **Perenyi's fluid.** *Formula:* 10% aq. sol. nitric acid, 4 parts; 95% alcohol, 3 parts; $\frac{1}{2}$ % aq. sol. chromic acid, 3 parts. An embryological fixer of much value. It is also serviceable for general work.

Fix tissue for 4-5 hours, place in 67% alcohol for 24 hours, 82% alcohol several days.

§ 36. **Picro-nitric.** *Formula:* Water, 95 c.c.; nitric acid, 5 c.c.; picric

acid, to saturation. This is a valuable embryological fixer, especially serviceable with eggs that have a good deal of yolk.

Fix for 4–12 hours, transfer to 67% alcohol for 1 day, 82% alcohol, several days. It is necessary to wash the tissue well in several changes of the alcohol, as the picro-nitric is washed out with difficulty.

§ 37. **Picro-sulphuric.** *Formula:* Distilled water, 100 c.c.; sulphuric acid, 2 c.c.; picric acid, to saturation.

This may be used full strength or diluted with 1–3 volumes of distilled water. It is an embryological fixer, useful for many eggs, chiefly invertebrate, and for many invertebrate animals. In general, fix for 1–6 hours, remove to 67% (70%) alcohol for a day, and place in 82% alcohol, in which it should remain until most or all of the yellow color has been extracted.

§ 38. **Nitric acid.** A 10% solution of nitric acid is serviceable in fixing the blastoderm of the chick.

SECTIONING.

§ 39. In addition to the examination of tissue by the separation of the component elements—*isolation*—it may be examined microscopically after cutting very thin slices or sections of it. This may be done *free-hand* or by means of a special machine, a microtome, and with or without an imbedding and supporting mass.

For the finer work an imbedding mass and a microtome must be used. Free-hand sectioning without an imbedding mass, and even without previous hardening, is, however, necessary or advisable when economy of time is a desideratum, as in clinical examinations of tissue, when one wishes to study the part alive or *fresh* (i. e., not treated with reagents), or if the reagents necessary for fixing and imbedding destroy or alter the structural features to be investigated.

The ability to recognize tissues and organs unaffected by reagents and without the employment of methods involving the expenditure of time and effort is very desirable, especially in pathological work, when haste often forbids the employment of the finer methods, were facilities for their use available, as in many cases they are not. Great skill in the use of simple tools may be gained and counts for much. It should be remembered also that the greater one's knowledge of a structure the less the need to resort to special methods of preparation for its recognition.

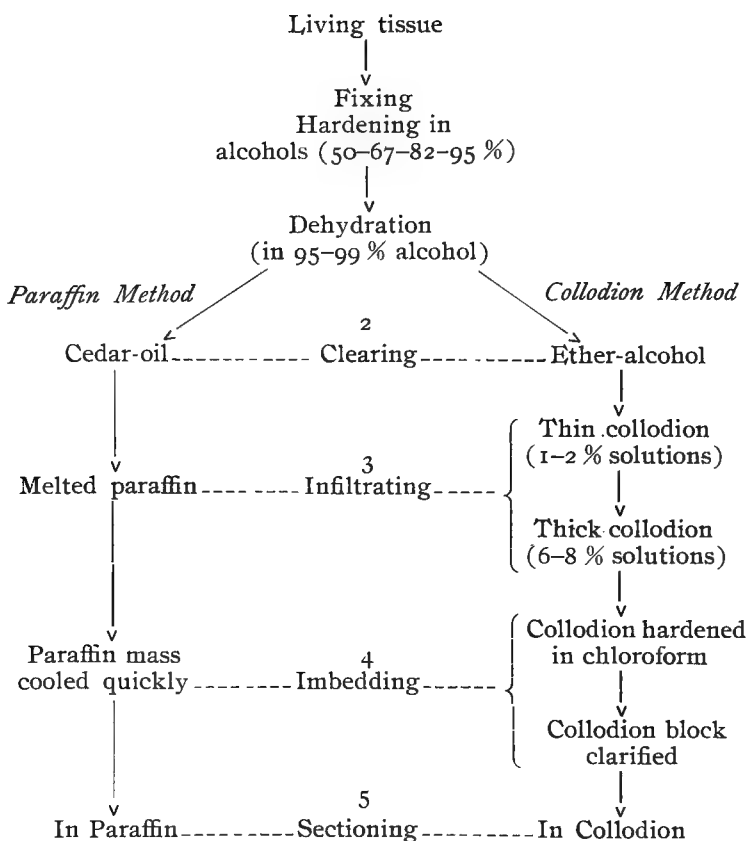
IMBEDDING METHODS.

§ 40. When the consideration of time is not so important and finer results are more to be desired, the sections should be prepared according to some method in which an imbedding mass is used. The interstices of the tissue are completely filled with some substance that will give support and greater consistency and homogeneity to the tissue, and thereby enable the cutting of much thinner and more perfect sections.

There are three methods that are generally employed, (a) the *Paraffin method*, (b) the *Collodion method*, and (c) the *Freezing method*; the imbedding masses to fill the spaces being respectively paraffin, collodion and a congelation mass,—ice. The last is the simplest; it requires less expenditure of time, fewer reagents, and its results are the crudest. As in cutting free-hand sections without imbedding, the freezing microtome should be employed when haste is necessary and finer detail unimportant, as in clinical work. The two remaining methods may be employed in most cases and give good results. A choice between them must be determined by the following considerations and the special exigencies of the case:

(1) As a general rule paraffin may be employed when very thin sections are desired and the piece or organ is not very large; collodion, when larger sections are necessary but which need not be so thin. (2) For paraffin, heat is necessary, which is not required in the collodion method. (3) In the case of paraffin, the imbedding mass is removed from the sections before they are stained and mounted; the collodion is (usually) not dissolved out. With most nuclear stains the collodion is colored more or less, affecting the appearance and excellence of the preparation unless it is bleached, a process not possible in many cases. (4) In paraffin sections there is apt to be more or less crushing together of the parts of the tissue; by the employment of collodion, the *form* of the organ may be more exactly preserved, sometimes an important consideration.

§ 41. The following will indicate the steps in the employment of the two methods:



THE PARAFFIN METHOD.

§ 42. As seen by the above scheme, the aim is to fill all the interstices of the tissue with paraffin of the right degree of hardness to have it cut well. Paraffin is not soluble in water or alcohol, but *is* soluble in a number of fluids which in turn are miscible with alcohol. Hence the following steps are necessary: (1) the tissue must be first water-rid, thoroughly *dehydrated* with strong alcohol; (2) freed from the alcohol, *cleared* by a fluid that mixes with melted paraffin, which (3) takes the place of the clearer in the tissue, *infiltrates* it, filling the spaces; (4) finally, the tissue is *imbedded* in paraffin of the right degree of hardness, the mass cooled, and it is ready (5) to *cut*, or section.

§ 43. **Dehydration.** After the various steps pertaining to the proper fixing and hardening (§ 21) of the tissue have been properly pursued it may be stored in alcohol of 82%–95% strength depending on the tissue and its purpose. The dehydration necessary in imbedding may be accomplished by immersion in alcohol of 95% strength. For more delicate work it is perhaps better to employ stronger (absolute) alcohol.

Immerse small pieces 2–3 mm. in diameter for at least 6–8 hours in 95% alcohol changed once or twice. A longer time, even days, does no harm and is preferable to ensure complete dehydration. For larger pieces of tissue or entire organs a correspondingly longer period of dehydration should be employed, a several days' stay, with the alcohol changed daily, being often advisable. In any case, *dehydrate thoroughly*, changing the alcohol 1–3 times, letting the tissue remain in it for a longer rather than a shorter period.

§ 44. **Clearing.** The alcohol must next be replaced by some solvent of paraffin which is miscible with alcohol,—a step spoken of as *clearing*. Cedar-wood oil is perhaps most generally serviceable, although for special purposes other media, such as xylol, bergamot oil, or chloroform may be preferred. When the tissue is dehydrated, it is removed to a vial of thickened cedar-wood oil. It will float at first, but as the alcohol used for dehydration is displaced by the oil, it sinks to the bottom, the currents of alcohol rising from it. When the alcohol is entirely removed by the oil, such currents will have ceased to rise from it and the tissue will be clear and translucent,—except, of course, such as is dark in color.

§ 45. **Infiltration.** After the tissue is completely cleared by the cedar-wood oil, remove it to a dish of melted infiltration paraffin and place in the paraffin oven for 2 to 24 hours, depending on the size of the piece. Quite large pieces may be left longer. The melted paraffin replaces the cedar-wood oil, filling in the interstices of the tissue. Paraffin melting at about 48° C. is used, and is prepared by mixing equal parts of 43° and 54° paraffin. It is best not to expose to a higher temperature than is necessary, or for a long period of time. The paraffin oven will be maintained at a temperature of 50°–52° C.

§ 46. **Imbedding.** It is best to use fresh paraffin for imbedding and generally with a melting point higher than that of the infil-

tration paraffin,—50° C. paraffin (42° paraffin 1 part, 54° paraffin 2 parts), answers well in a room of 19° to 20° C., and will be generally used. If the cutting is to be done in a room of lower temperature, a softer grade of paraffin may be used for imbedding; if at a higher temperature, a harder paraffin should be chosen; 54° C. paraffin giving good results when summer work is necessary.

Make a small paper box, fill it with the melted imbedding paraffin; transfer to it the tissue from the paraffin oven, arrange it carefully in the box in the way you wish it for cutting, and cool the mass by floating the box on a dish of cold water.

§ 47. In imbedding in paraffin observe the following rules; (1) Take no more paraffin (no larger box) than is needed to form a mass of convenient size around the specimen. The aim is to have as homogeneous a mass as possible; paraffin tends to crystallize if it cools slowly, hence the smaller the mass the more rapidly may it be cooled. (2) Let the imbedding paraffin when poured into the box be several degrees above its melting point, and the tissue likewise should have an equal temperature. Should the imbedding paraffin (or the tissue) be too cool it will not set well around the specimen, and a film of air may be enclosed. On the other hand, take care that the paraffin is not hot enough to "cook" the tissue, thereby shrinking it and rendering it hard and tough or ruining it altogether. (3) Cool by *floating on cold water*. Paraffin in cooling must contract greatly if it does not crystallize; the more homogeneous it is the more it must contract, and if it is cooled on all sides it will crystallize in the center of the mass, because it cannot shrink.

§ 48. **Cutting the sections.** The essentials for good paraffin sectioning are (1) well-imbedded tissue, (2) a sharp knife (or section razor), (3) a room of the proper temperature, and (4) the paraffin block properly trimmed and arranged in the microtome. Furthermore, tissue fixed and hardened in different ways cuts very differently. Tissue fixed in Hermann's, Flemming's, Müller's, or Zenker's fluid cuts well; picric acid and mercuric chlorid tissue is more apt to be tough or hard, etc. The different organs and tissues have of course very different adaptabilities to the method.

After the imbedding mass is well cooled, remove the paper box and trim the part containing the tissue in a pyramidal form, two of

the sides at least being as nearly parallel as possible. Clamp the block of paraffin in the holder of the microtome so that the tissue will be at the proper level for cutting, being careful to have the parallel sides also parallel to the edge of the knife. If a ribbon microtome is used, heat the holder and melt the end of the block upon it. Cool and place the holder in its place in the microtome, again having the parallel sides and the edge of the knife parallel. Use a very sharp, dry razor for cutting the sections. Clamp it in the (Minot) microtome slightly inclined to the cutting surface of the tissue. If the temperature of the room is right for the paraffin used, the sections will remain flat, and if the directions given above for trimming and arranging the block be observed, they will adhere and thus form a ribbon. If the room is too cold or the paraffin too hard, the sections will roll; if it is too warm, the sections will crush or be imperfect. If a microtome in which the knife is not fixed, is used, make the sections with a rapid straight cut as in planing. Do not try to section with a drawing cut as used in collodion sectioning. 10μ will be found the most convenient thickness for the sections, though in special cases they should be thinner or even thicker.

Remember to have the paraffin block trimmed with two sides parallel and the knife edge parallel to these. Also, do not attempt to cut if the temperature of the room is too high,—above 21° C.

§ 49. **Resumé of the method.** To obtain as good results as possible with a certain organ fixed and hardened in a certain way, the steps must be carefully and exactly followed. Let the dehydration be complete, clearing thorough, infiltration sufficient; imbed, carefully observing the three cautions mentioned; and in cutting, remember to have a sharp knife, a cool room, and the imbedding block properly trimmed. Success also depends largely on the previous treatment in the fixer and on the care with which the fixer is washed out.

Properly employed, the paraffin method is widely serviceable, being only useless where the tissue is very large, very hard, hardened or injured by heat, or where the exact form of a large organ is important.

THE COLLODION METHOD.

§ 50. A comparison with the paraffin method has already been given (§ 40); there may be emphasized here three points: (1)

with paraffin heat is required, with collodion no heat; (2) paraffin must be removed from the sections subsequently, collodion need not and usually is not dissolved out; (3) by the paraffin method may be obtained small sections (2 cm. square or less), and thin, by the collodion, larger sections, but thicker. With paraffin heat (melting and cooling) is necessary, and the mass is sometimes spoken of as a *fusion* imbedding mass; collodion is a solution, and the mass is left in the tissues by *evaporation* or its equivalent.

In the collodion method the imbedding mass with which the spaces of the tissue are to be filled is collodion, a solution of pyroxylin (soluble cotton) in ether and alcohol, hence the steps, which are comparable with those of the paraffin method (see § 41), are (1) *Dehydration*, removal of the water; (2) *Saturation* with ether-alcohol, the solvent of the collodion; (3) *Infiltration* with collodion solutions, a thin and a thick; (4) *Imbedding* in a thick collodion mass, which is *hardened* and (as employed in this course) *clarified* and (5) sections *cut*.

§ 51. **Dehydration.** Let it be complete, as in the preparation for paraffin imbedding (§ 43). Immerse the tissue in 95% alcohol for 12–24 hours or longer, changing 1–3 times. Consult also § 43 upon the dehydration of tissue.

§ 52. **Saturation with ether-alcohol** (equal parts). Remove the tissue from the strong alcohol and place it in a vial of ether-alcohol for 12–24 hours. In addition to preparing the tissue for the collodion solutions, it completes the dehydration, should it be imperfect. In special cases, or if the dehydration is very thorough and the specimen small, this step may be omitted. A satisfactory infiltration is, however, more certain if ether-alcohol be used.

§ 53. **Infiltration: (a) with thin collodion.** Pour off the ether-alcohol and add the thin (1½%) solution of collodion (§ 154). This, being a solution in ether-alcohol with which the tissue is saturated, readily permeates it. It is best to allow at least a day for this to take place, although if there is time a stay of several days is better, there being little or no danger of deterioration while in the solution. With large (1 c. c.+) objects an infiltration of a week or even a month is advisable.

§ 54. **Infiltration: (b) with thick collodion.** Pour off the

thin collodion solution and add thick (6%) solution. In this there is gradual concentration of the solution in the tissue. Allow small specimens to remain a day, or, better, several days; larger objects should be given a proportionately longer time, a week to a month, or even longer.

If the object to be imbedded, such as many embryological specimens, is one with large interior cavities with thin walls the transfer from the thin solution to the thick solution may be attended by a collapse of the walls and a consequent shriveling and distortion of the specimen. Avoid this by allowing the thin solution to thicken very gradually by evaporation until the solution has attained the right consistency. To accomplish this it is only necessary to have the cork of the vial containing the specimen perforated by a small hole. A small piece of paper may be inserted with the cork, or with porous corks no special effort need be made. Unless the thick solution has itself thickened by evaporation, with large specimens it is advisable to follow the 6% bath with a stay in a thicker solution, as 8%, for a day or so.

§ 55. **Imbedding.** Pour off the 6% solution and add for a short time at least an 8% solution of collodion. The tissue is now ready for imbedding in 8%, which may be accomplished in either of two ways: (a) *on a cork* or other holder that may be clamped in the microtome, or (b) *in a paper box*. Only those specimens need be imbedded in a box that, from their shape, or for purposes of careful orientation or serial sectioning, require a larger imbedding mass around them.

(a) *On a holder (cork).* Choose a cork of a convenient size; put a drop or two of collodion upon one end and insert a pin vertically to the surface near the edge. Transfer the tissue from the vial of thick collodion to the cork and lean it against the pin. The shape of many tissues will obviate the need of a pin. Pour the thick collodion onto the tissue, drop by drop, moving the cork in such a way that the thick viscid mass may be made to surround and envelop the tissue. Continue to add drops of collodion at intervals until the tissue is well surrounded, and then as soon as a slight film hardens on the surface invert the cork bearing the tissue in a shell-vial of large diameter containing enough chloroform to float the specimen and cork. If the piece of tissue is of awkward

size and shape, oiled paper may be wound around the end of the cork and tightly tied, the projecting hollow cylinder being long enough to receive the object. The tissue may be put into the cylinder as before, the collodion slowly poured in drop by drop until the specimen is completely covered. When a film has formed, place in chloroform as before.

(b). *In a paper box.* When a box is required for imbedding proceed as follows: The inside of the paper box should be slightly oily to prevent the collodion from sticking to it. Rub upon the paper that is to be folded to form the box a little vaseline, and then with a cloth or lens paper remove as much as possible. Fold the paper into a box of convenient size and shape. Remove the object from the thick collodion and place it in the box, arranging it in the manner wished with a view to sectioning it later. Pour over it slowly, drop by drop or a little at a time, an 8% solution of collodion until the specimen is well covered and the box sufficiently filled. It is better to have a deep layer over the specimen. The 8% solution does not afford the best mass for cutting, so that, with large objects, it is better to allow the mass in the box to thicken by evaporating it slowly under a bell-jar (aquarium jar) until it has attained the consistency of a very thick syrup. When thick enough allow a film to harden upon the surface and immerse it in a glass box or jar of chloroform.

§ 56. **Hardening and clarifying.** The chloroform into which the collodion mass is placed takes out the ether-alcohol and *hardens* the collodion mass, for which a few hours is sufficient. Allow the chloroform to act for 6–24 hours. If it acts long enough the imbedding mass is rendered entirely transparent when no water is present. The hardening action of the chloroform may be quickened and intensified by carefully heating the chloroform until bubbles of ether begin to come from the specimen.

When the collodion mass is hard, whether clear or not, pour off the chloroform and add castor-xylene *clarifier* (§ 151), in which the tissue is to remain until the sections are cut.

In a few hours the collodion mass will become quite transparent (clarified) and hardly discernable, so that the tissue is readily seen. Sometimes, however, the collodion remains white and opaque, due to the presence of moisture, and considerable time is required for its

clarification. In such cases the process may be hastened by placing the tissue in the clarifier in a warm place, and changing the clarifier several times. If the block still remains opaque, remove to 95% alcohol for a day for dehydration, pass through chloroform, and into clarifier. In this way the mass may usually be cleared perfectly. Change the clarifier to fresh after the first and second days. The sectioning may be done after a few hours' immersion, although a several days' clarification is preferable.*

If a paper box were used, after the collodion is hardened and clarified, remove the paper box, absorb the castor-xylene on the surface, trim the end and put some fresh, thick collodion on the cork or other holder. Press the block firmly against the holder; within two minutes it will be firmly cemented and one may proceed at once to clamp the holder in the microtome and commence cutting (§ 57).

§ 57. **Cutting the sections.** For collodion sectioning, a long drawing cut is necessary in order to obtain thin, perfect sections. The knife should, therefore, be set at an obliquity of 15–20° or less, so that half or more of the blade is used in cutting the section. Recall that in the paraffin method the knife is set at right angles to the direction of the cut, and the stroke is a rapid straight one. Trim away the surrounding collodion mass, as in sharpening a lead pencil, so that there is not more than a thickness of about two millimeters all around the tissue, being careful, however, to leave a broad base as a support to the tissue and prevent its bending under the impact of the knife; if the collodion mass is too tapering, bending will occur and thin sections cannot be cut.

Clamp the object in the jaws of the microtome, placing it so that the mass of collodion is opposite the side to which the pressure of the knife is applied in cutting. It is advantageous also to have the object placed with its long diameter parallel with the edge of the knife.

When knife and tissue are properly arranged wet the tissue well with clarifier and flood the knife with the same. Make the sections with a slow, steady motion of the knife. With a small object (3x5 mm.) and a good sharp knife, sections 5 μ to 6 μ can be cut without difficulty. In addition to a sharp knife, however, there are

*The imbedded object may remain in the castor-xylene clarifier indefinitely without harm. The collodion grows somewhat tougher by a prolonged stay in it. After cutting all the sections desired at one time, the imbedded tissue is returned to the clarifier for future sectioning.

necessary well-infiltrated tissue and a hard, firm collodion mass.

§ 58. **Transferring the sections.** If the sections are quite thick they may be transferred from the knife to a slide or a dish by means of forceps or a brush ; if they are thin, however, it is better to handle them by means of an absorbent tissue paper, as follows : Flood the sections well with clarifier and then by means of a pipette remove the clarifier from the knife and place over the sections the end of a piece of the tissue paper, pressing it down upon the sections if necessary. Carefully pull the paper off the edge of the knife ; the sections will adhere to the paper. Place the paper, sections down, on a slide, taking care that the sections are in the desired position. With the finger carefully press the sections (through the transfer paper) to the slide, and then lift the paper, with a rolling motion, from the slide ; the sections will adhere to the slide. Should they stick to the paper instead, lower the paper again and again firmly press the section to the slide. For further procedure see §§ 66, 68. If it is not desired to mount the sections upon a slide immediately, or if they are to be kept in bulk, as for class work, the transfer paper may be shaken gently in a dish of clarifier or 95% alcohol and the section (or sections) will float free and sink to the bottom.

§ 59. If it is desired to mount the sections in a series, proceed as follows : With an artist's brush draw the first section, when cut, up toward the back of the knife and make the next section. Place this section to the right of the first, and so on, arranging them in serial order, section after section, and line below line, until enough are cut to fill the area that the cover-glass will cover. Flood the sections as before by letting the clarifier flow over them, being careful, however, not to float them from their places. Absorb the clarifier from the knife with a pipette, and place over the sections a piece of the transfer paper twice the width of a slide ; press it down if necessary, and slowly draw it off the edge of the knife. Should some of the sections adhere to the knife instead of the paper, it means that the clarifier had been allowed to thicken* on them,

* If one is a long time cutting a series of sections, it sometimes occurs that the xylene evaporates leaving the castor oil that is thick and viscid and also a solvent of the collodion, so that the sections are not easily transferable but stick rather firmly to the knife. In such a case, fresh clarifier or even a little xylene to dissolve the castor oil must be used.

cementing them to the slide, and the preliminary flooding to insure their being free, was insufficient. In that case it is best to flood the paper with clarifier, carefully lift it, arrange the sections again, flood them with clarifier, place a clean piece of transfer paper over them and try again. One soon becomes accustomed to the behavior of the sections, and accidents are rare. In cutting a series of many small sections, some time is consumed and it is necessary to flood the sections frequently with clarifier while cutting in order to prevent the clarifier thickening and cementing them to the knife.

§ 60. **Resumé of the method.** Success in the employment of the collodion method depends upon the thorough infiltration with the collodion solutions, requiring days or even months, and the employment of a thick imbedding mass giving when hardened a firm unyielding support to the tissue. This may be gained by employing a relatively long period of infiltration, and taking pains in imbedding to have the collodion mass well thickened.

Observing these two cautions, collodion may be used in almost all cases as an imbedding mass, except such as are affected by the conditions of the methods already mentioned (§§ 40 and 50).

THE FREEZING METHOD.

§61. This method is expeditious and of use in the rapid examination of tissues, and therefore especially serviceable in the pathological laboratory and in clinical diagnoses. It may also be used in cutting tissues that are too hard to be cut satisfactorily by means of either the collodion or paraffin methods. Both fresh and fixed tissue may be cut by means of the freezing microtome and with or without any special mass such as is used in paraffin or collodion imbedding.

When no mass is employed the tissue is simply frozen and cut, or, if it is fixed tissue, soaked well in water first and then frozen. When extreme haste is not so essential it is better to first saturate the tissue with some solution that does not crystallize on freezing, but simply hardens, since the formation of the ice crystals is hurtful to the tissue. Such are solutions of *gum arabic* or *sugar* and *anise-seed oil*, and they are spoken of as *Congelation masses*.

§ 62. **Infiltration.** Gum arabic or anise-seed oil may be used. (a) *Gum arabic.* If the tissue has been fixed and is in alco-

hol remove the alcohol by soaking it for several hours to 1 day in water. Remove to a thick solution of gum arabic in water, in which it may remain for about 24 hours. It is then ready to freeze and cut.

(b) *Anise-seed oil*. For this method the tissue should be first dehydrated (§ 43). When dehydration is complete, transfer the tissue to anise-seed oil, in which it may soak for 12–24 hours; it is then ready to freeze and cut.

§ 63. **Cutting**. Place a drop of the solution of gum arabic (or anise-seed oil) upon the object carrier of the freezing microtome and turn on the carbonic acid (or ether) spray. When the mixture begins to harden, place the object upon it in an abundance of the solution and freeze it solid. Covering with an inverted cup hastens the freezing.

When the tissue is completely frozen, cut it with a straight movement of the knife, as in the paraffin method, holding it firmly upon the knife rest and making the strokes as rapidly as possible, at the same time rapidly raising the tissue a few microns at a time by means of the microtome screw. For cutting frozen sections, a strong, wedge-shaped knife must be used.

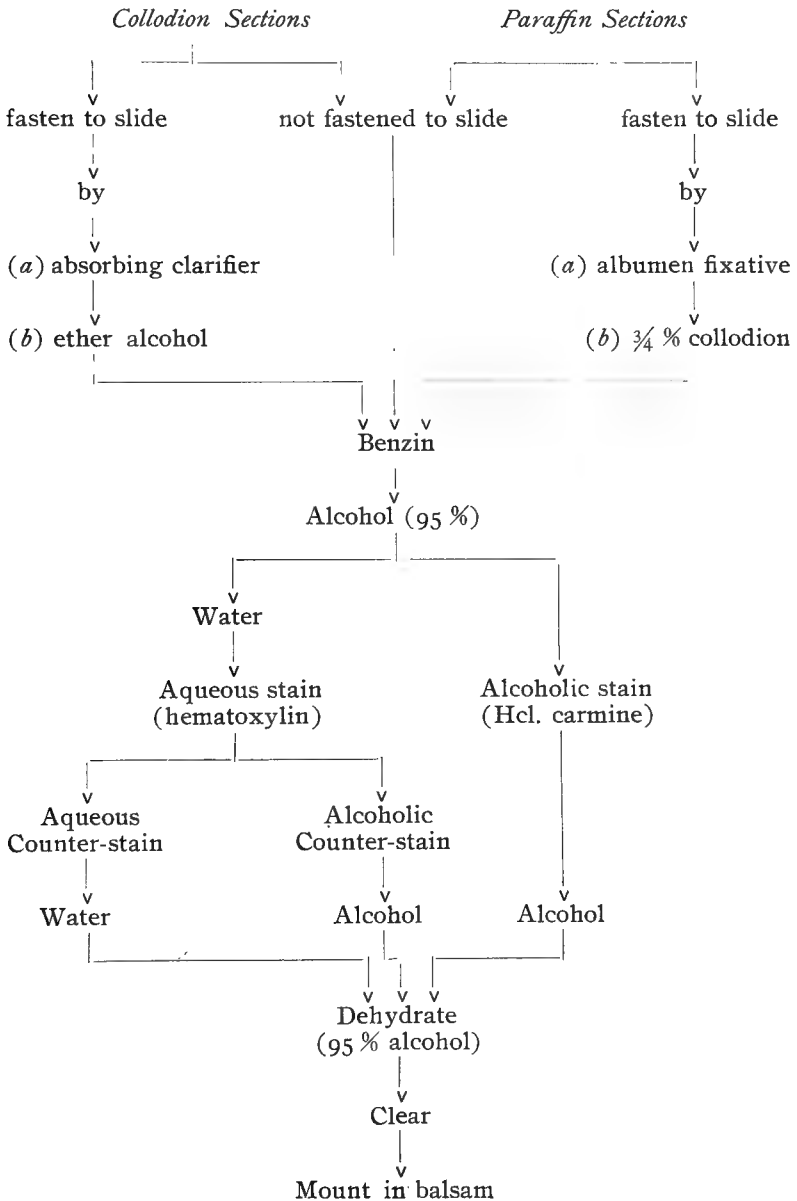
The mass of sections is transferred to a dish of water in which the gum arabic is dissolved away and the sections are ready for staining (§§ 71–79). If anise-seed oil is used, the sections are to be transferred to 95% alcohol which will dissolve out the oil; stain (§§ 69–79). If the tissue has been stained *in toto* the sections may be transferred to anise-seed oil (or other clearer) and mounted in balsam directly.

STAINING AND MOUNTING.

§ 64. The remaining steps in making permanent histological preparations are usually done at one time and are conveniently considered together. In all the processes seemingly complicated, if it is remembered that the succession of media, as in paraffin imbedding, depends on their miscibility, and the *reason* for the various steps is recognized, much of the difficulty in remembering the order in which they come will be avoided.

There are here to be considered, (a) Paraffin and Collodion sections, (b) Free-hand and Frozen sections, (c) Isolation preparations. Of these, the paraffin and collodion sections require some prelimi-

nary treatment not needed with the others, and to them only, therefore, §§ 65-70 apply.



PARAFFIN AND COLLODION SECTIONS.

§65. These may be carried on (a) as *loose* sections, or (b) *fastened to the slide*.

(a) Sections not fastened to the slide may be carried on in watch glasses, or larger glass vessels if there are many of them, the sections either being transferred from vessel to vessel by means of forceps or a section-lifter, or the fluid decanted, care being taken not to pour off the sections, and the succeeding medium added. Single sections may best be carried on upon the slide, which must be kept horizontal. When the fluid is to be changed place a brush or needle gently on one corner of the specimen and pour off the liquid, if necessary first absorbing most of it by means of a pipette; in this way the section may be retained on the slide.

(b) **Fastening the Sections to the slide.** This is of great advantage in carrying the sections on through the different steps. With serial sections it becomes an absolute necessity. Different methods are employed for collodion and for paraffin sections.

§ 66. (1) **Collodion sections.** If the sections are transferred to the slide from clarifier, absorb the oil thoroughly by placing over the section some absorbent paper and pressing it down gently and firmly, repeating the operation several times with fresh paper. After the oil is well absorbed, with a pipette drop upon the section enough ether-alcohol to moisten it (1-2 drops). This softens the collodion and fastens the section to the slide. Allow the ether-alcohol to evaporate until the collodion has again set and the surface of the section looks dull or glazed, and then place it in a jar of benzin. Take care that the specimen does not dry.

If the sections are in series, it is better to put the ether-alcohol on one end of the slide and let it run quickly over the sections and drain from the other end of the slide, repeating the operation two or three times. If it is found that the sections float off of the slide in the process of staining, their adhesion may be insured by using albumenized slides or removing the slides from the alcohol (§ 69) and again treating with ether-alcohol.

§ 67. (2) **Paraffin sections.** If the sections are unwrinkled, or with a few wrinkles that may be easily "ironed out," fasten them to the slide with (a) albumin fixative and $\frac{3}{4}\%$ collodion, or (b)

albumin fixative and heat ; if the sections are wrinkled, they may be extended and the wrinkles removed by the method given below (c).

(a) *Albumin fixative and $\frac{3}{4}$ % collodion.* Place upon the slide a small drop of albumin fixative, spreading it out with a clean finger into a very thin, even layer. Place the paraffin section in position upon the slide and with a clean finger, press the section into the albumin fixative, beginning at one edge of the section and by a rolling motion of the finger, ironing out any wrinkles there may be. With a camel's hair brush and by a single sweep, spread over the section a thin coating of $\frac{3}{4}$ % collodion. Allow it to dry in the air for a minute or so and then place the slide in a jar of benzin. Be sure that the $\frac{3}{4}$ % collodion in the bottle has not thickened, and spread as little over the section as possible, otherwise a much longer time in the benzin will be necessary.

(b) *Albumin fixative and heat.* The employment of $\frac{3}{4}$ % collodion causes the benzin to dissolve out the paraffin from the sections slowly, and the collodion also stains intensely with certain dyes, such as safranin, gentian violet, methylgreen, methylene blue, iron hematoxyline, etc. When these stains are to be used, fasten to the slide in the manner following : Prepare the slide with albumin fixative and press the section to the slide as directed above. Look upon the reverse side of the slide to see if the section really adheres to the albumen fixative, as in some cases it does not. Heat the slide gently and slowly over a small flame until the paraffin melts and begins to run away from the specimen. Keep the paraffin just melted for a minute or so, and then transfer to the benzin. A minute or two in benzin will suffice. Should the paraffin section not adhere to the albumin fixative when well pressed down, it can in many cases be made to do so by briskly rubbing the reverse side of the slide with a woolen or silk cloth.

(c) *Extending sections with warm water.* If the sections are wrinkled, as they often are, remove the wrinkles by extending the sections on warm water, as follows : Place the sections upon a slide prepared with a very thin, even layer or film of albumin fixative (§ 67, a), and add at the side enough water to float them. Warm the slide carefully and slowly over a small flame until they begin to straighten out. Do not let the water become warm enough to melt

the paraffin. When the sections have become quite flat and smooth, drain off the water and allow the slide to stand 2-3 hours, or better over night, when a thin coating of $\frac{3}{4}\%$ collodion is given (§ 67, a) and they are placed in benzin.

If the sections are large and thin, the coating with $\frac{3}{4}\%$ collodion may be omitted; in this case, let the sections stand 12-24 hours after spreading, or for 2-3 hours if left in a warm place, as in an incubator.

The sections may also be straightened out by placing them on a dish of water, such as the waste-jar, and hot water added slowly until the sections extend, when, after the water has cooled, they may be transferred to albuminized slides and carried on as before.

PREPARATION FOR STAINING.

§ 68. **Benzin.** Both paraffin and collodion sections are transferred to benzin, which in the first case dissolves out the paraffin, in the second serves to remove the clarifier still present in the tissue and collodion.

Leave paraffin sections in benzin until the paraffin is entirely dissolved, requiring from a minute or so to 10-15 minutes, if $\frac{3}{4}\%$ collodion was used in fastening the sections to the slide.

Collodion sections should remain in the benzin 5-15 minutes or longer, according to the thickness of the sections. Benzin may be omitted and a proportionately longer time in the alcohol given.

Sections may be left in benzin over night, and 2-3 days even might do no harm, but it is better to proceed at once to the other operations.

§ 69. **Alcohol.** Transfer from benzin to 95% alcohol to remove the benzin, leaving the section in the alcohol 5-10 minutes; or, if you wish, shorten the period to a minute or so by waving the slide gently to and fro in the alcohol. A stay of a day or so in alcohol does no harm. Collodion sections generally require a longer period than paraffin sections because of the collodion mass present and their greater thickness.

§ 70. **Water.** Remove the 95% alcohol from the section by plunging the slide into a jar of tap water and gently waving it about in it. Should the stain to be employed be an alcoholic solution this step may be omitted.

STAINING.

§ 71. While staining has a value in histology in coloring the preparation as a whole and thus making its parts stand out more sharply, the aim is to employ such stains as by their *selectivity* give different parts or structures different colors or intensities of color, thus *differentiating* them the better.

In histology, selective stains are employed (a) to color the nucleus differentially, thus distinguishing it sharply from the cell body, and by means of the nucleus setting apart groups of cells; (b) to distinguish between different kinds of tissue, as, for example, connective tissue and muscle.

§ 72. The following two general rules may be given :

(1) The preparation should be transferred to the stain from the fluid in which the staining principle is dissolved. The majority of the stains employed are aqueous solutions; some, however, such as hydrochloric acid carmine, are alcoholic; with these alcoholic stains the last preparatory step (§ 70), removal of the alcohol by water, should be omitted. Many stains may be used either in aqueous or in alcoholic solution.

(2) The stain should be washed out with the solvent of the dye,—water or alcohol as the case may be.

With many aniline dyes (§ 74) one may, and in many cases should, employ alcohol for washing out, even though the staining solution is aqueous.

§ 73. **Differentiation.** To bring out the differential or selective coloring of the dye. This is necessary with many stains, especially anilines, and may often be satisfactorily accomplished by the use of 95% alcohol and made a part of the washing out. Alcohol acidified with hydrochloric acid (§ 149) is sometimes used, or a special differentiator is required.

§ 74. **Classification.** (a) According to their *chemical* nature the stains generally used are (1) hematoxylin stains, (2) carmine stains, (3) aniline stains.

(b) According to their *selectivity*. Stains as used in histology may for convenience be classified as (1) *nuclear*, (2) *general*, and (3) *special*. These are often used in combinations of two or three, either together in the same solution or separately in solutions used

successively. *Double* and *triple* stains are usually combinations of nuclear with general or special stains. *Quadruple* stains are less serviceable; see, however, p. 68, 154.

(c) According to the mode of employment, staining may be either (1) *in toto*, or (2) *section* staining. When *in toto* staining is employed the piece of tissue is stained entire, and imbedded and sectioned afterwards. In this case the tissue should be stained before the process of imbedding is begun, after the washing out of the fixer has been completed (§ 19, 21). But a single stain may be given, and the one chosen is generally a nuclear one—hematoxylin or carmine.

(2) *Section staining*, i. e., after the tissue is imbedded and sections cut. This is more serviceable, especially if highly differential results are desired.

§ 75. **Impregnations.** In addition to the typical methods of coloring tissue by means of stains there is a group of methods in which the coloring matter is deposited in the cell or tissue that it is desired to differentiate, in the form of a precipitate. These are known as impregnation methods and are of great value, especially as applied to nervous tissues. A hard and fast line, however, cannot be drawn between true staining methods and impregnations. Silver nitrate and gold chlorid are the substances most generally employed in the impregnation of tissue (§ 146).

§ 76. **Choice of stains.** Remember that the staining is greatly affected by the previous treatment; brilliancy or selectivity in the result being in many cases dependent on the fixer employed or impaired by the improper or incomplete washing out of the fixer.

In staining, therefore, consider three things, (a) what it is desired to bring out,—what kinds of stains you need to employ, (b) the mode of fixation that has been employed, and (c) the imbedding method must also be considered in the choice, since if collodion is employed certain stains that color it deeply should be avoided.

§ 77. **The time of staining.** Although in general certain time limits can be given to the period during which a stain should be allowed to act; with most stains, especially those with which no differentiation is needed, such as hematoxylin, and most carmines, the correct intensity of color should be determined by examining the preparation with the microscope. One soon becomes able to judge

of the right stain in this way better than if a given time were adhered to.

In the use of stains requiring a subsequent differentiation, the rule is to over-stain and watch the differentiation carefully with the microscope, stopping it when sufficient. In this case it is the differentiation and not the staining that should be carefully regulated.

§ 78. In this course are employed : (1) Chloral hematoxylin, (2) Ehrlich's acid hematoxylin, (3) Delafield's hematoxylin, (4) Weigert's hematoxylin, (5) Borax carmine, (6) Alum carmine (Grenacher's), (7) Paracarmine, (8) Hydrochloric acid carmine, (9) Picro-carmine, (10) Safranin, (11) Gentian violet, (12) Methyl-green, (13) Ehrlich's triacid mixture, (14) Eosin, (15) Erythrosin, (16) Picric alcohol, (17) Picro-fuchsin ; also (18) Heidenhain's iron hematoxylin, and special stains given subsequently under "Special Methods."

§ 79. The combinations most employed are (*a*) hematoxylin and eosin (or erythrosin), and (*b*) hematoxylin and picrofuchsin, the former a double and the latter a triple combination.

The following scheme indicates the manner of their employment :

Paraffin or Collodion Sections
(§§ 66 and 67)

↓
Benzin

↓
95 % Alcohol

↓
Water

↓
Hematoxylin, 10-30 min.

↓
Water

↓
Picrofuchsin, eosin
or erythrosin, $\frac{1}{2}$ -2 min.

↓
Distilled water or 67 % alcohol

↓
Dehydrate (95-99 % alcohol)

↓
Clear
(carbol-xylene)

↓
Mount in Balsam

STAINS.

§ 80. **Chloral Hematoxylin.** (*Proc. Am. Micr. Soc.*, vol. XIV, pp. 125-127). *Formula:* (A) Hematoxylin crystals, $\frac{1}{10}$ gram, dissolved in 10 c.c. of 95% alcohol; (B) distilled water, 100 c.c., potash alum, $3\frac{3}{4}$ grams; boil for 5 minutes in an agate-ware or glass vessel and add sufficient boiled water to bring the volume back to 100 c.c. When cool, mix (A) and (B) and add chloral hydrate, 2 grams. Allow the solution to ripen for a week or two in the air and sunlight, or add 1-2 c.c. hydrogen dioxid, when it is ready for use. Its staining quality improves up to an optimum and then begins to deteriorate. Old hematoxylin generally contains a precipitate and should be filtered often or before using.

Stain sections from water for 5-30 minutes according to the age of the solution, the character of the tissue and the fixation employed. After staining,

wash well with tap water to give a blue tone to the stain. Counter-stain as desired.

‡ 81. Ehrlich's acid hematoxylin. *Formula*: Water, 100 c.c.; 95% alcohol, 100 c.c.; glycerin, 100 c.c.; glacial acetic acid, 10 c.c.; alum in excess. Let the mixture ripen in the light until a dark red. Sections stain in this hematoxylin in a short time, generally 5-10 minutes. Wash with water after staining.

‡ 82. Delafield's hematoxylin. *Formula*: Saturated aqueous solution of ammonia alum, 200 c.c.; 16% alcoholic solution of hematoxylin crystals, 12½ c.c. (hematoxylin crystals 2 grams, 95% alcohol 12½ c.c.). Allow the mixture to stand in the light and air in an unstoppered bottle for 4 or 5 days; filter and add glycerin, 50 c.c., and methylic alcohol, 50 c.c. Permit it to stand for a week or so to ripen; filter and keep in a stoppered bottle. The staining power increases for several months. In using, dilute 3 or 4 times with distilled water.

Stain sections from water; 4-5 minutes will generally be sufficient. Wash well with water after staining.

This is a very strong hematoxylin stain and may be used to advantage with tissues that stain with difficulty. It is likewise a more diffuse stain than either chloral or Ehrlich's hematoxylin, staining cell-body as well as nucleus,—a feature having its advantages and disadvantages. Old solutions (several months to a year) should be filtered before using.

‡ 83. Weigert's hematoxylin. *Formula*: Hematoxylin, 1 gram, dissolved in 95% alcohol, 10 c.c.; distilled water, 90 c.c.; saturated aqueous solution of lithium carbonate, 1 c.c. This stain may be used at once or (better) be allowed to ripen for 2-3 days.

Tissue should be stained from water and rinsed in water after staining. This is a powerful stain and is used in Weigert's method of staining myelinic nerve fibers (‡ 136).

‡ 84. Borax carmine. (Grenacher). *Formula*: Borax, 4 grams; carmine, 3 grams; water, 100 c.c.; allow the mixture to stand for several days, shaking occasionally when most of the carmine will have dissolved; filter and add 100 c.c. of 70% alcohol. Let the mixture remain for several days, filter again and the solution is ready for use.

This is a good carmine stain for *in toto* staining. Stain objects *in toto* for one to several days, according to size; remove to 67% (70%) alcohol, acidulated slightly with hydrochloric acid, (4 drops in each 100 c.c.), for a day and then remove to 82% alcohol. It affords a bright red stain that is quite transparent.

‡ 85. Alum carmine. (Grenacher). *Formula*: Carmine, 1 grm; potash (or ammonia) alum, 4 grams (1-5 grams); water, 100 c.c.; boil for 15-20 minutes, allow it to cool and filter.

A good carmine stain for sections. Stain 5-30 minutes, or longer if necessary; rinse off the excess of stain with distilled water. The stain is a purple-red.

‡ 86. **Paracarmine** (Mayer). *Formula*: Carminic acid, 1 gram; aluminum chlorid, .5 gram; calcium chlorid, 4 grams; 70% (67%) alcohol, 100 c. c. Allow it to stand a day or so, shaking occasionally until the carminic acid has quite dissolved, and then filter.

This is an excellent carmine stain for *in toto* staining. The tissue may be stained 1-several days (1 week), then washed in 67% and 82% alcohols to remove the excess of staining fluid. A red nuclear stain, more opaque than borax carmine. It does not over-stain readily, and since it is an alcoholic solution (70%) it is quite penetrating and may be allowed to act for a greater length of time, being thus suited for staining *in toto* objects of considerable size.

‡ 87. **Hcl. carmine**. *Formula*: Carmine, 2 grams; concentrated hydrochloric acid, 3 c. c.; 70% alcohol, 100 c. c. Boil gently for 15-20 minutes to dissolve the carmine; cool and filter.

This is a strong carmine stain, quite suitable for sections, especially such as stain with difficulty. It may also be employed for staining *in toto*. Stain sections from alcohol or water for 5-15 minutes; rinse away the superfluous stain with 67% (70%) alcohol and differentiate for a few seconds to a minute with acid alcohol (95% alcohol 100 c. c., concentrated hydrochloric acid $\frac{1}{3}$ c. c.). Wash away the acid alcohol with ordinary 95% alcohol. If a pure nuclear stain is not desired the differentiation may be omitted.

Picric alcohol may be used as a counter stain, and in that case differentiation is ordinarily not required.

‡ 88. **Picro-carmine**. Employ a $\frac{1}{2}$ % aqueous solution of the dry picro-carmine, made according to Ranvier's formula. Stain sections $\frac{1}{2}$ -1 hour or longer and rinse well in water. If the sections are over-stained they may be differentiated by means of acid alcohol as used with Hcl. carmine.

While it is itself a good stain, it may be used with hematoxylin as a counter-stain with good results. It is an alkaline solution, and the hematoxylin stain is intensified. As employed in this way, stain in hematoxylin the usual length of time, rinse in water and stain 2-3 hours in the picro carmine solution; rinse in water; dehydrate, clear, and mount in balsam. As used in this way, there is afforded an excellent stain for developing bone.

‡ 89. **Safranin**. *Formula* (Babes'): Concentrated aqueous solution of safranin, 1 part; concentrated alcoholic solution of safranin, 1 part.

Stain sections 1-4 hours, or over night; wash away excess of stain with 95% alcohol, differentiate with acid alcohol (95% alcohol, 100 c.c., hydrochloric acid, $\frac{1}{10}$ c.c.) for a few seconds, rinse with 95% alcohol and clear in carbonylene or bergamot oil. If a pure nuclear stain is not required, the differentiation may be omitted. This gives a good stain with tissue fixed in Hermann's or Flemming's fluid. It is a brilliant, transparent red. (See ‡ 99).

‡ 90. **Gentian violet**. *Formula*: A concentrated solution in distilled water. Stain (paraffin) sections from water for 5-10 minutes, rinse in water, dehydrate and differentiate with 95% alcohol and complete the differentiation with clove oil. When the differentiation is sufficient, clear with bergamot oil

and mount in balsam. This may be used alone to give a blue stain with tissue fixed in Hermann's or Flemming's fluid.

‡ 91. **Methyl green.** This is an nuclear stain of much value, besides being an important ingredient of triple stains (*e. g.*, Ehrlich's triacid mixture). In very dilute solutions it is serviceable in staining the nuclei of fresh tissue and of isolated cells (formula below). A 1% aqueous solution is used with hematoxylin and picrofuchsin in differentiating the structure of the hair follicle. (See 154).

‡ 92. **Methyl green and eosin.** *Formulas:* (a) Aqueous solution. 1% aqueous solution of methyl green, 1½ c.c.; ½% aqueous solution of eosin, 1 c.c.; normal salt solution, 100 c.c.

(b) Glycerin solution (for mounting). 1% aqueous solution of methyl green, 2 c.c.; ½% aqueous solution of eosin, 1 c.c.; glycerin, 100 c.c.

These solutions may be used for staining isolated cells; formula (a) for temporary examination, formula (b) as a mounting and staining medium combined.

‡ 93. **Ehrlich's triacid mixture.** *Formula:* Saturated aqueous solution of orange G, 12 c. c.; saturated aqueous solution of acid fuchsin, 8 c. c.; saturated aqueous solution of methyl green, 10-12 c. c.; distilled water, 30 c. c.; alcohol (95%+), 18 c. c.; glycerin, 5 c. c. Mix the orange G and acid fuchsin and add drop by drop, or a few drops at a time, the solution of methyl green, stirring or shaking between each addition; then add the alcohol, water, and glycerin. Shake thoroughly and allow the mixture to stand for 24 hours. Do not filter or shake, but take the stain from the bottle by means of a pipette.

Stain sections for 10-15 minutes, rinse off the superfluous stain with distilled water and dehydrate and clear as quickly as possible; this is necessary since the alcohol washes out the methyl green (nuclear stain) very rapidly. This stain colors collodion very deeply, hence it cannot well be used with collodion sections. It affords a good and often valuable stain. The sections should, however, be thin, and dehydration must be rapid. For the use of the mixture in staining blood films, see ‡ 125.

‡ 94. **Eosin.** *Formulas:* (a) ½% aqueous solution; (b) 2% aqueous solution; (c) 1% solution in water or 50% alcohol. Formula (a) is preferable for most work; (b) affords a stronger and (c) a weaker stain. This may be used as a counter-stain with hematoxylin to differentiate nucleus from cell-body. Stain sections after hematoxylin for 10-30 seconds, wash away the excess of stain with distilled water or 67% alcohol. Since alcohol tends to wash out the eosin, unless the color is too strong it is advisable to hasten the process of washing out and dehydration.

‡ 95. **Erythrosin.** *Formulas:* (a) ½-1% solution in 67% alcohol, (b) ½-1% aqueous solution, (c) 1% aqueous solution. This is a general stain similar to eosin in its staining properties, but gives a redder color. Formulas (a) and (b) may be used with sections and in the same way as eosin. Formula (c) is used with tissues dissociated in formaldehyde dissociator.

‡ 96. **Picric alcohol (acid).** *Formula:* Picric acid, .2 grams; distilled

water, 50 c.c. ; 95% alcohol, 50 c.c. A good counter-stain with hematoxylin or carmine. Stain in hematoxylin or carmine, rinse in water (or alcohol if Hcl. carmine is used), and stain with picric alcohol 10-30 seconds ; wash off with 67% alcohol, etc. Since picric acid tends to wash out the nuclear stain, it is best to over-stain somewhat with the nuclear dye and regulate carefully the time of staining with the picric alcohol.

‡ 97. **Picro-fuchsin.** *Formulas:* (a) *General stain*,—1% aqueous solution of fuchsin acid, 10 c. c. ; saturated aqueous solution of picric acid, 75 c.c. ; distilled water, 25 c.c. (b) For *nervous tissue*,—1% aqueous solution of fuchsin acid, 15 c.c. ; saturated aqueous solution of picric acid, 50 c.c. ; distilled water, 50 c.c. This is a valuable counter-stain to hematoxylin, especially serviceable in the differentiation of white connective tissue fibers. The nuclei are a purplish brown (hematoxylin stain), the connective tissue red, cell bodies and muscle yellow-orange. In special cases the relative amount of fuchsin acid may be decreased or increased, thus giving a preponderance to the yellow or red in the general stain.

Stain well with hematoxylin, rinse in water, and stain with the picro-fuchsin 15-30 seconds ; wash away the excess of stain with distilled water or 67% alcohol. Picro-fuchsin will gradually wash out the hematoxylin, therefore stain strongly with hematoxylin and regulate carefully the time of staining with picro-fuchsin. Picro-fuchsin is quite sensitive to alkalies, so that tap-water (unless slightly acidulated) should not be used for washing out, and the mounting medium should be slightly acid or neutral, *not* alkaline.

‡ 98. **Heidenhain's Iron Hematoxylin.** Three steps are necessary, (a) *mordanting*, (b) *staining*, (c) *differentiating*.

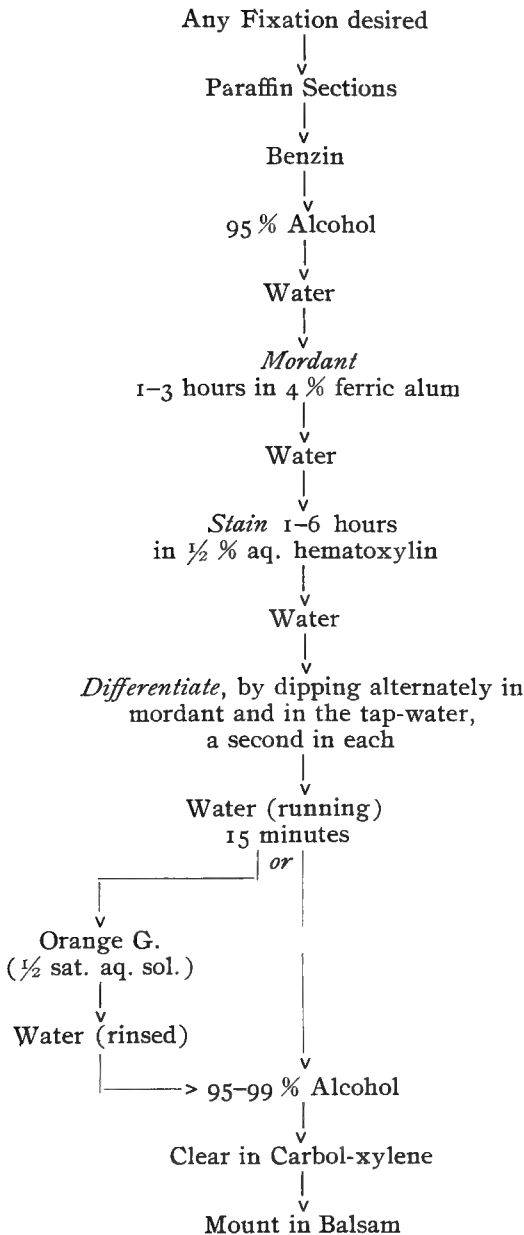
1. *Mordant* sections 1-2 hours in a 4% aqueous solution of ferric alum (iron-ammonium-persulphate), rinse in water a few (5-10) minutes, and

2. *Stain* for 1-3 hours in a ½% aqueous solution of hematoxylin (formula : 16% alcoholic solution of hematoxylin 3 c. c., water 97 c. c., chloral hydrate 2 grams), rinse in water, and

3. *Differentiate* by dipping the slide into the mordant for a few seconds and then rinsing in tap-water, repeating the operation until the correct differentiation has been attained, as ascertained by examination under the microscope. The chromatin (nucleus) should be a deep blue or blue-black, the cytoplasm (cell-body) gray or light blue. After differentiating it is necessary to wash the section well in running water for about 20 minutes to ensure the complete removal of the ferric alum. The above times are for tissue fixed in Flemming's or Hermann's fluid ; shorter times may be given for tissue fixed by most other methods.

A counter-stain is ordinarily not needed, but, if desired, the sections may be stained for 10 seconds to 2-3 minutes with a ½ saturated aqueous solution of orange G.

This is a valuable stain in all cytological work, and for all muscular tissue.

Iron Hematoxylin

§ 99.

*Staining with Safranin*Flemming's or Hermann's
fluid fixation (best)↓
Paraffin sections↓
Benzin↓
95 % Alcohol↓
Safranin (Babes'),
2-12 hours↓
Distilled water
(rinsed)↓
95 % Alcohol↓
Acid 95 % alcohol ($\frac{1}{10}$ HCl.)
for a few seconds↓
95-99 % Alcohol↓
Carbol-xylene↓
Mount in Balsam

MOUNTING.

§ 100. Whether stained or unstained, prepared for microscopical examination by isolation or sectioning, and especially if it is desired to keep the preparation, it is necessary to *mount* it in some way,—*i. e.*, so arrange it upon some suitable support (glass slide) and in some suitable mounting medium that it may be satisfactorily studied with the microscope.

Mounting may be

- I. Temporary, or
- II. Permanent,—as
 - A. Dry, or in air,
 - B. In a medium miscible with water, or
 - C. In a resinous medium, in which case it is neces-

sary first to remove all water by either (*a*) drying—*Desiccation*, or (*b*) a series of displacements, *i. e.*, 1. Removing the water with strong alcohol—*Dehydration*; 2. Removing the alcohol with clearer—*Clearing*; 3. Replacing the clearer with balsam or other resinous mounting medium.

§ 101. **Temporary mounting.** Used in this course principally in the examination of blood corpuscles and living ciliated cells (§ 2). Temporary examination of tissues is quite simple, though important, and for this it is only necessary to place the teased tissue or section on the slide in a drop of the fluid in which it is at the time, normal salt solution, dissociator, or alcohol, and cover. The examination of preparations intended for permanent mounts during the staining or before mounting will often serve to detect faulty treatment at a time when it may be remedied without great expenditure of time, or discard the specimen as worthless.

§ 102. **Permanent mounting.** In this course are employed (*a*) mounting dry on a ring or in a cell, (*b*) in glycerin or glycerin jelly, media miscible with water, and (*c*) in xylene balsam, a resinous medium.

§ 103. **Mounting dry.** The preparation may be either upon the under side of the cover-glass (best if possible) or rest upon the bottom of the cell.

In the first case a shallow cell made by a shellac ring will be sufficient; in the second, a shellac ring may not give a deep enough cell and a paper, hard rubber, or metal ring may be cemented to the slide.

(*a*) *When the preparation is on the cover.* Prepare a shellac cell (§ 106) on the slide of a size slightly smaller than the cover to be used, and allow it to dry for a day or so. Warm the cover bearing the preparation to remove the last traces of moisture, and place it film side down upon the ring. Warm the slide until the edge of the cover may be made to adhere to the shellac ring and press the cover down until it adheres all the way round. Seal the cover with shellac and label (§§ 111, 113).

(*b*) *Mounting in a paper or rubber cell.* With a brush, cover one side of the ring with a layer of shellac and place it on the center of the slide, shellac side down; place within the cell the preparation, arranging it in the manner desired, and place upon the ring a cover-glass of a suitable size, and seal it with shellac; label.

§ 104. **Mounting in glycerin media.** (a) Pure glycerin ; (b) glycerin and acetic acid, 1 %; (c) glycerin, alum carmine and eosin (§ 156).

Glycerin and glycerin-jelly are most serviceable in mounting isolation preparations. For both of these mounting media the object must be mounted from water or an aqueous solution.

Arrange the section or teased tissue in the center of the slide, drain off the water or aqueous solution in which the preparation is and add a small drop of glycerin. Take a clean cover in the forceps, breathe on the under side and carefully lower it upon the object ; gently press it down. It is best to use only a small drop of glycerin so as not to get it outside the cover, as it is hard to clean away satisfactorily. Clean carefully and seal with shellac in accordance with § 111.

§ 105. **Mounting in glycerin-jelly.** The preparation should be mounted from some aqueous solution. Warm the slide gently and put it upon the centering card ; in the center of the slide place a drop of warmed (melted) glycerin-jelly. Remove the object from the water or aqueous solution and arrange it in the glycerin-jelly. Grasp a cover-glass with the fine forceps, breathe on the lower side, gradually lower it upon the object and gently press it down. Allow the glycerin-jelly to set, keeping the slide horizontal meanwhile. Scrape away the superfluous glycerin-jelly around the cover-glass and seal with shellac (§ 111).

§ 106. **Preparation of shellac mounting cells.** Place the slide upon the turn table and center it (i. e., get the center of the slide over the center of the turn table). Select a guide ring on the turn table which is a little smaller than the cover-glass to be used ; take the brush from the shellac, being sure that there is not enough cement adhering to it to drop. Whirl the turn table and hold the brush lightly on the slide just over the guide ring selected. An even ring of the cement should result. If it is uneven, the cement is too thick or too thin or too much, was on the brush. After a ring is thus prepared, remove the slide and allow the cement to dry spontaneously, or heat the slide in some way. Before the slide is used for mounting, the cement should be so dry when it is cold that it does not dent when the finger nail is applied. A cell of considerable depth may be made with shellac by adding successive layers as the previous one dries.

§ 107. **Mounting in balsam.** Certain preparations may be mounted in balsam by drying, the method of desiccation (§ 100), e. g., cover-glass preparations of bacteria, stained cover-glass preparations of blood, etc. For this it is only necessary that the preparation be absolutely dry, a small drop of balsam placed upon it or upon the under side of the cover-glass, which is carefully placed over the specimen and pressed down.

Mounting in balsam by desiccation is serviceable for but few preparations in histology, and in most cases the removal of the water by a series of displacements is resorted to (§ 100). For this the following steps are necessary: Dehydration, Clearing, Mounting in balsam.

Dehydration. The sections are entirely freed from water by the use of 95% or absolute alcohol. The slide or free section may either be placed in a jar of alcohol or alcohol from a pipette be poured over it. Treat the preparation to be mounted for 5-15 minutes. The thicker the section the longer the time required; colloidal sections require a longer time than paraffin sections. In any case, be sure that the dehydration is complete, giving a longer rather than a shorter time, and then clear.

§ 108. **Clearing.** This is accomplished by putting the slide in a jar of clearer or dropping the clearer upon the section from a pipette. When the section is cleared it will be transparent. Test it by holding it against a dark background; if it is not cleared it will be cloudy, white, and opaque.

§ 109. **Mounting in balsam.** Drain off the clearer and allow the section to stand until there appears the first sign of dullness from evaporation of the clearer from the surface. Then place a small drop of balsam upon the section or upon the cover-glass which is then inverted over the specimen.

Remember that in mounting in this way you must always "*Dehydrate, Clear and Mount in Balsam,*" and that the three steps are inseparable.

SEALING THE PREPARATIONS.

This is only necessary when the preparation is a glycerin or glycerin-jelly mount. It is better not to seal balsam preparations, or only quite late after the balsam has thoroughly dried out.

§ 110. **Sealing glycerin mounted specimens.** Wipe away the superfluous glycerin as carefully as possible with a moist cloth or a piece of lens paper. Place four minute drops of cement carefully at the edge of the cover at the four quarters and allow them to harden for half an hour or more ; these will anchor the cover-glass and the preparation may then be placed upon the turn-table and a ring of shellac cement put round the edge while revolving the turn-table.

§ 111. **Sealing glycerin-jelly mounts.** Allow the glycerin-jelly to harden for 12 hours or longer. With a knife scrape away the superfluous jelly and then carefully wipe around the cover-glass with a cloth moistened with water. Place the slide on a turn-table, carefully center the cover-glass, and with a brush seal the edge of the cover by a ring of shellac while revolving the turn-table. A second coating may be given subsequently if needed, after the first coat has dried.

§ 112. **Sealing balsam mounts.** This is necessary only with special preparations, and should in any case be done only after the preparations have dried out for several weeks. With a knife scrape off all superfluous balsam from around the cover-glass and wipe it carefully with a cloth moistened with alcohol or benzin (or xylene). Seal as with glycerin-jelly mounts. When the oil immersion is to be used often, it is advantageous to seal the preparation with shellac (after it has dried) to facilitate cleaning away the immersion fluid.

LABELING MICROSCOPIC SLIDES.

§ 113. Every permanent microscopic preparation should be carefully and neatly labeled in ink, the label being placed upon the right hand end of the slide. The label should furnish at least the following information :

EXAMPLE.

(1) The number of the preparation, the thickness of the cover- glass and of the section.	No.	C. 15. S. 10 μ .
(2) The name, kind, and source of the preparation.		Ileum of Cat. Transection.
(3) The date of the specimen.		November, 1898.

In the case of specimens with which it is advantageous to have more information at hand a second label may be placed upon the other end of the slide, and it may bear the following information :

- (1) Mode of fixation.
- (2) Imbedding method.
- (3) Stains employed.
- (4) Mounting medium (generally not necessary).
- (5) Special purpose of the preparation.

A catalog giving the full data of the specimen,—age, condition of the animal, mode of preparation in detail, special points illustrated, etc., is not required for the preparations in this course, but is valuable particularly in special investigations and with standard specimens.

CLEANING SLIDES AND COVER-GLASSES.

§ 114. **Cleaning cover-glasses.** Fill the large glass box one-half full of cleaning mixture and put in the new covers, one at a time, being sure that they are entirely immersed and the cleaning mixture reaches all points. The one cover may be pushed under by the next. Let them remain over night (or longer) and then wash them thoroughly in running water, until all trace of the cleaning mixture is removed. Then place the covers in 50 or 67% alcohol.

§ 115. **Wiping the cover-glasses.** When ready to wipe the cover-glasses, remove several from the alcohol and put them on a soft, dry cloth, or on some of the lens paper to let them drain. Grasp a cover-glass by its edges, cover the thumb and index finger of the other hand with a soft, clean cloth, or some of the lens paper. Grasp the cover between the thumb and index finger and rub the surfaces. In doing this it is necessary to keep the thumb and index well opposed on directly opposite faces of the cover so that no strain will come on it, otherwise the cover is liable to be broken.

When a cover is well wiped, hold it up and look through it toward some dark object. The cover will be seen partly by transmitted and partly by reflected light, and any cloudiness will be easily detected. If the cover does not look clear, breathe on the faces and wipe again. If it is not possible to get a cover clear in this way it should be put again into the cleaning mixture. When the covers

are wiped, put them in a clean glass box. Handle them always by their edges, or use fine forceps. Do not put the fingers on the faces of the covers for that will surely cloud them.

§ 116. **Measuring the thickness of the cover-glasses.** With the cover-glass measurer determine the thickness of the cover-glasses and sort them into three groups: (*a*) those with a thickness of .13-.17 mm., (*b*) those less than .13 mm., and (*c*) those thicker than .17 mm. Groups (*a*) and (*b*) only should be used; (*c*) should be discarded or used only with objects for low magnification.

It is advantageous to know the thickness of the cover-glass on an object for the following reasons: (*a*) That one do not try to use objectives in studying the preparation of a shorter working distance than the thickness of the cover-glass (Microscopical Methods, § 57); (*b*) In using adjustable objectives with the collar graduated for different thicknesses of cover, the collar might be set at a favorable point without loss of time; (*c*) For unadjustable objectives the thickness of cover may be selected corresponding to that for which the objective was corrected (see Microscopical Methods § 27 table). Furthermore if there is a variation from the standard one may remedy it in part at least by lengthening the tube if the cover is thinner and shortening it if the cover is thicker than the standard (Micr. Meth. § 96).

§ 117. **Cleaning slides.** Rinse new slides thoroughly in clean water and then wipe them with a soft towel. In cleaning the slides handle them by their edges to avoid soiling the face of the slide. After the slides are cleaned, to keep them free from dust store them again in the box in which they came, or in a covered glass dish or jar.

§ 118. **Cleaning used slides and covers.** If only water, glycerin or glycerin-jelly has been used on them, they may be cleaned with water, preferably warm water, and then, if necessary, wiped out of 50% alcohol. If balsam has been used, heat the slides until the balsam is soft and then remove the cover-glasses. Scrape from the slides all the balsam possible and place them (and cover-glasses) in cleaning mixture for several days. If then they cannot be readily cleaned, place them in fresh cleaning mixture for a period of several days. Wash away the cleaning mixture thoroughly with water and wipe them with a clean towel.

SPECIAL METHODS.

THE BLOOD.

§ 119. Special methods in the examination of the blood include (1) Examining fresh ; (2) Technic of staining blood films ; (3) Determination of the number of red and white corpuscles per cubic millimeter ; (4) Determination of the relative amount of hemoglobin ; (5) Spectroscopic examination of blood (hemoglobin). (1) and (2) are briefly given here ; for (5) see Microscopical Methods, §§ 201-203.

§ 120. **Examining fresh.** This consists in covering a drop on a slide and immediately sealing the cover-glass to prevent evaporation, observing the following cautions : (1) The drop of blood (from the finger or the lobe of the ear) should flow freely and not be obtained by pressure. The drop should be a medium-sized one, which will spread out in an even, thin layer under the cover. (2) The drop should be received upon a cover or slide, covered, and sealed at once with castor oil.

Examination of fresh blood may be used in clinical examination for the detection of some abnormal conditions, and it is of value in the rough diagnosis of many others.

§ 121. **Stained preparation of blood.** (a) *Preparing the blood film.* This may be best done in one of two ways : (1) The edge of a slide is first drawn through a drop of fresh blood and then moved quickly across the surface of a clean cover-glass, in this way spreading the blood in a thin, even layer upon the cover. Success depends upon getting the right amount of blood upon the edge of the slide and the quick, even movement by which it is spread upon the cover-glass. A second, possibly better, method is the following :

(2) Have ready two thin *clean* cover-glasses and obtain a drop of fresh blood. Take one of the covers in the forceps, touch it to the drop of blood and place it upon the second cover-glass eccentrically, with one edge projecting slightly. *Slip* the two covers apart in the plane of their surfaces and dry them quickly by waving them in the air or by passing them rapidly over the tip of a flame. The lower cover-glass will have the better film.

(b) *Fixing the hemoglobin* with (a) ether-alcohol or (b) heat.

§ 122. **Fixing with ether-alcohol.** When the blood films on the covers are dry, place them in ether-alcohol (equal parts) for $\frac{1}{2}$ -1 or several hours. Let them fix for a longer rather than a shorter time, as the quality of the stain (with triacid mixture) will be improved. After they have fixed a sufficient time remove and again dry them in the air. They may now be stained, immediately or at convenience.

§ 123. **Fixing with heat.** Place a gas or alcohol flame under the apex of a triangular copper table (or other similar warm table or incubator). When it is well heated determine the region that has a temperature equal to the boiling point of water (100° C) by placing on it drops of water at varying distances from the flame. Just *within* the point so determined (nearer the flame) place the covers bearing the dried film of blood, film side down upon the copper plate. Leave them for 15-30 minutes or longer. When the covers have cooled they are ready to be stained.

(c) *Staining* with (a) Eosin and Hematoxylin, (b) Ehrlich's Triacid Mixture, or (c) Methylene Blue.

§ 124. **Eosin and hematoxylin.** Stain the fixed blood films for 2-3 minutes with a $\frac{1}{2}\%$ aqueous solution of eosin, rinse with water and stain for 10-15 minutes with hematoxylin, rinse again with distilled water and allow the film to dry. When dry, warm the cover gently to remove the last traces of moisture and mount in balsam. This gives a good general stain of the blood corpuscles, both red and white. Red corpuscles will be stained red or pink, the nuclei of the white corpuscles will be blue, and their cell bodies but faintly stained; eosinophile granules, a bright pink.

§ 125. **Ehrlich's triacid mixture** (§ 93). Place a drop or two of the mixture upon the film side of the cover. Stain for 10-15 minutes, rinse in distilled water, dry, and mount in balsam.

If the stain is successful, red corpuscles will be orange-yellow, nuclei of white corpuscles, blue, cell bodies, pale pink, eosinophile granules, copper red. This stain is used a great deal in the clinical examination of blood and is a valuable one. Should the red corpuscles be colored red instead of orange-yellow, it means that the fixation has been insufficient; if ether-alcohol was used for fixing, the time was too short; if heat was employed, the degree of heat was insufficient or the time too short. The right time of fixation and staining must be, in many cases, determined by experiment.

§ 126. **Methylene blue.** *Formula:* Methylene blue, saturated alcoholic solution, 1 part; distilled water, 2 parts.

This is for staining "basophile" granules in mast cells. Preparations fixed by heat or ether-alcohol are stained 15 minutes or so, washed with water, dried, and mounted in balsam. Nuclei and basophile granules stain blue; all else is colorless, or nearly so. This stain has but little value in the study of normal blood, since basophile leucocytes are of rare occurrence.

FINE INJECTION.

For the purpose of examining microscopically the finer arteries and veins and the capillaries in a tissue, and their relation to the other parts, it is necessary to fill them with some colored injection mass, or otherwise stain or color them. The masses employed for the fine injection of tissue in this course are Carmine Gelatin Mass (red) and Berlin Blue Gelatin Mass.

§ 127. **Carmine gelatin mass.** *Formula:* Dry gelatin, 75 grams; carmine (No. 40), 10 grams water, 90 c.c.; ammonia, 10 c.c.; acetic acid, *q. s.*; chloral hydrate, 10 grams.

Soak the gelatin in water until it is soft; pour off the superfluous water and melt it (in an agate or porcelain dish) over a water bath. Grind the carmine to a paste with water; add all the ammonia and water; filter, warm to 80° or 90° C., and add to the warm gelatin. Then add slowly the acetic acid diluted with an equal volume of water, while constantly stirring the mass, until the mass smells very slightly of the acid. Filter through fine flannel. If the mass is acid, the chloral hydrate may be safely added (as a preservative); if any ammonia is present it will decompose it forming chloroform and a granular precipitate. If too much acid is added, the gelatin will not set.

§ 128. **Berlin blue injection mass.** *Formula:* Dry gelatin, 75 grams; saturated aqueous solution of Berlin blue, 150 c.c. chloral hydrate, 10 grams. Prepare the gelatin in the manner given above (§ 127); warm the Berlin blue solution (to 80° or 90° C.), and add it to the hot gelatin. Heat the mixture for 10 minutes or more, stirring it occasionally, and filter it through fine flannel and add the chloral hydrate.

§ 129. For securing the best results in injecting the following conditions should be observed: (1) A young but nearly mature, lean animal is to be preferred. (2) Kill the animal with an anesthetic (chloroform) and leave it in the anesthetic at least half an hour before beginning the injection; do not, however, wait until *rigor mortis* sets in. (3) Inject only the part desired, tying all anastomosing vessels and all vessels to other parts. Inject into the artery of the part, leaving the vein open until nearly pure injection mass escapes, then tie it and continue the injection until the part feels hard and is the color of the injection mass. (4) When the injection is finished cool the part injected by means of cold water, ice, or snow.

(5) *Harden* the injected tissue 1 or 2 days in 50% alcohol, 2 or 3 days in 67% and 82% alcohols. The acidity of the alcohols should be insured by adding to the 50% alcohol a few drops of acetic acid. The tissue may be stored in 82% alcohol until ready for sectioning. For sectioning the collodion method is usually preferable.

§ 130. **Silvering blood vessels.** Silver nitrate may be used for coloring blood vessels, and thus differentiating them. See § 147.

CALCIFIED STRUCTURES,—BONE AND TOOTH.

(A). *Decalcification.*

§ 131. For the purpose of investigating the soft structures of tissues containing lime salts, such as bone, teeth, and calcified cartilage, it is necessary to remove the lime salts before sections can be prepared in the usual way by a process known as *decalcification*. Solutions of a large number of acids, combined or uncombined with other substances, may be used as decalcifiers. Very satisfactory are: (1) nitric acid, 3 c.c.; 70% (67%) alcohol, 97 c.c., and (2) nitric acid, 5 c.c.; saturated aqueous solution of (potash) alum, 50 c.c.; water, 50 c.c. In the first formula the alcohol, in the second the alum acts as a restrainer of the nitric acid. The first of these formulas is, perhaps, better for bone; the second has a more rapid action and is possibly a better decalcifier for teeth.

§ 132. **Directions for use.** The tissue to be decalcified must be first thoroughly fixed and hardened by one of the approved methods,—picric alcohol is quite satisfactory,—and should be in

82% alcohol. In fixing, structures not needed should be removed,—muscles trimmed away from the bone, etc. Bones or teeth should be opened with nippers or a saw, so that the fluid may reach the marrow or pulp cavity.

Place the hardened tissue in the decalcifier, where it should remain until the lime salts have been entirely removed, as may be ascertained by inserting a fine needle ; if any calcified matter remains there will be a gritty feeling on using the needle. The time necessary for complete decalcification will depend upon the size and density of the calcified tissue, and will vary from 3 to 15 days or longer. The decalcifier should be changed after the first day, and if the tissue is large it is best to change it subsequently two or three times at intervals of two or three days.

When decalcification is complete rinse the tissue well in water for a few minutes and place it in 67% alcohol for one or two days and then in 82% alcohol for several days, or until ready to imbed. The 82% alcohol should be changed once or twice in order that the nitric acid may be well washed out. Although paraffin in many cases may be employed for imbedding, the collodion method is generally more satisfactory.

Hematoxylin with eosin, hematoxylin with picrofuchsin, and hematoxylin with picrocarmine afford good stains ; by staining thoroughly with hematoxylin a differential staining of bone and cartilage may be obtained.

(B). *Sections of Dry Bone or Tooth.*

§ 133. Though the general structure of bone and teeth is shown moderately well when the tissue has been decalcified (§ 131), the Haversian canals, canaliculi and lacunae of bone and the dentinal tubules of the teeth are shown much better in sections of dried, non-decalcified tissue, rendered sufficiently thin for microscopic examination by grinding or filing.

§ 134. **Directions for procedure.** Prepare thin transverse sections of dried bone in accordance with the directions below. Longitudinal (radial) sections and tangential (surface) sections may also be prepared in the same manner, the former to show the Haversian canals and their anasomoses, the latter to indicate the shape of the lacunae as seen in a different plane.

1. *Sawing the section.* Make an exact transection of a part of the shaft of a long bone. The section should be about 1 cm. long and include the thickness of the shaft from the surface to the medullary cavity. Make the sections about 1 mm. thick.

2. *Grinding the sections.* Place the piece of bone on a cork or piece of soft wood and wet it with water. File it on one side until smooth and then turn it over. Continue the filing till the piece is from .05 to .10 mm. thick, using the cover-glass measurer to determine the thickness. In the beginning one can press quite hard in filing; as the section thins, more care should be exercised and the pressure should lessen.

3. *Washing and drying the section.* When the section is thin enough, rinse it and dry it with lens paper.

4. *Mounting the sections in hard balsam.* To prepare the balsam, put two or three large drops on the middle of a slide and heat the slide in some way to drive off the volatile constituents. Do not heat the balsam hot enough to produce bubbles. When the balsam chips after cooling, it is ready for use.

In mounting, have the section and a clean cover so placed that they may be easily and quickly grasped. A cork somewhat smaller than the cover-glass should be within reach, and also a stone or piece of glass upon which to quickly cool the specimen as soon as it is mounted.

Heat the slide until the balsam is well melted. Put the slide upon a piece of paper, grasp the piece of bone with the forceps and plunge it into the melted balsam; put on the cover as quickly as possible and press it down with the cork; finally put the slide on the stone or glass to cool the balsam quickly. All of this should be done as rapidly as possible, and if done rapidly, the air will be retained in the lacunae and canaliculi, and cause them to stand out as black spots and lines. If soft balsam were used it would soon drive out the air, and being of nearly the refractive index of bone, it would obliterate the lacunae and canaliculi. Further, if the hot balsam were not *cooled quickly*, the air would be driven out and balsam would take its place in the spaces.

CENTRAL NERVOUS SYSTEM.

§ 135. There are two special groups of methods employed in the microscopical examination of the central nervous system, (*a*)

Weigert Hematoxylin Methods, for differentiating myelinic nerve tracts, and (b) the *Chrome-silver Impregnation Methods*, to bring out the form of the cells and differentiate the amyelinic nerve-fibers.

These have their greatest value when used in conjunction with more general staining methods, which supplement the first and give a basis for the correct interpretation of the appearances produced by the second method. In addition, there are other stains helpful in bringing out the finer structure of the cells.

§ 136. **The Weigert hematoxylin methods.** These methods all involve (a) mordanting the tissue with a chromium or copper salt, (b) staining (over-staining) with a strong hematoxylin stain, and (c) decolorizing (differentiating) the sections in a bleacher until the myelinic fibers are blue, all else (except blood) white to brown.

§ 137. The following method is serviceable: Harden the tissue in a 3% aqueous solution of potassium dichromate for about 2 weeks, and in a 5% aqueous solution for an equal period (§ 31). Imbed in collodion; paraffin may be used if the piece of tissue is small. The sections should not be thicker than 25μ . Wash the sections in water (§§ 68-70) and (a) *Mordant* them 1-12 hours in a half-saturated aqueous solution of copper acetate; rinse them well in water and (b) *Stain* them for 1-24 hours (until black) in Weigert's hematoxylin (§ 83); rinse well in water and (c) *Differentiate* in the Weigert's bleacher (Formula: Water, 200 c. c.; borax, 2 grams; potassium ferricyanide, 2.5 grams). Watch the differentiation carefully and when the cinerea has become a golden brown and the myelinic fibers a rich blue, stop the action and wash the sections in water, running or changed several times, for at least $\frac{1}{2}$ hour. Dehydrate, clear, and mount in alkaline balsam (best) (§ 158). If the specimens are to be left for some time before mounting, place them in 95% alcohol with sodium carbonate added to render it alkaline.

§ 138. **Pal's method** may be used if it is desired to stain the nerve cells subsequently.

Harden the tissue thoroughly in solutions of potassium dichromate (3% solution, 2 weeks; 5%, 2 weeks or so). Imbed in collodion (paraffin, if the sections are small). Stain the sections in Weigert's hematoxylin (§ 83) until a blue black; rinse in tap-water.

Treat for a *short time*—20–30 seconds—with a $\frac{1}{4}\%$ aqueous solution of potassium permanganate and *decolorize* in Pal's bleacher until the cinerea is grey (white), the myelinic fibers blue. The action will be very rapid and must be carefully watched; a few seconds will suffice. Wash the sections thoroughly ($\frac{1}{2}$ hour or more) in running water. If it is desired, counter-stain with a red stain,—eosin, erythrosin or carmine.

This method is not as reliable as the method first given; great care must be exercised in the differentiation with the bleacher.

§ 139. **Chrome-silver impregnation methods.** In this group of methods the tissue is *hardened* a certain length of time in a fluid containing a chrome salt, especially potassium dichromate, and then placed in an aqueous solution of silver nitrate ($\frac{1}{4}\%$ and $\frac{3}{4}\%$ solutions generally employed). If successful, the cells and their processes, amyelinic and, to a certain extent, myelinic nerve fibers, are outlined by a black precipitate (black by transmitted light; brown by reflected light).

§ 140. *Success depends on (a) the kind of animal; different parts and tissues react more satisfactorily in some animals or classes of animals than in others. (b) The age of the animal; young or fetal animals give better results than do adults. (c) The time of hardening; it is necessary that the tissue be hardened a certain length of time, constant (relatively) for a certain kind of tissue under the conditions above (a and b). It is necessary that the correct degree of hardening be carefully regulated. (d) Different organs and regions of the central nervous system vary greatly in the ease with which they can be made to furnish satisfactory impregnations. Almost certain impregnations of hippocamp can be gained; cerebral cortex is likewise quite easy to stain. With the olfactory bulb the action is not constant though fairly complete. The optic lobes and retina of birds and large reptiles are more satisfactory than those of mammals. The myel (spinal cord) of embryo birds (7–14 day chick best) is generally more satisfactory than that of mammals; in any case, fetal or new-born animals should be employed. Difficult are satisfactory impregnations of sympathetic ganglia, organs of special sense and the intrinsic nerves of the viscera.*

§ 141. **Golgi's Rapid Method.** This is the most generally serviceable of the different methods.

§ 142. *Directions for use.* Tissue of a (preferably) young animal is placed in a mixture of 4 parts of 3% potassium dichromate and 1 part of 1% osmic acid. The amount of the fluid should be at least twenty times the bulk of the tissue and should be changed as soon as it grows turbid or loses the strong characteristic odor of the osmic acid.

After the hardening has proceeded to the right degree (§ 143), rinse the tissue in water for about 5 minutes and place for 15 minutes in a $\frac{1}{4}$ % solution of silver nitrate, and then for 2 or more days in a $\frac{3}{4}$ % solution of silver nitrate, preferably keeping it in the dark.

Without washing, imbed rapidly in collodion as follows :

(a) Dehydrate 2-3 hours in 95% alcohol, changed two or three times ; (b) place in thin collodion for 20 minutes, in thick collodion for 20-30 minutes ; (c) imbed in thick collodion, on a cork or block of wood (best ; § 55, a) ; (d) harden the mass in chloroform for 20-30 minutes, and (e) place the block in clarifier and cut, sections being 50-100 μ thick, according to the nature of the tissue and the character of the impregnation.

(f) Place the sections in 95% alcohol for a few minutes ; clear in carbol-xylene and mount in balsam by placing the section on the slide, absorbing the clearer *thoroughly* by means of tissue paper and spreading over it thick xylene balsam. Do not cover. Later, when the balsam has hardened somewhat, it may be melted by heat and much of the superfluous balsam drained from the section and scraped away with a knife.

§ 143. *Time of hardening.* The following periods will probably be found approximately correct. In general : The best results are to be obtained with kittens 3-20 days old, puppies 2 weeks old, rats 8-10 days, rabbits 8 days. (a) For cerebral cortex (and hippocamp) : New-born kitten, 1-2 days ; kitten half grown (3-4 months), 3-4 days ; new-born rabbit, 24 hours ; rabbit one month old, 2-3 days, etc.

(b) For spinal cord : Chick of 5-6 days' incubation, 24 hours ; chick, 14-15 days' incubation, 3 days ; new-born kitten or puppy, 2-3 days.

(c) Cerebellum : New-born kitten, 1-2 days ; kitten half grown, 4 days.

§ 144. **Methylene blue.** Imbed in paraffin tissue that has been hardened in 95% alcohol ; cut sections rather thick, 15-20 μ ,

or even thicker. Fasten the sections to the slide or carry them through in watch-glasses. Stain the sections in a .5% aqueous solution of methylene blue for 5-10 minutes, heating it until it steams; rinse in water and dehydrate, clear in oil of origanum or cajuput, and mount in balsam. The nerve cells and nuclei will be stained blue, all else colorless. In the cell bodies the corpuscles of Nissl will be stained. Should the stain be not selective enough, differentiate for a few seconds before dehydrating with a mixture of aniline oil, 1 part, 95% alcohol, 9 parts.

§ 145. **General methods.** vom Rath's and Zenker's fluids are recommended for the fixation of nervous tissue; either paraffin or collodion may be used in imbedding; Delafield's hematoxylin with picrofuchsin (strong formula, *b*) as counter-stain is recommended for staining, though other hematoxylin may be used as well.

SILVER NITRATE IMPREGNATIONS.

§ 146. The preparations stained by means of nitrate of silver were prepared as follows: The *fresh* tissue was washed well for a minute or so in distilled water to remove from the surface all albuminous substance, and then transferred for 2-5 minutes or longer to a $\frac{1}{2}\%$ aqueous solution of silver nitrate; it was again rinsed in water and in it exposed to direct sunlight until a light brown. When, by examination with the microscope, the stain was found to be sufficient it was again rinsed in water and placed in glycerin or alcohol. Employed in this manner with fresh tissue, silver nitrate stains the cell cement, affording thus negative images of the cells.

§ 147. **Silvering Vascular Epithelium.** In order that the vascular epithelium of small arteries, veins, and capillaries should be well demonstrated, silver nitrate solutions of $\frac{1}{4}$ to $\frac{1}{2}\%$ strength must be injected into the vessels.

§ 148. *Procedure.* Connect a canula with the artery supplying the alimentary canal (superior mesenteric) or the brain (carotid) and inject distilled water until the water flows out of the returning vein colorless. Then immediately inject the silver solution until it runs from the vein. After a minute or two follow with distilled water. Place the intestines and mesentery in water and expose them to the light until they become slightly browned. Strips of the muscular coat of the intestines, especially of the rabbit, will show

capillaries well. Veins and arteries side by side may be found in the mesentery. If the brain vessels are injected one can get admirable preparations showing nuclei as well as cell outline by staining in hematoxylin. Mount in glycerin, or, if desired, dehydrate and mount in balsam. The tissue may be kept in 50% alcohol or in 50% glycerin for several months before mounting if it is kept in the dark.

For large vessels and endocardial epithelium open the vessels or the heart and silver as directed above for mesentery. It may be necessary to make thin free-hand sections so that the preparation will be thin enough for high powers.

FORMULAS.

In addition to those given elsewhere; see also *The Microscope*, 7th ed., §§ 297-316.

§ 149. *Acid alcohol*. 95% alcohol, 100 c.c.; hydrochloric acid, $\frac{1}{10}$ c.c. For Hcl carmine, use 95% alcohol, 100 c.c.; hydrochloric acid, $\frac{1}{2}$ c.c.

§ 150. *Alcohol*. (1) 67%. Take 95% alcohol, 2 parts; water, 1 part.
(2) 82%. Take 95% alcohol, 5 parts; water, 1 part.

§ 151. *Clarifier*. (Castor-xylene). Castor oil, 1 part; xylene, 3 parts.

§ 152. *Clearer*. (Carbol-xylene). Melted carbolic acid crystals, 1 part (by volume); xylene, 3 parts.

§ 153. *Normal salt solution*. NaCl. (common salt), .6 gram; distilled water, 100 c.c.

§ 154. *Collodion*. (1) *Thick collodion*, 8% solution. Ether-alcohol, 100 c.c.; soluble cotton, 8 grams. (2) 6% solution. Ether-alcohol, 100 c.c.; soluble cotton, 6 grams. (3) *Thin collodion*, $1\frac{1}{2}\%$, ether-alcohol, 100 c.c.; soluble cotton, $1\frac{1}{2}$ grams.

§ 155. *Ether-alcohol*. Sulphuric ether, 1 part; 95% alcohol, 1 part.

§ 156. *Glycerin, eosin and alum carmine*. Glycerin, 85 c.c.; alum carmine, $7\frac{1}{2}$ c.c.; $\frac{1}{2}\%$ aq. sol. eosin, $7\frac{1}{2}$ c.c.

§ 157. *Lampblack mixture*. Lampblack, 1 gram; gum arabic, 1 gram; common salt, $\frac{1}{10}$ gram; water, 20 c.c.

§ 158. *Neutral (alkaline) balsam*. Canada balsam is liable to be slightly acid. This is of advantage for mounting sections stained with carmine or with acid fuchsin (as when picro-fuchsin is used), and for injected preparations where carmine or Berlin blue is used as the coloring matter. For hematoxylin and other stains easily affected by acid media it is often advantageous to use neutral or slightly alkaline balsam as a mounting medium. To obtain this slightly alkaline balsam, add some pure sodium carbonate to the thin xylene balsam and shake thoroughly at intervals for a day or so. Allow the balsam to stand until the soda has settled, then decant and thicken by evaporation till of the desired consistency. (*The Microscope*, 7th ed., p. 176, § 300).

