




3 1761 06705823 0





Digitized by the Internet Archive
in 2007 with funding from
Microsoft Corporation





MP
G

Guy's Hospital. Museum

DESCRIPTIVE CATALOGUE
OF THE
PATHOLOGICAL SPECIMENS
CONTAINED IN
THE MUSEUM
OF
GUY'S HOSPITAL.
THIRD EDITION.

VOLUME I.
MORBID CONDITIONS OF THE RESPIRATORY
ORGANS AND ALIMENTARY TRACT.

BY

52191
1901

LAURISTON E. SHAW, M.D. (LOND.), F.R.C.P.,
ASSISTANT PHYSICIAN AND CURATOR OF THE MUSEUM,

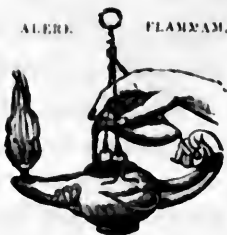AND

E. COOPER PERRY, M.A., M.D. (CANTAB.), F.R.C.P.,
ASSISTANT PHYSICIAN AND DEMONSTRATOR OF MORBID ANATOMY.

LONDON :
J. & A. CHURCHILL,
11, NEW BURLINGTON STREET.
MDCCCXCIV.

ALERE.

FLAMMAM.



PRINTED BY TAYLOR AND FRANCIS,
RED LION COURT, FLEET STREET.

P R E F A C E .

THE first printed Catalogue of the Pathological Specimens contained in the Museum of Guy's Hospital was arranged and edited by Dr. Hodgkin, and was published in 1829. The second edition, published in seven parts between the years 1857 and 1863, was the work of Dr. Wilks and of the late Dr. Habershon. The present volume, the first instalment of the third edition, has been written by Dr. Perry and Dr. Shaw, and is published in pursuance of a resolution of the Medical School, and with the sanction of the Treasurer and Governors of the Hospital.

In introducing this volume the writers desire to express as fully as possible their sense of obligation to previous editors, and to those who since the publication of the last Catalogue have successively acted as curators of the Museum: Dr. Hilton Fagge, Dr. Goodhart, Dr. Carrington, Dr. Newton Pitt, and Mr. J. H. Targett, M.S. At the same time, to make clear their own responsibilities, they must add that the greater number of preparations described in this volume have been submitted to further examination and dissection before being remounted, and the descriptions given of them have almost in every case been rewritten upon a uniform plan. All references to post-mortem inspections have been verified; and in the belief that the study of a pathological specimen is made at once more interesting and of more practical utility when combined with a study of the history during life of the

case from which the preparation has been derived, clinical accounts have wherever possible been appended to the descriptions of the specimens, and where they were already given in the old Catalogue they have in many cases been amplified.

The progress of knowledge in the department of morbid histology during the thirty years that have elapsed since the publication of the last Catalogue has rendered it necessary to submit a very large number of preparations to microscopical examination in order to bring the work into conformity with modern views. In determining the nature of the histological changes thus demonstrated the Editors desire to acknowledge with sincere thanks the advantage they have gained from consultation with Mr. J. H. Targett, Pathological Curator of the Museum of the Royal College of Surgeons of England.

GUY'S HOSPITAL,

August 10th, 1894.

T A B L E
OF THE
CONTENTS OF THE FIRST VOLUME.

	Page	Number
Section I.		
INJURIES AND DISEASES OF } THE LARYNX }	1	1 to 89
Section II.		
DISEASES OF THE THYROID } GLAND }	29	90 to 124
Section III.		
DISEASES OF THE THYMUS } GLAND }	41	125 to 128
Section IV.		
INJURIES AND DISEASES OF } THE TRACHEA }	43	129 to 172
Section V.		
INJURIES AND DISEASES OF } THE BRONCHIAL TUBES . }	58	173 to 212

	Page	Number
Section VI.		
INJURIES AND DISEASES OF } THE LUNG }	72	213 to 344
Section VII.		
INJURIES AND DISEASES OF } THE PLEURA }	115	345 to 397
Section VIII.		
INJURIES AND DISEASES OF } THE DIAPHRAGM AND } MEDIASTINUM }	131	398 to 414
Section IX.		
DISEASES OF THE LIPS AND } MOUTH }	139	415 to 424
Section X.		
DISEASES OF THE SALIVARY } GLANDS }	142	425 to 436
Section XI.		
DISEASES OF THE GUMS. . .	146	437 to 443
Section XII.		
INJURIES AND DISEASES OF } THE TONGUE }	148	444 to 470
Section XIII.		
DISEASES OF THE TONSILS, } PALATE, AND FAUCES . }	159	471 to 498

TABLE OF CONTENTS.

vii

	Page	Number
Section XIV.		
INJURIES AND DISEASES OF } THE PHARYNX }	168	499 to 526
Section XV.		
INJURIES AND DISEASES OF } THE ŒSOPHAGUS }	179	527 to 584
Section XVI.		
INJURIES AND DISEASES OF } THE STOMACH }	203	585 to 725
Section XVII.		
INJURIES AND DISEASES OF } THE DUODENUM }	262	726 to 759
Section XVIII.		
INJURIES AND DISEASES OF } THE INTESTINE (EXCLUD- } ING DUODENUM, CÆCAL } APPENDIX, AND RECTUM). }	276	760 to 952
Section XIX.		
DISEASES OF THE CÆCAL } APPENDIX }	351	953 to 973
Section XX.		
INJURIES AND DISEASES OF } THE RECTUM AND ANUS . }	359	974 to 1039

	Page	Number
Section XXI.		
FOREIGN BODIES AND CONCRE- TIONS FROM THE INTESTINE }	382	1042 to 1059
Section XXII.		
INTESTINAL OBSTRUCTION (EX- CLUDING STRICTURES AND EXTERNAL HERNIÆ) . . }	387	1060 to 1110
Section XXIII.		
THE ANATOMY AND RESULTS } OF HERNIA }	406	1111 to 1191
Section XXIV.		
INJURIES AND DISEASES OF } THE PERITONEUM . . . }	434	1192 to 1245

SECTION I.—INJURIES AND DISEASES OF THE LARYNX.

- Congenital Malformation : 1.
- Eversion of Sacculus : 2.
- Injuries : 3-10.
- Foreign Bodies : 11-14.
- Œdema : 15-17.
- Membranous Inflammation and Diphtheria : 17-27.
- Ulceration : 28-33.
- Phlegmonous Inflammation : 33, 34.
- Necrosis of Cartilages : 35-43, 56.
- Syphilis : 44-51.
- Tubercle : 52-56, 61.
- Lupus : 57.
- Leprosy : 58-61.
- Variola : 62, 63.
- Typhoid : 64, 65.
- Xanthoma : 66.
- Atrophy of Muscles : 67, 68.
- Fixation of Joints : 69.
- Papilloma : 70-74.
- Fibroma : 75.
- Polypus : 76.
- Carcinoma : 77.
- Epithelioma : 78-86.
- Sarcoma : 87, 88.
- Cyst : 89.

1 **Congenital Adhesion of the Vocal Cords.**

A larynx mounted to shew the rima glottidis converted into a small oval opening one eighth of an inch in its longer diameter, situated at the hinder part of the vocal

cords, the anterior extremities of which are adherent to each other by a smooth fibrous band.

Herbert H., æt. 9 months, was admitted under Dr. Goodhart for laryngeal dyspnoea, from which he died during the operation of tracheotomy. The child had been feeble from his birth, and had never "cried properly." At the autopsy the soft palate was found to be cleft. *See Insp.* 1892, No. 222.

2 Eversion of a Sacculus Laryngis.

A larynx shewing the left sacculus everted. It could be replaced.

Philip S., a school-master, æt. 45. He died of carcinoma of the stomach, and presented no laryngeal symptoms during life. *See Trans. Path. Soc.* 1868, p. 65; and *Prep.* 712.

3 Fracture of the superior cornua of the Thyroid Cartilage.

A skeleton of a larynx, from the thyroid cartilage of which both superior cornua have been fractured. The fragments are suspended above their normal position. *See Trans. Path. Soc.* vol. 36, p. 82.

Presented by Mr. Arbuthnot Lane.

4 Fractures of the Larynx.

The hyoid bone with the thyroid and cricoid cartilages, from which the soft parts have been removed. The hyoid bone is fractured just below the right lesser cornu. Both superior cornua of the thyroid are fractured at their bases, and on the left side there is a second fracture running from the middle of the posterior border of the ala to the angle formed between its upper border and the superior cornu. In front is a vertical fracture running downwards from the notch, and separating the two alæ. The cricoid cartilage is fractured on the right side towards the front.

From William K., æt. 42, who was "garrotted," and twenty minutes afterwards was brought into the hospital dead. At the

autopsy a small bruise was found on the right side of the larynx, and there were a few petechiæ on the scalp and forehead. The lungs presented on their surface "silvery patches of emphysema." See *Insp.* 1892, No. 361; and *Guy's Hosp. Rep.* 1892, p. 105.

5 **Cut Throat.**

A larynx and trachea shewing a transverse incision dividing the thyro-hyoid membrane and the base of the epiglottis. There is considerable œdema of the glottis. The blue rod indicates a tracheotomy wound.

Richard N., æt. 47, was admitted under Mr. Poland with a cut throat. He did well for a few days, but afterwards urgent dyspnoea came on, and tracheotomy had to be performed. He died from broncho-pneumonia five days after the injury, which was self-inflicted. See *Insp.* 1869, No. 56.

6 **Cut Throat.**

A pharynx, tongue, and larynx shewing a large opening below and parallel to the hyoid bone. The upper edge of the thyroid cartilage is divided, and the pharynx laid open.

Richard L., æt. 60, was admitted under Mr. Key with a cut throat. He died fifty-three days after the injury, which was self-inflicted. At the autopsy gangrene of the lung was found. See *Insp.* vol. 14, p. 68.

7 **Cut Throat. Necrosis of the Thyroid Cartilage.**

A larynx laid open shewing a wound which has divided the left ala of the thyroid cartilage, and penetrated the larynx a little above the left vocal cord. A piece of necrosed cartilage, incompletely severed from the thyroid, is seen projecting into the wound.

Owen E., æt. 67, was admitted under Mr. Durham with his throat cut. There were several loose fragments of thyroid cartilage in the wound. Death resulted from broncho-pneumonia and cirrhosis of the liver five weeks after admission. See *Insp.* 1888, No. 250.

8 Cut Throat.

A larynx shewing a transverse incision through the thyroid cartilage between the true and false vocal cords. There is a second incision through the cricoid cartilage.

William H., æt. 33, was admitted in 1827 under Mr. Key, having cut his throat in two places. He died the day after admission. *See Insp.* vol. 14, p. 4.

9 Cut Throat. Wound of the Internal Jugular Veins.

A larynx and trachea with the œsophagus. There is a transverse incision through the thyroid gland completely dividing the trachea immediately below the cricoid cartilage, and exposing the œsophagus, which is uninjured. Both jugular veins were wounded. The blue rod indicates the left one.

William T., æt. 30, was admitted under Mr. Bransby Cooper in 1830 with his throat cut. He died six days after the injury from hæmorrhage. The wound was self-inflicted. *See Insp.* vol. 15, p. 9; and *Prep.* 1521 (45) [2nd Edit.]

10 Cut Throat.

The anterior part of a neck shewing a gaping wound extending down to the upper part of the trachea, which is divided in front. There is a ligature around the inferior thyroid artery.

From a man who cut his throat, and died from hæmorrhage sixteen days after the infliction of the wound.

11 Old Cut Throat.

A part of the front of the neck with the larynx and œsophagus. The opening in the neck, the edges of which are covered with skin, communicates with the upper part of the trachea, and through it with the œsophagus. Above the situation of the opening the

trachea is impervious, and the œsophagus much contracted.

John S., æt. 28, was admitted under Mr. Key in 1837. He had attempted suicide by cutting his throat several years before admission, and had since taken food by means of a pipe. He died of phthisis. See *Insp.* vol. 36, p. 114; *Drawing* 244 (50); *Preps.* 1076 (85), and 1592 (60) [2nd Edit.].

12 Piece of Meat impacted in the Larynx.

A piece of meat, two inches and three quarters long, is lodged in the pharynx, and its smaller end is wedged into the larynx, which it completely occludes.

Edward W., æt. 41, came out of an eating-house and fell down, apparently in a fit. He was dead when brought to the hospital. See *Insp.* 1887, No. 53.

13 Foreign Body in the Larynx.

A larynx and upper part of the trachea laid open to shew an irregular piece of bone lying in the interior of the larynx, in the position in which it was found at the autopsy. In front there is a tracheotomy wound.

Florence H., æt. 11 months, was admitted under Mr. Cooper Forster for laryngeal obstruction, which had come on suddenly whilst drinking broth. Tracheotomy was performed, and the child died a few hours later. See *Insp.* 1857, No. 39.

14 Foreign body removed by Laryngotomy.

Two portions of cancellous bone, the larger measuring three quarters of an inch in its longest axis, which were firmly impacted below the vocal cords, and were removed by the operation of laryngotomy.

William C., æt. 63, was admitted under Dr. Taylor in 1881 for cough and expectoration with very slight laryngeal stridor. The laryngoscope shewed a fragment of bone fixed within the larynx. Mr. Golding-Bird performed laryngotomy and extracted the foreign body. The bone stuck in the man's throat four months before the operation, and was forced into the larynx by his wife while endeavouring to dislodge it with a table-spoon. He was discharged well a fortnight after its removal. See *Clin. Soc. Trans.* vol. 17, p. 214.

15 Œdema of the Glottis.

A larynx with œdema of the epiglottis and arytaeno-epiglottidean folds. On the anterior wall of the larynx above the vocal cords there are several small superficial ulcers having their edges well defined, and their bases covered with sloughs.

16 Œdema of the Glottis.

A larynx and pharynx shewing extreme œdema of the epiglottis and arytaeno-epiglottidean folds.

Francis J., æt. 20, was admitted under Dr. Back with anasarca of five months' standing. Six weeks before death, his anasarca having left him, pain in the throat, with difficulty of breathing, came on. *See Insp.* vol. 14, p. 77.

17 Œdema of the Glottis.

A larynx and upper part of the trachea shewing considerable œdema of the arytaeno-epiglottidean folds with deformity of the epiglottis due to syphilitic contraction.

From a patient who was admitted with slight ulceration of the fauces, and while in the hospital was seized with dyspnoea, and died in three days.

18 Membranous Laryngitis from a Scald.

A larynx and upper part of the trachea shewing œdema of the glottis, with shreds of membrane upon the under surface of the epiglottis. The blue rod indicates a tracheotomy wound.

William C., æt. 5, drank from a kettle of boiling water, and twenty hours later was tracheotomised by Mr. Birkett for laryngeal obstruction. He died the following day. *See Insp.* 1862, No. 23.

19 Membranous Laryngitis from a Scald.

A larynx and upper part of the trachea shewing extensive destruction of the epiglottis, which is almost

separated from its basal attachment. There is a shreddy membrane on the interior of the larynx.

William B., æt. 18 months, was admitted under Mr. Davies-Colley, having drunk at the spout of a kettle a few hours previously. The fauces were scarified, but the child died a few days later from broncho-pneumonia. A membranous exudation was also found in the œsophagus. *See Insp.* 1882, No. 37; and *Trans. Path. Soc.* vol. 33, p. 34.

20 Membranous Laryngitis.

A larynx and part of the trachea shewing adherent false membrane.

Maria L., æt. 5, was admitted under Dr. Addison for urgent dyspnoea following upon a chronic cough. She died the day after admission.

21 Membranous Laryngitis.

A larynx and upper part of the trachea shewing a thick adherent false membrane.

From an infant who died thirty-six hours from the commencement of her illness.

Presented by Mr. Hardy.

22 Membranous Laryngitis.

A larynx and upper part of the trachea with adherent false membrane.

23 Membranous Laryngitis.

A larynx and upper part of the trachea. The mucous membrane is covered with a thin shreddy pellicle; and there is œdema of the arytaeno-epiglottidean folds.

Matilda S., a sempstress, æt. 17, was admitted under Dr. Barlow for urgent dyspnoea of six days' duration, and died the next day. She had suffered from convulsions for six weeks, and her kidneys were found to be contracted and degenerated, one ureter being much dilated. There was no anasarca. *See Insp.* 1854, No. 35.

24 Membranous Laryngitis following Measles.

A larynx and upper part of the trachea, the mucous membrane of which is covered by a thin layer of adherent false membrane.

Ethel C., æt. 2, was admitted under Dr. Hale White for laryngeal obstruction, the symptoms of which were first noticed five days after the appearance of the rash of measles. She died rather suddenly forty-eight hours after the onset of the obstruction. *See Insp.* 1890, No. 398.

25 Faucial and Laryngeal Diphtheria.

A larynx and part of the pharynx. The tonsils, pharynx, epiglottis, and interior of the larynx are covered with false membrane.

George S., æt. 16, was admitted under Mr. Cock for spinal caries. He contracted diphtheria in the ward, and died in a few days. The membrane did not extend below the cricoid cartilage. *See Insp.* 1862, No. 79.

26 Faucial and Laryngeal Diphtheria.

A larynx and part of the pharynx shewing adherent false membrane. There is a small excavated ulcer below the left vocal cord, and a tracheotomy wound.

Rosaline P., æt. 4, was admitted under Dr. Pye-Smith for a croupy cough of two days' duration, with membrane on the fauces, and albuminuria. Tracheotomy was performed on the evening of admission. She died three days later. False membrane was found covering some small ulcers in the stomach. *See Insp.* 1872, No. 192.

27 Faucial and Laryngeal Diphtheria.

A larynx and upper part of the trachea affected with tuberculous ulceration. The mucous membrane is covered in parts with a dense false membrane.

Emily N., æt. 22, was admitted under Dr. Addison for general tuberculosis, following pulpy disease of the ankle joint. Symptoms of acute laryngitis appeared a few hours before death. *See Insp.* 1857, No. 222.

28 Ulceration of the Larynx and Fauces.

A larynx with a portion of the pharynx and tongue mounted to shew extensive ulceration of the interior of the larynx above the vocal cords, which has in great part destroyed the arytaeno-epiglottidean folds. On the left wall of the pharynx there is a patch of more superficial ulceration.

John D., æt. 12 months, was admitted under Dr. Taylor for dyspnœa and a cough of two days' duration, with the physical signs of broncho-pneumonia. He died six days after admission, and at the autopsy there were numerous hepatised patches in both lungs, and recent lymph upon the pleura. *See Insp.* 1890, No. 167.

29 Ulceration of the Larynx.

A larynx and part of the trachea shewing a deep circular ulcer behind and below the left vocal cord. There is a linear ulcer between this excavation and the posterior end of the cord.

George H., æt. 56, died from gangrene of the extremities following degeneration of the arteries, there being no sign of tubercle, syphilis, or enterica. He was under the care of Dr. Habershon. *See Insp.* 1866, No. 323.

30 Ulceration of the Larynx.

A larynx and upper part of the trachea laid open to shew severe ulceration of the parts above the vocal cords. Below the cords the ulceration is more superficial. The upper part of the epiglottis is unaffected.

George T., æt. 42, was admitted under Dr. Taylor for symptoms suggesting insular sclerosis. There was a sloughing lymphosarcoma on the back, with sores over the body, and chronic epididymitis. It was thought that in the main the disease was syphilis, and he was treated with iodide of potassium in full doses. There was hoarseness for four weeks before death. *See Insp.* 1883, No. 72; *Trans. Path. Soc.* vol. 34, p. 247; and *Prep.* 1657 (11) [2nd Edit.].

31 Ulceration of the Larynx.

A larynx and fauces with the tongue attached. The fauces are irregularly scarred, and there is a deep ex-

cavation at the base of the tongue. The epiglottis and vocal cords are almost entirely destroyed by ulceration.

Elizabeth A., æt. 36, was admitted under Dr. Bright in 1842. She had been suffering for one year with partial aphonia and constant pain referred to the larynx. There were occasional severe exacerbations with hæmoptysis. She died of phthisis with ulceration of the intestines. There was no history of syphilis. *See Insp.* vol. 32, p. 115.

32 **Ulceration of the Larynx.**

A larynx and upper part of the trachea. There is a deep ulcer between the base of the tongue and the epiglottis, which is swollen and presents on its inner surface a worm-eaten appearance due to numerous small and irregular ulcers. There is superficial ulceration about the vocal cords, and a deep excavation at the posterior attachment of the left vocal cord.

From a woman, æt. 43. The ulceration was supposed to be syphilitic.

Presented by Mr. Bryant.

33 **Phlegmonous Laryngitis.**

A tongue with the larynx attached, in which the epiglottis and rima are thickened by submucous purulent infiltration. *See Drawing No. 237 (50).*

34 **Phlegmonous Laryngitis.**

A larynx and upper part of the trachea. The arytæno-epiglottidean folds are much swollen, especially the left. There was purulent infiltration of their submucous tissue, as well as of that of the pharynx and base of the tongue. The kidney mounted behind is contracted and granular.

Henry B., æt. 27, was admitted under Dr. Habershon for chronic Bright's disease, from which he died in a condition of uræmia. He had sore throat and dyspnœa a few days before death, but no special disease of the larynx was suspected. *See Insp.* 1878, No. 168.

35 Necrosis of the Arytænoid Cartilages with Gangrene of the Lung.

This preparation contains two specimens from the same case. The larynx shews a deep ulcer over each arytænoid cartilage, with superficial linear ulceration of the vocal cords. The right arytænoid cartilage is bare and ossified. The portion of lung shews the lower lobe breaking down into a gangrenous pulp.

George M., æt. 50, was admitted under Dr. Pavy for cough, dyspnœa, and dysphagia of three weeks' duration. Signs of pneumonia developed, and he died exhausted. *See Insp.* 1874, No. 118.

36 Necrosis of an Arytænoid Cartilage.

A larynx shewing two small perforating ulcers over the position of each arytænoid cartilage. The right cartilage is necrosed.

James S., æt. 69, died of carcinoma of the pancreas with jaundice, under the care of Dr. Pye-Smith. He suffered from a very troublesome cough with viscid expectoration. *See Insp.* 1879, No. 267.

37 Necrosis of an Arytænoid Cartilage.

A larynx and part of the trachea opened from the front. The right arytænoid cartilage is necrosed and bare, and there is extensive ulceration around it. The soft parts behind the arytænoïds are much swollen, and form a valve-like projection into the pharynx. Histologically there is no evidence of tubercle or new growth.

Jemima W., æt. 47, was admitted under Mr. Cooper Forster for dysphagia of three years' duration. She had some dyspnœa and bronchitis, and died in her sleep. There was no history or sign of syphilis. *See Insp.* 1873, No. 244.

38 Necrosis of the Thyroid Cartilage.

A larynx shewing the posterior portion of the left ala of the thyroid cartilage ossified and necrosed. A piece of it, an inch and a half in length, is detached. The pharynx is ulcerated.

39 Necrosis of the Thyroid Cartilage.

A larynx with the pharynx opened from behind. The left ala of the thyroid cartilage is necrosed and bare, lying in an abscess cavity, which opens into the pharynx, and has also an external opening through the skin. There is a similar cavity on the right side. *See Note Book, No. 2, p. 44. Presented by Mr. Gibson, 1837.*

40 Abscess of the Larynx with absence of part of the Cricoid Cartilage.

A larynx opened from behind. The incision has gone through a small abscess cavity, which was rather "larger than a pea." Into this cavity are now seen projecting the smooth bluish-white ends of the lateral portions of the cricoid cartilage, the back part of which is deficient.

Hannah D., æt. 18 months, was admitted under Dr. Habershon for diarrhœa and wasting. She had considerable dyspnoea of a "croupy" character. There was no evidence of rickets, syphilis, or tuberculosis. *See Insp. 1874, No. 313.*

41 Necrosis of the Cricoid Cartilage.

A larynx and part of the trachea. A blue rod indicates the cavity, from which the necrosed right half of the cricoid cartilage was removed.

James W., æt. 9, was admitted under Mr. Cooper Forster for laryngeal obstruction, which had come on after an exanthem a few weeks before admission. Tracheotomy was performed, and the child died suddenly during the night some months later, probably from the falling out of the cannula. *See Insp. 1861, No. 47.*

42 Necrosis of the Thyroid Cartilage.

A larynx and part of the trachea shewing necrosis of the right ala of the thyroid cartilage. A suppurating cavity, in which the dead cartilage lay, opens into the pharynx, and also into the larynx between the vocal cords, which are swollen. There is a laryngotomy wound.

John M., æt. 42, was admitted under Mr. Cock. Four years

previously he had a venereal sore and a bubo. Laryngeal symptoms developed three months before death, which was due to gangrenous lobular pneumonia. Urgent dyspnoea necessitated laryngotomy. *See Insp.* 1856, No. 92.

43 Necrosis of the Cricoid Cartilage.

A cricoid cartilage shewing necrosis of a portion of its body with partial separation of the sequestrum.

John C., æt. 25, was brought to the Hospital, and died in the Surgery, having been driving a van a few hours previously. There was a scar of a former chancre, and fibrosis of the testis. The cavity in which the dead cartilage lay contained three drachms of pus. *See Insp.* 1868, No. 73.

44 Syphilitic Laryngitis.

A larynx and upper part of the trachea. The vocal cords and the parts above them are thickened, and the mucous membrane deeply corrugated.

William U., æt. 47, was admitted under Dr. Rees. He died of acute pneumonia supervening upon chronic disease of the lung. At the autopsy one testis was found to be fibroid. *See Insp.* 1871, No. 6.

45 Syphilitic Laryngitis.

A larynx and base of the tongue shewing complete destruction of the epiglottis with cicatrisation of the neighbouring parts.

46 Syphilitic Laryngitis.

A larynx and upper part of the trachea opened from behind. The incision through the cricoid cartilage shews it to be surrounded by a gummatous material, which on the left side has separated the perichondrium. The mucous membrane covering the cricoid cartilage is ulcerated. In front there is an opening left after tracheotomy. The portions of lung and liver mounted behind shew small gummata.

Eliza B., æt. 47, was admitted under Mr. Hilton, having suffered from hoarseness for five weeks and from urgent dyspnoea

for a few days. Tracheotomy was performed, and the patient was able to breathe without a tube. She died with cerebral symptoms a few days later. At the autopsy there were found gummata of the lung and liver, and softening of the brain. See *Insp.* 1866, No. 281; and *Guy's Hosp. Repts.* 1867, p. 357.

47 Syphilitic Laryngitis.

A larynx shewing cicatricial narrowing of its superior aperture with complete destruction of the epiglottis. The interior of the larynx is much ulcerated and scarred, and the left vocal cord is destroyed. There is a superficial ulcer in the trachea. The portion of trachea suspended below the preparation shews a healed tracheotomy wound.

Leonard C., æt. 24, was admitted under Dr. Pye-Smith with a history of sore-throat, hoarseness, and dyspnoea of eighteen months' duration. Tracheotomy was performed two months after admission for the relief of dyspnoea. After some time the wound was allowed to heal. He died six months after admission from gangrene of the lung. There was a smooth-walled cavity at the right apex, but no other evidence of tuberculosis. There was no definite syphilitic history. See *Insp.* 1887, No. 211.

48 Syphilitic Ulceration of the Larynx.

A larynx and upper part of the trachea shewing widespread ulceration, which extends from the base of the epiglottis to about the tenth ring of the trachea. There is little, if any, scarring, and the ulceration in the trachea presents a well-defined circular margin.

From a potman, who died suddenly while drinking in a public-house.

Presented by Dr. Withers Green, 1890.

49 Syphilitic Ulceration of the Larynx.

A larynx laid open from the front to shew deep irregular ulcers with considerable scarring and destruction of the vocal cords.

Elizabeth S., æt. 30, was admitted under Dr. Goodhart in 1888 for aphonia and dysphagia. Six months before her admission she

had been treated in the out-patient department for syphilitic ulceration of the larynx and pharynx. After remaining in the hospital four or five months she was discharged much relieved, but died rather suddenly one week later from laryngeal obstruction. *See Medical Reports*, vol. 108, case 153.

Presented by Dr. Maxwell.

50 Syphilitic Ulceration and Stenosis of the Larynx.

A larynx and upper part of the trachea opened from the front. On the posterior wall of the larynx there is an irregular deeply excavated ulcer with a smooth base. The parts around are thickened and contracted, and there is a pyriform swelling of the arytæno-epiglottidean folds.

Frederick P., æt. 29, was admitted under Mr. Lucas. He contracted syphilis ten years before admission. He had been voiceless for three months, and on admission was suffering from laryngeal obstruction, for which laryngotomy was performed. He died a fortnight later. Syphilitic disease of the skull and abdominal viscera was found at the autopsy. *See Insp.* 1882, No. 98

51 Syphilitic Stenosis of the Larynx.

A larynx and upper part of the trachea shewing partial destruction of the epiglottis with narrowing of the superior aperture of the larynx from swelling of the arytæno-epiglottidean folds.

52 Tuberculous Laryngitis.

A larynx and part of the trachea with a pyriform swelling of the arytæno-epiglottidean folds, and ulceration exposing the arytænoid and cricoid cartilages. The epiglottis is thickened, and its posterior surface is dotted with tubercles and small ulcers. The vocal cords and trachea are thickly beset with ulcers.

William D., æt. 31, was admitted under Dr. Goodhart. Three years before admission he had inflammation of the lungs and pleurisy. Soreness of the throat had existed for three months. He died of phthisis with ulceration of the intestines. *See Insp.* 1887, No. 166.

53 Tuberculous Laryngitis.

A larynx and part of the trachea. There is partial destruction of the upper margin of the epiglottis with ulceration of its under surface. The mucous membrane lining the interior of the larynx is ulcerated throughout. The blue rod indicates a perforation of the right sacculus laryngis.

Daniel McC., æt. 29, was admitted under Dr. Moxon for sore throat and hoarseness of two months' duration. About six months before death he had hæmoptysis and cough. There was a history of gonorrhœa and venereal sores nine years before. He died of phthisis. *See Insp.* 1874, No. 220.

54 Tuberculous Laryngitis.

A larynx and upper part of the trachea. The epiglottis is thickened and recurved so that its upper border is continuous with the thickened arytaeno-epiglottidean folds. The interior of the larynx is extensively ulcerated, and a deep excavation in the middle line above the vocal cords exposes a necrosed portion of the thyroid cartilage.

John A., æt. 32, was admitted under Dr. Wilks with evident signs of phthisis and dysphagia. There had been sore throat and hoarseness for eighteen months. *See Insp.* 1879, No. 377.

55 Tuberculous Laryngitis.

A larynx and upper part of the trachea with its mucous membrane worm-eaten and roughened from tuberculous ulceration. The cartilage of the epiglottis is in parts necrosed. There is a deep ulcer at the posterior extremity of each vocal cord.

Walter J., æt. 26, was admitted under Dr. Pavy. He died of miliary tuberculosis of the lungs and kidneys. There had been hoarseness and dysphagia for about three months. *See Insp.* 1882, No. 244.

56 Tuberculous Laryngitis. Necrosis of the Cricoid Cartilage.

A larynx with part of the trachea opened from the

front. Behind the vocal cords are two deep excavations leading down to necrosed cricoid cartilage. The ary-tæ-noid cartilages have disappeared. There is also destruction of the anterior wall of the pharynx exposing dead cartilage.

William H., æt. 64, was admitted under Dr. Moxon for aphonia, sore throat, and slight hæmoptysis of twelve months' duration. He died of chronic phthisis and recent broncho-pneumonia, tracheotomy having been performed one week before death. *See Insp.* 1879, No. 8.

57 **Lupus of the Larynx and Fauces.**

A larynx with the fauces and a part of the pharynx. The hard and soft palate, the back of the pharynx, and the larynx are extensively thickened and ulcerated. The uvula and part of the soft palate are destroyed.

Mary W., æt. 41, was admitted under Mr. Bryant. The lupus began upon the cheek thirteen years before the patient's death. It had affected the mucous membrane of the mouth for more than six years. The last operation of scraping the ulcerated surface was performed ten days before death, which resulted from chronic phthisis with miliary tuberculosis of the lungs. *See Insp.* 1883, No. 230.

58 **Leptous Laryngitis.**

A larynx laid open, the epiglottis of which is thickened, distorted, and partially destroyed by ulceration. A similar condition of ulceration and thickening affects the ary-tæno-epiglottidean folds and the interior of the larynx. There is a large tracheotomy wound in front, and the mucous membrane of the trachea is covered with recent lymph.

Richard S., æt. 22, was admitted under Dr. Taylor with tubercular leprosy. The face was swollen and covered with dry scaly tubercles, the hands and feet were cedematous, and the limbs and trunk presented numerous ulcers. Tracheotomy was performed on account of urgent dyspnoea. The patient lived in India until he was six years old, the disease first appearing when he was

fourteen. Post mortem the specific bacillus was found in great number in the testes, larynx, skin, and ulnar nerve. *See Disp.* 1888, No. 278; and *Trans. Path. Soc.* vol. 40, p. 307.

59 Leprous Ulceration of the Larynx.

A larynx and upper part of the trachea shewing ulceration of the epiglottis, which is thickened and recurved. There are superficial ulcers below the arytaenoid cartilages. *Presented by Dr. Beavan Rake.*

60 Stenosis of the Larynx from Leprosy.

A larynx and upper part of the trachea shewing narrowing of the superior laryngeal aperture from thickening of the arytaeno-epiglottidean folds and the base of the epiglottis. The rest of the epiglottis has been destroyed by ulceration.

Joseph S., æt. 21, was an inmate of the Trinidad Leper Asylum from the age of nine years. At the time of his death he had been the subject of leprosy for fourteen years. There were ulcerated tubercles on the face, destruction of the nasal bones, and great distortion of the fingers. He died from chronic laryngeal obstruction. Numerous bacilli were found in the larynx and other organs. *See Note Book*, No. 3, p. 7.

Presented by Dr. Beavan Rake.

61 Tuberculous Ulceration of the Larynx in a Leper.

A larynx shewing severe ulceration of its interior surface with complete destruction of the vocal cords. The ulceration extends as high as the middle of the epiglottis, and in front exposes the anterior angle of the thyroid cartilage, the two halves of which have become separated.

James E., a negro, æt. 14, was admitted into the Trinidad Leper Asylum for severe laryngeal symptoms, which had first appeared a year before his admission. He died six months later from tuberculosis of the lungs. Bacilli found in the larynx were thought to be those of tuberculosis. *See Note Book*, No. 3, p. 3.

Presented by Dr. Beavan Rake.

62 Acute Laryngitis complicating Variola.

A larynx and upper part of the trachea affected with acute inflammation. The mucous membrane of the larynx was covered with a delicate false membrane, velvety, and intensely congested.

Francis R., æt. 16, was admitted under Dr. Addison. He died from confluent smallpox on the ninth day of the eruption, with inflammation of the larynx, pharynx, bronchi, and with pleuro-pneumonia. *See Insp.* 1854, No. 204; and *Drawing* No. 246 (26).

63 Variolous Ulceration of the Larynx and Trachea.

A larynx and trachea shewing numerous small superficial ulcers with swollen edges.

From a patient who died in one of the smallpox hospitals.

Presented by Dr. Bingham, 1879.

64 Typhoid Ulceration of the Larynx.

A larynx and upper part of the trachea shewing two small deep excavations below the posterior attachments of the vocal cords. The piece of intestine mounted behind shews typhoid ulceration.

Henry B., æt. 21, was admitted under Dr. Addison for typhoid fever, and died at the end of the second week of the disease. No laryngeal symptoms were noted. *See Insp.* 1859, No. 162.

65 Typhoid Ulceration of the Larynx.

A larynx and upper part of the trachea shewing a deep excavation at the posterior attachments of each vocal cord. There is also some superficial ulceration of the interior of the larynx. The blue rod on the left indicates the connection between the ulcer and the cellular tissue outside the larynx. The piece of intestine suspended behind shews typhoid ulceration.

Ferdinando B., æt. 10, was admitted under Dr. Addison with

typhoid fever. In the second week of his illness he became affected with general cellular emphysema, starting about the neck. He was unable to swallow, and died a week later. There was no tuberculosis. *See Insp.* 1857, No. 191.

66 **Larynx and Trachea affected by Xanthoma.**

A larynx and upper part of the trachea, shewing extensive ulceration of the base of the epiglottis and the upper part of the larynx; below this there are numerous yellowish patches, while still lower the patches are less numerous, and have a circular form with a diameter varying from a line to an eighth of an inch, with a depressed centre from superficial ulceration. Between the tracheal rings are yellow bands encircling the trachea. Behind is mounted a portion of the heart shewing yellow patches in the endocardium of the left auricle.

Louisa L., æt. 43, died from hæmatemesis and cirrhosis of the liver. She had suffered from jaundice continuously for seven years, and for about six years from xanthoma planum et tuberosum, the affection being general and severe. Four years before her death she was admitted under the care of Dr. Pavy. *See Guy's Hosp. Reps.* vol. 12, p. 276. At the autopsy the liver was found large and cirrhotic; the spleen was enlarged, and there were yellow patches in the aorta and pulmonary artery. *See Trans. Path. Soc.* vol. 34, p. 242; and *Skin Models*, Nos. 378 to 380.

67 **Atrophy of the Right Posterior Crico-Arytænoid Muscle.**

A larynx and trachea shewing wasting of the right posterior crico-arytænoid muscle. There is a saccular aneurysm of the innominate artery, bulging into the trachea, and closely adherent to the subclavian artery, which is indicated by a blue rod.

Henry P., æt. 28, a sailor, was admitted under Mr. Bryant for thoracic aneurysm. The chief symptoms, among which was a marked alteration of voice, had been noticed for five months. Dyspnoea came on one week before death. *See Insp.* 1878, No. 81.

68 Atrophy of the Posterior Crico-Arytænoid Muscles.

A larynx shewing wasting of both posterior crico-arytænoid muscles. The wall of the œsophagus is infiltrated with an epithelioma a little above the bifurcation of the trachea, and both recurrent laryngeal nerves are compressed by the new growth.

William H., æt. 66, was admitted under Dr. Pye-Smith for difficulty in swallowing, aphonia, and bronchitis. The symptoms had been noticed for one month before admission. At the autopsy it was found that there was thrombosis of the left innominate vein with pulmonary embolism. *See Insp.* 1886, No. 151.

69 Fixation of the Arytænoid Joints.

A larynx and trachea laid open from the front to shew the inter-arytænoid space occupied by a cicatrix, which has drawn the arytænoid cartilages into close apposition, and caused fixation of their joints. There is an opening left after tracheotomy, the edges being covered with smooth skin. The interior of the larynx is healthy.

George B., æt. 32, was admitted under Mr. Durham with stricture of the urethra and ascending nephritis, from which he died. Eight years previously he was tracheotomised for syphilitic laryngitis, and had worn a tracheotomy tube continuously since the operation. *See Insp.* 1889, No. 396.

70 Papillomata of the Larynx.

A larynx and upper part of the trachea shewing warty growths attached along the upper margin of the right vocal cord.

Edwin H., æt. 4, had "wheezing at the chest" for six weeks. His mouth and throat became covered with membrane, and he died from laryngeal obstruction. A croupous membrane which lined the air passages has been removed from the interior of the larynx.

Presented by Dr. Wilks, 1858.

71 Papillomata of the Larynx.

A larynx with the upper part of the trachea laid open

from behind to shew the mucous membrane from the base of the epiglottis to the third ring of the trachea, thickly beset with small cauliflower-like excrescences, which histologically have the structure of papillomata. A glass rod indicates the opening left after tracheotomy.

Presented by Dr. H. V. Hickman, 1893.

72 **Papillomata of the Larynx.**

A larynx and upper part of the trachea shewing large masses of warty growths, some upon the left vocal cord, and some immediately above the opening left after tracheotomy.

Ellen M., æt. 2, was admitted under Dr. Taylor for hoarseness and dyspnœa, which had been gradually increasing for one year. Tracheotomy was three times performed, on the first two occasions with temporary success, but after the last operation the child contracted diphtheria from which she died. *See Insp.* 1883, No. 153.

73 **Papillomata of the Larynx.**

A larynx and upper part of the trachea shewing warty growths, some upon the left vocal cord, and other larger ones upon the posterior wall of the larynx.

From a middle-aged woman who died suddenly.

Presented by Mr. Hawkins.

74 **Papillomata from the Larynx.**

A large number of minutely lobulated "cauliflower-like" excrescences removed from the interior of the larynx. The preparation contains two series.

The growths were removed by Mr. Durham by laying open the larynx in the middle line. The lower series was removed from Mary F., æt. 13. She had suffered from chronic laryngeal obstruction, and was compelled to wear a tracheotomy tube during the four years preceding the operation. *See Guy's Hosp. Reps.* vol. 12, p. 540, Case 1.

75 Symmetrical Sessile Laryngeal Fibromata.

A larynx and upper part of the trachea laid open from behind. Below each vocal cord at its posterior attachment is an oval flat-topped elevation, having somewhat the appearance of the crown of a molar tooth. Histologically the structure consists chiefly of fibrous tissue, and beneath the epithelium, in some places, there is evidence of slight inflammation.

Henry B., æt. 55, was admitted under Dr. Moxon. He died of bulbar paralysis and fibroid heart. His voice had been noticed to be "thick" four months before death. *See Insp.* 1877, No. 125.

76 Polypus of the Larynx.

A larynx laid open to shew a small pendulous growth attached to the left false cord. There is an opening left after laryngotomy. Histologically the growth is a fibrous polypus.

Sarah H., æt. 45, having suffered from laryngeal symptoms for some months, was suddenly attacked with severe dyspnoea, for which laryngotomy was performed by Mr. Birkett. She wore a tube till her death, which occurred three months later from suffocation due to the accidental removal of the tube.

77 Carcinoma of the Epiglottis.

A soft ovoid tumour, measuring two inches by an inch and a half, which appears to have been attached by its smaller end. A microscopical examination of the growth shews the normal squamous epithelium of the epiglottis, beneath which are large rounded and branching spaces filled with round and oval cells and lined with a single layer of columnar epithelium. The spaces are separated by a scanty nucleated fibrous stroma.

A woman, æt. 50, admitted in 1804. The tumour could be seen growing from the epiglottis, and interfered much with respiration and deglutition. Sir Astley Cooper twice removed it with his finger, but it again enlarged and bled profusely, and thus caused the death of the patient three months after admission. *See Old Mus. Book*, No. 46.

78 Epithelioma of the Epiglottis.

An epiglottis seen from behind, the surface of which is covered with a large number of cauliflower-like growths having the histological characters of squamous-celled epithelioma.

William K., æt. 62, was admitted under Mr. Symonds in 1892 for a malignant growth of the epiglottis with enlarged glands on the right side of the neck. The whole of the growth and affected glands were removed, and the patient was discharged relieved six weeks after the operation. *See Surgical Reports*, vol. 162, Case 36.

79 Epithelioma of the Larynx.

A larynx with a growth occupying its left wall above the vocal cord and almost completely obstructing the rima glottidis. The laryngeal surface is warty and ulcerated. The growth has penetrated the thyroid cartilage, and appears externally. Between the hyoid bone and the thyroid cartilage it forms a firm rounded tumour about the size of a pigeon's egg. Histologically the growth is a squamous epithelioma.

Abraham R., æt. 65, was admitted under Dr. Barlow in 1845. He had been ill for six months, and a few hours before death had several epileptic fits. No malignant disease of other structures was found. *See Insp.* vol. 34, p. 66.

80 Epithelioma of the Larynx.

A larynx and upper part of the trachea shewing a growth which involves the right vocal cord and the aryæno-epiglottidean fold of the same side. The neighbouring cervical glands are enlarged by secondary deposits. There is a tracheotomy wound. Histologically the growth is a squamous epithelioma.

John T., æt. 65, was admitted under Mr. Cock for laryngeal obstruction and a swelling in the neck. Tracheotomy was performed and the patient died from hæmorrhage. No growth was found elsewhere. *See Insp.* 1865, No. 90.

81 Epithelioma of the Larynx.

A larynx and upper part of the trachea. In the situation of the right vocal cord, which is destroyed by ulceration, there is a deep excavation with overhanging edges, exposing necrosed cartilage. The ulceration extends across the middle line as far as the anterior third of the left vocal cord. There is an opening left after tracheotomy.

From a clergyman, æt. 85, who had suffered from hoarseness and hæmoptysis for eighteen months. Later he expectorated foul pus. Tracheotomy was performed, the patient living eighteen weeks after the operation.

Presented by Mr. Cooper Forster, 1867.

82 Epithelioma of the Larynx.

A larynx laid open to shew an ulcer extending from the left vocal cord downwards for an inch and a quarter. Its edge is raised and everted, and its base covered with prominent granulations. The new growth spreads upwards beneath the left sacculus laryngis, and on the floor of the ulcer a piece of necrosed cartilage is seen. There is considerable œdema of the glottis. Histologically the growth is a squamous epithelioma.

Charles P., æt. 65, was admitted under Dr. Pye-Smith for bronchitis and granular kidneys. A month before death he had an attack of urgent dyspnoea, for which laryngotomy was performed. See *Insp.* 1887, No. 307.

83 Epithelioma of the Larynx.

A larynx and part of the trachea. On the inner aspect of the larynx is a deep ragged ulcer about one inch in diameter, extending from the left vocal cord, which is destroyed, to the lower border of the cricoid cartilage. The ulcer has partly destroyed the cricoid, and extending between it and the thyroid cartilage leads by a sinus to the skin. A rod has been passed into this sinus. There is also a small circular ulcer with raised edges on the

inner aspect of the epiglottis on the right side. Histologically the ulceration is epitheliomatous.

Presented by Sir Astley Cooper.

84 **Epithelioma of the Larynx.**

A larynx and part of the trachea shewing extensive destruction of the epiglottis and laryngeal cartilages on the right side. A deep ulcer extends from the epiglottis to below the right vocal cord, and exposes in its base ossified necrosed portions of the hyoid bone and thyroid and cricoid cartilages. There is a tracheotomy wound. Histologically the ulceration is epitheliomatous.

Mary B., æt. 34, admitted under Dr. Rees for chronic disease of the larynx producing dyspnoea. Tracheotomy was performed, and the patient died of broncho-pneumonia and gangrene of the lung. *See Insp.* 1859, No. 192.

85 **Epithelioma of the Larynx removed by Operation.**

Two portions of a larynx removed at successive operations. The upper, the first removed, consists of the posterior part of the left ala of the thyroid cartilage with the true and false cords and the left arytaenoid cartilage. The true cord is thickened and ulcerated, and its middle portion has been removed for histological examination. The lower portion consists of the remainder of the larynx, and shows a large mass of new growth projecting from the right sacculus and the junction of the alæ of the thyroid cartilage. This mass depresses the anterior end of the right vocal cord. Histologically the growth is a squamous epithelioma.

From a man, æt. 41, who, after progressive aphonia for six months, was found to have an epitheliomatous growth involving the vocal cords. The whole of the projecting growth was removed by the forceps, but six months later it reappeared, and Mr. Symonds excised the left half of the larynx with the anterior part of the right vocal cord. Recurrence rapidly took place, and two months after the second operation the remainder of the larynx

was extirpated. The patient recovered from the operation, and was able to speak with a fairly strong voice. He remained well for some months, but subsequently a tumour appeared in the anterior triangle of the neck, and there was some hæmoptysis. He rapidly emaciated, and died about two years after the commencement of his illness. *See Clin. Soc. Trans.* vol. 22, p. 245.

86 **Epithelioma of the Larynx and Pharynx.**

A larynx and base of the tongue shewing ulceration extending from the anterior pillar of the fauces on the right side to the upper end of the œsophagus. The base of the tongue and the right half of the larynx including the epiglottis are also ulcerated. The neighbouring cervical glands are enlarged from secondary deposits. In front is an opening left after tracheotomy. Histologically the ulceration is epitheliomatous.

Richard B., æt. 52, was admitted under Dr. Moxon. There was a history of cough for six months, and of aphonia and dysphagia for one month. Tracheotomy was performed five weeks before death, which resulted from broncho-pneumonia. *See Insp.* 1879, No. 112.

87 **Sarcoma of the Larynx.**

A larynx and part of the pharynx shewing the left arytæno-epiglottidean fold occupied by a growth, which projects inwards, almost occluding the larynx, and downwards beneath the mucous membrane of the pharynx as far as the commencement of the œsophagus. The upper portion of the tumour overhangs the aperture of the larynx, and is black and sloughing. Histologically the growth is a round-celled sarcoma.

Jenkins J., æt. 59, was admitted under Mr. Cooper Forster. Three months before admission he noticed a soft swelling above the left clavicle with soreness of the throat and shortness of breath. He died from suffocation. At the autopsy secondary deposits were found in the cervical glands, forming a large tumour extending to the base of the skull. There were no other secondary deposits. *See Insp.* 1878, No. 160.

88 Sarcoma of the Larynx.

A larynx, in the right half of which is a solid globular mass, pushing up the right arytaeno-epiglottidean fold, and bulging into the laryngeal cavity ; the upper orifice of the larynx is thus reduced to a narrow semilunar slit. At the back of the specimen, by the removal of a portion of the thyroid cartilage, the new growth is seen to extend down to the right vocal cord between the mucous membrane and the subjacent cartilage, entirely obliterating the sacculus laryngis of that side. The chief portion of the tumour is situated to the right of the base of the tongue and hyoid bone, and running through it are branches of the external carotid artery. Microscopic examination of the tumour shows masses of round cells held together by a few broad strands of fibrous tissue.

Elizabeth J., æt. 21 ; a swelling was first noticed in the neck near the angle of the jaw. It steadily enlarged, displacing the trachea, and compressing the pharynx and larynx. The patient died suddenly of dyspnœa in the sixth month of her illness.

Presented by Mr. Jacobson, 1887.

89 A Cyst on the Epiglottis.

A larynx shewing a thin-walled cyst, about the size of a pea, projecting from the upper free margin of the epiglottis on the right side.

SECTION II.—DISEASES OF THE THYROID GLAND.

Suppuration : 90.
 Lardaceous Disease : 91, 92.
 Myxœdema : 93, 94.
 Cretinism : 95.
 Hypertrophy : 96-98.
 Graves' Disease : 99-102.
 Adenoma : 103-105.
 Cystadenoma : 106, 107.
 Carcinoma : 108-111.
 Sarcoma : 112-115.
 Cystic Disease : 116-123.
 Hydatid Cyst : 124.

90 **Suppuration of the Thyroid Gland.**

A larynx with the thyroid gland attached. Both lobes of the gland have been incised to shew numerous small abscesses. In the interior of the larynx there is a slight deposit of false membrane. There is a tracheotomy wound.

John B., æt. 21, was admitted under Dr. Rees with Bright's disease. Two days before his death he was seized with urgent dyspnœa, accompanied by stridulous breathing and aphonia. On this account trachœotomy was performed. At the autopsy he was found to have tubal nephritis, and some slight œdema of the glottis. *See Insp.* 1862, No. 126.

91 **A Lardaceous Thyroid Gland.**

A portion of a thyroid gland shewing lardaceous change.

Lilian H., æt. 18, was admitted under Dr. Pye-Smith for lardaceous disease of the liver and kidneys following upon prolonged suppuration due to a fecal fistula, the result of perityphlitis. *See Insp.* 1885, No. 314.

92 A Lardaceous Thyroid Gland.

A larynx and upper part of the trachea with the thyroid gland attached, which is uniformly enlarged, and shews lardaceous change.

George B., æt. 56, was admitted under Dr. Wilks for ulceration of the pharynx and palate with profuse diarrhoea. There was a history of syphilis. At the autopsy the kidneys were found to be lardaceous. *See Insp.* 1871, No. 267.

93 The Thyroid Gland in Myxœdema.

A larynx and upper part of the trachea, to which is attached a much atrophied thyroid gland.

Eliza C., æt. 57, was admitted under Dr. Moxon with myxœdema. She had also albumen and sugar in the urine. The symptoms of the disease had existed altogether for twenty-three years. Just before her death a subcutaneous abscess in front of the elbow-joint was opened, and upon this gangrene supervened. *See Insp.* 1885, No. 378.

94 The Thyroid Gland in Myxœdema.

A larynx and upper part of the trachea with the thyroid gland attached, of which the lateral lobes are small, but the pyramid is long and well developed. Microscopic examination shewed complete atrophy of the gland structure, and substitution of fibrous tissue.

Arthur A., æt. 41, was admitted in a semi-comatose condition under Dr. Carrington with the symptoms of myxœdema; he died in a few hours with a large pericardial effusion. *See Insp.* 1886, No. 221.

95 Sporadic Cretinism.

A dissection of the front of the neck shewing the thyroid gland, of which the left lobe and isthmus are small, while the right lobe is the seat of a goitrous enlargement. External to the sterno-mastoids on each side are elongated masses of fat.

A. B., a male, æt. 23, was an inmate of an idiot asylum for thirteen years before his death. His height was two feet seven and three-quarter inches; his weight, two stone and five pounds.

He had not the power of speech, and could only walk with assistance. His features were "cretin-like in an extreme degree." Soft swellings were felt above the clavicles, and though at first the thyroid was thought to be atrophied, during the last few months of his life a goitrous tumour was discovered. A sister of the patient was said to be similarly affected. At the autopsy, besides the condition shewn in the preparation, there was found much deformity of the posterior part of the base of the skull, and an excessive development of fat. See *Med. Chir. Trans.* vol. 54, p. 162; and *Trans. Path. Soc.* vol. 25, p. 268.

96 Enlarged Thyroid Gland.

The left lobe of an enlarged thyroid gland which was removed by operation. The lobe measures four and a half inches in length, three and a half inches in width, and three inches in thickness. It has been incised to shew that the enlargement is partly due to overgrowth and partly to the formation of cysts.

Mabel A., æt. 22, was admitted under Mr. Lucas in 1892 for an enlargement of the left side of the thyroid gland, which had been slowly growing for two years, and more rapidly during the six months preceding her admission. The right lobe and the isthmus had been removed for a similar enlargement eight years previously, and are preserved in the museum. The patient was discharged well one month after the second operation. See *Surgical Reports*, vol. 110, Case 41; and vol. 160, Case 35; and *Prep.* No. 98.

97 Enlarged Thyroid Gland.

A lobe of a thyroid gland considerably enlarged, and presenting on its surface several rounded outgrowths. The gland has been incised, and its cut surface shews a matrix of fibrous tissue, in which are embedded numerous gelatinous nodules which histologically consist of colloid material contained in alveolar spaces.

Presented by Mr. Jacobson, 1887.

98 Hypertrophy of the Thyroid Gland.

A simple hypertrophy of the thyroid gland. This lobe was removed during life. It measures $5 \times 3 \times 2\frac{1}{2}$ inches.

Presented by Mr. Lucas.

99 The Thyroid Gland in Graves' Disease.

A larynx and upper part of the trachea with the thyroid gland attached, which shews considerable and uniform enlargement of both lobes.

Charles H., æt. 26, was admitted under Dr. Wilks with very acute Graves' disease, which proved fatal within five months of its onset. See *Insp.* 1869, No. 1; and *Guy's Hosp. Reps.* 1869-70, p. 22.

100 The Thyroid Gland in Graves' Disease.

A thyroid gland with the larynx, pharynx, and the hinder part of the tongue. The gland is moderately and uniformly enlarged. There is also considerable enlargement of the tonsils and the follicles at the root of the tongue.

Jane E., æt. 29, was admitted under Dr. Habershon for Graves' disease of four years' duration. She died rather unexpectedly of lobar pneumonia. See *Insp.* 1870, No. 47.

101 Thyroid Gland with other organs in Graves' Disease.

A larynx with the thyroid gland, which shews moderate and uniform enlargement. The tonsils and thymus mounted below are also greatly enlarged, and the piece of ileum shews prominent and enlarged solitary and agminated follicles.

Mary M., æt. 21, was admitted under Dr. Fagge, and died rather suddenly after having suffered from the symptoms of Graves' disease for three and a half months. Death was attributed to a follicular inflammation of the intestines and stomach. See *Insp.* 1878, No. 290.

102 Enlargement of the Thyroid Gland in Graves' Disease.

A thyroid gland shewing uniform enlargement. Histologically there are seen projecting into some of the numerous small cysts delicate processes covered with

columnar epithelium. There is also much colloid degeneration.

Emily R., æt. 23, was admitted under Dr. Taylor with exophthalmos, enlargement of the thyroid gland, and rapid pulse. The symptoms of the disease had existed for six months. At the autopsy the thymus was found much enlarged. *See Prep.* 123; and *Insp.* 1889, No. 360.

103 **Adenoma of the Thyroid Gland.**

A larynx and upper part of the trachea with the thyroid gland attached. In the left lobe of the gland are two nodules each about the size of a hazel nut with fibrous capsules. In the fresh state the upper one was soft and dark brown from internal hæmorrhage; the lower one was of a similar consistency, but of a pinkish white colour. Histologically the tumours consist of groups of small spheroidal cells arranged in follicles, among which ramify widely-dilated capillaries filled with red blood corpuscles. The adenoma is of foetal type.

Maria B., æt. 48, was admitted under Dr. Pye-Smith for cerebral hæmorrhage. At the autopsy there was found mitral and tricuspid stenosis, with tuberculous disease of the suprarenals and fallopian tubes. *See Insp.* 1889, No. 450; and *Trans. Path. Soc.* vol. 41, p. 270.

104 **Adenomata of the Thyroid Gland.**

A thyroid gland seen from behind shewing the left lobe to be almost entirely occupied by a globular encapsuled tumour about an inch and a half in diameter. Its cut surface presents numerous small cysts containing colloid material embedded in a spongy and vascular matrix. Histologically the adenoma has a basis of fibro-hyaline tissue, in which are numerous vesicles of various sizes, some of which are filled with epithelial cells, while others have a lining of cubical epithelium, and contain colloid material. At the apex of the right lobe there is a second encapsuled adenoma half an inch in diameter, consisting of a homogeneous soft material, which in the

recent state was pink and vascular. Histologically this adenoma differs from the adult thyroid in the smaller amount of fibrous tissue and the greater proportion of colloid material.

Mary B., æt. 49, was admitted under Dr. Horrocks for inversion of the uterus of long standing, and died the day after the operation of vaginal hysterectomy. *See Insp.* 1890, No. 265.

105 **Adenoma of the Thyroid Gland.**

The left lobe of a thyroid gland containing at its upper part an encapsuled adenoma, ovoid in shape and measuring one inch and three quarters in its longest diameter. Histologically the tumour has the structure of normal thyroid gland.

Richard McM., æt. 51, was admitted under Dr. Taylor for phthisis and lardaceous disease, from which he died. *See Insp.* 1890, No. 88.

106 **Cyst-Adenoma of the Thyroid Gland.**

A larynx and trachea with the left half of the thyroid gland greatly enlarged by a growth. The growth is irregular in shape, soft, and of loose texture. A nodule the size of a large pea projects into the upper part of the trachea. Histologically the growth is a cyst-adenoma.

Isaac H., æt. 72, was admitted under Mr. Bryant with a tumour of the neck which had been growing for five years, and had caused dysphagia for three months. Cystic portions of the tumour were at first tapped, and afterwards freely incised. At the autopsy secondary growths were found in the lungs. *See Insp.* 1873, No. 121.

107 **Cyst-Adenoma of the Thyroid Gland.**

A portion of a thyroid gland shewing on section a number of small cysts embedded in tough fibrous tissue. They are filled with soft white material, which has fallen out in places, leaving smooth-walled cavities. Microscopically the cysts contain delicate papillary in-

growths lined with cylindrical epithelium. Some have undergone colloid degeneration.

Thomas L., æt. 63, had noticed a swelling on the right side of the neck for two months, which had slowly enlarged. The right lobe of the thyroid was excised, but the growth recurred in the glands of the neck on the same side, and the patient died about four months after the operation. *See Trans. Path. Soc.* vol. 39, p. 341.

Presented by Dr. Farrant Fry, 1889.

108 **Carcinoma of the Thyroid Gland.**

A larynx and upper part of the trachea with the thyroid gland attached. The right lobe of the gland is enlarged by a growth which chiefly occupies its lower end. The growth is hard and somewhat fibrous on section. Histologically it is a carcinoma.

Catherine F., æt. 42, had been an out-patient for some time under Mr. Callaway's care with an enlarged thyroid gland. She was subsequently admitted into the hospital, and died. Secondary deposits were found in the lungs, and the left suprarenal capsule formed a large cancerous mass. *See Prep.* 2021 (83) [2nd Edit.]; and *Insp.* vol. 32, p. 84.

109 **Carcinoma of the Thyroid Gland.**

A lobe of the thyroid gland incised to shew at its upper end two white nodules, one about an eighth of an inch and the other half an inch in diameter. These deposits are clearly defined from the parenchyma of the gland, and histologically consist of spheroidal-celled carcinoma with scanty stroma.

George F., æt. 59, was admitted under Dr. Pye-Smith with cirrhosis of the liver and carcinoma of the stomach, from which he died. At the autopsy secondary deposits were found in the kidney, liver, pancreas, pericardium, and adrenal, and in the glands of the mesentery and lesser omentum. *See Insp.* 1892, No. 101; *Prep.* 689; *Drawing*; and *Trans. Path. Soc.* 1892, p. 166.

110 **Carcinoma of the Thyroid Gland.**

A larynx and part of the trachea with the thyroid gland attached. The right lobe of the gland is greatly en-

larged and infiltrated with a firm uniform growth. In front the tumour is adherent to the skin, which is extensively ulcerated over it. Histologically the growth is a medullary carcinoma.

James M., æt. 60, was admitted under Mr. Birkett. He had had a swelling in his neck for ten years, which had incapacitated him for five years. The tumour was tapped several months before death, and a pint of bloody fluid withdrawn. At the autopsy secondary deposits were found in the liver and lungs. See *Insp.* 1857, No. 230.

111 **Carcinoma of the Thyroid Gland.**

A larynx and part of the trachea with the thyroid gland, both lobes of which are uniformly enlarged by growth. On section the tumour presents many cysts, and for the rest its structure is firm and fibrous. Histologically it is a medullary carcinoma.

Sarah G., æt. 40, was admitted under Mr. Key's care with carcinoma of the breast, and secondary deposits in the axillary glands. She died from an attack of erysipelatos inflammation. She was a native of Berkshire, and from childhood had been the subject of enlargement of the thyroid. See *Drawing*, No. 413; and *Insp.* vol. 11, p. 21.

112 **Sarcoma of the Thyroid Gland.**

A larynx and trachea with the thyroid gland dissected. The right lobe and pyramid are normal, but the left is entirely replaced by a tumour, measuring four inches in length and two inches and a half across. The internal jugular vein is adherent to its outer margin, and is filled by a large thrombus partly composed of growth. On the reverse of the specimen the tumour has been laid open, shewing a cavity in the soft degenerated growth. An extension of the tumour has taken place between the trachea and œsophagus, forming an oval prominence in the latter. Histologically the growth is a round-celled sarcoma.

Alexander D., æt. 65, was admitted under Mr. Howse for a swelling on the left side of his neck, which had been noticed about

three weeks. It very rapidly increased, causing aphonia and great irregularity of the pulse. He died suddenly. At the autopsy the left vagus was found embedded in the tumour, and there was a large ante-mortem clot in the right ventricle. See *Insp.* 1886, No. 434; and *Trans. Path. Soc.* vol. 38, p. 398.

113 **Sarcoma of the Thyroid Gland perforating the Œsophagus.**

A larynx and trachea with the œsophagus and the vessels of the neck. The right lobe of the thyroid gland is seen to be greatly enlarged and firmly adherent to the adjacent structures. Its anterior portion has been removed to expose an excavation with ragged walls in which the trachea is laid bare. The yellow rod indicates the opening left after tracheotomy. On the reverse of the specimen the œsophagus is seen to be compressed by the growth, and shews upon its anterior wall, an inch from its commencement, a small ragged perforation communicating with the excavation in the gland. Histologically the growth is a sarcoma, many of the cells of which are multinucleated.

Eliza B., æt. 57, was admitted under Mr. Symonds for dysphagia associated with cystic enlargement of the right lobe of the thyroid. An attempt was made to excise the goitre, but only the anterior part of it could be removed. The patient had several attacks of recurrent hæmorrhage, and died three weeks after the operation, death being preceded by a sudden attack of dyspnoea, for which tracheotomy was performed. At the autopsy no secondary deposits were found. See *Insp.* 1892, No. 123.

114 **Sarcoma of the Thyroid Gland.**

An œsophagus and larynx with the thyroid gland uniformly enlarged by a growth, which is histologically a small round-celled sarcoma.

From Henry P., æt. 3 $\frac{3}{4}$. A swelling in the neck had been noticed three months before death; two months later masses were felt in the abdomen, which rapidly increased in size. At the autopsy growth was found in the liver, kidneys, and mesenteric glands. See *Note Book*, No. 2, p. 73.

115 Sarcoma of the Thyroid Gland.

A larynx and œsophagus with the thyroid gland attached. The right lobe of the gland is greatly enlarged. On the right side of the larynx is a firm fibrous tumour continuous with the right lobe of the thyroid. The adjacent cervical glands are also affected. Histologically the older portions of the growth have the structure of a fibro-sarcoma, while in the area adjoining the normal thyroid tissue round and oval cells predominate.

A man, æt. 53, was admitted under Mr. Bryant for a tumour of the neck, which had been growing six months, and was thought to be a goitre. Fourteen days before death it rapidly increased in size, and caused severe pressure symptoms. *See Insp.* 1871, No. 251.

116 Cystic Thyroid Gland.

A larynx to which is attached a large unilocular cyst formed by the right lobe of the thyroid gland. The wall of the cyst is thick, and its inner surface roughly nodulated. The trachea is flattened, and the carotid artery and jugular vein are displaced outwards.

Presented by Mr. Joseph Towne.

117 Cystic Thyroid Gland.

The right lobe of a thyroid gland converted into a large goitre, which weighed 62 oz., and contained 32 oz. of dark fluid.

Dinah F., æt. 47, was admitted under Mr. Durham for a tumour of the neck, which had been growing for twenty years. The tumour was removed, and the patient died on the following day. The trachea was found to be much compressed. The other lobe of the thyroid gland was healthy. *See Insp.* 1873, No. 168; and *Prep.* 168.

118 Cystic Thyroid Gland.

One half of the thyroid gland, much enlarged, and shewing a thin-walled cyst at its upper part.

Mary M., æt. 37, was admitted under Mr. Jacobson, in 1885,

for a tumour of the neck of seven years' duration. The cyst was at first tapped, and afterwards excised with the isthmus of the thyroid. The patient did well. *See Surgical Reports*, vol. 118, Case 28.

119 **Cyst of the Thyroid Gland.**

The cyst is unilocular, and measures about four inches in diameter. Its wall is thick, and its interior is rough and ragged.

Removed during life by Mr. Jacobson. The patient recovered.

120 **Cystic Adenoma of the Thyroid Gland.**

An adenoma of the left lobe of the thyroid gland partially converted into a spheroidal cyst, about two and a half inches in diameter.

Keziah W., æt. 41, was admitted under Mr. Symonds for left-sided enlargement of the thyroid gland. The swelling had been noticed for nine years, but had increased rapidly in the three months preceding admission. The patient made a good recovery after the removal of the adenoma. *See Surgical Reports*, vol. 144, Case 34; and *Trans. Clin. Soc.* 1890, p. 60.

121 **Calcified Thyroid Gland.**

The right lobe of the thyroid gland, the greater part of which is occupied by an encapsuled mass measuring two inches from above downwards, two inches transversely, and an inch in thickness. This mass consists almost entirely of calcareous material.

Alice S., æt. 58, was admitted under Dr. Goodhart for diabetes. She became comatose, and died three days after her admission. At the autopsy a calcareous nodule was found in the left lobe of the thyroid gland. *See Insp.* 1891, No. 88.

122 **Calcified Thyroid Cyst.**

Presented by Mr. D. Crompton.

123 Calcified Thyroid Cyst.

A larynx and trachea with the thyroid gland attached. The right lobe of the gland shews at its upper part a calcified cyst about an inch in diameter.

William H., æt. 60, was admitted under Dr. Habershon and died of facial erysipelas and pyelo-nephritis. No history was obtained of any symptoms which could be referred to the condition of the thyroid. *See Insp.* 1879, No. 155.

124 Hydatid Cyst of the Thyroid Gland.

The remains of a hydatid cyst removed from the thyroid gland. Histologically the wall of the cyst is composed of characteristic laminated membrane.

Emma W., æt. 15, was admitted under Mr. Cock for a swelling of the neck of seven years' duration. It was thought to be a bronchocele. The swelling was twice incised, and pus evacuated; subsequently the cyst was removed, and the patient made a good recovery. *See Surgical Reports*, 1855, Case 274; and *Trans. Path. Soc.* 1890, p. 270.

SECTION III.—DISEASES OF THE THYMUS GLAND.

125 **Enlarged Thymus.**

A thymus gland shewing general enlargement.

Thomas C., æt. 29, was admitted under Dr. Fagge for general purpura. He died after three weeks' illness with enlargement of the liver and spleen, and of the lymphatic glands. *See Insp.* 1867, No. 71.

126 **Enlarged Thymus.**

A thymus gland weighing 740 grains, preserved to shew marked enlargement of both its lobes.

From an infant, æt. 5 months, who was brought in dead. Nothing definite as to the cause of death could be ascertained. The lungs were congested, and the thymus was three times the average weight at that period of life. The other viscera were normal. *See Insp.* 1888, No. 270.

127 **Enlarged Thymus in Leucocythæmia.**

A thymus gland uniformly enlarged, presenting at the upper part of the left lobe a distinct yellow discoloration, which on microscopical examination is shewn to consist of an aggregation of small round cells.

Elizabeth R., æt. 2½, was admitted under Dr. Goodhart suffering from enlargement of the spleen and the lymphatic glands, with leucocytosis and anasarca. She was well until a month before admission, and died nine days later. At the autopsy the liver and spleen were found enlarged as in splenic leuchæmia. *See Insp.* 1889, No. 175.

128 **Enlarged Thymus in Graves' Disease.**

A thymus shewing uniform enlargement. Histo-

logically there is simple hypertrophy of the gland. Hassall's corpuscles are numerous.

Emily R., æt. 23, was admitted under Dr. Taylor with exophthalmos, enlargement of the thyroid gland, and rapid pulse. The symptoms of the disease had existed for six months. She was much exhausted by her journey to the hospital from Wales, and on admission became maniacal, refused her food, and sank in two days. *See Insp.* 1889, No. 360.

SECTION IV.—INJURIES AND DISEASES OF THE TRACHEA.

- Injuries : 129.
 Operations and their Results : 130-139.
 Foreign Bodies : 140-142.
 Membranous Inflammation : 143-146.
 Specific Inflammation : 147.
 Simple Ulceration : 148.
 Fistulæ : 149-153.
 Syphilitic Ulceration : 154, 155.
 Syphilitic Stenosis : 156-160.
 Tuberculous Ulceration : 161-163.
 Ossification of Cartilages : 164-167.
 Compression : 168, 169.
 Secondary Affections in Malignant Disease : 170-172.
-

129 **Torn Trachea.**

A trachea completely torn across about one inch above its bifurcation. In the fresh state the divided ends were separated by an interval of one and three quarter inches.

Christian K., æt. 40, was admitted under Mr. Durham, having been crushed between a barge and a ship. He became very emphysematous, and died fifty hours after the accident. He did not suffer from dyspnœa. There was a fracture of the lower jaw, and a separation between the second and third cervical vertebræ. The spinal cord was uninjured. *See Insp.* 1876, No. 184.

130 **Traumatic Stenosis of the Trachea.**

A larynx with the upper part of the trachea, which shews cicatricial narrowing at its commencement. The blue rod indicates the opening left after tracheotomy. Below this there is a recent tracheotomy wound.

William J., æt. 2, was admitted under Mr. Davies-Colley for laryngeal obstruction due to a scald. Tracheotomy was performed.

Four months later the tube was removed, and the wound closed. The following night the child was attacked with urgent dyspnoea, and though tracheotomy was attempted, he died. See *Insp.* 1874, No. 203.

131 Ulceration of the Trachea caused by a Tracheotomy Tube.

A larynx and upper part of the trachea shewing an opening left after tracheotomy, and half an inch below it a large circular patch of ulceration on the anterior wall of the trachea. Five of the tracheal rings are partly laid bare.

Eliza H., æt. 2, was admitted for a scald of the larynx for which tracheotomy was performed. The tube was removed nine days after the operation, and replaced three days later. The child died a few hours after the second introduction.

132 Ulcerative Tracheitis caused by a Tracheotomy Tube.

A larynx and trachea shewing an opening left after tracheotomy, the edges of which are cicatrized. Below and around the opening the mucous membrane is thickened and corrugated. Half an inch from the tracheotomy wound the trachea presents on its anterior wall two small irregular ulcers, one of which exposes a portion of cartilage.

Ellen M., æt. 2, was admitted under Dr. Moxon with diphtheria, for which tracheotomy was performed. A silver tube was worn for three or four days, after which a rubber one was substituted for it. She wore the latter till her death five weeks after the operation. The lungs were much affected with broncho-pneumonia. See *Insp.* 1884, No. 81; and *Trans. Path. Soc.* vol. 35, p. 78.

133 Ulceration of the Trachea perforating the Innominate Artery.

A larynx and trachea with the arch of the aorta and its branches. In the trachea are two openings, the upper

left after tracheotomy, the lower the result of ulceration caused by the end of the tracheotomy tube. In the innominate artery is a small opening into which a piece of catgut has been passed.

Alice R., æt. $2\frac{1}{2}$, was admitted under Dr. Rees with laryngeal obstruction, for which tracheotomy was performed. The child did well for five days, but was suddenly seized with profuse hæmorrhage from the trachea; and presently died. *See Insp.* 1865, No. 329.

134 **Ulceration of the Trachea perforating the Innominate Artery.**

A larynx and trachea with the arch of the aorta and its branches. The vessels have been laid open, and about the middle of the innominate artery is a small punched-out hole, through which a blue rod has been passed into the trachea. In the trachea is a ragged opening about three quarters of an inch long by three eighths of an inch wide, the upper part of which communicates with the tracheotomy wound, and the lower with the opening in the innominate artery.

Emily J., æt. 4, was admitted under Dr. Wilks with membranous laryngitis, for which tracheotomy was performed. The child did well, and the tube was removed in a few days. She subsequently became worse, and five days after the removal of the tube died suddenly from profuse hæmorrhage. *See Insp.* 1866, No. 265.

135 **Stenosis of the Trachea after Tracheotomy.**

A larynx and the trachea, which is narrowed in two places by cicatrisation following ulceration after tracheotomy. The upper cicatrix is at the seat of the operation, and the second corresponds to the situation of the lower end of the tracheotomy tube.

William T., æt. 2, was tracheotomised for diphtheria, and discharged two months afterwards with the wound closed, but breathing with some difficulty. One month later the dyspnœa became suddenly urgent, and the child was brought into the hospital dead. *See Insp.* 1885, No. 123.

136 Stenosis of the Trachea following Tracheotomy.

A larynx and trachea shewing an opening left after tracheotomy, below which for the distance of about one inch the wall of the trachea is scarred, and the lumen of the tube slightly narrowed. The larynx shews a narrow vertical scar left after median division of the thyroid cartilage.

Augustus W., æt. 2½, was tracheotomised for laryngeal obstruction. He recovered, but subsequent attempts extending over several months to remove the tube were unsuccessful. Thyrotomy was performed by Mr. Golding-Bird, and a mass obstructing the glottis removed; but it was still found impossible to dispense with the tracheotomy tube. After many attacks of bronchitis and broncho-pneumonia the child was one morning found dead in his bed. *See Insp.* 1888, No. 409.

137 Perforation of the Trachea by a Clamp.

A trachea with an enlarged thyroid gland, of which the right lobe has been removed by operation. There is an oval perforation of the trachea situated one and a half inches below the glottis, which was produced by the pressure of the end of a clamp.

Mary W., æt. 17, was admitted under Mr. Howse for an enlarged thyroid gland. The right lobe was removed, and a clamp applied to the pedicle. The patient died on the seventh day after the operation from acute bronchitis. *See Insp.* 1887, No. 114.

138 Corrosion of a Tracheotomy Tube.

From a woman, æt. 45, under the care of Mr. Bryant in 1861. Tracheotomy was performed for syphilitic disease of the larynx. The tube shewn was worn continuously for six months, with the result that it became blackened and almost destroyed by corrosion.

139 Blood-clot in the Trachea.

A larynx and upper part of the trachea containing a large firm clot almost occluding the lumen of the tube.

There is a laryngotomy wound to the right of the middle line.

Thomas P., æt. 45, was admitted under Mr. Davies-Colley for injuries received through falling twenty feet. He had a fractured jaw, and a wound of the forehead. Three days after admission laryngotomy was performed for increasing dyspnœa, but the patient died three hours later. The source of the hæmorrhage was not clearly made out at the autopsy; it was thought to have resulted from the accident and not from the operation. *See Insp.* 1875, No. 214.

140 Foreign Body from the Trachea.

A piece of twisted tape which was removed from the trachea.

Sarah C., æt. 40, had worn a tracheotomy tube for twelve years, which she was accustomed to clean with a piece of tape. One day the tape broke, and the twisted end was left in the trachea. Mr. Hilton, under whose care she was admitted, enlarged the tracheotomy wound and removed the foreign body. *See Guy's Hosp. Repts.* 1860, p. 25.

141 Foreign Body from the Trachea.

The foreign body is a piece of apple core.

From a child, æt. 15 months, from whose trachea Mr. Hilton removed the obstruction by tracheotomy. The patient recovered.

142 Foreign Body in the Trachea.

A larynx and the trachea with a piece of meat impacted at its bifurcation. There is a tracheotomy wound.

Henry M., æt. 34, under the care of Mr. Howse. He was suffocated by the entrance of food into the air-passages during vomiting after the administration of an anæsthetic. *See Insp.* 1876, No. 366.

143 Membranous Tracheitis.

The larynx and trachea of an adult. The whole of the trachea, with the greater part of the larynx, is covered by a thick false membrane, which extends downwards to the bronchi, almost occluding the right bronchus.

144 Membranous Inflammation of the Air-Passages.

A larynx, trachea, and part of the right lung. The whole length of the air-passages down to the smallest visible ramifications of the bronchi is lined with a thick and firm false membrane. There is a tracheotomy wound.

Elizabeth T., æt. 32, was admitted under Dr. Fagge with aphonia and dyspnœa, which had come on suddenly ten days before admission. The dyspnœa became urgent, and tracheotomy was performed, shortly after which the patient died. There was no membrane on the fauces. *See Insp.* 1867, No. 77.

145 Membranous Cast from the Trachea.

A tube of false membrane, three and a half inches long, marked on its outer surface by the orifices of the mucous follicles.

Thomas S., æt. 30, was admitted to the hospital in 1807 suffering from dyspnœa. He had been ill for eight days, and just before admission had expectorated the cast shewn in the preparation. He died the following day, and at the autopsy membrane was found throughout the air-passages with the exception of the trachea. *See Old Museum Book*, No. 61.

146 Membranous Cast of the Trachea and Bronchi.

A complete hollow cast of the lower end of a trachea and of the main divisions of the bronchi, which was expectorated from the air-passages after the operation of tracheotomy.

Richard H., æt. 7, was admitted under Dr. Goodhart for attacks of laryngeal obstruction, one of which, occurring fourteen days after admission, was so severe as to necessitate tracheotomy. Two days after the operation the cast which forms the preparation was expelled through the tube. There was at no time any membrane seen upon the fauces, and on one occasion only was albumen found in the urine. He was discharged cured five weeks after the onset of his illness. *See Medical Reports*, vol. 131, Case 152; and *Guy's Hospital Gazette*, 1893, p. 20.

147 Tracheitis after Measles.

A larynx and upper part of the trachea, the mucous membrane of which shews the remains of the puriform mucus, with which it was coated in the fresh state. Immediately below the vocal cords is a granulating wound left after operation.

Louisa K., æt. 2, was admitted under Dr. Goodhart with laryngeal obstruction on the third day of an attack of measles. Tracheotomy was at once performed, and the tube removed after six days. Two hours later the child died suddenly. No membrane was found at the autopsy. *See Insp.* 1880, No. 218.

148 Ulceration of the Trachea.

A larynx and trachea presenting numerous small circular ulcers situated upon the mucous membrane between the tracheal rings. There are similar ulcers in the bronchi.

149 Tracheo-Œsophageal Fistulæ.

A larynx, trachea, and œsophagus shewing three irregular openings between the upper part of the œsophagus and the trachea. The mucous membrane of the œsophagus is extensively destroyed and undermined. A blue rod has been passed into the œsophagus, which is displaced to the left. There is an opening left after tracheotomy.

Sarah B., æt. 24, was admitted under Dr. Barlow for extreme dysphagia. For six months she had suffered from difficulty of swallowing, pain, and shortness of breath. There had been some swelling of the throat, which was reported to have disappeared suddenly a short time before admission. She was a married woman, and had never had syphilis. Tracheotomy was performed one month before her death. There was no evidence of cancer. *See Insp.* 1855, No. 21; and *Drawing* No. 246 (24).

150 Tracheo-Œsophageal Fistulæ.

A larynx and upper part of the trachea, laid open from the front to shew a rounded opening, about half an inch

in diameter, situated in the middle line immediately below the cricoid cartilage. This and four neighbouring slit-like apertures have a common opening into the œsophagus. The rings of the trachea are ossified, and there is an ulcer at the posterior attachment of the right vocal cord. There is no appearance of malignancy.

William W., æt. 42, a carrier, was ill for some time with profuse expectoration and crowing inspiration, unaccompanied by serious dyspnoea. Six months before death, and again six weeks later, he coughed up several portions of ossified tracheal cartilages. At the autopsy there was broncho-pneumonia of the lower lobe of the right lung. There was no evidence of malignant disease nor tuberculosis. See *Note Book*, No. 2, p. 70; *Guy's Hosp. Repts.* 1856, p. 216; *Drawing*, 246 (23); and *Prep.* 164.

Presented by Mr. Holleston.

151 **Tracheo-Œsophageal Fistula.**

A larynx, trachea, and œsophagus, with a communication between the œsophagus and the trachea. The opening is oval in form, about two inches in length, and has smooth rounded edges. It appears to have been the result of ulceration.

152 **Tracheo-Œsophageal Fistula.**

A trachea and œsophagus communicating with each other by a large round opening about an inch and a quarter in diameter. The edges of the opening are thin and smooth, and the mucous membrane of the œsophagus projects beyond the tracheal margin. There is superficial scarring throughout the trachea, probably the result of syphilis.

Arthur S., æt. 34, was admitted under Mr. Bryant for complete inability to swallow of two days' duration, which the patient attributed to inhaling the fumes of ammonia. When an attempt was made to introduce an œsophageal bougie, it passed into the trachea; and the patient was therefore fed by enemata. He died twelve days after admission from broncho-pneumonia. See *Insp.* 1884, No. 240.

153 Tracheo-œsophageal Fistulæ ; Epithelioma of the Œsophagus.

A larynx and trachea with the œsophagus. The trachea has been laid open from the front to shew upon its posterior wall halfway between its bifurcation and the cricoid cartilage two rounded openings with raised warty edges. These openings lead to a small cavity behind the trachea which also communicates with the œsophagus by means of two oval perforations. At the junction of the œsophagus and pharynx there is an irregular ulcer, the edge of which is seen under the microscope to be infiltrated with a growth of squamous-celled epithelioma.

William J., æt. 57, was admitted under Mr. Howse for difficulty in swallowing of one month's duration, and died on the following day from gangrenous broncho-pneumonia. See *Insp.* 1891, No. 316.

154 Syphilitic Ulceration of the Trachea.

A trachea, in the interior of which are situated deep irregular ulcers with overhanging edges interspersed with bands of cicatricial tissue. There is extensive destruction of the tracheal cartilages.

Matilda C., æt. 25, was admitted under Mr. Birkett in 1870 with constitutional syphilis. She had been complaining of cough and cold for eight weeks without marked dyspnoea. At the autopsy there was gangrenous broncho-pneumonia, with gummata of the liver and ensiform cartilage. See *Surgical Reports*, vol. 22, Case 156; and *Prep.* 241.

155 Syphilitic Ulceration of the Trachea perforating the Aorta.

A trachea of which the interior is diffusely ulcerated and scarred. An inch above its bifurcation there is a small punched-out opening communicating with the transverse part of the arch of the aorta. The aorta itself is extremely atheromatous.

Thomas C., æt. 51, was admitted under Dr. Rees for chronic

laryngeal obstruction. He was thought to have an aneurysm, and died suddenly from profuse hæmoptysis. *See Insp.* 1865, No. 62.

156 **Syphilitic Stenosis of the Trachea.**

A larynx and upper part of the trachea shewing extreme narrowing of the first few rings, with dilatation of the part below. The interior of the larynx is much ulcerated and scarred.

Philip D., æt. 37, was admitted in 1835 under the care of Dr. Bright. His voice had been affected for nine years. He died of suppurative meningitis with pneumonia. There was a scar on the forehead, beneath which the skull was thickened. *See Misc. Insp.* vol. 7, p. 52.

157 **Syphilitic Stenosis of the Trachea.**

A trachea shewing extreme stenosis of its upper half. Its inner surface is puckered and crossed by bands of fibrous tissue, a condition which exists also in the lower part of the larynx. The first few rings of the trachea have disappeared. There is a small tracheotomy wound.

Thomas W., æt. 48, was admitted under Dr. Wilks for tracheal obstruction. He had suffered from occasional dyspnoea for six years. Tracheotomy was attempted, but it was found impossible to introduce a tube. There was a history of syphilis many years before. At the autopsy the kidneys were granular, and the testes fibroid. *See Insp.* 1867, No. 49; and *Guy's Hosp. Repts.* 1867, p. 365.

158 **Syphilitic Stenosis of the Trachea.**

A larynx with the trachea shewing considerable scarring with contraction of the calibre of the tube and thickening of its wall. The epiglottis and aryæno-epiglottidean folds are enormously thickened and corrugated. There is a tracheotomy wound.

Letitia B., æt. 33, was admitted under Mr. Lucas, in 1883, for dyspnoea and aphonia. The symptoms had been gradually increasing for four years. Tracheotomy was performed with slight relief to the breathing, but the patient died four hours later. At the autopsy nodes were found upon the frontal bone. *See Surgical Reports*, vol. 104, Case 37.

159 Syphilitic Stenosis of the Trachea.

A trachea with portions of the bronchi, the mucous membrane of which is entirely replaced by irregular fibrous bands and scar tissue. A section, removed from the middle of the trachea and suspended below the specimen, shews the extreme thickening of the wall and the contraction of the respiratory passage. There is a sinus burrowing outside the mucous membrane. Histologically there is well-marked perichondritis with small-celled infiltration of the submucous tissue.

Isaac H., æt. 28, was admitted under Dr. Pavy with urgent dyspnoea, for which tracheotomy was performed; he died two days later. The left bronchus was almost obliterated, and the upper lobe of the corresponding lung was fibroid, the bronchi being much dilated. There was a scar on the penis, and the testes were fibroid. *See Insp.* 1887, No. 415.

160 Syphilitic Stenosis of the Trachea.

A larynx and trachea with the right and left bronchus. The trachea is thickened and narrowed throughout, and its mucous membrane is thrown into longitudinal folds. There is no appearance of ulceration or cicatrisation. The stenosis extends into the bronchi, while the larynx is quite free from any evidence of disease. Histologically there is well-marked perichondritis with fibroid thickening of the submucous tissue.

Charles C., æt. 46, was admitted under Dr. Goodhart for cough and dyspnoea. No history of syphilis was obtained. The dyspnoea became extreme, and he died cyanosed with anasarca and albuminuria. At the autopsy there was found considerable bronchopneumonia of the base of the left lung. *See Insp.* 1888, No. 122.

161 Ulceration of the Trachea.

A trachea shewing extensive ulceration deepest over the position of the rings. The cartilages are in many places laid bare, and are partly ossified.

Philip M., æt. 58, was admitted under Dr. Rees with signs of

cavitation at the left apex, having suffered from symptoms of phthisis for some months. At the autopsy tuberculous disease of the lungs and intestines was found. *See Insp.* 1857, No. 147.

162 Ulceration of the Trachea and Larynx.

A larynx and upper part of the trachea laid open from the front. The mucous membrane of the trachea is extensively ulcerated, particularly over the cartilaginous rings, which are in some places laid bare. About the middle of the posterior surface there is a large oval patch denuded of mucous membrane. There is a small excavated ulcer at the posterior attachment of each vocal cord. *See Drawing* No. 246.

163 Tuberculous Ulceration of the Trachea and Larynx.

A larynx and upper part of the trachea, showing two circular patches of shallow ulceration situated at the posterior attachment of the vocal cords. On the anterior wall of the trachea, at about the level of the third ring, there is a deep transverse ulcer with thickened edges, and one or two smaller superficial ulcers below it. The thyroid gland is lardaceous.

Edith B., æt. 13, was admitted under Dr. Taylor for chronic phthisis, with lardaceous disease of the liver and kidneys. There was a sinus, which had been discharging for four years, in connection with a carious rib. At the autopsy tuberculous ulceration of the intestines was also found. *See Insp.* 1889, No. 198.

164 Portion of Ossified Tracheal Ring.

This fragment was expectorated by the patient from whom Preparation No. 150 was taken.

165 Ossification of Tracheal Cartilages.

Portions of five rings of a trachea. The cartilages are partly ossified, and have become deformed by the ankylosis of adjacent rings.

166 Ossification of Laryngeal and Tracheal Cartilages.

A larynx and part of the trachea dissected to show extensive ossification of the laryngeal cartilages with a similar condition of portions of the tracheal rings.

Presented by Mr. Jarret Dashwood.

167 Osseous Nodules in the Trachea.

A larynx and trachea presenting numerous nodules of true bone beneath the mucous membrane of the trachea. The rings themselves are not ossified, but these bony growths lie in many places between them. The internal surface of the larynx and upper part of the trachea is ulcerated.

William W., æt. 38, a bricklayer of intemperate habits, was admitted under Dr. Hughes for cough and expectoration of seven years' duration. He died two and a half months after admission from phthisis with ulceration of the intestines. *See Insp.* 1856, No. 166.

168 Obstruction of the Trachea from Pressure.

A larynx and upper part of the trachea, which shews the lumen of the tube to be much diminished. The trachea had been compressed for many years by a goitrous tumour of the right lobe of the thyroid gland.

For clinical history and reference see Prep. 117.

169 Trachea eroded by Aneurysm.

The arch of an aorta with the lower end of the trachea. There is a saccular aneurysm, about the size of a Tangerine orange, situated between the origins of the innominate and the left common carotid arteries, in the posterior wall of which are exposed portions of seven tracheal rings, some of them being eroded. On the reverse of the specimen the mucous membrane of the trachea presents just above its bifurcation an opening,

through which protrudes a small pea-shaped nodule of firm decolorised blood-clot.

Michael C., *æt.* 48, was admitted under Dr. Perry for aphonia and dyspnoea. His dyspnoea became urgent, and he died from venous hæmorrhage while tracheotomy was being performed for its relief. *See Insp.* 1890, No. 357.

170 **Epitheliomatous Growth ulcerating into the Trachea.**

Portions of a trachea and œsophagus with the cords of the right brachial plexus. There is a large cancerous mass on the right side of the trachea pressing upon but not invading the subclavian artery. Blue rods are placed beneath the nerves of the right brachial plexus, which are much compressed. There is an irregular cavity in the growth, which communicates with the back of the trachea by a ragged opening about half an inch in diameter. At the lower margin of this opening is a small nodule of growth projecting beneath the mucous membrane. The œsophagus is also slightly encroached upon. Histologically the growth is a squamous epithelioma, and its primary seat is uncertain.

From a patient, *æt.* 50, admitted under Dr. Addison for difficult noisy respiration with dysphagia. There was intense pain down the right arm with symptoms of pressure upon the trachea. No tumour was perceptible in the neck. At the autopsy the anterior surfaces of the bodies of the vertebræ in the neighbourhood of the growth were eroded.

171 **The Trachea invaded by Mediastinal Growth.**

A larynx and upper part of the trachea opened from the front to shew a tuberculated nodule, about the size of a horsebean, projecting into the trachea on the left side. The greater part of the mucous membrane of the trachea is thickened and infiltrated by new growth, and presents a coarsely granular appearance. On either side of the trachea, extending up to the thyroid body, is a mass of growth with secondary deposits in the lymphatic glands.

The recurrent laryngeal nerves are involved, and the left posterior erico-arytæmoid muscle is wasted. Below is suspended a transverse section through the lower end of the trachea, shewing the cartilaginous part of the tube to be entirely surrounded by growth. The wall of the trachea is thickened, and its cartilages are partly ossified. The innominate artery is surrounded but not invaded by the tumour. Histologically the growth is a small round-celled sarcoma with large necrotic arææ.

Hugo A., æt. 49, was admitted under Dr. Taylor with symptoms of a mediastinal tumour. There was paresis of both vocal cords, the left being more severely affected. The patient became much cyanosed, and died comatose. At the autopsy a large mass of growth was found in the mediastinum compressing the superior vena cava. There were secondary deposits in the liver. *See Insp.* 1882, No. 94.

172 **The Trachea invaded by Mediastinal Sarcoma.**

A trachea, the lower part of which is compressed and invaded by a mass of growth situated in the anterior mediastinum. The superior vena cava is almost occluded by growth, and the right pulmonary artery, into which a blue rod has been passed, is surrounded by the tumour, and is much compressed. Histologically the growth is a round-celled sarcoma.

William L., æt. 26, was admitted under Dr. Barlow for symptoms of intrathoracic growth with pressure on the trachea. Two months before admission he had pleurisy; after which he suffered from dyspnœa, cough, and occasional hæmoptysis. At the autopsy secondary deposits were found in the liver. *See Insp.* 1856, No. 206.

SECTION V.—INJURIES AND DISEASES OF THE BRONCHIAL TUBES.

- Foreign Bodies: 173-176.
 Abnormalities: 177.
 Rupture: 178.
 False Membrane and Casts: 179-185.
 Hypertrophied Longitudinal Striæ: 186.
 Compression: 187, 188.
 Dilatation: 189-200.
 Stenosis: 201-204.
 Ulceration: 205, 206.
 Invasion by Caseous Glands: 207, 208.
 Perforation by Aneurysm: 209.
 Invasion or Compression by Growth: 210-212.

173 **Foreign Body in the Right Bronchus.**

A heart and lungs with the air-passages. The trachea and left bronchus have been laid open to shew a bean lodged in the right bronchus. There is a tracheotomy wound.

George K., æt. 3, was admitted under Mr. Cooper Forster with urgent dyspnoea, and absence of breath sounds over the right chest. He was said to have "swallowed" a bean about eighteen hours before admission. Tracheotomy was performed, but the foreign body could not be dislodged; and the patient died three days after the accident. *See Insp.* 1859, No. 88.

174 **Foreign Body in the Right Bronchus.**

A larynx and trachea shewing a date-stone impacted in the right bronchus. There is a deep ulcer in the wall of the trachea caused by the pointed end of the stone. There is a tracheotomy wound.

Mary C., æt. 2½, was admitted under Mr. Poland for urgent

dyspnoea, having drawn a date-stone into the air-passages some hours previously. Attempts were made to shake the stone out and subsequently tracheotomy was performed; but the foreign body could not be dislodged, and the child died three days after the accident. At the autopsy patches of broncho-pneumonia were found in both lungs. *See Insp.* 1864, No. 75.

175 Foreign Body in the Right Bronchus.

The lower end of a trachea with part of the right lung, shewing a button lodged at the first division of the right bronchus, where it has caused much ulceration and thickening of the mucous membrane.

Michael P., æt. 49, fell asleep while sucking a tin button, and awoke suddenly, gasping for breath. He was admitted under Mr. Bryant in 1886 with cough and expectoration, and with diminished breath sounds on the left side. Operation was declined; and he died fifteen weeks later from pneumonia with bronchiectasis. *See Surgical Reports*, vol. 119, case 272; and *Med. Chir. Trans.* vol. 72, p. 441.

Presented by Dr. Gross.

**176 Foreign Body in the Right Bronchus.
Bronchiectasis.**

A larynx and trachea with part of the right lung, shewing a pea firmly wedged in the lower division of the right bronchus. The upper lobe of the lung is healthy; but the remainder of the organ is densely fibroid, and riddled with smooth-walled intercommunicating cavities. There is extreme dilatation of the bronchial tubes, and shaggy lymph upon the pleura.

Joseph A., æt. 3, was admitted under Dr. Pavy in 1886 for a cough of two weeks' duration, and for vomiting which had come on a few days before admission. There were symptoms of pleuritic effusion and meningitis. He died one month after the onset of the illness from empyema and cerebral abscesses. *See Medical Reports*, vol. 94, case 185.

177 Abnormal Division of the Right Bronchus.

The lower end of a trachea and part of the right lung

showing the division of the right bronchus which supplies the upper lobe arising higher than the origin of the left bronchus.

From John M., æt. 16, who died of heart disease. *See Insp.* 1888, No. 105.

178 **Ruptured Bronchus.**

The lower end of a trachea with the main divisions of the bronchi. A branch of the left bronchus is torn through at a point just below the second bifurcation of the tube.

From a woman, æt. 51, who was brought in dead, with fractured ribs and lacerated lung.

179 **Membranous Cast of the Trachea and Bronchi.**

The lower end of a trachea and the main divisions of the bronchi containing a very perfect cast formed of thick coherent membrane.

George W., æt. 5, was admitted under Dr. Wilks for some chronic disease of the joints, and remained in the hospital for twelve months. A few days before his death he contracted diphtheria; and died from broncho-pneumonia. *See Insp.* 1885, No. 29.

180 **False Membrane in the Bronchi.**

A portion of lung shewing the bronchi and smaller tubes filled with hollow casts formed of thick coherent membrane.

Frederick J., æt. 15, was admitted under Dr. Hughes in 1844 with acute broncho-pneumonia and laryngitis. He had been ill for twenty-four days before admission, and was brought to the hospital suffering from urgent dyspnoea. He died the following day. The left lung was consolidated; the right similarly affected, but in rather less degree. There was membrane upon the fauces and in the trachea. *See Insp.* vol. 32, p. 290.

181 **False Membrane in the Trachea and Bronchi.**

The respiratory organs shewing the bronchi filled with membranous exudation, which extends from the smaller

branches to the opening in the trachea left after tracheotomy.

Louisa J., æt. 3½, was admitted under Mr. Birkett, having drunk boiling water from a kettle eight hours previously. The urgent symptoms were relieved by tracheotomy, and the child did well for nine days, when suppuration occurred around the wound, and symptoms of broncho-pneumonia supervened, from which the child died four days later. At the autopsy a non-adherent membrane was found lining the trachea, and there was extensive suppuration in the mediastinum. *See Insp.* 1855, No. 74.

182 **Fibrinous Casts in the Bronchi.**

A portion of the right lung consolidated by pneumonia and shewing the smaller bronchial tubes occupied by fibrinous material. There is recent lymph on the pleura.

John J., æt. 47, was admitted under Dr. Addison for pneumonia of seven days' duration, and died in a few hours. At the autopsy the right lung was consolidated; the left crepitant, but œdematous. *See Insp.* 1855, No. 42; and *Drawing*, No. 248 (49).

183 **Casts from the Bronchial Tubes. Plastic Bronchitis.**

Two branching solid casts expectorated from the larger bronchial tubes.

Thomas L., æt. 26, was admitted under Dr. Gull for dyspnoea and cough. Six weeks before admission, having previously enjoyed good health, he began to suffer from dyspnoea, and shortly afterwards spat up a bronchial cast. From that time his symptoms became worse, and on one occasion he had slight hæmoptysis. During the six weeks he was in the hospital he frequently expectorated casts of the bronchial tubes more or less perfectly formed. He was discharged relieved. *See Medical Reports, Dr. Gull*, 1863, Case 301.

184 **Casts from the Bronchial Tubes. Plastic Bronchitis.**

Three branching solid casts expectorated from the bronchial tubes. Histologically the casts are composed

of a large number of delicate concentric laminae. These laminae consist of a homogeneous membrane with a tendency to fibrillation, containing numerous small bright rounded particles, smaller than a blood-corpuscle.

E. T., a girl æt. 7, suffered from a severe paroxysmal cough for ten days with mucous expectoration, which on two occasions was blood-stained. For the next three days, after very violent fits of coughing, she expectorated casts of the bronchial tubes, and on the fourth day died suffocated in one of the attacks. Pertussis was epidemic in the neighbourhood at the time, but no case of diphtheria had been recently observed. At the autopsy the upper air-passages were found healthy; but the lower part of the trachea was occupied by a large fibrinous mass of the same size as that which had been expectorated on the morning of the girl's death. The ramifications of this cast extended into the right bronchus and its branches, but its larger end lay across the bifurcation of the trachea, occluding the entrance of the left bronchus, but not extending into it. The air-tubes contained no other masses of fibrin. *See Trans. Path. Soc.* vol. 16, p. 48; and *Drawing* No. 248 (54).

185 **Blood Cast from the Air-passages.**

A cast of the trachea and main divisions of the bronchi formed by coagulated blood.

Expectorated by a patient suffering from hæmoptysis.

Presented by Mr. Atkins, 1873.

186 **Hypertrophied Longitudinal Striæ of the Bronchi.**

A trachea and the main divisions of the bronchi laid open to shew marked longitudinal striation of the mucous membrane.

Sarah F., æt. 47, was admitted under Dr. Moxon for chronic bronchitis with cyanosis and albuminuria. She had been subject to winter cough for many years. At the autopsy the lungs were found very emphysematous, and the right side of the heart was dilated. *See Insp.* 1869, No. 26.

187 Compression of the Left Bronchus.

The bifurcation of a trachea with the right and left bronchus mounted to shew the latter flattened by the dilated left auricle.

Frederick W., æt. 15, was admitted under Dr. Bright in 1834. Five years previously he had had rheumatism, which was followed by palpitation of the heart and dyspnœa. There was general anasarca. At the autopsy the pericardium was universally adherent; the heart, especially the left side, was dilated and hypertrophied: the mitral valve was opaque and granular. The pleural cavity was obliterated, except at the left base, where there was considerable serous effusion. *See Insp.* vol. 18, p. 135.

188 Compression of the Bronchus by the Left Auricle.

Three specimens of the bifurcation of the trachea with the first parts of the bronchi to illustrate Dr. Wilkinson King's paper in the Guy's Hospital Reports upon the compression of the bronchus by a dilated left auricle.

The upper preparation is from Robert M., æt. 28, who died from mitral stenosis with adherent pericardium.

The middle preparation is from Lydia P., æt. 21, who died from mitral and tricuspid stenosis.

The lowest preparation is from a child, æt. 2, who died from congenital heart disease. *See Guy's Hosp. Repts.* vol. 3, p. 175, Cases 2, 3, and 4; and *Insp.* vol. 19, p. 137, vol. 22, p. 73, and vol. 25, p. 88.

189 Dilated Bronchi.

The main divisions of the bronchi with the lower part of the trachea, shewing considerable dilatation.

From a boy, æt. 11, who had suffered from dyspnœa and palpitation of the heart for four years. At the autopsy the right pleura was found thickened and adherent, and the lung much compressed. There was also recent pleurisy, with acute pericarditis and peritonitis. *See Insp.* vol. 2, p. 140.

Presented by Dr. Hodgkin, 1827.

190 Dilated Bronchial Tube.

A portion of a lung shewing at its lower part a smooth-walled cavity which communicates directly with a bronchial tube. The neighbouring pulmonary tissue appears to be normal, and there are no pleural adhesions.

Kate H., æt. 30, was admitted under Mr. Cock for erysipelas from which she died. *See Insp.* 1863, No. 145.

191 Dilated Bronchial Tubes.

A marginal portion of lung in which are numerous uniformly dilated bronchial tubes. The lung is emphysematous and there are old pleural adhesions.

192 Dilatation of the Bronchial Tubes.

A portion of a right lung, the upper lobe of which shews extreme dilatation of the bronchial tubes, which lie in a dense mass of fibroid material replacing the lung tissue. The pleura over the fibroid portion of the lung is much thickened. The tubes of the lower lobe are also somewhat dilated.

Eliza H., æt. 26, was admitted under Dr. Wilks for bronchitis, ascites, and albuminuria. She had suffered from cough for many years. At the autopsy there was found hypertrophy of the right side of the heart with nutmeg liver and indurated kidneys. The left lung was emphysematous. *See Insp.* 1879, No. 24.

193 Dilatation of the Bronchial Tubes.

A right lung shewing general enlargement of the bronchial tubes, most marked at the upper lobe where the pulmonary tissue has almost entirely disappeared. There is slight thickening of the pleura with old adhesions.

Louisa L., æt. 16, was admitted under Dr. Pavy with cough and dyspnoea, which were said to have existed since infancy. There was œdema of the legs and cyanosis. At the autopsy the right ventricle was found greatly hypertrophied. *See Prep.* 1392 (10) [2nd Edit.]; and *Insp.* 1862, p. 87.

194 Dilated Bronchial Tubes.

A portion of a left lung, shewing its upper lobe to consist of a congeries of dilated tubes with diminution of the intervening pulmonary tissue. The pleura shews loose adhesions. The lower lobe is slightly emphysematous, but without dilatation of the bronchial tubes.

Sarah C., æt. 39, was admitted under Dr. Wilks for severe bronchitis and œdema of the legs. She had suffered from cough for many years. At the autopsy the lungs appeared very emphysematous, and the right side of the heart was dilated. No tubercles were found in any organ. *See Insp.* 1861, No. 70.

195 Dilatation of the Bronchial Tubes.

The apex of a right lung shewing a thick mass which looks like a much thickened pleura, but which contains largely dilated and sacculated bronchial tubes, proving that it is in great measure obsolete lung tissue.

Samuel H., æt. 48, was admitted under Dr. Goodhart for profuse hæmoptysis, and died two days after admission. At the autopsy the lungs were found very emphysematous with recent and chronic phthisis at both apices. There was tuberculous ulceration of the colon. *See Insp.* 1884, No. 121.

196 Dilatation of the Bronchial Tubes.

A section of a right lung shewing in its upper lobe a large number of dilated bronchial tubes surrounded by lung tissue, which is generally of very open texture, but is in parts consolidated. In the lower lobes are scattered patches of broncho-pneumonia.

Richard C., æt. 27, was admitted under Dr. Pye-Smith for bronchitis and anasarca. At the autopsy there was hypertrophy and dilatation of the right side of the heart. The upper lobe of the left lung was healthy, while in the lower lobe the tubes were dilated, as shewn in the preparation of the right lung. *See Insp.* 1885, No. 144.

197 Saccular Dilatation of the Bronchial Tubes.

A portion of a left lung shewing in all parts of its cut surface small rounded cavities with smooth thin walls,

formed by saccular dilatation of the bronchi, which communicate by comparatively narrow apertures with the tubes above. The lung is not emphysematous, nor indurated. The pleura is thickened, and was adherent.

From a man who was killed by a fall from a warehouse. At the autopsy the cavities were filled with pus. *See Insp.* 1874, No. 252.

198 **Saccular Dilatation of the Bronchial Tubes.**

A portion of a left lung of which the lower lobe is converted into a congeries of thin-walled globular sacs, formed by dilatation of the bronchial tubes. These sacs communicate with one another by small sinuous passages. The main bronchus is healthy. There are filamentous pleuritic adhesions over the affected lobe.

Maria G., æt. 22, was admitted under Dr. Goodhart with bronchitis and pyrexia. She died five days after admission from lobar pneumonia of the apex of the right lung. *See Insp.* 1886, No. 97.

199 **Saccular Dilatation of the Bronchial Tubes.**

A portion of a lung occupied almost entirely by greatly dilated bronchial tubes. The pleura is thickened.

William T., æt. 34, died immediately after his admission under Dr. Bright in 1841. At the autopsy there were firm pleural adhesions with bronchiectatic cavities. The left lung was emphysematous, and the bases of both lungs were affected with gangrenous pneumonia. *See Insp.* vol. 31, p. 137.

200 **Dilatation of Bronchial Tubes following an Empyema.**

The lower half of a right lung shewing dilated bronchial tubes forming large cavities. One of these is two and a half inches in diameter. On the reverse of the specimen the pleura is seen to be shaggy, and a superficial cavity has been laid open, and its outer wall reflected.

Elizabeth G., æt. 33, was admitted under Dr. Bright with signs of contraction and cavitation of the right lung, with profuse

expectoration and hectic fever. Two years previously she had been under Dr. Hughes' care for empyema. At the autopsy the left lung was healthy but œdematous. The right pleural cavity was obliterated by dense adhesions above, and below was traversed by a few bands and bridles of fibroid tissue. The upper lobe of the right lung was dense and airless. *See Insp.* vol. 32, p. 55.

201 Syphilitic Stenosis of the Right Bronchus.

A larynx and trachea, with a portion of the right lung. The right bronchus is considerably narrowed, and its walls are thickened. The lung is dense and shrunken, and interlaced with bands of fibroid tissue. The mucous membrane of the trachea is in parts ulcerated and puckered. There is an opening left after tracheotomy. The right vagus and its recurrent laryngeal branch have been dissected from a mass of fibroid material in which they were involved.

John M., æt. 38, was admitted under Dr. Moxon for dyspncea with a "brassy" cough. He had syphilis when eighteen years old. There was extreme laryngeal stridor, with immobility of the vocal cords, for which tracheotomy was performed. He died a month later. At the autopsy there was collapse of the lower lobe of the left lung, and gummata were found in the liver. *See Insp.* 1883, No. 159.

202 Syphilitic Stenosis of the Left Bronchus.

The left bronchus is much contracted at its commencement, and there is irregular ulceration with scarring of the trachea and larynx.

Emily B., æt. 35, a married woman without children, was admitted under Dr. Taylor for sore throat and expectoration of about one year's duration. She died of a chronic affection of the lungs (phthisis and bronchiectasis). The Fallopian tubes were thickened and adherent. *See Insp.* 1883, No. 393.

203 Stenosis of the Left Bronchus.

The lower part of a trachea and the left bronchus, the latter shewing an annular constriction about half an inch from its commencement. The bronchial tubes below

are much dilated, and the longitudinal striation prominent. The mucous membrane appears healthy.

Charles C., *æt.* 32, was admitted under Mr. Birkett for laryngeal obstruction. He was an intemperate dissipated man, and had had syphilis. Paroxysms of very urgent dyspnoea came on, and tracheotomy was performed in one of these attacks a short time before his death. At the autopsy the opening of the glottis was found much narrowed by swelling and induration of its walls. There was slight enlargement of the bronchial glands, but they did not exert any pressure upon the bronchus. The liver was lardaceous. *See Insp.* 1856, No. 191.

204 Syphilitic Stenosis of the Bronchi.

The lower part of a trachea, with the main divisions of the bronchi which shew considerable narrowing. Their mucous membrane is thickened and scarred, a condition which is found in a slighter degree in the trachea.

Mary D., a married woman, *æt.* 41, was admitted under Dr. Wilks with dyspnoea, cyanosis, and anasarca. She had suffered from winter cough for eighteen years. At the autopsy the connective tissue about the trachea and bronchi was adherent as from chronic inflammation, and the liver was much scarred. *See Insp.* 1873, No. 163.

205 Syphilitic Ulceration of the Bronchi.

The lower part of a trachea with the right and left bronchus. The walls are thickened, and the mucous membrane extensively and deeply ulcerated.

Jessie B., *æt.* 46, was admitted under Dr. Habershon, and died from cirrhosis of the liver and bronchitis. At the autopsy the whole of the trachea was found to be ulcerated. *See Insp.* 1858, No. 22.

206 Syphilitic Disease of the Root of the Lung.

A trachea and oesophagus with a portion of the right lung. There is an irregular cavity with thick shaggy walls at the root of the lung. It measures about two inches in length and three quarters of an inch in width, and communicates at its upper end with the main

bronchus. The mucous membrane of the bronchus shews irregular scarring and deep ulceration. There is a large mass of gummatous and fibroid material compressing the lower end of the œsophagus.

From a gentleman, æt. 53, who died of profuse hæmoptysis. The symptoms during life were thought by different physicians to indicate phthisis, cancer of the lung, or syphilis. At the autopsy a pint of serous effusion was found in the right pleural cavity. There was no glandular enlargement.

Presented by Dr. Miller.

207 Perforation of a Bronchus by an Adherent Lymphatic Gland.

The bifurcation of a trachea with the right and left bronchi. The left bronchus shews a small black patch where an adherent gland has penetrated its wall. Behind the trachea is an enlarged and calcareous gland.

Mary Ann W., æt. 60, was admitted under Dr. Barlow for general dropsy and bronchitis. She died of nephritis. At the autopsy the lungs were found in a condition of senile emphysema. *See Insp.* 1865, No. 267.

208 Bronchus opened by a Suppurating Gland.

A larynx and trachea with part of the right lung attached, mounted to shew, at the commencement of the right bronchus, an irregular opening which communicates with a suppurating caseous gland situated at the bifurcation of the trachea. The mediastinal glands are many of them enlarged and caseous. There is extensive tuberculous ulceration of the trachea and the cut surface of the lung shews many scattered patches of caseous broneho-pneumonia. There is recent lymph upon the pleura.

Sarah S., æt. 2, was admitted under Dr. Pavy for cough and wasting. A fortnight before her death sudden dyspnœa came on, for which tracheotomy was about to be performed when the attack passed off. At the autopsy general tuberculosis of the viscera was found. *See Insp.* 1882, No. 116.

209 Bronchus opened by Aneurysm.

The lower end of the trachea with the bronchi and the arch of the aorta. At the commencement of the left bronchus there is a ragged opening half an inch in diameter communicating with a sacular aneurysm about the size of a pigeon's egg, which arises from the transverse arch of the aorta. The aneurysm is nearly filled with laminated clot.

George W., a sailor, æt. 30, was admitted under Dr. Wilks suffering from hæmoptysis with the physical signs of pressure on the left bronchus. He died from gangrenous broncho-pneumonia. *See Insp.* 1877, No. 181.

210 Bronchus invaded by Sarcoma of the Mediastinal Glands.

The lower part of a trachea with the right lung attached. The upper division of the right bronchus, indicated by a blue rod, is surrounded and much constricted by a soft white growth which is continuous with a mass at the root of the lung. Almost the whole of the lower lobe is occupied by a cavity with rough trabeculated walls surrounded by pneumonic lung. There are similar smaller cavities in the middle lobe and the lower part of the upper lobe, and numerous small excavations elsewhere in the pulmonary tissue. On the reverse of the specimen the mediastinal growth may be seen to surround and invade the superior vena cava. The pleura is greatly thickened. Histologically the tumour is a small round-celled sarcoma.

Ellen S., æt. 38, was admitted under Dr. Taylor with physical signs indicating destruction of the right lung. She died a few hours after admission. At the autopsy nodules of growth were found in the mesenteric glands, ovary, and pancreas. The left lung was quite healthy. *See Insp.* 1885, No. 306.

211 Bronchus invaded by Sarcoma.

The lower end of the trachea with a portion of the right lung. There is a large mass of firm growth surrounding,

infiltrating, and compressing the right bronchus. It invades the adjacent pleura, extending to the apex of the upper lobe. Histologically the growth is a spindle-celled sarcoma.

Henry W., æt. 62, was admitted under Dr. Pavy for œdema of the arms and dyspnoea, with distension of the veins over the thorax and abdomen. The lower part of the right chest was dull on percussion. His illness had lasted nine months before his admission to the Hospital. At the autopsy no growth was found in any other organ. *See Insp* 1868, No. 25.

212 **Bronchus compressed by Mediastinal Sarcoma.**

The lower part of a trachea with the main divisions of the bronchi. The left bronchus is invaded and compressed by a soft white growth at the root of the lung. Histologically the growth is a round-celled sarcoma.

Charles K., æt. 42, was admitted under Dr. Goodhart for effusion into the left chest, which was found upon aspiration to be blood-stained. A month later twenty-four ounces of pus were removed from the chest. He died fifteen weeks from the commencement of his illness. At the autopsy there were secondary deposits in the left pleura, and the lung was in a condition of disintegrating broncho-pneumonia. *See Insp*. 1890, No. 304.

SECTION VI.—INJURIES AND DISEASES OF THE LUNG.

- Wounds : 213, 214.
- Lacerations : 215-218.
- Foreign bodies : 219, 220.
- Compression : 221-224.
- Red Induration : 225.
- Brown Induration : 226.
- Apoplexy : 227, 228.
- Infarction : 229, 230.
- Thrombosis of Pulmonary Artery : 231.
- Broncho-Pneumonia : 232, 233, 237, 238.
- Anthraxis : 234-236.
- Pyemic Abscess : 239.
- Gangrene : 240-243, 220, 230, 247-250, 296, 297.
- Lobar Pneumonia : 244-246.
- Actinomycosis : 251.
- Syphilis : 252-257.
- Miliary Tuberculosis : 258-265.
- Tuberculous Broncho-Pneumonia : 266-272.
- Phthisis : 273-303, 308.
- Cavitation : 286-295, 297-307, 322.
- Aneurysm of Pulmonary Artery : 298-303.
- Emphysema :
 - Interlobular : 309-311.
 - Vesicular : 312-320.
 - Compensatory : 318-319.
- Epithelioma : 321-323.
- Carcinoma : 324-328.
- Carcinoma with Tuberculosis : 327, 328.
- Sarcoma : 329-336.
- Hydatid : 337-344.

213 **Perforating Wound of the Lung.**

The lower lobe of a left lung shewing a perforation extending vertically downwards from the middle of the

interlobar border to the diaphragmatic surface. The perforation is about an inch and a half in diameter, and is plugged with fragments of clothing. There is recent lymph upon the pleura and some consolidation of the lower part of the lobe.

William M., a sailor, æt. 20, was admitted under Mr. Bransby Cooper in 1830, having fallen from a mast sixty feet high upon a belaying-pin, which perforated his chest. He died twenty-four hours after the accident. *See Insp.* vol. 15, p. 23.

214 **Bayonet Wound of the Lung.**

A right lung shewing in its middle lobe the track of a bayonet wound. The triangular shape of the perforation is well seen.

Robert C., æt. 16, was admitted under Mr. Durham for stabs in several places, and other severe injuries, from which he died thirty-six hours after admission. *See Insp.* 1879, No. 209.

215 **Traumatic Hæmorrhage into the Lung.**

The lower lobe of a left lung shewing a blood-clot two inches in diameter embedded in the pulmonary tissue towards the base. On the reverse of the specimen the pleura is seen to be lacerated in several places.

Henry B., æt. 40, was admitted under Mr. Durham having been struck on the left side by a lever. There was some hæmoptysis. He died one week after admission. At the autopsy the left pleural cavity contained much blood, and five ribs on that side were fractured and had lacerated the parietal pleura. The spleen was also torn. *See Insp.* 1890, No. 266.

216 **Ruptured Lung.**

A right lung shewing a deep vertical rent on its lateral aspect from apex to base. On the reverse of the specimen the pleura covering the back of the lung shews a vertical tear about two inches long produced by the ends of fractured ribs.

John S., æt. 4, was admitted under Mr. Hilton for injuries

received by being run over. The fourth to the eighth ribs on the right side were fractured at their angles. The pleural cavity was nearly full of blood. *See Insp.* 1869, No. 205.

217 **Ruptured Lung.**

A right lung shewing a large laceration on the under surface of its upper lobe, in the interlobar fissure.

John L., æt. 35, was admitted under Mr. Poland for injuries received by the fall of a cylinder upon him. At the autopsy the first five ribs on the right side were broken and the pleural cavity contained three pints of uncoagulated blood. *See Insp.* 1865, No. 206.

218 **Laceration of the Lung.**

A right lung shewing a deep laceration extending upwards for two inches from the inferior margin of the upper lobe. There are two smaller lacerations at the root of the lung on either side of the bronchus.

George T., æt. 10, was admitted under Mr. Davies-Colley. He was knocked down by a waggon which passed over his chest, and on admission was found to have a pneumothorax of the right side of his chest. At the autopsy the pleural cavity contained air and several ounces of bloody fluid, but the ribs and chest wall were found uninjured. *See Insp.* 1888, No. 219.

219 **Foreign Body from the Lung.**

An ear of bearded grass removed from an abscess which pointed by the side of the vertebral border of the scapula. It was probably swallowed and drawn into the lungs, and assisted by its spikelets, worked its way to the surface. *See Trans. Path. Soc.* vol. 33, p. 420.

Presented by Dr. Wilks.

220 **Gangrene of the Lung from Foreign body in the Bronchus.**

A right lung the lower and middle lobes of which shew pneumonic consolidation which has in many parts broken down, producing irregular ragged cavities of various

sizes. There is a similar condition of that part of the upper lobe which lies over the middle lobe.

William C., æt. 39, was admitted under Dr. Wilks for cough and dyspnœa of fourteen days' duration. There were physical signs of consolidation of the base of the right lung with extremely fœtid expectoration. He died fourteen days after admission. At the autopsy a large angular piece of bone was found impacted in the right bronchus just below the bifurcation of the trachea. See *Insp.* 1877, No. 223.

221 **Compressed Lung.**

The lower lobe of a left lung much shrunken and wrinkled on its surface. The pleura is covered with a reticulated layer of recent lymph.

Samuel W., æt. 16, was admitted under Mr. Key in 1835, for strumous disease of the cervical glands. At the autopsy the left pleural cavity was full of serum and there was general tuberculosis of the viscera. See *Insp.* vol. 20, p. 74 ; and *Prep.* 1541 (24) [2nd Edit.].

222 **Compressed Lung.**

A right lung the upper lobe of which is somewhat distended and covered with flocculent adhesions. The middle and lower lobes are much shrunken and almost solid ; the pleura covering them is thickened and for the most part quite smooth.

Ada V., æt. 24, was admitted under Dr. Newton Pitt for chronic endocarditis, with the signs of effusion of fluid into the right chest. It was stated that pleuritic effusion had existed for the preceding eleven months. At the autopsy thirty ounces of serum were found in the right chest, and the aortic and tricuspid orifices were narrowed. See *Insp.* 1891, No. 419.

223 **Contraction of the Left Lung with Compensatory Enlargement of the Right.**

The lower part of a trachea with the bronchi and lungs attached. The left lung shews the pleura thickened, in some places to the extent of half an inch ; the pulmonary tissue is condensed and fibroid and the bronchial

tubes are thickened and dilated. The right lung is greatly enlarged and its anterior edge extended in the recent state two inches beyond the middle line.

James K., æt. 4, was admitted under Dr. Wilks. He died from lardaceous disease of the kidneys, resulting from the prolonged suppuration of the empyema, which was probably the initial cause of the fibrosis of the left lung. *See Insp.* 1873, No. 7.

224 **Atrophy of the Middle Lobe of the Lung.**

A right lung the middle lobe of which is represented by a fibrous lamina one eighth of an inch thick, which was adherent to the upper lobe.

Ruth A., æt. 20, was admitted under Dr. Wooldridge, and died of acute nephritis. *See Insp.* 1888, No. 18.

225 **Red Induration of the Lung.**

A portion of a left lung the cut surface of which shews the greater part of the organ to be reddish in colour and less spongy in texture than the healthy lung tissue of which small areas may still be distinguished. The pleura is slightly thickened.

Caroline A., æt. 28, whilst pregnant, was admitted under Dr. Habershon for heart disease. She died from exhaustion during parturition. At the autopsy the mitral valve was contracted, and the right side of the heart greatly hypertrophied. *See Insp.* 1872, No. 286.

226 **Brown Induration of the Lung.**

A portion of the lower lobe of a lung the cut surface of which shows the pulmonary tissue to be unusually firm, and in parts consolidated. In the recent state the consolidated portions were brown in colour. There is flocculent lymph upon the pleura. Histologically the alveolar walls are thickened, and many of the spaces are filled with red blood-corpuscles.

Alfred W., æt. 12 years, was admitted under Dr. Pavy for mitral stenosis. He had an attack of acute rheumatism six years previously. During the last month of his life he suffered from

hæmoptysis and occasional pyrexia. At the autopsy both lungs were partly consolidated, and in the upper lobe of the right lung there was a localised extravasation of blood. *See Insp.* 1890, No. 358.

227 Pulmonary Apoplexy.

A portion of lung presenting a large well-defined reddish area, solid from effused blood, and projecting above the surrounding tissue. On the reverse of the specimen two branches of the pulmonary artery which are cut across are shewn filled with thrombus.

From S. M., a male, æt. 17, who had suffered from palpitation of the heart and dyspnœa for eight months, and more recently from œdema of the lower extremities and occasional hæmoptysis. At the autopsy there was chronic endocarditis of the aortic and mitral valves with recent lymph upon the pericardium. *See Insp.* vol. 9, p. 77; and *Prep.* 1414 (32) [2nd Edit.].

Presented by Mr. Chapman, 1830.

228 Pulmonary Apoplexy.

A marginal portion of lung shewing a circumscribed area, solid, reddish in colour, and slightly raised above the surrounding tissue.

From the same case as the preceding specimen (227).

229 Infarction of the Lung.

A right lung the greater part of the lower lobe of which is consolidated as a result of infarction of branches of the pulmonary artery.

Thomas W., æt. 60, was admitted under Dr. Pavy for heart disease, œdema of the lower extremities, and hæmoptysis. At the autopsy all the valves of the heart were found thickened, the mitral and aortic orifices being contracted. *See Insp.* 1883, No. 353.

230 Gangrene of a Pulmonary Infarct.

The lower lobe of a left lung incised to shew several large infarcts, in one of which sloughing has occurred

with perforation of the pleura over it. Branches of the pulmonary artery are seen filled with blood-clot.

Mary W., æt. 40, was admitted under Dr. Habershon for cough and hæmoptysis of four months' duration. She died from mitral stenosis. At the autopsy the main branches of the pulmonary artery were obstructed by blood-clot, and ante-mortem thrombi were found in both auricles. There was infarction of the kidneys. *See Insp.* 1869, No. 84.

231 **Thrombosis of the Pulmonary Artery.**

A section of a lung the central portions and base of which are fibroid and contracted, the rest of the lung being extremely emphysematous. On the cut surface may be seen numerous branches of the pulmonary artery filled with firm adherent clot. The pleura is thickened at the lower part of the lung, and was adherent.

Richard B., æt. 57, was admitted under Dr. Moxon for dyspnoea, and dropsy of the lower extremities. His illness had existed six years. At the autopsy there was atheroma and dilatation of the pulmonary artery, which contained an adherent thrombus softening in the centre; the right ventricle was hypertrophied. *See Insp.* 1883, No. 207.

232 **Broncho-Pneumonia.**

A portion of lung, partially injected, shewing small areas of consolidation, which under the microscope present the appearance of broncho-pneumonia.

Presented by Sir Astley Cooper.

233 **Broncho-Pneumonia.**

A section of a left lung "stuffed from apex to base with defined grey points of hepatisation granular on section." Histologically the appearances are those of non-tuberculous broncho-pneumonia. There is a cretaceous nodule with some excess of fibroid tissue at the apex.

Joseph P., æt. 41, was admitted under Mr. Cooper Forster with most of his ribs on the right side fractured. He died seventeen days later. *See Insp.* 1873, No. 143.

234 Carbonaceous Lung.

A lung shewing coal-black fibrous consolidation of its upper part. The lower part of the lung is emphysematous and contains scattered black nodules. The pleura is greatly thickened, especially over the upper lobe.

William C., æt. 42, a miner in tin mines in Cornwall and afterwards in California, was admitted under Dr. Goodhart for chronic disease of the lungs. There was some hæmoptysis a few days before death. At the autopsy the right lung was similarly affected to the left but in a less degree. The bronchial glands were exceedingly black. *See Insp.* 1878, No. 118.

235 Carbonaceous Lung.

A portion of lung indurated and blackened by carbonaceous deposit.

236 Miners' Phthisis.

A portion of lung exceedingly black from carbonaceous deposit, presenting a large irregular cavity and many flocculent adhesions of the pleura.

237 Broncho-Pneumonia with Cavitation of the Lung.

A right lung which has been injected and shews on section numerous small rounded cavities, the largest the size of a dried pea. These cavities are more numerous in the upper than in the lower lobe, and when near the surface appear as bullæ beneath the pleura, somewhat resembling emphysematous blebs. Throughout the lung there are small patches of broncho-pneumonia. Histologically there is no clear evidence of tubercle. Many of the patches of broncho-pneumonia are softening in the centre; the largest cavities are lined with a definite membranous wall.

From an infant who died from hydrocephalus.

Presented by Mr. P. A. S. Dodd.

238 Broncho-Pneumonia with Cavitation and Bronchiectasis.

Portions of lung shewing scattered patches of broncho-pneumonia and numerous minute cavities. Some of these are formed by dilatations of the bronchial tubes and others are excavations in the pneumonic lung. There is granular lymph upon the pleura. Histologically there is no evidence of tubercle.

Ernest E., æt. 2, was admitted under Dr. Pye-Smith for broncho-pneumonia and died two days after admission. *See Insp.* 1890, No. 142.

239 Pyæmic Abscesses of the Lung.

A portion of lung the cut surface of which is for the most part of a reddish colour and less spongy than normal. There are several circumscribed yellow patches of commencing suppuration. On the reverse of the specimen similar patches are seen to form slight projections beneath the pleura.

Henry J., æt. 50, was admitted under Mr. Birkett for stone in the bladder, and died with symptoms of pyæmia. At the autopsy there was chronic cystitis, with abscesses in the kidneys. *See Insp.* 1856, No. 26.

240 Gangrene of the Lung.

A portion of the lower lobe of the right lung, presenting an irregular cavity, the walls of which are ragged and covered with purulent secretion. The cavity is surrounded by solid lung, and there is granular lymph on the pleura.

Charles B., æt. 48, was admitted under Dr. Addison in 1853. He had suffered from winter cough for five years, which had been very severe for the three weeks preceding admission. At the autopsy the cavity in the lung contained a loose slough; the liver was contracted. *See Insp.* vol. 37, p. 224.

241 Gangrene of the Lung.

A section of a right lung shewing in the upper and middle lobes numerous minute cavities with ragged walls. At the back of the specimen is hung a section of the left lung, in the upper lobe of which the destructive process is more advanced, while the lower lobe is in great part consolidated by broncho-pneumonia.

Matilda C., æt. 25, was admitted under Mr. Birkett with constitutional syphilis. She had been complaining of cough and cold for eight weeks. At the autopsy there was syphilitic ulceration of the trachea, with gummata of the liver and ensiform cartilage. See *Insp.* 1870, No. 313; and *Prep.* 154.

242 Gangrene of the Lung.

The upper preparation is a piece of gangrenous lung tissue which was detached and is said to have been found in the pleural cavity. Below is mounted a portion of the opposite lung of the same patient shewing a small shaggy-walled cavity.

243 Gangrene of the Lung.

A section of a left lung shewing scattered throughout it numerous small cavities with shaggy walls, imbedded in consolidated pulmonary tissue. The pleura is thickened and there is an increase of the fibrous tissue between the lobules.

Bridget M., æt. 26, was admitted under Dr. Gull suffering from dyspnoea from syphilitic laryngitis for which tracheotomy was performed. At the autopsy the right lung was found similarly affected, though in a less degree, to the left. See *Insp.* 1866, No. 111.

244 Early Lobar Pneumonia.

A portion of the upper lobe of a right lung shewing incomplete pneumonic consolidation. The pleura is covered with a thin layer of opaque lymph.

From a butler, æt. 48, who died from acute pneumonia of ten

days' duration. He had suffered for many years from biliary colic and at the autopsy there was found an early condition of Bright's disease of the kidneys. The left lung was healthy. *See Insp.* vol. 8, p. 28; and *Prep.* 1925 (25) [2nd Edit.].

245 **Lobar Pneumonia.**

A section of a right lung the lower lobe and hinder half of the upper lobe of which are consolidated by lobar pneumonia. In the midst of the consolidated lower lobe is a tract of indurated tissue over the surface of which the pleura is greatly thickened.

Thomas W., æt. 23, was admitted under Dr. Habershon for supposed relapsing fever. At the end of the third week of his illness symptoms of acute pneumonia supervened, and he died two days later. At the autopsy the spleen, which weighed 15 oz., was thickly beset with small softened yellow patches. *See Insp.* 1870, No. 15; and *Prep.* 1999 (16) [2nd Edit.].

246 **Lobar Pneumonia.**

A section of the upper lobe of a lung, which is solid throughout, and presents a granular surface. There is a thin layer of lymph on the pleura.

George S., æt. 19, was admitted in 1832 for fever and emaciation, with bedsores on the hips and buttocks. He had previously suffered from diarrhœa. The fever subsided, but he gradually became weaker, and died. At the autopsy several healing ulcers were found in the lower part of the ileum. *See Insp.* vol. 11, p. 126.

247 **Gangrene of the Lung.**

A left lung the lower lobe of which has been cut to shew a large gangrenous area, surrounded by pneumonic lung. The slough has separated from the pleura covering it, and at its upper part from the lung tissue. The pleura generally is covered with a thick layer of yellow lymph.

Presented by Dr. Bright.

248 **Gangrenous Pneumonia. Intra-pleural Hæmorrhage.**

A right lung a portion of the upper lobe of which has

been removed to exhibit, towards its base, a ragged cavity about an inch in diameter. The lung tissue around the cavity is consolidated by pneumonia. Within the cavity the blue rod indicates a large branch of the pulmonary artery, the ulceration of which led to fatal hæmorrhage. A communication between the excavation in the lung and the pleural cavity is marked by a red rod. There is recent lymph upon the pleura.

William L., æt. 45, was admitted under Dr. Perry for hæmoptysis and pyrexia, with dullness at the lower part of the front of the right chest. He died the day after admission with symptoms of internal hæmorrhage. At the autopsy 52 ounces of clotted blood were found in the right pleural cavity. *See Insp.* 1891, No. 119.

249 Gangrene of the Lung perforating the Œsophagus and Bronchus.

A right lung the greater part of the hinder portion of which is occupied by an irregular cavity with shaggy sloughing walls, surrounded by consolidated pulmonary tissue. The cavity communicates with the œsophagus, and with the main division of the right bronchus. On the lateral aspect of the lung is seen an opening made by operation into the lowest part of the cavity. The pleura is covered with recent lymph.

Alexander S., æt. 12, was admitted under Dr. Shaw for pain in the right side, with pyrexia. Expectoration was profuse and fetid, and there were physical signs of cavitation at the base of the lung. An attempt was made to drain the cavity through an opening in the wall of the chest, and the patient died on the fifth day of his illness, sixteen hours after the operation. *See Insp.* 1893, No. 151.

250 Gangrene of the Lung.

A section through a right lung the upper part of which is occupied by a spherical cavity measuring three inches in diameter, which is separated from the pleura at its posterior part by a layer of hepatised lung, in some places less than an eighth of an inch in thickness. The

interior of the cavity is irregular, and attached to its wall there are numerous small shaggy sloughs. - Around it is solid lung, which, under the microscope, presents the appearances of lobar pneumonia. There is recent lymph upon the pleura.

From F. C., a nurse *æt.* 29, who was attacked with epidemic influenza followed by symptoms of acute pneumouia at the apex of the right lung, and died sixteen days after the onset of her illness. *See Guy's Hospital Gazette*, 1893, p. 132.

Presented by Dr. H. E. Harris.

251 **Actinomycosis of the Lung.**

A section of the lower lobe of a lung the cut surface of which presents several nodules of consolidated lung tissue about half an inch in diameter. In the recent state these nodules consisted of a soft central white area surrounded by a deep red zone. Under the microscope the centre of the nodule is seen to be made up of small round cells, among which are numerous actinomyces, while in the periphery the alveoli of the lung are filled with extravasated red blood-corpuscles.

Henry L., an engraver, *æt.* 42, was admitted under Dr. Taylor for an abscess in the lumbar region, which was incised and drained. He was much emaciated, and had been ill for three months before admission. The discharge from the abscess almost ceased and the cavity contracted, but the temperature remained high, and the patient becoming gradually exhausted, died during an attack of syncope six weeks after the operation. At the autopsy the lumbar abscess was found to communicate with a ragged cavity at the lower part of the right lobe of the liver, in the walls of which were found numerous ray fungi. Several smaller actinomycotic nodules were found in the rest of the liver and throughout both lungs. *See Insp.* 1890, No. 330.

252 **Diffuse Syphilitic Fibrosis of the Lung.**

Portion of a right lung, in which there is a considerable excess of fibroid material appearing on the cut surface as a delicate network traversing the pulmonary tissue in all directions. This fibroid change is less marked at

the apex than at the base ; in the latter situation the air-vesicles are many of them dilated. The pleura is slightly thickened, and was adherent. Histologically the dense fibroid tissue that pervades the lung shews scattered through it numerous collections of small round cells not undergoing caseation. No giant cells are seen. The walls of the small arteries are thickened.

John A., æt. 54, was admitted under Dr. Taylor with severe bronchitis and dyspnœa of one week's duration. He had suffered from winter cough for some years. At the autopsy the testes were fibroid, the liver was scarred, and the kidneys were lardaceous. The left lung was affected in the same way as the right. *See Insp.* 1889, No. 451.

253 Syphilis of the Lung.

A section of a right lung shewing at the upper part of the lower lobe a circumscribed patch of fibroid material with radiating processes extending into the surrounding pulmonary tissue. The interlobar septum is thickened, and from its upper portion similar fine fibrous strands radiate into the upper lobe. Other portions of this lobe are very emphysematous, and the pleura over it is much thickened.

John S., æt. 36, was admitted under Mr. Cooper Forster with a broken neck. At the autopsy the testes were fibrous, and there was lardaceous disease of the liver, spleen, and kidneys. No tubercle was found in any organ. *See Insp.* 1871, No. 18 ; and *Trans. Path. Soc.* vol. 22, p. 38.

254 Gummata of the Lung.

A portion of the upper lobe of a lung shewing on the cut surface two masses, one of which was described in the recent state as "consisting of a circumscribed nodule of a firm yellowish dry substance corresponding in all particulars to that in the liver [gumma], except in being somewhat less firm." The other is "softening, breaking up, and in process of forming a cavity."

Histologically the nodules are seen to consist of fibroid tissue with many areas of caseation and a few giant cells.

Sidney S., æt. 29, a sailor, was admitted under Dr. Rees in a moribund condition, suffering from laryngeal obstruction and hæmoptysis. There was a scar of a chancre upon the penis. At the autopsy gummata were found in the liver. See *Insp.* 1858, No. 85; and *Trans. Path. Soc.* vol. 9, p. 55.

255 **Gummata of the Lung.**

The lower lobe of a left lung shewing at its hinder part a large yellowish mass partially separated from the surrounding tissue. Smaller nodules are seen in the adjacent lung. The pleura over the gumma is much thickened. Histologically the nodule consists of fibrous tissue which is stained with difficulty.

Jenkins J., æt. 27, was admitted under Dr. Moxon for acute laryngitis with severe dyspnoea, for which tracheotomy was performed. He died three days later. He had had a chancre with suppurating buboes. At the autopsy the lungs were generally healthy except for some bronchitis. Both testes were fibrous, and there were many gummata in the liver. See *Insp.* 1882, No. 171.

256 **Gummata of the Lung.**

A portion of a lung shewing scattered through it several small masses of irregular shape, yellowish in colour, and firm on section. These masses are easily separable from the surrounding pulmonary tissue which is healthy. Histologically the nodules shew a central area of caseous material surrounded by a narrow zone of fibrous tissue in which are many small round cells.

Robert R., æt. 39, was admitted under Dr. Taylor for hepatic ascites with slight jaundice. Paracentesis abdominis was twice performed; he became comatose and died. He had suffered from cough and dyspnoea for six months. At the autopsy several gummata were found in the testes, and one in the liver, which was in a condition of diffuse syphilitic hepatitis. See *Insp.* 1875, No. 206.

257 Lung invaded by Gumma.

The first two ribs with the apex of the right lung, shewing a large fibroid mass invading the first rib, and surrounding the pulmonary tissue. The cut section of lung shews several firm yellowish nodules with thin fibrous capsules. Histologically the growth is gummatous.

William B., æt. 36, was admitted under Dr. Wilks having suffered from constitutional syphilis for eight years. On admission there was œdema of the right arm, and distension of the veins over the chest. At the autopsy there was found syphilitic disease of the liver, skull, spleen, and testes. The superior vena cava was obliterated. *See Insp.* 1875, No. 88½.

258 Miliary Tubercles of the Lung.

Pieces of a lung closely studded with minute nodules which histologically have the structure of tubercle.

From Mary D., æt. 3 months, both of whose parents were phthisical. She herself was a delicate child, and suffered from shortness of breath from birth. She died from bronchitis.

Presented by Dr. Burne.

259 Miliary Tuberculosis of the Lung.

A section of a lung, the cut surface of which is of open texture, and shews numerous very minute white points, which are thought to be tubercles in a very early stage. Towards the upper part of the lung there is an area of consolidation, which the microscope shews to be the result of tuberculous broncho-pneumonia. The small points above mentioned consist of aggregations of small cells within the alveoli of the lung without giant cells or caseation.

John F., æt. 54, was admitted under Dr. Pavy suffering from obscure cerebral symptoms; he died the next day. At the autopsy miliary tubercles were found in the liver, spleen, and kidneys. There was ulceration of the larynx. *See Insp.* 1863, No. 172.

260 Miliary Tuberculosis of the Lung.

A section of an injected lung studded with numerous miliary tubercles. There is a caseous bronchial gland.

From a lad, æt. 14, who was admitted under Dr. Bright in 1831, with symptoms of fever and much cerebral disturbance. At the autopsy there were no tubercles found in the brain, but they were very numerous in the lungs, peritoneum, and spleen. See *Insp.* vol. 10, p. 140.

261 Miliary Tubercles of the Lung.

A section of a lung shewing the pulmonary tissue densely crowded by miliary tubercles, and in part replaced by fibroid material.

John W., æt. 29, was admitted under Mr. Cooper Forster for disease of the knee joint, and died shortly after amputation through the thigh. At the autopsy there was found congenital stenosis of the pulmonary artery and ulceration of the ileum. See *Insp.* 1871, No. 352.

262 Acute Tuberculosis of the Lung.

A portion of a lung thickly beset with very minute tubercles.

Jane W., æt. 3, was admitted under Dr. Wilks fourteen days after an attack of measles, and died six weeks later from tuberculous meningitis. At the autopsy there were caseous bronchial glands and miliary tubercles in the liver and spleen. See *Insp.* 1883, No. 63.

263 Acute Tuberculosis of the Lung.

A portion of a lung the cut surface of which is studded with numerous miliary tubercles. Similar tubercles project beneath the slightly thickened pleura.

George B., æt. 6, was admitted under Dr. Rees for emaciation and bronchitis, following an attack of measles eight weeks before admission. At the autopsy there were found caseous bronchial glands, and miliary tubercles in the spleen, liver, and kidneys. See *Insp.* 1856, No. 132.

264 **Caseous Bronchial Glands with Miliary Tuberculosis of the Lung.**

A portion of a lung shewing large caseous bronchial glands one of which is surrounded by pulmonary tissue. There are numerous miliary tubercles scattered through the lung and filamentous adhesions upon the pleura.

From a boy, *æt.* 5, who was brought to the Hospital dead. He was said to have been quite well until the evening before admission, when he brought up a large quantity of blood and presently died. At the autopsy there was miliary tuberculosis of the spleen and liver with severe ulceration of the intestines. *See Insp.* 1869, No. 9.

265 **Miliary Tuberculosis with Cavitation of the Lung.**

A portion of the lower lobe of a right lung the cut surface of which is studded with miliary tubercles. At the lower and hinder part of the lobe there are numerous small excavations with ragged walls, which in the recent state contained pus. There is granular lymph upon the pleura. Histologically there are patches of tuberculous broncho-pneumonia with central disintegration.

Henry S., *æt.* 5, was admitted under Dr. Shaw with general tuberculosis and physical signs of broncho-pneumonia. The duration of his illness was seven weeks. At the autopsy tubercles were found in the kidneys, spleen, and liver, and some of the branches of the pulmonary veins contained adherent thrombus. *See Insp.* 1890, No. 305.

266 **Tuberculous Broncho-Pneumonia.**

A portion of the lower lobe of a lung shewing beneath the pleura a yellow wedge-shaped mass about the size of a hazel nut. The bronchial glands are caseous. Histologically the nodule presents the appearance of caseous broncho-pneumonia with numerous giant cells.

Ellen H., *æt.* 12, was admitted under Dr. Habershon with dropsy following scarlet fever. At the autopsy there was tubal nephritis. *See Insp.* 1867, No. 7.

267 Tuberculous Broncho-Pneumonia.

A section of the upper lobe of a left lung shewing the pulmonary tissue consolidated throughout with the exception of a small area at the apex. In the recent state the lung presented the appearance of the grey hepatization found in croupous pneumonia, but histological examination shews that the condition is due to a very diffuse tuberculous broncho-pneumonia. There is a thin layer of recent lymph upon the pleura.

Thomas B., æt. 24, was admitted under Dr. Washbourn with pain in the left side and rusty expectoration. He died eight days later from pulmonary embolism, and at the autopsy a small vomica with caseous walls was found in the axillary portion of the upper lobe of the left lung; the mediastinal glands were tuberculous, and an *ante-mortem* thrombus occupied the main trunk of the left pulmonary artery. The proximal end of this thrombus had become detached, and had blocked the lower division of the right pulmonary artery. *See Insp.* 1891, No. 353.

268 Tuberculous Broncho-Pneumonia.

The upper and middle lobes of a right lung injected with carmine and incised to shew the upper lobe, with the exception of its apex, consolidated by caseous broncho-pneumonia. The lymphatic glands at the root of the lung are greatly enlarged and caseous.

Ada B., æt. 8, was admitted under Dr. Shaw with signs of consolidation of the upper part of the right lung, and died six weeks later from tuberculous meningitis. *See Insp.* 1892, No. 339.

269 Tuberculous Broncho-Pneumonia.

A section of a portion of an injected lung shewing extensive consolidation from caseous broncho-pneumonia. There are a few scattered miliary tubercles, and at the lower part of the preparation, which is the apex of the lung, there is cavitation.

270 Tuberculous Broncho-Pneumonia with Dilated Tubes.

A section of the upper lobe of a right lung shewing

numerous cavities, some of which are dilated bronchial tubes, whilst others are irregular excavations surrounded by pneumonic lung. On the reverse of the specimen some of these cavities are seen as flaccid bullæ beneath the pleura. Histologically there are patches of tuberculous broncho-pneumonia with central disintegration. Many of the bronchioles are inflamed and dilated.

W. B., æt. 12 months, was admitted under Dr. Hodgkin in 1829. He had suffered from bronchitis and dyspnœa for some months. At the autopsy caseous glands were found in the mediastinum and abdomen, and there was some ulceration of the small intestine. *See Insp.* vol. 8, p. 9.

271 **Tuberculous Infection of Lung from contiguous Bronchial Glands.**

A right lung the middle lobe of which is large, white, and solid, and is in contact with a mass of caseous bronchial glands. There are a few scattered tubercles in the other lobes. Histologically the middle lobe shews caseous broncho-pneumonia.

Amy S., æt. 2, was admitted under Dr. Pavy for marasmus. At the autopsy there was tuberculous meningitis and general tuberculosis. *See Insp.* 1876, No. 255.

272 **Caseous Nodules in the Lung.**

A section of a left lung originally mounted as a specimen of syphilitic disease. At the apex, where the pleura is much thickened, there is a small cavity with dense fibroid walls, and in other parts of the upper lobe there are found irregular firm nodules, yellowish in colour, varying in size from a line to a quarter of an inch in diameter. There is also a considerable increase of fibroid tissue in the upper part of the lung. Histologically the caseous foci are surrounded by small cells, among which are some well-defined giant cells. In some parts there is also a great excess of fibrous tissue. The evidence derived from examination by the micro-

scope is rather more in favour of tubercle than of syphilis as the origin of the disease.

Louisa K., æt. 59, was admitted under Dr. Pavy for profuse hæmoptysis, which proved fatal. At the autopsy a gumma was found in the liver. *See Insp.* 1873, No. 414; and *Trans. Path. Soc.* vol. 25, p. 31.

273 **Chronic Phthisis with Miliary Tuberculosis.**

A section of a lung shewing a cavity at the apex of both the upper and lower lobes. The walls of the cavities are smooth, and the pleura covering the upper lobe is much thickened. Among the fibroid material in the neighbourhood of the cavities there are clusters of miliary tubercles.

From a man, æt. 60, who died from senile gangrene.

274 **Chronic Phthisis with Acute Tuberculosis of the Lung.**

A section of a right lung shewing the pulmonary tissue at the hinder part of the upper lobe and at the apex of the lower lobe to be largely replaced by fibroid material. The air-vesicles which remain are dilated, and the lung surrounding the fibroid patch shews irregular excavations. The rest of the lung is slightly emphysematous and presents numerous solitary and aggregated tubercles. The pleura shews on its surface a few filamentous adhesions, and over the fibroid patch is deeply puckered.

George G., æt. 23, was admitted under Dr. Pavy for otorrhœa and facial paralysis. He had suffered from cough for six weeks. At the autopsy there was ulceration of the larynx and intestines. There was no evidence of syphilis. *See Insp.* 1870, No. 167.

275 **Chronic and recent Tuberculosis of the Lung.**

The apices of both lungs, the cut surfaces of which shew diffuse scarring from the presence of fibroid tissue, around which there are scattered miliary tubercles.

Thomas F., æt. 44, was admitted under Mr. Durham and died from the effects of head injuries sustained in falling a distance of 40 feet. *See Insp.* 1872, No. 306.

276 Basic Fibrosis with Apical Tuberculosis of the Lung.

A portion of a left lung the lower lobe of which shews extreme fibrosis and bronchiectasis, while the upper lobe is crepitant and studded with miliary tubercles. The pleura over the lower lobe is thickened and adherent to the diaphragm.

Arthur S., æt. 3, was admitted under Mr. Durham for hip-joint disease with an abscess in the thigh. He had had otorrhœa, following an attack of scarlet fever, for eighteen months, and died of suppurative meningitis. The right lung was healthy. *See Insp.* 1882, No. 82.

277 Fibroid Lung with Dilated Bronchial Tubes.

A right lung the entire pleura of which is greatly thickened, while the pulmonary tissue is diminished in volume and very fibroid. The bronchi, especially of the upper lobe, are thickened and dilated, forming, in many places, smooth-walled cavities which communicate with each other.

James A., æt. 25, was admitted under Dr. Fagge with contraction of the right lung and displacement of the heart's impulse to the right of the sternum. He died three days after admission. *See Insp.* 1869, No. 39.

278 Fibroid Lung with Dilated Bronchial Tubes.

A section of a right lung shewing the pulmonary tissue almost entirely replaced by fibroid material, in which are seen the bronchial tubes, in some places greatly thickened, in others dilated into large intercommunicating thin-walled cavities. The pleura is much thickened.

Dennis R., æt. 13, was admitted under Dr. Taylor for severe cough, and dropsy of the lower extremities. There was a history of cough for seven years. Soon after admission fluid accumulated in the abdomen, and he was on several occasions tapped for ascites. At the autopsy the right side of the heart was found much hypertrophied; the left lung was similarly but not so severely affected as the right. *See Insp.* 1888, No. 191.

279 Fibroid Phthisis.

A section of a left lung, which is contracted from the presence of fibrous material replacing the pulmonary tissue, and compressed by a greatly thickened pleura. The pericardium is partly covered by granular lymph.

Ellen C., æt. 21, was admitted under Dr. Moxon for phthisis. Subsequently she had albuminuria and anasarca, with frequent diarrhoea. At the autopsy there were tubercles in the right lung; the viscera were lardaceous, and there were a few ulcers in the large intestine. *See Insp.* 1868, No. 33.

280 Healed Phthisis.

A portion of a right lung shewing the greater part of the upper lobe to be converted into a smooth-walled cavity about two inches in diameter. The rest of the lung is generally emphysematous and contains some fibroid and calcareous nodules and patches of pneumonic consolidation.

Cornelius S., æt. 27, was admitted under Dr. Moxon for chronic bronchitis and anasarca. At the autopsy there was hypertrophy of the right side of the heart, and the liver was nutmegged. *See Insp.* 1868, No. 27.

281 Healed Phthisis.

A section of a left lung, at the upper part of which the pulmonary tissue is replaced by a dense mass of fibroid material containing small cavities and dilated bronchial tubes. This fibroid change occupies the whole of the upper lobe and the apex of the lower lobe, resulting in extreme contraction of the parts affected. The rest of the lower lobe is emphysematous. The pleura is very much thickened over the upper part of the lung.

Elizabeth C., æt. 36, was admitted under Dr. Habershon for chronic bronchitis and emphysema. She had been ailing for fourteen years. At the autopsy there was dilatation of the right ventricle with ascites and dropsy of the lower extremities. *See Insp.* 1870, No. 316.

282 Calcareous Nodule in the Lung.

A small portion of lung containing an earthy concretion about the size of a pea.

283 Calcareous Nodule from the Lung.

An irregular mass of cretaceous material found in a cavity in a lung.

284 Calcareous Nodule from the Lung.

A rough calcareous nodule which was expectorated.

285 Calcareous Particles from the Lung.

Several fragments of earthy matter which were expectorated.

286 Tuberculosis of the Lung with Cavitation.

A portion of a lung the cut surface of which presents numerous anfractuons cavities freely communicating with each other. Some of these cavities are lined with smooth fibrous tissue and project as bullæ beneath the pleura, while in others the interior is rough from caseous deposit. The intervening lung is solid, and presents under the microscope the appearance of tuberculous broncho-pneumonia.

Sarah G., æt. 20, was admitted under Dr. Baek in 1828 for cough, having previously been under treatment in the Surgical Wards for disease of the knee joint. She died ten days after her admission. At the autopsy the knee joint was found to be disorganised, and there was tuberculous disease of the Fallopian tubes. *See Insp.* vol. 6, p. 121.

287 Acute Phthisis.

A section of a left lung shewing extensive cavitation. The vomicæ, which are irregular in shape and traversed by fibrous trabeculæ, for the most part occupy the upper part of each lobe. The rest of the lung is solid from pneumonia, and the pleura is much thickened.

The right lung which is suspended behind shews more recent tuberculous consolidation.

William M., æt. 38, a cabman, was admitted under Dr. Moxon with signs of consolidation of the left lung. The disease was supposed to have originated from an injury to the chest, occasioned by the overturning of a cab three months before death. There was hæmoptysis on two occasions. At the autopsy no sign of injury was discovered. The larynx and intestines were ulcerated, the intestinal affection being distinctly tuberculous. *See Insp.* 1881, No. 35.

288 Chronic Phthisis with Cavitation.

A portion of a left lung shewing a very large smooth-walled cavity surrounded by dense iron-grey fibroid tissue. The cavity is traversed by numerous bands, the remains of pulmonary vessels and bronchi. The pleura is thickened, and at its upper part was densely adherent.

Caroline D., æt. 30, was admitted under Dr. Barlow in 1853. She had had symptoms of phthisis for two years. General slight anasarca came on soon after admission. At the autopsy the kidneys were found to be "granular." *See Insp.* vol. 37, p. 291.

289 Chronic Phthisis with Cavitation.

A section of a lung, the upper lobe of which is occupied by a large vomica with thick fibrous walls. The lower lobe is full of caseous masses, and the pleura is greatly thickened. *Presented by Dr. Goodhart.*

290 Tuberculous Excavation of the Lung.

A section of a lung shewing a large vomica excavating the upper lobe and extending into the lower lobe. The cavity is crossed by fibrous trabeculæ composed of vessels and bronchial tubes. Some of the latter have been slit up to shew that they are still patent. There are numerous tubercles scattered through the rest of the lung, and the pleura is greatly thickened.

Charles J., æt. 35, was admitted under Dr. Wilks for cough

and expectoration, his illness having begun eight months before admission. At the autopsy no tubercles were found in any other organ. *See Insp.* 1870, No. 184.

291 **Tuberculous Excavation of the Lung.**

The upper lobe of a lung, almost entirely excavated by a large phthysical cavity, which is traversed by long ragged bristles through some of which bristles have been passed from the bronchial tubes and the pulmonary artery. The wall of the cavity is in great measure formed by thickened pleura.

292 **Tuberculous Excavation of the Lung.**

The upper lobe of a lung occupied by a large vomica, which has a smooth lining, and is bounded externally by densely thickened pleura.

293 **Basal Phthisis.**

A section through a right lung the lower lobe of which is contracted and presents a considerable excess of fibrous tissue. The bronchial tubes in this lobe are somewhat dilated, and the pulmonary tissue is in parts consolidated by caseous broncho-pneumonia. There are one or two small ragged excavations in the lung. The upper lobe is unaffected. There is considerable thickening of the pleura, more marked at the base than at the apex.

Walter S., æt. 21, was admitted under Dr. Goodhart with a very deformed chest and symptoms of chronic lung disease. He had had a bad cough for many years. There were physical signs of consolidation of the lower part of both lungs, and tubercle bacilli were found in the sputum. At the autopsy the lower lobes of both lungs were found to be similarly affected, and there was a patch of tuberculous consolidation at the anterior part of the left upper lobe. The right side of the heart was dilated. A caseous nodule was found in one of the kidneys. *See Insp.* 1890, No. 471.

294 Tuberculous Cavitation of the Lower Lobe of the Lung.

A section of the left lung shewing at the upper part of the lower lobe a large cavity with ragged walls. There are similar smaller cavities in the upper lobe with scattered tuberculous broncho-pneumonia. There is recent lymph on the pleura.

William C., æt. 10, was admitted under Dr. Wilks with symptoms of phthisis and tuberculous disease of the abdomen. At the autopsy the larynx and intestines were found ulcerated. See *Insp.* 1871, No. 187; and *Prep.* 860.

295 Caseous Pneumonia with Basic Cavitation.

A right lung shewing numerous caseous masses about the size of peas surrounded by a zone of fibrous tissue, situated for the most part in the lower lobe. On the reverse of the specimen at the level of an old fracture of a rib the pleura is greatly thickened, and in the lung immediately beneath it are two smooth-walled cavities.

Abraham C., æt. 38, was admitted under Mr. Hilton, having fractured his spine in the cervical region. He died three days afterwards. At the autopsy there was found a healed fracture of the seventh rib on the right side close to the angle. No tubercles were found in any organ. See *Insp.* 1869, No. 33; and *Prep.* 1052 (10) [2nd Edit.].

296 Gangrene of the Lung in Phthisis.

A right lung shewing scattered caseous tubercles and considerable cavitation. The two largest cavities are situated one at the apex of the lower lobe, and the other at the base of the upper lobe. Adherent to the smooth fibroid wall of the latter may be seen a small shaggy mass of gangrenous lung tissue.

Mary R., æt. 26, was admitted under Mr. Birkett for a pelvic abscess which was many times operated upon, and proved fatal seven months after admission. At the autopsy there was found lardaceous disease of the kidneys and liver with ulceration of the cæcum. The left lung was healthy. See *Insp.* 1868, No. 251.

297 Gangrene of the Lung in Phthisis.

A right lung the middle and upper lobes of which shew extensive consolidation. At the lower part of the upper lobe there is a large cavity at the bottom of which is a small, partially detached, slough.

Thomas K., æt. 34, was admitted under Dr. Habershon for syphilis and lardaceous disease. Before his death signs of cavitation of the lung developed. *See Insp.* 1867, No. 299.

298 Phthisis with Ulceration opening a Branch of the Pulmonary Artery.

A portion of lung containing a vomica about two inches in diameter, and having a smooth lining. The lung tissue surrounding it is crepitant. The cavity was filled with blood, and in it is a truncated and perforated vessel through which a bristle has been passed. The vessel is filled with coagulum.

Presented by Dr. Addison, 1850.

299 A Vomica of the Lung communicating with a Branch of the Pulmonary Artery.

A portion of the apex of the right lung, partially dissected to shew a secondary branch of the right pulmonary artery opening into a smooth-walled cavity.

John B., æt. 46, was admitted under Dr. Rees. There had been several slight attacks of hæmoptysis before the last, from which he died. *See Insp.* 1861, No. 120.

300 Blood-clot in a cavity of the Lung.

The central portion of a right lung shewing a smooth-walled cavity into which open branches of the pulmonary artery and of the bronchus. Lying in the cavity is a large laminated blood-clot, which has been cut across to shew its structure.

Michael N., æt. 37, was admitted under Dr. Bright in 1835, and died from hæmoptysis. At the autopsy there was found ulceration of the ileum. *See Insp.* vol. 19, p. 146.

301 Phthisis with Aneurysm of the Pulmonary Artery.

The lower portion of a lung shewing several vomicæ, one of which contains an aneurysm of a branch of the pulmonary artery. The sac is pear-shaped, and is lined with laminated blood-clot.

John S., æt. 47, was admitted under Dr. Bright in 1833. He had suffered from occasional hæmoptysis for twelve months. At the autopsy there was cirrhosis of the liver. *See Insp.* vol. 17, p. 59.

302 Aneurysm of the Pulmonary Artery in Phthisis.

A section through a right lung extensively affected by phthisis showing in its lower lobe a large aneurysmal dilatation of a branch of the pulmonary artery traversing a vomica. The aneurysm, the sac of which has been partly removed, measures two inches in length and three quarters of an inch in its transverse diameter. It has the shape of an hour-glass, and its lower half is filled with adherent thrombus, between which and the wall of the sac a blue rod has been passed.

Elizabeth G., æt. 30, was admitted under Dr. Pye-Smith for phthisis of about eighteen months' duration, from which she died four months after admission. One month before her death she suffered from hæmoptysis. *See Insp.* 1892, No. 366.

303 Ruptured Aneurysm of the Pulmonary Artery.

The upper portion of a right lung showing a cavity with smooth fibroid walls. Projecting into this cavity there is a nodule about the size of a pea, which is the truncated end of a large branch of the pulmonary artery. This sac was ruptured along its attachment, and has been pinned back to shew the opening of the vessel.

John L., æt. 30, was admitted under Dr. Rees for cough, fever, and hæmoptysis. He died a few hours after admission from profuse hæmorrhage. *See Insp.* 1862, No. 222.

304 A Cavity in the Lung.

A right lung the greater part of which is consolidated by pneumonia. In the middle of the lung, occupying portions of both upper and lower lobes, there is a large, rather irregular, smooth-walled cavity which is stated to have resulted from circumscribed gangrene.

Charles J., æt. 40, was admitted under Mr. Cock, and died from malignant disease of the upper jaw. At the autopsy a large calcareous gland was found compressing the right bronchus. The left lung was studded with patches of broncho-pneumonia. See *Insp.* 1867, No. 48.

305 Cavitation of the base of the Lung with Spinal Caries.

A portion of a left lung shewing a large cavity at the base with extreme thickening of the pleura over it. The cavity has an uneven fibroid wall, and projecting into it are the fibrous remains of the bronchi and pulmonary vessels.

Charles M., æt. 9, was admitted under Dr. Moxon with spinal caries and complete dulness over the back of the left lung. At the autopsy an angular curvature of the spine was found with ankylosis of several of the dorsal vertebræ. There were evidences of previous suppuration in the neighbourhood, and it was thought that the spinal abscess had opened into the left lung. See *Insp.* 1881, No. 195.

306 Chronic Cavitation of the base of the Lung.

A right lung considerably reduced in size, and closely invested with a thick adventitious layer by which it was firmly united to the parietes. The substance of the lung is condensed, and is of a deep grey colour. A cavity extends almost from the apex to the base of the lung, and is much constricted at the interlobar fissure. It has a smooth lining membrane and communicates freely with the bronchial tubes.

From E. H., who had suffered from disease of the lung for

twenty years, following acute pneumonia. There was great deformity of the chest. At the autopsy no tubercles were found in either lung.

Presented by Dr. Hodgkin.

307 Basal Cavity in the Lung associated with Cerebral Abscess.

The lower lobe of a right lung, presenting a smooth-walled cavity, with the upper part of which several bronchial tubes communicate. The pleura covering the surrounding indurated lung is thickened and was adherent.

From a gentleman, æt. 34, who died from cerebral abscess supposed to be secondary to the condition of the lung. Two years and three months before his death he suffered from pleuro-pneumonia from which he never perfectly recovered. At the autopsy no trace of tubercle was found in any organ. *See Guy's Hosp. Reps.* 1857, p. 305; and *Prep.* 1565 (40) [2nd Edit.].

Presented by Dr. Gull.

308 Pneumonic Phthisis of Addison.

The lungs of a cat mounted by Dr. Wilks for Dr. Addison as an illustration of pneumonic phthisis.

Presented by Dr. Wilks.

309 Interlobular Emphysema of the Lung.

A portion of lung beneath the pleura of which are air-containing spaces, arranged in lines irregularly disposed over the surface.

Charles R., æt. 30, was admitted under Dr. Pye-Smith for bronchitis and pyrexia with extreme dyspnoea. At the autopsy an aneurysm of the transverse branch of the aorta was found compressing the trachea. There was considerable broncho-pneumonia. *See Insp.* 1888, No. 151.

310 Interlobular Emphysema of the Lung.

A portion of lung beneath the surface of which are several thin-walled bullæ of various sizes.

311 Interlobular Emphysema of the Lung.

A lung shewing bullæ of various sizes beneath the pleura.

John S., æt. 14, was admitted under Mr. Hilton for a severe burn. He died three weeks after admission from broncho-pneumonia. *See Insp.* 1860, No. 12.

312 Emphysema of the Lung.

A portion of lung shewing considerable dilatation of the air-vesicles.

Francis N., æt. 48, was admitted under Dr. Cholmeley in 1831. He had suffered from dyspnœa from infancy. At the autopsy there was general emphysema of the lungs with hypertrophy of the right side of the heart. The pulmonary artery was much enlarged. *See Insp.* vol. 15, p. 44.

313 Emphysema of the Lung.

A portion of lung with a large cyst immediately beneath the pleura. The wall is thin and translucent, but shews some adhesions over part of its outer surface.

314 Emphysema of the Lung.

A portion of lung shewing a large bulla, with membranous walls, projecting from its surface.

315 Emphysema of the Lung.

The preparation shews an extremely emphysematous portion of lung. Beneath the pleura are two large cavities with thin translucent walls.

*Presented by Dr. Clarke, Professor of Anatomy,
Cambridge.*

316 Emphysema of the Lung.

Portion of an emphysematous lung, shewing a large bleb beneath the pleura.

317 Superficial Cyst of the Lung.

A portion of the apex of a lung, projecting from the surface of which is a cyst, about half an inch in diameter. There was no emphysema of the rest of the lung, which presented about six similar cysts. In the recent state these cysts contained air.

James D., æt. 24, was brought to the hospital dead. At the autopsy the skull was found to be fractured and the brain bruised. There were no signs of tuberculosis nor syphilis. *See Insp.* 1887, No. 154.

318 Supplementary Emphysema of the Lung.

A left lung shewing deep scars and furrows on its surface, separating large irregular lobules of emphysematous tissue. The emphysema is very extreme producing in many places large blebs beneath the pleura, which is covered with filamentous adhesions. Cretaceous masses could be felt scattered through the organ.

Benjamin B., æt. 43, was admitted under Dr. Rees for general dropsy and Bright's disease. At the autopsy he was found to have granular kidneys and a hypertrophied heart. Scattered through the right lung were numerous fibroid and cretaceous nodules similar to those felt in the preparation. *See Insp.* 1867, No. 336.

319 Supplementary Emphysema of the Lung.

A portion of lung presenting on its surface a deep furrow, beneath which the tissue is dark and indurated. There is considerable emphysema of the rest of the lung with old adhesions of the pleura.

John M., æt. 50, was admitted under Dr. Back in 1830 for bronchitis, œdema of the legs, and albuminuria. At the autopsy the kidneys were found to be diseased, and the heart, especially the right side, was hypertrophied and dilated. *See Insp.* vol. 9, p. 100.

320 Empysema of the Lung with thickened Pulmonary Arteries.

A lung incised to shew extreme thickening of the branches of the pulmonary artery. The cut ends of the vessels stand out prominently above the surrounding lung tissue, which is of very open texture, dilated vesicles being distinctly visible.

John A., æt. 60, was admitted under Mr. Durham for strangulated hernia, from which he died. At the autopsy the right side of the heart was not enlarged; the aorta only slightly atheromatous. See *Insp.* 1885, No. 391.

321 Epithelioma of the Lung.

A section of a lung through which are scattered numerous nodules of growth varying in size from a hazel nut to a pin's head. In the fresh state the nodules were soft, and of a pinkish colour. Histologically the growth is a very vascular squamous epithelioma.

Mary J., æt. 35, was admitted under Dr. Mahomed with hæmoptysis, and the physical signs of a mediastinal tumour. She had been ill for six months. At the autopsy there was malignant ulceration of the vagina and œsophagus, with secondary deposits in the mediastinal glands and skin. It was not determined whether the primary source was in the œsophagus or in the vagina. See *Insp.* 1883, No. 212.

322 Epithelioma of the Lung with Cavitation.

A left lung the lower two thirds of which is hollowed out, forming a cavity measuring $4\frac{1}{2}$ inches in its vertical and antero-posterior diameters. The thin layer of pulmonary tissue and pleura which forms the wall on its lateral aspect has been partially removed, and shews the opening of the main bronchus into the cavity, which is indicated by a blue rod. In the recent state the interior was slaggy and covered with muco-purulent secretion. On the reverse of the specimen a section

through the consolidated base of the lung displays sinuous cavities resulting from dilatation of bronchial tubes. The pleura over the lower lobe is much thickened and was adherent. Histological examination of the wall of the cavity shews the pulmonary tissue to be infiltrated by a malignant growth having the characters of a squamous epithelioma.

William A., æt. 68, was an out-patient for some months suffering from profuse blood-stained muco-purulent expectoration, the quantity of secretion sometimes exceeding a pint in the twenty-four hours. This condition continued for twenty months, towards the end of which time the patient became affected with anasarca. He died from cardiac failure. The post-mortem examination was incomplete.

Presented by Dr. Newton Pitt.

323 **Squamous-celled Epithelioma of the Lung.**

A right lung mounted to shew the lower division of its bronchus surrounded and partially occluded by a mass of white growth. Communicating with the bronchus is a large excavation with shaggy walls occupying the greater part of the lower lobe, the pleura of which is thickened and was adherent. Histological examination of the growth shews it to be a squamous-celled epithelioma.

William W., æt. 43, was admitted under Dr. Taylor for cough and pain in the chest. An incision was made through the lower part of the right chest-wall, and half a pint of foul pus was evacuated. During the four weeks succeeding the operation the discharge from the wound was profuse and purulent, after which it became hæmorrhagic, and so continued till the patient's death three weeks later. At the autopsy the wound was found to communicate with the vomica in the base of the lung. The mediastinal glands were enlarged by a deposit of malignant growth, but there was no growth in any other part of the body. *See Insp.* 1891, No. 94; and *Guy's Hosp. Rep.* 1892, p. 150.

324 **Miliary Carcinoma of the Lung.**

A section of a right lung shewing numerous minute grey nodules scattered through it. They are more

numerous at the base than at the apex, and some rather larger than the rest appear as slight elevations beneath the pleura. Histologically the larger nodules in the lung consist of very small alveoli filled with large spheroidal epithelial cells. In the smaller nodules the spheroidal cells are fewer in number, while the fibrous stroma is more abundant. The growth is irregularly scattered through the pulmonary tissue, some deposits being found around the bronchioles and vessels, and others within the air-vesicles.

Thomas D., æt. 50, was admitted under Dr. Wilks for symptoms resembling broncho-pneumonia; he died four days after admission. At the autopsy minute cancerous nodules were found in the pericardium, in the heart muscle, and in the liver. It was thought that the lung was the primary seat of the growth. See *Insp.* 1866, No. 327; and *Trans. Path. Soc.* vol. 18, p. 29.

325 **Scirrhus Carcinoma of the Lung.**

A portion of a lung shewing upon its surface numerous puckered depressions caused by the contraction of secondary deposits of growth beneath the pleura. Upon the cut surface of the lung may be seen two nodules of growth, one towards the lower part of the preparation situated immediately beneath one of the depressions, the other at the apex embedded deeply in the pulmonary tissue. Histologically the growth is a spheroidal-celled carcinoma with much fibroid stroma.

Maria O., æt. 50, was admitted under Dr. Goodhart with a hard tumour of the breast, jaundice, and enlarged liver. Retraction of the nipple had been noticed for eight or nine years. At the autopsy the tumour of the breast was found to be a scirrhus carcinoma, and there were secondary deposits in the liver. See *Insp.* 1891, No. 18.

326 **Colloid Carcinoma of the Lung.**

A portion of a lung the cut surface of which shews many lobulated greyish-white masses of new growth, which are for the most part situated at the periphery of

the lung. In the recent state these masses presented the translucent appearance of colloid carcinoma. Histologically the growth is a spheroidal-celled carcinoma undergoing colloid degeneration.

Joseph L., æt. 58, was admitted under Dr. Wilks for pain in the lumbar region, and œdema of the legs. Later an abdominal tumour appeared, and during the last few weeks of life he suffered from bronchitis with some hæmoptysis. At the autopsy the primary growth was found in the stomach, and there were numerous secondary deposits in the retro-peritoneal glands. See *Insp.* 1882, No. 350; and *Preps.* 681 & 833.

327 **Tuberculosis and Carcinoma of the Lung.**

A section of a left lung presenting in the upper lobe and in the adjacent part of the lower lobe several large cavities with trabeculated walls. The rest of the lung is for the most part consolidated by cancerous deposit and contains numerous recent excavations. The pleura is much thickened, especially in the neighbourhood of the diaphragm to which it is adherent. Under the microscope, sections taken from the base shew the lung tissue uniformly infiltrated by carcinoma, while sections from the upper lobe shew the cancerous deposit co-existing with tuberculosis.

James B., æt. 42, was admitted under Dr. Bright in 1829 with a chronic cough and emaciation. At the autopsy malignant growth was found in the brain and liver, and in the cervical, axillary, and bronchial glands. There were vomicæ in the apex of the right lung. See *Insp.* vol. 8, p. 174.

328 **Tuberculosis of the Lung associated with Carcinoma.**

A section of a left lung shewing two large cavities, one at the apex and another at the upper part of the lower lobe. The latter, which is about $2\frac{1}{2}$ inches in diameter, has the greater part of its wall lined by a white flocculent deposit of carcinomatous tissue. A mass of growth is seen adhering to the pleural surface of the pericar-

dium. The rest of the lung is partly consolidated. Histologically the growth is a medullary carcinoma, and in other portions of the lung are evidences of tubercle.

Robert B., æt. 40, was admitted under Dr. Pavy for wasting, anæmia, and dyspnoea. His illness had lasted about six months. At the autopsy the left bronchus was found partly occluded by growth. There were well-marked tuberculous infiltration and cavitation of the right lung with ulceration of the larynx and intestines. No growth was found in any other organ. *See Insp.* 1882, No. 29.

329 **Sarcoma of the Lung.**

Portions of lung containing firm rounded masses which are situated beneath the pleura, but covered for the most part by a thin layer of pulmonary tissue. In the fresh state they were reddish, soft, and felt gritty. Histologically the growth is a sarcoma undergoing calcification. The portion of spine mounted with the specimen shews the body of one of the vertebræ softened and partially destroyed by secondary deposit.

George W., æt 18, was admitted under Mr. Birkett for malignant growth of the leg for which amputation was performed. Five months afterwards he became paraplegic, and died six weeks later from cystitis and pyelitis. *See Insp.* 1857, No. 194.

330 **Sarcoma of the Lung.**

A right lung in which are numerous firm white masses varying in size from a line to one inch in diameter. Some of these deposits are excavated in the centre, and many of them contain bony spicules. On the reverse of the specimen at the base of the lung is a large blood-clot situated in a cavity formed by the softening of one of the masses of growth. A blue rod indicates a bronchial tube which communicates with this cavity. Histologically the growth is a sarcoma undergoing calcification.

Martha N., æt. 27, was admitted under Mr. Birkett for a malig-

nant growth of the forearm. The arm was amputated, and the patient died six months later in St. Bartholomew's Hospital from hæmoptysis. At the autopsy there were no secondary deposits except in the lung. *See Guy's Hosp. Reps.* 1857, p. 336.

Presented by St. Bartholomew's Hospital.

331 **Sarcoma of the Lung.**

A right lung containing numerous bony deposits, some appearing as smooth whitish discs beneath the pleura, and others as rounded masses projecting from the surface of the organ. Histologically the growth is a sarcoma with imperfect formation of cartilage and bone.

Charles R., æt. 44, was admitted under Dr. Rees for paraplegia. At the autopsy there was found to be a growth in the head of the humerus and in the bodies of some of the lumbar vertebræ. *See Insp.* 1873, No. 29.

332 **Sarcoma of the Lung.**

The thoracic viscera mounted to shew the lungs extensively affected with secondary growth. On the left side the growth is chiefly situated in the pleura so that the lung is almost completely invested by a layer of sarcomatous tissue, in some places more than half an inch in thickness. On the right side the deposit forms bold rounded masses projecting from the surface of the lung. Histologically the structure is that of a round-celled sarcoma.

Emma B., æt. 7, was admitted under Dr. Wilks with symptoms of intra-thoracic tumour, her arm having been previously amputated for growth in the humerus. Death occurred eight months after the first recognition of the disease. At the autopsy there was serous effusion in the right pleural cavity. *See Insp.* 1867, No. 58.

333 **Myeloid Sarcoma of the Lung.**

A portion of a lung shewing on section a few nodules of new growth varying in size from an eighth to

half an inch in diameter. In the recent state they were soft and of a reddish colour. They are situated for the most part in the substance of the lung and do not project beneath the pleura. Histologically the growth is a very vascular sarcoma with round, oval, and large multi-nucleated cells.

Susan G., *æt.* 45, was admitted under Dr. Pavy with rapidly growing lumps beneath the skin and bleeding from the gums. Her illness, which had lasted three weeks before admission, ended fatally a fortnight later with cerebral symptoms. At the autopsy growths similar to those in the lungs were found in the brain, spleen, and liver. *See Insp.* 1861, No. 62; and *Prep.* 1914 (20) [2nd Edit.].

334 **Melanotic Sarcoma of the Lung.**

A portion of a lung shewing on its cut surface and also projecting beneath the pleura numerous rounded masses of new growth varying in size from a quarter of an inch to two inches in diameter. The tumours are soft and for the most part white on section, but some of them are slightly pigmented. Histologically they have the structure of spindle-celled sarcomata.

Thomas G., *æt.* 30, was admitted under Mr. Bryant with a large pigmented growth in the axilla and other smaller tumours in the skin. Twelve months before admission, and again three months later, a malignant growth which had developed in a mole upon the chest was excised at St. Thomas's Hospital. He died three months after admission, and a few weeks before his death he suffered from hæmoptysis. At the autopsy secondary deposits containing much pigment were found in the liver, spleen, and lymphatic glands. *See Insp.* 1863, No. 68.

335 **Melanotic Sarcoma of the Lung.**

A portion of a lung containing several rounded masses of new growth. The deposits are soft and much pigmented and histologically present the appearance of spindle-celled sarcoma.

From a patient who died from malignant disease of the eye, and whose liver contained secondary deposits similar to these shewn in the lung. *See Prep.* 1669 (32) [2nd Edit.].

336 Lung invaded by Sarcoma.

Sections of a lung infiltrated by a large mass of sarcoma from the mediastinum. The preparation shews the bronchial tubes to be in some places greatly dilated and invaded by growth. Histologically the tumour is a round-celled sarcoma.

Charles C., æt. 23, was admitted under Dr. Pavy with symptoms of mediastinal tumour. Laryngotomy was performed for urgent dyspnoea. At the autopsy a large mass of growth was found in the mediastinum invading the lung, and compressing, but not occluding, the right bronchus. There was a growth in the brain. *See Insp.* 1883, No. 427.

337 Hydatid of the Lung.

A left lung shewing at the anterior edge of the upper lobe a thin-walled cavity, about the size of a walnut, beneath the pleura. The tissues around are condensed and in the recent state contained some extravasated blood.

Priscilla H., æt. 9, was admitted under Dr. Pavy with headache and partial hemiplegia. A few days before death she had slight hæmoptysis. At the autopsy a hydatid cyst was found in the brain. *See Insp.* 1878, No. 110.

338 Hydatid of the Lung.

A portion of the lower lobe of a left lung laid open to shew a small cavity with thin rough walls. The larger part of the cavity, in the left half of the section, presents an opening through which a blue rod has been passed into a dilated pulmonary vein seen on the reverse of the specimen. The pink rod marks the entrance of a large bronchus into the other half of the cavity. Some small tubercles are seen scattered through the surrounding pulmonary tissue.

Robert A., æt. 17, was admitted under Dr. Habershon for profuse hæmoptysis, with signs of consolidation of the base of the left lung. He had previously while under treatment as an out-

patient expectorated portions of hydatid membrane. At the autopsy many tubercles were found in both lungs; there were no hydatid cysts in any organ. *See Insp.* 1872, No. 218 A; and *Guy's Hosp. Reps.* 1872, p. 373.

339 Hydatids of the Lung.

A section of a lung presenting numerous smooth-walled cavities, many of which contain shrunken hydatid cysts.

Presented by Dr. Cholmeley.

340 Hydatid of the Lung.

A trachea with the right lung, in the lower lobe of which there is a smooth-walled cavity two inches in diameter communicating freely with the descending branch of the right bronchus. No hydatid membrane was found within the cavity.

Louisa P., æt. 23, was admitted under Mr. Jacobson for an abdominal tumour of five years' duration. Laparotomy was performed, and eight pounds of hydatid material removed. The patient died on the following day. At the autopsy numerous hydatids were found in the liver, spleen, and subperitoneal tissue. There was no communication between the hydatids in the liver and the cavity in the lung. *See Insp.* 1885, No. 397; and *Prep.* 1244.

341 Hydatid of the Lung.

The apical portion of a left lung presenting a large ragged cavity with which the subclavian artery communicates by a small opening. In the fresh state the cavity contained a considerable quantity of old and recent blood-clot, and the two hydatid cysts which are seen at the bottom of the glass.

John B., æt. 45, was admitted under Dr. Cholmeley in 1835 for profuse hæmoptysis from which he died. He had had two slighter attacks shortly before admission. At the autopsy no tubercles were found in any organ. *See Insp.* vol. 12, p. 100.

342 Hydatid of the Lung.

A portion of a right lung shewing a large cavity

situated towards its base. The cavity is lined above with thin fibroid tissue and is crossed by trabeculæ, while below its wall is rough and densely fibrous and was continuous with the lining membrane of a hydatid cyst in the liver. At the bottom of the glass is seen a portion of the hydatid membrane removed from the cavity in the lung.

Edward L., æt. 43, was admitted under Dr. Cholmeley in 1832 with hæmoptysis and ascites. At the autopsy the cavity in the lung was lined by hydatid membrane. The liver, which contained a large hydatid cyst in its right lobe, was cirrhotic. *See Insp.* vol. 16, p. 84.

343 **Hydatids of the Lung and Liver.**

A portion of a right lung with the right lobe of the liver, shewing in both organs numerous hydatid cysts. Some of the membranes found in them are at the bottom of the glass. The pleura is much thickened and was universally adherent.

Joseph C., æt. 16, was admitted under Dr. Rees for swelling of the right side with great dyspnoea. His chest was tapped one week before his death and a small quantity of hydatid fluid was withdrawn. At the autopsy a chain of hydatid cysts was traced from the liver through the diaphragm into the lung. The specimen was thought to be an example of exogenous reproduction. *See Insp.* 1867, No. 225.

344 **Expectorated Hydatid Membrane.**

Numerous fragments of hydatid membrane which were expectorated. *Presented by Dr. Hilton Fagge.*

SECTION VII.—INJURIES AND DISEASES OF THE PLEURA.

- Injuries : 345, 346.
- Dilated Lymphatics : 347.
- Pleurisy : 348-354.
- False Membranes : 355.
- Pleuritic Adhesions : 356-359.
- Thickened Pleura : 360-362, 375.
- Fibroid Nodules : 363, 364.
- Tuberculous Pleurisy : 365-367.
- Empyema : 368-378.
- Pyo-pneumothorax : 379.
- Pneumothorax : 379, 380.
- Calcification : 381-387.
- Fibromata : 388, 389.
- Enchondroma : 390.
- Carcinoma : 391-393.
- Sarcoma : 394-396.
- Fat beneath the Pleura : 397.

345 **Pleural Adhesion after Fracture of a Rib.**

Portions of two ribs, one of which shews a firmly united fracture. At the situation of the injury the parietal pleura is thickened to the extent of half an inch, and is adherent to the subjacent lung.

346 **Omentum in the Pleural Cavity.**

A portion of the fifth rib from the left side shewing a partially united fracture. A piece of omentum has been included between the ends of the fractured bone.

Edward L., æt. 40, was admitted under Mr. Morgan in 1838. Nine months previously he fell from a ship's rigging, and received severe injuries which resulted in a diaphragmatic hernia. At the autopsy the stomach, part of the colon, and omentum were found lying in the pleural cavity. See *Insp.* vol. 26, p. 157; and *Preps.* 1072 (50) [2nd Edit.], and 1089.

347 Dilated Lymphatics beneath the Pleura.

A portion of lung the pleura of which is marked by white lines arranged as an irregular network. Histologically these appear to be dilated lymphatic channels immediately beneath the serous membrane. There is recent lymph upon the pleura.

Richard G., æt. 56, was admitted under Mr. Birkett for stricture of the urethra, and died from pyæmia after its forcible dilatation. See *Insp.* 1867, No. 270.

348 Pleurisy with Effusion.

The right lung with its visceral and parietal layers of pleura mounted to shew the effects of pleuritic effusion. Both layers of the pleura are much thickened, and their surfaces roughened by a deposit of lymph which is most abundant over the diaphragm. The lung, which is tuberculous and presents a small cavity at the apex, is compressed, and pushed upwards, and is partly adherent to the chest wall. The effusion, of which there was a large quantity in each pleural cavity, is stated to have been of a serous character.

Presented by Mr. G. Babington.

349 Pleurisy with Effusion.

A portion of lung shewing the pleura to be covered with a thick layer of granular lymph, part of which has been detached, and turned back exposing the dulled surface beneath. The small and wrinkled lung shews the effect of compression by fluid in the pleural cavity.

350 Pleurisy with Effusion.

A portion of a right lung covered with granular lymph and partially adherent to the parietal pleura. In the recent state there was pleural effusion. The lung is somewhat compressed, and under the microscope presents the appearance of tuberculous broncho-pneumonia.

351 Diaphragmatic Pleurisy.

A portion of a diaphragm the pleural surface of which is covered with a coherent layer of granular lymph, part of which has been reflected.

352 Fibrinous Mass from the Pleural Cavity.

A soft fibrinous mass about an inch and a half in diameter found in the pleural cavity. It is micaceous from the presence of crystals of cholesterin.

Presented by Dr. Hodgkin.

353 Recent and Chronic Pleurisy.

A right lung shewing fibroid thickening of the parietal and visceral layers of the pleura, which are not adherent to each other. Both surfaces are for the most part shaggy, and the space between them was in the recent state filled with a serous effusion.

Cornelius L., æt. 27, was admitted under Dr. Addison in 1829 for acute pulmonary symptoms supervening upon a condition of extreme cachexia from syphilis and mercury. At the autopsy there was effusion in the left pleura and in the pericardium. *See Insp.* vol. 8, p. 110.

354 Encysted Pleural Effusion.

A vertical section of a left lung shewing a large spherical sac, about five inches in diameter, situated in the anterior and lower part of the pleural cavity, and having behind it the lower lobe of the lung which is much compressed. The pleura is thickened, and its two layers are adherent to each other except where they form the dense wall of the cyst. The inner surface of the cavity is partially covered with flakes of lymph. Histological examination of the wall of the sac shews no hydatid membrane.

William W., æt. 27, was admitted under Dr. Goodhart for paraplegia due to caries of the lower dorsal spine. He died of pulmonary embolism. At the autopsy the cyst contained a quantity of brownish lymph and yellow serum. *See Insp.* 1886, No. 153.

355 False Membrane from the Pleura.

A portion of false membrane with a finely reticulated surface from the pleural cavity. The membrane was very abundant, and in the recent state was mixed with blood and serum.

Presented by Mr. T. W. King.

356 Adhesions of the Pleura.

A portion of the lower lobe of a lung shewing upon the pleura numerous flocculent adhesions. Beneath the pleura, which is scarcely thickened, and in the substance of the lung, are many miliary tubercles.

From a girl, *æt.* 12, who died from tuberculous meningitis with general tuberculosis. *See Insp.* vol. 14, p. 150; and *Prep.* 1211.

Presented by Dr. Addison.

357 Pleuritic Adhesions.

A portion of a lung with part of the parietes of the thorax shewing long filamentous adhesions between the parietal and visceral layers of the pleura.

John W., *æt.* 30, was admitted under Dr. Back in 1828 for delirium tremens. At the autopsy the pericardium was found to be adherent and there was some thickening of the mitral valve. *See Insp.* vol. 6, p. 4; and *Prep.* 1429 (16) [2nd Edit.].

358 Organised Pleuritic Adhesion.

A portion of a rib with a thin strip cut from the sub-jacent lung shewing a delicate membranous adhesion stretched between the visceral and parietal layers of the pleura. The preparation is injected, and shews numerous minute vessels in the adventitious membrane.

359 Membranous Septum in the Pleural Cavity.

The greater part of the right lung with a portion of two ribs. Between the ribs and the bottom of the fissure

separating the upper from the lower lobe of the lung there is stretched a thin false membrane extending along almost the entire length of the ribs. The pleural cavity, which in the recent state contained pus, was thus divided into two halves by a membranous septum. There is much lymph on the thickened pleura, and the lung shews extensive tuberculous excavation.

360 Thickened Pleura.

A vertical section through the lowest part of the pleural cavity shewing great thickening of the pleura in the angle between the ribs and the diaphragm. The two layers of the pleura are for the most part adherent, and measure about an inch in thickness. Between them at one part there is a narrow cavity, which in the recent state contained curdy pus.

Charles H., æt. 23, was admitted under Dr. Wilks for dyspnoea, and tumbling action of the heart. At the autopsy there was dilatation and hypertrophy of the heart, especially of the right side, the valves being healthy. The lungs were œdematous, and shewed a few traces of old phthisis. *See Insp.* 1869, No. 190.

361 Thickened Pleura.

A left lung invested by a tough fibroid pleura, measuring half an inch in thickness, at the base of the lung, and becoming gradually thinner towards the apex. The lung is compressed, and shews on its cut surface a few miliary tubercles.

362 Contraction of Pleura deforming the Lung.

A left lung shewing the pleura covering the lower half of each lobe to be opaque and thickened, but smooth upon its surface. The lung beneath the thickened pleura has been compressed, and is greatly altered in shape. Projecting from the lower border of the upper lobe behind there is a very remarkable cylindrical process about one inch and a quarter in length, and three eighths of an inch in diameter.

363 Pigmented Fibroid Nodules beneath the Pleura.

A lung, the pleura of which is studded with numerous slightly raised nodules having a white fibrous centre and surrounded by a black zone. The cut surface of the lung shews scattered miliary tubercles. Histologically the subpleural nodules consist of fibroid tissue with much surrounding pigmentation, and give no evidence of tuberculous origin.

William S., æt. circa 27, was admitted under Mr. Hilton, and died from tuberculous meningitis. *See Insp.* 1866, No. 164.

364 Fibroid Nodules upon the Pleura.

A portion of a left lung shewing upon its pleura numerous white fibroid nodules each surrounded by a zone of black pigment. There are also white linear thickenings running across the surface of the lung in the direction of the ribs. The lung is emphysematous, and contains numerous very minute dark nodules more easily felt than seen.

James K., æt. 42, was admitted under Dr. Goodhart in a cyanosed and delirious condition, and died in convulsions on the day after admission. At the autopsy the right side of the heart was found hypertrophied and dilated; the kidneys and liver were indurated. *See Insp.* 1884, No. 42.

365 Tuberculous Pleurisy.

A vertical section through a right lung and the diaphragm shewing considerable thickening of the pleura, the layers of which are adherent over the upper part of the lung, while elsewhere they are separated by a narrow interval crossed by thin membranous bands. The thickened pleura shews upon its cut surface numerous small yellow points of caseation. The lung is emphysematous and thickly beset with miliary tubercles. There is a small cavity in the middle of the upper lobe.

John L., æt. 43, was admitted under Dr. Pavy for progressive paraplegia of four months' duration. Subsequently the physical signs of phthisis and pleurisy developed, and he died one month after admission. At the autopsy there was a caseous mass in the spinal cord, and miliary tuberculosis of the viscera. *See Insp.* 1883, No. 112.

366 Tuberculous Pleurisy.

A section through a left lung shewing the visceral layer of the pleura and the interlobar septum universally thickened, in some places to the extent of one third of an inch. The surface presents delicate membranous adhesions, and in contact with it at the apex of the lung there are some caseous lymphatic glands. The pulmonary tissue contains miliary tubercles. Histologically the thickened pleura shews many caseous foci crowded with the bacilli of tuberculosis.

George R., æt. 10, was admitted under Dr. Goodhart for an abscess in the temporal region associated with caseous disease of the bone. Symptoms of bronchitis and pleurisy developed soon after admission, and the patient died six months from the first onset of his illness. At the autopsy there was found extension of the caseous disease of the temporal bone to the subjacent dura mater with general tuberculosis of the viscera. The right pleura was unaffected. *See Insp.* 1890, No. 95; and *Prep.* 1587 (25) [2nd Edit.].

367 Localised Pleurisy in Phthisis.

A section of a left lung shewing at its apex a patch of thickened pleura overlying a small and very superficial pulmonary cavity. The patch was firmly adherent to the chest wall, and beyond the limits of the adhesion there is recent lymph on the pleura. On the reverse of the specimen the lung is seen to be of very open texture, and its surface is studded with numerous tubercles.

Edward B., æt. 45, was admitted under Dr. Rees for cough and hectic fever of four months' duration. He died from severe diarrhoea. At the autopsy a large vonica was found at the apex of the right lung. There was slight ulceration of the intestines. *See Insp.* 1868, No. 146.

368 Chronic Empyema.

A vertical section through a left lung shewing between the two layers of the pleura a large smooth-walled cavity which in the recent state contained pus. Both layers of the pleura are thickened, and partially calcified.

James R. was admitted under Dr. Cholmeley in 1805 much emaciated and extremely feeble. He lay on his left side. Nine years previously he had been jammed between two vessels, and always afterwards suffered from pain in the left chest. *See Old Museum Book, Case 41; and Prep. 383.*

369 Chronic Empyema with Deformity of the Chest.

The greater portion of the left side of the thorax, shewing a lateral curvature of the spine with the convexity of the curve towards the right side. The ribs are crowded together, and the side of the chest is much flattened. The pleural cavity is lined with membranous lymph, and in the recent state contained pus. There is an opening in the sixth intercostal space just external to the cartilages of the ribs, indicated by a blue rod. The lung is compressed, and there is granular lymph on the pericardium.

Florence M., æt. 15, was admitted under Dr. Goodhart for empyema, which had spontaneously opened, and was discharging pus from a sinus in the sixth left intercostal space. The sinus was enlarged and a drainage tube inserted; the patient died one month after admission. At the autopsy there was pericarditis, but no lardaceous disease or tuberculosis. *See Insp. 1886, No. 187.*

370 Ulceration of the Parietal Pleura in Empyema.

Portions of six ribs from the left side shewing the parietal pleura over them to be thickened, and partially covered by a layer of granular lymph. In several places the pleura is deeply ulcerated exposing the intercostal muscles.

William H., æt. 27, was admitted under Dr. Wilks for an empyema of the left chest. Five and a half pints of foul pus were removed by incision. Three days later he died, and at the autopsy the lung was found to be gangrenous. There was recent lymph on the pericardium. *See Insp. 1882, No. 374.*

371 Ulceration of the Visceral Pleura in Empyema.

A portion of a right lung shewing the pleura to be considerably thickened, and in many places destroyed by ulceration exposing the pulmonary tissue. The lung is somewhat compressed.

Thomas T., æt. 41, was admitted under Dr. Cholmeley in 1831 with symptoms of chest disease of one month's duration. On two or three occasions he expectorated several ounces of pus. At the autopsy about three pints of pus were found in the right pleural cavity. No communication was discovered between the cavity of the empyema and the bronchial tubes. *See Insp.* vol. 16, p. 23.

372 Circumscribed Empyema.

A portion of the lower lobe of a right lung with the adjacent parts of the diaphragm and pleura. Just above the diaphragm there is a small cavity with shaggy walls between the two layers of the pleura, which elsewhere were adherent, and are very thick and fibrous. In the recent state the cavity contained curdy pus. In the lung are numerous miliary tubercles.

William W., æt. 32, was admitted under Dr. Barlow for phthisis. At the autopsy there was miliary tuberculosis of the lungs with tuberculous ulceration of the pleura. *See Insp.* 1862, No. 60.

373 Localised Empyema.

A portion of a left lung and of the wall of the chest to which it is adherent. The pleura is much thickened, and the two layers are united except where, above the diaphragm, there is a cavity which in the recent state contained pus.

374 Interlobar Empyema.

A portion of the right lung shewing a smooth-walled cavity, into which a blue rod has been passed, situated in the fissure between the upper and middle lobes. In the recent state it contained pus, and was separated from

an empyema that occupied the pleural cavity. Another loculus which contained pus is seen in close contiguity with the pericardium.

John B., æt. 25, was admitted under Dr. Bright in 1837 with the physical signs of pleuritic effusion. At the autopsy the right pleural cavity contained air and two pints of pus. There was pneumonic consolidation at the apex of the left lung. *See Insp.* vol. 23, p. 131; and *Prep.* 399.

375 **Thickened Pleura after Empyema.**

Portions of three ribs and costal cartilages mounted to shew the great thickening of the parietal pleura in empyema.

James R., æt. 12, was admitted under Dr. Barlow for a discharging empyema from which he had suffered for three years. At the autopsy the chest was much deformed, and the viscera were lardaceous. *See Insp.* 1863, No. 195.

376 **Healed Empyema.**

A left lung the surface of which is covered by loose flocculent adhesions. The pleura is little if at all thickened, and the pulmonary tissue is healthy.

Rhoda P., æt. 2½, was admitted under Mr. Bryant with an empyema, which was incised and drained, the wound closing within a month. Two years and a half afterwards she died of a severe burn. *See Surgical Reports*, vol. 106, Case 94.

377 **Empyema treated by Resection of Ribs.**

A portion of the wall of a left chest with the subjacent lung. A blue rod indicates a sinus left after resection of portions of the seventh, eighth, and ninth ribs. The divided ends of the ribs are seen to have become united, and there is a bony bridge between the sixth and seventh, and another between the seventh and eighth ribs. The sinus is situated just below the point of excision of the ninth rib. The lung is much compressed, and the pleura covering it is thickened.

Gertrude McK., æt. 6, was admitted into the Evelina Hos-

pital under Dr. Taylor for empyema. Six months from the commencement of her illness the chest was drained by an incision through an intercostal space. Two months later Mr. Howse excised portions of three ribs, and through the opening thus made the empyema continued to discharge till the patient's death two years from the first onset of symptoms. At the autopsy the cavity of the empyema was found to occupy the posterior part of the chest reaching from apex to base. See *Trans. Clin. Soc.* vol. 13, p. 19; and *Prep.* 378.

378 **Portions of Ribs resected for Empyema.**

Portions of the seventh, eighth, and ninth ribs, resected in a case of chronic empyema. Between the seventh and eighth ribs is the track of a drainage tube, around which is considerable osseous deposit.

For the history of the case see the preceding preparation (377).

379 **Pyo-pneumothorax.**

A portion of a left lung uniformly covered with a thick layer of recent lymph. On its lateral aspect, at the lower part of the upper lobe, there is an irregular opening in the pleura leading to a small cavity in the lung. The blue rod separates the pulmonary and thoracic walls, and exposes the posterior limit of the large cavity which in the recent state contained pus and air. On the reverse of the specimen the lung shews a few small cavities, and numerous miliary tubercles.

Henry D., æt. 47, was admitted under Dr. Moxon with the physical signs of air in the left pleural cavity. He had suffered from cough and occasional hæmoptysis for eighteen months. At the autopsy forty-four ounces of pus were found in the left chest together with much air. There were many caseous tubercles in both lungs, and the intestines were extensively ulcerated. See *Insp.* 1867, No. 19.

380 **Pneumothorax.**

A left lung with both the parietal and visceral layers of its pleura. The layers enclose a cavity which is crossed by two bridles, and in the recent state contained air and

one and a half pints of turbid serum. Over a small area on the lateral aspect of the lung the two surfaces of the pleura are adherent, and immediately in front of this adhesion there is a small opening into the lung, indicated by a blue rod, which was found to communicate with one of the small bronchial tubes. The lung is compressed, and contained a few tubercles; there is no appearance of cavitation.

Margaret G., æt. 38, was admitted under Dr. Habershon for shortness of breath and pain in the chest of six weeks' duration. She had suffered from cough and occasional hæmoptysis for two years. A fortnight after her admission there were the physical signs of air in the left pleural cavity, and eight weeks later the patient died. At the autopsy the right lung presented a large cavity at the apex with fibroid induration of the lower lobe. *See Insp.* 1868, No. 116.

381 **Calcification of the Wall of an Empyema.**

Portions of four ribs with the subjacent lung and pleura, which formed part of the wall of an empyema. The pleura is much thickened, and shews several calcareous masses partly embedded in its parietal layer.

From a man, æt. 60, who suffered for a considerable time from symptoms of pulmonary disease. At the autopsy the left lung was partially adherent and the pleural cavity contained at its lower part two pints of pus, and some loose calcareous masses, two of which form the following preparation. *See Note Book*, No. 1, p. 207; and *Prep.* 382.

Presented by Mr. Joseph Rix, 1833.

382 **Calcareous plates from an Empyema.**

Two irregular calcareous laminae found loose in the cavity of an empyema.

For history see the preceding preparation (381).

383 **Calcification of the Pleura.**

A portion of thickened pleura partially calcified.

For history see Preparation 368.

384 Calcification of the Pleura.

A large calcareous mass from the parietal pleura.

Presented by Mr. De Jersey, Clifton.

385 Calcification of the Pleura.

A portion of parietal pleura and several ribs from the left side. The pleura shews extreme calcareous degeneration, and the ribs are crowded together, and deformed.

Joseph G., æt. 40, was admitted under Mr. Bransby Cooper in 1833, and died from cerebral softening. At the autopsy the left lung was adherent and the chest much contracted. *See Insp.* vol. 26, p. 33.

386 Calcification of the Pleura.

A portion of parietal pleura showing calcareous degeneration.

William C., æt. 60, was admitted under Dr. Babington in 1844, and died from empyema. *See Insp.* vol. 33, p. 56.

387 Calcareous masses in the Pleura.

A portion of a diaphragm and of the base of the right lung. Attached to the margin of the lung is a pedunculated nodule the size of a pea. There is a larger mass like an oyster in shape and size suspended from the lung, which was found loose in the pleural cavity. Embedded in the diaphragm, and projecting from its pleural surface, there are many similar small nodules. On section they are seen to be composed of laminated fibrous tissue, some parts of which have undergone calcareous degeneration.

Robert P., æt. 58, was admitted under Dr. Rees with wasting and weakness of the left arm, and a malignant growth in the left side of the neck. At the autopsy several abscesses were found in the left lung. *See Insp.* 1870, No. 228.

388 Fibroma of the Pleura.

A small portion of parietal pleura shewing upon its sur-

face clusters of hard white pearly nodules, most of which are one eighth of an inch in diameter. Histologically they are composed of layers of fibrous tissue arranged concentrically.

From a lady who died from cancerous stricture of the œsophagus.

Presented by Mr. Samuel Hallam.

389 **Fibroma of the Pleura.**

A hard white tumour, about half an inch in diameter, the surface of which is nodular. There is a slender pedicle by which it was attached to the pleura. Histologically the tumour consists of hyaline fibrous tissue.

John C., æt. 50, was admitted under Dr. Hale White for mitral stenosis and bronchitis, from which he died. At the autopsy the left pleura, to the parietal layer of which the fibroma was attached, was found to be thickened, and its cavity almost obliterated by adhesions. *See Insp.* 1893, No. 25.

390 **Cartilaginous Body from the Pleural Cavity.**

An irregular mammillated semi-cartilaginous body about the size of a walnut found at the lower part of the left pleural cavity close to the spine, to which it was attached by very delicate membranous adhesions.

From the Dissecting Room. *See Note Book*, No. 1, p. 163.

Presented by Mr. T. W. King.

391 **Carcinoma of the Pleura.**

A portion of parietal pleura shewing upon its surface nodules of new growth about the size of peas, having a linear arrangement corresponding to the course of the intercostal vessels. Histologically the growth is a spheroidal carcinoma.

Martha D., æt. 40, was admitted under Dr. Bright in 1826 with ascites for which paracentesis was four times performed. At the autopsy numerous rounded masses of new growth were found upon the peritoneum. No visceral carcinoma was discovered. *See Red Insp. Book*, p. 153; and *Prep.* 1226.

392 Carcinoma of the Pleura.

A portion of parietal pleura presenting numerous small nodules projecting from its serous surface. Histologically they have the structure of spheroidal carcinoma.

Sarah G., æt. 45, was admitted under Mr. Bransby Cooper in 1827 for cancer of the breast. At the autopsy secondary deposits were found in the lungs and liver. *See Insp.* vol. 3, p. 15; and *Preps.* 1922, 2317 [2nd Edit.].

393 Carcinoma of the Pleura.

A portion of the parietal pleura from the right chest shewing at its upper part, to which the lung was adherent, numerous nodules of new growth, which histologically have the structure of spheroidal carcinoma. The lower part of the pleura is more uniformly thickened, and in the recent state was separated from the lung by a serous effusion.

Eliza F., æt. 43, was admitted under Mr. Durham for a tumour of the right breast which had been observed for eighteen months. A month after its removal there were physical signs of effusion into the right pleural cavity, and twenty-two ounces of blood-stained serum were withdrawn. The patient died six months after the operation. At the autopsy growth was found in the liver and peritoneum. *See Insp.* 1882, No. 164.

394 Sarcoma of the Pleura.

A portion of the lower lobe of a lung, the pleura covering which is thickened, and infiltrated with new growth, which in places invades the substance of the lung. Separate nodules of growth are also seen embedded in the pulmonary tissue. Histologically the growth is a spindle-celled sarcoma.

John W. was admitted under Mr. Morgan for malignant disease of the femur for which amputation was performed. *See Preps.* 1162 (82), 1162 (84) [2nd Edit.].

395 Secondary Sarcoma of the Pleura.

A portion of parietal pleura, projecting from the serous surface of which are numerous secondary deposits, most of which are about the size of a split pea. At the upper part of the preparation there is a large ovoid mass of secondary growth measuring four and a half inches in its longest diameter. Histologically the growth is a very vascular spindle-celled sarcoma.

Anne G., æt. 59, was admitted under Mr. Lucas for a periosteal sarcoma of the lower end of the femur, which was first noticed six months previously. The limb was amputated through the middle of the thigh, and the patient died six weeks later with symptoms of secondary growth in the thorax. At the autopsy secondary deposits were found in the lung and upon the pericardium. *See Insp.* 1891, No. 306.

396 Sarcoma of the Pleura.

A portion of the lower lobe of a lung shewing numerous small nodules projecting beneath the pleura. Histologically they have the structure of round-celled sarcoma.

John F., æt. 30, was admitted under Mr. Key in 1821 for paraplegia. At the autopsy growths were found in the spine and other organs. *See Preps.* 1028, 1042, 1449, 1544, 1548, 1927, and 2012 [2nd Edit.].

397 Fat beneath the Pleura.

A portion of the lower lobe of a right lung shewing a large mass of fat spread out beneath the pleura. There is a ragged cavity at the base of the lung, the walls of which present under the microscope the appearance of tuberculous broncho-pneumonia.

Ludwig S., æt. 53, was admitted under Dr. Wilks, and died from cirrhosis of the liver. At the autopsy there was general adhesion of the lungs to the chest wall. *See Insp.* 1869, No. 83.

SECTION VIII.—INJURIES AND DISEASES OF THE DIAPHRAGM AND MEDIASTINUM.

- Wound of the Diaphragm : 398, 399.
 Gumma of the Diaphragm : 400, 401.
 Dermoid Cyst of the Diaphragm : 402.
 Fibroma of the Diaphragm : 403, 404.
 Lipoma of the Diaphragm : 405.
 Carcinoma of the Mediastinum : 406, 407.
 Sarcoma of the Mediastinum : 408-412.
 Cyst of the Mediastinum : 413, 414.

398 **Bullet Wound of the Diaphragm.**

A part of the right half of a diaphragm with a portion of the lung adherent to it. On the peritoneal surface of the diaphragm a small bullet is seen, partly embedded in the muscle.

Charles J., æt. 45, was admitted under Mr. Cock for a bullet wound of the right side, and died one week later. At the autopsy three bullets were found in the chest, and the right pleural cavity contained two pints of foul serum, and some air. *See Insp.* 1857, No. 227.

399 **Diaphragm wounded in Paracentesis Thoracis.**

Parts of two ribs from the right side with the adjacent portion of the diaphragm. The diaphragm is drawn upwards and doubled upon itself, and the inner layer has been incised to shew the peritoneal surfaces of the two folds in close apposition to each other. The pleural surface of the diaphragm is rugose, and formed part of the wall of an empyema. The bristles mark the track of a trocar through the folds of the diaphragm.

John B., æt. 25, was admitted under Dr. Bright in 1837 for

pyo-pneumothorax. An unsuccessful attempt was made to evacuate the pus by paracentesis thoracis. See *Insp.* vol. 23, p. 131; and *Prep.* 374.

400 **Gumma of the Diaphragm.**

A strip of diaphragm with a portion of the subjacent liver. In the substance of the diaphragm is a yellowish mass about the size of an almond, and below it a nodule of similar material in the liver. At the situation of the gummata there are adhesions between the liver and diaphragm. Histologically the gumma of the diaphragm consists of a central caseous portion surrounded by a fibrous capsule, within which are numerous small round cells.

Richard J., æt. 31, was admitted under Dr. Rees for symptoms of cerebral syphilis, and died in a condition of coma. He had been in the Hospital nine years before with primary syphilis. At the autopsy there was cerebral softening, the liver contained numerous gummata, and the testes were fibroid. See *Insp.* 1871, No. 326.

401 **Gumma of the Diaphragm.**

An antero-posterior section through a portion of the right lobe of the liver and the adherent diaphragm. There is a soft gummatous mass the size of a pigeon's egg replacing a portion of the diaphragm, and adherent on either side to the liver and lung, neither of which organs are invaded by the growth. The liver is extremely lardaceous. Histological examination of the tumour shews the muscle to be not entirely destroyed, in some places traces of striation being visible, but for the most part the fibres are replaced by cells of various sizes undergoing degeneration. There are a few cholesterin crystals.

George T., æt. 41, was admitted under Dr. Habershon with dropsy of the lower part of the body and albuminuria. "Many times he had had syphilis." At the autopsy the mitral valve was contracted, and there was lardaceous disease of the liver, spleen,

and kidneys, the liver also presenting several deep cicatrices on its surface. There was lardaceous enteritis. The lungs were healthy. See *Insp.* 1867, No. 239; *Guy's Hosp. Reps.* 1867, p. 398, Case 26; and *Prep.* 802.

402 **Dermoid Cyst attached to the Diaphragm.**

A small spleen-shaped tumour, measuring one inch and a half long and half an inch wide, attached by its flattened surface to the peritoneal covering of the diaphragm. The cut surface of the tumour presents a sponge-like texture, which histologically consists of a fibroid matrix, in which are seen portions of cartilage and striated muscle surrounding irregular spaces lined with a layer of cylindrical epithelium, and filled with a granular material containing large spheroidal cells.

Presented by Mr. T. M. Day, 1893.

403 **Fibroma of the Diaphragm.**

A portion of a diaphragm having on the under surface of the central tendon a rounded flattened tumour, two inches in diameter, and three eighths of an inch thick. Its surface is smooth and free from adhesions, and histologically it is composed of very dense fibrous tissue.

Emma H., æt. 41, was admitted under Mr. Symonds. She contracted syphilis four months after marriage at the age of seventeen. Death resulted from stricture of the rectum, and ulceration of the colon. At the autopsy capsulitis of the liver and spleen, and old pelvic peritonitis were found. See *Insp.* 1887, No. 339.

404 **Fibroma of the Diaphragm.**

A portion of a diaphragm to the pleural aspect of which is attached a flattened oval tumour about an inch long by three quarters of an inch broad. The cut surface of the tumour presents a glistening cartilaginous appearance

and histologically the structure consists of well-formed fibrous tissue.

Richard C., æt. 54, was admitted under Mr. Bransby Cooper in 1845 for cancer of the tongue and died from pleuritic effusion. See *Insp.* vol. 33, p. 191.

405 **Lipoma of the Diaphragm.**

A portion of a diaphragm to which is attached by a broad base a round flattened body in size and shape resembling a large lupin seed. Histologically it consists of adipose tissue.

Mary S., æt. 30, was admitted under Dr. Cholmeley in 1831 and died from hæmatemesis. At the autopsy the nodule shewn in the preparation was found between the diaphragm and the liver. See *Insp.* vol. 15, p. 53.

406 **Carcinoma of the Mediastinum.**

The lower part of a trachea, with the heart and lungs displaced backwards by a nodular mass of firm new growth occupying the anterior mediastinum, and measuring ten inches from side to side, seven inches from above downwards, and four inches from before backwards. The lungs are compressed and there is recent lymph upon the pleura and pericardium. The great vessels are completely surrounded by the tumour and much obstructed. A section of the mass shews it to consist mainly of enlarged glands infiltrated by new growth, which histologically has the appearance of a spheroidal-celled carcinoma with much stroma.

Lucy W., æt. 27, was admitted under Dr. Barlow for a mediastinal growth. At the autopsy secondary deposits were found in the cervical and mesenteric glands. The primary seat of the disease was uncertain. See *Insp.* 1864, No. 56.

407 **Colloid Carcinoma of the Mediastinal Glands.**

A portion of lung shewing enlarged bronchial glands infiltrated with a soft white cancerous deposit. His-

tologically the growth consists of large alveoli filled with swollen gelatinous cells.

From a man, *æt.* 23, who was admitted under Mr. Howse in 1870, and died from hæmorrhage following the removal of warts from the prepuce. At the autopsy carcinoma was found in the skull, spine, and ribs. *See Trans. Path. Soc.* vol. 22, p. 206.

408 **Sarcoma of the Mediastinum.**

A median vertical section through a sternum and the subjacent structures shewing the anterior mediastinum to be occupied by a firm white growth lying in contact with the posterior surface of the bone throughout its length, and displacing backwards the trachea and pericardium. The innominate artery and the left innominate vein are surrounded by growth, the vein being almost obliterated. The growth has invaded and penetrated the upper part of the gladiolus, and the muscles of one of the neighbouring intercostal spaces. On the reverse of the specimen the left pleura is seen to be covered by masses of growth, and in the recent state the pleural cavity contained about a pint of serous effusion. The lung is compressed, and its surface partially covered by a thin layer of granular lymph. There are secondary deposits in the enlarged cervical glands. Histologically the tumour is a small round-celled sarcoma.

Augusta J., *æt.* 25, was admitted under Dr. Goodhart for enlarged glands in the neck, and symptoms of mediastinal tumour. The glands were first noticed three months before admission. She died three weeks later, and during this time paracentesis thoracis was three times performed. At the autopsy the viscera were hard and congested, and the right pleural cavity contained two and a half pints of serous effusion. *See Insp.* 1890, No. 244.

409 **Mediastinal Sarcoma perforating the Œsophagus and Aorta.**

The lower end of an œsophagus and trachea with the main divisions of the bronchi and the arch of the aorta. The parts are surrounded by a soft white growth which has destroyed the wall of the œsophagus at the level of

the bifurcation of the trachea, and has perforated the aorta at the origin of the left subclavian artery. A communication, indicated by a red rod, is thus established between the aorta and the gullet. Histologically the growth is a small round-celled sarcoma.

Michael H., æt. 30, was admitted under Dr. Hale White for dyspnœa and pain in the chest. He had had several attacks of hæmoptysis, the first occurring seven months before his admission. He was found to have dulness and diminished breath-sounds over the whole of the left side of the chest. One month after his admission he suddenly brought up a large quantity of blood, and died. At the autopsy the stomach and duodenum were found to be full of blood, and the pericardium and left auricle were invaded by growth. *See Insp.* 1893, No. 74.

410 **Sarcoma of the Mediastinal Glands.**

The lower part of a trachea, with portions of the great vessels and the heart, shewing a large lobulated mass of soft white growth which occupied the anterior mediastinum and invades the right auricle and the lower part of the superior vena cava, the lumen of which is considerably obstructed. Histologically the tumour is a round-celled sarcoma.

411 **Sarcoma of the Mediastinum.**

A right lung, at the back of which is seen a mass of soft white growth by which it was pushed forward and compressed. A section has been made through the mass, and shews its central part to consist of enlarged lymphatic glands surrounded by a thick layer of firmer material, which occupies the pleura and invaded the walls of the thorax. The edges of the upper and middle lobes present a fringe of growth. Histologically the tumour is a round-celled sarcoma.

Clarence B., æt. 6, was admitted under Dr. Taylor with paraplegia and a tumour at the back of the right chest. He died three months after the onset of his illness. At the autopsy the ribs and vertebræ were found to be invaded by growth, which had compressed the spinal cord. *See Insp.* 1891, No. 114.

412 Sarcoma of the Mediastinum.

The thoracic viscera shewing the anterior mediastinum to be occupied by a huge mass of soft white growth, enveloping the pericardium and displacing backwards the lungs. It extends almost as high as the cricoid cartilage above, and to the diaphragm below, and measures five inches from side to side. A blue rod indicates the œsophagus stretched over the posterior surface of the tumour. The cut surface of the growth is homogeneous, and histologically it has the structure of a small rounded sarcoma.

From a girl, æt. 7, who suffered for nine weeks from severe dyspnœa and wasting. A fortnight before her death there were well-marked signs of mediastinal tumour pushing forward the chest wall, over which the veins were greatly dilated. At the autopsy the other viscera were free from growth. *See Lancet*, 1884, vol. 1, p. 890.

Presented by Mr. Briscoe.

413 Mediastinal Cyst.

The lower end of a trachea shewing between the main divisions of the bronchi a globular cyst measuring one and a half inches in diameter, which in the recent state contained a yellowish-brown glairy fluid. The inner surface of the cyst is smooth, and shews no communication with the œsophagus or air-passages. Histologically the wall of the cyst is composed chiefly of unstriped muscular tissue.

James F., æt. 40, was admitted under Mr. Davies-Colley with fractures of his pelvis, femur, and ribs, from which he died three hours later. *See Insp.* 1892, No. 359.

414 Dermoid Cyst of the Mediastinum.

A heart shewing an ovoid cyst attached to the external surface of the pericardium over the situation of the right auricle. The cyst, which is of about the size of a

duck's egg, was slightly adherent to the right lung. It has a thin fibrous wall lined with squamous epithelium, to which in some places are attached long brown hairs. In the recent state it was filled with sebaceous material and a turbid fluid containing oil-globules and plates of cholesterine.

Maria J., æt. 20, was admitted under Dr. Hale White for cerebral symptoms of a fortnight's duration. She died the next day, and at the autopsy basal meningitis was found. *See Insp.* 1890, 126; and *Trans. Path. Soc.* vol. 41, p. 283.

SECTION IX.—DISEASES OF THE LIPS
AND MOUTH.

Horny tumour of Lip : 415.
Epithelioma of Lip : 416-421.
Cyst of the Lip : 422.
Gangrene of the Mouth : 423.
Stenosis of the Mouth : 424.

415 Horny Growth from the Lip.

A portion of a lower lip, from which projects a horny tumour about an inch long.

William A., æt. 53, a carpenter. The tumour, which had been growing for six years, was removed by Mr. Cock in 1856. *See Drawing*, No. 230 (80).

416 Epithelioma of the Lip.

A portion of a lower lip, on the margin of which is a new growth having a raised centre and everted edges. The surface is ulcerated.

From a man of middle age. The tumour was of four months' duration, and was attributed to holding rough packing string between the lips. It was removed by Mr. Aston Key.

417 Epithelioma of the Lip.

A portion of a lower lip on which is seen a growth about an inch and a half long and three quarters of an inch wide, situated at the junction of the skin with the mucous membrane. The surface presents numerous long and horny papillæ blackened by soot. Histologically the growth is a squamous-celled epithelioma.

Henry B., æt. 46, a chimney-sweep, was admitted under

Mr. Davies-Colley in 1892 for a growth on the lip which had been first noticed three years previously, and was attributed to the irritation of a clay pipe. The growth and an enlarged submaxillary lymphatic gland were freely excised, and the patient was discharged with the wounds healed a fortnight after the operation. See *Surgical Reports*, vol. 159, Case 30.

418 Epithelioma of the Lip.

The lower lip and left angle of the mouth and part of the upper lip are the seat of a raised warty growth, extensively ulcerated. Histologically the growth is a squamous epithelioma.

Removed by Mr. Morgan in 1830.

419 Epithelioma of the Lip.

A lower lip, nearly the whole of which presents extensive epitheliomatous ulceration with raised everted edges.

Removed by Mr. Morgan in 1829. See *Drawings*, 233, 234, 235. The first shews the condition of the lip before the operation, and the others its condition afterwards.

420 Epithelioma of the Lip with secondary Deposits.

The left angle of the mouth with a portion of the cheek, shewing upon the mucous surface an irregular oval ulcer about one inch and a half in its longest diameter, having a nodular base, and thick raised edges. Below is mounted the left submaxillary salivary gland, to which is attached a lymphatic gland much enlarged and presenting a central excavation from the softening of secondary deposit. Histological examination of the ulcer and the enlarged gland shew that the growth is a squamous epithelioma.

Cornelius P., æt. 48, was admitted under Mr. Davies-Colley in 1890 for an ulcer on the buccal surface of the left cheek, and a swelling in the submaxillary region. The ulcer began as a blister two years before admission, and the glandular swelling had been noticed for eleven weeks. The parts shewn in the preparation were excised, but the growth speedily recurred. See *Surg. Repts.* vol. 153, Case 36.

421 Epithelial Tumour of the Lip.

A portion of a lower lip presenting an egg-shaped tumour, measuring one inch and a quarter in its longest diameter, and situated immediately beneath the mucous membrane. The tumour has a distinct capsule, and is nowhere ulcerated. On section it has a firm fibrous appearance. Histologically it consists of an epithelial growth with abundant fibroid stroma and numerous cell nests.

Presented by Mr. Aston Key.

422 Cyst in the Lip.

The cyst is stated to be formed by the dilatation of a labial gland.

423 Gangrene of the Mouth from Mercurialism.

The lower part of a face shewing extensive sloughing affecting the lips and mouth. The lower jaw is bare and many of the teeth have fallen out. On the reverse of the specimen the gangrenous process is seen to have extended to the fauces and root of the tongue.

John T., æt. 65, was admitted under Dr. Cholmeley in 1806 for cough and shortness of breath. He was treated with mercury. At the autopsy an empyema of the left chest was found, and there was a cyst in one of the kidneys. *See Old Museum Book, Case 56.*

424 Stenosis of the Mouth.

The mouth and lips extremely contracted and rigid, the consequence of ulceration following the use of mercury.

From a man, æt. 22, who was admitted in 1829 under Mr. Morgan, suffering from syphilis and mercurial stomatitis. Three operations were performed for the purpose of enlarging the mouth; but the contraction increased, and the patient died of kidney disease, probably lardaceous. *See Insp. vol. 14, p. 86; and Drawing, No. 230.*

SECTION X.—DISEASES OF THE SALIVARY GLANDS.

Calculi : 425-429.

Enchondroma : 430-434.

Sarcoma : 435, 436.

425 **Salivary Calculus.**

A portion of a submaxillary salivary gland with its duct dilated, in which a calculus is lodged. A blue rod has been passed into the distal portion of the duct. Smaller calculi from the same case are seen at the bottom of the preparation glass.

John J., æt. 23, was admitted under Mr. Davies-Colley in 1890 for a swelling beneath the jaw on the right side, and a hard mass which could be felt on the floor of the mouth at the situation of the opening of Wharton's duct. Six months previously a calculus had been removed from the same duct. The submaxillary gland was excised at the second operation. *See Surgical Reports*, vol. 147, Case 111.

426 **Salivary Calculus.**

An oval calculus, about three quarters of an inch long by three eighths of an inch broad removed from the submaxillary gland. *Presented by Mr. Swift.*

427 **Salivary Calculus.**

A small calculus removed from the duct of the sublingual gland. *Presented by Mr. Callaway.*

428 Salivary Calculus.

A calculus about the size of a hazel nut discharged spontaneously from one of the salivary ducts.

From a patient, æt. 25.

Presented by Mr. J. Ward, 1866.

429 Salivary Calculus.

A longitudinal section of an almond-shaped calculus, measuring rather more than one inch in its longest diameter.

Samuel J., æt. 60, was admitted under Mr. Poland in 1868 for a swelling beneath the tongue which had been noticed for five months. He had been subject to occasional enlargements of the submaxillary gland for twelve years. The swelling in the mouth was incised, and the calculus removed. The patient recovered. *See Surg. Repts.* vol. 11, Case 9.

430 Enchondroma of the Submaxillary Gland.

One half of an enlarged submaxillary salivary gland measuring two and a half inches in length and two inches in breadth. Its surface is nodular, and the cut section presents numerous semi-transparent areas. Histologically the gland tissue is infiltrated by a growth of cartilage.

From a man aged about 40.

Presented by Mr. Arbuthnot Lane, 1891.

431 Enchondroma of the Parotid Gland.

An ovoid encapsuled tumour about the size of a hen's egg removed from the parotid gland. The cut surface has a white translucent appearance. Histologically the growth is an enchondroma, shewing in some parts mucoid degeneration. *Presented by Mr. Bryant, 1872.*

432 Enchondroma of the Parotid Gland.

An oval tumour measuring four inches in length by three and a half in breadth, and two in thickness. Its surface is nodular, and covered with a thin fibrous capsule. On section it has a "sago-grain" appearance due to a number of minute semi-transparent areas diffused throughout its substance. Histologically these are composed of fibro-cartilage, and are embedded in the normal glandular tissue.

Presented by Mr. Jacobson, 1888.

433 Fibro-cartilaginous Tumour of the Parotid Gland.

The half of an oval tumour one inch and a half in length which has a firm homogeneous surface and is encapsuled. Histologically it is composed of fibro-cartilage and gland tissue.

Henry S., æt. 29, was admitted under Mr. Birkett for a tumour in the parotid which had been noticed for twelve years. See *Drawing*, No. 197 (76).

434 Tumour of the Parotid Gland.

The half of a tumour removed from the parotid region. The growth measured seven inches from above downwards, five inches transversely, and four inches and a half in thickness, and weighed forty-eight ounces. Its surface is lobulated, and at one part where it has ulcerated through the skin presents a large convex mass, the central portions of which are occupied by a black slough. The cut surface shows irregular areas of soft friable growth separated by firmer fibrous-looking bands. Histologically the tumour consists of a cartilaginous and fibrous stroma forming irregular alveoli, in which are contained numerous spheroidal epithelial cells.

John C., æt. 64, was admitted under Mr. Howse in 1892 for a

tumour in the left parotid region which had been slowly growing for about twenty years, and more rapidly during the four months preceding admission. The tumour was excised, and the patient was discharged well one month after the operation. See *Surgical Reports*, vol. 164, Case 39.

435 Sarcoma of the Parotid Gland.

A soft tumour measuring about three by two inches which was removed from the parotid region. Histologically it is a sarcoma composed of round and spindle cells. *Presented by Mr. Hilton, 1850.*

436 Sarcoma of the Parotid Gland.

A tumour laid open by a longitudinal section. It is oval in shape, measuring three inches and a half by two inches, and attached to its lower border by fatty tissue is a small secondary growth. The convex surface is smooth and covered with a thin fibrous capsule. On section the tumour is composed of very friable white material, marbled with darker areas due to extravasation of blood. Histologically it consists of round and oval sarcomatous cells, among which are embedded a number of ducts and glandular acini.

From a man, æt. 54. The tumour was removed from the side of the neck behind the angle of the jaw.

Presented by Mr. Durham, 1888.

SECTION XI.—DISEASES OF THE GUMS.

Fibrous Epulis : 437-440.

Epithelioma : 441.

Myeloid Epulis : 442, 443.

437 **Fibrous Epulis.**

An irregular lobulated mass of growth measuring about two and a quarter inches by one inch and a half, which was removed from the gum of the lower jaw. Histologically it consists of fibrous tissue.

Presented by Mr. Hilton, 1860.

438 **Fibrous Epulis.**

The stump of a tooth from the upper jaw surrounded by an irregular mass of growth, which histologically has the structure of fibrous tissue.

Presented by Mr. Cooper Forster, 1866.

439 **Fibrous Epulis.**

The stump of a lateral incisor tooth from the upper jaw, surrounded by a firm lobulated growth about the size and shape of the terminal phalanx of an index finger. Histologically the tumour consists of fibrous tissue.

Removed from a man, *æt.* 31, who had noticed the growth for about one year. The teeth of the upper jaw were decayed and the gum was thickened from chronic inflammation produced by the irritation of a plate for artificial teeth. *See Note Book, No. 3, p. 11.*

Presented by Mr. Golding-Bird, 1889.

440 **Fibrous Epulis.**

A nodulated mass of growth measuring an inch and a quarter from above downwards, an inch from side to

side, and three quarters of an inch in thickness, the surface of which is covered with mucous membrane. Behind is seen a fang of the molar tooth around which the tumour had a broad attachment to the gum. Histologically the epulis consists of fibrous tissue.

Selina C., æt. 38, was admitted under Mr. Jacobson in 1893 or a tumour growing from the gum of the upper jaw by the side of the molar teeth. It had been noticed for eighteen months. The growth was removed, and a week later the patient was discharged cured. *See Surgical Reports*, vol. 167, Case 34.

441 **Epitheliomatous Epulis.**

Three portions of a soft tumour from the gum of the lower jaw, the largest removed at the first operation, the two others after the recurrence of the growth. Histologically it is a squamous epithelioma with numerous cell-nests.

Charles G., æt. 40, was admitted under Mr. Cock in 1856 for an epulis which had been growing for five months. It was removed, but the growth recurred and rendered a second operation necessary three months later.

442 **Myeloid Epulis.**

A portion of a small tumour partially covered with mucous membrane. Histologically it consists of a tissue composed of spindle cells among which are seen numerous multi-nucleated giant cells and a few islets of true bone.

Catherine F., æt. 23, was admitted under Mr. Birkett for a tumour growing from the gum of the lower jaw between the molar teeth. Its existence had been noticed for fourteen months. *See Guy's Hosp. Repts.* 1856, p. 5, and plate v, fig. 5.

443 **Myeloid Epulis.**

A molar tooth partially surrounded by a firm smooth mass of growth rather less than an inch in diameter. Histologically the tumour consists of fibrous tissue in which are numerous large multi-nucleated cells.

Presented by Mr. Poland, 1864.

SECTION XII.—INJURIES AND DISEASES
OF THE TONGUE.

- Sublingual Dermoid Cyst : 444.
Punctured Wound : 445.
Corrosion by Acid : 446.
Glossitis : 447-449.
Pyæmic Abscess : 450.
Leucoma : 451.
Ichthyosis : 452.
Hypertrophied Papillæ : 453, 454.
Pemphigus : 455.
Tuberculosis : 456-458.
Leprosy : 459.
Epithelioma : 460-467.
Sarcoma : 468.
Cyst : 469.
Hemiatrophy : 470.

444 Sublingual Dermoid Cyst.

An ovoid cyst two inches and a quarter long and one inch and three quarters broad which was removed from beneath the tongue. It contained pultaceous material, and the inner surface of its wall is lined with epithelium.

James R., æt. 24, was admitted under Mr. Bryant in 1886 for a painless swelling beneath the chin which had been noticed for five years. There was a rounded fluctuating tumour on the floor of the mouth covered in front by mucous membrane, and adherent behind to the lingual muscles. The cyst was removed through the mouth. *See Surg. Repts.* vol. 119, Case 61.

445 Punctured Wound of the Tongue.

A tongue with the fauces, shewing the stem of a tobacco-pipe protruding from a punctured wound at

the root of the tongue beneath the left tonsil. The end of the pipe has perforated the carotid artery just above the origin of its lingual branch and in the recent state rested between the transverse processes of the third and fourth cervical vertebræ. About the middle of the right edge of the tongue is seen the partially closed wound of entrance.

William H., æt. 20, was admitted under Mr. Bransby Cooper in 1830. Whilst he was smoking a clay pipe the elbow of another man struck the bowl and forced the stem into his mouth. The pipe broke and the man immediately fainted. On admission there was a wound in his tongue but no foreign body could be found. Two days after admission, and on several subsequent occasions he spat out large quantities of blood, and died a fortnight after the injury. At the autopsy water injected into the carotid artery flowed freely from the mouth. See *Insp.* vol. 15, p. 15; and *Guy's Hosp. Rep.* vol. 5, p. 404.

446 **Tongue corroded by Nitric Acid.**

A tongue with the œsophagus, larynx, and trachea. The tongue is in parts denuded of its epithelium, and shews a yellowish discoloration, which was more marked in the recent state. The mucous membrane of the larynx and œsophagus is shreddy. A similar condition is seen on the portion of hard and soft palate mounted behind.

Jesse M., æt. 21, was admitted under Dr. Pye-Smith after swallowing three ounces of strong commercial nitric acid with suicidal intent. He died seventeen hours after taking the poison. At the autopsy the stomach was found to be perforated. See *Insp.* 1871, No. 207; *Guy's Hosp. Reps.* 1872, p. 223; and *Prep.* 619.

447 **Acute Glossitis.**

A tongue with the tonsils and larynx. The tongue is enlarged, measuring four and a half inches in length and two and a half inches at its broadest part. On the dorsum about one inch behind the tip there is a semi-circular groove produced by the pressure of the teeth and the portion of the tongue which thus protruded

from the mouth is greatly swollen and shews several punctures. The tonsils and larynx are œdematous. Histologically there is a diffuse infiltration of the muscular tissue of the tongue by small round cells, with much extravasation of blood.

Mary J., æt. 44, was admitted under Dr. Hughes for bronchitis and heart failure. Three days before death her tongue became swollen and was protruded beyond the teeth. The organ was punctured without relief. At the autopsy the kidneys were found to be contracted and granular, and the heart weighed 22 ounces. There was œdema of the lungs, but no anasarca. *See Insp.* 1854, No. 246; *Drawing* 224 (41); and *Prep.* 1389 (25) [2nd Edit.].

448 **Acute Glossitis.**

A tongue with the larynx and upper part of the trachea. The tongue is much enlarged, measuring four inches in length and three inches in breadth. Upon its dorsum are seen the impressions of the teeth. The arytaeno-epiglottidean folds are wrinkled. Histological examination shews extreme infiltration of the organ with small round cells.

Joseph B., æt. 48, was admitted under Mr. Birkett for a great enlargement of his tongue which completely filled the mouth and protruded from between the teeth. He died a few hours after his admission from suffocation. At the autopsy there was œdema of the glottis and the kidneys were granular and contained many cysts. *See Insp.* 1863, No. 203.

449 **Chronic Enlargement of the Tongue.**

The anterior portion of a tongue, two and a half inches in length, removed by operation. It is much swollen and the papillæ of the mucous membrane are well marked.

Thomas L., æt. 53, was admitted under Sir Astley Cooper in 1807 with his tongue greatly enlarged and protruding from between the teeth, which were displaced forwards and had by their pressure produced a deep groove upon the organ. It was thought that the enlargement was due to mercury with which he was salivated, while under treatment for syphilis, six months

before admission to the hospital. The swelling was painless and the protruding portion was removed by ligature. The patient recovered. *See Old Museum Book, Case 53.*

450 **Pyæmic Abscess of the Tongue.**

A tongue divided along the middle line to shew in the muscle immediately beneath the mucous membrane covering the dorsum several small irregular cavities which in the recent state contained pus.

Jesse B., æt. 16, was admitted under Mr. Bryant with symptoms of pyæmia. He had suffered from a stone in the bladder for eight years. The tongue and fauces became much swollen and he died four weeks after admission. At the autopsy there were abscesses in the kidneys and lungs, and the glottis was very œdematous. *See Insp. 1861, No. 96.*

451 **Leucoma of the Tongue.**

A tongue the anterior third of which appears to be constricted and presents a smooth surface denuded of papillæ which in the recent state was white. The rest of the organ is normal. Histological examination shews that in the smooth parts the papillæ are very small or entirely obliterated, that the mucous membrane is thinner than elsewhere, and that the corium is infiltrated to a moderate degree with small round cells.

John K., æt. 69, was admitted under Dr. Moxon for chronic bronchitis and emphysema from which he died. At the autopsy the kidneys were granular and the surface of the liver was scarred. *See Insp. 1883, No. 45.*

452 **Ichthyosis of the Tongue.**

The anterior half of a tongue the dorsal surface of which is covered by a thick layer of fur and is broken up by irregular fissures, presenting a mosaic-like appearance similar to that of the skin in ichthyosis. The fur has been scraped from part of the surface to shew a considerable hypertrophy of the papillæ beneath. Histologically there is no evidence of inflammation.

453 Hypertrophied Papillæ of the Tongue.

A tongue the dorsal surface of which presents a "cauliflower-like" appearance, being broken up by deep irregular fissures separating clusters of elongated and thickened papillæ.

From a man who died from chronic intestinal obstruction.

454 Hypertrophied Papillæ of the Tongue.

A tongue shewing great enlargement of its papillæ, which is more marked towards the middle, where the surface is broken by deep fissures.

William L., æt. 46, was admitted under Mr. Howse with a fractured skull for which he was trephined. He died from erysipelas one month after the accident. At the autopsy gangrene of the lung was found, and the kidneys were granular. *See Insp.* 1883, No. 17.

455 Ulceration of the Tongue in Pemphigus.

A tongue shewing on the dorsum a large smooth patch of cicatricial tissue about an inch in diameter extending backwards as far as the circumvallate papillæ. In front of this patch there is a small ulcer with sharp edges. Over the rest of the tongue the mucous membrane is in some places thickened, in others partially detached.

George W., æt. 49, was admitted under Mr. Durham for severe pemphigus from which he had suffered at intervals during four years. He died from erysipelas. *See Insp.* 1878, No. 103.

456 Tuberculous Infiltration of the Tongue.

A tongue, with the larynx and upper part of the trachea, shewing at its root considerable swelling beneath the mucous membrane. The greater part of the epiglottis and the mucous membrane lining the larynx and trachea are destroyed by ulceration. Histological examination

of the base of the tongue shews that the mucous membrane is intact, but that the tissue beneath it is infiltrated with a deposit of tuberculous nodules crowded with the specific bacilli.

Alfred M., *æt.* 42, was admitted under Dr. Taylor for phthisis with ulceration of the larynx. During the three weeks before his death a rapid destruction of the epiglottis was observed. At the autopsy there was recent and chronic phthisis of both lungs with numerous tuberculous ulcers in the intestines. *See Insp.* 1889, No. 470.

457 **Tuberculous Ulceration of the Tongue.**

A portion of an injected tongue the tip and under surface of which as far as the frænum are denuded of mucous membrane. The ulcerated surface thus left has a finely granular appearance and its upper margin, which encroaches slightly upon the dorsum of the tongue, is somewhat raised and sinuous. Histologically the ulceration is tuberculous.

Perrette B., a man *æt.* 45, was admitted under Dr. Pye-Smith and died from acute phthisis with tuberculous laryngitis. *See Insp.* 1888, No. 413.

458 **Tuberculous Ulceration of the Tongue.**

An injected tongue, with the pharynx and larynx. At the tip of the tongue there is an irregular ulcer with a slightly raised border. In the recent state its base was covered with minute grey granulations. Histologically the ulceration is tuberculous. There is an enlarged bursa in front of the thyroid cartilage. On the reverse of the specimen the larynx shews advanced tuberculous disease.

Henry D., *æt.* 38, was admitted under Dr. Pitt for phthisis. The ulcer on the tongue had been noticed for six months. At the autopsy there was tuberculous ulceration of the intestines. *See Insp.* 1887, No. 388; and *Trans. Path. Soc.* vol. 29, p. 102.

459 Leprosy of the Tongue.

The tongue and larynx of a leper. The tongue is much tuberculated and in parts ulcerated. There is some ulceration of the epiglottis, which is greatly thickened, as also are the arytæno-epiglottidean folds.

Presented by Dr. Beavan Rake.

460 Epitheliomatous Ulcer of the Tongue.

A portion of a tongue shewing on its left edge a superficial ulcer about three quarters of an inch in diameter. The base of the ulcer is smooth and its border was indurated. On the reverse of the specimen the muscular tissue in the neighbourhood of the ulcer is seen to be infiltrated with a white growth which histologically has the characters of squamous epithelioma. The mucous membrane of the tongue is thickened and the papillæ are hypertrophied.

Eliza C., æt. 45, was admitted under Mr. Bryant in 1884 for a painful ulcer of the tongue which had been noticed for four months. She died during the administration of chloroform. At the autopsy the neighbouring lymphatic glands were enlarged. *See Surgical Reports*, vol. 106, Case 28.

461 Epithelioma of the Tongue.

A portion of an injected tongue presenting an ulcer upon its left edge. The specimen has been divided and the parts separated in order to shew a white growth dipping down into the muscular tissue. The ulcer measures about half an inch in diameter and has a slightly raised broad edge. In the recent state the dorsum of the tongue had the smooth white appearance of leucoma. Histologically the ulceration is epitheliomatous.

Ambrose N., æt. 47, was admitted under Mr. Howse in 1888 for an ulcer of the tongue of five weeks' duration. One half of the organ was removed and the patient made a good recovery. *See Surgical Reports*, vol. 134, Case 23 A.

462 Epithelioma of the Tongue.

The left half of a tongue removed by operation, and mounted to shew an oval growth one inch and a half long by one inch broad, situated upon the lateral aspect of the organ midway between the tip and the root. It projects above and overhangs the surrounding mucous membrane, and its surface is warty, and in parts superficially ulcerated. The growth has been incised, and is seen to invade deeply the muscular tissue. Histologically it is a squamous-celled epithelioma.

Presented by Mr. Symonds, 1891.

463 Epithelioma of the Tongue.

A portion of a tongue the right half of which is occupied by an ulcerating growth measuring about three inches long by an inch and a half wide. The edges of the ulcer are raised half an inch above the surrounding surface and are everted. Histologically the growth is a squamous epithelioma.

Sinball E., æt. 65, was admitted under Mr. Symonds in 1887 for a fungating mass on the right side of the tongue which had begun eight months previously as a pimple. The portion of the tongue which forms the preparation was removed by operation and the patient recovered. *See Surgical Reports, vol. 129, Case 21.*

464 Epithelioma of the Tongue.

A tongue with the fauces and larynx shewing a large ragged excavation which has destroyed the greater part of the tongue and the left tonsil. On the reverse of the specimen an ulcer is seen upon the laryngeal surface of the epiglottis. The glands on the left side of the neck are enlarged by infiltration with secondary deposit. Histologically the ulceration is epitheliomatous.

John C. was admitted under Mr. Key in 1827 for a fungating

growth of the tongue. Large abscesses formed in the glands on either side of the neck, and the patient died four months after admission. At the autopsy the lungs were found to be affected with disintegrating broncho-pneumonia. *See Insp.* vol. 5, p. 156.

465 **Epithelioma of the Tongue.**

A tongue divided along the middle line to shew towards its root a ragged cavity about one inch in diameter deeply embedded in its muscular substance. In the recent state the cavity contained a creamy fluid. The mucous membrane over the anterior third of the tongue is ulcerated and the neighbouring papillæ are much hypertrophied. The cervical glands are infiltrated with secondary deposit. Histological examination of the wall of the cavity shews that the muscle is invaded by a growth having the characters of squamous epithelioma.

Charles C., æt. 42, was admitted under Mr. Birkett for a swelling of the tongue and died five weeks after admission from laryngeal obstruction. At the autopsy the larynx was found to be œdematous and partly obstructed by the tumour. *See Insp.* 1859, No. 16.

466 **Epithelioma of the Tongue invading the Larynx.**

The base of a tongue with the larynx, shewing a nodular ulcerated growth situated between the root of the tongue and the epiglottis. The ulceration extends to the left side of the pharynx and has almost destroyed the arytæno-epiglottidean fold of that side. The epiglottis and the mucous membrane of the larynx are thickened by infiltration with the new growth, which histologically has the characters of a squamous epithelioma.

George G., æt 64, was admitted under Dr. Pye-Smith for swelling of the neck, dysphagia, and emaciation. His symptoms had existed for three months. At the autopsy secondary deposits were found in the pleura and liver, and in the cervical, bronchial, and portal lymphatic glands. *See Insp.* 1885, No. 201.

467 Epithelioma of the Tongue invading the Epiglottis.

A median vertical section through the tongue, larynx, and trachea, shewing the root of the tongue infiltrated with a firm white growth which involves the epiglottis. The mucous membrane covering the growth is ulcerated and the destructive process extends to the left tonsil. Histologically the growth is a squamous epithelioma.

William F., æt. 64, was admitted under Dr. Moxon for dyspnoea and difficulty in swallowing of six months' duration. He died from laryngeal obstruction. At the autopsy the base of the right lung was found consolidated by pneumonia. There were secondary deposits in the glands on the left side of the neck. See *Insp.* 1883, No. 9.

468 Sarcoma of the Tongue.

A portion of the left half of a tongue with the adjacent soft parts forming the floor of the mouth. Deeply embedded in the muscular tissue of the tongue there is a new growth about the size of a plover's egg. Below it there is a second tumour of similar size, which on the reverse of the specimen is seen projecting beneath the mucous membrane of the floor of the mouth. Histologically the tumours have the structure of round-celled sarcoma.

Joseph P., æt. 65, was admitted under Mr. Howse in 1888 for a tumour of the tongue which had been slowly growing for about twelve months. There was a second growth in the floor of the mouth. There was no difficulty either in swallowing or in speech. The tumours were removed, but secondary deposits occurred in the cervical glands, and the patient died in July 1891. See *Surg. Reps.* vol. 134, Case 37 A; *Guy's Hosp. Reps.* vol. 47, p. 21; and *Trans. Path. Soc.* vol. 41, p. 82.

469 Cyst in the Tongue.

The tongue of a child divided along the median line

to show a small thin-walled cyst situated beneath the mucous membrane immediately in front of the epiglottis.

Presented by Dr. Goodhart, 1884.

470 Hemiatrophy of the Tongue.

A tongue with the neighbouring parts, mounted to shew the disproportion in size between the two lateral halves of the organ. The partial atrophy of the left side, which was more obvious in the recent state, is due to the pressure exerted upon the hypoglossal nerve by the mass of carcinomatous glands on the left side of the larynx. Histological examination shews that there is a deposit of squamous-celled epithelioma in the cervical glands, and that the affected nerve and muscles have undergone degeneration.

Matthew J., æt. 60, was admitted under Mr. Durham for a tumour of the left side of the neck and paralysis of the corresponding half of the tongue. The swelling had been noticed for seven weeks. A portion of the tumour was removed, and the patient died two months after admission. The primary seat of growth was not discovered. *See Insp.* 1890, No. 483.

SECTION XIII.—DISEASES OF THE TONSILS, PALATE, AND FAUCES.

- Concretion from Tonsil: 471.
 Tonsillitis: 472, 473.
 Enlargement of Tonsils: 474, 475.
 Ulceration of Tonsils: 476.
 Epithelioma of Tonsil: 477, 478.
 Lymphadenoma of Tonsil: 479.
 Bifid Uvula: 480.
 Syphilis of Palate: 481, 482.
 Papilloma of Palate: 483-485.
 Fibroma of Palate: 486.
 Epithelioma of Palate: 487.
 Sarcoma of Palate: 488.
 Sloughing of Fauces: 489, 490.
 Ulceration of Fauces: 491-496.
 Syphilis of Fauces: 493, 494.
 Tubercle of Fauces: 495, 496.
 Sarcoma of Fauces: 497, 498.

471 **Concretion from the Tonsil.**

A nodular concretion of irregular shape about three quarters of an inch in its longest diameter which was expectorated from one of the crypts of the tonsil. It was analysed by Dr. Babington, and found to consist of phosphate of lime.

Presented by Mr. Hawkins.

472 **Phlegmonous Tonsillitis.**

The fauces and larynx shewing deep ragged excavations in both tonsils. There is a laryngotomy wound.

James B., æt. 24, was admitted under Dr. Pyc-Smith for profuse hæmorrhage from one of his tonsils which had been lanced to

relieve the swelling of quinsy. He had had several previous attacks of tonsillitis. After admission to the hospital the bleeding ceased, but he died a few hours later. *See Insp.* 1879, No. 493.

473 **Acute Suppurative Tonsillitis.**

A tongue with the fauces and larynx shewing both tonsils greatly enlarged. In the recent state the cut surfaces were "streaked with lines of pus."

William B., æt. 6, was under treatment for stone in the bladder in Mr. Cooper Forster's ward when he was attacked with sore throat and high temperature. He died on the following day from suffocation. *See Insp.* 1874, No. 79.

474 **Chronic Enlargement of the Tonsils.**

The root of a tongue with part of the fauces, shewing both tonsils to be enlarged.

475 **Chronic Enlargement of Tonsils.**

Enlarged tonsils removed during life by Mr. Hilton.

476 **Ulceration of the Tonsils in Scarlatina.**

The fauces and larynx shewing on either tonsil an excavated ulcer with undermined edges.

From a patient who died from scarlatina.

477 **Epitheliomatous Ulceration of a Tonsil.**

A pharynx with the larynx and base of the tongue shewing at the situation of the right tonsil a ragged excavation, the walls of which, as well as the neighbouring parts, are infiltrated with a soft white growth. The epiglottis and the right aryteno-epiglottidean fold are partially destroyed. A blue rod indicates the artery the ulceration of which led to fatal hæmorrhage. Histologically the growth is a squamous epithelioma.

James H., æt. 58, was admitted under Mr. Symonds for dysphagia of two months' duration. Five months before admission he

swallowed a fishbone, which stuck in his throat for five weeks. After it came away he noticed a swelling beneath the jaw. A week after admission he vomited blood and died almost immediately. At the autopsy the air-passages and stomach were found to contain a considerable quantity of blood. There were no secondary deposits. *See Insp.* 1833, No. 249; and *Prep.* 1201.

478 **Epithelioma of the Tonsil.**

A tongue with the fauces and pharynx mounted to shew the right tonsil occupied by a mass of growth which has invaded the soft palate, the right side of the pharynx, and the neighbouring structures. The growth is in parts deeply ulcerated, and histologically has the character of a squamous-celled epithelioma with numerous cell-nests.

Frank K., æt. 53, was admitted under Mr. Jacobson for dysphagia and pain at the back of the neck. On admission there was a nodular growth in the region of the right tonsil, which increased rapidly in size and sloughed. Thirty-seven days after admission the patient died, and at the autopsy the growth was found to have invaded the base of the skull, and there were secondary deposits in the submaxillary lymphatic glands. The lungs contained many small abscesses. *See Insp.* 1892, No. 80.

479 **Lymphadenoma of the Tonsils.**

The fauces with the epiglottis and posterior part of the tongue seen from behind. There is considerable enlargement of both tonsils from lymphadenomatous deposit. Nodules of similar growth are seen at the root of the tongue.

George B., æt. 48, was admitted under Dr. Pye-Smith for pleural effusion with the physical signs of pressure upon the left bronchus. He died twelve months from the commencement of his illness. At the autopsy lymphadenomatous growth was found in the mediastinal glands, and in the stomach and intestinal canal. *See Insp.* 1888, No. 131; *Trans. Path. Soc.* vol. 40, p. 80; and *Preps.* 716, 926, & 971.

480 **Bifid Uvula.**

A portion of a soft palate with the uvula attached.

The uvula is divided into two equal halves which are separated by rather more than a right angle from each other, the median cleft extending to the lower margin of the soft palate.

From the Dissecting Room.

Presented by Mr. Hilton.

481 Soft Palate deformed by Syphilis.

The base of a tongue with the fauces and larynx shewing the uvula attached to the free margin of the soft palate by several thread-like bridles of fibrous tissue.

Mary D., æt. 72, was admitted under Dr. Wilks for chronic bronchitis and emphysema, from which she died. At the autopsy cicatrices in the liver were found, and scars left after necrosis of the frontal bone. *See Insp.* 1870, No. 143.

482 Perforation of the Soft Palate.

A tongue with the fauces and larynx, shewing an oval perforation of the soft palate on the left side. The base of the tongue and the soft palate are extensively ulcerated and scarred; the tip of the uvula is bifid.

Richard T., æt. 26, was admitted in 1832 for stricture of the urethra, and died suddenly from laryngeal obstruction. At the autopsy the bladder was found to be inflamed, and the left kidney was in a condition of pyo-nephrosis with two calculi in the dilated pelvis. There was extreme œdema of the glottis. *See Insp.* vol. 11, p. 151.

483 Papilloma of the Palate.

An oval warty tumour about three quarters of an inch in its longest diameter removed by Mr. Hilton in 1855 from the soft palate at the right side of the uvula, which it somewhat resembles in size and shape.

See Drawing, No. 277 (90).

484 Papillomata of the Palate.

Two small warty growths, one pedunculated, the other sessile, which were attached to the mucous membrane of the soft palate.

Both were removed by Mr. Birkett. The patient from whom the sessile growth was taken was 25 years of age.

485 Papilloma of the Uvula.

A warty growth of the size and shape of a pea with a soft and thick pedicle by which it was attached to the side of the uvula.

Removed by Mr. Bryant in 1864 from a girl, æt. 18, who had noticed the presence of the tumour for two years.

486 Fibroma of the Palate.

A sessile button-shaped tumour about three quarters of an inch in diameter the surface of which bears delicate papillæ and presents about its centre a small patch of superficial ulceration. Histologically the growth is composed of fibrous tissue and the papillæ are covered by squamous epithelium.

Removed by Mr. Birkett in 1856 from the hard palate of a woman æt. 20, who had noticed the presence of the tumour for four years. A short time before the operation there had been slight hæmorrhage from the ulcerated surface.

487 Epithelioma of the Soft Palate.

A section of a firm oval tumour one and a half inches in its longest diameter removed from the soft palate. Histologically it is a squamous epithelioma.

Thomas J., æt. 33, was admitted under Mr. Bryant in 1872 for a tumour which was attached to the right side of the soft palate, and had been noticed for two years. It was covered by healthy mucous membrane, and was readily enucleated. The patient recovered. *See Surg. Repts.* vol. 33, Case 66.

488 Sarcoma of the Soft Palate.

Numerous small polypoid masses connected to each other by delicate processes forming a pendulous botryoidal growth which was attached to the middle line of the soft palate by a thin pedicle and projected into the cavity of the mouth. Histologically the polypi have the structure of sarcoma with large round cells, and are covered by squamous epithelium.

John H., æt. 34, was admitted under Mr. Birkett in 1859, for a tumour of the soft palate which was known to have existed for two months. It was easily removed, but recurred three months later both in the original site and in the cervical glands. The patient died seven months after the operation. See *Drawing*, 277 (95); and *Trans. Path. Soc.* vol. 11, p. 233.

489 Sloughing of the Fauces.

A tongue with the fauces and larynx, shewing a ragged slough attached to the left tonsil and to the corresponding half of the soft palate. The epiglottis presents evidences of former ulceration, the apex being destroyed and the base thickened and scarred.

Fanny S., æt. 62, was admitted under Mr. Poland for sloughing sores of the leg and of the mouth. She died from gangrenous broncho-pneumonia. There is no mention of the administration of mercury. See *Insp.* 1869, No. 128.

490 Sloughing of the Fauces in Scarlatina.

A larynx and trachea with the fauces, shewing extensive sloughing of the tonsils, palate, and neighbouring parts. The epiglottis is greatly thickened and the superior aperture of the larynx is narrowed.

From a child who died from scarlatina.

491 Ulceration of the Fauces and Larynx.

A pharynx and larynx shewing ulceration which has destroyed the left pillar of the fauces and the aryteno-

epiglottidean folds. The epiglottis is thickened and ulcerated.

Harold H., æt. 18 months, was admitted under Dr. Taylor for wheezing respiration and paroxysmal cough of two weeks' duration. There was a family history of phthisis, and some signs of rickets. A few days before death rapid ulceration of the angle of the mouth appeared. There was considerable broncho-pneumonia. *See Insp.* 1886, No. 107.

492 **Ulceration of the Fauces in Scarlatina.**

A tongue with the pharynx and larynx attached, shewing extensive ulceration of the tonsils, fauces, and upper part of the pharynx. The interior of the larynx above the vocal cords is slightly ulcerated.

From Henry O., æt. 6, who died in the sixth week of an attack of scarlatina, and suffered from suppurative inflammation of some of his joints a few days before death. The integuments of the neck on the left side were destroyed by extension of the inflammation from the fauces.

493 **Syphilitic Ulceration of the Fauces and Larynx.**

A larynx and base of the tongue. There is considerable ulceration of the tonsils, pharynx, and base of the tongue extending to the upper part of the larynx, destroying the epiglottis and laying bare the os hyoides. Microscopically the floor of the ulcer shews granulation tissue, and beneath this the muscular coat is invaded and the fibres broken or replaced by fibroid growth.

Anne A., æt. 22, was admitted under Mr. Bryant for ulcerated throat. Syphilis was suspected, but there was no history nor other evidence of this disease. She died of pneumonia. *See Insp.* 1860, No. 22.

494 **Syphilitic Ulceration of the Fauces.**

A tongue with the fauces and larynx shewing severe ulceration of the base of the tongue and neighbouring parts which has destroyed the epiglottis and laid bare the right cornu of the hyoid bone. Below the

vocal cords the ulceration is more superficial, and extends to the upper part of the trachea. Behind the preparation are suspended a testis containing a gumma, and a portion of thickened frontal bone.

George H. æt. 21, was admitted under Mr. Cock for sloughing sore-throat. No definite history of syphilis was obtained. The patient died from pleuro-pneumonia. At the autopsy the calvarium and the left tibia were thickened. *See Insp.* 1865, No. 169.

495 **Tuberculous Ulceration of the Fauces.**

A portion of a soft palate with the pillars of the fauces and the base of the tongue. The mucous membrane covering these parts is extensively and deeply ulcerated. Histologically the ulceration is tuberculous.

Charles C., æt. 18, was admitted under Dr. Rees for phthisis of six months' duration and died from hæmoptysis. At the autopsy the whole of the pharynx and larynx were found to be ulcerated. *See Insp.* 1869, No. 188.

496 **Tuberculous Ulceration of the Fauces.**

A tongue with a portion of the fauces and larynx shewing extensive ulceration at the root of the tongue and the neighbouring part of the pharynx. The epiglottis is partially destroyed and the interior of the larynx is superficially ulcerated. Histologically the process is tuberculous.

Elizabeth McK., æt. 45, was admitted under Dr. Pavy for sore throat and aphonia of three months' duration. At the autopsy there was tuberculous ulceration of the intestine with miliary tubercles in the lungs. *See Insp.* 1873, No. 162.

497 **Sarcoma of the Fauces.**

A soft oval tumour about the size of a pigeon's egg which was attached by a pedicle to the pillars of the fauces, and is covered by healthy mucous membrane. Histologically it is an unusual form of sarcoma undergoing mucoid degeneration.

Presented by Mr. Birkett.

498 Sarcoma of the Fauces.

The hinder part of a tongue with the pharynx and the thyroid gland. A sloughy growth occupies the left side of the pharynx and extends to the base of the tongue. The larynx is pushed over to the right and its aperture is narrowed. The thyroid gland is enlarged by infiltration with new growth. A blue rod passes from the external carotid artery into its lingual branch, which has been opened by ulceration. A ligature is seen around the common carotid artery. Histologically the growth is a sarcoma with small round cells.

Reuben A., æt. 22, was admitted under Mr. Cooper Forster for a large ulcer involving the left side of the fauces and the root of the tongue. Six weeks after admission the left common carotid was tied for profuse hæmorrhage. The patient died one week later. At the autopsy no growth was found elsewhere. *See Insp.* 1860, No. 75.

SECTION XIV.—INJURIES AND DISEASES OF THE PHARYNX.

- Pouch : 499, 500.
 Cyst : 501.
 Hypertrophied Lymphoid Tissue : 502.
 Foreign Body : 499-503.
 Ulceration : 504-506.
 Tubercle : 507, 508.
 Syphilis : 509.
 Polypus : 510, 511.
 Epithelioma : 512-523.
 Sarcoma : 524, 525.
 Post-Pharyngeal Lipoma : 526.
-

499 **A Pouch in the Pharynx.**

A larynx with part of the pharynx attached. On the left pharyngeal wall by the side of the epiglottis is a shallow oval depression one inch by half an inch in diameter. The base is smooth and its edge, which is undermined anteriorly, is thin and regular. There is no appearance of inflammatory action either old or recent. The piece of meat mounted behind was found occluding the larynx.

From a man who was brought into the hospital dead, having been suffocated by a piece of meat. *See Insp.* 1866, No. 147.

500 **A Pouch in the Pharynx.**

A portion of a pharynx and œsophagus shewing in the former a pouch about one and a half inches in diameter. The opening into it is circular, measuring half an inch across, and its margin is corrugated.

501 A Cyst communicating with the Pharynx.

The fauces and part of the pharynx of a lad shewing on the left side the inner half of a cyst about the size of a tangerine orange which is lined with a laminated material. The blue rod indicates the communication between the cyst and the pharynx behind the left tonsil.

502 Local Hypertrophy of Pharyngeal Lymphoid Tissue.

A part of the posterior wall of a pharynx, the mucous membrane of which is raised and thrown into deep folds. Histologically the condition is found to depend on a great increase in the lymphoid tissue in the submucous coat.

William N., æt. 16 months, was admitted under Dr. Wilks, and died from pleurisy and pericarditis. *See Insp.* 1885, No. 65.

503 Foreign Body in the Pharynx.

A pharynx into which a pocket-handkerchief has been stuffed, probably with suicidal intent.

Presented by Dr. Braidwood.

504 Ulceration of the Pharynx from Pressure.

A pharynx and upper part of the œsophagus shewing a deep oval ulcer about half an inch from above downwards and a quarter of an inch across situated upon the anterior wall of the pharynx. The ulceration lays bare the cricoid cartilage, and there is a corresponding ulcer upon the posterior wall of the pharynx.

Elizabeth H., æt. 24, was admitted under Dr. Halo White for headache, vomiting, and extreme retraction of the head, and died six weeks after the onset of symptoms. At the autopsy suppurative cerebro-spinal meningitis was found. *See Insp.* 1886, No. 172; and *Trans. Path. Soc.* vol. 38, p. 14.

505 Sloughing of the Pharynx from Pressure.

A pharynx laid open to shew upon its posterior wall a round sloughing ulcer, about an inch in diameter. Corresponding to this upon the anterior wall over the right half of the cricoid cartilage there is a similar smaller ulcer.

Robert C., æt. 45, was admitted under Dr. Hale White for chronic intestinal ulceration, and died from exhaustion four weeks after his admission. *See Insp.* 1892, No. 169; and *Prep.* 804.

506 Ulceration of the Pharynx.

A pharynx with the larynx shewing extensive ulceration. On the right side the ulceration has divided the arytæno-epiglottidean folds, attacked the base of the epiglottis, and exposed a large part of the thyroid cartilage. There is œdema of the glottis and the tonsils are enlarged.

Florence P., æt. 3, was admitted under Dr. Pavy, with symptoms of laryngeal obstruction which had existed for four days. It was thought that the child was suffering from diphtheria, and tracheotomy was performed. Death occurred four days later. *See Insp.* 1886, No. 50.

507 Tuberculous Ulceration of the Pharynx.

A larynx with the pharynx and upper part of the œsophagus. There is severe ulceration partially destroying the epiglottis and the arytæno-epiglottidean folds, and extending to the anterior and lateral walls of the pharynx.

Hannah B., æt. 22, was admitted under Dr. Perry for symptoms of phthisis, with dyspnoea and pain in swallowing. She was seven months pregnant, and died a week after her premature confinement. At the autopsy extensive tuberculous excavation of the lungs was found, and there were numerous ulcers in the ileum. *See Insp.* 1891, No. 157.

508 Tuberculous Ulceration of the Pharynx.

A pharynx with the larynx shewing tuberculous ulceration. The interior of the larynx is destroyed by

ulceration, which has spread backwards and involved the anterior wall of the pharynx. The affected area has a worm-eaten appearance from the presence of numerous small irregular ulcers separated by swollen mucous membrane.

Elizabeth S., æt. 14, was admitted under Dr. Taylor with phthisis, from which she died. She was aphonic, but had no difficulty in swallowing. *See Insp.* 1892, No. 174.

509 **Syphilitic Ulceration of the Pharynx.**

A pharynx with the larynx and upper part of the trachea. Extending from the superior aperture of the larynx to the commencement of the œsophagus there is a large ulcer, which has deeply destroyed the mucous membrane of the pharynx. The base of the ulcer is sloughy, and its edges are well-defined and thickened. Histological examination gives no clear indication of the origin of the ulcerative process.

Helena P., æt. 43, was admitted under Mr. Poland for ulceration of the throat. At the autopsy there was extensive bronchopneumonia affecting the bases of both lungs. *See Insp.* 1865 No. 262.

510 **Polypus of the Pharynx.**

The half of a pear-shaped polypus about an inch and a half long, which histologically consists of very vascular fibrous tissue.

The growth was removed by Mr. Birkett in 1851 from the pharynx of James G., æt. 16, who had known of its existence for three or four years.

511 **Polypus of the Pharynx.**

A smooth firm ovoid tumour two and a half inches long by one and a half inches broad and half an inch in thickness, which was attached by its smaller end to the posterior wall of the pharynx near the base of the skull.

Histologically the growth consists of very vascular fibrous tissue.

George E., æt. 16, was admitted under Mr. Bryant in 1867 for a polypus which obstructed the posterior nares and hung down into the mouth. It had been noticed for two years and was removed by ligature. The patient recovered. See *Surg. Reps.* vol. 5, Case 872; and *Trans. Path. Soc.* vol. 18, p. 106.

512 **Epithelioma of the Pharynx.**

A pharynx and upper part of the œsophagus shewing the anterior walls of the former occupied by a rough warty growth which extends from the arytaeno-epiglottidean folds, which are thickened and infiltrated by it, to the commencement of the œsophagus. Histologically it is a squamous epithelioma.

Anne J., æt. 53, was admitted under Mr. Durham for dysphagia. She was fed for nearly seven months through an œsophageal tube. At the autopsy gangrenous broncho-pneumonia was found. See *Insp.* 1881, No. 366.

513 **Epithelioma of the Pharynx.**

A pharynx with the larynx and upper part of the trachea shewing a lobulated mass of soft white new-growth attached to the anterior wall of the pharynx and extending as high as, and slightly overlapping the arytaeno-epiglottidean folds. The lower end of the tumour almost entirely occludes the œsophagus at its commencement. On the left side is seen a portion of an enlarged cervical gland infiltrated with secondary deposit. The larynx is laid open to shew its interior covered with slightly adherent false membrane. Histologically the growth is a squamous epithelioma.

Charlotte W., æt 32, was admitted under Mr. Coek for dysphagia of three months' duration. She died some weeks later from asphyxia. See *Insp.* 1856, No. 56; and *Guy's Hosp. Reps.* 1857, p. 225.

514 Epithelioma of the Pharynx.

A pharynx and upper part of the œsophagus shewing the anterior and right lateral wall of the former occupied by a mass of new-growth, the surface of which is extensively and deeply ulcerated. The growth reaches from the commencement of the œsophagus, where there is considerable constriction of the tube, to the level of the superior aperture of the larynx, which it overhangs and partially occludes. The right lobe of the thyroid gland is invaded by the growth, which histologically is a squamous epithelioma.

Sarah B., æt. 38, was admitted under Mr. Bryant for dysphagia and dyspnœa. Tracheotomy was performed, and three days later the patient died. At the autopsy broncho-pneumonia was found affecting both lungs. *See Insp.* 1864, No. 173.

515 Epithelioma of the Pharynx.

A pharynx laid open to shew extensive ulceration which involves the whole circumference of the tube and is two inches in length commencing on a level with the upper orifice of the larynx. The edge of the ulcer is thickened, raised, and everted, while its base is nodular and irregularly excavated. There is an abscess cavity on the left side just external to the muscular coat of the pharynx. Histologically the ulceration is epitheliomatous.

From a woman æt. 24, who had suffered from severe dysphagia and emaciation for one year, and for six months had been unable to swallow solids. At the autopsy all the other viscera were healthy except the lungs, which contained patches of pneumonic consolidation.

Presented by Mr. C. A. Lumley, 1888.

516 Epithelioma of the Pharynx invading the Thyroid Gland.

A larynx and the upper portion of the trachea with a portion of the pharynx. Upon the posterior wall of

the pharynx towards the left are three excavated ulcers leading to a mass of growth which has invaded the left lobe of the thyroid gland. Histologically the ulceration is epitheliomatous.

From a potman, who had suffered for two months from sore-throat, and died rather suddenly from asphyxia. *See Note Book, No. 3, p. 6.*

Presented by Mr. Symonds, 1887.

517 Epithelioma of the Pharynx.

A pharynx with the larynx and upper part of the œsophagus and trachea, shewing a deep excavation on the anterior wall of the pharynx, opening the trachea and exposing the cricoid cartilage. The parts around the excavation are infiltrated with softening growth, reaching from the upper opening of the larynx to the level of the twelfth ring of the trachea. Histologically the growth is a squamous epithelioma. The ulceration has extended to the left lobe of the thyroid gland, which is infiltrated and softened by secondary deposit. The cavity thus produced communicates with the trachea by a second opening in its lateral wall.

Mary P., æt. 31, was admitted under Mr. Hilton with dysplasia of four months' duration, and died one week after admission. At the autopsy gangrenous broncho-pneumonia was found, and there were secondary deposits in some of the cervical glands. *See Insp. 1864, No. 15.*

518 Epithelioma of the Pharynx.

A larynx and pharynx laid open to shew extensive ulceration destroying the upper part of the trachea, and exposing the cartilages of the larynx.

Presented by Mr. Cock.

519 Epithelioma of the Pharynx.

A pharynx and larynx shewing extensive ulceration, with ossification and necrosis of the thyroid and cri-

coid cartilages. The ulceration extends from the upper border of the epiglottis to a point an inch below the commencement of the œsophagus. The blue rod indicates an opening between the œsophagus and the trachea. In front there is an opening left after tracheotomy. Histologically the ulceration is epitheliomatous.

Susan B., æt. 33, was admitted under Mr. Bryant for dyspnœa and dysphagia of six months' duration. An œsophageal bougie could not be passed. Tracheotomy was performed and death occurred two months later from broncho-pneumonia. *See Insp.* 1885, No. 120.

520 **Epithelioma of the Pharynx.**

A pharynx and upper part of the œsophagus occupied by a fungating growth which extends from the base of the epiglottis above to the level of the tenth ring of the trachea below. The ulceration has destroyed the back of the cricoid cartilage and the posterior wall of the trachea at its upper part, and exposes the right inferior cornu of the thyroid cartilage. There is an opening left after tracheotomy. Histologically the growth is a squamous epithelioma.

Frances P., æt. 32, was admitted under Mr. Poland in 1849 with urgent dyspnœa for which tracheotomy was performed. She died three months after the operation.

521 **Epithelioma of the Pharynx.**

A pharynx with the upper part of the œsophagus shewing extensive ulceration which in the pharynx affects only the sides, but in the œsophagus also involves the anterior wall. The blue rods mark the situation of two sinuses which open externally on either side of the neck. Histologically the ulceration is epitheliomatous.

522 **Epithelioma of the Pharynx.**

A pharynx, larynx, and upper part of the trachea. There is extensive ulceration of the lower part of the

pharynx and upper part of the œsophagus. On the right side of the trachea, at the level of the tracheotomy wound, there is an oval opening leading into a cavity about the size of a walnut, which has resulted from the breaking down of one of the glands affected with secondary growth. Histologically the ulceration is epitheliomatous.

Jane B., æt. 57, was admitted under Dr. Bird. Twelve months previously she had an attack of sore-throat and bronchitis; this was followed by dysphagia, pain, and occasional dyspnoea. The dysphagia gradually increased, and on the morning of admission she appeared to be dying from suffocation. Tracheotomy was performed, and the patient was relieved; but she died twelve days later from exhaustion and bronchitis. See *Guy's Hosp. Reps.* 1851, p. 322.

523 **Epithelioma of the Pharynx ; Œsophagostomy.**

A larynx and trachea with the pharynx and œsophagus, shewing the gullet narrowed and encircled by an ulcerated growth which extends from the interarytenoid space downwards for about two inches. On the left lateral wall of the œsophagus, half an inch below the inferior limit of the growth, there is a rounded opening which communicated with the front of the neck by a wide channel between the trachea and the common carotid artery. Histologically the growth is a squamous-celled epithelioma.

Eliza G., æt. 60, was admitted under Mr. Davies-Colley for a stricture of the pharynx through which no instrument could be passed. There had been dysphagia for six months before admission. Œsophagostomy was performed, and the patient died six days later. At the autopsy recent lymph was found upon the left pleura, and there were several patches of broncho-pneumonia, one of which was gangrenous. See *Insp.* 1891, No. 204.

524 **Sarcoma of the Pharynx.**

A pharynx and upper part of the œsophagus shewing two large masses of new growth attached to the sides of

the pharynx at the level of the thyroid cartilage, and almost occluding the tube. In the recent state the growth was of a dark red colour, and parts of it were in a sloughing condition. The thyroid gland and larynx are free from disease. Histologically the tumour is a sarcoma with round and spindle cells.

Ann M. was under the care of Dr. Bright for dysphagia and a tumour of the neck resembling incipient bronchocele. Some time before her death a portion of the growth came away by the mouth. *See Drawing*, No. 283.

525 **Sarcoma of the Pharynx.**

A tongue with the pharynx and larynx attached. At the upper part of the pharynx on the right side there is a growth which occupies the tonsil, and infiltrates the soft palate and uvula. The growth is firm and nodular, and the mucous membrane over it is not ulcerated except behind the right tonsil, where there is sloughing which extends into the tissues of the neck. Histologically the growth is sarcomatous, consisting of round and spindle cells.

Martha B., *æt.* 31, was admitted under Dr. Addison for difficulty in swallowing, and enlargement of the cervical glands. These symptoms had been noticed for fourteen months. At the autopsy the cervical glands were infiltrated with secondary deposit; the lungs were tuberculous. *See Insp.* 1855, No. 233.

526 **Post-Pharyngeal Lipoma.**

A pharynx and œsophagus with the neighbouring parts, shewing a lobulated fatty tumour about three inches wide and one inch in thickness which extended from the base of the skull to the first dorsal vertebra. It is situated behind the pharynx, thus displacing and obstructing the œsophagus and respiratory passages. The pharynx has been partially dissected from the front of the tumour, but on the right side a portion of its wall

remains and shews the punctured wounds made at the exploratory operation.

Elizabeth B., æt. 4, was admitted into the Evelina Hospital for dyspnoea. Noisy respiration during sleep had been noticed for fifteen months. On admission there was a swelling of the neck somewhat resembling a much enlarged thyroid, and a soft tumour behind the pharynx which was punctured on two occasions. Subsequently the dyspnoea became urgent and tracheotomy was performed without relief. *See Trans. Path. Soc.* vol. 23, p. 216.

Presented by Dr. Taylor, 1877.

SECTION XV.—INJURIES AND DISEASES OF THE ŒSOPHAGUS.

- Pouch : 527-529.
 Cyst : 530, 531.
 Post-mortem Digestion : 532-536.
 Poisons : 537-539.
 Scarring : 540.
 Stenosis (Traumatic) : 541-543, 574.
 Foreign Body : 544-546.
 Acute Inflammation : 547-549.
 Keratoma : 550.
 Hypertrophy : 551, 552.
 Dilatation : 552, 553.
 Chronic Ulcer : 553, 554.
 Variola : 555.
 Myoma : 556, 557.
 Epithelioma : 558-574.
 Carcinoma : 575.
 Sarcoma : 576, 577.
 Adherent to Bronchial Glands : 578.
 Perforated by Caseous Glands : 579, 580.
 Perforated by Carcinomatous Glands : 581.
 Perforated by Aneurysm : 582.
 Abscess behind : 583.
 Injury : 584.

527 **Œsophageal Pouch.**

A portion of the œsophagus with the roots of the lungs, shewing a pouch projecting from the lateral wall of the gullet below the right bronchus. The adjacent lung is adherent to the outer wall of the sacculus, the lining membrane of which is continuous with the mucous coat of the œsophagus, and is roughened by partial gastric solution.

William K., æt. 78, was admitted under Mr. Jacobson for

retention of urine caused by enlargement of the prostate. The bladder was punctured above the pubes, and the patient died four days later from pyelitis and broncho-pneumonia. *See Insp.* 1884, No. 15.

528 Œsophageal Pouch.

A portion of an Œsophagus with the bifurcation of the trachea attached, shewing below the right bronchus a lateral pouch about the size of a pigeon's egg. The margin of its orifice is smooth, and the mucous membrane of the Œsophagus is continuous with the lining of the sacculus.

William A., æt. 74, was admitted under Mr. Lucas for severe injuries received in being run over, and died one week after admission from septicæmia. At the autopsy the mediastinal glands were found to be large and pigmented. *See Insp.* 1884, No. 37.

529 Œsophageal Pouch.

An Œsophagus with the lower end of the trachea and the main divisions of the bronchi. On the anterior wall of the Œsophagus on the right side is a circular opening about half an inch in diameter leading to a thin-walled sacculus the size of a pigeon's egg. Above this aperture there is a shallow depression of the mucous membrane produced by the adhesion of the Œsophagus to a mass of caseous glands situated at the bifurcation of the trachea.

George W., æt. 79, was admitted under Mr. Cooper Forster with a fracture of the leg, and died from pulmonary embolism and uremia. *See Insp.* 1880, No. 77.

530 A Cyst of the Œsophagus.

A portion of an Œsophagus shewing upon its internal surface the opening of a cyst the size of a small pea, situated beneath the mucous membrane. By the side of the cyst there is a small pouch in the wall of the Œsophagus, which is crossed by a band consisting of fibrous tissue covered by mucous membrane.

Thomas H., æt. 51, was admitted under Mr. Davies-Colley for

long-standing stricture of the urethra, and died from suppurative nephritis. See *Insp.* 1884, No. 294; and *Prep.* 2087 (41) [2nd Edit.].

531 **A Cyst of the Œsophagus.**

A portion of an œsophagus, projecting from the outer surface of which there is a cyst about the size of a cherry. The mucous membrane is healthy, and the muscular coat forms the thin external wall of the cyst. In the recent state it contained a viscid glairy fluid which is now coagulated, and is seen at the bottom of the preparation glass.

John C., æt. 28, was admitted under Dr. Rees for typhoid fever, and died the following day from perforation of the ileum. See *Insp.* 1858, No. 237.

532 **Post-mortem Digestion of the Œsophagus.**

An œsophagus, the mucous membrane of which has been almost entirely removed by the action of gastric juice. The only vestiges which remain are seen as narrow longitudinal ridges.

From James D., æt 22, who died of phthisis. See *Insp.* vol. 31, p. 245.

533 **Post-mortem Solution of the Œsophagus.**

An œsophagus, the mucous membrane of which has been for the most part removed by the action of gastric juice, leaving numerous well-defined patches somewhat resembling small warts. In the recent state they were easily detached, and histological examination shews them to consist of normal epithelium without papillary hypertrophy.

William R., æt. 50, was admitted under Dr. Moxon for gastric pain and vomiting of thirteen months' duration. He died one month after admission. At the autopsy there was malignant disease of the stomach, and stenosis of the pylorus. See *Insp.* 1877, No. 73.

534 Post-mortem Perforation of the Œsophagus.

The lower part of an œsophagus shewing an oval perforation about an inch long, the result of solution by gastric juice, which has also removed the surrounding mucous membrane.

William M., æt 39, was admitted under Dr. Cholmeley in 1834, and died from traumatic meningitis. *See Insp.* vol. 18, p. 17.

535 Post-mortem Solution of the Œsophagus.

The lower end of an œsophagus, part of which has been dissolved by the action of gastric juice. The remainder presents an irregular flocculent margin.

Elizabeth B., æt. 19, was admitted under Dr. Cholmeley in 1833, and died from typhoid fever. At the autopsy the contents of the stomach were found to have perforated the œsophagus and the connective tissue of the mediastinum, and to have partially dissolved the pleura covering the back of the right lung. *See Insp.* vol. 18, p. 1.

536 Erosion of the Œsophagus.

The lower end of an œsophagus, the inner surface of which is corrugated. The rugæ have a longitudinal direction, and the mucous membrane covering them is intact, while in the intervals between them its superficial layer has in parts entirely disappeared, and elsewhere presents a worm-eaten appearance produced by numerous small erosions. It is probable that this condition is due to post-mortem digestion.

Caroline J., æt. 40, was admitted under Dr. Wilks for cough, albuminuria, and anasarca. At the autopsy there was tuberculosis of the lungs, and the kidneys were scarred. *See Insp.* 1873, No. 247.

537 Corrosion of the Œsophagus by Sulphuric Acid.

A portion of a pharynx and œsophagus, the mucous membrane of which is shreddy and partially detached

from the action of sulphuric acid. The interior of the larynx is ulcerated, and is partly covered by a membrane.

538 **Poisoning by Soap-Lees.**

A portion of a pharynx, with the œsophagus and stomach, shewing the mucous membrane from the level of the tonsils to the cardiac end of the stomach darkened and partly denuded of epithelium by the corrosive action of soap-lees. The epiglottis and arytenoid folds are much swollen. The mucous membrane of the stomach was in the recent state slightly discoloured towards the pyloric end.

Charles C., a child, was admitted under Mr. Hilton having an hour previously swallowed a mouthful of soap-lees. Soon after admission some difficulty of breathing was noticed, and he died twelve hours after the accident. *See Insp.* 1857, No. 166.

539 **Poisoning by Chloride of Zinc.**

A portion of an œsophagus, the mucous membrane of which is wrinkled and has an unusual glistening appearance from the action of chloride of zinc.

From a man, æt. 62, who died four hours after swallowing two ounces of a solution of chloride of zinc. *See Brit. Med. Journ.* 1883, vol. 2, p. 820.

Presented by Mr. Crosse.

540 **Scarring of the Œsophagus.**

The upper portion of an œsophagus, the inner surface of which presents a scarred and puckered appearance ; the muscular coat is unaffected.

John P., æt. 62, was admitted under Dr. Habershon with cough and expectoration, and œdema limited to the upper extremities. At the autopsy the connective tissue of the mediastinum was indurated ; the kidneys were slightly granular, and there were patches of pneumonic consolidation in the lungs. *See Insp.* 1864, No. 220.

541 Traumatic Stenosis of the Œsophagus.

An œsophagus and stomach shewing the lower three inches of the gullet uniformly narrowed so as barely to admit a No. 5 catheter. The walls of the constricted portion are thickened by inflammatory material, and the œsophagus above is somewhat dilated. On the reverse of the specimen may be seen the opening left after gastrostomy, around which there are several lacerations of the serous coat of the stomach produced by the giving way of the stitches which attached the viscus to the abdominal wall.

Percy H., æt. 11, was admitted under Mr. Symonds for difficulty in swallowing, having three months previously drunk a mouthful of carbolic acid. Before and after his admission to the Hospital attempts were made to relieve the obstruction by the passage of bougies and by intubation. Eventually gastrostomy was performed, and ten days later the patient died from peritonitis. See *Insp.* 1890, No. 75.

542 Traumatic Stricture of the Œsophagus.

An œsophagus about the middle of which there is a fibroid stricture, which in the recent state admitted the little finger with difficulty. Above the stricture the œsophagus is extensively and deeply ulcerated, while an inch from the cardiac end the mucous membrane is scarred.

John L., æt. 33, was admitted under Mr. Key in 1840 and died four days after admission. He was supposed to have swallowed sulphuric acid. See *Insp.* vol. 30, p. 60.

543 Traumatic Stricture of the Œsophagus.

An œsophagus and stomach mounted to shew a constriction of the former about an inch and a half in length, the middle of which was at the level of the bifurcation of the trachea. The walls are considerably thickened and the lumen is narrowed so as barely to admit a No. 6 catheter. On the reverse of the specimen is the opening

left after gastrostomy. It is situated an inch and a half from the splenic end of the stomach.

Leonard W., æt. 10, was admitted under Mr. Davies-Colley with dysphagia and stricture of the œsophagus. Two years before admission he had swallowed oxalic acid. Gastrostomy was performed and the patient died fourteen months later from gangrene of the right lung with empyema. *See Insp.* 1885, No. 225.

544 Foreign body in the **Œsophagus.**

The lower end of an œsophagus in which a vulcanite tooth-plate is impacted.

Edward W., æt. 44, was admitted under Mr. Jacobson seven weeks after he had swallowed a tooth-plate. Gastrotomy was performed, but it was found to be impossible to dislodge the foreign body. *See Insp.* 1889, No. 199.

545 **Œsophagus obstructed by food.**

An œsophagus obstructed by a piece of pudding which is lodged about the middle of the tube.

From a child aged 2 years.

546 Foreign body from the **Œsophagus.**

A halfpenny incrustated by food.

Henry L., æt. 2½ years, was admitted under Mr. Durham in 1863 having three days previously swallowed a halfpenny. After the accident he was unable to take solid food, and frequently vomited. The halfpenny was removed by a whalebone coin-catcher.

547 Acute Inflammation of the **Œsophagus.**

An œsophagus denuded of epithelium throughout its length. In the upper third the condition is due to post-mortem solution, the limit of which is clearly defined at the junction of the pharynx and œsophagus. Below this part the walls of the tube are somewhat thickened, and its inner surface is rough and shaggy. Histological examination of the lowest portion of the œsophagus shews the submucous tissue to be much thickened and densely

infiltrated with small round cells. The blood-vessels are dilated and filled with red corpuscles ; the epithelium has disappeared.

John McL., æt. 78, was admitted under Mr. Davies-Colley in January, 1890, for a fracture of the femur and other injuries received by being run over. For three days after admission he frequently vomited "coffee-ground" material, which gave the reaction for blood. He died ten days after the accident. At the autopsy blood-stained mucus was found in the œsophagus, but no food. The stomach was healthy. *See Insp.* 1890, No. 36.

548 **Phlegmonous Inflammation of the walls of the Œsophagus.**

An œsophagus, with the larynx and trachea attached, which shews a thickening of its coats occupying the middle third of its length. In the recent state the wall was infiltrated with pus, which partially separated the longitudinal from the circular fibres of the muscular coat.

Benjamin L., æt. 61, was admitted under Mr. Bryant for epithelioma of the right arm, for which amputation was performed through the upper third of the humerus. The flaps sloughed, and the patient died three weeks after the operation. At the autopsy the cellulitis of the arm was found to have extended to the mediastinum. *See Insp.* 1879, No. 35.

549 **Membranous Inflammation of the Œsophagus.**

An œsophagus, the lowest five inches of which are acutely inflamed. The wall of the affected part is thickened, and the mucous surface is covered with a firmly adherent membranous deposit. Histological examination shews the wall of the gullet to be infiltrated with small round cells, and the epithelium to be replaced by a richly corpuscular fibrinous exudation.

Sarah B., æt. 59, was admitted under Dr. Perry for ascites of four months' duration. She was tapped four times, and died nine weeks after her admission. At the autopsy the liver was found to be cirrhotic. The mucous membrane of the stomach was normal.

It was thought certain that the condition of the œsophagus was not due to the administration of stimulants or other irritant. See *Insp.* 1892, No. 369.

550 Local Hypertrophy of the mucous membrane of the Œsophagus.

An œsophagus laid open to shew upon its mucous membrane numerous raised patches, round and oval in shape, and varying in size from a pin's head to a split pea. These nodules have a smooth convex surface, and histologically are seen to be due to local thickenings of the epithelium. The muscular coat at the lower end of the œsophagus is seen to be hypertrophied.

Thomas H., æt. 62, was admitted under Dr. Pavy for albuminuria and dilated heart. At the autopsy the heart was found to weigh $18\frac{1}{2}$ ounces, and the kidneys were granular. See *Insp.* 1866, No. 160.

551 Hypertrophy of the Œsophagus.

An œsophagus shewing marked hypertrophy of its muscular coat, especially of the circular fibres. The thickening, which is most marked an inch above the cardiac orifice, affects the lower two-thirds of the tube. The mucous membrane is shaggy, probably from partial post-mortem solution.

Louisa J., æt. 68, was admitted under Dr. Goodhart in an unconscious state, and died the next day. At the autopsy cerebral hæmorrhage was found, and the kidneys were granular. The heart weighed 21 ounces. See *Insp.* 1887, No. 271; and *Trans. Path. Soc.* vol. 39, p. 107.

552 Hypertrophy and Dilatation of the Œsophagus.

An œsophagus and stomach shewing the former greatly dilated and its muscular coat hypertrophied throughout its whole length. It is 11 inches long, and $6\frac{1}{2}$ inches in external circumference at its widest part. The cardiac orifice is laid open, and measures only $1\frac{1}{4}$ inches transversely. There is no appearance of fibroid thickening or cicatrisation of this orifice, the small size of which is

thought to be the cause of the enlargement of the œsophagus. The stomach is large, and "the pyloric ring is more distinct than usual, but quite free from disease."

From J. K., a farmer, æt. 74, who from boyhood had found difficulty in swallowing solid food, small quantities of which usually regurgitated after meals. At the autopsy the body was well nourished. See *Guy's Hosp. Repts.* 1872, p. 416; and *Trans. Path. Soc.* vol. 17, p. 138.

Presented by Mr. O. Rootes.

553 **Dilatation and Ulceration of the Œsophagus.**

A greatly dilated œsophagus, the circumference of which measures $2\frac{1}{2}$ inches at its upper end and 4 inches just above the cardiac orifice. The mucous membrane of the upper 3 inches of the œsophagus is healthy, while below this it is extensively destroyed by numerous ulcers of various sizes, the larger ones exposing the muscular coat. At the upper limit of the ulceration there is a flat wart one third of an inch in diameter. The muscular coat is somewhat hypertrophied, and the lymphatic glands at the bifurcation of the trachea are much enlarged.

From a young lady, aged 19, who from the time she was nine years old was noticed to have some peculiarity in her manner of swallowing, the cause of which could not be determined. She, however, enjoyed fair health till within about a year of her death, when signs of œsophageal obstruction developed and she became emaciated. At the autopsy the stomach was found enormously dilated, but apparently healthy. Nothing was found to explain the condition of the œsophagus.

Presented by Dr. Blasjon, 1884.

554 **Chronic Ulcer of the Œsophagus.**

A portion of an œsophagus presenting an oval ulcer half an inch in its longest diameter. The margin is slightly raised, and the base is formed by the exposed muscular coat of the tube.

Henry A., æt. 53, was admitted under Dr. Gull for dyspepsia and gastric pain, and died rather suddenly from internal hæmorrhage. At the autopsy two ulcers were found in the wall of the stomach,

one of which was about three inches in diameter, and had opened a branch of the cœliac axis, while the other was smaller, and closely resembled the ulcer seen in the preparation. *See Insp.* 1866, No. 25.

555 Œsophagus affected in Variola.

An œsophagus shewing upon its mucous membrane several small rounded papules, and a few minute circular ulcers.

From a patient who died in one of the Small-Pox Hospitals.

Presented by Dr. Bingham, 1879.

556 Myoma of the Œsophagus.

A portion of an œsophagus shewing an oval tumour projecting into the lumen of the tube about two inches above its cardiac end. The tumour measures one and a half inches from above downwards and about an inch from side to side. It is covered internally by mucous membrane and externally some of the longitudinal fibres of the muscular coat can be traced over it. The cut section has a fibrous appearance, and histologically the growth consists for the most part of unstriated muscular tissue.

William N., æt. 38, was admitted under Mr. Bryant for an injury to the knee, from the effects of which he died. He was not known to have suffered from dysphagia. *See Insp.* 1874, No. 411; and *Trans. Path. Soc.* 1875, p. 94.

557 Myoma of the Œsophagus.

An œsophagus shewing about two inches from its cardiac end an oval tumour placed transversely between its mucous and muscular coats. The tumour measures an inch in its longer diameter and about half an inch in thickness and projects from the outer wall of the tube. The mucous membrane over it is normal, and histologically the growth consists of unstriated muscular tissue.

Anne C., æt. 59, was admitted under Dr. Pavy for diabetes, and died of phthisis. *See Insp.* 1881, No. 367.

558 Epithelioma of the Œsophagus.

A pharynx and upper part of the œsophagus shewing at their junction a funnel-shaped stricture about three quarters of an inch in length which at its narrowest part in the recent state admitted only a small probe. The wall is thick and fibrous and is infiltrated by a growth which histologically has the characters of a squamous epithelioma.

Hannah W., æt. 43, was admitted under Mr. Cooper Forster, and died a week afterwards from pneumonia. She was said to have eaten "scarcely anything" for several months. See *Insp.* 1863, No. 7.

559 Epitheliomatous Stricture of the Œsophagus.

The upper part of an œsophagus with the pharynx shewing at their junction an annular stricture about three quarters of an inch in length which in the recent state admitted a small bougie. At the seat of the constriction the wall of the œsophagus is thickened and its surface corrugated. Above this the mucous membrane of the pharynx is superficially ulcerated almost as high as the upper opening of the larynx. On the left side there is a ragged opening leading to the posterior border of the thyroid cartilage, which with its inferior cornu is denuded of perichondrium, and ossified. Histologically the stricture is epitheliomatous.

Mary B., æt. 32, was admitted under Dr. Rees and died from inanition. See *Insp.* 1864, No. 45.

560 Epithelioma of the Œsophagus.

A pharynx and larynx with the upper part of the œsophagus and of the trachea. There is a warty growth on the anterior wall of the gullet extending from the level of the upper opening of the larynx to the ninth ring of the trachea, and considerably obstructing the tube. The tumour has encroached on the trachea and

appears on its posterior wall as a raised mass, part of which is still covered by mucous membrane while elsewhere it is papillomatous. The growth is deeply excavated by ulceration which has perforated the trachea; histologically it has the characters of a squamous epithelioma.

Henry D., æt. 48, was admitted under Dr. Pavy for dysphagia of five days' duration. He rapidly wasted, and died ten days after admission. At the autopsy the smaller bronchial tubes were found to be full of purulent secretion, and the lungs shewed a few small patches of pneumonic consolidation. See *Insp.* 1868, No. 276; and *Trans. Path. Soc.* vol. 20, p. 28.

561 **Epithelioma of the Œsophagus.**

An œsophagus, with the trachea and a portion of the right lung, shewing a deep excavated ulcer extending from the level of the bifurcation of the trachea almost as high as the pharynx. The ulceration involves the whole circumference of the tube except at its upper part where the edge is seen to be raised and everted. All the coats of the œsophagus are infiltrated with new growth which has invaded the right lung and perforated the trachea an inch above its bifurcation. Histologically the growth is a squamous epithelioma.

Benjamin B., æt. 55, was admitted under Dr. Moxon for dysphagia of about six weeks' duration. A fortnight before his death any attempt at deglutition caused severe coughing. At the autopsy the body was emaciated and there was great œdema of the lungs with gangrenous pneumonia of the right upper lobe. See *Insp.* 1882, No. 169.

562 **Epithelioma of the Œsophagus.**

A pharynx and upper part of the œsophagus in which about an inch below its commencement there is a deep excavation measuring an inch and a half from above downwards, and two and a half inches transversely. The base of the excavation is nodular and sloughy, and shews a small clean-cut opening leading into the trachea.

The edges are undermined, thickened, and rolled inwards, and histologically have the structure of squamous epithelioma.

John H., æt. 50, was admitted under Mr. Hilton with extreme dyspnoea, for which tracheotomy was immediately performed. He died the next day, and at the autopsy the œsophagus was found firmly adherent to the spinal column, and the pneumogastric nerves were implicated in the new growth. The kidneys were granular, and there was extensive broncho-pneumonia. See *Insp.* 1856, No. 55; and *Guy's Hosp. Reps.* 1856, p. 222.

563 Epitheliomatous Stricture of the Œsophagus.

A pharynx and œsophagus shewing a well-marked annular stricture about half an inch in length, the upper border of which is situated an inch and a quarter below the commencement of the œsophagus. The lumen of the tube is narrowed at the seat of the constriction so as barely to admit a No. 12 catheter, and its walls are thickened and infiltrated by a growth which histologically is a squamous epithelioma. The adjacent lymphatic glands, though excavated, shew no secondary deposit under the microscope.

564 Epitheliomatous Stricture of the Œsophagus treated by Intubation.

An œsophagus with the cardiac end of the stomach shewing a stricture which commences four inches below the level of the cricoid cartilage, and is about four inches in length. A soft rubber tube is seen passing through the stricture and projecting into the stomach. Above the stricture the mucous membrane of the gullet is healthy. Histologically the constriction of the œsophagus is seen to be due to infiltration of its walls with squamous epithelioma.

From James M., æt. 40, who was kept alive for eight months in comparative comfort by means of intubation, and eventually died from gangrene of the lung. See *Trans. Clin. Soc.* vol. 18, p. 155.

Presented by Mr. Symonds, 1887.

565 Epitheliomatous Tumour of the Œsophagus.

A portion of an œsophagus shewing the lumen of the tube to be obstructed by a conical tumour about two and a half inches long and one inch and a half in diameter. The upper part of the tumour is free, and presents a ragged sloughy surface, while the lower half has a broad attachment to the posterior wall of the œsophagus. Immediately below the tumour, at the level of the bifurcation of the trachea, the wall of the gullet is much thickened by infiltration with growth and its mucous membrane is ulcerated. On the reverse of the specimen the growth is seen to have invaded and destroyed the muscular coat. There is a slight dilatation of the œsophagus above the obstruction. Histologically the tumour is a squamous epithelioma.

John T., æt. 55, was admitted under Mr. Symonds for dysphagia of five months' duration. For nine weeks he had been able to swallow only liquid food. Unsuccessful attempts were made to pass bougies down the œsophagus. At the autopsy bronchopneumonia was found. There were no secondary deposits. See *Insp.* 1890, No. 369; and *Trans. Path. Soc.* vol. 42, p. 89.

566 Epithelioma of the Œsophagus.

A portion of an œsophagus shewing at the level of the bifurcation of the trachea a shallow ulcer about the size of a sixpenny piece with firm, raised, and slightly everted edges. A section through the border of the ulcer shews the muscular coat to be unaffected, while the mucous membrane is increased to the thickness of three eighths of an inch by infiltration of a growth, which histologically has the characters of a squamous epithelioma.

Edwin R., æt. 52, was admitted under Dr. Mahomed for severe girdle pains, and shortly afterwards became paraplegic. At the autopsy, a month later, the spinal cord was found to be compressed by a carcinomatous growth infiltrating the bodies of several of the vertebræ. Secondary deposits were also found in the pleura and liver. See *Insp.* 1883, No. 424.

567 Epitheliomatous Stricture of the Œsophagus.

An œsophagus shewing at its lower part an annular stricture about three quarters of an inch long, which in the recent state barely admitted a small probe. The mucous membrane at the seat of constriction is corrugated and superficially ulcerated; the subjacent structures are considerably thickened and infiltrated by a new growth, which histologically is a squamous epithelioma. There is a small nodule projecting from the mucous membrane at the upper part of the tube having the same histological characters as the growth below. The œsophagus above the stricture is dilated and hypertrophied, while below it is considerably contracted.

John S., æt. 70, was admitted under Dr. Burrow extremely emaciated, and unable to swallow food, and died one week later. *See Insp.* 1863, No. 196.

568 Epitheliomatous Stricture of the Œsophagus.

The lower part of an œsophagus with the cardiac end of the stomach shewing just above their junction an annular stricture about an inch long which in the recent state barely admitted a small probe. Above the stricture the blue rod indicates a small sinus which opens externally. At the seat of constriction the walls of the œsophagus are adherent to the surrounding parts, and are infiltrated by a new growth, which histologically is a squamous epithelioma. The mucous membrane of the stomach is healthy.

James S., æt. 57, was admitted under Dr. Habershon for dysphagia of two months' duration, and died five weeks later. At the autopsy a small sloughing cavity was found at the base of the right lung communicating with the œsophagus. There were no secondary deposits. *See Insp.* 1858, No. 108.

569 Epithelioma of the Œsophagus perforating the Aorta.

The lower part of an œsophagus with the arch of the

aorta and the roots of the lungs. There is an excavated ulcer destroying the walls of the œsophagus from the level of the bifurcation of the trachea to the cardiac end of the stomach. On the anterior surface the ulceration has exposed two pigmented bronchial glands at the root of the lung, and laterally it has perforated the descending part of the arch of the aorta, and one of the upper intercostal arteries. Microscopical examination of the thickened wall of the cavity shews it to be infiltrated by a growth having the characters of a squamous epithelioma.

Margaret H., æt. 60, was admitted under Dr. Wilks, greatly emaciated and suffering from occasional spitting of blood. The hæmorrhage became more profuse, and she died three months after admission. There was no dysphagia. At the autopsy the stomach was found distended by coagulated blood. *See Insp.* 1861, No. 84.

570 **Epithelioma of the Œsophagus.**

An œsophagus shewing a little above its cardiac end a pouch about the size of a walnut projecting from its anterior surface. The wall of the pouch is formed of the surrounding parts matted together by inflammation, and presents an oval opening into the left bronchus which admits the little finger. For a short distance above the pouch the mucous membrane of the œsophagus is destroyed by ulceration, and its wall is infiltrated by a new growth, which histologically has the characters of a squamous epithelioma. At the back of the cricoid cartilage is seen a linear groove produced by the pressure of an œsophageal tube.

Joseph S., æt. 60, was admitted under Mr. Durham for dysphagia and frequent vomiting of three weeks' duration. He was fed through a long tube fastened at the mouth, which he wore at intervals during the four months he was under treatment. He suffered from dyspnœa for two days before death. At the autopsy secondary deposits were found in the kidney, and there was acute broncho-pneumonia, more advanced in the left lung. *See Insp.* 1885, No. 13.

571 Destruction of the Œsophagus by Epithelioma.

The lower end of an œsophagus, shewing a deep ulcer which extends from the bifurcation of the trachea to within half an inch of the cardiac orifice of the stomach. For a distance of two inches the wall of the œsophagus is entirely destroyed, so that anteriorly the base of the ulcer is formed by the pericardium, which presents an irregular perforation about the size of a sixpenny piece. Some of the gastric branches of the right vagus are exposed in the floor of the ulcer. Histologically the ulceration is epitheliomatous.

Jane B., æt. 63, was admitted under Dr. Addison for dysphagia of nine months' duration, and died seven months later. At the autopsy secondary deposits were found in the visceral pericardium, the pancreas, the lungs, and in the suprarenal capsules. See *Insp.* 1856, No. 70; *Guy's Hosp. Reps.* 1856, p. 224; and *Preps.* 1938 (76) & 2022 (13) [2nd Edit.].

572 Epithelioma of the Œsophagus.

A pharynx and œsophagus with the bifurcation of the trachea and the neighbouring mediastinal glands. The lower end of the œsophagus is infiltrated and surrounded by a firm new growth having the histological characters of a squamous epithelioma. Its lower border is about one inch above the stomach, and it extends upwards for three inches. The mucous membrane of this part of the œsophagus is destroyed by ulceration, and the lumen of the tube is slightly narrowed. The growth has penetrated the œsophagus and infiltrated the surrounding structures. On the anterior wall of the pharynx there is a linear ulcer exposing the cricoid cartilage, which is superficially necrosed. This ulcer is due to the pressure of an œsophageal tube.

Susannah S., æt. 48, was admitted under Mr. Symonds for dysphagia, which was treated by intubation for about six months. At the autopsy pus was found in the smaller bronchial tubes, and

there was an effusion of serum into the right pleural cavity. The growth in the mediastinum had extended into the subjacent vertebræ, and into the glands in the neighbourhood of the stomach. *See Insp.* 1885, No. 399.

573 **Epitheliomatous Ulceration of the Œsophagus.**

An œsophagus with the cardiac end of the stomach. The wall of the gullet from the level of the bifurcation of the trachea downwards to its lower end is destroyed by ulceration presenting an extremely ragged and sloughy surface. At its upper part the ulcerative process has perforated the left bronchus, and below it has extended through the diaphragm, producing a gangrenous cavity which communicated with the cardiac end of the stomach by an opening on its posterior wall. The communication is indicated by a blue rod. Histologically the ulceration is epitheliomatous.

George W., æt. 53, was admitted under Dr. Habershon with dysphagia and vomiting of six weeks' duration, and died five days later. At the autopsy secondary deposits were found in the cervical and mediastinal glands. *See Insp.* 1856, No. 173.

574 **Stenosis of the Œsophagus followed by Epithelioma.**

An œsophagus shewing just above its cardiac orifice a simple stricture about an inch and a half in length which barely admits an ordinary lead pencil. Immediately above the stricture there is an oval ulcer about two and a half inches long by two inches broad, the edge of which is undermined, while in its base the muscular coat is exposed. At this part the œsophagus is adherent to the lung and to the adjacent lymphatic glands. Above the ulcer the œsophagus is dilated and measures two and a half inches in circumference. Histologically the edge of the ulcer has the structure of squamous epithelioma, and there is a secondary deposit in the glands of a similar character. The ragged opening

in the base of the ulcer was probably produced artificially.

From John L., æt. 84, who had suffered from difficulty in swallowing solid food for 40 years, but was able to swallow fluids to the time of his death. At the autopsy the body was not emaciated, and there was no evidence of disease in any other organ. See *Guy's Hosp. Reps.* 1872, p. 413.

Presented by Dr. Hilton Fagge.

575 Carcinoma of the Cardiac end of the Oesophagus.

The lower end of an oesophagus with a small portion of the cardiac end of the stomach laid open from the front. There is a deep ulcer encircling the last two inches of the gullet, and extending for a short distance into the stomach. The ulceration has perforated the walls of the oesophagus on either side, and communicates with the right lung. Histologically the base of the ulcer is infiltrated with a growth having the characters of a spheroidal carcinoma.

Presented by Mr. Cook.

576 Sarcoma of the Oesophagus.

A portion of an oesophagus laid open to shew a tongue-shaped tumour measuring four and a half inches from above downwards, two inches from side to side, and one inch in thickness, which in the recent state almost occluded the lumen of the tube. The broad attachment of the tumour occupies the whole circumference of the oesophagus with the exception of a small area about an inch wide on its posterior wall. The edges of the growth are overhanging, and its surface is shaggy from sloughing. The vertical section made through the margin of the tumour shews the muscular coat of the oesophagus to be for the most part free from growth, though on the reverse of the specimen a small nodule projects upon the outer surface of the tube. Histo-

logically the growth is a sarcoma with round and spindle cells.

William G., æt. 70, was admitted under Dr. Habershon for dysphagia of one month's duration, and died two months later. At the autopsy there was broncho-pneumonia of both lungs and cirrhosis of the liver. *See Insp.* 1857, No. 31; and *Trans. Path. Soc.* vol. 40, p. 76.

577 **Sarcoma of the Œsophagus.**

A pharynx and œsophagus with the larynx and trachea. An inch below the level of the cricoid cartilage there is the raised upper border of an ulcer three inches in length, which occupies the entire circumference of the wall of the œsophagus. On the posterior wall the ulceration is superficial, the muscular coat being unaffected; while in front it extends deeply, invading the neighbouring lymphatic glands and perforating the trachea a short distance above its bifurcation. Histologically the base of the ulcer is infiltrated by growth having the characters of sarcoma with round and oval cells.

Charlotte S., æt. 38, was admitted under Dr. Barlow for dysphagia of six months' duration. She was exceedingly emaciated, and any attempt to swallow was followed by regurgitation through the nostrils and produced a rattling noise in the chest. She died one week after admission. At the autopsy some purulent serum was found in the left pleural cavity, and there were secondary deposits in the lungs and kidney. *See Insp.* 1855, No. 68; and *Trans. Path. Soc.* vol. 42, p. 90.

578 **Œsophagus adherent to Bronchial Glands.**

An œsophagus shewing two depressed black scars over adherent bronchial glands.

Charles B., æt. 44, was admitted under Dr. Habershon and died of phthisis. *See Insp.* 1867, No. 291.

579 **Œsophagus perforated by Caseous Glands.**

A portion of an œsophagus, the wall of which shews

several irregular perforations communicating with caseous glands, the remains of which are seen adherent to the muscular coat.

Mary S., æt. 67, was admitted under Mr. Symonds for abscesses of the cervical region. She died of spinal caries and general tuberculosis. At the autopsy there was extensive caseation of the cervical and bronchial glands. *See Insp.* 1887, No. 317; and *Trans. Path. Soc.* vol. 39, p. 107.

580 **Œsophagus perforated by Caseous Glands.**

An œsophagus shewing on its anterior wall the opening of a sinus, which communicates with a cavity produced by the suppuration of a mass of caseous glands surrounding the lower part of the trachea.

Herbert S., æt. 18 months, was admitted under Dr. Pavy with an empyema of the left chest. The child had suffered from cough and dyspnoea for three months. At the autopsy, pus from softening mediastinal glands was found to have made its way into the left pleural cavity. The left pulmonary artery was occluded by thrombus. *See Insp.* 1885, No. 192.

581 **Œsophagus opened by Carcinomatous Glands.**

A portion of an œsophagus with the descending part of the aorta, shewing between them an elongated cavity in the anterior wall of which there is a small round opening communicating with the œsophagus. The cavity has arisen from the breaking down of mediastinal glands infiltrated with secondary deposit, a nodule of which is seen in contact with the aorta. Histologically the deposit has the structure of a columnar-celled carcinoma.

Mary J., æt. 53, was admitted under Dr. Pavy for constant vomiting and extreme emaciation. The duration of her illness was eleven months. At the autopsy a carcinomatous growth was found at the cardiac end of the stomach involving the lower end of the œsophagus. There were secondary deposits in the kidneys, liver, and pleura. *See Insp.* 1863, No. 268.

582 Œsophagus perforated by an Aneurysm.

An œsophagus with the lower end of the trachea and the ascending portion of the arch of the aorta. Just below the level of the bifurcation of the trachea there is a small clean-cut opening in the wall of the œsophagus, communicating with an aneurysm of the aorta. The sac of the aneurysm is lined with laminated clot which partly occludes the perforation. On the opposite wall of the œsophagus at the corresponding level there is a deep oval ulcer.

From a man, who was carried to the Hospital dead, having immediately before brought up a large quantity of blood. At the autopsy the stomach contained more than a pint of blood-clot. See *Insp.* 1890, No. 393.

583 Retro-œsophageal Abscess compressing the Trachea.

A pharynx and œsophagus with the upper part of the air-passages. Behind the middle third of the œsophagus is a thick-walled caseous abscess, which extends forwards on both sides of the tube, and in the recent state compressed the trachea. The neighbouring lymphatic glands are greatly enlarged, and are caseous.

Charles D., æt. 2 years, was admitted under Dr. Taylor for urgent dyspnoea, for which tracheotomy was hastily performed. The child had been subject to attacks of croupy cough and shortness of breath. At the autopsy caries of the first dorsal vertebra was found, and there was considerable caseous broncho-pneumonia. See *Insp.* 1887, No. 293.

584 Ruptured Œsophagus.

The lower end of an œsophagus with a portion of the stomach shewing a longitudinal rent four inches in length, beginning in the œsophagus an inch above its termination and extending into the cardiac end of the stomach. In the œsophagus the edges of the rent are abrupt and well-defined, while in the stomach they are

ragged, and the coats of the organ are thinned as from post-mortem digestion.

From M. C., a cabinet-maker, æt. 24, who was taken ill at 9 P.M. during a public supper, and shortly afterwards vomited. At 2 A.M. he complained of severe epigastric pain with dyspnoea. At 7 A.M. the dyspnoea had increased, and he was found to have cellular emphysema of the chest, neck, and face. He died fifteen hours after the commencement of his symptoms, the stomach-pump having been used without success two hours before death. At the autopsy some of the contents of the stomach were found in the lower end of the oesophagus and in the left pleural cavity. There was recent lymph on the pericardium. *See Insp.* vol. 32, p. 40.

Presented by Mr. Curtis, 1842.

SECTION XVI.—INJURIES AND DISEASES OF THE STOMACH.

- Pouch : 585.
 Hour-glass Contraction : 586-590.
 Laceration : 591-595.
 Gastrostomy : 596-599.
 Post-mortem Solution : 600-604.
 Hæmorrhagic Erosion : 605.
 Perforated Varicose Vein : 606.
 Effects of Poisons : 607-628.
 Phlegmonous Inflammation : 629, 630.
 Membranous Inflammation : 631.
 Ulcer : 632-657.
 Tuberculosis : 658-662.
 Anthrax : 663, 664.
 Dilatation : 665.
 Hypertrophy : 666.
 Mammillation : 667-669.
 Papilloma : 670-672.
 Polypus : 673, 674.
 Villous Tumour : 675-677.
 Fibro-myoma : 678.
 Cylindrical-celled Carcinoma : 679-687.
 Spheroidal-celled Carcinoma : 688-715.
 Lymphadenoma : 716.
 Sarcoma : 717-721.
 Perforation from without : 722-725.

585 **Pouch in the Stomach.**

A portion of the cardiac end of a stomach, shewing a pouch about the size of a cherry projecting from its serous coat. The mucous membrane lining the sac is healthy.

Sarah F., æt. 56, was admitted under Mr. Cooper in 1847 and died from phlegmonous laryngitis. At the autopsy the stomach presented no other abnormal appearance. *See Insp.* vol. 34, p. 203.

586 Hour-glass Stomach.

A stomach divided into two pouches by an annular constriction, which is half an inch long, and is situated three and a half inches from the œsophagus. The cardiac pouch holds thirteen, and the pyloric six ounces of water. In other respects the stomach appears normal. *See Trans. Path. Soc.* vol. 33, p. 132.

587 Hour-glass Stomach.

A stomach, the cavity of which is divided into two unequal parts by a narrow neck, situated nearer to the pyloric than to the cardiac end. In the recent state the constricted portion would admit the thumb. There is neither thickening of the wall, nor ulceration of the mucous membrane in any part of the organ.

From the Dissecting-room. *See Trans. Path. Soc.* 1884, p. 196.

Presented by Dr. Hale White.

588 Hour-glass Stomach.

A stomach divided into two pouches by a tubular constriction, which begins two and a half inches from the œsophagus, is one inch in length, and easily admits the fore finger. The cardiac pouch holds seven, and the pyloric five fluid ounces. In other respects the stomach appears to be normal.

From a woman, æt. 75. *See Trans. Path. Soc.* vol. 33, p. 150.

Presented by Dr. Carrington, 1881.

589 Hour-glass Stomach.

A stomach divided into two pouches by a constriction situated two and a half inches from the œsophagus. The constriction, which is tubular, is three quarters of an inch long, and will just admit an ordinary lead pencil. The cardiac sac will hold nine, and the pyloric

four ounces of water. In other respects the stomach appears to be normal. *See Trans. Path. Soc.* vol. 33, p. 131. *Presented by Sir Astley Cooper.*

590 Dilated Hour-glass Stomach. Pyloric Stenosis.

A greatly dilated stomach divided into two pouches by a constriction situated nearer to the cardiac than to the pyloric end. The length of the cardiac sac is about eight inches, and of the pyloric nearly twenty, while the transverse diameter of each at the widest part is five inches and a half. In the recent state these pouches contained 40 and 90 fluid ounces respectively. The thumb could be easily passed through the constriction, at which point the gastric wall is somewhat thickened and indurated. Upon the lesser curvature towards the cardiac side of the prominent ridge of mucous membrane surrounding the constriction there is a small oval ulcer with punched-out edges and a smooth base. There is a second similar but somewhat larger ulcer just within the pylorus upon the anterior wall of the stomach. The pyloric ring is narrowed so as barely to admit the little finger.

Jane L., æt. 38, was admitted under Dr. Hale White for constant vomiting, from attacks of which she had suffered for several years. Some relief was afforded by washing out the stomach. She died ten days after admission from coma following general convulsions. At the autopsy the brain and kidneys were normal. *See Insp.* 1891, No. 301.

591 Laceration of the Gastric Mucous Membrane.

A portion of a stomach shewing on its mucous membrane near the opening of the œsophagus a rent one and a half inches in length, supposed to have been produced by the distension of the viscus by blood-clot.

Henry G., æt. 40, while under the care of Mr. Key in 1829 for fistula in ano, became suddenly faint, vomited a pint of blood, and shortly afterwards died. At the autopsy it was found that an aneurysm of the aorta had ruptured into the œsophagus, and that the stomach was greatly distended by blood-clot. *See Insp.* vol. 8, p. 4.

592 Laceration of the Gastric Mucous Membrane.

A stomach laid open to shew its mucous membrane lacerated and detached over an area about two inches wide, extending transversely around the middle of the organ to within an inch on either side of the greater curvature.

John C., æt. 9, was admitted under Mr. Bransby Cooper in 1843 for injuries received by being run over by an omnibus. Shortly after admission he vomited blood-stained fluid, and died the next day. At the autopsy there was blood in the cellular tissue behind the pancreas; the liver was lacerated, and the thigh broken. *See Insp.* vol. 32, p. 249.

593 Laceration of the Stomach.

A stomach with a portion of the left lobe of the liver shewing upon the anterior surface of the stomach an inch below the middle of its lesser curvature an irregular laceration of the mucous membrane, about an inch long by a quarter of an inch wide, the edges of which are slightly raised and rounded. At one end the laceration has perforated the peritoneal coat, and around this opening in the recent state the liver was adherent to the stomach. There is granular lymph upon the serous surfaces of both organs.

James S., æt. 37, was admitted under Mr. Hilton for injuries received by being crushed between two railway buffers. He died nineteen days after the accident. At the autopsy several ribs were found to be fractured, and the peritoneal cavity contained altered blood and much "stringy lymph." The left lobe of the liver was lacerated. *See Insp.* 1867, No. 248.

594 Laceration of the Stomach.

A stomach shewing two extensive lacerations, one situated close to the œsophageal orifice, the other along the greater curvature three inches from the pylorus. In both cases the outer coats are more extensively torn than the mucous membrane.

From a man brought to the Hospital dead, having three

hours before fallen thirty feet on to the deck of a vessel. The peritoneal cavity was found to contain about a pint of the contents of the stomach mixed with blood, and there was laceration of the liver and spleen. *See Insp.* 1874, No. 363.

595 **Stomach of the "Knife Eater."**

A stomach with portions of the œsophagus and duodenum thus described by Sir Astley Cooper:—"The œsophagus at its lower part and the upper orifice of the stomach were thicker than natural. The left extremity of the stomach, where the spleen adheres to it, had its usual texture; but the right was exceedingly thickened. The rugæ in the mucous membrane were unusually prominent; and there were granulated projections from the edges of the rugæ. The membrane was still coloured by the steel. The pylorus was natural, but the duodenum had a greater thickness than usual."

John C., an American sailor, æt. 32, was admitted under Dr. Curry in 1808 for abdominal pain and vomiting. In 1779 he swallowed four clasp-knives, three of which were discharged from the bowels. In March, 1805, he swallowed fourteen knives, and in December of the same year he swallowed fifteen to twenty more. His health became impaired. He vomited the handle of one knife, and passed portions of the blades of others, and in 1809 he died from exhaustion. At the autopsy numerous knife-blades partly dissolved were found in the stomach. One blade had perforated the colon, and another was fixed transversely in the rectum. *See Preps.* 963, 964 [2nd Edit.], & 1044; and *Med.-Chir. Trans.* vol. 12, p. 52.

596 **Gastrostomy.**

A portion of the abdominal wall with some of the costal cartilages from the left hypochondriac region shewing, at the upper part of the linea semilunaris, an incision, to the margin of which is attached a part of the anterior wall of the stomach. The gastric fistula thus produced is situated halfway between the greater and lesser curvatures, and rather nearer to the cardiac

than to the pyloric end of the organ. Behind is mounted the pharynx and upper part of the œsophagus, the lumen of which is almost occluded by an ulcerated growth, which histologically has the characters of a squamous-celled epithelioma.

Walter H., æt. 47, was admitted under Dr. Habershon with urgent dyspnoea, which was treated by tracheotomy with slight relief. Subsequently he became unable to swallow food, and Mr. Cooper Forster performed the operation of gastrostomy. The patient survived twenty-four hours. It is believed that this was the first time that this operation was performed in England. At the autopsy a communication was found between the œsophagus and trachea, and there were patches of disintegrating broncho-pneumonia in the lungs. There was no peritonitis. See *Insp.* 1858, No. 64; and *Guy's Hosp. Reps.* 1858, p. 1.

597 **Gastrostomy.**

A stomach with the œsophagus and a portion of the abdominal wall shewing the condition of the parts four days after the operation of gastrostomy. The sutures by which the stomach was attached to the abdominal wall are loose, and there is much recent lymph on the peritoneum. The opening in the stomach is situated on the anterior surface about the middle of the greater curvature just above the attachment of the omentum. The wall of the gullet exhibits considerable fibroid thickening with contraction of the lumen of the tube.

James G., æt. 4, was admitted under Dr. Addison for inability to swallow solid food, and emaciation, having seventeen weeks before swallowed some corrosive poison. Gastrostomy was performed by Mr. Cooper Forster, and the patient died from peritonitis four days after the operation. At the autopsy food was found in the abdominal cavity. See *Insp.* 1859, No. 50; and *Guy's Hosp. Reps.* 1859, p. 1.

598 **Gastrostomy.**

A stomach with a portion of the abdominal wall to which it is firmly united around the opening left after gastrostomy. The fistula is situated upon the greater

curvature at a distance of two and a half inches from the pyloric ring.

William M., æt. 46, was admitted under Mr. Howse for dysphagia of six months' duration, for which gastrostomy was performed. He died one month later from gangrene of the lung. At the autopsy an epithelioma of the œsophagus was found, which had invaded the trachea. *See Insp.* 1878, No. 210.

599 **Gastrostomy.**

A stomach with a portion of the abdominal wall to which it is firmly united, shewing a fistula left after the operation of gastrostomy performed eight months before death. The orifice is situated a little to the right of the middle line of the organ and rather nearer to the greater than to the lesser curvature. Around the external opening there is a narrow ring of prolapsed mucous membrane, while internally the wall of the stomach is puckered and presents a very slight hour-glass contraction. *Presented by Mr. Howse.*

600 **Post-mortem Digestion of the Stomach.**

A stomach everted to shew the inner surface of its cardiac half denuded of mucous membrane, smooth, and clearly defined from the rugose lining of the pyloric portion. A large part of the anterior wall has been completely dissolved, producing a perforation with flocculent edges.

James B., æt. 23, was admitted under Mr. Aston Key for lumbar abscess. He died from suppurative meningitis. The autopsy was made on October 23rd, 1828, two days after death. *See Insp.* vol. 7, p. 16.

601 **Post-mortem Digestion of the Stomach.**

A stomach of which the part to the left of the œsophageal opening has been destroyed by the solvent action of gastric juice. The edge of the perforation is thin and ragged.

Catherine N., æt. 3, was admitted under Dr. Addison with

suppurative meningitis, from which she died. The autopsy was made on January 23rd, twenty-two hours after death. *See Insp.* 1856, No. 19.

602 Post-mortem Digestion and Perforation of the Stomach.

A stomach everted to shew its cardiac half to be denuded of mucous membrane by the digestive action of the gastric juice. The smooth surface of this part contrasts with the rugose condition of the pyloric end of the organ. There is a perforation about the size of a shilling-piece on the greater curvature two and a half inches from the œsophagus.

James B., æt. 11, was admitted under Dr. Wilks for nephritis, from which he died. The autopsy was made on March 2nd, thirty-six hours after death. *See Insp.* 1857, No. 40.

603 Localised Post - mortem Solution of the Stomach.

A portion of the cardiac end of a stomach shewing over a small area numerous circular depressions varying in size from a sixth to a tenth of an inch in diameter. In the deepest of them the muscular coat is exposed. Histologically the mucous membrane has disappeared; there is no evidence of inflammation.

Mary N., æt. 40, was admitted under Mr. Morgan with severe burns about the face and neck, from which she died two days after the accident. *See Insp.* vol. 12, p. 26.

604 Post-mortem Solution of the Stomach.

A portion of the anterior wall of a stomach, shewing upon its mucous membrane numerous excavations, oval or round in shape, and varying in size from one to five millimetres in diameter. Towards the greater curvature these excavations are so closely aggregated as to produce a worm-eaten appearance of the lining of the

stomach. Their edges are for the most part abrupt and the deeper ones expose the muscular coat. The intervening mucous membrane appears healthy, and histologically shews no sign of inflammatory action.

James H., æt. 42, was admitted under Dr. Taylor with an empyema following lobar pneumonia. The thorax was incised and the patient died three days after the operation. *See Insp.* 1891, No. 116.

605 **Hæmorrhagic Erosion of the Stomach.**

A portion of a stomach from the lesser curvature shewing three superficial patches of ulceration. The largest is one and a half inches long and half an inch broad, and its base is occupied by an adherent brownish membrane, which histologically has the structure of blood-clot.

Stephen F., æt. 51, was admitted under Dr. Hughes for albuminuria and "dropsical attacks," to which he had been subject for eight years. At the autopsy the kidneys and spleen were found to be lardaceous, and there was chronic pleuro-pneumonia. *See Insp.* 1855, No. 69.

606 **A Perforation in a Varicose Vein of the Stomach.**

A portion of the cardiac end of a stomach shewing upon its anterior wall, two inches from the œsophageal opening, a minute circular aperture with thin membranous edges. On the reverse of the specimen may be seen a dilated tortuous branch of the gastric vein, its communication with the opening on the mucous surface being indicated by a red rod.

John E., æt. 17, was admitted under Dr. Taylor for hæmatemesis, and died four days after admission from continual loss of blood. At the autopsy the liver was found to be cirrhotic and contracted. Water injected into the coronary vein of the stomach flowed freely from the opening in the mucous membrane. *See Insp.* 1889, No. 211.

607 Corrosion of the Stomach by Caustic Alkali.

A portion of a stomach shewing along its greater curvature towards the pyloric extremity a well-defined area, about two inches long by an inch broad, over which the mucous membrane is deeply corrugated and charred. Behind are mounted the tongue, larynx, and trachea to shew the effect of corrosion upon the fauces and epiglottis. There is the opening left after tracheotomy.

From a child who swallowed caustic alkali, and subsequently suffered from dyspnoea for which tracheotomy was performed.

Presented by Mr. Chapman of Tooting, 1859.

608 Gastritis produced by Arsenic.

A portion of a stomach shewing a depressed oval patch about three inches long and an inch and a half in width, which is coated with a thin shaggy layer of inflammatory exudation mingled with particles of arsenious acid. In the recent state the wall of the stomach at this part was twice as thick as elsewhere, and the mucous membrane was deeply injected, soft, and ecchymosed. The inflamed area was situated along the greater curvature, reaching to within one inch of the pylorus.

Harriet H., æt. 25, was admitted under Mr. Cooper in 1836, having swallowed about forty grains of arsenious acid in water. She died during a convulsion fifteen hours after the accident. See *Insp.* vol. 22, p. 45; *Wax Model*, No. 59; and *Guy's Hosp. Repts.* No. 4, 1837, p. 68.

609 Membranous Gastritis produced by Arsenic.

A portion of a stomach shewing at its pyloric end an area about two inches in diameter, the mucous membrane of which is covered by a thin, loosely adherent layer of fibrinous material. The rest of the stomach is healthy. Histological examination shews that there is an inflam-

matory exudation upon the mucous surface with small-celled infiltration of the submucous coat.

William S., æt. 36, was admitted under Dr. Wilks immediately after having swallowed arsenic. He suffered from vomiting and diarrhoea, and died twelve hours after admission. At the autopsy the mucous membrane of the small intestine was found congested, and there were petechiæ beneath the pleura and pericardium. See *Insp.* 1861, No. 243.

610 **False Membrane from the Stomach.**

A piece of thick whitish membrane found in the stomach of a patient who was poisoned by arsenic. In the recent state it shewed "the impressions of the rugæ of the stomach, and presented numerous bright bloody spots. There was no visible breach of substance in the surface of the stomach." Histologically the membrane consists of fibrinous material, in the meshes of which are aggregations of small round cells.

From William S., æt. 16, who died in 1829, about twenty-six hours after having swallowed some arsenic. See *Insp.* vol. 8, p. 95; and *Drawing*, 290.

611 **Gastritis from Carbolic Acid Poisoning.**

A stomach laid open along its greater curvature to shew the effects of corrosive poisoning. The mucous membrane is brown and corrugated. In the recent state the submucous tissue was infiltrated with extravasated blood.

From a young man who committed suicide by swallowing strong carbolic acid.

Presented by Mr. John Alexander, 1893.

612 **Poisoning by Hydrochloric Acid.**

Portions of a stomach and œsophagus mounted to shew their coats blackened by the action of hydrochloric acid.

Presented by Dr. Birt, 1889.

613 Poisoning by Hydrochloric Acid.

A stomach laid open to shew its mucous membrane markedly corrugated and thickened, particularly towards the pyloric end. On the summits of the rugæ, which have a longitudinal direction, the mucous membrane presents numerous small excavations, some of which contain white sloughs.

Charles T. was admitted under Dr. Wilks, having previously swallowed two or three ounces of hydrochloric acid with suicidal intent. He died a few hours after admission. At the autopsy the epiglottis was swollen, and the mucous membrane of the œsophagus was shreddy and could be easily detached. The jejunum and the lower part of the colon were acutely inflamed. *See Insp.* 1880, No. 415.

614 Corrosion of the Stomach by Hydrochloric Acid.

A stomach the wall of which, except for a small area at the pyloric end, is blackened by extravasation of blood beneath the mucous membrane. At the cardiac end, especially over the greater curvature, the wall is very thin and translucent, and appears to be formed by the serous coat alone, while nearer the pylorus the mucous surface is shaggy, and the subjacent tissues are thickened by inflammatory exudation. In the recent state the stomach contained about a pint and a half of acid fluid, like soot and water, in which, under the microscope, were seen blood-corpuscles and débris of mucous membrane.

John S., æt. 62, was admitted under Dr. Pye-Smith immediately after drinking about an ounce and a half of hydrochloric acid, and died nine and a half hours later. At the autopsy the soft palate and fauces were whitened and œdematous, and the mucous membrane of the œsophagus resembled "soaked tissue paper." The first four feet of the small intestine shewed signs of the corrosive action of the poison, and contained blood-stained fluid. *See Insp.* 1872, No. 170.

615 Sloughing of Gastric Mucous Membrane in Corrosive Poisoning.

A stomach seen from behind, shewing upon its anterior wall towards the pyloric end a yellow slough which consists of mucous membrane separated from the muscular coat of the organ. There is a smaller slough at the cardiac end of the stomach and the intervening mucous membrane presents several deep ulcers.

Anne P., æt. 18, was admitted under Dr. Hale White, having swallowed some chloride of zinc dissolved in hydrochloric acid. She died on the eleventh day after the accident, having suffered from hæmatemesis and melæna on the day before her death. At the autopsy the cæcum was much congested. *See Insp.* 1887, No. 287.

616 Gastric Mucous Membrane ejected after Poisoning.

A portion of the mucous membrane of a stomach detached and ejected by vomiting. In the recent state it was of a yellowish-brown colour, and shewed numerous ecchymoses.

From a woman who swallowed hydrochloric acid in 1864. She made a good recovery. *See Drawing*, 302 (80).

617 Traumatic Stenosis of the Pylorus.

A stomach and part of the duodenum, shewing considerable thickening of the pyloric ring with narrowing of its orifice so that in the recent state it barely admitted a No. 4 catheter. The stomach is small and its walls are thickened, especially towards the pyloric end. There is no ulceration nor scarring of its inner surface. Half an inch from the pyloric ring and parallel to it there is upon the anterior surface of the organ an incision about an inch long, around the margin of which there are the marks of sutures and a little granular lymph.

Henry G., æt. 43, was admitted under Dr. Hale White for vomiting and dilatation of the stomach. Seven weeks before ad-

mission he drank some "spirits of salts" and suffered for three days from symptoms of corrosive poisoning. A month later vomiting came on which was unassociated with pain and gradually increased in frequency. On admission he was extremely emaciated. Mr. Lane opened the stomach and passed a catheter into the duodenum through which the patient was fed. He died on the sixth day after the operation. At the autopsy some of the sutures uniting the stomach to the abdominal wall were found to be loose, and there was food in the peritoneal cavity. There was no general peritonitis, and it was thought that the loosening of the sutures was the result of post-mortem digestion. See *Insp.* 1890, No. 381; and *Trans. Clin. Soc.* 1891, p. 108.

618 **Contraction and Perforation of the Stomach from Corrosive Poisoning.**

A stomach with the spleen, and portions of the diaphragm, œsophagus, and duodenum. The stomach, which is opened along its lesser curvature, is much contracted, measuring only five inches along its greater curvature. The greater surface is ulcerated, superficially towards its cardiac end and more deeply towards the pylorus, the intervening mucous membrane being apparently healthy. The pink rod at its cardiac end passes through a sinus in the wall of the stomach into a small abscess-cavity between the spleen and the diaphragm. The blue rod indicates a second perforation close to the pyloric ring, which in the recent state was closed by adhesion of the stomach to the colon.

Sarah R., æt. 22, was admitted under Dr. Wilks for persistent vomiting after food. Three months previously she had swallowed a wineglassful of a strong solution of chloride of zinc (Burnett's Disinfecting Fluid). A few days before her death, which occurred a fortnight after admission, she suffered from severe abdominal pain and collapse. At the autopsy recent peritonitis was found, and the lower lobe of the left lung was consolidated by pneumonia. See *Insp.* 1857, No. 5.

619 **Corrosion and Perforation of the Stomach by Nitric Acid.**

A stomach everted to shew its mucous membrane to be charred brown, and either completely detached or hanging

in shreds. Towards the cardiac end there is a small perforation in the anterior wall. In the recent state the peritoneum around the perforation was ecchymosed, but no lymph was exuded.

Jesse M., æt. 21, was admitted under Dr. Pye-Smith, having swallowed three ounces of strong commercial nitric acid with suicidal intent. He died seventeen hours after taking the poison. At the autopsy the lips, angles of the mouth, and anterior two-thirds of the tongue were yellow. The mucous membrane of the fauces and œsophagus was whitened; the larynx shewed extensive hæmorrhage into the submucous tissue. The small intestine contained tarry fluid. *See Insp.* 1871, No. 207; and *Guy's Hosp. Reps.* vol. 17, p. 223.

620 **Corrosion of the Stomach by Sulphuric Acid.**

The lower end of a child's œsophagus and a portion of the stomach. Towards the cardiac end of the greater curvature of the stomach there is a small area over which the mucous membrane has been partly destroyed, leaving a brownish granular surface. The epithelium of the œsophagus is shreddy.

Presented by Mr. T. Hardy.

621 **Corrosion of the Stomach by Sulphuric Acid.**

A stomach shewing the mucous membrane of its middle third thrown into deep folds, blackened, and partly detached. At the pyloric end the mucous membrane is smooth, lax, and gelatinous looking. At the cardia the wall is thin, and shews no sign of corrosive action.

William V., æt. 56, was admitted under Mr. Hilton, having a few hours previously drunk by mistake about three drachms of oil of vitriol. His mouth and lips were brown. He walked to the hospital, and did not appear to suffer much. He died rather unexpectedly on the third day after the accident. At the autopsy the first two inches of the duodenum were purple in colour and the rest of the intestines normal. The œsophagus was thickened at its lower end, and its epithelium was partially removed. *See Insp.* 1856, No. 211.

622 Corrosion of the Stomach by Sulphuric Acid.

A stomach everted to shew a charred and excoriated area upon the greater curvature extending from the middle of the organ to within an inch of the pylorus. The peritoneal coat is unaffected.

Eliza B., æt. 17 months, was admitted under Mr. Cooper Forster, having a few hours previously swallowed a teaspoonful of oil of vitriol. On admission there was urgent dyspnoea for which tracheotomy was performed, but the child died seven hours after the accident. At the autopsy the tongue and pharynx were found to be excoriated, and there was considerable œdema of the glottis. See *Insp.* 1857, No. 146.

623 Detachment of the Mucous Membrane of the Stomach by Sulphuric Acid.

A portion of a stomach seen from behind shewing a large piece of detached mucous membrane, which in the recent state corresponded to the pyloric end and the lesser curvature. The mucous membrane over the fundus is corrugated and in parts removed. The lower end of the œsophagus is unaffected.

Charlotte D., æt. 55, a woman of weak intellect, was admitted under Mr. Cock, having two hours previously, before breakfast, drunk about three ounces of dilute sulphuric acid (1 to 4). On admission she was collapsed and pulseless. She suffered from vomiting and diarrhoea, the vomited matter and motions at first containing blood. Her condition gradually improved, but she was found dead in her bed eleven days after the accident. At the autopsy the colon and lower part of the ileum were found to be inflamed and covered with false membrane. See *Insp.* 1855, No. 182; *Prep.* 816; and *Drawings*, 304 (5) & 318 (11).

624 Cast of the Stomach and Œsophagus.

A membranous cast of the stomach and œsophagus which was ejected by vomiting. Histological examination shews it to consist of mucous membrane.

Elizabeth J., æt. 25, was admitted under Dr. Pavy in 1879,

having swallowed an ounce of sulphuric acid. The membrane shewn in the preparation was vomited eight days after the accident. The patient was discharged cured three weeks later. See *Medical Reps.* vol. 63, Case 299.

625 Perforation of the Stomach by Sulphuric Acid.

The lower end of an œsophagus with a part of the stomach seen from behind. The posterior wall of the viscus has been destroyed by the action of sulphuric acid with the exception of a small area at the pyloric extremity. On the anterior wall towards the cardiac end the muscular and serous coats are exposed, while elsewhere the mucous membrane appears only slightly affected. The margin of the perforation is abrupt and in the recent state some "sooty fragments" were attached to it.

Ann N., æt. 9 months, was admitted under Dr. Fagge, having swallowed sulphuric acid. She died six hours after the accident. At the autopsy the mouth, lips, and neck were excoriated by the acid, and in the peritoneal cavity several ounces of dark thick fluid were found. Some of the smaller bronchi and alveoli of the lung were filled with chalk-mixture. See *Insp.* 1868, No. 174.

626 Gastritis produced by Irritant Poisoning.

A stomach the inner surface of which is markedly rugose. The mucous membrane covering the rugæ is slate-coloured, and partially covered by a false membrane resembling a white incrustation. In the furrows between the rugæ the mucous coat appears to be normal. Behind is mounted the œsophagus, the lining of which is grey, and partially covered by a shreddy membrane.

Jane G., æt. 29, was admitted under Dr. Pavy, having swallowed a mixture of white precipitate and carbolic acid. She suffered from hæmatemesis, diarrhœa, and suppression of urine, and died five days after taking the poison. At the autopsy false membrane was found on the back of the tongue and on the fauces. There was also membranous inflammation of the ileum, colon, and vagina. See *Insp.* 1877, No. 55; and *Prep.* 748.

627 Contraction of the Stomach and Pylorus.

A stomach and œsophagus with a portion of the abdominal wall. The lower half of the œsophagus is irregularly narrowed, and its mucous membrane replaced by cicatricial tissue. The stomach is much contracted, its wall thickened, and its mucous membrane, especially along the lesser curvature, covered with scar-tissue and fibrous trabeculæ. Its pyloric orifice is extremely small, and the first part of the duodenum is adherent to the abdominal wall; an artificial opening in the bowel is marked by a red rod.

Charles C., æt. 34, was admitted under Dr. Pavy for hæmæstesis, dysphagia, and epigastric pain of ten weeks' duration. He gradually became weaker, vomited very frequently, and lost flesh. Duodenostomy was performed, but he died nine days later. He denied that he had swallowed poison; but at the inquest it appeared that he had been admitted to an infirmary about three months before his death with symptoms of acute gastritis, which suggested irritant poisoning to his medical attendant. *See Insp.* 1889, No. 40.

628 Chronic Inflammation and Contraction of the Stomach.

The lower end of an œsophagus with the stomach, the cavity of which is so greatly contracted as barely to hold an ounce of fluid. The walls of the organ are thickened to the extent of half an inch, and the mucous membrane is for the most part replaced by cicatricial tissue. On the anterior wall there is an irregular patch of ulceration exposing the muscular coat. There is a small ulcer at the commencement of the duodenum. Histological examination shews a large amount of fibroid material in the submucous tissue, and small-celled infiltration of all the coats of the organ. There is no evidence of malignant growth.

Thomas F., æt. 34, was admitted under Dr. Habershon for regurgitation of food with emaciation. His illness had lasted for

eight months. He died five days after admission from lobar pneumonia. No history of irritant poisoning was obtained. See *Insp.* 1854, No. 142; *Drawing*, 296 (20); and *Trans. Path. Soc.* vol. 42, p. 104.

629 **Phlegmonous Gastritis.**

A portion of the pyloric end of a stomach, the mucous membrane of which is smooth, while its walls are unusually thick. In the recent state "the coats were of a greenish colour, exceedingly soft and flaccid, and universally infiltrated with pus cells." Histologically the submucous coat is enormously thickened by infiltration with small round cells. The muscular coat shews a similar infiltration; the mucous membrane appears unaltered.

From a gentleman who was seized with violent abdominal pain, and died about twenty-four hours from the commencement of his illness. At the autopsy no irritant poison nor other cause of gastritis was discovered. See *Trans. Path. Soc.* 1875, p. 81.

Presented by Dr. Wise.

630 **Circumscribed Phlegmonous Gastritis.**

The pyloric end of a stomach shewing on its outer surface a raised oval swelling, which extends from the pyloric ring four and a half inches along the greater curvature of the organ and measures two and a half inches transversely. A section made through the swelling displays the thickened submucous areolar tissue, the loose meshes of which, in the recent state, contained pus. On the reverse of the specimen the mucous membrane corresponding to this area is smooth, and slightly raised, and when fresh was "dotted over its whole surface with spots of ecchymosis."

Eliza J., æt. 40, was admitted under Dr. Babington in 1847 for constant vomiting and abdominal tenderness. She died five days after admission. At the autopsy suppurative peritonitis was found. See *Insp.* vol. 34, p. 197; and *Prep.* 1012.

631 Membranous Gastritis.

A portion of a stomach laid open to shew its mucous surface covered by a thin granular layer of thin false membrane. On histological examination the epithelium is seen to be in parts replaced by fibrinous exudation, and there is an infiltration of the submucous tissue by small round cells.

James C., æt. 39, was admitted under Dr. Pavy for gout, from which he had long suffered. At the autopsy there was urate of soda in the joints; the colon was ulcerated; and the kidneys were small and granular. See *Insp.* 1870, No. 238; and *Trans. Path. Soc.* vol. 22, p. 139.

632 Multiple Ulcers of the Stomach.

A portion of a stomach shewing minute superficial ulcers scattered over its mucous membrane. The edges of the ulcers are sharply defined, and not thickened. The portion of ileum mounted behind shews similar ulcers of somewhat larger size. Histologically there is no evidence of tubercle.

Anne P., æt. 4 months, was admitted under Dr. Pavy for vomiting and diarrhœa. She was extremely emaciated, and died from exhaustion one week after admission. At the autopsy the other viscera were healthy. See *Insp.* 1888, No. 358.

633 Ulceration of the Stomach.

A stomach, the anterior wall of which has been in part removed to shew a tract of ulceration, which encircles the organ just within the pylorus, and extends along the lesser curvature halfway towards the œsophageal opening. The ulceration exposes the muscular coat; its border is clearly defined; the surrounding tissues are not thickened. Histologically there is no evidence of malignant growth.

From a middle-aged woman, who had suffered from "obstinate irritability of the stomach."

634 Ulcers of the Stomach and Pylorus.

The first part of a duodenum with the adjacent portion of the stomach shewing two deep ulcers situated upon the pyloric ring and extending into the intestine. On the pylorus the ulceration is superficial, while in the intestine the process has extended more deeply and in the base of the larger ulcer exposes the serous coat. There are two small round ulcers upon the lesser curvature of the stomach, about an inch and a half from the pylorus.

William W., æt. 39, was admitted under Mr. Davies-Colley with cellulitis of the neck, and died fourteen days from the onset of his illness. At the autopsy the thyroid cartilage was found to be necrosed, and there was a cellular abscess in the lumbar region. See *Insp.* 1891, No. 118.

635 Chronic Gastric Ulcer.

A stomach laid open to shew an irregular ulcer about two inches in diameter situated upon the lesser curvature rather nearer to the pyloric than to the œsophageal opening. The floor of the ulcer is smooth, and in the exposed muscular coat are seen the orifices of several small blood-vessels. Towards the pylorus the edge of the ulcer is flat and undermined, whilst elsewhere the surrounding mucous membrane is hypertrophied, and presents a papillomatous appearance.

From a gentleman, æt. 64, who suffered from gastric symptoms for eighteen months, and died from the effects of hæmorrhage into the stomach.

Presented by Dr. Goodhart, 1889.

636 Chronic Ulcer of the Stomach.

A portion of a stomach shewing an oval ulcer, the shorter axis of which occupies two inches of the lesser curvature immediately within the pyloric ring. In its long diameter it measures six inches, and extends about

equally on the anterior and posterior walls of the organ. Its border is somewhat thickened, abrupt, and in parts undermined: its base is smooth, and on the anterior surface is partly formed by the adherent left lobe of the liver, while, behind, the pancreas is exposed in the floor of the ulcer.

John H., æt. 54, was admitted under Dr. Gull for gastric symptoms, from which he suffered four years. *See Insp.* 1865, No. 74.

637 **Chronic Ulcer of the Stomach.**

The pyloric end of a stomach shewing a transverse ulcer, about two inches long and three quarters of an inch broad, situated on the anterior wall close to the pyloric ring. It has a smooth fibrous base, and sinuous clean-cut edges.

Margaret M., æt. 50, was admitted under Dr. Bright for sudden abdominal pain and collapse. She died from pelvic peritonitis. *See Insp.* vol. 15, p. 80.

638 **Chronic Ulcer of the Stomach.**

A portion of a stomach shewing a small oval ulcer situated upon the lesser curvature just within the pyloric ring. The ulcer has thickened rounded edges, and its base is formed by the exposed muscular coat of the organ.

Eliza M., æt. 35, was admitted under Dr. Wilks for syphilis with lardaceous disease, and died from uræmia. There was no history of any gastric symptom. *See Insp.* 1869, No. 147.

639 **Pyloric Obstruction from Duodenal Ulcer ; Loreta's Operation.**

The pyloric end of a stomach with a portion of the duodenum laid open to shew a chronic ulcer an inch in length and three quarters of an inch in width, situated upon the upper and posterior wall of the intestine, and extending to the pyloric ring. On the anterior wall of the stomach is seen an oblique incision made in the

operation of gastrotomy, the edges of which are firmly sutured together. On the reverse of the specimen the situation of the ulcer is marked by an adherent mass of fat and inflammatory tissue.

From a man, æt. 19, who was admitted into the General Infirmary, Northampton, with symptoms of pyloric obstruction. He had suffered from dyspepsia and wasting for eighteen months. Gastrotomy was performed, and the pyloric ring was dilated from the size of a No. 4 catheter until it would easily admit two fingers. The patient died six days after the operation, and at the autopsy the bases of the lungs were found to be consolidated by acute pneumonia. There was no peritonitis.

Presented by Dr. G. H. Percival, 1892.

640 **Stenosis of the Pylorus from Ulceration.**

A much dilated stomach shewing a funnel-shaped constriction at its pyloric extremity about two inches in length. At this part the walls of the organ measure five eighths of an inch in thickness, the increase being chiefly due to hypertrophy of the muscular coat and fibroid thickening of the submucous tissue. Upon the posterior wall at the middle of the constriction there is a deep ulcer with smooth base and shelving edges surrounded by rugose mucous membrane. On the reverse of the specimen the serous coat at the pyloric end exhibits numerous organised adhesions. Histological examination shews that the condition is due to chronic inflammation.

Mary W., æt. 22, was admitted under Dr. Addison for gastric pain and vomiting of three years' duration. A tumour was present in the right hypochondriac region. She died three months after admission, and at the autopsy the lungs were found to contain tubercle. *See Insp. 1857, No. 51.*

641 **Stricture of the Pylorus and Œsophagus.**

A stomach somewhat dilated and hypertrophied, and shewing a chronic ulcer situated upon the lesser curvature close to the pyloric ring. On the anterior wall

are two openings just above the greater curvature, one seven inches and the other eleven inches from the pylorus. Around the former is seen a portion of the skin of the abdominal wall, and to the latter is sutured a piece of jejunum with which communication had been established.

William B., *æt.* 47, was admitted under Dr. Goodhart with dysphagia and dilatation of the stomach. About five years previously he had been a patient in the hospital, suffering from hæmatemesis associated with gastric ulcer. For the last two years he had regularly washed out his stomach, but three weeks before his admission he became unable to pass the tube. On admission a stricture was discovered at the lower end of the œsophagus. A month later gastrostomy and gastro-jejunosomy were performed. He died shortly after the operation, and at the autopsy the lungs were found to be tuberculous, and in the œsophagus was an epitheliomatous growth. *See Insp.* 1892, No. 209.

642 **Stenosis of the Pylorus from Chronic Ulcer.**

A pylorus with the adjacent portions of the stomach and duodenum, shewing the pyloric orifice narrowed to about an eighth of an inch in diameter. The cause of the narrowing is the cicatricial contraction dependent upon a chronic ulcer, oval in shape, and three quarters of an inch in its longer diameter, which is situated upon the gastric surface of the pylorus on the lesser curvature.

William W., *æt.* 39, was admitted under Dr. Pye-Smith for dilated stomach, with occasional attacks of vomiting, in one of which he brought up four pints of fluid. He had suffered from dyspeptic symptoms for sixteen years, and had twice vomited blood. He died rather suddenly, and at the autopsy the stomach was found to measure thirty inches along its greater curvature, and nine inches transversely at its widest part. *See Insp.* 1892, No. 203.

643 **Healed Ulcer of the Stomach.**

A portion of a stomach shewing, about the middle of the lesser curvature, a circumscribed patch of fibroid

thickening, about the size of a two-shilling piece, in the centre of which there is a smooth shallow depression of the mucous surface. The peritoneal coat over this area is covered by firm adhesions.

James H., æt. 55, was admitted under Mr. Hilton for an injury to his elbow, for which his arm was amputated. He died from cellulitis and exhaustion. *See Insp.* 1854, No. 254.

644 **Healed Ulcer of the Stomach.**

A portion of a stomach shewing upon the lesser curvature about two inches from the œsophageal opening a shallow depression, roughly diamond-shaped, with the longer axis placed transversely. Its base is fibrous, and there is puckering of the parts around.

William B., æt. 70, was admitted under Dr. Addison for nephritis, from which he died. At the autopsy the stomach presented an hour-glass contraction. *See Insp.* 1857, No. 164.

645 **Healed Ulcer of the Stomach.**

A portion of a stomach shewing a little below the middle of the lesser curvature a small puckered cicatrix. The laceration of the neighbouring mucous membrane was probably produced after death.

Jemima D., æt. 24, was admitted under Dr. Gull for empyema, from which she died. *See Insp.* 1859, No. 63.

646 **Chronic Ulcer of the Stomach with Perforation.**

A stomach laid open to shew a large chronic ulcer upon its lesser curvature close to the pylorus. It is oblong in shape, measuring three and a half inches in length by two inches broad, and extends about equally upon the anterior and posterior surfaces of the organ. Its edges are thickened and abrupt. On the posterior wall the ulceration has destroyed the whole thickness of the stomach, and the base of the ulcer is partly formed by

adherent fatty tissue. On the anterior wall there is a perforation, admitting the little finger, which communicates with the peritoneal cavity.

From Mary H., æt. 63, who had suffered from gastric symptoms for two or three years.

647 **Perforating Gastric Ulcer.**

A portion of a stomach shewing close to the anterior margin of the pyloric orifice a triangular perforation with thick clean-cut edges. Around the perforation the wall of the stomach is considerably thickened, and its serous surface is coated with recent lymph. Histological examination of the border of the ulcer shews no evidence of malignant growth.

Edward W., æt. 51, was admitted under Dr. Pitt for a sudden attack of abdominal pain and collapse, and died twenty-four hours from the onset of his illness. He had suffered from indigestion for twenty-four years, and two years before his death had a profuse attack of hæmatemesis. At the autopsy the peritoneal cavity contained gastric contents, and there was general peritonitis. *See Insp.* 1887, No. 200.

648 **Perforating Ulcer of the Stomach.**

A portion of the anterior wall of a stomach with the lower end of the œsophagus seen from behind beneath the left lobe of the liver. Two inches from the cardiac orifice there is a small triangular ulcer with a circular perforation, a quarter of an inch in diameter, in its base. Around the ulcer the wall of the stomach is five eighths of an inch in thickness, and there is considerable thickening also of that part of the capsule of the liver which lies above the ulcer. There is granular lymph upon the adjacent surfaces of the two organs.

Robert D., æt. 54, was admitted under Dr. Rees with severe abdominal pain and collapse, and died twenty-two hours later. There was a history of a previous attack of severe abdominal pain. At the autopsy there was general peritonitis. *See Insp.* 1868, No. 128.

649 Perforating Ulcer of the Stomach.

The œsophageal end of a stomach shewing on its anterior surface an inch from the lesser curvature and three inches from the cardiac orifice an oval ulcer with clean-cut slightly thickened edges, which exposes and perforates the serous coat. Corresponding to it on the posterior wall of the viscus is a somewhat smaller and shallower ulcer, the base of which is formed by muscular fibres. On the reverse of the specimen the peritoneum surrounding the perforation is seen to be thickened and rough, as if from fibrous adhesions.

Harriet B., æt. 22, was seized with abdominal pain, and vomiting immediately after food; and died twenty hours from the commencement of the attack. At the autopsy there was general peritonitis. *See Guy's Hosp. Reps.* 1855, p. 113.

Presented by Mr. May.

650 Perforating Ulcer of the Stomach.

The cardiac half of a stomach, shewing two ulcers situated halfway between the œsophageal and pyloric orifices, one upon the anterior, the other upon the posterior wall of the organ. The edges of the former are somewhat thickened and sharply defined, and the opening through the peritoneal coat is sealed by a firm layer of recent lymph. The serous coat, which is exposed in the base of the other ulcer, is extremely thin.

Christina F., æt. 19, was admitted under Dr. Shaw for abdominal pain and collapse, for which an exploratory laparotomy was performed. She had suffered from dyspepsia and vomiting after food for eighteen months. Her death took place five days from the onset of urgent symptoms. At the autopsy general peritonitis was found. *See Insp.* 1890, No. 352.

651 Perforating Ulcer of the Stomach.

A stomach shewing in the mucous membrane of its anterior wall, toward the cardiac end, a minute circular

ulcer with raised edges, which has perforated the serous coat.

From a newly-born infant, who died of hæmorrhage from the ulcer.

Presented by Mr. Cock, 1883.

652 Perforating Ulcer of the Pylorus.

A portion of a stomach with the first part of the duodenum shewing upon the anterior aspect of the pyloric ring a small excavated ulcer, which has perforated the peritoneal coat. The ulcer is oval, and measures half an inch in its longest diameter, the opening in the serous coat being considerably smaller. The margin is abrupt, and there is little if any thickening of the surrounding tissues. On the reverse of the specimen the peritoneum around the perforation is seen to be covered by a thin layer of granular lymph.

John B., æt. 45, was admitted under Dr. Pavy for sudden abdominal pain and collapse, and died on the following day. At the autopsy gastric contents were found in the peritoneal cavity, and there was recent lymph upon the liver and intestines. *See Insp.* 1888, No. 119.

653 Gastric Ulcer opening an Artery.

A portion of the cardiac end of a stomach shewing on its mucous surface an oval ulcer measuring about three eighths of an inch in its longest diameter. In the base of the ulcer is seen a minute perforation of a tortuous branch of the gastric artery. A bristle has been passed into each end of the vessel.

Charles R., æt. 57, was admitted under Mr. Cooper in 1842 for hæmorrhoids. Two days after admission he was attacked by profuse hæmatemesis, from which he died. At the autopsy a large quantity of blood was found in the alimentary canal. *See Insp.* vol. 31, p. 268; and *Prep.* 734.

654 Gastric Ulcer perforating an Artery.

A portion of a stomach shewing upon its lesser curvature

a circular ulcer, about half an inch in diameter, in the base of which is seen a small perforation opening a branch of the coronary artery. The edges of the ulcer are abrupt and not thickened.

Jacob G., *æt.* 53, was admitted under Dr. Addison for profuse hæmatemesis, which continued for five days. He died a week after admission. At the autopsy the stomach was empty; the large intestine contained black blood. *See Insp.* 1857, No. 45.

655 Gastric Ulcer opening the Pancreatic Duct.

A portion of a stomach shewing upon its lesser curvature rather nearer to the pylorus than to the œsophageal opening an oval ulcer, three inches in its longest diameter, having sharply defined edges. The base of the ulcer is formed partly by the liver and partly by the pancreas, both of which are firmly adherent to the wall of the stomach. On that part of the base which is formed by the pancreas are seen the openings of two vessels, one an artery, the other the pancreatic duct.

Charlotte T., *æt.* 55, was admitted under Dr. Hughes for prolapse of the uterus, and died rather suddenly from internal hæmorrhage. She had suffered from hæmatemesis six years before her death. At the autopsy the stomach was found to be distended by coagulum, and was firmly adherent to the neighbouring organs. *See Insp.* 1857, No. 44.

656 Chronic Gastric Ulcer becoming Carcinomatous.

A stomach suspended from the pylorus together with a portion of the abdominal wall to which it is firmly adherent. Completely encircling the organ at a point about an inch within the pyloric ring there is a cicatrised ulcer about two and a half inches wide. The base of the ulcer is for the most part formed by the exposed muscular coat, whilst at the point of adhesion to the parietes the entire wall of the viscus is destroyed. The edge of the ulcer towards the œsophagus is sloping, but towards the pylorus it is much raised and infiltrated

with growth which histologically has the character of spheroidal-celled carcinoma with much stroma.

Isabel H., æt. 39, was admitted under Dr. Gull for gastric pain and vomiting of eight months' duration. She died two months after admission, and at the autopsy no secondary deposits of malignant growth were found in any organ. *See Insp.* 1860, No. 70.

657 **Pyloric Ulcer becoming Carcinomatous.**

A portion of a stomach and duodenum laid open to shew a small oval ulcer situated upon the lesser curvature just within the pyloric ring. Its edges are sharply defined, its base is smooth and fibrous, and the surrounding tissues are thickened and infiltrated with a growth having the characters of spheroidal-celled carcinoma.

Elizabeth R., æt. 65, was admitted under Dr. Pavy for pain after food and vomiting. She had suffered from indigestion for the greater part of her life, but acute symptoms first manifested themselves nine months before death. At the autopsy the pyloric orifice was found to be obstructed, and there were secondary deposits in the glands of the lesser omentum. *See Insp.* 1888, No. 242.

658 **Tuberculous Ulcer of the Stomach.**

A stomach shewing upon the posterior wall, about one inch from the pylorus, a minute circular ulcer with undermined edges. Histologically the ulcer appears to be tuberculous. The lymphatic glands along the lesser curvature are enlarged and caseous.

Tom D., æt. 2, was admitted under Dr. Fagge for tuberculous broncho-pneumonia, from which he died. At the autopsy there were yellow masses in the brain, and caseous enlargement of the lymphatic glands. *See Insp.* 1881, No. 70.

659 **Tuberculous Ulcers of the Stomach.**

A stomach shewing an ulcer situated upon its posterior wall one inch from the pylorus. The ulcer measures

three quarters of an inch in its longest diameter, and its edges are much undermined. In the recent state its base presented several caseous nodules, but histological examination gives no clear evidence of its tuberculous origin. The loop of intestine included in the preparation has its serous surface thickly beset with tuberculous nodules, and the neighbouring lymphatic glands are enlarged and caseous.

Florence C., æt. 8, was admitted under Dr. Pavy for great emaciation, and died one week later from phthisis with tuberculous ulceration of the ileum, and peritonitis. *See Insp.* 1880, No. 352.

660 **Tuberculous Ulceration of the Stomach.**

A stomach laid open to shew upon its posterior wall, rather nearer to the pyloric than to the cardiac end, an irregular patch of superficial ulceration with sinuous edges and ragged base. On the reverse of the specimen the serous coat corresponding to the position of the ulcer is covered with miliary tubercles, and the lymphatic glands in the lesser curvature are enlarged and caseous.

William S., æt. 7, was admitted under Dr. Hale White for wasting, with painful and swollen abdomen, from which symptoms he had suffered for six weeks. He died two months after admission, and at the autopsy the peritoneum was covered with tubercles, and tuberculous lesions were found in the lungs, kidneys, intestines, and lymphatic glands. *See Insp.* 1892, No. 173.

661 **Tuberculous Infiltration of the Wall of the Stomach.**

A portion of a stomach shewing its greater curvature and posterior wall to be considerably thickened by a deposit of caseous material beneath the serous coat. The mucous membrane is unaffected. Histologically the deposit consists of small round cells with numerous areas of caseation.

William G., æt. 48, was admitted under Dr. Barlow for

tuberculous peritonitis of seven months' duration. At the autopsy the peritoneal cavity was found to be obliterated by adhesions, and there were numerous ulcers in the ileum. *See Insp.* 1856, No. 168.

662 Submucous Abscess of the Stomach.

A portion of a stomach, taken from near the pylorus, shewing upon its mucous surface an oval nodule which in the recent state was about the size of a hazel nut, and contained thick pus. The abscess cavity is seen to be situated in the submucous tissue. On the reverse of the specimen the peritoneal surface of the stomach is studded with minute yellow tubercles. Histological examination of the wall of the abscess shews no clear evidence of tuberculous deposit.

Samuel J., æt. 18, was admitted under Dr. Habershon for tuberculous peritonitis, and died from perforation of the colon with faecal extravasation. At the autopsy there were miliary tubercles in the lung. There was a second abscess of the stomach near to the œsophageal opening. *See Insp.* 1867, No. 231.

663 Anthrax of the Stomach.

A portion of a stomach shewing several small rounded ulcers upon its mucous surface. The edges of the largest ulcer, which is about one quarter of an inch in diameter, are sharply defined, and the exposed muscular coat which forms its base has a small brown slough adhering to it.

William S., æt. 33, a worker among hides, was admitted under Mr. Bryant for a malignant pustule upon the cheek, which was first noticed five days before his death. At the autopsy characteristic nodules and ulcers were found in the small intestine, and in the upper part of the colon. *See Insp.* 1883, No. 81; and *Trans. Path. Soc.* 1883, p. 293.

664 Anthrax of the Stomach.

A portion of a stomach shewing upon its posterior wall two or three slightly raised brownish patches, some of

which present superficial ulceration. There is a small raised nodule in the first part of the duodenum.

Patrick G., æt. 23, while handling dry hides, became infected with anthrax. He was admitted under Mr. Bryant with fever and delirium, and in a few hours became comatose. He died four days from the period of infection. At the autopsy the lungs and intestines were found to be affected with anthrax, and there was considerable hæmorrhagic effusion into the meninges of the brain and spinal cord. See *Insp.* 1884, No. 132; *Trans. Path. Soc.* vol. 37, p. 550; and *Prep.* 885.

665 **Acute Dilatation of the Stomach.**

A stomach considerably dilated, which in the recent state when first removed from the body measured eleven inches from the pylorus to the convexity of the fundus. Beneath the mucous membrane are seen a few punctate ecchymoses. The serous coat is marked by numerous parallel striæ running from the greater to the lesser curvature, which have been likened to lineæ gravidarum. The pylorus is healthy.

William S., æt. 30, was admitted under Dr. Rees for wasting and slight hæmoptysis. About a week after his admission he was attacked with repeated vomiting, which was attributed to the cod-liver oil he was taking. The abdomen became tympanitic except in the hypogastric region, and succussion was obtained. There was no distension. The patient continued to vomit till his death, three days after the onset of the attack. At the autopsy the stomach was found to be greatly distended, and was in contact with the anterior abdominal wall as low as the symphysis pubis. The intestines were empty. "No disease was found in the body to which the death of the patient could be attributed except the dilatation of the stomach." See *Insp.* 1870, No. 311; and *Guy's Hosp. Reps.* 1872, p. 10.

666 **Hypertrophied Pylorus.**

A stomach the coats of which are slightly hypertrophied throughout. A section through the pylorus shews a fusiform thickening of this part, about an inch in length, due to a more considerable hypertrophy of its muscular wall. In the recent state a small probe

could with difficulty be passed through the pyloric orifice.

Albert E., æt. 5 weeks, was admitted under Dr. Goodhart for vomiting of eight days' duration with constipation. He died in convulsions thirteen days after admission. At the autopsy the other viscera were normal. *See Insp.* 1891, No. 91.

667 Mammillation of the Stomach.

A stomach laid open to shew mammillation of its mucous membrane, which is most distinct at the pylorus, and gradually becomes less marked towards the œsophageal opening. Histologically the prominences seem to be due to corrugation of the mucous membrane, perhaps by contraction of the muscularis mucosæ. There is no inflammatory exudation or overgrowth.

Isabella M., æt. 19, was admitted under Mr. Hilton for an ovarian tumour, and died from peritonitis following tapping. *See Insp.* 1854, No. 203.

668 Mammillation of the Stomach.

A stomach laid open to shew the mucous membrane studded all over with small rounded elevations like closely-set warts. On the summits of the rugæ the mammillæ are larger and more closely aggregated than elsewhere. In the recent state the mucous membrane "was distinctly gritty to the touch."

William D., æt. 61, was admitted under Dr. Wilks three hours after having swallowed half an ounce of laudanum. He was a heavy drinker and was accustomed to take opium. The stomach was washed out with warm water and a pint of strong coffee with a little brandy was introduced. At the autopsy the lungs were emphysematous, and the kidneys slightly granular. *See Insp.* 1882, No. 300.

669 Local Rugosity of the Stomach.

A portion of a stomach shewing at its pyloric end a well-defined area three inches in length over which the

mucous membrane is unusually rugose. The rest of the mucous membrane is smooth. Histological examination of the rugose portion affords no evidence of hypertrophy or inflammation.

George P., æt. 62, was admitted under Dr. Addison for chronic pulmonary disease with dilatation of the right side of the heart, from which he died. *See Insp.* 1859, No. 203. -

670 Papillomata of the Stomach.

A portion of a stomach shewing upon its mucous membrane two raised flattened tumours measuring about three quarters of an inch in diameter. Attached by the side of one of them there is a pedunculated growth half an inch in length. The surface of these masses bears irregular papillæ, giving them a flocculent appearance. Histologically they consist of hypertrophied mucous membrane, the deeper coats of the stomach being unaffected.

From a woman, æt. circa 70.

671 Papillomata of the Stomach.

The pyloric half of a stomach shewing upon its inner surface numerous sessile wart-like excrescences, most of which are about the size of a split pea. Histologically they shew local overgrowth of the mucous membrane, the deeper tissues being unaffected.

Daniel S., æt. 61, was admitted under Dr. Habershon for jaundice and vomiting, and died from carcinoma of the pancreas. *See Insp.* 1880, No. 259.

672 Papillomata of the Stomach.

A portion of a stomach shewing upon its mucous surface a large number of rounded sessile polypi, most of which are less than a line in diameter, while one measures half an inch across. Histologically they consist of hypertrophied mucous membrane.

Presented by Dr. Goodhart, 1885.

673 Polypus of the Stomach.

A portion of a stomach shewing a small polypus attached by a broad pedicle to the mucous membrane about two inches from the pylorus.

Hannah B., æt. 41, was admitted under Dr. Hughes in a comatose condition, and died some hours afterwards. At the autopsy there was softening of the brain, and the mitral valve was contracted. *See Insp.* 1856, No. 74.

674 Polypus of the Stomach.

A portion of a stomach shewing a small polypus attached to a prominent ridge of mucous membrane about one inch from the pylorus.

John C., æt. 45, was admitted under Dr. Wilks for chronic bronchitis and emphysema. At the autopsy the mucous membrane of the stomach was healthy. *See Insp.* 1864, No. 22.

675 Villous Tumour of the Stomach.

A stomach shewing large masses of soft shaggy growth projecting into its cavity. These masses, which vary in length from half an inch to three inches, have a broad attachment along the greater curvature and anterior wall of the organ about the size of the palm of the hand. Except at the seat of attachment, where the wall is slightly thickened, the coats of the organ appear to be normal. Histologically the tumour consists of mucous membrane supported upon delicate processes of fibrous tissue. There is no appearance of malignant growth.

Isabella D., æt. 65, was admitted under Dr. Addison for cirrhosis of the liver, from which she died. There were no special symptoms of gastric disorder. *See Insp.* 1855, No. 145.

676 Villous Tumour of the Stomach.

A portion of a stomach shewing upon its posterior surface, four inches from the pyloric opening, a cauli-

flower-like mass of growth projecting about half an inch above the surrounding mucous membrane. The tumour occupies an area about one and a half inches long by three quarters of an inch in width, and does not extend into the submucous or muscular coats of the organ. Histologically the growth consists of mucous membrane covering delicate processes of fibrous tissue.

From a man, *æt.* 49, who suffered for eleven months before his death with *anæmia* and gradually increasing debility. There was no history of vomiting or hæmorrhage.

Presented by Dr. Gull, 1859.

677 **Carcinomatous Polypus of the Stomach.**

A portion of a stomach laid open to shew upon its anterior wall, an inch from the cardiac orifice and from the lesser curvature, a lenticular mass of growth three quarters of an inch in diameter, and projecting one third of an inch above the mucous surface. The rest of the mucous membrane is healthy. The glands in the lesser curvature are enlarged by secondary deposits. On the reverse of the specimen are seen small nodules of growth in the serous coat. Histologically the polypus has the structure of a spheroidal-celled carcinoma with scanty stroma.

Thomas S., *æt.* 47, was admitted under Dr. Goodhart with jaundice of three weeks' duration and severe pain in the lumbar region, the latter symptom having been present about four months. Vomiting and *melæna* supervened, and he died seventeen days after admission. At the autopsy the peritoneum was found to be studded with small nodules of growth, and there were secondary deposits in the liver and supra-renal capsules, and in the mediastinal, mesenteric, and aortic glands. There was a mass of growth in the portal fissure compressing the bile-duct, and the nerves of the lumbar plexus were implicated in the cancerous mass which lay along the spine. *See Insp.* 1892, No. 48.

678 **Fibro-myoma of the Stomach.**

A portion of stomach, taken from the middle of the greater curvature, shewing a rounded tumour, about as

large as a pigeon's egg, projecting into the cavity of the viscus. The mucous membrane covering it is healthy. Histologically the tumour consists of unstriped muscle and fibrous tissue.

Eliza H., æt. 40, was admitted under Dr. Taylor for chronic nephritis, from which she died. *See Insp.* 1885, No. 311.

679 **Cylindrical-celled Carcinoma of the Stomach.**

A stomach with the first part of the duodenum and a portion of the liver. The lesser curvature and a part of the posterior wall of the stomach are occupied by a mass of villous growth with raised everted edges. The growth has invaded the left lobe of the liver, and by its softening formed a ragged cavity which communicates with the stomach, and with the duodenum just beyond the pyloric ring. Histologically the growth is a cylindrical-celled carcinoma.

Elizabeth C., æt. 56, was admitted under Dr. Owen Rees for pain in the stomach, and occasional slight hæmatemesis. At the autopsy no new growth was found except in the stomach and liver. *See Insp.* 1871, No. 23.

680 **Carcinomatous Ulcer of the Stomach.**

A portion of a stomach shewing a large irregular ulcer situated upon its posterior wall about two inches from the pylorus. The ulceration exposes the muscular coat of the organ, and has a thick everted margin, infiltrated with growth. Continuous with this thickened edge there is a large fungating mass obstructing the pyloric orifice. Histologically the growth is a cylindrical-celled carcinoma.

John D., æt. 72, was admitted under Dr. Bright in 1826 with symptoms of phthisis and dyspepsia. At the autopsy the lungs were found to be tuberculous, and there were secondary deposits of malignant growth in the pleura, peritoneum, and in one of the suprarenal capsules. *See Red Insp. Book*, p. 166.

**681 Cylindrical-celled Carcinoma of the Stomach
 (Colloid).**

A stomach the front of which has been removed to shew about the middle of its posterior wall a rounded mass three inches in diameter at its thickest part and projecting one inch above the surrounding mucous membrane. The edges of the growth are well defined; its surface is ulcerated and has a gelatinous appearance somewhat resembling boiled sago-grains. On the reverse of the specimen the growth is seen projecting beneath the serous coat, and there is an enlarged gland in the greater omentum. Histologically the growth is a cylindrical-celled carcinoma, in which many of the cells have undergone colloid degeneration.

Joseph L., æt. 58, was admitted under Dr. Wilks for pain in the left side of four months' duration. Whilst in the Hospital he suffered from cough and hæmoptysis, and died three months after admission. At the autopsy secondary deposits were found in the lungs, liver, and in the mesenteric glands. See *Insp.* 1882, No. 350; and *Preps.* 326 & 833.

**682 Diffuse Cylindrical-celled Carcinoma of the
 Stomach.**

A stomach laid open to shew its walls thickened by a diffuse deposit of new growth, which occupies chiefly the submucous tissue, and infiltrates the subjacent muscle. Upon the lesser curvature there is a large irregular ulcer with sharply-defined edges. The organ is somewhat contracted, and its mucous membrane is smooth, the smaller rugæ being completely obliterated. The neighbouring lymphatic glands contain secondary deposits. Histologically the growth is a cylindrical-celled carcinoma.

From Mr. W., æt. 50, who suffered for some months from constant vomiting, and became greatly emaciated. At the autopsy no other secondary deposits were found. See *Insp.* vol. 8, p. 103.

Presented by Dr. Babington, 1829.

683 Cylindrical-celled Carcinoma of the Stomach.

A stomach, the whole of which, except a small portion at the cardiac end, is thickened and infiltrated by new growth. The organ has been laid open along its greater curvature, and shews projecting from its mucous surface an ulcerated mass, which occupies the middle third of the viscus save for a narrow tract corresponding with the lesser curvature. A section through the walls of the stomach shews that the growth has extended through the mucous to the serous coat, which is thickened and nodulated. Histologically the growth is a cylindrical-celled carcinoma.

Job S., æt. 38, was admitted under Dr. Goodhart with indigestion and occasional attacks of vomiting. A hard tumour was felt in the umbilical region. He died twelve months after the onset of his illness, and at the autopsy secondary deposits were found in the skull, sternum, and most of the viscera. *See Insp.* 1888, No. 234.

684 Cylindrical-celled Carcinoma of the Pylorus.

The pyloric end of a stomach shewing a raised and deeply ulcerated mass of new growth, which encircles the pylorus, and extends for two and a half inches into the body of the organ. The growth penetrates the wall of the stomach, and projects from the serous surface. Its inner aspect presents numerous delicate villous processes.

685 Cylindrical-celled Carcinoma of the Pylorus.

A stomach the pyloric extremity of which is considerably narrowed by a thick deposit of growth infiltrating its walls and extending from the pylorus three and a half inches into the body of the organ. The rest of the viscus is somewhat dilated. Histologically the growth is a cylindrical-celled carcinoma.

Presented by Sir Astley Cooper.

686 Cylindrical-celled Carcinoma of the Stomach.

The pyloric half of a stomach shewing an ulcer about two inches in diameter. Towards the pylorus the base of the ulcer is smooth and in it is seen the muscular coat, whilst towards the body of the organ it is infiltrated with growth, and the edge is raised and everted. There is considerable thickening of the wall narrowing the pyloric orifice. Adherent to the organ are several lymphatic glands which are much enlarged and caseous. Histologically the wall of the stomach is infiltrated by cylindrical-celled carcinoma, and the glands contain a deposit of caseating tubercle.

Susan V., æt. 45, was admitted under Dr. Bright in 1835 for anorexia and vomiting of three months' duration. She died two months after admission, and at the autopsy secondary deposits were found beneath the pleura, and in the liver and spleen. See *Insp.* vol. 21, p. 135.

687 Cylindrical-celled Carcinoma of the Stomach.

A portion of a stomach shewing upon its posterior wall just within the pylorus a deep ulcer, in the base of which the muscular coat of the viscus is exposed. The edges of the excavation are abrupt and thick, and are infiltrated by a growth which extends for about two inches into the body of the organ. The orifice of the pylorus is narrowed. Histologically the growth is a cylindrical-celled carcinoma.

Sarah C., æt. 47, was admitted under Dr. Fagge for gastric pain and vomiting, with a well-defined tumour in the abdomen. She had been ill for about a year, and died two months after admission to the Hospital. No secondary deposits were found at the autopsy. See *Insp.* 1879, No. 370.

688 Carcinoma of the Stomach and Œsophagus.

A stomach with a portion of the anterior abdominal wall, to which it is firmly adherent. The organ has been laid open from behind, and shews a small growth

about one and a half inches in diameter encircling the œsophageal opening, and invading the last inch of the gullet. The growth has destroyed the mucous membrane, invaded the parts beneath, and appears as a prominent mass externally. On the anterior wall of the stomach there is a depression corresponding to its point of attachment to the abdominal wall. Histologically the growth is a spheroidal-celled carcinoma.

Richard W., æt. 48, was admitted under Mr. Bryant for difficulty in swallowing of four months' duration. The stomach was attached to the abdominal wall as a preliminary step to the operation of gastrostomy, but as the patient was afterwards able to swallow food more easily, the stomach was not opened. He died ten days after the operation. *See Insp.* 1878, No. 351.

689 **Carcinomatous Ulcer of the Stomach.**

A portion of a stomach laid open to shew upon its posterior wall, four inches from the œsophageal orifice and two and a half inches below the lesser curvature, an oval mass of growth an inch long by half an inch broad, the margin of which projects about a quarter of an inch above the surrounding mucous membrane. The surface of the growth is cup-shaped, the central parts being excavated by ulceration, and histological examination of the raised edge shews the wall of the stomach at this part to be infiltrated by a growth having the characters of a spheroidal-celled carcinoma with scanty stroma. The rest of the organ is normal.

George F., æt. 59, was admitted under Dr. Pye-Smith in a condition of delirium, and two days later became comatose. He had been a heavy drinker, and his liver was enlarged and hard. He died six days after admission, and at the autopsy the liver was found to be cirrhotic and to contain carcinomatous deposit. Similar deposits were found in the kidney, pancreas, thyroid, supra-renal capsule, and pericardium, and in the glands of the mesentery and lesser omentum. *See Insp.* 1892, No. 101; and *Prep.* 109.

690 **Spheroidal-celled Carcinoma of the Stomach.**

The cardiac end of a stomach with the lower part of the

œsophagus. Surrounding the œsophageal orifice and somewhat obstructing it is an irregular mass of growth measuring two by one and a quarter inches. The edges of the growth are thick, raised, and everted, while the central portion is so deeply ulcerated as in parts to expose the serous coat. On the reverse of the specimen the peritoneum is roughened by old adhesions. Histologically the growth is a spheroidal-celled carcinoma with much stroma.

691 Spheroidal-celled Carcinoma of the Stomach.

A stomach laid open along its lesser curvature to shew a rounded area, roughly corresponding to the fundus of the organ, over which the mucous membrane is hypertrophied and markedly rugose, while beneath it the walls of the viscus are thickened and leathery to the touch. Histological examination shews that the sub-mucous and muscular coats are infiltrated by a growth having the character of spheroidal-celled carcinoma.

Presented by Mr. A. T. Davies, 1887.

692 Spheroidal-celled Carcinoma of the Stomach (Colloid).

A stomach laid open to shew a rounded ulcer occupying the œsophageal half of the lesser curvature and measuring about three and a half inches transversely. The ulcer has a sloping margin, and the base presents a reticulated appearance. The walls of the stomach are thickened and infiltrated by growth, which has invaded the lesser omentum and the lower end of the œsophagus. The muscular fibres of the gullet are considerably hypertrophied. Histologically the growth is a spheroidal-celled carcinoma with colloid degeneration. There were numerous secondary deposits in the mesenteric glands and in the liver.

Presented by Mr. Callaway.

693 Colloid Carcinoma of the Stomach.

A stomach from which the posterior wall has been removed to shew an infiltrating growth involving the lesser curvature throughout its length and extending along the anterior surface of the organ almost as far as the greater curvature. The great omentum is much thickened and contracted and there are secondary deposits in the lymphatic glands of the lesser curvature. Histologically the growth is a carcinoma, the cells of which have undergone colloid change.

John C., æt. 47, was admitted under Dr. Barlow for pain and vomiting associated with an abdominal tumour. He died ten weeks from the onset of his illness. At the autopsy numerous secondary deposits were found in the peritoneum, and there was a malignant stricture of the rectum. See *Insp.* vol. 37, p. 116; and *Guy's Hosp. Repts.* 1855, p. 127.

694 Spheroidal-celled Carcinoma of the Stomach.

A stomach with the pancreas and a portion of the liver. On the posterior wall of the stomach there is an ulcerated growth reaching from the œsophageal opening to within two and a half inches of the pylorus. The edges of the growth project half an inch from the surrounding healthy mucous membrane, and in the base of the ulcer is exposed a portion of the pancreas, to which, as well as to the liver, the stomach is bound by adhesions. Histologically the growth is a carcinoma, most of the alveoli being filled with spheroidal cells, whilst a few are lined with cylindrical epithelium.

Job S., æt. 62, was admitted under Dr. Habershon with gastric symptoms, and died two months later. At the autopsy no secondary deposits were found in any organ. See *Insp.* 1863, No. 19.

695 Spheroidal-celled Carcinoma of the Stomach (Colloid).

A stomach laid open to shew a slightly raised ulcerated

growth extending from just within the pyloric ring along the lesser curvature for a distance of five inches and affecting both walls of the organ so as almost to reach the greater curvature. The edges of the growth are raised and slightly everted, and its ulcerated surface presents numerous gelatinous-looking nodules. On the reverse of the specimen the growth is seen to project as a lobulated mass beneath the serous coat. Histologically it is a spheroidal-celled carcinoma, many of the cells of which have undergone colloid degeneration.

Elizabeth P., æt. 81, was admitted under Mr. Davies-Colley for a strangulated femoral hernia, from which she died. There was no history of vomiting or other symptom of disease of the stomach until the onset of the intestinal obstruction four days before her death. At the autopsy no secondary deposits were found. *See Insp.* 1890, No. 390.

696 **Spheroidal-celled Carcinoma of the Stomach.**

A portion of a stomach and of the neighbouring structures to which it is firmly united. The mucous membrane has been for the most part removed by ulceration, and thus is exposed a ragged surface consisting of growth which has invaded the surrounding parts. In front the whole thickness of the stomach wall is destroyed, and its cavity is bounded by the muscular tissue of the abdominal parietes. Behind and below there are huge masses of soft gelatinous material. Histologically the growth is a spheroidal-celled carcinoma with scanty stroma.

Eleanor M., æt. 32, was admitted under Dr. Barlow for vomiting and anæmia. On admission there was a prominent abdominal tumour which had been noticed "for a long time." She died nine months after admission, and at the autopsy a large mass of secondary growth was found in the liver. *See Insp.* 1865, No. 109.

697 **Spheroidal-celled Carcinoma of the Stomach.**

A stomach from which the anterior wall has been

removed to shew an infiltrating growth which extends from the pylorus towards the œsophagus along the whole extent of the lesser curvature and about halfway along the greater curvature. The stomach is small, and where the malignant growth is most considerable its wall is thickened to the extent of half an inch. The mucous membrane is rugose, and but very slightly ulcerated. The muscular coat is hypertrophied, and together with the submucous tissue is infiltrated with a growth having the histological characters of spheroidal-celled carcinoma.

Jane H., æt. 54, was admitted under Dr. Pye-Smith for vomiting and wasting of three months' duration. She had been subject to bilious attacks and indigestion for many years, and for the six weeks preceding her admission had been jaundiced. She died fifteen weeks after the onset of acute symptoms, and at the autopsy secondary deposits were found in the liver and peritoneum, and in the aortic and mesenteric glands. In the portal fissure was a large hard mass of growth surrounding and compressing the bile-ducts. *See Insp.* 1892, No. 26.

698 **Spheroidal-celled Carcinoma of the Stomach.**

A stomach laid open to shew its pyloric half affected by a primary growth, and its fundus invaded by cancerous deposit spreading from a secondary growth in the tail of the pancreas. Seen from within, the secondary deposit appears as a rounded plaque, about an inch and a half in diameter, over which the mucous membrane is smoothly stretched. The glands of the lesser curvature are enlarged and infiltrated by a malignant deposit which has the histological characters of spheroidal-celled carcinoma.

Thomas I., æt. 56, was admitted under Dr. Hale White for jaundice of three months' duration accompanied by progressive wasting. No tumour was at any time felt in the abdomen. He died four and a half months after the onset of symptoms, and at the autopsy secondary deposits were found in the rectum and in the portal and mesenteric glands. *See Insp.* 1892, No. 416; and *Prep.* 1016.

699 Diffuse Carcinoma of the Stomach (Colloid).

A somewhat contracted stomach, the walls of which are thickened throughout by a deposit of gelatinous material which is most abundant towards the pylorus, where the submucous tissue is half an inch in thickness. Upon the inner surface the growth appears as small translucent nodules resembling boiled sago-grains. On the reverse of the specimen it projects beneath the thickened serous coat. Histologically the growth is a spheroidal-celled carcinoma with much colloid change and scanty stroma.

William C., æt. 57, was admitted under Dr. Bright in 1828 for dysentery, nausea, and pain in the epigastrium. He died five months after admission. *See Insp.* vol. 14, p. 48.

700 Diffuse Carcinoma of the Stomach (Colloid).

A stomach from which a portion of the posterior wall has been removed to exhibit the cavity of the organ to be somewhat contracted and its walls universally thickened. The section shews the thickening to be chiefly due to a white deposit in the submucous tissue, which in some places is more than half an inch in depth. The mucous membrane over the pyloric half presents unusually large rugæ, while towards the cardiac end it is flattened, gelatinous, and pitted. The peritoneal covering is thick and opaque. Histologically the growth is a spheroidal-celled carcinoma with colloid degeneration.

Elizabeth T., æt. 37, was admitted in 1850 for pain after food and emaciation of four months' duration. She died one month after her admission, and at the autopsy a growth was found in the ascending colon resembling that in the stomach. There were several pints of serous fluid in the peritoneal cavity. *See Guy's Hosp. Repts.* 1855, p. 126.

701 Diffuse Carcinoma of the Stomach.

A stomach contracted so as to measure only eight and a half inches along its greater curvature and two and a half inches transversely at its widest part. The wall

is thickened throughout, partly by a deposit of growth in the submucous tissue, and partly by muscular hypertrophy. The mucous membrane is slightly ulcerated and there are secondary deposits in the glands of the lesser curvature. Histologically the growth is a spheroidal-celled carcinoma.

Joshua B., æt. 71, was admitted under Dr. Habershon for gastric pain of three months' duration. He died three months after admission, and at no time did he suffer from vomiting. At the autopsy the stomach was found to be closely adherent to the neighbouring organs, and the peritoneum was studded with nodules of growth. See *Insp.* 1866, No. 56.

702 **Diffuse Carcinoma of the Stomach.**

A contracted stomach measuring eight inches along its greater curvature and two and a half inches transversely at its widest part. The walls of the organ are universally thickened, in some places to the extent of half an inch, by infiltration of growth in the submucous tissue and by hypertrophy of the muscular coat. The lining of the stomach is slightly ulcerated and externally there are numerous adhesions to the neighbouring structures. Histologically all the coats of the organ are seen to be infiltrated by a growth having the characters of spheroidal-celled carcinoma.

Joseph R., æt. 37, was admitted under Dr. Pye-Smith for vomiting with ascites. Nine days before admission he had a severe attack of hæmatemesis. At the autopsy secondary deposits were found in the omentum, and the wall of the œsophagus was much hypertrophied. See *Insp.* 1885, No. 385; and *Trans. Path. Soc.* vol. 37, p. 236.

703 **Diffuse Carcinoma of the Stomach.**

A stomach measuring seven inches along its greater curvature and two inches transversely at its widest part. Its walls are three eighths of an inch thick, and on section shew a white deposit in the submucous tissue. The mucous membrane is smooth and free from ulceration.

The omenta are puckered and contain secondary deposits in their lymphatic glands. The portion of colon adherent near the pylorus is considerably narrowed. Histologically all the coats of the organ are seen to be infiltrated by spheroidal-celled carcinoma.

From a man, *æt.* 77, who suffered from pain after food, vomiting, and progressive emaciation. A tumour was felt in the epigastric region nine months before his death. At the autopsy the other viscera were healthy. *See Guy's Hospital Gazette*, 1889, p. 77.

Presented by Dr. E. A. Starling.

704 **Diffuse Carcinoma of the Stomach.**

A somewhat contracted stomach laid open to shew its walls thickened by hypertrophy of its muscular coat and by adventitious deposit in the submucous tissue. The deposit is general but is greatest towards the pylorus, where the wall is three quarters of an inch in thickness. There is no ulceration of the mucous membrane. The omenta are thickened and contain some slightly enlarged lymphatic glands. Histological examination of the wall of the organ shews an excess of fibroid material in the submucosa, with no clear evidence of growth, but in one of the adjacent lymphatic glands there is a deposit of spheroidal-celled carcinoma.

Mary F., *æt.* 44, was admitted under Dr. Rees for ascites with no definite symptoms of disease of the stomach. At the autopsy the peritoneum was found to be thickened and its cavity to contain several pints of serum. *See Insp.* 1862, No. 21; and *Trans. Path. Soc.* vol. 13, p. 83.

705 **Spheroidal-celled Carcinoma of the Stomach.**

A portion of the pyloric extremity of a stomach shewing just within the pylorus a small area over which the mucous membrane is raised and has a polypoid appearance. The surface of this raised patch is not ulcerated. Histological examination shows that there is a growth of

spheroidal-celled carcinoma which infiltrates the sub-mucous tissue, but does not invade the muscular coat.

Emma P., æt. 34, was admitted under Dr. Lever for puerperal pyæmia from which she died. At the autopsy no malignant growth was found in any other organ. *See Insp.* 1857, No. 109.

706 **Spheroidal-celled Carcinoma of the Stomach.**

The pyloric half of a stomach shewing a flat mass of growth occupying the entire circumference of the organ and extending from the pylorus four inches along the lesser, and five inches along the greater curvature. The surface of this mass is irregular and in parts ulcerated and its edge towards the fundus is well-defined. A section through the affected part shews all the coats of the organ to be destroyed by infiltration with a growth which histologically has the characters of a spheroidal-celled carcinoma with scanty stroma. There are numerous adhesions upon the serous coat.

Joseph P., æt. 67, was admitted under Dr. Taylor for pain after food and vomiting of six weeks' duration. On admission a large tumour was felt below the umbilicus on the right side. He died three months from the onset of his illness. At the autopsy the stomach was found to be dilated, and one or two neighbouring lymphatic glands were slightly enlarged. There were no other secondary deposits. *See Insp.* 1876, No. 239.

707 **Spheroidal-celled Carcinoma of the Stomach.**

The pyloric half of a stomach shewing upon its posterior wall, immediately above the greater curvature and just within the pylorus, a tumour measuring six inches long by four inches transversely and projecting an inch and a half above the surrounding parts. The growth presents numerous bossy prominences over which the mucous membrane is smoothly stretched. On the summits of some of the prominences are small crater-like depressions, and in the central part of the mass there is an oval ulcer, about three quarters of an inch in its longest diameter, the edges of which are undermined, and its base formed

by the exposed substance of the tumour. On the reverse of the specimen are seen portions of the neighbouring structures to which the stomach is adherent. Histologically the growth is a spheroidal-celled carcinoma with scanty stroma.

From William W., who suffered from hepatic ascites.

708 Spheroidal-celled Carcinoma of the Stomach (Colloid).

A portion of a stomach divided to shew its pyloric extremity encircled and narrowed by a growth which extends from the duodenum five inches towards the fundus of the organ. The surface of the growth has a granular and gelatinous appearance and its edge towards the fundus is well defined. The section shews that the mucous and submucous coats are thickened and infiltrated by growth, and that the muscular layer is greatly hypertrophied. The connective tissue along the lesser curvature is thickened and the glands are enlarged by secondary deposits. Histologically the growth is a spheroidal-celled carcinoma with colloid degeneration.

Presented by Sir Astley Cooper.

709 Carcinomatous Stenosis of the Pylorus.

A greatly hypertrophied and dilated stomach, the pyloric extremity of which is encircled and narrowed by a thick mass of growth extending inwards from the duodenum two and a half inches. A section through the wall of the stomach at the affected part shews the muscle to be greatly hypertrophied and the submucous tissue to be thickened by an infiltrating growth over which the mucous membrane forms large polypoid rugæ. Histologically the growth is a spheroidal-celled carcinoma with slight colloid degeneration.

710 Scirrhus Pylorus.

A portion of a stomach originally mounted as an example of spindle-celled sarcoma of the pylorus. The pyloric extremity of the stomach is encircled by a growth which extends from the duodenum four inches towards the body of the organ. The mucous membrane is stretched over the thickened area, the margin of which is well defined. The growth is situated chiefly in the sub-mucous tissue, and is in parts half an inch thick, the muscular coat being also somewhat hypertrophied. Histological examination of the adventitious material shews it to consist of well-formed fibrous tissue, while in the periphery of an adjacent lymphatic gland there were found small alveoli filled with spheroidal epithelial cells.

Rachel B., æt. 47, was admitted under Dr. Habershon for severe vomiting from which she had suffered for about twelve months. At the autopsy the stomach was found to be hypertrophied and dilated, and there was a large quantity of milky fluid in the peritoneal cavity. There were no other secondary deposits. *See Insp.* 1870, No. 263.

711 Carcinoma of the Stomach invading Gastric Veins.

A portion of a stomach and liver seen from behind, and mounted to shew the gastric veins along the lesser curvature distended by cancerous thrombus, which has spread into the portal vein. There are numerous soft secondary deposits in the liver. On the reverse of the specimen is seen a primary growth encircling the pyloric extremity of the stomach, and directly invading the gall-bladder. Histologically it is a spheroidal-celled carcinoma with much stroma.

James S., æt. 49, was admitted under Dr. Wilks for hæmatemesis, abdominal pain, and gradual emaciation. He died six weeks after his admission, and at the autopsy no other secondary deposits were found. *See Insp.* 1867, No. 106.

712 Carcinoma of the Stomach opening the Splenic Artery.

A portion of a stomach shewing an ulcerated growth occupying its lesser curvature and part of the anterior and posterior walls. In the sloughy base of the ulcer is seen the splenic artery, which has been opened by ulceration. The course of the artery is indicated by a red rod. Histologically the growth is a spheroidal-celled carcinoma with scanty stroma.

Philip S., æt. 45, was admitted under Dr. Wilks for anorexia and vomiting. He died suddenly from hæmorrhage into the stomach. At the autopsy a large infarct was found in the spleen. *See Insp.* 1867, No. 81; and *Prep.* 2.

713 Carcinoma of the Stomach with Perforation.

A portion of a stomach shewing an ulcerated growth in the centre of which there is an oval perforation about one eighth of an inch in diameter. There is some granular lymph on the serous coat. Histologically the growth is a spheroidal-celled carcinoma.

From a patient who, while suffering from gastric symptoms, was suddenly seized with peritonitis and died. At the autopsy some of the contents of the stomach were found in the peritoneal cavity.

Presented by Mr. Lacey, 1864.

714 Carcinoma of the Stomach causing Perforation.

A stomach laid open to shew the greater part of its wall occupied by a prominent ulcerated growth. Upon the posterior wall and along the greater curvature all the coats of the organ are invaded by the growth which projects from the serous surface. At about the middle of the greater curvature there is a ragged perforation marked by a blue rod. Histologically the growth is a cylindrical-celled carcinoma.

Samuel A., æt. 42, was admitted under Dr. Taylor for a tumour in the epigastric region and progressive emaciation. He had

suffered from occasional attacks of vomiting and hæmatemesis for two years. He died four months after admission. At the autopsy the stomach was found firmly adherent to neighbouring organs, and there was general suppurative peritonitis. There were secondary deposits in the liver and in the mediastinal glands. See *Insp.* 1891, No. 415.

715 **Carcinomatous Gastro-colic Fistula.**

A portion of a stomach laid open along its lesser curvature and of the transverse colon to which it is adherent. There is a circular mass of growth about four inches in diameter extending from the pyloric ring along the greater curvature of the organ. The surface of the growth is sloughy, and its edge overhangs the surrounding mucous membrane and is raised about an inch above it. Upon the greater curvature and distinct from the main mass there is a secondary deposit of growth in the mucous membrane. The blue rod indicates a small communication between the affected portion of the stomach and the transverse colon. Histologically the growth is a spheroidal-celled carcinoma with small alveoli and scanty stroma.

John T., æt. 67, was admitted under Dr. Hughes for gastric pain, emaciation, and an ill-defined tumour in the region of the stomach. He had suffered from dyspepsia for one year. At the autopsy a growth similar to that in the stomach was found in the cæcum. There were secondary deposits in the mesenteric glands. See *Insp.* 1855, No. 170.

716 **Lymphadenoma of the Stomach.**

A stomach shewing upon its inner surface numerous masses of growth situated for the most part upon either side of the greater curvature, the parts about the cardiac and œsophageal orifices being less affected. The growths are covered by normal mucous membrane, the smaller being flattened, while the larger project considerably, and have the contour of the rugæ of the organ. Histo-

logically the growths consist of uniform small round cells aggregated in the submucous tissue.

George B., æt. 48, was admitted under Dr. Pye-Smith for pleural effusion with the physical signs of pressure upon the left bronchus. At the autopsy lymphadenomatous growths were found in the mediastinal glands, in the tonsils, and in the intestinal canal. *See Insp.* 1888, No. 131; *Trans. Path. Soc.* vol. 40, p. 80; and *Preps.* 479, 926, & 971.

717 **Melanotic Sarcoma of the Stomach.**

A stomach shewing in its mucous membrane a large number of minute brown dots resembling patechiae. Histologically they consist of aggregations of round pigmented cells situated entirely within the mucous coat.

John B., æt. 35, was admitted under Dr. Habershon for enlargement of the liver, which had been noticed for six weeks. He died on the day of his admission. At the autopsy melanotic growths were found in all parts of the body. The liver weighed 188 ounces. *See Insp.* 1875, No. 230; and *Prep.* 2012 (57) [2nd Edit.].

718 **Sarcoma of the Stomach.**

A stomach laid open to shew the lesser curvature throughout its whole length to be occupied by a mass of growth. Towards the pylorus the growth infiltrates the submucous tissue, and appears as a thick plaque, whilst elsewhere there are several isolated nodules projecting beneath the mucous membrane. Attached to the lesser omentum and surrounding the pylorus and duodenum are seen the remains of a large mass, which in the recent state involved the pancreas and neighbouring lymphatic glands. Histologically the growth is a round-celled sarcoma.

Thomas S., æt. 67, was admitted under Dr. Barlow with symptoms of malignant disease of the stomach, and died a fortnight later. At the autopsy secondary deposits were found in the peritoneum and in the right suprarenal capsule. *See Insp.* 1863, No. 78.

719 Sarcoma of the Stomach.

A stomach from which a portion of the anterior wall has been removed to shew a rounded mass of growth about the size of a pigeon's egg projecting from its posterior wall an inch and a half from the pylorus. Around this mass the walls of the stomach are thickened and infiltrated by growth. The area thus affected extends from the pyloric ring along the lesser curvature to the œsophageal opening, and for six inches along the greater curvature, and is separated by a well-defined margin from the healthy parts beyond. Externally there is a considerable deposit of growth, embedded in which is seen the colon closely adherent to the stomach. Histologically the growth is a sarcoma with round and spindle cells.

Louisa B., æt. 38, was admitted under Dr. Goodhart for vomiting and diarrhœa with distension of the abdomen of four weeks' duration. She died a fortnight after admission. At the autopsy the peritoneal cavity was found to be nearly obliterated by adhesions. There were no secondary deposits. *See Insp.* 1887, No. 116.

720 Sarcoma of the Stomach.

A portion of a stomach and duodenum shewing a flat mass of growth, measuring four by six inches, which occupies the pyloric half of the stomach and extends a short distance into the duodenum. The mucous membrane covering the growth is smooth and in parts superficially ulcerated. Towards the œsophageal orifice the edge of the plaque is abrupt, and overhangs the healthy wall beyond, which is bent back, and fixed behind it. In the opposite direction the limit of the growth is ill-defined, and the pyloric ring is obliterated. A section through the infiltrated wall shews the submucous and muscular coats of the organ to be replaced by a growth which histologically has the character of a round-celled sarcoma.

Elizabeth S., æt. 18, was admitted under Dr. Addison for a

tumour in the abdomen, associated with frequent vomiting, and died five months from the onset of her illness. At the autopsy the stomach was found to be dilated, and there were secondary deposits in the gastric and lumbar lymphatic glands, and in both ovaries. The left pleural cavity contained several pints of pus. *See Insp.* 1858, No. 61.

721 **Sarcoma of the Stomach and Duodenum.**

A portion of a stomach and duodenum shewing an infiltrating growth occupying the pyloric half of the stomach and extending about an inch into the duodenum. The surface of the affected area is in parts covered by stretched mucous membrane, and in parts ulcerated. Towards the cardia the edge of the growth is well defined and a section through the thickened pylorus shews the infiltration to be greatest in the submucous tissue. Histologically the growth is a round-celled sarcoma.

Frederick W., æt. 15, was admitted under Dr. Gull for an abdominal tumour with jaundice. At the autopsy there were secondary deposits in the mesenteric glands and in one of the kidneys. *See Insp.* 1864, No. 65.

722 **Subdiaphragmatic Abscess communicating with the Stomach.**

A portion of the posterior wall of a stomach shewing two small perforations which communicate with a smooth-walled cavity behind the viscus. On the reverse of the specimen this cavity is seen to consist of two portions separated for the most part by a layer of fibroid material, but communicating with each other just behind the perforations in the stomach. One portion of the cavity is filled with a mass of laminated blood-clot; the other, which is now empty, contained in the recent state thick pus.

Annie W., æt. 38, was admitted under Dr. Hale White for hæmatemesis, from which she had been suffering for one week. Four months previously she had on two occasions vomited large quantities of blood. At the autopsy infarcts were found in the

spleen, and it was thought that the splenic artery was the source of the hæmorrhage. There was a second abscess in the posterior mediastinum immediately above the diaphragm. *See Insp.* 1887, No. 149.

723 Perforation of the Stomach.

A portion of a stomach shewing on its anterior surface, an inch and a half from the pylorus, a small round perforation with smooth edges about the size of a crow-quill, which in the recent state communicated with a collection of pus in the peritoneal cavity. The mucous membrane surrounding the opening is healthy.

Anne J., æt. 25, was admitted under Dr. Barlow for peritonitis five weeks after her confinement, and died seven weeks after admission. At the autopsy the abdominal viscera were matted together, but no cause for the peritonitis could be discovered. It was thought that the perforation of the stomach was produced by the bursting inwards of the abscess. *See Insp.* 1865, No. 88.

724 Perforation of the Stomach in Tuberculous Peritonitis.

The anterior wall of a stomach with a portion of the liver, to which it is firmly adherent. About the middle of the greater curvature and an inch above it there are two small perforations leading into a cavity between the stomach and liver, containing caseous material. In a corresponding position upon the posterior wall there is an irregular patch of ulceration exposing the muscular coat.

Henry L., æt. 9, was admitted under Dr. Goodhart with fever, abdominal pain, and diarrhœa. Three days later he died, and at the autopsy the bronchial and mesenteric glands were found to be caseous, and there was tuberculous deposit in the lungs, spleen, and kidneys. *See Insp.* 1892, No. 124.

725 Stomach opened by Hepatic Abscess.

A pylorus with the adjacent portions of the stomach and duodenum, and the anterior part of the right lobe

of the liver. The gall-bladder is almost obliterated, and to it is firmly adherent the first part of the duodenum. Within the liver are two ragged cavities, which in the recent state contained half a pint of foetid pus. They communicate with each other, and the larger one opens by a short sinus into the stomach close to the pyloric ring.

Joseph F., æt. 59, was admitted under Dr. Hale White with periodic rigors, thought to be due to quotidian ague, from which he had suffered many years previously. Pressure upon the epigastrium was somewhat painful. Eighteen days after admission he became comatose, and died in a few hours. At the autopsy an abscess was found in the lower lobe of the right lung. *See Insp.* 1892, No. 150.

SECTION XVII.—INJURIES AND DISEASES OF THE DUODENUM.

- Pouch : 726-728.
 Congenital Occlusion : 729, 730.
 Laceration : 731.
 Post-mortem Digestion : 732.
 Hæmorrhagic Erosion : 733.
 Blood Cast : 734.
 Enlarged Glands : 735.
 Ulceration : 736-747.
 Perforating Ulcer : 742-746.
 Tuberculous Ulceration : 747.
 Anthrax : 748.
 Papilloma : 749.
 Sarcoma : 750, 751.
 Constriction : 752.
 Perforation from without : 753-758.
 Ankylostomum Duodenale : 759.

726 **Pouch in the Duodenum.**

A portion of a duodenum shewing a globular pouch, the mouth of which measures about an inch in diameter, situated by the side of the papilla at the opening of the pancreatic and common bile-ducts. The mucous membrane lining the sac is normal, and its wall is stretched and thin. The pouch is not adherent to the neighbouring structures.

Jane B., æt. 74, was admitted under Mr. Durham for a strangulated femoral hernia. Herniotomy was performed, and she died three days afterwards. *See Insp.* 1889, No. 356.

727 **Pouch in the Duodenum.**

The pyloric end of a stomach, with a portion of the

duodenum laid open to shew a globular pouch, about an inch in diameter, projecting from the outer wall of the intestine one inch from the biliary papilla. The wall of the pouch is thin and free from adhesions. There is a healed gastric ulcer situated upon the lesser curvature an inch from the pyloric ring.

Mary W., æt. 72, was admitted under Dr. Hale White for chronic Bright's disease, and died from uræmia. *See Insp.* 1892, No. 13.

728 **Pouch in the Duodenum.**

A portion of a duodenum shewing upon its posterior wall three inches from the pylorus a pouch measuring one inch across and one and a half inches in depth. The mucous membrane lining it is scarred, and a small pedunculated nodule projects at the bottom of the pouch. On the reverse of the specimen a mass of dense fat is seen closely surrounding the sac and adherent to the liver.

Charles W., æt. 39, was admitted under Dr. Goodhart for pneumonia and died on the seventh day of his illness. *See Insp.* 1889, No. 93.

729 **Congenital Occlusion of the Duodenum.**

A stomach and duodenum shewing a membranous septum situated just above the opening of the bile-duct and completely obstructing the bowel. The duodenum above the septum is greatly dilated, while below, though pervious, it is very small. The pyloric ring is enlarged and measures an inch and a quarter in circumference.

From a well-developed infant who died thirty-eight hours after its birth. It vomited frequently during the last fourteen hours of its life; no fæcal material or meconium was passed per anum. *See Trans. Path. Soc.* vol. 12, p. 101.

Presented by Mr. John Galton, 1860.

730 Congenital Occlusion of the Duodenum.

A duodenum and stomach laid open to shew a congenital occlusion of the former measuring half an inch in length and situated one and a quarter inches from the pyloric ring. Above the obstruction the duodenum is considerably dilated.

From Amy W., a full time child, who suffered from constant vomiting from within an hour of her birth until her death five days later. For three days the vomited material was colourless mucus and afterwards resembled coffee-grounds. On three or four occasions a small quantity of meconium was passed per anum. *See Trans. Path. Soc.* vol. 31, p. 114.

Presented by Mr. George Eastes, 1880.

731 Laceration of the Duodenum.

The upper half of a duodenum with a portion of the stomach. Two inches from the pylorus there is in the duodenum an irregular perforation, which in the recent state admitted the middle finger. On the reverse of the specimen the mucous membrane is seen to project through the opening; the peritoneal coat is lacerated and partly detached.

Emily H., æt. 14, was admitted under Mr. Lucas in a state of collapse, having been struck on the abdomen by a swing. She died twelve hours after admission. At the autopsy there was general peritonitis. *See Insp.* 1889, No. 257.

732 Post-mortem Digestion of the Duodenum.

A stomach with the first part of the duodenum mounted to shew the results of post-mortem digestion. The wall of the duodenum is much thinned and presents numerous perforations, the edges of which are ragged and flocculent.

William B., æt. 4, was admitted under Dr. Habershon for symptoms of meningitis of three weeks' duration. He died comatose one week after admission, and at the autopsy miliary

tubercles were found on the pia-mater and in most of the viscera. The examination was made on July 23rd, fourteen hours after death. Some of the contents of the stomach were found in the peritoneal cavity. See *Insp.* 1856, No. 141.

733 **Hæmorrhagic Erosions of the Duodenum and Stomach.**

A part of a duodenum with the pyloric end of the stomach. In the duodenum, an inch from the pyloric ring, there is a shallow transverse ulcer, about an inch in length, the sloping edges of which shew a brownish discoloration. In the recent state the erosion was surrounded by "extravasated blood, effused into the mucous membrane, and blackened by gastric juice." A similar condition is seen in the gastric mucous membrane just within the pylorus.

Eliza T., æt. 13, was admitted under Dr. Pavy for heart disease following acute rheumatism, and died four months from the onset of symptoms. At the autopsy the aortic valves were found to be incompetent, and the viscera were indurated. See *Insp.* 1878, No. 94.

734 **Blood-cast from the Duodenum.**

A mass of blood-clot about two and a half inches in length, bearing upon its surface the impressions of the valvulæ conniventes of the duodenum in which it was found.

William R., æt. 57, was admitted under Mr. Cooper in 1842 for hæmorrhoids, and died suddenly from profuse hæmatemesis. At the autopsy a small ulcer was found in the stomach. See *Insp.* vol. 31, p. 268; and *Prep.* 653.

735 **Enlarged Solitary Follicles in the Duodenum.**

The upper half of a duodenum, the solitary glands of which are enlarged and prominent.

Elizabeth H., æt. 9, was admitted under Mr. Hilton for

extensive burns, and died from tetanus nine days after the accident. At the autopsy the condition of the glands shewn in the preparation was found throughout the small intestine. *See Insp.* 1855, No. 66.

736 **Ulceration of the Duodenum.**

A portion of the first part of a duodenum mounted to shew a patch of superficial ulceration. In the centre of the patch the muscular coat of the intestine is exposed.

Eliza G., æt. 30, was admitted under Dr. Addison in 1847 for phthisis and pericarditis. There was a large sloughing bed sore upon the sacrum. *See Insp.* vol. 34, p. 255.

737 **Chronic Ulcer of the Duodenum.**

The first four inches of a duodenum seen from behind with a portion of the pancreas to which it is adherent. There is a large oval ulcer with thin clean-cut edges, the greater diameter of which corresponds to the long axis of the intestine and measures about two inches. The floor of the ulcer is formed by the head of the pancreas, and in it is exposed the divided end of the superior pancreatico-duodenal artery indicated by a red rod.

Thomas L., æt. 60, was admitted under Mr. Golding-Bird for a severe injury to the leg, for which amputation was performed. He died eleven days after the operation with symptoms of severe internal hæmorrhage. At the autopsy much blood was found in the intestines. *See Insp.* 1884, No. 53.

738 **Chronic Ulcers of the Duodenum.**

The first five inches of a duodenum mounted to shew a large oval ulcer, which measures two and a half inches transversely, and has a thick abrupt edge and smooth fibrous base. In the floor of the ulcer is seen the head of the pancreas with the openings of the pancreatic and common bile-duets indicated by white and yellow rods. A second ulcer, situated close to the first and an inch

and a half from the pyloric ring, is circular in shape and about the size of a sixpenny piece. It has a clean-cut edge, and its base is formed by adherent fatty tissue.

Sam R., *æt.* 44, was admitted under Dr. Hughes in 1838 for an empyema, and died fifteen months after the onset of his illness. There were no symptoms of intestinal disease. At the autopsy the right pleural cavity contained three quarts of pus. *See Insp.* vol. 29, p. 106.

739 **Ulcer of the Duodenum following a Burn.**

A portion of the pyloric end of a stomach and of the first part of the duodenum, shewing a small circular ulcer situated a quarter of an inch from the pyloric ring. The edge of the ulcer is raised, and in the deepest part of its base the serous coat is exposed.

Thomas W., a young child, was admitted in 1847 for severe burns of the chest and head. Free suppuration followed, and the occipital bone was laid bare. He died comatose twenty-five days after the accident. At the autopsy the cerebral sinuses were found to be filled with purulent thrombus. *See Insp.* vol. 34, p. 196.

740 **Ulcer of the Duodenum following a Burn.**

The first part of a duodenum shewing a clean-cut oval opening in its posterior wall, the upper limit of which is about half an inch from the pylorus. The ulcer is one and a half inches long, and in the recent state its base was formed by the pancreas, which was eroded. The ulcerative process had exposed and opened the superior pancreatico-duodenal artery.

Herbert E., *æt.* 4, was admitted under Mr. Durham for severe burns upon the lower extremities and buttocks. The child did well for sixteen days, after which he began to pass blood with his motions. The hæmorrhage proved fatal on the nineteenth day after the accident. At the autopsy the intestines were found to contain much black blood. *See Insp.* 1867, No. 176.

741 Ulcer of the Duodenum following a Burn.

The pyloric end of a stomach with the first part of the duodenum. Just beyond the pyloric ring there is a round punched-out ulcer about a quarter of an inch in diameter, in the base of which is exposed the muscular coat of the intestine.

Mariau C., æt. 13, was admitted under Mr. Durham for severe burns of the trunk. She died from tetanus about a fortnight after the accident. At the autopsy the skin over the injured parts was sloughing. See *Insp.* 1875, No. 70.

742 Perforating Ulcer of the Duodenum.

The first inch of a duodenum with the adjacent portion of the stomach, shewing an oval ulcer, half an inch in its longest diameter, situated, one half of it upon the pyloric ring and the other half within the duodenum. Its edges are thin, and slope downwards to a small perforation in the base of the duodenal portion of the ulcer. On the reverse of the specimen the peritoneum is seen to be partially covered with a thin layer of fibrinous exudation.

743 Perforating Ulcer of the Duodenum.

The first part of a duodenum with the adjacent portion of the stomach shewing just beyond the pyloric ring a small perforating ulcer, the edge of which is abrupt and measures one third of an inch in thickness. The perforation in the serous coat is considerably smaller than the opening upon the mucous surface. On the reverse of the specimen the peritoneum beneath the ulcer is seen to be thickened.

From a middle-aged man who had long suffered from dyspepsia with pain in the epigastrium. He was suddenly seized with acute symptoms and died twelve hours afterwards.

Presented by Mr. Key.

744 Perforating Ulcer of the Duodenum.

The first two inches of a duodenum shewing close to the pyloric ring a small oval perforation with thin clean-cut edges.

From Mrs. R., æt. 67, who was suddenly seized with acute abdominal pains and vomiting, and died thirty-six hours afterwards. She had had a somewhat similar attack some three years previously. At the autopsy acute peritonitis was found, and there was a second ulcer in the duodenum, the base of which was formed by the neighbouring structures to which the intestine was firmly adherent.

Presented by Mr. Bryant, 1858.

745 Perforating Ulcer of the Duodenum.

The first part of a duodenum with the adjacent portion of the stomach shewing, just beyond the pylorus, a small oval perforation around which the wall of the intestine is thickened. There is a smaller and more superficial ulcer at a spot exactly opposite to it.

Charles W., æt. 66, was admitted under Dr. Rees for albuminuria and œdema of the legs. He died one week after admission, and at the autopsy turbid serum was found in the abdominal cavity, and the peritoneum was "coated with lymph." The kidneys were granular, and there was a hæmorrhagic cyst in the pons Varolii. *See Insp.* 1870, No. 132.

746 Perforating Ulcer of the Duodenum.

A pylorus with the adjacent parts of the stomach and duodenum laid open to shew a perforating ulcer of the intestine. The perforation is oval, measuring half an inch in its longer diameter, and is situated upon the anterior wall half an inch from the pylorus. Its edges are abrupt, and the intestinal wall around it is somewhat thickened. Immediately opposite to it, upon the posterior wall, there is a second ulcer, similar in shape and size, whose base is formed by the thickened serous coat of the bowel.

Frederick G., æt. 21, was admitted under Dr. Perry eighteen

hours after the onset of an acute attack of abdominal pain, shortly followed by vomiting and collapse. Laparotomy was performed, and a large quantity of dark brown acid fluid, without fecal odour, was evacuated from the peritoneal cavity; there was much lymph upon the coils of intestine. Four hours later the patient died. *See Insp.* 1892, No. 238.

747 **Tuberculous Ulceration of the Duodenum.**

A portion of the first part of a duodenum shewing a small rounded ulcer with thickened edges, situated half an inch from the pylorus. The base of the ulcer is formed by the muscular coat of the bowel, and miliary tubercles are visible beneath the peritoneum. Below is mounted a small piece of the ileum, exhibiting a well-marked tuberculous ulcer.

Stephen W., æt. 26, was admitted under Dr. Bright in 1837 for chronic phthisis. At the autopsy there were numerous ulcers throughout the intestines and the mesenteric glands were caseous. *See Insp.* vol. 25, p. 97.

748 **Anthrax of the Duodenum.**

Three pieces of a duodenum mounted to illustrate the effects of anthrax. The topmost piece shews beneath the mucous membrane a flattened nodule measuring about half an inch in diameter and a sixteenth of an inch in thickness. It was situated at the lower end of the duodenum, and in the recent state the mucous membrane covering it presented a small central slough. The two lower pieces shew brown dots and patches resulting from submucous hæmorrhage.

Walter B., æt. 39, was admitted under Mr. Durham for a "malignant pustule" upon the neck, which had been first noticed as a little pimple four days before admission. The pustule was immediately excised. Two days later the patient died. At the autopsy the cellular tissue of the neck was found to be œdematous, and there was considerable hæmorrhage beneath the arachnoid. No part of the alimentary canal appeared to be affected with anthrax except the duodenum. The peritoneal cavity contained about thirty ounces of yellowish fluid. *See Insp.* 1884, No. 113.

749 Papilloma of the Duodenum.

A portion of a duodenum mounted to shew a cauliflower-like mass of growth having a broad attachment to the mucous membrane around and below the papilla of the common bile-duct, into which a yellow rod has been inserted. The mass is about one and a half inches long, three quarters of an inch broad, and projects half an inch above the surrounding mucous membrane. Close to the growth at its upper part there is a small shallow pouch in the wall of the duodenum.

Elizabeth D., æt. 49, was admitted under Dr. Goodhart for jaundice, with pyrexia and hæmorrhage from the intestine. She died three months from the commencement of her illness. At the autopsy two chronic ulcers were found in the rectum, and there were numerous small abscesses in the liver. The common bile-duct was not obstructed. *See Insp.* 1890, No. 385.

750 Sarcoma of the Duodenum.

A duodenum with the stomach suspended from the pylorus. The duodenum is considerably dilated, and its walls are thickened by a deposit of growth which extends into the connective tissue and glands about the head of the pancreas. The mucous surface is extensively ulcerated, and presents numerous prominent nodules of growth. On the reverse of the specimen several isolated button-like secondary deposits are seen beneath the mucous membrane of the stomach. Histologically the growth is a round-celled sarcoma which invades the muscular coat of the intestine.

John C., æt. 21, was admitted under Dr. Addison and died three days later. At the autopsy secondary deposits were found in the jejunum and ileum, and the whole of the large intestine was acutely inflamed. *See Insp.* 1858, No. 55.

751 Sarcoma of the Duodenum.

A duodenum with the pancreas and pyloric end of the stomach. The head of the pancreas is surrounded by a

mass of enlarged, soft, lymphatic glands to which the duodenum is adherent. The wall of the descending portion of the duodenum is thickened and infiltrated by a deposit of growth, the limits of which above and below are clearly defined. The calibre of the bowel at this part is widened, and its mucous surface is considerably ulcerated. Histologically the growth has the structure of a small round-celled sarcoma, the elements of which invade and destroy the muscular coat of the intestine. The pancreatic and common bile-ducts are dilated. There is a small ulcer in the stomach.

John W., æt. 38, was admitted under Dr. Wilks for jaundice with persistent vomiting, from which he died twenty-three weeks after the onset of his illness. At the autopsy no malignant growth was found in any other part of the body. *See Insp.* 1871, No. 53.

752 **Constriction of the Duodenum.**

A duodenum with portions of the stomach, pancreas, liver, and transverse colon seen from behind. The stomach and transverse colon are drawn up behind the liver and united to it in the region of the gall-bladder by firm adhesions. By the contraction of the inflammatory tissue the lumen of the duodenum is narrowed from the pylorus to the entrance of the common bile-duct, and in the recent state the narrowed portion barely admitted the index finger. On the reverse of the specimen the gall-bladder is seen embedded in the right lobe of the liver, and containing numerous faceted gall-stones. The wall of the bladder is scarred, and thickened by inflammatory deposit.

Susan G., æt. 68, was admitted under Dr. Shaw for chronic intestinal obstruction, having suffered from obstinate constipation for two years. The bowels were opened by enemata, but the vomiting continued, and the patient died a week after her admission. At the autopsy the stomach was found to be dilated, and there was no evidence of intestinal obstruction except in the duodenum. *See Insp.* 1893, No. 168.

**753 Duodenum opened by Carcinoma of the Colon.
Colotomy.**

A cæcum and the adjacent parts of the small and large intestine together with a portion of the duodenum and the tissues of the lumbar region. At the commencement of the ascending colon there is an ulcerated growth which has invaded and perforated the duodenum. The fistulous communication thus formed is indicated by a red rod. The connective tissues surrounding the sinus left after the operation of colotomy are seen to be infiltrated with new growth, which histologically has the characters of cylindrical-celled carcinoma.

Robert W., æt. 60, was admitted under Mr. Golding-Bird for intestinal obstruction for which colotomy was performed. He died six months after the operation, having for some weeks before his death suffered from diarrhœa with dark and offensive motions. *See Insp.* 1880, No. 141.

754 Perforation of the Duodenum.

A portion of a stomach with the first part of the duodenum in which, at a distance of one inch from the pylorus, is seen the opening of a sinus which leads from the intestine to a mass of soft caseous glands situated in the lesser omentum.

Jane B., æt. 18, was admitted under Dr. Rees for emaciation and occasional vomiting, and while in the hospital developed symptoms of tabes mesenterica. She died seven months after her admission. At the autopsy the mesenteric and lumbar glands were found enlarged and caseous, and there was tuberculous ulceration of the ascending colon. The lungs contained tubercles. *See Insp.* 1860, No. 155.

755 Perforation of the Duodenum.

The first inch of a duodenum with the adjoining portion of the stomach mounted to illustrate perforation from without. The peritoneal surface of the duodenum exhibits on its anterior aspect an oval ulcer three quarters of an inch in its longest diameter, situated just

beyond the pylorus. The edges of the ulcer are clean-cut, and in its base, which is formed by mucous membrane, is seen a small perforation, through which, in the recent state, pus escaped into the intestine. Elsewhere the outer surface of the stomach and duodenum is eroded by superficial ulceration and roughened by a deposit of fibrinous material.

Emma L., æt. 18, was admitted under Dr. Goodhart with signs of chronic peritonitis. She died eight months after the commencement of her illness. At the autopsy the uterus and Fallopian tubes were found to be tuberculous; the abdominal cavity was distended with gas, and there were numerous collections of pus between the matted intestines. *See Insp.* 1889, No. 327.

756 **Cholecysto-duodenal Fistula.**

The pyloric end of a stomach with the first part of the duodenum and a portion of the liver with the gall-bladder seen from behind. There is a fistulous communication, marked by a red rod, between the fundus of the gall-bladder and the duodenum. The opening in the duodenum is just beyond the pylorus, which is thickened and narrowed. A gall-stone is seen impacted in the cystic duct, and there are one or two others within the bladder.

Martha G., æt. 52, was admitted under Dr. Pavy for progressive weakness and vomiting, with the physical signs of pyloric obstruction, and died two months after admission. *See Insp.* 1885, No. 22.

757 **Pancreatico-duodenal Fistula.**

A duodenum with the pancreas and a part of the stomach mounted to shew a communication between the duodenum and a cavity in the head of the pancreas, which in the recent state contained blood-clot. The perforation is situated on the concave border of the duodenum two inches below the pyloric ring, and an inch and a half above the biliary papilla. Histological

examination of the walls of the cavity in the pancreas shews an excess of fibrous tissue between the acini of the gland, but no evidence of malignant growth.

Lizzie C., æt. 29, was admitted under Dr. Hale White for severe hæmatemesis and melæna, which began eight days before admission. Five days later an exploratory laparotomy was performed, but the source of hæmorrhage was not discovered. She died on the following day. *See Insp.* 1891, No. 357.

758 **Duodenum opened by a Spinal Abscess.**

A pylorus with a portion of the liver and the duodenum, shewing close to the biliary papilla an oval perforation in the wall of the bowel, about a third of an inch long, which in the recent state communicated with a large spinal abscess.

Ellen M., æt. 24, was admitted under Mr. Davies-Colley for an angular curvature of the spine in the lumbar region, attributed to a fall experienced four years previously. Eight days after admission an abscess was opened in the back, the pus from which had a very fetid odour. Eleven days later she died, and at the autopsy the fourth and fifth lumbar vertebræ were found to be carious, and the right kidney, with which the spinal abscess was in contact, was filled with caseous deposit. *See Insp.* 1885, No. 365; and *Trans. Path. Soc.* 1886, p. 561.

759 **Ankylostomum Duodenale.**

A portion of a duodenum shewing between the valvule conniventes numerous specimens of ankylostoma mounted upon black paper. These nematode helminths, the sclerostoma duodenale of Cobbold, are about a third of an inch in length, the females being longer than the males, but always measuring less than half an inch. They have a uniform cylindrical body one eightieth of an inch in thickness, with a head slightly tapering and pointed, and a tail sharply pointed in the female and blunt in the male. In the recent state the heads were buried in the submucous coat of the intestine. *Presented by Dr. Beavan Rake, 1887.*

SECTION XVIII.—INJURIES AND DISEASES OF
THE INTESTINE.

(Excluding Duodenum, Cæcal Appendix, and Rectum.)

- Diverticula : 760-765.
 - Sacculi : 766-769.
 - Congenital Occlusion : 770-772.
 - Wounds : 773-775.
 - Lacerations : 776-790.
 - Operations : 791-793.
 - Enlarged Glands : 794-796.
 - Enteritis : 797-808.
 - Colitis : 808-826.
 - Follicular Colitis : 821-824.
 - Membranous Colitis : 789, 815-822.
 - Ulcerative Colitis : 821-839.
 - Simple Stricture : 840-844.
 - Distension Ulceration : 843, 844.
 - Tuberculosis : 845-863.
 - Tuberculous Ulcers : 847-855.
 - Tuberculous Perforation : 856, 859.
 - Tuberculous Stricture : 860-863.
 - Typhoid : 864-883.
 - Typhoid Ulceration : 865-872.
 - Typhoid Perforation : 873-878.
 - Healed Typhoid Ulceration : 879-883.
 - Anthrax : 884, 885.
 - Hypertrophy and Dilatation : 886-888.
 - Polypi : 890-894, 937.
 - Squamous Epithelioma : 895.
 - Cylindrical Carcinoma : 897-914.
 - Spheroidal Carcinoma : 896, 915-925.
 - Lymphadenoma : 926-932.
 - Sarcoma : 933-937.
 - Perforation from without : 938-945.
 - Intestinal Fistulæ : 889, 945, 946.
 - Thrombosis of Veins : 947-949, 951.
 - Chyle Cyst : 950.
 - Trichocephalus : 952.
-

760 Diverticulum of the Ileum.

A portion of an ileum shewing a tubular diverticulum arising from its free border and attached to the umbilicus. It is about three inches long, and equals in diameter the intestine from which it springs. It was situated about eighteen inches from the ileo-cæcal valve. The blue rod in the umbilical scar indicates a small opening through which fæces were discharged from the diverticulum.

From a male child who died at the age of two years from bronchitis. Ten days after birth fæces were noticed to ooze from an opening at the umbilicus. Subsequently a few inches of intestine protruded from the aperture during fits of coughing. At the age of fifteen months the prolapse had ceased, and cicatrisation was complete except for a "central spot of granulation as wide as a pea." See *Guy's Hosp. Repts.* 1843, p. 471.

Presented by Mr. Gunthorpe.

761 Diverticulum of the Ileum.

A piece of small intestine with a pouch an inch in length projecting from its lateral wall. There is a membranous fold resembling a mesentery by which the diverticulum is attached to the portion of intestine immediately above it. It was situated two feet above the ileo-cæcal valve.

John B., æt. 32, was admitted under Dr. Bright in 1828, and died from cirrhosis of the liver. See *Insp.* vol. 7, p. 78.

762 Diverticulum of the Ileum.

A portion of an ileum which is united to the abdominal wall at the situation of the umbilicus by means of a diverticulum three inches in length. The umbilicus is completely cicatrised.

John C., æt. 14 months, was admitted under Mr. Key for a fæcal fistula at the umbilicus. It was closed by operation and the child discharged cured. Subsequently he died from

intestinal obstruction caused by a band which compressed the ileum just below its connection with the diverticulum. *See Guy's Hosp. Repts.* 1843, p. 470.

Presented by Mr. Allwork.

763 Diverticulum of the Ileum.

A portion of small intestine with a diverticulum projecting from its lateral wall. The pouch is an inch in length, half an inch in diameter, and presents two short lateral projections from its blunt extremity.

James R., æt. 31, was admitted under Dr. Newton Fitt for a swelling in the right loin, and died from sarcoma of the suprarenal capsule. *See Insp.* 1889, No. 376.

764 Diverticulum of the Ileum.

A piece of small intestine shewing a diverticulum about an inch in length, the diameter of which is about one third of that of the intestine.

765 Diverticulum of the Ileum.

A piece of small intestine shewing a diverticulum projecting obliquely from its wall between the attached and free margins. The pouch is one inch long, and the opening into it is of the same size as the lumen of the intestine, from which it is separated by a valvular fold of mucous membrane.

766 Sacculation of the Ileum.

Coils of small intestine united by organised adhesions and shewing at their mesenteric attachment several saccular diverticula lined with mucous membrane and varying in size from half an inch to an inch in diameter.

From a man who was brought to the hospital having died suddenly apparently from cardiac failure. At the autopsy a second mass of adherent small intestines similar to that shewn in the preparation was found and it was noted that the condition resembled that produced by incarceration in a hernia. No sac of a hernia could, however, be discovered. *See Trans. Path. Soc.* 1876, p. 147.

767 Sacculus of the Colon.

A portion of the sigmoid flexure of a colon laid open to shew an aperture in its wall one eighth of an inch in diameter, which communicates with a sacculus about the size of a pea, the interior of which is lined with healthy mucous membrane. In the recent state the pouch contained fæcal matter and puriform mucus.

James C., æt. 73, was admitted under Mr. Morgan in 1831, for fractured ribs with emphysema, from which he died. See *Insp.* vol. 15, p. 51; and *Prep.* 1501 (90) [2nd Edit.].

768 Sacculi of the Colon.

A portion of a descending colon laid open to shew the orifices of numerous sacculi which project from the outer surface of the bowel. Most of the sacculi are the size of a pea, and in the recent state they contained mucus and fæcal material.

William H., æt. 50, was admitted under Dr. Pavy in a condition of uræmic coma. He died a few hours later, and at the autopsy the kidneys were found in a condition of suppurative inflammation. See *Insp.* 1834, No. 410; and *Trans. Path. Soc.* vol. 36, p. 215.

769 Perforated Sacculus of the Colon.

A portion of a colon, the interior of which presents the orifices of numerous pouches and sacculi. Some of the deeper ones have been opened in preparing the specimen. At the bottom of the preparation one of the sacculi shews a small perforation, through the edges of which the mucous membrane is everted.

From Caleb E., æt. 60, who for ten years had suffered from attacks of constipation and abdominal pain. Six weeks before his death an abscess formed in the left side of the abdomen. At the autopsy a cavity containing pus was found between the spleen, left kidney, and colon, which communicated with the bowel through the perforation shewn in the preparation. See *Museum Note Book*, No. 3, p. 14.

Presented by Dr. Prance, 1886.

770 Congenital Occlusion of the Ileum.

A portion of the lower end of an ileum laid open to shew a membranous diaphragm completely occluding the intestine at a point nine inches from the cæcum. Above the obstruction the gut measures two inches in circumference, and below barely half an inch. The blue rod indicates an artificial anus, above which there is a superficial ulcer about the size of a threepenny piece.

Isabella P., æt. 6 days, was admitted under Mr. Davies-Colley for constant vomiting and obstipation. An artificial anus was made in the right groin, and the child died two days later from peritonitis. See *Insp.* 1877, No. 317; and *Trans. Path. Soc.* vol. 29, p. 115.

771 Congenital Occlusions of the Ileum.

The colon and a portion of the small intestine of a child shewing the bowel occluded at two points, one sixteen and the other four inches above the cæcum. The ends of the loop of intestine, thus isolated, are conical and separated by short fibrous cords from the bowel above and below. These fibrous cords are united to one another by a mesentery. The peritoneum presents numerous filamentous adhesions.

From a seven-months' male infant who survived his birth three days, during which time he constantly vomited greenish fluid. It was thought that the intestine had been ruptured during a severe fit of coughing, with which the mother was seized two months before delivery. See *Trans. Path. Soc.* vol. 34, p. 217.

Presented by Mr. Hobson, 1885.

772 Congenital Occlusion of the Colon.

A rectum with a portion of the colon mounted to shew a membranous septum completely occluding the bowel at a point nine inches above the anus. Above the obstruction the bowel is much dilated, and below it is

pervious, though contracted to the size of a cedar pencil.

Albert K., æt. 7 days, was admitted under Mr. Howse for obstipation from birth. An artificial anus was made by attaching a coil of small intestine to the abdominal wall in the left inguinal region, and the patient died the following day. *See Insp.* 1889, No. 129.

773 **Incised Wound of the Jejunum.**

A portion of a jejunum, shewing a transverse wound about an inch in length, the edges of which have been sutured and are firmly united. The wound was situated four inches from the duodenum.

George M., æt. 50, was admitted under Mr. Cooper Forster for a stab in the abdominal wall, through which about eighteen inches of small intestine protruded. A wound in the intestine was sutured and the gut returned. He died sixty hours after the injury, and at the autopsy a considerable quantity of blood and lymph was found in the peritoneal cavity. *See Insp.* 1870, No. 210.

774 **Punctured Wound of the Ileum.**

A portion of an ileum, shewing a perforation produced by the point of a trocar. On the serous coat there is a lacerated wound, about half an inch in length, and in the mucous membrane a small round hole. The peritoneum is partially covered with a layer of recent lymph.

William H., æt. 30, was admitted under Mr. Birkett for suppression of urine. An attempt was made to puncture the bladder per rectum and the patient died three days later. At the autopsy the end of the cannula was found projecting into the peritoneal cavity and there was suppurative peritonitis. The kidneys were granular. *See Insp.* 1868, No. 299.

775 **Incised Wound of the Intestine.**

A portion of small intestine, shewing a longitudinal wound about half an inch in length. The edges have

been united by suture, and the stitches are partially covered by a thin layer of lymph.

John A., æt. 48, was admitted under Mr. Birkett for a stab in the abdominal wall through which a coil of intestine protruded. The gut which was wounded was sutured and returned. The patient died twenty-five hours after the injury, and at the autopsy a large effusion of blood was found in the abdominal wall. There was no general peritonitis. *See Insp.* 1869, No. 276.

776 **Laceration of the Colon by an Enema-tube.**

A portion of a colon, mounted to shew an irregular laceration measuring about half an inch longitudinally, and an inch from side to side. The laceration, which was situated at the lower end of the sigmoid flexure, involves the muscular and serous coats, the mucous membrane being entire except for a small perforation about an eighth of an inch in diameter. There is much lymph upon the peritoneum.

From R. B., a male, æt. 75, who suffered from fæcal impaction for the relief of which an enema was administered through a long tube. Shortly afterwards he became collapsed and died on the next day. At the autopsy acute peritonitis was found.

Presented by Dr. Habershon, 1864.

777 **Perforation of the Colon by a Bougie.**

A portion of the sigmoid flexure of a colon with the rectum laid open to shew an oval perforation measuring rather more than an inch longitudinally and half an inch across. The laceration involves all the coats of the bowel to an equal extent, and its lower border is situated twelve and a half inches from the anus.

From a gentleman, who had long suffered from fæcal impaction, which was attributed to stricture of the rectum, and for the relief of which bougies were passed.

Presented by Dr. Hodgkin and Mr. Callaway.

778 Traumatic Perforation of the Jejunum.

A portion of a jejunum mounted to shew two oval perforations about half an inch in diameter, around which the mucous membrane is puckered. On the reverse of the specimen the edges of the perforations are seen to be surrounded by extroverted mucous membrane which forms a raised crinkled border. There is much lymph upon the peritoneum.

From Charles F., æt. 30, who was struck by a brick upon the abdomen in an explosion at Lambeth in 1852.

779 Rupture of the Jejunum.

A coil from the upper part of a jejunum mounted to shew a lacerated wound completely dividing the intestine, and extending for an inch into the mesentery. The divided ends of the gut are considerably narrowed and surrounded by everted mucous membrane. There is recent lymph upon the adjacent serous coat.

Alonso H., æt. 29, who was admitted under Mr. Cock for injuries caused by a beer barrel falling upon the left side of his abdomen. He died the next day, and at the autopsy the peritoneal cavity contained much blood; the psoas muscle was found to be completely torn through. *See Insp.* 1863, No. 249.

780 Traumatic Perforation of the Jejunum.

A small portion of a jejunum mounted to shew an oval perforation about a quarter of an inch in length. On the serous surface the laceration is seen to be more extensive and the opening is surrounded by a narrow ring of everted mucous membrane.

From a man who was kicked in the abdomen, and died forty-eight hours after the injury from peritonitis with fecal extravasation.

Presented by Dr. Gull.

781 Rupture of the Ileum.

A small portion of an ileum shewing two lacerated wounds, one completely dividing the intestine and its

mesentery, and the other extending through two thirds of its calibre. The mucous membrane is slightly everted, and there is much lymph upon the serous coat. The larger laceration was situated two feet from the cæcum.

John A., æt. 46, was admitted under Mr. Aston Key in 1831, having been run over by a chaise. He died twenty-four hours after the accident, and at the autopsy nearly three quarts of blood were found in the peritoneal cavity. *See Insp.* vol. 15, p. 20; and *Drawing*, No. 317.

782 Perforation of the Ileum.

A portion of an ileum shewing a small round perforation. On the serous surface the mucous membrane is seen to be everted through the opening which is surrounded by recent lymph. The perforation was situated at the middle of the small intestine.

Thomas T., æt. 10, was admitted under Mr. Cock for injuries received by falling on a curbstone in the street. He was playing with other boys when he slipped and fell, and his companions fell over him. He died fifteen days after the accident, and at the autopsy general peritonitis was found, and a faecal abscess extended from the right iliac region upwards to the liver. *See Insp.* 1856, No. 182.

783 Rupture of the Ileum.

A portion of an ileum shewing an oval perforation about a quarter of an inch in length through the edges of which the mucous membrane is everted. There is recent lymph upon the serous surface. The perforation was situated six feet from the cæcum.

Walter C., æt. 30, was admitted under Mr. Cock for injuries received in raising a cask the edge of which he had placed against his abdomen. Whilst straining he felt "something give way inside," and was seized at once with severe pain followed by sickness. He died 30 hours after the accident, and at the autopsy a considerable quantity of gas, fæces, and lymph was found in the peritoneal cavity. There was no lesion in any other part of the intestine. *See Insp.* 1864, No. 138.

784 Laceration of the Colon.

The sigmoid flexure of a colon shewing an oval perforation about an inch and a half in length. Opposite to this there is an extensive laceration involving only the outer coats of the intestine.

From Mr. H., æt. 50, who was thrown from a gig and struck his abdomen against a post. He died thirty-four hours after the accident, and at the autopsy intestinal contents and lymph were found in the peritoneal cavity. *See Note Book, No. 1, p. 148.*

785 Laceration of the Colon.

A portion of a descending colon and sigmoid flexure mounted to shew an extensive laceration of the serous and muscular coats. The mucous membrane is entire.

Edward T., an army pensioner, was admitted under Mr. Cock, having been run over by a brewer's dray. He died about an hour after the accident, and at the autopsy a considerable quantity of blood was found in the peritoneal cavity. The small intestine was at one part completely torn across. *See Insp. 1858, No. 185.*

786 Rupture of the Colon.

A portion of a colon, measuring five inches in circumference, laid open to shew an oval transverse perforation one and a half inches long and three eighths of an inch in width. The opening upon the serous surface is much smaller than the laceration of the mucous membrane. Except at this spot the mucous membrane is intact.

From a patient who for the last fortnight of her life suffered from obstipation, and ten hours before her death was seized with abdominal pain and vomiting. At the autopsy a malignant stricture was found in the rectum and there was extravasation of fæces into the peritoneal cavity. *See Prep. 1018.*

Presented by Mr. Hardy.

787 Rupture of the Muscular Coat of the Colon.

A portion of the hepatic flexure of a colon, mounted to shew two diamond-shaped translucent areas situated

with their long axes on one of the longitudinal muscular bands. At these places the muscular coat is almost entirely deficient, only a few transverse fibres being visible. The edges of the separated muscle have been rounded by a process of repair, and the serous and mucous coats are intact.

Frederick E., æt. 60, was admitted under Mr. Bryant with a malignant stricture of the rectum for which colotomy was performed. Six days later he died and at the autopsy there was recent peritonitis and the colon above the stricture was greatly dilated. *See Insp.* 1885, No. 233.

788 **Colic Fistula.**

A portion of the descending colon with the neighbouring parts mounted to shew a funnel-shaped depression at the bottom of which is a sinus opening externally in the left loin indicated by a blue rod. The pink rod has been passed from the colon into a second sinus which communicated with an abscess behind the peritoneum in the left iliac fossa.

James B., æt. 22, was admitted under Dr. Habershon for Bright's disease, from which he died. In April 1855 he received a gunshot wound in the right loin as he was returning on his hands and knees to the trenches before Sebastopol. Three days after the injury the flattened bullet was passed per anum. In June 1856 he was admitted under Mr. Birkett for a fistula in the right loin, which was closed before he left the hospital in September. In March 1857 he was again admitted with an abscess in the *left* lumbar region, which opened spontaneously, leaving a persistent faecal fistula. In January 1858 his legs became anasarctous, and in February 1859 he died, three years and ten months after the injury. At the autopsy it was found that the bullet had entered the right loin, had passed obliquely upwards to the left side, injuring the laminae of the third and fourth lumbar vertebræ on its way, and had then penetrated the descending colon. A fragment of lead was embedded in the spleen. An abscess cavity extended upwards from the opening in the colon towards the diaphragm in the cellular tissue behind the peritoneum, and the last two ribs on the left side were necrosed. The kidneys were large and white. *See Insp.* 1859, No. 29; *Prep.* 1047; and *Guy's Hosp. Repts.* 1859, p. 173.

789 Membranous Colitis from Injury.

A portion of an ascending colon, laid open to shew a thin deposit of granular lymph upon its mucous membrane, which in the recent state was deeply injected. On the reverse of the specimen the muscular and serous coats are seen to be lacerated in several places, and there is adherent decolorised blood-clot.

Thomas M., æt. 4, was admitted under Mr. Howse, having been run over by a cab. The front wheel passed over and fractured his right thigh, and the hind wheel crossed his abdomen. He died on the third day after the accident, and at the autopsy there was hæmorrhage into the cellular tissue of the right iliac fossa and into the peritoneum. There was no peritonitis. See *Insp.* 1891, No. 108.

790 Laceration of the Serous Coat of the Intestine.

A portion of an ascending colon with the cæcum and lower end of the ileum which in the recent state were in a condition of invagination. The specimen is mounted to shew numerous oblique lacerations of the serous covering of the colon probably produced by artificial distension.

Harry W., æt. 7 months, was admitted under Dr. Moxon for vomiting and the passage of blood at stool. A small tumour was felt at the left side of the abdomen, and disappeared during inflation. On the next day the tumour was again felt and water was injected into the bowel, and the child died five days after the onset of symptoms. At the autopsy the intussusception was found to be partly reduced; there was no general peritonitis. See *Insp.* 1871, No. 180.

791 Enterectomy.

A portion of an ileum with its mesentery mounted to shew the condition left after resection of a loop of intestine. The cut ends of the bowel have been firmly united by Joubert's sutures, and in the recent state coaptation was so perfect that there was no leakage of water even under considerable pressure. Above the

line of suture the gut is dilated, whilst below it is of less than normal size.

Mary L., æt. 53, was admitted under Mr. Howse with a right-sided femoral hernia which had been strangulated for twelve days. While she was being carried into the ward the sac ruptured, and feces escaped freely through the opening. Six days later Mr. Howse resected the strangulated portion of intestine, about four inches in length, through an incision in the median line of the abdomen. The next day the patient died, and at the autopsy the ileum was found to have been sutured two feet above the cæcum, and there was evidence of general peritonitis. See *Insp.* 1892, No. 21.

792 **Artificial Anus in the Small Intestine.**

A piece of small intestine shewing considerable hypertrophy and dilatation, and presenting upon its free border an opening left after Littre's operation. There is firm union between the abdominal wall and the bowel.

Benjamin R., æt. 33, was admitted under Mr. Golding-Bird for intestinal obstruction which was relieved by enterostomy. Some months later a portion of the colon, which was the seat of carcinomatous growth, was removed, and the patient died from acute peritonitis. See *Insp.* 1883, No. 355; and *Prep.* 897.

793 **Prolapse of the Colon after Colotomy.**

The parts surrounding an artificial anus made in the operation of lumbar colotomy, together with the splenic flexure and the descending portion of the colon. The splenic flexure and its opening at the upper part of the artificial anus are indicated by a blue rod. The descending colon is prolapsed through the lower part of the anus, and forms a cylindrical tumour about six inches in length. The mucous membrane covering it is ulcerated, and by the side of the apex is seen the slit-like opening of the returning layer of the invagination.

Mary S., æt. 38, was admitted under Mr. Bryant for a fibrous stricture of the rectum, for which colotomy was performed. Twelve months after the operation the bowel began to protrude, and

twenty-one months later when she was readmitted the prolapse measured six or seven inches in length. It could be easily reduced. Ten days after her admission she died from suppurative peritonitis. At the autopsy the liver and kidneys were lardaceous, and no local cause for the peritonitis was discovered. *See Insp.* 1876, No. 262.

794 Enlargement of Peyer's Patches and Solitary Glands.

A piece of small intestine laid open to shew a prominent patch of aggregated glands of unusual length. The solitary follicles are also enlarged.

From a child, *æt.* 6 years, who was under the care of Dr. Babington in 1828 for diabetes, from which she died. *See Insp.* vol. 6, p. 138.

795 Enlargement of the Solitary Glands.

Portions of small intestine mounted to shew the solitary glands enlarged and prominent.

From a patient who died of Asiatic cholera in 1849.

796 Enlargement of the Solitary and Agminated Glands.

The last five inches of an ileum mounted to shew the solitary glands and Peyer's patches unusually large and prominent. There is no appearance of ulceration.

Richard W., *æt.* 22, was admitted under Dr. Barlow for aortic regurgitation, from which he died suddenly. At the autopsy the stomach was found to contain much food, and the lacteals were full of chyle. *See Insp.* 1855, No. 86.

797 Enteritis.

The last foot of an ileum laid open to shew two inflamed areas, the lower one immediately above the ileo-cæcal valve, and the other five inches higher up. At the inflamed parts the intestine is thickened and contracted, and its mucous membrane exhibits transverse folds,

which are covered by loosely adherent granular lymph. Histologically all the coats of the bowel are seen to be infiltrated with small round cells.

Mary S., æt. 35, was admitted under Dr. Newton Pitt for hæmatemesis with severe anæmia. She became comatose, and died five days after her admission. At the autopsy the left lobe of the cerebellum was found to be softened, and there was a large chronic ulcer in the stomach. There are a few patches of superficial ulceration in the upper part of the colon. See *Insp.* 1891, No. 292.

798 **Membranous Enteritis.**

The lower end of an ileum with the cæcum and the commencement of the colon, the mucous membrane of which presents narrow transverse bands of brownish colour, covered with granular lymph.

Jane G., æt. 29, was admitted under Dr. Pavy, having swallowed a mixture of white precipitate and carbolic acid. She suffered from hæmatemesis, diarrhœa, and suppression of urine, and died five days after taking the poison. At the autopsy false membrane was found on the back of the tongue and on the fauces, and there was membranous inflammation of the stomach and vagina. The condition shewn in the preparation extended throughout the colon. See *Insp.* 1877, No. 55; and *Prep.* 626.

799 **Enteritis in Bright's Disease.**

A portion of the lower end of an ileum the mucous membrane of which is in parts destroyed and in other parts covered with a white pellicle. In the recent state the intestine was congested and its coats thickened.

Robert E., æt. 14, was admitted under Dr. Wilks in a condition of uræmic coma and died two days later. His illness began two and a half years previously in an attack of acute Bright's disease following scarlatina. At the autopsy the kidneys shewed tubal and interstitial nephritis; the heart was hypertrophied, and the vessels of the brain were atheromatous. The condition shewn in the preparation existed to a less degree throughout the small intestine. See *Insp.* 1878, No. 487.

800 Ulceration of the Ileum in Bright's Disease.

A portion of the upper part of an ileum laid open to shew numerous small oval and linear ulcers, transverse in direction, situated chiefly upon a Peyer's patch.

Sarah P., æt. 54, was admitted under Dr. Fagge for symptoms of peritonitis, following occasional attacks of severe abdominal pain and constipation extending over five weeks. She died about thirty-six hours after admission, and at the autopsy recent lymph was found in the peritoneal cavity, and there were numerous sloughing ulcers throughout the colon. The upper third of the small intestine appeared normal. There was interstitial nephritis. See *Insp.* 1882, No. 22; and *Prep.* 808.

801 Lardaceous Enteritis.

A portion of an ileum, the mucous membrane of which is partially covered with a granular deposit of lymph. The wall of the intestine is slightly thickened and there is some appearance of superficial ulceration. In the recent state the ulcerated patches gave the lardaceous reaction with iodine.

Charles F., æt. 9, was admitted under Mr. Lucas for an abscess on the outer side of the right thigh, associated with caries of the lumbar vertebræ of "many years' " duration. He died six months after admission, and at the autopsy the spleen and liver were found to be lardaceous and the lumbar glands were caseous. There was advanced parenchymatous nephritis. See *Insp.* 1883, No. 97.

802 Gangrenous Enteritis with Lardaceous Disease.

A portion of an ileum laid open to shew a gangrenous patch about four inches in length, which in the recent state was thin and blackened, and contrasted strongly with the oedematous less severely inflamed parts at either end. There is a little recent lymph upon the serous surface. Histological examination of the thickened portion shews the vessels of the wall of the intestine to be dilated and the connective tissue to be infiltrated with small round cells.

George T., æt. 41, was admitted under Dr. Habershon with

dropsy of the lower part of the body and albuminuria. "Many times he had had syphilis." At the autopsy acute peritonitis was found, and the intestines, liver, spleen, and kidneys were lardaceous. The liver was scarred, and there was a gumma in the diaphragm. See *Insp.* 1867, No. 239; *Guy's Hosp. Repts.* 1867, p. 398; and *Prep.* 401.

803 **Ulcerative Enteritis with Purpura.**

The lower end of an ileum laid open to shew the mucous membrane extensively destroyed by ulceration. The ulcerated patches are indefinite in shape and do not specially involve the solitary or agminated follicles. Irregular islets and narrow bands of healthy mucous membrane stand out conspicuously above the exposed muscular coat. There is no lymph upon the serous surface. In the recent state the whole small intestine was injected and a similar condition of ulceration was present in the jejunum.

James F., æt. 36, was admitted under Dr. Moxon for purpura, tonsillitis, and swelling of some of the joints. He died on the twenty-fourth day from the appearance of the purpuric eruption. During his illness he suffered from vomiting and diarrhoea, and had an attack of facial erysipelas. At the autopsy the tympanic cavity was full of pus, there was an abscess beneath the scalp, and the uvula was covered with a greyish slough. See *Insp.* 1874, No. 66; and *Trans. Path. Soc.* vol. 26, p. 84.

804 **Chronic Contracting Ulcers of the Small Intestine.**

Portions of small intestine mounted to shew several encircling ulcers, occupying, the shortest half an inch, and the longest more than two inches, of the length of the bowel. At the situation of the ulcers the mucous membrane is for the most part destroyed and replaced by fibrous tissue, the contraction of which has led to considerable narrowing of the lumen of the gut. The intestine between the ulcers is healthy, but somewhat dilated and hypertrophied. Histological examination of the base of the ulcers shews no tuberculous deposit.

With the specimen is mounted the last two inches of the rectum, exhibiting an anal ulcer.

Robert C., æt. 45, was admitted under Dr. Hale-White for chronic diarrhœa of three years' duration, the motions often containing blood. When young he had suppurating glands in the neck, and on admission two ulcers were found on his tongue. He had never had syphilis. At the autopsy the apices of the lung were adherent to the chest-wall, and contained an excess of fibrous tissue. Ten ulcers in all were found in the small intestine. The colon was healthy. *See Insp.* 1892, No. 169; and *Prep.* 505.

805 **Stricture of the Ileum from Ulceration.**

A portion of an ileum shewing an annular constriction which in the recent state would barely admit the end of a finger. At the seat of constriction the mesentery is thickened and a portion of omentum is adherent to the bowel. Upon the mucous surface there is an encircling ulcer about three quarters of an inch wide, having thin edges and a base formed by the exposed muscular coat.

Mary B., æt. 40, was admitted under Dr. Cholmeley in 1828 for "bilious fever" of six weeks' duration. She suffered from vomiting, prostration, and diarrhœa, and died three weeks after her admission. At the autopsy a similar contraction was found in another part of the ileum. The Fallopiian tubes were distended with pus and the kidneys were granular. *See Insp.* vol. 14, p. 19.

806 **Chronic Contracting Ulcer of the Ileum.**

A portion of an ileum laid open to shew an ulcer, one inch and a quarter in length, which completely encircles and somewhat obstructs the lumen of the bowel. At the situation of the ulcer the wall of the intestine is thickened, and presents a small perforation. Above the ulcer the bowel measures four inches, and below an inch and a half in circumference. At the lower limit of the dilated portion is an irregular ulcer, the edges of which are thin and undermined, and its base formed by the muscular coat of the intestine.

Sarah D., æt. 43, was admitted under Dr. Pitt with symptoms

of chronic intestinal obstruction, from which she died four and a half months after the onset of her illness. Eleven weeks before her admission two femoral herniæ from which she had long suffered descended, and were not reduced till seven days had elapsed. It was thought that the ulcer in the ileum was caused by the incarceration of the bowel in one of the hernial sacs. At the autopsy there were signs of early peritonitis, a chronic ulcer in the cæcum, and fibroid phthisis at the apex of the left lung. The ulcer in the ileum was examined microscopically, and afforded no evidence of a tuberculous origin. *See Insp.* 1890, No. 227; and *Trans. Path. Soc.* 1891, p. 119.

807 **Ulceration of the Ileum with Adhesion. Perforation.**

A portion of an ileum shewing a rounded ulcer, the base of which is adherent to the bladder and to the omentum. By the side of the ulcer is an oval perforation, and there is granular lymph upon the serous coat. At the situation of the ulcer the lumen of the bowel is somewhat narrowed.

Ellen H., æt. 44, was admitted under Dr. Addison, in 1835, for paralysis and rigidity of the arms and legs. When turning in bed she was suddenly seized with intense abdominal pain, followed by collapse. She died five days later, and at the autopsy the peritoneal cavity was found to contain fecal material, and there was suppurative peritonitis. There were no signs of tuberculosis or pelvic cellulitis. *See Insp.* vol. 20, p. 136.

808 **Ulcerative Entero-Colitis in Bright's Disease.**

The lower end of an ileum, the wall of which has been partially removed to shew the mucous membrane in great part destroyed by ulceration. The ulcers have a transverse direction and are separated by narrow bands of mucous membrane, which in the recent state was swollen and claret-coloured. There is a little lymph upon the serous coat.

Sarah P., æt. 54, was admitted under Dr. Fagge for symptoms of peritonitis, following occasional attacks of severe abdominal pain and constipation, extending over five weeks. She died about thirty-six hours after admission, and at the autopsy recent lymph was found

in the peritoneal cavity, and there were numerous sloughing ulcers throughout the colon. The upper third of the small intestine appeared normal. There was interstitial nephritis. *See Insp.* 1882, No. 22; and *Prep.* 800.

809 Colitis in Bright's Disease.

A portion of a colon somewhat thickened, and presenting upon its mucous surface numerous ragged partially-detached sloughs. These are situated for the most part upon the prominences of mucous membrane between the sacculi. Elsewhere there are scattered patches of superficial ulceration.

John S., æt. 33, a plumber, was admitted under Dr. Cholmeley in 1828, for anasarca. Three days before his death profuse diarrhœa came on. At the autopsy the kidneys were found to be large and white. *See Insp.* vol. 7, p. 72; and *Prep.* 1222.

810 Colitis in Bright's Disease.

A cæcum with a portion of the colon mounted to shew an inflammatory condition of the colon more marked at the lower than at the upper part. Immediately below the cæcum, which is unaffected, the mucous membrane is thickened, and presents a few raised oval patches, in the centre of which are partially detached black sloughs. Lower down the whole of the mucous membrane is blackened and gangrenous.

William A., æt. 45, was admitted under Dr. Wilks for constant vomiting and profuse diarrhœa. He had had two attacks of hæmaturia, one three years, the other four months previously, and at the time of admission the urine contained much albumen. At the autopsy the left kidney and ureter, and the bladder and prostate were found to be tuberculous. There was advanced tubal inflammation of both kidneys. *See Insp.* 1879, No. 69.

811 Colitis in Bright's Disease.

An ascending colon with the cæcum laid open to shew numerous irregular superficial ulcers to some of which thin ragged sloughs are adherent. Histologically the

submucous tissue is infiltrated with small round cells, and its vessels are engorged and dilated.

Robert T., æt. 25, was admitted under Dr. Moxon for albuminuria and dysenteric diarrhœa. Before his death he had numerous convulsive attacks. At the autopsy the kidneys were found to be affected by tubal and interstitial inflammation. The heart was hypertrophied, and there was much pneumonic consolidation of the right lung. *See Insp.* 1879, No. 107.

812 Colitis in Lobar Pneumonia.

Portions of a colon mounted to shew several small rounded ulcers, in the bases of which the muscular coat is exposed. The wall of the intestine is thickened and in the recent state the mucous membrane was red and velvety and covered with a layer of tenacious lymph.

James S., æt. 20, was admitted under Dr. Barlow with the physical signs of consolidation of the lung, and rusty sputa. His febrile symptoms lessened, but diarrhœa came on, and he sank into a typhoid condition, and died about three weeks from the onset of severe symptoms. At the autopsies the lower lobe of the right lung was hepatised, and there was a slight recent peritonitis. The whole of the large intestine was in a state of acute inflammation. *See Insp.* 1855, No. 150.

813 Ulceration of the Colon in Pneumonia.

Portions of a colon, mounted to shew numerous irregular shallow ulcers, which for the most part have a transverse direction. In the bases of some of them the muscular coat is exposed.

Henry C., æt. 32, was admitted under Dr. Pye-Smith for acute pneumonia, complicated with delirium tremens, of five days' duration. On the eleventh day of his illness diarrhœa supervened, and six days later he died. At the autopsy the lobar pneumonia was in a condition of resolution, but there were numerous patches of more recent lobular inflammation. The small intestine was healthy. *See Insp.* 1890, No. 382.

814 Congestion of the Cæcum.

A portion of a cæcum, mounted to shew its mucous

membrane of a deep purple colour, the result of congestion.

Henry J., æt. 64, was admitted under Mr. Bransby Cooper, in 1831, for intestinal obstruction, for which active purgatives were administered. He died eight days from the onset of acute symptoms, and at the autopsy a carcinomatous stricture was found in the sigmoid flexure of the colon, and the large intestine above was extremely distended. *See Insp.* vol. 4, p. 24.

815 Membranous Colitis.

A portion of a colon mounted to shew its mucous membrane covered with a thick deposit of granular lymph. At the upper part of the preparation, where the lymph has been partially removed, numerous minute follicular ulcers may be seen.

Elizabeth H., æt. 7, was admitted under Dr. Barlow for chorea, which was treated with a salt of zinc. When almost recovered, blood was noticed in her motions, and shortly afterwards profuse diarrhoea came on. She died five days after the onset of intestinal symptoms. At the autopsy the large intestine was inflamed throughout, and there were vegetations upon the mitral valve. *See Insp.* 1855, No. 102; and *Drawing*, No. 318 (10).

816 Membranous Colitis.

A portion of a colon, the mucous membrane of which is partially covered by a layer of granular lymph, and in the recent state was of a deep red colour from inflammatory congestion.

Charlotte D., æt. 55, a woman of weak intellect, was admitted under Mr. Cock having two hours previously, before breakfast, drunk about three ounces of dilute sulphuric acid (1 to 4). On admission she was collapsed and pulseless. She suffered from vomiting and diarrhoea, the vomit and motions at first containing blood. Her condition gradually improved, but she was found dead in her bed eleven days after the accident. At the autopsy a large portion of the mucous membrane of the stomach was found to be detached, and the colon and lower part of the ileum were covered with false membrane. *See Insp.* 1855, No. 182; *Drawings*, 304 (5) & 318 (11); and *Prep.* 623.

817 Membranous Colitis.

A cæcum with a part of the ascending colon mounted to shew the mucous membrane considerably swollen, and for the most part covered with a thin granular layer of inflammatory exudation. On the reverse of the specimen a similar condition is seen to affect the lower end of the ileum, with the exception of the three inches immediately above the ileo-cæcal valve. The cæcal appendix contained about a dozen shot.

Hannah H., æt. 64, was admitted under Mr. Hilton for a strangulated hernia of five days' duration. Before her admission she had taken much purgative medicine, and had swallowed a quantity of duck-shot. The hernia was easily reduced, but profuse diarrhœa supervened, and she died three weeks from the onset of her illness. At the autopsy the knuckle of ileum which had been strangulated was found to be situated eight feet above the ileo-cæcal valve, and was in the process of recovery. The mucous membrane of the whole of the colon, and of the last three feet of the ileum, was covered with membranous exudation, and the rest of the intestinal tract was acutely congested. *See Insp.* 1857, No. 29; and *Drawing*, 318 (15).

818 Membranous Colitis.

A portion of a colon laid open to shew numerous patches of granular lymph upon its inner surface. In the recent state the mucous membrane of the intestine was of a purple colour, and beneath some of the patches it was sloughing.

Elizabeth W., æt. 33, was admitted under Mr. Cock, having swallowed a quantity of corrosive sublimate. She died ten days after admission, and at the autopsy the colon was found to be inflamed throughout, and there was patchy congestion of the small intestine. Mercury was detected by Dr. Odling in the liver, spleen, kidneys, and brain. *See Insp.* 1862, No. 78.

819 Membranous Colitis.

A portion of a colon shewing upon its mucous membrane linear incrustations of granular lymph, corresponding in position with the longitudinal muscular

bands of the large intestine. Histologically the mucous membrane is seen to be infiltrated with small round cells, and there is some thickening of the submucous tissue.

William W., æt. 39, was admitted under Mr. Davies-Colley for cellulitis of the neck of six days' duration. An abscess containing foul pus was opened, and the patient died one week after admission. At the autopsy there was necrosis of the thyroid cartilage, and the mucous membrane of the first part of the colon was congested. *See Insp.* 1891, No. 118.

820 **Gangrenous Colitis.**

The first eight inches of a colon shewing its mucous membrane in great part destroyed by ulceration. The ulcers are irregular in shape, and in many of them are partially detached flocculent sloughs, which in the recent state were black. The wall of the intestine is thickened and its calibre somewhat diminished.

James V., æt. 30, a worker in lead, was admitted under Dr. Back, in 1827, for abdominal pain and constipation. He was treated with purgatives, and afterwards suffered from uncontrollable diarrhoea with vomiting. There was blood in the motions. He died ten days after admission, and at the autopsy there was general peritonitis. The condition of the bowel shewn in the preparation existed throughout the large intestine as far as the sigmoid flexure, and was more marked above than below. The kidneys were healthy. *See Insp.* vol. 2, p. 97.

821 **Membranous Colitis with Follicular Ulceration.**

A portion of a colon laid open to shew its inner surface, for the most part covered with a thin layer of granular lymph. Where the exudation has been removed the mucous membrane presents numerous small circular ulcers.

John B., æt. 44, was admitted under Dr. Addison for diarrhoea of eighteen months' duration. At the autopsy the condition shewn in the preparation was found throughout the whole of the large intestine as well as in the lower part of the ileum. *See Insp.* 1857, No. 120; and *Drawing*, 318 (20).

822 Membranous Colitis with Ulceration.

A cæcum and the ascending colon laid open to shew the mucous membrane for the most part covered with a layer of granular lymph. There are also numerous irregular ulcers with partially detached sloughs adherent to them.

Edward W., æt. 28, was admitted under Dr. Gull for dysentery and the expectoration of pus from an hepatic abscess. He died two months after his admission, and at the autopsy a large excavation was found, partly in the liver and partly in the lower lobe of the right lung, communicating with the pleural cavity, in which, as well as in the abscess, there were several pints of foetid pus. The last foot of the ileum, and the whole of the colon, presented patches of ulceration and membranous exudation. See *Insp.* 1860, No. 153.

823 Follicular Ulceration of the Colon.

A portion of a colon, the mucous membrane of which is thickly beset with small circular ulcers apparently arising in the solitary follicles.

John D., æt. 23, who had been a good deal abroad, and had suffered from dysentery in Calcutta nine months previously, was admitted under Dr. Pavy for hepatic abscess. A fortnight after his admission the liver was incised and thirty ounces of pus were evacuated. A month later he was seized with left hemiplegia and died in twenty-four hours. At the autopsy an abscess was found in the hinder part of each of the cerebral hemispheres, and there was a cavity four inches in diameter in the right lobe of the liver containing viscid chocolate-coloured pus. The interior of the cæcum was puckered and scarred by healing ulcers, and there was extensive superficial ulceration in the rectum. The colon was affected throughout in the manner shewn in the preparation. See *Insp.* 1883, No. 354.

824 Follicular Ulceration of the Colon.

A portion of a colon, the mucous membrane of which is thickly beset with small punched-out ulcers, some of which expose the muscular coat, while in others there is an adherent central slough.

Patrick K., æt. 33, was admitted under Dr. Pavy for abdo-

minal pain and persistent diarrhoea, from which he died. At the autopsy a carcinomatous growth was found in the rectum. The muscular coat of the colon was hypertrophied, and its mucous membrane ulcerated throughout. *See Insp.* 1884, No. 336.

825 **Superficial Ulcerative Colitis.**

A portion of a descending colon, the mucous membrane of which is for the most part destroyed by ulceration. The tracts and islets of mucous membrane which remain are thin and healthy in appearance, and are separated by a clean-cut edge from the smooth bare submucous coat.

From Anne D., *æt.* 38, a married woman without family who died in 1832. At the autopsy the pelvic viscera were firmly united by old adhesions, and the condition of the intestine shewn in the preparation extended from the middle of the transverse colon to the anus. *See Insp.* vol. 11, p. 189.

826 **Ulcerative Colitis.**

A portion of the sigmoid flexure of a colon injected and laid open to shew irregular ulceration destroying a large part of its mucous membrane. The ulcerated surface presents numerous granulations. Histologically there is no clear evidence of tubercle.

Margaret F., *æt.* 54, was admitted under Dr. Bright in 1829 for general dropsy with albuminous urine. She had a cough with profuse expectoration. The bowels were loose, and the motions contained blood and mucus. At the autopsy there were softening tubercles in the right lung, and the peritoneal cavity contained some gallons of clear serum. The liver was pale and firm, and the kidneys somewhat granular upon the surface. The small intestine was healthy. From the caecum to the sigmoid flexure the mucous membrane of the colon was wholly removed, with the exception of a few irregular spots. *See Insp.* vol. 7, p. 131; and *Prep.* 827.

827 **Ulcerative Colitis.**

A portion of a colon, the mucous membrane of which is extensively eroded and presents a worm-eaten ap-

pearance. In parts where the destructive process is less advanced numerous small round ulcers are visible exposing the muscular coat. Histologically there is no evidence of tubercle.

For History and Reference, see *Prep.* 826.

828 **Ulcerative Colitis.**

A cæcum with the ascending colon shewing numerous sinuous ulcers which have destroyed more than half of the mucous membrane. The edges of the ulcers are sharply defined and somewhat undermined, and in their bases the muscular coat of the intestine is exposed. On the reverse of the specimen is mounted a portion of the descending colon, in which are a few scattered ulcers, the intervening mucous membrane being healthy.

Charles H., æt. 30, was admitted under Dr. Barlow for an empyema and died three months later. At the autopsy the left thoracic cavity was found to contain several pints of pus. There were no signs of tuberculosis. The ulcerative process was confined to the large intestine. See *Insp.* 1859, No. 58.

829 **Ulcerative Colitis.**

A portion of a colon mounted to shew very extensive ulceration of its mucous membrane. The ulcers are irregular in shape and size, and in the bases of many of them the muscular or peritoneal coat is exposed. The lacerations in the serous coat were made in separating the bowel where it was adherent to neighbouring parts.

Thomas W., æt. 25, was admitted under Mr. Cooper Forster for extreme disorganisation of the knee-joint. A fortnight before his death he was attacked by uncontrollable diarrhoea. At the autopsy a perforation was found in the transverse colon, which had given rise to faecal extravasation and peritonitis. The condition shewn in the preparation existed throughout, and was limited to the large intestine. See *Insp.* 1863, No. 221.

830 Ulcerative Colitis.

A portion of ascending colon, the mucous membrane of which presents numerous rounded ulcers, varying in size from a line to half an inch in diameter. By the coalescence of some of the larger ulcers considerable areas of the bowel have become denuded of mucous membrane. In some of these areas the muscular coat is exposed, in others it is covered by adherent sloughs.

Jane M., a married woman, *æt.* 19, who had never been out of England, was admitted under Dr. Rees for gradually increasing weakness and emaciation of three months' duration. She suffered much from diarrhoea. At the autopsy there was an abscess "as large as a child's head" in the right lobe of the liver and several smaller collections of pus throughout the organ. There were three or four ulcers in the lowest part of the ileum; the colon was ulcerated throughout, but in very varying degrees of intensity in different parts. *See Insp.* 1867, No. 335.

831 Ulcerative Colitis.

A portion of a colon, the interior of which presents numerous small ulcers, some of them circular and others sinuous in outline. The aggregation of these ulcers causes the mucous surface of the bowel to present a worm-eaten appearance. There is recent lymph upon the serous coat.

Thomas U., *æt.* 30, was admitted under Mr. Bryant for disease of the left hip-joint and very severe diarrhoea. He died three weeks after his admission. At the autopsy several perforations of the colon were found through which gas and fæces had escaped into the peritoneal cavity. The condition shewn in the preparation extended from the cæcum to the descending colon. *See Insp.* 1870, No. 314; and *Prep.* 2031 (10) [2nd Edit.].

832 Ulcerative Colitis.

The upper part of a colon much dilated and presenting widespread ulceration of its inner surface. Above the ulcers are isolated, but below the mucous membrane

is entirely destroyed, except for undermined bridles and loose tags crossing the exposed muscular coat.

Emily A., æt. 34, was admitted under Dr. Moxon for severe diarrhoea which had been gradually increasing for six weeks. During the preceding year she had frequently passed blood and mucus per anum. On admission there was a membranous exudation upon the fauces, and she was extremely anæmic. She died three weeks later, and at the autopsy there was recent subacute peritonitis, and the whole of the large intestine was ulcerated, the condition being more advanced at its lower than at its upper part. *See Insp.* 1872, No. 198.

833 **Ulcerative Colitis.**

A portion of a colon shewing on its inner surface numerous oval transverse ulcers, some of which almost encircle the bowel. In parts the ulcers are so closely set together that the intervening mucous membrane presents a trabeculated appearance. The intestine is not dilated.

Joseph L., æt. 58, was admitted under Dr. Wilks for an abdominal tumour with severe bronchitis and occasional attacks of hæmoptysis. He died eight weeks after admission, and at the autopsy a cancerous growth was found in the stomach, and there were secondary deposits in the lung and retroperitoneal glands. The condition shewn in the preparation was found throughout the whole of the large intestine, but was less marked in the descending colon than in the parts above. *See Insp.* 1882, No. 350; and *Preps.* 326 & 681.

834 **Ulcerative Colitis.**

A cæcum with the greater part of the colon, the interior of which presents a warty appearance. It is thickly beset with villous masses varying in size from one eighth to one third of an inch in diameter, and about one eighth of an inch in thickness. These poly-poid excrescences are islets of the thickened mucous membrane around which the muscular coat has been laid bare by ulceration. Histologically the prominences are seen to consist of localised thickenings of highly vascular submucous tissue, which, together with the

mucous membrane covering it, is infiltrated with small round cells.

Jane T., æt. 19, was admitted under Mr. Durham for hæmorrhoids, from which she had suffered for five years. Five months before admission she began to pass blood in her motions. Eight days after her admission diarrhœa came on, and on the seventh day clots of blood were present in the motions, two days after which she passed a tape-worm. She died seven months after her first attack of internal hæmorrhage. At the autopsy a sessile polypus was found in the ileum two feet above the cæcum. *See Insp.* 1885, No. 87.

835 **Ulcerative Colitis.**

An anus with the last ten inches of the large intestine shewing two ulcerated areas, one just within the anus, and the other at the upper part of the preparation. The intervening mucous membrane appears to be healthy.

William H., æt. 54, was admitted under Mr. Jacobson for a stone in the bladder, which was removed by supra-pubic lithotomy. Two months after the operation troublesome diarrhœa supervened, and he died ten days later. At the autopsy the whole of the large intestine was ulcerated, the ulceration in parts being limited to the solitary follicles. *See Insp.* 1890, No. 379.

836 **Ulcerative Colitis.**

A portion of a colon, the mucous membrane of which is in parts completely destroyed by ulceration, and in parts separated from the deeper tissues. The exposed muscular coat of the bowel is crossed by bridges of mucous membrane, beneath which rods have been passed. In the regions where the destructive process is less advanced the ulcers are small, round, and punched-out, and their edges are thin and undermined.

Sarah W., æt. 25, was admitted under Dr. Goodhart for high fever, with diarrhœa and abdominal pain of three days' duration. She died three weeks later, having passed blood in her motions for the first time the day before her death. At the autopsy the small intestine was normal, and the condition shewn in the preparation was found throughout the colon. *See Insp.* 1890, No. 309.

837 Ulcers of the Colon.

A portion of a colon laid open to shew numerous round ulcers, varying from an eighth to three quarters of an inch in diameter. In some of them the muscular coat of the intestine is exposed, in others the floor is covered with a thin pellicle.

Joseph L., æt. 51, was admitted under Mr. Lane for a fracture of the spine in the lumbar region with complete paraplegia. The spine was trephined, and the patient died fourteen days after the accident, having suffered for some days from profuse diarrhoea. At the autopsy a similar condition to that shewn in the preparation was found throughout the large intestine. *See Insp.* 1890, No. 283.

838 Ulceration of the Colon.

The commencement of a large intestine shewing in the cæcum and the first four inches of the colon numerous ulcers, some small and round, others larger and irregular in shape, with thin undermined edges, presenting partially detached flocculent sloughs, which in the recent state were of an "ashen hue."

Elizabeth B., æt. 41, was admitted under Dr. Fagge for an hepatic abscess. Thirteen years previously she had returned from Calcutta with an enlarged liver, which was thought to be due to suppuration. Soon after admission, and again on two subsequent occasions, pus was removed by aspiration, but she gradually sank and died nine days after the last operation. At the autopsy a communication was found between a large localised abscess in the liver and an empyema containing three pints of pus. Except for the first four inches of the colon the alimentary canal was healthy. *See Insp.* 1874, No. 465.

839 Healed Ulcers in the Colon.

A cæcum with the first part of the colon laid open to shew several polypoid tags attached to its inner surface. The mucous membrane is marked by the scars of former ulceration.

From a patient who gave no history of previous disease or ulceration of the intestine.

840 Stricture of the Colon.

An ascending colon presenting a stricture about three inches long, which in the recent state would barely admit an ordinary lead pencil. The stricture is due to a very hard fibrous deposit in the wall of the bowel, which is much thickened by it, and in some parts measures nearly one inch. Histological examination shews fibrous inflammatory thickening of the coats of the intestine, but no evidence of malignant growth.

Charles G., æt. 49, was admitted under Dr. Habershon for a painful swelling on the right side of the abdomen associated with wasting and constipation. He remained at the hospital for two months, during which time his symptoms somewhat improved. After returning home he gradually became worse and died three months from the first appearance of the abdominal tumour. At the autopsy an abscess-cavity was found between the colon and the liver, which communicated with the bowel above the stricture, and contained four plum-stones. *See Guy's Hosp. Repts.* 1877, p. 296.

Presented by Dr. Cortis.

841 Stricture of the Sigmoid Flexure.

A portion of the sigmoid flexure of a colon laid open to shew an annular stricture an inch in length, above which the bowel is dilated. At the situation of the stricture there is a transverse ulcer, in the floor of which the muscular coat is exposed. The edge of the ulcer is thin and undermined, and histologically presents no evidence of malignant growth.

From Mrs. H., æt. 60, who died from peritonitis after five weeks' complete obstipation. During the six months preceding the onset of her fatal illness she suffered from occasional attacks of intestinal disturbance, sometimes from diarrhoea, at others from obstinate constipation. Colotomy was proposed but the patient refused her consent.

Presented by Dr. Gull, 1854.

842 Stricture of the Sigmoid Flexure.

A portion of the sigmoid flexure of a colon, the lumen

x 2

of which is narrowed for a distance of two inches by the contraction of inflammatory deposit in its wall. The mucous membrane at this part is smooth and presents the orifices of several deep sacculi.

From James W., a middle-aged man, who died from symptoms of chronic intestinal obstruction. Some time before his death an abscess formed in the left iliac region, which "was opened and found to communicate with the intestine." At the autopsy a cicatrised ulcer was found just within the anus, and there were peritoneal adhesions confined to the left iliac fossa. He had formerly suffered from dysentery and syphilis.

843 Dilatation and Ulceration of the Colon from Stricture.

A portion of a colon measuring five and a half inches in circumference, the mucous membrane of which shews a large number of superficial transverse ulcers, many of them encircling the bowel.

From a patient who died from carcinomatous stricture of the sigmoid flexure of the colon. *See Drawing, No. 323 (20).*

Presented by Dr. Gull, 1858.

844 Stricture of the Sigmoid Flexure. Distension Ulcers with Perforation.

A portion of a colon shewing at the bottom of the preparation, which is the upper part of the sigmoid flexure, a stricture barely admitting a No. 6 catheter, which has resulted from the cicatrisation of an ulcer encircling the bowel. Above the stricture the colon is dilated and its mucous membrane is most extensively ulcerated. There are several perforations of the wall, one of which is five inches in length and an inch wide. In the recent state communication between most of these openings and the peritoneal cavity was prevented by contact with the omentum, which was scarcely, if at all, adherent to the bowel. There is recent lymph upon the serous coat.

Elizabeth W., æt. 50, was admitted under Dr. Moxon for

complete constipation of a fortnight's duration, which was gradually relieved by the administration of opium. Diarrhoea supervened, and she died four weeks after her admission. At the autopsy cicatrices of old phthisis were found in the left lung, but there was no recent tuberculosis. The condition shewn in the preparation existed throughout the colon, and there was some hypertrophy of the small intestine. A small quantity of liquid fæces was found in the peritoneal cavity. *See Insp.* 1869, No. 127; and *Trans. Path. Soc.* vol. 20, p. 181.

845 **Tuberculosis of the Ileum.**

Two portions of the lower end of an ileum shewing a general enlargement of the agminated and solitary glands, which histologically are seen to be infiltrated with characteristic tuberculous deposit. There is little if any ulceration.

Alfred W., æt. 23, was admitted under Dr. Pye-Smith with pyrexia and the physical signs of tuberculosis of the lungs. He had been ill for three years, and died a few days after his admission. At the autopsy there was old and recent tuberculous disease in the lungs, with dilatation of the bronchial tubes. *See Insp.* 1891, No. 417.

846 **Tuberculous Nodule in the Colon.**

A portion of a colon shewing an oval nodule measuring about an inch in length, and projecting a third of an inch from the mucous membrane. There is a small patch of superficial ulceration at the central part of the nodule. Histological examination shews that the sub-mucous tissue is infiltrated with tuberculous deposit.

Mary Y., æt. 42, was admitted under Dr. Pye-Smith for phthisis and tuberculous laryngitis, from which she died. At the autopsy a few tuberculous ulcers were found in the ileum. *See Insp.* 1890, No. 314.

847 **Tuberculous Ulcers in the Jejunum.**

A portion of jejunum shewing several oval transverse ulcers with thick undermined edges. In some of the ulcers the base is formed by the muscular coat of the

intestine, in others by peritoneum alone. On the reverse of the specimen miliary tubercles are visible beneath the serous coat.

Louisa D., æt. 40, was admitted under Dr. Hughes for wasting and severe diarrhœa of three months' duration. She died two months later, and at the autopsy there was tuberculous disease of the lungs, larynx, and Fallopian tubes. *See Insp.* 1855, No. 126.

848 **Tuberculous Ulceration of the Ileum.**

The lower end of an ileum which has been injected and is mounted to shew extensive tuberculous ulceration. On the reverse of the specimen miliary tubercles are seen as yellow dotted lines running in the course of the lymphatics beneath the serous coat. The mesenteric glands are caseous.

Robert H., æt. 31, was admitted under Dr. Bright in 1841 for phthisis and anasarca of four months' duration. At the autopsy the liver was found to be cirrhotic and there was considerable ascites. *See Insp.* vol. 31, p. 177; and *Prep.* 1554 (54) [2nd Edit.].

849 **Tuberculous Ulceration of the Ileum.**

The last six inches of an ileum shewing the agminated and solitary glands to be infiltrated with tuberculous deposit and in parts ulcerated. The ulcers are irregular in outline and their edges are somewhat thickened. Miliary tubercles are seen beneath the serous coat.

George J., æt. 22, was admitted under Dr. Barlow for phthisis. At the autopsy the bronchial and mesenteric glands were caseous and the peritoneum was covered with minute tubercles. *See Insp.* 1860, No. 66.

850 **Tuberculous Ulceration of the Ileum.**

The lower part of an ileum mounted to shew an extreme condition of tuberculous ulceration, which is most marked just above the ileo-cæcal valve. Higher up several of the transverse, thick-edged, ulcers present at their centres partially detached brown sloughs. There are numerous

subserous tubercles and tags of fibrous tissue, the latter resulting from old adhesions, at the situation of the ulcers.

Jane R., æt. 44, was admitted under Dr. Pavy for chronic phthisis, and died from pulmonary embolism. *See Insp.* 1879, No. 386.

851 **Tuberculous Ulcers of the Ileum with Adhesion.**

A coil of ileum with its mesentery, beneath the serous covering of which numerous miliary tubercles are visible. The intestine has been opened at one part to shew a tuberculous ulcer. The blue rod indicates a perforation in the base of a similar ulcer, which in the recent state was closed by adhesion to the neighbouring intestine.

From Miss P., æt. 13, who died from phthisis of three months' duration. At the autopsy the Fallopian tubes were caseous and an abscess was found in the ischio-rectal fossa. *See Insp.* vol. 8, p. 55.

852 **Tuberculous Ulceration of the Cæcum.**

A cæcum, the walls of which are greatly thickened by tuberculous infiltration. The mucous membrane of the cæcum is ulcerated and presents a worm-eaten appearance, and in the ileum there is a transverse ulcer encircling the gut. On the reverse of the specimen numerous miliary tubercles are visible beneath the peritoneum.

Ellen R., æt. 4, was admitted under Dr. Taylor for cough and swelling of the abdomen of six months' duration, and died a fortnight later. At the autopsy the mesenteric and mediastinal glands were found to be enlarged and caseous, the peritoneum was studded with miliary tubercles, and there were tuberculous ulcers scattered throughout the small intestine. *See Insp.* 1883, No. 333.

853 **Tuberculous Ulceration of the Large Intestine.**

A cæcum with the adjacent portions of the ileum and colon mounted to shew tuberculous ulceration. In the large intestine the mucous membrane is almost entirely

destroyed, the ulcerated surface having a rough and pitted appearance, contrasting with the smooth islets of persistent mucous membrane. The cæcal appendix is distended and ulcerated, and at the lower end of the preparation is seen a caseous lymphatic gland.

William S., æt. 20, was admitted under Dr. Barlow for diarrhoea and phthisical symptoms of seven months' duration. He died a month later and at the autopsy extensive vomicæ were found in the lungs; the larynx, trachea, and lower part of the ileum were ulcerated. See *Insp.* 1855, No. 197; *Prep.* 1540 (50) [2nd Edit.]; and *Drawing*, 49 (5).

854 Tuberculous Ulceration of the Colon.

A part of a colon with the cæcum and the last two inches of the ileum affected by tuberculous ulceration. In the large intestine the greater part of the mucous membrane is destroyed and the muscular coat is thus exposed. The mucous membrane that remains is thickened and projects from the ulcerated surface as flat polypoid masses. In the ileum are a few irregular ulcers. Beneath the serous coat of the intestine numerous miliary tubercles are visible.

Charlotte J., æt. 38, was admitted under Dr. Habershon for dysenteric diarrhoea of about five months' duration, with the physical signs of phthisis. She died one month after admission, and at the autopsy there was tuberculous excavation of the lungs, and scattered ulcers were found throughout the small intestine. There was caseous inflammation of the ovaries and Fallopian tubes. See *Insp.* 1856, No. 62.

855 Tuberculous Ulceration of the Colon.

A portion of a colon, the mucous membrane of which is almost entirely destroyed by ulceration. The ulcerated surface is roughened, and in some places the muscular coat is exposed. The edges of the persistent mucous membrane are irregular in outline, prominent, and undetermined.

Philip W., æt. 25, was admitted under Dr. Pavy for wasting

and constant diarrhoea of three months' duration. He died ten days after admission, and at the autopsy there was tuberculous disease of the lungs and larynx. There were numerous ulcers in the small intestine, in which the bacilli of tuberculosis were found. See *Insp.* 1890, No. 86 A.

856 **Tuberculous Perforation of the Ileum.**

A portion of the lower end of an ileum, the mucous membrane of which is extensively destroyed by tuberculous ulceration. At the lowest part of the preparation a minute perforation is seen which was situated eight inches above the cæcum.

Mary T., æt. 47, was admitted under Dr. Wilks for obstinate diarrhoea with the physical signs of phthisis. At the autopsy the peritoneal cavity contained about two pints of yellow fæculent lymph, and there was tuberculous excavation of the lungs. See *Insp.* 1868, No. 81.

857 **Tuberculous Perforation of the Ileum.**

A portion of the upper end of an ileum mounted to shew a transverse tuberculous ulcer in the base of which there is a perforation about a quarter of an inch in diameter. There are miliary tubercles beneath and lymph upon the serous coat.

Catherine H., æt. 34, was admitted under Dr. Rees with well-marked signs of phthisis, and died with symptoms of acute peritonitis. At the autopsy there was fæcal extravasation, and the intestines were covered with recent lymph. See *Insp.* 1869, No. 220.

858 **Peri-Cæcal Abscess opening externally.**

A portion of the abdominal wall from the right iliac region to which the cæcum is firmly adherent. Beneath the wall is seen the end of the vermiform appendix into which a red rod has been passed. The blue rod indicates a sinus leading from the cæcum through the abdominal muscles.

Michael R., æt. 34, was admitted under Mr. Key in 1835 for

pain and swelling in the right iliac region of three months' duration. A month later the swelling was incised and foul pus and gas evacuated : through the sinus thus formed fæces subsequently escaped. He died six months from the onset of his illness. At the autopsy the cæcum was found to be firmly adherent to the neighbouring structures. There were numerous tuberculous vomiceæ in the lungs. *See Insp.* vol. 21, p. 57.

859 **Tuberculous Ulceration and Perforation of the Cæcum.**

A cæcum with the adjacent parts of the large and small intestine. There is a thick tuberculous deposit in the wall of the cæcum and in the first three inches of the colon producing a contraction of the gut. The mucous membrane of the affected part is destroyed by ulceration and at the base of the vermiform appendix there is a perforation through which a blue rod has been passed. Miliary tubercles are visible beneath the serous coat.

Florence L., æt. 7, was admitted under Dr. Carrington for diarrhœa with signs of consolidation at the apices of both lungs. At the autopsy fæcal matter was found in the peritoneal cavity, and there was tuberculous broncho-pneumonia. The mesenteric glands were enlarged and caseous, and there were numerous tuberculous ulcers throughout the ileum. *See Insp.* 1885, No. 134.

860 **Tuberculous Contraction of the Jejunum.**

A portion of a jejunum shewing two irregular transverse ulcers in the bases of which the muscular coat is exposed. The wall of the intestine at these parts is much thickened and its lumen narrowed. Numerous tubercles are visible beneath the serous coat.

William C., æt. 10, was admitted under Dr. Wilks with symptoms of strumous peritonitis and phthisis. At the autopsy there was tuberculous excavation of the lungs, and the mesenteric glands were caseous. The peritoneal cavity contained three pints of serum and there were numerous ulcers throughout the intestine. *See Insp.* 1871, No. 187; and *Prep.* 294.

861 **Tuberculous Stricture of the Ileum.**

A portion of an ileum laid open to shew an annular

constriction half an inch in length due to the contraction of an irregular ulcer which encircles the bowel. Above the constriction the gut is much dilated and its wall hypertrophied. On the reverse of the specimen miliary tubercles are visible beneath the serous coat, which is roughened by filamentous adhesions.

From a woman who was admitted under Dr. Barlow in 1851 for constipation, vomiting, and distension of the abdomen. These symptoms were relieved by the administration of opium, and diarrhoea supervened. She died from phthisis.

862 **Multiple Tuberculous Strictures of the Ileum.**

A coil of intestine from the lower end of an ileum, mounted to shew its calibre considerably narrowed at several points from contraction consequent upon tuberculous ulceration. Numerous tubercles can be seen beneath the serous coat, and there are enlarged caseous glands in the mesentery.

Ann B., æt. 12, was admitted under Dr. Barlow for tabes mesenterica of four months' duration and died about a fortnight after admission. At the autopsy there was old and recent tuberculous disease of the lungs, and the bronchial glands were caseous. There were numerous ulcers in all parts of the intestines. See *Insp.* 1858, No. 215.

863 **Tuberculous Strictures of the Ileum.**

A portion of an ileum laid open to shew two strictures resulting from contraction following tuberculous ulceration. At the seat of constriction the gut is narrowed to about one half its normal diameter, and its lumen is crossed by several fibrous bands covered by mucous membrane. Histologically the muscular and submucous coats are infiltrated by small cells, some of which have undergone caseation. There are a few giant-cells.

Sarah L., æt. 18, was admitted under Dr. Goodhart for abdominal pain and diarrhoea of about one year's duration. She died the day after her admission, and at the autopsy the intestines were firmly matted together, and the pelvis contained a pint of foul sero-

pus. There were several chronic ulcers scattered through the ileum, and there was a perforation in the cæcum. There was no evidence of tuberculous disease in any other part of the body. *See Insp.* 1891, No. 24.

864 **Ileum in Typhoid Fever.**

Two portions of ileum injected and mounted to shew Peyer's patches and the solitary glands greatly enlarged. The neighbouring lymphatic glands are swollen and histologically shew no evidence of tubercle.

From a young woman who died four days after she had been attacked with symptoms of fever. The affection was described by Dr. Hodgkin as of scrofulous character.

865 **Typhoid Ulceration of the Ileum.**

The lower end of an ileum shewing its agminated and solitary glands much enlarged in typhoid fever. Some of the glands present adherent brown sloughs.

Alfred M., æt. 18, was admitted under Dr. Hughes for well-marked typhoid fever, and died on the eleventh day of his illness. *See Insp.* 1854, No. 161.

866 **Typhoid Ulceration of the Ileum.**

The lower end of an ileum shewing its agminated and solitary glands considerably swollen. In some of the glands there are irregular excavations from which sloughs have become detached.

Francis W., æt. 18, was admitted under Dr. Barlow, and while in the hospital developed typhoid fever. He had an unusually profuse rash, and died on the eighteenth day of his illness. *See Insp.* 1859, No. 208; and *Wax Model of Skin*, No. 83 (10).

867 **Typhoid Ulceration of the Ileum.**

A portion of an ileum shewing its Peyer's patches and solitary glands swollen and in parts sloughing.

Ann W., æt. 69, was admitted under Dr. Barlow in a condition of extreme prostration with delirium and died in a few hours. She had been ill for a fortnight. *See Insp.* 1861, No. 176.

868 Typhoid Ulceration of the Ileum.

The lower part of an ileum severely affected in typhoid fever. The Peyer's patches and solitary glands are enlarged, and most of them are occupied by prominent brown sloughs which are becoming detached at their borders.

Samuel D., æt. 20, was admitted under Dr. Barlow and died a fortnight afterwards. *See Insp.* 1862, No. 142.

869 Typhoid Ulceration of the Ileum.

Three portions of ileum showing the agminated and solitary glands affected by typhoid fever. The glands are greatly swollen and most of them are free from ulceration or sloughing. A few present central excavations, the edges of which are prominent and undermined, while their bases are covered with granulations.

Thomas T., æt. 18, was admitted under Dr. Barlow for continued fever, and died thirty days from the onset of symptoms. A week before his death he appeared to be convalescent. At the autopsy a deep ulcer was found at the posterior part of the larynx. There was no peritonitis. *See Insp.* 1862, No. 179.

870 Typhoid Ulceration of the Ileum.

The lower part of an ileum the mucous membrane of which is extensively ulcerated and presents a shaggy appearance, less marked above than below and strictly limited by the ileo-cæcal valve. By transmitted light in the position of the agminated and solitary glands there are seen excavated ulcers in the bases of which the muscular or serous coat is exposed. Their edges are not thickened and to some of them ragged sloughs are loosely adherent. The mesenteric glands are very large.

Nicholas V., a Greek sailor, æt. 16, was admitted under Dr. Wilks for fever, with purging and vomiting, and died on the ninth day from the onset of severe symptoms. At the autopsy there was lymph upon the serous coat of the ileum. The spleen weighed forty ounces. *See Insp.* 1869, No. 70.

871 Typhoid Ulceration of the Ileum.

A portion of an ileum shewing some of its Peyer's patches and solitary glands swollen, and others ulcerated, as a result of typhoid fever. The ulcers present evidence of repair.

Alexander A., æt. 6, was admitted under Dr. Pavy for typhoid fever and died on the thirtieth day of his illness. Eight days before his death, he had severe hæmorrhage from the bowel. He was thought to be doing well when he died suddenly. At the autopsy there was fatty degeneration of the heart-muscle and the left ventricle was dilated. There were numerous small ulcers in the descending colon, in the bases of two of which there was adherent blood-clot. *See Insp.* 1879, No. 400.

872 Typhoid Ulceration of the Colon.

A cæcum with the ascending colon mounted to shew extensive ulceration affecting the solitary follicles of the colon. The mucous membrane has a pitted appearance compared by Dr. Wilks to a variolous eruption. The ileo-cæcal valve and a Peyer's patch above it are swollen and ulcerated. On the reverse of the specimen the appendix has been laid open to shew its upper part similarly affected.

James K., æt. 20, was admitted under Dr. Barlow in a comatose condition and died two days later. At the autopsy the ulcerative process was found to extend as low as the sigmoid flexure. *See Insp.* 1864, No. 191.

873 Typhoid Ulceration of the Ileum with Perforation.

The lower part of an ileum shewing numerous typhoid ulcers, in one of which, situated nine inches above the ileo-cæcal valve, perforation has occurred.

John C., æt. 28, was admitted under Dr. Rees with peritonitis and died a few hours later. He was seized with abdominal pain twenty-four hours before admission and stated that he had been quite well up to the time of the attack. At the autopsy the peritoneal cavity was distended with gas and contained faecal matter. *See Insp.* 1858, No. 237.

874 Typhoid Ulceration of the Ileum with Perforation.

The lower part of an ileum mounted to shew the condition of its agminated and solitary glands in typhoid fever. The glands are greatly swollen and in many of them there are sloughs. In some of them the sloughs have become detached and the muscular or serous coat of the intestine is exposed in the base of the ulcers. On the reverse of the specimen two perforations of the intestine are seen situated about a foot above the ileo-cæcal valve, which marks the lower limit of the ulceration.

William P., æt. 10, was admitted under Dr. Gull for typhoid fever, and died thirteen days later from acute peritonitis. *See Insp.* 1864, No. 70.

875 Typhoid Ulcers of the Ileum with Perforation.

The lower part of an ileum with a portion of the colon, shewing ulceration of Peyer's patches and of the solitary follicles. The ulcers have raised and undermined edges and most of them exhibit a partially detached central slough. About fifteen inches from the ileo-cæcal valve there is a perforation in the base of one of the ulcers.

William F., æt. 36, was admitted under Mr. Hilton for stricture of the urethra, and when about to be discharged after a week's treatment was suddenly seized with vomiting and collapse, and died in seven hours. At the autopsy general peritonitis was found with fæcal extravasation. *See Insp.* 1864, No. 219.

876 Typhoid Perforation of the Ileum.

A portion of the lower end of an ileum laid open to shew a small transverse ulcer with undermined edges. In its base, which is formed by the serous coat, there is a minute perforation. There is a thin layer of granular lymph upon the peritoneum.

Richard E., a young child, was admitted under Dr. Addison

in 1827 for abdominal pain and diarrhoea with bloody motions. At the autopsy the peritoneal cavity contained about a pint of yellow puriform fluid and the agminated and solitary glands at the lower end of the ileum were enlarged and ulcerated. *See Insp.* vol. 2, p. 13.

877 **Typhoid Perforation of the Ileum.**

The lower end of an ileum, shewing an irregular longitudinal ulcer two inches in length and one inch transversely. The edge of the ulcer is undermined and slightly thickened. Its base is formed by the muscular coat and at its centre there is a small oval perforation. There is a deposit of granular lymph upon the peritoneum.

From Thomas H., æt. 35, who, after a short walk, was seized with severe abdominal pain and died in a few hours. He had been ailing for one week before the attack. At the autopsy faecal extravasation was found with general peritonitis.

Presented by Mr. Cookson, 1862.

878 **Typhoid Perforation of the Cæcum.**

A cæcum with the lower part of the ileum affected in typhoid fever. In the cæcum are several small transverse ulcers with thin edges, in the base of one of which there is a perforation. A Peyer's patch a little above the ileo-cæcal valve and several of the solitary follicles are ulcerated. There is recent lymph upon the peritoneum.

David B., æt. 21, was admitted under Dr. Pavy for typhoid fever. At the autopsy there was general peritonitis, and ulceration of the larynx. *See Insp.* 1867, No. 254.

879 **Ulceration of the Ileum in Relapsing Typhoid Fever.**

Portions of an ileum mounted to shew various stages in the ulceration of typhoid fever. In most of the ulcers the sloughs are detached and in some of them cicatrization has begun.

From Mr. E. P., æt. 37, who was attacked with the symptoms

of typhoid fever on September 7th, 1879, and died from intestinal hæmorrhage on November 22nd. It was thought that death occurred in the course of a second relapse which began on November 7th, the first relapse having begun on October 9th. *See Guy's Hosp. Repts.* vol. 42, p. 271.

Presented by Sir William Gull.

880 Healing Typhoid Ulceration of the Ileum.

A portion of ileum shewing several small ulcers in the agminated and solitary glands. The glands are little, if at all, enlarged, and the ulcers are in process of repair.

Henry H., æt. 19, was admitted under Dr. Barlow with well-marked symptoms of typhoid fever and died twelve days later. Before death there was hæmorrhage from the nose and bowels, and a purpuric rash appeared on the legs. *See Insp.* 1862, No. 141.

881 Healed Typhoid Ulcer.

The lower end of an ileum mounted to shew the condition of Peyer's patches five months after typhoid fever. Just above the ileo-cæcal valve there is a long narrow agminated gland, at the lower end of which is seen a shallow cicatrix, oval in shape, and measuring about half an inch in its longest diameter. The lumen of the intestine is not narrowed.

From Henry G., æt. 15, who died from rheumatic pericarditis.

882 Healed Typhoid Ulcers.

The lower end of an ileum mounted to shew just above the ileo-cæcal valve two slightly depressed cicatrices corresponding in shape and position with Peyer's patches. There is no appearance of contraction and the peritoneum is free from adhesions.

Charles S., æt. 33, was admitted under Dr. Gull for typhoid fever from which he made a good recovery. Nineteen weeks from the onset of the fever he was attacked with typhus and died in a few hours. *See Insp.* 1856, No. 73.

883 Healed Typhoid Ulcers.

The lower end of an ileum mounted to shew the con-

dition of the intestine after typhoid fever. There are several shallow depressions in the mucous membrane, corresponding in shape and position to Peyer's patches. Their edges are slightly thickened and their bases covered with thin mucous membrane. The serous coat is free from adhesion, smooth, and polished. There is no contraction of the intestine.

James L., æt. 14, was admitted under Dr. Addison for typhoid fever and died from bed-sores and exhaustion eight weeks after the onset of symptoms. *See Insp.* 1859, No. 211.

884 **Anthrax of the Intestine.**

A portion of ileum shewing an inflamed area about three inches in length. The coats of the intestine at this part are greatly thickened, and the valvulæ conniventes are large and prominent. In the recent state the mucous membrane was "pink and fleshy-looking." There is a thin layer of granular lymph upon the serous surface.

John O., a tanner, æt. 47, was admitted under Mr. Howse for a "malignant pustule" of the cheek which was first noticed fourteen days previously. The pustule was at once excised, but the patient died four days later. At the autopsy the stomach and other parts of the small intestine were affected in a manner similar to that shewn in the preparation. *See Insp.* 1877, No. 313.

885 **Anthrax of the Intestine.**

Portions of small intestine shewing patches of phlegmonous enteritis. At the parts affected the inflammatory infiltration of the submucous tissue causes the valvulæ conniventes to be thick and prominent. The mucous membrane covering them is granular and in the recent state was deeply congested.

Patrick G., æt. 23, whilst handling dry hides became infected with anthrax. He was admitted under Mr. Bryant with fever and delirium, and in a few hours became comatose. He died four days from the period of infection. At the autopsy the lungs and stomach were found to be affected with anthrax and there was

considerable hæmorrhagic effusion into the meninges of the brain and spinal cord. See *Insp.* 1884, No. 132; *Trans. Path. Soc.* vol. 37, p. 550; and *Prep.* 664.

886 **Hypertrophy and Dilatation of the Jejunum.**

A portion of jejunum the lumen of which is greatly dilated and its muscular coat hypertrophied.

Joseph A., æt. 17, was admitted under Dr. Back in 1830 for an abdominal swelling which followed a blow received two years before his death. He suffered from vomiting, diarrhœa, and tympanites. At the autopsy a mass of malignant growth was found in the mesentery about the commencement of the ileum, and the intestine at this part was contracted so as barely to admit a quill. See *Insp.* vol. 9, p. 152; *Prep.* 1237; and *Drawing*, No. 460.

887 **Hypertrophy and Dilatation of the Colon.**

A portion of an infant's colon measuring three inches in circumference the wall of which is considerably hypertrophied. The mucous membrane presents several superficial ulcers some of which are cicatrised.

From an infant, aged 7 months, who from the age of two months until death suffered from obstinate constipation with vomiting and distension of the abdomen. On one or two occasions diarrhœa was produced by strong purgatives. See *Mr. Bryant's Catalogue*, *Prep.* No. 8.

888 **Hypertrophy and Dilatation of the Colon.**

The anus with the last eighteen inches of the large intestine shewing extreme hypertrophy and dilatation of the rectum and sigmoid flexure. Just within the anus the mucous membrane presents several deep ulcers with somewhat thickened edges. Higher up there are larger ulcerated areas, and a small perforation, surrounded by recent lymph, is visible on the serous surface of the sigmoid flexure.

Emma R., æt. 17, was admitted under Dr. Goodhart for gradually increasing abdominal distension of nine months' duration, with occasional sudden attacks of pain. For some time her bowels had been very irregular, sometimes constipated, at others loose. For three weeks there had been diarrhœa with inconti-

nence of fæces. Six days after admission she died, twelve hours after the onset of symptoms of acute peritonitis. At the autopsy the peritoneal cavity was found to contain a quantity of foul gas, and there was some greenish pus upon the coils of intestine. The enlargement of the intestine extended from the anus to the hepatic flexure of the colon, where it suddenly ceased. There was no stricture. See *Insp.* 1880, No. 309; and *Trans. Clin. Soc.* vol. 14, p. 84.

889 **Fæcal Fistula.**

A cæcum with a portion of the anterior abdominal wall to which it is adherent. A blue rod has been passed along a sinus which leads through the abdominal wall into the intestine, the mucous membrane of which around the perforation is deeply ulcerated.

From Henry F., who died in 1807 from stricture of the rectum.

890 **Polypus of the Jejunum.**

A portion of a jejunum shewing a tumour about the size of a haricot bean, situated upon one of the valvulæ conniventes. Histologically the polypus consists of a collection of lymphoid cells in the submucous tissue.

Presented by Dr. Barker.

891 **Polypus of the Ileum.**

A portion of an ileum laid open to shew a polypus covered with mucous membrane the core of which is composed of adipose tissue. It appears to be produced by the inversion of a small diverticulum which has drawn in with it its mesentery.

Alfred H., æt. 29, was admitted under Dr. Gull in 1854 for typhus fever from which he died. See *Insp.* vol. 37, p. 382.

892 **Filiform Polypi of the Ileum.**

A portion of the lower end of an ileum shewing upon its mucous surface numerous thread-like polypoid processes some of which are nearly half an inch in length.

Histological examination shews that they are covered with normal mucous membrane.

Dennis D., æt. 44, was admitted under Mr. Cock and died from pyæmia following upon a comminuted fracture of the femur. *See Insp.* 1854, No. 233.

893 Filiform Polypi of the Colon.

A portion of a colon shewing upon its mucous surface numerous slender polypi varying from one sixteenth of an inch to one inch in length.

Presented by Dr. Barker.

894 Polypus of the Colon.

A portion of the sigmoid flexure of a colon, shewing a pedunculated polypus attached to its mucous membrane by a stalk about an inch and a half in length. The polypus is oval in shape, measuring about an inch in length and five eighths of an inch across; the mucous membrane covering it is traversed by irregular fissures. Histologically it consists of a central core of fibrous and muscular tissue, covered with branched villous processes of mucous membrane.

Matilda M., æt. 69, was admitted under Dr. Perry for acute peritonitis, from which, twelve hours later, she died. At the autopsy the peritonitis was found to be caused by suppuration of the gall-bladder. *See Insp.* 1892, No. 272; and *Prep.* 898.

895 Squamous Epithelioma of the Small Intestine.

A portion of a jejunum shewing on its inner surface an oval nodule of secondary deposit about the size of a lentil. There is slight ulceration of the mucous membrane covering it. Histologically the nodule has the structure of a squamous epithelioma with cell-nests.

John A., æt. 69, was admitted under Dr. Wilks for a malignant stricture of the œsophagus and died about nine months after the onset of his illness. At the autopsy malignant growth was found in the œsophagus, with secondary deposits in the stomach, duodenum, small intestine, liver, spleen, and kidneys. *See Insp.* 1867, No. 253.

896 Carcinoma of the Jejunum.

A portion of the jejunum laid open to shew a fungating growth which encircles the bowel for a distance of one inch. The central parts of the growth are excavated by ulceration, and communicate with a carcinomatous mass outside the bowel formed partly by an extension of the growth into the mesentery and partly by infiltrated lymphatic glands. Histologically the growth is a spheroidal-celled carcinoma.

Hannah G., æt. 52, was admitted under Dr. Goodhart for abdominal pain, vomiting, anæmia, and anasarca. A fortnight later an enlargement of the liver was observed, accompanied by ascites. She died about five weeks after her admission, and at the autopsy the liver was found to weigh 123 ounces and to contain a large deposit of colloid growth. *See Insp.* 1892, No. 457.

897 Carcinoma of the Colon. Colectomy.

A portion of a colon removed during life, shewing a flat circular mass of growth which measures two and a half inches in diameter and projects about half an inch above the surrounding mucous membrane. Its surface is free from ulceration, and in the recent state presented a slightly papillomatous appearance. Histologically its structure is that of a cylindrical-celled carcinoma. Below are mounted portions of the colon shewing the condition of the parts left after the operation.

Benjamin R., æt. 33, was admitted under Dr. Mahomed with symptoms of chronic intestinal obstruction, which were relieved by Littre's operation. Some months later his symptoms returning laparotomy was performed by Mr. Symonds, and an intussusception was discovered in the sigmoid flexure. This was reduced and a portion of the colon affected by growth was removed. The patient died a few hours later and at the autopsy there was acute general peritonitis. *See Insp.* 1883, No. 355; and *Prep.* 792.

898 Carcinomatous Ulcer of the Colon.

A portion of a colon shewing an oval transverse ulcer, which was situated three feet from the ileo-cæcal valve.

The ulcer measures an inch in its longest diameter, and its base is formed by thickened submucous tissue. Its border is considerably raised above the surrounding mucous membrane, and on histological examination is found to be infiltrated by a growth having the characters of a cylindrical-celled carcinoma. About four inches above the ulcer is seen a button-like polypus half an inch in diameter, the mucous membrane of which is somewhat blackened from congestion.

Matilda M., æt. 69, was admitted under Dr. Perry for acute peritonitis, from which she died twelve hours later. At the autopsy the peritonitis was found to be caused by suppuration of the gall-bladder. *See Insp.* 1892, No. 272; and *Prep.* 894.

899 **Villous Carcinoma of the Colon.**

A cæcum with the adjacent parts of the small and large intestine mounted to shew two cauliflower-like masses of growth situated about the middle of the ascending colon. The growths, which are covered by delicate villous processes, are attached by short broad pedicles to a prominent fold of mucous membrane, and project about an inch into the lumen of the gut. The intestine above the obstruction thus produced is dilated and its muscular coat greatly hypertrophied. A blue rod indicates an opening made by operation midway between the commencement of the colon and the seat of obstruction. Histologically the growth is a cylindrical-celled carcinoma.

William C., æt. 27, was admitted under Mr. Durham for chronic intestinal obstruction for the relief of which Amusat's operation was performed. The patient died seven days later and at the autopsy the peritoneum presented signs of recent inflammation. *See Insp.* 1864, No. 204.

900 **Cylindrical Carcinoma of the Ileo-cæcal Valve (Colloid).**

The last three inches of an ileum with the commencement of the cæcum showing the wall of the intestine at

the situation of the ileo-cæcal valve infiltrated by malignant growth. A section through the growth shews that all the coats of the gut are involved, and that the muscular layer is in parts destroyed. A portion of the growth which has undergone colloid degeneration presents a reticulated appearance. A lymphatic gland in the neighbouring fatty tissue is enlarged by secondary deposit. Histologically the growth is a cylindrical-celled carcinoma. The ileum is considerably dilated and its mucous membrane presents numerous distension ulcers, some of which have perforated its wall. There is recent lymph upon the serous surface. *See Drawing, No. 322.*

Presented by Dr. Addison.

901 **Carcinomatous Tumour of the Colon.**

Four transverse sections of the sigmoid flexure of a colon the lumen of the bowel being almost entirely occluded by a growth. The cut surface presents an alveolated structure consisting of a fibrous stroma with white material in its meshes. The free surface of the growth which is seen in the lowest of the sections is covered with short slender papillæ. Histologically it is a cylindrical-celled carcinoma.

Ellen M., æt. 52, was admitted under Dr. Pavy for emaciation with occasional attacks of vomiting, and an enlarged liver. Four months before admission she passed blood and mucus per rectum. The bowels were opened four or five times a day. Jaundice and ascites came on and she died ten weeks after coming into the hospital. At the autopsy a growth was found occupying about two inches of the sigmoid flexure and there were secondary deposits in the liver, lungs, and in the lumbar glands. The glands in the portal fissure, which were also enlarged and infiltrated by growth, compressed and obstructed the hepatic duct and portal vein. *See Insp. 1883, No. 417.*

902 **Carcinomatous Polypus of the Colon.**

A portion of the sigmoid flexure of a colon mounted to shew a polypus about the size of a small cherry attached

to the mucous membrane by a thin pedicle half an inch in length. Histologically the nodule consists of cylindrical-celled carcinoma undergoing colloid change.

903 **Carcinomatous Stricture of the Colon.**

A portion of a colon laid open to shew a constriction situated at the hepatic flexure, through which, in the recent state, water passed with difficulty. At this point the intestine is partly encircled by a growth, the surface of which is thickly set with short and slender villous processes. Histologically the muscular coat is seen to be invaded by a deposit of cylindrical-celled carcinoma. Above the stricture the bowel is dilated and hypertrophied.

George P., æt. 58, was admitted under Dr. Babington in 1853 for chronic intestinal obstruction with constipation of one week's standing. A scrotal hernia from which he had long suffered was explored, and he died four days later. At the autopsy there was general peritonitis, and a few secondary growths were found in the omentum. See *Insp.* vol. 37, p. 55; and *Drawings*, 323 (9 & 10).

904 **Carcinomatous Stricture of the Colon.**

A portion of the large intestine laid open to shew an annular stricture situated at the lowest part of the descending colon. At the constricted part, which is about half an inch in length, the wall of the gut is infiltrated by a firm fibrous growth which has produced much puckering and contraction of the serous coat. The mucous membrane is free from ulceration. Above the stricture the colon is much dilated and its wall hypertrophied. The blue rod indicates an opening made by operation. Histologically the growth is a cylindrical-celled carcinoma with abundant stroma.

Mary L., æt. 19, was admitted under Dr. Taylor with intestinal obstruction for the relief of which, five days later, Mr. Davies-Colley opened the descending colon. The patient died a few hours after the operation, and at the autopsy the peritoneal cavity contained a few ounces of blood-stained purulent fluid. See *Insp.* 1873, No. 314.

905 Carcinomatous Stricture of the Colon. Colectomy.

A small portion of the descending colon removed by operation. It has been laid open to shew a growth about an inch in length which encircles and considerably narrows the lumen of the bowel. At the seat of constriction the mucous membrane is partly destroyed by ulceration and presents a warty appearance. Histologically the wall of the colon is seen to be infiltrated by a growth having the characters of cylindrical-celled carcinoma.

From Mrs. D., æt. 50, who for some years had been subject to constipation and for eight weeks suffered from complete intestinal obstruction. During the operation for left lumbar colotomy a growth was discovered and the diseased segment of bowel resected. The patient made a good recovery. *See Medico-Chirurgical Trans.* vol. 65, p. 131.

Presented by Mr. Thomas Bryant, 1881.

906 Carcinomatous Stricture of the Sigmoid Flexure.

A portion of the sigmoid flexure of a colon presenting at its lower end an annular stricture about an inch long which in the recent state barely admitted a goose-quill. At the situation of the stricture the wall of the gut is thickened by infiltration with growth which histologically has the characters of cylindrical celled carcinoma. Above the stricture the intestine is much dilated and its muscular wall is hypertrophied. Some of the neighbouring lymphatic glands are enlarged.

Donald H. was admitted under Dr. Back in 1827 for chronic intestinal obstruction, which for the last three weeks of his life was complete. *See Insp.* vol. 3, p. 10.

907 Carcinomatous Stricture of the Sigmoid Flexure.

A portion of a colon mounted to shew an annular stricture of the sigmoid flexure. The stricture has been laid

open and exhibits a deep and narrow longitudinal ulcer with raised warty edges infiltrated with a growth of cylindrical-celled carcinoma. Above the stricture the muscular coat of the intestine is hypertrophied. There is recent lymph upon the serous coat.

Ralph G., æt. 44, was admitted under Dr. Habershon for intestinal obstruction of two weeks' duration with occasional vomiting. Symptoms of peritonitis supervened and he died five days after his admission. At the autopsy the peritoneal cavity contained about three pints of turbid serum, and there were secondary deposits in the liver and mesenteric glands. *See Insp.* 1854, No. 147.

908 **Carcinomatous Stricture of the Sigmoid Flexure.**

A portion of a colon laid open to shew an annular stricture about half an inch in length at the lowest part of the sigmoid flexure. At the seat of constriction the intestine is infiltrated by a growth of cylindrical-celled carcinoma.

Ellen H., æt. 53, was admitted under Dr. Hughes for chronic intestinal obstruction which was relieved for nearly four months by the administration of enemata and opium. She died two months after her admission, and at the autopsy the mitral valve was found to be much contracted. There were no secondary deposits. *See Insp.* 1856, No. 10.

909 **Cylindrical Carcinoma of the Sigmoid Flexure.**

A portion of the sigmoid flexure of a colon laid open to shew a mass of growth about one and a half inches in length, encircling and narrowing the lumen of the gut. The surface of the growth is rugose and but slightly ulcerated, and its edges are thick and overhanging. Immediately above the stricture there is a small rounded perforation which in the recent state communicated with an abscess-cavity circumscribed by peritoneal adhesions.

Sarah O., æt. 42, was admitted under Dr. Hughes with symptoms of general peritonitis and died on the following day. She had

for three months suffered from increasing constipation. At the autopsy the large intestine, especially the cæcum, was greatly distended and ulcerated. At the commencement of the colon one of the distension ulcers presented a perforation in its base. *See Insp.* 1856, No. 222.

910 **Carcinoma of the Colon opening the Stomach.**

The transverse arch and splenic flexure of a colon, with the spleen and stomach. Encircling the colon, just above the splenic flexure, there is a mass of growth, two inches wide, the surface of which is deeply ulcerated. In the transverse colon at the border of the growth there is a perforation, indicated by a red rod, communicating with the stomach at the middle of its posterior wall an inch from the greater curvature. Blue rods have been passed from the bowel into two sinuses, which in the recent state communicated with abscess-cavities between the neighbouring viscera. Above the growth the transverse colon is greatly dilated, measuring six inches in circumference. Histologically the growth is a cylindrical-celled carcinoma.

John S., æt. 36, was admitted under Dr. Goodhart for abdominal pain of four months' duration. Vomiting came on three weeks before admission, and four days after admission the material vomited was distinctly fecal. An exploratory laparotomy revealed a large mass of growth in the left hypochondriac region. Right inguinal colotomy was performed, and subsequently an artificial anus was made in the small intestine. The patient died eight days after admission. At the autopsy the small intestine was found to have been opened eighteen inches below the duodenum. There were no secondary deposits of growth. *See Insp.* 1892, No. 231.

911 **Carcinoma of the Colon opening the Duodenum.**

A cæcum and the adjacent portions of the large and small intestine together with the duodenum to which they are adherent. At the commencement of the colon there is a rugose mass of growth about two and a half

inches in length encircling the gut and projecting prominently on the mucous surface. On the inner wall the growth is ulcerated and presents a fistulous communication with the second part of the duodenum. The opening in the duodenum is surrounded by an extension of the growth. Histologically its structure is that of a cylindrical-celled carcinoma.

Annie S., æt. 47, was admitted under Dr. Gull for diarrhoea with blood and pus in the motions, symptoms from which she suffered for the five weeks preceding her death. A tumour in the right iliac region had been noticed for two years. *See Insp.* 1860, No. 69.

912 **Carcinoma of the Cæcum perforating the Ileum.**

A cæcum with the lower end of the ileum and a part of the ascending colon laid open to shew a growth encircling and partly occluding the cæcum. The growth is three inches in length and projects into the lumen of the bowel in bossy masses some of which are an inch in thickness. The mucous membrane covering it is ulcerated and the green rod indicates a communication between the cæcum and an adherent coil of small intestine. This perforation is situated about a foot above the ileo-cæcal valve. Below the growth the wall of the colon is thickened. Histological examination of the tumour shews it to be a cylindrical-celled carcinoma.

William J., æt. 56, was admitted under Dr. Hughes for a painful swelling as large as a foetal head in the right iliac region, which was first noticed ten months previously. After his admission the tumour diminished in great part under the administration of purgatives, but the pain continued, and seventeen days later a faecal abscess was opened below Poupart's ligament. He occasionally passed motions per rectum, but the faeces came for the most part through the artificial anus. Three months after admission he died, and at the autopsy the faecal fistula was found to open into the cæcum, which was adherent to the anterior abdominal wall. There were no secondary deposits. On the right side was the empty sac of an inguinal hernia. *See Insp.* 1856, No. 212.

913 Carcinoma of Sigmoid Flexure opening the Ileum.

A portion of the sigmoid flexure laid open to shew a malignant ulcer about an inch in length encircling the bowel, which is distended above the obstruction and slightly ulcerated. At the situation of the growth a portion of ileum is adherent and communicates with the large intestine by two fistulæ. Its mucous membrane is thickly beset with irregular ulcers. Histologically the growth is a cylindrical-celled carcinoma.

Martha F., æt. 55, was admitted under Dr. Taylor for chronic intestinal obstruction, which was partially relieved by enemata. Subsequently colotomy was performed and the patient died on the following day. At the autopsy secondary deposits were found in the liver and kidneys. *See Insp.* 1888, No. 27.

914 Colloid Carcinoma of the Sigmoid Flexure. Fæcal Fistula.

A portion of a colon mounted to shew a globular mass of growth about three inches in diameter situated at the commencement of the sigmoid flexure. The intestine has been laid open and exhibits an extensive ulcer the edges of which are formed by thickened and infiltrated mucous membrane, and its base by an alveolated structure in the meshes of which is seen a gelatinous material resembling boiled sago grains. The blue rod has been passed into a perforation which communicated externally with an opening in the groin. Histological examination shews the growth to be a cylindrical-celled carcinoma with much colloid degeneration.

Thomas C., æt. 56, was admitted under Mr. Cock with an abscess in the left iliac region which opened spontaneously immediately below Poupart's ligament. He died eight weeks after his admission and at the autopsy the sinus in the groin was found to communicate with an opening in the colon. There were secondary deposits in the quadratus lumborum and in the mesenteric glands. *See Insp.* 1855, No. 165.

915 Carcinomatous Tumour of the Colon.

The ileo-cæcal segment of an intestine mounted to shew a carcinomatous tumour attached to the wall of the ascending colon at its commencement. The mass, which is flat and very lobulated, measures three and a half inches across, and projects more than an inch from the surrounding mucous membrane. Histologically its structure is that of a carcinoma with scanty stroma, the alveoli of which are filled with very large epithelial cells. The lumen of the colon is quite filled by the growth, but the cæcum and the lower end of the ileum are not dilated.

From W. A. C., æt. 53, who suffered for months from progressive wasting and hæmaturia with a tumour in the left side of the abdomen. At the autopsy the tumour was found to consist of a mass of enlarged glands surrounding the left kidney and weighing four and a half pounds. There was a deposit of growth in the right kidney.

Presented by Mr. Charles Fagge.

916 Carcinomatous Ulcer of the Small Intestine.

A portion of small intestine shewing an oval transverse ulcer which measures two inches in its longer and one inch in its shorter diameter. The ulcer is deeply excavated, its base in parts being formed only by the serous coat of the bowel. Its edge is ragged and considerably elevated above the surrounding mucous membrane. Histological examination shews it to be infiltrated with a deposit having the characters of spheroidal-celled carcinoma.

917 Carcinomatous Ulceration of the Ileum.

A portion of an ileum encircled by an irregular ulcer situated eighteen inches from the ileo-cæcal valve. The edges of the ulcer are ragged, undermined, and thickened by infiltration of a new growth which histologically is a spheroidal-celled carcinoma. On the

reverse of the specimen the mesentery may be seen to be enlarged by malignant deposit.

Mary R., æt. 44, was admitted under Dr. Gull with signs of phthisis. At the autopsy tubercles were found in the lungs, and there were secondary deposits of malignant growth in the pleura and peritoneum. There were no symptoms of intestinal obstruction during life. *See Insp.* 1836, No. 60.

918 Spheroidal Carcinoma of the Cæcum. (Colloid.)

A cæcum with the adjacent parts of the large and small intestine seen from behind. The cæcum, the ascending colon, and the last inch of the ileum are greatly thickened by a growth which has destroyed the muscular coat of the bowel, and appears in large rounded masses beneath the serous covering. The mucous membrane is extensively ulcerated, and in the interior of the bowel is seen a reticulated structure the meshes of which are filled with a gelatinous deposit. A similar material is visible in the thickened peritoneum and enlarged lymphatic glands. The cæcum is much contracted. Histologically the growth is a spheroidal-celled carcinoma with much colloid degeneration.

Ann C., æt. 28, was admitted under Dr. Barlow with jaundice and a tumour in the right iliac region which had been noticed for about three months. She suffered much from constipation and died three weeks after her admission with symptoms of cholæmia. At the autopsy secondary growths were found in the peritoneum and kidneys, and the common bile-duct was compressed by a mass of lymphatic glands enlarged by carcinomatous deposit. *See Insp.* 1861, No. 9.

919 Spheroidal Carcinoma of the Cæcum. (Colloid.)

The ileo-cæcal segment of an intestine laid open to shew the cæcum contracted and thickened by a deposit which histologically is a spheroidal-celled carcinoma with colloid degeneration. The mucous membrane has been

destroyed by ulceration, and in its place is seen a gelatinous material which has infiltrated and destroyed the muscular coat of the bowel, and projects beneath the serous covering. The growth has a raised and overhanging border and extends for a short distance into the ileum. In the ascending colon, two inches from the distal edge of the growth, is seen the opening left after colotomy.

Harriet C., æt. 52, was admitted under Dr. Fagge for intestinal obstruction with a tumour in the right iliac fossa. She had suffered from occasional attacks of pain in this region for eighteen months. Eight days after her admission right lumbar colotomy was performed by Mr. Durham, and the patient died thirty-six hours later. At the autopsy general peritonitis was found, and the whole of the small intestine shewed great hypertrophy and dilatation. *See Insp.* 1868, No. 134; and *Guy's Hosp. Reps.* 1868, p. 310.

920 **Colloid Carcinoma of the Colon and Peritoneum.**

The commencement of the large intestine shewing the wall of the first four inches of the colon increased in thickness, in some parts to the extent of one inch, by a deposit of gelatinous carcinoma. The growth has destroyed and replaced the coats of the bowel and extended into the mesocolon, forming a large lobulated tumour. On the reverse of the specimen is seen the transverse arch of the colon, with the great omentum, the latter being enormously thickened by a deposit of similar colloid material. Histologically those parts of the growth in which colloid degeneration has not occurred are seen to have the structure of a spheroidal-celled carcinoma with scanty stroma.

Harriet K., æt. 32, was admitted under Dr. Rees for enlargement of the abdomen with œdema of the left leg. She died a week after her admission, and at the autopsy no growth was found except in the intestine, the peritoneum, and mesenteric glands. There was thrombosis of the left femoral vein. *See Insp.* 1861, No. 67; and *Prep.* 1231.

921 Carcinomatous Stricture of the Colon. Distension Ulcers.

A portion of a colon shewing a stricture due to a deposit of spheroidal-celled carcinoma, situated just above the sigmoid flexure. Above the constriction the intestine is much dilated and its wall somewhat hypertrophied. The mucous membrane presents numerous ulcers irregular in size and shape, most of which have their long axis placed transversely. The edges of the ulcers are thin and undermined, and their bases are formed by the muscular or serous coat of the bowel. The perforations which are seen were produced post-mortem.

From a man, *æt.* 40, who was admitted under Mr. Cooper-Forster in 1861 with symptoms of acute intestinal obstruction. He had previously suffered from "disorder of the bowels." At the autopsy there was no evidence of fæcal extravasation.

922 Carcinomatous Stricture of the Colon.

The splenic flexure of a colon mounted to shew an annular stricture almost entirely occluding the lumen of the gut. At the situation of the stricture the serous coat presents a deep groove as though a piece of string had been tied round it. Histological examination of the intestine at this part shews it to be infiltrated by a growth having the characters of a spheroidal-celled carcinoma. Two long and slender polypi are attached to the mucous membrane immediately below the stricture.

John H., *æt.* 26, was admitted under Dr. Moxon for chronic intestinal obstruction, and died seven weeks after the onset of symptoms. At the autopsy general peritonitis was found, and there were numerous distension ulcers in the intestine extending as high as the upper part of the jejunum. *See Insp.* 1884, No. 55.

923 Multiple Carcinomatous Contractions of the Ileum.

A piece of the lower end of the ileum laid open to shew

three annular constrictions produced by the contraction of secondary malignant deposit in the serous coat. The mucous membrane at the seat of stricture is free from ulceration. Histologically the growth is a spheroidal-celled carcinoma.

Jemima H., æt. 38, was admitted under Dr. Shaw for intestinal obstruction of ten days' duration. Laparotomy was performed, and the patient died the following day. At the autopsy the right ovary was enlarged by a deposit of spheroidal carcinoma. There was a similar growth in the wall of the stomach which was thought to be secondary. *See Insp.* 1891, No. 191.

924 **Double Carcinomatous Stricture of the Colon.**

The transverse part of a colon presenting at either end an annular stricture, one of which is half an inch and the other an inch in length. At the situation of the stricture the mucous membrane is ulcerated and the wall of the gut is somewhat thickened by a deposit of spheroidal-celled carcinoma.

From a woman, æt. 57.

Presented by Sir William Gull.

925 **Carcinomatous Perforation of the Colon.**

A portion of the transverse arch of a colon which is encircled towards its splenic flexure by a deep carcinomatous ulcer completely destroying the coats of the bowel. In the base of the ulcer there is a large perforation, indicated by a blue rod, communicating with a ragged cavity, the walls of which are infiltrated with a deposit of spheroidal-celled carcinoma. The boundaries of the cavity were formed by the stomach, the left half of the pancreas, the colon, and in front by several coils of small intestine with which it communicated by two wide openings.

Mary N., æt. 40, was admitted under Dr. Hughes for abdominal pain with frequent attacks of vomiting and diarrhoea. A tumour was felt in the left hypochondriac region. Her illness was attributed to a severe blow upon the abdomen two years before her death. *See Insp.* 1856, No. 201.

926 Lymphadenoma of the Jejunum.

A portion of jejunum mounted to shew its mucous surface studded with nodules varying from an eighth to a third of an inch in diameter. The surface of some of the nodules is slightly ulcerated. At the back of the preparation is mounted a portion of the ileum in which the growths appear as raised plaques occupying Peyer's patches.

George B., æt. 48, was admitted under Dr. Pye-Smith for pleural effusion with the physical signs of pressure on the left bronchus. At the autopsy lymphadematous growths were found in the tonsils and stomach, and in the mediastinal glands. *See Insp.* 1888, No. 131; *Preps.* 479, 716, & 971; and *Trans. Path. Soc.* vol. 40, p. 80.

927 Lymphadenoma of the Small Intestine.

A portion of small intestine shewing its wall infiltrated for a length of three inches with a deposit of soft white growth. The calibre of the bowel is somewhat widened and its wall measures half an inch at its thickest part. The mucous membrane is smoothly stretched over the growth and presents a few patches of superficial ulceration. The cut edge shews that the greater part of the deposit is situated between the serous and muscular coats. Histologically the whole thickness of the intestinal wall is infiltrated by small round cells.

John S., a middle-aged man, was admitted under Dr. Moxon for ascites and œdema of the legs. Diarrhœa came on and he gradually sank. At the autopsy there was a considerable quantity of milky fluid in the pleural and peritoneal cavities, and the lumbar and mesenteric glands were greatly enlarged by soft white growth which extended along the mesentery to the bowel. A similar condition to that shewn in the preparation was found in isolated patches throughout the small intestine. There were no other secondary deposits. *See Insp.* 1871, No. 321.

928 Lymphadenoma of the Small Intestine.

A portion of small intestine laid open to shew an area two and a half inches in length in which the circum-

ference of the bowel is more than twice as great as that of the parts immediately above and below. At this situation the wall of the intestine is thickened, and the mucous membrane is smooth and presents patches of superficial ulceration. Histologically all the coats of the intestine are infiltrated and in parts destroyed by a deposit of uniform small round cells.

From a child who died in the Evelina Hospital under the care of Dr. Fagge in 1872. At the autopsy the mesentery was found to be thickened and contracted from a lymphadenomatous deposit. There were several white patches in one of the kidneys, which under the microscope were seen to be produced by infiltration of the tissues with lymphoid cells. *See Prep.* 1235.

929 **Lymphadenoma of the Ileum.**

A portion of an ileum laid open to shew a circumscribed mass of growth projecting from the mucous membrane opposite to the attachment of the mesentery and almost filling the lumen of the bowel. The growth appears to have its origin in a Peyer's patch. Histological examination of similar deposits in the same intestine shews them to consist of collections of uniform lymphoid cells which do not invade the muscular coat.

Alice MacG., *æt.* 50, was admitted under Dr. Goodhart for emaciation with general enlargement of the lymphatic glands. There was no leucocytosis nor decrease in the number of the red blood corpuscles. She died about six months after the onset of her illness. At the autopsy the spleen was greatly enlarged and contained a diffuse deposit of soft white growth. The mediastinal and mesenteric glands were swollen and there was hypertrophy of the lymphoid tissue in the stomach and in the intestinal canal. *See Insp.* 1883, No. 64; and *Preps.* 930, 931, & 932.

930 **Lymphadenoma of the Ileum.**

A portion of an ileum laid open to shew three Peyer's patches considerably enlarged by lymphadenomatous deposit. The surface of the patches is smooth and free from ulceration. One or two solitary glands are also seen to be similarly affected.

For history and reference *see Prep.* 929.

931 Lymphadenoma of the Cæcum.

A cæcum which is considerably dilated and has been laid open to exhibit a mass of growth about the size of a man's fist attached to its wall around the opening of the ileum indicated by a blue rod. The growth is soft and lobulated and its surface presents patches of superficial ulceration. The mucous membrane lining the cæcum and the commencement of the ascending colon is much thickened and marked by transverse rugæ having the appearance of enormous valvulæ conniventes. Under the microscope the new-formation is seen to be due to an infiltration of the mucous and submucous tissues with uniform small round cells which do not invade the muscular coat of the intestine.

For history and reference *see Prep. 929.*

932 Lymphadenoma of the Colon.

A portion of large intestine laid open to shew numerous masses of growth projecting beneath its mucous membrane. The masses are for the most part oval in shape with the long axis placed transversely. Some of them are very narrow in proportion to their length and almost encircle the bowel. They vary in thickness from an eighth to half an inch, and present a flat convex or cupped surface over which the mucous membrane is free from ulceration. Histologically the masses consist of a deposit of lymphoid cells in the mucous and submucous tissue, the muscular coat being free from infiltration. The glands of the mesocolon are enlarged.

For history and reference *see Prep. 929.*

933 Melanotic Sarcoma of the Jejunum.

A portion of a jejunum the wall of which for a distance of three inches is thickened by a deposit of melanotic growth. The mucous membrane at this part is slightly ulcerated and the calibre of the gut is somewhat widened.

There is a similar black deposit in the lymphatic glands and in the mesentery. Histologically the growth is a sarcoma consisting of round and oval cells, many of which contain brown pigment.

Ann O., æt. 40, was admitted under Dr. Moxon for ascites. She had previously suffered from pain in the back with frequent attacks of vomiting, and died one month after the onset of her illness. At the autopsy melanotic growth was found in the skin, pleura, peritoneum, lungs, liver, kidneys, and spleen. *See Insp.* 1885, No. 99; and *Preps.* 2012 (80) & 2062 (5) [2nd Edit.].

934 Sarcoma of the Jejunum.

A portion of a jejunum laid open to shew a mass of growth about four inches long and half an inch thick, completely encircling the wall of the intestine. At this part the lumen of the bowel is considerably widened and the valvulæ conniventes are obliterated. The upper and lower limits of the growth are ill-defined, the infiltration becoming gradually less as the border is reached. Histologically the mucous and submucous tissues are seen to be infiltrated with small round cells which invade the muscular coat of the intestine.

Samuel S., æt. 16, was admitted under Dr. Rees for paraplegia of about five weeks' duration and died a fortnight later from paralysis of the muscles of respiration. A tumour was felt in the lower part of the abdomen. At the autopsy malignant growth was found in the spine, heart, kidneys, testes, and lymphatic glands. *See Insp.* 1862, No. 1.

935 Sarcoma of the Ileum.

Three portions of an ileum, each of which shews a discoid mass of growth projecting about a quarter of an inch above the mucous membrane, the largest measuring two and a half inches, and the smallest about one inch in diameter. In all the specimens the growth presents an ulcerated surface, and in one it has penetrated the wall of the intestine, which has yielded, producing a globular pouch projecting externally. In the wall of the pouch there is a perforation, which in the recent

state was closed by adhesion to a neighbouring coil of intestine. Histologically the growth is a round and oval celled sarcoma.

William L., æt. 45, was admitted under Mr. Jacobson for a growth in the right tonsil, which was first noticed seven weeks before admission. He died about six weeks later, and at the autopsy secondary deposits were found in the cervical and bronchial glands and in the pleura. *See Insp.* 1891, No. 343.

936 **Sarcoma of the Colon.**

A portion of a colon laid open to shew two circular masses of growth about an inch in diameter the borders of which project a third of an inch above the surrounding mucous membrane. The surface of one growth is ulcerated and exhibits a shallow central depression. In the other the ulcerative process has extended more deeply and exposes the muscular coat. On the reverse of the specimen are seen several mesenteric glands infiltrated by a very vascular secondary deposit. Histologically the growth is a small round-celled sarcoma.

Mary G., æt. 23, was admitted under Dr. Bright for wasting and diarrhœa from which she died. At the autopsy, malignant growth was found in the small intestine, the right lung, the bronchial glands, and around the head of the pancreas. *See Insp.* vol. 10, p. 163; and *Prep.* 1989 (50) [2nd Edit.].

937 **Sarcomatous Polypi of the Colon.**

A portion of a colon laid open to shew numerous single and compound polypi, the smallest the size of a pea and the largest measuring two inches long by an inch broad and projecting three quarters of an inch into the lumen of the bowel. The mucous membrane over them is smooth and free from ulceration. At the situation of the growths and above them the calibre of the intestine is widened and its wall is thickened. On the reverse of the specimen several adherent lymphatic glands are seen to be enlarged. Histological examination of the

polypi and of the lymphatic glands shews the growth to have the characters of a sarcoma composed of oval and spindle cells. *Presented by Sir Astley Cooper.*

938 Perforation of the Jejunum from without.

A portion of a jejunum presenting an irregularly quadrilateral perforation about a quarter of an inch across.

Harriet B., æt. 20, was admitted under Dr. Oldham for peritonitis from which she died. At the autopsy numerous intra-peritoneal abscesses were found some of which had perforated the intestine from without. It was thought that the peritonitis originated from the perforation of an ulcer which was found in the colon. *See Insp.* 1867, No. 264.

939 Ileum perforated by a Caseating Gland.

A portion of an ileum shewing upon its attached border an opening which communicates with a smooth-walled cavity in the mesentery which in the recent state contained the débris of a caseating lymphatic gland. Above the opening the bowel is puckered as a result of the contraction of the mesentery.

John S., æt. 51, was admitted under Dr. Goodhart for phthisis and an empyema from which he died. At the autopsy tuberculous ulcers were found in the cecum and the upper part of the colon. *See Insp.* 1892, No. 294.

940 Perforation of the Ileum in Tuberculous Peritonitis.

The hinder wall of a pelvic abscess partly formed by adherent coils of small intestine. The gut is completely divided in several places and the projecting mucous membrane is turned back upon the serous coat and presents an appearance which has been likened to a rosebud.

Joseph H., æt. 10, was admitted under Dr. Addison in 1840, for chronic peritonitis from which he had suffered for six months. Ten weeks later he died and at the autopsy tubercle was found in

the lungs and in the peritoneum. Except where the intestine was perforated from without the mucous membrane was free from ulceration. See *Insp.* vol. 30, p. 206; and *Drawing*, 455 (50).

941 Perforation of the Intestine from without.

Portions of the small and large intestine laid open to shew several perforations of the mucous membrane resulting from the burrowing inwards of circumscribed peritoneal abscesses. On the reverse of the specimen the serous coat is seen to be thickened and roughened by a deposit of lymph.

Annie R., æt. 18, was admitted under Mr. Davies-Colley for an irregular enlargement of the abdomen associated with pyrexia. Her illness began five weeks previously with severe abdominal pain, and the sudden cessation of the menstrual discharge. A week after admission an abscess was opened above the umbilicus from which foul pus was evacuated and eight days later a similar abscess was opened in the right iliac region. She died nineteen days after the second operation. At the autopsy numerous collections of pus were found between the matted coils of intestine. See *Insp.* 1883, No. 146.

942 Perforation of the Colon from without.

A cæcum with the ascending colon shewing numerous irregular perforations of the wall, the destruction of tissue being greater upon the serous than upon the mucous surface.

From Anne D., æt. 37, a married woman who miscarried five weeks before her death and shortly afterwards was seized with abdominal pain and rectal tenesmus. On the third day after the attack she had a rigor and noticed a swelling on the right side of the abdomen. The swelling increased at first and distinctly fluctuated, but subsequently it gradually disappeared and just before her death she passed several large motions containing clotted blood. At the autopsy a ragged cavity was found in the position of a psoas abscess, but there was no disease of the vertebræ or other bones.

Presented by Mr. R. G. Hardwick.

943 Colon perforated by Hydatid of the Liver.

A portion of an ascending colon shewing two inches from the cæcum a rounded perforation produced by

the opening into the bowel of a hydatid cyst of the liver. The mucous membrane is everted through the perforation. *Presented by Dr. Charlton, 1863.*

944 Colon opened by an Iliac Abscess.

A portion of a descending colon together with a part of the posterior abdominal wall to which it is adherent. On the inner surface of the bowel is seen a small opening, indicated by a blue rod, which in the recent state communicated with an abscess behind the peritoneum.

Eliza R., æt. 39, was admitted under Dr. Habershon for pains in the joints thought to be rheumatic. Six weeks later a swelling was felt in the left iliac region which was opened and proved to contain fetid pus. At the autopsy the iliac abscess was found to extend behind the peritoneum as high as the last rib. No dead bone or other cause of suppuration was discovered. *See Insp. 1855, No. 115.*

945 Sigmoid-vesical Fistula.

A portion of the sigmoid flexure of a colon with the posterior wall of the bladder, to which it is firmly adherent. There is a fistulous communication, indicated by a blue rod, between the colon and the bladder. Neither viscus shews any sign of ulceration.

Hans K., æt. 65, was admitted under Mr. Bryant for the passage of wind and feces by the urethra. Wind was passed twelve years previously, but no solid feces until six weeks before admission. Colotomy was performed, and the patient died three days later. He had been in the tropics, but had never had symptoms of dysentery. At the autopsy there were signs of former ulceration in the rectum six inches from the anus, but none in the bowel higher up. *See Insp. 1882, No. 19.*

946 Umbilical Fistula.

A portion of intestinal mucous membrane which prolapsed through a fistula at the umbilicus, and was removed by operation. The prolapse resembles a glo-

bular polypus with a short pedicle, measures about three quarters of an inch in diameter, and presents a central canal through which a rod has been passed.

Walter M., æt. 15 months, was admitted under Mr. Lucas in 1893, with a "warty mass" situated at the umbilicus. During the first year of the child's life feces frequently escaped through the fistula. The prolapsed mucous membrane was removed, and the patient made a good recovery. *See Surgical Reports*, vol. 166, Case 239.

947 Thrombosis of Mesenteric Veins.

A portion of small intestine laid open to shew its wall thickened and its mucous surface partially covered with shreddy exudation. The mesenteric veins are distended with thrombus.

948 Thrombosis of the Superior Mesenteric Vein.

A portion of small intestine laid open to shew its mucous membrane for the most part covered with a layer of inspissated mucus. In the recent state it was thickened and deeply congested, and contained a thin reddish fluid. The veins in the mesentery are distended with thrombus.

From a lady, æt. 34, who while convalescent from an attack of phlegmasia dolens, following her first confinement, was suddenly seized with acute abdominal pain, vomiting, and collapse, and died within eleven hours of her seizure. At the autopsy the upper half of the small intestine, with the exception of the duodenum and the first four inches of the jejunum, was deeply congested and thickened. The superior mesenteric vein and the trunk of the portal vein were distended with adherent coagulum. The inferior vena cava and its branches above the renal veins were also plugged. *See Path. Trans. Soc.* vol. 27, p. 124.

Presented by Dr. Finch, 1875.

949 Thrombosis of a Varicose Vein in the Jejunum.

A portion of a jejunum laid open to shew a small area of its mucous membrane raised and smoothly stretched

over a firm thrombus contained in a dilated vein. The bowel is otherwise normal.

Eliza B., æt. 63, was admitted under Dr. Perry for enlargement of the liver and chronic bronchitis. She died nine months after admission from acute pneumonia. At the autopsy the liver was found to be cirrhotic, and the spleen was enlarged. *See Insp.* 1893, No. 166.

950 **Chylous Cyst of the Intestine.**

A portion of small intestine laid open to shew a thick-walled cyst, about half an inch in diameter, projecting into the lumen of the bowel at the situation of the attachment of the mesentery. The mucous membrane covering the cyst is healthy. In the recent state it contained a milky fluid, and was thought to be due to the retention of chyle in one of the lacteals.

John R., æt. 9, was admitted under Dr. Goodhart for acute pneumonia, and died from suppurative pericarditis. *See Insp.* 1893, No. 91.

951 **Mucous Membrane of Intestine passed per Anum.**

A slough consisting of a considerable part of the mucous lining of a portion of intestine ten inches in length, in which the arrangement of the valvulæ conniventes is still apparent. It was evacuated during life.

From a gentleman, æt. 23, who while suffering from syphilis was seized with severe abdominal pain which was followed by profuse hæmorrhage from the bowel. Eight days later small sloughs of mucous membrane were found in the motions and continued to be passed for seven days, after which the intestinal symptoms subsided. Throughout the illness and for some months afterwards the urine contained blood or albumen. It was thought that the lesions of the bowel and of the kidney were produced by thrombosis of the mesenteric and renal veins. *See Guy's Hosp. Reps.* 1883-84, p. 15.

Presented by Sir William Gull.

952 Trichocephalus Dispar in the Colon.

A cæcum with the first part of the ascending colon laid open to shew numerous specimens of *Trichocephalus dispar* attached to the mucous membrane by their long hair-like anterior extremity from which this nematode derives its name. Some of the worms have been mounted on black paper to make more evident the spirally incurved tail by which the male is readily distinguished from the female.

William N., æt. 6, was admitted under Dr. Pitt with heart disease, from which he died. See *Insp.* 1892, No. 384.

SECTION XIX.—DISEASES OF THE CÆCAL
APPENDIX.

Operations: 953, 954.
Ulceration: 955-958.
Tubercle: 957.
Typhoid: 958.
Sloughing: 959.
Perforation: 960-964.
Obliteration: 965.
Dilatation: 966-971.
Lymphadenoma: 971, 972.
Growth: 973.

953 Cæcal Appendix removed during Life.

A cæcal appendix laid open to shew its muscular wall greatly hypertrophied. The mucous membrane about the middle of the appendix is ulcerated, and the muscular coat beneath it is partly replaced by fibrous tissue. The serous surface is covered by flocculent adhesions.

Edward C., æt. 18, was admitted under Dr. Pye-Smith for recurrent attacks of pain in the right iliac fossa. Two years from the onset of symptoms, and after medical treatment in the hospital for four months, Mr. Lane removed the appendix. The patient made a quick recovery, and eighteen months after the operation had had no recurrence of pain. *See Medical Reports*, vol. 105, Case 203.

954 Stump of Cæcal Appendix.

A cæcum mounted to shew the condition of the parts one month after amputation of the vermiform appendix. There is complete union.

Margaret H., æt. 16, was admitted under Dr. Goodhart with

symptoms of perityphlitis of eight days' duration. A fortnight after admission the vermiform appendix was removed by Mr. Lane. The patient died a month later from pyæmia. *See Insp.* 1890, No. 149.

955 Ulcerated Cæcal Appendix.

A portion of a cæcum with the vermiform appendix laid open to shew the mucous membrane of the lower half of the appendix deeply ulcerated. The walls are thickened and covered externally by granular lymph.

Harriet H., æt. 23, was admitted under Dr. Bright in 1831 in a "typhoid" condition. At the autopsy an abscess was found in the right iliac fossa, and there was recent lymph upon the pericardium and pleura, with suppurative peritonitis chiefly affecting the right side of the abdomen. *See Insp.* vol. 15, p. 56.

956 Ulceration of Cæcal Appendix and Cæcum.

A portion of a colon with the cæcum and its appendix. At its origin the appendix presents a considerable dilatation, from which a concretion has been removed. The mucous membrane of the appendix at this part and of the cæcum is extensively ulcerated and undermined. There is another patch of superficial ulceration at the tip of the appendix, where a second concretion was lodged.

Ellen P., æt. 14, was admitted under Dr. Hale White for a cerebellar tumour, from which she died suddenly. There were no symptoms of intestinal disease. *See Insp.* 1889, No. 412.

957 Tuberculous Ulceration of Cæcal Appendix.

A cæcal appendix injected and laid open to shew numerous irregular ulcers upon its mucous surface. Beneath its serous coat are seen several miliary tubercles.

958 Typhoid Ulceration of the Cæcal Appendix.

A vermiform appendix with a portion of the cæcum and ileum affected in typhoid fever. There is a large

ulcer occupying the upper two thirds of the appendix, and there are numerous follicular ulcers in the large intestine. The ileum is also ulcerated, and attached to it are two enlarged lymphatic glands.

James U., æt. 30, was admitted under Dr. Cholmeley in 1831 for diarrhœa and fever. At the autopsy the spleen was found to be enlarged and there were numerous typhoid ulcers throughout the intestine. See *Insp.* vol. 15, p. 143.

959 Sloughing Cæcal Appendix.

A cæcum and the vermiform appendix with a portion of the colon. The appendix which is adherent to the back of the colon is about four inches long, and is perforated in three places. Through the large oval opening near its cæcal attachment a fæcal concretion was removed. There is recent lymph upon the serous covering of the intestine.

George L., æt. 18, was admitted under Dr. Pavy for vomiting and pain in the right side of the abdomen of two days' duration. On admission there was a large tender lump in the right iliac region. He died on the fifth day of his illness, with symptoms of general peritonitis. At the autopsy the intestines were found to be matted together with recent lymph. See *Insp.* 1889, No. 254.

960 Perforation of the Cæcal Appendix.

A cæcum, to the back of which the vermiform appendix is bound by firm adhesions. The appendix is laid open to shew its wall considerably thickened, and its mucous membrane corrugated and in parts destroyed by ulceration.

John H., æt. 36, was admitted under Dr. Barlow for general peritonitis, his illness having begun suddenly five days previously. He died on the day after his admission. There was a history of a severe attack of abdominal pain twelve months before. At the autopsy the peritoneum was covered with recent lymph and two oval concretions were found, one loose in the peritoneal cavity, the other impacted at the root of the cæcal appendix. See *Insp.* 1855, No. 153; *Prep.* 1053; and *Drawing*, 325 (27).

961 Perforation of the Cæcal Appendix.

A vermiform appendix shewing a small perforation about half an inch from its apex. It has been laid open to shew its mucous membrane ulcerated and in parts covered by a fibrinous exudation. There is recent lymph upon its outer surface.

From Robert R., æt. 14, who was seized five days before death with pain in the right iliac fossa. At the autopsy a concretion was found in the vermiform appendix, and there was general peritonitis. *See Insp.* vol. 22, p. 81.

Presented by Mr. Cock, 1836.

962 Perforating Ulcer of the Cæcal Appendix.

The tip of a cæcal appendix adherent to a piece of small intestine. The mucous membrane of the appendix presents several ulcers, in the base of one of which is a small perforation indicated by a bristle. There is recent lymph upon the peritoneum.

Annie C., æt. 14, was admitted under Dr. Wilks for phthisis and was suddenly seized with symptoms of acute peritonitis. At the autopsy there were numerous tubercles in both lungs, and the abdominal cavity contained thirty ounces of turbid serum having a fecal odour. There was extensive tuberculous ulceration of the ileum and colon. *See Insp.* 1868, No. 69.

963 Retro-cæcal Abscess.

A cæcum with the vermiform appendix firmly bound behind it. The appendix, which in the recent state communicated with an abscess-cavity, is seen to be much thickened, and in its middle third dilated to more than twice its normal size. The ileum immediately above the valve formed part of the wall of the abscess and is covered with lymph.

Christopher B., æt. 21, was admitted under Dr. Wilks with symptoms of acute peritonitis of six days' duration, and died the

following day. Two years previously he had received a severe blow in the right iliac region, which was immediately followed by pain and swelling. Some time later he passed a quantity of pus by the rectum. At the autopsy general peritonitis was found. No concretion was discovered. *See Insp.* 1859, No. 104.

964 Ulceration of the Cæcal Appendix communicating with the Rectum.

A cæcum with its vermiform appendix adherent to, and communicating with, the rectum four inches above the anus. Below the opening the walls of the rectum are thickened, and its mucous membrane is destroyed by ulceration. There is a second sinus leading from the rectum through a mass of inflammatory tissue surrounding the left ovary, which, with the uterus, is firmly united to the rectum.

Mary G., æt. 30, was admitted under Dr. Gull in 1853 for phthisis, from which she died. *See Insp.* vol. 37, p. 44.

965 Obliterated Cæcal Appendix.

A slender cæcal appendix measuring three inches in length, the lumen of which is for the greater part obliterated.

Jane C., æt. 52, was admitted under Mr. Morgan in 1842 for a broken leg, from the effects of which she died. *See Insp.* vol. 31, p. 247; and *Prep.* 1266 (50) [2nd Edit.].

966 Dilatation of the Cæcal Appendix.

A vermiform appendix laid open to shew its cavity uniformly dilated, and shut off from the intestine by a thick fibrous septum occluding the lumen of the tube at its attachment to the cæcum for a distance of about a third of an inch.

From James S., a patient of Dr. Curry's in 1805, who died suddenly from the rupture of a thoracic aneurism. *See Old Museum Book*, No. 16.

967 Distended Cæcal Appendix.

Portions of a cæcum and cæcal appendix mounted to shew a thin membranous diaphragm projecting into the cæcum and completely occluding the opening of the appendix. The cavity of the appendix is much dilated, measuring an inch in diameter at its upper part. In the recent state it contained pus.

Maria P., aged 50, was admitted under Dr. Barlow for chronic bronchitis, from which she died. There were no intestinal symptoms. *See Insp.* 1860, No. 23.

968 Dilated Cæcal Appendix.

A cæcal appendix measuring four inches in length and one inch in diameter, which in the recent state contained four ounces of odourless mucus. It is completely shut off from the cæcum by a membranous septum.

Elizabeth S., æt. 76, was admitted under Mr. Cock for a strangulated hernia and died two days after herniotomy. *See Insp.* 1862, No. 243.

969 Dilated Cæcal Appendix.

A cæcal appendix laid open to shew considerable dilatation of its cavity, which in its recent state contained watery mucus. Towards its lower end there is a small circular opening leading into a thin-walled sacculus projecting from the outer surface. At the junction of the appendix with the cæcum there is a membranous septum which completely shuts off the appendix from the rest of the intestine.

Philip B., æt. 42, was admitted under Dr. Bright in 1842 for phthisis. At the autopsy the muscles were found to contain numerous trichinæ spirales. *See Insp.* vol. 32, p. 61.

970 Distension Sacculus of the Cæcal Appendix.

A short vermiform appendix laid open to shew its walls thickened and its cavity shut off from the cæcum by a

complete septum. Just below its origin is a small rounded opening leading into a thin-walled sacculus which in the recent state contained mucoid fluid.

971 Lymphadenoma of the Cæcal Appendix.

A vermiform appendix with the cæcum and lower end of the ileum mounted to shew lymphadenomatous deposit in the wall of the intestine. The vermiform appendix has been converted by the abundance of the deposit into a globular mass about two and a half inches in diameter connected by a narrow neck with the cæcum. A Peyer's patch immediately above the ileo-cæcal valve and the valve itself are much thickened.

George B., æt. 48, was admitted under Dr. Pye-Smith for pleural effusion with the physical signs of pressure on the left bronchus. At the autopsy lymphadenomatous growths were found in the mediastinal glands, in the tonsils, and in the stomach. *See Insp.* 1888, No. 131; *Trans. Path. Soc.* vol. 40, p. 80; and *Preps.* 479, 716, & 926.

972 Lymphadenoma of the Cæcal Appendix.

A vermiform appendix with the cæcum and a portion of the ileum shewing a general overgrowth of lymphoid tissue. The mucous membrane of the appendix is markedly rugose, and much thickened by a deposit of small round cells in the submucous tissue. Elsewhere the agminated and solitary glands are unusually prominent. The lymphatic glands are also enlarged.

Harry B., æt. 15, was admitted under Dr. Pye-Smith for Hodgkin's disease, and died seven months from the onset of his illness. At the autopsy there was enlargement of the lymphatic glands, liver, and spleen. *See Insp.* 1891, No. 344.

973 Nodule in the Cæcal Appendix.

The last two inches of a cæcal appendix shewing at its termination an oval nodule about half an inch in its longest diameter projecting from the mucous surface

and filling the lumen of the tube. In the recent state it was firm and yellowish on section, and histologically it consists of large and small alveoli filled with spheroidal epithelial cells. There are small ulcers in the mucous membrane above it.

Thomas F., æt. 31, was admitted under Dr. Babington in 1842 for phthisis, from which he died. *See Insp.* vol. 31, p. 236.

SECTION XX.—INJURIES AND DISEASES OF THE RECTUM AND ANUS.

- Imperforate Anus: 974-983.
 Wounds: 984-988.
 Inflammation: 989, 990.
 Ulceration: 991-1002.
 Recto-vaginal Fistula: 999, 1000, 1023.
 Stricture: 1001-1008, 1018-1021.
 Polypus: 1009-1011.
 Papilloma: 1012-1014.
 Carcinoma: 1015-1025.
 Sarcoma: 1026.
 Opened by Abscess: 1027-1030.
 Prolapse: 1031, 1032.
 Fistula in Ano: 1033-1035.
 Anal Pouch: 1036.
 Hæmorrhoids: 1037, 1038.
 Condyloma: 1039.

974 Imperforate Rectum.

A pelvis with the pelvic viscera. The lower end of the rectum is dilated and terminates in a cul-de-sac which is attached by a solid fibrous cord to the under surface of the prostate.

Thomas H., æt. 2 days, was admitted under Mr. Jacobson for imperforate rectum. There was a well-formed anus, through which an unsuccessful attempt was made to reach the bowel. The first stage of Littre's operation was then performed and shortly afterwards the child died. At the autopsy the colon was much distended, and there was general suppurative peritonitis. *See Insp.* 1877, No. 393.

975 Imperforate Rectum.

The lower end of a rectum, with the sacrum and the prostatic portion of the urethra mounted to shew the

rectum dilated and terminating in a cul-de-sac. There is no fibrous cord connecting the lower end of the bowel with the spinal canal.

From a male infant who survived his birth eight days.

Presented by Mr. Aston Key.

976 Rectum terminating in the Urethra.

The rectum with the bladder and urethra of a male infant. The rectum is much dilated and terminates by a small aperture in the urethra immediately in front of the verumontanum.

Presented by Mr. Callaway.

977 Imperforate Anus; Rectum terminating in the Urethra.

The male pelvic viscera divided by sagittal section. The anus is imperforate, and the rectum communicates by a small rounded opening with the prostatic portion of the urethra. This opening is indicated by a yellow rod. The pink rod shews the track of the operation wound whereby communication was established between the bowel and an artificial anus made in the natural position.

Thomas P. was admitted 36 hours after birth under Mr. Davies-Colley for imperforate anus. Meconium had been passed *per urethram*. An artificial anus was made in the perinæum, and the child died three days later. The right forearm was deformed. There was no peritonitis. *See Insp.* 1893, No. 242.

978 Rectum terminating in the Urethra.

A sagittal section through a rectum, bladder, and penis shewing the bowel ending by a narrow orifice in the urethra. The opening is situated in the middle of the verumontanum, which forms a ridge on either side of it. The wall of the bladder is somewhat thickened. The pink rod indicates the orifice of the right ureter.

Frank G. was operated on for imperforate rectum three days

after birth. A fortnight later the wound closed and feces and wind passed by the urethra. At the age of nine months he was admitted under Mr. Lucas, who performed colotomy on the left side. On the next day the patient died, and at the autopsy the bladder was found to be intensely inflamed and to contain fecal concretions. The left ureter was occluded at its lower end, and the corresponding kidney was small and fibrous. *See Insp.* 1884, No. 284.

979 Rectum terminating in the Bladder.

The lower end of the rectum with the bladder of a male infant. The bowel is dilated, and at its extremity there is a small orifice which opens into the bladder close to the commencement of the urethra. Through this opening a bristle has been passed. *Presented by Mr. Beck.*

980 Imperforate Rectum. Operation.

A rectum with the bladder and a portion of the pelvis. The rectum is dilated and imperforate and the site of the anus is marked by a depression in the skin. The blue rod indicates the course of a trochar which was thrust through the anus into the recto-vesical pouch in an attempt to reach the bowel.

Presented by Mr. Hilton.

981 Rectum terminating in the Vagina.

A rectum with the genito-urinary organs mounted to shew the bowel dilated and terminating by a rounded orifice in the upper part of the vagina. Into this orifice a blue rod has been passed. The yellow rod indicates a fistulous communication between the perinaeum and the bowel effected by operation. The right kidney, which is larger than its fellow, has two ureters and the uterus is bicorned. *Presented by Dr. Lever.*

982 Imperforate Rectum. Laparotomy.

The pelvic viscera of a female infant mounted to shew

the colon dilated and the rectum terminating in a cul-de-sac. In the sigmoid flexure is seen the opening made in establishing an artificial anus.

Eliza S., æt. 17 days, was admitted under Mr. Bryant in 1862 for imperforate anus. An attempt was made to reach the rectum from the perinæum, which failing the bowel was opened in the right groin.

983 **Partial occlusion of the Rectum. Congenital.**

The lower end of a rectum with the anus laid open to shew its lumen narrowed at a point an inch above the external orifice, by a semilunar septum covered by mucous membrane. This condition, which has been called "hymen of the rectum," is said to arise from the incomplete coalescence of the hind-gut and proctodæum of the fœtus.

David D., æt. 5 months, was admitted under Mr. Bryant for epispadias and extroversion of the bladder, for the relief of which a plastic operation was performed. The child died from suppurative peritonitis. See *Insp.* 1886, No. 98.

984 **Perforation of the Rectum by an Enema-tube.**

The lower end of a rectum laid open from behind to shew a perforation in its anterior wall an inch and a half from the anus. The perforation is in the base of an irregular ulcer the edge of which is thin and undermined.

Joseph B., æt. 50, was admitted under Dr. Hughes with symptoms of gastric disease thought to be malignant. In the course of his illness an injection was ordered, and wishing to administer it to himself the patient introduced the enema-tube and thereupon was at once seized with abdominal pain. Next day the whole of the lower half of the body was emphysematous. At the end of three weeks the emphysema had much diminished, and at the time of death, a week later, it had disappeared. At the autopsy the stomach was found to be hypertrophied and dilated, and the pylorus was obstructed by a cancerous growth. There were secondary deposits in the gastric lymphatic glands. See *Insp.* 1856, No. 130.

985 Rectum perforated by a Bougie.

A portion of a rectum shewing an oblique rent in its wall about three quarters of an inch in length.

From a man who died about ten hours after attempting to pass upon himself a rectal bougie.

Presented by Mr. Callaway.

986 Rectum perforated by a Bougie.

A portion of a rectum shewing a longitudinal perforation which was situated five inches from the anus.

James A., æt. 67, was admitted under Mr. Bransby Cooper in 1834 for a strangulated inguinal hernia, which was reduced "en masse." The symptoms being unrelieved a rectal tube was passed and the bowel accidentally perforated, as shewn in the preparation. *See Insp.* vol. 19, p. 63; and *Drawing*, 474.

987 Perforation of the Rectum by a Bougie.

A rectum laid open to shew a ragged perforation about half an inch in diameter, which was situated on the front aspect of the bowel opposite to the promontory of the sacrum. At the lower end of the rectum the mucous membrane is smoothly stretched over the subjacent tissues, which are thickened by fibroid inflammatory material.

Mary W., æt. 63, was admitted under Mr. Hilton for stricture of the rectum. Two days before her death, after the administration of an enema, she was suddenly seized with acute peritonitis. At the autopsy the intestines were coherent by recent lymph; there was chronic pelvic cellulitis. *See Insp.* 1861, No. 86.

988 Gunshot wound of the Rectum.

A rectum mounted to shew two oval perforations, one on either lateral wall, produced by a bullet. The bullet also injured the obturator nerve. *See Prep.* 1616 [2nd Edit.].
Presented by Mr. Gaitskell.

989 Phlegmonous Inflammation of the Rectum.

The lower end of a rectum shewing just within the anus a raised oval patch about two and a half inches in its longest diameter. In the recent state the mucous membrane covering it appeared œdematous and sloughing, and the cellular tissue beneath was infiltrated with pus.

Hercules W., a sailor, æt. 16, was admitted under Dr. Barlow for Asiatic cholera, from which he died four days after the onset of symptoms. On admission an enema of starch containing opium and chloroform was administered. At the autopsy a similar patch was found above the one shewn in the preparation. *See Insp.* 1854, No. 173.

990 Sloughing of Rectal Mucous Membrane.

An almost complete cast of the lower end of a rectum consisting of its mucous membrane detached by sloughing and passed per anum after the administration of an enema containing ammonia.

Presented by Mr. Davies-Colley, 1884.

991 Ulcer of the Rectum.

The lower part of a rectum opened from the front and presenting just within the anus an ulcer which encircles the bowel and extends two inches upon the anterior and one inch upon the posterior wall. The edge of the ulcer is well defined, and in its base is exposed the muscular coat.

Eliza S., æt. 22, was admitted under Dr. Bright in 1829 for lobar pneumonia, from which she died. She had previously been a patient in the hospital for stricture of the rectum, which had been relieved by the passage of bougies. At the autopsy the genitalia were found to be healthy. *See Insp.* vol. 8, p. 128.

992 Ulceration of the Rectum.

The lower end of a rectum laid open to shew two rounded ulcers half an inch in diameter situated on the

anterior wall of the bowel just within the anus. The margins of the ulcers are thin and undermined, and their bases are formed by the cellular tissue external to the rectum. On the reverse of the specimen are seen portions of the bladder and penis, the urethra having been laid open to shew the absence of stricture and ulceration.

William MacM., æt. 60, was admitted under Mr. Hilton with cellulitis of the perinæum, which came on a day or two before admission. The inflammation extended over the anterior wall of the abdomen as high as the chest, and resembled that caused by extravasation of urine. An ordinary sized catheter was easily passed into the bladder. He died six days after his admission. See *Insp.* 1858, No. 94.

993 **Ulceration of the Rectum.**

The last three inches of a rectum laid open to shew several irregular ulcers which expose the muscular coat. At the upper part of the preparation the wall of the bowel is thickened and its lumen narrowed.

Jane E., æt. 25, was admitted under Dr. Taylor for phthisis, and died from hæmoptysis. Two years previously she had been under treatment in the hospital for stricture of the rectum, the symptoms of which had reappeared a few months before death. At the autopsy there was lardaceous disease of the intestines with a few small tuberculous ulcers in the ileum. The ulceration of the rectum extended five inches above the anus. See *Insp.* 1883, No. 62.

994 **Ulceration of the Rectum.**

A portion of a rectum shewing at its lower end an irregularly ulcerated area about three inches long occupying the entire circumference of the bowel. In some places the ulcerative process has exposed the muscular coat; in others cicatrisation has taken place.

From a patient, æt. 33, who two years before his death had some "fibro-cellular growths" at the anus removed by Mr. Bryant. Subsequently he passed five or six ounces of pus daily, and died from lardaceous disease of the viscera.

Presented by Mr. William Toulmin.

995 Ulceration of the Rectum.

The lower part of a large intestine with the vagina and uterus mounted to shew extensive ulceration of the bowel. In the sigmoid flexure and upper part of the rectum where the ulceration is superficial the lumen is somewhat dilated. In the four inches above the anus the destructive process has extended to the external cellular tissue, and the interior of the bowel is crossed by fibrous bridges, and presents numerous fistulous communications with the vagina. The lacerations of the intestine were made in removing the parts from the body. The uterus and its appendages appear healthy.

Charlotte P., *æt.* 42, was admitted under Dr. Habershon with profuse diarrhoea, from which she died six weeks after admission. At the autopsy the whole of the descending colon was found to be ulcerated. The patient had had eighteen children, of whom fourteen died before the end of the third month. *See Insp.* 1870, No. 244.

996 Syphilitic Ulceration of the Rectum.

A rectum with the uterus and vagina to which it is firmly united by dense fibrous tissue. The interior of the rectum is denuded of mucous membrane, and presents a fibrous surface crossed in parts by bands of cicatricial tissue, beneath which blue rods have been passed. Two of the rods are inserted into sinuses which open into the upper part of the vagina.

Sarah N., *æt.* 37, was admitted under Mr. Durham for ulceration of the rectum and fistulæ about the anus. She was believed to have been a prostitute, and had suffered from condylomata and venereal sores. She died nine weeks after admission, and at the autopsy the kidneys were found to be granular and there was recent peritonitis. The liver was lardaceous. *See Insp.* 1862, No. 210.

997 Tuberculous Ulceration of the Rectum.

The last five inches of a rectum laid open to shew three ulcers with thick undermined edges, and smooth

bases formed by the exposed muscular coat of the bowel. The mucous membrane between the ulcers is healthy, and there is no appearance of cicatrisation. Histological examination gives no clear proof of the tuberculous origin of the ulceration.

Frederick B., æt. 10, was admitted under Dr. Shaw for chronic diarrhœa of 12 months' duration, and died from general tuberculosis. At the autopsy numerous recent and chronic ulcers were found scattered throughout the intestine, and there were miliary tubercles in the lungs, kidneys, and spleen. *See Insp.* 1893, No. 195.

998 **Healed Ulceration of the Rectum.**

The lower end of a rectum the inner surface of which for a distance of four inches from the anus presents a scarred and puckered appearance, the result of healed ulceration. At this part the wall of the intestine is thickened, and histologically shews much fibroid induration with no evidence of tubercle.

Emily H., æt. 25, was admitted under Mr. Hilton for pain and hæmorrhage during defæcation due to ulceration of the rectum. The ulceration rapidly healed, but she died about two months later from phthisis. *See Insp.* 1860, No. 84.

999 **Ulceration of the Rectum. — Recto - vaginal Fistula.**

The lower end of a rectum with the vagina and uterus. The rectum has been laid open from behind, and shews an encircling ulcer which extends from the anus upwards for five inches. The edge of the ulcer is thin and well-defined; its base, which is chiefly formed by the muscular coat, is smooth, and presents a small fistulous communication with the upper part of the vagina.

Sarah E., æt. 35, was admitted under Mr. Birkett with symptoms of pelvic cellulitis, and died from acute peritonitis. At the autopsy the pelvic organs were matted together by firm adhesions. No perforation into the peritoneal cavity could be discovered. *See Insp.* 1863, No. 149.

**1000 Ulceration of the Rectum. — Recto - vaginal
 Fistulæ.**

The lower part of a rectum with the uterus and vagina. There is a narrow stricture of the bowel about two inches in length, the lower border of which is situated an inch from the anus. At either end of the stricture there is a fistulous communication with the vagina. At the constricted part the mucous membrane of the rectum is destroyed by ulceration, and its wall thickened by inflammatory tissue. With the exception of the fistulæ the vagina appears healthy.

Emily W., æt. 37, was admitted under Mr. Cooper Forster for a stricture of the rectum. Three years before admission she had been delivered of a living child by forceps, having previously had one miscarriage and one still-born child. Three weeks after parturition she noticed that flatus passed per vaginam. Since that date she had three times suffered from symptoms of rectal obstruction and was admitted during the last attack. Diarrhœa supervened, and she died ten days after admission. At the autopsy pus was found in the cellular tissue around the rectum, and there was recent peritonitis. *See Insp.* 1873, No. 139.

1001 Ulceration and Stricture of the Rectum.

The rectum of a male laid open from behind to shew its mucous membrane entirely destroyed by ulceration for a distance of seven inches from the anus. The calibre of the bowel is narrowed and its wall considerably thickened by fibrous deposit. The interior of the rectum is scarred and nodular.

1002 Ulceration and Stricture of the Rectum.

The lower end of a rectum with the anus laid open to shew the results of healed ulceration. For two inches above the anus, where the ulceration has been most severe, the mucous membrane is completely destroyed and the bowel is considerably narrowed and lined by dense fibrous tissue. Above this there are irregular

superficial ulcers partly cicatrised. The anal orifice is surrounded by large hæmorrhoids.

William R., æt. 37, was admitted under Dr. Barlow for jaundice with pyrexia of one week's duration. He had for some time suffered from symptoms of stricture of the rectum. He died two days after admission, and at the autopsy suppurative hepatitis was found, and there were softening thrombi in the trunk of the portal vein and in some of its branches in the liver. The rest of the alimentary tract was healthy. *See Insp.* 1860, No. 5.

1003 **Stricture of the Rectum.**

A rectum greatly dilated so as to measure two inches in diameter. The anus is contracted.

From a child, æt. 5 months, who was successfully operated upon for imperforate anus. Subsequent treatment was neglected and stricture followed.

Presented by Mr. Key.

1004 **Stricture of the Rectum.**

The female pelvic viscera divided by sagittal section to shew the rectum narrowed and surrounded by dense fibrous tissue. The inner surface is smooth and denuded of mucous membrane.

Elizabeth B., æt. 42, was admitted under Mr. Bryant for stricture of the rectum of four and a half years' duration. Colotomy was performed, and she died four days later of suppurative peritonitis. At the autopsy the condition of the interior of the bowel shewn in the preparation was found to extend as high as the splenic flexure of the colon. There was early lardaceous disease of the liver and small intestine. The uterine appendages were matted together by adhesions. *See Insp.* 1883, No. 53.

1005 **Stricture of the Rectum.**

The last five inches of a rectum with the female genitalia. From the anus upwards for four inches the bowel is thickened and contracted by chronic inflammation. At this part the interior is denuded of mucous membrane and presents an irregular surface crossed by prominent fibrous bands. At the upper part of the

bowel the ulceration is more superficial, affecting only the mucous membrane.

Hannah C., æt. 30, was admitted under Mr. Cock for stricture of the rectum from which she had suffered for five years. Bougies were passed, and she died seven days after her admission from peritonitis. At the autopsy six ounces of pus were found in the abdominal cavity. The Fallopian tubes were firmly adherent to the ovaries, and there were chronic ulcers in the vagina. *See Insp.* 1869, No. 63.

1006 **Fibrous Stricture of the Rectum.**

A portion of a rectum laid open to shew an annular stricture about an eighth of an inch in diameter. The stricture is not more than a quarter of an inch in length, and histological examination of the wall at this part shews much fibroid thickening with no evidence of malignant disease.

1007 **Syphilitic Stricture of the Rectum.**

The lower end of a rectum laid open from behind to shew its inner surface, scarred and crossed by numerous fibrous trabeculæ. Blue rods indicate the orifices of several fistulæ, some of which communicate with the vagina. Above is mounted a transverse section through the parts, in which the bowel is seen to be surrounded by dense fibrous tissue. A pink rod has been passed through the lumen of the rectum, which in the recent state measured half an inch in diameter.

Susan S., æt. 40, was admitted under Mr. Bryant with a stricture of the rectum for which she had been under treatment in the hospital three years previously. For the twelve months preceding her readmission most of the fæces had passed per vaginam. Colotomy was performed, and she died eight weeks after her admission. She was married and had had several miscarriages, but there was no definite history of syphilis. At the autopsy the ulceration of the large intestine was found to extend as high as the splenic flexure of the colon. The aorta was markedly atheromatous and the left Fallopian tube was adherent to the ovary. *See Insp.* 1881, No. 178.

1008 Stricture of the Rectum following Dysentery.

The lower end of a rectum laid open from behind to shew its interior denuded of mucous membrane. The surface, which in the recent state was of a slaty black colour, is smooth and marked by the openings of several short fistulous channels in the surrounding tissues, which are thickened by inflammatory material.

William P., æt. 31, was admitted under Mr. Durham for stricture of the rectum following upon dysentery contracted in India. He died from pyæmia and peritonitis. At the autopsy the peritonitis appeared to have begun in the pelvis. The whole of the rectum was ulcerated, the rest of the alimentary canal shewing no sign of old or recent disease. Pus was found in the knee and shoulder joints. *See Insp.* 1875, No. 151.

1009 Polypus of the Rectum.

A globular polypus about half an inch in diameter with a small portion of a rectum to the interior of which it is attached. The surface is smooth and covered by normal mucous membrane. Histologically the polypus consists of fibro-myomatous tissue.

George F., æt. 40, was admitted under Dr. Mahomed for heart disease, from which he died. At the autopsy the polypus was found to be situated three inches above the anus. *See Insp.* 1883, No. 347.

1010 Polypus of the Rectum.

An oval polypus measuring about an inch in its longest diameter, the surface of which is smooth and slightly lobulated. Histologically it consists of fibrous tissue covered by squamous epithelium.

Annie C., æt. 35, was admitted under Mr. Golding Bird in 1881 for a polypus of the rectum which had probably existed since infancy. It was removed by means of the cauterizer. *See Surgical Reports*, vol. 93, case 81.

1011 Polypi of the Rectum.

Three globular polypi, the smallest of which is about

one third of an inch and the largest three quarters of an inch in diameter. They have slender pedicles and are covered by smooth mucous membrane. Histologically they consist of a central core of fibro-cellular tissue in which are seen numerous tubes lined with cylindrical epithelium.

Removed from three different patients by Mr. Bryant.

1012 **Papilloma of the Rectum.**

A portion of a rectum, to the mucous surface of which is attached a pedunculated polypus, about the size of a small cherry. The polypus is covered with delicate papillæ; its pedicle is broad and smooth. Histologically the tumour has the structure of a simple papilloma.

Eliza J., æt. 40, was admitted under Dr. Babington in 1847, and died from suppurative peritonitis. At the autopsy there was a circumscribed phlegmon in the wall of the stomach. *See Insp.* vol. 34, p. 197; and *Prep.* 630.

1013 **Villous Tumour of the Rectum.**

A portion of the mucous membrane of a rectum the inner surface of which is covered by a flattened mass of villous growth. Below is mounted a globular tumour of similar appearance and structure. Histologically the growth is a papilloma.

From Mr. T., æt. 58, who had suffered for seven months from rectal tenesmus and a discharge of blood-stained mucus, symptoms which were relieved by the removal of the tumour from the rectum four inches above the anus. The disease gradually returned, and seven years later the whole rectum was found to be filled with villous growth producing intestinal obstruction. Left lumbar colotomy was performed, and the condition was discovered to extend as high as the descending colon. The patient survived the operation six years, and eventually died from lung disease at the age of 71.

Presented by Mr. Bryant, 1879.

1014 Villous Tumour of the Rectum.

Three portions of a large sessile tumour removed from the rectum by operation. The masses are made up of closely-set polypoid outgrowths from the mucous membrane giving to the surface a cauliflower-like appearance. Histologically the growth is a papilloma shewing no evidence of malignancy.

Thomas M., *æt.* 73, was admitted under Mr. Symonds in 1888 for obstinate constipation and a profuse discharge of clear mucoid fluid from the rectum. These symptoms had existed for eighteen months. The tumour was situated three and a half inches from the anus. After its removal the patient made a good recovery. *See Surgical Reports*, vol. 138, Case 24.

1015 Carcinomatous Tumour of the Rectum.

A portion of the upper part of a rectum laid open to shew, numerous polypoid masses projecting from the mucous membrane and encircling the bowel. The masses vary in size from a pea to a chestnut, and their surface is in some parts ulcerated and in others covered by slender papillæ. Except around the attachment of the tumours, where the mucous membrane for a distance of two inches is deeply ulcerated, the interior of the bowel is healthy. Histologically the growth is a cylindrical-celled carcinoma. *Presented by Mr. Aston Key.*

1016 Carcinoma of the Rectum.

The lower end of a rectum laid open to shew upon its anterior wall two nodules of growth of which the lower is situated four inches above the anus, corresponding to the lowest limit of the recto-vesical pouch, and measures about two thirds of an inch in diameter. The mucous membrane covering it appears normal, but that covering the other nodule is for the most part destroyed by ulceration.

Thomas I., *æt.* 56, was admitted under Dr. Hale White with

jaundice of three months' duration and progressive emaciation. A nodule of growth was felt in the rectum. He died about four and a half months after the onset of symptoms, and at the autopsy a spheroidal-celled carcinoma was found in the stomach, and there were secondary deposits in the glands of the portal fissure. *See Insp.* 1893, No. 416; and *Prep.* 698.

1017 Colloid Carcinoma of the Rectum invading the Bladder.

A sagittal section through the male pelvic viscera shewing the wall of the rectum to be infiltrated by a gelatinous growth which fills the recto-vesical pouch and has invaded the posterior wall of the bladder. Histologically the growth is a cylindrical-celled carcinoma the greater part of which has undergone colloid degeneration.

Mark B., æt. 41, was admitted under Mr. Howse for difficulty in defæcation of seven months' duration. Three months before admission he passed flatus by the urethra and his urine sometimes contained pus and blood. Colotomy was performed, and two days later the patient died suddenly. At the autopsy the left pulmonary artery was found to be occluded by thrombus. *See Insp.* 1882, No. 371.

1018 Carcinomatous Stricture of the Rectum.

A portion of a rectum shewing an annular stricture which barely admits the tip of the little finger. At the situation of the stricture the wall of the bowel is thickened and presents a deep groove, in the bottom of which is seen fat and condensed cellular tissue. The bowel above is hypertrophied. Histological examination shews the stricture to be due to a contracting growth of cylindrical-celled carcinoma.

From a patient who died from rupture of the colon with fecal extravasation into the peritoneal cavity. *See Prep.* 786.

Presented by Mr. Hardy.

1019 Carcinomatous Stricture of the Rectum.

A portion of a rectum shewing a stricture about two

inches long, the lower border of which was situated three inches from the anus. At the seat of the constriction the mucous membrane is for the most part smooth and free from ulceration, and the wall of the bowel is greatly thickened by a dense fibrous growth. Histologically the growth is a carcinoma, a few of the alveoli of which are lined with cylindrical epithelium, the rest being filled with spheroidal cells.

Annie S., æt. 26, was admitted under Dr. Lever for chronic intestinal obstruction the symptoms of which had been noticed for five months. On admission a stricture of the rectum was found barely admitting an "ordinary sized" catheter. She died seventeen days later, and at the autopsy the colon was found to be much distended. There were secondary deposits of growth in the ovaries and peritoneum. *See Insp.* 1856, No. 81.

1020 **Carcinoma of the Rectum. Colotomy.**

A rectum with the pelvic viscera and a part of the ascending colon. The rectum has been laid open from behind and shews a tubular stricture about two inches in length, the lower border of which is situated two and a half inches above the anus. At the constriction the wall of the rectum is infiltrated and partly destroyed by a dense white growth, having the characters of a spheroidal carcinoma, though in a few places alveoli are seen under the microscope which are lined with cylindrical epithelium. Above the stricture the bowel is distended and greatly hypertrophied. On the right side is seen the ascending colon in which is the opening made in colotomy.

From Miss B., æt. 18.

Presented by Mr. Bryant, 1872.

1021 **Carcinomatous Stricture of the Rectum.**

The upper part of a rectum divided by a median section to shew an annular stricture, which in the recent state barely admitted the tip of the little finger. The section

through the stricture shews the mucous and submucous tissues to be infiltrated by a growth which has in parts destroyed the muscular coat and invaded the fat external to the bowel. Histologically the growth is a cylindrical-celled carcinoma.

Caroline H., *æt.* 52, was admitted under Dr. Fagge for chronic intestinal obstruction, for the relief of which left lumbar colotomy was performed. Six days later she died from lobar pneumonia. There were no secondary deposits of growth. *See Insp.* 1883, No. 113.

1022 **Carcinomatous Recto-vesical Fistula.**

A portion of a rectum with the bladder to the fundus of which it is firmly adherent, and with which it communicates by a ragged opening readily admitting the index-finger. At the situation of the fistula the rectum is encircled by a deep ulcer about an inch in width, the edges of which are but slightly thickened. The opening in the fundus of the bladder is surrounded by a prominent mass of growth. The walls of both rectum and bladder are infiltrated by a carcinoma, most of the alveoli of which are filled with spheroidal cells, while a few are lined by cylindrical epithelium.

Henry C., *æt.* 68, was admitted under Mr. Poland for the passage of fecal matter by the urethra. He died a fortnight after his admission and at the autopsy suppurative nephritis was found. There were no secondary deposits. *See Insp.* 1863, No. 314.

1023 **Carcinoma of the Rectum. Recto - vaginal Fistula.**

The lower part of a rectum with the vagina and uterus shewing a fistulous communication between the bowel and the posterior fornix of the vagina. In the rectum the perforation is seen to be situated in the base of a rounded ulcer about an inch and a half in diameter, the edges of which are thick and overhanging. Histological examination of the edge of the ulcer shews it to be

infiltrated by a growth having the characters of cylindrical-celled carcinoma. At the situation of the ulcer the bowel is narrowed, and above it is greatly dilated and hypertrophied.

1024 Carcinoma of the Rectum. Intussusception.

A rectum divided by a median section to shew an intussusception about two inches in length, the apex of which is situated four inches from the anus. At the lowest part of the intussusception the wall of the bowel is thickened and infiltrated by a growth the cut surface of which shews numerous alveoli filled with gelatinous material. Histologically the growth is a carcinoma with colloid degeneration.

Louis S., æt. 44, was admitted under Mr. Birkett for intestinal obstruction for which colotomy was performed. Four days later the patient died from erysipelas and peritonitis. See *Insp.* 1872, No. 84; and *Trans. Path. Soc.* vol. 23, p. 116.

1025 Rectum invaded by Carcinoma.

The lower end of a rectum shewing an oval nodule an inch and a half long and three quarters of an inch broad projecting beneath the healthy mucous membrane and partly obstructing the lumen of the tube. The nodule is continuous with a mass of soft growth which was situated in Douglas's pouch. Histologically the growth is a cylindrical-celled carcinoma with much colloid change.

Anne B., æt. 50, was admitted under Mr. Cock for a malignant growth at the umbilicus. Three months later she died, and at the autopsy the uterus was found to be affected with carcinoma and there were secondary deposits in the liver, peritoneum, mesenteric glands, lungs, and suprarenal capsule. See *Insp.* 1861, No. 101.

1026 Melanotic Sarcoma of the Rectum.

The lower end of a rectum laid open to shew an irregular superficial ulcer about two inches long by one inch wide,

the inferior margin of which is situated half an inch from the anus. A section through the ulcer shews in its base a mass of pigmented growth half an inch in thickness which extends to and in parts destroys the muscular coat. Histologically the growth is a melanotic sarcoma the cells of which are mostly oval in shape.

Richard B., æt. 58, was admitted under Dr. Pavy for dulness at the base of the right chest and an irregular enlargement of the liver. He became jaundiced, and died two months after his admission, having at no time suffered from any symptoms of intestinal disease. At the autopsy numerous masses of melanotic growth were found in the liver and in the portal glands. There was a small black nodule in the skin of the right forearm. *See Insp.* 1872, No. 202.

1027 Rectum opened by Pelvic Abscess.

A rectum with the uterus to which it is firmly united, Douglas's pouch being entirely obliterated by adhesions. The bowel has been laid open from behind and shews on its anterior wall two orifices, one above the other and two inches apart, which lead into a smooth-walled cavity to the right of the uterus. Above and below these apertures the mucous membrane of the rectum presents a number of shallow irregular ulcers.

Presented by Sir Astley Cooper.

1028 Rectum opened by Pelvic Abscess.

A rectum with the uterus and vagina. The bowel is laid open and shews in its right lateral wall about four inches from the anus two rounded perforations communicating with an abscess cavity surrounded by dense inflammatory material. On the reverse of the specimen is seen a globular sac which in the recent state contained pus and is apparently formed by dilatation of the right Fallopian tube.

Ann C., æt. 35, was admitted under Dr. Rees with œdema from chronic nephritis. Ten years before admission she fell and struck the lower part of her abdomen, and soon after an abscess

formed and opened into the rectum. Pus had been passed with the motions ever since. On digital examination the rectum was found much narrowed. She died seventeen days after admission, and at the autopsy the kidneys were found to be large and white, and there was general chronic peritonitis. *See Insp.* 1857, No. 60.

1029 **Rectum opened by Pelvic Abscess.**

A sagittal section through the female pelvic organs shewing behind the uterus a rough-walled cavity which extends downwards between the rectum and vagina almost to the perinæum. About an inch from its lowest limit there is a perforation in the anterior wall of the bowel indicated by a blue rod. Above the uterus and bladder is seen a part of the wall of the abscess cavity which in the recent state was roofed in by adherent coils of intestine.

Rebecca F., æt. 21, was admitted under Dr. Habershon for chronic diarrhoea associated with slight pyrexia and progressive emaciation. She died six months after the onset of her symptoms. At the autopsy the apices of the lungs were scarred and the pelvis of one of the kidneys was dilated. *See Insp.* 1871, No. 372.

1030 **Perforation of the Rectum from without.**

A portion of a rectum firmly adherent to a thick mass of chronic inflammatory tissue and presenting on its mucous surface the orifice of a small sinus. In the recent state this sinus opened upon the buttock by a track which passed through the necrosed ala of the ilium.

James L., æt. 27, was admitted under Mr. Hilton for traumatic synovitis of the right knee joint, for which the limb was amputated nine months after the injury. Eight months after the operation he was readmitted for an abscess about the left hip joint. Three months later he died, having some time previously passed pus by the rectum. At the autopsy the left ilium was necrosed and there was pelvic cellulitis. The spleen, liver, and kidneys were lardaceous. *See Insp.* 1856, No. 95; *Preps.* 1318 (65) & 1335 (10) [2nd Edit.]; and *Drawing*, 33 (13).

1031 Prolapse of the Rectum.

An anus through which is protruded a portion of inverted rectum forming a conical tumour about an inch in length. Through the apex of the prolapse a blue rod has been passed into the lumen of the bowel. At the margin of the anus there is a hæmorrhoid.

1032 Prolapse of the Rectum.

A prolapse of the rectum which presented at the anus and was removed by ligature.

Sophia P., æt. 46, was admitted under Dr. Lever with a sloughing tumour projecting apparently from the vulva. A ligature was placed around it and some days later the mass was cut off. At the autopsy it was found that the prolapse had been attached to the anterior wall of the rectum three inches above the anus, and that by its removal the peritoneal cavity had been opened. There were large blood-clots in Douglas's pouch and there was early peritonitis. *See Insp.* 1857, No. 101.

1033 Anal Abscess.

The lower end of a rectum laid open to shew an abscess cavity about the size of a filbert situated immediately above the anus. The abscess has separated the mucous membrane from the deeper tissues and in the recent state shewed no communication with the bowel.

1034 Fistula in Ano.

The lower end of a rectum with the anus and a portion of the skin of the perinæum. In the anterior wall of the bowel is a longitudinal fistula about two inches in length, the openings of which are equidistant above and below the sphincter. On the reverse of the specimen the red rod indicates an extension of the fistula having a transverse direction.

1035 Anal Fistula.

The lower part of a rectum mounted to shew a fistula opening internally three quarters of an inch above the

margin of the anus, and externally an eighth of an inch below it. On either side of the fistula are large internal and external hæmorrhoids.

Joseph C., æt. 42, was admitted under Dr. Pye-Smith for phthisis, from which he died. He had suffered from piles and diarrhœa for ten years. *See Insp.* 1893, No. 145.

1036 Anal Pouches.

The margin of an anus mounted to shew just within the sphincter several prominent folds of mucous membrane separated from each other by saccular depressions.

1037 Hæmorrhoids.

Four specimens shewing the lower end of the rectum with the margin of the anus mounted to illustrate the appearance presented by piles. There are prominent longitudinal folds of mucous membrane surrounding the orifice. One of these folds has been incised and shews within it a plexus of dilated veins filled with blood-clot.

Presented by Mr. Hilton.

1038 Hæmorrhoids.

The lower end of a rectum from which the external tissues have been removed to expose in the submucous layer numerous small varicose dilatations of the branches of the hæmorrhoidal veins filled with coagulum.

1039 Venereal Condylomata.

Two warty masses removed from the region of the anus. Histologically they consist of branched processes of fibrous tissue covered with a thick layer of squamous epithelium.

SECTION XXI.—FOREIGN BODIES AND CONCRETIONS FROM THE INTESTINE.

Foreign Bodies: 1042-1051.

Intestinal Concretions: 1052-1059.

1042 **Stones passed per Rectum.**

Numerous stones passed in one stool by a lunatic who had swallowed nearly three hundred with suicidal intent. They are seventy-two in number and weigh seven ounces.

The case is reported in the 'Lancet' for August 6th, 1853.

Presented by Mr. W. P. Kirkman.

1043 **Foreign Body passed per Rectum.**

A farthing which was swallowed by a child and passed two days afterwards.

1044 **Knives swallowed by the "Knife-Eater."**

Portions of the blades and handles of several knives together with a metal button, some of which were passed per anum and others were found in the stomach of the "Knife-eater." The steel blades are greatly corroded.

For the history of the case see *Prep.* 595.

1045 **Foreign Body from the Rectum.**

A blade of a penknife measuring one and three quarter inches in length which was passed per anum.

From John N., æt. 8, who swallowed the detached blade of a penknife. It was passed fourteen days after the accident.

Presented by Dr. Babington.

1046 Masses of Fat passed per Rectum.

Numerous masses of fat collected from the evacuations of a patient who suffered from jaundice.

Presented by Dr. Bright, 1836.

1047 Bullet passed per Anum.

A flattened bullet passed per anum.

For history and reference *see Prep. 788.*

1048 Foreign Body from the Rectum.

A piece of bone thought to be the spinous process of a vertebra which was removed from the rectum.

William G., æt. 52, was admitted under Dr. Rees in 1862 for a malignant stricture of the rectum. The bone was impacted in the stricture and was removed by Mr. Bryant.

1049 Foreign Body from the Rectum.

A sickle-shaped piece of bone, an inch in length, which was removed from the rectum.

From a patient who had suffered from an anal abscess. The bone was supposed to have been swallowed in soup.

From Mr. T. E. Bryant's Collection.

1050 Foreign Body from the Cæcal Appendix.

A grain of corn removed through a perforation at the tip of the vermiform appendix.

From a man, æt. 33, who died from acute obstruction of the ileum caused by peritoneal adhesions the result of perityphlitis. *See Trans. Path. Soc.* vol. 36, p. 210.

Presented by Dr. Hale White, 1885.

1051 Foreign Body from the Cæcal Appendix.

A pin an inch long which was found in a cæcal appendix. It is rusted and covered by a white deposit.

George A., æt. 37, was admitted under Dr. Addison in 1836,

for jaundice and enlargement of the liver. At the autopsy a large hepatic abscess was found and the intestines were ulcerated. The pin which forms the preparation was discovered in the cæcal appendix head downwards, with its point projecting through the wall which at this spot only was thickened. *See Insp.* vol. 23, p. 89.

1052 Calculus from the Cæcal Appendix.

An ovoid calculus about a quarter of an inch in its longest diameter which was found in the cæcal appendix. It is white, laminated on section, and apparently phosphatic. There is no visible nucleus.

1053 Concretion from the Cæcal Appendix.

Half of an ovoid concretion about a third of an inch long which was found in the cæcal appendix. It is white and laminated. The nucleus is composed of phosphate of lime with a small amount of triple phosphate, and is surrounded by hardened fæces.

John H., æt. 36, was admitted under Dr. Barlow for general peritonitis from which he died. At the autopsy two concretions were found, one loose in the peritoneal cavity, the other impacted at the root of the cæcal appendix, which was perforated. *See Insp.* 1855, No. 153; *Prep.* 960; and *Drawing*, 325 (27).

1054 Concretions from the Cæcal Appendix.

Several irregular white concretions which were found in a cæcal appendix.

From Mr. C., æt. 22, who was suddenly seized with abdominal pain, vomiting, and collapse. He died five days later from acute peritonitis, and at the autopsy the cæcal appendage was found to be dilated and perforated. *See Insp.* vol. 8, p. 12.

1055 Concretion from the Cæcal Appendix.

A hard whitish ovoid concretion measuring about half an inch in its longest diameter, which was removed by

operation from the cæcal appendix. It has been divided and shows a concentric laminated structure.

Charles S., æt. 23, was admitted under Dr. Mahomed for perityphlitis, of which he had had repeated attacks during the preceding six months. Six weeks later the vermiform appendix was opened and a concretion removed from it by Mr. Symonds. No abscess was found. The patient made a satisfactory recovery and was in good health twenty months after the operation. *See Trans. Clin. Soc.* vol. 18, p. 285.

1056 Intestinal Concretion.

An intestinal calculus about the size of a pigeon's egg which was extracted during life from the rectum. It was analysed by Dr. Odling and found to contain 36.6 per cent. of organic matter, the rest being mineral and consisting almost entirely of phosphate of magnesia with a small quantity of carbonate of magnesia.

Presented by Dr. Addison.

1057 Intestinal Concretion.

A half of a large fæcal concretion roughly quadrilateral in shape, measuring about an inch from side to side. It is brown and hard, and is stated to consist of "siliceous deposit from oatmeal."

1058 Intestinal Calculus.

Half of an intestinal calculus about the size of a pigeon's egg. Its outer surface is granular and nodulated and its cut section shows a brown nucleus of fæcal origin surrounded by a white chalky-looking material. This was analysed by Dr. Rees and found to "consist of phosphate of lime with traces of alkaline chloride cemented by fæcal matter."

From John J., a boy, who died from tuberculous disease of the mesenteric glands, peritoneum, and pleura associated with a large fæcal abscess. The calculus was found in a sinus which led from the cæcum through the abdominal parietes. *See Note Book*, No. 2, p. 39.

Presented by Dr. Bright.

1059 Fæcal Calculus.

A brown oval concretion measuring one and a quarter inches in its longer diameter, the cut surface of which presents concentric laminæ.

Eliza G., æt. 56, was admitted under Mr. Durham in 1882 with an umbilical hernia which had been strangulated for nine days. Herniotomy was performed, and the sac was found to contain gangrenous omentum and a portion of colon. The calculus which forms the preparation escaped during the operation from a sacculus of the colon in which it was lodged. The patient made a good recovery. *See Surgical Reports*, vol. 95, Case 73.

SECTION XXII.—INTESTINAL OBSTRUCTION.

(Excluding Strictures and External Herniæ.)

- Strangulation by a Diverticulum: 1060-1065.
 „ by Cæcal Appendix: 1066-1068.
 „ by Fallopian Tube: 1069.
 „ by Appendices Epiploicæ: 1070, 1071.
 „ by Peritoneal Bridle: 1072-1075.
 Obstruction from Contraction of Mesentery: 1076-1078.
 „ from Kinking of Bowel: 1079-1081.
 Retroperitoneal Hernia: 1083, 1084.
 Diaphragmatic Hernia: 1085-1089.
 Volvulus: 1090.
 Intussusception: 1091-1110.

1060 Strangulation by a Diverticulum.

A portion of the lower end of an ileum shewing a diverticulum about four inches long which is pervious and attached to the umbilicus. The diverticulum, which arises from the free border of the intestine, is bent over towards the mesentery, thus compressing and obstructing the bowel. Above the obstruction the gut is dilated and below it is contracted.

Elizabeth W., æt. 10, was admitted under Dr. Wilks for symptoms of intestinal obstruction of nine days' duration. She died two days after admission, and at the autopsy acute peritonitis was found. *See Insp.* 1864, No. 193.

1061 Strangulation of the Ileum by a Diverticulum.

A portion of the lower end of an ileum mounted to shew a diverticulum about three inches long, the apex of which is attached by a thin fibrous cord to the mesentery. Through the loop thus formed a coil of intestine passed and became strangulated.

Presented by Dr. Gull, 1865.

1062 Strangulation by a Diverticulum.

A portion of an ileum shewing a short diverticulum which was situated twenty-four inches above the ileo-cæcal valve. From the free end of the diverticulum a thin fibrous cord passes to the mesentery, thus forming a loop. The mesenteric glands are enlarged.

William B., æt. 15, was admitted under Dr. Moxon with symptoms of acute intestinal obstruction, from which he died ten days from the onset of his illness. At the autopsy the jejunum was found enormously distended and a coil of ileum which had slipped through the loop was strangulated. The diverticulum contained a fæcal concretion. *See Insp.* 1871, No. 291.

1063 Ileum strangulated by a Diverticulum.

A considerable portion of an ileum mounted to shew a loop, about two and a half feet long, strangulated by a diverticulum situated thirty inches above the ileo-cæcal valve. This foetal relic passes around the entering and returning parts of the gut and forms a loop, the free end of which is secured between the strangulated bowel and its own proximal portion. The blue and red rods indicate the course of the bowel and of the diverticulum respectively.

From G. B., a porter, who was admitted into St. George's Infirmary with symptoms of acute intestinal obstruction of fifteen hours' duration. A round swelling, with ill-defined outline, was felt in the right iliac region extending up towards the umbilicus. The patient declined operation, and died twenty hours after the onset of his illness. At the autopsy it was found that the portion of ileum strangulated was that immediately above the origin of the diverticulum. *See Guy's Hospital Gazette*, vol. 7, p. 183.

Presented by Mr. C. Pollard, 1893.

1064 Constriction of the Ileum by a Diverticulum.

Two portions of ileum with the ileo-cæcal valve. The proximal portion shews a diverticulum about three inches long from the apex of which a short fibrous cord

passes over and partly encircles the distal portion, to the mesentery of which it is attached four inches above the ileo-cæcal valve. Where the bowel is encircled by the band its lumen is considerably narrowed.

Alfred T., æt. 60, was admitted under Mr. Bryant for cystitis of three years' duration. Two calculi were removed from the bladder by lithotomy, and the patient died three days later from peritonitis. At the autopsy a perforating ulcer of the bladder was found associated with diffuse pelvic cellulitis. *See Insp.* 1885, No. 83.

1065 Diverticulum attached by a Band to the Mesentery.

A portion of an ileum from which springs a diverticulum, its course being indicated by a light blue rod. At its commencement the diverticulum is about the thickness of a goose quill; its distal portion is dilated, forming a globular sac as large as a pigeon's egg. An inch from the extremity of the diverticulum there is attached a thin fibrous cord which is connected with the mesentery close to the origin of the diverticulum. Through the loop thus formed, beneath which a red rod has been passed, a coil of ileum has slipped, and though constricted shews no signs of strangulation. The wall of the dilated portion of the diverticulum is thickened and its serous surface is covered with granular lymph.

Mary F., æt. 49, was admitted under Mr. Howse with a femoral hernia which had been strangulated for nine days. Herniotomy was performed, and the patient died three days after admission. At the autopsy it was found that the diverticulum of the ileum had formed the contents of a hernial sac. There was general peritonitis. *See Insp.* 1884, No. 418.

1066 Strangulation of the Ileum by Adherent Cæcal Appendix.

The lower end of an ileum with the cæcum. The appendix is bent round over the ileum just above the valve, and its apex is adherent to the free border of the bowel two feet higher up. At these two points the gut

is thus tightly constricted by a band, and the intervening coil of ileum was in the recent state deeply congested.

Henry H., æt. 46, was admitted under Dr. Taylor for vomiting and abdominal pain, with which he was suddenly seized two days previously. He died three days after admission, and at the autopsy tuberculous consolidation of the lungs was found, and the aortic valves were incompetent. *See Insp.* 1890, No. 31.

1067 Strangulation by Adherent Cæcal Appendix.

A cæcum with the lower part of the ileum mounted to shew the vermiform appendix adherent by its extremity to the mesentery. Through the loop thus formed a large coil of intestine has slipped and become strangulated.

1068 Strangulation by adherent Cæcal Appendix.

A cæcum with the lower end of the ileum. The cæcal appendix which has a well marked mesentery is attached by its apex to the mesentery of the ileum and thus forms a loop beneath which a coil of intestine was strangulated. *Presented by Mr. Callaway.*

1069 Strangulation of Ileum by adherent Fallopian Tube.

The female pelvic viscera with a portion of the ileum mounted to shew the right Fallopian tube turned upwards and backwards and firmly attached by its fimbriated extremity to the rectum. A loop is thus formed through which a coil of intestine about six inches in length has passed and become strangulated. Douglas's pouch is obliterated by old adhesions.

Elizabeth N., æt. 60, was admitted under Dr. Goodhart with intestinal obstruction. Her bowels had been confined for three weeks and she had been frequently vomiting during the seven days previous to her admission. Two days after admission laparotomy was performed and on the next day she died. At the autopsy the strangulated loop of bowel was found to be a portion of the ileum immediately above the cæcum. *See Insp.* 1884, No. 138.

1070 Strangulation of the Ileum by Appendices Epiploicæ.

A portion of the sigmoid flexure of a colon coated with fat, and presenting large appendices epiploicæ. Two of these are adherent to each other by their tips, and through the aperture thus formed a loop of ileum five inches in length has slipped and become strangulated.

Annie H., æt. 48, was admitted under Dr. Perry for intestinal obstruction of six days' duration. Laparotomy was performed, but the cause of the obstruction was not discovered, and the patient died the next day. At the autopsy the strangulated loop of bowel was found to be four inches above the cæcum. See *Insp.* 1888, No. 302; and *Trans. Path. Soc.* 1889, p. 93.

1071 Strangulation of the Ileum by Adherent Appendices Epiploicæ.

A portion of the sigmoid flexure of a colon, two of the appendices epiploicæ of which are adherent to the mesentery of the ileum just above the cæcum.

Robert D., æt. 51, was admitted under Mr. Davies-Colley for anal fistulæ. An enema was administered and was followed by pain and vomiting, to which he rapidly succumbed. At the autopsy a loop of ileum eight feet in length was found to have slipped beneath the band formed by the sigmoid flexure and its appendices, and to have become strangulated. See *Insp.* 1891, No. 153.

1072 Compression of the Ileum by a Band.

A portion of an ileum with a large diverticulum four inches in length and two inches in diameter. Crossing the ileum and somewhat constricting it there is a rounded fibrous cord four and a half inches long, one end of which is attached to the side of the diverticulum and the other to the mesentery of the constricted portion of bowel.

John L., æt. 40, was admitted under Dr. Bright in 1829 for ascites and anasarca and died six weeks after his admission. At the autopsy the omentum was contracted and there was recent

peritonitis. There was considerable distension of the bowel above the constriction, which was situated about the middle of the ileum. See *Insp.* vol. 14, p. 108.

1073 Strangulation of the Ileum by a Band.

A portion of ileum mounted to shew the condition left after constriction by a band. At this point the bowel is narrowed, marked by a deep groove, and bent upon itself by contraction of the mesentery.

Frederick B., æt. 21, was admitted under Dr. Fagge for acute intestinal obstruction of three days' duration. Two days after admission laparotomy was performed and a fibrous band divided. The patient died five days after the operation. At the autopsy the stricture was found to be situated four feet four inches above the cæcum. See *Insp.* 1883, No. 118.

1074 Obstruction of the Colon by a Band.

A cæcum with the anterior edge of the liver and a portion of the abdominal parietes. Passing between the liver and the lateral wall of the abdomen there is a short fibrous band which crosses over and obstructs the ascending colon. The vermiform appendix, indicated by a blue rod, is turned upwards and attached by old adhesions to the margin of the liver. The cæcum is greatly distended.

George H., æt. 62, was admitted under Dr. Pitt for intestinal obstruction of three days' duration. Left lumbar colotomy was performed and the patient died seven days after the onset of symptoms. See *Insp.* 1887, No. 309.

1075 Double Strangulation of the Intestine.

A uterus with a coil of small intestine which presents a double strangulation, one produced by a band, the other by a hole in the broad ligament. The band arises from the right horn of the uterus and passes to the fimbriated end of the Fallopian tube. Of the three or four feet of bowel which have passed through the loop formed by the band twenty-one inches were tightly constricted by the margins of the hole in the broad ligament.

From a married woman, æt. 36, who died three days after the onset of symptoms of acute intestinal obstruction.

Presented by Mr. H. Taylor.

1076 Intestinal Obstruction from Contraction of the Mesentery.

A portion of small intestine the coats of which are greatly hypertrophied, the lumen being narrowed at one part by contraction of the mesentery, which is greatly thickened and presents several enlarged glands in some of which there are caseous deposits.

Charles S., æt. 29, was admitted under Dr. Rees for symptoms of chronic intestinal obstruction. He died four days after the onset of his illness, and at the autopsy the intestine was found to have given way above the obstruction and there was general peritonitis. *See Insp.* 1861, No. 211.

1077 Intestinal Obstruction from Carcinomatous Contraction of the Mesentery.

The lower end of an ileum with the uterus and appendages of the right side. The mesentery is infiltrated and contracted by carcinomatous deposit and the bowel at this part is twisted upon itself and considerably narrowed. Above the obstruction the gut is dilated and its mucous membrane ulcerated. The ovary is enlarged by similar malignant growth.

Mary C., æt. 33, was admitted under Dr. Rees for intestinal obstruction of three days' duration, from which she died twelve days later. She had suffered for two years from vomiting and epigastric pain. At the autopsy malignant growth was found in the stomach and in both ovaries. *See Insp.* 1868, No. 137.

1078 Carcinoma of the Ileum and Mesentery. Obstruction.

A coil of intestine about a foot long taken from the lowest part of the ileum. The ends of the loop are firmly united by a mass of growth in the mesentery. The bowel has been laid open and shews at its upper

end the prominent edge of a growth which is deeply ulcerated and communicates by a sinus with a cavity between the bowel and adherent abdominal parietes. There is a second sinus leading from this cavity into the distal end of the coil of bowel. Histologically the growth is a cylindrical-celled carcinoma.

From Mrs. M., æt. 59, who after suffering for four months from intermittent attacks of abdominal pain and constipation, was seized with definite symptoms of intestinal obstruction. A tumour was felt in the abdomen, and she died sixteen days after the onset of urgent symptoms. At the autopsy the tumour was found to consist of a carcinomatous mass in the omentum and there were numerous other secondary deposits on the peritoneum. See *Guy's Hosp. Reps.* vol. 68, p. 328.

Presented by Mr. Ray.

1079 Peritoneal Adhesion leading to Kinking of the Ileum.

A coil of ileum adherent by a short diverticulum to the abdominal wall in the region of the umbilicus. At this point the intestine presents a V-shaped bend and the portion of bowel which forms one limb of the V has become laterally adherent to the fold of mesentery stretched between it and the other limb.

Isaac L., æt. 43, was admitted under Dr. Bright in 1828 for intestinal obstruction of two weeks' duration. He had suffered from some severe abdominal attack three years previously. He died three days after admission, and at the autopsy it was thought that the obstruction had been caused by kinking of the bowel at the situation of the adhesion. See *Insp.* vol. 7, p. 8.

1080 Obstruction of the Colon by Kinking.

A portion of a colon crossed at its splenic flexure by a band one end of which is adherent to the serous coat of the bowel, and the other to the parietal peritoneum of the flank. Above the obstruction thus produced the bowel is greatly distended.

Samuel P., æt. 48, was admitted under Dr. Rees for intestinal obstruction of seven days' duration. He died a week later and at

the autopsy the colon was found to be bent upon itself at an acute angle at the situation of the peritoneal band. There was recent lymph upon the serous membrane. *See Insp.* 1867, No. 165.

1081 Intestinal Obstruction from Kinking.

A portion of jejunum with its mesentery the lymphatic glands of which are enlarged. The bowel is seen to be sharply bent upon itself at a spot where the mesentery is shortened by old inflammation. Above the obstruction thus produced the intestine is considerably dilated.

Robert G., *æt.* 10, was admitted under Dr. Hale White for acute intestinal obstruction, from which he died five days after the onset of symptoms. *See Insp.* 1887, No. 303.

1082 Opening in Omentum. Strangulation.

A piece of omentum shewing a circular hole about an inch in diameter through which a loop of bowel slipped and became strangulated.

James A., *æt.* 61, was admitted under Dr. Moxon with symptoms of acute intestinal obstruction of three days' duration. He died three days after admission, and at the autopsy it was found that the last three feet of the ileum had passed through the aperture in the omentum. *See Insp.* 1871, No. 15.

1083 Retroperitoneal Hernia.

The splenic flexure and descending part of a colon, in the angle between which is situated a globular peritoneal sac measuring about four inches in diameter and containing several feet of small intestine. The mouth of the sac is directed towards the vertebral column and along its anterior margin is seen the left colic artery.

Presented by Dr. Pyc-Smith.

1084 Retroperitoneal Hernia.

A *cæcum* with the ascending and transverse colon and a coil of ileum: About eighteen inches of the coil of ileum is contained in a sac formed from the peritoneum and situated between the ascending colon and the verte-

bral column. The mouth of the sac is directed downwards towards the pelvis and does not appear to have constricted the hernia.

1085 Diaphragmatic Hernia.

The viscera of a fœtus exposed to shew a congenital deficiency of the greater part of the left leaf of the diaphragm. The left lobe of the liver, the stomach, and most of the intestines are seen in the thoracic cavity.

1086 Diaphragmatic Hernia.

The trunk of a fœtus from which the anterior wall of the thorax and abdomen has been removed to shew the left side of the chest occupied by the stomach and the rest of the alimentary canal as far as the splenic flexure of the colon, which have passed through a congenital deficiency in the left half of the diaphragm.

The case is reported in the *Trans. Path. Soc.* 1892, p. 79.

Presented by Dr. Wills.

1087 Diaphragmatic Hernia.

A diaphragm with the neighbouring structures mounted to shew the arrangement of the parts in a diaphragmatic hernia. In the position of the œsophageal opening through the diaphragm there is a circular aperture measuring nearly three inches in diameter through which has passed into the right side of the chest the pyloric half of the stomach with a portion of the transverse colon and the omentum. The edge of the aperture is smooth and fibrous and by constricting the central part of the stomach has given an hour-glass shape to that organ.

Presented by Dr. Hales.

1088 Diaphragmatic Hernia.

A portion of a diaphragm with the stomach and spleen mounted to shew a smooth-edged perforation of the

diaphragm measuring about two inches in diameter through which part of the stomach and great omentum has passed into the thoracic cavity and become strangulated. Below the diaphragm the stomach is seen with its lesser curvature and its œsophageal and pyloric orifices directed downwards.

1089 Diaphragmatic Hernia.

The left leaf of a diaphragm presenting a circular opening with smooth fibrous edges which measures two and a half inches in diameter. To the margin is attached a small piece of omentum.

Edward L., æt. 40, was admitted under Mr. Morgan in 1838 and died after amputation of the leg. Nine months previously he had received severe injuries to his chest in falling from the rigging of a ship. At the autopsy the left lung was found to be pushed upwards and its lower part compressed. Below it in the thoracic cavity lay the stomach with the transverse part of the colon. There was a healed fracture of the fifth rib on the left side. See *Insp.* vol. 26, p. 157; and *Preps.* 1072 (50) [2nd Edit.] & 346.

1090 Volvulus of the Ileum.

A loop of ileum laid open to shew its central portion dilated and thickened as the result of strangulation. The part thus affected is thirty inches long, and at either end its condition contrasts with that of the thin healthy gut. In the descending limb of the loop is seen the opening made by operation.

Alfred H., æt. 2 days, was admitted under Mr. Lucas for intestinal obstruction, supposed to be due to imperforate rectum. The bowel was opened in the left inguinal region, and the infant died on the same day. At the autopsy the volvulus was found to have its commencement two feet above the ileo-cæcal valve. See *Insp.* 1890, No. 397.

1091 Intussusception (Jejunal).

A duodenum with the upper part of the jejunum shewing an intussusception about nine inches long. The

neck of the intussusception is at the top of the jejunum. There is a polypoid growth at the apex of the intussusception, and others are seen in the duodenum upon the returning layer, the wall of which is much thickened and folded upon itself.

From Eliza W., æt. 19, who suffered from periodical attacks of vomiting and abdominal pain for a year and three quarters before her death. A kidney-shaped tumour was felt in the lower part of her abdomen which towards the end of her illness was observed to undergo "slow rhythmic alterations, being alternately hard and well-defined and soft and ill-defined." At the autopsy the stomach was found to be greatly dilated. *See Trans. Clin. Soc.* vol. 19, p. 146.

Presented by Mr. Sandford Arnott, 1886.

1092 **Intussusception (Enteric).**

A portion of small intestine shewing an intussusception which measures seven inches along its convex border. The receiving layer is of normal thickness, while the entering and returning layers are much swollen. The opening at the apex of the intussusception is slit-like and drawn towards the mesenteric attachment of the intestine.

From Dr. B., who while suffering from epidemic influenza in 1833, manifested symptoms of pulmonary affection for which he was treated by an emetic and by castor oil. During the four days preceding his death he vomited frequently. *See Insq.* vol. 20, p. 37.

1093 **Intussusception (Enteric).**

A portion of ileum two and a half feet above the cæcum shewing an intussusception which in the recent state measured five inches. The sheath has been laid open and turned back to expose the intussusception. The returning layer, the wall of which is about one third of an inch in thickness, has been partially removed to shew the entering layer collapsed but not otherwise altered. In the space between the entering and returning layers there is a considerable quantity of coagulated lymph.

Thomas P., æt. 25, was admitted under Dr. Pavy four hours after the onset of acute symptoms of intestinal disturbance. He died the day after his admission. At the autopsy acute peritonitis was found and the intestine below the intussusception contained "glutinous black blood." See *Insp.* 1866, No. 190; and *Guy's Hosp. Repts.* 1868, p. 298.

1094 Intussusception (Enteric).

A small enteric intussusception beneath which is mounted a mass of coagulated lymph and blood-clot, which, in the recent state, occupied the space between the sheath and the intussusception.

Presented by Sir Astley Cooper.

1095 Intussusception (Ileic).

A portion of ileum shewing an intussusception about three inches long. The sheath has been laid open to expose the lower part of the returning layer, the mucous membrane of which is dark, and in the recent state exhibited signs of gangrene. Just below the apex of the intussusception is a short diverticulum which was situated two feet above the ileo-cæcal valve. There is recent lymph upon the peritoneum.

Eliza N., æt. 16, was admitted under Mr. Birkett for a deformed toe and was attacked with acute rheumatism. Ten days before her death she complained of abdominal pain, and three days later urgent vomiting came on. At the autopsy the intussuscepted portion of bowel extended as far as, and partially filled the diverticulum. There was a small perforation in the ensheathing layer and the peritoneum was inflamed. See *Insp.* 1867, No. 230; and *Guy's Hosp. Repts.* 1867, p. 467.

1096 Intussusception (Ileo-cæcal).

A cæcum with parts of the ileum and colon in a condition of invagination. The intussusception has been dissected to expose the cæcal appendix lying between the entering and returning layers and opening close beside the apex of the intussusception, which is

formed by the ileo-cæcal valve. The middle layer is thickened.

From an infant, æt. 3½ months, who was suddenly seized with vomiting, and subsequently passed more than a tea-cupful of fluid blood. The child died three days after the onset of symptoms. See *Guy's Hosp. Repts.* 1838, p. 347.

1097 Intussusception (Ileo-cæcal).

The lower end of the ileum with the cæcum and the greater part of the colon shewing the condition of invagination. The sigmoid flexure which forms the lower part of the receiving layer has been slit open and partially exposes the intussuscepted portion of gut. A vertical section made through the parts thus exposed shews that the opening at the apex of the intussusception leads into two cavities, one which is the lumen of the entering portion of ileum, the other which is the inverted cæcum at the upper end of which is seen the orifice of the vermiform appendix. A blue rod which has been introduced into the ileum at the apex of the intussusception protrudes through an opening in the gut four inches higher up, around which there is considerable ulceration. Upon the mucous surface of the sigmoid flexure there is an irregular ulcer, the perforation of which led to fatal peritonitis. The ileum above the intussusception is greatly hypertrophied.

Daniel D., æt. 15, was admitted under Dr. Hughes for colicky pains, tenesmus, and the passage of bloody motions. He passed a lumbricus and vomited another. He died ten weeks from the onset of symptoms. At the autopsy general peritonitis was found. See *Insp.* 1856, No. 67; and *Drawing*, No. 315 (80).

1098 Intussusception (Ileo-cæcal).

A cæcum with the adjacent portions of the ileum and colon, shewing an invagination about two inches in length. The colon forms the receiving layer and the apex of the intussusception corresponds with the situation of the ileo-cæcal valve. The lower end of the

entering gut is indicated by a yellow rod, by the side of which is seen the orifice of the appendix cæci, into which a red rod has been passed. This variety of intussusception is commonly called ileo-cæcal.

From a child, æt. 8 months, who died with symptoms of intestinal obstruction of three days' duration.

Presented by Mr. Collambell, 1857.

1099 **Intussusception (Ileo-colic).**

A cæcum with the first part of the ascending colon laid open to shew a prolapse of the apex of an ileic intussusception through the ileo-cæcal valve. The prolapsed portion of gut is about four inches long and its mucous membrane is thickened and partially covered with fibrinous exudation. The entering angle of the intussusception is about two inches above the valve.

Presented by Dr. William Gull.

1100 **Intussusception (Double).**

A cæcum with the lower end of the ileum and the greater part of the colon shewing invagination. The ensheathing layer has been laid open to expose the thickened returning layer, both layers being formed entirely by the colon. By the removal of a part of the returning layer the entering portion of the intestine is shewn to consist of the cæcum and lower part of the ileum. At the junction of the ileum and cæcum, indicated by the attachment of the cæcal appendix, into which a pink rod is passed, is seen a groove, marked by a yellow rod, corresponding to the entering angle of a very short intussusception of the ileum through the ileo-cæcal valve.

W. B., a boy, æt. 5, was admitted under Dr. Fagge in 1868 for abdominal pain with a tumour in the hypochondriac region. His illness began two months previously with severe colic, which continued in a less degree at irregular intervals until his admission. He died one month later, having passed blood and mucus per

anum during the last week of his illness. There was no general peritonitis. *See Guy's Hosp. Repts.* 1868, p. 289.

1101 Multiple Intussusceptions.

A portion of the small intestine of a child mounted to shew three short intussusceptions. There is little if any change in the portion of gut involved, and it is probable that they have arisen in articulo mortis.

Presented by Mr. R. Stocker.

1102 Retrograde Intussusception.

A portion of ileum shewing three short intussusceptions, of which the upper and lower are "progressive," and the middle one, which is best seen on the reverse of the specimen, is "retrograde."

From a patient who died from diabetes. There were no symptoms of intestinal obstruction, and the intussusceptions were probably formed in articulo mortis.

1103 Intussusception.

A portion of intestine consisting of the lower end of the ileum and the cæcum which formed an intussusception. The invagination has been reduced and the specimen is mounted to shew the swollen state of the solitary and agminated glands resulting from venous obstruction.

William T., æt. 4 months, was admitted under Mr. Howse for sudden abdominal pain associated with vomiting and the passage of slimy motions containing blood. He died two days after the onset of his illness, and at the autopsy an intussusception was found in the ileo-cæcal region which could with some difficulty be reduced by inflation. *See Insp.* 1885, No. 174.

1104 Intussusception passed per Anum.

A cæcum with the whole of the ascending colon passed during life. The gut has been laid open and shews extensive superficial ulceration of the mucous surface.

From W. P., a boy, æt. 6, who was seized with vomiting and abdominal pain, and eleven days after the onset of symptoms

passed the portion of intestine which forms the preparation. He completely recovered and forty years afterwards was treated at the Out-patient department for indigestion. *See Lancet*, June, 1854; and *Drawing*, 321 (22).

1105 Intussusception passed per Anum.

A cæcum with the last inch of the ileum and the upper part of the colon, the whole measuring twelve inches in length. The intestine is turned inside out, and the orifice of the cæcal appendix is seen upon its external surface.

From a child, æt. 12 months, who had passed blood by the bowel. It recovered. *See Guy's Hosp. Reps.* 1868, p. 302.

Presented by Dr. Heginbothom.

1106 Intussusception passed per Anum.

A portion of small intestine eighteen inches in length the ends of which are ragged and partially destroyed.

Ellen H., æt. 33, was seized with symptoms of intestinal obstruction and twelve days later passed three large motions, one of which contained the piece of bowel forming the preparation, which when first expelled was invaginated. Two years later the patient was alive and well.

Presented by Dr. Ewen, 1888.

1107 Diverticulum of the Ileum causing intussusception.

A portion of an ileum shewing a short diverticulum which is inverted and formed the apex of an intussusception. There are patches of inflammatory exudation upon the mucous membrane lining the tip of the inverted diverticulum and upon the part of the gut immediately above it. The solitary glands are ulcerated.

James C., æt. 22, was admitted under Dr. Fagge for constipation, vomiting, and abdominal tenderness of five days' duration. Laparotomy was performed the day after admission, and an intussusception was found and reduced without difficulty; the patient

died some hours later. At the autopsy general peritonitis was found. The diverticulum was situated thirty inches above the ileo-cæcal valve. *See Insp.* 1874, No. 173.

1108 **Intussusception caused by a Polypus.**

A portion of an ileum shewing an intussusception measuring seven inches along its convex border. The sheath has been laid open at its lower end to shew the apex of the intussusception formed by a polypus about the size and shape of a chestnut. The polypus is attached to the intestine by a broad pedicle, at the side of which is seen the lower opening of the entering portion of gut. The tumour which is superficially ulcerated consists of well-formed fibrous tissue. The intussusception was situated about three feet above the cæcum.

Hannah K., æt. 42, was admitted under Dr. Moxon for gnawing pain at the umbilicus of nine months' duration, associated with diarrhœa, vomiting, and abdominal distension. She died five weeks after admission, and at the autopsy the peritoneal cavity contained lymph and feculent material. *See Insp.* 1879, No. 88.

1109 **Chronic Intussusception from Growth.**

A vertical section through the intestine in the cæcal region to shew the condition of the parts in chronic intussusception dependent upon growth. The portion of the intestine forming the apex and the returning layer of the intussusception is enormously thickened partly by inflammatory œdema and partly by infiltration of growth, which histologically has the characters of spheroidal-celled carcinoma with much colloid degeneration. To the naked eye the carcinomatous deposit presents a gelatinous appearance. In the colon below there is a sloughing mass of growth attached by a slender pedicle to the apex of the intussusception.

From a woman, æt. 50, who was admitted in 1882 for "chronic intestinal disturbance and a lump in the right flank. She passed a large shred of sloughing tissue."

1110 Intussuscepted Growth in the Colon.

A portion of a colon in a condition of invagination. The intussusception is about five inches in length. The wall of the intestine at the returning angle is greatly thickened, and the mucous membrane of the entering layer is partially destroyed by ulceration. Histological examination shews that the wall of the gut at this part is infiltrated by a growth of cylindrical-celled carcinoma.

Presented by Mr. Birkett, 1867.

SECTION XXIII.—THE ANATOMY AND RESULTS OF HERNIA.

- Infantile Hernia : 1111-1113.
 Congenital Hernia : 1114-1121, 1144.
 Inguinal Hernia : 1122-1137.
 Oblique : 1122, 1123, 1123, 1129.
 Direct : 1124-1129.
 Femoral Hernia : 1138-1143.
 Umbilical Hernia : 1144-1149.
 Ventral Hernia : 1150.
 Obturator Hernia : 1151-1154.
 Littre's Hernia : 1155-1158.
-
- Double Sac : 1120, 1132, 1154, 1159.
 Suppurating Sac : 1160.
 Cartilaginous Sac : 1161.
 Carcinomatous Sac : 1162.
-
- Omental Hernia : 1121, 1142, 1163, 1164.
 Hernia of the Stomach : 1165.
 " " the Cæcal Appendix : 1166.
 " " the Sigmoid Flexure : 1167.
 " " an Appendix Epiploica : 1168.
 " " a Fallopian Tube and Ovary : 1169.
 " " the Bladder : 1170.
-
- Strangulated Bowel in Hernia : 1171-1174.
 Gangrenous Bowel in Hernia : 1175-1181.
 Perforated Bowel in Hernia : 1179-1182.
 Ulcerated Bowel in Hernia : 1183, 1185.
 Adhesions following Hernia : 1186, 1187.
 Stricture following Hernia : 1184.
 Artificial Anus following Hernia : 1188, 1189.
-
- Radical Cure : 1137.
 Reduction *en masse* : 1134-1136, 1143.
 Bowel ruptured by Taxis : 1190.
 Bowel wounded in Herniotomy : 1191.
 Enterectomy : 1158, 1171.
-

1111 Infantile Hernia.

The sac of an oblique inguinal hernia laid open to shew the anatomy of the condition known as infantile hernia or encysted hernia of the tunica vaginalis. The thin external sac at the bottom of which lies the exposed testis is the vaginal process of the peritoneum, which persists though shut off at its upper part from the abdominal cavity. Into this projects the thick-walled sac which contained the hernial protrusion of the bowel.

1112 Strangulated Infantile Hernia.

The parts concerned in a strangulated inguinal hernia of the so-called infantile variety. The strangulated knuckle of bowel projects through the external abdominal ring into a small thin-walled sac which is contained within the persistent vaginal process of the peritoneum. The two sacs are entirely distinct except around the neck, where, as is characteristic of this form of hernia, the vaginal process has been shut off from the general peritoneal cavity.

William C., æt. 31, was admitted under Dr. Thompson Forster in 1801 for a strangulated inguinal hernia on the right side. The hernia could not be reduced by taxis and the patient refusing operation died three days after the onset of acute symptoms. See Astley Cooper on 'Hernia;' second edition, edited by Aston Key, pt. i. p. 80, and pl. 11. fig. 2.

1113 Infantile Hernia.

The sac of an oblique inguinal hernia on the right side with the omentum which was contained in it. The omentum has been withdrawn from the sac, but is still adherent around the neck. The persistent vaginal process of the peritoneum has been laid open and is seen to contain the thick-walled sac of the hernia, the lower end of which is in contact with the testicle. The two sacs are distinct anteriorly but united behind.

William H., æt. 30, was admitted under Mr. Cooper Forster with a hernia from which he had suffered for six years

and which had been strangulated for two hours. Herniotomy was performed and a large piece of omentum contained in the sac was ligatured and removed; the intestine was reduced. The patient died three days later, and at the autopsy the portion of bowel that had been strangulated was found to be situated at the lower end of the ileum, and there was general peritonitis. *See Insp.* 1876, No. 137.

1114 **Congenital Funicular Hernia.**

A hernial sac formed by the patent funicular process of the peritoneum, below which the testis is seen in the closed tunica vaginalis. The contents of the sac, which consist of the cæcum and a portion of the ileum, have been withdrawn and are attached to the neck of the sac by a fold of peritoneum proceeding from the ileum.

William S., æt. 13 months, was admitted under Mr. Durham with bronchitis and an inguinal hernia which had been noticed for some months. He died from convulsions. *See Insp.* 1885, No. 343.

1115 **Congenital Hernia.**

The parts concerned in a congenital hernia of the right side. A blue rod has been passed from the internal ring into the vaginal process of peritoneum which formed the sac of the hernia and has been laid open to expose the testis.

James B., æt. 26, was admitted under Mr. Bransby Cooper in 1827 for a hernia which had existed from birth and had been strangulated for some hours. The sac was opened, the intestine returned, and a portion of omentum removed. He died two days later, and at the autopsy the abdominal cavity contained a pint and a half of blood which was thought to have proceeded from the omentum. *See Insp.* vol. 4, p. 37.

1116 **Strangulated Congenital Hernia.**

The parts concerned in a right inguinal hernia. The sac has been laid open and is seen to contain a knuckle of small intestine and a piece of omentum in close contact with the testis. There is recent lymph upon the serous lining of the sac.

1117 Incarcerated Congenital Hernia.

The right half of a scrotum incised to shew the thickened sac of a large congenital hernia. The contents of the sac have been pulled upwards and are seen to consist of a globular mass of coherent coils of ileum measuring three and a half inches in diameter. A section has been made through the incarcerated intestine and shews the serous and subserous coats to be enormously thickened. At the upper part of the hernia is seen an opening into the bowel made by operation. The intestine is partially adherent to the neck of the sac but is not strangulated.

William C., æt. 42, was admitted under Mr. Bryant for a swelling affecting the right side of the scrotum. It had been noticed for twenty years and had been frequently tapped as a hydrocele. On admission paracentesis was again resorted to and was followed by abdominal pain, constipation, and sickness. Four days later the swelling was found to be a hernia and an exploratory incision was made, the bowel being opened. Fæces passed through the wound, but the patient died ten days after the operation, and at the autopsy general peritonitis and recent pleurisy were found. *See Insp.* 1874, No. 43.

1118 Congenital Hernia. Partial Closure of Sac.

The parts concerned in a congenital hernia on the right side. The walls of the sac are thickened and its inner surface and the testis are partially covered with lymph. On the reverse of the specimen the neck of the sac is seen to be almost obliterated, the course of the epigastric artery to its inner side being indicated by a red rod.

Robert G., æt. 27, was admitted under Mr. Durham with a strangulated hernia which was relieved by operation. The patient died a week later from peritonitis, and at the autopsy the tunica vaginalis on the left side was also found to communicate with the peritoneal cavity. *See Insp.* 1864, No. 278.

1119 Congenital Hernia. Undescended Testis.

The sac of a left scrotal hernia, the anterior wall of which has been removed to shew in its upper part, close to the outer side of its neck, the undescended testis. Above the testis the sac is prolonged upwards for a short distance forming a pouch, which in the recent state lay upon the iliacus muscle.

William G., æt. 24, was admitted under Mr. Hilton with a congenital hernia on the left side which had been strangulated for some days. Herniotomy was performed, and the patient died four hours later. At the autopsy the strangulated portion of intestine, which was situated four feet above the cæcum, was found to have been cut through at its upper end by constriction. *See Insp.* 1860, No. 25; and *Prep.* 1182.

1120 Congenital Hernia with Double Sac.

The parts concerned in a right congenital hernia. The sac is hour-glass in shape, the constriction being situated at the external ring, close below which, in the lower sac, is seen the undescended testicle. The upper sac extends upon the anterior abdominal wall for a distance of two inches above the widely dilated internal ring.

Thomas S., æt. 36, was admitted under Mr. Cock with symptoms of strangulated hernia of twenty-four hours' duration. He was found to have one tumour in the scrotum and another in the groin. The scrotal tumour was reduced by taxis. On the following day the patient died, and at the autopsy nearly a foot of ileum was found strangulated in the upper sac. *See Insp.* 1861, No. 37.

1121 Congenital Omental Hernia.

The sac of a large scrotal hernia filled with a mass of omentum which is in parts adherent to its wall. The testis lies exposed at the bottom of the sac.

1122 Oblique Inguinal Hernia.

The parts concerned in an oblique inguinal hernia on the right side. The sac of the hernia is small, extending

downwards from the external ring for a distance of two inches, and its lowest part is an inch and a half above the testicle. On the reverse of the specimen the injected epigastric artery is seen lying internal to the neck of the sac.

1123 Oblique Inguinal Hernia.

The parts concerned in a large oblique inguinal hernia on the right side, the sac of which is filled with omentum. On the reverse of the specimen the neck of the sac is seen to be widely open and to be situated external to the deep epigastric artery.

1124 Direct Inguinal Hernia.

The parts concerned in a direct inguinal hernia on the right side, the sac of which contains a knuckle of strangulated intestine. The sac extends about an inch and a half below the external ring, and its wall has been dissected to shew its various layers.

1125 Direct Inguinal Hernia.

The parts concerned in a right inguinal hernia. The neck of the hernial sac is seen to be situated to the inner side of the deep epigastric artery, and about one and a half inches distant from the internal abdominal ring.

1126 Direct Inguinal Hernia. Pouched Sac.

The parts concerned in a large scrotal hernia on the right side. The sac of the hernia is five inches in length, and from its inner side, at the upper part, there projects a globular pouch about an inch and a half in diameter. The tunica vaginalis has been opened, and shews that the testis is not contained in the hernial sac. On the reverse of the specimen the epigastric artery is seen to the inner side of the sac.

Robert C., æt. 56, was admitted under Mr. Lucas in a moribund condition. Herniotomy was performed, and the patient died a few hours later. At the autopsy it was found that about four feet of small intestine had been strangulated, and there was early peritonitis. *See Insp.* 1875, No. 298.

1127 **Direct Inguinal Hernia in a Female.**

The parts concerned in an inguinal hernia on the left side. To the inner side of the epigastric artery is an opening in the abdominal wall about half an inch in diameter, through which there passes a considerable coil of intestine together with some omentum, which is firmly adherent to the margin of the ring. On the reverse of the specimen the contents of the hernial sac have been exposed, and are seen to consist of several inches of strangulated bowel.

Elizabeth R., æt. 81, was admitted under Mr. Hilton with an inguinal hernia, which had existed for twenty-five years, and had given rise to symptoms of strangulation nine hours before admission. Herniotomy was performed, and the bowel being ruptured was stitched to the edge of the wound. The patient died forty-one hours later, and at the autopsy general peritonitis was found. *See Insp.* 1856, No. 30.

1128 **Direct and Oblique Inguinal Hernia.**

The anterior abdominal wall from the inguinal region on the right side, seen from within, and shewing the openings of two small hernial sacs, one to the outer and the other to the inner side of the deep epigastric artery, beneath which a red rod has been passed.

Presented by Mr. Hilton.

1129 **Double Inguinal Hernia. Direct and Oblique.**

A frontal section through a pelvis, with the lower part of the anterior abdominal wall seen from within, and shewing a hernial protrusion in each inguinal region.

On the left side the sac is about an inch in diameter, and its neck lies to the inner side of the deep

epigastric artery, beneath which a red rod has been passed. On the right side the internal abdominal ring measures about half an inch in diameter and leads into the sac of a small bubonocoele. On the reverse of the specimen a dissection has been made to expose the coverings of the hernia.

1130 Inguinal Hernia.

The sac of a scrotal hernia laid open to shew the relation of the sac to the tunica vaginalis, in which the testis is exposed.

1131 Omental Inguinal Hernia.

The sac of an inguinal hernia laid open to shew its contents to consist of a mass of omentum which is partly adherent.

1132 Inguinal Hernia with double Sac.

The parts concerned in an inguinal hernia on the right side mounted to shew a globular dilatation of the sac situated beneath the peritoneum at the internal abdominal ring to the outer side of the inguinal canal. The diameter of the internal ring is three quarters of an inch, and the pouch into which it leads is of about the size of a pigeon's egg. On the reverse of the specimen are seen the sutures left after herniotomy.

From a patient who died from strangulated hernia. At the autopsy a knuckle of sloughing bowel was found within the secondary sac.

Presented by Mr. Bryant, 1869.

1133 Inguinal Hernia associated with Hydrocele.

The lower portion of the sac of a right inguinal hernia, below which is seen the testicle lying in the distended tunica vaginalis.

Samuel C., æt. 78, was admitted under Mr. Birkett for in-

continence of urine. He had long suffered from an irreducible hernia, and died from cystitis and chronic interstitial nephritis. *See Insp.* 1868, No. 11.

1134 Strangulated Inguinal Hernia. Reduction en Masse.

The parts concerned in a right congenital inguinal hernia, seen from within. The knuckle of intestine which forms the hernia is seen to be contained in a small sac situated beneath the peritoneum immediately below the internal ring. The yellow rod indicates the course taken by the hernia through a rent in the neck of the sac. The red rod passes into the funicular process of the peritoneum, which is now empty.

1135 Strangulated Inguinal Hernia. Reduction en Masse.

The parts concerned in a congenital inguinal hernia. The strangulated bowel is no longer in the hernial sac, but has passed through a rent in its neck into a space between the abdominal muscles and their peritoneal covering. The course of the inguinal canal is indicated by a red rod, and the yellow rod has been passed through the perforation in the neck of the sac produced by taxis.

William G., æt. 46, was admitted under Mr. Cock for a strangulated hernia in the left inguinal region. Herniotomy was performed, and two days later the patient died. At the autopsy general peritonitis was found. *See Insp.* 1858, No. 124; and *Drawings*, 474 (10 & 11).

1136 Strangulated Inguinal Hernia. Reduction en Masse.

The parts concerned in a right inguinal hernia seen from within, and shewing below and to the outer side of the internal ring a large cavity between the peritoneum and the muscles lining the iliac fossa. The cavity contains a coil of small intestine about six inches in

length which has entered it through a rent in the neck of the hernial sac. On the reverse of the specimen the sac, which has been laid open, is seen to be empty.

George T., æt. 68, was admitted under Mr. Lucas with an inguinal hernia which had been strangulated for twelve hours. Herniotomy was performed and the bowel "reduced" without opening the sac. The symptoms persisted and four days later the patient died, having refused further operative treatment. *See Insp.* 1880, No. 350.

1137 **Inguinal Hernia. Radical Cure.**

The parts concerned in a right inguinal hernia for which the operation for radical cure had been twice performed. A cul-de-sac about a third of an inch deep marks the site of the internal ring, and externally the integuments of the groin present a puckered scar. The sac of the hernia is almost obliterated.

George H., æt. 27, was admitted under Mr. Davies-Colley with an inguinal hernia the size of a hen's egg which had been strangulated for thirteen hours. Four years previously he had been operated on by Mr. John Wood for the radical cure of a very large scrotal hernia of the congenital form. From the time of this operation the hernia had not appeared until the day of his admission into Guy's Hospital. Mr. Davies-Colley performed herniotomy, returned the bowel and inserted deep sutures so as to include the whole of the serous lining of the sac. The patient was discharged well two months after the operation, and had no return of the hernia until his death, which occurred three years later as the result of the perforation of a duodenal ulcer. *See Trans. Path. Soc.* 1882, p. 164.

1138 **Femoral Hernia.**

The parts concerned in a right femoral hernia. On the front of the specimen is seen the spermatic cord passing through the inguinal canal and having below it the cremasteric branch of the deep epigastric artery. Separated from these structures by Poupart's ligament is the sac of the hernia, lying to the inner side of and partly overlapping the femoral vessels. The wall of the sac has been dissected to shew its three layers. A

blue rod has been passed into the sac through the femoral ring and a yellow rod between the peritoneum and the outer coats. On the reverse of the specimen is seen a portion of the omentum with which the sac is filled.

1139 Femoral Hernia.

The parts concerned in a right femoral hernia, the sac of which overlaps the femoral vessels so that its greater part lies to their outer side. On the reverse of the specimen is seen a portion of omentum passing through the crural canal to form the contents of the hernia.

Sarah J., æt. 62, was admitted under Mr. Birkett for a femoral hernia, from which she had suffered for many years and which had given rise to symptoms of strangulation for three days. Herniotomy was performed, and two days later the patient died. At the autopsy the strangulated portion of intestine, three inches in length, was found to be situated at the commencement of the ileum. *See Insp.* 1854, No. 160; and *Drawing*, 485 (20).

1140 Femoral Hernia.

The parts concerned in a right femoral hernia, the sac of which is ovoid and measures about two inches in its longest diameter. The wall is partially dissected, the outer layer having been reflected to expose the fascia propria, which is said to have been first described by Sir Astley Cooper from this preparation.

1141 Femoral Hernia.

The parts concerned in a right femoral hernia. The outermost layer of the sac, which is about the size of a pigeon's egg, has been removed to shew the fascia propria and beneath it the peritoneum.

1142 Omental Femoral Hernia.

The parts concerned in a femoral hernia upon the left side in a male subject. The sac, which measures four inches in diameter, is filled with omentum.

1143 Strangulated Femoral Hernia. Reduction en Masse.

The parts concerned in a femoral hernia upon the left side. The sac of the hernia is egg-shaped and measures two and a half inches in its longest diameter. The hernia which is still contained within the sac consists of omentum and a small knuckle of intestine firmly adherent to each other.

Sarah T., æt. 58, was admitted under Mr. Durham with a strangulated femoral hernia, for the relief of which herniotomy was performed. The sac was exposed and the hernia apparently reduced. Her symptoms persisted and she died two days after admission. At the autopsy "the sac with its contents was found to have been returned behind the peritoneum and to be lying on the outer side of the femoral ring." There was general peritonitis. *See Insp.* 1865, No. 17.

1144 Congenital Umbilical Hernia.

The upper part of an umbilical cord shewing its foetal extremity dilated into an ovoid sac two and a half inches in its longest diameter. The sac presents at the umbilicus a small opening by which it communicated with the peritoneal cavity.

From a male infant, one day old, who was admitted under Mr. Durham in 1893 with a hernia as large as a man's fist in the umbilical cord. The sac was laid open and the bowel returned; the child died two days after the operation. *See Surgical Reports*, vol. 163, Case 161.

1145 Traumatic Umbilical Hernia.

A portion of the anterior abdominal wall from the region of the umbilicus presenting a circular opening through the peritoneum and the rectus muscle about one and a quarter inches in diameter. Through this aperture has passed a coil of small intestine twelve inches in length, together with a portion of the omentum which presents a rent corresponding in situation to the perforation in the abdominal wall. In the recent state the

extruded bowel was found in a sac formed in the subcutaneous tissue.

Emily N., æt. 33, was admitted under Mr. Poland for injuries received by falling between a railway train and the platform. On admission there was a small wound to the left and above the umbilicus communicating with the peritoneal cavity. At this situation a soft swelling appeared which was readily reduced by pressure. Five days after admission the patient was delivered of a five months' fœtus, and the next day she died. At the autopsy the right ureter was found to be ruptured and the transverse processes of some of the lumbar vertebræ were fractured. There was no peritonitis. See *Insp.* 1868, No. 25½; and *Guy's Hosp. Reps.* 1868, p. 85.

1146 **Strangulated Umbilical Hernia.**

A portion of the anterior abdominal wall presenting in the region of the umbilicus a hernial sac about four inches in diameter. The sac has been opened to expose a large mass of omentum partly adherent to its wall and a knuckle of intestine, a rent in which is indicated by a red rod.

Elizabeth H., æt. 65, was admitted under Mr. Hilton with an umbilical hernia which had been strangulated for six days. Herniotomy was performed, and during the attempt to reduce the gangrenous contents of the sac the bowel gave way. Six hours later the patient died, and at the autopsy a considerable quantity of recent lymph was found in the peritoneal cavity. The strangulated loop of ileum was situated four feet above the cæcum. See *Insp.* 1856, No. 24.

1147 **Umbilical Omental Hernia.**

A portion of the anterior abdominal wall with an umbilical hernia containing omentum. The neck is about three quarters of an inch in diameter and the sac is globular and measures five inches across. On the reverse of the specimen is seen a portion of transverse colon which is dragged towards but not included in the hernia.

Maria D. was admitted into the hospital in 1862. She had suffered for a long time from constipation and died from peritonitis due to the perforation of the cæcum, which together with the ascending colon was found at the autopsy to be greatly distended.

1148 Irreducible Umbilical Hernia.

A vertical section through a small umbilical hernia and the surrounding abdominal wall. The sac, which measures about two inches in diameter, is filled with adherent omentum.

Emma M., æt. 74, was admitted under Mr. Howse for a compound fracture of the lower jaw from the results of which she died. *See Insp.* 1886, No. 404.

1149 Ulceration of Colon in an obstructed Hernia.

A cæcum with the ascending colon which formed part of an obstructed umbilical hernia. The bowel is laid open to shew extensive ulceration and sloughing of the mucous membrane, which in parts is covered with a fibrinous exudation.

Catherine C., æt. 51, was admitted under Mr. Davies-Colley with an umbilical hernia which had been incarcerated for two days. Four days later herniotomy was performed and the bowel, which was gangrenous, was incised and left in the sac. The patient died on the following day, and at the autopsy the coil which formed the hernia shewed no marks of constriction but contained a large number of melon seeds. There was general peritonitis. *See Insp.* 1884, No. 330.

1150 Ventral Hernia.

A portion of the anterior abdominal wall shewing in the middle line, two and a half inches above the umbilicus, the sac of a ventral hernia about the size of a hen's egg. On the reverse of the specimen is seen the neck of the sac measuring three quarters of an inch in diameter.

The specimen is said to have been taken from an elderly female patient upon whom Mr. Bransby Cooper performed herniotomy.

1151 Obturator Hernia.

A portion of the left os innominatum surrounding the obturator foramen. The muscles attached have been dissected to expose a small hernial sac protruded through

the foramen at its upper part. On the reverse of the specimen the neck of the sac is seen to occupy the small oval canal, through which pass the obturator vessels and nerve.

From a lady, æt. 36, who was seized with symptoms of acute intestinal obstruction, for which Mr. Hilton performed laparotomy eleven days after the onset of symptoms. The portion of strangulated bowel, an inch and a half in length, was withdrawn from the sac, but the patient died a few hours after the operation. See *Drawing*, 488 (50).

Presented by Mr. Blackmore, 1848.

1152 **Strangulated Obturator Hernia.**

The parts surrounding the thyroid foramen on the right side, from which the muscles have been dissected to expose a portion of the sac of a hernia protruding through the opening in the obturator membrane that transmits the obturator nerve and artery. On the reverse of the specimen a dimple in the peritoneum is seen marking the situation of the orifice of the sac.

Mary N., æt. 49, was admitted under Mr. Bransby Cooper in 1853, with symptoms of strangulated bowel of sixty-five hours' duration. She suffered from pain in the upper and inner part of the right thigh, extending down the front of the leg to the great toe. She was a very thin woman, and a deep-seated swelling could be felt at the upper part of the thigh. An incision was made, as in the operation for femoral hernia, the pectineus was cut through, and the sac exposed. The hernia was reduced without opening the sac, and the patient made a slow recovery. She subsequently died in the Medical Wards from bronchitis and heart disease.

1153 **Incarcerated Obturator Hernia.**

The left innominate bone dissected to shew a knuckle of ileum protruding through the upper part of the thyroid foramen. To the outer side of the sac are seen the obturator nerve and vessels. The sac, as it appears outside the pelvis, is ovoid in shape, and measures four and a half inches in its longest diameter.

Susan G., æt. 66, was admitted under Mr. Bryant for chronic

intestinal obstruction, from which, five weeks later, she died. At the autopsy the bowel forming the hernia was found adherent to the sac but not strangulated. It was situated two feet above the cæcum. There was general suppurative peritonitis. *See Insp.* 1876, No. 59; and *Trans. Path. Soc.* vol. 27, p. 161.

1154 **Obturator Hernia with Double Sac.**

The right half of a pelvis, with the uterus and its appendages. Opposite to the upper part of the thyroid foramen there is in the pelvic peritoneum a rounded opening which led through an aperture in the obturator membrane into a hernial sac, a portion of which is seen outside the pelvis in close proximity to the obturator nerve. Passing through the neck of the hernia and tightly strangulated by it is a portion of small intestine, a knuckle of which is contained in a lateral protrusion of the hernial sac lying between the pelvic fascia and the peritoneum.

Sarah F., æt. 38, was admitted under Mr. Cooper Forster for acute intestinal obstruction, and died nine days after the onset of symptoms. At the autopsy the strangulated portion of ileum was found to be situated just above the cæcum. The extra-pelvic hernial sac was empty, and it was thought that its contents had been reduced by muscular action, and had been forced into the second sac after the manner of reduction "en masse." *See Insp.* 1864, No. 80; and *Guy's Hosp. Repts.* 1864, p. 143.

1155 **Littre's Hernia.**

A portion of small intestine shewing a pouch projecting from its free border and adherent to the sac of a femoral hernia. The mesentery, which is covered with recent lymph, is not involved in the hernia.

Elizabeth B., æt. 56, was admitted into the hospital with a left femoral hernia, which had been strangulated for nine days. The hernia was explored and thought to contain omentum, but not intestine. Two days later the patient died. *See Insp.* 1858, No. 62.

1156 **Littre's Hernia.**

A portion of ileum shewing upon its lateral aspect a

small pouch about one third of an inch in diameter, the serous covering of which is coated with recent lymph. Below is mounted the sac of the hernia, which, in the recent state, contained the strangulated protrusion of the bowel.

Maurice C., æt. 55, was admitted under Mr. Durham with a small painful tumour in the right groin and symptoms of intestinal obstruction. Herniotomy was performed and the gut partially reduced. The patient's bowels were freely opened, but peritonitis supervened, and he died six days after the onset of acute symptoms. *See Insp.* 1863, No. 88.

1157 **Littre's Hernia.**

A portion of ileum shewing upon its free border a rounded protrusion about an inch in length, which formed the contents of the sac of a femoral hernia. There is recent lymph upon the mucous and serous surface of the strangulated bowel.

Jane D., æt. 48, was admitted under Mr. Golding-Bird with a strangulated femoral hernia, for which herniotomy was performed and the gut reduced. During a fit of retching shortly afterwards the bowel gave way and fæcal matter escaped from the wound. Ten hours later the patient died, and at the autopsy a small perforation was found in the strangulated knuckle which was situated three feet above the ileo-cæcal valve. *See Insp.* 1882, No. 307.

1158 **Littre's Hernia. Enterectomy.**

A piece of small intestine excised during life. It has been laid open along its mesenteric attachment to shew a hemispherical sacculus about the size of a walnut. The walls of the sacculus are thin and lined with mucous membrane, which is superficially ulcerated. At the operation the protrusion filled the sac of the hernia.

Elizabeth C., æt. 52, was admitted under Mr. Lane in 1890 with a strangulated femoral hernia, for which herniotomy was performed. A loop of intestine, including the strangulated portion was excised, and the patient made a good recovery. *See Surgical Reports*, vol. 156, Case 129; and *Trans. Clin. Soc.* vol. 24, p. 182.

1159 Multilocular Hernial Sac.

Two thin membranous sacs communicating with each other and having a common opening at what appears to be the internal abdominal ring. They are said to have "been formed in a hernial sac, and to have contained about a quart of ascitic effusion."

From a dropsical patient of Mr. Aston Key.

1160 Suppurating Hernial Sac.

The parts concerned in a right inguinal hernia mounted to shew the tissues of the scrotum affected by phlegmonous inflammation, which has led to the formation of an abscess cavity separating the sac of the hernia from its superficial coverings. A blue rod indicates an opening by which the abscess communicated with the lowest part of the hernial sac, the peritoneal lining of which is covered with granular lymph.

Thomas U., æt. 52, was admitted under Mr. Poland with an inflamed scrotal hernia and symptoms of peritonitis. The parts were incised and pus evacuated. The inguinal canal was found to be empty. The patient died four days after admission from general peritonitis. *See Insp.* 1863, No. 284.

1161 Cartilaginous Hernial Sac.

The lower portion of the sac of a large inguinal hernia, at the bottom of which is seen a smooth fibrous plaque measuring two and a half inches in diameter and an eighth of an inch in thickness.

Presented by Mr. A. Carey.

1162 Secondary Carcinoma of a Hernial Sac.

A portion of a hernial sac laid open to shew its peritoneal surface infiltrated by a nodular deposit of malignant growth.

William P., æt. 70, was admitted under Dr. Owen Rees with

jaundice and ascites. At the autopsy the peritoneum was found to be covered with numerous small carcinomatous nodules. *See Insp.* 1858, No. 34.

1163 **Hernial Sac lined with Omentum.**

The parts concerned in a left femoral hernia, the sac of which has been laid open to expose a mass of omentum, which during life completely enveloped the knuckle of intestine which is mounted at the back of the specimen.

Sarah R., æt. 27, was admitted under Mr. Hilton for a femoral hernia, which had been strangulated for three days. Herniotomy was performed and the bowel exposed and returned. The patient died nine hours later, and at the autopsy the strangulated intestine was found to be situated at the upper end of the ileum. *See Insp.* 1855, No. 22.

1164 **Hernial Sac lined with Omentum.**

The sac of a femoral hernia measuring about three inches in diameter and filled with omentum, with the exception of a central cavity, which in the recent state contained a strangulated knuckle of intestine.

Sarah F., æt. 70, was admitted under Mr. Birkett in 1855 with a femoral hernia on the right side, which had existed about forty years, and had been strangulated for eleven hours. Herniotomy was performed, and two days later the patient died.

1165 **Hernia of the Stomach.**

The ensiform cartilage with a portion of the abdominal wall immediately below it mounted to shew the sac of a ventral hernia about three inches in diameter, the upper limit of which is situated half an inch from the tip of the cartilage. On the reverse of the specimen the neck of the sac is seen as an oval opening measuring one and a half inches from above downwards.

From Peter P., a lunatic. The dissection was made by Sir Astley Cooper, who found a portion of the stomach contained in the hernial sac. *See Prep.* 1111 [2nd Edit.].

1166 Hernia of the Cæcal Appendix.

A section through the sac of a femoral hernia which contains the distal extremity of the cæcal appendix and a mass of fat.

Susanna V., æt. 65, was admitted under Mr. Davies-Colley for vomiting, constipation, and abdominal pain of three days' duration. She had noticed a femoral hernia for three months. Herniotomy was performed, and the sac was found to contain the cæcal appendix, which was gangrenous, and from which a pin was extracted. The symptoms of intestinal obstruction continuing an exploratory laparotomy was performed with the view of forming an artificial anus. The patient died three days after admission, and at the autopsy general peritonitis was found. *See Insp.* 1885, No. 93.

1167 Hernia of the Sigmoid Flexure.

The sac of a left inguinal hernia, in which is contained a portion of the sigmoid flexure of the colon. One of the appendices epiploicæ is adherent to the wall of the sac.

James D., æt. 60, was admitted under Mr. Cock for injuries to his leg, from which he died. *See Insp.* 1863, No. 21.

1168 Hernia of an Appendix Epiploica.

An appendix epiploica which was found in the sac of an inguinal hernia. The appendix, which arises from the sigmoid flexure of the colon, is stretched out so as to measure five inches in length.

Richard V., æt. 52, was admitted under Mr. Cock with a strangulated scrotal hernia, for which herniotomy was performed. The intestine was returned and a large mass of omentum was cut off. The wound sloughed, and three days after the operation the patient died. *See Insp.* 1863, No. 279.

1169 Hernia of the Fallopian Tube and Ovary.

A right femoral hernia, the sac of which has been laid open, and is seen to contain an ovary and the distal end of the Fallopian tube.

1170 Vesical Hernia.

A bladder, a considerable portion of which has passed through the abdominal ring on the right side, and in the recent state occupied the scrotum, where it lay behind the sac of an inguinal hernia. The anterior part of the sac has been removed, and thus is exposed its hinder wall, consisting of the peritoneal covering of the fundus of the bladder.

From an elderly gentleman who had suffered for many years both from a ventral and scrotal hernia. The latter was found by Sir Astley Cooper to be of the vesical kind, and the specimen was procured and dissected by him after the patient's death. In the recent state the sac in front of the bladder contained omentum and intestine. *See Astley Cooper on 'Hernia,' ed. ii. pt. 2, p. 63.*

1171 Strangulated Intestine ; Enterectomy.

A piece of intestine removed during life from the ileum just above the ileo-cæcal valve, and shewing upon its serous surface two narrow transverse furrows produced by constriction. The intervening portion of intestine, which is two and a half inches in length, is covered with a thin layer of granular lymph, and in the recent state was congested, and of a dark red colour. On the mucous surface the strangulated portion is sharply defined from the healthy bowel on either side of it by two deep linear ulcers corresponding to the marks of constriction seen on the peritoneum.

Alfred R., æt. 45, was admitted under Mr. Lane with a strangulated inguinal hernia on the left side. Herniotomy was performed, and a tight stricture was divided at the internal abdominal ring. The piece of bowel which forms the preparation was removed, and intestinal anastomosis was established by Senn's plates. About twenty-four hours later the patient died, and at the autopsy general peritonitis was found. *See Insp. 1891, No. 445.*

1172 Strangulated Intestine from Hernia.

A portion of ileum which was strangulated in a hernial

sac, and is mounted to shew extreme congestion with thickening of the mesentery and of the wall of the intestine. There is recent lymph upon the peritoneal surface.

From an adult who died from internal hæmorrhage after herniotomy performed for the relief of a strangulated congenital hernia.

1173 Intestine from a Hernial Sac.

A coil of ileum which was contained in the sac of a scrotal hernia. The intestine is greatly enlarged and puckered, and presents on the surface numerous old and recent adhesions.

William D., æt. 65, was admitted under Mr. Poland with a strangulated scrotal hernia and peritonitis. Herniotomy was performed, but the bowel could not be reduced. An incision was made into the intestine and its contents evacuated. Three days later the patient died, and at the autopsy the cæcum and four feet of the ileum were found to be contained in the sac. *See Insp.* 1860, No. 136.

1174 Strangulated Intestine in Hernia.

A piece of small intestine, eighteen inches in length, which was contained in a hernial sac. Surrounding the lower end is seen a transverse mark of constriction an inch in width, from which the mucous membrane has been removed by ulceration. At the upper end, which is seen on the reverse of the specimen, there is a similar ulcer partially encircling the bowel. Perforations are seen in the bases of the two ulcers, and there is recent lymph upon the serous surface of the bowel.

William A., æt. 56, was admitted under Mr. Cooper Forster for a large scrotal hernia on the right side, which had been strangulated for four days. Herniotomy was performed and the bowel reduced. Four days later the patient died, and at the autopsy faecal matter and recent lymph were found in the peritoneal cavity. *See Insp.* 1856, No. 225.

1175 Gangrene of the Intestine in Hernia.

A portion of ileum, a small knuckle of which was nipped in the sac of a femoral hernia. In the recent state it was of a dark purple colour. It has been laid open to shew the mucous membrane partly covered with a fibrinous exudation.

Elizabeth C., an elderly women, was admitted under Mr. Morgan, in 1829, with a femoral hernia which had been strangulated for some time. Herniotomy was performed and the intestine incised. Four days later she died, and at the autopsy general peritonitis was found. *See Insp.* vol. 9, p. 1.

1176 Gangrene of the Intestine in Hernia.

A portion of the lower end of an ileum mounted to shew a knuckle measuring four inches along its convex border, which was contained in the sac of a femoral hernia. The strangulated knuckle is sharply defined from the healthy bowel, and presents a large perforation at its most dependent part. There is recent lymph upon the serous coat.

Elizabeth W., æt. 66, was admitted under Mr. Morgan, in 1830, for a strangulated femoral hernia on the right side. Herniotomy was performed and the gangrenous intestine was punctured and left in the sac. Two days later the patient died, and at the autopsy the strangulated portion of bowel was found to be situated four inches above the cæcum, and there was general peritonitis. *See Insp.* vol. 15, p. 18.

1177 Gangrene of the Intestine in Hernia.

The parts concerned in a right femoral hernia, the sac of which has been opened, and shews at its upper part a small piece of intestine which is perforated as the result of the gangrene.

From a woman who died from strangulated hernia. No operation was performed.

Presented by Mr. Bryant.

1178 Sloughing of Intestine in Hernia.

A portion of small intestine measuring five and a half inches in length which was detached by sloughing and discharged through the wound made in the operation of herniotomy. Below is mounted a coil of ileum shewing the narrow gap left after the detachment of the slough.

David D., æt. 17, was admitted under Mr. Lucas with a congenital inguinal hernia which had been strangulated four days. Herniotomy was performed, and the bowel being found sloughing and perforated, was left in the sac. Six days later the slough seen in the preparation came away, and the next day the patient died. At the autopsy, the gap in the bowel was found to be situated two inches above the cæcum. There was general peritonitis. *See Insp.* 1876, No. 118.

1179 Gangrene and Perforation of the Intestine in Hernia.

A portion of ileum laid open to shew an area four inches in length, in which are several irregular perforations resulting from gangrene. There is much recent lymph upon the serous coat.

Joseph W., æt. 44, was admitted under Mr. Hilton with an inguinal hernia which had been strangulated seven days. The scrotum was sloughing, and an incision made into the sac evacuated fecal matter. The patient died a few hours later, and at the autopsy there was general peritonitis. *See Insp.* 1863, No. 186.

1180 Gangrene and Rupture of Intestine in Hernia.

A portion of the lower end of the ileum, presenting on its free border a small protuberance, in the centre of which there is a ragged perforation.

Anne T., æt. 72, was admitted under Mr. Bransby Cooper, in 1833, with a femoral hernia which had been strangulated seven days. She died shortly after admission, and at the autopsy the sac of the hernia was found to be gangrenous, and just within its neck was the strangulated portion of the bowel. There was general suppurative peritonitis. *See Insp.* vol. 18, p. 56.

1181 Gangrenous Omentum and Bowel in Hernia.

The sac of a small umbilical hernia, which has been laid open to shew a gangrenous piece of omentum and a knuckle of ileum, the latter being perforated.

Elizabeth S., æt. 45, was admitted under Mr. Bransby Cooper, in 1837, with a strangulated umbilical hernia, for which herniotomy was performed. *See Insp.* vol. 25, p. 33.

1182 Intestine partially divided by Strangulation.

A portion of ileum, the greater part of which was contained in a hernial sac. At the lower border of the strangulated knuckle, the constriction has been so severe as to divide the intestine almost up to the attachment of the mesentery, while the upper limit of the strangulation is scarcely discernible. There is recent lymph upon the serous coat.

William G., æt. 24, was admitted under Mr. Hilton for a congenital hernia which had been strangulated for several days, and died shortly after the operation of herniotomy. *See Insp.* 1860, No. 25; and *Prep.* 1119.

1183 Ulceration of Intestine from Strangulation.

A portion of ileum laid open to shew a narrow transverse ulcer, extending nearly to the mesentery, and exposing in its base the serous coat. This partial division of the wall of the bowel is due to constriction, and marks the upper limit of a knuckle which has been contained in a hernial sac.

Elizabeth D., æt. 38, was admitted under Mr. Cock for a femoral hernia on the right side, which had been strangulated for five days. Herniotomy was performed and the bowel returned. The patient died in a few hours. At the autopsy there was general peritonitis. *See Insp.* 1856, No. 150.

1184 Stricture of Ileum following Hernia.

A portion of ileum laid open to shew an annular constriction about an inch in length and an inch and a quarter

in circumference. The bowel above the stricture has a circumference of two and a quarter inches. The wall of the intestine where it is narrowed is thickened, and its serous surface is covered with rough adhesions.

Isabella H., æt. 52, was admitted under Mr. Bryant with a strangulated inguinal hernia, which was relieved by operation. Subsequently symptoms of chronic intestinal obstruction supervened, from which, ten weeks later, the patient died. At the autopsy no cause of obstruction was found to exist except the stricture seen in the preparation. *See Insp.* 1870, No. 154.

1185 **Ulceration of the Ileum above a Hernia.**

A portion of ileum laid open to shew numerous ulcers, the smaller of which are circular in outline, and the larger oval and transverse. The edges of the ulcers are thin and undermined, and in their bases is exposed the muscular coat of the bowel. There is recent lymph upon the serous surface.

Jane N., æt. 44, was admitted under Mr. Jacobson with a femoral hernia on the right side which had been strangulated for two days. The sac was opened and the neck divided, the bowel being left undisturbed. A week after the operation both parotid glands became inflamed, and five days later the patient died. At the autopsy the condition of bowel shewn in the preparation was found to extend for twelve feet above the strangulated knuckle, which was situated immediately above the cæcum. *See Insp.* 1881, No. 212.

1186 **Peritoneal Adhesions following Hernia.**

A portion of a jejunum, the coils of which are united to each other by smooth fibrous adhesions.

William P., æt. 63, was admitted under Mr. Birkett with an inguinal hernia, from which he had suffered for two years, and which for seven days before admission had been strangulated. The hernia was reduced, and four days later diarrhœa supervened. He died eleven days after his admission, and at the autopsy a foot of ileum twelve inches above the cæcum was found to be acutely inflamed. It was thought that the coils of bowel which form the preparation had at some previous time been contained in the hernial sac. *See Insp.* 1871, No. 213.

1187 **Fistulous Communication between Coils of Ileum.**

Two pieces of ileum firmly united to each other and presenting a fistulous communication at the point of adhesion. At one part the adhesion between the two coils has given way, and thus is established an opening from the interior of the bowel into the peritoneal cavity. There is recent lymph upon the serous coat.

Abraham S., *æt.* 58, was admitted under Mr. Birkett with severe abdominal pain and collapse. An inguinal hernia, which had six months previously been incarcerated for thirteen days, was explored. No intestine was found in the sac, but there was a slight fecal discharge from the wound. The patient died thirty-six hours after the onset of acute symptoms, and at the autopsy the peritoneum was found to be covered with a thick layer of recent lymph. *See Insp.* 1858, No. 100.

1188 **Artificial Anus following Hernia.**

The parts concerned in a right femoral hernia, dissected to shew an opening in the groin communicating with a knuckle of ileum, which is firmly adherent to the neck of the sac. The bladder and a small portion of omentum are seen united to the bowel.

Mary W., *æt.* 72, was admitted under Mr. Hilton for a femoral hernia which had been strangulated for a few hours. Herniotomy was performed, the sac not being opened. Nine days later a fecal discharge occurred from the wound, and continued until the patient's death, three weeks after the operation. *See Insp.* 1855, No. 31.

1189 **Artificial Anus following Hernia.**

The parts concerned in a right femoral hernia, mounted to shew an artificial anus, resulting from sloughing of the strangulated bowel. The intestine is firmly adherent to the neck of the sac, the upper part being considerably larger than the lower.

James W., *æt.* 65, was admitted under Mr. Hilton with a femoral hernia on the right side, which had been strangulated for

four days. Herniotomy was performed, and a knuckle of gangrenous bowel was opened. Fæces passed freely by the wound until the patient's death, fourteen days after the operation. At the autopsy the kidneys were found to be small and granular. See *Insp.* 1855, No. 29.

1190 Intestine Ruptured by Taxis.

A portion of the upper part of the ileum, shewing on its lateral aspect a hemispherical pouch an inch and a half in diameter, at the summit of which is seen a small ragged perforation. There is recent lymph upon the serous coat.

Jane G., æt. 47, was admitted under Mr. Morgan, in 1834, and operated on for piles. While in the hospital she was seized with abdominal pain and vomiting. A femoral hernia was discovered and forcibly reduced. The patient immediately complained of great pain, and her symptoms became more urgent. She died about twelve hours after the taxis and three days from the onset of her symptoms. At the autopsy the peritoneal cavity was found to contain pus and extravasated fæces. See *Insp.* vol. 19, p. 83.

1191 Intestine wounded in Herniotomy.

A piece of small intestine presenting an incised wound about an inch in length. It is longitudinal in direction and has divided the peritoneum and the outer fibres of the muscular coat.

Anne W., æt. 50, was admitted under Mr. Bransby Cooper in 1830 with a strangulated femoral hernia, for which herniotomy was performed. Three days later she died from suppurative peritonitis. See *Insp.* vol. 9, p. 37.

SECTION XXIV.—INJURIES AND DISEASES OF THE PERITONEUM.

- Wounds: 1192-1193.
 Foreign Body: .1194.
 Acute Inflammation: 1195-1198.
 Chronic Inflammation: 1199, 1200, 1207.
 Adhesions: 1201-1206.
 Tuberculosis: 1208-1216.
 Abscess: 1217, 1218.
 Appendices Epiploicæ: 1219-1221.
 Loose Bodies: 1222, 1223.
 Lipoma: 1224, 1225.
 Carcinoma: 1226-1234.
 Lymphadenoma: 1235.
 Sarcoma: 1236-1238.
 Cysts: 1207, 1239-1241.
 Hydatid: 1242-1245.

1192 **Punctured Wound of the Peritoneum.**

A portion of the anterior abdominal wall shewing a punctured wound transverse in direction and half an inch in length, which was situated two and a half inches to the left of the umbilicus. On the reverse of the specimen a portion of omentum is seen to be caught in the wound.

Maria J., æt. 8, was admitted under Mr. Morgan for a punctured wound in the abdomen which was inflicted by a knife thrown by her father at a cat. On admission a portion of omentum protruded through the wound. The patient died four days later from suppurative peritonitis. *See Insp.* vol. 12, p. 151.

1193 **Subperitoneal Hæmatoma.**

A portion of the anterior abdominal wall mounted to shew a mass of coagulated blood between the peritoneum

and the muscles about the size of the hand. The peritoneum around is stained with blood.

Thomas H., æt. 43, was admitted under Dr. Addison with ascites for which paracentesis was performed. Shortly afterwards he died, and at the autopsy the peritoneal cavity was found to contain several pints of blood-stained fluid and the liver was lardaceous and cirrhotic. The hæmatoma shewn in the preparation corresponded in situation with the puncture made in tapping. *See Insp.* 1857, No. 58.

1194 Foreign Body in the Omentum.

A piece of omentum loaded with fat and mounted to shew a small button lodged in it as the result of a gunshot wound.

Presented by Mr. Tucker.

1195 Acute Peritonitis.

A piece of small intestine laid open to shew its serous surface covered with a thin layer of granular lymph. The layer has been partially detached, and beneath it the peritoneum is seen to have lost its polish.

1196 Acute Peritonitis.

A piece of small intestine distended with fluid and mounted to shew its serous coat marked with dilated vessels and partly covered with granular lymph.

Eliza R., æt. 23, was admitted under Mr. Key in 1829 with anal fistula for which an operation was performed. Erysipelas ensued, and she died from peritonitis eight weeks after her admission. At the autopsy the peritoneal cavity was found to contain about two pints of turbid serum. *See Insp.* vol. 14, p. 117.

1197 Hæmorrhagic Peritonitis.

A portion of parietal peritoneum mounted to shew its surface covered with membranous exudation and black masses of coagulated blood.

John W., æt. 48, was admitted under Dr. Bright in 1834 with general anasarca and albuminuria. He died from uræmia, and at

the autopsy the kidneys were found to be small and granular, and the peritoneal cavity contained blood-stained fluid. *See Insp.* vol. 19, p. 51.

1198 **Fibrinous Coagulum from Peritoneal Fluid.**

A stringy mass consisting of fibrin which separated spontaneously from a peritoneal effusion removed after death.

William A., æt. 40, was admitted under Dr. Bright in 1840, and died from a suppurating hydatid of the liver and pericarditis. *See Insp.* vol. 9, p. 151; and *Prep.* 1242.

1199 **Chronic Peritonitis.**

A considerable length of small intestine the coils of which are drawn together by contraction of the mesentery and united to each other by a firm membranous deposit on the serous surface.

Sarah T., æt. 31, was admitted under Dr. Back in 1829 for ascites, which had been first noticed six weeks previously. She died a fortnight after her admission, and at the autopsy the peritoneal cavity was found to contain several pints of straw-coloured fluid. No local cause for the peritonitis was discovered. *See Insp.* vol. 8, p. 24.

1200 **Chronic Peritonitis.**

The whole of the small intestine the coils of which are coherent and form a globular mass about the size of the human brain. Enclosing the mass there is an adventitious investment of organised inflammatory exudation. There is no appearance of cancerous deposit in any part of the specimen, nor was any found upon histological examination of the lymphatic glands.

Emma F., æt. 45, was admitted under Dr. Wilks for swelling of the abdomen of three months' duration, associated with progressive emaciation. At the autopsy there was a primary growth in the breast with secondary deposits in the pleura, pericardium, ovaries, and liver. *See Insp.* 1871, No. 219.

1201 Peritoneal Adhesions.

A portion of small intestine mounted to shew the adjacent coils firmly united to each other by peritoneal adhesions. The mesentery is thickened.

James H., æt. 58, was admitted under Mr. Symonds for epitheliomatous ulceration of the tonsil, and died from hæmorrhage. There were no symptoms of intestinal obstruction. *See Insp.* 1883, No. 249; and *Prep.* 478.

1202 Peritoneal Bridle.

Portions of large and small intestine connected by a slender bridle of fibrous tissue six inches in length.

William H., æt. 45, was admitted under Dr. Addison in 1829 with symptoms of intestinal obstruction which subsided under treatment. He died of phthisis six weeks after his admission. At the autopsy old adhesions were found around the cæcal appendix, and there were several bridles similar to that shewn in the preparation. *See Insp.* vol. 8, p. 154.

1203 Peritoneal Adhesions.

A portion of ileum and of the abdominal parietes closely united to each other by firm membranous adhesions.

Elizabeth H., æt. 31, was admitted under Dr. Cholmeley in 1835 for ascites. At the autopsy the liver was found to be contracted, the kidneys were large and granular, and the pericardium was adherent. *See Insp.* vol. 22, p. 57.

1204 Peritoneal Adhesions. Gunshot Wound.

A portion of a colon firmly united to the abdominal parietes. The skin at the situation of the adhesion is marked by indentations and cicatrices produced by a gunshot wound.

1205 Peritoneal Adhesions.

A portion of a liver and of the thickened parietal peritoneum stripped from the under surface of the diaphragm and from the muscles of the anterior ab-

dominal wall. There are numerous strong filamentous bands, some measuring five inches in length, attaching the diaphragm to the convex surface of the liver. Histological examination shews the liver to be fatty and cirrhotic.

Eliza S. was admitted under Dr. Bright in 1826 with ascites of several months' duration, for which paracentesis was performed. She died a week after the operation, and at the autopsy two gallons of clear colourless effusion were found in the peritoneal cavity. *See Insp.* vol. 1, p. 1; and *Prep.* 2252 [2nd Edit.].

1206 **Peritoneal Adhesions.**

Portions of a liver and diaphragm connected to each other by numerous filamentous adhesions, some of which measure two inches in length.

1207 **Peritoneal Cysts. Chronic Peritonitis.**

A spleen, with a portion of the stomach and diaphragm matted together by fibrous adhesions. There are several pedunculated cysts with thin translucent walls, which in the recent state contained ascitic fluid.

Maria B., æt. 40, was admitted under Dr. Bright in 1829 with ascites, for which paracentesis was on several occasions performed. She died three weeks after admission, and at the autopsy the liver was found to be cirrhotic. *See Insp.* vol. 9, p. 30.

1208 **Tuberculosis of the Peritoneum.**

A portion of parietal peritoneum mounted to shew the granular appearance produced by a deposit of miliary tubercle.

Margaret M., æt. 59, was admitted under Dr. Habershon for pain in the chest and dyspnoea of ten weeks' duration. She died four and a half months after the onset of her illness, and at the autopsy the pleura and peritoneum were found to be thickly studded with miliary tubercle, and there was recent pericarditis. *See Insp.* 1866, No. 357.

1209 **Tuberculosis of the Omentum.**

One half of an omentum, greatly thickened by a firm

uniform deposit. On close inspection the surface is seen to be studded with numerous miliary tubercles, and to be covered in places with a thin layer of granular lymph.

Thomas T., æt. 46, was admitted under Dr. Moxon for dyspnoea, having been attacked with symptoms of fever three weeks previously. Paracentesis thoracis was performed, and the patient died five weeks after admission. At the autopsy the peritoneum and pleura were found to be infiltrated with tuberculous deposit. The lungs and other viscera were free from tubercle. *See Insp.* 1884, No. 39.

1210 Tubercle of the Peritoneum.

A portion of small intestine injected and mounted to shew beneath its serous coat numerous nodules which have the histological characters of tubercle.

1211 Tuberculosis of the Peritoneum.

A portion of the abdominal wall mounted to shew beneath the peritoneum numerous nodules which have the histological characters of tubercle.

From a girl, æt. 12, who died from meningitis and general tuberculosis. *See Insp.* vol. 14, p. 150; and *Prep.* 356.

1212 Miliary Tuberculosis of the Omentum.

A portion of omentum thickly studded with small nodules which histologically have the character of miliary tubercles containing many giant-cells.

Samuel P., æt. 40, was admitted under Dr. Pavy, and died from chronic phthisis. At the autopsy tuberculous ulceration was found throughout the large intestine, and there were miliary and caseous tubercles on all parts of the peritoneum. *See Insp.* 1860, No. 58.

1213 Tuberculosis of the Omentum.

The greater part of an omentum much contracted and infiltrated with a firm deposit, which has the histological characters of caseating tubercle.

John W., æt. 15, was admitted under Dr. Cholmeley in 1827

for phthisis, from which he died. At the autopsy the peritoneum was found to be covered with tubercles, and the abdominal viscera were united to each other by adhesions. There was a congenital deficiency of the anterior half of the third rib. *See Insp.* vol. 4, p. 150; and *Prep.* 1044 [2nd Edit.].

1214 **Tuberculosis of the Peritoneum.**

The anterior wall of a stomach mounted to shew the serous coat covered with masses of caseating tubercle. The mucous surface is unaffected.

From a boy who suffered from ascites.

1215 **Caseous Tubercle of the Peritoneum.**

A portion of the abdominal wall mounted to shew large irregular masses of a firm yellow material, situated beneath the serous membrane. Histological examination shews the deposit to consist of caseating tubercle.

1216 **Tuberculous Peritonitis. Artificial Anus.**

Several coils of small intestine firmly united to each other and to a portion of the abdominal wall. At the point of adhesion to the parietes there is an artificial anus. A probe introduced into this aperture passes directly into one of the coils of the intestine, and also into an irregular cavity, from which there are numerous openings into other adjacent coils. Histological examination shews that the material matting the intestines together contains caseating tuberculous deposit.

From a girl, *æt.* 6, who was admitted into the hospital in 1829. She had been suffering from some abdominal affection for about a year, and some months before her death a swelling appeared near the umbilicus, which broke and discharged feces. At the autopsy the lungs were found to contain tubercle and there were numerous tuberculous ulcers in the ileum. The Fallopian tubes contained caseous matter. *See Insp.* vol. 8, p. 50.

1217 **Peritoneal Abscess perforating the Colon.**

A portion of the abdominal wall, with a part of the liver and ascending colon, mounted to shew an abscess

cavity with ragged walls situated between the liver and the abdominal muscles and opening at its lower part by a narrow sinus into the bowel.

John F., æt. 14, was admitted under Dr. Back in 1834, with a painful tumour in the right hypochondriac region. Before his death, which was attributed to pneumonia, the tumour diminished in size. At the autopsy the cæcal appendix was found to be unusually long and directed upwards. Its distal extremity was ulcerated and communicated with the lowest part of the abscess cavity. See *Insp.* vol. 17, p. 135.

1218 **Pelvic Abscess opening the Rectum and Bladder.**

The female pelvic viscera mounted to shew an abscess on the right side, situated between the upper part of the bladder and the rectum. The right uterine appendages are lost in the mass of inflammatory tissue forming the wall of the abscess. The left Fallopian tube is thickened and dilated, and in the recent state contained pus. In the rectum and bladder are seen the openings through which the contents of the abscess discharged. Histological examination of the wall of the uterus shews the mucous membrane and the muscular tissue to be infiltrated with caseous deposit.

Mary C., æt. 32, was admitted under Dr. Horrocks with symptoms of pelvic cellulitis attributed to a miscarriage. A week before her death, which took place a fortnight after admission, the urine was observed to be ammoniacal and to contain albumen. At the autopsy tubercles were found in the lungs, peritoneum, liver, and kidneys. See *Insp.* 1892, No. 471.

1219 **Enlarged Appendices Epiploicæ.**

A portion of colon the appendices epiploicæ of which are greatly enlarged owing to an inordinate increase in the amount of the subperitoneal fat.

From a man, æt. 50, who had been bedridden from paraplegia for five years and whose "organs had all undergone fatty degeneration." See *Preps.* 1668 (32) & 2089 (25) [2nd Edit.].

1220 Pedunculated Appendix Epiploica.

A portion of a colon to which is attached by a slender pedicle a rounded nodule about the size of a pea. The nodule, which appears to be an appendix epiploica in process of detachment, is seen under the microscope to consist of fat enclosed in a fibrous capsule.

1221 Appendices Epiploicæ in Process of Detachment.

Appendices epiploicæ, some more and some less closely attached to the intestine from which they arise, and others which were found as loose bodies in the peritoneal cavity. Some have the normal fatty structure, others are fibrous or calcareous.

From dissecting-room subjects.

Presented by Dr. Burton Brown.

1222 Loose Body in the Peritoneal Cavity.

An ovoid body found loose in the peritoneal cavity. It is about one third of an inch in its longer diameter and consists of a smooth fibrous capsule enclosing a calcareous nucleus.

John S., æt. 33, was admitted under Dr. Cholmeley in 1828 and died from Bright's disease. At the autopsy the loose body was found "perfectly unattached in the great omentum." See *Insp.* vol. 7, p. 72; and *Prep.* 809.

1223 Loose Body in the Peritoneal Cavity.

A flattened oval body about an inch in length and a quarter of an inch in thickness, which was found free in the peritoneal cavity. It has been laid open and is seen to consist of calcareous material contained within a smooth fibrous capsule.

1224 Lipoma from the Mesentery.

A portion of a very large tumour removed during life

from the mesentery. Histologically it consists of fibroid adipose tissue.

James B., æt. 60, was admitted under Dr. Pavy for a gradual enlargement of the abdomen which had been first noticed fifteen months previously. Paracentesis was attempted but no fluid withdrawn. Mr. Bryant performed laparotomy, and a tumour having a broad attachment to the mesentery and weighing fifty pounds was removed. The patient died on the day following the operation, and at the autopsy several small fatty tumours were found in the mesentery and one five inches long and two inches broad was situated behind the peritoneum in front of the spine. *See Insp.* 1885, No. 339.

1225 **Abdominal Lipoma.**

A portion of an enormous fatty tumour which was removed after death from the abdomen of a woman. The section shows the tumour to be made up of well-defined lobules of fat united by fibrous tissue. The whole mass weighed fifty-five pounds.

Presented by Mr. Cooper Forster, 1868.

1226 **Carcinoma of the Omentum.**

A portion of the transverse colon with the omentum which is greatly enlarged by a nodular deposit of new growth. At the thickest part the omentum measures three inches antero-posteriorly. Histologically the growth is a spheroidal-celled carcinoma.

Martha D., æt. 40, was admitted under Dr. Bright in 1826 with ascites, for which paracentesis was four times performed. At the autopsy secondary deposits were found upon the pleura. No visceral growth was discovered. *See Red Insp. Book*, p. 153; and *Prep.* 391.

1227 **Carcinoma of the Peritoneum.**

A portion of a transverse colon and the omentum mounted to shew the peritoneum thickly studded with rounded tumours, the largest measuring three inches and the smallest less than a twelfth of an inch in diameter. Histologically the tumours have the structure of spheroidal-celled carcinoma.

roidal-celled carcinoma with abundant stroma. The peritoneum forming the omentum is remarkably free from fat.

William G., æt. 21, was admitted under Dr. Cholmeley in 1828 for ascites and died three weeks after his admission. At the autopsy growths similar to those shewn in the preparation were found on all parts of the peritoneum and in the liver. *See Insp.* vol. 6, p. 109; and *Preps.* 1931 (32) & 1931 (64) [2nd Edit.].

1228 **Carcinoma of the Peritoneum.**

Portions of a diaphragm the peritoneal surface of which is covered by a thick layer of growth having the histological characters of spheroidal-celled carcinoma. The surface of the growth has a remarkably shaggy appearance from the presence of numerous flocculent processes.

John G., æt. 18, was admitted under Dr. Cholmeley in 1830 for a tumour occupying the greater part of the left side of the abdomen. He died a fortnight after admission, and at the autopsy a large growth was found in the left kidney, and there were secondary deposits in the pleura, peritoneum, and lymphatic glands. *See Insp.* vol. 10, p. 47; and *Prep.* 2057 (80) [2nd Edit.].

1229 **Carcinoma of the Peritoneum.**

A portion of parietal peritoneum the surface of which is covered by numerous small nodules of growth. There is a single larger growth, spherical in shape and measuring half an inch in diameter, attached to the serous membrane by a narrow base. Histological examination shews that these growths are secondary deposits of cylindrical-celled carcinoma.

From a male æt. 70.

1230 **Carcinoma of the Peritoneum and Pleura.**

A portion of a diaphragm presenting several isolated nodules of growth upon its peritoneal covering. On the reverse of the specimen similar nodules are seen upon the pleura. The growths appear to have an independent origin in the two serous membranes and have not

invaded the muscle of the diaphragm. Histologically the secondary deposits have the structure of carcinoma with very large cells, suggesting that the primary growth was a squamous-celled epithelioma.

1231 **Colloid Carcinoma of the Peritoneum.**

A portion of parietal peritoneum covered by a thick layer of growth the surface of which is fissured and nodular. Histologically the growth is a spheroidal-celled carcinoma many of the cells of which have undergone colloid change.

Harriet K., æt. 32, was admitted under Dr. Rees for enlargement of the abdomen. She died a week after her admission, and at the autopsy a colloid growth was found in the ascending colon and there were numerous secondary deposits in the omentum, mesentery, and lymphatic glands. *See Insp.* 1861, No. 67; and *Prep.* 920.

1232 **Colloid Carcinoma of the Peritoneum.**

A portion of an immense mass of colloid growth in which were embedded the stomach and transverse colon. The mass has the appearance of a sponge the fibrous groundwork of which contains within its meshes cysts of various sizes filled with a gelatinous material. Histologically the growth is a carcinoma the cells of which have undergone colloid change.

James K., æt. 55, was admitted under Dr. Pye-Smith for progressive enlargement of the abdomen first noticed six months before admission. A solid mass was felt in the right hypochondrium. Paracentesis was attempted, but no fluid was withdrawn. The patient died three months after admission from persistent vomiting and gradual emaciation. At the autopsy the peritoneal cavity was found to be obliterated and occupied by an enormous mass of colloid growth which invested, but did not invade, the abdominal viscera. It was thought that the omentum was the starting-point of the disease. *See Insp.* 1876, No. 146.

1233 **Colloid Carcinoma of the Peritoneum.**

The pyloric half of a stomach with the great omentum

and the transverse colon. The omentum and the wall of the stomach are greatly thickened by infiltration with new growth, which histologically has the characters of a spheroidal-celled carcinoma undergoing colloid degeneration. To the right and at the back of the preparation is seen the distended lesser sac of the omentum, which in the recent state was filled with fluid.

James P., æt. 25, was admitted under Dr. Moxon for ascites. He had suffered for two months from occasional abdominal pain and vomiting. Two months after admission the patient died, his abdomen having been tapped several times while in the hospital. At the autopsy the peritoneal cavity was found to be filled with chocolate-coloured fluid containing a quantity of thick pus. It was thought that the peritoneum was the seat of the primary growth. See *Insp.* 1883, No. 431; and *Prep.* 1234.

1234 **Colloid Carcinoma of the Peritoneum.**

A portion of a diaphragm the peritoneal surface of which is covered by a flat cauliflower-like mass of gelatinous growth. Where the growth is most abundant it projects three quarters of an inch above the surface of the diaphragm. In some places it has perforated the muscle and invaded the pleura.

For history and reference see *Prep.* 1233.

1235 **Lymphadenoma of the Mesentery.**

Four feet of ileum the mesentery of which is greatly enlarged, thickened, and contracted by infiltration with a soft white growth. At either end the bowel has been laid open to shew that its mucous surface is not invaded. Histologically the growth is a lymphadenoma.

From a child who died in the Evelina Hospital under the care of Dr. Fagge in 1872. At the autopsy a portion of the small intestine was found to be infiltrated by lymphadenomatous deposit, and there was a similar growth in one of the kidneys. See *Prep.* 928.

1236 Sarcoma of the Mesenteric Glands.

A coil of ileum in the mesentery of which is seen a tumour about the size of an orange, consisting of several lymphatic glands enlarged by a deposit of small round-celled sarcoma. The peripheral portion of the tumour is soft, while its centre is more fibrous and contains calcareous spicules.

Thomas G., æt. 18, was admitted under Dr. Gull for anæmia associated with dropsy and albuminuria. He had previously suffered from persistent epistaxis. A tumour was felt in the abdomen and was thought to be a movable kidney. The patient died apparently from uræmia three months after admission. At the autopsy secondary deposits of growth were found in the kidneys. There was chronic interstitial nephritis, and the renal tissue as well as the liver and spleen presented advanced lardaceous change. The abdominal tumour was found to consist of the enlarged glands which form the preparation. *See Insp.* 1864, No. 49.

1237 Sarcoma of Mesenteric Glands. Intestinal Obstruction.

A portion of the lower end of a jejunum the mesentery of which is occupied by a nodular mass consisting of several lymphatic glands infiltrated by malignant deposit. The growth is hard and fibrous, and histologically has the characters of a sarcoma with round and oval cells. At one point the contraction of the mesentery has so narrowed the lumen of the bowel that it will barely admit a crowquill. Above the obstruction the intestine is dilated and its wall considerably hypertrophied.

Joseph A., æt. 17, was admitted under Dr. Back in 1830 for great distension of the abdomen and frequent vomiting. His illness was attributed to a blow on the abdomen received two years before admission. "He was reported to have passed loose motions if not to have had some diarrhœa while in the hospital." At the autopsy "a considerable portion of the small intestine was about as large as a moderate-sized arm." Some of the

pelvic lymphatic glands were enlarged by malignant disease. No visceral growth was found. *See Insp.* vol. 9, p. 152; and *Prep.* 886.

1238 Melanotic Sarcoma of the Peritoneum.

A portion of a colon the serous covering of which presents numerous black nodules, varying in size from a pin's head to a pea. Histologically the deposits have the structure of a round-celled sarcoma containing much brown pigment.

From a woman, æt. 46, who suffered from a large melanotic growth upon the shin, and after death was found to have similar metastatic deposits in the heart, periosteum of the tibia, and in the lymphatic glands. *See Preps.* 1257 (50), 1400 (20), 1559 (35) [2nd Edit.]; *Drawing*, 52 (25); and *Skin Catalogue*, 2nd Edit. 1854, No. 292.

1239 Cystic Disease of the Omentum.

A greatly thickened omentum the substance of which is converted into a congeries of thin-walled translucent cysts. The cysts vary in size from that of a small orange to a pea, and in the recent state contained a watery fluid. Histologically the walls of the cyst are composed of fibrous tissue, and present no evidence of malignant disease.

James C., æt. 45, was admitted under Mr. Cock for a gunshot wound of the knee, and died from tetanus. *See Insp.* 1865, No. 5.

1240 Peritoneal Cyst. Sloughing Pancreas.

The posterior wall of a stomach, the duodenum, and a portion of the transverse colon seen from behind. The preparation is mounted to shew a cyst about three inches in diameter, occupying the situation of the upper part of the lesser sac of the peritoneum. The hinder wall of the sac has been partly removed and shews at its upper limit a mass of sloughing tissue consisting of the right half of the pancreas, the head of which has

almost entirely disappeared. The rest of the gland, which is outside the sac, appears to be normal.

From Mr. G., æt. 53, who was suddenly attacked with severe abdominal pain and vomiting, symptoms which recurred at intervals until his death three months later. A fortnight after the onset of his illness a pulsating tumour, resonant on percussion, was discovered situated between the umbilicus and the ensiform cartilage. At the autopsy no disease was found in any other part of the body except the condition shewn in the specimen, which is described in the report as an "abscess of the lesser sac of the omentum." See *Guy's Hosp. Reps.* 1863, p. 97.

Presented by Dr. Habershon.

1241 **Peritoneal Cyst. Sloughing Pancreas.**

A stomach with the duodenum and pancreas. The stomach has been raised to shew in the situation of the upper part of the lesser sac of the peritoneum a cavity about six inches in diameter with thick fibrous walls and roughened inner surface. The cavity has been laid open and within it is seen a partially detached dark mass, consisting of the body and tail of the pancreas, the head of which is represented by a few shreds of sloughing tissue. In the recent state the cyst contained "two or three pints of a light brown, slightly acid, inodorous fluid, in which were floating loose shreds of membrane and tissue, in some of which earthy matter could be felt."

James P., æt. 60, was admitted under Dr. Habershon with an abdominal tumour situated in the epigastric and umbilical regions. He had been suffering from vomiting and abdominal pain for four months, and these symptoms continued until his death four days after admission. At the autopsy the peritoneal cavity was found to contain a small quantity of brown fluid which had escaped from the cyst, and there was evidence of recent peritonitis. See *Insp.* 1861, No. 129.

1242 **Hydatid of the Mesocolon.**

A portion of an ascending colon in the mesentery of which is seen a thick-walled hydatid cyst measuring

about four inches in diameter. Within the cavity are seen partially detached hydatid membranes.

William A., æt. 40, was admitted under Dr. Bright in 1830 with jaundice, and a tumour in the epigastrium which proved to be a suppurating hydatid of the liver. The patient died six weeks after admission, and at the autopsy the pericardium was found to be acutely inflamed. See *Insp.* vol. 9, p. 121; and *Prep.* 1198.

1243 **Hydatid Cysts from the Abdomen.**

Numerous hydatid cysts, some entire and others ruptured, and varying in size from a foetal head to a pea. The walls of some are thin and translucent and others shrivelled and opaque.

Mrs. L., æt. 35, was admitted under Dr. Oldham and Mr. Bryant for an abdominal tumour which had been gradually increasing in size for fourteen years. It was thought to be an ovarian cyst, and on one occasion it had been punctured and seven pints of clear fluid withdrawn. An exploratory incision was subsequently made in the median line of the abdomen and a large cavity, apparently shut off from the peritoneum, was laid open and found to contain seven quarts of hydatid fluid and cysts. One of the cysts, stained with bile, was thought to be the parent hydatid. The patient made a good recovery. See *Guy's Hosp. Reps.* 1868, p. 235.

1244 **Hydatids of the Peritoneum.**

A collection of hydatid cysts united to each other by fatty and fibrous tissue, and presenting on their outer surfaces shaggy adhesions. The cysts vary in size from a hazel-nut to an orange, and in the recent state some of them were distended with daughter cysts and others were barren.

Louisa P., æt. 23, was admitted under Mr. Jacobson with a lobulated tumour almost filling the abdomen. The swelling had been noticed for five years. Laparotomy was performed and eight pounds of hydatid material were removed. The patient died the next day, and at the autopsy hydatids were found in the lungs, liver, spleen, and pelvic viscera. See *Insp.* 1885, No. 397; and *Prep.* 340.

1245 Hydatid of the Pelvis.

The female organs of generation mounted to shew on the anterior aspect of the left broad ligament a thin-walled globular cyst measuring two inches in diameter. At the bottom of the preparation jar are seen portions of the hydatid membrane which lined the cyst.





