


UC-NRLF



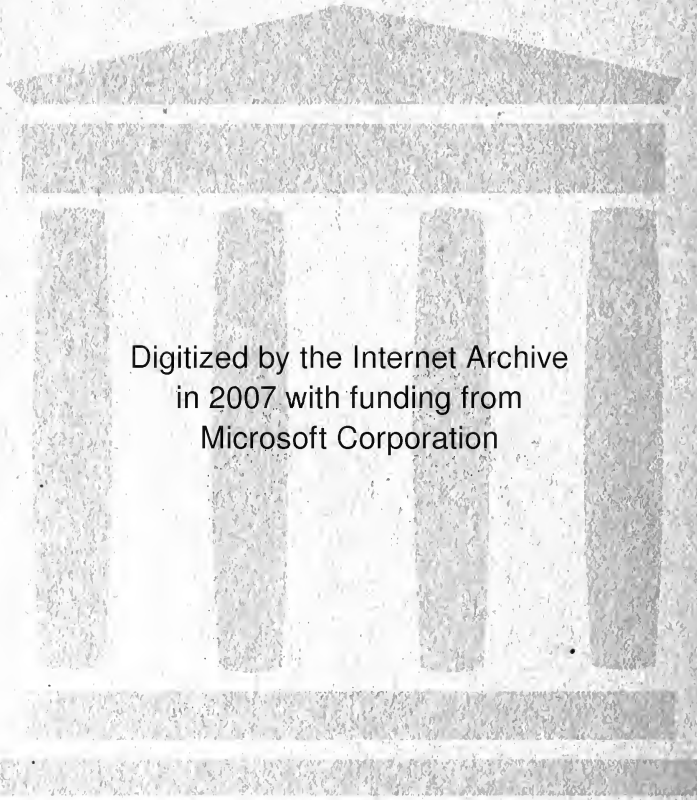
B 4 100 238

MEDICAL SCHOOL
LIBRARY



Dr. Aaron Schloss
Memorial.

Achloss



Digitized by the Internet Archive
in 2007 with funding from
Microsoft Corporation

DEVELOPMENT AND ANATOMY
OF THE
**NASAL ACCESSORY
SINUSES**
IN MAN

Observations Based on Two Hundred and
Ninety Lateral Nasal Walls, Showing the
Various Stages and Types of Development of
the Accessory Sinus Areas from the Sixtieth
Day of Fetal Life to Advanced Maturity

BY
WARREN B. DAVIS, M.D.

CORINNA BORDEN KEEN RESEARCH FELLOW OF JEFFERSON
MEDICAL COLLEGE; ASSISTANT DEMONSTRATOR OF ANATOMY
IN THE DANIEL BAUGH INSTITUTE OF ANATOMY, PHILADELPHIA

From the Laboratories of the Friedrichshain Krankenhaus, Berlin,
Germany, and the Daniel Baugh Institute of Anatomy, Philadelphia

DRAWINGS BY DOROTHY PETERS

PHILADELPHIA AND LONDON
W. B. SAUNDERS COMPANY

1914

R



Copyright, 1914, by W. B. Saunders Company

PRINTED IN AMERICA

© 1914 W. B. Saunders Company
All rights reserved
Published by W. B. Saunders Company
Philadelphia, Pa.

26
14

FOREWORD

THE literature concerning the embryology, later development, and adult anatomy of the nasal accessory sinuses is rather abundant, yet the differences in the views expressed—especially concerning the extent of development during the years of childhood—seemed sufficiently great to warrant further study.

The author therefore has collected and carefully studied this series of preparations of the accessory sinus areas—which series covers the various stages of development from the sixtieth day of intrauterine life to advanced maturity—hoping to supply information regarding some few points with which we have been imperfectly acquainted, on account of the scarcity of specimens showing the conditions present during the years of childhood.

Deductions drawn from a few observations are open to fallacy, owing to variations in the extent and type of development as found in different specimens of approximately the same age. In this series an endeavor has been made to obtain a sufficient number of cases showing the various stages of development to make the general averages of practical value.

The bodies of children between the ages of two and sixteen years being seldom obtainable in the dissecting rooms of European institutions as well as in America, it was necessary, in order to complete such a series, to develop a technic by which the accessory sinus areas could be removed en

masse at the time of postmortem examinations, and still allow reconstruction of the face without marked disfigurement. Ninety-six of the cases in this series were thus obtained from the postmortem room of the Friedrichshain Krankenhaus, Berlin, for which privilege and for courtesies shown me while using the laboratories of that institution I wish to express grateful appreciation to Dr. Ludwig Pick, Professor of Pathology, University of Berlin.

The material for the other post-natal preparations was furnished by the Daniel Baugh Institute of Anatomy of Philadelphia. For this material, for laboratory facilities, and for many valuable suggestions regarding the work, I am under obligations to Professor Edward Anthony Spitzka, Dr. H. E. Radasch, and Dr. Howard Dehoney.

For the embryologic and fetal material I wish to thank the Gynecological and Obstetrical Departments of Jefferson Medical College, also Dr. Wilhelm Bode, Assistant Pathologist to Friedrichshain Krankenhaus.

The illustrations, which are natural size, unless otherwise stated in the legends, are from the very accurate drawings made by Miss Dorothy Peters, who has given the most careful attention to detail.

The majority of the dissections will be permanently mounted and placed in the museum of the Daniel Baugh Institute of Anatomy.

WARREN B. DAVIS

1700 WALNUT STREET, PHILADELPHIA.

February, 1914.

CONTENTS

	PAGE
FOREWORD	7
ANATOMIC MATERIAL USED	11
METHOD USED IN OBTAINING AND PREPARING SPECIMENS	15
EMBRYOLOGIC CONSIDERATIONS	19
THE CELLULÆ ETHMOIDALES	44
CELLULÆ ETHMOIDALES ANTERIOR	46
CELLULÆ ETHMOIDALES POSTERIOR	77
CELLULÆ CONCHALES	78
THE SINUS MAXILLARIS	79
THE SINUS FRONTALIS	132
SUPERNUMERARY SINUS FRONTALES	146
THE FORM AND BOUNDARIES OF THE SINUS FRONTALIS	157
THE SINUS SPHENOIDALIS	160
BIBLIOGRAPHY	166
<hr/>	
INDEX	171

THE DEVELOPMENT AND ANATOMY OF THE NASAL ACCESSORY SINUSES IN MAN

ANATOMIC MATERIAL USED

The anatomic material upon which the observations given in this report are based consists of the following specimens:

(a) Serial sections for microscopic study of the nasal areas of 14 embryos and fetuses, the ages of which were reckoned as closely as possible by estimates based upon the measurements of total length (Dührssen's method), and also upon length from vertex to buttocks. The ages expressed in days of embryonal life were as follows: 60, 63, 65, 85, 91, 95, 98, 100, 115, 117, 118, 121, 126, and 133 days.

(b) Sagittal and coronal sections for macroscopic study of the heads of 8 fetuses, aged respectively 137, 139, 151, 188, 196, 202, 224, and 246 days.

(c) Sagittal and horizontal sections of the heads of 4 full-term fetuses.

(d) Sagittal, coronal, and horizontal sections of the nasal and accessory sinus areas of 101 postnatal heads, the mucosa remaining intact in each case. The exact ages of cases from which specimens were obtained are given in the following table:

SERIES D Case Number	AGE			SEX	PLANE OF SECTIONS
	Years	Months	Days		
1.....	8	Female	Sagittal
2.....	..	1	8	Male	Coronal
3.....	..	3	15	"	"
4.....	..	4	..	Female	Horizontal

SERIES D	AGE			SEX	PLANE OF SECTIONS
	Years	Months	Days		
Case Number					
5.....	..	4	27	Male	Sagittal
6.....	..	5	..	"	Horizontal
7.....	..	6	15	Female	Coronal
8.....	..	8	..	Male	Sagittal
9.....	..	10	..	"	"
10.....	..	10	6	"	Coronal
11.....	1	..	4	"	"
12.....	1	2	3	Female	"
13.....	1	2	15	"	Sagittal
14.....	1	4	7	Male	"
15.....	1	6	6	"	Coronal
16.....	1	7	26	"	Sagittal
17.....	1	8	1	"	Coronal
18.....	1	8	14	Female	Horizontal
19.....	1	9	..	Male	Coronal
20.....	1	10	13	Female	Sagittal
21.....	2	..	14	Male	"
22.....	2	3	..	"	"
23.....	2	5	20	"	Coronal
24.....	2	6	7	"	"
25.....	2	6	12	Female	Sagittal
26.....	2	7	8	"	"
27.....	2	8	24	Male	"
28.....	2	11	21	"	Coronal
29.....	3	2	..	Female	Horizontal
30.....	3	4	6	"	Coronal
31.....	3	4	6	"	Sagittal
32.....	3	5	8	Male	Coronal
33.....	3	9	10	"	Sagittal
34.....	3	11	..	Female	"
35.....	4	..	5	"	"
36.....	4	2	..	Male	Coronal
37.....	4	3	2	"	Sagittal
38.....	4	3	5	Female	"
39.....	4	6	8	Male	Coronal
40.....	4	7	19	"	"
41.....	4	10	4	"	"
42.....	4	10	5	Female	Sagittal
43.....	5	..	17	"	Coronal
44.....	5	6	3	Male	Sagittal
45.....	5	10	22	"	"
46.....	6	"	"
47.....	6	1	..	Female	"
48.....	6	2	..	Male	"
49.....	6	6	15	Female	"
50.....	6	7	7	"	Coronal
51.....	6	8	28	Male	Sagittal
52.....	6	9	24	Female	Coronal
53.....	6	10	20	Male	Sagittal
54.....	7	1	..	Female	"
55.....	7	2	2	Male	"
56.....	7	6	4	Female	"

SERIES D	AGE			SEX	PLANE OF SECTIONS
	Years	Months	Days		
57.....	7	7	20	Female	Coronal
58.....	7	9	12	"	"
59.....	8	2	10	Male	Sagittal
60.....	8	2	12	"	"
61.....	8	2	25	Female	"
62.....	8	7	3	Male	Coronal
63.....	8	8	1	Female	Sagittal
64.....	9	1	9	"	"
65.....	9	10	19	Male	Coronal
66.....	10	1	7	"	Sagittal
67.....	10	7	27	"	"
68.....	11	Female	"
69.....	12	9	12	Male	Coronal
70.....	13	"	Sagittal
71.....	13	2	8	"	"
72.....	13	6	19	"	Coronal
73.....	14	7	..	Female	Sagittal
74.....	15	Male	Horizontal
75.....	15	5	..	"	Coronal
76.....	15	9	26	"	Sagittal
77.....	16	"	Horizontal
78.....	16	2	17	"	Sagittal
79.....	16	5	21	Female	"
80.....	16	8	2	"	Coronal
81.....	17	Male	Sagittal
82.....	17	"	Coronal
83.....	17	"	Sagittal
84.....	17	11	..	Female	"
85.....	18	11	10	Male	"
86.....	19	..	28	Female	"
87.....	19	6	15	Male	"
88.....	19	7	15	Female	"
89.....	20	Male	"
90.....	20	5	..	Female	Coronal
91.....	21	6	29	"	Sagittal
92.....	22	"	"
93.....	22	6	11	"	"
94.....	23	7	13	Male	"
95.....	25	"	"
96.....	25	3	..	Female	"
97.....	28	Male	"
98.....	50	"	"
99.....	56	Female	"
100.....	62	Male	"
101.....	68	Female	"
				Males . . . 59	Sagittal 64
				Females . 42	Coronal 31
					Horizontal 6

(e) Eighteen macerated skulls were prepared for study

by sectioning in the various planes, the majority being horizontal. The skulls were evidently those of middle-aged individuals, but the exact ages could not be obtained.

Thus the total number of cases studied was 145, or 290 lateral nasal walls and accessory sinus areas. The specimens in each case were prepared by sectioning and dissecting, so that the nasal cavities and all accessory sinuses on each side could be thoroughly examined.

METHODS USED IN OBTAINING AND PREPARING SPECIMENS

(a) Method Used in Removing the Nasal Accessory Sinus Areas en Masse at Postmortem Examinations Without Producing Marked Disfigurement of the Face.—The skull having been opened by the usual circumferential saw-cut and the brain removed, further detach the skin and subcutaneous structures from the frontal area to the level of the nasion. With the saw make in the sagittal direction cuts through the frontal bone just lateral to each supra-orbital notch, and extending through the supra-orbital plates. Remove with bone-forceps the portion of supra-orbital plates lying lateral to the sagittal cuts, thus obtaining room to detach the eyeballs posteriorly and turn them forward. Dissect the skin and muscles from the nasal, lacrimal, and maxillary bones; then from the anterior end of the nasal bones cut through the nasal septum and lateral nasal cartilages to the anterior nasal spine of the maxilla. With a chisel cut through the basi-occipital bone; thence lateral to the body of the sphenoid extend the cuts to the sphenomaxillary fissure. With a saw or with a costotome cut through the maxillary processes of the malar bones and remove the specimen en masse.

To reconstruct the face, fill the oral cavity and the space previously occupied by the specimen with cotton packed firmly to the level of the orbital floor. Turn the eyeballs back into place, and pass two sutures through the sub-

cutaneous structures just posterior to the inner canthi, and tighten them until the eyes are held the proper distance apart. Pack cotton anterior to these sutures to form a bridge for the nose, and by pressure and adjustment of position of cotton mold the nose into its original shape. Fill the remaining portion of the cranial cavity with cotton or oakum and make the interfrontal area smooth and firm by means of plaster-of-Paris. Replace the calvarium in the usual way.

The above-described method was devised by the author for obtaining anatomic and pathologic specimens from cases in which it was necessary to avoid undue disfigurement of the face. The majority of the figures illustrating this work were drawn from specimens obtained in this manner from the postmortem rooms of Friedrichshain Krankenhaus, Berlin. In only one out of 97 cases was the disfigurement sufficient to cause criticism or dissatisfaction on the part of parents or other relatives of the individuals. In that case it was necessary to replace the specimen.

(b) Methods Used in Preparing Specimens.—1. Serial sections for microscopic study were made of the youngest 14 embryos and fetuses of the series. Specimens were fixed in 10 per cent. formalin. Those in which ossification had advanced sufficiently to interfere with sectioning with microtome were decalcified in a solution of 10 per cent. nitric acid in 4 per cent. formalin. The usual technic for celloidin infiltration and blocking was used in 9 cases and the paraffin method in the remaining 5. The celloidin sections were more satisfactory. Hematoxylin and eosin staining was used for all sections.

2. The heads of fetuses prepared for macroscopic study and the 96 postnatal specimens from Friedrichshain Krank-

enhaus were placed in 10 per cent formalin immediately after removal from the bodies and allowed to harden in this solution for a period of from eight to ten weeks, at the end of which time they were sectioned in the desired plane by means of very small, narrow saws. Jewelers' saws were used for sectioning through the teeth, and small scroll saws were used for other parts. The mucosa remained perfectly attached in nearly all instances, and in no case were the relations of the delicate bones of the ethmoid areas disturbed.

3. In 5 cases frozen sections were made at various levels in the horizontal plane.

4. In the 18 skulls from which the soft parts had been removed by maceration all accessory sinus areas were completely filled with paraffin before sectioning with a thin saw, thus avoiding fractures of the delicate plates of bone in the ethmoid area. The paraffin was removed by placing the specimens in hot water. This method is of great value in obtaining nearly perfect bony specimens.

The ostia of the accessory sinuses, however, can be accurately studied as to size, location, and exact communications only when the mucosa is intact. Thus these 18 osseous specimens were used only in the study of size, extent, and relations of the sinus cavities and their walls, and were not included in any of the estimations regarding the ostia.

From the previously given lists it is seen that the stages of development shown by these preparations form a continuous series from the sixtieth day of intra-uterine life up to maturity, and then a few specimens from the aged.

The development of the nasal areas earlier than the sixtieth day of embryonal life will be considered only in the

form of a brief summary, expressing the consensus of opinions held by embryologic observers. The statements regarding the development later than the sixtieth day of embryonal life are based upon conditions as shown in this series, unless otherwise stated.

EMBRYOLOGIC CONSIDERATIONS

During the third week of embryonal life there is evidence of beginning development of the nasal areas as shown by increasing thickness of the ectoderm on the anterolateral portions of the forebrain. At the end of the third week, or during the fourth week, the nasal area appears as a depression which is brought about by the increased thickness of the surrounding mesenchyme. In the mesenchyme investing the anterior portion of the notochord is the first appearance of the primordial cranium; this then extends dorsally to inclose the anterior portion of the medullary canal, which will later become the cerebral part of the central nervous system. The primitive nasal capsule develops as a part of the primordial cranium. From that part which extends forward beyond the anterior portion of the notochord a core is formed for the frontonasal process—a relatively broad mass of tissue separating the nasal pits. The nasal pits are symmetric depressions, at first pyriform in outline, with the small ends toward the primitive mouth cavity. As the *processus globularis* on the lateral portion of the medial nasal process approximates the lateral nasal and maxillary processes, there is a deepening of the primitive nasal fossæ and a change in their form, which becomes oval and bordered by broad folds. The broad median process separating the depressions later becomes narrowed and forms the *septum nasi*. By the approximation of the nasal processes inferiorly, their ectodermal coverings are brought into contact. The

intervening ectoderm is resorbed, and the processes become united by mesoderm, which forms the floor of the primitive anterior nares. In the fifth week, or shortly thereafter, by the partial resorption of ectodermal cells filling the remaining interspaces between the median and lateral nasal processes, there is formed behind the *os intermaxillare* the primitive *ductus nasopharyngeus*. Posteriorly, there persist for a short while the *membranæ buconasales*, which break through and form the primitive choanæ at a time somewhere between the twenty-eighth and fortieth day—the observations of the different embryologists varying to that extent.

The basal part of the primordial cranium develops into chondrocranium. Laterally, the basal plates develop as the periotic capsules; ventrally they form the mesethmoid plate (from the lower portion of which the vomer later develops), and anterolaterally they enter into the formation of the nasal capsule. In the second month the nasal capsule becomes clearly differentiated from other mesoderm and shows beginning cartilaginous development.

The palatal ridges appear on the medial sides of the maxillary processes from the forty-fifth to forty-eighth day of embryonal life (J. P. Schaeffer), and by their approximation the palate is formed.

Concerning the early development of the conchæ, Schaeffer records in his very thorough studies of the embryologic development of the lateral nasal wall that the *concha nasalis inferior* appears in embryos of thirty-eight to forty days as a bulging of the inferior portion of the lateral nasal wall immediately superior to the portion from which the palatal processes develop. From the fortieth to the forty-

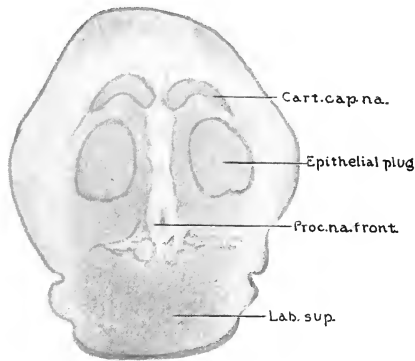


FIG. 1.—DIAGRAM DRAWN FROM A CORONAL SECTION THROUGH ANTERIOR PORTION OF NASAL AREA OF A SIXTY-DAY EMBRYO. (Series A, No. 1, slide 2, section 4. $\times 16\frac{2}{3}$.)

Cart.cap.na., Cartilago capsulae nasalis, showing the portion which later forms the anterior extremity of the nasal bone; *Epithelial plug*, a mass of epithelial cells completely filling the anterior nares; *Proc.na.front.*, antero-inferior portion of the processus nasofrontalis; *Lab.sup.*, labium superius.

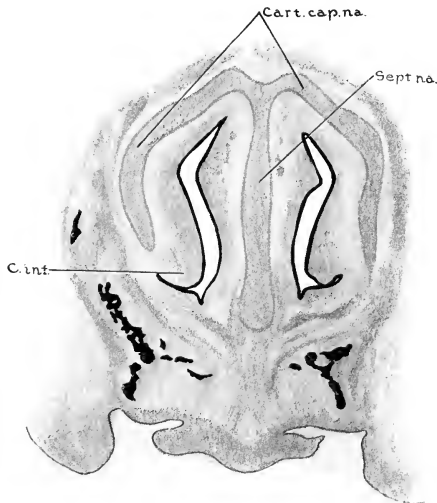


FIG. 2.—DIAGRAM DRAWN FROM A CORONAL SECTION, 0.82 MM. POSTERIOR TO THAT SHOWN IN FIG. 1. (Series A, No. 1, slide 4, section 12. $\times 16\frac{2}{3}$.)

Cart.cap.na., Cartilago capsulae nasalis; *Sept.na.*, septum nasi; *C.inf.*, concha inferior.

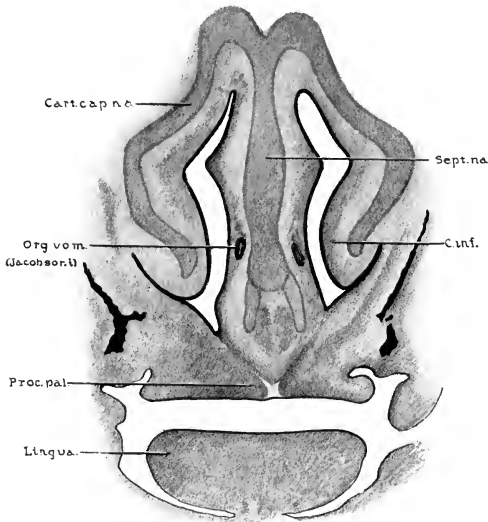


FIG. 3.—DIAGRAM DRAWN FROM A CORONAL SECTION THROUGH NASAL AREA OF A SIXTY-DAY EMBRYO, 0.45 MM. POSTERIOR TO THE SECTION SHOWN IN FIG. 2. (Series A, No. 1, slide 6, section 6. $\times 16\frac{2}{3}$.)

Sept.na., Septum nasi; note relative thickness at this stage of development; *C.inf.*, concha inferior; *Proc.pal.*, processus palatinus of maxilla; *Org.vom.*, organon vomeronasale (Jacobsoni); *Cart.cap.na.*, cartilago capsulae nasalis.

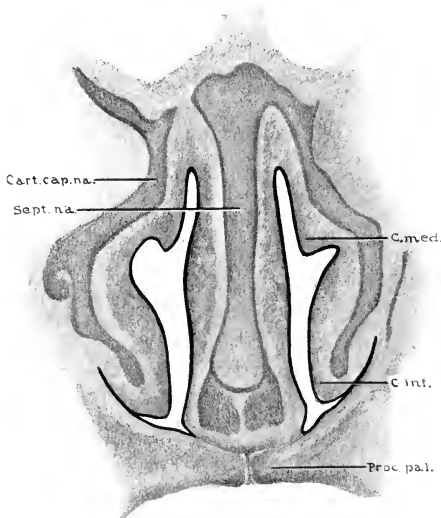


FIG. 4.—DIAGRAM DRAWN FROM A CORONAL SECTION THROUGH NASAL AREA OF A SIXTY-DAY EMBRYO, 0.25 MM. POSTERIOR TO SECTION SHOWN IN FIG. 3. (Series A, No. 1, slide 7, section 4. $\times 16\frac{2}{3}$.)

C.med., Concha media (note that cartilage has not yet developed in this portion of concha); *C.inf.*, concha inferior; *Proc.pal.*, processus palatinus of maxilla; *Sept.na.*, septum nasi; *Cart.cap.na.*, cartilago capsulae nasalis.

third day the ethmoidal fold appears superior and slightly dorsal to the fold representing the concha inferior, and from this ethmoidal fold the ethmoidal conchæ are developed as the nasal cavity increases in its supero-inferior diameter.

Coming now to the conditions shown in the sixty-day embryo (the youngest studied in this series), we find the cartilaginous development in the nasal capsule well advanced. The anterior nares are filled by the masses of epithelial cells (Fig. 1), a condition persisting in some specimens up to one hundred and fifteen days. The lateral nasal wall shows two distinct folds (Fig. 4), the lower being the concha nasalis inferior and the superior one the ethmoidal fold, which is beginning to assume the form of the concha nasalis media. In its posterosuperior portion, the ethmoidal fold shows a further differentiation, indicating the early formation of the concha superior (Fig. 5). The conchæ, in their earlier stages of development, do not contain cartilage, but are folds of mesenchyme covered by nasal epithelium. In the sixty-day embryos (Figs. 1-5) the central portion of the concha inferior and the concha media shows condensation of the mesenchyme and its transformation into cartilage. In the concha superior, however, cartilaginous development has not yet begun. As the central portion of the mesenchyme entering into the formation of the conchæ becomes more dense and is transformed into cartilaginous structures, it appears as an extension of or a projection from the cartilage forming the lateral portion of the nasal capsule.

As the conchæ become more prominent medially, there is also a lateral deepening of the grooves immediately beneath

the conchæ, each groove becoming a meatus which is named in accordance with the concha beneath which it lies.

A sixty-day fetus further shows on the anterosuperior portion of the lateral nasal wall, just anterior to the ethmoidal fold, a smaller prominence representing the early formation of the agger nasi or nasoturbinal. From the posterior portion of the agger nasi there is seen in the sixty-five-day embryo (Fig. 6) a ridge of mesenchyme extending in a postero-inferior direction along the superior curved border of the concha inferior.

This ridge, which has its free edge directed postero-superiorly and slightly medially, is the early processus uncinatus, in which there soon appears a thickening or condensation of the mesoderm in its central portion, followed by transformation into cartilage (Fig. 9). The agger nasi with the processus uncinatus together form the "Erste Hauptmuschel" of Killian. However, in this work it will not be listed as one of the conchæ, for, although comparative anatomy shows these structures to be the homologue of the inferior olfactory concha as found in lower mammalia, yet the form and position which they have assumed in the human type are such that we deem it best not to consider them as forming one of the true nasal conchæ.

Shortly after the appearance of the processus uncinatus there is seen, just inferior to the attachment of the middle portion of the concha media, another projection, which also develops from the lateral nasal wall, with its free border facing in an antero-inferior and slightly medial direction (Fig. 9). This fold is the early bulla ethmoidalis, which develops from the lateral ethmoidal mass as one of its secondary folds.

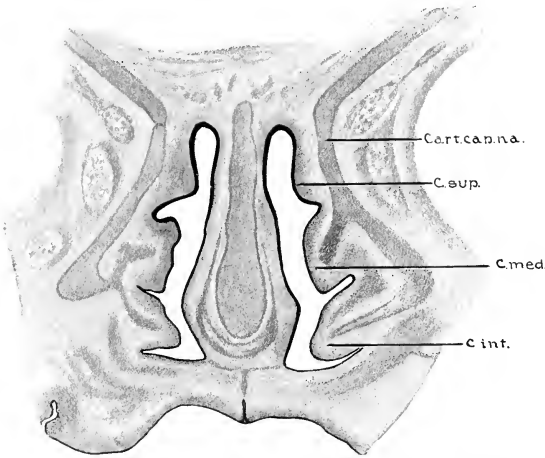


FIG. 5.—DIAGRAM DRAWN FROM A CORONAL SECTION, 0.97 MM. POSTERIOR TO THAT SHOWN IN FIG. 4. (Series A, No. 1, slide 10, section 6. $\times 16\frac{2}{3}$.)

Cart.cap.na., Cartilago capsulae nasalis; *C.sup.*, concha superior (note that at this stage of development there is no cartilage in this concha); *C.med.*, concha media; *C.inf.*, concha inferior.

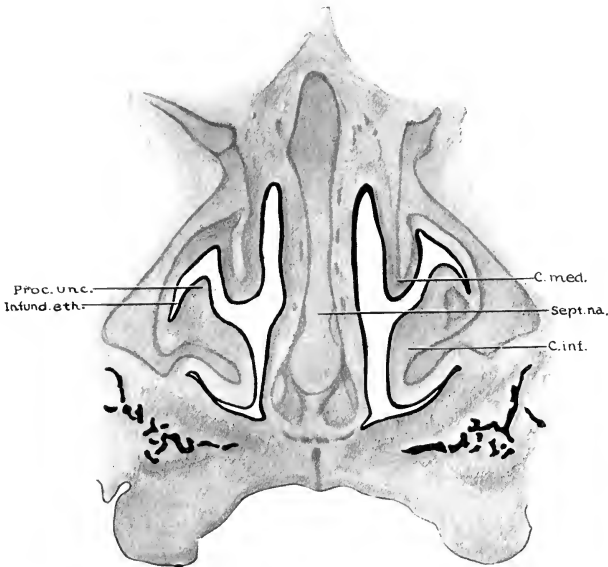


FIG. 6.—DIAGRAM DRAWN FROM CORONAL SECTION THROUGH ANTERIOR THIRD OF NASAL AREA OF A SIXTY-FIVE-DAY EMBRYO, SHOWING THE DEVELOPMENT OF THE PROCESSUS UNCINATUS, WHICH AT THIS PERIOD APPEARS AS A RIDGE ALONG THE SUPERIOR CURVED BORDER OF THE CONCHA INFERIOR. (Series A, No. 3, slide 5, section 11. $\times 16$.)

C.med., Concha media; *Sept.na.*, septum nasi; *C.inf.*, concha inferior; *Infund.eth.*, infundibulum ethmoidale; *Proc.unc.*, processus uncinatus.

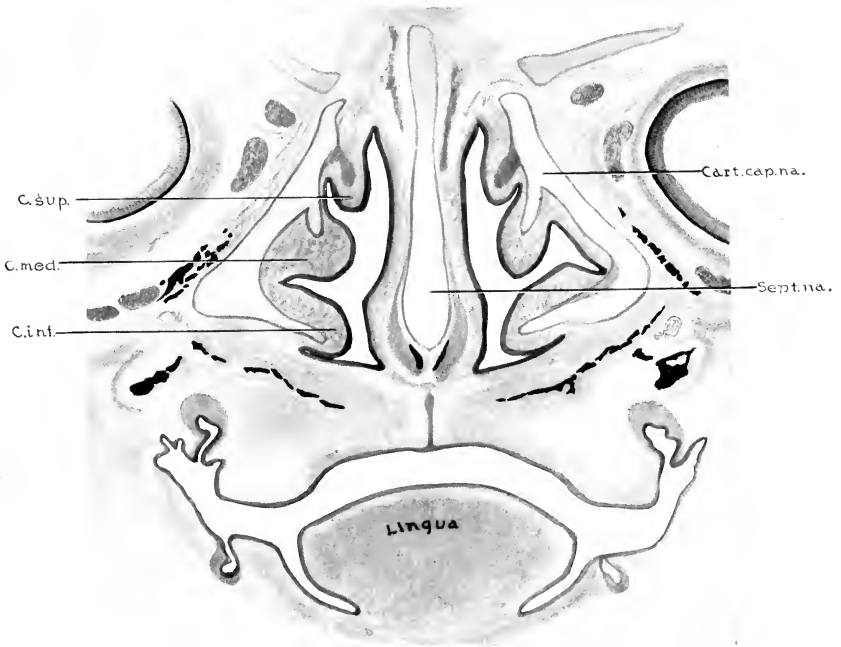


FIG. 7.—DIAGRAM OF CORONAL SECTION THROUGH NASAL AREA, 0.45 MM. DORSAL TO SECTION SHOWN IN FIG. 6, SHOWING RELATIONS OF DEVELOPING CONCHÆ. CONCHA SUPERIOR SHOWS IN ITS CENTRAL AREA A THICKENING OF THE MESODERM WHICH LATER BECOMES CARTILAGE. (Series A, No. 3, slide 7, section 3. $\times 16$.)

Cart.cap.na., Cartilago capsulae nasalis; *Sept.na.*, septum nasi; *C.inf.*, concha inferior; *C.med.*, concha media; *C.sup.*, concha superior.

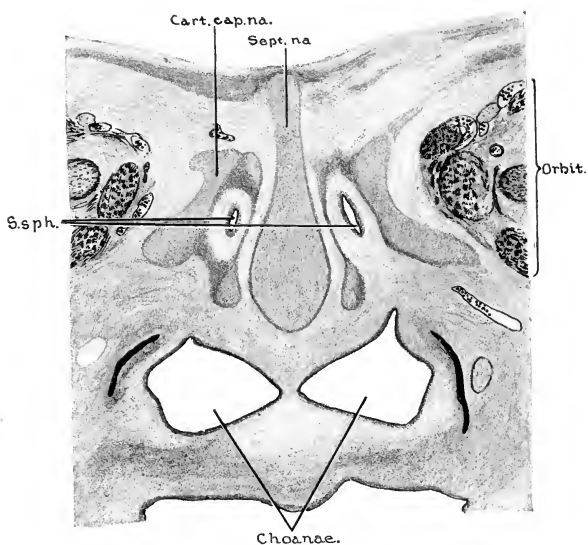


FIG. 8.—DIAGRAM DRAWN FROM A CORONAL SECTION JUST POSTERIOR TO THE RECESSUS SPHENO-ETHMOIDALIS, SHOWING THE PRIMITIVE SINUS SPHENOIDALES WHICH DEVELOP AS INVAGINATIONS OF MUCOSA INTO THE POSTERIOR NASAL CAPSULE. (Series A, No. 3 (sixty-five-day embryo), slide 10, section 10. $\times 16$.)

S.sph., Sinus sphenoidales; *Cart.cap.na.*, cartilago capsulae nasalis; *Sept.na.*, septum nasi.

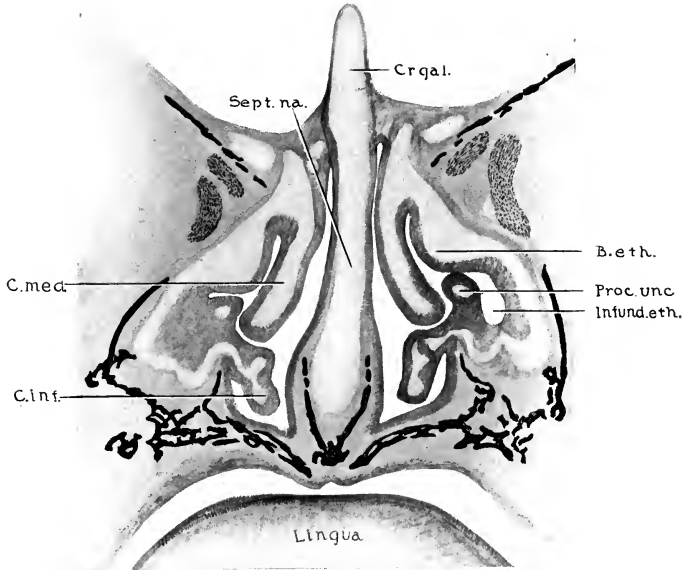


FIG. 9.—DIAGRAM OF CORONAL SECTION THROUGH THE ANTERIOR THIRD OF THE NASAL AREA OF A NINETY-FIVE-DAY EMBRYO, TO SHOW THE EXTENT OF DEVELOPMENT AND RELATIONS OF THE PROCESSUS UNCINATUS AND THE BULLA ETHMOIDALIS. (Series A, No. 6, slide 11, section 6. $\times 10$.)

Cr.gal., Crista galli; *B.eth.*, bulla ethmoidalis; *Proc.unc.*, processus uncinatus; *Infund.eth.*, infundibulum ethmoidale; *C.inf.*, concha inferior; *C.med.*, concha media; *Sept.na.*, septum nasi.

Between the free antero-inferior surface of the bulla and the posterosuperior surface of the processus uncinatus is a narrow interval, the primitive hiatus semilunaris, which is the opening or means of communication between the meatus medius and the infundibulum ethmoidale, the infundibulum developing as the gutter-like channel lateral to the processus uncinatus (Figs. 9, 12, and 14). It is these structures which make the lateral wall of the meatus medius rather complicated. Their variations in form and type of development give rise to different locations of the ostia of the anterior ethmoidal cells, and thus influence the manner in which the frontal sinus communicates with the middle meatus.

The bulla ethmoidalis in some instances appears as a smooth bulging fold in which the cartilage, developing as an extension from the lateral nasal capsule, is evenly rounded in its outline,—thus making a single oval fold (Fig. 9). In other cases the cartilage shows a double fold or a deep groove in the single fold, and in some instances two such grooves are seen (Fig. 12). Evidence of this type of formation is sometimes seen in early childhood as a slight groove in the overlying mucosa along the middle portion of the bulla, but in no case did we find the ostium of a bullar cell located so as to indicate that it had its origin in such a furrow.

The number of ethmoidal conchæ into which the lateral ethmoidal mass becomes differentiated varies from three to five. The majority of fetuses examined had three ethmoidal conchæ—four were not uncommonly present; but only on one side of one specimen were five demonstrable (Fig. 16). Killian would count such a specimen as having six ethmoidal conchæ, since he counts the agger nasi plus the processus uncinatus as the first ethmoidal concha,—“Erste Haupt-

muschel,"—and believes that such a condition represents the typical number of conchæ originally possessed by all ethmoidal areas at some time in early fetal life. He concludes, therefore, that specimens showing fewer conchæ do so because of the fusing of two or more of the primitive ethmoidal folds. However, since his own large series of fetuses showed only two specimens in which so many conchæ were distinctly differentiated, and since such specimens are so seldom found by other observers of embryologic and fetal conditions, it seems more probable that the number found in any given case depends more upon the extent to which differentiation was carried than it does upon the fusing of conchæ already formed. Zuckerkandl gives three ethmoidal conchæ as the typical number, but found four present in 6.7 per cent. of cases. Seydel found no specimens showing more than three, while Schaeffer found four to be rather common. E. Kellius believed the development of five to be very seldom. The nomenclature for the conchæ nasales should be applicable to adult conditions and also cover the highest number found in fetal life (Fig. 16). This is satisfactorily done by the terms used by Schaeffer, which are as follows:

Concha nasalis inferior	
“	“ media
“	“ superior
“	“ suprema I
“	“ suprema II
“	“ suprema III

The meatus beneath each concha is similarly designated. In my own series of 202 postnatal lateral nasal walls having

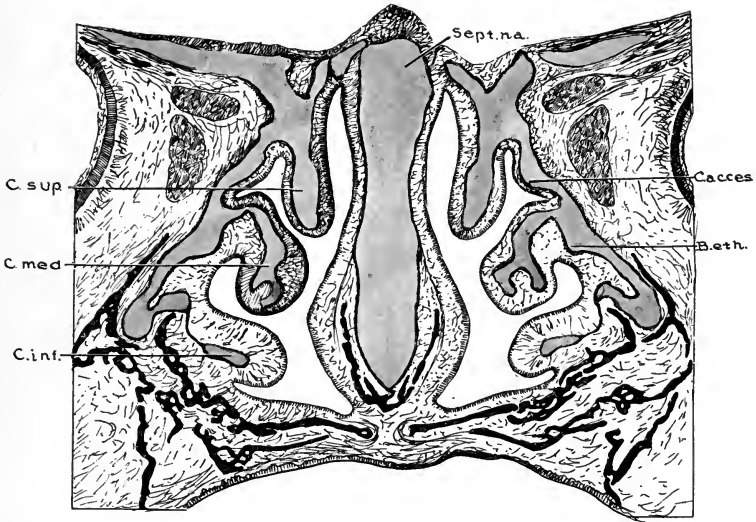


FIG. 10.—DIAGRAM DRAWN FROM A CORONAL SECTION THROUGH THE MIDDLE THIRD OF THE NASAL AREA OF A ONE-HUNDRED-DAY EMBRYO. (Series A, No. 8, slide 14, section 4. $\times 10$.)

Sept. na., Septum nasi; *C. acces.*, concha accessoria, a fold which bears a relation to the meatus superior somewhat similar to that which the bulla ethmoidalis bears to the meatus medius. The concha accessoria, however, is not always so distinctly marked. *B. eth.*, posterior end of bulla ethmoidalis; *C. inf.*, concha inferior; *C. med.*, concha media (note the inferior and medial grooves in the cartilage of this concha); *C. sup.*, concha superior.



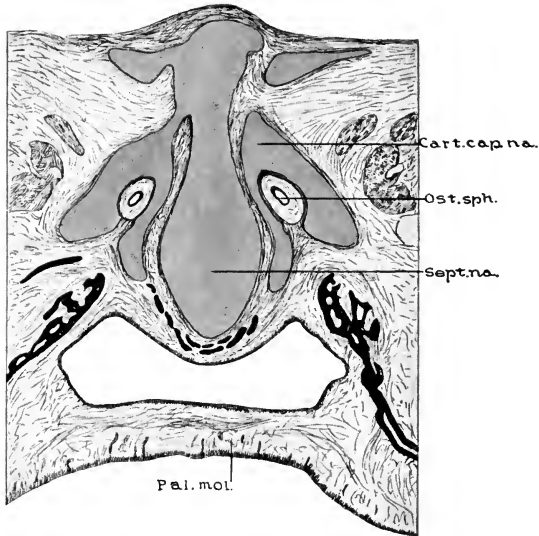


FIG. 11.—DIAGRAM DRAWN FROM A CORONAL SECTION JUST DORSAL TO THE RECESSUS SPHENO-ETHMOIDALIS OF A ONE-HUNDRED-DAY EMBRYO, SHOWING THE DEVELOPMENT OF THE SINUS SPHENOIDALES INTO THE POSTERIOR PORTION OF THE CARTILAGINOUS NASAL CAPSULE. (Series A, No. 8, slide 18, section 6. $\times 10$.)

Cart. cap. na., Cartilago capsulae nasalis, posterior portion; *Ost. sph.*, ostium sphenoidale; *Sept. na.*, septum nasi, most posterior portion; *Pal. mol.*, palatum molle.

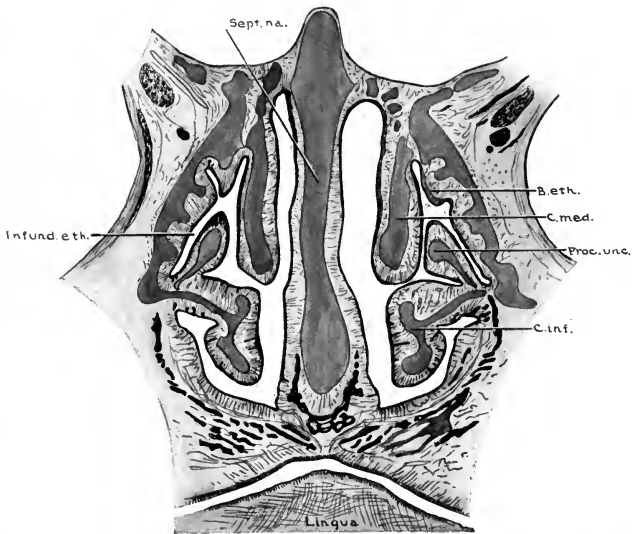


FIG. 12.—DIAGRAM DRAWN FROM A CORONAL SECTION NEAR THE MIDPOINT ANTEROPOSTERIORLY OF THE LATERAL NASAL WALL. (Series A, No. 12 (one-hundred-and-twenty-one-day fetus), slide 8, section 1. $\times 6$.)

B.eth., Bulla ethmoidalis; *C.med.*, concha media; *Proc.unc.*, processus uncinatus; *C.inf.*, concha inferior; *Infund.eth.*, infundibulum ethmoidale; *Sept.na.*, septum nasi.

mucosa attached, four ethmoidal conchæ were present in 2 per cent. of the cases, three in 92 per cent., and two in only 6 per cent., yet two is the number most frequently described in anatomic works.

All ethmoidal cells, the frontal and maxillary sinuses, have their origin from preformed grooves or furrows between the folds which develop on the lateral nasal wall. The meatus nasi medius soon becomes the most complex portion of the nasal cavity, and developing from it and extending into the surrounding areas are extensive processes of pneumatization which are termed the cellulæ ethmoidales anterior, the sinus maxillaris, and the sinus frontalis.

THE CELLULÆ ETHMOIDALES

The cellulæ ethmoidales are often considered as forming anterior, middle, and posterior groups of cells. However, we believe a classification more satisfactory from an anatomic viewpoint, and more practical from the clinical aspect to be one which divides them primarily into anterior and posterior groups, each of which is further subdivided.

All ethmoidal cells having their ostia inferior to the attachment of the concha nasalis media belong to the anterior group, while those having their ostia superior to the concha media belong to the posterior group (Fig. 43). This classification holds good regardless of how far the more distant portions of any irregularly developed cell of either group may invade the region ordinarily occupied by cells of the other group. In considering the cells entering into the formation of these two primary groups the following classification will be used:

Cellulæ ethmoidales anterior:	{	Cellulæ frontales.
		Cellulæ infundibulares.
		Cellulæ bullæ ethmoidales.
Cellulæ ethmoidales posterior:	{	Cells communicating with the meatus superior.
		Cells communicating with the meatus supremus I.
		Cells communicating with the meatus supremus II.

Seydel observed that an ethmoid cell, having its origin from any given meatus, did not communicate with any cell having its origin from any other meatus. Zuckerkandl took exception to this statement, but certainly every specimen in this series supports Seydel's view.

DEVELOPMENT OF THE CELLULÆ ETHMOIDALES

In the latter part of the third month of intra-uterine life the conchæ nasales assume approximately their definitive outlines, and the corresponding meatuses become well marked. In the meatus medius two accessory folds are distinctly demonstrable,—the previously mentioned processus uncinatus and the bulla ethmoidalis,—which, by their variations in types and positions, play such an important part in determining the locations of the ostia of the cellulæ ethmoidales anterior. In the meatus superior there is often found an accessory fold (Fig. 10), which, though smaller, resembles in general outline the bulla ethmoidalis. In no instance was such an accessory fold found in any of the supreme meatuses.

The cellulæ ethmoidales develop as invaginations of the nasal mucosa, extending into the lateral masses of the ethmoid from the primitive grooves or furrows in the lateral nasal wall. These invaginations, representing the primitive ethmoidal cells, appear in the fourth fetal month as cylindrical extensions of the mucosa, in which the epithelial surfaces are in contact. As the diameters of the invaginations increase there gradually develop lumina within the cylindrical processes (Fig. 13), which, by the sixth fetal month, usually show distinct cell formation.

CELLULÆ ETHMOIDALES ANTERIOR

Primitive cells of the anterior ethmoidal group develop earlier and more rapidly than those belonging to the posterior group. In the anterior group the bullar cells are usually the first to be distinctly demonstrable. It was found that in this series 81.7 per cent. of the bullar cells had their origin from the suprabullar furrow, and 18.3 per cent. from the infrabullar furrow. In a small percentage of fetal as well as postnatal cases a shallow groove or furrow was found on the inferomedial surface of the bullar fold, but in no such case was the invagination sufficiently deep to be indicative of actual cell formation.

During the fourth fetal month there is also demonstrable an expansion of the meatus medius which extends in an anterosuperior direction, forming the recessus frontalis of Killian. We believe that the study of the cellulæ ethmoidales anterior and the relations of the ostia frontalia is simplified by subdividing this recess as follows: (a) That portion of the recess lying lateral to the processus uncinatus is the anterior portion of the infundibulum, and will be termed the recessus infundibularis. From this recess smaller invaginations are demonstrable in late fetal and in early childhood specimens. These invaginations are the primitive cellulæ infundibulares. (b) That portion of the recessus frontalis lying medial to the processus uncinatus forms a concavity beneath the extreme anterosuperior attachment of the concha media, and will be termed the recessus conchalis. On the superior portion of the anterolateral wall of the recessus conchalis a large majority of late fetal and early childhood specimens show from one to three

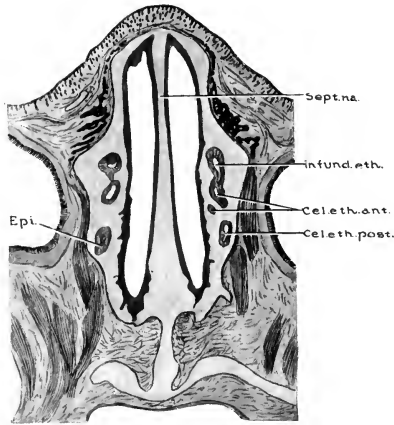


FIG. 13.—DIAGRAM DRAWN FROM A HORIZONTAL SECTION JUST ABOVE THE ANTERIOR ATTACHMENT OF THE CONCHA SUPERIOR. (Series A, No. 13 (one-hundred-and-twenty-six-day fetus), slide 10, section 1. $\times 3$.)

Specimen shows the processes of pneumatization developing superiorly into the lateral masses of the ethmoid, thus forming the primitive cellulæ ethmoidales. *Sept.na.*, Septum nasi; *Infund.eth.*, infundibulum ethmoidale; *Cel.eth.ant.*, cellulæ ethmoidales anterior; *Cel.eth.post.*, cellulæ ethmoidales posterior; *Epi.*, epithelial invagination from meatus superior.

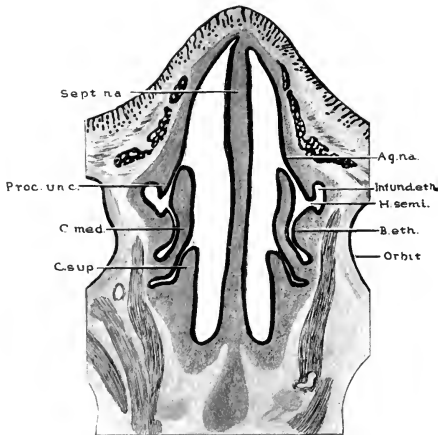


FIG. 14.—DIAGRAM DRAWN FROM A HORIZONTAL SECTION JUST BELOW THE ANTERIOR ATTACHMENT OF THE CONCHA MEDIA OF A FETUS ONE HUNDRED AND TWENTY-SIX DAYS OLD. (Series A, No. 13, slide 14, section 1. $\times 3$.)

Shows well the relations of the developing infundibulum, the hiatus semilunaris, and the bulla ethmoidalis. *Ag.na.*, Agger nasi; *Infund.eth.*, infundibulum ethmoidale; *H.semi.*, hiatus semilunaris; *B.eth.*, bulla ethmoidalis; *C.sup.*, concha superior; *C.med.*, concha media; *Proc.unc.*, processus uncinatus; *Sept.na.*, septum nasi.



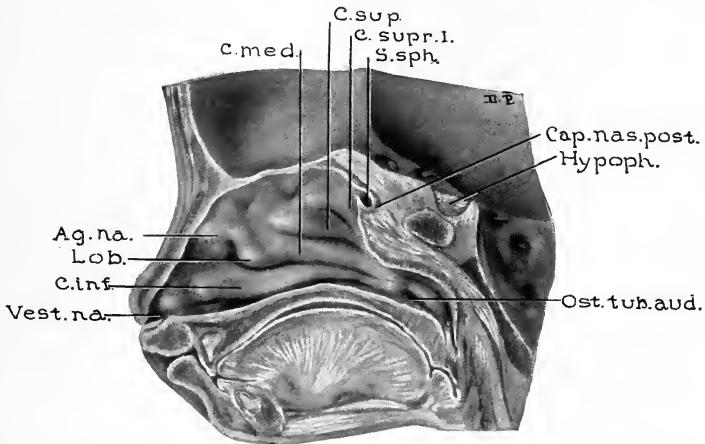


FIG. 15.—SAGITTAL SECTION $\frac{3}{4}$ MM. TO THE RIGHT OF MEDIAN LINE ANTERIORLY AND $1\frac{1}{4}$ MM. TO RIGHT OF MEDIAN LINE POSTERIORLY THROUGH THE BODY OF THE SPHENOID. (Fetus one hundred and thirty-five days old. Series B, No. 1. $\times 1\frac{1}{3}$.)

Shows the lateral nasal wall and the developing sinus sphenoidalis which extends into the remnant of the posterior portion of the cartilaginous nasal capsule. The concha sphenoidalis (ossiculum Bertini) develops in that portion of the cartilage which forms the antero-inferior boundary of the primitive sinus sphenoidalis. *Cap.nas.post.*, Capsula nasalis posterior; *Hypoph.*, hypophysis; *Ost.tub.aud.*, ostium tubæ auditivæ; *Vest.na.*, vestibulum nasi; *C.inf.*, concha inferior; *Lob.*, lobulus; *Ag.na.*, agger nasi; *C.med.*, concha media; *C.sup.*, concha superior; *C.supr.I.*, concha suprema I; *S.sph.*, sinus sphenoidalis.

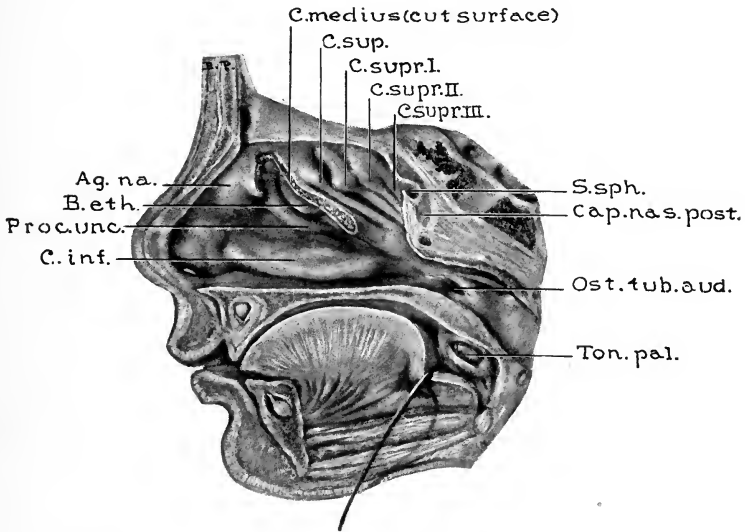


FIG. 16.—SAGITTAL SECTION, MEDIAN ANTERIORLY, POSTERIORLY $1\frac{1}{4}$ MM. TO THE RIGHT OF MEDIAN LINE. (Fetus one hundred and eighty-eight days old. Series B, No. 4.)

The greater portion of the concha media has been removed in order to show the relations of the recessus conchalis, processus uncinatus, hiatus semilunaris, and bulla ethmoidalis. This specimen shows the presence of five conchæ ethmoidales, the only specimen in the entire series having so great a number. Note the extent of development of the sinus sphenoidalis. *C.med.*, Concha media (cut surface); *C.sup.*, concha superior; *C.supr.I*, concha suprema I; *C.supr.II*, concha suprema II; *C.supr.III*, concha suprema III; *S.sph.*, sinus sphenoidalis; *Cap.nas.post.*, capsula nasalis posterior; *Ost.tub.aud.*, ostium tubæ auditivæ; *Ton.pal.*, tonsilla palatina; *C.inf.*, concha inferior; *Proc.unc.*, processus uncinatus; *B.eth.*, bulla ethmoidalis; *Ag.na.*, agger nasi.

small ridges developing from the posteromedial surface of the processus frontalis of the maxilla. These small ridges are the conchæ frontales, and from the furrows or depressions between them, or between them and the surrounding walls of the recess, the cellulæ frontales develop. In Killian's studies of a large number of specimens from late fetuses and infants three conchæ frontales were found to represent the complete number; thus four cellulæ frontales may develop. This type of development is shown in Fig. 36. However, the development is usually not so complete (Figs. 20, 21, 38, 43, 51, and 53). Two conchæ frontales are usually found in postnatal specimens, though in some cases only one, and in still others none, is demonstrable.

All the furrows between the frontal conchæ (whatever number may be present) do not necessarily develop into cells. Specimens from older children, as well as from adults, show that some form distinct cells, some persist as simple concavities in the anterolateral wall of the recess, and others have disappeared or else were never present. These cells are important factors in the development of the sinus frontalis, 59.4 per cent. of the sinus frontales in this series having had their origin from one of the cells lying medial to the processus uncinatus.

The manner in which the processus uncinatus is attached to the agger nasi, its relations to the bulla ethmoidalis, and the character of the attachment of the anterior portion of the concha media, exert the greatest influence upon the proportion between the number and size of the cellulæ frontales and the cellulæ infundibulares. If the processus uncinatus is attached to the posterolateral portion of the agger nasi and the anterosuperior attachment of the concha media is

high up on the lateral nasal wall, then the cellulæ frontales are apt to be well developed. However, if the anterior attachment of the processus uncinatus is more medial in position and the anterosuperior attachment of the concha media is situated lower on the lateral nasal wall, then the recess is small, the cellulæ frontales are apt to be deficient in development, and there is usually a corresponding increase in both the number and the extent of development of the cellulæ infundibulares.

In some instances the infundibulum ethmoidale terminates anteriorly as an expansion into a single cell. However, there are usually two or three cellulæ infundibulares present, and in some instances in which the cellulæ frontales were poorly developed four were found. In 15.6 per cent. of cases the sinus frontalis developed directly from the infundibulum ethmoidale (Fig. 35), in which class of cases there were cells anterior and lateral to the ostium. The adult cellulæ infundibulares are usually bordered superiorly by the frontal bone, and often the lateral extent is such that they extend well into the supra-orbital plate. Not infrequently in specimens from adults and also from older children one of the infundibular cells (Fig. 47) forms a projection into the postero-inferior portion of the floor of the sinus frontalis, termed by Logan Turner the bulla frontalis. Observations on specimens showing the conditions present during the developmental period indicate that the cell developed into such a position at an earlier period than that at which the sinus frontalis reached so far in its lateral development. Thus the developing sinus frontalis, as its pneumatization extends laterally, passes around the superior wall of the cell in a manner which makes the appearance,

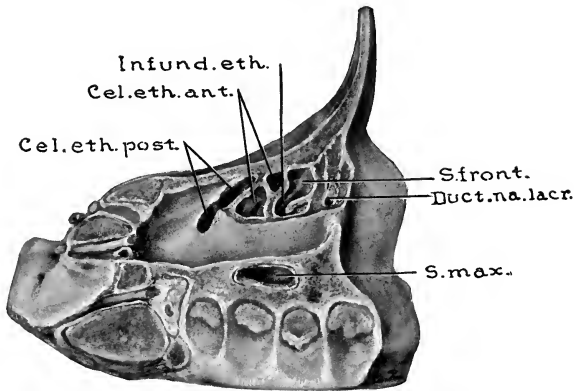


FIG. 17.—SPECIMEN FROM A CHILD EIGHT DAYS OLD. (Series D, No. 1.)

By sagittal sections removing the lateral portion of frontal bone, lamina papyracea of ethmoid, and lateral portion of maxilla—the sinus maxillaris, cellula ethmoidales, anterior and posterior, infundibulum ethmoidale, and the primitive sinus frontalis are brought into view. *S.front.*, Primitive sinus frontalis; *Duct.na.lacr.*, ductus nasolacrimalis; *S.max.*, sinus maxillaris; *Cel.eth.post.*, cellula ethmoidales posterior; *Cel.eth.ant.*, cellula ethmoidales anterior; *Infund.eth.*, infundibulum ethmoidale.

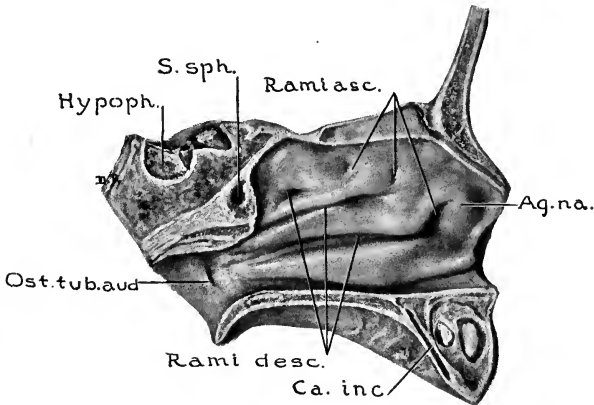


FIG. 18.—SPECIMEN FROM A CHILD EIGHT DAYS OLD. (Series D, No. 1.)

Sagittal section in median line through frontal and maxillary bones and 3 mm. to left of median line through sphenoid bone. Shows the left lateral nasal wall, the ascending and the descending rami of the meatuses, also the extent of development of the sinus sphenoidalis. Note that the antero-inferior wall of the sinus sphenoidalis (concha sphenoidalis or ossiculum Bertini) is well ossified. *Ag.na.*, Agger nasi; *Ca.inc.*, canalis incisivus; *Rami desc.*, rami descendens of ethmoidal meatuses; *Ost.tub.aud.*, ostium tubae auditivae; *Hypoph.*, hypophysis; *S.sph.*, sinus sphenoidalis; *Rami asc.*, rami ascendens of ethmoidal meatuses.

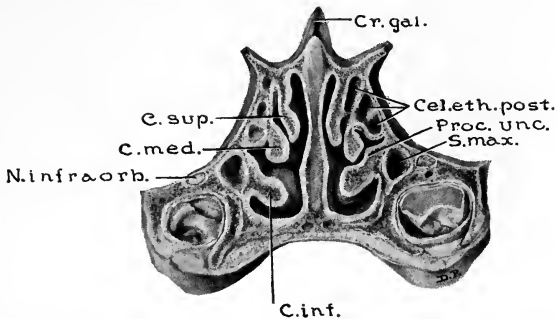


FIG. 19.—SPECIMEN FROM A CHILD ONE MONTH AND EIGHT DAYS OLD. (Series D, No. 2.)

Posterior view of coronal section cut 16 mm. posterior to the nasion, showing the extent of supero-inferior and lateral development of sinus maxillaris and cellulæ ethmoidales posterior. Note the proximity of developing teeth to the orbital floor. *Cr. gal.*, Crista galli; *Cel. eth. post.*, cellulæ ethmoidales posterior; *Proc. unc.*, posterior extremity of processus uncinatus; *S. max.*, sinus maxillaris; *C. inf.*, concha inferior; *N. infraorb.*, nervus infraorbitalis; *C. med.*, concha media; *C. sup.*, concha superior.

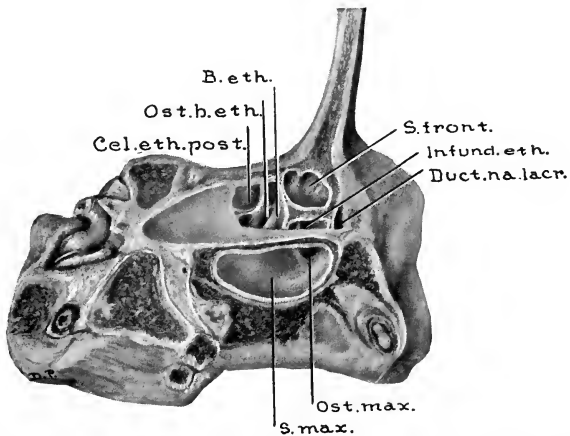


FIG. 20.—SPECIMEN FROM A CHILD FOUR MONTHS AND TWENTY-SEVEN DAYS OLD. (Series D, No. 5.)

Lateral portions of frontal, ethmoidal, and maxillary areas have been removed to show the extent of pneumatization. *S. front.*, sinus frontalis developing from a furrow in the recessus conchalis; *Infund. eth.*, infundibulum ethmoidale; *Duct. na. lacr.*, ductus nasolacrimalis; *Ost. max.*, ostium maxillare; *S. max.*, sinus maxillaris; *Cel. eth. post.*, cellula ethmoidalis posterior; *Ost. b. eth.*, ostium bullæ ethmoidalis, opening into the suprabullar furrow; *B. eth.*, bulla ethmoidalis.

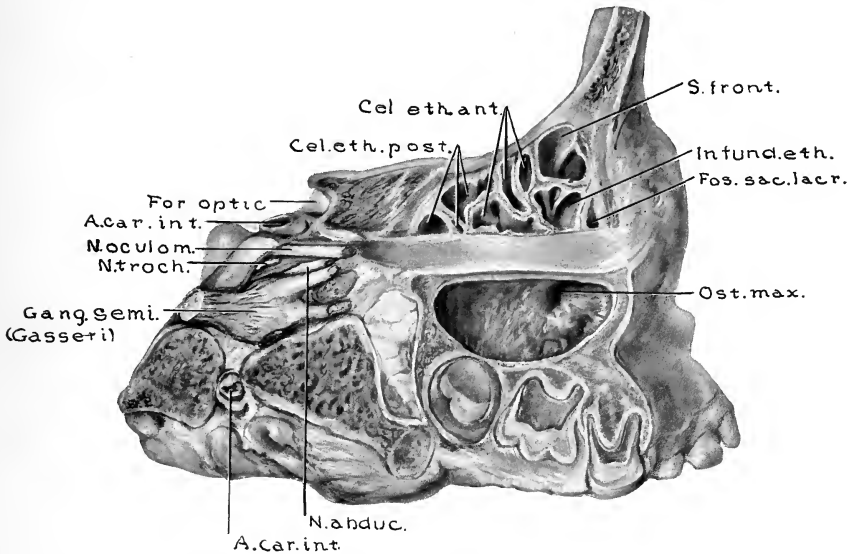


FIG. 21.—SPECIMEN FROM A CHILD ONE YEAR, FOUR MONTHS, AND SEVEN DAYS OLD. LATERAL VIEW OF FRONTAL, ETHMOIDAL, AND MAXILLARY SINUS AREAS. (Series D, No. 14.)

S. front., Sinus frontalis developing from a frontal cell; *Infund. eth.*, infundibulum ethmoidale; *Fos. sac. lac.*, fossa sacculi lacrimalis; *Ost. max.*, ostium maxillare; *N. abduc.*, nervus abducens; *A. car. int.*, arteria carotis interna; *Gang. semi.*, ganglion semilunare (Gasserii); *N. troch.*, nervus trochlearis; *N. oculom.*, nervus oculomotorius; *For. optic.*, foramen opticum; *Cel. eth. post.*, cellulæ ethmoidales posterior; *Cel. eth. ant.*, cellulæ ethmoidales anterior.

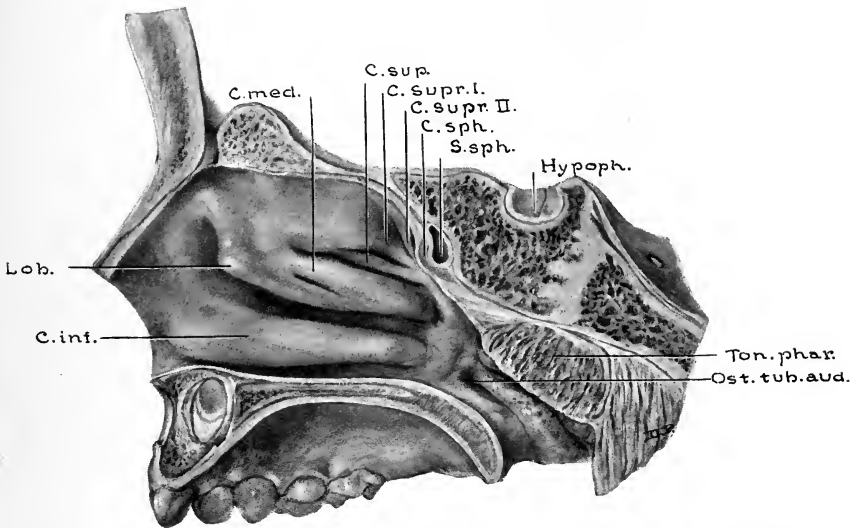


FIG. 22.—SPECIMEN FROM A CHILD ONE YEAR, TEN MONTHS, AND THIRTEEN DAYS OLD. SAGITTAL SECTION SHOWING LATERAL WALL OF THE NASAL CAVITY AND THE SINUS SPHENOIDALIS. (Series D, No. 20.)

Note the overlapping of the concha superior by the anterior portion of the concha supra I; also note the accessory furrow on the medial surface of the concha media. In a plane more lateral than that shown in the illustration, the sinus sphenoidalis is more extensively developed in the posterolateral direction, its inferolateral wall being only 1 mm. from the fossa pterygopalatina and 2 mm. from the foramen rotundum. *C.med.*, Concha media; *C.sup.*, concha superior; *C.supr. I*, concha supra I; *C.supr. II*, concha supra II; *C.sph.*, concha sphenoidalis (ossiculum Bertini); *S.sph.*, sinus sphenoidalis; *Hypoph.*, hypophysis; *Ton.phar.*, tonsilla pharyngea; *Ost.tub.aud.*, ostium pharyngem tubæ auditivæ; *C.inf.*, concha inferior; *Lob.*, lobulus.

as found in some adult specimens, such that the cell might readily be regarded as having caused the projection into the floor of a previously developed sinus. Cells of this group may also extend far anteriorly—sometimes even anterior to the anterior wall of the ductus nasolacrimalis (Fig. 47).

A majority (65 per cent.) of specimens from cases over two years of age show a cell or a part of a cell which has developed so as to produce pneumatization of the prominence termed the agger nasi or nasoturbinal. The agger nasi appears in the latter part of the second or the first part of the third fetal month as a prominence on the anterior portion of the lateral nasal wall, extending antero-inferiorly from the anterior attachment of the concha media, approximately parallel to the nasal bones. As a rule, the agger nasi is relatively more prominent in late fetuses and infants than it is in older individuals. Of the 65 per cent. of cases over two years old showing pneumatization of the agger nasi, it was found that in 60 per cent. of such cases the pneumatization had extended from the anterior cellula frontalis (Figs. 36 and 51), and in 40 per cent. from the anteromedial cellula infundibularis (Fig. 27). The location of these cells is such as to require careful inspection by operating surgeons, lest their presence be overlooked when wishing to eradicate frontal and infundibular cells.

The bulla ethmoidalis may contain either a single large cell or else from two to four smaller ones. One bullar cell was present in 25 per cent. of specimens, two cells in 62 per cent., three cells in 10 per cent., and four cells in 3 per cent. of 202 postnatal lateral nasal walls. Of these cells, 81.7 per cent. had their origin from the suprabullar furrow, and 18.3 per cent. from the infrabullar furrow. Whatever the num-

ber of cells may be, or from whatever point they may have had their origin, pneumatization extends from the medial wall of the bulla to the lamina papyracea; and in many instances for a variable distance into the supra-orbital plate of the frontal bone. Occasionally there is a less marked extent into the infra-orbital plate of the maxilla.

The inferomedial wall of the bulla is usually a well-rounded one (Figs. 9, 27, and 36), but in some cases (Figs. 16, 51, and 53) it forms a narrower projection. The variations in the size and form of the bulla not only influence the bullar cells, but also, in conjunction with the variations in the processus uncinatus, determine the width and length of the hiatus semilunaris,—the interval between the antero-inferior surface of the bulla and the posterosuperior surface of the processus uncinatus,—which is the opening by means of which the meatus medius communicates with the infundibulum ethmoidale. The length of the hiatus semilunaris varies in adult types from 14 to 27 mm., this wide variation being due to the manner in which the anterosuperior end of the processus uncinatus is attached to the bullar fold. Cases in which the hiatus is short show at its anterior border a wide plate, passing between the bulla and the processus uncinatus (Figs. 36, 51, and 56).

The width of this plate varies from 11 mm. to complete absence. In cases in which the plate is absent (Figs. 27 and 38) the hiatus extends upward to the level of the cribriform plate, thus allowing a closer communication between the recessus infundibularis and the recessus conchalis than is usually found.

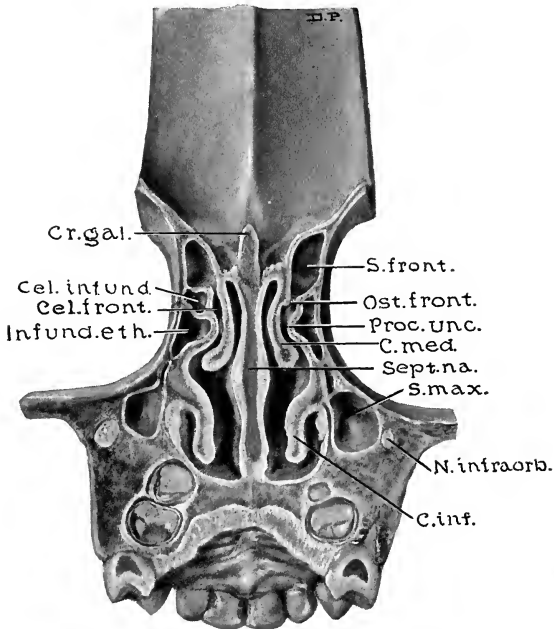


FIG. 23.—SPECIMEN FROM A CHILD TWO YEARS, SIX MONTHS, AND SEVEN DAYS OLD. (Series D, No. 24.)

Posterior view of a coronal section 11 mm. posterior to nasion. Note that the ostia of the frontal sinuses are medial to the uncinatè processes, thus do not communicate with the infundibulum ethmoidale. *S.front.*, Sinus frontalis; *Ost.front.*, ostium frontale; *Proc.unc.*, processus uncinatus; *C.med.*, concha media; *Sept.na.*, septum nasi; *S.max.*, sinus maxillaris; *N.infraorb.*, nervus infraorbitalis; *C.inf.*, concha inferior; *Infund.eth.*, infundibulum ethmoidale; *Cel.front.*, cellula frontalis; *Cr.gal.*, crista galli.

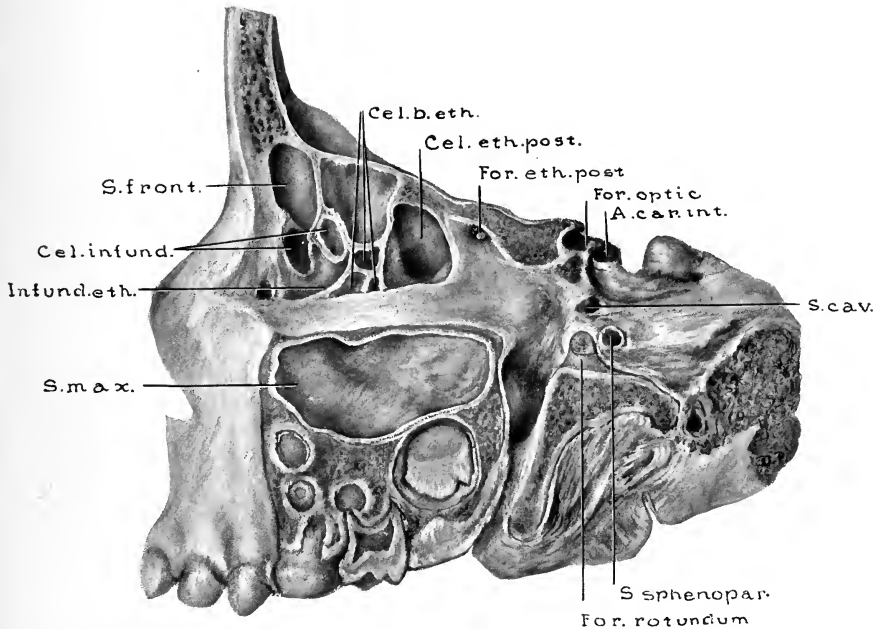


FIG. 24.—SPECIMEN FROM A CHILD TWO YEARS, SIX MONTHS, AND TWELVE DAYS OLD. (Series D, No. 25.)

Lateral view of left frontal, ethmoidal, and maxillary sinus areas. Note advance of sinus frontalis into the vertical portion of the frontal bone. *Cel. b. eth.*, Cellulæ bullæ ethmoidales; *Cel. eth. post.*, cellula ethmoidalis posterior; *For. eth. post.*, foramen ethmoidale posterius; *For. optic.*, foramen opticum; *A. car. int.*, arteria carotis interna; *S. cav.*, sinus cavernosus; *S. sphenopar.*, sinus sphenoparietalis; *For. rotundum.*, foramen rotundum; *S. max.*, sinus maxillaris; *Infund. eth.*, infundibulum ethmoidale; *Cel. infund.*, cellulæ infundibulares; *S. front.*, sinus frontalis.

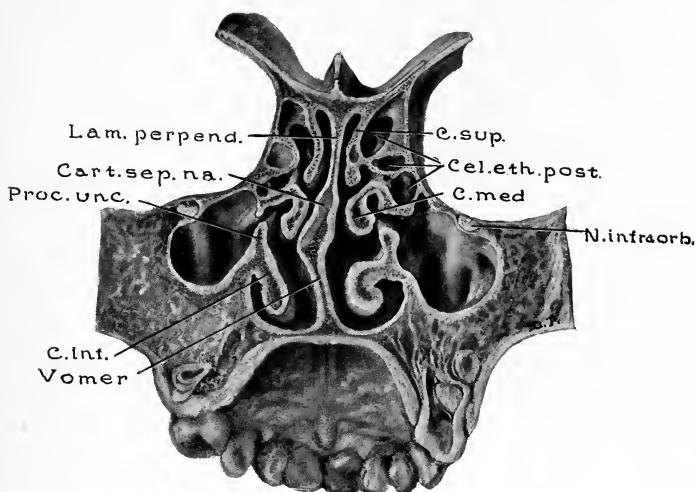


FIG. 25.—SPECIMEN FROM A CHILD, THREE YEARS FIVE MONTHS, AND EIGHT DAYS OLD. (Series D, No. 32.)

Posterior view of coronal section cut 23.5 mm. posterior to nasion, showing the extent of lateral and supero-inferior development of sinus maxillaris, the osseous ridge beneath nervus infraorbitalis, cellulæ ethmoidales posterior, and small conchal cells developing in each concha nasalis superior. The ostia maxillaria are larger than usual in the anteroposterior diameter. Note deflection of septum nasi and its influence on each concha media. *C. sup.*, Concha superior; *Cel. eth. post.*, cellulæ ethmoidales posteriores; *C. med.*, concha media; *N. infraorb.*, nervus infraorbitalis; *C. inf.*, concha inferior; *Proc. unc.*, processus uncinatus; *Cart. sep. na.*, cartilago septi nasi; *Lam. perpend.*, lamina perpendicularis.

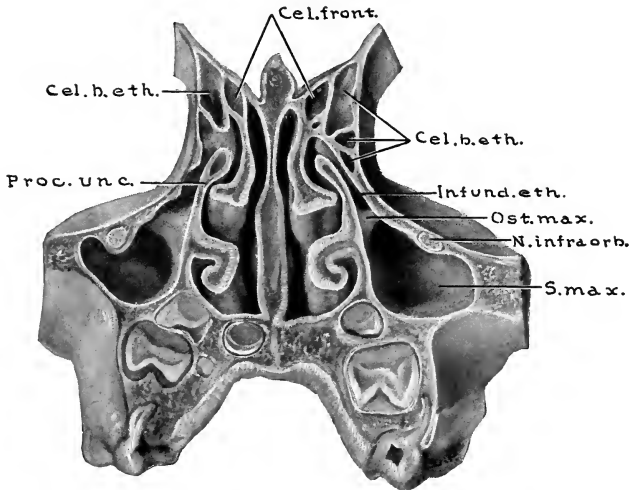


FIG. 26.—SPECIMEN FROM A CHILD FOUR YEARS, SEVEN MONTHS, AND NINETEEN DAYS OLD. (Series D, No. 40.)

Anterior view of coronal section, cut 16 mm. posterior to the nasion, showing the lateral and supero-inferior extent of the maxillary sinuses, their relations to developing teeth, and the relations of the ostium maxillare to the infundibulum ethmoidale. Note ridge beneath the right nervus infraorbitalis. The bullar cells have their ostia in the suprabullar furrow. The ostia of the cellulæ frontales are medial to the processus uncinatus and the bulla ethmoidalis. *Cel. front.*, Cellulæ frontales; *Cel. b. eth.*, cellulæ bullæ ethmoidales; *Infund. eth.*, infundibulum ethmoidale; *Ost. max.*; ostium maxillare; *N. infraorb.*, nervus infraorbitalis; *S. max.*, sinus maxillaris; *Proc. unc.*, processus uncinatus.

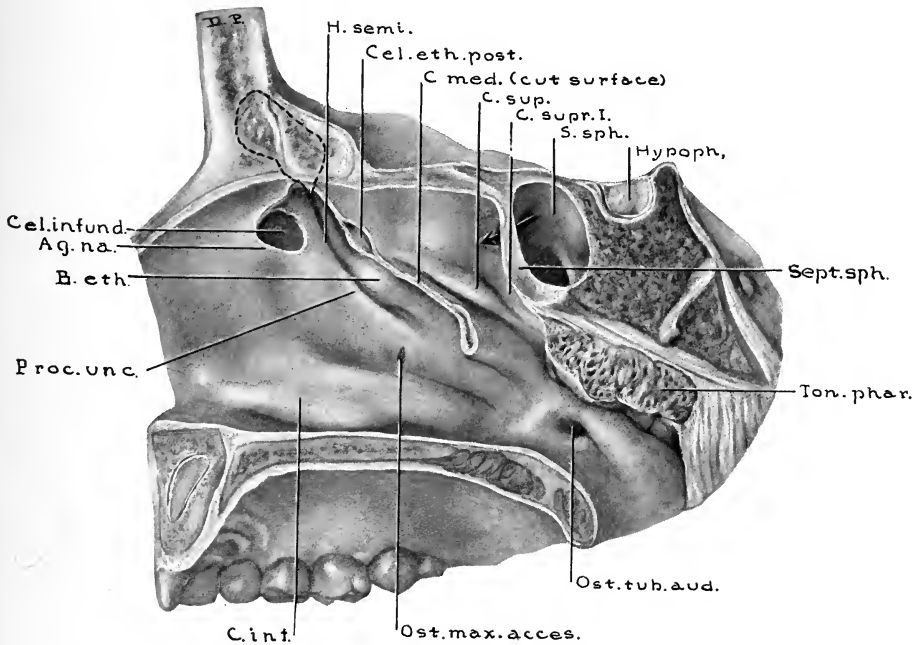


FIG. 27.—SPECIMEN FROM A CHILD FIVE YEARS, TEN MONTHS, AND TWENTY-TWO DAYS OLD. (Series D, No. 45.)

Sagittal section, $\frac{3}{4}$ mm. to the right of median line anteriorly; section through body of the sphenoid 2 mm. to the right of median line. Anterior portion of concha media has been removed to show the lateral nasal wall. Medial wall of an infundibular cell was removed with the anterior attachment of the concha media. Ostium frontale in this case communicates both with infundibulum and with the recessus conchalis medial to the processus uncinatus. Dotted line indicates outline of sinus frontalis. *H. semi.*, Hiatus semilunaris; *Cel. eth. post.*, cellula ethmoidalis posterior, extending into concha media; *C. med.*, concha media (cut surface); *C. sup.*, concha superior; *C. supr. I.*, concha suprema I; *S. sph.*, sinus sphenoidalis; *Hypoph.*, hypophysis; *Sept. sph.*, septum sphenoidale (anterior portion); *Ton. phar.*, tonsilla pharyngea; *Ost. tub. aud.*, ostium pharyngeum tubæ auditivæ; *Ost. max. acces.*, ostium maxillare accessorium; *C. inf.*, concha inferior; *Proc. unc.*, processus uncinatus; *B. eth.*, bulla ethmoidalis; *Ag. na.*, agger nasi; *Cel. infund.*, cellula infundibularis.

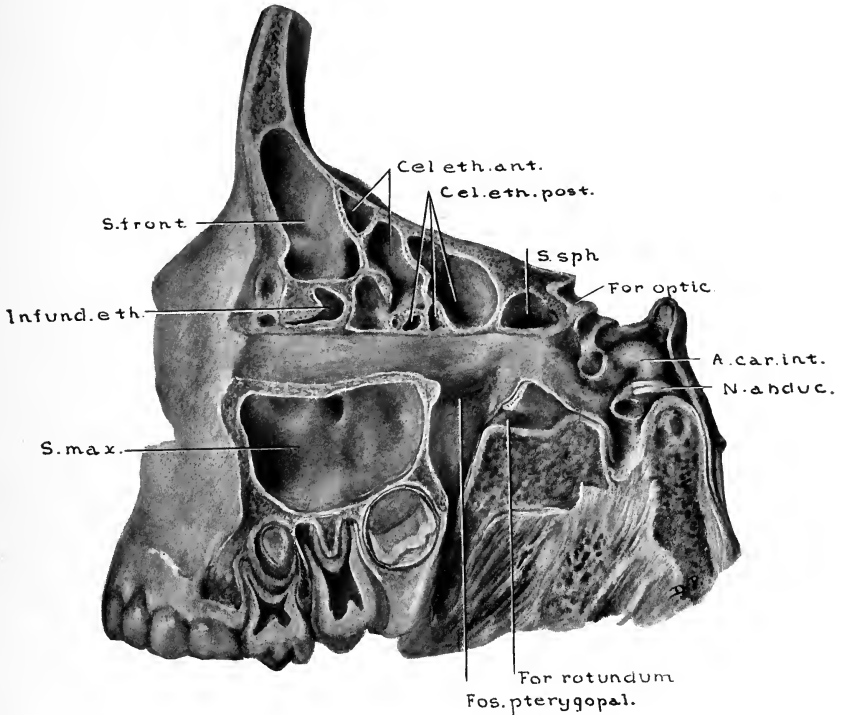


FIG. 28.—SPECIMEN FROM A CHILD FIVE YEARS, TEN MONTHS, AND TWENTY-TWO DAYS OLD. LATERAL VIEW OF FRONTAL, ETHMOIDAL, SPHENOIDAL, AND MAXILLARY AREAS TO SHOW THE EXTENT OF PNEUMATIZATION PRESENT AND THE RELATIONS OF THE SINUSES. (Series D, No. 45.)

Osseous wall, between sinus sphenoidalis and fossa pterygopalatina, is $\frac{1}{2}$ mm. thick, while from sinus cavity to foramen rotundum is 1 mm. Sinus frontalis developed from an infundibular cell. *Cel.eth.ant.*, Cellulæ ethmoidales anterior; *Cel.eth.post.*, cellulæ ethmoidales posterior; *S.sph.*, sinus sphenoidalis; *For.optic.*, foramen opticum; *A.car.int.*, arteria carotis interna; *N.abduc.*, nervus abducens; *For.rotundum*, foramen rotundum; *Fos.ptyergopal.*, fossa pterygopalatina; *S.max.*, sinus maxillaris; *Infund.eth.*, infundibulum ethmoidale; *S.front.*, sinus frontalis.

CELLULÆ ETHMOIDALES POSTERIOR

The cellulæ ethmoidales posterior vary in number from one to five on each side, the general average in 202 lateral nasal walls being 2.62. The origin of the posterior cells was found to be as follows:

81.1	per cent.	from the meatus superior
18.4	“ “ “ “ “	supremus I
0.5	“ “ “ “ “	“ II

The ostia of the cells vary from oval openings 0.5 mm. to 3 mm. in diameter, to slit-like openings from 3 to 14 mm. long and from 1 to 3 mm. wide. The most constant location for an ostium is at the anterolateral extremity of the meatus superior. In only one instance was a superior meatus found which contained no ostium for an ethmoidal cell. In that case posterior ethmoidal pneumatization was entirely from the meatus supremus I.

The extent of pneumatization shows marked variations. Posterior cells often extend for variable distances into the supra-orbital plate of the frontal bone, into the orbital process of the palate bone, into the infra-orbital plate of the maxilla, and in rare instances may invade the body of the maxilla, forming, when the pneumatization is extensive, what has been termed a double maxillary sinus. Fig. 50 shows an aberrant cell which had its origin in the superior meatus, invading the posterosuperior portion of the maxilla, but the invasion in this case is not sufficient to justify its classification as a double maxillary sinus.

The most posterior ethmoidal cell frequently develops dorsally until a portion of it lies superior to the ventral portion of the sinus sphenoidalis, but in no case was there a

communication found between a posterior ethmoidal cell and the sphenoidal sinus.

CELLULÆ CONCHALES

Pneumatization of the conchæ ethmoidales is a rather common condition, occurring in from 4 per cent. to 18 per cent. of cases studied by various observers. In this series such cells were found in 8 per cent. of cases over ten years of age, and in 3 per cent. under that age. Observations as to their possible points of origin are in accord with the studies made by J. P. Schaeffer. In the majority of instances such cells developed as extensions of posterior ethmoidal cells communicating with the superior meatus, but other cases showed origins from the posterior extremity of the infundibulum ethmoidale, and still others from the suprabullar furrow (Fig. 46).

The mucosa lining these cells was similar to that lining other ethmoidal cells. In none of these cases did the cells contain fluids or granulation tissue. However, one can readily see how some of the earlier observers, who found such turbinates in diseased condition, came to regard the conchal cells as cysts.

In many instances the stimulus exciting the development of these cells seems to have been produced by a deflection of the septum nasi,—the concha media on the side of the concavity showing the presence of an air-cell in its anterior portion,—thus aiding in its compensatory hypertrophy. Fig. 46 illustrates such a case, but the stimulus in all cases cannot be attributed to such a cause, since occasionally specimens have been observed in which both middle conchæ contained such cells.

THE SINUS MAXILLARIS

The sinus maxillaris is the most constant of the nasal accessory sinuses. Reschreiter mentions reports of four cases in which a sinus maxillaris was absent. We have found no other instances in which complete failure of its development has been recorded. The extent of its development is also more regular than that of any of the other sinuses, as was shown by comparing the tables of measurements given by the various observers.

In embryos eighty-five days old there is a lateral out-pouching of mucosa, demonstrable in the inferolateral portion of the wall of the infundibulum ethmoidale, slightly anterior to its midpoint anteroposteriorly. This is the primitive sinus maxillaris, which gradually develops as an oblong recess, extending first into the lateral nasal capsule, after the resorption of which it continues its advance and development into the maxilla. The point of primary lateral pouching persists as the ostium maxillare.

As the expansion in the maxilla increases anteroposteriorly much more rapidly than does the diameter of the ostium, there is thus developed a medial wall, which, by the latter part of the sixth or early in the seventh fetal month, is sufficient to make the outline of the pouching demonstrable as an oblong sinus. The relatively small vertical diameters of fetal and infantile maxillæ and the close approximation of the developing teeth to the orbital floor preclude the possibility of a rapid increase in the vertical and lateral

diameters of the sinus during these early periods. In the case of a child eight days old the sinus diameters were found to be 8.2 mm. anteroposteriorly, 3.3 mm. vertically, and 2.8 mm. laterally (Fig. 17 was drawn from this specimen). As the body of the maxilla increases in size there is a corresponding increase in the extent of pneumatization. Up until the eighth year the diameters of the sinus maxillaris increase at a rate which was found to average approximately 2 mm. each year in both the vertical and the lateral diameters, and 3 mm. anteroposteriorly. After the eighth year the development of the sinus advances more slowly in all directions, reaching in the fifteenth to the eighteenth year a form which approximates the adult type, later changes being shown chiefly in the postero-inferior angle, which descends as the third molar tooth erupts.

The following table shows the average diameters of the ostia maxillaria and of the sinus maxillares, as found in the various ages. All measurements are given in millimeters. (In considering the relation of the sinus floor to the nasal floor, measurements preceded by a plus sign indicate that the average sinus floor was found to be the given distance *above* the level of the nasal floor. Measurements preceded by a minus sign indicate that the average sinus floor was the given distance *below* the level of the nasal floor.)

From this table it is seen that the floor of the sinus maxillaris, in an average case, reaches a level equal to that of the floor of the nasal fossa during the eighth year, and in the majority of older cases is from 1 mm. to 5.5 mm. below the level of the nasal floor, regardless of the sex of the individual. Reschreiter regarded a floor of the sinus maxillaris below the level of the nasal floor as a male characteristic.

TABLE OF AVERAGES OF THE SINUS MAXILLARIS

AGE	NUM- BER OF CASES	SIDE	DIAMETERS OF OSTIA	DIAMETERS OF SINUS			RELATION TO NASAL FLOOR
				Vertical	Lateral	Antero- posterior	
8 days-1 yr.	10	Left	1.5 x 0.6	5.7	4.6	13.3	+4.3
		Right	1.5 x 0.6	5.4	4.7	13.4	+4.0
1-2 yrs.	10	Left	2.1 x 0.8	8.3	6.7	17.9	+3.7
		Right	2.0 x 0.7	8.0	6.6	17.9	+3.7
2-3 yrs.	8	Left	2.0 x 0.8	9.2	7.9	20.2	+3.6
		Right	2.4 x 0.8	9.3	8.0	20.3	+3.6
3-4 yrs.	6	Left	3.9 x 0.8	11.1	9.1	21.9	+2.6
		Right	4.1 x 0.8	11.3	9.5	22.3	+2.4
4-5 yrs.	8	Left	2.7 x 1.0	12.3	13.1	25.0	+2.7
		Right	3.4 x 1.1	12.8	13.3	25.6	+2.1
5-6 yrs.	3	Left	3.3 x 1.1	12.3	14.0	26.2	+2.5
		Right	3.4 x 1.0	12.7	13.2	27.0	+2.0
6-7 yrs.	8	Left	3.6 x 1.1	17.7	16.8	28.5	+0.6
		Right	4.0 x 1.3	17.2	16.6	28.3	+0.9
7-8 yrs.	5	Left	3.9 x 1.0	19.1	15.2	27.2	-0.2
		Right	3.7 x 1.0	19.1	14.7	26.7	-0.1
8-9 yrs.	5	Left	3.7 x 1.4	21.4	17.9	29.5	-0.6
		Right	3.2 x 1.1	21.9	17.8	30.2	-1.4
9-10 yrs.	2	Left	4.0 x 2.5	18.5	19.0	30.5	+1.0
		Right	2.8 x 1.0	18.5	16.5	29.5	+0.5
10-11 yrs.	2	Left	4.5 x 1.3	21.0	18.0	27.5	+1.0
		Right	5.0 x 1.3	21.5	17.5	27.7	+0.2
11-12 yrs.	1	Left	3.0 x 1.0	22.0	18.5	29.0	-2.0
		Right	3.0 x 1.0	22.5	19.0	29.0	-2.0
12-13 yrs.	1	Left	3.5 x 1.5	19.0	15.0	25.0	+1.0
		Right	2.5 x 0.8	17.5	15.0	25.0	+2.0
13-14 yrs.	3	Left	3.7 x 1.1	23.6	18.0	31.1	-1.0
		Right	3.4 x 0.8	23.8	17.6	30.3	-0.8
14-15 yrs.	1	Left	3.0 x 1.0	25.0	18.0	28.0	-2.0
		Right	2.5 x 1.0	25.0	17.5	29.0	-2.0
15-16 yrs.	3	Left	3.7 x 1.3	33.0	26.2	39.2	-7.5
		Right	3.3 x 1.8	32.2	26.5	39.0	-7.0
16-17 yrs.	4	Left	4.7 x 2.0	24.7	20.8	35.0	-0.3
		Right	5.0 x 3.0	25.8	21.1	33.8	-1.5
17-18 yrs.	4	Left	3.3 x 1.5	32.2	24.5	36.0	-5.5
		Right	3.4 x 1.6	32.0	24.6	36.2	-5.2
18-19 yrs.	1	Left	3.5 x 1.0	29.0	25.5	28.0	-0.2
		Right	3.0 x 1.0	30.0	21.0	25.0	-1.0
19-20 yrs.	3	Left	4.1 x 1.3	32.3	21.3	32.3	-2.5
		Right	4.5 x 1.4	32.1	21.6	33.6	-3.6
20-21 yrs.	2	Left	3.5 x 1.0	26.5	20.0	32.0	-1.7
		Right	3.5 x 1.0	26.5	20.0	32.5	-1.7
21-22 yrs.	1	Left	4.5 x 2.0	27.0	18.0	34.0	-3.5
		Right	5.0 x 1.5	23.0	17.5	26.5	+1.5
22-23 yrs.	2	Left	3.5 x 1.7	29.5	24.5	34.5	-3.5
		Right	4.0 x 2.2	29.2	23.8	35.0	-2.8
23-24 yrs.	1	Left	2.5 x 1.3	27.0	15.0	24.0	-2.0
		Right	3.0 x 1.2	29.0	17.5	31.0	-4.0
25 yrs.	2	Left	7.0 x 1.5	27.8	20.5	32.5	-4.2
		Right	7.5 x 1.6	29.0	21.5	32.8	-5.5

However, in this series there was found no definite relationship between the sex of the individual and the level of the floor of the sinus maxillaris.

In early childhood the general outline of the sinus is rather ovoid (Figs. 20, 21, 24, and 25), but in later childhood it is gradually changed into a pyramidal form (Figs. 28, 30, 33, 37, and 52), which persists as the usual adult type. The base is directed toward the nasal fossa, and corresponds to the medial wall, while the apex extends into the processus zygomaticus.

The form of the sinus maxillaris is usually described as a three-sided pyramid with irregularly rounded corners. In such descriptions the portion overlying the alveolar process is separately classed as the floor, without giving it a part in the formation of the triangular pyramid. We believe it more consistent to consider the form as quadrilateral at its base, but becoming triangular as the apex is approached. The anterior and the posterior walls, being more closely approximated inferiorly than superiorly, as the apex of the pyramid is approached, the rounded inferior angles are brought so close together that the resulting single rounded angle becomes the inferior boundary in the apical portion. Examples of the usual quadrilateral type of the base are seen in Figs. 30, 33, 45, and 49. A much less frequent type is shown in Figs. 50 and 55, in which variety there is a somewhat triangular basal outline. This type is found only in association with a very deep fossa canina.

In its lateral development the average sinus maxillaris, at the end of the first year, has come into close relation with the nervus infraorbitalis. During the second year the most lateral portion of the sinus passes beneath the nerve, leaving

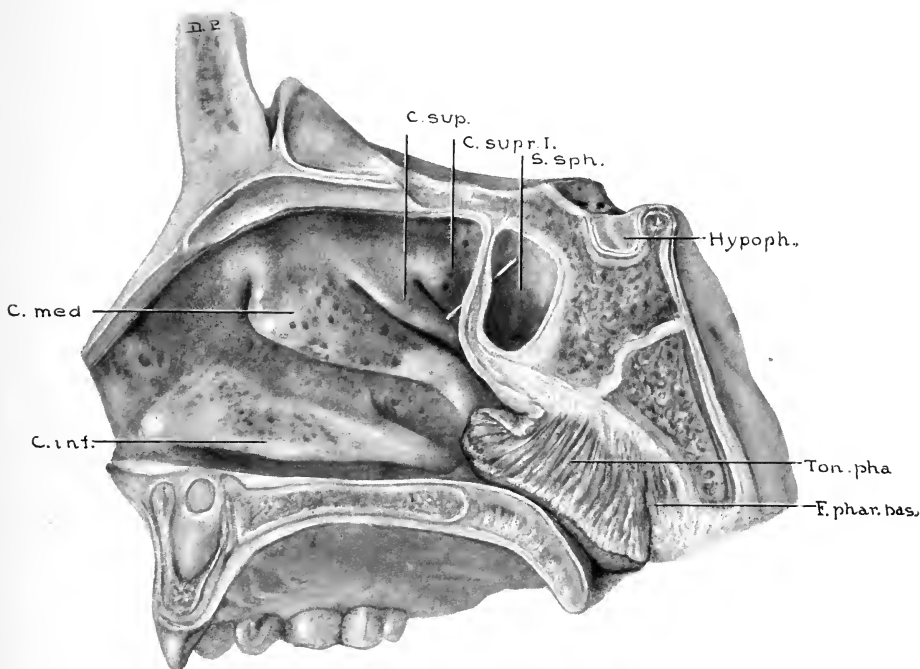


FIG. 29.—SPECIMEN FROM A CHILD SIX YEARS OLD. SAGITTAL SECTION SHOWING EXTENT OF SPHENOIDAL PNEUMATIZATION. (Series D, No. 46.)

The child from whom this specimen was taken died of nasal diphtheria. Note areas of submucous hemorrhages. The nasal cavities were completely filled with pseudomembrane, as were also the frontal sinuses and ethmoidal cells, while the maxillary and sphenoidal sinuses were approximately half filled. Also note the enormous tonsilla pharyngea, which nearly fills the posterior naris. *C. sup.*, Concha superior; *C. supr. I.*, concha suprema I; *S. sph.*, sinus sphenoidalis; *Hypoph.*, hypophysis; *Ton. pha.*, tonsilla pharyngea; *F. phar. bas.*, fascia pharyngobasilaris; *C. inf.*, concha inferior; *C. med.*, concha media.

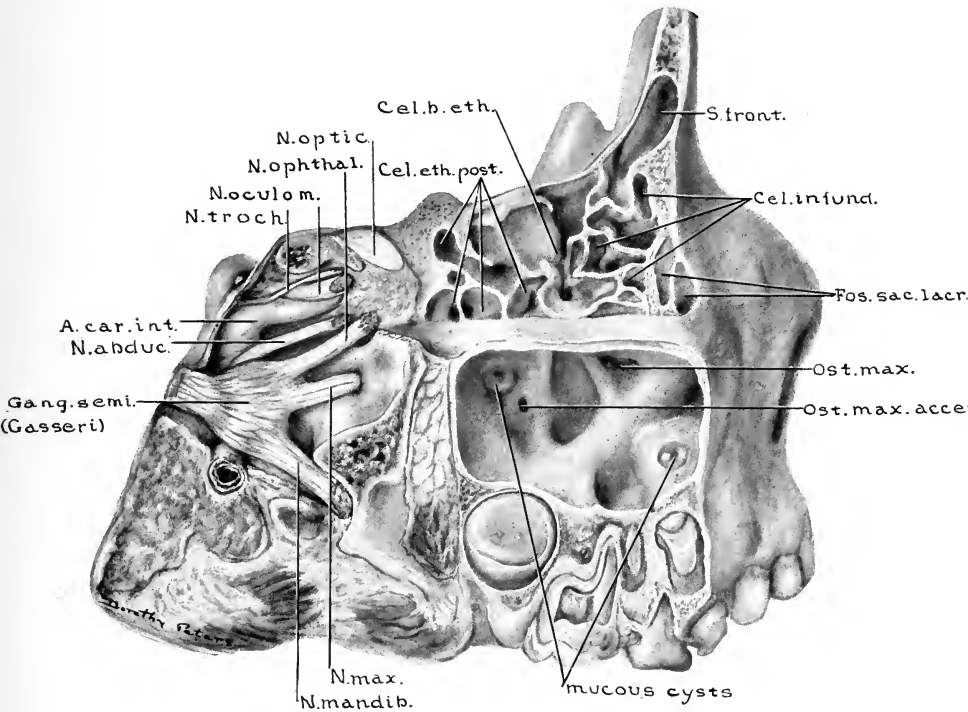


FIG. 30.—SPECIMEN FROM A CHILD SIX YEARS, TEN MONTHS, AND TWENTY DAYS OLD. BY SAGITTAL SECTIONS THE LATERAL PORTIONS OF THE FRONTAL, ETHMOIDAL, AND MAXILLARY AREAS HAVE BEEN REMOVED. (Series D, No. 53.)

The osseous ridges on the medial wall of the sinus maxillaris are unusually prominent. The largest one overlies the ductus nasolacrimalis. There were two lacrimal sacs present, the superior portion of the duct being bifid. Note presence of ostium maxillare accessorium and the proximity of the mucous cyst. *S.front.*, Sinus frontalis; *Cel.infund.*, cellulae infundibulares; *Fos.sac.lacr.*, fossae sacci lacrimales; *Ost.max.*, ostium maxillare; *Ost.max.acce.*, ostium maxillare accessorium; *N.max.*, nervus maxillaris; *N.mandib.*, nervus mandibularis; *Gang.semi.*, ganglion semilunare (Gasseri); *N.abduc.*, nervus abducens; *A.car.int.*, arteria carotis interna; *N.troch.*, nervus trochlearis; *N.ocolom.*, nervus oculomotorius; *N.ophthal.*, nervus ophthalmicus; *N.optic.*, nervus opticus; *Cel.eth.post.*, cellulae ethmoidales posterior; *Cel.b.eth.*, cellula bullae ethmoidalis.

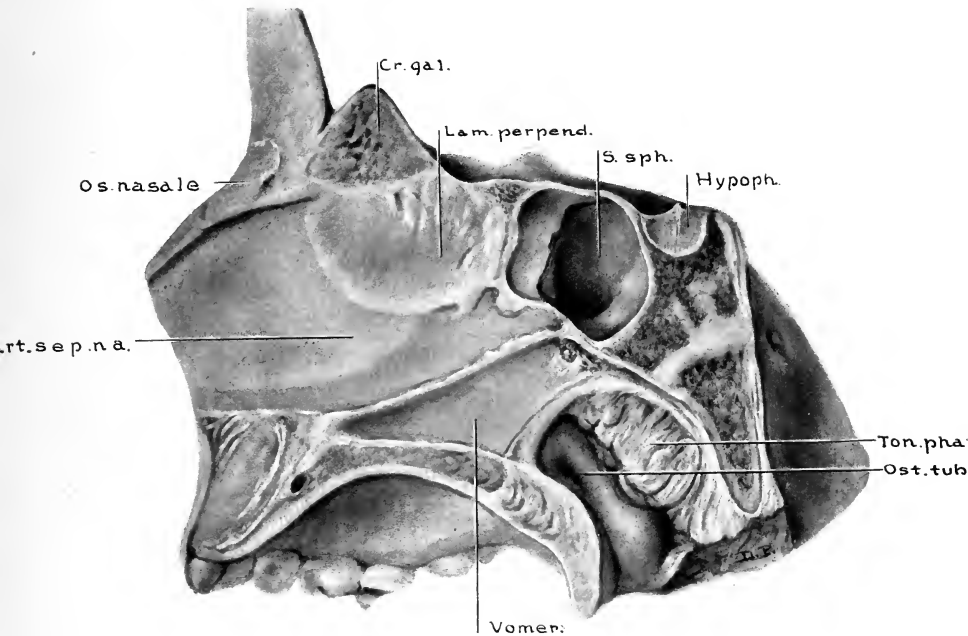


FIG. 31.—SPECIMEN FROM A CHILD SIX YEARS, TEN MONTHS, AND TWENTY DAYS OLD. LATERAL VIEW OF THIS SPECIMEN IS SHOWN IN FIG. 30. (Series D, No. 53.)

Sagittal section $\frac{1}{2}$ mm. to the left of median line, showing extent of sinus sphenoidalis and also the relation of the structures entering into the formation of the septum nasi. *Cr.gal.*, Crista galli; *Lam.perpend.*, lamina perpendicularis; *S.sph.*, sinus sphenoidalis; *Hypoph.*, hypophysis; *Ton.phar.*, tonsilla pharyngea; *Ost.tub.aud.*, ostium pharyngeum tubae auditivae; *Cart.sept.na.*, cartilago septi nasi.

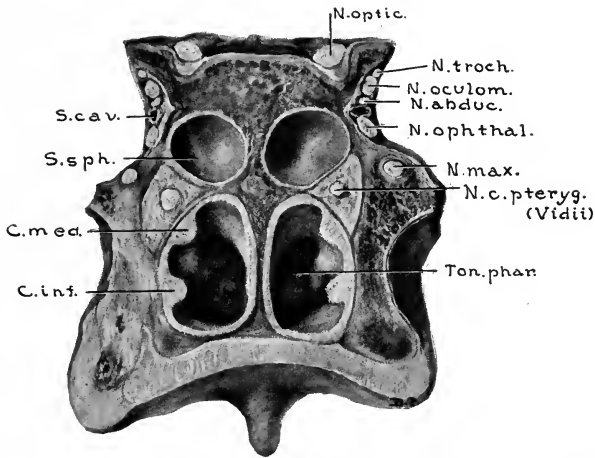


FIG. 32.—SPECIMEN FROM A CHILD SEVEN YEARS, NINE MONTHS, AND TWELVE DAYS OLD. (Series D, No. 58.)

Coronal section through the anterior portion of the body of the sphenoid bone, to show the relations of the cranial nerves to the sphenoidal area. The sphenoidal sinuses in this specimen show less extensive pneumatization of the body of the sphenoid than is usually seen at this age. *N.optic.*, Nervus opticus; *N.troch.*, nervus trochlearis; *N.oculom.*, nervus oculomotorius; *N.abduc.*, nervus abducens; *N.ophtal.*, nervus ophthalmicus; *N.max.*, nervus maxillaris; *N.c.pteryg.*, nervus canalis pterygoidei (Vidii); *Ton.phar.*, tonsilla pharyngea; *C.inf.*, concha inferior; *C.med.*, concha media; *S.sph.*, sinus sphenoidalis; *S.cav.*, sinus cavernosus.

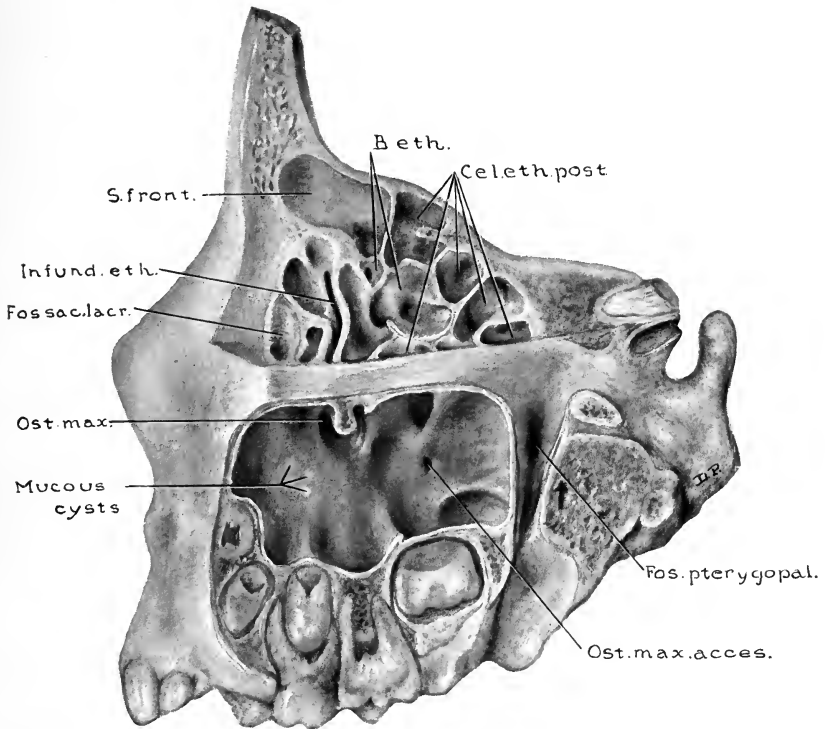


FIG. 33.—SPECIMEN FROM A CHILD EIGHT YEARS, TWO MONTHS, AND TEN DAYS OLD. (Series D, No. 59.)

Lateral view of frontal, ethmoidal, and maxillary areas. Note that the sinus frontalis developed from a cell having its origin from the suprabullar furrow. The right sinus frontalis had a similar origin, these two being the only such instances found in the entire series. The supero-inferior extent of the cellulae ethmoidales is in this case greater than usually found at this age. *B.eth.*, Cellulae bullae ethmoidales; *Cel.eth.post.*, cellulae ethmoidales posterior; *Fos.pterygopal.*, fossa pterygopalatina; *Ost.max.acces.*, ostium maxillare accesorium; *Ost.max.*, ostium maxillare; *Fos.sac.lacr.*, fossa saci lacrimalis; *Infund.eth.*, infundibulum ethmoidale; *S.front.*, sinus frontalis.

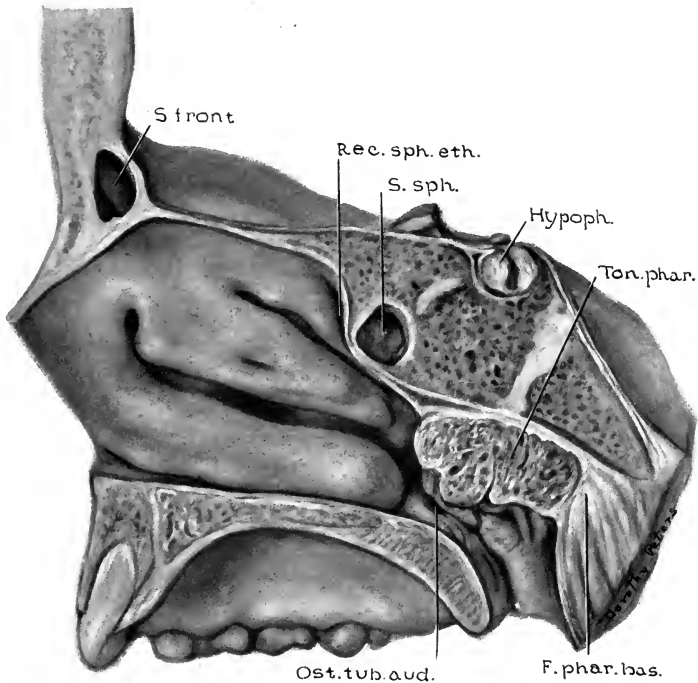


FIG. 34.—SPECIMEN FROM A CHILD EIGHT YEARS, EIGHT MONTHS, AND ONE DAY OLD. (Series D, No. 63.)

Sagittal section cut 1 mm. to the right of median line. Pneumatization of the sphenoid bone is less extensive than is usually found at this age. (Compare with Figs. 27, 29, and 31.) *S. front.*, Sinus frontalis; *Rec. sph. eth.*, recessus sphenothmoidalis; *S. sph.*, sinus sphenoidalis; *Hypoph.*, hypophysis; *Ton. phar.*, tonsilla pharyngea; *F. phar. bas.*, fascia pharyngobasilaris; *Ost. tub. aud.*, ostium pharyngum tubae auditivae.

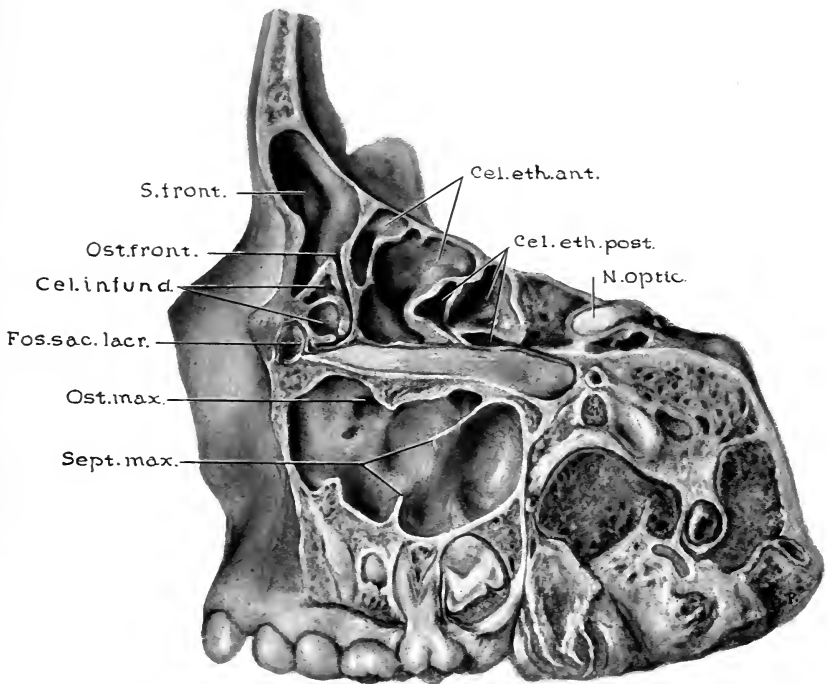


FIG. 35.—SPECIMEN FROM A CHILD EIGHT YEARS, EIGHT MONTHS, AND ONE DAY OLD. (Series D, No. 63.)

Lateral view of frontal, ethmoidal, and maxillary sinus areas, the lateral portion of each having been removed by sagittal cuts. Note that the sinus frontalis developed directly from the infundibulum ethmoidale. Note also the incomplete septa in the sinus maxillaris. *Cel.eth.ant.*, Cellulæ ethmoidales anterior; *Cel.eth.post.*, cellulæ ethmoidales posterior; *N.optic.*, nervus opticus; *Sept.max.*, septulæ maxillares; *Ost.max.*, ostium maxillare; *Foss.sac.lacr.*, Fossa sacci lacrimalis; *Cel.infund.*, cellulæ infundibulares; *Ost.front.*, ostium frontale; *S.front.*, sinus frontalis.

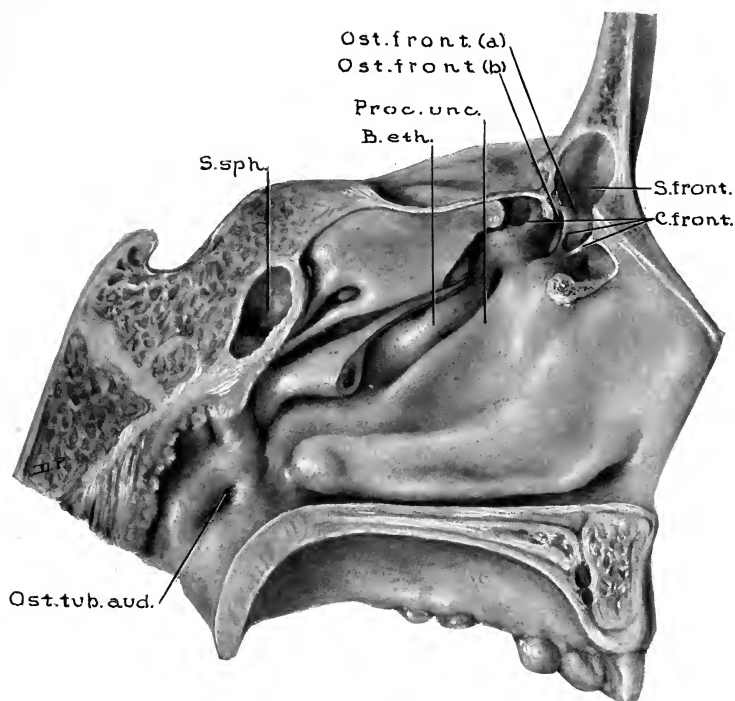


FIG. 36.—SPECIMEN FROM A CHILD NINE YEARS, ONE MONTH, AND NINE DAYS OLD. (Series D, No. 64.)

Incision through maxilla is $\frac{1}{2}$ mm. to the right of median line; in the frontal region 1 mm. to the left, and through the body of the sphenoid is 5 mm. to the left of median line. The anterior portion of the concha media and a small portion of the frontal bone have been removed to show the structures entering into the formation of the lateral nasal wall, and also the location of the ostia frontalia. In this case there are three sinus frontales—one in the right side and the two in the left side here illustrated. Of the more lateral sinus frontalis, only the ostium is shown (*Ost. front. (b)*); the sinus, however, extends to the same height as the medial one shown in the illustration. Note that neither ostium comes into direct relation to the infundibulum ethmoidale. In the suprabullar furrow ostia of bullar cells are shown. *S. front.*, Sinus frontalis; *C. front.*, conchæ frontales; *Ost. tub. aud.*, ostium pharyngeum tubæ auditivæ; *S. sph.*, sinus sphenoidalis; *B. eth.*, bulla ethmoidalis; *Proc. unc.*, processus uncinatus; *Ost. front. (b)*, ostium of the lateral sinus frontalis; *Ost. front. (a)*, ostium of the medial sinus frontalis.

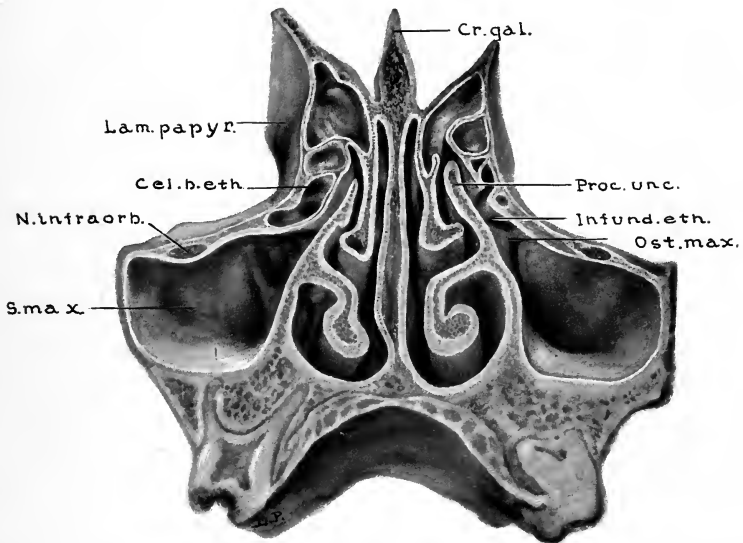


FIG. 37.—SPECIMEN FROM A CHILD NINE YEARS, TEN MONTHS, AND NINETEEN DAYS OLD. (Series D, No. 65.)

Anterior view of coronal section, cut 20 mm. posterior to the nasion, showing the size and relations of the sinus maxillaris, the ostium maxillare, and its manner of communication with the infundibulum ethmoidale, the bulla ethmoidalis, processus uncinatus, and cellulae ethmoidales anterior. *Cr.gal.*, Crista galli; *Proc.unc.*, processus uncinatus; *Infund.eth.*, infundibulum ethmoidale; *Ost.max.*, ostium maxillare; *S.max.*, sinus maxillaris; *N.infraorb.*, nervus infraorbitalis; *Cel.b.eth.*, cellula bulla ethmoidalis; *Lam.papyr.*, lamina papyracea.



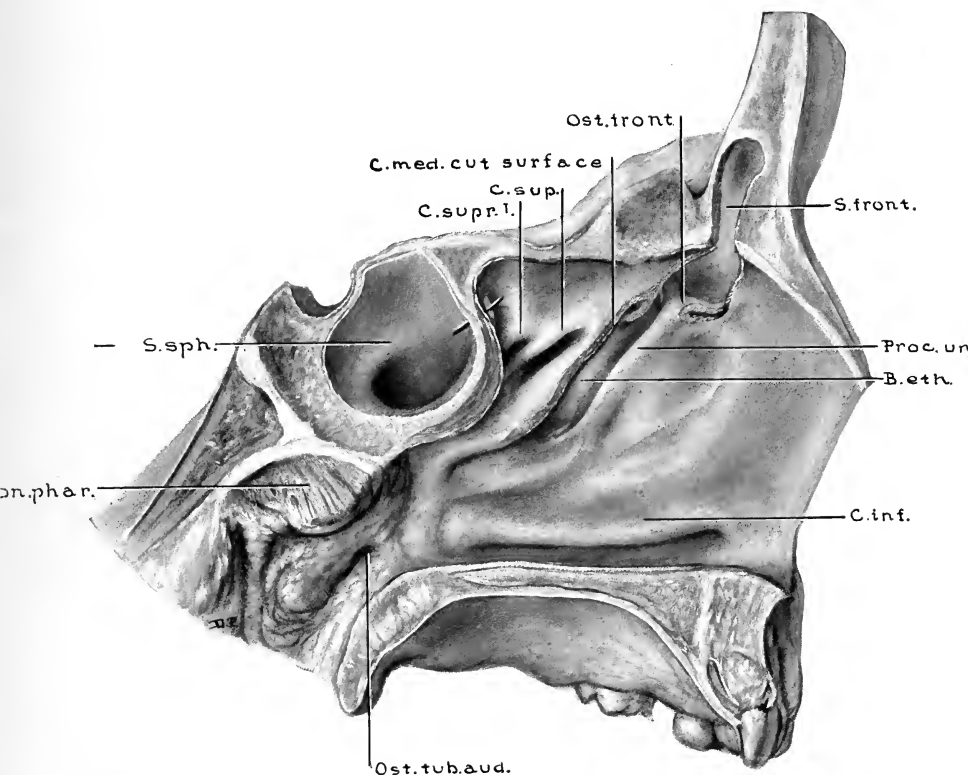


FIG. 38.—SPECIMEN FROM A CHILD TEN YEARS, ONE MONTH, AND SEVEN DAYS OLD. (Series D, No. 66.)

Sagittal section 1 mm. to the left of the median line. The anterior portion of the concha media and a portion of the medial wall of the sinus frontalis have been removed. Note that sphenoidal pneumatization has extended beneath the anterior portion of the sella turcica. *S. front.*, Sinus frontalis; *Proc. unc.*, processus uncinatus; *B. eth.*, bulla ethmoidalis; *C. inf.*, concha inferior; *Ost. tub. aud.*, ostium pharyngaeum tubae auditivae; *Ton. phar.*, tonsilla pharyngea; *S. sph.*, sinus sphenoidalis; *C. sup. I.*, concha superiora I; *C. sup.*, concha superior; *C. med.*, concha media; *Ost. front.*, ostium frontale.

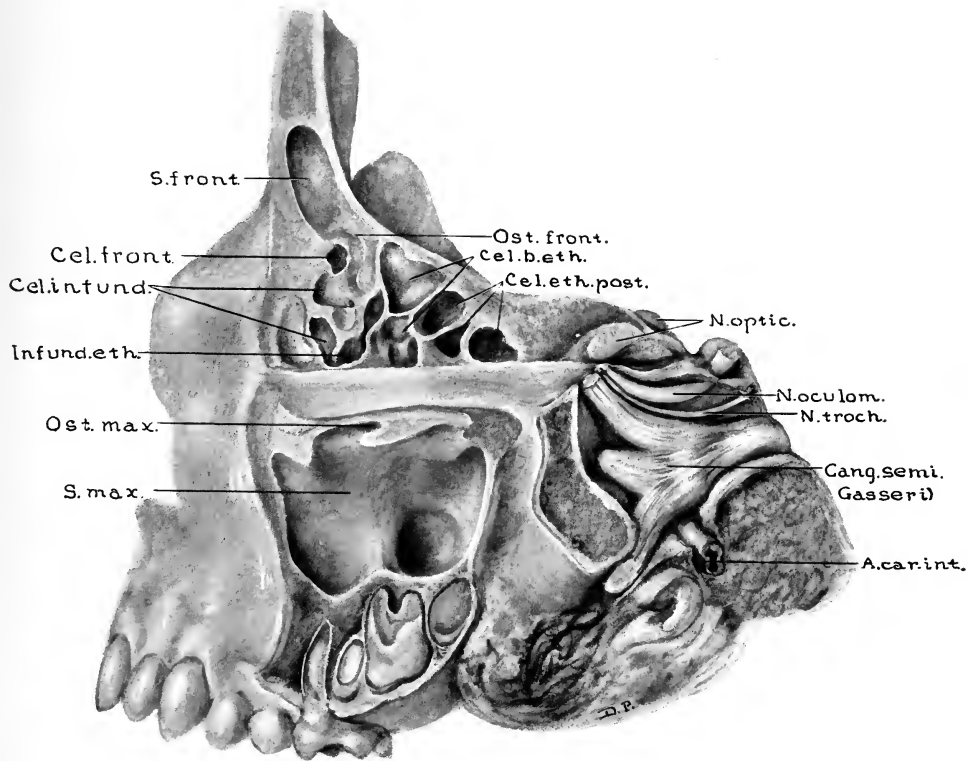


FIG. 39.—SPECIMEN FROM A CHILD TEN YEARS, SEVEN MONTHS, AND TWENTY-SEVEN DAYS OLD. (Series D, No. 67.)

Lateral view of the left frontal, ethmoidal, and maxillary sinus areas, the lateral portions of which have been removed by sagittal sections. Note the relations of the cranial nerves to that portion of the body of the sphenoid which forms the lateral wall of the sinus sphenoidalis. The nervus maxillaris is 0.9 mm. lateral to the sinus sphenoidalis. *Ost.front.*, Ostium frontale; *Cel.b.eth.*, cellulae bullae ethmoidales; *Cel.eth.post.*, cellulae ethmoidales posterior; *N.optic.*, nervus opticus; *N.oculom.*, nervus oculomotorius; *N.troch.*, nervus trochlearis; *Gang.semi. Gasseri*, ganglion semilunare (Gasseri); *A.car.int.*, arteria carotis interna; *S.max.*, sinus maxillaris; *Ost.max.*, ostium maxillare; *Infund.eth.*, infundibulum ethmoidale; *Cel.infund.*, cellulae infundibulares; *Cel.front.*, cellula frontalis; *S.front.*, sinus frontalis.

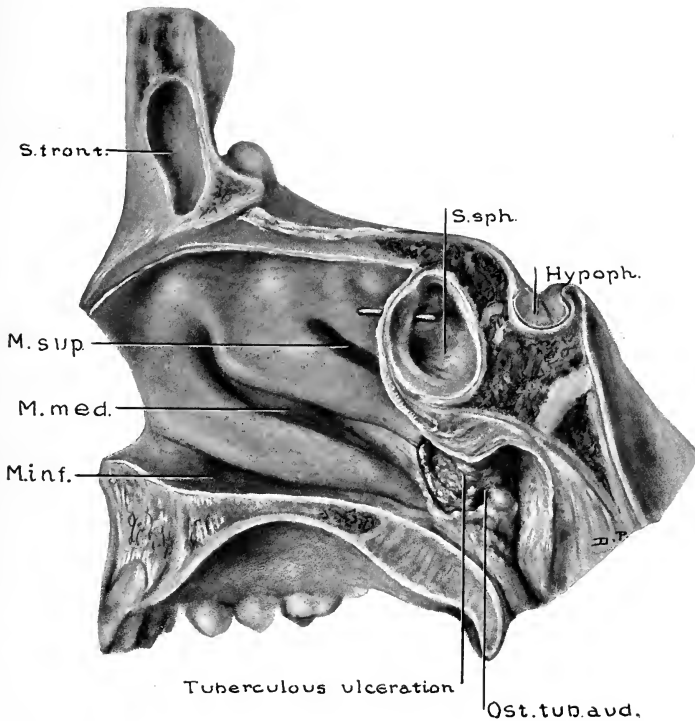


FIG. 40.—SPECIMEN FROM A CHILD ELEVEN YEARS OLD. (Series D, No. 68.)

Sagittal section showing the conchæ nasales, the sinus sphenoidalis, the septum frontale, and the portion of the left sinus frontalis extending to the right of the median line. *S.sph.*, Sinus sphenoidalis; *Hypoph.*, hypophysis; *Ost.tub.aud.*, ostium pharyngeum tubæ auditivæ; *M.inf.*, meatus inferior; *M.med.*, meatus medius; *M.sup.*, meatus superior; *S.front.*, sinus frontalis.

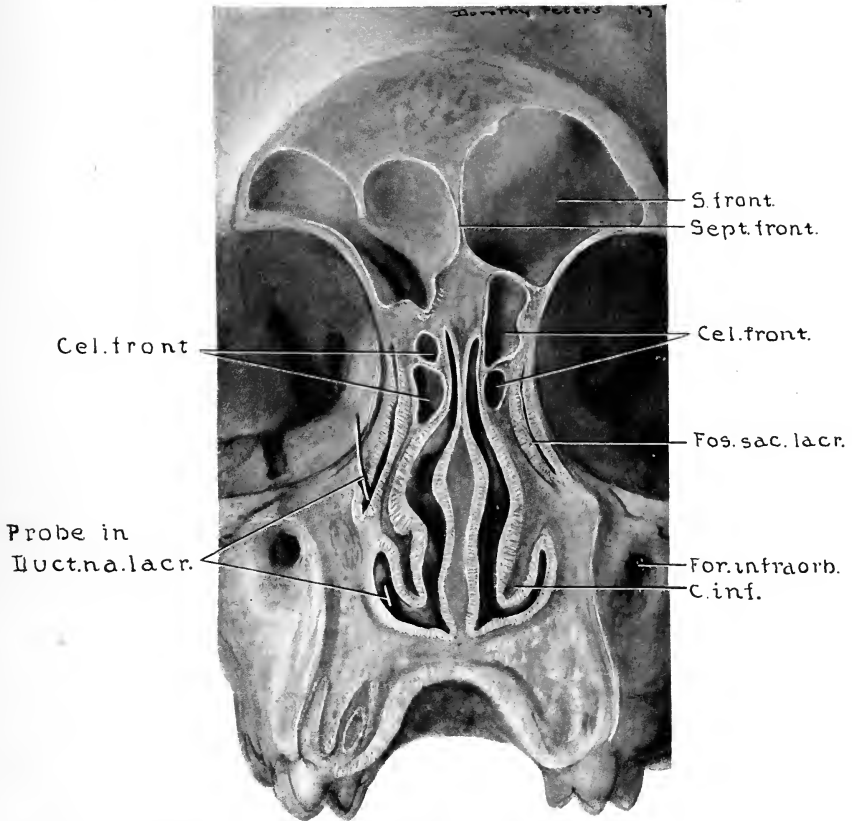


FIG. 41.—SPECIMEN FROM A CHILD TWELVE YEARS, NINE MONTHS, AND TWELVE DAYS OLD. (Series D, No, 69.)

Anterior view of a coronal section cut 12 mm. posterior to the nasion, to show superior and lateral extent of the sinus frontales, also the relations of the cellulae frontales. The frontal sinuses and all cells shown in this illustration have their ostia medial to the uncinatè processes. Note the relations of the ductus nasolacrimalis. *S. front.*, Sinus frontalis; *Sept. front.*, septum frontale; *Cel. front.*, cellulae frontales; *Fos. sac. lacr.*, fossa sacci lacrimalis; *For. infraorb.*, foramen infraorbitale; *Duct. na. lacr.*, ductus nasolacrimalis.

after that age a ridge on the roof of the sinus, which distinctly indicates the course of the nerve in its canal. The degree of prominence which the ridge may assume varies greatly in the different specimens (Figs. 25, 26, 42, and 52). In the vast majority of cases there is thus formed a complete osseous canal for the *nervus infraorbitalis*; but in some few instances its osseous structure is incomplete, so that the mucosa of the sinus becomes a part of the immediate support for the nerve.

The osseous framework of the medial wall of the sinus maxillaris consists of the thin portion of the *corpus maxillæ* surrounding the hiatus maxillaris, and also of the laminae from contiguous bones partially filling in the hiatus. The laminae, which form the incomplete portion of the wall, are the *processus maxillaris* and the *processus ethmoidalis conchæ nasalis inferior*, the *pars perpendicularis ossis palatina*, the *processus uncinatus ossis ethmoidalis*, and the postero-inferior portion of the *os lacrimale* (Fig. 56). With the mucosa intact, the interstices between these laminae are bridged over, leaving normally the *ostium maxillare* as the only opening between the sinus and the nasal cavity. The wall thus covered by mucosa usually forms a rather smooth surface (Figs. 28, 45, and 49), but in some cases distinct ridges may be produced by irregularities in the underlying bone (Fig. 30).

The *ostium maxillare* is in the anterosuperior portion of the medial wall of the sinus maxillaris (Figs. 39, 45, and 49), and is the point of communication between the sinus and the *infundibulum ethmoidale* (Figs. 26, 37, and 52). The *ostium* varies from a narrow, slit-like opening to forms oblong or ovoid in outline. The average diameters of the ostia.

as found in cases of different ages, are given in the above table of measurements of the sinus maxillares. The relations of the ostium to the infundibulum are fairly constant. The opening is in the inferolateral wall of the infundibulum, the situation of the midpoint of the ostium corresponding approximately to the anterior portion of the middle third of the infundibulum.

Communication between the sinus maxillaris and the meatus medius is via the ostium maxillare, the infundibulum ethmoidale, and the hiatus semilunaris (Figs. 26, 37, and 53). The distance between the ostium maxillare and the hiatus semilunaris varies in adult cases from 4 to 12 mm., according to the width of the processus uncinatus and also to the degree of the medial inclination of its free or postero-superior portion.

Through the anterior portion of the infundibulum the sinus maxillaris is brought into close relationship with the cellulæ infundibulares, and to all sinus frontales having their ostia lateral to the processus uncinatus (Figs. 35, 49, and 52). In this series the ostia of 39.6 per cent. of the frontal sinuses were so located. These relations are important when dealing with suppurative conditions in this area; also, as observed by Keen, in those cases of sarcoma of the maxilla in which a portion of the growth has extended toward or into the frontal region, partially or completely filling the infundibulum, the cellulæ infundibulares, or even the sinus frontalis.

Duplication of the ostium maxillare is a condition in which the sinus maxillaris has two ostia, *both* of which communicate with the infundibulum ethmoidale. Such a condition was present in only one specimen in this series (Fig. 54). Dupli-

cation of the ostium is, we believe, due to a developmental process similar to that producing the ostia maxillaria accessoria, which will be considered below, differing only in that accessory ostia are located posterior to the infundibulum and thus communicate directly with the meatus medius.

Schaeffer found the primitive maxillary pouch duplicated in some of his fetal specimens, and suggested that this may explain some of the duplications of the ostium maxillare of the adult sinus, the two pouches fusing distally, forming a single cavity with duplicated ostia. To us, however, this does not seem probable, since we find that accessory sinuses which have developed from separate ostia do not directly communicate, except in instances where the intervening wall has been destroyed by a suppurative process. In the development of accessory sinuses the pouching mucosa rests upon a layer of compact bone as the process of pneumatization extends into the body of the bone—whether it be the maxillary, the frontal, or the sphenoid bone. The layer of compact bone advances as the process of resorption goes on in the underlying cancellous bone. When two advancing layers of compact bone are brought into contact by the resorption of the intervening cancellous bone, resorption ceases and a permanent layer of compact bone remains between the layers of mucoperiosteum lining the sinus cavities. Irregularities in the rate of resorption of the cancellous bone surrounding any individual sinus may be of a character in which the advancing layers of compact bone surrounding different recesses of that sinus are brought into contact, in which case a ridge or an incomplete septum persists. The sinus maxillaris in Fig. 35, and the superior portion of the left sinus frontalis in Fig. 52, show incomplete septa

formed in this way. In view of these facts we are inclined to believe that if two pneumatization pouches were to advance into the maxilla the result would be a double maxillary sinus, instead of the only remains being simply the duplicated ostia. In rare instances double maxillary sinuses are present, but we have found no report of a case in which both of the ostia opened into the infundibulum. Double maxillary sinuses will be considered later.

The ostium maxillare accessorium (Figs. 27, 30, 33, and 48) is an opening which is sometimes found in the medial wall of the sinus maxillaris, forming an additional communication with the meatus nasi medius. Such openings vary from 0.5 to 15 mm. in diameter, and are most frequently situated at a point 5 to 10 mm. above the superior border of the concha inferior, at the junction of its posterior and middle thirds. The majority of observers have found accessory ostia present in about 10 per cent. of adult cases. Schaeffer, in 80 cases, found accessory ostia in 43 per cent. of them. In my own series, 114 lateral nasal walls from cases between four and twenty-four years of age show accessory ostia in 15 per cent. of cases. The youngest specimen showing an accessory ostium was from a child four years, three months, and two days old; thus cases under four years of age were excluded in estimating the frequency of its occurrence. Two accessory ostia (Fig. 48) were present in two specimens.

The ostium maxillare accessorium evidently has no embryologic significance in its development; neither can it be considered as a compensatory opening which has developed because of a deficiency in the size of the normal ostium maxillare, for in no case showing the presence of an

accessory ostium was the normal ostium found to be smaller than the average for the given age. The process of its development is apparently a progressive thinning of the medial wall of the sinus at a point where the wall is naturally thin, and where there is no osseous lamina between the mucosa lining the sinus and that lining the meatus medius, the thinning continuing until an actual opening through the membranes occurs. In a great majority of the cases in which accessory ostia were found there were pathologic processes present to give evidence of lowered vitality in those immediate areas, and in several instances the situation of mucous cysts was such as to interfere with the normal circulation of the medial sinus wall.

In 76 per cent. of cases showing accessory ostia there were mucous cysts (retention cysts) in the mucosa lining the medial walls of the sinus maxillares (Figs. 30 and 33). The cysts varied from 0.5 to 9 mm. in diameter. In 19 per cent. of cases the mucosa was distinctly granular in appearance, but showed no cysts. In the remaining 5 per cent. of cases the surrounding mucosa was apparently normal.

The cases in this series suggest the possibility of pulmonary tuberculosis having some influence upon the frequency of the occurrence of the ostia accessoria, but we do not regard the series as sufficiently large to establish this relationship as a definite fact. However, we submit the observation that in 114 lateral nasal walls from cases between four and twenty-two years of age, 15 per cent. showed the presence of accessory ostia. Of the 114 specimens, 42 per cent. were from patients who had died from pulmonary tuberculosis. In the specimens from tuberculous cases, 37.5 per cent. had

accessory ostia, while in all other specimens accessory ostia were present in only 7.7 per cent. of cases.

Zuckerkandl regarded pressure from septal spurs or from enlarged middle conchæ as occasional factors in the production of ostia accessoria. In this series no case with an accessory ostium showed these conditions to be present in a sufficient degree to exert any apparent influence on the development of an accessory opening.

The superior wall, or roof, of the sinus maxillaris is a thin plate of bone (its superior surface being the facies orbitalis maxillæ), the central and posterior portions of which vary from 0.5 to 1.5 mm. in thickness. Along two ridges which project into the sinus and near the anterior margin, the bone is usually of a greater thickness. The more constant of the two ridges is the one which forms the inferior wall of the above-mentioned canalis infraorbitalis (Figs. 25, 26, 42, and 52). The second ridge is well marked in the majority of cases, and extends laterally along the roof from the posterior margin of the ostium maxillare (Figs. 33, 39, 45, and 54). Its prominence decreases as it passes laterally, and usually disappears just medial to the canalis infraorbitalis.

Not uncommonly the cellulæ ethmoidales, in their infero-lateral development, extend for a short distance (2 to 4 mm.) into the roof of the sinus; and in rare instances the development may be such that an aberrant posterior ethmoidal cell occupies the area which would ordinarily be the postero-superior angle of the sinus maxillaris (Fig. 50).

The posterior wall of the sinus maxillaris is the most regular of all its boundaries. In an average case it varies from 0.5 to 3 mm. in thickness, the portions near the angles

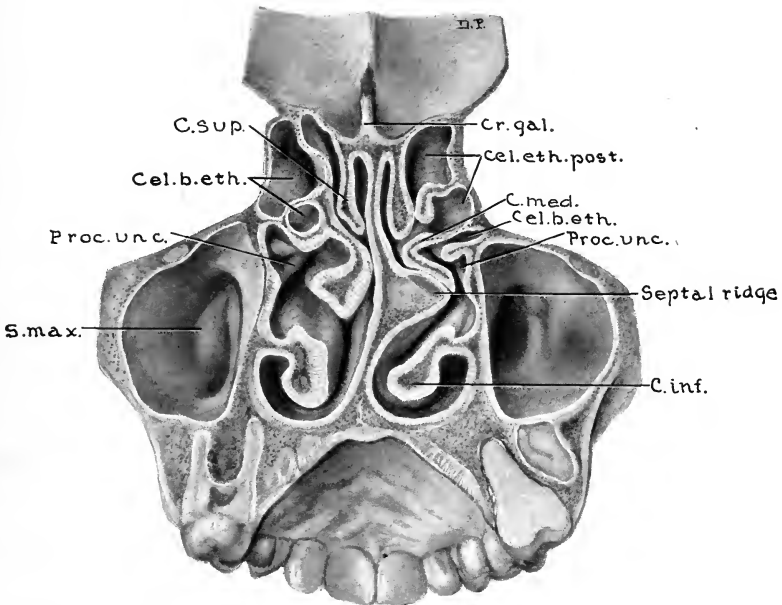


FIG. 42.—SPECIMEN FROM A CHILD THIRTEEN YEARS, SIX MONTHS, AND NINETEEN DAYS OLD. (Series D, No. 72.)

Posterior view of a coronal section 31 mm. posterior to the nasion, showing maxillary sinuses, bullar and posterior ethmoidal cells. Note the influence of septal ridge and deviation of septum upon the form of each concha media; also upon the degree of medial inclination of each processus uncinatus, thus producing a marked difference in the width of the hiatus semilunaris and the infundibulum ethmoidale of each side. *Cr.gal.*, Crista galli; *Cel.eth.post.*, cellulae ethmoidales posterior; *C.med.*, concha media; *Cel.b.eth.*, cellula bullae ethmoidalis; *Proc.unc.*, processus uncinatus; *C.inf.*, concha inferior; *S.max.*, sinus maxillaris; *C.sup.*, concha superior.



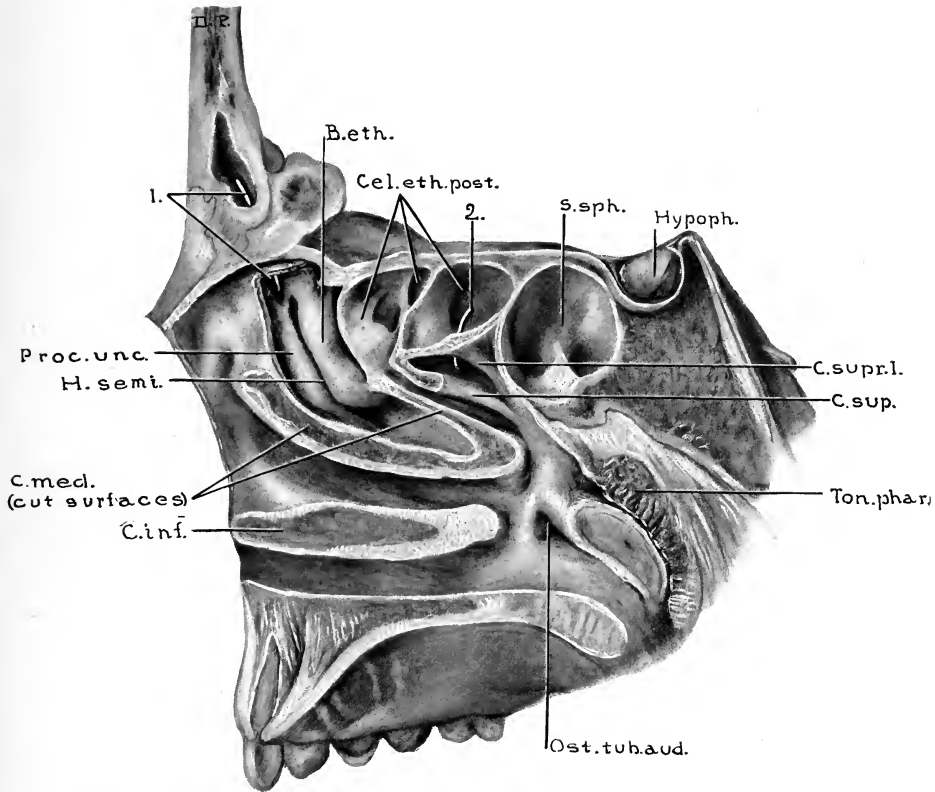


FIG. 43.—SPECIMEN FOURTEEN YEARS AND SEVEN MONTHS OLD. (Series D, No. 73.)

Sagittal section, cut 4 mm. to the right of the median line, thus removing the medial portions of the concha inferior and concha media, and the medial anterosuperior portions of the concha superior and concha suprema I. The relations of the structures forming the lateral nasal wall and the positions of the ostia of the cellulae ethmoidales are thus clearly shown. 1., Probe through ostium frontale; *B.eth.*, bulla ethmoidalis; *Cel.eth.post.*, cellulae ethmoidales posterior; 2., probe through ostium of most posterior ethmoidal cell; *S.sph.*, sinus sphenoidalis; *Hypoph.*, hypophysis; *C.supr.I.*, concha suprema I; *C.sup.*, concha superior; *Ton.phar.*, tonsilla pharyngea; *Ost.tub.aud.*, ostium pharyngem tubae auditivae; *C.inf.*, concha inferior; *C.med.*, concha media; *H.semi.*, hiatus semilunaris; *Proc.unc.*, processus uncinatus.

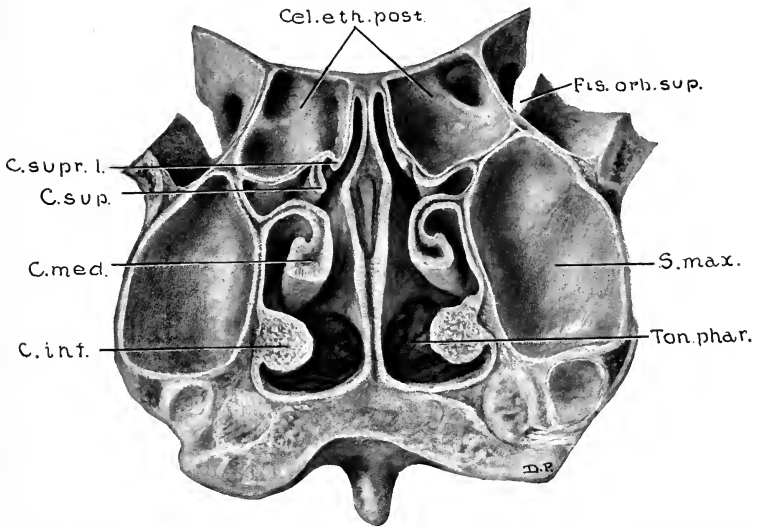


FIG. 44.—SPECIMEN FIFTEEN YEARS AND FIVE MONTHS OLD. (Series D, No. 75.)

Coronal section cut 44 mm. posterior to nasion, showing posterior portions of the conchæ and the posterior walls of maxillary sinuses. *Fis. orb. sup.*, Fissura orbitalis superior; *S. max.*, sinus maxillaris; *Ton. phar.*, tonsilla pharyngea; *C. inf.*, concha inferior; *C. med.*, concha media; *C. sup.*, concha superior; *C. supr. I.*, concha suprema I.

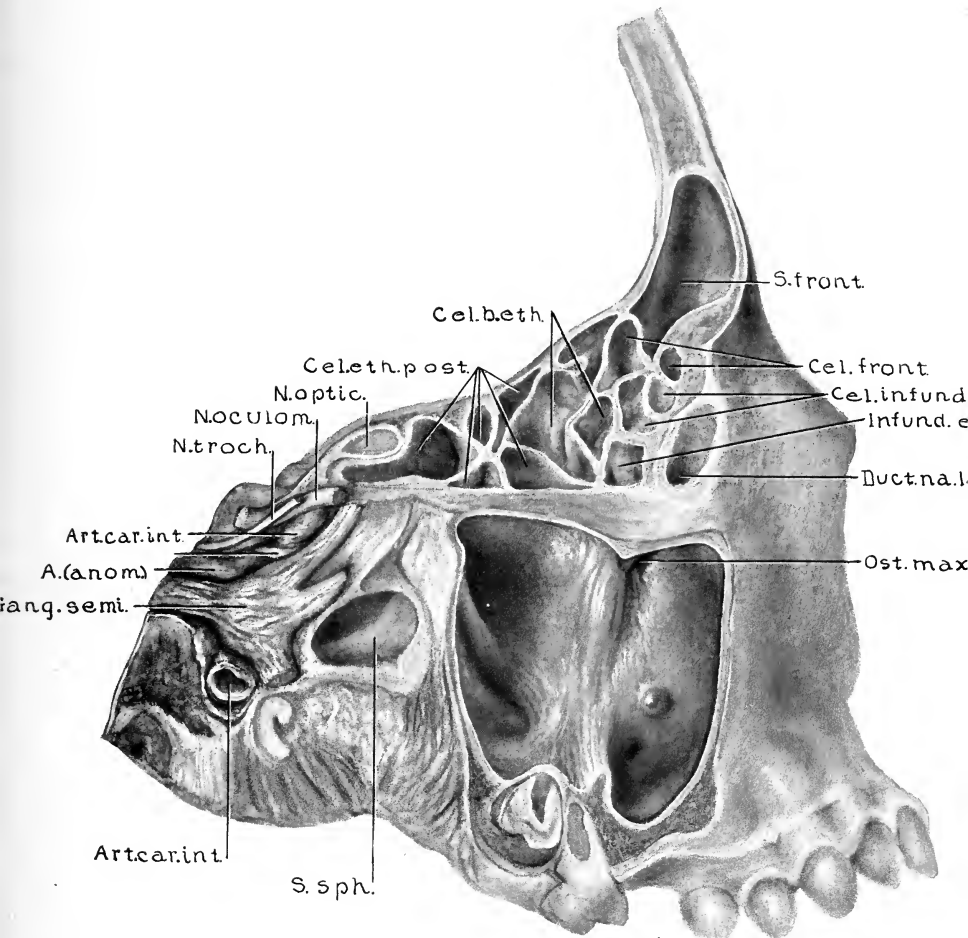


FIG. 45.—SPECIMEN FIFTEEN YEARS, NINE MONTHS, AND TWENTY-SIX DAYS OLD. (Series D, No. 76.)

Lateral portions of the frontal, ethmoidal, maxillary, and sphenoidal areas have been removed by sagittal incisions. Note the marked extent of the sinus sphenoidalis into the pterygoid process. The ridge which is seen on the floor of the sinus sphenoidalis overlies the nervus canalis pterygoidei (Vidii). The sinus maxillaris extends 11 mm. below the level of the nasal floor. *S.front.*, Sinus frontalis; *Cel.front.*, cellulae frontales; *Cel.infund.*, cellulae infundibulares; *Infund.eth.*, infundibulum ethmoidale; *Duct.na.lacr.*, ductus nasolacrimalis; *Ost.max.*, ostium maxillare; *S.sph.*, the portion of sinus sphenoidalis extending into the pterygoid area; *Art.car.int.*, arteria carotis interna; *Gang.semi.*, ganglion semilunare; *A.anom.*, anomalous branch of carotid artery; *N.troch.*, nervus trochlearis; *N.oculom.*, nervus oculomotorius; *N.optic.*, nervus opticus; *Cel.eth.post.*, cellulae ethmoidales posterior; *Cel.b.eth.*, cellulae bullae ethmoidales.

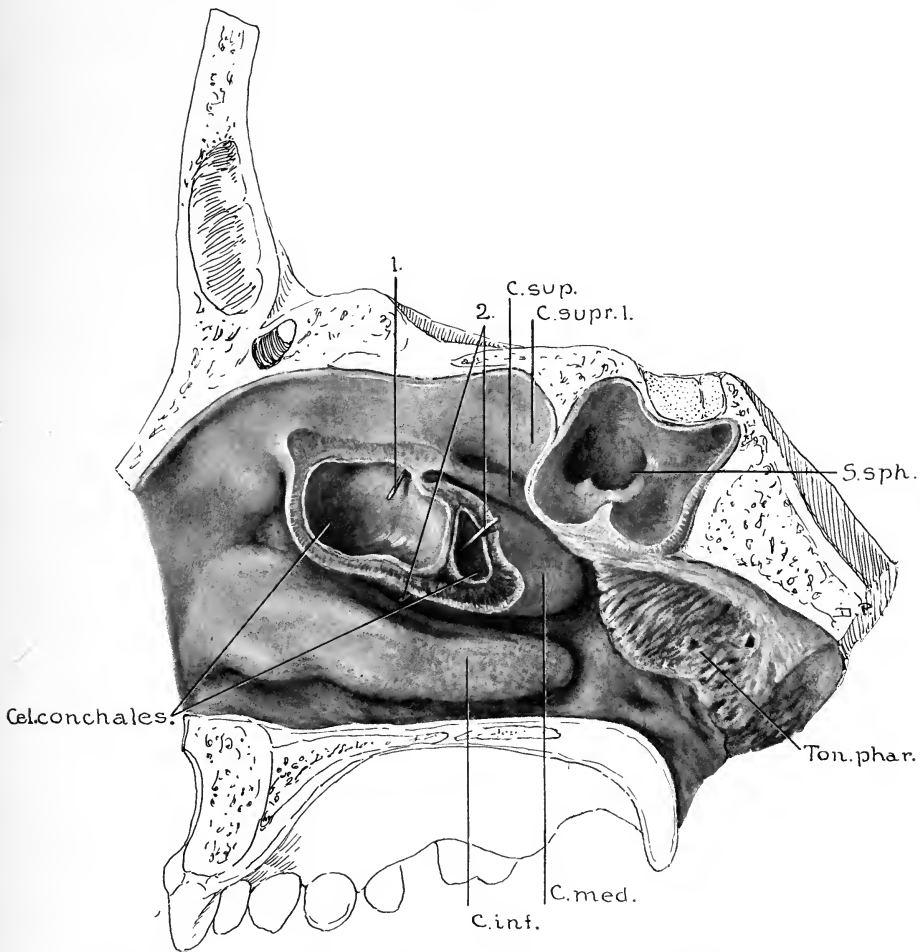


FIG. 46.—SPECIMEN FIFTEEN YEARS, NINE MONTHS, AND TWENTY-SIX DAYS OLD. (Series D, No. 76.)

Lateral view of this specimen is shown in Fig. 45. Sagittal section, showing the sinus sphenoidalis and a portion of the lateral nasal wall. There was in this case a marked deviation of the septum nasi toward the left, and a compensatory increase in the size of the concha media. Note the presence of the cellulae conchales. The anterior conchal cell has its origin as an extension from a posterior ethmoidal cell, just anterior to the superior meatus, while the posterior conchal cell developed from the posterior portion of the suprabullar furrow. 1, Probe through ostium of the anterior conchal cell; 2, probe through ostium of the posterior conchal cell; *C.sup.*, concha superior; *C.supr.1.*, concha superior I; *S.sph.*, sinus sphenoidalis; *Ton.phar.*, tonsilla pharyngea; *C.med.*, concha media; *C.inf.*, concha inferior; *Cel.conchales*, cellulae conchales.

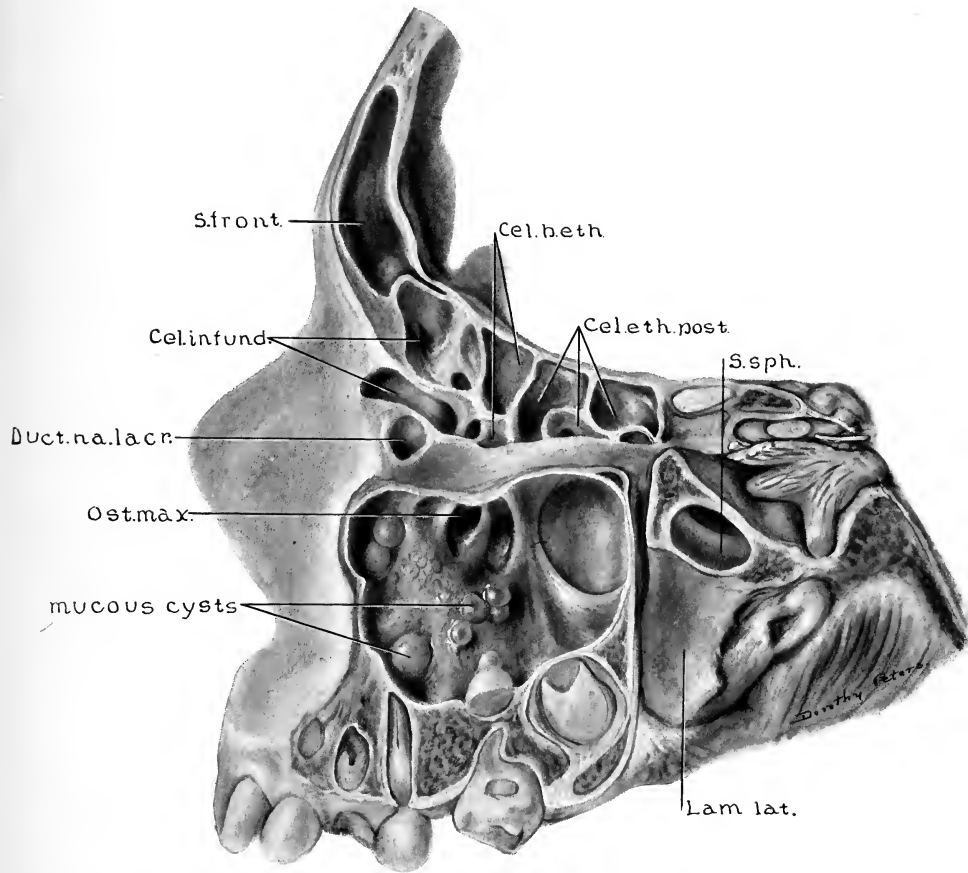


FIG. 47.—SPECIMEN SIXTEEN YEARS, FIVE MONTHS, AND TWENTY-ONE DAYS OLD. (Series D, No. 79.)

Lateral view of frontal, ethmoidal, maxillary, and a portion of the sphenoidal areas. Maxillary sinus contains mucous cysts. The ridge which is seen on the floor of the sphenoidal sinus overlies the nervus canalis pterygoidei (Vidii). Note the extent of sphenoidal sinus into the pterygoid area, also the extent of an infundibular cell far into the frontal process of the maxilla. *Cel.b.eth.*, Cellulæ bullæ ethmoidales; *Cel.eth.post.*, cellulæ ethmoidales posterior; *S.sph.*, sinus sphenoidalis; *Lam.lat.*, lamina lateralis processus pterygoidei; *Ost.max.*, ostium maxillare; *Duct.na.lacr.*, ductus nasolacrimalis; *Cel.infund.*, cellulæ infundibulares; *S.front.*, sinus frontalis.

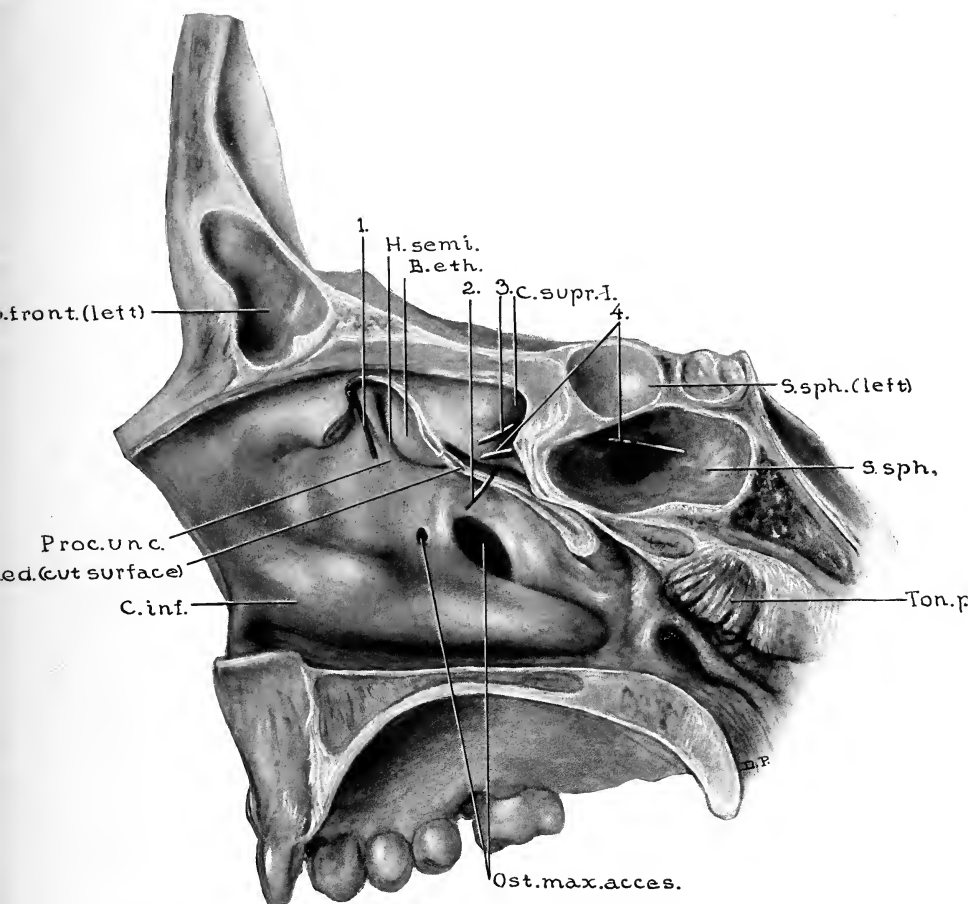


FIG. 48.—SPECIMEN SEVENTEEN YEARS OLD. SAGITTAL SECTION 1 MM. TO THE LEFT OF THE MEDIAN LINE. THE SEPTUM NASI AND THE ANTERIOR PORTION OF THE CONCHA MEDIA HAVE BEEN REMOVED. (Series D, No. 83.)

Note the presence of two accessory ostia maxillaria. Similar ostia were found opening into the left sinus maxillaris of this case. Both sinus maxillares contained mucous cysts near the accessory ostia. 1, Probe in ostium frontale; 2 and 3, probes in the ostia of cellulae ethmoidales posterior; 4, probe through ostium sphenoidale; *H.semi.*, hiatus semilunaris; *B.eth.*, bulla ethmoidalis; *C.supr.1.*, concha suprema I; *S.sph.*, sinus sphenoidalis; *Ton.phar.*, tonsilla pharyngea; *Ost.max.acces.*, ostia maxillaria accessoria; *C.inf.*, concha inferior; *C.med.*, concha media; *Proc.unc.*, processus uncinatus; *S.front.*, sinus frontalis (medial portion of left sinus extending slightly to the right of median line).

being thicker than the central area. The medial portion of the wall forms the anterior boundary of the fossa pterygopalatina (Fig. 33).

The anterior or facial wall of the sinus maxillaris varies from 2 to 5 mm. in thickness, and is, with the exception of that portion of the floor which is formed by the alveolar process, the thickest and the strongest of all the walls. It faces in an anterolateral direction, with a varying antero-inferior obliquity. This obliquity, which depends upon the degree of approximation of the inferior portion of the wall toward the posterior wall, produces the variations in the number of teeth which are in relation to the sinus floor, and greatly influences the capacity of the sinus. The anterior surface presents, below the infra-orbital margin, the foramen infraorbitale, beneath which is a variable depression, the fossa canina (Fig. 55).

The inferior wall of the pyramid, the floor of the sinus maxillaris, is formed near the medial wall by the processus alveolaris, and, more laterally, by the well-rounded angle produced by the approximation of the inferior portions of the anterior and posterior walls.

The floor of the sinus maxillaris, in all stages of its development, is in close relation to the teeth (Figs. 17, 21, 28, 30, and 33), and the increase in the vertical diameter of the sinus is found to be much more of a process of expansion as the body of the maxilla increases in size, than it is one of resorption of cancellous bone previously occupying the area.

The number of teeth, the roots of which are in close relation to the floor of the sinus, shows marked variations (Figs. 45, 47, 50, 54, and 55). However, the typical floor may be

considered as one which overlies the roots of all the molars and the posterior portion of the second premolar. In many cases only the molars come into close relation, and in a few cases only the second and third molars are beneath the floor. It is a very extensive floor, which advances so far anteriorly as to overlie the first premolar, and in this series no case was found in which the root of the canine was in relation to the floor. In a few of the larger sinuses, however, the root of the canine extended well up into the anterior wall of the sinus.

Regardless of the extent of the irregularities in the floor of the sinus produced by resorption of the cancellous bone surrounding the roots of the teeth, in no instance was the mucosa lining the sinus found in direct contact with the root of a healthy tooth. In all normal cases a thin layer of compact bone was present between the roots of the tooth and the mucosa; but in a few instances, where there had been abscess formation at the root of a tooth, this intervening plate of bone had been destroyed, thus allowing the root to project into the sinus cavity, in direct contact with the overlying mucosa.

Besides the recesses produced by the ridges on the alveolar surface, pockets may be formed by osseous projections on the anterior, or less frequently on the posterior, wall, or by folds of mucosa independent of any irregularity in the underlying bone, as found in the posteromedial angle of the sinus shown in Fig. 47. Osseous ridges may, in rare instances, extend sufficiently far toward the central portion of the sinus as to form incomplete septa, or septulæ (Fig. 35). Such formations have no embryologic significance, and are entirely due to irregularity in the process of resorption. Ridges and

folds of any of the above-mentioned varieties probably assume an important rôle from a practical viewpoint, only in the presence of suppurative conditions within the sinus, when the recesses or pockets make the thorough cleansing of the cavity more difficult.

A few cases have been reported in which there was a complete osseous septum dividing the sinus maxillaris into two distinct cavities, each having its independent ostium communicating with the nasal fossa. According to Zuckerkandl, the anterior sinus, in such cases, communicates with the infundibulum ethmoidale through the normal ostium maxillare, while the posterior sinus communicates with the meatus superior. Thus it is seen that the posterior sinus is in reality an aberrant posterior ethmoidal cell which invaded the body of the maxilla and there developed extensively. In this series no such development was found sufficiently extensive to justify terming it a double sinus; but in one instance (Fig. 50) such an aberrant posterior ethmoidal cell is shown, and indicates the manner in which greater pneumatization by such a cell would produce a double maxillary sinus.

THE SINUS FRONTALIS

The areas from which the sinus frontalis may have its origin were considered above in discussing the development of the cellulæ ethmoidales anterior. (See pp. 45-6, 53-4.) We found that during the fourth month of fetal life there are two expansions usually demonstrable in the anterosuperior portion of the meatus medius. The expanding areas are separated by the anterior attachment of the processus uncinatus. The recess beneath the anterosuperior attachment of the concha media and medial to the processus uncinatus is termed the recessus conchalis. The recess lateral to the anterior portion of the processus uncinatus is termed the recessus infundibularis, being the anterosuperior termination of the infundibulum ethmoidale. From the recessus conchalis the cellulæ frontales develop between the conchæ frontales and between the conchæ and the walls of the recess, while from the recessus infundibularis the cellulæ infundibulares have their origin. A sinus frontalis may develop as an anterosuperior extension of a cell originating from either of these two recesses, as a direct extension of the infundibulum ethmoidale, as a direct extension of a recessus conchalis in which no frontal cells have developed, or, in rare instances, as an extension from a cell originating in the suprabullar furrow.

Although the primitive recessus conchalis and the recessus infundibularis are usually demonstrable during the fourth fetal month, and distinct cellulæ ethmoidales anterior de-

velop during the latter months of fetal life, yet, in the average case, one cannot say definitely which of the extending processes of pneumatization represents the primitive sinus frontalis until after the sixth month of postnatal life. In some specimens the probable route of development can be determined with a fair degree of certainty at the time of birth or shortly thereafter (Figs. 17 and 20), while in other cases the distinct beginning of a sinus frontalis is not demonstrable until near the end of the first year.

From whichever of these sources a frontal sinus may have its origin, the process of pneumatization gradually extends from that portion of the anterior ethmoidal area toward and into the inferior portion of the frontal bone. The sinus, surrounded as it is by a thin lamina of compact bone, then advances toward the ascending portion of the frontal bone, advancing as the cancellous bone is resorbed. This rate of resorption, in an average case, is such that the sinus begins its ascent into the vertical portion of the bone during the second year, and in the third year is 3.8 mm. above the level of the nasion.

As the sinus frontalis advances into the vertical portion of the bone, its posterior wall is always thin and is composed almost entirely of compact bone, while the anterior wall, as found in the different specimens, varies greatly in its thickness and usually contains a considerable amount of diploë.

In the following table we have given the average diameters and the level at which the ostia frontalia were found, the origin of the sinuses, the thickness of the walls, the level reached by the superior border of the sinus, and the vertical, lateral, and anteroposterior diameters of the average sinus as found in the given number of cases at the various ages.

TABLE OF AVERAGES OF THE SINUS FRONTALIS

AGE	NUM- BER OF CASES	SIDE	SIZE OF OSTIUM	LEVEL OF OSTIUM	ORIGIN FROM			THICK- NESS OF SEPTUM	THICK- NESS ANTE- RIOR WALL	THICK- NESS POSTE- RIOR WALL	SUPERIOR LEVEL OF SINUS	VER- TICAL DIAM- ETER	LAT- ERAL DIAM- ETER	AN- TE- RIO- R DIAM- ETER
					Infundibulum	Infundibular Cell	Frontal Cell							
8 days-1 yr.	10	Left	2.5 x 0.75	-4.6	1	3	6	9.6	4.0	2.0	-1.3	2.7	1.6	3.3
		Right	2.5 x 0.65	-4.6	1	2	7		4.0	2.0	-1.1	3.3	1.8	3.6
1-2 yrs.	10	Left	2.3 x 0.75	-2.4	1	2	7	9.7	3.2	1.3	+1.6	4.0	2.5	3.8
		Right	2.0 x 0.75	-2.8	2	3	5		3.0	1.3	+1.4	4.3	2.8	4.2
2-3 yrs.	8	Left	2.0 x 0.87	-2.5	2	1	4	9.9	4.5	1.3	+3.8	6.5	3.1	5.4
		Right	1.9 x 0.82	-2.9	3	1	4		4.6	1.3	+3.9	6.5	3.3	5.4
3-4 yrs.	6	Left	2.2 x 0.75	-3.4	0	3	3	10.2	4.7	1.5	+1.5	5.5	2.8	4.9
		Right	2.2 x 0.75	-3.3	0	2	4		4.4	1.5	+2.6	6.1	3.9	6.5
4-5 yrs.	8	Left	2.0 x 0.81	-4.4	3	1	4	7.0	3.3	1.1	+4.8	9.0	4.3	7.3
		Right	2.6 x 1.1	-3.7	1	1	6		4.3	1.3	+4.4	8.0	4.7	5.7
5-6 yrs.	3	Left	3.5 x 1.8	-5.3	0	3	0	10.3	4.1	1.1	+3.6	9.0	5.1	7.0
		Right	2.0 x 0.83	-3.6	0	2	1		4.5	1.7	+2.2	5.5	3.2	6.0
6-7 yrs.	8	Left	2.2 x 1.9	-3.0	1	1	6	6.1	3.6	1.1	+7.1	9.4	5.9	6.1
		Right	2.3 x 1.7	-3.0	1	3	4		3.4	1.0	+8.1	9.5	6.9	7.4
7-8 yrs.	5	Left	2.4 x 1.4	-2.8	2	0	3	2.8	3.2	0.8	+10.1	12.7	11.8	8.8
		Right	2.4 x 2.0	-2.6	1	1	3		2.9	0.9	+9.2	12.0	10.7	8.4
8-9 yrs.	5	Left	2.1 x 1.7	-1.9	0	2	3	4.9	2.6	1.1	+11.3	12.7	9.4	10.7
		Right	2.6 x 1.4	-1.6	1	2	2		2.8	1.1	+10.6	10.8	11.0	10.8
9-10 yrs.	2	Left	3.5 x 2.0	-2.0	0	0	2	6.2	3.1	0.7	+6.5	8.5	6.2	7.5
		Right	2.0 x 1.2	-2.5	0	0	2		2.3	0.7	+7.5	9.5	8.2	7.8
10-11 yrs.	2	Left	3.2 x 1.5	-3.3	0	1	1	2.3	2.6	1.2	+13.5	17.0	12.0	8.0
		Right	2.3 x 1.2	-7.7	0	1	1		4.7	1.3	+5.8	13.5	6.5	7.5
11-12 yrs.	1	Left	3.0 x 3.0	Nasion	0	0	1	0.6	1.7	0.7	+17.5	17.0	15.0	9.0
		Right	3.0 x 2.0	Nasion	0	0	1		1.7	0.7	+14.0	10.0	13.0	8.5
12-13 yrs.	1	Left	3.0 x 1.0	Nasion	0	0	1	0.7	1.2	0.7	+20.0	20.0	26.0	13.5
		Right	2.0 x 1.0	Nasion	0	0	1		1.2	0.7	+18.0	18.0	30.0	14.0

13-14 yrs.....	3	Left	4.1 x 1.7	-1.8	0	1	2	3.5	4.4	0.8	+11.2	11.3	11.8	12.3
		Right	2.8 x 1.5	-4.0	1	0	2	2.8	2.8	0.8	+9.6	12.3	10.3	13.3
14-15 yrs.....	1	Left	3.0 x 1.0	-2.0	0	0	1	0.7	1.5	1.0	+16.0	18.0	19.0	10.0
		Right	3.0 x 1.5	-2.0	0	0	1	1.3	1.3	1.0	+16.0	18.0	22.0	11.0
15-16 yrs.....	3	Left	2.7 x 1.4	-2.0	0	1	2	0.6	1.5	0.9	+29.0	31.0	28.0	11.5
		Right	2.6 x 1.3	-2.0	0	1	2	1.5	1.5	0.9	+26.0	27.0	29.5	12.5
16-17 yrs.....	4	Left	2.9 x 1.0	+0.6	1	1	2	0.7	1.5	0.8	+20.0	17.6	16.0	14.0
		Right	3.0 x 1.7	-1.7	1	1	2	2.6	2.6	0.9	+20.2	22.0	18.1	9.6
17-18 yrs.....	4	Left	2.8 x 1.4	-1.5	1	1	0	0.7	2.1	1.1	+25.2	26.2	26.5	10.6
		Right	3.5 x 1.0	-1.7	1	1	2	2.0	2.0	1.2	+24.4	25.6	23.5	13.7
18-19 yrs.....	1	Left	2.5 x 1.5	-2.0	0	1	0	0.7	2.0	1.1	+36.0	38.0	38.5	20.0
		Right	10.0 x 1.5	+3.0	1	0	0	1.8	1.8	1.2	+36.0	34.0	37.0	19.0
19-20 yrs.....	3	Left	3.6 x 1.2	-1.0	1	0	2	0.8	2.0	1.1	+27.3	28.3	26.6	18.6
		Right	4.2 x 1.9	-1.1	1	0	2	2.1	2.1	1.3	+24.0	26.1	20.1	14.2
20-21 yrs.....	2	Left	5.0 x 3.1	-3.6	1	1	0	0.6	1.5	0.7	+24.6	26.6	19.0	18.2
		Right	3.8 x 2.6	-0.6	0	1	1	1.9	1.9	0.7	+22.0	21.3	14.3	14.3
21-22 yrs.....	1	Left	6.0 x 1.5	-3.0	0	0	1	1.0	2.7	1.5	+25.0	28.0	36.0	8.5
		Right	6.0 x 1.7	Nasion	0	0	1	2.8	2.8	1.5	+25.0	25.0	34.0	8.0
22-23 yrs.....	2	Left	3.0 x 1.3	-1.3	0	0	2	0.8	2.5	1.4	+24.0	25.2	23.0	11.0
		Right	2.8 x 2.0	+0.2	0	0	2	2.2	2.2	1.4	+24.5	25.5	21.5	12.0
23-24 yrs.....	1	Left	3.0 x 1.5	-4.0	0	1	0	0.5	5.0	1.0	+30.0	38.0	32.0	24.0
		Right	8.0 x 6.0	-4.0	0	1	0	4.5	4.5	1.0	+29.0	33.0	30.0	24.0
25 yrs.....	2	Left	5.5 x 1.6	-2.0	0	0	2	0.7	2.8	0.8	+20.0	22.0	17.0	11.5
		Right	5.2 x 3.0	-1.5	1	0	1	2.0	2.0	0.8	+19.5	21.0	19.5	16.0

All measurements are given in millimeters. The level of the ostia and the superior level of the sinuses were in all cases measured from the level of the nasion. Thus measurements preceded by a minus sign indicate that the average level was the given distance *inferior* to the nasion, while those preceded by a plus sign indicate the given distance *superior* to the nasion.

The resorption of the diploë in the vertical portion of the frontal bone is seldom such as to make the sinuses of the two sides quite symmetric. The general outline of the sinuses often suggests an attempt at symmetry, although one or more of the diameters may show considerable variation. Not uncommonly, however, the two sinuses are of an entirely different form. Irregularity in the rate of resorption on the two sides often produces a deviation of the septum frontale. The position of the septum frontale is, in the great majority of cases, median at its inferior portion, but in a few instances this portion showed variations of from 2 to 6 mm. from the median line. The superior portion of the septum, however, usually shows a slight deviation to one side or the other, the deviation being away from the more rapidly developing sinus. Occasionally a case is found in which one of the sinuses is poorly developed and the sinus from the other side has developed so far past the median line that the resulting deviation of the septum is such that it forms a part of the anterior wall of the deficiently developed sinus. However, in cases where the interfrontal suture persisted (metopic skulls), no instance was found in which a sinus had extended past the median line, regardless of the extent of pneumatization on the opposite side.

In 101 cases (202 frontal sinus areas) having the mucosa

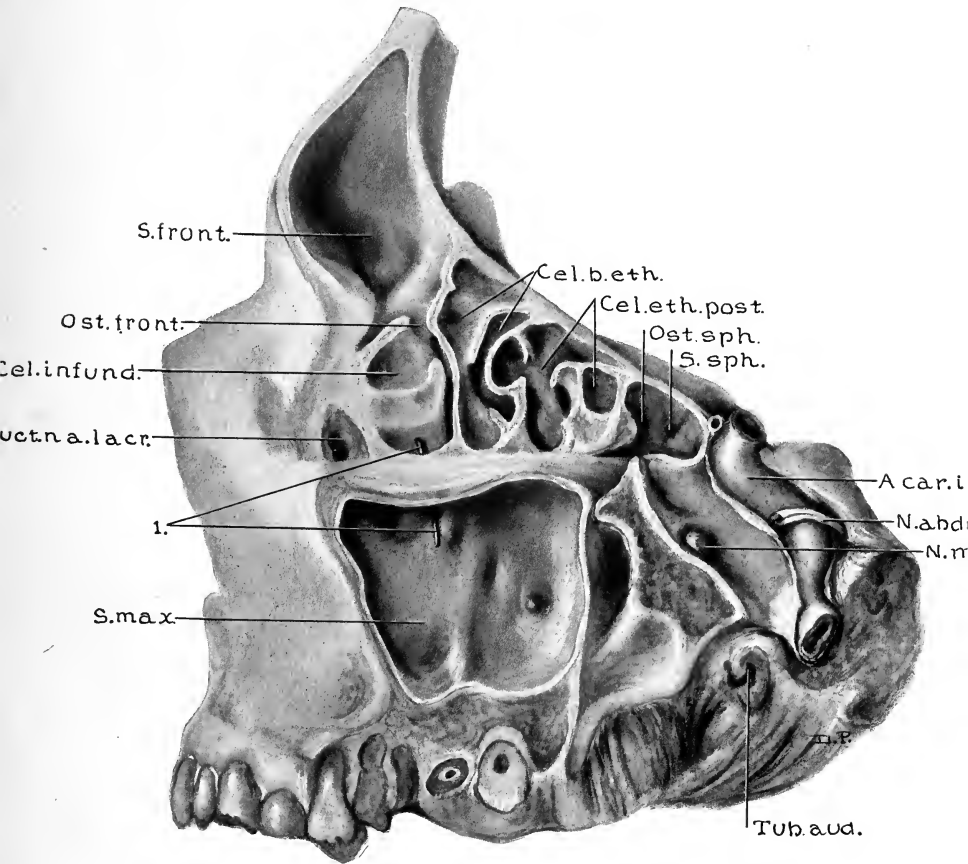


FIG. 49.—SPECIMEN, EIGHTEEN YEARS, ELEVEN MONTHS, AND TEN DAYS OLD.
(Series D, No. 85.)

Lateral view of the frontal, ethmoidal, maxillary, and a portion of the sphenoidal areas. Sinus frontalis developed from an infundibular cell. Note that the ostium frontale is not in the most inferior portion of the floor of the sinus. *Cel.b.eth.*, Cellulae bullae ethmoidales; *Cel.eth.post.*, cellulae ethmoidales posteriores; *Ost.sph.*, ostium sphenoidale; *S.sph.*, sinus sphenoidalis; *A.car.int.*, arteria carotis interna; *N.abduc.*, nervus abducens; *N.max.*, nervus maxillaris; *Tub.aud.*, tuba auditiva (Eustachii); *S.max.*, sinus maxillaris; *1.*, probe through ostium maxillare; *Duct.na.lacr.*, ductus nasolacrimalis; *Cel.infund.*, cellula infundibularis; *Ost.front.*, ostium frontale; *S.front.*, sinus frontalis.

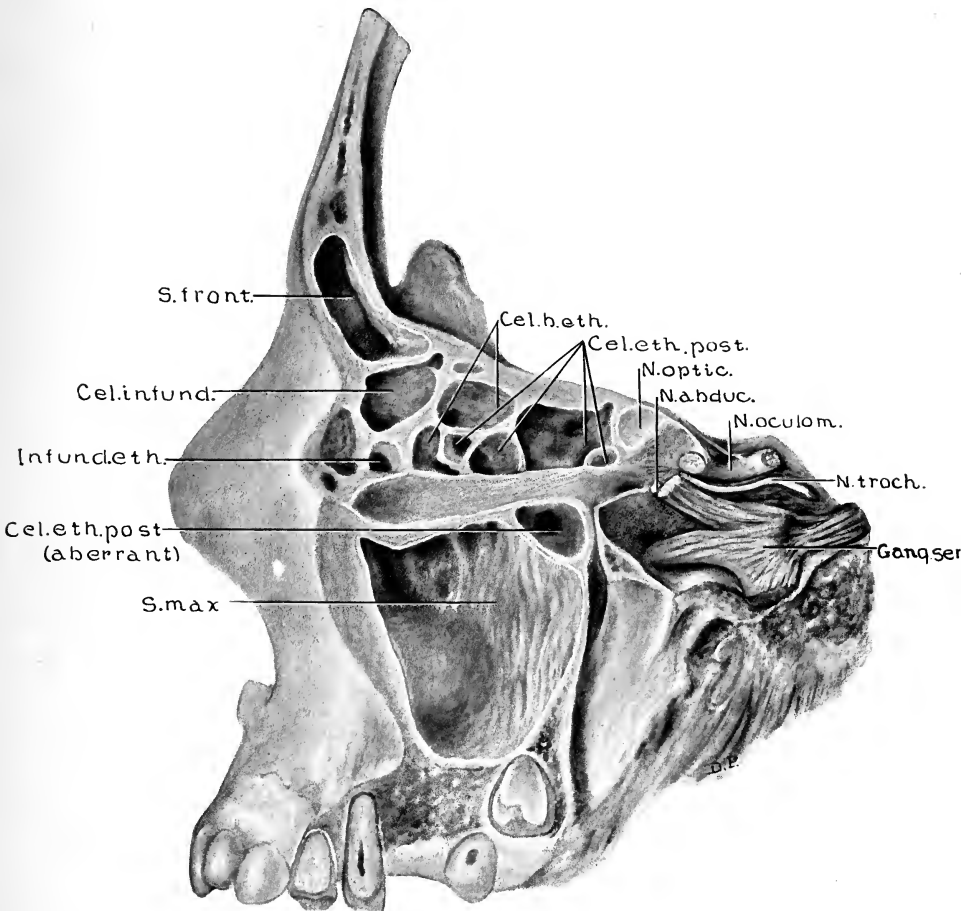


FIG. 50.—SPECIMEN NINETEEN YEARS AND TWENTY-EIGHT DAYS OLD. LATERAL VIEW OF FRONTAL, ETHMOIDAL, AND MAXILLARY AREAS. (Series D, No. 86.)

Note presence of an aberrant ethmoidal cell which has invaded the postero-superior portion of the maxilla. The ostium of this cell is in the midportion of the lateral wall of the meatus superior. When this type of development is more extensive, a "double maxillary sinus" is formed, as described by Zuckerkandl. *Cel. b. eth.*, Cellulae bullae ethmoidales; *Cel. eth. post.*, cellulae ethmoidales posterior; *N. optic.*, nervus opticus; *N. abduc.*, nervus abducens; *N. oculom.*, nervus oculomotorius; *N. troch.*, nervus trochlearis; *Gang. semi.*, ganglion semilunare; *S. max.*, sinus maxillaris; *Cel. eth. post. (aberrant)*, aberrant cellula ethmoidalis posterior; *Infund. eth.*, infundibulum ethmoidale; *Cel. infund.*, cellula infundibularis; *S. front.*, sinus frontalis.

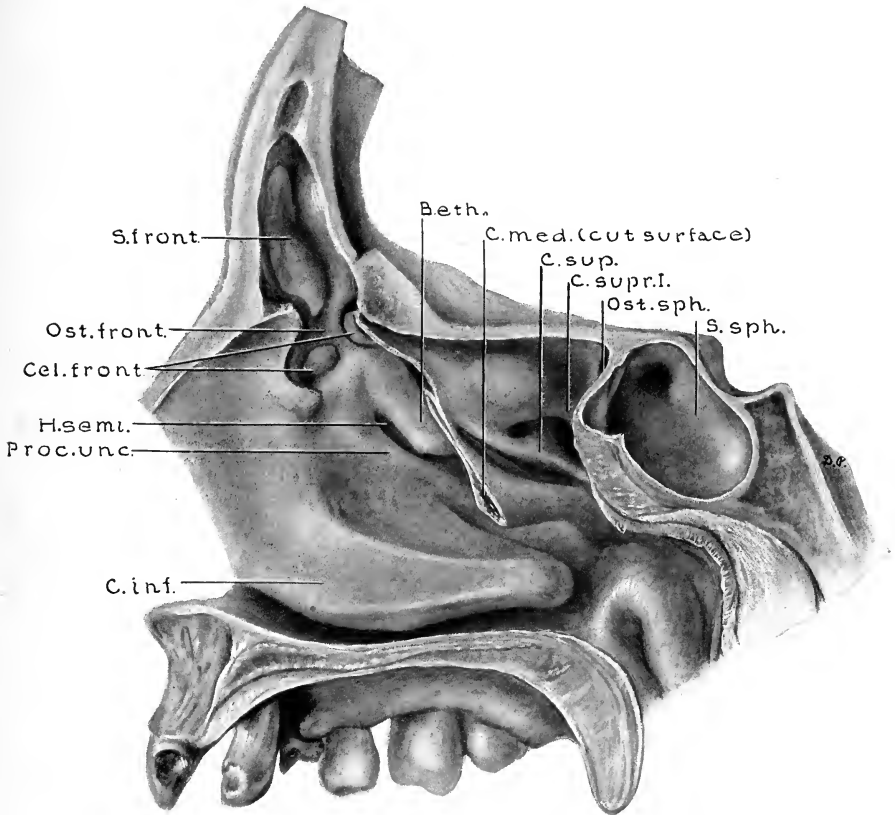


FIG. 51.—SPECIMEN NINETEEN YEARS, SEVEN MONTHS, AND FIFTEEN DAYS OLD. (Series D, No. 88.)

Median sagittal section. The anterior portion of the concha media and a portion of the frontal bone have been removed to show the anterolateral nasal wall. The hiatus semilunaris is in this instance unusually short. *B.eth.*, Bulla ethmoidalis; *C.med.*, concha media (cut surface); *C.sup.*, concha superior; *C.supr.I.*, concha suprema I; *Ost.sph.*, ostium sphenoidale; *S.sph.*, sinus sphenoidalis; *C.inf.*, concha inferior; *Proc.unc.*, processus uncinatus; *H.semi.*, hiatus semilunaris; *Cel.front.*, cellulae frontales; *Ost.front.*, ostium frontale; *S.front.*, sinus frontalis.

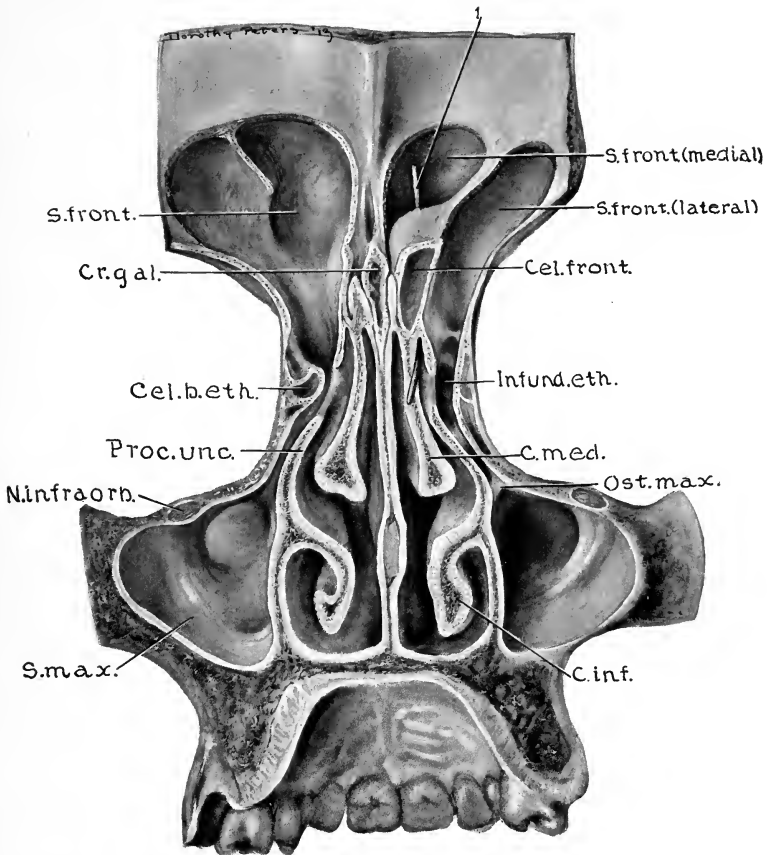


FIG. 52.—SPECIMEN TWENTY YEARS AND FIVE MONTHS OLD. (Series D, No. 90.)

Posterior view of a coronal section 18 mm. posterior to the nasion. The posterior walls of the sinus have been removed to show the relations of the sinuses and their ostia. Note that on the right side there are two distinct sinus frontales present. The more medial of these two sinuses developed from a cellula frontalis, medial to the processus uncinatus, while the lateral one developed from the infundibulum. 1, Probe through the ostium of the medial sinus frontalis, the ostium being anterior to the cellula frontalis shown in illustration; *S.front.*, sinus frontalis; *Cel.front.*, cellula frontalis; *Infund.eth.*, infundibulum ethmoidale; *C.med.*, concha media; *Ost.max.*, ostium maxillare; *C.inf.*, concha inferior; *S.max.*, sinus maxillaris; *N.infraorb.*, nervus infraorbitalis; *Proc.unc.*, processus uncinatus; *B.eth.*, bulla ethmoidalis (extreme anterior portion); *Cr.gal.*, crista galli.

attached, the following were the five ways in which development of the sinus frontalis occurred and the percentage of each variety:

1. By the extension of one of the cellulæ frontales in 41 per cent. of cases. Such development is shown in Figs. 21, 23, 36, 41, 45, 47, and 51. The development of the cellulæ frontales, the variations in their number, and the irregularities in the degree of prominence attained by the conchæ frontales were considered on pages 46 and 53.

2. By the extension of the recessus conchalis—no cellulæ frontales being demonstrable—in 18.4 per cent. of cases. Figs. 38, 43, and 48 show this type of development. In this class of cases the conchæ frontales have either failed to develop or else were represented by such slight folds that they were completely resorbed during the expansion of the recessus conchalis.

3. By the extension of a cellula ethmoidalis anterior having its origin from the suprabullar furrow, in 1 per cent. of cases. Such development is distinctly shown in Fig. 33.

4. By the direct extension of the infundibulum ethmoidale, in 15.6 per cent. of cases. (See Figs. 35 and 56.)

5. By the extension of one of the cellulæ infundibulares in 24 per cent. of cases. Variations in this type of origin are shown in Figs. 28, 39, 49, and 55.

Summarizing the above classification of origins, we find that sinus frontales developing by the first three methods—a total of 60.4 per cent. of the cases in this series—communicate with the meatus medius without communicating with the infundibulum ethmoidale. Sinuses which develop by the fourth and fifth methods, however,—a total of 39.6 per cent. of the cases in this series,—communicate with the

meatus medius via the infundibulum and the hiatus semilunaris. Thus in these cases there is a close relationship between the sinus frontales and the sinus maxillares, since the ostium maxillare in all cases is situated in the inferolateral wall of the infundibulum.

SUPERNUMERARY SINUS FRONTALES

Ordinarily only one frontal sinus develops on each side, but in a few instances supernumerary sinuses are found. The term supernumerary sinuses must not be used in describing sinuses incompletely divided by a partial septum or septa, but is restricted to cases in which more than one distinct process of pneumatization from either lateral nasal wall develops sufficiently to invade the vertical portion of the frontal bone—the sinuses being separated by a complete septum and having independent ostia.

It would be possible to have supernumerary sinuses develop by extensions from two cellulæ infundibulares, from two cellulæ frontales, or from any combination of the above-described five routes of development of sinus frontales.

In 101 cases (202 frontal areas) having mucosa attached, we found two cases showing the presence of two frontal sinuses on each side, and three cases which had two sinuses on one side and the usual one sinus on the other side. Thus of the 202 frontal areas, 7 of them had double sinuses. In 4 of these instances the double sinuses were on the right side, and in 3 on the left. The ways in which these 7 double sinuses originated were as follows:

1. By the extension of two cells medial to the processus uncinatus (cellulæ frontales) in three instances (Fig. 36).

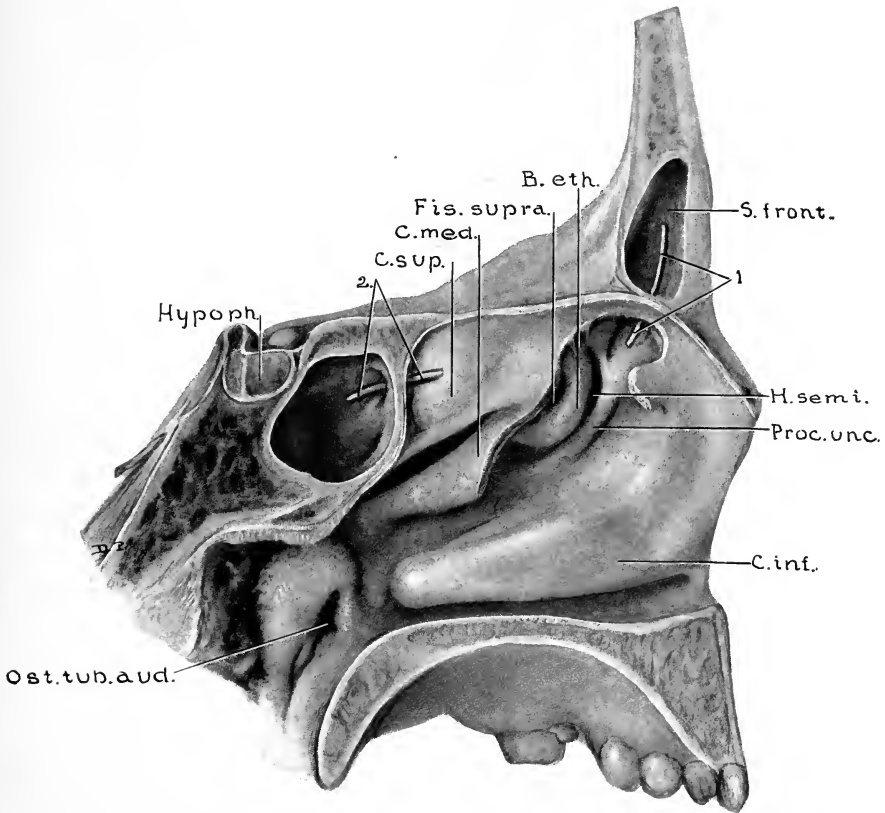


FIG. 53.—SPECIMEN TWENTY-ONE YEARS, SIX MONTHS, AND TWENTY-NINE DAYS OLD. (Series D, No. 91.)

Sagittal section, 1.5 mm. to the left of median line. Anterior portion of concha media has been removed to show the relations of structures forming the lateral nasal wall. 1, Probe through ostium frontale; 2, probe through ostium sphenoidale; *S. front.*, sinus frontalis; *H. semi.*, hiatus semilunaris; *Proc. unc.*, processus uncinatus; *C. inf.*, concha inferior; *Ost. tub. aud.*, ostium pharyngeum tubæ auditivæ; *Hypoph.*, hypophysis; *C. sup.*, concha superior; *C. med.*, concha media; *Fis. supra.*, fissura suprabullaris; *B. eth.*, bulla ethmoidalis.

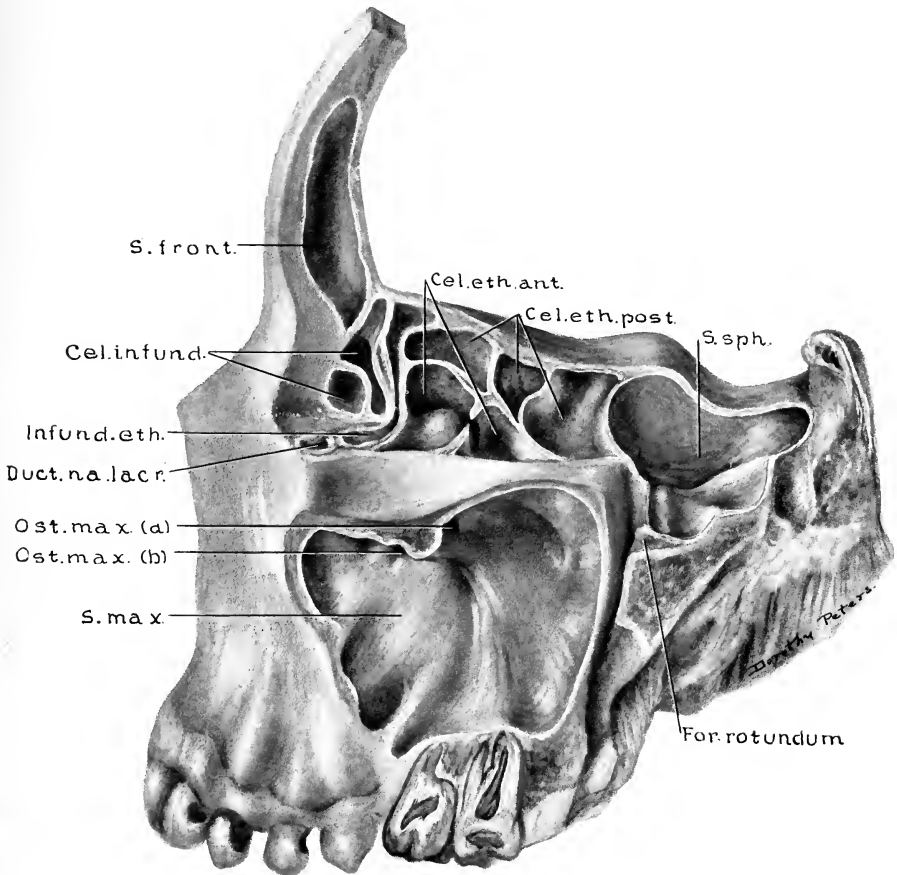


FIG. 54.—SPECIMEN TWENTY-TWO YEARS, SIX MONTHS, AND ELEVEN DAYS OLD. (Series D, No. 93.)

Lateral portions of the frontal, ethmoidal, maxillary, and sphenoidal areas have been removed to show the extent and relations of the sinuses. Note that two ostia maxillaria are present, both communicating with the infundibulum ethmoidale. (This is the only instance of this kind found in the entire series.) *Cel.eth.ant.*, Cellulae ethmoidales anterior; *Cel.eth.post.*, cellulae ethmoidales posterior; *S.sph.*, sinus sphenoidalis; *For.rotundum*, medial wall of foramen rotundum; *S.max.*, sinus maxillaris; *Ost.max.(b)*, ostium maxillare; *Ost.max.(a)*, duplication of ostium maxillare; *Duct.na.lacr.*, ductus nasolacrimalis; *Infund.eth.*, infundibulum ethmoidale; *Cel.infund.*, cellulae infundibulares; *S.front.*, sinus frontalis.

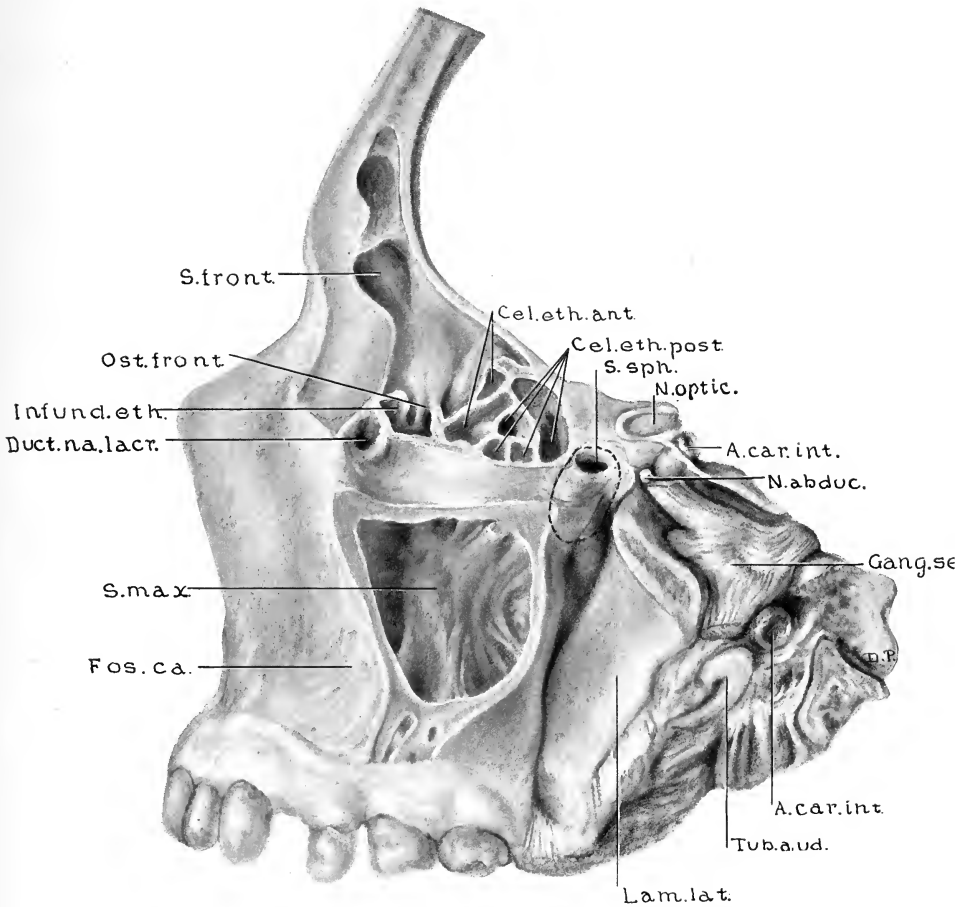


FIG. 55.—SPECIMEN TWENTY-THREE YEARS, SEVEN MONTHS, AND THIRTEEN DAYS OLD. LATERAL VIEW OF FRONTAL, ETHMOIDAL, MAXILLARY, AND A PORTION OF THE SPHENOIDAL AREAS. (Series D, No. 94.)

The dotted line outlines the extent of the sinus sphenoidalis. The sinus sphenoidalis and the sinus maxillaris are both unusually small for an adult. (Compare with preceding figures.) Note also the unusually large fossa canina. The sinus frontalis developed from an infundibular cell. *Cel.eth.ant.*, Cellulæ ethmoidales anterior; *Cel.eth.post.*, cellulæ ethmoidales posterior; *S.sph.*, sinus sphenoidalis; *N.optic.*, nervus opticus; *A.car.int.*, arteria carotis interna; *N.abduc.*, nervus abducens; *Gang.semi.*, ganglion semilunare; *Tub.aud.*, tuba auditiva; *Lam.lat.*, lamina lateralis processus pterygoidei; *Fos.ca.*, fossa canina; *Duct.na.lacr.*, ductus nasolacrimalis; *Infund.eth.*, infundibulum ethmoidale; *Ost.front.*, ostium frontale; *S.front.*, sinus frontalis.

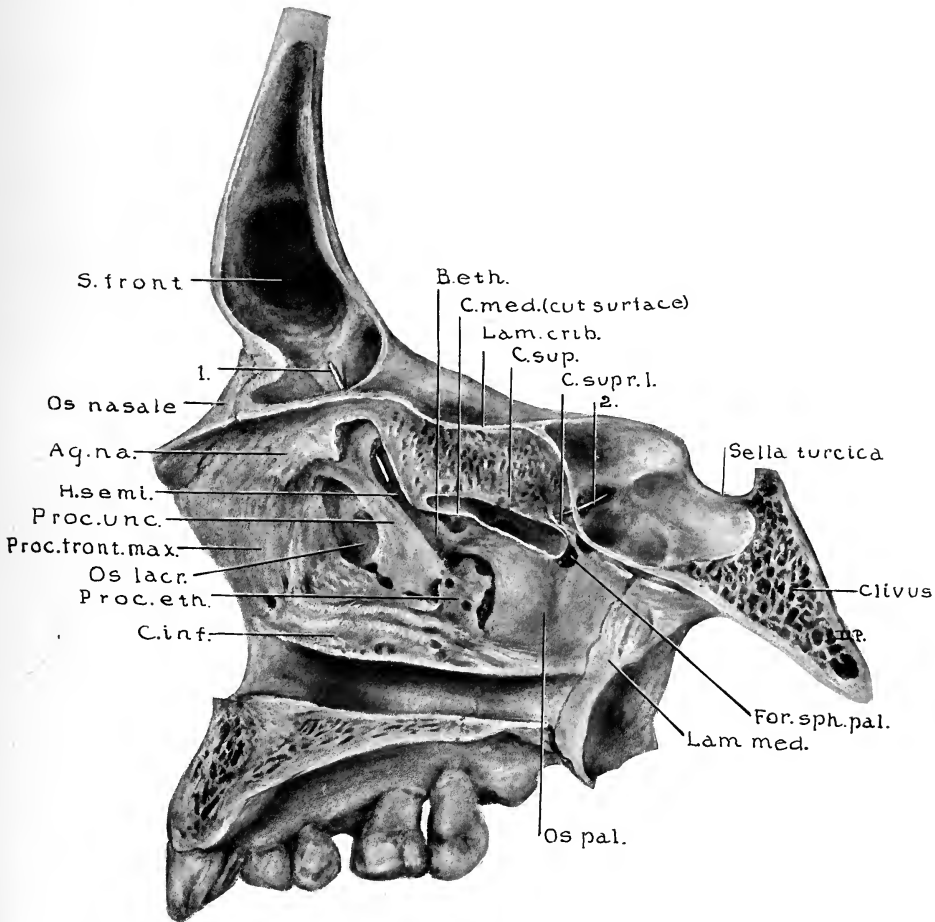


FIG. 56.—SPECIMEN THIRTY-FIVE YEARS OLD. SAGITTAL SECTION FROM WHICH THE SOFT PARTS HAD BEEN REMOVED BY MACERATION. (Series E, No. 5.)

Concha nasalis media has been removed to allow a better view of the processus uncinatus and the bulla ethmoidalis. The sinus frontalis developed from an infundibular cell. 1., Probe through ostium frontale; 2., probe through ostium sphenoidale; *B.eth.*, bulla ethmoidalis; *C.med.*, concha media (cut surface); *Lam.crib.*, lamina cribrosa; *C.sup.*, concha superior; *C.supr.I.*, concha suprema I; *For.sph.pal.*, foramen sphenopalatinum; *Lam.med.*, lamina medialis processus pterygoidei; *Os pal.*, pars perpendicularis ossis palatina; *C.inf.*, concha inferior; *Proc.eth.*, processus ethmoidalis concha nasalis inferior; *Os lacr.*, os lacrimale; *Proc.front.max.*, processus frontalis maxillae; *Proc.unc.*, processus uncinatus; *H.semi.*, hiatus semilunaris; *Ag.na.*, agger nasi; *S.front.*, sinus frontalis.

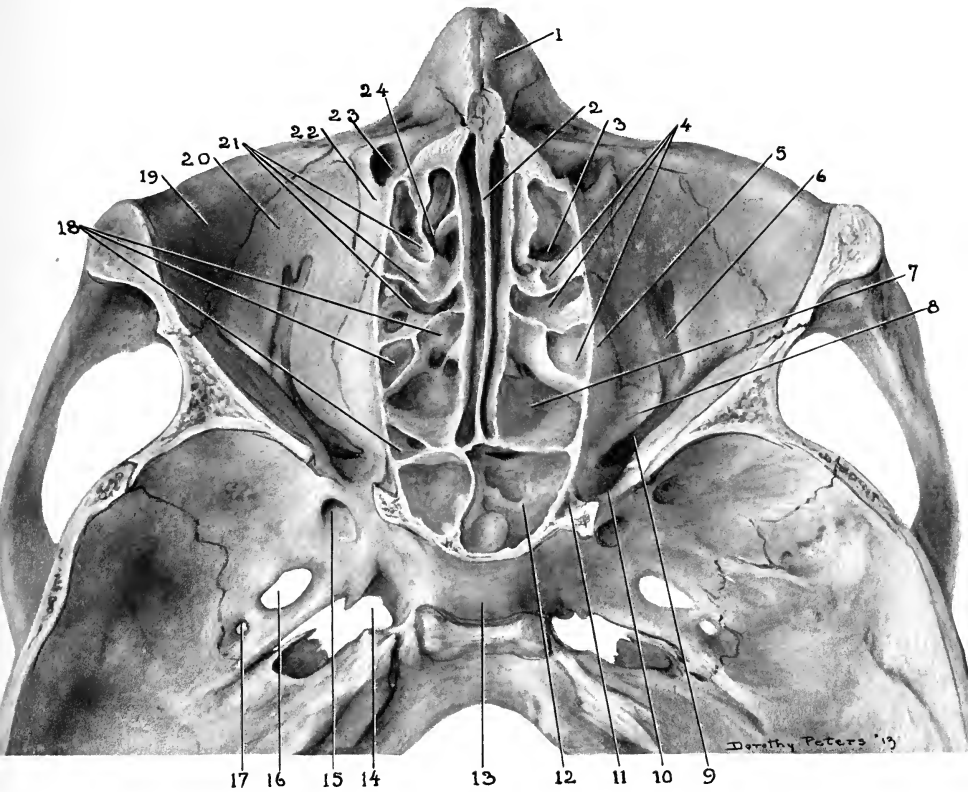


FIG. 57.—SPECIMEN THIRTY-EIGHT YEARS OLD. HORIZONTAL SECTION FROM WHICH THE SOFT PARTS HAD BEEN REMOVED BY MACERATION. (Series E, No. 15.)

Plane of section is 9 mm. inferior to the level of nasion, or 4 mm. inferior to the level of the sutura zygomaticofrontalis. 1, Os nasale; 2, lamina perpendicularis ossis ethmoidalis; 3, infundibulum ethmoidale; 4, cellulae ethmoidales anterior; 5, lamina papyracea ossis ethmoidalis; 6, sulcus infra-orbitalis; 7, cellula ethmoidalis posterior; 8, processus orbitalis ossis palatini; 9, fissura orbitalis inferior; 10, fissura orbitalis superior; 11, foramen opticum (inferior surface); 12, sinus sphenoidalis; 13, sella turcica; 14, foramen lacerum; 15, foramen rotundum; 16, foramen ovale; 17, foramen spinosum; 18, cellulae ethmoidales posterior; 19, os zygomaticum; 20, facies orbitalis maxillae; 21, cellulae ethmoidales anterior; 22, os lacrimale; 23, ductus nasolacrimalis; 24, infundibulum ethmoidale.

2. By the extension of two cells lateral to the processus uncinatus (cellulæ infundibulares) in two instances.

3. By the extension of an infundibular cell and the direct extension of the infundibulum ethmoidale in one instance.

4. By the extension of one of the cellulæ frontales and the direct extension of the infundibulum ethmoidale in one instance (Fig. 52).

THE FORM AND BOUNDARIES OF THE SINUS FRONTALIS

The shapes of the frontal sinuses, as well as the extent of their pneumatization, show a wide variation in the different specimens of approximately the same age. In average cases, however, sinuses which have not extended into the vertical portion of the frontal bone (infantile types of sinuses) are rather ovoid in outline (Figs. 21, 24, 27, 33, and 36). When pneumatization has extended into the vertical portion of the bone (Figs. 49, 51, 53, 55, and 56), the outline of the average sinus resembles somewhat a three-sided pyramid—as described by Boege and by Miloslawski in their studies of adult sinuses. Boege found, in his study of the frontal sinuses in 203 adult macerated skulls, that in 4.9 per cent. of cases the sinuses on both sides failed in their superior development to reach the level of the supra-orbital margins; while in 4.4 per cent. of cases the right sinus alone, and in 2.5 per cent. of cases the left sinus alone, failed to reach a height equal to that of the supra-orbital margin. The average diameters of the frontal sinuses as found in Boege's 203 cases are 23.6 mm. laterally, 20.8 mm. supero-inferiorly, and 16.1 mm. anteroposteriorly. The average diameters of developing sinuses as found in the various ages in this series are given in the table on pp. 134 and 135.

The anterior wall of the fully developed sinus is formed by the anterior plate of the vertical portion of the frontal bone. This is the thickest of the sinus walls, different specimens varying from 1 to 8 mm., but averaging in adult cases 2.5 mm. in thickness. The thicker walls contain considerable diploë. All observers agree that the prominence of the superciliary ridges bears no constant relationship to the size of the sinuses found beneath them.

The posterior wall of the fully developed sinus is formed by a part of the posterior plate of the vertical portion of the frontal bone and also, in some cases, by a part of the horizontal portion. This wall is composed almost entirely of compact bone and averages 1.2 mm. in thickness.

The medial wall is formed by the septum frontale, which frequently shows deviations toward one side or the other. The percentage of cases showing deviations toward the right and the percentage toward the left are approximately equal. In no instance was the septum frontale found to be incomplete. In average adult cases its thickness varies from 0.5 to 1 mm.

The floor of the fully developed sinus is usually quite uneven. Laterally it is formed by the orbital roof, while medially it overlies the anterior ethmoidal cells. In the posteromedial portion of the floor is the ostium frontale, which is usually situated in the most dependent portion of the sinus (Figs. 28, 33, 45, and 52), but is not invariably so—an antero-inferior recess sometimes being on a lower plane (Figs. 35 and 49). The average diameters and levels of the ostia, as found in the various ages, are given in the table on pp. 134-5. Irregularities in the floor of the sinus, due to underlying anterior ethmoidal cells, were considered on pp. 54 and 63.

A "ductus nasofrontalis" is mentioned by many writers, but we have seldom found one distinctly demonstrable. In the vast majority of cases the ostium frontale communicates directly with a frontal cell, with the recessus conchalis, with the infundibulum ethmoidale, or with an infundibular cell without the interposition of a duct (Figs. 35, 36, 38, 51, 53, 55, 56). In some very few instances, however, where the sinus has developed either from an infundibular cell or from a frontal cell which is pressed upon and narrowed by the partially surrounding cells of that group, the resulting constriction may resemble a duct, as in Fig. 39, and in the right medial sinus in Fig. 52. In the latter figure the probe shows the position of the narrowed cell, or so-called ductus nasofrontalis.

The freedom of communication between the sinus frontalis and the meatus medius is often interfered with by an enlarged concha media, which narrows the opening into the recessus conchalis, or which comes into close contact with the hiatus semilunaris. In other cases a malposed small or narrowed concha may produce a similar result. In Fig. 42 the influence of pressure from a septal ridge, as exerted upon the concha media, and the narrowing of the hiatus semilunaris and the infundibulum ethmoidale, which results from the change in the degree of medial inclination of the processus uncinatus, is clearly shown. Slight swelling in such a case would completely occlude the communication between the sinus frontalis and the meatus medius.

THE SINUS SPHENOIDALIS

The sinus sphenoidalis differs in its early development from the other accessory sinuses in that the primitive sinus does not have its origin from one of the furrows situated on the lateral nasal wall, but develops as an invagination extending from the posterosuperior portion of the recessus sphenoeethmoidalis.

In the narrowed posterosuperior portion of the recessus sphenoeethmoidalis there is demonstrable in sixty-five-day embryos an invagination of the mucosa extending into the posterior portion of the nasal capsule (Fig. 8). The site of this primitive invagination persists as the ostium sphenoidale. Embryos of eighty-five to one hundred days show the development into the nasal capsule more distinctly (Fig. 11), the advancement of the pouching process being most frequent in a postero-inferior and slightly lateral direction. The primitive sphenoidal sinuses thus come to lie posterior to the nasal capsule and anterolateral to the body of the sphenoid bone (Figs. 15 and 16). In that portion of the nasal capsule which forms the antero-inferior wall of the primitive sinus there develops an ossification center for the concha sphenoidalis or ossiculum Bertini. Ossification of this concha sphenoidalis is in many instances well advanced in term fetuses and infants (Fig. 18), but it is not until the second or third year that this bone becomes firmly attached to and continuous with the body of the sphenoid.

The extent of development of the sinus sphenoidales

during childhood has evidently been underestimated. Many writers quote Toldt's statement, that in the development of the sinus sphenoidalis the resorption process is noticeable in the third year, reaches the sphenoid bone in the sixth or seventh year, and in the eighth to the tenth year really becomes a cavity in the sphenoid bone. The scarcity of anatomic material showing the conditions present during childhood is probably responsible for such conclusions. Figs. 15, 16, 18, 22, 27, 29, and 31 show approximately the average development as found in the given ages in this series, and the extent of pneumatization is seen to be much greater than in the cases observed by Toldt.

The average diameters of the sinus sphenoidales as found in the specimens of the various ages studied in this series are given in the following table. The average distance from the superior border of the ostia sphenoidalia to the level of the cribriform plate of the ethmoid, the average diameters of the ostia, and the thickness of the sphenoidal septum are also given. All measurements are in millimeters.

The marked tendency of the sinus sphenoidalis to develop posterolaterally more rapidly than it does directly posteriorly (Fig. 22) is such that in the average case the lateral wall of the sinus becomes quite thin (one millimeter or less in the thinnest portion) by the end of the second or during the third year, while the septum sphenoidale still remains relatively thick—first reaching an average of one millimeter or less in the ninth year. (See table p. 162.) Thus this early posterolateral resorption of the osseous wall soon brings the sinus into close relation to those cranial nerves which pass just lateral to the body of the sphenoid (Figs. 21, 30, 32, 39, 45, 47, 50, and 55), and shows an anatomic basis for

TABLE OF AVERAGES OF THE SINUS SPHENOIDALIS

AGE	NUMBER OF CASES	SIDE	DISTANCE FROM OSTIUM TO LEVEL OF CRIBIFORM PLATE	DIAMETERS OF OSTIA	DIAMETERS OF SINUSES			THICKNESS OF SEPTUM
					Vertical	Lateral	Antero-posterior	
8 days-1 yr.....	10	Left	3.0	0.7 x 0.7	2.8	2.0	1.6	7.0
		Right	3.0	0.7 x 0.7	2.9	2.0	1.5	
1-2 yrs.....	10	Left	3.9	0.9 x 0.7	4.5	3.4	2.2	8.1
		Right	3.9	0.9 x 0.7	4.4	3.3	2.1	
2-3 yrs.....	8	Left	4.0	1.0 x 0.7	5.4	4.1	2.8	6.4
		Right	4.2	1.0 x 0.7	5.3	4.2	2.7	
3-4 yrs.....	6	Left	4.0	0.7 x 0.6	5.2	3.6	2.9	7.6
		Right	4.1	0.7 x 0.6	5.4	4.0	3.0	
4-5 yrs.....	8	Left	4.3	1.2 x 0.9	6.9	6.5	4.4	4.6
		Right	4.2	1.4 x 1.3	6.7	6.4	4.6	
5-6 yrs.....	3	Left	4.2	1.6 x 1.3	7.0	5.4	5.0	7.0
		Right	3.9	1.0 x 1.0	7.3	4.7	4.8	
6-7 yrs.....	8	Left	4.1	1.9 x 1.1	10.4	7.2	8.2	5.0
		Right	4.3	1.9 x 1.2	10.5	7.3	7.9	
7-8 yrs.....	5	Left	3.9	2.3 x 1.2	12.1	10.0	9.4	3.0
		Right	3.7	2.0 x 1.0	11.3	9.1	8.8	
8-9 yrs.....	5	Left	3.8	1.8 x 1.3	14.0	11.8	11.9	0.9
		Right	3.6	1.7 x 1.1	14.8	11.6	11.4	
9-10 yrs.....	2	Left	2.5	3.2 x 2.0	11.0	12.2	7.3	1.4
		Right	4.2	2.3 x 1.4	9.0	11.5	7.8	
10-11 yrs.....	2	Left	3.8	2.0 x 1.4	14.0	12.0	15.5	1.3
		Right	3.3	2.3 x 1.4	11.5	10.8	13.5	
11-12 yrs.....	1	Left	5.0	1.5 x 0.8	8.0	8.0	5.0	0.5
		Right	5.0	1.5 x 0.8	16.0	12.0	11.5	
12-13 yrs.....	1	Left	4.0	1.5 x 1.0	6.0	6.5	6.0	4.5
		Right	5.0	1.0 x 0.8	12.0	13.5	15.0	
13-14 yrs.....	3	Left	2.5	3.0 x 1.3	10.8	11.1	11.7	3.3
		Right	3.5	3.3 x 1.4	15.8	14.0	12.7	

14-15 yrs.....	1	Left	4.0	1.5 x 1.0	17.0	11.0	12.5	0.5
		Right	3.0	1.5 x 1.0	17.0	10.0	12.5	
15-16 yrs.....	3	Left	6.0	2.8 x 1.4	24.5	22.2	24.0	0.7
		Right	6.7	2.8 x 1.5	21.0	20.5	20.0	
16-17 yrs.....	4	Left	2.5	1.7 x 1.3	20.0	20.3	25.0	0.6
		Right	3.8	1.8 x 1.2	21.0	18.2	19.8	
17-18 yrs.....	4	Left	4.6	3.0 x 1.0	21.0	15.3	20.2	0.7
		Right	5.0	3.5 x 1.0	19.0	18.0	21.3	
18-19 yrs.....	1	Left	3.0	3.0 x 2.5	20.0	17.0	16.0	0.8
		Right	6.0	2.0 x 1.0	17.0	13.0	13.5	
19-20 yrs.....	3	Left	3.0	2.0 x 1.2	22.0	16.6	23.2	0.6
		Right	2.9	2.3 x 1.1	12.0	11.0	16.3	
20-21 yrs.....	2	Left	3.0	2.5 x 0.9	22.0	15.3	18.0	0.5
		Right	3.5	2.7 x 0.9	19.0	14.0	16.0	
21-22 yrs.....	1	Left	3.0	3.5 x 1.3	17.0	15.5	16.5	0.5
		Right	3.0	4.0 x 1.8	19.0	15.5	15.0	
22-23 yrs.....	2	Left	2.0	2.7 x 2.0	16.0	20.0	23.3	0.7
		Right	2.5	2.6 x 1.7	15.0	15.0	16.0	
23-24 yrs.....	1	Left	3.0	3.0 x 1.5	8.0	7.5	4.5	10.0
		Right	5.0	2.0 x 1.7	10.0	7.5	6.0	
25 yrs.....	2	Left	4.0	2.0 x 1.5	19.5	19.5	22.0	0.5
		Right	4.5	2.5 x 1.5	18.0	15.5	18.5	

the clinical observations of Dr. Greenfield Sluder, of St. Louis, regarding neuralgias from irritations of the fifth nerve by infectious processes in the sinus sphenoidalis—such irritation in some reported instances having first occurred in early childhood.

In all cases in this series one sinus sphenoidalis was found on each side, and in no instance was more than the one present. The septum sphenoidale was in all cases complete. The position of the septum was usually vertical and median in the anterior portion, but deviating slightly from these planes posteriorly. In some instances, however, the inequality in the rate of resorption had been sufficient to produce a more marked deviation of the septum, even to an extent which made the septum form the posteromedial wall of the smaller sinus—a process similar to that described when considering deviations of the septum frontale.

The extent of sphenoidal pneumatization, like that of all other nasal accessory sinuses, may show wide variations in specimens of approximately the same age. The development during childhood may be slow, as is shown in Figs. 32, 34, and 36, and marked deficiency in resorption may persist in adult specimens (Fig. 55). The sinus shown in Fig. 56 may be taken as the form to illustrate approximately the average adult type. In many instances, however, the sinuses not only fill the body of the sphenoid, but may extend far into the clivus, or recesses may develop into the processus pterygoideus (Figs. 45, 47, and 54), into the greater or the lesser wings of the sphenoid, or, in some instances, into the orbital process of the palate bone. (Pneumatization of the orbital process of the palate bone, however, was found to be more frequently produced by the extension of a

recess from the most posterior of the ethmoidal cells.) The extent of pneumatization of the sphenoid bears in no way a constant relationship to the size of the other accessory nasal sinuses, nor was there found to be any definite proportion between the size of the sphenoidal sinus and the size of the nasopharynx. In average cases the rate of resorption of the body of the sphenoid is such that by the eighth to the tenth year the posterosuperior portion of the sinus lies beneath the anterior portion of the sella turcica (Fig. 38), and by the fifteenth year is usually separated from the hypophysis by a very thin lamina of compact bone (Fig. 46). Anterosuperiorly, the sinus sphenoidalis is in close relation to the most posterior of the ethmoidal cells (Figs. 28, 43, 49, 54, and 57), but in no case was there a communication between the sinus and such cells. Deficiencies in the lateral osseous wall of the sinus have been described by Zuckerkandl and by Craig, but in this series we have found no such conditions present.

Irregularities in the resorption of the bone may leave ridges similar in character to those found in the frontal and in the maxillary sinuses. Varying types of such ridges are seen in Figs. 31, 46, 48, 54, 56, and 57. In addition to these ridges, when there is a recess extending well into the pterygoid process, there is on the floor of the sinus a distinct ridge (Figs. 45 and 47) which overlies the nervus canalis pterygoidei (Vidii).

BIBLIOGRAPHY

- Allen, Harrison: "The Anatomy of the Nasal Chambers,"
The New York Medical Journal, 1889.
- Bardeen, Charles R.: "Development of the Skeleton and of
the Connective Tissues," Manual of Human Embry-
ology, Keibel and Mall, 1910, vol. i.
- Boege, K.: "Zur Anatomie der Stirnhöhlen," Königsberg,
1902.
- Braune, W., und Classen, F. E.: "Die Nebenhöhlen der
menschlichen Nase, ihrer Bedeutung für den Mechan-
ismus des Riechens," Zeitschr. f. Anat., Leipzig,
1877, vol. ii.
- Bryan, J. H.: "A Contribution to the Study of the Anatomy
of the Fronto-ethmoidal Region," British Medical
Journal, London, 1897.
- Callender, G. W.: "The Formation and Early Growth of the
Bones of the Human Face," Trans. Royal Society of
London, 1870, vol. clix.
- Chauveau-Arloing-Lesbre: *Traite d'anatomie comparée des
animaux domestiques*, Paris, 1903, vol. i; 1905, vol. ii.
- Craig, R. H.: "Some New Features of the Accessory Cavi-
ties of the Nose," *Lancet*, London, 1898, vol. ii.
- Cryer, M. H.: "Some Variations in the Frontal Sinuses,"
Jour. Amer. Med. Assoc., Chicago, January, 1907,
vol. xlviii.
- Cunningham, D. J.: *Text-book of Anatomy*, 1905.
- Froriep, A.: "Entwicklungsgeschichte des Kopfes," *Ergeb-
nisse der Anat. und Entwicklungsgeschichte*, 1894,
vol. iii.
- Gibson, James A.: "The Sphenoidal Sinus," Report of the
Laboratory of Pathology of the University of Buffalo,
1909.

- Goodwillie, D. H.: "The Antrum of Highmore and Some of its Diseases," *Med. News*, Philadelphia, 1884, vol. xlv.
- Hartman, A.: *Atlas der Anatomie der Stirnhöhle, der vorderen Siebbeinzellen und des Ductus Nasofrontalis*, Wiesbaden, 1900.
- Heymann: *Handbuch der Laryngologie und Rhinologie*, 1900.
- Ingersoll, J. M.: "The Function of the Accessory Cavities of the Nose," *Annals of Otology, Rhinology, and Laryngology*, December, 1906.
- "The Nose and Nasopharynx in Infants and Young Children," *Papers from the Lakeside Hospital*, series 4, 1910.
- Jhering, H. v.: "Die Entwicklungsgeschichte des menschlichen Stirnbeines," *Arch. f. Anat. u. Physiol. u. wiss. Medizin*, Jahrg. 1872, pp. 649-658.
- Killian, G.: "Zur Anatomie der Nase menschlicher Embryonen," *Archiv für Laryngologie*, 1895-96, vols. ii, iii, iv.
- Der Nebenhöhle der Nase in ihren Lagebeziehungen zu Nachbarorganen, Jena, 1902.
- Kollman, J.: *Entwicklungsgeschichte des Menschen*, Jena, 1898.
- Loeb, H.: "A Study of the Anatomy of the Accessory Cavities of the Nose by Topographic Projections," *Trans. Amer. Laryn., Rhinol. and Otolog. Soc.*, St. Louis, 1907.
- Lothrop, H. A.: "The Anatomy and Surgery of the Frontal Sinus and Anterior Ethmoidal Cells," *Annals of Surgery*, November and December, 1898; January and February, 1899.
- Löwe, L.: *Beiträge zur Anatomie der Nase und Mundhöhle*, Leipzig, 1883.
- Mall, F. P.: "On Ossification Centers in Human Embryos," *Amer. Jour. Anat.*, 1906, vol. v.

- Menzel, K. M.: "Nebenhöhlenanomalien," *Monatsschr. f. Ohrenh.*, Berlin, 1905, vol. xxxix.
- Mihalkovics, V. v.: "Anatomie und Entwicklungsgeschichte der Nase und ihrer Nebenhöhlen," *Heymann's Handbuch d. Laryngol. u. Rhinologie*, 1900, vol. iii.
- Miloslawski, M. V.: "Die Stirnhöhlen. Eine anatomisch-topographische und craniologische Untersuchung," *Moscow, Bericht in Ergebn. Anat. u. Entwicklungsg.*, 1903, vol. xiii.
- Murphy, J. W.: "Head Sections Showing the Relations Existing Between the Nose and its Accessory Sinuses," *Laryngoscope*, St. Louis, 1901, vol. xl.
- Ónodi, A.: *Die Nasenhöhle und ihre Nebenhöhle*, Vienna, 1893.
Die Nebenhöhlen der Nase beim Kinde, Würzburg, 1911.
- Patel: "Sinus frontaux et cellules ethmoidales anormalement développés," *Lyon. med.*, 1902.
- Paulli, Simon: "Über Pneumaticität des Schädels bei den Säugetieren," *Morphol. Jahrb.*, 1900, vol. xxviii, part 4.
- Peter, Karl: "Entwicklung des Geruchsorganes in der Reihe Wirbeltiere," *Handb. d. Entwicklungslehre von O. Hertwig*, Jena, 1906.
- Preiswerk, Gustav: "Beiträge zur Corrosionanatomie der pneumatischen Gesichtshöhlen," *Zeitschrift f. Ohrenheilkunde*, Wiesbaden, 1899.
- Read, Effie A.: "A Contribution to the Knowledge of the Olfactory Apparatus in Dog, Cat and Man," *Amer. Jour. Anat.*, 1908, vol. viii, No. 1.
- Reschreiter, Carl: "Zur Morphologie des Sinus Maxillaris," *Stuttgart*, 1878.
- Schaeffer, Jacob Parsons: "The Sinus Maxillaris and its Relations in the Embryo, Child and Adult Man," *Amer. Jour. Anat.*, 1910, vol. x, No. 2.

"On the Genesis of Air Cells in the Conchæ Nasales," *Anatomical Record*, vol. iv, No. 4, 1910.

"The Lateral Wall of the Cavum Nasi in Man, with Especial Reference to the Various Developmental Stages," *Journal of Morphology*, vol. xx, No. 4, 1910.

"The Genesis and Development of the Nasolacrimal Passages in Man," *Amer. Jour. Anat.*, vol. xiii, No. 1, 1912.

Seydel, O.: "Ueber die Nasenhöhle der höheren Säugetiere und des Menschen," *Morphol. Jahrb.*, 1891, vol. xvii.

Sobotta-McMurrich: *Atlas and Text-book of Human Anatomy*, 1909.

Spalteholz: *Hand-Atlas of Human Anatomy*, 1906.

Steiner, F.: "Ueber die Entwicklung der Stirnhöhlen und deren krankhafte Erweiterung durch Ansammlung von Flüssigkeiten," *Arch. f. klin. Chir.*, 1872, vol. xiii.

Strasser, H.: "Sur le développement des cavités nasales et du squelette du nez," *Arch. des Sc. Phys. et Nat.*, Geneva, 1901.

Sutton, J. Bland: "Observations on the Parasphenoid, the Vomer and the Palato-pterygoid Arcade," *Proceedings Zool. Soc.*, London, 1884.

Tilley, Herbert: "An Investigation of the Frontal Sinuses in 120 Skulls from a Surgical Aspect," *The Lancet*, September, 1896.

Turner, A. L.: *The Accessory Sinuses of the Nose: Their Surgical Anatomy and the Diagnosis and Treatment of Their Inflammatory Affections*, Edinburgh, 1901.

Ward, Charles H.: "Nasal Characteristics, Human and Comparative," *Trans. Amer. Laryngolog. Assoc.*, 1895.

Zuckerkanndl, C.: "Zur Anatomie und Entwicklungsgeschichte der Nasoethmoidalregion," *Med. Jahrb.* Herausg. v. d. k. Gesellsch. d. Aerzte, Vienna, 1878.

"Normale und pathologische Anatomie der Nasen-

höhle und ihrer pneumatischen Anhänge," Vienna, 1882, vol. i.

"Die Siebbeinmuscheln des Menschen," Anat. Anz., Jahrg. 7, 1892.

"Die Entwicklung des Siebbeins," 6. Verhandlg. d. Anat. Gesellschaft (Vienna), Anat. Anz., 1892, vol. vii.

"Ueber die Entwicklung der Concha bullosa," Montasschr. für Ohrenheilk. sowie Kehlkopf-, Nasen-, und Rachenkrankheiten, n. F., Jahrg. 33, 1899.

Anatomie der Nasenhöhle, Vienna, 1902, vol. i.

INDEX

- AGGER nasi, 26, 53
 pneumatization of, 63
Anatomic material used, 11-14
- BULLA ethmoidalis, 26, 35, 63, 64
 frontalis, 54
- CAPSULE, nasal, 19, 20, 25
Cellulæ conchales, 78
 ethmoidales, 44
 anterior, 46
 classification of, 44
 development of, 45
 ostia of, 77
 posterior, 77
 frontales, 53
 infundibulares, 46, 54
Choanæ, primitive, 20
Conchæ frontales, 53
 nasales, early development of, 20,
 25, 35, 36
 nomenclature of, 36
 number of, 35, 36, 43
 sphenoidales, 160
- DEVELOPMENT, early, of nasal conchæ,
 20, 25, 35, 36
 of nasal areas, 19
Ductus nasofrontalis, 159
- ETHMOID cells, 44
 anterior, 46
 classification of, 44
- Ethmoid cells, development of, 45
 ostia of, 77
 posterior, 77
 fold, primitive, 25
Ethmoidal bulla, 26, 35, 63, 64
 infundibulum, 35, 54, 64, 79, 110,
 146, 159
- FRONTAL bulla, 54
 cells, 53
 conchæ, 53
 ostium, 133, 134, 135, 159
 septum, 136
 sinus, 132
 average measurements of, 134,
 135
 form and boundaries of, 136, 157
 routes of development, 132, 145
 supernumerary, 146, 157
 walls of, 133, 158
- HIATUS semilunaris, 35, 64, 110, 159
- INFUNDIBULAR cells, 46, 54
 recess, 46, 64, 132
Infundibulum ethmoidale, 35, 54, 64,
 79, 110, 146, 159
- MATERIAL (anatomic) used, 11-14
Maxillary ostium, 79, 109, 146
 accessory, 112, 113
 duplication of, 110, 111
 sinus, 79
 average measurements of, 80, 81

- Maxillary sinus, double, 131
 form of, 82
 incomplete septa in, 130
 relation to teeth, 79, 129, 130
 walls of, 109, 114, 129
- NASAL areas, development of, 19
 capsule, 19, 20, 25
 conchæ, early development, 20, 25,
 35, 36
 nomenclature of, 36
 number of, 35, 36, 43
 pits, 19
 septum, 19
- Nasofrontal duct, 159
- Os palatinum, pneumatization of, 164
- Ostium frontale, 133, 134, 135, 159
 maxillare, 79, 109, 146
 accessorium, 112, 113
 duplication of, 110, 111
 sphenoidale, 160, 161
- PNEUMATIZATION of agger nasi, 63
 of os palatinum, 164
- Processus uncinatus, 26, 53, 64, 109,
 110, 159
- RECESSUS conchalis, 46, 64, 132
 infundibularis, 46, 64, 132
- SEMILUNAR hiatus, 35, 64, 110, 159
- Septum frontale, 136
 nasi, 19
- Septum sphenoidale, 164
- Sinus frontalis, 132
 average measurements of, 134,
 135
 form and boundaries of, 136, 157
 routes of development, 132, 145
 supernumerary, 146, 157
 walls of, 133, 158
- maxillaris, 79
 average measurements of, 80, 81
 double, 131
 form of, 82
 incomplete septa in, 130
 relation to teeth, 79, 129, 130
 walls of, 109, 114, 129
- sphenoidalis, 160
 average measurements of, 161,
 162, 163
 forms of, 164
 ridges in, 165
- Specimens, method of obtaining, at
 postmortem examination, 15
 used in preparing, 16, 17
- Sphenoid conchæ, 160
 ostium, 160, 161
 septum, 164
 sinus, 160
 average measurements of, 161,
 162, 163
 forms of, 164
 ridges in, 165
- TEETH, relation of, to sinus maxillaris,
 79, 129, 130
- UNCINATE process, 26, 53, 64, 109,
 110, 159

DATE DUE SLIP


UNIVERSITY OF CALIFORNIA MEDICAL SCHOOL LIBRARY

**THIS BOOK IS DUE ON THE LAST DATE
STAMPED BELOW**

MAR 14 1928

JUL 1 2 1934

1m-9,'26

A tilted grid of empty cells, possibly a ledger or data table, is shown. The grid is composed of approximately 15 rows and 3 columns. The cells are empty and the grid is tilted clockwise. The grid is positioned in the lower right quadrant of the image, overlapping the dark shadow area.

