

MBL/WHOI



0 0301 0050245 6

THE DEVELOPMENT OF THE CHICK
AN INTRODUCTION TO EMBRYOLOGY

THE DEVELOPMENT OF THE CHICK

AN INTRODUCTION TO EMBRYOLOGY

BY

FRANK R. LILLIE

PROFESSOR IN THE UNIVERSITY OF CHICAGO

SECOND EDITION, REVISED




NEW YORK
HENRY HOLT AND COMPANY

COPYRIGHT, 1908, 1919,
BY
HENRY HOLT AND COMPANY

COPYRIGHT, 1936,
BY
FRANK R. LILLIE

January, 1940



PREFACE TO FIRST EDITION

THIS book is a plain account of the development of the never-failing resource of the embryologist, the chick. It has been necessary to fill certain gaps in our knowledge of the development of the chick by descriptions of other birds. But the account does not go beyond the class Aves, and it applies exclusively to the chick except where there is specific statement to the contrary. Projected chapters on the integument, muscular system, physiology of development, teratology, and history of the subject have been omitted, as the book seemed to be already sufficiently long. The account has been written directly from the material in almost every part, and it has involved some special investigations, particularly on the early development undertaken by Doctor Mary Blount and Doctor J. T. Patterson, to whom acknowledgments are due for permission to incorporate their results before full publication by the authors. As the book is meant for the use of beginners in embryology, references to authors are usually omitted except where the account is based directly on the description of a single investigator. A fairly full list of original sources is published as an appendix.

Figures borrowed from other publications are credited in the legends to the figures. The majority of the illustrations are from original preparations of the author: Figures 46, 48, 50, 51, 52, 58, 59, 60, 61, 62, 63, 64, 65, 66, 67, 71, 72, 73, 74, 75, 99, 105 and 106 were drawn by Mr. K. Hayashi; the remainder of the original drawings were executed by Mr. Kenji Toda. The photographs in Figures 118, 119, 120, 168, 181, 182, 189, 194, 197, and 231 are the work of Mr. Willard C. Green. Some of the figures may be studied with advantage for points not described in the text.

Acknowledgments are also due my colleague, Professor W. L. Tower for much assistance, and to Doctor Roy L. Moodie for special work on the skeleton, and photographs of potash preparations reproduced in Figures 242, 246, 249 and 250.

The best introduction to the problems opened up by the study

of embryology is a careful first-hand study of some one species. It is in this sense that the book may serve as an introduction to embryology, if its study is accompanied by careful laboratory work. In some respects it is fuller, and in others less complete, than other books with which it might be compared. On its comparative and experimental sides, embryology is the only key to the solution of some of the most fundamental problems of biology. The fact that comparative and experimental embryology receive bare mention is not due to any lack of appreciation of their interest and importance, but to the conviction that the beginner is not prepared to appreciate these problems at the start; to the belief that our teachers of embryology are competent to remedy omissions; and finally to the circumstance that no one book can, as a matter of fact, cover the entire field, except in the most superficial way.

The development before laying and the first three days of incubation are treated by stages as far as possible, and this matter constitutes Part I of the book. It involves the study of the origin of the primordia of most of the organs. The matter concerning the later development is classified by the organs concerned, which seems to be the only possible way, and this constitutes Part II. The first part is complete in itself, so far as it goes, and no doubt it will be the only part consulted by some students.

The attempt to present a consecutive account of the development of the form on which so many classics in the history of embryology have been based is no slight undertaking. The author can hardly hope that he has avoided omissions and errors, and he will be sincerely grateful to those who call such to his attention.

CONTENTS

INTRODUCTION

	PAGE
I. THE CELL THEORY	1
II. THE RECAPITULATION THEORY	3
III. THE PHYSIOLOGY OF DEVELOPMENT	6
IV. EMBRYONIC PRIMORDIA AND THE LAW OF GENETIC RESTRICTION	8
V. GENERAL CHARACTERS OF GERM-CELLS	9
<i>The Spermatozoon</i>	9
<i>The Ovum</i>	10
<i>Comparison of the Germ-cells</i>	12
VI. POLARITY AND ORGANIZATION OF THE OVUM	14

PART I

THE EARLY DEVELOPMENT TO THE END OF THE THIRD DAY

CHAPTER I. THE EGG	17
<i>Chemical Composition of the Hen's Egg</i>	20
<i>Formation of the Egg</i>	21
<i>Abnormal Eggs</i>	26
<i>Ovogenesis</i>	26
CHAPTER II. THE DEVELOPMENT PRIOR TO LAYING	32
I. MATURATION	32
II. FERTILIZATION	35
III. CLEAVAGE OF THE OVUM	38
<i>The Hen's Egg</i>	39
<i>The Pigeon's Egg</i>	43
IV. ORIGIN OF THE PERIBLASTIC NUCLEI, FORMATION OF THE GERM-WALL	47
V. ORIGIN OF THE ECTODERM AND ENTODERM	52
CHAPTER III. OUTLINE OF DEVELOPMENT, ORIENTATION, CHRONOLOGY	61
<i>Orientation</i>	63
<i>Chronology (Classification of Stages)</i>	64
<i>Tables of the Development of the Chick</i>	68

16161

	PAGE
CHAPTER IV. FROM LAYING TO THE FORMATION OF THE FIRST SOMITE	69
I. STRUCTURE OF THE UNINCUBATED BLASTODERM	69
II. THE PRIMITIVE STREAK	69
<i>Total Views</i>	69
<i>Sections</i>	74
<i>The Head-process</i>	80
<i>Interpretation of the Primitive Streak</i>	83
III. THE MESODERM OF THE OPAQUE AREA	86
IV. THE GERM-WALL	90
CHAPTER V. HEAD-FOLD TO TWELVE SOMITES (From about the twenty-first to the thirty-third hour of incu- bation)	91
I. ORIGIN OF THE HEAD-FOLD	91
II. FORMATION OF THE FORE-GUT	93
III. ORIGIN OF THE NEURAL TUBE	95
<i>The Medullary Plate.</i>	95
<i>The Neural Groove and Folds</i>	97
<i>Primary Divisions of the Neural Tube</i>	105
<i>Origin of the Primary Divisions of the Embryonic Brain</i>	108
IV. THE MESOBLAST	109
<i>Primary Structure of the Somites</i>	114
<i>The Nephrotome, or Intermediate Cell-mass (Middle Plate)</i>	114
<i>The Lateral Plate</i>	115
<i>Development of the Body-cavity or Calome</i>	115
<i>Mesoblast of the Head</i>	116
<i>Vascular System</i>	117
<i>Origin of the Heart</i>	119
<i>The Embryonic Blood-vessels</i>	121
V. DESCRIPTION OF AN EMBRYO WITH 10 SOMITES	122
<i>The Nervous System</i>	124
<i>Alimentary Canal</i>	126
<i>Vascular System</i>	126
<i>General</i>	127
<i>Zones of the Blastoderm</i>	127
CHAPTER VI. FROM TWELVE TO THIRTY-SIX SOMITES. THIRTY-FOUR TO SEVENTY-TWO HOURS	130
I. DEVELOPMENT OF THE EXTERNAL FORM, AND TURNING OF THE EMBRYO	130
<i>Separation of the Embryo from the Blastoderm</i>	130

	<i>The Turning of the Embryo and the Embryonic Flexures</i>	133
II.	ORIGIN OF THE EMBRYONIC MEMBRANES	135
	<i>Origin of the Amnion and Chorion</i>	135
	<i>The Yolk-sac</i>	143
	<i>Origin of the Allantois</i>	143
	<i>Summary of Later History of the Embryonic Membranes</i> .	145
III.	THE NERVOUS SYSTEM	147
	<i>The Brain</i>	147
	<i>The Neural Crest and the Cranial and Spinal Ganglia</i>	156
IV.	THE ORGANS OF SPECIAL SENSE (EYE, EAR, NOSE) .	164
	<i>The Eye</i>	164
	<i>The Auditory Sac</i>	168
	<i>The Nose (Olfactory Pits)</i>	169
V.	THE ALIMENTARY CANAL AND ITS APPENDAGES	170
	<i>The Stomodæum</i>	173
	<i>The Pharynx and Visceral Arches</i>	173
	<i>Œsophagus and Stomach</i>	179
	<i>The Liver</i>	179
	<i>The Pancreas</i>	181
	<i>The Mid-Gut</i>	181
	<i>Anal Plate, Hind-gut, Post-anal gut and Allantois</i>	182
VI.	HISTORY OF THE MESODERM	183
	<i>Somites</i>	183
	<i>The Intermediate Cell-mass</i>	190
	<i>The Vascular System</i>	197
VII.	THE BODY-CAVITY AND MESENTERIES	205

PART II

THE FOURTH DAY TO HATCHING, ORGANOGENY,
DEVELOPMENT OF THE ORGANS

CHAPTER VII. THE EXTERNAL FORM OF THE EM-		
BRYO AND THE EMBRYONIC MEMBRANES		211
I.	THE EXTERNAL FORM	211
	<i>General.</i>	211
	<i>Head</i>	213
II.	EMBRYONIC MEMBRANES	216
	<i>General.</i>	216
	<i>The Allantois</i>	220
	<i>The Yolk-sac</i>	225
	<i>The Amnion</i>	231
	<i>Hatching</i>	232

	PAGE
CHAPTER VIII. THE NERVOUS SYSTEM	233
I. THE NEUROBLASTS	233
<i>The Medullary Neuroblasts</i>	233
<i>The Ganglionic Neuroblasts</i>	236
II. THE DEVELOPMENT OF THE SPINAL CORD	239
<i>Central Canal and Fissures of the Cord</i>	242
<i>Neuroblasts, Commissures, and Fiber Tracts of the Cord</i>	244
III. THE DEVELOPMENT OF THE BRAIN.	244
<i>The Telencephalon</i>	245
<i>The Diencephalon</i>	249
<i>The Mesencephalon</i>	251
<i>The Metencephalon</i>	251
<i>The Myelencephalon</i>	252
<i>Commissures of the Brain</i>	252
IV. THE PERIPHERAL NERVOUS SYSTEM	252
<i>The Spinal Nerves</i>	252
<i>The Cranial Nerves</i>	261
CHAPTER IX. ORGANS OF SPECIAL SENSE	271
I. THE EYE	271
<i>The Optic Cup</i>	271
<i>The Vitreous Humor</i>	275
<i>The Lens</i>	276
<i>Anterior Chamber and Cornea</i>	278
<i>The Choroid and Sclerotic Coats</i>	279
<i>The Eyelids and Conjunctival Sac</i>	279
<i>Choroid Fissure, Pecten and Optic Nerve</i>	281
II. THE DEVELOPMENT OF THE OLFACTORY ORGAN	285
III. THE DEVELOPMENT OF THE EAR	288
<i>Development of the Otocyst and Associated Parts</i>	289
<i>The Development of the Tubo-tympanic Cavity, External Auditory Meatus and Tympanum</i>	297
CHAPTER X. THE ALIMENTARY TRACT AND ITS AP- PENDAGES	301
I. MOUTH AND ORAL CAVITY	301
<i>Beak and Egg-tooth</i>	302
<i>The Tongue</i>	305
<i>Oral Glands</i>	306
II. DERIVATIVES OF THE EMBRYONIC PHARYNX	306
<i>Fate of the Visceral Clefts</i>	307
<i>Thyroid</i>	307

	PAGE
<i>Visceral Pouches</i>	307
<i>The Thymus</i>	308
<i>Epithelial Vestiges</i>	309
<i>The Postbranchial Bodies</i>	309
III. THE ŒSOPHAGUS, STOMACH AND INTESTINE	309
<i>Œsophagus</i>	312
<i>Stomach</i>	313
<i>Large Intestine, Cloaca, and Anus</i>	314
IV. THE DEVELOPMENT OF THE LIVER AND PANCREAS	319
<i>The Liver</i>	319
<i>The Pancreas</i>	323
V. THE RESPIRATORY TRACT	325
<i>Bronchi, Lungs and Air-sacs</i>	325
<i>The Laryngotracheal Groove</i>	331
 CHAPTER XI. THE BODY-CAVITIES, MESENTERIES AND SEPTUM TRANSVERSUM	
I. THE SEPARATION OF THE PERICARDIAL AND PLEUROPERITONEAL CAVITIES	333
<i>Septum Transversum</i>	334
<i>Closure of the Dorsal Opening of the Pericardium</i>	337
<i>Establishment of Independent Pericardial Walls</i>	338
<i>Derivatives of the Septum Transversum</i>	339
II. SEPARATION OF PLEURAL AND PERITONEAL CAVITIES; ORIGIN OF THE SEPTUM PLEURO-PERITONEALE	340
III. THE MESENTERIES	342
<i>The Dorsal Mesentery</i>	342
<i>The Origin of the Omentum</i>	343
<i>Origin of the Spleen</i>	345
 CHAPTER XII. THE LATER DEVELOPMENT OF THE VASCULAR SYSTEM	
I. THE HEART.	348
<i>The Development of the External Form of the Heart</i>	348
<i>Division of the Cavities of the Heart</i>	350
<i>Fate of the Bulbus</i>	357
<i>The Sinus Venosus</i>	357
II. THE ARTERIAL SYSTEM	358
<i>The Aortic Arches</i>	358
<i>The Carotid Arch</i>	361
<i>The Subclavian Artery</i>	362
<i>The Aortic System</i>	362

	PAGE
III. THE VENOUS SYSTEM	363
<i>The Anterior Venæ Cavae</i>	363
<i>The Omphalomesenteric Veins</i>	364
<i>The Umbilical Veins</i>	367
<i>The System of the Inferior Vena Cava</i>	368
IV. THE EMBRYONIC CIRCULATION	372
CHAPTER XIII. THE URINOGENITAL SYSTEM	378
I. THE LATER HISTORY OF THE MESONEPHROS	378
II. THE DEVELOPMENT OF THE METANEPHROS OR PERMANENT KIDNEY	384
<i>The Metanephric Diverticulum</i>	384
<i>The Nephrogenous Tissue of the Metanephros</i>	387
III. THE ORGANS OF REPRODUCTION	390
<i>Development of Ovary and Testis</i>	391
<i>Development of the Genital Ducts</i>	401
IV. THE SUPRARENAL CAPSULES	403
<i>Origin of the Cortical Cords</i>	405
<i>Origin of the Medullary Cords</i>	406
CHAPTER XIV. THE SKELETON	407
I. GENERAL	407
II. THE VERTEBRAL COLUMN	411
<i>The Sclerotomes and Vertebral Segmentation</i>	412
<i>Membranous Stage of the Vertebrae</i>	414
<i>Chondrification</i>	418
<i>Atlas and Axis (Epistropheus)</i>	420
<i>Formation of Vertebral Articulations</i>	421
<i>Ossification</i>	421
III. DEVELOPMENT OF THE RIBS AND STERNAL APPARATUS.	424
IV. DEVELOPMENT OF THE SKULL	427
<i>Development of the Cartilaginous or Primordial Cranium.</i>	428
<i>Ossification of the Skull</i>	432
V. APPENDICULAR SKELETON	434
<i>The Fore-limb</i>	434
<i>The Skeleton of the Hind-limb</i>	438
APPENDIX	
GENERAL LITERATURE	443
LITERATURE — CHAPTER I	443
LITERATURE — CHAPTER II	444
LITERATURE — CHAPTER III	445
LITERATURE — CHAPTERS IV AND V	445

CONTENTS

	PAGE
LITERATURE — CHAPTER VII	447
LITERATURE — CHAPTER VIII	449
LITERATURE — CHAPTER IX	450
LITERATURE — CHAPTER X	453
LITERATURE — CHAPTER XI	457
LITERATURE — CHAPTER XII	458
LITERATURE — CHAPTER XIII	459
LITERATURE — CHAPTER XIV	461
INDEX	465

THE DEVELOPMENT OF THE CHICK

INTRODUCTION

I. THE CELL THEORY

THE fundamental basis of the general conceptions of embryology, as of other biological disciplines, is the cell theory. The organism is composed of innumerable vital units, the cells, each of which has its independent life. The life of the organism as a whole is a product of the combined activity of all the cells. New cells arise always by subdivision of pre-existing cells, and new generations of the organism from liberated cells of the parental body. The protozoa, however, have the grade of organization of single cells, and the daughter-cells arising by fission constitute at the same time new generations. In some metazoa new generations may arise asexually by a process of budding, as in *Hydra*, or of fission, as in some *Turbellaria*; such cases constitute exceptions to the rule that new generations arise from liberated cells of the parental body, but the rule holds without exception for all cases of sexual reproduction.

The body consists of various functional parts or organs; each of these again consists of various tissues, and the tissues are composed of specific kinds of cells. The reproductive organs, or gonads, are characterized by the production of germ-cells, ova in the female gonad or ovary, and spermatozoa in the male gonad or testis. However large the ovum may be, and in the hen it is the part of the egg known as the yolk, it is, nevertheless, a single cell at the time that it leaves the ovary in all animals. Similarly the spermatozoön is a single cell. An ovum and spermatozoön unite, in the manner to be described later, and constitute a single cell by fusion, the fertilized ovum or oöperm. This cell divides and forms two; each of the daughter-cells divides, making four, and the number of cells steadily increases by successive divisions of all daughter-cells, so that a large number of cells is rapidly produced. Organs are formed by successive

and orderly differentiation among groups of these cells. Among these organs are the gonads, consisting of cells which trace a continuous lineage by cell-division back to the fertilized ovum, and which are capable of developing into ova or spermatozoa according to the sex of the individual.

The lives of successive generations are thus continuous because the series of germ-cells from which they arise shows no break in continuity. All other kinds of cells composing the body finally die. In view of this contrast the non-germinal cells of the body are known collectively as somatic cells. In some way the germ-cells of a species maintain very constant properties from generation to generation in spite of their enormous multiplication, and this furnishes the basis for hereditary resemblance.

The establishment of the fact that in all animals the ovum is a single cell, and that the cells of all tissues of the body are derived from it by a continuous process of cell-division, completes the outline of the cycle of the generations, and furnishes the basis for a complete theory of development. The full significance of this principle can only be appreciated by learning the condition of embryology before the establishment of the cell-theory in the eighteenth century. The history of our knowledge of the development of mammals is particularly instructive in this respect: some knowledge had been gained of the anatomy of the embryos, mostly relatively advanced, of a few mammals; but the *origin* of the embryo was entirely unknown; the ovum itself had not been discovered; the process of fertilization was not understood. In the knowledge of the cycle of generations there was a great gap, and the embryo was as much a mystery as if it had arisen by a direct act of creation. To be sure Harvey in 1651 had propounded the theorem, *omne vivum ex ovo*, but no one had ever seen the egg of a mammal, and there was no clear idea in the case of other forms what the egg signified.

In 1672, de Graaf (who died in 1673 at the age of 32) published a work, "de mulierum organis generationis inservientibus," in which he attempted to show that the vesicles seen on the surface of the ovaries contained the female reproductive material in bladder-like form. But he could not reconcile this view of the Graafian follicle with the fact that the earliest embryos discovered by him were smaller than the follicles. For this reason his views were opposed by Leeuwenhoek and Valisnieri; and the later re-

searches of Haller and his pupil Kuhlmann seemed to establish a view which banished all possibility of a rational explanation of development, viz., that, in the highest group of animals (the mammalia) the embryo arose after fertilization out of formless fluids.

In 1827 v. Baer discovered the mammalian ovum within the Graafian follicle. But no correct interpretation of this discovery was possible until the establishment of the cell-theory by Theodore Schwann in 1839; Schwann concluded as the result of his investigations that there was one general principle for the formation of all organisms, namely, the formation of cells; that "the cause of nutrition and growth resides not in the organism as a whole, but in the separate elementary parts, the cells." He recognized the ovum as a single cell and the germinal vesicle as its nucleus. But on account of his erroneous conception of the origin of cells as a kind of crystallization in a primordial substance, the cytoblastema, he was unable to form the conception of continuity of generations which is an essential part of the modern cell-theory.

Schwann's theory as regards the ovum was not at once accepted. Indeed, for a period of about twenty years some of the best investigators, notably Bischoff, opposed the view that the ovum is a single cell, and the so-called germinal vesicle its nucleus. It was not, indeed, until 1861 that Gegenbaur decisively demonstrated that the bird's ovum is a single cell. Even after that it was maintained for a long time by His and his followers that all the cells were not derived from the ovum directly, but that certain tissues, notably the blood and connective tissues, were to be traced to maternal leucocytes that had migrated into the ovum while it was yet in the follicle. This view was decisively disproved in the course of time.

II. THE RECAPITULATION THEORY

Haeckel's formula, that the development of the individual repeats briefly the evolution of the species, or that ontogeny is a brief recapitulation of phylogeny, has been widely accepted by embryologists. It is based on a comparison between the embryonic development of the individual and the comparative anatomy of the phylum. The embryonic conditions of any set of organs of a higher species of a phylum resemble, in many essential par-

ticulars, conditions that are adult in lower species of the same phylum; and, moreover, the order of embryonic development of organs corresponds in general to the taxonomic order of organization of the same organs. As the taxonomic order is the order of evolution, Haeckel's generalization, which he called the fundamental law of biogenesis, would appear to follow of necessity.

But it never happens that the embryo of any definite species resembles in its entirety the adult of a lower species, nor even the embryo of a lower species; its organization is specific at all stages from the ovum on, so that it is possible without any difficulty to recognize the order of animals to which a given embryo belongs, and more careful examination will usually enable one to assign its zoölogical position very closely.

If phylogeny be understood to be the succession of adult forms in the line of evolution, it cannot be said in any real sense that ontogeny is a brief recapitulation of phylogeny, for the embryo of a higher form is never like the adult of a lower form, though the anatomy of embryonic organs of higher species resembles in many particulars the anatomy of the homologous organs of the adult of the lower species. However, if we conceive that the whole life history is necessary for the definition of a species, we obtain a different basis for the recapitulation theory. The comparable units are then entire ontogenies, and these resemble one another in proportion to the nearness of relationship, just as the definitive structures do. The ontogeny is inherited no less than the adult characteristics, and is subject to precisely the same laws of modification and variation. Thus in nearly related species the ontogenies are very similar; in more distantly related species there is less resemblance, and in species from different classes the ontogenies are widely divergent in many respects.

From this it follows that inheritance of the life-history or ontogeny is the fundamental basis of the recapitulation theory. In the course of evolution terminal or late stages of the life history are modified more rapidly in a visible morphological sense, and earlier stages are more conservative in the same sense. Hence ancestral resemblances adhere incomparably longer to the embryo than to the adult. Ontogenies receive something from every stage of evolution, but they retain most of the previous ontogenetic forms, especially of the early stages, in

each succeeding evolutionary stage; hence the appearance of recapitulation of the ancestral history.

Some of these considerations may be represented graphically as follows: let us take a species D that has an ontogeny A, B, C, D, and suppose that this species evolves successively into species E, F, G, H, etc. When evolution has progressed a step, to E, the characters of the species established develop directly from the ovum, and are therefore, in some way, involved in the composition of the latter. All of the stages of the ontogeny leading up to E are modified, and we can indicate this in the ontogeny

1. A B C D	of E as in line 2; similarly, when evolu-
2. A ¹ B ¹ C ¹ D ¹ E	tion has progressed to species F, seeing
3. A ² B ² C ² D ² E ¹ F	that the characters of F now develop
4. A ³ B ³ C ³ D ³ E ² F ¹ G	directly from the ovum, all the onto-
5. A ⁴ B ⁴ C ⁴ D ⁴ E ³ F ² G ¹ H	genetic stages leading up to F are mod-

ified, line 3. And so on for each successive advance in evolution, lines 4 and 5. It will also be noticed that the terminal stage D of species 1, becomes a successively earlier ontogenetic stage of species 2, 3, 4, 5, etc., and moreover it does not recur in its pure form, but in the form D¹ in species 2, D² in species 3, etc. Now if the last five stages of the ontogeny of species 5 be examined, viz., D⁴, E³, F², G¹, H, it will be seen that they repeat the phylogeny of the adult stages D, E, F, G, H, but in a modified form.

This is in fact what the diagram shows; but it is an essential defect of the diagram that it is incapable of showing the character of the modifications of the ancestral conditions. Not only is each stage of the ancestral ontogenies modified with each phylogenetic advance, but the elements of organization of the ancestral stages are also dispersed so that no ancestral stage hangs together as a unit. The embryonic stages show as much proportional modification in the course of evolution as the adult, but this is not so obvious owing to the simpler and more generalized character of the embryonic stages.

The recapitulation theory as outlined above is obviously a corollary of the theory of organic descent; it was in fact developed in essentially its present form, soon after the publication of the "Origin of Species," by Fritz Müller and Ernst Haeckel. But the data on which it was based were known to the earlier embryologists; and Meckel, for instance, insisted very strongly on the resemblance between the ontogenetic and the taxonomic series

(1821). v. Baer opposed Meckel's view that higher organisms pass through the definitive stages of the lower organisms, and formulated his conclusions on the subject in 1828 in the following theses:

1. "The more general features of a large division of animals arise in the embryo earlier than the more special features."
2. "From the most general features of structure arise those that are less general, and so on until the most specific features arise."
3. "The embryo of any definite species tends away from the specific forms of other species instead of passing through them."
4. "Fundamentally, therefore, the embryo of any higher species is never like a lower species, but only like its embryo."

Some embryologists profess to prefer the laws of v. Baer to the recapitulation theory as a formulation of the actual facts. But it is obvious that the only possible explanation of the facts is found in the theory of descent, and that therefore they must be formulated in terms of this theory. The method of formulation will depend on the conception of the nature of the factors of organic evolution. Haeckel stated his theory in Lamarekian terms, which renders it unacceptable in many places to those who cannot accept the Lamarekian point of view. But as the basis of any theory of descent is heredity, and it must be recognized that ontogenies are inherited, the resemblance between the individual history and the phylogenetic history necessarily follows. If one holds, as does the present writer, that phylogenetic variations are germinal in their character, then one must admit that every phase of development of every part has two aspects, viz.: the modern, specific, or coenogenetic, and the ancestral or palingenetic aspect. The latter aspect may be more or less completely obscured in the course of evolution, but it can never entirely vanish because it is the original germ of the specific form acquired. It is not correct from this point of view to classify some features of development as coenogenetic and others as palingenetic, though it is obvious that some characters may exhibit the ancestral conditions in more apparent and others in less apparent form.

III. THE PHYSIOLOGY OF DEVELOPMENT

To explain how a germ possessed the potency of forming an adult, the *preformationists* of the eighteenth century assumed

that it contained a miniature adult, and that the process of development consisted essentially in enlargement and completion in detail of that which was already preformed. They solved the problem of development, therefore, by denying its existence: In the beginning the Creator had not only made all species of animals and plants in essentially their present forms, but had at the same time created the germs of all the generations that were ever to come into existence. The ovum of any species, therefore, contained encapsuled the germ of the next generation; this, likewise encapsuled, the germ of the generation next following, and so on to the predetermined end of the species. This was known as the doctrine of evolution or preformation. In opposition to this conception, those of the same period who believed in epigenesis maintained the apparent simplicity of the germ to be real, and development to be actual. But, as there was no conception of the continuity of generations, the adherents of this point of view had to assume the spontaneous generation of the embryo.

A great advance over the preformation theory of development was made in the modern theory of determinants. This conception, which forms the basis of Darwin's theory of pangenesis as well as of Weismann's germ-plasm theory of development, is, essentially, that all the diverse components of the organism are represented in the germ by distinct entities (pangens of Darwin, determinants of Weismann) which are germs of the parts that they represent, and which are so distributed in the process of development that they produce all the parts of the embryo in their proper sequence and relations. This is not the place to enter into the numerous and diverse variations of the determinant hypothesis. It was an advance over the preformation theory of development in so far as it was reconcilable with the cell and protoplasm theories of organization, but it has a real relationship to the preformation theory inasmuch as it denies the simplicity of the germ and avoids any real explanation of the *modus operandi* of development.

Development is as truly a physiological process as secretion, and as such is to be studied by similar methods, mainly experimental. The limits of pure observation without experiment are soon reached in the analysis of such a complex subject as the physiology of development; experiment then becomes necessary

to push the analysis of the subject farther, and to furnish the true interpretation of the observations. In some cases experiments have confirmed the physiological deductions of pure observation, and in many cases have decided between conflicting views. Not all embryological experiments, however, are essays in the direction of a physiology of development; some are directed to the solution of morphological problems, as, for instance, the origin of the sheath cells of nerves, or the order of origin of somites, or the relation of the primitive streak to the embryo. Experimental embryology is, therefore, not synonymous with physiology of development.

Physiology of development must proceed from an investigation of the composition and properties of the germ-cells. It must investigate the role of cell-division in development, the factors that determine the location, origin, and properties of the primordia of organs, the laws that determine unequal growth, the conditions that determine the direction of differentiation, the influence of extraorganic conditions on the formation of the embryo, and the effects of the intraorganic environment, *i.e.*, of component parts of the embryo on other parts (correlative differentiation). Each of these divisions of the subject includes numerous problems, which have attracted many investigators, so that the materials for a consistent exposition of the physiology of embryonic development are being rapidly accumulated. This direction of investigation is, however, one of the youngest of the biological disciplines. It will be seen how far it is removed from attempts to explain embryonic development by a single principle.

IV. EMBRYONIC PRIMORDIA AND THE LAW OF GENETIC RESTRICTION

In the course of development the most general features of organization arise first, and those that are successively less general in the order of their specialization. For every structure, therefore, there is a period of emergence from something more general. The earliest discernible germ of any part or organ may be called its *primordium*. In this sense the ovum is the primordium of the individual, the ectoderm the primordium of all ectodermal structures, the medullary plate the primordium of the central and part of the peripheral nervous system, the first thickening

of the ectoderm over the optic cup the primordium of the lens, etc. Primordia are, therefore, of all grades, and each arises from a primordium of a higher grade of generality.

The emergence of a primordium involves a limitation in two directions: (1) it is itself limited in a positive fashion by being restricted to a definite line of differentiation more special than the primordium from which it sprang, and (2) the latter is limited in a negative way by losing the capacity for producing another primordium of exactly the same sort. The advance of differentiation sets a limit in all cases, in the manners indicated, to subsequent differentiation, a principle that has been designated by Minot the law of genetic restriction.

This law has not been sufficiently investigated in an experimental fashion to demonstrate its universal validity, but enough is known to establish its general applicability. A very important property of primordia in many animals is their capacity for subdivision, each part retaining the potencies of the whole. Thus, for instance, in some animals two or several embryos may be produced from parts of one ovum. Similarly two or more limbs may be produced in some forms by subdividing a limb-bud, etc.

V. GENERAL CHARACTER OF GERM-CELLS

As already remarked the ovum and spermatozoön have the character of single cells in all animals. They are, however, specialized for the performance of their respective functions. The ovum is relatively large, inert, and usually rounded in form. Its size is due to the presence of a sufficient quantity of protoplasm to serve as the primordium of an embryo, and of a greater or less amount of yolk for its nutrition. The spermatozoön, on the other hand, is relatively minute and capable of locomotion. It contains no food substances, and only sufficient protoplasm to serve as transmitter of paternal qualities and for organs of locomotion.

The Spermatozoön. The spermatozoön (Fig. 1) is an elongated flagellated cell in which three main divisions are distinguished, viz., head (caput), neck (collum) and tail (cauda). The head contains the nucleus, and the neck the centrosomes of the sperm mother-cell or spermatid. The tip of the head is often transformed into a perforatorium. Three parts may be recog-

nized in the tail, viz., the connecting piece (*pars conjunctionis*) next to the neck, frequently called the middle piece, the main piece (*pars principalis*) and the end-piece or terminal filament (*pars terminalis*). The entire tail is traversed by an axial filament; in the region



FIG. 1. — Spermatozoon of the pigeon from the vas deferens. (After Ballowitz.)

of the connecting and main pieces the axial filament is surrounded by a protoplasmic sheath (*involverum*) which may be variously modified in different animals. The end-piece is made up of the axial filament alone.

The Ovum. The ova of different phyla and classes of animals vary greatly in size, in organization, and in the nature of their envelopes. In considering these variations we shall limit ourselves to the vertebrates. Within the ovary the ovum receives two envelopes, viz., a primary envelope, the so-called vitelline membrane, which is supposed to be secreted by the ovum itself, and a secondary or follicular membrane, which is secreted by the follicular cells. (See Chap. I). Theoretically the distinction between vitelline membrane and follicular membrane (primary and secondary egg-membranes) is perfectly clear; but practically it is impossible in most cases to make such a distinction. Therefore the membrane that surrounds the ovarian ovum will be termed the vitelline membrane or *zona radiata* without reference to its theoretical mode of origin.

The ovum escapes from the ovary (ovulation) by rupture of the wall of the follicle, and, in most vertebrates, is taken up by the oviduct through which it passes on its way to the exterior. Within the oviduct it may become surrounded by tertiary membranes secreted by the wall of the oviduct itself. Tertiary membranes are lacking in some vertebrates, in others they are of great importance. Thus in birds the albumen, the shell-membrane and the shell itself are tertiary membranes.

The principal differences to be emphasized in the ova of vertebrates are, however, in the amount and arrangement of the yolk contained within the ovum proper. All ova contain more

or less yolk. In the case of mammals (excepting the monotremata: Ornithorhynchus, Echidna, etc., which have large ova) the yolk is scanty in amount, and quite uniformly distributed in the form of fine granules; the ovum is, therefore, relatively very small (mouse, 0.059 mm.; man, 0.17 mm.). Such ova are often termed *alecithal*, which means literally without yolk. In the literal sense, however, no ova are entirely alecithal, so that it will be better to use the term of Waldeyer, *isolecithal*. In the amphibia the yolk is much greater in amount and it is centered towards one pole of the ovum; the germinal vesicle (nucleus of the egg-cell), which occupies the center of the protoplasm of the ovum, is therefore displaced towards the opposite pole of the ovum. Such ova are termed *telolecithal*. In the ova of Selachia, reptiles and birds, the yolk is very much greater in amount and in consequence the protoplasm containing the germinal vesicle appears as a small disc, the germinal disc, on the surface of the huge yolk-mass.

But no matter how large the ovum may become by deposition of yolk, its unicellular character is not altered. The deposition of yolk is simply a provision for the nutrition of the embryo. In the mammals the nutrition of the embryo is provided for by the placenta; therefore yolk may be dispensed with. In the absence of such provision the amount of yolk is a measure of the length of the embryonic period of development. In the amphibia, for instance, this is relatively brief, for the yolk is soon used up, and the larva must then depend on its own activities for its nutrition. Therefore the development involves a metamorphosis: the embryo is born in a very unfinished condition, as a larva (the tadpole in the case of amphibia), which must undergo an extensive metamorphosis to reach the adult condition. In the reptiles and birds, however, the amount of yolk is sufficient to carry the development through to a juvenile condition, before an extraneous food-supply is necessary. The metamorphosis, therefore, which takes place in free life in amphibia, goes on within the egg in reptiles and birds. The first form of development is known as larval, the second as foetal.

The amount and arrangement of yolk also influences very profoundly the form of the early stages of development. Ova are classified in this respect as holoblastic and meroblastic. Holoblastic ova are those in which the process of cell division (cleav-

age or segmentation of the ovum), with which development begins, involves the entire ovum. This occurs where the amount of the yolk is relatively small and where it is completely interpenetrated by sufficient protoplasm to carry the planes of division through the inert yolk. But where the amount of yolk becomes very large, or where it is not interpenetrated sufficiently by the protoplasm, the division planes are confined to the protoplasmic portion of the ovum, and the yolk remains undivided. Such ova are known as meroblastic. In these ova the cellular part of the ovum forms a blastodisc (germinal disc) on the surface of the yolk. The ova of Amphioxus, Petromyzontidæ, Ganoidea, Dipnoi, Amphibia, Marsupialia, and Placentalia are holoblastic; those of Myxinoidea, Teleostei, Selachia, Reptilia, Aves, and Monotremata are meroblastic.

It is obvious that transitional conditions between holoblastic and meroblastic ova may occur; such are in fact found among the ganoids. In *Lepidosteus*, for instance, the quantity of protoplasm in the lower hemisphere is so slight that the division planes form with extreme slowness. On the other hand, it should be emphasized that the distinction between holoblastic and meroblastic ova is not so much due to amount of yolk as to the definiteness of its separation from the protoplasm. Thus the ova of some teleosts, particularly of the viviparous forms described by Eigenmann, are many times smaller than the ova of *Necturus* or *Cryptobranchus* among amphibia. Yet the teleost ovum is meroblastic, because the protoplasm does not penetrate sufficiently into the yolk, and the amphibian ovum is holoblastic.

Comparison of the Germ-cells. Although it is not within the province of this book to enter fully into a discussion of this question, yet it should be pointed out that, in spite of the extreme differences in the structure of the germ-cells, they are exactly equivalent in hereditary potency, as is proved by the similar nature of reciprocal crosses. Their resemblances are in fact fundamental and their differences must be regarded as adaptations to secure their union. The comparative history of the germ-cells, that is a comparison of ovogenesis and spermatogenesis, brings out their fundamental similarity as germ-cells. In both the ovogenesis and spermatogenesis three periods are clearly distinguishable, viz.: a period of multiplication, a period of growth, and a period of maturation. In the period of multiplication

the primordial germ-cells, known as ovogonia and spermatogonia are very similar in their morphological characters; both kinds are small, yolkless cells containing the typical or somatic number of chromosomes; they multiply rapidly by karyokinetic division.

At the end of this period multiplication ceases and the germ-cells increase in size (period of growth). They are now known as ovocytes and spermatocytes of the first generation. The growth of the ovocyte is much greater than that of the spermatocyte; deposition of yolk occurs in the ovocyte during this period, whereas in the spermatocyte no yolk is ever deposited, though mitochondria may simulate it in appearance. Another characteristic feature of the period of growth is the reduction of the number of chromosomes to one half of the typical number, which takes place, according to the current conception, by union of the chromosomes in pairs (synapsis) forming one half of the somatic number of chromosomes, which are, however, bivalent and are known as tetrads.

At the end of the period of growth the ovocyte of the first generation is usually many times larger than the spermatocyte, owing mainly to the amount of yolk formed. But the two kinds of cells are precisely alike in nuclear constitution. Then comes the period of maturation, which is the same in both kinds of cells with reference to the nuclear phenomena, but very different as regards the behavior of the cell-body. The maturation consists of two rapidly succeeding karyokinetic divisions: in the case of the spermatocyte the first division results in the formation of two similar cells, the *spermatocytes of the second order*, and the second maturation division divides each of these equally, forming two similar *spermatids*, so that four equal and similar spermatids arise from each spermatocyte of the first order. Each spermatid then differentiates into a single spermatozoön. In the case of the ovocyte of the first order, the first maturation division is exceedingly unequal; the smaller cell is known as the first polar body, but both cells are ovocytes of the second order. The second maturation division usually involves only the *large secondary ovocyte*; it is as unequal as the first division and results in the formation of a second polar body. The division of the first polar body, where it occurs, is equal. Thus the net result of the maturation division of the ovum is the production of three cells (four if the first polar body divides), viz., the two (or three) polar bodies

and the ovum. The size of the polar globules is usually so small that their elimination makes no appreciable difference in the size of the ovum proper, but they have, nevertheless, the same nuclear constitution as the ovum.

The mature ovum (oötid) and the polar bodies are the precise equivalent of the four spermatids, but whereas each of the latter becomes a functional spermatozoön, only the ovum on the female side is functional; the polar bodies lack the necessary protoplasm and yolk for development, and they therefore die. The polar bodies must be regarded as abortive ova; and a teleological explanation of the form of maturation of the ovum is afforded by the consideration that equal maturation divisions would reduce the amount of protoplasm and yolk in the products below the minimum desirable for perfect development.

Although the maturation divisions of the ovum and spermatozoön are so dissimilar externally, yet the nuclear phenomena are exactly alike. The net result of the maturation divisions is to produce definitive germ-cells containing one half of the somatic number of chromosomes owing to the reduction by pairing (synapsis) that occurs in both at the beginning of the period of growth. The somatic number is again restored when the sperm-nucleus and the egg-nucleus unite in fertilization. Questions of fundamental importance for the problems of heredity arise in connection with the phenomena of maturation and fertilization, but their consideration lies without the scope of the present book.

VI. POLARITY AND ORGANIZATION OF THE OVUM

Although the ovum is morphologically a single cell, yet, as the primordium of an individual, it has certain specific properties that predelineate or foreshadow the main structural features of the embryo. Polarity is the most general of these features: all the axes of the ovum are not similar, though they may be equal; there is one axis around which the development centers; the ends of this axis are known as the animal and the vegetative poles of the ovum, and the hemispheres in which they lie are named correspondingly. In telolecithal ova the yolk is centered in the vegetative hemisphere, the protoplasm in the animal hemisphere; even in ova which are called isolecithal there is a tendency for the yolk to be more abundant in the vegetative hemisphere. The polar globules are formed at the animal pole; hence their


name; they often furnish the only clear indication of polarity before cleavage begins.

With reference to the heteropolar ovic axis a series of meridians may be defined, drawn from pole to pole over the surface; likewise an equator and a series of horizontal zones parallel to the equator. Thus directions on the surface of the ovum may be defined as meridional, equatorial, or oblique.

Cleavage takes place with reference to the axis of the ovum. Thus in holoblastic vertebrate ova the first and second cleavage planes are meridional, and the third usually equatorial. The mammalian ovum may form an exception to this rule, though little is known, as a matter of fact, about the polarity of the mammalian ovum. The cleavage of meroblastic ova takes place likewise with reference to the polarity (see Chap. II); and the location of the primary germ-layers is determined by the polarity.

Not only is the ovum heteropolar, but in many bilateral animals, and perhaps in all, it is bilaterally symmetrical before cleavage begins; that is to say, one of the meridional planes defines the longitudinal axis of the future embryo, and the direction of anterior and posterior ends is also predetermined in this meridian, so that halves of the egg corresponding to future right and left sides of the embryo may be distinguished. In the frog's egg the plane of symmetry is marked by a gray crescent that appears above the equator on the side of the egg that corresponds to the hinder end of the embryo. This crescent is bisected by the meridional plane of symmetry. In the hen's egg the plane of symmetry of the embryo appears on the surface of the yolk in a line at right angles to the axis of the shell, and the left side of the embryo is turned towards the broad end, the right side towards the narrow end of the shell. The same plane of symmetry must exist in the ovum prior to cleavage for reasons explained beyond, although there is no morphological differentiation in the ovum proper, *i.e.*, the germinal disc or yolk, that indicates it.

This predelineation of embryonic axes within the unsegmented ovum has been interpreted physiologically as due to gradients in rate of metabolic processes along the embryonic axes (Child), which determine the localization of the main developmental events.



PART I

THE EARLY DEVELOPMENT TO THE END OF THE THIRD DAY

CHAPTER I

THE EGG

THE parts of a newly laid hen's egg are the shell, shell-membrane, albumen, and yolk. In an egg that has been undisturbed for a short time the yolk floats in the albumen with a whitish disc, the blastoderm about 4 mm. in diameter, on its upper surface. If the yolk be rotated, it will return to its former position in a few minutes, owing to the slightly lower specific gravity of the hemisphere containing the blastoderm. The blastoderm is the living part of the egg, from which the embryo and all its membranes are derived. It is already in a fairly advanced stage of development when the egg is laid. The yolk and blastoderm are enclosed within a delicate transparent membrane (vitelline membrane) which holds the fluid yolk-mass together. We may now consider some details of the structure and composition of the parts of the egg.

The shell is composed of three layers: (1) the inner or mammillary layer, (2) the intermediate spongy layer, and (3) the surface cuticle. The mammillary layer consists of minute calcareous particles about 0.01–0.015 mm. in diameter welded together, with conical faces impinging on the shell-membrane; the minute air-spaces between the conical inner ends of the mammillæ communicate with the meshes of the spongy layer, which is several times as thick, and which is bounded externally by the extremely delicate shell cuticle. The spongy layer consists of matted calcareous strands. The shell cuticle is porous, but apparently quite structureless otherwise. The cuticular pores communicate with the mesh-work of the spongy layer; thus the entire shell is permeable to gases, and permits of embryonic respiration, and evaporation of water.

The shell-membrane consists of two layers, a thick outer layer next to the shell and a thinner one next the albumen. Both are composed of matted organic fibers (more delicate in the inner than in the outer layer), crossing one another in all directions. At the blunt end of the egg the two layers are separated and form a chamber containing air that enters after the egg is laid (Fig. 2).

The physical characteristics of the albumen are too well known to require description. A dense layer immediately next

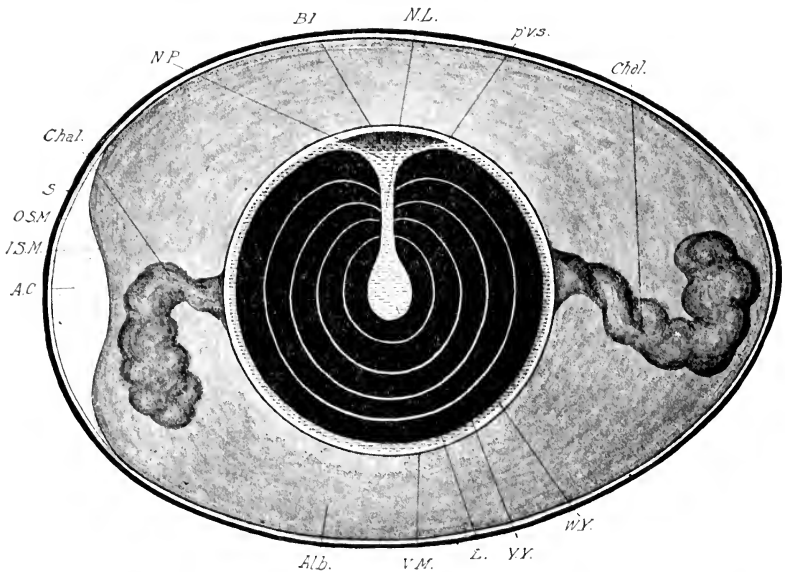


FIG. 2. — Diagram of the hen's egg in section to show relations of the parts.

A. C., Air chamber. Alb., Albumen. Bl., Blastoderm. Chal., Chalaza. I. S. M., Inner layer of the shell membrane. L., Latebra. N. L., Neck of Latebra. N. P., Nucleus of Pander. O. S. M., Outer shell membrane. p'v. s., Perivitelline space. S., Shell. V. M., Vitelline membrane. W. Y., White yolk. Y. Y., Yellow yolk.

to the vitelline membrane is prolonged in the form of two spirally coiled opalescent cords towards the blunt and narrow ends of the egg respectively; these are the chalazæ, so called from a fanciful resemblance to hail stones. The two chalazæ are twisted in opposite directions. In a hard-boiled egg it is possible to strip off the albumen in concentric spiral layers from left to right from the broad to the small end of the egg.

The yolk and blastoderm are enclosed within the delicate vitelline membrane; the yolk is a highly nutritious food destined to be gradually digested and absorbed by the living cells of the blastoderm and used for the growth of the embryo. It is not of uniform composition throughout, but consists of two main ingredients known as the yellow and the white yolk. The yellow yolk makes up the greater part of the yolk-sphere; the main part of the white yolk is a flask-shaped mass, the bulb of which, known as the latebra, is situated near the center of the whole yolk, the neck rising towards the surface and expanding in the form of a disc (nucleus of Pander) situated immediately beneath the blastoderm (Fig. 2); at its margin this disc is continuous with a thin peripheral layer of white yolk that surrounds the entire mass. In addition there are several thin layers of white yolk concentric to the inner bulb-shaped mass.¹ If an egg be opened, a delicate hair inserted in the blastoderm to mark its position, and then boiled hard, a section through the hair and center of the yolk will show the above relations quite clearly. The white yolk does not coagulate so readily as the yellow yolk, and it may be distinguished by this property as well as by its lighter color.

Both kinds of yolk are made up of innumerable spheres which are, however, quite different in each (Fig. 3). Those of the yellow yolk are on the whole larger than those of the white yolk (about 0.025–0.100 mm. in diameter) with extremely fine granular contents. There is no fluid between the spheres. Those of the white yolk are smaller and more variable in size, ranging from the finest granules up to




FIG. 3. — Yolk-spheres of the hen's egg; highly magnified. (After Foster and Balfour.)
 A. Varieties of white yolk-spheres.
 B. Yellow yolk-sphere.

¹ The assertion that the thin layers that define the concentric stratification of the yellow yolk are of the nature of white yolk is traceable to Meckel V. Hemsbach, Leuckart, and Allen Thomson. His was not able to satisfy himself that the characteristic elements of the white yolk occur within these thin concentric lamellæ (Untersuchungen ueber die erste Anlage des Wirbeltierleibes, p. 2).

about 0.07 mm. The larger spheres of the white yolk contain several highly refractive granules of relatively considerable size as compared with those of the yellow spheres (Fig. 3), and such granules may have secondary inclusions. As we shall see later, the smaller granules of the white yolk extend into the germinal disc (forerunner of the blastoderm) and grade into minute yolk-granules contained within the living protoplasm.

The earlier investigators from the time of Schwann regarded the white yolk-spheres as actual cells (Schwann, Reichert, Coste, His). His especially laid great stress on this interpretation; he believed that they were derived from the cells of the ovarian follicle which migrated into the ovum in the course of ovogenesis, that they multiplied like other cells, and took part in the formation of certain embryonic tissues. Subsequently he abandoned this position as untenable. The white yolk spheres are now universally regarded as food matters of a particular sort.

The yolk and albumen are complex mixtures of many different substances, organic and inorganic, containing all the elements necessary for the growth of the embryo. Very little is known concerning the series of chemical changes that go on in them during incubation.

Chemical Composition of the Hen's Egg. — The following data on the chemical composition of the hen's egg are taken from Simon's *Physiological Chemistry*. For details and literature the student is referred to the standard text-books of physiological chemistry.

GENERAL COMPOSITION OF THE YOLK

	PER CENT.
Water	47.19–51.49
Solids	48.51–42.81
Fats (olein, palmitin, and stearin)	21.30–22.84
Vitelline and other albumens	15.63–15.76
Lecithin	8.43–10.72
Cholesterin	0.44– 1.75
Cerebrin	0.30
Mineral salts	3.33– 0.36
Coloring matters }	0.553
Glucose }	

ANALYSIS OF THE MINERAL SALTS

Sodium (Na_2O)	5.12– 6.57
Potassium (K_2O)	8.05– 8.93
Calcium (CaO)	12.21–13.28

	PER CENT.
Magnesium (MgO)	2.07- 2.11
Iron (Fe ₂ O ₃)	1.19- 1.45
Phosphoric acid, free (P ₂ O ₅)	5.72
Phosphoric acid, combined	63.81 66.70
Silicic acid	0.55- 1.40
Chlorine	Traces.

GENERAL COMPOSITION OF THE ALBUMEN

Water	80.00-86.68
Solids	13.22-20.00
Albumens	11.50-12.27
Extractives	0.38- 0.77
Glucose	0.10- 0.50
Fats and Soaps	Traces
Mineral salts	0.30- 0.66
Lecithins and Cholesterin	Traces.

ANALYSIS OF THE MINERAL ASH

Sodium (Na ₂ O)	23.56-32.93
Potassium (K ₂ O)	27.66-28.45
Calcium (CaO)	1.74- 2.90
Magnesium (MgO)	1.60- 3.17
Iron (Fe ₂ O ₃)	0.44- 0.55
Chlorine (Cl)	23.84-28.56
Phosphoric acid (P ₂ O ₅)	3.16- 4.83
Carbonic acid (CO ₂)	9.67-11.60
Sulphuric acid (SO ₃)	1.32- 2.63
Silicic acid (SiO ₂)	0.28- 0.49
Fluorine (F)	Traces.

The shell consists of an organic matrix of the nature of keratin impregnated with lime salts: calcium and magnesium carbonates about 97 %, calcium and magnesium phosphates about 1 %, keratin and water about 2 %, trace of iron.

The shell-membrane and the vitelline membrane are stated to consist of keratin or a closely allied substance.

Formation of the Egg. The organs of reproduction of the hen are the ovary and oviduct of the left side of the body. Although the right ovary and oviduct are formed in the embryo at the same time as those of the left side, they degenerate more or less completely in the course of development (see Chap. XIII), so that only functionless rudiments remain. This would appear to be correlated with the large size of the egg and the delicate

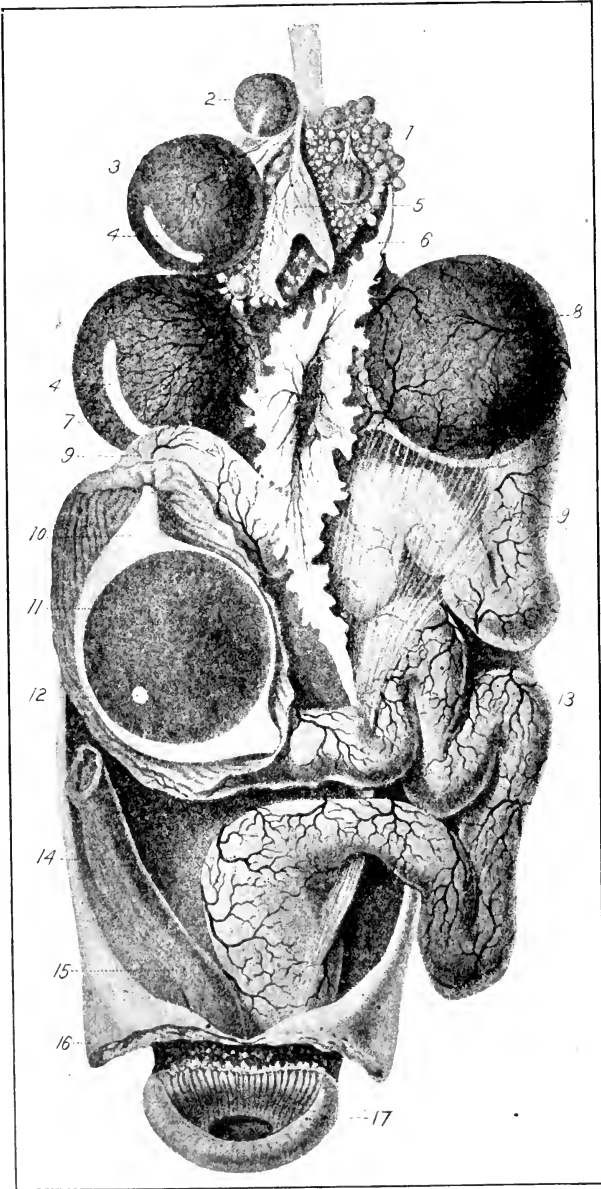


FIG. 4. — Reproductive organs of the hen. (After Duval, based on a figure by Coste.) The figure is diagrammatic in one respect, namely, that two

nature of the shell, as there is not room for two eggs side by side in the lower part of the body-cavity.

The ovary lies at the anterior end of the kidney attached by a fold of the peritoneum (mesovarium) to the dorsal wall of the body-cavity. In a laying hen ova of all sizes are found from microscopic up to the fully formed ovum ready to escape from the follicle. Such an ovary is shown in Figure 4; the gradation in size of the ova will be noticed up to the one fully formed and ready to burst from its capsule. At 5 in this figure is shown a ruptured follicle, and the ovum which has escaped from this follicle is shown in the oviduct at 8. It will be seen that the part of the definitive hen's egg produced in the ovary is the so-called yolk. The blood-supply of the very vascular ovary is derived from the dorsal aorta, and the veins open into the vena cava inferior.

The oviduct is a large coiled tube (Fig. 4) which begins in a wide mouth with fringed borders, the *ostium tubæ abdominale* (funnel or infundibulum) opening into the body-cavity near the ovary. It is attached by a special mesentery to the dorsal wall of the body-cavity, and opens into the cloaca. The following divisions are usually distinguished: (1) the funnel or infundibulum, (2) the albumen secreting portion, (3) the isthmus, (4) the uterus or shell-gland, (5) the vagina (Fig. 4). The albumen secreting portion includes all of the coiled tube; the isthmus is a short section next to the dilated uterus, and the vagina is the short terminal portion opening into the cloaca (Figs. 4 and 5).

The formation of an egg takes place as follows: the yolk, or ovum proper, escapes by rupture of the follicle along a preformed band, the stigma (Fig. 4-4), into the infundibulum, which swallows it, so to speak, and it is passed down by peristaltic contractions

ova are shown in the oviduct at different levels; normally but one ovum is found in the oviduct at a time.

1, Ovary, region of young follicles. 2 and 3, Successively larger follicles. 4, Stigmata, or non-vascular areas, along which the rupture of the follicle takes place. 5, Empty follicle. 6, Cephalic lip of ostium. 7, Funnel of oviduct (*ostium tubæ abdominale*). 8, Ovum in the upper part of the oviduct. 9, Region of the oviduct in which the albumen is secreted. 10, Albumen surrounding an ovum. 11, Ovum. 12, Germinal disc. 13, Lower segment of albumen-secreting portion. 14, Lower part of the oviduct ("uterus," shell-gland). 15, Rectum. 16, Reflected wall of the abdomen. 17, Anus, or external opening of cloaca.

of the oviduct. The escape of the ovum from the follicle is known as the process of ovulation. During its passage down the oviduct it becomes surrounded by layers of albumen secreted by the oviducal glands. The shell-

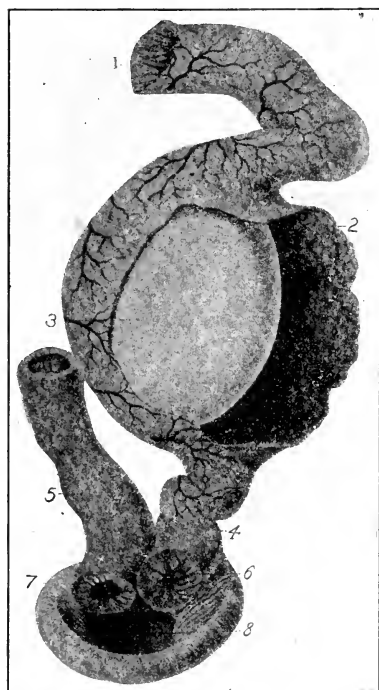


FIG. 5. — Uterus (shell-gland) of the hen cut open to show the fully formed egg. (After Duval.)

1, Cut surface of oviduct, region of isthmus. 2, Reflected flap of uterus. 3, Egg ready to be laid. 4, Lower extremity, or vaginal portion, of the oviduct. 5, Rectum. 6, Opening of the oviduct into the cloaca. 7, Opening of the rectum into the cloaca. 8, Cloaca.

membrane is secreted in the isthmus and the shell in the uterus (Fig. 5). The ovum is fertilized in the uppermost part of the oviduct and the cleavage and early stages of formation of the germ-layers take place before the egg is laid. The time occupied by the ovum in traversing the various sections of the oviduct is as follows: Glandular portion of the oviduct three hours, isthmus one hour, uterus and laying sixteen to seventeen hours (combined observations of Patterson, and Pearl and Curtis). If the hen be disturbed eggs may be retained long after they are ready to be layed.

Some of the details of these remarkable processes deserve attention: the observations of several naturalists demonstrate that the ripe follicle is embraced by the funnel of the oviduct before its rupture so that the ovum does not escape into the body-cavity, but into the oviduct itself. Coste describes

the process in the following way: "In hens killed seventeen to twenty hours after laying I have observed all the stages of this remarkable process. In some the follicle, still intact and enclosing its egg, had already been swallowed, and the mouth of the oviduct, contracted around the stalk of the capsule, seemed to exert some pressure on it, in other cases the ruptured capsule still partly

enclosed the egg which projected from the opening; in others finally the empty capsule had just deposited the egg in the entrance of the oviduct." According to Patterson the funnel of the oviduct becomes inactive as soon as an egg is received, but about the time of laying it becomes highly active and again clasps an egg follicle.

The existence of double-yolked eggs renders it probable that the oviduct can pick up eggs that have escaped into the body-cavity. But in some cases ova that escape into the body-cavity undergo resorption there.

Immediately after the ovum is received by the oviduct a special layer of albumen is secreted which adheres closely to the vitelline membrane and is prolonged in two strands, one extending up and the other down the oviduct; these strands become the chalazæ; the layer to which they are attached may, therefore, be called the chalaziferous layer (Coste) of the albumen. The line joining the attachments of the chalazæ is at right angles to the main axis of the ovum (that passing through the germinal disc); it is obvious, therefore, that there must be some antecedent condition that determines the position of the ovum in the oviduct; this is probably the position of the ovum in the follicle, *i.e.*, the relation of the germinal disc to the stigma, for the follicular orientation is apparently preserved in the oviduct. The question is of considerable importance because, as we shall see, the axis of the embryo is later bisected by a plane passing through the chalazæ, and is therefore certainly determined at the time that the chalazæ are formed, and Bartelmez even traces it back to the earliest stages of the ovocyte.

After formation of the chalazæ the ovum passes down the oviduct, rotating on the chalazal axis, and thus describing a spiral path; the albumen which is secreted abundantly in advance of the ovum is therefore wrapped around the chalaziferous layer and chalazæ in successive spiral layers and the chalazæ are revolved in spiral turns.

Only about 50 % of the white of the egg is formed by the albumen secreting portion of the oviduct; this is in the form of a dense layer formed of matted fibers; the shell membrane is deposited directly on this; and the more fluid portion of the albumen constituting 50 % or more of its entire bulk enters through the shell membrane while the egg is in the isthmus and uterus (Pearl and Curtis, 1912).

Abnormal eggs are of two main kinds: those with more than one yolk, and enclosed eggs (ovum in ovo). Double-yolked eggs are obviously due to the simultaneous, or almost simultaneous, liberation of two yolks, and their incorporation in a single set of egg-membranes. The two yolks are usually separate in such cases and are derived, presumably, from separate follicles. But two yolks within a single vitelline membrane have been observed; such are in all probability products of a single follicle. Cases of three yolks within a single shell are extremely rare. The class of enclosed eggs includes those in which there are two shells, one within the other. In some cases the contents of the enclosed and the enclosing eggs are substantially normal, though of course the enclosing shell is abnormally large; in others the enclosed egg may be abnormal as to size (small yolk), or contents (no yolk). In all cases described, the enclosing egg possesses a yolk (Parker). Abnormal eggs of these three classes are of either ovarian or oviducal origin; doubled-yolked eggs and eggs with abnormal yolks are due to abnormal ovarian conditions; enclosed eggs to abnormal oviducal conditions, or to both ovarian and oviducal abnormalities. Assuming the normal peristalsis of the oviduct to be reversed when a fully formed egg is present, the egg would be carried up the oviduct a greater or less distance and might there meet a second yolk. If the peristalsis became normal again, both would be carried to the uterus and enclosed in a common shell. (For a fuller discussion of double eggs see G. H. Parker.)

Ovogenesis. The ovogenesis, or development of ova, may be divided into three very distinct stages. The first stage, or period of multiplication, is embryonic and ends about the time of hatching (in the chick); it is characterized by the small size of the ova and their rapid multiplication by division. The multiplying primitive ova are known as ovogonia. At the end of this period multiplication ceases and the period of growth begins. The ova, known as oocytes of the first order, become enclosed in follicles; the size of the ovum constantly increases and the yolk is formed. The third period, known as the period of maturation, is characterized by two successive exceedingly unequal divisions of the egg-cell, producing two minute cells, the polar globules, that take no part in the formation of the embryo, but die and degenerate. The process of maturation begins in the

fully ripe follicle and is completed after ovulation in the oviduct, while the ovum is being fertilized.

The origin of the primitive ova, their multiplication and the formation of the primordial follicles is described in Chapter XIII. In the young chick all the cell cords and cell nests (described in Chapter XIII) become converted into primordial follicles. During the egg-laying period there is a continuous process of growth and ripening of the primordial follicles, which takes place successively; the immense majority at any given period remain latent, but all stages of growth of egg follicles may be found in a laying hen.

A primordial follicle consists of the ovum surrounded by a single layer of cubical epithelial cells (granulosa or follicle cells); the fibers of the adjacent stroma have a concentric arrangement around the follicle forming the theca folliculi (Fig. 6 Str.). The ovum itself is a rounded cell with a large nucleus placed excentrically so as to define a primary axis of the ovum. In the protoplasm on one side of the nucleus is a concentrated mass of protoplasm, the yolk-nucleus, from which rays extend, and minute fatty granules.

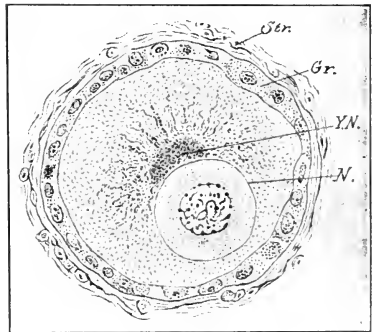


FIG. 6.—Primordial follicle from the ovary of the hen. (After Holl.)

Gr., Granulosa. N., Nucleus. Str., Stroma. Y. N., Yolk nucleus.

Holl derives the follicular cells in birds from the stroma, but on insufficient grounds. According to D'Hollander, they are derived, like the primitive ova, from the germinal epithelium, in which he agrees with the majority of his predecessors. He states that the period of multiplication of the ovogonia ends about the time of hatching; that the period of growth of the oocytes begins at about the fourteenth day of incubation (seven days before hatching), and before the formation of the primordial follicle, which begins on the fourth day after hatching. Thus the periods of multiplication and growth overlap.

Although the nucleus (germinal vesicle of authors) is strongly excentric in position in the youngest oocytes, it occupies a more nearly central position in those slightly older. When the ovum is about 0.66 mm. in diameter, it moves to the surface along the shortest radius and comes to lie almost in contact with the vitel-

line membrane (Fig. 7). It becomes elliptical, and later the outer surface is flattened against the vitelline membrane, the inner surface remaining convex (Fig. 8). The point on the surface to which the germinal vesicle migrates is situated away from the surface of the ovary, and thus in the position of the pedicle of

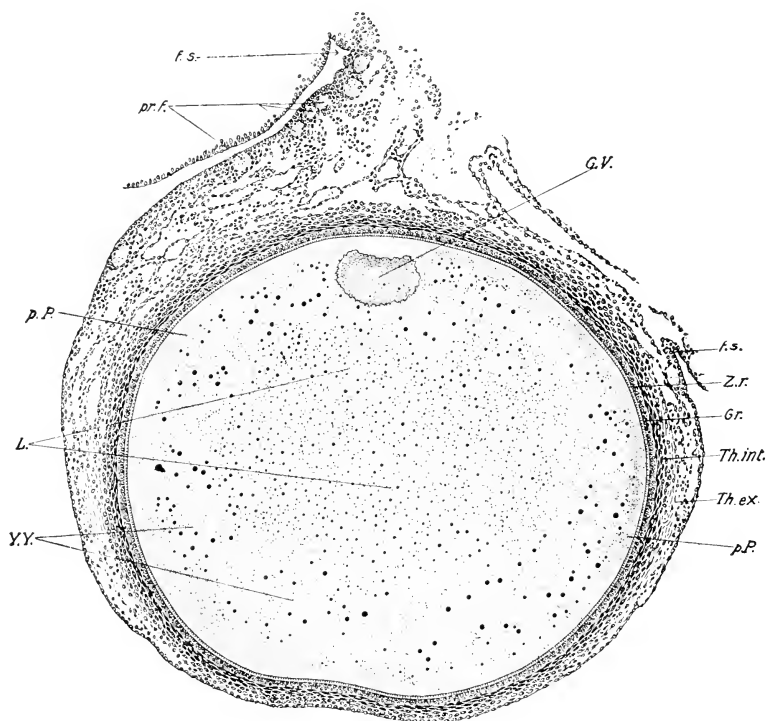


FIG. 7. — Section of an ovarian ovum of the pigeon; drawn from a preparation of Mr. J. T. Patterson. The actual dimensions of the ovum are 1.44 x 1.25 mm.

f. s., Stalk of follicle. G. V., Germinal vesicle. Gr., Granulosa. L., Latebra. p. P., Peripheral protoplasm. pr. f., Primordial follicles. Th. ex., Theca externa. Th. int., Theca interna. Y. Y., Yellow yolk. Z. r., Zona radiata.

the follicle, when the latter projects from the surface of the ovary (Fig. 7). This determines the position of the future germ disc. The nucleus increases in size with the growth of the ovum; in the youngest oocytes its diameter is about $9\ \mu$; in the ripe ovum it is flattened and may measure $455\ \mu$ in diameter by $72\ \mu$ in thickness.

While the nucleus is still near the center of the egg a very dense deposit of extremely fine granules is formed around it, and gradually extends out towards the periphery of the cell, but does not involve the peripheral layer of protoplasm. This central aggregation of yolk-granules represents the primordium of the latebra or central mass of the white yolk.

The ovum grows very slowly up to a diameter of about 6 millimeters, and all of the yolk found during this period belongs to the category of white yolk. Certain of these ova, but only a few at any one time, then suddenly begin to grow at an enormously increased rate, adding about 4 mm. to their diameter every twenty-four hours until the full size of about 40 mm. in diameter is attained. It is during this period that the concentric layers of yellow and white yolk are laid down in the periphery.

Riddle has studied this period by the ingenious method of feeding the stain Sudan III, which has an especial affinity for fat, to laying hens at definite time intervals. The stain attaches itself to fatty acids of the food which are taken up unchanged by the egg. The consequence is that during any period of Sudan III feeding a red stained layer of yolk is formed; so that it is possible by regulating the dose and interrupting the feedings to obtain ova with alternate bands of stained and unstained yolk. In this way he was able to show that a layer of yellow and of white yolk about 2 mm. in combined thickness on the average is laid down each twenty-four hours.

In a previous study the same author had shown that there is a daily rhythm of nutrition, associated with high and low blood pressure, which is responsible for the formation of the alternate fault-bars and fundamental bars of birds' feathers. It is this same daily rhythm that determines the concentric stratification of the yolk, yellow yolk being formed during the longer period of high blood pressure, and white yolk during the briefer nocturnal period of low pressure.

"The layer of white yolk of the hen's egg is then a growth-mark left at the ever changing boundary of the ovum; it represents the result of yolk formation under sub-optimal conditions." (Riddle.)

The germinal vesicle lies in a thickening of the peripheral layer of protoplasm known as the germinal disc, which is continuous, like the remainder of the peripheral protoplasm, in early

stages with the protoplasmic reticulum that forms the walls of the yolk-vacuoles. The germinal disc increases in extent and thickness, and the peripheral protoplasm disappears over most of the yolk. An inflow of the peripheral protoplasm into the disc appears very probable by analogy with the bony fishes where this process can be studied with great ease.

The method of formation of the neck of the latebra and the so-called nucleus of Pander, or peripheral expansion of the neck, follows more or less directly from the preceding account: As the circumference of the ovum enlarges, the germinal disc is carried out and leaves behind it a trail in which yellow yolk is not formed. When the ovum is fully grown, the exact boundaries between the protoplasmic germinal disc and the yolk are not determinable. The disc itself is charged with small yolk-granules which grade off very gradually into the white yolk lying around and beneath the disc.

The mode of nutrition of the ovum and the formation of the vitelline membrane remain to be considered. The nutrition is conveyed from the highly vascular theca folliculi by way of the follicular cells, or membrana granulosa, to the ovum. The nutriment enters by diffusion; at no stage is there any evidence of immigration of solid food particles, let alone entire cells, into the growing ovum. At an early stage a definite membrane is formed between the ovum and the follicular cells, the zona radiata or primordium of the vitelline membrane (Fig. 7). This is pierced by innumerable extremely minute pores which become narrow canals as the zona radiata increases in thickness. The follicular cells and the peripheral layer of protoplasm of the ovum are connected by extremely delicate strands of protoplasm that pass through the pores (Holl). In some way the nutriment of the ovum is conveyed through these strands.

The discussion as to whether the zona radiata is a product of the ovum itself or of the follicular cells seems to me to be largely academic and will not be summarized here. There seems to be sufficient evidence of a primary true vitelline membrane secreted by the ovum itself, though this may not represent the entire zona radiata of older ova.

The third phase of oögenesis, maturation or formation of the polar globules, is transferred to the next chapter, because it is overlapped by the process of fertilization. It is not definitely

known if maturation in birds may be completed without fertilization, but it seems probable that, as in many other animals, the completion of maturation is dependent on the stimulus of fertilization. It is, however, essentially a process absolutely distinct from fertilization, and in some animals (*e.g.*, echinids) is completed without fertilization.



CHAPTER II
THE DEVELOPMENT PRIOR TO LAYING

I. MATURATION

DURING the growth period the germinal vesicle has increased to an enormous size ($455 \times 72 \mu$ in an ovum 37 mm. in diameter, Fig. 8). It lies in contact with the vitelline membrane. The margins of the lenticular nucleus are folded into the interior in such a way that sections give an effect of rod-shaped bodies springing from the membrane which were doubtfully interpreted as




FIG. 8. — Vertical section of germinal vesicle of hen's egg after Sonnenbrodt. Size of egg 37 mm. in diameter; size of nucleus $455 \mu \times 72 \mu$.

chromosomes by Holl. The real chromosomes are however in the center in the form of double rods (Fig. 8). The maturation divisions of the hen's egg have not been described, but we have fortunately a very good account of the maturation and fertilization of the pigeon's egg by E. H. Harper, which furnishes the basis of the following description:

The wall of the germinal vesicle begins to break down in ovarian eggs of about 18.75 mm. diameter, the full size of the egg of the pigeon being about 25 mm. Part of the fluid contents of the germinal vesicle flows out and forms a layer outside the disinte-

grating wall (Fig. 9). The chromosomes and nucleoli form a group near the center of the upper plane surface of the germinal

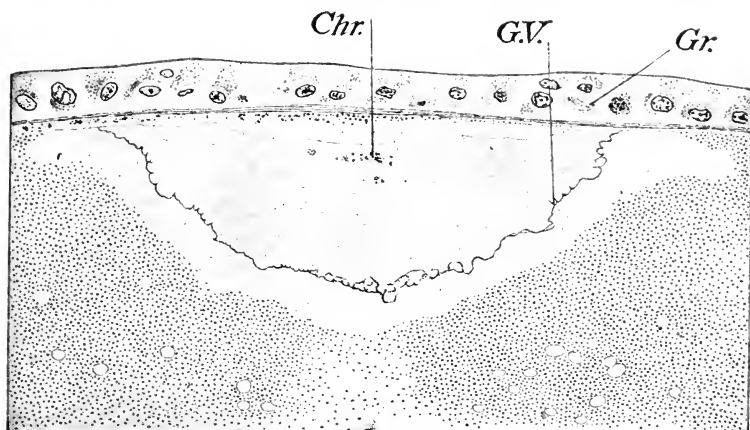


FIG. 9. — Vertical section of the germinal vesicle and part of the germinal disc of an ovarian ovum $\frac{3}{4}$ inch in diameter; pigeon. $\times 385$. (After Harper.)

Chr., Chromosomes. Gr., Granulosa. G. V., Wall of germinal vesicle.

vesicle. The first maturation spindle is formed before ovulation, containing eight quadruple chromosomes (tetrads). The spindle is still in the equatorial plate stage when the ovum is grasped by the mouth of the oviduct (Fig. 10). The bulk of the substance of the germinal vesicle soon forms a yolk-free cone extending from the maturation spindle deep into the superficial yolk. The outer end of the spindle is in almost immediate contact with the surface of the ovum. In the later stages of formation of the first polar body each tetrad, or quadruple chromosome, separates into two dyads or double chromosomes, and the members of each pair of dyads separate and approach opposite ends of the spindle (anaphase).

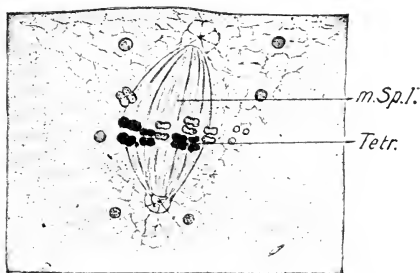


FIG. 10. — Vertical section of the germinal disc of the pigeon's egg showing the first maturation spindle. The egg was clasped by the funnel of the oviduct. 8.50 p.m. $\times 2000$. (After Harper.)

m. Sp. I., First maturation spindle. Tetr., Tetrad.

m. Sp. I., First maturation spindle. Tetr., Tetrad.

Thus at each end of the spindle there are eight dyads. Those at the outer end then enter a little bud of protoplasm projecting above the surface of the germinal disc, and this bud with the dyads is cut off as the first polar body, which lies in a depression of the germinal disc beneath the vitelline membrane (Fig. 11). Eight dyads, therefore, remain within the germinal disc.

A second maturation spindle is then formed almost immediately, apparently without the intervention of a resting stage of the nucleus, and takes a radial position similar to that occupied by the first, with the dyads forming an equatorial plate (Fig. 11).

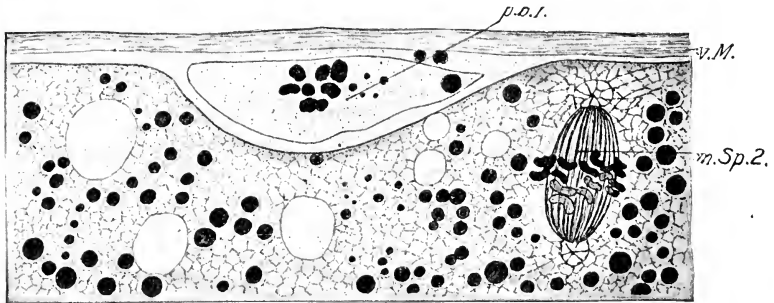


FIG. 11. — Second maturation spindle and first polar body of the pigeon's egg; a combination of two sections. 8.15 P.M. x 2000. (After Harper.)
 m. Sp. 2, Second maturation spindle. p. b. 1, First polar body. v. M., Vitelline membrane.

Each dyad then divides along the preformed plane of division, and the daughter-chromosomes diverge towards opposite poles of the spindle. The outer end of the second maturation spindle then enters a superficial bud of the protoplasm of the germinal disc similar to that of the first maturation spindle; and this bud together with the contained chromosomes becomes cut off as the second polar body.

The result of these processes of maturation is the formation of three cells, viz., the two polar bodies and the mature egg. The polar bodies are relatively very minute and soon degenerate completely.

After the formation of the second polar body there remain in the egg eight chromosomes, each of which represents one quarter of an original tetrad. These form a small resting nucleus known as the egg-nucleus or female pronucleus. It is many times smaller than the original germinal vesicle (Fig. 12), and

it rapidly withdraws from the surface of the egg to a deeper position near the center of the germinal disc. (Concerning the

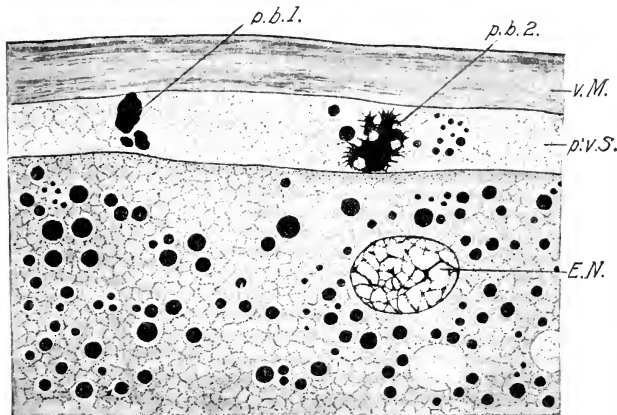


FIG. 12. — Egg nucleus (female pronucleus) and polar bodies of the pigeon's egg. (After Harper.) 8.30 P.M. x 2000.

E. N., Egg nucleus. p. b. 1, First polar body. p. b. 2, Second polar body. p'v. S., Perivitelline space. v. M., Vitelline membrane.

general theory of the maturation process see E. B. Wilson, "The Cell in Development and Inheritance," the Macmillan Company, New York.)

II. FERTILIZATION

The spermatozoa traverse the entire length of the oviduct and are found in the uppermost portion in a fertile hen. The period of life of the spermatozoa within the oviduct is considerable, as proved by the fact that hens may continue to lay fertile eggs for a period of at least three weeks after isolation from the cock. After the end of the third week the vitality of the spermatozoa is apparently reduced, as eggs laid during the fourth and fifth weeks may exhibit, at the most, abnormal cleavage, which soon ceases. Eggs laid forty days after isolation are certainly unfertilized, and do not develop (Lau and Barfurth). The so-called parthenogenetic cleavage of such eggs is merely a phenomenon of fragmentation of the protoplasm; there is no true cell-division.

The ovum is surrounded immediately after ovulation, that is in the infundibulum, by a fluid containing spermatozoa in suspension. In the egg of the pigeon from twelve to twenty-five sperm-

atozoa immediately bore through the egg-membrane and enter the germinal disc, within which the heads, which represent the nuclei of the spermatozoa, enlarge and become transformed into sperm-nuclei (Fig. 13). In the hen's egg five or six usually enter. The fate of the middle piece and tail of the spermatozoa is not known in

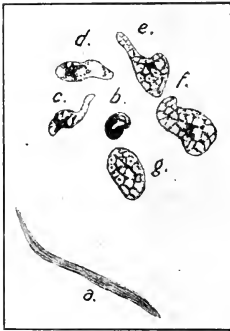

FIG. 13. — Stages in the transformation of sperm heads into the sperm nuclei from the ovum of the pigeon. x 2000. (After Harper.) The order of stages is indicated by the letters a—g.

birds, but it is improbable that they furnish any definitive morphological element of the fertilized egg. At the time of entrance of the spermatozoa the first maturation spindle is in process of formation; it lies in the center of a group of granules at the surface of the egg, which is bounded by a non-granular zone of protoplasm, called by Harper the polar ring, in which the sperm-nuclei accumulate. External to the polar ring the protoplasm is granular again (Fig. 14).

The sperm-nuclei remain quiescent while the polar bodies are being formed, and, when the egg nucleus is reconstituted, one of them, which may be called the male pronucleus or primary sperm nucleus, moves inwards and comes into contact with the egg nucleus (Fig. 15). The opposed faces of the conjugating nuclei become flattened together, until the contours form a single sphere, the first segmentation nucleus, in which a partition separates the original components, viz., the sperm and egg nucleus. The partition apparently disappears. However, it is very unlikely that a complete intermingling of the contents of the two germ-nuclei takes place, because in other groups of animals where the processes have been more fully studied, it has been determined that each germ-nucleus forms an independent group of chromosomes of the same number in each.

Shortly after its formation, the first segmentation nucleus prepares for division in the usual karyokinetic way. The first segmentation (or cleavage) spindle thus formed lies near the center of the germinal disc a short distance beneath the surface and its axis is tangential to the surface, or, in other words, at right angles to the axis of the egg. The fertilization may be considered to be completed at this stage.

The entrance of several spermatozoa appears to be characteristic of vertebrates with large ova; thus for instance, it has been described in selachii, some amphibia, reptiles, and birds. Such a condition is known as polyspermy; it is normal in the forms mentioned, but occurs only under abnormal conditions in the

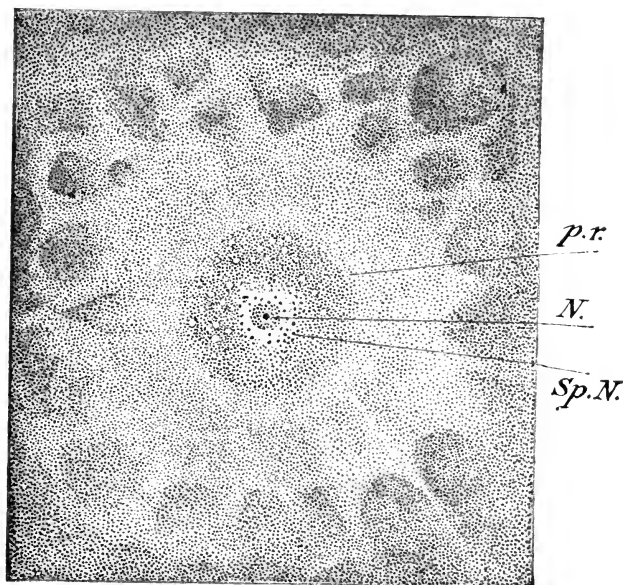


FIG. 14. — Horizontal section of the germinal disc of a pigeon's ovum immediately after ovulation. $\times 125$. (After Harper.)

N., Nucleus, probably first maturation spindle. p. r., Polar ring. Sp. N., Sperm nuclei.




FIG. 15. — Vertical section of the pigeon's egg showing germ nuclei (pronuclei) in the center of the disc. $\times 2000$. 10.40 P.M. (After Harper.)

great majority of animals. Harper observed that the number of sperm-nuclei formed in the pigeon varied from twelve to twenty-five in different cases. Only one of these serves as a functional sperm-nucleus; the remainder or supernumerary sperm-nuclei migrate, as though repelled, from the center towards the margins and deeper portions of the germinal disc, where they become temporarily active, dividing and furnishing a secondary area of small cells (accessory cleavage) surrounding the true cleavage-cells produced by division of the central portion of the disc around the descendants of the segmentation nucleus. It has been supposed by some authors who studied the selachii that the descendants of the supernumerary sperm-nuclei form functional nuclei of the so-called periblast, but this view has been disproved for the pigeon (Blount), in which it can be demonstrated that the supernumerary sperm-nuclei have but a brief period of activity, and then degenerate.

III. CLEAVAGE OF THE OVUM

The fertilized ovum is morphologically a single cell, with a single nucleus, the first segmentation nucleus. The living protoplasm is aggregated in the germinal disc, and the remainder of the ovum is an inert mass of food material destined to be assimilated by the embryo which arises from the germinal disc. The first step in the development is a series of cell-divisions of the usual karyokinetic type, restricted to the germinal disc, which rapidly becomes multicellular. As the early divisions take place nearly synchronously in all the cells, there is a tendency for the number of the cells to increase in geometrical progression, furnishing 2-, 4-, 8-, and 16- etc., celled stages; but sooner or later the divisions cease to be synchronous. All of the cells of the body are derived from the germinal disc, and the nuclei of all cells trace their lineage back to the first segmentation nucleus. The supernumerary sperm-nuclei do not take part in the formation of the embryo.

Cell-division is the most conspicuous part of the early development; hence this period is known as the cleavage, or segmentation, period. But it should be remembered first, that cell-division is as constant a process in later embryonic stages as in the cleavage period, and second, that it is probable, though little is known yet about this subject in the bird's egg, that

other important phenomena are going on during the cleavage period.

The type of cleavage exhibited by the bird's egg is known as meroblastic, for the reason that only a part of the ovum is concerned, viz., the germinal disc. This is obviously due to the great amount of yolk (see Introduction, pp. 11 and 12).

To understand the form and significance of the cleavage of the bird's egg, it is necessary first of all to gain a clear idea of the structure of the germinal disc and its relations to the yolk. At the time of the first cleavage the germinal disc is round in surface view and about 3 mm. in diameter; the center is white and is surrounded by a darker margin about 0.5 mm. wide. These two zones have been compared to the pellucid and opaque areas of later stages. We shall call the outer zone the periblastic zone, or simply periblast. In section, the germinal disc is biconvex, but the outer surface which conforms to the contour of the entire egg is much less arched than the inner surface. The disc is everywhere separated from the yellow yolk by a layer of white yolk (Fig. 2); on the other hand, there is no sharp separation between the disc and the white yolk. The granules of the latter are largest in the deeper layers and there is a gradual transition from them to the smaller yolk-granules with which the disc is thickly charged (Fig. 19). It is practically impossible in a section to say where the protoplasm of the disc ceases; it is indeed probable that it extends some distance into the white yolk both beneath and around the margins of the disc. Thus in Figure 21 a cone, apparently of protoplasm, extends into the neck of the latebra a considerable distance. In other cases it does not extend so far.

The Hen's Egg. The form of cleavage of the hen's egg is illustrated in Fig. 16, A-E. The first cleavage appears in surface view as a narrow furrow extending part way across the germinal disc (Fig. 16 A). According to Patterson it occurs just as the egg is entering the isthmus about three hours after the estimated time of fertilization. While the ends of the first cleavage furrow are still extending towards the periblast, the second division begins. It is a vertical division in each cell like the first, and the two furrows meet the first cleavage furrow at right angles. They may meet the first furrow at approximately the same point, in which case they form an approximately straight line (Fig. 16 B), or they

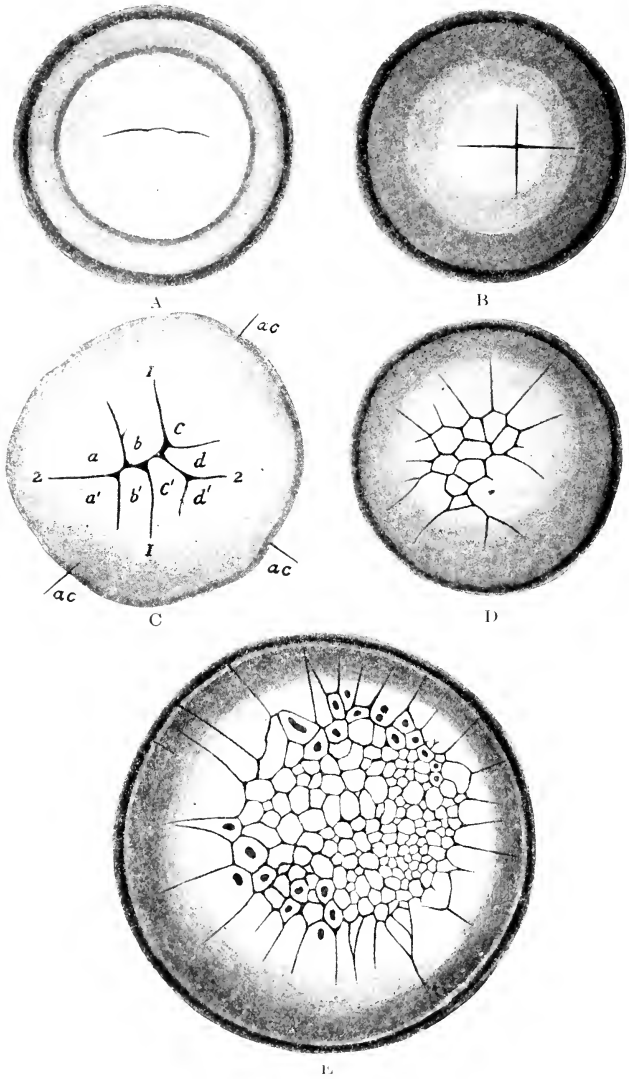


FIG. 16. — Five stages of the cleavage of the hen's egg. (A, B, D and E after Kölliker; C after Patterson.)
 A. First cleavage furrow (x 14). The egg came from the lower end of the oviduct.
 B. Four-celled stage (x 17); from the uterus.
 C. Eight-celled stage (x 18).
 D. Nine central and sixteen marginal cells (x about 16).
 E. Late cleavage stage (x about 22).

may meet the first cleavage furrow at separate points, in which case the intervening part of the first furrow becomes bent at an angle, forming a cross furrow. The third set of cleavage planes are vertical like the preceding planes, but they tend to be variable otherwise. In Fig. 16 C there is shown an eight-celled stage in which three of the new furrows are approximately at right angles to the second cleavage plane, but other arrangements are found.

Before describing the later cleavage stages, we should note certain important relations of the first four or eight cells: First, these are not complete cells in the sense that they are separate from one another. They are, indeed, areas with separate nuclei marked out by cleavage furrows in a continuous mass of protoplasm. The furrows do not cut through the entire depth of the germinal disc, and the cells are therefore connected below by the deeper layer of the protoplasm; nor do the furrows extend into the periblast, and all the cells are therefore united at their margins by the unsegmented ring of periblast. Second, according to several observers, the center of the cleavage, *i.e.*, the place where the first two cleavage furrows cross, is sometimes excentric. It was believed by those who emphasized this point, that the displacement is towards the posterior end of the blastoderm; but Coste, for instance, failed to note any excentricity, and Patterson noticed both conditions, and showed that the displacement might even be towards the anterior end of the blastoderm. In the pigeon, according to Miss Blount's observations recorded below, excentricity appears to be exceptional; moreover, the excentric area may bear any relation whatever to the future hind end of the embryo, so that in the pigeon it will not bear the interpretation that has been placed on it in the hen's egg.

The following cleavages (after the eight-celled stage) in the hen's egg are very irregular, but two classes of furrows may be distinguished in surface view: (1) those that cut off the inner ends of the cells, and (2) those that run in a radial direction. The furrows of the first class produce a group of cells that are bounded on all sides in surface view, but these are, at first, still connected below by the deeper protoplasm. They may be called the central cells. These are bounded by cells that are united in the marginal periblast, and thus lack marginal boundaries as

well as deep boundaries; they may be called the marginal cells (Fig. 16 D). The distinction between central and marginal cells is one of great importance which should be clearly grasped.

In the surface views of later cleavages the following points should be noted: (1) the group of central cells increases by the addition of cells cut off from the inner ends of the marginal cells, and by the multiplication of the central cells themselves; (2) the marginal cells increase by the formation of new radial furrows. The increase of the central cells is much more rapid than that of

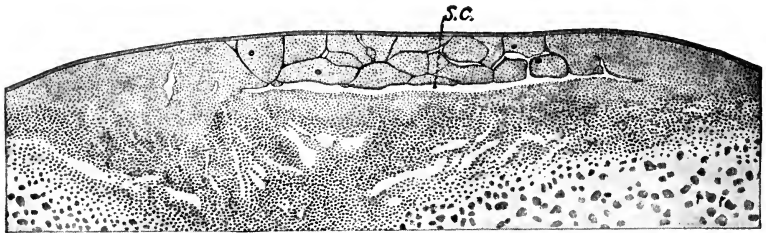


FIG. 16 A. Median section of a blastoderm of the hen's egg which showed about 64 cells in surface view (after Patterson). S.c., segmentation cavity.

the marginal cells, and the cells themselves are much smaller than the marginal cells, both because of their mode of origin and also because of their more rapid multiplication. The area of the central cells is also constantly increasing, with consequent reduction of the marginal zone (Fig. 16 E). Emphasis has been laid by several authors on the excentric position of the smallest cells, and the inference has been drawn that these represent the hinder end of the blastodisc. Similar excentricity in the pigeon's egg is without reference to the future embryonic axis (see Fig. 18).

But the surface views do not show what is going on in the deeper parts of the germinal disc. At the eight-celled stage a narrow space appears in the depth of the central portion of the blastoderm approximately between protoplasm and yolk; this is

the segmentation cavity which furnishes a lower boundary to the central cells. In later stages it extends peripherally to the inner margin of the periblast, and thus all of the central cells become completely bounded. A new class of cleavage planes then forms in these cells after the thirty-two-celled stage, horizontal or parallel to the surface; in this way the central part of the blastoderm becomes two cell-layers deep, and later several layers deep. The segmentation cavity never cuts under the marginal cells, which remain united below and at their margins by the periblast (Fig. 16 A).

In the older accounts of the horizontal cleavages by Kölliker, Duval and others these are represented as forming before the segmentation cavity, thus leaving the deeper cell in continuity with the yolk. Such cells are then supposed to continue budding off cells from their upper surfaces. But this view has been shown to be incorrect by the observations of Miss Blount on the pigeon described below and by Patterson on the hen included above.

The Pigeon's Egg. The cleavage of the pigeon's egg has been worked out in detail by Miss Blount; as it must be made the basis of the description of the formation of the germinal wall and the germ-layers in the absence of any consistent account for the hen's egg, it will next be described. The fundamental features of the cleavage are the same as in the hen's egg, so that the description need not be repeated.

The feature to be particularly emphasized in the cleavage of the pigeon's egg is the occurrence of a secondary or accessory cleavage in the marginal zone or periblast (Figs. 17 and 18 A). When the origin of these cells is traced it is found that they arise around the supernumerary sperm-nuclei, which accumulate and multiply in the periblast. The complete history of these nuclei has been worked out by Harper and Blount, so that there can be no doubt as to their derivation. Another interesting point illustrated by the figures is that the marginal cells have a peripheral wall wherever the accessory cleavage occurs, but between the groups of accessory cleavage cells the marginal cells are continuous with the periblast (Figs. 17 and 18 A,) as they are

everywhere in the hen's egg. In a section of a germinal disc, showing the accessory cleavage (Fig. 20), it is seen that the peripheral boundary of the marginal cells cuts under the margin for a considerable distance.

The accessory cleavage becomes manifest at the time of appearance of the first cleavage plane, and increases in amount

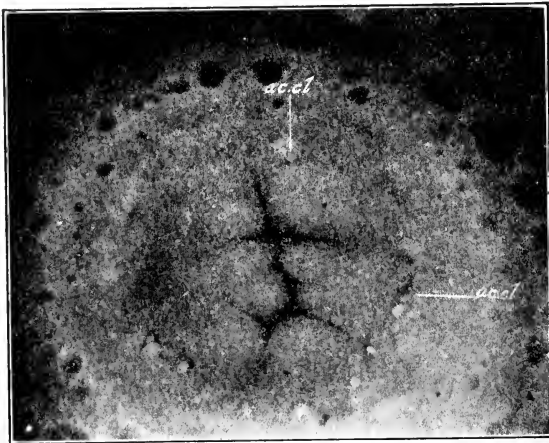


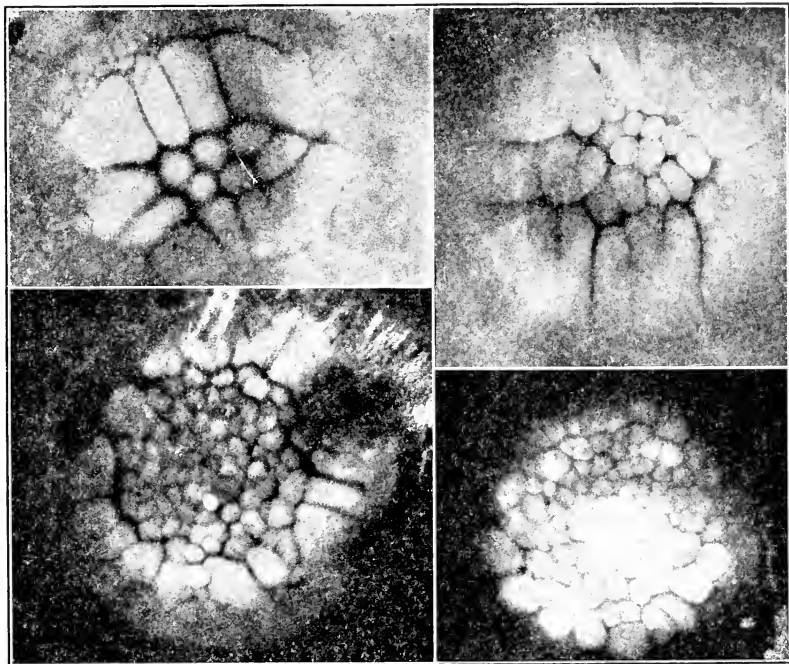
FIG. 17. — Photograph of an eight-celled pigeon ovum (after Mary Blount). 2.45 A.M. Accessory cleavage (ac. cl.) in the marginal zone bounding the segmented area. Vesicles, appearing black in the photograph, are seen on the surface of the yolk beyond the marginal zone of the germinal disc. Orientation as in Fig. 18.

up to about the 32-celled stage, and thereafter gradually decreases until it completely disappears (Figs. 18 B, C, and D). The peripheral boundaries of the marginal cells disappear *pari passu*, and, when the accessory cleavage is finally wiped out, the marginal cells are everywhere continuous with the periblast, as in the hen's egg (Figs. 18 B and C). In some eggs the accessory cleavage is much more extensive than in others; indeed, in some it appears to be entirely absent, but this is relatively rare. In the stage shown in Fig. 18 B, for instance, there is usually considerable accessory cleavage; but in this egg there is none. The variation is obviously due to variations in the number of supernumerary spermatozoa, such as may readily occur.

The question arises whether the disappearance of the cell-walls around the sperm-nuclei is caused by degeneration of the latter, or is simply a later syncytial condition in the periblast in

A

B



C

D

FIG. 18. — Photographs of the cleavage of the pigeon's ovum (after Mary Blount). The figures are so arranged that the axis of the shell is across the page with the large end to the left. The future axis of the embryo is therefore inclined 45° to the margin of the page with the anterior end to the right above.

A. A very regular sixteen-celled stage; accessory cleavage well shown; though not well focused on the lower margin. 3.45 A.M.

B. Approximate thirty-two celled stage. There is no accessory cleavage in this case. The formation of the central from the marginal cells may be readily observed in this figure. 5.15 A.M.

C. Later stage of cleavage. 7.10 A.M.

D. Cleavage at 9.30 A.M. The marginal cells are now becoming separated peripherally from the periblast which has received its nuclei from them.

which the sperm-nuclei are embedded. There can be little doubt that the former alternative is correct. While in the stages of the accessory cleavage, sperm-nuclei are readily found both in

the accessory cleavage-cells and also in the unsegmented periblast (Figs. 19 and 20), they decrease in number as the accessory cleavage planes disappear, and when the latter are entirely lost

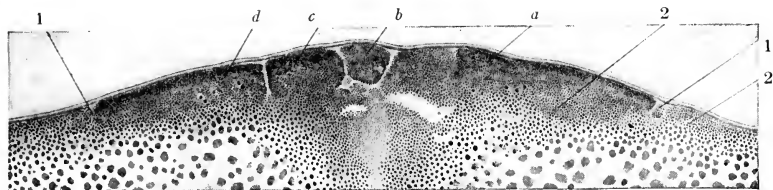


FIG. 19. — Transverse section of the blastoderm of a pigeon's egg about 8½ hours after fertilization (4.45 A.M.). (After Blount.)

1, Accessory cleavage. 2, Migrating sperm-nuclei. a, b, c, d, Cells of primary cleavage.

the periblast is absolutely devoid of nuclei. Fragmentation of the sperm-nuclei is a frequent accompaniment of their disappearance.

Thus the accessory cleavage is a secondary and transient feature of the cleavage of the pigeon's egg due to polyspermy. After it has passed, the ovum is in precisely the same condition

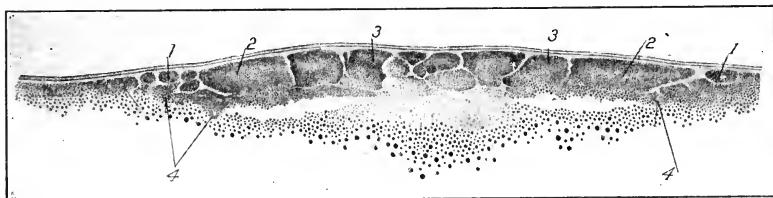


FIG. 20. — Transverse section of the blastoderm of a pigeon's egg at the end of the period of multiplication of sperm-nuclei, about 10 hours after fertilization (6.30 A.M.). (After Blount.)

1, Accessory cleavage around the sperm-nuclei. 2, Marginal cells; sharply separated from the sperm-nuclei. 3, Central cells. 4, Sperm-nuclei.

as the hen's ovum of the same stage of development. In the hen's egg Patterson has shown that there is a very limited and inconspicuous accessory cleavage (see Fig. 16 C) around the fewer supernumerary sperm-nuclei that occur. But most of these nuclei in the hen tend to pass into deeper portions of the disc and there undergo complete fragmentation without producing superficial furrows.

Another feature brought out by these photographs requires emphasis. The periblast ring shows no definite outer margin,

but beyond the zone of the accessory cleavage there may occur two or three concentric circles variously indicated (Fig. 17). Vacuoles, appearing black in the photographs, are very common in the outer zones. These appearances indicate that the periblastic protoplasm extends farther out in the superficial white yolk than is usually believed to be the case; and this suggests an interesting comparison with the teleost ovum, where the periblastic protoplasm surrounds the entire yolk as a very thin layer. Sections confirm the idea that the periblastic protoplasm has an extension beyond the so-called margin of the blastodisc. Some eggs show a more definite margin than others; it may be that there is a periodic heaping of the periblast at the margins, for which again an analogy may be found in teleosts.

Although the smallest cells may be more or less excentric in the segmented germinal disc of the pigeon, their position bears no constant relation to the future embryonic axis. They may lie in this axis in front of or behind the middle, or to the right or left of it (cf. Fig. 18 A-D).

At the eight-celled stage a horizontal fissure begins to appear beneath the central cells (Fig. 19). This marks the full depth of the blastoderm at all stages, and the several-layered condition arises by horizontal cleavages between this and the surface. Comparison of Figs. 19, 20, and 22, drawn at the same magnification, will show that the depth does not increase by addition of cells cut off from below, as was once supposed to be the case in the bird's ovum. The horizontal fissure not only marks the full depth of the blastoderm, but it also indicates the site of the segmentation cavity which arises gradually by accumulation of fluid between the cells and the underlying unsegmented protoplasm and yolk. The segmentation cavity gradually extends towards the margin of the blastoderm, but it is bounded peripherally by the zone of junction between the marginal cells and the periblast.

IV. ORIGIN OF THE PERIBLASTIC NUCLEI, FORMATION OF THE GERM-WALL

Our knowledge of this part of the subject in the hen's egg is very incomplete, and the various accounts are contradictory. The reason for this is the great difficulty of securing a complete series of stages, and of arranging them in proper sequence. There

is no way of timing the development, so that one has to judge the sequence of the stages, all of which come from the uterus, by the degree of formation of the shell, by the size of the cells and by the appearance of the sections. This can be at best only approximate; and, as the securing of any given stage is largely a matter of chance, no one has, as a matter of fact, secured a complete series. In the pigeon, on the other hand, the time since laying the first egg is a fairly exact criterion of the stage of development of the second egg. It has, therefore, been possible to secure a complete series, and the subject has been worked out by Miss Blount, whose publications furnish the basis of the following account.

The periblast ring is entirely devoid of nuclei after the supernumerary sperm-nuclei have degenerated. The marginal cells become greatly reduced in size owing to multiplication and continuous production of central cells, and their nuclei thus approach more and more closely to the periblastic ring. The scene then changes; the marginal cells cease to produce central cells; when their nuclei divide the peripheral daughter-nuclei move out into the periblast, which is thus converted into a nucleated syncytium. The periblastic nuclei multiply rapidly and invade all portions of the periblastic ring, which maintains its original connection with the white yolk. Not only do the periblastic nuclei invade the periblastic ring, but some of them also migrate centrally into the protoplasm forming the floor of the segmentation cavity. They do not, however, reach the center, but leave a non-nucleated sub-germinal area, corresponding approximately to the nucleus of Pander, free from nuclei. The subgerminal syncytium may be known as the central periblast to distinguish it from the marginal periblast. They are, of course, continuous. In sections one has the appearance of nuclei in the yolk, for there is no sharp boundary between periblast and yolk (Fig. 22). The syncytium, which has received its nuclei from the marginal cells, is the primordium of the germ-wall (Figs. 21, 22, 23, 24).

There is a sharp contrast between the segmented blastoderm and the syncytial periblast not only in structure but also as regards fate. The marginal cells constitute a zone of junction between blastoderm and periblast. Thus in Fig. 22 it will be ob-

served that the large marginal cells on each side are continuous with the periblast, and nuclei are found in the periblast both central and peripheral to the zone of junction. The latter forms

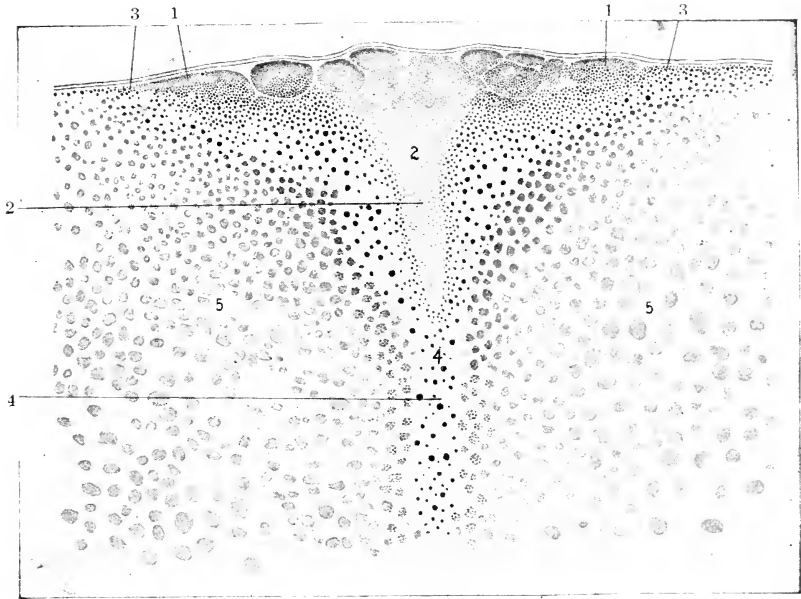


FIG. 21. — Longitudinal section of the blastoderm of a pigeon's egg at the time of disappearance of the sperm-nuclei. On the left (anterior) margin, the marginal cells have become open, that is, continuous with the periblast, as contrasted with Fig. 20. About 11 hours after fertilization (7.00 A.M.). (After Blount.)

1, Marginal cells. 2, Cone of protoplasm. 3, Marginal periblast. 4, Neck of latebra. 5, Yellow yolk.

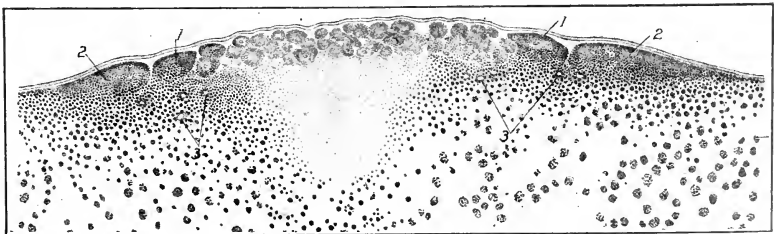


FIG. 22. — Transverse section through the center of the blastoderm of a pigeon's egg, 14½ hours after fertilization (10.30 A.M.). (After Blount.)

1, Marginal cells. 2, Marginal periblast. 3, Nuclei of the subgerminal periblast.

a ring around the blastoderm. It persists during the expansion of the blastoderm over the surface of the yolk.

The blastoderm now begins to expand, owing largely, at first, to additions of cells to its margin cut off from the periblast. The central as well as the marginal periblast contributes to the blastoderm, but the former appears to be rapidly used up. The marginal periblast, which is commonly called the germ-wall from this stage, on the other hand grows at its periphery while it adds cells to the blastoderm centrally, and thus it moves out in the white yolk, building up the margin of the blastoderm at the same time. The original group of central cells appears to correspond approximately to the pellucid area; the additions from the germ-wall would thus constitute the opaque area.

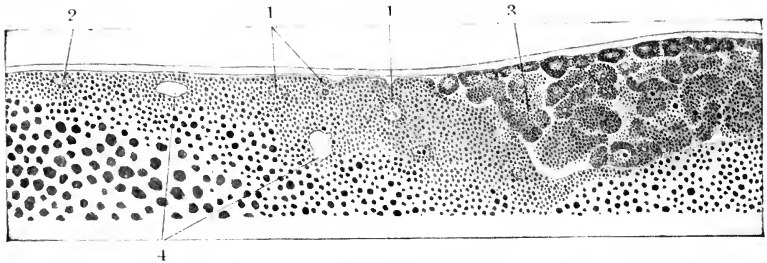


FIG. 23. — Posterior end of a longitudinal section through the blastoderm of a pigeon's egg about 25 hours after fertilization (8.50 P.M.). (After Blount.)

1, Nests of periblast nuclei. 2, Periblast nucleus in marginal position. 3, Syncytial mass derived presumably from the periblast, in process of organization into cells. 4, Vacuoles.

Some phases of these processes are illustrated in Figs. 23 and 24. In the vertical section, Fig. 23, the surface of the germ-wall next the blastoderm is indented as though for the formation of superficial cells. Along the steep central margin of the germ-wall groups of cells are apparently being cut off and added to the cellular blastoderm. In the horizontal section, Fig. 24, the process of cellularization at the central margin of the germ-wall is apparently proceeding rapidly.

The superficial cells thus added to the margin of the cellular blastoderm become continuous with the ectoderm, and the deeper layers later form the yolk-sac entoderm which becomes continuous with the embryonic entoderm secondarily. We can

thus distinguish a syncytial, more peripheral, and a cellular, more central, portion of the germ-wall.

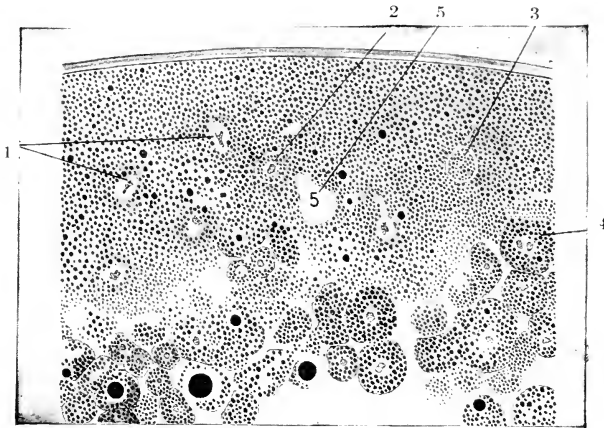


FIG. 24. — Part of the margin of a horizontal section through the blastoderm of a pigeon's egg about 25 hours after fertilization (8.50 P.M.). (After Blount.)

1, Periblast nuclei. 2, 3, Cells organized in the periblast. 4, A cell apparently added to the blastoderm from the periblast. 5, Vacuoles.

In later stages the central margin of the syncytial part of the germ-wall becomes much less steep, owing apparently to active proliferation of cells. This is illustrated in Fig. 25. Later yet

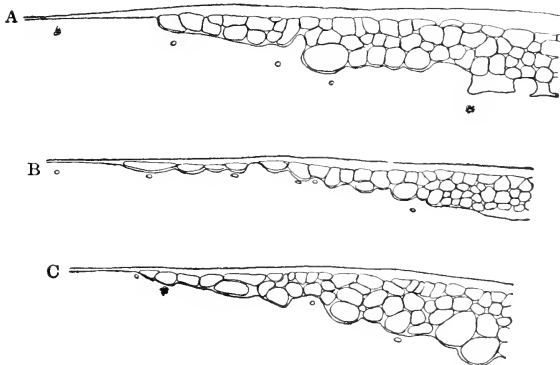


FIG. 25. — Outlines of the margins of transverse sections of the blastoderm of pigeon's eggs; 26 (A), 28 (B), and 32 (C) hours after fertilization. (After Blount.)

the external margin extends out peripherally and forms a short projecting shelf, appearing wedge-shaped in section (Figs. 28 A, etc.). This we shall call the margin of overgrowth.

Thus we may distinguish the following zones: (1) margin of overgrowth; (2) zone of junction with the yolk (syncytial germ-wall); (3) the inner zone of the germ-wall, and (4) the original cellular blastoderm (pellucid area) Fig. 29.

V. ORIGIN OF THE ECTODERM AND ENTODERM

The ectoderm and entoderm are the primary germ-layers, out of which all organs of the embryo differentiate; hence great importance attaches to the mode of their origin. But until recently it was not possible, in the case of the chick, to decide between three conflicting views. These are: (1) The theory of delamination, viz., that the superficial cells of the segmented blastoderm form the ectoderm and the deeper cells the entoderm; in other words, that the blastoderm splits into the two primary germ-layers. This is the oldest view, but it has not lacked support in recent times, *e.g.*, by Duval. (2) The theory of invagination, viz., that the primary entoderm arises as an ingrowth from the margin of the blastoderm. This view, which was supported by Haeckel, Goette, Rauber, and some others, brings the mode of gastrulation in the bird into line with lower vertebrates. (3) A third and relatively recent point of view is that the primary entoderm arises as an ingrowth of cells from the germ-wall, more particularly from the posterior portion. This view, put forward by Nowack, has been adopted in substance by O. Hertwig (*Handbuch der vergl. u. exp. Entwicklungslehre der Wirbeltiere*).

The conflict of opinion was due to the fact that the critical stages occur prior to laying, and no one had investigated a complete series of stages until recently. The investigations of J. T. Patterson on the pigeon have, however, cleared the matter up. A very complete series of stages of the pigeon's ovum was studied, with results that are consistent in themselves and that agree with the principles of formation of the primary germ-layers in the lower vertebrates.

The first step in the process of gastrulation, or formation of

the primary entoderm, is a thinning of the blastoderm, which begins slightly posterior to the center and rapidly involves a sector of the posterior third of the blastoderm. This process occurs between twenty and thirty-one hours after fertilization. It is due apparently to the gradual rearrangement of the cells in a single layer. A late stage of this process is shown in Figure 26, which represents a complete longitudinal section through the blastoderm thirty-one hours after fertilization. It will be observed that the anterior portion of the blastoderm is several cells thick (26 A), but as one passes towards the posterior end the number of layers becomes less, and is reduced to a single layer at the extreme posterior end. Here and there, *e.g.*, at X, the arrangement of the cells indicates that cells of the lower layer are entering the upper layer. It is obvious that such a process must result in increase of the diameter of the blastoderm, and Patterson states that the average diameter twenty-one hours after fertilization is 1.915 mm. and 2.573 mm. ten hours later. The thinning also involves enlargement of the segmentation cavity, which may now be known as the subgerminal cavity.

Hand in hand with the thinning out there takes place an interruption of the germ-wall at the posterior end, so that in this region the margin no longer enters a syncytium but rests directly on the yolk (*cf.* anterior and posterior ends of Fig. 26).

Figure 27 is a reconstruction of the stage in question. The germ-wall, represented by the parallel lines, is absent at the posterior end. Here the cells of the blastoderm rest directly on the yolk. The sector bounded by this free margin and the broken line represents the area of the blastoderm that is approximately one cell thick. The figures 2 to 7 indicate regions approximately two to seven cells thick.

Gastrulation begins by an involution or rolling under of the free margin, as though the free edge were tucked in beneath the blastoderm. The involuted edge then begins to grow forward towards the center of the blastoderm, and thus establishes a lower layer of cells, the primary entoderm. As soon as this process is started the margin of the blastoderm begins to thicken, and thus the inner layer of cells (entoderm) and the outer layer of cells (ectoderm) are continuous with one another in a marginal thickening (Fig. 28).

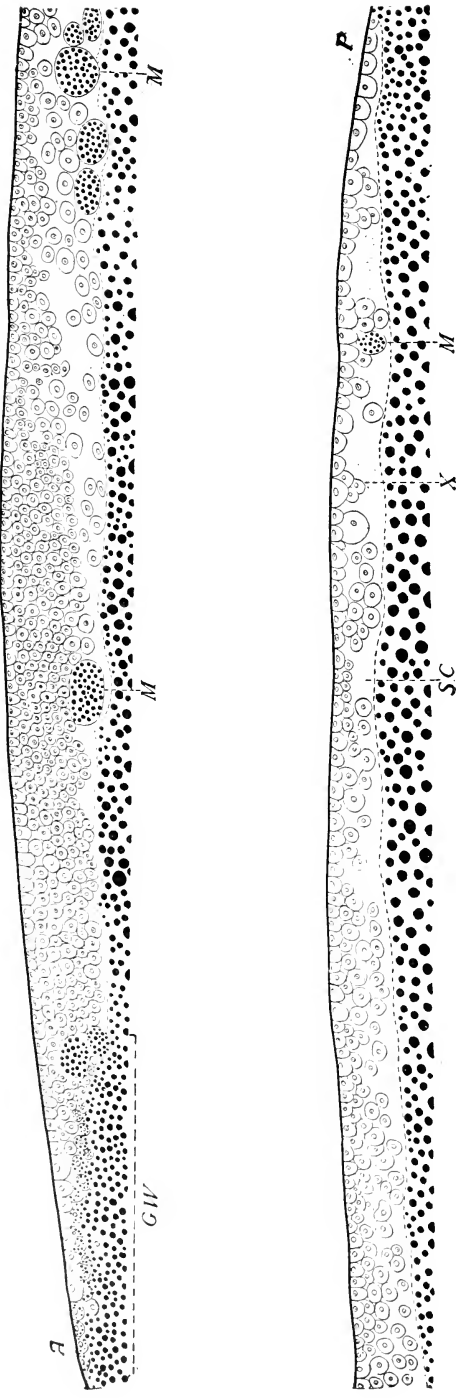


FIG. 26. — Median longitudinal section of the blastoderm of a pigeon's egg, 31 hours after fertilization, x 129.5. (After Patterson.)
 A., Anterior end of section. G.W., Germ-wall. M., Masses of yolk granules in the segmentation cavity. P., Posterior end of section.
 S.C., Segmentation cavity. X., Cells which may later enter the single layer.

The margin of invagination is known as the lip of the blastopore or primitive mouth; the space between this margin and the yolk is the blastopore, and the space between the entoderm and yolk, derived from part of the subgerminal cavity, is the archenteron or primitive intestine.

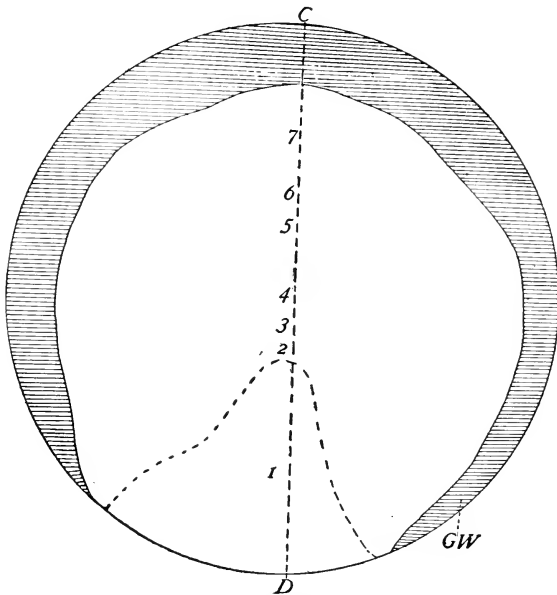


FIG. 27. — Diagrammatic reconstruction of the blastoderm of which a longitudinal section is shown in Fig. 26.

C-D., Plane of Fig. 26.

G. W., Germ-wall. 1, 2, 3, 4, 5, 6, and 7 indicate regions of the blastoderm which are approximately from 1 to 7 cells deep respectively. The broken line around 1 indicates the region where the blastoderm is approximately one cell deep. $\times 27.2$. (After Patterson.)

The first stage in the formation of the entoderm is interpreted as involution of the free margin, and this view is supported by the fact, determined by Patterson, that the antero-posterior diameter of the blastoderm is shorter than the transverse diameter during this process, whereas previously the blastoderm was approximately circular. An even stronger support of this view is furnished by experiments which demonstrate that injuries to the margin made just prior to gastrulation appear later in an

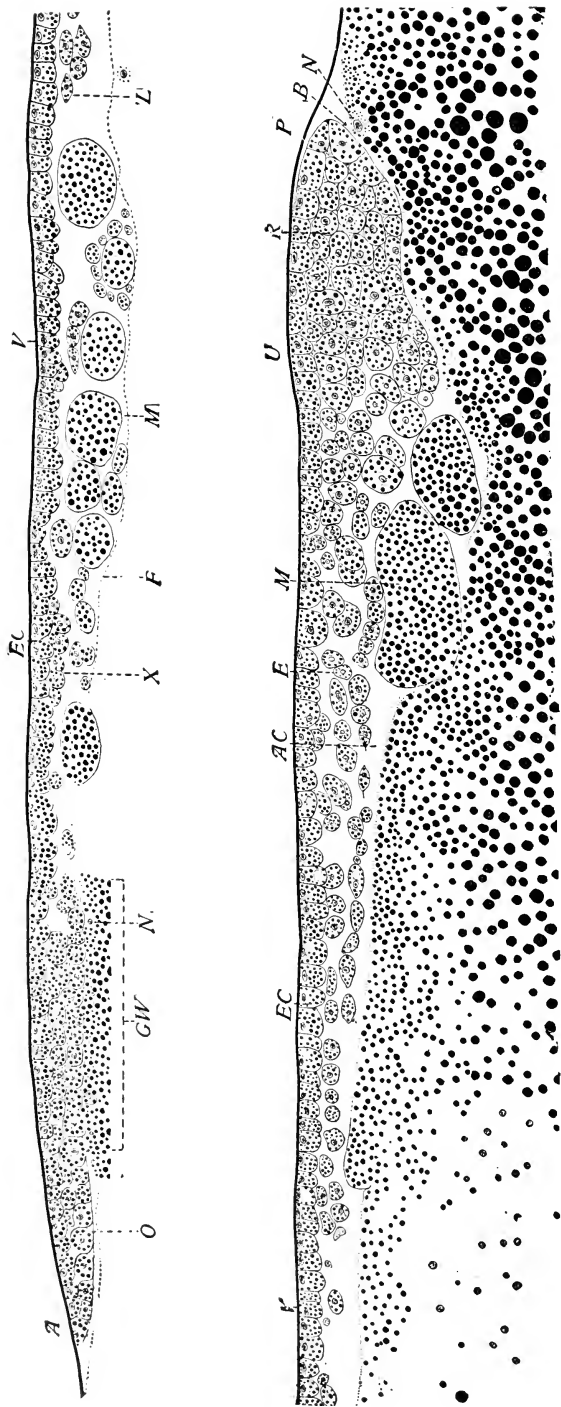


Fig. 28. — Gastrulation in the pigeon; longitudinal section about through the line C. D. Fig. 29. (After Patterson.) 36 hours after fertilization. Anterior half of section above. Posterior half of section below. B., Blastopore. E., Entoderm. EC., Ectoderm. F., Floor of segmentation cavity. G.W., Germ-wall. M., Yolk mass in the segmentation cavity. N., Nuclei of the germ-wall. O., Margin of overgrowth. R., Margin of invagination (dorsal lip of blastopore). V., Vitelline membrane. X., Segmentation cells apparently entering the single-layered ectoderm. Z., Anterior limit of invaginated entoderm.

anterior position in the entoderm (Patterson). But after the margin has thickened the farther extension of the entoderm is due, largely at least, to ingrowth from the marginal thickening.

Patterson also believes that the thickening of the margin is due not so much to multiplication of cells *in situ* as to immigration of cells from the sides. This view is also supported by experiments.

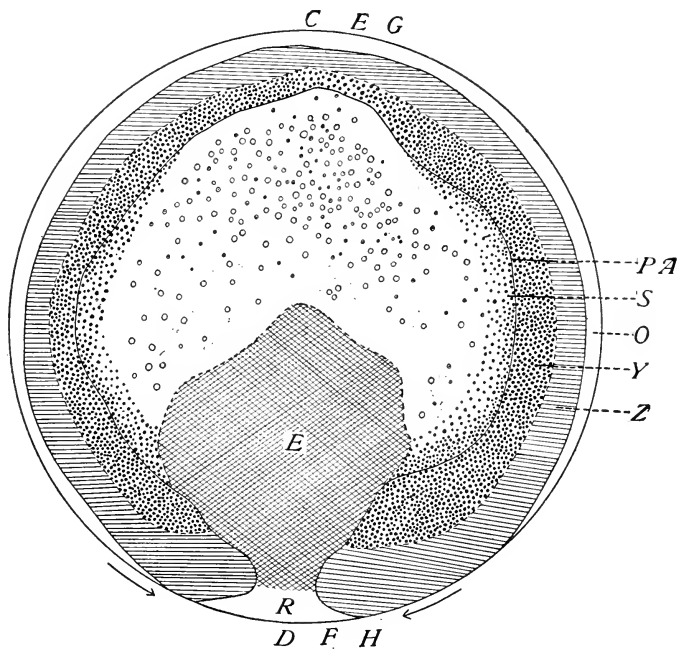


FIG. 29. — Diagrammatic reconstruction of the blastoderm of a pigeon's egg, 36 hours after fertilization; from the same series as Fig. 28. x 27.2. (After Patterson.)

E., Invaginated or gut entoderm. O., Margin of overgrowth. PA., Outer margin of pellucid area. R., Margin of invagination (dorsal lip of blastopore). S., Beginning of yolk-sac entoderm. Y., Yolk zone. Z., Zone of junction.

The arrows at the posterior margin indicate the direction of movement of the halves of the margin. The circles in the pellucid area indicate yolk masses in the segmentation cavity.

Figure 29 is a reconstruction of a blastoderm in the stage of Fig. 28, that is at the height of gastrulation. The margin of overgrowth (cf. Fig. 28 O) is represented by the area O; the zone of junction by the ruled area Z; the inner portion of the

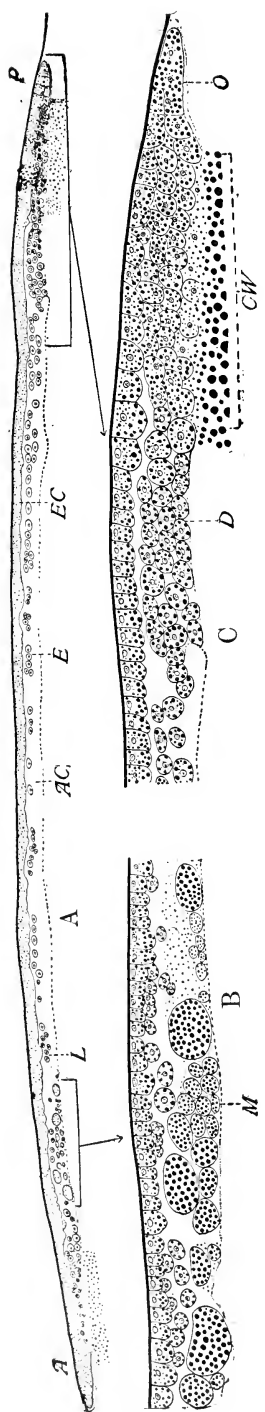


FIG. 30. — Median longitudinal section of the blastoderm of a pigeon's egg 38 hours after fertilization. (After Patterson.)
 A. x 72. B and C. Parts of the section indicated, x 169.

A., Anterior. A. C., Subgerminal cavity. D., Mass of cells left after closure of blastopore. E., Entoderm. EC., Ectoderm. L., Anterior end of invaginated entoderm. O., Margin of overgrowth. P., Posterior.

germ-wall by the area with large granules *Y*. These zones constitute the opaque area. The circles in the pellucid area represent megaspheres, that is yolk-masses cut off from the floor of the subgerminal cavity and lying in the latter (cf. Fig. 28 *M*). The invaginated entoderm is represented by the crossed area *E*; the lip of the blastopore, where ectoderm and entoderm are continuous, by the region *R*.

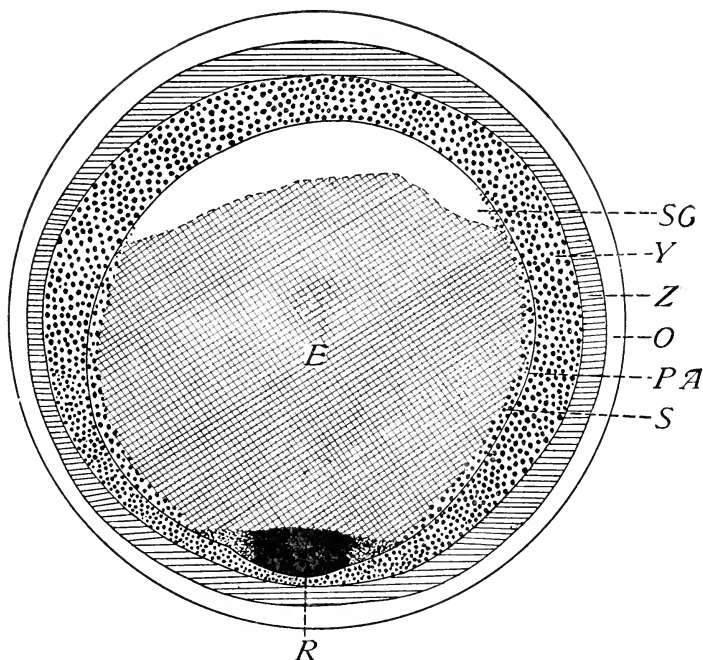


FIG. 31. — A diagrammatic reconstruction of the blastoderm represented in Fig. 30. (After Patterson.)

R., Mass of cells left after closure of blastopore. *S.G.*, Anterior portion of subgerminal cavity not yet crossed by the entoderm. Other abbreviations as in Fig. 29.

The last three or four hours prior to laying witness the closure of the blastopore. A comparison of Figs. 27 and 29 will show that the blastopore has become considerably narrower in the later stage. It will be observed that the posterior ends of the germ-wall are approaching. Finally they come into contact, and the blastopore is closed. During this process the lip of the blastopore is not cut off externally, but on the contrary comes

to lie within the germ-wall at the posterior margin of the pellucid area.

This is illustrated by Figs. 30 and 31, representing a longitudinal section and a reconstruction of a blastoderm three hours before laying. Considering the reconstruction first, it will be noted that the lip of the blastopore, R, now lies within the blastoderm at the posterior margin of the pellucid area. The greater portion of the pellucid area is now two-layered owing to the continued expansion of the entoderm E, which has met and united with the germ-wall at the sides. The section (Fig. 30) passes longitudinally through the center of the blastoderm. The mass of cells at D represents the original lip of the blastopore. It is continuous with the germ-wall behind and with the entoderm in front. The latter is not a continuous layer (Fig. 30 A), and the cells are not coherent. It is probable that the extension of the entoderm is due largely to independent migration of the cells. Subsequently the entoderm cells unite to form a coherent layer of flattened cells. (See Chap. IV.)

In some cases the closure of the blastopore takes place in such a way as to produce a marginal notch, which is referred to again in connection with the primitive streak (Chap. IV).

CHAPTER III

OUTLINE OF DEVELOPMENT, ORIENTATION, CHRONOLOGY

THE preceding chapters have traced the development up to the time of laying. The formation of the germ-layers has begun; and the stage of development is fairly definite, though not absolutely constant. When the egg cools, after laying, the development ceases, but is renewed when the temperature is raised to the required degree by incubation.

On the surface of the yolk is a whitish disc about 4 mm. in diameter, known as the blastoderm. Edwards gives the average diameter of the unincubated blastoderm (59 eggs) as 4.41 mm., of the area pellucida (50 eggs) as 2.51 mm. The central part of the blastoderm is more transparent and is hence known as the area pellucida; beneath it is the subgerminal cavity. The less transparent periphery is known as the area opaca. In the course of development the embryo, and the embryonic membranes which serve for the protection, respiration, and nutrition of the embryo, arise from the blastoderm.

The embryo proper arises within the area pellucida, which becomes pear-shaped as the embryo forms; the remainder of the blastoderm beyond the embryo is extra-embryonic. From it arise the embryonic membranes known as the amnion, chorion, and yolk-sac. The allantois (Fig. 33 B) arises as an outgrowth from the hind-gut of the embryo, and spreads within the extra-embryonic body-cavity; it thus becomes an extra-embryonic membrane secondarily. The growth of the embryo and of the extra-embryonic blastoderm are distinct, though interdependent, processes going on at the same time.

During the first four days of development the blastoderm spreads very rapidly (Figs. 32 and 33). Thus on the fourth day (Fig. 33 A) the greater portion of the yolk is already covered. Thereafter the overgrowth of the yolk proceeds much more slowly (cf. Fig. 33 B). In the opaque area there arise, as concentric zones, the area vasculosa distinguished by its blood-vessels and the area

vitellina, which may be divided into inner and outer zones (Figs. 32 and 33). The development of the embryo during the same period is indicated in the same figures.

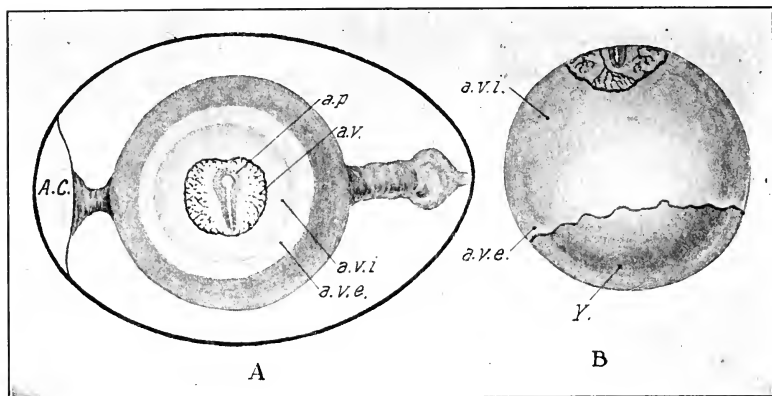


FIG. 32. — A. Hen's egg at about the twenty-sixth hour of incubation, to show the zones of the blastoderm and the orientation of the embryo with reference to the axis of the shell. (After Duval.)

B. Yolk of hen's egg incubated about 50 hours to show the extent of overgrowth of the blastoderm. (After Duval.)

A. C., Air chamber. a. p., Area pellucida. a. v., Area vasculosa. a. v. e., Area vitellina externa. a. v. i., Area vitellina interna. Y., Uncovered portion of yolk.

The blastoderm early becomes divided in two layers as far as the margin of the vascular area. The outer layer, known as the somatopleure, is continuous with the body-wall, which is open ventrally in the young embryo. The inner one, known as the splanchnopleure, is continuous with the wall of the intestine which is likewise open ventrally. The space between these two membranes, the extra-embryonic body-cavity, is continuous with the body-cavity of the embryo. Ultimately, the splitting of the blastoderm is carried around the entire yolk, so that the latter is enclosed in a separate sac of the splanchnopleure, the yolk-sac, which is connected by a stalk, the yolk-stalk, to the intestine of the embryo. This stalk runs through an opening in the ventral body-wall, the umbilicus, where the amnion, which has developed from the extra-embryonic somatopleure, joins the body-wall (Fig. 33 B).

About the nineteenth day of incubation the yolk-sac is drawn

into the body-cavity through the umbilicus, which thereupon closes. The young chick usually hatches on the twenty-first day.

Orientation. It is an interesting and important fact that the embryo appears in a definite relation to the line drawn through the axis of the entire egg, or to the line joining the bases of the two chalazæ, which is usually the same thing. If the egg be placed as in Fig. 32 A, with the blunt end to the left, the head of the embryo will be found directed away from the observer when the blastoderm is above; the left side of the embryo is therefore towards the broad end, and the right side towards the narrow end of the egg. According to Duval this orientation is

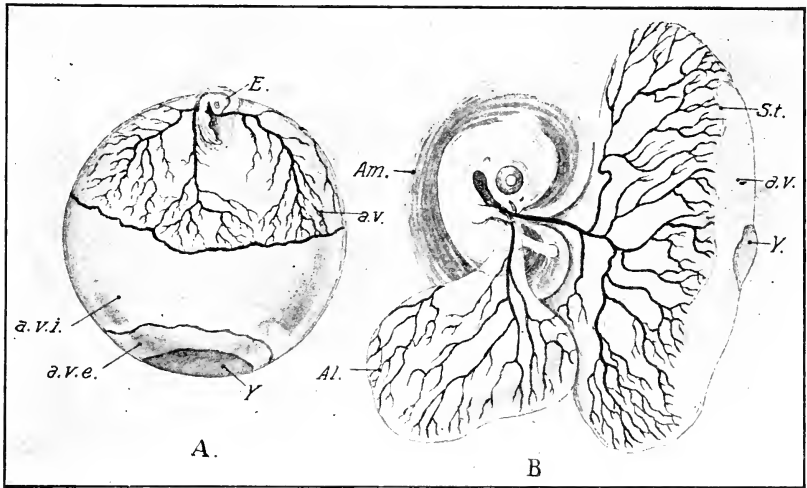


FIG. 33. — A. Yolk of hen's egg incubated 84 hours. (After Duval.)

B. Embryo and membranes of the hen's egg on the seventh day of incubation. (After Duval.)

Al., Allantois. Am., Amnion. a. v., (in B) Area vitellina. E., Embryo. S. t., Sinus terminalis. Other Abbreviations as in Fig. 32.

found in about 98.5 % of eggs: of 166 eggs observed, in which the embryo was formed, Duval found 124 oriented exactly in this manner, 39 in which the axis of the embryo was slightly oblique, 2 in which the head was towards the broad end, and 1 in which the usual position was completely inverted. In the pigeon's egg the orientation of the embryo is equally definite, but slightly different. The axis of the embryo cuts the axis of the entire egg at an angle of about 45°, the head of the embryo being

directed away from the observer to the right, when the broad end of the egg is to the observer's left as in Fig. 32 A.

The definiteness of orientation of the embryo with reference to the axis of the egg enables one to distinguish anterior and posterior ends of the blastoderm before there is any trace of an embryo; and while there is no possibility of orientation by examination of the blastoderm itself, or when such orientation is otherwise extremely difficult. By the method of orienting the blastoderm with reference to the axis of the shell, observers have been able to discover important features of the early development which would otherwise, no doubt, have escaped observation. The relation is of interest in other respects discussed in their appropriate places. (See p. 15.)

Chronology (Classification of Stages). The development of an animal is an absolutely continuous process, but for purposes of description it is necessary to fix certain stages for comparison with those that precede and those that follow. Each stage has a certain position in the continuous process, and the correct arrangement of stages is therefore a *sine qua non* for their correct interpretation. This may seem a very simple matter seeing that development is in general from the more simple to the more complex. And it would be so if it were not for the fact that embryonic stages, like the adult individuals of a species, vary more or less, so that no one embryo is ever exactly like another. These embryonic variations involve (1) the rate of development of the whole embryo, so that at a given time in the process no two embryos are in exactly the same stage; (2) the relative rates of development of different organs; (3) the size of the embryo, for embryos of the same stage of development may vary somewhat in size.

Although the total period of incubation is fairly constant in the hen's egg, about twenty-one days, yet there is great variation in the grade of development of embryos of the same age, especially during the first week. This is due to two main factors: first, variation in the latent period, that is the time necessary to start the development of the cooled blastoderm after the egg is put into the incubator, and second, to variation in the temperature of incubation. Individual eggs may vary in rate of development when these two factors are constant, but this difference is relatively slight. Other things being equal, the latent period

varies with the freshness of the egg; it is relatively short in eggs that are newly laid, and long in eggs that have remained quiescent some time after laying. It is obvious that the latent period will form a more considerable portion of the entire time of incubation in early than in late stages. Hence the difficulty of classifying embryos, particularly in the first four or five days of incubation, by period of incubation. Eggs procured from dealers usually show such great variations in degree of development, at the same time of incubation, that it is quite impossible to grade them with any high degree of accuracy by time of incubation. It is stated also that the rate of development varies considerably at different seasons, other factors being constant. But this has not been found to be a serious matter in my own experience.

Variations in temperature, either above or below the normal, also seriously affect the rate of development, and produce abnormalities when extreme. If the temperature be too low, the rate is slower than normal; if too high, the rate increases up to a certain point, beyond which the egg is killed.

The physiological zero, that is the temperature below which the blastoderm undergoes no development whatever, has been estimated differently by different authors. Some place it at about 28° C., others at about 25°; Edwards places it as low as 20–21° C. At the last temperature, apparently, a small percentage of eggs will develop in the course of several days to an early stage of the primitive streak, but most eggs show no perceptible development. In very warm weather, therefore, the atmospheric temperature may be sufficient to start eggs. The following table is given by Davenport based on Féré's work:

Temperature	34°	35°	36°	37°	38°	39°	40°	41°
Index of Development	0.65	0.80	0.72		1.00	1.06	1.25	1.51

The index of development represents the proportion that the average development at a given temperature in a given time bears to the normal development (*i.e.*, development at the normal temperature for the same time). There is an increase in the rate up to 41°; a maximum temperature, which cannot be much above 41°, causes the condition of heat-rigor and death.

There would seem to be no better way to determine the normal temperature for incubation than by measuring the temperature

of eggs incubated by the hen throughout the entire period of incubation. This has been done very carefully by Eycleshymer, who finds the internal temperature of such eggs to be as follows:

Day of incubation	1	2	3	4	5
Temperature of hen	102.2	103.0	103.5	104.0	103.8
Temperature of egg	98.0	100.2	100.5	100.5	100.4
Day of incubation	6	7	8	9	10
Temperature of hen	105.0	104.6	104.5	105.0	105.0
Temperature of egg	101.0	101.8	102.5	101.6	102.0
Day of incubation	11	12	13	14	15
Temperature of hen	104.8	105.2	104.5	105.0	105.2
Temperature of egg	101.8	102.2	102.0	102.5	102.0
Day of incubation	16	17	18	19	20
Temperature of hen	105.0	104.6	104.8	104.5	104.5
Temperature of egg	103.0	102.4	103.0	103.0	103.0

The temperature of the hen is seen to be somewhat higher than that of the eggs. In an artificial incubator where 85 % of the fertile eggs hatched on the twentieth and twenty-first days, the temperatures were as follows:

Day of incubation	1	2	3	4	5
Temperature of incubator	102.0	102.0	103.0	102.0	102.5
Temperature of egg	99.5	100.0	101.0	100.5	100.5
Day of incubation	6	7	8	9	10
Temperature of incubator	103.0	102.5	102.0	103.0	103.5
Temperature of egg	101.0	100.0	100.0	101.0	101.5
Day of incubation	11	12	13	14	15
Temperature of incubator	103.0	103.5	104.0	103.5	104.0
Temperature of egg	101.5	101.8	102.0	102.5	103.0
Day of incubation	16	17	18	19	20
Temperature of incubator	104.5	104.0	103.5	104.0	104.5
Temperature of egg	103.0	103.0	102.5	102.5	103.5

It would be possible then to establish a normal rate of development, by using perfectly fresh eggs incubated at a normal temperature. In practice I have found that the times given in Duval's atlas are approximately normal, and these are, therefore, adopted so far as given. But even under the best conditions the variations are sufficient to prevent close grading of stages by time of incubation in the first three days. This may be due to differences in the grade of development at the time of laying, owing to varia-

tions in the time of development in the oviduct and uterus, or to slow development before incubation in warm weather, or to individual variation. It becomes necessary, therefore, to find some other system. The method followed by a considerable number of investigators, namely to classify by the number of somites, has been found to be best between about the twentieth and ninety-sixth hours of incubation. In the table which follows, therefore, this method of classification is used. For the sake of brevity throughout the book a stage reckoned by the number of somites will be written 1 s, 2 s, 3 s, etc. It is true that the relative rate of the development of organs varies slightly. Nevertheless, classification by number of somites is unquestionably the most exact method up to the end of the fourth day at least. Beyond this stage the method is difficult to apply, and after about the sixth day the number of somites becomes constant. After the fourth day the time of incubation is usually a sufficiently exact criterion for most purposes: the latent period has become a relatively inconsiderable fraction of the whole time of incubation, and the embryos that survive, assuming fresh eggs and normal temperature of incubation, are in about the same stage of development.

Classification of embryos by length is a favorite method particularly in Germany, and it offers many advantages in the case of some animals; under many conditions it is the only available method. But it offers considerable difficulties, the most serious of which come from the varying degrees of curvature of the embryo. In early stages of the chick, for instance, up to about 12 s, the total length of the embryonic axis may be measured, for the embryo is approximately straight. The cranial flexure then begins to appear, and slowly increases to a right angle; during this period there may be an actual reduction in length of the embryo (cf. table, 14-16 s). Conditions are also complicated by the fact that the head of the embryo is turning on its left side at the same time. The cervical flexure then appears and causes a second reduction of the total length (cf. table 29-32 s). Later still the curvature of the trunk and particularly of the tail develops in somewhat varying degrees and makes bad matters worse. After these flexures are formed, let us say at about eighty hours in the chick, it is customary to take the so-called neck-tail measurement, that is, from the cervical flexure

to the apex of the tail flexure. But even then it is questionable if this measurement is as accurate a means of classification as the age of normally incubated embryos; particularly as the cervical flexure is secondarily eliminated by raising of the head. It is probable that the measurement from the tip of the head to the apex of the cranial flexure (head-length) would be best for classification of chick-embryos by measurement. This dimension may be readily taken, after the cranial flexure begins, throughout the entire period of incubation. However, it has been relatively little used up to the present time.

The following tables give the chronology of development up to the end of the fourth day, the period usually covered in laboratory courses. For the later chronology the student is referred to Keibel and Abraham's *Normaltafeln zur Entwicklungsgeschichte des Huhnes (Gallus domesticus)*, Jena, Gustav Fischer, 1900. In the various chapters of Part II, the later chronology of the various organs is given here and there throughout the text. It is believed that these references will be sufficient on the whole to enable the student to determine what embryos to select for the desired stage of most organs. The tables have been made practically continuous from 1 s up to 41 s, because these cover the period of development in which the primordia of most organs are formed. They have been constructed mostly from entire mounts. The corresponding tables in Keibel and Abraham's work are noted by number in the right-hand column.

CHRONOLOGICAL TABLES OF THE DEVELOPMENT OF THE CHICK

I. Before Laying:

1. Maturation and fertilization; found in the oviduct above the isthmus.
2. Early cleavage up to about the thirty-two celled stage found in the isthmus of the oviduct during the formation of the shell-membrane (Patterson).
3. Later cleavage, formation of periblast and entoderm, etc., found in the uterus up to time of laying.

Data for the pigeon given in Chapter II; see legends to figures.

II. Incubation to Formation of the First Somite:

The period may be divided in three parts: (1) before the appearance of the primitive streak; (2) primitive streak formed but no head process; (3) after the appearance of the head-process. These stages may be subdivided by time or by length of the primitive streak.

l
l
l

t
r
t
s
l
o
l
t
t
p
tl
a
n
w

I.

II.

of
(3)
div

CHAPTER IV

FROM LAYING TO THE FORMATION OF THE FIRST SOMITE

I. STRUCTURE OF THE UNINCUBATED BLASTODERM

THERE is more or less variation in the stage of development of unincubated blastoderms; in exceptional cases these variations may be extreme. However, the usual condition may be described very briefly as follows (see Fig. 34): Beneath the pellucid area is the subgerminal cavity bounded marginally by the germ-wall. The posterior part only of the pellucid area is two-layered. The lower layer or gut-entoderm terminates posteriorly at the germ-wall, with which, however, it is not united. It is composed of spindle-shaped cells which form a coherent layer, perforated by numerous small openings that appear as breaks in the layer in section. In front of the gut-entoderm a few scattered cells appear in the subgerminal cavity. The gut entoderm does not reach the germ-wall either laterally or anteriorly, but in the course of a few hours' incubation it spreads so as to unite with the germ-wall around the entire margin of the pellucid area.

The germ-wall is slightly thicker at the posterior than at the anterior end, that is to say, that the nuclei extend deeper into the yolk (Fig. 34). There is a broad zone of junction and beyond this the margin of the blastoderm overlaps the yolk a short distance. The germ-wall has not yet become organized as a layer separate from the yolk.

The ectoderm is thicker in the region of the area pellucida than in the area opaca; and slightly thicker in the center than at the margin of the area pellucida.

II. THE PRIMITIVE STREAK

Total Views. The primitive streak is the first sign of formation of the embryo proper; it appears early on the first day of incubation as an elongated slightly opaque band occupying

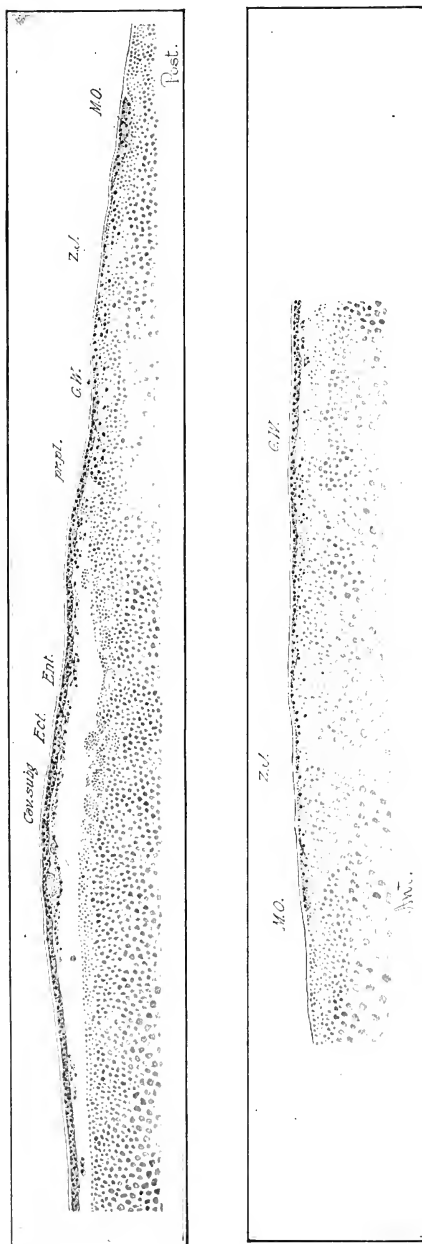


FIG. 34. — Median longitudinal section of an unincubated blastoderm of the hen. The posterior end is to the right in the upper division of the figure; the anterior end to the left in the lower division.
 Ant., Anterior. Cav. subg., Subgerminal cavity. Ect., Ectoderm. Ent., Entoderm. G. W., Germ-wall. M. O., Margin of overgrowth. Post., Posterior. pr. pl., Primitive plate. Z. J., Zone of junction.

the posterior half or two fifths of the circular pellucid area (Fig. 35 B). It is relatively narrow in front and widens posteriorly, where it is at the same time less dense. Its anterior end usually does not quite reach the center of the pellucid area. It rapidly increases in length; the anterior end appears to be practically a fixed point, and growth takes place posteriorly probably not by addition, but between the two ends. The posterior half of the pellucid area elongates simultaneously, keeping pace with the

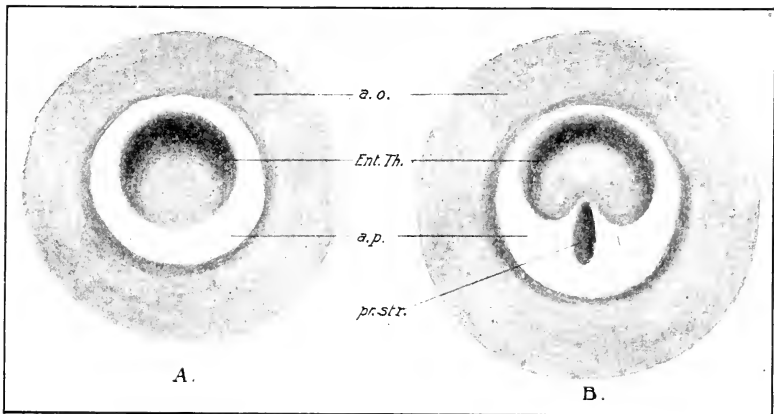


FIG. 35. — Surface views of two stages of the blastoderm of the egg of the sparrow. (After Schauinsland.)

A. Before the appearance of the primitive streak.

B. The first appearance of the primitive streak.

a. o., Area opaca. a. p., Area pellucida. Ent. Th., Thickening of entoderm. pr. str., Primitive streak.

primitive streak which lies entirely within it in the chick and most other birds. Thus the area pellucida becomes oval, then pear-shaped, and the primitive streak bisects the greater part of its length (Figs. 35, 36, 44, etc.).

According to Koller the primitive streak takes its origin from a crescentic area at the posterior margin of the pellucid area, which he terms the sickle. The primitive streak appears as a process extending forward from the center of the sickle, and, as it grows forward, the lateral horns of the sickle are gradually taken into its posterior end. Koller's observations and interpretations have not, however, been confirmed by subsequent investigators and they would appear to rest on rather exceptional and inessential conditions.

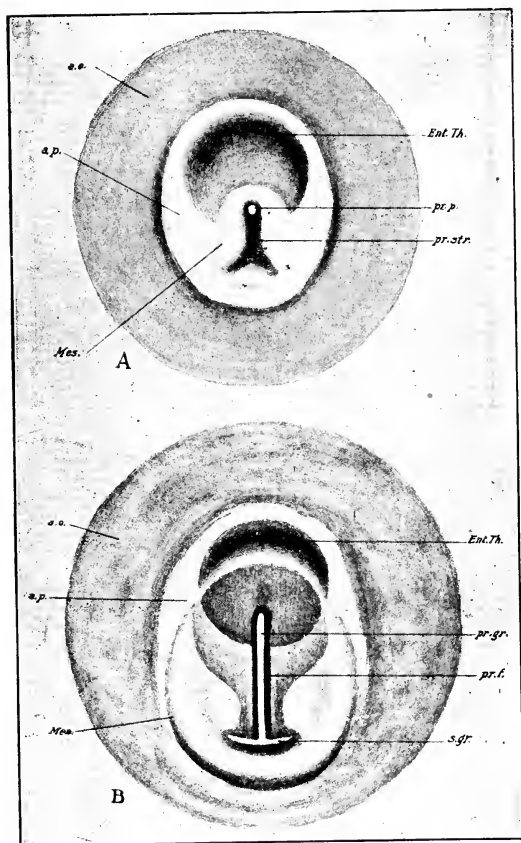


FIG. 36. — A. Intermediate stage of the formation of the primitive streak of the sparrow. (After Schauinsland.)

B. Fully formed primitive streak of the sparrow. (After Schauinsland.)

a. o., Area opaca. a. p., Area pellucida. Ent. Th., Thickening of entoderm. Mes., Mesoderm. pr. f., Primitive fold. pr. gr., Primitive groove. pr. p., Primitive pit. pr. str., Primitive streak. s. gr., Sickle groove.

At first the surface of the primitive streak is even, but, as it elongates, a groove appears down its center. This groove is known as the primitive groove; it is bounded by the primitive folds and terminates abruptly in front in a pit, the primitive pit, which corresponds to the neurenteric canal of other verte-

brates (Figs. 35, 36, 44, etc.). The primitive groove does not involve the extreme anterior end of the primitive streak, which forms a little knot in front of it, the primitive knot ("Hensen's knot"). The posterior end of the primitive streak terminates in an expansion which is not very obvious in surface view, and hence is not usually described; it may be called the primitive plate (Figs. 36, 44 A, 44 B, etc.). In some cases the primitive streak and groove are bifurcated at the posterior end (Fig. 44 B). The primitive streak is the first clear indication of the axis of the embryo.

The neurenteric canal is a canal that connects the posterior end of the central canal of the neural tube with the intestine. It arises from the anterior end of the primitive mouth, and is typically developed in Selachia, Amphibia, reptiles, some birds (*e.g.*, duck, goose, *Sterna*, etc.). It begins in the primitive pit and extends forward into the head-process (p. 80). Subsequently the primitive pit becomes surrounded by the medullary folds, and thus opens into the neural canal. An opening is later formed through the entoderm so that the definitive canal connects neural tube and hind-gut. In the chick the neurenteric canal is never typically developed. Usually it is represented only by the primitive pit. In exceptional cases I have found traces of it in the head-process.

The so-called head-process appears in front of the primitive knot (Figs. 36 B and 44 B). In surface view it appears not unlike the primitive streak itself, but is fainter and less clearly defined. It is continuous with the primitive streak at the primitive knot, but its axis is usually a little out of line with the axis of the primitive streak.

Figs. 35 and 36 exhibit four stages of the development of the primitive streak of the sparrow (after Schauinsland). The darker area in the anterior part of the area pellucida is caused by a thicker region of the entoderm which in the course of time becomes of uniform thickness with the remainder. It will be observed that the primitive streak arises entirely within the area pellucida (Fig. 35 B). In later stages its posterior end is bifurcated (Figs. 36 A and B), and we have the appearance of a sickle somewhat similar to Koller's description for the chick. The primitive groove begins near the anterior end of the primitive streak in an especially deep pit just behind the primitive knot, and extends back the entire length of the primitive streak into the horns of the sickle. The head-process is barely indicated in Fig. 36 B.

The later history of the primitive streak is illustrated in Figs. 44, 51, 61, 65, etc.: the embryo arises in front of it around the head-process as a center; the anterior end of the primitive streak marks the hind end of the differentiated portion of the embryo. As the embryo grows in length the primitive streak decreases (cf. measurements in table), until finally, when the completion of the embryo is indicated by the formation of the tail-fold, the primitive streak disappears. The primitive knot and primitive pit occupy its anterior end at all stages, and, as the embryo differentiates from the anterior end of the primitive streak, the primitive pit must be regarded as moving back along the line of the primitive groove, always representing its anterior end.

Sections. The preceding sketch of the superficial appearance of the primitive streak must now be followed by a careful examination of its structure and rôle in the development.

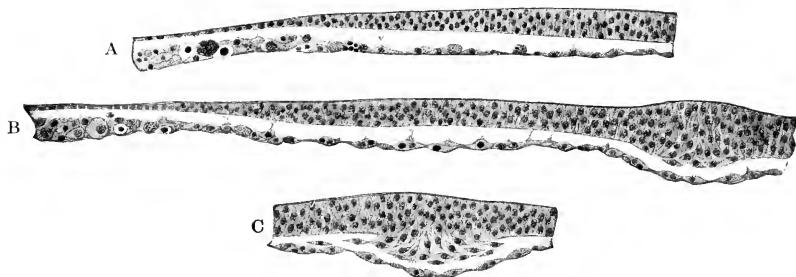


FIG. 37. — Three sections through the primitive streak of a sparrow at a stage intermediate between Figs. 35 and 36. $\times 230$. (After Schauinsland.)

A. In front of the primitive streak.

B. Through the anterior end of the primitive streak (primitive knot).

C. About through the center of the primitive streak.

All recent authors are agreed that the primitive streak owes its origin to a linear thickening of the ectoderm, from which cells are proliferated between the ectoderm and the entoderm, forming a third layer, the mesoderm. Figs. 37 A, B, C show three transverse sections through a blastoderm of the sparrow slightly more advanced than the stage shown in Fig. 35 B. The first section is just in front of the primitive streak. The ectoderm is thick in the center and thins gradually toward the margin of the area pellucida, becoming decidedly thin in the region of the area opaca. The thin entoderm of the area pellucida unites peripherally with the thick yolk-sac entoderm of the area opaca. The second

section passes through the anterior end of the primitive streak; the ectoderm is greatly thickened (primitive knot); the basement membrane is interrupted below, and the lowermost cells are becoming loose. The third section is through a more posterior portion of the primitive streak. The proliferation from the ectoderm is more extensive, the cells are looser and are begin-

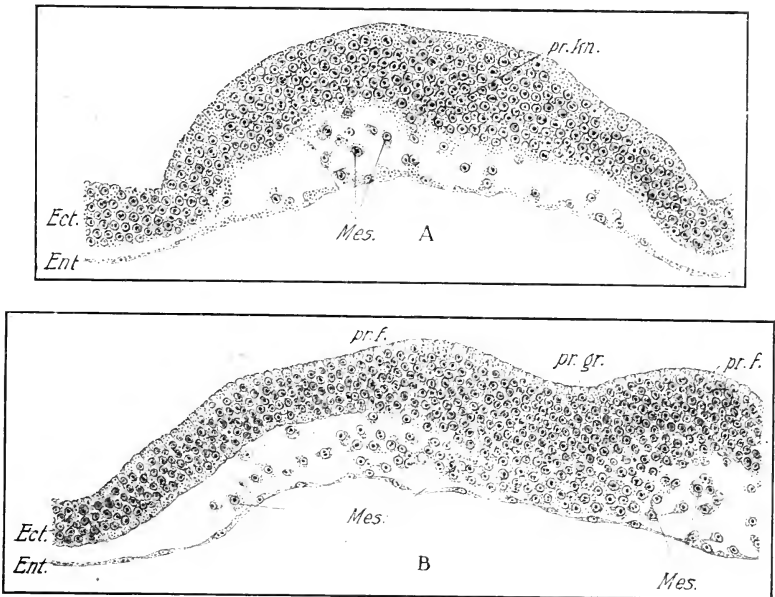


FIG. 38. — Transverse sections through a very short primitive streak of the chick. Incubated $17\frac{1}{2}$ hours; no head-process.

A. Through the anterior end of the primitive streak (primitive knot). Mesodermal cells are being proliferated from the ectodermal thickening; some are scattered between the two primary germ layers. The entoderm shows no proliferation, though some mesoderm cells are adhering to it.

B. Fourteen sections posterior to A. (Entire length of the primitive streak is 80 sections.) The mesoblast wings are forming; the primitive groove and primitive folds are indicated. The entoderm is free from the mesoderm.

Ect. Ectoderm. Ent., Entoderm. Mes., Mesoderm. pr. f., Primitive fold. pr. gr. Primitive groove. pr. kn., Primitive knot.

ning to spread out laterally. The entoderm is a continuous membrane without any connection with the primitive streak, and there are no cells between ectoderm and entoderm save those derived from the primitive streak.

Figs. 38 A and B show the structure of the primitive streak

of the chick at a more advanced stage, but before the formation of the head-process. Sections in front of the primitive streak show no cells between ectoderm and entoderm. In the region of the primitive knot (A) the ectoderm is greatly thickened, forming a projection above and below. Cells become detached from the lower surface of the ectoderm, and are converted into migratory cells between the two primary layers. Immediately behind the primitive knot the primitive groove begins abruptly; it is the seat of active proliferation from the lower layer of the ectoderm, and the cells migrate out laterally forming wings of cells, which do not, however, reach the area opaca (Fig. 38 B). Conditions are very similar along the entire length of the primitive streak at this time; but near the posterior end a few cells of the mesoderm reach the area opaca and begin to insinuate themselves between the ectoderm and the germ-wall. There is no evidence at any place that any of the mesoderm cells are derived from the entoderm. The axial thickening of the primitive groove comes in contact with the entoderm and appears in places fused to it.

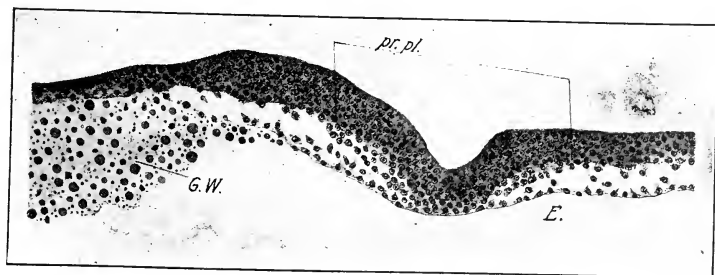
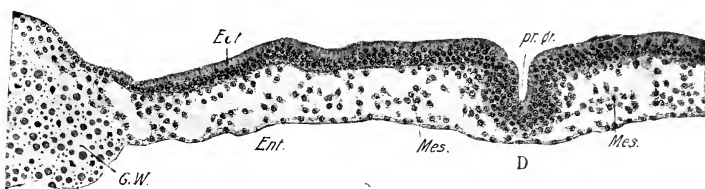
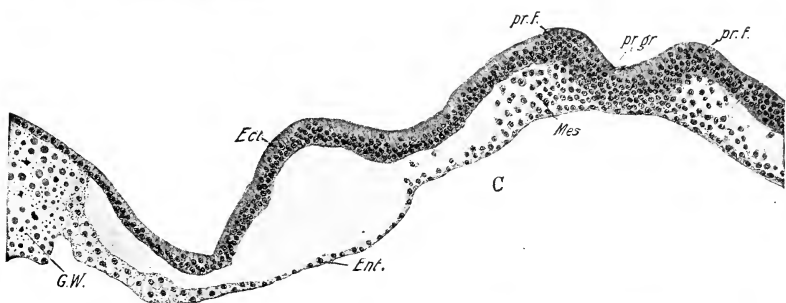
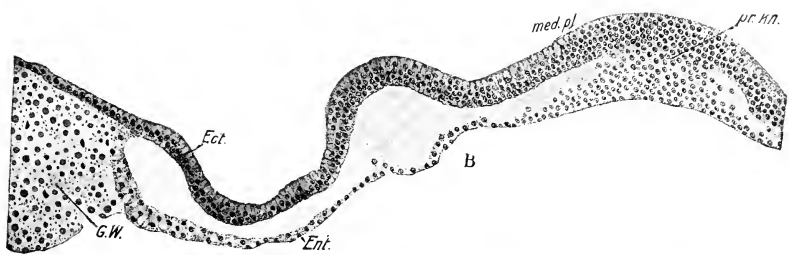
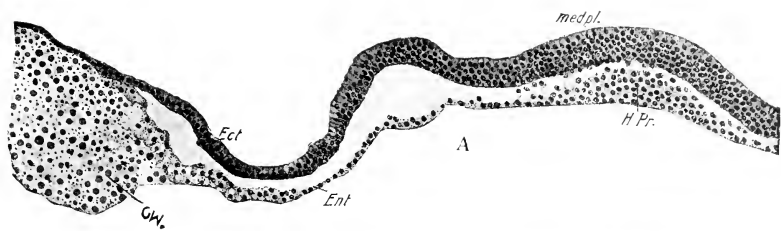
Figures 39 A-E represent five sections through the head-process and primitive streak of a chick embryo at a time when the head-process is still very short. The first section through the head-process is described beyond. B is through the primitive knot; the ingrowth of cells is more extensive than in the preceding stage and it will be observed that they are now fused with the entoderm, so that the latter no longer appears as a distinct layer. C is through the primitive groove near its anterior end. D is a little behind the center of the primitive groove, and E is through the primitive plate. Behind the center of the primitive streak the entoderm is again free (D). It will be observed that the area of proliferation in the primitive plate is very wide.

FIG. 39. — Five sections through the head-process and primitive streak of a chick embryo. The head-process is very short.

- A. Through the head-process, now fused to the entoderm.
- B. Through the primitive knot.
- C. Through the anterior end of the primitive groove.
- D. A little behind the center of the primitive streak.
- E. Through the primitive plate.

The total number of sections through the head-process and primitive streak of this series is 102. B. is 4 sections behind A. C. is 12 sections behind A. D. is 59 sections behind A. E. is 87 sections behind A.

Ect., Ectoderm. Ent., Entoderm. G. W., Germ-wall. H. Pr., Head-process. med. pl., Medullary plate. Mes. Mesoblast. pr. f. Primitive fold pr. gr., Primitive groove. pr. kn., Primitive knot. pr. pl., Primitive plate

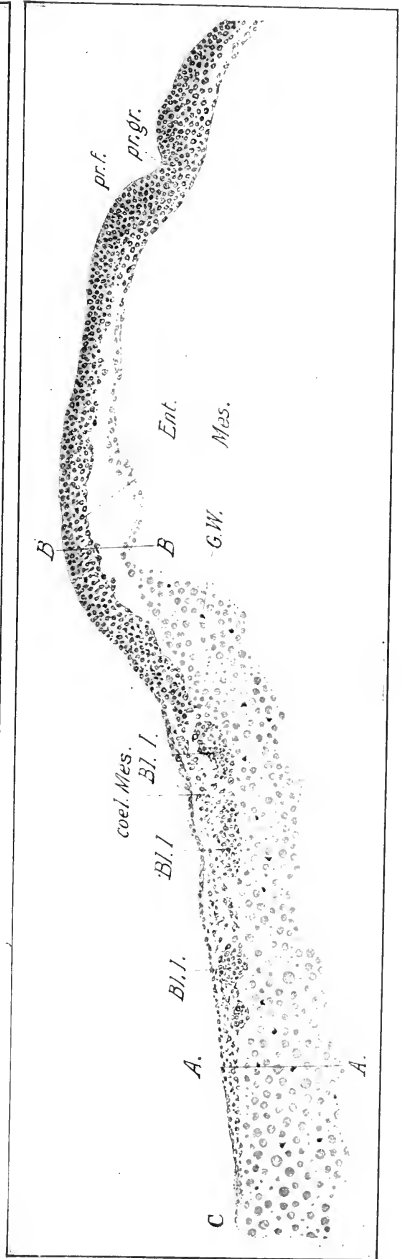
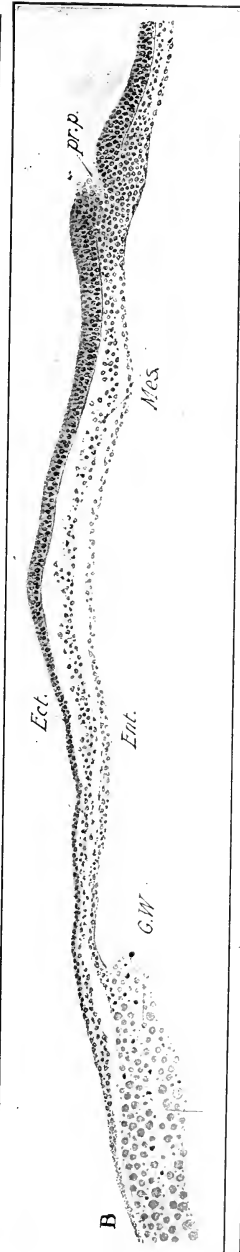
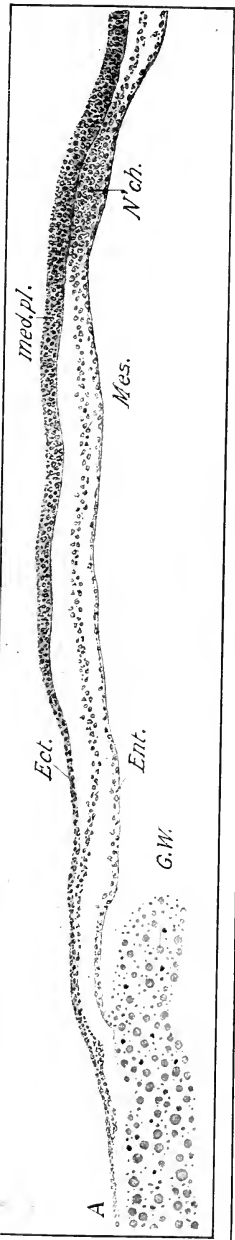


The mode of origin of the mesoderm of birds has been a very puzzling question as is proved by the numerous views that have been in vogue from time to time. One of the earliest views was that the mesoderm arose by splitting of the primary entoderm (Remak). This view survives in part even at the present time (mesoblast of the opaque area). Balfour believed that the mesoblast in the region of the embryo "originates as two lateral plates split off from the primitive hypoblast," and that the primitive streak mesoblast is extra-embryonic, or at most enters into the formation of mesoblast of the extreme hind end of the embryo (allantois mesoblast in part). This view is found in the "Elements of Embryology" of Foster and Balfour. A third view, now of historical interest only, was that the mesoblast cells arose peripherally and migrated between the two primary germ-layers (Peremeschko, Goette). The latter author even attempted to derive the primitive streak from an aggregation of such inwandering cells. The view that the primitive streak arises as a thickening of the ectoderm and that it is the source of all the mesoderm was first stated by Kölliker, and has been accepted by Hertwig, Rabl, and many others. It may, indeed, be regarded as definitely established for the embryonic mesoblast. Others, however, believe with His that the mesoblast of the opaque area arises by delamination from the germ-wall; this question is discussed beyond. It should also be noted that it is probable that the primitive embryonic mesoblast is supplemented in certain regions at later stages by cells proliferated from both entoderm and ectoderm, particularly in the region of the head. (See pp. 116, 117.)

In early stages of the primitive streak the mesoblast cells are relatively sparse and bear every appearance of migrating separately. But as the ingrowth progresses and the cells become more numerous, the mesoderm becomes converted into coherent plates. These are wedge-shaped, the central broad ends fused with the primitive streak and the narrow margins extending laterally (Figs. 40 A, B, C). They soon overlap the margin of the opaque area and thus is produced a three-layered portion of

FIG. 40. — Three transverse sections of a late stage (corresponding to about Fig. 44 B), through the head-process and primitive streak of a chick embryo.
 A. Near the hind end of the head-process.
 B. Through the primitive pit.
 C. A short distance behind the center of the primitive streak. The region between the lines A-A and B-B is represented under a high magnification in Fig. 41.

Bl. I., Blood island. coel. Mes., Coelomic mesoblast. Ect., Ectoderm. Ent., Entoderm. G. W., Germ-wall. med. pl., Medullary plate. Mes., Mesoderm. N'ch., Notochord. pr. f., Primitive fold. pr. gr., Primitive groove pr. p., Primitive pit.



the latter which corresponds to the future vascular area. The mesoblast grows out, not only from the sides of the head-process and primitive streak, but also from the hind end of the latter, that is from the primitive plate. The mesoblast thus extends into the opaque area behind the embryo at a very early stage (Figs. 42 and 44).

The primitive groove must be regarded as an expression of the forces of invagination of the mesoblast, and the primitive folds as the lips of this invagination.

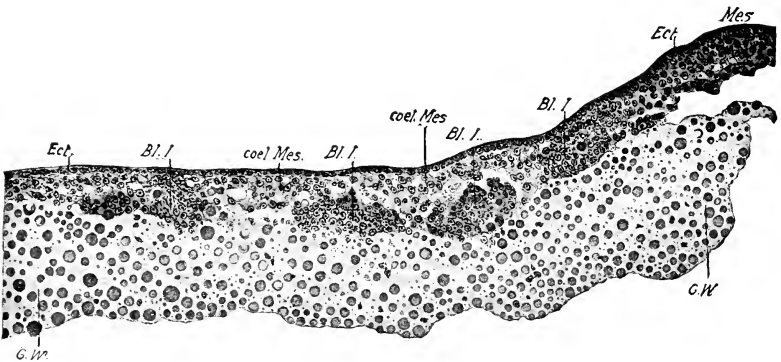


FIG. 41. — The part of the section shown in Fig. 40 C, between A-A and B-B more highly magnified.

Abbreviations same as Fig. 40.

The Head-process. Two stages of the head-process are shown in transverse section a short distance in front of the primitive knot in Figs. 39 A and 40 A. It consists of a thicker central mass of cells with lateral wings; the central part, or primordium of the notochord, is continuous posteriorly with the axis of the primitive streak. These two portions of the mesoblast are often termed gastral and prostomial, connected with the head-process and primitive streak respectively. The head-process becomes inseparably fused with the entoderm in the middle line immediately after its formation; and this fusion is continued back along the axis of the primitive streak (Figs. 39 and 40). The fusion is particularly intimate and persistent at the extreme anterior end of the head-process; behind this point the notochord and entoderm soon separate again in the course of development. But the anterior end of the notochord remains attached to the

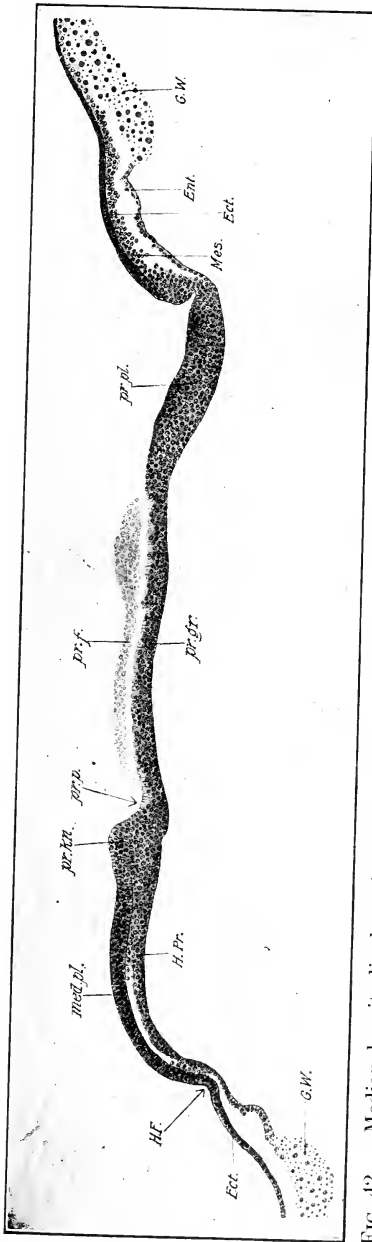


FIG. 42. — Median longitudinal section along the line of the primitive groove at a stage corresponding approximately to Fig. 44 B.

Ect., Ectoderm. Ent., Entoderm. G. W., Germ-wall. H. F., Head-fold. H. Pr., Head-process. med. pl., Medullary plate. Mes., Mesoderm. pr. f., Primitive fold. pr. gr., Floor of primitive groove. pr. kn., Primitive knot. pr. p., Primitive pit. pr. pl., Primitive plate.

entoderm for a considerable period after the formation of the head-fold. A longitudinal section shows the head-process as an appendage to the anterior end of the primitive streak, or the primitive knot (Fig. 42).

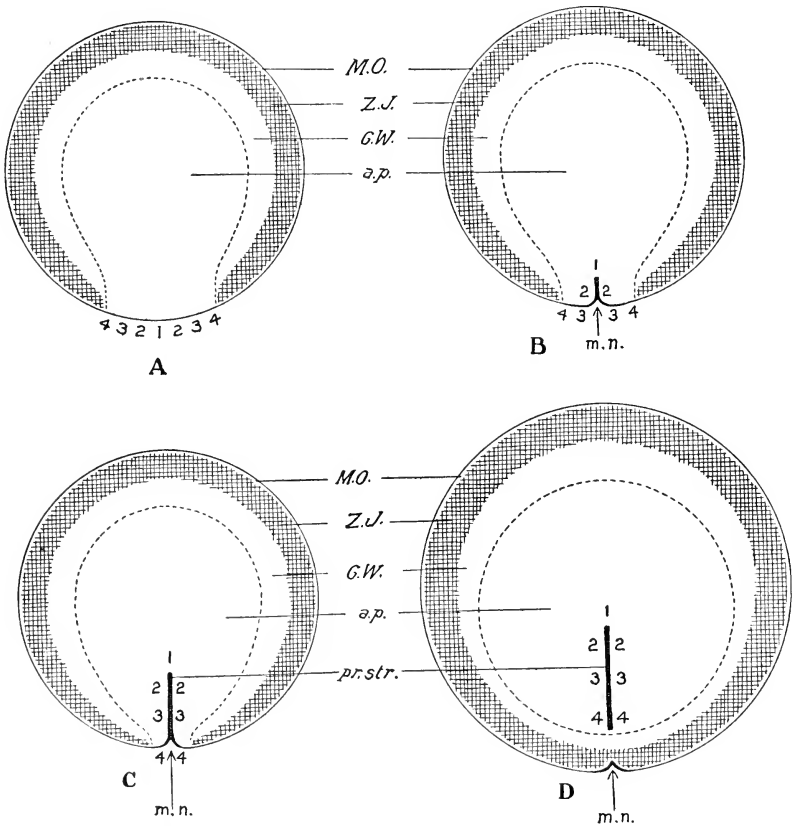


FIG. 43. — Diagrams to illustrate the theory of concrescence as applied to the primitive streak of the bird. The central area bounded by the broken line represents the pellucid area; external to this is the area opaca, showing as concentric zones the germ-wall (G. W.), the zone of junction (Z. J.), and the margin of overgrowth (M. O.). m. n., Marginal notch. For description see text.

The most obvious interpretation of the head-process is as an outgrowth from the primitive knot. But another, and more probable interpretation in view of all the facts, is that the head-process is a later stage of the anterior end of the primitive streak;

that a gradual separation of the ectoderm takes place in the axis of the primitive streak beginning at the anterior end, and progresses posteriorly. That part in which the ectoderm is separated represents the head-process; it has therefore the same composition as the primitive streak, except that the ectoderm has become independent.

Interpretation of the Primitive Streak. The discussion of the significance of the primitive streak involves two parts: (1) its morphological significance, and (2) its rôle in the formation of the embryo. The first question involves knowledge of comparative embryology, which is not assumed for the purposes of this book, and it will therefore be considered very briefly. The fundamental relations of the primitive streak must define its morphological interpretation; the first thing to be noted is that the germ-layers, more especially the ectoderm and mesoderm, are fused in the primitive streak; second, the differentiated part of the embryo is formed in front of it; third, the neurenteric canal occupies the anterior end of the primitive streak; fourth, the anus forms at its posterior end. Now these characters are exactly those of the blastopore or primitive mouth of lower vertebrates, that is of the aperture of invagination of the archenteron. For these reasons, and because in all other essential respects the primitive streak corresponds to the blastopore, it must be interpreted as the homologue of the latter. It is to be regarded, therefore, as an elongated blastopore, and the primitive groove as a rudimentary archenteric invagination.

This interpretation raises the question as to its relation to the original marginal area of invagination of the entoderm. Can these two things be really different stages of the same thing? The concrescence theory gives a theoretical basis for their identification. It will be remembered that the margin of invagination represents a small section of the margin of the primitive blastoderm in the pigeon, and, by inference, in the chick also. The remainder of the margin where the zone of junction persists is the margin of overgrowth. Now we assume that the closure of the original marginal area of invagination proceeds by concrescence or coalescence of its lips, beginning in the middle line behind, thus producing a suture which is the beginning of the primitive streak. Let the above circles (Fig. 43) represent the blastoderm in four stages of closure of the original area of invag-

ination. The shaded margin represents the zone of junction, the unshaded portion of the margin represents the area of invagination of the entoderm. The dotted contour represents the margin of the pellucid area. In A the middle of the area of invagination is marked 1, and corresponding points to the right and left 2, 3, and 4. In diagram B it is supposed that the margin of invagination is turned forward at 1, and that the lateral portions are brought together as far as 2, thus producing a suture in the middle line 1-2 continuous with the margin 3-4. The zone of invagination is correspondingly reduced in extent and the zone of junction increased. In diagram C the lateral lips of the zone of invagination are represented as completely coneresced, thus producing a median suture 1, 2, 3, 4, extending through the posterior half of the area pellucida to the margin. The zone of junction is on the point of closing behind the line of conerescence which is the primordium of the primitive streak. In diagram D, finally, the opaque area has closed in behind the line of conerescence which occupies the hinder half of the pellucid area.

To apply this theory to the actual data of the development, it is only necessary to assume that the entoderm separates from the ectoderm along the line of conerescence, and that the primitive streak arises subsequently along the same line. The actual demonstration of the truth of this conception cannot be furnished by observation alone, however detailed. It is, however, possible to test it by experiment, though difficult because the conerescence must take place, if at all, prior to laying. The strong support of the theory lies at present in the data of comparative embryology; in the lower vertebrates the mesoderm and entoderm are both formed from the margin of invagination.

Summarizing the matter, we may say that in the chick gastrulation is divided into two separate processes: the first is the invagination of the entoderm from the margin, and the second is the ingrowth (or invagination) of mesoblast and notochord from the primitive streak, which represents the coalesced lips of the margin of invagination; the primitive groove is therefore the expression of a second phase of invagination.

The genetic relation of the primitive streak to the margin of the blastoderm is well illustrated by an abnormal blastoderm described by Whitman in which the primitive groove was continued across the area opaca to a marginal notch at the posterior

end. A similar marginal notch at the hinder end of the blastoderm in the line of prolongation of the primitive streak has been described also by His and Rauber, but in the cases observed by them there was no connection with the primitive groove. It suggested to them, however, the idea of genetic connection between the two, and was used as argument for the derivation of the primitive streak from the margin by conrescence.

The second question concerning the primitive streak, its rôle in the formation of the embryo, may be answered very briefly by saying that it is itself the primordium of the greater portion of the axis of the embryo; some indeed maintain that it represents the entire embryonic axis excepting the short pre-chordal part (Kopsch). The view of Balfour and Dursy that it takes no essential part in the formation of the embryo, but atrophies as the embryo forms, is now of historical interest only. The question is how much of the embryo is represented by the primitive streak. But this question is by no means easy to answer, and there is no complete agreement in regard to it. The one point that is definitely settled is that the anus arises at the hinder end of the primitive streak; but what point in the embryo corresponds to the anterior end of the primitive streak, or, in other words, how much of the embryo is laid down in the blastoderm in front of the primitive streak, is a disputed question. The attempt has been made to solve the problem by destroying the anterior end of the primitive streak by a hot needle, or by electrolysis, then sealing up the egg and permitting it to develop farther and finally locating the resultant injury in the embryo. But, while one worker finds the injury at the anterior end of the notochord (Kopsch), that is in the region of the fore-brain, another finds it in the region of the heart, that is in the hind-brain (Peebles). The reasons for this discrepancy in results are two: (1) the methods employed are not sufficiently exact, and (2) it is difficult in the living egg to determine the exact location of the anterior end of the primitive streak, and sometimes even to distinguish it from the head-process. Owing to the extremely rapid growth of all parts of the embryonic axis, a minute division of the primitive streak becomes a relatively long part of the embryonic axis in a very short time. It is obvious, therefore, that the slightest deviation of the injury from the point aimed at may lead to

considerable error in the results. The result of Kopsch, however, is more consistent with our knowledge of other forms.

III. THE MESODERM OF THE OPAQUE AREA

We have seen that the mesoderm arises from the sides of the head-process and the primitive streak, and grows out between the ectoderm and the entoderm to the margin of the pellucid area; it then begins to overlap the opaque area at first behind, later at the sides, appearing between the ectoderm and the germ-wall. Figs. 44 A, B, C, and 45 illustrate its peripheral extension; at first it spreads most rapidly behind the embryo, but soon extends with equal speed opposite the primitive streak, and thus a considerable portion of the area opaca becomes three-layered, consisting of ectoderm, mesoderm, and germ-wall (Figs. 40 C and 41). The contour of the anterior margin of the mesoderm is at first rounded, convex anteriorly (Figs. 44 A and B). Then the antero-lateral angles of the mesoblast begin to extend forward so that the anterior boundary becomes concave (Fig. 44 C); the lateral horns thus established continue to grow forward and ultimately meet in front of the head (Fig. 45); they thus bound a mesoblast-free area in front of and beneath the head, known as the proamnion, into which the mesoderm does not penetrate until a relatively late stage of development.

Blood-islands (Figs. 44 C and 45) develop early in the three-layered part of the opaque area; appearing first behind the embryo, they rapidly differentiate forward opposite the sides of the embryo and follow the expansion of the mesoblast. This three-layered portion of the opaque area is known as the vascular area (*area vasculosa*) after the appearance of the blood-islands. It soon acquires a very definite peripheral boundary by the formation of the *vena (sinus) terminalis* at its margin (Fig. 45). The two-layered peripheral portion of the opaque area is known as the vitelline area (*area vitellina*), and here again we distinguish two zones, an outer including the zone of junction, and an inner one (Figs. 32, 33).

The first blood-islands are masses of cells lying on the germ-wall behind the embryo; the first blood-cells (erythrocytes) and blood-vessels arise from them, hence their name. Soon after their origin the blood-islands appear red owing to the formation of hæmoglobin. Between the blood-islands and the ectoderm

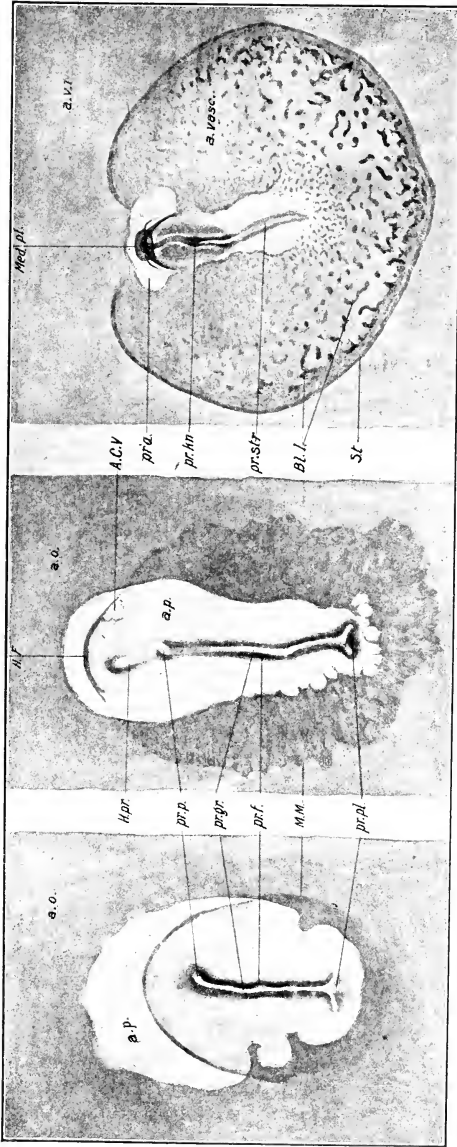


FIG. 44 — Three stages of the blastoderm to show the extension of the mesoblast.

A. Before formation of the head-process; the head fold in process of formation.
 B. The head-process is formed; the head fold in process of formation.
 C. Later stage shortly before the appearance of the first intersomitic groove.
 A. C. V., Amnio-cardiac vesicle. a. o., Area opaca. a. p., Area pellucida. a. vasc., Area vasculosa. a. v. i., Area vitellina interna. Bl. l., Blood island. H. F., Head-fold. H. pr., Head-process. Med. pl., Medullary plate. M. M., Margin of the mesoblast. pr'a., Proamion. pr. f., Primitive fold. pr. gr., Primitive groove. pr. kn., Primitive knot. pr. p., Primitive pit. pr. pl., Primitive plate. pr. str., Primitive streak. S. t., Sinus terminalis.

is a layer of the mesoderm (Fig. 41). If the blood-islands be reckoned as mesoderm we must distinguish two layers of the latter, viz., a deep or vascular layer (angioblast) lying next the germ-wall, and an upper layer next the ectoderm, which may be called the cœlomic mesoderm, inasmuch as the body-cavity (cœlome) develops within it later.

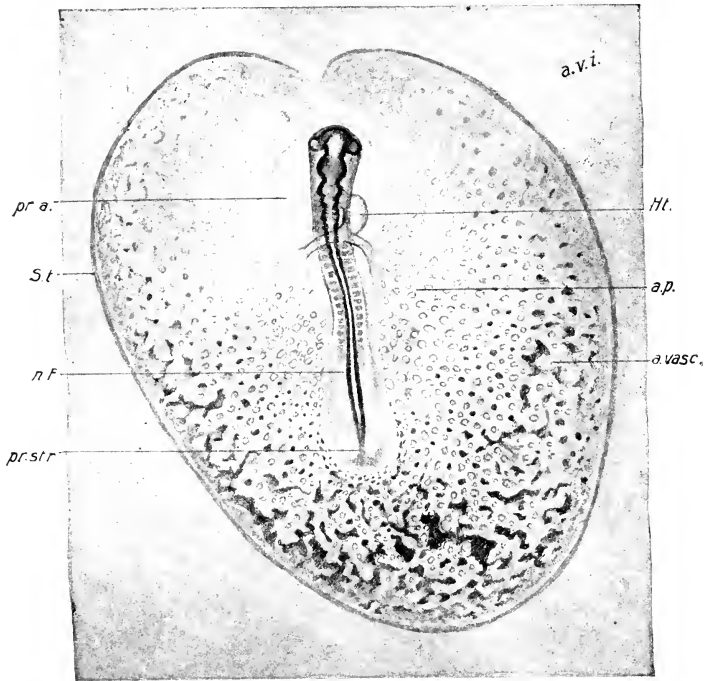


FIG. 45. — Blastoderm and embryo at the stage of fourteen somites. The horns of mesoblast are on the point of meeting in front of the head.

a. p., Area pellucida. a. vase., Area vasculosa. a. v. i., Area vitellina interna. Ht., Heart. n. F., Neural folds. pr'a., Proamnion. pr. str., Primitive streak. S. t., Sinus terminalis.

There are two sharply contrasted views concerning the origin of the mesoblast in the area opaca. According to the one point of view it is simply a peripheral extension of the primitive streak mesoblast with which as a matter of fact it is continuous (Hertwig, Rabl, and others). According to the other point of view

it is split off from the germ-wall (His and others). One thing is perfectly clear, viz., that the mesoderm of the opaque area arises in continuity with the primitive streak mesoderm; the second view would therefore be better expressed, as Rückert states it, that the primitive streak mesoderm grows in the region of the area opaca at the expense of elements of the germinal wall.

If the cells of the primitive streak mesoblast be compared with the cells of the forming blood-islands a sharp contrast is observed; the mesoblast cells of the area pellucida are devoid of yolk-granules; young blood-islands on the other hand contain yolk-granules of precisely the same character as those of the germ-wall (Fig. 41), which must have been derived from the latter. If the origin of the blood-islands be carefully traced, they are found to be rooted in the protoplasm of the germ-wall; and prior to the appearance of the blood-islands proper, protoplasm and nuclei of the germ-wall aggregate superficially in a manner that appears to foreshadow the blood-islands. Therefore, either the blood-islands are derived from the cells of the germ-wall, or cells of the mesoderm growing over the germ-wall burrow into the latter, engulf yolk-spheres, and reappear in masses as blood-islands. Patterson (1909) has shown by an experimental study that in any region in which primitive streak mesoblast is prevented from reaching the germ-wall, blood-islands fail to develop. The second alternative is therefore probably right in principle.

Another question concerns the origin of the layer of cœlomic mesoblast that overlies the blood-islands: is it derived from the primitive streak mesoblast, or is it split off from the blood-islands? When the latter first appear, in the periphery of the vascular area at least, there is no cœlomic mesoblast above them. It appears later, at first not as a coherent layer, but as scattered cells that rapidly unite to form a layer. In many places the microscopical appearances indicate strongly that the cells are split off from the surface of the blood-islands; but, as they are usually not far from the edge of the advancing cœlomic mesoblast, it may be that they are derived from the latter. Rückert states, however, that, in the case of some isolated blood-islands behind the embryo, a layer of mesoblast is formed over them while they are still isolated. This would render the derivation from the blood-islands probable in such cases. It is possible, therefore, that the cœlomic mesoblast grows partly, at least, at the expense of the superficial cells of blood-islands.

As rapidly as they are formed the various blood-islands connect and anastomose with one another, forming a vascular network lying between the cœlomic mesoblast and the remains of the germ-wall. This network spreads throughout the vascular area, and appears later in the pellucid area, and communicates with the blood-vessels of the embryo (Figs. 44 and 45). In the next chapter we shall consider the manner in which the extension takes place, and the origin of the blood-vessels and blood-cells.

IV. THE GERM-WALL

The germ-wall arises, as we have seen, through infiltration of the superficial white yolk by the periblast. These cells multiply and anastomose and form a multinucleated syncytium with the yolk-granules in its meshes. By degrees the protoplasm itself takes up the yolk-granules, which are gradually digested, and the germ-wall thus becomes organized as a coherent layer. It then separates from the underlying yolk. The next period in the history of the germ-wall is its differentiation, which takes place in the vascular area concomitantly with the formation of the blood-islands: a considerable proportion of the protoplasm and nuclei of the germ-wall accumulates at the surface and forms the vascular mesoderm in the manner already described. The part of the germ-wall that remains after the separation of the mesoderm then differentiates into the characteristic entodermal epithelium of the opaque area, which is known as the yolk-sac epithelium (entoderm) because it is destined to form the lining of the yolk-sac.

After the formation of the vascular area the term germ-wall must be restricted to the lower layer of the vitelline area, because within the vascular area it has already differentiated into the mesoderm and yolk-sac entoderm. The development of the germ-wall takes place in a centripetal direction; at any period during the overgrowth of the yolk the three stages of the germ-wall may be found in the concentric zones. The first stage, that of periblast, is found in the zone of junction (area vitellina externa); the second stage, that of organization of the germ-wall, is found in the area vitellina interna; and the third stage, that of differentiation, is found at the margin of the area vasculosa. Within the latter area the differentiation is completed.

CHAPTER V

HEAD-FOLD TO TWELVE SOMITES

(From about the twenty-first to the thirty-third hour of incubation)

I. ORIGIN OF THE HEAD-FOLD

At the end of the period described in Chapter IV, the embryo is represented by a central differentiated area of the blastoderm, lying within the area pellucida, distinguished anteriorly by the medullary plate and head-process, and posteriorly by the primitive streak. The layers of the embryonic area are everywhere continuous with the corresponding layers of the extra-embryonic blastoderm, with no clear line of division between the two. In the course of the second and third days the embryo becomes clearly defined by its own growth, and by the formation of bounding folds.

The delimitation of the embryo from the blastoderm begins immediately after the formation of the head-process by the formation of a fold at the anterior end of medullary plate known as the head-fold (Fig. 42). Seen from the surface, this fold has a semicircular outline, the concavity of which is directed posteriorly (Fig. 44). It involves both the ectoderm and entoderm. A later stage is shown in sagittal section in Figs. 46 and 47: the ectoderm and entoderm immediately in front of the medullary plate make a sharp bend downwards and backwards, and then turn forward again. The head-fold thus produces an internal bay in the entoderm, the beginning of the fore-gut. There is similarly an external bay, the posterior angle of which is the head-fold proper, lying beneath the projecting head. These bays are of course turned in opposite directions, the internal one opening into the subgerminal cavity posteriorly, and the external one opening anteriorly on the surface of the blastoderm.

The transition from the ectoderm of the medullary plate into that of the under surface of the head and the proamnion is a gradual one. The difference is, however, very strongly marked (Fig. 47). The formation of the head-fold is due to the more rapid

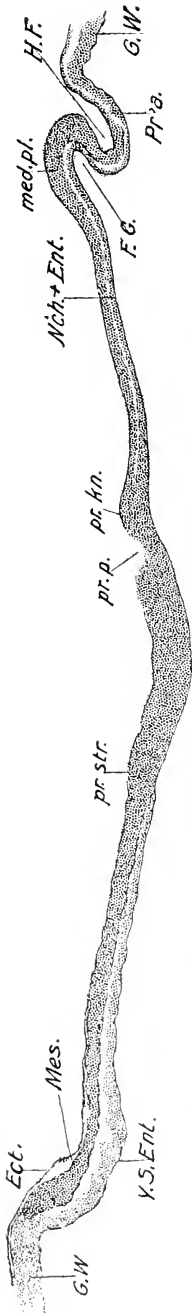


FIG. 46. — Median sagittal section. Stage of the first intersomitic groove. (Cf. Fig. 48.) Owing to the bending of the primitive streak the section passes to one side of the middle line posteriorly.

Ect., Ectoderm. F. G., Fore-gut. G. W., Germ-wall. H. F., Head-fold. med. pl., Medullary plate. Mes., Mesoderm. N'ch.+Ent., Notochord and entoderm. Pr'a., Proaunium. pr.kn., Primitive knot. pr.p., Primitive pit. pr.str., Primitive streak. Y. S. Ent., Yolk sac entoderm.

growth of the medullary plate, which causes the latter to extend forward above the thinner and more pliable membrane in front. The entoderm is attached to the inner surface of the anterior end of the medullary plate (Fig. 47), and is apparently carried forward with the latter to form the anterior portion of the fore-gut. The actual form of the fold depends upon the mechanical properties of the membranes concerned, especially the unequal thickness of their parts produced by unequal growth.

Although the head-fold thus appears to be a single fold involving the two primary layers, it is convenient, for purposes of description, to consider it as two separate folds, ectodermal and entodermal. The deepening of these folds takes place at the same rate up to the time when four somites are formed (Fig. 49). At about this time the paired primordia of the parietal cavity (amnio-cardiac vesicles), which appear in the mesoblast in the lateral extensions of the head-fold (Fig. 50), push in towards the middle line so as to separate the ectodermal and entodermal limbs (Figs. 52 and 58). When six somites are formed, these cavities fuse in the middle line, thus effecting a complete separation of the two limbs. The further progression of the head-fold, after this union, takes place separately in the two limbs.

II. FORMATION OF THE FORE-GUT

The extension of the amnio-cardiac vesicles between the ectodermal and entodermal layers of the head-fold introduces a section of the body-cavity (pericardium) between these layers and at the same time converts the ectodermal limb into a portion of the somatopleure, and the entodermal limb into a portion of the splanchnopleure. (See p. 115.) The splanchnopleuric head-fold extends posteriorly very rapidly after the invasion of the body-cavity, while the somatopleuric fold apparently remains fixed for some time, though the head-fold appears to

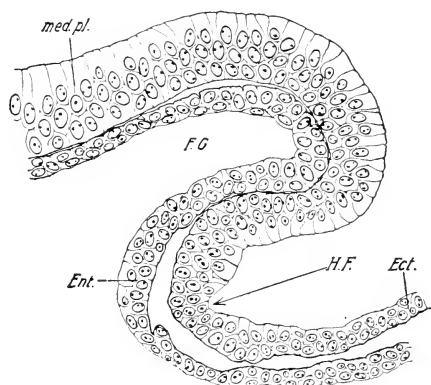


FIG. 47. — Head-fold region of Fig. 46 highly magnified.

For abbreviations see Fig. 46.

become deeper, owing to the forward extension of the head above the blastoderm. The posterior extension of the splanchnopleuric head-fold lengthens the floor of the fore-gut; it is caused by the median growth and concrescence of folds of the splanchnopleure (Fig. 53). Along with this process is involved the development of the heart described farther on. The growth in length of the fore-gut may be realized by a comparison of Figs. 50, 52, 62, etc.

Thus by the 12 s stage a considerable section of the fore-gut is already established (Fig. 63); this is the pharyngeal division: from the first it is extremely broad, and lunate in cross-section (Fig. 54), the floor being composed of columnar cells, and the roof

of very flat cells. The lateral extensions may be regarded as diverticula; subsequently these grow more rapidly at four places along their length, and come in contact with the ectoderm. Thus four pouches are established on each side as described in detail

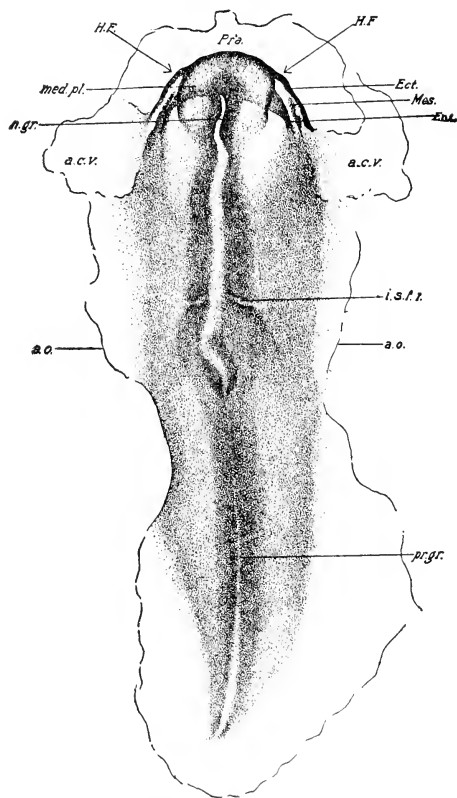


FIG. 48. — Stage of first intersomitic groove drawn from an entire mount in balsam by transmitted light.

a. c. v., Amnio-cardiac vesicle. a. o., Inner margin of Area opaca. Ect., Ectoderm. Ent., Entoderm. H. F., Head-fold. i. s. f. l., First intersomitic furrow. med. pl., Medullary plate. Mes., Mesoderm. n. gr., Neural groove. pr. gr., Primitive groove. Pr'a, proamnion.

in the next chapter. At the 12 s stage one such place of contact is already formed, lying a short distance in front of the thickened ectoderm destined to form the auditory pit.

Another place of fusion between the fore-gut and the ectoderm is the so-called oral plate (pharyngeal membrane), which occupies a mid-ventral position at the extreme anterior end. The parietal cavities meet posterior to the oral plate (Figs. 67 and 75). Transverse sections show the oral plate to be depressed beneath the level of the ventral surface of the head at the stage of 10 somites (Fig. 55), a condition that increases, as development

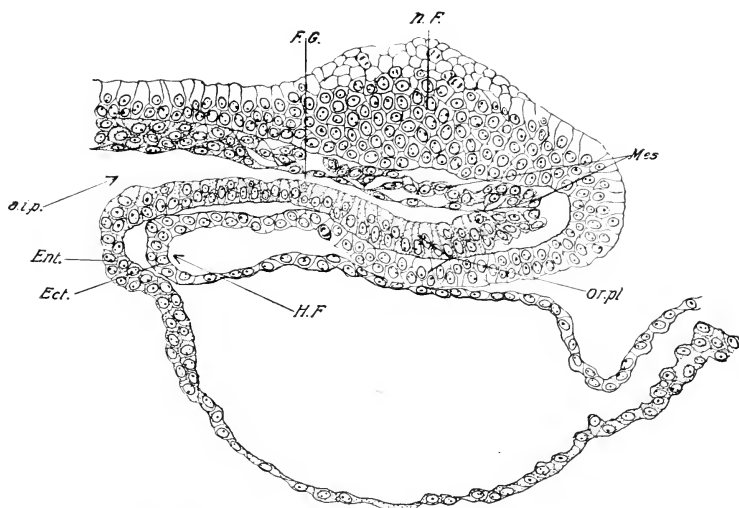


FIG. 49. — Median sagittal section of the head at the stage of 4 s.

a. i. p., Anterior intestinal portal. F. G., Fore-gut. Ect., Ectoderm. Ent., Entoderm. H. F., head-fold. Mes., Mesoblast. n. F., Neural fold. or. pl., Oral plate.

proceeds, by the formation of the cranial flexure, and by the up-growth of the tissues behind and at its sides; thus will be established a deep depression lined by ectoderm, the floor of which is formed by the oral plate, and which is destined to form a large part of the mouth. The depression is known as the stomodæum

III. ORIGIN OF THE NEURAL TUBE

The Medullary Plate. The medullary plate is the primordium of the central nervous system. At the time of formation of the head-fold it is broad in front and narrower posteriorly, ending opposite the posterior end of the primitive streak. Its central portion is not a separate plate of cells in the region of the primi-

tive streak, but this part becomes distinct as the primitive streak splits into its derivatives. It is therefore only when the latter is entirely used up that the entire length of the medullary plate is established. However, long before this time the greater portion has become converted by folding into the neural tube, a process that proceeds in general from in front backwards. Thus

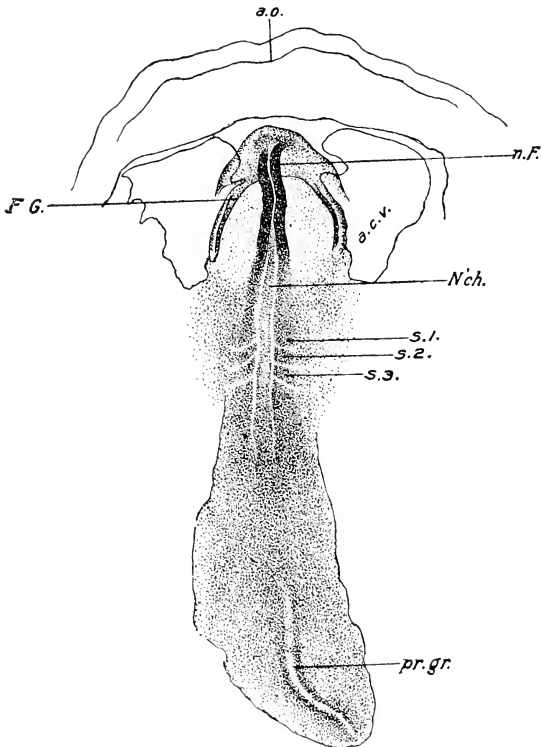


FIG. 50. — Embryo of 3 s from above, drawn in balsam with transmitted light.

a. c. v., Amnio-cardiac vesicle. a. o., inner margin of Area opaca. F. G., Fore-gut. N'ch., Notochord. n. F., Neural fold. pr. gr., Primitive groove. s. 1, s. 2, s. 3, First, second and third somites.

successive stages may be studied in serial sections of the same embryo; an anterior section, for instance, showing the completed tube, one farther back, the folded medullary plate, and yet more posteriorly the central part of the medullary plate disappears in

the undifferentiated mass of the primitive streak. These conditions must be born in mind in the following description.

The Neural Groove and Folds. Shortly after the formation of the head-fold the center of the medullary plate becomes sunk in the form of a deep groove beginning a short distance behind the

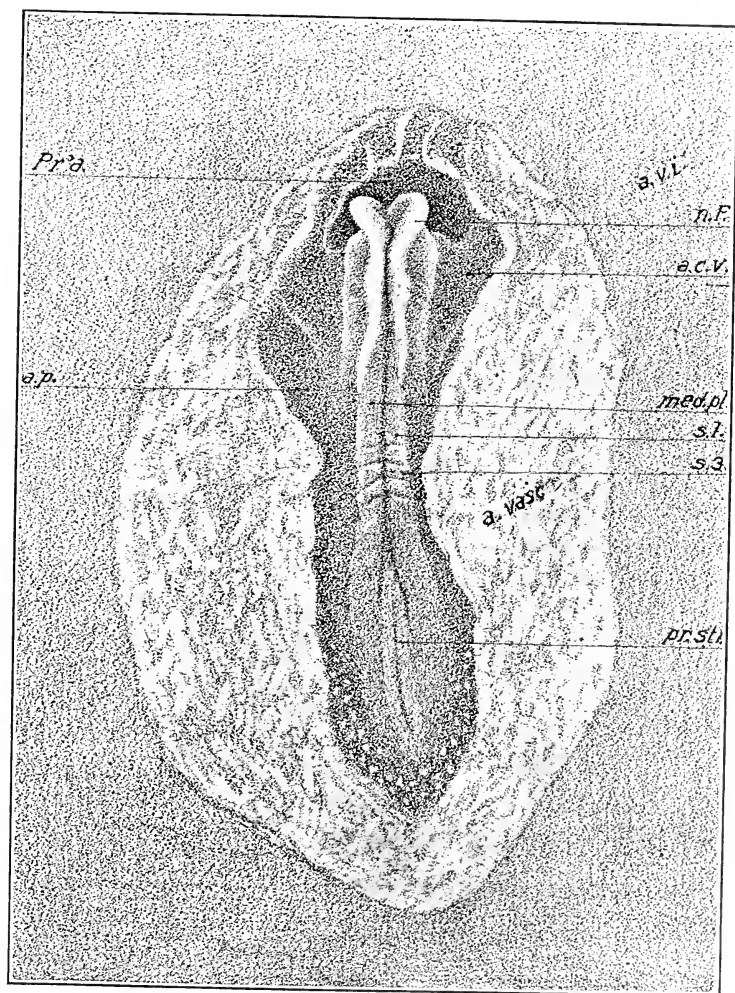


FIG. 51.—Embryo of 4 s from above, drawn in alcohol by reflected light.

a. c. v., Amnio-cardiac vesicle. a. p., Area pellucida. a. v. i., Internal vitelline area. med. pl., Medullary plate. n. F., Neural fold. Pr'a., Proamnion. pr. str., Primitive streak. s. 1, s. 3, First and third somites.

anterior end of the plate (Fig. 48) (the neural groove); the margins of the anterior portion of the medullary plate then become elevated somewhat above the surrounding blastoderm, forming

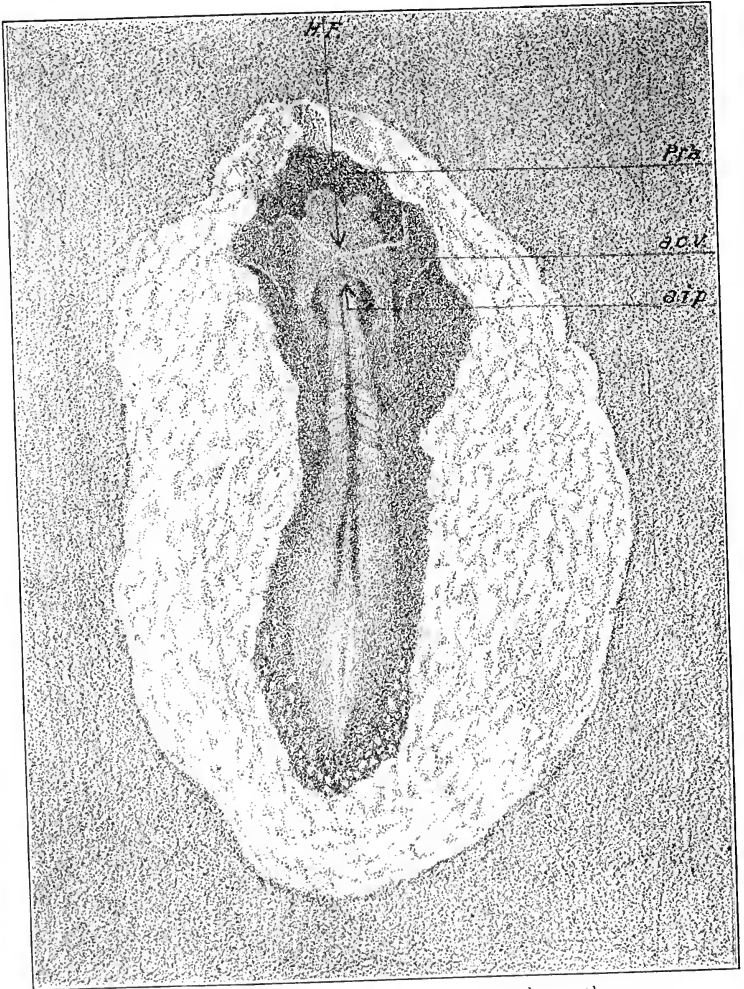


FIG. 52. — The same embryo from beneath.

a. c. v., Amnio-cardiac vesicle. a. i. p., Anterior intestinal portal.
H. F., Head-fold. Pr'a., Proamnion.

the neural folds (Figs. 51 and 56). The latter rise very rapidly, thus deepening the neural groove, and bend in towards the middle line (Figs. 53, 54, etc.) meeting, by the time four or five somites are

formed, a short distance back of the anterior end of the medullary plate (Figs. 50 and 51). The posterior ends of the neural folds do not, at this time, reach the region of the first somite. The region where the neural folds first come in contact corresponds approximately with the region of the future mid-brain, or anterior part of the hind-brain.

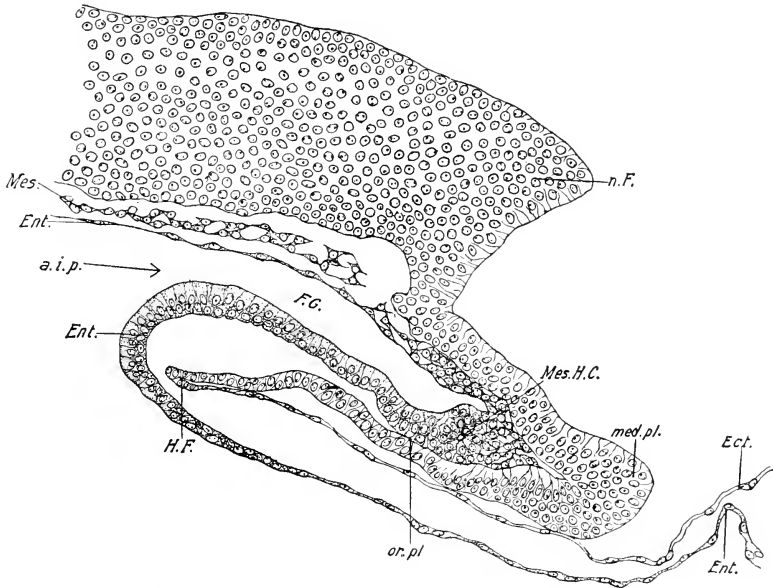


FIG. 52 A. — Median longitudinal section of the head, stage of 4 s. The section passes through the length of one of the neural folds just behind the anterior end. (Cf. Fig. 51.)

a. i. p., Anterior intestinal portal. Ect., Ectoderm. Ent., Entoderm. F. G., Fore-gut. H. F., Head-fold. Mes., Mesoderm. Mes. H. C., Mesoblastic head cavity. n. F., Neural fold. or. pl., Oral plate.

The process of closure itself is essentially the same in all regions of the neural tube. Each neural fold has two limbs: an inner thick limb, belonging to the medullary plate, and an outer, thin limb, continuous with the general ectoderm (cf. Fig. 68 B). When the folds of opposite sides come in contact, the inner limbs of the two sides become continuous with one another, and also the outer limbs, the ectoderm then passing continuously over a closed neural tube.

Certain cells in the suture and in the walls of the tube next

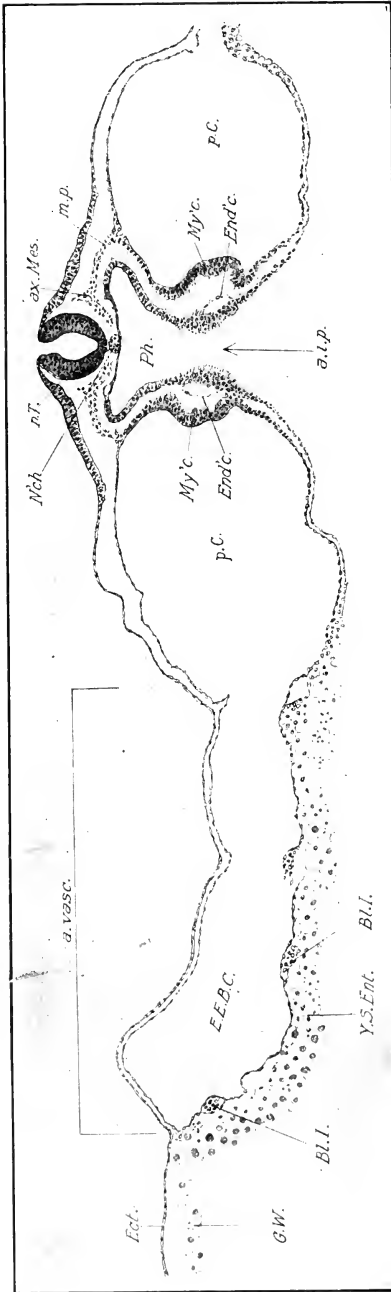


FIG. 53.—Transverse section just behind the anterior intestinal portal at the stage of 7 s, to show the way in which the gut is formed by convergence of lateral folds. The formation of the heart by union of lateral halves is also illustrated.

a. vase., Area vasculosa. ax. Mes., Axial mesoblast. Bl. I., blood island. Ect., Ectoderm. E. E. B. C., Extra-embryonic body cavity. End'c., Endocardium. G. W., Germ-wall. My'c., Myocardium. m. p., Middle plate. N'ch., Notochord. n. T., Neural tube. p. C., Parietal cavity. Y. S., Ent. Yolk-sack entoderm.

the ectoderm are destined to form the neural crest, a structure of great significance, inasmuch as the series of cranial and spinal ganglia is derived from it. (See following chapter.)

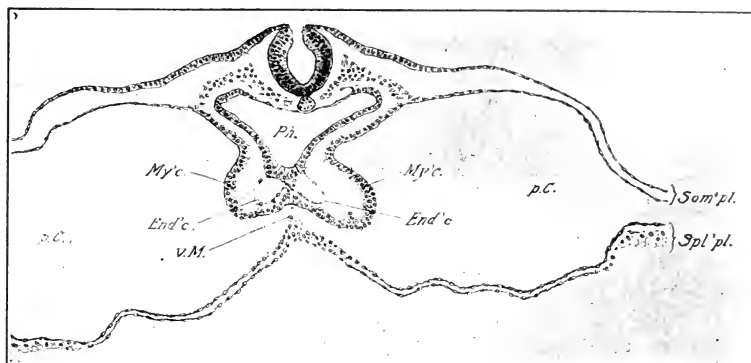


FIG. 54. — Transverse section through the same embryo a short distance in front of the anterior intestinal portal. For explanation of letters see preceding figure; in addition: Ph., Pharynx. Som'pl., Somatopleure. Spl'pl., Splanchnopleure. v. M., Ventral Mesentery.

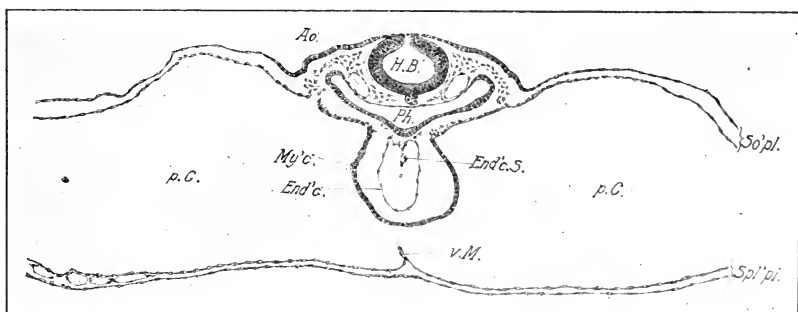


FIG. 54 A. — Transverse section through the head of a 10 s embryo. The region of the section is near the center of the hind brain.

Ao., Aorta. End'c., Endocardium. End'c.S., Endocardial septum. H. B., Hind brain. My'c., Myocardium. p. C., Parietal cavity. Ph., pharynx. So'pl., Somatopleure. Spl'pl., Splanchnopleure. v. M., Ventral mesentery.

The Neuropore. From the place where the neural folds first meet, the elevation and fusion proceed both forwards and backwards in a continuous fashion (cf. Figs. 59, 61, 65, etc.). Although the open anterior stretch of the neural tube is very short in comparison to the posterior open part, it is not until about the 12 s

stage that the former closes completely (cf. Fig. 64). The final point of closure at the anterior end, known as the neuropore, is supposed by some to be a point of great morphological significance, and to mark the extreme anterior end of the original neural

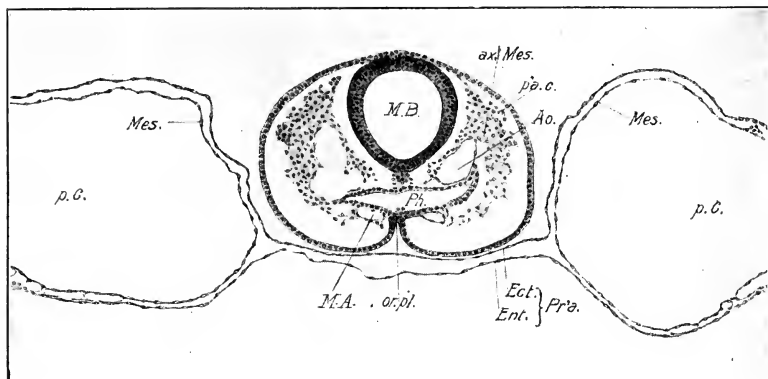


FIG. 55. — Transverse section through the head immediately behind the optic vesicles; stage, 10 s.

Ao., Aorta. ax. Mes., Axial mesoblast. Ect., Ectoderm. Ent., Entoderm. M. A., Mandibular arch. M. B., Mid-brain. Mes., Mesoderm. or. pl., Oral plate. p'a. c., Periaxial cord. p. C., Parietal cavity. Pr'a., Proamniom. Ph., Pharynx. v. Ao., Ventral aorta.

axis. It is identified by these writers with the permanent neuropore of *Amphioxus*. However, this is open to question. Posteriorly the closure of the neural tube proceeds much more rapidly, though, of course, it is not fully completed until after the disappearance of the primitive streak.

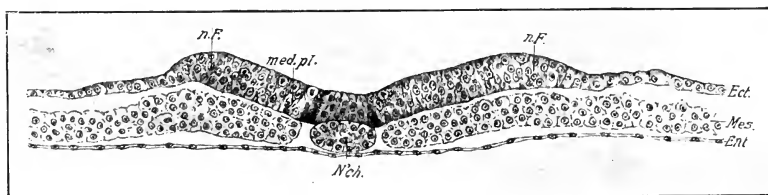


FIG. 56. — Early stage of the neural folds. Transverse section through a 4-5 s embryo between the last somite and the anterior end of the primitive streak.

Ect., Ectoderm. Ent., Entoderm. n. F., Neural fold. N'ch., Notochord. med. pl., Medullary plate. Mes., Mesoderm.

The question as to the position of the anterior end of the original neural axis is one of great morphological significance. Accompanying the closure of the neural tube in this region the

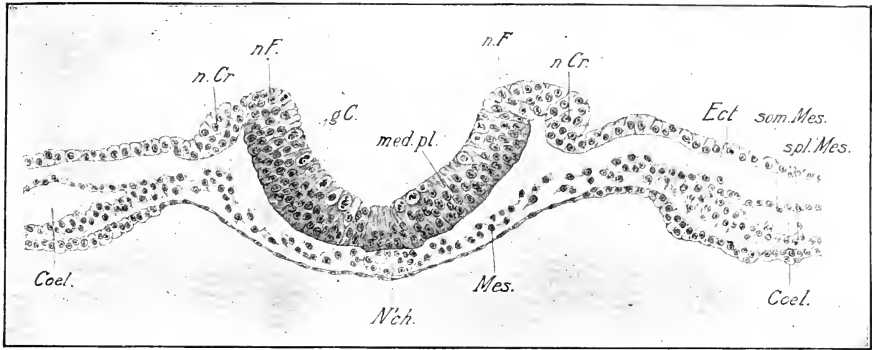


FIG. 57. — Later stage of the neural folds. Section through the head of an embryo of 2-3 s; corresponding to about the future mid-brain region. Coel., Coelome. g. C., Germinal cells. med. pl., Medullary plate. Mes., Mesoblast. n. F., Neural fold. n. Cr., Neural crest. N'ch., Notochord. som. Mes., Somatic layer of mesoblast. spl. Mes., Splanchnic layer of mesoblast.

anterior end rapidly grows forward beyond the anterior end of the fore-gut. The floor of the neural tube does not, however, take part in this extension, the consequence being that the summits of the neural folds form arching knees extending in front of the original anterior end of the medullary plate (Figs. 51 and 52). The extreme anterior end of the neural tube formed in this way has a ventral as well as a dorsal defect, and when it closes there is a ventral as well as a dorsal suture. The end of the ventral suture marks the original anterior end of the medullary plate, and this lies at the stage of 10 somites a short distance in front of the anterior end of the oral plate in the region of the future recessus opticus (Fig. 62). (Goronowitsch calls the anterior fissure, *sutura cerebralis anterior*; His divided it into two

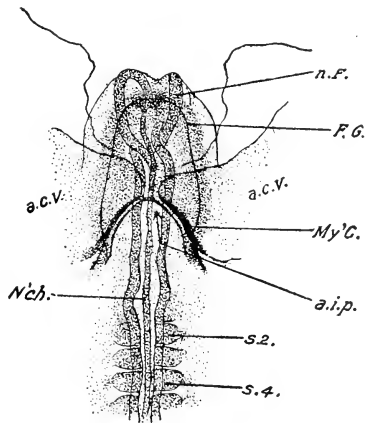


FIG. 58. — Ventral view of the head region of an embryo of 5 somites, drawn in balsam with transmitted light. x 30. a. e. v., Amnio-cardiac vesicle. a. i. p., Anterior intestinal portal. F. G., Fore-gut. My'c., Myocardium. N'ch., Notochord. n. F., Neural fold. s 2, s 4, Second and fourth somites.

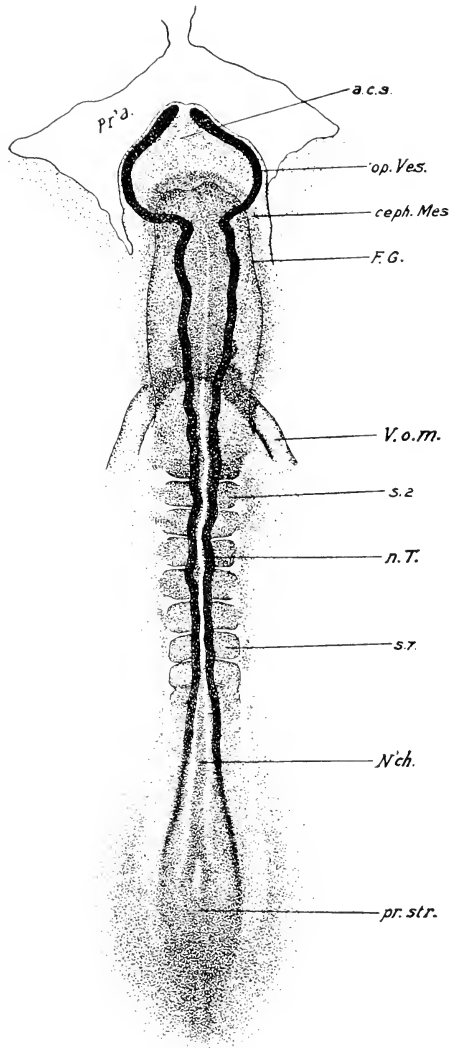


FIG. 59. — Embryo of 7 s from above drawn in balsam with transmitted light. x 30.

a. c. s., Anterior cerebral suture. ceph. Mes., Cephalic Mesoblast. F. G., Fore-gut. N'ch., Notochord. n. T., Neural tube. op. Ves., Optic vesicle. Pr'a., Proamnion. pr. str., Primitive streak. s 2, s 7, Second and seventh somites. V. o. m., Omphalo-mesenteric vein.

parts, *sutura neurochordalis seu ventralis and sutura terminalis anterior.*)

The neuropore question resolves itself into this: What part of the sutura cerebralis anterior is to be called neuropore? As the suture extends from near the infundibulum to the pineal region at least, there is a wide range of choice. However, there is a point in the suture near its dorsal end where the separation of the ectoderm from the neural tube takes place later than elsewhere. This may be regarded as the equivalent of the neuropore. The suture is the site of formation of the *lamina terminalis* (Chap. VIII).

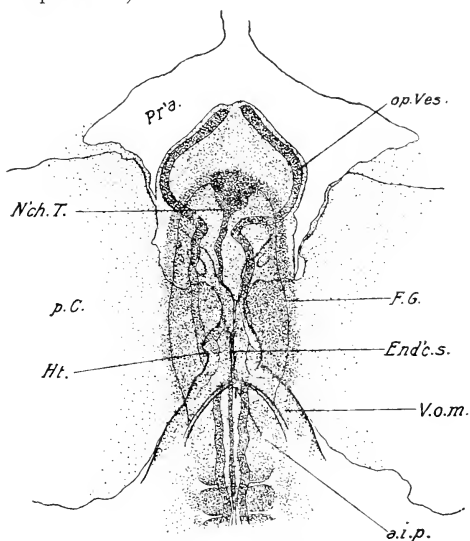


FIG. 60. — The head of the same embryo from below x 30.

a. i. p., Anterior intestinal portal. End'c. s., Endocardial septum. F. G., Fore-gut. Ft., Heart. N'ch. T., Termination of Notochord. op. Ves., Optic vesicle. p. C., Parietal cavity. Pr'a., Proamion. V. o. m., Omphalo-mesenteric vein.

It will be seen that according to this account most of the primary fore-brain includes no part of the original floor of the neural tube.

Primary Divisions of the Neural Tube. The neural tube is the primordium of the brain and spinal cord. Its cavity becomes the ventricles of the brain and the central canal of the cord. There

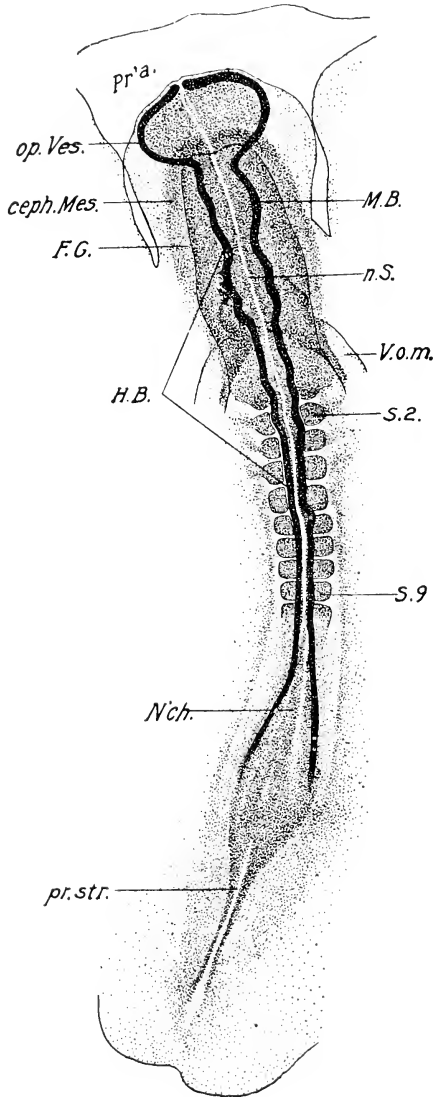


FIG. 61. — Embryo of 9 s from above drawn as a transparent object with transmitted light. x 30.

Abbreviations same as before; in addition: H. B., Hind brain. M. B., Mid brain. n. S., Neural suture.

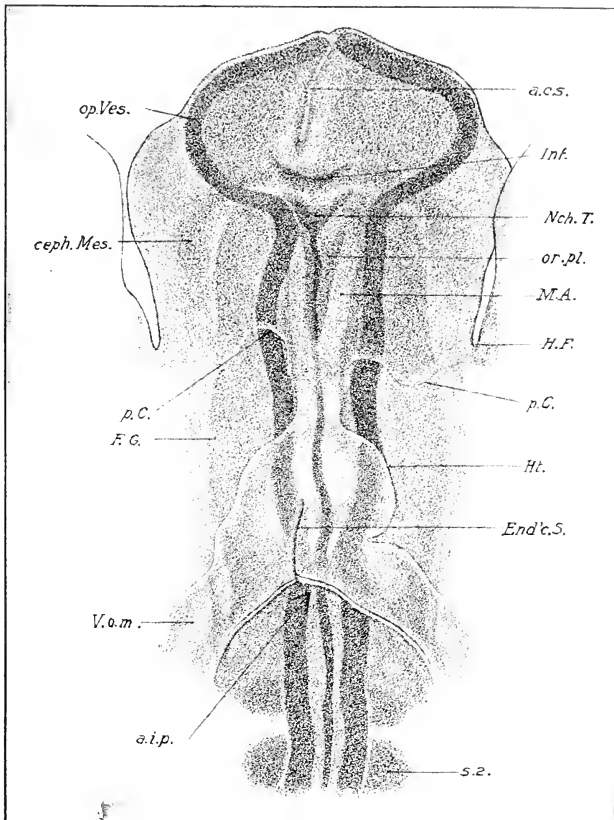


FIG. 62. — The head of the same embryo from beneath more highly magnified. In this drawing an attempt is made to show different levels of the embryo superposed: thus the heart is uppermost in the figure, beneath this the fore-gut (F. G.), beneath this the notochord, and at the lowest level, the neural tube.

a. c. s., Anterior cerebral suture. Inf., Infundibulum. M. A., Mandibular arch. p. C., represents the anterior boundary of the parietal cavity. or. pl., Oral plate. Other abbreviations as before.

is no clear distinction between brain and cord at first, the one passing without any anatomical landmark into the other. Now the brain is the central nervous system of the head, so it is not until one can determine the posterior boundary of the embryonic head that it becomes possible to determine the hind end of the

brain. The first clear landmark is given by the mesoblastic somites, because it is known that the four anterior somites are cephalic. All of the neural tube in front of the fifth somite is therefore cranial. What a large proportion of the neural tube this is in early stages may be seen by comparison of figures of embryos in the period covered by the chapter (cf. Fig. 61). Before the appearance of the first somite the entire medullary plate in front of the primitive streak is in fact cranial.

Origin of the Primary Divisions of the Embryonic Brain. The embryonic brain is divided into three divisions of unequal length, viz., the *fore-brain* (*prosencephalon*), *mid-brain* (*mesencephalon*), and *hind-brain* (*rhombencephalon*). The first division is characterized in the period we are considering by its very considerable lateral expansions, the rudiments of the optic vesicles (Figs. 59, 61, 63, etc.), and also by the fact that there is a suture in the anterior portion of its floor owing to the mode of its origin (Fig. 62). A definite constriction between it and the following division first appears in embryos with six or seven somites (Fig. 59). At the stage of 9-10 somites the next division (mid-brain) becomes clearly marked off by a constriction from the hind-brain (Fig. 61). The latter is relatively very long, and its anterior half is characterized in the 12-somite stage by the existence of five divisions (neuromeres) separated by constrictions (Fig. 63).

It will be noted that the first neuromere of the hind-brain appears about twice as large as the succeeding ones; it really includes two neuromeres according to some authors. Similarly, it is maintained that the mid-brain includes two neuromeres and the fore-brain three.

According to Hill's account the entire brain of the embryo chick is composed of eleven neuromeres or neural segments, which are formed even in the 1 s stage. The first three enter into the composition of the fore-brain; the next two, viz., 4 and 5, form the mid-brain, and the last six the hind-brain.

The three that enter into the composition of the primary fore-brain have the following fate according to Hill: the first forms the telencephalon, the second the anterior division (parencephalon) and the third the posterior division (synencephalon) of the diencephalon. The cerebellum arises from the first neuromere of the hind-brain, sixth of the series. This question is more fully discussed in Chapter VI. (See Fig. 83.)

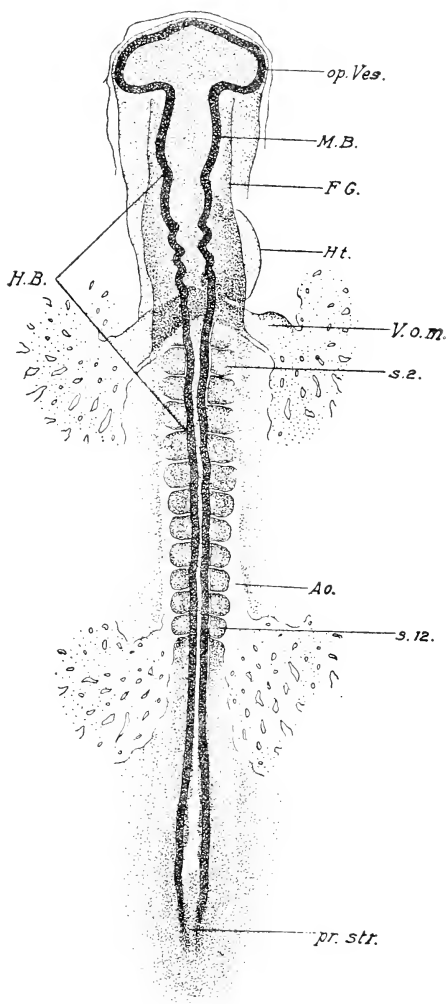


FIG. 63. — Embryo of 12 s, from above, drawn as a transparent object with transmitted light. x 30. Abbreviations as before.

IV. THE MESOBLAST

The changes in the mesoblast during this period are of great importance. At the time of appearance of the head-fold it consists of two great sheets of cells between ectoderm and entoderm

beginning on each side of the head-process and primitive streak, and extending laterally and posteriorly to the margin of the vascular area. The lateral margins at this time extend anterior to the embryonic axis, so that the anterior margin of the mesoblast forms a curve with the concavity directed forward.

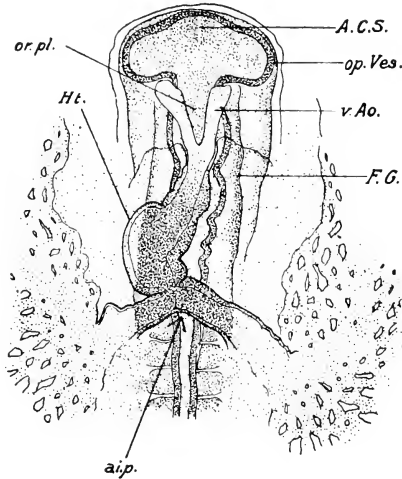


FIG. 64. — Head of the same embryo from below. x 30. Abbreviations as before.

The mesoblast in the region in front of the primitive streak is known as *gastral mesoblast*, and in the region of the primitive streak as *prostomial mesoblast*; the latter is fused with the primitive streak. However, the distinction between the gastral and prostomial mesoblast is not of permanent significance, because the latter is being continually converted into the former as the primitive streak undergoes separation into ectoderm, notochord, and mesoderm.

Confining our account now to the gastral mesoblast: a transverse section across an embryo in which the head-fold is forming shows a sheet of cells lying on each side of the notochord between the ectoderm and entoderm. It is several cells deep near the notochord, and thins gradually peripherally (cf. Fig. 56). The thicker portion next the notochord is distinguished as the *paraxial mesoblast* (vertebral plate) from the more peripheral portion or *lateral plate*. The mesoblast is sparser, the cells more scattered,

and the whole tissue of much looser texture in the more anterior portions of the embryo.

The paraxial mesoblast increases rapidly in thickness and thus becomes clearly distinguishable from the lateral plate. Shortly after the formation of the head-fold a transverse cleft appears in the paraxial mesoblast a short distance in front of the anterior end of the primitive streak (Fig. 48). This is soon followed by a second cleft, a very short distance behind the first, and thus a complete *mesoblastic somite* is established. The division is accomplished rather by segregation of the cells than by an actual folding. The mesoblast cells immediately in front of the first cleft aggregate so as to form a somite continuous anteriorly with the mesoblast of the head, thus lacking an anterior boundary; this is the first somite, and the one formed between the first two clefts in the mesoblast is the second.

The first somite established is first, not only in point of time, but also in position, all the remainder forming in succession behind this (cf. Figs. 48, 50, 51, 59, 61, etc.). As this is a point of considerable importance for understanding the topography of the embryo, and as previous text-books have a different account of it, it is worth while to give the evidence for this position in some detail. It has been believed up to a very recent time that from two to four somites were formed in front of the first one. This belief was due very largely to a misconception of the nature of the primitive streak, which was believed by some to be extra-embryonic, that is to lie behind the embryo and not to be a part of the embryo itself. The first somite lies so near to the anterior end of the primitive streak that it was difficult to believe that room could be made by growth between it and the primitive streak with sufficient rapidity to accommodate the rapidly forming somites. In the entire absence of differentiated organs it was impossible to find landmarks by which to distinguish the first somite among the first five or six; hence it was natural to suppose that a certain number of somites arose in front of the first, especially as it was not known how much of the anterior portion of the embryonic axis represented the head. However, in the absence of natural landmarks identifying the first somite formed, it is quite possible to create artificial ones, and in this way to identify it in later stages. This has been done by Miss Marion Hubbard and by Patterson in the following manner: The posi-

tion of the first somite was marked immediately after the appearance of the first cleft with a delicate electrolytic needle which left a permanent scar. The eggs thus operated on were closed up and permitted to develop to a stage of from 10

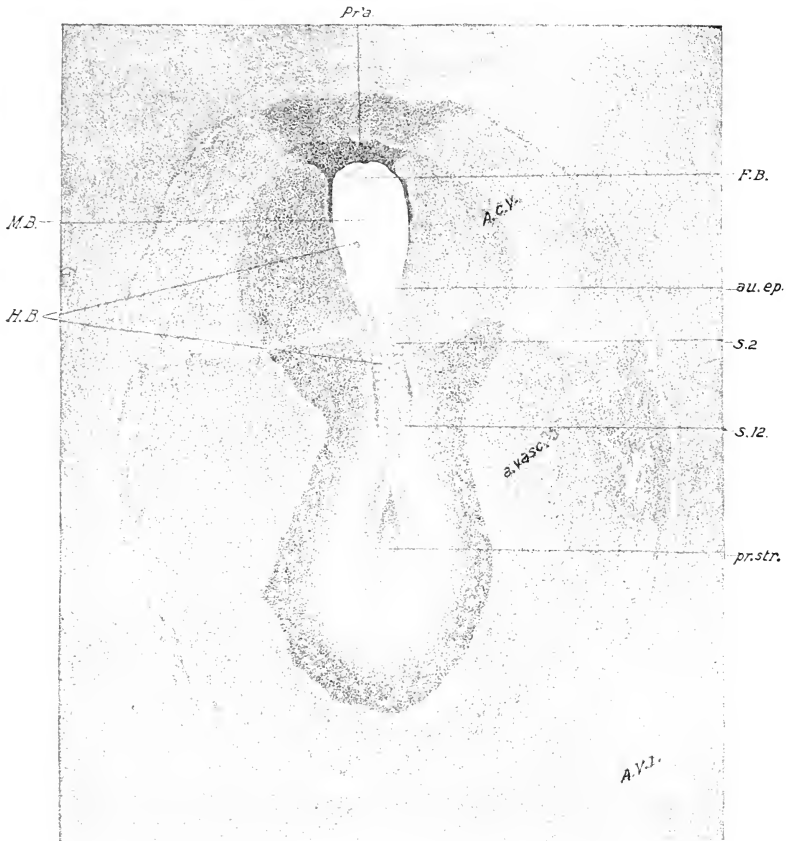


FIG. 65.—Embryo of 12 s, from above, drawn in alcohol with reflected light.

au. ep., Auditory epithelium. Other abbreviations as before.

to 25 somites; and then the mark was found to coincide with the first somite of the series. In the next place it was possible by similar means to mark out the topography of the embryonic head in the stage of one or two somites. Thus it was determined that a mark made immediately in front of the first somite formed appeared later in the region of the otocyst;

but this arises normally at the stage of 12-14 somites, a very short distance in front of the first somite of the series, which is thus shown to have the same position as the first somite formed. On the other hand, if one assumed that the first somite formed

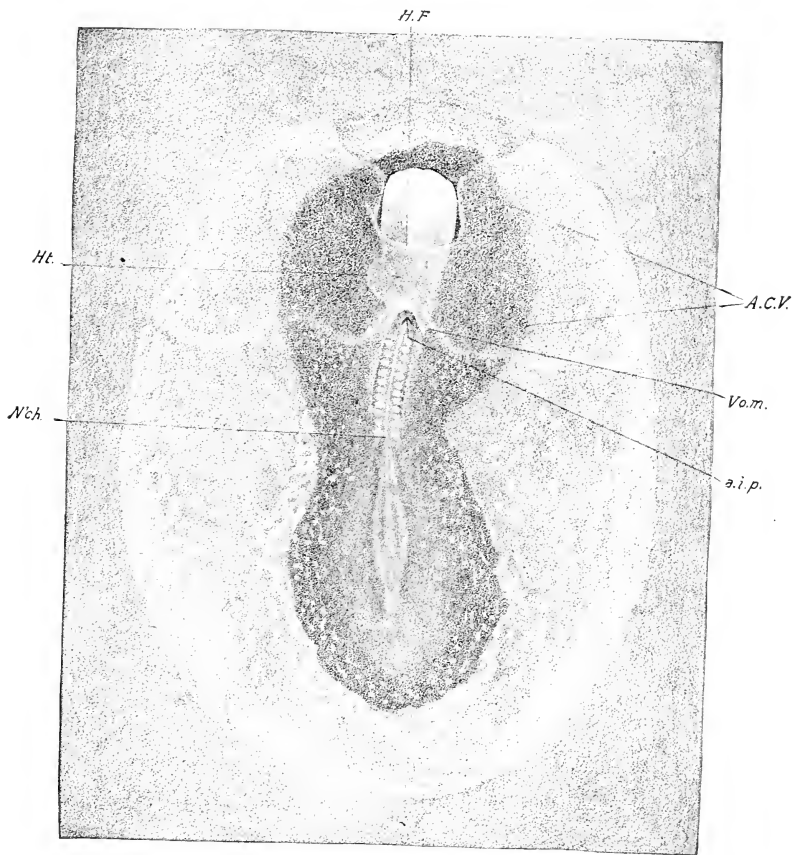


FIG. 66. — The same embryo from beneath, drawn in alcohol with reflected light. Abbreviations as before.

became the third or fourth of the series, it is clear that one would have to make a mark some distance in front of the first somite formed, to strike the place of origin of the otocyst. Marks made on this theory were always found a considerable distance in front of the otocyst. Altogether a large number of experiments

was made, the concurrent testimony of which was perfectly conclusive.

The somite formed in front of the first cleft is thus the first in position of the definitive series and the remainder arise in succession behind it. The formation of the somites therefore follows the usual law of antero-posterior differentiation.

There is always a stretch of unsegmented paraxial mesoblast between the last somite and the anterior end of the primitive streak.

The first four somites belong to the head, and enter into the composition of the occipital region. The more anterior part of the mesoblast of the head never becomes segmented in the chick. In the anamniote vertebrates, segmentation of the mesoblast extends farther forward, and there is a greater number of cephalic somites. This may be taken as evidence that a large part, at least, of the head was primitively segmented like the trunk. As we shall see later, the primitive metamerism of the head is also expressed in other ways: neuromeres, branchiomeres, etc.

The segmentation of the mesoblast finally extends to the hind end of the tail, new segments being continually cut off from the anterior end of the paraxial mesoblast until it is all used up. This is not complete until the fifth day. The number of somites thus formed is perfectly constant, as is also the fate of the individual somites.

Primary Structure of the Somites. Each somite is primarily a block of cells arranged in the form of an epithelium around a small central lumen, towards which the inner ends of all the cells converge (Fig. 68 B). The central cavity (myocoële) is, however, filled with an irregularly arranged group of cells, and, though the cavity must be regarded as part of the primitive body-cavity, or coelome, it has no open communication with it. After the somites are formed they rapidly become thicker so that their lateral boundary becomes very sharply marked; this is not due to a longitudinal constriction external to the paraxial mesoblast, as usually stated. Each somite has six sides, of which five are free, viz., dorsal, ventral, anterior, posterior, and median. The sixth or lateral side is continuous with the nephrotome.

The Nephrotome, or Intermediate Cell-mass (Middle Plate).

The somites and the lateral plate are not in immediate contact but are separated by a short stretch of cells continuous with both, known as the nephrotome or intermediate cell-mass or middle plate. The intersegmental furrows do not extend into the intermediate cell-mass, and the latter therefore remains unsegmented like the lateral plate. It consists fundamentally of two layers of cells, dorsal and ventral, of which the former is continuous with the dorsal wall of the somite and the somatic layer of the lateral plate, and the latter with the ventral wall of the somite and the splanchnic layer of the lateral plate (Fig. 68 B). Thus if the two layers of the intermediate cell-mass were separated the space between them would be continuous with the cœlome that arises secondarily in the lateral plate. This condition actually exists in some of the Anamnia (Selachii, for instance) in which the intermediate cell-mass is also segmented.

The Lateral Plate. This name is given to the lateral mesoblast within which the body-cavity arises. It is separated from the somite by the nephrotome and its lateral extension coincides with the margin of the vascular area.

Development of the Body-cavity or Cœlome. The cœlome or body-cavity arises within the lateral plate as a series of separated small cavities, distributed throughout its whole extent, which appear first in the anterior portion (1-3 s stage). By successive fusion of these cavities and their extension centrally and laterally, there arises a continuous cavity, the cœlome, which extends from the nephrotome to the margin of the vascular area (Fig. 68), and which becomes the pleuroperitoneal and pericardial cavities in the embryo, and the extra-embryonic body-cavity beyond the boundaries of the embryo.

Of the two layers of the lateral mesoblast thus established, the external is known as the *somatic* and the internal as the *splanchnic* layer. In the course of development the somatic layer becomes closely bound to the ectoderm, thus constituting the *somatopleure*, and the splanchnic layer becomes similarly united to the entoderm, thus establishing the *splanchnopleure*. The somatopleure is destined to form the body-wall and the extra-embryonic membranes known as the amnion and chorion; from the splanchnopleure is derived the alimentary canal with all its appendages, and the yolk-sac. As described in detail in the next chapter, this splitting of the mesoblast progresses with

the overgrowth of the yolk until it extends completely around the latter

Returning now to the first stages in the formation of the coelome. In the 3 s stage it undergoes a precocious expansion in the region lateral to the head of the embryo (Figs. 51, 52, etc.), forming a pair of large cavities known as the amnio-cardiac vesicles, because they participate in the formation of the amnion and pericardium. These cavities extend in rapidly towards the middle line, and enter the head-fold in the 4-5 s stage (Figs. 52, 58). At the stage of 6-7 s they meet in the floor of the fore-gut immediately behind the oral plate and fuse together, thus dividing the head-fold into somatic and splanchnic limbs, as previously described. A median undivided portion of the body-cavity known as the parietal cavity (forerunner of the pericardium) is thus established beneath the fore-gut; and it extends backward with the elongation of the fore-gut in the manner already described. A pair of blind prolongations of this cavity extends a short distance forward at the sides of the oral plate at the 10-12 s stage (cf. Fig. 62), lying lateral and ventral to the ventral aortæ.

The median angle of the body-cavity, where the somatic and splanchnic layers meet, is a point of fundamental morphological importance. In the region of the somites the nephrotome is attached here, and in the head the wing of cells leading to the axial mesoblast (cf. Figs. 68 B, 53, and 54). In an embryo with ten somites this angle may be traced forward to near the hinder end of the oral plate, lying beneath the lateral angles of the pharynx.

Mesoblast of the Head. Mesoblast exists in two forms in the embryo: (1) in the form of epithelial layers or membranes (mesothelium), and (2) in the form of migrating cells which usually unite secondarily to form a syncytium in the form of a network, the meshes of which are filled with fluid; the nuclei lie in the thickened nodes. This form of the mesoblast is known as mesenchyme. It is always derived from a pre-existing epithelial layer, usually, but not necessarily, mesothelium, for, as we shall see, parts of it are derived from ectoderm and entoderm; on the other hand, mesenchyme may secondarily take on an epithelial arrangement (endothelium). The terms mesothelium and mesenchyme have therefore merely descriptive significance in the early embryonic stages. The mesenchyme has no single

embryonic significance either as to origin or fate, but is to be regarded as a mixed tissue.

The mesoblast of the head is derived from several sources: (1) from a continuation forward of the paraxial mesoblast; (2) by proliferation from the fore-gut; and (3) from proliferations of ectoderm.

(1) The axial mesoblast of the head is an anterior continuation of that of the trunk; it terminates at the anterior end of the fore-gut with which it is continuous from the stage of the head-process up to about the 6 s stage (Figs. 43 and 49). In the anterior part of the head it is mesenchymal in its general structure, grading posteriorly into the mesothelial paraxial mesoblast of the hinder part of the head and trunk. It is continuous at first with the lateral mesoblast in which the amnio-cardiac vesicles are forming; but this connection is lost in the anterior part of the head that projects forward above the blastoderm; that is, in front of the head-fold.

(2) The anterior end of the fore-gut proliferates mesenchyme from the time of its first formation to about the 6 s stage (Fig. 49). The proliferation is so rapid that it may give rise to the appearance of diverticula. The extreme anterior end of the floor forms a sac which lies just in front of the oral plate at the 4 s stage (Fig. 52 A), but soon after breaks up into mesenchyme. There is a considerable mass of mesenchyme formed from this source in the space bounded by the anterior end of the fore-gut, the neural tube and the ectoderm; at the 4 s stage this appears fused with the floor of the neural tube and the surface ectoderm, and probably receives cells from both; the anterior end of the notochord also disappears in this mass (cf. Fig. 67).

(3) Ectodermal proliferations forming mesenchyme in the head. (This subject is discussed in the next chapter.)

Vascular System. The origin of the blood-islands in the opaque area was described in the preceding chapter. They lie between the cœlomic mesoblast and the yolk-sac entoderm derived from the germ-wall. When the somatopleure and splanchnopleure are formed the blood-islands lie between the two layers of the latter, and the somatopleure is entirely bloodless. About the stage of 1 somite a vascular network continuous with the original network of the opaque area begins to appear in the pellucid area, at first at the margin of the opaque area, but by

degrees nearer and nearer to the embryo, until, by the 7 or 8 s stage, blood-vessels begin to appear in the embryo itself. It is important to note that the order of appearance of the vascular primordia is first in the area opaca in the order previously described, then in the pellucid area and finally in the embryo itself. Moreover, the parts appearing later are, usually at least, in continuity with those first formed.

Before discussing the way in which the blood-vessels arise in the pellucid area and in the embryo, we should consider the first differentiation within the original, or peripheral, blood-islands. Between the 3 and 5 s stage it may be noticed in sections that vacuoles are forming within the peripheral blood-islands near the entodermal surface. The expansion of these vacuoles carries the peripheral layer of cells away from the main mass of cells composing the blood-islands, and by degrees the process is carried completely around the blood-island, so that the peripheral layer becomes entirely separated from the central mass and encloses it (See Fig. 68 C.). The enclosing cells become flattened during this process to form an endothelium; inasmuch as the blood-islands are not separate, but anastomose to form a network, the process results in the formation of a network of endothelial tubes enclosing cell-masses. Thus arise the first blood-vessels. The enclosed masses of cells rapidly acquire hæmoglobin, become separated from one another, and form blood-cells.

There is a great difference in the relative amounts of blood-cells formed in different regions. Thus in the anterior part of the opaque area and in the pellucid area the original blood-islands are relatively small (Figs. 44 and 45), and furnish material sufficient only for the formation of the blood-vessels. On the other hand, in the peripheral part of the vascular area, especially towards its posterior end, the largest masses of blood-cells are found; and these conditions grade into one another. In other words, the formation of blood-cells is restricted at this time to the opaque area, and is most abundant posteriorly. In the pellucid area only empty blood-vessels are formed. Similarly the blood-vessels of the embryo itself are at first empty; they become filled secondarily from the opaque area when circulation begins.

The appearance of blood-vessels within the pellucid area

and the embryo has been interpreted in two principal ways: (1) that they are an ingrowth from the original vascular primordium of the opaque area; and (2) that they arise by differentiation *in situ*. The first view was originally stated by His, and has been supported by Kölliker and others. The second is supported by Rückert, P. Mayer and others. The observations, on which the ingrowth theory of His were based, were made originally on whole blastoderms of the chick, and concerned primarily the order of origin of the blood-vessels, which is centripetal and continuous. But it is obvious that such observations do not in themselves demonstrate the existence of an independent ingrowing primordium; they are not altogether inconsistent with the view that the blood-vessels differentiate from cells *in situ*. Within the embryo itself parts of certain vessels appear in sections to arise separately, and form secondary connections with the vessels formed at an earlier time; this is the case for instance with the dorsal aorta in the region of the head. But such appearances seen in sections may be deceptive, as Evans has shown by injections of the ingrowing vascular system of early chick embryos. The entire system appears in such injections to be continuous from the first and there was found no evidence of independently formed parts.

Origin of the Heart. The embryonic heart possesses two layers: an internal delicate endothelium, the endocardium, and an external strong muscular layer, the myocardium. The endocardium arises in continuity with the blood-vessels of the pellucid area, and is in no wise different from them; the myocardium, on the other hand, arises from the splanchnic mesoblast. The heart is thus to be regarded as a portion of the embryonic vascular system, specially provided with a muscular wall for the propulsion of the blood. The first indication of the heart is a thickening of the splanchnopleure of the amniocardiac vesicles, which forms the primordium of the myocardium. This is situated a short distance lateral to the hind-brain region of the embryo, and makes its appearance between the stage of 3 and 5 somites.

The endocardium soon appears between the thickened entoderm and the myocardium, in the form of a delicate endothelial vessel on each side, continuous with the extra-embryonic blood-vessels. This is, indeed, the place where the blood-vessels first

reach the embryo. The myocardium then becomes arched towards the body-cavity and includes the endocardium in its concavity (Fig. 53). The heart thus comes to consist of two parts on each side: a myocardial gutter semicircular in cross section, open towards the entoderm, and an endothelial tube lying in the gutter, and in contact with the entoderm. At this time the lateral limiting sulci appear in the splanchnopleure just central to the endocardium on each side, and, as the fore-gut closes from in front backwards, the following changes take place (Figs. 54 and 54 A): (1) the entoderm withdraws completely from the fused apices of the lateral folds in the splanchnopleure, and thus a wide separation is made between the floor of the pharynx and the splanchnopleure below; (2) the right and left endocardial tubes come into immediate contact in the floor of the pharynx; (3) the two myocardial gutters coming together form a single tube around the endocardium, suspended by a double mesodermal membrane (*mesocardium* or *dorsal mesentery of the heart*) to the floor of the pharynx, and attached by a similar mesentery (*ventral mesentery of the heart*) to the splanchnopleure beneath (Fig. 54). The latter connection is ruptured almost as soon as formed, so that the floor of the myocardium becomes complete (Fig. 54 A). Soon after the completion of the floor of the pharynx the two endocardial tubes press together until the common wall becomes reduced to a vertical partition, which then ruptures; and finally (10–12 s) all traces of the original duplicity of the heart disappear (Figs. 60, 62, 64).

The heart thus arises from two lateral halves which fuse secondarily to form a single tube. This fusion takes place from in front backwards, hence the anterior end of the heart is formed first. Indeed, the full length of the cardiac tube is not formed in the period covered by this chapter; the definitive hindermost division is established by conerescence after the 12 s stage. But the actual hind end is always continuous with the extra-embryonic network of blood-vessels and this connection develops into the main splanchnic veins.

As a rare abnormality the lateral primordia of the heart may meet and fuse dorsal to the embryo, instead of in the floor of the pharynx. This condition is known as omphalocephaly; in other rare cases the lateral halves may fail to unite, and two hearts may be formed.

There are three views concerning the origin of the endocardium:

(1) that it is an ingrowth of the extra-embryonic vessels, (2) that it arises from the mesoblast *in situ*, (3) that it arises from the entoderm *in situ*. Appearances such as that shown in Fig. 53 favor the last view.

The heart is then a double-walled tube attached to the floor of the pharynx. The posterior end rests squarely against the anterior intestinal portal and is continuous with the rudiments of the splanchnic veins running in the diverging folds of the portal; the anterior end of the heart is continued as a simple endothelial tube (ventral aorta) as far forward as the oral plate, where it is divided in two (Figs. 62, 64, etc.).

This primitive simplicity of the cardiac tube continues throughout the period considered in this chapter without substantial alteration. The heart increases in length with considerable rapidity, but being attached at its anterior and posterior ends by the aortic and venous roots respectively, it is forced to bend, nearly always to the right, so that a convexity of the heart appears to the right of the embryonic head, at about the 11–12 s stage (Figs. 63, 64). About this time the mesocardium (dorsal mesentery of the heart) disappears except at the posterior end, and the cardiac tube thus becomes free except at its two ends.

The Embryonic Blood-vessels. The dorsal aorta arises from the median edge of the vascular network, which extends across the pellucid area in the splanchnopleure. At the stage of 7–9 somites, it has reached the nephrotomic level. The marginal meshes gradually straighten themselves out into a longitudinal vessel, continuous with the net-work at the sides and behind. Only the trunk part has been shown to arise in this manner. The cephalic part may arise by a forward growth of the trunk part or from mesenchyme *in situ*. A connection is formed around the anterior end of the fore-gut with the ventral aortæ (Fig. 55), and an arterial pathway is thus established from the heart by way of the ventral and dorsal aortæ to the vascular network of the splanchnopleure.

The arterial system consists at thirty-three hours (12 s stage) of the following parts: (1) ventral aorta; (2) first visceral or mandibular arteries connecting 1 and 3; (3) dorsal aortæ; (4) segmental branches of the dorsal aortæ. The ventral aorta is, as

we have seen, the anterior prolongation of the endocardium extending between the extreme anterior end of the heart proper and the oral plate. At the oral plate it divides into two branches, right and left mandibular arteries or arches, that surround the anterior end of the fore-gut, and arch over to be continued into the two dorsal aortæ. The tissue in which these arches run is destined to form the mandibular arch or lower jaw. The two dorsal aortæ are very large vessels running above the roof of the pharynx near its lateral angles. They give off no branches in the head. In the trunk they pass backwards in the splanchnopleure beneath the somites (Fig. 68 B), and are connected at intervals with the extra-embryonic blood-vessels. These connections are more important in the region of the primitive streak (Fig. 63) where the dorsal aortæ disappear in the general extra-embryonic network. Slight diverticula of the dorsal aortæ ascend in the interspaces between successive somites (segmental arteries).

Concerning the veins in the period under consideration there is nothing additional to be said.

V. DESCRIPTION OF AN EMBRYO WITH 10 SOMITES

It will now be in place to describe rather fully the anatomy of the stage at which we have arrived; this will serve as a point of departure for the next chapter.

The blastoderm is a circular membrane covering a considerable portion of the yolk (cf. Fig. 32 A). The embryo appears to the naked eye as a whitish streak in the central pear-shaped pellucid area. The surface views and the two views of the embryo viewed as a transparent object show the topography of the various parts of the embryo (Figs. 63-66).

A section across the entire blastoderm at the stage of 10 s, through the sixth somite (Fig. 68), shows the following parts:

The *ectoderm* bounds the section above; it is thickened in the angle between the neural tube and the somites, and becomes thinner as it is traced peripherally; at the extreme periphery of the blastoderm it merges into a mass of cells that interpenetrate the yolk. Ventrally the boundary of the section is formed by the *entoderm* which is slightly arched upwards in the middle line.

In the region of the area pellucida the entoderm is very thin; at its boundary it passes rather abruptly into the large rounded vesicular cells of the yolk-sac entoderm, which becomes continuous at the margin of the vascular area with the germ-wall; the latter continues to the periphery where it merges in the undifferentiated cell-mass (zone of junction) (Figs. 68 A-68 E). The large neural tube is not yet closed. Beneath the neural tube is a section of the solid rod-like *notochord*.

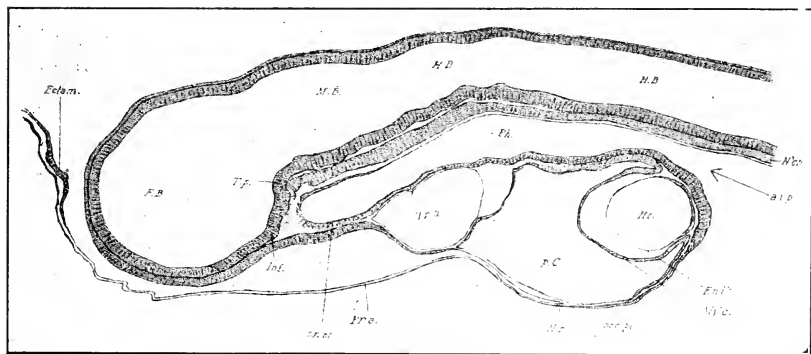


FIG. 67. — Median longitudinal section of the head of an embryo of 13 s.

Ectam., Ectamnion. F. B., Fore-brain. H. B., Hind-brain. Inf., Infundibulum. M. B., Mid-brain. pr.c. pl., Precardial plate. T. p., Tuberculum posterius. Other abbreviations as before.

The *mesoderm* (Fig. 68 A, B, C) lies between the parts already named; it consists on each side of the middle line of the following parts: (1) the *mesoblastic somite*, a block of cells that radiate from a central cavity filled with irregularly disposed cells; (2) the intermediate *cell-mass* or *nephrotome*, forming a narrow connecting bridge between the somite and the lateral plate; (3) the *lateral plate*, split into two layers, external, known as the *somatic layer*, and internal or *splanchnic layer*. The cavity between the two layers is the *coelome* or *body-cavity*; it is very narrow next the nephrotome, but widens as it extends laterally to the margin of the vascular area, and is divided by various strands of cells, extending from somatic to splanchnic layers, thus indicating its origin by fusion of coelomic vesicles.

The ectoderm plus the somatic layer constitute the *somato-pleure*, from which the body-wall, amnion, and chorion are derived, and the entoderm plus the splanchnic layer form the *splanchno-*

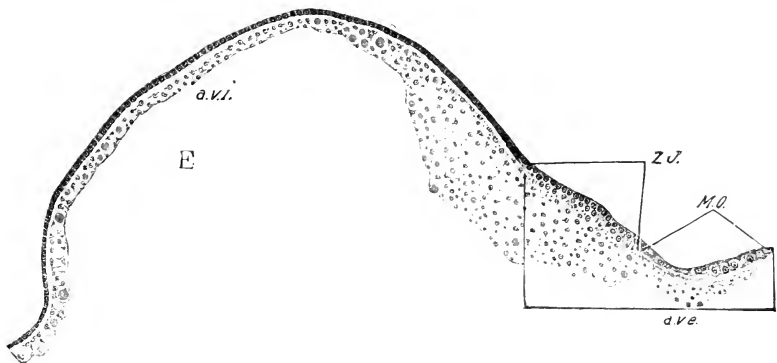
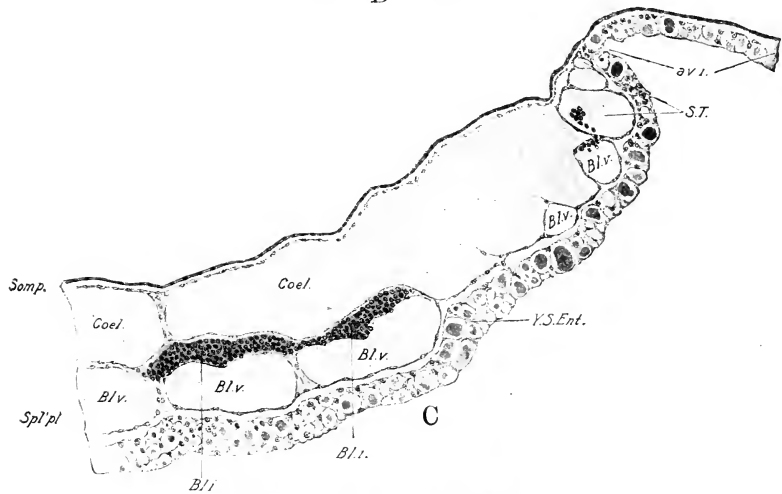
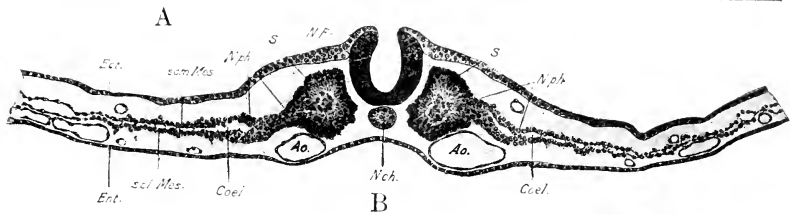
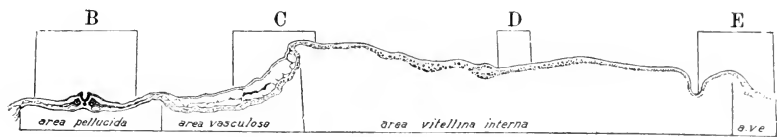pleure, from which arises the intestine and all its appendages, including the allantois and the yolk-sac. Blood-vessels lie between the splanchnic mesoblast and the entoderm. The large vessels beneath the somite and nephrotome are the *dorsal aortæ*; small vessels are present in the area pellucida, and there are many large ones in the area vasculosa. The walls of the vessels are constituted of a single layer of flat endothelial cells bulging in the region of the nuclei; in the vascular area are true blood-islands with embryonic blood-cells more or less fully filling the cavity.

In a median sagittal section (Fig. 67) the following points should be noticed: (1) the neural tube is enlarged in the region of the head to form the brain, more fully described below; (2) the entoderm forms a tube in the head known as the pharynx or cephalic enteron (cephalic part of the fore-gut), opening behind the heart into the space between the entoderm and yolk. The floor of the anterior end of the fore-gut is fused to the ectoderm in the middle line forming the oral plate. The entoderm forming the floor of the fore-gut turns forward around the hind end of the heart, and beneath the anterior part of the head forms part of the proamnion or mesoderm-free region of the pellucid area; (3) the large pericardial (parietal) cavity lies beneath the floor of the fore-gut. Attached to the posterior wall of the pericardium one sees the hind end of the heart with its two walls, the endocardium and the myocardium a fold of the mesoblastic lining of the pericardium. Between the anterior end of the pericardium and the oral plate is seen the endothelial ventral aorta; (4) the notochord lies between the fore-gut and neural tube and ends anteriorly in a mass of mesenchyme lying between the infundibulum and fore-gut.

The Nervous System. The neural tube is closed at the 12 s

FIG. 68. — A. Transverse section across the axis of the embryo and the entire blastoderm of one side. The section passes through the sixth somite of a 10 s embryo, and is intended to show the topography of the blastoderm. The regions B, C, D, E are represented under higher magnification in the Figs. B, C, D, E.

a. v. e., Area vitellina externa. a. v. i., Area vitellina interna. Bl. i., Blood island. Bl. v., Blood vessel. Coel., Cœlome. G. W., Germ-wall. M. O., Margin of overgrowth. N'ph., Nephrotome. S., Somite. Som'pl. Soma-
 ðopleure. Spl'pl., Splanchnopleure. Som. Mes., Somatic layer of mesoblast. spl. Mes., splanchnic layer of the mesoblast. S. T., Sinus terminalis. Y. S. Ent., Yolk-sac entoderm. Z. J., Zone of junction.



stage (Figs. 63 and 65) to a point a little behind the last meso-blastic somite; beyond this the medullary folds diverge and are lost to view towards the hind end of the primitive streak. We may distinguish a cephalic portion (*brain or encephalon*) and a trunk portion (*spinal cord or myelon*) of the neural tube; the boundary lies between the fourth and fifth somites, for the first four somites enter into the composition of the head. The brain is thus at this time about as long as the portion of the cord formed or indicated by the medullary folds. For description, see p. 108.

Alimentary Canal. The alimentary canal and its appendages exist only potentially in this embryo in the form of the splanchnopleure, except in the head. The cephalic enteron of this stage corresponds to a large part of the pharynx. The oral plate has already been described in connection with the sagittal section (Fig. 67). In transverse section the extreme anterior end of the fore-gut is quite narrow, elsewhere it is very wide laterally, and in one place its lateral expansions come in contact with the ectoderm on each side and fuse to it, thus indicating the *hyomandibular cleft*. The floor and lateral walls of the pharynx are composed of columnar cells, the roof of flattened squamous cells (Fig. 54).

Vascular System. The heart lies in the parietal cavity beneath the pharynx; it is bent near its middle to the right. It is an undivided double-walled tube, the internal wall or endocardium being a continuation of the blood-vessels, and the external wall, myocardium or muscular heart, being a duplication of the wall of the pericardium. It has not yet reached the stage of regular contraction, though it may be observed to twitch from time to time. The chambers of the heart are indicated, but not clearly defined at this time; one can only say that the posterior end is the venous end from which the sinus and auricles are to form, and the anterior two thirds, the arterial end, destined to form the ventricles and bulbus.

The endocardium is continued anteriorly into the *ventral aorta*, which divides on each side of the oral plate (Fig. 64), to form the mandibular arches that describe a loop around the anterior end of the fore-gut and are continued posteriorly as the *dorsal aorta*, which run above the roof of the pharynx, lateral to the notochord, into the trunk, where they lie ventral to the nephrotome, and send off short blind branches (segmental arteries)

between the somites. Near the primitive streak they disappear by merging in the vascular network of the blastoderm.

The posterior end of the endocardium divides in two branches that pass out along the postero-lateral margins of the fore-gut into the general vascular network of the blastoderm (Fig. 64). This connection constitutes the beginning of the vitelline veins through which the blood from the yolk-sac enters the posterior end of the heart.

General. The elongated form of the entire embryo and the preponderance of the head are marked features of this stage. The latter condition is largely due to the order of origin of parts: the anterior parts preceding the more posterior in their appearance. The head is really, therefore, in a more advanced stage of development than the trunk, hence larger. The elongated condition of the head and the arrangement of all its organs in longitudinal sequence, however, are probably conditions of phylogenetic significance, and point towards an ancestral condition. The topographical values of the divisions of the embryonic head are very different from those of the adult, to attain which certain regions develop to a relatively enormous extent, and others comparatively little.

A number of features in the anatomy of the 12 s stage are purposely omitted from this description, as they represent the primordia of structures described more fully beyond; such, for instance, are the neural crest, the pronephros, etc.

Zones of the Blastoderm. The following zones may be recognized in the blastoderm : (1) the pellucid area surrounding the embryo; (2) the vascular zone of the opaque area; (3) area vitellina interna; (4) area vitellina externa. The pellucid area is readily defined by its transparency and by the existence of the subgerminal cavity beneath it. The vascular zone is most readily defined by the extension of the blood tissue which has a very definite margin, coincident with the extension of the mesoblast. The area vitellina includes all of the blastoderm peripheral to the vascular area, and it is characterized by the presence of two layers only, ectoderm and entoderm (germ-wall). It is again divided into two concentric zones, internal and external. The internal is much the wider (Fig. 32 A), and is characterized by the existence of a perilecithal space, *i.e.*, a slight fluid-filled cavity between the entoderm and yolk continuing the subgerminal

cavity peripherally. The external vitelline area is relatively narrow, and consists (1) of the zone of junction adjoining the internal vitelline area, and (2) a free margin separate from the yolk (margin of overgrowth). The zone of junction is the persistent embryonic or formative part of the blastoderm from which the extra-embryonic ectoderm and entoderm arises. Thus as it spreads peripherally over the surface of the yolk, it leaves on its central margin the differentiated extra-embryonic ectoderm and entoderm; in other words, the zone of junction is the youngest part of the blastoderm, and the concentric zones that may be drawn within it represent successively older stages in a centripetal direction. Therefore in a transverse section through the entire blastoderm successive stages of differentiation of the ectoderm and particularly of the entoderm are met as one passes from the zone of junction towards the center.

The free margin arises from the zone of junction in the manner already described in Chapter II. It may be considered as a part of the ectoderm and it terminates in a row of enlarged cells that often exhibit amœboid prominences on their margins. It would appear that these cells have the function of a marginal wedge that separates the vitelline membrane and yolk.

The germ-wall has been the subject of many extended researches, but a definitive solution of its origin and function has not hitherto been obtained, mainly on account of the incomplete knowledge of its early history. The ground here taken is in some respects different from that of the various authors, but it is based on a study of its early history given in Chapter II. There is no deviation from the mode of formation of the zone of junction in the stage under consideration from what was found in earlier stages, and there is no reason to believe that its subsequent history varies in any important respect. It appears to be produced by continuous proliferation of the cells in the yolk as in earlier stages (see Fig. 68 E). These cells actively engulf the large yolk granules, and the histological structure becomes in consequence difficult of analysis. The cells lose their individuality and constitute an extended syncytium, the protoplasm of which is packed with yolk-granules. In removing the blastoderm from the egg in salt-solution one finds always, after removing the yolk that may be washed off, a narrow submarginal zone of adherent yolk that is not readily removed, and this is the site of the zone of junction.

Centrally to the zone of junction we have the differentiated ectoderm and germ-wall sharply separated from the yolk by the perilecithal space. The ectoderm of the inner zone of the vitelline area requires no extended notice; it consists at this time of a single layer of flattened cells. The germ-wall next to the zone of junction consists of two or three layers of large, more or less rounded, cells with definite boundaries, each of which contains one or more yolk-spheres and smaller yolk-granules (Fig. 68 E). We may say roughly that whereas in the zone of junction we have cells in the yolk, in the vitelline area we have yolk in the cells. This may indicate sufficiently the way in which a several layered epithelium becomes differentiated from the zone of junction. As this epithelium is traced centrally we find usually a short distance from the zone of junction a thinner area (Fig. 68 D), and beyond this again the several layers of cells even more laden with yolk-spheres and granules than previously; so that it would appear that these cells may actively engulf yolk-granules. At the margin of the vascular area the entoderm becomes one-layered, and is composed of columnar cells with swollen free margins turned towards the yolk and still containing some yolk-granules and spheres (Fig. 68 C). At the margin of the pellucid area there is a rather sudden transition to the flat entodermal epithelium characteristic of this area.

CHAPTER VI

FROM TWELVE TO THIRTY-SIX SOMITES. THIRTY-FOUR TO SEVENTY-TWO HOURS

I. DEVELOPMENT OF THE EXTERNAL FORM, AND TURNING OF THE EMBRYO

IN the embryo of twelve somites only the head is distinctly separated from the blastoderm; and there is no sharp boundary between the embryonic and extra-embryonic portions of the blastoderm in the region of the trunk; but this changes very rapidly. The progress of the developmental processes, that have marked out an embryonic axis in the blastoderm, produces in the course of about eighteen hours a sharp distinction everywhere between embryo and extra-embryonic blastoderm. The latter, together with an outgrowth of the embryonic hind-gut (allantois), then constitute the so-called *embryonic membranes*, which become very complicated, and which provide for the protection, respiration, and nutrition of the embryo. We shall consider the formation of the embryonic membranes separately in order not to confuse the account of the development of the external form of the embryo.

In considering the development of the external form of the embryo, we must distinguish between those processes that separate it from the extra-embryonic blastoderm, and those that occur within its own substance leading to various characteristic bendings and flexures; we may consider them separately, although they are going on at the same time.

Separation of the Embryo from the Blastoderm. The separation of the embryo from the blastoderm takes place by the formation of certain folds or sulci that may be named: (1) the head-fold or *anterior limiting sulcus*; (2) the *lateral limiting sulci*, appearing as prolongations of the head-fold along the sides of the embryonic axis; and (3) the tail-fold or *posterior limiting sulcus*.

The head-fold has been described in detail in the preceding

chapter. The lateral limiting sulci are a continuation of the lateral limbs of the head-fold; they owe their origin to the folding of the splanchnopleure and somatopleure adjacent to the embryo towards the yolk, at the line of junction of embryonic and extra-embryonic parts. The tail-fold arises about the stage of 26 to 27 somites (Fig. 93), and is similar to the head-fold, except that it is turned in the opposite direction. The sulci combine to form a continuous ring around the embryo and gradually pinch it off, so to speak, from the extra-embryonic blastoderm.

In the splanchnopleure the lateral limiting sulci (Fig. 69)

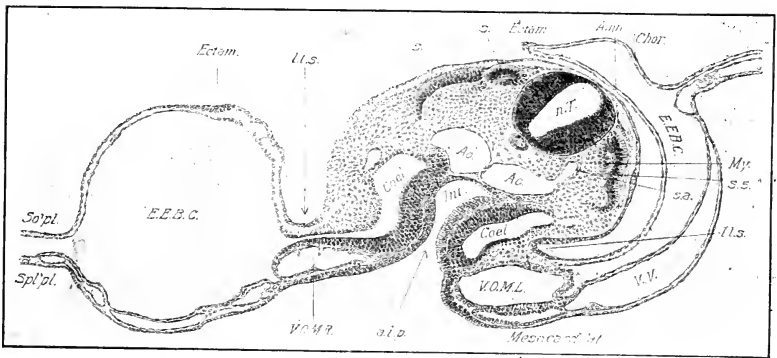


FIG. 69. — Transverse section through the fifth somite of the 23 s stage.

Amn., Amnion. Ao., Aorta. a. i. p., Anterior intestinal portal. Coel., Coelome. Chor., Chorion. Ectam., Ectamnion. E. E. B. C., Extra-embryonic body-cavity. Int., Intestine. l. l. s., Lateral limiting sulcus. My., Myotome. s. a., Segmental artery. So'pl., Somatopleure. Spl'pl., Splanchnopleure. s., Somite. s. 5, Fifth somite. V. O. M. R. and L., Right and left omphalo-mesenteric veins. V. V., Vitelline vein.

come together and fuse both in a caudal direction from the fore-gut, and subsequently in a cephalic direction from the hind-gut (see below), so as to convert the splanchnic gutter into a tube (the alimentary canal). There is thus a ventral suture along the alimentary canal in which the entoderm of the alimentary canal becomes separated from the extra-embryonic entoderm, leaving a double layer of the splanchnic mesoblast (ventral mesentery) connecting the alimentary canal with the extra-embryonic splanchnopleure; but this disappears everywhere as soon as formed, except in the region of the posterior part of the heart and the liver, where it forms the dorsal mesocardium and gastro-hepatic ligament (Fig. 118), and in the region of the neck of the allantois.

The fore-gut is thus being continually lengthened backwards by fusion of the lateral limbs of the splanchnopleure. At the 31 s stage this has proceeded about to the fourteenth somite. At about the 21 s stage the tail-fold appears in the splanchnopleure, thus establishing the hind-gut (Fig. 70) which gradually

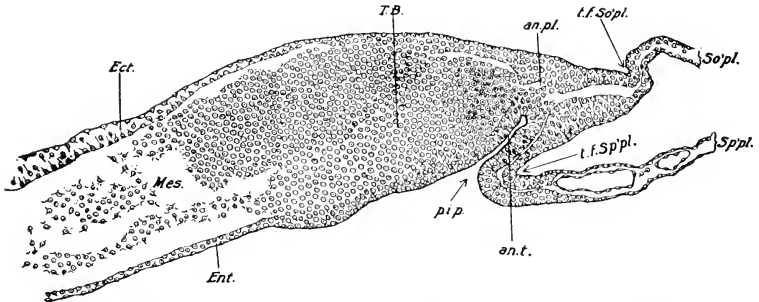


FIG. 70. — Median longitudinal section through the hind end of an embryo of about 21 s.

an. pl., Anal plate. an. t., Anal tube. p. i. p., Posterior intestinal portal. T. B., Tail-bud. t. f. So'pl., Tail fold in the Somatopleure. t. f. Sp'pl., Tail fold in the splanchnopleure. Other abbreviations as before.

elongates forwards. There remains then an open portion of the alimentary tract, where its walls are continuous with the extra-embryonic splanchnopleure or yolk-sac. This is known as the yolk-stalk. The entrance from the yolk-sac into the fore-gut is known as the anterior intestinal portal, and that from the yolk-sac into the hind-gut as the posterior intestinal portal (Fig. 70). At the 27 s stage the yolk-stalk is long and narrow (Fig. 106); the stems of the splanchnic (omphalo-mesenteric) veins run to the heart in its anterior portion, and the omphalo-mesenteric arteries pass out about its center. As it gradually closes, the stems of the omphalo-mesenteric arteries and veins are brought closer together. At about five days it becomes a tubular, thick-walled stalk, connecting intestine and yolk-sac, and so remains throughout embryonic life.

The limiting sulci in the somatopleure lead to the formation of the body-wall. In the trunk the somatopleure is separated from the splanchnopleure by the cœlome (Fig. 69), and the folds in the somatopleure take the same general direction as those in the splanchnopleure; they thus lead to the formation of a tube (body-wall) outside of a tube (alimentary canal), the intervening

cavity being the body-cavity. The unclosed part of the body-wall is continuous with the extra-embryonic somatopleure, more specifically the amnion (see below), and this connection is known as the somatic stalk or umbilicus. The yolk-stalk and neck of the allantois pass out of the body-cavity through the somatic stalk, which therefore remains open until near the end of incubation.

The Turning of the Embryo and the Embryonic Flexures.

We have described the separation of the embryo from the extra-embryonic blastoderm without reference to its turning from a prone to a lateral position or to the formation of the flexures of the entire head and body that are so characteristic of amniote embryos generally. These changes begin about the 14 s stage and are first indicated by a slight transverse bending of the originally straight axis of the head in the region of the mid-brain (Fig. 67). By means of this bending, known as the *cranial flexure*, the fore-brain is directed toward the yolk; but almost simultaneously another tendency manifests itself, viz., rotation of the head on its side, at first affecting only the extreme end. (See Figs. 71, 73, 99, etc.) By the 27 s stage these two processes have resulted in the conditions shown in Fig. 105: by the cranial flexure the fore-brain is bent at right angles to the axis of the embryo, and owing to the rotation the head of the embryo lies on its left side. But inasmuch as the trunk is still prone on the surface of the yolk the axis of the embryo is twisted in the intermediate region. This twist is transferred farther and farther backwards as the turning of the head gradually involves the trunk, until finally, at about ninety-six hours, the embryo lies entirely on its left side.

Exceptionally the rotation may be in the inverse direction (heterotaxia); in such cases it is often associated with situs inversus viscerum. Heterotaxia has been produced experimentally (Fol and Warynsky).

After the appearance of the cranial flexure a second transverse flexure appears in the embryo, this time at about the junction of head and trunk, hence known as the *cervical flexure* (Figs. 73, 99, etc.). This flexure gradually increases in extent until the head forms a right, or even smaller, angle with the trunk; thus the fore-brain is turned to such an extent that its anterior end points backwards and its ventral surface is opposed to the ventral surface of the throat (Fig. 117).

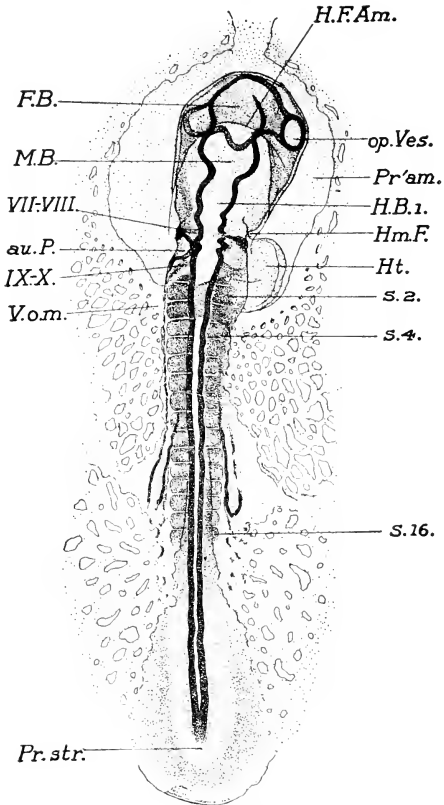


FIG. 71. — Entire embryo of 16 s, drawn from above as a transparent object. Note the cranial flexure; the rotation of the head on its left side is beginning.

au. P., Auditory pit. F. B., Fore-brain. H. B. 1, First division of the hind brain. H. F. Am., Head-fold of the amnion. Hm. F., Hyomandibular furrow. Pr'am., Proamnion. M. B., Mid-brain. op. Ves., Optic vesicle. pr. str., Primitive streak. s 2, s 4, s 16, Second, fourth, and sixteenth somites. V. o. m., omphalo-mesenteric vein. VII-VIII, The acustico-facialis primordium. IX-X, Primordium of the glossopharyngeus and vagus.

The entire trunk tends also to bend ventrally, *i.e.*, to develop a dorsal convexity, and this approximates its posterior end to the tip of the head. These flexures are characteristic of amniote

vertebrate embryos; the cause appears to lie in the precocious development of the central nervous system, of which more hereafter. Only the cranial flexure remains as a permanent condition.

II. ORIGIN OF THE EMBRYONIC MEMBRANES

The period from about 12 to 36 somites also includes the early history of the embryonic membranes, amnion, chorion, yolk-sac and allantois. The first three arise from the extra-embryonic blastoderm, and the allantois arises as an outgrowth of the ventral wall of the hind-gut.

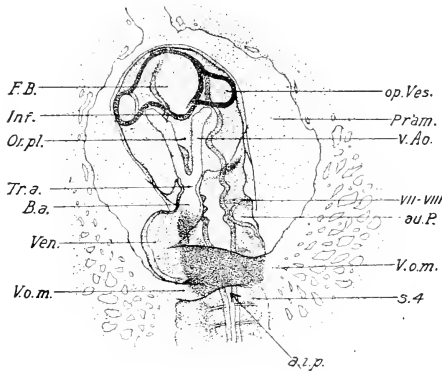


FIG. 72. — The head of the same embryo from below.

a. i. p., Anterior intestinal portal. B. a., Bulbus arteriosus. Inf., Infundibulum. or. pl., Oral plate. Tr. a., Truncus arteriosus. Ven., Ventricle. v. Ao., Ventral aorta.

Origin of the Amnion and Chorion. The amnion is a thin membranous sac, forming a complete investment for the embryo and continuous with the body-wall at the umbilicus; it lies beneath the chorion to which it remains attached throughout incubation by a plate of tissue (sero-amniotic connection), and it arises in common with the chorion from the extra-embryonic somatopleure. The entire somatopleure external to the embryo is used up in the formation of these two membranes. The amnion arises from a portion immediately adjoining the embryo itself; the remainder of the somatopleure peripheral to the amniogenous part forms the chorion. Thus the extra-embryonic somatopleure may be divided into two zones; an *amniogenous zone* immediately adja-

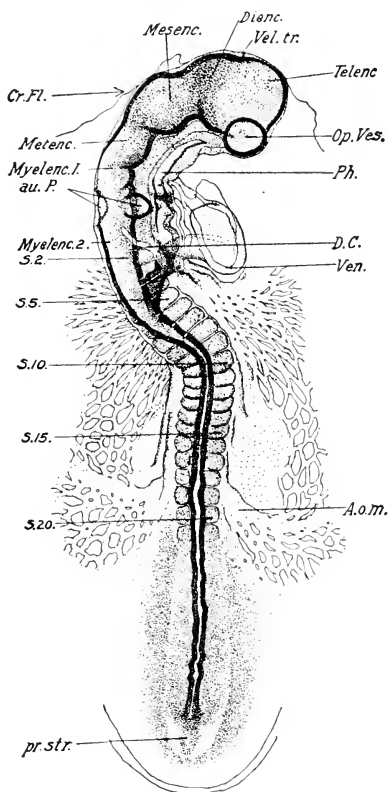


FIG. 73. — Entire embryo of 20 s, viewed as a transparent object from above. The cranial flexure and the rotation of the head of the embryo have made considerable progress.

A. o. m., Omphalo-mesenteric artery. Cr. Fl., Cranial flexure. D. C., Duct of Cuvier. Dianc., Diencephalon. Mesenc., Mesencephalon. Metenc., Metencephalon. Myelenc. 1, and 2, Anterior and posterior divisions of the myelencephalon. Telenc., Telencephalon. Vel. tr., Velum transversum. Other abbreviations as before. x 30.

cent to and surrounding the embryo, and a *choriogenous zone*, comprising the remainder.

The method of formation of amnion and chorion is as follows:

(a diagrammatic outline is first given and a detailed description follows). The somatopleure becomes elevated in the form of a fold surrounding the embryo; this fold begins first in front of the head of the embryo as the *head-fold* of the amnion, which

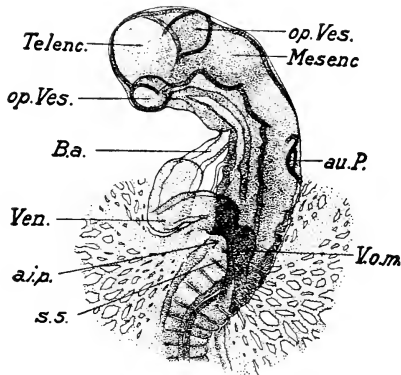


FIG. 74. — Head of the same embryo from the ventral side. Abbreviations as before.

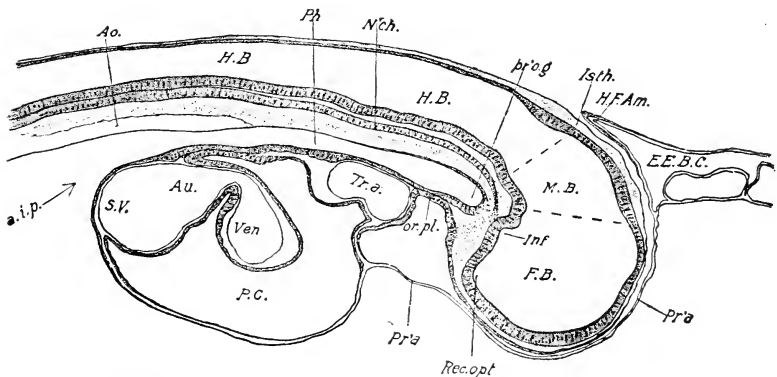


FIG. 75. — Median sagittal section of the head of an embryo of 18 s.
 H. F. Am., Head-fold of the amnion. Ph., Pharynx. Isth., Region of the isthmus, pr'o. g., Preoral gut. or. pl., Oral plate. Rec. opt., Recessus opticus. S. v., Sinus venosus. Other abbreviations as before.

immediately turns backwards over the head, forming a complete cap (Figs. 67, 71, 75, etc.); the side limbs of the head-fold are then elongated backwards, and are here known as the lateral folds of the amnion; these rise up and arch over the embryo

(Figs. 109 and 110). In each fold one can distinguish an amniotic or internal limb, and a chorionic or external limb meeting at or near the angle of the folds, the line of junction being marked by an ectodermal thickening, the *ectamnion*. Fusion of the right and left lateral folds begins at the head-fold, and progresses backwards in such a way that the right and left amniotic limbs become continuous with one another, similarly the right and left chorionic limbs; and, when fusion is complete, the amnion and chorion become separate continuous membranes. In this way the amnion extends, by the 27 s stage, back to the seventeenth somite (Fig. 105). At this time a new fold arises behind the rudimentary tail-bud and covers the tail precisely as the head-fold covers the head (Fig. 105); the tail-fold of the amnion then apparently is prolonged forward a short distance and soon meets the anterior lateral folds, forming a continuous lateral fold. Fusion continues until, about the 31 s stage, the opening into the amniotic cavity is reduced to a small elliptical aperture lying above the buds of the hind-limbs (Fig. 99). This then rapidly closes, but a connection, sero-amniotic connection, remains at the place of final closure. Elsewhere the separation of chorion and amnion is complete.

The formation of the amnion is an extremely interesting process from the standpoint of developmental mechanics, and involves a number of details that are best understood after such a general review of the process as has been given in the preceding paragraphs. Returning then to the 12 s stage for consideration of these details, we must first note that the extension of the mesoblast prior to this period has left an area situated in front of the head free from mesoblast (Figs. 65, 67, 71, 75, etc.). This area, in which the ectoderm and entoderm are in contact, is known as the *proamnion*. The formation of the amnion begins within this area by a thickening in the ectoderm (*ectamnion*) near the anterior boundary of the proamnion at a stage with about eight or nine somites. The thickening, which is very narrow, extends right and left, and turns backwards along the sides of the head to about the region of the middle of the heart, gradually becoming more peripheral in position and fading out (Fig. 76). It represents the junction of the amniogenous and choriogenous somatopleure and thus corresponds to the angle of the future amniotic folds. The head of the embryo lies in a

depression bounded in front by the ectamnion, and on the sides by the amnio-cardiac vesicles of the body-cavity (Fig. 65). The floor of the depression is the proamnion. Just before the formation of the head-fold proper, the ectamnion in front of the head becomes irregularly thickened to such an extent as sometimes to present an actually villous surface (Fig. 77; cf. Fig. 67).

The head-fold of the amnion begins to form at about the same time as the cephalic flexure. The great expansion of the body-cavity on each side of the head (amnio-cardiac vesicles) causes an elevation of the anterior angle of the ectamnion, and a pocket is formed by fusion of its lateral limbs. This slips over the head of the embryo with aid of the ventral flexure of the head just developing. Inasmuch as the anterior angle of the ectamnion is in the proamnion, where there is no mesoderm, and where the ectoderm is in immediate contact with the entoderm, the entoderm as well as the ectoderm of the proamnion is drawn into the head-fold, so that the latter is not at first a fold of the somatopleure. But in the chick the proamniotic part of the head-fold is never very extensive and does not at any time extend back of the beginning of the mid-brain. Moreover, it is soon invaded (Fig. 75) by the body-cavity, and then the entoderm is withdrawn and becomes part of the general splanchnopleure. The proamnion ventral to the head is not invaded by mesoderm until a much later period.

The ectodermal thickening marking the junction of amniotic and chorionic somatopleure extends backwards very rapidly and always precedes the origin of folds in any region. The lateral folds themselves appear to owe their origin to the progressive

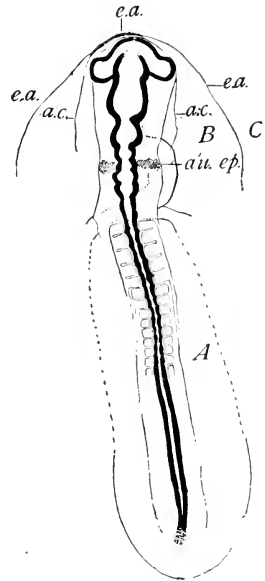


FIG. 76. — Entire embryo of 13 s, to show the relations of the ectamnion.

a. c., Inner margin of amnio-cardiac vesicles.
e. a., Ectamnion.

A. Region of the somatopleure destined to form the body-wall.

B. Amniogenous somatopleure.

C. Choriogenous somatopleure.

fusion of the ectodermal thickenings of the opposite sides, beginning at the posterior angle of the head-fold and proceeding backwards. The energy of fusion is sufficient in itself to lift the somatopleure up in the form of a fold around the body of the embryo. Thus new parts of the ectodermal thickening are constantly being brought together and the fusion progresses steadily, and this in its turn prolongs the lateral amniotic folds. These possess no independent power of elevation of any considerable amount, for, when the initial fold of one side is destroyed by cauterization, the fold of the opposite side remains as an insignificant elevation in the somatopleure a long distance lateral to the embryo.

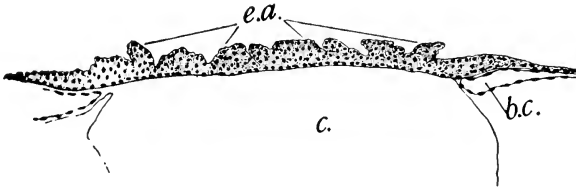


FIG. 77. — Transverse section through the anterior angle of the ectamnion a few sections in front of the tip of the head. Stage of 14–15 s.

b. c., Extra-embryonic body-cavity. c., Cavity in the entoderm. e. a., Ectamnion.

The tail-fold arises in an analogous manner to the head-fold, except that there is no proamnion here. The progress of the various folds and their final fusion follows from what has already been said.

Practically all of the somatopleure of the pellucid area is amniogenous with the exception, naturally, of that part internal to the limiting sulci that forms the body-wall. What effect has the turning of the embryo on its left side on the amniogenous somatopleure? We will suppose that the latter is primitively of equal width on both sides and that the notochord represents approximately the axis of rotation. During the process of rotation, the embryo sinks and the lateral limiting sulci become deeper. A direct consequence of the rotation must be, therefore, a strong tension on the somatopleure belonging to the under (left) side, *a-b*, and practically none on the upper (right) side, *c-d*. (See Fig. 78 A, B).

Even though the difference may be partly compensated by drawing of the embryo to the left, the tendency would be to stretch $a-b$. If there were no such compensation and a and b were practically fixed points, the length of $a-b$ at the conclusion of the rotation would much exceed that of $c-d$ (Fig. 78 B), and

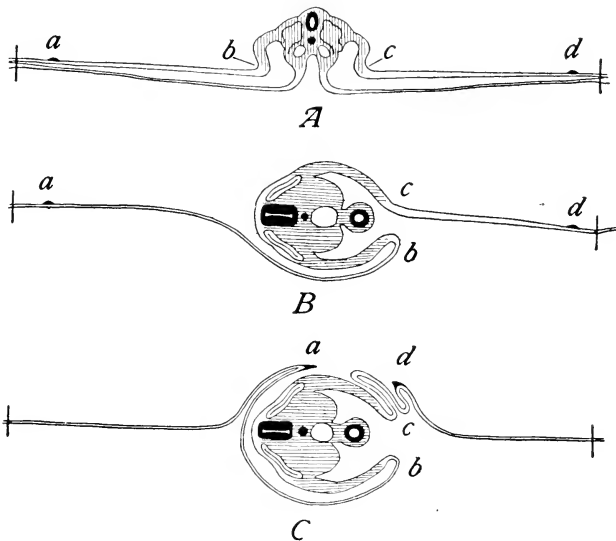


FIG 78. A, B, and C. Diagrams to represent the effect of rotation of the embryo on the amniogenous somatopleure. a represents in all figures the position of the ectamnion on the left (lower) side; d represents in all figures the position of the ectamnion on the right (upper) side. b and c represent the junction of amnion and body-wall on left and right sides respectively. In Fig. A, $a-b$ and $c-d$ are equal. In Fig. B, rotation of the embryo is assumed to have taken place without formation of the amnion; the distance $a-b$ has become greater than $c-d$. In Fig. C is represented rotation of the embryo with synchronous formation of the amniotic folds, as is actually the case; $c-d$ is inevitably thrown into secondary folds. The vertical lines at the extreme right and left represent the margins of the pellucid area.

if, during this process, there were actual independent growth of $a-b$ and $c-d$, the latter would of necessity be thrown into folds, but not the former. Finally, if the amniotic folds were forming at the same time (as is actually the case), the right one would

inevitably be thrown into secondary folds by the approximation of points *c* and *d* (Fig. 78 C).

Study of the fusion of the amniotic folds in actual sections shows, that the line of fusion of the opposite amniotic limbs is over the dorsal surface of the embryo only so long as the latter lies flat on the yolk; it does not follow the turning of the embryo on to its left side, and the consequence is that, after rotation of the embryo, the line of fusion lies over the upper (right) side of the embryo, often opposite the horizontal level of the intestine (Fig. 79). Thus one fold of the amnion passes all the way from the under side over the back of the embryo and around on the other side to the line of fusion, and thus is several times as long as the opposite limb. Moreover, the amniotic fold of the right

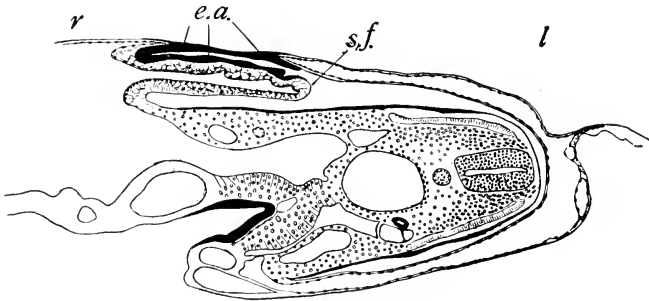


FIG. 79.—Section of an embryo of about 60 hours to show the secondary fold (*s. f.*) of the amnion on the right side.
e. a., Ectamnion. *s. f.*, Secondary fold. *l.*, Left. *r.*, Right.

side is invariably thicker than that of the left side, and is always thrown into secondary folds at the place of turning (Fig. 79). These conditions are satisfactorily explained, as noted above, by the mere turning of the embryo on its side.

One must therefore distinguish in the upper limb of the amnion two kinds of folds: (1) The ordinary amniotic fold induced by the fusion of the right and left folds, and (2) secondary folds formed simply by the process of twisting of the embryo.

These secondary folds of the amnion are very transitory, except in two regions: (1) Above the hind end of the heart (apex of ventricle), and continuing a short distance behind it; (2) in the region immediately in front of the allantois, at sixty to seventy hours, thus in the neighborhood of the final closure of the amniotic

folds. The former are of very constant occurrence and persist a long time (Fig. 93).

Elsewhere the effect of the twisting of the embryo is rapidly compensated so that the secondary folds of the right half of the amnion do not persist long.

The subsequent history of the amnion and chorion is given in another place. It should be noted here that the chorion, at the stage of seventy-two hours, is continuous peripherally with the splanchnopleure at the margin of the vascular area, and that it becomes separate from it only as the body-cavity extends more and more peripherally. The sero-amniotic connection remains throughout the entire embryonic period and modifies in an important fashion the subsequent history of the membranes.

The yolk-sac is the name given to the extra-embryonic splanchnopleure, because in the course of expansion of the blastoderm and extension of the extra-embryonic body-cavity over the surface of the yolk, it finally becomes a separate sac enclosing the yolk. It remains connected by the yolk-stalk with the intestine until finally, some time after hatching, it is absorbed completely. The yolk is absorbed by the entodermal lining and is carried to the embryo in solution by means of the vitelline veins.

Origin of the Allantois. The allantois arises as a diverticulum of the hind-gut soon after the formation of the latter by the tail-fold. It is not indicated before the formation of the tail-fold as stated by some authors, but the tube identified by them as the primordium of the allantois at this early stage is really the intestinal diverticulum leading to the anal plate (Fig. 70). At the stage of twenty-eight somites the allantois is indicated by the depth of the hind-gut, the ventral portion of which in front of the anal plate soon becomes constricted from the upper portion, and forms the primordium of the allantois. In longitudinal sections of an embryo of about thirty-five somites it can be seen to include nearly the entire floor of the hind-gut between the anal plate and the posterior intestinal portal (Fig. 80). It is lined with entoderm and has a thick mesodermal floor in which numerous small blood-vessels are already present. A transverse section (Fig. 81) shows that the thick mesodermal wall is broadly fused with the somatopleure in the region of the neck. In other words, the allantois is developed within the ventral mesentery. It will also be seen by comparing these figures that the amnion

arises from the neck of the allantois both behind and also at the sides. (cf. Fig. 82.)

During the fourth day the distal portion of the allantois pushes out into the portion of the extra-embryonic body-cavity beneath the hind end of the embryo and rapidly expands to form a relatively large sac. But the neck of the allantois remains embedded in the ventral mesentery and does not expand; the terminal portion of the intestine has in the meantime formed

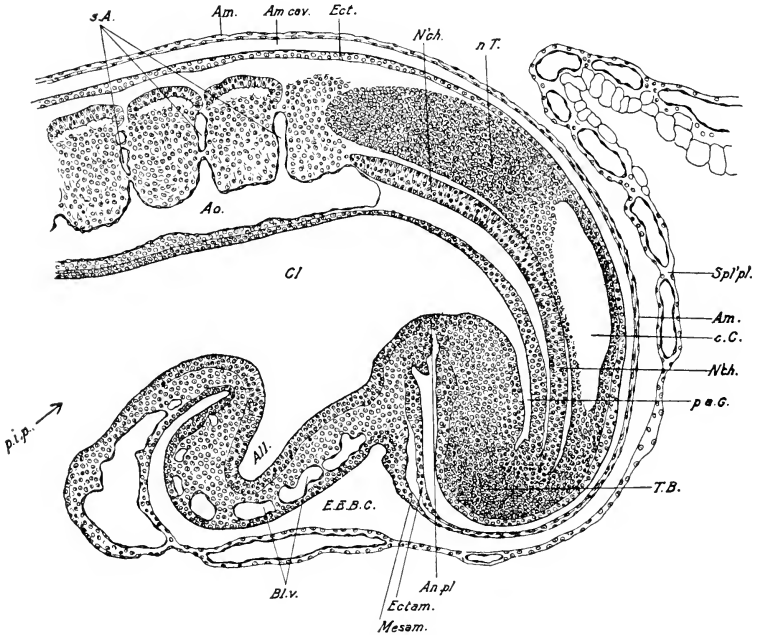


FIG. 80. — Sagittal section through the tail of an embryo of about 35 s.

All., Allantois. An. pl., Anal plate. c. C., Central canal of the neural tube. Cl., Cloaca. Ectam., Ectoderm of the amnion. Mesam., Mesoderm of the amnion. p'a. G., Post-anal gut. p. i. p., Posterior intestinal portal. s. A., Segmental arteries. Other abbreviations as before.

the primordium of the cloaca, from which, therefore, the neck of the allantois appears to arise (Fig. 183); at all stages of incubation the neck of the allantois forms an open connection between the cloaca and the allantoic sac.

The Umbilicus. The closure of the body-wall progressively reduces the communication between the embryonic and extra-embryonic body-cavity to a narrow chink between the yolk-stalk

and allantoic stalk on the one hand and the attachment of the amnion on the other. The umbilical cord thus consists of an outer tube (somatic stalk) continuous with the body-wall, enclosing the yolk-stalk and the stalk of the allantois, together with the arteries and veins of yolk-sac and allantois. It is important to bear in mind that in the region of the neck of the allantois the amnion is attached to the latter at the sides and behind; only the anterior wall of the allantoic stalk is free (Fig. 82). In other words, the somatic umbilical stalk is fused with the lateral and caudal wall of the neck of the allantois, a relation that is common to all amniota.

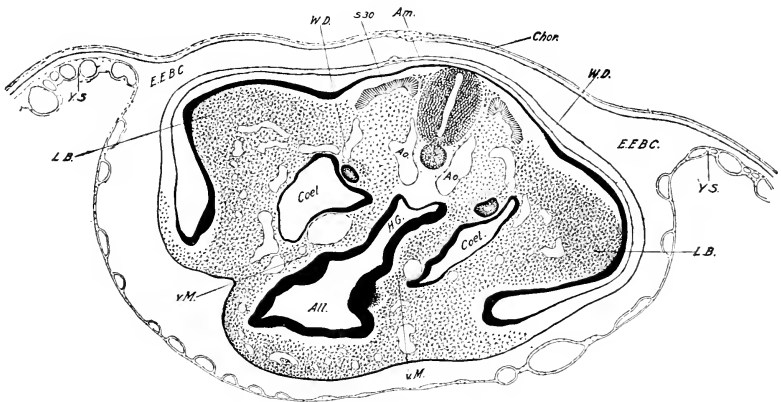


FIG. 81. — Transverse section through the hind-gut and allantois of an embryo of 35 s; the section passes through the thirtieth somite. Details diagrammatic.

All., Allantois. H. G., Hind-gut. L. B., Leg bud. v. M., Ventral mesentery. W. D., Wolffian duct. Other abbreviations as before.

Summary of Later History of the Embryonic Membranes.

The full history of the embryonic membranes will be given later (Chap. VII), but it seems desirable to give an outline here in order to avoid repeated recurrence to this subject. The extension of the body-cavity in the blastoderm is at first very rapid, but about the fifth day it becomes slow, and the yolk-sac is never completely separated from the chorion. The allantois extends out into the extra-embryonic body-cavity as a small pear-shaped vesicle by the end of the fourth day. It then enlarges very rapidly and extends in the form of a flattened sac over and around the embryo immediately beneath the chorion with which it forms

an inseparable union. As the extra-embryonic body-cavity extends, the allantois continues its expansion between the chorion and the yolk-sac, and finally wraps itself together with a duplication of the chorion, completely around the albumen of the egg, which has become very viscid, and aggregated in a lump opposite to the embryo. The allantois is very vascular from the start, and serves as an embryonic organ of respiration. It also receives the excretion of the embryonic kidneys and absorbs the albumen.

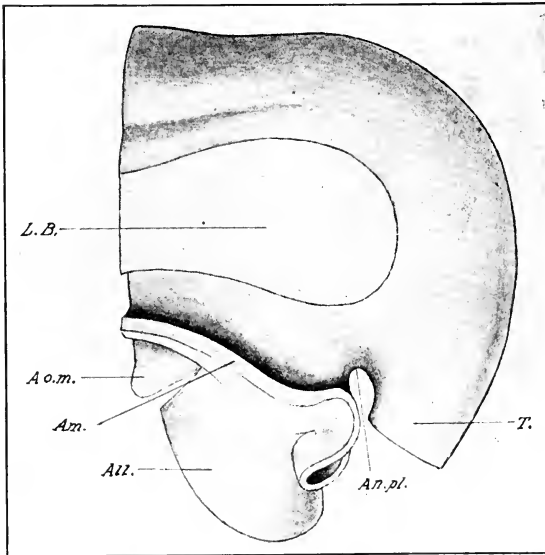


FIG. 82. — Model of the caudal end of a four-day chick to show the relations of the amnion to the allantois and umbilicus. (After Ravn.)

All., Neck of the Allantois. Am., cut surface of the amnion. A. o. m., Omphalo-mesenteric artery. an. pl., Anal plate. L. B., cut surface of leg bud. T., Tail.

The yolk-sac becomes much shriveled during incubation owing to absorption of its contents, and on the last day of incubation is withdrawn into the body-cavity through the umbilicus, which finally closes. The chorion, amnion, and allantois shrivel up when the chick begins to breathe air, and are cast off with the shell at hatching.

III. THE NERVOUS SYSTEM

The Brain. The description of the nervous system in the preceding chapter forms our starting-point. During the period now under consideration the foundation of the main parts of the adult brain are laid down, and its five chief divisions become sharply characterized. It is important to correlate these with the earliest morphological characters (original anterior end of medullary plate, neuromeres, etc.) in order to trace these fundamental landmarks through to definitive structures.

As we have already seen, the primary fore-brain includes the first three neuromeres, the mid-brain the fourth and fifth, and the hind-brain the sixth to the eleventh, as well as the region opposite to the first four mesoblastic somites. It is clear that a second point of fundamental morphological significance is the original anterior end of the medullary plate which would naturally form the center for a description of the anterior part of the neural axis, if recognizable throughout the development. This point may be recognized for a considerable period after the closure of the anterior part of the neural tube, as the ventral end of the anterior cerebral fissure (Fig. 62), opposite the center of the primary optic vesicles, thus in the region of the recessus opticus (Figs. 87 and 88), which is to be regarded as marking the original anterior end of the neural axis. Even after closure of the anterior cerebral fissure a connection remains at its dorsal end between the ectoderm and the neural tube. To this we may apply the name *neuropore*, though no actual opening is found here at this time. The median stretch of tissue between the recessus opticus and the neuropore constitutes the *lamina terminalis* which remains as the permanent anterior wall of the neural tube. It must not be forgotten that the original anterior end of the medullary plate lies at the ventral end of the lamina terminalis, *i.e.*, in the recessus opticus. A third landmark of fundamental morphogenic significance is the infundibulum, which coincides in position, as we have seen, with the anterior end of the notochord. Thus we may distinguish prechordal and suprachordal portions of the neural axis (cf. Fig. 67).

Dorsal and Ventral Zones in the Wall of the Brain. The conception of His, that the walls of the neural tube may be considered as formed of four longitudinal strips, viz., floor, roof, and

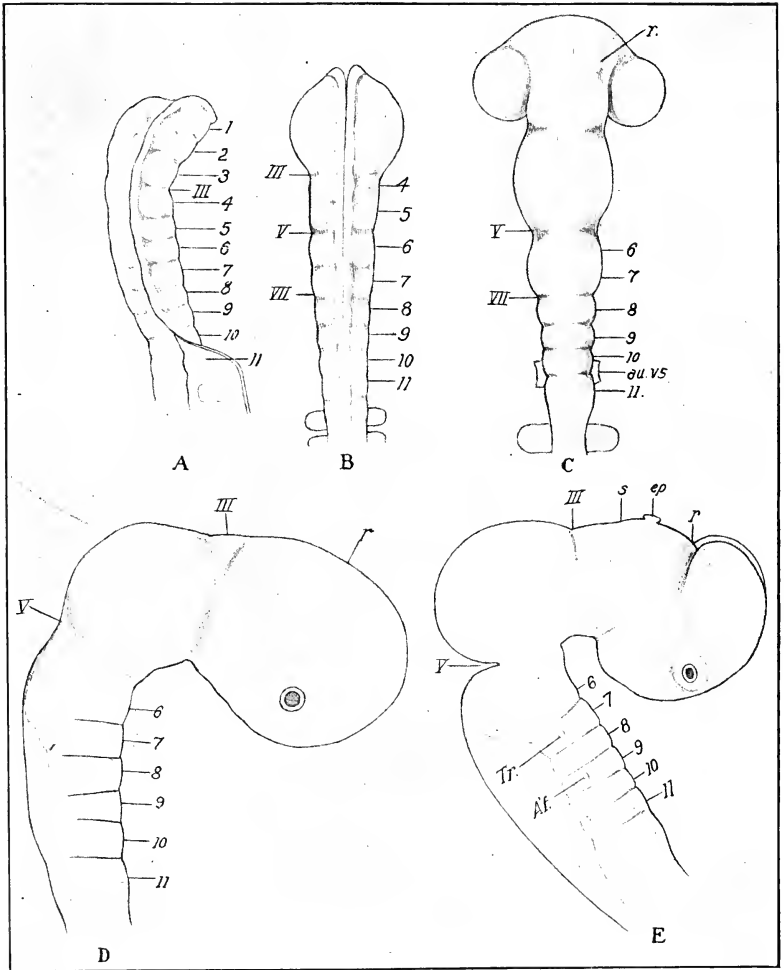


FIG. 83. — Five stages in the history of the neuromeres of the brain of the chick. (After Hill.) All figures drawn from preparations of the embryonic brain dissected out of the embryo.

A. Neural groove in an embryo with 4 somites. Right profile view. x 44.

B. Brain of a 7 s embryo, 26 hours old. Dorsal view; the three anterior neuromeres are practically obliterated. x 44.

C. Brain of 14 s embryo. Dorsal view. x 44. The neuromeres have now disappeared in the mid-brain region.

D. Right side of the brain of a chick embryo, 47 hours old. x 44.

E. Right side of the brain of an embryo, 80 hours old. x 17.

1-11, Neuromeres 1 to 11. III, V, VII, interneuromeric grooves. Af., Root of acustico-facialis (seventh and eighth cranial nerves). au. vs., Auditory pit. ep., Epiphysis. r., Groove between the tel- and diencephalon. s., Groove between the par- and synencephalon. Tr., Root of trigeminus.

two lateral walls, is a useful one. Each lateral wall may also be divided into a dorsal and ventral zone, the former of which is related to the sensory nerve roots and the latter to the motor.

Cerebral Flexures. The cerebral flexures correspond to the cranial and cervical flexures of the entire head already described. Their form and rate of progress may be more readily learned from the figures (Figs. 67, 73, 83, etc.) than from any verbal description. Only the cranial flexure is permanent, and the angle thus formed ventrally in the floor of the mid-brain is known as the *plica encephali ventralis*. A third flexure is formed later in the anterior portion of the hind-brain, by a ventral bending of the floor which is barely indicated in the period now under description, but becomes much more pronounced later; this is known as the *pontine flexure*.

We may now take up separately the changes in each of the primary cerebral vesicles.

The Prosencephalon. The principal events in the early development of the prosencephalon are: (a) the separation of the optic vesicles; (b) the delimitation of the tel- and diencephalon; (c) special differentiation of the walls.

(a) A section across the optic vesicles of the 12 s chick shows the prosencephalon as a central division with its cavity widely confluent with the cavities of the optic vesicles. This wide communication is rapidly narrowed by a ventrally directed fold of the roof at the line of junction of the optic vesicles and prosencephalon proper (Fig. 84); the fold also involves to a certain extent the anterior and posterior line of junction. In the 20 s embryo the connection of the optic vesicles and prosencephalon has been reduced in this way to about one third of its original diameter (from actual measurements), forming a narrow tubular stalk, the optic stalk, attached to the ventral portion of the fore-brain (Figs. 73 and 74); the cavities of the optic vesicles are still continuous through the stalk with the cavity of the prosencephalon, dipping into the recessus opticus; the ventral wall of the optic stalk thus becomes continuous with the floor, and the dorsal wall with the lateral wall of the prosencephalon (Fig. 84). Growth of the mesenchyme situated above the original optic stalk appears to be an active factor in the separation; at least it grows at a rate sufficient to fill in the space produced by the constriction. At the same time there is a slight increase in the dorso-ventral

diameter of the fore-brain itself, though this is relatively slight up to twenty somites, but it enhances the general effect of the change in position of the optic stalk. The subsequent history of the optic vesicles is given beyond.

(b) The delimitation of the tel- and diencephalon is initiated by a forward expansion of the anterior end of the primary fore-brain, which becomes the telencephalon or secondary fore-brain, the remainder being then known as the diencephalon or 'tween brain. The expansion proceeds very rapidly from the 14 s stage, and it is probable that it involves only the dorsal zones. It is,

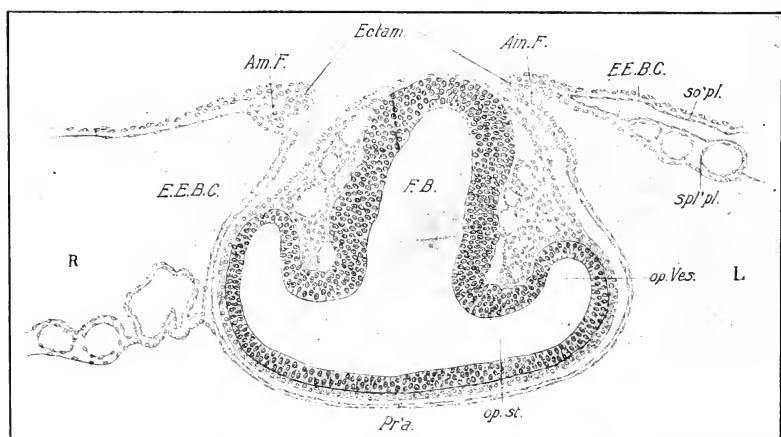


FIG. 84. — Transverse section through the fore-brain and optic vesicles of a 16-s embryo.

Am. F., Amniotic fold. Ectam., Ectamnion. L., Left side. op.st., Optic stalk. R., Right side. Other abbreviations as before.

however, difficult to establish an exact line of demarcation between the two subdivisions of the primary fore-brain, until about the 18 to 20 s stage, when a slight transverse fold or indentation in the roof (velum transversum) gives a dorsal landmark (Figs. 73, 85); the recessus opticus forms the ventral boundary between the two. The velum transversum lies a considerable distance above the dorsal end of the lamina terminalis, but it is difficult to say just how far, owing to the indefiniteness of this point for some time after the disappearance of the neuropore. A line drawn between the velum transversum and the recessus opticus may be taken as the boundary between the two divisions of the

primary fore-brain; but, owing to the simultaneous lateral expansion of the telencephalon, the line of separation in the lateral walls forms a curve with the convexity directed posteriorly (Figs. S3 E and S6).

(c) The next stage in the differentiation of the telencephalon (20 s to 36 s) is characterized by a rapid expansion and evagination of its lateral walls, while the entire median strip extending from the velum transversum to the recessus opticus remains prac-

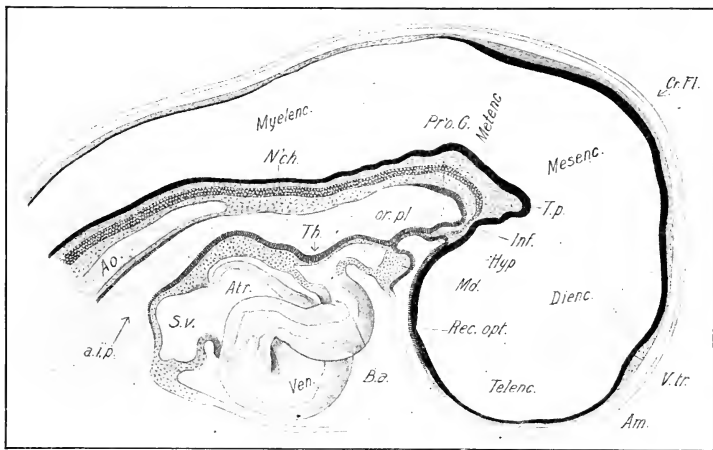


FIG. S5. — Optical sagittal section of the head of an embryo of 22–23 s. The heart is represented entire.

Atr., atrium. Hyp., anterior lobe of the Hypophysis. Inf., Infundibulum. Md., Mandibular arch. or. pl., Oral plate. Pr'o. G., Pre-oral gut. Th., First indication of thyroid. T. p., Tuberculum posterius. V. tr., Velum transversum. Other abbreviations as before.

tically unaltered, and thus acts like a rigid band stretched over the surface between these two points. The effect of this is to form a pair of outgrowths that soon begin to project dorsally, anteriorly, and posteriorly (Fig. S3 E); these are the primordia of the cerebral hemispheres, the cavities of which thus appear as lateral diverticula of the median cavity of the telencephalon (Fig. S6). The central part of the telencephalon may be called the *telencephalon medium*, and the lateral outgrowths the hemispheres. The walls of the hemispheres become considerably thicker in this period, but quite uniformly at first, so that the distinction between mantle and basal ganglia is indicated only by position. (See Chap. VIII.)

The median strip includes the *tela choroidea*, beginning at the diencephalon, and the *lamina terminalis*, which ends at the recessus opticus. These divisions are of great prospective significance, though at the stage of 36 s they are but slightly differentiated, save by their position. A slight thickening of the lamina terminalis just in front of the recessus opticus marks the site of the future anterior commissure (Figs. 87 and 88).

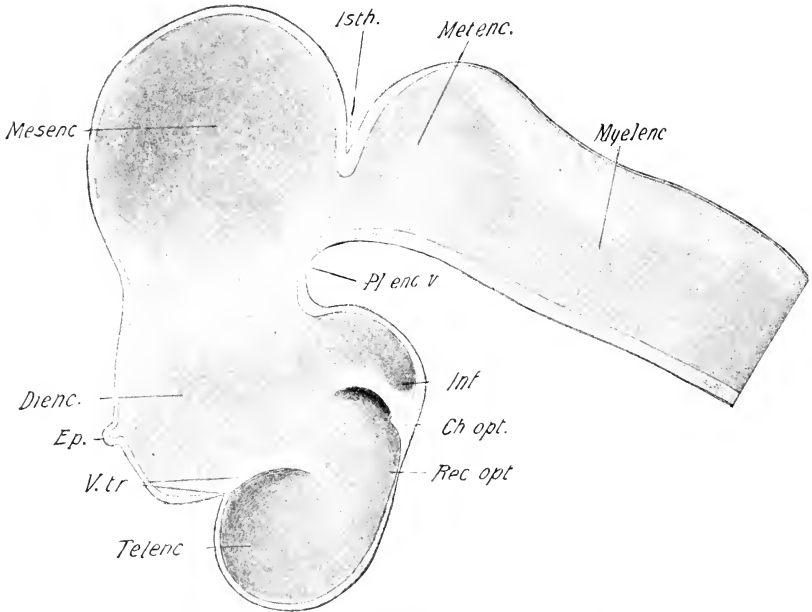


FIG. 86. — Inner view of the brain of a chick of about 82 hours, drawn from a dissection.

Ch. opt., Chiasma opticum. Ep., Epiphysis (pineal gland). Istch., Isthmus. Pl. enc. v., Plica encephali ventralis. Rec. opt., Recessus opticus. V. tr., Velum Transversum. Other abbreviations as before.

The Diencephalon. The portion of the primary fore-brain posterior to the telencephalon is known as the diencephalon. It includes the second and third neuromeres and probably also the ventral zones and floor of the first (Fig. 83). A slight constriction in the roof that appears about the 18 to 20 s stage near the junction of the middle and last third may represent the boundary between the second and third neuromeres; this persists for a long time and may be traced in the lateral walls to the region of the

infundibulum (Fig. 83 E); thus the diencephalon may be divided into an anterior and posterior division, parencephalon and synencephalon (Kupffer) (Fig. 87). The optic stalks are attached to the floor and ventral zones at the extreme anterior end. The diencephalon includes part of the roof, floor, and dorsal and ventral lateral zones of the original neural tube. These may be described as follows (Figs. 87 and 88):

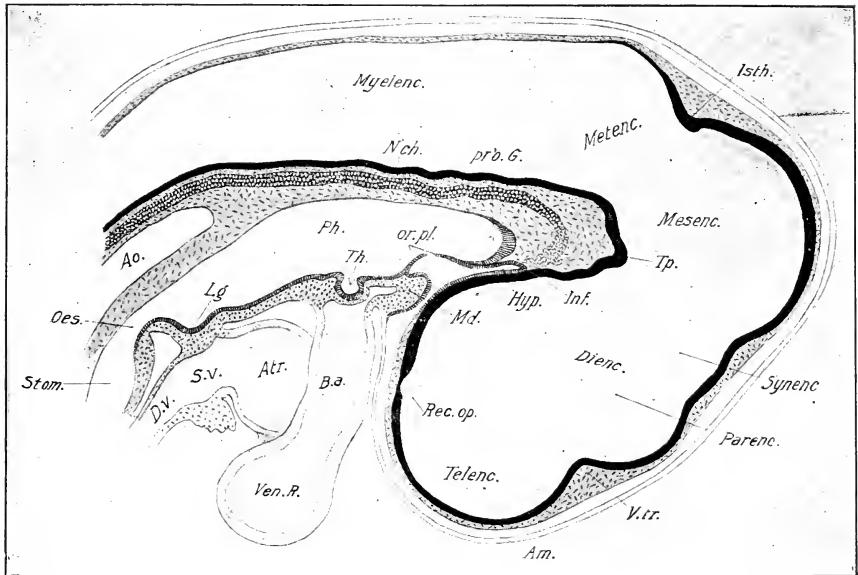


FIG. 87. — Optical longitudinal section of the head of an embryo of 30 s.

The heart is represented entire.

Atr., Atrium (auricles). B. a., Bulbus arteriosus. D. v., Ductus venosus. Lg., Laryngo-tracheal groove. Oes., Oesophagus. or. pl., Oral plate, which has begun to rupture. Parence., Parencephalon. Ph., Pharynx. Stom., Stomach. Synenc., Synencephalon. Th., Thyroid. S. v., Sinus venosus. Ven. R., Right ventricle. Other abbreviations as before.

The roof rises quite sharply from the velum transversum, and is indented between the parencephalic and synencephalic divisions as already noticed. It is relatively thin. About the 30–35 s stage the epiphysis (pineal body) begins to form as an evagination from about the middle, and by the 36 s stage is a small hemispherical protuberance (Figs. 86 and 88). The floor becomes extremely thin in the center of the recessus opticus, which marks its anterior end; immediately behind this is a sudden and

conspicuous thickening, the optic chiasma, which is continued as a ridge in the lateral ventral zones on each side (Fig. 86). The infundibulum follows just behind this, and constitutes a considerable pouch-shaped depression from which the saccus infundibuli grows out later. The posterior wall of this depression rises sharply and joins the thickened tuberculum posterius which is the end of the floor of the diencephalon. The diencephalon is compressed laterally (Fig. 97); the dorsal zones are slightly thickened, indicating the future *thalami optici*.

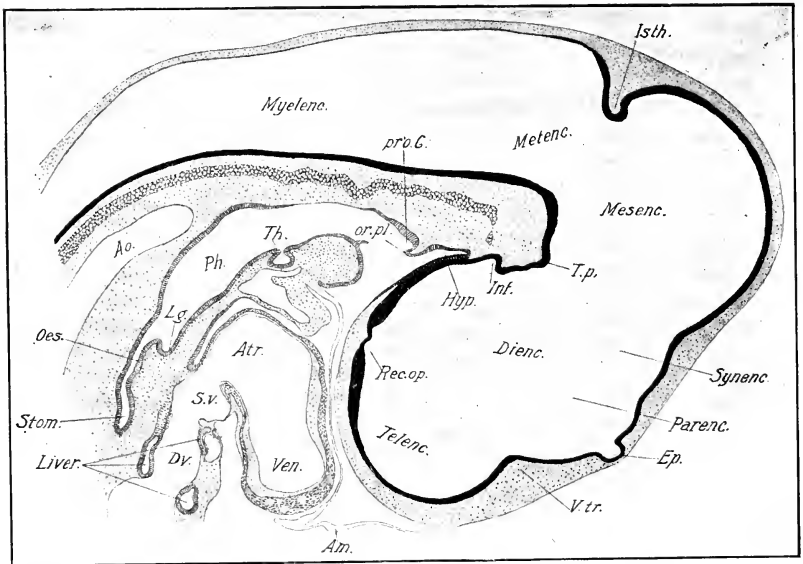


FIG. 88. — Optical longitudinal section of the head of an embryo of 39 s. Abbreviations as before.

The anterior lobe of the *hypophysis* should be mentioned here, although it is not embryologically a part of the brain. It arises as a median tubular invagination of the ectoderm of the ventral surface of the head immediately in front of the oral plate at about the 20 s stage (Fig. 85), and grows rapidly inward in contact with the floor of the diencephalon. At about the 30 s stage its end reaches nearly to the infundibulum (Fig. 87). At first part of its wall is formed by the oral plate, and when this ruptures the effect is to shorten the apparent length of the hypophysis (Fig. 88). At about the 36 s stage its distal portion flattens laterally

and shows indication of branching. Subsequently it becomes much branched and quite massive and unites with the infundibulum to form the pituitary body. (See Chap. VIII.)

The Mesencephalon. This portion of the brain comes to occupy the summit of the cranial flexure, which indeed owes its origin largely to the rapid growth in extent of the roof of the mesencephalon. In longitudinal section it thus appears wedge-shaped, with short floor and long arched roof (Figs. 87 and 88). Its walls remain of practically uniform thickness up to the seventy-second hour. The lateral walls expand more rapidly than the roof and thus form the optic lobes. But these are barely indicated at the 36 s stage.

Isthmus. The great expansion of the mesencephalon does not involve the portion immediately adjacent to the hind-brain, which is henceforth known as the *isthmus* (Figs. 87, 88).

The Rhombencephalon (Primary Hind-brain). Two divisions of the embryonic brain arise from the rhombencephalon, viz., the metencephalon and the myelencephalon; the former becomes the region of the cerebellum and pons of the adult brain, and the latter the medulla oblongata. The metencephalon is a relatively short section of the original rhombencephalon, and includes only the most anterior neuromere of the rhombencephalon or the sixth of the series (Fig. 83 D, E). It may be distinguished at the beginning of the period under consideration by the fact that its roof remains as thick as that of the mesencephalon. At the end of this time, *i.e.*, seventy-two hours, the roof in sagittal sections appears to rise sharply from the isthmus and thins towards the summit, where it passes into the thin epithelial roof of the myelencephalon (Figs. 87 and 88). The rudiment of the cerebellum is slightly thicker on each side of the middle line at seventy-two hours.

The myelencephalon becomes sharply characterized by the thinness of its roof and thickening of ventral lateral zones and floor. The epithelial roof has a triangular form, the base resting against the metencephalon. The neuromeres remain very distinct (Figs. 83, 89), but change their form. Up to about twenty-three somites they still form external expansions, but as the wall thickens the external surface becomes smooth, and the neuromeres may now be recognized as a series of concavities in the lateral wall, with intervening projections (Fig. 89). The arrange-

ment of the nuclei leaves thin non-nucleated strips (septa) between adjacent neuromeres. The interneuromeric projections are most pronounced laterally and fade out dorsally and ventrally.

Behind the neuromeric portion of the hind-brain is a portion extending to the posterior end of the fourth mesoblastic somite from which the twelfth cranial nerve arises.

The Neural Crest and the Cranial and Spinal Ganglia. The cranial and spinal ganglia owe their origin to a structure known as the *neural crest*, which is a practically continuous cord of cells, lying on each side in the angle between the neural tube and the ectoderm, extending from the extreme anterior to the posterior end. Like other meristic structures the anterior portion

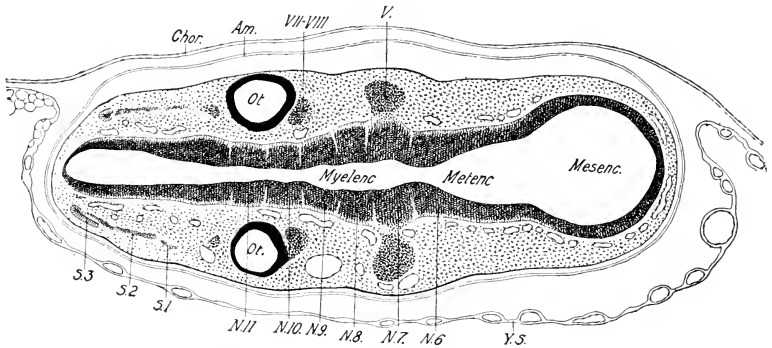


FIG. 89. — Frontal section of the hind-brain region of an embryo of about 36 s.

Ot., Otocyst. N. 6, N. 7, N. 8, N. 9, N. 10, N. 11, Neuromeres, 6 to 11, according to Hill's enumeration. s. 1, s. 2, s. 3, First, Second, and third somites. V, Primordium of the trigeminus. VII-VIII, Primordium of the acustico-facialis.

of the neural crest is the first to arise (at about 6-7 s stage), and the remainder appears in successive order during or shortly after the closure of the neural tube in each region; thus it is not until after the completion of the neural tube that the last portion of the neural crest is established.

But before this time successive enlargements of the cranial part of the crest have formed the primordia of the cerebral ganglia, and similar successively arising enlargements of the parts of the crest opposite the mesoblastic somites form the rudiments of the spinal ganglia. The intervening portions of the crest form the so-called interganglionic commissures, which subsequently

appear to form mesenchyme. The formation of mesenchyme from certain parts of the neural crest is most marked in the region of the brain.

The primordia of the ganglia contain the cells (neuroblasts) which form the dorsal root fibers of the spinal nerves and parts of certain cranial nerves. They also appear to contain the cells from which the sheaths of the nerve fibers are formed; thus three kinds of cells at least are found in the neural crest, viz., mesenchyme forming cells, neuroblasts, and sheath cells.

The Cranial Neural Crest and its Derivatives. The neural crest in the head may be divided into pre- and post-otic divisions, and these arise at different times.

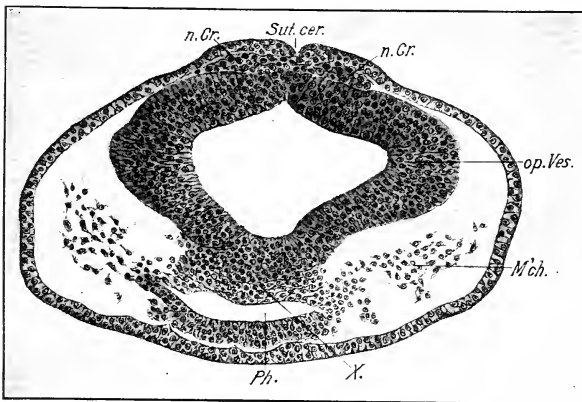


FIG. 90. — Transverse section of the fore-brain, and optic vesicles at the stage of 7 s.

M'ch., Mesenchyme. n. Cr., Neural crest. Ph., Pharynx. Sut. cer., Anterior cerebral suture. X., Mass of cells in which the anterior end of the intestine, the neural tube and the notochord fuse.

(1) The pre-otic division, which extends from the extreme anterior end of the neural tube to about the center of the auditory pit, is well developed at a stage of 7-8 somites, but it is not found at the 5 s stage. The origin is everywhere the same, viz., from the dorsalmost cells of the medullary plate and the ectoderm immediately adjacent; it arises at the time of contact of the medullary folds and is thus thickest in the region of the suture. Fig. 90 is a section through the developing optic vesicles, and shows the neural crest continuous with the tube and ectoderm

in the neural suture; it is separated from the mesenchyme in the region of the fore-gut by a considerable space. (We shall call the latter portion of mesenchyme the axial mesenchyme of the head, to distinguish it from the mesenchyme derived from the

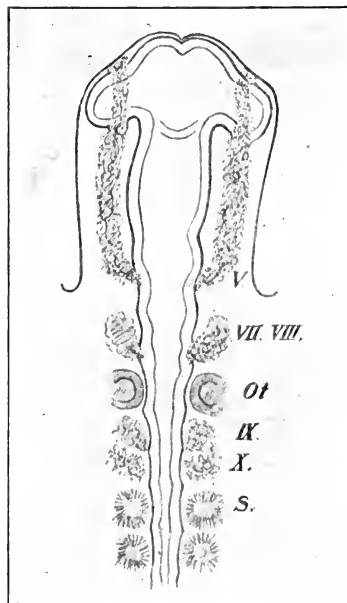


FIG. 91. — Diagram of the cephalic neural crest of a chick of about 12 s. (After Wilhelm His.)

neural crest, which later lies lateral to it, and which may thus be known as the periaxial layer.) The crest may be followed anteriorly to the extreme tip of the neural tube, and posteriorly to the region of the anterior intestinal portal, which lies at about the transverse level of the future auditory pit (cf. Fig. 91). In the region of the mid-brain it spreads out laterally until its peripheral cells reach the axial mesenchyme.

Goronowitsch divides the pre-otic portion of the neural crest into primary and secondary ganglionic crests, the post otic portion being the tertiary crest. According to his account there is a decided difference in time of origin of the primary and secondary crests; the primary, involving the region of fore- and mid-brain, arising before the secondary which includes the region of the trigeminus and acustico-facialis. I have not, however, found such a difference in my preparations.

At the stage of 10 somites the cells of the pre-otic neural crest have lost their connection with the neural tube. Behind the optic vesicles they have spread out laterally between the axial mesenchyme and the ectoderm, where they form a practically continuous periaxial layer, distinguishable from the axial mesenchyme by its greater density, and hence deeper stain; but apparently mingling with it at the surface of contact.

In the stages immediately following (10–20 s), the portions of the periaxial layer lying above the mandibular and the hyoid arches condense and thicken, and form strong cords extending

from the superior angles of the neural tube into the arches in question; here they form connections with the ectoderm of the arches, which proliferates so as to contribute to their substance (Fig. 92). Elsewhere the periaxial layer gradually merges with the axial mesenchyme. The periaxial cords are the primordia of the trigeminus and acustico-facialis ganglia, and mark the paths of the trigeminal and facial nerves. Their connection with

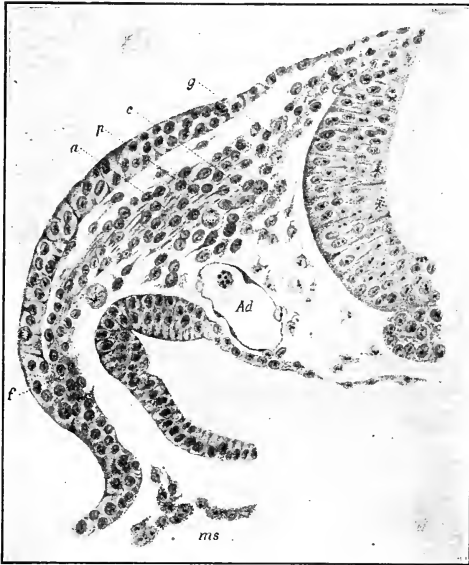

FIG. 92. — Transverse section immediately behind the first visceral pouch of a chick embryo of thirteen somites. (After Goronowitsch.) Note connection of the periaxial cord with the ectoderm of the visceral arch.

Ad., Aorta descendens. c. Rounded mesenchyme cells. g. Place where cells derived from neural crest unite with the mesenchyme cells of the periaxial cord. f. Fusion. p. Spindle-shaped peripheral mesenchyme cells.

the ectoderm in the neighborhood of the first visceral pouch must not be confused with the so-called branchial sense-organs, for the primary connection is soon lost, and secondary connections arise at about the 27 s stage, and constitute the true branchial sense-organs of these arches.

The acustico-facial periaxial cord attains definiteness some time before the trigeminal (cf. Fig. 71), and indeed appears almost from the first as a specially strong part of the periaxial layer: whereas in the region of the trigeminus the cells of this layer are first widely dispersed and secondarily aggregate, between the stages of 14 and 18 somites. Both cords are attached to the brain, the trigeminus to the first neuromere of the myelencephalon, and the acustico-facialis to the third (Fig. 83 E).

The trigeminal and facial periaxial cords are supplemented, as we have seen, by proliferations of the ectoderm on each side of the first visceral pouch; the trigeminal cord then enters the mandibular arch, and the facial the hyoid arch, and in the stages between 20 and 27 somites form at least part of the mesenchyme of these arches. The axial mesoblast likewise contributes to the mesenchyme of these arches, and it becomes impossible in later stages to separate these two mesenchymal components. The ganglia proper differentiate from the upper portions of the cords. The trigeminal periaxial cord divides over the angle of the mouth and sends out a process into the rudimentary maxillary process. A third projection of the same cord towards the eye forms the path of the ophthalmic division of the trigeminus (Fig: 117).

At the stage of about 27 s the trigeminus forms a connection with a thickening of the ectoderm (placode of the trigeminus) situated in front of and above the first visceral cleft; and the facial connects similarly with a larger ectodermal thickening (placode of the facialis) situated on the posterior margin of the uppermost part of the first visceral furrow. These ectodermal thickenings are rudimentary structures of very brief duration, representing parts of the sensory canal system of the head of aquatic vertebrates. Their occurrence in the chick is an interesting example of phylogenetic recurrence. A third and fourth like organ arises in connection with the post-otic ganglia.

At the stage of 72 hours there are two ectodermal thickenings (placodes) in connection with the trigeminus, one in front of the other, derived probably by division of the original first. The facialis placode is more fully developed.

(2) The post-otic ganglionic crest is a direct continuation of the pre-otic behind the ear, and it is at first difficult to make an exact boundary between them. At the stage of 13 s the pre-otic crest extends beneath the auditory epithelium nearly to its middle

in the form of a thick mass of cells in the roof of the neural tube. Towards the posterior end of the auditory epithelium the crest becomes smaller, and this is the beginning of the post-otic crest. Behind the ear the crest becomes larger again and extends laterally so as to form a periaxial layer between the ectoderm and the axial mesoblast which extends back, above the first, second, and third somites to the middle of the fourth. The part between the ear and the first somite is, however, by far the best developed, the continuation behind being a relatively slight cord of cells.

At about the stage of 17 somites the anterior part of the crest condenses to form a well-defined periaxial cord, which arises from the neural tube above the middle of the auditory pit, arches back behind its posterior margin and extends down into the third visceral arch, where it enlarges. This is the glossopharyngeal periaxial cord. There is an enlarged portion of the crest just behind this overlying the site of the future fourth and fifth arches, but its substance is not yet condensed to form a distinct periaxial cord.

At the stage of 20 somites the anterior cardinal vein and the duct of Cuvier form the posterior boundary of the enlarged portion of the post-otic crest (Fig. 73). The part of the periaxial layer immediately in front of this is somewhat condensed to form the periaxial cord of the vagus, and this is only indistinctly separated from that of the glossopharyngeus.

The formation of the third visceral cleft definitely splits the periaxial layer into the periaxial cords of the glossopharyngeus and vagus (25 s). This division is carried up indistinctly, at first, into the roots which occupy the space between the auditory sac and the first somite. The formation of the fourth visceral pouch similarly divides the distal portion of the vagus cord, so that part of it lies in front of the pouch and part behind.

At the stage of seventy-two hours the ganglion petrosum (glossopharyngeus) is definitely formed by an enlargement of the cord just above the third visceral arch, and the ganglion nodosum (vagus), similarly formed from the vagus cord, lies above the fourth visceral pouch, thus extending over the fourth and fifth arches. Branchial sense organs are formed at the dorsal angles of the second and third visceral furrows in connection with the IX and X nerves respectively.

It would appear that the neural crest in the head is the

source of much of the mesenchyme, and it is an interesting question whether or not such mesenchyme has a different fate from that of different origin. Nothing definite, however, is known in regard to this, owing to the impossibility of separating the various kinds after they have once merged.

The Neural Crest in the Region of the Somites. The neural crest is very slightly developed in the region of the first five somites, which is correlated with the fact that these somites are devoid of ganglia. But the mode of origin is the same throughout the somitic region. Shortly after the closure of the neural tube in any region the neural crest forms an aggregation of cells in the roof, more or less sharply separated from the remainder of the tube both by the arrangement of the cells and also by their lighter stain (Figs. 107, 109, 112, 113). The early history may be followed in a single embryo, by comparing the conditions opposite the last somite with that of more anterior somites where development is more advanced. Figs. 107, 108, 109, 110 represent transverse sections through the twenty-ninth, twenty-sixth, twentieth, and seventeenth somites of a 29 s embryo. In Fig. 107 the cells of the crest are extending towards the upper angle of the somite, with which they are connected by protoplasmic strands. The aggregation in the roof of the neural tube is thus decidedly diminished; the lateral wings of the crest lie in the angle between the neural tube and the ectoderm. In the twenty-sixth somite (Fig. 108) the lateral wings extend farther from their point of origin, and appear to have a more intimate connection with the myotome. In the more anterior and older somites, twenty and seventeen (Figs. 109 and 110), the process has progressed much farther and the neural crest cells are completely expelled from the neural tube, which closes after them (Fig. 110). A yet later stage is shown in Fig. 111, through the twenty-third somite of a 35 s embryo.

The dorsal commissure uniting the right and left sides of the crest ruptures, and the cells of the crest aggregate so as to form a pair of ganglia in each somite. Thus, although the neural crest is primarily a median structure, it becomes divided into two lateral halves, and although it is primarily a continuous structure it becomes divided into a series of pairs of metameric ganglia. The fate of the interganglionic commissures is conjectural. The ganglia are ill-defined from the mesenchyme when they are first

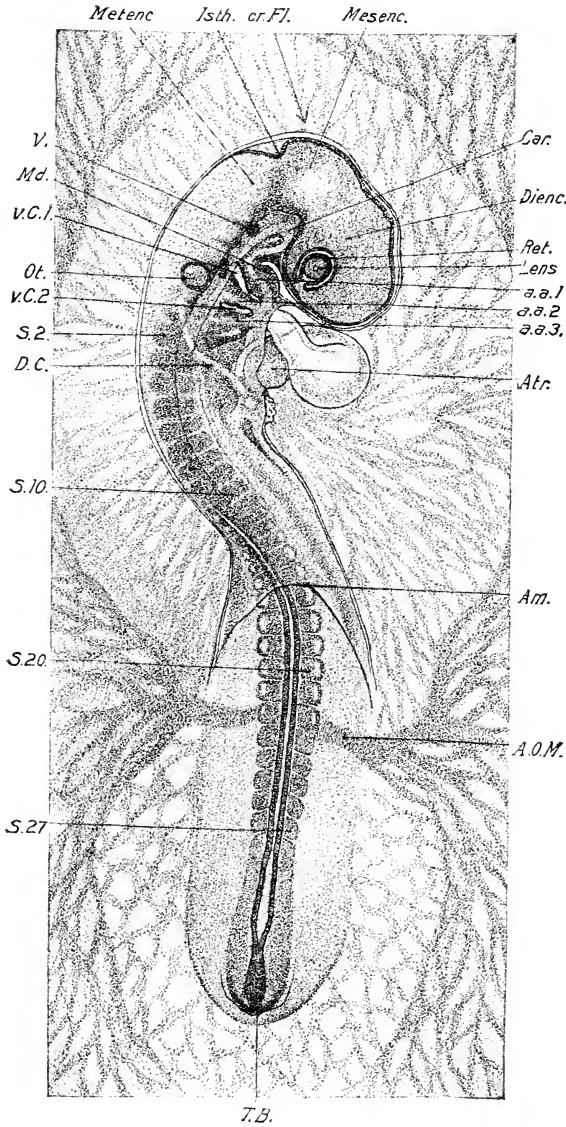


FIG. 93. — Entire embryo of 27 s viewed as a transparent object from above.

a. a. 1, a. a. 2, a. a. 3, First, second, and third aortic arches. Car., Carotid loop. Ret., Retina. v. C. 1, v. C. 2, First and second visceral clefts. (Other abbreviations as before. x 20.

formed, but they rapidly become well differentiated.

IV. THE ORGANS OF SPECIAL SENSE (EYE, EAR, NOSE)

Embryologically a sharp distinction must be drawn between the essential percipient part of the organs of sense (retina of the eye, olfactory epithelium, and epithelium of the membranous labyrinth) and the parts formed for protection and for the elaboration of function. The sensory part proper is the first to arise in the embryo, and is protected later by modifications of surrounding tissues or parts. We may thus distinguish between primary and secondary parts in the case of all organs of sense. Only the early history of the primary parts falls within the period covered by this chapter, except the formation of the lens in the case of the eye.

The Eye. The primary optic vesicles arise, as we have seen, as lateral expansions of the anterior end of the neural tube; their position is indicated by an enlargement of the neural tube even before the meeting of the medullary folds in this region. The shape and relations of the early optic vesicles have already been described and figured. The cavity may be called the *Ventriculus opticus*. The origin of the optic stalk by constriction of the base of the vesicle was described in a preceding section of this chapter (p. 149). The stalks remain attached to the ventral end of the lateral walls of the diencephalon in the region of the *recessus opticus*, and constitute tubular connections between the vesicles and the brain, in the walls of which the optic nerve develops later (Fig. 84).

Locy found six pairs of "accessory optic vesicles" occurring in series immediately behind the true optic vesicles; they form low rounded swellings of the side-walls of the neural folds before the true brain vesicles are indicated, and last only about three hours in the chick (twenty-fourth to twenty-seventh hours of incubation). "Their existence supports the hypothesis that the vertebrate eyes are segmental, and that the ancestors of vertebrates were primitively multiple-eyed." (Locy.)

The external surface of the optic vesicle early reaches the ectoderm, to which it appears to be cemented at the 10 s stage. In the 17-18 s stage, the optic vesicles project decidedly behind the attachment of the optic stalk, and the external wall is slightly thicker than that next the brain. The ectoderm then becomes thickened over a circular area in contact with the optic vesicle

and this constitutes the primordium of the lens (Fig 94). The thickening of the external wall of the optic vesicle and of the lens primordium now proceed rapidly, and soon an invagination is formed in each (Fig. 95).

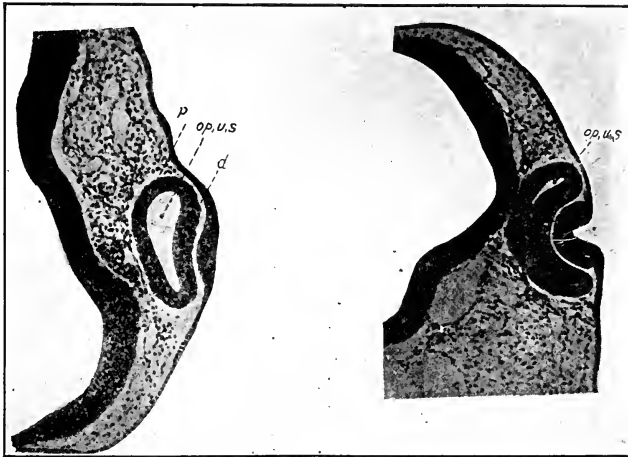


FIG. 94. — Section through the primordium of the eye of a chick embryo of 21 s. (After Froriep.)

d., Distal wall of optic vesicle. p., Proximal wall of optic vesicle.

FIG. 95. — Section through the primordium of the eye of a chick embryo at the end of the second day of incubation. (After Froriep.)

It is probable that a stimulus is exerted by the optic vesicle on the ectoderm with which it is in contact, causing it to thicken and become the primordium of the lens. This has been demonstrated experimentally to be the case in the embryo of the frog, and the morphological relations are the same in the chick. The invagination of the primary optic vesicle to form the secondary optic vesicle is not mechanically produced by the growth of the lens, as some have supposed, for it has been shown (see Fol and Warynsky) that the secondary optic vesicle is formed in the absence of the lens.

We may now consider the formation of the optic cup and of the lens separately.

The Optic Cup. The invagination of the outer wall of the primary optic vesicle gradually brings this wall into contact with the inner wall and obliterates the primary cavity. Thus

is established the secondary optic vesicle or optic cup (*cupula optica*). Special attention must be given to the form of the invagination, for this determines relations of fundamental importance. The invagination may be stated to consist of two parts. The first is directly internal to the lens primordium, and the second, which is continuous with the first, involves the ventral wall of the primary optic vesicle as far as the optic stalk. Two parts may thus be distinguished in the mouth of the optic cup — (1) an external part, which becomes the pupil of the eye, and (2) a ventral part, continuous with the pupil, which is known as the *choroid fissure*. Figs. 96 A, B, and C exhibit these relations better than a detailed description.

The choroid fissure is a transitory embryonic structure, subsequently closing by fusion of its lips. However, it establishes a relation of fundamental importance in that the ventral wall of the optic-stalk is kept continuous in this way with the inner or retinal layer of the secondary optic vesicle (Figs. 96 B, and 97), and thus a path is provided for the development of the optic nerve (see Chap. IX). It also provides an aperture in the wall of the optic cup for the entrance of the *arteria centralis retinae*.

The optic primordium at the 36 s stage, with the omission of the lens, is composed as follows:

(1) Optic-stalk attached to the floor of the brain; this is still tubular.

(2) The optic cup or secondary optic vesicle consisting of two layers, viz., (a) a thick internal or retinal layer continuous at the pupil and choroid fissure with (b) the thin external layer. The cavity of the cup is the future posterior chamber of the eye; it has two openings, viz., the pupil filled by the primordium of the lens, and the slit-like choroid fissure extending from the pupil to the optic stalk along the ventral surface. The retinal layer is continuous with the floor of the optic-stalk, and thus with the diencephalon.

The optic cup expands with extreme rapidity between the stages of 26 and 36 somites, as may be seen from the figures by comparing the relative size of the lens and optic cup at different stages.

The Lens. The invagination of the thickened ectoderm external to the optic vesicle soon leads to the formation of a deep, thick-walled pit which rapidly closes (26–28 somites) and thus

forms an epithelial sac, which at first practically fills the cavity of the optic cup. However, it very soon becomes detached from the posterior wall of the optic cup, which expands with great rapidity, and the lens is left at the mouth of the cup. The walls

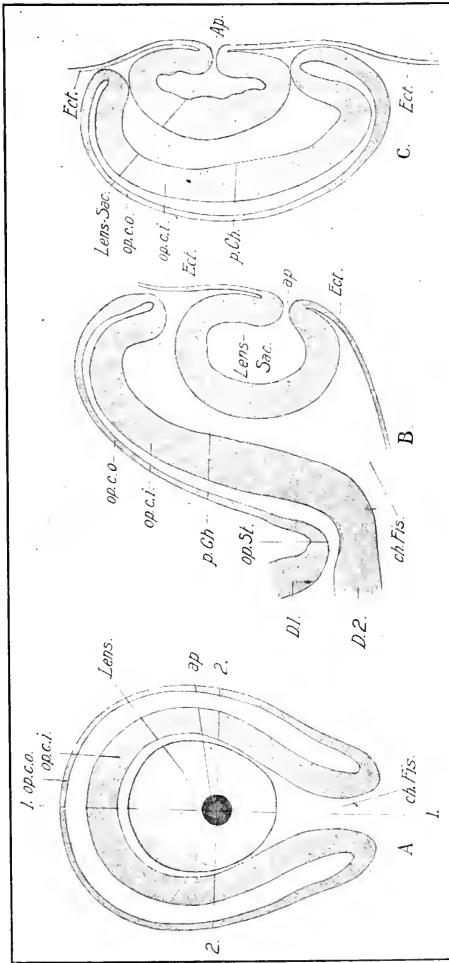


FIG. 96. — Semi-diagrammatic representation of the eye of an embryo of about 27-30 s.
 A. The eye as seen in a lateral view of the head (compare Fig. 93). The walls of the optic cup are represented in optical section; but the lens is represented as a solid body; the lens-sac is still open.
 B. Section in the plane 1-1 of Fig. A.
 C. Section in the plane 2-2 of Fig. A.
 ap., Aperture of lens-sac. ch. Fis., Choroid fissure. D. 1, Lateral wall of diencephalon. D. 2, Floor of diencephalon. Ect., Ectoderm of the surface of the head. op. c. i., Inner layer of optic cup. op. c. o., Outer layer of optic cup. op. St., Optic stalk. p. Ch., Posterior chamber of the eye.

of the lens sac are at first of practically even thickness (28 s), but by the 35 s stage a great difference has arisen by the elongation of the cells of the inner wall, which are destined to form lens fibers: the cells of the anterior (outer) wall elongate much

less during this period, and are destined to form the epithelium of the lens (Fig. 97). Intermediate conditions are found around the equator of the lens. The subsequent history is given in chapter IX.

The Auditory Sac. At about the 12 s stage the first evidence of the auditory sacs is found in the form of a pair of circular patches of thickened ectoderm situated on the dorsal surface of the head opposite to the ninth, tenth, and eleventh neuromeres, and thus a short distance in front of the first mesoblastic somite; it lies between the rudiments of the acustico-facialial and glosso-pharyngeal ganglia. In the 14 s stage the auditory epithelium

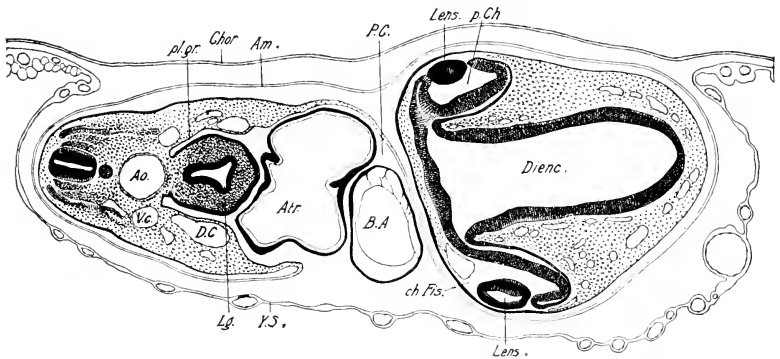


FIG. 97. — Transverse section through the eyes and heart of an embryo of about 35 s. The plane of the section will be readily understood by comparison of Fig. 117.

ch. Fis., Choroid fissure. D. C., Duct of Cuvier. Lg., Lung. pl. gr., Pleural groove. V. c., Posterior cardinal vein. Y. S., Yolk-sac. Other abbreviations as before.

is slightly depressed, and in the 16 s stage it forms a wide-open pit. At about the 20 s stage the mouth of the pit narrows slightly, and gradually closes (28–30 s), thus forming the auditory sac or vesicle (otocyst) (cf. Figs. 71, 73, 89, and 93).

The method of closure of the pit, which is of interest, may readily be observed in mounts of entire embryos; at first the lips fold over most rapidly from the anterior and posterior margins; thus the mouth of the pit becomes elliptical with the long axis vertical (stage of 22 somites) and extending from the apex nearly to the base. The ventral lip then begins to ascend (stage of 24 somites) and the closure gradually proceeds towards the

apex, so that by the stage of 29 somites the opening is reduced to a minute ellipse situated on the external side of the dorsalmost portion of the otocyst (see Fig. 93). This portion of the otocyst now begins to form a small conical elevation, and the final closure takes place on the external side of this elevation, which is destined to form the endolymphatic duct. The latter remains united to the epidermis at this point for a considerable period of time by a strand of cells which may preserve a lumen up to 104 hours (Fig. 98). The final point of closure of the otocyst is thus very definitely placed, and it coincides with the middle of the endolymphatic duct, that is, with the junction of the later formed saccus and ductus endolymphaticus. In the *Selachia* this duct remains in open communication with the exterior throughout life; the relatively long persistence of its connection with the epidermis in the chick may thus be interpreted as a phylogenetic reminiscence of the ancestral condition.

The Nose (Olfactory Pits). At about the 28 s stage, the ectoderm on the sides of the head a short distance in front of the eyes appears thickened. Two circular patches of ectoderm are thus marked off, the beginning of the olfactory epithelium; at first this grades almost imperceptibly into the neighboring ectoderm. In the stages immediately following the olfactory plates appear to sink down towards the ventral surface of the head, due no doubt to more rapid growth of the dorsal portion of the head. Thus they appear at the ventro-lateral angles of

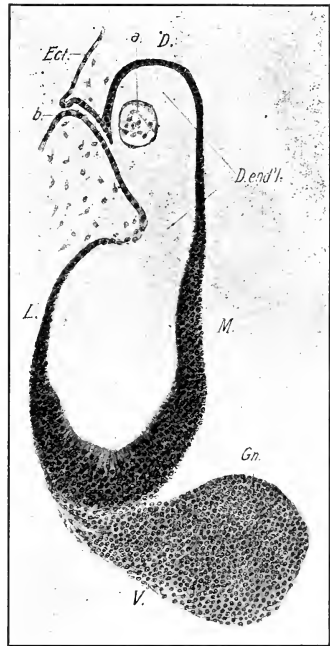


FIG. 98. — Section of the otocyst of an embryo of 104 hours. The original opening of the otocyst is drawn out into a narrow canal which connects with the endolymphatic duct (recessus labyrinthi).

a., Ball of cells in the otocyst (otolith?). b., Canal leading from the surface to the otocyst. D. end'l., Endolymphatic duct. D., Dorsal. Ect., Ectoderm of the surface of the head. Gn., Auditory ganglion. L., Lateral. M., Median. V., ventral.

of the head. Thus they appear at the ventro-lateral angles of

the anterior part of the head at the stage of 36 somites. During the displacement a depression appears in the center of each olfactory plate, and as this becomes deeper, the olfactory pits are formed (Figs. 99 and 117). At the stage of 36 somites each is a deep pit situated at the junction of the sides and ventral surface of the anterior portion of the head, with the wide mouth opening outwards and ventrally.

The olfactory epithelium now becomes sharply differentiated from the ectoderm of the head, owing to the formation of a superficial layer of cells (teloderm, see p. 285) above the columnar cells in the ectoderm, but not in the region of the sensory epithelium, where the cells still form a single layer. In the center of the olfactory pit the epithelium is very much thickened owing to elongation of the cells, and the nuclei lie in five or six layers; there is a gradual thinning of the epithelium to the lips of the pit and then a sudden, but graduated, decrease to the general ectoderm. The line of junction of olfactory epithelium and indifferent ectoderm of the head is a little distance beyond the margin of the pit, as may be determined by the edge of the telodermic layer; in other words, all of the olfactory epithelium is not yet invaginated.

It is probable that the invagination of the olfactory plates is due mostly, up to this time, to the processes of growth within the plates themselves, although there has been considerable accumulation of mesenchyme in this region. But the subsequent deepening of the pits appears to be due largely to the formation of processes around the mouths of the primary pits. (See Chap. IX.)

V. THE ALIMENTARY TRACT AND ITS APPENDAGES

We have already learned that the main portion of the alimentary tract arises from the splanchnopleure; a portion of the mouth cavity is, however, lined with ectoderm and arises from an independent ectodermal pit, the *stomodæum*, which communicates only secondarily with the entodermal portion; similarly the last portion, external to the cloaca, arises from an ectodermal pit, the *proctodæum*, which communicates only secondarily with the entodermal part. We shall thus have to consider the origin of the stomodæum and the proctodæum in connection with the alimentary tract.

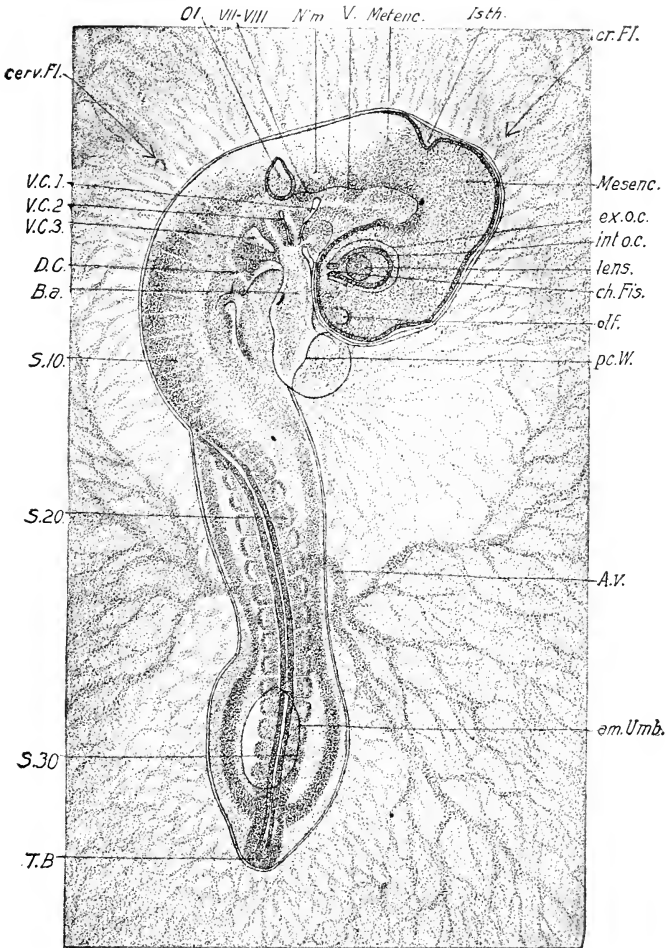


FIG. 99. — Entire embryo of 31 somites viewed as a transparent object.

am. Umb., Amniotic umbilicus. B. a., Bulbus arteriosus. cerv. Fl., Cervical flexure. ch. Fis., Choroid fissure. cr. Fl., Cranial flexure. D. C., Duct of Cuvier. ex. o. c., External layer of the optic cup. int. o. c., Internal layer of the optic cup (retina.) N'm., Neuromere of myelencephalon. olf., Olfactory pit. pc. W., Line of attachment of amnion to pericardial wall. V. C. 1, 2, 3, First, second, and third visceral clefts. Other abbreviations as before.

From the embryological point of view the alimentary tract may be divided into fore-, mid-, and hind-gut. The fore-gut includes the anterior portion as far back as the liver diverticula, the mid-gut extends from here to the cœcal appendages, and the hind-gut includes the remainder. From each division there arise certain outgrowths which may be termed collectively appendages of the alimentary tract, and these will also be considered here, so far as they arise within the period covered by this chapter. Thus from the fore-gut there arise the visceral pouches, the thyroid and thymus glands, the postbranchial bodies, the respiratory tract, and the liver and pancreas; from the mid-gut the yolk-sac, and from the hind-gut the cœcal appendages and allantois.

The enlargement of the body-cavity towards the middle line gradually reduces the broad mesodermal septum situated between its inner angles to a relatively narrow plate, which forms the dorsal mesentery of the intestine (Figs. 107, 109, 110, and 111). This elongates in the course of development and forms a sheet of tissue suspending the intestinal tube to the mid-dorsal line of the body-cavity. It is composed of two layers of mesothelium (peritoneum) continuous with the lining of the body-cavity and enclosing a certain amount of mesenchyme; the dorsal mesentery extends along the entire length of the intestinal canal.

A ventral mesentery uniting gut and yolk-sac is also established by the meeting of the limiting sulci in the splanchnopleure. When the body-wall closes, the ventral mesentery consists of two layers of mesothelium attaching the intestinal canal to the mid-ventral line of the body-wall. The dorsal and ventral mesenteries, together with the alimentary canal, thus constitute a complete partition between the right and left halves of the body-cavity. However, the ventral mesentery is a very transient structure except in the region of the fore-gut and liver, and in the extreme end of the hind-gut. In these places it is persistent and is the seat of formation of important organs.

The wall of the intestine contains three embryonic layers: viz., entoderm, mesenchyme, and mesothelium. The first forms the lining epithelium of the intestine, and of all glandular attachments, as well as of the respiratory tract and allantois; the last forms the serosa; and the mesenchyme the intermediate layers.

We shall now consider the development of each region of the

alimentary tract and the appendages proper to each in the following order: (1) Stomodæum, (2) Pharynx, (3) Esophagus, (4) Stomach, (5) Hepato-pancreatic division of the fore-gut, (6) Mid-gut, (7) Hind-gut.

The stomodæum owes its origin to an expansion of the embryonic parts surrounding the oral plate, and it gives rise to a large part of the buccal cavity, which is therefore lined by ectoderm. (See Chap. X.) It will be remembered that at the 12 s stage the oral plate lies between the pericardium and the fore-brain (Fig. 67), and that it consists of a fusion between the ectoderm of the ventral surface of the head and the entoderm composing the floor of the anterior end of the fore-gut. It lies in a slight depression on the under surface of the head which is the beginning of the oral cavity. This small beginning owes its enlargement (1) to the cranial flexure, by which the ventral surface of the head becomes bent at right angles to the oral plate instead of forming a direct continuation of it, and (2) to the formation and protrusion of the mandibular arches and maxillary processes at the sides and behind. (See fuller account in Chap. VII.) In this way it becomes a deep cavity closed internally by the oral plate. The series of figures of sagittal sections through the head illustrates very well the gradual deepening of the stomodæum by these processes (Figs. 75, 85, 87, 88).

The oral plate thins gradually from the 12 to the 30 s stage when it breaks through (Figs 87 and 88), thus establishing an opening into the alimentary tract. The remnants of the oral membrane then gradually disappear and leave no trace. The subsequent extension of the maxillary region to form the upper jaw greatly enlarges the extent of the ectodermal portion of the buccal cavity. It will have been noted (Figs. 85 and 87) that the hypophysis opens in front of the oral plate on the ectodermal side, and this constitutes a most important landmark for determining the limit of the ectodermal portion of the buccal cavity in later stages.

The Pharynx and Visceral Arches. The pharynx may be briefly defined as the alimentary canal of the head. It is the most variable part of the alimentary canal in the series of vertebrates. Modified, as it is in all vertebrates, for purposes of respiration, the transition from the aquatic to the terrestrial mode of respiration brought about great changes in it. It is thus marked em-

bryologically first by the development of structures, the visceral arches and clefts, whose primary function was aquatic respiration, and second by the development of the air-breathing lungs. Such fundamental changes in function have left a deep impression, not only on the embryonic history of the pharynx itself, but also on the development of the nervous and vascular systems.

The extreme anterior end of the pharynx extends at first some distance in front of the oral plate, and may hence be called the pre-oral gut (Figs. 75, 85, etc.). After the rupture of the oral plate, the pre-oral gut appears like an evagination of the pharynx immediately behind the hypophysis and is now known as Seessel's pocket (Fig. 87), but it gradually flattens out and disappears (Fig. 88).

The form of the pharynx at thirty-three hours has been already described; briefly, it is much expanded laterally, exhibiting a crescentic form in cross-section (Fig. 54 A). The horns of the crescent are in contact with the ectoderm in front of the auditory pit, marking the site of the future *hyomandibular* cleft, which arises by perforation in the fused area at about forty-six hours. A second pair of lateral expansions brings about a second fusion of the lateral wings of the pharynx just behind the auditory pit at about the stage of 19–20 somites. This is followed by the formation of a third and a fourth pair of lateral evaginations of the pharynx which reach the ectoderm at about 23 s and 35 s respectively. The walls of the pharynx appear considerably constricted between the evaginations which are known as *visceral pouches* (Figs. 100 and 101).

Corresponding to each visceral pouch there is formed an ectodermal invagination of much lesser extent, which may be known as the visceral furrow. The furrows do not form directly opposite the pouches, but slightly behind them so as to overlap the margins of the latter (Fig. 101). The ectoderm of the visceral furrows forms a close union with the entoderm of the pouches, and openings arise within these areas, excepting the fourth, forming transitory visceral *clefts*.

There are thus four pairs of visceral pouches and furrows, known as the first, second, third, and fourth; the first is sometimes called the *hyomandibular*.

According to Kastschenko, there are evidences of three pairs of

visceral furrows in front of the first at the 14-16 s stage. These he interprets as phyletic rudiments. It is certain that the lower vertebrates had pouches posterior to the fourth. The post-branchial bodies (see p. 309) are probably rudiments of a fifth pair of pouches.

The tissue between the visceral pouches thickens, by accumulation of mesenchyme, to form the visceral *arches*, of which there are five, viz.: (1) the *mandibular* in front of the first pouch, forming also the posterior boundary of the oral cavity, (2) the *hyoid* between the first and second pouches, (3) the *third visceral arch* between the second and third pouches, (4) the *fourth visceral arch* between the third and fourth pouches, and (5) the *fifth*

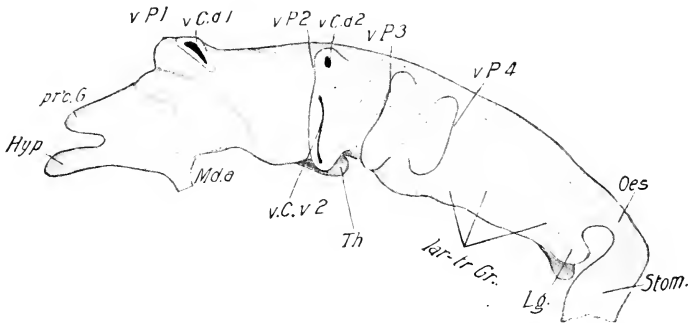


FIG. 100. — Reconstruction of the fore-gut of a chick of 72 hours. (After Kastschenko.)

Hyp., Hypophysis. lar-tr. Gr., Laryngotracheal groove. Lg., Lung. Md. a., Mandibular arch. Oes., Oesophagus. pr.o. G., Preoral gut. Stom., Stomach. Th., Thyroid. v. C. d. 1, 2, Dorsal division of the first and second visceral clefts. v. C. v. 2, Ventral division of the second visceral cleft. v. P. 1, 2, 3, 4, First, second, third, and fourth visceral pouches.

visceral arch behind the fourth pouch. Each arch is bounded internally by entoderm, externally by ectoderm. The main portion of its substance is formed of mesenchyme; each contains also a branch of the ventral aorta (aortic arch) and a branch of a cranial nerve. Understanding of their relations is therefore essential to knowledge of the development of the nervous system, vascular system, and skull.

We shall now consider the history of each visceral pouch and arch separately:

The first visceral pouch becomes adherent to the ectoderm of the first visceral furrow at its dorsal and ventral ends, leaving

an intermediate free portion. At about the 26 s stage an opening (cleft) forms at the dorsal adhesion, but none at the ventral; thus the first visceral cleft is confined to the dorsalmost portion of the pouch (Fig. 100). This opening closes about the end of the fourth day; the ventral portion of the pouch then flattens out, and the dorsal portion expands upwards towards the otocyst (Fig. 102).

The first visceral (mandibular) arch thickens greatly between the 14 and 35 s stages, the ventral ends project a little behind the oral invagination, and subsequently meet to form the primordium of the lower jaw (Figs. 125 and 126, Chap. VII). A pro-

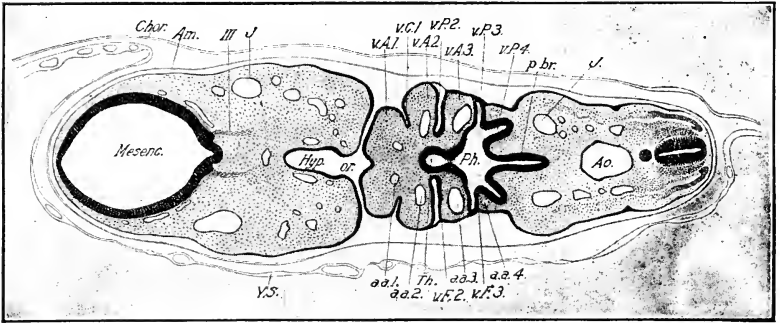


FIG. 101. — Frontal section through the pharynx of a 35 s embryo.

a. a. 1, 2, 3, 4, First, second, third, and fourth aortic arches. Hyp., Anterior lobe of the Hypophysis. J., Jugular vein. or., Oral cavity. p.br., Post-bran- chial portion of pharynx. Ph., Pharynx. Th., Thyroid. v. A. 1, 2, 3, First, second, and third visceral arches. v. C. 1, First visceral cleft. v. F. 2, 3, Second and third visceral pouches. v. P. 2, 3, 4, Second, third, and fourth visceral furrows.

III, Third cranial nerve.

jection of the upper anterior border just behind the eye is the beginning of the maxillary process, or primordium of the maxillary portion of the upper jaw.

The second visceral pouch likewise becomes adherent to the ectoderm of the second visceral furrow at its dorsal and ventral ends, and openings are formed in each adhesion by the 35 s stage (Fig. 190); the dorsal opening is small and oval (later becoming more elongated) while the ventral one is a long, narrow fissure; they are separated only by a narrow bridge of tissue, and close during the fourth day.

The third visceral pouch behaves like the second, forming a

small round dorsal, and long fissure-like ventral cleft at about the 40 s stage (Fig. 102). These close during the fifth day.

The significance of the separate dorsal and ventral divisions of the visceral clefts is an interesting question. It is probable that the dorsal division had a special function, as they have a special connection with the branchial sense organs.

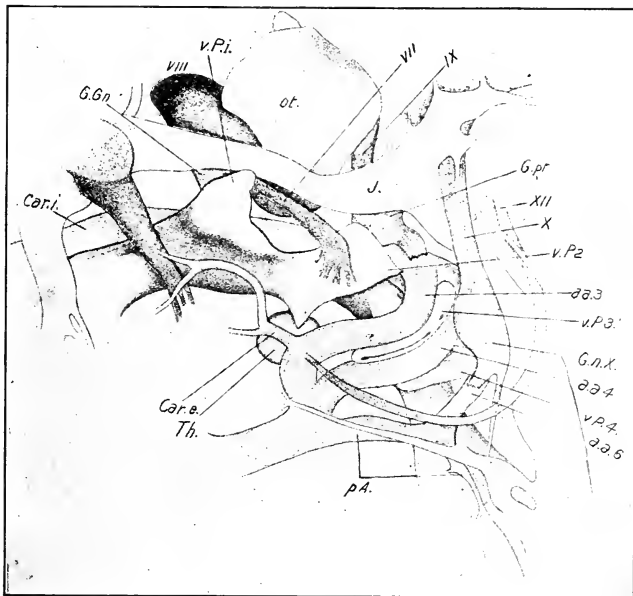


FIG. 102. — Reconstruction of the pharyngeal organs of the chick at the end of the fourth day of incubation. (After Kastschenko.)

a. a. 3, a. a. 4, a. a. 6, Third, fourth, and sixth aortic arches. Car. e., External carotid. Car. i., Internal carotid. G. Gn., Geniculate ganglion. G. n. X., Ganglion nodosum. G. pr., Ganglion petrosus. ot., Otocyst. p. A., pulmonary artery. Th., Thyroid. v. P. 1, 2, 3, 4, First, second, third, and fourth visceral pouches.

V, VII, VIII, IX, X, XII, Cranial nerves and ganglia.

The fourth visceral pouch connects with the ectoderm at its dorsal end, about the 35 s stage, but no cleft develops. Its posterior wall develops an evagination (postbranchial body) which by some is considered to be a rudimentary fifth pouch, and which contributes to the formation of the thymus. (See Chap. X.)

The second visceral arch is the largest of the arches and overlaps both the first and third. See Figs. 117 and 125 in place of description. All of the arches are wedge-shaped, corresponding to the wedge-like form of the hind-brain region. The fourth arch is small and incomplete ventrally; the fifth a mere transitory rudiment. The greatest development of the arches is at about the end of the fourth day.

According to Kastschenko the closure of the visceral clefts takes place external to the meeting-place of the visceral furrows and clefts, and in this way some of the ectoderm of the furrows remains attached to the visceral pouches.

The thyroid arises as a small, spherical evagination of the epithelium of the floor of the pharynx situated between, and a little in front of, the ventral ends of the second pair of visceral pouches (Figs. 85, 87, 88, 101). In the 18–20 s stage, it is represented by a sharply defined plate of high, columnar cells in the same situation, which may be recognized even at the stage of 12 s. At the stage of 26 s this plate forms a deep, saucer-shaped depression, and at the 30 s stage it is a well-developed sac with wide-open mouth which gradually closes, thus transforming the sac into a small spherical vesicle lying beneath the floor of the pharynx (Fig. 102).

The Pulmonary Tract. The portion of the pharynx that includes the visceral pouches may be called the *branchial* portion, because it is homologous to the gill-bearing portion in fishes and amphibia, and because the visceral pouches are phylogenetic rudiments of branchial clefts. The *larynx*, *trachea*, and *lungs* develop from the ventral division of the postbranchial portion of the pharynx. At about the 23 s stage a reconstruction shows this respiratory division of the pharynx slightly constricted from the broader branchial portion, enlarged on each side at its posterior end and with a ventral depression; the latter rapidly deepens to form a narrow groove, the primordium of the larynx and trachea, while the posterior lateral expansion begins to form outgrowths, the primordia of the lungs and air-sacs. By the stage of 35 s (Fig. 100) the postbranchial portion of the pharynx has become narrow transversely and its ventral half is a deep groove (laryngotracheal groove) leading back to the lung primordia. A true median sagittal section at this time shows the

floor of the laryngotracheal groove directly continuous with the floor of the branchial portion of the pharynx at its hind end; the former bends up at about right angles to enter the narrow œsophagus (Figs. 87 and 88).

Thus the whole pulmonary tract communicates widely with the pharynx at the 35 s stage. Its complete delimitation falls within the period covered by Chapter X. The continuity of the expansions that form the lung primordia, with the series of visceral pouches as shown in Fig. 100, is especially noteworthy as suggesting a theory of the phylogenetic derivation of the lungs.

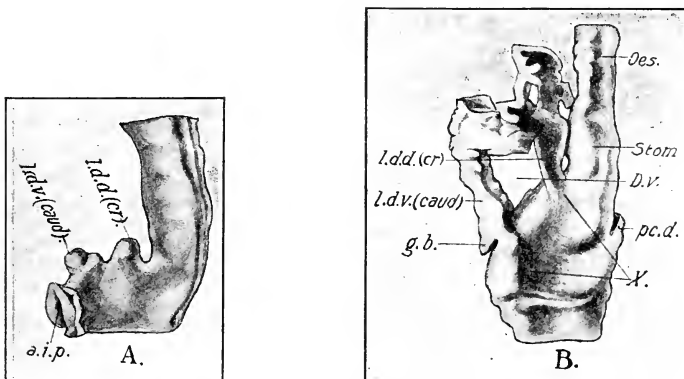


FIG. 103.—Reconstructions of the liver diverticula of the chick. (After Hammar.)

A. On the third day of incubation; from the left side; the diverticula arise from the anterior intestinal portal.

B. Beginning of the fourth day; from the left side.

a. i. p., Anterior intestinal portal. D. V., Indicates position of ductus venosus. g. b., Gall bladder. l. d. d. (cr.), Dorsal or cranial liver diverticulum. l. d. v. (caud.), Ventral or caudal liver diverticulum. pc. d., Dorsal pancreas. X., Marks the depression in the floor of the duodenum from which the common bile duct is formed.

Œsophagus and Stomach. Immediately behind the pharynx, at the stage of 36 s, the intestine narrows suddenly (primordium of œsophagus) and enters a small, spindle-shaped enlargement, the primordium of the stomach (Figs. 87, 88, 100).

The liver arises in the chick as two diverticula of the entoderm of the anterior intestinal portal, one situated immediately above and the other below the posterior end of the ductus venosus, or fork of the omphalomesenteric veins (Fig. 103 A). This portion

of the anterior intestinal portal becomes incorporated in the floor of the intestine as the anterior intestinal portal retreats backwards, and the original dorsal liver diverticulum therefore becomes anterior or cephalic and the ventral becomes posterior or caudal (Fig. 103 B). Before this transposition occurs, however, the diverticula have grown forward towards the sinus venosus in the ventral mesentery of the stomach, the anterior diverticulum above and the posterior diverticulum below the ductus venosus. The stretch of entoderm between the two liver diverticula thus lies in the angle made by the union of the two omphalomesenteric veins. At the stage of 26 somites, the anterior diverticulum has grown forward above the ductus venosus to the level of the Cuvierian veins and is large and flattened laterally. The posterior diverticulum is barely indicated at this time.

The anterior diverticulum was originally described as left and the posterior as right (Goette, 1867), and this description was taken up by Foster and Balfour. This was corrected by Felix (1892). Subsequent writers do not agree exactly as to the time or precise relations of the diverticula; however, it is generally agreed that the two diverticula are subdivisions of a common hepatic furrow, inasmuch as the entoderm between them lies below the level of the entoderm in front and behind (Fig. 103 B). Brouha maintains that at first the hepatic furrow lies in front of the anterior intestinal portal, and that the latter secondarily moves forward so as to include the hepatic furrow, which later again comes into the floor of the intestine with the definitive retreat of the anterior intestinal portal. This view does not rest on very secure evidence, and is probably based on interpretation of slight individual variations as successive stages of development. Choronschitzky places the time of appearance of the hepatic diverticula at about the thirty-sixth hour. It is probable, however, that this is too early. I have found the first unmistakable diverticulum at a stage of 22 somites, a slight rudiment of the anterior diverticulum in the anterior intestinal portal.

At the 30 s stage the anterior or dorsal diverticulum has expanded much more, mainly to the left of the middle line, as though to embrace the ductus venosus, and the posterior or ventral diverticulum has an even greater development and embraces the right side of the ductus venosus, but it does not extend as far forward as the anterior diverticulum. Both diverticula now branch rapidly and profusely, forming secondary anasto-

moses where branches meet, so that a complete ring of anastomosing columns of hepatic cylinders is rapidly formed around the center of the ductus venosus (Figs. 103 B and 104, cf. also Figs. 119 and 120). But the anterior and posterior ends of the ductus venosus are not yet completely surrounded by the basket-work of liver substance, owing to the absence of any part of the posterior diverticulum in its anterior portion, and of the anterior diverticulum in its posterior portion.

The floor of the intestine between the anterior and posterior liver diverticula is depressed; later it becomes separated from the intestinal cavity to form a temporary common bile-duct; which then receives the two primary diverticula (Figs. 103 B, 104 and 187).

The *pancreas* arises from a dorsal and a pair of ventral primordia. The former is an outgrowth of the dorsal wall of the intestine immediately above the posterior liver diverticulum (Figs. 103 B and 104). At the 35 s stage it is a solid thickening of the dorsal wall of the intestine of considerable extent; a little later the base of the thickening is hollowed out, and the free margin sends off solid buds into the dorsal mesentery just behind the stomach. The ventral primordia arise from the posterior liver diverticulum in a manner to be described later (Chap. X).

Mid-gut. At the 35 s stage the mid-gut is still open to the yolk-sac. Its subsequent history is given in Chapter X.

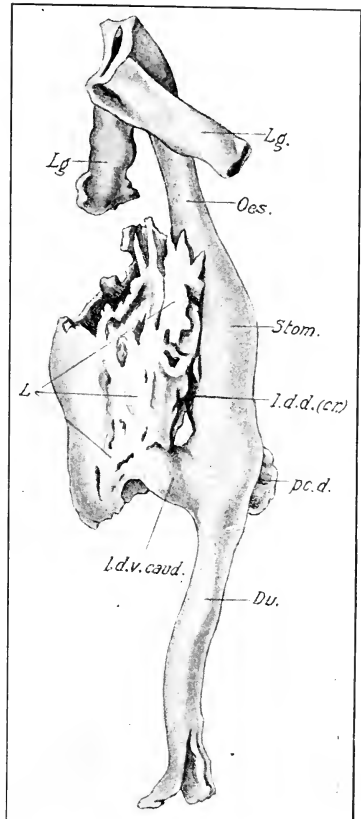


FIG. 104. — Reconstruction of the liver of the chick at the end of the fourth day of incubation. (After Hammar.)

du., Duodenum. L., Substance of liver. Other abbreviations as before.

Anal Plate, Hind-gut, Post-anal Gut, and Allantois. At about the 14s stage a thickening of the ectoderm in the middle line just behind the primitive streak extends towards the entoderm which is folded up so as to nearly meet it, thus cutting off the extra-embryonic mesoblast from the primitive streak. The ectoderm and the entoderm then come into contact here, and form a firm union, the anal plate (Fig. 70), which is subsequently perforated to form the anus. At first, however, the anal plate lies entirely behind the embryo, and the post-anal portion of the embryo arises from the thickened remnant of the primitive streak (tail-bud) which grows backwards over the blastoderm beyond the anal plate. Even before this, however, the hind-gut begins to be formed by a fold of the splanchnopleure directed forwards beneath the tail-bud, and the hind end of the tube thus formed ends at the anal plate (Fig. 70). The entoderm in front of the anal tube is fused with the substance of the tail-bud, and as the latter grows backwards beyond the anal plate it carries with it a pocket of the hind-gut, and this forms the post-anal gut (Fig. 80).

The formation of the tail brings the anal plate on to the ventral surface of the embryo at the junction of tail and trunk, and the post-anal gut then appears as a broad continuation of the hind-gut extending behind the anal plate, and ending in the tail at the hind end of the notochord (Fig. 80). The further elongation of the tail draws out the post-anal gut into a narrow tube lying beneath the notochord in the substance of the tail; it then gradually disappears and leaves no trace.

The formation of the hind-gut takes place prior to the formation of the embryonic body-cavity at this place. It thus happens that the splanchnic mesoderm, forming the floor of the hind-gut, is directly continuous with the somatic mesoderm. When the body-cavity does penetrate this region it is without direct lateral connections with the extra-embryonic body-cavity, so that the connection of the splanchnic and somatic mesoderm persists, forming the *ventral mesentery* of the hind-gut (Fig. 81). This is a thick mass of mesoblast binding the hind-gut to the somatopleure. The hind-gut is deep from the first, and its ventral division soon begins to extend into the ventral mesentery as a broad evagination, the allantois (see p. 143).

VI. HISTORY OF THE MESODERM

The history of the extra-embryonic mesoderm is considered sufficiently in the first part of this chapter. The history of the embryonic mesoderm will be considered under the following heads: (1) Somites, (2) Intermediate Cell-mass, (3) Vascular System, (4) Lateral Plate and Body-Cavity, (5) Mesoblast of the Head.

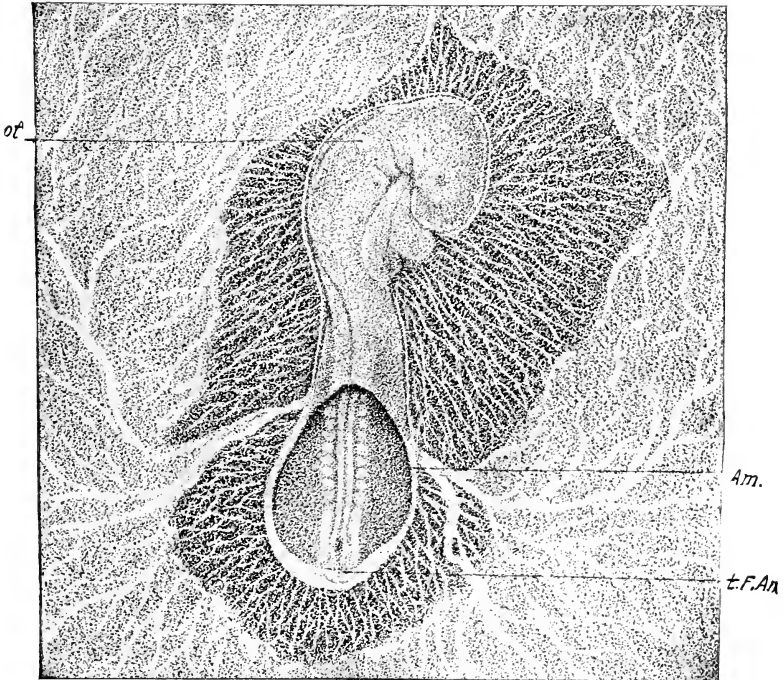


FIG. 105. — Embryo of about 27 somites drawn in alcohol by reflected light; upper side. $\times 10$.

Am., Amnion. ot., Otocyst. t. F. Am., Tail fold of amnion.

(1) **Somites.** The rate of formation of the somites from the segmental plate and their number at different times is given in the normal table of embryos (p. 68), and may be seen in various figures of entire embryos. The formation of new somites continues after the end of the period discussed in this chapter, up to about the sixth day. Each somite has a definite value in the developmental history.

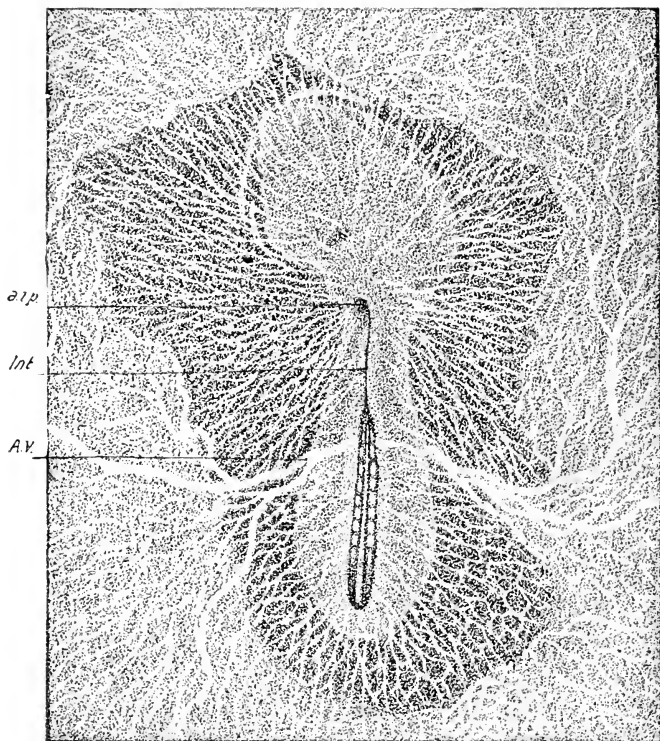


FIG. 106. — The same embryo from beneath. x 10.

a. i. p., Anterior intestinal portal. A. V., Vitelline artery.
Int., Intestinal groove.

In an embryo of 42 somites (about ninety-six hours), the value of the somites as determined by their relations and subsequent history is as follows:

- 1 to 4. Cephalic; entering into the composition of the occipital region of the skull.
- 5 to 16. Prebrachial; *i.e.*, entering into the region between the wing and the skull.
- 17 to 19. Brachial.
- 20 to 25. Between wing and leg.
- 26 to 32. Leg somites.
- 33 to 35. Region of cloaca.
- 36 to 42. Caudal.

More somites are formed later, the maximum number recorded being

52, (see Keibel and Abraham, *Normaltafeln*). In an eight-day chick the number of somites is again about 42, including the four fused with the skull. Thus the ten somites formed last are again lost. This points towards a long-tailed ancestry for birds.

“Although the somites have the same fundamental structure in all parts of the body, they differ greatly in many respects” (Williams). It is not, however, our purpose to consider the individual characters of each pair of somites, but rather the relations common to all.

Each somite is composed of an epithelial wall of high, columnar cells, enclosing a core of cells that nearly fills the cavity (Figs. 112, 113, etc.). From each somite there arise three parts of fundamental significance, viz., the sclerotome, the muscle plate, and the cutis plate (dermatome), the primordium of the axial

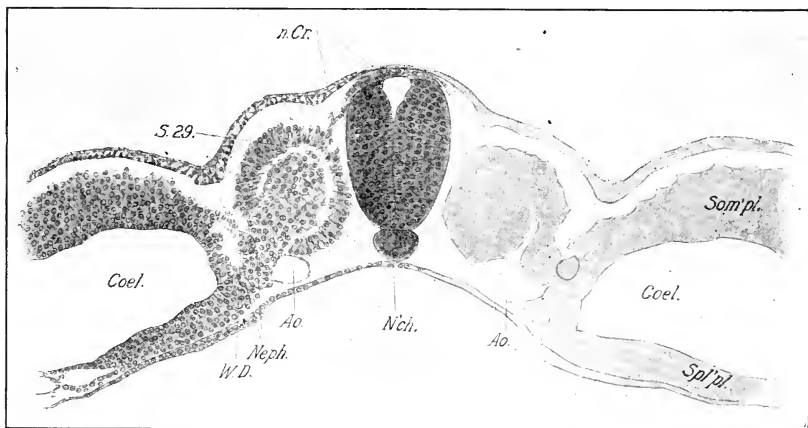


FIG. 107.—Transverse section through the last somite of a 29s embryo.
n. Cr., Neural crest. Neph., Nephrotome. W. D., Wolffian duct. Other abbreviations as before.

skeleton, the voluntary muscles (excepting those of the head), and derma respectively. The manner of origin of these parts may be studied fully in an embryo of 25 to 30 somites, by comparing the most posterior somites, in which the process is beginning, with somites of intermediate and anterior positions in the series, which show successively later stages.

Figs. 107, 108, 109, and 110 represent transverse sections through the twenty-ninth, twenty-sixth, twentieth, and seventeenth somites of a 29s embryo. In the twenty-ninth somite

(Fig. 107) the primitive relations of the parts are still preserved. In the twenty-sixth somite (Fig. 108) it will be seen that the cells of the core and of the ventral and median wall of the somite extending from the nephrotome to about the center of the neural tube are becoming mesenchymal; they spread out towards the notochord and the space between the latter and the dorsal aorta. These cells constitute the sclerotome. The muscle plate extends from the dorsal edge of the sclerotome to the dorso-median angle of the wall of the somite, and the dermatome from this point to the nephrotome.

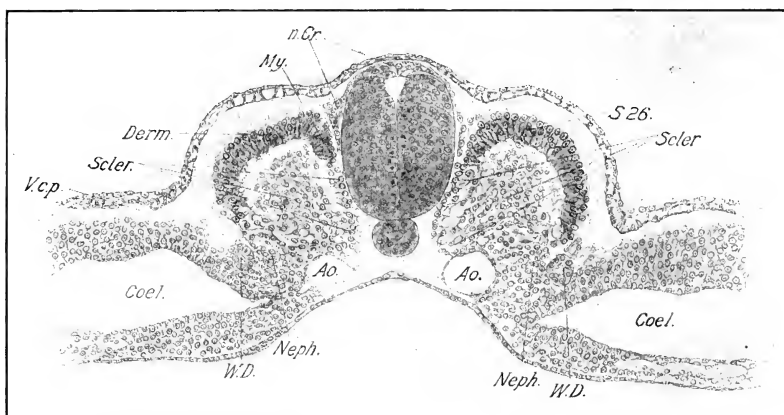


FIG. 108. — Transverse section through the twenty-sixth somite of a 29 s embryo. (Same embryo as Fig. 107.)

Derm., Dermatome. My., Myotome. Scler., Sclerotome. V. c. p., Posterior cardinal vein. Other abbreviations as before.

Fig. 109 is a section through the twentieth somite of the same embryo. The sclerotome is entirely mesenchymal, and its cells are extending between the notochord and aorta, and along the sides of the neural tube. The muscle-plate has now bent over so that its inner surface is being applied against the dermatome, but there is still a considerable cavity (myocœle) between the two, at the lateral angle of the dermo-myotomic plate. The lateral edge of the dermatome is freed from the nephrotome, and turns in to a slight extent. Other details are readily understood from the figure.

The growth of the free edge of the muscle-plate towards the free lateral edge of the dermatome continues as illustrated in

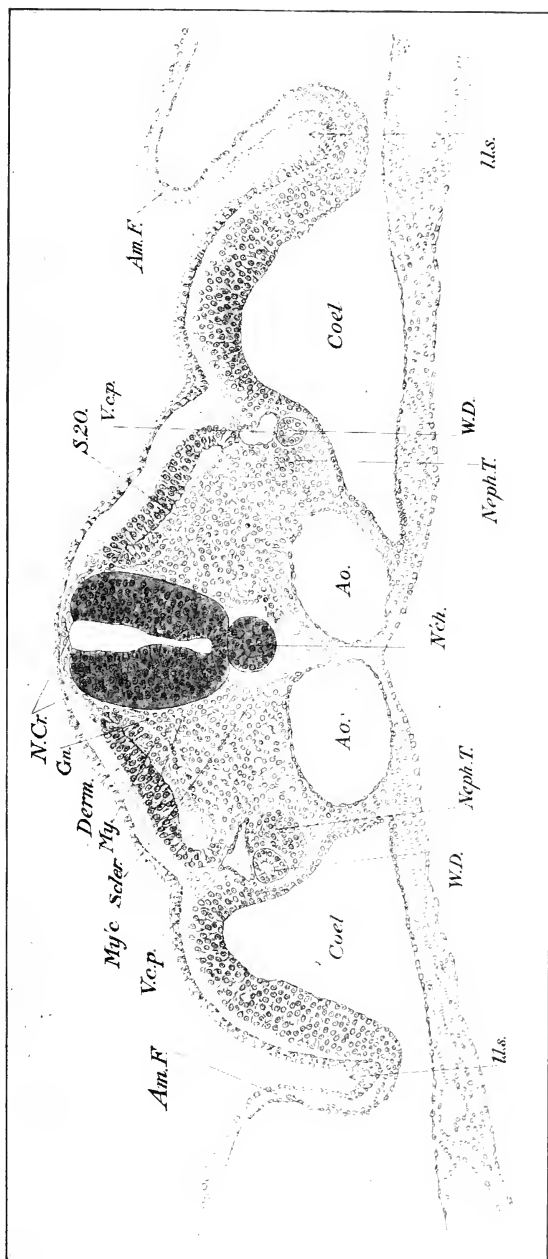


FIG. 109. — Transverse section through the twentieth somite of a 29s embryo. (Same embryo as Fig. 107.)
 Am. F., Amniotic fold. My'c., Myocel. Neph. T., Nephrogenous tissue. Other abbreviations as before.

Figs. 109 and 110, until complete union of the two takes place (Fig. 111) and there is established a complete dermo-myotomic plate in each somite, which therefore includes two layers: the external cutis-plate or dermatome, and the internal muscle-plate or myotome. With the elevation of the axis of the body, the dermo-myotome gradually assumes a nearly vertical position.

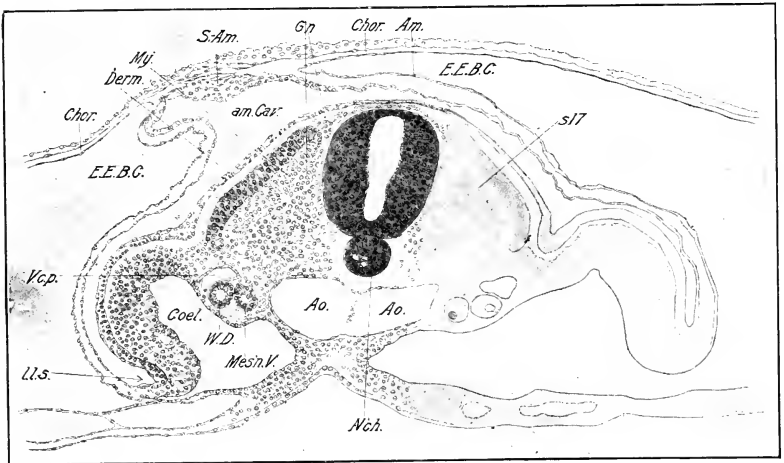


FIG. 110. — Transverse section through the seventeenth somite of a 29s embryo. (Same embryo as Fig. 107.)

am. Cav., Amniotic cavity. E. E. B. C., Extra-embryonic body-cavity. Gn., Ganglion. mes'n. V., Mesonephric vesicle. S.-Am., Sero-amniotic connection. Other abbreviations as before.

Other details concerning the early history of the sclerotome are given in Chapter XIII, and it remains to add here only a short description of certain changes in the cells of the myotome (myoblasts). In longitudinal sections the cells of the myotome are seen to become spindle-shaped soon after the folding towards the dermatome begins. The nuclei of the myoblasts are large and stain less deeply than those of adjoining tissues. They become elliptical in correspondence with the form of the cell-bodies. Each myoblast soon stretches from anterior to posterior faces of the somite, and this represents the first stage in the differentiation of the voluntary muscles.

In later stages the myotomes send outgrowths into the limb-buds and ventral body-wall for the formation of the voluntary

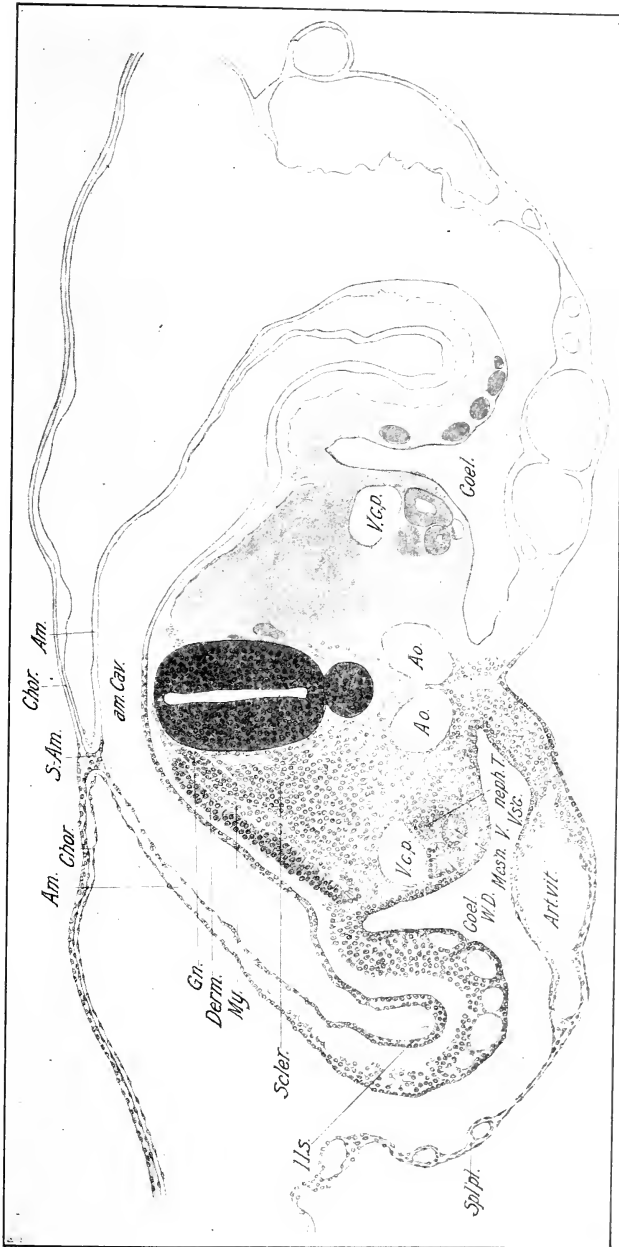


FIG. III.—Transverse section through the twenty-third somite of a 35s embryo.
V. s.c., Sub-cardinal vein. Other abbreviations as before.

muscles of these parts. The voluntary muscles of the head, on the other hand (excepting the hypoglossus musculature), arise in front of the somites; the mesoblast from which they arise is, however, part of the original paraxial mesoblast, in large part at least. It is important to note that the voluntary muscles are epithelial in origin. The involuntary, or smooth, muscle fibers, on the other hand, are mesenchymal in origin.

The dermatome remains epithelial in all the somites well into the third day; the cells then begin to separate and form mesenchyme; this process begins at the anterior somites and proceeds backwards. The mesenchyme thus formed is the foundation of the derma.

The Intermediate Cell-mass or Nephrotome. This is the cord of cells uniting somite and lateral plate; it reaches its typical development only from the fifth to the thirty-third somites, in which it contributes to the development of the excretory system. Behind the cloaca, that is in the region of the tail, there is no lateral plate and no nephrotome.

Origin of the Excretory System. The history of the excretory system in Amniota is of particular interest, because it shows a succession of three separate organs of excretion or kidneys, the first of which is a mere functionless rudiment, the second is the principal organ of excretion during embryonic life (at least in reptiles and birds), and the third finally becomes substituted for the second, which degenerates and is mostly absorbed; however, parts of the second remain and contribute to the formation of the organs of reproduction. The first, known as the head kidney or pronephros, is probably homologous to the permanent kidney of *Amphioxus*; the second or mesonephros, is the homologue, in part, of the permanent kidney of *Anamnia*, and the third or metanephros is the permanent kidney. The secreting parts of all arise from the intermediate cell-mass, though not in the same manner. The development of the metanephros does not begin until the fourth day; it is therefore not considered in this chapter.

Pronephros and Wolffian Duct. The pronephros extends over only eleven or twelve somites, viz., from the fifth to the fifteenth or sixteenth inclusive; it consists originally of as many parts or tubules as the somites concerned. Each tubule arises as a thickening of the somatic layer of the intermediate cell-

mass, which grows out towards the ectoderm in the form of a blind, solid sprout. The distal end of each turns backwards and unites with the one behind so as to form a continuous cord of cells, which is thus united with the intermediate cell-mass in successive somites by the original outgrowths. This cord of cells is the beginning of the Wolffian duct. Behind the sixteenth somite, the latter grows freely backwards just above the intermediate cell-mass until it reaches the cloaca with which it unites about the 31 s stage.

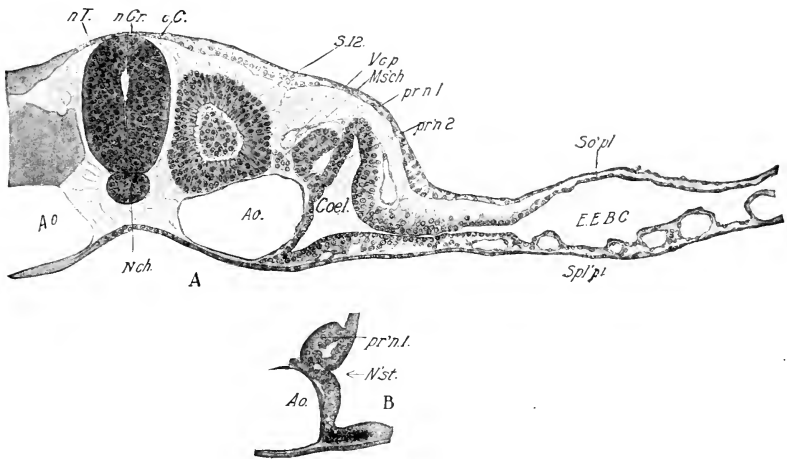


FIG. 112. — A. Transverse section through the twelfth somite of a 16s embryo.

B. Three sections behind A to show the nephrostome of the same pronephric tubule.

V. c. p., Posterior cardinal vein. c. C., Central canal. Ms'ch., mesenchyme. n. Cr., Neural crest. N'st., Nephrostome. n. T., Neural tube. pr n. 1, 2, Distal and proximal divisions of the pronephric tubule.

The primary pronephric tubules are originally attached to the nephrotome opposite the posterior portion of the somite, about half-way between the somite and the lateral plate (Figs. 112 and 113). The part of the nephrotome between the attachment of the primary tubule and the lateral plate is continuous with the primary tubule and forms a supplementary part of the complete pronephric tubule; the remainder of the nephrotome then becomes converted into mesenchyme and the connection with the somites is lost (Figs. 112 and 113). Thus each pronephric tubule forms a connection between the Wolffian duct

and the angle of the body-cavity; it consists of two parts, viz., the primary tubule and the supplementary part. It never possesses a continuous lumen, though there is often a cavity in the supplementary part, which opens into the body-cavity through the nephrostome (Fig. 112 B).

The pronephros of the chick is a purely vestigial organ, of no apparent functional significance. Its development is accordingly highly variable, and it often happens that the right and left sides of the same embryo do not correspond. It is also of very short duration and is usually completely lost on the fourth day. The tubules in the fifth to the tenth somites, moreover,

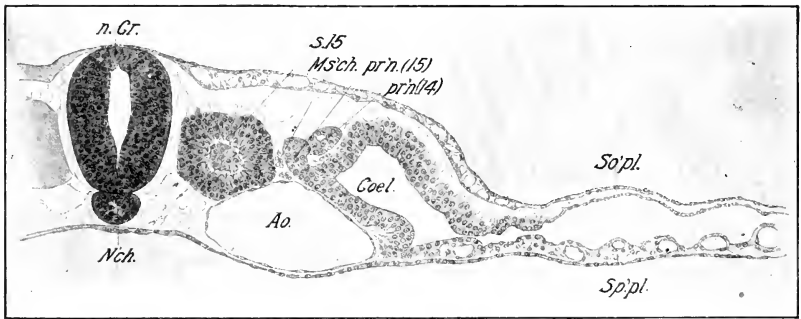


FIG. 113. — Transverse section through the fifteenth somite of the same embryo.

pr'n. (14), (15), Pronephric tubules of the fourteenth and fifteenth somites, respectively.

hardly pass the first stage when they appear as thickenings of the somatic layer of the somitic stalk; thus the Wolffian duct does not extend into this region, and the best developed pronephric tubules are confined to the tenth to the fifteenth somites.

The pronephric tubules do not form Malpighian corpuscles; but glomeruli develop as cellular buds at the peritoneal orifices of the posterior tubules, projecting into the coelome near the mesentery. Curiously enough these do not form at the time of greatest development of the tubules, but subsequently to this when the tubules themselves are in process of degeneration. Moreover, they are extremely variable as to number, and degree of development. They appear to be best developed on the third and fourth days. They agree in many respects with the so-called external glomeruli of the pronephros of *Anamnia*, and should be

homologized with these. On the other hand, they appear at the same time as the first glomeruli of the mesonephros (q. v.) and possess, by way of the intermediate tubules, undeniable resemblance to the latter.

At the stage of 10 somites the pronephros is represented by a series of thickenings of the somatic layer of the intermediate cell-mass extending from the fifth somite backward to the segmental plate. In an embryo of 13 somites the connection between the somite and nephrotome is lost, and the pronephric tubules from the ninth to the thirteenth somites have united to form the beginning of the Wolffian duct.

In an embryo of 16 somites a single pronephric tubule was found at the level of the hind end of the fifth somite, and was very distinct on one side but hardly discernible on the other. Its posterior continuation was soon lost, and the next distinct tubules were between the ninth and tenth somites; from here back there was a tubule opposite the hind end of each somite to the fifteenth, which was the last, and the duct was continuous.

In an embryo of 21 somites, one finds only isolated remnants of the pronephros in front of the eleventh somite; from here to the fifteenth the tubules are well developed and retain their connection both with the Wolffian duct and the lateral plate. The Wolffian duct extends back of this place to the region of the posterior half of the segmental plate.

At the 35 s stage the pronephric tubules are much degenerated, but the nephrostomes usually remain. In one embryo there was found a well-developed pronephric tubule on each side in the thirteenth somite. That of the left side had a wide nephrostome, the lumen of which stopped short of the tubule; the nephrostome of the right side was rudimentary. On the right side the Wolffian duct extended no farther forward, but on the left side it was continued to the eleventh somite, and rudimentary pronephric strands uniting it to the cœlomic epithelium existed in both eleventh and twelfth somites. Here the Wolffian duct stopped. But isolated pronephric rudiments and minute nephrostomes were found on both sides as far forward as the tenth somite.

The Wolffian Duct. The Wolffian duct consists according to the foregoing account of two parts, (1) an anterior division formed by the union of the pronephric tubules, and (2) a posterior division that arises as an outgrowth of the anterior part. The latter grows backward above the intermediate cell-mass as a solid cord (Fig. 107), apparently by active multiplication of its own cells, without participation of the neighboring mesoderm or

ectoderm, until it reaches the level of the cloaca at about the sixtieth hour (30–31 s). It acquires a narrow lumen anteriorly at about the 25 s stage; but the remainder is solid. At about the sixtieth hour the ends of the ducts fuse with broad lateral diverticula of the cloaca, and the lumen extends backwards until the duct becomes viable all the way into the cloaca (at about seventy-two hours, 35 s stage).

The Mesonephros or Wolffian Body. The mesonephros develops from the substance of the intermediate cell-mass between the thirteenth or fourteenth somites and the thirtieth somite. There are slight local differences in the relations of the tubules in front and those behind the nineteenth and twentieth somites, but in general the tubules may be stated to arise as epithelial vesicles derived from the intermediate cell-mass, which become transformed into tubules, one end of which unites with the Wolffian duct and the other forms a Malpighian corpuscle in the manner described below. It will be seen that the anterior mesonephric tubules which are relatively rudimentary and of brief duration overlap the posterior pronephric tubules; they may possess nephrostomes, whereas the typical mesonephric tubules formed behind them, which constitute the main bulk of the mesonephros, never possess peritoneal connections.

An embryo with 29–30 somites is in a good stage for considering the early development of the mesonephric tubules. If one examines a section a short distance behind the last somite, one finds that the intermediate cell-mass is a narrow neck of cells uniting the segmental plate and the lateral plate, and that the cells composing it are arranged more or less definitely in a dorsal and ventral layer, though some occur between. The primordium of the Wolffian duct occurs in the angle between the somatic mesoblast and the intermediate cell-mass, and the aorta lies in the corresponding angle of the splanchnic mesoblast. In the last somite (Fig. 107) one finds two important changes: (1) the intermediate cell-mass is much broader owing to multiplication of its cells, and as a consequence the two-layered arrangement is lost; (2) whereas the cells of the intermediate cell-mass in the region of the segmental plate could not be delimited accurately from either the segmental or lateral plate, it is now easy in most sections to mark its boundary on both sides. It now constitutes, therefore, a rather well-defined but unorganized mass

of cells between the somite and lateral plate, aorta and Wolffian duct; the posterior cardinal vein appears above the Wolffian duct.

The next change, found to begin in about the twenty-sixth somite, is a condensation of a portion of the cell-mass lying median to and below the Wolffian duct (Fig. 108), rendered evident by the deeper stain in this region; the condensed portion of the original intermediate cell-mass is not, however, sharply separated from the remainder, but shades gradually into it both dorsally and ventrally, so that it can be seen to represent approximately the central part of the original middle plate. In view of its prospective function it may be called the *nephrogenous tissue*. Following it yet farther forward one finds that it is a continuous cord of cells with alternating denser and less dense portions, until in the twentieth somite (Fig. 109), the denser portions become discrete balls of radially arranged cells. In the eighteenth and seventeenth somites (Fig. 110) these become small thick-walled vesicles, which are situated median and ventral to the duct. Each vesicle is the primordium of a complete mesonephric tubule. Farther developed tubules are found in the fifteenth and sixteenth somites, and it is probable that the nephrogenous tissue forms mesonephric tubules in the fourteenth, thirteenth, and perhaps yet more anterior segments.

The formation of the tubules proper from the vesicles may be studied satisfactorily in a 35 s embryo (seventy-two hours). In the twenty-third somite of such an embryo the nephrogenous tissue and the nascent tubules lie median to the Wolffian duct and below the median margin of the cardinal vein (Fig. 111). The Wolffian duct is triangular in cross-section with its longest and thinnest side next the coelome. The most advanced vesicle in this region possesses a hollow sprout extending laterally to the Wolffian duct with which it is in close contact; this is the primordium of the tubular part of the mesonephric tubule (cf. Fig. 114 A and B). In more anterior somites it is found that such sprouts have fused with the wall of the duct in such a manner that the lumen of the tubule now communicates with that of the duct.

Simultaneously the median portion of the original vesicle has been transformed into a small Malpighian corpuscle in the following manner: it has first become flattened so that the lumen is reduced to a narrow slit; then this double-layered disc becomes concave with the shallow cavity directed posteriorly and dorsally;

at the same time the convex wall becomes thin, and the concave thick. The entire tubule thus becomes S-shaped. Figs. 114 A, B, C, D illustrate the corresponding processes in the duck, which are similar in all essential respects to the chick.

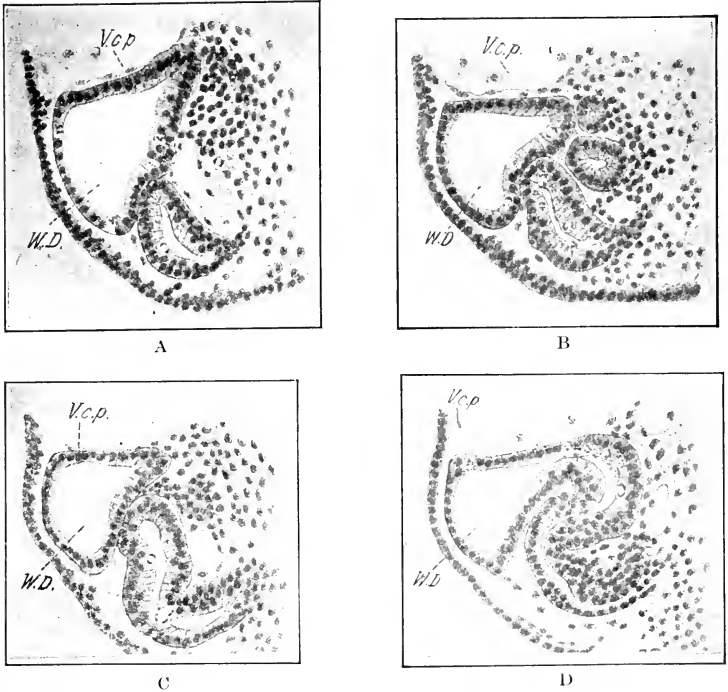


FIG. 114. — From a transverse series through a duck embryo of 45 s, to show the formation of the mesonephric tubules. (After Schreiner.)

Fig. 218 shows the position of the sections A, B, and C.

V. c. p., Posterior cardinal vein. W. D., Wolffian duct.

A. and B. represent tubules of the twenty-ninth segment.

C. of the twenty-seventh segment.

D. of the twenty-fourth segment.

In the chick embryo of 35 somites the only differentiated tubules are in front of the twentieth somite, a region of the mesonephros that never develops far, and such tubules do not appear ever to become functional. In the region of the subsequent functional mesonephros (twentieth to thirtieth somites) the development has not progressed beyond the stage of the vesicles showing the first indications of budding.

The main part of the mesonephros is thus between the twentieth and thirtieth somites. In the anterior half of this region three or four rudiments of tubules are formed in each somite by the seventy-second hour. Subsequently five or six tubules are formed in each segment between the twentieth and thirtieth. Tubules are formed first from the ventral portions of the nephrogenous tissue (see Fig. 111); those formed later arise from the unused portions. There is no evidence that they ever arise in any other way. The tubules may thus be divided according to the time of origin into primary, secondary and tertiary sets, but there is no morphological or functional distinction between the successive sets. (See Chap. XII.)

The collection of tubules causes a projection or fold on each side of the mesentery into the body-cavity, known as the *Wolffian body*, the detailed history of which is given in Chapter XII.

In conclusion it should be noted that the most anterior tubules of the Wolffian body possess peritoneal funnels like the pronephric tubules. Thus in an embryo of 30 somites I have noticed open peritoneal funnels in the eighth, ninth, twelfth, thirteenth, fourteenth, fifteenth, sixteenth, and seventeenth somites. It seems quite certain that the last of these belong to the mesonephros, though the most anterior are undoubtedly pronephric rudiments. In the eighteenth, nineteenth, twentieth, and twenty-first somites, small depressions of the peritoneum were noticed opposite tubules, but not communicating with them.

The Vascular System. Soon after the thirty-third hour the heart begins to twitch at irregular intervals, and by the forty-fourth hour its beatings have become regular and continue uninterrupted. The contraction proceeds in the form of a rapid peristaltic wave from the posterior to the anterior end of the cardiac tube, and the blood, already present, is forced out in front. Through the aortic arches it reaches the dorsal aorta which distributes part to the body of the embryo, but most of the blood enters the vascular network of the yolk-sac. It is returned to the heart by various veins in the yolk-sac and embryo, and recommences the circuit.

The development of the vascular system will be more readily understood if we preface the account with a brief description of the anatomy of the system early in the fourth day (Fig. 115, cf. also Figs. 135 and 136).

The heart consists of four chambers, viz., the sinus venosus,

the atrium, the ventricular loop, and the bulbus arteriosus (Fig. 116).

The truncus arteriosus lies in the floor of the pharynx and gives off the following vessels: (1) a short branch, the external carotid, extending into the mandibular arch; (2) complete arches in the second, third, and fourth visceral arches which join the

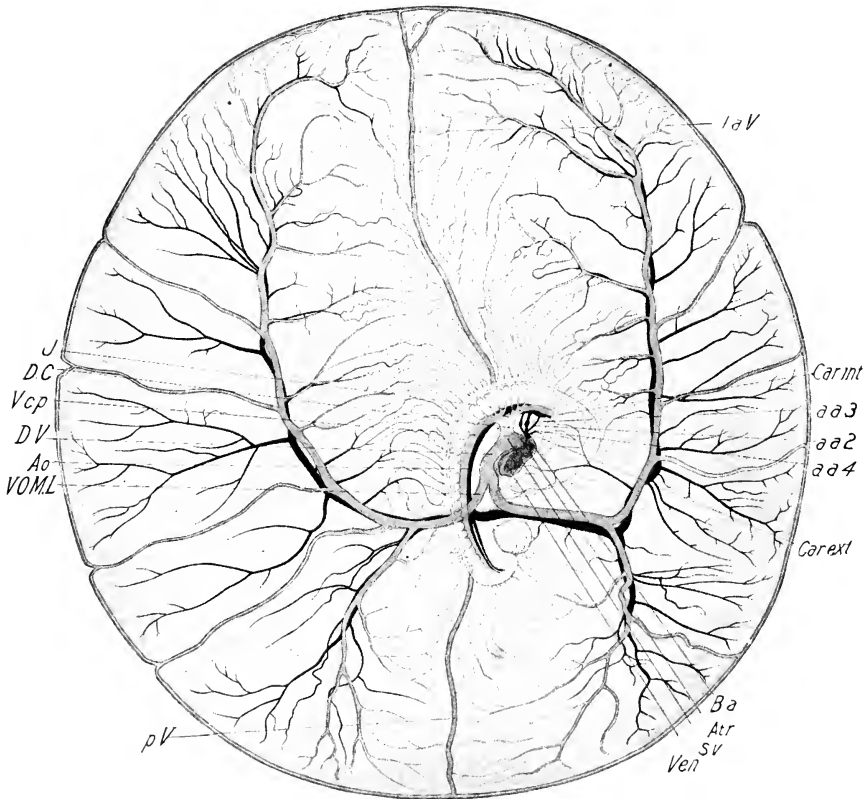


FIG. 115. — The circulation in the embryo and yolk-sac between the eightieth and ninetieth hours of incubation, drawn from a photograph by A. H. Cole. The arteries are represented in solid black; the veins in neutral tint. A fold of the yolk-sac covers the fore part of the head.

a. a. 2, 3, 4, Second, third, and fourth aortic arches. Ao., Aorta. Atr., Atrium. B. a., Bulbus arteriosus. Car. ext., External carotid. Car. int., Internal carotid. D. C., Duct of Cuvier. D. V., Ductus venosus. J., Jugular vein (anterior cardinal). I. a. V., Left anterior vitelline vein. p. V., Posterior vitelline vein. S. V., Sinus venosus. V. c. p., Posterior cardinal vein. Ven., Ventricle. V. O. M. L., Left omphalomesenteric vein.

dorsal aorta; these are known as the second, third, and fourth aortic arches; the third arch is the largest.

The original mandibular aortic arches unite with the anterior ends of the dorsal aortæ, forming a loop on each side at the base of the fore-brain (Fig. 93), and they have, therefore, a different relation from the other aortic arches; it seems probable also that they have a different morphological value. The ventral limb of this loop disappears in its pre-oral part after this stage and a new vessel is formed entirely within the mandibular arch, bearing the same relation to the visceral arch as the other aortic arches. At the stage of 35 somites it is a complete arch, in some embryos at least (Fig. 117), though of very small caliber and very transitory, possibly sporadic, in its occurrence. It is possible that this is the true mandibular arch, and the pre-oral portion of the original mandibular arch should have another interpretation. Kastschenko suggests that it may have been related to lost pre-mandibular gill-clefts.

The roots of the dorsal aorta above the pharynx receive the aortic arches and are continued forward as the internal carotid arteries, branching in the fore part of the head. Posteriorly the right and left aortic roots unite just behind the fourth visceral pouch to form the dorsal aorta, and this continues as an undivided vessel to about the level of the twenty-second somite, where it divides into right and left dorsal aortæ, and at the same time sends out a large omphalomesenteric artery into the yolk-sac on each side, and these branch as shown in Figure 115 into the capillary network of the yolk-sac. The dorsal aortæ, now much diminished in size, continue back into the tail where they are known as the caudal arteries. The dorsal aorta also sends off a pair of segmental arteries into each intersomitic septum, and a pair of small allantoic (umbilical) arteries into the primordium of the allantois.

The veins enter the heart through three main trunks: (1) the ductus venosus, (2 and 3) the paired ducts of Cuvier. These are made up as follows: (1) the ductus venosus is formed at the level of the posterior liver diverticulum by the right and left omphalomesenteric veins, which arise in the yolk-sac by union of the capillaries of the vascular area; the right vitelline vein also receives two veins coming directly from the anterior and posterior ends respectively of the *sinus terminalis*, the anterior of these is frequently partly double owing to its mode of origin. (See beyond, Chap. VII.) The vascular area in the yolk-sac thus

appears strikingly bilateral at this time. (2 and 3) The ducts of Cuvier are made up by the union of all the somatic veins. Each is formed primarily by the union of the anterior and posterior cardinal veins. The anterior cardinal vein receives all the blood of the head, and thus includes the first three segmental veins. It also receives at its point of junction with the posterior cardinal vein a branch from the floor of the pharynx, the external jugular vein. The posterior cardinal vein receives (1) all the segmental veins of the trunk, of which there are twenty-nine pairs, running in the intersomitic septa between the fourth and thirty-third somites, and the veins of the Wolffian body of which there are several to each somite concerned, as described in the account of that organ.

The development of the vascular system up to the stage just described will now be taken up.

Development of the Heart. (a) Changes in the External Form. In the last chapter we traced the origin of the heart up to the time when it is a practically straight, undivided, somewhat spindle-shaped tube lying below the floor of the pharynx, to which it is attached by its dorsal mesentery (mesocardium). Posteriorly its cavity divides into the omphalomesenteric veins which run in the side-walls of the anterior intestinal portal. The heart is lengthened backwards by the conerescence of the omphalomesenteric veins and the most posterior division of the heart (the sinus venosus) is established in this way between the stages of 12 and 18 somites; it is marked by a broad fusion with the somatopleure (mesocardia lateralia) through which the ducts of Cuvier enter the heart.

At the stage of sixteen somites the duct of Cuvier lies opposite the hind end of the second somite on the right side, and a little farther back on the left side; and the somato-cardiac fusion (*mesocardium laterale*) in which it lies is of the width of about one and a half somites. On the right side the duct of Cuvier lies a little in front of, and on the left side a little behind, the point of union of the omphalomesenteric veins; thus the posterior end of the heart is not fully formed at the stage of 16 s, but is at the stage of 18 s. The subsequent fusion of the omphalomesenteric veins produces the so-called ductus venosus, or main splanchnic vein, which is therefore a posterior continuation of the sinus venosus.

The cardiac tube proper lies between the origin of the aortic

arches at the anterior end and a point a little behind the entrance of the ducts of Cuvier into the heart at the posterior end.

Two main changes characterize the development of the heart in the period under consideration: (1) folding of the cardiac tube and (2) differentiation of its walls in successive regions to form the four primary chambers of the heart, viz. (from behind forwards), the *sinus venosus*, the *auricular division (atrium)*, the *ventricular division* and the *bulbus arteriosus*.

The folding of the heart is caused by the rapid growth between its anterior and posterior fixed ends, and the places of folding are determined largely by differences in the structure of the walls at various places. The folding begins by a curvature to the right, and this proceeds until the tube has an approximately semicircular curvature (Fig. 72). At a certain place in the curved tube a very pronounced posterior projection takes place (Figs. 73 and 74), and at the same time this bent portion turns ventrally; the apex of the bend represents the future apex of the ventricles. The continuation of these two directions of folding then brings the ventricular division of the heart immediately beneath the sinu-auricular division which is attached dorsally by the somato-cardiac connections; further continuation brings the apex of the heart a little behind the auricular portion (Figs. 85, 87, 88, 93, 99). During all this period the distance between the two fixed ends has remained practically constant.

During the process of folding, constrictions have arisen between successive portions of the cardiac tube, owing to expansion of intervening portions, and thus at the stage of seventy-two hours the heart shows the following divisions and form. From the dorsal surface (in a dissection, Fig. 116) one sees (1) the sinus venosus, broad behind and narrow in front where it joins the auricular division; it receives three veins: (*a*) the large ductus venosus, appearing as a direct posterior continuation of the sinus, and separated from it by only a slight constriction; and (*b* and *c*) the right and left ducts of Cuvier entering the sinus laterally and dorsally near its enlarged posterior end; (2) the sinus enters the atrium through the dorsal wall; the atrium shows two lateral expansions, the future auricles, of which the left is much the more expanded at this time; the sinus appears partly sunk in the right auricle. (3) Only the right limb of the ventricular loop is visible from the dorsal surface at this time, and is separated

from (4) the bulbus arteriosus by a slight constriction. The bulbus thus lies on the right side; it sweeps around the atrium anteriorly to the middle line and then bends up to enter the floor of the pharynx.

From the ventral side one sees the looped ventricular division behind, in which we distinguish right and left limbs, the former of which enters the bulbus in front, and the latter the auricles. These two limbs represent approximately the future right and left ventricles (Fig. 198, Chap. XII).

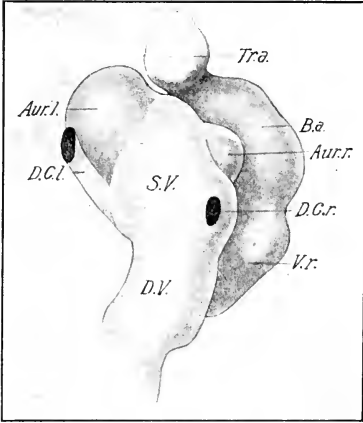


FIG. 116. — Heart of a chick embryo of 72 hours, dissected out and drawn from the dorsal surface.

Aur. l., Left auricle. Aur. r., Right auricle. B. a., Bulbus arteriosus. D. C. r. l., Right and left ducts of Cuvier. D. V., Ductus venosus. S. V., Sinus venosus. Tr. a., Truncus arteriosus. V. r., Right limb of ventricle.

broadened (seventy-two hours).

(b) *Changes in the Internal Structure of the Heart.* We have already seen that the heart consists of two primary layers, viz., the endocardium, which is endothelial in nature, and the myocardium, which is derived from the splanchnic mesoblast. The distinction between the sinu-auricular and the bulbo-ventricular divisions of the heart is indicated internally at about the time the first external evidence is seen, by the fact that the endocardium is more closely applied to the myocardium in the former than in the latter division. In the sinus and atrium but little change takes place in the period under consideration. In the ventricle, on the other hand, and especially in the right limb, the wide space originally existing between endocardium and

In an ordinary entire mount of this stage the heart is seen from the right side, and the disposition of the parts may be readily understood by reference to Fig. 117, and the preceding description.

Another change that should be noted here is the disappearance of the mesocardium during the folding of the cardiac tube, except in the region of the sinus venosus where it remains permanently and becomes much

myocardium becomes more or less filled by multiplication of the endocardial cells. On the side of the myocardium there is first a thickening, and then anastomosing processes are sent out towards the endocardium. Cavities also arise within the thickened myocardium and all communicate. The endocardial cells then form a covering to all myocardial processes and cavities, and the cavities thus lined communicate with the main endocardial cavity. Thus the wall of the ventricles becomes spongy and all the cavities in it are lined by a layer of endocardium and communicate with the endocardial cavity. In the bulbus finally there is a great thickening of the endocardium produced by multiplication of its cells, but no corresponding change in the myocardium; thus the bulbus at seventy-two hours shows a thin myocardial and a thick endocardial wall. The later development is described in Chapter XII.

The Arterial System. The description of the development of the arterial system proceeds from the stage of 12 somites described in the last chapter.

The primitive vascular system of vertebrate embryos is a capillary network in all parts of the blastoderm and of the embryo. Main trunks arise by development of parts of the network corresponding to the rate and direction of embryonic growth and thus answering to the vascular needs of growth. The vascular system forms at all stages a continuous endothelial tree whose primitive form in all parts is a capillary network. This idea, which we owe originally to Aeby, has been worked out in a masterly way by H. M. Evans. (See lit. Chap. V.)

The Aortic Arches. An arch of the aorta is formed in each visceral arch; they arise successively as buds from the roots of the dorsal aorta in the order and time of formation of the visceral arches. Thus the first or mandibular aortic arch is formed at the stage of 9-10 somites; the second or hyoid aortic arch arises from the dorsal aorta at about the stage of 19 s and joins the ventral aorta at about the 24 s stage. The third is completely formed at the stage of 26 somites. The fourth is completely formed at the stage of 36 somites; and the fifth and sixth arise during the fourth and fifth days. (See Chap. XII for account of the fifth and sixth arches.)

The first aortic arch loses its connection with the dorsal aorta at about the stage of 30 somites, and the second arch similarly during the fourth day; the ventral ends of these arches retain their connection with the ventral aorta and constitute the beginning of the external carotid. Thus the third, fourth, fifth and sixth aortic arches remain. Their transformation belongs to the subject-matter of Chapter XII.

The *pulmonary artery* appears as a posterior prolongation of the ventral aorta on each side at about the 35 s stage. It thus appears successively in later stages as a branch from the base of the fourth and sixth aortic arches.

The Internal Carotids. The loop where the mandibular arch joins the dorsal aorta may be called the carotid loop; it is situated in front of the oral plate at the base of the fore-brain on each side (Fig. 93). It enlarges to form a sac, and when the connection with the mandibular arch is lost, sends out branches into the tissue surrounding the brain. These are of course a direct continuation of the dorsal aorta on each side.

The *segmental arteries* are paired branches of the dorsal aorta in each intersomitic septum. They pass dorsally to about the center of the neural tube and arch over laterally to enter the segmental veins, and thus unite with the cardinal veins.

The Development of the Venous System. The main outlines of the development of the venous system have been already considered.

The somatic veins, i.e., the anterior and posterior cardinal veins and their branches, enter the sinus venosus through the ducts of Cuvier. The original position of this duct as we have seen is about the level of the second somite. The formation of the cervical flexure, however, carries a number of somites forward above the heart, so that at about the stage of 32 s it comes to lie in the region of the eighth and ninth somites. The relation between the somatopleure and the heart in this region has been already described.

The anterior cardinal veins are the great blood-vessels of the head, and become the internal jugulars in the course of development. Owing to the order of development of the body, the anterior cardinals are formed before the posterior cardinals. At the 15-16 s stage they lie at the base of the brain, dorsal and lateral to the dorsal aortæ, and extend forward to the region of

the diencephalon. They lie internal to the cranial nerves and pass just beneath the auditory pits.

As the brain develops many branches of the anterior cardinal veins arise, the most conspicuous of which at seventy-two hours are a large branch just behind the auditory sac, one between the auditory sac and the trigeminal ganglion, an ophthalmic branch extending along the base of the brain to the region of the optic stalks and a network of vessels on the lateral surfaces of the fore-brain. The other branches of the anterior cardinal vein are the three anterior intersomitic veins (Fig. 115); the external jugular from the floor of the pharynx enters the duct of Cuvier just beyond the union of the anterior and posterior cardinal veins.

Up to about forty-eight hours the anterior cardinal veins lie median to the cranial nerves, but between this time and seventy-two hours the facial and glossopharyngeal nerves cut completely through the vessel and thus come to lie median to it; the trigeminus and vagus continue to lie lateral to it.

The posterior cardinal arises as a posterior prolongation from the duct of Cuvier and grows backward above the Wolffian duct, keeping pace with the differentiation of the intermediate cell-mass, as far as the thirty-third somite. It does not enter the caudal region of the body. As already described it receives twenty-nine intersomitic veins and the veins of the Wolffian body. At first its connection with the duct of Cuvier is by means of a network of vessels, which gradually gives place to a single trunk (cf. Fig. 117).

The Splanchnic Veins. The ductus venosus is the unpaired vein immediately behind the sinus venosus, formed by fusion of the two omphalomesenteric veins. It is fully formed at the stage of 27 somites. Its relations to the liver have already been described in connection with that organ. Its subsequent changes are described in Chapter XII.

The vitelline veins are united at about the stage of seventy-two hours by a loop passing over the intestine immediately behind the pancreas. (See Chap. XII.)

VII. THE BODY-CAVITY AND MESENTERIES

The origin of the dorsal and ventral mesenteries was considered in the section of this chapter dealing with the alimentary canal. As noted there, the dorsal mesentery extends

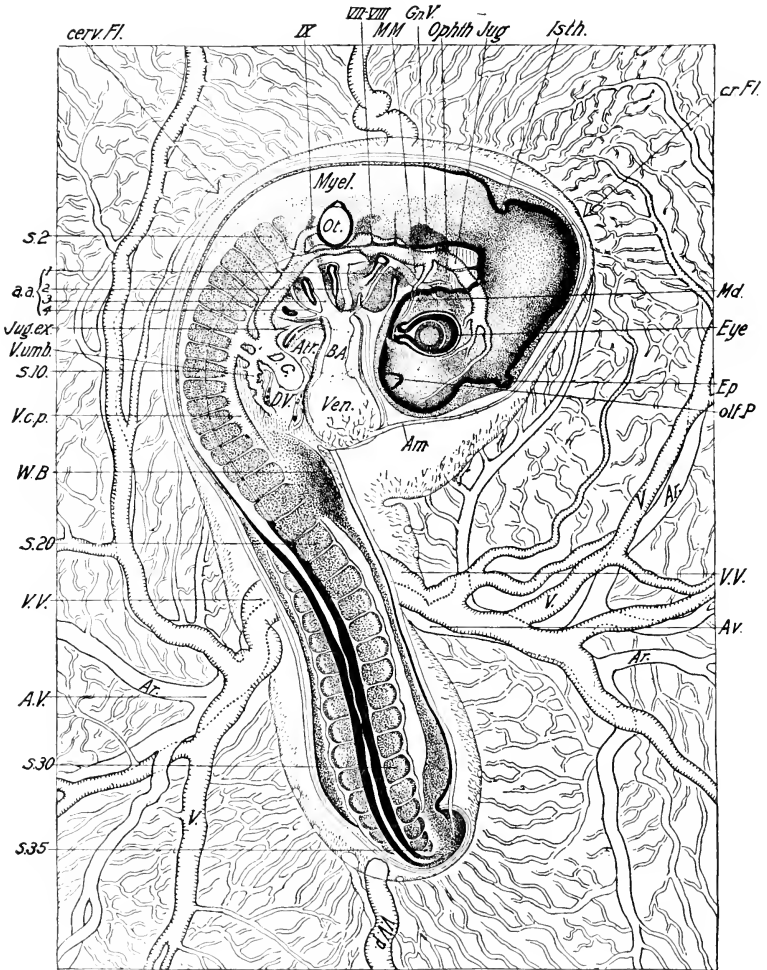


FIG. 117. — Entire embryo of 35 s, drawn as a transparent object.

a. a. 1, 2, 3, 4, First, second, third, and fourth aortic arches. Ar., Artery. A. V., Vitelline artery. cerv. Fl., Cervical flexure. cr. Fl., Cranial flexure. D. C., Duct of Cuvier. D. V., Ductus venosus. Ep., Epiphysis. Gn. V., Ganglion of trigeminus. Isth., Isthmus. Jug. ex., External jugular vein. Md., Mandibular arch. M. M., Maxillo-mandibular branch of the trigeminus. olf. P., Olfactory pit. Ophth., Ophthalmic branch of the trigeminus. Ot., otocyst. V., vein. W. B., Wing bud. V. c. p., Posterior cardinal vein. V. umb., Umbilical vein. V. V., Vitelline vein. V. V. p., Posterior vitelline vein.

the entire length of the alimentary canal, while the ventral mesentery persists only in the region of the fore-gut and the cloaca.

The embryonic body-cavity shows two divisions from a very early stage, viz., (1) the large cephalic or parietal cavity situated in the pharyngeal region of the head and containing the heart, and (2) the general pleuroperitoneal cavity of the trunk. After the heart is established in the middle line the parietal cavity is bounded posteriorly by the wall of the anterior intestinal portal (Figs. 75, 85, etc.), but it communicates with the pleuroperitoneal cavity around the sides of the portal, in which the vitelline veins run. Laterally the parietal cavity communicates with the extra-embryonic body-cavity.

The mesocardia lateralia are also an important landmark in the embryonic body-cavity because from them proceed the partitions that subsequently separate the pericardial and pleural cavities on the one hand, and the pleural and peritoneal body-cavities on the other. (See Chap. XI.) The primordium of the lateral mesocardia may be recognized in the 10 s stage: just behind the heart the median portion of the body-cavity is thick-walled, the peritoneal cells being actually columnar. At this place, a short distance lateral to the median angle of the body-cavity, and at the junction of the cylindrical and flat mesothelium, a fusion of considerable longitudinal extent is formed between the somatopleure and the proximal portion of the vitelline veins, projecting up from the splanchnopleure; this fusion is the beginning of the lateral mesocardium. It separates a more median portion of the body-cavity from a more lateral, and in it the duct of Cuvier soon develops.

When this portion of the body of the embryo becomes elevated (forty to fifty hours) the portion of the body-cavity lateral to the mesocardia lateralia comes to lie ventrally to the median portion (cf. Fig. 69), and at the same time the lateral mesocardia rotate around a longitudinal axis through an angle of about 90° , so that the original median border becomes dorsal, and the original lateral border becomes ventral. The dorsal divisions, right and left, of the pleuroperitoneal cavity may now be called the pleural grooves. Inasmuch as the parietal cavity has receded considerably at the same time into the trunk with the elongation of the fore-gut, it comes to lie beneath the pleural grooves

instead of in front of them as before. Therefore in cross-sections, in front of the lateral mesocardia, the pleural grooves appear as dorsal projections of the parietal (later pericardial) cavity, separated from one another in the middle line by the œsophagus (Fig. 118).

The relations of the three divisions of the embryonic body-cavity thus established may be described as follows: the parietal cavity contains the heart, and is therefore the prospective peri-

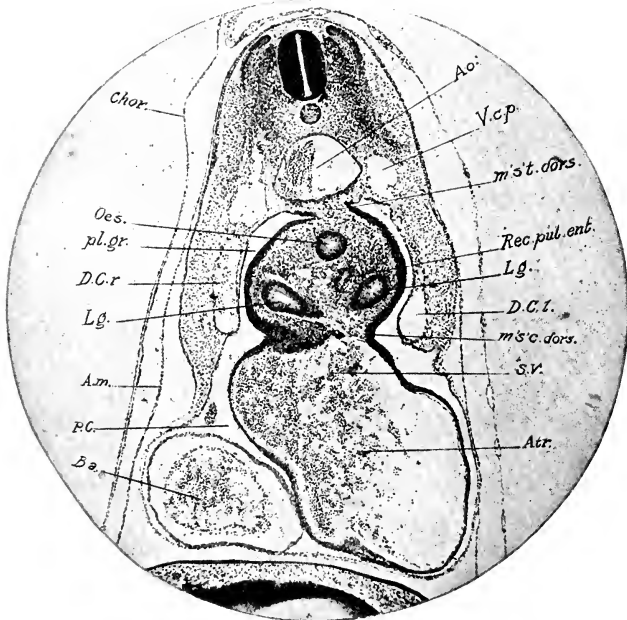


FIG. 118. — Transverse section of an embryo of 35 s, immediately in front of the lateral mesocardia.

Ao., Aorta. Atr., Atrium. B. a., Bulbus arteriosus. D. C. r., and l., Right and left ducts of Cuvier. Lg., Lung. m's.c. dors., Dorsal mesocardium. m's't. dors., Dorsal mesentery. P. C., Pericardial cavity. pl. gr., Pleural groove. Rec. pul. ent., Recessus pulmo-entericus. S. V., Sinus venosus.

cardial cavity. It is not, however, a closed cavity, but communicates in front of the lateral mesocardia with the pleural grooves (Fig. 118), and by way of the latter above the lateral mesocardia with the peritoneal cavity (Figs. 119 and 120); a second communication of the parietal cavity with the peritoneal cavity is beneath the lateral mesocardia around the sides of the anterior intestinal portal, now being converted into the septum transversum (cf.

Fig. 120). A more complete description of the cavities is given in Chapter XI.

The median wall of the pleural grooves forms much mesoblast during the formation of the lung diverticula, and thus initiates the formation of lobes enclosing the lungs (Figs. 118 and 119). These lobes descend ventrally and unite with the septum transversum (see below), thus producing blind bays of the cœlome

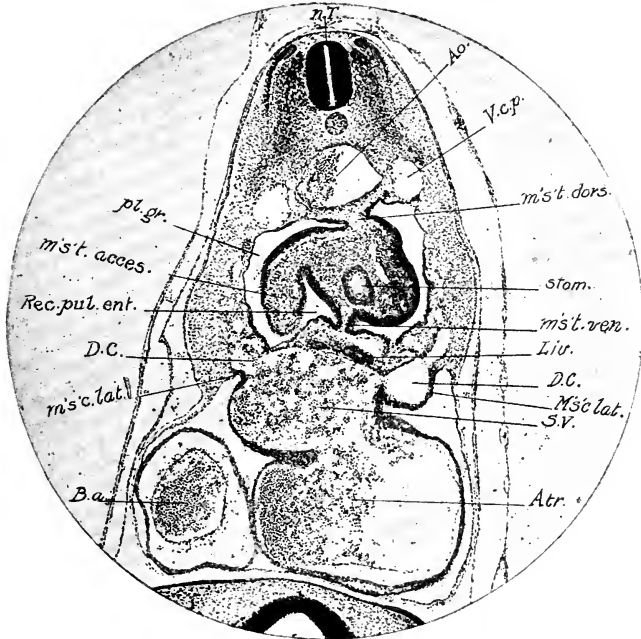


FIG. 119. — Transverse section of the same embryo through the lateral mesocardia.

Liv., Liver. m's.c. lat., Lateral mesocardium. m's't. acces., Accessory mesentery. m's't. ven., Ventral mesentery. Other abbreviations as before.

at the sides of the œsophagus, known as the superior recesses of the peritoneal cavity or pulmo-enteric recesses.

The ventral mesentery extends from the anterior end of the sinus venosus to the hind end of the fore-gut, where it unites with the ventral body-wall. It includes the sinus venosus and the ductus venosus, together with the hepatic diverticula. The median and lateral mesocardia, together with the ventral mesentery of the fore-gut, form a mass known as the *septum transversum*.

At the stage of seventy-two hours, then, the pleural, pericardial and peritoneal divisions of the body-cavity are indicated, but all are in communication. The pleural cavities connect with the peritoneal cavity posteriorly, and with the pericardial cavity anteriorly in front of the lateral mesocardia (Figs. 118, 119, 120); and the pericardial cavity communicates also with the

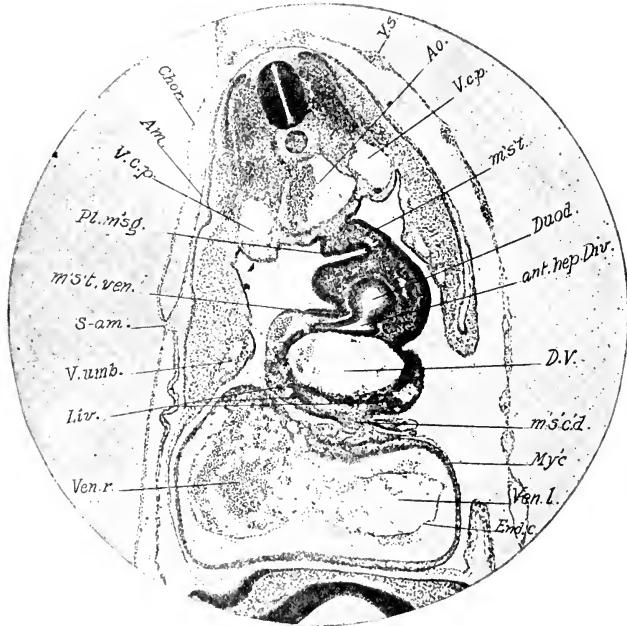


FIG. 120. — Transverse section of the same embryo immediately behind the lateral mesocardia.

ant. hep. Div., Anterior hepatic diverticulum. Duod., Duodenum. End'c., Endocardium. D. V., Ductus venosus. My'c., Myocardium. Pl. m's'g., Plica mesogastrica. S-am., Sero-amniotic connection. ven. r., l., Right and left limbs of the ventricle. V. umb., Umbilical vein.

peritoneal cavity beneath the lateral mesocardia around the roots of the vitelline veins (sides of the anterior intestinal portal). Thus the ducts of Cuvier and the vitelline veins are the agencies that introduce the separation of the body-cavities.

The tail-fold forms blind coelomic pockets in the region of the hind-gut, which end in the region of the thirty-third somite. (Cf. Fig. 81.)

PART II
THE FOURTH DAY TO HATCHING
ORGANOGENY, DEVELOPMENT OF THE ORGANS

CHAPTER VII

THE EXTERNAL FORM OF THE EMBRYO AND THE
EMBRYONIC MEMBRANES

I. THE EXTERNAL FORM

General. The development of the external form of the embryo is conditioned by the order of development of the organs. The early form is thus given by the nervous system, somites

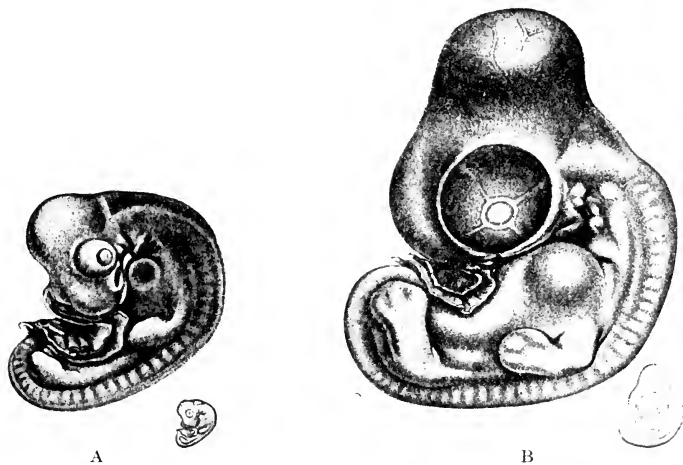


FIG. 121.—A. Embryo of 3 days' and 16 hours' incubation. x 5.

B. Embryo of 5 days' incubation. x 5. (After Keibel and Abraham.)

and viscera. The development of muscles, bones, limbs, etc., that define the form of the fowl, begins relatively late, and only gradually conceals the outlines of the internal parts.

Figs. 121 to 124 illustrate the development of the external

form from three days sixteen hours to ten days. In Fig. 121 A (three days sixteen hours) the form of the head is defined by the brain, eyes, and visceral arches. The cervical flexure is strongly marked. There is no neck. The heart makes a large protuberance immediately behind the head. The limb-buds are rounded swellings. In Fig. 121 B (five days one hour) the cervical flexure is less marked; the enlargement of the mid-brain

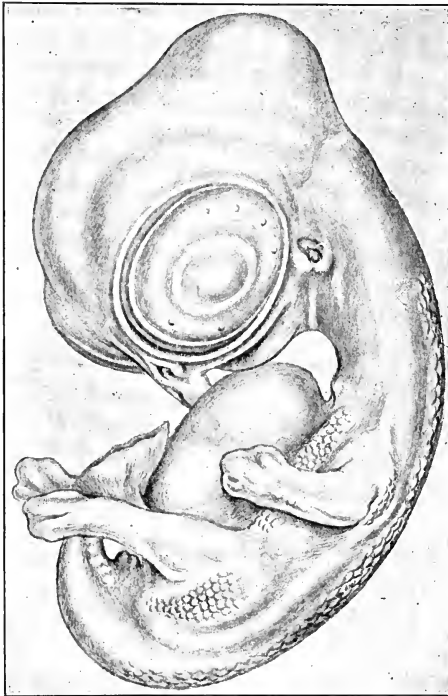


FIG. 122. — Embryo of 7 days' and 7 hours' incubation x 5. (After Keibel and Abraham.)

makes a more pronounced protuberance of the head in this region; the heart has retreated farther back into the thorax, and the neck is thus indicated. The main divisions of the limbs are beginning to appear. In Fig. 122 (seven days seven hours) there are marked changes: The cervical flexure is practically lost. The elevation of the head and retreat of the heart into the thorax have produced a well-marked neck. The upper

portion of the first visceral cleft alone is visible as the external auditory meatus; the other visceral arches and clefts have practically disappeared, excepting the mandibular arch, forming the lower jaw. The abdominal viscera begin to protrude. Feather germs have appeared in definite tracts. In the next stage, Fig. 123 (eight days), the contours of the body are decidedly bird-

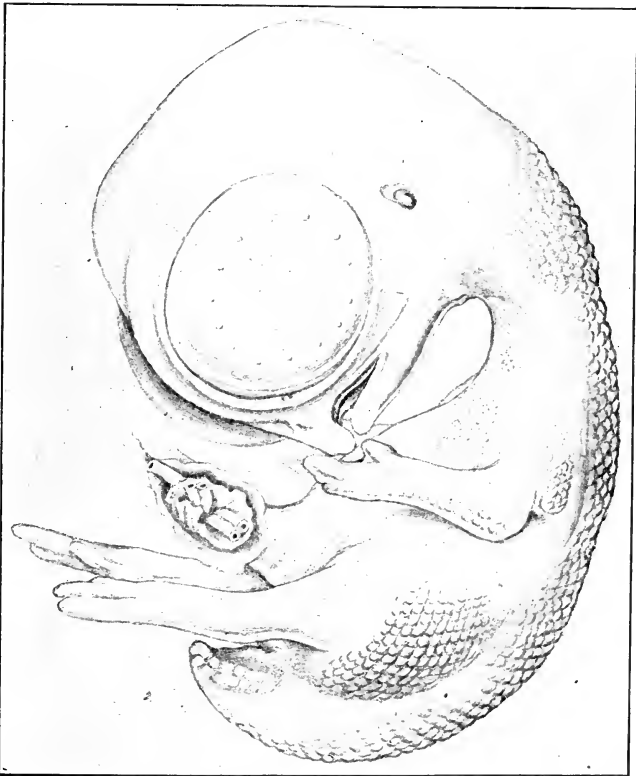


FIG. 123. — Embryo of 8 days x 5. (After Keibel and Abramam.)

like; the fore-limbs are wing-like. The contours of the head are much smoother, and determined more by the development of the facial region and skull than by the brain. The protuberance of the ventral surface caused by the viscera is strongly marked. Fig. 124 finally shows a ten-day embryo.

Head. The embryonic development of the head depends on the changes in three important classes of organs, together with

their supporting and skeletal structures and accessory parts: (a) the central nervous system, (b) the organs of special sense, and (c) the visceral organs, mouth and pharynx. The origin of all these parts has been considered, and it is proposed to take




FIG. 124. — Embryo of 10 days and 2 hours x 5. (After Keibel and Abraham.)

up here only the development of the external form of the head. The preceding section gives an account sufficient for our present purposes, except in the case of the facial region. At four days this region appears as follows (Fig. 125): the mouth is a large, ill-defined opening, bounded behind by the mandibular arches,

at the side by the maxillary processes, and in front by the naso-frontal process, which is a broad projection below the cerebral hemispheres overhanging the mouth. On each side of the naso-frontal process are the olfactory pits, the cavities of which are continuous with the oral cavity. Lateral to the olfactory pits are the external nasal processes, abutting against the eye and separated from the maxillary process by the lachrymal groove. The portion of the naso-frontal process bounding the olfactory pits on the median sides may be called the internal nasal process.

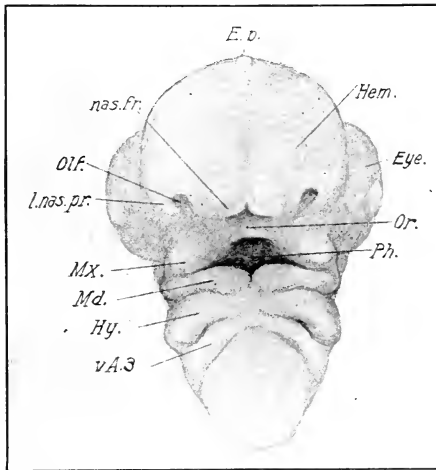


FIG. 125. — Head of an embryo of 4 days' incubation, from the oral surface (N. L. 6 mm.)

Ep., Epiphysis. Hem., Cerebral hemisphere. Hy., Hyoid arch. l.nas.pr., Lateral nasal process. Md., Mandibular arch. Mx., Maxillary process. nas.fr., Naso-frontal process. Olf., Olfactory pit. Or., Oral cavity. Ph., Pharynx. v. A. 3, Third visceral arch.

During the fourth and fifth days a fusion is gradually formed between the internal nasal process on the one hand, and the external nasal and maxillary processes on the other (Fig. 126), thus forming a bridge across the open mouth of the olfactory pits and dividing the openings in two parts, one within the oral cavity, which becomes the internal nares or choanæ, and one without, which becomes the external nares or nostrils. During the same time the whole naso-frontal process begins to project

forward to form the tip of the upper jaw. The two mandibular arches have also fused in the middle line and begin to project forward to form the lower jaw. This projection of upper and lower jaw causes a great increase in the depth of the oral cavity (Fig. 148).

The upper jaw is thus composed of three independent parts: viz., the median part formed from the naso-frontal process and

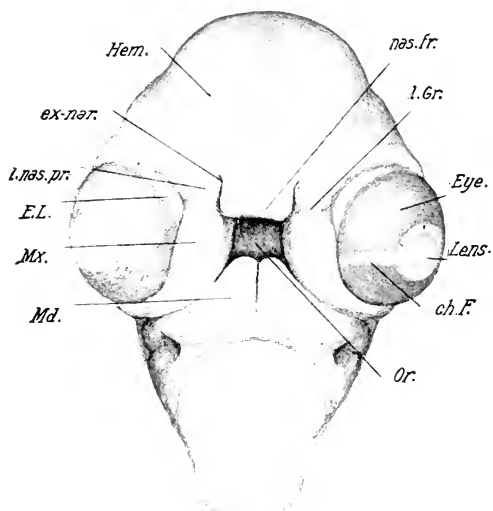


FIG. 126. — Head of an embryo of about 5 days from the oral surface. (N. L. 8 mm.)

ch. F., Choroid fissure. E. L., Eye-lid (nictitating membrane). ex. nar., External nares. l. Gr., Lacrymal groove. Other abbreviations as before.

the two lateral parts formed from the maxillary processes. The former becomes the intermaxillary and the latter the maxillary region.

II. EMBRYONIC MEMBRANES

General. The extension of the blastoderm over the surface of the yolk goes on very rapidly up to the end of the fourth day of incubation (Fig. 33), at which time there is left a small circumscribed area of uncovered yolk, that may be called the umbilicus of the yolk-sac, which remains uncovered for a long time. Its final closure is associated with the formation of the albumen-sac.

The splitting of the mesoblast of the blastoderm is never complete; but on the contrary the undivided margin begins to thicken after the fourth day, and gradually forms a ring of connective tissue that surrounds the umbilicus of the yolk-sac (Figs. 128 and 129). When this ring closes, about the seventeenth day, it forms a mass of connective tissue uniting the yolk-sac and albumen-sac. (See below.)

During the first few days of incubation the albumen loses water rapidly, and becomes more viscid, settling, as this takes place, towards the yolk-sac umbilicus. Thus the amniotic sac containing the embryo lies above; beneath the amniotic sac comes the yolk, and the main mass of the albumen lies towards the caudal end of the embryo (Figs. 128 and 129).

The allantois expands very rapidly in the extra-embryonic body-cavity, and the latter extends by splitting of the mesoblast into the neighborhood of the yolk-sac umbilicus. When the allantois in its expansion approaches the lower pole of the egg, it begins to wrap itself around the viscid mass of the albumen accumulated there. In so doing, it carries with it a fold of the chorion, as it must do in the nature of the case, and thus the albumen mass begins to be surrounded by folds of the allantois with an intervening layer of the duplicated chorion. These relations will be readily understood by an examination of the accompanying diagrams (Figs. 128 and 129). In this way an albumen-sac, which rapidly becomes closed, is established outside of the yolk-sac, and the two are united by the undivided portion of the mesoblast around the yolk-sac umbilicus. This connection is never severed, and in consequence the remains of the albumen-sac is drawn with the yolk-sac into the body-cavity towards the end of incubation.

The sero-amniotic connection, which persists throughout incubation, has an important effect on the general disposition of the embryonic membranes. It is formed, as we have seen, in the closure of the amnion, by the thickened ectoderm of the suture; this ectodermal connection is, however, absorbed and replaced on the fifth to the seventh days by a broad mesodermal fusion, which maintains a permanent connection between amnion and chorion. One important result of this relation is that the albumen-sac, which is formed by the duplication of the chorion, is prolonged by a tubular diverticulum to the sero-amniotic

plate (see Figs. 128 and 129). The latter becomes perforated after the eleventh day, and there is thus direct communication between the albumen-sac and the amniotic cavity. Hirota

FIGS. 127, 128, and 129. — Diagrams of the relations of the embryonic membranes of the chick, constructed from preparations, and from figures and descriptions of Duval, Hans Virchow, Hirota and Fülleborn. In these figures the ectoderm and entoderm are represented by plain lines: The mesoderm by a cross-hatched line or band. The yolk-sac is represented by broken parallel lines. In Fig. 127 the allantois is represented as a sac. In Figs. 128 and 129, where it is supposed to be seen in section, its cavity is represented by unbroken parallel lines. The stalk of the allantois is exaggerated in all the diagrams to bring out its connection with the embryo. The actual relations of the stalk are shown in Figures 33 and 82.

Alb., Albumen. Alb. S., Albumen-sac. All., Allantois. All. I., Inner wall of the allantois. All. C., Cavity of allantois. All. S., Stalk of allantois. All. + Am., Fusion of allantois and amnion. Am., Amnion. Am. C., Amniotic cavity. Chor., Chorion. C. T. R., Connective tissue ring. Ect., Ectoderm. E. E. B. C., Extra-embryonic body-cavity. Ent., Entoderm. Mes., Mesoderm. S.-Am., Sero-amniotic connection. S. Y. S. U., Sac of the yolk-sac umbilicus. Umb., Umbilicus. V. M., Vitelline membrane. Y. S. S., Septa of the yolk-sac.

FIG. 127. — Fourth day of incubation. The embryo is surrounded by the amnion which arises from the somatic umbilicus in front and behind; the sero-amniotic connection is represented above the tail of the embryo; it consists at this time of a fusion of the ectoderm of the amnion and chorion. The allantois is represented as a sac, the stalk of which enters the umbilicus behind the yolk-stalk; the allantois lies in the extra-embryonic body-cavity, and its mesoblastic layer is fused with the corresponding layer of the chorion above the embryo. The septa of the yolk-sac are represented at an early stage. The splitting of the mesoderm has progressed beyond the equator of the yolk-sac, and the undivided portion is slightly thickened to form the beginning of the connective tissue ring that surrounds the yolk-sac umbilicus. The ectoderm and entoderm meet in the zone of junction, beyond which the ectoderm is continued a short distance. The vitelline membrane is ruptured, but still covers the yolk in the neighborhood of the yolk-sac umbilicus. The albumen is not represented in this figure.

FIG. 128. — Ninth day of incubation. The yolk-sac umbilicus has become much narrowed; it is surrounded by the mesodermal connective tissue ring, and by the free edges of the ectoderm and entoderm. The vitelline membrane still covers the yolk-sac umbilicus and is folded into the albumen. The allantois has expanded around the amnion and yolk-sac and its outer wall is fused with the chorion. It has pushed a fold of the chorion over the sero-amniotic connection, into which the mesoderm has penetrated, and thus forms the upper fold of the albumen-sac. The lower fold of the albumen-sac is likewise formed by a duplication of the chorion and allantois; it must be understood that lateral folds are forming also, so that the albumen is being surrounded from all sides.

The stalk of the allantois is exaggerated so as to show the connection of the allantois with the embryo; it is supposed to pass over the amnion, and not through the cavity of the latter, of course.

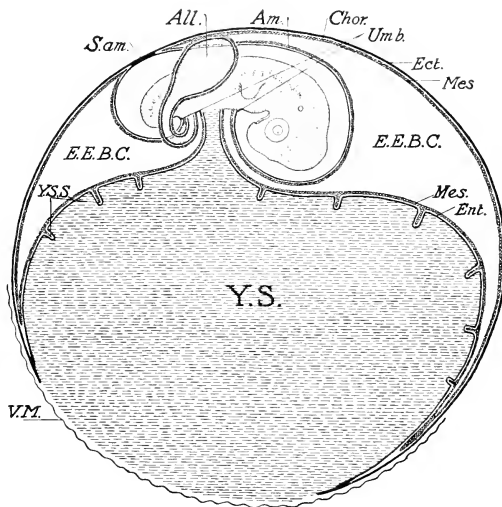


FIG. 127

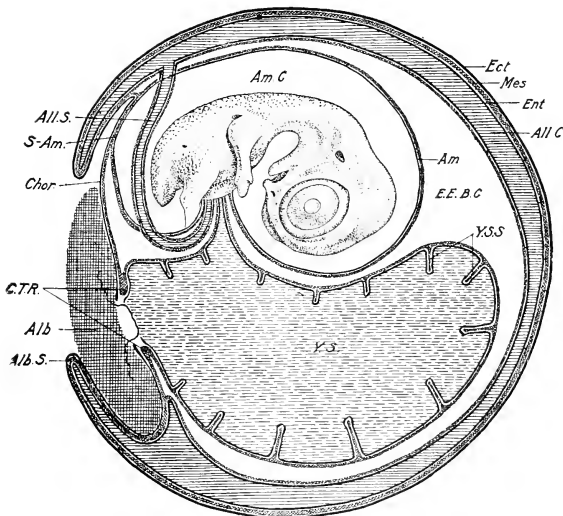


FIG. 128

states that, after this connection is established, the amniotic fluid coagulates in alcohol, "just like the fluid in the albumen-sac; owing, presumably, to the presence of albumen which has found its way through the perforations into the amniotic fluid." This observation is confirmed by Fülleborn.

The Allantois. The part of the wall of the allantois that fuses with the chorion may be called the outer wall; the remainder of the sac of the allantois constitutes the inner wall. The distal intermediate part of the allantois is specialized with the chorion as the wall of the albumen-sac.

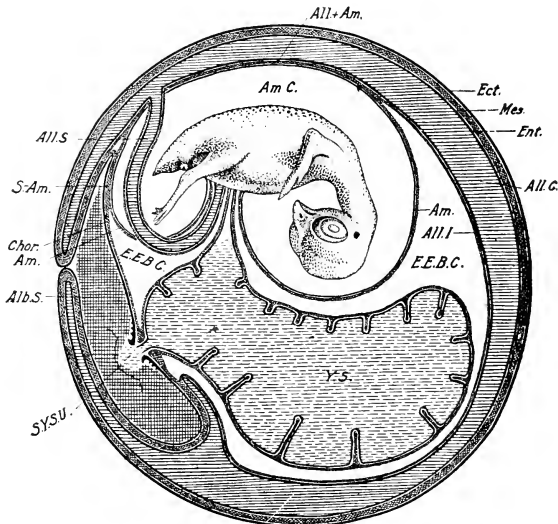


FIG. 129. — Twelfth day of incubation. The conditions represented in Fig. 128 are more advanced. The albumen-sac is closing; its connection with the cavity of the amnion by way of the sero-amniotic connection will be obvious. The inner wall of the allantois has fused extensively with the amnion. The umbilicus of the yolk-sac is much reduced, and some yolk protrudes into the albumen (sac of the yolk-sac umbilicus).

In the outer wall there are three layers, viz., an internal epithelial layer, formed by the entoderm of the allantois; a thick very vascular middle or mesodermal layer, formed by fusion of the mesoblast of allantois and chorion; and a thin, outer, ectodermal layer derived from the chorion.

Rate of Growth of the Allantois. As the embryo lies on its left side, the allantois grows out on the right side of the embryo (Figs. 127 and 130 A) and unites with the chorion about the one hundredth hour. It then spreads rapidly as a flattened sac over the embryo, increasing the extent of the fusion with the

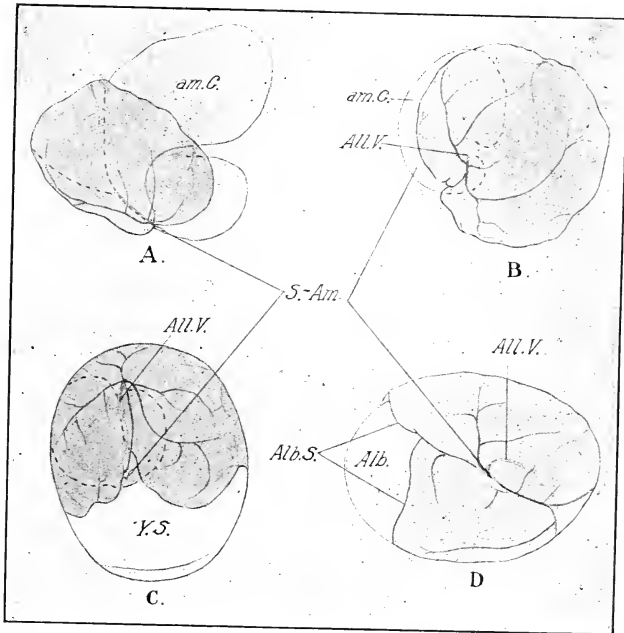


FIG. 130. — Diagrams showing the relations of the allantois, represented by the tinted area, at different ages. (After Hirota.)

Alb., Albumen. Alb. S., Edge of albumen-sac. All. V., Allantoic vein. am. C., Amniotic cavity. S.-Am., Sero-amniotic connection. Y. S., Yolk-sac.

A. At 120 hours showing only the amniotic cavity and allantois x 2.

B. At 144 hours, showing only the amniotic cavity and allantois x 1.2.

C. At 192 hours; the entire yolk x .66. The dotted outline represents the amniotic cavity.

D. At 214 hours. The entire egg after removal of the shell, x .66. The albumen mass is at the left; the albumen-sac is beginning to form.

chorion, hence of its outer wall *pari passu*. At the end of the fifth day it covers more than half of the embryo (Fig. 130 A); at the end of the sixth day the embryo is entirely covered by

the allantois (Fig. 130 B); at the end of the eighth day the allantois has covered half of the yolk-sac (Fig. 130 C). At the end of the ninth day, the formation of the albumen-sac is begun (Fig. 130 D). At the end of the eleventh day, the albumen-sac is practically closed at the lower pole. On the twelfth day, the albumen-sac is closed, and on the sixteenth day the contents are practically entirely absorbed.

Blood-supply of the Allantois. There are two allantoic (umbilical) arteries and one allantoic vein. (See Chap. XII.) Both arteries persist throughout the period of incubation, but the left is much the better developed. It passes out along the stalk of the allantois to the inner wall of the allantoic sac, where it divides in two strong branches, one running cephalad and the other caudad to the margins of the sac where they pass over to the outer wall; The allantoic vein runs in the inner wall and passes over to the outer wall near the sero-amniotic connection. Both arteries and veins inhibit the expansion of the allantoic sac where they surround the margin; but the vein has by far the greatest effect, as its action is supplemented by the sero-amniotic connection. Thus indentations, gradually growing deeper, are established along the margins of the allantoic sac, and the outgrowth of the latter on each side of the indentations produce overlapping lobes (Figs. 130 C and D).

The arrangement of the smaller vessels and capillaries is very different in the outer and inner walls. In the outer wall the arteries and veins branch and interdigitate in the deeper portions of the mesoblast, and end in an extraordinarily fine-meshed capillary network situated immediately beneath the thin ectoderm. "The capillaries form such narrow meshes, and have relatively so wide a lumen, that they can be compared only with those of the lungs of higher animals, and of the choroidea of the eye; indeed, instead of describing it as a vascular network embedded in tissue, one could as well describe it as a great blood-sinus interrupted by strands of tissue" (Fülleborn.) This capillary network of the outer wall constitutes the respiratory area of the allantois. At the margins it passes gradually into the incomparably wider meshed capillary network of the inner wall. An extensive system of lymphatics is developed, both in the outer and inner walls of the allantois, accompanying all the blood-vessels, even to their ultimate terminations.

Structure of the Allantois. (1) *Inner wall.* The inner wall of the allantois consists primarily of two layers, an inner entodermal and outer mesodermal layer. The latter soon becomes differentiated into two layers, an external, delicate, limiting layer of flat polygonal cells, with interlocking margins, and an intermediate layer of star-shaped cells embedded in a homogenous mucous ground substance. Parts of the inner wall become extremely thin, and in these regions the intermediate layer may become entirely absent. Elsewhere, particularly around the larger arteries and veins, the intermediate layer may attain considerable thickness. The entoderm becomes reduced to a layer of flat, interlocking cells. On the eighth day, spindle-shaped muscle cells begin to appear in the mesoderm of the inner wall, and undergo rapid increase in numbers. Their distribution is somewhat irregular; in certain places they may even form several layers, and in others are practically wanting.

On the seventh day the inner wall of the allantois begins to fuse with the amnion in the neighborhood of the sero-amniotic connection, and this fusion rapidly extends over the area of contact between the two membranes. Within the area of fusion the muscle layers of the allantois and amnion mutually reinforce each other, and in places no boundary can be found between them (Fülleborn). But during the latter half of incubation the musculature of the fused area of allantois and amnion degenerates almost completely.

Towards the end of incubation, part of the inner wall of the allantois fuses also with the yolk-sac, and is therefore carried with the latter into the body-cavity of the chick.

(2) *The Outer Wall of the Allantois.* As already noted, the outer wall of the allantois fuses with the chorion. The compound membrane, which is respiratory in function, must be considered, therefore, as one. Over the entire respiratory area the ectoderm, belonging primarily to the chorion, which is elsewhere two layers of cells in thickness, becomes reduced to an exceedingly thin layer in direct contact with the walls of the capillaries internally and the shell membrane externally. According to Fülleborn, the ectoderm cannot be distinguished as a separate layer in the latter half of incubation, and the capillaries appear to be in immediate contact with the shell-membrane. No muscular tissue appears to develop in the outer wall of the allantois.

(3) *The Albumen-sac.* The allantois in the course of its expansion over the embryo, between amnion and chorion, reaches the sero-amniotic connection; it must then either divide and grow round on each side of the connection, or evaginate the chorion above the connection and carry it as an overlapping fold on beyond. The latter is what actually happens, and there is established as a consequence an overlapping fold of the chorion containing an extension of the allantois (Fig. 128); the space beneath this fold terminates, naturally, at the sero-amniotic connection. In the meantime the cleavage of the mesoblast has separated chorion and yolk-sac as far as the neighborhood of the yolk-sac umbilicus, where the viscid albumen has accumulated. The latter is situated not opposite to the yolk-stalk, but near the posterior pole of the yolk-sac, with reference to the embryo, *i.e.*, usually towards the narrow end of the shell. Now the allantois growing around the yolk-sac from all sides reaches the neighborhood of the albumen and enters an evagination of the chorion that wraps itself around the albumen, thus initiating the formation of a double sac of the chorion enfolding the albumen and containing between its two layers an extension of the allantois. The latter is therefore separated everywhere from the albumen by the thickness of the chorion. The superior fold of the albumen-sac is the same fold that overgrows the sero-amniotic connection, and the albumen-sac is therefore prolonged beneath this fold to the sero-amniotic connection itself, which, as we have seen, becomes perforated, thus admitting albumen into the amniotic cavity.

The ectoderm lining the albumen-sac is two-layered, and the cells next the albumen tend to be cubical or swollen, and frequently vesicular, owing apparently to absorption of albumen. In the neighborhood of the yolk-sac umbilicus, papilla-like projections of the ectoderm into the albumen are common (Fig. 129). But these do not occur over the remainder of the albumen-sac of the chick, as described by Duval for the linnet; nor do they possess a mesodermal core.

Prior to the union of the mesoderm over the yolk-sac umbilicus, the yolk forms a hernia-like protrusion into the albumen-sac (sac of the yolk-sac umbilicus, see Fig. 129), which is, however, retracted as the mesoderm ring closes over the yolk-sac umbilicus. The vitelline membrane ruptures at an early period of the incu-

bation over the embryonic pole and gradually slips down over the yolk, and is finally gathered together in the albumen-sac.

(4) The allantois also serves as a reservoir for the secretions of the mesonephros, and subsequently the permanent kidney, which reach it by way of the cloaca and neck of the allantois. The fluid part of the embryonic urine is absorbed, but the contained salts are deposited in the walls and cavity of the allantois. If the connection between the Wolffian ducts and cloaca be interrupted, the former become enormously extended by the secretions of the mesonephros.

The Yolk-sac. The yolk-sac is established in the manner already described; it is constituted by the extra-embryonic splanchnopleure, and is permanently united to the intestine by the yolk-stalk. A narrow lumen remains in the stalk of the yolk-sac throughout, and even after, incubation, but the yolk does not seem to pass through it into the intestinal cavity. The walls of the yolk-sac, excepting the part derived from the pellucid area, are lined with a special glandular and absorbing epithelium, which digests and absorbs the yolk and passes it into the vitelline circulation, through which it enters the hepatic portal circulation and comes under the influence of the hepatic cells. The yolk-sac is thus the primary organ of nutrition of the embryo, and it becomes highly elaborated for the performance of this function. Contrary to the statements found in many text-books, it does not reach its maximum development until the end of incubation. Throughout incubation it steadily increases in complexity and efficiency so as to provide for the extremely rapid growth of the embryo.

The functions of the yolk-sac manifestly require a large surface area, which is provided for by foldings of the wall projecting into the yolk. At the height of its development the inner surface of the yolk-sac is covered with numerous folds or septa projecting into the yolk, which are highest at the equator and decrease in both directions away from the equator. In general, these folds follow the direction of the main arteries, *i.e.*, they run in a meridional direction, repeatedly bifurcating distally (Fig. 132). Moreover, each one is perforated by numerous stomata, and the yolk-sac epithelium covers all free surfaces, and a capillary network is found in every part. So far do they project into the interior towards the close of incubation, that those of opposite

sides may be approximately in contact, and the cavity of the yolk-sac is thus broken up into numerous connecting compartments filled with yolk. The outer wall of the yolk-sac is smooth and not involved in the folds. The beginning of the folds of the yolk-sac may be found at the time of appearance of the vascular area of the blastoderm, and they develop *pari passu*, with the vessels of the yolk-sac (Fig. 131).

Fig. 131 shows the appearance of the folds at the stage of twelve somites. It is a view of the blastoderm from below,

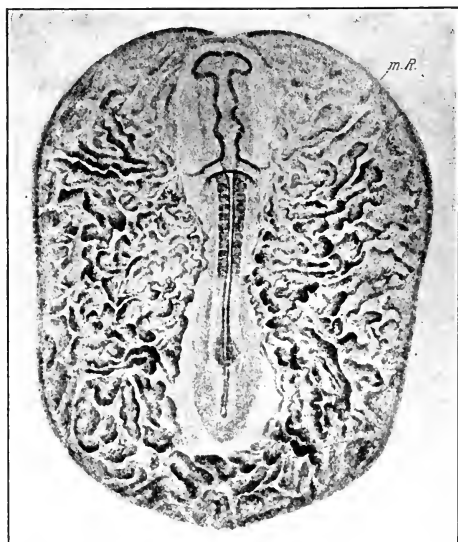


FIG. 131. -- Septa of the yolk-sac as seen on the lower surface of the blastoderm at the stage of 12 s. (After Hans Virchow.)

m. R., Marginal ridge of entoderm overlying the sinus terminalis.

drawn as an opaque object, and it shows the incipient folds of the yolk-sac in an arrangement that corresponds roughly, but not accurately, with that of the blood-islands, which lie in large part in the bases of the folds. The site of the vena terminalis is marked by a circular fold of the entoderm. The folds of the yolk-sac thus coincide in their distribution with the vascular area and are so limited at all times, being absent in the vitelline blood-

vessels and the folds of the yolk-sac, which will be considered more fully beyond.

The interior of the yolk-sac is lined with entoderm which differs in its structure in different regions: In the area pellucida the cells are flattened; in the vascular zone of the area opaca are found the columnar cells with swollen ends described previously. After the third or fourth day these are found filled with yellow fatty droplets, which give a yellow tone to the interior of the living yolk-sac, and which are so abundant in later stages as to render the layer perfectly opaque. These cells do not con-

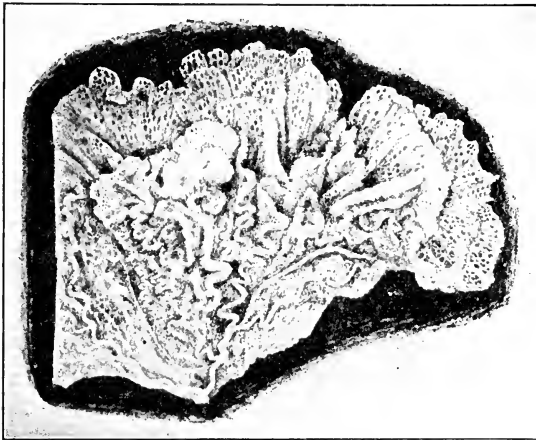


FIG. 132. — Part of the interior of the yolk-sac of a duck at the time of hatching. In the upper part of the figure the septa are seen from the side showing the stomata. In the lower part they are seen on edge. Note the sinuous course of the arteries along the free edges of some of the septa. (After H. Virchow.)

tain entire yolk-granules; apparently, then, the yolk-granules are digested before absorption in this region. In the region of the inner zone of the vitelline area, the entoderm is composed of several layers of large cells containing yolk-granules, constituting the germ-wall, and in the outer vitelline zone we come to the periblast. The germinal wall and inner zone of the vitelline area represent the formative region of the yolk-sac epithelium in the manner already described (Chap. V).

Blood-vessels of the Yolk-sac. The development of the circu-

lation in the yolk-sac may be divided into the following stages (following Popoff):

1. Indifferent network bounded peripherally by the vena terminalis, connected by two anterior vitelline veins with the heart; no arterial trunks.

2. Origin of an arterial path in the network; the right anterior vitelline vein begins to degenerate.

3. Origin of intermediate veins; the (left) posterior vein begins to develop.

4. Development of collateral veins; further degeneration of the right anterior vein; complete formation of the posterior vein.

5. Further branching; development of a rich venous network; the vena terminalis begins to degenerate.

6. Definitive condition; development of a rich venous network in the folds or septa of the yolk-sac; anastomosis of vessels of the yolk-sac and allantois.

The changes can be followed only in outline. The earliest condition has been described in Chapters IV and V. Fig. 133 shows a condition intermediate between stages 1 and 2 above. The network is entirely arterial, except towards the anterior end, *i.e.*, the blood flows outwards away from the heart. It enters the vena terminalis and is returned by right and left anterior vitelline veins to the heart. The beginning of arterial trunks in the network is indicated particularly on the left side (right side of the figure). The connection of the arterial network with the dorsal aorta is still net-like.

Fig. 134 shows an advance of the same processes. The trunks of the vitelline arteries are better differentiated from the network, and the blood is still returned to the heart entirely by way of the vena terminalis and the right and left anterior vitelline veins, which have come in contact distally, circumscribing in their proximal parts the mesoderm-free area of the blastoderm. The beginning of the lateral vitelline veins is indicated, particularly on the right side (left of the figure).

Fig. 135 represents a great advance. The vitelline arteries arise from the dorsal aortæ as single trunks, and branch in the vascular network, some of them reaching as far as the vena terminalis. The two anterior vitelline veins have fused in front, and the right anterior vein is reduced in size so that most of the blood reaches the heart through the left anterior vein. But the



FIG. 133. -- Circulation in the embryo and the yolk-sac. Stage of about 16 s; from below. The vitelline arteries are beginning to differentiate out of the vascular network particularly on the left side. (Observer's right.) Injected. (After Popoff.)

1, Marginal vein. 2, Region of venous network. 3, First and second aortic arches. 4r, 4l, Right and left anterior vitelline veins. 5, Heart. 6, Anterior intestinal portal. 7, Aortæ. 8, Vitelline arteries in process of differentiation. 9, Blood islands.




FIG. 134. — Circulation in the embryo and the yolk-sac at the stage of about 22 s, drawn from below. Note differentiation of branches of the vitelline arteries. Injected. (After Popoff.)

1, Marginal vein. 2, Region of venous network. 3, Carotid loop. 4 r, 4 l, Right and left anterior vitelline veins. 5, Heart. 6, Anterior intestinal portal. 7, Dorsal aorta. 8, Branches of vitelline arteries.

most striking change is the transformation of part of the vascular network into channels in which the blood flows towards the heart. Of these there may be recognized the following: 1. Intermediate veins arising from the vena terminalis at various places and gradually losing themselves centrally in the vascular network. 2. The vascular network immediately behind the embryo has assumed a venous character and likewise a large part of the network immediately surrounding the embryo. 3. Lateral vitelline veins are beginning to develop from the anterior intestinal portal backwards.

Fig. 136, representing the circulation at a stage of about 40 somites, shows the completion of the primary circulation in the yolk-sac. The vitelline arteries branch richly, and end in a capillary network; very few arterial branches reach the vena terminalis as such, and then only very fine ones. The vena terminalis itself is relatively reduced; the lateral vitelline veins have absorbed the network between themselves and the intermediate veins, which now appear as prolongations of the lateral veins. The right anterior vitelline vein has disappeared almost entirely and the posterior vitelline vein is well developed, emptying into the left lateral vein.

The lateral vitelline arteries and veins are superposed as far peripherally as the original intermediate veins, which lie between the arterial trunks. Wherever there is superposition of arteries and veins, the latter are superficial and the former deep in position *as seen from above*. The figure also shows the vascular network in the budding allantois, and some of the embryonic blood-vessels.

In the later stages of development the arteries are carried in by the septa of the yolk-sac and lie near their free edges; the veins, on the other hand, remain superficial in position. The terminal vein becomes progressively reduced in importance up to about the tenth day, and then gradually disappears as such, being taken into the terminal capillaries. After the tenth day the anterior and posterior vitelline veins decrease in importance and finally become almost unrecognizable. The lateral veins, on the other hand, increase in importance and return all of the blood to the embryo.

The rich network of venous capillaries in the septa of the yolk-sac is shown in Fig. 137. It lies immediately beneath the

epithelium over the entire extent of the septa and forms loops along the free border. The arteries do not communicate directly with this network according to Popoff, and the course of the circulation from arteries to veins is not clearly described by this author.

The allantois fuses with the yolk-sac in the region of the yolk-sac umbilicus, and anastomoses arise between the veins of the allantois and those of the yolk-sac.

Ultimate Fate of the Yolk-sac. On the nineteenth day of incubation, the yolk-sac slips into the body-cavity through the umbilicus; which thereupon closes. The mechanism of this process is of considerable interest. The yolk-sac is still a voluminous organ, and equal to about one sixth the weight of the embryo. It is therefore inconceivable that it could be "drawn into" the body-cavity by means of its stalk, which has only the intestine for attachment. The process is much more complex and may be briefly described as follows: We have already seen that the inner wall of the allantois fuses with the amnion on the one hand; distally it is connected with the yolk-sac. Now this wall of the allantois is muscular, and it is probable that its contraction is the first act in the inclusion of the yolk-sac within the body-wall. It is aided in this, however, by the inner wall of the amnion, *i.e.*, that part of the amnion arising from the umbilicus and not fused with the allantois. This part of the amnion surrounds the yolk-stalk, and is itself richly provided with muscle cells, forming a crossing and interlacing system. It is carried down and over the yolk-sac to about its equator by the allantois, and when the yolk-sac is half taken into the body-cavity, it reaches its distal pole and fuses there. Now if the egg be opened at this stage in the process and this wall of the amnion cut through, it contracts rapidly to a fraction of its former area (Virchow). It is apparent, then, that the tension of this membrane on the yolk-sac must exert a continuous pressure that tends to force it into the body-cavity. It is in this way, then, by contraction of the inner walls of the allantois and of the amnion, that the yolk-sac is pressed into the body-cavity.

The umbilicus is therefore closed by the mere act of inclusion of the yolk-sac, for the inner amniotic wall is attached on the one hand to the body-wall, and on the other to the distal pole of the yolk-sac. A minute opening is left in the center of the

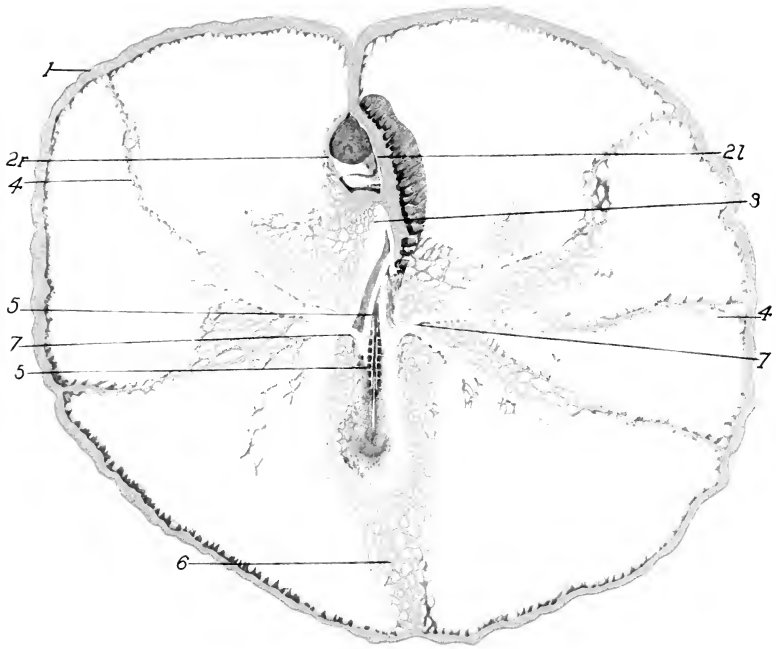


FIG. 135. — Circulation in the embryo and yolk-sac after 74 hours' incubation. Stage of about 27 s from below. Injected. (After Popoff.)

1, Marginal vein. 2 r, 2 l, Right and left anterior vitelline veins surrounding the mesoderm-free area. 3, Anterior intestinal portal. 4, Intermediate veins connecting with the venous network centrally. 5, Right dorsal aorta. 6, Posterior vitelline vein in process of formation. 7, Vitelline arteries.

Note that the right anterior vitelline vein (2 r) is much atrophied.

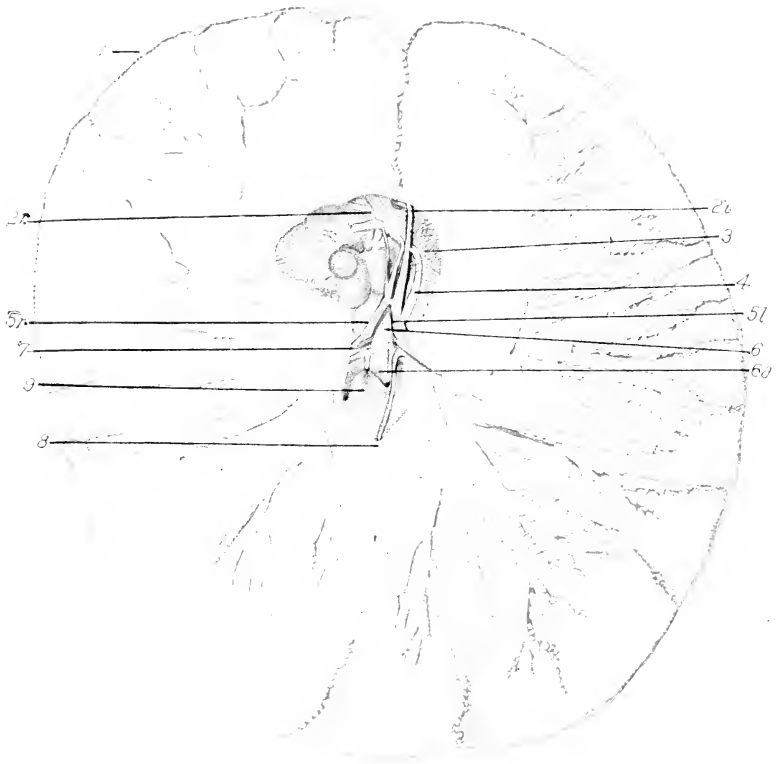


FIG. 136. — Circulation in the embryo and yolk-sac of an embryo of about 40 s, showing the later development of the lateral and intermediate vitelline veins. Reduction of vena terminalis (marginal vein). Almost complete atrophy of the right anterior vein. Injected. (After Popoff.)

1, Marginal vein. 2 r, 2 l, Right and left anterior vitelline veins. 3, Arch of aorta. 4, Left posterior cardinal vein. 5 r, 5 l, Right and left omphalomesenteric veins. 6, Aorta. 6 a, Left dorsal aorta. 7, Vitelline artery. 8, Posterior vitelline vein. 9, Vascular network in the allantois.

umbilical field, through which dried remnants of the inner wall of the allantois, which is likewise attached to the distal pole of the yolk-sac, protrude for a short time. On the inner side the yolk-sac is attached to the umbilicus by its distal pole, and by its stalk to the intestine. The absorption of the yolk-sac then goes on with great rapidity, being reduced from a weight of 5.34 gr. twelve hours after hatching to 0.05 gr. on the sixth day after hatching, according to a series of observations of Virchow.

The Amnion. The amnion invests the embryo closely at the time of its formation, but soon after, fluid begins to accumulate within the amniotic cavity, which gradually enlarges so that the embryo lies within a considerable fluid-filled space, which increases gradually up to the latter part of the incubation, and then diminishes again, so that the embryo finally occupies most of the cavity. The connections of the amnion with the chorion, and later with the allantois, albumen-sac, and yolk-sac, have been already described.

Muscle fibers appear in the walls of the amnion on the fifth or sixth day and gradually increase in number; though they subsequently degenerate over the area of fusion with the allantois. They persist elsewhere, however, and are active in the inclusion of the yolk-sac in the manner already described. Shortly after the appearance of the muscle fibers slow vermicular or peristaltic contractions of the amnion begin, and the embryo is rocked within the amniotic cavity. Apparently, adhesions are thus prevented, but they are sometimes formed and lead to various malformations of the embryo. In some cases the amnion fails to develop; in such cases, the embryo usually dies at a relatively early stage, though Dareste records an anamniotic embryo of thirteen days, apparently full of life and vigor.

The amnion apparently acts first as a protection against all mechanical shocks and jars which are taken up by the fluid; second, by protecting the embryo against the danger of desiccation; third, by protecting it against adhesions with the shell-membrane and embryonic membranes, and lastly by providing space for the expansion of the allantois and consequent increase of the respiratory surface. It also has secondary functions in the chick in connection with the absorption of the albumen and the inclusion of the yolk-sac. It will be readily understood, then, why anamniotic embryos usually do not develop far.

Hatching (*after von Baer*). About the fourteenth day the growing embryo accommodates itself to the form of the egg so as to lie parallel to the long axis with its head usually towards the broad end near to the air-chamber. Sometimes, however, the embryo is turned in the reverse position (*von Baer*). The head is bent towards the breast, and is usually tucked under the right wing. Important changes preparatory to hatching take place on the seventeenth to the nineteenth days. The fluid decreases in the amnion. The neck acquires a double bend so that the head is turned forward, and, in consequence, the beak is towards that part of the membranes next to the air-chamber. The intestine is retracted completely into the body-cavity, and on the nineteenth day the yolk-sac begins to enter the body-cavity. On the twentieth day the yolk-sac is completely included, and practically all the amniotic fluid has disappeared. The chick now occupies practically all the space within the egg, outside of the air-chamber. The umbilicus is closing over. The ductus arteriosi begin to contract, so that more blood flows through the lungs. The external wall of the allantois fused with the chorion still remains very vascular.

Now, if the chick raises its head, the beak readily pierces the membranes and enters the air-chamber. It then begins to breathe slowly the contained air; the chick may be heard, in some cases, to peep within the shell two days before hatching, a sure sign that breathing has begun. But the circulation in the allantois is still maintained and it still preserves its respiratory function. When the chick makes the first small opening in the shell, which usually takes place on the twentieth day, it begins to breathe normally, and then the allantois begins to dry up and the circulation in it rapidly ceases. It then becomes separated from the umbilicus, and the remainder of the act of hatching is completed, usually on the twenty-first day.

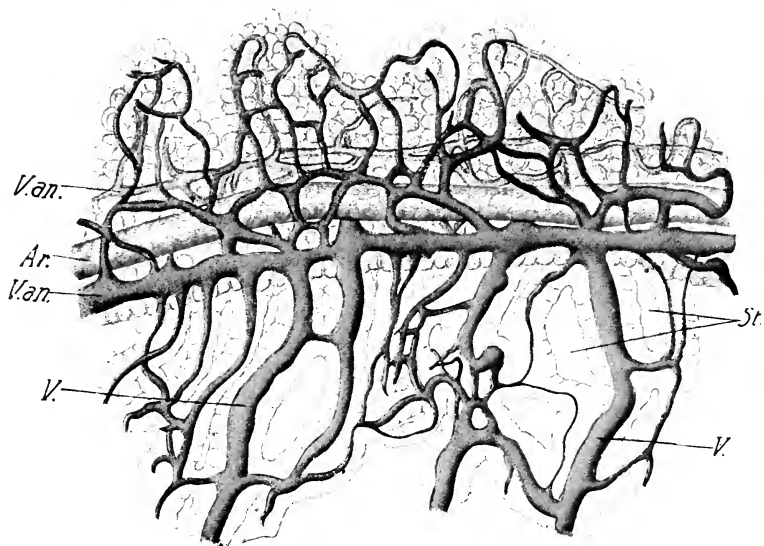


FIG. 137. — Part of a septum of the yolk-sac. Injected. 20 days' incubation. The free edge is above. (After Popoff.)

Ar., Artery. St., Stomata. V. an., Longitudinal anastomoses of venous network. V., vein.

CHAPTER VIII

THE NERVOUS SYSTEM

I. THE NEUROBLASTS

THE account given in Chapters V and VI outlines the origin of the larger divisions of the central nervous system and ganglia. The subsequent growth and differentiation is due to multiplication of cells, aggregation of embryonic nerve-cells, or neuroblasts, in particular regions or centers, the formation and growth of nerve-fibers which combine to form nerves and tracts, and the origin and differentiation of nerve-sheaths, and the supporting cells, neuroglia, of the central system. The most important factors are the origin of the neuroblasts and of nerve-fibers in connection with them; these fibers form the various nerve-tracts and commissures within the central nervous system and the system of peripheral nerves. The origin of neuroblasts and the development of fibers is the clue to differentiation in all parts of the nervous system.

Neuroblasts are found in two primary locations in the embryo; (1) in the neural tube, and (2) in the series of ganglia derived from the neural crest; these are known as medullary and ganglionic neuroblasts respectively.¹

The Medullary Neuroblasts. In the neural tube of the chick, up to about the third day, there are present only two kinds of cells, the epithelial cells and the germinal cells (Fig. 138).

The epithelial cells constitute the main bulk of the walls, and extend from the central canal to the exterior; their inner ends unite to form an internal limiting membrane lining the central canal, and their outer ends to form an external limiting membrane. Each cell in the lateral walls of the tube is much elongated and usually shows three enlargements, viz., at each end and in the region of the nucleus, the cell being somewhat constricted between the nucleus and each end. In different

¹ Neuroblasts arise also in the olfactory epithelium. (See Chap. IX.)

cells the nuclei are at different levels; thus in a section several layers of nuclei appear. These cells are not closely packed together, except at their outer ends, but are more or less separated by intercellular spaces that form a communicating system of narrow channels.

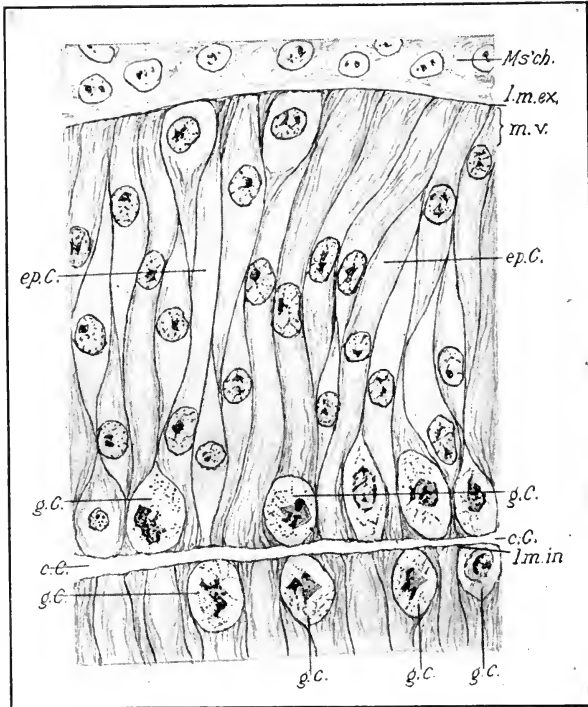


FIG. 138. — Section of the neural tube, 29 s embryo.

c. C., Central canal. ep. C., Epithelial cells. g. C., Germinal cells. l. m. ex., External limiting membrane. l. m. in., Internal limiting membrane. Ms'ch., Mesenchyme. m. v., Marginal velum.

The germinal cells are rounded cells situated next the central canal between the inner ends of the epithelial cells; karyokinetic figures are very common in them. According to His the germinal cells are the parent cells of the neuroblasts alone; it is probable, however, that they are not so limited in function, and that they represent primitive cells from which proceed other epithelial cells and embryonic neuroglia cells as well as neuroblasts.

A narrow non-nucleated margin, known as the marginal velum, appears in the lateral walls of the neural tube external to the nuclei (Fig. 138). This is occupied by the outer ends of the epithelial cells. At this time, therefore, three zones may be distinctly recognized in the walls of the neural tube, viz., (1) the zone of the germinal cells, including also the inner ends of the epithelial cells, (2) the zone of the nuclei of the epithelial cells, (3) the marginal velum. No distinctly nervous elements are yet differentiated.

Such elements, however, soon begin to appear: Fig. 139 represents a section through the cord of a chick embryo of about the end of the third day; it is from a Golgi preparation in which the distinctly nervous elements are stained black, and the epithelial and germinal cells are seen only very indistinctly. The stained elements are the neuroblasts, and it will be observed that they form a layer roughly intermediate in position between the marginal velum and the nuclei of the epithelial cells. They are usually regarded as derived from germinal cells that have migrated from their central position outwards; but it is possible that some of them may have been derived from epithelial cells. However this may be in such an early stage, it is certain that the neuroblasts formed later are derived from germinal cells.

It will be observed that each neuroblast consists of a cell-body and a process ending in an enlargement. The process arises as an outgrowth of the cell-body, and forms the axis cylinder or axone of a nerve-fiber; the terminal enlargement is known as the cone of growth, because the growth processes by which the axone increases in length are presumably located here. It may be stated as an invariable rule that each axone process of a medullary neuroblast arises as an outgrowth, and grows to its

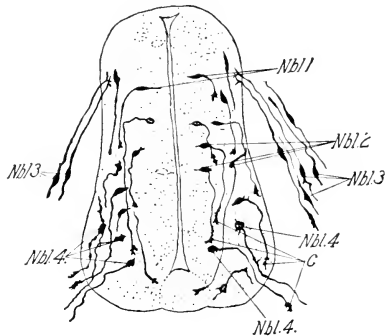


FIG. 139.—Transverse section through the spinal cord and ganglion of a chick about the end of the third day; prepared by the method of Golgi. (After Ramon y Cajal.)

C., Cones of growth. Nbl. 1, 2, 3, 4, Neuroblasts of the lateral wall (1 and 2); of the spinal ganglion (3); of the ventral horn (motor neuroblasts) (4).

final termination without addition on the part of other cells. The body of the neuroblast forms the nerve-cell, from which, later on, secondary processes arise constituting the *dendrites*.

The view that each nerve-cell with its axone process and dendrites is an original cellular individual, is known as the neurone theory. For the central nervous system this view is generally held, but its extension to the peripheral system is opposed by some on the ground that the axone in peripheral nerves is formed within chains of cells, and is thus strictly speaking not an original product of the neuroblast, though it may be continuous with the axis cylinder process of a neuroblast. This view is discussed under the peripheral nervous system.

Each medullary neuroblast is primarily unipolar and the axone is the original outgrowth.

Soon, however, secondary protoplasmic processes arise from the body of the nerve-cell and form the dendrites. These appear first in motor neuroblasts of the ventrolateral portion of the embryonic cord, whose axones enter into the ventral roots of spinal nerves (Fig. 140). The extent and kind of development of these dendritic processes of the nerve-cells varies extraordinarily in different regions; Figs. 139, 140, and 141 give an idea of their rapid development in the motor neuroblasts up to the eighth day.

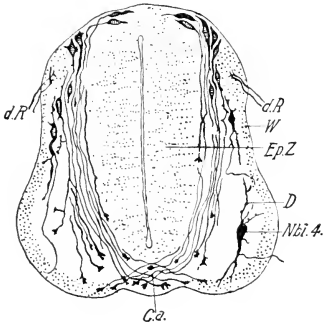


FIG. 140. — Transverse section through the spinal cord of a chick on the fourth day of incubation; prepared by the method of Golgi. (After Ramon y Cajal.)

C. a., Anterior commissure. D., Dendrite. d. R., Dorsal root. Ep. Z., Ependymal zone. W., White matter (marginal velum). Nbl. 4, Neuroblast of the ventral horn (motor).

The Ganglionic Neuroblasts. The ganglionic neuroblasts are located, as the name implies, in the series of ganglia derived from the neural crest. It must not be supposed, however, that all of the cells of the ganglia are neuroblasts, for the ganglia contain, in all probability, large numbers of cells of entirely different function. (Sheath-cells, see peripheral nervous system.) It is probable also that the neuroblasts of the spinal ganglia and some cranial ganglia, at least, are of two original kinds, viz., the neuroblasts of

the dorsal root and of the sympathetic system. The first kind only is considered here, and they are usually called the ganglionic neuroblasts s.s., because they alone remain in the spinal ganglia. Like the medullary neuroblasts these neuroblasts form outgrowths that become axis cylinder processes; but they differ from the latter in that each ganglionic neuroblast forms two outgrowths, one from each end of the spindle-shaped cells, which are arranged with their long axes parallel to the long axis of the ganglion (Fig. 139). Thus we may distinguish a central process and a peripheral process from each neuroblast (Fig. 139); the former corresponds to the axone and the latter to the dendrites of the medullary neuroblast. The central axone enters the dorsal zone of the neural tube, and the peripheral process grows out into the surrounding mesenchyme.

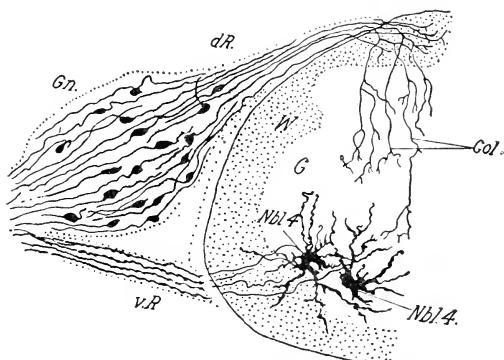


FIG. 141. — Transverse section through the spinal cord of a 9-day chick, prepared by the method of Golgi. (After Ramon y Cajal.)

Col., Colliaterals. d. R., Dorsal root. G., Gray matter. Gn., Ganglion. Nbl. 4, Neuroblast of the ventral horn (motor). v. R., Ventral root. W., White matter.

In the course of the later development the cell-body moves to one side so that the central and peripheral branches appear nearly continuous (Fig. 141). Farther shifting of the cell-body produces the characteristic form of the ganglionic nerve-cell with rounded body provided with stem from which the central and peripheral branches pass off in opposite directions. The central process enters the marginal velum near its dorsal boundary and

there bifurcates, producing two branches, one of which grows towards the head and the other towards the tail in the dorsal

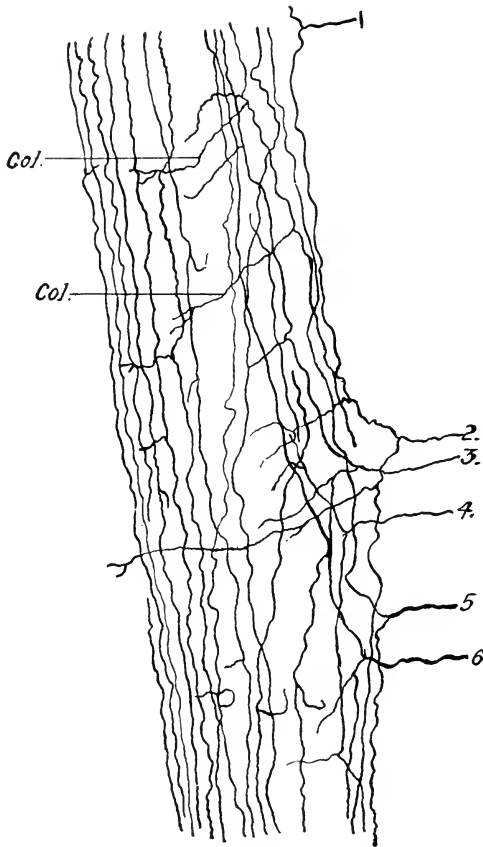


FIG. 142. — Six centripetal axones of the dorsal root, rigorously copied from a good preparation prepared according to the method of Golgi. From a longitudinal and tangential section of the dorsal column of the spinal cord of an 8-day chick. (After Ramon y Cajal.)

Col., Collaterals. 1, 2, 3, 4, 5, 6, the axones entering the cord.

column of the white matter. The ascending and descending branches send off lateral branches, collaterals, which pass deeper into the cord, and ramify in the gray matter of the dorsal horn.

Fig. 142 represents six central processes of ganglionic neuroblasts entering the cord and branching as described.

After this preliminary account of the neuroblasts we may take up the development of the spinal cord, brain, and peripheral nervous system.

II. THE DEVELOPMENT OF THE SPINAL CORD

We have seen that the epithelial cells of the neural tube stretch from the lumen of the central canal to the exterior, and that the nuclei are arranged so as to leave the outer ends free, thus forming the marginal velum.

In the roof and floor the epithelial cells are relatively low, and in the lateral zones much elongated. The epithelial cells are added to at first by transformation of some of the germinal cells; but they do not appear to multiply by division, and as development proceeds they become more and more widely separated, the interstices being filled up by neuroblasts, embryonic glia cells, and fiber tracts. As the wall of the neural tube grows in thickness, the epithelial cells become more and more elongated, seeing that both external and internal connections are retained; and, as the growth takes place mainly external to their nuclear layer, the latter becomes reduced, relative to the entire thickness of the neural tube, to a comparatively narrow zone surrounding the central canal, and is now known as the *ependyma* (Fig. 143). Cilia develop on the central ends of the ependymal cells in the central canal, and from the outer end of each a branching process extends to the periphery anastomosing with neighboring ependymal processes so as to form a skeleton or framework enclosing the other cellular elements and fibers of the central system.

Beginning with the third day a new layer appears between the nuclei of the epithelial cells and the marginal velum. This layer, known as the mantle layer, is composed of neuroblasts and embryonic glia cells, and represents the gray matter (Figs. 140 and 144). The white matter of the cord is laid down in the marginal velum. The sources of the cells composing the mantle layer may be twofold, viz., from the young epithelial cells or from the germinal cells. According to some authors young epithelial cells may be transformed into either neuroblasts or neuroglia cells. Thus the form of the youngest neuroblasts in Fig. 139 indicates derivation from epithelial cells, but this

cannot be regarded as proved. Similarly intermediate stages between epithelial and true glia cells are apparently shown in Fig. 143. However, there can be but little doubt that the principal source of the neuroblasts of the mantle layer is the germinal cells, that migrate outwards between the bodies of the epithelial cells. The germinal cells continue in active division up to at least the eleventh day, and their activity seems sufficient to provide for all the cellular elements of the mantle layer, whereas the epithelial cells apparently do not divide at all. Moreover, mitoses are not infrequent in some cells of the mantle layer itself.

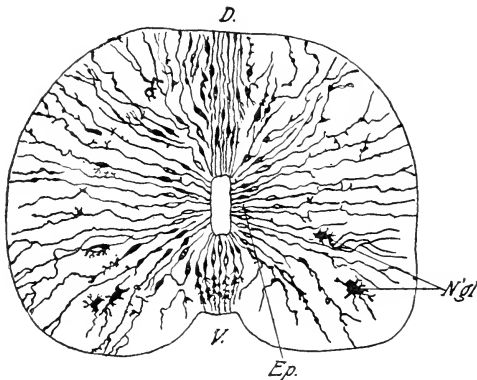


FIG. 143. — Transverse section of the cord of a nine-day chick to show neuroglia and ependymal cells; prepared by the method of Golgi. (After Ramon y Cajal.)

D., Dorsal. Ep., Ependymal cells. N'gl., Neuroglia cells. V., Ventral.

The form of the gray matter in the cord in successive stages is shown in Figs. 144, 145, and 146, representing sections of the cord at five, eight, and twelve days. It will be seen that the gray matter gains very rapidly in importance between the fifth and the eighth days.

Attention should be directed to a group of neuroblasts situated at the external margin of the white matter just above the ventral roots. This is known as Hoffmann's nucleus; it extends the entire length of the cord (Fig. 146, twelve days).

The white matter of the cord gains in importance at an equal rate (Figs. 144, 145, 146). Its production is due to ascending

and descending tracts of fibers derived from medullary and ganglionic neuroblasts. The dorsal and ventral roots of the spinal nerves divide it on each side into three main columns, viz., dorsal situated above the dorsal root, lateral situated between dorsal and ventral roots, and ventral situated below the

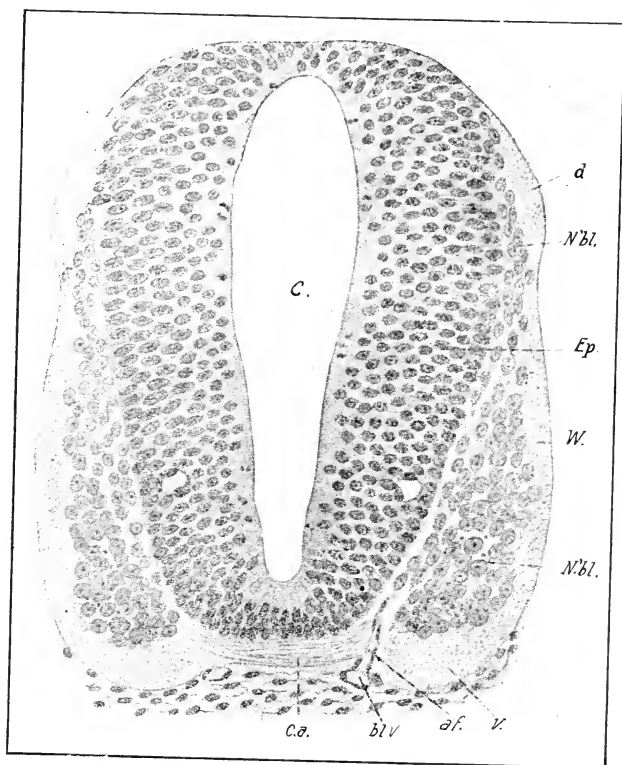


FIG. 144. — Transverse section through the cervical swelling of the spinal cord of a chick, middle of the fifth day. (After v. Kupffer.)

bl. V., Blood vessel. C. a., Anterior commissure. C., Central canal. d., Group of axones at the level of the dorsal root. Ep., Ependyma. N'bl., Neuroblasts. V. Ventral column of white matter.

ventral roots. The dorsal column begins first as a bundle of fibers at the entrance of the fibers of the dorsal root (Fig. 144). Subsequently, other fibers come in this region and gradually extend towards the dorsal middle line, displacing the ependyma

and gray matter (Fig. 145, eight days), but the dorsal columns of the two sides are still separated in the median line by a broad septum of ependymal cells. Later (Fig. 146, twelve days) this septum becomes very narrow, and the accumulation of fibers in the dorsal columns causes the latter to project on each side of the middle line, thus forming an actual fissure between them.

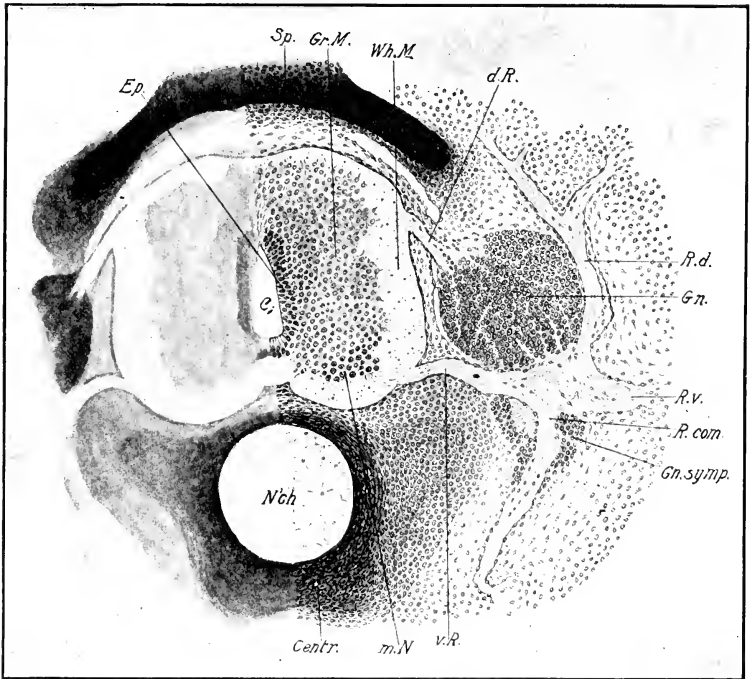


FIG. 145. — Transverse section through the spinal cord, and the eighteenth spinal ganglion of an eight-day chick.

Centr., Centrum of vertebra. d. R., Dorsal root. Ep., Ependyma. Gn., Spinal Ganglion. Gn. symp., Sympathetic ganglion. Gr. M., Gray matter. m. N., Motor nucleus. R. com., Ramus communicans. R. d., Ramus dorsalis. R. v., Ramus ventralis. Sp., Spinous process of vertebra. v. R., Ventral root. Wh. M., White matter.

Central Canal and Fissures of the Cord. The central canal passes through a series of changes of form in becoming the practically circular central canal of the fully formed cord. Up to the sixth day it is elongated dorso-ventrally, usually narrowest in the middle with both dorsal and ventral enlargements. About

the seventh day the dorsal portion begins to be obliterated by fusion of the ependymal cells, and is thus reduced to an ependymal septum. On the eighth day this process has involved the upper third of the canal; the form of the canal is roughly wedge-shaped, pointed dorsally and broad ventrally (Fig. 145). The continuation of this process leaves only the ventral division as the permanent canal.

At the extreme hind end of the cord the central canal becomes dilated to form a relatively large pear-shaped chamber with thin undifferentiated walls (Fig. 148); the terminal wall is still fused with the ectoderm at eight days, and the chamber appears to have a maximum size at this time. At eleven days the fusion with the ectoderm still exists, and the cavity is smaller.

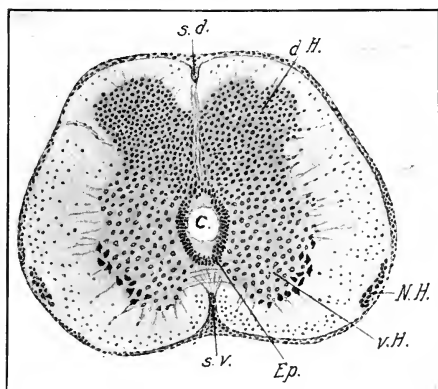


FIG. 146. — Transverse section through the cervical swelling of the spinal cord of a 12-day chick. (After v. Kupffer.)

C., Central canal. d. H., Dorsal horn of the gray matter. Ep., Ependyma. N. H., Nucleus of Hoffmann. s. d., Dorsal fissure. s. v., Ventral fissure. v. H., Ventral horn of the gray matter.

The development of the so-called dorsal and ventral fissures is essentially different. The entire ventral longitudinal fissure of the cord owes its origin to growth of the ventral columns of gray and white matter which protrude below the level of the original floor (Figs. 145 and 146), and the latter is thus left between the inner end of the fissure and the central canal. The dorsal longitudinal fissure on the other hand is for the most part

a septum produced by fusion of the walls of the intermediate and dorsal portions of the central canal; there is, however, a true fissure produced by protrusion of the dorsal columns of white matter (Fig. 146). This is, however, of relatively slight extent. The original roof of the canal is therefore found between the dorsal septum and the fissure.

Neuroblasts, Commissures, and Fiber Tracts of the Cord. The medullary neuroblasts may be divided into four groups: (1) The first group, or motor neuroblasts, form the fibers of the ventral roots of the spinal nerves. These are situated originally in the ventro-lateral zone of the gray matter (Figs. 144, 145, 146); they are relatively large and form a profusion of dendrites (Figs. 140, 141). As they increase in number and size they come to form a very important component of the ventral horn of the gray matter and contribute to its protrusion. (2) The second group may be called the commissural neuroblasts. These are situated originally mainly in the lateral and dorsal portions of the mantle layer, but are scattered throughout the gray matter, and their axis cylinders grow ventrally and cross over to the opposite side of the cord through the floor (Figs. 139 and 140), and thus form the anterior or white commissure of the cord. (3) The cells of the fiber tracts are scattered throughout the gray matter, and are characterized by the fact that their axis cylinders enter the white matter of the same side; here they may bifurcate, furnishing both an ascending and a descending branch, or may simply turn in a longitudinal direction. (4) Finally there are found certain neuroblasts with a short axis cylinder, ramifying in the gray matter on the same side of the cord. These are found in the dorsal horn of the gray matter and develop relatively late (about sixteen days, Ramon y Cajal).

III. THE DEVELOPMENT OF THE BRAIN

Unfortunately the later development of the brain of birds has not been fully studied. The following account is therefore fragmentary. It is based mainly on a dissection and sections of the brain of chicks of eight days' incubation.

Fig. 147 is a drawing of a dissection of the brain of an eight-day embryo. The left half of the brain has been removed, and the median wall of the right cerebral hemisphere also. The details of the cut surfaces are drawn in from sections. Figs. 148

and 150 show median and lateral sagittal sections of the same stage.

The flexures of the brain at this stage are: (1) the cranial flexure marked by the *plica encephali ventralis* on the ventral surface, (2) the cervical flexure at the junction of myelencephalon and cord, somewhat reduced in this stage, and (3) the pontine flexure, a ventral projection of the floor of the myelencephalon.

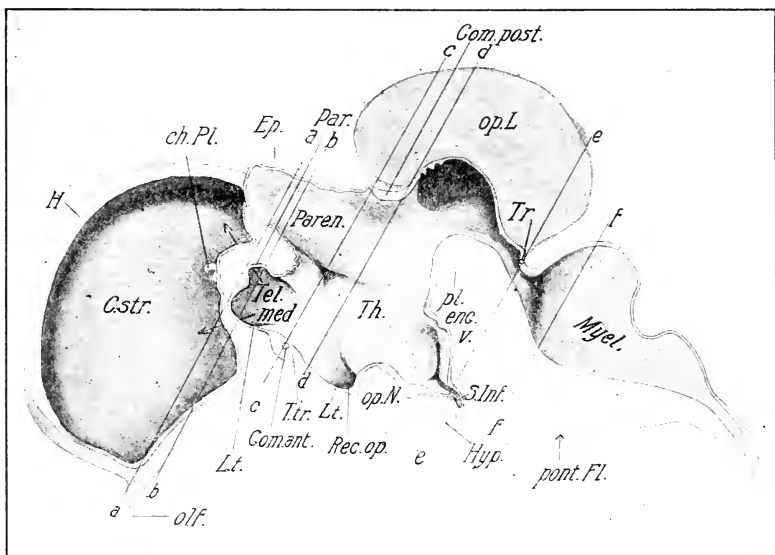


FIG. 147. — Dissection of the brain of an 8-day chick. For description see text. The arrows shown in the figure lie near the dorsal and ventral boundaries of the foramen of Monro.

ch. Pl., Choroid plexus. Com. ant., Anterior commissure. Com. post., Posterior commissure. C. str., Corpus striatum. Ep., Epiphysis. H., Hemisphere. Hyp., Hypophysis. L. t., Lamina terminalis. Myel., Myelencephalon. olf., Olfactory nerve. op. N., Optic chiasma. op. L., Optic lobe. Par., Paraphysis. Paren., Parencephalon. pl. enc. v., Plica encephali ventralis. pont. Fl., Pontine flexure. Rec. op., Recessus opticus. S. Inf., Saccus infundibuli. Tel. med., Telencephalon medium. Th., Thalamus. T. tr., Torus transversus. Tr., Commissura trochlearis.

The lines a-a, b-b, c-c, d-d, e-e, f-f, represent the planes of section A, B, C, D, E, and F of Fig. 151.

Telencephalon. The telencephalon is bounded posteriorly, as noted in Chapter VI, by the line drawn from the velum transversum to the recessus opticus. The telencephalon medium has grown but little since the fourth day, but the hemispheres

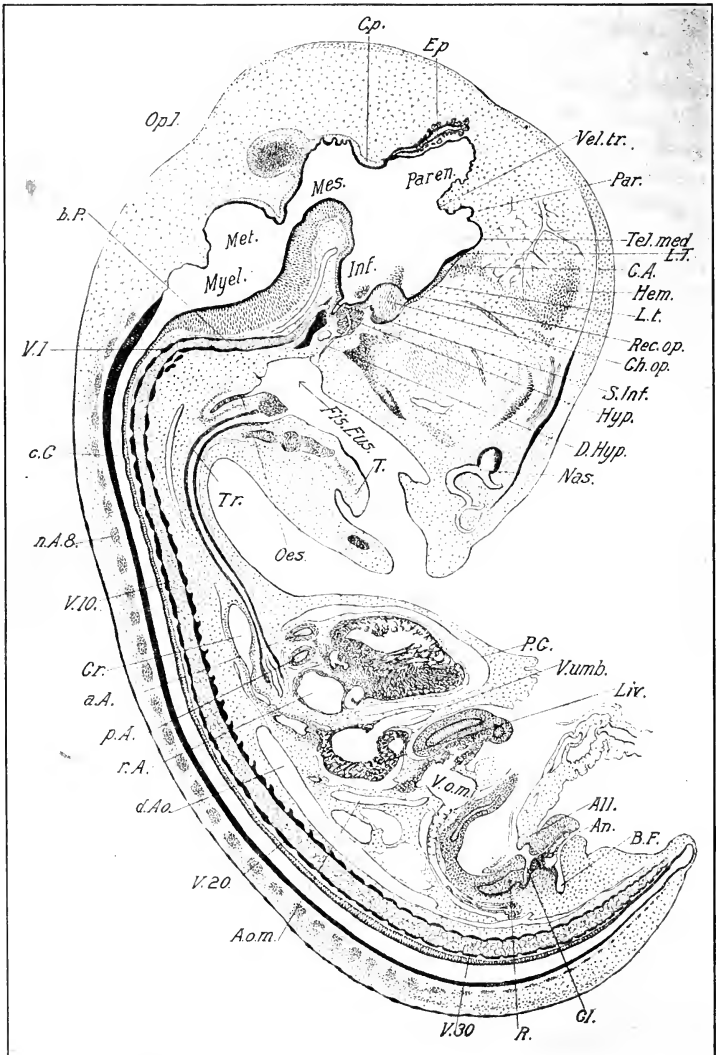


FIG. 148. — Median sagittal section of an embryo of eight days.

a. A., Aortic arch. All., Allantois. An., Anus. A. o. m., Omphalomesenteric artery. B. F., Bursa Fabricii. b. P., Basilar plate. C. A., Anterior commissure. c. C., Central canal. Ch. op., Optic chiasma. C. p., posterior Commissure. Cl., Cloaca. Cr., Crop. d. Ao., Dorsal aorta. D. Hyp., Duct of the hypophysis. Ep., Epiphysis. Fis. Eus., Fissura Eustachii. Hem., Surface of hemisphere barely touched by section. Hyp., Hypophysis. L. t., Lamina terminalis. n. A. 8, neural arch of the eighth vertebra. Nas., Nasal

have expanded enormously, particularly anteriorly and dorsally, and their median surfaces are flattened against one another in front of the lamina terminalis, which forms the anterior boundary of the telencephalon medium (Figs. 148, 149). Posteriorly the cerebral hemispheres extend to about the middle of the diencephalon and their lateral faces are rounded. The lateral walls of the hemispheres have become enormously thickened to form the *corpora striata* (Figs. 147 and 151 A), and the superior and lateral walls have remained relatively thin, forming the mantle of the cerebral hemispheres (pallium). Thus the cavity of the lateral ventricle is greatly narrowed.

The dissection (Fig. 147) shows the corpus striatum of the right side forming the lateral wall of the hemisphere, and extending past the aperture (foramen of Monro) between the lateral and third ventricles towards the recessus opticus, where it comes to an end.

The olfactory part of the hemispheres is not well differentiated from the remainder in the chick embryo of eight days. There is, however, a slight constriction on the median and ventral face (Fig. 147) which may be interpreted as the boundary of the olfactory lobe.

The telencephalon medium is crowded in between the hemispheres and the diencephalon; its cavity forms the anterior end of the third ventricle, and communicates anteriorly through two slits, the foramina of Monro, with the lateral ventricles in the hemisphere. In Fig. 147, the upper and lower boundaries of the foramen of Monro, are indicated by the grooves on either side of the posterior end of the corpus striatum. A hair introduced from the third ventricle into the lateral ventricle through the foramen of Monro in the position of the arrow in Fig. 147, can be moved up and down over the whole width of the striatum. The lateral walls of the telencephalon medium are formed by the posterior ends of the corpora striata and are therefore very thick.

The lamina terminalis passes obliquely upwards and forwards

cavity. Oes., Oesophagus. p. A., Pulmonary arch. par., Paraphysis. P. C., Pericardial cavity. Rec. op., Recessus opticus. R., Rectum. S. Inf., Saccus infundibuli. T., Tongue. Tel., Med. Telencephalon medium. Tr., Trachea. V. 1, 10, 20, 30, First, tenth, twentieth and thirtieth vertebral centra. r. A., right auricle. Vel. tr., Velum transversum. V. o. m., Omphalomesenteric vein. V. umb., Umbilical vein.

from the recessus opticus to the region between the foramina of Monro. It is very thin, excepting near its center, where it is thickened to form the *torus transversus*, containing the anterior commissure. At its dorsal summit it is continuous with the roof of the telencephalon medium, which has formed a pouch-like evagination, the *paraphysis*. Just behind the paraphysis

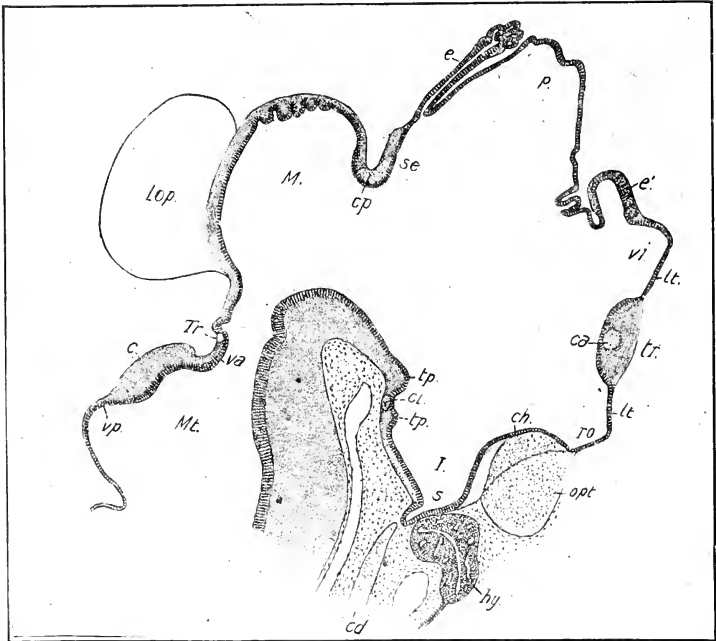


FIG. 149. — Median sagittal section of the brain of a chick embryo of 7 days. (After v. Kupffer.)

e., Cerebellum. ca., Anterior commissure. ed., Notochord. ch., Projection of the optic chiasma. ep., Posterior commissure. e., Epiphysis. e', Paraphysis. hy., Hypophysis. I., Infundibulum. lt., Lamina terminalis. Lop., Optic lobe. M., Mesencephalon. Mt., Metencephalon. opt., Chiasma of the optic nerves. p., Parencephalon. ro., Recessus opticus. s., Saccus infundibuli. se., Synencephalon. tp., Mammillary tubercle. tp., Tuberculum posterius. tr., Torus transversus. Tr., Decussation of the trochlear nerves. Va., Velum medullare anterius. Vi., Ventriculus impar telencephali. vp., Velum medullare posterius.

is the velum transversum, where the roof bends upwards sharply into the roof of the diencephalon. The epithelial wall around the bend is folded to form the choroid plexus of the third ventricle, which is continued forward into the lateral ventricle along

the median wall of the hemisphere, ending anteriorly in a free branched tip (Fig. 147, ch. Pl.)

The principal changes in the telencephalon since the third day comprise: (1) great expansion of the hemispheres and thickening of the ventro-lateral wall to form the corpora striata; (2) origin of the paraphysis which arises as an evagination of the roof just in front of the velum transversum about the middle of the fifth day; (3) formation of the choroid plexus; (4) origin of the anterior commissure within the lamina terminalis; (5) development of the olfactory region. The general morphology of the adult telencephalon is thus well expressed at this time.

The Diencephalon has undergone marked changes since the third day. The roof of the parencephalic division has remained very thin, and has expanded into a large irregular sac (Figs. 147 and 148), situated between the hinder ends of the hemispheres. The attachment of the epiphysis has shifted back to the indentation between parencephalic and synencephalic divisions, and the epiphysis itself has grown out into a long, narrow tube, dilated distally, and provided with numerous hollow buds. In the roof of the synencephalic division the posterior commissure has developed (Fig. 147). In the floor the chiasma has become a thick bundle of fibers, and the infundibulum a deep pocket, from the bottom of which a secondary pocket (*saccus infundibuli*) is growing out in contact with the posterior face of the hypophysis. Following the posterior wall of the infundibulum in its rise, we come to a slight elevation, the rudiment of the mammillary tubercles; just beyond this is a transverse commissure (the inferior commissure); and the diencephalon ends at the *tuberculum posterius*.

The hypophysis has become metamorphosed into a mass of tubules enclosed within a mesenchymatous sheath; the stalk is continuous with a central tubule representing the original cavity from which the other tubules have branched out (Fig. 148), and it may be followed to the oral epithelium from which the whole structure originally arose. (See note at end of this chapter.)

The lateral walls of the diencephalon have become immensely thickened, both dorsally and ventrally, and a deep fissure (Fig. 147) is found on the inner face at the anterior end, between the dorsal and ventral thickenings. The deepest part of the fissure is a short distance behind the velum transversum; from this a

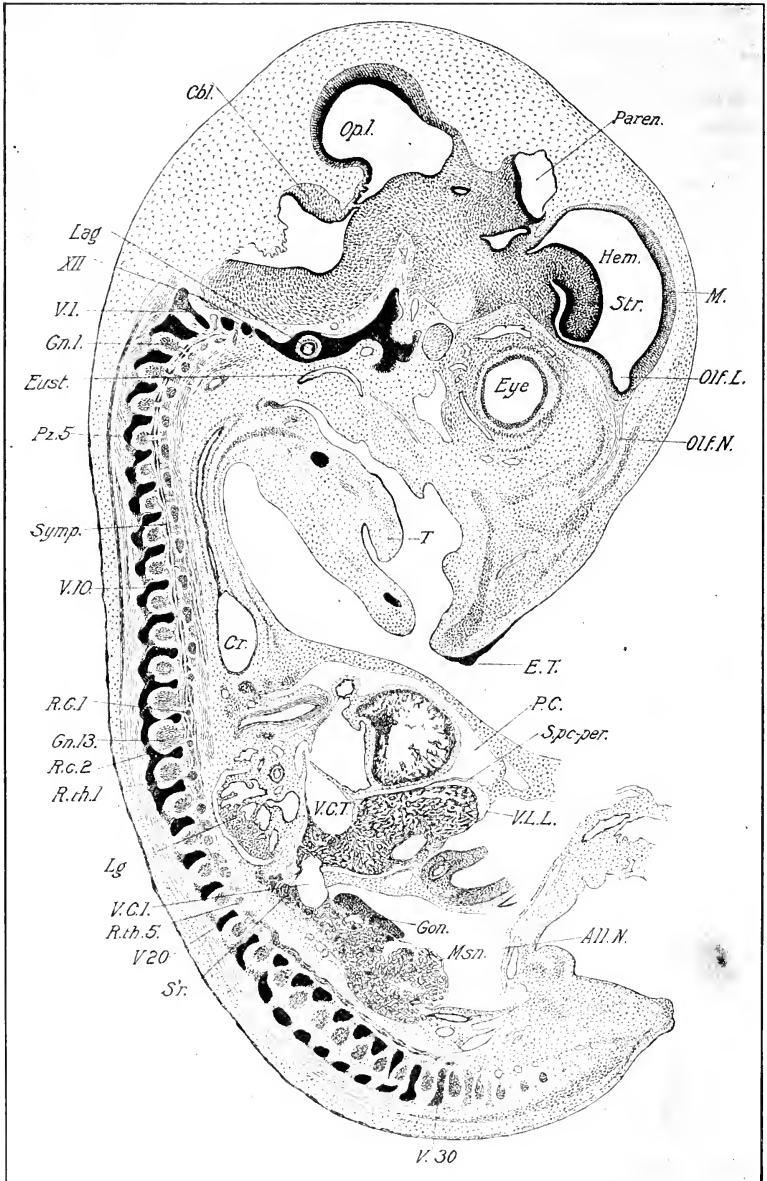


FIG. 150. — Lateral sagittal section of an embryo of 8 days. Right side of the body.

All. N., Neck of the allantois. Cbl., cerebellum. Cr., Crop. E. T., Egg

short spur runs forward, a still shorter one ventrally, and the longest arm extends backwards, gradually fading out beyond the middle of the diencephalon. This fissure is not a continuation of the *sulcus Monroi*, or backward prolongation of the foramen of Monro, but is, on the contrary, entirely independent.

The lateral thickenings of the diencephalon constitute the thalami optici, each of which may be divided into epithalamic, mesothalamic, and hypothalamic subdivisions. In the chick at eight days there is a deep fissure between the epi- and mesothalamic divisions (the thalamic fissure, Fig. 147). The substance of the epithalamus forms the ganglion habenulæ. The mesothalamic and hypothalamic divisions are not clearly separated. The transition zone between the diencephalon and mesencephalon is sometimes called the metathalamus.

The mesencephalon has undergone considerable changes since the third day. The dorso-lateral zones have grown greatly in extent, at the same time becoming thicker, and have evaginated in the form of the two large optic lobes. Hence the median portion of the roof is sunk in between the lobes (Fig. 147), and is much thinner than the walls of the lobes. The dorso-lateral zones and roof thus form a very distinct division of the mesencephalon, known as the *tectum lobi optici*. The ventro-lateral zones and floor have thickened greatly and form the basal division of the mesencephalon. The ventricle of the mesencephalon thus becomes converted into a canal (aqueduct of Sylvius), from which the cavities of the optic lobes open off.

In **the metencephalon** likewise there is a sharp distinction between the development of the dorso-lateral zones and roof, on the one hand, and the ventro-lateral zones and floor on the other. From the former the cerebellum develops in the form of a thickening overhanging the fourth ventricle. This thickening is relatively inconsiderable in the middle line (cf. Figs. 148 and 150). Thus the future hemispheres of the cerebellum are

tooth. Eust., Eustachian tube. Gn. 1, 13, First and thirteenth spinal ganglia. Gon., Gonad. Hem., Hemisphere. Lag., Lagena. Lg., Lung. M., Mantle of Hemisphere. Msn., Mesonephros. Olf. L., Olfactory lobe. Olf. N., Olfactory nerve. P. C., Pericardial cavity. Pz. 5, The fifth post-zygopophys. R. C. 1, 2, Last two cervical ribs. R. th. 1, 5, First and fifth thoracic ribs. S. pc-per., Septum pericardiacoperitoneale. Sr., Suprarenal. Symp., Main trunk of the sympathetic. Str., Corpus striatum. V. 1, 10, 20, 30, First, tenth, twentieth and thirtieth vertebral arches. V. C. I., Vena cava inferior. V. L. L., Ventral ligament of the liver.

indicated. The surface is still smooth at the eighth day, but on the tenth and eleventh days folds of the external surface begin to extend into its substance, without, however, invaginating its entire thickness. These are the beginnings of the cerebellar fissures.

The floor and ventro-lateral zones of the metencephalon enter into the formation of the pons.

In the roof of the isthmus, or constricted region between cerebellum and mesencephalon, is found a small commissure produced by decussation of the fibers of the trochlearis (Fig. 147).

In the wall of **the myelencephalon** the neuromeres have disappeared. The thin epithelial roof has become more expanded in the anterior part (Figs. 147 and 148). Floor and sides have become greatly thickened.

Commissures. The brain commissures existing at eight days are the anterior, posterior, inferior, and trochlearis (Fig. 149). In the next four or five days two more appear, viz., the commissura pallii anterior (Kupffer), corresponding to the corpus callosum of mammalia and the commissura habenularis.

The development of the various nuclei and fiber tracts of the bird's brain is entirely unknown and affords an interesting topic for research.

IV. THE PERIPHERAL NERVOUS SYSTEM

The peripheral nervous system comprises the nerves which span between peripheral organs and the central nervous system. There are fifty pairs in a chick embryo of eight days, of which twelve innervate the head, and thirty-eight the trunk, distinguished respectively as cranial and spinal nerves. It is convenient for purposes of description to consider cranial and spinal nerves separately, and to take up the spinal nerves first because they are much more uniform in their mode of development than the cranial nerves, and also exhibit a more primitive or typical condition, on the basis of which the development of the cranial nerves must be, in part, at least, explained.

The Spinal Nerves. Each spinal nerve may be divided into a somatic portion related primarily to the somatopleure and axis of the embryo, and a splanchnic portion related primarily to the splanchnopleure and its derivatives. In each of these again a motor and sensory component may be distinguished. Thus each

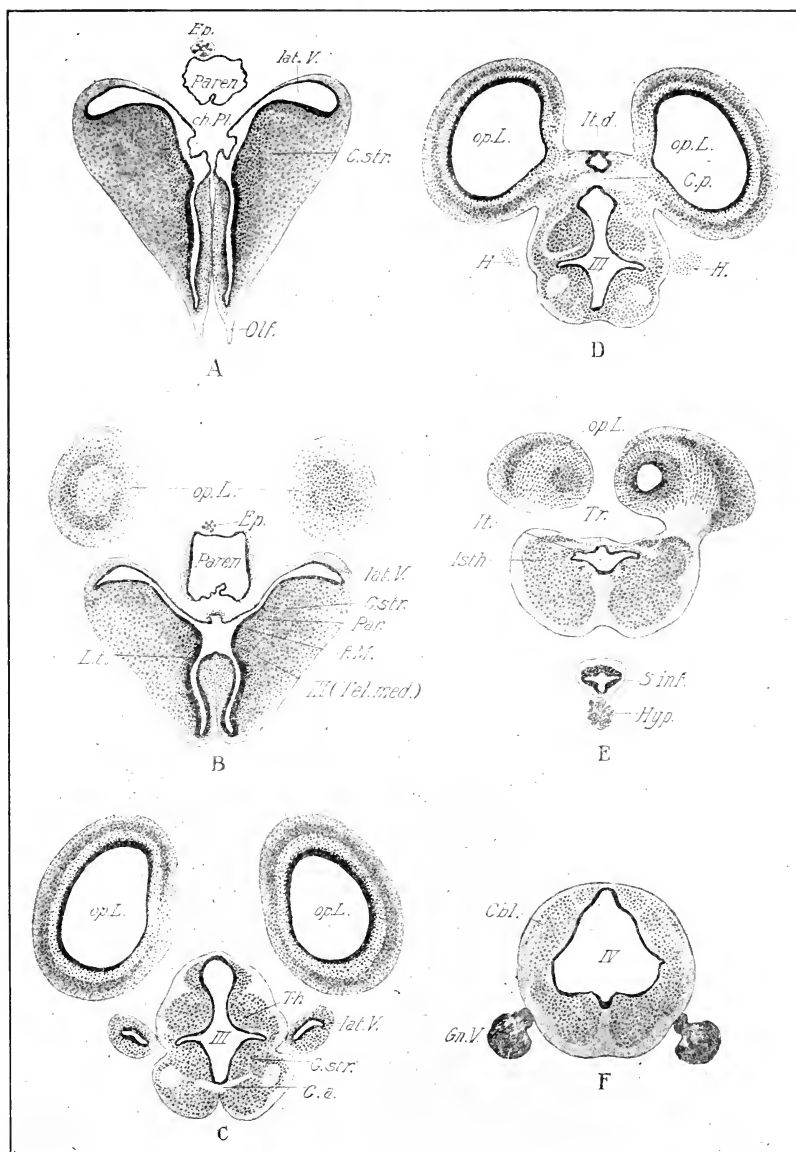


FIG. 151. — Six transverse sections through the brain of an 8-day chick in the planes represented in Fig. 147.

Cbl., Cerebellum. F. M., Foramen of Monro. Gn. V., Ganglion of the trigeminus. Isth., Isthmus. It. d., Diverticulum of the iter. lat. V., Lateral ventricle. Other abbreviations as before (Fig. 147).

spinal nerve has four components, viz., somatic motor, somatic sensory, splanchnic motor, and splanchnic sensory, the two latter constituting the so-called sympathetic nervous system. It is obvious, of course, that the splanchnic components must be missing in the caudal nerves. The somatic and splanchnic components will be considered separately.

Somatic Components. Each spinal nerve arises from two roots, dorsal and ventral (Fig. 145). The fibers of the former arise from the bipolar neuroblasts of the spinal ganglia; the fibers of the ventral root, on the other hand, arise from a group of neuroblasts in the ventral portion of the cord. The roots unite in the intervertebral foramen to form the spinal nerve. Typically, each spinal nerve divides almost immediately into three branches, viz., a dorsal branch, a ventral branch, and a splanchnic branch to the sympathetic cord; the last is known as the *ramus communicans*.

Fig. 145 represents a section passing through the twentieth spinal nerve of an eight-day chick. The dorsal and ventral roots unite just beneath the spinal ganglion; fibers are seen entering the sympathetic ganglion (*ramus communicans*); the ventral branch passes laterally a short distance where it is cut off; beyond this point it can be traced in other sections in the next posterior intercostal space more than half-way round the body-wall; that is, as far as the myotome has extended in its ventral growth. The dorsal branch arises at the root of the ventral and passes dorsally in contact with the ganglion to branch in the dorsal musculature and epidermis. This nerve may be regarded as typical of the spinal nerves generally.

There are thirty-eight spinal nerves in an embryo of eight days. The first two are represented only by small ventral roots.

The first two spinal ganglia are rudimentary in the embryo and absent in the adult, hence the ganglion illustrated in Fig. 145 is the eighteenth of the functional series (see Fig. 149); it lies between the nineteenth and twentieth vertebrae.

The fourteenth, fifteenth, and sixteenth are the principal nerves of the brachial plexus, and have unusually large ganglia. The twenty-third to the twenty-ninth are the nerves of the leg plexus, the thirtieth to the thirty-second innervate the region of the cloaca and the remainder are caudal. The special morphology of the spinal nerves does not belong in this description.

There are one or two vestigial ganglia behind the thirty-eighth nerve, evidently in process of disappearance at eight days.

The early history of the spinal nerves is as follows: The axis cylinder processes of the fibers begin to grow out from the neuroblasts about the third day (cf. p. 235). At this time the myotomes are in almost immediate contact with the ganglia; thus the fibers have to cross only a very short space before they enter the myotome. The further growth is associated with the growth and differentiation of the myotome between which and the embryonic nerve there is a very intimate relation of such a sort that the nerve follows the myotome and its derivatives in all changes of position. Thus nerves do not need to grow long distances to establish their connections, but these are formed at a very early period. This accounts for the motor fibers; the way in which the sensory fibers, that arise from the spinal ganglia, reach their termination is not known.

Sheath-cells and Cell-chain Hypothesis. No embryonic nerve consists entirely of axones, but, from the start, each nerve trunk contains numerous nuclei. The latter belong to cells which have been given two radically different interpretations, corresponding to two distinct theories concerning the neuraxone.

(1) The first theory, known as the neurone theory, is the one tacitly followed in the preceding description and may be stated as follows: the nerve-cell, dendrites and axone, including the terminal arborization, constitute a single cellular individual or unit, differentiated from the neuroblast alone. The nuclei in the embryonic nerves therefore belong to cells that are foreign to the primary nerve. Their function is to form the various sheaths of the nerves, viz., the sheaths of the individual axones and the endo-, peri-, and epineurium. The sheath of Schwann arises from such cells that envelop the individual fibers at suitable distances and spread longitudinally until neighboring sheath cells meet; each such place of meeting constitutes a node of Ranvier. Until recently it has been universally believed that the sheath cells arose from the mesenchyme; but recent observations on Amphibia and Selachia have shown that they arise from the ganglia in these forms; their original source is therefore the ectoderm. It is probable that they have the same origin in the chick, though this has not been demonstrated by direct observation or experiment.

(2) The second theory is known as the cell-chain hypothesis.

According to this the axones of peripheral nerves arise as differentiations of the sheath-cells *in situ*; continuity of the axone is established by arrangement of these cells in rows, and union with the neuroblast is essentially secondary. The entire axone is thus by no means an outgrowth of the neuroblast; at most its proximal portion is.

Bethe (1903) expresses the idea thus: "Between the cord of the embryo and the part to be innervated there is formed primarily a chain of nuclei around which the protoplasm is condensed. This is fundamentally an extended syncytium in which the nuclei of the neuroblasts and of the nerve-primordium lie. Within the denser protoplasm which appears as the body of the nerve-cells, axones differentiate by condensation, and these extend from one cell to the next, and so on to the condensations which are called neuroblasts. The differentiated axones tend more and more to occupy the center of the embryonic nerve, where they appear to lie free, though as a matter of fact they are still embedded in the general plasma which is no longer distinctly visible on account of its lesser density. Since the axones remain in firm connection with the neuroblasts, it appears in later stages as if they were processes of these and had nothing to do with their original formative cells."

This view is essentially that of Balfour, Beard, and Dohrn; the neurone hypothesis was first clearly formulated in embryological terms by His, and has been supported by the investigations of a considerable number of observers, notably Ramon y Cajal, Lenhossek and Harrison.

The neurone hypothesis has far stronger embryological support than the cell-chain hypothesis; moreover, it is the only possible hypothesis of the development of nerve tracts in the central system, because cell-chains are entirely lacking here during the formation of these tracts. In recent years it has been demonstrated that isolated neuroblasts in culture media produce complete axones, sheath cells being entirely absent. Thus the cell-chain hypothesis has received its final quietus, and is now of historical interest only. (Burrows 1911, Lewis and Lewis 1911.)

Splanchnic Components (Sympathetic Nervous System). Two views have been held concerning the origin of the sympathetic nervous system: (a) that it is of mesenchymal origin, its elements arising *in situ*; (b) that it is of ectodermal origin, its elements

migrating from the cerebro-spinal ganglia to their definitive positions. The first view was held by the earlier investigators and was originally associated with the extinct idea that the spinal ganglia were mesenchymal in origin; the view has been entirely abandoned. The second view was partly established with the discovery that the spinal ganglia are of ectodermal origin, and that the ganglia of the main sympathetic trunk arise from the spinal ganglia; but there is some difference of opinion yet in regard to the peripheral ganglia of the sympathetic system, and especially the plexuses of Meissner and Auerbach in the walls of the intestine. However, the preponderance of evidence and logic favors the view of the ectodermal origin of the entire sympathetic nervous system.

The first clear evidences of the sympathetic nervous system of the chick are found at about the end of the third or the beginning of the fourth day; at each side of the dorsal surface of the aorta there is found in cross-section a small group of cells massed more densely than the mesenchyme and staining more deeply. Study of a series of sections shows these to be a pair of longitudinal cords of cells beginning in the region of the vagus, where they lie above the carotids, and extending back to the beginning of the tail; the cords are strongest in the region of the thorax; and slightly larger opposite each spinal ganglion. Cells similar to those composing the cords are found along the course of the nerves up to the spinal ganglia, and careful study of earlier stages indicates that the cells composing the cords have migrated from the spinal ganglia. The two cords constitute the primary sympathetic trunks.

Fig. 152 is a reconstruction of the anterior spinal and sympathetic ganglia of a chick embryo of four days. The primary sympathetic trunk is represented by a cord of cells enlarged opposite each ganglion and united to the spinal nerve by a cellular process, the primordium of the *ramus communicans*. In the region of the head the segmental enlargements are lacking.

No other part of the sympathetic nervous system is formed at this time with the exception of a group of cells situated in the dorsal mesentery above the yolk-stalk; these are destined to form the ganglion and intestinal nerves of Remak. They have not been traced back to the spinal ganglia, but it is probable that such is their origin.

In the course of the fourth and fifth days aggregations of sympathetic ganglion cells begin to appear ventral to the aorta, and in the mesentery near the intestine. The connection of these with the primary cord is usually rendered evident by agreement in structure, and by the presence of intervening strands of cells; moreover, in point of time they always succeed the primary cord, so that their origin from it can hardly be doubted.

About the sixth day the secondary or permanent sympathetic trunk begins to appear as a series of groups of neuroblasts situated just median to the ventral roots of the spinal nerves. They

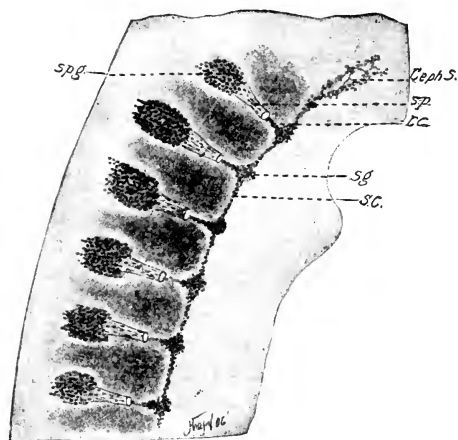


FIG. 152. — Reconstruction in the sagittal plane of the anterior spinal and sympathetic ganglia of a chick embryo of 4 days. (After Neumayer.)

Ceph. S., Cephalic continuation of the sympathetic trunk. S. C., Sympathetic cord. Sg., Sympathetic ganglion. sp., Spinal nerve. spg., Spinal ganglion. R. C., Ramus communicans.

are thus separated from the spinal ganglia only by the fibers of the ventral roots between which neuroblasts may be found, caught apparently in migration from the spinal to the sympathetic ganglion. The number of these secondary sympathetic ganglia is originally 30, one opposite the main vagus ganglion, and each spinal ganglion to the twenty-ninth (Fig. 150). Soon after their origin they acquire three connections by means of axones, viz., (a) central, with the corresponding spinal nerve-

root by means of strong bundles of fibers; (b) peripheral, with certain parts of the original primary sympathetic cord; (c) longitudinal, the entire series being joined together by two longitudinal bundles of fibers uniting them in a chain. The central connections constitute the *rami communicantes*, and are as numerous as the sympathetic ganglia themselves; but so close is the approximation of the sympathetic ganglion to the roots of the spinal nerves that they are not visible externally, the ganglion appearing to be sessile on the root (Fig. 145); sections, however, show the fibers. The peripheral connections constitute the various nerves of the abdominal viscera; these are not metameric; their number and arrangement is shown in Figure 153.

In the period between the fourth and the eighth day the primary sympathetic cord becomes resolved into the various ganglia and nerves constituting the aortic plexus, the splanchnic plexus, and the various ganglia and nerves of the wall of the intestine. Remak's ganglion has grown and formed connections with the splanchnic plexus, and other parts of the primary sympathetic cord. The details of these various processes are too complex for full description; they are included in part in Figs. 153 and 154.

Ganglia and Nerves of the Heart. The development of the cardiac nerves is of special interest on account of its bearing on the physiological problem of the origin of the heart-beat. The heart of the chick begins to beat long before any nervous connections with the central system can have been established; indeed, the rhythmical pulsation begins at about the stage of 10 somites when the neural crest is yet undifferentiated, and no neuroblasts are to be found anywhere. Either, then, the heart-beat is of muscular origin (myogenic), or, if of nervous origin, the nerve-cells concerned must exist in the wall of the cardiac tube *ab initio*.

The first trace of nerve-cells is found in the heart of the chick about the sixth day. These cells are at the distal ends of branches of the vagus, with which they have grown into the heart. Previous to this time these neuroblasts are found nearer to the vagus along the course of the arteries. There can be but little doubt that they have arisen from the vagus ganglion and that they reach the heart by migration. Such an origin has been demonstrated with great probability for all the known nervous elements of the heart of the chick. (See Wilhelm His, Jr., *Die Entwicklung des Herznervensystems bei Wirbelthieren.*)

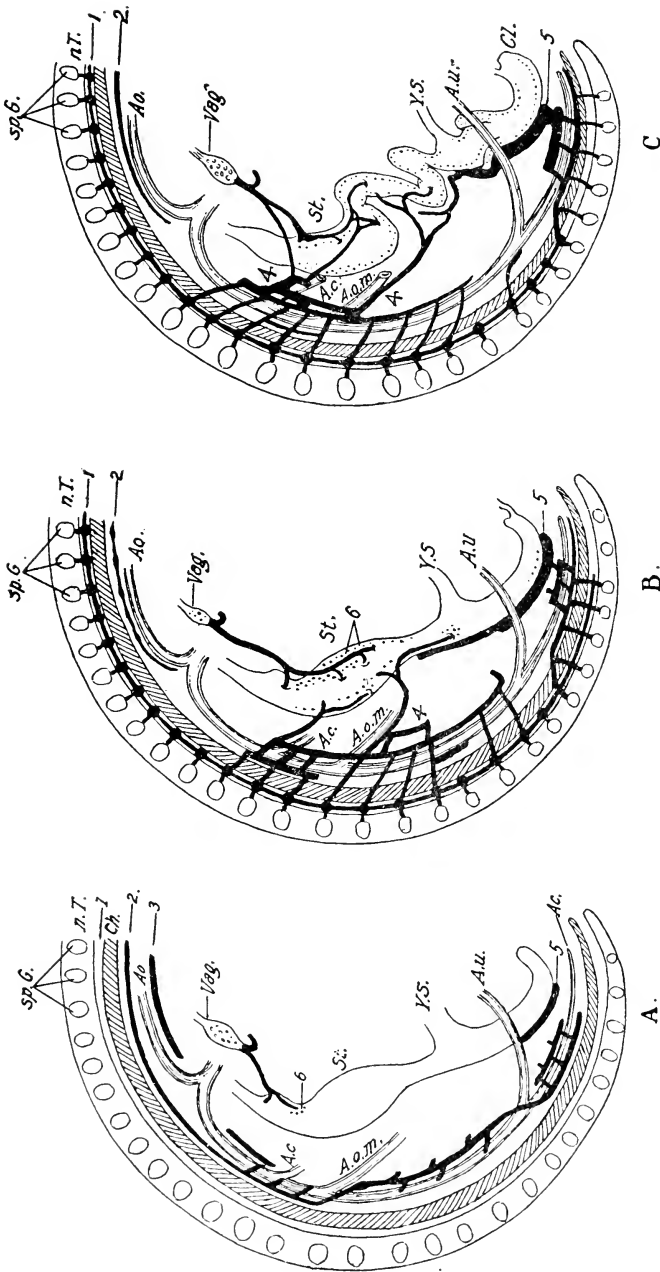


FIG. 153. — Diagrams of the abdominal sympathetic of the chick embryo, from the right side.

A, represents the fourth day, B, the sixth day, and C, the tenth day of incubation. (After His, Jr.)
 A. c., Coeliac artery. Ac., Caudal artery. Ao., Aorta. A. o. m., Omphalomesenteric artery. A. u., Umbilical artery. Ch., Notochord. Cl., Cloaca. n. T., Neural tube. sp. G., Spinal ganglia. St., Stomach. Y. S., Stalk of the yolk-sac.
 1, Secondary sympathetic cord. 2, Primary sympathetic cord. 3, Aortic plexus. 4, Splanchnic plexus. 5, Ganglion of Remak. 6, Ganglia and nerves of the intestinal wall.

If any cardiac nervous elements arise *in situ*, they certainly remain undifferentiated until those that have a ganglionic origin have already entered the heart.

The Cranial Nerves. The nerves of the head exhibit a much greater degree of heteronomy than the spinal nerves, and, in spite of much study, knowledge of their embryonic development is still in a very unsatisfactory condition. The same principles, however, apply to the development of both cranial and spinal nerves; the axones of the former like those of the latter arise either from medullary or ganglionic neuroblasts which are respectively unipolar and bipolar; but the cranial ganglionic and

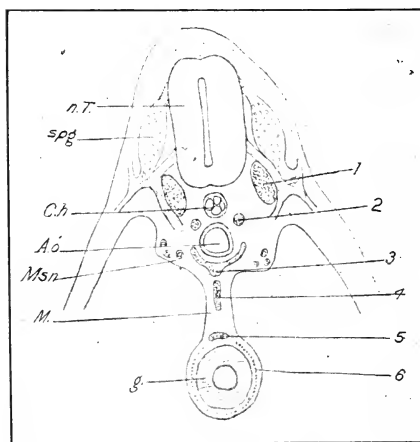


FIG. 154. — Diagram of the relations of the parts of the sympathetic nervous system as seen in the cross-section. (After His, Jr.)

M., mesentery. Msn., Mesonephros. Other abbreviations same as Fig. 153.

medullary nerve-nuclei are not similarly segmented, as in the case of the spinal nerves, and hence the axones are not related as dorsal and ventral roots of single nerve trunks; nor has the attempt to interpret the cranial nerves as homologues of dorsal and ventral roots respectively been successful in the case of the most important nerves. Moreover, the olfactory and optic nerves differ from the spinal type even more fundamentally. The olfactory is a sensory nerve that arises apparently from the olfactory

epithelium, and the optic is really comparable to an intramedullary nerve tract, seeing that its termination lies in a part of the original wall of the neural tube, viz., the retina.

Groups of medullary neuroblasts giving rise to axones of motor cranial nerves are located in the brain as follows, according to His:

Oculo-motor nucleus in the mid-brain.

Trochlearis nucleus in the isthmus.

Motor trigeminus nucleus in the zone of the cerebellum, including the descending root.

Abducens and facialis nuclei, beyond zone of greatest width of the fourth ventricle (auditory sac zone).

Glossopharyngeus, vagus, in the region of the calamus scriptorius.

Accessorius and hypoglossus, in the region extending to the cervical flexure.

These constitute the cranial motor nerve nuclei, and are more or less discontinuous.

The ganglionic nerves or nerve-components of the head arise from the following primitive embryonic ganglion-complexes:

1. Complex of the trigeminus ganglia.
2. Complex of the acustico-facialis ganglia.
3. Complex of the glossopharyngeus ganglia.
4. Complex of the vagus ganglia.

The early history of these ganglion-complexes has already been considered; they are called complexes because each forms more than one definitive ganglion. It is probable also that each contains sympathetic neuroblasts, which may separate out later as distinct ganglia, thus resembling the spinal sympathetic neuroblasts.

There is no close agreement in the segmentation of the motor neuroblasts within the brain and that of the ganglion complexes. For instance, in the region of the trigeminal ganglionic complex, the motor nuclei of the oculo-motor, trochlearis, and trigeminus are found, and in the region of the vagus ganglionic complex, the motor nuclei of vagus, accessorius, and hypoglossus. Thus the medullary and ganglionic nerves of the head are primitively separate by virtue of their separate origins. They may remain entirely so, as in the case of the olfactory, trochlearis, and abducens, or they may unite in the most varied manners to form mixed nerves.

The motor nuclei of the oculo-motor, trochlearis, abducens, and hypoglossus nerves lie in the same plane as the motor nuclei of the spinal nerves, *i.e.*, in the line of prolongation of the ventral horns of the gray matter. The motor nuclei of the trigeminus, facialis, glossopharyngeus, vagus, and spinal accessory on the other hand lie at a more dorsal level, and the roots emerge therefore above the level of origin of the others. It will be noted that these are the nerves of the visceral arches, whereas those cranial nerves that continue the series of spinal ventral roots innervate myotomic muscles, like the latter. Similarly the ganglia of the pharyngeal nerves (V, VII, IX, and X) differ from spinal ganglia in certain important respects: the latter are derived entirely from the neural crest, whereas a certain portion of each of the primary cranial ganglia is derived from the lateral ectoderm of the head, as noted in the preceding chapter. Thus the pharyngeal nerves form embryologically a class by themselves, both as regards the medullary and also the ganglionic components.

1. *The Olfactory Nerve.* The embryonic origin of the olfactory nerve has been a subject of much difference of opinion: thus it has been maintained by a considerable number of workers that it arises from a group of cells on each side situated between the fore-brain and olfactory pits; some of these maintained that these cells arose as an outgrowth from the fore-brain, others that they came from the epithelium of the olfactory pit, and yet others that this group of cells, or olfactory ganglion, was derived from both sources. This group of cells was supposed by some to include a large number of bipolar neuroblasts, one process of which grew towards the olfactory epithelium and the other towards the fore-brain, entering the olfactory lobe and ending there in terminal arborization. This view is, however, in conflict with the ascertained fact that the fibers of the fully formed olfactory nerve are centripetal processes of olfactory sensory cells situated in the olfactory epithelium.

The most satisfactory account of the origin of the olfactory nerve in the chick is that of Disse. This author finds two kinds of cells in the olfactory epithelium of a three-day chick, *viz.*, epithelial cells, and germinal cells which become embryonic nerve-cells or neuroblasts. At this time the olfactory epithelium is separated from the wall of the fore-brain by only a very thin layer of mesenchyme. Early on the fourth day axones arise

from the central ends of the neuroblasts and grow into the mesenchyme towards the fore-brain. At the same time groups of epithelial cells free themselves from the inner face of the olfactory epithelium, and come to lie between this and the fore-brain. The axones of the neuroblasts grow between these cells until they reach the base of the fore-brain over which they spread out, entering the olfactory lobe about the sixth day (Figs. 155 and 156). In the meantime the peripheral ends of the olfactory neuroblasts have extended out as broad protoplasmic processes to the surface of the olfactory epithelium, and thus form the recipient part of the olfactory sense-cells.

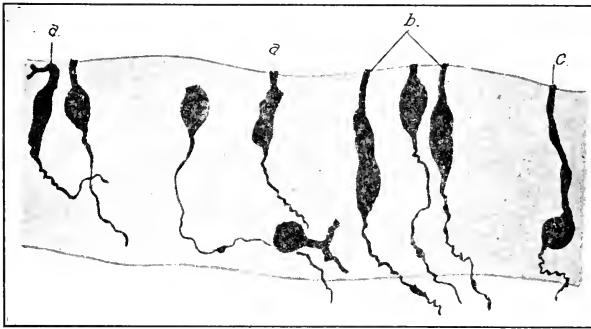


FIG. 155. — Olfactory epithelium of a chick embryo of 5 days, prepared by the method of Golgi. (After Disse.) a, b, and c indicate different forms of neuroblasts in the olfactory epithelium.

The epithelial cells between fore-brain and olfactory pit, through which the axones of the olfactory neuroblasts grow, are for the most part supporting and sheath-cells of the nerve, but they include a few bipolar neuroblasts (Fig. 156). The latter are to be considered as olfactory neuroblasts with elongated protoplasmic processes.

Rubaschkin finds a ganglion, which he calls ganglion olfactorium nervi trigemini, situated beneath the olfactory epithelium in a nine-day chick. The bipolar cells send out processes peripherally which end in fine branches between the cells of the olfactory mucous membrane, and centrally, which go by way of the ramus olfactorius nervi trigemini towards the Gasserian ganglion.

2. *The Second Cranial or Optic Nerve.* The course of this

nerve is entirely intramedullary, the retina being part of the wall of the embryonic brain; its development will therefore be considered in connection with the development of the eye.

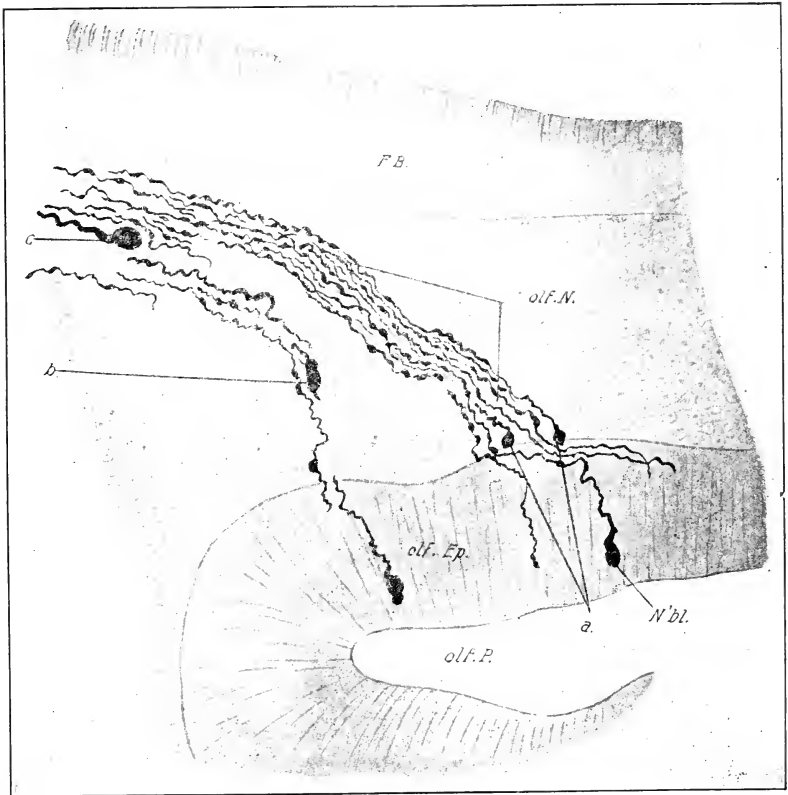


FIG. 156. — Sagittal section through the head of a chick embryo of 5 days, showing the floor of fore-brain, olfactory pit, and developing olfactory nerve between. (After Disse.)

a., Unipolar neuroblasts near the olfactory epithelium. b., Bipolar cell in the olfactory nerve. c., Unipolar cell near the brain. F. B., Floor of fore-brain. N'bl., Neuroblast in the olfactory epithelium. olf. Ep., Olfactory epithelium. olf. N., Olfactory nerve. olf. P., Cavity of olfactory pit.

3. *The third cranial or oculo-motor nerve* arises from a group of neuroblasts in the ventral zone of the mid-brain near the median line, and appears external to the wall of the brain at about sixty hours (about 28-30 somites). At this time it appears as a small group of axones emerging from the region of the *plica encephali*

ventralis, and ending in the mesenchyme a short distance from its point of origin. At seventy-two hours the root is much stronger, interpenetrated with mesenchyme and ends between the optic cup and floor of the brain behind the optic stalk (cf. Fig. 101). At ninety-six hours the root is broad and fan-shaped, the nerve itself is comparatively slender, and passes downwards and backwards behind the optic-stalk where it enters a well-defined ganglion situated just median to the ophthalmic branch of the trigeminus; this is the ciliary ganglion; beyond it the fibers of the oculo-motor turn forward again to enter the region of the future orbit.

According to Carpenter (1906) the ciliary ganglion arises from two sources: (a) migrant medullary neuroblasts that pass out into the root of the oculo-motor, and follow its course to the definitive situation of the ciliary ganglion, and (b) a much smaller group of neuroblasts that migrate from the ganglion of the trigeminus along the ophthalmic branch, and by way of a ramus communicans to the ciliary ganglion. The adult ciliary ganglion shows correspondingly two component parts: (a) a larger ventral region composed of large bipolar ganglion cells, and (b) a smaller dorsal region containing small ganglion cells with many sympathetic characters. It is probable that the medullary fibers of the oculo-motor nerve are distributed entirely to the muscles innervated by it, viz., the superior, inferior, and internal rectus and inferior oblique muscles of the eye. The fibers arising from the neuroblasts of the ciliary ganglion terminate peripherally in the intrinsic muscles of the eye-ball, and centrally (in the case of the bipolar cells) in the brain, which they reach by way of the medullary nerve. The motor branches leave the trunk of the nerve a short distance centrally to the ciliary ganglion.

4. *The trochlearis or fourth cranial nerve* is peculiar inasmuch as it arises from the dorsal surface of the brain in the region of the isthmus. It arises entirely from medullary neuroblasts and innervates the superior oblique muscle of the eye. Marshall states that it may be readily seen in a five-day embryo; in an embryo of eight days it is a slender nerve arising from the dorsal surface of the isthmus immediately in front of the cerebellum; the fibers of the two sides form a commissure in the roof of the isthmus (Fig. 148).

5. *The trigeminus or fifth cranial nerve* consists of motor and sensory portions. The latter arises from the trigeminal ganglion, the origin of which has already been described. The ganglionic rudiment appears roughly Y-shaped even at an early stage (cf. Figs. 105 and 117), the short stem lying against the wall of the brain and the two branches diverging one in the direction of the upper surface of the optic cup (ophthalmic branch) and the other towards the mandibular arch. The original connection of the ganglion with the roof of the neural tube is lost during the second day and permanent connection is established during the third day, presumably by growth of axones into the wall of the brain. The new connection or sensory root of the trigeminus is attached to the myelencephalon in the region of greatest width of the fourth ventricle near the ventral portion of the lateral zone.

During the fourth day the peripheral axones follow the direction of the ophthalmic and mandibular branches of the ganglion and grow out farther as the ophthalmic and mandibular nerves; the former passes forward between the optic vesicle and the wall of the brain; the latter runs ventrally towards the angle of the mouth, over which it divides, a smaller maxillary branch entering the maxillary process of the mandibular arch, and a larger one, the mandibular nerve, runs into the mandibular arch. (For an account of the branchial sense organ of the trigeminus, see Chap. VI.)

A medullary component of the trigeminal nerve arises from the wall of the brain just median to the ganglionic root during the fourth day; it runs forward parallel to the ganglionic ophthalmic branch, and sends a twig to the ciliary ganglion. Beyond this point it unites with the ganglionic branch.

A connection of the trigeminus with the olfactory sensory epithelium is described under the olfactory nerve.

6. *The sixth cranial or abducens nerve* is stated to arise about the end of the fourth day. It is a purely motor nerve, and has no ganglion connected with it; it innervates the external rectus muscle of the eye. At 122 hours it arises by a number of slender roots attached to the myelencephalon near the mid-ventral line, beneath the seventh nerve. Its roots unite into a slender trunk that runs directly forward beneath the base of the brain to the region of the orbit. The sixth nerve thus corresponds more

nearly than any other cranial nerve to a ventral spinal nerve-root.

7 and 8. *The Facial and Auditory Nerves.* The ganglia of these nerves at first form a common mass, the acustico-facialis. But during the course of the fourth day the anterior and ventral portion becomes distinctly separated from the remainder and forms the geniculate ganglion; the remainder then forming the auditory ganglia (cf. Fig. 102). The acustico-facialis ganglion complex moves from its original attachment to the dorsal surface of the brain and acquires a permanent root during the third day, attached ventrally just in front of the auditory sac.

(a) The seventh cranial or facialis nerve arises during the fourth day from the geniculate ganglion which is situated just above the second or hyomandibular branchial cleft. It grows first into the hyoid arch (posttrematic branch), but towards the end of the fourth day a small branch arises just above the cleft and arches over in front of it and runs down the posterior face of the mandibular arch (pretrematic branch). The origin of the motor components is not known.

(b) The further history of the auditory nerve is considered with the development of the ear.

9. The ganglion of *the ninth cranial or glossopharyngeal nerve* (ganglion petrosum cf. Fig. 102) arises from the anterior part of the postotic cranial neural crest as already described. Early on the fourth day the ganglionic axones enter the base of the brain just behind the auditory sac and establish the root, which consists of four or five parts on each side. From the ganglion which is situated at the summit of the third visceral arch a strong peripheral branch develops on the fourth day, and extends into the same arch; a smaller anterior branch develops a little later which passes over the second visceral pouch and enters the second visceral arch. About the same time an anastomosis is formed with the ganglion of the vagus.

10. *The tenth cranial or vagus (pneumogastric) nerve* is very large and complex. Its ganglion very early shows two divisions, one near the roots (ganglion jugulare) and the other above the fourth and fifth visceral arches (ganglion nodosum cf. Fig. 102). It arises by a large number of fine rootlets on each side of the hind-brain behind the glossopharyngeus, and the roots converge in a fan-like manner into the proximal ganglion; from here a stout

nerve passes ventrally and enters the ganglion nodosum situated above the fourth and fifth visceral arches. Branches pass from here into the fourth and fifth arches, and the main stem is continued backward as the pneumogastric nerve s.s. From the hinder portion of the spreading roots a strong commissure is continued backward parallel to and near the base of the neural tube as far as the fifth somite; this is provided with three small ganglion-like swellings. This condition is found about the end of the fourth day. Later this commissure unites with the main sympathetic trunk, and part of the vagus ganglion separates from the remainder as the ganglion cervicale primum of the sympathetic trunk.

During the fifth and sixth days the main stem of the vagus grows farther back and innervates the heart, lungs, and stomach. Neuroblasts of the sympathetic system accompany the vagus in its growth, and form the various ganglion cells of the heart, and other organs innervated by the vagus.

During the fifth and sixth days the ganglion nodosum, which originally lay at the hind end of the pharynx, is carried down with the retreat of the heart into the thorax, and on the eighth day it is situated at the base of the neck in close contact with the thymus gland.

11. *The Eleventh Cranial or Spinal Accessory Nerve.* No observations on the development of this nerve in the chick are known to me.

12. *The twelfth cranial or hypoglossus nerve* appears on the fourth day as two pairs of ventral roots opposite the third and fourth mesoblastic somites; each root is formed, like the ventral roots of the spinal nerves, of several bundles that unite in a common slender trunk; ganglia are lacking, as in the first and second cervical nerves. The roots of the hypoglossus are a direct continuation of the series of ventral spinal roots, and as they are related to somitic muscle plates in the same way as the latter, there can be no doubt of their serial homology with ventral roots of spinal nerves. The first four mesoblastic somites are subsequently incorporated in the occipital region of the skull, and thus the hypoglossus nerve becomes a cranial nerve. No nerves are formed in connection with the first and second mesoblastic somites. As the occipital region of the skull forms in the region of the occipital somites, two foramina are left on each side for exit of the roots of the hypoglossus (Figs. 150 and 244).

During the fourth and fifth days the nerve grows back above the roof of the pharynx, then turns ventrally behind the last visceral pouch and forward in the floor of the pharynx.

According to Chiarugi minute ganglia are formed in the second, third, and fourth somites: but they soon degenerate (fourth day) without forming nerves.

NOTE: The structure called "hypophysis" on p. 249, sometimes called Rathke's pouch, forms only the anterior lobe or glandular part of the hypophysis of adult anatomy; the posterior lobe of the hypophysis is derived from the structure called "saccus infundibuli" in this chapter, which is a derivation of the floor of the brain.

CHAPTER IX

ORGANS OF SPECIAL SENSE

I. THE EYE

THE development of the eye up to the stage of 36 somites has been already described. We shall now consider the subsequent changes in the following order: (1) optic cup, (2) vitreous body, (3) lens, (4) anterior chamber, cornea, iris, etc., (5) choroid and sclerotic, (6) the conjunctival sac and eyelids, (7) the choroid fissure and the optic nerve.

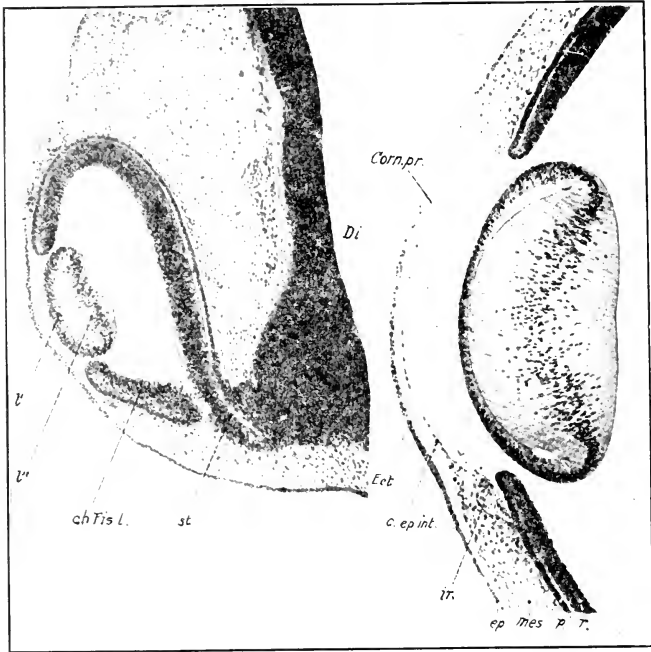
1. **The optic cup** at the stage of 36 somites is composed of two layers, an inner, thicker layer, known as the retinal layer, and an outer, thinner layer, known as the pigment layer; these are continuous with one another at the pupil and choroid fissure. The inner and outer layers come into contact first in the region of the fundus, and the cavity of the original optic vesicle is gradually obliterated. The choroid fissure is in the ventral face of the optic cup; it is very narrow at this time, and opens distally into the pupil; centrally it ends at the junction of optic stalk and cup, not being continued on the stalk as it is in mammals (Fig. 157).

The walls of the optic cup may be divided into a lenticular zone (*pars lenticularis* or *pars caeca*) and a retinal zone; the former includes the zone adjacent to the pupil, not sharply demarcated at first from the remainder or retinal zone, but later bounded distinctly by the ora serrata. The retinal zone alone becomes the sensitive portion of the eye; the lenticular zone develops into the epithelium of the iris and ciliary processes.

In the lenticular zone the inner and outer layers become actually fused, but in the retinal zone they may always be separated; indeed, in most preparations they are separated by an actual space produced by unequal shrinkage.

The differentiation of the lenticular from the retinal zone begins about the seventh day, when a marked difference in thick-

ness appears. The transition from the thinner lenticular to the thicker retinal zone soon becomes rather sudden in the region of the future ora serrata. About the eighth or ninth day a further differentiation arises within the lenticular zone, marking off the regions of the iris and ciliary processes (Fig. 159). The region



157

158

FIG. 157. — Section through the eye of a chick embryo at the beginning of the fourth day of incubation. (After Froriep.)

ch. Fis. l., Lip of the choroid fissure. Di., Lateral wall of the diencephalon. l', l'', Distal and proximal walls of the lens. st., Optic stalk.

FIG. 158. — Section of the distal portion of the eye of a chick, second half of the fifth day of incubation. (After Froriep.)

c. ep. int., Internal epithelium of the cornea. Corn. pr., Cornea propria. Ect., Ectoderm. ep., Epidermis. ir., Iris. mes., Mesoderm. p., Pigment layer of the optic cup. r., Retinal layer of the optic cup.

of the iris is a narrow zone bounding the pupil in which the two layers of the optic cup become blended so that pigment from the outer layer invades the inner layer; the epithelia are decidedly

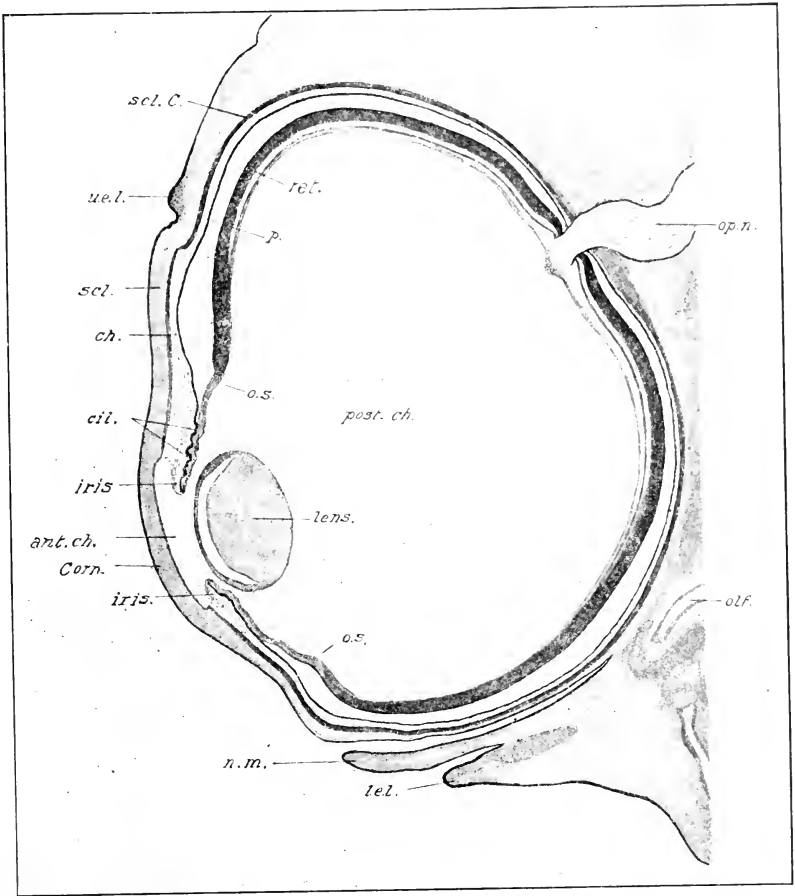


FIG. 159. — Frontal section of the eye of an eight day chick. Shrinking in the process of preparation has caused a separation between the retinal and pigment layers.

ant. ch., Anterior chamber of the eye. ch., Choroid coat. cil., Ciliary processes. Corn., Cornea. l. e. l., Lower eyelid. n. m., Nictitating membrane. olf., Olfactory sac. op. n., Optic nerve. o. s., Ora serrata. p., Pigment layer of the optic cup. post. ch., Posterior chamber of the eye. ret., Retina. scl., Sclerotic coat. scl. C., Sclerotic cartilage. u. e. l., Upper eyelid.

thinner than in the ciliary region. The mesenchyme overlying the iris early becomes condensed to form the stroma of the iris; the epithelia form the uvea of the developed iris (Fig. 159).

The muscles of the iris (sphincter pupillæ) are stated by

Nussbaum, Szily, and Lewis to arise from epithelial buds of the pupillary margin and the adjacent portion of the pigment layer of the iris. The marginal buds (Fig. 160) begin to form during the seventh day, the more peripheral ones somewhat later; the former are less numerous and larger than the latter. The observations are well supported, and appear to leave no doubt that the specificity of the ectoderm cells of the iris is not fixed. According to Lewis the wandering pigmented cells of the anterior portion, at least, of the choroid also arise from the pigment layer of the optic cup.

The ciliary processes begin to form from the ciliary region of the lenticular zone on the eighth day (Fig. 159); the epithelium

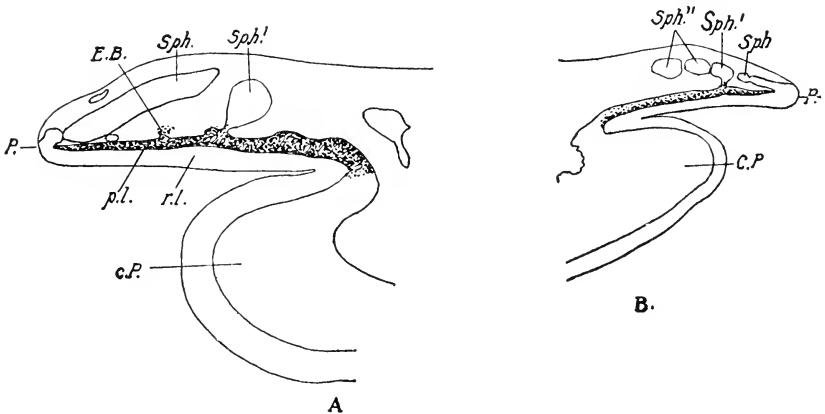


FIG. 160.—Two sections of the pupillary margin of the eye of a chick of 13 days' incubation. A., X 260. B., 130. (After Lewis.)

e. P., Ciliary process. E. B., Epithelial bud. P., Margin of pupil. p. l., Pigment layer of Iris. r. l., Retinal layer of iris. Sph., Bud for the formation of the sphincter muscle of the iris, derived from the margin. Sph.', Sph.', Submarginal buds of the sphincter.

becomes thrown into folds projecting towards the posterior chamber, the cavity of the folds being filled by the mesenchyme of the developing choroid coat. The muscles of the ciliary body develop from the mesenchyme of the processes, which acquire a connection with the lens through a special differentiation of the vitreous body, the zonula ciliaris (zonula Zinnii).

In the retinal portion of the optic cup the inner layer forms the entire retina proper from the internal limiting membrane to the rods and cones inclusive. The outer layer forms the pig-

ment layer of the retina. About the middle of the fourth day pigment begins to develop in the outer layer and extends throughout it, even to the distal portion of the optic-stalk at first (Ueke, '91). The histogenesis of the retina of the chick has been described by Weysse (1906).

2. The Vitreous Humor (Corpus Vitreum). Until comparatively recently embryologists have adhered to the view stated by Schoeler (1848) and Kölliker (1861) that the vitreous body arises from mesenchymal cells that enter the eyeball through the choroid fissure. The fact that the embryonic vitreous humor of birds is almost entirely devoid of cells was a serious difficulty. The cells are in fact so scanty as to be absent in many entire sections. Moreover, in character they resemble embryonic blood-cells and not mesenchyme, and disappear entirely by the eighth day. It seems impossible that they should play any important part in the origin of the massive vitreous body. Researches of the last few years have demonstrated that the vitreous body is primarily of ectodermal origin, its fibers arising as processes of cells of the inner layer of the optic cup and the matrix as secretion. According to some the cells of the lens are responsible wholly (Lenhossek) or in part (Szili) for the fibers; this view, however, has been strongly combatted (Kölliker and Rabl) and requires further evidence to substantiate it.

Both retinal and cæcal parts of the cup take part in the formation of the fibers of the vitreous body; the retinal part is at first the most important, and the primary vitreous body is almost entirely retinal in its origin. But after the cæcal part is differentiated the activity of the retinal part becomes less, and the greater part of the fibers of the vitreous body appears to be formed from cells of the cæcal part, that send out branching and anastomosing processes into the posterior chamber. There is no sharp boundary between the fibers that form the vitreous body and those that form the zonula; and the fibers of the latter may be regarded as homologous to those of the former. The matrix of the embryonic vitreous body may be regarded as a secretion of the walls of the optic cup. Later, the secretion appears to be confined to the ciliary processes. It is possible that the mesenchyme plays some part in the formation of the vitreous body after the formation of the pecten begins; but there is no evidence that it does so at first.

3. **The Lens.** The account of the development of the lens is mainly after Rabl. The wall of the lens-sac is everywhere a single-layered epithelium, though the nuclei are at different levels in the cells.

Shortly after the lens-sac has become separated from the ectoderm the proximal wall (that next the cavity of the optic cup) begins to thicken by elongation of the constituent epithelial cells (Figs. 157 and 158). During the fourth day the elongation of the cells increases greatly as the first step in the formation of the lens fibers, while those of the distal wall remain practically unchanged, being destined to form the epithelium of the lens. Between the cells of the proximal and distal walls are found cells of an intermediate character, bounding the equator of the lens (Fig. 158).

During the fifth day the elongation of the cells of the proximal wall proceeds apace; those in the center of the wall are most elongated and there is a gradual decrease towards the equator of the lens. In this way the face of the proximal wall gradually approaches the distal wall and meets it on the fifth day, thus obliterating the central part of the lens cavity, though the peripheral part remains open for a considerably longer time (Fig. 158). The nuclei of the lens fibers occupy approximately their center, and thus form a fairly broad curved band, concave towards the optic cup. At the same time the lens is increasing very rapidly in size.

During the sixth, seventh, and eighth days the same processes continue and the elongation of the lens fibers makes itself felt on the inner face of the lens which becomes convex. The form and arrangement of the parts is shown in Figure 159. The fibers already present are destined to form only the core of the adult lens; and a new process begins at this time, leading to the formation of fibers that wrap themselves around this core in a meridional direction and form many concentric layers (666 according to Rabl). These new concentric fibers proceed from cells situated between the core fibers and the lens epithelium, that is, around the equator of the lens. There is a very rapid multiplication of cells here; those next the core transform into fibers arranged meridionally on the surface of the core; others develop over these and thus the original fibers come to be surrounded by more and more concentric layers. At first these are disposed rather irregularly, but soon the arrangement becomes extraordinarily regular.

This process is kept up not only during embryonic life, but during the entire growth of the fowl; thus the thickness of the superimposed lamellæ is only 0.60 mm. at hatching, but is 2.345 mm. in the adult (Rabl).

In the fowl the lens includes three concentric layers of fibers: (1) the central mass or core formed by the proximal wall of the original lens-sac; this has the same diameter (0.80 mm.) as the entire fiber mass at eight days. Nuclei are entirely absent. (2) An intermediate layer of meridional rows of fibers rather irregularly arranged, which shade gradually into the fibers of the core and into those of (3) the radial lamellæ, which form the greater part of the substance of the adult lens. The meridional rows and the radial lamellæ proceed from the cells of the intermediate zone of the original lens-sac. Fig. 161 shows a sector of an equatorial section through the lens of a chick. The three zones are well marked; the extraordinary regularity of the superimposed layers of the radial lamellæ is well shown.

The lens epithelium of birds and reptiles also produces a peculiar structure which may be called the equatorial ring (Ringwulst, Rabl).

It will be seen in the figures




FIG. 161.—Equatorial section through the lens of a chick embryo of eight days. The main mass of the entire lens is represented by irregularly arranged central fibers. Towards the surface (above) the fibers are arranged in rows and are quite regularly six sided. (After Rabl.)

that the epithelium is originally thinnest distally and thickens towards the equator. This condition increases up to the eighth day, at which time the thickening increases more a short distance from the equator, so that there is a broad ring-shaped thickening of the anterior epithelium separated by a narrow thinner zone from the cells of the equatorial zone (cf. Fig. 159). This ring increases in thickness during the greater part of the period of incubation, and its cells become fibers arranged in a radial direction. The meaning of this curious structure is somewhat obscure, but from the fact that it shows on its surface the impression of the ciliary processes, Rabl was of the opinion that it served in accommodation of the eye as an intermediary between the ciliary processes and the true lens-fibers.

4. Anterior Chamber and Cornea, etc. When the optic vesicle is first formed it is in immediate contact with the ectoderm. After its invagination the lips of the optic cup withdraw a short distance from the surface. At the same time the lens invaginates and is cut off from the ectoderm, but remains in contact with it during the third day. There is thus a ring-shaped space between the lens and optic cup on the one hand and the ectoderm on the other, which is the beginning of the anterior chamber of the eye (cf. Fig. 96 C). With the formation of the cornea the lens withdraws somewhat from the surface and the space spreads over the whole external surface of the lens; at first it is very narrow, but increases in size by the formation of the iris and the bulging of the cornea.

The cornea itself develops from two sources: (1) the external epithelium is derived from the ectoderm overlying the anterior chamber, (2) the *cornea propria* and the internal epithelium lining the anterior chamber develop from the surrounding mesenchyme but in somewhat different ways.

The *cornea propria* appears on the fourth day as a delicate structureless membrane beneath the corneal epithelium. During the fifth day it increases to about the thickness of the overlying ectoderm (Fig. 158). About this time mesenchyme cells from the margin of the optic cup begin to migrate between the *cornea propria* and lens, and soon form a single complete layer of cells on the inner face of the *cornea propria*; this layer becomes the inner epithelium of the cornea (Fig. 158). The *cornea propria* is still devoid of cells, but on the sixth and

seventh days the mesenchyme surrounding the eyeball begins to penetrate it from all sides in the form of a compact wedge, which, advancing in the substance of the cornea propria, soon meets in the center. These cells form the so-called corpuscles of the cornea. They appear arranged in strata from a very early period.

The anterior chamber is bounded by the cornea externally; its margins, which are at first coincident with the lips of the optic cup, soon extend peripherally over the iris (Fig. 159). The inner epithelium ceases at the margin of the cavity or is continuous with the cells of the sclerotic; it does not appear, in an eight-day chick at any rate, to be reflected over the iris, but the epithelium of this structure next the anterior chamber appears to be simply a special differentiation of its own superficial cells. The anterior chamber is closed centrally by the lens, but communicates more or less for a considerable period around its margin with the posterior chamber. This is at least the appearance in good sections; it seems probable, though, that in life there is contact between the optic cup and lens.

The stroma of the iris proceeds from that portion of the mesenchyme left in association with the pars iridis retinae after the peripheral extension of the anterior chamber. It becomes very vascular at an early stage. The canal of Schlemm arises as a series of vacuoles just peripheral to the margin of the anterior chamber about the eighth day. These soon run together to form a ring, which is separated from the anterior chamber by the *ligamentum pectinatum iridis*.

5. **The choroid and sclerotic coats** are differentiations of the mesenchyme surrounding the optic cup. But little is known concerning the details of their development in the chick. A figure of Kessler's shows chromatophores developed in the choroid coat at twelve days; I find a very few already formed at eight days. Cartilage begins to appear in the sclerotic at eight days, the forerunner of the sclerotic ossicles (Fig. 159).

6. **The Eyelids and Conjunctival Sac.** The integument over the embryonic eyeball remains unmodified until about the seventh day. At this time a circular fold of the integument forms around the eyeball with the pupil as its center. At the same time a semi-lunar fold develops within the first on the side of the eyeball next the beak. (See Figs. 122-124.) From the

first fold the upper and lower eyelids are developed, and from the second the third eyelid or nictitating membrane. The area bounded by the outer ring-shaped fold becomes the conjunctival sac.

From their place of origin the free edges of these folds then grow towards the center, and thus a cavity, the conjunctival sac, is formed between the folds and the integument over the eyeball (conjunctiva scleræ). The outer fold grows more rapidly above and below than at the sides and the opening narrows, becoming, therefore, gradually elliptical and finally somewhat spindle-shaped. Thus the upper and lower eyelids are established. The semi-lunar fold of the embryonic nictitating membrane also grows towards the pupil, most rapidly in its center. The conjunctival sac also expands peripherally, especially at the inner angle of the eye, and thus accommodates itself to the increasing size of the eyeball (Fig. 159).

The Harderian gland is visible on the eighth day as a solid ingrowth of ectodermal cells of the conjunctival sac at the innermost angle of the nictitating membrane.

Feather germs develop on the outer surface of both upper and lower lids especially at their edges. The ectoderm covering the inner faces of the upper and lower lids, both faces of the nictitating membrane and the remainder of the conjunctival sac becomes modified into a moist mucous membrane. Over the cornea the ectoderm is especially modified as already noted.

Papillæ Conjunctivæ Scleræ. On the seventh day of incubation papillæ begin to appear on the surface of the conjunctiva scleræ and soon form a ring surrounding the iris at some distance peripheral to its margin (Figs. 122, 123 and 124). The number of these papillæ appears to be quite constantly fourteen. They are at first fully exposed owing to the undeveloped condition of the eyelids, but the latter overgrow them about the eleventh or twelfth days. Degeneration of the papillæ begins about this time, and on the thirteenth day they have entirely disappeared. In section they are found to be thickenings of the ectoderm, produced by multiplication of the cells. They may rise above the surface; but more frequently project inwards towards the connective tissue. There is apparently no accompanying hypertrophy of the latter. Thus they differ quite essentially from feather germs with which it seems natural to compare them; and their significance is entirely problematical (see Nussbaum).

7. **Choroid Fissure, Pecten, and Optic Nerve.** The pecten of the hen's eye is a pigmented vascular plate inserted in the depression occupying the center of the elongated blind spot, or entrance of the optic nerve, which extends meridionally from the fundus nearly to the ora serrata. The pecten projects a considerable distance into the posterior chamber and its free edge is much longer than its base, being consequently folded like a fan; hence the name. The optic nerve runs along the base of the pecten, its fibers passing off on either side into the retina; thus it continually diminishes in size until it disappears. The pecten is consequently separated from the choroid coat by the optic nerve. It is supposed to function as a nutrient organ for the layers of the retina, by means of lymph channels that pass off from its base into the retina. There is no *arteria centralis retinae* in the bird's eye.

These structures develop in connection with the choroid fissure as follows: On the fourth day the choroid fissure has become a very narrow slit, and by the middle of the day its edges are in apposition in the *pars caeca* of the bulbus. Proximally, however, the meeting of the lips of the fissure is prevented by the mesoblast, in which the basal blood-vessel runs along the entire length of the open portion of the fissure. During the fourth day this blood-vessel enters the posterior chamber with its enveloping mesenchyme along the entire length of the open portion of the choroid fissure, and forms a low mesenchymal ridge connected by a narrow neck of mesenchyme in the fissure with the mesenchyme outside. During the fifth day the ridge becomes higher and keel-shaped, and a thickening appears along part of its free edge above the blood-vessel. During this day also fusion of the lips of the choroid fissure has taken place in the *pars caeca*. At the same time an important change begins in the proximal portion of the choroid fissure that leads to the formation of the pecten proper. This is an involution of the lips of the optic cup bounding the choroid fissure on each side of the mesodermal keel, and their continuous ingrowth until they meet over the keel and fuse above it in a mass in which the outer and inner layers of the retina are indistinguishably fused. Thus the proximal portion of the mesodermal keel is enclosed in a kind of tunnel composed of the involuted edges of the optic cup. The formation of this tunnel progresses gradually from the fundus towards

the ora serrata by the same process of involution, until on the eighth day the mesodermal keel is completely covered up.

Fig. 162 gives a diagrammatic view of the condition of the pecten in the middle of the seventh day of incubation. Figs. 163 and 164 show sections through this at the points *a*, *b*, *c*, *d*, *e*, indicated in the figure. The formation of the tunnel will be readily understood by study of the figures. It will be seen that the major portion of the embryonic pecten is of ectodermal origin, and that the mesoderm forms a relatively inconspicuous part of it. Later, on the same day, it becomes increasingly difficult

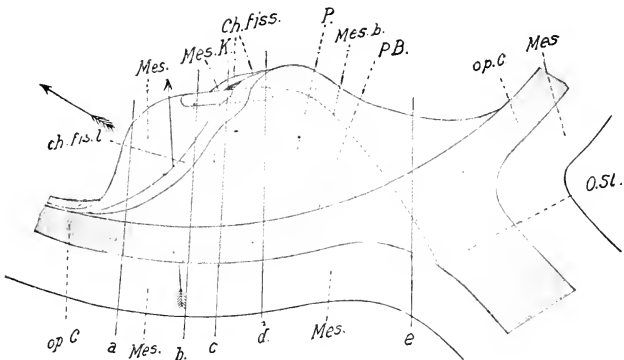


FIG. 162. — Diagrammatic reconstruction of the pecten of the eye of a chick embryo of 7½ days' incubation. (After Bernd.)

Ch. fis. l., Lip of the choroid fissure. Ch. fiss., Choroid fissure. Mes., Mesoblast. Mes. b., Boundary of the mesoblast within the choroid fissure. Mes. K., Thickening of the mesoblastic keel. op. C., Optic cup. O. St., Optic stalk. P., Pecten. P. B., Base of the pecten.

The arrow indicates the direction of growth of the ectodermal tunnel.

The lines *a*, *b*, *c*, *d*, *e* show the planes of the sections reproduced in Fig. 163 (*a*, *b*, *c*, *e*) and in Fig. 164 (*d*).

to distinguish ectodermal and mesodermal portions of the pecten, and thereafter it is quite impossible to say which parts of it are of ectodermal and which are of mesodermal origin. During the eighth and ninth days the pecten increases greatly in height, and becomes relatively very much narrower.

The folds of the pecten now begin to develop and, by the seventeenth day their number is 17-18, the same as in the adult. The pigment does not begin to appear until about the twelfth day. The details of the development of the blood-vessels are not known.

The Optic Nerve. Owing to the relations established by the choroid fissure, the floor of the optic stalk is continuous from the first with the inner layer of the retina (Fig. 96 B), and it furnishes the path along which the optic nerve grows. The axones of the optic nerve originate, for the most part, from the retinal neuroblasts, composing the layer next to the cavity of the optic cup, and their growth is thus centripetal. They are first formed in the fundus part of the retina, and grow in the direction of the

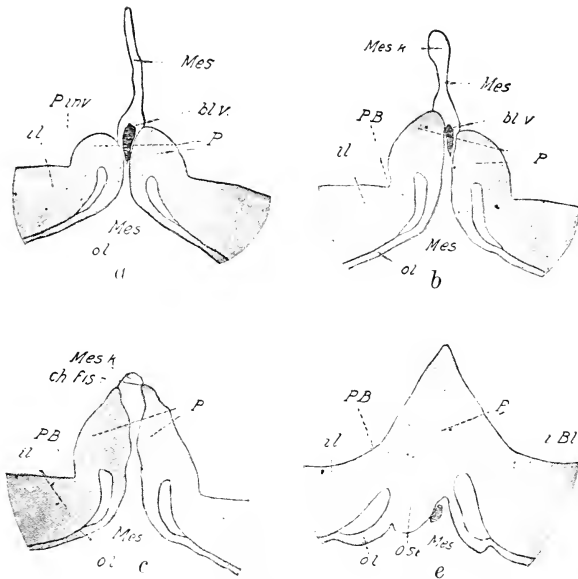


FIG. 163. — Outlines of sections in the planes a, b, c, e, of Fig. 163. (After Bernd.)

bl. v., Blood vessel. i. l., Inner or retinal layer of the optic cup. o. l., Outer or pigment layer of the optic cup. P. inv., Angle of invagination of the pecten. Other abbreviations as before. (Fig. 162.)

optic stalk between the internal limiting membrane and the neuroblast layer (ganglion cell layer), thus forming a superficial layer of axones; their formation begins on the fourth day, and there is a period about the end of this day when axones are found in the distal part of the optic stalk, next to the bulbus oculi, but not in the proximal part, next to the brain. This observation affords conclusive proof of the retinal origin of the fibers of the optic

nerve; moreover, at an early stage of their differentiation it is possible to trace their connection with retinal neuroblasts.

The first fibers of the optic nerve are formed, as already stated, from the fundus part of the retina; the fibers, therefore, pass directly to the floor of the optic stalk; but on the fifth day the formation of fibers begins from more distal portions of the retina and these do not grow towards the insertion of the optic stalk, but towards the choroid fissure; arrived there, they bend centrally and run in a bundle on each side along the floor of the bulbus oculi to the optic stalk, where they join with the fibers first formed. The later formed fibers pass to still more distal portions

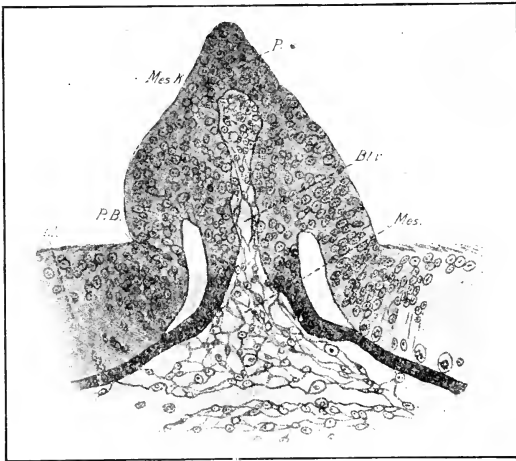


FIG. 164. — Section in the plane of *d* of Fig. 162, to show the histological structure. (After Bernd.) Abbreviations as before.

of the choroid fissure, and, as the pecten forms in the manner already described, the fibers of the optic nerve all unite beneath it on their way to the original optic stalk. Thus, the optic nerve obtains an insertion coincident in length with the base of the pecten, and its fibers, radiating off into the retina on each side of the pecten, separate the latter completely from the choroid coat of the eyeball.

The optic stalk is at first a tubular communication between the optic vesicle and the fore-brain, and its walls are an epithelial layer of the same thickness throughout. The fibers of the optic

nerve grow into its ventral wall exclusively, between its epithelial cells, which gradually become disarranged and irregular. Thus the ventral wall becomes increasingly thick and the lumen excentric. By the sixth day the lumen appears in cross-section as a narrow lenticular space with an epithelial roof, above the large optic nerve. Soon after, the lumen disappears entirely; no trace of its former existence is to be found on the eighth day.

II. THE DEVELOPMENT OF THE OLFACTORY ORGAN

The origin of the olfactory pit, external and internal nares, and olfactory nerve, has already been considered (pp. 169, 215, and 263). Before the formation of the internal and external nares, not only has the entire olfactory epithelium become invaginated, but, owing to the elevation of internal and external nasal processes, the pit has become so deepened that the margin of the olfactory epithelium proper now lies a considerable distance within the cavity. That part of the nasal cavity thus lined with indifferent epithelium is known as the olfactory vestibule. After the fusion of the internal nasal process with the external nasal and maxillary processes, the cavity deepens still more.

The choanæ lie at first just within the oral cavity, but the palatine processes of the maxillary process, growing inwards across the primitive oral cavity (pp. 298, 299), unite on the sixth or seventh day at their anterior ends with the internal nasal processes, and thus cut off an upper division of the primitive oral cavity at its anterior end from the remainder; in this way the internal openings of the nasal cavities into the oral cavity are carried back of the primitive choanæ; they are henceforward known as the secondary choanæ. Further growth of the palatine processes brings them nearly together in the middle line along the remainder of their length, about the eleventh day; but fusion does not take place, the birds possessing a split palate. Thus the superior division of the primitive oral cavity is added to the respiratory part of the nasal passages.

The nasal cavity is further elaborated between the fourth and eighth days by ingrowths from the lateral wall (turbinals) and by the formation of the supraorbital sinus as an evagination that grows outwards above the orbit. Three turbinals are formed in the nasal cavities, viz., the superior, middle, and inferior turbinals. These arise as folds of the lateral wall projecting into

the lumen, the superior and middle from the olfactory division proper, and the inferior from the vestibulum; on the middle turbinal, however, the sensory epithelium gradually flattens out to the indifferent type. The middle turbinal appears first in the ventral part of the olfactory division, about the beginning of the fifth day, and the superior somewhat later, immediately above the former, the two being separated by a deep groove (Fig. 165). The vestibular turbinal arises still later, and is well formed on the eighth day.

Fig. 166 shows a reconstruction of the nasal cavity, seen from the lateral side, of an embryo of about seven days. It is a reconstruction of the epithelium, and thus practically a mold of the cavity; therefore projections into the cavity appear as depressions in the model, and the grooves and outgrowths of the external wall as projections. The superior turbinal has an oval shape with the long axis in an apical direction; it is bounded by a fairly deep depression, the elevated margin of the model, from the lower end of which the supra-orbital sinus (S. s'o.) passes off ventrally and externally. The deep depression immediately below the superior turbinal lodges the median turbinal. A fairly long passage leads off from its neighborhood to the choanæ and a shorter one, the vestibulum, to the external nares. The depression in the wall of the vestibulum is caused by the vestibular or inferior turbinal. The palatine and maxillary sinuses are not yet formed.

The external nares are closed during the greater part of the period of incubation by apposition of their walls. The form and dimensions of the nasal cavities change greatly during incubation, owing to shifting in the original positions of the turbinals, outgrowth of the facial region, and development of sinuses. The details are not very well investigated, and an examination of them would lead too far.

There has been a good deal of discussion as to the existence of an organ of Jacobson in the nose of birds; it has usually been assumed that it is entirely absent even in the embryo. Others have identified the ducts of nasal glands as a modification of this organ. Recently, however, Cohn has described a slight evagination in the median wall of the primary olfactory pit, that agrees precisely in its form and relationship with the first rudiment of the organ of Jacobson in reptiles. Although it persists only from the stage of about 5.3 mm. to about the stage of

5.9 mm. head-length, he identifies it positively as a rudimentary organ of Jacobson.

The septal gland arises on the eighth day from the inner wall of the vestibulum, opposite the base of the vestibular tur-

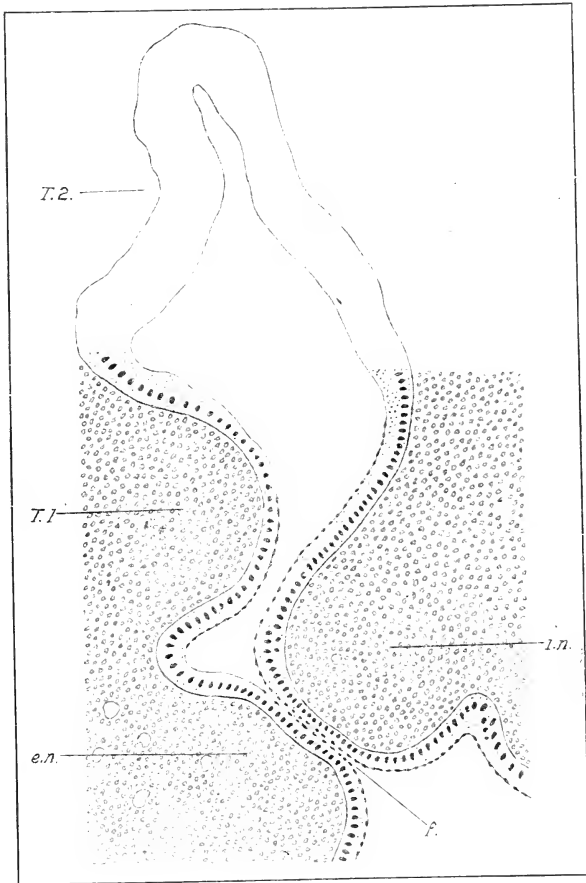


FIG. 165. — Transverse section of the olfactory organ of a chick embryo, of 7.5 mm. head length. (After Cohn.)

f., Line of fusion. e. n., External nasal process. i. n., Internal nasal process. T. 1, T. 2, Intermediate and superior turbinals.

binal, as a solid cord of cells. This grows backwards in the nasal septum and passes to the outer side and branches, subsequently acquiring a lumen.

III. THE DEVELOPMENT OF THE EAR

The ear develops from two entirely different primary sources, viz., the otocyst, and the first visceral or hyomandibular cleft: The former furnishes the epithelium of the membranous labyrinth; the entodermal pouch of the latter becomes the tympano-eustachian cavity; and part of the external furrow forms the external auditory meatus; the tissue between the internal pouch and the external furrow develops into the tympanum. The mesenchyme in the neighborhood of each of these primordia becomes modified,

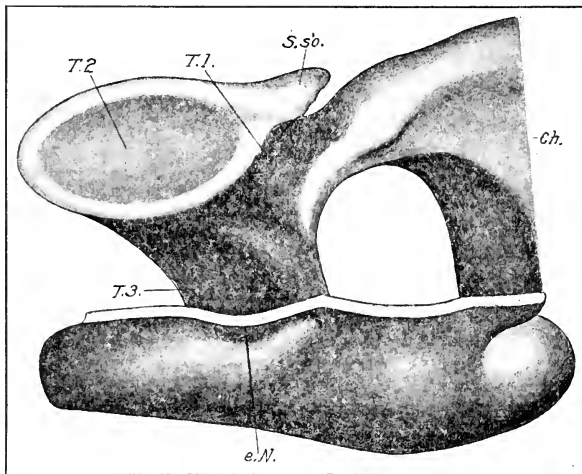


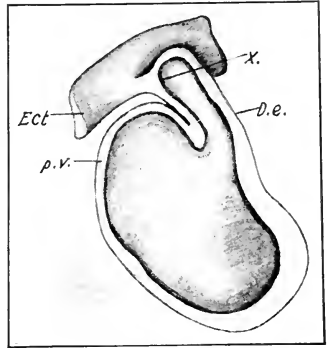
FIG. 166. — Reconstruction of the nasal cavity of a chick embryo of about 7 days; lateral view. (After Cohn.)

Ch., Choanae. e. N., External nares. S. s'o., Supra-orbital sinus. T. 1, T. 2, T. 3, Intermediate, superior and inferior (vestibular) turbinals.

(1) to form the bony labyrinth, perilymph, and other mesenchymal parts of the internal ear, and (2) to form the auditory ossicles of the middle ear. Thus the ear furnishes a striking example of the combination of originally diverse components in the formation of a single organ. The course of evolution of this complex sense-organ is thus illustrated in the embryonic development; in the *Sclachia* the hyomandibular cleft is a communication between pharynx and exterior, like the branchial clefts, and still preserves to a certain extent the respiratory function. The embryonic history furnishes a summary of the way in which it was gradually

drawn into the service of the otocyst in the course of evolution.

Development of the Otocyst and Associated Parts. In Chapter VI we took up the formation of the otocyst and the origin of the endolymphatic duct. The latter is at first an apical outgrowth from the otocyst, but its attachment soon becomes shifted to the median side of the otocyst, owing to the expansion of the dorsal external wall of the latter (Fig. 167). Three divisions of the otocyst may now be distinguished: (a) ductus endolymphaticus or recessus labyrinthi; (b) pars superior labyrinthi; (c) pars inferior labyrinthi. The boundary between the two latter is rather indistinctly indicated at this stage by a shallow groove on the median face of the otocyst. The development of these parts may now be followed separately.



(a) *The Development of the Ductus Endolymphaticus.* It was noted in Chapter VI that the ductus endolymphaticus is united to the epidermis by a strand of cells that preserves a lumen up to the stage of 104 hours at least (Fig. 98). Shortly after, this connection is entirely lost.

FIG. 167. — Model of the otocyst of a chick embryo shortly before its separation from the ectoderm. (After Krause.)

D. e., Endolymphatic duct. Ect., Ectoderm. p. v., Pocket for formation of vertical semicircular canals. X indicates the strand of cells uniting the endolymphatic duct to the ectoderm.

The opening of the endolymphatic duct into the otocyst appears to be shifted more and more ventrally along the median surface, with the progress of differentiation of the other parts of the otocyst, until it lies in the region of communication of the utriculus, sacculus and lagena (Figs. 168 and 171). This is brought about by the various foldings and expansions of the wall of the otocyst described in *b* and *c*. In the meantime the endolymphatic duct has increased in length with the growth of the surrounding parts, and on the sixth day the distal half begins to expand to form the saccus endolymphaticus, lying between the utriculus and the hind-brain. The elongation of the entire endolymphatic duct and the enlargement of the saccus continue during the seventh day, and on the eighth day the saccus overtops

the hind-brain and bends in above it towards the middle line (Fig. 168). The right and left sacci are, however, still separated by a considerable space. The walls of the saccus already form a large number of low folds, presumably glandular, the first begin-

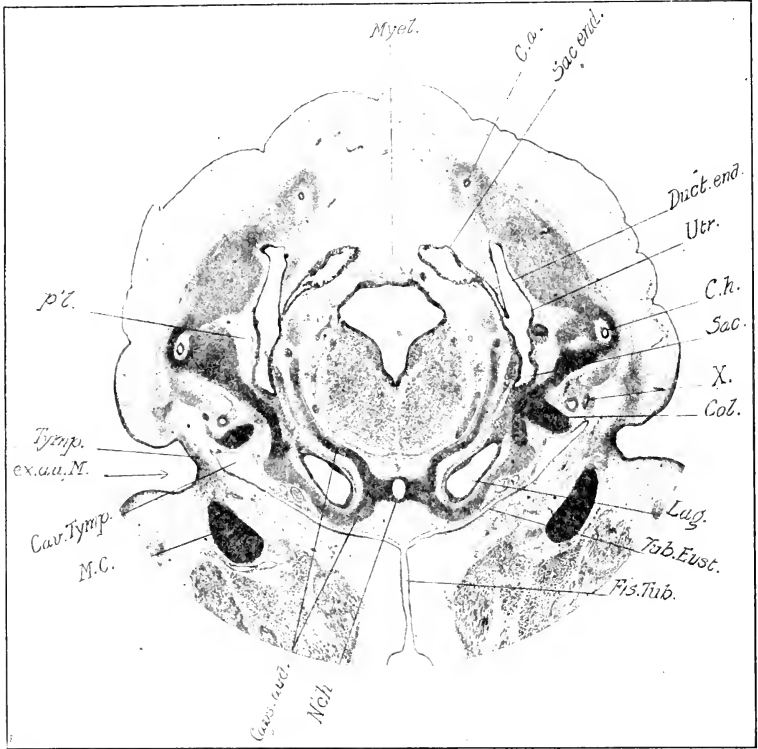


FIG. 168. — Transverse section through the head of a chick embryo of eight days in the region of the ear (photograph).

C. a., Anterior semicircular canal. C. h., Horizontal semicircular canal. Caps. aud., Auditory capsule. Cav. Tymp., Tympanic cavity. Col., Columella. Duct. end., Endolymphatic duct. ex. au. M., External auditory meatus. Fis. Tub., Tubal fissure. Lag., Lagena. M. C., Meckel's cartilage. Myel., Myelencephalon. N. ch., Notochord. p.l., Perilymph. Sac., Sacculus. Sac. end., Endolymphatic sac. Tub. Eust., Eustachian tube. Tymp., Tympanum. Utr., Utriculus. X., Sac derived from the inner extremity of the tympanic cavity.

nings of which were visible on the sixth day. The form of the saccus and ductus endolymphaticus at a somewhat later stage is shown in the reconstruction (Fig. 173).

It is interesting to note that the epidermic attachment to the endolymphatic duct is about at the junction of the saccus endolymphaticus and ductus endolymphaticus s.s. If this may bear a phylogenetic interpretation, it would seem that the saccus should be regarded as an addition to the primitive ductus of *Selachii*, which opens on the surface.

(b) *Development of the Pars Superior Labyrinthi; Origin of the Semicircular Canals.* We have already seen that the shifting of the ductus endolymphaticus to the median surface of the otocyst is brought about by a vertical extension of the superior lateral wall of the otocyst, which forms a shallow pocket opening widely into the otocyst (Fig. 167). Slightly later a second pocket is formed by a horizontally extended evagination of the lateral wall of the pars superior directed towards the epidermis. These two pockets, known as the vertical and horizontal pockets, are the fore-runners of the semicircular canals: the vertical of both anterior and posterior, and the horizontal of the horizontal semicircular canal. The horizontal pocket forms at about the middle of the external surface on the fifth day; immediately above it is a roughly triangular, pear-shaped depression in the wall of the otocyst, bounded by the vertical pocket on the other two sides. Thus the vertical pocket consists of two divisions, anterior and posterior, meeting at the apex of the otocyst (Fig. 169).

The pockets gradually deepen; and the semicircular canals arise from them by the fusion of the walls of the central part of each pocket, thus occluding the lumen except at the periphery (Fig. 170). The fused areas subsequently break through. The peripheries thus form semicircular tubes communicating at each end with the remainder of the superior portion of the otocyst, or *utricle*, as it may now be called. Three semicircular canals are thus formed, one from each division of the original vertical pocket and one from the horizontal pocket. The upper ends of the anterior and posterior semicircular canals, formed from the anterior and posterior divisions of the vertical pocket, open together into

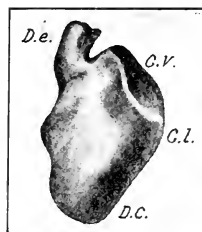


FIG. 169.—Model of the auditory labyrinth (otocyst) of a chick embryo of undetermined age; view from behind. (After Röthig and Brugsch.)

C. l., Pocket for the formation of the lateral (horizontal) semicircular canal. C. v., pocket for formation of vertical semicircular canals. D. C., Primordium of ductus cochlearis and lagena. D. e., endolymphatic duct.

the apex of the utriculus; and the horizontal canal formed from the external pocket extends between the separated lower ends of the other two.

We must now proceed to a more detailed examination. In

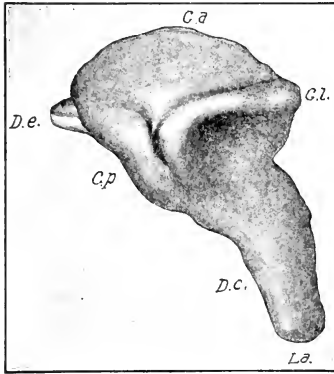


FIG. 170. — Model of the auditory labyrinth of a chick embryo of 6 days and 17 hours; external view. (After Röhlig and Brugsch.)

C. a., Pocket for formation of anterior semicircular canal. C. l., Pocket for formation of lateral semicircular canal. C. p., Pocket for formation of posterior semicircular canal. D. c., Ductus cochlearis. D. e., Endolymphatic duct. L. a., Lagena.

point of time the anterior (sagittal) semicircular canal is the first to be formed (Fig. 171); the external (horizontal or lateral) canal comes next, and considerably later the posterior (frontal). Thus the anterior canal is at first the largest, the external next, and the posterior the smallest. These differences are, however, largely compensated in the course of the embryonic development. The ampullæ appear as dilations in the pockets even before the canals are formed, and are conspicuous dilations by the time that the central parts of the pockets have broken through (Fig. 172).

Figs. 170–173 show the pockets and canals at six days seventeen hours, seven days seventeen hours, eight days seventeen hours, and eleven days seventeen hours. It will be seen that, whereas the anterior and lateral canals are formed from the start in planes at right angles to one another, viz., the sagittal and horizontal, the posterior canal is not at first in the third or transverse plane, but gradually assumes it.

The form of the utriculus is gradually assumed during the formation of the semicircular canals; it becomes drawn out into a roughly triradiate form, so that it consists of a central cavity and three sinuses, viz., the median sinus which receives the end of the anterior and posterior semicircular canals, the posterior sinus situated above the ampulla of the external semicircular canal, and the anterior sinus in the region of the ampullæ of the horizontal and sagittal semicircular canals (cf. Fig. 173). A short distance in front of the posterior sinus on the median face of

the utriculus occur the openings of the ductus endolymphaticus, sacculus, and ductus cochlearis; the two latter derived from the pars inferior of the otocyst, to the development of which we now turn.

(c) *Development of the Pars Inferior Labyrinthi; Lagena, Ductus Cochlearis, and Sacculus.* During the changes described in the pars superior labyrinthi, the pars inferior has developed into the ductus cochlearis and lagena on the one hand, and the sacculus on the other. Throughout the series of the vertebrates

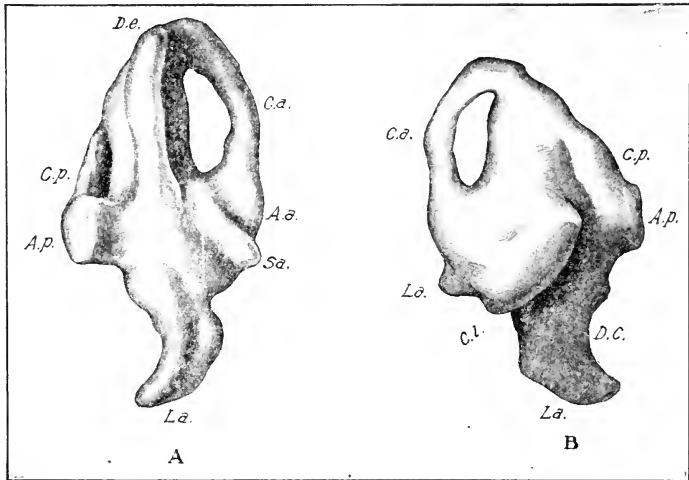


FIG. 171. — Model of the auditory labyrinth of the left side of a chick of 7 days and 17 hours. A. Median view. B. External view. (After Röhlig and Brugsch.)

A. a., Ampulla of the anterior semicircular canal. A. p., Ampulla of the posterior semicircular canal. C. a., Anterior semicircular canal. C. l., Pocket for formation of the lateral semicircular canal. C. p., Pocket for formation of the posterior semicircular canal. S. a., Sacculus. Other abbreviations as before.

the structure of the pars superior is very uniform; the pars inferior, on the other hand, has a characteristic structure in each class and exhibits in general a progressive evolution. The condition in the chick is characteristic on the whole for the class of birds.

At six days the lower division of the otocyst has grown out ventralward into a deep pouch which is curved posteriorly and towards the middle line (Fig. 170); the terminal portion is the rudiment of the lagena, and the intermediate portion of the ductus

cochlearis; the tip of the lagena in its growth ventralward has reached the horizontal level of the notochord. The sacculus is barely indicated yet, but is clearly seen on the seventh day as a slight protuberance on the median surface of the uppermost part of the pars inferior; it lies in front of the lower end of the endolymphatic duct at a slightly lower level and is separated by two depressions above and below, from the anterior ampulla and the ductus cochlearis respectively. The furrows above the sacculus and below the ampulla of the frontal semicircular canal mark the boundary between the pars superior and inferior.

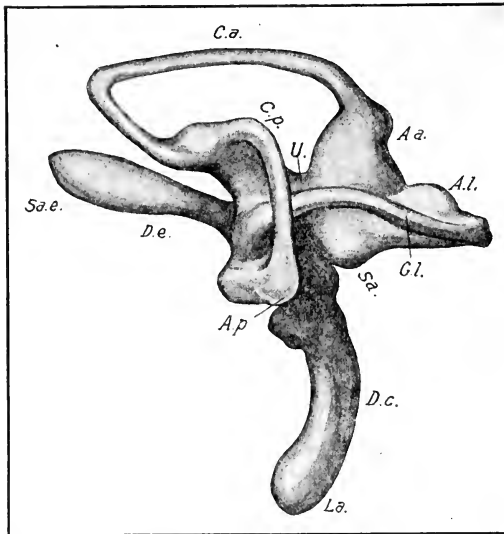


FIG. 172. — Model of the auditory labyrinth of the right side of a chick embryo of 8 days and 17 hours; external view. (After Röthig and Brugsch.)

A. a., Ampulla of the anterior semicircular canal. A. l., Ampulla of the lateral semicircular canal. A. p., Ampulla of the posterior semicircular canal. C. a., Anterior semicircular canal. C. l., Lateral semicircular canal. C. p., Posterior semicircular canal. S. a. e., Endolymphatic sac. U., Utriculus. Other abbreviations as before.

A day later (Fig. 172), these furrows have cut in deeper and have become continuous on the median surface; the lagena has enlarged distally, and the sacculus is a hemispherical protuberance. The tip of the lagena lies beneath the hind-brain (Fig.

168). The condition shown in Fig. 173, at eleven days seventeen hours is substantially the same as in the adult.

(d) *Development of the Auditory Nerve and Sensory Areas of the Labyrinth.* During the changes in the form of the labyrinth described in the preceding section, the lining epithelium has become thin and flattened except in eight restricted areas: viz., the three *cristæ acusticæ*, one in each of the ampullæ of the semi-circular canals, the *macula utriculi*, the *macula sacculi*, the *papilla*

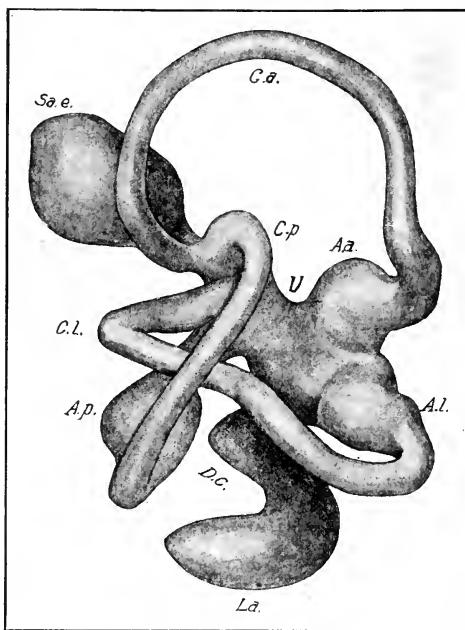


FIG. 173. — Model of the auditory labyrinth of the right side of a chick embryo of 11 days and 17 hours; external view. (After Röhlig and Brugsch.) Abbreviations as before.

lagenæ, the *papilla basilaris* and the *macula neglecta*. Each of these contains sensory cells ending in fine sensory hairs projecting into the endolymph, or fluid of the labyrinth, and receives a branch of the auditory nerve proceeding from the acoustic ganglia.

Returning to an early stage to follow the development of sensory areas and nerves, we note first that the acoustic ganglion from which the auditory nerve arises takes its origin from the acustico-

facialis ganglion which lies in front of and below the center of the auditory pit. During the closure of the latter, the acoustic ganglion becomes fused with part of the wall of the otocyst in such a way that it becomes impossible to tell in ordinary sections where the epithelial cells leave off and the ganglionic cells begin. This fused area may be called the auditory neuro-epithelium. At the 36 somite stage the neuro-epithelium is confined to the lower (ventral) fourth of the otocyst, covering the entire tip, the anterior face, and a small portion of the median face (cf. Fig 98). The neuro-epithelium is the source of all the sensory areas, which arise from it by growth and subdivision. The branching of the auditory nerve follows the subdivision of the neuro-epithelium.

The exact manner in which the changes take place has not been made a subject of special investigation in the chick, so far as the author knows. However, it can be said in general that there is first a partial division of the neuro-epithelium into a pars superior and a pars inferior, and that the former divides into the *cristæ acusticæ* (sensory areas of the three ampullæ) and the *macula utriculi*, while the latter furnishes the *macula sacculi*, *papilla basilaris* and *papilla lagenæ*.

The sensory cells differentiate from the epithelium of the labyrinth, and the nerve fibers from the bipolar neuroblasts of the acoustic ganglion, the peripheral process growing into the epithelium and branching between the sensory cells, while the central process grows into the brain.

(e) *Bony Labyrinth, Perilymph, etc.* The loose mesenchyme that entirely surrounds the otocyst, differentiates in the course of development into the *membrana propria* and perilymphatic tissue of the membranous labyrinth, the perilymph and the bony labyrinth in the following manner; on the sixth day a single layer of mesenchyme cells in contact with the cells of the otocyst are arranged with their long axes parallel to the wall, and show already in places a slight fibrous differentiation. These gradually form the *membrana propria*, which appears on the eighth day as an extremely thin adherent layer with protruding nuclei at intervals. The mesenchyme external to this delicate layer is already differentiated on the sixth day into a perilymphatic and a procartilaginous zone; in the former the mesenchyme is of loose consistency, and in the latter zone it has become dense

as a precursor to chondrification. The distinction between the perilymphatic and cartilaginous zones is most distinct (on the sixth day) on the median surface of the ductus cochlearis and lagena. The differentiation proceeds rapidly, however, and on the eighth day the entire membranous labyrinth is surrounded by a mass of embryonic cartilage, the foundation of the bony labyrinth, excepting around the endolymphatic duct (Fig. 168). Between the bony and membranous labyrinths is a thick layer of perilymphatic tissue composed of very loose-meshed mesenchyme, which in the course of the subsequent development breaks down to form the perilymphatic space. Portions of the perilymphatic tissue, however, remain attached to the membranous labyrinth and form a support for its blood-vessels and nerves.

The Development of the Tubo-tympanic Cavity, External Auditory Meatus and Tympanum. These structures develop directly or indirectly from the first or hyomandibular visceral cleft and the adjacent wall of the pharynx. In a preceding chapter the early development of this cleft was described; we saw that the pharyngeal pouch forms two connections with the ectoderm, a dorsal one corresponding to a pit-like depression of the ectoderm, and a ventral one corresponding to an ectodermal furrow. The latter connection is soon lost, the ectodermal furrow slowly disappears, and the ventral portion of the pouch flattens out. In the dorsal connection, however, an opening is formed which closes on the fourth day, and the dorsal division of the pouch then frees itself from the ectoderm and expands dorsally and posteriorly until it lies between the otocyst and the ectoderm, still preserving its connection with the pharynx (Fig. 102).

(a) *The Tubo-tympanic Space.* The dorsal portion of the first visceral pouch forms the lateral part of the tubo-tympanic space, but the greater portion of the latter is derived from the lateral wall of the pharynx itself, immediately adjacent to the entrance into the first visceral pouch; the region concerned extends from near the anterior edge of the second visceral pouch forwards, and ends a short distance in front of the first pouch. The original transverse diameter of the pharynx in this region increases in the course of development, and a frontal partition grows across the pharynx forming a dorsal median chamber into

which the two tubo-tympanic cavities open. The median chamber communicates by a longitudinal slit (tubal fissure) in the roof of the pharynx with the oral cavity (Figs. 168 and 175).

The frontal partition in question is a posterior prolongation of the palatine processes of the maxillary arch, and forms as follows:

If the head of a four-day chick be halved by a sagittal plane, and the interior of the pharynx and mouth cavity be then viewed by reflected light, an elongated lobe will be seen on the median surface of the mandibular arch and maxillary process (Fig. 174 A). This lobe begins far forward on the median surface of the maxillary process and may be followed posteriorly over the median surface of the mandibular arch to the first visceral pouch, where it ends with a free rounded extremity. The lobe itself is called by Moldenhauer the colliculus palato-pharyngeus; it is bounded above and below by depressions, viz., the sulcus tubo-tympanicus dorsally and the sulcus lingualis ventrally, both of which end behind in the first visceral pouch;

anteriorly the ventral furrow disappears at the margin of the mouth, and the dorsal furrow near Seessel's pocket. The maxil-

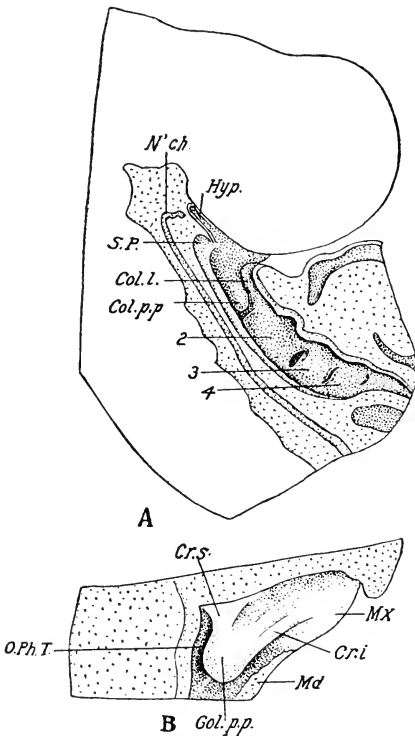


FIG. 174. — A. Head of a chick embryo of 4 days, halved by median section and viewed from the cut surface. (After Moldenhauer.)

B. Internal view of the pharynx of a pigeon embryo, corresponding in development to a chick of 10 days. (After Moldenhauer.)

Col. l., Colliculus lingualis. Col. p. p., Colliculus palato-pharyngeus. Cr. i., Crus inferior. Cr. s., Crus superior. Hyp., Hypophysis. Mx., Maxilla. N'ch., Notochord. O. Ph. T., Ostium tubae pharyngae. S. P., Seessel's pocket. 2, 3, 4, Second, third, and fourth visceral arches.

anteriorly the ventral furrow disappears at the margin of the mouth, and the dorsal furrow near Seessel's pocket. The maxil-

lary portion of the colliculus palato-pharyngeus corresponds to the palatine processes of mammals; the mandibular portion is peculiar to Sauropsida.

If the interior of the pharynx and oral cavity of a ten-day chick be examined (Fig. 174 B), it will be found that the colliculus has undergone important changes. Its maxillary or anterior division divides in two limbs, crura superior and inferior, diverging anteriorly and separated by a depression which continues the nasal cavity backward; its free posterior end extends farther backwards than before, and is more elevated. The bounding sulci are both deeper than before. The sulcus tubo-tympanicus, with which we are specially concerned, now extends on to the median surface of the hyoid arch. Subsequently, the crura superiores of the opposite side meet in the middle line and fuse together; in a similar fashion the posterior ends of the colliculi fuse; thus the sulci tubo-tympanici open into a dorsal chamber common to both, which communicates with the ventral division of the pharynx by a slit remaining between the two fused areas. The crura inferiores also approach one another in the middle line but do not fuse, thus leaving the typical split palate of birds in front of the fused lower ends of the crura superiores. In this way the typical adult condition of the bird's palate is established.

From this description it will be seen that only the most lateral portion of the tubo-tympanic cavity is directly derived from the first visceral pouch. In later stages it is quite impossible to say exactly what part, but it is quite certain that it lies within the tympanic part of the cavity. About the end of the fifth or the beginning of the sixth day the tubo-tympanic canal begins to enlarge distally to form the tympanic cavity proper (cf. Fig. 168); the auditory ossicles (see chapter on skull) are beginning to form just above its dorsal extremity, and as the tympanic cavity enlarges it expands around them, displacing the mesenchyme, and finally meets above the auditory ossicles, so that these appear to lie within it, though as a matter of fact the relation is analogous to that of the entodermal alimentary tube to the body-cavity. The process of inclusion of the auditory ossicles is not, however, concluded until about the twelfth day. The blind end of the tympanic cavity attains a level dorsal to the external auditory meatus. (See below.)

During the seventh and eighth days the enlarging cartilaginous labyrinth presses down on the Eustachian tube and hinders its further enlargement. On the eighth day the tube is a wide but narrow slit which appears crescentic in a sagittal section of the head (Fig. 150).

Some rather obscure details about the formation of the tubo-tympanic canal are mentioned here as suggestions for further work on the subject. On the sixth day almost the entire roof is composed of flattened cells similar to the roof of the pharynx; the floor, however, is lined with a columnar epithelium which extends out to and surrounds the distal extremity; it seems probable that this terminal chamber lined on all sides by columnar epithelium represents the first visceral pouch proper. On the eighth day the cavity of this distal chamber is completely constricted off from the main tympanic cavity, though it is still connected with the latter by a solid rod of cells, which gives unequivocal evidence of its origin. I do not know what becomes of this separated cavity later. (See Fig. 168 X.)

(b) *The External Auditory Meatus and the Tympanum.* We have already seen that on the ectodermal side there are originally two depressions corresponding to the first visceral pouch, viz., a dorsal round one in which a temporary perforation is formed, and an elongated ventral furrow. Between these is a bridge of tissue within which the external auditory meatus arises as a new depression, first clearly visible on the sixth day, when it is surrounded by four slight elevations, two on the mandibular and two on the hyoid arch. The meatus gradually becomes deeper and tubular, mainly owing, I think, to the elevation of the surrounding tissue, the bottom of the meatus, or tympanic plate, being held in position by the forming stapes. The meatus is directed in a general median direction with a slight slant dorsally and posteriorly, and the tympanic plate is placed obliquely, not opposite the lateral extremity of the tympanic cavity, but ventrally to this (cf. Fig. 168).

Even on the sixth day the position of the head of the stapes may be recognized by the density of the mesenchyme internal to the bottom of the meatus. During the seventh and eighth days the stapes becomes sharply differentiated, and the internal face of the tympanum is established in proportion as the tympanic cavity expands around the cartilage (cf. Fig. 168). Thus the tympanum is faced by ectoderm externally, by entoderm internally, and includes an intermediate mass of mesenchyme, which differentiates by degrees into the proper tympanic substances.

CHAPTER X

THE ALIMENTARY TRACT AND ITS APPENDAGES

THE origin of the alimentary canal and of its various main divisions and appendages has been considered in preceding chapters. The subsequent history will now be taken up in the following order:

1. The mouth and oral cavity.
2. The pharynx and its derivatives.
3. The œsophagus, stomach and intestine.
4. The liver and pancreas.
5. The respiratory tract.

The history of the yolk-sac and allantois was considered with the embryonic membranes (Chap. VII); the detailed history of the mesenteries will be taken up in connection with the body cavities (Chap. XI).

I. MOUTH AND ORAL CAVITY

The oral cavity may be defined embryologically as that part of the alimentary canal formed on the outer side of the oral plate. Anatomically, however, such a definition is unsatisfactory both because it is impossible to determine the exact location of the oral plate in late stages, and also because of the difference in extent of the ectodermal component in roof and floor of the mouth; the definitive mouth cavity includes part of the floor of the embryonic pharynx. It is, however, of interest to determine as nearly as possible the limits of the ectodermal component of the oral cavity. In the roof this is not difficult because the hypophysis, which arises just in front of the oral plate, retains its connection with the mouth cavity until definitive landmarks are formed. The median sagittal section of an eight-day chick (Fig. 148) shows that this point is situated almost immediately opposite to the glottis, that is, between the palatine and tubal fissures in the roof (cf. Fig. 175). In the floor the extent of the ectodermal component is much less. If the tongue is entirely

a pharyngeal structure (in the embryological sense) the limit of the ectoderm would lie near the angle between the tongue and the floor of the mouth. In the side walls the boundary must be near the lines uniting the dorsal and ventral points as thus determined.

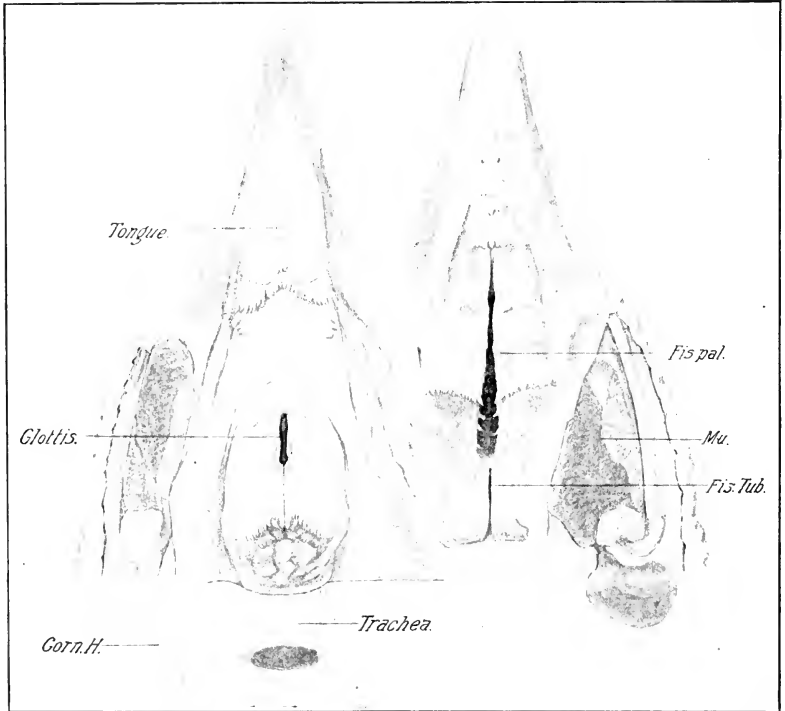


FIG. 175. — Floor and roof of the mouth of the hen. The jaw muscles were cut through on one side, the lower jaw disarticulated and the entire floor drawn back.

Corn. H., Cornu of the hyoid. Fis. pal., Palatine fissure. Fis. Tub., Tubal fissure. Mu., cut surface of jaw muscles.

We have already considered the formation of the boundaries of the mouth (Chap. VI and Chap. VII), and of the palate (Chap. IX, page 299). These data need not be repeated, so we have left to consider only the development of the beak, egg-tooth, tongue, and oral glands.

Beak and Egg-tooth. The beak is a horny structure formed by cornification of the epidermal cells around the margins of

the mouth: the egg-tooth is a mammiform hard structure with pointed nipple (Figs. 176 and 177) situated on the dorsum of the upper jaw near its tip (cf. Fig. 150). Its function is to aid in breaking the shell-membrane and the shell itself at the time of hatching; shortly afterwards it is lost. It is, therefore, an organ concerned with a single critical event in the life of the individual; nevertheless fully developed like the instinct of its use, needed only for the same critical event. Though its structure is different from that of the beak, it develops in connection with the latter, and the two will, therefore, be considered together.

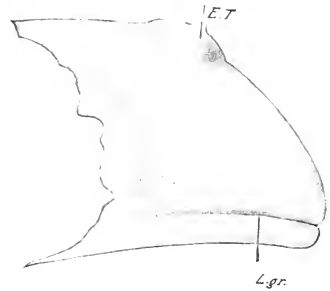


FIG. 176. — Outline of the upper jaw of a chick embryo of 18 days' incubation. (After Gardiner.)

E. T., Egg tooth. L. gr., Lip groove.

The formation of the egg-tooth begins on the sixth day from an area situated in the middle line near the tip of the upper jaw, distinguishable in the living embryo by its opacity, which contrasts with the translucency of the surrounding parts; in profile view, the area is seen to be slightly elevated.

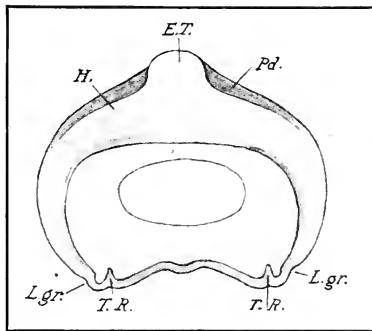


FIG. 177. — Transverse section through the upper jaw of a chick embryo of 11 days. (After Gardiner.)

E. T., Egg tooth. H. Horn. L. gr., Lip groove. Pd., Periderm. T. R., Tooth ridge.

Without losing their rounded shapes this mass of cells gradually assumes the form of the egg-tooth by the fourteenth day. The overlying layer of periderm is lost during

the act of hatching. During their differentiation the cells of the egg-tooth secrete an intercellular substance of horny consistency in which intercellular protoplasmic connections are found. The

protoplasm of the cell-bodies themselves becomes densely packed with granules, apparently also of a horny nature, and the boundaries of the cells and outlines of the nuclei become indistinct.

Reptiles with a horny egg-shell are provided with a true dentinal tooth on the premaxilla, which has the same function as the egg-tooth of birds and of those reptiles that have a calcareous shell (crocodiles, turtles, and *Trachydosaurus*). The latter is, however, as we have seen, a horny structure, and therefore not a tooth morphologically. Röse therefore proposes the term "Eischwiele" for the horny tooth-like structure, to distinguish it sharply from the real egg-tooth.

The formation of the upper beak begins in the neighborhood of the egg-tooth and spreads towards the tip and the angle of the mouth. Similarly, in the lower jaw the differentiation begins near the tip. It is a true process of cornification, that takes place beneath the periderm and involves many layers of cells. It is therefore preceded by a rapid multiplication of cells of the mucous layer of the epidermis. Soon after the appearance of the horn a groove appears a little distance above and parallel to the margin of the upper beak, extending from the anterior end a short distance backwards (Fig. 176). In sections, this appears as an invagination of the epidermis; a similar but shallower invagination appears on the lower beak. In the upper beak the lips of the invagination fuse together and thus close the groove; in the lower beak the groove flattens out and disappears. These grooves correspond in many respects to the grooves that form the lips of other vertebrates, and they may be interpreted as a phylogenic reminiscence of lip-formation.

Teeth. All existing species of birds are toothless, but some of the most ancient fossil birds possessed well-developed teeth; it is natural, therefore, to expect that rudiments of teeth might be found in the embryos of some existing birds. In the early part of the nineteenth century some observers interpreted papillæ on the margin of the jaws of certain young birds as rudimentary teeth; these were, however, shown to be horny formations, and therefore not even remotely related to teeth. Gardiner was one of the first to call attention to a thickening of the ectoderm forming a ridge projecting slightly into the mesenchyme, just inside the margin of the jaw of chick embryos about six days old (Fig. 177). The ridge disappears shortly after cornification sets in. Gardiner discussed the possibility of this represent-

ing a stage in tooth formation, and rejected the interpretation. Röse, however, has found the same ridge still better developed in embryos of the tern and ostrich, and identifies it very positively with the tooth-ridge or first step in the formation of the enamel organ of other vertebrates. It seems probable that this is the case, and that in this ridge we have the very last stage of the disappearance of teeth.

The Tongue. The tongue develops from two primordia in the floor of the embryonic pharynx, one situated in front of, and the other behind the thyroid diverticulum. The former, or *tuberculum impar*, becomes manifest on the fourth day as a slight rounded swelling situated between the lower ends of the first and second visceral arches. The swelling is bounded behind by a groove that has the ductus thyreoglossus for its center, and in front by a shallow groove, that represents the frenulum, on the posterior margin of the mandibular arches. The second primordium, or *pars copularis*, arises just behind the thyroid and includes the lower ends of the second visceral arches, a small part of the lower ends of the third, and the region between these arches. According to Kallius the tuberculum impar forms only the center of the fore part of the tongue, and the lateral parts arise from two folds that form right and left of it (lateral tongue-folds). The tuberculum impar thus expanded and the pars copularis constitute two very distinct components in the development of the tongue.

Soon after the closure of the thyroid duct the two tongue components become confluent, but the zone of junction remains visible for a long time as a groove (cf. Fig. 148). Moreover the epithelium of the forward component soon becomes thickened and stratified, while in the pars copularis the epithelium remains thin and simple for a long time. With the elongation of the jaws the tip of the tongue grows forward above the frenulum (Fig. 148) and the shape of the entire organ conforms itself to the shape of the mouth cavity.

Figure 175 shows the tongue of the adult fowl. The anterior half is pointed and horny and is bounded from the posterior half by a double crescent whose posterior convexity is beset with horny spines. It seems probable that the anterior portion is derived from the precopular part, though this has not been demonstrated by continuous observation. Cornification of the precopular part

sets in about the eighth day, and the early thickening of the epithelium of this part already referred to is undoubtedly the first stage in the process.

The development of the musculature of the tongue has not been followed. The development of the skeletal parts is considered under the head of the skeleton.

Oral Glands. The following oral glands occur in the hen: 1, lingual glands; 2, mandibular glands; 3, glands opening at the angle of the mouth; 4, palatine glands in the neighborhood of the choanæ. The only account of their development known to me is the brief one of Reichel. All the glands begin as solid ingrowths of the mucosa, which may branch more or less, and secondarily acquire a lumen. Their development begins relatively late. The mandibular glands appear first on the eighth day as a series of solid ingrowths of the mucosa extending on both sides of the base of the tongue forward to near the mandibular symphysis. They are still mostly solid on the eleventh day, and very slightly branched, if at all. The lingual glands arise beneath the lateral margin of the tongue and grow up on each side of the lingual cartilage towards the upper surface where they branch out. They begin to form on the eleventh day. No glands form on the upper surface of the tongue. The glands of the angle of the mouth appear on the eleventh day, *in situ*, as slight epithelial ingrowths. Their further history has not been followed. Anterior and posterior palatine glands can be distinguished; the first in front of the choanæ, the latter at the sides of and behind the choanæ. They begin to appear after the eleventh day.

II. DERIVATIVES OF THE EMBRYONIC PHARYNX

The pharynx, which is such an extensive and important region of the early embryo owing to the development of the visceral arches and clefts, becomes relatively much reduced in the process of development, though of course it becomes much larger absolutely. In the adult it is a somewhat ill-defined cavity from which the œsophagus leads away posteriorly, and which is confluent with the mouth anteriorly. The tubal fissure opens in its roof and the glottis in its floor. During the course of development, however, certain more or less persistent structures form from its walls, or from the epithelium of the pouches. Although these are relatively inconspicuous organs in the adult, they are of

considerable morphological importance, being of very ancient origin and common to the whole series of vertebrates. They are the thyroid body or gland, the thymus, the postbranchial or suprapericardial bodies, and certain epithelial vestiges.

Fate of the Visceral Clefts. The times of opening and closing of the visceral clefts have been already given (pp. 176 and 177). The later history of the first visceral pouch has been described (p. 297). The second, third, and fourth pouches retain their connections with the corresponding ectodermal grooves for a long time during the thickening of the visceral arches. The consequence is, that not only the pouches, but also the ectodermal furrows, are drawn out into long epithelial tubes, and the original closing plate is thus deeply invaginated. In the case of the second cleft the tube ruptures and begins to degenerate on the sixth day, leaving no remnants. In the case of the third and fourth clefts the ectodermal components become solid on the sixth day, and form strands (*funiculi prae-cervicales*) connecting the entodermal pouches with the *sinus cervicalis*. These strands are subsequently broken through and disappear. Parts of the entodermal pouches, however, persist in the thymus, suprapericardial bodies and other epithelial remains. (See below.)

Thyroid. The thyroid sac (median thyroid of authors) loses all connection with the pharyngeal epithelium on the fourth day, and on the seventh day it becomes divided in two massive lobes placed bilaterally (see Fig. 178). These then migrate backwards on each side of the trachea towards the hinder end of the derivatives of the third visceral pouch (Verdun) and become lodged in the junction of the subclavian and common carotid arteries, where they are found in the adult just internal to the jugular vein.

The so-called lateral rudiments of the thyroid, or postbranchial bodies, are histologically entirely different from the thyroid proper. They are described below.

Visceral Pouches. The second visceral pouch leaves no derivatives in the adult; during the fourth day, however, a considerable thickening of the epithelium appears on its dorsal and posterior aspect, near its opening into the pharynx; though this disappears very soon, it may be considered to represent the thymus II of Selachia and Anura.

The third visceral pouch loses its connection with the pharynx by atrophy of its internal portion between the seventh and eighth

days, and its intermediate portion persists as an epithelial pocket on the ventral face of the jugular vein (Fig. 178). This pocket soon divides into dorsal and ventral moities of which the former develops into the chief part of the thymus (thymus III) and the latter into the so-called epithelial vestige III. (See below.)

The fourth visceral pouch likewise separates from the pharynx on the seventh day, and furnishes from its dorsal portion the thymus IV, and from its ventral portion epithelial vestige IV. (See below.)

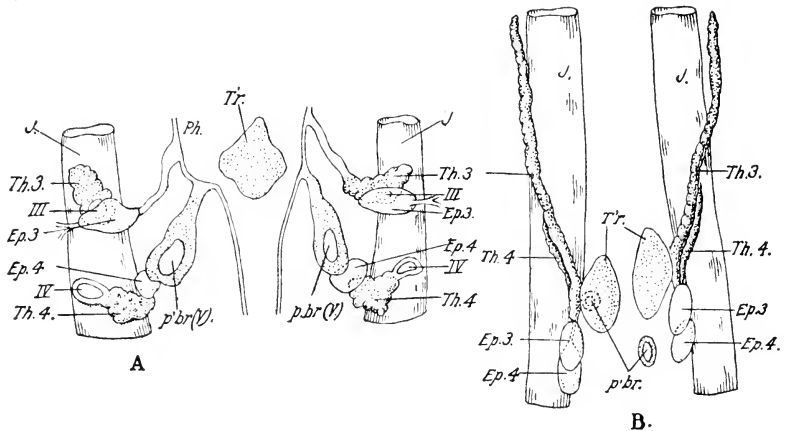


FIG. 178. — The derivatives of the embryonic pharynx of the chick. (After Verdun from Maurer.)

A. Of 7 days' incubation.

B. Of 8 days' incubation.

Ep. 3, Ep. 4, Epithelial bodies derived from the third and fourth visceral pouches. J., Jugular vein. p'br (V), Postbranchial bodies derived from the fifth visceral pouch. Ph., Pharynx. Th. 3, Th. 4, Parts of the thymus derived from the third and fourth visceral pouches respectively. T'r., Thyroid. III, IV, third and fourth visceral clefts.

The fifth pouch (postbranchial body) likewise becomes isolated on the seventh day as a closed vesicle; its differentiation is considered below.

The Thymus. According to the above, the thymus of the chick has a double origin on each side; the main portion (thymus III) is derived from the dorsal wall of the intermediate part of the third visceral pouch. This soon elongates to form an epithelial cord extending along the jugular vein; a smaller portion (thymus IV) of the thymus is derived from a corresponding part of the fourth visceral pouch, and fuses with thymus III (Fig. 178).

In the young chick the thymus forms a voluminous tract of lobulated aspect, extending the entire length of the neck; later it atrophies and in old subjects one finds only traces of it. (Verdun.)

Epithelial vestiges are formed from the ventral wall of the intermediate portions of the third and fourth visceral pouches; these come to lie together at the hinder end of the thymus in the base of the neck. They are found in the adult near the lower pole of the thyroid (Fig. 178).

The postbranchial bodies have been called lateral rudiments of the thyroid; in their differentiation, however, they do not form thyroid tissue, but two main kinds of epithelial tissues similar to the tissues of the thymus and epithelial vestiges respectively. They are to be regarded, therefore, as a fifth pair of visceral pouches, for which there are other reasons, as we have seen before. The constituent elements, however, do not separate as in the case of the third and fourth visceral pouches, but form a rather ill-defined mass situated a short distance behind the thyroid (Fig. 178).

The epithelial derivatives of the embryonic pharynx in the chick are, therefore; 1. thyroid; 2. thymus (from III, IV); 3. epithelial vestiges (from III, IV); 4. postbranchial bodies, including thymus V and epithelial vestiges V. The thyroid develops in essentially the same manner in all vertebrates. In the case of the thymus it may be said in general that more visceral pouches are concerned in the lower than in the higher vertebrates.

III. THE ŒSOPHAGUS, STOMACH AND INTESTINE

During the third and fourth days a very pronounced lateral curvature of the alimentary canal develops, the convexity being turned to the left and the concavity therefore to the right. The part involved extends from the posterior portion of the œsophagus to the end of the duodenum. As the duodenum is at first very short, the stomach is the part principally affected at the start. The depth of the mesogastrium (dorsal mesentery of the stomach) is considerably increased by the displacement; in the region of the greatest curvature it descends directly in the middle line, then bends sharply to the left and is attached to the dorsal wall of the stomach; the accessory mesentery arises at the bend. (See Chap. XI.) The stomach does not rotate on its long axis so as to carry the attachment of the mesogastrium to the extreme

left, as in mammals; in the chick the lateral bending of the stomach appears to be uncomplicated by any such rotation. The curvature leaves a large space within it to the right containing the meatus venosus and liver, in short, the entire median mass of the septum transversum.

The main divisions of the intestine are marked out by their position, size-relations and structure before the closure of the yolk-stalk; thus on the third day the œsophagus appears as a constricted portion immediately behind the pharynx, and the stomach as a spindle-shaped enlargement behind the œsophagus; the duodenum is indicated at the same time by the hepatic and

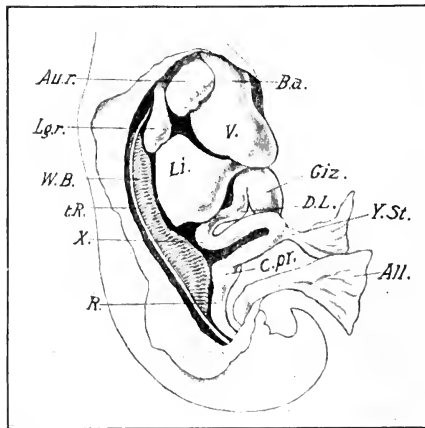


FIG. 179. — Viscera of a chick embryo of 6 days, seen from the right side. (After Duval.)

All., Allantois. Au. r., Right auricle. B. a., Bulbus arteriosus. c. pr., Caecal processes. D. L., Loop of the duodenum. Giz., Gizzard. Lg. r., Right lung. Li., Liver. R., Rectum. t. R., Tubal ridge. V., Ventricle. W. B., Wolffian body. Y. St., Yolk stalk. X., Duodeno-jejunal flexure.

pancreatic outgrowths. The form of the intestine on the sixth day is illustrated in Figure 179. Behind the stomach, the intestine forms two loops descending ventrally. The first or duodenal loop is relatively slightly developed at this time, and forms an open curve just beneath the right lobe of the liver. Its ascending limb rises to a high dorsal position just behind the liver, and

bends sharply to enter the descending limb of the second loop. This bend or duodeno-jejunal flexure (X, Fig. 179) is a relatively fixed point in the growth of the intestine, and marks the boundary between the duodenum and succeeding parts of the small intestine. The second loop descends deep into the umbilical cord, and the yolk-stalk is attached to its lowermost portion. A bilateral swelling at the upper end of its ascending limb is the primordium of the cæcal processes, and marks the anterior end of the large intestine, which passes in a slight curve to the cloaca.

In the subsequent growth of the intestine the fixed point referred to above at the hinder end of the duodenum is held in its place, and the duodenal loop in front of it simply becomes longer

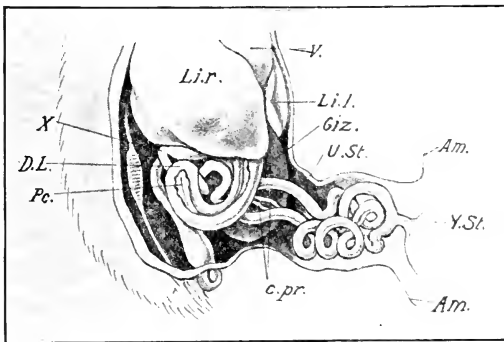


FIG. 180. — Viscera of a chick embryo of 17 days' incubation from the right side. (After Duval.)

Am., Attachment of amnion to umbilical stalk. Li. r., l., Right and left lobes of the liver. Pc., Pancreas. U. St., Umbilical stalk. Other abbreviations same as Fig. 179.

without forming secondary convolutions; the pancreas comes to lie in this loop. The second loop, on the other hand, forms numerous secondary convolutions (Fig. 180) which lie at first in the umbilical cord, but which are gradually retracted (seventeenth to eighteenth day) into the abdominal cavity.

The two intestinal cæca begin to grow out as finger-shaped processes from the swelling already referred to, about the seventh day, and rapidly attain considerable length. The large intestine elongates only about in proportion to the growth of the entire embryo.

Having thus noted the general gross anatomy of the embry-

onic intestine, we may next note a few details concerning some of its divisions. The history of the mesenteries is considered in (Chapter XI).

Œsophagus. Owing to the rapid elongation of the neck the œsophagus quickly becomes a long tube. On the sixth day its lumen becomes very narrow, and on the seventh day completely occluded immediately behind the glottis, owing to proliferation of the lining cells. On the eighth day the occluded portion

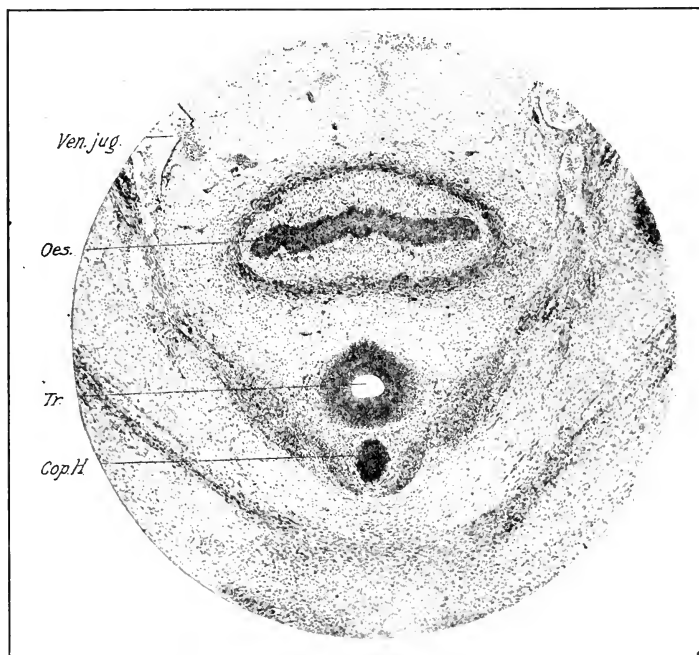


FIG. 181. — Photograph of a transverse section through the œsophagus and trachea of an 8-day chick.

Cop. H., Copula of the hyoid. Oes., Œsophagus. Tr., Trachea. Ven. jug., Jugular vein.

extends only a short distance behind the glottis; it is compressed dorso-ventrally and extended laterally throughout the occluded region (Fig. 181). On the eleventh day it is open again along its entire length. The crop arises as a spindle-shaped dilatation of the œsophagus at the base of the neck; on the eighth day it is about double the diameter of the parts immediately

in front of and behind it (Fig. 150). No detailed account of its development exists.

Stomach. It is well known that the stomach of birds exhibits two successive divisions, the proventriculus and the gizzard, the former of which has a digestive function and is richly provided with glands, while the latter has a purely mechanical function, being provided with thick muscular walls, within which is the compressed cavity lined on each side by tendinous plates.

On the third day of incubation, the divisions of the stomach are not recognizable, either by the form of the entire organ or by the structure of the walls. On the fifth day, however, the first indications of the formation of the compound glands of the proventriculus may be seen in the cardiac end; the posterior or pyloric end occupies the extreme left of the gastric curve and forms the rudiment of a blind pouch projecting posteriorly, that develops into the gizzard. On the sixth and seventh days this pouch expands farther in the same direction (cf. Fig. 179), and a constriction forms between the anterior portion of the stomach, or proventriculus, and the gizzard, as thus marked out. The gizzard grows out farther, to the left and posteriorly, at the same time undergoing a dorso-ventral flattening, owing to the formation of the large muscle-masses. According to this account, therefore, the greater curvature of the gizzard would represent the original left side of the portion of the embryonic stomach from which it is derived, and the original right side would be represented by the lesser curvature.

The large compound glands of the proventriculus are indicated on the fifth or sixth days as slight depressions of the entoderm towards the mesenchyme; on the seventh day these become converted into saccular glands with narrow necks (Fig. 182). Each sacculus becomes multilobed about the twelfth or thirteenth days, and each lobulus includes a small number of culs-de-sac, lined with a simple epithelium. The last subsequently become tubular, and the original sacculus then represents the common duct of a large compound gland. (See Cazin.)

The simple, tubular glands of the gizzard begin to form about the thirteenth or fourteenth day, and the lining of the gizzard is simply the hardened secretion of these glands; it is thus essentially different from cuticular and corneous structures of the surface of the body. According to Cazin, the glands of the gizzard

are formed as folds and culs-de-sac excavated in the thickness of the original epithelial wall, by elevations of the subjacent connective tissue. It should be noted finally, that from the eighth day on, the surface of the mucosa, both in the proventriculus and in the gizzard, is covered with a thick layer of secretion; subsequently replaced in the gizzard by the corneous lining.

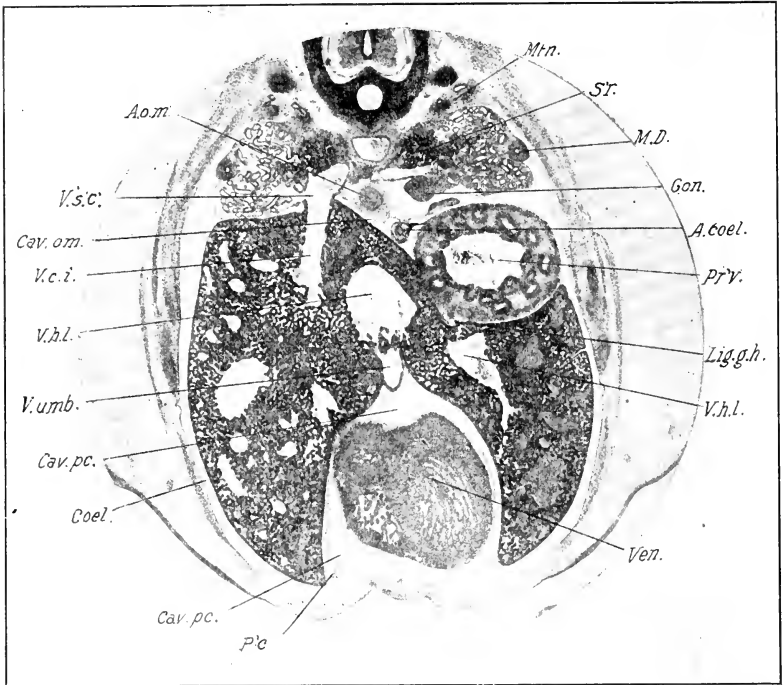


FIG. 182. — Photograph of a transverse section of an 8-day chick through the region of the proventriculus and tip of the heart.

A. coel., Coeliac artery. A. o. m., Omphalomesenteric artery. Cav. om., Cavum omenti. Cav. pc., Pericardial cavity. Coel., Coelome. Gon., Gonad. Lig. g-h., Gastro-hepatic ligament. M. D., Müllerian duct. Mtn., Metanephros. p'e., Membranous pericardium. Pr'v., Proventriculus. S'r., Supra-renal. V. c. i., Vena cava inferior. Ven., Ventricle of heart. V. h. l., Left hepatic vein. V. s'c., Subcardinal vein. V. umb., Umbilical vein.

Large Intestine, Cloaca, and Anus. The cloaca of the adult is a large chamber opening to the exterior by the anus; it consists of three divisions: the proctodæum or terminal chamber is capable of being closed by the sphincter muscle, the bursa Fabricii opens into its dorsal wall, and it is separated by a strong circular fold

from the intermediate section of the cloaca or urodæum; this is a relatively short division of the cloaca which receives the renal and reproductive ducts in its dorsal wall by two pairs of openings; it is bounded from the larger anterior division, coprodæum, by a rather low circular fold; the coprodæum passes gradually, without a sharp line of division, into the rectum.

The early embryological history of these parts has been considered in the preceding chapters. The condition on the fourth day is shown in the accompanying figure (Fig. 183) representing a

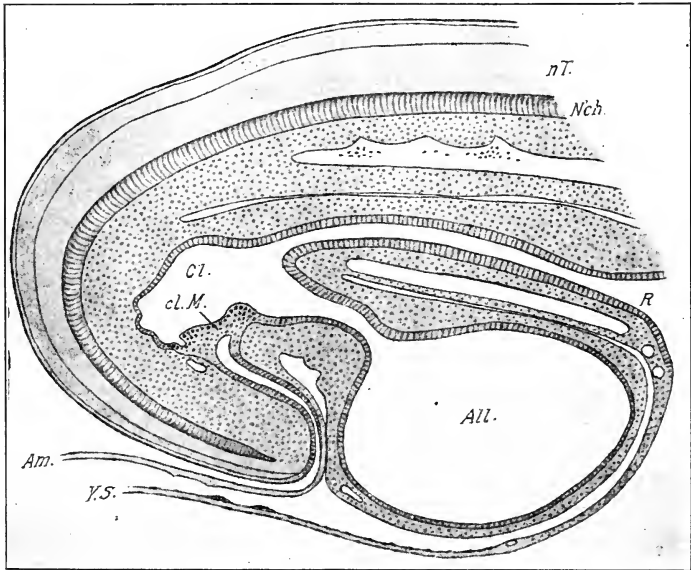


FIG. 183. — Median sagittal section of the hind end of a chick embryo on the fourth day of incubation. (After Gasser from Maurer.)

All., Allantois. Am., Tail fold of amnion. cl. M., Cloacal membrane. Cl., Cloaca. N'ch., Notochord. n. T., Neural tube. R., Rectum. Y. S., Wall of yolk-sac.

sagittal section of the hind end of the embryo. The cloaca is the large terminal cavity of the intestine, closed from the exterior by the cloacal membrane, in which the entoderm of the floor of the cloaca is fused to the superficial ectoderm at the base of the tail. The line of fusion is a long, narrow median strip, extending from just below the neck of the allantois to the hinder end of the cloaca. Leading out from the cloaca ventrally, in front of the

cloacal membrane, is the neck of the allantois, and dorsal to this, the large intestine. Though not shown in the figure, it may be noted that the Wolffian ducts open into the cloaca behind and dorsal to the opening of the rectum.

The appearance of the cloaca in a longitudinal section does not, however, give an adequate idea of its form. The anterior portion of the cloaca which receives the rectum, stalk of the allantois and Wolffian ducts is expanded considerably in the lateral plane, and thus possesses a large cavity. The posterior

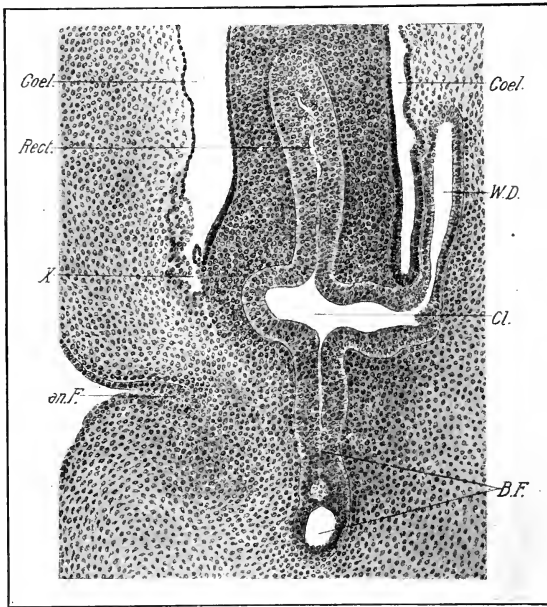


FIG. 184. — Frontal section through the region of the cloaca of a 5½-day chick embryo.

an. F., Anal fold. B. F., Bursa Fabricii. Cl., Cloaca. Coel., Coelome. Rect., Rectum. W. D., Wolffian duct. X., Posterior angle of the body-cavity; the epithelium is invaginated and folded so as to simulate a glandular structure.

portion, on the other hand, is greatly compressed laterally and the cavity is extremely narrow. During the fifth day the walls of this part of the cloaca become actually fused together, and its cavity obliterated, or rendered virtual only (Fig. 184). Thus the anterior part of the cloaca is prolonged backwards by a

median plate which is continuous ventrally with the cloacal membrane.

This plate was interpreted by all the earlier observers (up to Wenckebach) as the hypertrophied cloacal membrane. It is, however, not difficult to demonstrate in good series of sections, that this is not the case; the cloacal membrane forms only a small part of this plate, and its ectodermal component is thin.

During the fifth and sixth days, vacuoles appear in the posterior and dorsal part of the fused portion of the cloaca, and these soon run together in the uppermost part, but remain as a chain of vacuoles ventrally (Fig. 184). The vacuolated portion is the primordium of the bursa Fabricii and its duct. Its cavity, which is extremely narrow and ill-defined at this time, may be regarded as a re-establishment of the cavity of the posterior division of the embryonic cloaca; its communication with the anterior portion of the cloacal cavity is soon closed.

At this stage the lining epithelium of the rectum is much thickened, and the lumen has therefore become narrow (Fig. 184).

During the seventh day the conditions change very rapidly and on the eighth day the relations are as shown in Figure 185. The anterior portion of the original cloaca, or urodæum, has become compressed in an antero-posterior direction; the allantois leads off from it anteriorly and ventrally, and the rectum with its cavity now obliterated is attached to its anterior face; the dorsal extension, above the rectum (see Fig. 185), is related to the urinogenital ducts. The bursa Fabricii has now a well-defined cavity that no longer communicates with the urodæum. The tissues surrounding the cloacal membrane have grown out to form a large perianal papilla, and the cloacal membrane is therefore invaginated; its direction also is so altered that the invaginated cavity or proctodæum now lies behind it; the bursa Fabricii is on the point of opening into the highest point of the proctodæum. Vacuolization of the tissue between the cloacal membrane and the urodæum indicates its subsequent disappearance.

At eleven days (Fig. 186) the general arrangement is essentially the same, but there are important differences in detail. The bursa Fabricii has now become a long-stalked sac, opening into the proctodæum at the level of the urodæal membrane. The latter is still quite a thick plate, but the vacuoles in it fore-

shadow its final rupture. The lower end of the large intestine is perfectly solid, and higher up, somewhat vacuolated. (The solid stage begins on the seventh day.) The urinogenital ducts open into the urodæum above the solid end of the large intestine. It will be seen, therefore, that the urodæum is transformed into a passageway between the urinogenital ducts and the allantois, being closed anteriorly by the solid large intestine and posteriorly by the urodæal (cloacal) membrane.

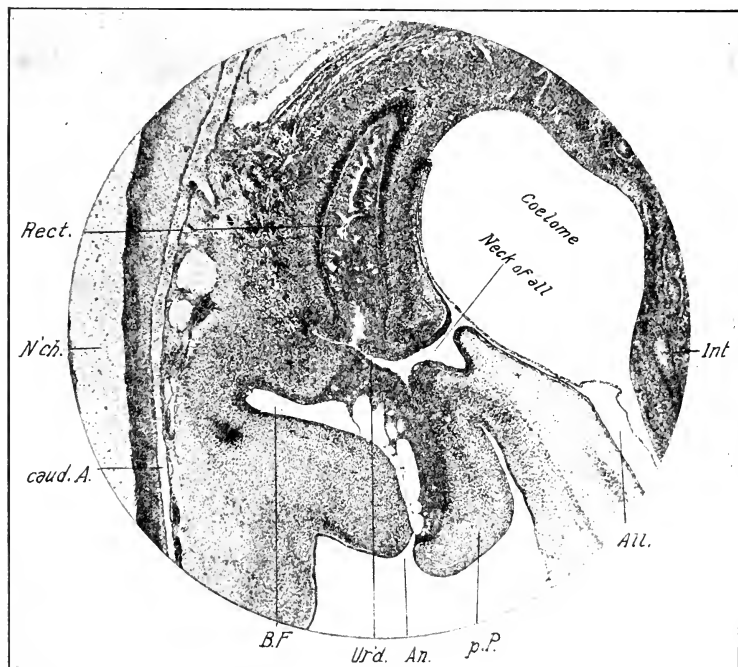


FIG. 185. — Photograph of the region of the cloaca in a median sagittal section of an 8-day chick.

All., Allantois. An., Anus. B. F., Bursa Fabricii. caud. A., Caudal artery. Int., Intestine. N'ch., Notochord. p. P., Perianal papilla. Rect., Rectum. Ur'd., Urodæum.

During the twelfth and thirteenth days, the vacuoles in the upper part of the large intestine flow together and re-establish the cavity, but the lower end still remains closed by a solid plug of cells; immediately anterior to the latter the large intestine is dilated, and this apparently corresponds to the coprodæum of

the adult cloaca. Even on the seventeenth day the large intestine appears to be still closed at its lower end, and the urodeal membrane still persists as a plug of vacuolated cells. (Gasser.) Both plugs must, however, disappear soon after.

It would thus appear that the urodæum only of the adult cloaca corresponds to the embryonic cloaca; the proctodæum is certainly derived from an ectodermal pit, and it is probable that

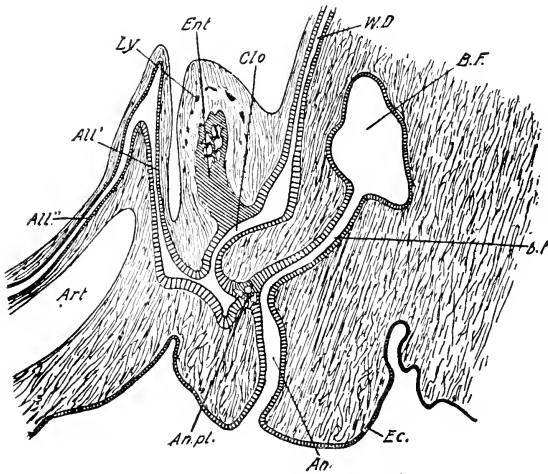


FIG. 186. — Chick embryo of 11 days, sagittal section through the region of the cloaca. Reconstructed from several sections. (After Minot.)

All', Ascending limb of the allantois. All'', Descending limb of the allantois. An., Anal invagination. An.pl., Urodeal membrane. Art., Umbilical artery. B. F., Bursa Fabricii. b. f., Duct of the bursa. Clo., Cloaca. Ec., Ectoderm. Ent., Entoderm of the rectum. Ly., Nodules of crowded cells, probably primordia of lymphoid structures in the wall of the large intestine. W. D., Wolffian duct.

the coprodæum represents the enlarged lower extremity of the embryonic large intestine. The bursa Fabricii is an entodermal structure derived from the posterior portion of the embryonic cloaca.

IV. THE DEVELOPMENT OF THE LIVER AND PANCREAS

The Liver. The anterior and posterior liver diverticula, described in Chapter VI, constitute the rudiments from which the

substance of the liver is derived. A third diverticulum is distinguished by Brouha as the right posterior diverticulum; this is an early outgrowth of the posterior diverticulum. Hepatic cylinders arise from both primary diverticula at an early stage, and these, branching and anastomosing, soon form a basket-work of liver tissue around the intermediate portion of the meatus venosus. The anterior diverticulum alone extends forward to the anterior

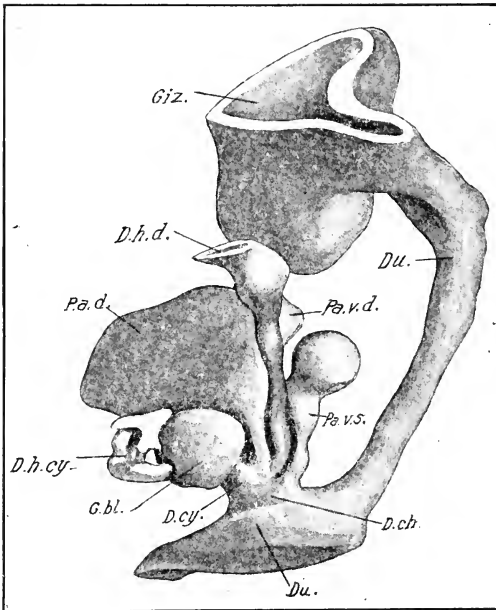


FIG. 187. — Reconstruction of gizzard, duodenum, and hepato-pancreatic ducts of a chick embryo of 124 hours. (After Brouha.)

D. ch., Ductus choledochus. D. cy., Ductus cysticus. D. h. cy., Ductus hepato-cysticus. D. h. d., Dorsal or hepato-enteric duct. Du., Duodenum. G. bl., Gall bladder. Giz., Gizzard. Pa. d., Dorsal pancreas. Pa. v. d., Right ventral pancreas. Pa. v. s., Left ventral pancreas.

end of the meatus, and it even encroaches on the sinus venosus, as we have already seen; in the posterior part of the meatus venosus, on the other hand, the liver tissue is derived entirely from the posterior diverticulum. The mesenchyme in the interstices of the hepatic framework is replaced almost immediately by blood-

vessels that empty into the meatus, and thus appear as branches of the latter.

The gall-bladder is a very early formation, arising from the hindermost portion of the posterior hepatic diverticulum, as a distinct bud about the stage of 68 hours (Fig. 103), and forming a pyriform appendage at 84 hours. It may reasonably be regarded as derived from the most posterior portion of the primitive hepatic gutter, an interpretation that agrees with the condition found in more primitive vertebrates.

At the stage of 68 hours (cf. Fig. 103B), the anterior and posterior diverticula proceed from a common depression of the ventral wall of the duodenum, the ductus choledochus. By means of an antero-posterior constriction, the latter becomes much more clearly defined as development proceeds (Fig. 187); there arise from it also the right and left ventral primordia of the pancreas (see below), so that it receives at this stage four main ducts, viz.: the right and left ventral pancreatic diverticula and the cephalic and caudal hepatic diverticula. On the sixth day these four ducts obtain independent openings into the duodenum and the common bile duct thus ceases to exist. The relations thus established are practically the same as in the adult.

As the caudal hepatic diverticulum grows out it carries the attachment of the gall-bladder with it, so that the latter is then attached to the caudal diverticulum, which is thus divided in two parts, a distal or ductus hepato-cysticus, and a proximal or ductus cystico-entericus. That portion of the liver arising from the cephalic diverticulum is thus without any connection with the gall-bladder. There seem, however, to be anastomoses between the ductus hepato-cysticus and the original cephalic duct (ductus hepato-entericus) in the adult, lying in the commissure of the liver; the embryological origin of these appears, however, to be unknown. In the course of the development, the openings of the two original ducts into the duodenum come to lie side by side instead of one behind the other, and the original cephalic duct (ductus hepato-entericus) appears to be derived mainly from the left lobe, and the ductus cystico-entericus mainly from the right lobe of the liver. The actual distribution is, however, by no means so simple; the mode of development of the lobes of the liver (see below) would explain a preponderant dis-

tribution of the cephalic duct to the left, and the caudal duct to the right lobe.

The liver is primarily an unpaired median organ. Its division into right and left lobes is therefore secondary and has no fundamental embryological significance. The factors that determine its definitive external form are the following: (a) the relative power of growth of its various parts; (b) limitation of its extension to the septum transversum and its connections; (c) the limitations of space in the *cœlome*.

Bearing these principles in mind, the growth of the liver may be described as follows: three primary divisions succeeding one another in a cranio-caudal direction, may be distinguished at an early stage, viz., an antero-dorsal division, abutting on the postero-dorsal part of the sinus venosus, formed by the anterior end of the cephalic hepatic diverticulum; an intermediate division, surrounding the meatus venosus in which both cephalic and caudal hepatic diverticula are concerned; and a postero-ventral division, beneath the posterior end of the meatus venosus and the right omphalomesenteric vein, formed exclusively by the caudal diverticulum.

The growth of the liver causes expansion of the median mass of the septum transversum in all directions, excepting anteriorly, and the substance of the liver extends more or less into all the connections of the latter, viz., the lateral mesocardia, the lateral closing plates associated with the umbilical veins, the primary ventral ligament, the mesentery of the vena cava, the gastro-hepatic ligament, and that part of the hepatic portal vein formed by the right omphalomesenteric vein.

At the stage of 96 hours the anterior division spreads out in the lateral mesocardia behind the Cuvierian ducts nearly to the lateral body-wall on each side. The intermediate division, on the other hand, lies largely on the right side of the middle line, owing to the displacement of the stomach to the left and the meatus venosus to the right. A small lobe is, however, pushing itself to the left beneath the gastro-hepatic ligament. The posterior division lies entirely on the right ventral side of the hinder end of the meatus venosus and right omphalomesenteric vein, as far back as the dorsal anastomosis. There are, of course, no sharp lines of demarcation between the divisions, so that in general it may be said that the liver substance tends more and

more to the right side of the body from its fairly symmetrical anterior end backwards.

The lines of development of the liver are thus marked out. On the sixth day the anterior division is larger on the left than on the right side, owing no doubt to the incorporation of the sinus venosus into the right auricle, thus leaving more room for the liver on the left side. Passing backwards in a series of sections to the region of the center of the meatus venosus, we find the liver larger on the right than on the left side, being centered around the meatus, but a small lobe extends over to the left side ventral to the stomach. The posterior division, again, is confined to the right side and ends in a free right lobe projecting caudally to the region of the umbilicus. The division of the liver into right and left lobes thus takes place on each side of its primary median ligaments, dorsal or gastrohepatic, and primary ventral; expansion being inhibited in the median line by the stomach above and heart below, it takes place on both sides, but particularly on the right side where there is more space.

The reader is referred to Chapter XI for description of the origin of the ligaments of the liver and the relations of the liver to the pericardium and other structures; also to Chapter XII for description of its blood-vessels.

The histogenesis of the liver should be finally referred to. This organ is remarkable in possessing no mesenchyme in the embryonic stages (Minot, 1900); but from the start the hepatic cylinders are directly clothed with the endothelium of the blood-vessels, so that only the thickness of the endothelial wall separates the hepatic cells from the blood in the sinusoids. The hepatic cylinders have been described as arising in the form of solid buds from the primary diverticula; the buds first formed branch repeatedly, forming solid buds of the second, third, etc., orders, and wherever buds come in contact they unite, forming thus a network of solid cylinders of hepatic cells. The solid stage does not, however, last very long, for on the fifth day it can be seen that many of them have developed a small central lumen by displacement of the cells. Thus there gradually arises a network of thick-walled tubes instead of solid cylinders, and the whole system opens into the primary diverticula from which it arose.

The Pancreas. The pancreas arises as three distinct entodermal diverticula, the origin of which has been already described, and

has correspondingly in the adult three separate ducts opening into the duodenum. (Two pancreatic ducts is the rule in *Gallus*, according to Gadow in Bronn's *Thierreich*.) Of the three pancreatic diverticula, the dorsal one arises first (about 72 hours) then the right ventral slightly earlier than the left ventral (about 96 hours). The two latter arise from the common

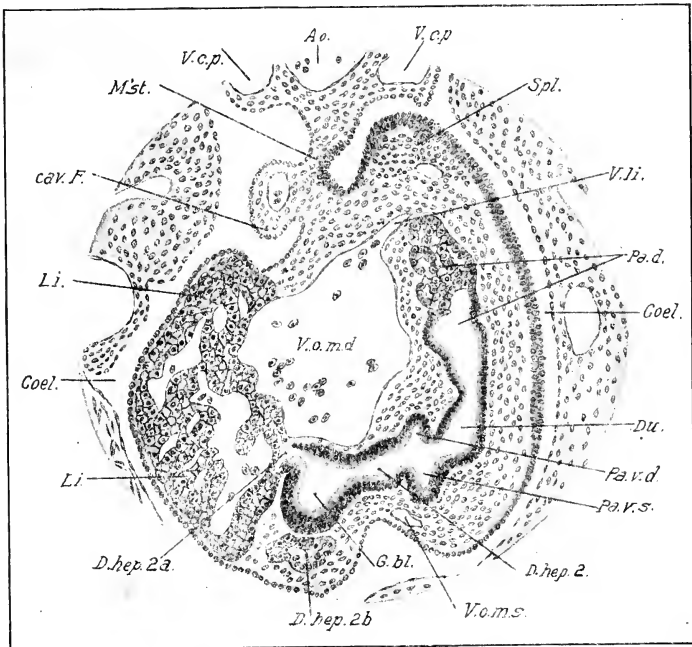


FIG. 188. — Transverse section through the duodenum and hepatopancreatic ducts of a chick embryo of 5 days. (After Choronschitzky.)

Ao., Aorta. cav. F., Caval fold. Coel., Cœlome. D. hep. 2, 2 a, 2 b, Posterior hepatic diverticulum and branches of same. Du., Duodenum. Li., Substance of liver. M'st., Dorsal mesentery. Pa. d., Dorsal pancreas. Pa. v. d., Right ventral pancreas. Pa. v. s., Left ventral pancreas. Spl., Spleen. V. c. p., Postcardinal vein. V. li., Vena lienalis. V. o. m. d., Right omphalomesenteric vein. V. o. m. s., Left omphalomesenteric vein.

hepatic diverticulum near its junction with the duodenum (Fig. 188). The differentiation of the three parts is essentially similar, and proceeds naturally in the order of their origin. Solid buds arise from the ends of the diverticula, and these branch repeatedly in the surrounding mesenchyme, but do not anastomose; the

final terminations of the buds form the secreting and the intermediate portions the various intercalated and excretory ducts that form a branching system opening into the main ducts.

The successive stages in the development of the pancreas may be stated thus (following Brouha): At 124 hours the two ventral pancreatic ducts pass anteriorly and a little to the left, crossing the cephalic hepatic duct which lies between them. They are continued into ramified pancreatic tubes which already form two considerable glandular masses. The right ventral pancreas is united by a very narrow bridge to the dorsal pancreas, and the latter is moulded on the left wall of the portal vein, while its excretory duct has shifted on the left side of the duodenum nearer the ductus choledochus. At 154 hours the duct of the dorsal pancreas is still nearer to the others, and the three pancreatic ducts enter a single glandular mass, the dorsal portion of which, derived from the primitive dorsal pancreas, is moulded on the left wall of the portal vein, and is continued into a smaller ventral portion formed by the fusion of the two ventral pancreases.

Subsequently, the pancreatic lobes fill up the duodenal loop (Figs. 179 and 180), and elongate with this so as to extend from one end of it to the other in the adult; the three ducts open near the termination of the duodenum (end of distal limb) beside the two bile ducts.

V. THE RESPIRATORY TRACT

The origin of the laryngotracheal groove and the paired primordia of the lungs was described in Chapter VI. At the stage of 36 somites the laryngotracheal groove includes the ventral division of the postbranchial portion of the pharynx, which is much contracted laterally so as to convert its cavity into a deep and narrow groove. This communicates posteriorly with right and left finger-shaped entodermal diverticula (the entodermal lung-primordia) extending into the base of the massive pear-shaped mesodermal lung-primordia attached to the lateral walls of the œsophagus. The mesodermal lung-primordia are continuous with the accessory mesenteries, as described in Chapter XI; and by them attached to the septum transversum.

Bronchi, Lungs and Air-sacs. The primitive entodermal tubes form the primary bronchi, in which two divisions may be distinguished on each side, viz: a part leading from the end of

the trachea to the hilum of the lung (extra-pulmonary bronchus), and its continuation within the lung, extending its entire length (mesobronchus). All the air passages of the lung, and the air-sacs, arise from the mesobronchi by processes of budding and branching, enlargement of buds to form air-sacs, and by various secondary anastomoses of branches. The mesobronchi are surrounded from the first by a thick mass of mesenchyme, covered of course towards the body cavity by a layer of mesothelium. In the early development the mesenchyme of the lung-primordia grows so rapidly as to provide adequate space for the branching of the mesobronchi entirely within the mesenchymal tissue.

Although the development of the lungs of the chick was studied by several earlier investigators, our principal reliance in this subject rests on the beautiful and complete study by Loey and his students.

We may note the general topographical development as follows: The expansion of the lungs takes place into the pleural cavities; they therefore raise themselves from their surfaces of attachment, œsophagus and pleuroperitoneal membrane, and project in all directions, but especially dorsally and anteriorly (Fig. 189). We may thus distinguish free and attached surfaces; the latter is nearly a plane surface and on the whole ventral in position, and the free arched surfaces are dorsal. However, it should be remembered that the pleuroperitoneal membrane which forms the attached surface, lies at first in a sagittal plane, and only secondarily becomes frontal. In successive stages, the attached surface of the lung (pleuroperitoneal membrane) rotates from a sagittal to an approximately frontal plane (Chap. XI). An anterior lung lobe grows out in front and dorsal to the mesobronchus, beginning at six days, and the extra-pulmonary bronchus thus acquires a ventral insertion into the lung.

Stages in the development may be described as follows: At 96 hours, the bronchi arise from the end of the trachea, ventral to the œsophagus and pass back on either side of the latter, describing near their centers a rather sharp curve that brings the dorsal ends to a higher level than the œsophagus. A very slight dilatation at the extreme end of the mesobronchus is usually interpreted as the beginning of the abdominal air-sac.

At six days the mesobronchus within the lung describes a course nearly parallel to the œsophagus as far as the middle of the lung; in this part of its course it lies near the median surface and ascends very slightly. About the middle of the lung it makes a sharp bend, and passes toward the lateral and dorsal surface of the lung; here it enters a considerable thin-walled dilatation from which it is continued straight backwards by means

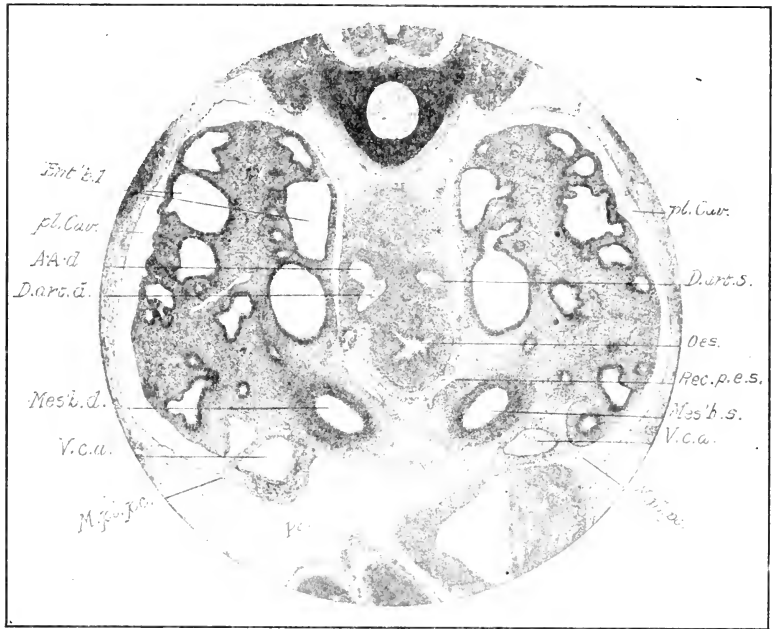


FIG. 189. — Photograph of transverse section through the lungs of an 8-day chick embryo.

A. A. d., Right aortic (systemic) arch. D. art. d. s., Right and left ductus arteriosi. Ent'b.l., Branches of first entobronchus. M. pl. pc., Pleuropericardial membrane. Mes'b. d. s., Right and left mesobronchia. Oes., Oesophagus. Pe., Pericardial cavity. pl. Cav., Pleural cavity. Rec. p. e. s., Left pneumato-enteric recess. V. e. a., Anterior vena cava.

of a second curve, and ends in the same slight thick-walled dilatation that we noted on the fourth day. There are thus three very distinct divisions of the mesobronchus which we may name the anterior, the middle, and the posterior.

Four evaginations arise on the sixth day from the mesial

wall of the anterior division of the mesobronchus, which is otherwise unbranched. These represent the entobronchi; they arise in antero-posterior order, and the first is therefore the largest. The part of the mesobronchus from which they arise will form the vestibulum of the adult lung.

Later on the same day the ectobronchi, six in number, begin to arise from the dorsal surface of the dilated portion of the middle division of the mesobronchus. Other independent out-growths of the same division of the mesobronchus are the so-called laterobronchi and dorsobronchi (Loey). These four groups of out-growths may be classed as secondary bronchi (Fig. 191).

On the ninth day (Fig. 191) the first entobronchus has formed a number of branches in the anterior lobe of the lung, and two of its terminal twigs, one in the antero-dorsal, the other in the antero-ventral tip of the lung, are slightly dilated and project as primordia of the cervical and interclavicular air-sacs respectively. The second entobronchus is also subdivided several times; its terminal branches extending to the dorsal surface of the lung. The third entobronchus bends ventrally, and from its base a narrow canal extends into the pleuroperitoneal membrane, where it expands into the anterior thoracic air-sac, which is much the largest of the air-sacs at this time.

Between the eighth and eleventh days, numerous tertiary bronchi (parabronchi) arise from the secondary bronchi (Fig. 190). These are considerably smaller than the tubes from which they arise, and are extremely numerous, radiating from all parts of the secondary bronchi towards the free surfaces and interior of the lungs. They are embedded in the mesenchyme of the lung, which is already marked out into areas hexagonal in cross-section, with the parabronchi in the centers, by the developing pulmonary blood-vessels.

From the twelfth to the eighteenth days parabronchi of different origin meet and fuse in a most extensive fashion, thus forming an intercommunicating net-work of tubes throughout the lung. Air-capillaries finally arise from the parabronchi in the centers of the hexagonal areas and form an anastomotic net-work arising from and surrounding the parabronchi. This completes the system of tubes arising from the secondary bronchi; but

another system, that of the recurrent bronchi, develops from the air-sacs which we now go on to consider.

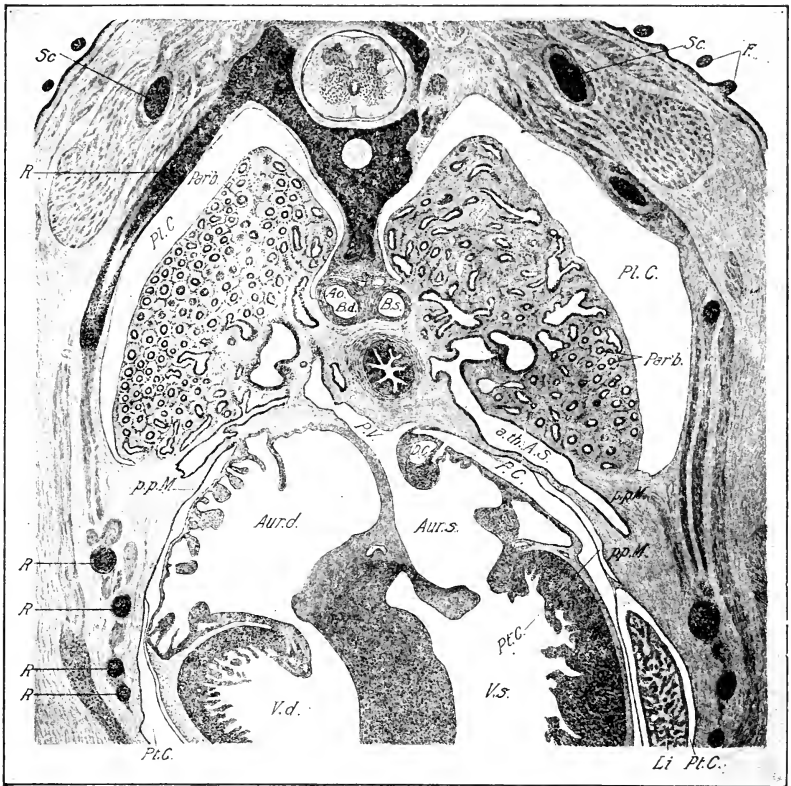

Fig. 190.—Transverse section through the lungs of a chick embryo of 11 days.

a. th. A. S., Anterior thoracic air-sac. Ao., Aorta. Aur. d., s., Right and left auricles. B. d., s., Right and left ducts of Botallus. F., Feather germs. Li., Liver. P. C., Pericardial cavity. p. p. M., Pleuroperitoneal membrane. P. V., Pulmonary vein. Par'b., Parabronchi. Pl. C., Pleural cavity. Pt. C., Peritoneal cavity. R., Rib. Sc., Scapula. V. d., s., Right and left ventricles.

The expanding lungs nearly fill the pleural cavities on the eleventh day. Subsequently, the pleural cavity is obliterated by fusion of the free surfaces of the lungs with the wall of the pleural cavities. Thus it happens that the dorsal surfaces of the

lungs of the adult "have no peritoneal covering," although this is denied by other authors.

The air-sacs are terminal expansions of entobronchi or of the mesobronchus (Fig. 191). From all of them with the exception of the cervical sac there grow bronchial tubes which connect with parabronchi secondarily within the lung proper. Owing to their method of origin, and also to the fact that the current of air through them in the functional lung is from the air-sacs, these tubes are known as recurrent bronchi. The lungs of birds thus differ from

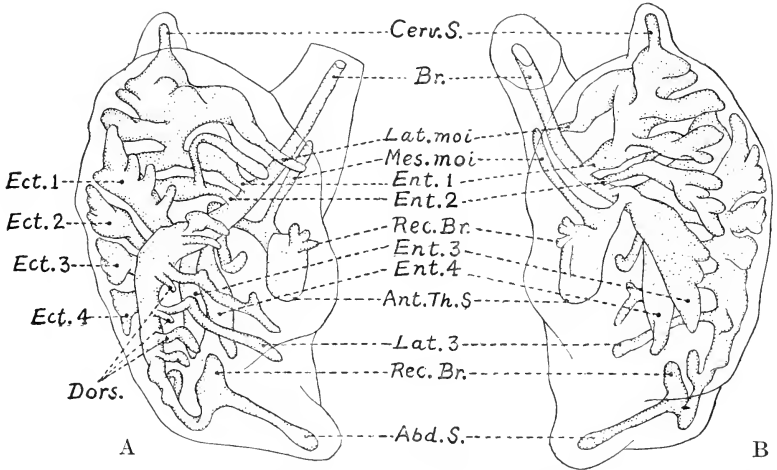


FIG. 191. — The air passages of the lung of the chick early on the ninth day of incubation. A Lateral view; B. Mesial view. (After Loey and Larsell.) Abd. S., Abdominal Air-sac. Ant. Th. S., Anterior thoracic air-sac. Br., Bronchi. Cerv. S., Cervical air-sac. Dors., Dorsibronchi. Ect. 1, Ect. 2, etc., First to fourth Ectobronchi. Ent. 1, Ent. 2, etc., First to fourth Entobronchi. Lat. 3, Third laterobronchus. Lat. moi.; Mes. moi., Lateral and mesial moieties of the interclavicular air-sac. Rec. Br., Recurrent bronchi.

those of other vertebrates in having no terminal alveoli, containing residual air; there is instead a system of communicating tubes through which the air flows.

The abdominal air-sacs do not undergo any considerable expansion until after the eighth day (cf. Fig. 191). Then they push through the hinder end of the pleuroperitoneal membrane, now fused with the lateral body-wall, and penetrate the latter just beneath the peritoneum. About the tenth day they begin to expand into the abdominal cavity just behind the liver, thus evaginating the peritoneum. The left sac is somewhat larger

than the right. The expansion goes on rapidly and by the thirteenth to the fifteenth day they have reached the hinder end of the body cavity, and have already expanded into it so far as to form fusions with the mesentery. Recurrent bronchi begin to develop from their base about the ninth day.

The cervical sacs appear early from an anterior branch of the first entobronchus (Fig. 191). They form no recurrent bronchi (Loey).

The interclavicular sac, which is single in the adult, arises from two sacs on each side, a lateral moiety from the first entobronchus, and a mesial moiety from the third. These four parts fuse to form the single sac of the adult (Loey). These sacs form recurrent entobranchi.

The anterior thoracic sac forms about the seventh day as a dilatation of the ventral wall of the third entobronchus projecting into the pleuroperitoneal membrane near its median edge; it thus lies just lateral to the pneumato-enteric recesses. From this position it expands laterally and posteriorly in the pleuroperitoneal membrane and thus gradually splits it in two layers (Fig. 190, 11 days).

The posterior thoracic air-sac arises from the third laterobronchus somewhat later than the others, and grows at first through the hinder portion of the pleuroperitoneal membrane to enter the lateral body wall. In its subsequent expansion, it splits the posterior portion of the pleuroperitoneal membrane, as the anterior thoracic air-sac does the anterior portion of the same membrane. Anterior and posterior thoracic air-sacs then come into contact, forming a septum. Both form recurrent bronchi.

The lower layer of the pleuroperitoneal membrane, split off from the upper layer by expansion of anterior and posterior thoracic air-sacs, constitutes the oblique septum. The most posterior portion of the oblique septum, however, is derived from the peritoneum of the lateral body wall by expansion of the posterior thoracic air-sacs behind the pleuroperitoneal membrane.

Like the abdominal air-sacs, "the remainder expand rapidly, particularly from the fourteenth day on, among the thoracic viscera, and fuse intimately with these and the walls of the body cavity in a few days, the cœlomatic fluid being in the meantime absorbed. The interclavicular air-sac grows out to form the subscapular air-sac and at the time of hatching has approached close to the humerus." (Selenka.)

The Laryngotracheal Groove. The embryonic primordium of the larynx and trachea communicates at first along its entire length with the postbranchial division of the pharynx (72 hours). At 96 hours the hinder portion of the groove is already converted into a tube lying beneath the anterior end of the œsophagus; this is the beginning of the trachea; the anterior part of the original groove represents the larynx, and its opening into the pharynx the glottis. It is not clear whether the trachea arises as an outgrowth of the hinder end of the laryngotracheal groove, or from the hinder portion of the groove itself, by constriction from the pharynx. At 96 hours the lumen of the lower end of the trachea and adjoining portion of the two bronchi is obliterated by thickening of the walls; this is, however, a very transitory condition.

The growth of the trachea in length is extremely rapid, keeping pace, of course, with the elongation of the neck. At six days the trachea is a long epithelial tube with thick walls branching into the two bronchi at its lower end. At its cephalic end the lumen opens into a considerable cavity, representing the larynx; the glottis appears to be closed by a plug of epithelial cells continuous with the solid wall of the œsophagus. At eight days the lumen of both larynx and glottis is completely closed by the thickened epithelium; at eleven days the cavity of the lower end of the larynx is re-established, and the cell mass at the upper end is converted into a mesh-work by vacuolization; the lips of the glottis still show a complete epithelial fusion. Thus it is apparent that the cavity of the larynx is established by the formation of vacuoles within the solid cell-mass, and by their expansion and fusion. I cannot say how soon the glottis becomes open.

The development of the laryngotracheal apparatus, including the cartilages and muscles, has not been specially investigated in the chick. In general, it can be said that the parts external to the epithelium arise from the mesenchyme, which begins to condense around the epithelial tube on the fifth day. On the eighth day the glottis forms a decided projection into the pharynx. Distinct cartilaginous rings in the trachea are not visible on the eighth day, but are well formed on the eleventh day. As regards the syrinx it has been established by Wunderlich for *Fringilla domestica* that the tympanic cartilage arises from the lower tracheal rings. The origin of the musculature of the syrinx is not known.

CHAPTER XI

THE BODY-CAVITIES, MESENTERIES AND SEPTUM TRANSVERSUM

THE development of these parts is one of the most difficult subjects in embryology, involving, as it does, complex relations between the viscera, vascular system, and primitive body-cavity, on which the definitive relations of the body-cavities and mesenteries depend.

The pericardial and pleuroperitoneal cavities are completely separated in all vertebrates excepting *Amphioxus*, cyclostomes and some *Selachii* and ganoids, in which narrow apertures exist between the two. The pleural and peritoneal divisions of the cœlome of the trunk communicate widely in amphibia; among reptiles completely closed pleural cavities are found apparently only in *Crocodylia*; in birds and mammals they are completely closed.

As we have seen, in the early embryo of the chick there is free communication between all parts of the body-cavity. We have to consider, therefore, (1) the separation of the pericardial and pleuroperitoneal cavities, (2) the separation of pleural and peritoneal cavities, and (3) development of the mesenteries.

I. THE SEPARATION OF THE PERICARDIAL AND PLEUROPERITONEAL CAVITIES

The pericardial cavity proceeds from the cephalic division of the primitive cœlome (parietal cavity of His). We may review its primitive relations as follows (stage of 10 somites; see Chap. V): it contains the heart which divides it into right and left parts so long as the dorsal and ventral mesocardia persist; these, however, disappear very early. Laterally, the parietal cavity communicates with the extra-embryonic body-cavity (Figs. 53 and 54); posteriorly it is bounded by the wall of the anterior intestinal portal (Fig. 67), on which the heart is seated like a

rider in his saddle, the body of the rider being represented by the heart, and his legs by the omphalomesenteric veins. On each side of this posterior wall the parietal cavity communicates with the cœlome of the trunk. The floor of the parietal cavity comprises two parts meeting at the head-fold, the anterior part being composed of somatopleure, and the posterior part of splanchnopleure; the former is part of the definitive pericardial wall, the latter, known as the precardial plate, is provisional (Fig. 67).

The lateral mesocardia also take part in bounding the parietal cavity. It will be remembered that these arise as a fusion on each side between the somatopleure and the primitive omphalomesenteric veins, and that the ducts of Cuvier develop in them. As the blastoderm is spread out flat at the time that they form, they constitute at first a lateral boundary to the posterior part of the parietal cavity; but as the embryo becomes separated from the blastoderm they assume a frontal position between the sinus venosus and body-wall, the original median face becoming dorsal and the lateral face ventral. Thus they come to form a dorsal wall for the posterior part of the parietal cavity (Fig. 119). The communication of the parietal cavity with the cœlome of the trunk is thus divided into two, known respectively as the dorsal parietal recess and the ventral parietal recess. The former is a passageway above the lateral mesocardia, communicating in front with the parietal (pericardial) cavity and behind with the trunk cavity; the latter is a communication on each side of the wall of the anterior intestinal portal ventral to the lateral mesocardia.

The completion of the posterior wall of the pericardium is brought about by the formation and development of the *septum transversum*.

Septum Transversum. The septum transversum arises from three originally distinct parts, viz., (1) a median mass, (2) the lateral mesocardia, and (3) lateral closing folds arising from the body-wall between the umbilicus and the lateral mesocardia.

1. The median mass proceeds from the ventral mesentery of the fore-gut. The location of the heart and liver in the ventral mesentery divides it in three parts, viz., (*a*) a superior part, comprising the mesocardium and dorsal ligament of the liver (gastrohepatic ligament), uniting the floor of the fore-gut and

the heart and liver, (b) a median portion comprising the sinus venosus, ductus venosus and liver, and (c) an inferior portion. The superior part persists in the region of the sinus venosus and liver, and the inferior part only as the primary ventral ligament of the liver.

The median mass of the septum transversum thus includes the sinus venosus, liver, and dorsal and ventral ligaments of the liver.

At sixty hours the median mass includes chiefly the sinus and ductus venosus and their mesenteries. At eighty hours (Fig. 192) a constriction begins to appear between sinus and

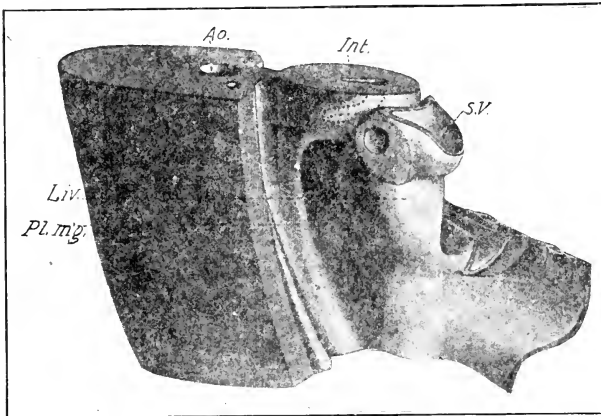


FIG. 192. — Reconstruction of the septum transversum and associated mesenteries of a chick embryo of 80 hours. (After Raven.)

Ao., Aorta. Int., Intestine. Liv., Liver. Pl. m'g., Plica mesogastrica. S.V., Sinus venosus.

ductus venosus, and the walls of the latter are expanded by the formation of liver tissue, so that the cylindrical form characteristic of sixty hours is lost, and the lateral walls of the ductus venosus bulge considerably. The continued growth of the liver causes a rapid lateral expansion of this portion of the septum transversum (Fig. 193 A).

The primary ventral ligament of the liver is included within the wall of the anterior intestinal portal up to about eighty hours. But, as the yolk-sac shifts farther back, this ligament appears as a separate membrane (inferior part of the primary ventral

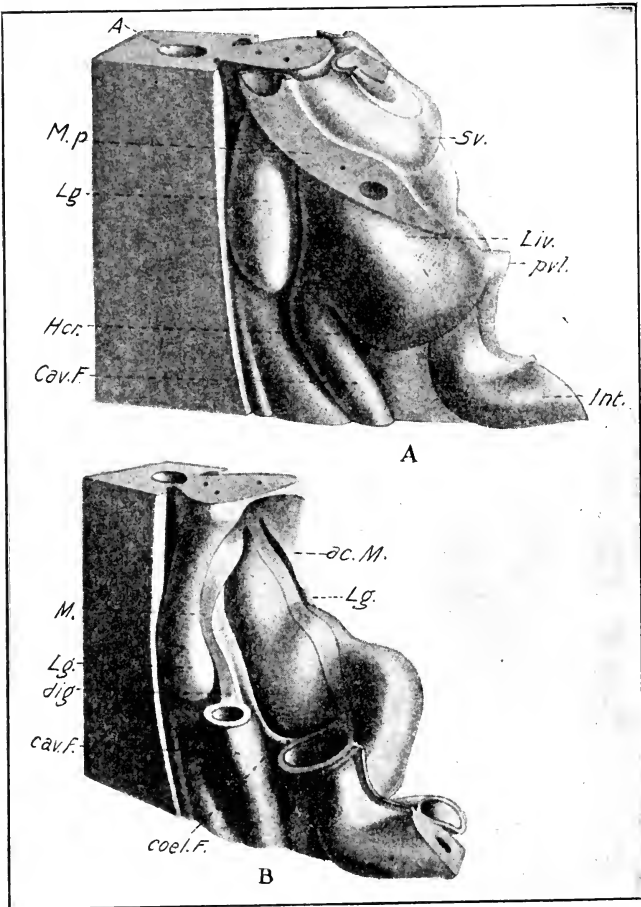


FIG. 193. — Reconstruction of the septum transversum and associated mesenteries of a chick embryo of 5 to 6 days. (After Ravn.)

A. Entire.

B. After removal of the liver and sinus venosus.

A., Aorta. ac. M., Accessory mesentery. cav. F., Caval fold. coel. F., Coeliac fold. Hcr., Hiatus communis recessus. Int., Intestine. Lg., Lung. Liv., Liver. m. p., Pleuro-pericardial membrane. pvl., Primary ventral ligament of the liver. Sv., Sinus venosus.

mesentery), uniting the ventral and posterior face of the liver to the body-wall just in front of the umbilicus (Fig. 193 A, pvl.).

For the purposes of these figures the body-wall is cut away. Nevertheless, it can be seen that the pericardial cavity communi-

cates with the peritoneal cavity around the median mass of the septum transversum beneath the lateral mesocardia.

2. The lateral mesocardia constitute the second component of the septum transversum. At the stage of sixty hours they are nearly round in section. At eighty-six hours the substance posterior to the duct of Cuvier begins to thicken (Fig. 192) so that the section is no longer round but elongated towards the umbilicus. They still extend almost transversely to the lateral body-wall. However, the retreat of the heart backwards soon changes their direction (Fig. 193 A) so as to form a long oblique partition between the pericardium and the dorsal parietal recess, the direction of the ducts of Cuvier being changed at the same time. The lateral mesocardia are directly continuous with the anterior portion of the median mass of the septum transversum.

3. The lateral closing folds arise as ridges of the lateral body-wall extending obliquely from the primary ventral ligament of the liver upwards and forwards to the lateral mesocardia. They arise along the course of the umbilical veins which open at first into the ducts of Cuvier. As the lateral closing folds develop first at their anterior ends, they appear as direct backward prolongations of the lateral mesocardia. They fuse with the lateral ventral surface of the liver (median mass of the septum transversum), and when they are completed back to the primary ventral ligament of the liver, they completely close the ventral communication of the pericardium with the peritoneal cavity. They mark out a triangular area on the cephalic face of the liver with postero-ventral apex and antero-dorsal base, which forms the median portion of the posterior wall of the pericardium (cf. Fig. 193 A). At six days the ventral communication of the pericardium is reduced to a very small opening, and at eight days it is entirely closed.

Closure of the Dorsal Opening of the Pericardium. As already noted the pericardial cavity communicates with the peritoneal cavity above the lateral mesocardia by way of the dorsal parietal recesses, which are destined to form a large part of the pleural cavities. We have, therefore, to consider next the closure of the aperture between the pleural and pericardial cavities. We have already seen that the heart shifts backwards very rapidly between the third and sixth days, and this draws out the lateral mesocardia in an oblique plane directed from dorsal anterior to

ventral posterior (Fig. 193); the ducts of Cuvier thus become oblique also, and the lateral mesocardia become converted into an oblique septum between the posterior parts of the incipient pleural cavities and the pericardial cavity (pleuro-pericardial membrane). In front of the sinus venosus, however, the pleural and pericardial cavities communicate with one another between the ducts of Cuvier, which form a projection from the lateral body-wall, and the bronchi which project laterally beneath the œsophagus. These apertures are gradually closed by fusion of the walls of the bronchi with the projecting duct of Cuvier, beginning in front and extending back to the sinus venosus. Thus the incipient pleural cavities come to end blindly in front, though they still communicate widely behind with the peritoneal cavity. The membrane thus established between pleural and pericardial cavities is known as the pleuro-pericardial membrane.

Establishment of Independent Pericardial Walls. With the formation of the ventral body-wall the precardial plate (a portion of the splanchnopleure, which at first forms part of the floor of the pericardial cavity) is gradually replaced by the ventral body-wall. The pericardial cavity is thus bounded ventrally and laterally by the body-wall and posteriorly by the median mass of the septum transversum. It has no independent walls at first. The definitive pericardium is, however, a membranous sac, and this is formed by two main processes: in the first place the membrane of the anterior face of the liver (median mass of the septum transversum) which forms the posterior boundary of the pericardium becomes much thickened, and gradually splits off from the liver (cf. Figs. 148 and 150), the peritoneal cavity extending *pari passu* between the liver and the *membrana pericardiaco-peritoneale* thus formed. The suspensory ligament of the liver, however, remains in the middle line, and the membrane is also directly continuous with the liver dorsally around the roots of the great veins. Thus a membranous wall is established for the posterior part of the pericardium. In the second place the peritoneal cavity extends secondarily into the body-wall bounding the pericardium ventrally and laterally, and thus splits a membranous pericardial sac off from the body-wall. In this process the liver appears to play an active rôle. At least its anterior lobes occupy the peritoneal spaces thus established (Fig. 194). In the mammals, on the other hand, it is the ex-

tension of the pleural cavities ventrally that splits the membranous pericardium from the body-wall.

Derivatives of the Septum Transversum. From the preceding account it will be seen that the following are derivatives of the septum transversum: (1) The posterior part of the pericardial membrane. (2) The pleuro-pericardial membrane. (3) The liver with its vessels and gastro-hepatic and primary ventral ligaments.

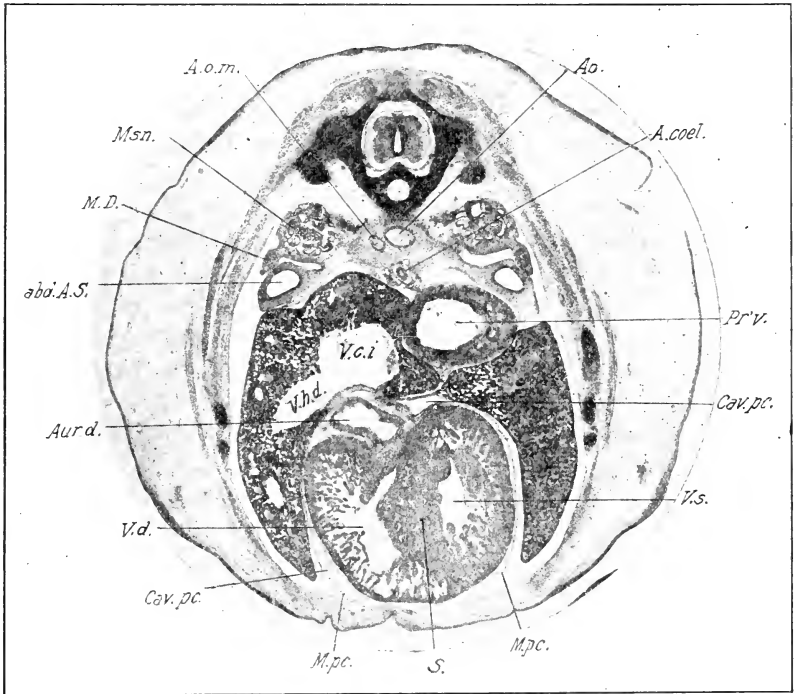


FIG. 194. — Photograph of a transverse section of an 8-day chick.

abd. A. S., Abdominal air-sac. A. coel., Coeliac artery. Ao., Aorta. A. o. m., Omphalomesenteric artery. Aur. d., Right auricle. Cav. pc., Pericardial cavity. M. D., Müllerian duct. M. pc., Membranous pericardium. Msn., Mesonephros. Pr.v., Proventriculus. S., Septum ventriculorum. V. c. i., Vena cava inferior. V. h. d., Right hepatic vein. V. d., Right ventricle. V. s., Left ventricle.

(4) A small part of the heart (the sinus venosus). As regards the last, it should be noted that the anterior portion of the original septum transversum is gradually constricted from the major posterior portion and becomes established as the sinus venosus;

this subsequently becomes incorporated in the right auricle of the heart. (See Chap. XII).

II. SEPARATION OF PLEURAL AND PERITONEAL CAVITIES; ORIGIN OF THE SEPTUM PLEURO-PERITONEALE

The pleuro-peritoneal septum arises from the so-called accessory mesenteries, the origin of which must now be described. At first the septum transversum has only a median dorsal mesentery, viz., the superior part of the primary ventral mesentery that unites the septum transversum to the floor of the fore-gut, and so by way of the dorsal mesentery of the latter to the dorsal body-wall. Subsequently, however, there arises a pair of mesenteries extending from the lateral wall of the œsophagus to the septum transversum. These are the accessory mesenteries, and they arise as follows: about the sixtieth hour they appear as mesenchymatous outgrowths, forming elongated lobes, projecting from the side walls of the œsophagus opposite the hind end of the lung rudiments. The right and left lobes are practically the same size at first and they bend over ventrally and soon fuse with the median mass of the septum transversum, represented at this time by the sinus and meatus venosus (cf. Figs. 118–120, Chap. VI). Thus are produced a pair of bays of the peritoneal cavity ending blindly in front, bounded laterally by the accessory mesenteries, and in the median direction by the intestine and its mesenteries. These are the pneumato-enteric recesses.

These bays have received different names from the various authors: thus His named only the right one as *recessus superior sacci omenti*; the left one being practically absent in mammals; Stoss called both *recessus pleuro-peritoneales*; Mall called them *gastric diverticula*; Hochstetter, *recessus pulmo-hepatici*; Maurer, *bursa hepatico-enterica*; Ravn, *recessus superior* for the right one and *recessus sinister* for the left. We may call them the pneumato-enteric recesses (*recessus pneumato-enterici*), following Broman.

At seventy-two hours the entodermal lung-sacs extend to the base of the accessory mesenteries, ending at the anterior end of the pneumato-enteric recesses. On the left side at this time the recess is fully formed back to near the anterior end of the cephalic hepatic diverticulum, on the right side considerably farther back; that is, the accessory mesentery is already longer on the right than on the left side, and the mesenchymatous lobe

from which it arises (*plica mesogastrica*, Broman) can be traced back, shifting its attachment to the dorsal mesentery, as far as the anterior intestinal portal and a little farther (Fig. 192, cf. also Fig. 120).

At ninety-six hours the entodermal lung-sacs extend far into the accessory mesenteries, and thus lie laterally to the pneumato-enteric recesses. On the left side the accessory mesentery ceases opposite the tip of the lung, but on the right side it is continued back by the mesentery of the vena cava as far as the middle of the stomach, and in this region its ventral attachment is to the superior lateral angle of the liver.

The growth of the lung-sacs into the accessory mesenteries divides the latter into three parts, viz., a superior portion uniting the lung to the dorsal mesentery, a median portion enclosing the lung, and an inferior portion uniting the lung-sacs to the median mass of the septum transversum. Now, as the liver expands laterally the ventral attachment of the accessory mesentery is carried out towards the lateral body-wall, inasmuch as its attachment is to the lateral superior face of the liver (cf. Fig. 231, Chap. XIII). Thus the accessory mesenteries are gradually shifted from their original almost sagittal plane to a plane that is approximately frontal. The developing lungs project dorsally from the accessory mesenteries, which may now be called the pleuro-peritoneal membranes, into the pleural cavities (Fig. 189); and the latter communicate with the peritoneal cavity only laterally to the liver. These communications are then soon closed by a fusion between the lateral edges of the pleuro-peritoneal membrane and the lateral body-wall; this fusion is not completely established on the eighth day, but it is on the eleventh day.

In reptiles and mammals the so-called mesonephric mesentery plays an important part in the closure of the pleural cavities. It arises from the apex of the mesonephros at its cephalic end, and fuses with the septum transversum. It thus forms a partition between the hinder portion of the pleural cavity and the cranio-lateral recesses of the peritoneal cavity. Subsequently, in mammals, its posterior free border fuses with the caudal bounding folds of the pleural cavity that arise as forwardly directed projections from the accessory mesentery on the right side and the wall of the stomach on the left. Hochstetter states that such a mesonephric fold is found in the chick but that it does not appear to play any essential part in the formation of the septum pleuro-peritoneale.

I find it in the chick as a very minute vestige at the cranial end of the mesonephros associated with the funnel of the Mullerian duct. It aids in the final closure of the pleural cavity by bridging over the narrow chink between the lateral angle of the pleuro-peritoneal membrane and the lateral body-wall. (See Bertelli, 1898.)

The oblique septum of birds arises as a layer split off from the septum pleuro-peritoneale (pulmonary aponeurosis or pulmonary diaphragm of adult anatomy) by the expansion of the anterior and posterior thoracic air-sacs within it. This mode of formation is clearly seen, particularly on the right side, in a series of transverse sections of a chick embryo of eleven days (Fig. 190). Thus the cavity between the oblique septum and the pulmonary diaphragm (cavum sub-pulmonale of Huxley) is not a portion of the body-cavity and bears no relation to it. The ingrowth of muscles into the pulmonary diaphragm can be observed in the same series of sections. It begins on the tenth day according to Bertelli.

III. THE MESENTERELS

The dorsal mesentery is originally a vertical membrane formed by reduplication of the peritoneum from the mid-dorsal line of the body-cavity to the intestine; mesenchyme is contained from the outset between its peritoneal layers, and serves as the pathway for the development of the nerves and blood-vessels of the intestine. In the course of development, its lower edge elongates with the growth of the intestine, and is thrown into folds, or twisted and turned with the various folds and turnings of the intestine. Detailed studies of its later development in the chick have not been published, but the principal events in its history are as follows: For convenience of description the dorsal mesentery may be divided into three portions corresponding to the main divisions of the alimentary tract, viz., an anterior division belonging to the stomach and duodenum, sometimes known as the mesogastrium; an intestinal division belonging to the second loop of the embryonic intestine that descends into the umbilicus; and a posterior division belonging to the large intestine and rectum. Inasmuch as the duodeno-jejunal flexure (Figs. 179 and 180, X) retains from an early stage a short mesenterial attachment, there is quite a sharp boundary in the chick between the first and second divisions of the dorsal

mesentery. The mesogastrium becomes modified by the displacement of the stomach, the outgrowth of the duodenal loop, the formation of the omentum, and by the development of the pancreas and spleen in it. (See below.)

The second division of the mesentery is related to the longest division of the intestine, but as this arises from a relatively very small part of the embryonic intestine, its dorsal attachment is short and the roots of the mesenteric arteries are grouped together. The third division is relatively long and not very deep; at its base it approaches near to the mesogastrium, to which it is attached by the root of the intermediate division.

The Origin of the Omentum (*mainly after Broman*). In a preceding section we saw that the accessory mesentery is continued back on the right side (at the stage of seventy-two hours) by a fold of the dorsal mesentery of the stomach known as the plica mesogastrica (Fig. 120). The stomach is already displaced somewhat to the left, hence the dorsal mesentery is bent also, and the plica mesogastrica arises from the angle of the bend (Fig. 120). The ventral mesentery of the stomach, including the meatus venosus and liver, remains in the middle line. Thus the body-cavity on the right of the stomach is divided into two main divisions, viz., the general peritoneal cavity *lateral* to the plica mesogastrica and liver, and another cavity between the plica mesogastrica and liver on the one hand, and the stomach on the other; the latter cavity has two divisions, a dorsal one between the plica mesogastrica and upper half of the stomach (*recessus mesenterico-entericus*) and a ventral one between the liver (*meatus venosus*) and stomach (*recessus hepatico-entericus*), which are continued anteriorly into the pneumato-enteric recesses. Subsequently, they become entirely shut off from the peritoneal cavity, but at present (stage of Fig. 120) they communicate with it by a long fissure bounded by the accessory mesentery in front, by the plica mesogastrica above, and the meatus venosus below; this opening may be called the *hiatus communis recessum*; it corresponds to the foramen of Winslow of mammals (cf. Fig. 193 A).

As development proceeds, a progressive fusion of the right dorsal border of the liver with the plica mesogastrica takes place in a cranio-caudal direction, thus lessening the extent of the hiatus.

At about ninety-six hours, the plica mesogastrica divides to form two longitudinal folds, in the lateral one of which the vena cava inferior develops (cf. Fig. 193 B); it is hence known as the caval fold; the more median division is the cœliac fold including the cœliac artery. Between them is a subdivision of the recesses known as the cavo-cœliac recess, which corresponds to the atrium bursæ omentalis of mammals. The fusion of the right lateral border of the liver continues along the course of the caval fold, and the vena cava inferior is soon completely enveloped in liver tissue. Behind the point where the vena cava inferior enters the liver, the latter fuses with the ventral edge of the right mesonephros, thus progressively diminishing the opening of the collective recesses into the peritoneal cavity. At about the one hundred and sixtieth hour, the fusion reaches the portal vein, and the recesses are thus completely shut off from the peritoneal cavity. Thus a lesser peritoneal cavity is completely separated on the right side of the body from the main cavity; and from the former both lesser and greater omental spaces develop on the right and left sides respectively of the cœliac fold. (Bursa omenti minoris and bursa omenti majoris of the bursa omentalis dextra.)

The communication of the lesser and greater omental spaces in front of the cœliac fold is closed by fusion of the latter with the right side of the proventriculus at about the one hundred and sixtieth hour, though it remains open throughout life in some birds. The two omental spaces are also elongated in a posterior direction by the caudal prolongation of the right lobe of the liver and of the gizzard respectively (Fig. 195). The lateral wall of the omentum minus is attached to the lateral dorsal border of the right lobe of the liver as already described, and it is therefore carried back by the elongation of this lobe; but as the vena cava inferior is inserted about the middle of this wall and cannot be drawn back, it results that there is a deep median indentation of the lateral wall of the omentum minus, at the bottom of which lies the vena cava inferior.

The condition of both right and left omental spaces at 154 hours is shown in Figures 195 and 196. Subsequently, about the eleventh day, the mesogastrium behind the spleen becomes perforated, and the greater omental space thus opens secondarily into the left side of the body-cavity. A true omental fold exists only for a short time in the development of the chick, and is

soon taken up by the caudal elongation of the stomach. Obliteration of the cavity of the omentum by fusion of its walls takes place at its caudal end. (Broman.)

Spaces corresponding to the omental cavities are also formed on the left side of the body, but they are of much less extent. (See Fig. 196.) The communication of these spaces with the greater peritoneal cavity is not, however, shut off as on the right side. However, a secondary and later fusion of the left lobe of the liver with the lateral body-wall, and of the gizzard with

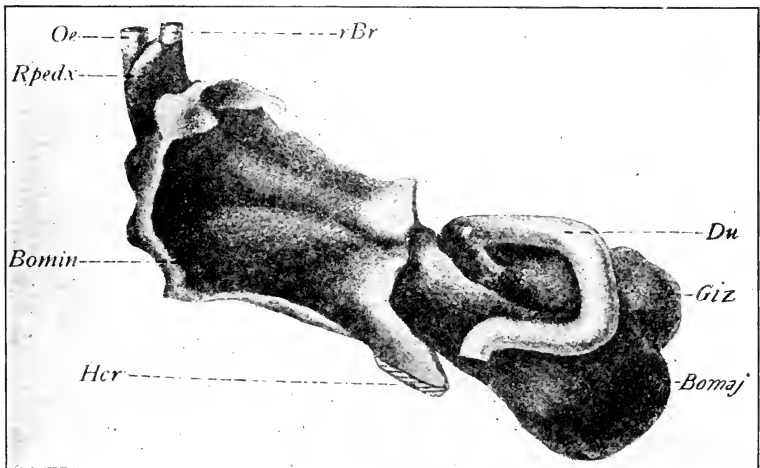


FIG. 195. — Reconstruction of the omental space of a chick embryo of 154 hours from the right side. (After Broman.)

Bomaj., Bursa omenti majoris. Bomin., Bursa omenti minoris. Du., Duodenum. Giz., Gizzard. Hcr., Hiatus communis recessum. α ., Oesophagus. rBr., Right bronchus. Rpedx., Right pneumato-enteric recess.

the ventral body-wall does isolate a portion of the peritoneal cavity from the remainder on the left side. Into this the pneumato- and hepato-enteric cavities of the left side open; however, it is obvious that this space is not analogous to the omental spaces on the right.

Origin of the Spleen. The spleen arises as a proliferation from the peritoneum clothing the left side of the dorsal mesentery just above the extremity of the dorsal pancreas. This proliferation forms the angle of a cranio-caudal fold of the dorsal mesentery which is caused by the displacement of stomach and intestine

to the left side of the body-cavity (Fig. 188), and which is exaggerated by the rapid growth of the dorsal pancreas (Choronschitzky). The spleen is thus genetically related to the wall of the great omentum, and lies outside the cavity of the latter. The cells of the spleen are proliferated from a peritoneal thickening, which may be compared in this respect to the germinal epithelium. It is recognizable at ninety-six hours, and the mass formed by its proliferation grows rapidly, forming a very considerable projection into the left side of the body-cavity above the stomach, at six days (cf. Fig. 197).

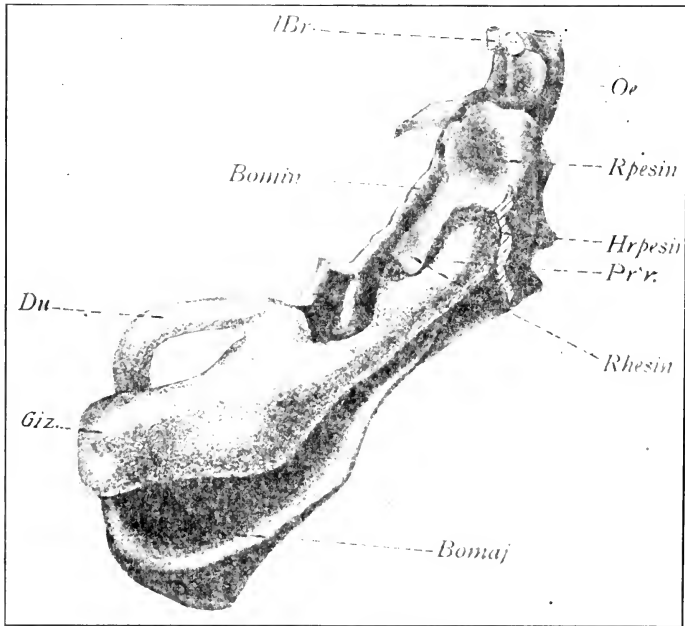


FIG. 196. — The same model from the left side. (After Broman.)

Hrpesin., Hiatus recessus pneumato-entericus sinister. *l. Br.*, Left bronchus. *Pr'v.*, Proventriculus. *Rhesin.*, Recessus hepato-entericus sinister. *Rpesin.*, Right pneumato-enteric recess. Other abbreviations as in Fig. 195.

According to Choronschitzky, the peritoneal cells invade the neighboring mesenchyme, and, spreading through it, form an ill-defined denser area, the fundamental tissue of which is therefore mesenchymal. The meshes of the latter are in immediate continuity with the vena lienalis, but the vascular endothelium is

not continued into these meshes. Thus free embryonic cells of the primordium of the spleen enter the venous circulation directly, and become transformed into blood-corpuseles.

On account of the intimate relation between the pancreas and spleen in early embryonic stages, certain authors (see esp. Voit) have asserted a genetic connection, deriving the spleen from the pancreas. There is, however, no good evidence that the relation is other than that of propinquity.

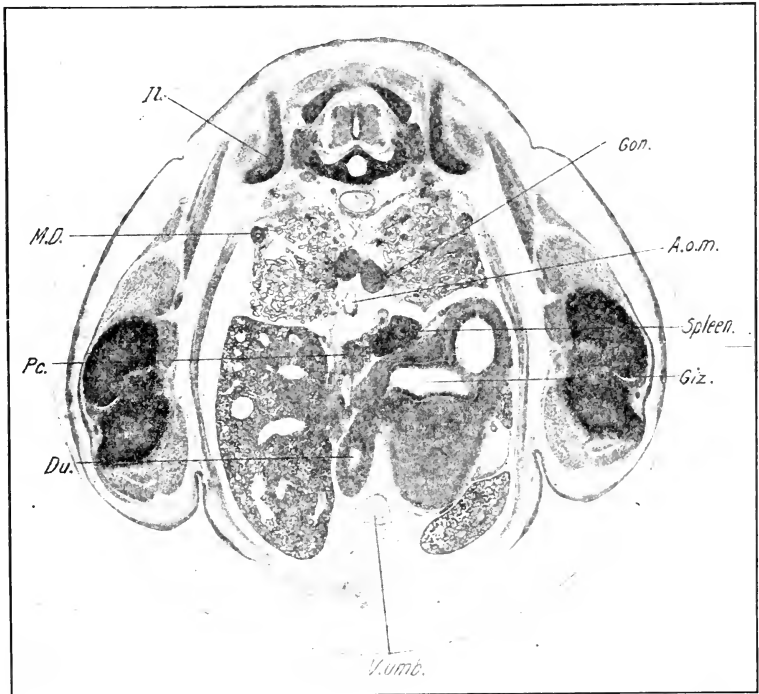


FIG. 197. — Photograph of transverse section through a chick embryo of 8 days.

A. o. m., Omphalomesenteric artery. Du., Duodenum. Giz., Gizzard. Gon., Gonad. Il., Ilium. M. D., Müllerian duct. Pc., Pancreas. V. umb., Umbilical vein.

It should also be noted that the absence of rotation of the chick's stomach (as contrasted with mammals) and the lesser development of the great omentum appear to be the causes of the more primitive position of the spleen in birds as contrasted with mammals.

CHAPTER XII

THE LATER DEVELOPMENT OF THE VASCULAR SYSTEM

I. THE HEART. (For an account of the earlier development, see Chapters V and VI.)

At the stage of seventy-two hours (Fig. 198), the ventricle consists of a posterior transverse portion and two short parallel limbs; the right limb is continuous with the bulbus arteriosus from which it may be distinguished by a slight constriction, and the left limb with the atrium. The constriction between the latter is the auricular canal.

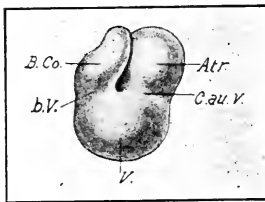


FIG. 198. — Ventral view of the heart of a chick embryo of 2.1 mm. head length. (After Greil from Hochstetter.)

Atr., Atrium. B. co., Bulbus cordis. b. V., The constriction between bulbus and ventricle. C. au. v., Auriculo-ventricular canal. V., Ventricle.

Between the two limbs in the interior of the ventricle is a short bulbo-auricular septum separating the openings of bulbus and atrium into the ventricle. A slight groove, the interventricular sulcus, that extends backwards and to the right from the bulbo-auricular angle, marks the line of formation of the future interventricular septum (Fig. 199).

The Development of the External Form of the Heart. We have seen that in the process of development the heart shifts backwards into the thorax. The ventricle undergoes the greatest displacement, owing to its relative freedom of movement, and thus comes to lie successively to the right of, and then behind the atrium. A gradual rotation of the ventricular division on its antero-posterior axis accompanies its posterior displacement; and this takes place in such a way that the bulbus is transferred to the mid-ventral line, where it lies between the auricles (Figs. 199 and 200).

The auricles arise as lateral expansions of the atrium, the

left one first at an early stage and the right one later. The left auricle is thus larger than the right for a considerable period of time in the early development. When the right auricle grows out it passes above the bulbus, which is already in process of rotation, and the two auricles then expand ventrally on each side of the bulbus. The apex of the ventricle belongs primarily to the left side and this remains obvious as long as the external interventricular groove exists. In the adult the apex of the heart belongs to the left ventricle.

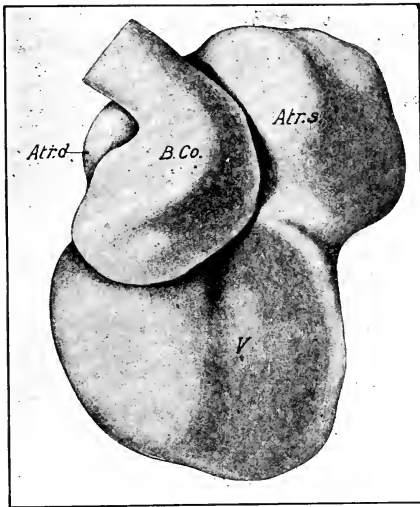


FIG. 199. — Ventral view of the heart of a chick embryo of 5 mm. head-length. (After Masius.)

Atr. d., s., Right and left auricles.
B. Co. Bulbus cordis. V. Ventricle.

The varying positions occupied by the chambers of the heart in relation to the body axes constitute a serious difficulty in describing the development. For instance, the auricular canal is at first in front of the atrium (before any bending of the heart takes place). As the ventricular loop turns backward and beneath the atrium, the auricular canal is ventral to the atrium; and finally, as the ventricles assume their definitive position behind the auricles, the derivatives of the auricular canal (auriculo-ventricular openings) come to lie behind the atrium. In other words, the atrium rotates around a transverse axis through nearly 180 degrees in such a way that its original anterior end becomes succes-

sively ventral and posterior. The definitive ventral surface of the heart is a cranial rather than a ventral surface during the critical period of development described below, up to eight days (cf. Figs. 148 and 150). In other words, the apex of the heart is directed ventrally rather than posteriorly, though it has a posterior inclination. For simplicity of description, however, it seems better to use the definitive orientation in the following account; that is, to regard the apex of the heart as posterior instead of ventral, and the bulbus face of the heart as ventral instead of cranial, in position.

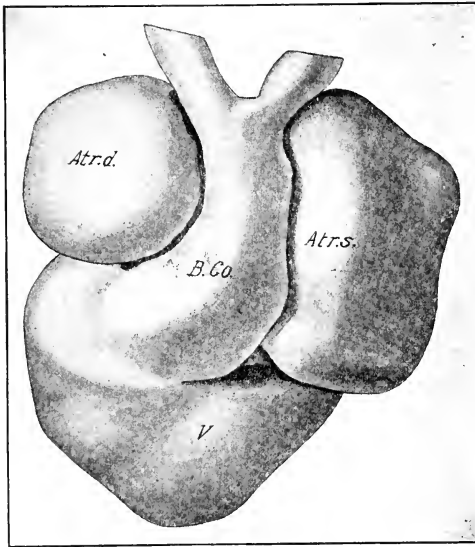


FIG. 200. — Ventral view of the heart of a chick embryo of 7.5 mm. head-length. (After Masius.)

Atr. d., s., Right and left auricles. B. Co., Bulbus cordis. V., Ventricle.

Division of the Cavities of the Heart. The embryonic heart is primarily a single continuous tube; during development a complex series of changes brings about its complete division into right and left sides, corresponding to the pulmonary and systemic circulations. Partitions or septa arise independently in each primary division of the cardiac tube, excepting the sinus venosus, and subsequently these unite in such a way as to make two independent circulatory systems. During this time the

appropriate valves are formed. We have thus to describe the origin of three primary septa, viz., the interauricular septum, the interventricular septum, and the septum of the truncus and bulbus arteriosus. These do not, however, themselves unite directly, but are joined together by the intermediation of a fourth, large, cushion-like septum formed in the auricular canal, *i.e.*, in the opening between the primitive atrium and ventricle.

In general it may be said that the development of the three primary septa takes place from the periphery towards the center, *i.e.*, towards the cushion-septum of the auricular canal, and that it is practically synchronous in all three, though there is a slight precedence of the interauricular septum. During the same time the cushion-septum of the auricular canal is formed. We may then consider first the origin of these septa separately, and second their union.

(a) *The Septum Trunci et Bulbi Arteriosi (Septum Aortico-Pulmonale)*. This septum divides the truncus and bulbus arteriosus into two arteries, the aorta and pulmonary artery. Three divisions may be distinguished, viz., a part in the truncus arteriosus, a part in the distal division of the bulbus extending to the place of formation of the semilunar valves, and a part in the proximal portion of the bulbus, which subsequently becomes incorporated in the ventricles. In mode of formation these are more or less independent, though they unite to form a continuous septum.

The septum of the truncus arteriosus arises on the fifth day as a complete partition extending from the cephalic border of the two pulmonary arches into the upper portion of the bulbus arteriosus; the blood current flowing through the bulbus that passes behind this partition enters the pulmonary arches exclusively, that passing in front enters the two remaining pairs of aortic arches. During the latter half of the fifth day and on the sixth day the septum of the truncus is continued into the proximal portion of the bulbus and divides it in two stems. Here, however, it co-operates with three longitudinal ridges of the endocardium of the bulbus, one of which is in the direct line of prolongation of the septum of the truncus, which therefore is continued along this one and between the other two as far as the place of formation of the semilunar valves (Fig. 201). The entire septum thus formed has a slightly spiral course, of such a nature that

the pulmonalis, which lies dorsal to the aorta distally, is gradually transposed to its left side. The third division of the aortic-pulmonary septum arises near the opening of the bulbus into the ventricle in the form of two ridges of the endocardium on the right and left sides respectively of the bulbus, the pulmonary

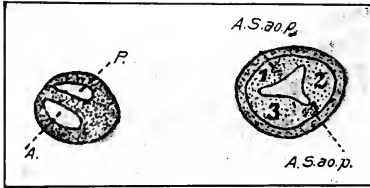


FIG. 201. — A. Section through the truncus arteriosus of an embryo of 5 mm. head-length.

B. Section through the distal portion of the bulbus arteriosus of the same embryo. (After Greil.)

A., Aorta. P., Pulmonalis. A. S. a.o. p., Plane of the septum aortico-pulmonale. 1, 2, and 3, Ridges prolonging the septum aortico-pulmonale.

division lying ventral and the aortic division dorsal to the incipient partition. A third slight endocardial ridge of the proximal part of the bulbus is described (Hochstetter, Greil) at this stage, but it soon disappears. The proximal bulbus ridges may be seen on the fifth day; on the sixth day they are well formed; on the seventh day they have united to form a partition which becomes continuous with the partition in the distal portion of the bulbus.

Thus the separation of the aortic and pulmonary trunk is completed down to the ventricle.

The semilunar valves arise by excavation of three endocardial thickenings in each trunk formed at the caudal end of the distal division of the bulbus (Hochstetter, Greil). The origin of these thickenings is as follows. Both the aortic and pulmonary trunks receive one each of the original endocardial ridges of the distal portion of the bulbus owing to the course of the aortic-pulmonary septum. Each also receives half of the ridge along which the septum of the truncus is prolonged. A third ridge arises subsequently in each between these two. A cavity then arises in each ridge and opens distally into the aorta and pulmonary artery respectively, thus forming pockets open in front. These valves are fully formed at eight days.

The aortic-pulmonary septum becomes thick early in its history and the muscular layers of the vascular trunks, which at first form a common sheath for both, gradually constrict into the septum, and separate when the constriction brings them together, so that each vessel obtains an independent muscular wall. Subsequently, a constriction extends from the outer layer

of the truncus and bulbus along the entire length of the septum, and thus completely separates the aorta and pulmonary arteries from each other. On the eighth day each vessel has independent muscular walls, and the external constriction has made some progress.

(b) *The Interventricular Septum.* As noted before, the interventricular sulcus that extends from the bulbo-auricular angle towards the apex of the heart marks the line of development of the interventricular septum. The right division of the primitive ventricle is therefore continuous with the bulbus and the left with the atrium. However, the partition, bulbo-auricular septum, which at first separates the primitive right and left limbs of the ventricle, undergoes rapid reduction and becomes a mere ridge by the stage of ninety-six hours. Thus the opening of the bulbus and the auricular canal lie side by side, separated only by this slight ridge. The rotation of the ventricle brings the bulbus from the right side into the mid-ventral line so that the opening of the bulbus comes to lie ventral to the auricular canal on its right side (cf. Figs. 199 and 200).

In the interior of the heart the development of the interventricular septum is associated with the formation of the trabeculæ or ramified and anastomosing processes of the myocardium that convert the peripheral part of the ventricular cavity into a spongy mass at an early stage. Along the line of the interventricular sulcus these trabeculæ extend farther into the cavity than elsewhere, and become united together at their apices by a slight thickening of the endocardium, which clothes them all, thus originating the interventricular septum (Fig. 202). This process begins at the apex of the ventricle, and extends towards the base, the fleshy septum becoming gradually higher and thicker and better organized. It thus has a concave free border, directed towards the bulbo-auricular ridge and continued along both the ventral and dorsal surfaces of the ventricle. The septum develops more rapidly along the dorsal than the ventral wall and on the fifth day reaches the neighborhood of the auricular canal on this side, and unites with the right side of the fused endocardial cushions which have in the meantime developed in the latter. (See below.) Thus the interventricular foramen, or communication between the ventricles, is gradually reduced in extent and limited to the ventral anterior portion of the septum. It is never completely

closed, but, as we shall see later, the interventricular foramen is utilized in connecting up the aorta with the left ventricle.

It will be seen that if the original direction of this septum, as indicated by the interventricular groove on the surface, were preserved (Fig. 199), the interventricular septum would fuse with the bulbo-auricular ridge and the right ventricle would then be continuous with the bulbus only, and the left ventricle with the atrium, and circulation of the blood would be impossible. The avoidance of this condition is due to the rotation of the bulbus by which it is brought beneath the auricular canal, and by widening of the auricular canal to the right. Thus the inter-

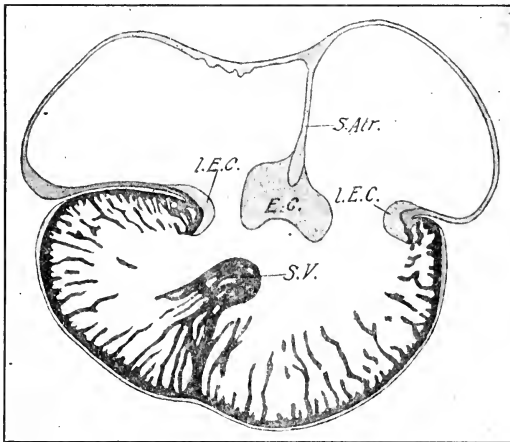


FIG. 202. — Frontal section of the heart of a chick embryo of 9 mm. head-length. (After Hochstetter.)

E. C., Median endothelial cushion. L. E. C., Lateral endothelial cushion. S. Atr., Septum atriorum. S. V., Septum ventriculorum.

ventricular septum meets the right side of the cushion-septum and divides the auricular canal, though the opening of the bulbus remains on its right.

(c) *The interauricular septum* forms at the same time as the septum between the ventricles, as a thin myocardial partition arising from the vault of the atrium between the openings of the sinus venosus and pulmonary vein; it extends rapidly with concave free border towards the auricular canal, and soon fuses

completely along its entire free border with the endothelial cushions of the latter. It would thus establish a complete partition between the two auricles were it not for the fact that secondary perforations arise in it before its free edge meets the endothelial cushions (Fig. 203). These have the same physiological significance as the foramen ovale in the mammalian heart, and persist through the period of incubation, closing soon after hatching.

(d) *The Cushion-septum (Septum of the Auricular Canal)*. This septum completes the entire system by uniting together the three septa already considered. It forms as two cushion-like thickenings of the endothelium in the floor and roof respectively of the auricular canal (cf. Figs. 202, 203 and 204). These cushions rapidly thicken so as to restrict the center of the atrioventricular aperture, and finally, fusing together, divide the latter into two vertically-elongated apertures, right and left respectively. The time of formation of this large endocardial cushion dividing the auricular canal is coincident with the formation of the other septa.

(e) *Completion of the Septa*. Thus by the end of the fifth or the beginning of the sixth day of incubation, the heart is prepared for the rapid completion of a double circulation. The embryonic circulation is never completely double, however, for the reason that the embryonic respiratory organ (allantois) belongs to the aortic system, and full pulmonary circulation does not begin until after hatching. However, between the sixth and eighth days the right and left chambers of the heart become completely separated, except that the interauricular foramina

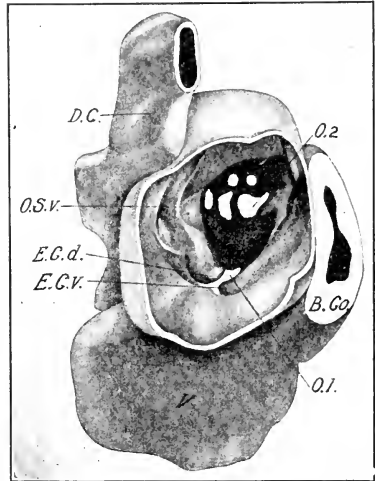


FIG. 203. — Reconstruction of the heart of a chick embryo of 5.7 mm. head-length, seen from right side. Part of the wall of the right auricle is cut away. (After Masius.)

B. Co., Bulbus cordis. D. C., Duct of Cuvier. E. C. d., v., Dorsal and ventral endothelial cushions. O. S. v., Opening of the sinus venosus into the right auricle. O. 1, O. 2, Primary and secondary ostia or inter-auricular connections.

remain until hatching, and serve as a passageway of blood from the right side to the left side.

The completion of the cardiac septa takes place in such a way that the aorta becomes connected with the left ventricle, the pulmonary artery remaining in connection with the right. To understand how this occurs it is necessary to remember that, although the bulbus arteriosus is primitively connected with the right side of the ventricle, the revolution of the latter has transferred the bulbus to the middle line where it lies to the right of

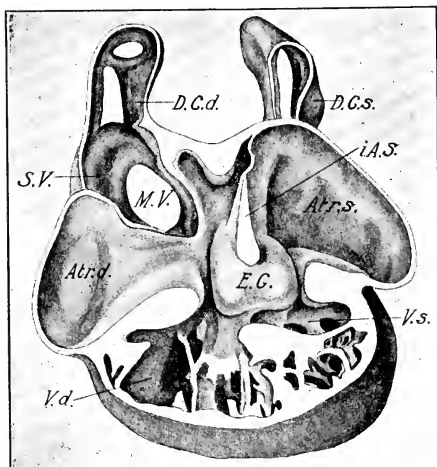


FIG. 204. — Reconstruction of the heart of a chick embryo of 5.7 mm. head-length. Ventral face removed; interior of the dorsal half. (After Masius.)

Atr. d., s., Right and left auricles. *D. C. d., s.*, Right and left ducts of Cuvier. *E. C.*, Endothelial cushion. *i. A. S.*, Interauricular septum. *M. V.*, Opening of the meatus venosus into the sinus. *S. V.*, Sinus venosus. *V. d., s.*, Right and left ventricles.

the interventricular septum, and ventral to the right division of the auricular canal. The bulbo-auricular ridge thus forms the floor of this side of the auricular canal. The interventricular septum is attached to the right side of the cushion-septum and its foramen and the aperture of the bulbus lie side by side. It will also be remembered that the proximal portion of the bulbus is divided by a partition formed by right and left endocardial

ridges, and that the aortic division of the bulbus lies above the pulmonary division, that is, next the bulbo-auricular ridge. The left bulbus ridge is thus continuous with the interventricular septum immediately beneath the foramen of the latter, and the right bulbus ridge lies on the opposite side.

The bulbus septum now becomes complete by fusion of the right and left sides. The blood from the left ventricle is then forced in each systole through the interventricular foramen and along a groove in the right side of the cushion-septum into the aortic trunk. This groove, however, is open to the right ventricle also above the septum of the bulbus; but it is soon bridged over by an extension of the cushion-septum along the bulbo-auricular ridge as far as the right side of the septum of the bulbus; in this way the space existing between the interventricular septum and the opening of the aorta is converted into a tube, and thus the aorta is prolonged through the cushion-septum, and by way of the interventricular foramen into the left ventricle.

Fate of the Bulbus. The distal portion of the bulbus is converted into the proximal parts of the aorta and pulmonary artery. The part proximal to the semilunar valves is gradually incorporated into the ventricles, owing to extension of the ventricular cavities into its wall, and subsequent disappearance of the inner wall of the undermined part.

The Sinus Venosus. (For earlier development see Chap. VI; relation to septum transversum, Chap. XI.)

In the course of development, the sinus venosus gradually separates from the septum transversum, though always connected with the latter by the vena cava inferior. In early stages (up to about 24 somites) it is placed quite symmetrically behind the atrium, and extends transversely to the entrance of the ducts of Cuvier on each side. The sinu-auricular aperture is approximately in the median line at first, so that the right and left divisions of the sinus are nearly symmetrical. The condition of approximate bilateral symmetry of the sinus is, however, rapidly changed by shifting of the sinu-auricular aperture to the right side with the outgrowth of the right auricle (24-36 somites); thus the left horn of the sinus becomes elongated; moreover, the main expansion of the sinus takes place in the region of the sinu-auricular aperture, and thus the left horn appears relatively narrow in diameter. The interauricular septum forms to the left of the sinu-

auricular aperture (Fig. 204). At the stage of ninety-six hours the general form of the sinus is that of a horseshoe situated between the atrium and the septum transversum; the ends of the horseshoe, or horns of the sinus venosus, are continued into the ducts of Cuvier. The sinu-auricular aperture lies on the right, and here the cavity of the sinus is largest; the right horn of the sinus is relatively short and the left horn forms a transverse piece on the anterior face of the septum transversum, which gradually curves dorsally and enters the left duct of Cuvier.

The right and left boundaries of the sinu-auricular aperture project into the cavity of the right auricle as folds that meet below the aperture and diverge dorsally (Fig. 204), thus forming sinu-auricular valves; a special development of the muscular trabeculæ running along the roof of the right auricle from the angle of these valves corresponds to the septum spurium of mammalia. The *sinus septum* arises as a fold of the roof of the sinus between the entrance of the left horn and the vena cava inferior; it grows across the sinus into the sinu-auricular aperture and thus divides the latter (cf. Fig. 231). Subsequently, the sinus becomes incorporated in the right auricle, and the systemic veins thus obtain independent openings into the latter (see account of development of the venous system). The sinu-auricular valves disappear during this process.

II. THE ARTERIAL SYSTEM

The Aortic Arches. In the Amniota six aortic arches are formed connecting the truncus arteriosus with the roots of the dorsal aorta. The first four lie in the corresponding visceral arches; the fifth and sixth are situated behind the fourth visceral pouch; the fifth is a very small and transitory vessel, the existence of which was not suspected until comparatively recently (v. Bemmelen, Boas), and the sixth or pulmonary arch was previously interpreted as the fifth. The discovery of the fifth arch has brought the Amniota into agreement with the Amphibia as regards the number and significance of the various aortic arches.

The fate of the aortic arches in the chick is as follows (see Figs. 205, 206): the first and second arches disappear as already described (Chap. VI), and the anterior prolongation of the dorsal aortæ in front of the third arch constitutes the internal carotid; the ventral ends of the first and second arches form the external

carotid. The third arch on each side persists as the proximal portion of the internal carotids; and the dorsal aorta ruptures on each side between the dorsal ends of the third and fourth arches. The fourth arch and the root of the dorsal aorta disappear on the left side, but remain on the right as the permanent arch of the aorta. The fifth arch disappears on both sides; the sixth arch persists throughout the period of incubation and forms an important arterial channel of the systemic circulation until hatching. Then the dorsal portion (duct of Botallus or ductus arteriosus) becomes occluded, and the remainder of the sixth arch becomes the proximal portion of the pulmonary arteries.

The details of these changes are as follows: On the third and fourth days of incubation the first and second aortic arches disappear (Fig. 102). The lower ends of these arches then appear as a branch from the base of the third arch on each side, extending into the mandible and forming the external carotid artery. The dorsal aorta in front of the third arch constitutes the beginning of the internal carotid. During the fourth day the sixth pair of aortic arches is formed behind the fourth cleft, and the origin of the pulmonary arteries is transferred to them (Fig. 102). The fifth pair of aortic arches is also formed during the fourth day (Fig. 206.) It is a slender vessel passing from near the base to near the summit of the sixth arch. As it has been entirely overlooked by most investigators, it is certain that it is of very brief duration, and it may even be entirely absent in some embryos. Apparently it has no physiological importance, and it can be interpreted only as a phylogenetic rudiment.

Thus at the beginning of the fifth day the entire series of aortic arches has been formed, and the first, second, and fifth

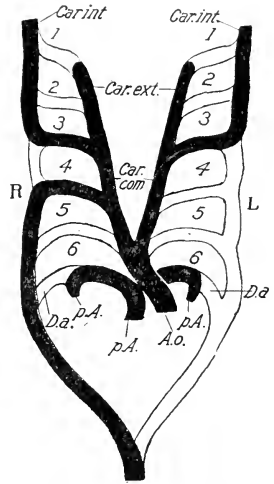


FIG. 205. — Diagram of the aortic arches of birds and their fate. (After Boas.)

Car. com., Common carotid. Car. ext., External carotid. Car. int., Internal carotid. D. a., Ductus arteriosus. L., Left. p. A., Pulmonary artery. R., Right.

1, 2, 3, 4, 5, and 6, First, second, third, fourth, fifth, and sixth aortic arches.

have entirely disappeared. The surviving arches are the third or carotid arch, the fourth or aortic arch, and the sixth or pulmonary arch. Up to this time the development is symmetrical

on both sides of the body. During the fifth and sixth days the two sides become asymmetrical, the fourth arch becoming reduced on the left side of the body and enlarged on the right. Fig. 207 shows the condition on the two sides of the body on the sixth day. If the fourth arch of the two sides be compared it will be seen that the left one is reduced to a very narrow rudiment which has lost its connection with the bulbus arteriosus, while on the right side it is well developed.

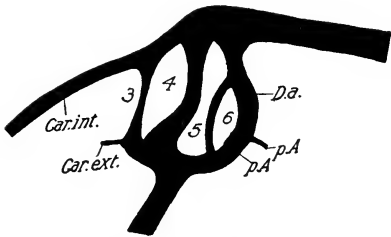


FIG. 206. — Camera sketch of the aortic arches of the left side of a chick embryo 4½ days old. From an injected specimen. (After Locy.)
Abbreviations as in Fig. 205.

Another important change illustrated in the same figure is the reduction of the dorsal aorta between the upper ends of the carotid and aortic arches to a narrow connection. Two factors co-operate in the diminution

of the dorsal aorta between the upper ends of the carotid and aortic arches to a narrow connection. Two factors co-operate in the diminution

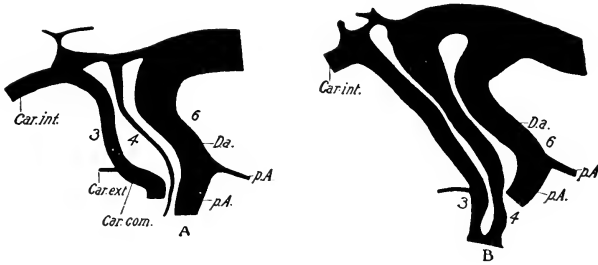


FIG. 207. — Reconstruction of the aortic arches of a 6-day chick embryo from a series of sagittal sections.
A. Left side.
B. Right side.
Car. com., Common carotid. Car. ext., External carotid.
Car. int., Internal carotid. D. a., Ductus arteriosus.
3, 4, and 6, Third, fourth, and sixth aortic arches.

and gradual disappearance of this part of the primitive dorsal aorta, viz., the elongation of the neck and the reduction of the blood current. It will be seen that relatively little circulation is possible in this section, because the current up the carotid

arch turns forward and that up the aortic arch turns backward, hence there is an intermediate region of stagnation, and here the obliteration occurs.

On the eighth day the changes indicated on the sixth day are completed. The left aortic arch has entirely disappeared, and the connection between the upper ends of the carotid and aortic arches is entirely lost on both sides (Fig. 208), though lines of apparently degenerating cells can be seen between the two. On the other hand, the upper end of the pulmonary arch (duct of Botallus) is as strongly developed on both sides as the right aortic arch itself. The pulmonary artery proper is relatively very minute (Fig. 208), and it can transmit only a small

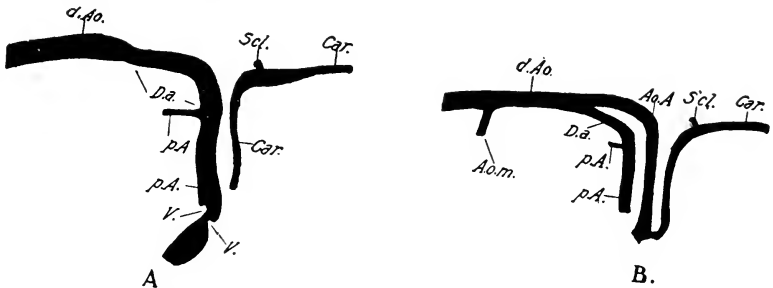


FIG. 208. — Reconstruction of the aortic arches of an 8-day embryo from a series of sagittal sections.

- A. Left side.
- B. Right side.

A. o. m., Omphalomesenteric artery. Ao. A., Aortic (systemic) arch. Car., Carotid. D. a., Ductus arteriosus. d. Ao., Dorsal aorta. p. A., Pulmonary artery. S'cl., Subclavian artery. V., Valves of the pulmonary artery.

quantity of blood; the principal function of the pulmonary arch is obviously in connection with the systemic circulation. In other words, both sides of the heart pump blood into the aorta during embryonic life; after hatching, the duct of Botallus becomes occluded as already noted, and the pulmonary circulation is then fully established.

The Carotid Arch. With the retreat of the heart into the thorax, the internal and external carotids become drawn out into long vessels extending through the neck region. The internal carotids then become approximated beneath the vertebral centra. The stem of the external carotid forms an anastomosis with the internal carotid in the mandibular region, and then disappears,

so that its branches appear secondarily as branches of the internal carotid. The common carotid (*car. communis*) of adult anatomy is derived entirely from the proximal part of the internal carotid.

The Subclavian Artery. The primary subclavian artery arises on the fourth day from the fifteenth (eighteenth of entire series) segmental artery of the body-wall when the wing-bud forms, and gradually increases in importance with the growth of the wing. During the fifth day a small artery that arises from the base of the carotid arch grows backwards and unites with the primary subclavian at the root of the wing. Thus the subclavian artery obtains two roots, a primary one from the dorsal aorta and a secondary one from the carotid arch (Fig. 209). As the latter grows in importance the primary root dwindles and finally disappears (about the ninth day). Apparently the Crocodilia and Chelonia agree with the birds in this respect, while the other vertebrates retain the primary root.

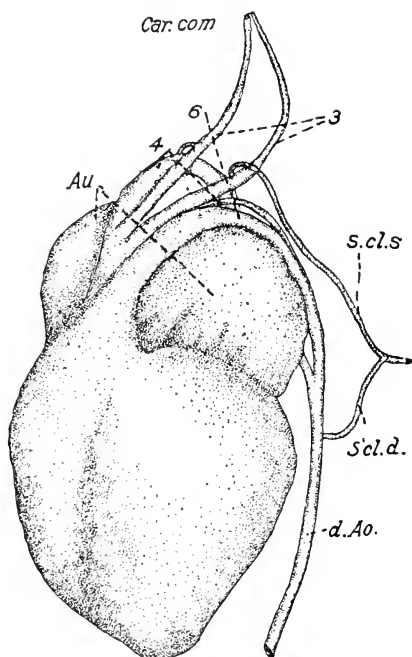
FIG. 209. — Dissection of the heart and aortic arches of a chick embryo in the latter part of the sixth day of incubation. (After Sabin.)

Au., Auricle. Car. com., Common carotid. S'cl. d., s., primary and secondary subclavian artery.

3, 4, 6, Third (carotid), fourth (systemic), and sixth (pulmonary) arches.

with its branches (Fig. 216).

The segmental arteries belong to the primitive dorsal aorta; originally there is a pair in each intersomitic septum, but their fate has not been thoroughly worked out in the chick. At six days the cervical segmental arteries are united on each side by



The Aortic System includes the aortic arch and the primitive dorsal aorta

The Aortic System includes the aortic arch and the primitive dorsal aorta

a longitudinal anastomosis communicating with the internal carotid in front.

The two omphalomesenteric arteries are originally independent (Chap. V), but as the dorsal mesentery forms, they fuse in a common stem extending to the umbilicus. The anterior mesenteric artery arises from this. The cœliac and posterior mesenteric arteries arise independently from the dorsal aorta (Fig. 216).

Mesonephric arteries arise from the ventro-lateral face of the dorsal aorta and originally supply the glomeruli; they are very numerous at ninety-six hours, but become much reduced in number as the renal portal circulation develops; some of them persist as the definitive renal and genital arteries.

The umbilical arteries arise from the same pair of segmental arteries that furnishes the primitive artery of the leg. Thus on the fourth day the umbilical arteries appear as branches of the sciatic arteries; but later the umbilical arteries become much larger than the sciatic (Fig. 216). The right umbilical artery is, from the first, smaller than the left. On the eighth day its intermediate portion in the region of the neck of the allantois is much constricted, and it gradually disappears. The caudal artery is the narrow posterior extremity of the dorsal aorta behind the umbilical arteries.

I do not find a stage in the chick when the umbilical arteries unite directly with the dorsal aorta by way of the intestine and dorsal mesentery, though no doubt indirect connections exist at an early stage. In mammals (Hochstetter) the primitive umbilical artery has such a splanchnic course, but a secondary connection in the somatopleure soon replaces the primary splanchnic path.

III. THE VENOUS SYSTEM. (See Chapter VI for origin of the first venous trunks)

We shall take up the development of the venous system in the following order: (*a*) the system of the anterior venæ cavæ (venæ cavæ superiores); (*b*) the omphalomesenteric and umbilical veins and the hepatic portal system; (*c*) the system of the inferior vena cava.

The anterior venæ cavæ are formed on each side by the union of the jugular, vertebral, and subclavian veins. The jugular is derived from the anterior cardinal veins, which extend down the neck in close proximity to the vagus nerves. The embryonic

history of its branches is not known in detail (see Chap. VI and Fig. 162 for the first branches). The history of the vertebral veins, which open into the jugular veins near the base of the neck, formed by union of anterior and posterior branches, is likewise unknown. Presumably they are formed in part by anastomoses between segmental veins. The subclavian vein arises primitively as a branch of the posterior cardinal vein; it receives the blood from the wing and walls of the thorax. The part of the posterior cardinal behind the entrance of the subclavian vein disappears on the sixth day, and its most proximal part represents then the anterior continuation of the subclavian vein (Fig. 216). The part of the superior vena cava proximal to the union of jugular and subclavian veins is derived from the duct of Cuvier, and on the left side also from the left horn of the sinus venosus.

The primitive omphalomesenteric veins unite behind the sinus venosus to form the meatus venosus, around which the substance of the liver develops as described in Chapters VI and X; the union extends back to the space between the anterior and posterior liver diverticula, where the omphalomesenteric veins diverge and pass out to the yolk-sac along the margins of the anterior intestinal portal (Fig. 210 A). In the latter part of the third day (34-36 somites) an anastomosis forms between the right and left omphalomesenteric veins above the intestine just behind the dorsal pancreas, and thus establishes a venous ring around the intestine, the upper portion of which is formed by the anastomosis, the lower portion by the meatus venosus, and the sides by the right and left omphalomesenteric veins respectively (Fig. 210 B). Even during the formation of this first venous ring it can be seen that its left side is becoming narrower than the right side, and in less than a day it disappears completely (Fig. 210 C). Thus the blood brought in by the left omphalomesenteric vein now passes through the dorsal anastomosis to the right omphalomesenteric vein, and the latter alone connects with the meatus venosus.

While this is taking place (seventy-two to ninety-six hours) the intestine has elongated, the anterior intestinal portal has shifted backwards, and a second anastomosis is formed between the two omphalomesenteric veins ventral to the intestine and immediately in front of the intestinal portal (Fig. 210 D). Thus

a second venous ring is established around the alimentary canal, the lower portion of which is formed by the second anastomosis,

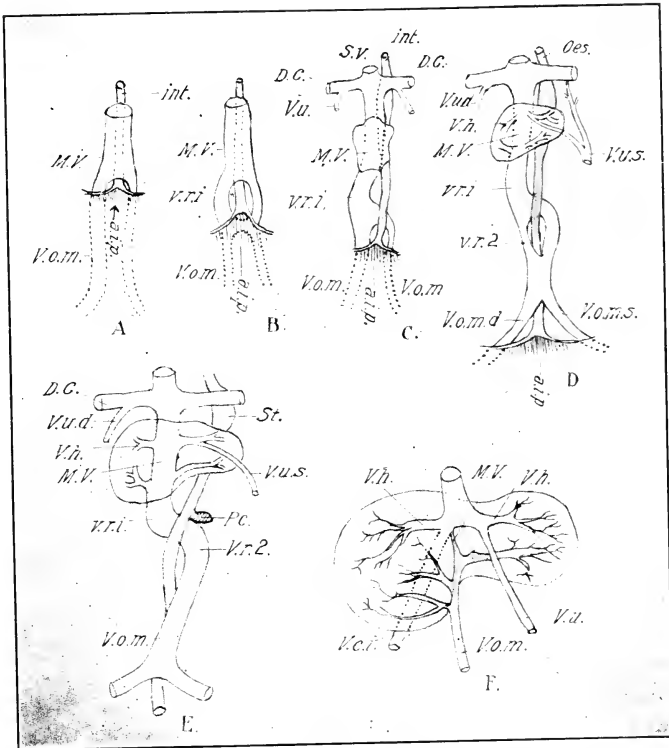


FIG. 210. — Diagrams illustrating the development of the hepatic portal circulation. (After Hochstetter.)

- A. About the fifty-eighth hour.
- B. About the sixty-fifth hour; first venous ring formed around the intestine.
- C. About the seventy-fifth hour; the left limb of the first venous ring has disappeared.
- D. About the eightieth hour; the second venous ring is established.
- E. About the one hundredth hour; the right limb of the second venous ring has disappeared.
- F. Hepatic circulation about the one hundred and thirtieth hour, immediately before the disappearance of the intermediate portion of the meatus venosus.

a. i. p., Anterior intestinal portal. D. C., Duct of Cuvier. int., Intestine. M. V., Meatus venosus. Oes., Oesophagus. Pe., Pancreas. St., Stomach. S. v., Sinus venosus. V. c. i., Vena cava inferior. V. h., Hepatic veins. V. o. m., Omphalomesenteric vein. v. r. 1, First venous ring. v. r. 2, Second venous ring. V. u. d., Right umbilical vein. V. u. s., Left umbilical vein.

the upper portion by the first anastomosis, and the sides by the right and left omphalomesenteric veins respectively. This ring is also soon destroyed, this time by the narrowing and disappearance of its right side (Fig. 210 E).

Thus at about 100 hours the condition is as follows (Fig. 210 E): the two omphalomesenteric veins unite to form a single trunk in front of the anterior intestinal portal and ventral to the intestine (second anastomosis), the single trunk then turns to the left (left side of second ring), passes forward and above the intestine to the right side (first or dorsal anastomosis), and then farther forward on the right side of the intestine (right side of first venous ring) to enter the liver, where it becomes continuous with the meatus venosus.

The Hepatic Portal Circulation becomes established in the following manner: The meatus venosus is primarily a direct passageway through the liver to the sinus venosus (Fig. 210 C); but, as the liver trabeculae increase, more and more of the blood entering the meatus venosus is diverted into the vascular channels or sinusoids that occupy the spaces between the trabeculae. By degrees these secondary channels through the liver substance form two sets of vessels, an afferent one, branching out from the caudal portion of the meatus venosus, in which the blood is flowing into the hepatic sinusoids, and an efferent set branching from the cephalic portion of the meatus venosus in which the blood is flowing from the hepatic sinusoids into the meatus (210 D and E). By degrees the circulation through the liver substance gains in importance, and liver trabeculae grow across the intermediate portion of the meatus venosus (six to seven days cf. Fig. 216), thus gradually occluding it as a direct path through the liver (Fig. 210 F).

In this way there arises a set of afferent veins of the liver, branches of the omphalomesenteric or hepatic portal vein, and a set of efferent vessels which unite into right and left hepatic veins opening into the cephalic portion of the original meatus venosus. These veins begin to be differentiated after the one hundredth hour of incubation, and the disappearance of the intermediate portion of the meatus venosus as a direct route through the liver is completed on the seventh day.

The original hepatic portal circulation is thus supplied mainly with blood from the yolk-sac. But on the fifth day the mesen-

teric vein begins to form as a small vessel situated in the dorsal mesentery and opening into the omphalomesenteric vein behind the dorsal pancreas. This vein increases in importance as the development of the viscera proceeds, and becomes the definitive hepatic portal vein; it receives branches from the stomach, intestine, pancreas, and spleen. The development of these branches proceeds *pari passu* with the development of the organs from which they arise, and does not require detailed description. It should be noted, however, that part of the veins from the gizzard and proventriculus form an independent vena porta sinistra which enters the left lobe of the liver.

A distinct subintestinal vein extends forward from the root of the tail at the stage of ninety-six hours to the posterior intestinal portal, where it opens into the branch of the left omphalomesenteric vein, that extends forward from the posterior end of the sinus terminalis. This vein appears to take up blood from the allantois at an early stage. However, it disappears at about the time when the umbilical vein becomes the functional vein of the allantois. Originally it appears to open into symmetrical right and left branches of the omphalomesenteric vein that encircles the splanchnic umbilicus. The right branch is, however, much reduced at ninety-six hours (cf. Hochstetter, 1888).

The Umbilical Veins. The umbilical veins appear as vessels of the lateral body-wall opening into the ducts of Cuvier (Fig. 210 C; cf. Fig. 117); at first they show anastomoses with the latter, which, however, soon disappear. They are subsequently prolonged backwards in the somatopleure along the lateral closing folds of the septum transversum (Chap. XI). Up to the end of the third day of incubation they have no direct connection with the blood-vessels of the allantois, and function only as veins of the body-wall.

However, they obtain connection with the efferent vessels of the allantois during the fourth day, apparently by widening of parts of an intervening vascular network, and then the allantoic blood streams through them to the heart. The right umbilical vein disappears on the fourth day, and the left one alone persists.

In the meantime the central ends of the umbilical veins have acquired new connections. (Middle of third day, Fig. 210 D.) This takes place through the formation of anastomoses, especially on the left side, between the umbilical vein and the hepatic

vessels. (On the right side similar connections appear, according to Brouha, but as the entire right umbilical vein soon degenerates they need not be considered farther.) The blood of the left umbilical vein thus divides and part flows into the duct of Cuvier by way of the original termination, and part flows through the liver into the meatus venosus. The original connection is then lost and all of the blood of the umbilical vein flows through the liver into the meatus venosus. Although the intrahepatic part is at first composed of several channels, yet the blood of the umbilical vein flows fairly directly into the meatus venosus, and thus takes no part in the hepatic portal circulation. On the eighth day the entrance of the umbilical vein into the cephalic part of the meatus venosus is still broken into several channels by liver trabeculæ (Fig. 182); these, however, soon disappear, and the vein then empties directly into the meatus venosus, which has in the meantime become the terminal part of the inferior vena cava. As the ventral body-wall closes, the umbilical vein comes to lie in the mid-ventral line, and in its course forward it passes from the body-wall in between the right and left lobes of the liver. The stem of the umbilical vein persists in the adult, as a vein of the ventral body-wall opening into the left hepatic vein.

The System of the Inferior Vena Cava (Post-cava). The post-cava appears as a branch of the cephalic portion of the meatus venosus, and in its definitive condition the latter becomes its cephalic segment; thus the hepatic and umbilical veins appear secondarily as branches of the post-cava. The portion of the post-cava behind the liver arises from parts of the postcardinal and subcardinal veins, and receives all the blood of the posterior portion of the body and viscera, that does not flow through the hepatic portal system. The history of the development of this vein, therefore, involves an account of (1) the origin of its proximal portion within the liver, and (2) of the transformation of the postcardinals and subcardinals.

The proximal portion of the post-cava arises in part from certain of the hepatic sinusoids in the dorsal part of the liver on the right side at about the stage of ninety hours, and in part from a series of venous islands found at the same time in the caval fold of the plica mesogastrica (Figs. 211 and 212. See Chap. XI). As the caval fold fuses with the right dorsal lobe of

the liver, the venous islands flow together and establish a venous trunk extending along and within the right dorsal lobe of the liver, and opening anteriorly into the meatus venosus. At first the connection with the meatus venosus lies near the sinus venosus, but in later stages is some distance behind the latter. Behind the liver the dorsal attachment of the caval fold is to the ventral surface of the right mesonephros, and at this place the vena cava enters the mesonephros and connects with the subcardinal veins (cf. Fig. 182).

The latter vessels arise as a series of venous islands on the median surface of the mesonephros and lateral to the aorta on each side. Such disconnected primordia are first evident at

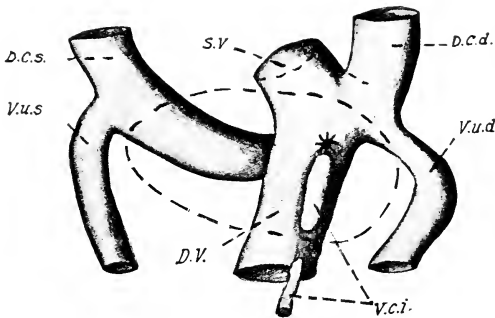
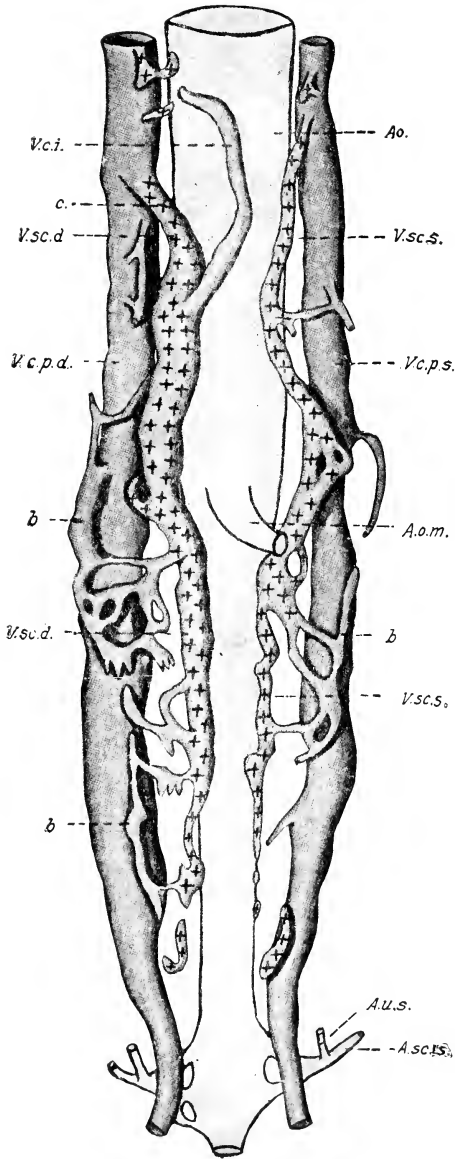


FIG. 211. — A drawing of a wax reconstruction of the veins in the region of the liver of a sparrow embryo. Outline of the liver represented by broken lines. Dorsal view. (After Miller.)

D. C. d., s., Right and left ducts of Cuvier.
 D. V., Ductus (meatus) venosus. S. V., Sinus venosus. V. c. i., Vena cava inferior. V. u. d., s., Right and left umbilical veins.

about the seventieth hour, and soon they run together to form a longitudinal vessel on each side, which has temporary direct connections with the postcardinals (Fig. 212), replaced afterwards (fifth day) by a renal portal circulation through the substance of the mesonephros. As the subcardinal veins enlarge, they approach one another just behind the omphalomesenteric artery beneath the aorta and fuse together (sixth day, Fig. 213). In the meantime, the post-cava has become continuous with the anterior end of the right subcardinal (Fig. 213).

The venous circulation is then as follows: The blood from



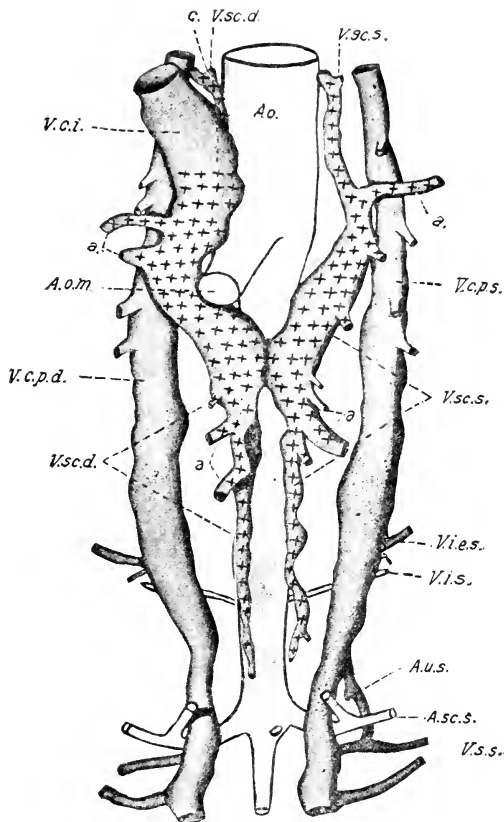


FIG. 213. — Reconstruction of the venous system of a chick of 5 days. Ventral view. (After Miller.)

a., Mesonephric veins. Ao., Aorta. A. sc. s., Left sciatic vein. Other abbreviations as before.

the right and left postcardinal veins passes through the vascular network of the mesonephros, and empties into the subcardinal veins, from which it flows into the vena cava inferior, and so through the meatus venosus to the heart. Prior to the sixth day, however, the greater portion of the blood in the pos-

FIG. 212. — Reconstruction of the venous system of a chick of 90 hours, ventral view. (After Miller.)

A. o. m., Omphalomesenteric artery. a. sc. s., Left sciatic artery. A. u. s., Left umbilical artery. b., Vessels enclosed within ventral side of mesonephros. V. c. p. d., s., Right and left posterior cardinal veins. V. c. i., Vena cava inferior. V. sc. d., s., Right and left subcardinal veins.

terior cardinals passes forward to the ducts of Cuvier without entering the mesonephric circulation. On the fifth and sixth days the cephalic ends of the postcardinals gradually dwindle and disappear (cf. Fig. 216); thus all of the blood entering the postcardinals must pass through the mesonephros to the subcardinals, which thus become efferent vessels of the mesonephros; and a complete renal-portal circulation is established.

This form of circulation continues during the period of functional activity of the mesonephroi, and as the latter gradually atrophy, the portions of the subcardinals posterior to the anastomosis gradually disappear. A direct connection between the post- and subcardinals is then established on each side, by way of the great renal veins, which have in the meantime formed in connection with the development of the kidney (Fig. 214).

The crural and ischiadic veins have, in the meantime, developed in connection with the formation of the hind limbs, as branches of the postcardinals. Thus the hinder portion of the latter becomes transformed into the common iliac veins, and at the hinder end the postcardinals form an anastomosis (Fig. 214).

IV. THE EMBRYONIC CIRCULATION

On the fourth day the blood is driven into the roots of the dorsal aorta through three pairs of aortic arches, viz., the third or carotid, the fourth or aortic, and the sixth or pulmonary. The fifth pair of aortic arches is also functional for a time during this day, but soon disappears. The blood passing up the third or carotid arch is directed forward through the internal and external carotid arteries to the head; that passing up the fourth and sixth arches turns backwards to enter the dorsal aorta, so that there is an intermediate area of stagnation in the roots of the dorsal aorta between the carotid and aortic arches; though this is more or less problematical, the arrangement of the vessels renders such a condition very probable. A very small proportion of the blood enters the rudimentary pulmonary arteries from the sixth arch. The blood in the dorsal aorta passes backwards and enters (1) the segmental arteries, (2) the omphalomesenteric arteries, (3) the (rudimentary) umbilical arteries, and behind the latter passes into the narrow continuation of the dorsal aortæ, still separate in this region, known as the caudal arteries.

The blood is returned to the heart through the sinus venosus

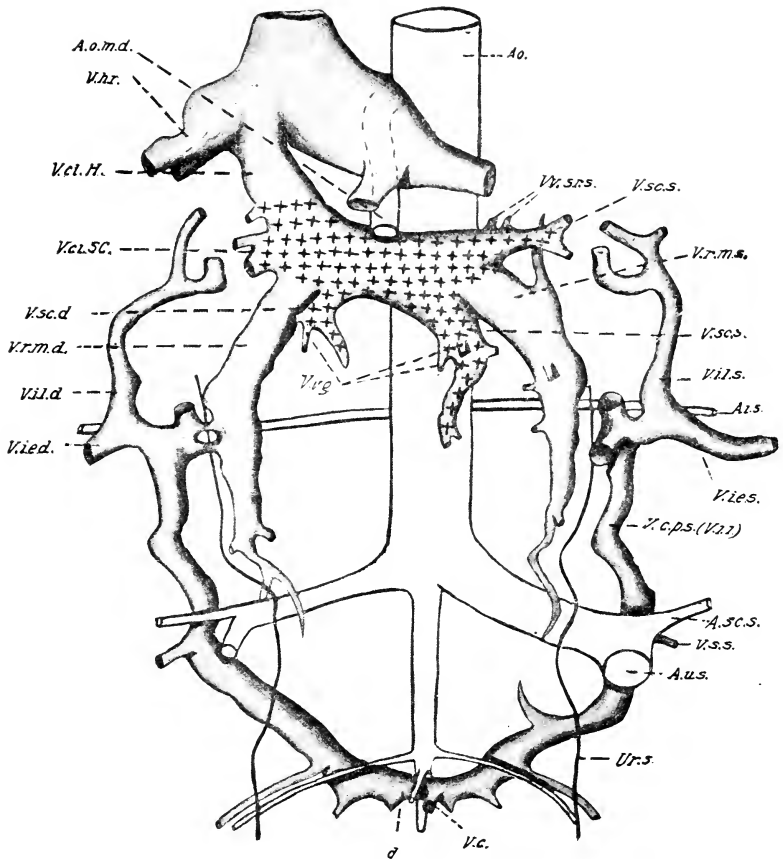


FIG. 214. — Reconstruction of the venous system of a sparrow embryo, corresponding to a chick of about 14 days. (After Miller.)

V. c. i. H., Intra-hepatic part of the vena cava inferior. V. c. i. SC., Part of the vena cava inferior derived from the subcardinal vein. V. v. g., Genital veins. V. i. e. d., s., Right and left vena iliaca externa. V. i. i., Vena iliaca interna. V. i. l. d., s., Right and left vena intervertebralis lumbaris. V. r. m. d., s., Right and left great renal veins.

almost exclusively, the pulmonary veins being very rudimentary at this stage. The veins entering the sinus venosus are the ducts of Cuvier, and the meatus venosus. The former are made up on each side by (1) the anterior cardinal vein, returning blood from the head, (2) the posterior cardinal vein returning blood from the veins of the Wolffian body, and the intersomitic veins, (3) the umbilical veins returning blood mainly from the body-

wall, inasmuch as direct connection with the veins of the allantois is not yet established. The meatus venosus receives the omphalomesenteric veins, and the blood of the allantois by way of the subintestinal vein (the latter arrangement of very brief duration).

Thus at this time all of the blood is mixed together in the

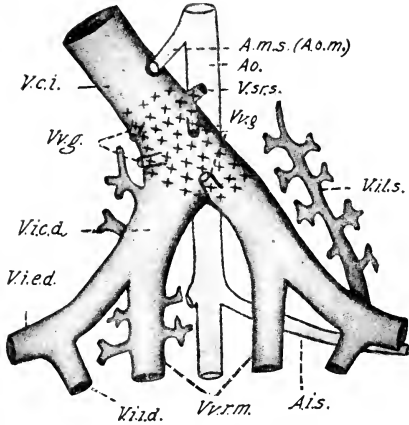


FIG. 215. — Region of the bifurcation of the post-cava in the adult fowl. Ventral view. (After Miller).

A. m. s. (A. o. m.), Omphalomesenteric artery. A. i. s., Left internal iliac artery. V. c. i., Vena cava inferior. V. i. e. d., Right common iliac vein. V. i. e. d., Right external iliac vein. V. i. i. d., Right internal iliac vein. V. i. l. s., Left vena intervertebralis lumbalis. V. s. r. s., Left suprarenal vein. V. v. g., Genital veins. V. v. r. m., Great renal veins.

sinus venosus, viz., that received through the ducts of Cuvier, presumably venous, and that received through the meatus venosus, presumably arterial, owing to its circulation in the superficial vascular network of the yolk-sac. Apparently there is no arrangement for separation or discrimination in the redistribution of the blood. But on the other hand it should be noted that most of the blood comes from the yolk-sac, owing to the slight development of the vessels of the embryo at this time; and that the blood of the embryo itself cannot be highly venous owing to the shortness of the circuit and the delicate nature of the

embryonic tissues, which, no doubt, permit direct access of oxygen.

On the sixth day the embryonic circulation enters on a second phase, owing to the changes in the structure of the heart and arrangement of the vessels described in detail in the preceding part of this chapter.

On the eighth day the circulation is as follows: The right and left ventricles are completely separate, and the former pumps the blood into the pulmonary trunk, the latter into the aortic trunk. The carotid arteries arise from the base of the aortic arch and convey the blood to the head, and also, by way of the subclavians, to the walls of the thorax and to the wing. The left aortic arch has disappeared, and the right arch is con-

tinuous with the dorsal aorta. The pulmonary trunk divides into right and left arches from which the small pulmonary artery is given off on each side, and the arch is continued without perceptible diminution in size as the ductus Botalli (ductus arteriosus) to the dorsal aorta. Thus the greater quantity of blood pumped by both sides of the heart passes into the dorsal aorta by way of the right aortic arch, and the right and left ductus Botalli; but part of the blood from the left ventricle passes into the carotids. The main branches of the dorsal aorta are (1) cœliac, distributed to stomach and liver mainly, (2) omphalo-mesenteric to the yolk-sac and mesentery, (3) right and left umbilical arteries (of which the left is much more important, the right soon disappearing), to the allantois and leg, (4) segmental arteries to the body-wall, (5) the caudal arteries.

The anterior venæ cavæ (former ducts of Cuvier) return the blood from the head, wing, and walls of the thorax to the right auricle; but owing to the formation of the sinus septum, the left vena cava opens directly into the right auricle to the left of the sinus valves, and the right one, also independently, to the right of the sinus valves. The proximal portion of the vena cava inferior is the original meatus venosus, and it receives the right and left hepatic veins, the last of which receives all the blood from the allantois through the umbilical vein (original left).

There is also an hepatic portal and a renal portal circulation. The hepatic portal system is supplied with blood mainly from the yolk-sac, but also from the veins of the alimentary canal by the mesenteric vein; the latter is a relatively unimportant vessel at eight days, but grows in importance and becomes the entire hepatic portal vein after absorption of the yolk-sac. The hepatic portal vein branches within the liver into a system of capillaries which reunite to form the right and left hepatic veins. Thus all the absorbed nutrient material passes through the capillaries of the liver, where certain constituents are no doubt acted on in some important, but little understood, way.

The renal portal circulation persists through the period of functional activity of the mesonephros. The afferent vein is the posterior cardinal which is supplied by the segmental veins and the veins of the leg and tail. The blood flows through the capillaries of the mesonephros into the subcardinal veins, and

hence to the vena cava inferior. With the degeneration of the mesonephros, the subcardinals disappear in large part and the postcardinals then empty directly into the vena cava inferior by way of the renal veins, which have formed in the meantime. The embryonic renal portal system of birds is similar in all essential respects to the permanent system of amphibia and constitutes a striking example of recapitulation. The left auricle of the heart receives the small pulmonary veins.

Thus practically all of the blood is returned to the right auricle of the heart; a considerable part of it is diverted into the left auricle through the foramina in the septum atriorum, and thus the blood reaches both ventricles. Complete systems of valves prevent its regurgitation in any direction.

It is an interesting question to what extent the different kinds of blood received by the right auricle remain separate and receive special distribution through the body. The blood poured in by the anterior venæ cavæ is purely venous, and it seems probable from the arrangement of the sinus valves that it passes into the ventricle of the same side, and so into the pulmonary arch and through the ductus Botalli into the dorsal aorta, and thus in part at least to the allantois where it is oxygenated. The blood coming in through the posterior vena cava is purified and rich in nutrition, for part of it comes from the allantois, where it has been oxygenated, and part has passed through the renal portal circulation, where, no doubt, it has been purified of nitrogenous excretory matter, and the remainder is mostly from the yolk-sac and hence laden with nutrition. This blood appears to be diverted through the foramen of the septum atriorum into the left auricle, and thence to the left ventricle, and so out into the carotids and aortic arch. It would seem, therefore, to be reasonably certain that the carotids receive the purest and most nutritious blood, for the blood in the dorsal aorta is mixed with the blood from the right ventricle. There can be no reasonable doubt that the heart is a more effective organ for separate and effective distribution of the various kinds of blood received by it than this account would indicate. But further investigation is necessary to determine in what ways and to what extent this takes place.

At the time of hatching the following changes take place: the umbilical arteries and vein are obliterated in the allantois, owing to drying up of the latter; their stems remaining as relatively

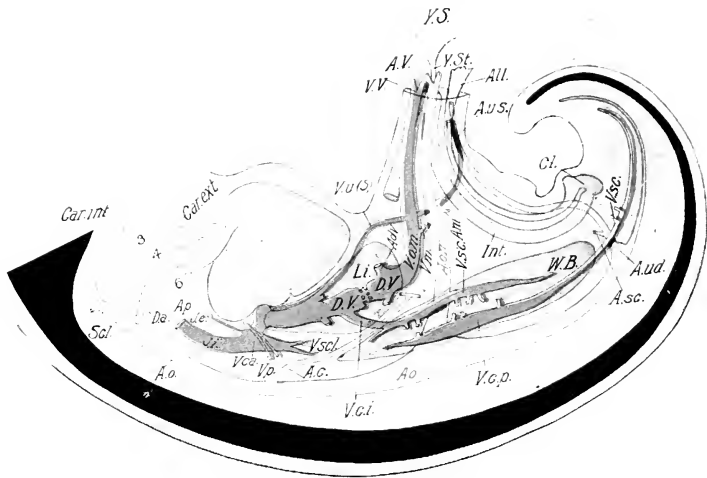


FIG. 216. — Diagram of the relations of the main splanchnic blood vessels on the sixth day of incubation.

A. c., Coeliac artery. Adv., Vena advehens. All., Allantois. A. m., Mesenteric artery. Ao., Aorta. A. o. m., Omphalomesenteric artery. A. p., Pulmonary artery. A. se., Sciatic artery. A. u. d., Right umbilical artery. A. u. s., Left umbilical artery. A. V., Vitelline arteries. Car. int., Internal carotid. Car. ext., External carotid. Cl., Cloaca. D. a., Ductus arteriosus. D. V., Ductus (meatus) venosus. Int., Intestine. J. e., External jugular vein. J. i., Internal jugular vein. Li., Liver. Sel., Subclavian artery. V. c. a., Anterior vena cava. V. c. i., Inferior Vena cava. V. c. p., Posterior cardinal vein. V. m., Mesenteric vein. V. o. m., Omphalomesenteric vein. Vp., Pulmonary vein. V. s'c., Subcardinal vein. V. s'cl., Subclavian vein. V. u. (s.), Umbilical vein (left). V. V., Vitelline vein. W. B., Wolffian body. Y. S., Yolk-sac. Y. St., Yolk-stalk.

insignificant vessels. The veins of the yolk-sac likewise disappear. The ductus arteriosus (Botalli) is obliterated on both sides, and becomes a solid cord uniting the pulmonary arteries and arch of the aorta. Thus the blood from the right ventricle is driven into the lungs, and the pulmonary artery enlarges. The foramina in the septum atriorum gradually close, and so a complete double circulation is established. The right auricle receives all the systemic (venous blood), which is then driven through the lungs by way of the pulmonary artery, and returned in an oxygenated condition through the pulmonary veins to the left auricle; thence to the left ventricle and out through the aorta into the systemic circulation again.

CHAPTER XIII

THE URINOGENITAL SYSTEM

THE history of the pronephros and the origin of the mesonephros have been already described (Chap. VI). We have now to consider (1) the later history of the mesonephros, (2) the development of the metanephros or permanent kidney, (3) the development of the reproductive organs and their ducts, and (4) the development of the suprarenals. All these organs form an embryological unit, by virtue of their mode of origin and their interrelations. Thus we find that the intermediate cell-mass is significant for the development of all: its growth causes the formation of the Wolffian body, on the median face of which the gonads arise. The secreting tubules and renal corpuscles of the permanent kidney are also derivatives of the intermediate cell-mass. The Wolffian duct is derived from the same source, and by change of function becomes the vas deferens, after functioning for a while as the excretory duct of the mesonephros. Certain parts of the mesonephros also enter into the construction of the testis. And the Müllerian duct, which forms the oviduct of the female, is derived from the epithelium covering the Wolffian body.

I. THE LATER HISTORY OF THE MESONEPHROS

In Chapter VI we traced the origin of the nephrogenous tissue, and the differentiation of the first mesonephric tubules within it. We saw that in each of the segments concerned a number of balls of cells arises by condensation within the nephrogenous tissue, and that these become converted into vesicles. We saw also that each vesicle sends out a tubular sprout from its lateral side to the Wolffian duct, with which it unites; and that its median face becomes converted into a renal corpuscle. These processes take place successively in antero-posterior order within the somites concerned, so that a series of stages in the development of the tubules may be studied in the same embryo. Moreover, all the tubules of a given somite do not develop simul-

taneously: primary tubules are formed in each somite from the most ventral portion of the nephrogenous tissue; then secondary tubules later from an intermediate portion, and tertiary tubules later yet from the dorsal portion.

Fig. 217 represents a transverse section through the middle

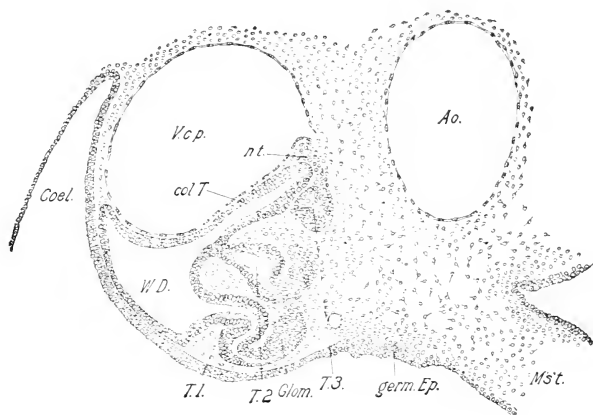


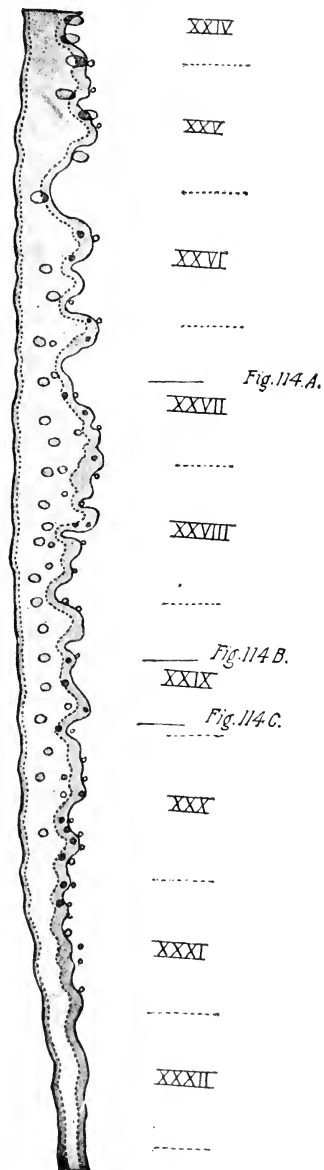
FIG. 217. — Transverse section through the middle of the Wolffian body of a chick embryo of 96 hours.

Ao., Aorta. Coel., Coelome. Col. T., Collecting tubule. Glom., Glomerulus. germ. Ep., Germinal epithelium. M's't., Mesentery. n. t., Nephrogenous tissue. T. 1, 2, 3, Primary, secondary, and tertiary mesonephric tubules. V. c. p., Posterior cardinal vein. W. D., Wolffian duct.

of the Wolffian body at the stage of ninety-six hours, showing a primary, secondary, and tertiary tubule. The primary tubule is typically differentiated; the secondary has formed the secreting tubule and the rudiment of the renal corpuscle, but the tubule does not yet open into the Wolffian duct, though it is connected with it; the tertiary tubule is still in the vesicular stage. Some undifferentiated nephrogenous tissue remains above the rudiment of the tertiary tubule, which makes it possible that quaternary tubules may be formed later.

Referring still to the same figure, it will be noted that the Wolffian duct itself has formed a considerable evagination dorso-medially (collecting tubule), with which both secondary and tertiary tubules are associated as well as the undifferentiated nephrogenous tissue. Similar evaginations are formed along the entire length of the functional portion of the mesonephros.

Figs. 218 and 219 illustrate the form of these evaginations in duck embryos of 40 and 50 somites respectively, as they appear in reconstructions of the posterior portion of the mesonephros.



It will be seen that they gradually form sacs opening into the Wolffian duct. Subsequently, by elongating, these sacs form collecting tubules that gather up the secretions of the mesonephric tubules proper and conduct them to the Wolffian duct. These conducting tubules are stated to branch more or less; it is also said that they are more highly developed in the duck than in the chick. Felix proposes to call them mesonephric ureters.

In the case of the secondary and tertiary tubules, three parts may be distinguished: parts one and two (derived from the nephrogenous tissue) are the renal corpuscle and secreting tubule respectively; the third part is the collecting tubule derived by evagination from the Wolffian duct. In the case of the primary tubules, a conducting part appears to be formed secondarily, though in what way is not clear.

The formation of new tubules ceases on the fifth day, all the nephrogenous tissue being then used up. Up to the eighth day at least the tubules grow rapidly in length and become more differentiated. The result is a relatively enormous protrusion into the body-cavity on each side of the dorsal mesentery. Degeneration of the tubules sets in about the tenth or eleventh days, and the tissue is gradually absorbed;

this process extends over the whole of the latter period of incubation, and is completed at hatching. Parts, however, remain in the male in connection with the testis; non-functional remnants

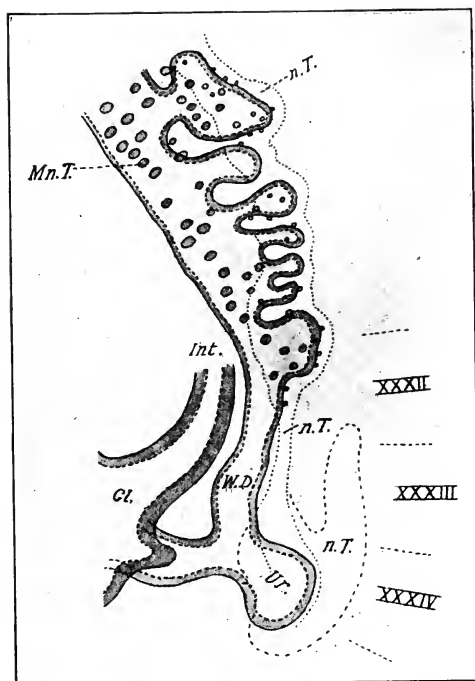


FIG. 219. — Profile reconstruction of part of the mesonephros and diverticulum of the ureter of a duck embryo of 50 somites. (After Schreiner.)

Cl., Cloaca. Int., Intestine. Mn. T., Mesonephric tubules. n. T., Nephrogenous tissue. Ur., Ureter. W. D., Wolffian duct.

XXXII, XXXIII, XXXIV, Somites of the same number.

may also be detected in the female (p. 401). It is difficult to state the exact period of beginning and cessation of function of the mesonephric tubules. Judging from the histological appear-

FIG. 218. — Profile reconstruction of part of the Wolffian duct and primordia of mesonephric tubules (represented by circles) of a duck embryo of 45 somites. (After Schreiner.)

XXIV, XXV, etc., position of the corresponding somites. Lines 114 A, 114 B, 114 C, represent the positions of the sections shown in these figures.

ances, however, it is probable that secretion begins in the tubules on the fifth day and increases in amount up to the eleventh day at least, when signs of degeneration become numerous. Presumably the functional activity diminishes from this stage on, being replaced by the secretion of the permanent kidney.

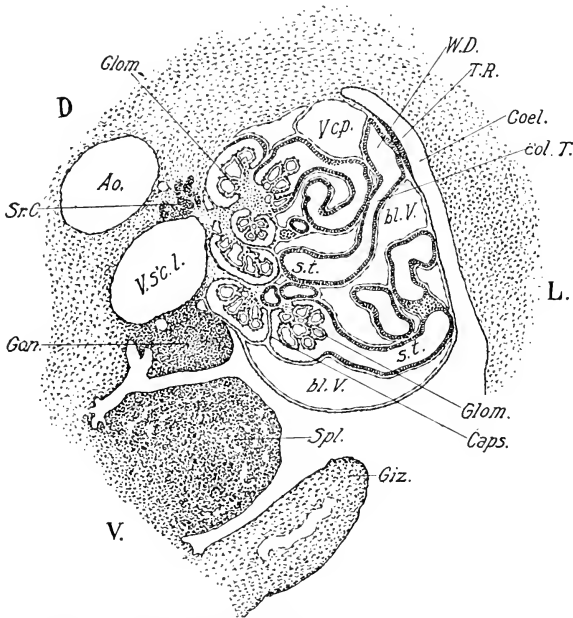


FIG. 220. — Transverse section through the mesonephros and neighboring parts of a 6-day chick, in the region of the spleen.

Ao., Aorta. bl. V., Blood vessels (sinusoids). Caps., Capsule of renal corpuscle. Coel., Coelome. col. T., Collecting tubule. D., Dorsal. Giz., Gizzard. Glom., Glomerulus. Gon., Gonad. L., Left. Spl., Spleen. Sr. C., Cortical substance of the suprarenal. s. t., Secreting tubule. T. R., Tubal ridge. V., Ventral. V. c. p., Posterior cardinal vein. V. s'c. l., Left subcardinal vein. W. D., Wolffian duct.

Figs. 220 and 221 represent sections through the mesonephros on the sixth and eighth days respectively (see also Fig. 222, eleven days). The renal corpuscles show the typical capsule and glomerulus, and relation to the secreting tubules. The latter are considerably convoluted on the sixth day, much more so on the eighth day. The conducting tubules can usually be distinguished by their smaller caliber and thinner walls. The Wolffian

duct is situated near the dorso-lateral edge of the mesonephros, and the opening of a collecting tubule into it is shown in Figure 220. The renal corpuscles are situated next the median face of the Wolffian body. The space between the tubules is occupied

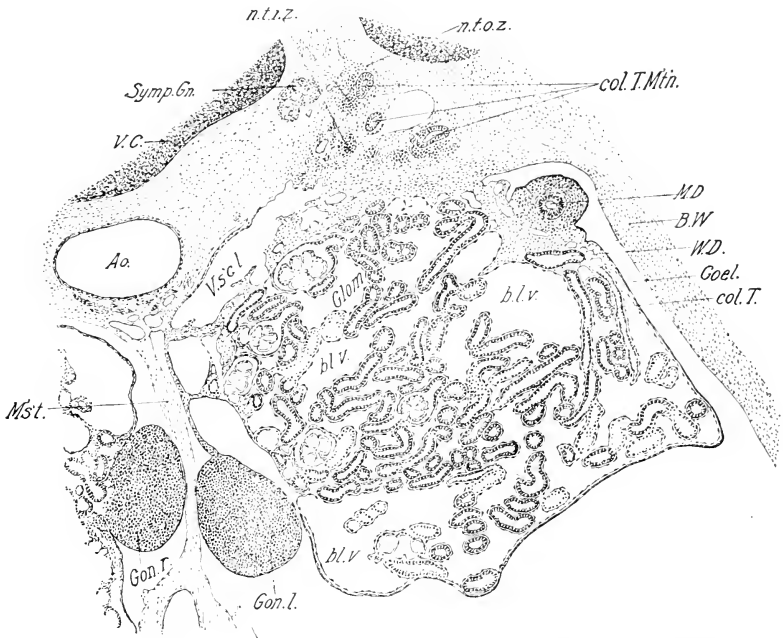


FIG. 221.—Transverse section through the metanephros, mesonephros, gonads and neighboring parts of an 8-day chick.

bl. v., Blood vessels (sinusoids). B. W., Body-wall. col. T. M't'n., Collecting tubules of the metanephros. M. D., Müllerian duct. M's't., Mesentery. n. t. i. z., Inner zone of nephrogenous tissue (metanephric). n. t. o. z., Outer zone of the nephrogenous tissue. Symp. Gn., Sympathetic ganglion of the twenty-first spinal ganglion. V. C., Centrum of vertebra. Other abbreviations as before.

almost entirely by a wide vascular network of sinusoidal character; that is, the endothelial walls of the vessels are moulded directly on the basement membrane of the tubules without any intervening connective tissue. The circulation is described in the chapter on the vascular system.

II. THE DEVELOPMENT OF THE METANEPHROS OR PERMANENT KIDNEY

The metanephros or permanent kidney supplants the mesonephros in the course of development. It is derived from two distinct embryonic primordia: (1) the nephrogenous tissue of the two or three posterior somites of the trunk (31 or 32 to 33), which furnish the material out of which the renal corpuscles and secreting tubules develop; and (2) a diverticulum of the posterior portion of the Wolffian duct (Fig. 219), which develops by branching into the collecting tubules and definitive ureter. The development of the kidney takes place in a mass of mesenchyme, known as the outer zone of the metanephrogenous tissue, that furnishes the capsule and connective tissue elements of the definitive kidney, in which also the vascular supply is developed (Figs. 221 and 222). The cortical tubules of the kidney are thus derived mainly from the nephrogenous tissue, and the medullary tubules and ureter from the metanephric diverticulum.

Thus the definitive kidney is analogous in mode of development to the mesonephros, and is best interpreted as its serial homologue. This point of view may be regarded as definitely established by the work of Schreiner, to which the reader is referred for a full account of the history of the subject.

The metanephric diverticulum, or primordium of the ureter and collecting tubules, arises about the end of the fourth day as a rather broad diverticulum of the Wolffian duct at the convexity of its terminal bend to the cloaca (Fig. 219). It grows out dorsally, forming a little sac, which, however, soon begins to grow forward median to the posterior cardinal vein and dorsal to the mesonephros (Fig. 224); by the end of the fifth day its anterior end has reached the level of the caecal appendages of the intestine, and on the eighth day its anterior end has reached its definitive position at the level of the vena cava inferior, near to the anterior end of the mesonephros (twenty-first definitive somite or twenty-fifth of the entire series; cf. Fig. 150).

It should be noted that the metanephric diverticulum is similar in its mode of origin to the so-called mesonephric ureters. It may in fact be regarded as the posterior member of this series, but it is separated from those that form the collecting tubules of the mesonephros by at least two somites in which no diverticula

of the mesonephros are formed (Fig. 219). During its growth forward a series of small diverticula arise from its wall and extend dorsally (Fig. 223); these branch secondarily in a generally dichot-

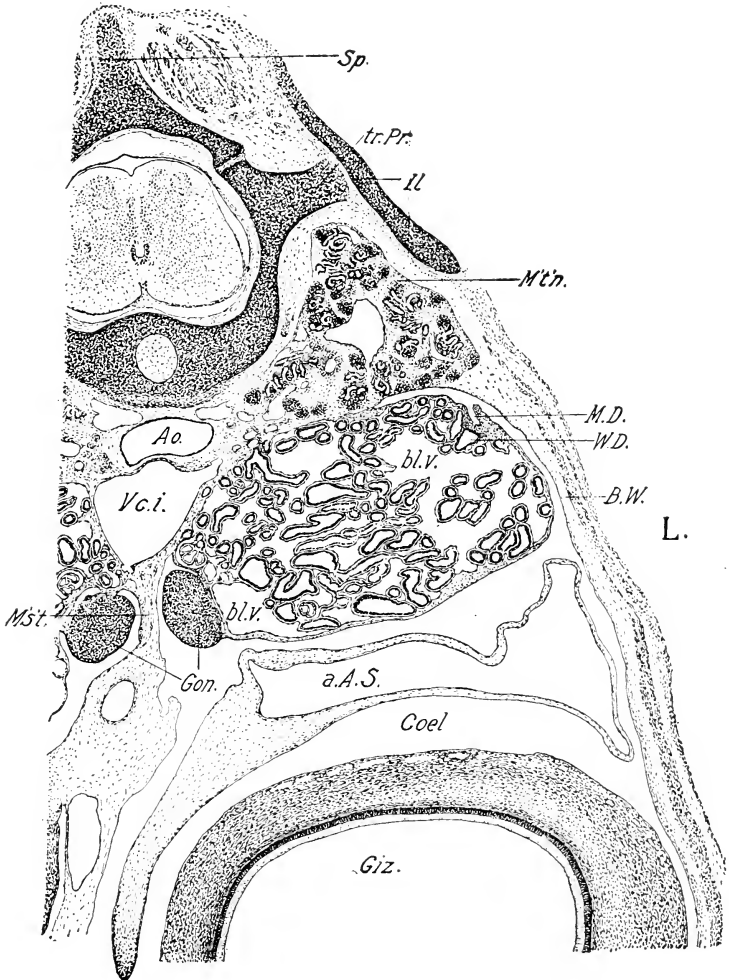


FIG. 222. — Transverse section through the metanephros, mesonephros, gonads and neighboring structures of an 11-day male chick.

a. A. S., Abdominal air-sac. Ao., Aorta. B. W., Body-wall. Coel., Coelome. Giz., Gizzard. Il., Ilium. M. D., Remains of degenerating Müllerian duct. M's't., Mesentery. M't'n., Metanephros. Sp., Spine of neural arch. tr. Pr., Transverse process of the neural arch. V. c. i., Vena cava inferior. W. D., Wolffian duct. Other abbreviations as before.

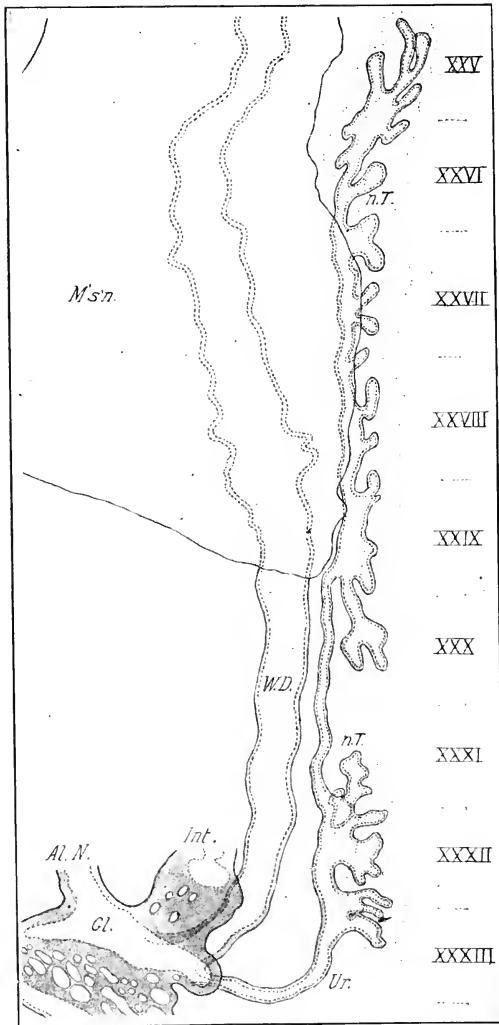


FIG. 223. — Profile reconstruction of the Wolffian duct and primordium of the metanephros of a chick embryo of 6 days and 8 hours. (After Schreiner.)

XXV to XXXIII, twenty-fifth to thirty-third somites. Al. N., Neck of allantois. Cl., Cloaca. Int., Intestine. M's'n., Mesonephros. n. T., Nephrogenous tissue of the metanephros included within the dotted lines. W. D., Wolffian duct. Ur., Ureter.

omous manner, and it is from them that the collecting tubules of the kidney arise; the posterior unbranched portion of the metanephric diverticulum represents the definitive ureter.

The following data concerning these branches should be noted: (1) the first ones are formed from the posterior portion of the metanephric diverticulum, and the process progresses in an anterior direction. This is the reverse direction of the usual order of embryonic differentiation, but the reason for the order is the same, viz., that differentiation begins in the first formed parts. (2) A posterior, smaller group of collecting tubules is separated at first by an unbranched portion of the ureter from an anterior larger group (Fig. 223). The unbranched region corresponds to the position of the umbilical arteries which cross here. (3) During the fifth and sixth days the terminal portion of the Wolffian duct common to both mesonephros and metanephros is gradually drawn into the cloaca, and thus the ureter obtains an opening into the cloaca independent of the Wolffian duct and posterior to it (Fig. 223).

The Nephrogenous Tissue of the Metanephros. The nephrogenous tissue of the thirty-first, thirty-second, and thirty-third somites is at first continuous with the mesonephros (Figs. 218 and 219), but on the fourth and fifth days that portion situated immediately behind the mesonephros degenerates, thus leading to a complete separation of the most posterior portion situated in the neighborhood of the metanephric diverticulum. This constitutes the metanephrogenous tissue proper (inner zone). It is important to understand thoroughly its relations to the metanephric diverticulum. This is indicated in Fig. 219, which represents a graphic reconstruction of these parts in a duck embryo of 50 somites. It will be seen that the metanephrogenous tissue covers nearly the entire metanephric diverticulum; a transverse section (Fig. 224) shows that it lies on its median side. The outer dotted line (Fig. 219) gives the contour of a dense portion of mesenchyme related to the diverticulum and nephrogenous tissue proper. In section this forms a rather ill-defined area shading into the nephrogenous tissue on the one hand and into the surrounding mesenchyme on the other.

Fig. 224 shows the relations of the three constituent elements of the kidney at the end of the fifth day, as seen in a transverse section. The metanephric diverticulum lies on the median side

of the cardinal vein, and is in contact, on its median face, with the proper nephrogenous tissue (inner zone); the latter shades into the outer zone, the cells of which are arranged concentrically with reference to the other parts. The relations subsequently established may be summarized in a few words; the inner zone of tissue grows and branches *pari passu* with the growth and branching of the metanephric diverticulum, so that the termination of every collecting tubule is accompanied by a portion of

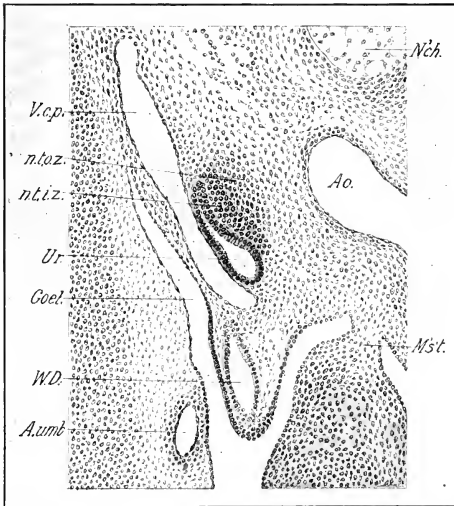


FIG. 224. — Transverse section through the ureter and metanephrogenous tissue of a 5-day chick.

A. umb., Umbilical artery. Coel., Coelome. M's't., Mesentery. n. t. i. z., Inner zone of the nephrogenous tissue. n. t. o. z., Outer zone of the nephrogenous tissue. Ur., Ureter. V. c. p., Posterior cardinal vein. W. D., Wolffian duct.

the inner zone, which is, however, always distinct from it. This conclusion is established by the fact that from the start the two elements, collecting tubules and inner zone, are distinct and may be traced continuously through every stage. The outer zone differentiates in advance of the two more essential constituents at all stages, and thus forms a rather thick investment for them.

The formation of the secreting tubules from the inner zone

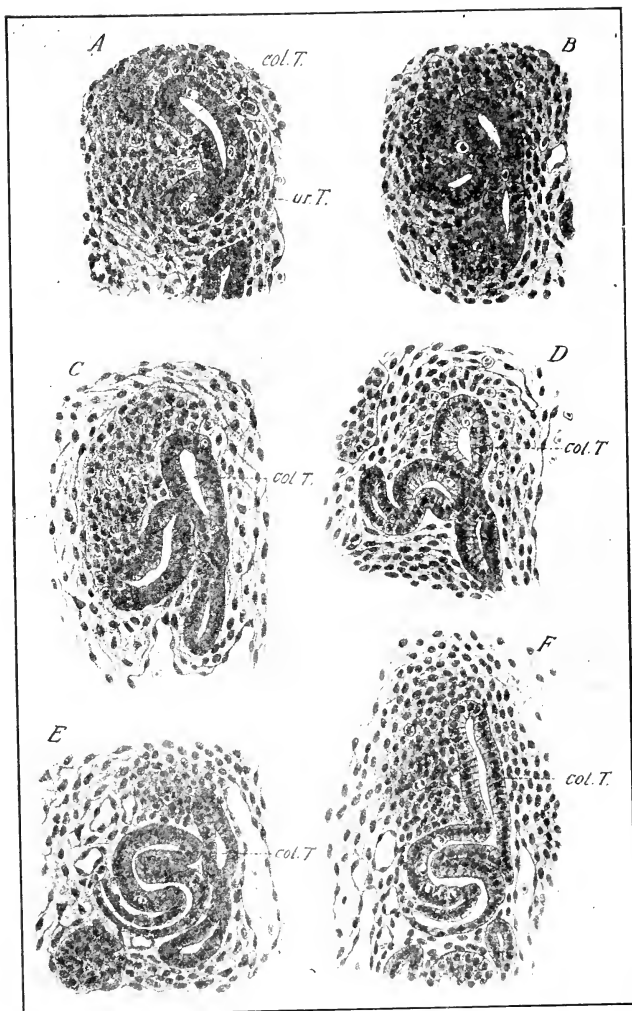


FIG. 225. — Sections of the embryonic metanephros of the chick to show developing tubules. (After Schreiner.)

A. Nephric vesicle or primordium of secreting tubule (ur. t.) and collecting tubule (col. T.); 9 days and 4 hours.

B. Elongation of nephric vesicle; same embryo.

C. Indication of renal corpuscle at the distal end of the forming tubule.

D. The secreting tubule appears S-shaped.

E. Secreting tubule well formed; 9 days and 21 hours.

F. Secreting tubule opening into collecting tubule; 11 days.

of the metanephrogenous tissue takes place in essentially the same manner as the formation of the mesonephric tubules. The first stages may be found in seven and eight-day chicks in the portion of the kidney behind the umbilical arteries. The inner zone tissue begins to arrange itself in the form of minute balls of cells in immediate contact with the secreting tubules; a small lumen then arises within the ball, transforming it into a thick-walled epithelial vesicle with radially arranged cells. The vesicle then elongates away from the collecting tubule and gradually takes on an S-shape. The distal end of the S becomes converted into a renal corpuscle as illustrated in Figure 225, and the proximal end fuses with the wall of the collecting tubule; an opening is then formed between the two.

On the eleventh day of incubation, secreting tubules are thus formed throughout the entire length of the kidney; but the histological structure does not yet give the effect of an actively secreting gland, although degeneration of the mesonephros has already begun. The full development of the nephric tubules in the chick has not been studied.

At all stages in its development the kidney substance is separated from the mesonephros by a distinct layer of undifferentiated mesenchyme, which is, however, at certain times extremely thin. But there is no evidence that at any time elements of the mesonephros, *e.g.*, undifferentiated nephrogenous tissue, extend up into the metanephric primordium which so closely overlies it (*cf.* Figs. 221 and 222).

The kidney is entirely retroperitoneal in its formation, and its primary capsule is established by differentiation of the periphery of the outer zone. This may be seen in process at eleven days (Fig. 222): the primary capsule is definitely established on its median and lateral sides; but is defective dorsally and at the angle next the aorta. With the subsequent degeneration of the mesonephros, and projection of the kidney into the *cœlome*, its ventral surface acquires a secondary peritoneal capsule.

III. THE ORGANS OF REPRODUCTION

The gonads are laid down on the median surface, and the ducts on the lateral surface of the Wolffian body, which thus becomes converted into a urinogenital ridge. The composition of the urinogenital ridge is at first the same in all embryos, whether

destined to become male or female. It has three divisions: (1) the anterior or sexual division, containing the gonad, involves about the anterior half of the Wolffian body; (2) a non-sexual region of the Wolffian body occurs behind the gonad, and (3) behind the Wolffian body itself the urinogenital ridge contains only the Wolffian and Müllerian ducts. A transverse section through the anterior division shows the following relations (Fig. 221): on the median surface the gonad, on the lateral surface near the dorsal angle of the body-cavity the Wolffian and Müllerian ducts, the latter external and dorsal to the former: between the gonad and ducts lie the tubules of the Wolffian body destined to degenerate for the most part.

There is an indifferent stage of the reproductive system during which the sex of the embryo cannot be determined, either by the structure of the gonad or the degree or mode of development of the ducts. In those embryos that become males the gonad develops into a testis, the Wolffian duct becomes the vas deferens, the tubules of the anterior part of the Wolffian body become the epididymis, those of the non-sexual part degenerate, leaving a rudiment known as the paradidymis, and the Müllerian duct becomes rudimentary or disappears. In embryos that become females, the gonad develops into an ovary; the Wolffian duct disappears or becomes rudimentary, the Müllerian duct develops into the oviduct on the left side and disappears on the right side, and the tubules of the Wolffian body degenerate, excepting that functionless homologues of the epididymis and paradidymis persist, known as the epoöphoron and paroöphoron respectively.

It is not correct to state, as is sometimes done, that the embryo is primitively hermaphrodite, for, though the ducts characteristic of both sexes develop equally in all embryos, the primitive gonad is, typically, only indifferent. Nevertheless, if the gonad be physiologically as well as morphologically indifferent in its primitive condition, the possibility of an hermaphrodite development is given. The primitive embryonic conditions appear to furnish a basis for any degree of development of the organs of both sexes.

Development of Ovary and Testis. *Indifferent Period.* The reproductive cells of ovary and testis alike arise from a strip of peritoneal epithelium, known as the germinal epithelium, which is differentiated on the fourth day by its greater thickness

from the adjacent peritoneum (Fig. 217). The germinal epithelium lies between the base of the mesentery and the mesonephros at first, but as the latter grows and projects into the body-cavity the germinal epithelium is drawn on to its median surface. It is difficult to determine its antero-posterior extent in early stages; it begins near the point of origin of the omphalomesenteric arteries, and its posterior termination is indefinite, but it certainly extends over seven or eight somites.

Two kinds of cells are found in the germinal epithelium, viz., the ordinary peritoneal cells and the primordial germ-cells. The latter are typically round, and several times as large as the peritoneal cells (Figs. 226 and 227); the cytoplasm is clear but contains persistent yolk granules and a large attraction sphere, and the nucleus contains one or two nucleoli; they are sharply distinguishable from the peritoneal cells, and they may be traced through a continuous series of later developmental stages into the ova and spermatozoa. The origin of these primordial germ-cells is therefore a matter of considerable interest.

Two views have been held: (1) that they are derived from the peritoneal cells, and (2) that they have an independent history antecedent to the differentiation of a germinal epithelium, representing in fact undifferentiated embryonic cells that reach the germinal epithelium by migration from their original source. The former view was due to Waldeyer, and was supported by observations of cells intermediate in structure between the primordial germ-cells and cells of the peritoneum (*e.g.* by Semon). These observations have, however, been shown to be erroneous. The second view has been demonstrated for a considerable number of vertebrates; and quite recently Swift has shown that the primordial germ-cells of the chick arise from the germ-wall at the anterior margin of the pellucid area in a late stage of the primitive streak; that they later enter the blood stream and are carried into the embryo; some, which reach various inappropriate positions, degenerate; but others leaving the blood near the base of the mesentery reach the germinal epithelium by migration. The independent and early origin of germ-cells has an obvious bearing on the theory of the continuity of the germ-plasm of Weismann.

Two other epithelial constituents enter into the composition of the indifferent gonad, viz.: the rete tissue or cords of the urino-genital union, and the sexual cords. These lie between the germinal epithelium and the glomeruli of the Wolffian body. Between these elements is a sparse mesenchyme continuous with the surrounding mesenchyme, constituting the stroma of the gonad.

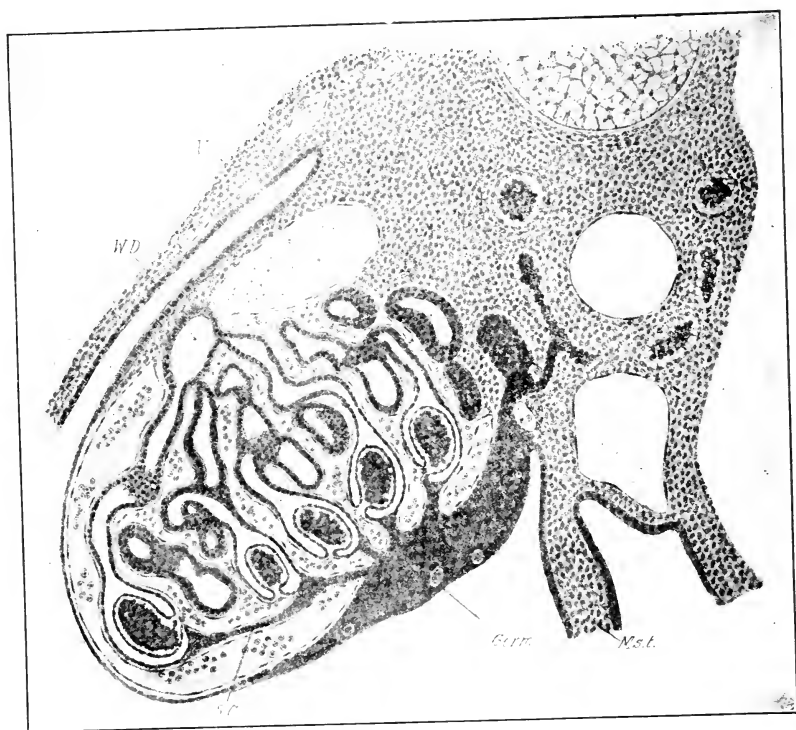


FIG. 226. — Cross-section through the genital primordium of *Limosa aegcephala*. (After Hoffmann, from Felix and Bühler.)
The stage is similar to that of a chick embryo of $4\frac{1}{2}$ days.

Germ., Germinal epithelium. Mst., Mesentery. S. C., Rete cords. V., Posterior cardinal vein. W. D., Wolffian duct.

Some primordial germ-cells occur in the stroma, though most are in the germinal epithelium.

The rete cords appear within the gonad on the fifth day; they are solid cords of epithelial cells that fill up the interior

of the gonad and cause it to protrude from the surface of the Wolffian body (Fig. 226); the cords extend from the germinal epithelium towards the hilum of the gonad (represented at this time by the broad surface opposed to the Wolffian body), and into the Wolffian body where they enter into close connection with the renal corpuscles. In the Wolffian body and intermediate zone they are very irregular in their course and connected by numerous anastomoses, corresponding to the rete region of the future testis. Strands of these cells pass dorsally, and, according to some authors, form the cortical cords of the suprarenal capsules (Fig. 226).

The following views of the origin of the rete cords in birds have been held: (1) That they arise as outgrowths of the capsules of renal corpuscles (Hoffmann, Semon) and the neck of the Wolffian tubules also (Semon); (2) that they are ingrowths of the germinal epithelium (Janosik); (3) that they differentiate from the stroma (Prenant, Firket). The subject is a somewhat difficult and complicated one, but the view that the rete cords arise as outgrowths of the capsules of renal corpuscles brings the birds into line, in this respect, with the reptiles and amphibia. Hoffmann's observation that the rete cords lie at first on the lateral side of the blood-vessels intervening between the germinal epithelium and the Wolffian body, and that the cells of the cords are directly continuous with those of the capsules, should be conclusive.

The sexual cords arise as proliferations of the germinal epithelium which appear as buds projecting into the stroma (Fig. 227). They are definitely limited in time of origin between the middle of the fifth and sixth days of incubation (Swift). They carry with them numerous primordial germ-cells from the germinal epithelium. About the end of the sixth day all free themselves from the germinal epithelium, and a layer of stroma begins to separate them sharply from the latter. They are destined to form the seminiferous tubules in the male, and the so-called medullary cords in the female.

Sexual Differentiation. The period of morphological indifference of the gonad is relatively long and the actual sexual differentiation appears slowly. It manifests itself (1) in differences in the behavior of the germinal epithelium; (2) of the sexual cords;

(3) larger size of the left ovary and ultimate disappearance of the right one; (4) behavior of the stroma, particularly the albuginea. The sex of the embryo can first be definitely determined about the 156th hour, by the relative sizes of the two gonads, by the behavior of the germinal epithelium and by the presence of a larger

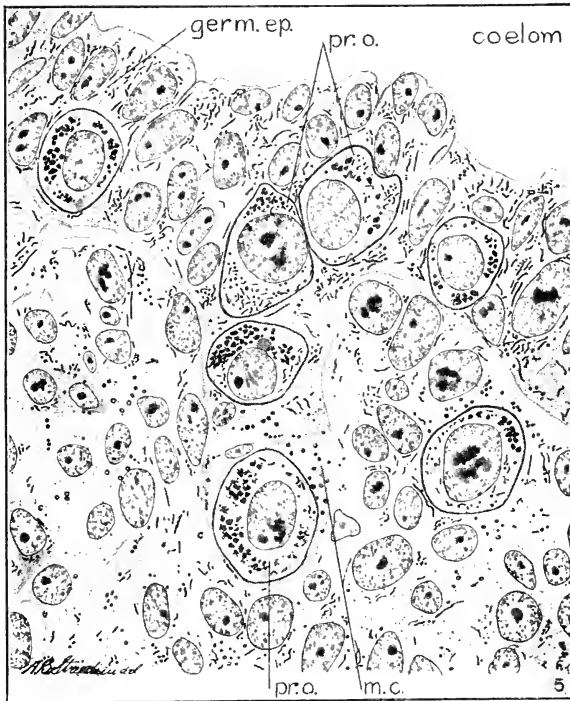


FIG. 227. — Portion of a transverse section through an ovary of a $6\frac{1}{2}$ day chick embryo (after Swift). germ. ep., germinal epithelium. m. c., sexual cord. pr. o., primordial germ-cells.

number of primordial germ-cells in the germinal epithelium of the female. (Swift.)

As already stated, the sexual cords form the seminiferous tubules of the testis; they are made up of two kinds of cells, viz.: the primordial germ-cells and the ordinary peritoneal cells derived from the germinal epithelium. After the seventh day they constitute most of the bulk of the testis, and the rete cords are pressed towards the hilum by the sexual cords which radiate in that direc-

tion. The sexual cords now begin to branch and anastomose, and soon form a reticulum with mesenchyme in the meshes. About the thirteenth day the primordial germ-cells, which have been inactive, begin to divide, and a rapid increase in numbers ensues.

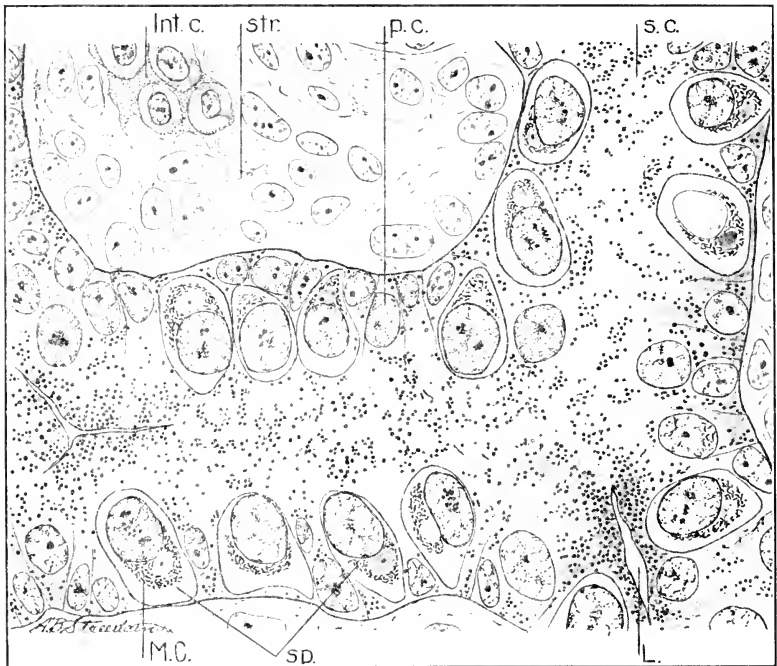


FIG. 228.—Portion of a transverse section through the right testis of a 20 day chick embryo. The section shows a seminiferous cord in which a lumen is beginning to develop. Note the position and polarization of the spermatogonia (after Swift).

Int. c., interstitial cells. L., beginning of lumen. M. C., Mitochondrial granules within a spermatogonium. p. c., supporting cells, derivatives of peritoneal cells of the sexual cords. s. c., seminiferous cord. sp., spermatogonia. str., stroma.

The sexual cords are solid up to about the twentieth day of incubation; a lumen then begins to appear and they become transformed into tubules (Fig. 228). The primordial germ-cells form the spermatogonia, and the peritoneal cells form the supporting cells of the seminiferous tubules (Swift).

After the sixth day the germinal epithelium of the testis rapidly retrogresses and becomes reduced to a thin peritoneal

endothelium. The stroma of the primitive testis remains scanty up to the eleventh day. It then increases rapidly between the sexual cords and also forms a layer between germinal epithelium and seminiferous tubules, which becomes the albuginea. *Interstitial cells* appear in the stroma of the testis about the thirteenth day and increase so rapidly as to form an immense amount by the twentieth day (Swift).

As the testis increases in size it projects more from the surface of the Wolffian body, and folds arise above and below it as well as in front and behind, that progressively narrow the surface of apposition, which in this way becomes gradually reduced to form the hilum of the testis, through which the rete cords pass to the neighboring renal corpuscles (cf. Figs. 221 and 222).

As the testis is attached to the anterior portion of the Wolffian body, the latter may be divided in two portions, an anterior sexual and a posterior non-sexual portion. In the latter part of the period of incubation the non-sexual portion undergoes absorption while the anterior portion becomes converted into the epididymis.

The irregularly anastomosing rete cords in the region of the hilum are united to the neighboring renal corpuscles by the original strands and these form the vasa efferentia. In order to complete the urinogenital union it is necessary that the rete cords unite with the seminiferous tubules. The exact manner in which this takes place has not been worked out for the chick; but there is no doubt that this union does take place so that the seminiferous tubules connect by way of the rete with the mesonephric tubules and thus with the Wolffian duct.

As regards the formation of the epididymis: the renal corpuscles of the Wolffian tubules concerned diminish in size, the glomerulus disappears and the cells of the capsule become cylindrical. These changes progress from the lateral side of the Wolffian body towards the testis; that is to say, the more lateral corpuscles are first affected. A rudiment of the non-sexual part of the Wolffian body persists in the mesorchium of the male, between testis and kidney. It is known as the paradidymis.

The development of the ovary in the chick has been studied in recent years by Firket and by Swift.

The right ovary never undergoes much development after

the indifferent stage; it is destined to retrogress, and finally it disappears.

In the indifferent gonad the sexual cords are formed in the same way whether the organ is to become ovary or testis; but, whereas in the case of the testis these cords are destined to form the functional seminiferous tubules, in the case of the ovary they form only the cords of the medulla. The cortex of the ovary which includes the functional follicles develops from a second

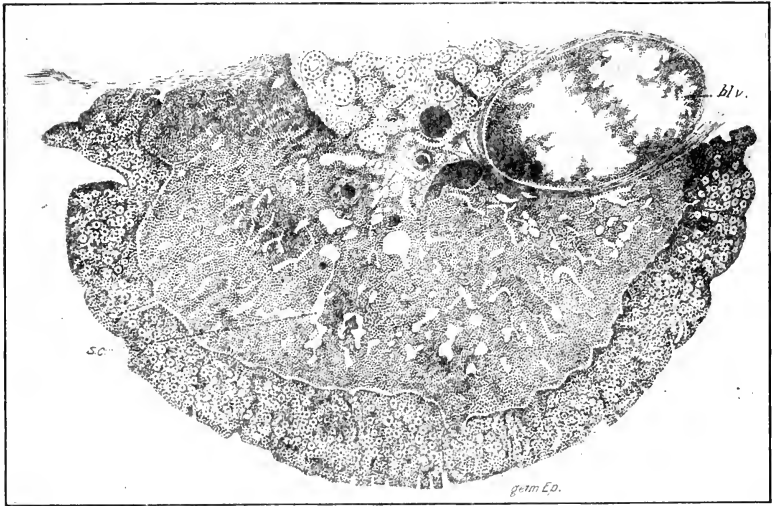


FIG. 229. — Cross-section of the ovary of a young embryo of *Numenius arcuatus*. (After Hoffmann.)

bl. v., Blood-vessel. germ. Ep., Germinal epithelium. r., rete ovarii. s. c., Sexual cord.

proliferation of the germinal epithelium. The sexual cords cease to grow, and become converted into tubes with a wide lumen, and low epithelium; shortly after hatching they entirely disappear.

The characteristic feature of the development of the ovary is a second period of intensive growth of the germinal epithelium accompanied by a rapid increase of the primordial germ-cells contained in it. This goes on very rapidly during the eighth to the eleventh days of incubation. The inner surface of the germinal epithelium, or ovigerous layer of the ovary, begins to form

low irregular projections into the stroma, or the latter begins to penetrate the ovigerous layer at irregular distances so as to produce elevations. This condition is well illustrated in Fig. 229.

In the course of development the ovigerous layer continually increases in thickness, and the projections into the stroma form veritable cords of ovigerous tissue, which correspond to the

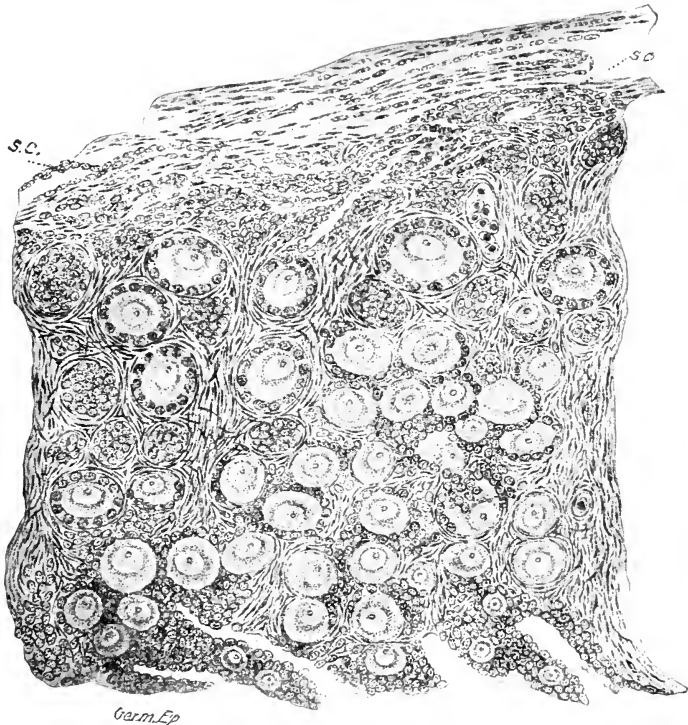


FIG. 230. — Cross-section of the ovary of a fledgling of *Numenius arcuatus* 3-4 days old. The germinal epithelium is below. (After Hoffmann.)

s. c., Sexual cords.

cords of Pflüger in the mammalian ovary. The cords carry the primitive ova with them. The surface of the ovary also begins to become lobulated by the extension of the stroma trabeculae. Successive stages in the growth and differentiation of the primitive ova occur from the surface towards the inner ends of the ovigerous strands. Fig. 230 represents a section through

the ovary of a fledgling of *Numenius arcuatus* three or four days old. The germinal epithelium covers the surface and is continuous with the ovigerous strands projecting far into the stroma. The strands are broken up in the stroma into nests of cells; next the germinal epithelium are found characteristic primitive ova, but in deeper situations the primitive ova are larger and each is accompanied by a group of epithelial cells, which are distinctly differentiated as granulosa cells of young follicles in the deepest. Thus the young follicles arise by separation of nests of cells from the ovigerous strands within the stroma; each nest includes a young ovocyte and a group of epithelial cells which arrange themselves in a single layer of cuboidal cells around the ovocyte. On each side of the free border of the ovary the embryonic state persists, and it is not known whether this condition is maintained permanently, as in some reptiles, or not.

The atrophy of the Wolffian body is much more complete in the female than in the male; no part of it remains in a functional condition, but the part corresponding to the epididymis of the male remains as a rudiment, known as the epoöphoron. It has almost the same structure in young females as in young males, but the rete cords uniting it with the ovary do not become tubular. A rudiment of the non-sexual part of the Wolffian body is also found in the hen between ovary and kidney in the lateral part of the mesovarium; it has been named the paroöphoron.

Development of the Genital Ducts. *The Wolffian Duct.* The origin and connections of the Wolffian ducts have been already sufficiently described. In the male they are connected with the seminiferous tubules by way of the epididymis, vasa efferentia, and rete, and function as vasa deferentia exclusively, after degeneration of the mesonephros. Subsequently they become somewhat convoluted, acquire muscular walls and a slight terminal dilatation. The details of these changes are not described in the literature. In the female the Wolffian duct degenerates; at what time is not stated in the literature, but presumably along with the Wolffian body.

The Müllerian Duct. The Müllerian duct, or oviduct, is laid down symmetrically on both sides in both male and female embryos; subsequently both right and left Müllerian ducts degenerate in the male; in the female the right duct degenerates, the

left only remaining as the functional oviduct. We have now to consider, therefore, (1) the origin of the ducts during the indifferent stage, and (2) their subsequent history in the male and in the female.

The origin of the Müllerian duct is preceded by the formation of a strip of thickened peritoneum on the lateral and superior face of the Wolffian body extending all the way to the cloaca (cf. Fig. 220). This strip, which may be called the tubal ridge, appears first at the anterior end of the Wolffian body on the fourth day, and rapidly differentiates backwards; it lies immediately external to the Wolffian duct. The anterior part of the Müllerian duct arises as a groove-like invagination of the tubal ridge at the cephalic end of the Wolffian body immediately behind the external glomeruli of the pronephros. The lips of this groove then approach and fuse on the fifth day, so as to form a tube which soon separates from the ridge. This process, however, takes place in such a way as to leave the anterior end of the tube open and this constitutes the coelomic aperture of the oviduct, or *ostium tubæ abdominale*. Moreover, the closure of the groove does not take place uniformly, and one or two openings into the Müllerian duct usually occur near the ostium on the fifth day. Typically, however, these soon close up, though persistence of one of them may lead, as a rather rare abnormality, to the occurrence of two ostia in the adult. There is no ground for the view (see Balfour and Sedgwick) that the two or three openings into the anterior end of the Müllerian duct correspond to nephrostomes of the pronephros; they are situated too far posteriorly and laterally to bear such an interpretation.

The anterior part of the Müllerian duct is thus formed by folding from the epithelium of the tubal ridge; it constitutes a short epithelial tube situated between the Wolffian duct and the tubal ridge, ending blindly behind. The part thus formed is relatively short; the major portion is formed by elongation of the anterior part, which slowly grows backwards between the Wolffian duct and the tubal ridge, reaching the cloaca on the seventh day. The growing point is solid and appears to act like a wedge separating the Wolffian duct and the tubal ridge, being thus closely pressed against both, but apparently without receiving cells from either. Balfour's view, that it grows by splitting off from the Wolffian duct or at the expense of cells contributed by the latter,

has not been supported by subsequent investigators. A short distance in front of the growing point the Müllerian duct receives a lumen, and mesenchyme presses in from above and below, and forms a tunic of concentrically arranged cells around it (Fig. 221).

The Müllerian duct thus begins to project above the surface of the Wolffian body, and, as it does so, the thickened epithelium of the tubal ridge becomes flat and similar to the adjacent peritoneum; whether it is used up in the formation of the mesenchymatous tunic of the epithelial Müllerian duct is not known. Up to this time the development is similar in both sexes and on both sides of the body.

In the male development of these ducts ceases on the eighth day; retrogression begins immediately and is completed, or at any rate far advanced, on the eleventh day. In this process the epithelial wall disappears first, and its place is taken by cells of mesenchymatous appearance, though it is not known that transformation of one kind into the other takes place. Retrogression begins posteriorly and proceeds in the direction of the head; the ostium is the last to disappear. The mesenchymatous tunic shares in the process, so that the ridge is no longer found (see Fig. 222). In the male the Müllerian ducts never open into the cloaca.

In the female the development of the right Müllerian duct ceases after the eighth day, and it soon begins to degenerate. Its lumen disappears and it becomes relatively shorter, so that its anterior end appears to slip back along the Wolffian body. On the fifteenth day slight traces remain along its former course and a small cavity in the region of the cloaca. It never obtains an opening into the cloaca (Gasser).

With the degeneration of the anterior end of the Wolffian body the ostium tubæ abdominale comes to be attached by a ligament to the body-wall (Fig. 231); farther back the ligamentous attachment is to the Wolffian body.

The fimbriæ begin to develop on the eighth day on both sides in both sexes. It is only in the left oviduct of the female, however, that development proceeds farther, and differentiation into ostium, glandular part, and shell gland takes place. This appears distinctly about the twelfth day. The lower end expands to form the primordium of the shell-

gland at this time, but does not open into the cloaca. Indeed, the opening is not established until after the hen is six months old (Gasser.)

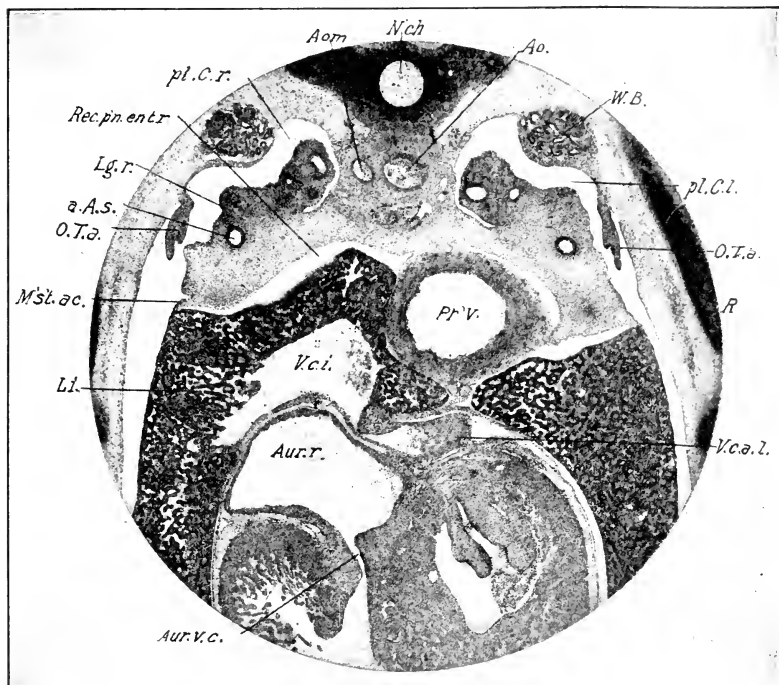


FIG. 231. — Photograph of a cross-section of an embryo of 8 days through the ostia tubæ abdominalia.

a. A. S., Neck of abdominal air-sac. O. T. a., Ostium tubæ abdominalia. M's't.ac., Accessory mesentery. pl. C. r., l., Right and left pleural cavities. Rec. pn. ent. r., Right pneumato-enteric recess. V. c. a. l., Left anterior vena cava. R., rib. Other abbreviations as before.

IV. THE SUPRARENAL CAPSULES

The suprarenals of the hen are situated medial to the anterior lobe of the kidney, in the neighborhood of the gonad and vena cava inferior. They have a length of about 8–10 mm. The substance consists of two kinds of cords of cells, known respectively as cortical and medullary cords, irregularly intermingled: the so-called cortical cords make up the bulk of the substance, and the medullary cords occur in the meshes of the cortical cords.

The terminology does not, therefore, describe well the topographical arrangement of the components; it was derived from the condition found in many mammals, the cortical cords of the birds corresponding to the cortical substance, and the medullary cords to the medullary substance of mammals. The medullary cords are often called phæochrome or chromaffin tissue on account of the specific reaction of the constituent cells to chromic acid, and their supposed genetic relation to tissue of similar composition and reaction found in the carotid glands and other organs associated with the sympathetic system.

The embryonic history has been the subject of numerous investigations, and has proved a particularly difficult topic, if we are to judge from the variety of views propounded. Thus for instance it has been maintained at various times: (1) that cortical and medullary cords have a common origin from the mesenchyme; (2) that they have a common origin from the peritoneal epithelium; (3) that the origin of the cortical and medullary cords is absolutely distinct, the former being derived from the sexual cords by way of the capsules of the renal corpuscles and the latter from the sympathetic ganglia; (4) that their origin is distinct, but that the cortical cords are derived from ingrowths of the peritoneum, and the medullary cords from sympathetic ganglia. The first view may be said now to be definitely abandoned, and no one has definitely advocated a common epithelial origin since Janosik (1883). Thus it may be regarded as well established that the two components have diverse origins, and it seems to the writer that the fourth view above is the best supported. (See Poll and Soulié.) The comparative embryological investigations strongly support this view.

Origin of the Cortical Cords. According to Soulié, the cortical cords arise as proliferations of a special suprarenal zone of the peritoneum adjacent to the anterior and dorsal part of the germinal epithelium. This zone is distinguishable early on the fourth day, and begins about half a millimeter behind the glomeruli of the pronephros, extending about a millimeter in a caudal direction. Proliferations of the peritoneal epithelium are formed in this zone, and soon become detached as groups of epithelial cells lying in the mesenchyme between the anterior end of the Wolffian body and the aorta. Such proliferation con-

tinues up to about the one hundredth hour or a little later, and a second stage in the development of the cortical cords then begins: The cords grow rapidly and fill the space on the medio-dorsal aspect of the Wolffian body, and then come secondarily into relation with the renal corpuscles of the latter and the sexual cords.

According to Semon and Hoffmann the relation thus established is a primary one, that is to say, that the cortical cords arise from the same outgrowths of the capsules of the renal corpuscles that furnish the sexual cords. Rabl agrees essentially with Soulié, and it seems probable that Semon and Hoffmann have overlooked the first stages in the origin of the cortical cords of the suprarenal corpuscles.

During the fifth, sixth, and seventh days there is a very rapid increase of the cortical cords accompanied by a definite circumscription of the organ from the surrounding mesenchyme; however, no capsule is formed yet. The topography of the organ on the eighth day is shown in Figs. 150 and 182. Whereas during the fourth, fifth, and sixth days the arrangement of the cortical cells is in masses rather than in cords, on the eighth day the cords are well developed, in form cylindrical with radiating cells, but no central lumen. The organ has become vascular, and the vessels have the form of sinusoids, *i.e.*, they are moulded on the surface of the cords with no intervening mesenchyme.

Origin of the Medullary Cords. The medullary cords take their origin unquestionably from cells of the sympathetic nervous system. During the growth of the latter towards the mesentery, groups of sympathetic cells are early established on or near the dorso-median surface of the cortical cords (Fig. 226). The ingrowth of the sympathetic medullary cords does not, however, begin until about the eighth day. At this time there is a large sympathetic ganglionic mass on the dorso-median surface of the anterior end of the suprarenal, and strands of cells characterized sharply by their large vesicular nuclei and granular contents can be traced from the ganglion into the superficial part of the suprarenal. These cells are precisely like the specific cells of the ganglion, perhaps a little smaller, and without axones. On the eleventh day these strands have penetrated through a full third of the thickness of the suprarenal, and are still sharply characterized, on the one hand by their resemblance to the

sympathetic ganglion cells, and on the other by their clear differentiation from the cells of the cortical cords. These occupy the relations characteristic of the differentiated medullary cords, and there can be little doubt that they develop into them.

CHAPTER XIV

THE SKELETON

I. GENERAL

FROM an embryological point of view, the bones of the body, their associated cartilages, the ligaments that unite them together in various ways, and the joints should be considered together, as they have a common origin from certain aggregations of mesenchyme. The main source of the latter is the series of sclerotomes, but most of the bones of the skull are derived from the unsegmented cephalic mesenchyme.

Most of the bones of the body pass through three stages in their embryonic development: (1) a membranous or prechondral stage, (2) a cartilaginous stage, (3) the stage of ossification. Such bones are known as cartilage bones, for the reason that they are preformed in cartilage. Many (see p. 433 for list) of the bones of the skull, the clavicles and the uncinatè processes of the ribs do not pass through the stage of cartilage, but ossification takes place directly in the membrane; these are known as membrane or covering bones. The ontogenetic stages of bone formation parallel the phylogenetic stages, membrane preceding cartilage, and the latter preceding bone in the taxonomic series. Thus, in *Amphioxus*, the skeleton (excluding the notochord) is membranous; in the lamprey eel it is partly membranous and partly cartilaginous; in the selachia it is mainly cartilaginous; in higher forms bone replaces cartilage to a greater or less degree. The comparative study of membrane bones indicates that they were primitively of dermal origin, and only secondarily grafted on to the underlying cartilage to strengthen it. Thus the cartilage bones belong to an older category than the membrane bones.

The so-called membranous or prechondral stage of the skeleton is characterized simply by condensation of the mesenchyme. Such condensations arise at various times and places described

beyond, and they often represent the primordia of several future bony elements. In such an area the cells are more closely aggregated, the intercellular spaces are therefore smaller, and the area stains more deeply than the surrounding mesenchyme. There are, of course, stages of condensation in each case, from the first vague and undefined areas shading off into the indifferent mesenchyme, up to the time of cartilage or bone formation, when the area is usually well defined. In most of the bones, however, the process is not uniform in all parts; the growing extremities may be in a membranous condition while cartilage formation is found in intermediate locations and ossification has begun in the original center of formation; so that all three stages may be found in the primordium of a single bone (*e.g.*, scapula). Usually, however, the entire element is converted into cartilage before ossification begins.

The formation of cartilage (chondrification) is brought about by the secretion of a homogeneous matrix of a quite special character, which accumulates in the intercellular spaces, and thus gradually separates the cells; and the latter become enclosed in separate cavities of the matrix; when they multiply, new deposits of matrix form between the daughter cells and separate them. As the original membranous primordium becomes converted into cartilage, the superficial cells flatten over the surface of the cartilage and form a membrane, the perichondrium, which becomes the periosteum when ossification takes place.

The process of ossification in the long bones involves the following stages in the chick:

(1) *Formation of Perichondral Bone.* The perichondrium deposits a layer of bone on the surface of the cartilage near its center, thus forming a bony ring, which gradually lengthens into a hollow cylinder by extending towards the ends of the cartilage. This stage is well illustrated in Fig. 231 A and in the long bones of Fig. 242; the bones of the wing and leg furnish particularly good examples; the perichondral bone is naturally thickest in the center of the shaft and thins towards the extremity of the cartilages.

(2) *Absorption of Cartilage.* The matrix softens in the center of the shaft and becomes mucous, thus liberating the cartilage cells and transforming the cartilage into the fundamental tissue of the bone marrow. This begins about the tenth

day in the femur of the chick. The process extends towards the ends, and faster at the periphery of the cartilage (*i.e.*, next to the perichondral bone) than in the center. In this way there remain two terminal, cone-shaped cartilages, and the ends of the cones project into the marrow cavity (Fig. 231 A).

(3) *Calcification of Cartilage.* Salts of lime are deposited in the matrix of the cartilage at the ends of the marrow cavity; such cartilage is then removed by osteoclasts, large multinucleated cells, of vascular endothelial origin, according to Brachet (seventeenth or eighteenth day of incubation).

(4) *Endochondral Ossification.* Osteoblasts within the marrow cavity deposit bone on the surface of the rays of calcified cartilage that remain between the places eaten out by osteoclasts, and on the inner surface of the perichondral bone.

These processes gradually extend towards the ends of the bone, and there is never any independent epiphysial center of ossification in long bones of birds, as there is in mammals. The ends of the bones remain cartilaginous

and provide for growth in length. Growth in diameter of the bones takes place from the periosteum, and is accompanied by enlargement of the marrow cavity, owing to simultaneous absorption of the bone from within. It is thus obvious that all of the endochondral bone is removed from the shaft in course of time; some remains in the spongy ends.

The details of the process of ossification will not be described here, and it only remains to emphasize a few points. At a stage shortly after the beginning of absorption of the cartilage in the

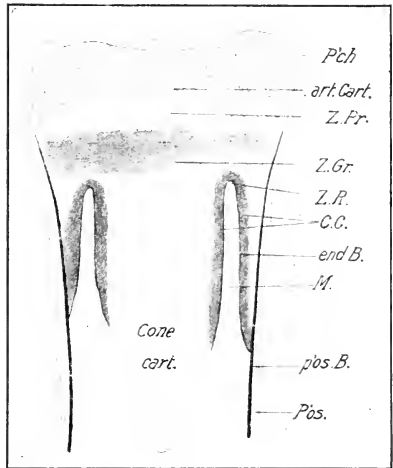


FIG. 231 A. — Longitudinal section of the femur of a chick of 196 hours' incubation; semi-diagrammatic. (After Brachet.)

art. Cart., Articular cartilage. C. C., Calcified cartilage. end. B., Endochondral bone. M., Marrow cavity. P'ch., Perichondrium. P'os., Periosteum. p'os. B., Periosteal bone. Z. Gr., Zone of growth. Z. Pr., Zone of proliferation. Z. R., Zone of resorption.

center of the shaft, the perichondral bone is invaded by capillary vessels and connective tissue that break through into the cavity formed by absorption; it is supposed by many that osteoblasts from the periosteum penetrate at the same time. The marrow of birds is derived, according to the best accounts, from the original cartilage cells, which form the fundamental substance, together with the intrusive blood-vessels and mesenchyme. The endochondral osteoblasts are believed by some to be of endochondral origin (*i.e.*, derived from cartilage cells), by others of periosteal origin. For birds, the former view seems to be the best supported.

In birds, calcification does not precede absorption of the cartilage, as it does in mammals, until the greater part of the marrow cavity is formed. The cones of cartilage, referred to above, that are continuous with the articular cartilages, are absorbed about ten days after hatching.

On the whole, perichondral ossification plays a more extensive rôle in birds than in mammals. The endochondral bone formation begins relatively much later and is less extensive. The bodies of the vertebræ, which ossify almost exclusively in an endochondral fashion, form the main exception to this rule.

Ossification in membrane proceeds from bony spicules deposited between the cells in the formative center of any given membrane bone. It spreads out from the center, the bony spicules forming a network of extreme delicacy and beauty. After a certain stage, the membrane bounding the surface becomes a periosteum which deposits bone in dense layers. Thus a membrane bone consists of superficial layers of dense bone, enclosing a spongy plate that represents the primitive bone before the establishment of the periosteum.

The formation of bones proceeds from definite centers in all three stages of their formation; thus we have centers of membrane formation, centers of chondrification and centers of ossification. Membranous centers expand by peripheral growth, cartilage centers expand by the extension of cartilage formation in the membrane from the original center of chondrification, and bony centers expand in the original cartilage or membrane. Several centers of chondrification may arise in a single primitive membranous center; for instance, in the membranous stage, the skeleton of the fore-limb and pectoral girdle is absolutely con-

tinuous; cartilage centers then arise separately in different parts for each of the bones: similarly for the hind-limbs and pelvic girdle, etc. Separate centers of ossification may likewise appear in a continuous embryonic cartilage, as for instance, in the base of the skull or in the cartilaginous coraco-scapula, or ischio-iliacum. Such centers may become separate bones or they may subsequently fuse together. In the latter case, they may represent bones that were phylogenetically perfectly distinct elements, as for instance, the prootic, epiotic, and opisthotic centers in the cartilaginous otic capsule; or they may be of purely functional significance, as for instance, the separate ossifications in the sternum of birds, or the epiphysial and diaphysial ossifications of the long bones of mammals. It is usually possible on the basis of comparative anatomy to distinguish these two categories of ossification centers.

Phylogenetic reduction of the skeleton is also usually indicated in some manner in the embryonic history. Where elements have completely disappeared in the phylogenetic history, as for instance, the missing digits of birds, they often appear as membrane formations in the embryo, which then fade out without reaching the stage of cartilage; if the latter stage is reached the element usually fuses with some other and is therefore not really missing, *e.g.*, elements of the carpus and tarsus of birds (though not all). But the ontogenetic reduction may go so far that the missing elements are never distinguishable at any stage of the embryonic history; thus, though the missing digits of birds are indicated in the membranous stage, their component phalanges are not indicated at all.

II. THE VERTEBRAL COLUMN

The primordia of the vertebral column are the notochord and sclerotomes. The former is the primitive axial support of the body, both ontogenetically and phylogenetically. In both components, notochord and sclerotomes, we may recognize a cephalic and trunk portion. The notochord, as we have seen, extends far into the head, and the sclerotomes of the first four somites contribute to the formation of the occipital portion of the skull. The cephalic parts are dealt with in the development of the skull. The history of the notochord and sclerotomes will be considered together, but we may note in advance that the

notochord is destined to be completely replaced by the bodies of the vertebræ, derived from the sclerotomes.

The Sclerotomes and Vertebral Segmentation. The vertebral segmentation does not agree with the primitive divisions of the somites, but alternates with it; or in other words, the centers of the vertebræ do not coincide with the centers of the original somites, but with the intersomitic septa in which the segmental arteries run. Thus each myotome extends over half of two vertebral segments, and the spinal ganglia and nerves tend to alternate with the vertebræ. It therefore happens that each myotome exerts traction on two vertebræ, obviously an advantageous arrangement, and the spinal nerves lie opposite the intervertebral foramina.

This arrangement is brought about by the development of each vertebra from the caudal half of one sclerotome and the cephalic half of the sclerotome immediately behind; parts of two somites enter into the composition of each vertebra, as is very obvious at an early stage: Fig. 232 represents a section through the base of the tail of a chick embryo of ninety-six hours; it is approximately frontal, but is inclined ventro-dorsally from behind forwards. The original somites are indicated by the myotomes and the segmental arteries. In the region of the notochord one can plainly distinguish three parts to each sclerotome, viz., (1) a narrow, median, or perichordal part abutting on the notochord, in which no divisions occur either within or between somites; (2) a caudal lateral division distinguished by the denser aggregation of the cells from (3) the cephalic division. Between the caudal and cephalic divisions of the sclerotome is a fissure (intervertebral fissure) which marks the boundary of the future vertebræ. Each vertebra in fact arises from the caudal component of one sclerotome and the cephalic component of the sclerotome immediately behind. Between adjacent sclerotomes is the intersomitic septum containing the segmental artery. If one follows these conditions back into successively earlier stages, one finds that the intervertebral fissure arises from the primitive somitic cavity, and that the distinction between caudal and cephalic divisions of the sclerotome is marked continuously from a very early stage by the presence of the intervertebral fissure and the greater density of the caudal division, *i.e.*, the cephalic component of each definitive vertebra.

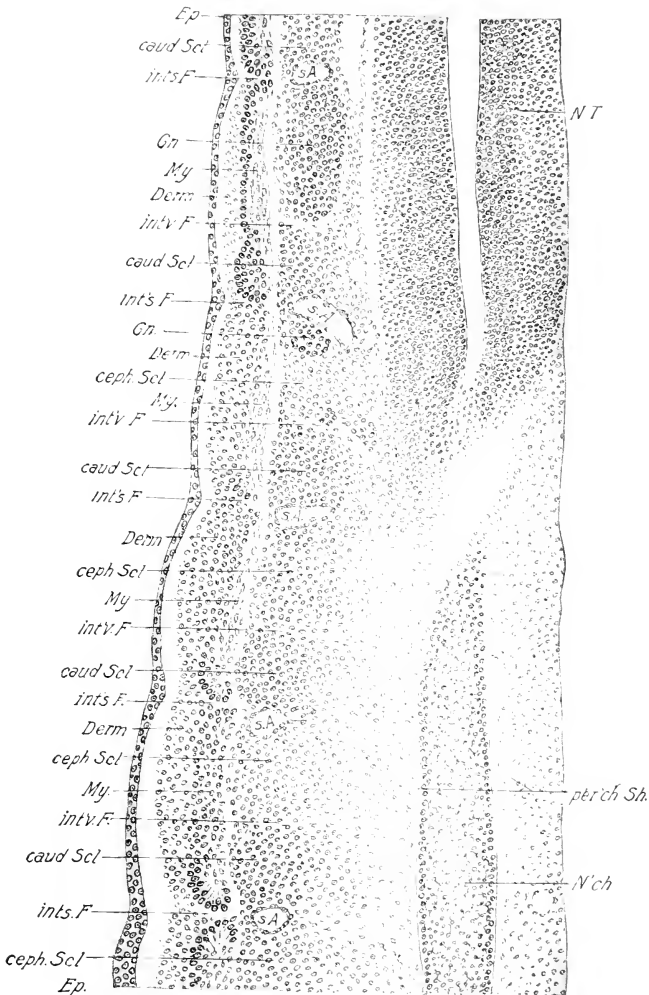


FIG. 232.—Frontal section through the base of the tail of a chick embryo of 96 hours. The anterior end of the section (above in the figure) is at a higher plane than the posterior end.

caud. Scl., Caudal division of the sclerotome. ceph. Scl., Cephalic division of the sclerotome. Derm., Dermatome. Ep., Epidermis. Gn., Ganglion. int's F., Intersomitic fissure. int'v. F., Intervertebral fissure. My., Myotome. N'ch., Notochord. N. T., Neural tube. per'ch. Sh., Perichordal sheath. s. A., Segmental artery.

Now, if one follows these components as they appear at successively higher levels in such a frontal section as Fig. 232, one finds that the perichordal layer disappears in the region of the neural tube, and that the spinal ganglia appear in the cephalic division of the sclerotome, and almost completely replace it. Thus the caudal division of the sclerotome is more extensive, as well as denser, than the cephalic division.

In transverse sections one finds that the sclerotomic mesenchyme spreads towards the middle line and tends to fill all the interspaces between the notochord and neural tube, on the one hand, and the myotomes on the other. But there is no time at which the sclerotome tissue of successive somites forms a continuous unsegmented mass in which the vertebral segmentation appears secondarily, as maintained by Froriep, except in the thin perichordal layer; on the contrary, successive sclerotomes and vertebral components may be continuously distinguished, except in the perichordal layer; and the fusion of caudal and cephalic sclerotome halves to form single vertebræ may be continuously followed. Thus, although the segmentation of the vertebræ is with reference to the myotomes and ganglia, it is dependent upon separation of original sclerotome halves, and not secondarily produced in a continuous mass.

Summarizing the conditions at ninety-six hours, we may say that the vertebræ are represented by a continuous perichordal layer of rather loose mesenchyme and two mesenchymatous arches in each segment, that ascend from the perichordal layer to the sides of the neural tube; in each segment the upper part of the cephalic sclerotomic arch is occupied almost completely by the spinal ganglion, but the caudal arch ascends higher, though not to the dorsal edge of the neural tube. The cranial and caudal arches of any segment represent halves of contiguous, not of the same, definitive vertebra.

Membranous Stage of the Vertebrae. In the following or membranous stage, the definitive segmentation of the vertebræ is established, and the principal parts are laid down in the membrane. These processes are essentially the same in all the vertebræ, and the order of development is in the usual antero-posterior direction. As regards the establishment of the vertebral segments: Figs. 233 and 234 represent frontal sections through the same vertebral primordia at different levels from

the thoracic region of a five-day chick. The notochord is slightly constricted intervertebrally, and the position of the intersegmental artery, of the myotomes and nerves, shows that each vertebral segment is made up of two components representing succeeding sclerotomes. In the region of the neural arches (Fig. 234) the line of union of cranial and caudal vertebral components is indicated by a slight external indentation at the place of union, and by the arrangement of the nuclei on each side of the plane of union.

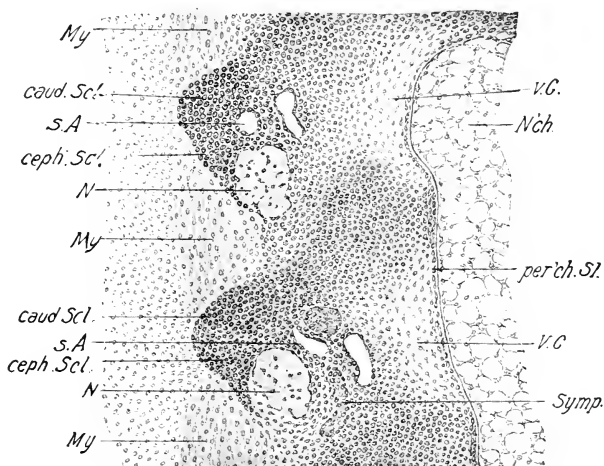


FIG. 233. — Frontal section through the notochord and primordia of two vertebrae of a 5-day chick; thoracic region. Note intervertebral constrictions of the notochord. The anterior end of the section is above.

N., Spinal nerve. Symp., Part of sympathetic cord. v. C., Region of pleurocentrum, in which the formation of cartilage has begun. Other abbreviations as in Fig. 232.

The parts of the vertebrae formed in the membranous stage are as follows: (1) The vertebral body is formed by tissue of both vertebral components that grows around the perichordal sheath; (2) a membranous process (neural arch) extends from the vertebral body dorsally at the sides of the neural canal; but the right and left arches do not yet unite dorsally; (3) a lateral or costal process extends out laterally and caudally (Fig. 233) from the vertebral body between the successive myotomes.

The union of the right and left cephalic vertebral components

(caudal sclerotome halves) beneath the notochord is known as the subnotochordal bar (Froriep). It forms earlier than the remainder of the body of the vertebra and during the membranous stage is thicker, thus forming a ventral projection at the cephalic end of the vertebral body that is very conspicuous (Fig. 235).

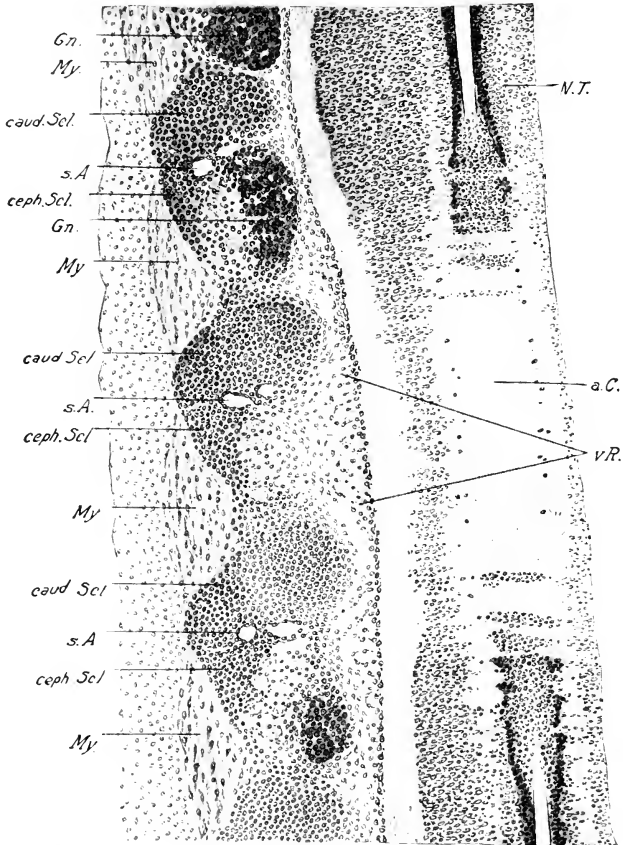


FIG. 234. — Frontal section including the same vertebral primordia as Fig. 233, at a higher level through the neural arches.

a. C., Anterior commissure of the spinal cord. v. R., Ventral root of spinal nerve. Other abbreviations as before (Fig. 232).

It chondrifies separately from the vertebral body and earlier. Except in the case of the first vertebra it fuses subsequently with the remainder of the vertebral body, and disappears as

a separate component. Schauinsland has interpreted it as the homologue of the hæmal arches of reptilia (*e.g.*, *Sphenodon*).

The membrane represents not only the future bony parts but the ligaments and periosteum as well. Hence we find that the successive membranous vertebræ are not separate structures but are united by membrane, *i.e.*, condensed mesenchyme, and are distinguishable from the future ligaments at first only by greater condensation. In the stage of Fig. 233, chondrification has already begun in the vertebral body, hence there is a sharp

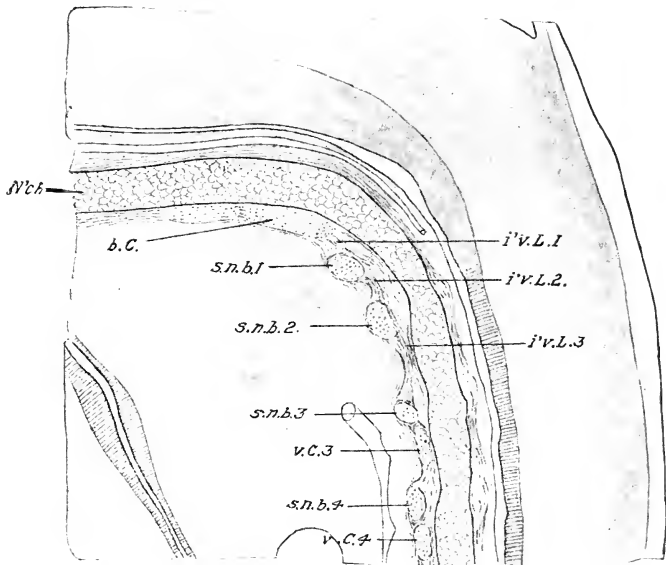


FIG. 235. — Median sagittal section of the cervical region at the end of the sixth day of incubation. (After Froiep.) x 40.

b. C., Basis cranii. i'v. L. 1, 2, 3, First, second, and third intervertebral ligaments. s. n. b. 1, 2, 3, 4, First, second, third, and fourth subnotochordal bars (hypocentra). v. C. 3, 4, Pleurocentra of third and fourth vertebræ.

distinction in this region between the vertebral body and intervertebral discs. The centers of chondrification, however, grade into the membranous costal processes and neural arches.

The vertebral segmentation has now become predominant as contrasted with the primitive somitic.

The development of the vertebræ during the fifth day comprises: (1) Fusion of successive caudal and cephalic divisions of

the sclerotomes to form the definitive vertebræ; (2) union of the cephalic vertebral components beneath the notochord to form the subnotochordal bar; (3) origin of the membranous vertebral bodies and of the neural arch and costal processes.

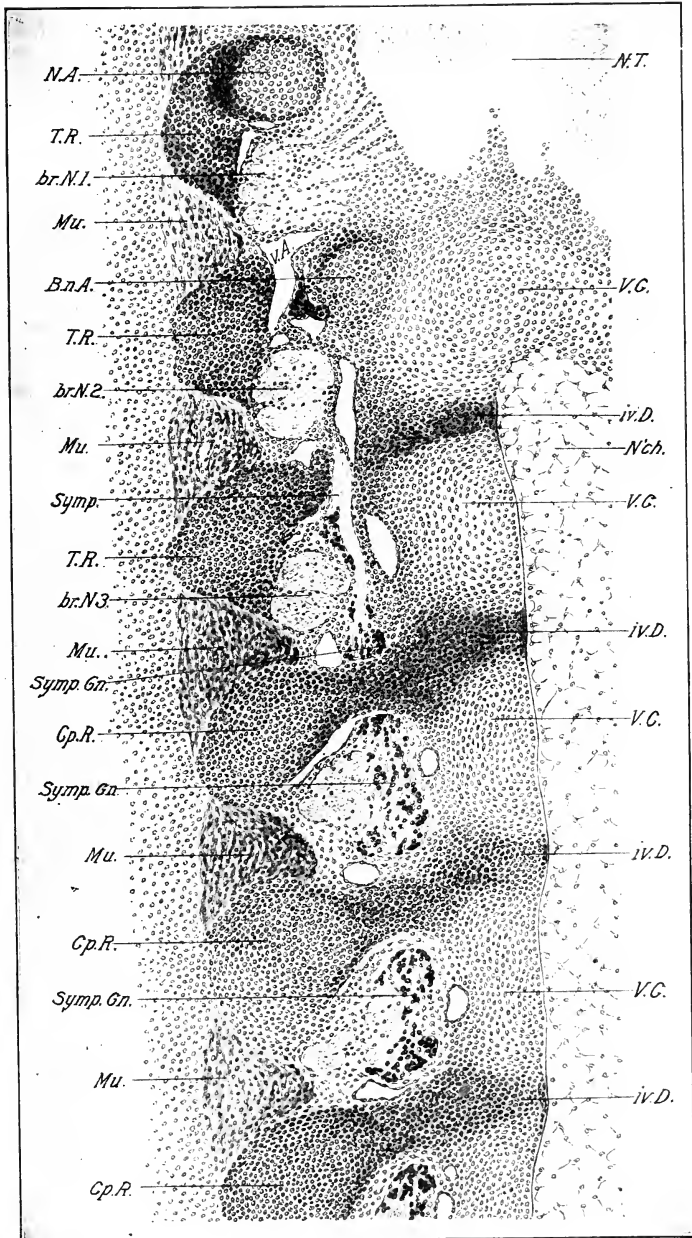
Chondrification, or development of cartilage, sets in from the following centers in each vertebra: (1) the cephalic neural arches and subnotochordal bar, forming a horseshoe-shaped cartilage at the cephalic end of each vertebra; (2) and (3) right and left centers in the body of each vertebra behind the subnotochordal bar, which soon fuse around the notochord; (the subnotochordal bar probably corresponds to the hypocentrum, and the lateral centers (2 and 3) to the pleurocentra of palæontologists); (4) and (5) centers in each costal process (Figs. 235 and 236). These centers are at first separated by membrane, but except in the case of the costal processes, which form the ribs, the cartilage centers flow together. The neural arches end in membrane which gradually extends dorsally around the upper part of the neural tube, finally uniting above with the corresponding arches of the other side to form the *membrana reuniens*. The chondrification follows the extension of the membrane. During this time the transverse processes of the neural arch and the zygo-physes are likewise formed as extensions of the membrane.

The distinction that some authors make between a primary vertebral body formed by chondrification within the perichordal sheath, and a secondary vertebral body formed by the basal ends of the arches surrounding the primary, is not a clear one in the case of the chick.

On the seventh and eighth days the process of chondrification extends into all parts of the vertebra; the entire vertebra is, in fact, laid down in cartilage on the eighth day, although the neural spine is somewhat membranous. Fig. 237 shows the right side of four trunk vertebræ of an eight-day chick, prepared according to the methylene blue method of Van Wijhe. The

FIG. 236. — Frontal section of the vertebral column and neighboring structures of a 6-day chick. Upper thoracic region. Note separate centers of chondrification of the neural arch, centrum, and costal processes. Anterior end of section above.

B. n. A., Base of neural arch. br. N. 1, 2, 3, First, second, and third brachial nerves. Cp. R., Capitulum of rib. iv. D., Intervertebral disc. Mu., Muscles. N. A., Neural arch. T. R., Tuberculum of rib. V. C., Centrum of vertebra. Other abbreviations as before.



notochord runs continuously through the centra of the four vertebræ shown. It is constricted intravertebrally and expanded intervertebrally, so that the vertebral bodies are amphicæulous. The intervertebral discs are not shown. A pre- and postzygapophysis is formed on each arch. It is by no means certain that the parts separated by the clear streak shown in the figure extending through centra and arches correspond to the sclerotomal components of the primitive vertebræ, though this was the interpretation of Schauinsland as shown in the figure; further study seems necessary to determine the exact relations of the primitive sclerotomal components to the parts of the definitive vertebra. The successive vertebræ have persistent membranous

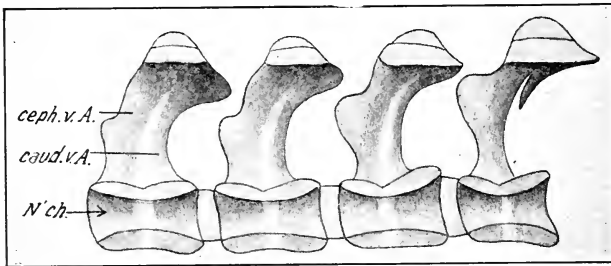


FIG. 237. — The right side of four bisected vertebræ of the trunk of an 8-day chick. (After Schauinsland.)

caud. v. A., Caudal division of vertebral arch. ceph. v. A., Cephalic division of vertebral arch. N'ch., Notochord.

connections in the regions of the neural spines, zygapophyses and centra. These are shown in Figs. 238 and 239 (cf. also Fig. 150); they are continuous with the perichondrium and all are derived from unchondrified parts of the original membranous vertebræ.

Atlas and Axis (epistropheus). The first and second vertebræ agree with the others in the membranous stage. But, when chondrification sets in, the hypochordal bar of the first vertebra does not fuse with the body, but remains separate and forms its floor (Figs. 238 and 239). The body of the first vertebra chondrifies separately and is attached by membrane to the anterior end of the body of the second vertebra, representing in fact the odontoid process of the latter. It has later a separate center of ossification, but fuses subsequently with the body of the second vertebra, forming the odontoid process (Fig. 240).

Formation of Vertebral Articulations. In the course of development the intervertebral discs differentiate into a peripheral intervertebral ligament and a central suspensory ligament which at first contains remains of the notochord. There is a synovial cavity between the intervertebral and suspensory ligaments. This differentiation takes place by a process of loosening and resorption

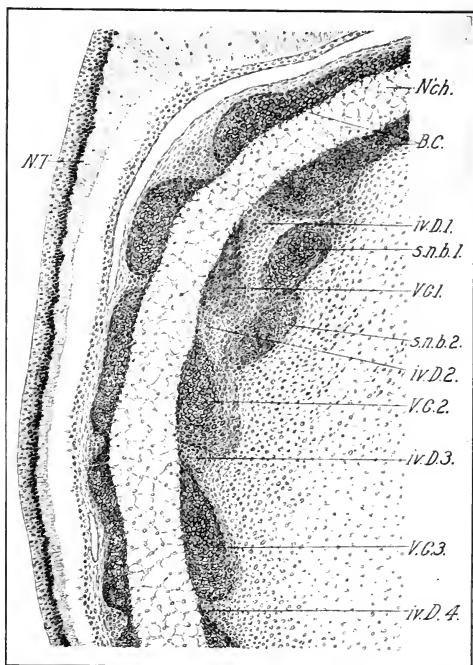


FIG. 238. — Median sagittal section of the basis cranii and first three vertebral centra of an 8-day chick.

B. C., Basi-cranial cartilage. iv. D. 1, 2, 3, 4, First, second, third, and fourth intervertebral discs. N. T., Floor of neural tube. s. n. b. 1, 2, First and second subnotochordal bars. V. C. 1, 2, 3, First, second, and third pleurocentra.

of cells just external to the perichordal sheath (Fig. 241). The intervertebral ligament takes the form of paired, fibrous menisci, or, in other words, the intervertebral ligaments are incomplete around the bodies of the vertebræ dorsally and ventrally (Schwarck).

Ossification is well advanced in the clavicles, long bones,

and membrane bones of the skull before it begins in the vertebræ. It takes place in antero-posterior order, so that a series of stages may be followed in a single embryo (cf. Fig. 242). There are three main centers for each vertebra, viz., one in the body and one in each neural arch. The ossification of the centrum is almost

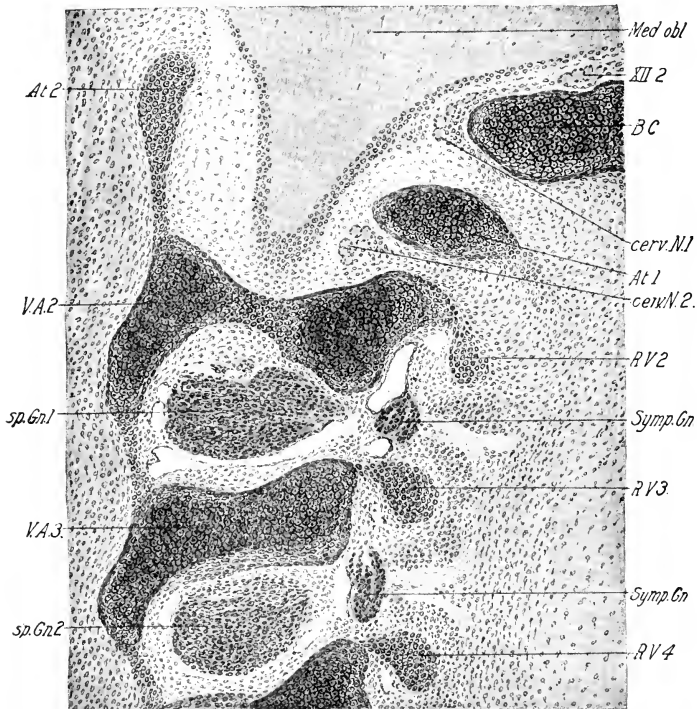


FIG. 239. — Lateral sagittal section of the same vertebra (as in Fig. 238).

At. 1, 2, Floor and roof of atlas. B. C., Basis cranii. Cerv. n. 1, 2, First and second cervical nerves. Med. Obl., Medulla oblongata. R. V. 2, 3, 4, Ribs of the second, third, and fourth vertebrae. V. A. 2, 3, Arches of the second and third vertebrae.

XII 2, Second root of hypoglossus.

entirely endochondral, though traces of perichondral ossification may be found on the ventral and dorsal surfaces of each centrum before the endochondral ossification sets in. The perichondral centers soon cease activity. The endochondral centers arise just outside the perichordal sheath near the center of each vertebra on each side of the middle line, but soon fuse around the

notochord, and rapidly spread in all directions, but particularly towards the surface, leaving cartilaginous ends (Fig. 241). The notochord is gradually reduced and exhibits two constrictions

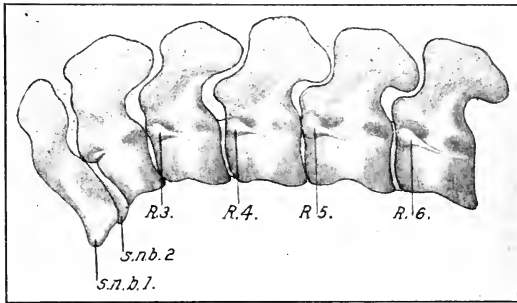


FIG. 240. — The first cervical vertebrae of a young embryo of *Haliplana fuliginosa*. (After Schauinsland.)

s. n. b. 1, 2, First and second subnotochordal bars.
R. 3, 4, 5, 6, Ribs of the third, fourth, fifth, and sixth cervical vertebrae.

and three enlargements within each centrum. The main enlargement occupies the center and the two smaller swellings the cartilaginous ends, the constriction occurring at the junction of the ossified areas and cartilaginous ends (Fig. 241).

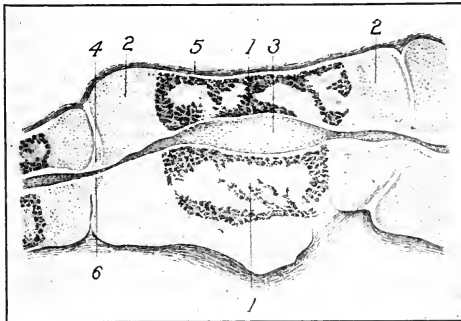


FIG. 241. — Section through the body of a cervical vertebra of a chick embryo of about 12 days. (After Schwarck.)

1, Endochondral ossification. 2, Articular cartilages. 3, Notochord. 4, Loosening of cells of the intervertebral disc, forming a synovial cavity. 5, Periosteum. 6, Ligamentum suspensorium surrounding the notochord.

The centers of ossification in the neural arches arise from the perichondrium a short distance above the body of the vertebra, and form bony rings about the cartilaginous arch. They gradually extend into all the processes of the neural arch. Thus the neural arches are separated from the vertebral centra by a disc of cartilage which is, however, finally ossified, fusing the arches and centra. At what time this occurs, and at what time endochondral ossification begins in the arches, is not known exactly for the chick.

The vertebral column of birds is characterized by an extensive secondary process of coalescence of vertebræ. Thus the two original sacral vertebræ coalesce with a considerable number of vertebræ, both in front and behind, to form an extensive basis of support for the long iliac bones. The definitive sacrum may be divided into an intermediate primary portion composed of two vertebræ, an anterior lumbar portion, and a posterior caudal portion. The development of these fusions has not been, apparently, worked out in detail for the chick. The bony centers are all separate on the sixteenth day of incubation (cf. Fig. 249). Similarly, the terminal caudal vertebræ fuse to form the so-called pygostyle, which furnishes a basis of support for the tail feathers.

III. DEVELOPMENT OF THE RIBS AND STERNAL APPARATUS

In the membranous stage of the vertebral column, all of the trunk vertebræ possess membranous costal processes the subsequent history of which is different in different regions. In the cervical region these remain relatively short, and subsequently acquire independent centers of chondrification and ossification. The last two cervical ribs, however, acquire considerable length. In the region of the thorax, the membranous costal processes grow ventralward between the successive myotomes and finally unite in the formation of the sternum (q.v.). In the lumbar and sacral regions the membranous costal processes remain short. The primary costal process is an outgrowth of the membranous centrum, corresponding in position to the capitulum of the definitive rib. The tuberculum arises from the primary costal process while the latter is still in the membranous condition and grows dorsalward to unite with the neural arch in the region of the transverse process. (See Fig. 236.)

The centers of chondrification and ossification of the typical

ribs (cervical and thoracic) arise a short distance lateral to the vertebral centers, with which they are connected only by the intervening membrane, which forms the vertebro-costal ligaments. Chondrification then proceeds distally.

The cervical ribs chondrify from a single center. The thoracic ribs have two centers of chondrification; a proximal one, corresponding to the vertebral division of the rib, and a distal one corresponding to the sternal division. The lumbar and sacral membranous costal processes do not chondrify separately from the vertebral bodies; if they persist at all, therefore, they appear as processes of the vertebræ, and are not considered further.

In the fowl the atlas does not bear ribs, and in the embryo the primary costal processes of this vertebra do not chondrify. The second to the fourteenth vertebræ bear short ribs, with capitulum and tuberculum bounding the vertebrarterial canal. The fourteenth is the shortest of the cervical series. The fifteenth and sixteenth vertebræ bear relatively long ribs, but, as these do not reach the sternum, they are classed as cervical. The entire embryonic history, however, puts them in the same class as the following sternal ribs; on an embryological basis they should be classed as incomplete thoracic ribs. They possess no sternal division, but the posterior one has an uncinatè process like the true thoracic ribs. The following five pairs of ribs (vertebræ 17-21) possess vertebral and sternal portions, but the last one fails to reach the sternal rib in front of it.

The vertebral and sternal portions of the true thoracic ribs meet at about a right angle in a membranous joint. This bend is indicated in the membranous stage of the ribs.

The membranous ribs growing downwards and backwards in the wall of the thorax make a sudden bend forward, and their distal extremities fuse (seven and eight days) in a common membranous expansion (primordium of the sternum), which, however, is separated from the corresponding expansion of the opposite side by a considerable area of the body-wall.

The vertebral and sternal portions of the ribs ossify separately; the ossification of the ribs is exclusively perichondral up to at least the sixteenth day (cf. Fig. 242).

The uncinatè processes were not formed in any of the embryos studied. Apparently they arise as separate membranous ossifications after hatching.

The sternum takes its origin from a pair of membranous expan-

sions formed by the fusion of the distal ends of the first four true thoracic ribs; the fifth pair of thoracic ribs does not take part in the formation of the sternum. The sternum thus arises as two distinct halves, which lie at first in the wall of the thorax at the posterior end of the pericardial cavity (eight days). The greatest extension of the sternal primordia is dorso-ventral, the

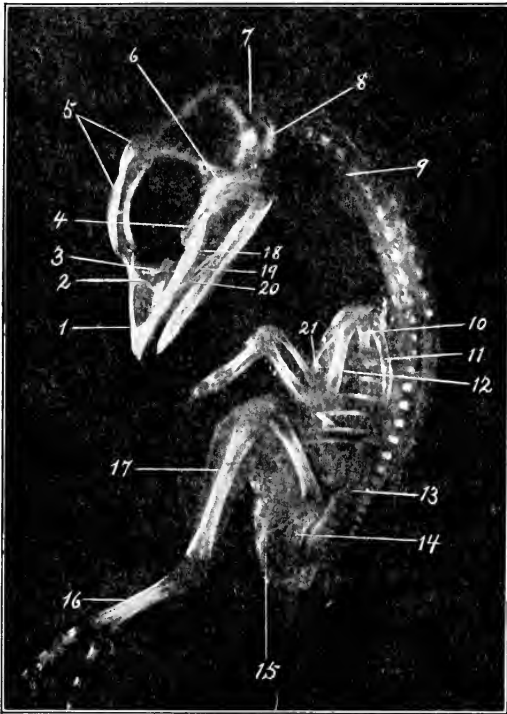


FIG. 242. — Photograph of the skeleton of a 13-day chick embryo. Prepared by the potash method. (Preparation and photograph by Roy L. Moodie.)

1, Premaxilla. 2, Nasal. 3, Lacrymal. 4, Parasphenoid. 5, Frontal. 6, Squamosal. 7, Parietal. 8, Exoccipital. 9, Cervical rib. 10, Coracoid. 11, Scapula. 12, Humerus. 13, Ilium. 14, Ischium. 15, Pubis. 16, Metatarsus. 17, Tibiofibula. 18, Palatine. 19, Jugal. 20, Maxilla. 21, Clavicle.

ventral extremities corresponding to the anterior end of the definitive sternum, which is formed by condescence of the lateral halves in the middle line beginning at the anterior end. The condescence

then proceeds posteriorly, as the dorsal ends of the primordia rotate backwards and downwards towards the middle line.

Although there are two lateral centers of chondrification, these soon fuse. The carina arises as a median projection very soon after concrescence in any region, and progresses backwards, rapidly following the concrescence. There is, therefore, no stage in which the entire sternum of the chick is ratite, though this condition exists immediately after concrescence in any region. The various outgrowths of the sternum (episternal process, antero-lateral and abdominal processes), arise as processes of the membranous sternum and do not appear to have independent centers of chondrification.

The sternum ossifies from five centers, viz., a median anterior center and paired centers in the antero-lateral and abdominal processes. The last appear about the seventeenth day of incubation. On the nineteenth day a point of ossification appears at the base of the anterior end of the keel. At hatching centers also appear in the antero-lateral processes. The centers gradually extend, but do not completely fuse together until about the third month. The posterior end of the median division of the sternum remains cartilaginous for a much longer period. In the duck and many other birds there are only two lateral centers of ossification; the existence of five centers in the chick is, therefore, probably not a primitive condition.

IV. DEVELOPMENT OF THE SKULL

The skull arises in adaptation to the component organs of the head, viz., the brain, the sense organs (nose, eye, and ear) and cephalic visceral organs (oral cavity and pharynx); it thus consists primarily of a case for the brain, capsules for the sense organs, and skeletal bars developed in connection with the margins of the mouth and the visceral arches. In the chick, the primordia of the auditory and olfactory capsules are continuous *ab initio* with the primordial cranium; the protecting coat of the eye (sclera) never forms part of the skull. Therefore, we may consider the development of the skull in two sections, first the dorsal division associated with brain and sense organs (neuro-cranium), and second, the visceral division or splanchnocranium. Although the investment of the eyes forms no part of the skull, yet the eyes exert an immense effect on the form of the skull.

Development of the Cartilaginous or Primordial Cranium.

(1) *The Neurocranium.* The neurocranium is derived from the mesenchyme of the head, the origin of which has been described previously. The mesenchyme gradually increases in amount and forms a complete investment for the internal organs of the head. It is not all destined, however, to take part in the formation of the skeleton, for the most external portion forms the derma and subdermal tissue; and, internal to the skeletogenous layer, the membranes of the brain and of the auditory labyrinth, etc., are formed from the same mesenchyme.

The notochord extends forward in the head to the hypophysis (Figs. 67, 88, etc.), and furnishes a basis for division of the neurocranium into chordal and prechordal regions. Within the chordal division again, we may distinguish pre-otic, otic, and post-otic regions according as they are placed in front of, around, or behind the auditory sac. The part of the postotic region behind the vagus nerve is the only part of the neurocranium that is primarily segmental in origin. The sclerotomes of the first four somites (Figs. 63 and 117) form this part of the skull; and at least three neural arches, homodynamous with the vertebral arches, are formed in an early stage, but fuse together while still membranous, leaving only the two pairs of foramina of the twelfth cranial nerve as evidence of the former segmentation. It is also stated that membranous costal processes are found in connection with these arches, but they soon disappear without chondrifying.

The *primordial neurocranium* is performed in cartilage and corresponds morphologically to the cranium of cartilaginous fishes. However, it never forms a complete investment of the brain; except in the region of the tectum synoticum it is wide open dorsally and laterally. It is subsequently replaced by bone to a very great extent, and is completed and reinforced by numerous membrane bones.

The neurocranium takes its origin from two quite distinct primordia situated below the brain, viz., the parachordals and the trabeculæ. The former develop on each side of and around the notochord, being situated, therefore, behind the cranial flexure and beneath the mid- and hind-brain; the trabeculæ are prechordal in position, being situated beneath the twixt-brain and cerebral hemispheres, and extending forward through the

interorbital region to the olfactory sacs. It is obvious, therefore, that the parachordals and trabeculæ must form with relation to one another the angle defined by the cranial flexure.

The parachordals appear in fishes as paired structures on either side of the notochord, uniting secondarily around the latter; but in the chick the perichordal portion is formed at the same time as the thicker lateral portions, so that the parachordals exist in the form of an unpaired basilar plate from the first. The trabeculæ are at first paired (in the earliest membranous condition), but soon fuse in front, while the posterior ends form a pair of curved limbs (*fenestra hypophyseos*) that surrounds the infundibulum and hypophysis, and joins the basilar plate behind the latter. At the same time that the parachordals and trabeculæ are formed by condensations of mesenchyme, the latter condenses also around the auditory sacs and olfactory pits in direct continuity with the parachordals and trabeculæ respectively; so that the auditory and olfactory capsules are in direct continuity with the base of the neurocranium from the beginning.

Chondrification begins in the primordial cranium about the sixth day; it appears first near the middle line on each side, and extends out laterally. Somewhat distinct centers corresponding to the occipital sclerotomes may be found in some birds, but they soon run together, and the entire neurocranium forms a continuous mass of cartilage (sixth, seventh, and eighth days).

During this process the trabecular region increases greatly in length simultaneously with the outgrowth of the facial region, and the angle defined by the cranial flexure becomes thus apparently reduced. The posterior border of the *fenestra hypophyseos* marks the boundary between the basilar plate and trabecular region.

In the region of the basilar plate the following changes take place: (1) in the post-otic or occipital region a dorso-lateral extension (Fig. 244) fuses with the hinder portion of the otic capsule, thus defining an opening that leads from the region of the cavity of the middle ear into the cranial cavity (*fissure metotica*). This expansion is pierced by the foramina of the ninth tenth and eleventh nerves. (2) The otic region becomes greatly expanded by the enlargement of the membranous labyrinth. The cochlear process grows ventrally and towards the middle line and thus invades the original parachordal region (Fig. 168). The

posterior region of the otic capsule expands dorsally above the hind-brain, and forms a bridge of cartilage extending from one capsule to the other, known as the *tectum synoticum* (Fig. 244, 33). (3) The preotic region expands laterally and dorsally in the form of a wide plate (alisphenoidal plate) which is expanded transversely, and thus possesses an anterior face bounding the orbit posteriorly and a posterior face forming part of the anterior wall of the cranial cavity. This plate arises first between the ophthalmic and maxillo-mandibular branches of the trigeminus, and subsequently sends a process over the latter that fuses with the anterior face of the otic capsule, thus establishing the foramen proöticum.

For an account of numerous lesser changes, the student is referred to Gaupp (1905), and the special literature (especially Parker, 1869). The various foramina for the fifth to the twelfth cranial nerves are defined during the process of chondrification; the majority of these are shown in the figures.

The trabecular region may be divided into interorbital and ethmoidal (nasal) regions. The basis of the skeleton in this region is formed by the trabeculæ already described. The median plate formed by fusion of the trabeculæ extends from the pituitary space (fenestra hypophyseos) to the tip of the head; a high median keel-like plate develops in the interorbital and internasal regions

FIG. 243. — Skull of an embryo of 65 mm. length; right side. Membrane bones in yellow. Cartilage in blue. (Drawn from the model of W. Tonkoff; made by Ziegler.)

FIG. 244. — View of the base of the same model.

243-244. — 1, Squamosum. 2, Parietale. 3, Capsula auditiva. 4, Capsula auditiva (cochlear part). 5, Fissura metotica. 6, Epibranchial cartilage. 7, Sphenolateral plate. 8, Foramen proöticum. 9, Columella. 10, Otic process of quadratum. 11, Basitemporal (postero-lateral part of the parasphenoid). 12, Articular end of Meckel's cartilage. 13, Angulare. 14, Supra-angulare. 15, Dentale. 16, Skeleton of tongue. 17, Pterygoid. 18, Palatine. 19, Rostrum of parasphenoid. 20, Quadrato-jugal. 21, Jugal (zygomatium). 22, Vomer. 23, Maxilla. 24, Premaxilla. 25, Anterior turbinal. 26, Posterior turbinal. 27, Nasale. 28, Prefrontal (lachrymale). 29, Antorbital plate. 30, Interorbital foramen. 31, Interorbital septum. 32, Frontale. 33, Tectum synoticum. 34, Foramen magnum. 35, Prenasal cartilage. 36, Orbital process of quadrate. 37, Articular process of Quadrate. 38, Fenestra basicranialis posterior. 39, Chorda. IX, Foramen glossopharyngei. X, Foramen vagi. XII, Foramina hypoglossi.

FIG. 245. — Visceral skeleton of the same model.

1, Dentale. 2, Operculare. 3, Angulare. 4, Supra-angulare. 5, Meckel's cartilage. 6, Entoglossum (cerato-hyal). 7, Copula (1). 8, Pharyngo-branchial (1). 9, Epibranchial. 10, Copula (2).

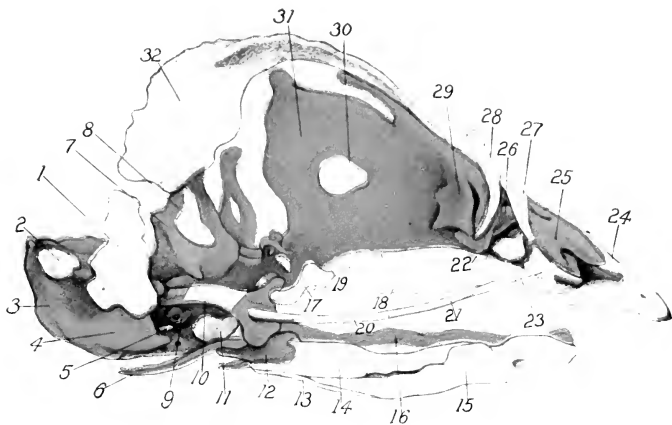


Fig 243

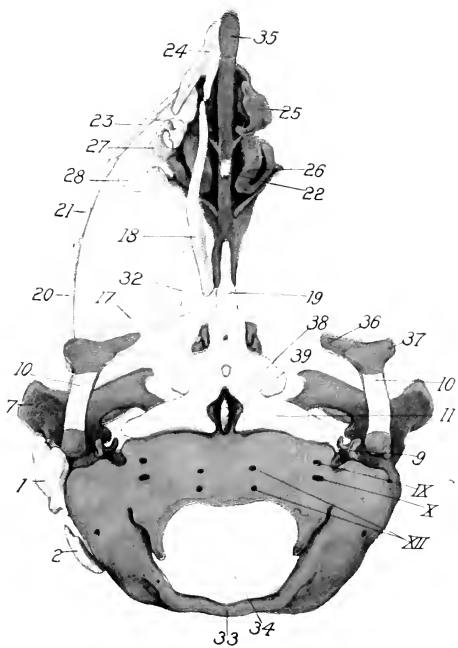


Fig. 244

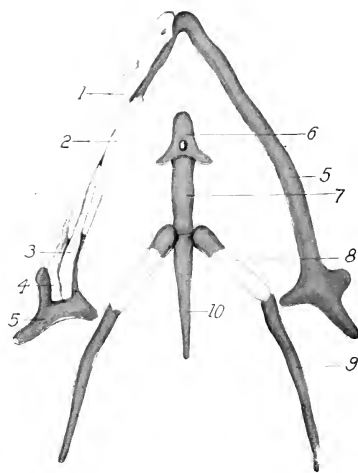


Fig 245

and fuses with the trabeculæ, forming the septum interorbitale and septum nasi (Fig. 243). The free posterior border of this plate lies in front of the optic nerves; an interorbital aperture arises in the plate secondarily (Fig. 243).

In the ethmoidal region the septum nasi arises as an anterior continuation of the interorbital plate; and the trabecular plate is continued forward as a prenasal cartilage in front of the olfactory sacs. Curved, or more or less rolled, plates of cartilage develop in the axis of the superior, middle, and inferior turbinals (see olfactory organ), and these are continuous with the lateral wall of the olfactory capsules, which in its turn arises from the dorsal border of the septum nasi (Figs. 243 and 244).

(2) *The Origin of the Visceral Chondrocranium (Cartilaginous Splanchnocranium)*. The visceral portion of the cartilaginous skull arises primarily in connection with the arches that bound the cephalic portion of the alimentary tract, viz., oral cavity and pharynx. In the chick, cartilaginous bars are formed in the mandibular arch, hyoid arch, and third visceral arch. In fishes, the posterior visceral arches also have an axial skeleton, but in the chick the mesenchyme of these arches does not develop to the stage of cartilage formation. The elements of these arches are primarily quite distinct. The upper ends of the mandibular and hyoid skeletal arches are attached to the skull; and the lower ends of the three arches concerned meet in the middle line. Two medial elements or copulæ are formed in the floor of the throat, one behind the angle of the hyoid arch, and one behind the third visceral arch (Fig. 245).

Mandibular Arch. Two skeletal elements arise in the mandibular arch on each side, a proximal one (the palato-quadrate) and a distal one (Meckel's cartilage). The former is relatively compressed, and the latter an elongated element (Fig. 243, 10). The palato-quadrate lies external to the antero-vertral part of the auditory capsule, and soon develops a triradiate form. The processes are: the *processus oticus*, which applies itself to the auditory capsule, the *processus articularis*, which furnishes the articulation for the lower jaw, and the *processus orbitalis*, which is directed anteromedially towards the orbit. A small nodule of cartilage of unknown significance lies above the junction of the processus oticus and otic labyrinth. Meckel's cartilage is the primary skeleton of the lower jaw, corresponding

to the definitive lower jaw of selachians. It consists of two rods of cartilage in the rami of the mandibular arch, which articulate proximally with the processus articularis of the palatoquadrate cartilage, and meet distally at the symphysis of the lower jaw. The form of the articulation of the lower jaw is early defined in the cartilage (seven to eight days).

Hyoid Arch. The skeletal elements of the hyoid arch consist of proximal and distal pieces (with reference to the neurocranium) which have no connection at any time. The former are destined to form the columella, and the latter parts of the hyoid apparatus. The columella apparently includes two elements (in *Tinnunculus* according to Susehkin, quoted from Gaupp): a dorsal element, interpreted as hyomandibular, in contact with the wall of the otic capsule, and a small element (stylohyal) beneath the former. The two elements fuse to form the columella, the upper end of which is shown in Fig. 168. The stapedia plate (operculum of the columella) is stated to arise in *Tinnunculus* from the wall of the otic capsule, being cut out by circular cartilage resorption and fused to the columella.

The distal elements of the hyoid arch consist of (1) a pair of ceratohyals, which subsequently fuse in the middle line to form the entoglossal cartilage, the proximal ends remaining free as the lesser cornua of the hyoid, and (2) a median unpaired piece (copula I or basihyal) behind the united ceratohyals (Fig. 245).

First Branchial Arch. The skeletal elements of the third visceral (first branchial) arch are much more extensive than those of the hyoid arch. They are laid down as paired cerato- and epi-branchial cartilages on each side, and an unpaired copula II (basibranchial I) in the floor of the pharynx, in the angle of the other elements (Fig. 245). The cerato- and epibranchials increase greatly in length, and form the long curved elements (greater cornua) of the hyoid, which attain an extraordinary development in many birds.

Ossification of the Skull. The bones of the skull are of two kinds as to origin: (1) those that arise in the primordial cranium, and thus replace cartilage (cartilage bones or replacement bones), and (2) those that arise by direct ossification of membrane (membrane or covering bones).

The cartilage bones of the bird's skull are: (*a*) in the occipital region; the basioccipital, two exoccipitals, and the supraoccipitals; (*b*) in the otic region: proötic, epiotic, and opisthotic;

(*e*) in the orbital region: the basisphenoid, the orbitosphenoids, the alisphenoids and ossifications of the interorbital septum; (*d*) in the ethmoidal region the bony ethmoidal skeleton; (*c*) the palatoquadrate cartilage furnishes the quadrate bone; (*f*) a proximal ossification, the articulare, arises in Meckel's cartilage and fuses later with membrane bones; (*g*) the upper part of the hyoid arch furnishes the columella, and the ceratohyals the os entoglossum; (*h*) the cerato- and epibranchials ossify independently, as also do the two copulæ. (See Figs. 243, 244 and 245.)

The membrane bones of the skull are: (*a*) in the region of the cranium proper: parietals, frontals, squamosals; (*b*) in the facial region: lachrymals, nasals, premaxillæ, maxillæ, jugals, quadrato-jugals, pterygoids, palatines, parasphenoid, and vomer; (*c*) surrounding Meckel's cartilage and forming the lower jaw: angulare, supra-angulare, operculare, and dentale. (See Figs. 243, 244 and 245.)

The embryonic bird's skull is characterized by a wealth of distinct bones that is absolutely reptilian; but in the course of development these fuse together so completely that it is only in the facial and visceral regions that the sutures can be distinguished readily.

In order of development the membrane bones precede the cartilage bones, though the latter are phylogenetically the older. Thus, about the end of the ninth day, the following bones are present in the form of delicate reticulated bars and plates: all four bones of the mandible, the faint outline of the premaxillæ, the central part of the maxillæ, the jugal and quadratojugal, the nasals, the palatines and pterygoids. The base of the squamosal is also indicated by a small triangular plate ending superiorly in branching trabeculæ, delicate as frost-work. A faint band of perichondral bone is beginning to appear around the otic process of the quadrate, the first of the cartilage bones to show any trace of ossification. These ossifications appear practically simultaneously as shown by the examination of the earlier stages.

On the twelfth day these areas have expanded considerably, and the frontals and prefrontals (lachrymals) are formed; the rostrum of the parasphenoid is also laid down, and the exoccipitals appear in the cartilage at the sides of the foramen magnum. The parietals appear behind the squamosal (Fig. 242) about the thirteenth day; the basioccipitals soon after. The supraoc-

cipital appears as a pair of ossifications in the tectum synoticum on each side of the dorsal middle line, subsequently fusing together.

A detailed history of the mode of ossification of all the various bones of the skull would be out of place in this book. The figures illustrate some points not described in the text. The reader is referred to W. K. Parker (1869) and to Gaupp (1905).

V. APPENDICULAR SKELETON

The appendicular skeleton includes the skeleton of the limbs and of the girdles that unite the limbs to the axial skeleton. The fore and hind-limbs, being essentially homonymous structures, exhibit many resemblances in their development.

The Fore-limb. The pectoral girdle and skeleton of the wing develop from the mesenchyme that occupies the axis and base of the wing-bud, as it exists on the fourth day of incubation. It is probably of sclerotomic origin, but it is not known exactly how many somites are concerned in the chick, nor which ones. After the wing has gained considerable length (fifth day) it can be seen from the innervation that three somites are principally involved in the wing proper, viz., the fourteenth, fifteenth, and sixteenth of the trunk. But it is probable that the mesenchyme of the base of the wing-bud, from which the pectoral girdle is formed, is derived from a larger number of somites.

It is important, then, to note first of all that the scapula, coracoid, clavicle, humerus, and distal skeletal elements of the wing are represented on the fourth day by a single condensation of mesenchyme, which corresponds essentially to the glenoid region of the definitive skeleton. From this common mass a projection grows out distally in the axis of the wing-bud, and three projections proximally in different directions in the body-wall. These projections are (1) the primordium of the wing-skeleton, (2) of the scapula, (3) of the coracoid, (4) of the clavicle.

The Pectoral Girdle. The elements of the pectoral girdle are thus outgrowths of a common mass of mesenchyme. The scapula process grows backward dorsal to the ribs; the coracoid process grows ventralward and slightly posterior towards the primordium of the sternum, thus forming an angle slightly less than a right angle with the scapular process; and the clavicular process grows

out in front of the coracoid process ventrally and towards the middle line. These processes are quite well developed on the fifth day, and increase considerably in length on the sixth day, when the hind end of the scapula nearly reaches the anterior end of the ilium, and the lower end of the coracoid is very close to the sternum. The elements are still continuous in the glenoid region.

About the end of the sixth day independent centers of chondrification appear in the scapula and coracoid respectively near their union; these spread distally and fuse centrally, so that on the seventh day the coraco-scapula is a single bent cartilaginous element. In the angle of the bend, however (the future coraco-scapular joint), the cartilage is in a less advanced condition than in the bodies of the two elements. The clavicular process, on the other hand, never shows any trace of cartilage formation, either in early or more advanced stages, but ossifies directly from the membrane. It separates from the other elements of the pectoral girdle, though not completely, on the eighth day.

The scapula and coracoid ossify in a perichondral fashion, beginning on the twelfth day, from independent centers, which approach but never fuse, leaving a permanent cartilaginous connection (Fig. 242). The clavicle, on the other hand, is a purely membrane bone; bony deposit begins in the axis of the membranous rods on the eighth or ninth days, soon forming fretted rods that approach in the mid-ventral line by enlarged ends, which fuse directly without the intervention of any median element about the twelfth to thirteenth day, thus forming the furcula or wish-bone (Fig. 246).

The nature of the clavicle in birds has been the subject of a sharp difference of opinion. On the one hand, it has been maintained that it is double in its origin, consisting of a cartilaginous axis (procoracoid) on which a true membrane bone is secondarily grafted (Gegenbaur, Fürbringer, Parker, and others); on the other hand, all cartilaginous preformation in its origin has been denied by Rathke, Goette, and Kulczycki. After careful examination of series of sections in all critical stages, and of preparations made by the potash method, I feel certain that in the chick at least there is no cartilaginous preformation. It is still possible (indeed probable on the basis of comparative anatomy) that the theory of its double origin is correct phylogenetically; but it is certain that the

procoracoid component does not develop beyond the membranous stage in the chick. It is interesting that the clavicle is the first center of ossification in the body, though perichondral ossification of some of the long bones begins almost as soon.

The Wing-bones. The primordium of the wing-bones is found in the axial mesenchyme of the wing-bud, which is originally continuous with the primordium of the pectoral girdle, and shows no trace of the future elements of the skeleton. The differentiation of the elements accompanies in general the external differentiation of the wing illustrated in Figs. 121 to 124, Chapter VII. The humerus, radius, and ulna arise by membranous differentiation in the mesenchyme in substantially their definitive relations; they pass through a complete cartilaginous stage and



FIG. 246. — Photograph of the pectoral girdle of a chick embryo of 274 hours; prepared by the potash method. (Preparation and photograph by Roy L. Moodie.)

1, Coracoid. 2, Clavicle. 3, Scapula.
4, Humerus.

then ossify in a perichondral fashion (see Fig. 242). In the carpus, metacarpus, and phalanges, more elements are formed in the membrane and cartilage than persist in the adult. Elimination as well as fusion takes place. These parts will therefore require separate description.

As birds have descended from pentadactyl ancestors with subsequent reduction of carpus, metacarpus, and phalanges, it is naturally of considerable interest to learn how much of the ancestral history is preserved in the embryology. The hand is represented in the embryo of six days by the spatulate extremity of the fore-limb, which includes the elements of carpus, metacarpus, and phalanges. From this expansion five digital rays grow out simultaneously, the first and fifth being relatively

small; the second, third, and fourth represent the persistent digits. In each ray is a membranous skeletal element, which, however, soon disappears in the first and fifth. Thus there are distinct indications of a pentadactyl stage in the development of the bird's wing.

In the definitive skeleton there are but two carpal bones, viz., a radiale at the extremity of the radius, and an ulnare at the extremity of the ulna. In the embryo there is evidence of seven transitory pieces in the carpus arranged in two rows, proximal and distal (Fig. 247). In the proximal row only two car-

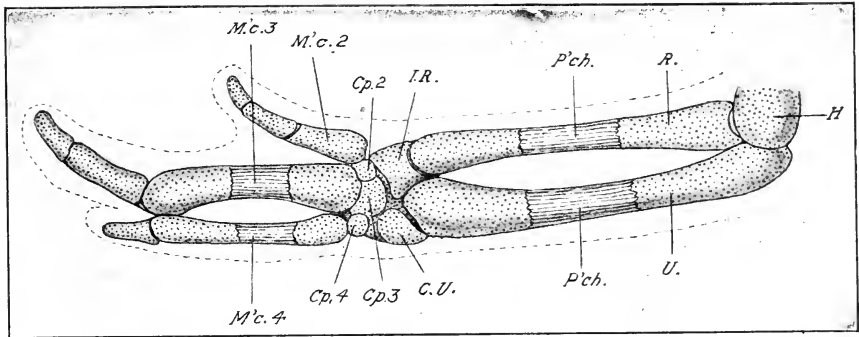


FIG. 247. — Skeleton of the wing of a chick embryo of 8 days. (After W. K. Parker.)

Cp. 2, 3, and 4, Second, third, and fourth carpalia. C. U., Centralo-ulnare. H., Humerus. I. R., Intermedio-radiale. M'c. 2, 3, 4, Second, third, and fourth metacarpalia. P'ch., Perichondral bone R., Radius. U., Ulna.

tilages appear, viz., the radiale and ulnare; but in earlier stages each appears to be derived from two centers: the radiale from a radiale s.s. and an intermedium, the ulnare from an ulnare s.s. and a centrale. Evidence of such double origin of each is found also in the cartilaginous condition (*v.* Parker, 1888). Four elements in all enter into the composition of this proximal row. In the distal row there are three distinct elements corresponding to the three persistent digits, and representing, therefore, carpalia II, III, and IV. These subsequently fuse with one another, and with the heads of the metacarpals to produce the carpo-metacarpus.

On the seventh day the metacarpus is represented by three cartilages corresponding to the three persistent digits, viz., II,

III, IV. Metacarpal II is only about one third the length of III. Metacarpal IV is much more slender than III, and is bowed out in the middle, meeting III at both ends. The elements are at first distinct, but II and III fuse at their proximal ends in the process of ossification. Cartilaginous rudiments of metacarpals I and V have also been found by Parker, Rosenberg, and Leighton.

As to the phalanges, Parker finds two cartilages in II, three in III, and two in IV on the seventh day; but already on the eighth day the distal phalanges of III and IV have fused with the next proximal one.

As regards the homology of the digits of the wing, the author has adopted the views of Owen, Mehnert, Norsa, and Leighton, that they represent numbers II, III, and IV, which seem to be better supported by the embryological evidence than the view of Meckel, Gegenbauer, Parker, and others, that they represent I, II, and III.

The Skeleton of the Hind-limb. The skeleton of the hind-limb and pelvic girdle develops from a continuous mass of mesenchyme situated at the base of the leg-bud. The original center of the mass represents the acetabular region; it grows out in four processes: (1) a lateral projection in the axis of the leg-bud, the primordium of the leg-skeleton proper, (2) a dorsal process, the primordium of the ilium; and two diverging ventral processes, one in front of the acetabulum (3) the pubis, and one behind (4) the ischium. In the membranous condition the elements are continuous. The definitive elements develop either as separate cartilage centers in the common mass (usually), or as separate centers of ossification in a common cartilaginous mass (ilium and ischium).

The Pelvic Girdle. The primitive relations of the elements of the pelvic girdle in *Larus ridibundus* is shown in Fig. 248, which represents a section in the sagittal plane of the body, and thus does not necessarily show the full extent of any of the cartilaginous elements, but only their general relations. The head of the femur is seen in the acetabulum, the broad plate of the ilium above and the pubis and ischium as cartilaginous rods of almost equal width below, the pubis in front and the ischium behind the acetabulum. In this stage the pelvic girdle, in this and many other species of birds, consists of three separate elements on each side in essentially reptilian relations.

In the chick at a corresponding age the ilium is much more extensive, and the ischium is united with it by cartilage; the pubis, however, has only a membranous connection with the ilium (*contra* Johnson). In the course of development the distal ends of the ischium and pubis rotate backwards until the two elements come to lie substantially parallel to the ilium (Figs. 242 and 249). The displacement of the ischium and pubis may

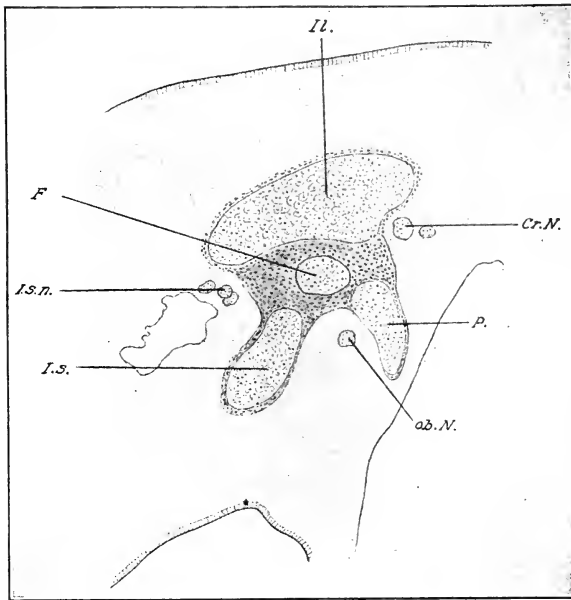


FIG. 248. — Sagittal section of the right half of the body of *Larus ridibundus*, to show the composition of the pelvic girdle; x 35. Length of the leg-bud of the embryo, 0.4 mm. (After Mehnert.)

F., Femur. cr. N., Crural nerve. Il., Ilium. I. s., Ischium. Is. N., Ischial nerve. ob. N., Obturator nerve. P., Pubis.

be associated with the upright gait of birds; it is fully established on the eighth day in the chick. The mode of ossification, which is perichondral, is shown in Fig. 249.

Later, the ilium obtains a very extensive pre- and post-acetabular union with the vertebræ. I have found no evidence in a complete series of preparations (potash) of attachment by ribs arising as independent ossifications. The ischium also fuses

with the ventral posterior border of the ilium, and the pubis, except at its anterior and posterior ends, with the free border of the ischium.

The spina iliaca, a pre-acetabular, bony process of the ilium,

requires special mention inasmuch as it has been interpreted (by Marsh) as the true pubis of birds, and the element ordinarily named the pubis as homologous to the post-pubis of some reptiles. There is no evidence for this in the development. The spina iliaca develops as a cartilaginous outgrowth of the ilium and ossifies from the latter, not from an independent center (Mehnert).

The Leg-skeleton. The skeleton of the leg develops from the axial mesenchyme, which is at first continuous with the primordium of the pelvic girdle. In the process of chondrification it segments into a larger number of elements than found in the adult, some of which are suppressed and others fuse together. The digits grow out from the palate-like expansion of the primitive limb in the same fashion as in the wing. In general the

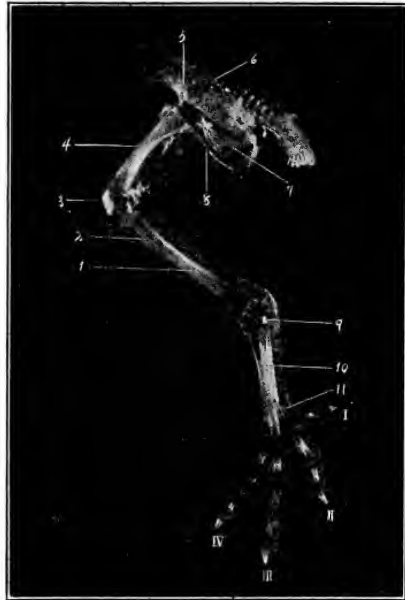


FIG. 249. — Photograph of the skeleton of the leg of a chick embryo of 15 days' incubation. Prepared by the potash method. (Preparation and photograph by Roy L. Moodie.)

1, Tibia. 2, Fibula. 3, Patella. 4, Femur. 5, Ilium. 6, Pleurocentra of sacral vertebrae. 7, Ischium. 8, Pubis. 9, Tarsal ossification. 10, Second, third, and fourth metatarsals. 11, First metatarsal. I, II, III, IV, First, second, third, and fourth digits.

separate elements arise in the proximo-distal order (Figs. 242 and 249).

The femur requires no special description; ossification begins on the ninth day.

The primordium of the fibula is from the first more slender than that of the tibia, though relatively far larger than the adult

fibula. The fibular cartilage extends the entire length of the crus, but ossification is confined largely to its proximal end; on the fourteenth day its lower half is represented by a thread-like filament of bone.

No separate tarsal elements are found in the adult; but in the embryo there are at least three cartilages, viz., a fibulare, tibiale and a large distal element opposite the three main metatarsals. In the course of development, the two proximal elements fuse with one another, and with the distal end of the tibia. The distal element fuses with the three main metatarsals, first with the second, then with the fourth, and lastly with the third (Johnson).

Five digits are formed in the membranous stage of the skeleton. In the case of the fifth digit, only a small nodule of cartilage (fifth metatarsal) develops and soon disappears. The second, third, and fourth are the chief digits; the first is relatively small. Metatarsals 2, 3, and 4 are long and ossify separately in a perichondral fashion. They become applied near their middle and fuse with one another and with the distal tarsal element to form the tarso-metatarsus of the adult (Fig. 250). The first metatarsal is short, lying on the preaxial side of the distal end of the others (Fig. 249); it ossifies after the first phalanx. The number of phalanges is 2, 3, 4, and 5 in the first, second, third, and fourth digits respectively (Fig. 249).

The patella is clearly seen in potash preparations of thirteen-day chicks. At the same time there is a distinct, though minute, separate center of ossification in the tarsal region (Fig. 249).

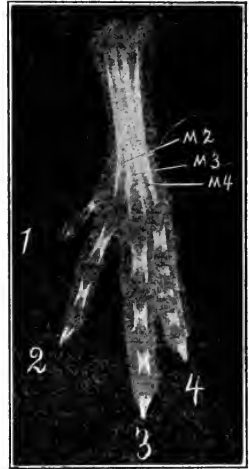


FIG. 250. — Photograph of the skeleton of the foot of a chick embryo of 15 days' incubation. (Preparation and photograph by Roy L. Moodie.)

1, 2, 3, 4, First, second, third, and fourth digits. M 2, M 3, M 4, Second, third, and fourth metatarsals.

APPENDIX

GENERAL LITERATURE

- v. BAER, C. E., Ueber Entwicklungsgeschichte der Tiere. Beobachtung und Reflexion. Königsberg, 1828 u. 1837.
id., 2. Teil — Herausgegeben von Stieda. Königsberg, 1888.
- DUVAL, MATHIAS, Atlas d'embryologie. (With 40 plates.) Paris, 1889.
- FOSTER, M., and BALFOUR, F. M., The Elements of Embryology. Second Edition revised. London, 1883.
- GADOW, HANS, Die Vögel, Bronn's Klassen und Ordnungen des Thier-Reichs, Bd. VI, Abth. 4, 1898.
- Handbuch der vergleichenden und experimentellen Entwicklungslehre der Wirbeltiere. Edited by Dr. Oskar Hertwig and written by numerous collaborators. Jena, 1901-1907.
- HIS, W., Untersuchungen über die erste Anlage des Wirbeltierleibes. Die erste Entwicklung des Hühnchens im Ei. Leipzig, 1868.
- KEIBEL, F., and ABRAHAM, K., Normaltafeln zur Entwicklungsgeschichte des Huhnes (*Gallus domesticus*). Jena, 1900.
- v. KÖLLIKER, A., Entwicklungsgeschichte des Menschen und der höheren Thiere. Zweite Aufl. Leipzig, 1879.
- MARSHALL, A. M., Vertebrate Embryology. A Text-book for Students and Practitioners. (Ch. IV, The Development of the Chick.) New York and London, 1893.
- MINOT, C. S., Laboratory Text-book of Embryology. Philadelphia, 1903.
- PANDER, Beiträge zur Entwicklungsgeschichte des Hühnchens im Ei. Würzburg, 1817.
- PRÉVOST ET DUMAS, Mémoire sur le développement du poulet dans l'œuf. Ann. Sc. Nat., Vol. XII, 1827.
- PREYER, W., Specielle Physiologie des Embryo. Leipzig, 1885.
- REMAK, R., Untersuchungen über die Entwicklung der Wirbelthiere. Berlin, 1855.

LITERATURE — CHAPTER I

- BARTELMEZ, GEORGE W., 1912, The Bilaterality of the Pigeon's Egg. A Study in Egg Organization from the First Growth Period of the Oocyte to the Beginning of Cleavage. Journ. of Morph. Vol. 23., pp. 269-328.
- COSTE, M., Histoire générale et particulière du développement des corps organisés, T. I. (Formation of Egg in Oviduct, see Chap. VI). Paris, 1847-1849.
- D'HOLLANDER, F., Recherches sur l'oogenèse et sur la structure et la signification du noyau vitellin de Balbiani chez les oiseaux. Archiv. d'anat. mier., T. VII, 1905.
- GEGENBAUR, C., Ueber den Bau und die Entwicklung der Wirbeltiereier mit partieller Dottertheilung. Archiv. Anat. u. Phys., 1861.

- GLASER, OTTO, 1913, On the Origin of Double-yolked Eggs. *Biol. Bull.*, Vol. 24, pp. 175-186.
- HOLL, M., Ueber die Reifung der Eizelle des Huhnes. *Sitzungsber. Akad. Wiss. Wien, math.-nat. Kl.*, Bd. XCIX, Abth. III, 1890.
- V. NATHUSIUS, W., Zur Bildung der Eihüllen. *Zool. Anz.* Bd. XIX, 1896.
Die Entwicklung von Schale und Schalenhaut des Hühnereies im Ovidukt. *Zeitschr. wiss. Zool.*, Bd. LV, 1893.
- PARKER, G. H., Double Hen's Eggs. *American Naturalist*, Vol. XL, 1906.
- PEARL, RAYMOND and CURTIS, M. R., 1912, Studies on the Physiology of Reproduction in the Domestic Fowl. V. Data Regarding the Physiology of the Oviduct. *Journ. of Exp. Zoology.* Vol. 12, pp. 99-132.
- RIDDLE, OSCAR, 1911, On the Formation, Significance and Chemistry of the White and Yellow Yolk of Ova. *Journ. of Morph.*, Vol. 22, pp. 455-490.
- SONNENBRODT, 1908, Die Wachstumsperiode der Oocyte des Huhns. *Arch. f. mikr. Anat. w. Entw.* Bd. 72, pp. 415-480.
- WALDEYER, W., Die Geschlechtszellen. *Handbuch der vergl. und exper. Entwicklungslehre der Wirbeltiere.* Bd. I, T. 1, 1901.

LITERATURE — CHAPTER II

- ANDREWS, E. A., Some Intercellular Connections in an Egg of a Fowl. *The Johns Hopkins University Circular.* Notes from the Biological Laboratory, March, 1907.
- BARFURTH, D., Versuche über die parthenogenetische Furchung des Hühnereies. *Arch. Entw.-mech.*, Bd. 2, 1895.
- BLOUNT, MARY, The Early Development of the Pigeon's Egg with Especial Reference to the Supernumerary Sperm-nuclei, the Periblast and the Germ-wall. *Biol. Bull.*, Vol. XIII, 1907.
- DUVAL, M., De la formation du blastoderm dans l'œuf d'oiseau. *Ann. Sc. Nat. Zool.*, Sér. 6, T. XVIII, 1884.
- GASSER, E., Der Parablast und der Keimwall der Vogelkeimscheibe. *Sitzungsber. der Ges. zur Beförd. d. ges. Naturwiss. zu Marburg*, 1883.
Eierstocksei und Eileiteri des Vogels. *Ibid.*, 1884.
- GÖTTE, A., Beiträge zur Entwicklungsgeschichte der Wirbeltiere, II. Die Bildung der Keimblätter und des Blutes im Hühnerei. *Archiv. mikr. Anat.*, Bd. X, 1874.
- HARPER, E. H., The Fertilization and Early Development of the Pigeon's Egg. *Am. Jour. Anat.*, Vol. III, 1904.
- KIONKA, H., Die Furchung des Hühnereies. *Anat. Hefte*, Bd. III, 1894.
- LAU, H., Die parthenogenetische Furchung des Hühnereies. *Inaug. Dissert.* Jurjew — Dorpat., 1894.
- OELLACHER, J., Untersuchungen über die Furchung und Blätterbildung im Hühnerei. *Studien über experimentelle Pathologie von Stricker*, Bd I, 1869.
- OELLACHER, J., Die Veränderungen des unbefruchteten Keimes des Hühnereies im Eileiter und bei Bebrütungsversuchen. *Zeitschr. wiss. Zool.*, Bd. XXII, 1872.

- PATTERSON, J. THOMAS, Gastrulation in the Pigeon's Egg; a Morphological and Experimental Study. The Journ. of Morph., Vol. 29, pp. 65-123, 1909.
- PATTERSON, J. THOMAS, Studies on the Early Development of the Hen's Egg. 1. History of the Early Cleavage and of the Accessory Cleavage. The Journ. of Morph., Vol. 21, pp. 101-134, 1910.
- RAUBER, A., Ueber die Stellung des Hühnehens im Entwicklungsplan. Leipzig, 1876.
- SOBOTTA, J., Die Reifung und Befruchtung des Wirbeltierereies. Ergeb. Anat. u. Entwicklungsgesch., Bd. V, 1895.

LITERATURE — CHAPTER III

- EDWARDS, C. L., The Physiological Zero and the Index of Development for the Egg of the Domestic Fowl, *Gallus Domesticus*. Am. Journ. Physiol., Vol. VI, 1902.
- EYCLESHYMER, A. C., Some Observations and Experiments on the Natural and Artificial Incubation of the Egg of the Common Fowl. Biol. Bull., Vol. XII, 1907.
- FÉRÉ, CH., Note sur l'influence de la température sur l'incubation de l'œuf de poule. Journ. de l'anatomie et de la physiologie, Paris, T. XXX, 1894.

LITERATURE — CHAPTERS IV AND V

- ASSHETON, R., An Experimental Examination into the Growth of the Blastoderm of the Chick. Proc. Roy. Soc., London, Vol. LX, 1896.
- BALFOUR, F. M., The Development and Growth of the Layers of the Blastoderm. Quar. Jour. Micr. Sc., Vol. XIII, 1873.
- On the Disappearance of the Primitive Groove in the Embryo Chick. *Ibid.*
- BALFOUR, F. M., and DEIGHTON, A Renewed Study of the Germinal Layers of the Chick. Quar. Jour. Micr. Sc., Vol. XXII, 1882.
- DISSE, J., Die Entwicklung des mittleren Keimblattes im Hühnerrei. Arch. mikr. Anat., Bd. XV, 1878.
- DURSY, EMIL, Der Primitivstreif des Hühnehens. Lehr, 1866.
- DUVAL, MATHIAS, Etudes sur la ligne primitive de l'embryon du poulet. Ann. Sc. Nat. Zool., Sér. 6, T. VII, 1878.
- De la formation du blastoderm dans l'œuf d'oiseau. Ann. Sc. Nat. Zool., Sér. 6, T. XVIII. Paris, 1884.
- EVANS, HERBERT M., On the Development of the Aorta, Cardinal and Umbilical Veins and other Blood-vessels of Vertebrate Embryos from Capillaries. Anatomical Record., Vol. 3, pp. 498-518, 1909.
- FOL, H., Recherches sur le développement des protovertèbres chez l'embryon du poulet. Arch. sc. phys. et nat. Genève, T. II, 1884.
- GASSER, Ueber den Primitivstreifen bei Vogelembryonen. Sitz.-Ber. d. Ges. z. Beförd. d. ges. Naturw. z. Marburg, 1877.
- Der Primitivstreif bei Vogelembryonen (Huhn w. Gans). Schriften d. Ges. z. Beförd. d. ges. Naturw. z. Marburg, Bd. XI, Suppl. Heft 1, 1879.

- GASSER, Beiträge zur Kenntnis der Vogelkeimscheibe. Arch. Anat. u. Entw., 1882.
- Der Parablast und der Keimwall der Vogelkeimscheibe. Sitz.-Ber. d. Ges. z. Beförd. d. ges. Naturw. z. Marburg, 1883.
- GOETTE, A., Beiträge zur Entwicklungsgeschichte der Wirbeltiere. II. Die Bildung der Keimblätter und des Blutes im Hühnerei. Arch. mikr. Anat., Bd. X, 1874.
- HERTWIG, O., Die Lehre von den Keimblättern. Handbuch der vergl. und exper. Entwicklungslehre der Wirbeltiere. Vol. I. Jena, 1903.
- HIS, W., Der Keimwall des Hühnereies und die Entstehung der parablastischen Zellen. Arch. Anat. und Entw., Bd. I, 1876.
- Neue Untersuchung über die Bildung des Hühnerembryo. Arch. Anat. und Entw., 1877.
- Lecithoblast und Angioblast der Wirbelthiere. Histogenetische Studien. Abh. der math.-phys. Klasse der Königl. Sächs. Ges. der Wissenschaften, Bd. XXVI. Leipzig, 1900.
- Die Bildung der Somatopleura und der Gefäße beim Hühnchen. Anat. Anz., Bd. XXI, 1902.
- HUBBARD, M. E., Some Experiments on the Order of Succession of the Somites of the Chick. Am. Nat., Vol. 42, pp. 466–471, 1908.
- JANOSIK, J., Beitrag zur Kenntnis des Keimwulstes bei Vögeln. Sitz.-Ber. Akad. Wiss. Wien, math.-phys. Kl., Bd. LXXXIV, 1882.
- KOLLER, C., Beiträge zur Kenntnis des Hühnerkeimes im Beginne der Bebrütung. Sitzungsber. Wien. Akad. Wiss., math.-nat. Kl., 1879.
- Untersuchungen über die Blätterbildung im Hühnerkeim. Arch. mikr. Anat., Bd. XX, 1881.
- v. KÖLLIKER, A., Zur Entwicklung der Keimblätter im Hühnerei. Verh. phys.-med. Ges. Würzburg, Bd. VIII, 1875.
- KOPSCH, FR., Ueber die Bedeutung des Primitivstreifens beim Hühnerembryo, und über die ihm homologen Theile bei den Embryonen der niederen Wirbeltiere. Intern. Monatschr. f. Anat. u. Phys., Bd. XIX, 1902.
- MITROPHANOW, P. J., Teratogene Studien. II. Experimentellen Beobachtungen über die erste Anlage der Primitivrinne der Vögel. Arch. Entw.-mech., Bd. VI, 1898.
- Beobachtungen über die erste Entwicklung der Vögel. Anat. Hefte, Bd. XII, 1899.
- NOWACK, K., Neue Untersuchungen über die Bildung der beiden primären Keimblätter und die Entstehung des Primitivstreifen beim Hühnerembryo. Inaug. Diss. Berlin, 1902.
- PATTERSON, J. THOS., The Order of Appearance of the Anterior Somites in the Chick. Biol. Bull., Vol. XIII, 1907.
- PATTERSON, J. T. An experimental Study on the Development of the Vascular Area of the Chick Blastoderm. Biol. Bull. XVI, pp. 83–90, 1909.
- PEEBLES, FLORENCE. Some Experiments on the Primitive Streak of the Chick. Arch. Entw.-mech., Bd. VII, 1898.
- A Preliminary Note on the Position of the Primitive Streak and its Relation to the Embryo of the Chick. Biol. Bull., Vol. IV, 1903.

- PEEBLES, FLORENCE, The Location of the Chick Embryo upon the Blastoderm. *Journ. Exp. Zool.*, Vol. I, 1904.
- PLATT, J. B., Studies on the Primitive Axial Segmentation of the Chick. *Bull. Mus. Comp. Zoöl. Harv.*, Vol. 17, 1889.
- RABL, C., Theorie des Mesoderms. *Morph. Jahrb.*, Bde. XV und XIX, 1889 and 1892.
- RAUBER, A., Primitivstreifen und Neurula der Wirbelthiere, in normaler und pathologischer Beziehung. Leipzig, 1877.
- Ueber die embryonale Anlage des Hühnchens. *Centralb. d. med. Wiss.*, Bd. XII, 1875.
- Ueber die erste Entwicklung der Vögel und die Bedeutung der Primitivrinne. *Sitz.-ber. d. naturf. Ges. zu Leipzig*, 1876
- REX, HUGO, Ueber das Mesoderm des Vorderkopfes der Ente. *Archiv. mikr. Anat.*, Bd. L., 1897.
- RÜCKERT, J., Entwicklung der extra-embryonalen Gefässe der Vögel. *Handbuch der vergl. w. exp. Entw.-lehre der Wirbelthiere*, Bd. I, T. 1, 1906.
- Ueber die Abstammung der bluthaltigen Gefässanlagen beim Huhn, und über die Entstehung des Randsinus beim Huhn und bei Torpedo. *Sitzungsber. der Bay. Akad. Wiss.*, 1903.
- SCHAUINSLAND, H., Beiträge zur Biologie und Entwicklung der Hatteria nebst Bemerkungen über die Entwicklung der Sauropsiden. *Anat. Anz.* XV, 1899.
- VIALLETON, Développement des aortes chez l'embryon de poulet. *Journ. de l'Énat.* T. XXVIII, 1892. See also *Anat. Anz.*, Bd. VII, 1892.
- VIRCHOW, H., Der Dottersack des Huhns. *Internat. Beiträge zur wiss. Med.*, Bd. I, 1891.
- WALDEYER, W., Bemerkungen über die Keimblätter und den Primitivstreifen bei der Entwicklung des Hühnerembryo. *Zeitschr. rationeller Medicin*, 1869.
- WHITMAN, C. O., A Rare Form of the Blastoderm of the Chick and its Bearing on the Question of the Formation of the Vertebrate Embryo. *Quar. Journ. Micr. Sc.*, Vol. XXIII, 1883.
- WILLIAMS, LEONARD W. The Somites of the Chick. *Am. Journ. of Anat.*, Vol. 11, pp. 55-100, 1910.

Literature to Chapter VI included in following chapters.

LITERATURE — CHAPTER VII

- CHARBONNEL-SALLE et PHISALIX, De l'évolution postembryonnaire du sac vitellin chez les oiseaux. *C. R. Acad. Sc.*, Paris, 1886.
- DARESTE, C., Sur l'absence totale de l'amnios dans les embryons de poule. *C. R. Acad. Sc.*, Paris, T. LXXXVIII, 1879.
- DUVAL, M., Etudes histologiques et morphologiques sur les annexes des embryons d'oiseau. *Journ. de l'anat. et de la phys.*, T. XX, 1884.
- Etude sur l'origine de l'allantoïde chez le poulet. *Rev. sc. nat.*, Paris, 1877.

- DUVAL, M., Sur une organe placentaire chez l'embryon des oiseaux. C. R. Acad. Sc., Paris, 1884.
- FROMANN, C., Ueber die Struktur der Dotterhaut des Huhnes. Sitz.-ber. Jen. Ges. Medizin u. Naturw., 1879.
- FÜLLEBORN, F., Beiträge zur Entwicklung der Allantois der Vögel. Diss., Berlin, 1894.
- GASSER, E., Beiträge zur Entwicklungsgeschichte der Allantois, der Müller'schen Gänge und des Afters. Frankfurt a. M., 1874.
- GÖTTE, A., Beiträge zur Entwicklungsgeschichte des Darmkanals im Hühnchen. Tübingen, 1867.
- HIROTA, S., On the Sero-amniotic Connection and the Foetal Membranes in the Chick. Journ. Coll. Sc. Imp. Univ. Japan, Vol. VI, Part IV, 1894.
- LILLIE, FRANK R., Experimental Studies on the Development of the Organs in the Embryo of the Fowl (*Gallus domesticus*): 1. Experiments on the Amnion and the Production of Anamniote Embryos of the Chick. Biol. Bull., Vol. V, 1903. 2. The Development of Defective Embryos and the Power of Regeneration. Biol. Bull., Vol. VII, 1904.
- MERTENS, H., Beiträge zur Kenntniss der Fötushüllen im Vogelei. Meckels Archiv, 1830.
- MITROPHANOW, P. J., Note sur la structure et la formation de l'enveloppe du jaune de l'œuf de la poule. Bibliogr. Anat., Paris, 1898.
- POPOFF, DEMETRIUS, Die Dottersackgefäße des Huhnes. Wiesbaden, 1894.
- POTT, R., and PREYER, W., Ueber den Gaswechsel und die chemischen Veränderungen des Hühnereies während der Bebrütung. Archiv. ges. Phys., 1882.
- PREYER, W., Specielle Physiologie des Embryo. Leipzig, 1885.
- RAVN, E., Ueber die mesodermfreie Stelle in der Keimscheibe des Hühnerembryo. Arch. Anat. u. Entw., 1886.
- Ueber den Allantoisstiel des Hühnerembryo. Verh. Anat. Ges., 1898.
- SCHAUMSLAND, H., Die Entwicklung der Eihäute der Reptilien und der Vögel. Handbuch der vergl. und exp. Entw.-lehre der Wirbeltiere. Bd. I, T. 2, 1902.
- Beiträge zur Entwicklungsgeschichte der Wirbeltiere. II. Beiträge zur Entwicklungsgeschichte der Eihäute der Sauropsiden. Bibliotheca Zoologica, 1903.
- SCHENK, S. L., Beiträge zur Lehre vom Amnion. Archiv. mikr. Anat., Bd. VII, 1871.
- Ueber die Aufnahme des Nahrungsdotters während des Embryonal-lebens. Sitz.-ber. Akad. Wiss. Wien, math.-nat. Kl., 1897.
- SHORE, T. W., and PICKERING, J. W., The Proamnion and Amnion in the Chick. Journ. of Anat. and Phys., Vol. XXIV, 1889.
- SOBOLEFF, Die Verletzung des Amnions während der Bebrütung. Mittheil, embryolog. Inst., Wien, 1883.
- STRAHL, H., Eihäute und Placenta der Sauropsiden. Ergeb. Anat. u. Entw.-gesch., Bd. I, 1891.
- STUART, T. P. A., A Mode of Demonstrating the Developing Membranes in the Chick. Journ. Anat. and Phys., London, Vol. XXV, 1899.
- VIRCHOW, H., Beobachtungen am Hühnerei; über das dritte Keimblatt im Bereiche des Dottersackes. Virchow's Arch., Bd. LXII, 1874.

- VIRCHOW, H., Ueber das Epithel des Dottersackes im Hühnerei. Diss., Berlin, 1875.
- Der Dottersack des Huhnes. Internat. Beiträge zur wissenschaft. Medizin, Bd. I, 1891.
- Das Dotterorgan der Wirbeltiere. Zeitschr. wiss. Zool., Bd. LIII, Suppl., 1892.
- Das Dotterorgan der Wirbelthiere. Arch. mikr. Anat., Bd. XI, 1892.
- Dottersyncytium, Keimhautrand und Beziehungen zur Konereszenzlehre. Ergeb. Anat. u. Entw., Bd. VI, 1897.
- Ueber Entwicklungsvorgänge, welche sich in den letzten Bruttagen am Hühnerei abspielen. Anat. Anz., Bd. IV, Berlin, 1889.
- VULPIAN, La physiologie de l'amnios et de l'allantoïde chez les oiseaux. Mém. soc. biol., Paris, 1858.
- WELDON, W. F. R., Prof. de Vries on the Origin of Species. (Includes experiments on amnion.) Biometrika, Vol. I, 1902.

LITERATURE — CHAPTER VIII

- BEARD, J., Morphological Studies, II. The Development of the Peripheral Nervous System of Vertebrates. Pt. I. Elasmobranchs and Aves. Quar. Journ. Micr. Sc., Vol. XXIX, 1888.
- BERANECK, E., Etudes sur les replis médullaires du poulet. Recueil Zool. Suisse, Vol. IV, 1887.
- BETHE, ALBRECHT, Allgemeine Anatomie und Physiologie des Nervensystems. Leipzig, 1903.
- BRANDIS, F., Untersuchungen über das Gehirn der Vögel. Arch. mikr. Anat., Bd. XLI, 1893; Bd. XLIII, 1894; Bd. XLIV, 1895.
- BURROWS, MONTROSE T., The Growth of Tissues of the Chick Embryo Outside the Animal Body, with Special Reference to the Nervous System. Journ. Exp. Zoology, Vol. 10, pp. 63-83, 1911.
- CAJAL, S. R. y., Sur l'origine et les ramifications des fibres nerveuses de la moelle embryonnaire. Anat. Anz., Bd. V, 1890.
- A quelle époque apparaissent les expansions des cellules nerveuses de la moelle épinière du poulet. Anat. Anz., Bd. V, 1890.
- FRORIEP, A., Ueber Anlagen von Sinnesorganen am Facialis, Glossopharyngeus und Vagus, über die genetische Stellung des Vagus zum Hypoglossus, und über die Herkunft der Zungenmuskulatur. Arch. Anat. u. Entw., 1885.
- CARPENTER, FREDERICK WALTON, The Development of the Oculomotor Nerve, the Ciliary Ganglion, and the Abducent Nerve in the Chick. Bull. Mus. Comp. Zool. Harv. Vol. XLVIII, 1906.
- DISSE, J., Die erste Entwicklung des Riechnerven. Anat. Hefte, Abth. I, Bd. IX, 1897.
- GOLOVINE, E., Sur le développement du système ganglionnaire chez le poulet. Anat. Anz., Bd. V, 1890.
- GORONOWITSCH, N., Die axiale und die laterale (A. Goette) Kopfmeterie der Vögelembryonen. Anat. Anz., Bd. VII, 1892.
- Untersuchungen über die Entwicklung der Sogenannten "Ganglienleisten" im Kopfe der Vögelembryonen. Morph. Jahrb., Bd. XX, 1893.

- HEINRICH, GEORG, Untersuchungen über die Anlage des Grosshirns beim Hühnchen. Sitz.-ber. d. Ges. f. Morph. u. Phys. in München, Bd. XII, 1897.
- HILL, CHARLES, Developmental History of the Primary Segments of the Vertebrate Head. Zool. Jahrbücher, Abth. Anat. Bd. XIII, 1900.
- HIS, W., Die Neuroblasten und deren Entstehung im embryonalen Mark. Abh. math.-physik. Klasse, Königl. Sächs. Ges. Wiss., Bd. XV, 1889.
Histogenese und Zusammenhang der Nerven-elemente. Arch. Anat. u. Entw., Suppl., 1890.
Ueber das frontale Ende des Gehirnrohres. Arch. Anat. u. Entw., 1893.
Ueber das frontale Ende und über die natürliche Eintheilung des Gehirnrohres. Verh. anat. Ges., Bd. VII, 1893.
- HIS, W. (JR.), Ueber die Entwicklung des Bauchsympathicus beim Hühnchen und Menschen. Arch. Anat. u. Entw., Suppl., 1897.
- v. KÖLLIKER, Ueber die erste Entwicklung der Nervi olfactorii. Sitz.-ber. phys. med. Ges. zu Würzburg, 1890.
- v. KUPFFER, K., Die Morphogenie des Centralnervensystems. Handbuch der vergl. und exp. Entwicklungslehre der Wirbeltiere, Kap. VIII, II³, 1905.
- LEWIS, M. R. and LEWIS, W. H., The Cultivation of Tissues from Chick Embryos in Solutions of NaCl, CaCl₂, KCl and NaHCO₃. Anatomical Record, Vol. 5, pp. 277-293. See also Anat. Rec., Vol. 6, nos. 1 and 5, 1911.
- MARSHALL, A. M., The Development of the Cranial Nerves in the Chick. Quar. Journ. Micr. Sc., Vol. XVIII, 1878.
The Segmental Value of the Cranial Nerves. Journ. Anat. and Physiol., Vol. XVI, 1882.
- v. MIHALCOVICS, V., Entwicklungsgeschichte des Gehirns. Leipzig, 1877.
- ONODI, A. D., Ueber die Entwicklung des sympathischen Nervensystems. Arch. mikr. Anat., Bd. XXVI, 1886.
- RABL, C., Ueber die Metamerie des Wirbelthierkopfes. Verh. anat. Ges., VI, 1892.
- RUBASCHKIN, W., Ueber die Beziehungen des Nervus trigeminus zur Riechschleimhaut. Anat. Anz., Bd. XXII, 1903.
- WEBER, A., Contribution à l'étude de la métamerism du cerveau antérieur chez quelques oiseaux. Arch. d'anat. microsc., Paris, T. III, 1900.
- VAN WIJHE, J. W., Ueber Somiten und Nerven im Kopfe von Vögel- und Reptilien-embryonen. Zool. Anz. Bd. IX, 1886.
Ueber die Kopfsegmente und das Geruchsorgan der Wirbelthiere. Zool. Anz., Bd. IX, 1886.

LITERATURE — CHAPTER IX

ORGANS OF SPECIAL SENSE

A. *The Eye*

- ADDARIO, C., Sulla struttura del vitreo embryonale e de' neonati, sulla matrice del vitreo e sull' origine della zonula. Ann. Ottalmol., Anno 36, 1901-1902.

- ADDARIO, C., Ueber die Matrix des Glaskörpers im menschlichen und thierischen Auge. Vorläuf. Mitth. Anat. Anz., Bd. XXI, 1902.
- AGABABOW, Untersuchungen über die Natur der Zonula ciliaris. Arch. mikr. Anat., Bd. L, 1897.
- ANGELUCCI, A., Ueber Entwicklung und Bau des vorderen Uvealtractus der Vertebraten. Arch. mikr. Anat., Bd. XIX, 1881.
- ARNOLD, J., Beiträge zur Entwicklungsgeschichte des Auges. Heidelberg, 1874.
- ASSHETON, R., On the Development of the Optic Nerve of Vertebrates, and the Choroidal Fissure of Embryonic Life. Quar. Journ. Micr. Sc., Vol. XXXIV, 1892.
- BERND, ADOLPH HUGO, Die Entwicklung des Pecten im Auge des Hühnchens aus den Blättern der Augenblase. Bonn, 1905.
- CAJAL, S. R. y., Sur la morphologie et les connexions des éléments de la rétine des oiseaux. Anat. Anz. Bd. IV, 1889.
Sur la fine structure du lobe optique des oiseaux et sur l'origine réelle des nerfs optiques. Int. Monatschr. Anat. u. Phys., Bd. VIII, 1891.
- CIRINCIONE, G., Ueber die Entwicklung der Capsula perilenticularis. Arch. Anat. u. Entw., Suppl. Bd., Jahrg. 1897.
Zur Entwicklung des Wirbeltierauges. Ueber die Entwicklung der Capsula perilenticularis. Leipzig, 1898.
Ueber die Genese des Glaskörpers bei Wirbelthieren. Verh. Anat. Ges., 17. Versamml. in Heidelberg, 1903.
- COLLIN, R., Recherches sur le développement du muscle sphincter de l'iris chez les oiseaux. Bibliog. Anat., T. XII, fasc. V. Paris, 1903.
- FRORIEP, A., Ueber die Entwicklung des Sehnerven. Anat. Anz., Bd. VI, 1891.
Die Entwicklung des Auges der Wirbeltiere. Handb. der vergl. u. exp. Entw.-l. der Wirbeltiere, Bd. II, 1905.
- HUSCHKE, E., Ueber die erste Entwicklung des Auges und die damit zusammenhängende Cyklopie. Meckel's Arch., 1832.
- KESSLER, L., Untersuchungen über die Entwicklung des Auges, angestellt am Hühnchen und Tauben. Dissertation. Dorpat, 1871.
Die Entwicklung des Auges der Wirbelthiere. Leipzig, 1877.
- v. KÖLLIKER, A., Ueber die Entwicklung und Bedeutung des Glaskörpers. Verh. anat. Ges., 17. Vers. Heidelberg, 1903.
Die Entwicklung und Bedeutung des Glaskörpers. Zeitschr. wiss. Zool., Bd. LXXVII, 1904.
- v. LENHOSSEK, M., Die Entwicklung des Glaskörpers. Leipzig, 1903.
- LEWIS, W. H., Wandering Pigmented Cells Arising from the Epithelium of the Optic Cup, with Observations on the Origin of the M. Sphincter Pupillæ in the Chick. Am. Journ. Anat., Vol. II, 1903.
- LOCY, W. A., Contribution to the Structure and Development of the Vertebrate Head. Journ. Morph., Vol. XI. Boston, 1895.
Accessory Optic Vesicles in the Chick Embryo. Anat. Anz., Bd. XIV, 1897.
- NUSSBAUM, M., Zur Rückbildung embryonaler Anlagen. (Corneal papillæ of chick embryos.) Archiv. mikr. Anat., Bd. LVII, 1901.

- NUSSBAUM, M., Die Pars ciliaris retinae des Vogelauges. Arch. mikr. Anat., Bd. LVII, 1901.
Die Entwicklung der Binnenmuskeln des Auges der Wirbeltiere. Arch. mikr. Anat., Bd. LVIII, 1901.
- RABL, C., Zur Frage nach der Entwicklung des Glaskörpers. Anat. Anz., Bd. XXII, 1903.
Ueber den Bau und die Entwicklung der Linse. II. Reptilien und Vögel. Zeitschr. wiss. Zool., Bd. LXV, 1899.
- ROBINSON, A., On the Formation and Structure of the Optic Nerve, and its Relation to the Optic Stalk. Journ. Anat. and Phys. London, 1896.
- SZILLI, A.V. Beitrag zur Kenntniss der Anatomie und Entwicklungsgeschichte der hinteren Irisschichten, etc. Arch. Ophthalm., Bd. LIII, 1902.
Zur Anatomie und Entwicklungsgeschichte der hinteren Irisschichten, etc. Anat. Anz., Bd. XX, 1901.
Zur Glaskörperfrage. Anat. Anz. Bd. XXIV, 1904.
- TORNATOLA, Origine et nature du corps vitré. Rev. génér. d'ophthalm. Année 14, 1897.
- UCKE, A., Epithelreste am Opticus und auf der Retina. Arch. mikr. Anat., Bd. XXXVIII, 1891.
Zur Entwicklung des Pigmentepithels der Retina. Diss. aus Dorpat. Petersburg, 1891.
- VIRCHOW, H., Fächer, Zapfen, Leiste, Polster, Gefässe im Glaskörperraum von Wirbelthieren, sowie damit in Verbindung stehenden Fragen. Ergebn. Anat. u. Entw., Bd. X. Berlin, 1900.
- WEYSSE, A. W., and BURGESS, W. S., Histogenesis of the Retina. Am. Naturalist, Vol. XL, 1906.

B. *The Nose*

- BORN, G., Die Nasenhöhlen und der Thränennasengang der amnioten Wirbelthiere II. Morph. Jahrb., Bd. V, 1879; Bd. VIII, 1883.
- COHN, FRANZ, Zur Entwicklungsgeschichte des Geruchsorgans des Hühnchens. Arch. mikr. Anat., B1. LXI, 1903.
- DIEULAFÉ, LEON, Les fosses nasales des vertébrés (morphologie et embryologie). Journ. de l'anat. et de la phys., T. 40 and 41, 1904 and 1905. (Translated by Hanau W. Loeb: Ann. of Otol., Rhin. and Laryng., Mar., June and Sept., 1906.)
- DISSE, J., Die erste Entwicklung des Riechnerven. Anat. Hefte, Bd. IX, 1897.
- GANIN, M., Einige Thatsachen zur Frage über das Jacobsohn'sche Organ der Vögel. Arb. d. naturf. Ges. Charkoff, 1890 (russisch). Abstr. Zool. Anz., 1890.
- V. KÖLLIKER, A., Ueber die Entwicklung der Geruchsorgane beim Menschen und Hühnchen. Würzburger med. Zeitschr., Bd. I, 1860.
- V. MIHALKOVICS, V., Nasenhöhle und Jacobson'sche Organ. Anat. Hefte, I. Abth., Bd. XI, 1898.
- PETER, KARL, Entwicklung des Geruchsorgans und Jakobson'sche Organs in der Reihe der Wirbeltiere. Bildung der äusseren Nase und des

Gaumens. Handbuch der vergl. und experiment. Entwicklungslehre der Wirbeltiere. II², 1902.

PREOBRASCHENSKY, L., Beiträge zur Lehre über die Entwicklung des Geruchsorganes des Huhnes. Mitth. embryol. Inst. Wien, 1892.

PUTELLI, F., Ueber das Verhalten der Zellen der Riechschleimhaut bei Hühnerembryonen früher Stadien. Mitth. embr. Inst. Wien, 1889.

C. *The Ear*

HASSE, C., Beiträge zur Entwicklung der Gewebe der häutigen Vogelschnecke. Zeitschr. wiss. Zool., Bd. XVII, 1867.

HUSCHKE, Ueber die erste Bildungsgeschichte des Auges und Ohres beim bebrüteten Hühnchen. Isis von Oken, 1831.

KASTSCHENKO, N., Das Schlundspaltengebiet des Hühnchens. Arch. Anat. u. Entw., 1887.

KEIBEL, Ueber die erste Bildung des Labyrinthanhanges. Anat. Anz., Bd. XVI, 1899.

KRAUSE, R., Die Entwicklung des Aquæductus Vestibuli, s. Ductus endolymphaticus. Anat. Anz., Bd. XIX, 1901.

Die Entwicklungsgeschichte des häutigen Bogenganges. Arch. mikr. Anat., Bd. XXXV, 1890.

MOLDENHAUER, W., Die Entwicklung des mittleren und des äusseren Ohres. Morph. Jahrb., Bd. III, 1877.

POLI, C., Sviluppo della vesicula auditiva; studio morfologico. Genoa, 1896.

Zur Entwicklung der Gehörblase bei den Wirbeltieren. Arch. mikr. Anat., Bd. XLVIII, 1897.

RETZIUS, G., Das Gehörorgan der Wirbelthiere. II. Theil, Reptilien Vögel, Säuger. Stockholm. 1881–1884.

RÖTHIG, P., und BRUGSCH, THEODOR, Die Entwicklung des Labyrinthes beim Huhn. Archiv. mikr. Anat., Bd. LIX, 1902.

RÜDINGER, Zur Entwicklung des häutigen Bogenganges des inneren Ohres. Sitzungsber. Akad. München, 1888.

LITERATURE — CHAPTER X

THE ALIMENTARY TRACT AND ITS APPENDAGES

A. *The Oral Cavity and Organs*

FRAISSE, P., Ueber Zähne bei Vögeln. Vortrag, geh. in der phys.-med. Ges. Würzburg, 1880.

GARDINER, E. G., Beiträge zur Kenntniss des Epitrichiums und der Bildung des Vogelschnabels. Inaug. Dissert. Leipzig, 1884. Arch. mikr. Anat., Bd. XXIV, 1884.

GAUPP, E., Anat. Untersuchungen über die Nervenversorgung der Mund- und Nasenhöhletrüsen der Wirbeltiere. Morph. Jahrb., Bd. XIV, 1888.

GIACOMINI, E., Sulle glanduli salivari degli uccelli. Ricerche anatomico-embriologiche. Monit. zool. Ital., Anno 1, 1890.

- GÖPPERT, E., Die Bedeutung der Zunge für den secundären Gaumen und den Ductus naso-pharyngeus. Beobachtungen an Reptilien und Vögeln. Morph. Jahrb., Bd. XXXI, 1903.
- KALLIUS, E., Die mediane Thyreoideaanlage und ihre Beziehung zum Tuberculum impar. Verh. anat. Ges., 17. Vers., 1903.
Beiträge zur Entwicklung der Zunge. Verh. anat. Ges., 15. Vers. Bonn, 1901.
- MANNO, ANDREA, Sopra il modo onde si perfora e scompare le membrana faringea negli embrioni di pollo. Ricerche Lab. Anat. Roma, Vol. IX, 1902.
- OPPEL, A., Lehrbuch der vergleichenden mikroskopischen Anat. der Wirbeltiere. Jena, 1900.
- REICHEL, P., Beitrag zur Morphologie der Mundhöhlendrüsen der Wirbeltiere. Morph. Jahrb., Bd. VIII, 1883.
- RÖSE, C., Ueber die Zahnleiste und die Eischwiele der Sauropsiden. Anat. Anz., Bd. VII, 1892.
- SLUITER, C. P., Ueber den Eizahn und die Eischwiele einiger Reptilien. Morph. Jahrb., Bd. XX, 1893.
- YARRELL, W., On the Small Horny Appendage to the Upper Mandible in Very Young Chickens. Zool. Journal, 1826.

B. *Derivatives of the Embryonic Pharynx*

- VAN BEMMELEN, J. F., Die Visceraltaschen und Aortenbogen bei Reptilien und Vögeln. Zool. Anz., 1886.
- HIS, W., Ueber den Sinus praecervicalis und die Thymusanlage. Arch. Anat. u. Entw., 1886.
Schlundspalten und Thymusanlage. Arch. Anat. u. Entw., 1889.
Der Tractus Thyreoglossus und seine Beziehung zum Zungenbein. Arch. Anat. u. Entw., 1891.
- KASTSCHENKO, N., Das Schlundspaltengebiet des Hühnchens. Arch. Anat. und Entw., 1887.
- LIESSNER, E., Ein Beitrag zur Kenntniss der Kiemenspalten und ihrer Anlagen bei amnioten Wirbelthieren. Morph. Jahrb., Bd. XIII, 1888.
- MALL, F. P., Entwicklung der Branchialbogen und Spalten des Hühnchens. Arch. Anat. und Entw., 1887.
- DE MEURON, P., Recherches sur le développement du thymus et de la glande thyroïde. Dissertation, Genève, 1886.
- MÜLLER, W., Ueber die Entwicklung der Schilddrüse. Jen. Zeitschr., Bd. VI, 1871.
- SEESSEL, A., Zur Entwicklungsgeschichte des Vorderdarms. Arch. Anat. und Entw., 1877.
- VERDUN, M. P., Sur les dérivés branchiaux du poulet. Comptes rendus Soc. Biol., Tom. V. Paris, 1898.
Dérivés branchiaux chez les vertébrés supérieurs. Toulouse, 1898.

C. *Œsophagus, Stomach, Intestine*

- BORNHAUPT, TH., Untersuchungen über die Entwicklung des Urogenital-systems beim Hühnchen. Inaug. Diss. Riga, 1867.
- CATTANEO, G., Intorno a un recente lavoro sullo stomaco degli uccelli. Pavia, 1888.
- Istologia e sviluppo del apparato gastrico degli uccelli. Atti della Soc. Ital. di Sc. Nat., Vol. XXVII, Anno 1884. Milano, 1885.
- CAZIN, M., Recherches anatomiques, histologiques et embryologiques sur l'appareil gastrique des oiseaux. Ann. Sc. Nat. Zool. 7 sér., Tom. IV, 1888.
- Sur le développement embryonnaire de l'estomac des oiseaux. Bull. de la société philomathique de Paris. 7 sér., Tom. XI, Paris, 1887.
- Développement de la couche cornée du gesier du poulet et des glandes qui la sécrètent. Comptes rendus, T. CI, 1885.
- CLOETTA, M., Beiträge zur mikroskopischen Anatomie des Vogeldarmes. Archiv. mikr. Anat., Bd. XLI, 1893.
- FLEISCHMANN, ALBERT, Morphologische studien über Kloake und Phallus der Amnioten. III. Die Vögel, von Dr. Carl Pomayer. Morph. Jahrb., Bd. XXX, 1902.
- GASSER, E., Beiträge zur Entwicklungsgeschichte der Allantois, Müllerschen Gänge und des Afters. Frankfurt a. M., 1893.
- Die Entstehung der Kloakenöffnung bei Hühnerembryonen. Arch. Anat. u. Entw., 1880.
- MAURER, F., Die Entwicklung des Darmsystems. Handb. d. vergl. u. exp. Entw.-lehre der Wirbeltiere. II¹, 1902.
- v. MIHALCOVICS, V., Untersuchungen über die Entwicklung des Harn- und Geschlechtsapparates der Amnioten. Internat. Monatschr. Anat. u. Phys., Bd. II, 1885-1886.
- MINOT, C. S., On the Solid Stage of the Large Intestine in the Chick. Journ. Bos. Soc. Med. Sc., Vol. IV, 1900.
- POMAYER, CARL. See Fleischmann.
- RETTNERER, E., Contributions a l'étude du cloaque et de la bourse de Fabricius chez des oiseaux. Journ. de l'anat. et de la phys. 21 An. Paris, 1885.
- SEYFERT, Beiträge zur mikroskopischen Anatomie und zur Entwicklungsgeschichte der blinden Anhänge des Darmcanals bei Kaninchen, Taube und Sperling. Inaug. Diss. Leipzig, 1887.
- SCHWARZ, D., Untersuchungen des Schwanzendes bei den Embryonen der Wirbeltiere. Zeitschr. wiss. Zool., Bd. XLVIII, 1889.
- STIEDA, L. LUDWIG, Ueber den Bau und die Entwicklung der Bursa Fabricii. Zeitschr. wiss. Zool., Bd. XXXIV, 1880.
- SWENANDER, G., Beiträge zur Kenntniss des Kropfes der Vögel. Zool. Anz., Bd. XXII, 1899.
- WEBER, A., Quelques faits concernant le développement de l'intestin moyen, et de ses glandes annexes chez les oiseaux. C. R. Soc. Biol., T. LIV. Paris, 1902.
- WENCKEBACH, K. F., De Ontwikkeling en de bouw der Bursa Fabricii. Inaug. Dissert. Leiden, 1888.

D. *Liver and Pancreas*

- BRACHET, A., Die Entwicklung und Histogenese der Leber und des Pancreas. Ergebnisse d. Anat. u. Entw.-gesch., 1896.
- BROUHA, M., Recherches sur le développement du foie, du pancréas, de la cloison mesentérique et des cavités hepato-entériques chez les oiseaux. Journ. de l'anat. et phys., T. XXXIV. Paris, 1898.
- Sur les premières phases du foie et sur l'évolution des pancréas ventraux chez les oiseaux. Anat. Anz., Bd. XIV, 1898.
- CHORONSCHITZKY, B., Die Entstehung der Milz, Leber, Gallenblase, Bauchspeicheldrüse und des Pfortadersystems bei den verschiedenen Abtheilungen der Wirbelthiere. Anat. Hefte, Bd. XIII, 1900.
- FELIX, W., Zur Leber und Pancreasentwicklung. Arch. Anat. u. Entw., 1892.
- FROBEN, F., Zur Entwicklung der Vogelleber. Anat. Hefte, 1892.
- GÖTTE, ALEX., Beiträge zur Entwicklungsgeschichte des Darmcanals im Hühnchen. Tübingen, 1867.
- HAMMAR, G. A., Ueber Duplicität ventraler Pancreasanlage. Anat. Anz., Bd. XIII, 1897.
- Ueber einige Hauptzüge der ersten embryonalen Leberentwicklung. Anat. Anz., Bd. XIII, 1897.
- Einige Plattenmodelle zur Beleuchtung der früheren embryonalen Leberentwicklung. Arch. Anat. u. Entw., 1893.
- MINOT, C. S., On a Hitherto Unrecognized Form of Blood-Circulation without Capillaries in the Organs of Vertebrata. Proc. Boston Soc. of Nat. Hist., Vol. XXIX, 1900.
- SCHREINER, K. E., Beiträge zur Histologie und Embryologie des Vorderdarms der Vögel. Zeitschr. wiss. Zool., Bd. LXVIII, 1900.
- SHORE, T. W., The Origin of the Liver, Journ. of Anat. and Phys., Vol. XXV, 1890-91.
- SAINT-REMY, Sur le développement du pancréas chez les oiseaux. Rev. biol. du Nord de la France. Année V, 1893.

E. *The Respiratory Tract*

- BÄR, M., Beiträge zur Kenntniss der Anatomie und Physiologie der Athemwerkzeuge bei den Vögeln. Zeitschr. wiss. Zool., Bd. LXI, 1896.
- BERTELLI, D., Sviluppo de sacchi aeriferi del pollo. Divisione della cavità celomatica degli uccelli. Atti della Società Toscana di scienze naturali residente in Pisa. Memorie, Vol. XVII, 1899.
- BLUMSTEIN-JUDINA, BEILA, Die Pneumatisation des Markes der Vogelknochen. Anat. Hefte, Abth. I, Bd. XXIX (Heft 87), 1905.
- CAMPANA, Recherches d'anatomie de physiologie, et d'organogénie pour la détermination des lois de la genèse et de l'évolution des espèces animales. I. Mémoire. Physiologie de la respiration chez les oiseaux. Anatomie de l'appareil pneumatique pulmonnaire, des faux diaphragmes, des scémus et de l'intestin chez le poulet. Paris, Masson, 1875.
- GOEPFERT, E., Die Entwicklung der luftführenden Anhänge des Vorderdarms. Handbuch d. vergl. u. exp. Entw.-lehre der Wirbelthiere, Bd. II, T. 1, 1902.

- LOCY, W. A. and LARSELL, O., The Embryology of the Bird's Lung, Based on Observations of the Domestic Fowl. *Am. Journ. of Anat.*, Vol. 19, pp. 447-504, and Vol. 20, pp. 1-44, 1916.
- RATHKE, M. H., Ueber die Entwicklung der Atemwerkzeuge bei den Vögeln und Säugetieren. *Nov. Act. Acad. Caes. Leop. Car.*, T. XIV. Bonn, 1828.
- SELENKA, E., Beiträge zur Entwicklungsgeschichte der Luftsäcke des Huhnes. *Zeitschr. wiss. Zool.*, Bd. XVI, 1866.
- STRASSER, H., Die Luftsäcke der Vögel. *Morph. Jahrb.*, Bd. III, 1877.
- WEBER, A., et BUVIGNIER, A., Les premières phases du développement du poumon chez les embryons de poulet. *Comptes rendus hébd. des séances de la société de Biologie*, Vol. LV. Paris, 1903.
- WUNDERLICH, L., Beiträge zur vergleichenden Anatomie und Entwicklungsgeschichte des unteren Kehlkopfes der Vögel. *Nova Acta Acad. Caes. Leop. Carol. Germanicae*, Bd. XLVIII, 1884.

LITERATURE — CHAPTER XI

- BEDDARD, F. E., On the Oblique Septa ("Diaphragm" of Owen) in the Passerines and some other Birds. *Proc. Zool. Soc. London*, 1896.
- BERTELLI, D., Sullo sviluppo del diaframma dorsale nel Pollo. Nota preventiva. *Monit. Zool. Ital.*, Anno IX, 1898.
Contributo alla morfologia ed allo sviluppo del diaframma ornitico. *Ibid.*, 1898.
- BRACHET, A., Die Entwicklung der grossen Körperhöhlen und ihre Trennung von einander, etc. *Ergebnisse d. Anat. u. Entw.-gesch.*, Bd. VII, 1897.
- BROMAN, IVAR, Die Entwicklungsgeschichte der Bursa omentalis und ähnlicher Recessbildungen bei den Wirbeltieren. Wiesbaden, 1904.
- BROUHA, M. See Chap. X.
- BUTLER, G. W., On the Subdivision of the Body Cavity in Lizards, Crocodiles and Birds. *Proc. Zoöl. Soc. London*, 1889.
- CHORONSCHITZKY, B. See Chap. X.
- DARESTE, C., Sur la formation du mésentère et de la gouttière intestinale dans l'embryon de la poule. *Comptes rendus*, T. CXII, 1891.
- HOCHSTETTER, F., Die Entwicklung des Blutgefässsystems. *Handbuch der vergl. und exp. Entw.-lehre der Wirbeltiere*. III², 1903.
- JANOSIK, J., Le paneréas et la rate. *Bibliographie Anat. Année 3*. Paris, 1895.
- LOCKWOOD, C. B., The Early Development of the Pericardium, Diaphragm and Great Veins. *Phil. Trans. Roy. Soc.*, London, Vol. CLXXIX, 1889.
- MALL, F. P., Development of the Lesser Peritoneal Cavity in Birds and Mammals. *Journ. Morph.*, Vol. V, 1891.
- MAURER, F., Die Entwicklung des Darmsystems. *Handbuch d. vergl. u. exp. Entw.-lehre d. Wirbeltiere*, Vol. II, 1906.
- PEREMESCHKO, Ueber die Entwicklung der Milz. *Sitzungsber. d. Akad. d. Wiss. in Wien, math., naturwiss. Klasse*, Bd. LVI, Abth. 2, 1867.
- RAVN, E., Die Bildung des Septum transversum beim Hühnerembryo. *Arch. Anat. u. Entw.*, 1896. See also *Anat. Anz.*, Bd. XV, 1899.

- REICHERT, *Entwicklungsleben im Wirbeltierreich*. Berlin, 1840.
 REMAK, *Untersuchungen über die Entwicklung des Wirbeltierreichs*, p. 60, 1850–1855.
 USKOW, W., *Ueber die Entwicklung des Zwerchfells, des Pericardium und des Coeloms*. Arch. mikr. Anat., Bd. XXII, 1883.
 WOIT, O., *Zur Entwicklung der Milz*. Anat. Hefte, Bd. IX, 1897.

LITERATURE — CHAPTER XII

- v. BAER, K. E., *Ueber die Kiemen und Kiemengefäße im den Embryonen der Wirbeltiere*. Meckel's Archiv., 1827.
 VAN BEMMELEN, J., *Die Visceraltaschen und Aortenbogen bei Reptilien und Vögeln*. Zool. Anz., 1886.
 BOAS, J. E. V., *Ueber die Aortenbogen der Wirbeltiere*. Morph. Jahrb., Bd. XIII, 1887.
 BROUHA. See Chap. X.
 HOCHSTETTER, F., *Die Entwicklung des Blutgefäßsystems (des Herzens nebst Herzbeutel und Zwerchfell, der Blut- und Lymphgefäße, der Lymphdrüsen und der Milz in der Reihe der Wirbeltiere)*. Handbuch der vergl. und exp. Entwicklungslehre der Wirbeltiere. III², 1903.
 Beiträge zur Entwicklungsgeschichte des Venensystems der Amnioten. I. Hühnchen. Morph. Jahrb., Bd. XIII, 1888.
 Ueber den Ursprung der Arteria Subclavia der Vögel. Morph. Jahrb., Bd. XVI, 1890.
 Entwicklung des Venensystems der Wirbeltiere. Ergeb. der Anat. u. Entw., Bd. III, 1893.
 HUSCHKE, E., *Ueber die Kiemenbogen und Kiemengefäße beim bebrüteten Hühnchen*. Isis, Bd. XX, 1827.
 LANGER, A., *Zur Entwicklungsgeschichte des Bulbus cordis bei Vögeln und Säugetieren*. Morph. Jahrb., Bd. XXII, 1894.
 LINDS, G., *Ein Beitrag zur Entwicklungsgeschichte des Herzens*. Dissertation. Dorpat, 1865.
 LOCY, W. A., *The Fifth and Sixth Aortic Arches in Chick Embryos with Comments on the Condition of the Same Vessels in other Vertebrates*. Anat. Anz., Bd. XXIX, 1906.
 MACKAY, J. Y., *The Development of the Branchial Arterial Arches in Birds, with Special Reference to the Origin of the Subclavians and Carotids*. Phil. Trans. Roy. Soc., London, Vol. CLXXIX, 1889.
 MASIUS, J., *Quelques notes sur le développement du cœur chez le poulet*. Arch. Biol., T. IX, 1889.
 MILLER, W. S., *The Development of the Postcaval Veins in Birds*. Am. Journ. Anat., Vol. II, 1903.
 POPOFF, D., *Die Dottersackgefäße des Huhnes*. Wiesbaden, 1894.
 RATHKE, H., *Bemerkungen über die Entstehung der bei manchen Vögeln und den Krokodilen vorkommenden unpaaren gemeinschaftlichen Carotis*. Arch. Anat. u. Phys., 1858.
 RÖSE, C., *Beiträge zur vergleichenden Anatomie des Herzens der Wirbeltiere*. Morph. Jahrb., Bd. XVI, 1890.

- RÖSE, C., Beiträge zur Entwicklungsgeschichte des Herzens. Inaug. Dissert. Heidelberg, 1888.
- TONGE, MORRIS, On the Development of the Semilunar Valves of the Aorta and Pulmonary Artery of the Chick. Phil. Trans. Roy. Soc., London, Vol. CLIX, 1869.
- TWINING, GRANVILLE H., The Embryonic History of the Carotid Arteries in the Chick. Anat. Anz., Bd. XXIX, 1906.
- VIALLETON, L., Développement des aortes postérieures chez l'embryon de poulet. C. R. Soc. Biol., T. III. Paris, 1891.
Développement des aortes chez l'embryon de poulet. Journ. de l'anat. et phys., T. XXVIII, 1892.
- ZUCKERKANDL, E., Zur Anat. und Entwicklungsgeschichte der Arterien des Unterschenkels und des Fusses. Anat. Hefte, Bd. V, 1895.
Zur Anatomie und Entwicklungsgeschichte der Arterien des Vorderarmes. Anat. Hefte, Bd. IV, 1894.

LITERATURE — CHAPTER XIII

- ABRAHAM, K., Beiträge zur Entwicklungsgeschichte des Wellensittichs. Anat. Hefte, Bd. XVII, 1901.
- BALFOUR, F. M., On the Origin and History of the Urogenital Organs of Vertebrates. Journ. of Anat. and Physiol., Vol. X, 1876.
- BALFOUR and SEDGWICK, On the Existence of a Rudimentary Head Kidney in the Embryo Chick. Proc. R. Soc., London, Vol. XXVII, 1878.
On the Existence of a Head Kidney in the Embryo Chick and on Certain Points in the Development of the Müllerian Duct. Quar. Journ. Micr. Sc., Vol. XIX, 1879.
- BORNHAUPT, TH., Zur Entwicklung des Urogenitalsystems beim Hühnchen. Inaug. Diss. Dorpat, 1867.
- BRANDT, A., Ueber den Zusammenhang der Glandula suprarenalis mit dem parovarium resp. der Epididymis bei Hühnern. Biolog. Centralbl., Bd. IX, 1889.
Anatomisches und allgemeines über die sog. Hahnenfedrigkeit und über anderweitige Geschlechtsanomalien der Vögel. Zeitschr. wiss. Zool., Bd. XLVIII, 1889.
- FELIX, W., Zur Entwicklungsgeschichte der Vorniere des Hühnchens. Anat. Anz., Bd. V, 1890.
- FELIX und BÜHLER, Die Entwicklung der Harn- und Geschlechtsorgane. I. Abschnitt — Die Entwicklung des Harnapparates, von Prof. Felix. Handbuch der vergl. u. exper. Entw.-lehre der Wirbeltiere, III², 1904.
- FIRKET, JEAN, Recherches sur l'organogenèse des glands sexuelles chez les oiseaux. Arch. de Biol. Tome 29, pp. 201-351. Pl. 5, 1914.
- FÜRBRINGER, M., Zur vergleichenden Anatomie und Entwicklungsgeschichte der Excretionsorgane der Vertebraten. Morph. Jahrb., Bd. IV, 1878.
- FUSARI, R., Contribution à l'étude du développement des capsules surrénales et du sympathétique chez le poulet et chez les mammifères. Archives. Ital. de biologie, T. XVI, 1892.

- GASSER, E., Beiträge zur Entwicklungsgeschichte der Allantois, der Müller'schen Gänge und des Afters. Frankfurt a. M., 1874.
- Die Entstehung des Wolff'schen Ganges beim Huhn. Sitz.-ber. Naturf. Ges., Marburg, Jahrg. 1875.
- Beobachtungen über die Entstehung des Wolff'schen Ganges bei Embryonen von Hühnern und Gänsen. Arch. mikr. Anat., Bd. XIV, 1877.
- GASSER, E., und SIEMMERLING, Beiträge zur Entwicklung des Urogenitalsystems bei den Hühnerembryonen. Sitz.-ber. Naturf. Ges., Marburg, 1879.
- GERHARDT, U., Zur Entwicklung der bleibenden Niere. Arch. mikr. Anat., Bd. LVII, 1901.
- HOCHSTETTER, F., Zur Morphologie der Vena cava inferior. Anat. Anz., Bd. III, 1888.
- HOFFMANN, C. K., Etude sur le développement de l'appareil urogenital des oiseaux. Verhandelingen der Koninklyke Akademie van Wetenschappen. Amsterdam, Tweede Sectie, Vol. I, 1892.
- JANOSIK, J., Bemerkungen über die Entwicklung der Nebennieren. Archiv. mikr. Anat., Bd. XXII, 1883.
- Histologisch-embryologische Untersuchungen über das Urogenitalsystem. Sitzungsber. Akad. Wiss. Wien, math.-nat. Kl., Bd. XCI, 3. Abth., 1885.
- KOSE, W., Ueber die Carotisdrüse und das "Chromaffine Gewebe" der Vögel. Anat. Anz., Bd. XXV, 1904.
- KOWALEVSKY, R., Die Bildung der Urogenitalanlage bei Hühnerembryonen. Stud. Lab. Warsaw Univ., II, 1875.
- KUPFFER, C., Untersuchungen über die Entwicklung des Harn- und Geschlechtssystems. Arch. mikr. Anat., Bd. I, 1865; and *ibid.* Bd. II, 1866.
- v. MIHALCOVICS, V., Untersuchungen über die Entwicklung des Harn- und Geschlechtsapparates der Amnioten. Intern. Monatschr. Anat. und Phys., Bd. II, 1885-1886.
- MINERVINI, R., Des capsules surrénales: Développement, structure, fonctions. Journ. de l'anat. et de la phys., An. XL. Paris, 1904.
- NUSSBAUM, M., Zur Differenzierung des Geschlechtes im Thierreich. Arch. mikr. Anat., Bd. XVIII, 1880.
- Zur Entwicklung des Geschlechts beim Huhn. Verh. anat. Ges., Bd. XV, 1901.
- Zur Rückbildung embryonaler Anlagen. Arch. mikr. Anat., Bd. LVII, 1901.
- Zur Entwicklung des Urogenitalsystems beim Huhn. C. R. Ass. d. An. Sess., 5. Liège, 1903.
- POLL, H., Die Entwicklung der Nebennierensysteme. Handbuch der vergl. und exper. Entwicklungslehre der Wirbeltiere. III¹, 1906.
- PRENANT, A., Remarques à propos de la constitution de la glande génitale indifférente et de l'histogénèse du tube séminifère. C. R. Soc. biol., Sér. 9, T. II, 1890.
- RABL, H., Die Entwicklung und Struktur der Nebennieren bei den Vögeln. Arch. mikr. Anat., Bd. XXXVIII, 1891.
- RENSON, G., Recherches sur le rein céphalique et le corps de Wolff chez les oiseaux et les mammifères. Arch. mikr. Anat., Bd. XXII, 1883.

- RUCKERT, J., Entwicklung der Excretionsorgane. Ergebnisse der Anat. u. Entw.-gesch., Bd. I, 1892.
- SCHREINER, K. E., Ueber die Entwicklung der Amniotenniere. Zeitschr. wiss. Zool., Bd. LXXI, 1902.
- SEDGWICK, A., Development of the Kidney in its Relation to the Wolffian Body in the Chick. Quart. Journ. Micr. Sc., Vol. XX, 1880.
- On the Early Development of the Anterior Part of the Wolffian Duct and Body in the Chick, together with Some Remarks on the Excretory System of Vertebrata. Quart. Journ. Micr. Sc., Vol. XXI, 1881.
- SEMON, RICHARD, Die indifferente Anlage der Keimdrüsen beim Hühnchen und ihre Differenzierung zum Hoden. Jen. Zeitschr. Naturwiss., Bd. XXI, 1887.
- SOULIÉ, E. H., Recherches sur le développement des capsules surrénales chez les vertébrés supérieurs. Journ. de l'anat. et phys., Paris, An. XXXIX, 1903.
- SWIFT, CHARLES H., Origin and Early History of the Primordial Germ-Cells in the Chick. American Journal of Anat., Vol. 15, pp. 483-516, 1914.
- Origin of the Definitive Sex-Cells in the Female Chick and their Relation to the Primordial Germ-Cells. *ib.* Vol. 18, pp. 441-470, 1915.
- Origin of the Sex-Cords and Definitive Spermatogonia in the Male Chick, *ib.* Vol. 20, pp. 375-410, 1916.
- WALDEYER, W., Eierstock und Ei. Ein Beitrag zur Anatomie und Entwicklungsgeschichte der Sexualorgane. Leipzig, 1870.
- WELDON, On the Suprarenal Bodies of Vertebrates. Quar. Journ. Micr. Sc., Vol. XXV, 1884.

LITERATURE — CHAPTER XIV

- AGASSIZ, L., On the Structure of the Foot in the Embryo of Birds. Proc. Boston Soc. Nat. Hist., 1848.
- BIZZOZERO, G., Neue Untersuchungen über den Bau des Knochenmarks der Vögel. Arch. mikr. Anat., Bd. XXXV, 1890. See also Arch. Ital. de Biol., T. XIV, 1891.
- BLUMSTEIN-JUDINA, BEILA, Die Pneumatisation des Markes der Vogelknochen. Anat. Hefte, Abth. I, Bd. XXIX, 1905.
- BRACHET, A., Etude sur la resorption de cartilage et le développement des os longs chez les oiseaux. Internat. Monatschr. Anat. und Phys., Bd. X, 1893.
- BRAUN, M., Entwicklung des Wellenpapageis. Arb. Zool. Zoot. Inst. Würzburg, Bd. V, 1881.
- BRULLÉ et HUGUENY, Développement des os des oiseaux. Ann. Sc. Nat., Ser. III, Zool. T. IV, 1845.
- BUNGE, A., Untersuchungen zur Entwicklungsgeschichte des Beckengürtels der Amphibien, Reptilien und Vögel. Inaug. Diss. Dorpat. 1880.
- CUVIER, Extrait d'un mémoire sur les progrès de l'ossification dans le sternum des oiseaux. Ann. des Sc. Nat., Sér. I, Vol. XXV, 1832.
- V. EBNER, V., Ueber die Beziehungen der Wirbel zu den Urvirbel. Sitzungsber. d. k. Akad. d. Wiss. Wien, math.-naturwiss. Kl., Bd. CI, 3. Abth., 1892.

- Urwirbel und Neugliederung der Wirbelsäule. Sitzungsber. d. k. Akad. d. Wiss. Wien, Bd. XCVII, 3. Abth. Wien, 1889, Jahrg., 1888.
- FRORIEP, A., Zur Entwicklungsgeschichte der Wirbelsäule, insbesondere des Atlas und Epistropheus und der Occipitalregion. I. Beobachtungen an Hühnerembryonen. Arch. Anat. u. Entw., 1883.
- GAUPP, E., Die Entwicklung des Kopfskelettes. Handbuch der vergl. u. exper. Entw.-lehre der Wirbeltiere, Bd. 3, 1905.
Die Entwicklung der Wirbelsäule. Zool. Centralbl., Jahrg. III, 1896.
Die Metamerie des Schädels. Ergeb. der Anat. u. Entw., 1897.
- GEGENBAUR, C., Untersuchungen zur vergl. Anat. der Wirbelsäule bei Amphibien und Reptilien. Leipzig, 1864.
Beiträge zur Kenntniss des Beckens der Vögel. Eine vergleichende anatomische Untersuchung. Jen. Zeitschr. Med. u. Naturw., Bd. VI, 1871.
Die Metamerie des Kopfes und die Wirbeltheorie des Kopfskelettes, im Lichte der neueren Untersuchungen betrachtet und geprüft. Morph. Jahrb., Bd. XIII, 1888.
- GOETTE, A., Die Wirbelsäule und ihre Anhänge. Arch. mikr. Anat., Bd. XV, 1878.
- HEPBURN, D., The Development of Diarthrodial Joints in Birds and Mammals. Proc. R. Soc. Edinb., Vol. XVI, 1889. Also in Journ. of Anat. and Phys., 1889.
- JÄGER, G., Das Wirbelkörpergelenk der Vögel. Sitzungsber. Akad. Wien, Bd. XXXIII, 1858.
- JOHNSON, ALICE, On the Development of the Pelvic Girdle and Skeleton of the Hind Limb in the Chick. Quar. Journ. Micr. Sc., Vol. XXIII, 1883.
- KULCZYCKI, W., Zur Entwicklungsgeschichte des Schultergürtels bei den Vögeln mit besonderer Berücksichtigung des Schlüsselbeines (Gallus, Columba, Anas). Anat. Anz., Bd. XIX, 1901.
- LEIGHTON, V. L., The Development of the Wing of *Sterna Wilsonii*. An. Nat., Vol. XXVIII, 1894.
- LÜHDER, W., Zur Bildung des Brustbeins und Schultergürtels der Vögel. Journ. Ornith., 1871.
- MÄNNICH, H., Beiträge zur Entwicklung der Wirbelsäule von *Eudypetes chrysocome*. Inaug. Diss. Jena, 1902.
- MEHNERT, ERNST, Untersuchungen über die Entwicklung des Os Pelvis der Vögel. Morph. Jahrb., Bd. XIII, 1887.
Kainogenesis als Ausdruck differenter phylogenetischer Energieen. Morph. Arb., Bd. VII, 1897.
- MORSE, E. S., On the Identity of the Ascending Process of the Astragalus in Birds with the Intermedium. Anniversary Mem. Boston Soc. Nat. Hist., 1880.
- NORSA, E., Alcune ricerche sulla morfologia dei membri anteriori degli uccelli. Ricerche fatte nel Laborat. Anatomico di Roma e alti laboratori biologici, Vol. IV, fasc. I. Abstract in French in Arch. Ital. biol., T. XXII, 1894.
- PARKER, W. K., On the Structure and Development of the Skull of the Common Fowl (*Gallus domesticus*). Phil. Trans., Vol. CLIX, 1869.

- PARKER, W. K., On the Structure and Development of the Birds' Skull.
Trans. Linn. Soc., 1876.
On the Structure and Development of the Wing of the Common Fowl.
Phil. Trans., 1888.
- REMAK, R., Untersuchungen über die Entwicklung der Wirbeltiere. Berlin,
1850-1855.
- ROSENBERG, A., Ueber die Entwicklung des Extremitätenskelets bei einigen
durch die Reduction ihrer Gliedmaassen charakteristischen Wirbeltiere.
Zeitschr. wiss. Zool., Bd. XXIII, 1873.
- SCHAUINSLAND, H., Die Entwicklung der Wirbelsäule nebst Rippen und
Brustbein. Handbuch der vergl. und exper. Entw.-lehre der Wirbel-
tiere, Bd. III, T. 2, 1905.
- SCHENK, F., Studien über die Entwicklung des knöchernen Unterkiefers
der Vögel. Sitzungsber. Akad. Wien, XXXIV Jahrg., 1897.
- SCHULTZE, O., Ueber Embryonale und bleibende Segmentirung. Verh.
Anat. Ges., Bd. X. Berlin, 1896.
- STRICT, O. VAN DER, Recherches sur les cartilages articulaires des oiseaux.
Arch. de biol., T. X, 1890.
- SUSCHKIN, P., Zur Anatomie und Entwicklungsgeschichte des Schädels der
Raubvögel. Anat. Anz., Bd. XI, 1896.
Zur Morphologie des Vogelskeletts. (1) Schädel von *Tinnunculus*.
Nouv. Mém. Soc. Imp. des Natur. de Moscow, T. XVI, 1899.
- SCHWARCK, W., Beiträge zur Entwicklungsgeschichte der Wirbelsäule bei
den Vögeln. Anat. Studien (Herausgeg. v. Hasse), Bd. I, 1873.
- WIEDERSHEIM, R., Ueber die Entwicklung des Schulter- und Beckengürtels.
Anat. Anz., Bd. IV, 1889, and V, 1890.
- WIJHE, J. W. VAN, Ueber Somiten und Nerven im Kopfe von Vögel- und
Reptilienembryonen. Zool. Anz., Jahrg. IX, 1886.

INDEX

- Abducens nerve, 267
 Abducens nucleus, 262, 263
 Abnormal eggs, 25
 Accessory cleavage of pigeon's egg, 38, 43, 44
 Accessory mesenteries, 340, 341
 Acustico-facial ganglion complex, 159
 160, 262, 268
 Air-sacs, 326, 330, 331
 Albumen, 18
 Albumen-sac, 217, 224
 Albuginea of testis, 397
 Alecithal ova (see isolecithal)
 Allantois, blood-supply of, 222; general, 217; inner wall of, 220; neck of, 143, 144, 316; origin of, 143, 144; outer wall of, 220; rate of growth, 221; structure of inner wall, 223; structure of outer wall, 223
 Amnion, effect of rotation of embryo on, 140, 141, 142; functions of, 231; head fold of, 137, 139; later history of, 231; mechanism of formation, 139, 140; muscle fibers of, 231; origin of, 135; secondary folds of, 142
 Amnio-cardiac vesicles, 92, 116
 Ampullæ of semicircular canals, 291
 Anal plate, 143, 182
 See also cloacal membrane
 Angioblast, 88
 Anterior chamber of eye, 278
 Anterior commisure of spinal cord, origin of, 244
 Anterior intestinal portal, 95 (Fig. 49), 121, 132
 Anterior mesenteric artery, 363
 Aortic arches, 198, 199, 203, 358-362; transformations of, 359-361
 Appendicular skeleton, 434
 Aqueduct of Sylvius, 251.
 Archenteron, 55
 Area opaca, 39, 50, 61, 86; pellucida, 39, 50, 61; vasculosa, 61, 86; vitellina, 61, 62, 86
 Arterial system, 121, 126, 198, 199, 203, 204, 228, 358-363
 Atlas, development of, 420
 Atrium bursæ omentalis, 344
 Auditory nerve, 295; ossicles, 299, 432; pit, 168
 Auricular canal, 354
 Auriculo-ventricular canal, 348; division of, 355
 Axis, development of, 420
 Axones, origin of, 235
 Basilar plate, 429
 Beak, 302, 304
 Biogenesis, fundamental law of, 4
 Blastoderm, 17; diameter of unincubated, 61; expansion of, 50, 53, 61
 Blastopore, 55, 82
 Blood-cells, origin of, 118
 Blood-islands, origin of, 86, 89
 Blood-vessels, origin of, 118
 Body-cavity, 115, 205-210, 333
 Bony labyrinth, 296
 Brain, primary divisions of, 108; early development of, 147, 156; later development of, 244-252
 Branchial arch, first, skeleton of, 432
 Bronchi, 325, 326
 Bulbus arteriosus, 198, 201, 202, 348; fate of, 357
 Bursa Fabricii, 314, 317, 319
 Bursa omenti majoris, 344
 Bursa omenti minoris, 344
 Canal of Schlemm, 279
 Cardinal veins, anterior, 200, 204, 205, 363; posterior, 200, 204, 205, 368
 Carina of sternum, 427
 Carotid arch, 361
 Carotid, common, 362; external 359, 361; internal, 359-361
 Carpus, 436, 437
 Cartilage, absorption of, 408; bones, definition, 407; calcification of, 409
 Caval fold, 344
 Cavo-celiac recess, 344
 Cavum sub-pulmonale, 342
 Cell-chain hypothesis, 255
 Cell theory, 1
 Central and marginal cells, 41, 42
 Central canal of spinal cord, 242

- Cerebellum, 155, 251
 Cephalic mesoblastic somites, 108, 269, 428
 Cerebral flexures, 149, 245
 Cerebral ganglia, 157-162, 262
 Cerebral hemispheres, origin of, 151; (see telencephalon)
 Cervical flexure, 133, 245
 Chalazæ, 18
 Chemical composition of parts of hen's egg, 20, 21
 Chiasma opticus, 154, 249
 Choanæ, 215, 285
 Chondrification, 408
 Chorion, 135, 217, 218, 220
 Choroid coat of eye, 279; fissure, 166, 281; plexus, 248
 Chromaffin tissue, 404
 Chronology, 64
 Cilary processes, 272, 274
 Circulation of blood, 121, 122, 197-200, 372-376
 Circulation of blood, changes at hatching, 376; completion of double, 355
 Classification of stages, 64-67
 Clavicle, 434, 435
 Cleavage of ovum (hen), 39-43
 Cleavage of ovum (pigeon), 43-47
 Cloaca, 314-319; (see hind-gut)
 Cloacal membrane, 315, 318; (see also anal plate)
 Celiac artery, 363
 Cœlome (see body-cavity)
 Cœnogenetic aspects of development, 6
 Collaterals, origin of, 238
 Collecting tubules of mesonephros, 379, 380
 Colliculus palato-pharyngeus, 398
 Commissura anterior, 252; inferior, 252; posterior, 252; trochlearis, 252
 Conrescence, theory of, 82, 84
 Cones of growth, 235
 Conjunctival sac, 279
 Coprodæum, 315, 318, 319
 Coracoid, 434, 435
 Cornea, 278
 Corpus striatum, 247
 Corpus vitreum, 275
 Cortical cords of suprarenal capsules, 405
 Cranial flexure, 133, 245; nerves, 261
 Cristæ acusticæ, 295
 Crop, 312
 Crural veins, 372
 Cushion septum, 355
 Cuticle of shell, 17
 Cutis plate, 185, 188
 Delimitation of embryo from blastoderm, 91
 Dendrites, origin of, 236
 Determinants, 7
 Diencephalon, early development of, 152; later development of, 249
 Dorsal aorta, origin of, 121
 Dorsal longitudinal fissure and septum of spinal cord, 243, 244
 Dorsal mesentery, 172, 342
 Duct of Botallus, 359, 361, 376
 Ducts of Cuvier, 200, 204, 207, 364
 Ductus arteriosus (see duct of Botallus); choledochus (common bile-duct), 181, 321; cochlearis, 293; cystico-entericus, 321; endolymphaticus, 169, 289; hepato-cysticus, 321; hepato-entericus, 321; venosus (see meatus venosus)
 Duodenum, 310, 311
 Ear, later development of, 288
 Ectamnion, 138
 Ectoderm and entoderm, origin of, 52
 Ectoderm of oral cavity, limits of, 301
 Egg, formation of, 22, 24, 25
 Egg-tooth, 302, 303
 Embryonic circulation, on the fourth day, 372-374; on the sixth day, 374; on the eighth day, 374-376
 Embryonic membranes, diagrams of, 219, 220; general, 216; origin of, 135; summary of later history, 145
 Endocardium, origin of, 119
 Endolymphatic duct (see ductus endolymphaticus)
 Endolymphatic sac (see saccus endolymphaticus)
 Entobronchi, 327, 328
 Entoderm, origin of, 52
 Ependyma, origin of, 239
 Epididymis, 391, 398
 Epiphysis, 153, 249
 Epiphyses (of long bones), 409
 Epistropheus, development of, 420
 Epithalamus, 251
 Epithelial cells of neural tube, 233, 234
 Epithelial vestiges of visceral pouches, 309
 Epôphoron, 401
 Equatorial ring of lens, 277-278
 Excentricity of cleavage, 41, 47
 Excretory system, origin of, 190
 External auditory meatus, 297, 300
 External form of the embryo, 211
 Eye, early development of, 164; later development of, 271
 Eyelids, 279-280

- Facial region, development of the, 214, 215, 216
 Facialis nerve, 268
 Facialis nucleus, 262, 263
 Femur, 440
 Fertilization, 35
 Fibula, 440
 First segmentation nucleus, 36
 Fissura metotica, 429
 Fœtal development, 11
 Fold of the omentum, 344, 345
 Follicles of ovary, 22, 26, 27, 28, 30, 400
 Follicular cells, origin of, 27, 400
 Foramen, interventricular, 353, 354; of Monro, 247; of Winslow, 343; ovale, 355
 Foramina, interauricular, 355
 Fore-brain, origin of, 108
 Fore-gut, 91, 93, 172
 Formative stuffs, 15
 Funiculi præcervicales, 307

 Gall-bladder, 321
 Ganglia, cranial and spinal, 156; cranial, 157, 158, 159, 262; spinal, later development of, 254, 257
 Ganglion, ciliare, 266; geniculatum, 268; jugulare, 268; olfactorium nervi trigemini, 264; nodosum, 161, 268; petrosus, 161, 268; of Remak, 257
 Gastric diverticula of body-cavity, 340
 Gastrulation, 53, 84
 Genetic restriction, law of, 8
 Genital ducts, development of, 401
 Germ-cells, general characters of, 9-12; comparison of, 12-14
 Germ-wall, 47, 48, 69, 90, 128, 129
 Germinal cells of neural tube, 233, 234
 Germinal disc, 11, 12, 35, 37, 39
 Germinal epithelium, 391, 392, 399
 Germinal vesicle, 27, 28
 Gizzard, 313, 314
 Glomeruli of pronephros, 192
 Glossopharyngeus, ganglion complex of, 161, 262, 268; nerve, 268; nucleus, 262, 263
 Glottis, 332
 Gray matter of spinal cord, development of, 240; origin of, 239

 Hæmal arch of vertebræ, 416, 417
 Harderian gland, 280
 Hatching, 232
 Head, development of, 213
 Head-fold, origin of, 91
 Head process, 73, 80

 Heart, changes of position of, 348, 349; development on second and third days, 200-203; divisions of cavities of, 350; ganglia and nerves of, 259; later development of, 348; origin of, 119
 Hensen's knot, 73
 Hepatic veins, 366
 Hepatic portal circulation, 366, 375
 Hermaphroditism of embryo, 391
 Heterotaxia, 133
 Hiatus communis recessus, 343
 Hind-brain, origin of, 108
 Hind-gut, 143, 172
 Hind-limbs, origin of skeleton, 438
 Hoffmann's nucleus, 240
 Holoblastic ova, 11, 12
 Humerus, 436
 Hyoid arch, 175; skeleton of, 432
 Hyomandibular cleft, 174, 297
 Hypoglossus nerve, 269
 Hypophysis, 154, 249
 Hypothalamus, 251

 Ilium, 438, 439
 Incubation, normal temperature for, 65, 66
 Indifferent stage of sexual organs, 391
 Infundibulum (of brain), 154, 249
 Infundibulum (of oviduct). See ostium tubæ abdominale
 Interganglionic commissures, 156
 Intermediate cell-mass, 114, 190
 Interventricular sulcus, 348, 353
 Intervertebral fissure, 412
 Intestine, general development of, 310, 311
 Iris, 272; muscles of, 273, 274
 Ischiadic veins, 372
 Ischium, 438, 439
 Isolecithal ova, 11
 Isthmus, of brain, 155; of oviduct, 22

 Jacobson, organ of, 286
 Jugular vein, 363

 Kidney, capsule of, 390; permanent, 384-389; secreting tubules of, 390

 Lagna, 293
 Lamina terminalis, 105, 152, 247, 248
 Larva, 11
 Laryngotracheal groove, 178, 331, 332
 Larynx, 332
 Latebra, 19
 Lateral plate of mesoblast, 115
 Lateral tongue folds, 305
 Lens, 166, 276-278

- Lenticular zone of optic cup, 271
 Lesser peritoneal cavity, 344
 Ligamentum pectinatum iridis, 279
 Limiting sulci, 130
 Lingual glands, 306
 Lip-grooves, 304
 Liver, histogenesis of, 323; later development of, 319-323; origin and early development of, 179, 180, 181; origin of lobes of, 322; primary ventral ligament of, 335
 Lungs, 178, 326

 Macula utriculi, sacculi, etc., 295
 Malpighian corpuscles (mesonephric) origin of, 195
 Mammillæ of shell, 17
 Mandibular aortic arch, 121, 122, 203, 204
 Mandibular arch, skeleton of, 431
 Mandibular glands, 306
 Mantle layer of spinal cord, origin of, 239
 Margin of overgrowth, 52, 57
 Marginal notch, 60, 84, 85
 Marginal velum, 235
 Marrow of bone, origin of, 410
 Maturation of ovum, 32
 Meatus venosus, 199, 364, 366, 368
 Medullary cords of suprarenal capsules, 405, 406
 Medullary neuroblasts of brain, 262
 Medullary plate, 95; position of anterior end of, in neural tube, 102, 103
 Megaspheres, 59
 Membrana reuniens, 418
 Membrane bones, definition of, 407
 Membranes of ovum, 10
 Membranous labyrinth, 289
 Meroblastic ova, 11
 Mesencephalon, 108, 155, 251
 Mesenchyme, definition of, 116
 Mesenteric artery, 363
 Mesenteric vein, 366, 367
 Mesenteries, 333
 Mesentery, dorsal, 172, 342; of the vena cava inferior, 341
 Mesoblast, gastral, 110; of the head, origin of, 116, 117; history of between 1 and 12 somites, 109; lateral plate of, 110, 115; of opaque area, origin of, 86, 88; origin of, 74, 78; paraxial, 110; prostomial, 110; somatic layer of, 115; splanchnic layer of, 115
 Mesobronchus, 326, 327
 Mesocardia lateralia, 200, 207, 334, 337
 Mesocardium, origin of, 120

 Mesogastrium, 309, 342, 343
 Mesonephric arteries, 363
 Mesonephric mesentery, 341
 Mesonephric tubules, formation of, 195
 Mesonephric ureters, 380
 Mesonephros, later history of, 378; origin and early history of, 194-197; see Wolffian body
 Mesothalamus, 251
 Mesothelium, definition of, 116
 Metacarpus, 436, 437, 438
 Metamorphosis, 11
 Metanephros, 384-389
 Metatarsals, 441
 Metathalamus, 251
 Metencephalon, 155, 251
 Mid-brain (see Mesencephalon)
 Mid-gut, 172, 181, 310
 Mouth, 301
 Müllerian ducts, 391; degeneration in male, 402, 403; origin of, 401, 402, 403
 Muscles of iris, 274
 Muscle plate, 185, 186
 Myelencephalon, 155, 252
 Myocardium, origin of, 119
 Myotome, 188

 Nares, 286
 Nephrogenous tissue, 195, 378; of metanephros, 384, 387
 Nephrotome, 114, 190
 Neural crest, 156
 Neural folds, 97, 99
 Neural groove, 97
 Neural tube, 95, 105
 Neurenteric canal, 73, 82
 Neuroblasts, 233-239; classes of, in spinal cord, 244
 Neurocranium, 427, 428
 Neuroglia cells, origin of, 239, 240
 Neuromeres, 108, 148, 152, 155
 Neurone theory, 236, 255, 256
 Neupore, 101, 105
 Notochord, later development of, 411 ff; origin of, 80; in the region of the skull, 428

 Oblique septum, 331, 342
 Oculo-motor nerve, 265; nucleus, 262, 263
 Odontoid process, origin of, 420
 Oesophagus, 179, 310, 312
 Olfactory lobe, 247
 Olfactory nerve, 263
 Olfactory pits, 169, 285
 Olfactory vestibule, 285
 Omentum, development of, 343
 Omphalocephaly, 120

- Omphalomesenteric arteries, 199, 363;
 veins, 364-366
 Oötid, 14
 Opaque area, see area opaca
 Optic cup, 165, 271; lobes, 251; nerve,
 283, 284, 285; stalk, 149, 164, 284,
 285; vesicles, accessory, 164
 Optic vesicles, primary, 108, 164;
 secondary, 166
 Ora serrata, 272
 Oral cavity, 215, 216, 301
 Oral glands, 306
 Oral plate, 95, 173
 Orientation of embryo on yolk, 25, 63
 Ossification, 408-411; endochondral,
 409; perichondral, 408
 Ostium tubæ abdominale, 23; devel-
 opment of, 402, 403; relation to
 pronephros, 402
 Otocyst, 168; later development of,
 289; method of closure, 168
 Ovary, 22, 398-401; degeneration of
 right, 398
 Oviductal membranes of ovum, 10
 Oviduct, 22; later development of,
 403
 Ovocyte, 13, 26, 27
 Ovogenesis, 12, 26
 Ovogonia, 12, 26
 Ovum, 2, 10; bilateral symmetry of,
 15; follicular membrane of, 10; or-
 ganization of, 14; polarity of, 14

 Palate, 285, 299
 Palatine glands, 306
 Palingentic aspects of development,
 6
 Pancreas, 181, 323-325, 347
 Pander's nucleus, 19
 Papillæ conjunctivæ scleræ, 280
 Parabronchi, 328
 Parachordals, 428, 429
 Paraidymis, 391, 398
 Paraphysis, 248
 Parencephalon, 108, 153, 249
 Parietal cavity, 92, 116, 207, 208,
 333, 334
 Paroöphoron, 401
 Pars copularis (of tongue), 305
 Pars inferior labyrinthi, 289, 293
 Pars superior labyrinthi, 289, 291
 Parthenogenetic cleavage, 35
 Patella, 441
 Pecten, 281, 282
 Pectoral girdle, 434-436
 Pellucid area (see area pellucida)
 Pelvic girdle, 438-440
 Periaxial cords, 158, 159, 161
 Pericardiac-peritoneal membrane,
 338
 Pericardial and pleuroperitoneal cav-
 ities, separation of, 333
 Pericardium, closure of dorsal open-
 ing of, 337; formation of mem-
 branous, 338; see parietal cavity.
 Periblast, 38, 43, 47; marginal and
 central 48; nuclei, origin of, 47, 48
 Perichondrium, 408
 Periderm, 304
 Perilymph, 296, 297
 Periosteum, 409
 Peripheral nervous system, develop-
 ment of, 252
 Pflüger, cords of, 399
 Phæochrome tissue, 404
 Phalanges, 436, 438; of foot, 441; of
 wing, 438
 Pharynx, derivatives of, 306; early
 development of, 93-95, 173; post-
 branchial portion of, 178
 Phylogenetic reduction of skeleton,
 411
 Physiological zero of development, 65
 Physiology of development, 6
 Pineal body, 153, 249
 Placodes, 160, 161
 Pleural and peritoneal cavities, sep-
 aration of, 340
 Pleural grooves, 208, 209
 Pleuro-pericardial membrane, 338
 Pleuroperitoneal membrane, 326;
 septum, 340, 341
 Plica encephali ventralis, 149, 245
 Plica mesogastrica, 341, 344, 368
 Pneumato-enteric recesses, 209, 340
 Pneumatogastric nerve, 268
 Polar bodies, 13, 34
 Polyspermy, 35, 36, 37
 Pons, 252
 Pontine flexure, 149, 245
 Postanal gut, 182
 Postbranchial bodies, 307, 309
 Posterior intestinal portal, 132
 Postotic neural crest, 160, 161
 Precardial plate, 334, 338
 Preformation, 6
 Pre-oral gut, 174
 Pre-oral visceral furrows, 174, 175
 Preotic neural crest, 158
 Primitive groove, 72
 Primitive intestine, 55
 Primitive knot, 73
 Primitive mouth, 55, 82
 Primitive ova, 26, 392, 399
 Primitive pit, 73
 Primitive plate, 73
 Primitive streak, 69; interpretation
 of, 82; origin of, 74; relation to
 embryo, 85
 Primordia, embryonic, 8

- Primordial cranium, development of, 428
- Primordial follicle, 27
- Proamnion, 86, 138
- Procoracoid, 435
- Proctodæum, 170, 314, 319
- Pronephros, 190-193
- Promucleus male and female, 34, 36
- Prosencephalon, 108, 149
- Proventriculus, 313
- Pubis, 438, 439
- Pulmo-enteric recesses (see pneumato-)
- Pulmonary arteries, 359
- Pupil of eye, 166, 272
- Radius, 436
- Ramus communicans, 254, 257, 259
- Recapitulation theory, 3; diagram of, 5
- Recessus hepatico-entericus, 343; recessus mesenterico-entericus, 343; recessus opticus, 153; recessus pleuro-peritoneales, 340; recessus pulmo-hepatici, 340; recessus superior sacci omenti, 340
- Rectum, 317
- Renal corpuseles, 378, 383
- Renal portal circulation, 369, 372, 375
- Renal veins, 372
- Reproduction, development of organs of, 390-403
- Respiratory tract, 178, 325
- Rete testis, 398
- Retina, 274, 275
- Retinal zone of optic cup, 271
- Rhombencephalon, 108, 155
- Ribs, development of, 424, 425
- s (abbreviation for somites), 67
- Sacrum, 424
- Sacculus, 293, 294
- Succus endolymphaticus, 169, 289, 290
- Succus infundibuli, 249
- Scapula, 434, 435
- Sclerotic coat of eye, 279
- Sclerotomes, and vertebral segmentation, 412; components of, 412; occipital, 428; origin of, 185, 186
- Seessel's pocket, 174
- Segmental arteries, 122, 199, 362
- Segmentation cavity, 43, 47, 53 (see also subgerminal cavity)
- Semeniferous tubules, 398
- Semicircular canals, 291
- Semi-lunar valves, 352
- Sensory areas of auditory labyrinth, origin of, 296
- Septa of heart, completion of, 355, 356, 357
- Septal gland of nose, 287
- Septum aortico-pulmonale, 351, 352; of auricular canal, 355; bulbo-auricular, 353; cushion, 351, 355; interauricular, 351, 354; interventricular, 351, 353, 354; of sinus venosus, 358
- Septum transversum, 208, 209, 334; derivatives of, 339; lateral closing folds of, 334, 337; median mass of, 335
- Septum trunci et bulbi arteriosi, 351
- Sero-amniotic connection, 138, 143, 217
- Sexual cords, 393, 394; of ovary, 398; of testis, 395
- Sexual differentiation, 394, 395
- Sheath cells, 255
- Shell, structure of, 17
- Shell membrane, 18
- Sickle (of Koller), 71
- Sinu-auricular aperture, 357, 358
- Sinu-auricular valves, 358
- Sinus terminalis 86 (see also vena terminalis)
- Sinus venosus, 197, 200, 201, 357; horns of, 358; relation to septum transversum, 339
- Skeleton, general statement concerning origin, 407
- Skull, chondrification of, 429-432; development of, 427; ossification of, 432, 433, 434
- Somatopleure, 62, 115
- Somite, first, position in embryo, 111
- Somites, of the head, 114; mesoblastic, origin of, 110, 111; mesoblastic, metameric value of, 184; primary structure of, 114
- Spermatid, 13
- Spermatocyte, 13
- Spermatogenesis, 12
- Spermatogonia, 13
- Spermatozoa, period of life within oviduct, 35
- Spermatozoön, 9
- Spina iliaca, 440
- Spinal accessory nerve, 269
- Spinal cord, development of, 239
- Spinal nerves, components of, 254; development of, 252, 255; somatic components of, 254; splanchnic components of, 256
- Splanchnocranium, 427
- Splanchnopleure, 62, 115
- Spleen, 345-347
- Spongy layer of shell, 17
- Stapes, 300

- Sternum, development of, 425-427
 Stigma of follicle, 25
 Stomach, 179, 313
 Stomodæum, 170, 173
 Stroma of gonads, 393; of testis, 397
 Subcardinal veins, 368, 369
 Subclavian artery, 362
 Subclavian veins, 363, 364
 Subgerminal cavity, 53, 61, 69
 Subintestinal vein, 367
 Subnotochordal bar, 416, 418
 Suleus lingualis, 298
 Suleus tubo-tympanicus, 298
 Supraorbital sinus of olfactory cavity, 285
 Suprarenal capsules, 403-406
 Sutura cerebralis anterior, 103-105; neurochordalis seu ventralis, 105; terminalis anterior, 105
 Sympathetic nervous system, 256-261; relation to suprarenals, 406
 Sympathetic trunks, primary, 257; secondary, 258
 Synencephalon, 108, 153, 249
 Syrinx, 332
- Tables of development, 68
 Tail-fold, 131
 Tarsus, 441
 Tectum lobi optici, 251
 Teeth, 304
 Tela choroidea, 152
 Telencephalon and diencephalon, origin of, 150
 Telencephalon, later development of, 245-249; medium, 151, 245
 Telolecithal, 11
 Ten somite embryo, description of, 122
 Testis, 395-398
 Tetrads, 33
 Thalami optici, 154, 251
 Thymus, 308
 Thyroid, 178, 307
 Tongue, 305
 Torus transversus, 248
 Trabeculæ, of skull, 428, 429; of ventricles, 353
 Trachea, 331, 332
 Trigeminal ganglion complex, 160, 267
 Trigemini nerve, 267; nucleus (motor), 262, 263
 Trochlearis nerve, 266; nucleus, 262, 263
 Truncus arteriosus, 198
 Tubal fissure, 298, 301
 Tubal ridge, 401
 Tuberculum impar (of tongue), 305
 Tuberculum posterius, 249
- Tubo-tympanic cavity, 297-300
 Tubules of mesonephros, degeneration of, 380-382; formation of, 195-196; primary, secondary, tertiary, 379, 380
 Turbinals, 285, 286, 431
 Turning of embryo, 133
 Tympanum, 297, 300
- Ulna, 436
 Umbilical arteries, 363; veins, 367, 368
 Umbilicus, 144; of yolk-sac, 216
 Unincubated blastoderm, structure of, 69
 Ureter, origin of, 384
 Urinogenital ridge, 390, 391; system, later development of, 378, etc.
 Urodæum, 314, 319
 Uterus, 22
 Utriculus, 291, 292
 Uvea, 273
- Vagina, 22
 Vagus, ganglion complex of, 161; nerve, 268; nucleus, 262, 263
 Variability, embryonic, 64
 Vas deferens, 401
 Vasa efferentia, 398
 Vascular system, anatomy of, on fourth day, 197-200; origin of, 117
 Venous system, 127, 199, 204, 205, 228, 363-372
 Velum transversum, 150, 248
 Vena cava, anterior, 363, 364; inferior, 368-372
 Vena porta sinistra, 367
 Vena terminalis, 228; see also sinus terminalis
 Ventral aorta, 121
 Ventral longitudinal fissure of spinal cord, 243
 Ventral mesentery, 131, 182, 343
 Vertebrae, articulations of, 421; coalescence of, 424; costal processes of, 418; hypocentrum of, 418; intervertebral ligaments of, 421; ossification of, 421-424; pleurocentrum of, 418; stage of chondrification of, 418; suspensory ligaments of, 421;
- Vertebral column, 411; condition on fourth day, 414; condition on fifth day, 415, 417; condition on seventh and eighth days, 418, 420; membranous stage of, 414
 Vertebral segmentation, origin of, 412 ff
 Visceral arches, 175; clefts, 174, 307; furrows, 174; pouches, 174;

- pouches, early development of, 175-178; pouches, fate of, 307, 308
 Vitelline membrane, 10, 30, 31
 Vitreous humor, 275
- White matter of spinal cord, origin of, 239, 241
- Wing, origin of skeleton of, 434, 436
- Wolffian body (see mesonephros); atrophy, 380, 382, 401; sexual and non-sexual portions, 396; at ninety-six hours, 379; on the sixth day, 382; on the eighth day, 382, 383; on the eleventh day, 385
- Wolffian duct, 191, 193, 194, 391, 401
- Yolk, 17, 19; formation of, 29
- Yolk-sac, 143, 225-231; entoderm of, 50; blood-vessels of, 227-230; septa of, 225-227; ultimate fate of, 230, 231
- Yolk-spheres, 19, 20
- Yolk-stalk, 132, 225
- Zona radiata, 10, 30, 31
- Zone of junction, 52, 57
- Zones of the blastoderm, 127-129

